

The Lymphatics.

Contributors

Cunéo, Bernard Joseph, 1873-1944. Special study of the lymphatics in different parts of the body.

Delamere, G. General anatomy of the lymphatics.

Poirier, Paul Julien, 1853-1907. Special study of the lymphatics in different parts of the body.

Leaf, Cecil H

University of Leeds. Library

Publication/Creation

Westminster [England] : A. Constable, 1903.

Persistent URL

<https://wellcomecollection.org/works/yd8qmy94>

Provider

Leeds University Archive

License and attribution

This material has been provided by This material has been provided by The University of Leeds Library. The original may be consulted at The University of Leeds Library. where the originals may be consulted.

Conditions of use: it is possible this item is protected by copyright and/or related rights. You are free to use this item in any way that is permitted by the copyright and related rights legislation that applies to your use. For other uses you need to obtain permission from the rights-holder(s).



Wellcome Collection
183 Euston Road
London NW1 2BE UK
T +44 (0)20 7611 8722
E library@wellcomecollection.org
<https://wellcomecollection.org>


THE LYMPHATICS

R. POIRIER, B. CUNEO, G. DELAMERE

TRANSLATED AND EDITED BY

CECIL H. LEAF

*The University Library
Leeds*



*Medical and Dental
Library*

STORE

WH 700
DEL




30106

004195060

A
248

UNIVERSITY OF LEEDS
MEDICINE



A TREATISE
OF HUMAN ANATOMY

EDITED BY

P. POIRIER . and . A. CHARPY

*Professeur d'Anatomie à
la Faculté de Paris,*

Chirurgien des Hôpitaux

*Professeur d'Anatomie à
la Faculté de Méde-
cine à Toulouse*

THE LYMPHATICS

THE LYMPHATICS

GENERAL ANATOMY OF THE LYMPHATICS BY

G. DELAMERE

SPECIAL STUDY OF THE LYMPHATICS

IN DIFFERENT PARTS OF THE BODY BY

P. POIRIER

and

B. CUNÉO

*Professeur d'Anatomie à la Faculté de
Médecine à Paris, Chirurgien des Hôpitaux*

*Professeur agrégé à la Faculté de
Médecine de Paris*

AUTHORISED ENGLISH EDITION

TRANSLATED AND EDITED BY

CECIL H. LEAF

*M.A., M.B. (Cantab.), F.R.C.S. (Eng.), Assistant Surgeon to
the Cancer Hospital, and to the Gordon Hospital for
Rectal Diseases. Late Demonstrator of
Anatomy, London Hospital*

WITH 117 ILLUSTRATIONS AND DIAGRAMS


WESTMINSTER

ARCHIBALD CONSTABLE & CO LTD

2 WHITEHALL GARDENS

1903

All rights reserved



604166

TO THE MEMORY OF
PROFESSOR SAPPEY



Editor's Preface

THIS work, a section of *The Treatise of Human Anatomy*, edited by P. Poirier and A. Charpy, is divided into two parts. The first—on the General Anatomy of the Lymphatic System—is by G. Delamere. The second—on the Special Study of the Lymphatics in different regions of the body—is by P. Poirier and B. Cunéo. The names of these authors are sufficient guarantee of the care and accuracy bestowed on their respective subjects.

From a practical point of view, a thorough knowledge of the histology and functions of the lymph, and definite ideas as to the arrangement and distribution of the lymphatic vessels, become more and more essential every day. In both these subjects it will be found that the present work considerably extends our knowledge.

Gerota's method of injection, which was advocated by Poirier in 1892, has been freely used by the authors, with the result that our knowledge of the lymphatics of certain regions of the body, which were not well adapted for injections by mercury, is more complete to-day than it was in the past.

In the work of translation I have endeavoured as far as possible to reproduce the French, but where there was any possibility of ambiguity resulting therefrom, I have not hesitated to give a free rendering.

I have much pleasure in acknowledging my indebtedness to my brother, F. Walton Leaf, for kindly overlooking the proof-sheets, and for many timely and valuable suggestions.

CECIL H. LEAF.

WIMPOLE STREET,

August, 1903.



The Lymphatics

FIRST PART

GENERAL ANATOMY OF THE LYMPHATIC SYSTEM

	Page
GENERAL CONSIDERATIONS	3
LYMPH	4
LEUCOCYTES	9
I. THE WHITE CORPUSCLE IN GENERAL	9
II. THE DIFFERENT LEUCOCYTES	32
THE LYMPHATIC VESSELS	56
THE LYMPHATIC GLANDS	81

SECOND PART

SPECIAL STUDY OF THE LYMPHATICS OF THE
BODY

CHAPTER I. LYMPHATICS OF THE LOWER LIMB	111
I. GLANDULAR GROUPS OF THE LOWER LIMB	112
II. LYMPHATIC VESSELS " " "	120
CHAPTER II. LYMPHATICS OF THE PELVIS AND ABDOMEN	129
I. GLANDULAR GROUPS OF THE PELVIS AND ABDOMEN	129
1. Ileo-pelvic Glands	129
2. Abdomino-aortic Glands	139
II. LYMPHATIC VESSELS OF THE PELVIS AND ABDOMEN	148
1. Lymphatics of the Abdominal Wall	148
2. " " External Genital Organs	152
3. " " Internal Genital Organs	160
4. " " Urinary Passages	175
5. " " Sub-diaphragmatic Portion of the Digestive Tube	186
CHAPTER III. LYMPHATICS OF THE THORAX	208
I. GLANDULAR GROUPS OF THE THORAX	208
1. Parietal Glands	208
2. Visceral " " " " "	212

	Page
II. LYMPHATIC VESSELS OF THE THORAX	215
1. Parietal Lymphatic Vessels	215
2. Visceral " "	228
CHAPTER IV. LYMPHATICS OF THE UPPER LIMB	233
I. LYMPHATIC GLANDS OF THE UPPER LIMB	233
II. LYMPHATIC VESSELS " " "	240
CHAPTER V. LYMPHATICS OF THE HEAD AND NECK	247
I. GLANDULAR GROUPS OF THE HEAD AND NECK	247
1. Peri-cervical Glandular Circle	247
2. Descending Cervical Chains	256
II. LYMPHATIC VESSELS OF THE HEAD AND NECK	263
1. Lymphatic Vessels of the Cranial Region	263
2. " " " Face	265
3. " " " Facio-Cervical Portion of the Digestive Passages	269
4. Lymphatic Vessels of the Facio-Cervical Portion of the Respiratory Passages	283
CHAPTER VI. TERMINAL COLLECTING TRUNKS OF THE LYMPHATIC SYSTEM	290
I. TERMINAL COLLECTING TRUNKS OF THE SUPRA-DIAPHRAGMATIC PORTION OF THE BODY	290
II. THORACIC DUCT	292

Introduction

EVER since the commencement of my works on anatomy (1876) I have been especially attracted towards the study of the lymphatic system. Admitted into the private laboratory of my master, the lamented Professor Sappey, I learnt from him the method of injecting by mercury. Under the direction and control of this kind and skilful master, I have studied the lymphatics of numerous organs, and I have been fortunate enough to be able to fill in the details of former works and supplement them on many points—

“Lymphatic Vessels of the Larynx : the Praelaryngeal Gland.” *Société Anatomique et Progrès Médical*, 1887.

“Lymphatic Vessels of the Articulations.” *Traité d'Anatomie Humaine*, vol. i. p. 557.

“Vessels and Lymphatic Glands of the Lower Limb and of the Inguinal Region” ; specimens placed in the Museum of the Faculty.

“Lymphatics of the Testicle and of the Spermatic Cord” ; specimens prepared for the meeting of Prosectors, 1883 ; placed in the Museum of the Faculty.

“Lymphatic Vessels of the Meninges, and of the Encephalon.” *Anatomie Médico-Chirurgicale*, pp. 164–165, 1892.

“Lymphatics of the Female Generative Organs : Uterus, Vagina, Fallopian Tube, Ovary.” *Société Anatomique et Progrès Medical*, 1890.

“Lymphatics of the Tongue.” *Traité d'Anatomie humaine*, t. iv. p. 105, 1895, and *Gazette Hebdomadaire*, 1902.

“Lymphatic Glands of the Axilla.” *Progrès Médical*, 1888.

Numerous illustrations accompany the various articles, of which a number have become classical, and have been reproduced in France and abroad.

In recent years a method of injection with Prussian blue,


called "Gerota's process," having been applied to the study of the lymphatic vessels and glands, I asked my pupil, colleague and friend Cunéo, who introduced this method into France, to teach me the technique, the use of which I had advocated since 1892 (*Anatomie-medico-chirurgicale*, pp. 164-165), and which he has applied with known success to the study of the lymphatics of the stomach, the bladder, the rectum, and genital organs. Together we have again undertaken the study of the lymphatics of the entire body, as much with the object of perfecting our knowledge on the subject as for adding to well-ascertained facts.

As I felt incompetent to adequately deal with the histology of the lymphatic vessels and glands and of the lymph, which is so important a matter, I entrusted this part of the work to my devoted pupil Delamere, who has personally undertaken these researches in the laboratory and under the guidance of Professor Mathias Duval.

It follows therefore that this portion of the treatise of Human Anatomy (the last but one) is, like the preceding ones, not simply a general review, a work of compilation, but is a record of opinions which have been formed as a result of personal researches. It shows the state of the science of to-day and indicates the lines on which the work must be conducted in the future.

General Anatomy of the Lymphatic System

BY
G. DELAMERE.



FIRST PART.

General Anatomy of the Lymphatic System

BY

GABRIEL DELAMERE.

THE Lymphatic System is made up of vessels which, after traversing the glands, bring the lymph into the venous system. The capillaries of origin have closed extremities which never penetrate beyond the epithelial linings; by their anastomoses they form primary networks, from which commence the first collecting trunks, which divide again into capillaries on traversing the gland. Passing out of the gland the efferent vessels join, and form the large terminal collecting trunks, tributaries of the vena cava superior.

In man, the terminal collecting trunks are usually two in number: the thoracic duct and the right lymphatic duct.

The interposition of glands during the passage of the lymph gives the lymphatic system an entirely peculiar character; in fact, it appears as though formed of a series of portal systems superposed.

The study of the lymph and the leucocytes, being necessary to the thorough comprehension of this system and that of the glands, we will study—

1. The lymph.
2. The leucocytes.
3. The lymphatic vessels.
4. The glands.

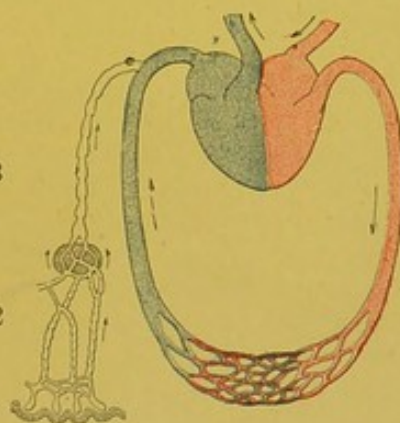


FIG. 1.—General scheme of the lymphatic system. 1. Origin of capillaries close under the epithelium; 2. Networks which give origin to the collecting trunks, which divide into capillaries in the gland; 3. Larger but less numerous efferent trunks which divert the lymph into the venous blood (portal lymphatic system of the gland).

The lymph is generally considered a tissue, of which the cells—the leucocytes—are placed in a fundamental liquid, the plasma. We consider, however, that the essential part of the lymph is the plasma; and the typical elements which it contains, and of which the most essential are the leucocytes, are only casual guests. Contrary to custom, we shall devote a separate chapter to their consideration.

The plasma, moreover, or, if one prefers to call it so, the lymph—for these are in our opinion two synonymous terms—ought not to be considered as a simple product of filtration, but rather as a secretion, the genuine result of cellular activity.

Claude Bernard, having shown that soluble salts such as iodide of potassium or prussiate of potash, injected into the blood, pass immediately into the lymph, and Noll and Ludwig having demonstrated the influence of blood pressure on the lymphatic flow, it has become customary to speak of the lymphatic plasma as being the result of capillary filtration from the serum of the blood.

In spite of this, it is only possible for us to regard it as a selective filtration process, seeing that Cheauveau found much less glucose in the lymph plasma than in the blood plasma. It should be added that for some time other authors have suspected that the lymph was not a simple product of filtration; thus, according to Ch. Robin, it is formed not only from substances derived from the blood plasma, but very probably also from the breaking up of anatomical elements. Longuet holds that it is a sort of chyle which is formed at the expense of the actual substance of the animal. But of late years one is compelled to strenuously oppose the idea, always a classical one, of the lymph being a mechanical product of filtration from the blood. It was Heidenhain originally, who seeing the lymph form and circulate one or two hours after a subdiaphragmatic ligature of the aorta, concluded that the lymph was not a product of filtration but a product of endothelial secretion. The same physiologist also remarks that certain substances act as lymphagogues as long as the blood pressure remains normal or a little under. The action of these bodies can only be explained on the supposition that they call upon the fixed elementary tissues for a supply of lymph. Starling contests these deductions: he thinks that in Heidenhain's experiment the lymph comes from the liver and that the subdiaphragmatic ligature of the aorta does not alter the pressure in the hepatic capillaries. According to him, the lymphagogues paralyze the muscular walls of the vascular system, and especially, by altering the endothelium, increase its permeability.

In order to verify Heidenhain's views, and to rebut the objections raised by Starling, Hamburger studied the behaviour of lymph in the neck of a horse whose head was rendered immobile, but whose body and limbs were allowed to move. Under these conditions, he has seen the quantity of lymph become tripled and quadrupled in spite of the diminution of pressure in the carotids and jugulars. Finally, by the haemolytic method he has found that the lymph possessed greater osmotic powers than the serum in the jugular. In the same way, by means of the cryoscope, Leathes, Fano and Bottazi, have shown that the coagulation point (Δ) of lymph is always higher (further removed from 0°) than that of the blood.

Δ (lymph)	Δ (serum) (Leathes).
— 0° 620	— 0° 610.
— 0° 630	— 0° 625.
— 0° 625	— 0° 617 (Fano and Bottazi).

According to Fano and Bottazi, injections of phosphorus, which destroy the endothelial wall, produce no effect upon the concentration of the blood, but diminish the concentration of lymph in the thoracic duct (before injection, $\Delta - 0^{\circ}63$; after injection, $\Delta - 0^{\circ}58$).

Tscherewkow positively states that, though venaesection diminishes the amount of solid elements in the blood serum to a marked degree, the lymph is unaffected.

Asher and Barbera find that lymph increases in the same proportions as the nitrogen in the urine; its toxicity is greater than that of blood. It is the result neither of a filtration (the classical theory), nor of an endothelial secretion (theory of Heidenhain): it owes its origin to the vital functions of cells.

Moussu does not regard the lymph as being secreted by the endothelium of the blood capillaries. Its production is aided by the blood pressure: above all it results from the functional activity of the tissues. In fact, both chemistry and the cryoscope, demonstrate the fact that lymph is different from blood; physiology makes us regard it not so much as a product of filtration as of a vital elaboration from cells. Containing the residual products of cellular life, we regard it as a kind of fluid excretion.

It would seem at first sight peculiar that such a fluid, instead of being eliminated externally, should be poured into the venous blood, and that it should afterwards pass again into the organs with the arterial blood. But is not this fluid at first modified in the lymphatic glands, and again perhaps in the pulmonary endothelium? Certain experiments of Brown-Séquard tend to prove the pathogenic properties of expired air, and it may be that their expiration is the result of the excretion of certain toxic matters from the lungs. Moreover, though the physiologists (Starling, Asher, Moussu), do not admit the existence of an endothelial secretion of blood capillaries, which is Heidenhain's view, Ranvier has shown the histological existence of an endothelial lymphatic secretion: the lymph is not only a liquid excretion, it is even more, a product of secretion. Therefore it is not surprising that, like the internal secretions of the thyroid gland and the suprarenals, it is poured into the blood.

The lymph contains leucocytes also, which are, so to speak, its casual guests. It is supplied with little or no oxygen in the trunks, and therefore affords a most unsuitable medium for their development. Later on we will speak of the morphological varieties which are met with; for the present, however, we will confine ourselves to the study of their number. The number is much greater at the centre than at the periphery of the system. Formerly, Frey had remarked that the commencing chyloferous vessels contained few or no cells at all. Recently Renaut has noted the absence of leucocytes in the capillaries of origin of the loose connective tissue of the marmot. All authors find that the number of leucocytes are considerably increased after their passage through the gland. Judging from the somewhat numerous ideas expressed in the older writings, the number of leucocytes in the lymph is very variable, not only in different animals, but also in different animals of the same species: thus Malassez counts only 180 in a cubic millimetre of frog's lymph, Ranvier counts 11,300 in the same quantity of rabbit's lymph, 4,800 and 7,500 in the lymph of the dog, and 8,200 in that of man.

Again one finds some red blood corpuscles in the lymph, but always in small quantities. They are, however, sometimes so numerous as to impart a rosy tint: this rose colouration was specially observed in the lymph coming from the spleen, or from lymphatic glands (Hewson, Gulliver, Lane and Ancel, Simon, Reuss and Emmert). It increases in the lymphatic vessels which have been blocked by a ligature (Elsner, Retterer), and when the blood pressure rises (Stricker, Hering, Laulanie). Finally, it would appear as though the lymph becomes reddest in starving animals (Collard de Martigny, Nasse). In contradistinction to these last-mentioned authors, I have noted the perfect whiteness of both chyle and lymph in a rabbit and a dog which have died from starvation. Similarly, I have bled some animals without being able to observe the slightest red colour in their lymph—an observation already made by Hayem.

The presence of red blood cells is not perhaps absolutely constant, since Kölliker has not found them in human chyle, but unquestionably they are frequently present. One cannot agree with Krause, who asserts that lymph collected without accidental mixing with blood, is always destitute of red blood corpuscles. It seems that the presence of some of them may be explained by the reflux of venous blood into the thoracic duct (Colin). In the case of hyperdistension, others come from blood vessels, either owing to rupture, or by diapedesis. However, it is not probable that such is their sole origin, and without affirming as the old authors have done, that the red blood corpuscles are always derived from the white corpuscles, we may ask if some of them do not come from lymphatic glands. We will study this question when dealing with the functions of these organs.

Before undertaking the chemical study of the plasma of the lymph, it is advisable to recall its histological characters. On the one hand, Renaut considers that this plasma contains no albuminoid matter in the capillaries of origin. On the other hand, Ranvier has observed in the trunks, granules of a hyaline substance, myeloid in nature, which are stained yellow by picrocarmin; these granules are manufactured by the endothelium. Retterer also found granules in the lymphatic plasma. I have observed the same thing in the contents of the lymphatic capillaries of the glands, and of that of the thoracic duct. These granules are more rare in the blood vessels, with the exception of those in the liver.

The origin of these granular coagula seems complex: the granules are apparently derived as much from the endothelium as from the protoplasm of the white blood corpuscles. Admitting that secretion takes place to a considerable extent within the intraglandular passages, it is possible that the formation of these granules is also one of the products of the secretion of the lymphatic gland.

All that we know of the lymph, its origin, and the alterations it most probably undergoes after traversing the gland, lead us to think that it possesses a very variable chemical composition, which depends not only upon the condition of the animal, but also upon the particular vessel from which the lymph is drawn. This explains the discrepancies which have been observed in the different analyses published up to the present time, notably by Schmidt, Gubler and Quévenne, Hensen and Dahnhardt; it also explains the difference which, it is now recognized, exists between the peripheral lymph and the mesenteric lymph or chyle. In reality, the difference simply amounts to this: that the chyle is loaded with fat derived from the lacteals of the intestine.

The lymph is a slightly viscous liquid, with no colour, or with a colour

varying from a slight lemon or hardly recognizable opal, to a yellow tint—that is, before its passage through the gland. The moment digestion commences it becomes milky. In the thoracic duct and in the efferent vessels of the spleen, we have seen that sometimes it is of a faint rosy tint.

It is as a rule inodorous; but some observers detect a faint odour, which varies in different kinds of animal. Others maintain that when cold, the chyle smells like spermatic fluid, and when heated, like fat. It is faintly alkaline to the taste. Its specific gravity varies between 1,015 and 1,045; that of chyle between 1,012 and 1,022. It is less alkaline than blood-lymph, requiring 0.35 gr. lactic acid to neutralize 100 grs., whereas blood, requires 0.50 gr. to neutralize the same quantity.

According to Krause, the total quantity of lymph equals one-third the weight of the body; according to Ludwig and Majendie, one fourth; Bidder says that in the cat and dog it is equivalent (approximately) to from $\frac{1}{5}$ to $\frac{1}{4}$ of the weight. In the case of the horse, Schmidt has obtained in twenty-four hours a quantity of lymph equal to the total quantity of blood. More recently Moussu has obtained in ten minutes, from different horses in a state of rest, quantities varying between 0.60 gr. and 6.50 gr.—on an average a little more than two grammes. In the ox he has also obtained in the same time quantities varying from 2–26 gr. In an ox of average weight the amount is a little more than 10 gr.

By making a fistula in the thoracic duct, Colin has obtained 95 kgs. 286 grammes in twenty-four hours. In the dog, Lesser has obtained 300 cubic centimetres in four hours; in man, 5 litres and a half have been collected in the same time. The quantity depends, we know, not only upon mechanical influences such as pressure, etc., but especially upon cellular activity in all its conditions; thus, Moussu has collected 5, 10, and even 20 times more lymph from an animal in a state of activity, than from the same animal in a state of rest.

Lymph increases fairly quickly under the influence of pilocarpine, less quickly under that of ergotine; it increases also after the injection of certain toxins (Charrin, Moussu); after a hypotensive dose of toxin, viz. diphtheria toxin, and also after a hypertensive dose of toxin, such as tuberculin. Though Beard and Wilcox, and Retterer, firmly believe they have seen the lymph increase after bleeding, Moussu, on the other hand, has stated that in the horse, bleeding to the extent of 4 litres has led to a marked diminution of this fluid. Ranvier has seen the lymph diminish considerably in frogs which have been placed in a vacuum, or kept in a dry place. In the case of the curarized frog, the lymph accumulates in the retrolingual space (Ranvier, Tarchanoff).

Regarding the numerous lymphagogues we ought, as Heidenhain suggests, to classify them, and place in the first class such as are of an albuminoid nature, or of animal origin, such as the muscle extract of the crayfish, head and body of leeches, bodies of anodons, the intestine and liver of the dog, and the peptones. In the second class, crystalloids: the sugar, salts, and urea, should be included. Outside the vessels lymph coagulates more slowly than blood, taking from five to twenty minutes. 1,000 parts of lymph yield 44.8 parts of clot (Schmidt); the same quantity of chyle produces only 32.6 of clot. The clot is soft, somewhat white, slightly retractile. The serum is colourless and transparent.

Coagulation yields considerably less fibrin than that given by the same quantity of blood. In 1,000 parts of lymph taken from the inguinal glands of the bull and cow, Schmidt finds 1.2 gr., 2 gr., and 2.2 gr. of fibrin. In the same quantity of human lymph, Hensen and Dahnhardt find 1.07 gr.

According to others, the amount varies between 0.4 gr. and 0.8 gr. The tendency to fibrin formation and coagulation becomes more rapid, after the passage of lymph through the glands (Chaussier, Albertoni, Hofmeister), and after the action of curare. On the contrary, coagulation takes place more slowly after the action of certain toxins (Charrin). Chemically, lymph is an aqueous liquid which contains albuminoid matters (globulin, serin, fibrin), fat, sugar, urea, salines and gas. The proportion of water is here much greater than it is in blood (from 929.7 to 987.7 in 1,000 parts); the water diminishes after the passage of lymph from the gland. In chyle there is usually less water than there is in lymph at the periphery (from 904.8 to 964.4).

On the contrary, the richness in albuminoid matter is less than that of blood. It ranges from 3.37 gr. to 52.9 gr. In the chyle it ranges from 22.25 gr. to 70.1 gr. Some of the proteid substances of chyle are precipitated by acetic acid, others by alcohol; their weight may be increased from 30 to 70 in every 1,000 during digestion. The albuminoids also increase in starvation.

Fats are met with in variable proportions—from a trace up to 30 for every 1,000; in the chyle, after a repast, up to 65 for every 1,000 parts: a part consists of neutral glycerides peculiar to the special animal under consideration, the other, of soaps of the fatty acid series, of lecithin (A. Gautier); in the chyle, cholesterine andamins are found (Dobroslavine). After passing from the gland, less fat is usually found.

The proportion of sugar is low, much lower than that of the blood (Chauveau). Wurtz only finds traces of it. Poiseulle and Lefort have obtained 0.016 gr. and 0.0098 gr. in 1,000 parts of lymph taken from the dog or cow. In 1,000 parts of human lymph Gubler and Quévenne have found 0.5 gr.

There is 0.1 gr. of glycogen for every 1,000 parts.

100 parts of lymph contain from 0.012 to 0.021 part of urea.

Saline matters (chloride of sodium, phosphates, sulphates and alkaline carbonates) are found in nearly the same proportions as in blood—from 7 to 15 gr.; on an average 8 gr. per litre in human lymph. There is some iron in lymph and chyle.

According to Hammersten, 100 gr. of lymph contain 42.28 gr. of gas in the following proportions: Carbonic acid gas, 40.32 gr. (from 28–40.32); nitrogen, 1.63 gr.; oxygen, 0.43 gr. (from 0 to 0.43).

In the chyle, Hensen has precipitated a diastatic ferment by alcohol; lymph also contains an amylase. Dastre has concluded that glycogen only exists in the plasma in the white corpuscles.

Floresco has affirmed that after an injection of propeptones, or of extract of leeches' heads, the incoagulable lymph of the thoracic duct causes coagulation of the casein of milk. It contains some rennet, which diminishes during fasting. The lipase exists only in very small quantities (Duclaux).

Lymph cannot be a reducing agent, seeing that Gautier (1881) and Ehrlich (1890) having injected coloured substances such as indigo, alizarin and cerulein blues, into a living animal, substances which become discoloured while absorbing hydrogen, have stated that it has a tint similar to blood and some of the other tissues.

BIBLIOGRAPHY.—Magendie. *Précis élémentaire de physiologie*, 1825, II.—Noll. *Zeitschrift f. ration. Medicin*, 1850, IX.—Cl. Bernard. *Leçons sur les anesthésiques et sur l'asphyxie*, 1875.—Lesser. Eine Methode um grosse Lymphmengen vom lebenden Hunde zu bekommen. *Arbeiten aus der phys. Anstalt zu Leipzig*, mitgetheilt durch Ludwig, 1872.—Hammarsten. Ueber

die Gase der Hundelymphe. *Arbeiten aus der phys. Anstalt zu Leipzig*, 1872.—Robin. *Leçons sur les humeurs*, 1874.—Frey. Ed. franç., 1877.—Albertoni. Ueber die Peptone. *Centralblatt für die med. Wiss.*, 1880, no. 32.—Hofmeister. U. das Schicksal des Peptons im Blut. *Zeit. f. phys. Chemie*, V.—Tarchanoff. De l'influence du curare sur la quantité de la lymphe et l'émigration des globules blancs du sang. *Arch. Physiologie*, 1785.—Krause. Zur Physiologie der Lymphe. *Zeitschrift f. rat. Medicin*, 1885, VII.—Colin, *Phys. comparee des animaux domestiques*, 1888, II.—Heidenhain. Verusche u. Fragen zur Lehre von des Lymphbildung. *Pflüger's Archiv*, 1891, XLIX.—Hambürger. *Zeit. f. Biol.*, 1894.—Charrin. *C. R. Soc. Biol.*, 1896.—Leathes. *Journ. of Phys.*, 1896.—Tscherewkow. *Archiv. f. die gesam. Phys.*, LXII.—Fano et Bottazi. *Arch. ital. biol.*, 1896, XXVI.—A. Gautier. *Leçons de chimie biol. et path.*, 1897.—Asher et Barbera. Untersuchungen über die Eigenschaften u. die Entstehung der Lymphe. *Zeitschr. f. Biol.*, 1898, XXXVI–XXXVII.—Duclaux. *Traite de Microbiologie*, 1899, II.—Moussu. Recherches sur l'origine de la lymphe de la circulation lymphatique périphérique. *Journal de l'anatomie et de la physiologie*, 1901, nos. 4–5.—Ranvier. *Traite d'Histologie pathologique*, 1901.—Retterer. *Journal de l'Anatomie et de la Physiologie*, 1901, no. 6.

LEUCOCYTES

Under the generic term leucocytes, or white blood corpuscles, are included a series of cells which are met with in the blood, the lymph, and connective tissue spaces. Ranvier has objected to this term ($\lambda\epsilon\upsilon\kappa\omicron\varsigma$ —white; $\kappa\upsilon\tau\omicron\varsigma$ —cell), which he says only causes confusion by leaving one to suppose that the white corpuscles are utricular bodies: which is not correct; others object to the term white blood corpuscle, observing that these bodies, colourless though they may be, or containing yellow, orange or black particles, are never white. Whilst entirely recognizing the justness of these remarks, we will retain these terms, which have been sanctioned by use, as we cannot replace them by such terms as "migratory" or "amoebic" cells. The amoebic movement is not a feature which is peculiar to leucocytes only; it is probably common to all cells at all times.

We will study:—

1. The structure, the physical, chemical and biological properties, the evolution (degeneration and death) of the leucocyte.
2. The different kinds of leucocytes.

1. THE WHITE CORPUSCLE IN GENERAL.

Structure.—We will consider (1) the nucleus; (2) the protoplasm.

NUCLEUS.—In the different kinds of leucocytes, the nucleus varies considerably, not only in its size, shape and situation, but also

in the arrangement and disposition of its chromatin. Large or small, placed in the centre or away from it, it is rounded, oval, elongated or polymorphous, and sometimes actually multiple. The polymorphism of these nuclei has actively engaged the attention of cytologists and given rise to many theories to account for it.

Even if we admit that by being split up and by a degenerative vacuolization, leucocytes can present multiple perforated nuclei, Flemming, Heidenhain and Vander Stricht, have proved that the polymorphism is not, as Ziegler and Schultze believed, a sign of degeneration, or even of age. For even if we support this latter theory by supposing that the nuclei of certain epithelial cells, which are rounded in young animals, become irregular and twisted as they get older, we must also admit that the mere fact of leucocytes possessing amoeboid properties, and being able to act as phagocytes to nuclei, does not fit in well with the theory that such cells are old or are about to die. We shall, when studying amoebic movements, meet with direct and indirect division of leucocytes, whatever the generic bearings may be which appear to exist between these phenomena and the irregularity of the nucleus. These phenomena apparently are not able to explain all cases of polymorphic nuclei. It is interesting to compare the budding nucleus of *leucocytes*—the *unicellular glands* (Ranvier, Löwit) to the ramified nucleus of the immobile glandular cells of certain Invertebrates (forms observed by Mayer, Heider, Korschett, Klaatsch, Montgomery). It is worth remarking that these modifications of the nucleus are temporary, and probably coincide with the secretory activity of the cell; perhaps the polymorphism, that is to say, the increase of the nuclear surface of certain leucocytes, bears some relation to their secretory activity.

Sometimes the chromatin is seen as a network of more or less close spaces, sometimes as rounded granules (pseudo-nucleoli): these latter are as a rule more or less central, bound or not to other peripheral granules which adhere to the nuclear membrane.

In the leucocytes of the salamander fixed by sublimate, M. Heidenhain has pointed out the existence of a coarse chromatin network, intimately bound up with a much more delicate network, formed by filaments of linin; in the meshes of which he has found albuminoid granules, which are well coloured with acid fuchsin. He calls this substance lanthin. Henneguy thinks that it is an albuminous fluid which has been precipitated by the sublimate; perhaps this fluid corresponds to paralinin.

Löwit, while studying the leucocytes of the crayfish with the reagents of Schwarze and Zacharias, found that their nuclei contained much pyrenin. Such, he thought, ought to divide directly. We shall see later on, that leucocytes frequently reproduce themselves by karyokinesis.

Hayem, Ehrlich, and Lazarus note the almost constant presence of one or two nucleoli in small leucocytes (lymphocytes), without stating definitely if they are made up of pyrenosomes or of pseudo-chromatin nucleoli.

In certain leucocytes (myelocytes, neutrophiles) Levaditi has coloured, without previous fixing with the brilliant Kresyl blue, forms which he considers resemble nucleoli?

PROTOPLASM.—We will study (1) its composition ; (2) its different forms, such as centrosomes and spheres of attraction ; (3) its contents—absorbed or manufactured by the cell.

Composition.—Sometimes simply an almost imperceptible stratum, sometimes well developed, it would appear that the protoplasm of the white blood corpuscles has the power of reacting in many different ways to stains ; at times it is neutral, and at others acidophile or basophile. Sometimes almost homogeneous, it almost always has, according to Flemming, Heidenhain, Schoefer, Arnold and Klemciewicz, a reticular or filamentous structure. In the meshes of the network one finds spaces filled with a homogeneous and liquid substance ; the vacuoles are more or less abundant, according to the cells considered.

Schoefer has stated that the leucocytes, which have been fixed on a slide by the rapid action of a jet of steam, present a reticular structure in the centre, whereas the pseudopods remain clear ; he therefore concludes that the latter are simply hyaloplasmic expansions ; Henneguy likewise, has found a structure purely vacuolar in the central part of the leucocytes of earthworms, in which the pseudopods are homogeneous. Arnold, after maceration in a solution of iodo-iodide, has seen corpuscles which are sometimes rounded, but which are more often elongated in the form of little rods (plasmosomes). These plasmosomes show filiform prolongations, which unite in a thousand ways so as to produce a filamentous, reticular or spongy appearance ; they traverse spaces filled with a hyaline paraplastm.

Klemciewicz observes a filamentous structure composed of vacuoles in the centre and an ectoplasm at the periphery : it is perhaps due to this ectoplasm that the cellular juice, in spite of

the large amount of water it contains, does not continually mix with this surrounding liquid: at all events, this structure enables us to understand the frequency and ease with which changes can take place between the cellular contents and the surrounding medium.

Centrosomes, and Spheres of Attraction.—The centrosomes of leucocytes have been studied by Flemming, Hansemann, M. Heidenhain, and Henneguy.

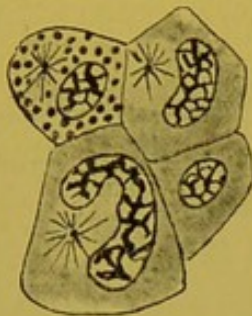


FIG. 2.—Centrosomes of cells from the lymphoid cortex of the liver of the Salamander (after Henneguy).

Hansemann has observed centrosomes with spheres of attraction and rays emanating from them in the leucocytes of young granulation tissue; Heidenhain, in human leucocytes and in those of the salamander, by means of iron haemotoxylin; after examining 1,000 cells in a state of rest, he found that 74·6 out of every 100, had two unequal centrosomes, and 19·1 out of every 100 two equal centrosomes. He admits as a rule, there are two centrosomes. In a certain number of cells, by the side of the two centrosomes, he has seen one or two accessory corpuscles, very small, and almost colourless. The three or four elements are joined together by brownish or grayish filaments, and the whole (*microcentre*) resembles a triangular or tetrahedric figure.

In the lymphoid cortex of the liver of urodelic amphibians, Henneguy has found in almost all the cells (leucocytes having a polymorphous nucleus or basophilic granules), a centrosome which appears like a coloured point, surrounded by an aster. The centrosome as a rule is situated in the concavity of the nucleus. In some cells in which the nucleus is about to divide, Henneguy has seen two centrosomes a little distance from each other.

The Contents.—The contents of the leucocytes, both naturally, and through production, are exceedingly variable and are numerous. We need only mention for the present—the particles of exocellular origin, debris of microbes, and of red blood corpuscles, iron granules, which are digested by the white corpuscle, also the presence of chromatin granules, excreted by the nucleus and the protoplasm (*Nebenkern* of certain authors). In the migratory cells of the intestine of the salamander during chromolysis, Lukjanow has seen juxtannuclear corpuscles coloured red-brown by the stain used by Biondi: but the most important contents are without doubt the cytoplasmic granules, recognized ever since Wharton Jones and Max

Schultze drew attention to them, and since studied by Semmer, Pouchet, Ranvier, Renaut and Hayem. The works of Ehrlich and his pupils have accurately determined their histochemical reactions and especially their affinity for aniline dyes, and in studying the behaviour of these granules towards stains, Ehrlich has recognized that they show a particular predilection for certain aniline colours. Admitting that the majority of these colouring matters are salts, he has *for the sake of convenience* called those in which the principal colouring is furnished by the base, *basic*; those in which the mixed colour is due to the acid and the base, *neutral*. Granules are termed *acidophiles*, *basophiles*, or *neutrophiles*, according to their affinity, that is to say, according to how deeply or how exclusively they stain with one or other of these colours, described above as *acid*, *basic*, or *neutral*. Eosin, orange, acid fuchsin, are acid colours; methylene blue, safranin, methyl green, are basic colours. *Amphophiles* are granules which, in a mixture of acid and basic colourings at the same time, retain the two colouring matters: the coarse refracting granules in the leucocytes of Semmer are eosinophiles, that is to say, acidophiles; they are also called oxyphiles, but Ehrlich designates them by the Greek letter α ; Ehrlich has also found two sorts of basophilic granules: γ and δ ; the granule γ is stained by basic colours without change of colour; the granule δ shows the phenomenon called *metachromasis*: it is coloured red by the polychromatic blue of Unna. In the leucocytes with a polymorphous nucleus, one finds a fine granule which in a mixture of methyl green, orange and acid fuchsin is stained violet: this is the neutrophile granule ϵ of Ehrlich.

The neutrophile of this granule has been discussed: Gulland, Kanthack, and Hardy, have asserted that Ehrlich's mixtures were not neutral, but acid, and that in reality the granule ϵ was acidophile (fine oxyphile granule). Others, Maragliano, Zapart, etc., think they have found all transitions in shape and in colour between α and ϵ . Perhaps we may consider this granule ϵ amphophile in nature? This is the opinion of Dominici, who, recalling the fact that Kanthack, Hardy and subsequently Jolly have stained it by eosine, adds that it is equally well stained by basic colours.

There is still another granule whose significance has given rise to numerous controversies: it is a smaller and more refracting granule than α , which in leucocytes with polymorphous nuclei, in

the blood of the rabbit and of the guinea pig, has been described by Ehrlich and Kurlow under the name of *pseudo-eosinophile*, and designated by the letters β E. Is this acidophile or amphophile? Should it be classed with α or ϵ ?

In favour of α should be mentioned not only its marked acidophile nature, but also its insolubility in water, ammonia, ether, alcohol, chloroform, turpentine, formalin, sublimate, and the fact that it stains yellow by iodo-iodide solution. It differs from α by its solubility in acetic acid, by the fact that it is more eosinophile than orangeophile, more indulinophile than eosinophile.

In favour of ϵ must be noted its violet colouration by the triacid,¹ its basophilism which some consider just as well marked as its acidiphilism. In a mixture of blue of toluidin and eosin, Dominici has stained it a violet red; it differs from ϵ in being larger, in its insolubility in water, and in its acidophile properties being more marked. (Its staining by eosin is not hindered by the haematoxylin.) It differs therefore both from α and ϵ .

It is interesting also to notice its presence in the leucocytes of the guinea pig and the rabbit, which by their number, dimensions, the polymorphism of the nuclei, and especially by their physiological properties (amiboism, phagocytosis), appear to be the homologues of polynuclear cells with neutrophile granules. Thus from one animal type to another, we find that the same cell manufactures products, which in appearance at any rate differ from each other.

In birds, various crystalloids appear to correspond to the granule α .

We may also observe that though the acidophile granules are very scattered in the animal series, and we find them not only in the vertebrates, but also in crustaceans, spiders, insects, oligochetae, sipunculae, the lamellibranchs, the psorobranchs, basophilic granules appear to be peculiar to the vertebrates and the sipunculae (Cuénot). According to this author, the white corpuscles of the pulmonate gasteropods alone, seem to be destitute of granules. On the other hand, it is quite possible that the absence which he mentions is more apparent than real, for, following the same line of thought, Ehrlich notices the fact that, though Hirschfield did not find neutrophile granules in white mice, Müller has done so by a special method.

¹ However, if I may judge from some of my own personal observations, its amphophilism is not constant. In Biondi's mixture, after fixation with sublimate, it has appeared to me, to be stained by acid fuchsin only.

The existence of these granules appears clearly proved, seeing that the largest of them are visible in the living cell, and nearly all may be made apparent by methods of fixation and by many different stains. By the so-called vital stain, from neutral red, the majority of them become stained an orange red, a few red only: their reaction is then nearly always alkaline (Ehrlich).

Though we know their morphology, their affinity for colours, and their solubilities, we are still very ignorant of their true nature: perhaps they are albumins (Weiss, Löwit, Sciawcillo). It is almost certain that they are not debris—blood-cellular or microbic, or former phagocytes, as has been thought by Sacharoff, Hardy, Lew Bonn Keng, Tettenhamer, Metchnikoff and Mensil. Are these bodies constituents or products of cytoplasm? Some have wished to identify them with the bioblasts of Altmann; Arnold, observing their arrangement (tendency to form little chains?), and their relations with the stable cellular bodies, thinks they represent transformed plasmosomes: this opinion, adopted by Schultze and Gulland, is contested by Ehrlich, Renaut, Löwit, and Heidenhain: Ranvier thinks the question is one of cellular secretions. Some cells seem to owe their preservation to the reserve material they possess, as is the case with vitelline granules. Others are expelled with or without preliminary dissolution. In the same way, granules secreted by certain granular cells dissolve themselves.

We may ask again whether these granules represent a particular elaboration, or whether they should be regarded as forming a substratum of soluble ferments, the presence of which in the protoplasm of leucocytes is demonstrated by chemistry. In this connection it is as well to remember that those white corpuscles, which have no granules, have the power of digestion, well marked: again the macrocytes (cells of Metchnikoff) which appear to possess a soluble ferment are capable of dissolving red blood corpuscles (macrocytase of Tarassewitch). On the other hand, there are ferments in the nucleus which has no granules.

After all, what is the physiological value of distinctions established by the study of colour reactions? Without attempting to settle this question off-hand, we must remark that differences in staining do not always imply important differences in chemical constitution, seeing that a simple dehydration is quite sufficient to alter the staining affinities of a granule: besides differences of chemical constitution do not always correspond to different physiological meanings: Haemoglobin of man does not crystallize like that of the guinea pig, yet both serve the same purposes. May not we suppose that the same is true for the granules βE and ϵ ? But the existence of granules in white corpuscles has raised other problems: It has been a moot point if cells with granules always come from granular cells, and if two kinds of granules, ϵ and δ for example, can be met with in the same cell. If it is quite certain that the granular cells can again reproduce themselves, it seems almost proved that, originally these cells are derived from non-granular elements. The place of production of these granules has given rise to much discussion: it does not seem probable that it habitually takes place in the blood. It is in the marrow of bones, sometimes even in the glands, and in the spleen that these granules develop. Can two different granules, viz. ϵ and δ , ϵ and α coexist in the same cell? At first sight it seems easy to reply in the affirmative, seeing that a number of authors (Ehrlich, Schwarze, Weiss, Schaffer, Fischl, Müller, Hirschfeld, Bettmann, Arnold, Engel, Levaditi, Jolly) have found in the

same cytoplasm two granules having inverse colouring affinities. In reality, however, the solution to this question is more complex, for the presence of basophile granules in an eosinophile cell does not necessarily prove the co-existence of granules α and δ . To demonstrate this fact, it should be proved that the superadded basophilic granule is identical with the true δ , not only in its colouring properties, but also in its morphology, and especially in its chemical properties (solubility or insolubility). Thus, for example, Arnold finds basophile granules by the side of granules α or β E, these not being metachromatic are not identical with δ . Engel finds in the same cell, granules δ , ϵ , and α , but as the histochemical characters are not given, it is impossible to know if the superadded granules are the true ϵ and α . Moreover, it can be understood how complex the question becomes, when even the coexistence of α and ϵ is in question. We know that ϵ has in turn been regarded as neutrophile, acidophile, and amphophile.

Though it has not been demonstrated that two granules *distinct* and *classified* (α , β , etc.) can coexist in the same element, it is quite certain that the same element can contain granules which colour differently. What is the significance of superadded granules which are still called heterochromatic?

Ehrlich having found indulinophile granules in the young eosinophiles, and having shown that they had the chemical reactions of α , and that when dehydrated, they distinctly became eosinophiles, thought that they were young forms in process of development. We know that other elements, such as the red blood corpuscles, are polychromatophile before becoming acidophiles. Bettman thinks on the contrary, that the presence of basophile granules is a sign of degenerative process.

Is this always so? It would seem not to be the case. Quite recently Levaditi has observed Ehrlich's cells (Mastzellen) which contained granules, colour reddish-violet by the triacid, and violet-red by the eosin blue of methyl-methylene. They resemble ϵ not only in their staining affinities, but also in their solubility in potash (2-100) and in acetic acid (3-100): they differ however in staining deeper red with the triacid, in their insolubility in distilled water, and in their larger size: they differ from δ in their colour and their shape: they resemble δ in their solubility in acetic acid. Levaditi thinks they are new granules, which bear no relation to those already known. While noting these mixed and complicated characteristics, we may perhaps ask whether forms intermediate between those of δ and ϵ cannot exist? For will it not be granted, that it is a property of intermediate forms to present *mixed characters*, which are no longer entirely those of the primitive form, but which already bear some resemblance to those in a later stage of development? Moreover, one can well understand how by their nature, such characteristics leave the field open to arbitrary interpretations, and the question of whether they are, or are not, transitional forms amongst the various kinds of granules pointed out by Ehrlich, will for some time remain a source of discussion.

Physical Properties.—Nearly always colourless but sometimes tinted, of a variable refraction, opaque or clear, the leucocytes are soft, protoplasmic, extensible masses, with no covering. They are heavier than plasma but lighter than red blood cells: they are viscous and adhere to the smoothest surfaces. When the circulation

slackens, they accumulate against the vessel-wall, and resist the current which carries them along. Placed upon a glass slide, they adhere to it, and are not carried away by a drop of water, which by its capillary action drives away the red corpuscle. As the researches of Berthold seem to show, that a protoplasmic drop, denuded of membrane, possesses the physical characteristics of a liquid, it may be supposed that at rest, the leucocyte is rounded by the superficial tension being equal at all points on its surface; this tension is similar to, but weaker, than that of globules of butter suspended in milk. Though this illustration is suggestive, it is not absolutely correct, for as we have seen, the protoplasm of the leucocyte is far from being homogeneous.

Chemical Constitution.—Though still far from perfect, our knowledge of the chemical constitution of leucocytes has in recent years been enriched, by interesting theories not only in cell, but also in general physiology.

In 1871, Hoppe-Seyler analyzed globules of pus which he separated from the liquid which contained them. He found in 100 parts of leucocytes—

13·762 undetermined albuminoids.

34·257 nuclein.

20·566 insoluble substances.

14·384 lecithin and fat.

7·400 cholesterin.

5·199 cerebrin.

4·433 extractives.

The ash contains phosphoric acid, chlorine and numerous metals (sodium, potassium, calcium, magnesium, iron). Quite recently, Stassano and Bourcet have found in the leucocytes of normal blood another metalloid, iodine.

As regards iron, the researches of Arnold, Hayem, Quincke, Barker, Hansermann, prove its presence in leucocytes, to be, if not constant, at least frequent. Arnold has seen leucocytes ingest exogenous iron, and Rouget has shewn that the same cells absorbed the old red corpuscles; and all pathologists after Virchow, know that residual pigments of old hæmorrhagic foci are carried away by leucocytes. According to Quincke, red blood corpuscles after being eaten are transformed, some into yellow granules, others into colourless albuminate of iron, which can only be detected by histochemical analysis. Barker believes in the presence of iron in eosinophile granules. Hayem says that certain leucocytes are overcharged with hæmoglobin, especially after bleeding. These last statements, and all those old, or new, which being founded on mere appearances, or colour reactions, allow us to infer the hæmoglobic degeneration of leucocytes, should be received with the greatest caution. It is, however, fairly certain that the protoplasm of leucocytes may contain the most various kinds of metals, iron frequently, if not always. This statement is not without interest, now that we are aware that their protoplasm is rich in soluble ferments. We may in fact, suppose that there, the metal, as shewn in the experiments of Bertrand, and Hanriot, plays a part in the action of the diastase. Before

studying these diastases, we ought to say a word about the ternary and quaternary substances of the leucocyte. As regards ternary substances, the white corpuscle may contain fats and glycogen.

The leucocyte of invertebrates sometimes accumulates fat in reserve without undergoing degeneration, exactly as the adipose connective tissue cell of higher vertebrates does. Cuénot expressly mentions that this is the case with the leucocytes of Tuniciers. Nevertheless, the same author remarks that in some leeches, and in some of the molluscs (*doris tuberculata*), ascidies, and batrachians, the fat is specially seen in old cells, or in cells of anæmic animals—and in fact, among the higher vertebrates, fat is scarcely seen except in disease or in dying leucocytes; it is not an *addition*, but obviously a *fatty degeneration*. In the same way, the dead leucocytes from pus are very rich in fat. Nevertheless, in mammals the white corpuscles, which, traversing the intestinal epithelium, absorb fat from the lacteals, are an exception to this rule.

In the lymphatic cell of cold blooded animals, Ranvier has noticed that the glycogen which was sticky, was somewhat diffused. In mammals, glycogen does not exist constantly in the protoplasm of the leucocytes. After injection with chloride of sodium, staphylococcus, and streptococcus, Salmon has seen glycogen appear in the lymphocytes, and in the polynuclear cells, but never in the macrophages. This simple fact should suffice to show how wrong this author is in maintaining that the glycogen takes a part in the mechanism of the defence of the organism, by means of the white corpuscles. All facts point to the contrary. In pus, the quantitative variations of glycogen are considerable (Kühne, Jaffé, Kramer, Lilienfeld). Hüppert has seen variations between mere traces and 1.67 gr. The glycogen of the leucocytes appears under the most diverse morbid circumstances (narcoses, diabetes, severe contusions, etc.).

According to Salmon, this glycogen presents itself in various forms, viz. as crescents, concentric rings with a cellular outline, or even balls, or excrescences which remind us of amoebic prolongations. Sometimes these balls leave the leucocyte and fall into the plasma.

The mahogany brown colour which iodine gives to glycogen becomes pale between 50° and 60° (Errera); and disappears between 65° and 73° (Cantorian).

This glycogen appears to be very stable (Lépine), and it probably has several sources; the leucocyte is in fact capable of absorbing either glucose, or starch. We shall see that it can convert the latter into sugar. We may then ask, can this white cell, like the liver cell, by hydrolysis, transform the sugars, ingested by it, into glycogen? It can be clearly seen, that after the peritoneal injection of glucose, the leucocytes become charged with glycogen; but, as the same thing happens after a simple injection of sodium chloride, we should be cautious in our interpretation of the fact.

On the other hand, we may imagine that this glycogen is formed at the expense of some of the albumins in the leucocytes; in fact, Kossel, has shown that nuclein and histon become decomposed in exonic bases, with which it is interesting to compare the products of the decomposition of polysaccharic bodies.

We know that Hoppe-Seyler mentions the existence of an undetermined albuminoid and of a nuclein; Gautier calls them nucleo-albumins (hyaline substance of Roviada, globulin of Halliburton). This study has been developed by Hofmeister, Lilienfeld and Kossel.

Hofmeister has found abundant peptones in the leucocyte. Lilienfeld

has obtained from the aqueous extract of leucocytes, after centrifugalizing and filtration, and then precipitating by acetic acid, a white powder insoluble in acids, but soluble in water and weak alkalies; this is the *nucleohiston* which, treated by alkalies, dilute acids, or boiling water, splits up into *leuconuclein*, (acid), and the *histon of Kossel* (basic). There is in every 100 parts of leucocyte 68.8 of leuco-nuclein and 8.7 of histon.

The nuclein is capable of giving rise to uric acid. The elimination of this acid in the urine increases considerably in certain leuchaemias. Thus, we may imagine that the leucocyte plays a part in the process of the breaking up of nitrogen within the organism.

From another point of view, it is no less curious that nuclein and histon, two protamines, which come from the same cell, or at least from the same kind of cell, possess antagonistic physiological properties:—the former favours coagulation, while the latter hinders the process.

Normally, there are pigments in some of the leucocytes of cold blooded animals (Cuénot, Renault), and, abnormally (foreign bodies, melanin), in those of warm blooded animals.

It is now a well established fact that leucocytes produce, or at any rate contain, soluble ferments, and that consequently, they are capable not only of absorbing foreign bodies, but also of actually digesting some of them.

Heckel, who has seen blue granules of litmus which have been digested by leucocytes become red, thinks that such digestion takes place in an acid medium. Metchnikoff thought at one time it took place in a neutral or alkaline medium; but having since recognized that the vacuoles were coloured brick red by the neutral red, he too now thinks that it takes place in a slightly acid medium.

Ever since 1888, Leber has affirmed that aseptic pus digested fibrin and liquefied gelatine; these properties he found were destroyed by heat. In the leucocytes of the tonsils, Rössbach has found an amylase; and more recently Zobolotny has found the same in the peritoneal leucocytes of the guinea pig. It would seem that the effects of this ferment are sometimes somewhat slow in manifesting themselves; but perhaps it does not exist in all leucocytes and in all animals. Such is doubtless the explanation of the negative results announced by Schoefer, Netchaeff and Salmon: nevertheless Salmon has seen ingested starch become dextrin.

According to Lépine, the glycolytic diastase, manufactured by the pancreas is apparently fixed in a provisional manner by the white corpuscle. Portier, and later on Brandenburg, have studied the oxidizable ferments of leucocytes. Mantegazza and Schmidt those of the plasma. The plasmase has been found by Jacob, Löwit, and Schattenfroh in extracts of leucocytes; it would seem to be very abundant in the nuclei. This fact proves that one must be slow in establishing a connexion between the presence of these ferments and those of cytoplasmic granules. Just as the holocrine glands, in order to set free the products of their elaboration, destroy themselves, so the leucocytes have to die, so that the plasmase may become diffused into the surrounding liquid. Also we have been enabled to state, that the coagulability of blood is more rapid, in proportion as the white corpuscles offer less resistance. In the macrocytes, Delezenne has found the enterokynase, and Tarassewitch, the macrocytase. In aseptic pus, obtained by injection of turpentine, Achalme has found the amylase, the oxydases, the ferment liquefying gelatine, and also a ferment allied to trypsin, a casein and a saponin.

Cuénot and Cattaneo think that in the white corpuscles of crustacean decapods there is a ferment which forms hæmocyanin. Thus, in spite of indi-

vidual variations, leucocytes can take on the many functions of hepatic, pancreatic and renal cells, functions which they exercise not only in definite places, but actually within the tissues themselves. In fact, like the hepatic cell, they are capable of manufacturing glycogen, of storing up fat; and like the pancreatic cell, they can produce an amylase and yield a glycolysin; like the renal cell, they can take part in the ultimate mutations of nitrogenous matter, inasmuch as they give rise to uric acid. These unicellular glands are then, not simply organs of assimilation and storehouses for the accumulation of nutritive stores, but they are also excretory organs.

Biological Properties.—The white cell possesses all the primordial properties of living matter: sensibility, mobility, powers of absorption, of secretion, of reproduction.

Mobility.—This has been recognized for a long time, in fact, ever since Wharton Jones in 1846, observed the pseudopodic displacements and expansions of leucocytes in the blood of the ray-fish and of the frog. Some years later, in 1850, Davaine made the same observations in the white corpuscles of human blood. These changes of form were compared by Lieberkühn to those of amœbae, and now, they are known by the term *Amibiosis*, or amœbic movement. The leucocyte becomes spheroidal, throws out a prolongation or pseudopod, which ramifies: then the cellular body becomes displaced and blends with this expansion, and so on. At one time, the protoplasmic expansions are lobed, rounded and fairly large; at another, they are broken up, or are filiform, like needles. The pseudopods of eosinophiles appear to be less slender than those of other leucocytes (Max Schultze, Jolly). According to Flemming and de Bruyne, there are no lobopods in circulating blood; the fine pseudopods are produced in corpuscles which have left the vessels. Side by side with these movements, there appear to exist endoplasmic movements which, without displacing the cell, displace the granule and perhaps the nucleus also.

According to Ranvier, this nucleus exhibits, under the influence of these protoplasmic movements, passive changes; the buds, the constrictions, and even the divisions which are seen, result from the activity of the protoplasm which constricts, by a kind of contraction, portions of the nuclear mass just as a ring does a sac. Sherrington, Dekhuysen, Gulland and Korschelt think the same; Jolly sees in the polymorphism of the nucleus a sign, and even in fact, a result of the amœbic activity of the cellular protoplasm.

Metchnikoff, and Heidenhain find in the appearance of the multi-lobed nucleus one of the indications of the adaptation of leucocytes to diapedesis. Ehrlich long ago remarked that the polynuclear

leucocytes shift their position more frequently and in greater numbers than is the case with other leucocytes. Metchnikoff insists on the relative rarity of this nuclear type amongst avascular invertebrates, and thinks it evident that a nucleus, which is broken into several fragments, must traverse the vascular wall much more easily than a large entire nucleus.

It is quite evident that neither the theory of Ranvier, nor that of Metchnikoff can explain the genesis of all the polymorphous nuclei. Do they hold good for any of them?

The observations of Ranvier and Jolly show the *concomitance* of nuclear and protoplasmic modifications, without establishing any evidences of casual relationship. In fact, they take for granted, but do not prove the passivity and immobility of the nucleus; they do not explain the polymorphism of the nucleus of certain immobile cells, and the almost absolute spheroidal shape of the nucleus of certain amœbic cells; Demoor, however, after paralyzing the protoplasm of the leucocyte by chloroform, has seen movements of the nucleus. While admitting with Jolly, that in the case of the leucocytes of the frog, these observations must be received with caution, it is none the less certain that, at certain periods of its life (direct and indirect division), the nucleus has the power of movement.

Jolly attempts to explain the twisted shape of the nucleus of immobile cells by supposing that the nucleus has not had time to return to its rounded shape. It is quite possible that this explanation may be true in some particular cases, but no generalizations should be made. Besides, this polymorphous nucleus is seen in cells which have never been mobile. When he discusses the rounded shape of the nucleus of amœbic cells, Jolly expresses the opinion that cells cannot exhibit exoplasmic movements without influencing the nucleus. Though doubtless such movements exist, the main point to be settled is, whether the mononuclear cells travel solely by means of similar movements. As so little is known about this question, we may conclude with Lavdovsky, Hardy and Wresbrock that, contrary to the opinion of Ranvier, it is not yet proved that abnormal nuclear shapes are purely passive formations, or are directly dependent on protoplasmic contractility.

The theory of Metchnikoff is open to the same and other objections besides. We will not return to the question of the diapedesis of mononuclear cells, or to the polymorphism of the nucleus of certain immutably fixed cells, but will content ourselves

with the remark that, though certain shapes of polynuclear cells appear well adapted for their passage across narrow intercellular spaces, there are others (shaped like an O in rose work) which, are certainly not adapted for endothelial migrations.

To change their position, the leucocytes make a considerable effort (Engelmann). To understand this, we must remember that they possess a superficial tension, feebler, but of the same kind as fat globules suspended in an aqueous liquid. In a damp chamber, Lavdovsky has seen leucocytes pass through and through a clot of blood. The white corpuscles of cold-blooded animals manifest their amœbic movements at the surrounding temperature; those of warm-blooded animals only between 20° and 37°. Heat excites this activity; a temperature of 43° kills them, producing at the same time a round shape. Oxygen is necessary for their life, and especially for a manifestation of their motor powers; thus if a small piece of phosphorus be introduced under the skin, absolutely no leucocytes will arrive on the spot, because phosphorus absorbs all the oxygen in the neighbourhood.

Rollett, Goluber and Engelmann have stated that under the influence of inductive shocks, leucocytes withdraw their pseudopods and assume a spherical form: strong currents kill them: weaker ones momentarily paralyze them. Ranvier thinks it is difficult in such experiments to entirely eliminate causes of error of chemical origin (electrolytic action of the current, etc.).

Carbonic acid, carbon monoxide, hydrogen, quinine, curare, and chloroform paralyse, and then kill the leucocytes.

The aqueous humour of the frog is an unfavourable medium for these cells.

Owing to their mobility, the leucocytes are well called migratory cells; they frequently leave the lymph and the blood to diffuse themselves into the neighbouring tissues (Recklinghausen, Waller, Cohnheim, Stricker and Sanderson, Metchnikoff, Sabatier, Pouchet, Kowalewsky, Durham, etc.). As is proved by a series of classical experiments, they can traverse porous bodies; at one time, they move in intercellular spaces, (*στωματα*): at another, they perforate cellular protoplasm (fenestrations of intestinal cells): a certain number of them definitely leave the internal medium to lose themselves—for good and all one may say—on the exterior, either on a cutaneous surface or within the intestinal canal. Thus we may conceive of the possibility of an elimination brought about by leucocytes.

Durham stated that in this way leucocytes excreted foreign substances, which had been experimentally introduced into the body of *Asterias rubens*. White corpuscles with similar functions have been noticed in the ovary of *Lacerta agilis*, and of mammals, by Strahl and Löwenthal.

Now, is mobility a property common to all leucocytes without exception? The problem is difficult, because it is always a difficult matter, without staining, to know with which variety of leucocyte one is dealing. Under these conditions, for example, it is impossible to know if one is observing an eosinophile or a leucocyte with basophilic granules, or even a small leucocyte with neutrophilic granules.

The most amœbic of all are the corpuscles with neutrophile granules. Next come the large corpuscles without granules, and the eosinophiles. In opposition to Renaut's views, the amœbic character of the latter has been shown by Max Schultze, Bizzozero, Mayer, Weiss, Müller and Rieder, Lavdovsky, and Jolly.

From his researches on leuchaemic blood, Jolly came to the conclusion that as a general rule, the small corpuscles without granule, are not mobile; sometimes, however, he has seen, as Rieder has, small mobile corpuscles. This fact has lately been confirmed by Hirschfield and Wolff.

The amœbic character of leucocytes, which has been affirmed by great observers, is easy to verify, and is a positive fact, which the dissentient opinions of Semper, Griesbach and Retterer cannot shake. We may remember that, according to Griesbach, the migration observed *in vitro*, is only the result of adherence, and of the diffusion and absorption of gas, and that, according to Retterer, the pseudopodic expansions are only "the result of hydration, and of the disintegration and exhaustion of the cellular body."

Now, can we conceive the mechanism of this mobility to be an elementary manifestation of a contractile substance of the most primitive kind? Engelmann has attempted to apply to the movements of this protoplasm, deprived of double refraction, his thermodynamic theory of muscular contraction. He supposes that there exists in the protoplasm of the amoeboid cell, innumerable contractile elements, too small to be visible even under the strongest magnifying powers; these elements, are heaped up without order, and are elongated, and when they swell become spherical. From this swelling results the formation of pseudospores. It will be seen that these are pure hypotheses which, are rejected with reason by Verworn. To the latter author we are indebted for a theory which at least is very ingenious. He thinks that, the mobility of the leucocytes, like all the phenomena of contraction, results from the alternation of two opposite phases; one, that of contraction, in which the surface dimin-

ishes in relation to its mass (spherical form), the other, that of expansion in which the surface increases (pseudopodic formations). The leucocytes, having a superficial tension analogous to that of liquids, we may suppose that when they are spherical, they possess a superficial tension equal at all points of their surface. In the same way, when they throw out a pseudopod, it is because their superficial tension diminishes at this point. What then are the causes of this augmentation or diminution of superficial tension? If we grant that pseudopods form in presence of oxygen, and disappear in its absence, and taking this gas as an example, Verworn supposes that it is the unilateral excitant capable of diminishing the superficial tension at any one point of the surface of the leucocyte, and consequently of producing pseudopods. It would diminish the superficial tension, and at the same time lessen the cohesion which exists between the different organic molecules.

Under the influence of oxygen, or of excitants of de-assimilation, the organic molecules would decompose spontaneously, the superficial tension increase, and the leucocyte again become spherical owing to the retraction of the pseudopod previously formed. Like all theories, that of Verworn is open to certain objections; in the first place, the protoplasm of the leucocyte is not homogeneous; and secondly, we do not know for certain in what manner the oxygen diminishes the superficial tension, etc. However, the theory has the merit of being suggestive, and of showing or, at least, attempting to explain the meaning of chemiotaxic phenomena, positive or negative. Chemiotaxis is not a mysterious attraction or repulsion; it comes from the kind of movement peculiar to the cellular form considered. In the instance given above, the one sided excitant is oxygen which, by diminishing the superficial tension, brings about the appearance of a pseudopod on the excited side; the leucocyte moves towards the oxygen, and then is said to have a positive chemiotaxis. Now, there are unilateral excitants which, on the contrary, increase the superficial tension at the excited point: the pseudopod forms on the opposite side, where the stimulus to contraction is small, and where the protoplasm can extend without hindrance; the leucocyte now moves away from the excitant, and there is negative chemiotaxis. Besides oxygen, albuminoid substances (casein of gluten, an emulsion of flour, peas and wheat); ferments (laccase); microbic toxines, and the greater number of pathogenic microbes or saphrophytes, produce positive chemiotaxis. Lubarsch has shown that living bacteria are productive of a positive chemiotaxis; more marked than that caused by the same bacteria previously heated. From the researches of Peckelharing, it follows that bacteria cause a more intense chemiotaxis than inert bodies such as filaments of cotton; on the other hand, quinine, jeguirity, chloroform, alcohol, glycerine, lactic acid, solutions of salts of soda and potash up to 10 per cent., the microbe of chicken cholera induce a negative chemiotaxis. In the curarized frog, there is no leucolysis as Drozdoff imagined, but emigration *en masse* of white blood corpuscles into the lymphatic channels (Tarchanoff). Water, weak solutions of salt, of soda, and potash, peptone, phloridzin, kreatin, kreatinin, and allantoin do not provoke chemiotaxis.

The sensibility of leucocytes varies according to the species of the animal, and the age of the individual. The leucocytes of mammals appear to be more sensitive than those of cold blooded animals (Gabritchevsky); and according to Borisoff, they are more sensitive in the young than the old. This author has stated that none of the substances used in his experiments attracted one variety of leucocyte rather than another. In the same subject, I have seen the same microbe provoke leucocytic reactions, varying in

kind according to the organ under observation. Sometimes, on the contrary, certain varieties of white cells are phagocytes to a certain microbe to the exclusion of all other kinds of microbe. Thus, Metchnikoff thinks that the polynuclear cells surround the streptococci of erysipelas and the gonococci, but this is not the case with the mononuclear cells; the latter, however, surround the bacillus of Hensen, but this is not the case with the polynuclear cells. Similarly, in the experiments of Besredka, it was the macrocytes (large mononuclear cells) which were invariably and exclusively attracted by the tersulphide of arsenic. Nevertheless, it cannot be supposed that as a general rule each type of leucocyte possesses a special chemiotaxis. Granted this fact, and granted that the same leucocyte, whether neutrophile or eosinophile, is attracted by the most different kinds of microbes, it may be seen that even for pure infections, the qualitative study of leucocytosis is of little use in aiding us in our clinical diagnosis.

*Absorption of solid particles and typical elements (Phagocytosis).—*For a long time it has been known that leucocytes absorb the solid amorphous particles of cellular débris. So long ago as 1862, Heckel discovered that the leucocytes of Thétys devoured grains of indigo. Recklinghausen, Preyer, Schultze and Balbiani have made similar observations on different objects. Virchow, Koelliker, and Langhans have seen that blood débris from old haemorrhagic foci was carried away by white cells. Arnold discovered the presence of iron, not only in protoplasm, but sometimes also in the nucleus; Jolly has seen grains of starch, depressing the nucleus, whilst others were found in its centre; producing an appearance like that of two projections from the nucleus, joined together behind the foreign body which is thus incorporated.

These facts ought to open new views in biology. Since leucocytes absorb solid particles of colouring matter, we may suppose that they do the same for insoluble chemical substances, whether useful or detrimental. As a matter of fact, Besredka has observed the phagocytosis of the tersulphide of arsenic; Arnozan, and Montel, that of calomel, and of salicylate of soda; Landerer, that of balsam of Peru. In the same way, contrary to the old dictum—*corpora non agunt nisi soluta*, we may imagine that the organism utilizes insoluble substances. We may and we must admit that assimilation takes place within the tissues themselves, and outside the digestive canal. In a word, since the leucocytes absorb cellular débris, we may suppose that they may also be capable of digesting animal or vegetable cells (microbian). Since 1874, Rouget has observed haematophagic leucocytes, which after destroying the red blood corpuscles ingested by them, changed into pigmentary cells. Metchnikoff has studied the histolysis of the Sponges, Echinoderms, and Amphibians. In the

same way, the works of Kowalewsky, and van Rees, have endeavoured to show the importance of the rôle of myophagic leucocytes in the histolytic phenomena of nymphosis. Metchnikoff and his pupils have shown that the white cell can eat up the most diverse kinds of microbial cells : this phagocytosis does not seem, however, to be a special and exclusive property of the white cell ; for example, though the histolysis of the tail of batrachians is attributed to leucocytes by Bataillon, it is attributed to muscular phagocytes by Metchnikoff and Soudakewitch ; similarly, though Kolesnikoff, Weller, Babès, Valenza, Pognat, Franca and Athias think that neuronophagocytosis is the work of leucocytes, it is according to the statements of Krauss, Marinesco, Nissl, Anglade, and Rispal, caused by a neuroglial cell. Moreover all leucocytes are not phagocytes ; the small corpuscles are not, and the eosinophiles only slightly so.

Now, are the cells absorbed by the leucocytes normal, or have they been previously altered ? It would appear that the answer is not the same for the animal and the microbial cell.

In the case of the microbial cell, it seems there is no doubt that it may be ingested while alive, because even when thus digested, it still sometimes retains its power of killing.

In the case of the animal cell, the problem is more complex, and the answer less easy. As a matter of fact, we should *à priori*, expect this phenomenon to depend either upon an anomalous exaltation of cytophagic activity of the white corpuscle, or upon a previous enfeeblement of, or the death of the phagocytic cell. The evolution of the process is often so rapid that histologically it is very difficult to determine the part played by these two factors respectively. On the other hand, a cell may be functionally weakened, and diseased, without this state of diminished resistance necessarily producing any morphological change. These considerations enable us to understand all the discussions which have been raised by the rôle played by phagocytes in the nymphal histolysis of insects or in that of the tailless batrachians : some maintaining that the cell disappears under the repeated efforts of the leucocytes : others, in fact the majority, asserting that the white corpuscles confine themselves to removing the residue from an organ which has already been altered. Without now entering into this question, we will simply remark that after studying the works of Loos, Eberth, Noetzel, etc., works which tend to prove that the solvent action of tissue juices and of blood is sufficient for this destruction, all the evidence goes to show that functionally at least

the cells thus digested are clearly in a state of inferiority owing to an arrest of their development, a considerable diminution or suspension of their nutritive changes, etc.

But what do we find is the case in mammals? If we leave on one side those epithelial cells which are casually destroyed by the migration of white corpuscles, we find that the latter attack the muscular cells in the course of infectious or toxic processes, and the red corpuscles in the case of the leuchaemias. This haematophagic action of leuchaemic leucocytes allows us logically to assume hyperactivity of the white corpuscles, as well as a diminution in resistance of the red. On the other hand, the myophagic action of leucocytes is more suggestive; it shows that the muscular fibres are not digested, unless their nutrition has previously been impoverished owing to a nerve lesion or the presence of a toxic agent. Admitting these facts, and admitting those observed in the physiological atrophy of invertebrates and batrachians, we shall not be illogical in thinking that, if phagocytes really do intervene in the processes of atrophy in general and of senile atrophy in particular, they only destroy cells which are already on the brink of ruin.

Reproduction.—Leucocytes reproduce themselves by direct division (amitosis) and by indirect division (karyokinesis). Arnold thinks he has found in the more or less filamentous arrangement of chromatin elements in certain leucocytes, a proof of the existence of a mode of division which is intermediate between direct and indirect division. But Flemming and Reinke are of opinion that it is a question either of indirect multipolar divisions, or else of figures altered by reagents. Leucocytes can divide in the blood, the lymph, the connective tissue, the haematopoietic organs, in the lymphatic glands, the spleen, and in the medulla of bones.

As a general rule, and with exceptions, which generally are pathological, we may say that the more numerous, and the better developed the haematopoietic organs, the less numerous are the divisions of white corpuscles in the circulation. For example, in the case of invertebrates, Cuénot found few or no divisions in the leucocytes of cephalopods, or of crustacean decapods, which possess lymphatic glands; divisions are, on the contrary, frequent in the circulating white corpuscles of the pulmonates, the gasteropods, the orthoptera, the araneids, the solifugae, the oligochetae, and leeches, which have or appear to have no lymphatic organs.

There are exceptions: thus the lamellibranchs possess lymphatic

glands, and though Apathy, de Bruyne, and Cuénot have seen mitoses: Knoll, Owsjannikow and Carazzi have seen amitoses on their free corpuscles. Similarly, among the vertebrates, and even in the mammals, where however the haematopoietic centres take on at certain times such an extraordinary development, it is possible to observe the division of white corpuscles wandering in the blood, the lymph, the connective tissue, and foreign bodies (pith of elder).

In the blood, we may find mitoses, or direct division. It was in the blood of the axolotl that Ranvier observed the direct division of leucocytes; and in the blood of the same animal that Lavdovsky found mitoses. Flemming doubts the accuracy of the observations of this latter author. Klein and Löwit have observed divisions in the blood of the triton.

Mitoses have been noticed in the blood of the dog, rabbit, human embryo, and infant by Kultchitsky, Spronck and Prins, Wertheim, Hock and Schlesinger. Roehmer also admits the possibility of the reproduction of leucocytes in the blood by one or other of the two modes of division; again, this reproduction in the blood is admitted by Medwedeff and Markewitsch: Wlaeff has observed it after splenectomy, and numerous authors have noticed it in leuchaemic blood.

Gourevitch has seen karyokinesis in the blood after injection of abrin, and of ricin, substances which at first provoke hypoleucocytosis, and then hyperleucocytosis.

In the lymph of the thoracic duct, Löwit has observed mitosis; I have observed numerous mitoses in leucocytes circulating in the cavernous spaces of the mesenteric gland of a rabbit into whose veins I had injected pilocarpin. The chromosomes of some of the white corpuscles were arranged in the shape of a crown; which arrangement has also been observed by Kostanecki. Meves and Henneguy have shown that this arrangement was due to the persistence of the sphere of attraction at the centre of the figure, and that in the Salamander, it involved the formation of the annular or perforated nucleus of the spermatogens. We may suppose that certain annular nuclei of leucocytes have a similar origin.

In the cerebrospinal fluid from a case of general paralysis, I have seen the direct division of the nucleus of some small white corpuscles which possessed no granules.

In the peritoneal serous fluid of *Lacerta viridis*, Jolly has noticed mitoses. Peremeschko, Kultchitsky, Muskabluth, Metchnikoff, Flemming, Giovannini, Dekhuysen, Van der Stricht, Denys, and

M. Heidenhain have described the mitoses of wandering cells of connective tissue; Arnold and Marchand those of leucocytes which had migrated into a fragment of the pith of elder (?). The mitoses observed by Heidenhain and du Bruyne, in the white corpuscles which infiltrate the intestinal epithelium; are not admitted by Nicolas. In the normal state, in mammals, the reproduction of free white corpuscles appears then quite certain; but as regards the blood it does not appear to be so frequent as certain writers would have us believe. As a matter of fact, Spronck and Prins counted 18 mitoses in 9653 leucocytes in sections of the vena cava of the rabbit, and 2 mitoses in 1901 leucocytes of human blood obtained by digital puncture. Now Löwit counted 5000 white corpuscles without finding a single kinesis. This author maintained that leucoblasts always divided directly; and the erythroblasts indirectly; but Denis and Van der Stricht have proved the reality of the mitosis of leucoblasts.

It was also believed that the polynuclear cells divided directly; and the mononuclears, indirectly. It is now, however, demonstrated that the polynuclears, like the eosinophiles, show karyokinesis. The one or the other mode of division should not therefore be regarded as the exclusive property of any particular variety of leucocyte.

On the other hand, amitosis seems, if not to exist exclusively, at any rate to predominate largely in the pulmonates, oligochetae, and leeches; while kinesis predominates in the orthopterae (Heidenhain), and in the solifugae. Again, amitosis seems to be more frequent in the axolotl than among mammals.

There is no object in here describing the karyokinesis of leucocytes, which in general, presents no special features. Let us confine ourselves to remembering the possibility of anomalous kinesis; those in which the chromosomes are arranged in the form of a crown about the centrosome, and which produce certain perforated nuclei; those with multiple poles which, unaccompanied by protoplasmic division, give rise to multinuclear cells. Van der Stricht, who like Heidenhain, does not admit any connexion between the polymorphism of the nucleus, and its direct division, thinks with van Bambeke and Kostanechi, that certain polymorphous nuclei result from the fusion of several smaller nuclei.

The amitosis of leucocytes, described by Ranvier, Bizzozero, and Arnold, will engage our attention longer. Ranvier has stated that at a temperature of 16° a white corpuscle of axolotl requires three hours

for its direct division. In ordinary direct division, the nucleus is seen to divide into two segments or buds, of nearly equal size, bound by a pedicle which, becoming thinner and thinner, finally breaks. The division of the protoplasm soon follows that of the nucleus. It is quite evident that if the division of the protoplasm does not take place, there results a multinuclear cell (Arnold). It also happens that the buds do not detach themselves or fuse again (Ranvier). When the nucleus divides directly into several unequal fragments, we can witness the process which has been described by Arnold under the name of *fragmentation*. Arnold thought that some relation might exist between this fragmentation and the production of certain perforated nuclei. Goeppert thought that the perforation of the nucleus was a secondary phenomenon, and resulted from an invagination of the wall which deepened until it reached the opposite surface of the nuclear membrane. The annular nuclei, he thought, divided directly by constriction into two half rings which afterwards separated into many fragments, again by constriction. We may inquire what becomes of the centrosomes in direct division? Flemming, stating that in the leucocytes of the salamander, the centrosome does not divide into two, thinks that the attraction sphere exercises an influence upon this division, for it is always placed opposite to the line of separation of the two portions of the nucleus.

What is the significance of the amitosis of leucocytes? Flemming thinks it is a phenomenon of degeneration which, most frequently, increases the surface of the nucleus while producing multinuclear cells. Zieyler and von Rath express an almost analogous opinion: namely, that when direct division takes place both in the nucleus and protoplasm, the daughter cells cannot subsequently divide. Löwit, on the contrary, is of opinion that by the side of this direct degenerative division, there is a direct regenerative division, following which cells may continue to multiply. This histologist is of opinion that the richness of the nucleus in pyrenin or chromatin is variable;—a nucleus rich in pyrenin divides directly, a nucleus rich in chromatin indirectly. Henneguy thinks that nuclei which divide directly are no richer in pyrenin than in chromatin.

Evolution, Degeneration, and Death.—Of the ancestral protoplasms with free and independent life, the leucocytes have preserved, in spite of adaptations necessary to new conditions of existence in cellular colonies, not only their sensitiveness, their motility, their powers of digestion and reproduction, but even their individuality,

and their remarkable resistance to destructive agencies. Twenty-four hours after the death of the human body, the greater number of leucocytes are still living and can, under favourable conditions, keep alive much longer (Verworn). Recklinghausen and Ranvier have shewn that they are capable of retaining their properties outside the organism, sometimes for a very long period, viz. 22 days.

It is difficult to know, even approximately, the duration of the normal life of a leucocyte. Everard, Massart and Demoor suppose it to be very short. Yet it may be fairly long, at least in the case of the aged. As the white corpuscles in the case of the aged do not appear to divide in the blood, or in the atrophic haematopoietic organs, we may admit, if not their permanence, at least their power of living a more or less long life.

Nevertheless, either spontaneously or under different physical or chemical influences, leucocytes may degenerate and die. The degenerative changes are numerous. In some of the anaemias, Hayem mentions

the surcharge of haemoglobin from certain mononuclears; other cells become infiltrated with fat, glycogen and pigments (see Chemical Constitution). Czerny and Grigorjeff think the leucocytes may become infiltrated with amyloid material; but this fact is contradicted by Obrzut. Ziegler describes a mucoid degeneration of these elements.

Heidenhain, Arnold, and Gunprecht have studied the chromolytic degeneration of leucocytes. The chromatin network becomes condensed, forming a compact and homogeneous mass which breaks into fragments: balls are thus formed which, after the rupture of the nuclear membrane are scattered throughout the protoplasm; the latter after swelling up and becoming vacuolated finally disappears, dissolved in the surrounding liquids. The nucleus thus altered is at first more readily stained than in the normal state, elsewhere it is pale, and its contour ill-defined. This last form of degeneration, described by Klein under the name of "leucocyte shadow," is perhaps artificial. Ranvier questions if leucocytes

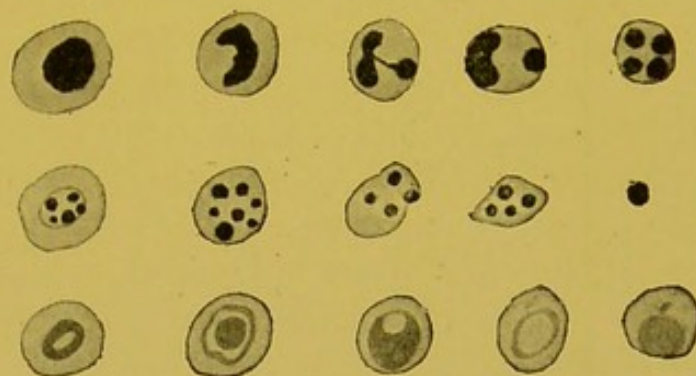

FIG. 3.—Degeneration of leucocytes: hyperchromasis and fragmentation of nucleus (chromolysis); vacuolization and hypochromasis of nucleus.

which are destroyed at the site of a lesion during the process of repair, do not thus furnish nutritive material to the tissues during the process of rebuilding. T. Botkine, Engel, Borissoff and Kheta-gouroff have studied the histolysis of the leucocytes in blood. Botkine has even supposed that many of the varieties of leucocytes met with are only different stages of their disintegration in the plasma.

In addition to this total histolysis there is a partial destruction by means of which the white corpuscle causes the disintegration of some of its granules or a portion of its protoplasm : this physiological degeneration has been described by Ranvier under the name of *clasmatosis*, and is regarded by him as a kind of secretion. Other leucocytes perish in this manner owing to a kind of continual wear of parts of their protoplasm against each other. Jolly thinks that, frequently eosinophile granules which have been suddenly separated from each other, and scattered over a fairly large surface (Klein) can join together again ; in such cases there would be an appearance of, but not a true destruction of the leucocyte. In all protoplasmic elements, in the Rhizopods for example, white corpuscles always die when they contract, that is to say when they assume a nearly spherical form. During the process of decomposition of the protoplasm, pale expansions shoot out which festoon its borders : these excrescences become detached in the form of clear, homogeneous, smooth balls (balls or sarcodic excrescences of Dujardin) and disappear without ever again returning to the cellular body. This process must not be confused with the formation of pseudopods.

Leucocytes, when destroyed by physical agents (electricity, heat) assume a round form. Amongst chemical substances, water and acetic acid attack their nucleus, then cause the protoplasm to swell, and eventually kills them. Carbonic acid gas makes them lose all their staining qualities (Yegorovski). The bases (ammonia, soda, and potassium) cause the nucleus to disappear, and little protoplasmic vacuoles to appear.

Iodine destroys them, and colours them a greenish yellow : it causes the appearance of colourless or slightly violet sarcodic excrescences.

Peptone does not destroy (Tchistovitsch and Schultze), but dissolves them (Botkine, Delezenne).

II. THE DIFFERENT LEUCOCYTES

There are numerous classifications of leucocytes. We will recognize the following varieties :—

- (1) *Microcytes* (lymphocytes of Einhorn, Ehrlich).
- (2) *Macrocytes* (large mononuclears).
- (3) *Cells with neutrophile granules* (neutrophile cells).
- (4) *Cells with acidophile granules* (eosinophile cells).
- (5) *Cells with metachromatic basophile granules* (cells of Ehrlich).

Before approaching the study of each of these varieties it is essential to point out the different classifications which have been proposed. From their study and criticism, we shall justify the nomenclature which we suggest.

HISTORICAL SKETCH OF THE CLASSIFICATIONS.—Leuwenhoek (1722), Della Tore (1776), and Mascagni (1780), saw rounded corpuscles in the lymph. In 1770, Hewson discovered leucocytes in the blood, and some time afterwards Recklinghausen, the migratory cells in the connective tissue. Several years were to elapse before the attention of histologists was drawn to the different varieties of white corpuscles. It was in 1845 and 1846 that Virchow, when studying leuchaemic blood, distinguished two kinds of leucocytes; one, the more numerous, were large; others were small and almost without protoplasm. He inquired into the signification of these different cells: at first he thought that they were separate elements with different origins. Later on he came to the conclusion that they represented evolutionary and functional stages of the same element. Since then, experiments have multiplied, methods have been perfected, and theories freely advanced, but the problem proposed long ago by the author of *Cellular Pathology* has not yet been definitely solved. In 1846 Wharton Jones recognized that amongst leucocytes, some were granular, and others were not. This observation has retained its importance in contemporary classifications, all of which under different titles, are based upon the very complete work of Max Schultze in 1865. In taking as a basis for classification their dimensions, the shape of their nucleus, the presence of granules, this histologist distinguished four kinds of leucocytes, which he called 1, 2, 3 and 4 varieties. The first variety comprises cells which are smaller than red blood corpuscles, and which are almost destitute of protoplasm; the second, larger cells, with more abundant protoplasm, and a rounded nucleus; the third, more numerous cells, with very finely granular protoplasm, with a single or multiple nucleus; the fourth, cells with coarse refracting granules: thus with the exception of the cells of Ehrlich, Max Schultze recognized all the varieties of leucocytes. Hayem's classification is very similar to that of Max Schultze, but a new observation was however made, for the French haematologist described two kinds of non-granular cells: one having clear protoplasm, the other, opaque coloured protoplasm. The old histologists, as may be seen, refrained from giving names to cells which they studied, but this reserve has not been observed by their successors. These names are either in accordance with the dimensions of the cell, the form of the nucleus, the nature of the granules, or in accordance with the presumed origin, or probable age of the white cell; sometimes again the names given suggest one of its physiological properties. Compromises have been established between terminologies founded on these different principles, and it may be said that the extreme difficulty of reading books of haematology is the least of the inconveniences caused by this system of nomenclature.

According to their dimensions and the shape of their nuclei, Löwit distinguishes amongst the white corpuscles:—

1. small mononuclears.
2. large mononuclears.
3. leucocytes with polymorphous nuclei.
4. polynuclears.

This terminology, which is still largely used to-day, has been the subject of criticisms, both numerous and well founded. Ranvier, Flemming, and Heidenhain having shown that the leucocyte called *polynuclear* was almost always a cell with a polymorphous nucleus, it became necessary to proscribe the term as being inaccurate, though unfortunately it is still sanctioned by usage. Again, as Metchnikoff has observed, it is just those cells which are called large mononuclears which as a matter of fact sometimes have two or three perfectly distinct nuclei. This scientist has given the name of *macrophages* to these large mononuclears, a name which while it involves no theories as to their origin, or the necessarily variable appearance of their nuclei, has the advantage of reminding us of their size, and their remarkable phagocytic properties. The other leucocytes (eosinophiles, cells with neutrophile granules) are called *microphages*. Such a terminology is not without inconvenience from the histological point of view; for it includes under the generic term of macrophage, elements of widely different origin and significance, viz., leucocytes, endothelial cells, neuroglia, and nervous cells. Neither does it do away with the necessity for using other terms to denote the different microphages, and for those white corpuscles which are not phagocytic.

Ouskoff classifies leucocytes as *young*, *mature*, and *old* according to their age. The *young* are the small and large lymphocytes, and the small transparent corpuscles. The *mature* are the large and lobulated transparent corpuscles, and the transitional forms, small, large, and lobulated. The *old* the mononuclears, and the polynuclears. In this system the eosinophiles are not included in any of the divisions established by the Russian histologist.

It is quite clear that the small mononuclears much resemble young cells and even embryonic cells. It is more difficult to admit the senility of the large mononuclears; and of the polynuclears; their amoebic and their phagocytic properties afford too much evidence of their powerful vitality.

Ehrlich describes six normal kinds of leucocytes—

- (1) Lymphocytes.
- (2) Large mononuclears.
- (3) Transitional forms.
- (4) Polynuclears.
- (5) Eosinophiles.
- (6) "Crammed cells" (Metchnikoff thus translates the expression, "Mastzellen"; they are also called "fattened cells." "Stuffed cells" is perhaps more accurate.

In addition Ehrlich admits four anomalous forms.

- (1) Neutrophile mononuclears (neutrophile myelocytes).
- (2) Small neutrophile pseudo-lymphocytes.
- (3) Eosinophile mononuclears (eosinophile myelocytes).
- (4) Irritation form of Türck.

It will be seen apart from the term lymphocyte (Einhorn), that Ehrlich, retains the terminology based on the appearance of the nucleus: but now that it is recognized that the lymphocyte is found not only in lymphoid organs (glands and spleen), but also in the marrow of bones (Dominici, Pap-

penheim) it seems that there is no advantage in substituting this term for that of small mononuclears. The transitional form may perhaps be described with the large mononuclear. And since the irritation form of Türck appears to represent a nucleated red blood corpuscle (Ehrlich, Engel), it is useless to retain the term here. The existence of this cell will suffice to prove how delicate is the distinction between a white and a red cell.

Though the eosinophile mononuclears constitute abnormal elements in human blood, they are constant in the blood of the pig and in that of the horse. They cannot be called eosinophile myelocytes seeing that they are sometimes formed in the lymphatic glands and in the thymus.

Notwithstanding its clearness, there are a great many objections to Denys's classification. This author lays down that all non-granular leucocytes are derived from lymphoid tissue; he mixes them up under the name of *lymphocytes*. All the granular leucocytes coming from the marrow of bone, are called *myelocytes*. Whatever may be the dimensions and shape of their nuclei, these myelocytes are *acidophile*, *basophile*, *neutrophile*, according to the nature of their granules. It is unfortunate that the brilliant simplicity of this conception accords so ill with the facts. First of all it takes for granted, what is far from being demonstrated, namely that leucocytes cannot originate except from bony marrow or lymphoid structures, and it does not even refer to the possibility of their origin from connective tissue. Now the white corpuscles are very constant formations in the animal series, and in the aged, and we might almost say, commonly found in all many-celled beings. In phylogenesis as in ontogenesis, they exist before the appearance of the haematopoietic organs. Whether they are of mesoblastic or entodermic (vascular endothelium) origin, some of them bear a strange resemblance to the fixed elements in connective tissue. These resemblances are such that even now there is much discussion as to whether the plasmatic cell of Waldeyer, and Unna, arises from connective tissue or from leucocytes. Whilst Unna, Menahem and Hodara uphold the connective tissue origin; Jadossohn, Marshalko and Dominici support the leucocyte origin (*lymphocyte*). On the other hand, the cells of Ehrlich (the fattened cells), which have been separated from the group of plasmatic cells on account of their metachromatic granules, are often more numerous in the connective tissue of viscera than in bony marrow. Moreover, in the fin of the tadpole, Metchnikoff has observed all transitions between the connective tissue cell and the white cell. Further, knowing that the fixed cells are not phagocytic and finding foreign substances within some of them, Metchnikoff concluded that the latter were old phagocytes which had become fixed. Finally, the splendid researches of Ranvier have shown that the clasmatocytes are fixed leucocytes, capable of movement. It is therefore quite certain that there is an intimate analogy between the connective tissue cell and the white cell; it is proved that a leucocyte can become a connective tissue cell, and it is at least very probable that a connective tissue cell can become a white cell. The majority of anatomo-pathologists admit that the embryonic connective tissue cell, which morphologically so resembles a young leucocyte is capable of movement, and therefore of physiologically resembling it.

Numerous observers having seen wandering leucocytes divide in the connective tissue meshes, it is certain that these elements can reproduce themselves elsewhere than in the large lympho-medullary centres.

Leucopoiesis, like haematopoiesis, appears to be an elaboration of many stages, varying according to the zoological species, and probably according to the age of the individual.

If we admit the lympho-medullary centres to be the sole sources of origin, and yet reject as improbable, the permanence or the reproduction of free elements in the blood plasma, the lymphatic, or the connective tissue systems; then it is very difficult to understand how blood renovations take place in the aged. A definite though intermittent leucopoiesis of connective tissue origin would perhaps furnish a more satisfactory explanation of this phenomenon.

We may now inquire what objections can be raised to the theory which, while it distinguishes two kinds of leucocytes, places the origin of some in the marrow, of others in the gland. This theory takes for granted that the various leucocytes bear no relation to each other: a point on which there has been much controversy.

Though it is not certain that transitional forms between the various granules exist; and though in the blood and lymph forms of transition between the granular and non-granular cells are few in number, and not sharply marked, the case is other with the haematopoietic organs. Here it is both possible and easy to see the white cell acquire granules.

Now while the bony marrow normally possesses non-granular cells which, whether small or large, are identical with those of the lymphatic gland, the latter can present in the normal state all the granular cells which are regarded as belonging exclusively to the bony marrow. But it has been argued, the presence of cells in the gland does not necessarily mean their production there: these wandering elements, which are produced elsewhere, become fixed there by unknown influences. It must be admitted that this objection may be raised against those authors who maintain that the marrow is the site for the formation of eosinophiles, and of the cells loaded with fat, cells which are far from presenting numerous mitoses in it.

But eosinophiles exist in lymph; and sometimes, even in the gland itself, they show indisputable signs of cytodieresis; sometimes again they possess but one nucleus, and a few granules. Finally their numbers increase in pathological hypertrophies or diseases of the lymphatic gland, in lymphadenoma, and after splenectomy. It is very possible that this last mentioned eosinophile springs not only from the gland, but also from the marrow. The latter is then hyperactive. The substitution of the spleen by an antagonistic organ is not easily intelligible, but it becomes so, if we assume that the marrow, the spleen and the glands are structures which were originally identical, differing more in appearance than in reality, and always ready to manifest their former energies. We know that in certain animals a single organ is quite sufficient to perform the duties which normally fall upon the marrow, the spleen and glands. A long time ago, Renaut and Metchnikoff observed that cyclostomes removed from the marrow of bones possessed eosinophiles. On the other hand, the aged in spite of the functional disappearance of the marrow, which has long since been invaded by fat, possess both eosinophiles and neutrophiles. How can we term *myelocytes*, cells which pre-exist and survive the organ considered as their only source of origin? How can we call *lymphocytes*, cells which exist in the marrow as well as in the spleen, or gland? In reality, even in the higher vertebrates, both the marrow and the gland preserve the imprint of their original fusion: there is no cell called myeloid which cannot exist in lymphoid organs, and inversely; on the contrary, many morbid influences can satisfactorily show this symbiosm of two lympho-medullary formations, a symbiosm which is also well proved by normal and comparative histology. Dominici has related many cases of this nature, and has grouped them under the name of myeloid transformation of the spleen.

If for all these reasons we find we have to sacrifice the terms, lymphocytes and myelocytes, it is well to remember that Denys is quite right in not making the form of the nucleus the basis of his classification, but simply classifying the granular cells according to the nature of their granules.

Without repeating all the drawbacks of Löwit's terminology, we may remark again that the shape of the nucleus represents a functional state, which in the most various kinds of cells is sometimes identical, and in a different way represents the distinctive sign of a definite cell species. In other words, cells of the same species, the eosinophiles for example, present different nuclei (single or double) according to the animal considered, and according to the part from which they are taken, etc.; inversely, cells which vary in size, physiological properties, such as the lymphocytes and the large mononuclears of Ehrlich, each have a single rounded nucleus.

Microcytes

Synonyms.—First variety of Max Schultze, globulins, free nuclei of Robin; nuclei of origin of Pouchet; lymphocytes of Einhorn and of Ehrlich; small clear and opaque mononuclears of Hayem; young leucocytes of Ouskoff; small lymphatic corpuscles of Engel; leucoblasts, primary leucocytes, small lymphocytes of Denys; small hyaline cells of Gulland.

These are cells whose dimensions are equal to, or smaller, or slightly larger than those of red blood corpuscles; the diameter of the smallest is from $5.5\ \mu$ to $6\ \mu$; that of the largest (the medium-sized mononuclears of Malassez) varies between $7.5\ \mu$ and $8\ \mu$. It is almost impossible to accurately fix the higher limit because, *as regards size*, we find all intermediate sizes exist between the leucocytes and the macrocytes.

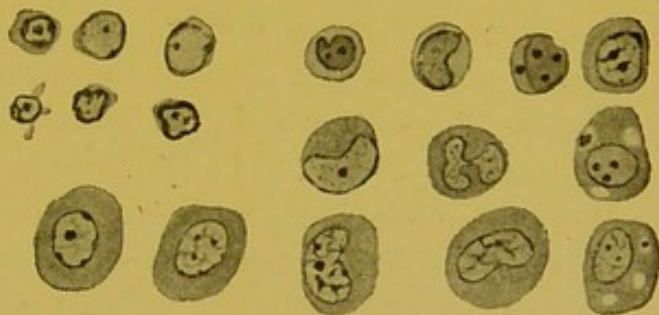

FIG. 4.—Microcytes and Macrocytes.

Rounded, oval, and sometimes polygonous, these elements possess a relatively large central nucleus, partly surrounded by a fine protoplasmic border, which it is frequently very difficult to see; this had escaped the observation of certain histologists who described these elements as free nuclei. The protoplasm is, proportionately to the nucleus, much more developed in the medium-sized elements (the medium-sized mononuclears of Malassez). This layer of protoplasm is somewhat irregular, and presents thickenings shaped like a cap; its external surface often bristles with points, or with detachable buds. The protoplasm is more refracting than

the nucleus. At one time it is like mother-of-pearl, colourless or light, at another opaque or coloured (Hayem). It may, on the other hand, appear homogeneous or very finely granular. (We are now dealing with cytoplasmic granules which have probably no connexion with the granules of leucocytes properly so called.) It has an alkaline reaction (Ehrlich). It may be (1) faintly stained, or slightly basophile; or, (2) strongly basophile, more so even than the nucleus. According to Hayem, the protoplasm of the small opaque mononuclears of human blood can be indiscriminately stained: it takes an intense stain with eosin or orange; it turns a greenish tint with methylene blue, and purple with thionin. Elsewhere, the same author states that the opaque mononuclears in horse's lymph are especially basophile. The nucleus is rounded; and may present, especially in the largest forms, a lateral depression (Ehrlich); when this indentation increases, the nucleus becomes polymorphous.

After fixation by heat, and staining with the triacid, the nucleus appears almost homogeneous, greenish or bluish black (Engel). By means of other fixing agents, we can distinguish the presence of granules, or masses of chromatin in the centre or in the periphery; the central chromatin either appears elongated, or looks like a rounded corpuscle: the peripherally placed chromatin forms a nuclear membrane which is thick in some places, and thin in others.

Sometimes, but not always, these cells possess one, or even two, true nucleoli, which are clearly brought out by fixation with chloride of platinum (Löwit). They may also be seen after fixing with sublimate, and staining with orange-haematoxylin.

In fact, all these cells have sufficient common characteristics to constitute, in appearance at least, a natural family. But side by side with these resemblances (small size, scantiness of protoplasm, an almost identical arrangement of nuclear chromatin, etc.), there are differences in their optical properties, in the staining affinities of their protoplasm, and in the outline of their cells which is sometimes regular, sometimes irregular. These differences are, in Hayem's opinion, sufficiently important to justify a distinction into two classes of cells: viz. the clear and the opaque mononuclears; the latter correspond to the lymphocytes of Ehrlich; they are met with only in the lymph; consequently this term, which indicates their origin, is very reasonable. Dominici makes further distinctions. He describes, by the side of the ordinary lymphocyte, with a deeply stained nucleus, dotted both centrally and peripherally with

granules of chromatin; with slightly basophile or clear protoplasm, identical elements, whose only special characteristic is their power of emitting protoplasmic buds which can detach themselves. He gives to this physiological stage the individuality of a cellular type which he defines as *the mother cell of globulins*. Then, under the name of *small plasmacell*, he describes a cell with a deeply stained nucleus, and extremely basophile protoplasm; under the name of *small basophile mononuclear*, he describes an element with homogeneous and extremely basophile protoplasm, but whose nucleus is clear, and almost destitute of chromatin.

We know that even the same cell, according to the state of its nutrition, its repose, and the mitotic activity of its nucleus, shews considerable variations in its nuclear chromatin contents and in its staining properties; and we also know that the staining reactions of protoplasm may vary in the same element, according to the phases of its evolution; in short, the power of detaching small fragments of their protoplasm into the surrounding media is a very common property of leucocytes. We may therefore suppose that the *mother cell of globulins*, the *little plasmacell*, and the *little nuclear basophile* are not so much true cellular types, with special characteristics and individualities, as phases of the same element, which vary with the state of its evolution, nutrition or degeneration.

The microcytes are not phagocytes (Metchnikoff). Their amoebic properties, which are altogether denied by some authors, seem limited; but they exist nevertheless (Laguesse Wolff, Hirschfeld); they are perhaps inconstant (Jolly).

The microcytes are met with normally in the blood, the lymph, the serous fluid from the peritoneum, in diffuse or circumscribed lymphoid formations near the epithelium, especially that of the digestive tract, in lymphatic glands, in the spleen, and in the marrow of bones.

In the blood, out of 100 white corpuscles, there are from 22 to 25 microcytes (Ehrlich and Lazarus); Ouskoff finds 20 to 25; Mathias Duval 23; and Dumont 28.5 out of every 100. They are more numerous in young children (Voïno-Oranski, Ehrlich, Engel), less so in old people, from 75 and upwards (especially rare in old people of 90) (Solovieff): they increase during lactation (Ostrogorsky), during digestion (Rieder), after injection of pilocarpin (Waldstein, etc.), after splenectomy (Uskow, Emilianoff, Hartmann and Vaquez). In the latter case, Koroboff has seen them diminish. They increase under most varied morbid causes, viz. lymphade-

noma, malignant lymphomas (Ehrlich, Karewski), in the deterioration of blood accompanying tuberculosis (Grawitz), in whooping cough (Meunier). They diminish after extirpation of the *pancreas of Aselli* (Rokitzy, Tchigaieff); after the extirpation of several important groups of glands, Ehrlich and Reinbach found 0.6 in every 100, instead of 25 for every 100. Koroboff observed their diminution after ligation of the thoracic duct; Omelianski, after section of the vasomotors.

These elements are most numerous in the lymph: Hayem found in the lymph taken from a lymphatic vessel running by the side of the carotid artery, only "opaque mononuclears." In the thoracic duct of the dog, out of 133 elements I found 128 microcytes. After fixation with sublimate, their protoplasm stained well with acid colours. They predominate also in the cavernous passages of the lymphatic gland.

Though they are usually regarded as very young elements by some authors, others look upon them as old and degenerate cells which have lost their protoplasm. When compared with other leucocytes, it is interesting to observe that in certain pathological circumstances, they may, without any increase in size, become charged with neutrophile granules (Rieder). They then become the "*small pseudo-lymphocyte neutrophiles*" of Ehrlich. In the same way, the eosinophile microcytes are sometimes found in the normal lymphatic gland.

We must again insist on the fact that there are no precise limits, in regard to size, between these elements and those which we are about to study under the name of macrocytes.

Macrocytes

Synonyms.—The second variety of Max Schultze, the large kinds of clear and opaque mononuclears of Hayem; certain macrophages of Metchnikoff; certain vacuolated cells of Renaut and Lacroix; megalocytes of Dumont; polyeidocytes of Darier; large mononuclears of Löwit, Ehrlich; large lymphocytes of Denys, Engel; mature and old leucocytes of Ouskoff; large hyaline cells of Gulland.

The Macrocytes are rounded or irregularly oval, and in the blood range from 15–17 μ ; in the tissues from 30–40 μ . They are the largest leucocytes. Their protoplasm is abundant and often presents vacuoles; it stains more feebly than the nucleus and appears slightly basophile (Ehrlich). The protoplasm of macrocytes which has been studied in the tissues (lymphoid tissues) is either extremely basophile or acidophile.

The nucleus is large, rounded, or nearly quadrangular ; it is also found to be reniform, cordiform, or shaped like a sac ; it is sometimes double or even triple : thus these cells are genuinely polynuclear. The nucleus, which is nearly always eccentrically placed, is somewhat pale, and presents one or two true central nucleoli and some chromatin granules ; the chromatin network is very delicate and disappears readily in sections which are badly fixed.

It is quite clear that we cannot agree with Botkine that the form and dimensions of these cells entirely depend upon artificial alterations taking place in a mononuclear medium.

Ehrlich does not include in the large mononuclear class, those elements in which the nucleus is reniform ; and as he finds in their protoplasm some neutrophile granules, he describes them under the name of *intermediate forms*, i.e. intermediate between non-granular leucocytes with a rounded nucleus, and granular leucocytes with a polymorphous nucleus. It has been remarked that these intermediate cells are larger than the polynuclears, and that they are rare in the blood ; Ehrlich, however, does not admit the existence of intermediary forms between his lymphocytes and his large mononuclears. Here, we find again the large opaque and clear mononuclears of Hayem. The large opaque mononuclears are always smaller than the clear mononuclears. If, as Hayem thinks, there are no intermediate forms between the clear and the opaque, all the intermediate forms exist between the large and the small forms of each of these two series.

The macrocytes are amoebic, and extremely phagocytic. They digest the bacillus of Hansen, red corpuscles, leucocytes, and particles of the sulphate of arsenic (Besredka).

They exist in the blood, the lymph, the peritoneal serous fluid, the connective tissue, lymphoid formations, lymphatic glands, the spleen and the bony marrow.

In the blood, out of 100 leucocytes, Ehrlich counts 1 large mononuclear, 2 to 4 transitional forms ; Dumont finds 1.5, and Hayem 13. per cent. This difference is evidently accounted for by the fact that these authors have not adopted the same arbitrary line of demarcation between the micro- and the macrocytes.

In the lymph, Hayem found only large opaque mononuclears. In that of the thoracic duct, Dominici found macrophages and basophilic myelocytes. In the thoracic duct of the dog, I have found some macrocytes with a reniform nucleus. I have also seen a fair number of vacuolated and non-vacuolated macrocytes

whose protoplasm almost always proved to be acidophile in the lymph spaces of the normal gland of the rabbit. These elements increase in leuchaemia, mycosis fungoides (Bensaude, Leredde), malaria, and after section of the vasomotors (Omelianski).

Cells with Neutrophile Granules

Synonyms.—Third variety of Max Schultze and Hayem; polynuclear, leucocyte, or rather leucocyte, with a polymorphous nucleus; one of the microphages of Metchnikoff; old leucocyte of Ouskoff; cell of Kanthack and Hardy with fine oxyphile granules; neutrophile myelocytes of Denys.

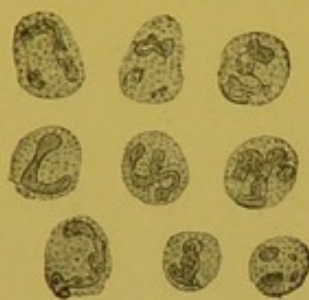

FIG. 5.—Cells with neutrophile granules.

These cells which range from 10 to 14 μ in normal blood, are easily recognizable by the well marked polymorphism of their nuclei. In the blood of certain leuchaemic cases and in the marrow of bones, there are larger cells with neutrophile granules, and a rounded nucleus; it is for these only that Ehrlich has reserved the name of neutrophile myelocytes (neutrophile mononuclears). It is only in exceptional cases, that cells as small as microcytes possess neutrophile granules (dwarf corpuscles of Spilling, Rieder and Jolly; small neutrophile pseudo-lymphocytes of Ehrlich).

The polymorphous nucleus is constricted into two parts, and twisted in a variety of ways so that it more or less resembles the letters E O S Y Z. It is often composed of 2, 3 or 4 rounded masses, or twined stalactiform figures, but more usually it is made up of chromatin filaments so fine as to be almost imperceptible. This nucleus is, in turn, moniliform, star-shaped, and bud-shaped.

We have seen that many causes appear to take part in the genesis of these capricious forms. Without here re-enumerating them all, we will simply add that it very frequently happens, as has been shewn by Denys and Jolly that the annu-

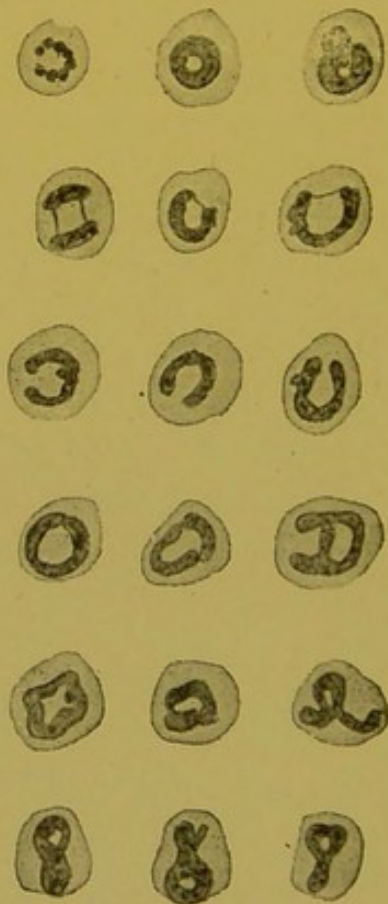


FIG. 6.—Annular and semi-annular nuclei. Those in the first row may perhaps be explained by supposing an anomaly of karyokinesis (crown-like arrangement of the chromosomes); an incomplete fragmentation may account for those in the second row. The others arise from the approximation of the two ends of the tube-shaped nucleus.

lar form, whether complete or incomplete, arises not from a caryodieretic anomaly, but from the simple junction of the free extremities of the arciform nuclear mass.

This nucleus possesses a network of strong dense chromatin; it is coloured greenish or bluish black by the triacid.

The single nucleus (myelocyte or neutrophile mononuclear of Ehrlich) is large and is perforated by holes through which the cytoplasmic granules may be seen.

The protoplasm, which is very refracting, stains well with the acid stains (Ehrlich). It is dotted with fine granules, which are coloured violet by the triacid (mixture of methyl green, orange, and acid fuchsin). These are the granules which Ehrlich calls neutrophiles. We have already alluded to the discussions which the staining affinities of these granules have provoked. They are soluble in distilled water, potash, and in acetic acid (3 in 100).

The cells with neutrophile granules are very amoebic, and very phagocytic. Like other leucocytes they can reproduce themselves by mitosis. They are found in the blood, but much more rarely in the lymph. They are rare in the glands and in the spleen, but in the marrow of bones they are again much more numerous.

They form the majority of the white corpuscles of the blood: 70 to 72 in 100 (Einhorn); 70 to 80 in 100 (Ouskoff); 75 in 100 (Ehrlich and Lazarus); 60 in 100 (Jolly); 66 in 100 (Leredde and Bezançon); 67 in 100 (Dumont). They appear to be less numerous in very young infants; viz. 28 to 40 in 100 (Goundobine); 40 in 100 (Jolly); 40 to 50 in 100 (Besredka). In old subjects Jolly finds 70 in 100.

They increase during digestion (Ouskoff, Leredde, and Loeper). They increase after various kinds of injections, and in certain intoxications (abrin, ricin) (Gourevitch). According to Yegorovski they are more numerous in arterial than in venous blood.

The introduction of oxygen into an arterial segment causes them to increase (Yegorovski, Markevitsch); but the introduction of the same gas into a venous segment causes them to diminish.

Under the influence of chloroform they diminish (Popoff); and the same thing happens with pressure (Vinogradoff).

Though Hayem did not find them in the lymph of the horse, Dominici has seen them in that of the thoracic duct, and out of 133 leucocytes counted in a dog's lymph (thoracic duct), I have observed 3 of these cells.

Cells with Acidophile Granules

Synonyms.—Fourth variety of Max Schultze and Hayem; leucocytes of Semmer; alexocytes of Hankin and Kanthack; Eosinophiles; Myelocyte Eosinophiles of Denys.

The eosinophiles are as a general rule slightly larger than the cells with neutrophile granules, and have a rounded or a polymorphous nucleus. Though it is normal to find only the leucocytes of Semmer with a polymorphous nucleus in the blood of the healthy man, the variety with the rounded nucleus exists in the blood of the healthy pig and horse (Hirschfield, Hayem). It is for this

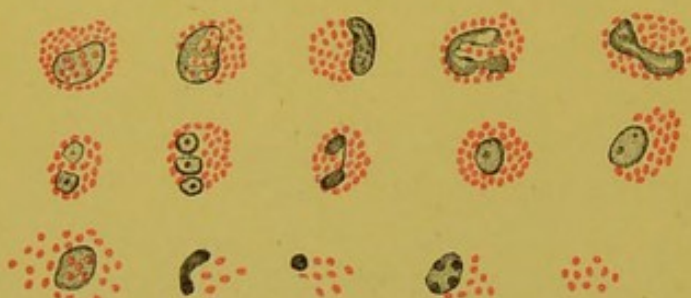

FIG. 7.—Eosinophiles with a single nucleus, and a polymorphous or multiple nucleus. Collection of granules; histolysis.

mononuclear type that Ehrlich reserves the name of eosinophile myelocyte.

The nucleus of the eosinophiles in man is, as a rule, a little less stainable than that of the neutrophils. Sometimes formed of three, it is usually made up of two nearly equal

rounded or oval masses, joined or not by a fine chromatin filament. Jolly lays stress on this arrangement, which has been figured, but not described by Hayem, Renaut, Hardy, and Westbrook, and Klein, etc.

This nucleus may be formed by an arciform mass almost identical with that of the neutrophile polynuclears. As it is frequently perforated the cytoplasmic granules may be seen.

In the protoplasm are found more or less numerous, somewhat coarse, spherical, or more rarely oval granules, which are very refracting and have a pale yellow tinge.

These granules are deeply stained by the acid stains, eosin, and especially by orange; the periphery stains more than the centre (Ehrlich). With thionin, the granules are stained a clear green (Dominici). They are not stainable with osmic acid. They are insoluble in alcohol, ether, chloroform, essence of turpentine, sulphide of carbon.

Unlike haemoglobin, and in spite of the fact that it contains iron, this granule, according to Barker, Löwit, Sacharoff, Tettenhamer, is insoluble in water (Schwarze, Robin, Malassez) and in glycerine. It is insoluble in oil of cloves, liquor potassae (3 in 100), acetic acid (which, by the way, is prejudicial to its ultimate stain-

ing), the alkaline bichromates, sublimate, formol, and chromic acid.

By reagents de Reichl and Mikosch, Renaut and Weiss have established that it is of an albuminoid nature (globulin); and Siawcillo also finds in it some of the properties of the albuminoids: he finds it is stained yellow by nitric acid, red by Millon's reagent, and brown by the iodo-iodide solution. It is generally agreed that it is coloured yellow by the latter reagent. Is this difference to be explained by the fact that Siawcillo studied the eosinophiles of the ray fish, and other histologists that of mammals? On the other hand, its insolubility in gastric juice renders it akin to the nucleins. If it has been clearly shown that the eosinophile granules represent neither remains of cells, as Tettenhamer and Sacharoff thought, nor phagocytosed microbes, as Metchnikoff and Mesnil asserted; if, contrary to the opinion of Pouchet and Hayem, it can be shown it is not a question of haemoglobin, it is more difficult to understand what ends these granules serve, which, after being manufactured and preserved like reserves of vitellin, are finally collected together in the tissues. Hankin and Kanthack regard their substratum as being composed of alexin, a mysterious bactericidal substance. Altmann imagines that they are ozonophores which play a rôle in the oxidations of the organism; Cattaneo, that they carry a ferment which is necessary for the assimilation of certain albuminoid substances. Wagner thinks they are necessary for the nutrition and formation of different cells.

In opposition to Renaut's views, several authors (Max Schultze, Bizzozero, Hayem, Tschlenoff, Müller and Rieder, Jolly) have upheld the existence of amoebic movements in the leucocytes of Semmer.

Their phagocytic properties, denied by Hankin and Kanthack, have been demonstrated by Dolega and Mesnil: they are, however, limited.

The eosinophiles exist in the blood, lymph, peritoneal serous fluid, the connective tissue (in the neighbourhood of salivary, gastric, intestinal, mammary and bronchial glands), in the lymphatic glands, the spleen, and in the marrow of bones.

Whereas Michaelis considers there is a relation between the abundance of eosinophile secretions and the suppression of an external secretion (viz. mammary), Bonne has more recently maintained that the bronchial and eosinophile secretions take place simultaneously.

In the blood, Ehrlich reckons 2 to 4 eosinophiles for every 100 white cells; Dumont, 2.5; Leredde and Loeper, 1 to 2; Engel, 2 to 3; Canon, 2. The last mentioned author found in infants 1.06, and 2.31 per cent, and in old subjects, 2.09; and 7 (in a man of 88 years of age) per cent.

Eosinophiles increase under the influence of pilocarpin (Neusser), and iron preparations, after splenectomy and in the most varied morbid conditions, viz. leuchaemia, cutaneous affections (pemphigus, pellagra, eczema, psoriasis, prurigo, schleroderma, syphilis), vaccinia, helminthiasis, scurvy, blennorrhagia, tuberculosis, scarlet fever, intermittent fever, asthma, emphysema, psychosis, neurosis. They diminish or disappear at the crisis of pneumonia (Bettmann, Engel), of typhoid, of rheumatism, of erysipelas (Bettmann).

I have found some eosinophiles in the lymph of the thoracic duct of the dog (1 in 133), as have also Hayem and Dominici.

Cells with Basophile Granules, Metachromatic, or Cells of Ehrlich

Synonyms.—Mastzellen of Ehrlich; isoplastic cells of Audry; basophile myelocyte of Denys.

These cells vary very much in size in different animals. They range between 8 and 12 μ in the case of mammals; and in batrachians they vary from 30 to 40 μ .

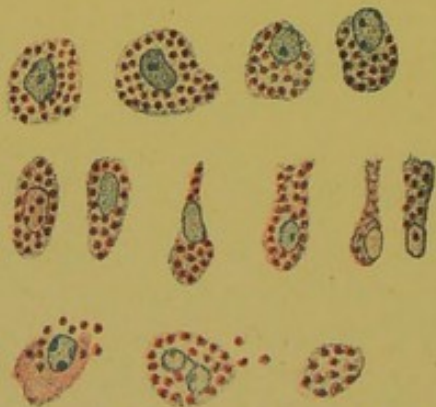


FIG. 8.—Cells of Ehrlich. In some of them, the granules are dissolved. It should be noticed how owing to their elongated form, certain cells in the second row resemble clasmatoocytes.

They are rounded, polygonal, elongated or even ramified; in the latter case, their nucleus is sometimes central, sometimes polar; they much resemble clasmatoocytes.

The nucleus, which is often masked by granules, is sometimes rounded, or more or less ovoid, or sometimes polymorphous (bi- or trilobed). In the cells of Ehrlich, taken from lymphatic glands, I have constantly found a rounded nucleus somewhat like that of microcytes. It differs from it in its lesser staining capacities (Pappenheim).

This nucleus is coloured pale blue by the polychromatic blue of Unna; it has a fine membranous capsule, and some fine chromatin

granules. In the protoplasm are found granules whose form, dimensions, and distribution are irregular.

Rounded or cocciform, these granules are sometimes finer than the eosinophiles, sometimes as coarse, sometimes even they are of larger size (Engel). In some cells, they are closely packed; in others, they are further apart.

These granules are soluble in distilled water, in acetic acid (3 in 100), and in Adam's fluid; they are insoluble in alcohol, and in alcoholic ether. They stain with Gram and Ziehl; also with dahlia, but, treated with carbonate of potash they become discoloured; this is not the case with microbes.

By analogy, it may be asked if these granules do not owe their resistance to decolorization by strong acids, to the presence of a fatty covering. In any case, they do not stain black with osmic acid.

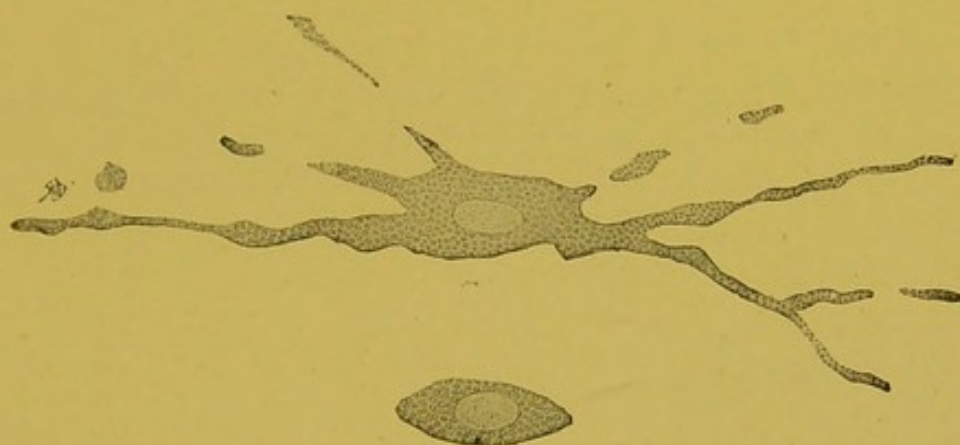

FIG. 9.—Clasmatoocytes of the triton (after Ranvier).

With thionin, and Unna's blue, they yield a red, that is to say metachromatic tint, analogous to that of mucus but more intense. They stain almost pure brown with extra-kresyl violet. Nordmann and Raudnitz think these granules are neither composed of amyloid material nor of mucus.

Besides, if the metachromatic red is obtained not only with the granules of Ehrlich's leucocytes, but also with mucus, and with the fundamental substance of hyaline cartilage and Wharton's Jelly, it also manifests itself with the most varied chemical substances, (nitric and sulphuric acids, potash, chloroform, acetone, anilin, oil of cedar).

It is not unusual to see Ehrlich's cells shed their granules around them; sometimes the granules are set at liberty after having been previously dissolved in the protoplasmic body.

By their form, their mode of secretion, the cells of Ehrlich are very similar to those of Ranvier (clasmatocytes). In the batrachians, the analogy is complete; in mammals, there is one difference, viz. metachromatism does not exist in the granules of the clasmatocytes (Jolly). Does this difference justify us in making a wide distinction between two elements which are similar in so many respects?

In the first place, it has not yet been proved that metachromatism is a chemical phenomenon; and even if we admit there is a difference of chemical constitution between the metachromatic basophile granules and the non-metachromatic, this difference does not seem sufficient to justify us in making a complete distinction between two orders of elements whose comparative anatomy shows them to have such intimate affinities. Besides, are not the red blood corpuscles of different animals morphologically and functionally identical, in spite of a very real difference in their chemical constitution?

The cells of Ehrlich exist in the blood, in serous liquids,¹ in the perivascular connective tissues of the great omentum, in the dermal papillae, in the submucous coat of the intestines, often in the connective tissue spaces of the liver, also in the lymphatic glands, the spleen, and the marrow of bones.

They are very rare in human blood; Ehrlich and Lazarus finding only 0.5 in 100 as the maximum, Canon 0.28 in 100. According to Canon, they are apparently more abundant in the blood of infants (0.88 to 1.86 in 100). Zollikofer has found them in larger numbers in the blood of subjects afflicted with sciatica, hysteria, and acute rheumatism. After the injection of pyrocin, Schmauch has seen them increase, as has Levaditi, after the injection of the toxins of staphylococcus.

In the blood of the rabbit, Bauer finds 2 to 5 in 100; Levaditi, 4.3 in 100. Now, these cells are without doubt very rare in the connective tissue of this animal. It is interesting to remark that Ehrlich's cell is as scarce in the blood, as it is abundant in the connective tissue. This is a law common to almost all the leucocytes of the higher normal vertebrates: thus the macrocytes and eosinophiles, which are rare in the blood, abound in the connective tissue; and the microcytes and neutrophiles, which are found in quantities in the blood, are rare or are absent in the connective tissues.

¹ Milchner has found several in ascites in a leuchaemic case, Neisser in the exudate of a blennorrhagia.

Ballowitz has stated that the cells of Ehrlich are scarce in the connective tissues of the rabbit, the hare, the guinea-pig, and birds ; but that he has observed many in the dog, the calf, the goat, the rat, and the bat. In the latter case, he has found them as numerous after, as before hibernation. On the contrary, in the case of a well nourished frog which has been kept warm, Korybutt, Daskiewicz, and subsequently Stassano and Hass, have seen both the cells of Ehrlich and the clasmatoocytes increase. According to Unger, the suppression of the lacteal secretion determines the increase of these elements in the breast. On the other hand, Westphal has found numbers of them in the cachectic. As Rosenheim has remarked, their multiplication is quite independent of hypernutrition, and Friedländer, Gleumann, and Ballowitz have quite rightly found but little to justify the expression of Mastzelle which has been given them by Ehrlich.

They are found in various pathological products, e.g. lipomata, cutaneous tubercles (Westphal, Bergonzini), urticaria pigmentosa (Unna), the peri-cancerous zone (Ballowitz), miliary epidermic vesicles, sarcomata (Ackermann), nodules of glanders, brown induration of the lung (Israel), acute neuritis (Rosenheim), foci of cerebral haemorrhage and multiple sclerosis (Neumann), in the skin of general paralytics (Franca and Athias), and in sleeping sickness (Athias). Even supposing that in some of these morbid cases there is really a local hypernutrition, it is quite evident that in certain others at least, there is on the contrary, a true diminution of the local nutrition (lipoma, sleeping sickness, general paralysis).

In speaking of each leucocyte, we have indicated the proportion in which it is found in the blood : this proportion is usually sufficiently variable to make it difficult to determine the normal and exact limits, of what has been called "*leucocytary equilibrium*." Besides, haematologists are hardly agreed in fixing the mean quantity of white corpuscles contained in a cubic millimetre of blood. Hayem fixes it at 6,000 ; Ranvier at 8,000 ; Dumont at 7,650. All numbers, therefore, above 7,500 cannot, as has been stated by Leredde and Loeper, be regarded as pathological.

BIBLIOGRAPHY.—Leuwenhœk. *Opera omnia s. arcana naturæ detecta*. Lugd. Batav., 1722.—Della Tore. *Nuove osservazione microscopiche*. Napoli, 1776.—Wharton Jones. The blood corpuscle considered in its different phases of development. *Philosophical Transactions*, 1846.—Davaïne. *Mémoires de la Société de Biologie*, 1850.—Moleschott. Ueber die Etwickne-

lung der Blutkörperchen. *Archiv f. Anat. u. Phys.*, 1853.—Virchow. *Verh. der phys. med. Ges. zu Würzburg*, II, p. 325;—*Virchow's Archiv*, 1853, V, p. 43.—Lieberkühn. U. Psorospermien. *Müller's Archiv*, 1854.—Robin. Sur quelques points de l'anatomie et de la physiologie des leucocytes. *Journ. de Phys.*, 1859, II, p. 41.—Heckel. *Die Radiolären*, 1862.—Recklinghausen. Ueber Eiter u. Bindegewebe-Körperchen. *Virchow's Archiv*, XXVIII.—Kuhne, Unters. ueber das Protoplasma u. die Contractilität, 1864.—Max Schultze. Ein heizbarer Objecttisch u. seine Verwendung bei Untersuch. des Blutes. *Arch. f. mikrosk. Anat.*, 1865, I.—Cohnheim. U. Entzündung u. Eiterung. *Virchow's Arch.*, 1867, XX.—Bizzozero. Sul processo di cicatrizzazione dei tendini tagliati. *Ann. univ. di medicina*, 1868, CCIIL.—Preyer. *Centralblatt f. die medic. Wissensch.*, 1869, p. 305.—Klein. U. die Theilung farbloser Blutkörperchen. *Centralbl. f. d. med. Wiss.*, 1870, n° 8, p. 17.—Rouget. Migrations et métamorphoses des globules blancs. *Arch. de Phys.*, 1874.—Semmer. *Inaug. Diss.*, Dorpat, 1874.—Ranvier. Recherches sur les éléments du sang. *Archives de Phys.*, 1875.—S. Mayer. *Arch. f. mikr. Anat.*, XIII.—Waldeyer, Ueber die Bindegewebszellen. *Arch. f. mikr. Anat.*, 1875, XI.—v. Roietzky. Contrib. à l'étude de la fonction hématop. de la moelle osseuse. *Arch. Sciences biol.*, Pétersbourg, 1877.—Vulpian. *C. R. Acad. Sciences*, 4 juin 1877.—Ehrlich. Beiträge zur Kenntniss der granulierten Bindegewebszellen u. der eosinoph. Leucocyt. *Archiv f. Anat. u. Phys.*, 1879;—Ueber die specifischen Granulationen des Blutes. *Verhandl. d. physiol. Gesellschaft zu Berlin*, 1878–1879–n° 20.—Peremeschko. U. die Theilung der Zellen. *Centralbl. f. d. med. Wissenschaft*, 1878.—Korybutt Daskiewicz. *Arch. f. mikr. Anat.*, 1878, XV;—*Arch. f. mikr. Anat.*, 1880, XVII.—Pouchet. Note sur les leucocytes et la régénération des hématies. *C. R. Soc. Biol.*, 5 janvier 1878;—Évolution et structure des noyaux des éléments du sang chez le triton. *Journ. de l'Anat. et de la Phys.*, 1879.—Hayem. Recherches sur l'évolution des hématies. *Arch. phys. norm. et path.*, 2^e série, VI, 1879.—Flemming. U. das Verhalten des Kerns bei der Zelltheilung u. über die Bedeutung mehrkernigen Zellen. *Virchow's Arch.*, 1879, LXXVII;—Beiträge zur Kenntniss der Zelle u. ihr. Lebenserscheinungen, I Theil. *Arch. f. mikrosk. Anat.*, 1879, XVI;—*Archiv. f. mikr. Anat.*, 1882, XX;—Zellsubstanz, Kern u. Zelltheilung, 1882.—Westphal. Ueber Mastzellen. *Inaug. Diss.*, Berlin, 1880.—Spilling. U. Blutuntersuchungen bei Leukämie. *Inaug. Diss.*, 1880.—Ehrlich. U. die Bedeutung der neutrophilen Körnung. *Charité Annalen*, XIII;—Methodologische Beiträge zur Phys. u. Pathol. der verschiedenen Formen der Leukocyten. *Zeitschrift f. klin. Med.*, 1880, I.—Schwarze, Ueber eosinoph. Zellen. *Inaug. Diss.*, Berlin, 1880.—Ch. Robin. Sur les corpuscules nucléiformes des leucocytes. *Journ. de Phys.*, 1881.—Certes. *C. R. Acad. Sciences*, 1881, XCII, n° 8.—Renaut. Recherches sur les éléments du sang. *Arch. de Phys.*, 1881.—Schöefer. *British Med. Jour.*, 1882, n° 1134, p. 573.—Israel, *Berlin. kl. Wochenschr.*, 1883.—S. Arnold. *Virchow's Archiv*, 1882;—Beobacht. u. Kerne u. Kerntheilungen in den Zellen der Knochenmarkes. *Virchow's Archiv*, 1883, LXXXVIII;—*Virchow's Arch.*, 1884, XCV.—Raudnitz. *Arch. f. mikrosk. Anat.*, 1883, XXII.—Ackermann. *Volkman's Sammlung, Klinischer Vorträge*, 1883.—Einhorn. *Inaug. Diss.*, Berlin, 1884.—Bizzozero. *Virchow's Arch.*, 1884.—Lavdovsky. Mikroskopische Untersuch. einiger Lebensvorgänge des Blutes. *Virchow's Arch.*, 1884, XCVI.—Bizzozero. U. die Bildung der rothen Blutkörperchen. *Virchow's Arch.*, 1884, XCV.—Nordmann. Beiträge zur Kenntniss u. namentlich zur Färbung der Mastzellen. *Diss.*,

Berlin, 1882;—*Internat. Monatsch. f. Anat. u. Hist.* 1885, II.—Löwit. U. die Bildung der rothen u. weissen Blutkörperchen. *Sitz. der K. Akad. der Wissensch. Wien*, 1883, III;—U. Neubildung u. Zerfall der weissen Blutkörperchen. *Sitz. der K. Akad. der Wissensch. Wien*, 1885, XCII, p. 121.—Neumann. Ueber Plasmazellen. Von d. med. Fakultät d. univ. Rostock gekrönte Preisschrift. Rostock, 1885.—Rosenheim. Ueber das Vorkommen u. die Bedeutung der Mastzellen im Nervensystem der Menschen. *Arch. f. Psych. u. Nervenkrank.*, 1886, XVII.—Prus. *Medycyna*, 1886, n^o 30 et 40.—Pfitzner. U. Theilungsvorgänge an den Leukocyten, ihre progressiven u. regressiven Metamorphosen. *Arch. f. mikr. Anat.*, 1887, XXX.—Denys. La cytodierèse des cellules géantes et des petites cellules incolores de la moelle des os. *La Cellule*, 1887, II, p. 245;—La structure de la moelle des os et la genèse du sang des oiseaux. *Ibid.*, 1887, IV.—Schultze Die vitale Methylenblaureaction der Zellgranula. *Anat. Anzeig.*, 1887.—Arnold. Ueber Theilungsvorgänge an der Wanderzellen. *Arch. f. mikrosk. Anat.*, 1887, p. 205;—Weitere Beobacht. u. Theilungsvorgänge an der Knochen Markszellen u. weissen Blutkörperchen. *Virchow's Arch.*, 1887, XCVII;—Alter u. Neues über Wanderzellen insbesondere deren Herkunft u. Umwandlungen. *Virchow's Arch.*, CXXXII.—Kultschitsky. Karyokinesis in farblosen Blutkörperchen. *Centralbl. f. die med. Wissenschaft*, 1887.—Leber. Fortschritte der Medicin, 1888, VI.—Lubarsch. *Fortschr. d. Medicin.*, 1888, VI, n^o 4;—*Centralbl. f. Bakt.*, VI, n^o 18, 20.—Spronck. Over Regeneratie in Hyperplasie van Leukocyten in het circuleirend bloed. *Nederlandsch Tydschrift voor Geneeskunde*, 29 mars 1889.—Prins. Karyokinese in het blood by intgebreide etherings processen. *Diss. Utrecht*.—Korschelt. *Zool. Jahr.* Abtheil. f. Anat. der Thiere, 1889.—Hermann. *Arch. f. mikr. Anat.*, 1889, XXXIV, p. 100.—Peckelharing. *Sem. méd.*, 1889, n^o 22, p. 184.—Marchand. *Ziegler's Beiträge*, 1889, IV.—Hayem. *Du sang et de ses altérations anatomiques*, Paris, 1889, p. 110.—Löwit. U. die Beziehung d. weissen Blutkörperchen zur Blutgerinnung. *Ziegler's Beiträge*, 1889, V.—Naumann. U. das Vorkommen der sogen. Mastzellen bei pathol. Veränderungen des Gehirns. *Virchow's Archiv*, 1890, CXXII, 2.—H. F. Muller. Zur Leukämiefrage. *Deut. Arch. f. klin. Med.*, 1890.—Obrastzow. *Deut. med. Woch.*, 1890.—Massart et Bordet. Recherches sur l'irritabilité des leucocytes et sur l'intervention de cette irritabilité dans la nutrition des cellules et dans l'inflammation. *J. de la Soc. R. des Sciences méd. et nat. de Bruxelles*, 1890.—Gabrichevsky. Sur les propriétés chimiotaxiques des leucocytes. *Annales de l'Institut Pasteur*, 1890.—Buchner. Die chemische Reizbarkeit der Leukocyten u. deren Beziehung zur Entzündung u. Eiterung. *Berlin. klin. Wochenschrift*, 1890.—Auerbach. U. die Blutkörperchen der Batrachier. *Anat. Anzeiger*, 1890.—Uskoff. *Le sang comme tissu*. Pétersbourg, 1890.—Ranvier. Des clasmatoocytes. *C. R. Acad. Sciences*, 27 janvier 1890;—Sur les éléments anatomiques de la sérosité péritonéale. *C. R. Acad. Sciences*, 14 avril 1890.—Rosbach. *Deut. med. Woch.*, 1890, p. 389.—Brigidi. *Lo Sperimentale*, settembre 1891.—Pacinotti. Intorno alle cellule granulose di Ehrlich o mastzellen. *Giorn. della R. Accad. di medicina di Torino*, 1891, n^o 6.—Flemming. U. Theilung u. Kernformen bei Leukocyten u. über deren Attractionsphären. *Arch. f. mikrosk. Anat.*, 1891, XXXVII;—Attractionsphären u. Centralkörper in Gewebszellen u. Wanderzellen. *Anat. Anzeiger*, 1891, VI.—V. der Stricht. Div. mitotique des érythroblastes et des leucoblastes à l'intérieur du foie embryonnaire des mammifères. *Anat. Anzeiger*, 1891.—Dekhuysen. U. Mitosen in frei im Bindegewebe gelegenen Leukocyten. *Anat. Anzeiger*, 1891, VI.—Gulland. The nature

and varieties of leucocytes. *Rep. Lab. Roy. Coll. Phys. Edinburgh*, 1891, III.—Weiss. Das Vorkommen u. die Bedeutung der eosinoph. Zellen u. ihre Beziehung zur Bioblastentheorie Altmann's. *Wien. med. Presse*, 1891 n^o 41–44.—Muller u. Rieder. U. das Vorkommen u. klinische Bedeutung der eosinoph. Zellen (Ehrlich) im circulirenden Blute der Menschen. *Deut. Arch. f. klin. Med.*, 1891, XLVIII, p. 96.—Ranvier. Transformation in vitro des cellules lymphatiques en clasmatoctes. *C. R. Acad. Sciences*, 6 avril 1891.—Griesbach. Beiträge zur Histologie der Blutes. *Arch. f. mikr. Anat.*, 1891, XXXVII, p. 22;—Struktur u. Plasmoschise der Amœbocyten. *Verhandl. d. Anat. Ges. München*, 1891.—Bergonzini. U. das Vorkommen von granulierten basophilen u. acidophilen Zellen im Bindegewebe u. über die Art sich sichtbar zu machen. *Anat. Anzeiger*, 1891.—H. F. Muller. U. Mitose an eosinoph. Zellen. *Arch. f. experim. Path.*, 1891.—Muller. *Deut. Arch. f. klin. Med.*, 1891, XLVIII.—Muir. *Journ. of Anat. and Phys.*, 1891, XXV.—Ballowitz. U. das Vorkommen der Ehrlich'schen granulierten Zellen, "Mastzellen" bei winterschlafenden Säugethieren. *Anat. Anzeig.*, 1891.—V. Bambeke et van der Stricht. Caryomitose et div. indirecte des cellules à noyau bourgeonnant. *Ann. Soc. de Méd. de Gand*, 1891.—Löwit. U. amitotische Kerntheilung. *Biol. Centralblatt*, 1891, XI:—*Anat. Anzeiger*, 1891;—U. Neubildung u. Beschaffenheit der weissen Blutkörper. *Beiträge z. path. Anat., von Ziegler*, 1891, X.—Ostrogorski. Contrib. à l'étude des modific. morphol. du sang pendant la grossesse, l'accouchement et la période postpuerpérale. *Th. Pétersbourg*, 1891.—Hansemann. Ein Beitrag zur Entstehung u. Vermehrung der Leukocyten. *Verh. der Anat. Gesellsch. München*, mai 1891;—*Anat. Anzeiger*.—Göppert. Kerntheilung durch indirecte Fragmentierung in der lymphat. Randschicht der Salamanderleber. *Arch. f. mikr. Anat.*, 1891, XXXVII.—Weiss. Eine neue mikrochemische Reaction der eosinoph. Zellen. *Centralbl. f. die medicin. Wissensch.*, 1891.—Cuénot. Étude sur le sang et les glandes lymphatiques dans la série animale. *Arch. Zoologie exp. et gén.*, 1891, 2^o série, 7–9.—Scarpaletti. U. die eosinoph. Zellen des Kaninchen-Knochenmarkes. *Arch. f. mikrosk. Anat.*, 1891.—Unna. *Monatschr. f. prakt. Dermat.*, 1891, XII.—Schaffer. Ueber das Vorkommen eosinoph. Zellen in der menschlichen Thymus. *Centralbl. f. d. med. Wissensch.*, 1891.—Hock u. Schlesinger. Blutuntersuchungen bei Kindern. *Centralbl. f. klin. Med.*, 1891, n^o 46.—Netchaeff. *Virchow's Arch.*, 1891, CXXV.—Wertheim. *Zeitschr. f. Heilkunde*, 1891, XII.—Noll. *Wiener med. Presse*, 1892.—Unna. *Zeits. f. wiss. Mikr.*, 1892, VIII 4; IX.—Bastianelli. *Boll. della R. accademia med. di Roma*, 1892, XVIII.—Voïno Oranski. Morphol. du sang chez les nouveau-nés. *Th. Pétersbourg*, 1892.—Goundobine. De la morphologie norm. et path. du sang chez les enfants. *Th. Pétersb.*, 1892.—M. Heidenhain. U. die Centralkörpergruppen in den Lymphocyten der Säugethiere während der Zellenruhe u. Zelltheilung. *Verhandl. d. anat. Gesellsch. Göttingen*, 1892;—*Festschr. Kölliker*, Leipzig, 1892.—Canon. U. eosinoph. Zellen u. Mastzellen im Blut Gesunder u. Krankheit. *Deut. med. Woch.*, 1892, n^o 10.—Muller. U. Mitose an eosinoph. Zellen. Beitrag zur Kenntniss der Theilung der Leukocyten. *Arch. f. exp. Path. u. Pharmak.*, 1892, XXIX.—Rieder. Beiträge zur Kenntniss der Leukocytose. Leipzig, 1892.—Löwit. *Studien zur Phys. u. Path. des Blutes u. der Lymphe*. Iéna, 1892.—Lilienfeld. Hämatol. Untersuchungen. *Arch. f. Anat. u. Phys.*, 1892.—Everard et Demoor. Les modifications des globules blancs dans les maladies infectieuses. *Soc. Sc. méd. et nat. Bruxelles*, 1892.—Éverard Massart et Demoor. *Annales de l'Institut Pasteur*, VII, p. 165.—Grawitz,

Ueber die schlummernden Zellen der Bindegewebes u. ihre Verhalten bei progressiven Ernährungsstörungen. *Virchow's Archiv.*, 1892, CXXVII.—Mesnil. *Annales de l'Institut Pasteur*, IX, p 301.—Zappert. U. das Vorkommen der eosinoph. Zellen im mensch. Blute. *Zeitschrift f. klin. Med.*, 1892, XXIII, p. 227.—Kourloff. *Wratch*, 1892.—Ranvier. Les clasmatoctes, les cellules fixes du tissu conjonctif et les globules du pus. *C. R. Acad. Sciences*, 1893, CXVI, n° 7, p. 295.—Héricourt et Richet. Modifications dans le nombre des leucocytes du sang après injection de diverses substances. *C. R. Soc. Biol.*, 1895, n° 35, p. 965.—Medwedeff. Comment se comportent les leucocytes vis-à-vis de certaines substances introduites dans le sang. *Thèse Pétersbourg*, 1893.—Golzmann. Contrib. à l'étude de la leucocytose. *Th. Pétersbourg*, 1893;—*Gaz. hebdom. méd. Russie mérid.*, 1894, n° 46.—Schulz. *Deut. Arch. f. klin. Med.*, 1873, LI.—E. Botkine. Influence de l'albumine et des peptones sur quelques fonctions de l'organisme. *Thèse Pétersbourg*, 1893.—Autonenko. Modific. morphol. du sang sous l'influence de la saignée. *Thèse Pétersbourg*, 1893.—Wladimiroff. Modific. morphol. du sang sous l'influence des modif. de la pression. *Th. Pétersb.*, 1893.—Cuénot. Evolution des amibocytes chez les crustacés décapodes. *Bibliogr. anat.*, 1893, p. 157.—V. der Stricht. Nature et div. mitosique des globules blancs des mammifères. *Verhandl. der anat. Gesellschaft in Göttingen*, 1893.—Klein. Die diagnostische Verwerthung der Leukocytose. *Sammlung. klin. Vorträge*, 1893, n° 87.—Tettenhamer. U. die Entstehung der acidophilen Leukocyten. Granula aus degenerirender Kernsubstanz. *Anat. Anzeig.*, 1893, VIII, p. 223.—Tschistowitsch. Contrib. à l'étude de la leucolyse. *Gaz. de Botkine*, 1894, n° 9.—E. Botkine. Solubilité des leucocytes dans la peptone. *Gaz. de Botkine*, 1894, n° 22.—Omelianski. De l'influence des troubles circulatoires locaux sur la morphologie du sang. *Thèse Pétersbourg*, 1894.—Yegorovski. Modific. morphologiques des globules blancs dans les vaisseaux sanguins. *Thèse Pétersbourg*, 1894.—Vinogradoff. Contrib. à l'étude de la pression artérielle sur la morphologie du sang. *Thèse Pétersbourg*, 1894.—Przevosky. *Soc. méd. de Varsovie*, nov. 1894.—Rokitzi. Modifications morphologiques du sang chez les chiens après l'ablation du pancréas d'Aselli. *Thèse Pétersbourg*, 1894.—Solovieff. Examen du sang chez les vieillards. *Th. Pétersbourg*, 1894.—Sherrington. *Proceedings of the Royal Society of London*, 1894, LX, p. 187.—Onimus. Naissance des leucocytes dans les liquides amorphes. *C. R. Soc. Biologie*, 1894, n° 25, p. 651.—Unna. *Zeit f. wiss. Mikr.*, 1894, XI, 4, p. 511;—*Monatsschrift f. prakt. Dermat.*, 1894, XVIII.—Zenoni. U. die Entstehung der verschied. Leukocytenformen des Blutes. *Zeigler's Beiträge*, 1894, XVI, p. 537.—M. Heidenhain. U. Bau u. Funktion der Riesenzellen (Megakaryocyten) im Knochenmark. *Würzburger Verhandl.*, 1894.—Kanthack a. Hardy. The morphology and distribution of the wandering cells of mammalia. *Journ. of physiol.*, 1894, XVII, p. 81.—Altmann. Ueber die Elementarorganismen u. ihre Beziehungen zu den Zellen. Leipzig, 1891–1894.—Muller. Die Morphol. des leukäm. Blutes. *Centralbl. f. allg. Path.*, Juli, 1894.—Barker. On the presence of iron in the granules of the eosinophile leucocytes. *John Hopkins Hosp. Bull.*, 2 oct. 1894, n° 4.—Ligouzat. Les cellules éosinoph. *Thèse Lyon*, 1894.—Leonard. Série de photomicrographies relatives aux mouvements amiboïdes des corpuscules blancs du sang. *C. R. Acad. Sciences*, 1894, CXIX, n° 4.—Maurel. *Recherches expérimentales sur les leucocytes du sang*. Paris, 1894;—Origine et évolution des éléments figurés du sang. *Assoc. franç. p. l'avancement des Sciences*, 22^e sess., Besançon, 1893–1894.—Kanter. U. das Vorkommen u. eosinoph. Zellen im malignen Lymphom u. bei einigen

anderen Lymphdrüsenkrankungen. *Centralbl. f. allg. Path.*, 1894.—Siawcillo. Cellules éosinophiles. *Annales de l'Institut Pasteur*, IX, p. 289.—De Bruyne. De la phagocytose observée sur le vivant dans les branchies des mollusques lamellibranches. *C. R. Acad. Sciences*, CXVI, n° 2, p. 65;—*Bibl. anat.*, 1895, n° 4.—E. Botkine. De la leucocytolyse. *Gaz. de Botkine*, 1895, n° 18—19.—Semakine. De la distribution inégale des leucocytes dans les vaisseaux sanguins. *Th. Pétersbourg*, 1895.—Popoff. Influence de l'anesthésie sur la leucocytose et l'aleucocytose. *Th. Pétersbourg*, 1895.—Markevitch. Étude de la modification des globules blancs dans les vaisseaux sanguins. *Thèse Pétersbourg*, 1895.—Gourevitch. De la leucocytose. *Thèse Moscou*, 1895.—Borrissoff. De la chimiotaxie des globules blancs. *Soc. des méd. russes de Pétersb. Vrach*, 1895, n° 18.—Messarosch. Modif. morphol. du sang chez les sujets sains sous l'influence du chauffage artificiel. *Thèse Pétersbourg*, 1895.—Arnold. Zur Morphologie u. Biologie der Zellen des Knochenmarkes. *Arch. f. path. Anat.*, 1895, CXXX.—Prus. Secretorische fuchsinophile Degeneration. *Centralblatt. f. allgem. Pathol. u. path. Anat.*, 1895, VI.—Marquevitch. Modific. des glob. blancs dans les vaisseaux sanguins. *Th. Pétersbourg*, 1895.—Broïdo. Travaux russes sur la leucocytose. *Gaz. hebdom. de méd. et de chirurgie*, 7 déc. 1895.—Demoor. Contribution à l'étude de la cellule. Individualité fonctionnelle du protoplasma et du noyau. *Bull. de la Soc. belge de microscopie*, 1893—1894, XX, n° 1, 3;—*Arch. biol.*, 1895, XXIII.—Hardy a. Westbrook. The wandering cells of the alimentary canal. *Journ. of Phys.*, nov. 1895, XVIII, p. 490.—Roule. La phagocytose normale. *Revue générale des Sciences*, 1895, n° 13, p. 586.—Marschalko. U. die sogenannten Plasmazellen. *Arch. f. Dermat.*, 1895.—Menahen Hodara. Cellules plasmatiques dans les organes hématopoiétiques normaux de l'homme? Grands mononucléaires. *Annales Dermat. et Syph.*, 1895, n° 10, p. 856.—Siedlicki. U. die Structur u. Kerntheilungsvorgänge bei den Leukocyten der Urodelen. *Anzeiger der Akad. der Wissenschaft. in Krakau*, avril 1895.—Chatin. De la phagocytose chez les huîtres. *C. R. Acad. Sciences*, 1896, CXXII, n° 8, p. 487.—Weiss. Hämatol. Unters. Pseudo-leukäm. als Sammelbegriff. *Prochask. Wien*, 1896.—Valenza. *C. R. Soc. Biol.*, 1890, n° 35.—Calleja. Distribucion y significacion de las celulas abædas de Ehrlich. *Rivista trimestr. micrografica*, 1896, 1.—Gulland. On the granular leucocytes. *Journ. of Phys.*, 1896, XIX, p. 385.—Botkine. Zur Morphol. der Blutes u. der Lymphe. *Virchow's Archiv*, 1896, CXLV, p. 369.—Vassale. *Centralbl. f. allgemein Path.*, 1896, IX.—Cuénot. Amibocytes et organes lymphoïdes. *Revue biol.*, Nancy, 13 janv. 1897;—*Bibl. anat.*, 1897, n° 1.—Ranvier. Rôle phys. des leucocytes à propos des plaies de la cornée. *C. R. Acad. Sciences*, 1897.—Muller u. Rieder. U. Vorkommen u. klinische Bedeutung der eosinoph. Zelle im circulierend. Blut des Menschen. *Deut. Arch. f. klin. Med.*, XLVIII.—Ribbert. Beiträge zur Entzündung. *Virch. Arch.*, CL, 3.—Besredka. L'état actuel de la question de la leucocytose. *Ann. de l'Institut Pasteur*, 1897, p. 726.—Przesmycki. U. die intravitale Färbung des Kernes u. Prot. *Biol. Centralbl.*, XVII, n° 9—10.—Hirschfeld. Beiträge zur vergleichenden Morphologie der Leukocyten. *Inaug. Diss.*, Berlin, 1897.—Lœb. U. die Entstehung von Bindegewebe: Leukocyten u. roten Blutkörperchen aus Epithel u. über eine Methode isolierte Gewebsteile zu züchten. *Chicago, M. Stern*, 1897.—Pappenheim. U. Enstammung u. Entstehung der rothen Blutzelle. *Virch. Arch.*, 1895.—Masslow. Einige Bemerkungen zur Morphologie u. Entwicklung der Blutelemente. *Arch. f. mikrosk. Anat.*, 1897, LI, p. 137.—Bogdanoff. Vorkommen u. Bedeutung der eosinoph. Granulat. *Biol. Centralbl.*, 1898, CLXXXI.—Ehrlich u. Lazarus.

Die Anæmie. Wien, 1898.—Engel. *Leitfaden zur klinischen Untersuchung des Blutes.* Berlin, 1898.—Jolly. Recherches sur la valeur morphologique et la signification des différents types de globules blancs. *Thèse Paris*, 1898.—Leredde et Bezançon. Principales formes cellulaires des tissus conjonctifs et du sang. *Presse médic.*, 1898, p. 305.—Unger. Das Colostrum. *Virch. Arch.*, 1898, CLV.—Denys. Lymphocytes et myélocytes. *Presse médicale*, 1898, p. 118;—5^e Congrès de Médecine, 1899.—Klemsiewicz. Neue Untersuchungen über den Bau u. Thätigkeit der Eiterzellen. *Mitteilung des Vereins der Aertzte in Steiermark*, 1898.—Lövy. Zur Biologie der Leukocyten. *Virchow's Archiv.*, 1898, CLI.—Chantemesse. Le globule blanc. *Presse médicale*, 7 déc. 1898.—Arnold. Ueber Struktur u. Architektur der Zellen: I, II, III. *Archiv. f. mikrosk. Anat.*, 1898, LII.—Lukjanow. Contrib. à l'étude des cellules migratrices. *Arch. Sc. biol.*, VI, n° 2;—*Inst. imp. méd. expér.*, Pétersbourg, février 1898.—Saint-Hilaire. Die Wanderzellen in der Darmwand der Seeigel. *Trav. Soc. imp. nat. Pétersbourg*, XXVII, liv. 3, Sect. Zool. et Phys.—Bettmann. Ueber das Verhalten der eosinoph. Zellen im Hautblasen. *Münch. med. Woch.*, 1898, n° 39.—Cardite. Sur la vie des leucocytes en dehors de l'organisme. *Archivio per le Scienze mediche.* Turin, 1898, XXIII, fasc. 4.—Rosa. Prétendus rapports génétiques entre lymphocytes et chloragogènes. *Arch. ital. Biol.*, 4 nov. 1898, XXX, n° 1.—Arnold. Die Farbwechsel der Zellgranula insbesondere der acidophilen. *Centr. f. allg. Path.*, 1899, X, n° 21–22.—Milchner. U. die Emigration von Mastzellen bei myelogen Leukämie. *Zeit. f. klin. Med.*, 1899, XXXVII.—Zollikofer. *Inaug. Diss.*, Berne, 1899.—Häusermann. Contenance en fer du plasma sanguin et des leucocytes. *Zeitschrift f. physiolog. Chemie*, 1891, XXVI, n° 5.—Kaminer. Leucocytose et réaction iodée des leucocytes. *Berlin. klin. Wochenschrift*, 7 fév. 1899.—Carrière et Bourneville. Genèse des éosinophiles. *Écho médic. Nord*, février 1899.—Leredde et Lœper. Équilibre leucocytaire. *Presse médicale*, 25 mars 1899.—Besredka. Étude sur l'immunité vis-à-vis des composés arsenicaux. *Annales de l'Institut Pasteur*, 1899, p. 49;—Du rôle des leucocytes dans l'intoxication par un composé arsenical soluble. *Ibid.*, p. 209.—Pio Foa. *Beit. zur path. Anat. u. zur allgem. Path.*, 1899, XXX, p. 2.—Tallquist u. Willebrand. Zur Morphologie der weissen Blutkörperchen des Hundes u. des Kaninchens. *Skandin. Arkiv. f. Phys.*, X, 72, p. 37.—Sicherer. Zur Chemiotaxie der Leukocyten in vitro. *Centralblatt f. Bakt.*, XXVI, n° 11, 12, p. 360.—J. Arnold. U. Granulafärbung lebender u. überlebender Leukocyten. *Virchow's Arch.*, 1899, p. 425.—Salmon. Glycogène et leucocytes. *Th. Paris*, 1899.—Pappenheim. Vergleich. Untersuch. u. die elementare Zusammensetzung des rothen Knochenmarkes einiger Säugthiere; Bemerkungen zur Frage des gegenärtigen Verhältnisse der verschiedenen Leukocyten-Formen zu einander. *Archiv. f. pathol. Anat. u. Phys.*, CLVII, I.—Hayem. Mononucléaires du sang humain. *C. R. Soc. Biol.*, 1899, p. 283;—De l'infiltration granuleuse des globules polynucléaires. *C. R. Soc. Biol.*, 1899, p. 434;—Leucocytes du sang de cheval. *C. R. Soc. Biol.*, 1899, p. 623;—Leucocytes de la lymphe de cheval. *C. R. Soc. Biol.*, 1899, p. 621.—Jolly. Leucocytes granuleux du sang humain. *C. R. Soc. Biol.*, 1899, p. 140.—Franca et Athias. *C. R. Soc. Biol.*, 1899, p. 317.—Malassez. Représentation graphique du nombre des leucocytes. *C. R. Soc. Biol.*, 1899, p. 181.—Dominici. Origine des leucocytes polynucléaires du lapin. *C. R. Soc. Biol.*, 1899, p. 168.—Achalme. *C. R. Soc. Biol.*, 1899.—Brandenburg. La réaction des leucocytes avec la teinture de gaïac. *München. medicin. Wochensch.*, 1900, n° 6, p. 183.—Ranvier. Des clasmatoctes. *Archiv. d'Anat. microscop.*, 15 mars 1900.—Grünwald. Die Bedeutung

der hypeosinophilen Granula. *Centralbl. f. innere Med.*, 1900, n° 14, p. 345.—Bettmann. *Volkman's Sammlung klin. Vorträge*, 1900, n° 266.—Zabolonty. Ferment amylolytique des globules blancs du sang. *Roussk. Arkh. Patol., klin. Med. i Bakteriolog.*, avril 1900.—Cabot. *A guide to the clinical examination of the blood*, London, 1900.—Michaelis. *Berlin. med. Gesellschaft*, 24 oct. 1900;—*Deut. med. Woch.*, 1900.—Jolly. Clasmatoocytes et Mastzellen. *C. R. Soc. Biol.*, 23 juin 1900.—Stassano et Hass. Contribution à la physiol. des clasmatoocytes, *C. R. Soc. Biol.*, 1900.—Tarchetti. Ferment diastasique dans les globules blancs. *Gaz. degli Osped.*, 29 juillet 1900.—Laguesse. La classification des leucocytes. *Echo médic. du Nord*, 1900, IV, n° 32, p. 359.—Hofbauer. Leucocytes iodophiles. *Centralblatt f. innere Med.*, 1900, n° 6.—Dominici. Éléments figurés du sang; leur morphologie. *Presse médicale*, 18 août 1900.—Arnozan et Montel. Rôle des leucocytes dans l'absorption des médicaments. *Congrès Paris*, août 1900.—Dominici. Eosinophilie. *C. R. Soc. Biol.*, 20 janvier 1900.—Rouget. Phagocytose et leucocytes hématophages. *C. R. Soc. Biol.*, 31 mars 1900.—Besredka. Leucotoxine. *Annales de l'Institut Pasteur*, 25 juin 1900.—Jolly. Karyokinèse des globules blancs dans la lymphe péritonéale du rat. *C. R. Soc. Biol.*, 21 juillet 1900.—Dumont. Formule hémoleucocytaire normale. Extr. des *Annales de la Polyclinique de Lille*, 1900.—Hayem. *Leçons sur les maladies du sang*, 1900.—F. Muller. U. einige pathol. Befunde bei der Ricinvergift. *Ziegler's Beitr.*, 1900, XXVII.—Levaditi. Un cas de leucémie myélogène. Consid. sur la mastzellen-leucocytose et sur l'hétérochromatie des granulations leucocytaires. *Journ. Phys. et Path. gén.*, 1901.—Lombard. Contrib. à la phys. des leucocytes. *C. R. Soc. Biol.*, mai 1901.—Michaelis et Wolff. *Deut. med. Woch.*, 10 sept. 1901.—Hirschfeld. *Berlin. klin. Woch.*, 7 oct. 1901.—Bonne. Leucocytose éosinoph. avec essaimage de granul. dans le voisinage d'une glande en suractivité. *C. R. Soc. Biol.*, 4 mai 1901.—Jolly. Sur quelques points de la morphologie des leucocytes. *C. R. Soc. Biol.*, 8 juin 1901.—Stassano. *Acad. des Sciences*, 4 mars 1901.—Stassano et P. Bourcet. Sur la présence et la localisation de l'iode dans les leucocytes du sang normal. *Ac. Sciences*, 24 juin 1901.—Brodie. On the destruct. of leucocytes. *Journ. of Anat. a. Phys.*, 1901, XXXV;—N. ser., XV.—Williams. *Boston med. Journ.*, sept. 1901.—Biffi. Sulla natura e s. signif. delle granulazioni iodofile e di quelle eosinofile nei leucociti. *Il Policlinico*, 1901, VIII, p. 299.—Grunberg. Beiträge zur vergleichenden Morphologie der Leucocyten. *Arch. f. Path. u. Phys. u. f. klin. Med.*, CLXIII (Folge 16, Bd III), 2, p. 303.—Poljakoff, Zur Frage von der Entstehung, dem Bau u. der Lebensthätigkeit des Blutes. *Arch. f. Anat. u. Phys.*, 1901: Anat. Abth., 1.—Wolff. Ueber die act. Beweglichkeit d. Lymphocyten. *Berlin. klin. Woch.*, 30 déc. 1901.—Dominici. *Arch. Méd. exp. et d'Anat. path.*, 1901-1902.—Levaditi. Contrib. à l'étude des Mastzellen, etc. *Thèse Paris*, 1902.

THE LYMPHATIC VESSELS.

HISTORICAL.—Aristotle (384-322 B.C.), as is evident from a phrase in the *History of Animals*, appears to have seen lymphatic vessels; but it is to Herophilus (300 B.C.) and to Herasistratus (280 B.C.) to whom we ought, according to the Galenic writings, to attribute the discovery of the chyloferous vessels. Herasistratus saw their milky contents; Herophilus their termination in the mesenteric glands. The former regarded them as arteries, the latter as veins. These observations, which were denied by Galen, were forgotten, and it was only in 1532, that Nicolas Massa apparently discovered some renal lymphatics. Then Fallopius discovered some white vessels which terminated in the peripancreatic glands.

In 1563, Eustachius discovered the thoracic duct in the horse, and described it under the name of *vena alba thoracis* as follows: "From the trunk of the left subclavian vein stretches a prolongation which is full of aqueous humour and which divides near its origin into two branches, which soon reunite to constitute a single trunk; the latter passes along the left side of the spinal column, traverses the diaphragm, arrives nearly to the centre of the lumbar region, where it enlarges, and surrounding the aorta becomes lost, presenting a mode of termination which hitherto has not been recognized." Eustachius therefore saw the inferior "enlargement" of the thoracic duct. Should this justify us in attributing to him, together with Winslow (*The Anatomical Exposition of the Structure of the Human Body*, MDCCLXI), the discovery of the cistern of Pecquet?

The right lymphatic duct was discovered by Stenon.

In 1622, Aselli made a new discovery, viz., the existence of chyliferous vessels. Seeing them in the dog, the cat, the lamb, the cow, the pig, and the horse, he noticed that they joined the mesenteric glands, and he imagined that they terminated in the liver. It fell to Pecquet (1649) to demonstrate their confluence at the swollen commencement of the thoracic duct, to which he gave the name of cistern or reservoir of the chyle.

But, as Galen had denied the existence of the canals of Herasistratus and Herophilus, so Riolan and Harvey denied the presence of the lacteal veins of Aselli. To definitely prove their existence, the works of Gassendi (1628), Vessling (1634), Folius and Tulpus (1639), Wallée (1641), and Pecquet (1649), were necessary.

Vessling and Rudbeck then described the lymphatics of the liver, the pancreas, the lungs, and the pelvis. Rudbeck concluded from his researches that "the serous vessels" exist not only in the mesentery, but throughout the organism, or that they form a special system. Bartholin and Jolyff did not delay matters by confirming this attempt at generalization, and the *serous system* of Rudbeck soon became the *lymphatic system*. This substitution of purely verbal terms, resulted in Bartholin being regarded as the author who first attempted to systematize the white vessels. As a result of this new and wider conception of the scope of general anatomy, works on the subject then began to increase, and became so numerous that it is impossible for us even to mention them all here.

After Rudbeck, Bartholin, Swammerdam and Blasius, Ruysch in 1665, studied the valves, and compared their shape to that of the crescent of the moon. Afterwards, Nuck, R. Hale, Meckel, Haller and Cruickshanks discovered new lymphatics in regions which had hitherto not been examined. Hunter found white vessels in the intima, and laid great stress on the important part played by the lymphatic system in the process of absorption.

Hewson studied the lymphatics in fishes. In mammals he thought that some of the vessels entered the thoracic duct without traversing the glands.

Mascagni, the author of an admirable ichnograph, demonstrated the incorrectness of this idea. With Haller and Cruickshanks, he rejected, in opposition to Sténon, Wepper, Schmiedel, Børhave, Bartholin, and Meckel, the view that there is any peripheral communication between the lymphatic and blood systems. According to him, communications with the white vessels take place in the connective tissue, for it is in their meshes that they originate. It so happened that Mascagni was singularly fortunate, for his views were adopted and generalized by Bichat, who admitted the presence of lymphatic openings, not only in the connective tissue, and in serous surfaces, but also in membranous coverings (pores of Haase).

This splendid anatomist remarked that "the lymphatic system essentially enters into the formation of the serous membranes"; he must regard the serous membranes "as large reservoirs intermediate between the exhalent and absorbent, where the lymph in going from one, remains some time before passing into the other, and where it doubtless undergoes various preparations."

Some years later, Lippi (1822) and Lauth (1824) discovered the existence of peripheral lymphatico-venous communications; further, Lauth established the fact that each lymphatic had its origin in a network.

Ever since 1832, important works in comparative anatomy by Müller, Panizza and Fohmann have appeared. Jean Müller discovered the posterior lymphatic heart of the frog. Panizza discovered the lymphatic hearts of the ringed adder and the frog. He considered them analogous to the supravalvular enlargements of the lymphatic trunks of mammals. These organs have been described in some birds by Panizza, Fohmann, and subsequently by Stannius and Gadow. They think these hearts communicate with the veins. Fohmann, who, in opposition to Panizza, regarded the lymphatic hearts as rudimentary glands, admitted with Tiedmann and Louth the existence of lymphatico-venous communications in the interior of the gland.

Rusconi described the perivascular lymphatic sheaths of the frog as a simple "muff" in whose lymph, the blood-vessels are bathed. Later on, Milne-Edwards compared them to the visceral serous membranes of mammals, and Ranvier demonstrated their double endothelium.

In 1847, Sappey commenced a long series of researches, which he continued until the publication of his large atlas in 1876. Though the descriptions contained therein, which have now become classical, only leave to modern investigators a restricted field of inquiry, it cannot be said that his attempts at general anatomy were so successful. In opposition to Mascagni, he maintains that "a fair number of the constituent parts of the body, viz. the nervous system, the heart and vessels, the mucous surfaces of the bladder, the ureters, the serous surfaces, and the connective tissue—elastic and bony, are absolutely and habitually destitute of lymphatic vessels." Further, he also considered that the white vessels take origin from a double network of capillaries and lacunae which are absolutely closed. Hitherto, problems for discussion had been solved almost entirely by the sole aid of microscopic anatomy. Virchow, in 1857, was the first to bring histological methods to bear on the long discussed question of the origin of lymphatics. An optical error made him describe the connective tissue cell, the *plasmatic cell*, as star-shaped, hollow, and anastomosing by its prolongations with neighbouring cells. He thought that in the *plasmatic system*, which is formed by a collection of such cells, circulated the plasma, which gave origin to the lymphatic system. Koelliker, who in 1846, had seen in the tail of the tadpole, lymphatics in process of development, thought that their hollow terminal point was continuous with the prolongations of neighbouring connective tissue-cells. He, as did Leydig, also regarded this as a new proof in support of Virchow's theory, which was opposed by Henle, and long since abandoned by Ludwig and Brücke, who were the first to revert to the opinions of Mascagni and Bichat.

Recklinghausen, who discovered the lymphatic endothelium, believed also in the existence of plasmatic canals. These "canals of the juice" (*Saftkanälchen*), have a wall of their own; they anastomose with each other; they also form cross-junctions, in the interior of which is found a cell composed of a mass of protoplasm. The same scientist demonstrated by a well known experiment, the existence of communications between the lymphatic

system and the serous cavities, the existence of which had previously been admitted by Bichat. This experiment, repeated and varied by Ludwig, Schweigger-Seidel, Dogiel, Dybkowsky, Wagner, Oedmanson, compelled us to admit the existence of wide orifices, which are always open, and which are situated between the serous and the lymphatic cavities. This conclusion was invalidated by the histological researches of Ranvier (1873), Hermann and of Tourneaux (1874). Ranvier believed in the existence of a kind of valve with mobile lips, which was capable of being widened by the lymphatic cells. Hermann and Tourneaux, whose views were confirmed by Bizzozero and Salvioli, denied the existence of these orifices, and thought that similar appearances were caused in places where the endothelium was in process of renewal.

In 1874, Arnold, again upheld the existence of peripheral communications between the lymphatics, the blood-vessels, and the connective tissue-cells. Tarchanoff (1875) showed that simple appearances might be deceptive.

Histological researches soon afforded valuable information regarding the structure of lymphatic channels of all kinds (Recklinghausen, Ranvier, Renaut, etc.), but it was long before they were the means of solving the much vexed question as to the real origin of the white vessels. It was only in 1893, and 1894, that Renaut, Regant and Ranvier definitely settled this question by showing, in accordance with the old opinions held by Belajeff, Dybrowsky, Cohnheim, Robin and Hoggan, that all lymphatics commence in a closed ampulla.

Ranvier (1895), studied the development, the involution, and the confluence of the lymphatic vessels. He concluded that the lymphatic system resembled a large vascular gland which, originating from the veins, poured into these vessels the product of its secretion, the lymph. Sala, following Budge, traced the formation of the lymphatic hearts and of the thoracic duct in the fowl. The thoracic duct, he regards as a mesenchymatous formation, which is at first absolutely independent of the venous system.

Kytmanoff (June 1901), applied Ehrlich's method to the discovery of the nerves of lymphatic vessels, a research which had already been undertaken by Timofejew, Dogiel, Smirnow, Weliki, Quénu and Darier.

TECHNICAL METHODS.—Though the thoracic duct and chyliferous vessels may be seen without previous preparation, the study of the other lymphatics necessitates the employment of methods which *render them distinct*, either *by distending their cavities*, or shewing their endothelial outline. The methods of *descriptive anatomy*, were confined to causing distension of the vascular wall, which was usually effected by placing an obstacle in the current of the lymph, together with the injection of some foreign substance.

To discover the white vessels of the lung, Willis stopped the flow of lymph, by placing a ligature on the superior extremity of the thoracic duct. With the same object, Ruysch and Cruikshanks ligatured the blood-vessels of the kidney in order to see its lymphatics.

By this method, the injection was made either directly into an artery, or in a *haphazard* way into the cellular tissue. The injection of lymphatics by means of the blood-system which was known to Mascagni and Meckel, is less in vogue to-day than interstitial injection, on account of the substances which were used.

It would be difficult to mention all the substances which have been tried, since the time of Swammerdann and Ruysch. To show their diversity we need only mention, water, gelatine, wax, oil, Chinese ink, Prussian blue,

carmine in solution or in suspension, mercury, and even microbic cultures. Though Sappey was able to see the deep lymphatics of the kidney by using water, this fluid is not much employed now. Chinese ink, microbes, and coloured gelatine, are especially adapted for histological work, though for macroscopical study mercury, used according to Meckel's method, and perfected, by Sappey, or the colouring matters used in Gerota's and Boddaert's method are used in preference.

SAPPEY'S METHOD.—First of all an adult subject, and one as thin as possible, should be selected. If putrefaction is so advanced that the skin is green, and the epidermis raised in large flakes, the injection of the cutaneous lymphatics is favoured, but that of the collecting trunks is hindered, while the study of the submucous and subserous vessels becomes impossible. The apparatus required for the injection of more than 120 centimetres, consists essentially of two tubes. One of these is made of glass and furnished at either extremity with a metal covering; at its upper end is a movable eye, by which it is suspended from a smooth pulley, which is attached to a horizontal bar of iron. To its inferior extremity is fixed a flexible tube, which is made of vulcanized caoutchouc, with very thick walls, but with a very small calibre. To the free extremity of the flexible tube is fitted a stopcock and a hollow adjustment with a screw thread; the glass tube, which has been drawn out in the flame to a fine point for puncturing the tissues, is introduced into the adjustment at its larger end, which has previously been wrapped round with waxed threads. The point of the glass tube must penetrate the superficial layer of the skin, and be worked under a thickness of 2–3 millimetres. The index finger of the right hand then turns the stopcock from right to left. If successful, the mercury fills the lymphatic network. After half a minute or at the most a minute, the tube is withdrawn, for, if it remains in longer, there is a risk of rupture. It often happens that though the lymphatic plexus is injected, the mercury does not penetrate into the trunks and reach the glands. In this case we must inject the vessel directly, after placing a ligature below the point at which it is proposed to penetrate it. To effect this, Sappey gently depressed the wall and quickly made a puncture into the concavity thus formed.

It goes without saying that the injection, should always be made in the direction of the current of the lymph.

After the completion of the injection, the connective tissue which surrounds the lymphatic vessels should be left undisturbed, for if a minute dissection is now attempted, there is a great risk that these vessels will be injured, whereas if allowed to dry the connective tissue will become transparent and enable us to see these vessels shining through. During the drying process the parts should be kept in the horizontal position.

GEROTA'S METHOD.—This author conceived the idea of using absolute black, extractum alkanæ, cinnabar and Prussian blue. The extractum alkanæ, whose colouring power is somewhat feeble, diffuses and stains the fat. The cinnabar, which is ground in linseed oil and chloroform, is only slightly penetrating. The Prussian blue succeeds the best. Its preparation is for the most part very simple, and is as follows; 2 grammes of Prussian blue kept in tin-foil tubes are taken, to which 3 grammes of pure spirit of turpentine are added; after the whole has been well rubbed down in a china mortar, 15 grammes of sulphuric ether are added, and filtered through a double layer of linen. The solution must be used at once for injection. The injection is made with a syringe, which holds from 10–20 cubic centimetres, at the end of which is fixed a small adjustment which receives the

glass needle for puncturing the tissues. To prevent leakage, the larger extremity of the glass needle is wrapped round with a waxed thread. The point is drawn out in the flame. *It must not be too fine nor too thick.*

Though Gerota's method may yield less beautiful preparations than those furnished by mercurial injections, it has a great many advantages from a research point of view. Without laying undue stress on the simplicity of the technique, and the cheapness of the preparation, we may observe that it defines lymphatic territories much better than does mercury. This difference between the two methods exists for the following reasons. Mercury often yields extended injections of networks, and always forcibly distends the vessels with very fine walls, of which the latter are composed, but the collecting trunks being more resistant, dilate less. The latter, therefore, are not easily to be distinguished from their plexus of origin. Now Gerota's mixture, which is always injected under low pressure, usually gives a limited injection of the plexus, and leaves to the collecting trunks their preponderance in volume; the result is that the latter are always well seen, and the limits of their boundaries are clearly marked. The possibility of injecting different systems of collecting trunks with different colouring materials, almost enables us to reduce to a system the mapping out of the different territories. Another advantage this method possesses is, that it enables us to study histology.

The fact is that microscopical anatomy utilizes methods, not only capable of shewing endothelium, but also methods whereby the vascular cavity is distended by coloured substances, or substances easily recognizable by their histo-chemical reactions. This result is obtained by *injection, physiological absorption, or imbibition.*

The injection may be made either into the dead or the living subject. Coloured substances, injected into the cadaver, are used for the study of blood-vessels. They should have the following qualities: they should be of easy penetration, homogeneous, transparent, and indiffusible. The more satisfactory are carmine substances and the soluble Prussian blues recommended by Ranvier. As Prussian blue does not diffuse in aqueous solution, the employment of gelatine, which by its rapid solidification always complicates the operation, can be avoided. Other vehicles, such as collodion, albumin, and glycerine yield indifferent or bad results.

Though it has been known for some time that the lymphatic vessels possess an absorbing power, it is only in recent years that a procedure known as *vital injection*, which is based on this fact, has been methodically practised. Whereas Boddaert injects fluoresceine, and D'Abundo and Guillain, Chinese ink, Albarran and subsequently Homen and Laitinen inoculate microbes.

Though it is well known that certain microbes under conditions as yet imperfectly understood, exercise a remarkable selective power in following their lymph channels, and thus yield marvellous injections, we cannot disguise from ourselves the fact that such cases are somewhat rare, and their explanation baffles us completely. It is difficult to make certain of obtaining a pure lymphatic injection, and to diminish the vitality and the natural mobility of microbes which, as Guillain has justly observed, can create lesions by themselves or by the toxins to which they give rise, or which may invade the circulatory system.

There is another method, based on the physiological absorption of fats by the intestinal lymphatics, which enables us to trace the latter in sections previously treated with osmic acid.

Altmann observed that when any tissue whatsoever *imbibes* fat, the lymphatics especially become impregnated with it. To bring into view the lymphatic network, he stains the fatty part of the body black with osmium, and destroys the other parts of the organism by corrosion. He immerses the fresh tissue in a mixture of oil and absolute alcohol, and keeps it in this liquid for five days; the parts are then washed for three or four hours in distilled water; this removes the superficial fat, and precipitates that which has penetrated into the lymphatic channels by imbibition; it is then placed for twenty-four hours in a solution of osmic acid (1 in 100), then submitted to slow corrosion in bleaching liquid diluted with three times its volume of water. We may actually dispense, as we have done, with the corrosion, and rapidly dehydrate with absolute alcohol and xylol. By this method, the contents of the vessels alone are coloured black, and stand out clearly on the red-brown background of the preparation.

There are several methods used for demonstrating endothelium, but they all reduce themselves to *impregnation*, obtained by a metallic salt, or an anilin colour, such as methylene blue. The silver salts are more used than the salts of gold (Hoggan's method with chloride of gold). Of all the silver salts which have been suggested, viz. picrate, acetate, lactate, (Alferow), nitrate (Recklinghausen), the latter, which is the oldest, is most widely used.

Aqueous solutions varying from 1 in 300 to 1 in 1,000 are sometimes used; sometimes gelatin (Malassez or picric or osmic acid (Renaut) is added.

The rectified methylene blue of Ehrlich (Grübler) and of Merck has yielded in the hands of Dogiel and Mayer exceedingly beautiful endothelial impregnations.

THE ARRANGEMENT AND GENERAL CHARACTERISTICS OF LYMPHATIC VESSELS

Originating in the meshes of the connective tissue, the white vessels, that is to say, the *lymph passages, which are provided with a wall of their own*, anastomose and form rich peripheral plexuses (the original capillary networks of Lauth, Fohmann, and Panizza). They then decrease in number and reach the glands, in which they again break up into capillaries. After traversing the glands, they pass into the large collecting trunks, viz. the thoracic duct and the right lymphatic duct, by means of which the lymph is conducted into the subclavian veins. Thus in each gland, *a true portal lymphatic system* exists, and, regarded as a whole, this vast system of branching lymphatics constitutes a cone-shaped figure whose central apex rests on the venous system.

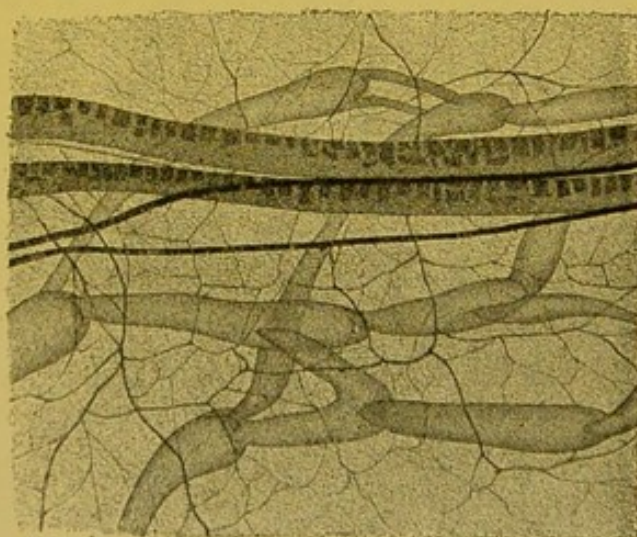
CAPACITY.—At their commencement, i.e. at the base of the cone, the lymphatics have a capacity equal to, and greater than, that of the veins. This diminishes the nearer we approach the thoracic duct, the calibre of which is much smaller than that of the vena-cava.

In distinction to the veins, the lymphatics diminish in number without proportionately increasing in calibre.

COLOUR.—If observed intact in the cadaver, or better still in the living animal, the milky whiteness of the contained lymph can be seen through their fine fragile walls; the name, *lacteal veins*, given by Aselli, exactly expresses this appearance.

FORM.—The lymphatics are sometimes cylindrical, sometimes moniliform, and again, may resemble sacs or crevices. The variations in their structure, and the different texture of tissues traversed, explains this polymorphism. It is only when they possess valves that they present that series of alternate swellings and constrictions to which they owe their characteristic resemblance to chaplets. In their course through the viscera, they are cylindrical. To this rule, which was enunciated by Sappey, there are numerous exceptions. In reality, their form varies according to whether they are isolated in a closely set, dense, connective tissue, or whether they are numerous and situated close together, in a lax connective tissue. If constricted by fascial aponeuroses, such as those in the centre of the diaphragm for example, they are reduced to mere crevices, but] in the meshes of a lax connective tissue they dilate to their maximum capacity, anastomose, and tend to run together. Sometimes they are sinuous or sacciform; thus by their irregularity, they form typical plexuses.

VALVES.—These do not exist throughout the whole extent of the lymphatic vessels; they are absent at their commencement, and in the capillaries, and are rare in the large collecting trunks (thoracic duct). Sappey has counted from 60 to 80 in the vessels extending from the fingers to the axillary glands, and from 80 to 100 in the lower limb. At first the valves are only a few millimetres apart from each other, but in the thoracic duct they are separated, by intervals varying from 6 to 10 centimetres,



A. Leitch

FIG. 10.—Valves of the mesenteric chyliferous vessels of the new born cat (picro-osmic mixture, Vénick oc. 2 obj. o). Notice the fineness of some of the anastomotic branches.

and sometimes more. They are arranged in pairs, and resemble the aortic semi-lunar valves, but do not always present at their free border a nodule comparable to the corpora Aurantii. The position of these valves is variable, since even in the same vessel, at one time we see their face, at another, their profile; and sometimes again we may see them occupying intermediate positions (Ranvier). Somewhat resembling a crescent, their free border is turned towards the heart; their adherent convex edge corresponds to the constriction in the vascular wall. Immediately above this, their vessel wall dilates.

ANASTOMOSES.—The anastomoses take place *by convergence*, or by *longitudinal communication* (Sappey). Frequently, the anastomotic branches are much finer than the trunks which they unite.

SITUATION, DIRECTION.—The lymphatics are almost exclusively situated in structures of the connective tissue-type, for, with the exception of the perivascular sheaths of the nervous system, whose functions are under discussion, they never encroach upon the epithelial structures or their derivatives (Renaut). According to their situation, that is, above or below the fascia, on the surface of, or within the viscera, the white vessels are termed either *superficial* or *deep*. As a rule, there is a communication between the superficial and deep visceral lymphatics; Mascagni thought that the same held good for the lymphatics of the limbs; Sappey, on the contrary, upheld the absolute independence of the epi- and subfascial plexuses. According to Poirier, it can only be a question of relative independence, for such communications are fairly common, especially in the articular regions.

Rarely sinuous, the lymphatics are almost always grouped together in the neighbourhood of blood-vessels, which they accompany in almost a straight line. Poirier observed that lymphatic vessels, which pursue a straight course in the different segments of the limbs become sinuous in the articular regions; similarly, in the case of the visceral lymphatics, the white vessels may be seen to describe many curves, varying with the displacements and changes in volume of the organ; thus they become flexuous at the sides of the uterus and in the neck (Poirier), and under the fraenum of the glans (Marchand), they become knotty, etc., etc. Beaunis and Bouchard reject the opinion that the mucocutaneous lymphatic networks lie above the blood-vessels; they state that the lymphatic vessels are always and everywhere more deeply situated than the arteries and veins. Ranvier makes

the same statement, and remarks, that it constitutes a law the physiological significance of which we can understand, seeing that the lymphatics receive material which the blood capillaries have been unwilling or unable to take. Poirier says that though this is true for the networks of origin, it does not hold good for the largest vessels. There, on the contrary, lymphatic vessels may be seen superposed on the larger veins, which they accompany for choice; in the popliteal space, in the inguinal region, in the iliac fossa, in the axilla, and in the neck, he affirms that the large lymphatic vessels and the glands which they unite in a chain, are placed immediately *over* the large veins of these regions; it is only rarely that we see some of the trunks pass behind the veins. We know of hardly an exception to this law established by our master. Surgeons, who frequently have to dissect out diseased lymphatic chains, will confirm the accuracy of this statement. Such an arrangement is fortunate, as it makes the dissection easier than it otherwise would be,

LYMPHATIC TERRITORIES.—The networks of origin, of a given organ, or a given region, often give rise to collecting-trunks, which leave the network at different points, thus constituting several distinct pedicles. Granting the continuity of these trunks with the networks of origin, it would seem at first sight, that an injection made at any point into the latter would fill the network, and then penetrate into the collecting trunks; and as a matter of fact, in certain organs where the network presents a particular kind of development, and where certain conditions prevail, which favour the passage of the mass, this total injection can be obtained; but it is no less true, that normally, the puncture of a given point of the network injects by preference certain collecting-trunks. We are led to believe that each group of pedicles more especially drains a definite portion of the organ punctured. It is therefore reasonable to assume that in this network, notwithstanding its continuity, there are really several territories, each of which corresponds to a given group of collecting-trunks. It is certain, however, and we cannot repeat it too often, that the independence of these territories is altogether relative, since we can, by a single puncture, and under favourable circumstances, inject all the collecting-trunks; similarly their limits are somewhat ill-defined.

We can, however, at least in certain organs, define their respective limits with sufficient accuracy. We can gauge their extent and thus determine the *principal lymphatic channel* of a given organ.

Now this knowledge is of considerable practical importance, for neoplastic formations to some extent exaggerate this arrangement.

UNEQUAL DISTRIBUTION.—The lymphatics are unequally distributed throughout the organism; and we are almost entirely ignorant of the reason of this apparently capricious distribution. Sappey was astonished to find that the large intestine possessed more white vessels than the small intestine. This fact well shows that the richness in lymphatics of a given organ is not directly proportionate to its absorbent functions; for the bladder, whose healthy mucous coat is impermeable, possesses lymphatics.

The number of lymphatics, moreover, apparently bears no constant relation to the elaboration of products, secreted and excreted by the glands, for they are numerous in the mamma and liver, but more scanty in the kidney, pancreas, and thyroid body; on the other hand, they are found in abundance in the centre of the diaphragm.

It seems as though the texture of the surrounding connective tissue influences their number as well as their shape. If the connective tissue is lax, their habitual tendency to run together renders them sinuous or sacciform. They are rarely very large. If the connective tissue is sufficiently dense to resist their dilation and fusion, they become numerous but smaller in size. Thus, Regaud observes that, in the same organ in different species, the lymphatic radicles increase or diminish in proportion as the meshes of the connective tissue are dense or lax; in other words, as the drainage of the lymph is difficult or easy.

Now do lymphatics exist in all parts of the organism? Sappey, as we know, denied their existence in the connective tissues, in bone, in the visceral and articular serous membranes, in the arterial walls, in the utero-vesical mucous membranes, and in the nervous system. Though it has been satisfactorily proved that the connective tissue is almost the exclusive seat of the white vessels, their presence in tendons and aponeuroses, which was demonstrated by Ludwig and Schweigger-Seidel is also clearly proved. Budge, following Cruikshanks, Brugmanns, and Bonamy, has found lymphatics in bone. Tillmanns has described the lymphatics of the articular serous membranes: and we cannot, after the labours of Recklinghausen and Ranvier, deny their existence in the visceral and serous membranes. The researches of Hoggan, d'Albarran, Pasteau, and Gerota demonstrate the existence of vesical lymphatics; but in spite of the assertions of Hunter, Cruikshanks, Mascagni, Lauth, and Breschet,

the existence of arterial lymphatics, however probable, is still a moot point.

As regards the nervous system, the question is far from being definitely solved. In fact, ordinary white vessels, perivascular sheaths, neuroglia spaces, and even serous clefts, have been described as lymph-channels. Mascagni, Fohmann, Arnold, and Breschet figured lymphatics which they had injected on the surface of the brain. Sappey thought this was a matter of injections having been made into the veins or into the cellular tissue, and this opinion has been generally accepted. Notwithstanding this, Poirier maintains that he has seen indisputable lymphatic vessels on the external surface of the brain in the arachnoid, and in the dura mater.

As regards the perivascular spaces of Robin and His, though their existence may be undeniable, their function has been much discussed. Their lymphatic nature, which was at first almost universally admitted, is now contested. Renaut does not admit the existence of the endothelium formerly described by His and Eberth; in his opinion these spaces are merely emanations from the amorphous part of the membrana propria which has been compressed by the blood-vessels.

Though the *spaces* studied by Obersteiner, Friedmann, Paladino, Klebs, Rossbach, Schrwald, Kadyi, d'Abundo and Guillain physiologically appear to have the significance of lymphatic passages, their morphology does not permit of our grouping them with ordinary white blood-vessels. The same remark holds good for the canal of the ependyma, and for the serous cavities. Later on, however, we shall have occasion to study the morphological affinities of the serous membranes and the lymphatics.

STRUCTURE.—According to their structure, lymphatic vessels belong, some to the type of *capillaries*, others to that of the *collecting-trunks*. In the capillaries, the lymph trickles rather than circulates, but even in the smallest trunks, the circulation is very active. If Prussian blue is injected, it quickly disappears (Ranvier).

The *capillaries* which

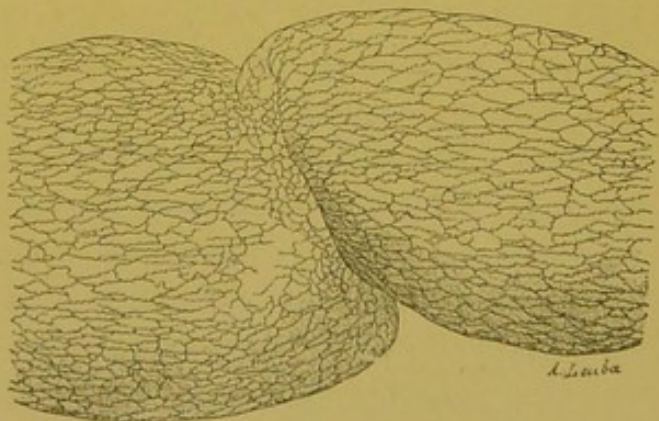


FIG. 11.—Lymphatic trunk of the subserous layer of the stomach of man (removed by operation). The lymphatic endothelium is stained with silver nitrate.

have no valves are reduced to an endothelial layer. The endothelium of the collecting-trunks, which always possess valves, is surrounded by an elastic and muscular sheath of connective tissue. The development of this musculature is somewhat variable; thus, certain trunks which run in the subcutaneous fibrocellular layer (*panniculus adiposus*) have no muscle (the lymphatic venules of Renault); again, the thoracic duct of man, which is more muscular than that of the dog, is a lymph propeller of the same type as the smaller trunks for which Renault reserves this term.

Collecting-Trunks.—With few exceptions, the lymphatic trunks, whatever their calibre, have the same fundamental structure.

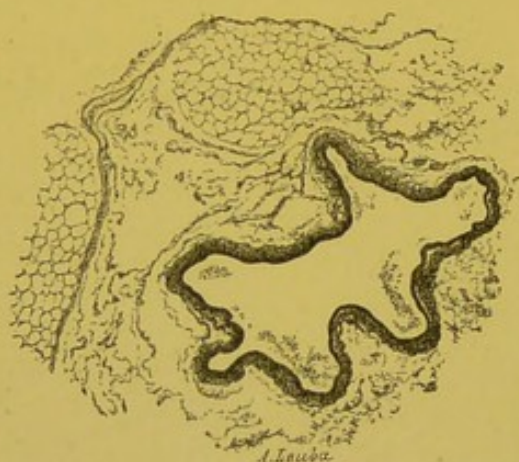


FIG. 12.—A transverse section of the thoracic duct of the dog.

For the sake of convenience, we may regard the wall of the thoracic duct as being formed of three coats, namely an internal or endothelial, a middle or muscular, and an external or connective tissue coat. In reality, the internal or endothelial coat is covered by a diffuse connective tissue sheath in which the elastic and muscular elements are irregularly scattered.

The endothelial cells which were discovered before those of the blood-vessels, are flat and elongated in the long axis of the vessel; their edges are straight in the subclavian region, and are wavy lower down. This is, says Ranvier, the elementary form of an arrangement which is very well marked in the capillaries. It is nevertheless to be borne in mind that, neither in the thoracic duct, nor in the mesenteric vessels of the rabbit have the endothelial cells the characteristic resemblance to an oak leaf. The endothelium of the thoracic duct in the subclavian region is the same as it is in that of a collateral vein. Renault has made the same observation in the horse; this fact appears to him to militate in favour of the venous origin, and centrifugal development of the thoracic duct. The valves are simple folds of endothelium; on their internal surface, the cells resemble those which line the vessel wall; on their external surface, they are polygonal and nearly equal in all their dimensions.

In a transverse section, the cells by no means resemble each

other. Some have a moderate amount of homogeneous protoplasm; and an oval nucleus with one or two granules of chromatin; others possess a fine protoplasmic border from which escape small spherical granules which may be stained by certain colouring acids (eosin, lichtgrün). The nucleus of the latter cells is more elongated, and flatter than those of the former: it nearly always stains diffusely and deeply. It may perhaps be that these cells destroy themselves during the process of secretion; in fact, the works of Heidenhain, and Hamburger lead us to think that the lymphatic endothelium, far from being a simple membrane endowed with physical properties, takes an active part in the elaboration of the lymph. Further, Ranvier has demonstrated the histological reality of this secretory function of the lymphatic endothelium, and has stated that the cells of the lymphatic vessels of the rabbit's ear, in the normal state, elaborate a hyaline substance, quite different from eleidin. This substance swells up as myelin does; it is cast off from the endothelium in the shape of balls, which when small appear homogeneous; but which, when larger, exhibit a clear centre and a refracting envelope. They finally fuse with each other and the figure formed resembles a network, with fibrillary arches. Picrocarmin does not stain them, or stains them only pale yellow, though it stains eleidin a vivid red.

The connective tissue envelope is composed of lax tissue and of fairly strong longitudinal fibres. In the dog and ass, Renault has seen the connective tissue cells, which were negatively stained by silver nitrate, shew beneath the endothelium, beautiful Langhans' bodies crossing each other in every direction. This sub-endothelial connective tissue layer is very scanty in the dog and in man. Externally, the connective tissue layer insensibly merges into that of the mediastinal cellulo-adipose tissue. Frequently, the lymphatic wall is penetrated by some fatty cells. This continuity with the surrounding tissue is one of the fundamental characteristics of the structure of white vessels. In the dog, some cells of

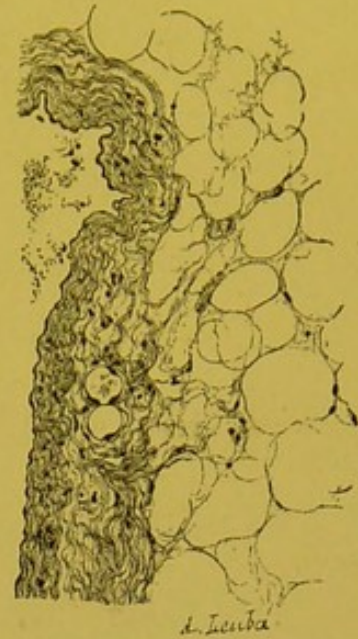

FIG. 13.—Transverse section of the thoracic duct of the dog. The adventitia is continuous with the surrounding cellulo-adipose tissue; in the middle portion sections of two blood-vessels are seen.

Ehrlich are found, around and even in the wall of the thoracic duct. In the small trunks, the tissue is lax and does not contain longitudinal fibres (Renaut).

By the side of the connective tissue fibres, are found very fine elastic fibres which constitute a delicate sub-endothelial network.

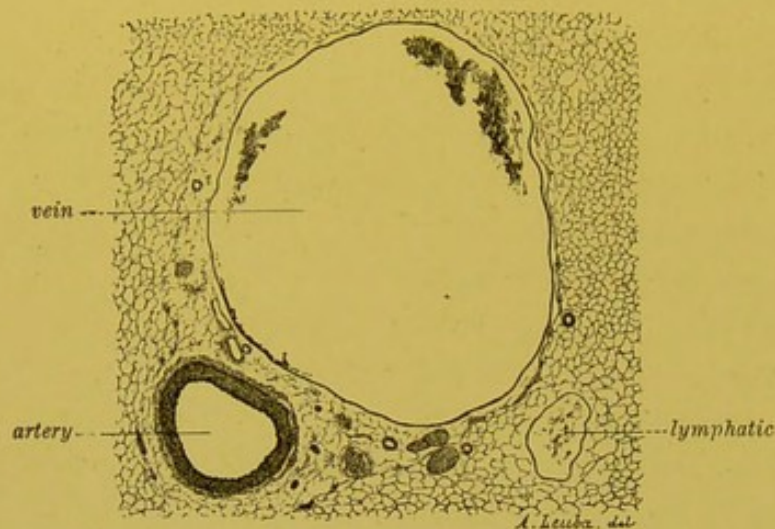


FIG. 14.—Transverse section of vessels and nerves in a dog's mesentery. Notice the thickness and relative dimensions of the artery, vein, and lymphatic.

In this elastic connective tissue layer, and especially in its middle portion, are scattered fine muscular fibres. In the dog, they are, for the greater part, transverse; but some are oblique. In man, they are longitudinal, oblique and transverse; the latter always predominating. In this case, doubtless on

account of the vertical position, the muscular coat is more developed; this forces the lymph onwards and enables it to overcome the action of gravity (Ranvier).

It is in the region of the lymphatic enlargements above the valves (which are numerous in the small collecting trunks) that the oblique fibres predominate. The fibres here intertwine in all directions and form rich plexuses. In this respect, these supra-valvular enlargements, which are really true contractile sacs, remind us of the lymphatic hearts of batrachians.

The presence of the three elements, viz. the elastic, the connective tissue and the muscular, explains the physical properties of the lymphatic wall which, in spite of its fineness is *resistant*, *extensible*, and *retractile*. Its resistance is fairly great, seeing that it can support without rupture the

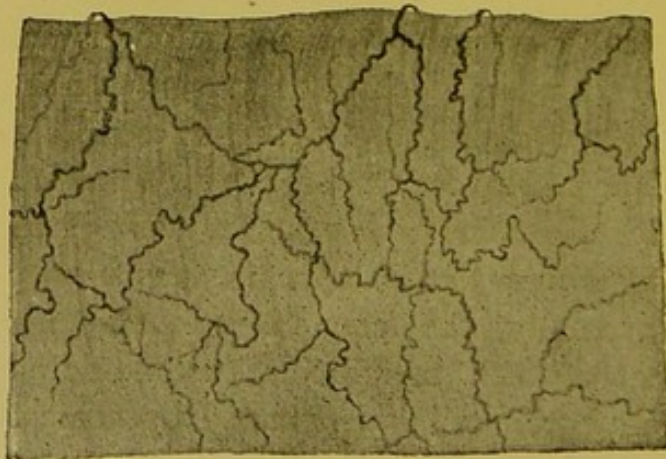


FIG. 15.—Nerves of the thoracic duct (stained with the methylene blue method). After Kytmanoff.

pressure of a column of mercury of from 30 to 40 centimetres, and sometimes even that of from 60 to 80 centimetres (Sappey). When injected, the lymphatic vessels dilate more than the arteries and less than the veins (Sappey).

The walls of the lymphatic trunks are rich in vessels and in nerves: each pulmonary lymphatic, for example, is interwoven with a network of blood-vessels with large longitudinal meshes (Sappey).

De Timofejew and Dogiel have seen nerve filaments surrounding the lymphatics of the cord, the prepuce, and the gall-bladder. Smirnow has found sensory and motor nerve-endings in the lymphatics of the cord. In the thoracic duct of the dog, Quénu and Darier have seen fibres, entirely destitute of myelin, form an adventitious plexus, without any ganglion cells. From his researches, carried out according to Ehrlich's method, Kytmanoff concludes that the nerves of lymphatics, which are chiefly formed by the fibres of Remak, also contain some fibres with myelin. He describes adventitious, supramuscular and sub-endothelial plexuses. The fine varicose fibres of the latter plexus resemble those of arterial vessels. There are motor terminations in the muscular fibres. The terminations of the sensory nerves of the external and middle coats are sometimes free, at others, end in small bunches, or in figures resembling a bush or small tree.

In the arrangement of their muscular fibres in rings, and in their sub-endothelial nerves (Kytmanoff), the lymphatic trunks resemble arteries; in the fineness of their wall, in their endothelium (Ranvier), and in the presence of valves they are much more similar to veins.

Capillaries.—The walls of lymphatic capillaries simply consist of a stratum of endothelial cells applied directly to a connective tissue framework. The form and calibre of these vessels is determined by the texture of the connective tissue in which they lie; an explanation which accounts for their polymorphism. Frequently, neighbouring connective tissue-bundles which are close to each other, entirely deprive a pliable membrane of its lymphatic, and cause its lumen to disappear entirely. The vessel then only manifests its presence by a collection of nuclei analogous to those of flat cells, which are found elsewhere between bundles of connective tissue. It is impossible to recognize it. The same difficulty presents itself when there are only one or two parietal nuclei visible in the section. Klein and Burdon Sanderson have remarked that, in sections, the endothelial cells were more prominent and more turbid than those of

blood-vessels. Their nuclei project into the vascular cavity, which appears, says Renaut, as though lined by a row of little pearls. This projection varies: thus if the vessel is distended, it is hardly apparent; if the vessel is not distended, it becomes more marked. This nucleus, which is almost oval, frequently presents a marginal notch; it is dotted with very fine chromatin granules which are sometimes scattered throughout its extent, sometimes arranged in linear and parallel series, and sometimes again they are grouped together at the periphery.

It is not uncommon to find some of these cells in process of degeneration: their protoplasm becomes vacuolated and their nucleus shrivels up or the chromatin granules run together. We may sometimes see the endothelial cells of the capillary lymphatics of the gland expel, not only chromatin particles, but also small albuminoid spherules, which have been stained by certain colouring acids (lichtgrün, eosin).

The lymphatic capillaries are more easily stained by silver nitrate than are the blood capillaries (Ranvier): thus stained, the endothelial cells which measure from 30 to 40 μ in their long axis, appear marked out by black lines, which, like the sutures in the bones of the cranial vault, are sinuous (Mathias Duval). It is usual to compare the borders of these cells to an oak-leaf or the dovetailed edge of a child's puzzle.

Here and there, little protoplasmic areas are found which have no nuclei and which have been described by Auerbach as "Schaltplatten." According to Renaut, these intercalary surfaces show that at a certain period of its development, the lymphatic capillary must have been formed from an undivided protoplasmic lamina interspersed with nuclei.

The diameter of the lymphatic capillaries varies between 30 and 60 μ ; it is therefore much larger than that of the blood capillaries which may be only 7 μ (Mathias Duval).

There is another difference between the blood-capillaries and the lymphatics. If we remove the capillaries from a lymphatic gland, we see that the white vessels, instead of being placed between those of ingress and egress, as is the case with the capillary blood-vessels, are placed at the peripheral end, at the very commencement, in fact, of the lymphatic system.

Origin of the Lymphatics.—The controversies and theories which have arisen as to the origin of lymphatics are well known. The larger number of theories, founded on errors of observation or upon

hypotheses which have since been invalidated, are only interesting as an historical curiosity. It is now quite certain that the "capillicules" of Bartholin, Arnold and Sappey, which are placed between the arteries and lymphatics, have no more

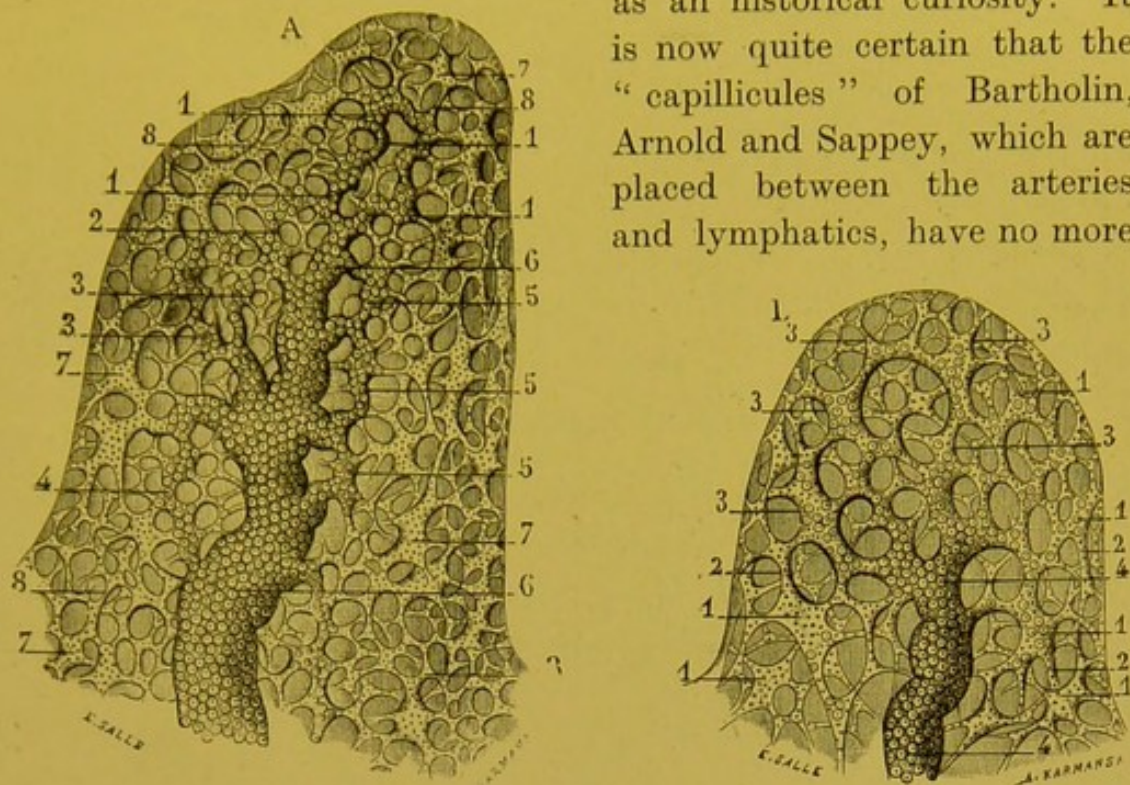


FIG. 16.—Origin of lymphatic vessels in a papilla of the hand (after Sappey).

A. Lymphatic vessels of a papilla of the palm of the hand.

1,1,1,1. Two lymphatic branchlets, composed of five lacunae which are continuous with each other. They occupy the summit of the papilla and in uniting give rise to the central trunk.—2. A curved lymphatic branchlet which opens into the highest part of this trunk.—3. Two other longer lymphatic branchlets which unite to form a network, which almost immediately joins the central trunk of the papilla.—4. A little branch opening by its two extremities into this trunk, and communicating in its course with the lacunae and small capillaries which surround it.—5,5,5. Three little branches which extend like so many longitudinal anastomoses from a point on this trunk to a part lower down.—6,6. Central trunk.—7,7,7,7. Lacunae which are continuous with the surrounding capillaries.—8,8. Capillaries which are continuous with each other and with neighbouring lacunae.

B. Lymphatic vessels from a papilla of the eyelid.

1, 1, 1, 1, 1. Isolated lacunae.—2,2,2. Capillaries.—3,3,3,3. Lacunae continuous with each other and forming little branches.—4. Trunk into which these little branches eventually open. existence than have the "juice canals" of Recklinghausen or the "serous vessels" of Boerhave. Contrary to the opinion originally held by Mascagni and Bichat, and at first adopted by Ranvier, it appears almost certain that the lymphatics have no openings in the meshes of the connective tissue. If such communications existed, the injection of capillary lymphatics would certainly be followed by extravasations; but this is not the case (Arloing). It is quite probable that interstitial injections penetrate into the lymphatics, because the point of the needle tears their frail endothelium.

In a word, no one has ever seen these alleged orifices, and nearly all contemporary histologists are unanimous in stating that in the

adult, as in the foetus, the lymphatic capillaries terminate by *absolutely closed culs de sac*.

The shape of these *culs de sac* varies: they are sometimes

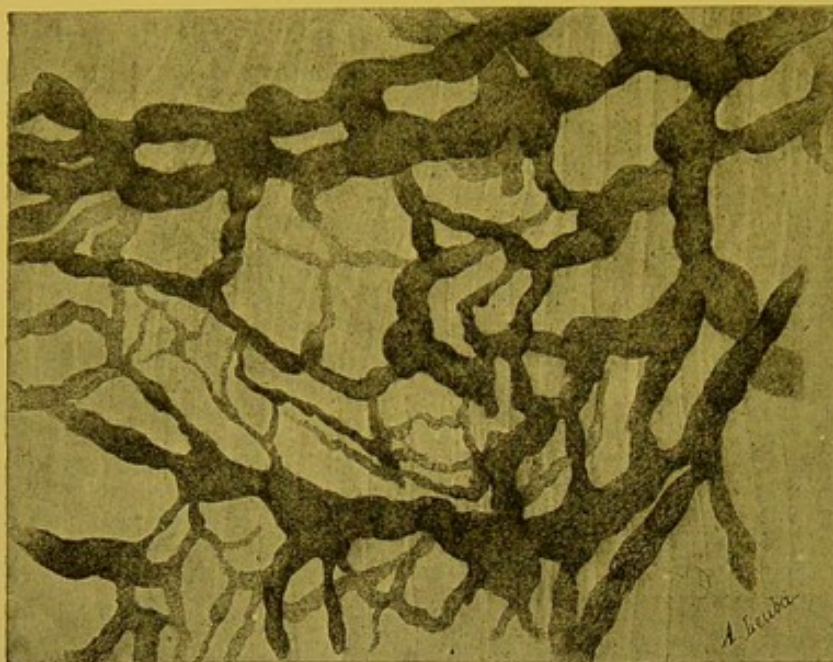


FIG. 17.—Lymphatic network of the submucous gastric layer of the rabbit: closed ampullae; small calibre of the anastomotic branches; dilatation of the confluent. (Intra-vascular injection of silver nitrate.)

ampullary, sometimes club-shaped, and may or may not, shew lateral bosses; they may be conical, digitiform or even pointed, and sometimes again, they may resemble a key ring. On the other hand, in spite of the presence of a continuous endothelium, the relations between

the vascular cavity and the connective tissue-spaces remain very close. Cellular migrations and osmotic exchanges can always take place, and the capillaries fulfil their function of *drains*, and perhaps if the observations of Renaut are confirmed, may even act as *selective drains*. In fact, as a result of his researches into the lymphatic capillaries of the lax connective tissue of the marmot, Renaut thinks he may legitimately conclude that these vessels contain neither white corpuscles nor albuminous plasma: and that the liquid they do contain, apparently consists solely of water, and crystalloids, which are unstained by osmic acid, and that it is only the lymphatics which possess valves which contain leucocytes and albuminoids. Now, do not the lymphatic capillaries communicate more constantly and directly with the serous membranes or with veins than with the connective tissue? *A priori*, our knowledge of the permeability of the lymphatic endothelium enables us to understand that it may be traversed by substances coming from the peritoneum or the blood, although it shows no open orifice. The experiments of Recklinghausen, Ludwig and Schweigger-Seidel do not necessarily imply the existence of channels

or orifices between the peritoneum and the lymphatics. In the same way, the possibility of injecting the lymphatics by the arteries, the presence of red blood corpuscles in the lymph, may be explained otherwise than by the presence of any kind of peripheral continuity between the two systems of vessels.

These theoretical inductions are confirmed by the data of direct observation which show, in the first place, that the lymphatic openings in the diaphragm are far from representing permanently open channels of communication, between the serous membranes and the vessels, and secondly, that the arterio-lymphatics do not exist.

To sum up. The lymphatic capillaries are invariably absolutely closed, and communicate neither with the connective tissue, nor with the serous membranes, nor with the blood-vessels. They are, however, none the less in very intimate physiological relation to these various structures, a relation which has been demonstrated by both normal and pathological physiology.

Development.—The embryonic lymphatic vessels cannot be stained with silver nitrate. To show them, we must use either an interstitial injection of a staining material, or osmic acid, which stains their outlines brown. The many technical difficulties presented by their study explain the scarcity of works on this subject.

Koelliker thought he saw in the tadpole's tail the lateral points of the embryonic lymphatics continuous with the connective tissue-cells. This old observation may be disregarded, says Ranvier.

Breschet made a more correct statement when he said that the lymphatic vessels always developed before the glands. This remark, which has since been verified by Ranvier, is interesting, for, in the animal series, the lymphatic vessels appear before the glands have any existence. Ranvier has stated that in pig-embryos which measure less than 9 centimetres from the snout to the commencement of the tail, the lymphatics are absent, but that in those measuring 10 centimetres, the thoracic duct is present, and the valves are perfectly efficient.

From the first, the trunks are distinguishable from the capillaries; the former very soon show their valves and develop from buds which are originally full; the latter spring from buds originally hollow and which have no valves.

The cells of the full buds soon secrete a liquid, the accumulation of which distends the vascular cavity and thrusts back the endothelium of the neck; this folded back endothelium, a true collar, represents

the primitive valve. The muscular connective tissue layer does not appear till later.

The initial lymphatic growth, which is at first very active, is sometimes followed by involution phenomena, which have been studied by Ranvier in the epiploon of the new-born cat. There, lymphatics are found in which the terminal *culs de sac* are twisted into the shape of a glomerulus like that of the sweat glands. In some cases, the lymph is retained by a pair of valves whose action is reversed; in others, closed, elongated, or actually pointed vesicles are seen, which represent portions of the lymphatic system which have become isolated in consequence of the atrophy of intermediate segments. Again, in the pig, vesicles may be found which are at times bound by a canaliculus to a completely closed valvular segment, and which at others, are isolated. They may be the origin of certain cystic formations.

Ranvier maintained also that wherever lymphatics are in contact with each other in a lax tissue, they tend to run together and to

become sacciform. He compares the development of lymphatics with that of the glands: the lymphatic system is, in his opinion, an immense gland which originates from the veins, into which it throws the product of its secretion—the lymph.

Sala has traced the formation

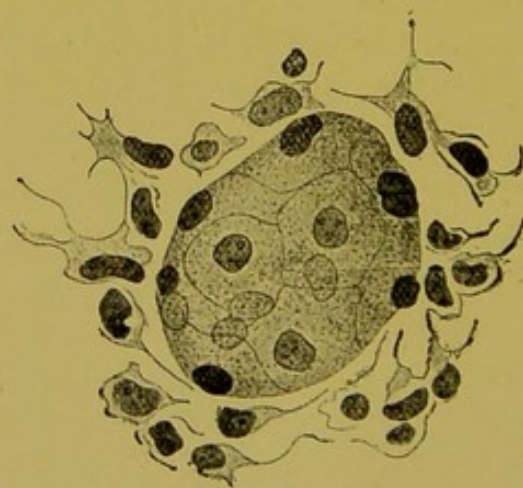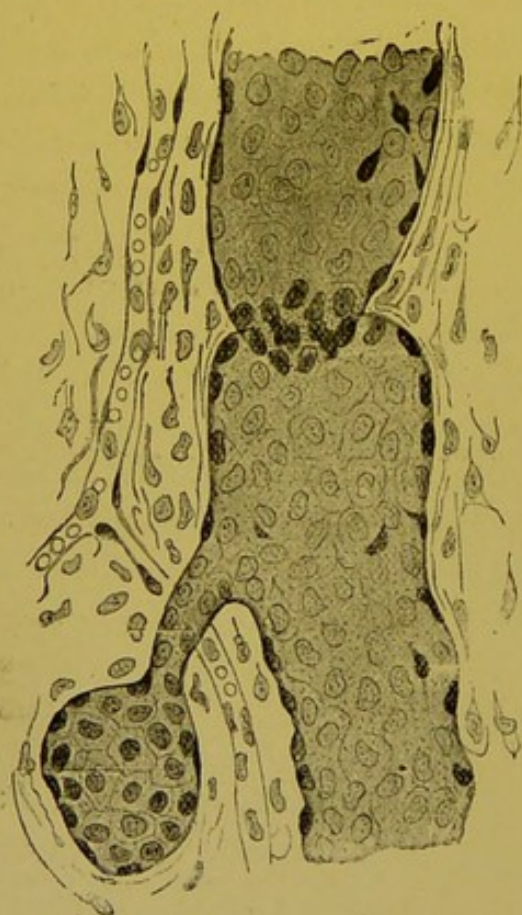


FIG. 18.—Lymphatics in involution: a lymphatic vesicle in continuity with the neighbouring trunk; isolated vesicle (after Ranvier).

of the thoracic duct in the chicken. The first indication of it appears a little later than that of the lymphatic hearts,

viz. in the second half of the eighth day. At this period, in the region extending from the commencement of the brachiocephalic trunk to the junction of the ductus arteriosus and aorta, are found groups of rounded mesenchymatous cells, with large nuclei rich in chromatin. These elements constitute a dense cord, which, on becoming hollowed out, shows the rudiments of the thoracic duct. It becomes hollowed out more quickly in the thoracic than in the cervical portion. Communication with the veins only takes place later on. Injection of the thoracic duct by puncture of the lymphatic heart is not possible before the twelfth day.

This author is of opinion that the lymphatic hearts appear, as irregular fissures of the mesenchyme, at the eighteenth hour of the sixth day. The wall is entirely formed of elongated mesenchymatous cells; the more internal are flattened so as to constitute the endothelium. All the lymphatic spaces appear as chinks in the mesenchyme in the latter hours of the ninth day. The researches of Sala confirm those of Bonnet, Gulland and Saxer; they clearly show that the lymphatic vessels are formed in the meshes of the connective tissue, in the *extra-cellular spaces*. This is contrary to the opinion of Klein (1873) and Retterer (1902), who maintain that the lumen of lymphatic radicles is formed in the mesenchymatous cells themselves.

A Review of the Lymphatic Vessels in the Animal Series.—The lymphatic vessels do not appear until a somewhat late period of ontogenesis, much later than the arteries and veins. The same remark applies to their phylogenesis, where they do not, except in the Teleosteans, appear with any certainty. Carl Vogt and Yung describe the lymphatic system of the perch as formed of two longitudinal canals situated subcutaneously in the middle of the flanks and ending in a pocket placed in the neighbourhood of the last vertebra. In front, these canals communicate by means of several anastomoses with the venous system.

The lymphatics are more developed in the tailless Batrachians. From the commencement there are *capillaries* in the interdigital membrane, absolutely similar to those found in mammals. These capillaries end in enormous *sacs*, which were formerly regarded as serous or connective tissue-spaces: in reality they are lymphatic capillaries which, having united together, have become sacciform and attained these unusual proportions. From these cutaneous sacs, the lymph passes to the *hearts*, which throw it into the venous system.

The frog possesses four lymphatic hearts, one at the base of each limb. The anterior hearts are situated under the scapula, and communicate with the subscapular vein. The posterior, the size of a pin's head, lie under the skin on either side of the coccyx.

They are formed of an endothelium which is lined externally with a layer of striated muscular fibres, the thick strands of which form the boundaries of somewhat shallow areolae.

At the venous orifice, there are placed two semilunar valves, which prevent the regurgitation of the lymph. In frog's hearts are found a large number of striated muscular bundles, which do not contain nuclei, but which possess multinuclear protoplasmic masses on their surfaces. These bundles are of variable sizes, and divide or anastomose just like the fibres of the blood-heart; these cells are not united end to end (Ranvier). The hearts possess a rich network of blood capillaries, with rounded irregular meshes, very different to those observed in ordinary muscle.

There are no nerve-cells; there are, on the contrary, many nerves with myelin, which terminate as in voluntary muscle, in bulbs and numerous arborizations (Ranvier).

In reptiles, there are two lymphatic hearts on each side of the body above the cloaca. They retrogress in birds (Gadow). According to Budge, they are present in the embryo of the chick, but disappear with the development of the allantois. Sala found traces of them in the chick thirty-five days old. In mammals they seem to disappear entirely, but in reality they are still represented here by the swellings above the valves.

In the mesentery of the frog, the lymphatic capillaries form true serous perivascular sheaths. Similar sheaths are found round the pulmonary artery of the ox (Renaut). Moreover, it is the perifollicular sheaths which in all mammals, exhibit the old tendency possessed by the white capillaries of grouping themselves round organs after the manner of serous membranes. This last property completes the series of characteristics which are common to the two classes. We have already remarked that in becoming confluent the lymphatics form vast endothelial pockets very similar to the large serous cavities. Budge and Sala have shown that the lymphatic spaces are formed from simple mesenchymatous fissures. Finally, from Sala's researches it follows that there is no fundamental difference between the vascular and serous endothelia. Embryology and comparative anatomy prove that the muscular structures are secondary and superadded.

There is then a striking resemblance between the white's capillaries and the visceral serous membranes; is this morphological resemblance a real identity? It was long believed to be so, as long, in fact, as investigators, impressed by the well known experiments of Recklinghausen, believed in the permanence of lymphatico-peritoneal communications. Since that time, however, the majority of authors, struck by the want of systematic arrangement of these communications, have endeavoured to discover distinctive characters between the capillaries and the serous membranes. Some, after making a special study of the walls, point out certain structural differences between the two endothelia, the common origin of which is known; others, after studying the contents, declare that the histochemical composition of the serous cavity is not identical with that of lymph. This is true, but, as a matter of fact, there is less chemical difference between the composition of the serous contents and the peripheral lymph, than between the latter and the chyle. It is therefore not justifiable to write that "the homology between the serous membranes and capillaries cannot be upheld, except by admitting that the lymph varies in constitution according to the parts at which it is studied. Such an hypothesis has not yet been established by experiment." (Vide this Treatise, vol. iv., page 1080.)

To sum up. From the above-mentioned facts it follows that, the system of lymphatic vessels is fundamentally identical in Batrachians and in mammals. All the structures found in the former are found at any rate in the vestigial state in the latter. The only important differences are the

following: the lymphatics in the Batrachians and in the Amphibians empty themselves into the venous system without passing through intermediate glands. It is known that glands are only present in birds, and then apparently, only in the cervical region. Mascagni's law therefore merely holds good for the lymphatics of mammals. Finally, in the Batrachians and even in the embryo bird, the points at which the lymphatics end in the veins are multiple: the two systems communicate in the region of each of the four lymphatic hearts.

BIBLIOGRAPHY.—Aristote. *Hist. Anim.*, lib. III;—*Phys.*, I, sect. III.—Galien. *An sanguis nat. in arteris contineatur*, cap. 5, ad. de Admin. Anat., lib. VII;—*De usu partium*, lib. IV, c. 19.—Nicolas Massa. *Lib. Introd. Anat.*, 1532.—Fallope. *Tractatus quinque de partibus similaribus*.—Hewson. An account of the lymphatic system in birds. *Phil. Trans.*, LVIII, 1768;—*Experimental inquiries on the blood*, with some remarks on it and an appendix relating to the lymphatic system in birds, fishes and amphibious animals. London, 1771.—Monro. *State of facts concerning the paracentesis of the thorax, on account of air diffused and lymphatic vessels in oviparous animals*. Edimbourg, 1770.—Mascagni. *Vasorum lymphaticorum corporis humani historia et iconographia*. Sienne, 1787.—Bichat. *Traité des membranes*, 1816.—Fohmann. *Anat. Untersuch. über die Verbindung der Saugadern mit den Venen*. Heidelberg, Neue Akad. Buchhand. v. Karl Groos, 1821.—Lauth. *Essai sur les vaisseaux lymphatiques*. Thèse Strasbourg, 1824.—Lippi. *Illustrazioni fisiologiche e patologiche del sistema linfatico chilifero*, mediante la scoperta di un gran numero di comunicazioni di esso col venoso. Firenze, 1824.—Fohmann. *Mémoires sur les communicat. der vaiss. lymphatiques avec les veines*. Liège, 1832.—J. Muller. *Annales de Poggendorff*, 1832.—*Philos. Trans.*, 1833.—Panizza. *Sopra il sistema linfatico dei rettili*, Pavia, 1833.—Stannius. Ueber die Lymphherzen der Vogel. *Muller's Archiv*, 1842.—Rusconi. *Reflessioni sopra il sistema linfatico dei rettili*, etc. Pavia, 1845.—Brucke. *Ueber die Chylusgefässe u. die Resorption des Chylus*. Wiener.—Kœlliker. Note sur le développement des tissus chez les batraciens. *Annales des Sciences Nat.*, 1846, IV;—*Eléments d'histologie humaine*, 2 éd.;—*Denkschriften*, 1854, VI.—Leydig. *Histologie*, 1857.—Milne-Edwards. *Physiologie et Anatomie comparée*, 1859, IV.—Virchow. *Path. cell.*, 1861;—Reklingshausen. *U. die Lymphgefässe u. ihre Beziehung zum Bindegewebe*. Berlin, 1862;—Zur Geschichte der Versilberungsmethode. *Virchow's Archiv*, 1863, XXVIII, p. 1119;—*Stricker's Handbuch*, 1872.—Ch. Robin. *Cours d'histologie*, 1864;—Article "Lymphatique" du *Dict. Dechambre*.—Auerbach. *Untersuch. über Lymph. u. Blutgefässe*. *Virchow's Archiv*, 1865, XXXIII.—Ludwig. u. Schweigger-Seidel. *Arbeiten aus der physiologischen Anstalt zu Leipzig*, 1867.—Tourneux. *Recherches sur l'épithélium des séreuses*. *Journ. de l'Anat.*, 1874.—Klein. *The anatomy of the lymphatic system: The serous membranes*. London, 1873.—Rouget. *Arch. Physiologie*, 1873.—J. Arnold. *U. die Beziehung der Blut;—U. Lymphgefässe zu den Saftkanälchen*. *Virchow's Archiv*, 1874.—Sappey. *Traité d'anatomie, physiologie et pathologie des vaisseaux lymphatiques*, 1874;—*Traité d'anat. descript.*, II.—Alferow. *Arch. Physiol.*, 1874.—Tarchanoff. *Des prétendus canaux qui feraient communiquer les vaisseaux sanguins et lymphatiques*. *Arch. de physiologie*, 1875.—Tourneux et Hermann. *Recherches sur quelques épithéliums plats dans la série animale*. *Journ. de l'Anat.*, 1876.—Altmann. *Arch. f. mikr. Anal.*, 1879, p. 471.—Thanhofer. *Das Mikroskop*, 1880.—Pierret et Renaut. *Mémoires sur les sacs lymphatiques périlobulaires du poumon de bœuf*. *Arch. Phys.*, 1881.—Budge U. das dem zweiten Blutkreislauf entsprechende Lymphgefässsystem

bei Hühnerembryonen. *Centralbl. Med. Wiss.*, 1881, n° 34 ;—Untersuch. über die Entwicklung des Lymphsystems Hühner embryo. *Arch. anat. Phys.* : Anat. Abth., 1887.—Weliki. *Einige Ergränzungen zur Histologie, Anat. u. Phys. der Lymphgefäße*, 1884.—Gierke. *Zeit. f. wiss. Mikr.*, 1884.—Hoggan. *Journ. of Anat. and Phys.*, 1885, XV.—Retterer. Disposition et connexions du réseau lymphatique dans les amygdales. *C. R. Soc. Biol.*, 23 janvier 1886.—Dekhuysen. *Anat. Anzeiger*, 1889, IV ;—*Zeit. f. wiss. Mikr.*, 1890, VII, 3.—Mayer. *Zeit. f. wiss. Mikr.*, 1889, VI, 4, p. 422.—Dogiel. *Arch. f. mik. Anat.*, 1889, XXXIII, 4, p. 440.—Bonnet. *Grundriss der Entwick. der Haussäugethiere*, 1891.—Regaud. Origine des vaisseaux lymphatiques de la mamelle. *C. R. Soc. Biol.*, 1894, n° 20, p. 495 ;—Étude histologique sur les vaisseaux lymphatiques de la glande mammaire. *Journ. Anat. et Phys.*, 1894, XXX, n° 6.—Ranvier. Chylifères du rat. *C. R. Acad. Sciences*, 1894, n° 12, p. 621 ;—Développement des vaisseaux lymphatiques. *C. R. Académie des Sciences*, 30 déc. 1895, p. 1105 ;—Circulation de la lymphe. *C. R. Acad. Sciences*, 1894, CXIX, n° 26.—Gley. Innervation des vaisseaux lymphatiques. *Bull. Muséum d'hist. nat. Paris*, 1895, n° 3, p. 127.—Regaud et Barjon. Vaisseaux lymphatiques des tumeurs épithéliales malignes. *C. R. Soc. Biol.*, 19 déc. 1896.—D'Abundo. Voies lymphatiques du système nerveux central. *Arch. ital. biologie*, 1895, XXIII, fasc. 1 et 2, p. 151 ;—*Annali di neurologia*, 1896, p. 229.—Ranvier. Morphologie du système lymphatique. De l'origine des lymphatiques dans la peau de la grenouille. *C. R. Acad. Sciences*, 1895, CXX, n° 3, p. 132 ;—Étude morphologique des capillaires lymphatiques des mammifères. *C. R. Acad. Sciences*, 1895, 121, n° 24, p. 856.—Goldscheider et Flatau, *Zeitschr. f. klin. Med.*, 1896, XXXI.—Gerota. Zur Technik der Lymphgefäß-injection. Eine neue Injectionsmasse für Lymphgefäße. Polychrom. Injection. *Anat. Anzeiger*, 1896, XII, n° 8, p. 216.—Timofejew. Ueber die Nervenendigungen in den männlichen Geschlechtsorganen des Menschen u. der Säugethiere, 1896.—Ranvier. Sur une substance colloïde, myélinéoïde élaborée par les lymphatiques à l'état normal. *C. R. Académie Sciences*, 1896, CXXII, n° 8, p. 428.—Boddaert. *Anat. Anzeiger*, Suppl. Band, 1897.—Ranvier. Morphologie et développement du système lymphatique. *Archives d'anatomie microscopique*, I, p. 137.—Dogiel. *Arch. f. mikrosk. Anat.*, 1897, XLIX.—Behre. Zur Frage der Lymphgefäßneubildung. *Inaug. Diss.* Kiel, 1898.—Homen et Laitinen. *Ziegler's Archiv.* Iéna, 1899, XXV, I.—Guillain. *C. R. Soc. Biol.*, mai 1899.—Creighton. A system of perivascular lymphatic cylinders and capsules in the united amnion allantois of the chick. *Journ. Anat. Phys.*, XXXIII, 1899, III.—Cunéo et Delamare. Note sur l'histologie des lymphatiques de l'estomac. *C. R. Soc. Biol.*, mai 1900.—Regaud. Origine des vaisseaux lymphatiques de la glande mammaire. Relations entre la richesse des radicules lymphatiques et la facilité plus ou moins grande du drainage de la lymphe dans le tissu conjonctif. *Bibl. Anat.*, 1900, VIII, fasc. 4, p. 261.—Sala. Sullo sviluppo dei cuori linfatici e dei dotti toracici nell' embrione di pollo.—Ousoff. Les vaisseaux lymphatiques du diaphragme et leurs rapports avec la cavité abdominale et avec le processus d'absorption. *Arch. russes de pathol.*, t. 7. n° 3.—Binswanger u. Berger. Beiträge zur Kenntniss d. Lymphcirculat. in der Grosshirnrinde. *Arch. f. path. Anat. u. Physiol.*, CLII, 3.—Dalla Rosa H. Lymphgefäßinject. *Verhandl. der anat. Gesellsch.*, 1900.—Renaut. Note sur les capillaires lymphatiques du tissu conjonctif lache. *Assoc. des Anatomistes.* Lyon, 1901, p. 223.—Kytmanoff. Ueber die Nervenendigungen in den Lymphgefäßen der Säugethiere. *Anat. Anzeig.*, 6 juin 1901, n° 15.

LYMPHATIC GLANDS.

HISTORICAL REVIEW.—The lymphatic glands, known since the most ancient times, were for a long time regarded as closed glands, and allied to the thymus and thyroid body; they constituted a part of the *conglobate glands* of Sylvius and Wharton. It was thought they modified the lymph. Wharton and Bartholin considered that they retained a part of the latter; whereas de Graaf and Malpighi, thought that they added to it the products of their secretion.

In support of these opinions, the differences shewn to exist between the afferent and efferent lymph, the considerable slowing of the glandular circulation, and also the direct communications between the white vessels and the bloodvessels, were adduced as evidence. Later on, Neumann firmly believed that the mesenteric glands which were placed on the channels in which intestinal absorption was taking place, were bound to take some part in the nutritive metabolism of the organism; he thought that these glands must transform matter coming from without, into internal or living substance. These physiological hypotheses were forgotten when anatomy, and especially histology, had raised other problems. Anatomists believed that the gland was simply a plexus of lymphatic vessels. This opinion, which was held by Hewson, Cruikshanks and Mascagni, was shared by Lauth, Breschet, and Richet. In Germany, the term lymphatic gland has been retained through custom; but in France, the term ganglion, given by Chaussier, has been preferred, seeing that Soemerring had found a rough resemblance between the nervous and lymphatic ganglia.

After Henle, Noll and Brücke had demonstrated the existence of the glandular substance, which had been suspected by Bichat, Cruveilhier and Béclard, histologists were compelled to describe its texture, and to determine the relations which existed between the leucocytes and the connective tissue.

Cells and a network were seen; the cells strangely resembled leucocytes, and the fibrillary network was not without apparent analogy to that of ordinary connective tissue. Did this as a whole, it was asked, correspond to a new tissue, or did it result from the association of two elements which were in other places known to be distinct and isolated, namely, the leucocyte and connective tissue? The likeness was so striking that all, with the exception of Robin, admitted that the glandular cells were leucocytes, or, at any rate, were produced from leucocytes.

It is true, the origin of these elements was discussed. Sertoli, Bonnet, Conil and Retterer thought they were autochthonous, and derived from the surrounding mesoblastic cells; Gulland, Larroque, Chiewitz, Ranvier, Champeil, Chandelux, Renaut, and Saxer considered they were leucocytes which had wandered into the meshes of the connective tissue.

The leucocytic origin of the cells of the lymphatic gland once admitted, then the efforts of histologists necessarily had to be directed towards the study of the reticulum, termed by Koelliker the cytogenous tissue, by His the adenoid tissue, and by Frey the reticular tissue.

To determine whether they were dealing with connective tissue, fibrillæ, or prolongations of anastomosing cells, it was essential to artificially remove the foreign cells which infiltrated the glands. With this object, Henle macerated the glands in water or liquor potassae, after previously drying them; and, since then, pepsin and trypsin have been used. His

devised the mechanical process known as *pencilling*. For a long time the results furnished by these crude methods were accepted without question; the results, however, did not agree.

Henle, Baumgarten, Ellenberger, Sussdorf, Bizzozero, Löwit, Ranvier, Renaut, Klein, Heidenhain, Stöhr, Gulland, Hoyer, Hoehl, Mall maintained that the reticulum was *purely fibrillary*; while Eckard, Leydig, His, Frey, Koelliker, Billroth, Rollett, Krause, Toldt, Orth, Schoefer, Schenk, Saxer, Gegenbaur, Chiewitz, Schieferdecker, Forster, and Huxley thought it was composed of a *cellular network*, that is to say, it was formed by the anastomosis of cellular prolongations. There are still the same divergences of opinion as to the nature of this reticulum. Amongst the upholders of the fibrillar theory, some maintain that the reticulum is made up of ordinary connective tissue, on the fibres of which endothelial cells are placed; others believe that it is composed of certain fibrillae, which are histochemically different from connective tissue and elastic tissues.

In fact, Recklinghausen has shown that, unlike elastic fibres, these fibrillae do not resist the action of acids and alkalies (soda and potash).

Orth has stated that they do not swell up with acetic acid as is the case with connective-tissue fibres; Mall has found that they resist the action of trypsin longer than the latter, and that when heated they do not yield gelatin. This reaction and the mesodermic origin of the reticulum identify it with embryonic connective tissue; but, as the tissue develops, and becomes subjected to different kinds of morbid influences, and as age advances, variations in its fibrous and elastic tissues are produced (Melnikow—Raswedenkow, Retterer). There is present then, at the same time, a reticulum composed of cells, and fibrous arches which are capable of supporting the endothelial cells; this was seen by Müller, Ribbert, Demoor, Sisto and Morandi. Therefore, those who held that the network was fibrillary, and those who maintained it was cellular, were both right, but knowing only a portion of the truth, they were wrong in generalizing their opinions and in regarding them as antagonistic.

During this time, the knowledge of glandular leucopoiesis was becoming established. In 1851, Heyfelder stated that the white corpuscles were much more numerous in the efferent than in the afferent vessels; Brücke and Frey confirmed this observation. Later on, after finding numerous mitoses in the germinative centres of the young or hypertrophied gland, Arnold, Bizzozero, Flemming, Paulsen, Löwit, Hofmeister and Müller showed the mechanism of this leucopoiesis; the reality of the process was afterwards confirmed by experimental and histo-pathological facts.

We must observe however that, some authors, convinced of the exogenous origin of the cells, regard the gland not so much as cytogenous in character as a *place for the formation* of leucocytes. This manufacturing centre is accessory, whereas the dilatation of lymphatic vessels is of fundamental importance. Ranvier too, thinks that, "the gland should be regarded simply as a pocket—a sort of bladder—in which the lymph circulates after it has passed out of the afferent and before it passes into the efferent vessels." It is curious to reflect that fifty years of histology should have given rise to this opinion, which so closely resembles that held by the anatomists of the eighteenth century.

Granted leucopoiesis, the question still remains as to what kinds of leucocytes are manufactured by the gland. The glandular cells have been studied by Arnold, Flemming, Hoyer, Schumacher, Benda, etc.

After that, attention was drawn to the histo-functional parallel of the gland to the spleen and marrow of bone. According to some, haematopoiesis, the production of granular amoebic cells and phagocytes, belongs to the marrow; haematolysis, and as an accessory, haematopoiesis, to the adult spleen, whereas the functions of the gland are confined to the production of lymph-cells.

Others think these organs, which appear so highly differentiated, were originally fused. On the one hand, Pappenheim and Dominici have found leucocytes in the marrow of bones, while on the other, Metchnikoff, Lacroix and Renaut, Rawitz and Demoor, have described giant cells in the lymphatic gland. Hoyer, Schafer, Kanter and Labbé have studied the eosinophiles, Dominici the amphophiles. On the other hand, the haematopoietic and haematolytic functions must be admitted. In the list of those who have worked at glandular haematolysis are inscribed the names of Hoyer, Koeppe, Gabbi, Schumacher, Masslow, Thomé, Sisto and Morandi, Scott Warthin; while glandular haematopoiesis has been made the special object of study in the works of Rindfleisch, Weigert, Neumann, Löwit, Kultschitzky, Lockart Gibson, Moses Grünberg, and Retterer.

Now, our knowledge of leucocytic ferments, and that of certain glandular ferments (amylase, lipase, plasmase, the enterokynase of Delezenne, the macrocytase of Tarassewitch) gives us reason for thinking that the old anatomists and Robin were not wrong in conceiving the existence of a secretion in the glands which, perhaps, might manifest itself histologically by the phenomena of cell destruction.

Having now indicated the general macroscopical characters (form, consistence, etc.) of the lymphatic glands, we will study their development, structure and functions.

MACROSCOPIC CHARACTERS.—*Form.* At times flat, at others elongated or cylindrical, the lymphatic glands are often prismatic or irregularly spherical, or more or less rounded or oval; sometimes they resemble a horse shoe (Cornil); they are nearly always reniform. The oblique afferent lymphatics approach their convex border; whereas the efferent vessels, which are larger and more numerous, escape from the hilum on their concave border.

Consistence.—The glands are not soft, but of a somewhat firm and elastic consistence. Sappey compares their feel to that of the liver, and Richet to that of the kidney.

Colour.—This varies in different regions, physiological states, and in different animals. In man, as we know, the bronchio-tracheal glands are infiltrated with small particles of carbon, and are coloured black; those of the liver are yellow, whereas those of the spleen are brown. The mesenteric glands, which are rosy-white, become whitish during digestion. In the horse, and the ox, the central portion is brown; in the rabbit, a more or less pronounced

greenish yellow tint is often found in some of the glands which constitute the pancreas of Aselli. The usual tint of normal glands seems to be about rosy-white. It is difficult to state the exact morphological significance of the haemo-lymphatic red glands, which have been studied by Gibbes, Robertson, Clarkson, Vincent and Harrison, Drummond, Haberer, Scott Warthin, Morandi and Piato. They seem to be present not only in man, in the pararenal and vertebral regions, but also in the horse, the sheep, the goat, the pig, the calf, the ox, the rat, the turkey and the owl. If, as Scott Warthin thinks, they have no afferent lymphatics, it is probable that they perform the functions of accessory spleens.

Dimensions.—Even in the same individual, the size of the glands varies, physiologically, within wide limits: while the larger are the size of an olive or even larger, the smallest are invisible to the naked eye. Letulle has described microscopical glands in the wall of the stomach; Gulland in the axilla; and in the mesentery there are numbers of them. These glands under different physiological or morbid influences, may become enlarged. Stiles has seen axillary glands appear during lactation and disappear on its cessation.

The glands tend to get smaller as age advances. They become so small in the aged that Cruikshanks, Mascagni, Ruysch and Haller believed that they completely disappeared.

The existence of these microscopical glands would be sufficient in itself to render numerical estimates laid down by anatomists extremely speculative, but there is another reason which renders such estimates valueless, viz., the existence of diffuse or circumscribed lymphoid formations (lymphatic points, amygdalae, Peyer's patches, etc.) which, so many morphological and functional affinities connect with the glands. Without here speaking of embryological differences, elsewhere discussed, we may add that there is only one difference between the amygdalæ and the glands, namely, that whereas the lymphatics traverse the gland, they actually arise in the amygdalæ, which from this point of view is comparable to the spleen.

Number.—Sappey estimates the number of apparent glands as from 6 to 700 approximately; others from 4 to 600. There is an inverse relation between the number and the volume of the glands: the surmulot (Norway rat), the hedgehog, the dog, the

daman,¹ the antelope, the seal, the dolphin, have *few* but *voluminous* glands: man has a *larger number of*, but proportionately *smaller glands*. This latter type seems to us to be the perfected form. It is interesting to note that this relation between the size and the number exists not only in the animal series, but even in the same individual. To convince ourselves of this fact, we need only compare the glands in different parts of the human body: sometimes we find they are *large and scarce*; sometimes *small and numerous*. Thus, in a given animal and in a given region, the quantity of glandular substance is always practically identical.

Situation.—The glands are almost always buried in a bed of adipose connective tissue. They are adherent only to a very slight extent, and are movable under the finger. In the limbs, they are termed superficial or deep, according to their situation, either above or below the aponeurosis. Generally speaking, they are more numerous on the flexor aspect.

Sometimes they are solitary, but are more often united in groups of from three to six, or even from ten to fifteen; they form *chains* or *chaplets*. According to Sappey, their situation is by no means fixed. In reality, in spite of somewhat wide variations, they are, speaking generally, *para-vascular*. In the limbs, they are arranged close to the vasculo-nervous bundles; in the abdomen, they are grouped round the aorta, and the inferior vena cava. The spleen is clearly peri-vascular.

The lymphoid masses are in preference para-epithelial. They are arranged on the circumference of the epithelium of the digestive track, sometimes even on the periphery of the hepatic, pancreatic, and supra-renal epithelium. We know that the diffuse lymphoid formations of batrachians are peri-vascular, peri-renal or peri-hepatic. Similarly, the lymphatic glands of invertebrates are sometimes peri-nervous (scorpions), and peri-digestive (oligochetæ), and more frequently, peri-vascular (cephalopods).

It should be observed that according to Cuénot, the Echinoderms and the Trochozoa, the Bryozoa, and the Polychætæ, actually combine the two cytogenous glands, namely the lymphatic and genital, in one structure.

In fact, lymphoid formations, whether diffuse or circumscribed,

¹ A small hyracoidean hoofed mammal (genus *Hydrax*) with rhinoceros-like molar teeth, especially *Hydrax Syriacus* of Asia Minor, which is probably the cony of the Scriptures.

are systematized by a relation to some other organ; this organ varies, and in man where the lymphatic apparatus attains its maximum complexity and extension, the systematization is at the same time, para-vascular and para-epithelial.

According to Stahr, the lymphatic vessels in a given region pass through three distinct glandular stages during their course. First of all, there are the small nodules of interrupted glands (*Schaltdrüsen*) whose presence is inconstant, and number variable, and which are always unaffected by injections; then, come the *regional glands* (*Regionardrüsen*), where the glands are larger and more constant. Finally, there are the *intermediary glands* (*Intermediarüsen*).

There are transitional forms between the "Schaltdrüsen" and the regional glands: such are the epitrochlear, and anterior tibial glands. But as Cunéo has observed, such a gland which may be *intermediate* for the cutaneous lymphatics of the face, becomes *regional* for those of the tongue. Stahr's classification has therefore only a relative value, and for this reason Cunéo only recognizes a first and a second class of glands.

The knowledge of these relays of glands placed in succession one behind the other in the lymph stream, is interesting from a pathological point of view, for they constitute so many stages at which the spread of infections and cancers is temporarily arrested.

DEVELOPMENT.—Though lymphatic glands exist in invertebrates, and lymphoid masses in the lower vertebrates, the phylogenic appearance of the gland properly so called is somewhat slow. It is seen in the cervical region in some birds; and it develops to a greater extent though it still remains rudimentary in certain mammals, such as the pig. Nevertheless, the ontogenic development of this highly specialized gland is less slow than Breschet imagined it to be. This anatomist found no trace of it in the human foetus of six months. On the other hand, Renaut has seen well-developed glands at the fifth month of intra-uterine life. In man, Conil has described them as always present on the 165th day of gestation. Labbé has found relatively large glands on the 90th day. In the neck of the human foetus of four months, I have seen very unequally developed glands lying side by side. In the inguinal region of the guinea pig, Retterer has observed the rudiments of a gland from the 35th to the 40th day of gestation.

On the other hand, certain infants born at seven or eight months and who died a few days afterwards, shewed large and but little differentiated mesenteric glands, with the rudiment of a cavern-

ous sinus, but no follicles. Similarly, in young animals, side by side with the fully-developed glands, rudimentary lymphoid formations are found. Are we here dealing with old rudiments whose development has been arrested or retarded? or with new organs in process of growth? Both suppositions are legitimate; if we adopt the latter, we may suppose that there are some glands which make their appearance very late. In either case, it is quite certain that the formation of the glands takes place later than that of the lymphatic vessels. This statement, already made by Lauth, Breschet, Teichmann, Engel and Sertoli has been confirmed by Ranvier.

The primitive nodule is highly vascularized. His laid stress on its hyperaemia, and since then, Ranvier, on account of its red tint has compared it to a piece of sealing wax. This primitive nodule, which is formed of cells heaped up one against the other, is homogeneous; it presents neither lacunae nor cavities, except at the periphery where endothelial spaces (lymphatic vessels) are seen in section. The origin of these cells which, by their agglomeration constitute the original nodule has, as we know, been the subject of discussion.

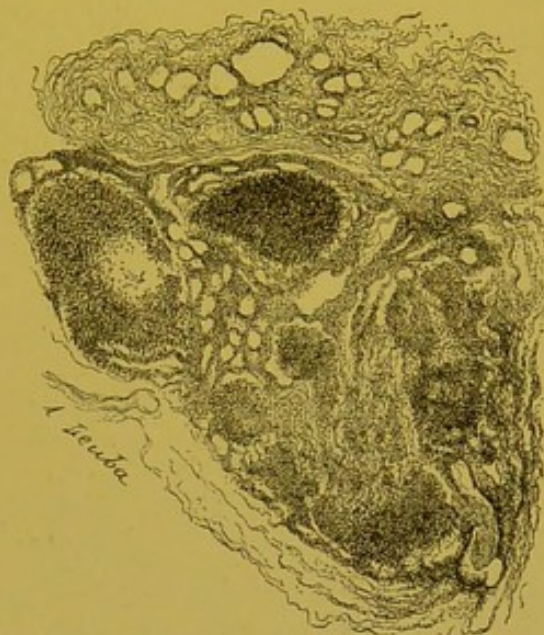


FIG. 19.—Cervical glands of a four months' human foetus. Above, the gland is homogeneous, and surrounded by a peripheral lymphatic sinus; below, the process of cavernization has commenced.

Many authors think that it is a case of leucocytes having wandered into the meshes of the connective tissue; this opinion only rests on indirect evidence, such as the pre-existence of vessels and of white corpuscles, and the amoebism of the latter. Owing to their oxyphilism, leucocytes would be attracted by their future germinal centres, which are highly vascularized and very oxygenated. Finally, as fine colouring matters can penetrate the follicle, we may suppose that amoebic leucocytes can do the same.

Others, on the contrary, think it is a case of autochthonic cells which have originated from mesodermic elements.

Let us now study the final modifications of this simple and hitherto homogeneous rudiment. At first, it looks like a large

lymphatic sinus, divided into compartments by trabeculae; this vessel runs round the edge of the nodule, and separates it from the connective tissue capsule, which now becomes quite distinct from it. Then, the lymphatic channels in the course of their development, penetrate one of the extremities of the homogeneous nodule. These vessels isolate segments of the glandular substance: the vessels we will call *cavernous sinuses*, and the irregular glandular and anastomotic segments, *follicular cords*. The whole constitutes the central or *medullary* part of the organ.

The peripheral part which is still homogeneous, corresponds to the cortical substance. It is the *intermediate tissue* (Zwischengewebe) of Schumacher, and the *reticulated sheet* of Bezancon and Labbé. In this homogeneous sheet, oval formations appear—the *nodules* or *cortical follicles*; then, prolongations from the capsule, and the advancement of lymphatics, which establish communications between the peripheral sinus and the cavernous channels, divide this hitherto homogeneous mass into segments. Though the development of the gland is not, as the old anatomists thought, limited to that of the white vessels, yet we may say, that its histological appearances are largely subordinated to the more or less precocious and more or less extensive penetration of the gland by lymphatics. Just as the liver is overrun by blood vessels, so is the gland by lymphatic channels.

How are the lymphatic vessels developed here? According to Engel, they divide into two; their branches multiply and become sinuous, while in their intervals, the glandular substance makes its appearance.

According to Ranvier, in the region of the nodule, the lymphatic vessel is interrupted by a regression or partial atrophy. Two trunks are formed, a superior and an inferior, the future efferent and afferent vessels. The inferior segment of the lymphatic, thus cut off, terminates in a *cul-de-sac*. This *cul-de-sac* buds and penetrates the vascular nodule. So far, lymph cannot permeate the gland, seeing that liquid injected by the afferent does not pass into the efferent. Eventually, however, this communication is established; and then, says Ranvier, the gland is comparable to a simple angioma. It soon becomes transformed into a cavernous angioma, for the different buds of lymphatic capillaries become confluent. The chief obstacle to the indefinite extension of this process of cavernization is effected by the blood vessels.

This development of glandular lymphatics has raised anew the

question, previously discussed, as to whether their lumen represents

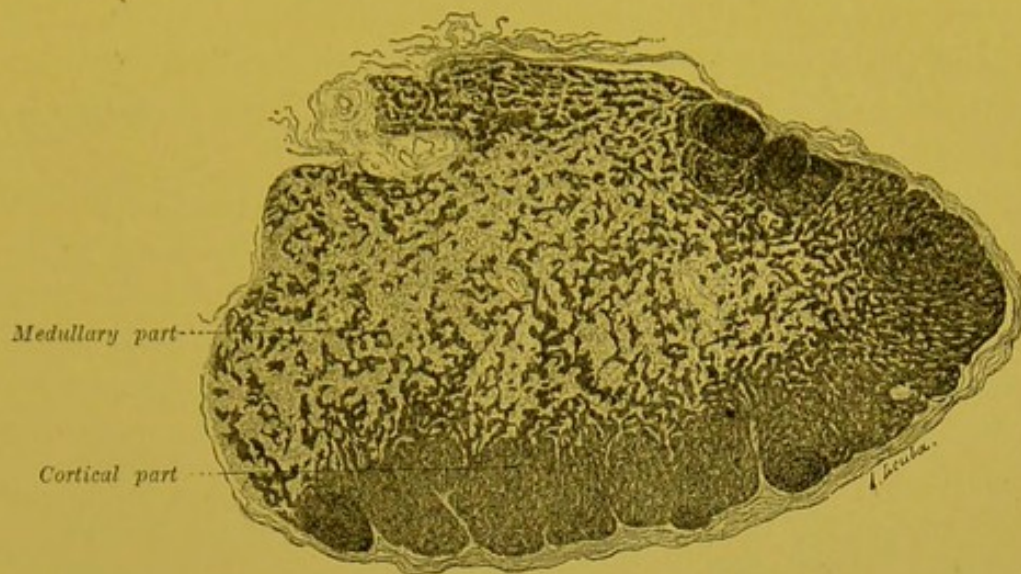


FIG. 20.—The mesenteric gland of the dog.

an inter or an intra-cellular space. We know that Koelliker, and subsequently Leydig and Virchow, believed in communications between the lymphatic cavity and the cavity of connective tissue cells. Klein maintained that the first rudiment of the lymphatic lumen was represented by an intra-cellular vacuole; similarly, Retterer believed that the cavity of the lymphatic vessel resulted from a liquefaction of part of the cell body, and the process of cavernization of the gland is identical with this. To understand why such apparently different views are held, we need only remember that for those who uphold the intra-cellular origin, the elements of the glandular rudiment have no precise limits, and constitute a vast plasmodium. Thus, Retterer speaks of the "full tissue" of the gland, as a protoplasmic layer strewn with nuclei. The "inter-nuclear substance" soon shows two differentiations; close to the nuclei, it remains homogeneous, and stains feebly with the colouring acids; this is the *hyaloplasm* which is broken up by irregular undulating tracts, which can be stained with haematoxylin. These tracts constitute the *chromophile reticulum* in the meshes of which we find the hyaloplasm. The chromophile reticulum produces elastic fibres. After swelling up, the hyaloplasm becomes vacuolated; remains of cells (leucocytes and cells which have undergone the haemoglobic degeneration) are set free. Later on, in places, the remains of this hyaloplasm may be seen giving birth to well developed connective tissue fibrillae of collagen.

STRUCTURE.—The gland is surrounded by a connective tissue capsule which, in almost all animals, sends out prolongations towards the interior of its parenchyma. If at this stage, a section, even under a low power, is examined, it is quite easy to recognize that the appearance of the glandular tissue varies in the centre and at the periphery.

The peripheral or cortical portion (*cortical substance*), appears as a homogeneous layer at the bottom of which rounded formations, the *follicles*, are visible. In the central or medullary part (*medullary substance*), irregular cords separated from each other by clear spaces may be seen: the *medullary cords* are separated from the cortical part; the clear intermediate spaces are the lymph channels, the *cavernous sinuses*.

We will now study the structure of each of these parts in turn:—

1. The capsule.
2. The cortical zone.
3. The medullary zone.

The Capsule.—This is somewhat thin in the hedgehog, the rabbit, and especially in the guinea-pig, but it is more marked in the dog and adult man. Fairly often, it increases in size and forms a fibrous nucleus at the hilum.

It is composed of fibres, connective tissue cells, and fine elastic networks, and in certain animals (mouse, ox, and horse,) at its deepest part, it contains delicate muscular fibres. According to Renault, muscular fibres are absent in the sheep and in man. At intervals, from the inner surface of this capsule, partitions arise, traversing the cortex; after successive divisions, they gain the central part, and sometimes even reach the hilum. These fibro-muscular prolongations which are well marked in the ox and dog, are not so plain in the rabbit; they are almost entirely absent in the guinea-pig. Externally, the capsule is continuous with the meshes of the cellulo-adipose tissue which surrounds it; within, it is almost entirely separated from the glandular substance, by a space whose dimensions are somewhat irregular (*peripheral lymphatic sinus*).

In places, the cavity of this sinus is narrowed by the embossments of the glandular cortex; at certain points, it disappears entirely and the peripheral part of the gland touches the capsule. This sinuous cavity is traversed by fibro-muscular arches which spring from the capsule, and on the surfaces of which may be seen some endothelial cells. In the interior of the lymphatic canal, large star-

shaped cells may be seen, whose filiform prolongations anastomose with each other, and form a network which loses itself in the capsule and in the cortical layer. The nucleus of these elements is sometimes rounded, more often elongated, and almost always, somewhat poor in chromatin.

The peripheral sinus contains microcytes, and macrocytes, some eosinophiles, and some red blood cells.

Cortical Portion (Cortical substance).—Below the sinus there is visible a large horse-shoe, the arms of which do not reach as far as the hilum: this is the *cortical part* which always diminishes or disappears before reaching the hilum of the organ. It thus encloses, within its concavity, the medullary part which is continued up to the hilum.

Though relatively small in the dog, the cortex is much more marked in the hedgehog, the rat, the guinea-pig and the rabbit. In these animals, it forms a homogeneous mass which occupies nearly the whole of the organ, excepting the immediate vicinity of the hilum. Moreover, in the same subject, the less developed the gland, the further does the cortex extend.

The cortex (intermediary tissue of Schumacher, reticulated layer of Labbé) is made up of a number of cells whose outlines are somewhat difficult to make clear. Fixation with Flemming's strong solution alone, shows the cell boundaries, and proves that it is not a true plasmodium. Between the cells, may be seen filaments well stained by all the plasmatic colouring agents (light green and acid fuchsin of Biondi's mixture, etc). With van Gieson's mixture, these filaments, unlike adult connective tissue, take picric acid, but not acid fuchsin. Of the cells of the cortical layer, the majority are small, and measure from 5 to 8 μ ; others measure from 9 to 15 μ . The nucleus of the small ones is rounded or quadrangular, and possesses a somewhat thick chromatin border; in the centre, one or two rounded or elongated chromatin granules are found. Sometimes, but not always, a true nucleolus is found. These elements are identical with the microcytes of blood and of lymph (lymphocytes).

The large cells correspond to macrocytes. Their nucleus is rounded, or oval, and sometimes slightly hollowed out along one of its borders. It presents a fine chromatin border, and a fine reticulum, in the meshes of which may be seen one, two, or even three, pyrenosomes. These pyrenosomes are round, elongated, or slightly constricted; they are central or eccentric. The protoplasm

of some is neutral, while that of others is either basophile or acidophile. We can thus easily distinguish in the cortical layer some large elements, whose protoplasm stained with orange or eosine, presents vacuoles, either empty, or filled with cellular débris, or sometimes, with red blood cells or pigment (mesenteric gland of the rabbit).

Here and there, endothelial cells may be seen, or, at least cells which are endothelial in form, whose clear elongated nuclei contain one or two true nucleoli, and whose chromatin appears as a delicate network or fine powder.

In the cortical layer, we may find eosinophiles scattered about, and red blood cells without a nucleus, and even the large or small cells of Neumann. This part of the gland is very poor in mitoses; but, in places rounded, oval or elongated masses of variable dimensions may be seen, which, arranged in one or two rows, project under the capsule and give to the gland its irregular bossed appearance; these are the *cortical follicles*, which by their marked agglomeration, and especially by the special disposition of their peripheral cells, encroach upon the uniformity of the cortical layer.

These follicles (alveoli, ampullae, glandular nuclei, nodosities, peripheral nodules) are secondary differentiations which are somewhat slow in appearing. They are transitory structures which atrophy and entirely disappear in the old. Some are of uniform appearance, while others present a clear centre (clear spot of Brücke, vacuole of His). Frey has observed that the follicles have no proper wall; they are limited by the endothelium of the lymphatic sinus, which surrounds them, which is elsewhere inconstant. They are easily permeated by finely ground matter, or by liquids injected into

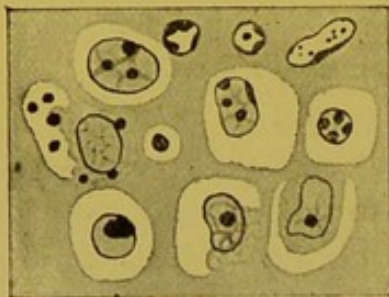

FIG. 21.—Central part of a follicle of the mesenteric gland of the rabbit (fixed with Flemming's strong solution): perinuclear vacuoles; nuclear degenerations (*colourable corpuscles* of Flemming).

the lymphatic channels.

At the periphery of the follicle, the microcytes which are in close contact with each other are arranged in concentric layers. Here and there, a larger cell may be seen in the midst of them. In the centre, microcytes are still found, but the macrocytes predominate and the elements are much further apart from each other. All the nuclei are not rounded. There are some which elongate or curve inwards and which are commencing to become polymorphous.

In sections coloured with haematoxylin-eosin, and safranin-green, the protoplasm is generally somewhat feebly stained by the staining plasmatic reagents. With Unna's blue, after fixation with sublimate, it may easily be shown that some of the macrocytes have, like the myelocytes, a strongly basophile protoplasm.

In places, the body cells become hollowed out by the peri-nuclear vacuoles. Between these neighbouring cavities protoplasmic bridges persist in the form of fine tracts which are stained by eosin, and the acid fuchsin of Biondi. Sometimes, but not always, this protoplasmic degeneration is accompanied by a nuclear degeneration: the nucleus becomes reduced to one or several rounded or sickle-shaped corpuscles, which can be highly stained, and which are homogeneous or perforated by a central aperture. Elsewhere, these *colourable corpuscles* are very numerous and very small: they form a mass which shows up clearly on the lighter background of the section. There are some which occupy the digestive vacuoles of a macrocyte, and which are the sole débris of a phagocytic cell. They usually stain with the nuclear stains; some of them take the acid fuchsin of Biondi.

This cytolysis explains the presence in the gland, of uric acid, leucin, tyrosin, and xanthin.

But, the follicle with the clear centre is essentially a seat of cellular reproduction; and Flemming himself has termed it the *germinative centre*. It was here, in fact, that the mitoses, discovered by Arnold in diseased glands, were again found by Bizzozero, Flemming, Paulsen, Löwit, Hofmeister and Müller, in normal glands.

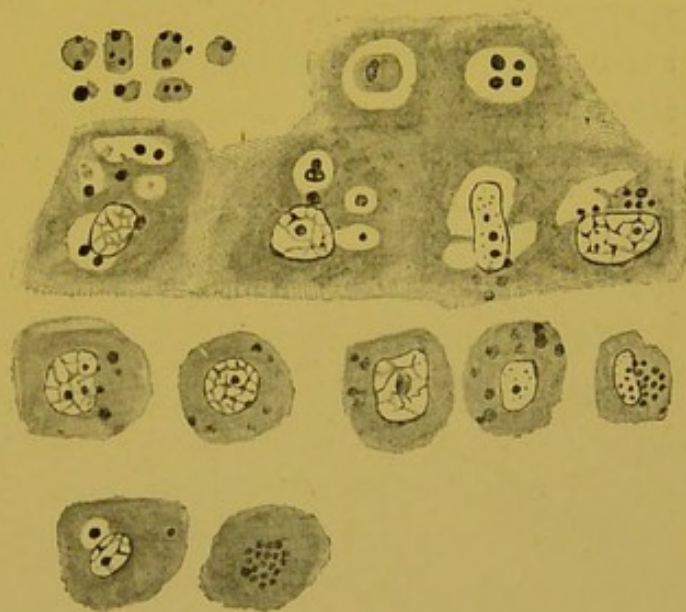


FIG. 22.—Stained corpuscles.

Baumgarten and Ribbert have maintained that the cells which exhibited karyokinesis were not white corpuscles, but were mother cells of leucocytes. Baumgarten considered they were of the nature of connective tissue, while Ribbert thought they were endothelial. In the adult, this karyokinesis is somewhat rare; but it is increased after

venaesection and after splenectomy.

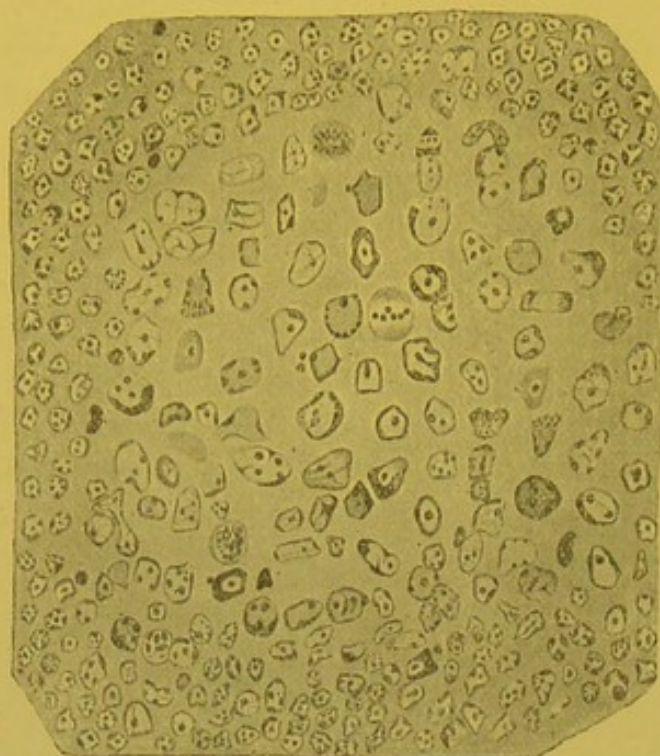


FIG. 23.—Follicle of a mesenteric gland of the guinea pig. Germinal centre presenting mitoses.

This increase is, however, inconstant, for though in the opinion of Mayer, Bennett, Gerlach and Kourloff, a glandular hypertrophy follows a splenectomy, this observation has not been confirmed by Mosler and Legros, Masoin and Ceresole. In the rabbit, some days or even months after splenectomy, I have never found a manifest hypertrophy; the mesenteric glands were of normal colour and volume, and their follicles presented no unusual number of mitoses.

Medullary Portion (medullary substance).—The

medullary portion of the gland, which is more or less completely surrounded by the cortex, presents cords, irregular in size, course and shape, which anastomose with each other, and which are separated from each other by large clear spaces, the cavernous sinuses.

The *medullary cords* (medullary utricles, lymphatic tubes, glandular cylinders, follicular cords), which are central prolongations from the cortical layer, are formed from the same cells, which are here sometimes less agglomerated. At the commencement of the medullary cords, the eosinophiles are more numerous. Some of them have a single round nucleus, similar to that of the non-granular elements; while others are somewhat deficient in granules. It is possible, but rare to find them in mitosis.

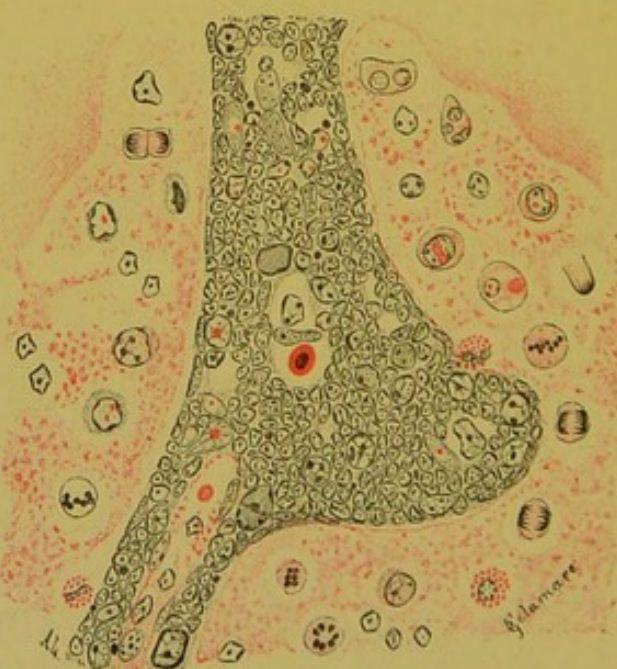

FIG. 24.—Medullary cord and cavernous sinus of a mesenteric gland of the rabbit, after intra-venous injection of pilocarpine.

Moreover, this part of the gland shows karyokinesis to a small extent. Frequently, it may happen that the section shews the medullary cords like the malpighian corpuseles of the spleen, traversed in their centre by an artery.

Between the cords, the cavernous sinuses afford us the best spot for studying phagocytosis of the gland, and of the reticulum; the latter, as can easily be seen, is formed by the anastomosis of cellular prolongations (vide Fig. 25).

Some of the cells of the reticulum have a rounded or elongated clear nucleus, with a pyrenosome and a delicate chromatin network; others have several very distinct nuclei.

In their acidophile protoplasm, are digestive vacuoles in which the débris of leucocytes, and sometimes red corpuscles, and often pigments, may be seen. Between the large star shaped cells of the reticulum and certain round and free macrocytes, all intermediate forms seem to exist. We may further call attention to the existence of giant cells with a budding nucleus, similar to those in the bony marrow. Rawitz has seen them in the monkey, Demoor in the cat.

As is the case with leucocytes, microcytes and macrocytes are always present. Some nuclei are polymorphous. According to Labbé, the eosinophiles are very numerous in the guinea-pig and in the rabbit, but very rare in the infant.

I have never found them very abundant in the cavernous sinuses of the normal rabbit, dog or cat.

Some leucocytes crumble up into small protoplasmic fragments. They thus assist in the formation of hyaline acidophile balls, which occasionally block up the lymphatic channels.

Here, mitoses are relatively rare. However, I have found some in the new-born cat and in the grey rat. I have noticed them to be much more abundant in the rabbit, into whose blood I had injected pilocarpine. In the rabbit, certain leucocytes present crown-shaped chromosomes; and it is not unusual to observe this arrangement in the cords, and even in the glandular follicles.

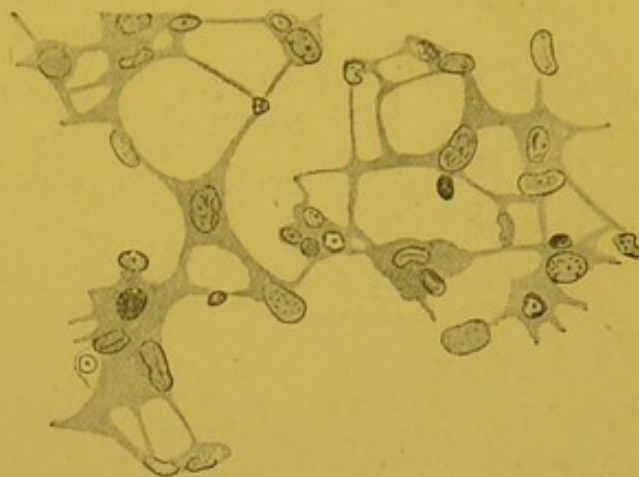


FIG. 25.—Reticular tissue of the mesenteric gland of a grey rat (fixed with alcoholic acetic sublimate, without pencilling. (Dum. oc. 3, ob. $\frac{1}{12}$).

Lymphatic Vessels.—The afferent lymphatics approach the convex

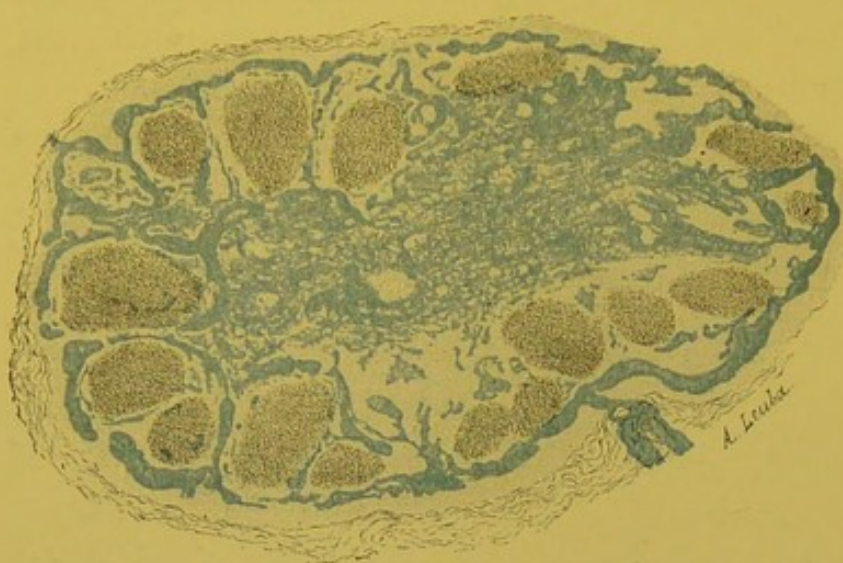


FIG. 26.—Lymphatic passages of the mesenteric gland of the guinea pig (injected by Gerota's method).

portion of the gland obliquely. As they pass through the capsule, they lose their adventitious connective tissue muscular coat, and like true capillaries, become reduced to their endothelium. The capillaries form,

by their anastomoses, a vast peripheral sinus, which, almost everywhere, separates the capsule from the follicles. From this sinus interfollicular branches run out, which reach the central or medullary part. In this part, they run between the follicular cords and finally, throw themselves into the afferents in the region of the hilum. We know that the latter are lymphatic trunks which are less numerous but larger than the afferents. Thus, the portions of glandular substance properly so called (i.e., the follicles and follicular cords), appear to us as islets which are plunged in a vast portal system which bathes them on nearly every side. By confluence and capillarization, the lymphatics form a vast pouch around the glandular substance in which the current is slackened, and the pressure lowered.

Blood Vessels.

—The gland receives its blood vessels, not only at its hilum, but also at several points in its circumference.

The larger vessels of the hilum traverse

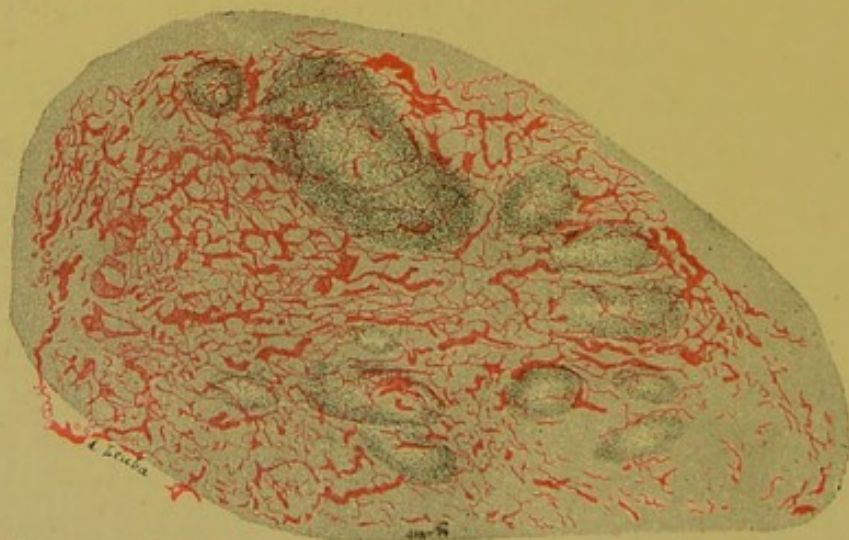


FIG. 27.—Blood vessels of the mesenteric gland of the guinea pig (injected by Gerota's method).

the central or medullary part of the gland. They follow the connective tissue arches, and give off numerous branches which, by their multiple anastomoses, constitute a very rich capillary network. They give off branches which run in the follicular cords, where they form networks with elongated meshes. It is interesting to observe that the follicular cords are pierced in the centre by an arteriole as are the malpighian corpuscles of the spleen.

The arteries reach the cortical layer and surround the follicles, to which they furnish little branches which converge towards the centre, like the spokes of a wheel towards the axle. Some vessels continue their course between the follicles and eventually anastomose with the capsular vessels. Quite recently, Calvert has insisted on this fact. According to this author, there is always an artery at the centre of the follicle, and the capillaries are directed from the centre to the periphery, where they join to form the venous radicles.

Nerves.—In the large glands of man, Koelliker saw small peri-arterial nervous trunks penetrating into the medullary mass; in the ox, he observed Remak's fibres without

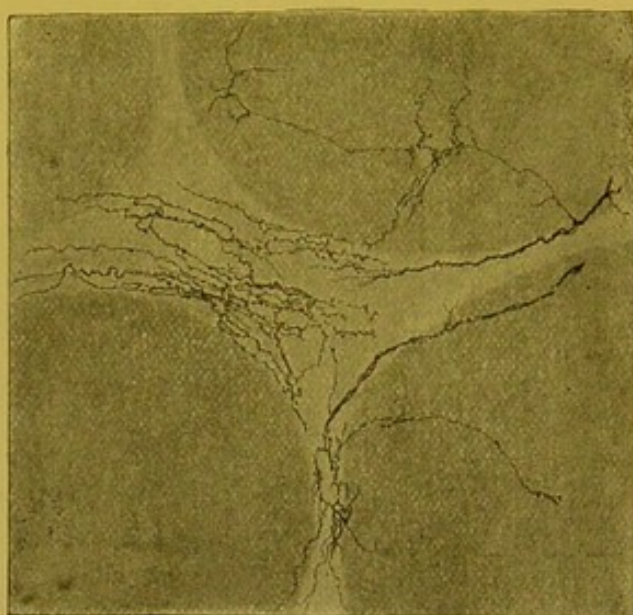

FIG. 28.—Nerves of the mesenteric gland of a new-born dog (Golgi's method. From an unpublished preparation of Manouélian).

being able to observe their modes of termination. Schaffner had described little glandular masses in the course of these nerves, which, however, have not since been found. By Golgi's method, Retzius stained the reticulum and showed the existence of perivascular nerve fibres which, leaving the vessels, terminate by fine branches, in the lymphoid tissue. He has therefore come to the conclusion that in lymphatic nodules, as in the spleen, there are other nerves than vascular nerves.

In figure 28, taken from a preparation of Manouélian, fine interfollicular plexuses are seen. Some of the trunks surround the follicles and give off finer branches which, taking an oblique course, reach the centre of the nodular structure, where they appear to terminate by free extremities. A suprafollicular and perhaps an intrafollicular plexus exists.

VARIATIONS.—The gland, the most highly developed and also the most complex of lymphoid organs, presents numerous variations which vary in different regions, in different species of animals, and especially in different stages of its evolution.

Regional Variations.—These are relatively of little importance. According to Frey, the medullary portion is more developed in the thoracic and abdominal glands than in those of the axilla or groin. We know, however, that all glands, to start with, have a scanty medulla.

According to Schmorl, the connective tissue is more developed in the peripheral than in the visceral glands.

The bronchial are more vascularized than the mesenteric glands. In the rabbit, the mesenteric glands contain in their medullary

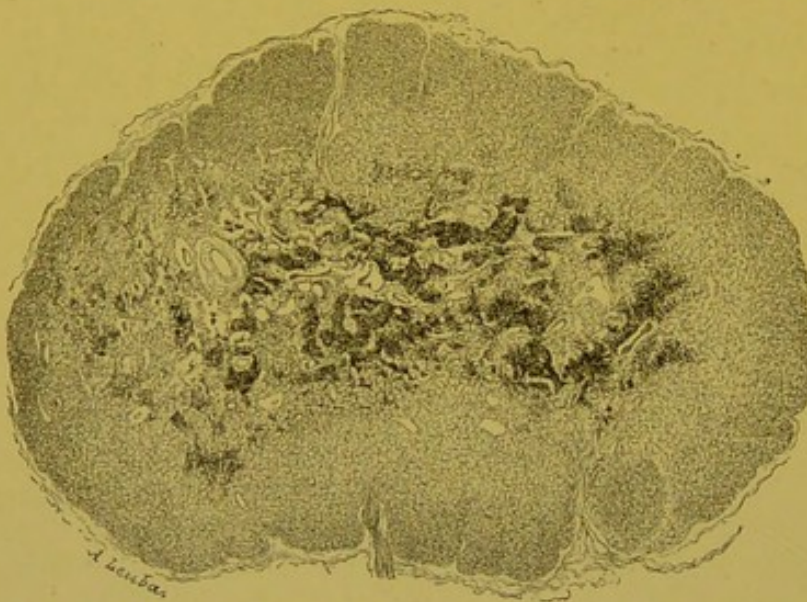

FIG. 29.—Bronchio-tracheal gland of the dog. Carbon particles.

sinuses, their cords, and even in their cortical layer, masses of yellowish granules which are insoluble in alcohol and chloroform, and are stained emerald green by Unna's blue. These granules are apparently not ferruginous. They do not disappear in

animals which have died from starvation.

Owing to their infiltration by carbon particles, the bronchial glands of man and of the dog are black. Particles of charcoal are deposited in the medullary cords, and sometimes, though very rarely, in the follicles. They are grouped in masses of unequal size; and are often enclosed within phagocytes. In the bronchial gland of the dog, I have seen fine ferruginous granules enclosed in the phagocytes of the sinuses, and in the perivascular cells. Chemical analysis showed this gland to contain 0.58 gr. per cent. of iron.

Variations in Different Animals.—We know that the cortical layer is more developed in small rodents than in the dog, in which latter, on the contrary, the connective tissue is more abundant. According to Labbé, the cat possesses a gland which is very rich in active follicles.

In a mesenteric gland of the grey rat, I have found nucleated red blood corpuscles, in somewhat large numbers, both in the cortical layer and in the sinus.

The gland of the hedgehog is remarkable for the scantiness of its follicular cords, between which are seen rounded or oval, large or small meshes, which may or may not be partitioned off by fine filaments.

In the follicular cords, in the connective tissue arches, and even in some of the sinuses I have found Ehrlich's cells rounded or elongated. Some of them were very small, and had a nucleus like that of microcytes. It is known that it

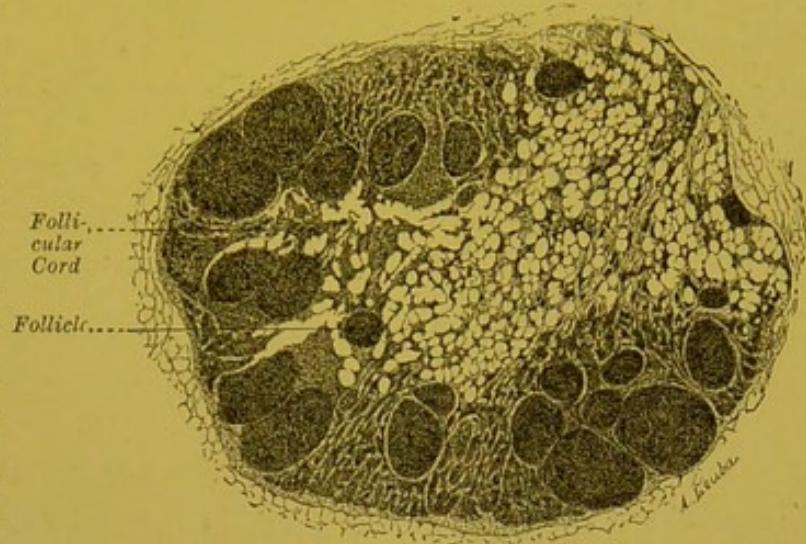


FIG. 30.—Mesenteric gland of the hedgehog.

is exceptional to find Ehrlich's cells in the glands of the rabbit and guinea-pig.

In the capsule, the cortical layer, and some of the medullary cords, were isolated eosinophiles, or eosinophiles in groups of four or five. The sinuses contained very few of them. One eosinophile of the cortical layer was in mitosis; several showed a single round nucleus, as colourable as that of the other leucocytes. In the follicles of this gland, macrocytes with basophile granules were seen.

The pig's gland is very simple. A connective tissue capsule, thick and quadangular in the region of the hilum, but elsewhere thin, more or less completely isolates it from neighbouring glands with which it shows a tendency to unite. It is reduced to an homogeneous layer which is precisely similar to the cortex of ordinary glands. In this layer, the follicles are scattered. Sinuses are seen only at the circumference of the follicles, and of the peripheral connective tissue arches. There are then, neither follicular cords, nor cavernous channels. The cells have a normal appearance. We may further note the presence of macrocytes with basophile protoplasm in the follicles. In the perifollicular layer, a fair number

of eosinophiles may be found, the majority of which have a nucleus which is identical with that of ordinary cells, and there are some in

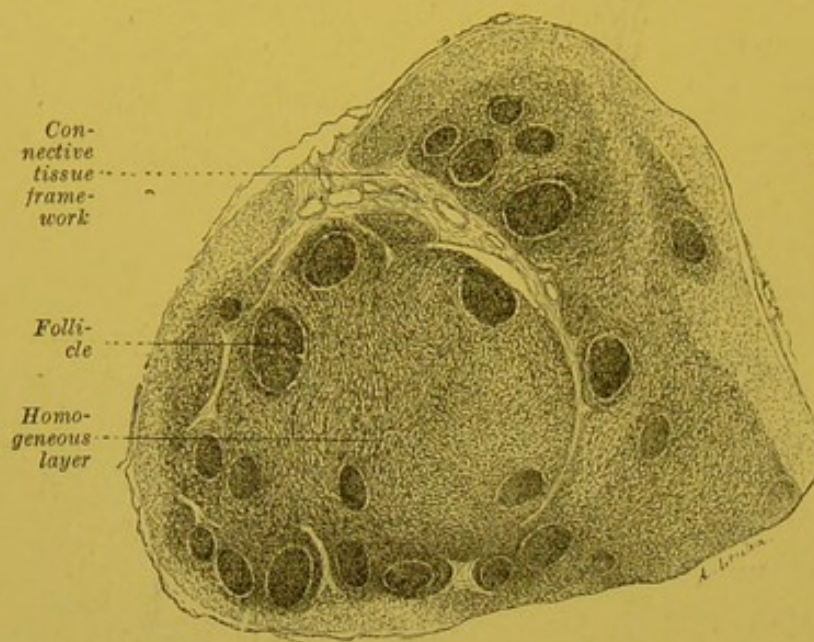


FIG. 31.—Mesenteric glands of the pig.

which the protoplasm contains three or four granules only. In the connective tissue arches, in the perifollicular layer, and sometimes even, on the border of the follicle, Ehrlich's cells may be seen isolated or massed together: there they are small or large, rounded or

elongated; the nucleus, which is usually oval, is at times coloured pale blue, and at others, a violet rose by Unna's blue.

I have examined six glands from the pig without being able to find the least trace of haematophagosis.

Schumacher, contrary to Rawitz's experience, has proved that the monkey's gland, like that of other mammals, has germinative centres.

Evolutionary Variations. — Insensescence. — The gland, a highly-developed organ, disappears early, without ever possessing a permanent structure to any great extent. These incessant variations result from the multiplicity of its functions, especially from its capability of performing the functions of other organs. We know how close are the ties which unite it to the paradigestive lymphoid formations, the spleen and even to the bony marrow.

The only differences are, that, while the tonsil and spleen constitute sites for the origin of the lymphatic vessels, the lymphatic glands, on the contrary, are placed in the course of the latter. The spleen is a gland interposed in the course of the blood stream.

Under these circumstances, we can well understand how, in spite of a specialization more apparent than real, numerous vicarious functions are possible which render the study of this organ a very complex one: for instance, after splenectomy, the eosinophiles of the gland increase; and haematophagosis, usually discreet or insignificant, now assumes larger proportions. Dominici says that

under these circumstances the gland undergoes *splenoid transformation*.

The iron in the gland may increase: with Guillemonat I have found, in such cases 0·06 gr. 0·08 gr. and even 0·11 gr. of this metal in each 100 parts. Twice, on the contrary, I have only found traces of it.

On the other hand, after bleeding and exhaustion it seems to diminish. We shall see, however, that some authors, on the contrary maintain that under these conditions, glandular haemato-poiesis is more active.

In an animal during gestation, it is not unusual to find a considerable number of nucleated red blood cells (Masslow). Dominici describes the gland of a pregnant female as a gland which is undergoing myeloid transformation. To glands which contain many Neumann's and Ehrlich's cells, eosinophiles, with a single nucleus, and polynuclears, Scott Warthin gives the name of *myelolymphatic glands*.

Insenescence.—Atrophy takes place prematurely, seeing that in the adult man, all mitoses may be observed to disappear, and sclerosis makes its appearance; the latter process invades the whole of the organ in the aged. This sclerosis is peripheral and central. At the periphery, it is the capsule which thickens; while at the centre, it is the excessive proliferation of the perivascular arches which transforms the medulla into a fibrous block; but, surrounded in this concentric sclerotic band, there still remains a fine band of cortical substance which is, in its turn, eventually split up and invaded by the sclerosis which makes its appearance round the vessels (vide fig. 32).

Demoor does not agree with Orth, His, and Billroth, who maintain that as age advances, the nuclei in the cells of the network eventually disappear completely. Contrary to Frey's experience, he did not observe the fatty degeneration or pigmentary infiltration of the cells of the network. I looked for one or the other of these changes in three or four very old dead subjects, but in vain. In

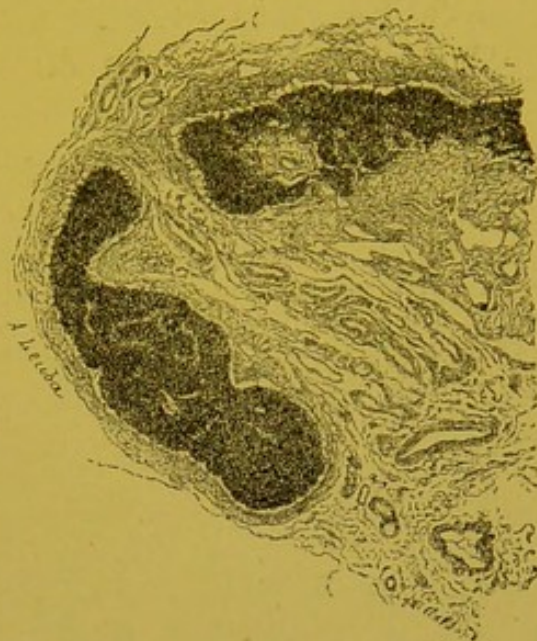


FIG. 32.—Mesenteric gland from an old man.

these fibrous glands there are no longer traces of macrocytes (macrophages) in the sinuses.

FUNCTIONS. — *Leucocyto-genesis*. — Whether glandular cells are fixed leucocytes or autochthonous derivatives of mesodermic elements, at any rate they produce the white corpuscles. In fact, the latter are more numerous in the efferent than in the afferent vessels; there is a close relation between blood leucocytosis, glandular hypertrophies, and the number of mitoses. Similarly, the experimental removal of certain important glandular groups produces hypoleucocytosis.

The glandular cells are therefore clearly lymphogenous, and the gland is a *cytogenous gland* like the testicle. In this connexion, it is interesting to recall the fact that these two mesodermic organs which are so distinct in vertebrates, are blended in certain invertebrates, viz. the lympho-sexual glands of the Bryozoeae, and of some of the Polychetae (Cuénot).

The gland specially produces microcytes (lymphocytes), and very probably, macrocytes (large mononuclears) also. The microcytes, numerous in the gland and in the efferent channels, increase in pathological or experimental (splenectomy) glandular hypertrophies.

On the other hand, they diminish after extensive glandular ablations (Rokitzi, Tchigaieff, Ehrlich and Reinbach), and after ligature of the thoracic duct (Koroboff).

There, eosinophiles are again formed and perhaps also, sometimes, cells with neutrophile granules. The eosinophiles, which are often numerous, rarely present mitoses: Jolly has seen one in the rabbit; I have seen one in the hedgehog: it is the eosinophiles with a single round nucleus which are more frequently observed in the gland or in the lymphoid portion of the thymus; Labbé notes the existence of similar cells in the guinea-pig, and I have found them in the rabbit, pig and hedgehog. Further, there are some eosinophiles with few granules, whose nucleus, in its shape, staining properties, and arrangement of its chromatin, resembles at times microcytes, and at others, ordinary macrocytes. It would seem as though we were witnessing the first appearance of granules and their progressive development in a cell which was at first destitute of them. We should also note the presence of the blood eosinophile which accompanies certain glandular hypertrophies (lymphadenoma, splenectomy). It is therefore almost certain that, following the opinion of Hoyer, Schaffer, and more recently of Labbé, there is sometimes, if not always, a production of eosinophiles in the lymphoid tissues (gland and thymus). In the normal frog,

eosinophiles are produced in the spleen. It has long been known that the gland encloses multinucleated cells, and cells with a polymorphous nucleus; but the polymorphism of the nucleus does not necessarily imply the presence of neutrophile granules. Quite recently, Dominici has seen cells with neutrophile granules develop in lymphoid tissue. This is the natural and almost necessary consequence of the presence in the tissue of basophile macrocytes analogous to myelocytes.

Haematopoiesis.—Now to complete its resemblance to the bony marrow and the embryonic spleen, we may inquire if the gland is, or at any rate can under any circumstances become, a centre of haematopoiesis?

The possibility of its acting as a substitute in this way seems demonstrated by a very suggestive observation of Rindfleisch. This pathological anatomist found Neumann's cells in the hypertrophied glands of a rachitic infant, in whom the bony marrow was absent.

Saxer attributes this function to the embryonic gland, and Retterer regards it as a fundamental property of adult lymphoid tissue. According to this histologist, the glandular cells elaborate red blood cells, either by means of their nucleus, or of their protoplasm: the "haemoglobic degeneration" of the nucleus gives rise to red discoid blood globules, while that of the protoplasm, which is less common, produces red nucleated corpuscles.

There are certain glandular cells, the nucleus of which when in a state of degeneration, stains with eosine or orange, and which in shape very closely resembles red corpuscles. Is this sufficient to prove that these elements are red corpuscles in process of formation? We may at least have our doubts on this point. The lymphoid tissue and the sinus may, however, contain red blood cells, which are sometimes nucleated. As regards the pathological condition, when there are congestions, or visceral haemorrhages, when the blood carries away Neumann's cells, this statement furnishes no decisive argument in favour of glandular haematopoiesis. Under these circumstances, it is, in fact, impossible to prove that the red blood cells found in the gland have originated there, and have not arrived there through diapedesis (Schumacher), or through a vascular rupture (Saltikow). On the other hand, we cannot assume a similar origin for the cells of Neumann which, while absent in the normal blood of adults, are sometimes present in the cortical layer and in the cavernous passages

of the gland. I observed this fact in the grey rat and in the pig : in the rat, we have to deal with giant nucleated red blood cells almost entirely, whose protoplasm is unequally rich in haemoglobin. Some possess a nucleus, in which a reticulum and chromatin nucleoli can be distinguished ; others have a smaller nucleus deeply and diffusely stained ; finally there are some in which the nucleus is very pale, poor in chromatin, and seems to be in process of disappearing. In the pig, the nucleated red blood cells, which are usually small, are transformed into ordinary red blood corpuscles by nuclear excretion.

Glandular haematopoiesis, though it sometimes undoubtedly takes place, seems very inconstant, or at any rate very intermittent : histological examination by no means always demonstrates the constant presence of Neumann's cells in glandular tissue : moreover, chemical analysis agrees with histology in proving this inconstancy. In glands taken from the slaughter house, Schmidt found no haemoglobin. In six out of fourteen examinations, we, agreeing with Guillemonat, found only inappreciable traces of iron (three times an infinitesimal amount, and three times larger traces).¹

Haematolysis and Phagocytosis.— In the pathological state owing to the presence of its macrocytes (macrophages of Metchnikoff), the gland may become an active centre of haematophagasis and consequently of haematolysis.

In intoxications caused by phosphorus and arsenic, and in poisoning by toluilin-diamin, Hoyer observed numerous examples of glandular haematophagasis, and though Retterer denies this function, Gabbi, Schumacher, and Thomé regard it as a constant function of the healthy gland. Scott Warthin localizes this function in certain glands, or rather in certain haemolymphatic or splenoidal glands, which have been studied by Leydig, Gibbes, Robertson, Clarkson, Sisto and Morandi, Morandi and Piato.

It is quite clear that if haematophagasis were present to any great extent in all normal glands the latter would be red and would always contain iron in fairly large proportion ; we know, however, that such is not the case.

Moreover, we do not always see the histological signs of an

¹ The estimations were carried out by Lapicque's method. The animals (pig, dog, rabbit, rat) were killed by bleeding, and the glands washed in distilled water. We have thus as far as possible avoided the cause of error due to the presence of blood ; this cause of error is more easily eliminated in the case of the gland than in that of the spleen.

extensive glandular haemolysis in the normal state. This process, which is often absent or insignificant, has not appeared to me so marked as it is in the mesenteric glands of the rabbit after splenectomy, or after the injection of pilocarpine.

Even after splenectomy, it is inconstant or transitory. At various times after this operation I have examined the mesenteric glands of eight rabbits, without ever observing (contrary to the experience of Lockart Gibson and Moses Grünberg), the slightest redness or the least macroscopic hypertrophy. The increase in the amount of iron is also inconstant. Though, on three occasions, 0.06 gr., 0.08 gr., and 0.11 in each 1000 parts were found, on two occasions, there were only traces.

We can understand how the same organ exercises these two antagonistic functions of haematolysis and haematopoiesis simultaneously or intermittently, seeing that the former furnishes the materials for the latter process.

Owing to its slow circulation and to its innumerable phagocytes, the gland is also a place where inert or living particles brought to it by the afferents are arrested. We are acquainted with the carbon infiltration of bronchial glands, and the yellowish green pigmentation of the mesenteric glands of the rabbit. Schmorl found that glands draining a pigmented or tattooed cutaneous area were blackish in colour.

The question of the presence of bacteria in the normal gland opens a wider field for discussion. Wissokowitch, Neisser and Labbé found the glands sterile; Loomis, Pizzini, and Kossel were able by inoculation to demonstrate the septic properties of some of them. Perey found in them both saprophytic and pathogenic agents; while Desoubry and Porcher, and Josué found microbes in the thoracic duct.

In the closed follicles of the appendix of the rabbit I have found, as Denys has, bacilli, even though the mucus membrane was histologically intact, and I have found the same thing in the pig's gland. The normal gland may then contain germs, and it is possible that these germs may not be entirely disconnected with the production of the numerous soluble ferments which are now being studied.

Amorphous Secretions.—Rossbach observed the presence of an amylase in the tonsil. Foa and Pellacani produced coagulation of the blood by the intravascular injection of glandular extracts; the lymphatic glands apparently contain thrombase. The difference in the amount of fat contained in the afferent and efferent chyle

had long been observed ; quite recently, Poulain found in the gland the lipase, the existence of which was known in the thymus. The recent researches of Arthus and Doyon however, take away all interest in this statement.

Delezenne has discovered in the mesenteric glands of the dog, the pig, and the rabbit an "*enterokynase*"—a ferment which aids the trypsin, and which exists also in Peyer's patches.

Metchnikoff notes the presence of a "fixer" in the mesenteric glands. Taressewitch states that, in a glandular extract, the red blood corpuscles are nearly always dissolved : this is not the case in the marrow of bone ; he attributes this action to the presence of a ferment (?)—the macrocytase.

Whatever the truth may be as to the real nature of this macrocytase, the gland contains ferments, the exact origin of which we have still to learn.

On the other hand, the gland is an important centre for cytolysis : its cells degenerate, become vacuolated, and shed their nuclei ; the eosinophiles, the cells of Ehrlich, there heap up their granules : regarded from these two points of view, it behaves like a secreting gland, that is to say, like an organ which, by a partial or total destruction of some of its elements, sets free into the circulation a product which is useful for the needs of the organism.

According to Asher, the products of katabolism provoke the glandular functions, and the result of this is the transformation of the waste products of cellular life.

In fact, the lymph, which is a product of organic work and therefore charged with poisons, is not eliminated externally : thrown into the general circulation, as it is, it can only undergo modification in the gland and lung.

On the other hand, the presence of an amylase, and of enterokynase seem to indicate that the gland which is capable of digesting certain bacteria, is also capable of digesting certain chemical substances.

According to the splendid conception of Metchnikoff, the actions of defence against microbic invasion, and the actions of an intimate nutrition are united in the same gland. These functions of the closed gland which can modify its contents, but about which we are still very ignorant, complete the analogy which it presents to other mesodermic and cytogenous glands such as the testicle and ovary.

BIBLIOGRAPHY.—Sylvius. *Disput. anat.*, V et VI.—Wharton. *Adenographia, sive glandularum totius, corporis descriptio*, 1664.—Nuck. *Adeno-*

graphia curiosa et uteri femineæ anat. nova, 1691.—Malpighi. *Marcelli Malpighi de structura glandularum conglobatarum consimiliumque partium epistolæ*, 1697.—de Graaf. *Opera omnia*, 1765.—Cruikshanks. *The anatomy of the absorbing vessels of the human body*, 1786.—Hewson. *The works of William Hewson*, 1846.—Mayer. *Salzb. med. ch. Zeitung*, 1815, IX.—Neumann. *Von der Natur des Menschen*, 1815.—Bichat. *Anatomie générale*, 1818, II.—Chaussier et Adelon. Art. "Lymphatique." *Dict. Sciences médic.*, 1818.—Lauth. *Th. Strasbourg*, 1824.—Breschet. *Le système lymph.* Paris, 1836.—Donders. *Physiologie*, übersetzt von Theile, Bd I.—Herbst. *Das Lymphgefäßsystem u. seine Verrichtung*. Göttingen, 1844.—Noll. U. den Lymphstrom. *Zeitschr. f. rat. Medicin.*, 1850.—Engel. Bau u. Entwicklung der Lymphdrüsen. *Prager Vierteljahrschrift für prakt. Heilkunde*, 1850, XXVI.—Heydfelder. U. den Bau der Lymphdrüsen. *Inaug. Diss.* Erlangen, 1851.—Gerlach. *Gaz. hebdom. méd.*, 1856, III.—Brücke. U. die Chylusgefäße u. die Fortbewegung der Chylus. *Acad. Sciences, Vienne*, 1853, IV et X.—Leydig. *Lehrbuch der Histologie*, 1857.—Billroth. *Müller's Archiv*, 1857;—*Beiträge zur path. Histologie*. Berlin, 1858.—Eckard. De glandul. lymphat. structura. *Diss. Inaug.* Berlin, 1858.—Henle. *Zeitschrift f. ration. Medicin*, 1860, 3 série, vol. VIII.—His. *Unters. über den Bau der Lymphdr.*, Leipzig, 1861.—Frey, *Unters. über die Lymphdr. der Menschen u. der Säugethiere*, Leipzig, 1861.—His. *Zeitschrift f. wissenschaftl. Zoologie*, 1862, XXI.—Billroth. Zur Structur der Lymphdrüsen. *Zeitschr. f. wissenschaftl. Zoologie*, 1861–1862, XI.—Schmidt. Das folliculäre Drüsengewebe der Schleimhaut der Mundhöhle. *Zeitschrift wiss. Zool.*, 1863, XIII.—Labédut. *Système lymphat. Thèse agrég.*, 1866.—Sertoli. Entwick. d. Lymphdrüsen. *Sitzungsber. d. Wiener Akad.*, 1866.—Crocq. *Gazette des hôpitaux*, 1868.—Orth. Unt. über Lymphdrüsenentwicklung. *Inaug. Diss.*, Bonn, 1870.—Bizzozero. Sulla struttura delle ghiandole linfatiche. *Rendi conti reale istituto lombardo*. Série II, vol. V, fasc. 2. Gennazo, 1872.—Klein. *The anatomy of the lymph. system: The serous membranes*. London, 1873.—Ducastel. *Anatomie normale et pathologique des ganglions lymphatiques*. *Soc. Anat.*, 1874.—Kupffer. Ueber die Sternzellen der Leber. *Arch. f. mikrosk. Anat.*, 1876, XII.—Bizzozero. Beiträge zur Kenntniss des Baues der Lymphdrüsen. *Moleschott's Untersuchungen zur Naturlehre*, 1876, II.—Pouchet. Note sur la structure des ganglions lymphatiques. *Gaz. méd. Paris*, 1879.—Arnold. Karyokinèses dans les ganglions hypertrophiés. *Virchow's Arch.*, 1879.—Rindfleisch. U. Knochenmark u. Blutbildung. *Arch. f. mikr. Anat.*, 1879, XVII.—Garel. Recherches sur l'anatomie générale comparée et la signification morphologique des glandes de la muqueuse intestinale et gastrique des animaux vertébrés. *Thèse Lyon*, 1879, 1^{re} série, n° 8.—Weigert. *Virchow's Archiv.*, LXXIX.—Chiewitz. Zur Anatomie einiger Lymphdrüsen. *Arch. f. Anat. u. Entwick.*, Anat., Abth., 1881.—Neumann. U. Blutregeneration u. Blutbildung. *Zeitschr. f. klin. Med.*, 1881, III.—Winogradow. *Centralbl. f. die med. Wissenschaft.*, 1882, n° 50.—Foa et Pellacani. Sur le ferment fibrinogène et sur les actions toxiques exercées par quelques organes frais. *Arch. Ital. de biol.*, 1883, IV, p. I.—Masoin. *Acad. méd. Belg.*, 1880, XIV, n° 11.—Kultschitzky. Die Entstehung der rothen Blutkörp. bei den Säugethiern. *Arbeiten der Naturforschergesellschaft in Charkow*, XV.—Einhorn. Ueber das Verhalten der Lymphocyten. *Inaug. Diss.* Berlin, 1884.—Drews. Zellvermehrung in der Tonsilla beim Erwachsenen. *Arch. f. mikr. Anat.*, 1884, XXIV.—Arnold. *Virchow's Archiv*, 1882, LXXXVII; 1884, XCV.—Toldt. *Lehrbuch der Gewebelehre*, 2^e éd., 1884.—Stöhr. Ueber Mandeln u. Balgdrüsen. *Virchow's Archiv*, 1884, XCVII.—Gibbes. *Microscopical Journ.*, 1884, XXIV;—*Amer.*

Journ. of med. Sciences, 1893.—Flemming. Die Zellvermehrung in den Lymphdrüsen. *Arch. f. mikr. Anat.*, 1885, XXIV, p. 50.—Baumgarten. *Zeit. f. klin. Med.*, 1885, IX et X.—Paulsen. Zellvermehrung in hyperpl. Lymphdrüsen. *Arch. f. mikr. Anat.*, 1885, XXIV.—W. His. *Anat. menschlich. Embryonem*: III. Zur Geschichte der Organen, Leipzig, 1885.—Retterer. Contrib. à l'étude du cloaque et de la bourse de Fabricius chez les oiseaux. *Journ. Anat. et Phys.*, 1885;—Sur le développement des tonsilles chez les mammifères. *C. R. Acad. Sciences*, 14 déc. 1885.—Lockart Gibson, The blood forming organs and blood formation. *Journ. for Anatomy and Physiol.*, 1886, XX.—Ayoama. *Virchow's Archiv*, 1886, CVI.—Henle. Zur Anat. der geschlossenen Drüsen u. der Lymphdrüsen. *Zeits. f. rat. Med.*, VIII.—Sussdorf. Lymphdrüsen. *Ellenberger's Handbuch der Histol. der Haussäugethiere*, 1887.—Hofmeister. *Arch. f. exp. Path. u. Pharm.*, 1887, XXII.—Orth. *Cursus der normalen Histologie*, 1888.—Davidoff. Untersuchungen ueber die Beziehungen des Darmepithels zum lymphoïden Gewebe. *Arch. f. mikr. Anat.*, 1887, XXIX.—Mall. Reticulated and yellow elastic tissues. *Anat. Anzeig.*, 1888;—Das reticulirte Gewebe u. seine Beziehungen zu den Bindegewebsfibrillen. *Abhandl. math. phys. Sachs. Gesellsch. Wiss.*, 1891, XVII.—Sanfelice. *Boll. della Soc. di natur. in Napoli*, 1889.—Stöhr. U. die Lymphknötchen des Darmes. *Arch. f. mikr. Anat.*, 1889, XXXIII.—Kourloff. *Wratch*, 1889, p. 515; 1892, p. 469.—Hoyer. Beitrag zur Kenntniss der Lymphdrüsen. *Arch. f. mikr. Anat.*, 1889, XXXIV.—Ribbert. Regeneration u. Entzündung der Lymphdrüsen. *Ziegler's Beiträge*, 1889, VI.—Kœppe. *Arch. f. Phys.* Supplement Heft, 1890.—Laguesse. Recherches sur le développement de la rate chez les poissons. *Th. Doct. ès sciences*;—*Journ. Anat. et Phys.*, 1890.—Robertson. *Lancet*, 1890.—Conil. Dével. du gangl. lymphat. *Thèse Bordeaux*, 1890.—Moses Grunberg. Experimentelle Untersuchungen ü. die Regeneration der Blutkörperchen in den Lymphknoten. *Thèse Dorpat*, 1890.—Löwit. *Wiener Sitzungsberichte*, 1883–1885–1887;—Die Anordnung d. Leukoblasten u. Erythroblasten in den Blutzellenbildenden Organen. *Anat. Anzeiger*, 1891, p. 344;—*Arch. f. mikr. Anat.*, XXXVIII.—Retterer. Origine et développement del plaques de Peyer chez le lapin et le cobaye. *C. R. Soc. Biol.*, 24 déc. 1891.—Zacharow. Zur Frage über die Veränd. der Lymphdr. im Greisenalter. *Th. Pétersb.*, 1891.—Rudinger. U. die Umbildung der Lieberkühn'schen Drüsen durch die Follikel im Wurmfortsatze des Menschen. *Verhand. der Anat. Ges. in München*, 1891.—Stöhr. Die Entwicklung des adenoïden Geweb. der Zungenbälge u. der Mandeln der Menschen. *Festschrift f. Nägeli u. Kölliker*. Zurich, 1891;—*Anat. Anzeiger*, 1891.—Gulland. The development of adenoid tissue. *Reports from laboratory of the royal college of Physicians*. Edimburg, 1891.—Oppel. U. Gitterfasern der menschlichen Leber u. Milz. *Anat. Anzeiger*, 1891, VI, p. 165.—Bonnet. *Grundriss der Entwick. der Haussäugethiere*, 1891, p. 173.—Bizzozero. *Atti R. Accad. Scienze Torino*, 1892, XXVII.—Ascoli. *Arch. f. mikr. Anat.*, LIII.—Muller. Zur Kenntniss der Bauesgesunder u. Krankhaft veränderter Lymphdrüsen. *Zeitschr. f. rat. Med.*, XX, 1 et 2.—Stiles. The surg. anat. of the breast a. axillary lymph. glands. *Edim. med. Journ.*, 1892.—Schmidt. *Zur Blutlehre*. Leipzig, 1892.—Gabbi. U. die normale Hämatolyse mit besonderer Berücksichtigung der Hämatolyse in der Milz. *Ziegler's Beiträge*, 1893, XIV.—Demoor. Recherches sur la structure du tissu réticulé. *Arch. Biol.*, 1893, XIX, fasc. 3, p. 575.—v. d. Stricht. Nature et division mitosique des globules blancs des mammifères. *Verhandlungen der anat. Gesellschaft*, 1893.—Retzius. *Biol. Untersuchung.*, V, 1893.—Boddaert. De l'œdème d'origine lymphatique. *Arch. Phys. norm. et path.*,

1894, p. 492.—Gulland. The developpt of lymphat. glands. *Journ. of pathol. and bact.* Edimb., 1894.—Kanter. *Centralblatt f. allgem. Pathol.*, 1894, V.—W. His. Die anatomische Nomenclatur. *Arch. f. Anat. u. Phys.*, Suppl. Band, 1895.—Rawitz. U. die Zellen in den Lymphdrüsen der *Macacus cynomologus*. *Arch. f. mikr. Anat.*, 1895, XLV.—Ranvier. Structure des ganglions mésentériques du porc. *C. R. Acad. Sciences*, 1895, CXXI, n° 23, p. 800 ;—*C. R. Soc. Biol.*, 1895, p. 774.—Tchigaieff. Rôle des ganglions lymphatiques dans l'organisme du chien. *Th. Pétersbourg*, 1895.—Saxer. U. Entwicklung u. Bau der normalen Lymphdrüsen. *Anat. Hefte*, 1896, VI, p. 349.—Ranvier. Dév. des ganglions lymphatiques. *C. R. Acad. Sciences*, 14 déc. 1896.—Retterer. Dév. des tissus conjonctifs muqueux et réticulé. *C. R. Soc. Biol.*, 1896, n° 1, p. 47.—Cantacuzène. Appareils et fonctions phagocytaires. *Année Biol.*, 1896.—Retterer. Origine des follicules clos du tube digestif. *Verhandl. der anat. Gesellschaft auf der neunten Versammlung in Basel*, 1896.—Naville. Dév. des follicules clos dans la conjonctive oculaire. *C. R. Soc. Biol.*, 1896, n° 15, p. 451.—Benda. Ueber den Bau der blutbildenden Organen u. die Re, generation der Blutelemente beim Menschen. *Physiol. Gesellsch.* Berlin-feb. 1896 ;—*Deut. Med. Woch.*, 1896, V, p. 41.—Clarkson. *British med. Journ.*, 25 July 1891 ;—*Textbook of histol.*, 1895.—Prenant. Sur la présence d'amas, leucocytaires dans l'épithélium pharyngien d'anguis fragilis. *Bibl. Anat.*, 1896, n° 1.—Schedel. In *Flemming's Studien ü. Regeneration der Gewebe*. Vergl., n° 3.—Disse. Anatomie des Rachens. *Heymann. Handbuch der Laryngologie*, 1896, III.—Ewald u. Kuhne. *Verhandlungen der naturhist. med. Vereines zu Heidelberg*, I, 5.—Höehl. Zur Histologie der adenoïden Gewebes. *Arch. f. Anat. u. Phys.*, 1897, fasc. I et II, p. 133.—Schumacher. U. die Lymphdrüsen der *Macacus Rhesus*. *Arch. f. Mikr. Anat.*, 1898, XLVIII ; 1899, LIV.—Retterer. *Journ. de l'Anat. et de la Phys.*, 1897, p. 463 ;—Origine épithéliale des leucocytes et de la charpente réticulée des follicules clos. *C. R. Soc. Biol.*, 20 mars 1897.—Cuénot. Les globules sanguins et les organes lymphoïdes des invertébrés. *Arch. d'Anat. microscopique*, 1897.—Ceresole. *Ziegler's Beitr. z. path. Anat.*, XVII, p. 602.—Vincent et Harriison. *Journ. of Anat. and Phys.*, 1897.—Jonnesco. *Congrès de Moscou*, août 1897.—Disse. Das retikuläre Bindegewebe. *Ergebnisse der Anatomie u. Entwicklungsgeschichte Merkel u. Bonnet*, 1897, VII.—Masslow. Einige Bemerkungen zur Morphologie u. Entwicklung der Blutelemente. *Arch. f. mikr. Anat.*, 1897, LI.—M. Labbé. Étude du ganglion lymphatique dans les infections aiguës. *Th. Paris*, 1898.—Stöhr. U. die Entwicklung der Darmlymphknötchen. *Arch. f. mikrosk. Anat.*, 1898, LI.—Thomé. Endothelien als Phagocyten. *Arch. f. mikr. Anat.*, 1898, LII.—Bezançon et Labbé. Le ganglion lymphatique normal. *Presse méd.*, 15 février 1899.—Melnikow Raswedenkow. Histologische Untersuchungen über das elastische Gewebe. *Ziegler's Beiträge*, 1899, XXVI, p. 546.—Retterer. Histogenèse de l'épiploon. *C. R. Soc. Biol.*, 1899, p. 614.—Dominici. Ilots périvasculaires chez le fœtus. *C. R. Soc. Biol.*, 1879, p. 72.—Lefas. Amas lymphoïdes dans la glande sous-maxillaire de l'homme. *C. R. Soc. Biol.*, 1899, p. 903.—Letulle. Les ganglions pariétaux de l'estomac. *Bull. Soc. Anat.*, 29 déc. 1899.—Creighton. A system of perivascular lymphatic cylinders and capsules in the united amnion allantois of the chick. *Journ. Anat. Phys.*, 1899, XXXIII, N. S. ; XIII, S. 527.—Saltikow U. bluthältige Lymphdrüsen beim Menschen. *Zeitschrift f. Heilkunde*, 1900.—Drummond. *Journ. of Anat. and Physiol.*, 1900.—Dominici. Considérations générales sur la structure des appareils hématopoiétiques chez le lapin. *C. R. Soc. Biol.*, 6 janvier 1900.—Sistio et Morandi. Contributo allo studio del reticolo delle linfoglandule. *Atti d. R. Accad. d. Sc. di Torino*, 1900, XXXVI.

—Retterer. *C. R. Soc. Biol.*, mars, avril, mai, juin 1900 ;—*XIII^e Congrès international de Médecine*. Paris, 1900 ; (*C. R. Sect. d'histologie*, p. 96) ; Recherches expérimentales sur l'élaboration d'hématies par les ganglions lymphatiques, janvier 1901 ;—De l'origine et de l'évolution des hématies et des leucocytes des ganglions lymphatiques. *C. R. Soc. Biol.*, 13 juillet 1901.—Dominici. Sur l'histologie de la rate à l'état normal et pathologique. *Arch de Méd. exp.*, janvier 1901, n^o 1 ;—Sur la réaction myéloïde. *Presse médicale*, 2 mars 1901.—Toukoff. Die Blutgefässe der Lymphdrüsen. *Intern. Monatsschr. f. Anat. u. Phys.*, XV, 9, p. 269.—Ribbert. Beiträge zur Kenntniss der Rhabdomyome. *Virchow's Archiv*, CXXX, p. 270.—de Bruyne. Contrib. à l'étude de l'union intime des fibres muscul. lisses. *Arch. Biol.*, XII, p. 345.—Haberer. *Arch. f. Anat. u. Phys.*, mars 1901.—Weidenreich. *Arch. f. mikr. Anat.*, juillet 1901.—Poulain. Sur la lipase des ganglions lymphatiques à l'état normal et path. *C. R. Soc. Biol.*, 15 juin, 17 juillet 1901.—Retterer. Des conditions expérimentales qui modifient la forme et la valeur des hématies élaborées par les ganglions lymphatiques. *C. R. Soc. Biol.*, 13 juillet 1901.—Beard. The source of leucocytes and the true function of the thymus. *Anat. Anzeiger*, XVIII, n^{os} 22, 23, 24.—Delamare. Note sur les cellules éosinophiles et les hématies nucléées du ganglion lymphatique normal. *C. R. Soc. Biol.*, 5 octobre 1901.—Guillemonat et Delamare. Le fer du ganglion lymphatique. *C. R. Soc. Biol.*, 26 octobre 1901.—Retterer. Structure, développement et fonctions des ganglions lymphatiques. *Journal de l'anatomie et de la physiologie*, 1901, n^{os} 5 et 6.—Scott Warthin. The normal histology of the human hemolymphglands. *American Journal of Anatomy*, 7 nov. 1901 ;—*Journ. of the Boston Soc. of med. Sciences*, avril 1901 ;—*Journ. of med. Research*, July 1901.—Morandi et Piato. *Arch. per le Scienze mediche*, vol. XXV.

Feb., 1902.

SECOND PART

Special Study of the Lymphatics of the Body

BY

P. POIRIER AND B. CUNÉO

WE will study in succession :—

1. The lymphatics of the lower limb (chap. i.).
2. „ „ „ pelvis and abdomen (chap. ii.).
3. „ „ „ thorax (chap. iii.).
4. „ „ „ upper limb (chap. iv.).
5. „ „ „ head and neck (chap. v.).

In each chapter we will first consider the different glandular groups and the arrangement of their afferent and efferent vessels. We will then return to the arrangement of the lymphatics of the organs and the tributary regions of these glands.

We will terminate this portion of the book by studying the two large collecting trunks into which almost all the lymphatic vessels of the human subject eventually pour their contents, viz. the thoracic duct and right lymphatic duct (chap. vi.).

CHAPTER I

THE LYMPHATICS OF THE LOWER LIMB

THE lymphatic vessels of the lower limb are arranged in two groups ; one (*the superficial lymphatics*) run in the subcutaneous cellular tissue, the other (*the deep lymphatics*) run under the aponeurosis. All converge towards the inguinal region, where they terminate in the superficial or deep inguinal glands. These inguinal glands thus form the common meeting place of almost all the lymphatics of the lower limb. However, some of these vessels have already traversed certain glands of much less importance, it is true, namely the anterior tibial and the popliteal glands. We will first of all describe the arrangement of these different glandular groups. We will

then give a description of all the lymphatic vessels of the lower limb.

§ 1. GLANDULAR GROUPS OF THE LOWER LIMB

WE will study in turn the *anterior tibial*, the *popliteal*, and the *inguinal glands*.

Anterior Tibial Gland. — The anterior tibial gland, described and figured for the first time by Mascagni (loc. cit. p. 39, and plate vi. fig. 2), is always very small. It is placed in the course of the anterior tibial vessels at their upper part; it rests on the interosseous ligament.

It is generally admitted that the anterior tibial gland receives an anterior tibial trunk, as an afferent, and gives off an efferent which ends in the popliteal glands. It would be perhaps more correct to say it is a simple nodule which interrupts the course of one of the anterior tibial trunks which end in the popliteal glands.

VARIETIES. — The existence of the anterior tibial gland is far from being constant. Cruikshank and Hunter make no mention of it. Bourguery and Leaf regard it as very inconstant. On the other hand it may be double (Mascagni, Hewson, Meckel), and descend as far as the middle of the limb (Hewson).

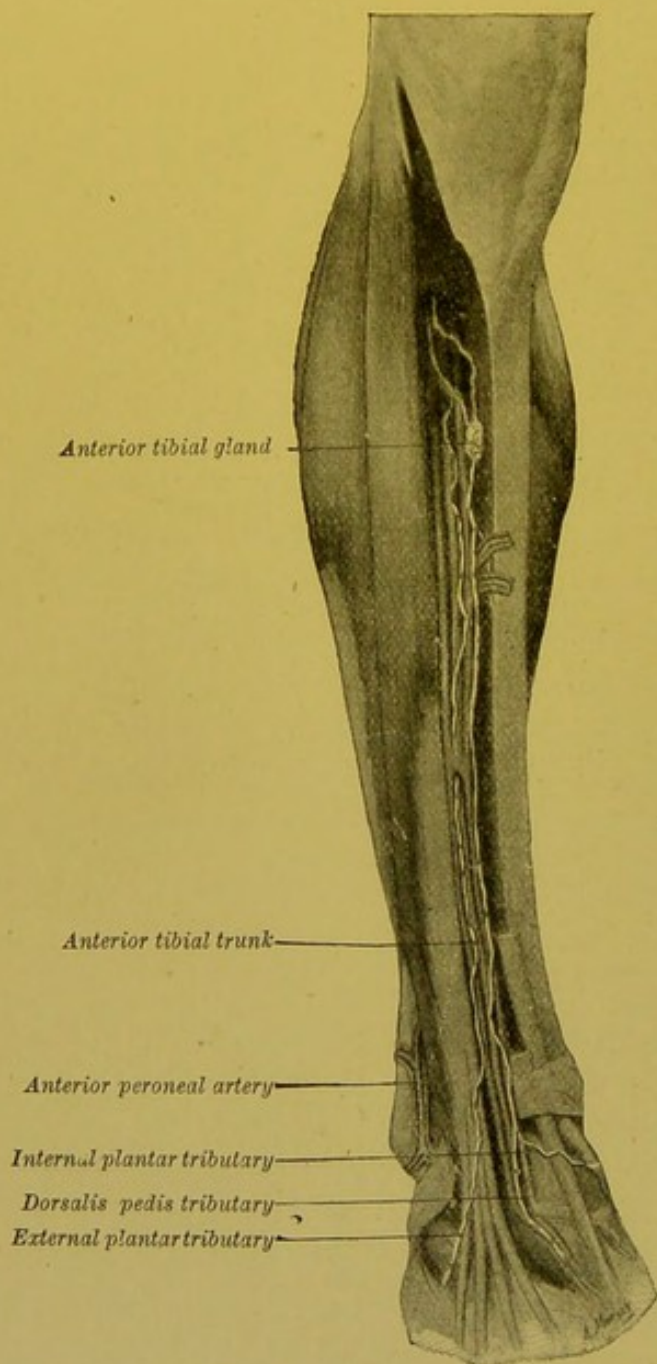


FIG. 33.—Anterior tibial lymphatics and anterior tibial gland (after Bonamy, Broca and Beau).

The inconstancy of this gland, its small size, its variations in number and situation, clearly prove that from the phylogenic point of view it is of

recent formation. In fact, it is not so much a gland properly so called as a simple interrupting glandular nodule (*Schalt-drüse*), which does not present the morphological fixity of the regional glands (*vide*, p. 86). But with our present knowledge of the general evolution of the glandular apparatus in the higher vertebrates, we are bound to admit that this nodule is in process of being raised to the dignity of a gland properly so called. In other words, its increase in size, and its division into two, should be regarded as *progressive anomalies*, its reduced size and its disappearance, as a return to the primitive state.

Popliteal Glands.—All the popliteal glands are sub-aponeurotic. As they are nearly always very small, and buried in the fatty tissue which fills the popliteal space, they are difficult to find unless their afferent vessels have been previously injected. They may be divided into three groups, which extend from the under surface of the aponeurosis to the posterior ligament of the knee joint.

(a) A primary gland is generally found beneath the aponeurosis, external to the terminal portion of the external saphenous vein, and internal to the external popliteal nerve. This is the external saphenous gland. Sometimes this gland is placed at a higher level, on an anastomotic branch between the external and internal saphenous vein.

(b) A second group (the middle glands), which is of much more importance, comprises 2 to 4 glands more deeply situated on the lateral parts of the popliteal vessels; these

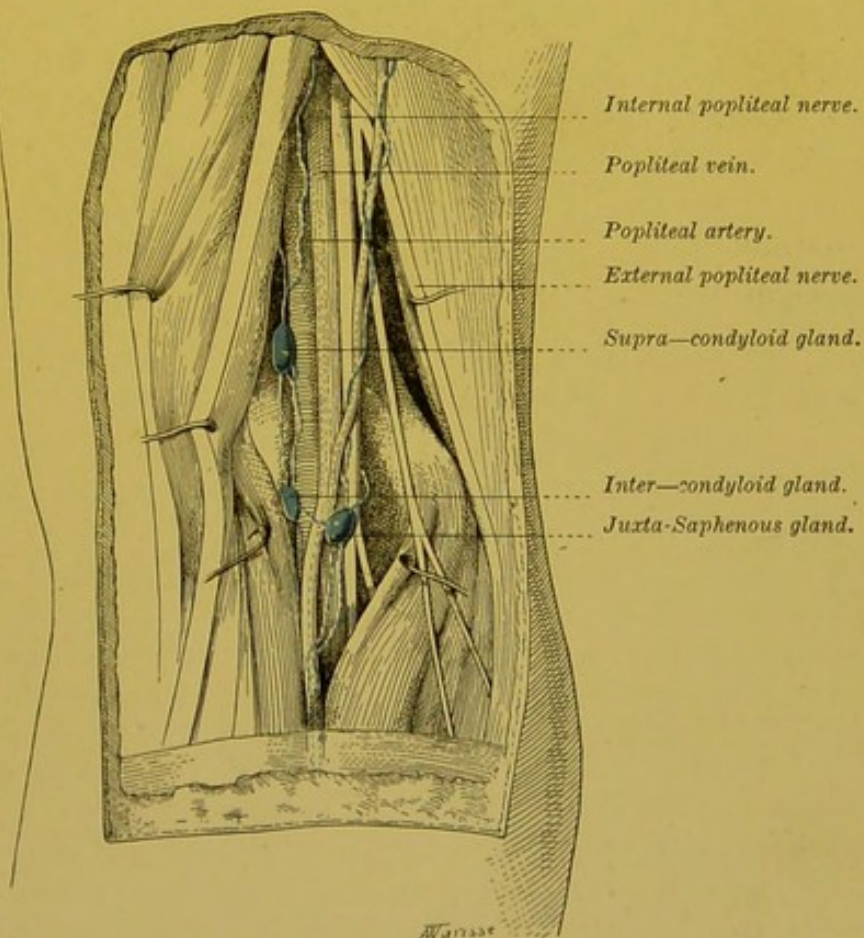


FIG. 34.—Glands of the popliteal space.

glands are situated some external to, and some internal to the vessels, and often form two distinct masses; one, the inferior, is placed at the level of the condyles, in the intercondyloid space (*intercondyloid glands*, Leaf); the other, the superior, is situated above these bony prominences (*supracondyloid glands*, Leaf) (vide fig. 40).

(c) Finally, a gland may be found attached to the posterior ligament of the knee joint, in front of the artery (juxta-articular gland).

AFFERENT VESSELS.—In each of these glandular groups, distinct afferents terminate. The external saphenous gland receives the vessels which accompany the external saphenous vein. These vessels come from the posterior third of the external border of the foot, from the outer part of the heel, and from the posterior surface of the limb.

The middle glands receive (1) the afferent lymphatics of the anterior tibial gland; (2) the deep lymphatics which accompany the posterior tibial and peroneal vessels.

The juxta-articular gland receives the lymphatics which come from the knee joint and accompany the articular arteries (Bardeleben, Naeckel and Frohse).

EFFERENT VESSELS.—The efferent vessels of the popliteal glands may be divided into two groups.

(a) A deep group which comprises 2 to 4 trunks which follow the popliteal vein, and then the femoral vein, and end in the deep inguinal glands.

(b) A superficial group comprising 1 to 2 trunks which follow the anastomotic branches between the external and internal saphenous veins, and which all unite with the satellite trunks of this vessel and terminate in the infero-internal group of inguinal glands. This latter route is less important than the former and may be absent.

Bardeleben, Naeckel and Frohse admit the further possibility of a third efferent route, which if present accompanies the great sciatic nerve.

VARIETIES.—The popliteal glands present numerous variations. We have taken as the type of our description the arrangement which has appeared to us to be the most frequent. Of the three groups which we have described, the most constant is the middle group. The external saphenous gland and the juxta-articular gland are not infrequently absent. A gland is sometimes found abnormally placed on the fibrous arch of the soleus muscle (tibio-popliteal, Bougery, loc. cit. vol. iv., plate 82).

Inguinal Glands.—The inguinal glands are much more numerous than the preceding, and constitute one of the more important glandular centres of the body. They are distinguished as superficial and deep.

SUPERFICIAL INGUINAL GLANDS.—The superficial inguinal glands occupy the whole of Scarpa's triangle. The space they occupy is limited above, by Poupart's ligament, externally by a vertical line passing through the anterior inferior iliac spine, internally, by a second vertical line drawn through the pubic spine, below, by a horizontal line placed six or seven centimetres below Poupart's ligament. They are placed in the deep layer of the superficial fascia, and are in relation with the following subcutaneous organs in this region: the subcutaneous abdominal arteries, viz. the superficial circumflex iliac, superficial external pudic; the corresponding veins, the terminal portion of the internal saphenous vein, and the crural branch of the genito-crural nerve.

The *number* of these glands is somewhat variable. Moreover, to succeed in estimating them accurately it is essential that their afferent vessels should be injected; for injections, and more particularly coloured injections, enable us to discover small glands which in a simple dissection would certainly escape notice. It may then be seen that they vary in number from 10 to 20; their *size* is no less variable than their number. As a result of the constant infections to which they are exposed, they are not infrequently found hypertrophied.

On account of their number, and the large space occupied by these glands, the majority of anatomists divide them into several groups. We must remark, however, that all these divisions are absolutely artificial. On the one hand, all of them as a matter of fact are scattered about without apparent order, so that it is impossible to group them into distinct masses, characterized by a constant topography. On the other hand, though each of the different regions whose lymphatics are tributaries of the inguinal glands send by preference their vessels to certain of these glands, there is no arrangement sufficiently constant to serve as a basis for a natural classification. We recognize, however, the necessity for dividing the superficial inguinal glands into several groups, though we would again insist on the purely conventional nature of any division.

With these reservations, we will adopt the following classification, which is almost identical with that proposed by Quénu and since accepted by Gerota, Bardeleben, Naeckel, and Frohse, etc.

A horizontal line passing through the saphenous opening, divides the superficial inguinal groups into two groups: a superior and an inferior. A vertical line passing through the saphenous opening, divides each of these groups into two secondary groups, one external

and the other internal. Finally, there is often a central group, formed by 1 to 3 small glands placed in the actual orifice of the internal saphenous opening. According to Leaf, it is not unusual to find one of these glands embedded in the fatty layer in the immediate vicinity of the saphenous opening, thus constituting a transition between the super-

ficial and the deep glands.

To sum up — The superficial inguinal glands may be divided into five groups :—

(1) supero-external, (2) supero-

internal,

(3) infero-

internal

(4) infero-external, (5) central group (parasphenous glands of Quénu ?).

The two superior groups are formed by a series of glands fairly regularly arranged below the crural arch, and having their long axis parallel to it. The arrangement of the lower groups is much more irregular. Though the lowest are usually elongated in the vertical direction, parallel to the axis of the limb, the majority of them are round or oval and irregularly scattered about.

There are many other classifications of the superficial inguinal glands. We are aware of the classical division into a superior or horizontal group (inguinal glands), and an inferior or vertical group (crural glands). The former would receive the genital, anal, abdominal, and gluteal lymphatics ; the latter, the lymphatics of the lower limb. Though this classification may suffice from the clinical, it does not do from the anatomical point of view. There are numbers of round glands situated in the centre of this region, and one does not know in which group they should be included. Moreover, we shall shortly see that the termination of the afferent lymphatics is far from being as systematic as this classification would seem to indicate. Sappey gives a different classification which we think it advisable to mention here, because it has been adopted by a certain number of authors. He describes a *superior* group which occupies the inguinal region ; an *inferior* group, the glands of which

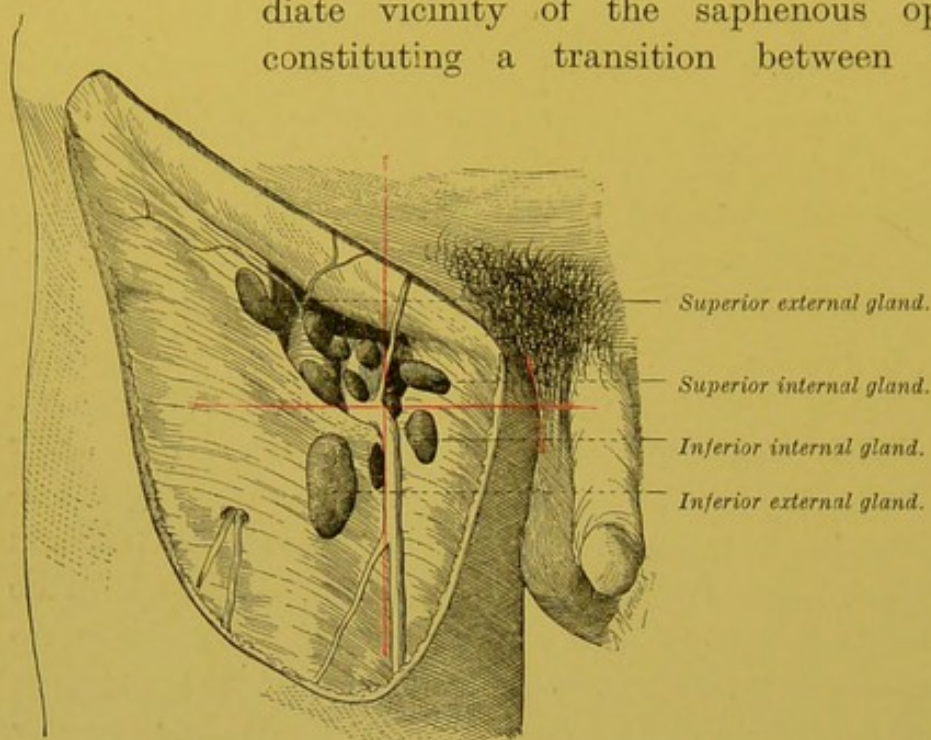


FIG. 35.—Superficial inguinal glands.

The cribriform fascia being removed, exposes the upper part of the femoral vessels.

are placed *round the internal saphenous vein* ; an *internal* group, placed within the saphenous opening ; an *external* group, situated external to the termination of this vessel ; and finally a *central* group, which has no fixed position or relation.

Aberrant Glands.—We may frequently come across aberrant superficial inguinal glands, situated external to the region which we have indicated above as being their more usual site. Thus Auspitz has observed the possible presence of little glands below the anterior superior iliac spine (extra-inguinal). Similarly, Lejars has come across glands placed above the crural arch and beneath the abdominal skin (supra-inguinal).

AFFERENT VESSELS.—The superficial inguinal glands receive the cutaneous lymphatics of the lower limb, the perineum, the scrotum, the penis, the prepuce of the clitoris, the anus, and the sub-umbilical portion of the abdominal wall. According to Sappey, the lymphatics of the glans penis, and glans clitoridis both throw themselves into the superficial inguinal glands ; but we shall see further on that this termination is exceptional and that these vessels are normally tributaries of the deep inguinal glands (vide pp. 156 and 159). It was formerly an accepted fact that each of the lymphatic territories which we are to describe, corresponds to a definite glandular group ; and it was, and for good reason, still is the custom to teach that, in certain symptomatic adenopathies it is possible, from the form and situation of the infected glands, to diagnose with certainty the position of the lesion. We will not repeat the different classifications which have been proposed, as none of them sufficiently indicate the facts. Recent researches have in fact satisfactorily shewn that the division of the inguinal glands into several groups is only of value for the sake of convenience, and that the lymphatics which come even from the same region, may terminate in different groups ; thus the lymphatics of the lower limb terminate both in the infero-external and in the infero-internal group.

Similarly, the lymphatics of the scrotum and the coverings of the penis usually end in the supero-internal group, but they may also end in the glands of the infero-internal group (vide p. 153). The same holds good for the lymphatics of the prepuce of the clitoris, the labia majora and minora (Bruhns) (vide p. 158).

The lymphatics of the perineum terminate in the supero-external and supero-internal groups.

The lymphatics of the anus usually pass into the supero-internal, but may terminate in the infero-~~external~~ glands, or again they may be tributaries to these two groups at the same time ; it is equally possible, though perhaps rather exceptional, to see one or several of them reach the central, or one of the external groups (Quenú, Gerota) (vide pp. 188 and 189).

The cutaneous lymphatics of the umbilicus and of the sub umbilical portion of the abdominal wall end in the supero-internal and supero-external glands (Bruhns, Cunéo and Marcille) (vide pp. 149 and 150).

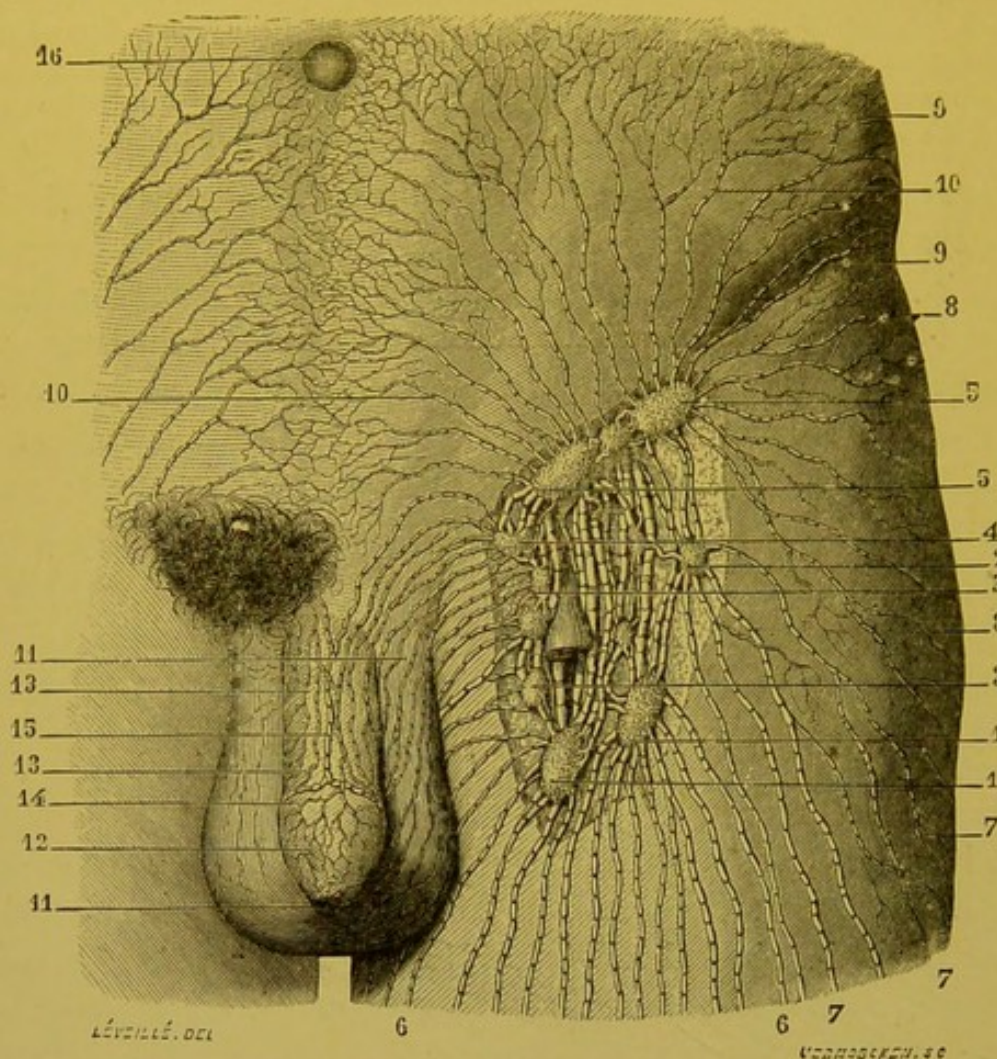


FIG 36.—Glands of the inguinal region; afferent and efferent lymphatics (taken from Sappey's atlas).

1,1. The two lowest glands of the inguinal region—both remarkable for their size.—2 Infero-external gland. 3,3. Internal inguinal glands to which pass the lymphatics of the scrotum, perineum, the anal region, and the supero-internal part of the integuments of the thigh.—4. Supero-internal inguinal gland; it receives vessels coming from the urethra, and from the surface of the glans and coverings of the penis.—5,5. Supero-internal and external inguinal glands, into which three or four lymphatics from the sub-umbilical portion of the abdomen terminate.—6,6. Lymphatic vessels from the antero-internal portion of the thigh.—7,7. Vessels from the external portion of the thigh.—8,8. Vessels from the gluteal region.—9,9. Vessels from the lumbar region.—10,10,10. Vessels from the sub-umbilical portion of the anterior wall of the abdomen.—11,11. Lymphatic vessels of the scrotum.—12. Lymphatic vessels of the prepuce.—13,13. Lymphatic vessels of the coverings of the penis.—14. Lymphatic trunk which surrounds the corona of the glans.—15. Median trunk which continues the course of the preceding.—16. Umbilicus.

The lymphatics of the buttock generally terminate in the supero-external group, but may also end in the infero-external glands.

EFFERENT VESSELS.—The efferent vessels of the superficial inguinal glands end in the deep inguinal, or in the external iliac glands. To

reach these glands they must pass through the femoral sheath: there are numerous orifices through which they pass, which give to the upper part of this sheath its characteristic stippled appearance.

The efferents which terminate in the deep inguinal glands are the least numerous. They come especially from the glands of the two lower groups.

The efferents which terminate in the pelvis are much more important; they vary in number from 8 to 12, and are always of considerable calibre. They pass into the pelvic cavity through the crural ring, and accompany the femoral vessels. Some of them pass in front of these vessels, but the majority run along the inner part of the ring, internal to the femoral vein. At this point, some of them may be interrupted by the gland of Cloquet; but the majority end in two glands, viz. the external and internal retro-crural (vide pp. 130 and 131, fig. 41).

DEEP INGUINAL GLANDS.—The deep inguinal or sub-aponeurotic glands are much less important than the superficial glands. They vary in number from 1 to 3, and are not usually of large size. In order to understand their precise arrangement and relations, their afferent vessels must be injected. It can then be seen that these glands are placed internal to the femoral vein. When there are three of them, the lowest is placed below the point where the external saphenous joins the femoral vein. The suprajacent gland is lodged in the crural canal. Finally, the superior gland occupies the external part of the crural canal, and protrudes through the septum crurale into the pelvic cavity. It is continuous in the pelvis with the internal chain of external iliac glands (vide p. 132). This gland of the crural ring, from the clinical point of view, has a certain amount of interest, for, on account of its situation, it may become inflamed, and may then simulate a strangulated femoral hernia. French authors generally call it the gland of Cloquet while the Germans call it the gland of Rosenmüller. ||

AFFERENT VESSELS.—The deep inguinal glands receive:—

1. Some of the afferents from the superficial inguinal glands.
2. The deep lymphatics which accompany the superficial femoral vessels.
3. The deep lymphatics which accompany the deep femoral vessels.
4. The lymphatics from the glands in the male, and the clitoris in the female.

EFFERENT VESSELS.—The efferent vessels penetrate into the pelvic cavity and almost all terminate in the retro-crural internal gland.

One or two may, however, end in the retro-crural external gland.

The most inconstant of these glands is the middle gland. The gland of Cloquet is also not uncommonly absent. Moreover, the total absence of the deep inguinal glands is far from being rare, but this statement cannot be made unless the deep femoral lymphatics have previously been injected. Unless this precaution is taken, these glands, which are lost in the fat, may not be recognized. In our view, certain authors, such as Auspitz, are quite wrong in regarding their absence as the rule.

Owing to the small size and inconstancy of the deep inguinal glands, Stahr regards them as simple nodules (Schalt-drüse), interposed in the course of the deep lymphatics of the lower limb (Stahr). This way of regarding them, we think incorrect, for it is at variance with the fact that the deep inguinal glands have other afferents than the femoral trunks, seeing that they receive the deep lymphatics from the penis and clitoris (Marcille). They are therefore true regional glands. On the other hand, we must recognize that the number and size of these glands is by no means proportionate to the importance of the deep femoral lymphatics: and it is difficult to understand what error caused Bourgery to estimate these glands as six or eight in number.

The gland figured by Bourgery in the course of the internal circumflex vessels (Bourgery, loc. cit. vol. 4, plate 82), and one or two small glands which are sometimes met with in the course of the femoral vessels in the middle part of the thigh may be regarded as aberrant elements of this group.

Upon the topography of the inguinal glands vide Mascagni, loc. cit. p. 37 et Tab., iv, viii, x.—Sappey, loc. cit. p. 63 et pl. vii, viii et xi.—Auspitz, die Bubonen der Leistengegend, *Arch. f. Dermat. u. Syphilis*, 1873, Bd v, p. 443.—Zeissl u. Horowitz, *Wiener klin. Wochenschr.*, 1890, p. 388, et *Wiener medicin. Presse*, Bd xxxviii, p. 761.—Leaf, loc. cit., p. 67.—Félizet, Note clinique sur les ganglions d'aboutissement des membres, *Bull. Soc. Chir.*, 1893, p. 521.—Quénu, *Journal de l'Anat.*, 1893, n. 4, p. 523.—Bruhns. Ueber die Lymphgefäße der äusseren männlichen Genitalien. u. der Zuflüsse der Leistendrüsen, *Arch. f. Anat. u. Phys.*, Anat. Abth., 1900, p. 281.

§ 2. LYMPHATIC VESSELS OF THE LOWER LIMB.

As we have seen above, we may divide the lymphatics of the lower limb into *superficial lymphatics*, which take origin in the integuments, the collecting trunks of which run in the subcutaneous cellular tissue, and into *deep lymphatics* which arise in the sub-aponeurotic organs, and end in trunks which closely accompany the vessels and nerves.

Superficial Lymphatics.—The superficial lymphatics emerge at all points from the cutaneous envelope of the limb; but it is in the foot that the network of origin presents its maximum development. It is in this situation too, and particularly on the lateral surfaces of the toes and margins of the sole of the foot, that the attempt must be made to inject these vessels. On the other hand, in the rest of the limb, with the exception perhaps, of the prae-patellar region, the network of origin has extremely fine meshes, and its injection offers great difficulties.

The collecting trunks which come from this network may be divided into three groups: (1) the collectors which accompany the internal saphenous vein, which are tributaries of the inguinal glands and which drain almost the entire cutaneous surface of the lower limb; (2) the collecting trunks which accompany the external saphenous vein, and which end in the

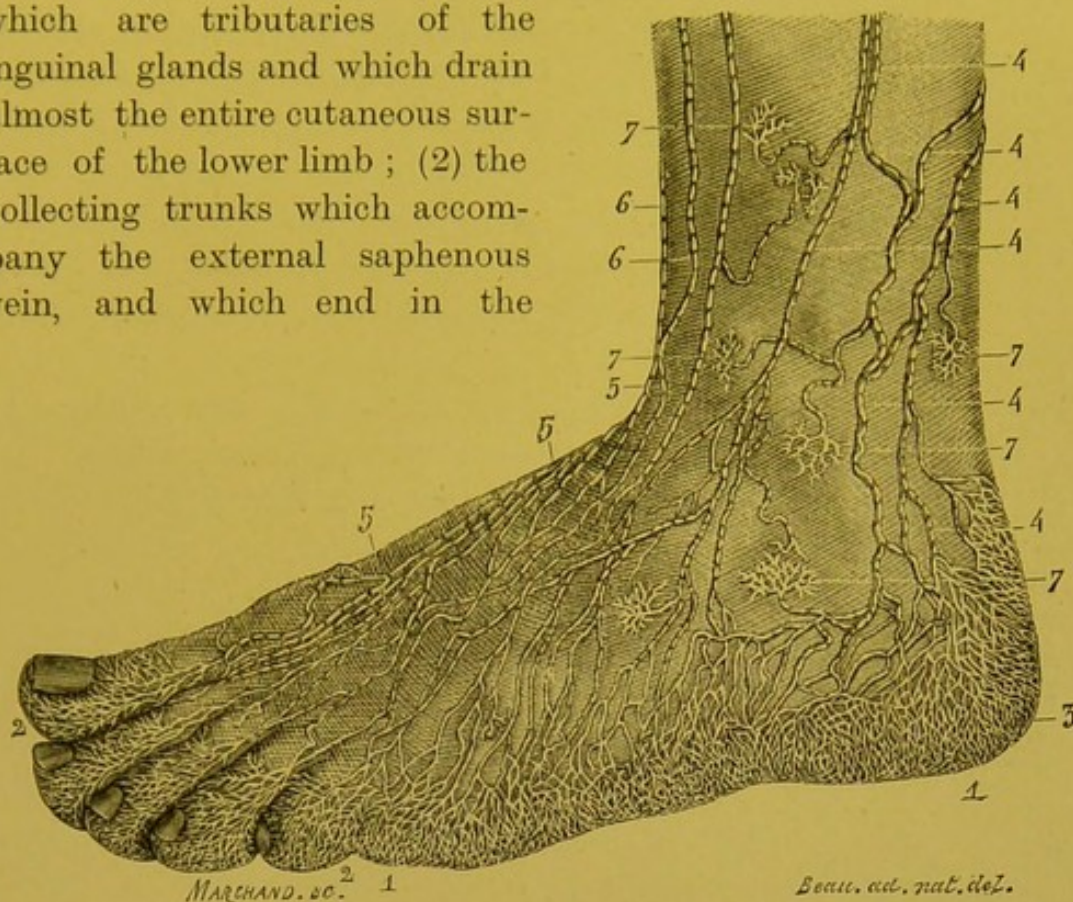


FIG. 37.—The superficial lymphatic vessels of the foot (after Sappey).

1, 1. Lymphatic network of the external border of the foot.—2, 2. Lymphatic network of the toes.—3. Lymphatic network of the skin of the heel.—4, 4, 4, 4. Lymphatic vessels which accompany the external saphenous vein and terminate in the popliteal glands.—5, 5, 5. Lymphatic trunks on the dorsal surface of the foot.—6, 6. Lymphatic trunks which run from the external towards the internal surface of the limb.—7, 7, 7, 7. Networks from each of which runs a little trunk, which terminates in one of the neighbouring trunks.

popliteal glands; (3) the collecting trunks of the gluteal region.

(1) THE COLLECTING TRUNKS WHICH FOLLOW THE COURSE OF THE INTERNAL SAPHENOUS VEIN.—These collecting trunks first appear in the toes. From the network which covers them, spring a considerable number of little trunks, some of which run towards the internal surface, and others towards the external surface of each toe, from both the dorsal and plantar aspect.

“In joining together, the dorsal and palmar trunks constitute on each lateral surface two principal trunks, parallel to the corresponding collateral artery, above which they are situated. At the level of the metatarso-phalangeal articulations, these trunks communicate with each other in various ways; sometimes, the external collaterals of one toe unite with the internal collaterals of a neighbouring toe; and sometimes, the four trunks from the same

toe unite to form a single trunk which divides a little farther up into two trunks which blend with the trunks which are nearest to them.

From these communications a large plexus results, the elongated meshes of which, from before backwards, are spread out under the integuments on the dorsal surface of the foot" (Sappey). In each interdigital space, this dorsal plexus is augmented by the trunks coming from the plantar region. These trunks, three or four for each space, originate at the level of the heads of the metatarsal bones, they converge from behind forwards towards the interdigital spaces, and then bend round to gain the dorsal surface of the foot.

From this dorsal network, several collecting trunks arise which, with Sappey, we may divide into internal and external.

The *internal collecting trunks* arise from the two inner toes and from the internal third of the dorsal network. Immediately after their origin, they are augmented by the internal plantar trunks which, as they turn round the internal border of the foot, number about twelve to fifteen, but become reduced to four or five after their arrival on the dorsal surface of the foot. The internal collecting

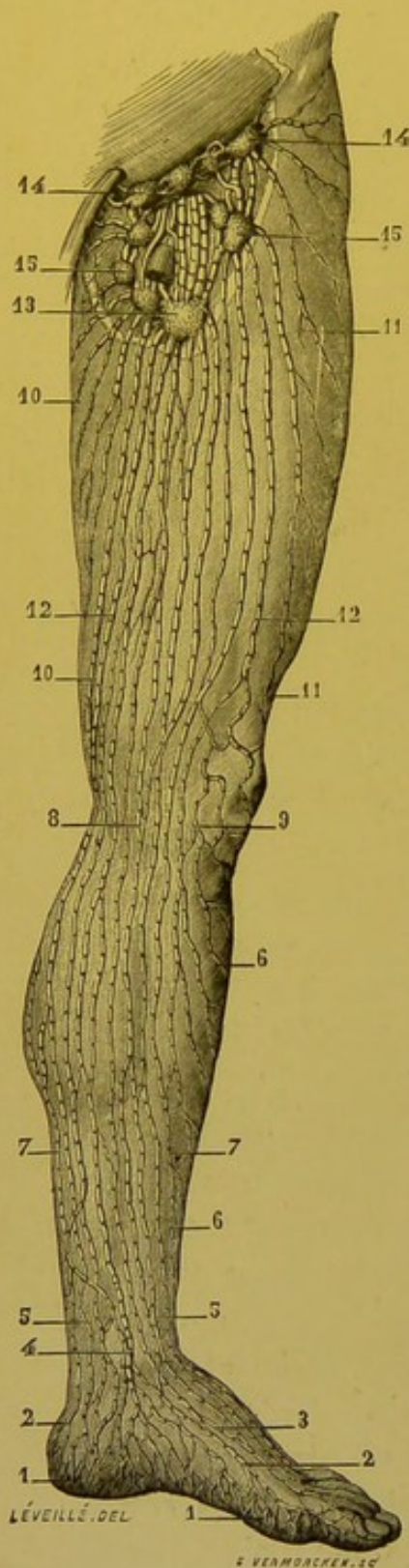


FIG. 38.—The superficial lymphatics of the internal surface of the lower limb (after Sappey).

13. Large glands in which the majority of superficial lymphatics of the lower limb end.—14, 14. Superior inguinal glands.—15, 15. Inferior inguinal glands; their afferent and efferent vessels.

1, 1. Lymphatic network of the internal portion of the sole of the foot.—2, 2. Lymphatic vessels which run from it.—3. Other lymphatic trunks of the dorsal surface of the foot.—4. Large trunk which passes in front of the internal malleolus.—5, 5. Vessels situated in front of and behind this trunk.—6, 6. Vessels coming from the external surface of the limb.—7, 7. General view of lymphatic vessels situated on the internal surface of the limb.—8. Vessels bending round the postero-internal part of the knee.—9. Vessels which skirt the front of the articulation; they differ from the preceding in their sinuosities.—10, 10. Vessels which take origin from the posterior portion of the thigh.—11, 11. Vessels which come from the antero-external part.—12, 12. Group of trunks which correspond to the antero-internal part.—

trunks then run upwards, being grouped round the internal saphenous vein to which they run parallel; for the most part they are placed either in front of or behind this vein; some of them may, however, cover it, or even be inserted between its deep surface and the aponeurosis. They thus pass as far as the inguinal glands.

The *external collecting trunks* arise from the three outer toes, from the outer two-thirds of the dorsal surface, and from the anterior half of its external border. Their arrangement is very different to that of the internal trunks. Instead of passing up vertically as the latter do, and being arranged in parallel columns, the external collecting trunks divide into secondary trunks which run in succession upwards and inwards to end in the internal collecting trunks. A comparison of fig. 38 with fig. 39 well shows the difference between the collecting trunks on the external and internal surface of the limb.

(2) COLLECTING TRUNKS WHICH FOLLOW THE COURSE OF THE EXTERNAL SAPHENOUS VEIN.—These vessels take origin from the posterior half of the external

1, 1. Lymphatic network of the external border of the foot.—2, 2. Two trunks springing from it; they pass backwards, and end in the popliteal glands.—3, 3. Lymphatic vessels of the dorsal surface of the foot coming from the toes and from the anterior portion of the plantar region.—4, 4. Vessels which cross the crest of the tibia, almost all of which come from one and the same trunk, which divides and subdivides; they are sinuous and frequently anastomose in their course.—5, 5. These are also very sinuous vessels which pass in front of the knee.—6, 6. Vessels which skirt the antero-external part of the knee joint, they are also remarkable for their sinuosities.—7, 7; Lymphatic vessels coming from the posterior portion of the thigh.—8, 8. Trunks which course along the antero-internal surface of the thigh.—9, 9. Trunks which correspond to its antero-external portion.—10, 10. Large glands in which the majority of superficial lymphatic vessels of the upper limb end.—11, 11. Superior inguinal glands; they are generally four in number, and are arranged in linear series.—12, 12. Other inguinal glands with afferent vessels.

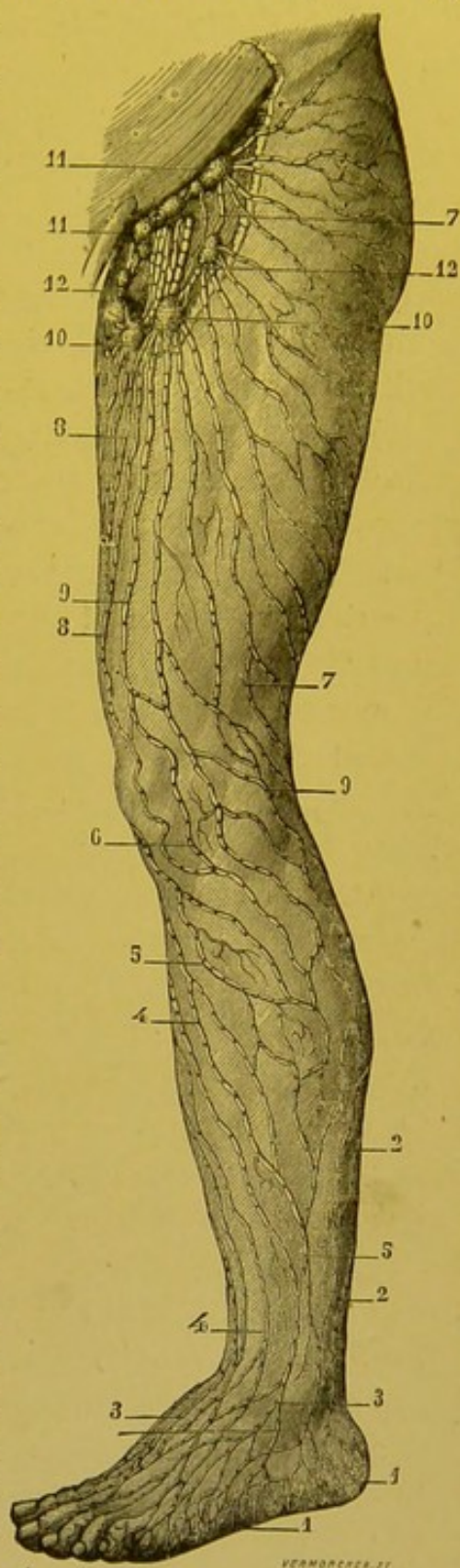


FIG 39 — Superficial lymphatics of the external surface of the lower limb (after Sappey).

border of the foot, and from the corresponding portion of the heel. From two to three in number, they run at first like the external saphenous vein between the external malleolus and the tendo Achillis, which they more or less closely embrace. Here they receive the lymphatics from the inferior part of the posterior surface of the limb. Always in close contact with this vein they are placed, like it; in the space between the two gastrocnemii. In the upper part of their course, they become sub-aponeurotic, and receive no more cutaneous branches. They terminate in the juxta-saphenous gland which is the most superficial of all the popliteal glands (vide p. 113).

(3) COLLECTING TRUNKS FROM THE GLUTEAL REGION.—The collecting trunks from the gluteal region may be divided into two groups,—external and internal.

(a) The external are the most important. They arise from the outer two-thirds of this region. They run at first downwards, outwards and forwards; they then turn round the great trochanter and eventually terminate in the supero-external group of superficial inguinal glands.

(b) The internal collecting trunks only drain the inner third of the buttock. They unite with the vessels coming from the integuments of the anal region (vide p. 187). Like the latter, they run downwards and forwards, and turning round the upper part of the thigh they end in the supero-internal, and infero-internal groups of superficial inguinal glands.

Deep Lymphatics.—The deep lymphatics of the lower limb may with sufficient accuracy be styled, “satellites” of the blood vessels. They comprise a *principal channel* which at first follows the different arterial trunks of the leg, and then keeps close to the popliteal and the femoral vessels, and *accessory channels*, which are satellites of the obturator, ischiatic and gluteal vessels.

THE PRINCIPAL CHANNEL.—In the foot and in the leg, the deep lymphatics may therefore be divided into three groups: the pedal and anterior tibial lymphatics, the plantar and posterior tibial lymphatics, and the peroneal lymphatics.

The pedal and anterior tibial lymphatics arise from the sole of the foot. The small trunks from which they originate spring from the deep plantar muscles. They unite into one or two trunks which run towards the dorsal surface of the foot, keeping close to the communicating branch between the external plantar and dorsalis pedis arteries. They then embrace the latter vessel

closely, and afterwards the anterior tibial. After being interrupted in the anterior tibial gland, they continue their course and never leaving the anterior tibial artery, terminate in the middle group of popliteal glands. In their course, they collect all the deep lymphatics of the dorsal surface of the foot and anterior aspect of the leg.

The plantar and posterior tibial lymphatics appear in the sole; they follow the two plantar arteries, then the posterior tibial, and terminate in the same glands as the preceding. It is in these glands that the *peroneal lymphatics*, satellites of the vessels of this name, terminate.

After being interrupted in the popliteal glands, all these vessels pass upwards, embracing the femoral vein. The latter is usually accompanied by four or five trunks, some of which are placed in front and some internal to it. According to our own observations, one or two small glands may be met with, in the course of these vessels in the region of the middle of the thigh. These vessels terminate in the deep inguinal glands.

Accessory Channels. — The obturator lymphatics which arise in the adductor muscles, are placed in the obturator foramen, and terminate in the obturator gland when this is present, or in the middle gland of the internal chain of the external iliac group (vide p. 132).

The ischiatic lymphatics, satellites of the artery of this name,

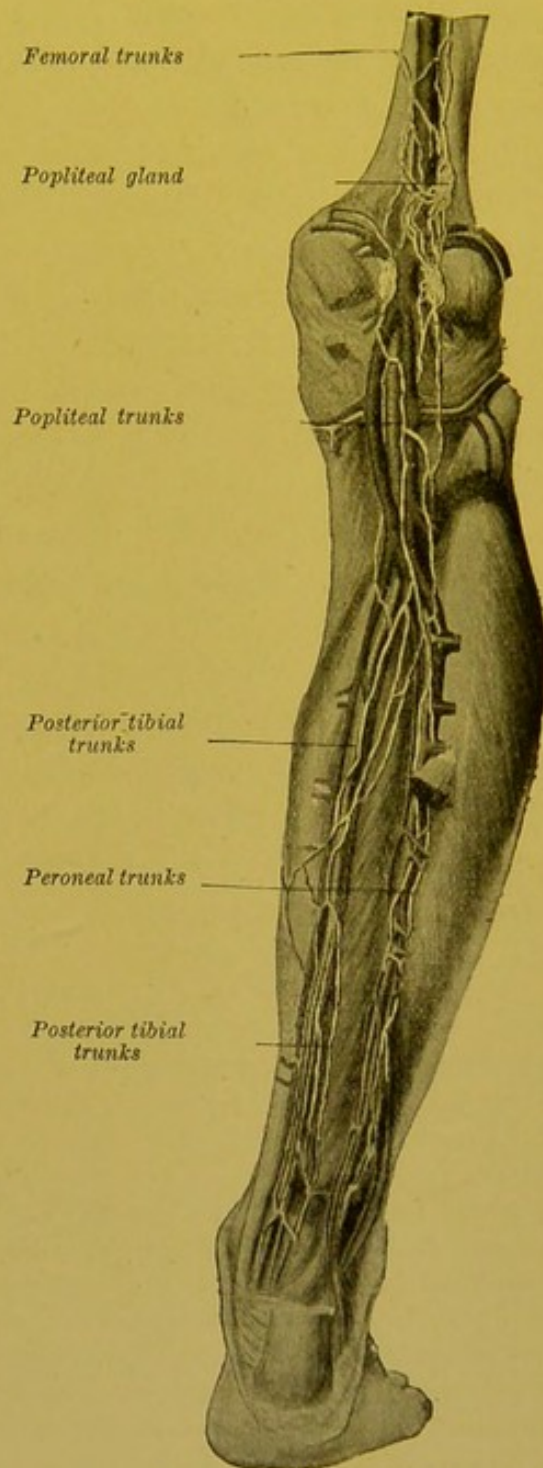


FIG. 40.—Deep lymphatics of the posterior surface of the limb (after Bourguery).

end in a hypogastric gland; this terminal gland rests on the anterior trunk of the internal iliac artery (vide p. 135). During their extra-pelvic course, the ischiatic vessels traverse some small glands placed below the pyriformis muscle (vide Bourgery, loc. cit. plate 82).

The lymphatics of the gluteal region come from the gluteal and the pelvi-trochanteric muscles; they terminate in an intra-pelvic gland, placed on the actual trunk of the artery, at the upper border of the great sacrosciatic notch (vide p. 135 and fig. 43). Like the preceding, they present in their course six to ten small interrupting glandular nodules (Mascagni, Sappey).

ANASTOMOSES.—The superficial and deep lymphatics are clearly independent of each other. Mascagni, however, saw one of the superficial trunks, a satellite of the internal saphenous vein, pierce the fascia lata in the middle third of the thigh and anastomose with the deep lymphatics (Mascagni, loc cit. tab. iv. fig. 2). Bonamy, Broca, and Beau figure a similar arrangement (*loc cit.*, t. 11, plate 45, fig. 2). Sappey on the other hand, declares that he was never able to prove the existence of an anastomosis between the superficial and the deep lymphatics. It is, however, important to notice that the efferent vessel which the popliteal glands send to the superficial inguinal glands (vide p. 114) constitutes a true anastomosis between the deep and the superficial lymphatics. This exception, however, does not invalidate the rule, and as a general proposition we may still maintain the independence of the superficial and deep lymphatic apparatus.

*Technique*¹—We will now describe in detail the mode of injecting the lymphatics of the lower limb; we will in fact indicate, in connection with this subject, the general rules which govern the injection of the superficial and deep lymphatics of the limbs, and the walls of the splanchnic cavities. Sappey laid down minute rules for the injection of the lymphatics of the lower limb with mercury. We will now merely reproduce his instructions, and then add a few words on the application of Gerota's method to the lower limb in particular. We will consider in turn the injection of the superficial and the deep lymphatics.

The Superficial Lymphatics.—To inject the superficial lymphatics, it is important to select a somewhat spare subject, aged from about fifteen to twenty. Wet compresses are first applied to the foot, to provoke a certain amount of maceration of the epidermis. The latter is then raised by scraping the skin with a convex scalpel. This removal of the softened epidermis by scraping is of the utmost importance; its object being to pre-

¹ On *General Technique*, vide p. 1118.

vent the blocking of the mouth of the injection tube, which is bound to take place if the horny layer is left in place. A column of 30 to 40 centimetres of mercury is used.

The first punctures are made on the lateral aspects of each toe, at the junction of the second and third phalanges. The puncture should be entirely superficial, and should hardly reach the subpapillary layer of the skin. If the point has been well directed, we shall immediately see a small ash coloured spot appear round the punctured point, which shows that the mercury has penetrated the lymphatic network. If, at the end of a few moments, this characteristic spot does not make its appearance, it is useless to persist, and a fresh puncture must be made. It is important, however, not to make too many punctures, for each one opens up the network of origin, and thus causes a number of very small leakages, through which the mercury escapes. After the injection of the toes, the sole of the foot must be punctured at many points, and more especially in the neighbourhood of its external and internal borders.

In this way the networks of origin and the trunklets which arise therefrom may be filled without much difficulty. Sometimes the mercury may actually be seen to pass into the large collecting trunks, and reach the inguinal glands; but it is usually impossible to succeed in injecting the entire lymphatic system of the lower limb at the first attempt. In this case one of the trunks originating from the toe must be sought for by carefully removing the skin from the dorsal surface of the foot, and the collecting trunk thus found must then be injected. The same process may be repeated on one or several of the trunks which spring from the external and internal borders of the foot, and in this way almost all the collecting trunks of the lower limb may be filled.

The skin is next carefully removed from the limb, working from below upwards, and the vessels now filled with mercury are dissected, the usual rules being followed (vide pages 59 and 60). The limb is then allowed to dry in the horizontal position; but when the drying process is almost completed, the vertical position must be maintained.

In order to inject the superficial lymphatics by Gerota's method, we proceed in the same way as for the injection by mercury. The sudden appearance of a blue tinge round the puncture will shew that the injected material has passed into the networks. We should remark that in this particular case, the method of Gerota has no great advantages over mercury, except perhaps in newborn subjects, in which we can, in certain favourable cases, obtain an injection of almost all the superficial lymphatics of the lower limb by making two or three punctures.

Deep Lymphatics.—The injection of the deep lymphatics is a much more delicate process, for with mercury, at any rate, it is practically impossible to fill them by direct puncture of their networks.

To inject them we use Mascagni's method. A young and somewhat spare subject is selected for preference, into whose arteries and veins an injection of gelatine is made. The injected mass to some extent always transudes through the vascular walls and penetrates into the lymphatic vessels, which it renders more apparent; one of the latter is then punctured directly, and very hot water run over the preparation to liquify the gelatine. The mercury then penetrates into the deep vessels without difficulty.

With Gerota's mixture, we may sometimes fill the deep lymphatics by directly puncturing the fleshy portion of the different muscles, or by

superficially puncturing certain tendons, such as the tendo Achillis, for example; but we must recognize the fact that these injection trials made through the medium of the networks of origin, usually end in failure; on the other hand, it is relatively easy to inject the satellite trunks of the femoral vessels by directly puncturing one of the popliteal glands.

CHAPTER II

LYMPHATICS OF THE PELVIS AND ABDOMEN

WE will study (1) the glandular groups of the pelvis and abdomen ; (2) the lymphatic apparatus of the different organs, the vessels of which are the tributaries of these glands.

§ 1. GLANDULAR GROUPS OF THE PELVIS AND ABDOMEN

Though the lymphatic glands of the pelvis are continuous without line of demarcation with the abdominal glands, we will divide them, for convenience of our description, into two groups, separated by an imaginary horizontal line passing through the bifurcation of the aorta ; an inferior group (ilio-pelvic) ; and a superior group (abdomino-aortic).

1. ILIO-PELVIC GLANDS.

Under the name of *ilio-pelvic* glands, we will describe the glands situated within the pelvic cavity or placed at the junction of the latter with the iliac fossae, at the level of the inlet of the true pelvis.

Generally speaking, the ilio-pelvic glands are disposed fairly regularly round the vessels. This paravascular arrangement enables us to divide them into three large groups : namely the *external iliac glands*, which run by the side of the vessels of this name ; the *hypogastric glands*, scattered along the trunk and branches of the internal iliac artery ; the *common iliac glands* placed round the vessels of the same name.

The older writings only furnish us with very incomplete and often incorrect ideas on the topography of the glands of the pelvis. Quite recently, Marcille and one of the authors have undertaken the study of these glands, and have given a new classification, which we here adopt.

Vide : Cunéo and Marcille, *Topographie des ganglions ilio-pelviens*. Commun. Soc. anat., decembre, 1901. Marcille, *Lymphatiques et ganglions ilio-pelviens*. Th. Paris, 1902.

1. The External Iliac Glands.—The glands grouped round the external iliac vessels usually present a constant arrangement. We may regard them as forming three chains which are more or less continuous, viz. an external, a middle, and an internal chain.¹

A. THE EXTERNAL CHAIN.—The external chain comprises three

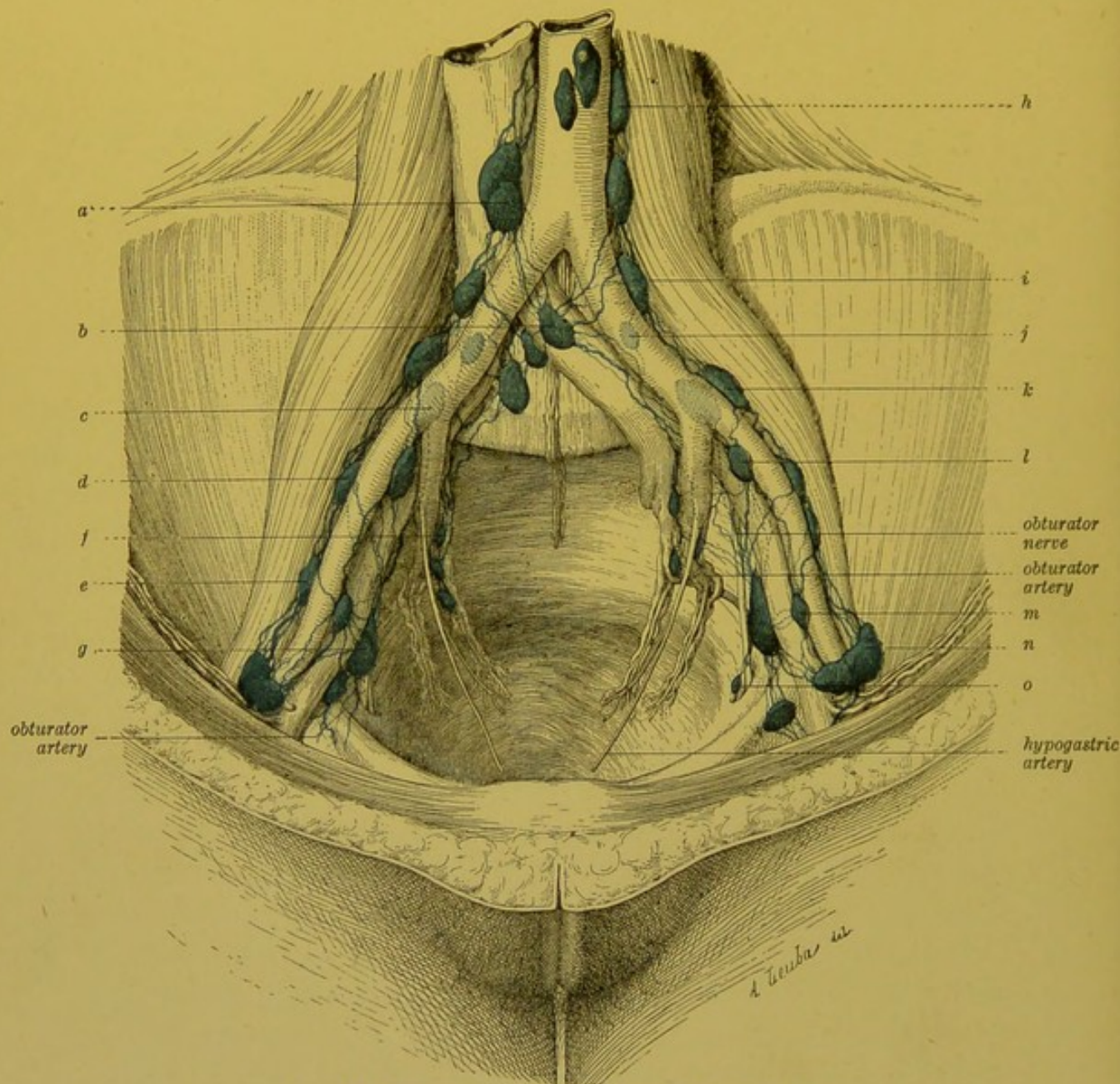


FIG. 41.—Ileopelvic glands (Cunéo and Marcille).

a. Right juxta-aortic gland.—b. Gland of the promontory.—c. Common iliac gland. (middle group).—d and e. External iliac glands (external chain).—f. Hypogastric gland.—g. External iliac gland (external chain).—h. Left juxta-aortic gland.—i, j. Common iliac glands.—k. External iliac gland (external chain).—l, m. External iliac glands (middle chain).—n. Retro-crural external gland.—o. Obturator gland.

¹To thoroughly grasp the topography of these glands we must recall the position of the external iliac vessels. The artery and vein do not lie, as is too often stated, on the psoas muscle; they are clearly internal to it, and lie on its inner border, overhanging the pelvic cavity.

to four glands which shew a tendency to insinuate themselves between the internal border of the psoas, and the external iliac artery. The lower gland of this chain is placed immediately behind the crural arch. It lies on the terminal portion of the external iliac artery, and covers the origin of the deep circumflex iliac and the deep epigastric arteries. It is underneath this gland, that the genito-crural nerve divides into its two terminal branches. This gland may be called the *external retro-crural gland*. It is usually a fair size; sometimes it is replaced by two smaller glands, the more internal of which then represents the commencement of the middle chain. The overlying glands are lodged in the interspace which separates the external iliac artery from the internal border of the psoas.

B. MIDDLE CHAIN.—The middle chain comprises two or three glands placed on the anterior surface of the external iliac vein. When there are three glands, the lowest is situated immediately behind the crural arch. We may term it the *middle retro-crural gland*. It is inconstant. It is in fact most usually fused with the adjacent gland of the preceding chain.—The middle gland is usually situated midway between the crural arch and the bifurcation of the common iliac artery.—As regards the superior gland, it is placed immediately in front of the origin of the internal iliac artery, and is often covered by the ureter. These two glands, i.e. the middle and superior of the middle chain, sometimes show a tendency to become situated on the internal surface of the vein, and are almost intrapelvic.

C. INTERNAL CHAIN.—The internal chain comprises three to four glands and is placed below the external iliac vein, against the lateral wall of the pelvic cavity, above the obturator nerve. The *inferior* gland of this chain is situated immediately behind the external or lymphatic portion of the crural ring, and lies upon the terminal portion of the ilio-pectineal line. It is placed next to the gland of Cloquet, or when this is absent, to the chain of deep inguinal glands. It may be styled the *internal retro-crural gland*.—The suprajacent gland (*the middle gland*) is remarkable for its size and constancy; it is elongated like a spindle, and situated on a slightly lower plane than the former, as though its weight were dragging it down into the pelvic cavity. It lies immediately above the obturator nerve.—The third gland (*superior gland*) is usually smaller, and is placed behind those already mentioned, in front of the trunk of the internal iliac artery.

This chain may be reduced to two or even a single gland, by fusion of its constituent elements, in which case an enormous elongated gland may be found lying on the lateral wall of the pelvis; extending from Gimbernath's ligament to the hypogastric artery.

Most authors regard this internal chain as belonging to the group of hypogastric glands, but we think this view has many inconveniences. Though prolapsed into the pelvis, this chain is obviously continuous with the deep inguinal glands, and remains a satellite of the external iliac vein. As figures 42 and 43 well show, it forms an integral part of the strong lymphatic current which runs upwards from the lower limbs towards the lumbar region. Further, as we shall see later on (vide p. 133), its pelvic affluents are relatively few, and are much less important than its afferent femoral lymphatics.

Obturator Gland.—In the above-mentioned chain may be included a small *inconstant* gland placed beneath the obturator nerve, on the actual level of the internal surface of the obturator foramen. This gland, which receives the deep lymphatics, the satellites of the obturator vessels, is attached by its efferents to the lower border of the large middle gland of the internal chain (vide Fig. 41). It is to this gland that the name of obturator should be confined.

This question regarding the obturator gland has given rise to numerous discussions. It was Cruveilhier who first insisted on the existence of a gland at the level of the internal orifice of the obturator foramen. "I shall regard as *constant a fair-sized* gland which occupies the internal orifice of the oval canal and which I have frequently seen inflamed or indurated in maladies of the uterus. It may be styled the gland of the oval foramen." Bouilly, and A. Guérin admitted the existence of this gland, and described its afferents as coming from the uterus, and considered that it played an important part in the pathogeny of certain varieties of phlegmonous parametritis. Sappey, on the contrary, does not mention any gland at the entrance of the obturator foramen. As one of the present writers long since observed, it is certain that *normally* no gland exists at this spot. The existence of the little gland mentioned above must be regarded as an anomaly, the frequency of whose presence it is most difficult for us to estimate. When this little glandular nodule is absent, the gland nearest to the obturator foramen is our middle gland of the internal chain, which is situated about 15 to 20 millimetres behind and above the entrance to the canal. It is to this gland that Cruveilhier must have alluded. The "voluminous and constant" gland of which he speaks cannot be this minute and often absent gland which we have just noted. It is moreover important to add at once that the middle gland of the internal chain receives no lymphatics coming from the uterus (vide *Uterine Lymphatics*, pp. 163 and 164).

BIBLIOGRAPHY.—Cruveilhier, *Anatomie descriptive*, 3^e édition, t. III,

p. 154.—Guérin, *Bull. de l'Ac. de méd.*, 1887, p. 533.—Cantin. Des lymphangites périutérines non puerpérales. *Th. Paris*, 1889.—Poirier. Lymphatiques des organes génitaux de la femme. *Progrès médical*, 1890.—Poirier et Picqué. Étude sur la hernie obturatrice. *Revue de Chirurgie*, 1891, t. XI, p. 693.

AFFERENT VESSELS.—Each of the three chains receives distinct afferents.

1. *External Chain.*—The majority of lymphatics which eventually terminate in the external chain, end in the inferior gland of this chain (the retro-crural gland). The other glands of the external chain simply constitute a second relay interposed in the course of afferents of the preceding gland.

This external retro-crural gland receives—

(a) Some of the efferents from the superficial and deep inguinal glands.

(b) The lymphatics from the glans or clitoris, which come to this gland per the inguinal canal.

(c) Some of the deep lymphatics from the sub-umbilical portion of the abdominal wall; these are satellites of the deep epigastric and deep circumflex iliac arteries (vide p. 151 and Fig. 50).

2. *Middle Chain.*—When the middle chain is reduced, as is usually the case, to two glands only, the inferior gland receives at first a double pedicle which comes to it from the external and internal retro-crural glands (vide Fig. 42). Vessels from the bladder, prostate, neck of the uterus, and from the upper portion of the vagina end in this chain.

3. *Internal Chain.*—This chain receives numerous afferents, which may be divided in the following way—

(a) Efferent vessels from the superficial and deep inguinal glands.

(b) Deep collecting trunks from the glans and clitoris, which pass *viâ* the crural canal.

(c) Deep collecting trunks from the umbilicus and subumbilical portion of the abdominal wall.

(d) Lymphatic satellites of the obturator vessels coming from the adductor muscles of the thigh.

(e) Lymphatics from the neck of the bladder, the prostate, and membranous portion of the urethra.

(f) Some efferents from the hypogastric glands, and more particularly from the middle haemorrhoidal gland.

As we have seen, the three external iliac chains receive lymphatics coming from the inguinal glands. The external and internal chains

receive these vessels directly; the middle chain only receives them after they have been interrupted in the external and internal retro-crural glands. It seems that the strong lymphatic current, which has its source in the lower limb, divides, in the region of the external iliac vessels into three secondary currents, corresponding to each of our three glandular chains.

On the other hand, the middle and internal chains are the only ones to receive lymphatics coming from the true pelvis. We may be surprised at this arrangement, whereby the middle chain, placed at the level of the inlet, receives lymphatics from the pelvic cavity and also from the prostate or vagina. The fact is, that these vessels have a somewhat long course to pursue before arriving at the middle chain, and it may appear singular that they are not arrested in the internal chain, which they are compelled to cross. Their termination in the middle chain is explained by their development. In the foetus, as is well known, the prostate and vagina occupy a much higher position than in the adult, and are placed at the actual level of the inlet. Their lymphatics have therefore only a very short course to pursue before reaching the middle chain. Later on, when these organs sink into the pelvic cavity, these vessels secondarily acquire a longer and more complicated course. We shall see an analogous but much more striking phenomenon manifest itself in the lymphatics of the ovary and testicle.

EFFERENT VESSELS.—Each gland belonging to these different chains sends its efferents to the gland above it, so that the highest gland of the chain continues the lymphatic circulation of those placed below it.

The efferents of the superior gland of the *external* chain terminate in the inferior gland of the external group of the common iliac glands. The efferents of the superior gland of the *middle* chain are divided into two groups: the external and the internal; the first, which is the most important, joins with the efferents of the external chain; the second joins the efferents of the internal chain.

The efferents of the *internal* chain are placed beneath the trunk of the internal iliac artery, and become united to the efferents of the hypogastric glands, and eventually terminate, like the latter, in the middle group of the common iliac glands (the group placed in the fossa for the lumbo-sacral nerve).

Epigastric and Circumflex Iliac Chain.—Two secondary chains should be included with the external iliac glands, viz. the deep epigastric and deep circumflex iliac chains.

The *epigastric chain* comprises three to six little glands placed over the course of the lower third of the deep epigastric artery. These glands, the size and number of which is very variable, may be wanting.

The *circumflex iliac chain* comprises two to four little glands placed over the artery of this name. They are even smaller than those of the preceding group, and are very frequently absent.

2. The Internal Iliac or Hypogastric Glands.—The hypogastric glands are connected to the branches of the artery of this name. Their number is somewhat variable. They are placed

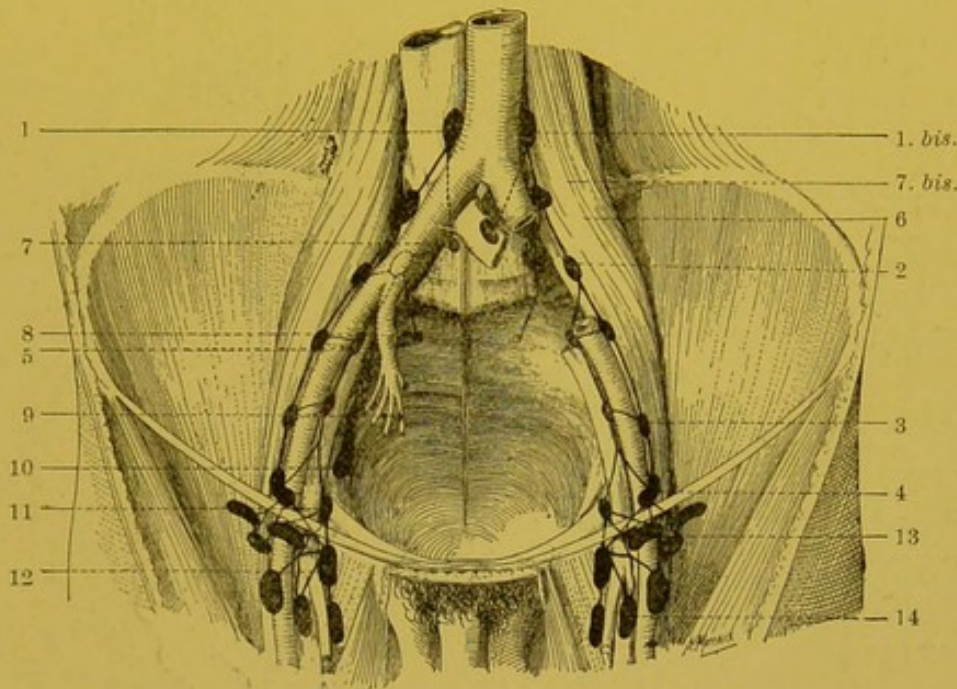


FIG. 42.—Scheme of the ileo-pelvic glands (Cunéo and Marcille).

1 and 1 bis.—Inferior glands of right and left lateral-aortic groups.—2. Common iliac group (external group).—3. Middle band of external chain of external iliac glands.—4. Retro-crural external gland.—5. Gland of the middle chain of external iliac glands.—6. Gland in fossa for the lumbo-sacral nerve.—7 and 7 bis. Group of the promontory; on the right, the gland is beneath the left common iliac vein; on the left, one of the glands is in front of the same vein.—8. Lateral sacral group.—9. Hypogastric group.—10. Gland of the internal chain of external iliac glands.—11. Retro-crural internal gland.—12. Deep inguinal gland.—13 and 14. Superficial inguinal glands.

near the origin of the different branches of the internal iliac artery, in the angles formed by their separation. The most anterior of these glands is placed between the hypogastric (umbilical) and the subjacent artery, which is usually the obturator. The most posterior is placed on the trunk of the gluteal artery. The others are placed between the two preceding and unite them, describing a fairly regular curve, the concavity of which points upwards and forwards. The arrangement of these intermediary

glands is somewhat inconstant. However they are generally arranged as follows—

The first is placed in the neighbourhood of the uterine or prostatic artery; the second, which is more posterior, rests on the common trunk of the sciatic and pudic; a third, placed apart from the preceding, is situated on the middle haemorrhoidal artery; it usually corresponds to the point at which this artery breaks up into its terminal branches, and is nearly in contact with

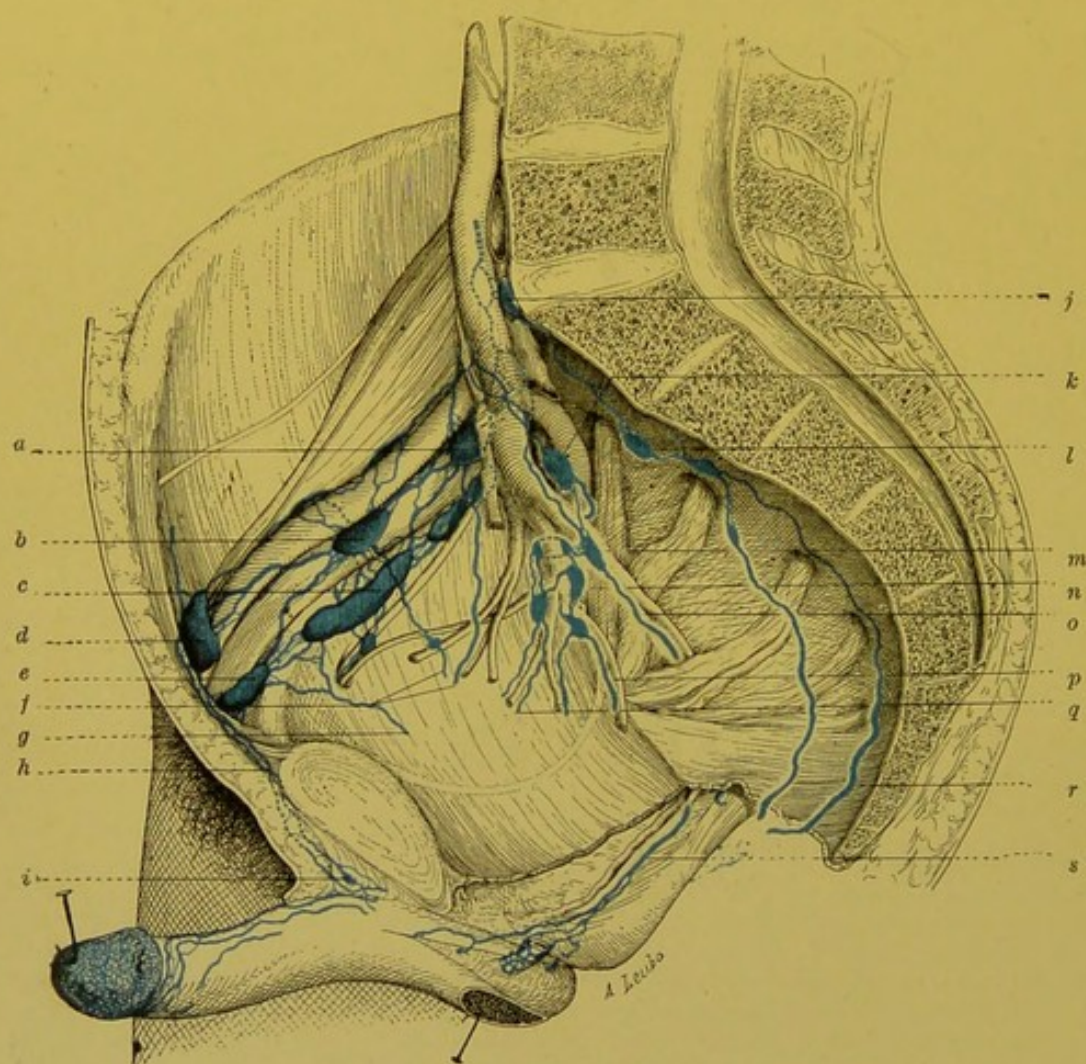


FIG. 43.—Ileo-pelvic glands (lateral view) (Cunéo and Marcille).

a and *b*. External iliac glands (middle chain).—*c*. External iliac gland (external chain).
d. Retro-crural external gland.—*e*. Retro-crural internal gland.—*f*, *g*. Lymphatics of the bladder.—*h*. Collecting trunks from the mucus membrane of the glans passing through the inguinal canal.—*i*. Praesymphysial glandular nodule.—*j*. Gland of the promontory.—*k*. Intra-pelvic gluteal gland.—*l*. Lateral sacral gland.—*m*, *n*. Hypogastric glands.—*o*. Satellite trunk of internal pudic vessels.—*p*. Middle haemorrhoidal trunk.—*q*, *r*. Prostatic collecting trunks.—*s*. Urethral collecting trunks.

the lateral wall of the rectum (middle haemorrhoidal gland). There is one more group, even more isolated, which is formed by two or three glands situated internal to the second or third sacral foramina, and on the course of the lateral sacral artery (lateral sacral gland).

All these glands rest on the inner surface of the pelvic fascia, and to show them, we need merely raise the peritoneum. Sometimes they are placed on the external surface of this aponeurotic layer, as may be seen when the latter is dissected off from the lateral wall of the pelvis. All these glands are united to each other by numerous anastomoses.

AFFERENT VESSELS.—The hypogastric glands receive afferents from all the pelvic viscera. We may thus see, ending in this glandular group, lymphatics from the membranous and prostatic portions of the urethra, prostate, bladder, vesiculae seminales, vasa deferentia, vagina, uterus, and rectum. All these vessels are more or less satellites of the branches to the different viscera, given off by the internal iliac artery.

They also receive the collecting trunks of the sub-aponeurotic portions of the perineum, the lymphatics from the penile portion of the urethra, and, according to the researches of Marcille, even certain trunks from the anus. These vessels follow the course of the internal pudic artery and its branches.

Finally, the deep lymphatics from the posterior surface of the thigh and gluteal region, satellites of the sciatic and gluteal vessels may be seen to terminate in these glands.

EFFERENT VESSELS.—The efferents of the hypogastric glands are directed upwards and outwards, and passing underneath the common iliac vein, terminate in the middle group of the common iliac glands. We shall see later on that this group, which is situated underneath the vessels, in the fossa for the lumbo-sacral nerve, itself sends its efferents to the inferior part of the lateral aortic chain of the corresponding side.

3. **The Common Iliac Glands.**—The glands grouped around the common iliac artery may be divided into three groups, viz. an external, a middle, and an internal.

The *external group* generally comprises two glands, which are placed external to the artery and which lie on the internal border of the psoas. This group is continuous with the external chain of the external iliac glands, and is continuous above without any line of demarcation with the juxta-aortic group of the corresponding side.

The *middle group* (deep or retro-vascular) is made up of two to four glands, which are entirely hidden behind the vessels. These glands occupy a fossa which has recently been well described by Marcille, and which is constituted as follows: Internally, it is limited by the body of the 5th lumbar vertebra; externally, by the internal border

of the psoas. Its base is formed by the upper border of the wing of the sacrum. This fossa is covered by the common iliac vessels, which tend to sink down within it. It is in the fat which fills this fossa, above the lumbo-sacral and obturator nerves which occupy its base, that we find the retro-vascular glands.

The *internal group*, with that on the opposite side, constitutes an uneven and mesially placed group in front of the body of the 5th lumbar, or on the disc between this and the sacrum. We may call it the *group of the promontory*. It is sometimes formed of two fairly distinct masses: one, the inferior and on the right side, lies underneath the left common iliac vein (subvenous collection); the other, the superior and on the left, lies on this vein (praevenous collection), vide Figs. 41 and 43.

AFFERENT VESSELS.—The *external* and the *middle groups* of the common iliac glands do not really receive any vessels emanating directly from the neighbouring organs. On the contrary, they form the terminus for the numerous and large efferents of the three external iliac chains and of the hypogastric glands.

The *internal group* or *group of the promontory*, receives (1) certain efferents from the lumbo-sacral group; (2) vessels coming from the majority of the pelvic organs; in fact, the lymphatics from the prostate, neck of the bladder, neck of the uterus, vagina, and perhaps also from the rectum, terminate in this group. The collecting trunks of the right side end in the subvenous glands, those on the left in the praevenous glands. All these vessels clearly take the same course (vide Figs. 55, 58, 68). At their commencement they are attached to the pelvic floor, they then ascend into the concavity of the sacrum, and passing slightly external to the middle line, reach the gland of the promontory, after pursuing a long course which on the whole describes a fairly regular curve.

EFFERENT VESSELS.—The efferents of the three common iliac groups converge towards the inferior part of the lateral aortic chain of the corresponding side.

All the ilio-pelvic lymphatics finally end therefore in the two right and left juxta-aortic chains. The inferior gland of these two chains represents the point of convergence of all the efferents of the glandular groups which we have just been studying. On the one hand, it receives the efferents of the external group of the common iliac glands which itself comprises the internal and middle chains of the external iliac glands. On the other hand, it receives the efferents of the group of the promontory, and the glands in the

lumbo-sacral fossa; and, as we have already seen, the latter is the terminus of the afferent vessels of the hypogastric glands and of the internal chain of the external iliac glands. There is then, in the lower portion of the lumbar region, a simplification of the lymphatic channels; they are reduced to two large lateral ascending currents; from this point it is true, we shall see a new current, uneven and median, making its appearance, the origin of which is entirely different, inasmuch as it conveys the lymph from the intestinal portion of the digestive canal.

2.—ABDOMINO-AORTIC GLANDS

The abdomino-aortic glands, which number from twenty to thirty, are grouped around the abdominal aorta. Basing our classification on their relations

to this arterial trunk, we may divide them into four groups: (1) The left juxta-aortic glands; (2) The right juxta-aortic glands; (3) The prae-aortic glands; (4) The retro-aortic glands.

Each of these groups possesses a special lymphatic

territory. The juxta-aortic glands receive the efferents of the common iliac glands, as well as the parietal lymphatics, and the lymphatics of the kidneys and genital glands. In the prae-aortic glands, the lymphatics from the digestive canal and its accessories more especially terminate. As regards the retro-aortic glands, they receive but few vessels coming directly from the abdominal viscera; they constitute a fresh relay interposed in the course of certain efferent vessels of the preceding groups, before these vessels join the thoracic duct.

1. Left Juxta-aortic Glands.—The left juxta-aortic glands form an almost continuous vertical chain, which runs along the left flank of the abdominal aorta. This chain reposes on the vertebral

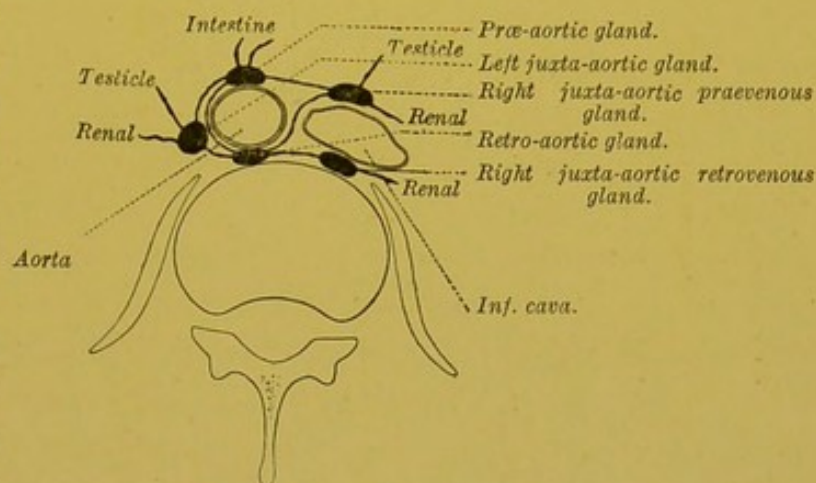


FIG. 44. — Transverse section (diagrammatic) showing the general arrangement of the abdomino-aortic glands.

attachments of the psoas muscle and on the left pillar of the diaphragm ; it is crossed on its anterior surface by the left renal artery and vein.

Afferent Vessels.—These glands receive : (1) the efferent lymphatics of the common iliac glands ; (2) the satellite lymphatics of the lumbar arteries, which come from the large abdominal muscles ;

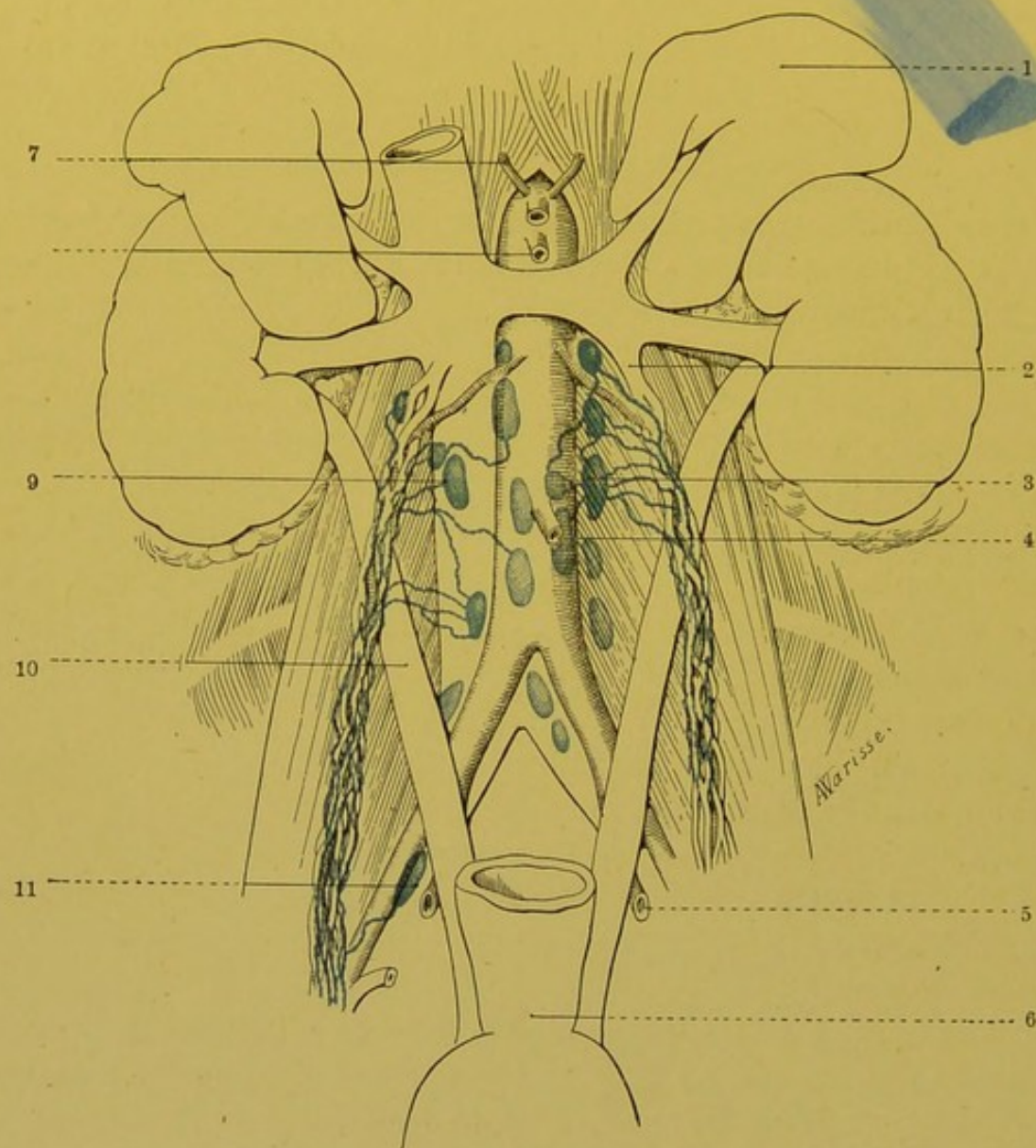


FIG. 45.—Abdomino-aortic glands in the new-born infant (after Cunéo).

1. Left supra-renal capsule.—2. Left spermatic vein.—3. Left juxta-aortic gland.—4. Inferior mesenteric.—5. Hypogastric artery.—6. Rectum.—7. Inferior phrenic artery.—8. Superior mesenteric artery.—9. Right juxta-aortic gland.—10. Ureter.—11. The posterior gland of the middle chain of the external iliac group.

(3) the lymphatics from the left testicle in the male, from the left annexa and corresponding half of the body the uterus in the female ; (4) the lymphatics of the kidney and the left supra-renal capsule.

Efferent Vessels.—The efferent vessels of the left juxta-aortic glands may be divided into four groups. Some of them empty their contents into the prae-aortic glands; others end in the retro-aortic glands; while others, more numerous, unite into a common trunk which ends in the receptaculum chyli; others finally, traverse the left pillar of the diaphragm and empty their contents into the thoracic duct a little above its origin (vide fig. 114). Some of these vessels are sometimes interrupted by glands placed between the posterior surface of the pillar of the diaphragm and the vertebral column.

2. Right Juxta-aortic Glands.—The right juxta-aortic glands are placed—some in front of the inferior vena cava, others behind it. There is a sort of adjustment between these two groups, so that when one of them is well developed, the other is, generally, sensibly reduced.

The *prae-venous glands*, from 3 to 6 in number, are usually found underneath the junction of the renal veins with the inferior vena cava. The *retro-venous glands* rest, as do the left juxta-aortic glands, on the origins of the psoas muscle and on the anterior surface of the corresponding pillar of the diaphragm.

Afferent Vessels.—The right juxta-aortic glands receive the same affluents as the homologous group of the other side. It is interesting to note that the genital lymphatics especially pass to the prae-venous glands, and the parietal lymphatics to the retro-venous glands. As regards the lymphatics of the kidney, they are divided between the two groups, as we shall see later on.

Efferent Vessels.—The efferents of the right juxta-aortic glands terminate in the same way as the juxta-aortic glands of the opposite side.

3. Prae-aortic Glands.—These glands sometimes form, at least in the new-born infant, a continuous chain situated on the anterior surface of the aorta; but most frequently they are grouped into three distinct masses, viz. an inferior, middle, and superior, placed on the origin of the three large trunks which the aorta sends to the abdominal portion of the digestive canal.

(a) The *inferior mass* is usually formed by two glands, which are elongated vertically and symmetrically placed on either side of the origin of the inferior mesenteric artery. In these glands terminate the lymphatics from the rectum, ileo-pelvic colon, and the ascending colon. These vessels, as we shall see later on (p. 191) have moreover already traversed one or two glandular relays.

(b) The *middle mass* is made up of a large collection of glands surrounding the origin of the superior mesenteric artery, and continuous without line of demarcation with the glands placed at the root of the mesentery. This mass receives the lymphatics coming from the small intestine, coecum, appendix, ascending colon, transverse colon, and pancreas.

(c) The *superior mass* is formed by one to three glands placed above the coeliac trunk. It is continuous without line of demarcation with the three chains: hepatic, coronary, and splenic, which are, so to speak, outward prolongations from it.

Afferent Vessels.—The prae-aortic glands receive certain efferents from the juxta-aortic group; but almost all their afferents are formed by vessels coming from the glandular groups, in connection with the mesenteric arteries or the coeliac trunk, and which receive the lymphatics of the intestine, the stomach, the liver, the pancreas, and the spleen.

Efferent Vessels.—The three prae-aortic glandular masses are joined together by numerous vessels. The efferent trunks to which these glands give origin turn round the lateral parts of the abdominal aorta. Their mode of termination varies at different levels. The inferior terminate in the retro-aortic glands subjacent to the receptaculum chyli. The superior end in this receptaculum. Though they sometimes terminate separately into the latter, they most commonly unite into a common trunk (*truncus intestinalis*), which runs side by side with the common trunk formed by the efferents of the left juxta-aortic group, and which simultaneously with the latter empties its contents into the receptaculum chyli.

In the prae-aortic group may be included all the glands placed on the various branches given off by the abdominal aorta to the subdiaphragmatic portion of the digestive canal. We shall therefore have to study—

- (1) The glands situated in the course of the two mesenteric arteries.
- (2) The glands attached to the branches of the coeliac axis.

(1) THE GLANDS ATTACHED TO THE MESENTERIC ARTERIES.—The glands attached to the two mesenteric arteries seem at first sight to be irregularly scattered over the course of these arteries and their branches: their general arrangement however is sufficiently definite to enable us to attempt its classification.

Some of these glands are placed beneath the last series of arches which the arterial branches destined for a given segment of intestine form by their anastomosis. These glands, thus attached to the

terminal arterioles, are very close to the intestinal insertion of the mesentery, and we may call them the juxta-intestinal glands. Nearly always of small size, they rarely retain artificial injections, and in the case of cancers only arrest the neoplastic elements for a short time. They are therefore comparable to those small glands which we have already had occasion to notice on the course of the lymphatics of the various organs, which the Germans call "Schalt-drüsen" (*vide* p. 86). These glands present no morphological fixity, and their number varies considerably in different subjects.

Other glands, which are larger and more constant in their presence

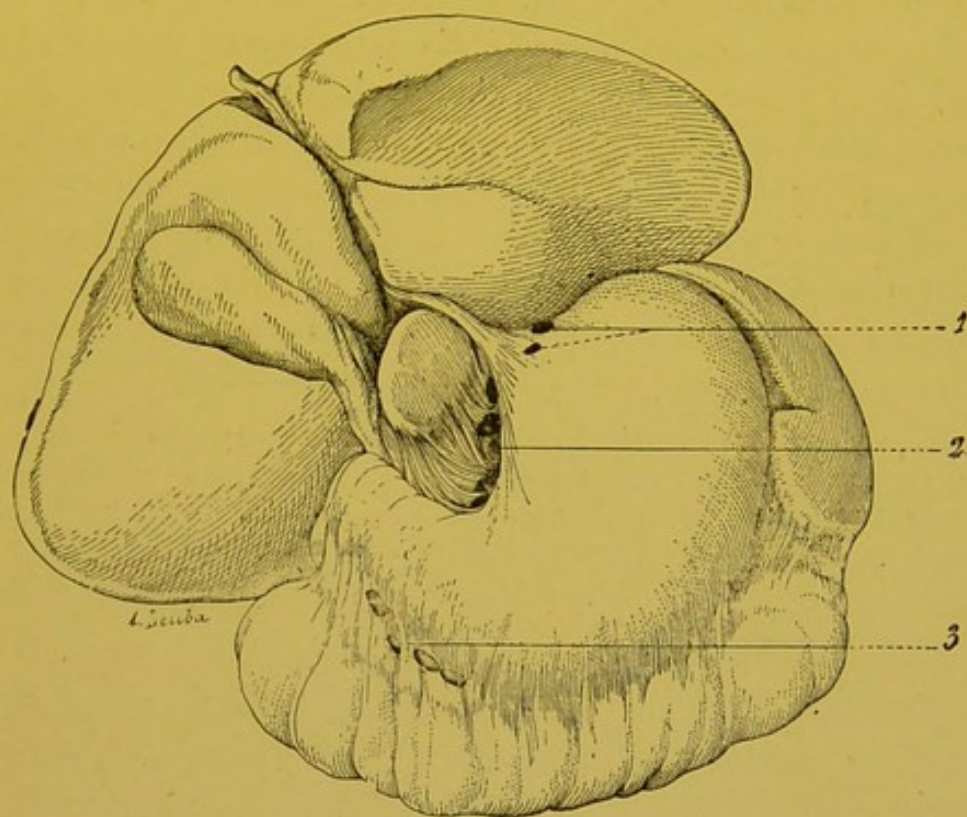


FIG. 46.—Glands of the small curvature and the subpyloric glands in the new-born infant.

1. Praecardiac glands.—2. Glands of the small curvature.—3. Subpyloric glands.

and situation, are placed in the course of the primary branches of the mesenteric arteries. They constitute the true regional glands of a definite segment of intestine.

Others, finally, are placed round the principal trunks of these vessels. They represent the glandular centres, which are usually common to many segments of the intestine. They receive the efferents from the preceding glands.

For the present we will rest content with these general data, and to avoid useless repetitions, we will study the exact topography of

these glands when we deal with the lymphatics of the different intestinal segments with which they are connected.

(2) GLANDS CONNECTED WITH THE BRANCHES OF THE COELIAC AXIS.

—The glands connected with the branches of the coeliac axis are arranged in three chains: viz. the coronary or gastric, the splenic, and the hepatic. In the latter we shall include the bile duct chain.

(1) THE CORONARY OR GASTRIC.—The glands of the coronary chain may be divided into two groups: the group of the *falx* of the coronary artery, and the group of the small curvature.

(A) The *group of the falx* is formed by glands situated by the side of the artery as it runs in the gastro-pancreatic ligament. They vary from two to six in number. They are never entirely absent.

(B) Under the term of *group of the small curvature*, we will include all those glands which are placed either on the trunk of or on the branches of the coronary artery after the latter has reached the stomach. These glands form two principal masses.

(a) Some accompany the left or ascending branches of the artery. They form a primary mass, which corresponds to the vertical portion of the small curvature, and to the gastric insertion of the thickened portion of the gastro-hepatic omentum.

With these glands we may include two smaller masses, placed one on the anterior surface, and the other on the posterior surface of the cardia. These two masses—the *prae-* and *retro-cardiac*—are sometimes joined, according to Sappey, by a gland placed on the left of the cardia. This left *juxta-cardiac* gland is, however, generally absent.

(b) The secondary mass is formed by glands placed on the course of the large right or descending branches of the gastric artery. These are usually grouped near the spot where the coronary approaches the border of the stomach. It is very rare to meet any of them in that part of the small curvature which corresponds to the pylorus and the pyloric vestibule. All these glands are placed between the two layers of the small omentum, in the midst of the dense network formed by the interlacing of branches of the coronary artery and the left pneumogastric nerve.

The coronary gastric glands receive as *afferents* the lymphatics coming from the stomach. As we shall see later on, their region is very extensive and constitutes the most important of the various lymphatic territories of the stomach. Their *efferent* vessels terminate in the *prae-aortic* glands which surround the coeliac axis.

(2) SPLENIC CHAIN.—The splenic chain comprises a very variable number of glands (four to ten), which accompany the artery of this

name. Like the artery, they are situated on the posterior surface, and near the superior border of the pancreas.

The extremity of this glandular chain is contained in the pancreatico-splenic omentum.

The *afferent* vessels of these glands come from the spleen,

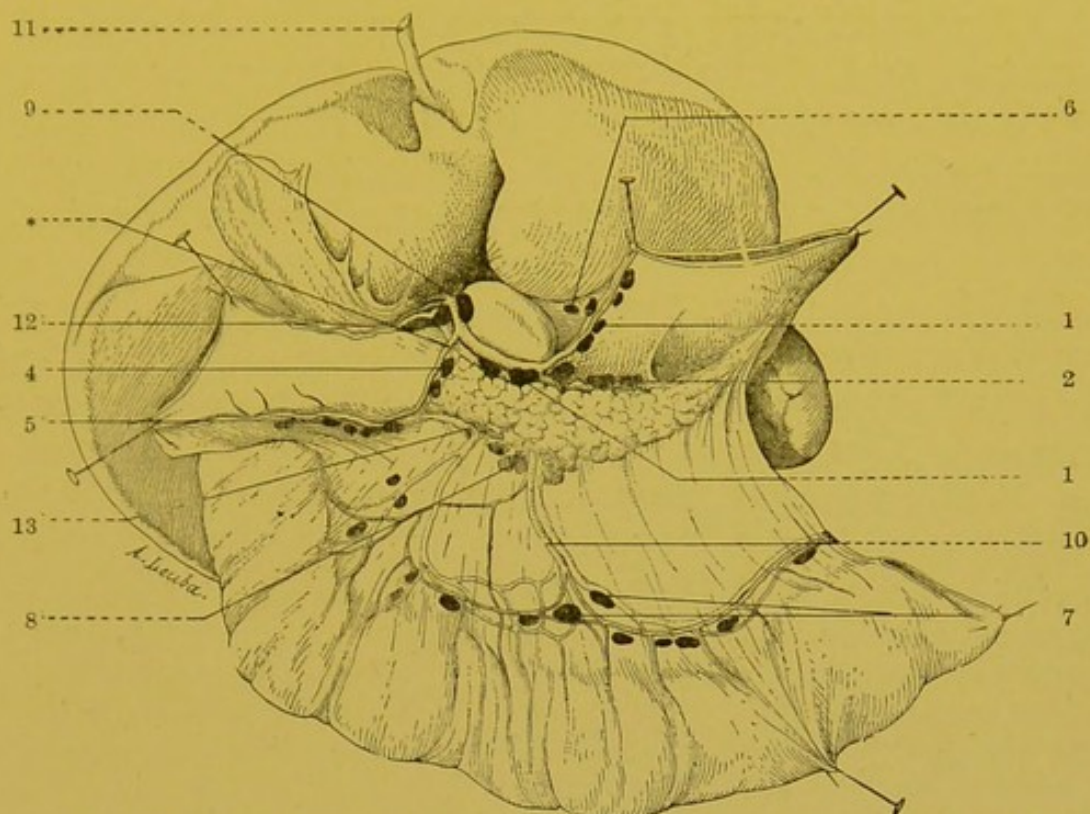


FIG. 47.—General view of the porastomachic glands in the new-born infant.

The stomach has been cut in the middle, and the two halves have been drawn aside—one to the right, and the other to the left, to show the origin of the coeliac axis. The liver is raised, and the transverse colon drawn well downwards and forwards.

—1. Glandular group of the coeliac axis.—2. Splenic chain.—3. Group of the falx of the coronary artery.—4. Retro-pyloric group.—5. Sub-epipyloric group.—6. Glands of small curvature.—7. Mesocolic glands.—8. Glands at the root of the mesocolon, seen through the mesocolon.—9. Gland of the hilum of the liver.—10. Middle colic artery.—11. Umbilical vein.—12. Pyloric vessels.—13. Right gastro-epiploic vein passing into the middle colic vein. *, Point at which the gastroduodenal artery should be tied when the retropyloric glands are extirpated.

the pancreas and fundus of the stomach. The *efferent* vessels terminate in the glands which are placed on the coeliac axis.

(3) THE HEPATIC CHAIN.—The hepatic chain comprises three to six glands which are situated in the course of the hepatic artery. Some of these glands are placed on the horizontal part of this vessel, and consequently correspond to the superior border of the pancreas and to the floor of the foramen of Winslow. Others are situated on the vertical portion of the artery, and correspond with the left side of the portal vein. These glands receive the lymphatics of the liver and

send out efferents which terminate in the glands which surround the origin of the coronary trunk.

The hepatic chain gives off a secondary chain which is a satellite of the right gastro-epiploic artery. This *gastro-epiploic chain* comprises two distinct glandular groups, viz., the subpyloric and retropyloric group.

(A) The *subpyloric group* on an average comprises three to six glands, which are placed between the layers of the great omentum, beneath the pyloric zone of the stomach. It is rare to find glands in the middle portion of the great curvature, and quite exceptional to meet with them in the region of the fundus. The relation of these glands to the gastro-epiploic vessels is somewhat variable; usually they are subjacent; in some cases, however, they may be placed between the vessels and the stomach; but it is exceptional to see them in close contact with the stomach, as is the case with the glands of the small curvature. Thus, in cases of cancer they are not blended with the growth in the pylorus until a well marked invasion of the great omentum has taken place.

In the subpyloric group may be included some *aberrant glands*, which are placed between the layers of the great omentum, along the descending branches of the gastro-epiploic arch. These glands, which are as variable in number as in arrangement, may be more than 5 to 6 centimetres distant from the great curvature. We can well understand how they may escape notice and be left *in situ*, during a gastrectomy, unless their increase in size renders them apparent.

The subpyloric glands receive as afferents the lymphatics coming from the inferior region of the stomach (vide pp. 197, 198 and Fig. 73), or the upper part of the great omentum. Their efferent vessels follow the course of the right gastro-epiploic artery and terminate in the retro-pyloric glands, but we may often see one or more of these efferents end in the glands which surround the superior mesenteric vessels, where the latter cross the third portion of the duodenum. These collecting trunks then follow the right gastro-epiploic vein, which, as we know, frequently joins the subpancreatic portion of the superior mesenteric, either directly, or by a trunk common to it and the middle colic vein (vide Fig. 47).

(B) The *retro-pyloric group* usually comprise two to three glands which are continuous with the preceding, and are also continuous, without any line of demarcation, with the glands of the principal hepatic chain. These glands, placed round the trunk of the gastro-duodenal, are in relation in front with the posterior surface of the pylorus, and behind with the pancreas. When they are degenerated they may be

firmly adherent to this organ from which it is difficult to separate them. This glandular group is not uncommonly absent.

The retro-pyloric glands receive as afferents the trunks coming from the sub-pyloric group, some of the lymphatics coming from the posterior surface and superior border of the pylorus, and also the trunks coming from the first portion of the duodenum.

THE GLANDULAR CHAIN OF THE CYSTIC AND COMMON BILE DUCT.—In the course of the extra hepatic biliary ducts, we find a series of glands which are arranged vertically and whose direction is parallel to

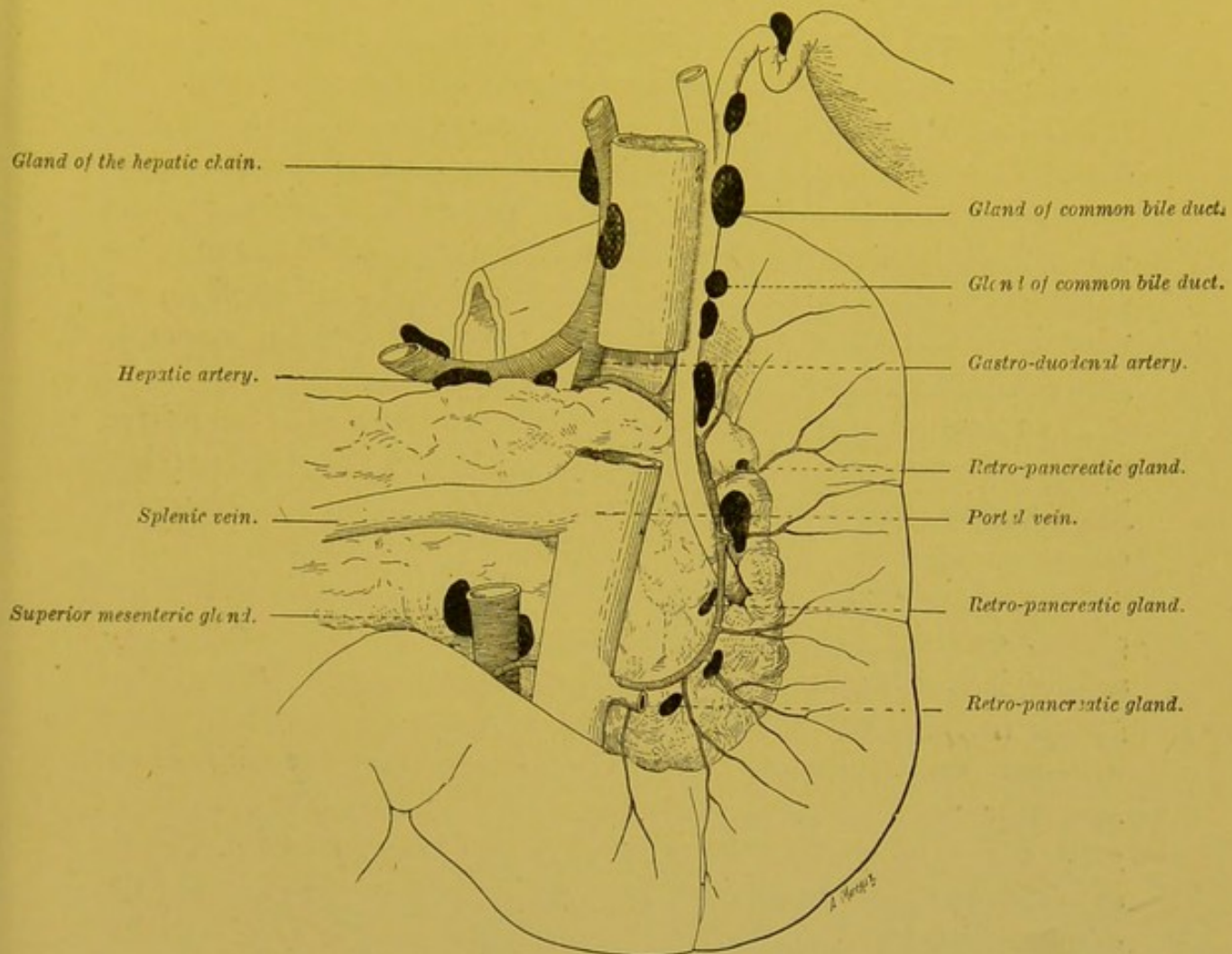


FIG. 48.—Posterior surface of duodenum and pancreas.

In this figure may be seen the glands of the hepatic artery, the cystic and common bile duct chains, and those corresponding to the vascular arch behind the pancreas.

that of these ducts. The highest of these is none other than the cystic gland; it is found in the angle which is open on the left, and which in front is bounded by the neck and body of the gall bladder. This gland which was pointed out by Mascagni, and since found again by Broca, is inconstant. The subjacent glands are arranged below one another along the course of the cystic and common bile

ducts, and are placed along the right-hand border or posterior surface of these ducts.

Their number and exact arrangement has appeared to us to be somewhat variable. There is, however, one gland which is fairly constant, namely, that placed at the junction of the cystic and hepatic duct (Quénu). Inferiorly, this chain blends with the satellite chain of the vascular arch behind the pancreas.

It may be seen therefore that in the hepatic pedicle there are two chains relatively distinct, one of which is a satellite of the two large biliary collecting ducts, while the other follows the course of the hepatic artery. Though this arrangement is not always met with, we think nevertheless it should be regarded as the usual type.

(4.) The Retro-aortic Glands.—The arrangement of the retro-aortic glands is much more variable than that of the preceding groups. From four to five in number they are placed in front of the 3rd and 4th lumbar vertebrae, immediately underneath the receptaculum chyli. Sometimes, (six out of sixteen times) some small glands placed between the aorta and vena cava unite the retro-aortic group to the glands placed in front of these vessels.

The retro-aortic glands receive the lymphatics coming from three of the preceding groups, viz. the prae-aortic and the right and left juxta-aortic groups. Their efferent vessels pass into the receptaculum chyli.

To sum up, the afferent vessels of the retro-aortic glands are almost entirely made up of the efferents of the prae and juxta-aortic glands; these retro-aortic glands are not therefore true *regional glands* (vide p. 86), but simply constitute a fresh relay interposed between the preceding groups and the receptaculum chyli. Moreover, we must recollect that certain efferents of the preceding groups end directly in the receptaculum, or even in a suprajacent segment of the thoracic duct, by passing through the pillars of the diaphragm (vide Fig. 114).

§ 11.—THE LYMPHATIC VESSELS OF THE PELVIS AND ABDOMEN.

We will now study the lymphatics of the abdominal wall, the lymphatics of the male and female external and internal genital organs, the lymphatics of the urinary organs, and finally the lymphatics of the subdiaphragmatic portion of the digestive tube and its annexa.

I. THE LYMPHATICS OF THE ABDOMINAL WALL.

We may divide the lymphatics of the abdominal wall into the

superficial or cutaneous lymphatics, and deep, aponeurotic or muscular lymphatics.

(1) THE SUPERFICIAL LYMPHATICS may themselves be divided into anterior and posterior.

(a) The *anterior* as they descend, converge towards the inguinal region and terminate in the supero-external and supero-internal groups of the superficial inguinal glands. The vessels which arise near the costal margin have however an entirely different termination, inasmuch as they are tributaries of the axillary glands.

(b) The *posterior* arise from the integuments of the lumbar region. Anastomosing above with the lymphatics of the back, and below with the lymphatics of the gluteal region, they give origin to three or four collecting trunks, which run downwards and forwards, coursing a little above and parallel to the iliac crest; they terminate in the supero-external group of the superficial inguinal glands.

(2) THE DEEP LYMPHATICS arise either from the different aponeuroses, or from the fleshy portions of the different muscles of the abdominal wall. They group themselves into four principal channels; (a) A channel which is a satellite of the deep epigastric artery, the constituent vessels of which, after traversing the epigastric glands, terminate in the external and internal retro-crural glands. (b). A channel which accompanies the deep circumflex iliac artery and ends in the external retro-crural gland. (c) A lumbar channel comprising four to five trunks, which are satellites of the lumbar arteries and tributaries of the juxta-aortic glands. (d) An ascending channel, which is a satellite of the abdominal branch of the internal mammary artery, the constituent vessels of which terminate in the internal mammary chain.

There is one region of the abdominal wall where the lymphatics from a practical point of view, have a particular interest: this is the umbilical region. We will therefore devote a few lines to the study of the lymphatics of the umbilicus.

LYMPHATICS OF THE UMBILICUS.—We may divide the lymphatics of the umbilicus into three groups: (1) The cutaneous lymphatics; (2) The lymphatics of the fibrous nucleus; (3) The lymphatics of the aponeurotic edge of the ring.

(1) The *cutaneous* lymphatics arise in the foetus and in the newborn infant from the *umbilical scrotum*, and in the adult from the skin which covers the fibrous nucleus of the umbilicus. Their network of origin, which is extremely close, is continuous with that of the surrounding skin. From this network four or five trunks on either

side run downwards and outwards towards the centre of the inguinal region ; these lymphatic trunks run immediately beneath the in-

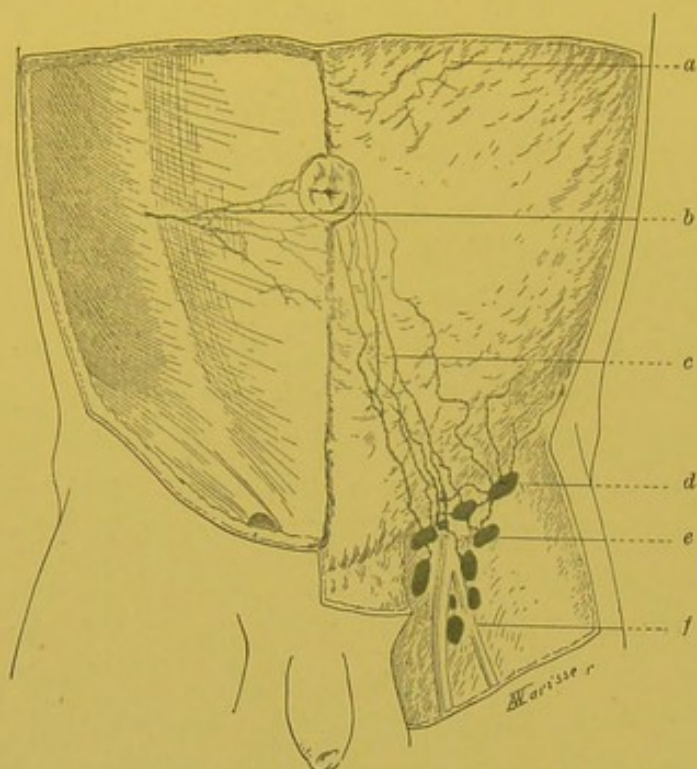


FIG 49.—Lymphatics of the umbilical coverings (Cunéo and Marcille).

a. Lymphatic tributary of the axillary glands.—b. Prae-aponeurotic network. c. Tributary trunk of the inguinal glands.—d. Supero-external inguinal gland.—e. Supero-internal inguinal gland.—f. Infero-external inguinal gland.

teguments in a more superficial plane than the subcutaneous abdominal lymphatics, whose course they follow. They terminate in the supero-internal and supero-external groups of superficial inguinal glands (vide p. 116). It is exceptional to see these descending trunks cross one another in the middle line. On the other hand, vessels of the same side often cross each other, and one of the most internal trunks may be seen to terminate in one of the more external of the superior inguinal glands (vide Fig. 51).

On puncturing at the actual level of the umbilicus, we never really inject any vessel terminating in the axillary glands. To inject the tributary trunks of these glands, the puncture must be made at some distance above the umbilicus (Cunéo and Marcille).

(2) The lymphatics of the *fibrous nucleus*, which are much more difficult to inject than the preceding, have an entirely different termination. On each side of the nucleus, three to four trunks may be seen to arise which at once penetrate the sheath of the recti, and embrace the deep epigastric artery, which at this level is intramuscular. Lower down, they are situated over the artery itself, between the muscle and the posterior part of its sheath : they then appear under the fold of Douglas, where they unite with the lymphatics which arise from the aponeuroses which form the posterior wall of the sheath of the recti muscles.

(3) The lymphatics of the *aponeurotic edge of the ring* are divided into *anterior* and *posterior*. The *anterior lymphatics* (vide Fig. 49, a)

arise from an extremely loose network, attached all round the umbilicus on the anterior surface of the aponeurotic sheath of

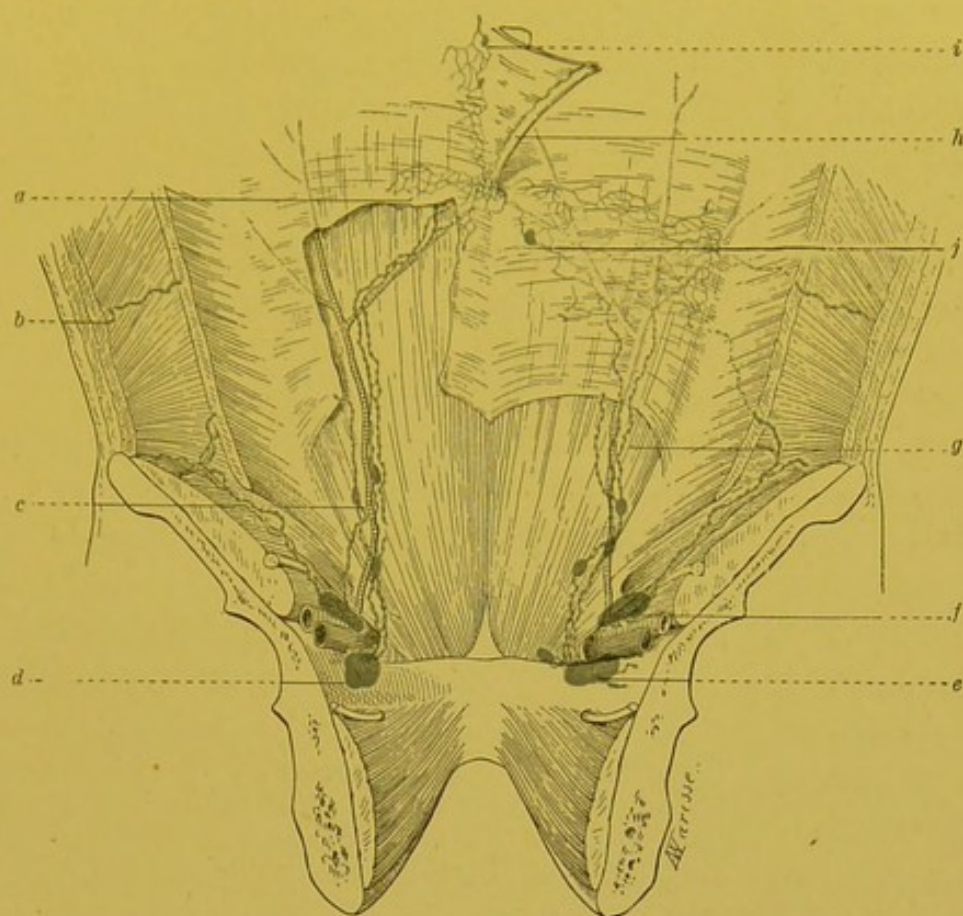


FIG. 50.—Lymphatics of the umbilicus (posterior view), (Cunéo and Marcille).

a. Retro-aponeurotic network.—*b.* Satellite trunk of the lumbar artery.—*c.* Gland of the epigastric chain.—*d, e.* Retro-crural internal gland.—*f.* Retro-crural external gland.—*g* Satellite trunks of deep epigastric artery.—*h.* Satellite trunk of the umbilical vein.—*i.* Supra-umbilical glandular nodules.—*j.* The infra-umbilical gland.

the recti. They terminate in two systems of collecting trunks. Some (*a*) perforate the aponeurotic lamina of the umbilicus, gain the sheath of the recti, and unite with the lymphatics of the fibrous nucleus. Others (*b*) pass externally, perforate the internal and external oblique muscles and blend with homologous trunks coming from the posterior part of the aponeurosis, the termination of which we will shortly indicate.

The posterior lymphatics (Fig. 50) give rise to a peri-umbilical network placed on the posterior surface of the sheath of the recti. From this network run two systems of collecting trunks. Some (*a*) run externally, perforate the transversalis, and run between this muscle and the internal oblique. Joining with homologous lymphatics coming from the anterior part of the aponeurosis they pass either to the external retro-crural gland (vide p. 130), following the course of the deep circumflex iliac artery, or accompanying a lumbar

artery, pass to a juxta-aortic gland. *Others (b)* run downwards, unite with the vessels coming from the fibrous nucleus, and keeping more or less in contact with the deep epigastric artery, terminate in the two external iliac glands which are placed immediately behind the crural ring, viz. the retro-crural external, and the retro-crural internal gland (*f* and *e*), Fig. 50 (vide p. 130).

In the lower third of the course of these lymphatic trunks, we meet with three to six glands, which are small but almost always present. These are the glands of the epigastric chain (the inferior epigastric glands of Gerota) which we have already had occasion to point out (vide pp. 134 and 135).

In some cases, we may come across a little gland in the subperitoneal retro-umbilical cellular tissue. Gerota, who was the first to point out its existence, met with it twice in ten subjects. This gland is usually 2 to 4 centimetres from the umbilicus and is almost always placed a little laterally. It presents a certain interest from the pathological point of view, for it may be the point from which certain suppurative processes in this region may start, and which clinically corresponds to what has been described as the phlegmon of Heurtaux (Cunéo and Marcille).

In the new-born infant Cunéo and Marcille have met with two small glands which are placed *above* the umbilicus in the subperitoneal cellular tissue (vide Fig. 50). These glands receive the lymphatics which come from the supra-umbilical portion of the network which is attached to the posterior portion of the sheath of the recti.

Finally, we may add that the lymphatics of the umbilicus communicate with those of the bladder by means of networks which surround the urachus, and with those of the liver by very fine vessels which run the whole length of the umbilical artery. These communications enable us to understand the pathogeny of certain cases of secondary cancers of the umbilicus.

BIBLIOGRAPHY.—SAPPEY, loc. cit., p. 50.—GEROTA. Ueber die Lymphgefäße und die Lymphdrüsen der Harnblase. *Anat. Anz.*, 1896, XII, p. 89.—CUNÉO et MARCILLE. Note sur les lymphatiques de l'ombilic. *Soc. anat.*, nov. 1901.

II. LYMPHATICS OF THE EXTERNAL GENITAL ORGANS.

We will study (*a*) the lymphatics of the external genital organs in the male and (*b*) in the female. As we shall see, these vessels have an arrangement which is identical in the two sexes.

(*a*) In the Male.

LYMPHATICS OF THE SCROTUM.—The lymphatics of the scrotum take origin from an extremely rich network; so that the injection of these vessels is extremely easy, at least in the infant. In the adult, the fragility of the meshes of the network renders their injection

a more delicate operation, especially when mercury is used. This network covers the entire surface of the scrotum, but is especially dense about the raphe, and it is there that it can be most easily injected. It is near the raphe, too, that the large collecting trunks appear which, later on in their course, collect the small branches coming from the lateral parts of the scrotal network. These trunks number from ten to fifteen on each side. They may be distinguished as *superior* and *inferior*.

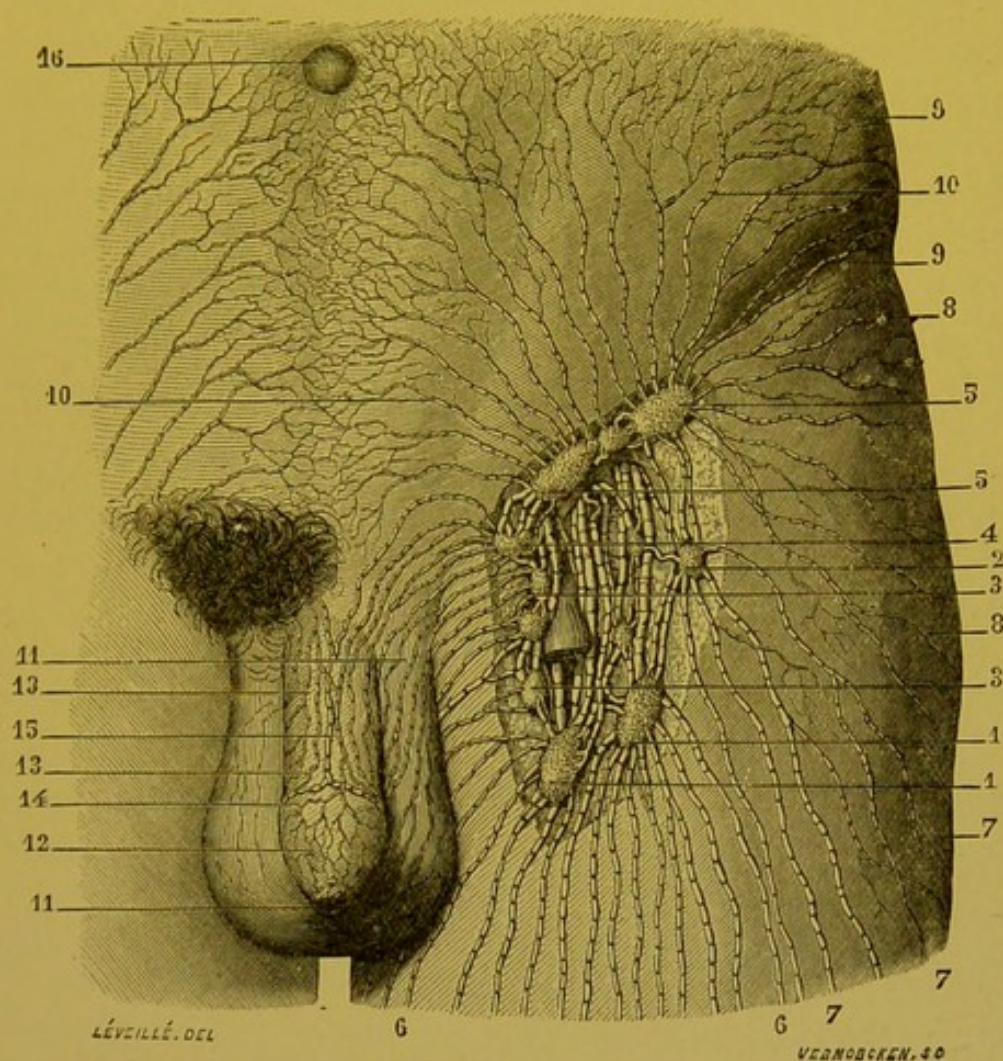


FIG. 51.—Glands of the inguinal region; afferent and efferent vessels. (From Sappey's Atlas.)

1, 1. The two lowest glands of the inguinal region are remarkable for their size.—2. Infero-external gland.—3, 3. Internal inguinal glands, in which terminate the vessels of the scrotum, perineum, anal region, and the supero-internal portion of the integuments of the thigh.—4. Superior and internal inguinal gland; it receives vessels coming from the urethral canal, from the surface of the glans, and from the integuments of the penis.—5, 5. Supero-internal and external inguinal glands; in these glands, which are three or four in number, terminate the vessels coming from the sub-umbilical portion of the abdomen.—6, 6. Lymphatic vessels from the antero-internal portion of the thigh.—7, 7. Vessels from the external portion of the thigh.—8, 8. Vessels from the gluteal region.—9, 9. Vessels from the lumbar region.—10, 10, 10. Vessels from the sub-umbilical portion of the anterior wall of the abdomen.—11, 11. Lymphatic vessels of the scrotum.—12. Lymphatic vessels of the prepuce.—13, 13. Lymphatic vessels of the integuments of the penis.—14. Lymphatic trunk which surrounds the corona of the glans.—15. Median trunk, which is continuous with the preceding.—16. Umbilicus.

(a) The *superior* trunks (median trunks of Sappey), arise from that portion of the scrotal raphe which is immediately continuous with the raphe of the penis. They run at first vertically upwards, then having reached the root of the penis, curve sharply outwards. They then run parallel to the collecting trunks of the penis, cross the spermatic cord and terminate in the supero-internal group of superficial inguinal glands. (On the nomenclature of these glands, vide pp. 114 and 115).

(b) The *inferior* trunks (lateral trunks of Sappey) arise from the raphe, below and behind the preceding. They run upwards and outwards towards the lateral parts of the scrotum; they then follow the cruro-scrotal groove, which they quickly leave, and then pass directly outwards and terminate in the infero-external and infero-internal glandular groups.

The collecting trunks of the scrotal network frequently anastomose with those from the penis, and perineum, and with the trunks coming from the supero-internal part of the skin of the thigh.

LYMPHATICS OF THE PENIS.—The lymphatics of the penis comprise: (1) the lymphatics of the cutaneous coverings of the penis; (2) the lymphatics of the glans; (3) the lymphatics of the penile portion of the urethra; (4) the lymphatics of the erectile structures. Our knowledge of the latter is still imperfect; moreover their collecting trunks are in all probability blended with those of the penile urethra, which we will study later on with the lymphatics of the other portions of the urethra (vide p. 175). We shall now only have to consider the cutaneous lymphatics and the lymphatics of the glans.

(1) THE CUTANEOUS LYMPHATICS.—The cutaneous lymphatics may be divided into two groups; the lymphatics of the sheath of the penis and the lymphatics of the prepuce.

(a) The lymphatics of the sheath of the penis are fairly numerous, but difficult to inject. They form a network with fairly regular meshes which is continuous in front with the network of the prepuce. At the raphe, the meshes become finer and closer.

In this situation also the collecting trunks appear. These are four or five in number and the more anterior their origin the longer they are. They turn round the lateral surfaces of the penis, and then run on its dorsal surface; they then pass directly backwards to the root of the organ, where they make a sharp bend, and turn outwards towards the inguinal glands.

(b) The lymphatics of the prepuce arise from a very fine network which follows in its plicature the skin of the praeputial fold. The lymphatics of the superficial portion are more developed than those of its deep or reflected portion. In the balanitic portion of the prepuce, the network is continuous with the lymphatic network of the glans.

The small trunks of this network end either in a single median collecting trunk, or in two juxta-median, or in multiple collecting trunks. Contrary to Sappey's views, Bruhns regards this latter arrangement as the rule. In any case whatever their number, these vessels run in the middle of the dorsum of the penis by the side of the superficial dorsal vein, and anastomose with each other by branches which are more or less developed in different subjects. These vessels are however especially remarkable for their sinuosities, on which point Gérard Marchant has laid stress: they are caused by alterations in size of the penis. When several trunks are present, they divide into two groups at the root of the organ; when only one trunk exists, it usually divides into two secondary branches, which are frequently unequal in size. This trunk may even be seen to remain undivided and end in the inguinal glands of one side.

Whether their point of exit be through the sheath of the penis or the prepuce, the cutaneous lymphatics pass towards the inguinal glands, running immediately underneath the integument. For the greater part, they terminate in the supero-internal group, but they may also end in the other glandular groups of this region (vide p. 119 and Fig. 51).

In the case of a neoplasm of the integuments of the penis, we must regard all the superficial inguinal glands as liable to become infected. Further, by reason of the inter-crossing or the bifurcation of the collecting trunks, there is a strong probability that a lesion which is quite clearly unilateral will affect the glands of the opposite side.

(2) LYMPHATICS OF THE GLANS.—The lymphatics of the glans arise from a network with very fine meshes, which has been perfectly described by Sappey. This network is partly continuous with the network of the prepuce, and that of the balanitic portion of the urethra. From this network run a series of small collecting trunks. "The direction of the latter is remarkable: all run from before backwards towards the fraenum of the penis, which invariably represents their centre of convergence. On the

right and left of the fraenum they receive two or three trunks coming from the mucuous membrane of the urethra, they then

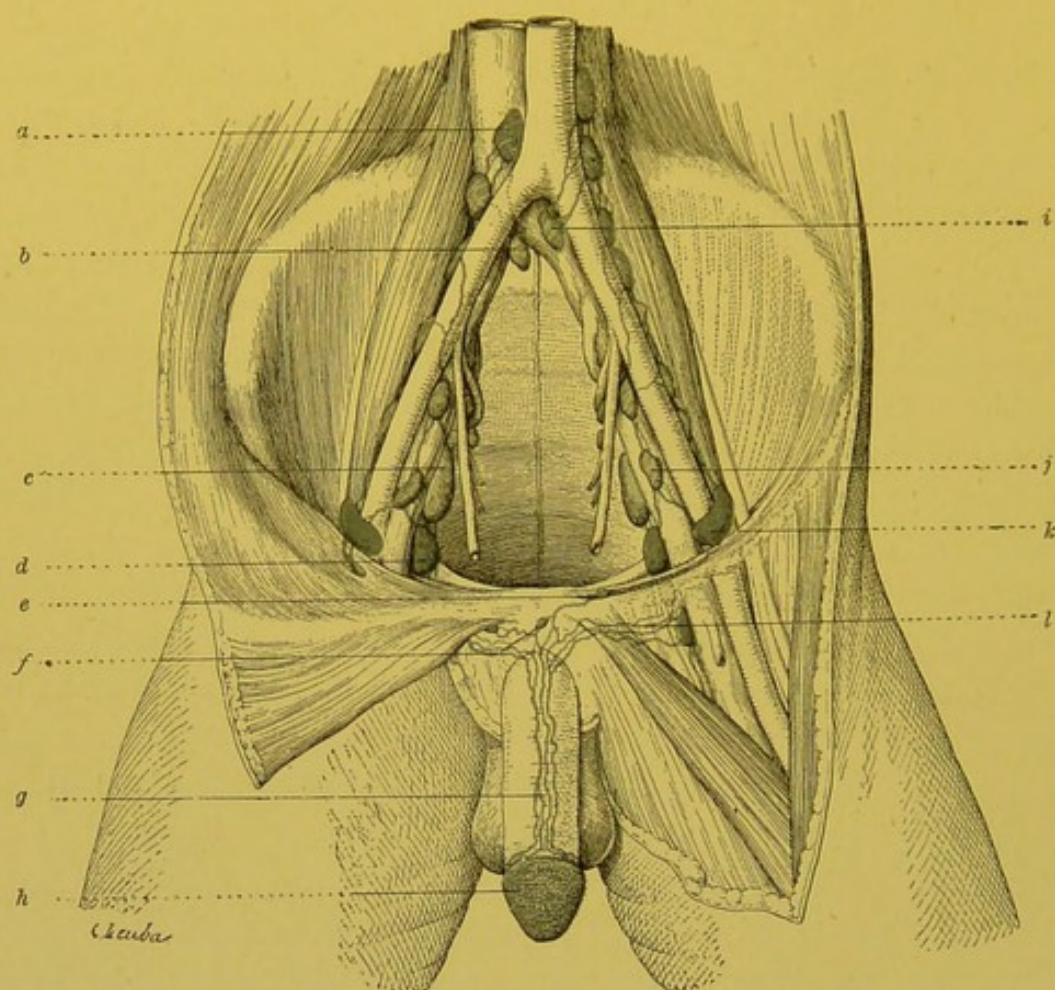


FIG. 52.—Lymphatics of the glans in the new-born infant (Cunéo and Marcille).

a. Lateral aortic gland.—*b.* Gland of the promontory.—*c.* External iliac gland (internal chain).—*d.* Retro-crural internal gland.—*e.* Glandular nodule placed at the entrance of the inguinal canal.—*f.* Praesymphysian glandular nodule.—*g.* Collecting trunks of the network of the mucous membrane of the glans.—*h.* Network of the mucous membrane covering the glans.—*i.* Gland of the promontory.—*j.* External iliac gland (middle chain).—*k.* Retro-crural external gland.—*l.* Crural collecting trunks of the glans.

bend backwards, and arrange themselves behind the corona of the glans round which they turn ; they then mount upwards as far as its median part, where those of one side unite with those of the opposite side" (Sappey). According to Sappey, they blend into a single trunk which ends in the superficial inguinal glands. The researches of Küttner, Bruhns, Cunéo and Marcille have not confirmed the description given by Sappey. According to these authors, the lymphatics of the glans end in multiple collecting trunks, which vary from two to four in number.

These vessels run parallel to the deep dorsal vein of the penis ; and so are sub-aponeurotic. They thus arrive at the root of the penis, in front of the symphysis, where they effect some anastomoses and thus form a sort of praesymphysian plexus with very

large meshes. At this spot may be found some small glands which belong to the group of interrupting glandular nodules (vide p. 86) and which we will term praesymphysial glandular nodules (vide Fig. 52).

From this praesymphysial plexus run several collecting trunks which follow a different course ; some run towards the crural canal (the crural route), others pass into the inguinal canal (the inguinal route).

(a) The *crural trunks*, three to four in number, run transversely outwards, passing beneath the femoral aponeurosis, in front of the pectineus. At first grouped in a single bundle, they soon diverge in the vertical direction. The lowest of them terminates in a *deep inguinal gland*, which is lodged in the crural canal, internal to the femoral vein. The suprajacent trunk terminates in the gland of Cloquet ; the third crosses the crural canal, enters the pelvis, and ends in the internal retro-crural gland (vide TOPOGRAPHY OF THE PELVIC GLANDS, p. 129).

In short, they all end in a series of glands vertically placed one above the other, and ranged along the femoral vein, and the external iliac vein. This route is therefore partly femoral, and partly pelvic.

(b) The *inguinal route* usually only comprises a single trunk, which passes into the inguinal canal, and which runs underneath the spermatic cord, which must be raised to see it. It may present in its course a small interrupting glandular nodule, which is usually placed at the entrance of the inguinal canal. This trunk terminates in the external retro-crural gland.

Bruhns maintains that some of the collecting trunks which come from the glans end in the superficial inguinal glands. We only admit this termination as an anomaly, and are of opinion that, when by puncturing, the glans, the superficial glands become injected, it is because the injection has penetrated into the plexus of the prepuce.

Küttner has seen a trunk embrace the large vessels, ascend beneath them to a gland placed on the spot where the ureter enters the pelvic cavity. This is a very rare arrangement. Küttner also described a trunk which, coming from the praesymphysian network, passed between the recti, and terminated in a hypogastric gland (?) and in a gland placed a little internal to the epigastric vessels. We think this too is an anomaly.

We should *a priori* expect to find the collecting trunks closely accompanying the dorsal artery of the penis, and then following the internal pudic. These vessels do exist, but do not come from the glans. According to Cunéo and Marcille, they come exclusively from the urethra.

BIBLIOGRAPHY.—MASCAGNI, loc. cit., p. 38 et tab. XI.—SAPPEY, loc. cit., p. 51 et pl. VII.—KÜTTNER. Zur Verbreitung und Prognose des Penis-

cinoms, *Arch. f. klin. Chir.*, 1899, LIX, 1, p. 180.—BRUHNS. Ueber die Lymphgefäße der äusseren männlichen Genitalien und die Zuflüsse der Leistendrüsen. *Arch. f. Anat. u. Phys.*, An. Abth., 1900, p. 281.—CUNÉO et MARCILLE. Note sur les lymphatiques du gland. *Bull. Soc. anat.*, décembre 1901.

(b) In the Female.

LYMPHATICS OF THE VULVA.—The lymphatics of the vulva arise from a network the extremely close meshes of which are superposed in several planes. "This network covers the fourchette, the meatus urinarius, the vestibule, the clitoris, the labia minora, and the internal surface of the labia majora; it is so loose and

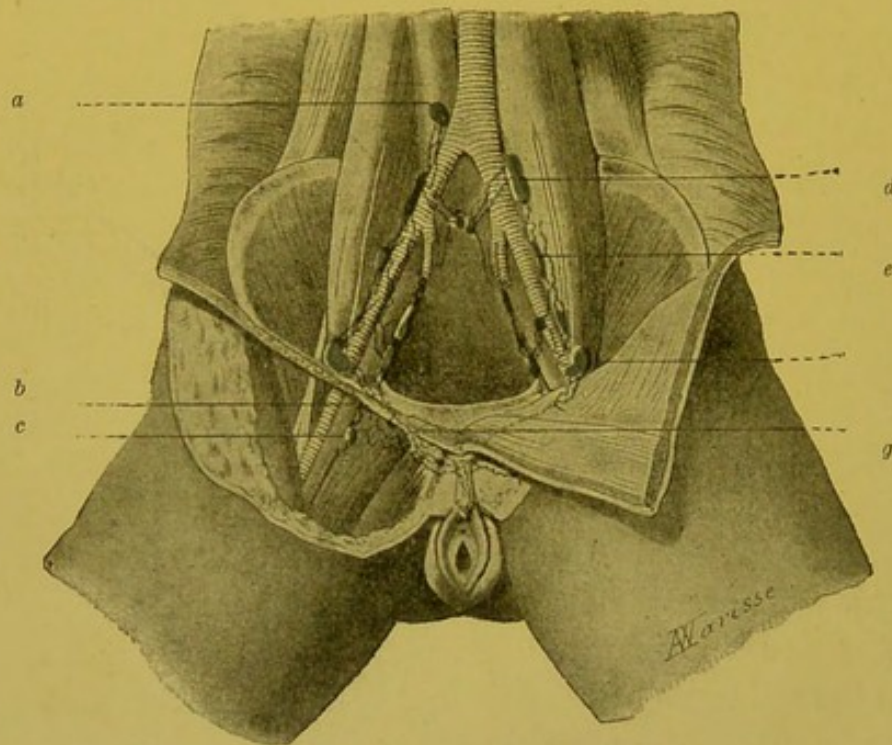


FIG. 53.—Lymphatics of the clitoris (Cunéo and Marcille).

a. Right juxta-aortic gland.—b. Gland of Cloquet.—c. Deep inguinal gland.—d. Common iliac gland (external gland).—e. External iliac gland (external chain).—g. Lymphatic vessel of the clitoris taking an inguinal course.

close throughout that when it has been well injected, it presents at first sight merely an ashy grey appearance. To distinguish the innumerable silvery filaments of which it is composed, we must use a magnifying glass. On the external surface of the labia majora, the network, composed of smaller and larger branches, becomes sufficiently distinct to be recognized by the naked eye." (Sappey.)

From the periphery of this network of origin run the collecting trunks. The direction of these trunks varies according to their points of origin. Those which come from the anterior third of the vulva, run directly upwards, and forwards towards the mons Veneris; there, they turn sharply and run transversely towards

the superficial inguinal glands. The trunks which come from the posterior two-thirds are directed upwards and outwards, and directly reach their terminal glands.

The majority of the lymphatics of the vulva terminate in the glands of the supero-internal group. Some of them may end in the infero-internal group. It is even possible, though much more rare, to see some of these vessels reach a gland belonging to one of the two external groups. As has been seen, the vulvar lymphatics are far from being confined to a perfectly definite glandular group.

When injecting one half of the vulva, the mass may frequently be seen to reach the glands of the opposite side. The injection of these glands may take place by a double process. Sometimes it is effected on account of the continuity of the network of origin of the two sides of the vulva in the middle line; at others it is due to the fact that some of the collecting trunks cross the middle line, and end in the inguinal region of the opposite side. In all cases, when dealing with an epithelioma of the vulva, the inguinal glands of both sides should be regarded as liable to infection.

LYMPHATICS OF THE CLITORIS.—The lymphatics of the clitoris deserve special mention. In fact, though the lymphatics of the prepuce of the clitoris pass into the superficial inguinal glands, like the other lymphatics of the vulva, this is not the case with the lymphatics of the glans of the clitoris. These latter, which were passed over in silence by the older writers, have recently been studied by Marcille and one of the present writers. As their general arrangement is identical with that of the lymphatics of the glans in the male, we will content ourselves by indicating it briefly.

As in the male, the network of origin gives rise to several collecting trunks which run on the dorsal surface of the clitoris, and reach the front of the symphysis; they anastomose at this spot, and form a praesymphysial network in which some small glands may be seen (vide Fig. 53). From this plexus run two sets of collecting trunks—(a). One of these vessels runs in the inguinal canal, and ends in the external retro-crural gland. This vessel is usually placed beneath the round ligament, and may show in its course a small interrupting glandular nodule. (b.) Other trunks run towards the crural canal and end in a deep inguinal gland, in the gland of Cloquet, and in the internal retro-crural gland.

BIBLIOGRAPHY.—SAPPEY, loc. cit., p. 54 et pl. VIII, Fig. 1, 2, 3.—BRUHNS.

Ueber die Lymphgefäße der weibl. Genitalien, etc. *Arch. f. Anat. u. Phys.*, Anat. Abth., 1898, p. 59.—CUNÉO et MARCILLE. Note sur les lymphatiques du clitoris. *Bull. Soc. anat.*, novembre 1901.

III. LYMPHATICS OF THE INTERNAL GENITAL ORGANS.

These we will study first in the male and then in the female.

(a.) In the Male.

LYMPHATICS OF THE TESTICLE.—The lymphatics of the testicle, whose mode of origin we will study further on (vide *Treatise of*

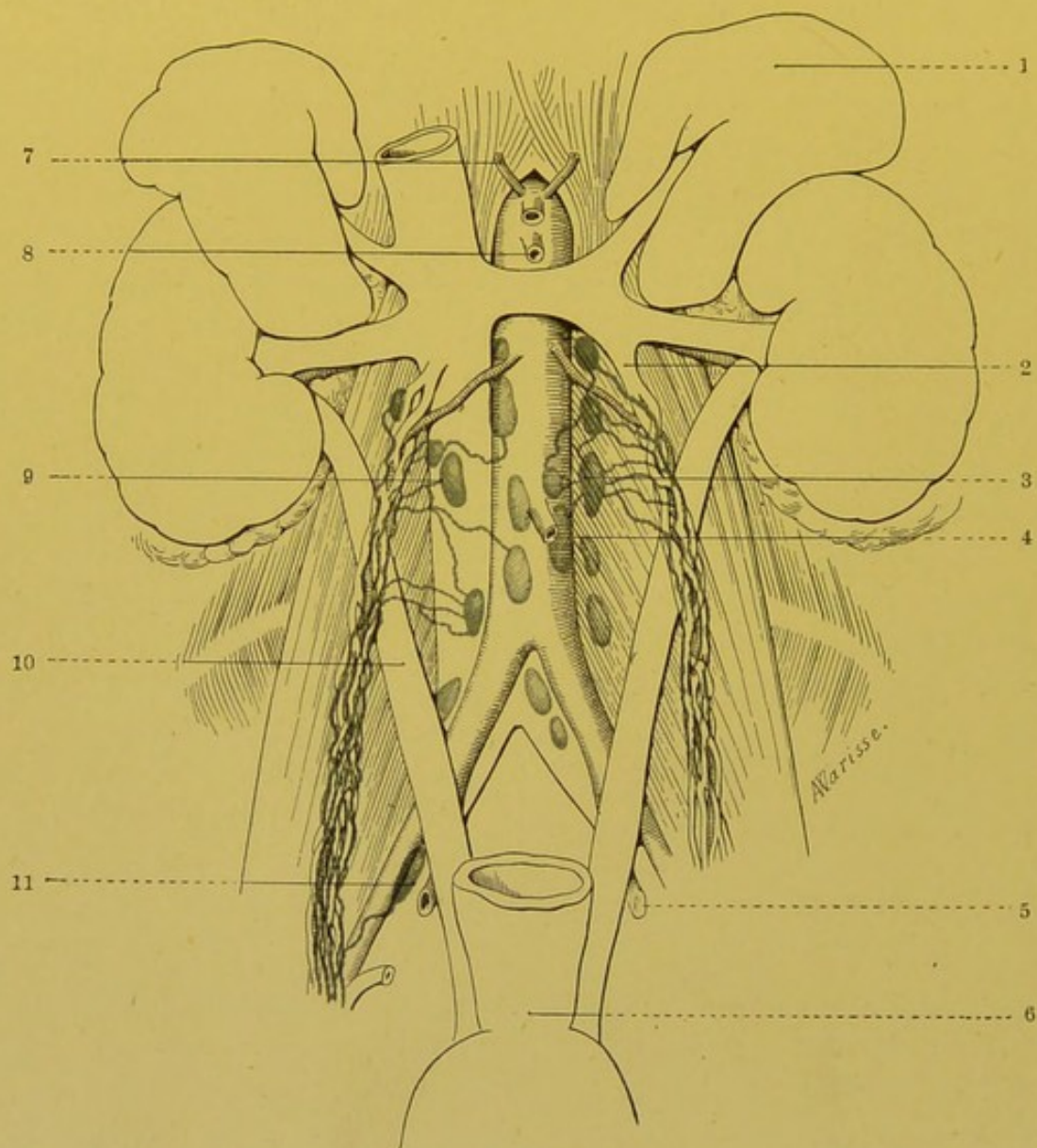


FIG. 54.—Terminal glands of the lymphatics of the testicle in a new-born infant.

1. Left supra-renal capsule.—2. Left spermatic vein.—3. Left juxta-aortic gland.—4. Inferior mesenteric artery.—5. Hypogastric artery.—6. Rectum.—7. Right phrenic artery.—8. Superior mesenteric artery.—9. Right juxta-aortic gland.—10. Ureter.—11. Posterior gland of the middle chain of the external iliac group.

Human Anatomy. Poirer and Charpy, vol. v. p. 269), unite with the lymphatics of the epididymis, and the visceral layer of the tunica vaginalis, and run towards the lumbar region along the spermatic cord.

They are usually more superficial than the blood-vessels with which they are in immediate contact. In our preparations they varied from four to eight in number. Owing to the division of some of these vessels, it has appeared to me that this number, far from becoming reduced during their course, on the contrary increases.

Having arrived in the lumbar region these trunks leave the spermatic vessels and run towards their terminal glands, either describing a fairly regular curve, or sharply bending at a right or even an acute angle.

The trunks coming from the right testicle terminate in the right juxta-aortic glands. The lowest of these glands situated immediately above the bifurcation of the inferior vena cava, always receives one or two afferent trunks. In a third of the cases one or two of these lymphatics empty themselves into one of the prae-aortic glands.

The trunks of the left side end in the three or four glands of the left juxta-aortic group, which are arranged in rows below the renal vessels, but here again, we may sometimes see that some lymphatics are not arrested in the glands of this group, but directly reach the prae-aortic glands.

Most remarks that the glands which receive the lymphatics of the left testicle, are placed at a somewhat higher level than those which receive the trunks coming from the right testicle. In a third of the cases, however, these two glandular groups are clearly placed at the same level.

Zeissl and Horowitz have described as constant, a vessel which they observed on puncturing the internal surface of the testicle: this vessel, at first a satellite of the vas deferens, leaves this duct and terminates in one of the glands of the external iliac chain. This vessel has not been noticed by the older writers. Most was unable to inject it in man, and was only successful in showing it in the rat and dog. One of the present writers has injected it in several subjects, and has seen it end in a gland placed on the external iliac vein immediately in front of the spot where this vein is crossed by the ureter. In all probability then, the arrangement is a constant one, but we must agree with Most that this vessel is somewhat difficult to inject.

In a full-term foetus, one of the authors noted the existence of three little glands placed over the lymphatics of the testicle, in their course through the iliac fossa. This arrangement must be somewhat rare, seeing that it has not been mentioned at all in anatomical literature, and that out of eighteen subjects examined by us we have only come across it once.

BIBLIOGRAPHY.—Pour les indications concernant l'origine des vaisseaux, voy. t. V, p. 270 et REGAUD, *Th. de Lyon*, 1897.—GERSTER. Ueber die Lymphgefäße des Hodens. *Zeitsch. f. Anat. u. Entwicklung.*, t. II, 1876.—ZEISSL u. HOROWITZ, *Wiener klinische Wochenschr.*, 1890, p. 388 et *Wiener*

medizinische Presse, XXXVIII, p. 761.—Most. Ueber maligne Hodentumoren u. ihre Metastasen. *Virchow's Arch.*, 1898, CLIV, p. 138.—Most. Ueber die Lymphgefäße u. Lymphdrüsen des Hodens. *Arch. f. Anat. u. Phys.*, Anat. Abth., 1899, p. 113, av. 1 fig.—CUNÉO. Note sur les lymphatiques du testicule, *Bull. Soc. anat.*, février 1901.

LYMPHATICS OF THE VAS DEFERENS.—Though it may be taken for granted that the lymphatics of the vas deferens arise from two networks, one of which is in connection with the mucous, and the other with the muscular coat; up to the present time no one has succeeded in injecting the mucous network. Moreover, the lymphatics of the vas deferens are remarkably thin, especially in its middle part (Sappey).—The collecting trunks pass to the external retro-crural gland and to the posterior gland of the middle chain of the external iliac glands.

LYMPHATICS OF THE VESICULAE SEMINALES.—The lymphatics of the vesiculae seminales are much easier to inject, and much more is known about them. They arise from two networks, one mucous, and the other muscular.

The trunks coming from this network anastomose one with another on the surface of the vesiculae, and thus constitute a third network, from which the collecting trunks originate. Though our researches have not been sufficiently numerous to enable us to determine with certainty the course of these collecting trunks, we would willingly regard as normal the existence of two vessels, one of which goes to the posterior gland of the middle chain of the external iliac glands, while the other terminates in a gland of the hypogastric group.

The lymphatics of the vesiculae seminales anastomose to a large extent with those of the bladder and especially with those of the prostate.

(b) In the Female.

LYMPHATICS OF THE OVARY.—The lymphatics of the ovary, whose mode of origin we shall study later on (*vide vol. v. p. 370*¹), are remarkable for their numbers. In well-injected preparations, they form, even at the hilum, a plexus of the greatest richness, the close-set meshes of which entirely prevent the subjacent venous plexus from being seen. Little by little the plexus diminishes in size: it finally resolves itself into four, five, or six lymphatic trunks, which immediately take an upward course; these trunks, which accompany the ovarian vessels, run with them under the peritoneum, pass in front of the common iliac vessels, then cross the ureter, and terminate in the lumbo-aortic glands. Our injections with mercury

¹ *Treatise of Human Anatomy*, Poirier and Charpy.

and with Gerota's solution have shown us that the arrangement of their terminal glands is precisely the same as that of the glands which receive the lymphatics of the testicle, that is to say, they terminate in the lateral-aortic glands of the corresponding side.

In this ascending course, the lymphatics of the ovary unite with the lymphatics coming from the fundus of the uterus and from the Fallopian tube; but at first they are simply placed next to these vessels, and it is only when they reach the level of the 5th lumbar vertebra, that they commence to exchange anastomoses with them (Poirier). In the course of the ovarian lymphatics, small interrupting glandular nodules may be found (Stahr, Marcille).

From the ovary also a vessel may be seen, which runs downwards and slightly outwards, into the upper part of the broad ligament

and ends in one of the glands of the middle chain of the internal iliac group (Marcille). In this connection we may recollect that Zeissl and Horowitz, and subsequently one of the authors, have seen one of the lymphatics of the testicle end in this same gland.

LYMPHATICS OF THE FALLOPIAN TUBE.—Arising from the three coats of this organ (vide vol. v. p. 393¹) the lymphatics of the tube unite with those of the uterus and ovary, and share with them their mode of termination in the two lateral chains of the abdomino-aortic group.

LYMPHATICS OF THE UTERUS.—As we shall see later on (vol. v. p. 481¹), the lymphatics of the uterus arise from three capillary

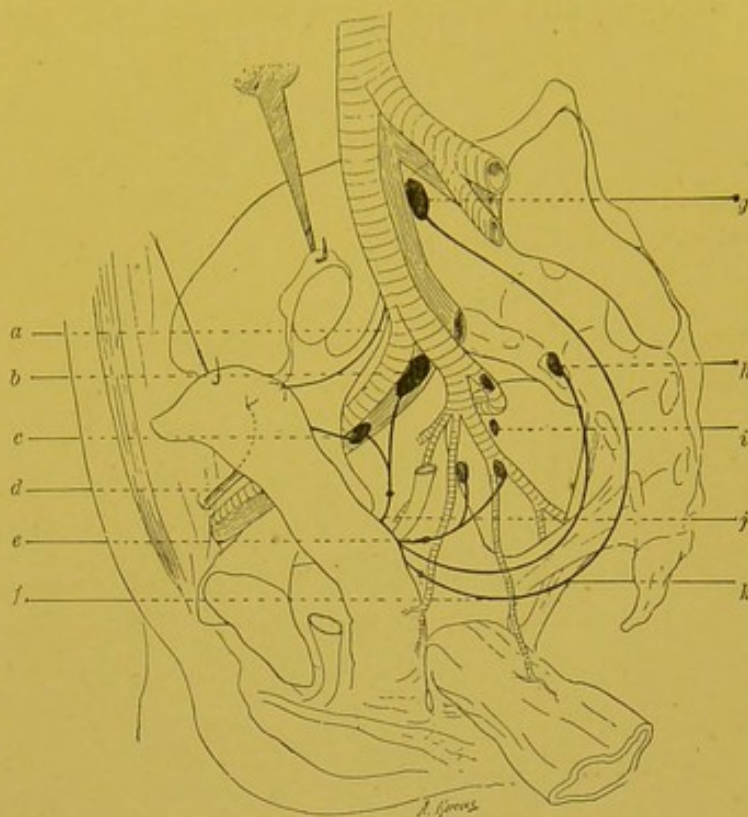


Fig. 55.—Scheme of the lymphatics of the uterus (Cunéo and Marcille).

a. Lumbar pedicle of the body.—b. External iliac gland.—c. External iliac pedicle of the body.—d. Pedicle of the round ligament.—e. Hypogastric pedicle of the neck.—f. Pedicle of the promontory.—g. Gland of the promontory.—h. Lateral sacral gland.—i. Hypogastric gland.—j. External iliac pedicle of the neck.

¹ *Treatise of Human Anatomy*, Poirier and Charpy.

networks, viz.: a mucous, a muscular, and a peritoneal network. The trunks originating from these three networks of origin all assemble on the surface of the uterine muscle in the sub-peritoneal cellular tissue, where they form by their anastomosis, a fourth and final network from which the collecting trunks start. Though the networks of origin of the cervix and of the body are

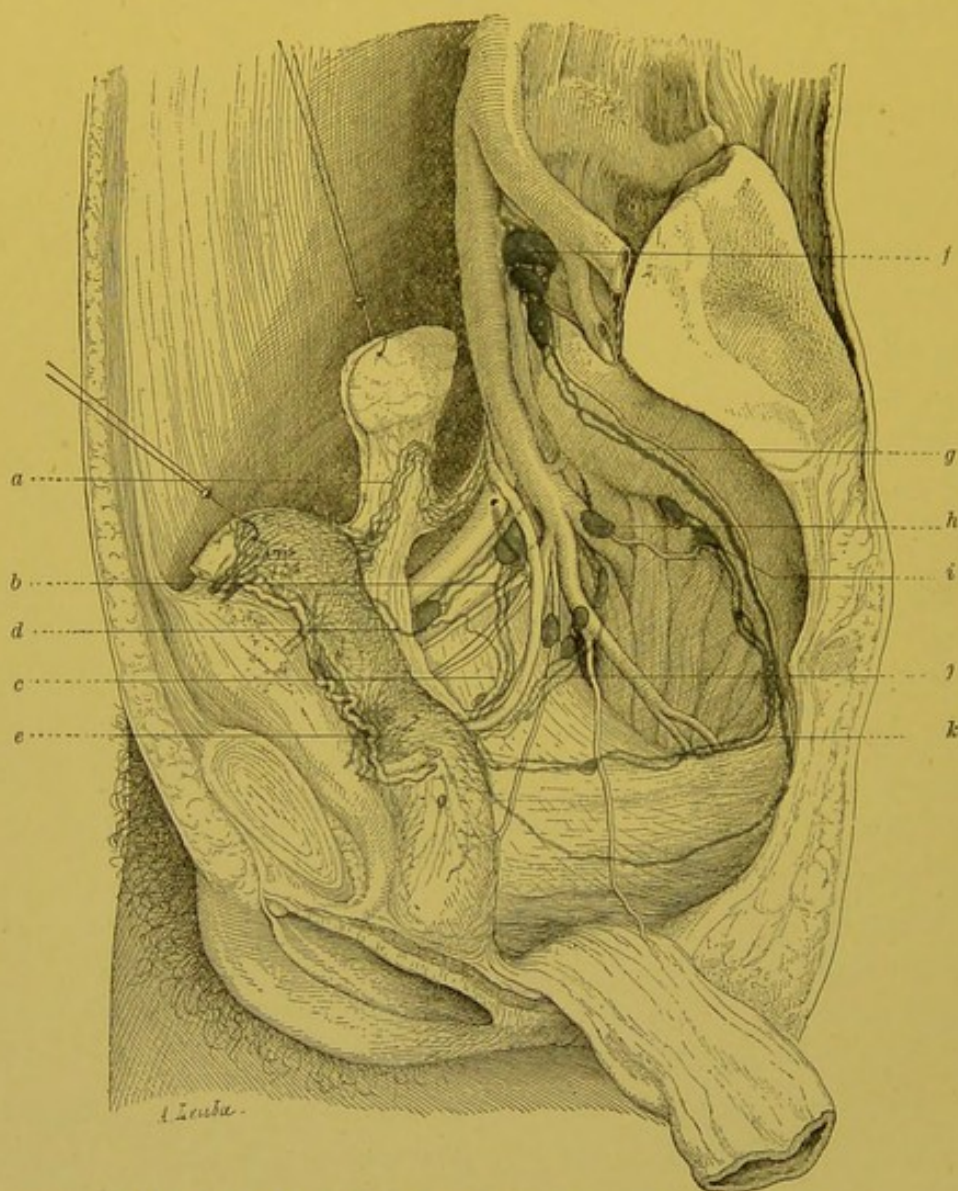


Fig. 56.—Lymphatics of the uterus (Cunéo and Marcille).

a. Lumbar pedicle of the body.—*b* and *c*. External iliac pedicle of the neck.—*d*. External iliac pedicle of the body.—*e*. Juxta-cervical lymphatic knot.—*f*. Gland of the promontory.—*g*. Pedicle of the promontory of the neck.—*h*. Intrapelvic gluteal gland.—*i*. Lateral sacral glands.—*j*. Hypogastric pedicle of the neck.—*k*. Lateral sacral pedicle of the neck.

continuous with each other without any line of demarcation, we will study the collecting trunks of these two portions of the uterus quite separately.

(1) COLLECTING TRUNKS OF THE NECK OF THE UTERUS.—The cervical collecting trunks converge towards the lateral portions of the body of the uterus. They vary in number from five to eight, and not from

two to four as the older writers stated. After leaving the cervix, these trunks, which are twisted and dilated, form a large lymphatic knot, which was well described by one of the present writers in 1890, and which we must avoid mistaking for a gland. This juxta-cervical knot, which is always well developed in the pregnant female, is, on the contrary, often absent in the new-born.

The cervical collecting trunks may be subdivided into three "pedicles."

(a) *A primary pedicle (external iliac pedicle, transverse or prae-ureteric pedicle)* comprises two to three trunks which run at first directly outwards, passing in front of and above the ureter. Exceptionally, one of them may pass behind and beneath this duct. At first satellites of the uterine artery, they soon leave this vessel. They then run up the lateral wall of the pelvic cavity, passing internal to the hypogastric artery, which they are obliged to cross in the foetus. They terminate in the middle and superior glands of the middle chain of the external iliac group (vide Fig. 56). At the level where these vessels cross the ureter, we may find as an abnormality, an interrupting glandular nodule, which, when of fair size, constitutes a true juxta-cervical gland.

Juxta-cervical gland.—The existence of this gland has been much discussed. Cruikshank, Mascagni, and nearer our own time, Henle, Luschka, and Cruveilhier do not mention it. M. Lucas Championnière was the first to notice the presence of a gland in the neighbourhood of the cervix of the uterus. "I have often seen, and have had a drawing made of a gland situated at the side and back of the cervix of the uterus." In his work on the lymphatic system, Sappey denies the existence of this gland, yet in one of his plates (plate xlvi., Fig. 9) he represents a gland over the cervical collecting trunks, and situated nearly midway between the cervix and pelvic wall.

One of the authors of this work has searched for this gland in more than 300 subjects without succeeding in discovering it; Bruhns on the contrary, declares he has met with it twice in eleven subjects, and more recently, Marcille and one of the present writers have found it five times in thirty subjects injected by Gerota's method. We shall shortly see that we may meet with analogous glandular nodules in the course of other trunks coming from the cervix of the uterus. Therefore one or several juxta-cervical glandular nodules may all exist. In normal subjects these nodules are always small, and exhibit the characteristics belonging to the *Schaltendrüse*. In mercury injected preparations, they easily escape detection; injection by Gerota's method shows them best. If any one of these nodules hypertrophies as the result of a pathological process, the operator will find a true gland lying by the side of the cervix of the uterus. This fact has been noticed several times during the course of an hysterectomy (Reynier).

(b) *A second pedicle (hypogastric pedicle)* arises from the same level as the preceding, but passes behind and below the ureter. It is formed by one or two vessels, which are directed obliquely

upwards, backwards, and outwards, and terminate in a gland of the hypogastric group. This gland is usually placed on the anterior terminal trunk of the hypogastric artery, at the level of origin of the uterine or vaginal arteries.

(c.) *A third pedicle (pedicle of the promontory and lateral sacral pedicle)* comprises two to three collecting trunks, which spring from the posterior surface of the cervix, and at first descend upon the vagina, then run backwards, crossing the lateral surfaces of the rectum, and passing within the sacro-rectal or utero-sacral ligaments; they then mount upwards into the concavity of the sacrum. The external, the shorter, are arrested in the lateral sacral glands; the internal, the longer, pass to the glands of the promontory.

As has been seen in Fig. 56, and especially in Fig. 55, all the lymphatics coming from the neck describe a series of concentric curves, arranged in different planes. The external iliac pedicle, the shortest, is almost transverse; the hypogastric pedicle which is longer, lies in an oblique plane which points backward, and outwards; the pedicles of the lateral sacral and promontory, still longer, are entirely sagittal.

In some cases, the lymphatics which end in the lateral sacral glands do not pursue such a long course as that we have just indicated. They are arrested as they pass under the peritoneum, either at the level of the free border of the utero-sacral ligaments or external to them.

A lymphatic of the cervix may pass through the broad ligament obliquely and join the vessels which constitute the lumbar pedicle of the body of the uterus (this was found three times in thirty subjects, Cunéo and Marcille). This trunk must not be confounded with the vertical juxta-uterine anastomosis which we shall describe further on.

(2) COLLECTING TRUNKS OF THE BODY OF THE UTERUS.—The collecting trunks of the body of the uterus may be divided into three groups, viz.: a principal and two accessory groups.

(a). The *principal pedicle* comprises four to five trunks, which appear beneath the cornu of the uterus. These vessels at first follow the terminal segment of the uterine artery, then pass beneath the ovary, where they are joined by the vessels coming from this gland. They then run in the suspensory ligament of the ovary with the ovarian vessels, and ascend towards the lumbar region, running round the blood vessels. Like the latter, they cross the ureter on its anterior surface. Having arrived at a spot slightly below the hilum of the kidney, they curve sharply, and “descend in showers” upon the juxta-aortic glands of the corresponding side. Some of them may, however, end in the prae-aortic group.

We may find in the course of these vessels, one or several small interrupting glandular nodules (Stahr, Marcille). They are comparable to those described by one of the authors as lying in the course of the lymphatics of the testicle.

(b) The *two accessory pedicles* pass, one, to the external iliac glands, the other, to the inguinal glands.

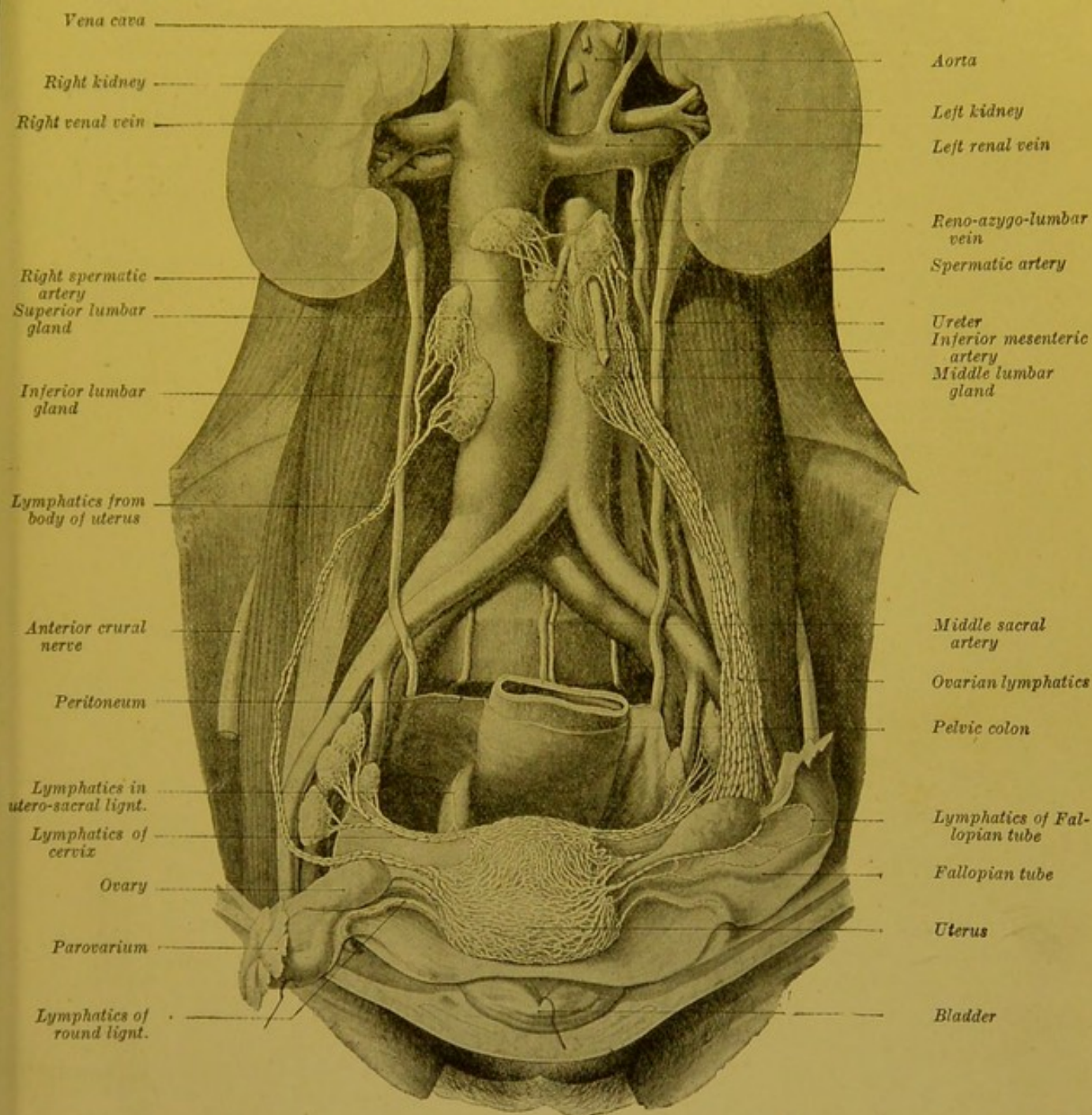


Fig. 57.—General view showing the lymphatics of the internal genital organs of the female (Poirier).

The *primary*, which was observed by Sappey (loc. cit. p. 129 and plate xlv. Fig. 9 and 10), and by Bruhns, is formed by one to two trunks, which take origin a little below the cornu of the uterus. They run directly outwards, and end in the glands of the

middle chain of the external iliac group. This chain therefore receives the lymphatics of the neck and body at the same time.

The *second* accessory pedicle as a rule only comprises a single trunk, which terminates in a superficial inguinal gland of the supero-internal group.

These lymphatics, which were observed by Mascagni (*loc. cit.*, p. 44), are difficult to inject. Whether mercury or Gerota's solution is used, it is rarely that we can trace them to their terminal glands; most frequently the injection is arrested at the internal orifice of the inguinal canal.

The lymphatics of the neck and body are not only united by

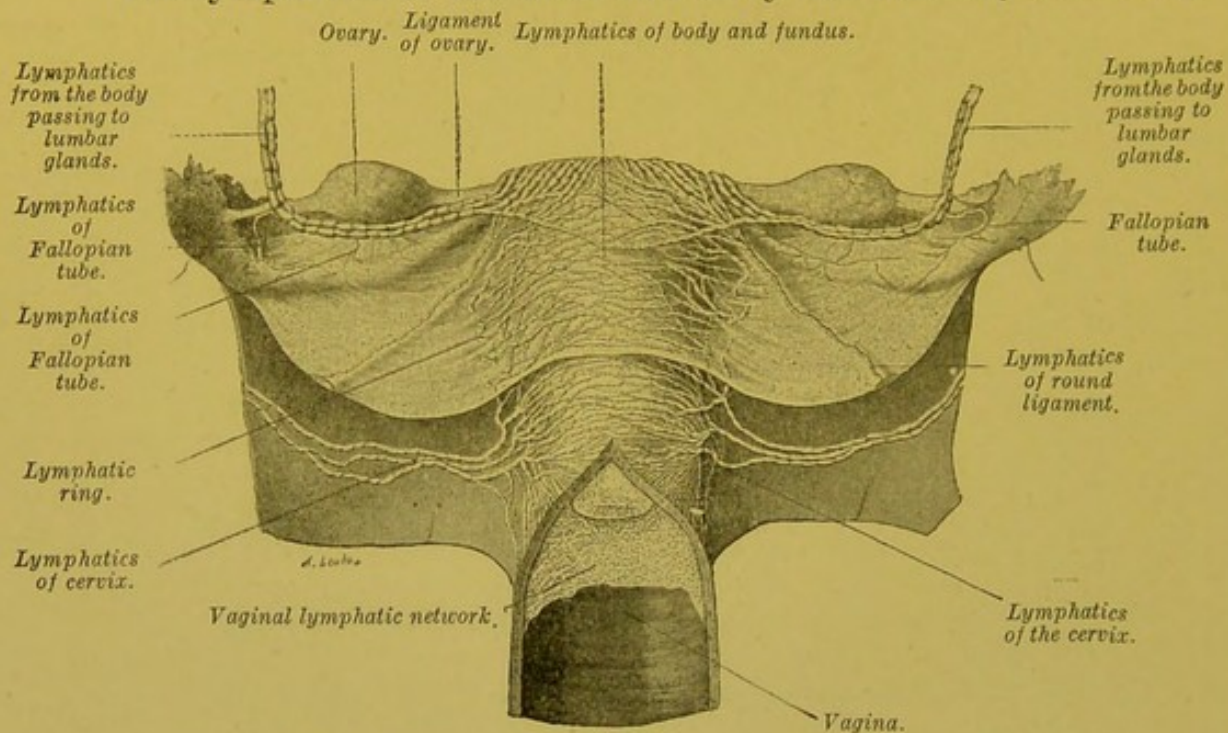


Fig. 58.—Lymphatic vessels of the uterus (Poirer).

the continuity of their networks of origin, but also by a long vertical juxta-uterine anastomosis (vide Fig. 58). One of the present writers some while ago described this anastomosis, and Bruhns is quite wrong in denying its existence. In a fresh series of researches we have again almost invariably found it (Cunéo and Marcille).

Uterine Lymphatics and the Obturator Gland.—There has been much discussion as to whether the lymphatics coming from the uterus end in the gland called "obturator." We have already explained our ideas on this gland (vide p. 132). We have seen that usually no gland exists at the actual level of the pelvic orifice of the obturator foramen, and that the small gland which may be found *abnormally* at this spot is simply an interrupting nodule placed over the lymphatics, the satellites of the obturator vessels. The gland to which authors alluded, when they spoke of the obturator gland does not at all correspond to this glandular nodule, but clearly does so to the middle gland of the internal chain of the external iliac group, a gland which is placed behind and below the obturator foramen, and at some distance from

the latter. Does this gland receive any lymphatics coming from the uterus? Cruveilhier and Lucas-Championnière are of this opinion, and on this hypothesis, A. Guérin rested his theory of sub-pubic obturator adeno-phlegmon. During the discussion at the Academy of Medicine originated by Guérin's communication, Sappey felt bound to contradict the statement that this gland receive any lymphatic tributaries from the uterus.

Later researches by Poirier, Bruhns, Peiser, Cunéo, and Marcille, etc., have confirmed Sappey's opinion. The fact that this gland may perhaps be affected during the progress of cancer of the uterus (Malartic and Guillot) is no proof at all that it directly receives any uterine lymphatics. This invasion is in fact easily explained by the numerous anastomoses which this gland effects with the first glandular relay of uterine lymphatics.

Technique. We will study in turn the injection of (a) the mucous membrane, (b) the muscle, (c) the uterine peritoneum.

(a) *Lymphatics of the Mucous Membrane.*—To see the lymphatics of the mucous membrane, a puncture must be made in the region of the cervix uteri. The procedure is as follows: The anterior wall of the cervix is incised, and after the two cut edges have been drawn well aside, the point of the tube is directed against the median column of the posterior wall. When the operation is successful, the lymphatic network of the mucous membrane instantly appears over the entire length of the mucous membrane of the cervix, and we see it becoming continuous below with that of the mucous membrane of the external os. While injecting the lymphatics of the mucous membrane of the cervix by this method, it often happens that we distend those of the mucous membrane of the body. On the other hand, the direct puncture of this mucous membrane gives negative, or only very incomplete results; though only three or four meshes have been injected, ruptures are produced at many points in the lymphatic network of this extremely friable mucous membrane.

(b) *The Lymphatics of the Muscular Coat.*—The injection of the lymphatics of the muscular coat is very easy. If the uterus has previously been placed for an hour in water at 40° so as to render its walls normally supple, it is very rarely that we fail after the first puncture to inject all or a part of the muscular lymphatic network. Moreover, as one of the present authors long since observed, of all selected spots it is here especially that punctures yield particularly good results; in this respect, the cervix and the uterine cornua should be placed in the first rank. When mercury is used, the first puncture must be made under a pressure of from 20 to 30 centimetres. When once the mercury has appeared in the collecting trunks, the pressure must be considerably diminished; unless this precaution is taken, the mercury bursts the vessels at their exit from the organ, and it is impossible to follow them to their terminal glands.

(c) *Lymphatics of the Serous Coat.*—The injection of these vessels is a much more delicate process. We have succeeded in filling them by very superficially puncturing the peritoneum which covers the uterus, and then introducing the fine point of a canula, in such a manner that it penetrates the subendothelial layer, without reaching the cellular tissue which unites the peritoneum to the uterus. This very fine network is easily distinguished from the subserous network, which represents the network of origin of the uterine collecting trunks.

We may remind ourselves that it was Mierzejewski, and subsequently one of the present authors, who placed the existence of this peritoneal network beyond a doubt.

To inject the collecting trunks of the uterus, it suffices to press the injected material into the uterine muscle. The uterus must be injected *in situ*, especially if Gerota's method is used. After the injected portions have by this method been fixed by formol, or Kaiserling's liquid, a section of one half of the pelvis may be made, which much facilitates the dissection of the uterine collecting trunks.

BIBLIOGRAPHY.—On account of their importance from a pathological point of view, the uterine lymphatics have been made the subject of numerous researches. Previously carried out with the object of determining, if possible, the pathogeny and the seat of peri-uterine suppurations, these researches have more recently been undertaken with the view of settling which glands are affected in cancer of the uterus. We will here confine ourselves to indicating the records of research dealing with the microscopic anatomy of the uterine lymphatics; and for works on the histology of these vessels will refer the reader to the article Uterus (vide ¹ vol. v, p. 481).

MASCAGNI, *loc. cit.*, p. 44 et pl. XIV.—SAPPEY, *loc. cit.*, pl. XLVI, Fig. 9 et 10.—LUCAS-CHAMPIONNIERE. Les lymphatiques utérins et la lymphangite utérine. *Th. Paris*, 1870.—FRIDOLIN. Des vaisseaux lymphatiques de l'utérus gravis. *Militärärzt. Zeitschr.*, Petersbourg, 1872.—LÉOPOLD. Lymphgefäße des Uterus, *Arch. f. Gynäkologie*, 1789, VI, p. 1.—FIOUPE. Lymphatiques utérins et parallèle entre la lymphangite et la phlébite utérines. *Th. Paris*, 1876.—MIERZEJEWSKI. Recherches sur les lymphatiques de la couche sous-séreuse de l'utérus. *J. de l'Anatomie*, 1879, p. 201.—CANTIN. *Th. Paris*, 1889.—WALLICH. Recherches sur les vaisseaux lymphatiques sous-séreux de l'utérus gravis et non gravis. *Th. Paris*, 1891.—POIRIER. Lymphatiques des organes génitaux de la femme. *Progrès médical*, 1890, II, p. 491.—MORAU. Remarques sur les vaisseaux lymphatiques des organes génitaux de la femme et leurs anastomoses avec ceux du rectum, *Comptes rendus Soc. Biol.*, 1894, n° 33, p. 812.—BRUHNS. Ueber die Lymphgefäße der weiblichen Genitalien nebst einigen Bemerkungen über die Topographie der Leistendrüsen. *Arch. f. Anat. u. Phys.*, Anat. Abth., 1898, p. 57.—PEISER. *Zeitschr. f. Geburt. u. Gynäk.*, 1898, t. XXXIX, 2e fasc., p. 259.—MALARTIC ET GUILLOT. Cancer utérin avec ganglion sous-pubien. *Bull. Soc. Anat.*, 1900, p. 123.

LYMPHATICS OF THE VAGINA.—The lymphatics of the vagina arise from two networks, which are attached, one to the mucous membrane, the other to the muscular coat.

The network of the mucous membrane is extremely rich, and its meshes so fine that the mercury which runs into them appears, at first sight, to form a continuous layer on the surface of the mucous membrane under the epithelium. The meshes of the network of the muscular coat are much larger and formed by coarser lymphatics. These two communicate with each other, and finally end in a third peri-vaginal network from which the collecting trunks emanate. All these collecting trunks pass to the glands of the pelvis. This exclusively pelvic termination of the vaginal lymphatics is particularly evident in the infant, where the hymen clearly indicates the limits of the vulva and vagina. "If a puncture is made internal to

¹ *Treatise of Human Anatomy.* Poirer and Charpy.

the hymeneal septum, one of the present writers affirmed some time ago that the mercury passes into the vessels which end in the pelvic glands; if the external or vulvar surface of the septum is punctured, the vessels which pass to the inguinal glands are injected.' In the adult female, it is possible, if the inferior part of the vagina is punctured, for the injected mass to pass to the inguinal glands, but it only does so through the numerous anastomoses which unite

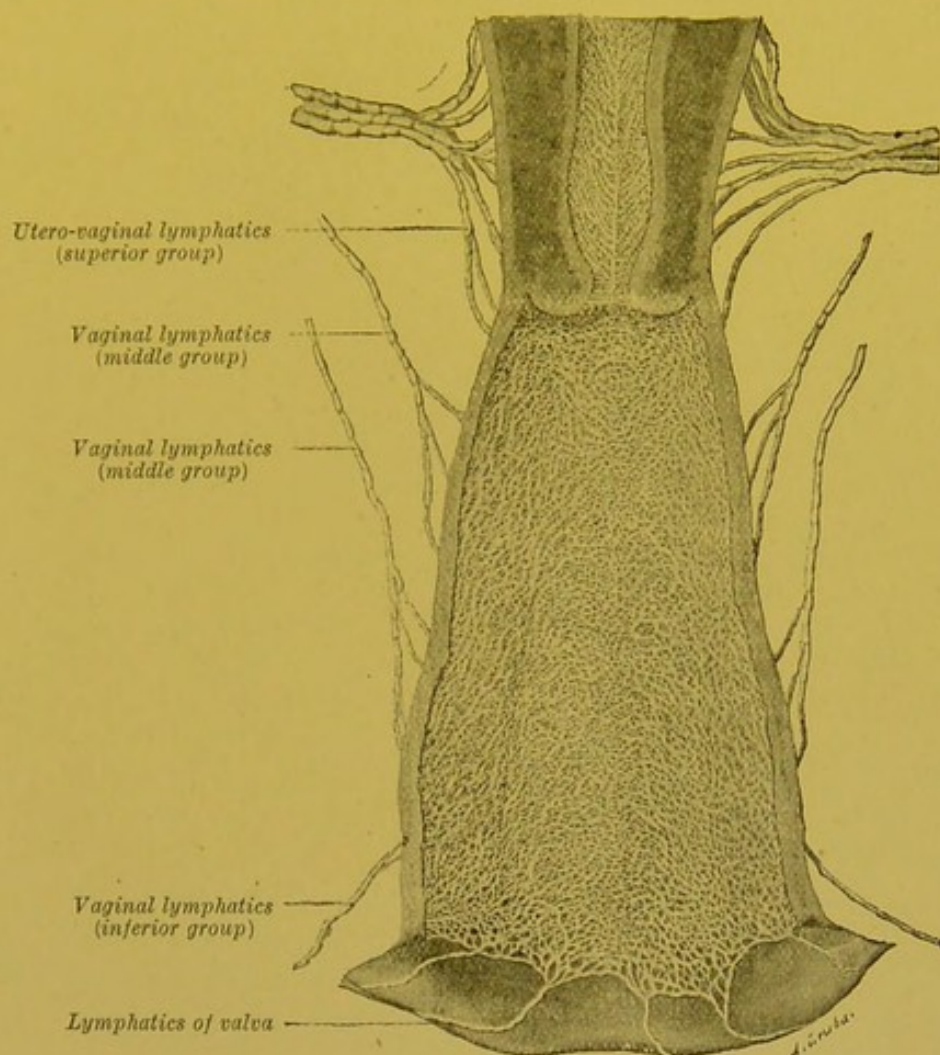


Fig. 59.—Lymphatic network of the mucous membrane of the vagina with their efferent trunks (Poirier).

the vaginal to the vulvar network, and not by direct collecting trunks.

But, though all the vaginal collecting trunks pass to the pelvic glands, we may, by taking their origin, course, and termination, as the basis of our scheme divide them into three groups: superior, middle and inferior.

(a) *The Superior Group*.—The superior lymphatics arise from the vaginal *culs de sac*, and are responsible for the lymphatic circulation of the upper third of the vagina. There are usually two trunks

on either side. One which springs from the anterior *cul de sac*, runs upwards and outwards, passes in front of the ureter, then, embracing several of the trunks coming from the cervix, terminates with the latter in the middle gland of the middle chain of the external iliac group. The other which comes from the posterior *cul de sac* also runs upwards and outwards and terminates either in the preceding gland, or in the posterior gland of the same chain (*a* and *b*, Fig. 60).

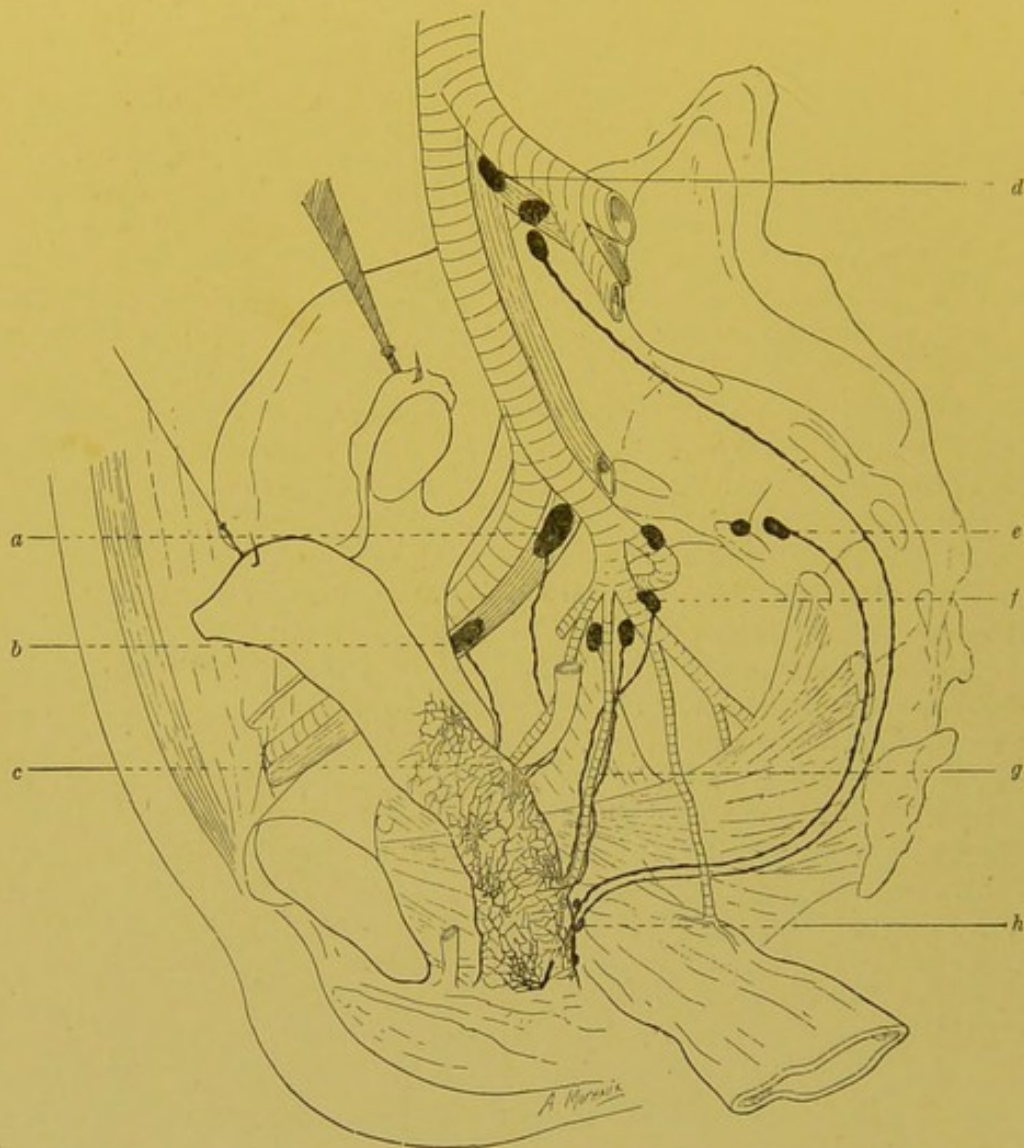


Fig. 60.—The lymphatics of the vagina (semi-diagrammatic) (Cunéo and Marcille).

a, b. External iliac glands (middle chain). *c.* Transverse external iliac pedicle. *d.* Gland of the promontory. *e.* Lateral sacral gland. *f.* Hypogastric gland. *g.* Hypogastric pedicle. *h.* Retro-vaginal glandular nodules.

(*b*) *The Middle Group.*—The lymphatics of this group come from the middle third of the vagina. They are satellites of the vaginal artery, and like this vessel, run obliquely upwards, backwards and outwards, and end in a gland of the hypogastric group, placed at the actual origin of the vaginal artery. These lymphatics and the glands in which they end are contained in the hypogastric space.

(c) *The Inferior Group.*—The collecting trunks of this group appear at the lower third of the recto-vaginal septum. At first descending, they then run outwards, then directly backwards, passing between the rectum and the sacro-recto-genital aponeurosis. They then pass upwards into the concavity of the sacrum, internal to the anterior sacral foramina, and terminate in the glands of the group of the promontory, or more rarely in a lateral sacral gland.

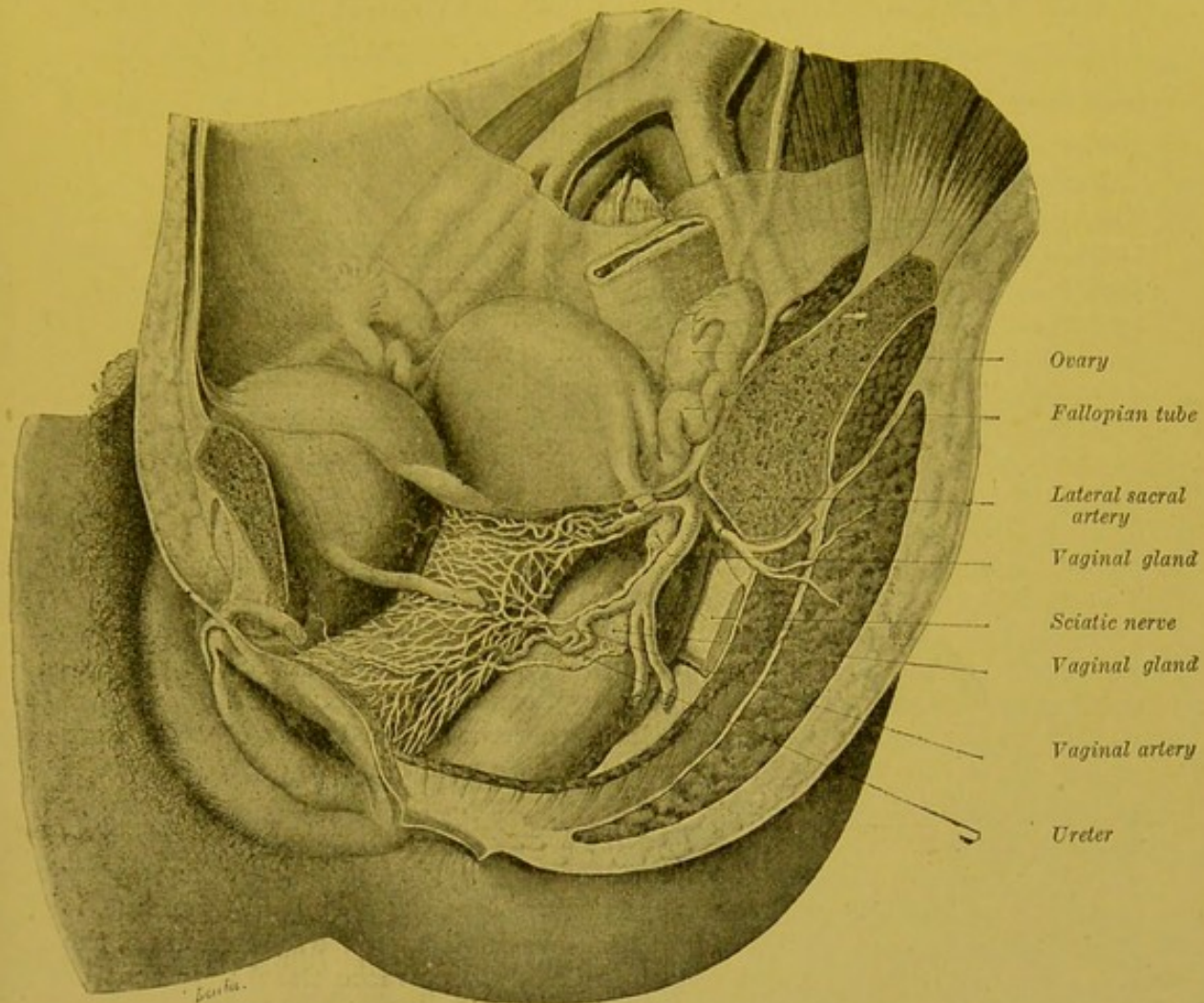


Fig. 61.—Lymphatic vessels of the middle third of the vagina and the glands in which they end (Poirier).

We may find some small interrupting glandular nodules lying on these different collectors, and in the case of the middle and inferior collectors they are constant. Some of them are even placed between the layers of the recto-vaginal septum. One of the authors pointed them out a long time ago, and our recent researches with Marcille's assistance have shown us that we may regard them as constant.

To sum up, the lymphatics of the vagina run to the pelvic glands in three groups of collecting trunks: (a) A superior transverse group, ending in the middle chain of the external iliac glands; (b) a middle group, which passes obliquely upwards and backwards, and terminates

in the hypogastric glands ; (c) an inferior sagittal group, which runs in front of the sacrum and ends in the glands of the promontory.

ANASTOMOSES.—The lymphatics of the vagina anastomose above, with those of the cervix uteri, and below, with those of the vulva, owing to the continuity of their networks of origin. Behind, they communicate with the lymphatics of the rectum ; Morau affirms that certain vessels which come from the anterior wall of the rectum join the collecting trunks which run in curves over the posterior surface of the vagina ; but to us, on the contrary, it seems that there is an absolute independence between the lymphatics of the vagina and those of the bladder.

Technique.—One of the present writers has laid down the following rules for the injection by mercury of the lymphatics of the vagina. “The organ must remain in situ and its normal relations preserved as far as possible. To effect this, after detaching all the soft parts which form the anterior wall of the hypogastric and pubic regions, we make four saw cuts, passing through the horizontal rami of the pubes, the ascending rami of the ischium, and all the anterior part of the pelvic girdle : then seizing the bladder with forceps, this organ together with the urethra is carefully separated from the anterior vaginal wall. The anterior wall of the vagina and uterus are thus preserved intact in front. By the aid of scissors with rounded extremities, we next incise the anterior wall of the vagina in the middle line, keeping to the antero-posterior axis, from the bulb of the vagina to its insertion into the cervix. To avoid the escape of mercury through the numerous lymphatics opened by this incision, I think it advisable to place on the lips of the incision a red hot stylet or the blade of a thermo-cautery. It is advantageous also, before proceeding with the injection, to thoroughly cleanse the mucous membrane of the vagina with a somewhat coarse cloth, to remove the layers of epithelium which cover it. Without this precaution we run the risk of blocking the mouth of the injection tube by the first puncture. Should this occur, another attempt must be made higher up, or at the side. The pressure necessary to effect a successful injection varies in different subjects : in infants, only a very low pressure (8 to 10 centimetres of mercury) is required, but in the adult, it often has to be raised. To inject the network of the mucous membrane, the puncture ought to be made very superficially, but more deeply for that of the muscular coat. Sometimes, especially in the infant, a single puncture is sufficient to inject all the vagina ; but to make a complete injection, two or three punctures at different points are usually necessary : In these cases, it is necessary to seal up the apertures made by the preceding punctures by lightly cauterizing with the red hot end of a stylet. If one or several punctures produce no result, the experiment must be repeated until the mercury is seen to spread into and invade the lymphatic network with its well known rapidity ; the pressure must now be diminished and, if the sides of the vagina are carefully watched, one or two strands of mercury will be seen to shoot over its lateral portions and pass to the glands. During the injection, two or three trunks opened by the scalpel while detaching the bladder, will cause some leakage, but this can easily be arrested by some light cauterizations.” The injection of the lymphatics of the vagina by Gerota's method may be effected by a similar process.

BIBLIOGRAPHY.—Vide UTERUS, pp. 166, 167 and 168.

4. LYMPHATICS OF THE URINARY PASSAGES.

LYMPHATICS OF THE URETHRA.—We will now study the lymphatics of the urethra in the male and in the female.

I. IN THE MALE.—The lymphatics of the urethra arise from a network attached to the mucous membrane of the urethra. The arrangement of this network of origin has been perfectly described by Sappey. “The lymphatic vessels of the mucous membrane of the urethra cover all its free surface, from the prostatic utricle to the meatus urinarius. Posteriorly, the network formed by these vessels and by the anastomoses which unite them, is continued on to the ejaculatory

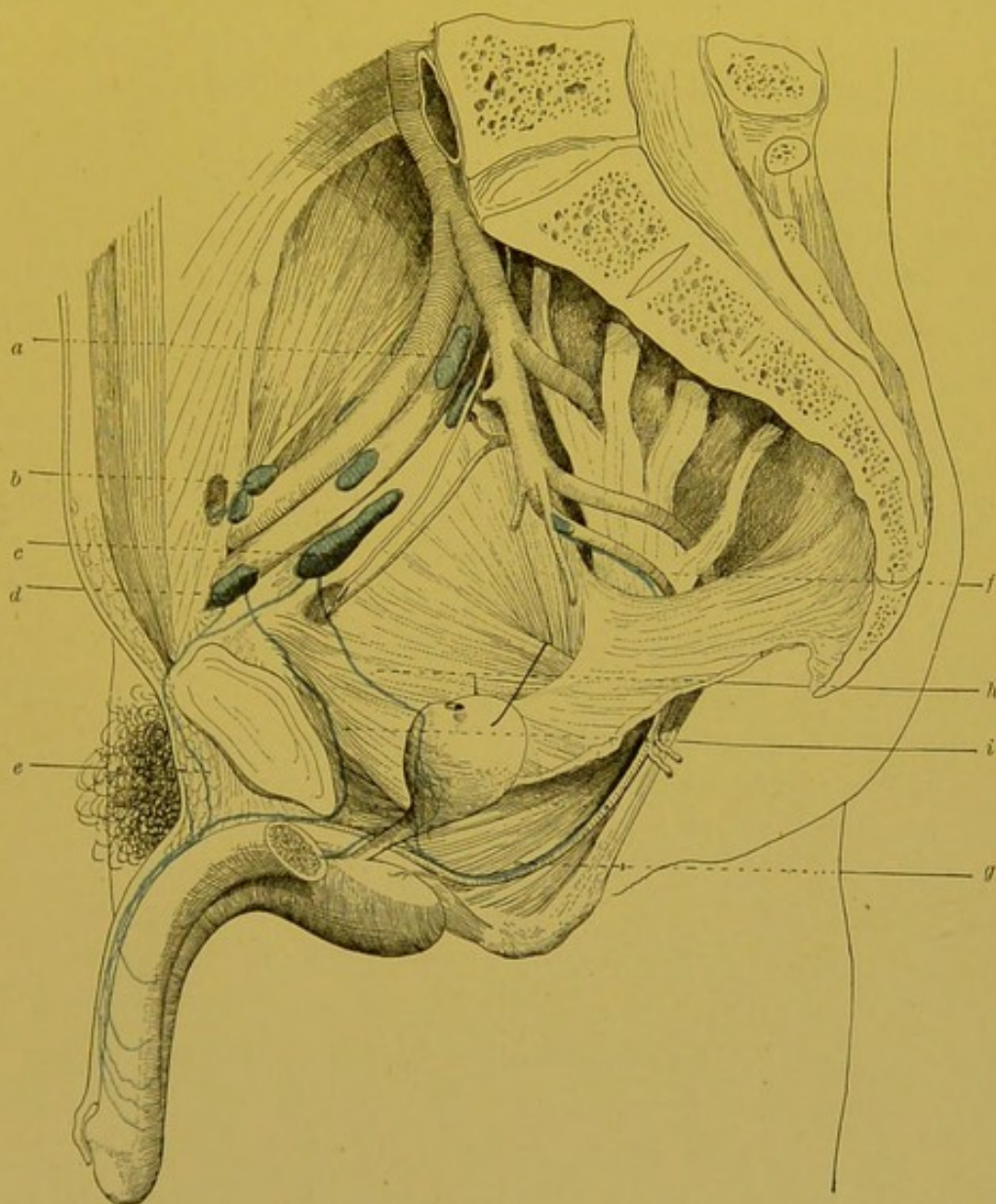


Fig 62.—Lymphatics of the penile and membranous portion of the urethra (Cunéo and Marcille).

a, b, c, d. External iliac glands. *e.* Penile prae-symphysian collecting trunk. *f, g.* Satellite trunk of internal pudic vessels. *h.* Collecting trunk coming from the anterior surface of the prostate. *i.* Penile retro-symphysian collecting trunk.

ducts, and is thus continuous with that of the vesiculae seminales and the vasa deferentia. In front, it is continuous with the tortuous branchlets on the surface of the gland. This network has an exceptional arrangement; the larger and smaller branches which form it, follow the direction of the urethral walls. By many transverse and oblique anastomoses, they unite very frequently and are grouped in parallel and unequal bundles, separated by longitudinal ridges." (Sappey).

From this network emanate several collecting trunks which may be divided into four groups :

1. The only collecting trunks which Sappey mentions are those *which come from the mucous membrane covering the glans*. They traverse the inferior wall of the urethra at the level of the fraenum, unite with the lymphatic trunks coming from the glans, and terminate in the same manner as those vessels (vide Fig. 52 and p. 157).

2. The collecting trunks which come from *the remainder of the penile portion* vary in number. They emerge on the inferior surface of the penis, turn round the lateral surfaces of the corpora cavernosa and unite with the trunks coming from the glandular portion. The majority run and terminate in the same way as the latter, but some take an entirely different course; for instance, one of these vessels passes over the symphysis, runs between the two recti muscles, then turns directly to the left and terminates in the internal retro-crural gland. More rarely, it may be found to terminate in the middle gland of the internal chain of the external iliac glands. Küttner was the first to note the presence of this vessel, but he was wrong in believing that it came from the mucous membrane of the glans. A second collector passes underneath the symphysis and unites with the vessels coming from the bulbar and membranous portions of the urethra.

3. The lymphatics of the *bulbar and membranous portions* end in the following three systems of collecting trunks :

- (a) One of these vessels makes its appearance on the upper surface of the bulb in the angle formed by the divergence of the two corpora cavernosa. It embraces either the transverse artery of the bulb, or the artery to the corpus cavernosum, it then becomes a satellite of the trunk of the internal pudic artery and terminates in the gland attached to the intra-pelvic portion of the trunk of this artery.

- (b) A second vessel runs towards the posterior surface of the symphysis, and then behind the pubes to terminate in the internal retro-crural gland.

(c) A third trunk ascends on the anterior surface of the bladder, and unites with the trunks coming from the inferior segment of this surface, and terminates with the latter in the middle gland of the internal chain of the external iliac glands.

4. The lymphatics of the *prostatic portion* pass into the collecting trunks which emerge from the glandular parenchyma.

The injection of the lymphatics of the urethra is a delicate process, and it is rather difficult to follow the somewhat complicated course of their collecting trunks. Sappey only mentions the vessels coming from the glandular portion of the urethra. More recently, Küttner incidentally mentions several other collecting trunks. The description we have just given is founded on the researches carried out by one of the present writers with the assistance of Marcille. It makes no pretence at being final. We ought to remark that some of the collecting trunks whose course we have described have only been met with in certain subjects, in spite of the considerable number of specimens we have injected. It is therefore difficult to say whether this inconstancy is real, or whether it is caused by the difficulties of injecting these vessels.

SAPPEY, loc. cit., p. 53 et pl. VII, Fig. 7.—KÜTTNER, Zur Verbreitung und Prognose des Penis-carcinoms. *Arch. f. klin Chir.*, 1899, LIX, 1, p. 180.

II. IN THE FEMALE.—The lymphatics of the urethra of the female have a precisely similar arrangement to that of the lymphatics of the membranous and prostatic portions in the male. They therefore end in the middle and internal chains of the external iliac glands, in the hypogastric glands, and in the glands of the promontory.

LYMPHATICS OF THE PROSTATE.—The lymphatics of the prostate arise by fine capillaries arranged in the form of a network round each glandular acinus. From these periacinous networks, run larger vessels which pass towards the periphery of the gland, and form at its surface a second network—the periprostatic network, from which the collectors start. The latter, which are symmetrically arranged on each side of the gland may run in four different directions :

1. A primary trunk (*a*, Fig. 63) starts from the posterior surface of the prostate, and runs on to the bladder in the triangle between the vasa deferentia. It ascends as far as the middle part of the postero-superior surface of the bladder, where it curves sharply outwards, crosses the hypogastric artery, and terminates in the middle gland of the middle chain of the external iliac group (vide p. 131). In its retro-vesical course, this trunk describes numerous curves ; it may pass through some small interrupting glandular nodules (Schalt-drüsen), close to the spot where it crosses the hypogastric artery. This ascending channel frequently consists of two trunks which then terminate in the middle and superior glands of the middle chain.

2. A second collector, arising like the preceding from the posterior surface of the prostate, accompanies the prostatic artery. Like the latter, it runs upwards, outwards and backwards, and terminates in one of the middle glands of the hypogastric group. In the neighbour-

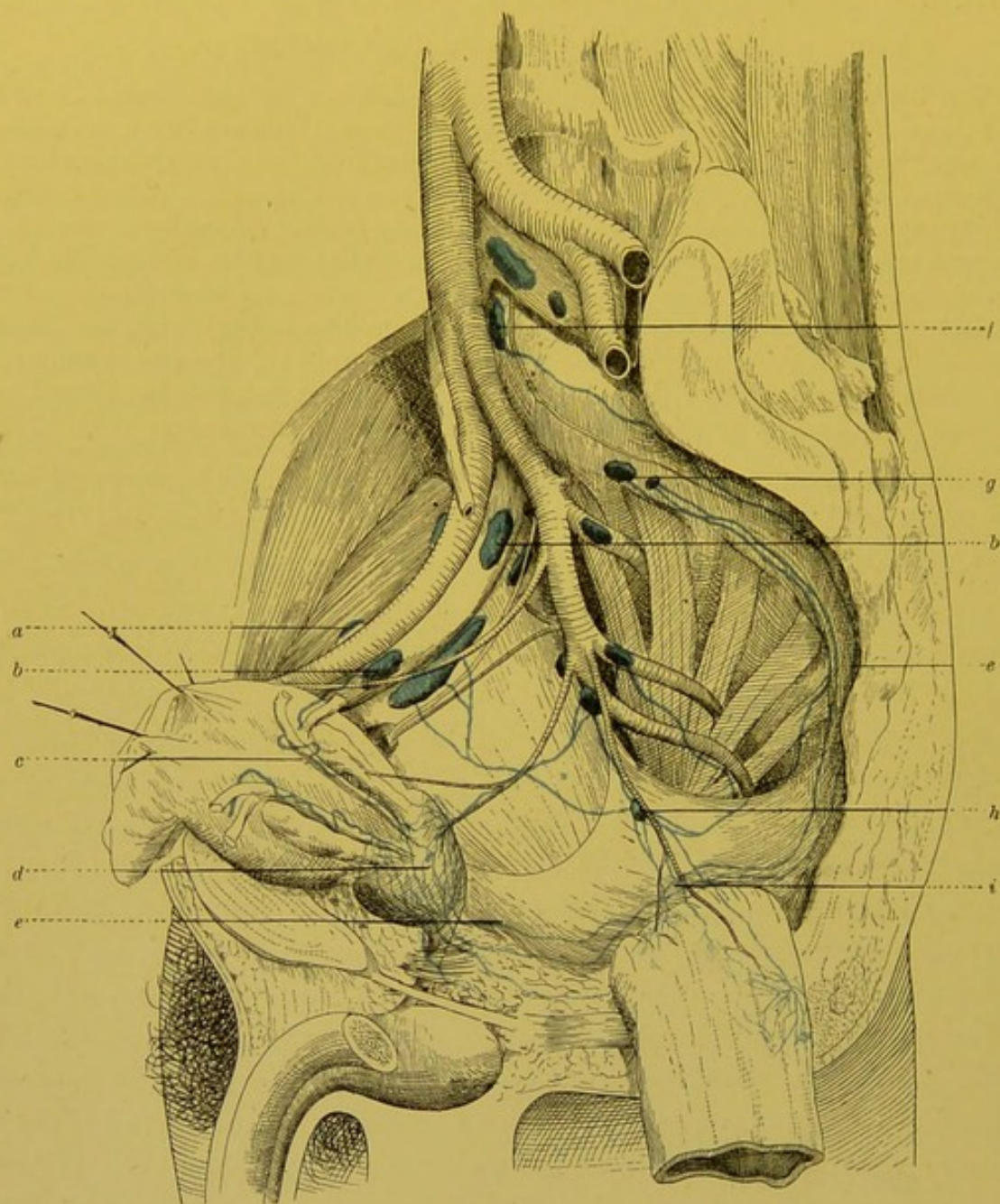


FIG. 63.—Lymphatics of the prostate (Cunéo and Marcille).

a, b. External iliac glands. *c.* External iliac prostatic pedicle. *d.* Retro-prostatic glandular nodules. *e.* Prostatic pedicle of the promontory. *f.* Gland of the promontory. *g.* Latero-sacral gland. *h.* Middle haemorrhoidal gland. *i.* Middle haemorrhoidal trunks.

hood of the prostatic origin of this trunk, two or three small glandular nodules are almost constantly found.

3. Two or three other collecting trunks also start from the posterior surface of the gland, and run at first downwards, and then backwards. They enter the sacro-recto-genital aponeurosis, cross

the lateral surfaces of the rectum, and then ascend on the anterior surface of the sacrum. They do not all terminate in the same manner. The shorter and more external (*b*, Fig. 63) end in the lateral sacral glands which, as we have already seen, are usually situated internal to the second sacral foramina. The longer and more internal (*e*, Fig. 63) pass as far as the promontory to terminate in the glands situated there.

4. Finally, from the anterior surface of the prostate may be seen a descending trunk which runs towards the pelvic floor, where it unites with the vessels coming from the membranous portion of the urethra. In company with the latter, it embraces the artery of the corpus spongiosum, and then runs with the internal pudic; it finally terminates in a gland of the hypogastric group, situated on the intra-pelvic portion of the trunk of the internal pudic artery. This descending prostatic channel, which was observed in the dog by Walker, has also been found in man by Marcille (three times in fifteen subjects).

The lymphatics of the prostate to which little attention was given by Mascagni, were for the first time described in some detail by Sappey in 1854; but this author hardly described in sufficient detail the course and termination of the prostatic collecting trunks. In 1899, Walker undertook the study of these vessels in the dog and in the monkey; and quite recently, Cunéo and Marcille have systematized the arrangement of the prostatic lymphatics in man.

BIBLIOGRAPHY. — MASCAGNI, loc. cit., p. 44 et tab. XII, Fig. 2. — SAPPEY, loc. cit., p. 134, pl. XLVIII, Fig. 4, et *Recherches sur la conformation de l'urètre*. Paris, 1854, p. 84. — WALKER. Ueber die Lymphgefäße der Prostata beim Hunde, *Arch. für Anat. u. Physiol.*, Anat. Abth., 1899, 1 et 2, p. 1 à 10. — STAHR. Bemerkungen über die Verbindungen der Lymphgefäße der Prostata mit denen der Blase. *An. Anz.*, 1899, n° 1, p. 27–29. — CUNÉO et MARCILLE. Note sur les collecteurs lymphatiques de la prostate. *Communication à la Soc. anat.*, 31 janvier 1902.

THE LYMPHATICS OF THE BLADDER.—The origin of the vesical lymphatics will be studied further on (vide vol. v. p. 123¹). Here we need only observe that the trend of modern scientists is to deny the existence of absorbent vessels in the vesical mucous membrane, and to maintain that the only network of origin which exists in the bladder is an intramuscular one. The emergent vessels of this network end in a second network placed on the outer surface of the vesical muscle, under the peritoneum or the umbilico-praevesical fascia.

The course and termination of the collectors of this network vary according to their situation on the anterior or posterior surface of the bladder.

¹ *Treatise of Human Anatomy*. Poirier and Charpy.

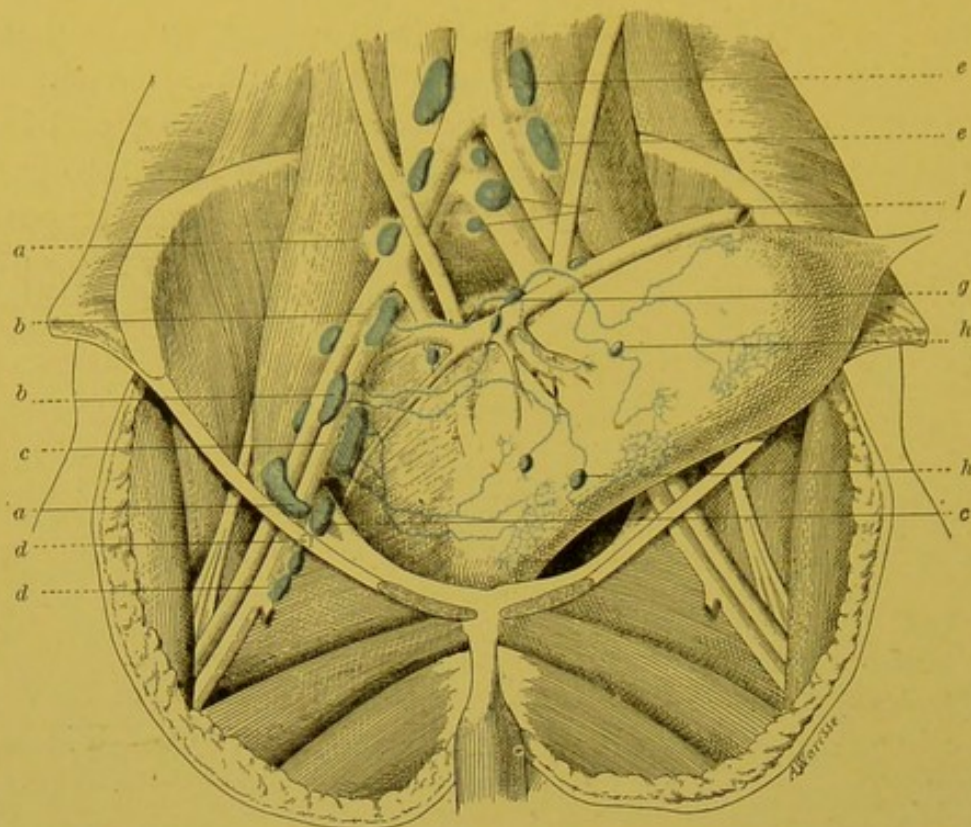


FIG. 64.—Lymphatics of the bladder in the new-born infant (Cunéo and Marcille).

a. External iliac gland (external chain). b. External iliac gland (middle chain). c. External iliac gland (internal chain). d. Deep inguinal glands. e. Left juxta-aortic gland. f. Gland of the promontory. g. Lateral vesical glands. h. Praevesical glands.

1. *Anterior Surface*.—The collecting trunks coming from the anterior surface form two groups. The trunks coming from the *inferior* segment of this surface run almost transversely outwards; and pass into a gland placed on the lateral surface of the pelvic cavity, between the external iliac vein and the obturator nerve, a few millimetres behind the crural ring. The trunks which come from the *superior* part of the anterior surface are remarkable for their sinuosities. They run upwards and outwards, cross the hypogastric artery, passing either above, or more frequently below it, and eventually terminate in the middle gland of the middle chain of the external iliac group. In the course of these lymphatic trunks are placed small glands, which are only visible after injection: they belong to the group of *interrupting glandular nodules* (vide p. 86). Some of these glands are placed in front of the bladder (praevesical glands); they may become hypertrophied in certain pathological conditions (Bazy), and may form the starting point of certain prae-vesical phlegmons. Others are placed at the spot where the lymphatic vessels cross the hypogastric artery (latero-vesical glands. Waldeyer, Gerota).

2. *Posterior Surface*.—The trunks which come from the posterior

surface also form several groups. (a) The trunks which come from the *superior* portion of this surface, run outwards describing several curves. They cross the hypogastric artery, where they traverse some small lateral-vesical glands, and terminate in the external iliac gland in which, as we have seen, the superior lymphatics of the anterior

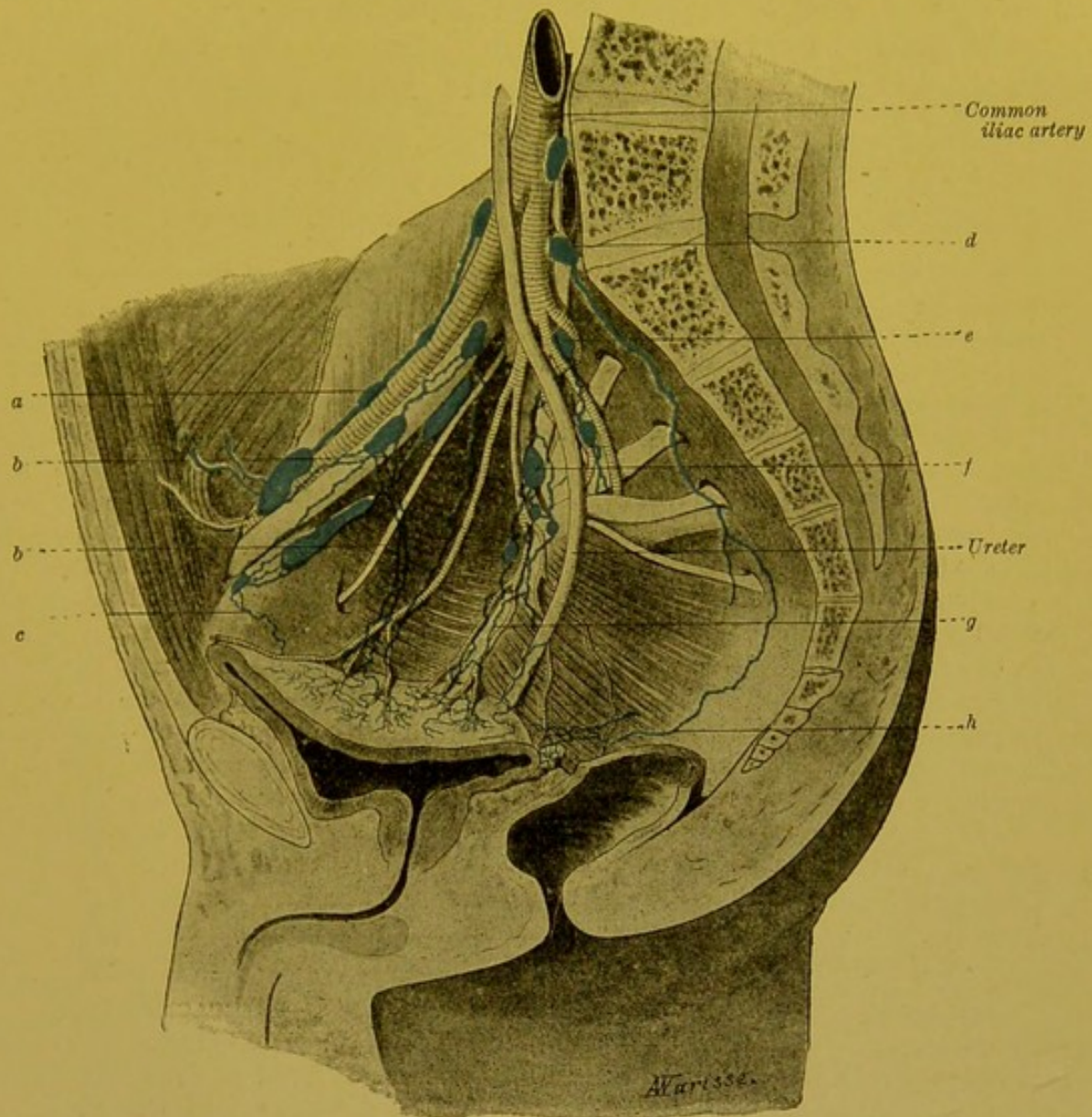


FIG. 65.—Lymphatics of the bladder (Cunéo and Marcille).

a. Gland of the external chain of the external iliac group. b, b. Collecting trunk of the upper portion of the posterior surface. c. Collecting trunk of the inferior portion of the anterior surface. d. Gland of the promontory. e. Hypogastric gland, situated on the gluteal artery. f. The hypogastric gland. g. Satellite collecting trunks of the inferior vesical artery. h. Collecting trunks about to end in the glands of the promontory.

surface also end. (b, Fig. 65). (b) Other trunks pass backwards following the course of the hypogastric artery, and end in a gland which is situated, like the preceding, on the external iliac vein, but more posterior to it, immediately in front of the bifurcation of the common iliac artery. (c) Other trunks which come from the middle

segment of the posterior surface, end in the hypogastric glands (*g*, Fig. 65). (*d*) Others finally arising from near the neck of the bladder run directly backwards, and crossing the lateral surfaces of the rectum, ascend on to the anterior surface of the sacrum and terminate in the glands situated in the angle of bifurcation of the abdominal aorta, in front of the promontory (*h*, Fig. 65).

To sum up, the vesical lymphatics end in the external iliac glands, in the hypogastric glands, and in the glands of the bifurcation of the aorta. We may add that the praevesical network is continuous with the network which surrounds the prostate, the vesiculae seminales, the vasa deferentia, and the terminal parts of the ureters.

Historical and Technical.—The lymphatics of the bladder have given rise to numerous researches. We will not here recall the discussions to which the question of the existence of these lymphatics has given rise; they will be found summarized in the excellent monograph of Pasteau. As regards the arrangement of the collecting trunks and the situation of their terminal glands, we find but very incomplete descriptions given in the classical works. Mascagni and Cruikshank, however, appear to have observed the lateral vesical glands. Sappey does not mention them, and wrongly concluded that the lymphatics of the bladder terminate exclusively in the external iliac glands. Pasteau publishes no original work, and confines himself to summarising previous researches. It is only in recent times, that Gerota, and more recently, Marcille and one of the present authors demonstrated the topography of the lymphatic glandular apparatus connected with the bladder.

The reason why anatomical literature only furnishes us with such vague information on this point is that, the injection of the vesical lymphatics is a somewhat difficult process. With mercury, we have only exceptionally succeeded in injecting them, but with Gerota's method they are shown much more readily. Again, certain rules must be carefully observed. It is useless to try and inject the perimuscular network, for this almost invariably results in the production of an extensive extravasation. The canula must be inserted into the actual thickness of the vesical muscle, and the injected mass must be pressed if possible into the intramuscular network (Cunéo and Marcille).

BIBLIOGRAPHY.—CRUIKSHANK, *loc. cit.*, p. 304.—MASCAGNI, *loc. cit.*, p. 44 et tabl. XII, Fig. 11.—SAPPEY, *loc. cit.*, p. 304.—GEROTA. Ueber Anatomie und Physiologie der Harnblase. *Arch. f. Anat. u. Physiol.*, Phys. Abth., 1897, p. 428.—GEROTA. Ueber die Lymphgefäße und die Lymphdrüsen der Nabelgegend und der Harnblase, *An. Anz.*, XII, 4 et 5, p. 89.—PASTEAU. État du système lymphatique dans les maladies de la vessie et de la prostate. *Th. Paris*, 1878 (contient une bibliographie très complète).—WALKER. Ueber die Lymphgefäße der Prostata beim Hunde. *Arch. f. Anat. u. Physiol.*, Anat. Abth., 1899, 1 et 2, p. 1 à 10.—CUNÉO et MARCILLE. Lymphatiques de la vessie. *Communic. Soc. anat.*, 29 novembre 1901.—BAZY, Rapport sur une note de Gerota. *Soc. Chirurgie*, 7 mai 1902.

LYMPHATICS OF THE URETER.—Our knowledge of the lymphatics of the ureter is still imperfect. Sappey was only able to inject them in the horse, and only met with them in the muscular coat. In the course of our injections of the vesical lymphatics, we have several

times seen the subserous network of the bladder extend itself a few millimetres round the ureter. The lymphatics of the ureter end in multiple collecting trunks which pass to the neighbouring glands.

LYMPHATICS OF THE KIDNEYS.—The lymphatics of the kidneys arise from two networks, one superficial, and the other deep.

The *superficial network*, which was observed by Mascagni, has not been seen by Ludwig and Kölliker. The now classical

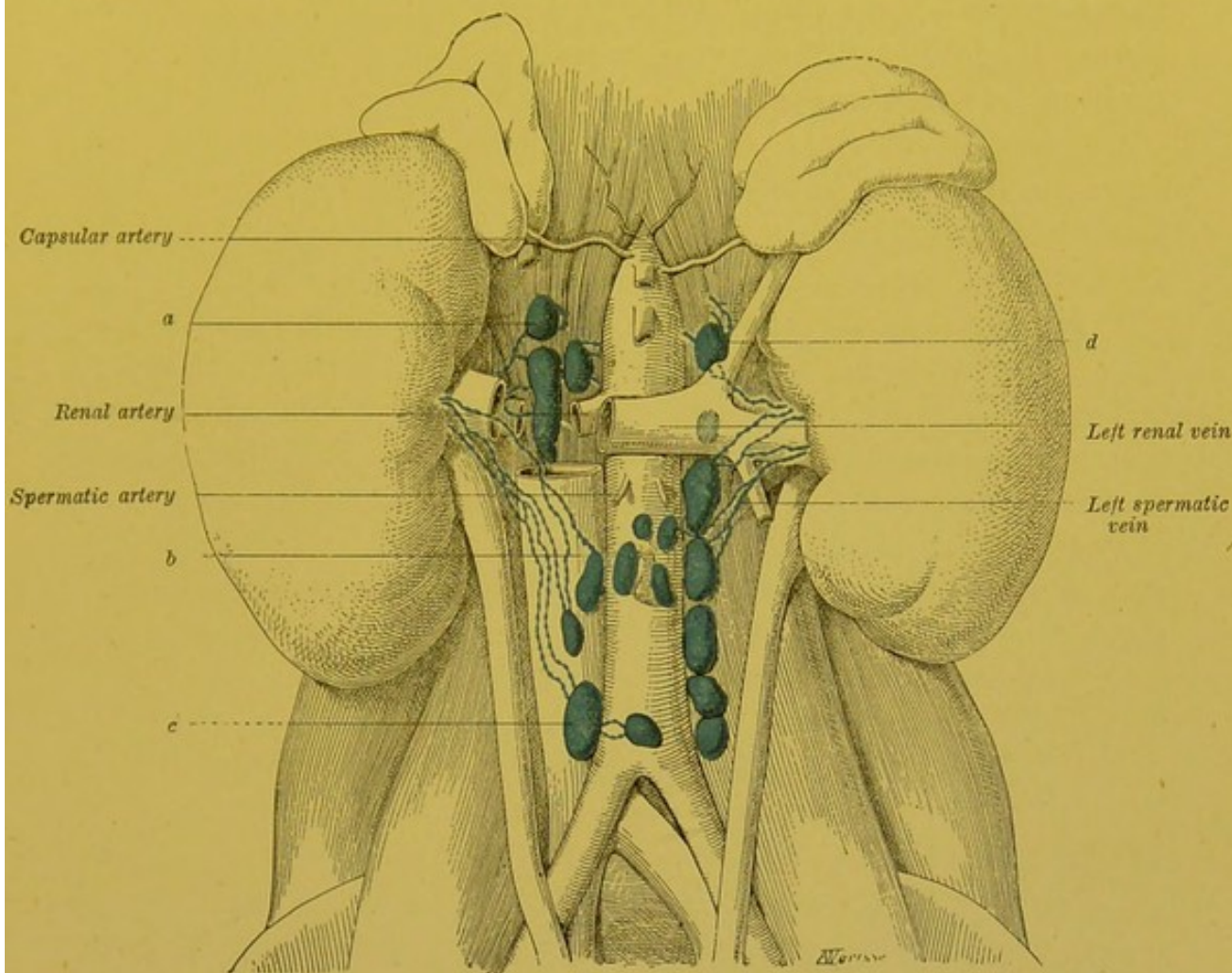


FIG. 66.—Lymphatics of the kidneys.

a. Right juxta-aortic gland (retro-venous). b. Prae-aortic gland. c. Right juxta-aortic gland (praevenous). d. Left juxta-aortic gland.

researches of Teichmann and Sappey, and the more recent works of Renaut and Stahr, however, leave no doubt as to its existence ; but it is extremely difficult to inject. Immediately underneath the capsule, it is remarkable for the tenuity of its meshes. From this network, two systems of collecting trunks arise which, following Sappey, we may divide into convergent and divergent. The convergent empty themselves into the collecting trunks of the deep network, either by immediately sinking into the depth of the kidney, or by running under the capsule only, to join the deep collecting

trunks near the hilum. The divergent trunks perforate the fibrous capsule, and pass into the network which we shall describe further on when dealing with the fatty capsule of the kidney.

The arrangement of the *deep network* has given rise to several discussions into which we need not enter here (vide¹ vol. v. pp. 49, 50). It eventually gives origin to large collecting trunks, varying in number from four to seven, which leave the kidney at the hilum. These trunks course round the artery and the renal vein. They are usually satellites of the vein, some running on its anterior, and some on its posterior surface.

The classical authors have only given us somewhat vague information as to the mode of termination of these vessels, simply stating that these lymphatics terminate in the glands of the hilum, which moreover is incorrect.

In his recent monograph on the lymphatics of the kidney, Stahr, who was much struck by the variations shown in different subjects, declares that he finds it impossible to formulate a general scheme for their mode of termination. After examining sixteen kidneys injected by Gerota's method, we have arrived at the following conclusions :

The mode of termination of the renal lymphatics varies on the two sides. *On the right*, we may divide the vessels into anterior and posterior. The *anterior* trunks run in front of the renal vein, and pass downwards and inwards and terminate in the prae-venous mass of right juxta-aortic glands (vide p. 139). They usually terminate in the group of the above-mentioned glands, which is situated on the anterior surface of the vena cava, immediately below the opening of the renal veins into the inferior cava, but one of them may often be seen to end in a gland belonging to the same group, placed much lower down, close to the bifurcation of the aorta. It is equally common to see one of these trunks end in a gland of the prae-aortic group. The *posterior* trunks are shorter than the preceding, and are placed behind the vein and renal arteries. They terminate in two or three large glands situated behind the inferior vena cava, in front of the right pillar of the diaphragm. These glands belong to the retro-venous group of the right juxta-aortic glands. Their efferent vessels pass through the right pillar of the diaphragm, traversing it through the same orifice as the great splanchnic nerve, and terminate in the thoracic duct. *On the left*, the collecting trunks, which leave the kidney at the hilum, terminate in four or five glands which belong to the juxta-aortic group of the correspond-

¹ *Treatise of Human Anatomy.* Poirier and Charpy.

ing side, which are thus ranged on the left side of the abdominal aorta. The highest of these glands are situated in front of the left pillar of the diaphragm, through which their efferent vessels pass on their way to join the thoracic duct (vide Fig. 66).

To sum up, the lymphatics of the kidneys end principally in the juxta-aortic glands of the corresponding side, and accessorially in the prae-aortic glands. In any case, it is, if not absolutely incorrect, at least insufficient, to state that the lymphatics of the kidney terminate in the glands placed at the level of the hilum of these organs. At the level of the hilum, however, we may meet with some small glandular nodules, but by reason of their contiguity and their small size, they should be regarded as belonging to that variety of gland which we have described above as the interrupting glandular nodule (Schaltdrüsen), and which it is important to distinguish from the regional glands which are much more constant in their presence and situation (Stahr). One of these nodules is, however, distinguishable by its relative frequency and by its fairly constant situation beneath the right renal vein, in the angle which this vessel forms with the inferior vena cava.

The *fatty capsule of the kidney* possesses a rich lymphatic network, which has recently been well described by Stahr. The efferents of this network end in the same glands as the collectors from the kidney itself. The network of the fatty capsule communicates, as we have seen, with the lymphatics of the kidney: and it is not rare to find, during the progress of epithelial cancers of this organ, lines of new growth in the fatty capsule.

Technique.—The injection of the *superficial* lymphatics of the kidney is extremely difficult, whatever method is employed. To show the deep lymphatics, Sappey advises that a current of water be passed through the renal artery. The water returns at once by the vein and by the lymphatics which are then rendered very apparent. We have always injected these vessels with the greatest ease by Gerota's method. All that is required is; to press the injected mass well into the parenchyma, and preferably into the medullary substance, where the vessels are more numerous and larger. The previous flushing of the kidney with water moreover much facilitates this injection. To distend the network of the fatty capsule, Stahr advises us to use subjects who have emphysema of the perirenal cellular tissue.

BIBLIOGRAPHY.—MASCAGNI, *loc. cit.*, p. 44 et tab. XIV.—SAPPEY, *loc. cit.*, p. 123 et pl. XLVI, Fig. 9.—TEICHMANN, *loc. cit.*, p. 8.—RINDOWSKY. Die Lymphgefäße der Niere. *Verh. d. 3. Vers. russ. Naturf. zu Kiew*, 1871.—DISSE. Zur Anatomie der Niere, *Sitzungsber. der Gesellsch. zur Beförderung der gesammten Naturwissenschaft. zu Marburg*, 1898, n° 8.—HERMANN STAHR. Der Lymphapparat der Niere, *Arch. f. Anat. u. Phys., Anat. Abth.*, 1900, p. 40.—CUNÉO. Note sur les lymphatiques du rein, *Bull. Soc. anat.*, Paris, 28 février 1902.

LYMPHATICS OF THE SUPRARENAL CAPSULES.—The lymphatics of the suprarenal capsules, whose mode of origin will be studied together with the structure of these organs, end in four or five collecting trunks, which emerge at the same point as the large central vein. These trunks terminate in the juxta-aortic glands of the corresponding side. In several subjects, we have seen some of these collecting trunks perforate the pillars of the diaphragm, and end in the glands placed between the posterior surface of these pillars and the vertebral column.

5. LYMPHATICS OF THE SUB-DIAPHRAGMATIC PORTION OF THE DIGESTIVE TUBE.

The lymphatics of the sub-diaphragmatic portion of the digestive tube are considerably developed, in proportion to the important part they have to play in the absorption of food which has already been altered by the digestive juices. We will not here consider the histological origin of these vessels within the intestinal coats; this will be described together with the structure of the different segments of the sub-diaphragmatic portion of the intestinal tube. We will now study more especially the macroscopic arrangement of the networks of origin, and the course and termination of the collecting trunks.

LYMPHATICS OF THE ANUS AND RECTUM.—(1) NETWORKS OF ORIGIN.—The lymphatic vessels of the anus and rectum arise from two networks; one is attached to the muco-cutaneous lining of the ano-rectal region; the other belongs to the muscular coat.

(A) The *muco-cutaneous network* may be divided into three regions: inferior, middle and superior.

(a) The *inferior region* corresponds to the skin at the margin of the anus. Here, there are two superposed networks, one is superficial or cutaneous, and is enclosed within the actual thickness of the skin, while the other is deep or subcutaneous. The injection of these networks is easy, and it generally suffices to make two or three punctures to fill them entirely. Their meshes are extremely close, and when the injection is made with mercury, the cutaneous network appears as a continuous layer, so that a lens is necessary to show the details (vide Fig. 67).

(b) The *middle region* corresponds to the skin bordered area of the anus; its upper limit is therefore formed by the ano-cutaneous line (white line). The meshes of this network, which are much coarser than those of the preceding region, have a vertical direction.

(c) The *upper region* corresponds to the anal mucous membrane

properly so called, and to the rectal mucous membrane. In the former, the lymphatic network is little developed. In the latter, on the contrary, it is extremely rich, but the fragility of its meshes

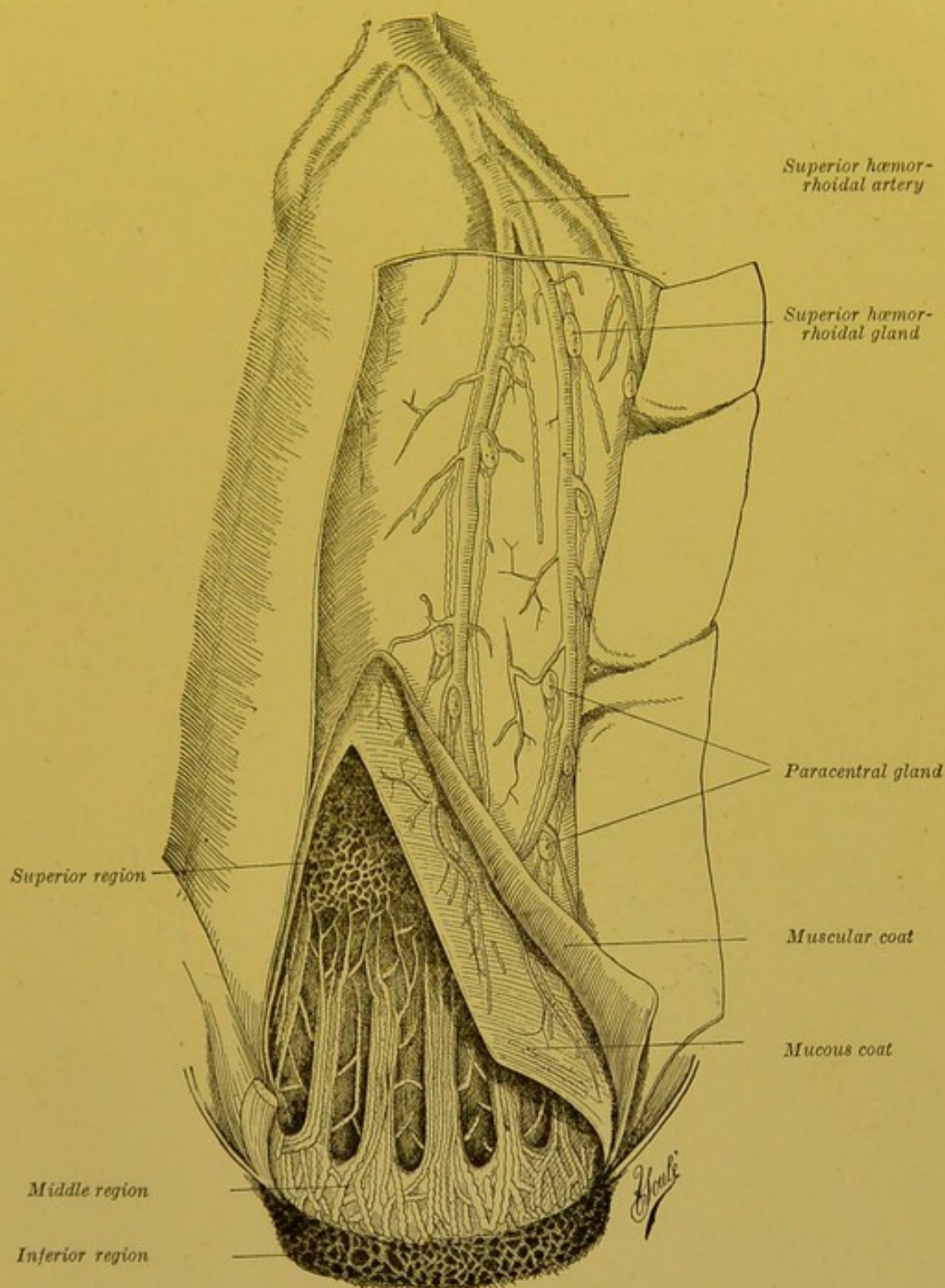


FIG. 67.—Lymphatics of the rectum (after Gerota).

The posterior wall of the rectum is cut to show the mucous membrane; through a large window made in the upper part through the fibrous coat, the blood vessels may be seen.

render its injection difficult. As is the case in the rest of the large intestine, there are two superposed networks, one mucous and the other sub-mucous.

(B) The network of the *muscular coat* is very difficult to inject. The trunks coming from this network unite with the collecting trunks from the muco-cutaneous networks.

(2) COLLECTING TRUNKS.—Each of the muco-cutaneous linings possesses distinct efferents.

(A) The *inferior region* gives rise to from three to five trunks on each side. These run towards the inguinal region, some coursing on the internal aspect of the thigh, others over the perineum, or at the level of the perineo-crural fold.

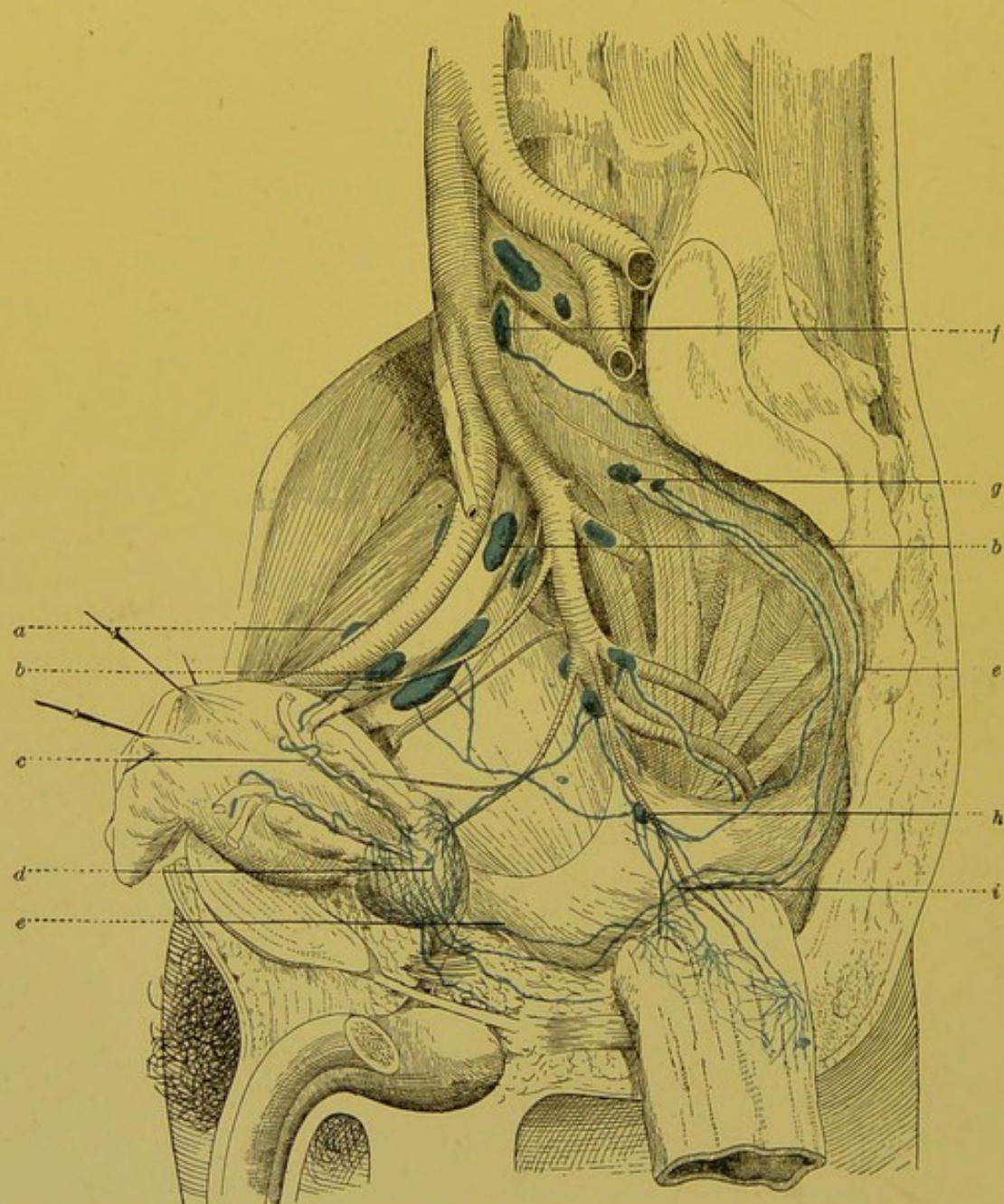


FIG. 68.—Lymphatics of the rectum. Middle haemorrhoidal channel (Cunéo and Marcille).

a. Gland of the external chain of the external iliac glands. *b.* Gland of the middle chain of the external iliac glands. *c.* Transverse lymphatic pedicle of the prostate. *d.* Retroprostatic glands. *e.* Posterior lymphatic pedicle of the prostate. *f.* Glands of the promontory. *g.* Lateral sacral glands. *h.* Middle haemorrhoidal gland. *i.* Rectal afferents of this gland.

Their course is very irregular. They describe numerous bends, and often bifurcate *en route*. They end in the superficial inguinal glands; but their mode of termination obeys no absolutely fixed rules. They are usually tributaries of the supero-internal group; but they may frequently be seen to terminate in the infero-internal group, or to empty themselves into both these two groups at the same time. It is much more rare to see them terminate in a gland belonging to one of the external groups.

In twenty-eight cases, Gerota has seen the cutaneous lymphatics of the anus end, fifteen times in the supero-internal group, eight times in the infero-internal group, four times in these two groups at the same time, and once in the supero-internal, infero-internal and infero-external groups.

(B) The *middle region* possesses numerous efferents which we may divide into indirect and direct. The former ascend in the columns of Morgagni, and terminate in the network of the rectal mucous membrane (vide Fig. 67). The direct efferents perforate the rectal wall and gain the neighbouring glands. Taking their course and termination as the basis for our classification we may divide them into three groups: (a) Some of them perforate the rectal wall slightly above the levator ani, then ascend on the lateral walls of the rectum, traverse the para-rectal glands which will be described further on, join the collectors coming from the superior region and terminate, as the latter do, in the glands of the meso-rectum. (b) Others, coming from the muscular walls of the rectum at the same level as the preceding, are satellites of the middle haemorrhoidal vessels: they constitute the *middle haemorrhoidal channel*. They usually terminate in a gland placed in the course of the middle haemorrhoidal artery at some distance from the lateral wall of the pelvis. (c) The collecting trunks of the third group (*inferior haemorrhoidal channel*), emerge beneath the insertion of the levator ani, and may be regarded as corresponding to the system of the inferior haemorrhoidal vessels. As a matter of fact, however, it is rarely that they follow these vessels closely. Most frequently they have a much more simple course; for, after running a very short distance in the adipose tissue of the ischio-rectal fossa, they perforate the levator ani and terminate in a gland situated at the commencement of the internal pudic artery, within the pelvis.

The satellite trunks of the middle haemorrhoidal vessels are somewhat difficult to inject, especially when mercury is used. The old authors made no mention of them. Quénu and Gerota observed them, but were only able to

inject them in a small number of cases. Marcille, on the contrary, employing Gerota's method was able to demonstrate these vessels in nearly every case. We therefore regard this middle haemorrhoidal channel as constant; but it does not always present the very simple arrangement which we have just indicated; in fact, one of the satellites of the middle haemorrhoidal artery may be seen to end in the middle gland of the internal chain of the external iliac group, or in the lateral sacral glands: Now it is important to notice that the glands into which these aberrant vessels empty themselves, are precisely those in which the normal efferents of the middle haemorrhoidal gland end (vide Fig. 68). We may therefore regard these lymphatic trunks as afferents of the middle haemorrhoidal gland which, having passed by their first glandular relay have directly reached their second.

The trunks which correspond to the system of the inferior haemorrhoidal vessels are passed over in silence by the majority of authors. Marcille and one of the present authors have injected them several times; but the number of our observations has been insufficient to enable us to affirm the constancy of this inferior haemorrhoidal route.

(C) The collecting trunks of the *superior region* pass through the muscular coat of the rectum at different levels. They are most frequently satellites of the vessels, and there are usually two for each artery. After perforating the muscular coat of the rectum, they run obliquely upwards and backwards, and reach the glands contained in the meso-rectum. In their perirectal course, they traverse some small glands which have been well described by Gerota and which we will call *para-rectal glands* (ano-rectal glands of Gerota). These glands vary in number from four to seven, and are placed on the muscular layer, and covered by the fibro-serous coat of the rectum. They are met with especially in the region of the ampulla. The lowest of them is situated immediately above the levator ani. The superior glands on the contrary, may be found projecting underneath the serous layer. We regard these glands as simple interrupting glandular nodules placed in the course of the juxta-rectal collecting trunks. Apart from pathological cases they are always very minute. As regards the glands placed in the meso-rectum, or, if we prefer to call it so, the terminal portion of the pelvic meso-colon, they are grouped round the trunk of the superior haemorrhoidal artery. They are always of considerable size: they are the true regional glands of the vessels which spring from the superior lymphatic region of the rectum.

The arrangement of the ano-rectal collecting trunks may be thus summarized: These vessels may be divided into three groups: an *inferior group*, which comes from the skin of the margin of the anus, and is a tributary of the superficial inguinal glands; a *middle group*, which comes from the region of the white line and ends in

the hypogastric glands; a *superior group*, which springs from the mucous membrane of the anus and rectum, and terminates in the glands of the meso-rectum, after traversing the para-rectal glandular nodules. The superior group corresponds to the superior haemorrhoidal vessels. The middle group corresponds to the middle and inferior haemorrhoidal vessels. The inferior group has no homologue in the arterial system.

LYMPHATICS OF THE ILIO-PELVIC COLON.—The lymphatics of the ilio-pelvic colon at first traverse some small glands which are attached to the terminal branches given off by the para-intestinal arch and formed by the anastomosis of the three sigmoid arteries. They then terminate in glands placed over the inferior mesenteric artery.

LYMPHATICS OF THE DESCENDING COLON.—The lymphatic vessels of the descending colon present a somewhat similar arrangement to that of the ilio-pelvic colon. We need only note the poorly developed glandular apparatus attached to this part of the large intestine.

LYMPHATICS OF THE TRANSVERSE COLON.—The lymphatic apparatus of the transverse colon is much more developed. The juxta-intestinal glands (vide p. 142) are here numerous, especially in the neighbourhood of the two extremities of the transverse colon. Further, one almost constantly finds one or two large glands situated in the angle of the bifurcation of the middle colic, as well as two or three others placed along the trunk of this artery. The trunks coming from the latter pass into the glands of the superior mesenteric chain.

The lymphatics of the transverse colon communicate to a large extent with those of the great omentum, so that they are brought into relation with the lymphatics of the inferior border of the stomach.

LYMPHATICS OF THE ASCENDING COLON.—The collecting trunks emanating from the ascending colon at first traverse some few juxta-intestinal glands: they then meet a gland, which is however inconstant, placed on the course of the ascending colic artery, and finally terminate in the glands of the superior mesenteric chain.

LYMPHATICS OF THE COECUM AND APPENDIX.—The lymphatics of the coecum and appendix are much more developed than those of the other segments of the large intestine. This is especially true in the case of the appendix, the lymphoid tissue of which is known to be abundant. The mode of origin of these vessels, and the arrangement of the appendicular lymphoid apparatus will be studied

further on (vide vol. iv. p. 334, Fig. 178¹). We will therefore confine ourselves here to indicating the arrangement of the collecting trunks of the coecum and the appendix, and the topography of their terminal glands.

The coeco-appendicular collecting trunks follow pretty closely the course of the blood vessels. This fact will enable us to divide them into three groups: the anterior coecal, the posterior coecal and the appendicular trunks, which respectively accompany the vessels of this name.

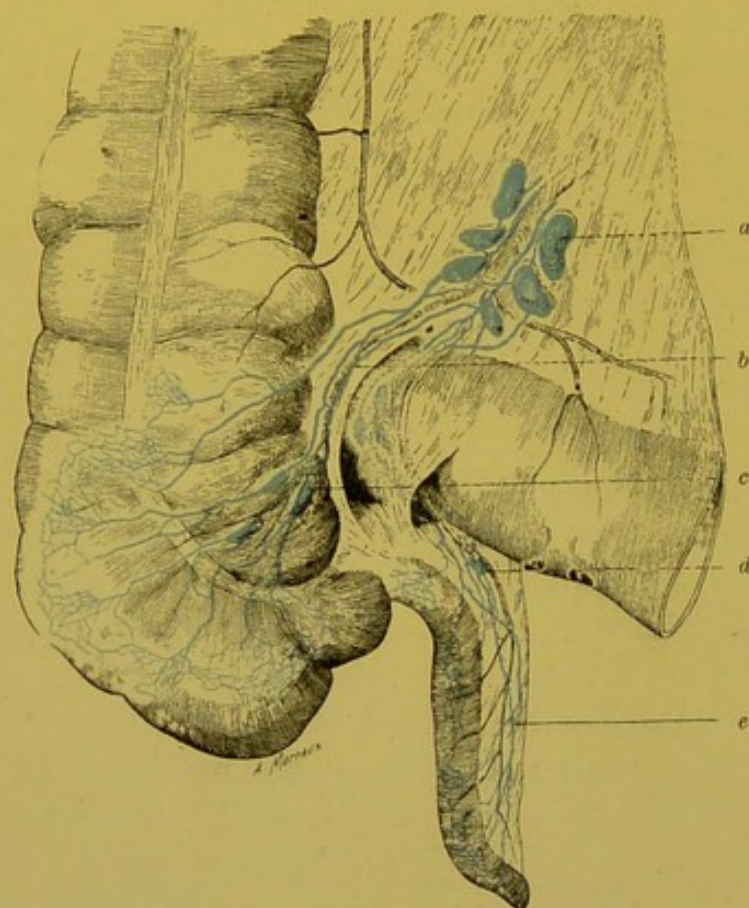


FIG. 69.—Lymphatics of the coecum and appendix (anterior view).

a. Ileo-coecal glands. b. Anterior coecal lymphatics. c. Anterior coecal glands. d. Gland of the appendix (sub-ileal group). e. Appendicular afferents of this gland.

(a) The *anterior coecal collecting trunks* appear on the anterior surface of the coecum. They run upwards and inwards, traversing one or two small glands situated in the thickness of the anterior ileo-coecal fold, and then terminate in a glandular mass placed on the terminal segment of the ileo-coecal artery (vide Fig. 69).

(b) The *posterior coecal collecting trunks* follow the course of the artery of this name. Like the pre-

ceding, they traverse some small glands—the posterior coecal. The latter, from three to six in number, are situated on the posterior aspect of the coecum, at the junction of this surface with the internal surface. Except in those rare cases where the coalescence of the posterior surface of the coecum and the parietal peritoneum is complete, these glands are covered by the visceral layer of peritoneum which binds them to the posterior surface of the coecum. The posterior coecal lymphatics terminate in the ileo-coecal glandular group (vide Fig. 70).

¹ *Treatise of Human Anatomy.* Poirier and Charpy;

(c) The *collecting trunks of the appendix*, four or five in number, run up between the layers of the meso-appendix, accompanying the appendicular artery. Like this artery, they cross the posterior surface of the terminal segment of the ileum, then penetrate into the mesentery, and terminate in the ileo-coecal glandular group (vide Fig. 70). In their course, these lymphatics traverse some small glands which we class under the generic term of *appendicular glands*. In the large majority of cases, these glands from one to three in number, are placed in the retro-ileal segment of the meso-

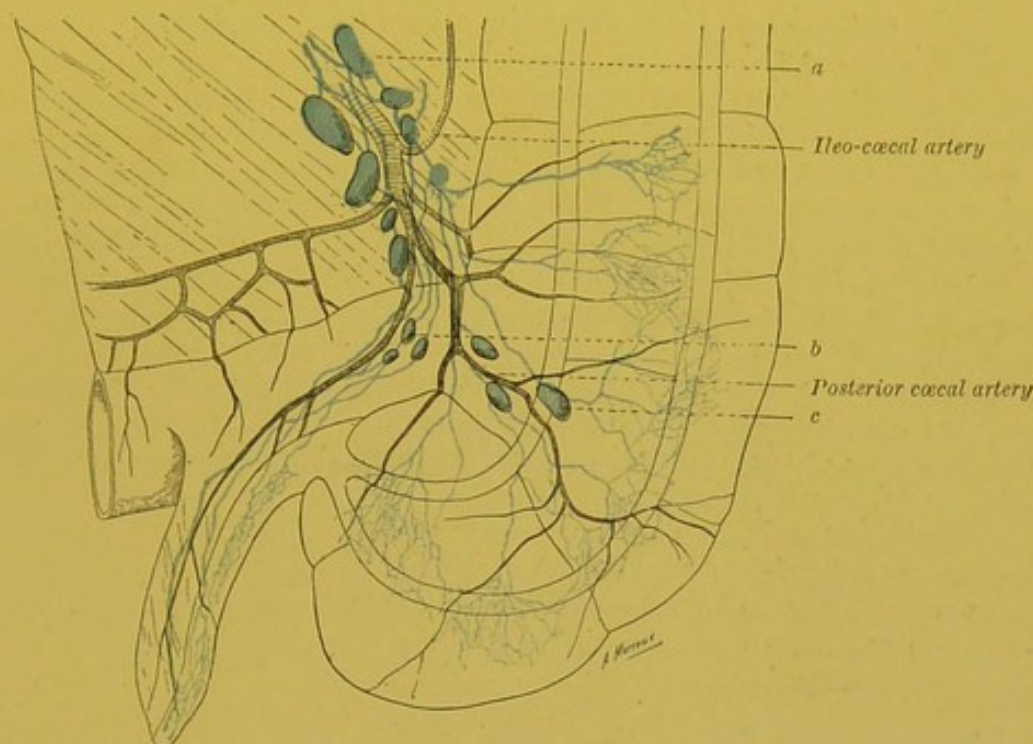


Fig. 70.—Lymphatics of the caecum and appendix (posterior view).

a. Ileo-coecal glands. b. Appendicular glands (retro-ileal group). c. Retro-coecal glands.

appendix; they may then be styled the *retro-ileal* appendicular glands. More rarely we find one or several glands in the sub-ileal portion of the meso-appendix; these are the *sub-ileal* appendicular glands. Finally, some of the glands of the meso-appendix may be placed immediately against the caecum, above the origin of the appendix; these are the *juxta-coecal* appendicular glands.

Tixier and Viannay, who have recently undertaken the study of the topography of the appendicular glands, have well described the arrangement of these three groups which we have styled the ileo-appendicular, appendicular and coeco-appendicular. The ileo-appendicular group (appendicular, retro-ileal group) is the most constant. It was present in 36 out of 100 cases. In 22 of these 100 cases, it was formed by only a single gland; in 10 of these 100 cases, 2 glands were present; in 4 of these 100 cases, there were more than 2 glands. The appendicular group (appendicular, sub-ileal group) was found in 12 out of 100 cases. In 14 of these, Tixier and Viannay proved the

presence of the coeco-appendicular group (appendicular juxta-coecal group). Finally in 6 per cent. there was no trace of glands in any part of the meso-appendix. This possible absence of appendicular glands well shows that these glands, like the prae- and retro-coecal glands, are simple interrupting glandular nodules (Schalt-drüse) interposed in the course of the coeco-appendicular lymphatics. The true regional glands of these vessels are the glands placed in the mesentery round the ileo-coecal artery.

The appendicular lymphatics are therefore, eventually, tributaries of the glands which form the terminal segment of the superior mesenteric chain.

Some authors are of opinion that the appendicular lymphatics have a much more complicated mode of termination. "I have so often found," says Lockwood, "a chain of inflamed lymphatic glands along the internal border of the colon, behind the ascending meso-colon, that I have arrived at the conclusion that this is the chief route followed by the lymphatics of the appendix. Other lymphatics without doubt pass into the mesenteric glands. The lymphatics of the appendix also empty themselves into the glands of the iliac fossa, lying one behind the other along the length of the external iliac artery. Some also run along the appendiculo-ovarian ligament which pass into the right broad ligament, and into the glands of the right lateral wall of the pelvis, close to the internal iliac artery." This classification, which is accepted by Tixier and Viannay, appears to us absolutely visionary. The only normal terminations of the coeco-appendicular lymphatics are the glands of the ileo-coecal group. However, the subserous network of the caecum anastomoses with that of the adjacent parietal peritoneum, and it is through this network that the coeco-appendicular lymphatics may communicate with some of the neighbouring glandular groups.

Clado has described an anastomosis between the lymphatics of the appendix and those of the right ovary; this anastomosis runs in the appendiculo-ovarian ligament. Tixier and Viannay have found a small lymphatic gland in this fold. We have never proved the existence of the anastomosis described by Clado, and we formally deny its presence.

BIBLIOGRAPHY.—TUFFIER. Étude sur le cæcum et ses hernies. *Archives générales de médecine*, 1887, p. 641.—CLADO. Appendice cæcal. *Mém. de la Soc. de biol.*, 1892.—LAFFORGUE. Recherches anatomiques sur l'appendice vermiculaire du cæcum. *Journ. de l'Anat. et de la Physiol.*, 1893.—LOCKWOOD. Note upon the lymphatics of the vermiform appendix, *Journ. of Anat. and Physiol.*, 1900, t. XXXIV, p. xiii.—TIXIER et VIANNAY. Note sur les lymphatiques de l'appendice iléocæcal. *Lyon médical*, 1901.—AUGUY. De l'adénopathie appendiculaire. *Thèse Lyon*, 1901.—BONJOUR. Des adénopathies péri-appendiculaires. *Thèse Paris*, 1901.—QUÉNU. *Communic. Soc. Chirurgie*, 7 mai 1902.

LYMPHATICS OF THE SMALL INTESTINE.—Like the lymphatics of the large intestine, the lymphatics of the small intestine form two systems relatively independent of each other, one of which is attached to the mucous layer, and the other to the muscular coat. Details of the origin of these vessels and their relations with the rich lymphoid tissue which is connected to them will be studied further on (vide vol. iv. p. 300¹). The mode of termination of the collecting trunks of the small intestine is not the same in the region of the jejuno-ileum as in that of the duodenum.

¹ *Treatise of Human Anatomy*. Poirier and Charpy.

LYMPHATICS OF THE JEJUNO-ILEUM.—The collecting trunks, which are extremely numerous, make their appearance in the neighbourhood of the mesenteric border of the intestine. If examined in the living subject, during intestinal digestion they appear as slightly bossed channels of varying calibre, especially noticeable on account of their milky appearance. They terminate in the glands contained in the mesentery. Though these glands appear, at first sight, to be indiscriminately scattered between the two folds of the mesentery, if observed more attentively, we may convince ourselves that they are arranged on some fairly definite plan. It is also possible to divide them into three groups which vary in importance and signification.

(a) A *primary group* comprises some small glands placed on the course of the terminal arterioles springing from the last anastomotic arch, or actually over the arch itself. Sometimes, especially at the commencement of the jejunum, these glands are immediately contiguous to the intestine and may even lie on the intestine itself. As we have seen, they are simple interrupting glandular nodules (*Schaltdrüse*) which have no morphological fixity.

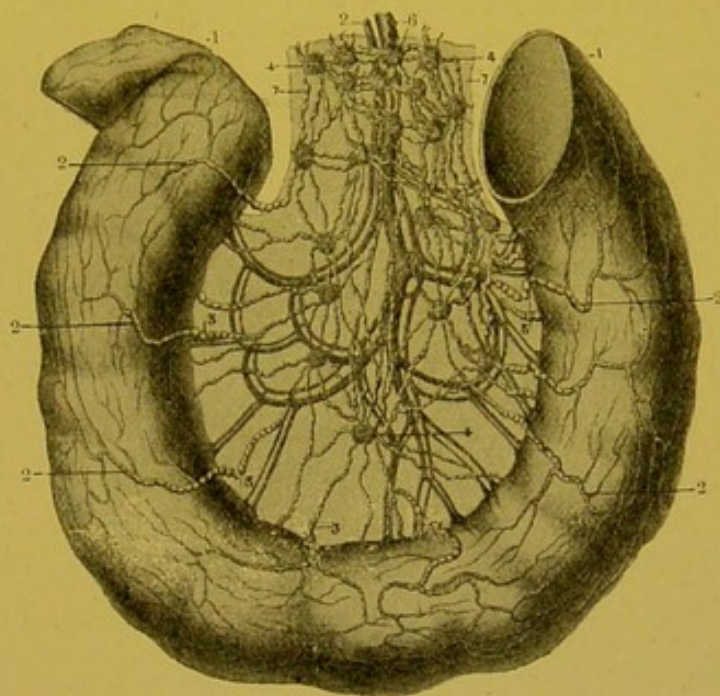


Fig. 71.—Lymphatics of the small intestines (after Sappey)

1. Loop of small intestine. 2, 3, 5, 7. Lymphatic collectors. 4. Juxta-intestinal gland. 6. Mesenteric vein. 8. Mesenteric artery.

(b) A *second group* comprises some glands placed in the course of the primary branches of the superior mesenteric artery and at the level of the first anastomotic arch formed by these vessels. These glands, which are much larger than the preceding, are the true regional glands of the jejuno-ileum.

(c) Finally, a *third group* of glands is found round the trunk of the superior mesenteric artery and more particularly round the commencement of this vessel. This group does not properly belong to the jejuno-ileum, nevertheless it receives the efferents of

the regional glands of the coecum, the ascending and transverse colon, the duodenum and even the afferents of certain glands connected with the stomach (vide p. 146).

The glands are especially numerous in that portion of the mesentery which corresponds to the jejunum. There is a progressive diminution in the number of glands in each given segment of the mesentery until the terminal segment of the ileum is reached.

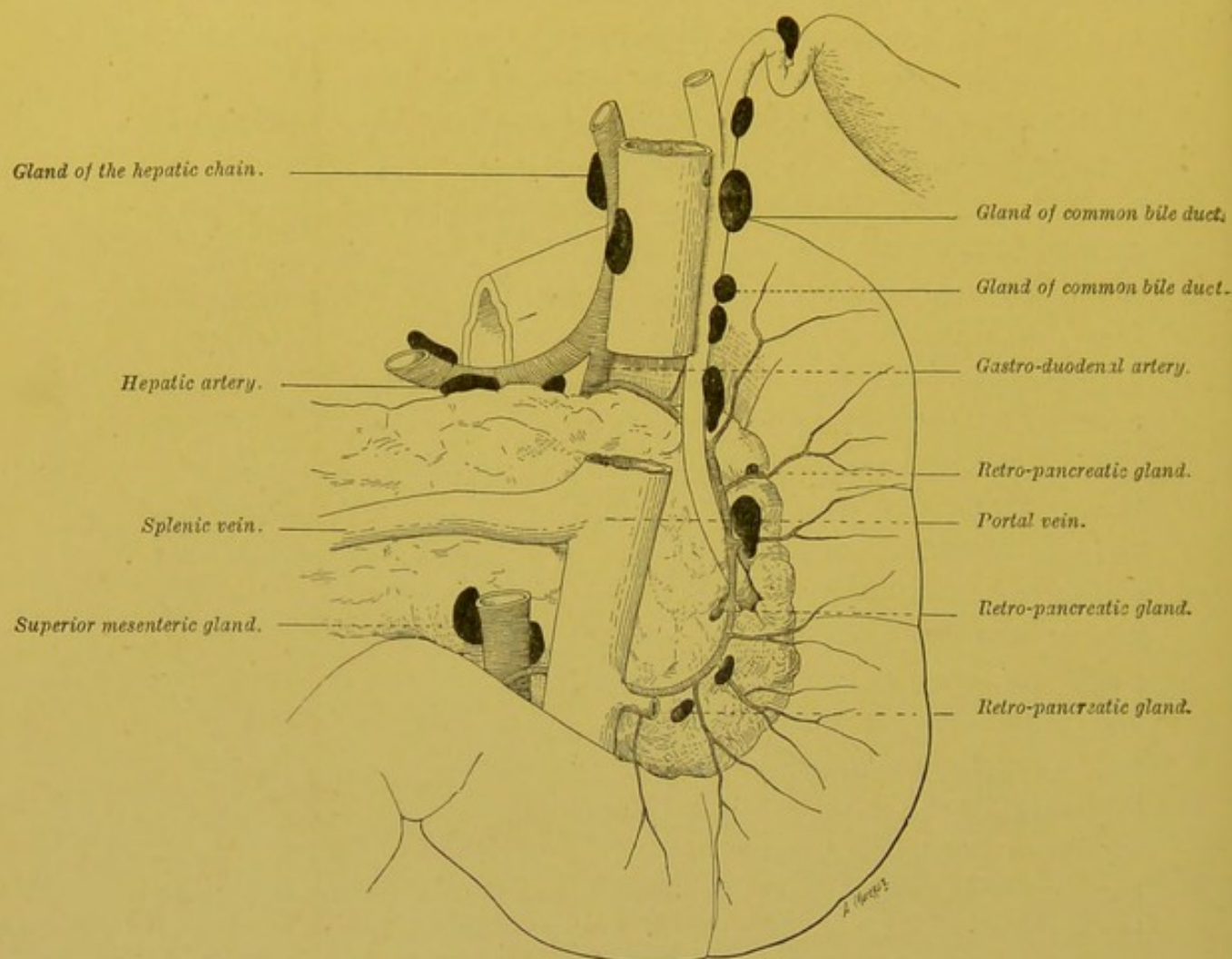


Fig. 72.—Retro-pancreatic glands.

We must, however, always remember that in the ileo-coecal region the glands again reappear in numbers and form an important mass round the ileo-coecal artery.

The mesenteric glands constitute one of the most important glandular centres in the human system. They vary in number from 130 to 150 (Quain), and their size varies greatly in different subjects. In certain pathological conditions they may form very large tumours which cause serious trouble in the abdominal circulation. In certain animals, they are grouped into a compact

mass which the old anatomists described under the name of pancreas of Aselli.

LYMPHATICS OF THE DUODENUM.—The lymphatics of the duodenum end in numerous collecting trunks which are arranged on the same plan as those of the jejuno-ileum, but the pancreas divides these vessels, like the corresponding blood vessels, into two groups: an *anterior* group, the vessels of which end in glands placed on the prae-pancreatic vascular arch; a *posterior* group, the lymphatics of which terminate in the satellite glands of the retro-pancreatic arch. From these glands, namely the prae- and retro-pancreatic, run two systems of efferents. Some, ascending, terminate in the glands of the hepatic chain. Others, descending, are grouped round the superior mesenteric artery, at the spot where this vessel crosses the third part of the duodenum.

The close relations which exist between the lymphatics of the duodenum on the one hand and those of the common bile-duct and pancreas on the other, should be noticed. We shall see later on that anastomoses are also present between the lymphatics of the duodenum and those of the pyloric portion of the stomach (vide p. 201).

LYMPHATICS OF THE STOMACH.—The origin of the lymphatics of the stomach will be studied together with the structure of that organ (vide vol. iv. p. 241). Here we need only call to mind the fact that the lymphatics of the stomach, like those of the intestine, ought to be divided into mucous and sero-muscular. The lymphatics which arise in the mucous membrane finally end in a submucous network; from this, collecting trunks arise which, in the neighbourhood of the curvatures, perforate the muscular coat and finally terminate in the sero-muscular collecting trunks. The latter spring from a sub-peritoneal network in which all the lymphatics which come from the muscular coat and serous layer end. These musculo-serous collecting trunks may be divided into three groups: some of which are directed towards the small, others towards the large curvature; while a third group runs towards the great tuberosity.

1. The collecting trunks of the *first group* (superior or converging trunks of Sappey) are the most important and the largest. According to Sappey, they may usually be reckoned as from six to eight. In different subjects they run either singly or in triplets. The majority of these trunks converge towards the glands of the small curvature, which are, as we have already seen (p. 143),

situated around the spot where the coronary artery approaches the small curvature. Their direction varies according to their origin; thus, the collecting trunks which spring from the body of the stomach are quite vertical, those which arise from the pyloric vestibule point obliquely upwards and to the left; and the trunks issuing from the pylorus run parallel to the small curvature. On

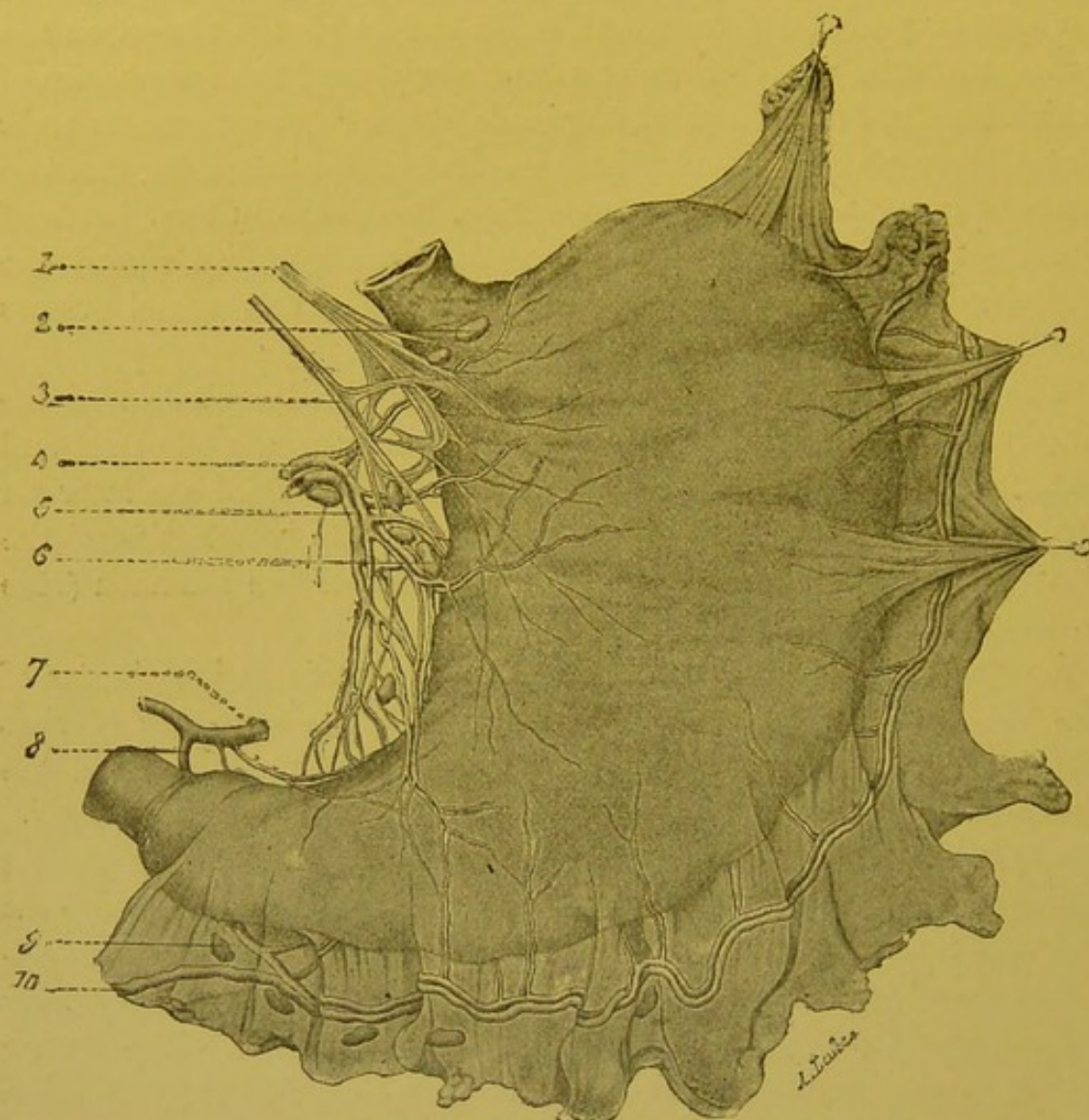


FIG. 73.—General view of the subperitoneal network of the stomach, injected by Gerota's method (Cunéo).

1. Left pneumogastric. 2. Praecardiac glands. 3. Right pneumogastric. 4. Coronary artery. 5. Coronary vein. 6. Gland of the small curvature. 7. Hepatic artery. 8. Right gastro-epiploic artery. 9. Sub-pyloric gland. 10. Right gastro-epiploic vein ending in the middle colic vein.

the contrary, the lymphatics which come from the cardia or the sub-cardiac zone, descend obliquely downwards and to the right towards the point of common convergence. In a general way then, all these trunks have a direction parallel to that of the coronary vessels.

However, one or two very fine vessels, which come from the upper

part of the pylorus, run from left to right towards the pyloric artery and join the efferent trunks of the retro-pyloric glands.

2. The collecting trunks of the *second group*, or collecting trunks of the large curvature, are more numerous but smaller than the preceding. They vary in number from twelve to eighteen. They usually, but not necessarily, accompany the branches sent by the gastro-epiploic vessels to the stomach. All these collecting trunks end in the sub-pyloric glands (vide p. 146).

The lymphatics coming from the pylorus or the pyloric vestibule soon join these glands by a vertical or slightly oblique course. As regards the other collecting trunks which come from the body of the stomach, instead of running directly downwards and to the left with an obliquity varying with their situation, they descend vertically as far as the vascular arch which runs along the great curvature; there they quickly change their direction and run parallel to this arch. During their course, they blend together, forming two or three trunks which anastomose with one another and finally end in the sub-pyloric glands (vide Fig. 73).

3. The *third group* includes all the trunks coming from the great tuberosity. They vary in number from three to six. They run in the gastro-splenic omentum, but do not accurately follow the course of the vasa brevia and the left gastro-epiploic arteries. They then penetrate the splenico-pancreatic omentum, and terminate in the glands placed in this omentum, close to the hilum of the spleen.

To sum up, we may say that, in a general way, the collecting trunks of the small curvature converge towards the point at which the coronary artery approaches the stomach, and pass into the glands of the coronary chain. The collecting trunks of the large curvature run from left to right towards the sub-pyloric glands. Finally, the trunks which spring from the great tuberosity are directed from left to right towards the hilum of the spleen, and end in the glands of the splenic chain.

We have already described these glandular groups (vide prae-aortic glands, p. 141, and Figs. 46 and 47) and therefore will not return to this point, but we must here note the possible presence of little interrupting glandular nodules in the course of these different collecting trunks. In certain cases, these nodules may be placed within the actual thickness of the walls of the stomach at a variable distance from the curvatures. Letulle (Soc. Anat., Dec. 29, 1897) was the first to draw attention to this arrangement, of which one of the present authors has met with three examples. These parietal gastric glands usually occupy the subserous layer or the superficial portion of the muscular coat.

Lymphatic Territories.—As we have seen, in the stomach there are three

distinct lymphatic territories, to the arrangement of which one of the present authors drew attention in his thesis. These territories correspond to the three groups of collecting trunks which we have described.

The territory of the collectors of the small curvature is divided from the others by a line which commences a little to the left of the cardia, and runs on both surfaces of the stomach following a line nearly parallel to the large curvature.

But this line which indicates the parting of the lymph, if one may so speak of it, is much nearer the large than the small curvature. We may reckon approximately that it leaves below it, a third only of the surface of the organ. It is important, however, to remark that in the pyloric region, this line tends to become raised and to be placed at an equal distance from the large and the small curvature.

The limit of the territories of the collectors of the second and third groups is more difficult to determine accurately; it is, moreover, of no great practical interest. It usually corresponds to the junction of the horizontal with the vertical portion of the large curvature.

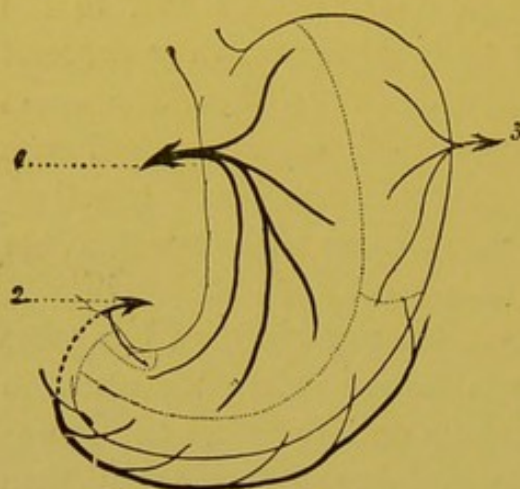


Fig. 74.—Lymphatic territories of the stomach (Cunéo).

1. The coronary or the principal current.
2. Right gastro-epiploic current. 3. Splenic current.

important relations with the lymphatics of neighbouring organs. These relations are of two kinds: some are effected by the anastomoses which exist between the different gastric networks with the two adjacent portions of the digestive tube, viz. the oesophagus and duodenum; others are the result of the presence of glandular groups which are common to the gastric lymphatics and those of neighbouring organs, viz. the liver, pancreas, and spleen. We shall here only lay stress on the former.

The two principal networks of the stomach, viz. the submucous and the subserous networks, communicate largely with the two homologous networks of the abdominal portion of the oesophagus. As is shown in Sappey's fine plates, there is even a true continuity between the gastric and oesophageal networks. This anatomical arrangement is thoroughly in accord with known facts of pathological anatomy, which teaches us that neoplasms of the cardia easily infect the inferior portion of the oesophagus and inversely.

Does the same hold good in the case of the duodenum? This question must be discussed separately for the subserous and for the submucous network.

Sappey's plate shows an absolute continuity between the subserous network of the stomach and that of the duodenum. According to Most, on the contrary, there is no communication between these two networks, and in the

This classification is the same on the two surfaces of the organ and applies as well to the lymphatics of the mucous membrane as to those of the musculo-serous coat. From this description it follows that the largest and most important of the three lymphatic territories of the stomach is that of the collectors of the small curvature; these collectors taken together represent the principal lymphatic channel, whereas the collecting trunks of the other two groups are only accessory channels.

Anastomoses.—The lymphatic apparatus of the stomach contracts im-

pyloric region a trunk having more or less annular direction forms a very clear limit to the subperitoneal gastric network.

Our researches have led us to the same conclusions as Most's, that is, so far as the absence of communication between the subserous network of the stomach and the corresponding part of the duodenum is concerned, but we have never been able to inject the annular vessel to which he alludes. In one case, we saw a collecting trunk of the pylorus break through the gastro-duodenal limit, and run a few millimetres on to the commencing portion of the duodenum, and reach a gland belonging to the sub-pyloric group, which was much drawn to the right side.

Nevertheless, we do not wish to raise the slightest doubt as to the existence of communications between the submucous networks of the stomach and duodenum. One of the present writers has several times shown the existence of these communications, and Most has even succeeded in filling the collecting trunks of the initial portion of the duodenum and their glands, by injecting the mucous membrane of the pylorus. We must, however, recognize the fact, that these anastomoses between the lymphatics of the gastric mucous membrane and those of the duodenal mucous membrane do not show a high grade of development; but none the less they play a very important part in those cases where the duodenum is invaded by cancer of the pylorus.

BIBLIOGRAPHY.—MASCAGNI, loc. cit., p. 49 et tab. XVIII.—SAPPEY, loc. cit., p. 76 et suiv., pl. XXV, Fig. 1.—MOST, Ueber die Lymphgefäße und die regionäre Lymphdrüsen des Magens, etc. *Arch. f. klin. Chir.*, LIX, 1, p. 175.—CUNÉO. De l'envahissement du système lymphatique dans le cancer de l'estomac et de ses conséquences chirurgicales. *Thèse Paris*, 1900.—CUNÉO et DELAMARE. Anatomie et Histologie des lymphatiques de l'estomac. *Journ. de l'Anat. et de la Physiol.*, 1900.

LYMPHATICS OF THE LIVER.—As we shall see further on (vide¹ vol. iv. p. 766), we have not yet any perfectly definite knowledge as to the arrangement of the lymphatic channels within the hepatic lobules. On the other hand, it is easy to demonstrate the lymphatic networks in the interlobular connective tissue. From this network numerous collecting trunks start, and these may be divided into two chief groups. Some, springing from the peripheral lobules, run towards the surface of the hepatic gland passing underneath the peritoneum: these are the superficial collectors. Others, coming from lobules more deeply situated, accompany the branches of the portal vein or the hepatic veins and emerge at the point of entrance or exit of these vessels. These are the deep collectors.

1. The Superficial Collecting Trunks.—We will study first the collecting trunks on the superior and then those on the inferior surface.

1. THE COLLECTING TRUNKS ON THE SUPERIOR SURFACE.—These may be divided into three groups: posterior, anterior and superior.

(a) The *posterior collecting trunks* run towards the posterior surface of the liver. They may be divided into right, middle and

¹ *Treatise of Human Anatomy.* Poirier and Charpy.

left. The right trunk, which is usually single, appears near the

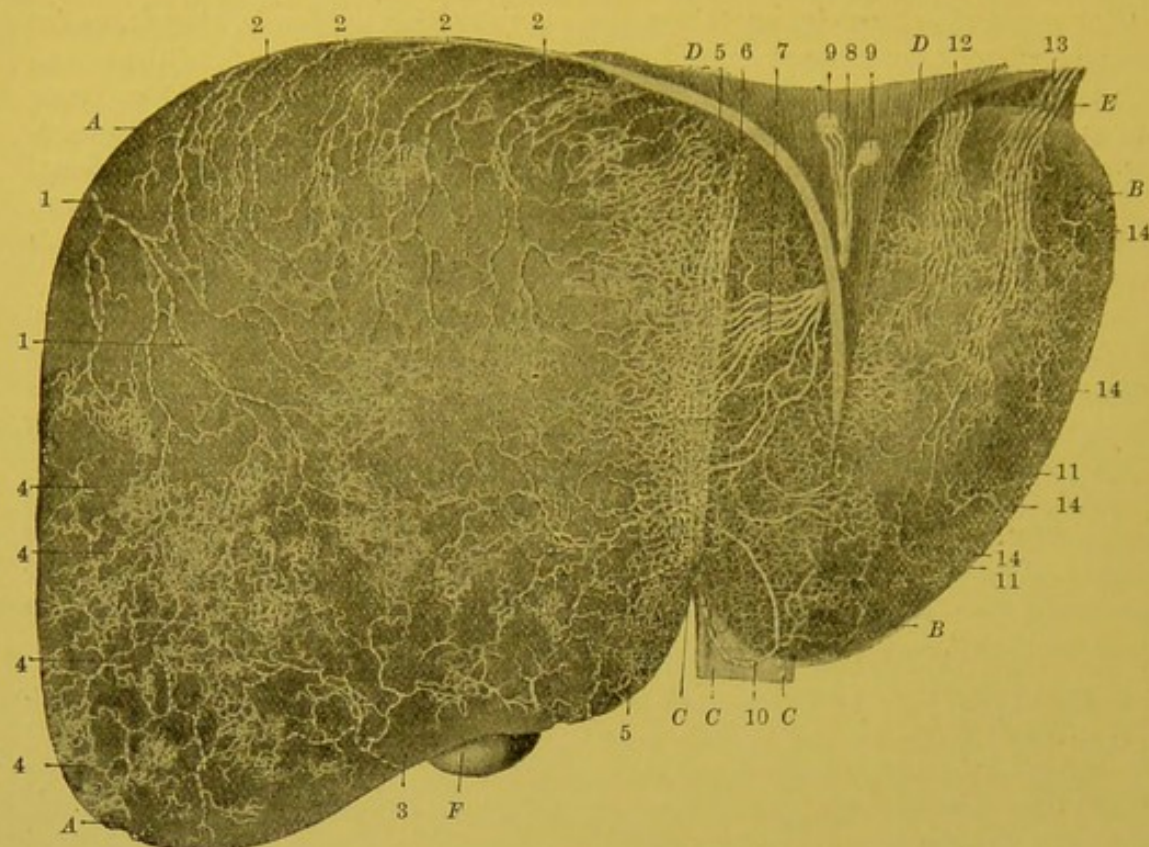


Fig. 75.—Lymphatics on the superior surface of the liver (Sappey).

A, A. Right lobe of liver. *B, B.* The left lobe. *C, C.* The suspensory ligament which partly hides the superior surface of the left lobe. *D, D.* A triangular segment of the diaphragm which has been incised at the level of the attachment of the suspensory ligament. *E.* Left triangular ligament of the liver. *F.* Inferior extremity or base of the gall bladder.

1, 1. Large lymphatic trunk situated on the right border of the right lobe; this trunk descends on to the concavity of the diaphragm and passes into one of the glands which lie on the head of the pancreas. 2, 2, 2, 2, 2. Smaller and shorter trunks which turn round the upper border of the liver; all terminate in the small glands situated round the inferior vena cava, immediately above the diaphragm. 3. Another trunk, which takes an opposite direction to the preceding, and which turns round the inferior border or edge of the gland, and then runs on to the opposite surface towards the glands of the hilum. 4, 4, 4, 4. Trunklets which spring from a small group of convergent branches on the surface of the liver, and which plunge almost at once into the hepatic tissue and then run in the channels of Glisson's capsule. 5, 5. A very beautiful network which corresponds to the adherent border of the suspensory ligament. 6, 6. Trunks in which all the little branches of this network end. 7. A group of convergent trunks which start from the same vessels and which run obliquely between the two layers of the suspensory ligament. 8. A very large trunk formed by the fusion of the preceding trunks; it also passes obliquely through the diaphragm, and then creeps along the anterior portion of its convex surface. 9, 9. Glands in which its branches end. 10. Another trunk also situated in the suspensory ligament; it arises from the network which corresponds to the base of this fold, is directed downwards, and then passes into the longitudinal fissure of the liver and ramifies in one of the glands of the hilum. 11, 11. Network resting on the left lobe of the liver; this is only seen owing to the transparency of the liver substance. 12. A group of trunks which ascend towards the superior border of the left lobe where they bend, and then run towards the glands situated round the inferior vena cava. 13. Another more important group which at first follows the same course, but, after traversing the left triangular ligament, is inclined downwards and inwards, towards the glands of the terminal part of the oesophagus, in which it is lost. 14, 14, 14. Trunks which disappear almost immediately, penetrating into Glisson's capsule.

right extremity of the liver. It runs downwards and backwards and penetrates into the right triangular ligament. It then attaches

itself to the concave surface of the diaphragm, then crosses the

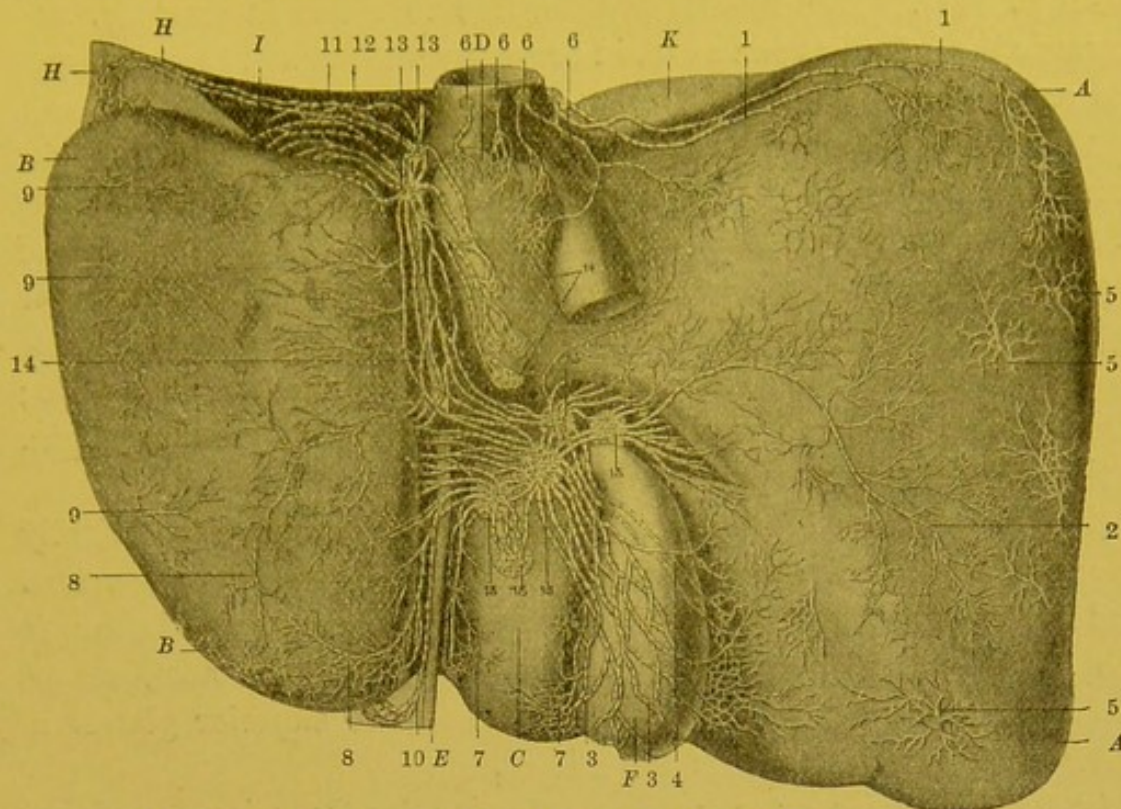


Fig. 76.—Lymphatics of the inferior surface of the liver (Sappey).

A, A. Large or right lobe of the liver. B, B. Small or left lobe. C. Quadrate lobe. D. Spigelian lobe. E. Cord resulting from the obliteration of the umbilical vein. F. Gall bladder. H. Left triangular ligament of the liver. I. Corresponding part of the diaphragm. K. The most projecting part of the superior or convex border of the liver.

1, 1. Two large lymphatic trunks which arise in the neighbourhood of the right border of the liver, and run along the superior border, terminating in one of the glands which surround the inferior vena cava at its entrance into the thorax. 2. Large lymphatic trunk coming from the central portion of the inferior surface of the right lobe, which runs towards the hilum of the liver and passes into the gland corresponding to the neck of the gall bladder. 3, 3. Other important trunks which also arise round the gall bladder, and anastomose on the inferior surface of the latter, and then pass to the glands situated on the inferior border of the hilum of the liver. 4. Two trunks which have the same origin as the preceding; but, instead of running on the free surface of the gall bladder, they pass in front of its attached surface, and end in the same glands; their course is indicated by dotted lines, and they are only visible when the gall bladder has been previously detached. 5, 5. Trunks which also arise from the inferior surface of the right lobe, in a lymphatic network, but which disappear almost at once and follow the course of the divisions of the portal vein, and are directed towards the hilum. 6, 6, 6. Small trunks which come from the Spigelian lobe, and the glands in which they terminate. 7, 7. Vessels springing from the quadrate lobe. 8, 8. Principal lymphatic trunks of the left lobe. 9, 9. Other trunks which arise from the surface of the same lobe, but which, immediately after their origin, plunge into the liver substance, to run with the vessels of Glisson's capsule. 10. Trunk which we have seen, arises from the superior surface of the left lobe; it accompanies the umbilical cord and terminates in one of the glands of the hilum. 11, 11. Two trunks, usually large, which also arise from the superior surface of the left lobe, and which traverse the corresponding triangular ligament and end in a gland situated at the posterior extremity of the longitudinal fissure; from this gland run vessels which end in the glands of the hilum. 12. Other trunks which also come from the superior surface of the left lobe and end in the same glands as the preceding. 13, 13. Glands in which the vessels coming from the superior surface of the liver, terminate. 14. Glands which correspond to the terminal portion of the oesophagus. 15, 15, 15, 15. Glands which receive all the satellite vessels of the portal vein, and the majority of those which run down from the inferior surface of the liver.

anterior surface of the right pillar of the diaphragm to terminate

in one of the glands placed round the origin of the coeliac axis (vide p. 141). The middle trunks, five to seven in number, run towards the inferior vena cava, in company with which they traverse the caval opening in the diaphragm and terminate in the glands situated in the thorax round the terminal segment of this venous trunk (middle and right groups of the diaphragmatic glands) (vide p. 209). The left trunks, which spring from the left extremity of the superior surface, penetrate into the thickness of the left triangular ligament, and are directed towards the oesophagus and terminate in the glands placed round the abdominal segment of this tube; these glands we have already described with the coronary chain, with which they are continuous.

(b) The *anterior collecting trunks* follow a course diametrically opposite to that of the preceding. They are much less important and rarely exist except in the right lobe. They are directed towards the anterior border of the liver, round which they turn, course along the quadrate lobe and terminate in the superior glands of the hepatic chain (glands of the hilum).

(c) The *superior or ascending collecting trunks* arise from that portion of the superior surface which is near to the insertion of the suspensory ligament. They are the most important of the three groups of the collectors of the superior surface. Within the suspensory ligament they exchange numerous anastomoses and terminate, according to Sappey, in the following manner: A posterior trunk turns round the posterior border of the liver, and embraces the inferior vena cava, in company with which it enters the thorax and terminates in the glands placed round the intra-thoracic portion of this large venous trunk. An anterior trunk turns round the anterior border of the liver, and in company with the umbilical cord on the inferior surface of the liver, reaches one of the superior glands of the hepatic chain. Many middle trunks "run from below upwards in the suspensory ligament; these, which may be eight or ten or only three or four in number, unite beneath the diaphragm, forming a very short enormous trunk which traverses the muscle, it then divides almost immediately into two or three branches which terminate in a small group of very small glands situated in front of the pericardium, behind the base of the xiphoid cartilage; these are the supra-xiphoid glands" (Sappey).

2. COLLECTING TRUNKS OF THE INFERIOR SURFACE.—We will study in turn—the collecting trunks of the right, the left, the Spigelian and the quadrate lobes.

(a) The *collecting trunks of the right lobe* may be divided into posterior, middle and anterior. The posterior collecting trunks, usually two in number, run to the junction of the inferior and posterior surfaces; they are directed transversely inwards, and embrace the inferior vena cava, and terminate in the glands placed round the intra-thoracic segment of this vessel. The middle collecting trunks, which spring from the middle portion of the lobe, run directly inwards towards the hilum and terminate in the superior glands of the satellite chain of the cystic duct and more particularly in the cystic gland. The anterior collecting trunks, smaller but more numerous, run backwards and inwards. Some pass above, and others beneath the gall bladder, and end in the same way as the former.

(b) The collecting trunks of *the left lobe* all terminate in the glands of the hilum and more particularly in the glands of the satellite chain of the hepatic artery. The middle collectors run transversely. The anterior collectors closely accompany the cord of the umbilical vein, the posterior accompany the vein and join their respective terminal glands.

(c) The collecting trunks of the *Spigelian lobe* terminate, some in the glands of the hilum, others in the glands placed round the thoracic segment of the inferior vena cava.

(d) The collecting trunks of the *quadrate lobe*, which are very numerous, but very fine, terminate in the glands of the hilum.

The trunks which we have just described on the superior and inferior surfaces of the liver do not collect all the lymphatics which come from the superficial lobules. Some of these lobules send their vessels into the deep collecting trunks. These superficial regions, tributaries of the deep vessels, appear as stellate figures, whose centre corresponds to the origin of the trunk which plunges into the depth of the organ. These figures are especially numerous in the neighbourhood of the two extremities of the liver (4, 4, Fig. 75).

II. Deep Collecting Trunks.—The deep collecting trunks form two absolutely distinct groups. Some, the descending, are satellites of the portal vein. Others, the ascending, accompany the hepatic veins.

1. The *descending collecting trunks* run in the thickness of the capsule of Glisson, and thus accompany the branches of the portal vein, the hepatic artery and the biliary passages. For each branch of the portal vein there are usually three or four lymphatic trunks which anastomose with each other. In their course, they unite

one with another and become progressively reduced in number: though their mode of branching does not approach in regularity that of the corresponding blood vessels. On emerging at the hilum, they number from fifteen to eighteen (Sappey). They are often grouped in two distinct bundles which are apparent at the two extremities of the transverse fissure. They terminate in the glands of the hilum.

2. The *ascending collecting trunks* which were discovered by Sappey in 1850, form round the branches of the hepatic veins a plexiform sheath which is easy to inject. "The larger and smaller trunks which contribute to the formation of this sheath creep along the adherent surface of the venous walls and, like the latter, are directed towards the inferior vena cava. The trunks are reduced to five or six in number on reaching the opening in the diaphragm, through which they pass to empty themselves into the glands situated immediately above" (Sappey).

To sum up, the lymphatics of the liver terminate in the following glandular groups: (1) The glands of the hilum. (2) The intra-thoracic glands placed round the terminal segment of the inferior vena cava. (3) The supra-xiphoid glands. (4) The peri-oesophageal glands, which are continuous with the gastric coronary chain group. (5) The glands placed round the coeliac axis.

The most important of these glandular groups, as far as the regional glands of the liver are concerned, are the glands of the hilum and the glands placed round the terminal segment of the inferior vena cava; these latter will be studied later on (vide p. 209). As regards the glands of the hilum, we must be careful to remember that it is very rare to see them arranged in a single bundle, placed transversely, below the transverse fissure. They usually form two vertical chains which are more or less continuous, one of which is a satellite of the hepatic artery, and the other of the cystic and common bile-duct (vide Fig. 48 and p. 147).

We should note the frequent but not constant presence of one or two glands sometimes of large size, in the depression for the inferior vena cava, in front of this vessel.

BIBLIOGRAPHY.—Sur les origines, voy. : T. IV, p. 766, et MALL. *Proceedings of the Assoc. of American Anatomists*, 1902.

Sur l'anat. macr. : MASCAGNI, *loc. cit.*, tab. XVII et XVIII, et p. 45.—SAPPEY, *loc. cit.*, pl. XXXV et XXXVI, et p. 94.

Lymphatics of the extra-hepatic biliary passages.—The lymphatics of the extra-hepatic biliary passages arise from two networks,

one mucous, and the other muscular. The collecting trunks which arise from these networks end in the glandular satellite chain which is a satellite of the cystic and common bile-duct. Intimate relations exist between the lymphatics of the terminal segment of the common bile-duct and the lymphatics of the duodenum and head of the pancreas.

LYMPHATICS OF THE PANCREAS.—The lymphatics of the pancreas arise from a perilobular capillary network which will be described further on (vide ¹ vol. iv. p. 830). From this network run numerous collecting trunks which after anastomosing on the surface of the gland, terminate in the peri-pancreatic glandular groups.

(1) The greater number of them reach the glands of the splenic chain (vide p. 144). (2) Others end in glands which are satellites of arches formed by the anterior and posterior pancreatico-duodenal arteries. (3) A third group empties itself into the glands placed round the commencement of the superior mesenteric artery. (4) Finally others, which spring from the posterior surface of the pancreas, terminate, according to Sappey, in the left juxta-aortic glands (?)

Technique.—The injection of the lymphatics of the pancreas is very difficult, and it is essential that perfectly fresh subjects should be used. On the other hand, when the injection succeeds, it is usually quite complete. Sappey recommends for choice the pancreas of old subjects.

THE LYMPHATICS OF THE SPLEEN.—The lymphatics of the spleen, whose mode of origin will be studied further on (vide ¹ vol. iv. p. 867), give origin to two kinds of collecting trunks which are distinguished as superficial and deep.

The *superficial collecting trunks*, which were observed by Mascagni, and then by Robin and Legros, are very difficult to inject in man. Sappey even denies their existence. They are, on the contrary, well developed in the ox and horse. In these animals they form a rich network, which is situated between the peritoneum and the fibrous capsule of the spleen. They then run towards the hilum of the spleen and terminate in the same way as the deep collecting trunks.

The *deep collecting trunks*, which are connected to the preceding by numerous anastomoses, are satellites of the blood vessels. In the hilum they are reduced to from six to ten trunks which end in the external glands of the splenic chain; these glands are placed above the tail of the pancreas in the splenico-pancreatic omentum. There are usually no glands in the gastro-splenic omentum; the glands which have been observed here by some authors are probably nothing but accessory spleens, which are very common in this situation.

¹ *Treatise of Human Anatomy.* Poirier and Charpy.

CHAPTER III

LYMPHATICS OF THE THORAX

WE will study in succession : (1) the different glandular groups of the thorax, (2) the arrangement of the lymphatic vessels of the walls of the thorax, and of the intra-thoracic viscera.

§ 1. GLANDULAR GROUPS OF THE THORAX.

The glandular groups of the thorax may be divided into parietal and visceral glands.

1. PARIETAL GLANDS

The parietal glands comprise : the diaphragmatic glands, the internal mammary or retro-sternal glands and the intercostal glands.

Some of the glands of the axilla belong to the lymphatic apparatus of the thoracic walls, but as it is impossible to subdivide our study of the axillary glands, we will leave aside for the present this thoracic group of axillary glands.

DIAPHRAGMATIC GLANDS.—Under the name of diaphragmatic glands, we will describe all the glands which lie on the convexity of the diaphragm. They may be divided into three groups : an anterior, a middle and a posterior group.

(a) The ANTERIOR GROUP rests upon the anterior fasciculi of the fleshy portion of the diaphragm, in front of the anterior leaflet of the central portion of the diaphragm. It is formed by three distinct masses : viz. a median and two lateral, symmetrically arranged.

The *median mass* comprises two or three glands, placed immediately behind the base of the xiphoid cartilage. These are the supra-xiphoid glands of Sappey. These glands receive their *afferents* from the superior surface of the liver (vide p. 203 and Fig. 75) : on the other hand, they receive no vessels coming from the diaphragm (Sappey). Their *efferents* pass into the inferior glands of the internal mammary chain.

The *lateral masses* are formed by two glands, often by a single one. This gland is placed opposite the anterior extremity of

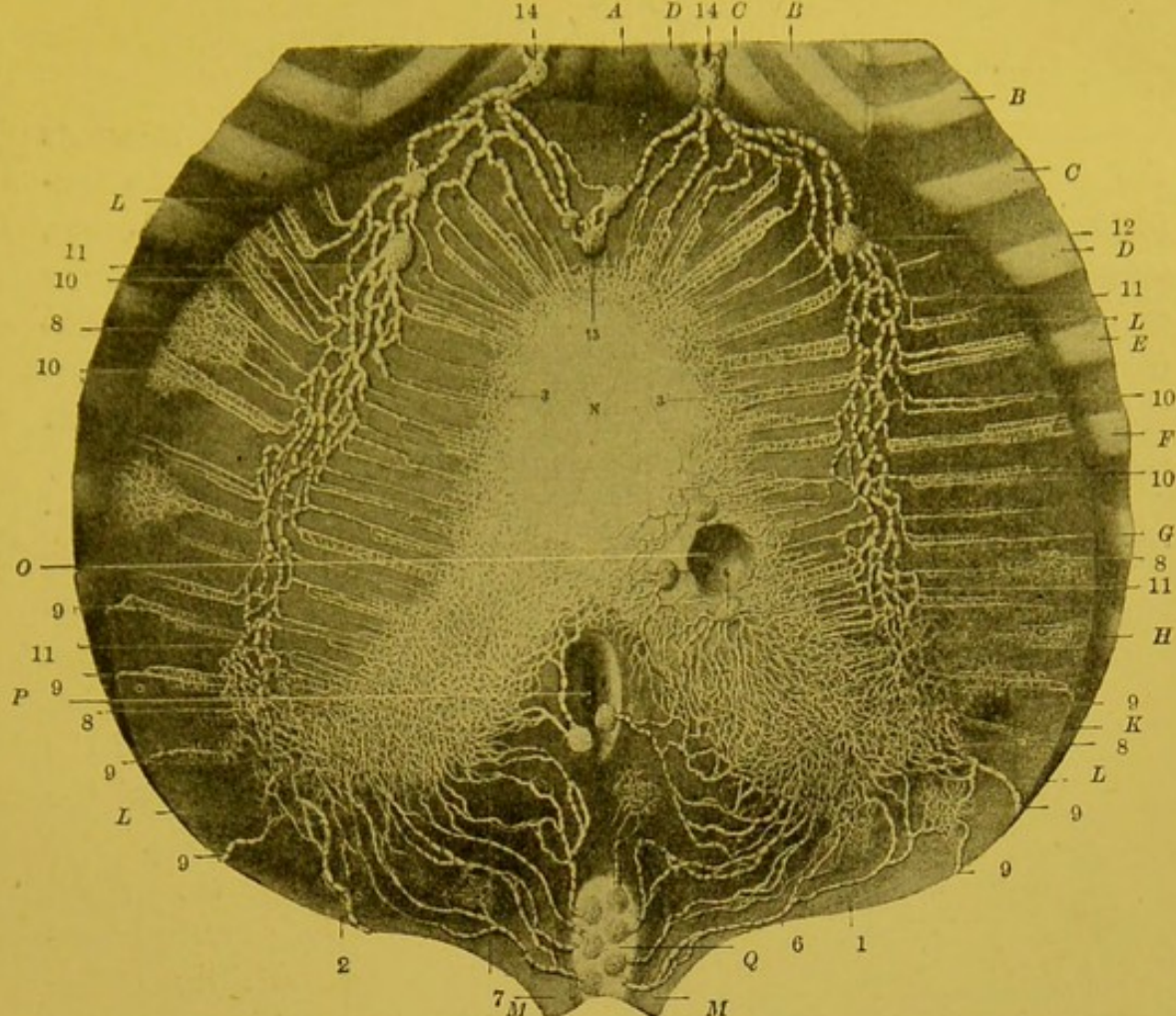


FIG. 77.—Lymphatics of the superior surface of the diaphragm (Sappey).

A. Xiphoid cartilage. B, B. Fifth rib. C, C. Sixth rib. D, D. Seventh rib. E. Eighth rib. F. Ninth rib. G. Tenth rib. H. Eleventh rib. K. Twelfth rib. L, L, L, L. Right and left halves of the muscular portion of the diaphragm. M, M. Pillars of the diaphragm. N. Central aponeurotic portion of the diaphragm with its three leaflets. O. Oesophageal opening. P. Opening for inferior vena cava, round which may be seen three and sometimes four glands. Q. Aortic orifice: the aorta has been removed; the glands which lie on its anterior portion only have been kept.

1. Lymphatic network of the right leaflet of the central portion of the diaphragm. 2. Network of the left leaflet. 3, 3. Network situated on the edge of the anterior leaflet; this leaflet being hidden in man by the pericardium which is closely adherent to it, its lymphatic network can only be injected from the opposite surface. In the human subject it can only be shown with great difficulty, but in mammals it can be injected with ease. 4, 4, 4. Glands in which some of the small trunks coming from the central portion of the diaphragm end. 5, 5. Two glands situated over the course of the oesophagus, immediately above the oesophageal opening; they receive the vessels which come from the inner portions of the right and left leaflets. 6. Lymphatic trunks which arise from the posterior portion of the right leaflet and right pillar of the diaphragm; these trunks, three or four in number, terminate in the prae-aortic glands. 7, 7. Lymphatic trunks which come from the posterior portion of the left leaflet and left pillar; they pass to the same glands as the preceding. 8, 8, 8. Lymphatic networks with close and superposed meshes, which cover the fleshy portion of the diaphragm. 9, 9, 9, 9, 9, 9, 9. Lymphatic trunks which arise from a network on the convex part of the fleshy portion of the muscle, and which then pass towards the lower intercostal spaces and end in the aortic glands. 10, 10, 10, 10. Other smaller networks which run parallel to the muscles which they surround; all of them converge, some running from without inwards, others from within outwards, and terminate in a small trunk which ends in the plexus of collecting trunks. 11, 11, 11, 11. Plexus of collecting trunks which extends from behind forwards and terminates in a large gland situated on the cartilages of the sixth and seventh ribs. 12. Gland in which the plexus of the collecting trunks terminates: this gland is single on the right and double on the left side. 13. Three small glands, situated in front of the pericardium, and to some extent hidden in the surrounding fat; they receive some lymphatic trunks which traverse first, the suspensory ligament of the liver, and then the fleshy portion of the diaphragm. From these glands run several trunks which pass into the glands on the right and left of the xiphoid cartilage, over the course of the internal mammary vessels. 14, 14. Glands in which the preceding vessels terminate, and which are continuous with the plexus of the collecting trunks.

the osseous portion of the seventh rib. It receives as afferents the anterior lymphatic trunks of the convex surface of the diaphragm (vide p. 209). Its efferents, usually two in number, empty themselves into the inferior gland of the internal mammary chain. This gland is always fairly large and is rarely absent (Sappey).

(b) The MIDDLE GROUP is formed by two glandular masses, one on the left and the other on the right.

On the left, these glands, three to six in number, are always somewhat small, and are grouped round the spot where the phrenic

nerve approaches the diaphragm. They are placed on the left of the fibrous sac of the pericardium.

On the right, their arrangement is slightly different. Here the glandular mass is of more importance than that of the opposite side, and includes two groups of glands.

Some, arranged like the preceding, are placed external to the pericardium, to the right of the in-

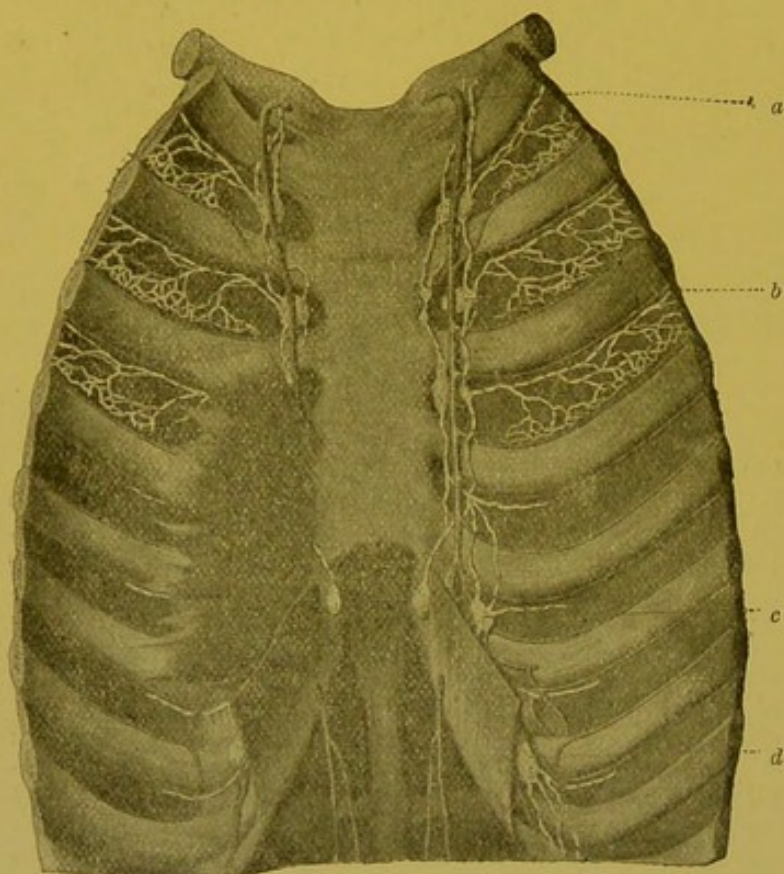


FIG. 78.—Internal mammary glands.

a. Efferent vessel of the internal mammary chain. b, c. Glands of this chain. d. Diaphragmatic gland (lateral mass of the anterior group).

ferior vena cava, and round the terminal segment of the right phrenic. Others are intra-pericardiac, and correspond to the anterior surface of the inferior vena cava.

The middle diaphragmatic glands receive their afferent vessels from the middle portion of the diaphragm. On the right side, they receive in addition numerous lymphatics coming from the liver (vide p. 202). Their efferent vessels pass into the posterior mediastinal glands.

(c) The POSTERIOR GROUP comprises four or five glands deeply situated between the posterior surface of the pillars of the diaphragm and the anterior surface of the eleventh and twelfth ribs. These glands are usually small and are intermediate between the abdomino-aortic glands and the posterior mediastinal glands.

THE INTERNAL MAMMARY GLANDS (Retro-sternal glands; praesternal glands, Sappey; sternal glands, Leaf).—The internal mammary glands are satellites of the vessels of this name, and form two ascending chains, which run parallel to the lateral borders of the sternum. Their number is very variable. Four to six are usually present on each side. The chain usually commences at the level of the third space. At the level of the fourth or fifth space these glands are almost always absent. Above the fourth rib a single gland is usually found in each space, fairly often two, and much more rarely three. The glands lie upon the internal intercostal muscle in front; the mammary vessels are usually posterior to them. Behind these vessels, a fine layer of cellular tissue separates the glands from the mediastinal pleura. We may add that the gland in the third space is sometimes hidden by the superior fasciculus of the triangularis sterni.

Above the first space, the internal mammary chain, which is always a satellite of the artery, runs like the latter backwards and outwards, then becomes attached to the dome of the pleura and terminates at the junction of the internal jugular and subclavian veins.

Afferent Vessels.—The internal mammary glands collect: (1) the efferents of the anterior diaphragmatic glands which themselves receive the lymphatics from the diaphragm and the liver; (2) the lymphatics from the superior portion of the rectus abdominis muscle; (3) the lymphatics from the anterior portion of the intercostal spaces; (4) the lymphatics from the integuments of the praesternal region; (5) the lymphatics from the mamma (vide pp. 221 and 222).

Efferent Vessels.—Their efferent vessels usually unite into a single trunk which empties itself into the anterior surface of the junction of the internal jugular and subclavian veins. On the left, this trunk may also terminate in the thoracic duct, and on the right, it frequently terminates in the subclavian trunk. It is more unusual to see it unite with the subclavian and the internal jugular and form a right lymphatic trunk such as our old authors have described (vide p. 291).

INTERCOSTAL GLANDS.—These glands are placed in the course of the intercostal vessels, some of them occupy the middle part of the space (lateral glands), and others, the posterior portion (the posterior glands).

The *lateral glands* are very inconstant. They are usually placed at the spot where the intercostal artery gives off its perforating lateral branch. They are always very small, and are really nothing but simple interrupting glandular nodules placed over the lymphatic trunks which come from the external intercostal muscles, and are satellites of the vessels and nerves of the intercostal space (vide further on. Lymphatics of the intercostal muscles, p. 224).

The *posterior glands* are much more important than the preceding. They occupy the posterior extremity of the intercostal spaces. They usually correspond to the middle portion of the neck of the rib: more rarely, they are situated over the costo-vertebral articulation. Behind they rest upon the external intercostal muscle, while in front they are covered by the pleura. Their relations with the artery which at this level gives off its dorso-spinal branch are somewhat variable; most frequently, they lie over it.

They receive as *afferents* the lymphatic trunks, satellites of the aortic intercostal arteries. The arrangement of their *efferent* vessels varies at different levels. The efferents of the glands of the four or five lower spaces unite to form a vertical trunk which as it descends increases in size and which terminates in the commencement of the thoracic duct. The efferents from the glands above have a transverse or ascending course and empty their contents into the upper portion of the duct. Sometimes several of these trunks unite to form a vertical ascending trunk which terminates in the thoracic duct at a point more or less close to its termination.

2. VISCERAL GLANDS.

The visceral glands of the thorax which are very numerous and very important, may be divided into three groups: an *anterior* group, formed by the glands in the anterior mediastinum; a *middle* group, comprising the *peritracheo-bronchial* glands, situated at the borders of the anterior and posterior mediastina; and a *posterior* group, formed by the glands in the posterior mediastinum.

ANTERIOR MEDIASTINAL GLANDS.—The glands placed in the anterior mediastinum occupy its upper portion. They are usually arranged in the following manner: They constitute a mass of

from four to six glands situated on the anterior surface of the convex surface of the transverse arch of the aorta. From this prae- and supra-aortic mass, glands detach themselves in chains which run towards the base of the neck. *On the right*, these glands are grouped, some in front of the right innominate vein, others between this vessel and the innominate artery, others again behind the latter. *On the left*, we see these glands surrounding the left common carotid, and the left subclavian vessels, some of them being placed in front of the carotid, others between it and the subclavian: finally, we commonly meet with some of them both on the internal and external surfaces of this vessel.

Some authors, agreeing with Baréty, describe these glandular chains, which are satellites of the large vascular trunks, as an intra-thoracic prolongation of the deep cervical chains. This mode of description does not represent the real facts, for the chains we have just described are ascending chains which run upwards towards the junction of the internal jugular and subclavian, in the same way as the descending cervical chains run towards this same junction.

PERITRACHEO-BRONCHIAL GLANDS. — The topography of the peritracheo-bronchial glands was minutely studied in 1874 by Baréty, whose description still remains classical. Agreeing with this author, we may divide the peritracheo-bronchial glands into four groups, viz. the right and left praetracheo-bronchial glands, and the intertracheo-bronchial, and the interbronchial glands.

1. The *right praetracheo-bronchial glands* are the most important of these groups on account of their number, the constancy of their arrangement and the frequency of the lesions to which they are subject. They are placed in the angle formed by the trachea and the right bronchus. This group usually comprises four or five glands, which normally, are about the size and shape of a large pea or haricot bean. These glands are in relation: in *front*, with the inferior vena cava; *internally*, with the trachea; *externally*, with the internal surface of the right lung; *below*, with the right bronchus, and the right branch of the pulmonary artery, and the terminal bend of the vena azygos major; *above*, this group reaches the subclavian arch, where it enters into relation with the loop of the recurrent laryngeal nerve and the glandular chain which accompanies it; finally, *behind*, it corresponds to the right pneumogastric nerve.

2. The *left praetracheo-bronchial glands*, which vary from three

to four in number, are usually smaller than the preceding. They are in relation, in *front*, with the ascending portion of the aortic arch; *internally*, with the trachea; *below*, with the left bronchus, and with the left pulmonary artery; *externally*, with the left lung; *behind*, with the left pneumogastric. *Above*, they enter into relation with the horizontal portion of the aortic arch and with the loop of the recurrent laryngeal nerve where they are continuous with the glandular chain accompanying this nerve.

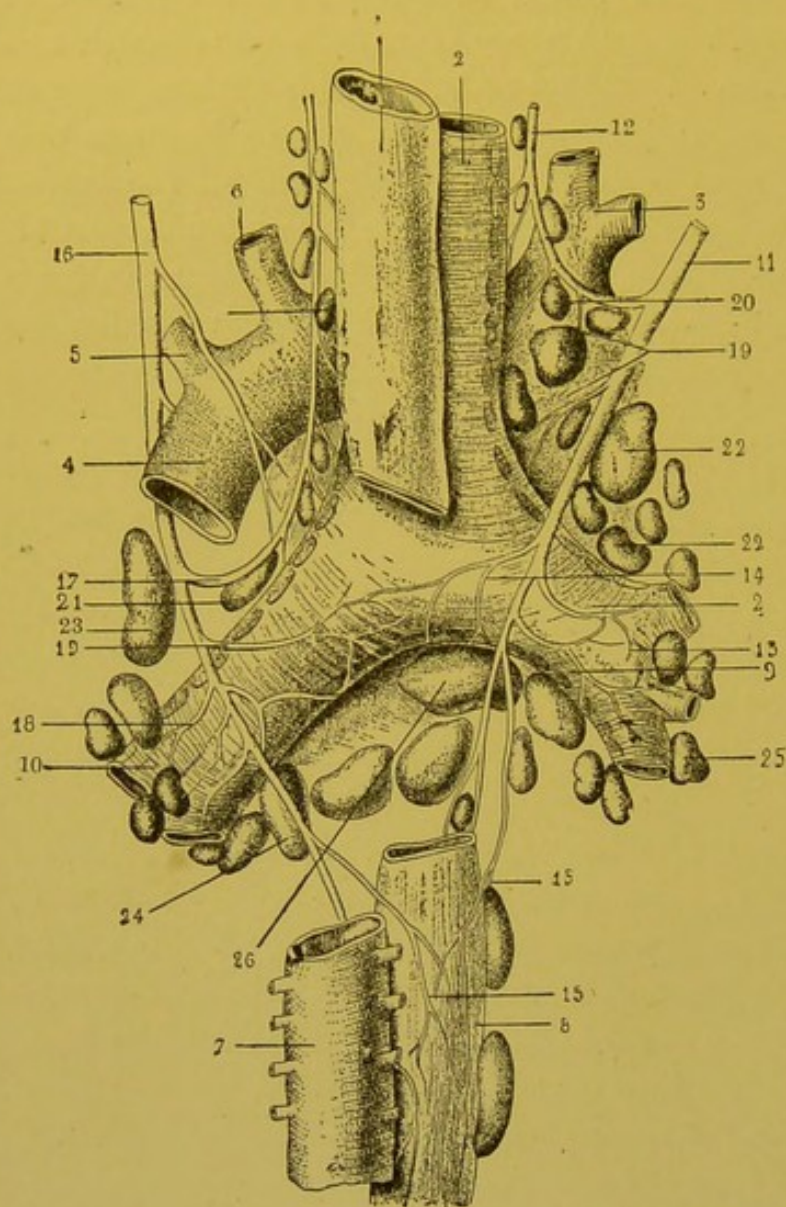


FIG. 79.—Arrangement and connections of the tracheo-bronchial glands (from a drawing by Hallé and borrowed from vol. iv. of *La Clinique Médicale*, by H. Guéneau de Mussy).

1. Oesophagus. 2. Trachea. 3. Innominate artery. 4. Arch of the aorta. 5. Left subclavian artery. 6. Left common carotid artery. 7. Thoracic aorta. 8. Oesophagus. 9. Right bronchus. 10. Left bronchus. 11. Right pneumogastric nerve. 12. Right recurrent nerve. 13. Bronchial filaments of right pneumogastric. 14. Anastomotic filaments. 15. Oesophageal filaments. 16. Left pneumogastric nerve. 17. Left recurrent laryngeal nerve. 18. Bronchial filaments of left pneumogastric. 19. Anastomotic filaments. 20. Glandular chain of right recurrent nerve. 21. Glandular chain of left recurrent nerve. 22. Right prætracheo-bronchial group. 23. Left prætracheo-bronchial group. 24, 25. Right and left interbronchial groups. 26. Intertracheo-bronchial group.

the right than under the left bronchus. They are in relation : *above*, with the bifurcation of the trachea ; in *front*, with the

3. The *intertracheo-bronchial glands* are placed in the angle of bifurcation of the trachea. This uneven and mesially placed group comprises from ten to twelve glands, which are usually more numerous and larger under

pericardium which separates them from the left auricle to which they send a small venous tributary, which was observed by Lannelongue, and again found by Baréty; *behind*, with the pulmonary plexus and the anterior surface of the oesophagus.

4. The *interbronchial glands* occupy the angles of division of the larger bronchi. According to Cruveilhier, glands may be found even in the divisions of the fourth order. These glands, completely buried in the pulmonary parenchyma, are in intimate relation with the branches of the pulmonary vessels and more particularly with those of the pulmonary artery, which they may compress when hypertrophied.

The peritracheo-bronchial glands are often enlarged, as a result of the frequent infections to which they are exposed. From the earliest years of life they present a blackish tint, due to the fact that they arrest the particles of carbon collected by the leucocytes on the surface of the bronchi. This normal anthracosis is accompanied by a progressive sclerosis which, in old people, transforms these glands into simple fibrous blocks.

POSTERIOR MEDIASTINAL GLANDS.—The *posterior mediastinal glands* are scattered round the oesophagus. They are usually placed on the anterior surface of this tube, behind the pericardium. Though it is more rare, we may also come across two or three small retro-oesophageal glands, situated by the side of the thoracic duct.

BIBLIOGRAPHY.—Sur les ganglions péritrachéo-bronchiques voy. : BECKER. De glandulis thoracis lymphaticis atque thymo. *Thèse Berlin*, 1827.—BARÉTY De l'adénopathie trachéo-bronchique. *Thèse Paris*. 1874.—GUENÉAU DE MUSSY. *Clinique médicale*, t. IV, 1885.—LEAF, loc .cit., p. 28 et Fig. 2, 3, 4 et 5.

§ 2. LYMPHATIC VESSELS OF THE THORAX.

WE will study in turn (1) the lymphatic vessels of the walls of the thorax, and (2) those of the intra-thoracic viscera.

1. PARIETAL LYMPHATIC VESSELS.

The parietal lymphatics may be divided into: cutaneous lymphatics, lymphatics of the mammary gland, lymphatics of the perithoracic muscles, lymphatics of the intercostal muscles, and finally, lymphatics of the diaphragm.

CUTANEOUS LYMPHATICS.—The integuments of the thorax may be divided into three lymphatic territories: viz. anterior, lateral and posterior. This division is artificial, in the sense that the three territories are far from possessing distinct limits, but it has the

advantage of enabling us to classify more clearly the collecting trunks of the cutaneous network of the thorax.

(1) **ANTERIOR TERRITORY.**—The anterior territory extends from the median line to the neighbourhood of the anterior axillary line.

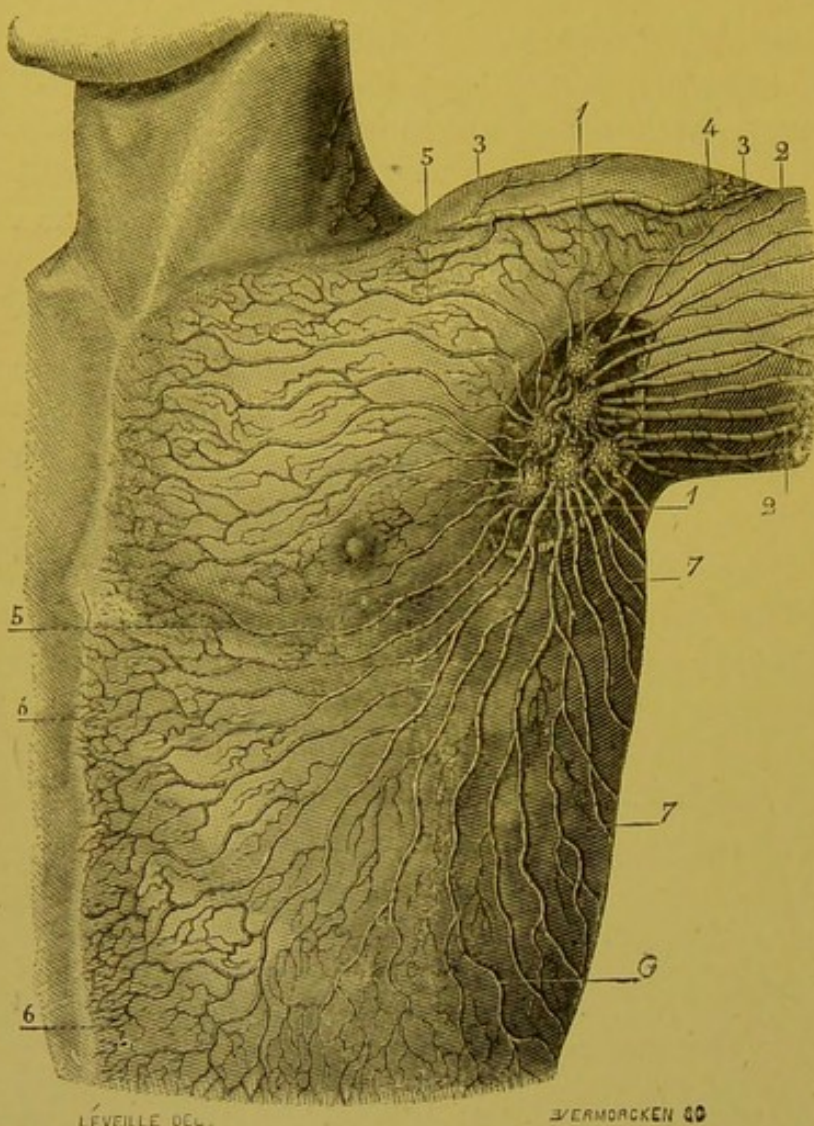


FIG. 80.—Lymphatic vessels of the antero-lateral portions of the thorax (Sappey).

1, 1. Axillary glands. 2, 2. Superficial lymphatic trunks of the upper limb. 3, 3. Large trunks which also come from the integuments of the upper limb, but which, instead of ending in the glands of the axilla, run in the space between the deltoid and pectoralis major, and terminate in a sub-clavicular gland. 4. A gland which is sometimes seen in the course of this trunk. 5, 5. Lymphatic vessels of the anterior superior part of the thorax. 6, 6, 7, 7. Lymphatic vessels which start from the integuments of the thorax.

We must notice that we cannot include in this region the lymphatics of the integuments which cover the central portion of the mamma. These vessels have a special arrangement which will be studied with the lymphatics of the mammary gland.

The collecting trunks which drain the anterior territory appear in the region of the median line. They run towards the axilla, passing some above, and some below the breast. We may here remark that it is not unusual to see trunks which arise somewhat low down, in the neighbourhood of the xiphoid car-

tilage, for instance, describe a very well marked curve and pass above the breast to reach the axilla. All these anterior trunks terminate in the thoracic group of axillary glands.

Mascagni figures in the course of one of these trunks, two small glands

placed near the inferior border of the pectoralis major, at the level of the nipple line. These glands are simple interrupting glandular nodules, and are usually absent. They must not be confounded with the paramammillary glands, described by Gerota, and to which we shall have to return later on (vide Mascagni, loc. cit., tab. xxiv. 68).

This homolateral axillary channel represents the principal lymphatic channel of the anterior region of the thorax, but accessory channels exist which we must shortly mention.

Thus some trunks arise below the clavicle and run upwards and outwards, and passing above this bone, terminate in the supra-clavicular glands. Similarly, when an injection is made at a little distance from the middle line, the injected mass may be observed to pass into the glands of the opposite side. Now this route is rendered possible not only in consequence of the absence of interruption between the networks of origin on either side of the middle line, but also on account of some of the trunks having a crossed origin. It is true that this discussion of the collecting trunks is not to be regarded as normal; Oelsner has only met with it twice in nine subjects. Finally, in the neighbourhood of the middle line we may, by injecting the cutaneous network, fill two or three collecting trunks which perforate the anterior extremity of the intercostal spaces, and which closely accompany the perforating branches of the internal mammary artery and reach the satellite glands of this artery. We are here dealing with an arrangement, which, if not constant, is at least very frequent, if we may judge by our own observations.

To sum up, the cutaneous territory of the anterior region of the thorax possesses a principal lymphatic channel, the homolateral axillary channel, and three accessory channels, viz. the contralateral, the ~~sub~~clavian and the internal mammary.

When, on account of an embolus in or neoplastic thrombosis of the lymphatic vessels, the chief axillary channel becomes obstructed, the accessory channels which we have just been considering may become of greater importance. We may then even see channels appear which are quite abnormal.

Thus, in a case of this kind, Gerota has seen the skin of the submammary region send out its lymphatics into the superficial inguinal glands and even into the external iliac glands, by means of trunks which became deeply placed, and embraced the deep epigastric artery.

This knowledge of the mode of termination of the lymphatics of the integuments of the anterior region of the thorax is of great

practical importance. When an epithelioma of the breast has reached a slightly advanced state of development, usually the invasion is not limited to the skin of the mammary region, but also extends into the peri-mammary integuments. As Oelsner remarked, it is therefore almost as essential to be acquainted with the arrangement of the lymphatics of the integuments as with those of the gland itself.

2. LATERAL TERRITORY.—In the lateral territory arise five or six trunks which ascend vertically, perforate the axillary aponeurosis and terminate, as do the anterior trunks, in the thoracic group of axillary glands.

3. POSTERIOR TERRITORY.—The posterior territory gives origin to ten or twelve trunks (Sappey). The lower trunks appear a little below the inferior border of the thorax. The middle trunks arise near the middle line throughout the dorsal region. The upper trunks spring from the lower part of the neck. All converge towards the axilla, thus presenting in their entirety a somewhat regular radial arrangement (vide Fig. 81). They terminate in the scapular group of axillary glands.

LYMPHATICS OF THE BREAST.—We will divide the lymphatics of the breast into cutaneous and glandular.

1. THE CUTANEOUS LYMPHATICS.—The arrangement of cutaneous lymphatics varies at the periphery and at the centre of the mammary region, i.e. in the region of the areola and the nipple.

The peripheral cutaneous lymphatics are in no way distinguishable from the cutaneous lymphatics of adjacent regions; they terminate in collecting trunks which carry the lymph from the integuments of the anterior portion of the thorax. Those which arise from the internal part of the gland may end in the axillary glands of the opposite side (Rieffel, Oelsner).

The central cutaneous lymphatics have, on the contrary, from the point of view of their origin and termination, a very peculiar arrangement. At their origin, they form a network with extremely fine meshes, arranged in several planes which, especially in the female subject who has died during a state of lactation, it is easy to inject. When, by using mercury, we succeed in entirely filling this sub-areolar and sub-mamillary network, all the central part of this region seems transformed into a silvered plate, and an examination with a lens is necessary to distinguish the meshes of which it is composed. From this network, run numerous trunklets which pass immediately into a lymphatic plexus, formed by larger trunks:

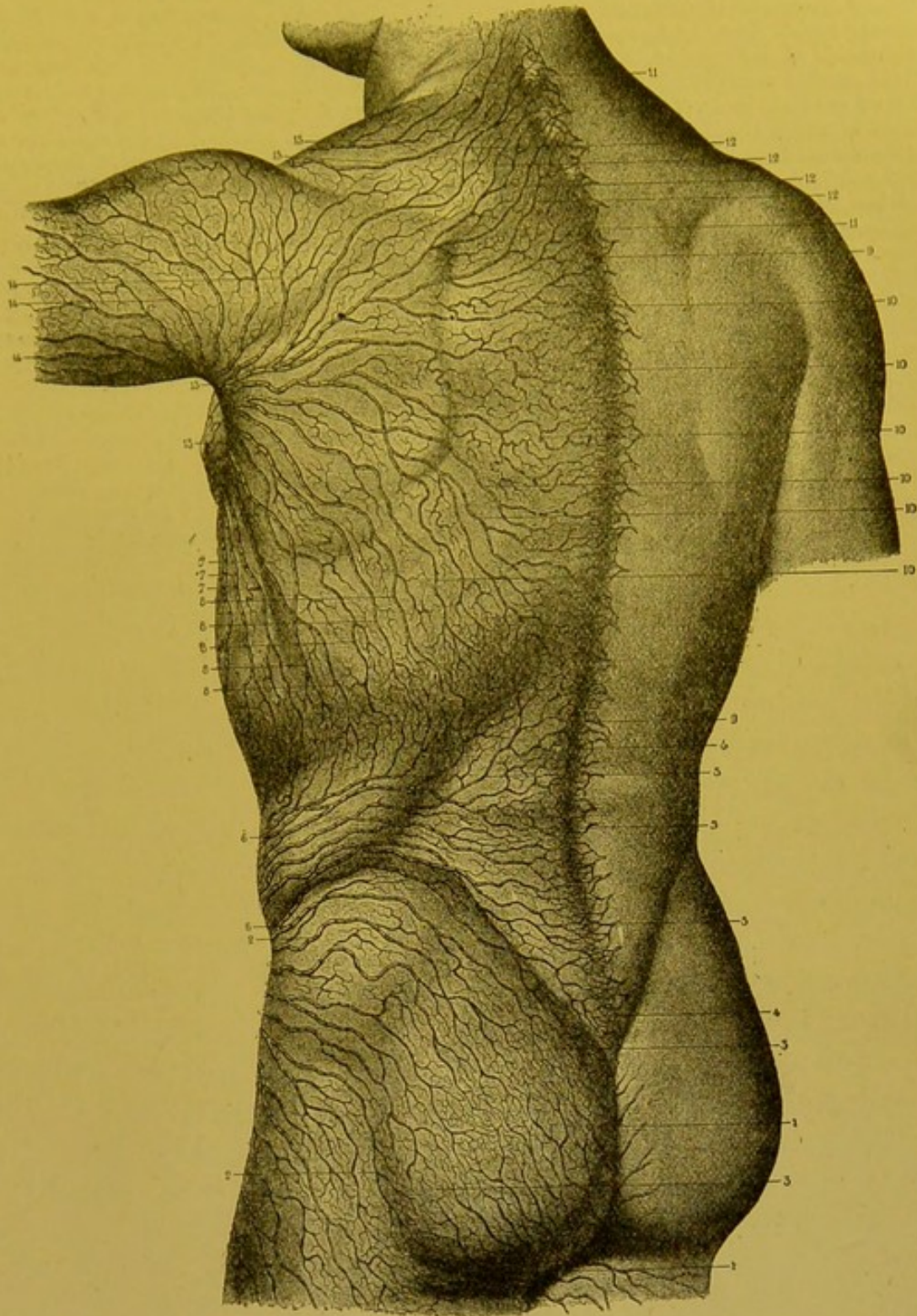


FIG. 81.—Cutaneous lymphatics of the gluteal region and the dorsal surface of the trunk (Sappey).

1, 1. Lymphatic vessels of the internal portion of the gluteal region, running downwards, inwards, and then forwards, to join those from the anus and perineum; like the latter, they terminate in the internal glands of the inguinal region. 2, 2. Lymphatic trunks which spring from the outer and upper two-thirds of the thigh: all these trunks are directed upwards and outwards, they then turn round the upper part of the limb to terminate in the external glands of the inguinal region. 3, 3. Branchlets which form junctions between the ascending and descending vessels of the gluteal region. By pricking the skin with the point of a syringe in this region which is common to the two groups of vessels, sometimes one, sometimes the other set of vessels may be injected. 4, 4. Median lymphatic network of the lumbar region. This network, like all others of the same kind, does not correspond

to any lymphatic trunk on its deep aspect. The latter spring from the right and left of its lateral parts. Mascagni committed an error in stating that the lymphatic vessels of the right side of the lumbar and dorsal regions might arise from the left side and *vice versa*. This error is attributable to the very defective mode of study which was then in vogue. In no part of the trunk or head, have I seen any vessel spring from the side opposite to that to which it belonged. 5, 5, 5. Trunks, six to eight in number, which run from this network and converge from behind forward. 6, 6. These same trunks which turn round the left flank to terminate in the glands of the inguinal region. 7, 7, 7. Lymphatic vessels of the lateral walls of the thorax, which are directed from below upwards towards the axillary glands. 8, 8, 8, 8. Lymphatic trunks springing from a network common to them and to those of lumbar region. 9, 9. Median lymphatic network of the dorsal region. 10, 10, 10, 10, 10. Trunks whose primary radicals come from this network and run from within outwards. 11, 11. Median lymphatic network of the posterior part of the neck. 12, 12, 12, 12. Trunks which come from this network; they converge from within outwards, running obliquely over the posterior and superior part of the shoulder; they then join those from the dorsal region to terminate in the glands of the axilla. 13, 13. Collection of trunks which take their origin from the posterior portion of the thorax. They turn round the posterior border of the axilla to terminate in the glands of this region. 14, 14, 14. Vessels, from the posterior and superior portion of the arm, also converging to the axilla to terminate like the preceding. 15, 15. Two trunks of the posterior part of the neck which turn round the superior border of the trapezius muscle to end in the supra-clavicular glands.

this is the sub-areolar plexus of Sappey, in which the majority of trunks coming from the mammary gland itself, also terminate.

2. THE LYMPHATICS OF THE MAMMARY GLAND.—We will not now approach the disputed question as to the origin of the lymphatics of the mammary gland (*vide* on this point vol. v. p. 697¹). Moreover, the researches of Regaud seem to have settled the question.

In the glandular lobules, the lymphatics arise from large peri-lobular sacs; these never penetrate into the interior of the lobules, but simply ramify on their surface to a greater or less extent. In the *galactophorous ducts*, the network of origin is formed by capillaries whose general direction is parallel to the excretory ducts, and which unite with each other by transverse anastomoses.

From the peri-lobular sacs spring two kinds of collecting trunks, some of which reach the sub-areolar plexus and thence pass to the axillary glands. They constitute the principal lymphatic channel of the breast. Others emerge from the periphery of the gland, and form several accessory channels which vary in their course and termination.

A. THE PRINCIPAL LYMPHATIC CHANNEL.—This channel is the only one described by Sappey, whose description has been adopted by Richet, Tillaux, Merkel, Nagel, Pierre Delbet, Sorgius. The collectors of which it is composed start from the peri-lobular sacs. They run towards the nipple, and passing between the galactophorous ducts collect as they go the capillaries attached to these ducts. They terminate in the sub-areolar plexus.

This plexus, in which, as we have already seen, the cutaneous lymphatics of the areola and nipple terminate, is formed by large

¹ *Treatise of Human Anatomy*, Porrier and Charpy.

embossed trunks. The entire plexus resembles a disc perforated at its centre by an orifice which circumscribes the base of the nipple. The periphery of this disc usually extends beyond the edge of the areola.

From this plexus usually run two large trunks which leave it, the

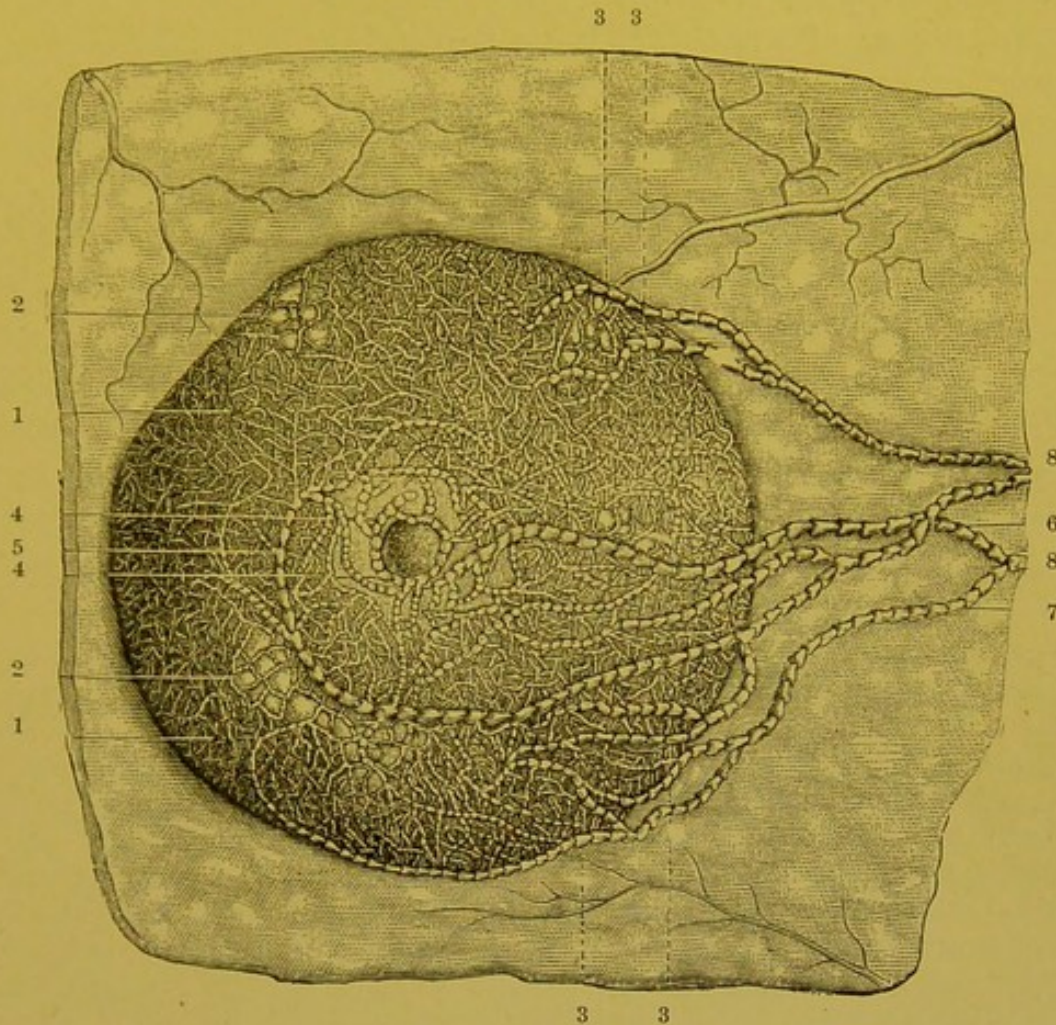


FIG. 82.—Lymphatic vessels of the anterior surface of the breast; the sub-areolar plexus and the trunks which run from it (Sappey).

1, 1. Lymphatic network of the anterior surface of the mammary gland. 2, 2. Lobules of the gland, the peripheral network of which has not been injected in order that the circumlobular network which encircles it may be seen. 3, 3, 3, 3. Trunks which arise from the upper and lower parts of the gland. 4, 4. Sub-areolar lymphatic plexus. 5. Lymphatic vessel which arises from the inner part of this plexus. 6. Vessel arising from the outer part of the same plexus. 7. Vessel coming from the lower part of the gland; after a long course it unites with the preceding to form one of two trunks in which all the others end. 8, 8. The two principal lymphatic trunks which extend transversely from the mamma to the axillary glands.

one on its internal, the other on its external part. The *internal trunk* runs at first downwards, and then outwards, turning round the inferior border of the sub-areolar plexus. It is thus directed towards the axilla, and runs in the subcutaneous cellular tissue, along the lower border of the pectoralis major, which it crosses at the level of the third rib to reach the base of the axilla. This

collecting trunk constantly receives as affluents, one or two fair-sized trunks coming directly from the inferior portion of the mammary gland. The *external trunk*, which is usually smaller than the preceding, runs directly outwards towards the axilla. Before it reaches the latter it is augmented by a vessel coming from the superior part of the gland.

At the base of the axilla, these two collecting trunks perforate the axillary aponeurosis and terminate in one or two glands, placed on the inner wall of the axilla on the third digitation of the serratus magnus.

These glands (the principal regional glands of the breast) may or may not be covered by the lower part of the pectoralis major according to the muscular development of the subject (Sorgius). They constitute the supero-internal group of the thoracic chain of axillary glands (the anterior thoracic lymph glands, Oelsner) (vide further on : Topography of axillary glands, pp. 234 and 235). On the course of these collecting trunks may sometimes be found a little interrupting glandular nodule (Schaltdrüse) ; this is the paramammary gland of Sorgius.

We must recollect here that the glands in which the emissaries of the sub-areolar plexus end, send their efferents into the central axillary glands, and by means of the latter, into the subclavian glands ; but these efferents may also end directly in the subclavian or in the other glandular groups of the axilla, viz. the humeral or scapular group. Further, Nagel has seen one of the collectors coming from the sub-areolar plexus, send a branch to a humeral gland, before itself terminating in the supero-internal thoracic glands. Similarly Grossmann, and Rieffel have seen a mammary collecting trunk pass directly into the subclavian glands. In cancer of the breast, we must regard all the glands of the axilla with suspicion (for further details, vide Axillary Glands, pp. 234 and 235).

B. ACCESSORY CHANNELS.—The accessory channels are three in number, viz. the axillary, the subclavian, and the internal mammary.

(a) *The Accessory Axillary Channels.*—This has been well described by Gerota. It comprises 1 to 3 collectors which detach themselves from the inferior part of the mamma and directly reach the axillary glands. These vessels may present in their course small glandular nodules, which are however often absent (paramammillary lymph glands of Gerota). This accessory axillary channel is inconstant ; in fact, the trunks which compose it often empty their contents into the principal lymphatic channel. Moreover it is not of much practical importance.

We may compare this channel to the trunks described by Heidenhain. This author admits the existence of collecting trunks which detach themselves from the posterior surface of the gland, and run within the pectoral

fascia to gain the axillary glands. We must observe that Heidenhain's description is only based on the examination of pathological specimens.

(b) *The Subclavian Channel*.—Grossmann has injected three times in thirty subjects, a trunk which detached itself from the

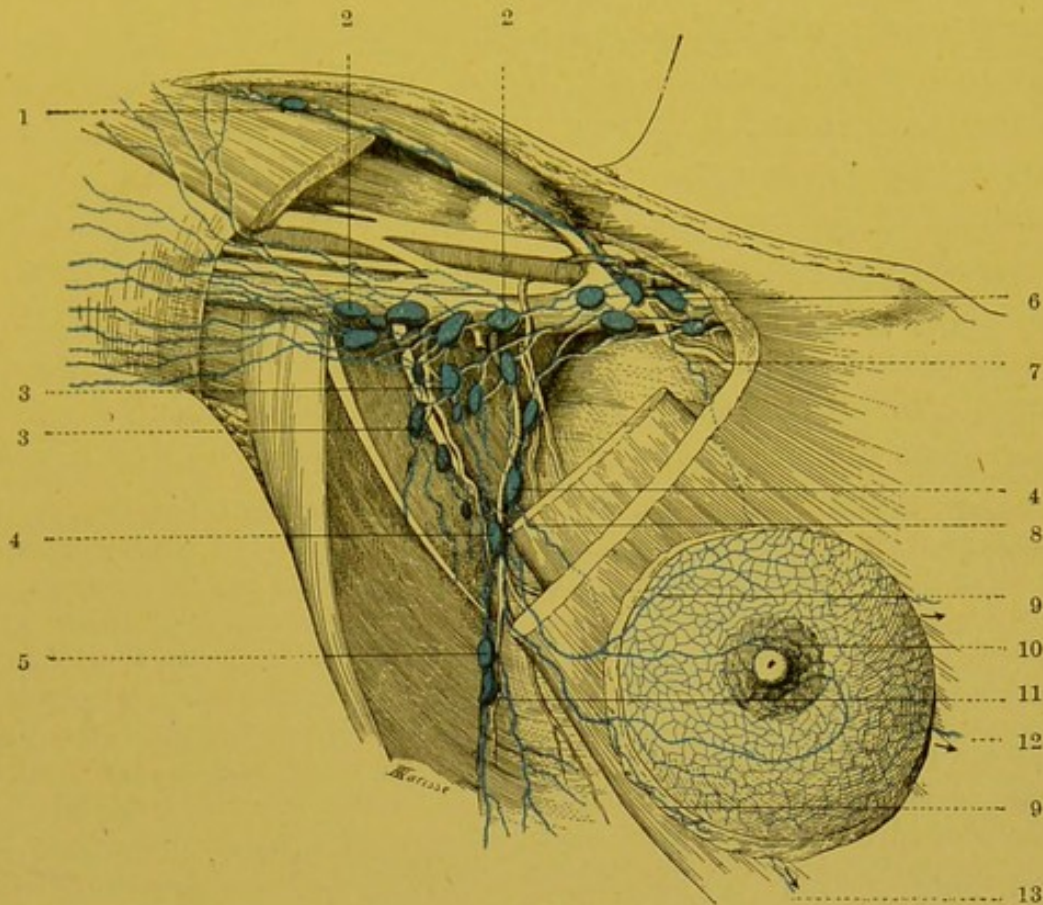


FIG. 83.—Lymphatics of the breast and axillary glands (semi-diagrammatic).

1. Delto-pectoral gland. 2, 2. Glands of the humeral chain. 3, 3. Glands of the central group and the scapular chain. 4, 4. Glands of the thoracic chain (supero-internal group). 5. Gland of the thoracic chain (infero-external group). 6. Subclavian glands. 7. Mammary lymphatic ending in the subclavian glands (inconstant). 8, 9. Mammary collecting trunks, ending in glands of the thoracic chain. 10. Sub-areolar plexus. 11. Cutaneous collecting trunk of the lateral walls of the thorax. 12, 13. Mammary collecting trunks about to end in the internal mammary glands.

posterior surface of the mamma, then perforated the pectoralis major, and running between this muscle and the pectoralis minor reached the subclavian glands. This trunk was a satellite of the superior thoracic artery (thoracic branch of the acromio-thoracic?), and presented in its course two or three small glandular nodules (*retro-pectoral glands*).

Rotter, basing his statements on the examination of specimens of cancer of the breast, admits the existence of this channel described by Grossmann. According to the author, the retropectoral glands exist in nearly half the cases and are situated not only in the course of the thoracic branch of the acromio-thoracic artery, but also along the branch which the external

mammary sends to the pectoralis major. We will return to these glandular nodules when studying the axillary glands.

(c) *The Internal Mammary Channel*.—The internal mammary channel is much more important than the preceding. Its presence was formally denied by Sappey, though it was observed a long time ago by Mascagni and Cruikshank. Henle mentions it incidentally. More recently Stiles, Schaffer, Symington, Gerota Poirier, Rieffel, and Oelsner have definitely proved its existence. The trunks which constitute this channel arise from the inner extremity of the mamma: they follow the course of the arterioles given off by the internal mammary artery to the gland. Like the latter, they perforate the pectoralis major and the internal intercostal muscles, and empty themselves into the glands of the mammary chain. Rotter saw a small glandular nodule within the fibres of the great pectoral lying on one of these vessels.

The lymphatics of the breast, which are tributaries of the internal mammary chain, may reach the above-mentioned glands by taking a very different course to that we have just indicated. Thus Oelsner has seen some small collectors running from the inferior border of the mamma which, after traversing the great pectoral, entered the thorax through the fourth intercostal space, at the level of the costo-chondral articulation. These vessels then resolved themselves into a single trunk which terminated in a gland belonging to the internal mammary chain, after presenting in its course a glandular nodule, placed about the centre of the fourth costal cartilage. One of the present writers has twice met with an arrangement identical with that described by Oelsner.

It is important to remark that we must not exaggerate the importance of this internal mammary channel. Though its presence is anatomically indisputable, facts none the less show that in the early stages of cancer of the breast, the invasion of the retro-sternal glands is exceptional. The fact that these glands are not usually involved is probably to be explained by the atrophy of this channel in senile mammae, in which cancer usually develops.

BIBLIOGRAPHY.—MASCAGNI, loc. cit., tab. XXIV.—SAPPEY, loc. cit., pl. XIII, Fig. 13, et p. 48.—SORGIUS. Ueber die Lymphgefäße der weiblichen Brustdrüse, *Dissert. Strassburg*, 1880.—HEIDENHAIN. Ueber die Ursachen der localen Krebsrecidive nach Amputatio Mammæ *Langenbeck's Arch.*, XXXIX, 1889.—RIEFFEL. De quelques points relatifs aux récidives et aux généralisations des cancers du sein chez la femme. *Thèse Paris*, 1890.—GROSSMANN. Ueber die Lymphdrüsen und -bahnen der Achselhöhle. Berlin, 1893.—GEROTA. Nach welchen Richtungen kann sich der Brustkrebs weiterverbreiten? *Archiv f. klin. Chir.* LIV, 1897.—ROTTER. Zur Topographie des Mammacarcinomes. *Arch. f. klin. Chir.* LVIII, 2, 1899.—L. OELSNER. Anatomische Untersuchung über die Lymphwege der Brust, etc. *Arch. f. klin. Chir.*, 1901, LXI, 1, p. 134.

LYMPHATICS OF THE THORACIC MUSCLES.—The lymphatics of the muscles attached to the external surface of the thorax end in the

axillary glands. The lymphatics of the great pectoral alone merit a special description on account of the frequent invasion of this muscle during the progress of cancer of the breast. These lymphatics have been recently thoroughly studied by Oelsner. They arise from cellular septa which ramify over the muscle, and are divided into several groups. Some run towards the subclavian glands, accompanying the thoracic branch of the acromio-thoracic artery. Others accompany the pectoral branch of the external mammary artery and end in the thoracic group of axillary glands. All these trunks present in their course small glandular nodules (Grossmann, Rotter) to which we have already alluded when studying the lymphatics of the breast. Finally, there are other trunks which end in the glands of the internal mammary chain.

It follows from this arrangement of the lymphatics of the great pectoral that, even if we reject the existence of mammary lymphatics ending in the retro-pectoral and in the internal mammary glands, we ought nevertheless to regard the invasion of these glands as possible, when the growth of the breast is adherent to the pectoralis major. As far as the inter-pectoral glands are concerned, Rotter has several times observed their infection.

LYMPHATICS OF THE INTERCOSTAL MUSCLES.—We must distinguish between the lymphatics of the internal and those of the external intercostal muscles. These two groups differ, in fact, not only in their origin, but also in their course and termination (Sappey).

The lymphatics which spring from the *internal intercostals* give origin to obliquely ascending branches, which pass into a trunk which runs along the lower border of the supra-jacent rib, travelling in the sub-pleural cellular tissue. There is a trunk for each intercostal space. They all run forwards. The trunks from the six or eight upper spaces terminate singly in the glands of the internal mammary chain or in the lymphatics uniting these glands. The trunks of the lower spaces usually fuse into a single trunk which reaches the lower portion of the mammary chain. The internal intercostal lymphatics receive the lymphatics of the parietal pleura.

The lymphatics which spring from the *external intercostal muscles* are much more developed than the preceding (Sappey). They give rise to trunks which run backwards, accompanying the vessels and nerves in the space. These trunks terminate in the *posterior intercostal glands*. We have observed that they frequently present in their course small glandular nodules, variable in number and arrangement, which we have termed the *lateral intercostal glands*. The external intercostal lymphatics receive some small branches which accompany the perforating branches of the intercostal

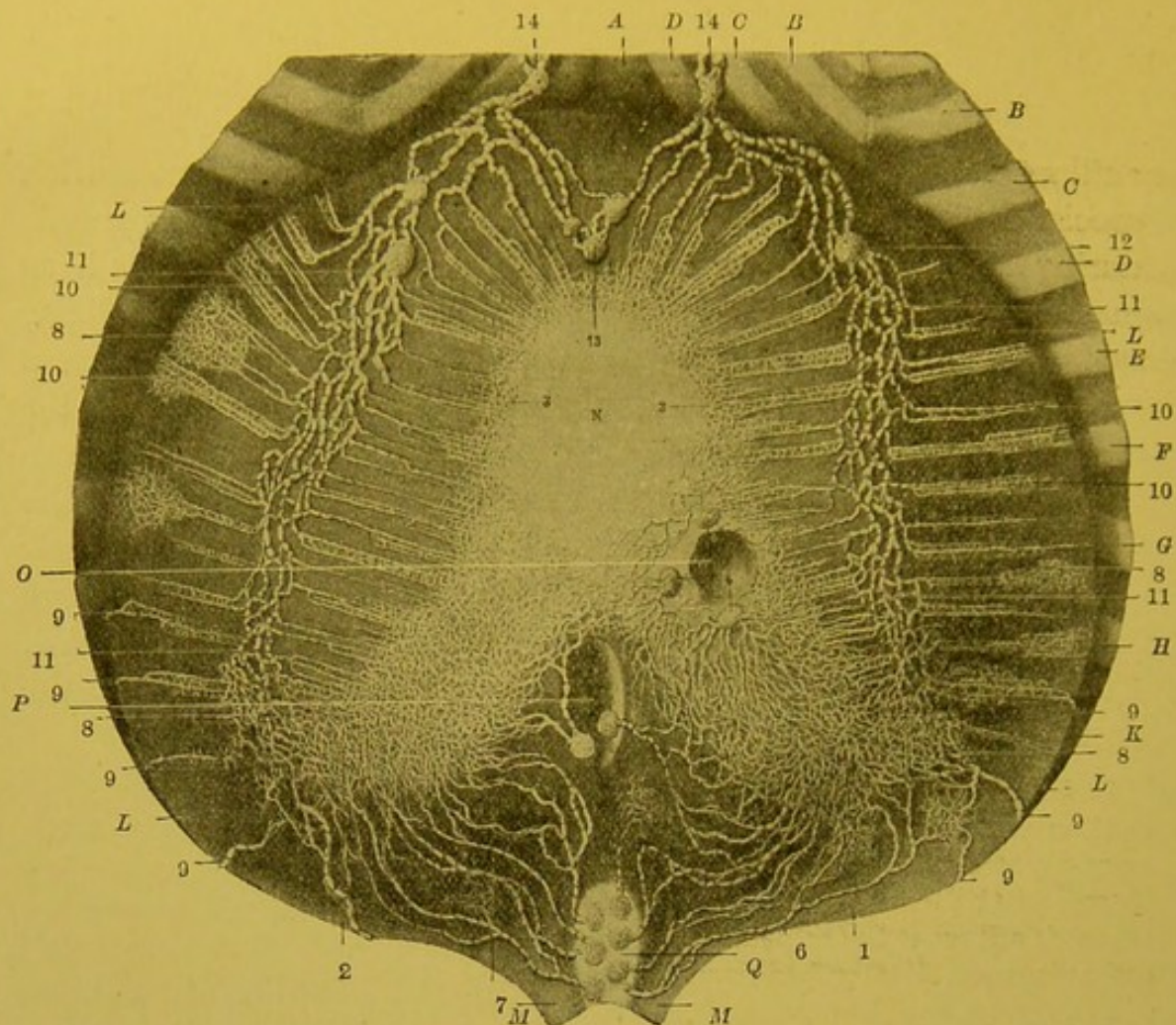


FIG. 84.—Lymphatics of the superior surface of the diaphragm (Sappey).

A. Xiphoid cartilage. B, B. Fifth rib. C, C. Sixth rib. D, D. Seventh rib. E, E. Eighth rib. F, F. Ninth rib. G, G. Tenth rib. H, H. Eleventh rib. K, K. Twelfth rib. L, L, L, L. Right and left halves of the muscular portion of the diaphragm. M, M. Pillars of the diaphragm. N. Central aponeurotic portion of the diaphragm with its three leaflets. O. Oesophageal opening. P. Opening for inferior vena cava, round which may be seen three and sometimes four glands. Q. Aortic orifice: the aorta has been removed; the glands which lie on its anterior portion only have been kept.

1. Lymphatic network of the right leaflet of the central portion of the diaphragm. 2. Network of the left leaflet. 3, 3. Network situated on the edge of the anterior leaflet; this leaflet being hidden in man by the pericardium which is closely adherent to it, its lymphatic network can only be injected from the opposite surface. In the human subject it can only be shown with great difficulty, but in mammals it can be injected with ease. 4, 4, 4. Glands in which some of the small trunks coming from the central portion of the diaphragm end. 5, 5. Two glands situated over the course of the oesophagus, immediately above the oesophageal opening; they receive the vessels which come from the inner portions of the right and left leaflets. 6. Lymphatic trunks which arise from the posterior portion of the right leaflet and right pillar of the diaphragm; these trunks, three or four in number, terminate in the prae-aortic glands. 7, 7. Lymphatic trunks which come from the posterior portion of the left leaflet and left pillar; they pass to the same glands as the preceding. 8, 8, 8. Lymphatic networks with close and superposed meshes, which cover the fleshy portion of the diaphragm. 9, 9, 9, 9, 9, 9, 9. Lymphatic trunks which arise from a network on the convex part of the fleshy portion of the muscle, and which then pass towards the lower intercostal spaces and end in the aortic glands. 10, 10, 10, 10. Other smaller networks which run parallel to the muscles which they surround; all of them converge, some running from without inwards, others from within outwards, and terminate in a small trunk which ends in the plexus of collecting trunks. 11, 11, 11, 11. Plexus of collecting trunks which extends from behind forwards and terminates in a large gland situated on the cartilages of the sixth and seventh ribs. 12. Gland in which the plexus of the collecting trunks terminates: this gland is single on the right and double on the left side. 13. Three small glands, situated in front of the pericardium, and to some extent hidden in the surrounding fat; they receive some lymphatic trunks which traverse first, the suspensory ligament of the liver, and then the fleshy portion of the diaphragm. From these glands run several trunks which pass into the glands on the right and left of the xiphoid cartilage, over the course of the internal mammary vessels. 14, 14. Glands in which the preceding vessels terminate, and which are continuous with the plexus of the collecting trunks.

arteries and which come from the muscles attached to the external surface of the thorax ; but as we have seen, these muscles send the majority of their lymphatics into the axillary glands.

The internal and external intercostal lymphatics anastomose with one another. Now, if we admit the relations which the first group bears to the lymphatic network of the pleura, and the second to the lymphatic tributaries of the glands of the axilla, it is conceivable that a lesion of the pleura may make itself felt in the latter.

Vide SOULIGOUX. Pathogénie des abcès froids du thorax. *Th. Paris*, 1894.

LYMPHATICS OF THE DIAPHRAGM.—The lymphatics of the diaphragm arise from a network of capillaries, within the interstices of the muscular fasciculi of the fleshy or tendinous fibres of the central portion of the diaphragm. From this network of origin run numerous small trunks, some of which descend and are carried towards the concave surface of the diaphragm, while others ascend and reach its convex surface. The *descending trunklets*, which are always very fine, constitute a somewhat scanty network beneath the peritoneum which it is difficult to inject, and which gives origin to trunks which ascend towards the convex surface. The *ascending trunklets*, which are much more important, come to the superior surface beneath the pleura, and arrange themselves in the following way (vide Fig. 84): In the central part of the diaphragm, they form a network with very close meshes, which is most developed on the lateral leaflets. In the fleshy portion the trunks sent out from the network of origin run parallel to the muscular fasciculi, and converge like the feathers of a quill towards the middle portion of the fleshy part. Here they empty themselves into the most important of the groups of collectors which we are now about to describe, viz. the anterior group.

The collecting trunks which carry on the lymphatic circulation of the diaphragm are all situated upon the convex surface of the latter. We may with Sappey divide them into three groups, viz. anterior, middle and posterior.

1. *The anterior collecting trunks* appear at the extremity of the lateral leaflets. They vary in number from 3 to 6. Anastomosing with each other, they form a kind of plexus with coarse meshes, the plexus of the collecting trunks (Sappey). These trunks run forwards, crossing the fleshy fibres in their central portion. In their course, they collect together all the interfascicular little trunks which implant themselves perpendicularly upon them. They thus come

to the anterior portion of the diaphragm and terminate in one or two glands placed opposite the outer end of the seventh costal cartilage. We have described these glands as the lateral glands of the anterior diaphragmatic group. In this connexion we should remember that the median glands of the same group receive no afferents from the diaphragm.

2. *The posterior collecting trunks* arise from a network which hides the lateral leaflets. From 4 to 6 in number on either side, they run downwards, backwards and inwards and terminate in the glands surrounding the aorta just as this vessel is leaving the thorax to enter the abdomen.

3. *The middle collecting trunks*, which spring from the middle part of the central part of the diaphragm, have a threefold termination. Some pass into the peri-oesophageal glands; others into the glands which surround the inferior vena cava; others, finally, end in the glands situated to the left of the pericardium. This inconstant group of glands is not represented in Fig. 84.

The lymphatics of the diaphragm anastomose with those of the peritoneum and with those of the pleura. The discussions raised as to the existence of communications between the lymphatics of the diaphragm and the peritoneal cavity are well known. We will not here dwell on this point which has been fully treated elsewhere (vide General Considerations, p. 75, and Peritoneum, vol. iv. p. 1062¹).

§ 2. VISCERAL LYMPHATIC VESSELS.

LYMPHATICS OF THE HEART.—The heart is the only part of the circulatory apparatus which contains lymphatic vessels. As we have seen when studying the structure of the heart (vide p. 603¹), the lymphatics of this organ belong exclusively to the myocardium. They are, moreover, placed at the peripheral part of the cardiac muscle, and are not to be found in its substance. They thus constitute two networks, one, deep and sub-endocardiac, and the other, superficial and sub-pericardiac.

It has never been found possible to inject the deep network, in man; its collecting trunks empty themselves into those of the superficial network, the meshes of which cover the whole of the external surface of the heart; but it is much more developed on the ventricles than on the auricles. On the latter, Sappey was unable to demonstrate the superficial network except in the case of the ox and horse.

¹ *Treatise of Human Anatomy.* Poirier and Charpy.

The collecting trunks of the sub-pericardiac network have an arrangement which, in the main, is similar to that of the coronary arteries. Thus we may divide them into the left or anterior and the right or posterior.

1. *The left or anterior collecting trunks*, which at first number two or more rarely three, appear on the anterior surface of the heart near its apex. They ascend, running parallel to the anterior interventricular furrow and, having arrived at the auriculo-ventricular groove, unite to form a single trunk which runs between the left auricle and the pulmonary artery. This trunk then passes on to the posterior surface of this large vessel, perforates the fibrous layer of the pericardium and terminates in one of the glands of the intertracheo-bronchial group.

In their interventricular course, these left or anterior coronary collectors receive several branches coming from the anterior surface of the two ventricles. In the interventricular furrow, they receive a large affluent, viz. the left auriculo-ventricular collector. This is of much more importance than the corresponding artery, and takes origin from the diaphragmatic surface of the heart, near the apex, enters the inferior inter-ventricular furrow, then turns round the left half of the auriculo-ventricular groove, and finally joins the anterior collectors. It drains the sub-pericardiac network of the inferior left surface of the left ventricle, and the corresponding network of the left auricle.

2. *The right or posterior collecting trunk* appears on the diaphragmatic surface near the apex; it then runs along the inferior interventricular groove, then along the right portion of the auriculo-ventricular groove and thus comes to the anterior surface of the heart. It then ascends between the pulmonary artery and the aorta, and terminates, like the common trunk of the left collectors, in one of the intertracheo-bronchial glands. It receives the lymphatics of the right auricle, and posterior surface and right border of the right ventricle. We have seen that the anterior portion of the sub-pericardiac network of the right ventricle was a tributary of the left or anterior collecting trunks.

LYMPHATICS OF THE LUNG.—The *origin* of the lymphatics of the lung will be studied further on together with the structure of that organ (vide vol. iv. p. 529¹). Here we need only remember that these vessels arise: (1) from perilobular networks, which in certain animals such as the ox are arranged in the form of sacs which are

¹ *Treatise of Human Anatomy.* Poirier and Charpy.

more or less divided off ; (2) from networks, which are attached to the bronchial divisions ; these networks are two in number (one submucous, the other peribronchial) in the large, but are a single in the small bronchi. According to Miller, this network extends to the alveolar passages.

From these networks of origin run two kinds of collectors, which after Cruikshank and Mascagni, we may divide into superficial and deep, this classification being based on the course they pursue to reach the hilum of the lung.

1. THE SUPERFICIAL COLLECTING TRUNKS arise from the sub-pleural lobules. At their origin they take the form of a plexus of which each mesh is polygonal in shape, and corresponds with the base of a sub-pleural lobule. Their ultimate course varies for each lobe. It has been perfectly described by Sappey, whose description we can only summarize.

In the upper lobe, they arise on the costal surface of the lobe and divide into three groups, one of which turns round the posterior border of the lung, the other the anterior border, while the third penetrates into the interlobar fissure to run on the inferior surface of the lobe : they thus reach the hilum and terminate in the glands placed there.

On the lower lobe, the superficial trunks are also divided into three groups. The superior trunks penetrate into the interlobular fissure ; the posterior and anterior trunks turn round the corresponding border of the lung and reach the internal surface on which they mount obliquely towards the hilum.

The trunks which spring from the middle lobe of the right lung are much less important than those of the superior and inferior lobes. Some unite with the trunks of the superior, others with the collecting trunks of the inferior lobe which run in the fissures.

2. THE DEEP COLLECTING TRUNKS run, some by the side of the bronchial ramifications, others along branches of the pulmonary artery, or the pulmonary veins (Miller). All run towards the hilum, where they terminate in the tracheo-bronchial glands, for the description of which we must refer the reader to the preceding paragraph.

It is generally admitted that the superficial communicate largely with the deep collectors, and that on puncturing the former the latter are readily injected. According to Miller, anastomoses between these two systems of collecting trunks are, on the contrary, very rare ; this author maintains that when after injecting the super-

ficial vessels, the deep vessels become filled, the passage of the injected material from the former into the latter is the consequence of the blending of these two systems of vessels at their termination in the glands of the hilum.

Lymphatics of the Pleura.—As we shall see later on, the existence of pleural lymphatics is now a well established fact. The lymphatics of the visceral layer empty themselves into the superficial collecting trunks of the lung. The lymphatics of the parietal layer terminate in the intercostal trunks for the costal pleura, in the diaphragmatic trunks for the diaphragmatic visceral pleura, in the glands of the posterior mediastinum for the mediastinal pleura. When adhesions exist between the two layers, the lymphatics of the visceral pleura may, by means of newly-formed lymphatics contained in these adhesions, communicate with the lymphatics of the thoracic wall.

TECHNIQUE.—The injection of the superficial lymphatics is fairly easy, whether mercury or Gerota's method is employed. It is facilitated by moderately insufflating the lungs and by the previous injection of the blood vessels.

Miller recommends the following process for injecting the deep lymphatics. A dog is fed for several days on a diet containing a great quantity of fat. It is then killed by chloroform. The heart and lungs are removed *en masse*, and the latter are moderately insufflated. One of the subpleural trunks near the hilum is then sought for, which with a little practice can be found without much difficulty. A direct puncture is then made into it with a fine canula, and a saturated aqueous solution of soluble Prussian blue is injected; the mass passes as far as the glands, then flows back into the deep lymphatics. In spite of the presence of valves we may obtain an almost complete injection of these vessels provided we employ a low pressure, and make the injection very slowly. For this purpose it will be useful to have an apparatus in which a continuous pressure can be maintained. The pressure employed should vary between 10 and 15 mm. of mercury.

HISTORICAL.—The lymphatics of the lungs have been made the subject of many works. They were noticed for the first time by Rudbeck (1654). Willis gave a detailed description of them some time afterwards; he described them in the dog, and demonstrated them by tying the thoracic duct at its termination (1675): but we must turn to Cruikshank and Mascagni to find a sufficiently exact description of these vessels in man (1780). Since then, Sappey has undertaken the study of the pulmonary lymphatics and definitely established their macroscopic arrangement. Latterly, the study of these vessels has been undertaken from the microscopic point of view. Grancher, Renaut and Pierret, Wywodzoff, Sikorsky, Klein, v. Wittich, and Hoffmann have studied the lymphatics of the lung and pleura from the histological point of view. We shall here confine ourselves to merely describing the gross anatomical appearances, and for the histological works would refer the reader to the bibliographical index of the article Lung (vide vol. iv. p. 546¹), and to a recent work by Miller in which the more important of these works are summarized.

¹ *Treatise of Human Anatomy*, Poirier and Charpy.

MASCAGNI, loc. cit., p. 53 et tab. XX.—SAPPEY, loc. cit., p. 113 et pl. XLII Fig. 1, 2, 3, 4.—MILLER, Das Lungenläppchen, seine Blut-u. Lymphgefäße. *Arch. f. Anat. u. Phys., Anat.*, 1900, p. 197.

LYMPHATICS OF THE THORACIC PORTION OF THE TRACHEA.—The lymphatics of the thoracic portion of the trachea arise from a sub-mucous network, which is richer than the corresponding network of the cervical portion of this organ. From this network run many trunks which perforate the wall of the trachea at the junction of its cartilaginous and membranous portions, and terminate in the right and left peritracheo-bronchial and intertracheo-bronchial glands.

LYMPHATICS OF THE THORACIC PORTION OF THE OESOPHAGUS.—The lymphatics of the intra-thoracic portion of the oesophagus arise from two networks, one sub-mucous, and the other intramuscular. From this network several collectors arise which empty themselves into the peri-oesophageal glands which we have described above (vide p. 215).

LYMPHATICS OF THE THYMUS.—The origin of the lymphatics of the thymus will be studied together with the structure of that organ (vide vol. iv. p. 565¹). We need now only call to mind the fact that these lymphatics arise within the lobules of the thymus from the peri- and interfollicular sinuses. They terminate in collecting trunks, which run in the interfollicular septa. Our knowledge of the terminal glands of the trunks which carry on the lymphatic circulation of the thymus is still imperfect. It is generally admitted, however, that these vessels end in the supra-aortic and praetracheo-bronchial glands and in the glands of the internal mammary chain.

¹ *Treatise of Human Anatomy.* Poirier and Charpy.

CHAPTER IV

LYMPHATICS OF THE UPPER LIMB

LIKE the lymphatics of the lower limb, the absorbent vessels of the upper limb may be divided into two groups. One, the *superficial lymphatics*, run in the subcutaneous cellular tissue. The other, the *deep lymphatics*, run under the deep fascia, and are satellites of the vessels and nerves. All finally converge towards the glands of the axilla, after presenting in their course glands which are very variable both in number and arrangement.

We will first indicate the arrangement of the glands in connexion with the lymphatic vessels of the upper limb, and then study these vessels themselves.

§ 1. LYMPHATIC GLANDS OF THE UPPER LIMB.

The glands connected with the lymphatic apparatus of the upper limb are situated principally in the axillary cavity at the root of the limb. These axillary glands form the common meeting-place of all the superficial and deep lymphatics of the upper limb, in the same way as the inguinal glands, their homologues of the lower limb, carry on all the lymphatic circulation of the latter.

But, in addition to these axillary glands, we meet with isolated or agminated glands scattered in small groups throughout the whole extent of the upper limb, whose signification is absolutely different. We must regard them as simple interrupting glandular nodules placed in the course of the different collecting trunks. It is important, however, to notice that some of these glands tend to acquire, by their frequency, size, and relatively constant position, the significance of regional glands. We here again find, as in other parts of the system, this tendency of central glands to extend towards the periphery, but it would seem that in the case of the upper limb this evolution is less advanced than in the case of the lower limb.

These interrupting glandular nodules, or, if we prefer to call them so, these aberrant glands, are placed, some in the subcutaneous

cellular tissue (*superficial glands*), others under the deep fascia (*deep glands*).

1. SUPERFICIAL GLANDS.—The superficial glands have two seats of election, viz. the supra-epitrochlear region and the groove between the deltoid and pectoralis major.

(a) *The supra-epitrochlear gland* is usually single, but we may meet with two or even three in this situation. The supra-epitrochlear gland is usually placed three or four centimetres above the epitrochlea. It lies immediately upon the deep fascia, and is therefore covered by the whole thickness of the subcutaneous adipose tissue. Thus, unless this gland is hypertrophied, it is difficult to detect it by palpation.

The supra-epitrochlear gland receives as *afferent vessels*, some of the superficial collectors which run along the ulnar border of the forearm, and which drain the three inner fingers and inner portion of the hand. But we must observe that, on account of the many anastomoses by which the different antibrachial collecting trunks are united, this gland may be affected by lesions situated at the external part of the forearm and hand.

The *efferent vessels* of this gland at first accompany the basilic vein, beneath which they run. In the middle part of the arm they pierce the deep fascia, together with the vein, and unite with the deep lymphatics, the satellites of the brachial vessels.

(b) *In the groove between the deltoid and the pectoral* we may meet with one, two, and sometimes three glands. These, which were pointed out by Aubry, are always very small. They are simple interrupting nodules placed in the course of the interdelto-pectoral collecting trunk, which we shall describe further on. According to Grossmann, these glands are present in 14 out of every 100 cases.

2. DEEP GLANDS.—Some small glands may be met with in the course of the deep lymphatics. They have been noticed along the radial, ulnar and interosseous arteries, but the only ones which appear with any constancy are those which are met with in the course of the brachial artery, where there are two to three small glands usually placed in the centre of the arm.

These deep glands were a long time ago figured by Mascagni (*loc. cit.*, plate xxv., Figs. 2 and 3) and have since been described and figured by Meckel, Michel, Dubois (*Soc. Anat.*, 1850), Bourguery (*loc. cit.*, plate 64, Fig. 1), Leaf (*loc. cit.*, p. 45, Fig. 10).

AXILLARY GLANDS.—The axillary glands constitute a very important glandular centre, for they receive not only the whole of

the absorbent vessels of the upper limb, but also the lymphatics from the skin of all the upper part of the trunk, as well as those from the subjacent muscles.

The *number* of axillary glands varies from twelve to thirty-six. According to Grossmann, there are usually more on the right than on the left side (?).

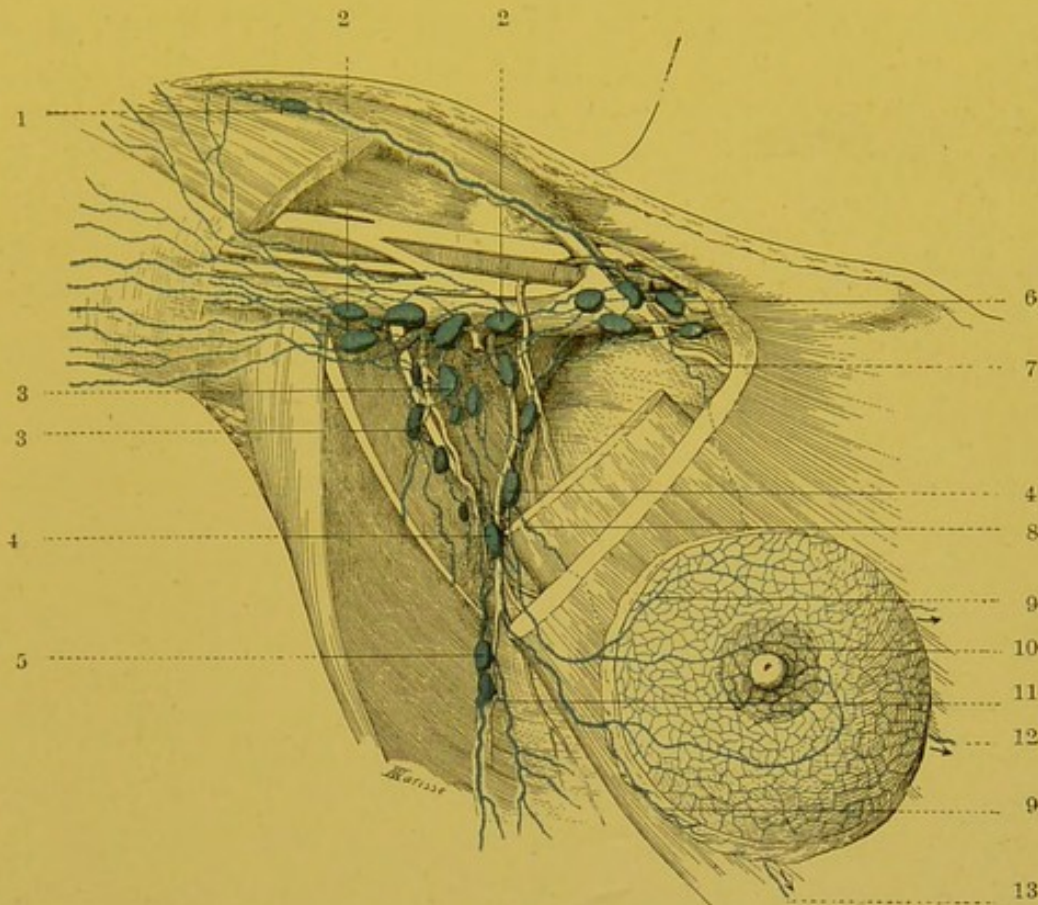


FIG. 85.—Lymphatics of the breast and axillary glands (semi-diagrammatic).

1. Delto-pectoral gland. 2, 2. Glands of the humeral chain. 3, 3. Glands of the central group and the scapular chain. 4, 4. Glands of the thoracic chain (supero-internal group). 5. Gland of the thoracic chain (infero-external group). 6. Subclavian glands. 7. Mammary lymphatic ending in the subclavian glands (inconstant). 8, 9. Mammary collecting trunks, ending in glands of the thoracic chain. 10. Sub-areolar plexus. 11. Cutaneous collecting trunk of the lateral walls of the thorax. 12, 13. Mammary collecting trunks about to end in the internal mammary glands.

The *topography* of the axillary glands has given rise to numerous discussions, and has originated a large number of works, amongst which we may mention those of Kirmisson, Poirier, Leaf, Oelsner, etc. We have recently studied these glands in some twenty specimens, after injecting their principal afferents by Gerota's method.

The general arrangement of axillary glands may be summarized as follows: the majority of these glands are sub-fascial; they are arranged in several chains, are attached to the different walls

of the axillary cavity, towards the summit of which they converge. The description of the relations between the axillary glands and the different layers of fascia varies according to the view we take of the arrangement of these fasciae. Denying the existence of a fascia¹ which closed in the lower part of the axillary cavity, one of the present writers admitted that some of the axillary glands were subcutaneous. Later researches have partially modified this view. With Langer, we admit the presence in the axilla of a fascia, which has, it is true, in its centre a large orifice bounded by the "armbogen" and the "achselbogen" (vide² vol. ii. part i., p. 164, and Figs. 126, 127, and 128). This being so, it is indisputable that the axillary glands are covered by this fascia; but even though some of them protrude through the central orifice, we should not for all that regard them as subcutaneous. On the other hand, it would be going too far to deny the possible existence of subcutaneous glands.

The "armbogen" is the inferior and outer, the "achselbogen" the superior and inner margins of an opening in the axillary fascia described by Langer (*Zur Anat. der Musc latissimus dors.* *Oester. Med. Woch.*, 1846, Nos. 15 and 16), and by Poirier (*Progres Medical*, 1888, pp. 68-71).

The axillary glands are embedded in the cellulo-adipose tissue which fills in the axilla. We may classify them as follows: At the base of the armpit they form three distinct chains. One of these chains (*the humeral chain*) is attached to the external wall of the axilla, and follows the principal vessels and nerves. A second chain (*the thoracic chain*) accompanies the external mammary artery as it runs on the internal wall. A third chain (*the scapular chain*), a satellite of the subscapular artery, is attached to the posterior wall of the axilla. Between these three chains a group of glands is found which, with Grossmann and Oelsner, we will term the *central group*. The scapular chain empties itself into the humeral chain, and the latter blends with the thoracic chain to form the *sub-clavicular group*, which occupies the summit of the axillary pyramid (vide Figs. 85 and 86).

1. The *humeral chain* comprises four to five glands, which are attached to the inner surface of the principal vessels and nerves. These glands are more particularly in relation with the axillary

¹ I denied the presence of the fascia at the base of the armpit, as it was then described, because the armpit which is a hollow pyramid, *has no base*. There as everywhere, the fasciae follow the muscular planes, and when a bundle of vessels and nerves is met with they divide and enclose them in a sheath: in this respect the axilla does not differ from the inguinal region.

² *Treatise of Human Anatomy*. Poirier and Charpy.

vein, behind which some of them sometimes insinuate themselves, and become inserted between this vessel and the subscapularis.

2. The *thoracic chain* is usually formed by two distinct masses. From their relative situation, we may divide them into supero-internal and ^{infero}supero-external. The *supero-internal mass* comprises two to three glands placed in the second or third intercostal space, in front of the trunk of the external mammary artery. These glands are hidden by the lower border of the pectoralis major if this muscle is well developed, but lie beneath its lower border in poorly developed subjects. This glandular mass corresponds to the *superficial thoracic glands* of Grossmann, and to the *anterior thoracic lymph glands* of Oelsner. It is also sometimes called the group of Sorgius. The *infero-external mass* comprises 2 to 3 glands placed behind or in the course of the external mammary vessels in the fourth and fifth intercostal spaces (the *deep thoracic glands*, Grossmann; the *inferior thoracic lymph glands*, Oelsner).

3. The *scapular chain* comprises 6 to 7 glands, which are ranged one above the other along the dorsalis scapulae artery, in the groove which separates the teres major from the subscapularis. In this chain we may include 2 or 3 little glands which are almost constantly found on the dorsal surface of the scapula near its inferior angle in the groove which separates the teres major from the teres minor (Oelsner).

4. The *central group* (intermediate glands, Grossmann, Oelsner) comprises 3 to 5 glands, placed between the preceding chains, to which they are united by several anastomoses. These glands are embedded in the cellulo-adipose tissue near the base of the axilla, and sometimes protrude through the foramen of Langer (orifice in axillary fascia).

5. The ^{subclavicular}subscapular group comprises 6 to 12 glands placed above the upper border of the pectoralis minor. The majority of these glands are situated internal to the axillary vein, between this vessel and the first digitation of the serratus magnus. We almost always find one of these glands lying in front of the vein, at the spot where it is joined by the cephalic; it is more rare to find them placed external to the vessels, in front of the roots of the brachial plexus.

The subclavian group is continuous below without any clear line of demarcation with the other groups of the axilla, and we cannot too forcibly insist on the extremely arbitrary character of this subdivision of the axillary glands into several groups. The group which we have just described under the name of sub-clavicular glands, contains according to Grossmann, two

secondary masses, viz. the infra-clavicular and the subpectoral glands. It does not appear to us that this distinction made by Grossmann (whose description moreover is most obscure) can be justified by the arrangement of the glands in question.

AFFERENT VESSELS.—Each glandular group of the axilla receives different afferents.

In the *humeral glands* terminate almost all the superficial and deep lymphatics of the upper limb. We have seen, in fact, that it is only the most external of the collecting trunks of the arm which runs up in the delto-pectoral groove and terminates directly in a subclavian, or more rarely a supraclavian gland. Again, it is important to observe that, according to Grossmann, this vessel only exists in 38 out of every 100 cases.

The *thoracic glands* receive the cutaneous lymphatics of the anterior and lateral parts of the thorax, the lymphatics of the subjacent muscles, and the lymphatics of the breast. The anterior cutaneous and the mammary lymphatics more particularly end in the supero-internal group; the absorbent vessels of the lateral wall of the thorax in the infero-external group.

The *glands of the scapular chain* receive the lymphatics of the integuments of the lower part of the neck, of the entire dorsal and posterior surfaces of the scapular region. They also receive the absorbents of the subjacent muscles (vide Fig. 81).

The *central glands* do not really receive any afferents coming directly from lymphatic territories, which are tributaries of the axillary glands. On the contrary, we shall presently see that they form the terminus for the majority of the efferents of the preceding groups.

The same remark applies to the *subclavian glands*. They receive as direct afferents hardly any but the satellite trunk of the cephalic vein and some collectors of small size which accompany the thoracic branch of the acromio-thoracic artery and which come from the great pectoral and possibly from the mammary gland (Grossmann, Rotter, vide p. 222). As a compensation, however, they receive almost all the efferent vessels of the other axillary glands.

This description of the afferent vessels of the different glandular groups is necessarily dogmatic. It is not rare to see a vessel, no matter from which of the lymphatic territories it may spring, end in a glandular group other than that which represents the usual terminus of the collectors of the territory in question; thus Nagel has seen one of the trunks coming from the subareolar plexus send a branch to a humeral gland before terminating in the supero-internal thoracic glands. Similarly, Grossmann and Rieffel have seen a mammary collector directly reach a subclavian gland. We may also

see a humeral or scapular collecting trunk terminate in a gland of the thoracic chain. It would be easy to multiply examples. It is none the less true that the classification we have given of the afferents of the axillary glands applies to the great majority of cases; and with the reservation that it may be subject to a certain number of exceptions, there is, in our opinion, an advantage in retaining it.

EFFERENT VESSELS.—The efferent vessels of the axillary glands are somewhat complex, and we may classify them as follows (vide Fig. 86)—

The efferents of the *humeral group* have a threefold termination; some pass into the central group; others into the subclavian glands; and others ascend into the region above the clavicle and terminate in one of the glands situated there. This latter mode of termination is, according to Oelsner, the most important and the most constant.

Abnormally we may see one of the efferent vessels of a gland of the humeral group perforate the anterior wall of the axilla from behind forwards, at the apex of the axilla, then cross the clavicle and end in a supra-clavicular gland (Grossmann).

The efferents of the *thoracic chain* end in the glands of the central group. Almost always, however, certain efferents which come from the supero-internal mass, directly reach the subclavian glands running either in front of or behind the pectoralis minor. In the latter case we may find little glandular nodules lying on the course of these vessels (Grossmann). The efferents of the glands of the *scapular chain* empty themselves into the humeral and central glands.

These *central glands* send their efferents into the subclavian glands; thus, in these subclavian glands nearly all the efferents of the four glandular groups of the axilla finally terminate.

The *subclavian glands* give rise to numerous efferents which by their anastomoses form a plexus (*infraclavicular plexus*). They soon resolve themselves into a single trunk, the *subclavian trunk*,

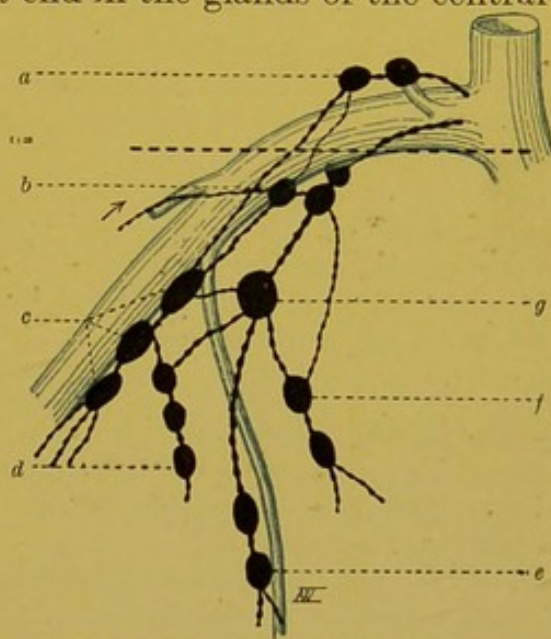


FIG. 86.—Scheme of the axillary glands.

a. Supra-clavicular glands. b. Subclavian glands. c. Humeral chain. d. Scapular chain. e. Infero-external portion of the thoracic chain. f. Supero-internal portion of the thoracic chain. g. Central group. The dark dotted line indicates the situation of the clavicle.

which runs in front of the subclavian vein, between the latter and the subclavius muscle, and terminates at the summit of the angle which the subclavian vein forms by its junction with the external jugular.

The arrangement of this subclavian trunk which carries on the lymphatic circulation of the upper limb is subject to variation. Most usually, this trunk ends by itself as we have just pointed out, in the junction of the internal jugular and subclavian veins. On the left, it may terminate in the thoracic duct; Grossmann has met with this arrangement twice in twenty-five subjects, but in these two cases the subclavian trunk was double, and only one of the two secondary trunks emptied its contents into the thoracic duct. It is still more rare to see the subclavian trunk unite with the jugular trunk before ending in the junction of internal jugular and subclavian. Grossmann has only met with this arrangement once in twenty-five subjects, and in this case, too, the subclavian trunk was double, and the larger of the two secondary trunks opened directly into the junction of the internal jugular and subclavian. The existence of a trunk common to the lymphatics of the right upper limb and corresponding side of the neck is therefore an exceptional arrangement, and the right lymphatic duct is most usually absent. However, we shall return to this point when we study the terminal collecting trunks of the lymphatic system (vide p. 291).

We have seen that the subclavian trunk usually ends at the apex of the angle formed by the junction of the subclavian and the external jugular veins. According to Grossmann, this arrangement is met with in 40 out of 100 cases. Fairly frequently (in 36 out of 100 cases), this trunk terminates on the anterior wall of the subclavian vein. In 10 out of 100 cases, it ends in the upper border of this vessel, about a centimetre from the venous angle. In 6 out of 100 cases, the subclavian trunk ends in the posterior wall of the subclavian vein.

Nearly always one or more of the efferents of the subclavian glands pass into one of the glands of the subclavian triangle. We may even see one of these vessels reach these glands by passing in front of the clavicle (Grossmann).

Sur les ganglions axillaires, voy. : KIRMISSON, Note sur la topographie des ganglions axillaires. Soc. anat., 1882, p. 453.—POIRIER, Notes anatom. sur l'aponévrose, le ligament suspenseur et les ganglions lymphatiques de l'aisselle. Progrès médical, 1888, p. 68.—GROSSMANN, Ueber die axillaren Lymphdrüsen. Th. Berlin, 1896.—LEAF, loc. cit., p. 39, fig. 8 et 9.—ÆLSNER, Anat. Unters. über der Lymphw. der Brust mit Bericht., etc. Arch. f. klin. Chir., 1901, p. 135.

§ 2. LYMPHATIC VESSELS OF THE UPPER LIMB.

As we have seen, the lymphatic vessels of the upper limb may be divided into two groups: the *superficial lymphatics*, which arise from the integuments, and whose collecting trunks run in the subcutaneous cellular tissue; and the *deep lymphatics*, which, springing from the sub-aponeurotic structures, end in the satellite trunks of the deep blood vessels.

SUPERFICIAL LYMPHATICS.—The superficial lymphatics come from all parts of the cutaneous covering of the limb, but it is in the fingers and the palm of the hand that the network of origin is the richest. It is therefore at these points, and more particularly on the palmar surface of the fingers, that punctures must be made for the injection of the lymphatics of the upper limb.

The collecting trunks of the superficial network appear at the roots of the fingers and at the base of the palm of the hand. They then run upwards on the forearm and arm, receiving as they ascend the lymph from other parts of the cutaneous covering. They terminate in the glands of the axilla. We will study first their digital and palmar origin, and then their course and termination.

Origins: (A) *In the fingers*, the network of origin presents its maximum of development on the palmar surface (vide Fig. 88). Here the meshes are so closely set, that it is only by a careful examination with a lens that they can be distinguished. The dorsal network is much less rich than the preceding (vide Fig. 89). From these two networks arise a considerable number of collectors, which converge towards the sides of the fingers and unite to form 2 or 3 trunks on each of these surfaces. These trunks at first follow the corresponding collateral artery, but, having arrived at the base of the finger, they incline backward, and run towards the interdigital space. They then pass to the posterior surface of the hand, and are directed towards the wrist, where we shall trace them again shortly. In their course on the dorsal surface of the hand, they effect numerous anastomoses. They cross one another frequently, and it is no unusual thing to see a collecting trunk, which has arisen for example in the fourth interdigital space, uniting with trunks which run along the external part of the dorsal surface of the hand.

(B) *In the palm of the hand*, the network of origin is also ex-

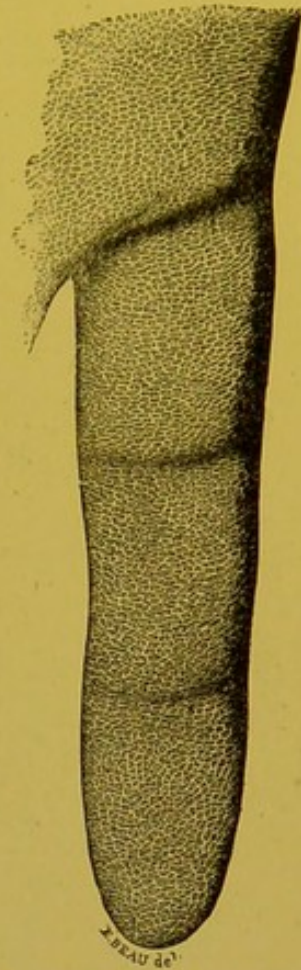


FIG. 87. — Lymphatic network of the palmar surface of the fingers (after Sappey).

This figure shows the capillaries which form the most superficial part of the lymphatic network of the fingers.

tremely rich. From this network run numerous trunklets which we may divide into external, internal, inferior, superior and central (vide Fig. 88).

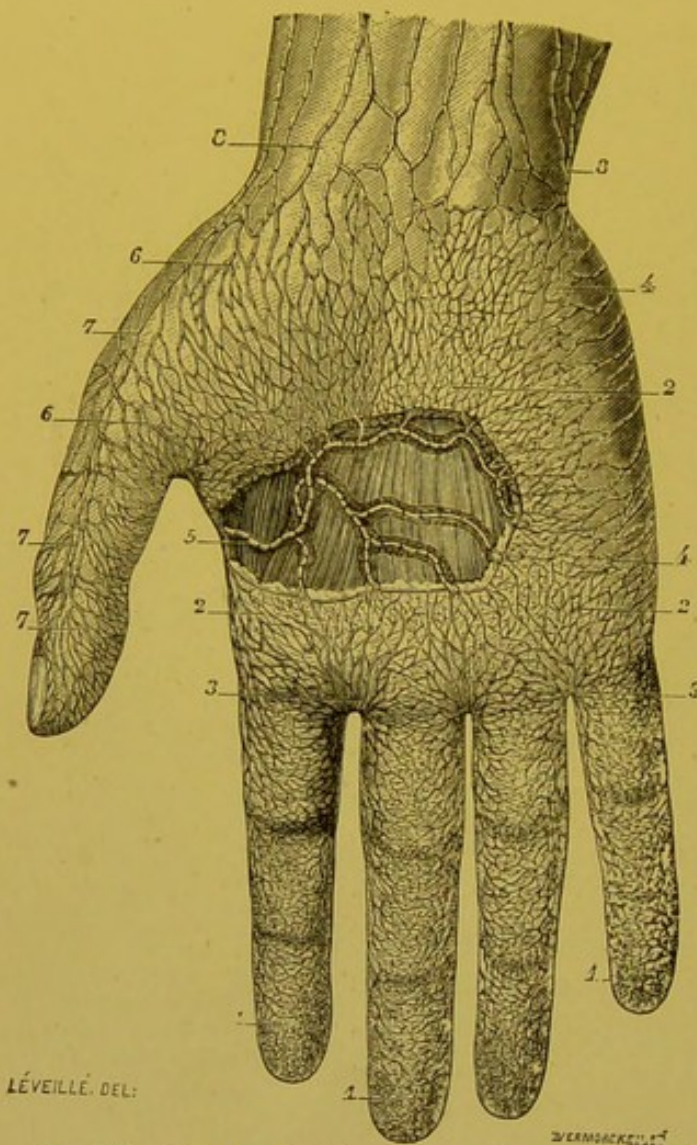


FIG. 88.—The lymphatics of the palmar surface of the hand (after Sappey).

1, 1, 1. Lymphatic branchlets of the palmar surface of the fingers. 2, 2, 2. Lymphatic branchlets of the palm of the hand. 3, 3. Small lymphatic trunks coming from the inferior part of the palmar region and converging towards the interdigital spaces to run on the dorsal surface of the metacarpus. 4, 4. Little trunks turning round the hypothenar eminence to terminate in the trunks which ramify on the dorsal surface of the fifth metacarpal. 5. Trunk which comes from the central part of the palm of the hand and is formed by six to eight trunklets. 6, 6. Little trunks coming from the thenar integuments. 7, 7, 7. Trunks in which they end. 8, 8. Smaller and larger trunks which arise from the anterior part of the wrist.

surface of the wrist, and unite to form 3 or 4 trunks, which ascend on the anterior surface of the forearm.

The external trunklets, 4 to 6 in number, run obliquely upwards and outwards, and crossing the surface of the thenar eminence in a slanting direction, terminate in the lymphatics coming from the integuments of the thumb.

The internal trunklets, more numerous than the preceding (8 or 10), run almost transversely inwards, and crossing the ulnar border of the hand, reach the dorsal surface, and empty themselves into the collecting trunks which arise from the integuments of the little finger.

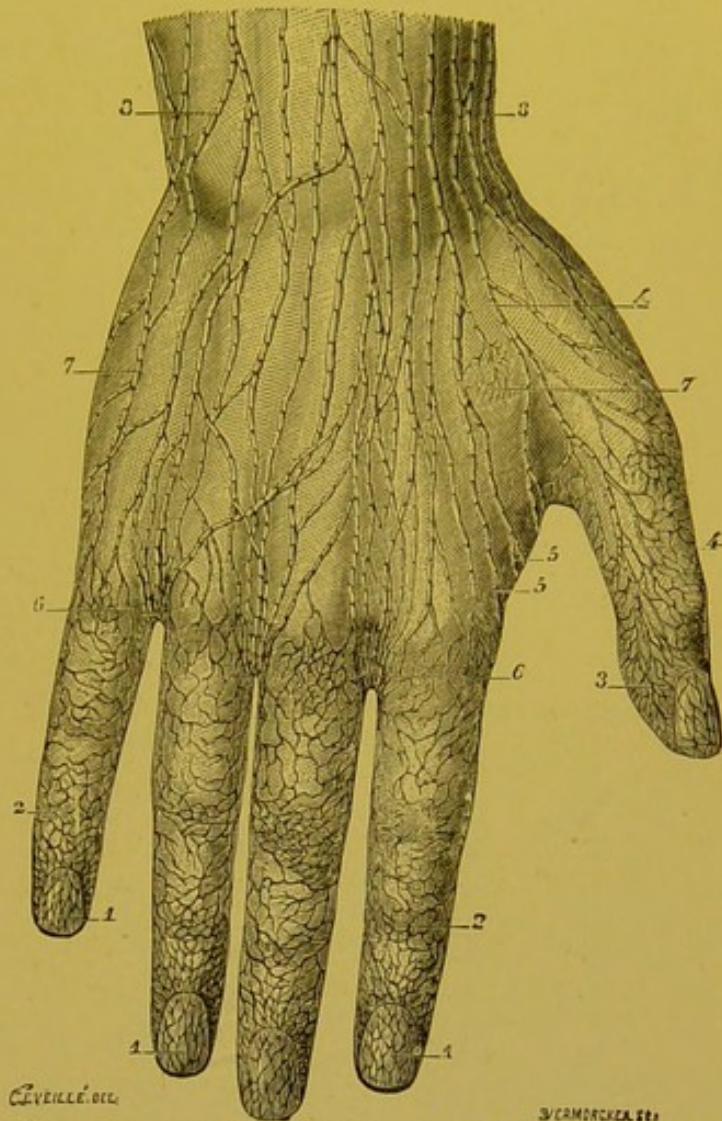
The inferior trunklets, which vary from 12 to 15 in number, are directed towards the interdigital spaces; they then reach the dorsal surface of the hand and terminate in the digital collecting trunks.

The superior trunklets reach the anterior

The *central trunklets* run towards the deep portion. They traverse the subcutaneous fatty layer and the superficial palmar fascia, and then usually unite into a single trunk. The latter, which has been well described by Sappey, takes the following course: It is directed immediately outwards, running underneath the fascia, in front of the flexor tendons. It thus comes to the adductor transversus pollicis, crosses the inferior border of this muscle, and then crosses the outer border of the first dorsal inter-osseous, on the posterior surface of which it ascends. It there joins collectors coming from the index finger and in company with the latter reaches the dorsal surface of the wrist.

COURSE: All these collecting trunks, which arise from the integuments of the fingers and hand, run in the subcutaneous cellular tissue towards the root

of the limb. They are usually more superficial than the veins whose trunks they cover. They diminish in number as they are traced upward. In the forearm there are about thirty but in the middle of the arm not more than 15 to 18 (Sappey).



G. VERILLÉ DEL.

J. CAMMACK SCULPT.

FIG. 89.—Lymphatic vessels of the dorsal surface of the hand (after Sappey).

- 1, 1, 1. Lymphatic branchlets of the subungual skin.
- 2, 2. Lymphatic branchlets arising from the dorsal surface of the fingers.
3. Truncules which run from the internal lateral surface of the thumb.
- 4, 4. Trunk formed by the union of these truncules.
- 5, 5. Truncules which come from the central part of the palm of the hand, and which, somewhat tardily, unite here to form a very large trunk.
- 6, 6. Lymphatic trunks coming from the fingers, and from the inferior part of the palmar region.
- 7, 7. Collection of trunks which run on the dorsal surface of the hand.
- 8, 8. These same trunks passing from the hand over the forearm.

In the wrist, they are divided into two groups, of which one runs on the dorsal, the other on the palmar surface of this part of the limb.

In the forearm, they tend to divide themselves into three groups, an *external group*, which ascends along the radial border of the forearm; an *internal group*, which follows the ulnar border; a *middle group*, which is a satellite of the median vein and runs between the two preceding.

A little below the bend of the elbow the two lateral groups come more and more to the anterior surface of the limb and unite with the median group: on the dorsal surface we find nothing but some rather small collecting trunks, which incline obliquely, some outwards, others inwards, and reach the anterior surface of the arm (vide Fig. 91). At the level of the olecranon these collecting trunks present remarkable sinuities.

In the arm, the different collecting trunks, henceforth united into a single bundle, show a tendency to arrange themselves on the external surface of the arm, parallel to each other.

TERMINATION: The majority of these collectors run as far as the neighbourhood of the base of the axilla. Here, they perforate the deep fascia, and terminate in the humeral chain of axillary glands. The collectors from the outermost and innermost parts have quite a different termination; thus two or three of the *most internal*

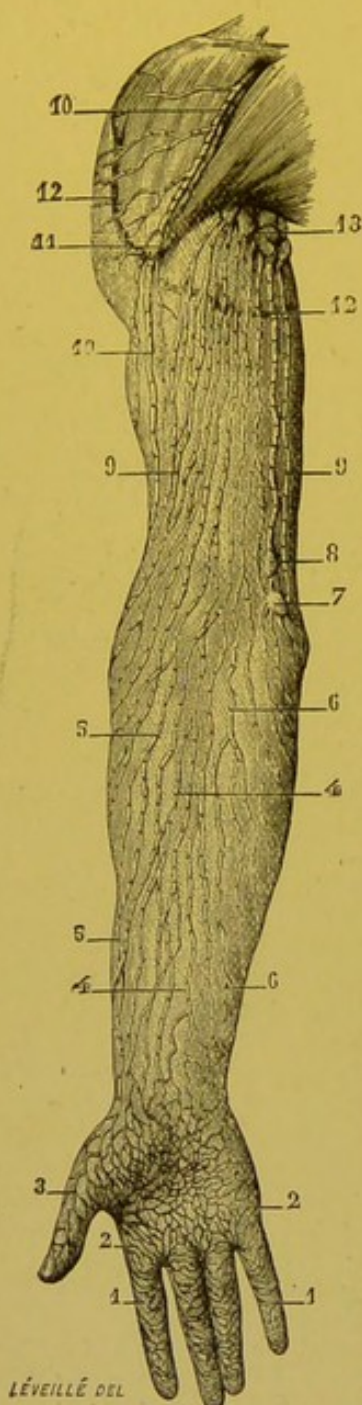


FIG 90.—Superficial lymphatics of the arm, anterior surface (after Sappey).

external part of the hand and forearm. 7. Supra-epitrochlear gland, into which some of these trunks pass. 8. Second gland which is sometimes found above the preceding. 9, 9. Collection of trunks which occupy the anterior surface of the arm. 10. Large trunk which occupies the interval between the deltoid and pectoralis major. 11. Gland situated in the course of this trunk. 12, 12. Semicircular section of integuments. 13. Axillary glands.

end in the supra-epitrochlear gland. We have already seen that the efferents of this gland perforated the deep fascia in the middle part of the arm and end in the deep vessels. When this gland is absent, we may nevertheless see the internal collectors perforating the fascia at the same point to reach the deep absorbents. The *most external trunk* is also remarkable for the special course it pursues. It separates itself from the other collectors in the region of the humeral insertion of the deltoid, then ascends in the delto-pectoral groove, where it may traverse one or several glands which we have indicated above (vide pp. 234 and 235). This trunk usually passes into a subclavian gland, placed at the spot where the cephalic joins the axillary vein. It may also be seen to pass above the clavicle, and to empty itself into a supra-clavicular gland. This arrangement, though somewhat infrequent, has been figured by Mascagni (loc. cit., tab. xix.). This delto-pectoral trunk is sometimes double and even triple.

DEEP LYMPHATICS.—The deep lymphatics follow the brachial artery and its chief branches. There are usually two lymphatic trunks for each artery. With Sappey, we will divide these deep lymphatics into radial, cubital, posterior, interosseous, anterior interosseous, and brachial.

The *radial trunks* arise from the subfascial portions of the palm of the hand. "One accompanies the deep palmar arch, turns round the head of the first metacarpal bone, and runs on the outer side of the carpus, and reaches the forearm, where it is situated on the external side of the radial artery; the

into two groups, of which one runs inwards, and the other which arise from the posterior surface of the arm. 6, 6. Vessels coming from the integuments of the shoulder.

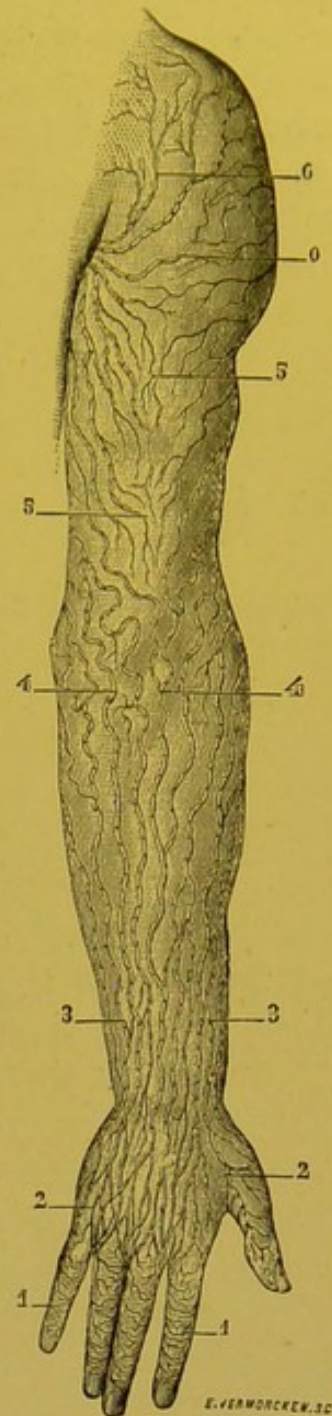


FIG. 91.—Superficial lymphatics of the upper limb (posterior surface) (Sappey).

1, 1. Lymphatic network of the dorsal surface of the fingers. 2, 2. Collection of trunks which cover the back of the hand. 3, 3. Trunks which run over the posterior surface of the forearm. 4, 4. These same trunks which, at the elbow, become extremely sinuous, divide outwards. 5, 5. Vessels which arise from the posterior surface of the arm. 6, 6. Vessels coming from the integuments of the shoulder.

other, whose origin is not so deep, follows, according to the sketch left us by Mascagni, the course of the radio-palmar artery, and also joins the forearm, where it is placed on the inner side of the radial. Both then ascend as far as the bend of the elbow, where they anastomose. In their anti-brachial course, they traverse one or two small glands, the existence of which is not constant" (Sappey).

The *ulnar trunks* are also two in number. They have a separate origin. One, in fact, appears by the side of the superficial palmar, while the other is a satellite of the deep palmar arch. They unite at the wrist, just above which they receive a large affluent which is a satellite of the dorsal branch of the ulnar. They then run parallel to the ulnar vessels as far as the bend of the elbow. During their course they sometimes present one or more small glands.

The *posterior interosseous trunks*, which arise from the deep muscles of the forearm, perforate the interosseous membrane and then unite at the bend of the elbow, with the preceding vessels.

The *anterior interosseous trunks* follow the vessels of this name, and, after presenting in their course one or two small glands, also end in the lymphatic meeting-place at the bend of the elbow.

The *humeral trunks* comprise all the above-mentioned anti-brachial collecting trunks. They vary from 2 to 3 in number. They run by the side of the humeral vessels, and terminate in the humeral group of the axillary glands. As we have already seen, they present in their course some small glands which appear to be nearly always present. In the middle part of the arm, they collect the efferent vessels from the supra-epitrochlear gland. They also receive some small trunks from the muscles of the arm (Mascagni, loc. cit., plate xxv.).

TECHNIQUE.—The method employed for the injection of the lymphatics of the upper limb is almost the same as that indicated for the lower limb (vide pp. 126 and 127). The most suitable points for the primary punctures are the palmar and lateral surfaces of the fingers.

CHAPTER V

LYMPHATICS OF THE HEAD AND NECK

WE will study in turn: (1): the glandular groups of the head and neck; (2). the lymphatic apparatus of the different organs whose vessels are tributaries of these glands.

§ 1. GLANDULAR GROUPS OF THE HEAD AND NECK.

The glandular apparatus of the head and neck presents a considerable degree of development. It is, moreover, in the cervical region that the first glands appear in the course of phylogenic development.

The general arrangement of these glands may be classified as follows: they form at first a kind of circle, a true glandular collar, placed at the junction of head and neck. From this, runs on either side a vertical chain which stretches underneath the sterno-mastoid, and accompanies the vessels and nerves as far as the junction of the neck with the thorax. This principal chain is flanked by several secondary chains of less importance.

1. PERI-CERVICAL GLANDULAR CIRCLE.

This glandular circle is divisible into a certain number of groups, which are named according to the region they occupy. Working from behind forwards we shall have to distinguish:—

1. *The sub-occipital group and the aberrant glands of the nape of the neck which hang from it.*

2. *The mastoid group.*

3. *The parotid and sub-parotid groups.*

4. *The sub-maxillary group, of which the facial glands form an offshoot.*

5. *The sub-mental glands.*

6. Finally, *the retro-pharyngeal glands*, which may be included with the preceding groups.

1. THE SUB-OCCIPITAL GLANDS.—The number of occipital

glands varies from 1 to 3. We have found 2 the most usual number. These glands, which are the size of a pea, are flattened and circular, and usually rest close to the occipital insertion of the complexus muscle, immediately external to the external border of the trapezius.

More rarely they are placed on this muscle, and in this case they are in intimate connexion with the terminal filaments of the great occipital nerve. The sub-occipital glands are always sub-aponeurotic.

One of the present writers found in several subjects, injected by Gerota's method, a gland placed on the posterior surface of the trapezius, at the level of the spinous process of the fourth cervical vertebra. This gland may be regarded as an aberrant element belonging to the sub-occipital group.

The sub-occipital glands receive their *afferent lymphatics* from the occipital portion of the hairy scalp. Their *efferent vessels* run downwards and forwards, some cours-

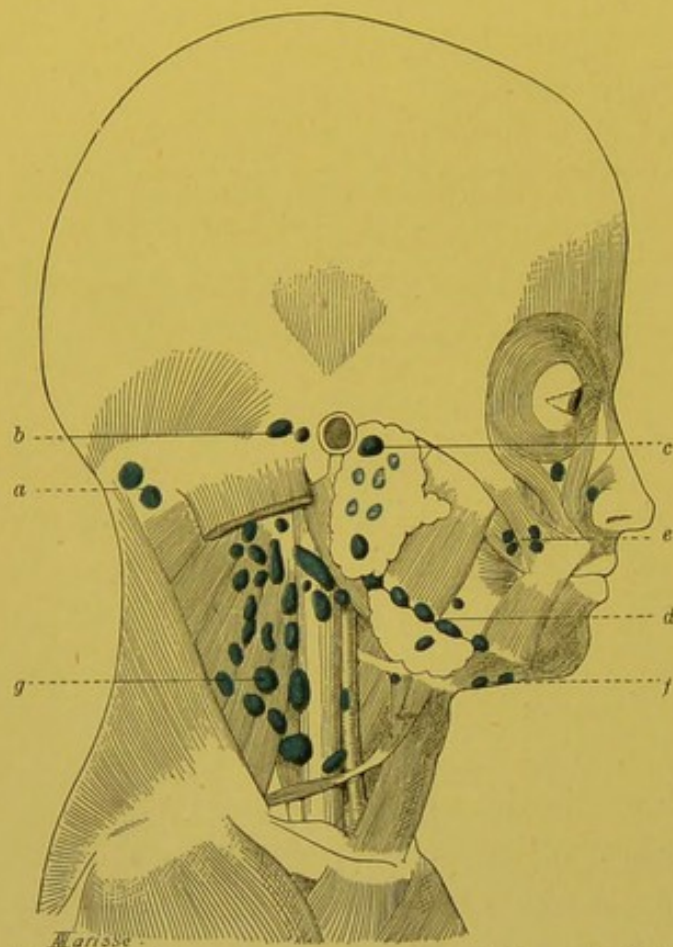


FIG. 92.—General arrangement of the glandular groups of the head and neck.

a. Occipital glands. b. Mastoid glands. c. Parotid glands. d. Submaxillary glands. e. Facial glands. f. Submental glands. g. Deep cervical chain.

ing above, and others below the splenius. They terminate in the highest glands of the substerno-mastoid group. We shall see later on that these latter also receive vessels coming directly from the occipital region.

2. MASTOID GLANDS (*Retro-auricular glands*).—The mastoid glands are usually two in number. Always clearly visible in the infant, they are often difficult to find in the adult. They are usually placed one behind the other, and are united by two or three lymphatic trunks. They are subjacent to the inferior border of the retrahens aurem, and lie on the mastoid insertion of the sterno-mastoid. A fine fibrous layer, which springs from the sheath of the sterno-mastoid, fixes them on to this muscle.

The mastoid glands receive their *afferents* from the temporal portion of the hairy scalp, from the internal surface of the auricle, with the exception of the lobule, and from the posterior surface of the external auditory meatus.

Their *efferent* trunks empty themselves into the superior glands of the sub-sterno-mastoid group, after traversing the superior insertions of this muscle. Some authors wrongly connect these deep glands with the mastoid glands, which they then reckon as being 4 or 6 in number.

3. PAROTID GLANDS.—The parotid group contains several masses, viz.

the sub-cutaneous glands, the glands contained in the parotid space, and the sub-parotid glands.

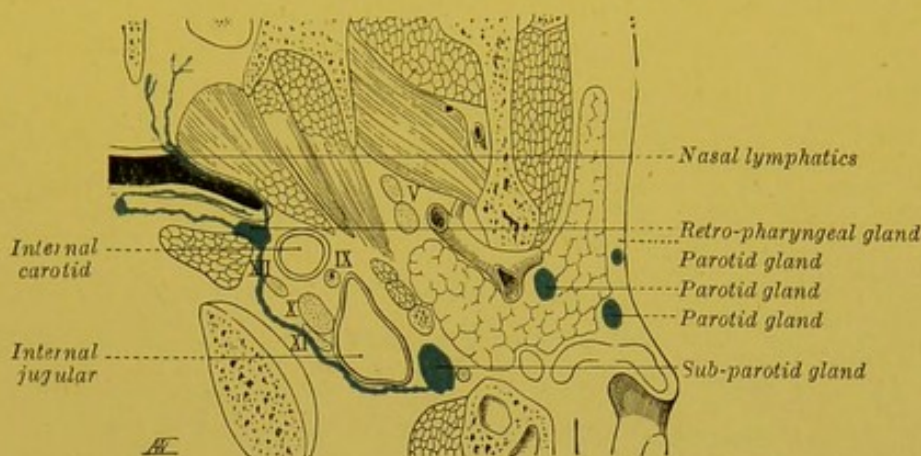


FIG. 93.—Scheme of the parotid and sub-parotid glands.

(a) The existence of *sub-cutaneous* glands is admitted by different authors, and notably by Richet (*Anatomie Medico-chirurgicale*, 4th edition, p. 193), and by Merkel (*Topogr. Anat.*, vol. i. p. 454). Sappey formally denies their existence. Without going as far as this, however, we may say that they are usually absent.

(b) The glands contained in the parotid space are situated, either external to the gland, immediately beneath the parotid fascia (superficial glands), or in the actual substance of the parotid (deep glands).

The superficial glands are usually placed immediately in front of the tragus. Sometimes 2 or 3 in number, they are not infrequently reduced to a single gland—the *prae-auricular* gland of authors (vide Fig. 92).

The deep glands are scattered throughout the entire gland, but are usually grouped along the external jugular and external carotid vessels. According to Poulsen (quoted by Stahr), one of these glands constantly occupies the lower part of the space, and is attached close to the angle of the jaw, in contact with the deep cervical fascia.

The parotid glands receive their *afferent lymphatics* from the external surface of the auricle, from the external auditory meatus, from the tympanum, from the skin of the temporal and frontal regions, from the eyelids and root of the nose (Küttner). They perhaps also receive vessels coming from the mucous membrane of the nasal fossae and from the posterior part of the alveolar border of the superior maxilla. Their *efferent vessels* pass into the glands grouped round the spot where the external jugular vein leaves the parotid, and into the sub-sterno-mastoid glands.

The number of glands contained in the parotid space is very

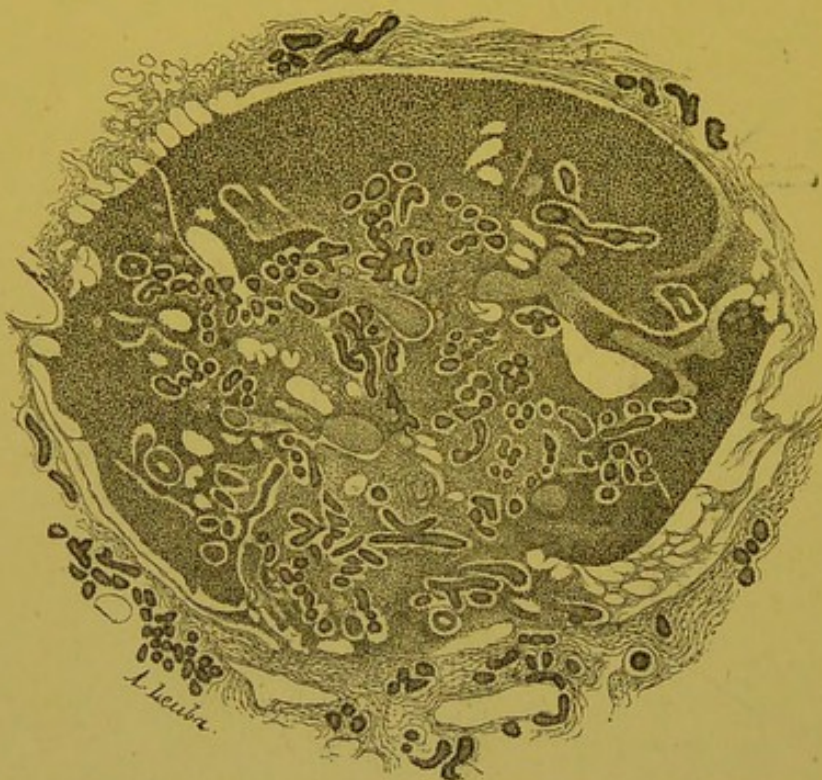

FIG. 94.—Section of a parotid gland (foetus of twenty-one centimetres) (Neisse).

In this figure may be seen the invasion of the lymphatic gland by several glandular acini which have penetrated into the gland as far as the hilum and show a tendency to reach its cortical substance.

difficult to estimate even approximately. Though their browner colour enables us to distinguish them from the parotid lobules, they are difficult to recognize unless their afferent vessels have been injected. On the other hand, in specimens treated by Gerota's method, we can convince ourselves that they exist in considerable numbers (10 to 16). Histological examinations prove them to exist in still greater numbers, for we can then see minute glands which are invisible in an ordinary dissection. The microscope, too, enables us to demonstrate the presence of lymphoid masses of variable shapes and sizes which surround the acini, and are analogous to the formations pointed out by Rawitz in the submaxillary gland.

When the parotid lymphatic glands are studied histologically, especially in the new-born, one is struck by finding glandular acini in several of

When the parotid lymphatic glands are studied histologically, especially in the new-born, one is struck by finding glandular acini in several of

them. These acini, though sometimes confined to the medullary portion of the gland, may pass as far as its cortical zone and even compress the glandular tissue which is reduced to a fine shell surrounding the glandular bud. This is clearly a case of an active penetration of acini into the interior of lymphatic glands. In studying sections of a foetus from three to six months old, Neisse was able to follow all the stages of this penetration. We must not, however, confuse this invasion of lymphatic glands by the elements of the secreting gland, with the peri-acinous lymphoid infiltration mentioned above. We should add that this penetration of the acini into the lymphatic glands is easily explained by the absence of encapsulation both of the salivary and of the lymphatic glands in the initial stages of their development.

From a pathological point of view, we may ask whether certain cases of glandular tuberculosis, which are apparently primary, may not be explained by these intimate connexions of certain acini with the lymphatic glands whose bacillary invasion is so frequent (?).

Vide R. Neisse Ueber den Einschluss von Parotisläppchen in Lymphknoten. *An. Hefte v. Merkel u. Bonnet*. Erste Abth., 1898, x, p. 287.

(c) *Sub-parotid Glands*.—The sub-parotid glands are placed between the parotid and the pharynx, in the latero-pharyngeal, or posterior sub-glandular space. They are in contact with the carotid and internal jugular veins. These glands are the starting-point of latero-pharyngeal abscess. They receive their *afferent* vessels from the nasal fossae, from the nasal pharynx, and from the Eustachian tube. Their *efferents* pass into the glands of the great deep cervical chain.

The majority of authors do not mention the existence of glands in the anterior sub-glandular space. Quain, however, mentions some small glands placed in the course of the internal maxillary. Leaf has never met with the glands described by Quain, but has seen, on the contrary, a small gland on the outer surface of the external pterygoid muscle immediately behind the frontal process of the malar bone.

4. SUBMAXILLARY GLANDS (*lateral supra-hyoid glands*). — The number of submaxillary glands varies from 3 to 6. They form a ring stretching along the inferior border of the maxilla, from the insertion of the anterior belly of the digastric to the angle of the jaw. They are therefore placed at the junction of the cutaneous and bony surfaces of the submaxillary gland, upon which they rest. They vary in size from a pea to a haricot bean. The largest and most constant of them usually occupies the centre of the chain (*the middle gland of Stahr*), and corresponds to the spot where the latter is crossed by the facial artery. It is frequently found that one of these glands isolates itself from the chain, and is situated over the course of the facial vein in the middle of the cutaneous

surface of the submaxillary. On the other hand, it is more rare to meet with the glands noticed by Leaf and Küttner, on the internal surface of the gland. All the submaxillary glands are sub-fascial.

The number of submaxillary glands is very differently estimated by authors. Roughly speaking, we may say that the numbers given by the older writers are much higher than we have allowed. W. Krause, Henle, Rauber, and Merkel speak of 3 to 10; Sappey, 12 to 15. With Gussenbauer, Leaf, and Stahr, we think these estimates are much too high, and that if we simply count the glands which can be seen after a simple dissection, and after injection of their afferents, we shall find that they rarely exceed 5 or 6.

Contrary to what we have noticed in the case of the parotid, there do not appear to be any lymphatic glands included in the submaxillary salivary gland. We may remark, however, that in the cercopithecus (long-tailed monkey), Rawitz has seen in the submaxillary gland, lymphoid masses surrounding the acini. But these structures are essentially variable in their size and arrangement and even in their existence, and should not be regarded as true lymphatic glands.

The submaxillary glands receive as *afferents* the lymphatics of the nose, the cheek, the upper lip, and the external part of the lower lip, almost the whole of the gums, and the anterior third of the lateral border of the tongue (vide p. 275).

Their *efferent vessels* descend on the cutaneous surface of the submaxillary gland, cross the hyoid bone and terminate in the glands of the deep cervical chain, and more particularly in the glands over the bifurcation of the common carotid. One or two of these trunks may, however, end in a gland situated much deeper, viz. at the point where the omo-hyoid crosses the internal jugular vein.

BIBLIOGRAPHY.—H. Stahr. Zahl und Lage der submaxillaren Lymphdrüsen, *Arch. f. Anat. u. Phys. Anat. Abth.*, 1898, p. 144.—Rawitz, Ueber Lymphknotenbildungen in Speicheldrüsen, *An. Anz.*; Bd. 14, n. 17–18, p. 463.

Facial Glands.—The afferent vessels of the submaxillary glands frequently traverse (20 times in 32 subjects according to Princeteau) some small glands, usually described as genial glands, but which, we think, are more suitably described under the more comprehensive term of facial glands.

These glands form three groups placed one above the other in the course of the facial vessels:

- (1) *The inferior or supra-maxillary group* rests on the external

surface of the inferior maxilla between the anterior border of the masseter and the posterior border of the depressor anguli oris, and beneath the platysma. This group comprises 1 to 13 glands which are in intimate connexion with the artery and the facial vein. It was met with by Princeteau fourteen times in thirty-two subjects (vide *b*, Fig. 95). It is sometimes joined to the submaxillary group by a gland which is placed on the actual lower edge of the inferior maxilla; this is the *infra-maxillary gland* (*a*, Fig. 95).

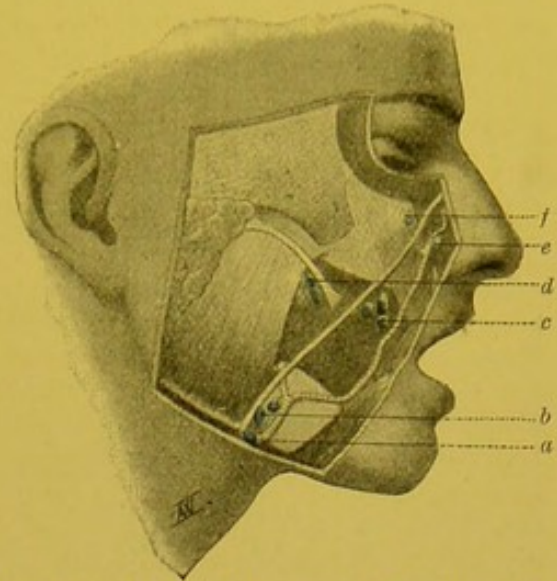


FIG. 95.—Facial glands (after Buchbinder).

a. Infra-maxillary gland. *b*. Sub-maxillary gland. *c*. Buccinator gland (middle mass). *d*. Buccinator gland (posterior mass). *e*. Gland of the naso-genial groove. *f*. Sub-orbital gland.

(2) *The middle or buccinator group* is somewhat deeply situated on the external surface of the buccinator muscle. It is less frequently present than that of the preceding group (ten times in thirty-two subjects, Princeteau). It includes three distinct masses, which may exist together or separately.

(*a*) A posterior or retro-vascular mass formed by one or two glands situated behind the facial artery, where Stenson's duct perforates the buccinator. This group must not be confused with the salivary glands which may be found in this region (*d*, Fig. 95).

(*b*) A middle inter-vascular mass which usually consists of two glands, placed between the artery and the vein. This mass is covered by the posterior fibres of the zygomaticus major (*c*, Fig. 95).

(*c*) An anterior prae-vascular gland may exceptionally be met with, situated on the external surface of the orbicularis oris, in the subcutaneous cellular tissue, 8 to 10 millimetres from the labial commissure. This is the *commissural gland* of Princeteau.

All these buccinator glands lie above the buccal fascia; Debierre, however, points out the possible existence of subfascial glands. Poncet has even met with a submucous gland.

(3) *The superior group* is of much less importance than the two preceding, and comprises several glands, viz. a gland of the nasogenial groove, pointed out by Tillaux and also found by Princeteau (*e*, Fig. 95), a suborbital gland (*f*, 95), and a malar gland, the exist-

ence of which has hardly been proved except clinically (Albertin, Vigier).

The majority of the older writers (Richet, Paulet, Beaunis and Bouchard, Sappey, etc., do not mention the facial glands. Mascagni, however, as long ago as 1787, had observed and described the facial glands and even distinguished the supra-maxillary and buccinator groups. Boyer, Cloquet, Bourguery and Jacob, and Cruveilhier mention them briefly. More recently (1887) the clinical observations of Poncet have again drawn attention to this point and several authors (Jaboulay, Vigier, Princeteau, Buchbinder, etc.) have resumed the study of them.

BIBLIOGRAPHY.—MASCAGNI, loc. cit., p. 61, pl. XXVI, Fig. 1.—VIGIER. Des adénites de la joue. *Gaz. hebd.*, 1892, et *Th. de Lyon*, 1892.—ALBERTIN. Adénites génienues. *Arch. prov. de Chir.*, 1895.—PRINCETEAU. Les ganglions lymphatiques de la joue, *Gaz. hebd. des sc. med. de Bordeaux*, 1899.—CAPETTE-LAPLÉNE. Les ganglions de la joue, *Th. Bordeaux*, 1899.—BUCHBINDER. Ueber die Lage u. die Erkr. der Wangenlymphdrusen, *Beitr. z. klin. Chir.*, 1899. THÉVENOT. Des adénites génienues, *Gaz. des Hôpitaux*, 21 avril 1900

5. SUBMENTAL GLANDS (*Synonym* Supra-hyoid median glands).—Under the term submental glands are described the glands contained in the triangle bounded by the anterior bellies of the two digastric muscles and the hyoid bone. The number of these glands vary from 1 to 4. Their arrangement is extremely variable; usually two in number, they are either transverse, in which case they are more or less in close proximity to the middle line, or else they are vertical. In the latter case, one is in close proximity to the mandible, and the other to the hyoid bone. A gland placed on the anterior belly of the digastric sometimes constitutes a transition stage between this group and the submaxillary glands.

The submental glands receive their *afferent vessels* from the integuments of the chin, from the central portion of the skin of the lower lip, from the mucous membrane of the corresponding portion of the alveolar border of the mandible, from the floor of the mouth, and finally from the tip of the tongue (on this latter origin, which is elsewhere discussed, vide p. 274).

Their *efferent vessels* follow a double course. Three or four trunks run outwards towards the submaxillary glands. One or two others are directed downwards, cross the hyoid bone and terminate in a gland placed on the anterior surface of the internal jugular vein, above the point where the latter is crossed by the omo-hyoid. One of these vessels sometimes describes a remarkable loop in front of the sub-hyoid muscles.

(6) RETRO-PHARYNGEAL GLANDS.—The retro-pharyngeal glands are placed behind the pharynx, at the junction of its posterior and lateral surfaces, at the apex of the lateral masses of the atlas.

These glands are usually 2 in number. According to Most, however, it is the rule for one gland only to be present. When these glands are 2 in number, they lie over one another in the vertical plane.

These glands are in relation : *in front*, with the posterior wall

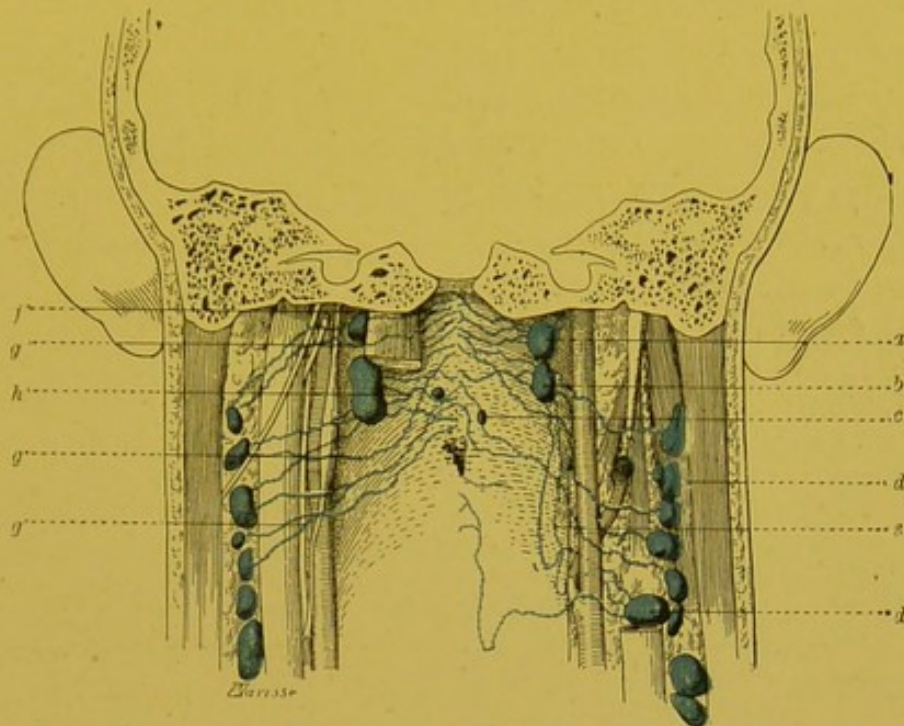


FIG. 96.—Retro-pharyngeal glands.

a, b. Retro-pharyngeal glands. *c.* Interrupting glandular nodule, placed in the course of the afferent vessels of these glands. *d.* Gland of the deep cervical chain. *e.* Efferent vessel of retro-pharyngeal glands, passing in front of the internal carotid artery. *f.* Afferent of the retro-pharyngeal glands, passing behind the right rectus capitis anticus major. *g.* Lymphatic of the pharynx, passing directly to a gland of the deep cervical chain. *h.* Afferent of retro-pharyngeal glands.

of the pharynx ; *behind*, with the rectus capitis anticus major, which separates them from the lateral masses of the atlas ; *externally*, with the constrictors of the pharynx, and through the latter, with the internal carotid artery ; *internally*, they are nearly 2 centimetres distant from the middle line (vide Figs. 93 and 96).

These glands are, as has been seen, purely lateral. If, in the case of a retro-pharyngeal abscess, the collection of pus tends to become central, the reason probably is that the abscess cavity being confined externally by the constrictors, cannot extend in that direction, but can do so internally where there is nothing to hinder it.

We may, however, find one or several small glands lying near the middle line, or on a level with it. Most even points out as a fairly frequent occurrence, a gland placed in front of the odontoid process ; but these are inconstant. These very small glands are moreover simple interrupting glandular nodules placed in the course of the afferents of the retro-pharyngeal glands properly so called

The retro-pharyngeal glands receive as *afferents* almost all the collectors coming from the mucous membrane of the nasal fossae, and the cavities in connection with it, the lymphatics of the nasal pharynx, those of the Eustachian tube, and perhaps some of the lymphatics from the cavity of the tympanum. As has been seen, their lymphatic area is very extensive, and the frequent infection of these glands is easily explained.

The *efferent vessels* of the retro-pharyngeal glands empty themselves into the superior glands of the internal jugular chain. To reach these, they pass, for the greater part, behind the vessels and nerves, and more particularly the superior cervical gland, the posterior surface of which they cross. Some of them, however, pass in front of the internal carotid artery and external jugular vein to reach their new glandular relay (*vide e*, Fig. 96).

Owing to the practical importance of the retro-pharyngeal glands several works have been produced. We will only mention the most important: Mascagni, *loc. cit.*, p. 63.—Tourtual. *Neue Untersuchungen über der Base des menschlich. Schlund. und Kehlkopfes*. Leipzig, 1846.—Gillette. *Th. Paris*, 1867.—Bokai. *Ueber Retropharyngealabscess. Jahrb. f. Kinderkrank.*, I, 1887.—Moreau. *Contribution à l'étude des abcès rétro-pharyngiens. Th. Paris*, 1896.—Most. *Zur Topographie und Aetiologie der retro-pharyngealen Drusenacbesse. Arch. f. klin. Chir.*, LXI, 3.

2. DESCENDING CERVICAL CHAINS.

We have seen that from the glandular collar formed by the different groups which we have just been studying, a chain of glands detached itself on either side, and descended with the large vessels as far as the root of the neck. This is the deep cervical chain. This principal chain is flanked by several secondary chains of more or less importance, viz. the external jugular chain, the two anterior cervical chains, superficial and deep, and the recurrent chain.

Deep Cervical Chain.—The deep cervical chain (*carotid chain, substerno-mastoid, deep glands of the neck*) constitutes one of the most important of the glandular regions of the system. It comprises from 15 to 30 glands, but this number is apt to vary considerably. Here, as is always the case, the number apparently varies inversely as the size (*vide pp.* 84 and 85). In certain pathological cases, it seems as though there is an actual increase, but this is only because glands which in the normal state were imperceptible, are now rendered visible.

The deep cervical chain really constitutes a large mass which extends beneath the sterno-mastoid, and in the subclavian tri-

angle disappears behind this muscle; further, although this glandular layer is in reality continuous, we may regard it as being formed of two groups: viz. the sub-sterno-mastoid and the supra-clavicular group (vide Fig. 92).

1. SUB-STERNO-MASTOID GLANDS.

—This group extends in the vertical plane from the tip of the mastoid process and the posterior belly of the digastric to the junction of the internal jugular and sub-clavian, but it is in the upper part of this region that the glands are

most numerous and largest. Frequently indeed, this group does not descend below the point where the omo-hyoid crosses the vessels and nerves. All these glands are covered by the sterno-cleido-mastoid, and are adherent to the deep layer of the sheath of this muscle.

Though they constitute in appearance a continuous glandular layer, we may divide them into two groups: an external and an internal, differing in their general arrangement, and in the source of their afferent vessels.

(1) The *external* glands are placed behind and external to the internal jugular vein. Usually of small size, round and scattered apparently indiscriminately, these glands rest on the insertions of the splenius, levator anguli scapulae, and the scalene muscles. They are embedded in the cellulo-adipose tissue which surrounds the branches of the deep cervical plexus. At the level of the

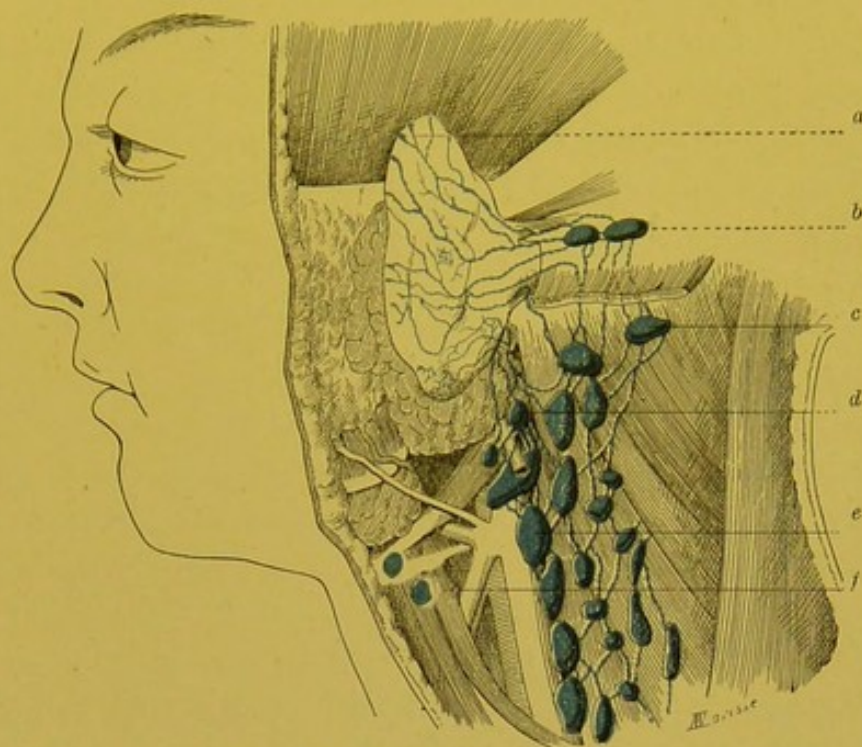


FIG. 97.—Deep Cervical Chain.

a. Collectors of the fossa of the auricle. *b.* Mastoid glands. *c.* Sterno-mastoid gland (external group). *d.* Gland of the external jugular chain. *e.* Sterno-mastoid gland (internal group, internal jugular chain). *f.* Sub-hyoid aberrant gland, placed in the course of the efferent vessels of the sub-mental glands.

posterior border of the sterno-mastoid, they are continuous without any line of demarcation with the glands occupying the subclavian triangle. In this external group in particular, the cutaneous lymphatics from the posterior segment of the head and upper portion of the neck, terminate.

(2) The *internal glands (internal jugular chain)* rest on the internal jugular, or are immediately adjacent to its external border (vide Figs. 97 and 105). Usually larger than the preceding, they are elongated vertically and arrange themselves in a chain parallel to the internal jugular. Some of these glands have a fairly fixed position; thus, one or two large glands are constantly found immediately beneath the posterior belly of the digastric, above the spot where the thyro-lingual-facial trunk opens into the internal jugular. We shall see that these glands represent the principal terminus of the lymphatics of the tongue (vide p. 279 and Fig. 105). Similarly, there is almost always a fair-sized gland above the point where the omo-hyoid crosses the internal jugular. Finally, we often find glands situated behind the internal jugular, between this vessel and the prevertebral muscles. In the glands of the internal group, terminate, with or without previous glandular interruption, the cutaneous lymphatics of the face, and the cervico-facial portions of the digestive and respiratory passages.

We should add that these two groups are united by a great many anastomoses, and that their subdivision, which makes their study easier, is arranged on a definite plan, to which we must draw attention.

We may include in the sterno-mastoid group, some small aberrant glands placed on the lateral parts of the larynx, in front of and internal to the large vessels. These inconstant glands are usually situated beneath the great cornu of the hyoid bone. We usually find one or two of them relatively superficial, and placed on the omo-hyoid a little below the insertion of this muscle on the hyoid bone (vide *f*, Fig. 97). At the same level, but more deeply placed, that is, underneath the thyro-hyoid muscle, two or three minute glands are also found lying on the thyro-hyoid membrane or on the upper part of the alae of the thyroid cartilage. These glands, not mentioned by Sappey, have been well shown by Bourguery and Jacob (*loc. cit.*, plates 86 and 91): they are not regional glands, but simple interrupting glandular nodules placed in the course of the visceral afferents of the sterno-mastoid glands properly so called. We shall, however, have occasion later on to return to these glandular nodules, when studying the lymphatics of the tongue, the pharynx and the larynx (vide p. 283 and Fig. 110).

Afferent Vessels.—(A) The *external group* of sub-sterno-mastoid glands receives:

1. The efferent vessels of the mastoid glands, sub-occipital glands, and some vessels coming from the glands placed round the external jugular, at the spot where the latter leaves the parotid.

2. A large collecting trunk which comes directly from the occipital portion of the hairy scalp (vide p. 264).

3. Some trunks (inferior trunks) coming from the auricle (vide p. 264).

4. Some cutaneous and muscular vessels from the upper part of the neck.

(B) The *internal group* at first receives the efferent vessels of the retro-pharyngeal, parotid and sub-parotid, submaxillary, and submental glands, the superficial and deep anterior cervical chains, and the recurrent chain. This internal group constitutes therefore a second glandular relay for the numerous lymphatics which are tributaries to the preceding glands.

Further, this group receives as direct afferents:

1. The majority of the lymphatics of the tongue (vide p. 278).

2. Certain lymphatics of the nasal pharynx and the whole of the lymphatics of the middle and inferior portions of the larynx (p. 281).

3. The lymphatics of the vault of the palate, and soft palate.

4. The lymphatics of the cervical portion of the oesophagus.

5. The lymphatics of the nasal fossae.

6. The majority of lymphatics of the larynx, and those from the cervical portion of the trachea.

7. The lymphatics of the thyroid body.

In studying the arrangement of the lymphatic apparatus of these different organs, we will note the exact position of the glands of the sterno-mastoid chain in which their absorbent vessels end.

Efferent Vessels.—The efferent branches of the internal jugular chain finally resolve themselves into one or two large vessels. The latter unite with the efferent vessels of the subclavian glands to constitute the jugular trunk. On the right side, this trunk terminates in the junction of the internal jugular and subclavian vein, at the apex of the angle which is open externally, and which is formed by the junction of these two vessels. On the left, it ends in the terminal bend of the thoracic duct; but it may also end directly in the junction of the two veins. (On the varieties of the terminal lymphatic trunks at the base of the neck, vide pp. 291 and 292, and Fig. 112.)

2. THE SUPRA-CLAVICULAR GLANDS.—These glands occupy the

supra-clavicular or subclavian triangle. Their relations vary in the upper and lower part of the triangle.

In the upper part of the triangle, these glands, which are extremely numerous, form a layer which is covered by the superficial cervical fascia, and rest on the splenius, the levator anguli scapulae, and the scalene muscles. They are embedded in the mass of adipose tissue described by Merkel under the name of *Fettpolster*, where they are in intimate relation with the branches of the cervical plexus, with the branch to the trapezius from the third and fourth cervical nerves, and with the ascending cervical artery.

At the base of the triangle, this group to some extent lies on the omo-hyoid and middle layer of cervical fascia. The majority of glands are placed in front of this layer; here, they enter into connexion with the terminal sub-fascial portion of the external jugular and the descending branches of the cervical plexus, where the latter perforate the superficial fascia above the clavicle and become sub-cutaneous. Others, placed more deeply, are situated behind the omo-hyoid and the middle layer of fascia, in front of the third portion of the subclavian, and the nerves of the brachial plexus.

The supra-clavicular glands receive as *afferent vessels* :

(1) The lymphatics coming from the posterior part of the hairy scalp, from the skin, and from the muscles of the neck.

(2) The lymphatics coming from the integuments of the pectoral region, and even from the mammary region (vide p. 216).

(3) The cutaneous lymphatics of the arm, satellites of the cephalic vein, which, instead of reaching the sub-clavian glands, their normal terminus, pass above the clavicle and empty themselves into the supra-clavicular glands (p. 244).

(4) Some of the afferents of the axillary glands and more particularly the afferents of these glands which constitute the humeral chain (vide p. 239).

On the other hand, these glands receive no vessels coming from the mediastinal glands. Cases of adenitis of the supra-clavicular glands following mediastinal or abdominal neoplasms, can only be explained by a retrograde thrombosis of the afferent vessels of these supra-clavicular glands.

As we have seen, the *efferent vessels* of the supra-clavicular glands unite with the efferent vessels of the sterno-mastoid glands to constitute a common trunk, the jugular trunk. On the right side,

this trunk terminates in the junction of the internal jugular and subclavian. On the left, it usually ends in the terminal bend of the thoracic duct.

Accessory Chains.—1. *The external jugular chain* is formed by 4 or 5 glands placed in the course of the external jugular vein. Normally this chain only comprises 2 or 3 glands situated at the spot where the external jugular leaves the parotid. These glands rest on the external surface of the sterno-mastoid beneath and a little behind the inferior extremity of the gland. More rarely, 1 or 2 glands are found on the middle part of the vein.

These glands receive their *afferent* vessels from the auricle and from the parotid region. Their *efferent* vessels turn round the anterior border of the sterno-mastoid and end in the superior glands of the deep cervical chain (vide Fig. 97). One of these efferents may follow the external jugular chain and pass into a supra-clavicular gland.

2. *The superficial anterior cervical chain* comprises 2 to 3 small inconstant glands, placed in the course of the anterior jugular vein.

3. Under the name *anterior deep cervical chain*, we may describe the collection of glands which are found below the sub-hyoid muscles, immediately in front of the larynx and trachea.

These glands may be divided into three distinct masses: the prae-laryngeal, the prae-thyroid, and prae-tracheal.

(a) *The prae-laryngeal mass* comprises 1 to 3 glands. Engel (*Compendium der Topographischen Anatomie*, Wien, 1859, p. 182) was the first to point out the presence of a gland in front of the larynx. Since then, one of the present writers has studied this glandular mass, and has endeavoured to establish its frequency and usual arrangement. As a matter of fact, this glandular group is inconstant. Prae-laryngeal glands are found in only 49 out of 100 cases (Poirier). Most frequently, only a single gland is present, which is situated in the middle of the V-shaped space bounded by the two crico-thyroids. Sometimes, this gland is hidden under the edge of one of these muscles. In some cases, there is a second gland subjacent to the preceding and occupying the summit of the V-shaped space. Again, we may find, though more rarely, another gland in front of the cricoid, above the isthmus of the thyroid body (Most, Roubaud).

These prae-laryngeal glands receive, as *afferents*, some of the lymphatics which constitute the middle lymphatic pedicle of the larynx (vide pp. 287 and 288). Their *efferent* vessels pass either to the

prae-tracheal glands, or to the inferior glands of the sterno-mastoid chain. It is more rare to see these vessels take an ascending course and unite with the vessels which constitute the superior lymphatic pedicle of the larynx.

(b) The *prae-thyroid mass* has been figured by Bourgery (loc. cit., plates 97 and 91). We regard its presence as exceptional.

(c) The *prae-tracheal mass* is much more frequently present. It comprises one or several glands. These are however, most frequently very small, and only visible in specimens injected with coloured material.

The prae-tracheal glands receive as *afferents*, the lymphatics which come from the thyroid body and some of the efferents of the prae-laryngeal glands. Their *efferent vessels* run downwards and outwards and pass into the inferior glands of the sterno-mastoid chain.

These three glandular masses are as inconstant in their presence as they are variable in their arrangement, and we are inclined to regard their constituent glands, not as true regional glands of the larynx or thyroid body, but as simple interrupting glandular nodules, placed in the course of the lymphatics coming from these two organs.

4. The *recurrent chain* comprises 3 to 6 minute glands, situated on the lateral parts of the oesophagus and trachea, along the recurrent laryngeal nerves. Unless their afferent vessels are injected, these glands, which are always very small, may pass unrecognized. Inferiorly, this chain is continuous, without clear line of demarcation, with the praetracheo-bronchial groups.

The glands of the recurrent chain receive as *afferents*, the lymphatics of the inferior pedicle of the larynx (vide p. 288), and the vessels coming from the cervical portion of the trachea and oesophagus, and some of the lymphatics of the thyroid body. Contrary to what we should at first expect, the *efferent* vessels of this chain do not end in the mediastinal glands; but incline outwards, and pass either in front of or behind the vessels and nerves of the neck, terminating either in the inferior glands of the sterno-mastoid chain, or in the supra-clavicular glands.

Gouguenheim and Leval-Piquechef, who have given a detailed account of this glandular chain, have described it as formed of three masses, viz. a superior, middle, and inferior. We have most frequently seen these glands arranged in a continuous chain, and this division into three masses does not seem to us to be justified. On the other hand, these authors have rightly drawn attention to the importance of this glandular chain in explaining certain cases of paralysis of the recurrent laryngeal nerve by compression.

Vide. Gouguenheim et Leval-Piquechef. *Annales des maladies de l'oreille et du larynx*, 1884, p. 15.

§ 2. LYMPHATIC VESSELS OF THE HEAD AND NECK.

WE will study in turn : (1) the lymphatics of the cranial region ; (2) the lymphatics of the face ; (3) the lymphatics of the facial and cervical segments of the digestive passages ; (4) the lymphatics of the corresponding portion of the respiratory passages.

1. LYMPHATIC VESSELS OF THE CRANIAL REGION.

The study of the lymphatic vessels of the cranial region resolves itself into that of the lymphatics of the corresponding integuments. The vessels of the subcutaneous soft parts in fact pursue a course exactly similar to that of the lymphatics of the skin. As regards the intra-cranial organs (the encephalon and its membranes), it is now generally agreed that they are without lymphatics.

Fohmann, Mascagni, Fr. Arnold have, however, described and figured meningeal lymphatics. They have clearly been deceived. If the nervous centres contain spaces which are to some extent comparable to lymphatic channels, they do not possess "lymphatic vessels" in the proper sense of the word. We should further add that these spaces are usually regarded as absolutely independent of the lymphatic system.

On the question of the lymphatics of the nervous centres, vide vol. iii. pp. 95 and 122.¹

The lymphatics of the integuments of the cranial region arise from a network with very close meshes. This network is most dense near the middle line and in the region of the vertex. As we approach the periphery of the hairy scalp, the meshes become larger and the network scantier, without however ceasing to be continuous.

The trunks arising from this network may be divided into anterior or frontal, lateral or parietal, posterior or occipital.

(1) The *frontal* are 10 to 12 in number. They run obliquely downwards and backwards, and approach more nearly to the horizontal as they go lower. Those situated nearest the orbital arch take their origin from the skin over the eyebrow and root of the nose (Küttner). All terminate in the parotid glands.

(2) The *parietal* or *temporal* are divisible into two groups: viz. anterior and posterior. The anterior trunks which vary from 3 to 5 in number, pass into the parotid glands. The posterior trunks are usually more numerous and end in the mastoid glands.

¹ *Treatise of Human Anatomy*, Poirier and Charpy.

(3) The *occipital* are also divided into two groups. The external trunks, which number 5 or 6, converge "to form a very remarkable single and constant trunk. This trunk is directed almost vertically downwards, is then attached to the posterior border of

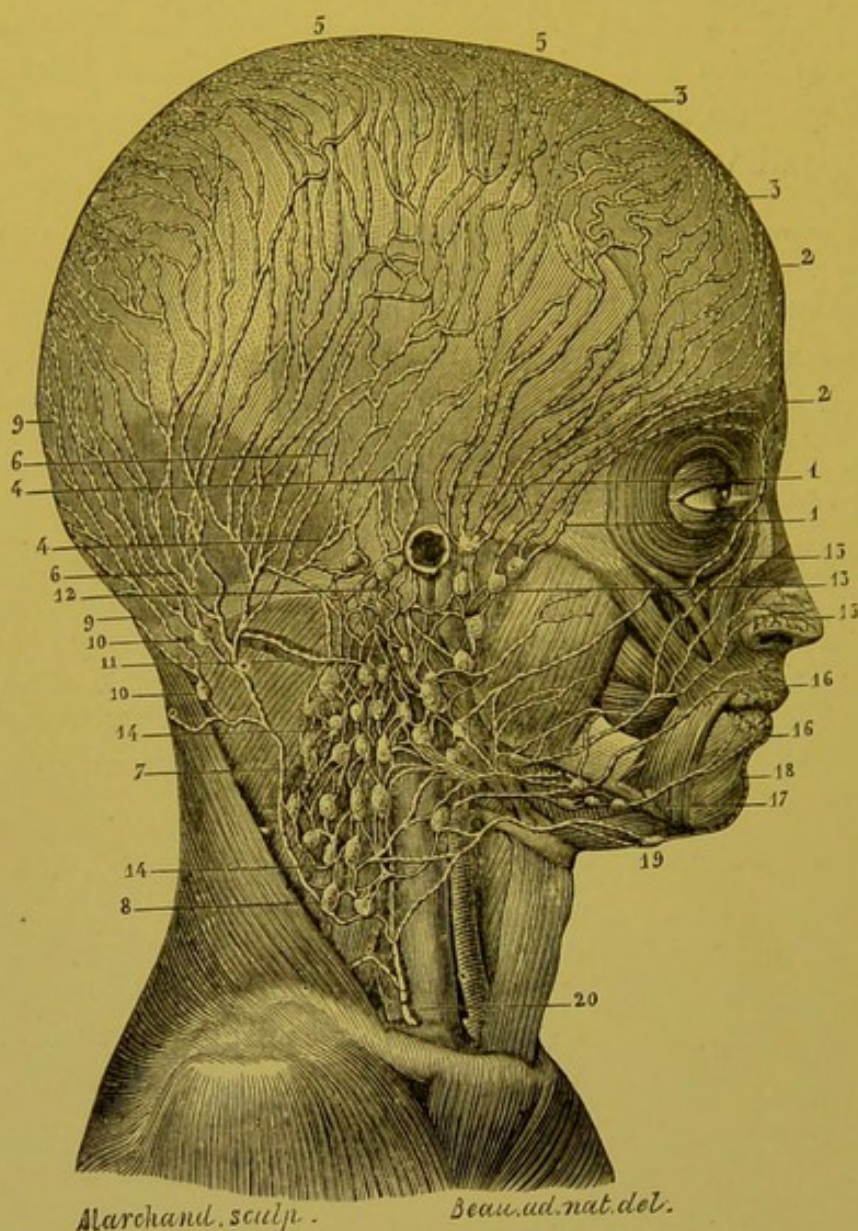


FIG. 98.—Lymphatics of the head and neck: right lymphatic duct (after Sappey).

1, 1. Lymphatic vessels which pass into the parotid glands. 2, 2. Inferior frontal lymphatics. 3, 3. Superior frontal lymphatics. 4, 4. Parietal lymphatic vessels; they descend vertically, and anastomosing with the neighbouring vessels, terminate in the mastoid glands. 5, 5. Origin of these vessels. 6, 6. Anterior sub-occipital vessels converging to form a single trunk which, after a long course, ends in one of the lowest of the cervical glands. 7. Trunk resulting from the convergence of these vessels. 8. Gland in which this trunk terminates. 9, 9. Posterior sub-occipital vessels ending in two glands situated on the anterior border of the trapezius. 10, 10. These two glands. 11. Large horizontal trunk coming from the higher of these glands, running underneath the splenius, and ending in the sub-mastoid glands. 12. Vessels which take origin from the superior mastoid glands and which traverse the sterno-mastoid and terminate in the glands situated beneath this muscle. 13. Parotid glands. 14, 14. Cervical glands, and afferent vessels of these glands. 15, 15. Lymphatic vessels which take origin from the integuments of the nose. 16, 16. Lymphatic vessels of the lips. 17. Sub-maxillary glands. 18. Lymphatic vessels coming from the middle part of the lower lip. 19. Supra-hyoid gland in which this vessel terminates. 20. Right lymphatic duct.

the sterno-mastoid, under which it passes and terminates in one of the external glands of the sterno-mastoid group. Sometimes it descends into the subclavian triangle, while at others it does not pass beyond the middle line of the neck" (Sappey). The internal trunks pass into the occipital glands. They may also pass into the aberrant glands of the neck, to the existence of which we have drawn attention (p. 248).

2. LYMPHATIC VESSELS OF THE FACE.

As we shall have to study separately the lymphatics of the mucous membranes of the different cavities of the face, we will here consider only the cutaneous lymphatics.

Very thin, and difficult to inject, these vessels terminate in the parotid, submaxillary and submental glands. Though their network of origin is absolutely continuous over the entire face, the lymphatics of certain regions, on account of their practical importance, merit a special description.

LYMPHATICS OF THE EYELID AND CONJUNCTIVA.—These vessels take origin from a network which occupies the entire cutaneous surface of the eyelids and the whole of the conjunctiva. At the free border of the lids this network becomes extremely close. The terminal trunks form two distinct groups.

Some of them, 2 or 3 in number, run inwards and terminate in a median or paramedian trunk which springs from the inter-superciliary space, and ends in the submaxillary glands. Others, which are much more important, and which

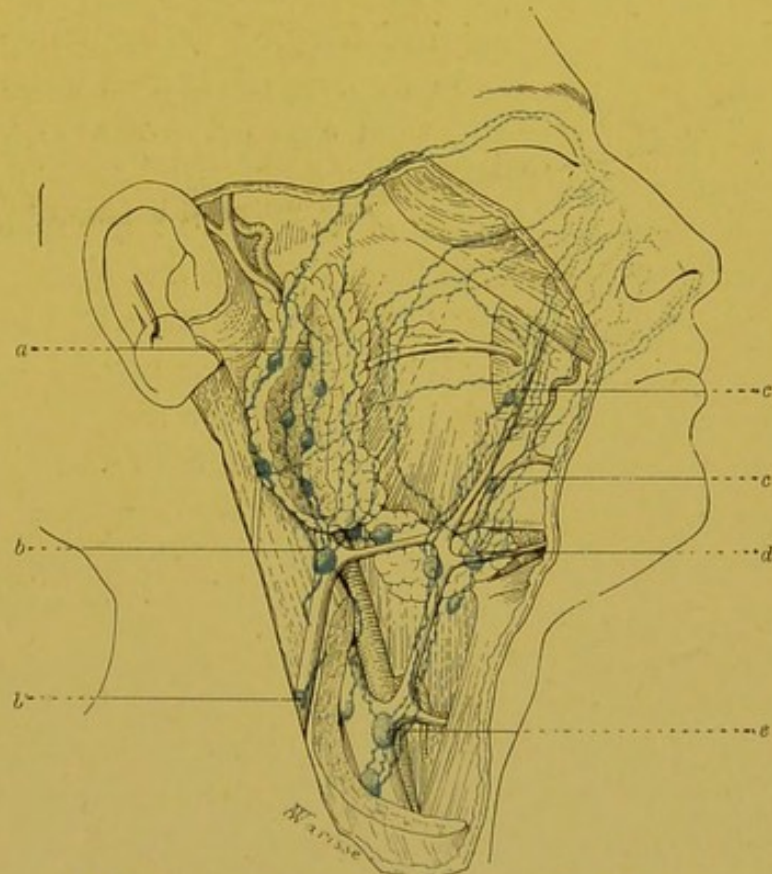


FIG. 99.—Lymphatics of the neck (after Küttner).

a. Parotid gland. b, b. Glands of the external jugular chain. c, c. Facial gland. d. Submaxillary gland. e. Gland of the internal jugular chain.

drain about the outer three-fourths of the two eyelids, run obliquely downwards and backwards and pass into the parotid glands.

LYMPHATICS OF THE NOSE.—The lymphatic vessels of the integuments of the nose, recently well studied by Küttner, arise from a network with somewhat large meshes at the root of the organ, but which, on the contrary, is very dense over the alae and lobule.

Injections easily pass beyond the middle line, and a lateral puncture may inject the collecting trunks of the opposite side. This cutaneous network is continuous with the lymphatics of the vestibule of the nasal fossae and through them with the lymphatics of the mucous membrane. Küttner, who lays stress on this communication, was able, by puncturing the integuments, to distend the mucous lymphatics and to follow their collecting trunks as far as the dorsal surface of the soft palate; but he makes no definite statements as to the arrangement of the anastomoses.

The trunks arising from the cutaneous network may be classified into three groups (Küttner) (vide Fig. 99).

(a) The lymphatics of the first group arise from the root of the nose, pass above the upper eyelid, and, running along the upper border of the orbit, then curve downwards and terminate in the superior parotid glands.

(b) The lymphatics of the second group are usually three in number. They arise from the root and sides of the nose; they are at first directed immediately backwards, at the level of the adherent border of the lower lid, they then run more or less vertically downwards, and passing in front of the parotid, which they penetrate near its lower extremity, terminate in the parotid glands situated there.

(c) The third group is the most important. It comprises 6 to 10 trunks which spring from the entire extent of the cutaneous network. They run with the facial vessels and terminate in the sub-maxillary glands. Some of them may be interrupted in one of the facial glands (vide p. 253).

BIBLIOGRAPHY.—KÜTTNER. *Über die Lymphgefäße der äusseren Nase und die zugehörigen Wangenlymphdrüsen in ihre Beziehung zur der Verbreitung des Nasenkrebs. Beiträge z. klin. Chir.*, 1899, XXV, p. 33.

LYMPHATICS OF THE LIPS.—The lymphatics of the lips arise from two networks, one cutaneous, and the other mucous, which are in continuity with each other at the free border. From these two networks run the collecting trunks which receive in their

course the lymphatic vessels of the muscular coat which are much less developed.

In the upper lip there are two sub-mucous, and two or three sub-cutaneous collecting trunks on either side. All pass to the sub-maxillary glands and more especially to the middle gland, placed at the spot where the facial artery crosses the inferior border of the maxilla. One of these collecting trunks may open into one of the trunks coming from the lower lip, or end in one of the glands placed round the external jugular at its exit from the parotid (Dorendorf) (vide Fig. 101).

In the lower lip, the subcutaneous vessels are from 2 to 4 in number on either side. The trunks coming from the middle portion of the lip end in the submental glands. Those which spring from the neighbourhood of the commissure reach the most anterior of the submaxillary glands. The submucous vessels, 2 or 3 in

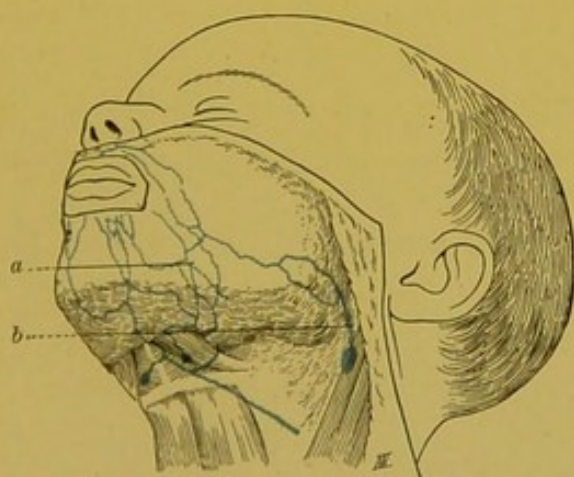


FIG 101.—Lymphatics of the lips (after Dorendorf).

a. Trunk ending in the submaxillary glands.
b. Collecting trunk of the upper lip terminating in a gland of the external jugular chain.

number on each half of the lip, run downwards and outwards, and embracing the facial artery, terminate in the submaxillary glands. As Sappey long since remarked, it is exceptional to see any of these vessels ending in the submental glands. Dorendorf has seen lymphatics springing from the gingivolabial groove, sink into the dental canal.

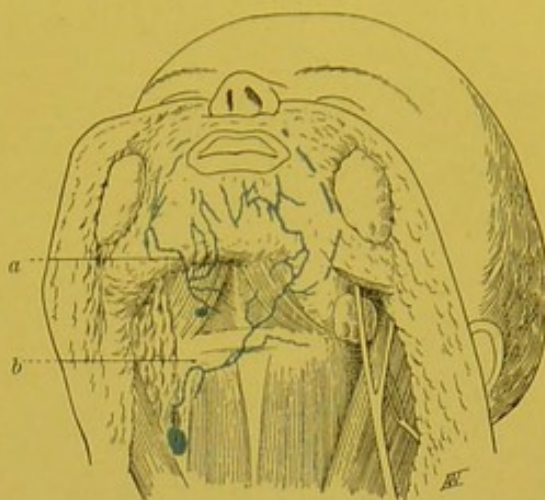


FIG. 100.—Lymphatics of the lower lip (after Dorendorf).

a. Trunk ending in the submaxillary glands. b. Trunk ending in the glands of the internal jugular chain (abnormal).

To sum up, the submaxillary and submental glands represent the first glandular relay of the lymphatics of the lips; it is only exceptionally that we see one of these vessels pass by this first station and directly

reach the deep cervical glands. Dorendorf has pointed out an example of this arrangement (vide Fig. 102).

The collecting trunks of the upper lip neither cross nor anastomose with one another. The same

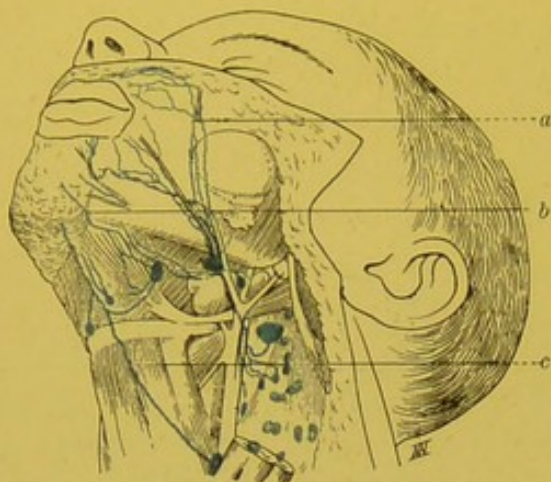


FIG. 102.—Lymphatics of the lips (after Dorendorf).

a. Collectors of the upper lip ending in the submaxillary glands. b. Collectors of the lower lip ending in the same glands. c. Vessel passing directly to a gland of the internal jugular chain.

remark applies to the submucous collectors of the lower lip. On the other hand, the right and left subcutaneous trunks of this lip frequently cross one another on the middle line, or present anastomoses which are practically equivalent to inter-crossing (vide Fig. 100). In the case of cancers of the lower lip, the submental and the submaxillary glands of both sides should be regarded as liable to become infected.

BIBLIOGRAPHY. — DOREN-
DORF. Ueber die Lymphgefäße und

Lymphdrüsen der Lippe mit. Beziehung . . . etc. *Internat. Monatschr. f. Anat. u. Physiol.*, 1900, XVII, p. 201.—STIEDA. Zur Lymphdrüsen-Exstirpation beim Unterlippenkrebs, *Arch. f. klin. Chirurgie*, 1901, p. 613.

LYMPHATICS OF THE AURICLE AND EXTERNAL AUDITORY MEATUS.—The lymphatics of the auricle and external auditory meatus take their origin from a cutaneous network the injection of which, at least in the infant, we have always found very easy. The collecting trunks coming from this network may be divided into three groups: posterior, anterior and inferior.

1. The *posterior* group has for its territory of origin a portion of the external surface of the auricle (viz. helix, anti-helix, and the fossa between them), the whole of the internal surface and posterior portion of the external auditory meatus. Numbering from 6 to 12, they end for the greater part in the mastoid glands. Some, however, avoid this first glandular relay and join the efferent vessels of the retro-auricular glands, and pass, with them into the glands placed beneath the sterno-mastoid. In their course, they perforate the superior insertions of this muscle or turn round its anterior border.

2. The *inferior* group includes a very variable number of trunks coming from the lobule, from the adjacent portions of the auricle

and from the lower wall of the external auditory meatus. Some of these trunks pass into the glands placed on the course of the external jugular vein, at its exit from the parotid. Others pass into the sub-sterno-mas-toid glands.

3. The *anterior* group is formed by 4 to 6 trunks which drain the lymph from the concha and the anterior wall of the

meatus. These vessels pass into the parotid glands and more particularly into the constant gland situated immediately in front of the tragus.

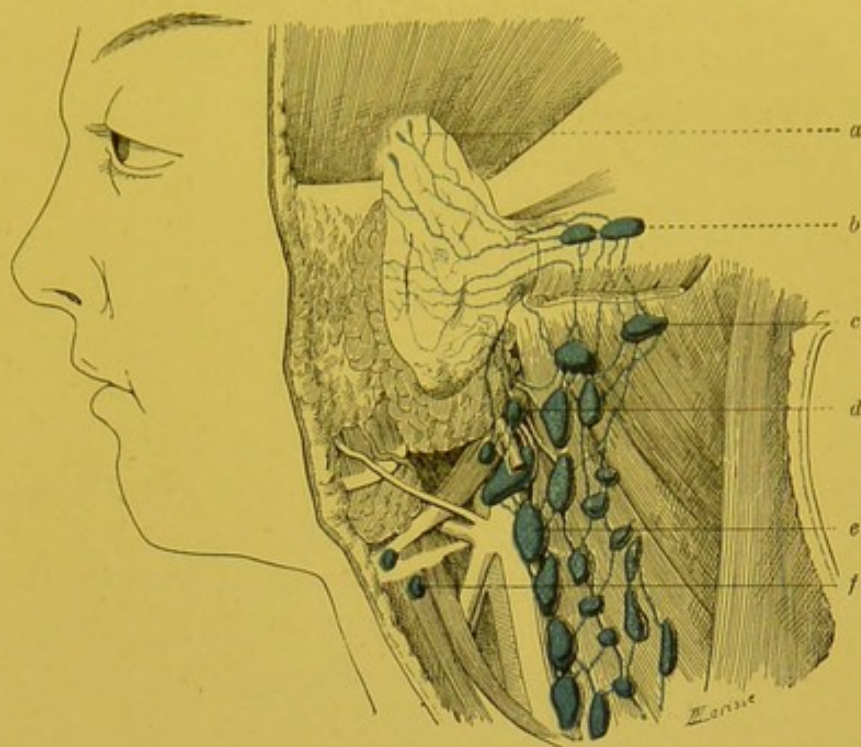


FIG. 103.—Lymphatics of the vestibule of the auricle (internal surface).

a. Collecting trunks of the auricle. *b.* Mastoid glands. *c.* Sterno-mastoid gland (external group). *d.* Gland of the external jugular chain. *e.* Sterno-mastoid gland (internal group, internal jugular chain). *f.* Sub-hyoid aberrant gland, placed in the course of the efferent vessels of the submental glands.

BIBLIOGRAPHY.—V. STAHR (H.) Ueber den Lymphapparat des äusseren Ohrs. *An. Anz.*, 1899, p. 381.

3. LYMPHATICS OF THE FACIO-CERVICAL PORTION OF THE DIGESTIVE PASSAGES.

LYMPHATICS OF THE GUMS.—The mucous membrane of the gums is covered by a network with extremely closely set meshes; its injection is nevertheless difficult. The collecting trunks of this network arise from the internal surface of the gums, then run outwards passing between the teeth; their number varies from 14 to 17 (Sappey). Having arrived on the outer side of the alveolar margins, they terminate in a large semicircular trunk which runs along the margins from before backwards, progressively increasing in size. At the level of the last molars, this trunk sinks into the

cheek and ends in the hindermost of the submaxillary glands (Sappey).

The lymphatic network of the gums is continuous, externally, with that of the mucuous surface of the lips and cheeks, and internally, with the network of the mucous membrane of the floor of the mouth in the case of the mandible, and with that of the palatine vault in the case of the maxilla.

LYMPHATICS OF THE TEETH.—The presence of lymphatic vessels in the dental pulp has not yet been demonstrated. Sappey vainly tried to inject them. Other authors, however, placed the existence of these vessels beyond a doubt (Arköwy, Odenthal, Wangermann, etc.). Their opinions, however, rest on *a priori* conceptions or on pathological deductions, but not upon direct observations.

Bödecker in 1896 observed in the dental pulp, vessels with the histological characteristics of lymphatic capillaries. More recently, Partsch and Körner have again tried to solve the question. Körner, using Gerota's method, attempted to inject the lymphatics of the pulp after exposing it. He failed in all his attempts; the mass passed exclusively into the blood vessels. On the other hand, when coloured particles were simply deposited in the dental pulp of young dogs, these particles were again found after some time in the submaxillary glands. But, though this observation may show that the inter-fascicular spaces of the pulp are in direct relation with the lymphatic system, it is insufficient to enable us to affirm the existence of lymphatic vessels in this pulp.

In short, these researches are incomplete. Körner ought to have examined, not only the submaxillary glands, but also the parotid glands. The lymphatics of the teeth, if such exist, would naturally pass into the parotid glands, following the dental vessels.

Of the relationship between dental lesions and certain affections, acute or chronic, of the submaxillary glands, there can be no doubt; but the existence of lymphatic vessels in the pulp is not necessary to explain them. The lesions of the alveolar-dental periosteum and the adjacent portion of the gum, which frequently, if not invariably, follow dental caries, are sufficient to explain the inflammation of the submaxillary glands.

BIBLIOGRAPHY.—Bædecker. *Die Anatomie und Pathologie der Zähne* (Wien u. Leipzig, Wilhem Braumüller, 1896).—Koerner. Ueber die Beziehungen der Erkrankungen der Zähne zu den chronischen Schwellungen der regionären Drüse, Berlin, 1897.—Ollendorff. Ueber den Zusammenhang der Schwellungen der regionären Lymphdrüsen . . . etc. *Deutsche Monatschrift für Zahnheilkunde*, juin 1898.—Partsch. *Odontologische Blätter*, 1899.

LYMPHATICS OF THE TONGUE.—On account of their practical

importance, we will devote more time to the consideration of the lymphatics of the tongue.

I. NETWORKS OF ORIGIN.—Some of the lymphatics of the tongue come from the mucous membrane (superficial lymphatics), others from the muscles (deep lymphatics).

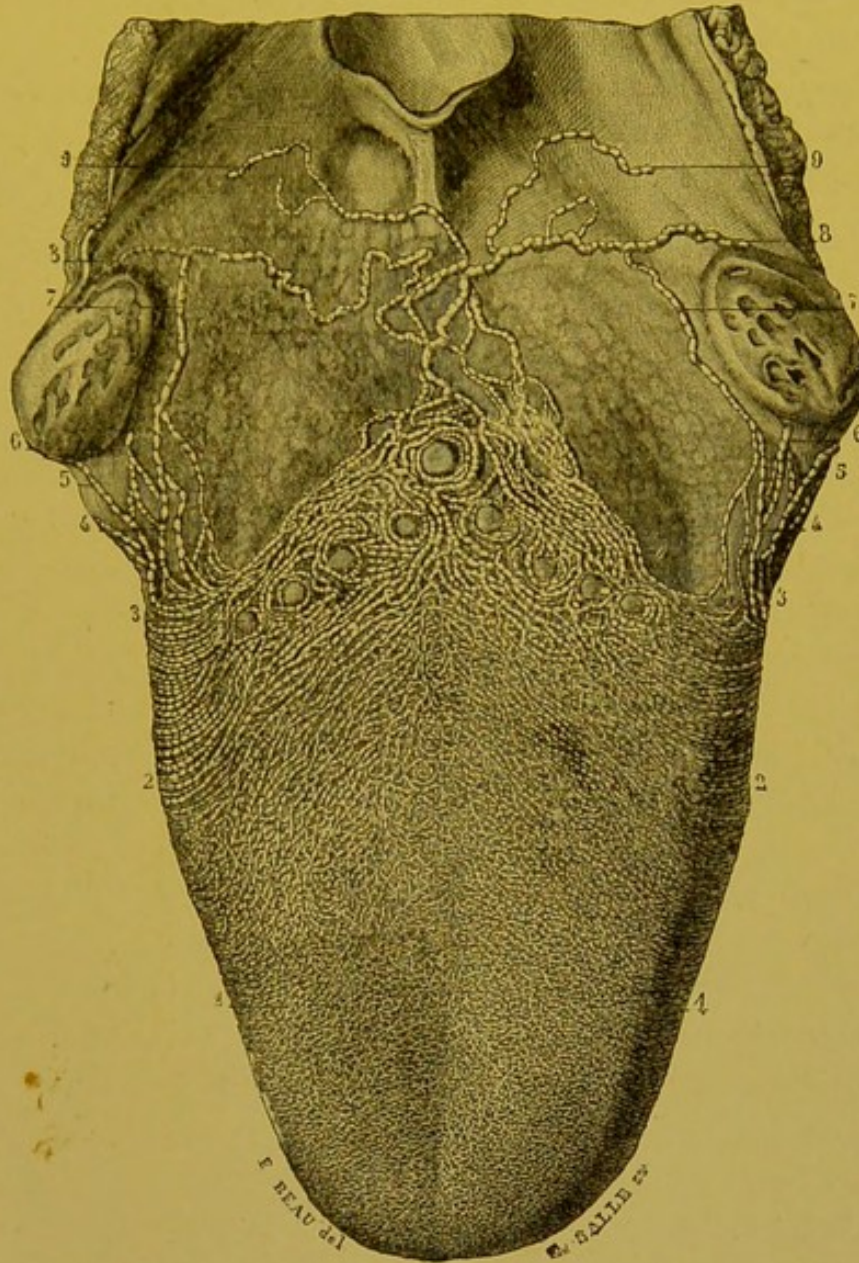


FIG. 104.—Lymphatic vessels of the dorsal surface of the tongue (after Sappey).

1, 1. Lymphatic network of the anterior third of the tongue, formed of radicles of extreme tenuity. 2, 2. Lymphatic network of the middle part, formed by larger radicles, especially on the borders of the tongue, converging from behind forwards, and from without inwards, and following the same course as the papillary grooves. 3, 3. Network which corresponds to the caliciform papillae: it is composed of much larger truncules which creep round and encircle these papillae. 4, 4. Lymphatic trunks which arise from the lateral parts of this network. 5, 5. One of these trunks which runs external to the tonsils, and passes into the middle glands of the neck. 6, 6. Anterior lymphatic glands of the soft palate anastomosing with the lateral trunks of the dorsal surface and forming with them a small plexus. 7, 7. Another lateral trunk which passes internal to the corresponding tonsil. 8, 8. Trunks which run from the middle part of this plexus. 9, 9. Other smaller trunks, stretching from the preceding, and disappearing like them through the walls of the pharynx.

1. Superficial lymphatics. — The network in the mucous membrane extends uninterruptedly over the whole of the lingual mucous membrane; at the edges of the latter, it is continuous without a clear line of demarcation with the homologous network of the adjacent mucous membrane. Sappey has given a description of this mucous membrane network which has become classical.

“When, after the injection of the lymphatic vessels of the entire free surface of the mucous membrane of the tongue, the network which covers it is examined, we notice that it differs somewhat considerably on the anterior, middle, and posterior third of the dorsal surface and on the edges of its inferior surface. *On the anterior third of the dorsal surface*, the network is remarkable for its uniform aspect, for the extreme tenuity of the radicles which go to form it, and the extreme smallness of its meshes.

“In the *middle third* it is more developed and presents a very different appearance. The papillae of the third order are arranged on this portion of the dorsal surface in linear series and parallel to the double row of caliciform papillae. We may see on either side of the median furrow, the network resolving itself into small parallel ridges like the nerves of a leaf, and having this furrow for their common centre which binds them together like the stem of a pen into which the feathers are inserted. The nearer we approach the caliciform papillae, the more important does this network become. Even in front of the caliciform papillae, the sub-papillary truncules are of considerable calibre, and are easily distinguishable to the naked eye. Passing between these papillae, they deflect and turn round them, some running on their inner and some on their outer aspect, anastomosing with each other all the way. Having arrived at the back of the caliciform papillae, they receive another multitude of branches and branchlets coming from the conical papillae which may be observed on their posterior part, to the extent of half a centimetre, then they converge and give origin to 6 or 8 large trunks. In the *posterior third*, which is vertical, only papillae of the fourth order, or extremely small papillae of hemispherical shape, exist. The lymphatic radicles which run from them are very numerous and pass almost at once into the subjacent trunks.

“At the *borders of the tongue*, the mucous membrane has as its own special attributes, folds perpendicular in direction, surmounted by tubercles or simple papillae, and separated by well marked furrows. All these folds are the starting-point of innumerable

lymphatic branchlets, which form under the base of the papillae, an extremely rich network continuous above with that on the dorsal surface and below with that on the inferior surface. This latter differs but slightly from that on the dorsal surface, and is especially characterized by the transverse direction of its meshes" (Sappey).

All the mucous lymphatics of the *body*¹ of the tongue communicate with one another, and, in some subjects, a single puncture suffices to inject them all. On the other hand, the lymphatics of the *base* of the tongue are to some extent independent, and require for their injection one or several special punctures (Küttner).

Is this independence due to the embryological difference in origin between the body and the base? We should add that the injection always passes beyond the middle line without difficulty, and that a unilateral puncture may inject the collecting trunks of both sides.

2. Deep Lymphatics.—It is almost impossible to demonstrate the muscular lymphatics by injection with mercury. They may, on the contrary, be injected by Gerota's method without much difficulty. By means of this process, we have been able to satisfy ourselves, as Küttner has done, that their collecting trunks, after a short course, unite with the efferents of the mucous membrane network.

II. COLLECTING TRUNKS.—From these networks of origin arise a considerable number of collectors, which may be divided into four groups—

1. An anterior or apical group.
2. A lateral or marginal group.
3. A posterior or basal group.
4. A median or central group.

(1) Apical Trunks.—We will reserve the name of apical trunks for those collectors which arise from the extreme point of the tongue. They are usually two in number on each side (*a* and *b*, Fig. 105), and are almost always very fine and run downwards and forwards, in or at the sides of the fraenum. They thus come in contact with the posterior surface of the mandible, where they separate. One (*b*), after being to some extent bent on the bone, runs downwards and backwards, passes between the genio-hyoglossus and the mylo-hyoid, then crosses the great cornu of the hyoid bone behind the pulley of the digastric. It then descends into the sub-hyoid region, and running along the external border of the omo-hyoid,

¹ Vide vol. iv., p. 97, *Treatise of Human Anatomy*. Poirier and Charpy.

empties itself into a gland which rests on the internal jugular immediately above the point where this vessel is crossed by the

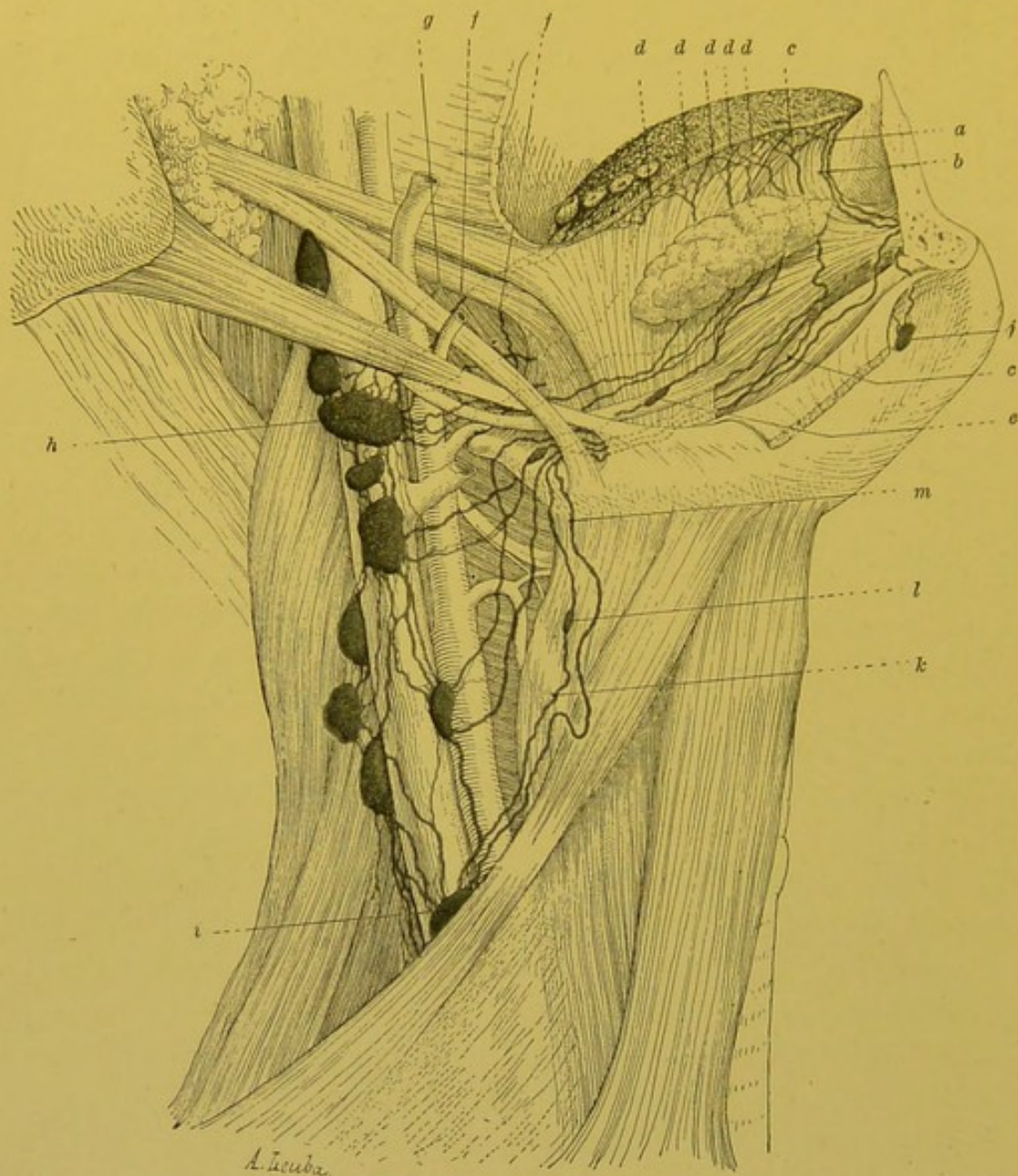


FIG. 105.—Lymphatics of the tongue, anterior view (Poirier).¹

a, b. Apical trunks. *c.* Marginal trunks. *d.* Marginal collecting trunks running with the hypoglossal nerve over the external surface of the hyoglossus. *e.* Interrupting nodule placed in the course of these vessels. *f, g.* Basal trunks. *h.* Principal gland. *i.* Supra-omo-hyoid gland. *j.* Submental gland. *k.* Central trunk ending in the supra-omo-hyoid gland. *l.* Interrupting nodule. *m.* Marginal trunk, ending in the supra-omo-hyoid gland.

omo-hyoid. The other trunk (*a*) perforates the mylo-hyoid and terminates in the supra-hyoid median glands. It usually ends in the gland nearest to the symphysis.

This termination of the lymphatics of the apex in the submental glands is not mentioned in our older works. Mascagni makes no mention of it, Sappey figures it (loc. cit., plate 21, Fig. 2), but does not describe it in his text.

In his monograph on the lymphatics of the tongue, Küttner declares he has never seen any of the lingual lymphatics terminate in the submental glands. However, there is no doubt on this point.

In twenty tongues, for the greater part taken from the new-born or very young subjects, injection of mercury has five times demonstrated this termination (Poirier, vol. v., note on p. 127). We have since met with it in several specimens injected by Gerota's method, but it must be realized that the injection of these vessels is somewhat difficult, and that success cannot be ensured except in the case of very young children.

(2) *Marginal Trunks*.—Under the name of marginal trunks, we will describe all the collectors which, arising from the network on the dorsal surface of the body of the tongue, cross the lateral borders of this organ, from its tip to the V-shaped groove on the dorsum. They vary in number from 8 to 12.

These marginal collectors at first descend almost vertically beneath the mucous membrane, then divide into two groups: an *external* which descends *external* to the sublingual gland, and an *internal* which runs *internal* to this gland.

(a) The *external collectors*, 3 or 4 in number, perforate the mylohyoid, turn round the inferior border of the mandible and terminate in the most anterior of the submaxillary glands.

(b) The *internal collectors*, usually more numerous (5 or 6), run obliquely downwards and backwards, remaining in contact with the muscular body of the tongue. Though the course of these trunks is subject to some variation, their usual arrangement may be thus classified. Some (*d*, Fig. 105) run on the external surface of the hyoglossus and are placed more or less parallel to the hypoglossal nerve. Others (*c*, Fig. 105), on the contrary, pass under this muscle and then become satellites of the lingual artery and its branches. All end in the glands of the internal jugular chain. Generally speaking, the more anterior their lingual origin the lower is the gland to which they pass.

The majority of them terminate in a large gland placed beneath the posterior belly of the digastric, and in which, as we shall shortly see, some of the collecting trunks which come from the base of the tongue, also terminate.

In the course of these marginal trunks, small glandular nodules are often met with, pointed out for the first time by Küttner and belonging to the special category of glands which we have termed para-visceral (vide General Considerations, p. 86). As may be seen in Fig. 104, these glandular nodules may be situated either under the sub-lingual or under the submaxillary gland, in the

anterior or posterior part of the digastric triangle. They may be termed lateral lingual glands.

(3) **Basal Trunks.**—We have seen (p. 272) that the rich network which surrounds the caliciform papillae gives origin to 7 or 8 large collectors. These are the posterior or basal trunks. They are always very large, and represent the principal lymphatic channel of the tongue. All these trunks at first creep underneath the mucous membrane of the base of the tongue, but at this point they may pursue two different courses, which we will designate *median* and *lateral*.

(a) The *median trunks* are 3 or 4 in number. They are always sinuous, and run at first directly from before backwards in the middle line as far as the lingual insertion of the median glosso-epiglottidean fold; here they divide into two groups of equal importance which run, one to the right, the other to the left, to join the lateral trunks. These median trunks often cross each other, and, further, it is not unusual to see one of them bifurcate at the glosso-epiglottidean fold and give rise to two secondary trunks which diverge at right angles. This posterior median pedicle is therefore really an uneven pedicle at the level of which the lymph from the two halves of the tongue mixes. The importance of this fact from a pathological point of view can be understood.

(b) The *lateral trunks*, two in number on either side, are smaller than the preceding. Springing from the lateral extremities of the network which surrounds the caliciform papillae, they run from before backwards, and unite with the preceding at the lower end of the tonsil. As they pass onwards, the posterior trunks receive some very delicate lymphatics coming from the mucous membrane of the base of the tongue. They all disappear by passing deeply in the sub-amygdaloid region, but traverse the pharyngeal wall at different points; a fact which we can readily prove in an injected specimen by looking for them on their emergence from the lateral wall of the pharynx.

It may then be observed that some, after traversing the superior constrictor near its lingual insertion, appear beneath the styloglossus, and at first embrace the dorsalis linguae and then the lingual artery itself (*f*, Fig. 105). Other trunks, more posterior, emerge behind the preceding through the superior border of the middle constrictor (*g*, Fig. 105). All terminate in a large gland placed on the internal jugular immediately beneath the posterior belly of the digastric. It is also in this gland that some of the marginal trunks

terminate as we have already seen (*d*, Fig. 105). It is therefore one of the most important of the glandular termini of the lymphatics

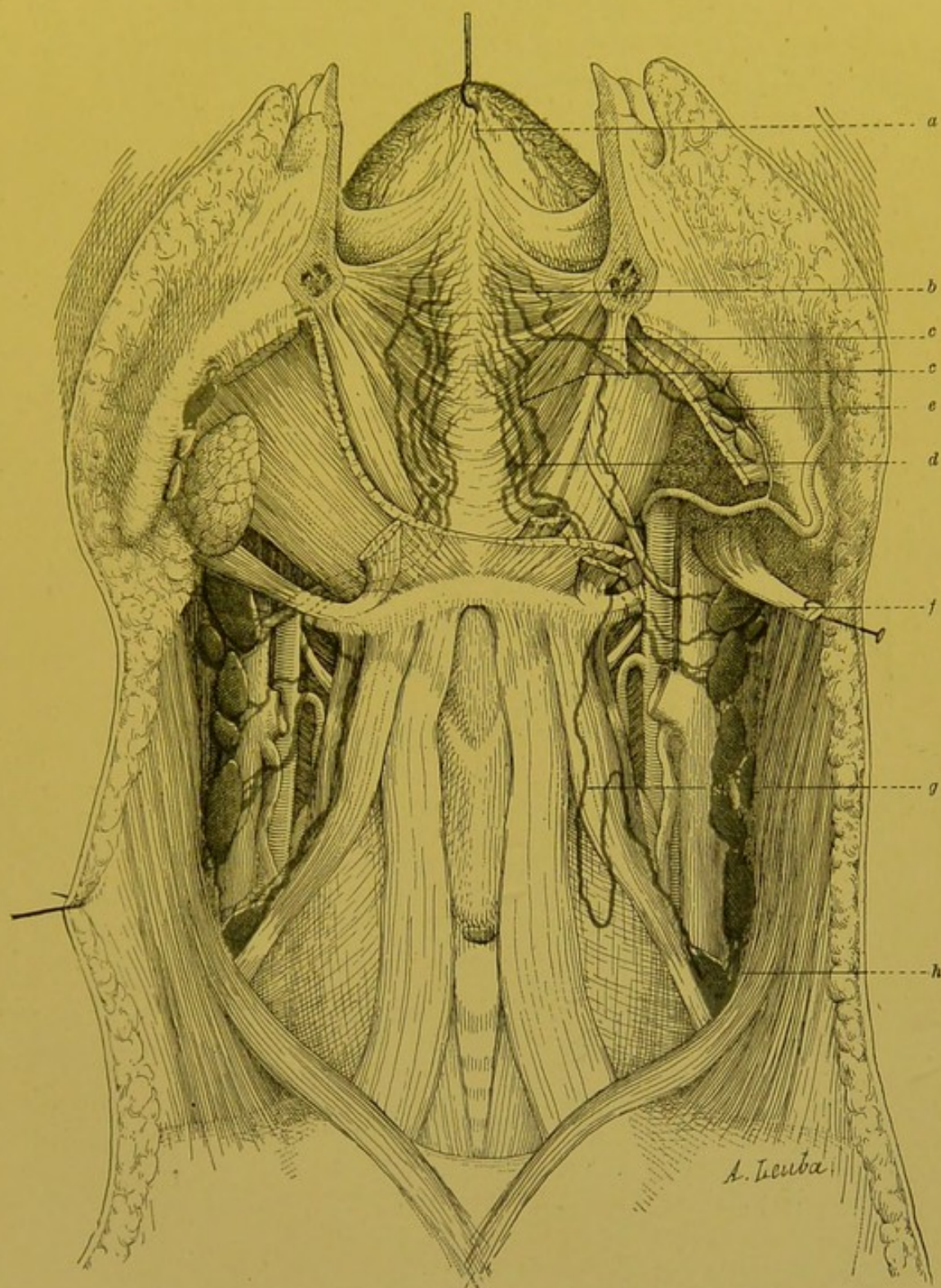


FIG. 106.—Lymphatics of the tongue, anterior view (Poirier).

The inferior maxilla has been sawn through in the middle line, and the two halves drawn aside. The two central trunks may be seen running between the two genio-hyoglossi which have been removed. *a*. Apical trunk. *b*. Inconstant trunk ending in a submaxillary gland. *c*, *c*. Central trunks. *d*. Intra-lingual glandular nodule. *e*. Submaxillary gland. *f*. Principal gland. *g*. Central trunk forming a loop in the supra-hyoid region before ending in the supra-omo-hyoid gland. *h*. Supra-omo-hyoid gland.

of the tongue: Küttner calls it by the expressive name of *Hauptganglion* (*h*, Fig. 105). Some basal trunks emerge still lower down; they perforate the thyro-hyoid membrane and appear beneath the hyoid bone and terminate in a gland which lies underneath the preceding. Küttner has seen one of these trunks end in a gland situated much deeper, a little above the omo-hyoid (*i*, Fig. 105).

(4) Central Trunks (vide Fig. 106).—The central trunks arise from the middle part of the dorsal network of the body of the tongue; instead of running towards the lateral parts, they descend in the middle line between the two genio-hyoglossi (*c*, Fig. 106). They thus

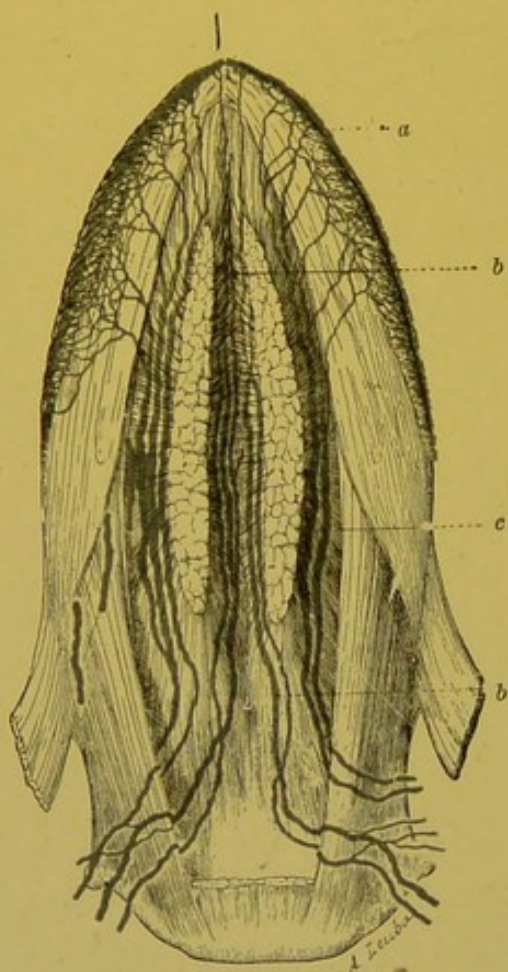


FIG. 107.—Lymphatics of the tongue inferior surface (Poirier).

The tongue has been detached from the maxilla; the two genio-hyoglossi being separated from each other, enable the central trunks to be seen, on which there are fusiform dilatations. *a*. Marginal network. *b*. Central trunk. *c*. Marginal trunk.

They may be called *intra-lingual glands* (*d*, Fig. 106). They must not be confused with the fusiform dilatations which these central trunks occasionally present.

form an unequal single and median pedicle which breaks up into two secondary pedicles at the inferior border of these muscles; at this point, in fact, they pass some to the right, others to the left. They are placed between the genio-hyoglossus and the genio-hyoid muscles, follow the deep surface of the mylo-hyoid, and then appear in the submaxillary space. They afterwards pass either in front of, or behind the pulley of the digastric, and crossing the hyoid bone terminate in the glands of the internal jugular chain. Some of them end in the chief gland; others in a gland lying above the omo-hyoid (*k*, Fig. 105, and *g*, Fig. 106), others finally, in glands lying between the two preceding.

We frequently see in the course of these vessels small glandular nodules, placed either between the two genio-hyoglossi, or between them and the genio-hyoids.

To sum up, the lymphatics of the tongue terminate in the supra-hyoid median, the submaxillary, and in the glands of the internal jugular chain, but the relative importance of these different glandular groups considered as termini of the lymphatics of the tongue is by no means the same. The supra-hyoid median glands only receive lymphatics from the extreme tip of the tongue. As regards the submaxillary glands, only the most anterior of them have lingual lymphatics as direct affluents, and the three or four trunks which do end in this gland drain a region which is limited to the lateral borders, and to the marginal part of the dorsum. On the other hand, all the glands of the internal jugular chain, included between the posterior belly of the digastric and the spot where the vessels are crossed by the omo-hyoid, may receive lymphatics coming from the tongue. But, here again, the exact number of affluents each receives has to be determined: and we have seen that the highest of these glands, i.e. the gland placed over the internal jugular, immediately beneath the posterior belly of the digastric, should be regarded as the principal meeting-place of the lingual lymphatics.

Voy. sur les lymphatiques de la langue: Kuttner. Ueber die Lymphg. u. Lymphdr. der Zunge mit Beziehung auf die Verbreitung des Zungencarcinoms. *Beitz. z. klin. Chir.*, 1898, xxi, 3, p. 732.—Poirier. Le système lymphatique et le cancer de la langue. *Gaz. hebdom.*, 11 Mai, 1902.

LYMPHATICS OF THE VAULT OF THE PALATE.—The lymphatics of the roof of the palate take origin from a network with very fine meshes, placed in the most superficial portion of the dermal mucous membrane. From this network start several branches which run in a deeper plane. All these branches run obliquely backwards and inwards towards the middle line. In the region of the latter, they unite into several small trunks which run directly backwards as far as the last molars. At this spot, they are directed outwards, pass in front of the anterior pillars of the fauces, and then perforate the superior constrictor of the pharynx. They terminate in the glands of the sub-sterno-mastoid chain, which are placed on the internal jugular vein, immediately beneath the point where this vessel is crossed by the posterior belly of the digastric.

The lymphatic network of the roof of the palate is continuous in front and at the sides with that of the gums, and behind with that of the inferior surface of the soft palate.

LYMPHATICS OF THE SOFT PALATE.—The mucous membrane of the soft palate is extremely rich in lymphatic vessels. The two

surfaces of the palate, its free border, and the pillars of the fauces are covered by an extremely fine network which is continuous, without a clear line of demarcation, with the homologous networks of neighbouring parts. It is in the uvula that this lymphatic network is richest. Here, "the lymph channels multiply in such abundance that, after successful injections, the uvula is transformed into a little knot of lymphatic vessels. It then increases to twice or three times its size, and one might think, from this turgidity, that we were witnessing a sudden erection" (Sappey).

The lymphatic collectors of the soft palate may be divided into three groups, according to their origin from the superior or inferior surfaces, or from the pillars of the fauces.

1. The collecting trunks of the *upper surface* of the soft palate run backwards and outwards below the pharyngeal orifice of the Eustachian tube: here, they unite with the collectors of the mucous membrane of the nasal fossae, and like the latter, divide into two groups: (a) some, the *ascending trunks*, run backwards and upwards under the mucous membrane which lines the lateral walls of the pharynx. Arrived at the junction of the lateral and posterior walls, they perforate the superior constrictor and pass into the retro-pharyngeal glands; (b) others, the *descending trunks*, run downwards and outwards, passing under the mucous membrane of the posterior pillars. A little above the great cornua of the hyoid bone, they traverse the constrictors and terminate in the glands placed on the internal jugular, beneath the posterior belly of the digastric.

2. The collecting trunks of the *inferior surface* appear on the lateral parts of this surface. They run downwards and forwards, under the mucous membrane of the anterior pillars. They unite with the collectors of the vault of the palate, then like the latter, turn round the anterior pillar, perforate the superior constrictors, and terminate in the glands of the internal jugular chain which are subjacent to the posterior belly of the digastric.

3. The collectors of the *anterior pillar* unite with the preceding, pursuing the same course and terminating in the same way. The *collectors of the posterior pillar* follow the same course as the descending collectors of the superior surface of the palate and terminate in the same glands as these vessels. However, some of these vessels which spring from the lower part of the pillar perforate the wall of the pharynx, below the hyoid bone, and terminate in

the glands placed over the internal jugular, at the level of the bifurcation of the common carotid.

LYMPHATICS OF THE PHARYNX.—The lymphatic apparatus of the pharynx is considerably developed as regards the richness of the pharyngeal mucous membrane in lymphoid tissue (*vide*¹ vol. iv. p. 162 et seq.).

NETWORKS OF ORIGIN.—The lymphatics of the pharynx arise from two networks, one mucous and the other muscular.

The *mucous network* spreads beneath the pharyngeal epithelium in the superficial layer of the mucous cutis. This network presents

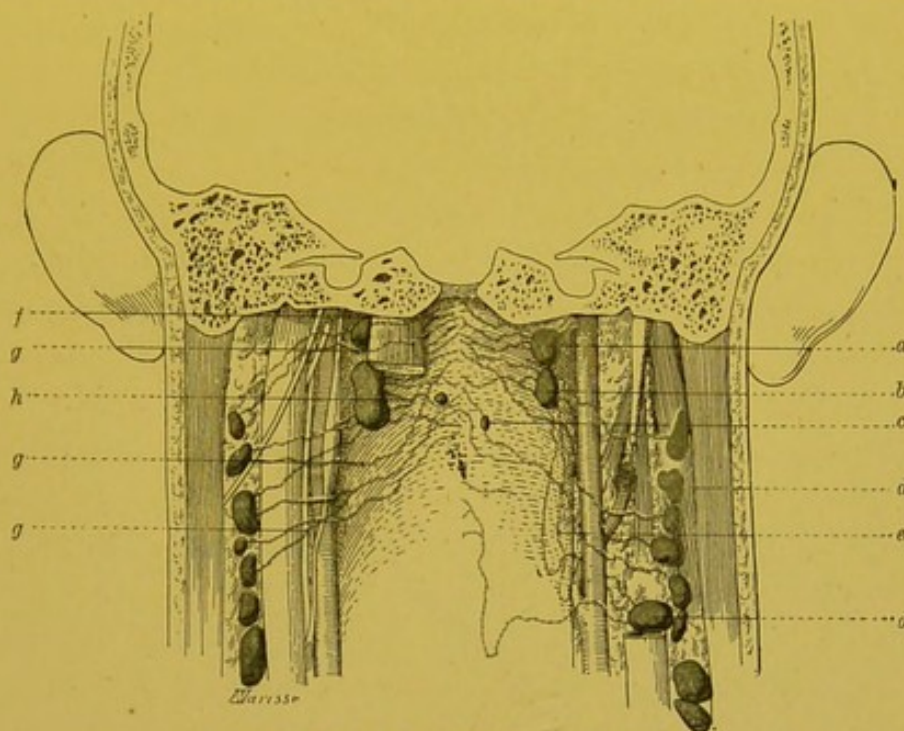


FIG. 108.—Lymphatics of pharynx.

a, b. Retro-pharyngeal glands. *c.* Interrupting glandular nodule, placed in the course of the afferent vessels of these glands. *d.* Gland of the deep cervical chain. *e.* Efferent vessel of retro-pharyngeal glands, passing in front of the internal carotid artery. *f.* Afferent of the retro-pharyngeal glands, passing behind the right rectus capitis anticus major. *g.* Lymphatic of the pharynx, passing directly to a gland of the deep cervical chain. *h.* Afferent of retro-pharyngeal glands.

its maximum of development in the mucous membrane which lines the posterior surface of the larynx, and the pharyngeal-laryngeal pouches. In the pharyngeal tonsil it is extremely rich, and its meshes become remarkably fine (On the histological origins of the lymphatics of the tonsil, *vide*¹ vol. iv. pp. 90, 92). The network is singularly scanty at the junction of the pharynx and oesophagus, and here a careful examination shows that the small branches to which it gives rise tend to group themselves into two streams, one ascending or pharyngeal, the other descending or oesophageal (Most).

¹ *Treatise of Human Anatomy.* Poirier and Charpy.

The *muscular network*, which is of much less importance, has only been injected by Sappey in the ox and horse.

COLLECTING TRUNKS.—From these two networks, but more particularly from the mucous network, run several *collectors* which may be divided into three groups: superior, middle and inferior.

1. The *superior* collecting trunks arise from the vault of the pharynx, from the lateral walls of the nasal pharynx, and from the upper half of the posterior wall.

The majority of these vessels are directed towards the posterior middle line, where they traverse the pharyngeal wall. They then run outwards, enclosed within the peri-pharyngeal fascia, and terminate in the retro-pharyngeal glands, situated, as we have seen, at the junction of the posterior lateral surfaces of the pharynx, internal to its sagittal fascia. In their course, these vessels may present small interrupting glandular nodules, which are in more or less close proximity to the middle line, and which must not be confused with the true regional glands, which are always lateral.

Some of the collecting trunks may have a different arrangement to that we have just indicated: thus, some may avoid the retro-pharyngeal relay, and pass directly to the superior and middle glands of the internal jugular chain, running obliquely behind the sympathetic and the large vessels and nerves. Some of these vessels pass behind the rectus capitis anticus major, between the latter and the vertebral column (vide Fig. 108).

Finally, some of the collecting trunks, instead of emerging from the posterior middle line, perforate the pharyngeal wall at the junction of its posterior and lateral surfaces, and terminate at once in the retro-pharyngeal glands; but this shortened course is the exception, and Most is right in insisting that the collecting trunks usually emerge from the middle line in the upper part of the pharynx (vide Fig. 108).

2. The *middle* collectors arise from the amygdaloid region and from the mucous membrane of the adjacent parts. These vessels perforate the muscular coat a little above the great cornu of the hyoid bone, and terminate in the glands placed on the internal jugular, immediately beneath the posterior belly of the digastric.

3. The *inferior* collectors arise from the whole of the inferior portion of the pharynx. They converge towards the middle portion of the pharyngeal-lateral pouches (sinus pyriformis), running underneath the mucous membrane. Here, they unite with the lymphatics which constitute the superior pedicle of the larynx, and have a

similar termination. They thus end in 4 or 5 glands of the internal jugular chain which lie along this vessel, or immediately behind it, between the posterior belly of the digastric and the middle part of the thyroid body. These collecting trunks usually present in their course small interrupting glandular nodules placed on the external surface of the thyro-hyoid membrane (vide Fig. 110).

To sum up, the lymphatics of the pharynx end either in the retro-pharyngeal glands or in the glands of the internal jugular chain. The glands of this chain which receive the lymphatics of the pharynx all belong to the internal group of the sub-sterno-mastoid glands (vide p. 257).

Surles lymphatiques du pharynx, voy.: Most. Ueber den Lymphgefäßsapparat von Nase und Rachen. *Arch. f. Anat. und Phys.*, Anat. Abth., 1901, p. 74.

LYMPHATICS OF THE CERVICAL PORTION OF THE OESOPHAGUS.—The lymphatics of the cervical portion of the oesophagus take origin from two networks, one mucous and the other muscular. As we have seen, the mucous network at its upper part is relatively independent of the homologous network of the pharynx. The collecting trunks coming from these two networks terminate in the sub-sterno-mastoid glands and in the glands of the recurrent chain.

4. LYMPHATICS OF THE FACIO-CERVICAL PORTION OF THE RESPIRATORY PASSAGES.

LYMPHATICS OF THE NASAL FOSSAE.—NETWORK OF ORIGIN.—The lymphatics of the nasal fossae arise from a continuous network, placed in the most superficial part of the corium of the mucous membrane. The appearance of this network varies considerably in different regions. At the posterior extremity, or tail of the superior turbinate bone, this lymphatic network presents its maximum development. It is here that the first attempt at injection must be made. It also presents somewhat closely set meshes on the inferior wall of the nasal fossae and over the turbinate bones and the middle and inferior meatuses. On the other hand, the small branches which compose it, become extremely fine on the superior turbinate bone and over the whole of the internal wall, and in these places, their injection presents great difficulties. This is also the case the nearer we approach the anterior orifice of the nasal fossae. As a general rule, the richness of the network and the ease with which it can be injected are here, as everywhere, in direct proportion to the thickness of the mucous membrane.

This network of origin is continuous in front with the cutaneous network of the vestibule of the nasal fossae. Behind, it is continuous with that of the pharynx and the upper surface of the soft palate. At the back part of the septum, there is a continuity between the networks of the two nasal fossae; thus, a unilateral puncture of the septum may inject the collectors of the nasal fossae of the opposite side.

In the olfactory region of the mucous membrane of the nasal fossae, there are present, by the side of the lymphatic networks properly so called, formations which are to a certain extent comparable with them; these are the meningeal sheaths of the filaments of the first pair of nerves. Now, when these sheaths are injected through the sub-arachnoidean space, it sometimes happens that the lymphatics of the nasal mucous membrane are filled at the same time (vide¹ vol. iii. p. 777, Fig. 421). Axel, Key and Retzius, who first pointed out this fact, have however never seen direct communications between the perolfactory sheaths and the lymphatics of the mucous membrane. The injection passed into the latter by means of fine canals which traversed the foramina of the cribriform plate at the same time as the olfactory filaments, though remaining independent of the lymphatic sheaths of the latter. According to Key and Retzius, there is therefore direct communication between the sub-arachnoidean space and the lymphatics of the pituitary body. We confess we are not absolutely convinced of the reality of this communication. On account of the practical interest which is attached to this question, from the standpoint of the pathogeny of certain cerebral lesions consecutive to nasal infections, we think it advisable that further researches should be undertaken on this particular point regarding the anatomy of the lymphatics of the pituitary body.

THE COLLECTING TRUNKS of the network of the nasal fossae form two groups: anterior and posterior.

(a) The *anterior trunks*, which are of much less importance, can only be injected by punctures made into the anterior third of the mucous membrane of the nasal fossae. Varying in number, they run either in the groove which separates the triangular cartilage of the nose from the bony orifice upon which it rests, or between the different cartilages, or even in front of them. They thus arrive at the cellulo-adipose subcutaneous tissue, where they unite into two trunks which more or less closely embrace the facial vein and terminate in the submaxillary glands (Most). They anastomose with the lymphatics of the integuments of the nose (vide p. 265).

(b) The *posterior trunks*, which are much larger than the preceding, constitute the *principal lymphatic channel* of the nasal fossae. They arise at the junction of the nasal fossae and the pharynx, below and a little in front of the pharyngeal orifice of the Eustachian tube. Here there is a kind of centre around which the meshes of the adjacent portions of the network appear to group themselves,

¹ *Treatise of Human Anatomy*, Poirier and Charpy.

and which constitutes the general meeting-place of the lymphatics of the pituitary. The trunks originating from this region may follow two courses: *a primary group* of collecting trunks (2 or 3) runs downwards and outwards, under the mucous membrane of the posterior pillar. Slightly above the great cornu of the hyoid bone, these vessels unite with the lymphatics coming from the tonsillar region, perforate the muscular coat of the pharynx and terminate in 1 or 2 glands lying on the internal jugular below the posterior belly of the digastric. As we have already seen (p. 257), these glands belong to the internal group of the sub-sterno-mastoid

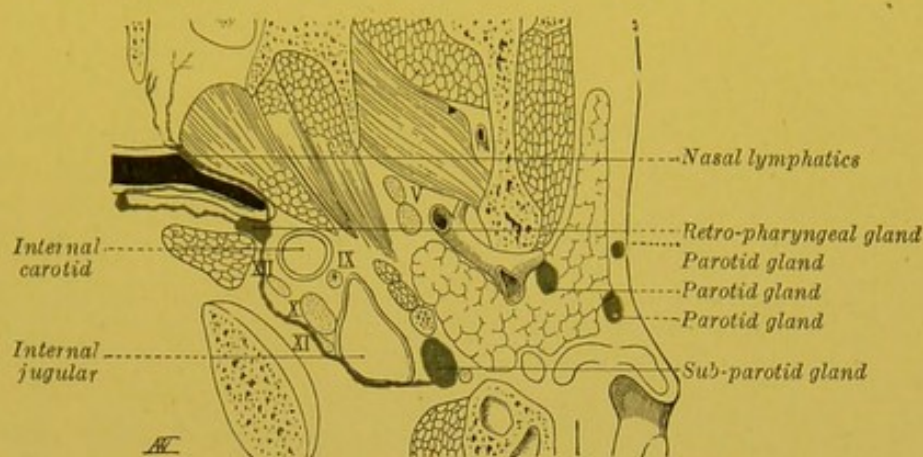


FIG. 109.—Scheme of the course of the collecting trunks of the nasal fossae ending in the retro-pharyngeal glands.

glands. The *second group* of these collectors comprises 2 to 4 vessels which are larger than the preceding. These run from before backwards on the lateral wall of the pharynx, coursing underneath the mucous membrane. When they arrive at the junction of the lateral and posterior walls of the pharynx, they perforate the superior constrictor, and terminate in the retro-pharyngeal glands (vide p. 257).

To sum up, the lymphatics of the mucous membrane of the nasal fossae terminate in the retro-pharyngeal glands, in the upper glands of the internal jugular chain, and very occasionally in the sub-maxillary glands. The retro-pharyngeal group is of particular importance, for, at whatever point the mucous membrane happens to be punctured, these glands are always coloured by the injected material (Most).

Lymphatics of the Sinuses.—Our knowledge of the lymphatics of the mucous membrane which lines the cells and sinuses of the nasal fossae is still imperfect. The small degree of development which these cavities present in the infant (the usual subject for experimentally injecting the lymphatics) renders the study of these lymphatics somewhat difficult. *A priori*, if we base our opinions on the origin of these cavities and the arrangement of

their blood vessels, as described by Zuckerkand, we may admit that their lymphatics end in the same glands as those of the nasal fossae. Moreover, this is what the researches of Most appear to demonstrate, in whose opinion, all the cells and sinuses, including the frontal sinuses, send their lymphatics into the retro-pharyngeal glands. The existence of lymphatics, traversing the outer wall of these cavities to join the lymphatics of the face, is, however, possible; but up to the present no one has succeeded in injecting them.

The lymphatics of the nasal fossae were well described for the first time by E. Simon (1859). Sappey injected them in man, the horse, the sheep and the ox, and gave an excellent description of their network of origin. Quite recently, Most has studied the collecting trunks of this network and has described them very completely.—Most. Ueber den Lymphgefäßapparat von Nase und Rachen. *Arch. f. Anat. u. Entwicklungsgesch.*, Anat. Abth., 1901, p.74.

LYMPHATICS OF THE MIDDLE EAR.—Our knowledge of the lymph-

phatics of the tympanum is still very imperfect. It is admitted that these vessels spring from a network attached to the mucous membrane, and terminate in the glands contained in the parotid space and in the retro-pharyngeal glands. The lymphatics of the Eustachian tube run towards its pharyngeal orifice and terminate in the retro-pharyngeal glands. On account of the importance of these vessels from a practical point of view, we think their study should be undertaken again.

LYMPHATICS OF THE LARYNX.—

NETWORK OF ORIGIN.—The network of origin of the lymphatics of the larynx extends over the whole of the internal surface of the organ. It is densest where the mucous membrane is thickest. We may regard it as formed of two distinct regions, corresponding respectively to the supra and infra-glottic zone of the larynx.

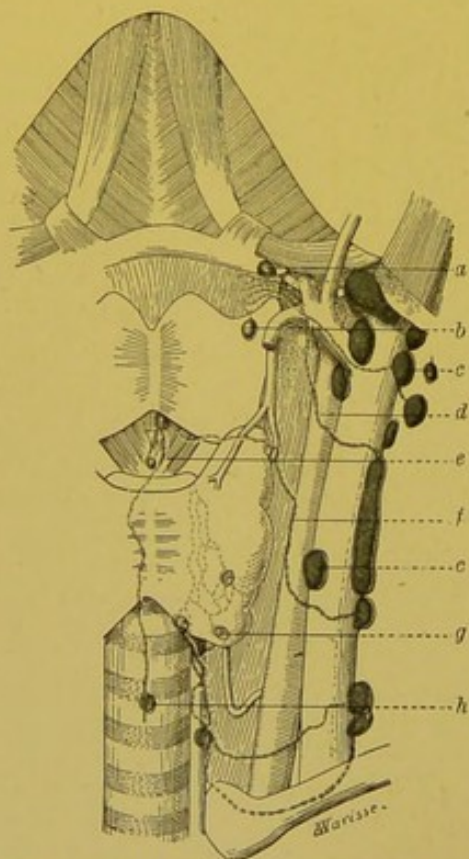


FIG. 110.—Lymphatics of the larynx (after Most).

a, b. Thyro-hyoid glandular nodules placed in the course of the collecting trunks coming from the pharyngo-laryngeal sinuses. *c, c.* Glands of the internal jugular chain. *d.* Collecting trunk of the superior pedicle. *e, f.* Collecting trunk of the middle pedicle. *g.* Gland of the recurrent chain. *h.* Prae-tracheal gland.

In the upper region, the network, which is extremely dense and very easy to inject, covers the epiglottis, the aryteno-epiglottic folds, the superior vocal cords, and the ventricles of the larynx. The network of the lower region, though equally well developed, is however not so plentiful as the supra-glottic network.

These two regions are separated by the inferior vocal cords, in the region of which the lymphatic vessels are very scanty and very thin. The drying of the mucous membrane, which is here very fine, renders the injection of this glottic network somewhat difficult (Poirier). When this network is injected, the injection usually passes into the vessels of the supra-glottic zone, more rarely into those of the sub-glottic zone (Most). Though the two lymphatic territories of the larynx largely communicate with each other in the posterior wall of the larynx, it is rare to obtain a complete injection of the endo-laryngeal network by puncturing only one of these territories. It may be added that the injections easily cross the middle line; but though the mass injected into one half of the larynx easily passes into the mucous membrane of the other side, it is, on the other hand, exceptional for it to pass as far as the corresponding glands of that side. The lymphatics of the larynx anastomose to a large extent with the networks of the adjacent organs (tongue, pharynx, trachea).

II. COLLECTING TRUNKS.—1. The trunks coming from the *supra-glottic network* are directed towards the lateral borders of the epiglottis and the aryteno-epiglottic folds; they afterwards descend into the sinus pyriformis, and then perforate the thyrohyoid membrane at the spot where the superior laryngeal artery enters. Here, they usually number from 4 to 5. After emerging, they diverge. One or two ascend, cross the hypoglossal nerve, and end in a sub-sterno-mastoid gland placed immediately below the posterior belly of the digastric. One or two middle trunks, horizontally placed, reach the glands placed on the internal jugular vein opposite the bifurcation of the common carotid. Finally, one or two descending trunks terminate in the glands belonging to the same chain, but situated lower down, at the level of the middle part of the lateral lobes of the thyroid body (vide Fig. 110).

2. The trunks coming from the *subglottic region* are grouped into two distinct pedicles, one anterior, and the other posterior.

(a) The *anterior* or *supra-cricoid* pedicle is formed by 3 or 4 trunks which come through the crico-thyroid membrane near the middle line. One and sometimes two of these trunks end in

the praelaryngeal glands (vide p. 261), while a third passes in front of the isthmus of the thyroid body and empties itself into a prae-tracheal gland (Most); one or several others run downwards

and outwards, towards one of the middle glands of the internal jugular chain (vide Fig. 110).

(b) The *posterior* or *sub-cricoid* pedicle traverses the crico-tracheal membrane at the junction of the lateral and posterior surfaces of the trachea. It includes several trunks which embrace the recurrent laryngeal nerve and the terminal part of the inferior laryngeal artery, and terminate in the glands of the recurrent chain. From the latter glands run some trunks which pass to the sub-sterno-mastoid and supra-clavicular glands (vide Fig. 111). The trunks of the posterior pedicle anastomose with the lymphatic vessels of the

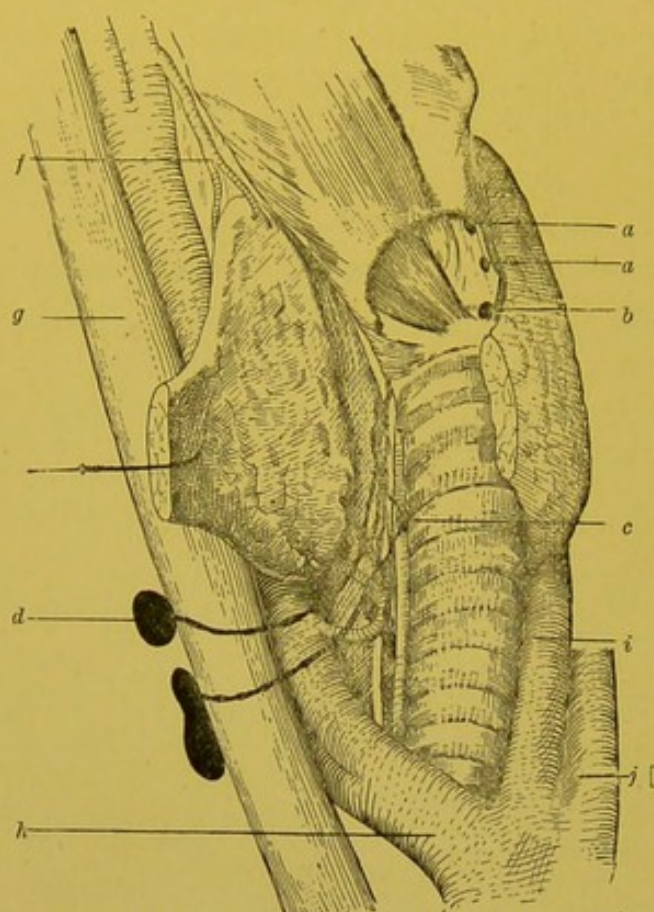


FIG. 111.—Recurrent chain (after Roubaud).

a, a. Praelaryngeal glands. *b.* Praecricoid gland. *c.* Gland of the recurrent chain. *d.* Gland of the external jugular chain. *f.* Superior thyroid artery. *g.* Internal jugular vein. *h.* Innominate artery. *i.* Left common carotid artery. *j.* Left sub-clavian artery.

thyroid body, and, when they are injected, we often obtain a partial injection of the perithyroidean network.

To sum up, the lymphatics of the larynx end in the glands of the recurrent chain, in the sub-sterno-mastoid glands, and accessorially in the supra-clavicular glands. The sub-sterno-mastoid glands represent their principal terminus. In this connexion we should remark that the laryngeal lymphatics, like the majority of the other lymphatics of the neck, are more particularly distributed to the inner glands of this group, i.e. to the glands arranged vertically along the internal jugular vein. As regards the praelaryngeal glands, we have seen above (p. 261) that they have to be regarded not as regional glands, but as simple interrupting

glandular nodules placed over the course of the collecting trunks of the middle group.

It is interesting to remark in passing that the small glands which are found on the thyro-hyoid membrane, near the spot where the trunks of the superior pedicle emerge, receive no lymphatics coming from the larynx. They are attached to the collectors which spring from the pharyngo-laryngeal sinuses; they therefore belong to the lymphatic apparatus of the pharynx (vide pp. 282 and 283).

BIBLIOGRAPHY—Poirier. Lymphatiques du larynx. *Progres medical*, 1887, No. 19.—Most. Ueber die Lymphgefäße u: Lymphdrüsen des Kehlkopfes. *Anat. Anz.*, 1899, pp. 387, 393.—Most. Ueber den Lymphgefäßapparat von. Kehlkopf u. Trachea, etc., *Deutsche Zeitschr. f. Chir.*, 1900, lvii. p. 199.—Roubaud. Contribution a l'étude des lymphatiques du larynx. *These Paris*, 1902.

LYMPHATICS OF THE CERVICAL PORTION OF THE TRACHEA.—These lymphatics arise from a submucous network, which is very scanty and difficult to inject. The trunks coming from it run in the intercartilagenous spaces, perforate the latter close to their posterior extremities, and terminate in the glands of the recurrent chain.

LYMPHATICS OF THE THYROID BODY.—NETWORK OF ORIGIN.—The lymphatic vessels of the thyroid body, the origin of which we need not here recall (vide vol. iv. pp. 578, 581¹), eventually terminate in a network placed within the actual thickness of the capsule of this organ. To this network may be attached some small glands to which Most has recently drawn attention. Legendre, too, some time ago pointed out the possible presence of a gland at the posterior border of the lateral lobes of the gland, slightly above their lower extremities; but these old observations must be accepted with reserve, on account of a possible confusion with the parathyroid glands, which were then unknown.

II. COLLECTING TRUNKS.—From the peri-thyroidean capsular network run two kinds of trunks, one ascending, the other descending.

1. The *ascending trunks* are partly median and partly lateral. The median trunks detach themselves from the superior border of the isthmus and reach the praelaryngeal gland (Legendre, Gerard, Marchant). The lateral more or less exactly follow the course of the superior thyroid artery, and end in the sub-sterno-mastoid glands, placed at the bifurcation of the common carotid.

2. The *descending trunks* also form two groups, some of which the median, reach the praetracheal glands; others, the lateral pass to the glands of the recurrent chain.

¹ *Treatise of Human Anatomy*. Poirier and Charpy.

CHAPTER VI

TERMINAL COLLECTING TRUNKS OF THE LYMPHATIC SYSTEM

THE terminal collecting trunks of the lymphatic system all finally end in the junction of the internal jugular and sub-clavian veins. It is quite exceptional to see lymphatic vessels terminate at other points of the venous system. The endings formerly described by Lippi (1830) in the inferior vena cava, portal vein, etc., and more recently by Leaf into the femoral vein, are not admitted to-day by any other anatomist.

The lymphatics of the sub-diaphragmatic portion of the body unite to form a single canal, the *thoracic duct*, which terminates in the junction of the internal jugular and left sub-clavian veins. The lymphatics of the sub-diaphragmatic portion resolve themselves both on the right and left sides, into three collecting trunks, viz. the *jugular*, the *sub-clavian*, and the *broncho-mediastinal*. On the left side, these vessels are often only simple affluents of the terminal segment of the thoracic duct. On the right, they sometimes unite, but not very often, into a common trunk—the right lymphatic duct.

§ 1. TERMINAL COLLECTING TRUNKS OF THE SUPRA-DIAPHRAGMATIC PORTION OF THE BODY.

As we have just seen, the lymphatics of each of the two halves of the supra-diaphragmatic portion of the body are finally reduced to three collecting trunks: the *jugular trunk*, which comprises the lymphatic circulation of the corresponding side of the head and neck, and is formed by the confluence of the efferent vessels of the inferior glands of the deep cervical chain; the *sub-clavian trunk*, which is formed by the union of the majority of the efferent vessels of the axillary glands, and drains the lymph from the upper limb of the corresponding side; the *broncho-mediastinal trunk*, which, on each side, results from the union of the efferents of the internal mammary chain and those of the anterior mediastinal and peritracheal-bronchial glands, and thus receives the majority of

parietal lymphatics and the whole of the visceral lymphatics of the thorax. Each of these trunks is often double, sometimes even triple. Their mode of termination in the venous junction varies on the two sides.

ON THE RIGHT, we may meet with the following arrangements :—

The three terminal collecting trunks may open separately into the venous junction. This is the most usual arrangement. The subclavian and internal jugular trunk then terminate very close to one another, near the apex of the angle which is open above and externally, and formed by the union of the internal jugular and subclavian. The broncho-mediastinal trunk terminates in the

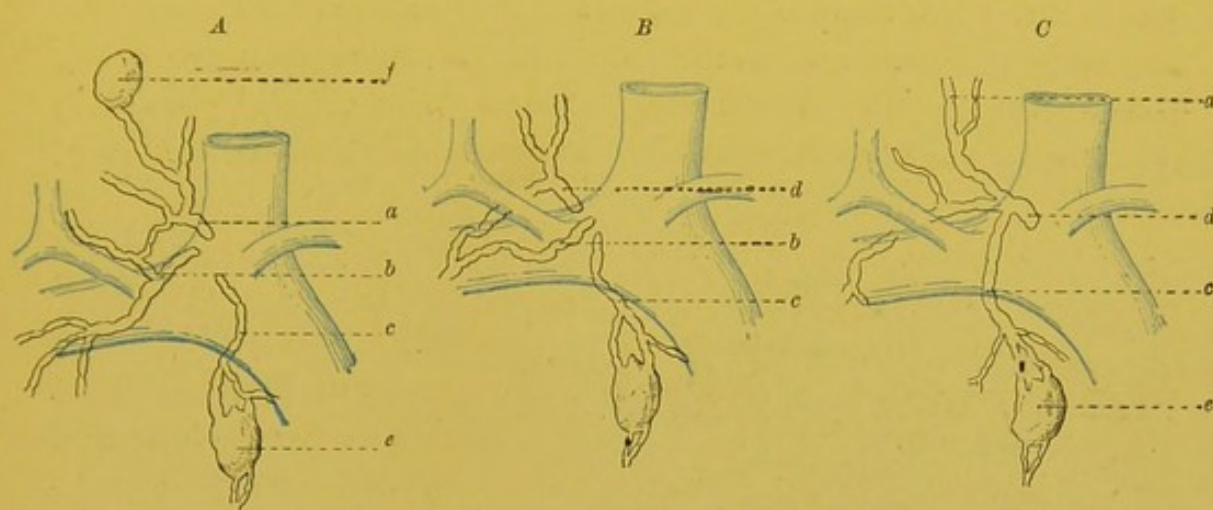


FIG. 112.—Terminal collecting trunks of the right half of the supra-diaphragmatic portion of the body.

a. Jugular trunk. b. Subclavian trunk. c. Broncho-mediastinal trunk. d. Right lymphatic duct. e. Gland of the internal mammary chain. f. Gland of the deep cervical chain.

anterior surface of the venous junction (vide *a*, Fig. 112).

In other cases, the sub-clavian and the jugular trunks unite into a common trunk (vide *b*, Fig. 112). This trunk is usually styled the *right lymphatic duct*. It is always very short and rarely exceeds 10 to 12 millimetres. This arrangement is moreover rare, seeing that Grossmann only met with it once in twenty-five subjects ; and further, it should be mentioned that in this case, the subclavian trunk was double and that the more important of the two secondary trunks passed directly into the venous confluence. The right lymphatic duct is therefore most usually absent. It is still more rare to see the bronchio-mediastinal trunk unite with the two preceding to form with them a single trunk (vide *c*, Fig. 112). It is less rare to see it unite with the subclavian trunk, and remain independent of the jugular trunk.

We may add that the possible division into two of the three trunks and the different terminations which each of their bifurcation branches may then show, increase so to speak, almost indefinitely the varieties which may be met with.

ON THE LEFT, the jugular trunk usually empties itself into the terminal bend of the thoracic duct. The subclavian trunk and the broncho-mediastinal trunk open directly into the venous confluence, either separately or else by forming a common trunk. These two vessels may also terminate in the thoracic duct, but it is true that this arrangement is somewhat rare. In twenty-five subjects, Grossmann has only twice seen the left axillary trunk empty itself into the thoracic duct. In these two cases, moreover, the axillary trunk was double, and one of its terminal branches passed directly into the venous junction. The termination of the left broncho-mediastinal trunk in the thoracic duct is still more rare.

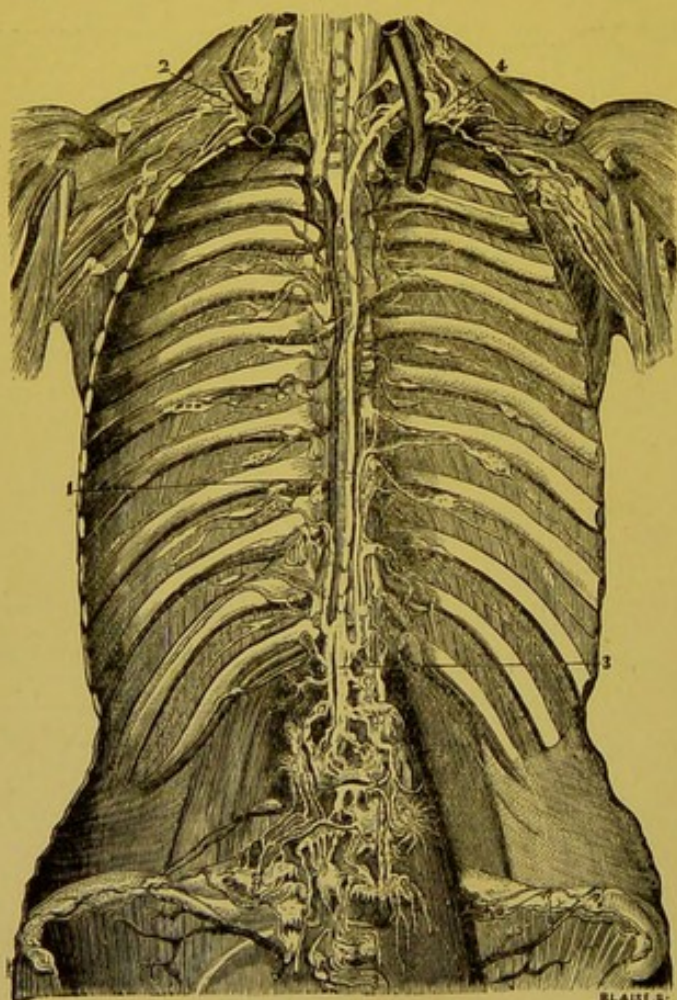


FIG. 113.—Thoracic duct (after Mascagni).
 1. Thoracic duct. 2. Right lymphatic duct. 3. Origin of thoracic duct. 4. Terminal part of the duct forming an arch and opening into the junction of the internal jugular and sub-clavian veins.

§ 2. THE THORACIC DUCT.

THE thoracic duct (*Ductus thoracicus*, *Milchbrustgang*) extends from the second lumbar vertebra where it originates, to the junction of the internal jugular and left subclavian veins, where it terminates. It is the common collector of all the lymphatic vessels of the sub-diaphragmatic portion of the body, and moreover, frequently, but not invariably receives the left jugular, subclavian, and internal mammary trunks which

bring the lymph from the left supra-diaphragmatic portion of the body.

COURSE, DIRECTION.—The thoracic duct usually commences at the upper border of the second lumbar vertebra. It is rare for it to arise below this point. On the other hand, it is often situated on the first lumbar or even on the twelfth dorsal. It runs at first vertically upwards, passing a little to the right of the middle line. Then from the sixth to the fourth dorsal, it changes its direction and runs obliquely upwards and to the left, in this manner crossing the anterior surface of the vertebral column in a slanting direction, and continuing its ascending course as far as a horizontal line drawn through the lower border of the body of the sixth cervical vertebra. At this point it quickly changes its direction, describes a curve with the concavity downwards, and runs downwards, outwards and forwards and terminates in the venous junction.

If the thoracic duct is considered from the point of view of its direction, we may regard it as being divisible into two portions: an *ascending* portion, measuring from 27 to 30 centimetres, and a *descending* portion, which is only 3 to 4 centimetres in length. The ascending portion is itself formed of two segments: one vertical and the other oblique; but this division into two segments is by no means always clear, and in a great many subjects, the thoracic duct inclines so gradually to the left, that it is impossible to state the precise spot at which the change of direction commences.

The thoracic duct is slightly sinuous. The

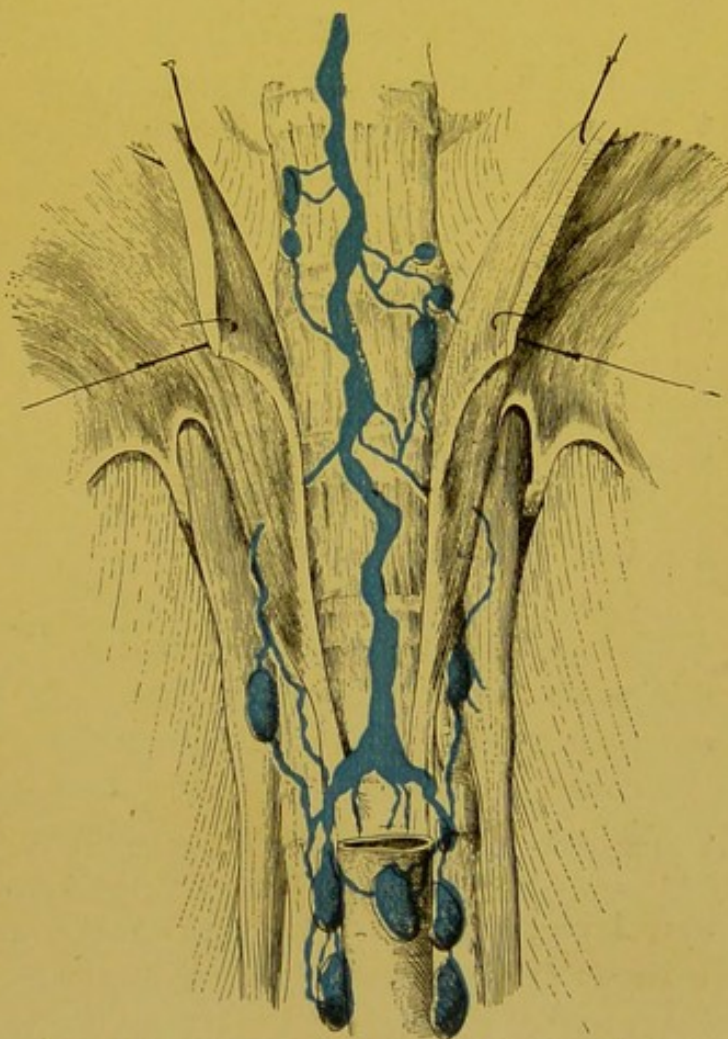


FIG. 114.—Abdominal portion of the thoracic duct.

more advanced in age the subject the more marked have the sinuositities appeared to be. In the new-born the duct is almost straight.

CALIBRE.—The calibre of the thoracic duct varies in different parts. At its origin, it has a dilated portion which is generally termed *reservoir* or *cistern of Pecquet* (*cisterna chyli*, *receptaculum chyli*). This enlarged portion, which may however be absent, is most frequently pyriform in shape; it usually terminates at the level of the body of the eleventh dorsal vertebra. It is in the middle part of its course that the thoracic duct is least developed. It here only measures from 4 to 6 millimetres in diameter. This calibre is much greater again near its termination. Here there is sometimes a slight dilatation, represented by Mascagni and called the *ampulla* of the thoracic duct.

RELATIONS.—From the point of view of its relations, the thoracic duct may be regarded as formed of three parts: viz. an abdominal, a thoracic and a cervical part.

ABDOMINAL PART.—The abdominal part extends from the superior border of the second lumbar vertebra to a horizontal line passing through the upper part of the aortic orifice of the diaphragm, and corresponding to the lower border of the twelfth dorsal vertebra. In this portion the thoracic duct, or more correctly speaking the *receptaculum chyli*, is in relation *in front*, with the right side of the abdominal aorta and with the origins of the middle suprarenal, the twelfth intercostal, and of the first lumbar arteries.

The two latter vessels may, however, pass behind the thoracic duct. *Posteriorly*, the duct is in relation with the body of the first lumbar, and that of the twelfth dorsal. *On the right*, it touches the tendinous border of the right pillar of the diaphragm. The vena azygos major, which is more external, is separated from it by the width of the internal portion of this pillar. *To the left*, the duct rests on the loose cellular tissue which separates the abdominal aorta from the longus colli muscle.

THORACIC PORTION.—The thoracic portion may be regarded as consisting of two segments, one inferior, or inter-azygo-aortic, and the other superior, or supra-azygo-aortic. The body of the fourth dorsal vertebra marks the limit between these two segments.

In its *inter-azygo-aortic segment*, the thoracic duct is in relation *behind*, with the vertebral column, from which it is separated by the right intercostal arteries and the terminal part of the vena azygos minor. *On the right*, it is in relation with the trunk of the vena

azygos major ; at first it is in contact with this vessel at the level of the body of the tenth dorsal vertebra, it then gradually passes to its side. *On the left*, it is in relation with the origin of the left intercostal arteries. *In front*, it is in relation with the right side

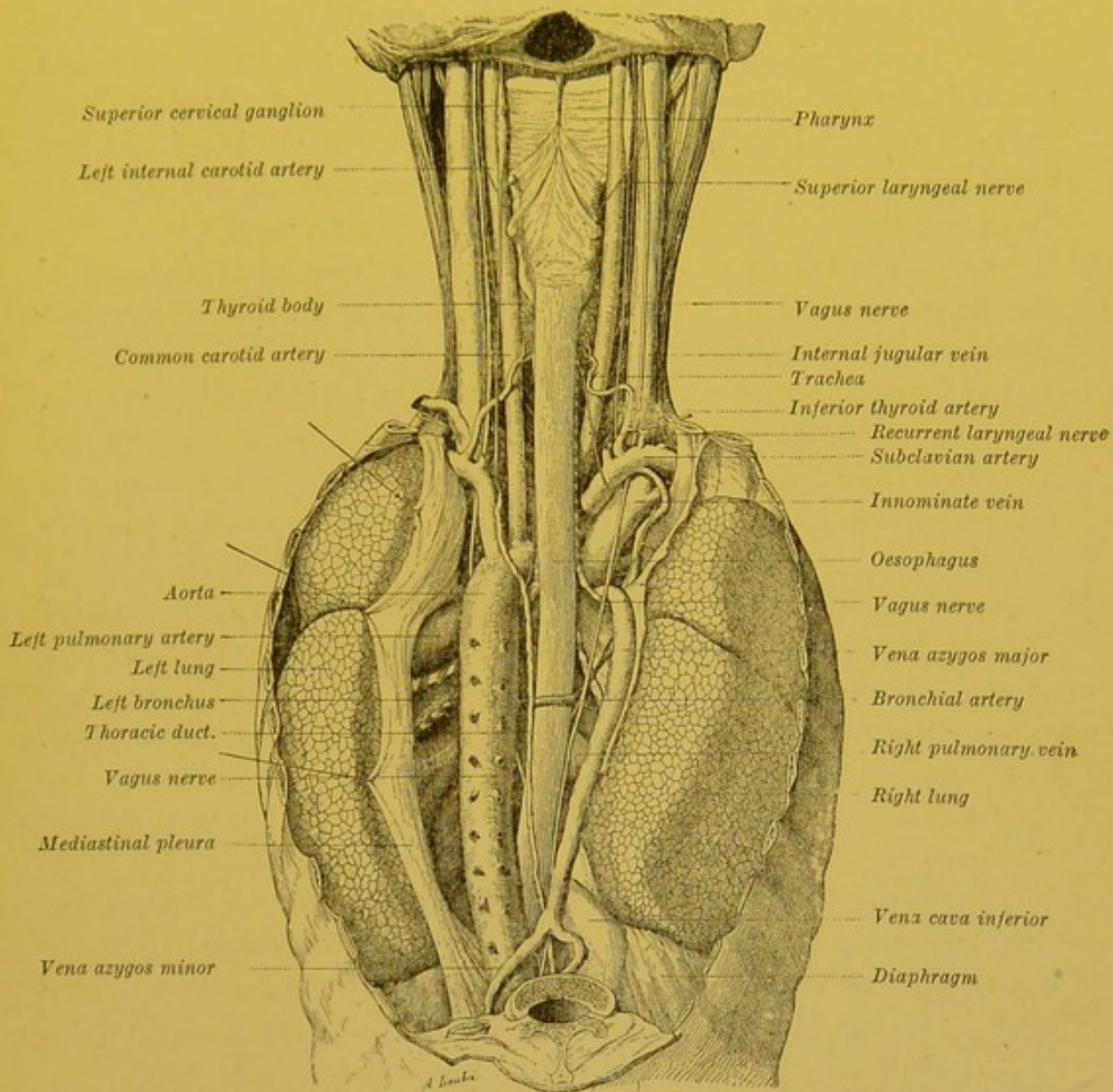


FIG. 115.—Situation and connections of the thoracic duct in the posterior mediastinum (posterior view).

The organs of the neck and mediastina have been reflected and displaced, to show the different levels. On the left, the mediastinal pleura has been partly preserved and hooked aside to show the pulmonary pedicle of that side (adult).

of the aorta, and then with the posterior surface of the oesophagus, from which it is always separated by a space of 5 to 6 millimetres. Higher up, when it begins to incline to the left, it leaves the oesophagus, enters into relation with the posterior surface of the hilum of the left lung, then again comes in contact again with the posterior

surface of the aorta, at the junction of the arch and commencing part of the thoracic aorta. We should add that at the level of the fifth or sixth dorsal vertebra, it is crossed by the right bronchial artery, which sometimes passes between it and the oesophagus, and by the trunk of the left bronchial vein when the latter passes into the azygos by a retro-oesophageal course.

The *supra-azygo-aortic segment* is in relation: *behind*, with the necks of the first three ribs which separate it from the bodies of the first three dorsal vertebrae; *in front*, with the origin of the left subclavian artery; *internally*, with the oesophagus and left recurrent laryngeal nerve; *externally*, with the left mediastinal pleura.

CERVICAL PORTION.—The cervical portion (the terminal bend of the thoracic duct) is in relation: *below*, with the trunk of the subclavian which it crosses at the spot where this artery inclines outwards to turn round the apex of the lung; *behind and externally*, with the inferior cervical ganglion, and origin of the artery and vertebral vein; *in front and internally*, with the left common carotid artery, with the pneumo-gastric nerve, and with the terminal part of the internal jugular vein (vide Fig. 116).

The thoracic duct usually terminates at the actual summit of the angle open above and externally, and formed by the junction of the left internal jugular and subclavian veins. It is more rare to see it terminating on the posterior surface of the venous junction. We shall see further on, when studying the anomalies of the thoracic duct, that the termination of this canal by two distinct branches is fairly frequent.

VALVES.—The thoracic duct has but few valves, and those it has are usually inefficient. There are, however, at the opening of the duct into the venous junction, two well developed valves which prevent the venous blood from flowing back into the thoracic duct.

AFFLUENTS.—The affluents of the thoracic duct may be divided into two groups; some of them unite to give origin to this duct, and form for it, true *radicular branches*; others terminate in the already formed duct, and are *collateral branches*.

(A) *Roots of the Thoracic Duct*.—The thoracic duct is formed by the union of the efferent vessels of the four glandular chains: viz. the prae-aortic, the retro-aortic, and right and left juxta-aortic. The mode of convergence of these vessels is very variable. The arrangement which we have found the most frequent is as follows: The efferent vessels of each juxta-aortic group unite into a large trunk (*truncus lymphaticus, lumbal. dext. et sinist.*,

Henle) which appears at the sides of the body of the twelfth lumbar vertebra. The two trunks right and left, thus formed run upwards and inwards and unite at an acute angle on the anterior surface of the vertebral column to give origin to the thoracic duct. On account of the slightly inclined position to the right at which these vessels unite, that on the left side is usually longer and more oblique than that on the right.

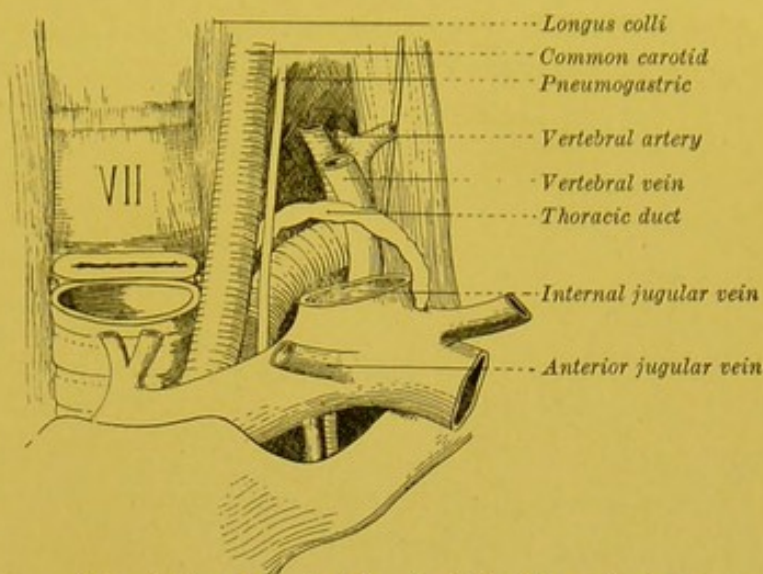


FIG. 116.—Terminal bend of the thoracic duct.

The efferent vessels of the prae- and retro-aortic glands, the number of which is very variable, empty themselves into the two preceding trunks, in the region of their termination. The thoracic duct then appears as though formed by the junction of two lateral roots, which are themselves enlarged by receiving a greater or less number of affluents (vide *a*, Fig. 117).

This arrangement, however, is far from being constant; thus we may frequently see afferent vessels of the prae-aortic group give origin to a single trunk (*truncus lymph. intestinalis*) which empties into one of the large lateral trunks, or ends at the same level as their point of convergence, thus forming a third uneven and median root of the thoracic duct (vide *b*, Fig. 117). Several authors, and notably Sappey and Henle, regard this latter arrangement as corresponding to the normal type.

(B) Collateral Branches.—The thoracic duct receives as collateral branches :

(1) A descending trunk, which is the common collector of the efferent vessels of the posterior intercostal glands of the six or seven lower spaces. This trunk terminates in the thoracic duct near its origin. Thus some authors, as Sappey, regard this vessel as one of the roots of the thoracic duct.

(2) A trunk formed by the junction of several vessels coming from the superior glands of the two juxta-aortic chains, right and left. This trunk traverses the pillar of the diaphragm and

empties itself into the thoracic duct at the level of the ninth or the tenth dorsal.

(3) The efferent vessels of the intercostal glands of the first five or six spaces.

(4) The efferent vessels of the posterior mediastinal glands.

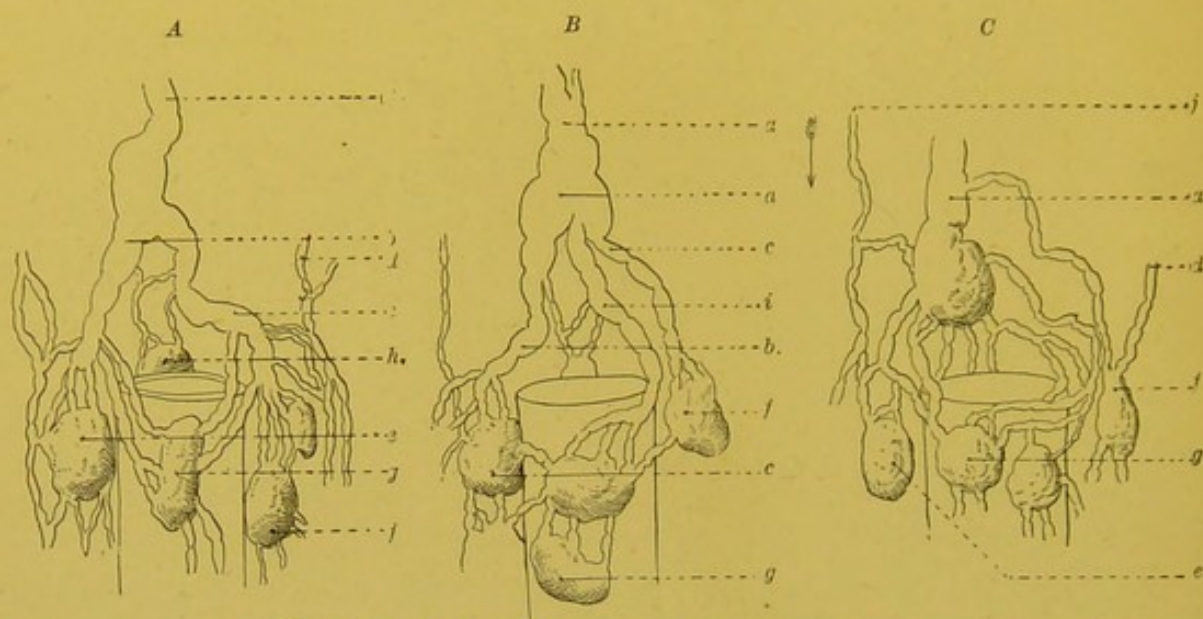


FIG. 117.—Modes of origin of the thoracic duct.

a. Thoracic duct. a'. Receptaculum chyli. b. Common trunk of the efferents of the right juxta-aortic glands. c. Common trunk of the efferents of the left juxta-aortic glands. d. One of these efferents passing into the thorax through the left pillar of the diaphragm. e. Right juxta-aortic gland. f. Left juxta-aortic gland. h. Retro-aortic gland. i. Common trunk of prae-aortic glands (*truncus intestinalis*). j. Collecting trunk of the intercostal lymphatics, which reaches the receptaculum chyli by taking a downward course.

Finally, we have seen that the left jugular trunk and much more rarely the sub-clavian and the corresponding broncho-mediastinal trunk may terminate in the thoracic duct near its termination.

On the STRUCTURE and DEVELOPMENT, vide pp. 67, 75.

Technique.—To study the thoracic duct it is essential to inject it. In the adult, the duct may be directly injected. The method of procedure is as follows: First of all, the thoracic duct must be obliterated at its terminal segment, and for this purpose the ligature may be used; but this is a difficult procedure and the same result may be much more easily obtained by simply injecting tallow grease into the subclavian vein. We then look for the origin of the thoracic duct. After removing the abdominal viscera, the right side of the abdominal aorta is cleaned at the level of the second lumbar vertebra, and this vessel is turned to the left. The receptaculum chyli is then found lying immediately internal to the right pillar of the diaphragm. The duct may be injected with mercury with the ordinary apparatus; but it is preferable to inject with tallow grease or gelatine, using the same method as that employed for the blood vessels. We advise the canula being placed not in the duct itself, but in its right root, for by so doing we nearly always obtain an injection of the other roots by regurgitation. It is essential to make use of a somewhat low pressure, for the duct easily breaks, especially near its origin. To facilitate the progress of the injected material it is

useful to fill the thoracic cavity, from which the contained viscera have been removed, with hot water.

In the new-born, the direct injection of the canal is impossible, but it can easily be filled by injecting Gerota's mass into the glands of the abdomino-aortic group; in this way an injection of all the roots of the canal may be obtained, and this method of procedure yields the happiest results for the study of these roots. In the new-born we have often filled the thoracic duct as far as its terminal bend by injecting the lymphatics of the testicle and uterus.

ANOMALIES OF THE THORACIC DUCT.—The description we have given of the thoracic duct corresponds with what is met with in the majority of cases; but the anomalies of this canal are extremely frequent, and we have here once again the proof of what we stated at the beginning of this section, namely, that the lymphatic is the most variable of all the systems. Though the number of anomalies is almost infinite we may group them in some of the following categories:—

- (1) Anomalies of course and relations.
- (2) Anomalies of number.
- (3) Anomalies of termination.

We may observe however, at once, that these different categories do not exclude one another and that they combine, giving rise to as many different types.

(1) **ANOMALIES OF COURSE AND RELATIONS.**—As regards the aorta, the thoracic duct may be placed on the anterior surface of this vessel, instead of on its posterior surface.

As we have already seen, the majority of the thoracic branches of the aorta pass behind the thoracic duct. According to Haller (*Disp. Anat. Halleri*, p. 197, vol. i.), the intercostals pass sometimes in front of, and sometimes behind the thoracic duct. Saltzmann, however, on the contrary, in his thesis (p. 178, Fig. 1), represents them as always passing in front, which is clearly an error.

The relations with the large vessels of the upper part of the thorax and of the base of the neck vary according to the mode of termination of the thoracic duct, and these, together with the anomalies of the termination of the duct, we will study later on.

One of the most variable features, however, of the topography of the thoracic duct is the situation of its terminal bend. M. Dorvel (*Todd's Encyclop.*, vol. iv., plate 2, p. 823) shows this terminal segment reaching the inferior thyroid artery, crossing its posterior surface and passing above this artery to terminate in the subclavian vein. According to Dietrich (*Das Aufsuchen der Schlagadern*, Nürnberg, 1831, p. 154), the summit of the bend may be more than five centimetres above the sternal notch, and reach as far as the inferior border of the thyroid body. Other authors, on the contrary, describe it as barely reaching the base of the neck. In fact, the highest point of the terminal bend of the thoracic duct lies at varying levels between the fifth cervical and the first dorsal vertebra.

(2) **ANOMALIES IN NUMBER.**—Nothing is commoner than to see the thoracic duct bifurcate into two branches which unite after a longer or shorter course, enclosing between them a space to which Haller (*Physiology*, p. 220) gives the name of *insula*. This arrangement is so frequent that Cruikshank (*loc. cit.*, p. 330) describes it as normal. Though lying, in the majority of cases, at the level of the thoracic portion of the canal, these insulae may also

occupy its superior extremity. The form and dimensions of these insulae are very variable; they are usually elongated, oval or lozenge shaped. In some cases, one or several small transverse anastomotic branches may be seen uniting the two branches limiting the insula (Breschet). In others, the duct divides into several branches which converge towards one another, giving origin to double or multiple insulae. In other cases again, of these two divisional branches, one remains single, while the other, on the contrary, ramifies and gives rise to several secondary insulae; then the small branches reunite into a single trunk which unites with the branch which has remained undivided and reconstitutes the single thoracic duct (Breschet, *Th. d'agregation*, p. 246).

These arrangements do not, however, properly speaking, constitute multiple thoracic ducts. Nuhn (*Unters und Beobacht ad Gebiete der Anatomie*, Heidelberg, 1849, p. 25) describes a very clear case of a double thoracic duct with a right trunk situated to the right of the aorta, and a left trunk situated to the left of this vessel, and united one to the other by transverse anastomoses. In the upper part of the thorax, the two canals united, passed in front of the innominate vein, then curved behind the internal jugular vein and passed into the angle which this vein forms with the sub-clavian. Henle cites a case where the thoracic duct was double as high up as the level of the ninth dorsal vertebra; here the two ducts joined, and formed a single trunk which was placed on the left of the aorta and continued its course in this situation.

These multiple thoracic ducts may terminate in many different ways; thus they may unite into a single trunk terminating in the left sub-clavian as in the two preceding cases, or in the sub-clavian of the right side (Otto, *Pathol. Anat.*, vol. i. p. 365), or they may remain separate, the right receiving the right lymphatic duct, and passing into the right sub-clavian, and the left into the left sub-clavian (Walther, Haller, Homel, Cruikshank, Sommering, Otto).

The anomalies of number of the thoracic duct at its terminal portion are intimately connected with the anomalies of its termination and will be studied with them.

(3) ANOMALIES OF TERMINATION.—We have already seen that the thoracic duct most frequently ends in the left sub-clavian vein, in the angle which this vessel forms with the internal jugular. Abnormally it may end in the subclavian vein external to this point. Sometimes we may see the terminal part of the bend divide into two trunks which terminate separately by two orifices in the sub-clavian vein. (Saltzmann, Meckel, Haller.)

Much more rarely, the thoracic duct remains undivided and terminates in the subclavian of the right side. In these cases the right lymphatic duct empties into the left subclavian (Meckel, *Diss. Epist. ad Haller*, Berol, 1772, p. 30. Haller, *Elem. Physiologiae*, vol. vii., p. 223. Cruikshank, Fleischmann, *Leichenöffnungen*, Erlangen, 1815, p. 237. Todd, *Encyclopedia*, vol. iii., p. 232. Watson, *Journ. of Anat.*, vol. vi., p. 427).

It is quite exceptional to see a single thoracic duct terminate in a vein at the base of the neck other than the left subclavian vein. Portal and Richerand, however, each mention a case where the thoracic duct passed into the right internal jugular; but what is much more frequently met with, is a division of the terminal segment of the thoracic duct into one or more trunks which terminate in different veins.


Thus Diemerbroek, A. Cloquet and E. A. Lauth, and Cruveilhier describe cases of bifurcation, in which one branch passed into the right subclavian,


while the other passed into the left. Mascagni, Bichat, Cruveilhier also noted the division into two branches, one of which passed into the subclavian, the other into the internal jugular of the left side. This terminal division is described as normal by Lower (*De Corde*, Lugd. Batav., 1728, p. 233).


The division into three or four branches has been pointed out by Verneuil (*Le Systeme Veineux*, 1855), who gives the following proportions: In twenty-four cases, the opening was eighteen times single, three times, double, and twice, triple. The same author reports a case of a sixfold terminal division of the thoracic duct, two branches of which went to the subclavian, two to the external jugular, and one to the vertebral. The Society (*Traite d'anatomie*, Paris, 1853) reports a case of quadruple division.


With this question of the anomalies of the termination of the thoracic duct, is connected the study of communications of this duct with veins other than the great trunks at the base of the neck. Albinus as well as Sandford describe communications with the azygos. Wutzer also mentions similar cases. Gayaut, Pecquet and Perrault have seen communications with the lumbar veins; finally Bartholin mentions a case of communication between the thoracic duct and the vena cava. According to Henle, who has subjected all these facts to severe criticism, only one of them is undeniable, namely the case reported by Wutzer in the *Archives de Muller* (1834, p. 311). This was a case of the thoracic duct ending in the azygos vein in the neighbourhood of the sixth dorsal vertebra by two trunks which ascended obliquely and ran parallel. Above this point the thoracic duct was obliterated. Whether this obliteration was congenital or acquired, it seemed, as Wutzer stated, that this communication existed previously to the obliteration.

The majority of these anomalies are normally found in certain mammals; thus in the horse, the thoracic duct is double up to the junction of the posterior two-thirds and the anterior third (Colin). In the ox, the terminal segment of the thoracic duct assumes a plexiform aspect. This plexiform arrangement may be found throughout the whole extent of the duct in certain marsupials (Hodgkin). As a matter of fact these isolated observations are not of much interest. The writings we possess on the comparative anatomy of the thoracic duct are still too few to enable us, even approximately, to formulate our knowledge of its phylogenic evolution.











The University Library
Leeds

*Staff and Research
Students*

Date issued

- 3 JUL 2010

Other Readers

Date due for return

~~7 NOV 1944~~

16 NOV 1951

~~- 2 OCT 1956~~

1-L-L

