

Appendicitis : its pathology and surgery / by Charles Barrett Lockwood.

Contributors

Lockwood, Charles Barrett, -1914.
University of Leeds. Library

Publication/Creation

London : Macmillan, 1906.

Persistent URL

<https://wellcomecollection.org/works/jns4ftny>

Provider

Leeds University Archive


License and attribution

This material has been provided by This material has been provided by The University of Leeds Library. The original may be consulted at The University of Leeds Library. where the originals may be consulted.

Conditions of use: it is possible this item is protected by copyright and/or related rights. You are free to use this item in any way that is permitted by the copyright and related rights legislation that applies to your use. For other uses you need to obtain permission from the rights-holder(s).



Wellcome Collection
183 Euston Road
London NW1 2BE UK
T +44 (0)20 7611 8722
E library@wellcomecollection.org
<https://wellcomecollection.org>



*The University Library
Leeds*



*Medical and Dental
Library*



30106

004196316

STORE

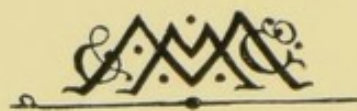
WI 535

LOC

STORE

SCHOOL OF MEDICINE,
UNIVERSITY OF LEEDS.

APPENDICITIS
ITS PATHOLOGY AND SURGERY



SCHOOL OF MEDICINE,
UNIVERSITY OF LEEDS.


APPENDICITIS

ITS PATHOLOGY AND SURGERY

BY

CHARLES BARRETT LOCKWOOD, F.R.C.S.

ASSISTANT SURGEON AND LECTURER ON DESCRIPTIVE AND SURGICAL ANATOMY IN
ST. BARTHOLOMEW'S HOSPITAL, ETC.




London

MACMILLAN AND CO., LIMITED

NEW YORK: THE MACMILLAN COMPANY

1901

All rights reserved



PHARMACEUTICALS
LONDON

UNIVERSITY OF LEEDS
MEDICAL LIBRARY.



605412

PREFACE

IN the following pages I have endeavoured to describe some of the diseased appendices which I have excised. As far as possible the clinical history, morbid anatomy, and morbid histology of each case are given and afterwards commented upon. This method is tedious and full of repetition. But I have adopted it because it seems the only way by which to learn how to infer the morbid condition of the appendix from the clinical symptoms, and ultimately place the treatment of appendicitis upon a scientific basis. I am indebted to Mr. Ernest Shaw for the great trouble he has taken with the histological sections, and to Mr. Albert Norman for the microphotographs.

C. B. LOCKWOOD.

UPPER BERKELEY STREET,
PORTMAN SQUARE, W.,
1900.



Digitized by the Internet Archive
in 2015

<https://archive.org/details/b21519249>

CONTENTS

CHAPTER I

	PAGE
INTRODUCTION	1

CHAPTER II

ANATOMY OF THE APPENDIX	7
-----------------------------------	---

CHAPTER III

ANATOMY AND HISTOLOGY—ARTERIES, VEINS, LYMPHATICS, AND NERVES	17
--	----

CHAPTER IV

APPENDICITIS WITH ULCERATION OF THE MUCOSA, WITH AND WITHOUT BACTERIAL INVASION	33
--	----

CHAPTER V

APPENDICITIS WITH ULCERATION OF THE MUCOSA AND BACTERIAL INVASION— <i>Continued</i>	46
--	----

CHAPTER VI

APPENDICITIS WITH ULCERATION OF THE MUCOSA AND BACTERIAL INVASION—THE MANNER IN WHICH BACTERIA PENETRATE, AND THEIR EFFECTS	56
---	----

CHAPTER VII		PAGE
APPENDICITIS WITH FÆCAL CONCRETIONS—THE FORMATION AND EFFECTS OF CONCRETIONS		74
CHAPTER VIII		
APPENDICITIS WITH STENOSIS AND ITS COMPLICATIONS—CYSTS—MUCOCELE—EMPYEMA—ULCERATION AND BACTERIAL INVASION OF MUCOSA—PERI-APPENDICITIS—PORTAL PYÆMIA		102
CHAPTER IX		
APPENDICITIS WITH COMPLETE OBLITERATION OF THE LUMEN		133
CHAPTER X		
APPENDICITIS WITH LYMPHADENITIS AND LYMPHANGITIS		140
CHAPTER XI		
TUBERCULOUS APPENDICITIS		151
CHAPTER XII		
THE PATHOLOGY OF CASES OF APPENDICITIS WHICH UNDERGO PERMANENT RECOVERY		161
CHAPTER XIII		
APPENDICITIS AND PERITONITIS—NON-SUPPURATIVE AND SUPPURATIVE		166
CHAPTER XIV		
APPENDICITIS WITH ACUTE SUPPURATION		177

	PAGE
CHAPTER XV	
CLINICAL SYMPTOMS OF APPENDICITIS	191
CHAPTER XVI	
CLINICAL SYMPTOMS— <i>Continued</i>	198
CHAPTER XVII	
DIFFICULTIES AND ERRORS IN DIAGNOSIS—COMPLICATIONS	207
CHAPTER XVIII	
DIFFICULTIES AND ERRORS IN DIAGNOSIS—COMPLICATIONS— <i>Continued</i>	213
CHAPTER XIX	
TREATMENT, EXPECTANT AND OPERATIVE	225
CHAPTER XX	
INCOMPLETE OPERATIONS	249
CHAPTER XXI	
THE AFTER-TREATMENT OF APPENDECTOMY	260
INDEX	283

LIST OF ILLUSTRATIONS

FIG.	PAGE
1. Ileo-cæcal fossa	13
2. Sub-cæcal fossa	14
3. Folds about the cæcum	15
4. Hiatus muscularis	20
5. Normal appendix	24
6. Cæcum and meso-appendix	30
7. Ulceration of the mucosa	38
8. Appendicular colic	42
9. Bacilli in lumen of appendix	48
10. Bacteria penetrating the mucosa	49
11. Lumen of appendix. Epithelial lining and tubular glands absent	53
12. Same section as Fig. 11, but showing part of submucous coat	53
13. Bacteria invading mucosa along tract of tubular gland	58
14. Abscess cavity, bounded by infected peritoneum	65
15. Portion of peritoneum bounding abscess cavity	65
16. Ulceration of mucosa opposite hiatus muscularis	67
17. Bacterial contents of lumen	71
18. Perforation almost filled with bacteria	72
19. Film preparation of faecal concretion	77
20. Wall of acutely inflamed perforated appendix which contained a concretion	78
21. Site of perforation and gangrene	83
22. Ulceration and bacterial invasion of mucosa	89
23. Contents of appendix showing formation of a faecal concretion	89
24. Site of perforation and gangrene	94
25. Appendix after upwards of twenty attacks of appendicitis	97
26. Effects of foreign bodies (shot) in appendix	100
27. Longitudinal section through cystic dilatation of appendix	107

FIG.	PAGE
28. Inner part of wall of mucocele	111
29. Inflammatory stenosis of appendix	117
30. Streptococci in lumen	117
31. Appendix beyond constriction in Fig. 29	118
32. Streptococci in lymph on peritoneum of appendix	121
33. Streptococci in lumen	123
34. Stenosis. Peritubular inflammation	127
35. Distal end. Lumen and wall of appendix	127
36. Complete obliteration of lumen	134
37. Do. do.	136
38. Lymphoid follicles, with dilated lymph sinuses and lymphatics	143
39. Tuberculous appendicitis	152
40. Tuberculous appendicitis, with tuberculous abscess or ulcer opening into lumen	153
41. Tuberculous appendicitis. Formation of perforation	155
42. Hiatus muscularis	162
43 and 44. Streptococcic peritonitis. Lymph (<i>a</i>) upon surface, (<i>b</i>) in depths of peritoneum	169
45. Diffuse septic peritonitis	170
46. Appendicitis with gangrene of the tip of the appendix	179
47. Appendicitis with peri-appendicular and pelvic abscesses	183
48. Pus from peritoneal cavity in diffuse septic peritonitis caused by appendicitis	185
49. Inflamed peritoneum (meso-appendix) in appendicitis without suppuration	241
50. Inflamed omentum. Acute appendicitis with perforation and localised fœtid abscess	243
51. Acute appendicitis with perforation	245
52. Appendicitis with perforation and abscess in Douglas's pouch	257

p

CHAPTER I

INTRODUCTION

Introduction and Method of Investigation.—It is hardly necessary to speak of the importance of a correct use of terms. A scientific terminology should, I think, be based upon pathology and not upon clinical histories. At present it is doubtful whether enough is known about the pathology of the various diseases grouped under the term appendicitis¹ to permit of a scientific nomenclature. We need not criticise authors who are so illogical as to perpetrate cross classifications, and who speak of “relapsing appendicitis,” “perforative appendicitis,” “recurrent appendicitis,” and so forth; or those who endeavour to evade the difficulty by ignoring the appendicitis and laying stress upon one of its frequent, although not invariable, complications, perityphlitis. Were we to speak of “relapsing” and “recurrent appendicitis,” some might be led to think that there was one sort of appendicitis which was prone to relapse, and another to recur. As a matter of fact, relapses are little or no clue to the morbid condition of the appendix. Were we to speak of “perforative appendicitis,” some might be led to think that there was a particular kind of appendicitis which was characterised by perforation. But many kinds of appendicitis may end in perforation, and instances will be given hereafter. The same reasoning applies to the terms “gangrenous appendicitis” and

¹ The philology of the word “appendicitis,” and the numerous and more classical substitutes which have been suggested in its place, will be found in Dr. Deaver's *Treatise on Appendicitis*, 2nd ed., Philadelphia, 1900.

"ulcerative appendicitis." Such a term as "appendicitis simplex" is open to similar objections. The word "simplex" is as misleading in its application to appendicitis as to fractures; it is a mere survival of an unscientific past.

Asked for an example of correct nomenclature, I should adduce the term "tuberculous appendicitis." It implies the cause of the inflammation, the presence of the tubercle bacillus, and a sequence of morbid changes, including ulceration and, perchance, perforation of the appendix. It permits us to speak correctly of "tuberculous ulceration" and of "tuberculous perforation," and, in either instance, the mind imagines a definite morbid process with a definite cause.

The temptation is great to apply to certain cases of appendicitis the term which Niemeyer did so much to popularise. Doubtless, cases may occur which come within his definition, that "catarrh consists in engorgement of the blood-vessels of any mucous membrane, accompanied by abnormal secretion, swelling, succulence of its tissues, and copious generation of young cells."¹ But I have found that modern methods of histological research almost invariably show that the appendicular catarrh is only a small part of the disease, and not the essential part. The belief in the existence of such a disease as "catarrhal appendicitis" might be an obstacle to the thorough investigation of appendicitis. Many of the cases which, on superficial examination, I used to think were simply catarrhal, have since proved to be cases of appendicitis with ulceration and bacterial invasion of the appendicular walls.² When this work was begun, I thought catarrh of the mucous lining one of the commonest of the causes of appendicitis, and therefore, paid much attention to the condition of the epithelium. I suppose we may assume that the histological evidences of catarrh are (*a*) an excessive number of goblet cells, (*b*) shedding of epithelium, (*c*) hyperæmia, and, (*d*) perhaps, cell infiltration. But, hitherto, I have not met with a case in which these have been the sole histological changes.

¹ *Text-book of Practical Medicine*, revised ed. 1878, vol. i. p. 1. Trans. by Humphreys and Hackley.

² I venture to think that this applies to a specimen which Dr. Hawkins figures as "catarrhal appendicitis" (*Diseases of the Vermiform Appendix*, p. 25, Fig. 1).

In some they have been associated with ulceration of the mucosa, and in others bacteria have penetrated the ulcer.

Talamon's expression "appendicular colic"¹ is also open to objection. In a typical case of appendicular colic, in which small concretions were present, although the appendix itself betrayed no disease to the naked eye, the following conditions were found:—(1) Edema of all the coats, (2) dilatation of lymphatics, (3) destruction of lining epithelium, (4) the lumen filled with pus cells, dense masses of bacteria, faecal particles, and a faecal concretion, and (5) the bacteria beginning to penetrate the mucosa where it had lost its epithelial lining (Case 7, p. 50).

Used in a purely clinical sense, the term "appendicular colic" is sometimes convenient as implying the clinical symptoms which are found in the early stages of ulceration of the mucosa, with or without the presence of concretion.

The term "suppurative appendicitis" is wanting in precision. We meet with instances of appendicitis with pus in the lumen of the appendix (Case 6, p. 46) or in the substance of its walls (Case 11, p. 61); but these would not usually be called cases of "suppurative appendicitis." As a matter of fact, the term is usually applied to cases of appendicitis in which an abscess has formed outside the appendix, and usually within the peritoneal cavity, where it may involve serious dangers (Case 12, p. 64).

Furthermore, the term "suppurative appendicitis" might give rise to the belief that there is a particular kind of appendicitis which ends in suppuration. But the cases which I have examined show that many forms of appendicular disease may give rise to suppuration in the neighbourhood of the appendix, in distant parts of the abdomen, or in other organs. For examples I would point to the case of suppuration in Douglas's pouch (Case 55, p. 180), and to those of hepatic and subphrenic abscess (Cases 31, 32, pp. 119, 123).

Owing to identity of blood, lymphatic, and nerve supply, to continuity of tissue, and to proximity, the caecum is nearly always inflamed in appendicitis. The effects of the

¹ *Appendicitis and Perityphlitis*, by Ch. Talamon, p. 24, *et seq.* Trans. by R. J. A. Berry. Edin. and Lond., 1893.

inflammation are easiest to be seen in the peritoneum in and about the cæcum. By some, great prominence is given to this perityphlitis.¹ But in appendicitis of any degree of severity, the inflammation involves not only the peritoneum but also the muscular and mucous coats of the cæcum, together with all the coats of the end of the ileum and the ileo-cæcal valve. This condition is not adequately implied by such a vague term as "perityphlitis." Moreover, I have come to the conclusion that perityphlitis is a complication which is usually preceded by warning symptoms, often overlooked, and that our aim should be to prevent its advent rather than wait helplessly for its onset.

The terms "recurrent" and "relapsing" are frequently used, and indicate some of the clinical peculiarities of appendicitis. They do not, however, indicate in the least the morbid changes in the appendix, which account for the relapse or recurrence.

In what follows I shall, in the hope of avoiding these pitfalls, use the word "appendicitis" to denote any kind of inflammation of the appendix; and it will be used in conjunction with other words intended to convey an idea of the leading characteristics of the disease. Thus cases will be described as "appendicitis with ulceration of the mucosa"; "appendicitis with ulceration of the mucosa, and bacterial invasion"; "appendicitis with ulceration of the mucosa, and perforation"; "appendicitis with gangrene," and so forth. Occasionally, when my observations permit, I shall speak of "tuberculous appendicitis," or of "streptococcic appendicitis," or (rather more vaguely) of "infective appendicitis." Peri-appendicular abscess and septic peritonitis are occasional complications of almost every variety of appendicitis. They are, therefore, of little value for purposes of classification. Instead of placing cases with abscess and septic peritonitis under a separate heading, I have given them in the class to which they belong, that is to say, they are, whenever possible,

¹ By perityphlitis we understand an inflammation of the connective tissue which intervenes between the cæcum and iliac fascia (Bull, "Perityphlitis," *New York Med. Journ.* 1873, vol. xviii. p. 240). By perityphlitis is understood a peritonitis localised in the region of the cæcum (*Perityphlitis*, Treves, 1897, p. 1).

classified according to the appendicular disease which preceded their occurrence. Each case is described in the following way: First, the clinical history; second, the operation and morbid anatomy; third, the morbid histology; fourth, a brief commentary upon any peculiarities that may have been observed. In describing the morbid histology, each layer of the appendix is taken in turn, beginning, as a rule, with the peritoneum, and ending with the mucosa and the contents of the lumen.

I am aware that this method is tedious and leads to repetition, but unfortunately the subject does not appear to me to be yet ready for more general treatment, even if I possessed the requisite ability. I have, however, endeavoured to give a brief *résumé* of the clinical features of appendicitis, the indications for operating, the operation, and the after-treatment.

Even such an arrangement as this is artificial. In most cases the groups do not consist of separate and distinct diseases of the appendix, but of phases or stages of the same disease. Classified according to their pathology, the cases fall into the following groups:—

First.—Appendicitis with ulceration of the mucosa.

Second.—Appendicitis with ulceration of the mucosa, and bacterial invasion.

Third.—Appendicitis with ulceration of the mucosa, and with faecal concretions—foreign bodies—and their complications.

Fourth.—Appendicitis with stenosis and its complications—cysts—mucocele—empyema—ulceration and bacterial invasion.

Fifth.—Appendicitis with sclerosis and obliteration of the lumen.

Sixth.—Appendicitis with lymphangitis and lymphadenitis.

Seventh.—Tuberculous appendicitis—actinomycotic appendicitis.

Eighth.—Appendicitis complicating malignant and other diseases.

Under each heading cases will be given to illustrate the complications which may supervene, such, for instance, as perityphilitis, inflammation of the pelvic contents, lymph-

angitis, pylephlebitis, perforation, gangrene, and intra- and extra-peritoneal suppuration.

The attempt to elucidate appendicitis by what may be termed clinical statistics has been made by Talamon,¹ Caley,² and others. But this method is saturated with fallacy. The death of a patient from appendicitis is a fact beyond dispute; the recovery from appendicitis must always remain dubious. For instance, some of those who seem to recover from their attacks may have kinks, strictures, chronic ulceration, or concretions.

As is well known, statistics can be made to prove anything; and, therefore, we are not surprised to find them used by some as arguments against operation, and by others as arguments in favour of it.

Without a histological examination it is dangerous to assert the absence of appendicular disease. In some of my own cases the appendix was normal to the naked eye, and Dr. Hawkins has given a remarkable instance in which the abdomen of a child was opened for peritonitis, and the appendix examined, but considered healthy. After death the microscope revealed extensive disease sufficient to explain the peritonitis. Evidently many cases of this kind are omitted from statistics.

¹ Talamon, "Médecine Moderne," Nos. 29, 31, 1897, abst. *Brit. Med. Journ.*, May 8 and June 26, 1897.

² Dr. Caley, "Prognosis in Appendicitis, with an illustrative Series of 200 Cases," *Lancet*, February 10, 1900, p. 378, *et seq.*

CHAPTER II

ANATOMY OF THE APPENDIX

The Appendix, its Colour and Consistence.—I have had many opportunities of seeing and feeling the normal living appendix. Its colour is yellowish pink, and it is soft and velvety to the touch. The subperitoneal vessels are barely visible to the naked eye, any distended encircling vessels are significant of inflammation, and hardness betokens disease. Concretions or foreign bodies in the appendix are easily felt, and are indications for removal. If the muscular coats of the appendix have not been damaged by inflammation they contract when it is seized, and the tube becomes shorter, thicker, and harder. This effect is most marked when the appendix is long and movable.

The vermiform appendix is usually about 8 or 9 cm. ($3\frac{1}{2}$ in.) in length. It is, however, a most variable structure, and from being a mere tag 2 or 3 cm. ($\frac{3}{4}$ to $1\frac{1}{5}$ in.) long, may attain a length of 23.5 cm.¹ ($9\frac{1}{4}$ in.).²

The Vermiform Appendix never Absent.—When I wrote upon the anatomy of the appendix in conjunction with Dr. Rolleston,³ we asserted our belief that the appendix was never absent, except as the result of disease. Probably in most of the cases in which its absence has been assumed by those who have failed to find it during the course of operations,

¹ It is now customary and convenient to use the metric system for microscopical measurements, and for the sake of uniformity I have in most instances used the same for the anatomical measurements. A centimètre is about $\frac{2}{5}$ in., a millimètre $\frac{1}{25}$ in.

² "Observations on Appendicitis," George R. Fowler, *Annals of Surgery*, 1894, vol. xix. p. 9.

³ *Journal of Anatomy and Physiology*, 1891, vol. xxvi. p. 131.

it has been hidden away in one of the retroperitoneal fossæ around the cæcum. Dr. Kelynack, who has recently touched upon the same point in his able memoir,¹ says: "Operating surgeons have also been known to fail to discover the appendix, and have closed the abdomen with the belief that it was absent. I have, however, myself never met with any case where the appendix could be said to be absent, except as the result of disease." In one of my operation cases (Case 28, p. 112) the appendix was hidden in a retroperitoneal fossa, and was only discovered after a prolonged and arduous search, the way into the fossa being marked by a delicate streak which ran across the iliac peritoneum. I have also operated upon other cases in which the appendix was in the ileo-cæcal fossa, but they did not present the same difficulties (Case 33, p. 125).

The importance of a clear appreciation of the truth of the proposition that the appendix is never absent, except as the result of disease, is sufficiently manifest. Failure in the attempt to remove a diseased appendix is a great calamity to the patient.²

The Surface Marking of the Appendix—M'Burney's Point.—

It is hardly possible to give any precise rule for marking on the surface of the body the position of the appendix. Perhaps Dr. M'Burney's view is the most accurate.³ He says: "I believe that in every case the seat of the greatest pain, determined by the pressure of one finger, has been very exactly between an inch and a half and two inches from the anterior spinous process of the ilium in a straight line drawn from that process to the umbilicus. This point indicates the situation of the base of the appendix where it arises from the cæcum, but does not by any means demonstrate, as one might conclude, that the chief point of disease is there." I have often observed that Dr. M'Burney's statement is accepted without his qualification, and consequently a case is examined and pro-

¹ *A Contribution to the Pathology of the Vermiform Appendix*, London, 1893. Dr. Kelynack gives an exhaustive Bibliography, and I have found his work of great value.

² Piquard and Fawcett have recently described cases in which the appendix was absent or rudimentary, but I do not know whether this was owing to a congenital defect or the result of disease. *Journal of Anatomy and Physiology*, vol. xxxv. p. 123, and lii.

³ *New York Med. Journ.*, Dec. 21, 1889, p. 678.

nounced not to be one of appendicitis because pain is absent at M'Burney's point. A rectal examination has often revealed abundant signs of inflammation within the pelvis, and I have no doubt whatever that the careless omission of the rectal examinations has lost many lives. The painful spot is very often in Douglas's pouch; I have, however, seen it in the right flank, in the iliac fossa, beneath the right linea semilunaris, beneath the right rectus, and almost at the umbilicus.

I have been much struck with the frequency with which the pain is referred by the patient to the region about the gall-bladder or right kidney (see Case 37, p. 133). This leads to renal or gall-stone colic being diagnosed in mistake for appendicitis.

The Mode of Origin and Position of the Appendix.—The position of the vermiform appendix is to some extent determined by its mode of origin from the cæcum. For instance, one which springs from the inner side of the cæcum is more likely to hang over into the pelvis than one which springs from the outer. The latter is more likely to lie outside the cæcum and colon, and perhaps run upwards into the right lumbar region, as far as the right kidney.

The appendix often hangs into the right side of Douglas's pouch. Bryant¹ found it in this position thrice in 40 females, and fourteen times in 86 males. In 109 consecutive operation cases I found the pelvic position present in 15. In 39 females it occurred 7 times, and in 78 males it occurred 8 times. Turner (quoted by Bryant) found it in the pelvic position in 51 cases out of 105. Hawkins found it in the pelvic position seventeen times in 100 examinations. In the pelvis the appendix may be in contact with the right ovary and Fallopian tube, so that appendicitis is often mistaken for ovaritis or salpingitis. The appendix may also adhere to the uterus (Case 24, p. 103). In addition, when an inflamed appendix lies in Douglas's pouch, the inflammation spreads direct to the pelvic peritoneum, including the false ligaments of the bladder. The act of micturition is then exceedingly painful, because the exquisitely tender peritoneum

¹ "The Relations of the Gross Anatomy of the Vermiform Appendix to some Features of the Clinical History of Appendicitis," *Annals of Surgery*, 1893, p. 177.

is stretched by the contracting bladder. Sometimes this pelvic peritonitis causes retention of urine (Case 55, p. 180). When the appendix is in the pelvis it may be felt *per rectum* (Case 78, p. 255). The appendix may enter the female pelvis in front of the broad ligament, and form adhesions with the peritoneum around the bladder. In the male, adhesions with the bladder are more likely to arise.

When an appendix, which hangs into the pelvis, inflames and causes septic peritonitis, the danger to life is greater than with one in the iliac fossa or outside the cæcum and colon. From the more central position, the peritonitis can spread in many directions, and an abscess becomes more difficult to reach and drain. Obviously the peripheral positions are less favourable to the spread of peritonitis, and much more favourable to its surgical treatment.

The following brief remarks upon the origin and position of the vermiform appendix, are mainly based upon the work which I did in conjunction with my friend, Dr. Rolleston.¹

The vermiform appendix usually begins at the back and inner side of the cæcum, about an inch from the ileo-cæcal valve. It there lies under the left or inferior layer of the mesentery, pointing in the direction of the spleen. The ileo-cæcal angle is, therefore, one of the guides to its locality. But from this position the distal end of the appendix very easily falls into the pelvis. Rolleston and myself met with this normal condition thirty times in 56 females, and sixty-three times in 104 males.

I have before me dried specimens of the cæcum and neighbouring structures. In some, the appendix opens into the cæcum by a funnel-shaped aperture; in others, the opening is oblique, like that of the ureter into the bladder. In the latter cases, the mucous membrane of the cæcum forms a valve, which is prolonged towards the right from the acute angle of junction of

¹ "On the Fosse round the Cæcum, and the Position of the Vermiform Appendix, with special reference to Retroperitoneal Hernia," by C. B. Lockwood and H. D. Rolleston, *Journal of Anatomy and Physiology*, 1891, vol. xxv. p. 130, *et seq.* Those who are interested in this subject will derive much information from Dr. Berry's admirably clear monograph, *The Cæcal Folds and Fossæ and the Topographical Anatomy of the Vermiform Appendix*, Edinburgh, 1897.

the cæcum and appendix.¹ This valve was originally described by Gerlach, and some importance has been attributed to it by him, and subsequently by Talamon. Its importance, however, is much diminished when we are aware that fæcal concretions originate within the appendix as the result of bacterial activity, and that they have not, therefore, to get into it from the cæcum.

In the condition of "floating cæcum," the cæcum and right colon fail to become attached to the back of the abdomen in the right lumbar and iliac regions, and, therefore, the right colon, cæcum, end of ileum, and the vermiform appendix have a considerable range of movement. In a case of this description the appendix of a male patient lay deep in the pelvis, whence it was pulled by traction upon the cæcum (Case 82, p. 277). The condition of floating cæcum is of interest and importance. I have met with it in ileo-cæcal intussusception and congenital umbilical hernia of the cæcum, ileum, and appendix. Others have met with it in volvulus of the cæcum. It is also associated with other congenital abnormalities of the colon and cæcum. ✓

The cæcum may fail to reach the iliac fossa, and, in such a case of non-descent, Fowler² found the inflamed appendix beneath the liver.

Instead of being situated at the ileo-cæcal junction, whence it may fall into the pelvis, the appendix may be beneath the cæcum and the lower end of the right colon. Here it is often coiled upon itself, and only separated from the iliacus muscle by the peritoneum and iliac fascia, so that the spread of inflammation may cause flexion of the thigh and lameness (Case 51, p. 171). This sub-cæcal position of the appendix favours the localisation of appendicular abscesses, and also makes them easier to open and drain. Dr. Rolleston and myself also met with instances in which the appendix ran upwards *behind* the right colon, so as to reach the right

¹ Mr. Treves writes, "The valve of Gerlach, which was supposed to protect the orifice of the appendix, has no existence." *Perityphlitis*, p. 4.

² *Annals of Surgery*, 1894, vol. xix. p. 159, and Fig. 10. I have placed a foetus in the teratological series of the Museum of St. Bartholomew's Hospital, which shows an undescended cæcum adherent to the under surface of the liver.

kidney. An abscess around the tip of such an appendix has simulated a lumbar or renal abscess, or even an empyema.

The vermiform appendix may spring from the *outer and back* part of the cæcum, and lie on the outer side of the cæcum and colon. A long appendix in this situation may reach the right lumbar region, and extend over the right kidney as far as the liver. This may cause an abscess, which may also resemble a renal or lumbar abscess or an empyema. This position is likewise favourable to the localisation and to the evacuation of pus (Case 17, p. 81, and 71, p. 249), but it usually necessitates a larger abdominal incision, because the overlying muscles in the flank are thick and fleshy.

The cæcum sometimes tapers off into a cone, which gradually becomes the vermiform appendix. In such cases, it is not easy to say where the cæcum ends or the appendix begins. As Mr. Treves¹ has pointed out, this is a persistence of the foetal condition, and is usually called the "foetal type of cæcum or of appendix." Where it exists, the appendix may occupy any of the recognised positions.

In the foetal type of cæcum and appendix, it is easy to see the three longitudinal muscular bands of the colon and cæcum converge at the base of the appendix, and become continuous with its longitudinal muscular coat. These muscular bands are, therefore, a guide to the origin of the appendix. The anterior band is the most constant and the easiest to trace into the appendix. The outer may also be traced, but the inner is much more difficult to follow owing to the presence of the ileum. The surgical value of the longitudinal bands is very small. When the appendix is difficult to find, owing to inflammation and adhesions, and when the assistance of the bands would be most valuable, they are themselves hidden and obscured.

After having originated from the lower or back part of the cæcum, the appendix may turn abruptly upwards over the front of the cæcum and colon, or over the end of the ileum and mesentery (Case 64, p. 216). In one case, an appendix which lay in front of the cæcum and colon ran

¹ "The Anatomy of the Intestinal Canal and Peritoneum in Man." *Brit. Med. Journ.* vol. i. 1885, p. 472, *et seq.* Fig. 12, p. 473.

upwards towards the umbilicus, and was difficult to find. All the usual positions were searched in vain, and it was only brought into view by enlarging the incision and drawing the cæcum down (Case 65, p. 219).

Retroperitoneal Hernia of the Vermiform Appendix.—The vermiform appendix may be herniated into either the ileo-cæcal or the sub-cæcal fossa, but the former position is much the more common. I have already pointed out the importance of this condition. The mouth of the ileo-cæcal fossa is situated at the ileo-cæcal angle (Fig. 1),¹ and is seen when the ileum and cæcum are lifted up. It runs upwards behind the ileo-

colic junction and parallel to the right colon. The fossa in the accompanying figure was almost three inches long, and would easily admit the finger or a loop of intestine. Sometimes the ileo-cæcal fossa reaches half-way up the ascending colon beyond the crest of the ileum, and ends close to the kidney

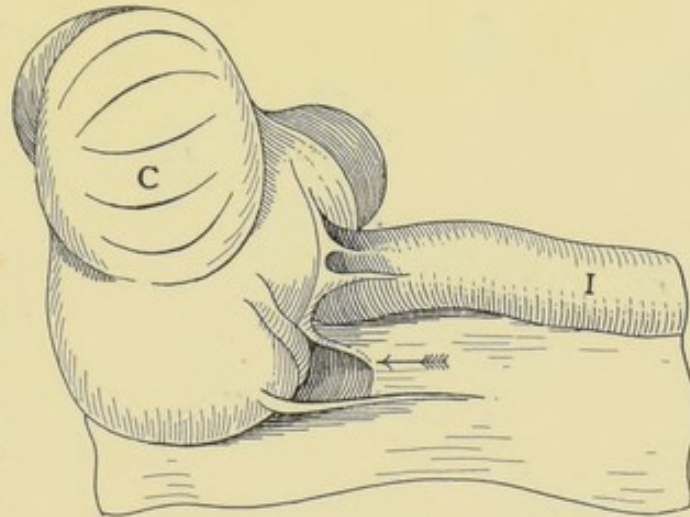


FIG. 1.—The ileo-cæcal fossa, to illustrate retroperitoneal hernia of the vermiform appendix into the ileo-cæcal fossa; the arrow marks the fossa. I, ileum; C, cæcum. (Lockwood and Rolleston.)

and duodenum. Here, again, an appendicular abscess may simulate one in connection with the kidney.

I have several times found the inflamed appendix in the ileo-cæcal fossa. When the hernia is but partial the appendix is easily found and withdrawn (Case 33, p. 125), but when the hernia is complete and the mouth of the fossa closed, the greatest difficulties may arise (Case 28, p. 112).

It is probable that accumulations, with their attendant troubles, are more likely to occur within herniated appendices.

The appendix may also enter the sub-cæcal fossa, the mouth of which is seen when the cæcum is lifted up. This

¹ Lockwood and Rolleston, *The Fossæ round the Cæcum*, Fig. 2, p. 135.

fossa runs upwards behind the right colon and between the layers of the mesocolon. The accompanying figure shows its position and appearance (Fig. 2). It is less constant than the ileo-cæcal fossa, and I have not, so far as I am aware, met with a case of hernia of the appendix into it during the course of an operation. It is, however, very difficult to discriminate between the sub-cæcal and ileo-cæcal fossæ through a small incision.

The surgical importance of the fossæ around the cæcum has

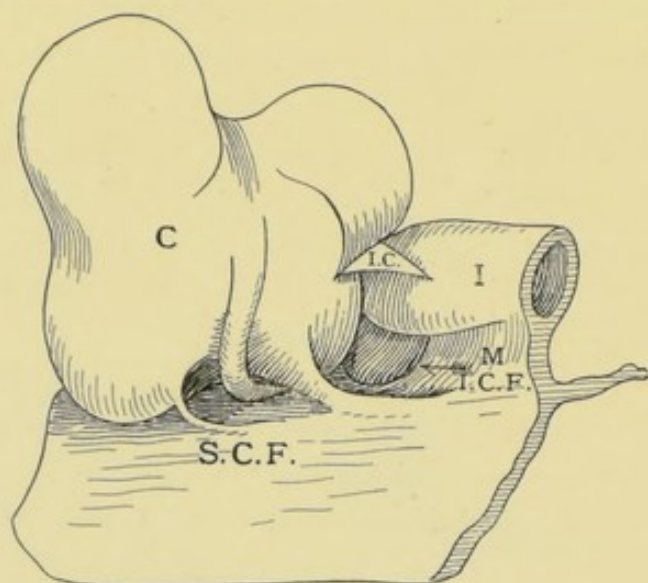


FIG. 2.—Sub-cæcal fossa, showing a hernia of vermiform appendix into it. C, cæcum; I, ileum; I.C., ileo-cæcal fold; I.C.F., ileo-cæcal fossa (the arrow points into the fossa); M, mesentery; S.C.F., sub-cæcal fossa. (Lockwood and Rolleston.)

hardly yet been properly recognised. Cases will presently be narrated which clearly prove their surgical and pathological importance.¹

Thus the positions of the vermiform appendix may be enumerated as follow:—(1) At ileo-cæcal angle; (2) sub-cæcal; (3) pelvic; (4) extra-cæcal; (5) retroperitoneal; (6) supra-cæcal; (7) in the sacs of inguinal, femoral, or umbilical

herniæ. I have given these in the order of their frequency in the course of my operations.

It is difficult, before removing the appendix, to infer its position, and the attempt to do so is not unlikely to end in failure. But, nevertheless, as will be shown hereafter, it is often possible to have a clear notion whether the appendix is in the iliac fossa or in the pelvis, and thus to remove it through a smaller incision, with less disturbance, and in a shorter time. The iliac and pelvic positions of the appendix are the easiest to diagnose.

¹ Mr. Mansell Moullin has described a case of strangulated hernia into the post-cæcal pouch (*Lancet*, April 1, 1899, p. 897).

The Mesentery and Connections of the Vermiform Appendix.

—In most operations the meso-appendix has to be secured and divided. It contains in addition to connective tissue, fat, and unstriated muscle fibres, the arteries, veins, nerves, and lymphatics of the appendix, and, at times, a lymphatic gland. I have more than once seen it mistaken for an adhesion, and carelessly torn across.

The meso-appendix is attached to about half or two-thirds of the length of the appendix. It does not always end abruptly

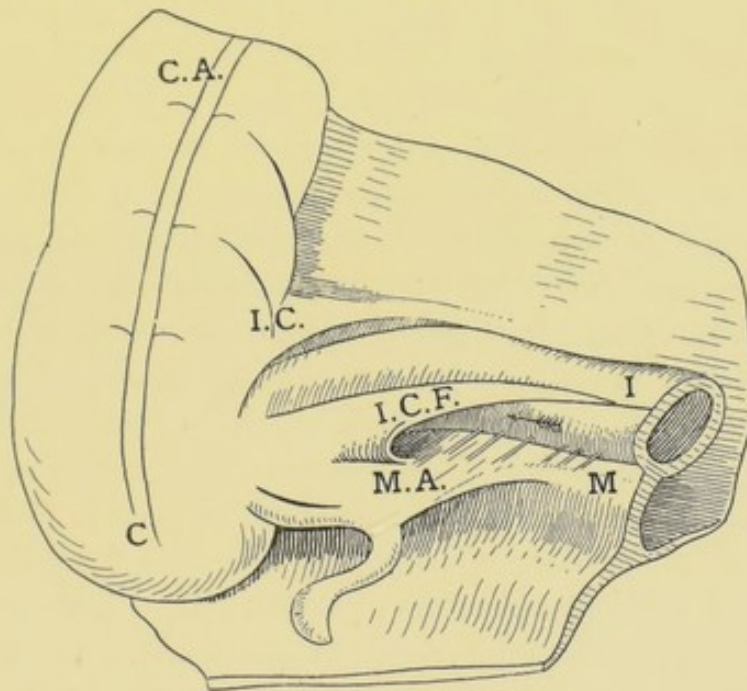


FIG. 3.—The folds about the caecum. C, caecum; C.A., ascending colon; I, ileum; I.C., ileo-colic fold; I.C.F., ileo-caecal fold; M, mesentery; M.A., meso-appendix. The arrow marks the superior ileo-caecal fossa. (Lockwood and Rolleston.)

at the junction of the middle with the outer third of the appendix, but its fore-edge is continued towards the tip in the form of a little ridge. This ridge can usually be seen in histological sections, and its presence has led Dr. Berry to state that the meso-appendix always reaches the tip of the appendix. Sometimes the meso-appendix is actually of the same length as the appendix, so that its free border and the tip of the latter coincide. It may be assumed that this extra development renders the blood supply of the appendix less precarious.

The distal part of the appendix beyond the meso-appendix is the part most liable to become gangrenous

(Fig. 6, p. 30). I have also observed that perforations frequently occur exactly opposite the end of the meso-appendix (Fig. 21, p. 83). The base of the meso-appendix is usually attached to the left or under layer of the mesentery. Its free edge contains an appendicular artery and vein of considerable size. Towards the right it ends at the cæcum. When this cæcal attachment is short, the meso-appendix is triangular; when it is long, the latter is quadrangular. But the meso-appendix is one of the most variable structures in the body. Sometimes, it is long and thin and easy to transfix and tie; at others, it is short and thick, and necessitates extreme caution; occasionally it is non-existent. Its attachments, too, may vary, and it may spring from the cæcum, the cæcum and colon, the ileum, the mesentery, or the iliac fossa. An appendix, which is held down in the iliac fossa by a scanty mesentery, is difficult to remove through a small incision, and the dangers of hæmorrhage are increased.

The vermiform appendix may also have other peritoneal connections, such as the ileo-cæcal fold, the appendiculo-ovarian ligament, or the plica vascularis. The ileo-cæcal fold (Fig. 3, p. 15) is almost bloodless and of hardly any surgical importance. The significance of the appendiculo-ovarian ligament is pointed out elsewhere (p. 26). The plica vascularis is the superior fold of the mesorchium, and runs downwards in the iliac fossa, from the appendix or its mesentery, towards the internal abdominal ring. It contains branches of communication between the spermatic and appendicular vessels, and has, therefore, to be properly secured when it is divided.

In retroperitoneal hernia of the vermiform appendix, the meso-appendix may be attached in the ileo-cæcal or sub-cæcal fossa, and then it may be rather more difficult to secure. In one instance, the appendix lay in the iliac fossa, with its distal third free, and its proximal two-thirds closely applied to the iliac fascia, and held down by the peritoneum which covered its abdominal aspect. Thus the hinder part, like the ascending or descending colon, had no peritoneal covering. In such cases it is easier for the pus from an appendicular abscess to find its way into the retroperitoneal tissues.

CHAPTER III

ANATOMY AND HISTOLOGY—ARTERIES, VEINS, LYMPHATICS, AND NERVES

Anatomy and Histology.—I propose to refer briefly to the normal anatomy and histology of the appendix. The necessity for this will be admitted, when we find that well-known authors are not in agreement upon points which one would think could hardly be open to doubt. For instance, Dr. Hawkins,¹ in his admirable monograph, says that the inner *muscular* coat is a stout layer, and that the outer is thinner. Mr. Treves² speaks of “the *so-called* muscular coats of the appendix”; and adds that they “are made up . . . mainly of fibrous tissue.” It would be easy to find other instances of contradictory teaching. The lymphatic system of the vermiform appendix plays a most important part in many of its diseases; yet, with the exception of some brief allusions to the lymphoid tissue and lymphoid follicles, the matter is passed over in silence. The same remarks apply to the nerves of the appendix.

Inasmuch as the vermiform appendix is simply a piece of large intestine on a small scale, the same nomenclature can be applied to the corresponding layers. Beginning from the exterior, the coats of the appendix are as follow:—(1) The peritoneal and subperitoneal; (2) the longitudinal muscular; (3) the circular muscular; (4) the submucosa; (5) the muscularis mucosæ; (6) the mucosa.

Before describing these layers in detail, the general

¹ *Diseases of the Vermiform Appendix*, London, 1895, p. 21.

² *Perityphlitis and its Varieties*, London, 1897, p. 5.

characters of a transverse section through a normal appendix will be given. Some allowances ought to be made for the shrinking which takes place during the process of hardening in Müller's fluid. The specimens have been prepared in the following manner:—After removal from the body, the vermiform appendix was placed in Müller's fluid; then it was imbedded in paraffin and made into histological specimens by Mr. Ernest Shaw. From the best of these, Mr. Norman has executed a series of microphotographs. I think that these will be found to throw some new light upon, and afford clear and truthful ideas of the diseases of the vermiform appendix. Where it has seemed at all doubtful whether a microphotograph was worth reproducing, I have nearly always had it reproduced. As a matter of fact, I have never seen two specimens exactly alike, just as I have never seen two cases exactly alike. As far as possible, I have given the clinical history and also the ultimate result of each case. Thus the clinical history, morbid anatomy, and morbid histology are presented to the mind and to the eye in a manner calculated to show their relation to one another.

I have before me a consecutive series of sections, sixty-three in number, made with a microtome from a normal appendix. After hardening, the largest sections are 4 mm. in diameter and almost circular. The centre is occupied by the lumen, which is trifoliate, and 2 mm. across at its widest part. Around the lumen is a deeply stained band, 1 mm. thick. This layer follows the outline of the lumen, and is, therefore, trifoliate. Its thickness is usually reduced one-half where it covers the ends of the limbs of the trefoil.

The trefoil is surrounded by a narrow circle of faintly stained tissue. Outside this is a more deeply stained ring, 1 mm. thick. The lumen is very variable in shape and may resemble a T, or H, or it may branch irregularly. Variations in shape occur in different parts of the appendix.

The layers thus seen with the naked eye are as follow:—The deeply stained trefoil is the mucosa with its lymphoid tissues; the clear ring is the submucosa; and the ring outside that is the muscular coat. The peritoneal coat is so thin that it can scarcely be seen with the naked eye.

This much having been premised, the following is the histology of the appendix as seen with low powers of the microscope ($\frac{1}{3}$ to $\frac{1}{8}$ in.):—

Peritoneum and its Continuity with the Submucosa—The Hiatus Muscularis.—The peritoneal covering of the appendix, as seen in sections, varies in thickness from a half to one millimetre, and is, as I have already said, almost invisible to the naked eye. When the appendix is empty and contracted, its outline is wavy. The endothelium covering its surface is supported by a basement membrane of extreme thinness. The rest of the peritoneum is a very delicate tissue of branched nucleated cells, waving fibres, elastic fibres, blood-vessels, nerves, and lymphatics. The delicate connective tissue penetrates between the fibres of the outer longitudinal muscular coat, carrying with it minute blood-vessels, nerves, and lymphatics.

The peritoneal coat of the appendix is continuous with the meso-appendix. Under low powers of the microscope, it looks as if the meso-appendix split to embrace and encircle the appendix. But, in addition, the subperitoneal tissue and the blood-vessels, nerves, and lymphatics which it contains are very intimately connected with the submucosa. This union takes place at certain gaps in the muscular coats. These gaps serve for the transmission of blood-vessels, nerves, and lymphatics from the meso-appendix to the mucous coat. They are situated at the junction of the meso-appendix with the appendix. In a specimen of an inflamed appendix (Fig. 4, p. 20) the gap, foramen, or hiatus is more than a millimetre wide, and can be clearly seen with the naked eye. In sections, the continuity of the inflamed submucous and subperitoneal coats is seen with the greatest clearness (see also Fig. 16, p. 67). The full significance of this fact becomes apparent, when we know that the mucosa and submucosa are the seat of bacterial invasion. The section also includes a portion of the meso-appendix, and the gap is obviously for the transmission of its vessels, nerves, and lymphatics to and from the submucosa and mucosa. In some specimens the vessels are of large size (Fig. 42, p. 162). As I do not possess a consecutive series of sections of the whole of a well-developed appendix, I am unable to give the exact number

of these gaps, foramina, or intervals. They are seen at the caecal end of the appendix, where it usually has a mesentery. The continuity of the submucosa and subperitoneal tissue is of great importance, as it is the chief road by which the infective inflammations of the mucosa reach the peritoneum.

Muscular Coats.—The outer longitudinal muscular coat varies in thickness from a half to one millimetre. Its fibres

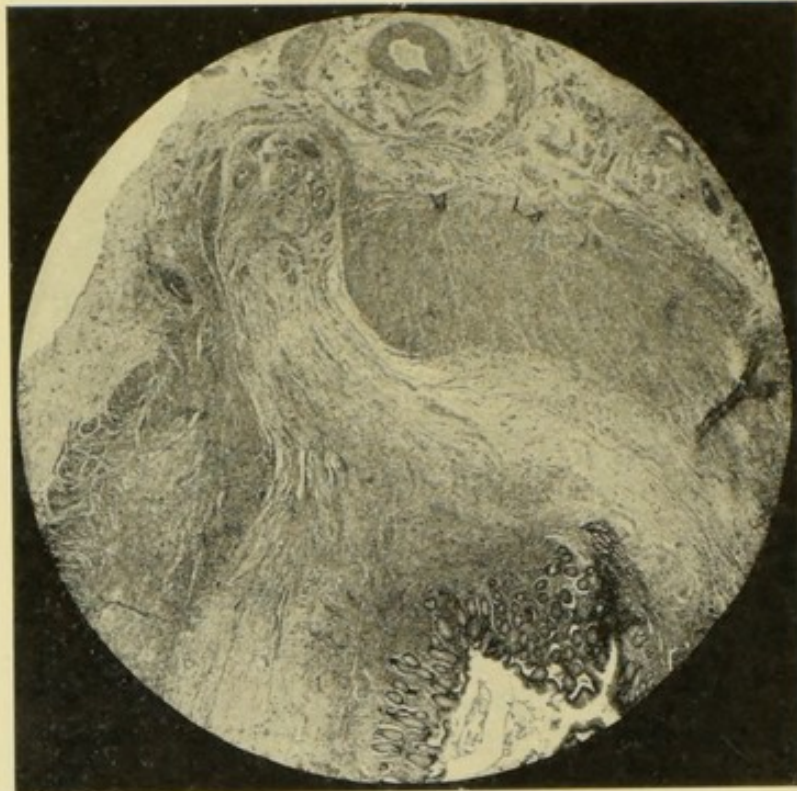


FIG. 4.—The hiatus muscularis. The continuity of submucosa with subperitoneal tissue and meso-appendix and carrying blood-vessels, lymphatics and nerves. $\times 11$. The lumen of the appendix below, the meso-appendix above. (See also Figs. 16 and 42.)

are irregularly distributed, being abundant at one part of the circumference and deficient at another. This irregular distribution of the fibres has been thought to indicate an incipient stage in the formation of the three longitudinal bands of the caecum and of the colon.

When the lumen of the appendix is distended with fluid or a concretion, or when the mucous membrane is swollen, then the longitudinal fibres are stretched apart until they become spread out into a thin layer, or until gaps occur. In

consequence of this peculiarity, the outer muscular coat is but an indifferent barrier against perforation.

The intervals between the longitudinal muscular fibres are occupied by delicate connective tissue, blood-vessels, and lymphatics derived from the subperitoneal coat.

The circular muscular coat is a ring of unstriated muscular fibres, about 1 millimetre thick. It has a dense appearance because it contains hardly any connective tissue cells, and but few blood-vessels. When the lumen of the appendix is distended, or when the mucous membrane is swollen, the circular muscular fibres are pushed together, and form a larger but thinner ring. They are a more efficient protection against perforation than the scattered longitudinal fibres. Here and there, the circular fibres are pierced by vessels running to and from the mucosa. The large gaps by which the subperitoneal and submucous coats become continuous have already been mentioned, and their pathological importance pointed out.

Submucosa.—The submucosa consists of delicate connective tissue, blood-vessels, nerves, and lymphatics. It is separated from the mucosa by the muscularis mucosæ. The latter, however, is sometimes absent, and often incomplete, so that the limits of the two layers may be rather indefinite. The submucosa varies in thickness more than any other layer of the appendix. When the appendix is inflamed, it may become exceedingly vascular and œdematous, with dilatation of its lymphatics (Figs. 26 and 52, pp. 100, 257). When the lumen is distended, or the mucosa swollen, it may be compressed against the circular muscular coat until it looks like a thin fibrous layer.

The Mucosa.—The mucosa consists of a single layer of columnar epithelial cells upon a delicate basement membrane, of tubular glands imbedded in adenoid or lymphoid tissue, and of lymphoid follicles. It also contains a vascular and a lymphatic system and nerve-endings. When the muscularis mucosæ is present, it forms a thin circle at the base of the tubular glands, but it is absent where the lymphoid follicles pierce it.

The tubular glands are usually about half a millimetre long. Their deep extremity is often bifid and sometimes trifid, which makes them look almost racemose.

The tubular glands are imbedded in lymphoid tissue, consisting of a delicate stroma or reticulum, endothelial plates, and small spheroidal nuclear cells. In inflammation, the latter are augmented by inflammatory corpuscles which hide the stroma or reticulum, and render the lymphoid tissue dense and opaque. The ease with which the reticulum can be seen is a rough indication of the degree of inflammatory change. The tubular glands are difficult to count, but usually there are from twenty-five to thirty in a single section. In ulceration of the mucosa they are destroyed; first they shed their epithelium, and afterwards the surrounding lymphoid tissue is removed, fragments of it breaking off and lying in the lumen amongst pus, bacteria, mucus, and epithelium. After the epithelium has been shed, the space which is left may become filled with bacteria from the lumen, and thus the deeper parts of the mucosa may be invaded (Fig. 14, p. 65).

When the appendix is distended with mucus or pus the tubular glands disappear in another way. They become gradually shorter and wider until a shallow bay remains, and at last that disappears.

The adenoid tissue which underlies the epithelial lining of the lumen, is the same as that in which the tubular glands are imbedded, and possesses, therefore, the same delicate reticulum of branched, anastomosing, nucleated cells, with lymphoid cells in the meshes. In thin and well-stained specimens of the uninflamed appendix the reticulum ought to be clearly visible, together with the endothelial plates which it contains. In inflammation of the mucosa, as I have just said, it is hidden from view, but at the same time, the capillary loops between the tubular glands may dilate and become engorged, and reveal their presence.

The epithelium is the great safeguard against infection spreading from the interior into the walls of the appendix. When intestinal bacteria accumulate in the lumen, the lining epithelium prevents their inroad into the mucosa; when the epithelium is lost, they are resisted by the basement membrane; but when that is destroyed, they meet with little opposition until the muscularis mucosæ is reached. As soon as the epithelium is destroyed, the lymphatic system of the appendix is laid open to admit whatever the lumen may con-

tain. The accompanying microphotograph gives an idea of the appearance of the mucosa in health (Fig. 5, p. 24), and its appearances in disease are shown in a great many of the other figures, *e.g.* Figs. 7, 11, and 22, and will be described more particularly as I proceed.

The Lymphoid Follicles and Lymphatics.—The lymphoid follicles are a striking feature of the mucosa. They are globular, ovoid, or pyriform bodies, distinctly visible to the naked eye, being usually about 1 mm. in diameter. A few are situated outside the muscularis mucosæ in the submucosa, but most of them lie among the tubular glands, which they may displace in order to reach the epithelial lining of the lumen (Fig. 5). When this epithelium is destroyed the lymph canaliculi of the follicle are exposed to whatever the lumen may contain—pus, fæces, concretions, or bacteria.

The substance of each follicle consists of two parts. In the centre is an oval or circular area which stains more lightly than the rest, and looks less dense, because its lymph canaliculi are more capacious (Fig. 5).

The cortical part of the follicle stains deeply. It looks denser and more opaque, because of the smallness of its lymph canaliculi. Where the follicle is not bounded by the basilar lymph sinus, which I am about to describe, it merges imperceptibly into the adenoid tissue of the mucosa, or into that of contiguous follicles (Fig. 5).

The number of follicles is very variable. I have counted twelve in a transverse section through the appendix of a girl aged thirteen years, sixteen in the case of a man aged thirty-five, nine in one aged thirty-seven, eight in one aged thirty-six, and five in another aged sixty-eight. The exact number contained in an appendix must depend upon a variety of circumstances, but especially upon its length and calibre. As a rule, five or six can be counted in a transverse section through the middle of the appendix. An appendix of the usual length of three and a half inches contains, I estimate, from one hundred and fifty to two hundred follicles.

Thus, the age of the individual has not a very marked influence upon the size or structure of the lymphoid follicles. They were well developed in the appendix of a man aged

sixty-eight, who happened to be the oldest person upon whom I have operated for appendicitis. The accompanying microphotograph was made from the appendix of a woman aged forty-seven (Fig. 5).

The lymphoid follicles are related to the lymphatic system in the following manner:—The base of the follicle reaches to the submucosa, where it is surrounded by a large semilunar lymph sinus lined with endothelium. In future, I shall refer

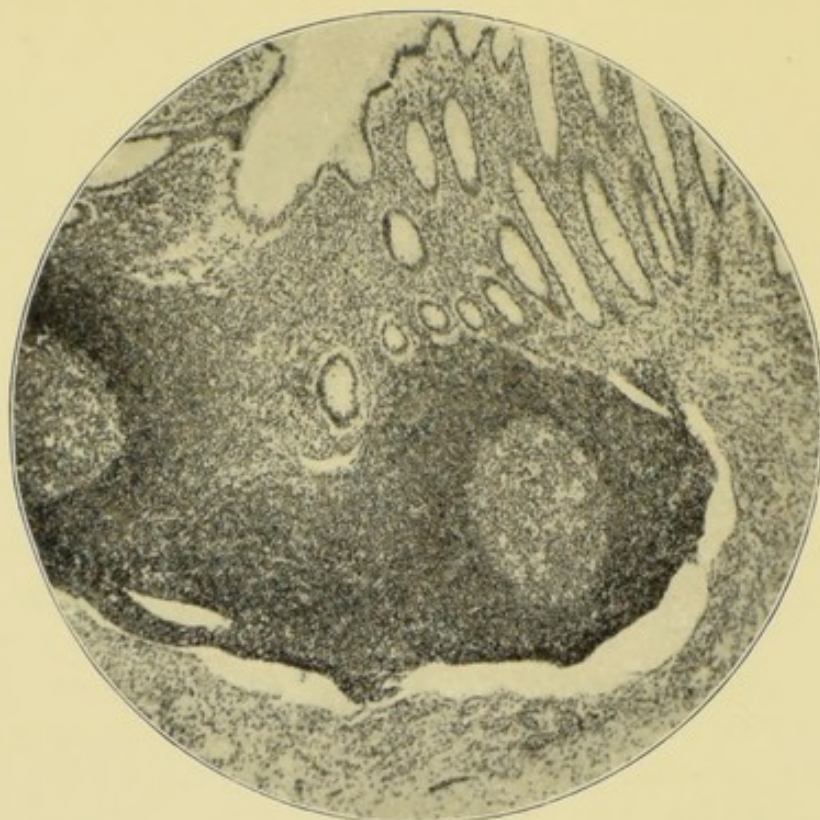


FIG. 5.—Normal appendix. $\times 55$. Showing (1) lining epithelium ; (2) tubular glands ; (3) lymphoid follicles ; (4) structure of follicle ; (5) follicular lymph sinus. The lumen is above.

to this as the follicular or basilar lymph sinus. In some respects it resembles the lymph paths of a lymphatic gland. The narrowest parts of the sinus are crossed by slender trabeculae. The sinus surrounds about half the circumference of the base of the follicle (Fig. 5), and opens freely into the lymphatics of the submucosa, which again communicate freely through the hiatus muscularis with those of the peritoneum and of the meso-appendix. In some inflammations of the appendix, the lymph sinuses are dilated and of greater extent, and their

endothelial lining in a state of proliferation (Fig. 38, p. 143); in others, they are crowded with inflammatory cells and bacteria (Fig. 11, p. 53), or obliterated by compression.

The follicular sinus is mentioned by Clado.¹ Speaking of the appendicular lymphatics, he says that they form spaces around the follicles and are applied like a cap to their deep part.

Dr. Klein, in his *Atlas of Histology*, depicts similar lymph spaces at the base of the lymph follicles of a rabbit's cæcum.² A drawing of the tonsil of a dog, in the same work, indicates, but less clearly, that the tonsillar follicles possess a basilar lymphatic.³

During the summer of 1899, Dr. D. J. Coffey described this lymph sinus before the Royal Academy of Medicine in Ireland.⁴

When we consider the anatomy of the lymphatic system of the vermiform appendix, it is easy to trace the path by which an infective inflammation can spread from the mucosa to the peritoneum. The following, as my microscopical specimens show, is a common sequence of events. An accumulation of bacteria in the lumen of the appendix; the gradual destruction of the lining epithelium; infection, inflammation, and ulceration of the mucosa, and of its lymphoid tissues and follicles; inflammation of the lymphatics of the follicles spreading to the lymphatics of the submucosa; and, finally, the spread of the inflammation, in the manner already described, from the submucosa, through the hiatus muscularis, to the subperitoneal tissues and lymphatics, and to the tissues and lymphatics of the meso-appendix, and so onwards to the peritoneum and to the mesenteric and iliac glands.

The lymphatics of the appendix enter the meso-appendix, where some of them pass through a lymphatic gland, situated at the ileo-cæcal angle. Clado⁵ believes that this gland is constant, and he describes and figures it as "the appendicular gland." I have not often seen it because, as Clado states, it may have been concealed by the ileum. From the meso-

¹ *Comptes Rendus de la Société de Biologie*, Paris, 1892, p. 155.

² *Atlas of Histology*, London, 1880, Plate XXIX. Fig. 10.

³ *Loc. cit.* Plate XXIX. Fig. 12.

⁴ Brief Report in *British Medical Journal*, July 22, 1899, p. 210.

⁵ *Comptes Rendus de la Société de Biologie*, Paris, 1892, p. 142, Fig. 1.

appendix the lymphatics enter the mesentery and then pass onwards. A small gland at the ileo-colic angle, and beneath the fossa, named the ileo-colic by Rolleston and myself, is constant, and one of the earliest to be implicated in diseases of the appendix. My own observations are based upon what I have seen in cases of appendicitis. And I have so frequently found a chain of inflamed lymphatic glands along the inner side of the right colon, behind the ascending meso-colon, that I have come to the conclusion that this is the course which the appendicular lymphatics mainly pursue. Others without doubt open into the mesenteric glands.

The arrangement of the appendicular lymphatics is of surgical and clinical importance. I have excised the lymphatic gland in the ileo-colic angle when removing the end of the ileum, the cæcum, and the vermiform appendix for carcinoma (Case 64, p. 216).

In a case of streptococcus appendicitis described elsewhere (Case 31, p. 119), pain was entirely absent in the region of the appendix, but was caused by digital pressure in the right linea semilunaris, almost up to the gall-bladder. A line of inflamed lymphatic glands was found running up the inner side of the right colon.

The lymphatics of the vermiform appendix empty into those in the iliac fossa, along the course of the external iliac artery. They also pass along the appendiculo-ovarian ligament into the right broad ligament of the uterus, and into the lymphatic glands in the right wall of the pelvis, in the neighbourhood of the internal iliac artery and vein.

Further on, I have described a case of appendicitis (Case 69, p. 231), in which the broad ligament was inflamed and swollen during an acute attack of appendicitis. Also one (Case 65, p. 219) in which the iliac lymphatic glands were enlarged, with inflammation of the right broad ligament. And another (Case 64, p. 216), in which carcinoma of the ileo-cæcal valve, involving the base of the appendix, caused a secondary growth in the right side of the pelvis.

Clado,¹ in his able memoir, gives the earliest description

¹ "Appendice Cæcal," *Comptes Rendus de la Société de Biologie*, t. iv., 2nd series, Paris, 1892, p. 133, etc.

of the passage of the appendicular lymphatics into the pelvis. On two occasions he saw infection pass from the appendicular lymphatics to the utero-ovarian. He considers this an explanation of the extension of purulent inflammation from the broad ligament to the cæcum, and *vice versa*. The lymphatics are transmitted by a peritoneal fold which Clado has named the appendiculo-ovarian ligament. This is a fold of peritoneum which is prolonged outwards from the infundibulo-pelvic ligament to the meso-appendix, and, I would add, in some cases to the cæcum and mesentery. On the left side it goes to the sigmoid flexure. This fold, however, is not always to be found. It has been identified by Durand¹ with the superior fold of the mesorchium or mesovarium, which I was the first to name "plica vascularis."²

Arterial supply of the Vermiform Appendix.—Authorities such as Henle, Krause, Sappey, Cruveilhier, and Quain give but scanty descriptions of the blood-vessels of the appendix. Most of these classical authors wrote before its surgical and pathological importance had been recognised, and, as a rule, they confine themselves to the statement that it receives an arterial supply from the posterior ileo-cæcal artery.

After having examined a number of injected specimens, I have come to the conclusion that the appendix has two principal sources of arterial supply, both derived from the posterior ileo-cæcal; but, before describing them in detail, a few words may be said about the anterior and posterior ileo-cæcal arteries. In the first place, it is to be noted that the names of these vessels do not convey an accurate idea of the structures which they supply. They both arise from the ileocolic artery at the ileo-colic angle, and run downwards over and under the ileum to supply the cæcum. In its course, the anterior ileo-cæcal artery supplies branches to the anterior surface of the right colon, to the superior and inferior segments

¹ "Le Ligament iléo-ovarien (appendiculo-ovarien de Clado), contribution à l'étude du ligament large," *Le Progrès Médical*, 6th July 1895, 3rd series, t. ii., No. 27, p. 1. Durand makes an error in referring to Clado's memoir giving the date "1891." Sonnenburg, *Pathologie und Therapie der Perityphlitis*, p. 53, repeats this mistake.

² "The Morbid Anatomy and Pathology of Encysted and Infantile Hernia," *Med.-Chir. Trans.* vol. lxix., 1886, p. 502.

of the ileo-cæcal valve, to the ileum, and to the cæcum. It does not, as a rule, send branches to the vermiform appendix; but, in a specimen before me, its branch to the ileum sends minute twigs to the base of the appendix, the posterior ileo-cæcal artery being too small to reach as far.

The posterior ileo-cæcal artery runs down behind the end of the ileum, and, after sending branches to the back of the right colon, to the end of the ileum, and to the inferior segment of the ileo-cæcal valve, divides into cæcal and appendicular branches.

The branches which the anterior and posterior ileo-cæcal arteries send to the valve, anastomose freely. I infer that, when the appendix is inflamed, the valve, owing to the source of its vascular supply, must also be inflamed. In this way, some of the obstruction to the onward passage of fæces and flatus may be explained.

The cæcal branch of the posterior ileo-cæcal artery courses over the inner and hinder wall of the cæcum close to the base of the vermiform appendix, to which it gives one or more branches. This is the earliest and most constant blood supply of the vermiform appendix, because during foetal life the appendix has no mesentery and is entirely dependent upon the cæcum for its blood supply.

As a rule, one of the cæcal appendicular arteries is much larger than the rest, and runs along the appendix at its junction with the meso-appendix. Here it anastomoses with the meso-appendicular arteries. This small cæcal appendicular artery bleeds rather freely when the appendix is amputated, and, if not previously secured in the ligature which includes the meso-appendix, has to be separately tied. Occasionally the cæcal artery sends another but smaller branch to the appendix. This runs along the wall of the appendix at the side farthest from the meso-appendix, and occasionally bleeds when the appendix is amputated.

In a certain proportion of cases, the appendix has neither a mesentery, nor any other kind of peritoneal fold; and is entirely dependent upon the cæcal artery for its blood supply. This is, as I have already said, its primitive state. The supply is evidently rather precarious and liable to interruption. But,

as a rule, the vermiform appendix receives its most abundant blood supply from the vessels which the posterior ileo-cæcal artery sends into the meso-appendix. I have before me a specimen such as is often met with during operations. The appendix springs from the inner and back part of the cæcum, an inch from the ileo-cæcal valve. Thence it runs upwards and inwards behind the end of the ileum. It is attached to the left side of the cæcum and ascending colon by a mesentery an inch wide and two inches long, which, therefore, only extends along two-thirds of the length of the appendix, the last inch being free and unattached.

As the appendicular branch of the posterior ileo-cæcal artery enters the meso-appendix, it divides into three branches. The largest¹ runs almost in the free edge of the meso-appendix, and is perhaps the most important, because the free end of the appendix depends upon it for its blood supply; the other two reach the appendix at intervals of half an inch. After the small branches have reached the appendix, they divide and encircle it, running in the subperitoneal coat, and also sending perforating branches to the submucous coat; these mainly enter by the hiatus muscularis (Fig. 42, p. 162). I do not know exactly to what extent the three branches of the appendicular branch of the posterior ileo-cæcal artery anastomose with one another, or with the cæco-appendicular arteries, but I am disposed to think that the anastomosis is not very abundant. In fact, they resemble in this respect the arteries which supply the other parts of the intestinal tract.

Owing to this arrangement, the part of the appendix which has a mesentery has the best blood supply, whilst the free end has the worst and most precarious. The part of the circumference of the appendix farthest from the mesentery is also less well supplied than the mesenteric side.

The peculiarities of the blood supply of the vermiform appendix were exemplified in a specimen I removed from a youth aged eighteen. The appendix sprang from the outer or

¹ R. T. Morris, *Lectures on Appendicitis*, New York and London, 1895, p. 24 (Fig. 15), gives a drawing of this artery obliterated by proliferating endarteritis.

right side of the cæcum and ran upwards beneath the outer side of the ascending colon. It was about 4 inches long,

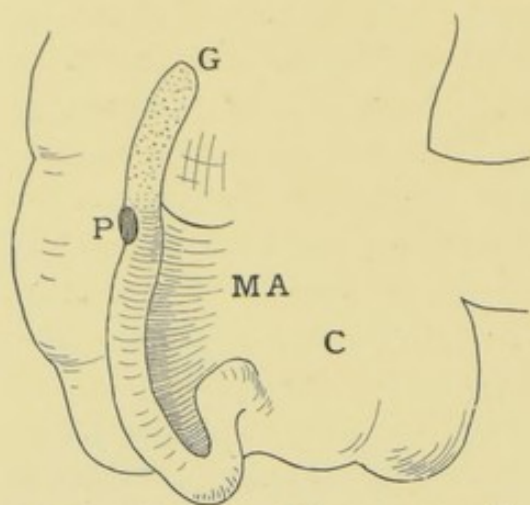


FIG. 6.—C, Cæcum ; MA, meso-appendix ; P, perforation ; G, gangrenous extremity.

and the meso-cæcum was attached to about 3 inches of it, the remaining inch being free. The coats of the appendix were perforated exactly opposite the point where the meso-appendix ceased, and the part of the appendix which had no mesentery was dead (Fig. 6).

The manner in which the gangrene of the free end occurred is far from clear. It is obvious that its blood supply must be more precarious than that of any other part of the alimentary canal. A calculus, distending the lumen, might cut off the arterial supply of all the part beyond it, or might prevent the return of its venous blood. The free end must also be more liable to suffer from mechanical obstructions to its vascular supply when the appendix gets bent or kinked. The minute size of its vessels probably renders stasis more likely to occur when the appendix is acutely inflamed. In acute inflammations, obliterative endarteritis is also seen, but I hesitate to assume that this is a primary and not a secondary change.

The appendix contained several small concretions which were in some way associated with the perforation. It may be noted that the perforation was situated in the appendicular wall opposite the attachment of the meso-appendix, or, in other words, in the part farthest from the blood supply.

The manner in which the gangrene of the free end occurred is far from clear. It is obvious that its blood supply must be more precarious than that of any other part of the alimentary canal. A calculus, distending the lumen, might cut off the arterial supply of all the part beyond it, or might prevent the return of its venous blood. The free end must also be more liable to suffer from mechanical obstructions to its vascular supply when the appendix gets bent or kinked. The minute size of its vessels probably renders stasis more likely to occur when the appendix is acutely inflamed. In acute inflammations, obliterative endarteritis is also seen, but I hesitate to assume that this is a primary and not a secondary change.

The Veins of the Appendix.—In sections, the veins of the meso-appendix have exceedingly thin walls. The smallest vessels consist of an endothelial layer and a little connective tissue ; the larger possess, in addition, a very thin layer of unstriated muscle, three or four cells thick, and a few scattered elastic fibres.

In proportion to the thickness of their walls, the lumens of the appendicular veins are of vast size, and it may safely be

inferred that they easily become distended with blood. Their anatomical relation to the rest of the portal system is also calculated to conduce to venous engorgement. With the exception of the sigmoid and hæmorrhoidal, the appendicular veins are its most dependent branches.

Owing to the stagnation of the blood stream, clots, as might be supposed, are nearly always present in the appendicular veins in acute infective appendicitis with perforation or gangrene, and, in the absence of valves, these clots can easily spread and become detached.

The appendicular veins begin in a subperitoneal and a submucous set. The subperitoneal veins run circularly in the subperitoneal tissue, and collect blood from the peritoneum and muscular coats. They empty themselves into the veins of the meso-appendix and into those of the cæcum.

The plexus of veins in the submucosa collects the blood from the capillary loops of the mucosa, and from the lymphoid follicles. The submucous plexus discharges its blood through veins which emerge through the hiatus muscularis, and thence enter the veins of the meso-appendix.

In the meso-appendix, the veins correspond with the arteries, although they do not actually accompany them. Their course towards the mesentery is straighter, and they converge towards the back of the lower end of the ileum to a posterior ileo-cæcal vein, which empties into the ileo-colic. The posterior ileo-cæcal vein also receives blood from the cæcum, ileum, and ileo-cæcal valve. At the base of the appendix, some of the appendicular veins empty themselves directly into the cæcal.

When, as is usual, the distal third of the appendix has no mesentery, its venous blood is collected into a vein which runs along its mesenteric edge, and empties into the main veins in the meso-appendix. A kink, a large concretion, or acute œdema, might easily occlude such a vessel. Gangrene of the distal third of the appendix is comparatively common.

The complete absence of the meso-appendix is rare, but when it does occur the return of the venous blood must be still more precarious.

The Nerves of the Appendix.—The appendix is well sup-

plied with nerves from the superior mesenteric plexus. With the microscope, several large nerve-trunks can be seen accompanying the arteries in the meso-appendix. Their branches are distributed to the appendix in two ways. A number run in the peritoneum and supply it and the muscular coats, and I suppose that this peritoneal plexus is stretched and inflamed in appendicitis, and thus accounts for the acuteness of the pain. Other branches pierce the muscular coats with the vessels which enter at the hiatus muscularis, and are distributed to the blood-vessels of the mucosa, having some ganglion cells upon them.

The plentiful nerve supply of the vermiform appendix, and its connections with the mesenteric and solar plexus, explain the shock which occasionally occurs as the appendix is being dragged out of the abdomen.

I am not aware that the nerves of the vermiform appendix have been systematically studied, and I regret that we have hitherto failed to obtain such properly stained specimens as would justify a more explicit description.

In the solar plexus, we may assume that the appendicular nerves form connections with the splanchnics, especially those of the right side. It is rather common, in appendicitis, to find the pain referred to the somatic and splanchnic distribution of the lower dorsal nerves, and that it is also felt in the umbilical region and in other parts of the body wall, and thus the disease is referred to the gall-bladder, pylorus, duodenum, or kidney.

CHAPTER IV

APPENDICITIS WITH ULCERATION OF THE MUCOSA, WITH AND WITHOUT BACTERIAL INVASION

I HAVE already remarked upon the artificiality of classifications of appendicitis, and now propose to try and group the 83 cases, which have been histologically examined, according to the pathological changes which have occurred.

As a rule, the changes are clear and distinct, and it is easy to say that the case is one of appendicitis with ulceration, or appendicitis with stenosis. A case of appendicitis due to tubercle would also present no difficulties.

But the pathological complications of appendicitis are numerous. For instance, ulceration of the mucosa is followed by bacterial invasion of the appendicular wall. This is effected in several ways, and produces several results, such as abscess, perforating ulcer, gangrene, and various forms of peritonitis and lymphangitis. In addition, ulceration of the mucosa is often associated with the accumulation of bacteria within the lumen of the appendix, and with the growth of fecal concretions, which are but masses of bacteria.

Stenosis of the appendix also has many pathological complications, such, for instance, as mucocele, empyema, ulceration of the mucosa, bacterial invasion of appendicular walls, and all its consequences, including various forms of peritonitis.

In the commonest form of appendicitis, that with ulceration of the mucosa and bacterial invasion, all the histological tissues which enter into the structure of the appendix may be involved. But, in some cases, the inflammatory changes in the lymphoid follicles and lymphatics are so marked, and the alterations

in any of the other tissues are so slight, that I have provisionally placed them in a separate class, as appendicitis with lymphadenitis and lymphangitis.

Some of the complications of appendicitis are anatomical, such, for instance, as retroperitoneal hernia of the appendix (Cases 28 and 112); but these hardly call for separate treatment, and are mentioned in the description of the respective cases.

The chief pathological complication of appendicitis is peritonitis. I doubt whether the peritonitis is, in all cases, caused by the actual passage of bacteria from the appendix, but, in most cases, it undoubtedly is. The peritonitis may result in suppuration, a complication fraught with the most deadly consequences. Wherever possible, I have grouped these cases according to the form of appendicitis which gave rise to the septic peritonitis; but, as this cannot always be done, many of the cases of intraperitoneal suppuration have been used to illustrate the clinical phases and peculiarities of that complication.

The study of the morbid histology of appendicitis would be devoid of practical interest to many, if it failed to throw light upon the clinical symptoms, or to offer guidance in the medical or surgical treatment.

A vast number of diseased appendices will still have to be examined before we know the correlation between the pathological changes and the clinical symptoms. But even the small amount of material at my disposal shows, that a relationship does exist between the degree of pathological changes in the appendix and the severity of the clinical symptoms. For instance, it will be noticed that I begin with cases of superficial ulceration of the mucosa and slight bacterial invasion. These had had symptoms of appendicular colic, or short and mild attacks of appendicitis.

Proceeding, we come to cases with deeper ulceration, bacterial invasion, and involvement of the submucosa. In these, the clinical symptoms were more pronounced, with severe attacks of appendicitis. But the submucosa and the peritoneum being continuous with one another, the peritoneum in such cases inflames and introduces fresh clinical symptoms. Thenceforth, the course pursued by the peritonitis becomes all-

important, and mainly determines the fate of the patient. Obviously the onset of peritonitis obscures the symptoms of appendicitis, and renders its true nature difficult to diagnose. The infecting bacteria being the same, they tend to produce the same effects, so that an acute septic peritonitis might lead one to infer an acute infective appendicitis, perhaps with perforation or gangrene.

But such calamities as these are, I believe, always preceded by a period of slight appendicitis, with ulceration of the mucosa and, perhaps, the growth of a concretion¹ (Case 19, p. 87). Obviously, if this be true, we shall, by learning to diagnose the earlier stages of appendicitis, be in a position to prevent many disasters.

Proceeding upon these lines, we begin with appendicitis with ulceration of the mucosa. In the first case, bacteria were looked for, but none were found; it is to be remembered, however, that the search was made during the period of quiescence.

CASE 1.—*Appendicitis with Ulceration of the Mucosa and without Bacterial Invasion.*—Mr. M., æt. thirty, had had two attacks of appendicitis of moderate intensity, each of which had kept him in bed for five days. During the first, he required opium on account of the pain. A month after the last attack and at the operation, a small tender swelling was felt in the right iliac fossa. He had been quite well between the attacks.

A small oblique incision was made, and the cæcum and vermiform appendix drawn out of the abdomen. The appendix was of the usual length, but much swollen. It had a mesentery which reached half its length. It was hard and inflamed but not adherent. The cæcum was rough and shaggy. The appendix was excised in the usual way. The small wound healed by first intention, and the patient was quite well a year after the operation.

Sections through the cæcal end of the appendix are 9 mm. across, twice the usual diameter. This is due to thickening of its coats, which are 4 to 5 mm. thick, instead of 2 mm. In consequence, the lumen is reduced to a narrow slit, 2 mm. long and .5 mm. wide. The lumen is half filled with mucus,

¹ See also White, *Lancet*, February 1895, p. 390.

epithelium, and nuclei, unmixed with bacteria. The mucosa is superficially ulcerated for about one-fifth of its extent, and, at two opposite points in the sections, it has lost its epithelium and basement membrane. Its tubular glands are few in number and full of goblet cells. The capillaries in the lymphoid tissue, between the tubular glands, are dilated and full of blood.

No lymphoid follicles can be seen, but a few aggregations of nucleated cells in the mucosa are probably traces of them. The submucosa is of twice the usual thickness and is very fibrous. The bundles of fibrous tissue penetrate into the mucosa, whose blood-vessels are numerous and large. Groups of inflammatory cells are scattered throughout the submucous, the muscular, and subperitoneal coats. The peritoneal endothelium is proliferating. Sections through the distal end of this appendix are almost the same as those through the proximal end. The lumen is wider and H-shaped. The various coats are not quite so thick. The submucous lymphatics are dilated to twice their normal size. No bacteria can be seen. There are no signs of tubercle.

This is evidently a case of appendicitis with slight ulceration of the mucosa, but with marked inflammation of the submucous and subperitoneal coats. The inflammation in the submucosa evidently tended to the formation of fibrous tissue, or, in other words, was reparative rather than destructive. The inflammatory products may also have begun to contract near the cæcal end and to narrow the lumen. The absence of bacteria explains, I think, the absence of any symptoms between the attacks. A similar coincidence is noted in other cases (Case 24, p. 103).

In the next case of appendicitis with commencing ulceration of the mucosa, the lumen of the appendix contained bacteria which were just beginning to penetrate at the ulcer. In this case, a distinct attack of appendicitis had not been known to occur, and the operation was exploratory.

CASE 2.—*Appendicitis with commencing Ulceration of the Mucosa and Bacterial Invasion.*—One of the earliest stages of appendicular ulceration was met with in the case of a young lady, aged twenty-four, who was placed under my care

by Dr. Gamble. Her history was peculiar. She had never had a distinct attack of appendicitis, but for two years had had a pain in the right iliac region, running down the inner side of the thigh. She described this pain as being like "something which was trying to burst," or "something which felt heavy and painful," "something heavy which pulled." She had been obliged to go to bed for several days at a time because of the pain. With rest in bed it got well, but latterly it had become worse. At the site of the vermiform appendix a very tender spot was found. The abdominal wall over this tender spot was rather rigid, but no actual tumour could be felt. She had had no symptoms pointing to any disease of the alimentary tract, but she made the significant remark that for two years she had been unable to eat fruit or vegetables without a great deal of discomfort "and indigestion." My colleague, Dr. Herringham, had seen her and advised an exploratory operation. I opened the abdomen by a small incision at the outer edge of the rectus abdominis, so as to be able to examine the uterus and ovaries as well as the appendix, as it had been stated that the pain was worse at the menstrual periods. Nothing was discovered in connection with the pelvic organs, with the exception of slight retroflexion of the uterus. The cæcum, near the base of the appendix, was adherent to the parietal peritoneum by a recent and firm adhesion. The appendix was a long one and lay beneath the ileo-cæcal junction, attached by a mesentery which extended throughout its whole length. To the naked eye the appendix presented no evidences of disease. An inch from the cæcum it was sharply bent upon itself and its distal end felt very hard. It was excised in the usual way. The wound healed by first intention, and the case would have been free from the slightest complication had she not had some swelling of the left leg after her return home.

The accompanying microphotograph (Fig. 7, p. 38) shows the ulceration of the mucous coat. Other evidences of inflammation were found in the peritoneal coat, but are not included in the photograph. They consisted of a development of new connective tissue in a few places. The muscular coats are unaltered. The submucosa is slightly infiltrated

with inflammatory cells, and its lymph channels dilated. The blood-vessels are unaltered. The muscularis mucosæ is absent. The lymphoid follicles are well developed, and five may be counted in one section. Their basilar lymphatics are dilated, and there is also dilatation of the minute lymph-paths of the substance of the follicles. The inner aspect of several of the follicles has lost its epithelial layer, so that the lymphoid tissue is bathed in the contents of the lumen of the appendix. These consist of detached epithelial cells, nucleated

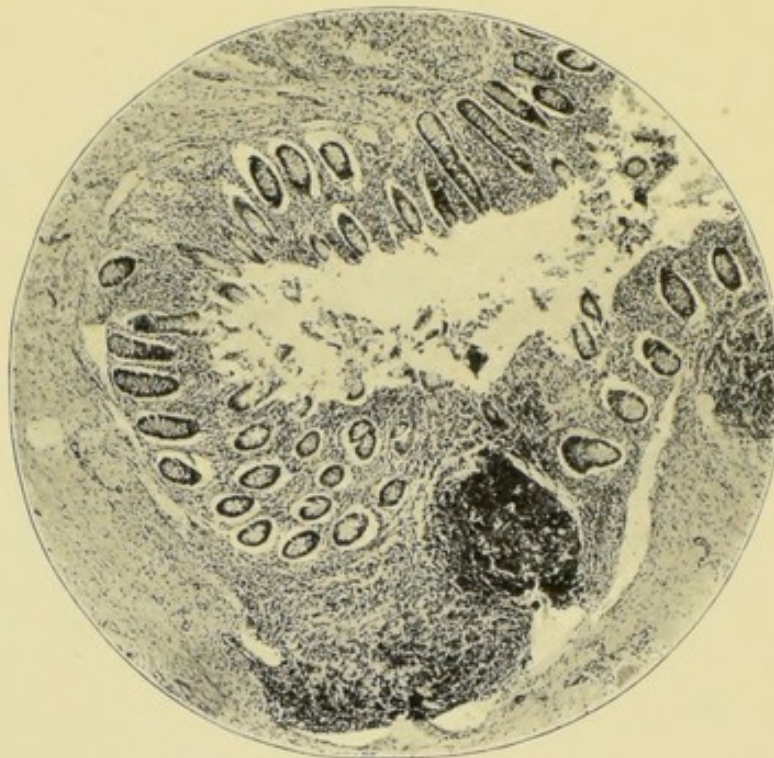


FIG. 7.—Ulceration of the mucosa. The follicular lymphatics are dilated, and the submucosa slightly oedematous. $\times 50$.

cells, pus cells, granules, mucus, and clumps of bacteria. The bacteria include pairs of diplococci, bacilli, spore-bearing bacilli, and diplobacilli, which probably have capsules. Some of the bacteria are upon the raw surface of the lymphoid follicles and, here and there, within their substance.

The epithelial lining of the appendix has been shed together with some of the epithelium of the mouths of the mucous glands. Some of the epithelial cells are swollen with mucus; others are irregular in outline; some granular and disintegrating; many contain two small nuclei; the tubular

glands are not so far involved. They all contain a number of goblet cells, and some have dilated lumens filled with mucus. As I have just stated, the epithelium around the mouths of some of them had been shed into the lumen of the appendix.

In commenting upon this case I would remark that, although the epithelial changes were so slight, they had, nevertheless, sufficed to uncover the lymph paths and lymph channels of the appendix so that the latter communicated directly with its interior. In this instance, the contents of the interior of the appendix were comparatively harmless, although bacteria of various kinds could be seen in considerable numbers, but not in the enormous quantities found in other cases which I am about to describe.

To my mind, this absence of very septic contents helps to explain the mildness of the clinical symptoms. But, although the clinical symptoms were mild, I think it will be conceded that the excision of the appendix was justified.

CASE 3.—Similar histological appearances were found in an appendix removed from a young married woman, *æt.* twenty-eight. In January, 1900, she had a sharp attack of appendicitis, which was followed by pain and discomfort in the right iliac fossa, and occasional attacks of diarrhœa. The appendix was excised during the month of May.

The distal end was normal, but its lumen was filled with a bacterial mass such as precedes the formation of a faecal concretion (Fig. 23, p. 89). The proximal end closely resembled the specimen which has just been described. It was swollen to twice the size of the distal end, owing to œdema of the submucosa and swelling of the lymphoid tissue and follicles of the submucosa. The lumen contained epithelium and nuclei, but only occasional minute groups of bacteria. Here, one feels tempted to attribute the morbid state of the proximal end to the deleterious effects of ptomaines or toxins, derived from the bacterial mass in the distal extremity.

The invasion of the ulcerated mucosa by bacteria from the lumen is well recognised, especially by American authors, to whose labours we owe so much. This bacterial invasion, as well as some of the destructive changes which it produces, will be fully illustrated by the accompanying microphotographs.

The clinical signs of ulceration and bacterial invasion of the mucosa are, I believe, more obvious than is usually thought. When once bacteria have invaded the ulcerated mucosa a *continuous* train of symptoms is produced. The general symptoms are those of a septic ulcer in any region, with occasional attacks of lymphangitis. The patient never feels well, the appetite is uncertain, the digestion disturbed, the pulse and temperature undergo small but capricious alterations. To these may be added more definite symptoms of appendicular disease, such as pain in the region of the appendix, constipation, abdominal distension, vomiting, and peritonitis; in fact, a typical attack of appendicitis.

The following cases have been arranged, to some extent, in accordance with the degree of their pathological changes and the severity of their clinical symptoms, which, generally speaking, coincide to a remarkable degree.

CASE 4.—*Appendicitis with Ulceration of the Mucosa and Bacterial Invasion—Appendicular Colic.*—I believe this to be the earliest case of ulceration of the mucosa of the appendix with bacterial invasion, which has hitherto been recorded. Miss F., aged thirty-two years, an unmarried woman, had been ill for eighteen months with obscure abdominal pains. During the last six months she had been unable to follow her occupation, that of teacher in a school. The pain was in the right side of the abdomen. A medical man had diagnosed stone in the right kidney, and it was rumoured that blood had been seen in the urine. Repeated examinations failed to disclose any blood, pus, crystals, or albumen. She had never had an attack of appendicitis. The alimentary tract seemed to perform its functions in a proper manner. At the request of my friend, Dr. Malcolm, I admitted her into the Great Northern Hospital. She always said that the pain was in the right iliac fossa. The usual remedies and dietings had no effect whatever. An anæsthetic was administered, but nothing abnormal was discovered. The abdomen was repeatedly examined, and at last, after nearly three weeks had elapsed, something was felt in the right iliac fossa which I considered to be a tender and inflamed appendix.

I therefore opened the abdomen through a small oblique

incision parallel to the outer half of Poupart's ligament. There was no sign of perityphlitis. The appendix was of the usual size and length, and its blood-vessels were not dilated. The meso-appendix reached as far as its tip. The appendix was kinked at the junction of its middle and distal thirds, and the part beyond the kink was slightly swollen and felt hard. I removed the appendix in the usual way, and the patient made a rapid recovery. Before departing for Australia, she said the pain was cured, and that her abdomen felt quite well again.

The sections of the appendix are 6 mm. in diameter, and present nothing abnormal to the naked eye. The lumen of the proximal end is the usual T-shape, whilst that of the distal portion is more extensive and about the shape of the letter H. The endothelial layer of the peritoneum is probably unaltered, the subperitoneal tissue of the distal end containing a few small groups of inflammatory cells. At the meso-appendix, the outer muscular coat is absent for about a quarter of the circumference; the circular muscular coat is normal. In some sections, the hiatus muscularis is well marked. The submucosa has undergone hardly any alteration except that its lymphatic spaces are dilated, and, towards the distal end, its blood-vessels are numerous and full of blood.¹ The mucosa is not thickened, and the muscularis mucosæ is absent. Five or six lymphoid follicles can be counted in each section, and their lymph sinuses are dilated. The tubular glands contain many mucous cells. The lining epithelium of the lumen is detached throughout about three-quarters of its extent, and, in places, its basement membrane is destroyed.

The lumen contains detached epithelium, mucus, nuclei, granules, and crystalloid bodies. This fluid is crowded with cocci, diplococci, small ovoid bacilli singly and in pairs, small clumps of staphylococci, streptococci in chains of four to six elements, also some long slender bacilli. As usual it is difficult to distinguish between small oval bacilli and micrococci.

Where the mucosa is ulcerated these bacteria have begun

¹ Perhaps caused partly by the fact that the meso-appendix was ligatured before the removal of the appendix. This remark applies throughout.

to penetrate its lymph canaliculi (Fig. 8). Cocci and diplococci have, perhaps, penetrated more than the rest, but at one point streptococci, together with large and small ovoid bacilli, have also made an invasion.

No evidence of tubercle could be discovered.

The histological structure of the appendix is the same throughout except, perhaps, that the distal third is slightly more inflamed. We cannot, therefore, attribute the hardness

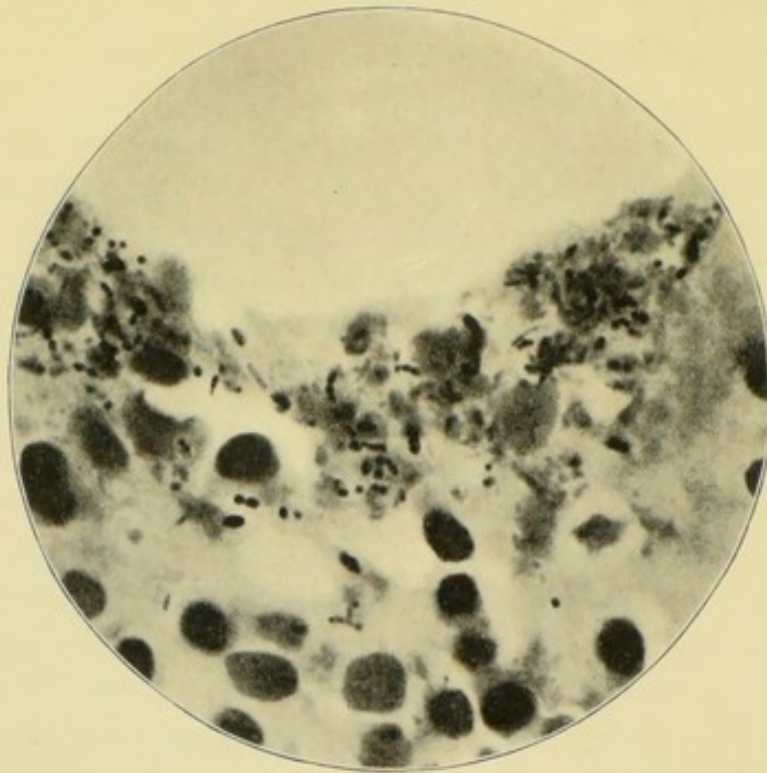


FIG. 8.—Appendicular colic. Ulceration and bacterial invasion of mucosa. $\times 1000$. The lumen is above.

of the distal end to an alteration in the structure of its coats, but rather to the accumulation of fluid in its interior.

This appendix was excised after a good deal of hesitation. I hardly felt sure that it was the cause of the continuous pain, although the patient had been kept under close observation for weeks, and had been examined under an anæsthetic.

Young women sometimes suffer from mysterious pains. The fact that the pain was cured is no proof that the appendix was diseased, although, perhaps, it justified the operation. But if additional justification were needed, it is to be found in the result of the histological examination. I venture to surmise

that the ulceration and bacterial invasion of the mucosa would have spread and ultimately led to a catastrophe.

In its morbid histology, the next case closely resembled the last, but the clinical symptoms were more severe, and typical attacks of appendicitis had occurred.

CASE 5.—*Appendicitis with Ulceration of the Mucosa and Bacterial Invasion—Appendicular Colic ending in Appendicitis.*—The case has an interesting feature of its own. The vermiform appendix looked perfectly healthy, and merely felt rather hard to the touch. The cæcum, on the other hand, was engorged with blood, its peritoneum rough, shaggy, and covered with small vascular adhesions. As is commonly the case, the naked-eye appearance of the appendix was no guide whatever to the pathological state of its interior. The mucosa was ulcerated and infiltrated with the purulent and bacterial contents of the lumen. The patient was a healthy young woman, aged twenty-six, a cook by occupation. In September, 1899, she first noticed a pain which began in the right inguinal region, and spread thence into the lumbar region, and over the rest of the abdomen. At its commencement the pain was very severe and “quite doubled her up” for about two hours; then it became less intense, and in two days had departed. During October and November, the attacks recurred once a week or oftener, but, in December, the pain in the right iliac fossa became continuous, and associated with troublesome constipation. Vomiting was absent throughout the illness. The temperature was not raised nor, I believe, the pulse accelerated. My friend, Mr. Chune Fletcher, saw her during one of the attacks, and diagnosed appendicitis. In December, she was obliged to give up her situation, and in January, 1900, about four months after the commencement of the attack, I removed the appendix. The only alternative to that course would have been a prolonged period of rest, careful diet, and intestinal antiseptics, such as salol or β -naphthol. Before the operation, no tumour could be felt either in the iliac fossa or *per rectum*, although the region of the appendix was tender, with slight rigidity of the abdominal wall.

The abdomen was opened by the usual small oblique

incision. The appendix was free and about 10 cm. ($4\frac{1}{2}$ in.) long, and had a meso-appendix for about half its length. As I have remarked, it presented no appearance of disease to the naked eye, but felt very hard. The right ovary and tube were normal. The patient made an uninterrupted recovery, the wound healed by first intention, and she was quite well some months after the operation.

The proximal and distal sections are not quite alike. They both measure 4 mm. in diameter, about the size of the ulnar artery, but the proximal has very thin walls (1 mm.), and a wide circular lumen, 2 mm. across; the distal lumen is a mere slit, 1 mm. long, narrowed by the swollen lymphoid follicles of the mucosa.

The peritoneal coat is normal and about .1 mm. thick. The longitudinal muscle coat is hardly any thicker, and its fibres are scattered. The circular muscular coat is also very thin, being about .25 mm. thick. These coats are otherwise quite normal. The submucosa is œdematous and its lymphatics dilated; it is, however, barely more than .25 mm. thick. Its blood-vessels are slightly dilated.

In its thickest parts, the mucosa is not more than .25 mm. thick, but, in places, it is ulcerated almost as far down as the submucosa.

The lymphoid tissue of the mucosa is so crowded with cells that the stroma is hidden. The remains of three or four lymphoid follicles can be traced; one is ulcerated and infiltrated with the purulent and bacterial contents which fill the lumen. The ulceration and infiltration have begun in the central medullary portion of the follicles. The follicular lymph sinuses are not dilated.

The tubular glands are dilated, and most have lost the epithelium at their mouths. They contain rather an excess of mucous cells. The epithelial lining of the lumen is detached, with the exception of a few small patches. The lumen is full of purulent and fœcal material. It contains masses of granules, yellow pigment, fibres, epithelial cells, mucus, pus cells, large nuclei, red blood corpuscles, and a great variety of bacteria, including cocci, diplococci, streptococci in chains of six or seven elements, small ovoid bacilli in pairs and swarms,

large ovoid bacilli, spores and spore-bearing bacilli, leptothrix, and large bacilli, like hay bacilli.

Wherever the mucosa is ulcerated, the remains of its substance is infiltrated with the purulent and infective fluid which fills the lumen, and here and there this dangerous mixture has reached as far as the submucosa. No bacteria can, however, be seen in the œdematous submucosa.

In the distal sections, the lumen is reduced to a narrow slit, which is partially filled with the same purulent and bacterial contents. Its epithelial lining is intact, and no infiltration has taken place. In each section, six or seven lymphoid follicles can be counted, some of which bulge into the lumen and are presumably inflamed and swollen. The submucosa is œdematous. The muscular and peritoneal coats are very thin, but, otherwise, normal. There is no evidence of tubercle.

This specimen is a very interesting one, because, I think, we may assume that it shows how much ulceration and bacterial invasion can occur in four months.

It also shows that, although the ulceration and bacterial invasion are confined to the proximal end of the appendix, yet the whole of its lymphoid tissue is inflamed, and there is œdema, with dilatation of the lymphatics of the whole submucosa. It is very strange that the appendicular peritoneum should be normal, whilst that covering the cæcum is markedly inflamed. I infer that, under these circumstances, the inflammation spreads along the lymphatics.

CHAPTER V

APPENDICITIS WITH ULCERATION OF THE MUCOSA AND BACTERIAL INVASION—*Continued*

WE now come to cases with more general infection of the mucosa, submucosa, and peritoneum, and with more severe clinical symptoms.

CASE 6.—*Appendicitis, with Ulceration of the Mucosa and Bacillary Invasion—Lumen of the Appendix filled with Bacilli.*—It seems reasonable to suppose that the clinical symptoms of appendicitis depend, to some extent, upon the variety of bacteria which is present. I have elsewhere given (Case 30, p. 116) a case in which the lumen was crammed with an almost pure culture of streptococci, and am now about to describe a closely similar one in which the lumen was full of bacilli.

The patient was a gentleman in his sixty-eighth year, who had long been a resident in South Africa. As yet he is the oldest patient on whom I have operated. His arterial system was sclerosed, but otherwise his general condition was not unfavourable. He had had four moderately severe attacks of appendicitis during the two previous years. During the attacks the temperature rose to 100° or 100·5° F., with pain in the right iliac fossa, constipation, and slight abdominal distension. I do not know whether vomiting occurred. In the intervals, he continued to feel discomfort in the right iliac fossa, and had to be extremely careful of his diet. A tender swelling could be felt in the right iliac fossa. The result of the rectal examination was negative. He was seen by Dr. Sidney Martin, who advised an operation. I concurred in this opinion, because so long as the appendix was inflamed

he was in danger of fresh attacks, and, during his travels, or whilst in Africa, these might occur when surgical help was not available; he was, moreover, almost an invalid. The appendix was excised by the usual small oblique incision. It was about 7 cm. long and very difficult to find, because it was hidden beneath a layer of dense adhesions, which bound it down to the end of the ileum and cæcum. After the operation, the patient did not vomit, and speedily resumed his usual diet. A catheter had to be passed once because of retention of urine. On account of his age and a slight tendency to bed-sores, he was placed upon a couch on the eighth day. He made a speedy recovery, and said the operation was only a little more painful than his attacks of appendicitis had been. A year after the operation he was quite well.

After removal, the appendix was rough and vascular. The sections, viewed with the naked eye, show with perfect clearness the muscular, submucous, and mucous coats. The microscope shows that the peritoneal and subperitoneal coats are inflamed, œdematous, and very vascular. The meso-appendix is in a similar condition. The muscular coats are normal, with the exception that they are pierced opposite the meso-appendix by an extra number of large blood-vessels. These run to the submucous coat, which is very vascular and œdematous. The muscularis mucosæ is thin and imperfect. Five lymphoid follicles can be counted in a section. They are of about the usual size and structure, and nearly all possess the usual semilunar basilar lymph space. The tubular glands are about half as numerous as usual, and, in consequence, the lymphoid tissue of the mucosa is rather abundant. When we recall that this specimen was obtained from a man in his sixty-eighth year, this abundance of follicles and of lymphoid tissue is noteworthy. There is a general belief that, as age advances, the various lymphoid tissues atrophy. But this and other specimens make me think that the lymphoid tissues of the vermiform appendix are much less altered by age than is commonly supposed.

The lumen of this appendix is denuded of epithelium, and the basement membrane partially, but not entirely destroyed.

The epithelium of the mouths of the tubular glands is shed. The tubular glands contain many mucous cells. One of them has three diverticula and looks like a rudimentary racemose gland.

The lumen is not dilated and is filled with a mixture of granules, epithelium from the lumen, rings of epithelium from the mouths of the mucous glands, pus cells, and nuclei. Amidst these, are quantities of bacilli of various types (Fig. 9):—long, slender, curved bacilli, in twos or short chains, and exactly like comma bacilli; short, thick bacilli,

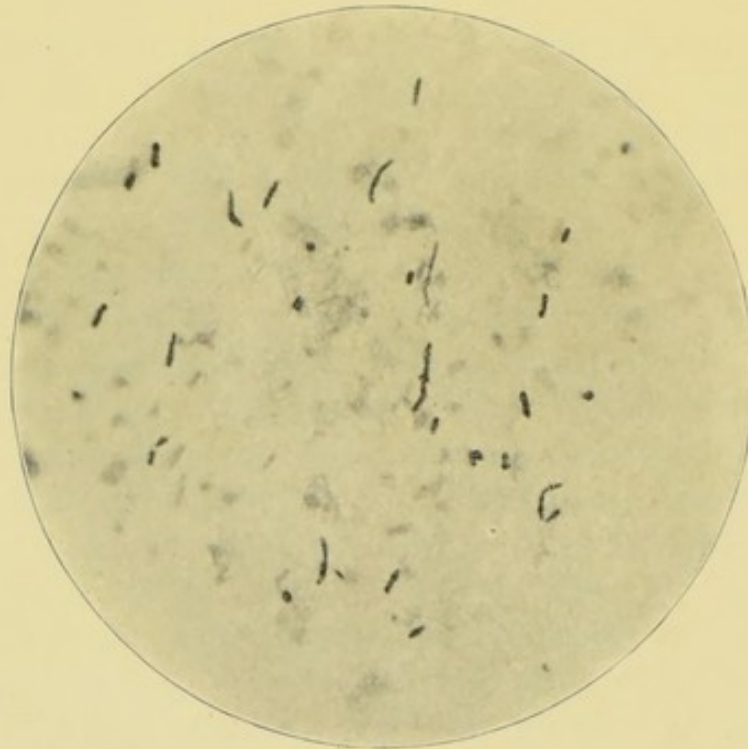


FIG. 9.—Bacilli in lumen of appendix. Recurrent appendicitis. $\times 1000$.

bulged by a spore which is usually situated at one end; these look like a club; small ovoid bacilli in chains of four or five; small ovoid bacilli with spores; small irregular groups of bacteria undergoing irregular fission; and lastly, some large bacilli with rounded ends. No true spherical bacteria seem to be present. Tubercle is also absent.

Thus the appendix is full of actively multiplying intestinal bacilli, which are in contact with the denuded and ulcerated lymphoid tissue. Where the basement membrane of the epithelial lining is intact, they have not penetrated its interstices; but where it is destroyed, they have penetrated to

almost half the depth of the tubular glands. The lymphoid tissue around them is full of granular cells, probably pus corpuscles.

Apparently, only one of the several species of bacilli which fill the lumen has invaded the mucous coat. The largest of the invaders are about $2\ \mu$ long and very slender; the smallest $1\ \mu$ long. The latter are single, in pairs, or in short chains. I find it difficult to say whether

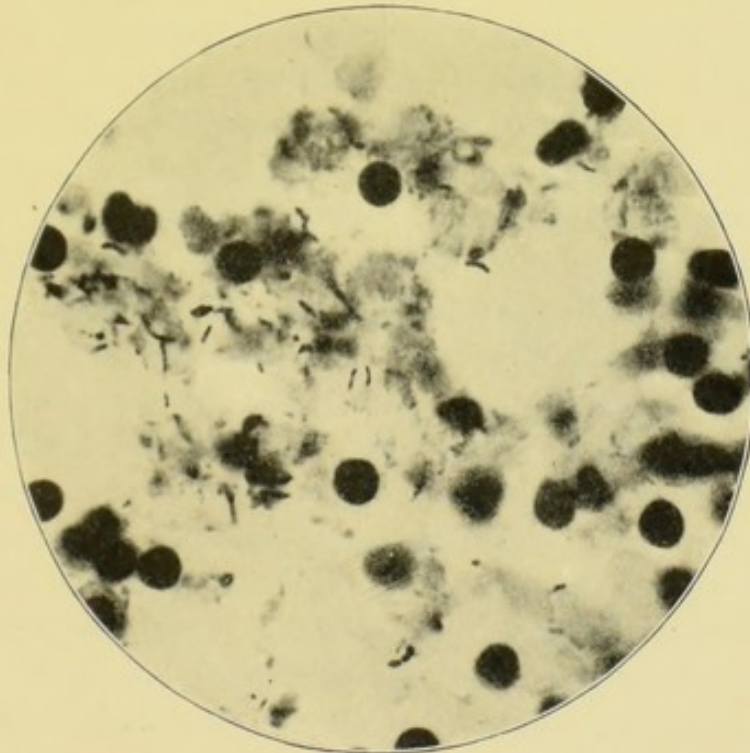


FIG. 10.—Bacteria penetrating the mucosa. $\times 1000$. The lumen of the appendix is above.

any of the bacteria are cocci, as bacilli, viewed endways, look so like cocci.

I did not see any of the attacks of appendicitis in this case. The description of them, however, shows that they were of the same type as those of another case (Case 30, p. 116), in which the contents of the appendix consisted of hardly anything else but cocci and streptococci.

But when we contrast these two cases more closely, decided differences appear. The defects of my method of investigation are also seen as well as the absence of the scientific precision of experimental pathology. The clinical symptoms were alike in

both cases. In one, the appendix was filled with cocci and few bacilli; in the other, with bacilli and few if any cocci. But here the resemblances cease. In one, the appendix was stenosed, but its epithelium intact; in the other, the appendix was not stenosed, but its epithelium was destroyed, and its substance invaded by bacilli.

CASE 7.—*Appendicitis with Ulceration of Mucosa, and Bacteria in Appendicular Walls after the Subsidence of the Acute Symptoms.*—What is the condition of the vermiform appendix in the intervals between recurrent attacks of appendicitis? The following case, which is one of a very common type, returns an instructive reply to this question.

The patient was a robust man, aged thirty-five years. His first attack of appendicitis began in October, 1897; this was followed by a second in November, 1897; a third in August, 1898; and a fourth in October, 1898. Dr. Ethelbert Collins, who attended him, told me that the last attack was so severe that he nearly died. He came under my care in St. Bartholomew's Hospital a fortnight after the cessation of the attack, but he still had pain, aggravated by pressure, in the right iliac fossa. The abdominal muscles were rigid, but under the anæsthetic a hard mass was felt in the iliac fossa. On rectal examination, a tender swelling could be felt towards the upper part of the right side of the pelvis.

The operation was one of the most arduous that I have ever had to perform. The usual oblique incision was made, and was soon lengthened to about 11 cm. (5 in.). Adherent omentum was first encountered, and three structures were isolated from its midst, all of which had the most exact resemblance to the vermiform appendix. In the last, the mimicry was so complete that we even thought we saw a lumen and mucous membrane; but when an attempt was made to follow these sham appendices to the cæcum, the fraud became apparent. Since this experience, I have wondered whether others may not have been actually deceived by similar sham appendices. This might explain some of those cases in which the operation of appendectomy has not been followed by relief of the symptoms. The sham appendix is usually either inflamed omentum, inflamed parietal peritoneum, or an

elongated and inflamed appendix epiploica. The ileo-colic fold of peritoneum may also prove deceptive.

By the time the nature of the sham appendices had been ascertained, the omental adhesions had been overcome. Then the most formidable adhesions between the coils of the small intestine were encountered. In separating these, the peritoneal and muscular walls of the ileum were slightly torn and bruised, and had to be sutured. After a long struggle, the appendix was at last found hanging into the recto-vesical pouch, and adherent over the region of the internal iliac vein and ureter. Fortunately, as I have observed on other occasions, the adhesions around the appendix itself were less formidable than those around the omentum and intestines, and I managed to withdraw it with reasonable ease, and without damage to the iliac veins or ureter. The whole operation lasted two hours and a quarter. I cannot remember ever to have taken so long over any operation. The patient made a safe recovery, but we felt anxious for a time. On the second day his pulse ran up to 132, and he continued to vomit. Flatus was, however, passed by a rectal tube, and, by dint of skilful rectal feeding and strychnine, he began to recover. A drainage tube, which had been passed into the pelvis, gave exit to a little pus which for a time was slightly *faeculent*. It is not improbable that some leakage occurred from the damaged intestines. Ultimately, he made a perfect recovery and was cured by the operation.

After hardening, the sections of this appendix present to the naked eye a roughness of the peritoneal covering, but no marked alteration of the muscular or submucous coats. There is, however, considerable thickening of the mucous coat with marked dilatation of the lumen. The greatest diameter of the sections is 11 mm., the least 9 mm., and the widest part of the lumen 7 mm. The outline of the lumen is very irregular, and its cavity is full of some loose material. The meso-appendix occupies a quarter of the circumference of the appendix. The microscopical examination shows that the peritoneal surface is very rough and devoid of endothelium; the subperitoneal tissue is *oedematous*, and its blood-vessels are dilated. These nearly all contain blood corpuscles, from some of which

the blood is extravasated. Here and there are groups of inflammatory cells. Some of these are in lymph spaces or small venules, and look like the minute miliary abscesses met with in pyæmia.

The longitudinal muscular coat is thin and irregular; the circular, of the usual thickness, but its fibres are separated, owing, I assume, to inflammatory œdema. The submucous coat is also loose, owing to œdema, and contains many dilated lymphatics, blood-vessels, and small groups of inflammatory cells. The muscularis mucosæ is irregular and can only be seen in part of the circumference of each section. The lymphoid follicles are abundant—I counted sixteen in one section. The basilar lymph spaces of most of these follicles are enormously dilated, and the lymph paths within the substance of the follicles unusually large. The tubular glands contain vast numbers of goblet cells, a few of which are dilated and full of mucus. The epithelial lining of the lumen is irregularly detached. The greater part of it is in process of conversion into mucous cells, but barely a fifth of it has actually disappeared. The lumen is filled with some yellow bodies, which I judge to be faecal in origin, with granules, pus cells, nucleated cells, epithelial cells, and vast quantities of bacteria. Among the latter are cocci, diplococci, streptococci, bacilli of various sizes and shapes, leptothrix, yeasts, and encapsuled diplococci or diplobacilli, for it is hard to say to which class they really belong. No tubercle bacilli could be found.

Wherever the epithelial lining of the appendix is detached, vast numbers of these bacteria have penetrated (Fig. 11); and, although the microphotograph does not show it clearly, it is quite evident that most of them have entered through the exposed lymph paths.

In the deeper parts of the mucosa and submucosa, a great many scattered bacteria are found, as well as many small groups of bacteria (Fig. 12). Many granular cells or granules surround these groups, and I think we may assume that suppuration is in progress. The bacteria have penetrated the muscularis mucosæ. This delicate layer is perforated by many lymph paths, so I doubt whether it forms the slightest barrier

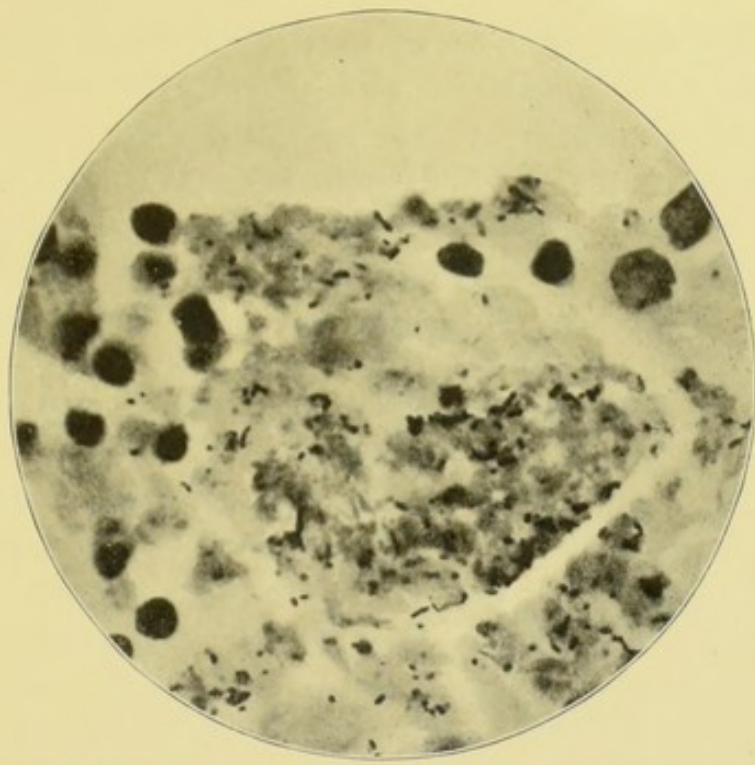


FIG. 11.—Part of the lumen of the appendix where the epithelial lining and tubular glands are absent, and where bacteria have invaded the walls of the appendix. A lymphoid follicle crammed with bacteria is seen. Its lymph sinus contains bacteria. $\times 1000$. The lumen is above.

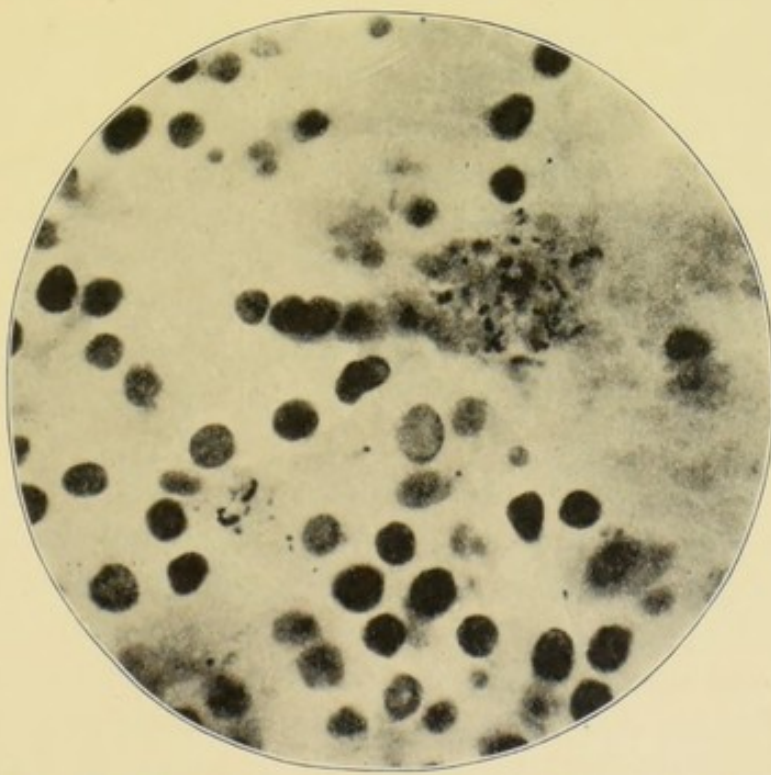


FIG. 12.—A part of the same section as that in microphotograph (Fig. 11), but showing a part of the submucous coat. Bacteria scattered and in groups; also sup-puration. $\times 1000$.

against the invasion. Some of the groups of bacteria are situated near the base of the mucous glands.

The innermost part of the submucous coat is œdematous, and the dilated intercellular spaces simulate the appearances of fat. In addition, its lymph channels are dilated, and in most of them the endothelial lining is actively proliferating. We thus find evidence of lymphangitis. I could see no bacteria in either the lymphatics or the blood-vessels.

The following also shows the condition of the inflamed appendix during the period of quiescence.

CASE 8.—*Appendicitis with Ulceration of the Mucosa and Bacterial Invasion—A preceding Attack of Typhoid Fever.*—Mr. L., æt. twenty-six, had a severe attack of enteric fever in India about Christmas, 1898. In October, 1899, he had a violent attack of typhlitis, with pain and tumour in the right iliac fossa. His temperature rose to 103° F., and his motions were loose. Since his recovery from this attack, he considered himself to have been "perfectly well," but nevertheless suffered from slight pain and discomfort. He had been invalided home from India because of this attack. After being six months at home the only suspicious signs were tenderness on pressure in the right iliac fossa and a slight rigidity of the overlying abdominal wall. Rest and treatment with salol brought about no improvement, and he said that he still felt discomfort in the right iliac fossa.

Inasmuch as he had to return to his duties in India, I excised the appendix. It was of the usual size and length, but adherent within the ileo-cæcal fossa, and by no means easy to separate. A 2-inch incision sufficed, and he made a rapid recovery.

I do not propose to describe the morbid histology at length. The proximal end of the appendix is 5 mm. in diameter, and is but slightly inflamed, with œdema of the submucosa, and superficial ulceration of the mucosa. All the coats are clearly defined, and their limits not obscured with cell infiltration.

The distal end of the appendix is swollen, and measures 8 mm. in its longest diameter. All its coats are inflamed and infiltrated with inflammatory cells, so that only the mucosa is differentiated from the others, being more deeply stained. The

epithelial lining of the lumen is nearly all shed, and, at places, ulceration has spread down to the submucosa. The lymphoid follicles are inflamed, their outlines obscured by cell infiltration, and the lymph sinus narrow or indistinguishable. The lumen contains a little mucus, granules, epithelial cells, pus cells, nuclei, and clumps of minute bacteria, which are round, ovoid, and elongated. They lie singly, in pairs, in groups, or in short chains. The gradation from round to elongated is so clear, that I infer that these bacteria are one variety of bacillus in different stages of development.

Wherever the mucosa is superficially ulcerated, these bacteria are penetrating the lymph canaliculi. The ingrowth at the base of the epithelium of some of the tubular glands is quite dense. Where the mucosa is deeply ulcerated, the bacteria have reached the submucosa.

This example of ulcerative appendicitis with bacterial invasion is interesting, because it followed typhoid fever; the extreme minuteness of the bacteria is also peculiar. The case is another instance illustrating the pathological condition of the appendix, between the attacks, when it is but slightly painful and uncomfortable, and without other clinical symptoms.

Elsewhere (p. 208) I have given another case in which appendicitis complicated typhoid fever. Dr. Horton Smith, in his able lectures,¹ states that the condition of the appendix was noted in 26 cases of death from typhoid; it was natural in 15, and ulcerated in 11.

¹ *Goulstonian Lectures on the Typhoid Bacillus and Typhoid Fever*, London, 1900, p. 42, of reprint from *Lancet*.

CHAPTER VI

APPENDICITIS WITH ULCERATION OF THE MUCOSA AND BACTERIAL INVASION—THE MANNER IN WHICH BACTERIA PENETRATE, AND THEIR EFFECTS

IN the foregoing cases, the bacteria invaded the mucosa by passing betwixt the inflammatory cells which form the floor of the ulcer, and thence along the lymph canaliculi and lymphatics, and when this takes place the epithelium, lining the lumen, has first of all to be removed by ulceration. But they also invade by growing along the sockets of the tubular glands, as is shown in the cases which follow.

CASE 9.—*Appendicitis with Ulceration of Mucosa and Bacterial Invasion by Way of the Tubular Glands—Long and Mobile Cæcum—Temporary Return of Symptoms due to Fæcal Accumulation in the Cæcum.*—Mr. C., æt. twenty-nine, had his first attack of appendicitis at the age of nineteen. Since then he had had so many attacks that he could not recall the number. They usually confined him to bed for a day or two, and hindered him from going to business.

The appendix was excised in the usual way. Owing to old-standing disease of the valves of the heart, he became very faint under the ether. The cæcum was about 7 cm. long, measured from its junction with the ileum, and was pulled out of the wound along with the vermiform appendix. The appendix was inadherent. It was engorged with blood, felt very hard, and was constricted about 2 cm. from its distal end. The wound healed by first intention.

The histology of the proximal end of the appendix is as follows:—The peritoneal coat is almost unaltered. The

outer muscular coat is .25 mm. thick; the inner .5 mm. I attribute this thinning to distension, caused partly by the contents of the lumen, and partly by the cedematous submucosa. The latter contains some large blood-vessels, but its most striking feature is the enormous distension of its cellular interspaces and lymph channels (same as Fig. 52, p. 257). The part next the mucosa is full of inflammatory cells. Inasmuch as the muscularis mucosæ is absent or concealed, it is impossible to tell where the submucosa and mucosa join one another. Four lymphoid follicles are seen in one section. They look denser than usual, and their nucleated cells reach some distance into the submucosa. They possess follicular lymph spaces, one of which is crammed with nucleated cells. Three of the lymphoid follicles almost project into the lumen of the appendix, being only separated from it by the basement membrane, which is thicker than usual.

The mucosa hardly exists and the epithelial lining of the lumen has gone. The remains of about six tubular glands can be traced in each section, but they have lost two-thirds of their epithelial lining. The deepest part contains some ill-developed epithelium in a confused mass (Fig. 13, p. 58). In some places, the ulceration has reached the submucosa. The lumen is filled with granules, crystalloid bodies, shreds of organic material, irregular pieces of deep brown, semi-translucent substance, and quantities of bacteria. These include many morphological varieties—cocci, diplococci, short ovoid bacilli, singly and in pairs, long, slender bacilli, short, thick bacilli, with rounded ends, long, thick bacilli, leptothrix, spores, and spore-bearing bacilli.

Where the bacterial mass is in contact with the ulcerated mucosa, the cocci and bacilli have penetrated its lymph canalicular system. The bacteria have also penetrated into the mucosa by growing along the tracts of the tubular glands. This penetration occurs in three stages. First, the epithelium of the mucous gland is shed, leaving a hollow tubular space, or socket, as Dr. Hawkins calls it, in the lymphoid tissue; second, the bacteria fill this hollow (see Fig. 13); and third, they spread thence into the lymph

canalicular system.¹ The next case shows another manner of invasion, and that the lumen of the tubular gland may be choked with bacteria as a preliminary to the destruction of its epithelium.

The distal end of the appendix possesses no trace of a lumen or of a mucosa. The centre of the section is occupied by connective tissue and inflammatory corpuscles. The sub-

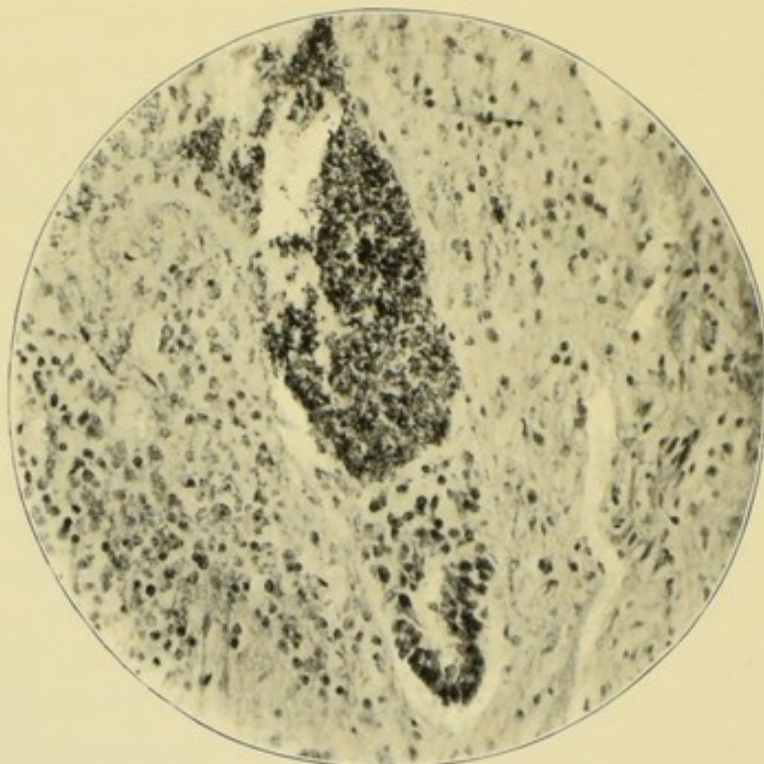

FIG. 13.—Bacteria invading mucosa along tract of tubular gland. A little of the epithelium still remains below. The lumen is above. $\times 200$.

mucous, muscular, and peritoneal coats are the same as in the proximal end.

This specimen is so clear that hardly any comment is needed. Penetration of bacteria by way of the tubular glands is, I believe, quite common. The contents of the lumen are such as one commonly meets with in chronically inflamed appendices, and, as we shall presently see, are such as usually lead to the formation of a concretion. Evidently, it was quite time that this appendix was excised. I believe the

¹ This last point is not well shown in the part of the section which has been photographed, as the magnification is too low.

operation had been deferred because the patient had valvular disease of the heart.

When removing this appendix, I was much struck by the great size and mobility of the cæcum. The immediate results of the operation were most satisfactory. For six months, the patient seemed perfectly well, and his brother-in-law, a medical man, said that he had been boasting that, since the removal of his appendix, he could eat anything, and did so. I was not surprised, therefore, when he came to complain that his symptoms had returned, and that he could again feel the lump in the iliac fossa. A short course of treatment, with careful diet, β -naphthol, enemas, and rest, speedily cured these symptoms, which, in my opinion, were caused by the accumulation of undigested vegetable matter in the capacious cæcum. It is right, however, to state that he was supposed to have torn or loosened an adhesion about the cæcum whilst playing cricket.

In the last case, we saw a rather advanced stage of the bacterial invasion of the appendicular walls along the tract of the tubular glands. In the following, the process has evidently just commenced, and, furthermore, the clinical symptoms have not got as far as an actual attack of appendicitis. It also shows how the lumens of the tubular glands become choked with bacteria as a preliminary to the destruction of their epithelium, thus allowing invasion of the lymphatic system.

CASE 10.—*Appendicitis with Ulceration of the Mucosa and Bacterial Invasion along the Tract of the Tubular Glands.*—Mr. S., aged thirty-nine years, had had pain in the right side for five years. It had never kept him away from business or interfered with his sleep. After exercise the pain became severe. During the past six months it had grown worse and caused him anxiety. His digestion was bad, but he could eat fruit and vegetables. He required aperients to move the bowels. No tumour could be felt in the iliac fossa or *per rectum*. He had a tender spot beneath the lower part of the right linea semilunaris and also some rigidity of the abdominal walls.

The appendix was removed through a small oblique incision. It was about 10 cm. long, inadherent, but deeply engorged with blood and its distal end felt hard. I inferred

that the condition betokened superficial ulceration of the mucosa with bacterial invasion. The patient made the usual rapid and uninterrupted recovery, and was cured of his complaint.

The distal sections are almost normal. They are 5 mm. in diameter, with a triangular lumen 2 mm. by 1 mm. at its widest part. The total thickness of the walls is from 1.5 mm. to 2 mm., all the coats being of about average thickness. The proximal sections have been altered by the accumulation of bacterial contents within the lumen. The sections are 5 mm. in diameter, but with walls hardly more than 1 mm. thick. All the coats are thinned, and especially the mucosa, which is hardly more than a quarter of a millimetre thick.

The endothelial layer of the peritoneum is proliferating, and has upon it some groups of granular nucleated cells. Its blood-vessels and lymphatics are dilated. The outer muscular coat is thin and scattered, and contains large numbers of nuclei, especially at the side next to the meso-appendix. The circular muscle coat is thin. The submucosa is fibrous and has very few blood-vessels, but some of its lymph spaces and lymphatics are dilated. The mucosa contains five flattened, crescentic lymphoid follicles. One has a wide basilar lymph sinus, whilst, in the others, inflammatory cells occupy its place and spread into the submucosa. In one or two follicles, the reticulum is seen, but, in others, it is hidden by inflammatory cells, which also hide the muscularis mucosæ.

The stroma of the lymphoid tissue of the mucosa can be seen. The proximal tubular glands are hardly a third of a millimetre long; the distal are .75 mm. long. In some, the epithelial cells are crowded together as if by pressure; the mouths of some are also dilated and charged with bacterial contents from the lumen. The epithelial lining of the lumen is lost over about one-third of the circumference, and part of the remainder is cubical. In places, too, the basement membrane is destroyed, and here the bacteria which crowd the lumen have entered the canaliculi. The bacterial contents of the lumen also penetrate the tubular glands along the base of the epithelium, where it is becoming detached.

The lumen is crammed with a mass of bacteria mixed

with pigment, pus cells, degenerated blood cells, epithelium, small fibres, crystalloid bodies, opaque, deeply staining masses, granules, and mucus. The bacteria mixed with these include a great diversity of morphological forms—cocci, diplococci, short chains, staphylococci, or clumps of minute ovoid bacilli, spores, spore-bearing bacilli, and bacilli of all sizes and shapes. There was no evidence of tubercle.

The distal sections are, as I have said, almost normal. The contrast between its tubular glands and lymphoid follicles and those of the proximal sections is most noticeable. The tubular glands are about .75 mm. long. Each lymphoid follicle has a normal basilar lymph sinus. The submucosa is not so densely fibrous, and contains many small blood-vessels. The lumen, which is not dilated, is about half filled with the same bacterial contents as the proximal. In places, its epithelium is shed, but the basement membrane is intact, and no bacterial invasion has taken place.

I have described this specimen at some length, because it seems to me to show the early effects of pressure caused by the accumulation of fluid in the lumen of the appendix. Whilst all the coats are thinned by pressure, the mucosa and submucosa have suffered most. It seems also safe to assume that pressure has helped to send the bacterial contents along the tubular glands.

It seems reasonable to suppose that the dangers of destruction of the appendicular walls and of perforation into the peritoneal cavity, are increased by the growth of bacteria along the tubular glands. The latter evidently provide a ready means of ingress as far as the submucosa, where an abscess may form, as in the following case:—

CASE 11.—*Appendicitis with Ulceration of the Mucosa and Bacterial Invasion along the Tubular Glands, Abscess in Submucosa, and Destruction of all the Coats except the Peritoneal.*—The patient was a young gentleman who had his first attack of appendicitis whilst travelling in August, 1899. The pain in the abdomen was intense and was followed by faintness, collapse, and vomiting. Three more attacks ensued, each worse than the one before, and the fourth occurred a week before the appendix was removed. It lasted thirty-six hours,

and was accompanied with vomiting and constipation, but not with abdominal distension. The temperature rose to 100° F., but the pulse rate was not taken. The pain began about the umbilicus, and then "settled" in the right iliac fossa. A week after the subsidence of the last attack, the abdominal wall was rather rigid over the right iliac fossa, and pressure caused pain. Nothing was felt *per rectum*, and he had had no urinary symptoms. I diagnosed an inflamed appendix situated in the right iliac fossa. The patient gave the usual history of digestive troubles and inability to eat fruit and vegetables.

The appendix was excised by the usual small incision. It lay in the right iliac fossa beneath the cæcum and the end of the ileum. It was acutely inflamed and adherent to the ileum, cæcum, and iliac peritoneum. It was about 10 cm. long, and acutely bent upon itself, 3 cm. from the cæcal end. The part beyond the bend was tense and very hard, and the meso-appendix extended as far as the acute bend. After the operation, the patient had some pain for twenty-four hours, and then made an uninterrupted recovery.

Sections were prepared from the proximal and distal ends, and also from the middle where the appendicular walls looked slightly bulged. The proximal and distal sections are almost alike, and can, therefore, be described together. The sections are ovoid (7 mm. × 6 mm.), with coats swollen by inflammation, especially the mucous and submucous. (The total thickness varies between 2.5 mm. and 4 mm.) The proximal lumen is ovoid (1.5 mm. × 1 mm.); the distal, arborescent (2 mm. × 1 mm.), and may, at some time, have been distended. The endothelial layer of the peritoneum is either absent or proliferating. The peritoneal blood-vessels and lymphatics are twice their usual size. Groups of inflammatory cells are collected around some of the blood-vessels, and others are scattered about the subperitoneal tissue.

The muscular coats are of the usual thickness. Their blood-vessels and lymphatics are slightly dilated, and they contain scattered groups of inflammatory cells. The submucosa is thick, œdematous, and infiltrated with exudation corpuscles; its blood-vessels and lymphatics are numerous and dilated.

The muscularis mucosæ consists of a few discontinuous muscle cells. The mucosa is not quite the same in the proximal and distal sections. In the proximal, five or six lymphoid follicles can be counted in a section, but their outlines are indistinct owing to cell infiltration. In some, the lymph sinus is absent; in others, it is dilated and lengthened. The stroma of the follicles is difficult to see, and where it can be seen is œdematous and swollen; the intertubular tissue is in a similar condition. The capillaries of the mucosa are dilated. At least half the tubular glands have disappeared and about a third of the epithelial lining of the lumen. The lumen contains a mixture of granules, nuclei, scraps of lymphoid tissue, pus cells, epithelial cells, red blood corpuscles in various stages of disintegration, cocci, diplococci, streptococci, small ovoid bacilli in pairs, short chains or clumps, short, thick ovoid bacilli, long, slender bacilli, and leptothrix. In many places, this bacterial mass has grown down the gap left by the shedding of the epithelium of the tubular glands, and where the epithelial lining of the lumen has disappeared they are penetrating the lymph canalicular system of the mucosa. They penetrate deepest by way of the tubular glands. The cells of the mucosa in the vicinity of the invading bacteria are granular, irregular in outline, and less stained than the others.

In the distal sections, the appearances are the same in character, but less in degree. The epithelium of the glands and of the lumen is intact, and no bacterial invasion has taken place. In places, the epithelial cells of the lumen are cubical or almost flat, presumably as the result of pressure and stretching.

In sections through the middle bulged part of the appendix, the structure of the peritoneal, muscular, submucous, and mucous coats and the contents of the lumen are alike in character. The lumen is oblong (2 mm. \times 1 mm.), and at one end of the oblong the mucosa is entirely destroyed (Fig. 14, p. 65). Through this gap in the mucosa, the lumen opens into a cavity which has taken the place of more than half of the submucosa and about half of both muscular coats. The outer wall of this space is the peritoneum, which is less than half a millimetre thick. Its contents are almost the same as those

of the lumen, except that it contains, in addition, some epithelium belonging to the tubular glands. Its bacteria are invading the peritoneum, and some of the diplococci are in the lymph canaliculi beneath the remains of the endothelium, having preceded the more bulky bacilli. None have actually reached the surface of the peritoneum (Fig. 15).

It seems reasonable to infer that the mucosa, submucosa, and muscular coats owed their destruction to the bacteria which penetrated along the tubular glands, although other possibilities are to be borne in mind. It is to be remembered, however, that the invasion can actually be seen taking place by way of the glands. In addition, it is clear that, owing to the acute bend in the appendix, the contents of the lumen were under considerable pressure, and might, therefore, have been forced into the spaces left by the shedding of the glandular epithelium. Clearly this patient was in great peril. The delicate layer of septic peritoneum might have given way at any moment. But septic peritonitis might have arisen without a mechanical solution of continuity. The specimen clearly shows how bacteria make their way through the serous membrane.

It is not always easy, during the course of operations, to say whether the appendix is actually perforated, because an accidental tear in the wall of an inflamed appendix may look like a perforation. But the point is not of much importance, because it is now well known that, in acute infective appendicitis, the bacteria reach the peritoneum from the interior of the appendix without the smallest solution of continuity. The foregoing cases show how the passage of bacteria begins; the following, how it proceeds.

CASE 12.—*Appendicitis with Ulceration of Mucosa—Relation of Ulcer to Hiatus Muscularis—Peri-appendicular Abscess.*—Within the short space of fifteen months, Miss —, aged forty-five years, had four attacks of appendicitis. I saw her towards the end of the last, which had been brought on by exposure to cold night air. It was accompanied with vomiting, constipation, abdominal distension, a temperature of 102° F., acceleration of the pulse, and great pain and tenderness over the right iliac fossa, where an ill-defined tumour was felt.

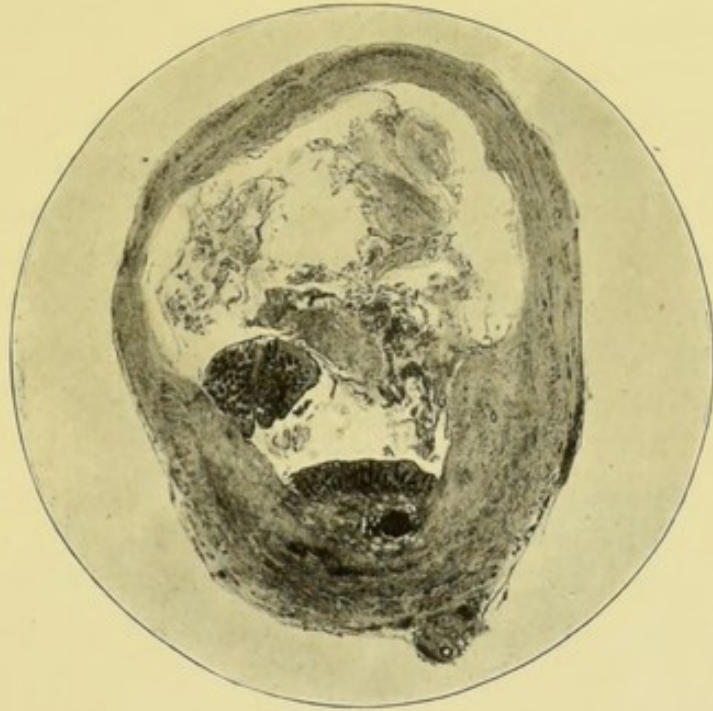

FIG. 14.—Abscess cavity, bounded by infected peritoneum (see Fig. 15). The remains of mucous membrane and of the lumen are below ; the abscess cavity above. $\times 6$.

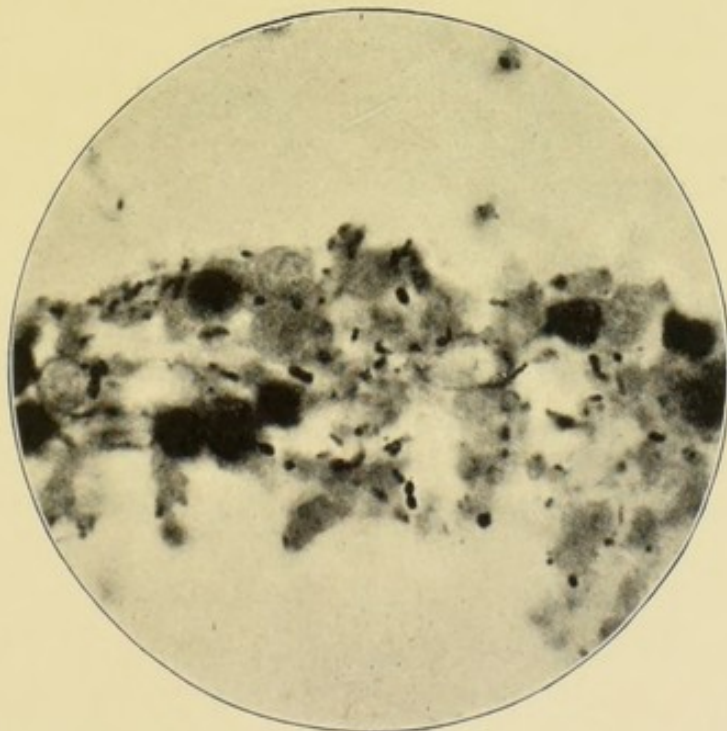


FIG. 15.—Portion of peritoneum bounding the abscess cavity and separating it from the abdomen. $\times 1000$. The remains of the peritoneum are less than half a millimetre thick.

Her health had not been good in the interval between the last two attacks.

The operation was performed through the usual oblique incision, a week after the subsidence of the attack. Under the anæsthetic, a small tumour was felt in the iliac fossa. The appendix lay beneath the cæcum, and was adherent to the iliac peritoneum. A little pus was seen as the appendix was being separated from the iliac fossa, and, therefore, catgut ligatures and sutures were applied. The appendix was swollen and inflamed, but not perforated. The inflamed peritoneum bled rather freely. The patient made a good recovery, and the wound healed by first intention.

The proximal sections are 6 mm. in diameter, and have an irregular lumen 2 mm. long and 1 mm. wide half full of some semi-transparent substance. The coats of the appendix are from 2 to 3 mm. thick.

The distal sections are 4 mm. in diameter, and have no lumen.

The following is the report of the histological examination of the proximal sections. The endothelial layer of the peritoneum is proliferating, and covered with irregular, nucleated cells, mixed here and there with small oval bacilli singly, in pairs, and small groups—doubtless bacillus coli communis. The subperitoneal tissue is œdematous, and dotted with nuclei and small collections of inflammatory cells. Its blood-vessels and lymphatics are numerous and dilated.

The outer muscular coat is thin and irregular, and penetrated by dilated blood-vessels; the circular is little altered, but contains a few groups of inflammatory cells. The muscular coats are broken by a "hiatus" 1 mm. wide. At this point the inflamed, subperitoneal, and submucous tissues are continuous; and the mucosa is destroyed by ulceration, which has reached as far as the submucosa (Fig. 16).

The submucosa consists of fibrous tissue with some dilated blood-vessels and lymphatics; but as these are not numerous, most of the submucosa looks solid and homogeneous. Many strands of fibrous tissue have spread into the mucosa and replaced its lymphoid tissue.

The mucosa has no muscularis mucosæ. Two or three

lymphoid follicles are seen in each section. Some are involved in the ulceration and are inflamed, but, nevertheless, the follicular lymph parts are of the usual size (Fig. 16).

The epithelial lining of the lumen is completely detached, and has accumulated within it. The mucosa is ulcerated throughout, and in places, as, for example, at the hiatus muscularis, the ulceration has reached as deep as the submucosa. The base of the ulcer is infiltrated with pus cells,

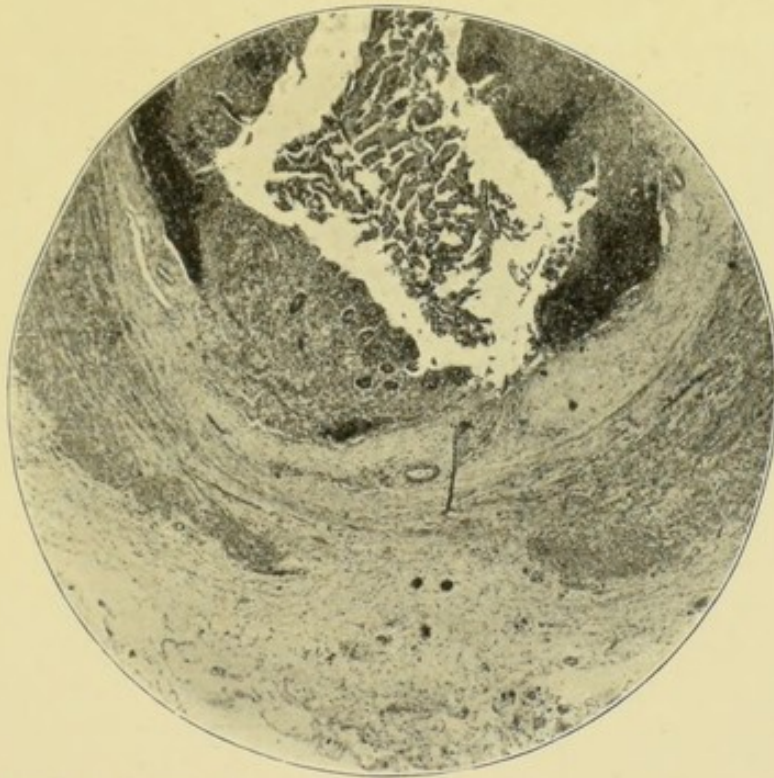


FIG. 16.—Appendicitis with ulceration of the mucosa opposite the hiatus muscularis. The continuity of the inflamed submucous and subperitoneal tissue is shown. $\times 25$. The lumen is above; the hiatus below.

and some small ovoid bacilli. The epithelium of the tubular glands is also being shed into the lumen, so that only the remains of about eight can be counted in a section. In some, the ring of epithelium at the mouth is separated; in others, the whole lining. The pit left in the mucosa then closes or is widened out by ulceration.

The epithelial cells are granular and opaque, and some are discharging mucus. Amidst the irregular mass of epithelium and mucus, which half fills the lumen, are some scattered ovoid bacilli.

A part of the meso-appendix is included in the sections. Its arteries, veins, and lymphatics are dilated, and the veins are full of blood. Its surface is covered with a layer of cells, which I judge to be pus cells. The thickness of this layer varies. Amidst the cells are short bacilli singly, in pairs, chains, and groups. In some places, the bacteria have invaded the peritoneum for 3 or 4 μ , and in others, in company with the pus cells, partially filled the lymphatics.

I cannot claim that this specimen demonstrates, with absolute certainty, the passage of bacteria from the lumen through the hiatus to the abscess; but clearly it affords proofs which almost amount to certainty, that that was the course which they pursued.

The distal sections are a third smaller than the proximal, and have no lumen. The peritoneal, subperitoneal, and muscular coats are alike, except that the inflammatory cells and bacteria are less abundant. The area within the compass of the circular muscular coat is filled with fibrous tissue, blood-vessels, lymphatics, and inflammatory cells. The latter are elongated, and arranged in strings which radiate from the centre of the appendix.

I have already observed that most specimens illustrate more than one phase in the evolution of appendicitis. This is so in the present instance, because it also shows the steps by which the lumen of the appendix is *obliterated*. First, the epithelium of the lumen and of the tubular glands is destroyed; second, the mucosa ulcerates; third, the submucosa inflames, the inflammatory material organises and cicatrises, and closes in the remains of the mucosa. The subperitoneal coat often undergoes the same inflammatory changes, and constrictions are produced. The lumen can be narrowed without complete removal of the mucosa by the organisation and cicatrisation of inflammatory products in the peritoneal, muscular, and submucous coats (Case 30, p. 116); and thus stricture of the appendix is formed in the same way as stricture of the urethra.

The following is another instance of the passage of sepsis through the appendicular walls, without breach of continuity.

CASE 13.—*Appendicitis with Bacteria in its Coats—Acute Septic Peritonitis and Intra-peritoneal Abscess.*—In the

course of an operation upon a boy, æt. twelve, I met with an acute suppurative peritonitis around an acutely inflamed, but not perforated appendix. The latter was adherent to the cæcum.

Before the operation, the temperature was 99° F. and the pulse 120. The abdomen was distended and rigid, and tender all over; it was especially rigid and tender at the right iliac fossa. The result of the rectal examination was negative. The appendix was excised and the abdomen drained. The patient made a good recovery.

The appendix possesses a peritoneal coat covered with a thick layer of fibrinous exudation; muscular coats which are œdematous and infiltrated with inflammatory cells; and a submucosa in the same condition. The mucosa has disappeared. All the blood-vessels and lymphatics are dilated, and many of the former full of blood.

What I take to be the lumen of the appendix is empty. The fibrinous exudation contains small oval bacilli singly, in pairs, and small clumps. Similar bacilli are scattered about the submucous coats, and probably about the muscular coats too.

The bacterial invasion of the appendicular walls may end in perforating ulcer. It may also end in partial or complete necrosis. The following is an instance of perforating ulcer.

CASE 14.—*Appendicitis with Ulceration of the Mucosa—Perforation and Acute Suppurative Peritonitis—Subsequent Ventral Hernia.*—B. C., a Polish Jewess, aged sixteen years, was admitted into St. Bartholomew's Hospital under my colleague, Dr. Norman Moore, who requested me to see her with a view to operation. Owing to her apathy and ignorance of English, a history was difficult to obtain. It seemed that two days previously (March 2, 1899) she had been seized, about 4 P.M., whilst tailoring, with a violent pain in the abdomen, followed by vomiting, and an action of the bowels. I saw her less than forty-eight hours after this attack. She was very pallid and listless, with a temperature 99° F. and pulse 104. No further vomiting had occurred, but the bowels had not acted again, and the passage of flatus was doubtful.

The house physician, Mr. Palgrave, said the pulse was becoming more rapid. The abdomen was distended, but moved

with respiration, and was not tender to the touch except in the right iliac fossa, where its walls were rigid, and where an almost painless tumour was felt. The right side of the pelvis was painful when examined *per rectum*, but, under the anæsthetic, no tumour could be felt at that tender spot. The tumour in the right iliac fossa was more distinct, owing to relaxation of the muscles, but it did not fluctuate.

Guided by her general condition, and by the acceleration of the pulse, I operated on March 4, about forty-eight hours after the onset. I expected to find an acutely inflamed appendix on the point of perforation. The abdomen was opened by the usual oblique incision. First some blood-stained serum escaped, and afterwards about two ounces of foetid pus gushed from beneath the cæcum. The abscess was around an acutely inflamed appendix, which was perforated about its middle. It was excised in the usual way, and the iliac fossa and pelvis drained.

The next day, March 5, the abdomen was distended, and vomiting became rather frequent. After two doses of calomel (gr. v. and iii.), and an enema, the bowels acted, and the crisis passed away. The wound healed by granulation.

The patient was provided with a belt, and sent to our convalescent home for another month. I did not see her again until the end of October, 1899, six months after the operation. She had worked as a tailoress, but had not troubled to wear the belt which had been provided. The scar was the seat of a large ventral hernia with thin walls. By her desire I operated upon it, uniting with successive layers of silk sutures—1st, the peritoneum; 2nd, the muscular fibres of the internal oblique and transversalis; 3rd, the aponeurosis of the external oblique; and 4th, the skin. The wound healed by first intention, and, after three weeks in bed, she was sent again to the convalescent home, and advised to wear the belt. The union of the abdominal wall seemed very strong and solid. This is the operation which I always endeavour to perform in cases of ventral hernia. It was very difficult and troublesome in this case owing to the matting of the different layers; and took an hour and forty minutes from beginning to end.

In sections through the perforated part of the appendix, the naked eye distinguishes two layers: the outer, lightly stained, consists of the peritoneal and muscular coats; the inner, deeply stained, is the mucous coat. Under the microscope, however, the various layers are almost indistinguishable, because they are so infiltrated with inflammatory cells. A few fibres of the muscular coat can with difficulty be seen.

At one point, a small abscess has taken the place of the

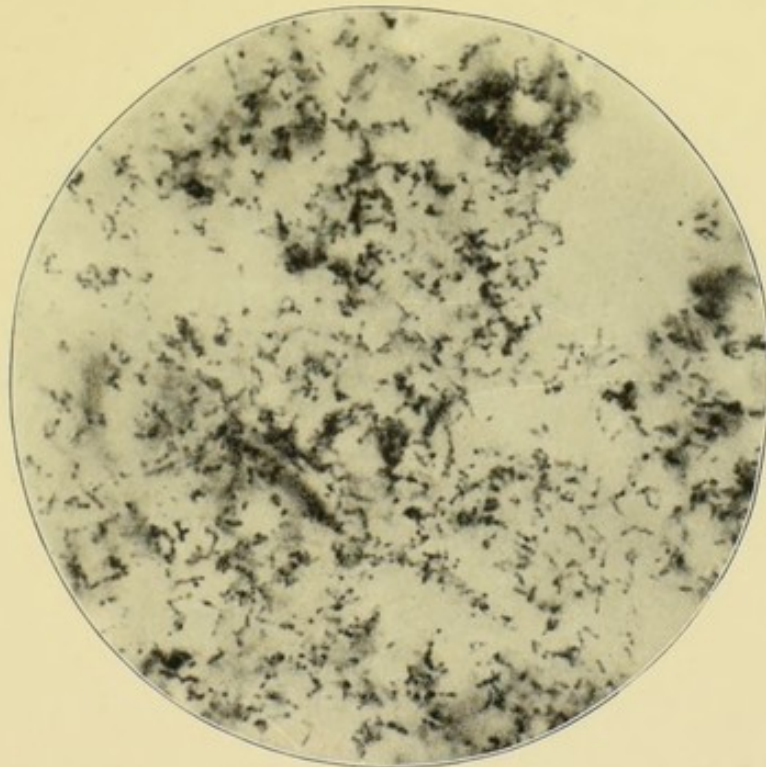


FIG. 17.—The bacterial contents of the lumen. They also fill the perforation and cover its ulcerated surface (see Fig. 18). $\times 1000$.

muscular coat. The epithelium and tubular glands of the mucosa have perished, as have also its lymphoid follicles. The remains of the mucosa and the submucosa are infiltrated with blood and inflammatory corpuscles. It is evident that the effused blood did not escape during the operation, because its red corpuscles are disintegrating. The lumen is dilated and filled with pus cells, fibrin, small oval bacilli, cocci, diplococci, chains of three or four cocci, and clumps of cocci. It is difficult to tell whether certain of the bacterial elements are slender bacilli or short chains of cocci (Fig. 17).

Some parts of the lumen look as though they contained a pure culture of staphylococci.

Similar bacteria are scattered throughout the coats of the appendix. The coccus forms preponderate, and are most abundant near the lumen and in the subperitoneal tissue. There is no evidence of the presence of tubercle.

The perforation is an irregular aperture surrounded by inflamed, ulcerated edges, everted by the protrusion of the

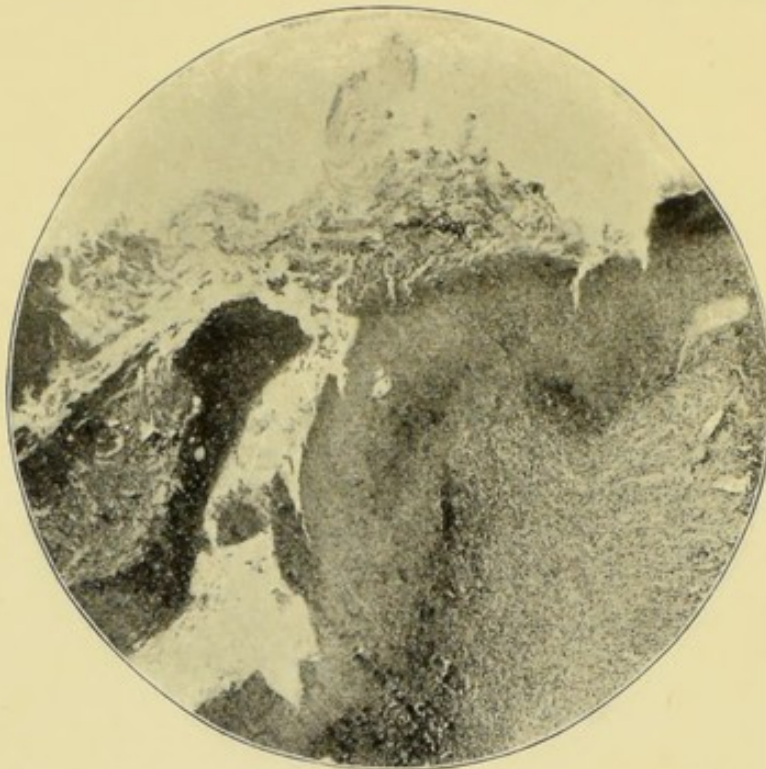


FIG. 18.—The perforation. The right-hand side shows the appendicular wall, which is full of bacteria and has a mass of bacteria adherent to it. To the left is a mass of bacteria plugging the perforation; the remains of the peritoneum are above. $\times 25$.

swollen remains of the mucous membrane. At the perforation, the mucous coat is joined to the subperitoneal by inflammatory exudation full of bacteria. The perforation itself is almost filled with masses of bacteria (Fig. 18). The sections show that the circular muscular coat was the last to give way.

So little is known about the history of this case, that it would be unsafe to assume that all the destruction took place in forty-eight hours. The mucosa may have been the seat of long-standing ulceration. The purulent inflammation and

bacterial invasion are, without doubt, of recent occurrence. The existence of an abscess in one part of the wall of the appendix affords an explanation of the mode of perforation.

It is also to be noticed, that we have here an instance of appendicitis in which acute symptoms and rapid pus-formation are associated with the presence of micrococci in vast numbers.

CHAPTER VII

APPENDICITIS WITH FÆCAL CONCRETIONS—THE FORMATION AND EFFECTS OF CONCRETIONS

SURGEONS and physicians have always attached great importance to fæcal concretions. This is natural because they are met with in such a large proportion of cases of perforation, and of cases operated upon during the period of quiescence. I myself have met with fæcal concretions 17 times in 109 consecutive operations for appendicitis, but, in at least seven others, the lumen was full of bacterial contents such as lead to the growth of concretions. I have never seen the proposition categorically stated, but doubtless surgeons assume that the presence of a concretion justifies the removal of the appendix, mainly on account of its mechanical dangers.

From what I have read and seen, I have come to the conclusion that the part played by bacteria in the formation of fæcal concretions and in the effects which fæcal concretions produce, has not yet had the attention that it deserves.

According to the best authors, a fæcal concretion is formed out of soft fæces. "The hardness of the fæcal mass and its pressure against the wall of the appendix depend on the peristaltic contraction of the tube."¹

Talamon² also attributes fæcal concretions to the mechanical action of the intestinal walls upon the fæces. He considers that they "rolled and moulded" out of fæces by the cæcum, and that they afterwards entered the appendix. He

¹ Hawkins, p. 34.

² *Appendicitis and Perityphlitis*, trans. by Berry; Edinburgh and London, 1893, p. 43, etc.

cannot conceive that a tube like the appendix could, by its movements, give them their peculiar shape.

I now propose to adduce the evidence which leads me to conclude that faecal concretions are the result of bacterial growth.¹ Also that they are a mass of bacteria, and that they owe the worst of their evil properties to this fact. I have further come to the conclusion that, in every case, the bacterial growth within the appendix precedes the growth of the concretion or concretions; and that this preliminary stage is associated with ulceration and bacterial invasion of the mucosa.

Something of the bacteriology of faecal concretions is shown by a specimen which was obtained under the following circumstances:—

CASE 15.—*Appendicitis with Faecal Concretion and Perforation—The Composition of Faecal Concretions or Enteroliths and their Pathological Effects.*—The patient was a married lady, forty-five years of age, rather corpulent, and the mother of a grown-up family. For some months she had had feelings of obscure pain and discomfort in the right iliac fossa. One day, after slight fatigue, the pain became worse and spread to the region of the umbilicus, and to the left side of the abdomen. A violent rigor ensued, and the temperature ran up to 105° F. The rigor was accompanied with vomiting and abdominal distension. Afterwards the pain in the right iliac fossa became intensified. About the fifth day of the attack, the bowels acted four or five times after castor oil, and the temperature fell from 102° F. to 98.5° F., but rose again to 102° F. When I saw her, on about the tenth day of her illness, she had had no further action of the bowels. The abdomen was distended, but was not tense. Milk had been taken without causing vomiting. The upper part of the abdomen moved during respiration, the lower part was still and rigid. Pressure caused great pain beneath the lower third of the right linea semilunaris. Pressure over the bladder also caused pain, and latterly the act of urination had been more frequent, and attended with pain. The result of

¹ Occasionally the bacterial growth takes place around a foreign body. In one of my cases a piece of glass was found in the centre of a small concretion. The patient said it had come from a broken jam pot.

the rectal and vaginal examination was negative. Her pulse was 80 at ordinary times, but, when I saw her, it had risen to not less than 120. The face was flushed and the cheeks rather blue from venous engorgement. A grain of morphia had been given every four hours to abate the pain, and, doubtless, this had masked the symptoms. Her expression was anxious and she felt exceedingly ill.

The rapidity of the pulse and the venous congestion of the face were unfavourable signs. The rapid pulse betokened a good deal of septic absorption, whilst the congestion showed that the heart was not quite strong enough to propel the blood.

I inferred from the clinical history and examination of the abdomen, that a very acute septic peritonitis had been set up by either perforation or gangrene of the vermiform appendix. The severe rigor, followed by a continuously high temperature, and the excessive pain, indicated an inflammation of a very severe type, and the presence of pyogenic cocci. The mobility and comparatively painless state of the upper two-thirds of the abdomen, led me to infer that the mischief was still localised. The fact that the attack had lasted ten days pointed in the same direction. The position of the pain beneath the right linea semilunaris and over the bladder, and the pain during micturition, showed that the peritoneum towards the inner part of the iliac fossa, and also the pelvic peritoneum were inflamed.

The abdomen was opened by a long incision in the right linea semilunaris. Inflamed and matted intestines were encountered. The cæcum and iliac fossa were first examined. The appendix was acutely inflamed and perforated. It was situated in the upper right-hand side of Douglas's pouch. It had been lifted up by a mass of subperitoneal uterine fibroids. To enable these to be diagnosed, about half of the right rectus abdominis muscle had to be cut through. As the finger overcame the adhesions to reach the appendix, a quantity of horribly foetid pus gushed up from the pelvis. As the appendix was seized, a concretion, the shape and size of a date-stone, slipped out of a perforation. The appendix was about three inches long and perforated midway at the side farthest from the mesentery. The pus had been localised by feeble adhesions, but all the peritoneum that came into view

was deeply congested. The wound in the linea semilunaris was packed with gauze, and a large rubber drainage tube inserted through an incision in the linea alba two inches and a half above the pubes.

Dr. H. F. Rutherford administered the anæsthetic during this formidable operation, and Dr. Bunn assisted me. I felt much obliged to both of those gentlemen for their skilful help.

The operation was followed by great shock. This was met

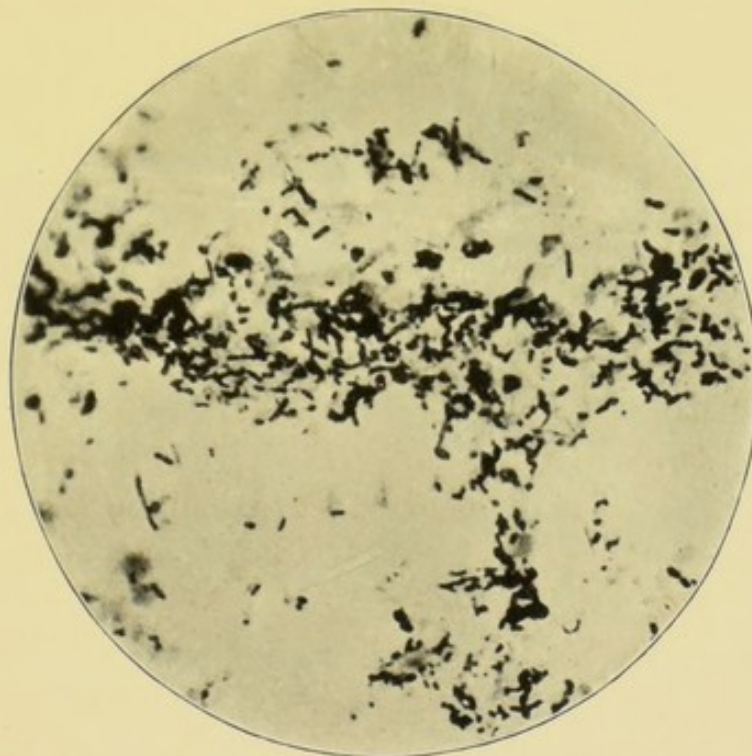


FIG. 19.—Film preparation of fecal concretion. $\times 1000$. Note the close correspondence with the contents of the appendix (Fig. 21).

with brandy, strychnine, and subcutaneous injections of ether. When I saw her, twenty-four hours after the operation, the pulse was 120, but feeble and tending to fail. The face was less blue and the expression better. The pain had ceased. A liquid motion and much flatus had followed a dose of calomel. The pulse afterwards rose to 132, and the temperature to 102° F. A quantity of foul discharge was washed from the tube. There was increasing frequency and feebleness of the pulse, and she died about thirty-six hours after the operation.

A portion of the concretion was made into a cover-glass

preparation and stained. A section would, perhaps, have been more instructive, but as yet we have failed to obtain one.

The microphotograph (Fig. 19) shows that a smear from a faecal concretion is composed almost entirely of a mass of bacteria. These comprise bacilli of the most varied types. Amongst them are long and slender, short and thick, small and ovoid, big and spore-bearing varieties, and so forth. The bacilli are single, in pairs, or short leptothrix. In addition many cocci, diplococci, and short chains of cocci are present. The preparation

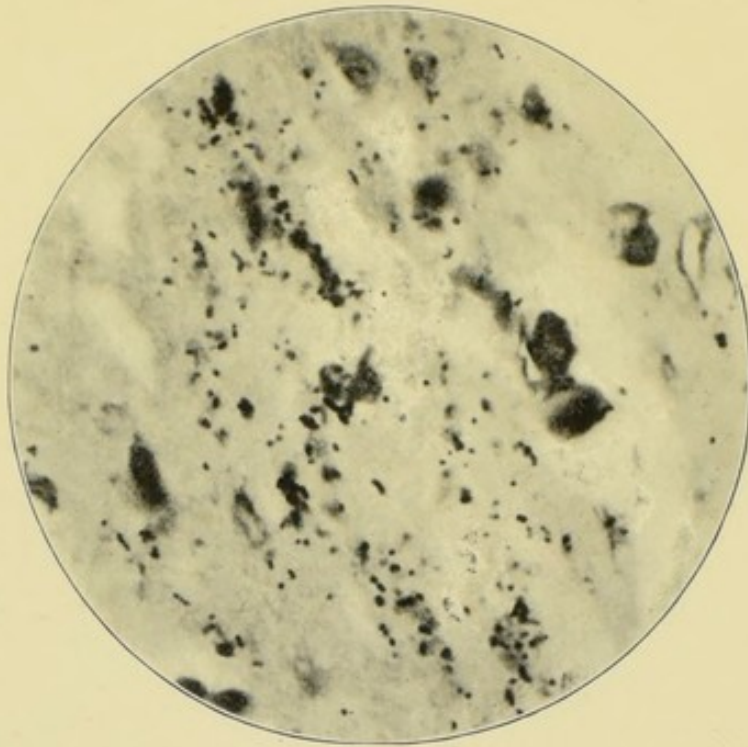


FIG. 20.—The wall of an acutely inflamed perforated appendix which contained a concretion. $\times 1000$.

also shows that the concretion contains yeasts and probably moulds. The usual vegetable fibres and crystalloid bodies are present in small quantities, but are not seen in the microphotograph. In truth, the concretion is simply an inspissated mass of bacteria.

The appendicular wall in the neighbourhood of the perforation is so altered by acute septic inflammation, that hardly any trace of muscular coats, and none of glands or epithelium, can be discovered. Amidst the purulent infiltration are vast numbers of bacteria (see Fig. 20).

In some parts, hardly any but micrococci can be seen. These are single, in pairs, in short chains of three or four, or in little groups. In other parts, the cocci are mixed with bacilli, amongst which are small ovoid bacilli, often in pairs, rather slender bacilli, about the size and shape of tubercle bacilli, and short thick bacilli. The bacteria are growing everywhere, but perhaps most are to be seen towards the lumen and upon the peritoneal surface. In short, the concretion contained a preponderance of bacilli; the inflamed appendix and peritoneum a preponderance of micrococci, probably streptococcus pyogenes. A search was made for tubercle bacilli, but with negative results.

The kind of infection which may be associated with the presence of a concretion, is also illustrated in the following case.

CASE 16.—*Appendicitis with Concretion—Perforation and Gangrene—Streptococcic Peritonitis.*—A schoolboy, aged ten, was quite well on April 4, 1899. Until then, he had had no symptoms whatever which pointed to appendicular disease. In the early morning of April 5, he awoke feeling very ill, vomited four times, and afterwards complained of pain in the right iliac region. Later, castor-oil was given, and the bowels were moved five times. The vomiting continued. In the evening, he walked to the hospital. At 11 P.M. the same day (April 5), his temperature was 101° F. and pulse 145. Vomiting had become persistent. The abdomen moved freely, except over the right iliac fossa, where it was almost still, and rather tender. No tumour could be felt, although the abdominal walls were not rigid, nor could any tumour be felt *per rectum*. Digital pressure caused pain in the recto-vesical pouch. I performed laparotomy, through the usual oblique incision, less than twenty-four hours after the onset of the symptoms. The vermiform appendix lay in front of the cæcum, wrapped in a cap of inflamed omentum. A quantity of thin, odourless pus was found beneath and around the cæcum. It was not confined by adhesions, but free in the peritoneal cavity. The fact of the pus being so thin, odourless, and without adhesions, led me to diagnose streptococcic peritonitis. The appendix, which contained two small fæcal concretions, was perforated in two places, and gangrenous throughout. Mr. B. Rowe, the house-

surgeon, had diagnosed gangrenous appendicitis. The appendix and the inflamed omentum were excised in the usual way. A second incision was made 2 inches above the symphysis pubis, and a large rubber tube placed in the recto-vesical pouch. The right iliac fossa and the pelvic peritoneum were then irrigated with many pints of biniodide of mercury lotion, 1 in 4000, and, by this means, some more pus was washed out of the pelvis. A gauze drain was placed beneath the cæcum, and brought out at the inner angle of the oblique incision.

The day after the operation, April 6, the patient continued exceedingly ill, and his abdomen began to be distended. On April 7, calomel was administered in two doses of three grains each. Several very offensive liquid motions resulted, and he began to amend, and ultimately made a complete recovery.

The various coats of this appendix can be seen with the naked eye. It is oval in section, and measures a centimetre in its longest diameter. The lumen has the usual trefoil shape, is filled with granular material, and surrounded with lymphoid tissue.

Throughout all the coats the evidences of an intense inflammation are to be found. The peritoneal surface is covered with granular pus cells and vast quantities of cocci, diplococci, and chains of from seven to twelve cocci.

The subperitoneal coat is full of dilated blood-vessels and small blood extravasations. It contains many cocci and diplococci. The muscular coats are of average thickness, but full of inflammatory corpuscles and dilated blood-vessels. The muscular coats contain hardly any bacteria.

The submucous coat likewise contains inflammatory cells, dilated blood-vessels, blood extravasations, and many cocci and diplococci. Its lymphatic and intercellular spaces are greatly dilated. The submucosa contains bands of muscular fibres, but no proper muscularis mucosæ can be found.

The mucosa has no columnar epithelium or tubular glands. Many of the engorged blood-vessels of the mucosa have ruptured, and a good deal of blood has been extravasated into its meshes. It likewise contains vast quantities of cocci, diplococci, short chains of cocci, slender bacilli, about the size and shape of tubercle bacilli, and some small ovoid bacilli in

pairs. The bacteria are most abundant towards the lumen, which is filled with an almost pure culture of streptococci. The chains are very short, the longest possessing only four or five elements. In addition, the lumen contains some bacilli, many pus cells, and some red blood corpuscles.

The omental cap, which enwrapped the appendix, is intensely inflamed. Its tissues are crowded with inflammatory cells, which have found their way between the individual fat cells. Its blood-vessels are dilated and engorged with blood which has here and there escaped. Some of the small venules are filled with recent blood-clots and fibrin. One of these clots contains streptococci.

The surface of the omentum is covered with pus cells mingled with cocci, diplococci, and streptococci. In places, these have penetrated as far as the omental vessels.

I have described this specimen in some detail, because the clinical history is so clear. In the absence of previous attacks, it is not easy to account for the entire destruction of the lining epithelium and of the tubular glands. The concretions were small, but, nevertheless, they may have existed for some months. Their presence indicates that the lumen must have been full of bacterial contents for many weeks or months, and it is not improbable that ulceration had also been going on. It is interesting to note that the histological examination confirmed the diagnosis of streptococcic peritonitis. Owing to the short duration of the peritonitis, the streptococci had not had time to penetrate far into the peritoneum. The successful issue is rather unusual, as generally in such cases, owing to delay, the peritoneum becomes so deeply penetrated with streptococci that surgical measures are unavailing. The patient probably owes his life to the sagacity and promptitude of Mr. B. Rowe, the house-surgeon.

The next case illustrates the common combination of ulceration, concretion, perforation, and gangrene. These, however, were associated with the presence of a bacterium of an unusual morphological appearance. The case is also of clinical interest. The symptoms proved misleading when the position of the diseased appendix was inferred from them.

CASE 17.—*Appendicitis with Ulceration, Concretion, Per-*

foration, and Gangrene—The Infective Properties of Concretions.—The dates of the onset of the appendicitis, and of the perforation were noted by Dr. Hayward, an accurate observer. Mr. T., æt. eighteen, began to have pain and discomfort on Wednesday, October 18. On the 19th he had diarrhœa. On the 20th he called on Dr. Hayward. On the 21st he had a violent pain in the right iliac fossa, and vomited. This was followed by a slight rigor, and the temperature rose to 103° F. I do not doubt that this crisis marked the occurrence of the perforation.

Sunday, 22nd, the temperature was 101° F., and the pulse 120; the abdomen was distended, the bowels confined, with vomiting and violent paroxysms of pain. The lower and right half of the abdomen were acutely tender and rigid, especially towards the lower third of the right linea semilunaris.

I diagnosed an acutely inflamed and perforated appendix with localised septic peritonitis. Also, as he had great difficulty in passing urine, and acute pain at the end of the act, I inferred that the appendix hung into the pelvis. This inference proved to be erroneous, and beyond what the clinical signs permitted. Evidently, the latter were characteristic of pelvic peritonitis, but that did not necessarily indicate that the appendix was in the pelvis. The spread of peritonitis from a septic focus is oftentimes rapid and extensive.

On October 23, I operated, although a spurious improvement had followed the administration of morphia. The usual oblique incision was made, and I expected to find the appendix hanging into the pelvis. The iliac fossa contained some serous effusion. The appendix lay external to the cæcum and colon, in the midst of a fœtid abscess. The incision had to be prolonged upwards and outwards to enable me to remove the appendix, which was about 10 cm. long, and attached to the outer side of the cæcum by a short meso-appendix. It was acutely inflamed, and perforated opposite the end of the mesentery. The part beyond the perforation was gangrenous (Fig. 21). A small concretion was felt slipping about within the lumen of the appendix. A drainage tube was placed in the abscess and brought out at the external angle of the wound. The patient made a rapid and complete recovery.

The sections are oval, 9 mm. in the long axis, and 6 mm. in the short. The coats are from 2 mm. to 4 mm. thick, the increase being caused by the swelling of the mucous membrane and of the peritoneum. The lumen is a slit 3 mm. long and 1 mm. wide at its broadest part.

The sections through the proximal part of the appendix show the effects of acute septic inflammation, but not in the same degree as those through the perforation. But, everywhere, the vascular engorgement is very great, and all the tissues are soaked with albuminous fluid, which has been coagulated in the process of hardening. The peritoneum has

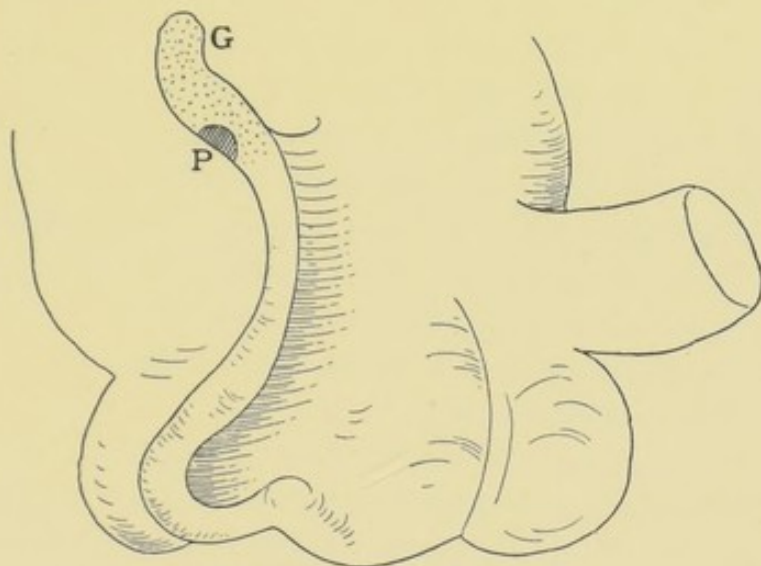


FIG. 21.—P, perforation ; G, gangrene, dotted.

lost its endothelial layer and the subperitoneal tissue is swollen and dotted with inflammatory cells. Its blood-vessels are numerous, dilated, and distended with blood. In places, the peritoneum and outer muscular coat have disappeared, exposing the circular muscular coat. The latter is thinned out and penetrated with inflammatory cells and blood-vessels. The submucosa is swollen, and covered with inflammatory cells. Its lymphatics are widely dilated, and its blood-vessels numerous and full of blood, some of which has extravasated.

At the site of the perforation, the structure of the mucosa is completely obscured by inflammatory exudation, and neither lymphoid follicles, tubular glands, nor epithelium can be seen ; towards the cæcum, however, it has not undergone any great

alteration. At the caecal end, some of the tubular glands have been destroyed by ulceration, but those which remain are merely dilated, and contain an excessive number of mucous cells. The lymphoid tissue is infiltrated with coagulated albumen, but some of the follicles can be discerned. They possess no lymph sinus, and, where the epithelium of the lumen is shed, some of them are laid bare. The caecal end of the lumen is almost empty, and merely contains a few pus cells, some mucus, and detached epithelium. At the perforation, the lumen and all the wall of the appendix contain swarms of bacilli and cocci. The cocci are of the ordinary type, and frequently in pairs. The bacilli differ morphologically from others that I have seen in the vermiform appendix. First, they are exceedingly thin, not more, perhaps, than a quarter of a micro-millimetre across. Secondly, their length varies from three to ten times their breadth, and the longer ones are slightly curved. Thirdly, the protoplasm of the long ones stains irregularly. The short bacilli are usually in pairs or swarms, the long form short leptothrix.

This appendix was examined for tubercle and tubercle bacilli, but none were found.

I have described this specimen in detail, because the course of events is by no means clear. In the first place, the perforation and gangrene ought not, I think, to be attributed to the mere mechanical pressure effects of the concretion. The concretion was small and slipped about quite freely within the lumen. In this respect, it resembled concretions met with in cases of ulceration of the mucosa with symptoms of appendicular colic. The swarms of peculiar bacilli at the perforation and throughout the walls of the appendix in its vicinity, were probably the cause of the perforation and of the gangrene.

I would read the history of the case in the following way. The appendix had been inflamed and its mucosa ulcerated for some time; it had also had bacterial contents which, besides producing a concretion or bacterial mass, had penetrated the mucosa. One day, from some unknown cause, the infective appendicitis became acute, pus and bacteria collected in the lumen, and at last escaped by perforation, whilst

the distal end of the appendix, having a precarious blood supply, became gangrenous.

The next case shows the reasonableness of this train of thought.

CASE 18.—*Appendicitis—Fæcal Concretion—Ulceration of Mucosa and Bacterial Invasion—One Attack of Appendicitis followed by Chronic Appendicitis.*—A young man, aged twenty-five years, was sent to me to have some varix of the internal saphenous vein treated by operation. He seemed out of health and anæmic, and inquiry elicited that he had not been well since an attack of "peritonitis" a year before. He thought he had not been well before the attack, and his abdomen had felt uncomfortable. During his acute illness he had had pain in the abdomen, vomiting, constipation, and distension. The temperature was raised, but how much he did not know. After being in bed four days he recovered, but had since had constant discomfort in the abdomen, with inability to eat fruit and vegetables. When asked to locate the pain his hand was placed over the right iliac fossa. Deep pressure, midway between the anterior superior spine of the ilium and the umbilicus, was attended with pain, but no tumour could be discovered. Nothing could be felt *per rectum*, and the bladder acted naturally.

The appendix was excised about a year after the attack. It was about 10 centimetres long, about three-quarters of a centimetre in diameter, and inadherent. It had a meso-appendix for two-thirds of its length. It felt hard, and its blood-vessels were distended with blood. A small concretion, about 2 mm. in diameter, could be felt slipping about in its interior. The cæcum was slightly inflamed and "shaggy." The patient made a good recovery, and reported himself three months afterwards as well and able to eat his usual food.

The sections through the distal end of the appendix are circular, and 5 mm. in diameter. The total thickness of the walls is 1.0 to 1.5 mm. Of this thickness, the mucosa is at least 1 mm., the remaining .5 mm. being peritoneum, muscular, and submucous coats, which are therefore exceedingly thin. The mucosa contains numbers of lymphoid follicles, and as many as eleven can be counted in a section. The lumen is irregularly ovoid, and contains some fæcal material.

The minute histology is as follows, beginning with the distal end:—The peritoneal coat is normal, except that its vessels are dilated and full of blood. The muscular coats are exceedingly thin, and the external absent in places. The submucosa is fibrous, and here and there infiltrated with cells. Its blood-vessels are numerous with thick walls. Its lymphatics and intercellular lymph spaces are dilated. The lymphoid follicles of the mucosa nearly all have dilated lymph canaliculi, and their reticulum is hidden by swollen lymphoid corpuscles. About half of them have widely dilated lymph sinuses; the others have no visible lymph sinus. The tubular glands are not dilated and are lined with epithelium, except at their mouths, where it has been shed, together with nearly all the epithelial lining of the lumen, but the basement membrane is still intact. The lumen contains granules, epithelium, old blood cells, pus cells, nuclei, crystalloid bodies, pigment, mucus, and vast quantities of bacteria, mostly bacilli. The bacilli are small, ovoid, single, in pairs, in short strings, long and slender, slightly curved, and short and thick. Cocci, diplococci, and short chains are also seen. This bacterial mass does not quite fill the lumen, and none of the bacteria are invading this part of the mucosa.

The proximal sections illustrate the effects of (*a*) ulceration of mucosa, (*b*) accumulation of faecal *débris* in lumen, (*c*) bacterial invasion.

The peritoneal, muscular, and submucous coats are the same as in the distal sections, but rather thinner. The sections are 8 mm. in diameter, the walls .75 to 1.5 mm. thick, and the lumen 6 mm. across and full of faecal *débris*, the same as that in the distal end. The mucosa is, in parts, entirely destroyed by ulceration, so that the contents of the lumen are in contact with the submucosa. Elsewhere, the mucosa consists of a little lymphoid tissue and short, dilated, tubular glands similar to those in Fig. 51. The epithelium of the lumen is entirely gone, and also that at the mouths of many of the tubular glands. The lymphoid follicles have almost disappeared, but the compressed remains of two or three are indistinctly seen. The lymphatics of the mucosa are widely dilated, and contain small quantities of bacteria such as fill

the lumen. The latter are also invading the mucosa along the empty sockets of the tubular glands (as in Fig. 13), and also by the lymph canaliculi. The blood-vessels and lymphatics of the meso-appendix are numerous and dilated, and it contains groups of inflammatory cells.¹

It is clear that the faecal concretion was far too small to exercise any mechanical pressure upon the mucous lining of the appendix. On the other hand, the bacterial growth had distended the lumen and forced its way along the lymph canaliculi and lymphatics. It is obvious that it had produced the concretion, and doubtless it had caused the ulceration of the mucosa.

As I have remarked, with the exception of vascular engorgement, the exterior of this appendix gave no indication whatever of the dangerous condition of its mucous lining.

The clinical history is interesting. One short, sharp attack, and then a year of chronic appendicitis.

I now propose to adduce some more evidence to prove that, when a faecal concretion is associated with ulceration of the appendix, the concretion is not necessarily the cause of the ulceration. Incidentally, the case illustrates the clinical symptoms associated with the growth of faecal concretions.

CASE 19.—*Appendicitis with Ulceration of the Mucosa and the Formation of a Faecal Concretion—Clinical Symptoms—Appendicular Colic.*—A young woman, aged twenty-three years, employed in the post-office, had had what I then considered to be "appendicular colic," all her symptoms accorded so well with Talamon's description. The complaint had lasted off and on for upwards of three years. In the beginning, the attacks of pain came on about every three months, then every month, and at last they prevented her following her occupation. Each attack lasted two or three days, and was usually brought on by exposure to cold, or by some indiscretion in diet. The pains were mostly in the right iliac region, and spreading over the abdomen. Pain was the great feature of her complaint, and was said not to have been accompanied by any rise of the body temperature or of the pulse rate. No vomiting

¹ I have recently found identical histological changes in a case of appendicitis associated with thrombosis of the superior mesenteric vein.

occurred, the abdomen did not become distended, and the bowels were not particularly constipated. With the exception of the colic, her health seemed to be excellent.

I removed the appendix in the usual way. It lay beneath the end of the ileum, attached to the mesentery by a meso-appendix. To the naked eye, it presented no sign whatever of disease, but the whole of it felt very hard, and it contained a small concretion which slipped about in its interior. Besides the concretion, the appendix was filled with some soft faecal material.

The sections of the appendix are half a centimetre across, and some contain six lymphoid follicles. The lumen is irregular, owing to the projection into it of the swollen follicles, and is 2 mm. across. The peritoneal and muscular coats are only half a millimetre thick. The microscope shows that their structure is normal. The submucosa contains some inflammatory cells, and its lymphatics are dilated. The lymphoid tissue and follicles of the mucosa are swollen and inflamed, with some dilatation of the basilar lymphatic sinuses. The tubular glands contain many mucous cells. Some of the specimens show the discharge of mucus very beautifully. In many of the sections, the epithelial lining of the lumen, and the epithelium of the mouths of the tubular glands are detached and mixed with the bacterial mass which fills the lumen. In some places, the basement membrane is also destroyed, and the bacteria have invaded the lymph canalicular system, so that ulceration of the mucosa has begun (Fig. 22).

The lumen is filled with a mass which consists mainly of bacteria of various kinds—cocci, diplococci, streptococci, and bacilli of all shapes and sizes (Fig. 23). These are intermingled with pus cells, epithelial cells, mucus, crystalloid bodies, and globules of some opaque substance. Starch corpuscles and fibres derived from food can also be seen. The lumen also contains a dark brown substance in small irregular masses. The origin of some of the pus corpuscles from the lymphoid cells of the ulcerated mucosa is well shown. I have no doubt that we have here a stage in the formation of a faecal concretion. As usual, specimens were stained for tubercle bacilli, but none were found.

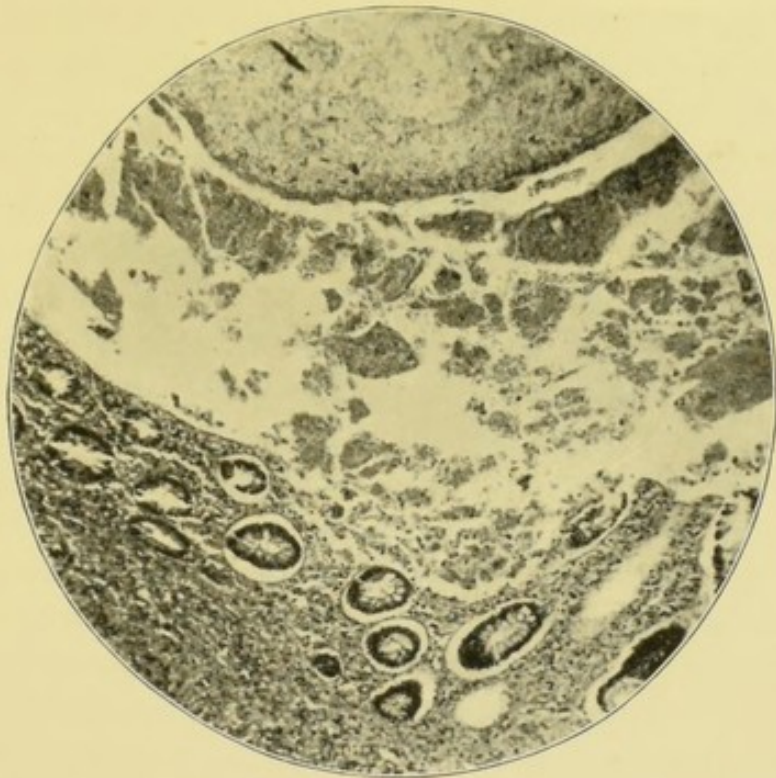

FIG. 22.—Appendicitis with ulceration and bacterial invasion of mucosa. Clinical symptoms, appendicular colic. $\times 65$. The lumen is above, the mucosa below.

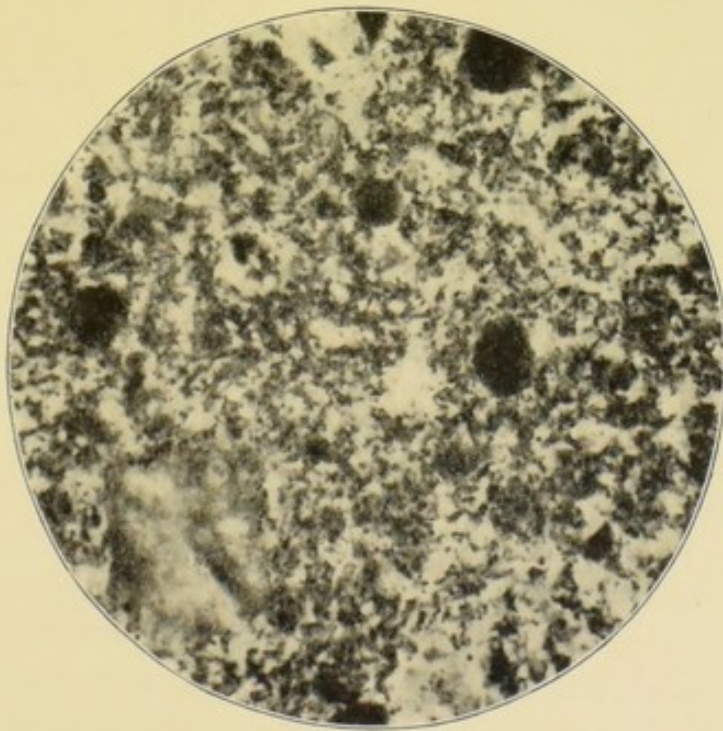


FIG. 23.—Contents of appendix showing the formation of a faecal concretion. $\times 500$. Compare with Fig. 19.

We may now recall that this appendix did contain a small concretion which slipped about in its lumen. The ulceration of the mucosa was extensive. It was found in sections through both the proximal and distal ends of the appendix. It is quite obvious that it could not have been caused by pressure exercised by the little concretion. Nor can I imagine the possibility of its having been caused by the friction of the concretion. On the other hand, we constantly find similar ulceration associated with similar bacterial contents, although no concretion has yet formed. I, therefore, prefer to believe that the ulceration and the concretion owed their origin to the same cause, namely, the bacterial accumulation. Nor is it likely that the small concretion was the cause of the pain. That is accounted for by the inflammation, swelling, and ulceration of the mucosa. The presence of an infected ulcer also casts doubt upon the statement that the pulse rate and temperature were not raised during the attacks. The commencing invasion of the mucosa by the bacteria, shows that the disease was of a more serious nature than the clinical symptoms and naked-eye appearances might have led one to suppose. This exemplifies one of the ways in which perforation or gangrene of the appendix begins.

That concretions do not necessarily cause ulceration of the mucosa is, I think, shown by the following case, which, besides throwing light upon this point, has peculiarities of its own.

CASE 20.—*Appendicitis with Concretions and Infection of the Peritoneum and Meso-appendix.*—Miss X., aged twenty-five, was, without apparent cause, suddenly seized with a violent pain in the abdomen. The pain was most intense beneath the upper part of the right rectus muscle, and was accompanied with continuous vomiting and diarrhoea. The temperature rose to 102° F. and the pulse to 120; but the latter shortly fell to 84. After some hours the pain “settled” in the right iliac fossa, and was intensified by pressure at M’Burney’s point. *Per rectum* the peritoneum was slightly tender, and any movement of the uterus was attended with pain. The right rectus and right side of the abdomen were rather rigid, and no tumour could be felt anywhere. For some years her appetite had been indifferent, and six months

before she had had a similar attack of pain, accompanied with vomiting and diarrhœa. She had recently made a long continental journey, during which she experienced pain in the right iliac fossa.

I excised the appendix through a small incision. The appendix lay beneath the cæcum. It was about 10 cm. long and engorged with blood. Its distal end felt hard, and two small concretions could be felt slipping about in its interior.

The patient made a rapid recovery and all her symptoms were cured. The effect upon the appetite was quite remarkable.

The sections of both the proximal and distal ends of this appendix are nearly alike, and do not, therefore, call for separate description. The sections are almost circular and 7 mm. in diameter. The lumen is ovoid and measures 4 mm. in its long diameter, and 3 in its short. The interior of the lumen is nearly filled with a homogeneous mass. The coats of the appendix vary in thickness from 2·5 mm. to 1 mm. The mucosa varies least and is by far the thickest coat. At the side furthest from the meso-appendix it measures 1·5 mm., and at the meso-appendix ·75 mm. At this point, the sub-mucous and muscular coats become too thin to be seen with the naked eye; elsewhere, they each measure about ·75 mm.

The contents of the lumen consist of granules, globular bodies, mucus, crystals, yellow pigment, fibres, nuclei, pus cells, and vast quantities of bacteria. Amongst the latter are cocci and diplococci; minute, short, ovoid bacilli, single, in pairs, and short chains; many bacilli about the size of tubercle bacilli, and often slightly curved; long, slender bacilli and short, thick bacilli; and numerous spores.

This bacterial mass has grown into the mouths of some of the tubular glands, and some of the bacilli look as though in the act of penetrating the epithelial lining of the mucosa. The latter is perfect in all the sections, although in places its cells are cubical or almost flat.

In the thicker part of the mucosa, the tubular glands are ·75 mm. long, and in the thinner part ·50 mm. Their epithelium is intact, although many goblet cells are present. Their lumens are not dilated.

The lymphoid tissue between the tubular glands is clear and distinct, and the stroma clearly defined. Perhaps its lymph canaliculi are rather wide. The same remarks apply to the structure of the lymphoid follicles, which are numerous and of large size. At least eight can be counted in each section. Most of the follicular sinuses are narrow, but some at the hiatus muscularis are very capacious. In three, the endothelial lining has proliferated, and formed a thin layer of pellucid, granular material in which some pairs of small ovoid bacilli are imbedded. At one point, the follicular sinus is almost directly continuous with the lymphatics of the meso-appendix. This direct continuity is permitted by the almost complete absence of submucous and muscular coats at the meso-appendix. The endothelial covering of the meso-appendix is proliferating, and mingled with the cells are numerous small ovoid bacilli, single and in pairs. Some pairs of larger ovoid bacilli are also present. The tissues of the meso-appendix are very loose, and contain a few small groups of inflammatory cells.

The veins and lymphatics of the peritoneal coat of the appendix are dilated and the former full of blood. The sub-peritoneal tissue is scanty but otherwise normal. The endothelial layer is proliferating and stands out from the basement membrane in tooth-like processes. Here and there, amidst the small groups of proliferation corpuscles, are small ovoid bacilli, singly and in pairs. A few larger pairs of ovoid bacilli are likewise present.

Clearly the concretions, which were present in this case, had not produced the clinical symptoms by causing ulceration of the mucosa, because none was found. Neither could they have acted mechanically, because they were much too small. On the other hand, the mass of bacteria in the lumen and the passage of some of them into the lymphatic system, and the consequent lymphangitis, are, I venture to urge, quite sufficient to explain the clinical phenomena.

The discovery of the presence of peritoneal changes, and of bacteria in the peritoneum and in the meso-appendix was unexpected. It is to be supposed that the latter had travelled from the lumen along the lymphatics, which were inflamed;

but it is difficult to see how they entered the lymphatics, because the epithelium of the lumen and of the tubular glands is still *in situ*. It is, however, much altered in shape, and perhaps otherwise damaged, so that it may have ceased to be an efficient barrier.

No two cases are alike. In the following the appendicitis, the ulceration, the concretion, the perforation, and the gangrene of a former case (Case 17, p. 81) were all reproduced with absolute fidelity; but, nevertheless, the disease ran a different course. This was determined in part by the fact that, although the two appendices were in exactly the same morbid state, they were differently situated within the abdomen, and a different kind of organism had infected the peritoneum.

CASE 21.—*Appendicitis with Ulceration—Concretion—Perforation and Gangrene—Subsequent Fæcal Fistulæ—The Mechanical Effects of Concretions.*—On February 2, Mr. X., æt. twenty-two, went to a dance where he was seized with colic. This became worse, and on February 3 his bowels acted thrice after a purge. The abdomen, nevertheless, began to be distended and he vomited. The pain was general, but worst around the umbilicus and beneath the lower part of the right linea semilunaris. The lower right side of the abdomen was still and rigid, but the rest moved a little with respiration. The whole abdomen was tender to the touch, especially at the lower part of the right linea semilunaris. The temperature was 100° F. and the pulse 95. The recto-vesical pouch was exceedingly tender. I thought the case one of acutely inflamed appendix, with a concretion, and that it was on the point of perforation.

On February 4, at 10 A.M., the condition was the same. In the afternoon he became excited and threw himself about when a relative arrived. The pain and distension increased, and the pulse ran up to 110. Perforation had taken place. The abdomen was opened in the right linea semilunaris. The appendix was in the midst of a little thin pus and was adherent in the iliac fossa, with its gangrenous end hanging into the pelvis. It was about 9 cm. long, and had a meso-appendix attached to the first 5 cm. The perforation was opposite the end of the meso-appendix, and the part beyond the perforation

was gangrenous (see Fig. 24). The appendix lay underneath the end of the ileum, which was acutely inflamed and

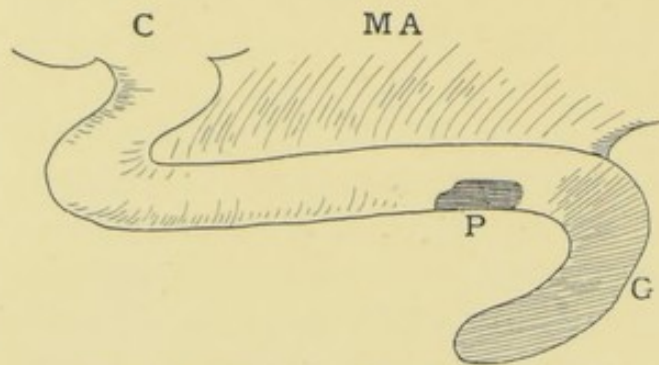


FIG. 24.—C, caecum ; MA, meso-appendix ; P, perforation ; G, gangrene.

spotted with black patches. A concretion, about a third of an inch in diameter, slipped out through the perforation, whilst the appendix was being separated.

The appendix was excised. The meso-appendix was too

rotten to hold ligatures. The suspicious part of the ileum was placed beneath the wound, which was partly closed, a rubber drain being left in the pelvis and a gauze drain beneath the caecum. Next day, the distension and vomiting persisted. Five, and then three grains of calomel, followed by an enema, emptied the bowels, and recovery ensued. About the fourth day, thin faeces began to escape from several small holes in the ileum, but after a time this ceased. Six months later, the patient had a strong abdominal wall and his health was excellent.

The histological changes are the same as in the previous case (Case 17, p. 81). In sections through the proximal part above the perforation, the peritoneum has lost its endothelial layer, which is replaced by inflammatory corpuscles. The subperitoneal tissue is thickened and infiltrated with inflammatory corpuscles and fibrin; but a good deal of the peritoneum has been torn off or destroyed. The subperitoneal vessels are numerous, dilated, and full of blood. The muscular coats are infiltrated with inflammatory cells, part of the longitudinal has disappeared; the circular has been, as usual, the last to give way.

The lymphatics of the inflamed and swollen submucosa are dilated to more than twice their usual size. The lymphoid tissue of the mucosa is hidden and replaced by purulent infiltration. Some of its capillaries are dilated and full of blood. About two-thirds of the tubular glands have dis-

appeared. The epithelium of those which remain has a large proportion of goblet cells. The epithelial lining of the lumen is destroyed, except a few small patches. The lumen contains pus mingled with quantities of cocci, diplococci, and bacilli. Some of the diplococci have capsules. The bacilli are small and ovoid, and often in pairs, or slender and slightly curved. Wherever the epithelium of the lumen has disappeared the bacteria have penetrated the mucosa and reached almost to the submucosa. The lymph on the peritoneal surface contains a few bacilli. No evidence of tubercle could be discovered.

I possess, unfortunately, no sections through the perforation; they might have thrown light upon the actual mode of its formation. The concretion was situated exactly opposite to it, and slipped out of it during the operation. This seems to me evidence that the concretion was the cause of the perforation. Next, the concretion was quite big enough to have ulcerated the coats of the appendix by its mechanical pressure. But I should imagine that the pressure only became deadly when the appendix itself became swollen, probably by a septic inflammation caused by infection from its lumen. This infection had, as a matter of fact, taken place wherever the epithelial lining of the lumen had been destroyed. Abundant evidence has been adduced to show that this bacterial invasion occurs long before the actual attack of appendicitis, the term being now used in its clinical sense.

The intensity of the peritonitis started by the perforation is shown by the injury to the ileum. I have not seen such small multiple perforations of the bowel in any other case. Morphologically, the bacteria in the appendix were of the ordinary type, unless we are to except those which were thought to possess a capsule.

How long may a concretion inhabit the appendix without causing perforation or gangrene? It is probable that the following is an example of the long-continued presence of concretions.

CASE 22.—*Appendicitis with Faecal Concretion—Condition of the Appendix after upwards of Twenty Attacks of Appendicitis, with a Comment upon the so-called Natural Process of*

Cure.—W. H., aged thirty-two years, a furniture salesman, was nineteen years old when he had his first attack of appendicitis. During the next thirteen years he had at least twenty attacks. On one occasion he went into St. Bartholomew's, and on another into the London Hospital. I saw him in the midst of the last attack. Whilst eating his dinner, he was suddenly seized with pain in the abdomen. This was followed by vomiting, and by a rigor. At first, the pain was worst across the abdomen and about the navel; afterwards it was confined to the right iliac fossa. Morphia was given to relieve the pain. The bowels were loose at first and then constipated. The abdomen was rather distended, with decided tenderness on pressure in the right iliac fossa. The result of the rectal examination was negative. At the height of the attack, the temperature was 102° F. and the pulse 104. The illness lasted about four days. He himself considered that, compared with some of the others, the attack had been a moderately severe one. A fortnight afterwards, all these symptoms, including the tenderness, had disappeared. The appendix was then excised through the usual oblique incision. It was about 7 cm. long, coiled upon itself, and closely adherent to the under surface of the cæcum. It was constricted close to its commencement, and its lumen contained a small concretion. The great omentum was vascular and inflamed but not adherent, and it was thought advisable to remove a portion of it. The patient made an uninterrupted recovery, and the wound healed by first intention.

The transverse section is 9 mm. across, and the walls are not less than 3 mm. thick. The lumen is a narrow irregular slit.

The microscopical examination shows that the endothelial layer of the peritoneum is destroyed, and the subperitoneal infiltrated with cells and full of small blood-vessels and dilated lymphatics. The longitudinal muscular coat is thicker than usual, the circular about twice the usual thickness. In both, the increase is due to inflammatory cells in process of conversion into fibrous tissue.

Owing to the inflammatory cell infiltration, it is not easy to say where the circular muscular coat ends and the sub-

mucous begins. The submucosa is inflamed and crossed by vast quantities of delicate interlacing bands of fibrous tissue. Its blood-vessels are numerous, but are not well shown in the piece which has been photographed (Fig. 25).

The submucosa also contains numerous dilated lymphatics and lymph spaces. The mucosa is profoundly altered, and its retiform tissue converted into an interlacing meshwork of delicate fibres, with a great number of nucleated cells in the meshes and along the fibres, probably the result of the

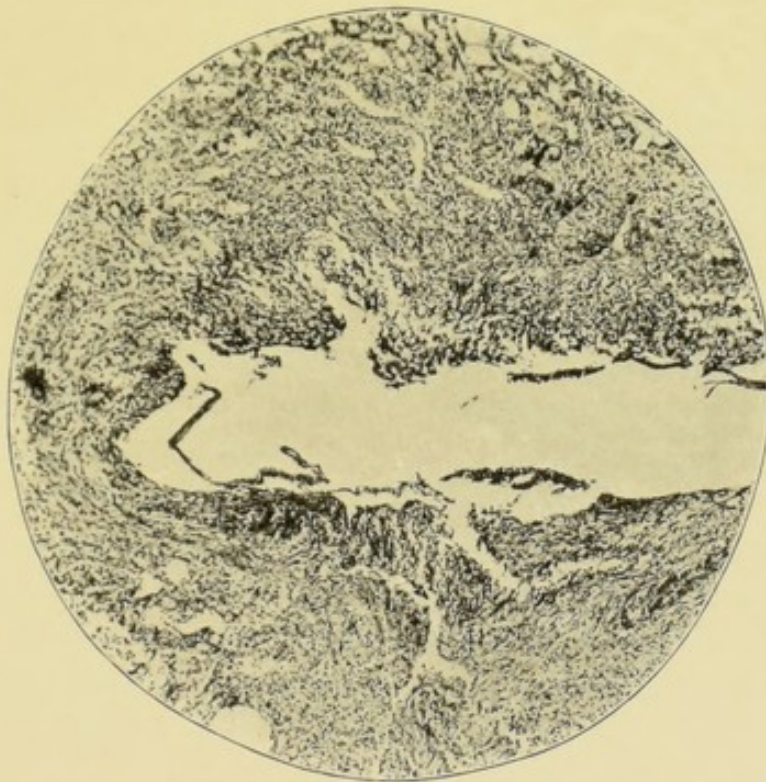


FIG. 25.—Appendix after upwards of twenty attacks of appendicitis. $\times 55$.

organisation of granulation tissue (Fig. 25). Around a portion of the lumen is a thin layer of altered and detached epithelial lining. In other sections, pieces of the epithelial lining are still to be found, but many of the cells are discharging mucus.

The tubular glands have almost disappeared. Here and there part of one is seen, or the gaps left by the shedding of their epithelium can be traced.

The lumen contains a little mucus, some nuclei, and detached epithelium. It is doubtful whether any bacteria

were mingled with these, and none could be seen in the mucosa or other layers.

It is strange that the inflammation caused the distal portion of this appendix to thicken, and the proximal to contract. The appearances in the thickened part remind one of those seen in hypertrophic cirrhosis of the liver.¹

Dr. Hawkins² has endeavoured to explain the way in which "acute catarrhal appendicitis" is cured. He says that after the acute stage has passed, "if by the pressure of the surrounding parts the opposed granulating surfaces are brought into contact, and if the whole organ remains at rest, union may take place, and the appendix as a source of disease ceases to exist. The bearing of this on treatment will be referred to subsequently. . . . As a final result the lumen may come to be occupied entirely by fibrous tissue springing directly from the submucous areolar tissue, and the natural cure is then complete."³

This patient was twice in great London hospitals, once under the care of a physician, and once under the care of a surgeon. It is possible that as no operation was performed, they were waiting for the achievement of the process described by Dr. Hawkins. The pressure which he says is to bring the granulating surfaces together before they unite is imaginary. In the case under discussion, the disease had lasted thirteen years, and caused more than twenty attacks, but, nevertheless, the lumen had not been obliterated. The reason is obvious; it contained a concretion.

Dr. Hawkins,⁴ in his admirable monograph, says that he had not had an opportunity of examining microscopically the appendix in a case of disease resulting from the presence of a foreign body. He goes on to say, that there is every reason to believe that the result is of the same character as that produced by a faecal concretion.

I am able to give an account of a case in which six or seven shot were found in the lumen of an appendix which I excised. Their presence was unknown until Mr. Shaw began

¹ Hamilton, *A Text-Book of Pathology*, London, 1894, vol. ii. p. 220, etc.

² *Diseases of the Vermiform Appendix*, p. 24.

³ *Loc. cit.* p. 27.

⁴ *Loc. cit.* p. 36, *et seq.*

to cut the sections. The shot were about No. 5 size. Strange to say, one of the shot had disintegrated. Unfortunately, the case is complicated by the fact that the inflamed appendix was adherent within the sac of a right complete inguinal hernia. But before giving an account of the specimen, I wish to take exception to Dr. Hawkins's inference. The effects produced by a shot or similar substance, and those produced by an enterolith cannot be, as he says, quite the same. A shot is not a solid mass of bacteria, whilst, as I have just shown, a concretion contains hardly anything else.

CASE 23.—*Appendicitis with Ulceration of Mucosa and Shot in Lumen—Appendix in the Sac of an Inguinal Hernia.*—A powerful man, aged thirty-seven, was admitted into the Great Northern Central Hospital suffering from a strangulated inguinal hernia of the right side. He was rather a stolid individual. He said the hernia had existed five or six years, and that he had been wearing a truss without discomfort. He had never had an attack of pain or of inflammation in the rupture until it became strangulated. The hernia was reduced by taxis, and the symptoms of strangulation relieved. Nevertheless, a swelling still remained in the inguinal canal, and it was evident that all the contents had not been reduced. The swelling was very tender, so that he could not wear a truss, and, therefore, the operation of radical cure was performed. I expected to find inflamed and adherent omentum. When the sac was opened, the swollen and thickened vermiform appendix was found adhering very firmly to its posterior wall. The cæcum was of the foetal type, its end having gradually tapered off and become the appendix. In removing the appendix, the funnel-shaped part was cut through, leaving a half-inch opening into the cæcum. The lumen of the appendix, too, was 5 to 7 mm. wide after it had been shrunk during the hardening. We have here an arrangement particularly favourable for the entrance of foreign bodies, such as shot. The opening into the cæcum was closed by a fine silk ligature around the mucous coat, and, with three points of Lembert's suture, through the peritoneum. The radical cure was completed in the usual way. The operation was followed after an interval, by subacute suppuration which seemed to

have originated near the stump of the appendix. This delayed the recovery, but not for long.

The microscopical report on the appendix is as follows. The peritoneal coat has no endothelial covering, and the subperitoneal tissue is very vascular. The small arteries and arterioles have exceedingly thick circular muscular coats, and so have the small arteries in the meso-appendix. The muscular coats of the appendix, especially the circular, are

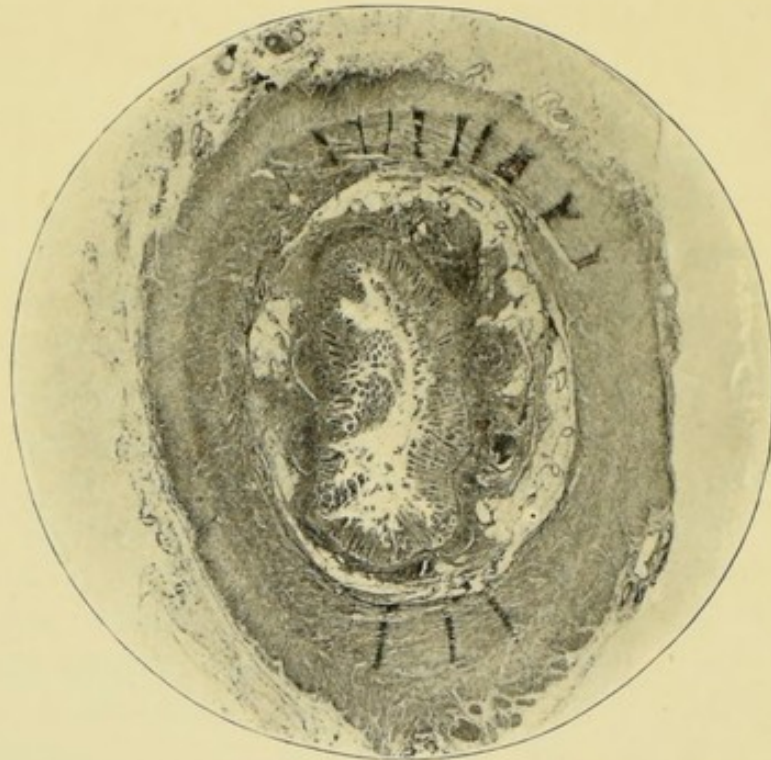


FIG. 26.—The effects of foreign bodies (shot); hypertrophy of muscular coats; slight inflammation of mucosa and great oedema of submucosa. The peritoneum is also inflamed. $\times 9$.

markedly hypertrophied, being at least 2 mm. thick (Fig. 26). The submucous coat is œdematous and fibrous, and is separated from the mucosa by a very thick muscularis mucosæ. Doubtless this layer is also hypertrophied. Nine lymphoid follicles can be counted in a section. They are rather smaller than the follicles of children, and their basilar lymph spaces are likewise smaller. Five of the lymphoid follicles are outside the muscularis mucosæ, but four pierce it, and become continuous with the lymphoid tissue of the mucosa. The tubular glands are almost normal, although some contain rather an

excess of mucous cells. The lining epithelium of the lumen is detached, but its basement membrane is everywhere intact.

The lumen is nearly empty, but amongst the remains of some mucus are a few yeast fungi and occasional bacilli. No trace of tubercle or of tubercle bacilli can be found.

This specimen shows, I think, quite clearly that the presence of non-infective, smooth, and small foreign bodies, like shot, causes the muscular coats of the appendix to hypertrophy. In this respect, the appendix resembles the other muscular organs, and we may assume that the hypertrophy was in some way related to attempts at the expulsion of the foreign body. The changes in the mucous membrane are very slight, and such as might have been set up by a small and smooth foreign body acting as a gentle mechanical irritant. The very marked inflammatory changes in the peritoneal coat are less easy to explain. They suggest that the peritoneum on the outside of the appendix is capable of a considerable degree of inflammation, without any marked participation of the mucous membrane lining its interior. In this respect, again, the appendix resembles the other parts of the alimentary canal. It is difficult to explain the peritonitis, but it may be attributed to the wearing of a truss.

When we pass in review cases of appendicitis with concretion, they do not seem to possess clear and distinct clinical peculiarities which might, in the future, enable us to diagnose the presence of a concretion. Some concretions are too small to cause pain by mechanical distension. Most are accompanied with widespread ulceration of the mucosa and bacterial invasion of its walls, and it is to the effects of these that the severity of the clinical signs ought to be attributed.

When perforation or gangrene or both have occurred, then all the appendicular symptoms are overshadowed by the consequent septic peritonitis.

CHAPTER VIII

APPENDICITIS WITH STENOSIS AND ITS COMPLICATIONS—CYSTS—
MUCOCELE—EMPHYEMA—ULCERATION AND BACTERIAL IN-
VASION OF MUCOSA—PERI-APPENDICITIS—PORTAL PYÆMIA

WE now come to appendicitis with stenosis, and its effects.

As the result of inflammatory cicatrisation one, two, or more strictures may develop at intervals along the appendix. Usually the constriction is so local that it looks as though a fine thread had been tightly tied round the tube.

The stricture is caused in most instances in the same manner as a urethral stricture—by the organisation and cicatrisation of inflammatory lymph in the submucous and subperitoneal tissue. I believe that narrowing is less frequently caused by the cicatrisation of an ulcer, which is asserted by some to be its ordinary mode of formation.

The lumen beyond the constriction is usually dilated. The mucous lining may be intact, altered, or destroyed. The contents may be mucus, pus, bacteria, or concretions.

There is another class of cases in which the inflammatory process causes obliteration of the whole lumen of the appendix. This is supposed to be the last stage in the "natural process of cure," but the few cases which I have seen throw doubt upon this assumption (Case 37, p. 133).

The following case of stenosis of the appendix shows that, a month after a rather severe attack of appendicitis, no bacteria may be present in the interior of the appendix, in its walls, or in the inflamed omentum. Incidentally, the importance of the rectal examination is illustrated, because the mere examination of the iliac fossa or front of the abdomen

failed to reveal the existence of the inflammatory mass, which was at once detected *per rectum*.

CASE 24.—*Appendicitis with Stenosis, Dilatation, and thinning of Mucosa—Bacteria absent.*—Mrs. X., aged twenty-eight, had just returned from a long journey by sea and rail. About November 9 she had what she considers to have been her first attack of abdominal pain. Whilst being examined and kept waiting by quarantine officials, she shivered, felt very ill, and had a violent pain in the abdomen, about the umbilical region, but did not vomit. The attack passed off, and she thought that she was well until a month later, when she was again seized with a violent abdominal pain, which felt worst about the umbilicus. The attack began during afternoon tea. It was accompanied with shivering, vomiting, and faintness, so that she fell upon the floor. Afterwards the bowels were constipated, and the abdomen swollen and very tender between the pubes and umbilicus; the pulse was accelerated, and the temperature 101° F. I saw her two days after this attack, when all the symptoms had subsided. The abdomen was very tender beneath the right rectus, and that muscle was rather rigid. No tumour or tenderness could be felt in the iliac fossa, but, *per rectum*, a hard and tender swelling was discovered in Douglas's pouch. Although there had been no difficulty in emptying the bladder, this swelling was inferred to be connected with an inflamed appendix hanging into the pelvis.

At the operation, this was found to be correct. The appendix was adherent to the outer wall of Douglas's pouch, to the right ovary and tube, and to the uterus, and was enveloped in a quantity of inflamed omentum. Hæmorrhage was rather free during the separation of the adhesions. The great omentum was so vascular and inflamed and oozed so much, that the wound was enlarged, and the greater part removed. After some vomiting, the patient made a rapid recovery.

Thus the patient certainly had had two attacks of appendicitis with an interval of a month between them. Whilst in India she had had diarrhœa, and two years previously a severe colic, which lasted a night, and was attributed to some article of diet. For some time, perhaps on account of the diarrhœa, she had been afraid to eat fruit and vegetables.

The appendix was about 9 cm. long, and the meso-appendix reached about half its length. It was constricted 3 cm. from its tip. The proximal part was about the usual size, the distal was distended into a cyst which felt stony hard, as if it contained a concretion.

The proximal sections are ovoid (6 mm. by 5 mm.), with a small ovoid lumen (2 mm. by 1 mm.). The coats are thick (2.5 mm.). The peritoneal coat is inflamed and studded with some groups of nucleated cells. The fibres of the muscular coats are rather loose, with dilatation of lymphatics and lymph spaces. The submucosa is infiltrated with cells, its lymph spaces and lymphatics and its vascular system are also dilated.

The epithelial lining of the mucosa is detached, and a quantity of it lies in the lumen, along with mucus and nuclei, but no bacteria. The tubular glands contain many goblet cells. Many of them are branched at their distal end, some are trifurcated. A well-marked muscularis mucosæ runs at the base of the tubular glands. This is pierced by some of the lymphoid follicles, of which about eight can be counted. They have an exceedingly loose appearance, with marked dilatation of their sinuses. Some of the lymphatics leading from the follicles contain thrombi of nucleated cells.

The dilated distal part of this appendix has the same general characters as the proximal, but is much larger in circumference (diameters 8 mm. by 6 mm.), with a capacious lumen (4 mm. \times 3 mm.), approximating to the ordinary T-shape. The coats vary in thickness from 1 mm. to 3 mm. at the places where the mucosa and submucosa are infolded. The thinning of the coats is at the expense of the mucosa and submucosa. The former is about .25 mm. thick. More than half its tubular glands have disappeared, and those which remain are very short, and in course of obliteration by a process of gradual widening out and withdrawal of their epithelium, until it becomes part of the lining of the lumen. The muscularis mucosæ is thick, and the remains of the lymph follicles are curiously loose in structure, with dilated lymph paths.

A few dense patches of nucleated cells are seen in the

follicles, and are similar to those which plug the lymphatics. Where the lining epithelium is detached, the lymph canalicular system of the mucosa and of the follicles is in direct communication with the lumen, which contains epithelium, mucus, and nuclei, but no bacteria.

The inflamed omentum is exceedingly vascular, with some cell infiltration and fibrin, and proliferation of endothelium. No bacteria can be identified in any part of it. There are no signs of tubercle or of tubercle bacilli.

Judging from the clinical symptoms of the last attack, and from the inflammation of the omentum and peritoneum, the appendicular inflammation must have been of rather a severe character, involving the whole appendix. Indeed, the part beyond the constriction does not seem to have suffered more than the rest, except that its mucosa is thinned by the pressure of its mucous contents.

And this brings us to the origin of the constriction and to the cause of the appendicitis. The dates of the different events are as follow:—November 8, the first attack; December 9, the second; January 4, second attack had quite subsided; January 15, appendix excised. Now it is difficult to conceive that the constriction formed betwixt November 8 and January 15; it must have existed before the first attack. Nevertheless, if inflammatory in origin, the clinical symptoms of inflammation seem to have been absent, unless we are to attach importance to the diarrhoea and to the attack of abdominal pain two years before. Ought we not to suppose that the constriction was congenital, and that it merely rendered the distal part more liable to distension when inflamed?

Next, the cause of the inflammation is quite obscure. No bacteria could be discovered. Had any been present during the attacks, they could not have escaped from the dilated distal lumen. Whatever the cause of the appendicitis may have been, it is clear that it left its mark upon the lymphoid follicles and lymphatics of the whole appendix.

The inflammation of the omentum is also somewhat mysterious. In infective appendicitis, it is easy to follow the passage of bacteria from the appendicular wall into the contiguous omentum. But in this case the mere presence of

bacteria is doubtful, and proofs of their activity are wanting. Neither in this nor in any other of my specimens is there anything which confirms an assertion made by Mr. Treves¹ that "these cysts are apt to perforate and burst. . . . If the patient recovers the perforation heals," etc.

No two cases of appendicitis are alike in clinical history, morbid anatomy, or morbid histology. In the following, the appendix was about 8 cm. long, had a complete mesentery, and was constricted at 3 cm. and 5 cm. from the cæcum. The part between the two constrictions was dilated in an oval cyst about 2 cm. long and 1 cm. in diameter.

CASE 25.—*Appendicitis, with Stenosis, Obliteration of the Lumen, and Cystic Dilatation.*—The patient was a young lady, aged twenty-four. She probably had had the first attack of appendicitis four years before, but it was not diagnosed as such. The abdominal pain was very violent, but not localised. The second attack occurred six months before the operation. The pain was general and violent, and accompanied with much vomiting, and some obstruction and abdominal distension. The temperature rose to 103° F.; the pulse was rapid. This attack lasted six weeks, and, six months afterwards, I found that the iliac fossa was still very tender, with rigidity of the muscles. She was anæmic, with poor digestion and inability to partake of many articles of diet.

As the attacks had been so violent, the question of inflammatory adhesions was mooted by those in attendance, but none were found at the operation. The appendix was removed in the usual way, and the patient made an uninterrupted recovery, the pulse never having risen above 80. She is now relieved of all her symptoms.

The proximal end of the appendix is 4 mm. in diameter, and the peritoneal and muscular coats are of normal thickness and slightly inflamed. The lumen and mucosa have disappeared, their position being occupied by a core of cedematous connective tissue, containing many blood-vessels and groups of inflammatory corpuscles.

The mucosa of the cystic portion of the appendix is inflamed and thinned by compression (Fig. 27). It is .5 mm.

¹ *Perityphlitis*, p. 13.

thick, and its tubular glands not much more than .25 mm. long. Some are dilated. Their epithelial lining and that of the lumen are intact. The lymphoid follicles are compressed until they have become thin crescents. Their outlines are obscured by inflammatory cells, and their lymph sinuses either obliterated or greatly narrowed.

The cyst contains the remains of some mucus, granules, nucleated cells, and blood corpuscles, but no bacteria.

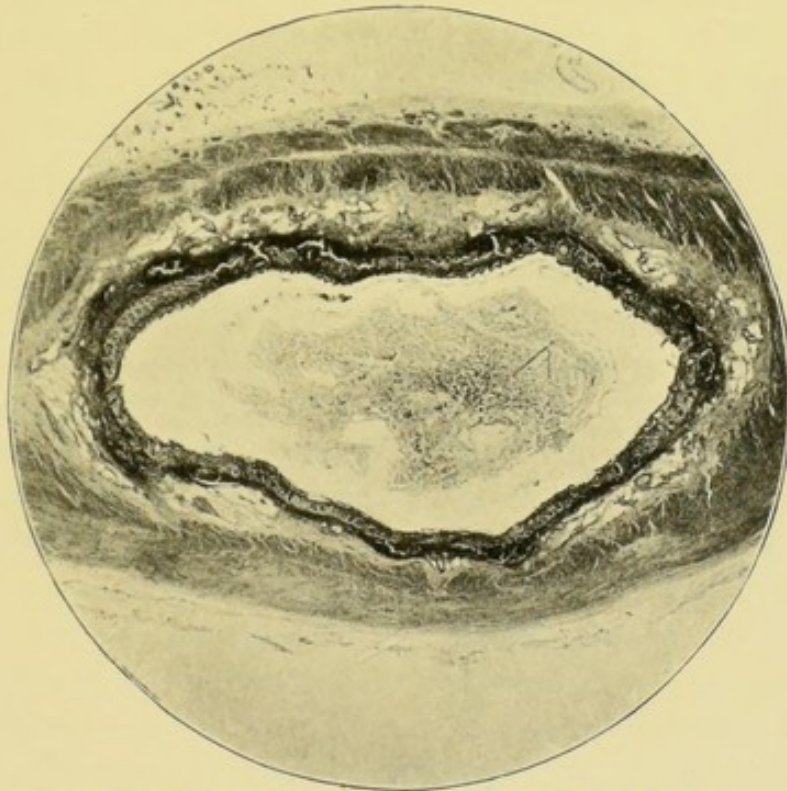


FIG. 27.—A longitudinal section through a cystic dilatation of the appendix, to show a complete mucous lining.¹ $\times 8$. Compare with Fig. 41.

The cyst walls are 2 mm. thick, and comprise all the coats of the appendix. The peritoneal and muscular coats are inflamed, the submucosa inflamed and cedematous, with some dilated lymphatics, dilated blood-vessels, and inflammatory cells.

It seems hardly worth while to speculate upon the con-

¹ Although it is difficult to get a good microphotograph of a cyst, I give this one for what it is worth. It demonstrates the mucous lining and also the cedema of the submucosa. The destruction of the mucous lining of a cyst is shown in Fig. 41, Case 46. Some very dogmatic statements have been made as to the absence of the mucous lining of these cysts.

dition of this appendix during the height of the attack, or upon the nature of its contents. The obliteration of the lumen and the formation of the strictures were gradual but continuous processes.

In stenosis of the appendix, several drachms of mucus may accumulate beyond the stricture. I believe it will ultimately be determined that a mucocele cannot develop unless the epithelium persists.

CASE 26.—*Appendicitis with Stenosis—Mucous Cyst of the Appendix.*—A mucous cyst of the appendix was met with in the case of a gentleman, aged thirty-eight years. It is probable that all the attacks of abdominal pain and inflammation from which he suffered were caused by appendicitis, although that disease was not actually diagnosed until the penultimate attack. It was only then that the pain localised itself in the right iliac fossa; previously, it had been general throughout the abdomen.

The first attack of abdominal pain occurred at the age of thirteen, after a hearty meal of pork. The illness kept him in bed for about three months, and his life was despaired of. A second, followed an accident at the age of twenty-six, and lasted three weeks. Afterwards, he was laid up for a few days at a time with minor attacks. Latterly the attacks of pain had become more frequent, sometimes accompanied with diarrhoea, sometimes with constipation, and abdominal distension. During the last illness the temperature was not raised.

For three months, a lump had been felt in the right iliac fossa. Although the abdominal wall was rather fat, an ovoid tumour about 3 inches long and 2 inches wide was felt in the right iliac fossa, an inch above and parallel to the outer half of Poupart's ligament. Its outlines were distinct, and it was slightly movable. When exposed, by an oblique incision, it looked like a dermoid cyst, lying beneath the cæcum, and apparently lifting up the iliac peritoneum. Its walls were exceedingly thin, and, when they burst, a quantity of opaque, yellowish-white, stringy substance bulged out. My colleague, Dr. Morley Fletcher, in speaking of another case, aptly compared this substance to the vitreous humour of the eye. That

simile gives a good idea of its consistence, but not of its appearance. When about two ounces of this had been dragged away, the cyst was with difficulty dissected from the cæcum and iliac fascia. During this dissection, an inch of the distal end of the appendix was found upon the lower part of the cyst; the upper end of the cyst was joined to the cæcum by a narrow neck. When this was divided, a gap remained in the cæcal wall, which required two or three points of suture for its closure. The patient made a rapid recovery, and is now quite well.

The histological conditions are as follow. The piece of appendix may be first described. Its peritoneal coat is without endothelium. The subperitoneal tissue is twice the usual thickness, and contains groups of inflammatory cells, dilated blood-vessels, and extravasated blood. Some of the corpuscles are beginning to disintegrate. The longitudinal muscular coat is absent in some parts, and, in others, is represented by scattered fibres. The circular muscular coat is thicker than usual, owing to the presence of inflammatory cells and of a delicate fibrillar tissue between its fibres. The submucosa occupies the centre of the appendix, the mucosa and the lumen being absent. The connective tissue of the submucosa is loose and full of spaces, some of which contain a pellucid, granular substance, which stains faintly and contains large, oval nuclei. The submucosa looks as if it were in a condition of myxœdema. The blood-vessels of the submucosa are numerous and of large size.

The cyst wall is 2 mm. thick. In section, it looks very like a piece of a large artery. Its inner edge is crenated, owing, no doubt, to relaxation after the escape of the mucoid contents. The endothelial covering is absent, but the subperitoneal is rather thick and vascular, and contains extravasated blood. The outer and inner muscular coats are of the usual thickness. Their fibres are swollen and separated by nucleated cells, delicate fibrillar tissue, and empty spaces. The submucosa is half the usual thickness, and looks as if it had been compressed against the circular muscular coat. It contains thin-walled blood-vessels, delicate connective tissue with a loose meshwork, and much extravasated blood. The

part of the submucosa next the cyst cavity is a layer of condensed fibrils. This layer is .02 mm. thick and with hardly any nuclei in it. Its free surface is wavy, and has a basement membrane with the remains of an epithelial lining of ill-formed columnar epithelial cells, actively proliferating and separating.

The mucous contents were inoculated into culture media, but nothing grew. Although some of them were smeared over the wound during the operation, healing proceeded by first intention, and the pulse and temperature were merely raised for a few hours during reaction. Had the contents not been sterile, it is unlikely that the course would have been so satisfactory.

It is quite clear that the cyst was a dilated part of the appendix. Doubtless the mucosa gave origin to the contents of ropy mucus. The hæmorrhage into the remains of the mucosa and into the submucosa is noteworthy. The commencing disintegration of the red corpuscles shows that it was not caused by the operation. I should say that it was a fortnight old, and coincident with the last attack of pain.

The question arises whether our present knowledge would enable us to diagnose a mucoid cyst of the appendix. Dr. Patterson, of Ascot, who saw the later attacks, considered that they were not ordinary attacks of appendicitis. There was less disturbance of the temperature, of the pulse, and of the bowels. The tumour had the characters of a simple cyst, being ovoid, regular in outline, movable, and painless.

I have said that this mucous cyst seemed to lie beneath the iliac peritoneum. The effects of inflammation are so deceptive, that this surmise may be incorrect; but, on the other hand, we have to remember that the appendix may have been herniated into the sub-cæcal or ileo-cæcal pouch.¹

My friend, Dr. Morley Fletcher, has generously given me a microscopical specimen, which shows the structure and epithelial lining of these mucous cysts of the appendix.

CASE 27.—*Appendicitis with Stenosis—Mucous Cyst of*

¹ Mr. Treves has written, "In no case have any adhesions been found associated with these cysts" (*Perityphlitis*, p. 12). But in this instance many were present, and also in another, upon which I have since operated.

Appendix, showing Epithelial Lining and Formation of Mucous Contents.—The clinical history of the case is unknown, because the specimen was met with accidentally during the course of a *post-mortem* examination. The subject was a woman, æt. thirty-nine, whose history was unknown, and who died of chronic heart disease and hydrothorax. The appendicular cyst was free in the abdomen without any trace of perityphlitis.

The cyst is pyriform, and about 6 cm. long and 3 cm. wide in its most dilated part. It was attached to the cæcum

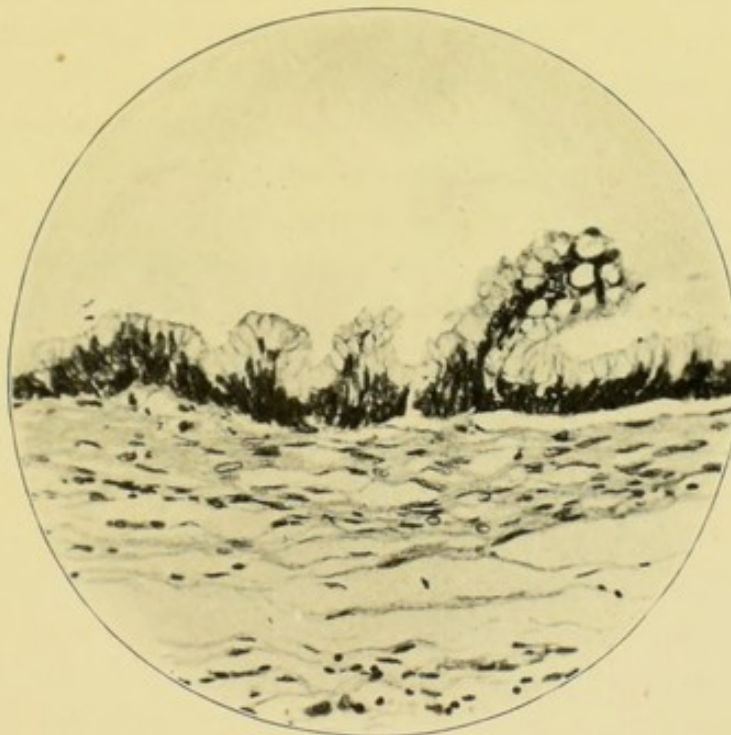


FIG. 28.—Inner part of wall of mucocele. $\times 200$. The lumen is above.

by a short impervious stalk. It was distended with thick mucus, which Dr. Fletcher described as looking exactly like the vitreous humour of the eye.

In the microscopical section, the cyst wall is 1 mm. thick. In structure, it closely resembles the last specimen, and need not therefore be described at length. The endothelial layer of the peritoneum is absent. The subperitoneal tissue is rather abundant, and consists of fine loose areolar tissue and a few small blood-vessels. Next to the outer muscular coat, is a thin layer of fibres running circularly in the direction of the fibres of the inner muscular coat. The outer and inner

muscular coats are exceedingly thin and undergoing fibrous degeneration. The outer is barely .2 mm. thick, and consists of a meshwork of granular substance with irregular nuclei scattered in the fibres. The inner muscular coat is about .25 mm. thick. Its muscular fibres and nuclei are but little altered. Towards the submucosa the fibres are more scattered. The submucosa is represented by a little areolar tissue, which is condensed into a thin layer of fibres to support a row of columnar epithelial cells. The latter are undergoing nuclear division and conversion into goblet cells. In places, the nuclei have multiplied and accumulated until they form a projection budding into the interior of the cyst (Fig. 28). This layer of columnar cells is very loosely attached to its basement membrane. The tubular glands, lymphoid tissue, and lymphoid follicles of the mucosa are all wanting.

In specimens stained by Weigert's method, the subperitoneal tissue contained numbers of bacteria of variable size and shape; small oval bacilli, singly, in pairs, and short chains; short, thick, almost round bacilli, often in pairs; and large, elongated bacilli, about twice the size of tubercle bacilli.

As these bacteria were only in the subperitoneal coat, and were unaccompanied by the usual morbid changes, and as the specimen was a *post-mortem* one, we may, I think, assume that the bacteria were of intestinal origin.

Specimens were stained for tubercle, but the result was negative.

In the following case, the appendix was stenosed close to the cæcum, and pus had accumulated beyond the constriction. In addition, the diseased appendix was hidden away in the ileo-cæcal fossa. The mouth of the fossa was sealed up and almost imperceptible, and it was only discovered after a prolonged and anxious search.

CASE 28.—*Appendicitis with Stenosis, Empyema, and Retroperitoneal Hernia.*—I first saw the patient, a schoolboy^{*} aged fourteen years, with Dr. Hope Murray. He was then in the midst of a rather severe attack of appendicitis. He had a very tender spot at the seat of the appendix, constipation, vomiting, and slight abdominal distension, with raised temperature and accelerated pulse. He had suffered from three

previous attacks of moderate severity. An anæsthetic was given by Dr. Bolus, and, with the assistance of Dr. Murray, the appendix was looked for through the usual oblique incision. As adhesions were absent, the usual localities were easily searched. The appendix could not be discovered at the ileo-cæcal angle, beneath the cæcum, or in the pelvis. Something hard was felt along the inner edge of the right colon. The wound was extended a little, and some enlarged and calcareous lymphatic glands brought into view. The anterior longitudinal muscular band of the cæcum afforded some assistance in the search for the appendix, but not much. Some years before I had given attention to retroperitoneal hernia of the vermiform appendix.¹ I had also, in conjunction with my friend, Dr. Rolleston, investigated the anatomy and positions of the vermiform appendix,² with the result that I am convinced that the vermiform appendix is never absent, except as the result of disease. I have also learnt that it is not infrequently hidden away in either the ileo-cæcal or sub-cæcal fossa; and that the mouth of the fossa may become occluded and be most difficult to find. Being unable, therefore, to discover the vermiform appendix in any of its usual situations, I began to seek for it in the ileo-cæcal and sub-cæcal fossæ. When the cæcum was raised, the peritoneum beneath looked perfectly smooth and without a trace of any fossa. A swelling of the most doubtful nature was felt beneath the commencement of the right colon. At length, a delicate streak was observed running across the peritoneum of the iliac fossa, close to the attachment of the ascending colon. A little pulling apart with dissecting forceps showed that this was the mouth of the fossa, within which the appendix lay concealed, and from which it easily turned out. It was distended with thin odourless pus into an oviform swelling, which measured about 6 cm. ($2\frac{1}{2}$ inches) in its longest diameter, and was continuous with the cæcum by a

¹ *Hunterian Lectures on Hernia*, by C. B. Lockwood, London, 1889, p. 83, *et seq.* Also, "Retroperitoneal Hernia of the Vermiform Appendix," by C. B. Lockwood, *Trans. Path. Soc.*, London, vol. xli., 1890, p. 118.

² "On the Fossæ round the Cæcum, and the Position of the Vermiform Appendix, with Special Reference to Retroperitoneal Hernia," by C. B. Lockwood and H. D. Rolleston, *Journal of Anatomy and Physiology*, vol. xxvi.

narrow stalk. The outer part of the wound suppurated very slightly, owing, we thought, to the escape of pus at the operation. The right leg also swelled for a time. These complications, however, soon subsided, and the patient got perfectly well.

For histological examination, sections were cut through the commencement of the cyst near the stalk which united it to the cæcum. The coats are 2 mm. thick, and nearly half their thickness consists of a ring of lymphoid tissue which surrounds the lumen. The peritoneal coat is rough and very vascular. The muscular coats are thin, especially the external. The submucosa is likewise thin (about .1 mm.) and its fibres close together. The mucosa is a thick ring of inflamed lymphoid tissue, in the midst of which are many follicles; I counted fourteen in one section. Some of these follicles have a basilar lymph path of unusual size, but most have none. Presumably it has become obliterated by pressure. The epithelial lining of the lumen, together with its basement membrane, has disappeared throughout about half the circumference. Some of the epithelium which still remains has become cubical, possibly another effect of pressure.

The tubular glands have almost disappeared, each section containing but a small fragment of one or two. These are not dilated and contain no mucous cells.

The lumen contains pus cells, detached epithelium, granules, and mucus, but no bacteria could be seen. I regret no cultures were taken at the operation.

I cannot help thinking that this case affords a clue to others in which the surgeon has failed to find the vermiform appendix. It also awakens an interesting train of thought as to the course the suppuration would have pursued had the appendix burst.

This case and another (Case 33, p. 125) are a commentary upon a statement made by Mr. Treves¹ that the fossæ around the cæcum possess little or no pathological importance.

The calcification of lymphatic glands suggested that, at the outset, this case might have been tuberculous. No trace of caseation, of giant cells, or of tubercle bacilli could be discovered.

¹ *Perityphlitis*, p. 4.

CASE 29.—*Appendicitis—Empyema of Appendix.*—An empyema of the appendix was met with in the case of a young woman, who was twenty-three years of age, and highly neurotic, and reported by the physician who sent her to me to be suffering from “functional hemiplegia.”

She had recently had an attack of pain in the lower part of the abdomen and right iliac fossa, which had been diagnosed as having been caused by appendicitis. When asked to point to the seat of pain, she at once indicated the region of the appendix. At that spot no tumour could be felt, but deep pressure there made her wince.

The whole course of the colon was painful, and the sigmoid flexure felt thick, hard, and tender. The bowels were constipated, and some mucus passed with the motions. The question arose—(1) as to whether she actually had appendicitis; and (2) whether appendicitis was the cause of the condition of the colon, or its effect.

As she was very consistent in always referring the pain to the right iliac fossa, I thought it right to explore. The appendix was dilated into a pyriform cyst about 2·5 cm. long and 1·5 cm. in diameter, and attached to the cæcum by a short and narrow stalk. It had a meso-appendix attaching it to the cæcum and ileum. It was removed in the usual way, and the patient made an uneventful recovery.

The specimen is cut longitudinally. The stalk is solid, and consists of peritoneal and muscular coats, and a central core of fibrous tissue. Its diameter is 3·5 mm.

The cyst is ovoid and, after hardening, measures 2 cm. × 1 cm. Its proximal end joins the stalk; the distal has the tip of the appendix upon it, and consists of peritoneum, muscular coats, submucous tissue, and some lymphoid follicles, with their lymphatics.

The walls of the cyst vary in thickness from ·5 mm. to 2 mm. The peritoneal coat is present throughout. Its surface is smooth and covered with endothelium, except in one or two places where some vascular lymph lies upon it. The subperitoneal tissue contains many thin-walled vessels full of blood.

Where the walls of the cyst are thinnest, the muscular coats are only four or five cells thick; the submucosa is absent; and the mucosa represented by a very thin layer of inflamed lymphoid tissue and some pus cells. All the epithelial structures have vanished. In the thick parts of the cyst, the peritoneal and muscular coats are of the ordinary thickness; the submucosa is very thin; the mucosa consists of a thin layer of inflamed lymphoid tissue and a few whole lymphoid follicles with the remains of others. Many of the follicular lymph sinuses have disappeared, but some are present though narrow. There is no trace of the tubular glands or of the epithelial lining of the lumen. Amidst the inflammatory cells of the mucosa are some multinuclear cells, such as are met with in tubercle, but caseation and tubercle bacilli are absent. A case of empyema of the appendix, caused by tubercle, is described hereafter.

The lumen contains pus cells, crystalloid bodies, fibres, and nuclei, but no bacteria.

The course of appendicitis with stenosis must depend, to some extent, upon the nature of the contents of the lumen. That these may be of the most dangerous character is shown by the following cases.

CASE 30.—*Appendicitis with Stenosis—The Bacterial Contents of the Appendix beyond the Constriction.*—Miss X., aged thirty-four, was robust and usually enjoyed good health. My friend, Dr. Lewis Jones, treated her at the age of twenty-three for an attack of perityphlitis. She had tenderness, pain, and resistance in the right iliac fossa, and the temperature rose to 102° F. She also had headache, vomiting, and diarrhoea. Similar attacks occurred in May, 1894, May, 1898, and August, 1898. I saw her with my colleague, Dr. F. W. Andrewes, between the last two attacks when the region of the appendix was still tender.

I removed the appendix through a small incision. It was not adherent, was about 10 cm. (4 in.) long, and constricted 2 cm. from the cæcum. In sections through the constriction, the lumen is not much bigger than one of the tubular glands (see Fig. 29). Two or three of the latter are seen by the side of the lumen, which is surrounded by the remains

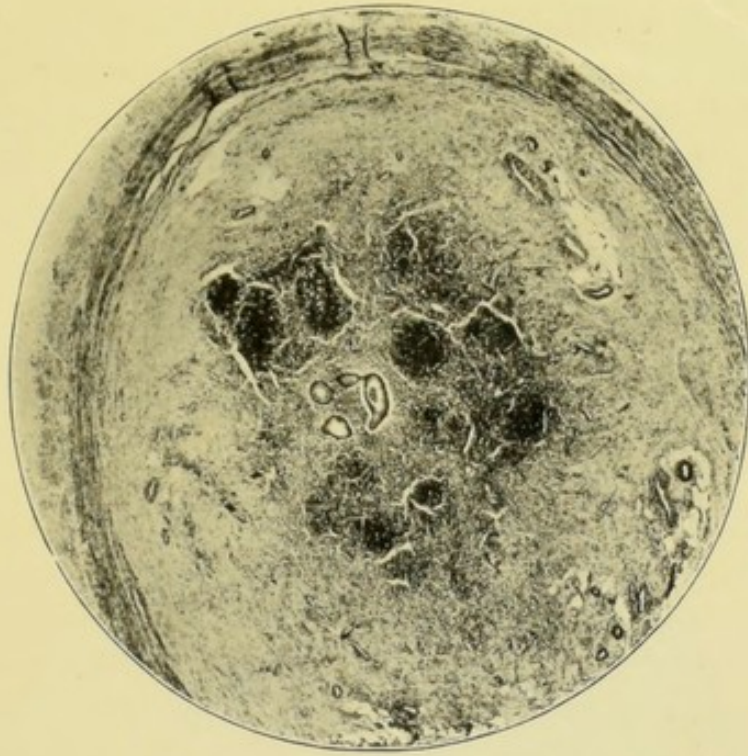

FIG. 29.—Inflammatory stenosis of vermiform appendix. A minute canal with an epithelial lining is seen near the centre. The others are probably glands. $\times 20$.

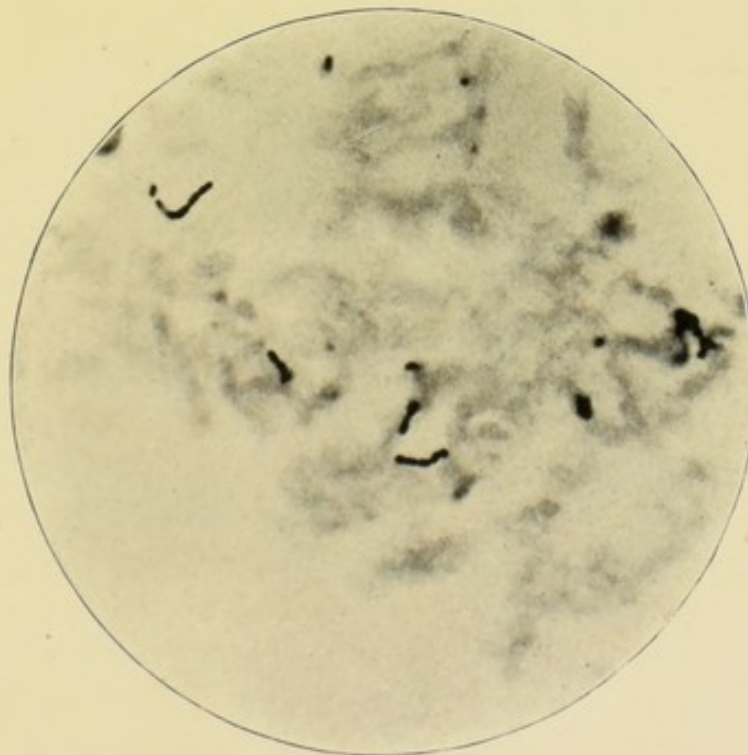


FIG. 30.—Streptococci in lumen of appendix beyond stenosis. $\times 1000$.

of lymphoid follicles, and a quantity of inflammatory exudation in the submucosa.

Beyond the stricture, the lumen is dilated and measures about 8 mm. across. It is full of muco-purulent fluid which contains a luxuriant growth of streptococci in almost pure culture (Fig. 30); and occasional bacilli are to be seen. I have not met with such numbers of cocci, except in the walls of pyæmic abscesses,¹ or in artificial cultures. The coats of the part of the appendix which held this fluid, were all inflamed

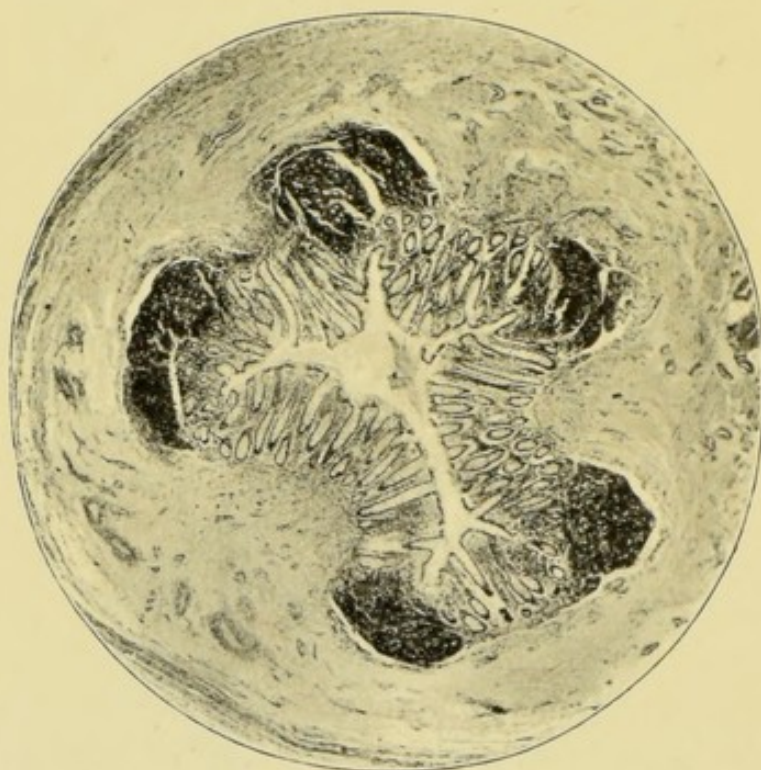


FIG. 31.—The appendix beyond the constriction shown in Fig. 29. The epithelial lining is almost perfect. $\times 20$.

with dilated follicular lymph paths and dilated lymphatics in the submucosa; but the epithelium, lining the lumen and tubular glands, was almost perfect, and merely had an abundance of goblet cells (see Fig. 31).

One cannot but wonder how long streptococci had inhabited this appendix, and what might have happened had the mucosa been ulcerated. The pathology of erysipelas teaches us that streptococci invade the lymphatic system, but none

¹ See *Lectures on Traumatic Infection*, Fig. 20, p. 92.

could be found in these dilated lymph paths or lymphatics. Their absence may have been owing to the fact that the specimen was obtained during a period of quiescence. That the dangers of such an invasion are not imaginary is demonstrated by the following.

CASE 31.—*Appendicitis with Stenosis (Streptococcic Appendicitis)—Ulceration of Mucosa—Bacterial Invasion and Portal Pyæmia.*—The patient, aged thirty-six years, was sent to me by Mr. M. B. J. Anderson, who considered him to be suffering from recurrent appendicitis. In the spring of 1897, he had a slight attack of pain in the right iliac fossa. This did not prevent him from going to his work, and, the same evening, he got relief after an attack of vomiting. In the autumn of 1897, he had a similar attack, but was well in a day or two. In June 1898, a third attack laid him up in bed for three days. Fourth and fifth attacks of a trivial sort took place in September and October, 1898. The sixth was, however, very severe, and had just subsided when I saw him on May 20, 1899. It was attended with vomiting, constipation, abdominal distension, and increase of temperature. The pain was severe over the front of the abdomen, and beneath the right costal margin. A few days after the subsidence of this attack, I could not find pain at the usual site of the vermiform appendix; but the abdominal wall was rigid, with pain on deep pressure, at a spot situated underneath the middle of the right rectus abdominis muscle, and about an inch below the level of the umbilicus.

The patient's wife expected to be confined in June, so I advised him to have the appendix removed after that event. With my then knowledge I thought there could be little danger in delay, especially as he had passed in safety through six attacks.

I lost sight of the patient until early in July, when Dr. Anderson wrote that he had had another attack, but that the pain was in a new place, and was most severe beneath the eighth costal cartilage of the right side, and that the area of liver dulness was increased. He had had several rigors. Since June 19, his temperature had ranged betwixt 98° F. and 102·2° F. Latterly, it had always been above 100° F. The pulse had

varied betwixt 80 and 108. He was admitted into St. Bartholomew's Hospital, and was obviously very ill. The appendicular region was devoid of pain and rigidity. Hard pressure along the right linea semilunaris caused pain, an inch above the level of the umbilicus. He himself located his pain beneath the eighth costal cartilage of the right side. The edge of the liver was felt in front, and the right side of the chest was absolutely dull as high as the ninth rib. An exploring needle was thrust into the liver, in several places, through the midst of the dull area. The lowest puncture drew off a little fluid which had the appearance of thick pus, and was pronounced to be such by the pathological department. On July 15, I resected part of the tenth rib, and, after sewing the costal pleura to the diaphragm, made an incision into the liver. I failed to find the abscess, although the liver was explored in all directions. This operation was followed by a fall in the temperature and pulse; but soon they both returned to their former high level, and he became steadily worse. A dose of tuberculin was given, in case we were mistaken, and had to do with a case of acute tuberculosis, but it was followed by no reaction.

On July 30, I explored the liver by means of an incision through the upper part of the right rectus. The liver was enlarged, but I could neither see nor feel an abscess in any part of it. Several hard lumps could be felt along the inner side of the right colon. A second incision was made, an inch and a half above and parallel to the outer half of Poupart's ligament. The lumps which had been felt, proved to be enlarged and inflamed lymphatic glands situated in the lower end of the mesentery and beneath the ascending mesocolon. Doubtless, their presence explained the pain which had been felt on deep pressure along the right linea semilunaris. The appendix was very hard to find. At last, it was found bound down by tough and vascular adhesions to the peritoneum of the iliac fossa. It sprang from the outer side of the cæcum, and was constricted close to its base. It was removed in the usual manner and the wounds closed.

This operation was rapidly performed, and on the following day he seemed rather better, with a lower temperature. As

I was leaving home my friend and colleague, Mr. Bruce Clarke, took charge of the case. The patient became worse with continuously high temperature. Mr. Bruce Clarke reopened the upper wound and again explored the liver. A soft spot was discovered, and an abscess full of odourless pus opened and drained. The shock of this was more than could be borne, and death ensued in five or six hours. Unfortunately, the pus from the abscess was not examined.

At the *post-mortem* examination other small abscesses were found in the liver. No evidence of pylephlebitis was

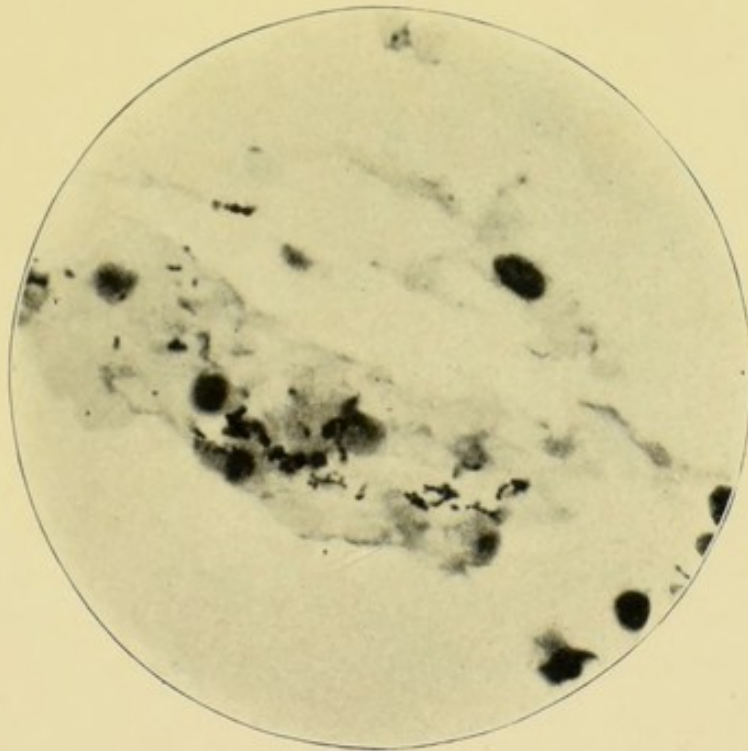


FIG. 32.—Streptococci in lymph on peritoneum of appendix. Note that streptococci out of focus look like bacilli. $\times 1000$.

discovered. There was slight localised peritonitis in the right iliac fossa.

The histological specimens made from the proximal and distal ends of the appendix are almost alike. To the naked eye the sections of the appendix look unaltered; its coats are of the usual thickness, and its lumen of the usual size and shape. Most of the peritoneum has been torn off, but that which remains is very vascular, and engorged with blood. Its surface is covered with lymph, which is crowded with cocci,

diplococci, and streptococci. The chains consist of from three to eight cocci. Small clumps of cocci, probably entangled chains, are also present. The cocci vary in size from $\cdot 5 \mu$ to $\cdot 75 \mu$ (Fig. 32). The lymph contains no bacilli.

The outer muscular coat is thin and irregular, the inner of the usual thickness, but œdematous and penetrated at the meso-appendix by many blood-vessels. In some sections, a wide hiatus muscularis is seen.

The submucous coat is vascular and œdematous, but with no cell infiltration; its lymphatics are larger than usual. At the hiatus muscularis, it is continuous with the subperitoneal tissue.

Eight lymphoid follicles can be counted in one section. Some are small, but most have dilated basilar lymph spaces. The lymphoid tissue of some of the follicles is broken up by enlarged lymph channels. I can discover no other signs of lymphangitis.

The muscularis mucosæ is well marked, and separates most of the lymphoid follicles from the tubular glands. The tubular glands are slightly dilated, and contain an excess of mucous cells. The epithelial lining of the lumen is detached. Where this is the result of disease, the basement membrane, tubular glands, and lymphoid tissue are destroyed by ulceration.

The lumen is almost full of a mixture of granules, nuclei, and epithelial cells, and these are mingled with numbers of cocci, diplococci, and streptococci. The chains usually consist of from five to eight cocci, and some of them are entangled into clumps (Fig. 33).

These bacteria are not actually seen in the substance of the appendicular walls, although diplococci lie just within the lymphoid tissue, at the place where the surface epithelium and its basement membrane are gone.

A small piece of the meso-appendix is cut in the section. Its surface has a little lymph upon it, and this contains cocci. Its vessels are engorged with blood, and some of its interstices are filled with old blood extravasation. A small vein contains a clot of some age, and its endothelial lining is actively proliferating. This clot probably has streptococci in it. I speak with reserve, because mistakes are easily made when the bacteria are few.

No traces of tubercle or of tubercle bacilli are to be found.

It is unnecessary to comment at length upon this case. The presence of streptococci accounts for the appendicitis and the inflamed mesenteric glands. The phlebitis of the small vein in the meso-appendix, shows the way by which the liver became infected.

The cessation of the pain in the appendix is very remarkable. I can recall another case in which a similar absence of pain occurred.

CASE 32.—*Appendicitis—Peri-appendicular Abscess*—

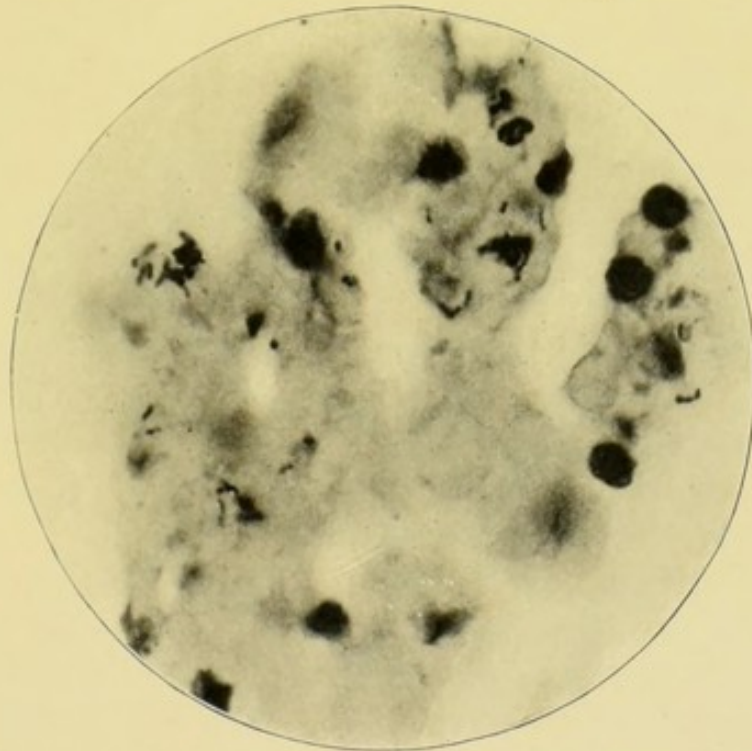


FIG. 33.—Streptococci in contents of the lumen of the vermiform appendix. $\times 1000$.

Portal Pyæmia — Subdiaphragmatic Abscess.— In February, 1896, I was requested by my colleague, Dr. Gee, to open a hepatic abscess. The patient was a young man, and some pus and bile had been obtained by aspirating through the eighth intercostal space behind. His condition was very critical, with a continuously high temperature. There was nothing that pointed to the cause of the abscess. I made an incision parallel to the lower margin of the twelfth rib, and managed to open the abscess by pushing a drainage tube along the back of the right lobe of the liver. The abscess

was full of foetid pus. A large drain was inserted, and the abscess washed out with biniodide of mercury lotion 1 in 1000—the general peritoneal cavity having been shut off with gauze packing. The patient improved for a time, but died of septicæmia on March 1, the fourth day after the operation. At the *post-mortem* examination the large abscess in the liver was found to have been efficiently drained. The liver contained, in addition, a number of small abscesses. There was no general peritonitis, but the vermiform appendix was inflamed and surrounded by an abscess. The note states that it had tracked up behind the peritoneum towards the liver. It seems sufficiently obvious, however, that the multiple hepatic abscesses did not arise by a direct extension of the suppuration.

Before operating I examined the abdomen. Pain and rigidity were absent throughout. I believe that I am right in saying that no one suspected the presence of the appendicular abscess.

The bacteria of the pus of the abscess were not investigated, but its highly foetid character was clear evidence of the presence of intestinal bacteria.

Appendicitis is a frequent and oftentimes unsuspected cause of abscess in or about the liver.¹

The subphrenic abscess may have originated in the usual way, by the extension of pus up behind the kidney and liver to the subphrenium.² But I think that, like the others in the substance of the liver, it was much more likely to have been caused by the portal pyæmia. In operating I certainly found no evidence of the tracking of pus behind the kidney; nor was any discovered at the examination.

The following illustrates the clinical history of stenosis of the appendix, and the specimen shows what is probably the most usual course of events in the part of the appendix beyond the stricture. Although the morbid changes are of the most marked character, the appendix looked almost

¹ Maydl, in his classical monograph, *Über subphrenische Abscess*, Wien, 1894, has collected a number of instances, p. 141, *et seq.*

² Carl Beck, "Subphrenic Abscess," *Medical Record*, N.Y., February 15, 1896, vol. xlix., No. 7, p. 215.

normal to the naked eye. It felt, however, very hard and incompressible.

CASE 33.—*Appendicitis with Stenosis and Bacterial Accumulation beyond the Narrowing, with Ulceration and Bacterial Invasion of Appendicular Walls.*—The history of this case is curious. A gentleman, aged thirty-six, was operated upon for hæmorrhoids. During his convalescence, he had a clear, but not very severe, attack of appendicitis. The temperature and pulse rose, and he had pain and tenderness on pressure in the right iliac fossa, with constipation and nausea. The pain was of a dragging character. We shall see presently that his appendix was herniated into the ileo-cæcal fossa. He said that he had had similar attacks very frequently during the preceding six years. They were brought on by riding on horseback or by other exertion. He took laudanum to relieve the severe pain. The appendix rose from the inner side of the cæcum and ran downwards for about 2 cm., where it was bent at an acute angle to disappear into the ileo-cæcal fossa. About 5 cm. more of the appendix were pulled out of the fossa, where it had been coiled upon itself. The last 2 cm. of the appendix was as hard as indiarubber, and resumed its curve after it had been straightened out. The ileo-cæcal fossa was from 4 to 5 cm. deep, and would just admit the first two joints of the index finger. The signs of disease in this appendix were hardly visible to the naked eye. Until a microscopical examination had been made, it was thought that the appendicular attacks were due to the kinking of the appendix interfering mechanically with the discharge of its mucus into the cæcum. In other words, that the patient suffered from what Talamon calls appendicular colic. A glance, however, at the accompanying photograph of the distal end, reveals a state of things which not only explains the attack, but also shows that he was in a perilous condition.

The lumen is full of pus cells, epithelial cells, fragments of fecal material, crystalloid bodies, and masses of bacilli of various sizes (Fig. 35). The appendicular wall is inflamed and without trace of epithelial lining, or of tubular glands. But, in addition, the ulcerated wall of the appendix is penetrated by bacilli as far as the muscular coat.

The dilated lymph spaces of the submucous coats contain cocci, diplococci, and short chains of cocci. Although not seen in the microphotograph, some of the bacteria probably possess capsules. Some belong to the yeasts.

At the proximal end, near the acute bend, some of the microscopical appearances are rather puzzling. In the accompanying microphotograph (Fig. 34), it is almost impossible to say which of the twenty tubules represents the remains of the lumen of the appendix. On the whole, I should be inclined to choose the one with a tubular gland springing from its side. Presently, I shall have to refer to another case in which the same condition occurred.¹ The tubes are all lined with healthy epithelium, but the surrounding connective tissue is inflamed, and in process of conversion into fibrous tissue. The lymph paths, too, are dilated.

To my mind the singularity of this case consisted in (*a*) the mildness of the appendicular attacks, which Dr. Tooth, who saw the patient in consultation, considered too mild to justify an operation; (*b*) the hernia of the appendix into the ileo-cæcal fossa; (*c*) the curious stenosis near the cæcal end; (*d*) the bacterial contents; (*e*) the bacterial invasion of the appendicular walls; (*f*) the entire absence of naked-eye signs when the appendix was excised.

As a result of the operation, this patient has been cured of his attacks, although he suffers from occasional slight inconvenience of some sort. Unfortunately he is now in Australia, so that I cannot tell what this may be.

It is difficult to guess the exact sequence of events in this case. Probably the herniated appendix was more predisposed to inflame than a normal one, because of the difficulty it had in discharging its secretions. Then it became inflamed and stenosed, so that more mucus and bacteria accumulated in its interior. This caused further inflammation and ulceration, and the latter permitted the bacterial invasion. The patient was in imminent peril of perforation

¹ Appearances similar to this are frequently seen at the distal end of the lumen of the appendix. I have recently operated upon another case in which at least two-thirds of the inflamed and adherent appendix was within the ileo-cæcal fossa.

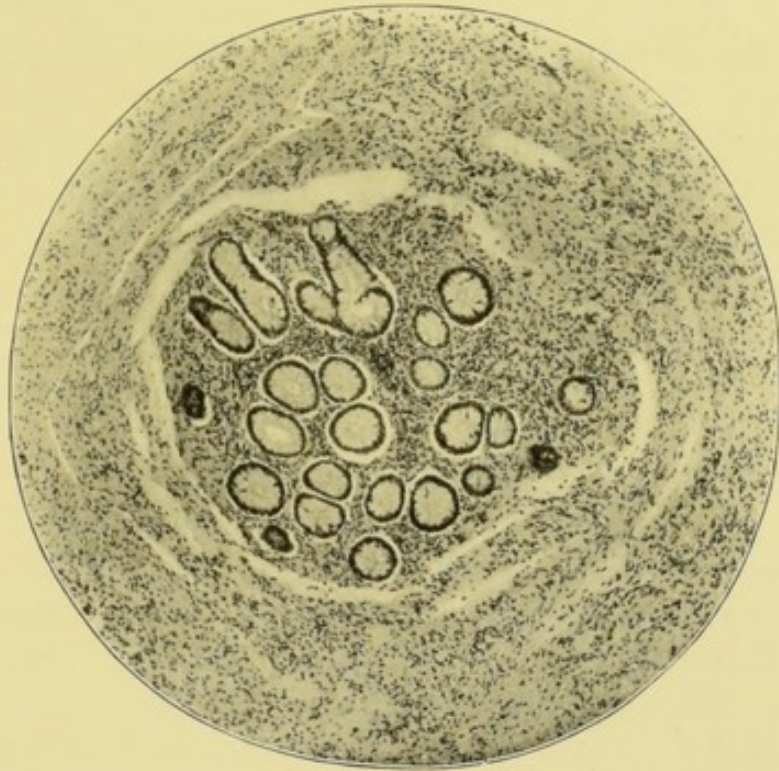

FIG. 34.—Stenosis of appendix. Peritubular inflammation. Dilatation of lymph spaces. This appendix was herniated into the ileo-colic fossa. $\times 65$.

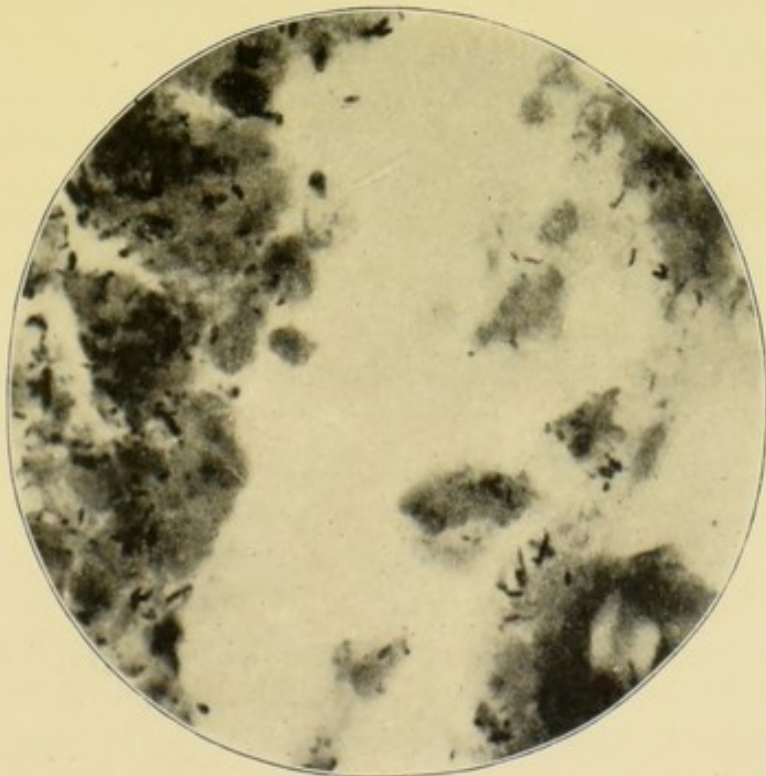


FIG. 35.—Distal end. To the right are the lumen and its contents, to the left the wall of the appendix, devoid of epithelium or glands, ulcerated and penetrated by bacteria. $\times 1000$.

or gangrene of the appendix. A case of acute strangulation of the appendix in the ileo-cæcal fossa has been briefly described by Mr. Heaton. The patient was a girl, æt. nine. She had had repeated acute attacks of appendicitis. The appendix was 5 inches long and only its distal end was caught in the fossa.¹

I shall now briefly give the notes of another case of stenosis of the appendix, and contrast it with the previous one. It helps, I think, to account for some of the clinical differences which are met with in recurrent appendicitis.

CASE 34.—*Appendicitis with Obliteration of Lumen—Recurrent Appendicitis after Interval of Fifteen Years.*—The patient was a widow, aged fifty-four years. She usually enjoyed good health, but latterly menstruation had become irregular. The first attack of appendicitis occurred when she was in her fortieth year. It was said to have been exceedingly severe. After an interval of fifteen years the second attack occurred.

Mr. Ethelbert Collins, who placed her under my care, said that she suffered from severe pain in the region of the appendix, accompanied by constipation, abdominal distension, vomiting, a high temperature, and accelerated pulse. The cause of the attack was unknown. When I saw her, two months after the commencement of this attack, the iliac fossa contained a tumour which was very tender and rather difficult to feel because of the rigidity of the abdominal walls. A month later the tumour was smaller and less tender. The appendix was removed through the usual small oblique incision. It was hidden beneath the cæcum, adhering very firmly to the cæcum, and to the peritoneum lining the iliac fossa. The patient made an uninterrupted recovery.

The appendix was about 6 cm. long and had no mesentery. It was continuous with the end of the cæcum by a slightly constricted neck. The first inch was about 1.2 cm. in diameter. The middle of the appendix was constricted, and adhered firmly to the cæcum, so that it was hard to separate. Beyond the constriction, the appendix was about 6 mm. in diameter, and felt very hard.

¹ *British Medical Journal*, vol. xi., 1898, p. 1618.

The proximal part of the appendix had no proper lumen, but, in its place, about a dozen tubular glands occupied the centre of the section. The appearances are almost exactly the same as in the photograph of another specimen (Fig. 34, p. 127). The tubules are imbedded in lymphoid tissue. It is impossible to say which, if any, of the tubules represents the real lumen. Although the patient was in her fifty-fifth year, a well-developed lymphoid follicle with its basilar lymph space is seen in the sections. The distal part of the appendix has no lumen, its centre being occupied by a little lymphoid tissue.

The peritoneal, muscular, and submucous coats contain much fibrous tissue, also inflammatory corpuscles in process of conversion into fibrous tissue. The peritoneal coat contains groups of newly formed inflammatory corpuscles. I could find no bacteria, nor any traces of tubercle.

When we contrast these two cases of stenosis of the appendix, it is clear why the first was accompanied with frequent attacks of appendicitis, and why the second had so few. In the first, the appendix beyond the stricture was ulcerated and crammed with bacteria. In the second, the appendix beyond the stricture had no lumen and no bacteria. It is probable that the obliteration occurred during the first attack. According to some, this obliteration "is one of the natural processes of cure in perityphlitis."¹ This assumption is unsupported by evidence, and is not borne out by the systematic microscopical examination of excised appendices. I could find nothing which threw any light upon the strange history of this case. The patient had had appendicitis at the age of thirty-nine, then fifteen years of health, and, at length, a severer attack when fifty-four.

In some cases of stenosis with ulceration, I have failed to find bacterial invasion of the ulcer, although the examination has been made soon after the subsidence of the acute symptoms.

CASE 35.—*Appendicitis with Stenosis and Ulceration of Mucosa, without Bacterial Invasion—Recurrence of Attacks after an Interval of Nine Years.*—The patient was a working man,

¹ Treves, *Perityphlitis*, etc., p. 11; also see Hawkins, p. 24.

aged thirty-eight years. In 1889, he was in Luke Ward, St. Bartholomew's Hospital, for nearly three weeks suffering from typhlitis. For the next nine years, he remained quite free from the complaint, but in 1898 and 1899 had five rather violent attacks. I saw him during the last. The abdomen was rigid and tender over the right iliac fossa, and a painful swelling could be felt just above the outer half of Poupart's ligament. The abdomen was slightly distended, and he suffered from constipation, vomiting, increase of temperature, and acceleration of the pulse.

The appendix was excised a week after the acute symptoms had subsided. It was very difficult to find and to dissect off the cæcum, which was rough, vascular, and inflamed. At this stage of the operation, a hole was made in the cæcum, and this had to be closed with Lembert's suture. The iliac fossa was drained with a large rubber tube. The patient made a complete recovery.

The appendix is circular and 7 mm. in diameter. It is characterised by the smallness of its lumen and the thickness of its coats. The lumen is 1 mm. to 1·5 mm. in its long axis, and ·5 mm. in its short. The coats are 3 mm. thick, nearly the whole increase being in the submucous and subperitoneal coats. The measurements are as follow:—Peritoneum, 1 mm.; muscular coats, ·5 mm. to 1 mm.; submucosa, 1 to 1·5 mm.; and the mucosa, ·5 mm.

The peritoneum has no endothelium, and the subperitoneal tissue contains quantities of developing fibrous tissue interlacing in all directions. Its lymph spaces and lymphatics are dilated, and its blood-vessels numerous and full of blood. As usual, some blood has been extravasated during the operation, but old disintegrating corpuscles are also present. The fibrous tissue and blood-vessels are penetrating the outer muscular coat, which, as usual, is irregular and partially absent. The circular muscular coat is broken by a large hiatus muscularis, where the subperitoneal and submucous coats are continuous. The circular muscular coat is vascular, with groups of inflammatory cells along the course of the blood-vessels.

The submucous coat is very œdematous and vascular. It contains a quantity of fibrous tissue, especially near the mucosa.

The mucosa is very fibrous, and contains but an occasional lymphoid follicle with a rudimentary sinus. The tubular glands are scanty in some sections and absent altogether in others; those which have survived are dilated and lined with cells discharging mucus.

The capillaries of the mucosa are dilated and full of blood. The epithelial lining of the lumen is absent for about one-third of its extent. In some places, the fluid contents of the lumen have infiltrated the dilated lymph canaliculi of the mucosa. The lumen contains a little mucus with nuclei, pus cells, and epithelium. It is doubtful whether either the fluid in the lumen or the tissues of the appendix contain any bacteria. Tubercle bacilli are also absent.

Thus the attacks were caused by an inflamed and stenosed appendix, in which some of the epithelial lining was destroyed, with purulent infiltration of the mucosa. The infiltration, however, was very slight, and bacteria were absent. Are we to assume that although the point of infection in the appendix was so slight, it nevertheless sufficed to cause a widespread and severe inflammation of the peritoneum? or are we to assume the absorption of some kind of toxin by the exposed lymphatic system?

CASE 36.—*Appendicitis with Stenosis, Superficial Ulceration of Mucosa, without Bacterial Invasion.*—At the age of twelve years, a schoolboy suffered from jaundice. A year later, he had the first attack of appendicitis, accompanied with pain and swelling in the right iliac fossa, constipation, vomiting, a rise of temperature, and acceleration of the pulse. He was in bed a fortnight. I saw him after this attack had subsided, and advised delay to see whether he would recover.

After two more attacks (æet. 15 years) the appendix was removed through a small oblique incision ten days after the subsidence of the last attack. Recovery was rapid and complete. He said he was quite well between the attacks, could eat fruit and vegetables, and play football and other games.

The appendix lay coiled away beneath the cæcum, to which it was adherent. Its length was probably 12 cm. A meso-appendix about 5 cm. wide attached the first 8 cm. to the

cæcum and mesentery. The appendix was constricted at the end of the meso-appendix, and 1 cm. nearer its tip.

The proximal part of the lumen is empty. The distal contains nuclei, blood corpuscles, granules, mucus, and a very few cocci and bacilli. The mucosa is superficially ulcerated, and its lymphoid follicles small and indistinct. Many goblet cells are seen in the remains of its epithelial lining, and also in the tubular glands. The submucous and subperitoneal coats are crowded with inflammatory cells undergoing elongation, and their blood-vessels and lymphatics are dilated. No bacteria can be seen in any of the coats, nor is there any trace of tubercle bacilli.

To sum up, this is a case of appendicitis with ulceration of the mucosa and inflammatory infiltration of the submucous and subperitoneal coats. The two constrictions owe their formation to the cicatrisation of this inflammatory material. The absence of changes in the lymphoid follicles is to be noted.

CHAPTER IX

APPENDICITIS WITH COMPLETE OBLITERATION OF THE LUMEN

IN the following group I have placed cases in which the lumen of the appendix has disappeared. With some observers, as I have shown before, the disappearance of the lumen marks the accomplishment of what is termed "the natural process of cure."

This assumption is not borne out by the facts, and the matter is by no means as simple as might be supposed. As regards the cases which I am about to narrate, it might be argued that in course of time the patients would have recovered. But in one, the pain was remarkably persistent over many years (Case 37); and in another, the attacks of appendicitis were frequent and severe (Case 38, p. 135).¹

CASE 37.—*Appendicitis with Sclerosis and Obliteration of the Lumen—The Difficulties of Diagnosis.*—Mr. H. was twenty-one years old when he began to suffer violent pains in the "pit of the stomach" and beneath the right costal arch. He was thirty-five years of age when I saw him. The pains occurred at intervals of weeks or months, and usually at night, obliging him to get out of bed and walk about the room. The pain ran down the right side of the abdomen and right thigh. It was unaccompanied by vomiting, and was unaffected by exercise or jolting.

¹ Under the designation of appendicitis obliterans, Senn has grouped a number of cases, but most belong to the class of stenosis with dilatation of the lumen (*The Journal of the American Medical Association*, Chicago, vol. xxii. p. 403, *et seq.*, 1894).

His bowels had been troublesome throughout, and about the beginning, whilst in Spain, he had pain in the lower abdomen and "swelling of the bowels." Since then his motions had been loose and light-coloured. He has not had jaundice. A variety of opinions prevailed concerning the cause of the pains. The pain and tenderness beneath the right costal arch led one surgeon to diagnose gall-stones. A physician thought, for what reasons I know not, that the vermiform appendix was diseased, although the appendicular

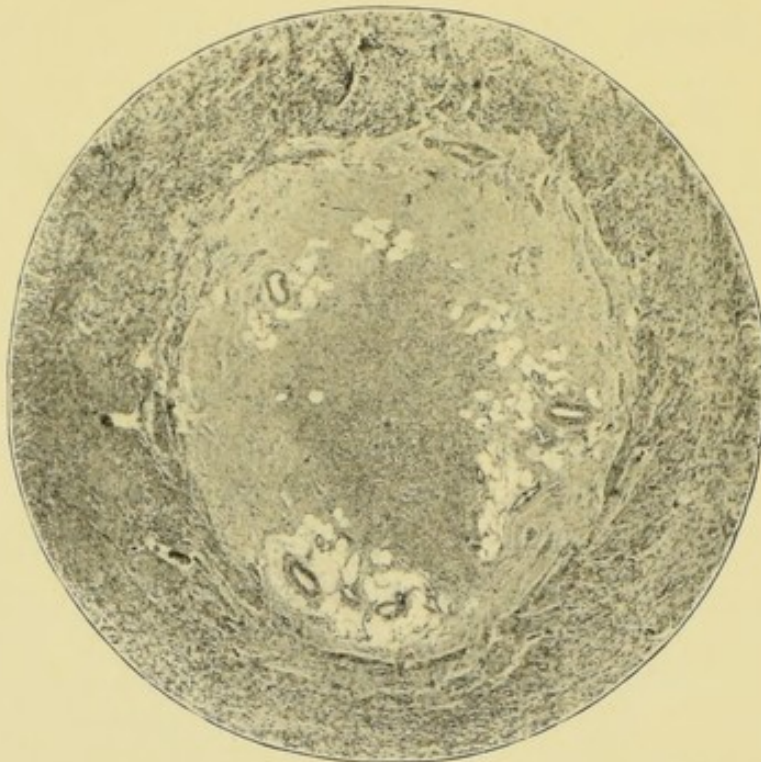

FIG. 36.—Complete obliteration of lumen of appendix. $\times 22$.

regions were all absolutely painless. A renal calculus was also to be suspected because the right kidney was tender, and he had uric acid crystals, and red blood corpuscles in the urine.

I made a small incision in the right linea semilunaris, and examined the gall-bladder, pylorus, right kidney, colon, and vermiform appendix. They were all healthy, except the last, which felt unusually hard. I removed it through an incision of less than 5 cm. It was very hard, and its blood-vessels engorged with blood.

The patient made an uninterrupted recovery, and three months afterwards considered himself quite well.

The result of the histological examination is as follows. The endothelium and basement membrane of the peritoneum are intact. The subperitoneal connective tissue is very fibrous, and contains numerous dilated blood-vessels. The outer muscular coat is thin, the inner of ordinary thickness, but its fibres are separated by œdema. The submucous coat is fibrous and œdematous (Fig. 36). The mucosa is absent, but is perhaps represented by a little adenoid tissue which occupies the place of the lumen.

CASE 38.—*Appendicitis with Obliteration of the Lumen.*
—The vermiform appendix of a young lady, æt. twenty-five (Miss D.), was removed for repeated attacks of appendicitis. For two and a half years she had had an attack every two or three months. During the attacks her temperature often rose to 102° F. She had great pain in the right iliac fossa, with vomiting, constipation, and abdominal distension. The vermiform appendix was but slightly inflamed, and quite in-adherent. It lay in the iliac fossa coiled upon itself. It was constricted an inch from the cæcum, and also half an inch from the tip. The last half-inch felt exceedingly hard. Sections of the cæcal and distal ends were cut. The accompanying microphotograph shows that the constricted part has no lumen, no trace of epithelial lining, or of tubular glands (Fig. 37, p. 136). The site of the lumen and mucous membrane is occupied by a new formation of vascular connective tissue. The lymphoid tissue, including the lymphoid follicles, has disappeared. The inflammatory tissue has replaced all the mucous coat, and invaded the innermost part of the circular muscular coat; the latter, together with the longitudinal, is penetrated by numerous small blood-vessels. The peritoneal coat is moderately inflamed, and, together with the meso-appendix, contains numerous small granular cells, like pus cells. Many of the small lymphatic spaces and channels of the peritoneum are full of these granular cells. This description also applies to the distal end of the appendix, except that its lymph follicles have not disappeared. Three lymph follicles, with their basilar

lymph spaces, were counted in one section. In all the sections little hæmorrhages had occurred. The blood cells had almost disappeared, leaving the pigment, which was most abundant in the peritoneal coat. No trace of tubercle or of tubercle bacilli could be found; nor could bacteria be seen in specimens stained by Weigert's method.

It is clear that this microscopical examination throws no light upon the repeated acute attacks of appendicitis. In-

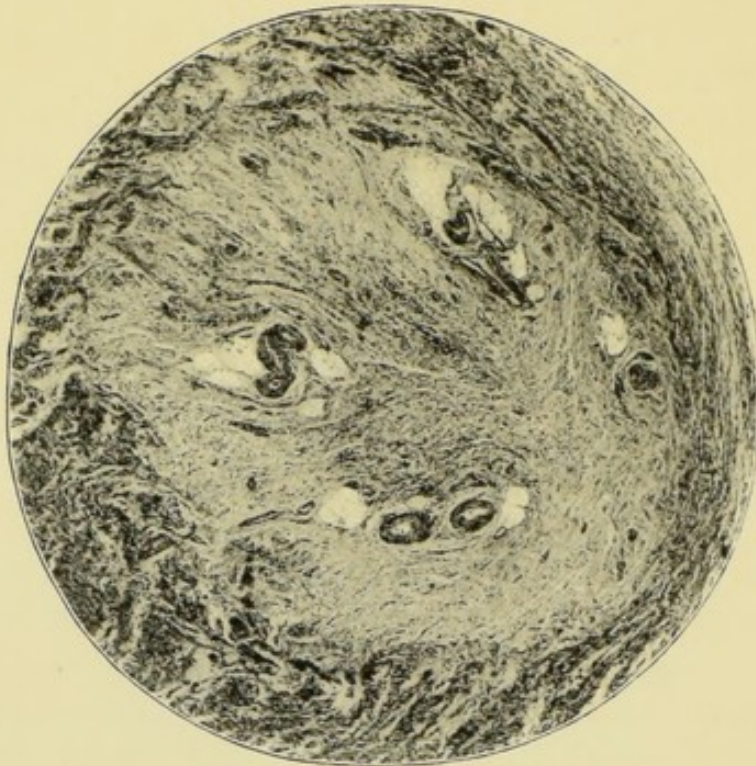


FIG. 37.—Inflammatory obliteration of the lumen of the vermiform appendix. $\times 45$.

asmuch as the lumen had disappeared, they could hardly be attributed to pent-up bacterial contents. It is, of course, not quite right to assume that all the lumen has gone without having seen a series of sections cut with a microtome. Nevertheless, its obliteration is almost a certainty.¹

CASE 39.—*The Mucosa of the Appendix destroyed, and its Lumen obliterated by one Attack of Appendicitis.*—The mucosa of the appendix may be destroyed, and the lumen obliterated

¹ M'Burney has also mentioned a case similar to these two. Evidently obliteration of the lumen does not bring the disease to an end (*Annals of Surgery*, vol. xxvii. p. 319).

by a single severe attack of appendicitis. Mr. X., aged twenty-four years, was suddenly seized with an "awful" pain in the right iliac fossa. This was followed by vomiting, constipation, and an inflammatory swelling in the right iliac fossa. The pulse was said to have been accelerated, and the temperature rose to 103° F. His condition was considered critical, and the question of operation was raised. The attack, however, subsided, and I saw him two months afterwards. His health seemed to be good, but a tender swelling could be felt in the right iliac fossa. He was unable to wait and see whether the tenderness would persist, or whether the appendicitis would recur, because he was anxious to join his regiment in South Africa. He was told that it was unsafe to do so as long as he had an inflammatory swelling. At the operation, which was done through the usual oblique incision, the layers of the abdominal wall were matted together, and the peritoneum vascular and thickened. The great omentum was inflamed, and adherent to the parietal peritoneum just above the opening.

Owing to adhesions the appendix was difficult to find. Its base sprang from the inner side of the cæcum. For the first 2 or 3 cm. it looked about the usual size, but then ended in a cord about 3 mm. in diameter and 7 or 8 cm. in length. The end of this thin part was adherent to the cæcum. The meso-appendix united about half the appendix to the ileum. The operation was completed in the usual way, and the wound, except one stitch hole, healed by first intention (see p. 247).

The result of the microscopical examination of the thick part of the appendix is as follows:—The endothelial layer of the peritoneum is replaced with inflammatory cells. The subperitoneal tissue is vascular and crowded with inflammatory cells. It also contains some old blood pigment. The muscular coats are encroached upon by the inflammatory exudation, but are easily distinguished, otherwise the specimen would be difficult to identify.

In some of the sections the muscular coats are deficient in two places; a gap at the meso-appendix is the hiatus; another, at the opposite side, suggests a perforation. At these places, the inflamed subperitoneal tissue is continuous with the submucosa. The submucosa and the mucosa have been replaced

with inflammatory connective tissue. There is no trace of epithelium or of a lumen, but the lymphoid follicles are probably represented by two small groups of cells. The structure of the cord-like part of the appendix was similarly affected, but on a smaller scale. Bacteria are not to be found anywhere, nor are there any signs of tubercle.

Special reasons existed for the removal of the appendix in this case, as the patient could not wait long enough to learn the probable course of the disease. Inasmuch as the mucous membrane had disappeared and the lumen had become obliterated, one might have surmised that the tenderness would have departed, and that no fresh attacks of appendicitis would have occurred.¹ But until the appendix had been excised, I did not know whether it might not contain a concretion, or be chronically ulcerated, or even perforated with a small localised abscess. All these conditions have been met with in cases with a similar clinical history. Furthermore, the belief that the appendix ceases to inflame when its lumen has been obliterated, rests upon a mere assumption. The cases already described and that which follows, have led me to doubt whether obliteration of the lumen brings appendicitis to an end.

CASE 40.—A. D., aged forty, a healthy man, had had two rather severe attacks of appendicitis. The first began in February, 1899, and kept him in bed for three weeks. The pain in the lower part of the abdomen was said to have been severe, and constipation was a marked feature of the illness. The pain subsided but did not entirely cease, and he resumed his occupation within a week. A second attack came on, and he was in bed for ten days. I excised the appendix within two months of the commencement of the illness. Before the operation, a tender swelling was felt in the right iliac fossa. The appendix was 8 or 9 cm. long and was inflamed, swollen, and adherent, throughout its whole extent, to the under surface of the cæcum. It had a meso-appendix for about 5 cm. of its length, the last 2 or 3 cm. being free. At the termination of the meso-appendix, the appendix was constricted and also sharply bent upon itself.

¹ I have recently found the same condition in a case of long-continued appendicitis.

Sections were cut from both the proximal and distal ends of the appendix, but the histological characters are the same throughout. The blood-vessels of all the coats are numerous and distended with blood. The peritoneum has lost its endothelial layer, and the subperitoneal tissue contains many groups of inflammatory corpuscles, some old extravasated blood, and a little brown pigment. The longitudinal and circular muscular coats are of the usual thickness; but many of the innermost fibres of the latter have been replaced with fibrous tissue, continuous with a core of the same tissue which has taken the place of submucosa, mucosa, and lumen. Thus every trace of epithelium, glands, or lymphoid tissue has vanished. Tubercle bacilli and other bacteria were sought for, but none were found.

This case affords much food for thought. If we may rely upon the clinical history, and I think we may, the whole of the mucosa disappeared and was replaced in the short space of two months with newly-formed connective tissue, which also took the place of the lumen. A previous case (Case 39, p. 136) shows that this can be effected by one attack of appendicitis; but in that instance the attack was very violent, judged from a clinical standpoint, and commensurate with the changes which were found in the appendix. In the present instance, the attacks were not at all out of the ordinary, so that we are compelled to entertain the idea that the whole mucosa may disappear, be replaced with fibrous tissue, and the lumen obliterated in the space of two months, and after two moderately severe attacks of appendicitis.

In this instance, we again find a continuance of the clinical symptoms after the mucosa and lumen have disappeared.

In this case, the abdominal wound was about two and a half inches long, and was closed with four layers of sutures placed in the peritoneum, muscle, aponeurosis, and skin. The dressing was removed on the eighth day, and the wound was found to have suppurated without any disturbance of pulse or temperature. In consequence, the deep stitches had all to be removed, a proceeding accompanied with much trouble and inconvenience. The ultimate result was perfect.

CHAPTER X

APPENDICITIS WITH LYMPHADENITIS AND LYMPHANGITIS

THERE is a class of cases of rather severe recurrent appendicitis, in which very characteristic changes are found in the lymphoid follicles and lymphatics. For brevity, we might speak of them as cases of appendicular lymphadenitis and lymphangitis.

The details of some of this class of cases are as follow:—The clinical history is a record of severe attacks, lasting about three weeks, during which the pain is so considerable that morphia is usually given for its relief. A hard and painful tumour is felt in the iliac fossa or in the pelvis; the abdomen is distended; vomiting occurs at the beginning; and there is disorder of the bowels and of the digestion; the temperature is raised and the pulse accelerated.

At the operation, the appendix is adherent and there is considerable typhlitis and perityphlitis. The lymphatic glands in the meso-appendix and mesentery are swollen and inflamed, as are sometimes those in the iliac fossa or pelvis. The great omentum is often adherent over the appendix.

The vermiform appendix is swollen to about double its usual thickness, and feels very solid. It looks red, succulent, and cedematous. In sections, the lumen may be slightly contracted or slightly enlarged and full of purulent fluid, but it is not distended. The submucous is the most swollen of the coats, and next the subperitoneal.

Histological sections show that the lymphoid follicles are swollen and that there is great dilatation of their lymph sinuses, of the lymph spaces and lymphatics of the submucosa, and of the meso-appendix. The other inflammatory

changes in the mucous, submucous, peritoneal, and muscular coats are evidently of a subsidiary character. The epithelial lining of the lumen may be intact or only detached in a few small patches.

At these places, the lymph canalicular system of the mucosa is opened, but it is hardly correct to say that ulceration of the mucosa is in progress. The purulent contents of the lumen contain various bacteria, but not in any great numbers; indeed, in most cases bacteria are rather difficult to find, and are seldom seen entering the open lymph canaliculi.

In the following case of appendicitis, the changes undergone by the appendicular lymphatic system were of the most marked character.

CASE 41.—*Appendicitis with Lymphadenitis and Lymphangitis.*—The specimen was removed by operation from a young lady, aged thirteen years, who was placed under my care by Dr. Hale. Her history was as follows:—During the eighteen months preceding the operation, not less than six attacks of appendicitis had occurred. Some of these had been very severe and alarming. For instance, during one which took place six months before the operation, the temperature rose to 103° F., the abdomen became exceedingly painful, and there was vomiting, constipation, and distension. It was stated, perhaps erroneously, that during this attack an abscess had burst *per vaginam*.

I first saw her when she was recovering from an attack which had been caused by a railway journey—a common exciting cause of appendicitis. A tender, ill-defined, ovoid swelling, 7 or 8 cm. in its longest diameter, was felt in the right iliac fossa, opposite the outer half of Poupart's ligament. This afterwards proved to be the omentum and appendix matted together, and adherent to the cæcum and intestines. In consequence of these adhesions, the appendix was difficult to find and remove. The progress of the case after the operation was quite uneventful. The temperature rose to 100° F., and the highest pulse rate was 108. The wound healed by first intention, and she was cured of her symptoms.

To the naked eye, the appendix presented nothing remarkable. It was red, swollen, and inflamed, with roughness of

its peritoneal coat. Histological sections merely confirm this observation, and show in addition the active proliferation of the peritoneal cells; also, that some of the blood of the engorged subperitoneal vessels had been recently extravasated into the tissues, probably during the operation.

Some parts of the subperitoneal tissue hold in their meshes a little fibrin. The muscular coats are rather thicker than usual, and contain many nuclei.

The blood-vessels of the submucous coat are numerous and rather large. With the exception of slight cellular infiltration, the submucous coat has hardly any other signs of inflammation.

The lymphoid follicles of the mucosa are most striking objects. At least twelve can be counted in each section. Their lymphoid tissue is less dense than usual, being broken up by small dilated lymph spaces; but the lymphoid corpuscles look cloudy and swollen, and the reticulum cannot be seen. The basilar lymph space, instead of being a semilune at the base of the follicle, is widely dilated and extended, in most instances, all round the follicle. Their endothelial lining is proliferating (see Fig. 38). The lymphatics of the submucous tissue are also dilated, and their endothelium proliferating, but not to the same extent as that of the sinus. The lumen of one of them is seen in the upper left of the microphotograph (see Fig. 38).

Some of the tubular glands are slightly dilated, and most of them contain an excessive proportion of mucous cells.

The lumen of the appendix is slightly dilated. Almost the whole of its muco-purulent contents escaped at the operation. Its epithelial lining is almost perfect. In some places, as in the microphotograph, it may have been detached when the section was cut, but, in others, its absence is the result of disease. The epithelial cells at the margin of the gap are evidently in active proliferation, and do not end abruptly, as they would if they had been torn off. Further, the basement membrane has also disappeared, and the exposed lymphoid tissue contains degenerated cells which look like pus corpuscles. The muscularis mucosæ is absent, so that little intervenes between the lymph follicles with their enormously dilated lymph spaces, and the lumen of the appendix. Where the

lining epithelium is absent, the lymph paths of the mucosa and of the follicles open freely into the lumen of the appendix. Thus the epithelial, submucous, and muscular tissues of this appendix are almost healthy. This renders all the more striking the marked dilatation of the lymphatic system as well as the inflammatory changes in the peritoneum, a structure which abounds in lymphatics.

I expected to find appendicitis, with shedding of epithelium

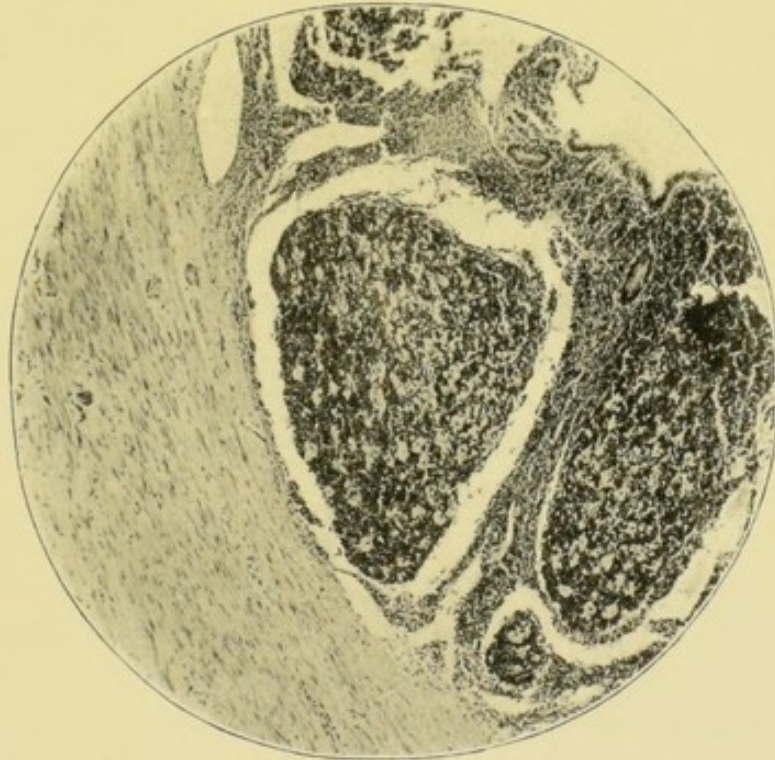


FIG. 38.—Lymphoid follicles, with dilated lymph sinuses and lymphatics. $\times 55$.
The lumen is above and to the right.

and ulceration, and the slightness of the epithelial changes came as a surprise.

In seeking for the causation of this disease, one at once searches for signs of a streptococcus invasion. As is well known, streptococci are the cause of acute lymphangitis and of erysipelas, its near ally; but no bacteria of any kind could be found in the lymph paths, or amongst any of the tissues. A little mucus, which had remained in the lumen, contained stray intestinal bacilli.

It is to be remembered that, though this examination was made during a period of quiescence, the signs of lymph-

angitis and of lymphadenitis are sufficiently clear. The road, moreover, was quite open for the passage of septic fluids from the interior of the appendix into the dilated lymphatics. Are we, therefore, to assume that we are watching the effects of an intestinal toxin?

It is also interesting to observe that marked evidences of inflammation are found in the peritoneal coat—a part of the appendix which is abundantly provided with lymphatics. Doubtless, this is no mere accident, but is due to the close intercommunications of the mucous and peritoneal systems of lymphatics.

Tubercle and tubercle bacilli were searched for with negative results.

I should estimate, that about a quarter of the cases of recurrent appendicitis have marked inflammatory changes in the lymphoid tissues and lymphatics. It is hardly necessary to give the minute details of additional cases, because only slight variations are met with in either the clinical symptoms or the morbid anatomy and histology, as exemplified in the following case:—

CASE 42.—*Appendicitis with Lymphadenitis and Oedema of Submucosa—The Causation of Acute Pain in Appendicitis.*—X., aged thirty-six years, had had five attacks of appendicitis during two and a half years. I saw him in the midst of the last, and was struck by the severity of the pain, which caused him to shout out and roll about in bed. Vomiting took place at the beginning of the attack, and constipation and abdominal distension followed. The pulse accelerated, and the temperature rose to 101° F.

The appendix was of average length, and lay in the iliac fossa beneath the cæcum. It was acutely inflamed and adherent, and felt very hard and solid. It was swollen to twice the average circumference. After hardening, the transverse sections were 10 mm. across. The coats were more than 4 mm. thick, and of this the peritoneal barely measured .25 mm.; the outer muscular coat, .50 mm.; the inner muscular, .75 mm.; the submucosa, 1.50 mm.; and the mucosa, 1 mm. Thus, with the exception of the peritoneal, all the coats were swollen, but especially the submucous.

The lumen was a slightly crenated slit, 2 mm. long and 1 mm. wide.

Although the peritoneal coat is so thin, it contains many dilated vessels and inflammatory exudation cells, which penetrate the outer muscular coat. The inner muscular coat also contains groups of inflammatory corpuscles. The submucosa is very œdematous. Its lymph spaces are so distended that it looks quite transparent, when viewed by transmitted light. Its blood-vessels are numerous and fully distended. The lymphoid tissue of the mucosa is 1 mm. thick. Eight lymphoid follicles can be counted in one section. The lymph canaliculi and the lymph sinuses of some of them are dilated, but only to a small extent. The greater part of the lymphoid tissue looks clouded, its cells irregular and imbedded in granular material. The endothelial plates of the lymph sinus and lymphatics are swollen and granular, as well as those in the lymphoid tissue. The tubular glands are about half as abundant as usual, and contain a good many mucous cells. The epithelial lining of the lumen is also discharging mucus. In some places it is completely detached and the mucosa is ulcerated, but not deeply.

The lumen contains a little fluid which is composed of nuclei, pus cells, a few red blood corpuscles, epithelium, and mucus. Small ovoid bacilli and occasional diplococci are present, but very sparsely scattered, and, therefore, difficult to identify.

No signs of tubercle or of tubercle bacilli can be discovered.

In some sections the hiatus muscularis is seen, and, as usual, the inflamed submucosa is directly continuous with the inflamed peritoneum. The meso-appendix contains dilated blood-vessels and lymphatics, and small groups of inflammatory cells, but otherwise it is not much altered.

This case is characterised by (*a*) an almost complete absence of bacteria; (*b*) an exceedingly slight degree of ulceration of the mucosa; (*c*) marked inflammation of the lymphoid tissues of the mucosa; and (*d*) great inflammatory œdema of the submucosa. It differs from some of the other cases in the small amount of inflammatory thickening of the peritoneum.

The diminution in the number of tubular glands is difficult to account for, in the absence of ulceration or distension.

It may be remembered that, during the attacks, pain was exceedingly severe. It is reasonable to suppose that when the appendicitis was at its height the swelling of the mucosa, and especially of the submucosa, was even greater than it was a week after its subsidence. Clearly, the stretching of the inflamed muscular coats and of the inflamed peritoneum must have been considerable and, possibly, rather sudden. Now the inflamed parietal peritoneum is exquisitely sensitive when touched or stretched, and, without doubt, the inflamed visceral peritoneum has the same properties. Thus we may partly explain the great pain in this and other cases of appendicitis with inflammatory œdema of the mucosa and submucosa. It is also probable that the appendicular nerves were inflamed, thus aggravating the pain.

This specimen shows that the submucosa may be very œdematous, without much distension of the lymphatic system of the mucosa.

The changes in the lymphatic system were also very marked in the following—

CASE 43.—*Appendicitis, with Lymphadenitis and Lymphangitis.*—Mrs. B., aged twenty-six, had her first attack of appendicitis in September, 1896; a second in March, 1897; a third in September, 1897; and a fourth in February, 1898. In May, 1897, she passed through an attack of enteric fever of moderate intensity without any appendicular trouble.

The attacks seem to have been much alike. In the notes mention is made of vomiting at the beginning, pain in the right iliac fossa, an ill-defined and tender swelling in the iliac fossa; a temperature of 102° F., and constipation. Usually, the symptoms were acute for four days, then began to subside, and in a fortnight had gone. But during the last attack, the symptoms were so severe that an abscess was suspected.¹

In July, 1898, I removed the vermiform appendix. Before

¹ I am indebted to Drs. Henderson and Robertson for the notes of this case.

the operation a small and tender, but very indistinct, tumour was felt in the right iliac fossa. The appendix sprang from the inner part of the cæcum, and was strongly adherent to it and to the end of the ileum. It was not more than 4 cm. long and bent upon itself. It was red and inflamed, and swollen to at least twice the usual thickness. The histological changes are the same as in the preceding cases. Owing to the sections having been cut longitudinally, the course of the dilated lymphatics are very clearly revealed.

The endothelial layer of the peritoneum is deficient; the subperitoneal tissue is from .5 to 1 mm. thick. It contains a few inflammatory corpuscles, many dilated and engorged blood-vessels, and many dilated lymphatics. The muscular coats are almost normal. The submucous tissue is very fibrous and infiltrated with inflammatory corpuscles; its blood-vessels are numerous and dilated; and its lymph spaces and lymphatics enormously dilated.

The lymphoid follicles of the mucosa are surrounded by a dilated lymph sinus (as in Fig. 38), which opens into the dilated lymphatics of the submucosa. The latter can be followed towards the base of the appendix, where they pass through a wide gap in the muscular coats, and enter the meso-appendix. The follicular lymph sinuses are crossed by delicate trabeculae. The lymph canaliculi of the follicles are dilated. The substance of the follicles and of the rest of the lymphoid tissue is clouded and opaque and its reticulum hidden. The lymphoid corpuscles are, in places, imbedded in lightly staining granular material.

In some of the dilated lymphatics, the endothelial lining is perfect; in others it is proliferating, or swollen and granular.

The epithelial lining of the tubular glands is complete and not undergoing any active change. The epithelial lining of the lumen is also complete throughout the greater part of its extent; but portions of it have been shed, allowing the lymph canaliculi of the mucosa and of the follicles to open into the lumen.

The lumen contains nuclei, pus cells, red blood cells, epithelium, mucus, and a few scattered cocci and small ovoid

bacilli. It is doubtful whether any of these have entered the lymph canaliculi.

When we compare the results of the histological examination and the clinical history together, it is clear that no contradictions arise. All the clinical symptoms are just what one would expect in a case of lymphangitis and lymphadenitis which did not end in suppuration.

Sometimes appendicitis is accompanied with an extraordinary degree of inflammatory œdema. The effects of this are most marked in the loose submucosa and subperitoneal coat, and it is nearly always associated with great distension of the lymphatics and lymph spaces throughout the appendix. The effects of this œdema were seen in the next specimen.

CASE 44.—*Appendicitis with great Inflammatory Œdema and Distension of Lymphatics.*—X., a musician, aged twenty-seven years, had had two violent attacks of appendicitis during the previous year. The first lasted five weeks, the second three. They were accompanied with great pain, constipation, vomiting, distension, acceleration of the pulse, and high temperature.

The abdomen was quite painless before the operation, and nothing whatever could be felt in the iliac fossa or *per rectum*. The appetite was good, and he could eat fruit and vegetables.

The appendix was excised through the usual incision. It was upwards of 8 cm. in length, and sprang from the outer part of the cæcum. Thence it ran upwards along the outer side of the colon, so that the oblique incision had to be extended to enable it to be removed. The first 4 or 5 cm. of the appendix were attached to the cæcum and colon by a mesentery 2 cm. wide.

The surrounding peritoneum was thickened and inflamed. A piece of non-vascular, yellow, friable material came away with the appendix. This consisted of branched anastomosing cells with oval nuclei. The protoplasm of most of the cells had undergone fatty degeneration. Signs of tubercle and tubercle bacilli were wanting.

The swollen appendix is circular in section, and 12 mm. in diameter. Nearly the whole of this enormous increase is

due to thickening of the submucous and subperitoneal coats. This is shown by the following measurements:—Peritoneum, 1 mm. to 1.5 mm.; muscular coats, 1.5 mm.; submucosa, 2 to 3 mm.; and the mucosa, .75 mm. The whole thickness varying from 4 to 6 mm. The lumen is circular and from 2 to 2.5 mm. across. It is full of granular material.

The endothelial layer of the peritoneum is destroyed. The subperitoneal tissue is thickened by masses of inflammatory cells, oedema, and some old and some recent blood extravasation. The subperitoneal vessels have thin walls and are distended with blood.

The muscular coats are oedematous and their fibres far apart. The submucosa contains great numbers of small blood-vessels with thick walls. Its lymph spaces and lymphatics are enormously dilated (same as in Fig. 52, p. 257), and give it a very loose appearance. It contains a good deal of fibrous tissue, but hardly any inflammatory cell infiltration.

The mucosa is half the usual thickness. It has been compressed between the swollen submucosa and the fluid in the lumen. Its lymphoid tissue is opaque, and the stroma granular and swollen. In one section, it possesses nine lymphoid follicles, each follicle being almost surrounded by a dilated lymph sinus as in the previous case (Case 41, p. 141). But the follicles themselves are small and crescentic, as if compressed. About a quarter of the tubular glands have disappeared, and those which remain are short and dilated. In some, the dilatation is so great that the gland is a wide bay opening into the lumen. This is one of the ways in which the tubular glands disappear, and the lumen grows larger.

The tubular glands are lined with epithelium which is actively discharging mucus. At the mouths of some of them, the epithelium has been entirely shed, the lymphoid tissue being laid bare. The lymph canaliculi do not, however, contain bacteria.

The lumen is also lined, but not completely, with epithelium in an extreme stage of mucous secretion. In some sections, it has been entirely shed, leaving the basement membrane in

contact with the fluid in the lumen. The state of the epithelium is the same throughout the appendix.¹

The lumen is full of mucus mingled with oval nuclei, pus cells, and masses of bacteria. Some of these are composed of minute ovoid bacilli which might easily be mistaken for staphylococci; others consist of larger bacilli, which look like *proteus vulgaris*. None of these bacilli are penetrating the mucosa.

Presently some evidence will be adduced to show that this lymphadenitis and lymphangitis may, as in other regions of the body, end in suppuration (Case 52, p. 172).

¹ I possess eighteen sections through all parts of this appendix. Its distal end is looped so that each section has two lumens.

CHAPTER XI

TUBERCULOUS APPENDICITIS

PRIMARY tubercle of the vermiform appendix is undoubtedly an exceedingly rare disease. In the following cases, the tuberculous appendicitis was always associated with tubercle elsewhere.

I have now made a histological examination of 83 cases of appendicitis. In every instance sections from more than one part of the appendix were stained for tubercle. The characteristic signs of tuberculous inflammation and of caseous degeneration and softening have only been seen in the three cases described below (Cases 46, 47, and 48). Tubercle bacilli were sought for but were not seen, with the doubtful exception of Case 46.¹

One of my specimens shows exceedingly well the invasion of the vermiform appendix by tubercle bacilli; also the course which the tuberculous process pursues. This is one of the few specimens which I did not excise myself.

CASE 45.—*Tuberculous Appendicitis*.—The patient was a man, aged sixty-three. He died of tuberculous disease of the lungs, complicated with tuberculous ulceration of the larynx and trachea, and of the intestinal mucous membrane. He had no symptoms which actually pointed to disease of the appendix, but only obscure abdominal pains. The microscopical sections show many groups of tubercle bacilli scattered throughout the mucous coats of the

¹ The lumen of the appendix and the ulcerated mucosa often contain bacilli which retain fuchsin after washing in dilute solution of mineral acid, but they do not possess the morphological characters of tubercle bacilli.

appendix (Fig. 39). As many as thirty may be counted in one field of the microscope. The usual inflammatory and degenerative changes have occurred. The accompanying microphotograph, which has been taken with a lower power (Fig. 40), shows that the lining epithelium of the lumen of the appendix, and of many of its tubular glands, has been shed. In some places, the tuberculous inflammatory material has degenerated and softened, and discharged itself into the lumen of the appendix. In this way, the interior of the small tuberculous

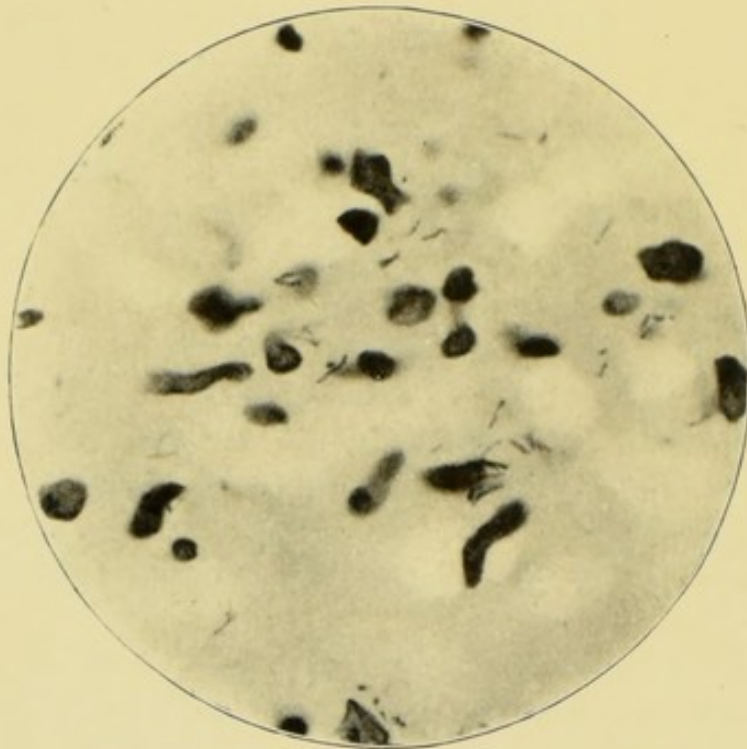


FIG. 39.—Tuberculous appendicitis. $\times 1000$.

abscess or ulcer has become exposed to the septic contents of the lumen, which consist of pus cells, granules, mucus, and scattered bacteria, mostly bacilli of various shapes and sizes. Evidently this appendix presents exactly the conditions which, as I have described elsewhere, are necessary for "consecutive infection."¹ But as yet none has occurred. The surface of the tuberculous ulcer has upon it many groups of bacilli, but these have only penetrated its tuberculous base to the most trifling extent.

¹ *Hunterian Lectures on Traumatic Infection*, Edinburgh and London, 1896, p. 123.

We may infer, therefore, that commencing tuberculous inflammation and ulceration of the mucous lining were insufficient to produce the clinical symptoms of appendicitis, but that the latter would have appeared if consecutive infection had taken place.

Presently, I intend to refer to an instance in which the tuberculous process had spread in the other direction, and was on the point of breaking into the general peritoneal cavity. In the present instance, such an eventuality was guarded

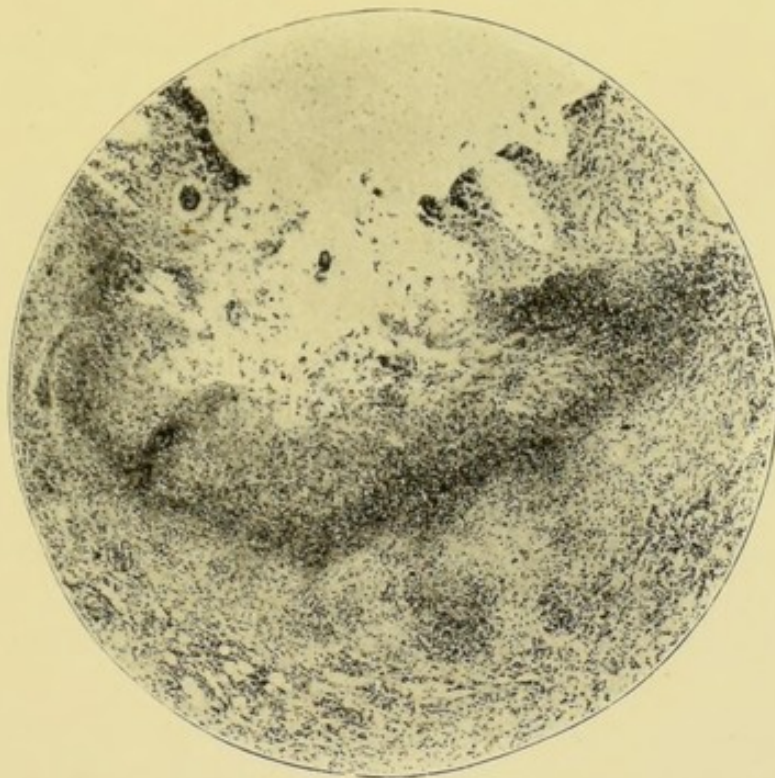


FIG. 40.—Tuberculous appendicitis, showing tuberculous abscess or ulcer opening into the lumen. $\times 50$. The lumen is above.

against by the peritoneal, muscular, and submucous coats, which were intact, although slightly inflamed.

This case does not tell us how the tubercle bacilli reached the appendix. Had they travelled with the blood stream, we might have expected to find tubercle in the other coats of the appendix, especially in the peritoneal coat. But when we recall that the patient had tuberculous ulceration of the trachea and larynx, we may infer that the bacilli may have been swallowed and thus reached the appendix.

CASE 46. — *Tuberculous Appendicitis — Empyema and*

Impending Perforation of Appendix.—When first I saw this patient, with Dr. Poulter, I strongly suspected that his disease was tuberculous. It is true that the first onset of the appendicitis itself had had no unusual features, but to my mind the general condition of the patient was such as to suggest more than a mere appendicitis. The boy was very anæmic, with general wasting and debility; each night his temperature rose two or three degrees, and this persisted for many weeks without any signs of improvement.

The patient was eleven years old, and at the beginning of September, 1897, had had a typical attack of appendicitis. A severe pain in the right iliac fossa was accompanied with fever, constipation, distension, and vomiting. He never actually recovered from this attack, but continued to lose weight. In January, 1898, three months after the commencement of the attack, I could still feel a tender and indurated swelling in the right iliac fossa, opposite the outer half of Poupart's ligament. Inasmuch as the appendix could not be felt through the rectum, and as bladder symptoms were absent, it seemed almost certain that the swelling indicated the position of the appendix, and that it lay in the iliac fossa. Also, since pressure caused pain along the outer side of the cæcum, I inferred that the diseased appendix probably extended in that direction.

The operation was done through the oblique incision, which was made a little further out than usual, because of the supposed position of the appendix. That organ was found behind the outer margin of the cæcum. It was inflamed, adherent, and distended with pus. No caseous material or caseous mesenteric glands were found. The subsequent progress of this case was as follows. After the reaction caused by the shock of the operation had passed away, the temperature fell to normal. On the ninth day, the wound was healed. But after awhile, the patient's temperature became the same as it had been before the operation, and a hard swelling formed under the scar and around the cæcum, then a little pus escaped. The swelling was very persistent. It was exposed under an anæsthetic, but no collection of pus could be found. Ultimately, it

subsided without a corresponding fall in the temperature. Four months after the operation, he had a considerable hæmorrhage which was thought to have come from the right kidney, because that organ was painful and slightly enlarged. It was supposed that the kidney was tuberculous, although Dr. F. W. Andrewes could find no tubercle bacilli in the urine.

When the appendix was examined with the naked eye, it looked as if the dilatation had not been accompanied by any

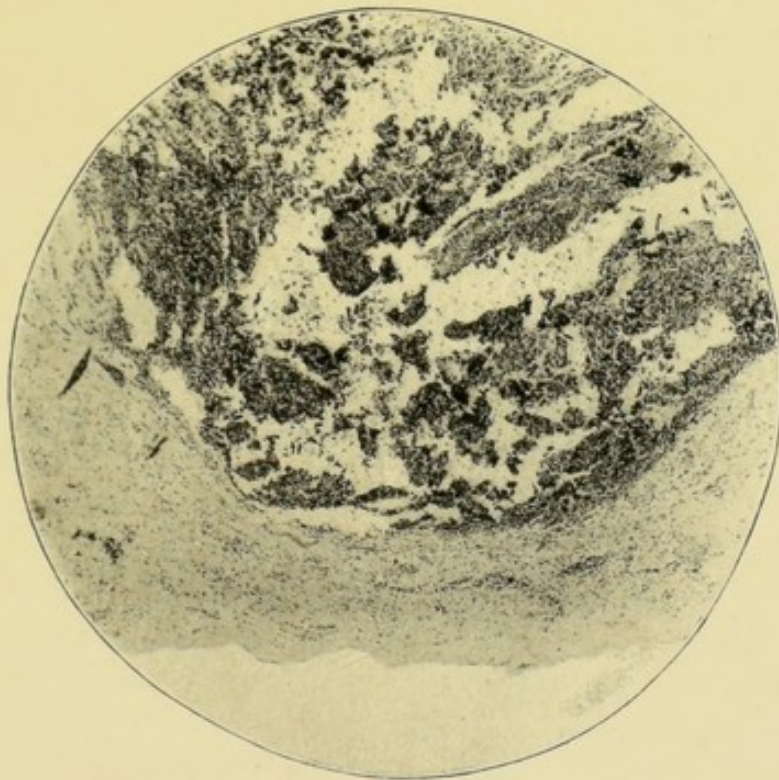


FIG. 41.—Tubercle of the vermiform appendix. The formation of a tuberculous perforation. $\times 35$. The lumen is above, the remains of the peritoneum are below.

actual thinning of its coats. Indeed, the swollen lymphoid tissue of the mucous coat and the inflammatory exudation made its walls look thicker.

At one point the muscular coats were almost absent, having been destroyed by the inflammatory process (Fig. 41). The inflammatory exudation had reached the peritoneal coat. A layer of peritoneal and subperitoneal tissue, not much more than half a millimetre thick, backed up by an uncertain quantity of adhesions, was all there was to prevent the escape of the pus into the general peritoneal

cavity.¹ Clearly this appendix was excised none too soon. It is interesting to speculate what the result would have been if perforation had taken place. The specimen shows very clearly how it would have occurred. The inflammatory material would have soon invaded the peritoneum, then it would have degenerated and softened, and allowed the pus to escape. I say this because it is clear that tuberculous disease pursues the same course in the vermiform appendix as in other tissues and organs. First, the invasion of tubercle bacilli; then an inflammatory process, followed by degeneration and caseation; and last, softening of the caseated material, with the formation of an abscess or ulcer.

My belief that this unfortunate boy was suffering from tubercle led me from the beginning to give a very guarded prognosis, and it is, perhaps, fortunate that I did so. Much remains to be learnt about tuberculous appendicitis, but we can safely say, first, that an operation may fail to remove the whole of the disease; secondly, that other organs may be tuberculous; and thirdly, that, in consequence, the illness may persist after the excision of the appendix. It may, however, be quite desirable to perform that operation. Otherwise, as the case which I have just described shows, the patient might be left with an empyema of the appendix upon the point of bursting.

CASE 47.—*Appendicitis with Tubercle of the Cæcum and Ileum.*—In January, 1896, my friend, Dr. Lovell Drage, placed under my care, in the Great Northern Central Hospital, a boy aged fourteen years. He seemed to have been a healthy youth until August, 1895, when, after a feast of apples, he was seized with an attack which Dr. Drage diagnosed as typhlitis. A lump was felt in the usual place beneath the right linea semilunaris. After some time in bed, the symptoms subsided and he was supposed to have got well.

About Christmas, 1895, he helped at a supper, and became ill again with constipation, vomiting, abdominal distension,

¹ I thought the pus and inflammatory products contained scattered tubercle bacilli, but, as is usual in chronic mycotic processes, there were very few and these difficult to identify.

and a painful tumour in the region of the appendix. About this time also some extraordinary vermicular movements of the small intestines were noticed. The pulse and temperature were raised.

When I saw him, towards the end of January, the abdomen was slightly distended. A hard irregular tumour was felt behind the right linea semilunaris, about midway between the umbilicus and anterior superior spine of the ilium. The tumour was about 3 inches across, movable, and painful on pressure. *Per rectum*, a round cord, about a third of an inch in diameter, was felt in the recto-vesical pouch. The pulse rate was about 90, and the temperature 101° F.

In the absence of any other indication, I attributed the tumour to an ordinary attack of appendicitis. When the abdomen was opened in the right linea semilunaris, about 8 ounces of clear fluid escaped, and a number of tuberculous nodules were found studded about the cæcum, the end of the ileum, and the mesentery. Many of the mesenteric glands were enlarged and caseous. One was removed, and the histological examination showed it to be tuberculous. The great omentum was inflamed, and adherent to the cæcum and to the end of the ileum, as in ordinary appendicitis. The vermiform appendix was very slender and difficult to find, because it was inflamed and adherent to the under surface of the cæcum; but as its removal was difficult, and as it appeared to be such a small part of the diseased condition, it was not excised. The wound healed by first intention, and the pain, which had previously been very severe, was completely relieved. The boy returned home and shortly afterwards died of general tuberculosis.

I am quite at a loss to tell how this rather acute tuberculosis of the cæcum, ileum, mesentery, and omentum could have been diagnosed, except by an operation. It is possible that a thorough examination, between the two attacks, would have shown that the pulse rate and temperature had not completely subsided, and also that the tumour was gradually growing larger.

CASE 48.—*Appendicitis with Early General Tuberculous Peritonitis*.—In the last case, the appendix was not excised, because the adhesions would have necessitated a prolonged

and difficult operation. This was thought unjustifiable in a patient with such extensive and acute general tuberculosis of the peritoneum. But tuberculous peritonitis was also met with unexpectedly in another case. In this, the disease was not far advanced and the appendix not very adherent. As excision seemed to offer but little additional risk, and to afford a prospect of relief from some of the symptoms, it was carried out.

The patient was a healthy-looking young man, aged twenty years. In March, 1899, he first suffered from an attack of abdominal pain, and had others in July, November, and January, 1900. These attacks were much alike. For the first twenty-four hours, the pain was acute all over the abdomen, but worst about the umbilicus. On one occasion, it did not subside for nearly three weeks. Latterly, the pain had been worst about midway between the umbilicus and the anterior superior spine of the ilium. The attack was sometimes accompanied with vomiting, and always with constipation. A relative, who was a medical man, could find no alteration in the pulse or temperature during the attacks. I saw the patient a few days after the last of them, and could discover nothing, except marked tenderness over the iliac fossa; and nothing abnormal could be felt *per rectum*.

The abdomen was opened by a small oblique incision. The peritoneum was of a deep red colour, about an eighth of an inch thick, and felt shotty. It was not at all easy to recognise. A little yellowish serous fluid ran out when the peritoneum was incised, and small, hard, white globular tubercles were found all over the parietal peritoneum, the omentum, intestines, and appendix. The latter was about 10 centimetres long, and had a mesentery for about two-thirds of its length. It lay beneath the cæcum, and was adherent to it, and to the iliac peritoneum. It was removed in the usual way, together with some of the omentum and parietal peritoneum. The patient made a rapid and uninterrupted recovery.

The proximal sections are ovoid, and measure 7 mm. in the long axis, and 6 mm. in the short. The coats taken together measure from 1.25 mm. to 3.25 mm. The lumen is the usual T-shape, and not dilated.

The peritoneal coat is the only one in which inflammatory changes are in progress. Its vessels and lymphatics are dilated and full of blood, and its tissues contain numbers of nucleated cells, which, in places, have collected into little groups. The muscular, submucous, and mucous coats are hardly altered. Some of the lymph spaces and lymphatics of the submucosa may be slightly dilated. The lymphoid tissue of the mucosa is abundant, but its delicate stroma is visible throughout. Nine or ten lymphoid follicles can be counted in a section. The central and peripheral parts of some of these have, I think, disappeared during the cutting. The tubular glands are normal; so is the epithelial lining of the lumen. The latter is absent in a few small areas, but its basement membrane remains. As no detached epithelium can be seen in the lumen, this, too, may have disappeared during the preparation of the section.

The lumen contains a little mucus, some nuclei, a few red blood corpuscles, and occasional small ovoid bacilli, single, in pairs, and short chains.

The distal specimens are slightly different. The sections are but half a centimetre in diameter, and the lumen is absent, the centre being occupied by a little lymphoid tissue. The peritoneum is inflamed as in the proximal sections, and, in addition, it is studded with several small tubercles, which display the histological structure of tubercle in perfection, and are especially rich in multinucleated giant cells. Although many sections were stained for tubercle bacilli by Ziehl's process, none could be discovered. The portions of tuberculous parietal peritoneum and of the omentum had the same histological characters.

Evidently, in this case, the inflammation was confined to the appendicular peritoneum, the muscular, submucous, and mucous coats being healthy. From this I infer that the appendix was not primarily affected, but that it became involved in the general tuberculous peritonitis. Also, if it be true that, when this is the case, the muscular, submucous, and mucous coats are healthy, and the lumen unoccupied by pus or bacteria, then the removal of the appendix is less imperative, and, as in the last case, it may be left behind if very adherent.

We may also speculate as to how far the clinical symptoms were caused by the general tuberculous peritonitis, and how far by the appendicitis. Doubtless some of the pain is attributable to the former, but the attack of vomiting, constipation, and pain in the right iliac fossa must, I think, have been due to the latter. If this be so, then it follows that inflammation of the appendicular peritoneum is alone sufficient to cause the clinical symptoms of appendicitis. In support of this inference, I would remark that this patient was seen three months after the operation, when he seemed to be in excellent health, and his abdominal symptoms had disappeared. A part of his wound had, however, become tuberculous.

CHAPTER XII

THE PATHOLOGY OF CASES OF APPENDICITIS WHICH UNDERGO PERMANENT RECOVERY

A PROPORTION of cases of appendicitis end in complete and permanent recovery. Thirteen years ago I saw a boy during an acute attack, and although he has been carefully watched ever since, there has not been the slightest sign of a fresh attack. I believe him to have had an attack of appendicular lymphadenitis and lymphangitis, but it is obviously impossible to obtain histological evidence of the condition of the appendix under these circumstances.

The nature, therefore, of the appendicitis in the cases of complete recovery must remain a matter for surmise. But, in one of my operation cases, the structure of the appendix was so little altered after three marked attacks that its complete recovery, *restitutio ad integratio*, seemed well within the range of possibility.

CASE 49.—*Appendicitis with Changes in Peritoneal and Submucous Coats—The Morbid Histology in Cases of Appendicitis which permanently recover.*—The patient was an undertaker's assistant, aged twenty-five years. Until July, 1899, he had had excellent health. One afternoon a severe abdominal pain was followed by appendicitis, which kept him in bed for five days, and away from work for ten. It was accompanied with pain and constipation, but not with vomiting. Within a month, he had a second attack with vomiting and marked pain in the right iliac fossa. In February, 1900, he had a third attack of a similar but less severe character. He was very anxious to have an operation performed. On

the fourth day after the subsidence of the last attack, I removed the appendix through a small incision. It was inadherent, and, easily withdrawn along with the cæcum from the abdomen. The appendix was 8 or 9 cm. long, and had a mesentery for half its length. Its blood-vessels were numerous and engorged, and its surface slightly rough. It felt exceedingly hard. The cæcum was rough and shaggy ;

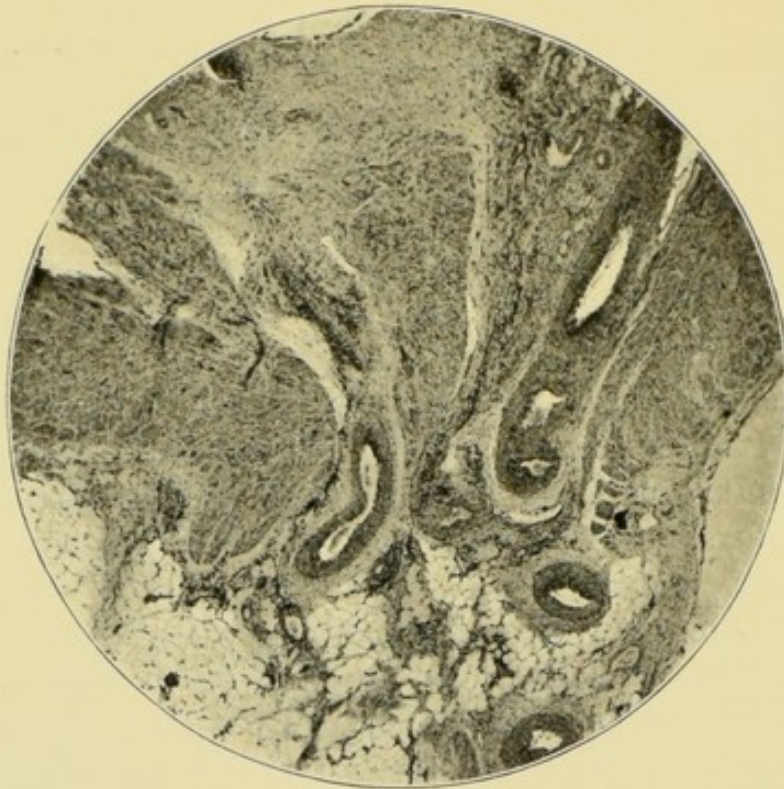


FIG. 42.—Hiatus muscularis. The lumen is above, the meso-appendix below. The continuity of the slightly inflamed submucosa with the meso-appendix is clearly seen. $\times 25$.

the operation was completed in the usual way, and the patient made an uneventful recovery.

The proximal and distal series of sections are alike, except that the distal have a hiatus muscularis. Here the dilated blood-vessels and lymphatics of the submucosa, and its inflamed tissues are continuous with those of the appendicular peritoneum and mesentery. This point is so clearly shown that the microphotograph has been reproduced (Fig. 42).

The sections are ovoid, and measure 7 mm. by 8 mm. The lumen is irregularly crescentic, and 3 mm. long and 1 mm. broad at its widest part. The coats together are from 2 mm.

to 4 mm. thick, chiefly owing to inflammatory œdema, so that the hardness of the appendix is sufficiently explained. The follicular lymph paths are distinctly visible to the naked eye.

The endothelial layer of the peritoneum is proliferating. The subperitoneal connective tissue contains many dilated blood-vessels and lymphatics, and groups of inflammatory exudation corpuscles. These evidences of inflammation are most marked next to the hiatus muscularis. The meso-appendix also contains dilated blood-vessels and lymphatics, and some groups of inflammatory corpuscles.

The muscular coats are of the usual thickness, but contain some dilated blood-vessels and lymphatics, and a rather greater number of nuclei than usual. In the distal sections, the muscular coats are broken by a hiatus muscularis, 1 mm. wide.

The submucosa is thick and œdematous; its blood-vessels are numerous, large, and dilated; its lymph spaces and lymphatics are widely dilated. Its tissues are rather thickly studded with nucleated cells which, in sections cut through the hiatus, all pass out into the meso-appendix and subperitoneal coat (Fig. 42).

The lymphoid follicles flank either side of the crescentic lumen. They are so close together that the exact number in a section is uncertain, probably from ten to twelve. They are absent at the hiatus muscularis. The structure of the follicles has undergone no alteration, but the follicular lymph paths, although empty, are widely dilated and very extensive, otherwise they seem uninfamed.

The epithelial lining of the lumen is intact, and many of its cells are full of mucus. The tubular glands are normal.

The lumen contains a little mucus and some nucleated cells. No bacteria can be seen, nor any trace of tubercle or of tubercle bacilli.

In this case of appendicitis, it is clear that the epithelial elements of the mucosa had hardly been involved. Furthermore, its lymphoid follicles and lymphatics had undergone no serious alteration, although it is probable that they had been inflamed. But the submucosa and subperitoneal coats still bear an imprint which proves them to have passed through an inflammatory attack sufficient in severity to account for the

clinical symptoms. None of the histological changes are, however, such as would preclude recovery. The inflammatory exudation corpuscles could have disappeared, and the dilated blood-vessels and lymphatics returned to their usual size.

CASE 50.—*Appendicitis with Repeated Attacks—Slight Histological Changes.*—A powerful young man, aged twenty-eight, returned from South Africa to have his vermiform appendix removed, because, as he said, he had had about twenty attacks of appendicitis. These were accompanied by the usual symptoms, pain in the right iliac fossa, constipation, vomiting, and slight abdominal distension. The changes in pulse rate and temperature were unknown. The attacks usually laid him up for from five to seven days. Pressure over the region of the appendix caused pain and muscular contraction, and an indistinct tumour could be felt.

The appendix was excised through a small oblique incision. It was from 8 to 9 cm. long, vascular, swollen, and adherent to the cæcum and iliac peritoneum. It was not constricted anywhere, and was of the same calibre throughout, having a diameter of 1 cm. The tip of the great omentum was also inflamed and adherent to the appendix and cæcum.

Thus it was clear that the attacks of appendicitis had been severe. The result of the microscopical examination is briefly as follows:—The peritoneal coat is denuded of endothelium, thick, very vascular, but with a moderate amount of cell infiltration. Its surface has upon it a few groups of inflammatory cells, but no bacteria can be seen amongst them. The muscular coats are thick, especially the inner (1.75 mm.). In the distal sections, there is a gap in the muscular coats opposite the meso-appendix, through which vast numbers of small blood-vessels enter and leave the submucous coat. The submucous coat is very vascular and full of inflammatory cells. At the gap in the muscular coats, its fibrous tissue, which is increased in quantity, becomes continuous with that of the meso-appendix and subperitoneal connective tissue.

The muscularis mucosæ is either very thin or altogether absent. Four lymphoid follicles are seen in a section. They are small, and possess no basilar lymphatic. The tubular glands have large lumens full of mucus. Their epithelial

linings are perfect, but have many goblet cells. The lumen of the appendix is lined with epithelium, which also has many goblet cells. It contains a little mucous secretion and a few nucleated cells. No bacteria can be seen. There is no evidence of tubercle.

Thus the chief histological changes are in the peritoneal and submucous coats. The mucosa is almost healthy. Evidently the lymphatic system had little share in the disease, the brunt of which seems to have fallen upon the peritoneal and submucous coats. Here again we have a specimen of inflamed appendix which has not undergone such changes as might forbid an eventual complete recovery.

CHAPTER XIII

APPENDICITIS AND PERITONITIS—NON-SUPPURATIVE AND SUPPURATIVE

IN appendicitis with superficial ulceration of the mucosa, the peritoneal covering of the appendix is usually smooth and polished, and betrays to the naked eye nothing abnormal beyond a slight vascular engorgement. The microscope, too, reveals little beyond some endothelial proliferation (Case 1, p. 35). Amongst the groups of cells which are thus produced, bacteria may be met with (Case 69, p. 231).

In these circumstances, I have often seen the peritoneal covering of the cæcum slightly rough and "shaggy." Perhaps, this curious typhlitis is in some way connected with the spread of inflammation along the lymphatics. In a recent case, the cæcum was healthy, and the curious shaggy appearance was confined to the last two or three inches of the ileum. In stenosis of the appendix, with mucocele, ulceration of the mucosa, or empyema, the peritoneal coat is usually rough and inflamed and adherent to contiguous structures. The microscope reveals vascular and lymphatic engorgement of the peritoneal coat, together with endothelial proliferation and cell infiltration. Bacteria may, or may not, be found during the period of quiescence. When, as a sequel to ulceration of the mucosa, the infection spreads to the submucosa and to the peritoneum, the appendix often becomes hidden amidst adhesions (Case 6, p. 46). Such a state of things easily leads to the formation of pus, so that small localised abscesses may be opened during the course of the operation. In some of these cases, the appendicular walls are

intact (Case 12, p. 64), but in others perforation or gangrene has occurred. The concomitant suppuration is, anatomically, circumscribed or diffused, and, clinically, chronic, subacute, or acute.

As the question is one of great importance, I propose to give some additional cases bearing upon suppuration in appendicitis. It is not always possible to infer, from the histological characters of the appendix, what sort of changes preceded the spread of bacteria to the peritoneum. Doubtless the final course of events was sudden and rapid, and such as is seen in other acute infective diseases, as, for instance, in cellulitis or traumatic gangrene.

When the question of operative interference is being discussed, the decision is often made to depend upon the supposed presence or absence of pus. The dangers of an intraperitoneal abscess are so obvious that when one was known to have formed few would shrink from an operation. Indeed, I cannot help thinking that there are some who believe that it is right to wait until suppuration has actually occurred. Clearly, it would be safer to endeavour to anticipate such a dangerous complication,¹ but before this can be done, the morbid condition of the appendix must be diagnosed. In nearly all cases, there is a stage in the disease which is antecedent to perityphlitis or to suppuration. In fulminating appendicitis with gangrene or perforation, the interval is short and may be measured by hours; but I do not doubt that increased experience will teach us how to recognise these, even in their earlier stages.

Sometimes, the appendicitis antecedent to perforation and suppuration is overlooked, although the indications may have been of the most obvious description. For instance, a lady who nearly died of intraperitoneal suppuration, said she had had severe pain in the iliac fossa for months before (Case 81, p. 274). In other cases, a severe appendicitis subsides, leaving the organ chronically inflamed, and with perhaps a concretion in its interior. Under these circumstances, an abdominal or rectal examination, and an inquiry into the clinical symptoms, would

¹ Mr. Treves estimates that the advent of suppuration at once increases the mortality of perityphlitis to 30 per cent, the average risk being about 5 per cent (*Perityphlitis*, p. 53).

afford clear evidence of the presence of the inflamed appendix. If it be not excised, the inflammation recrudesces and ends in perforation, gangrene, and suppuration. The removal of the chronically inflamed appendix, during comparative quiescence, would have been attended with trifling danger.

A rather exaggerated importance is given to the presence or absence of pus. The formation of pus may sometimes be a favourable sign, and some of the most rapidly fatal forms of peritonitis run their course without any having been formed. After death, the peritoneal cavity contains a little sanious fluid, teeming with bacteria; and small groups of bacteria, usually streptococci, are scattered like particles of oil over its intensely inflamed surface. As a matter of fact, it would be of far greater value to be able to ascertain, as early as possible, the nature of the infection, rather than its results.

The type of suppuration is determined by many circumstances. One of the most remarkable properties of the peritoneum is the rapidity with which it is able to adhere and surround a septic area with a barrier of lymph. Obviously, the formation of efficient adhesions is partly an anatomical problem. The ileo-cæcal angle, and the sub-cæcal recess are easily shut off, and are, therefore, the usual seats of localised abscesses. Similarly, a collection of pus at the bottom of Douglas's pouch, or of the recto-vesical pouch, tends to become hemmed in by a covering of adherent intestines. The recess to the right of the cæcum is also favourable to localisation.

In the second place, something depends upon the infecting organisms. I have given, elsewhere,¹ some account of streptococcic peritonitis. In this, the inflamed peritoneum looks as if it had been oiled, and its cavity contains some thin odourless pus. The inflammation is diffuse, involves a large area, and has little tendency to become circumscribed.

The inflamed surfaces adhere to one another, but are easily separated. In sections, the peritoneal vessels and lymphatics are engorged, and the surface covered with a little lymph mingled with vast quantities of streptococci. In places, the chains of cocci penetrate the substance of the peritoneum as

¹ *Hunterian Lectures on Traumatic Infection*, Edinburgh and London, 1896, p. 19 *et seq.*, Figs. 4 and 5.

far as the subperitoneal fat (see Figs. 43, 44). I have also

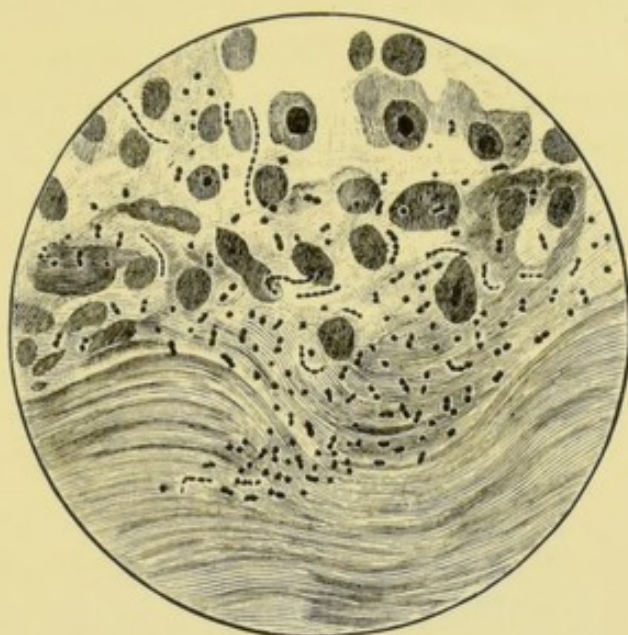


FIG. 43.¹—Streptococcic peritonitis. Lymph upon the surface of the peritoneum.
× 900.

described another form of peritonitis² in which the inflamed

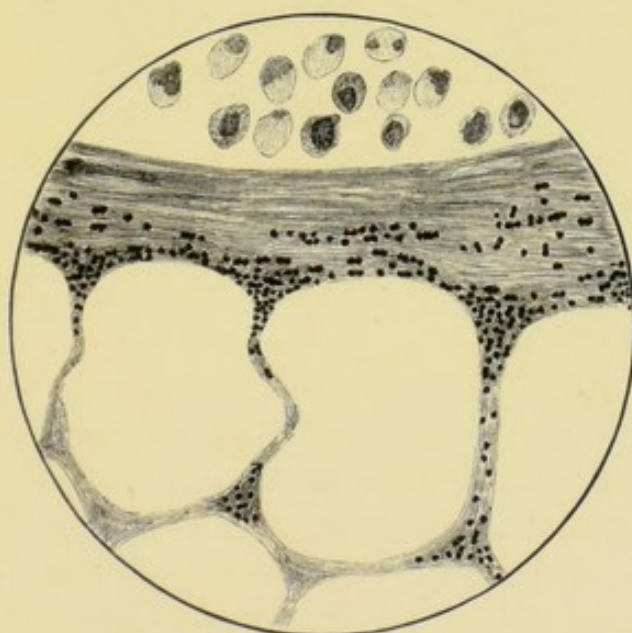


FIG. 44.—Streptococcic peritonitis. Streptococci in depths of the peritoneum.
× 900.

serous membrane is covered with lymph, crowded with intestinal bacilli. But these bacilli do not penetrate the substances

¹ Figs. 41, 42, and 43 are from *Hunterian Lectures on Traumatic Infection*, Lockwood (Figs. 4, 5, and 6).

² *Loc. cit.* p. 14, Fig. 3.

of the peritoneum, or only to a very small extent, perhaps for a hundredth of an inch. The surface fibrin and lymph may be very thick, and the bacilli do not seem to be particularly virulent. The prognosis is, therefore, extremely grave in acute peritonitis accompanied with odourless pus. Much can, however, be done by freely and abundantly washing and disinfecting the peritoneal cavity. I have also occasionally seen such striking results in streptococcic synovitis and cellulitis from the use of anti-streptococcic serum, that I am only waiting for an opportunity of using it in a case

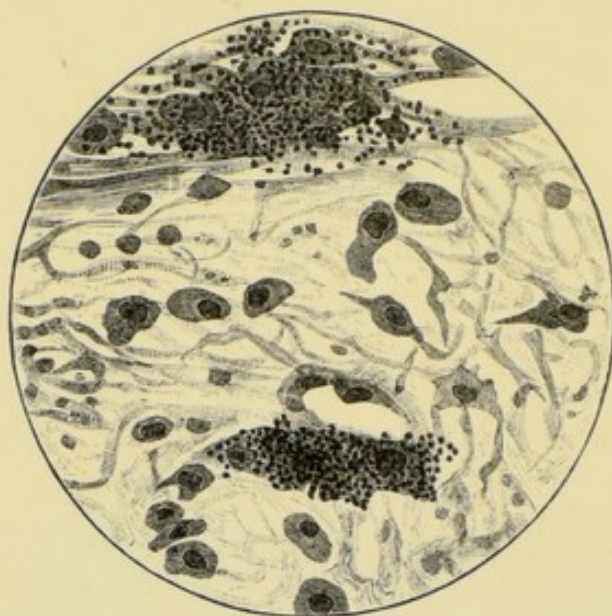


FIG. 45.—Diffuse septic peritonitis. Bacteria in the lymph upon the surface of the peritoneum and just within its substance. $\times 900$.

of streptococcic peritonitis. When the suppuration is circumscribed by firm fibrinous adhesions, we may infer that the infection is not virulent, that the peritoneum is resistant, and that these favourable conditions will persist after the operation. The introduction of fresh infection by the operation may be left out of the question. The results of operations, in which localised collections of pus are found, bear out those inferences, because the patients so seldom die of peritonitis. In truth, this chronic form of suppuration is not greatly to be feared as a complication of operations for removal of the appendix. The abscess is drained with a rubber tube, and the wound not infrequently heals by first intention.

The diagnosis of chronic appendicular abscess is usually very difficult or, perhaps, impossible. Owing to the smallness of the abscess and its position beneath the cæcum or in the pelvis, the ordinary physical signs are absent.¹ A tumour which was hot and painful, with the skin over it red and œdematous, and which fluctuated, would hardly permit of doubt. But such obvious signs are nearly always wanting, and reliance has to be placed upon the other clinical indications. The nature and value of these are illustrated by the following:—

CASE 51.²—*Appendicitis with Perforation and Chronic Appendicular Abscess.*—X., æt. twenty-six, a healthy countryman and baker by trade, was seized ten weeks before with a sudden pain in the right side of the abdomen. At the same time, he became constipated, his abdomen swelled, and he felt sick but did not vomit. Shortly afterwards, a swelling appeared in the right iliac fossa, and had never gone away. Before the operation, a fixed, indurated, and tender swelling was felt beneath the right linea semilunaris, but its characters were masked by the muscular rigidity. Fluctuation was absent. The result of the rectal examination was negative. The right hip was slightly flexed. Whilst under observation in the hospital, the evening temperature rose to about 100° F., and the pulse was 90, rather rapid for a stolid countryman. The pain, tenderness, and swelling also underwent a gradual increase. The patient's aspect was anxious. He had no night sweats.

Relying upon the continuous pain in the iliac fossa, the slight increase in the size of the tumour, the slight elevation of temperature, and the acceleration of the pulse, I inferred that an abscess had formed. At the operation, the vermiform appendix was found in the iliac fossa beneath the cæcum and end of the ileum, to both of which it adhered. Its end was perforated, and an abscess containing about an ounce

¹ Care ought to be exercised in feeling for fluctuation. Dr. Daniel (*British Medical Journal*, September 8, 1894, p. 531) has related a case in which an abscess burst into the general peritoneal cavity. Fortunately by incision, washing out, and drainage, the patient's life was saved.

² This case was described at length in *Clinical Journal*, May 26, 1897, p. 76 *et seq.*

of pus was found in its vicinity. The patient made a good recovery.

In spite of care and circumspection, I have several times found appendicular abscesses in cases in which they were not expected.¹ If many of these were put on record we might perhaps ultimately discover symptoms upon which a diagnosis could be based. The following is an illustrative case:—

CASE 52.—*Appendicitis—Subsidence of Acute Symptoms—Latent Peri-appendicular Pelvic Abscess.*—X. Y., æt. six, was seen at the height of an acute attack of appendicitis. On April 19, at 5 A.M., she was seized with violent pain in the abdomen, accompanied with vomiting, and a rigor. The temperature rose to 100° F. On April 19 and 20, she remained ill with acute abdominal pain, constipation, and slight distension, but the bowels acted with enemas. On April 21, the temperature was 102° F. and the pulse rate 120. On this day she cried out after micturition. On April 22, this pain was worse, and the pulse had risen to 130. The lower part of the abdomen was slightly rigid and tender, and a very tender tumour was felt high up the rectum, on the right side and in front. The right iliac fossa was not more tender than the left.

I diagnosed an acute appendicitis with pelvic position of the appendix. It was also inferred that, although acute, the inflammation was limited to the pelvis.

After April 22, the temperature and pulse fell, the pain on micturition disappeared, and the rectal swelling became smaller and only slightly tender to pressure.

By May 3, the child seemed quite well, although rather anæmic.

I decided, however, to excise the appendix, being mainly influenced by the following considerations:—First, the acuteness of the attack; second, the position of the appendix, which rendered another attack more dangerous; third, when at home the child was far from surgical aid; fourth, inquiry

¹ Krufft mentions similar cases. "The Early Operative Treatment of Perityphlitis Stercoralis from Perforation of the Vermiform Appendix" (*Annals of Surgery*, vol. x. p. 138. Trans. from Volkmann's *Klin. Vorträge*, No. 381, January 15, 1889).

revealed that there had probably been a previous attack. Eighteen months before she complained of great pain in the abdomen, and especially during and after micturition. The urine passed about this time contained pus cells and albumen. Tubercle was suspected and investigation made for it by Drs. Kanthack and Andrewes, but none was found, although inoculations were practised.

An incision was made in the right linea semilunaris, and the appendix was removed. It was not easy to discover, as it hung over into the pelvis, where its end was surrounded by an abscess containing about an ounce of foetid pus. With the exception of the drainage tube opening, the wound healed by first intention. I am unable to say whether the appendix was perforated or not, because it was much damaged in removal.

The histological sections throw hardly any clear light upon the cause of the abscess. The proximal sections have a small irregular lumen (.75 mm. in widest part) and thickened walls (2 mm. to 2.5 mm. thick), the distal sections have thinner walls (1.5 mm.), being less inflamed, and a wider lumen (2.5 mm.). The peritoneal coat is inflamed with proliferation of endothelium, some fibrinous exudation, groups of inflammatory cells, engorged blood-vessels, and dilated lymphatics. The muscular coats are infiltrated with inflammatory corpuscles. The submucosa looks condensed. Its blood-vessels are small and have thick walls. It is infiltrated with inflammatory cells in proximity to the lymphoid follicles and follicular lymphatics. Its lymphatics are numerous and dilated, and some of them are plugged with inflammatory corpuscles. The follicular sinuses are dilated to twice or even thrice their usual size, but the follicles themselves, although swollen and inflamed, still exhibit their usual structure; otherwise the mucosa is almost normal. The epithelium of the lumen and of the tubular glands is intact, and the stroma of the retiform tissue, in which the latter are imbedded, is quite clear and distinct. The lumen contains a little mucus, some blood corpuscles, and small clumps of nucleated cells, with the usual short ovoid bacilli amongst them. These are the only bacteria which can with certainty be recognised. There is no trace of tubercle or of tubercle bacilli.

In this case, the lymphatic tissues and lymphatics are most conspicuously at fault. The perfect preservation of the mucosa is rather remarkable, although occurring in a somewhat similar case of abscess (Case 55, p. 180), as well as in other cases of lymphangitis and lymphadenitis. The histological examination and clinical history, taken together, suggest very strongly that, as might be inferred from their course in other parts of the body, appendicular lymphangitis, and lymphadenitis may end in abscess. Unfortunately, neither this case nor any of the others affords any clear information as to the way in which the abscess originates. Presumably, an acute peritoneal lymphangitis ends in suppuration. On reflection, I am inclined to think that in estimating the possibility of suppuration, more importance ought to have been given to the history of the initial rigor. The subacute type of localised appendicular abscess is illustrated by the following. I am indebted to Mr. Cosens for a very clear and accurate history. Of course, it is to be remembered that the lines of demarcation between chronic, subacute, and acute abscess are purely arbitrary.

CASE 53.—*Appendicitis with Subacute Peri-appendicular Abscess—Abscess in Iliac Fossa.*—On July 27, Miss E., school-girl, aged fourteen years, had a paroxysmal pain in the right iliac fossa. The abdominal walls over the iliac fossa were rigid, and acute pain was caused by pressure half-way between the anterior superior spine of the ilium and the umbilicus. No tumour could be felt. The temperature was 100° F. and the pulse 96. The tongue was white and furred, and the bowels constipated.

The temperature rose steadily day by day until, on July 30, it was 102·4° F., and the pulse had reached 100 and more, with increased abdominal distension and vomiting. A painful tumour was now felt in the iliac fossa, and the thigh was flexed at the hip-joint. Opium had to be given for the relief of pain. On August 14, the temperature and pulse began to fall and, in a few days, became normal, but the tumour in the iliac fossa did not alter in size, and remained painful on pressure. Fluctuation was entirely absent. Any attempt at walking was followed by pain. Throughout the

illness, the result of rectal examination was negative; bladder symptoms were absent, and the urine normal.

The operation was performed on October 2, more than two months after the commencement of the attack, and more than six weeks after its subsidence.

I expected to find an inflamed, swollen, adherent appendix surrounded by adhesions and thickened indurated peritoneum. When the abdomen was opened, adherent omentum was first encountered, then an abscess containing about two ounces of pus. The pus was beneath the cæcum and right colon and around the end of the appendix. The cæcum was of the foetal type and the appendix ran round it from left to right, and then turned back again to end amidst some inflamed and suppurating tissues. Its distal end was probably ulcerated and perforated. No concretion was found.

The remains of the appendix vary in diameter from 6 to 9 mm. The lumen is irregular and from 1 to 1.5 mm. across. All the coats are thickened by inflammatory œdema and cell infiltration. Taken together they are about 3 mm. thick. The peritoneum has been partly torn off, and what remains is full of dilated blood-vessels and lymphatics, and groups of inflammatory cells. The muscular coats are penetrated by numerous blood-vessels, and their fibres separated by groups of inflammatory cells. The submucosa also contains many blood-vessels, lymphatics, and inflammatory cells, and its tissues are œdematous. Its continuity with the inflamed peritoneum, at the hiatus muscularis, is clearly seen in some of the sections.

The epithelial lining of the lumen is perfect, as is also that of the tubular glands. The lymphoid follicles form a continuous ring, and about seven can be counted in each section. Their ovoid centres can be seen, but most of their lymph canaliculi are full of ill-stained granules, presumably derived from pus cells. The reticulum of the lymphoid follicles, as well as that of the rest of the lymphoid tissue of the mucosa is hidden from view, the lymphoid cells being obviously swollen. The follicular lymph sinuses are not dilated, and some are evidently narrowed by compression.

The lumen contains a little mucus, together with a number

of nuclei. No bacteria can be seen in the lumen or elsewhere. There is no trace of tubercle or of tubercle bacilli.

The sections throw no clear light upon the way in which the appendicitis caused the abscess. Unfortunately, the distal end was lost amidst inflamed and suppurating tissues.

Here, again, we have abundant evidences of inflammation of all the coats of the appendix. But it is interesting to observe how little the epithelial elements had suffered. On the other hand, the lymphoid tissues and lymphatics had clearly been the seat of a severe inflammation.

When an abscess is encountered, special precautions have to be taken to avoid contamination of the general peritoneal cavity, to evacuate all the pus, and to provide for drainage. So much depends upon the management of suppuration, that I have discussed it at greater length elsewhere (pp. 184, 188).

CHAPTER XIV

APPENDICITIS WITH ACUTE SUPPURATION

THE following is an ordinary instance of acute suppuration in appendicitis. Several others are given elsewhere (Cases 15, 16, and 17).

CASE 54.—*Appendicitis with Gangrene and Acute Septic Peritonitis.*—The treacherous nature and perils of appendicitis were illustrated by the case of N., aged thirty-seven years. A severe, non-localised, abdominal pain began on March 4, and was accompanied with constipation and vomiting. After having been in bed at his own home until March 10, he got up, but had another attack the following day. Hitherto the abdominal pain had not been localised, but now it was beneath the lower part of the right linea semilunaris. The pulse and temperature were also raised, but to what degree is not known. On March 15, he was admitted into St. Bartholomew's Hospital, and I saw him for the first time on Friday, March 16. The attack had subsided, leaving a slight tenderness on deep pressure in the right iliac fossa, and a trifling degree of rigidity of the overlying abdominal muscles. The subcutaneous fat was at least an inch thick, so that it may have masked the pain caused by digital pressure, but the result of rectal examination was negative, and micturition normal. In addition, the pulse and temperature were normal, and the bowels had acted. I did not see this patient again until Monday, March 19, when I was sent for to perform laparotomy. On Sunday, March 18, he complained of abdominal pain, the temperature rose and the pulse accelerated. Two calomel and colocynth pills were

given, the significance of the symptoms not having been appreciated. It is said that afterwards, on Monday at 5 P.M., the pulse suddenly ran up to 140, and the temperature to 100.6° F. At the operation, the abdomen was distended; the peritoneum was inflamed and some ounces of thin pus escaped as soon as it was incised. The appendix was on the brim of the pelvis, surrounded by foetid pus and imbedded in a mass of septic and inflamed omentum. The pus was swabbed up and washed away with 1 in 1000 biniodide of mercury lotion, and the appendix and mass of septic omentum excised. The tip of the appendix was gangrenous. As soon as possible after the shock of the operation had been sufficiently got over, calomel and enemas were given, and the patient recovered. For some hours his condition was extremely critical. He certainly owed his life to calomel and enemas of assafœtida.

The vermiform appendix is swollen and measures 1 cm. in its largest diameter. Its walls are from 4 to 5 mm. thick, mainly owing to the swelling of the peritoneum and submucosa. The lumen is only .75 mm. in diameter, except in the tip, where it is of the usual size.

The mucosa has disappeared and the peritoneal, muscular, and submucous coats are crowded with inflammatory cells (Fig. 46). The blood-vessels of the peritoneum and submucosa are numerous and dilated. Some of the peritoneal vessels had burst, probably before the operation. At the hiatus muscularis, the septic and inflamed peritoneum and submucosa are continuous. The submucosa is very œdematous. Perhaps a little of the lymphoid tissue of the mucosa remains, but no trace of epithelium or of follicles can be found, except at the tip where the tubular glands and some of the lining epithelium persist, and the lumen is filled with blood clot and nucleated cells. Elsewhere the lumen contains some granules, pus cells, and large multinucleated cells, but the presence of bacteria is doubtful. In the pus and lymph on the peritoneal surface of the appendix and omentum, are some cocci, diplococci, and short bacilli, the latter usually in pairs. These bacteria are scanty and difficult to find. The omentum is a mass of exudation, corpuscles, and fibrin, with

numerous dilated vessels. Both in the omentum and in the meso-appendix, some of the arteries and veins are inflamed.

We may infer that the gangrene of the tip of the appendix took place about thirty hours before removal, and was marked clinically by the pain, rise of temperature, and acceleration of pulse. The sudden rise of the pulse rate, about six hours before the operation, was caused by the extension of the septic peritonitis. The origin of the appendicitis is unknown.

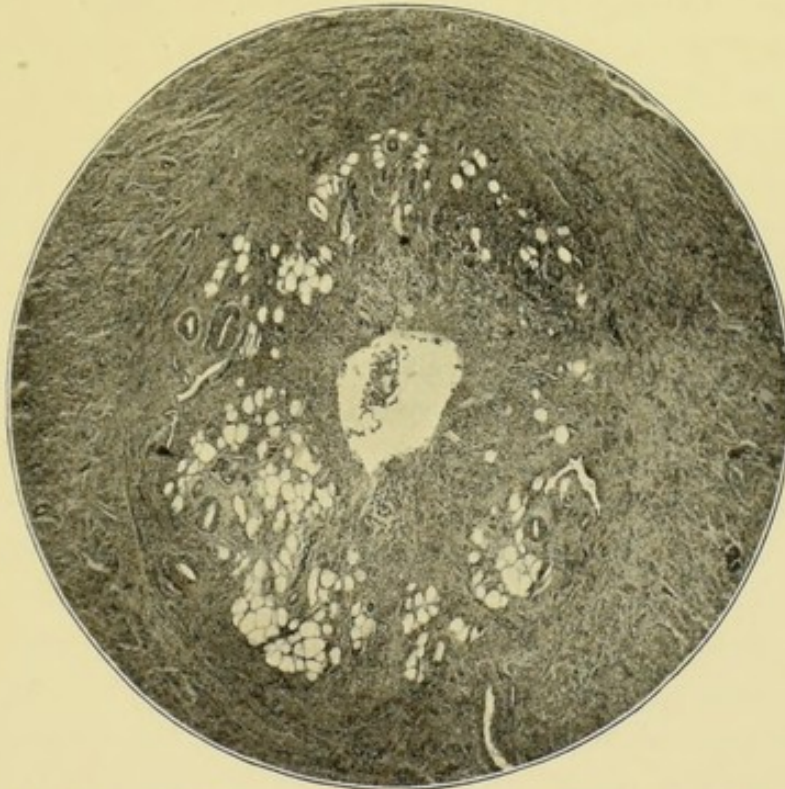


FIG. 46.—Appendicitis with gangrene of the tip of the appendix. All the epithelial and lymphoid elements of the mucosa have disappeared. The submucosa is oedematous, and the muscular and peritoneal coats infiltrated with inflammatory cells. $\times 19$. The section was cut through the middle of the appendix and above the gangrene.

Clinically, it seemed to me like a case of appendicitis with ulceration, fecal concretion, and perforation; but, nevertheless, no concretion was found.

The following is a case of acute localised suppuration in appendicitis, and is of especial importance, because it shows that the abscesses may be multiple and situated at some distance from the diseased appendix.

It is dangerous on all occasions to act upon the belief that in appendicular suppuration there is only one abscess. In the

more diffuse forms of acute septic peritonitis, separate collections of pus are frequently met with amongst the intestines (Case 81, p. 274). But the following shows that, in those which have a tendency to localisation, the abscesses may develop some distance apart from one another.

CASE 55.—*Appendicitis with Subcæcal and Pelvic Abscesses.*
—I. H., a little girl, æt. six, had been attended by Drs. Coleman and Colby for an attack of appendicitis. At the beginning, constipation was a marked feature, but was relieved by enemata, the evacuations being horribly offensive. The abdomen remained painful and distended, the tenderness being most marked in the right iliac fossa, where the abdominal wall was rigid. When I saw her on February 2, 1899, the illness had lasted three weeks, and latterly the temperature had ranged between 101° F. and 102° F. The pulse was 118 and becoming more rapid. The bowels had acted fourteen hours before, but since then no flatus had been passed. The abdomen was distended and the skin marked with red streaks of lymphangitis. The abdomen hardly moved with respiration. It was not very tender, except over the right iliac fossa and along both crural arches. The abdominal wall was particularly rigid over the right iliac fossa, so that no tumour could be felt. I was impressed by a point in the clinical history—the pain was intense whenever the bladder was emptied. I heard her shriek with pain when this was done, after the urine had been retained for nearly fourteen hours. A rectal examination caused intense pain when Douglas's pouch was pressed. A moderately tense swelling was felt *per rectum*. I thought that this was an abscess in Douglas's pouch, and that the pain on micturition was caused by the contraction of the bladder dragging upon the inflamed and exquisitely tender pelvic peritoneum.

Under an anæsthetic, an indurated mass was felt in Douglas's pouch, almost filling the pelvis. A separate tumour occupying the inner part of the iliac fossa was also felt beneath the right linea semilunaris. An incision was made along the right linea semilunaris, so as to give access to both the iliac and the pelvic tumours. The iliac mass consisted of an intensely inflamed vermiform appendix, coiled

upon itself, and so adherent to the iliac peritoneum that their separation was impossible. In the end, the appendix was removed together with a large piece of thickened peritoneum. During this proceeding, a small localised abscess was met with beneath the cæcum.

The pelvic abscess was then emptied by separating the adherent intestines from one another and from the back of the right broad ligament. It contained about two ounces of foetid pus, and was so deep in Douglas's pouch that the pus only appeared when pressure was made through the rectum. A long rubber drainage tube was required. A second tube and some gauze packing were placed in the iliac fossa, and the wound was partially closed to prevent extrusion of the intestines during vomiting. The whole area of the operation was thoroughly irrigated with biniodide of mercury lotion, 1 in 4000. Nothing was seen through the abdominal incision which would have led any one to suspect the existence of the pelvic abscess.

The subsequent history of this case is very instructive. After shock had passed away, the patient began to mend, and by February 5, the temperature had fallen to 99° F., the pulse to 90, and the bowels acted naturally. On February 10, the bowels acted at 10 P.M. and pain on micturition returned. Pain was also complained of in the lower part of the abdomen and about the umbilicus. On February 11, no flatus was passed, and the abdomen became distended. The obstruction was accompanied by occasional vomiting. On February 12, I saw the patient, and, as the temperature had remained about 99° F. and the pulse about 90, I came to the conclusion that the symptoms of obstruction were not due to an extension of the peritonitis, but to the matting of the intestines in the pelvis. An anæsthetic was again administered and a finger gently pushed into the pelvis through the wound, and all the adhesions thoroughly separated. Calomel was given as soon as she recovered from the anæsthetic, and next day the bowels were twice relieved, and she began to recover.

This was not, however, the final complication. On February 18, the temperature ran up to 103° F. and the pulse to 150. This had been preceded by some very foetid dis-

charge from the drainage tube in the pelvis. At first, it was thought that these alarming symptoms were due to septicæmia, but when I saw the patient on February 19, the pulse and temperature had both begun to fall.

The rapid pulse of septicæmia is associated, as I have shown elsewhere,¹ with the growth of bacteria in the vessels of the myocardium. In septicæmia, a constant cause is associated with a constant effect, so that the pulse continues to accelerate until the patient is moribund. Now, in the case under consideration, the pulse was falling, with slight improvement in other respects. The conclusion was, therefore, arrived at that we had to deal with a severe attack of sapræmia, caused by the putrid pus in Douglas's pouch. Thorough irrigation was employed, and ultimately the child made a complete recovery.

From the duration of the illness, it is clear that the peritonitis was not very virulent. The operation, moreover, showed that it had a decided tendency to cause adhesions and become localised. These two points permitted me to venture upon a rather favourable prognosis. But this tendency to form adhesions was the cause of a subsequent attack of acute intestinal obstruction. About a year after the peritonitis, Dr. McDougall, of Cannes, operated successfully, and released a loop of small intestine which had become strangulated by a band of adhesion in the pelvis. The child now enjoys excellent health.

The appendix is less altered than I expected (Fig. 47). The peritoneum is inflamed, infiltrated with cells and fibrinous exudation, and twice as thick as usual. Its junction with the inflamed iliac peritoneum is not very clear. The muscular coats are thin, and the fibres separated by inflammatory exudation.

The submucosa contains a moderate quantity of inflammatory cells, and its blood-vessels and lymphatics are dilated. The muscularis mucosæ is probably absent. The lymphoid follicles form almost a complete ring; as many as nine can be counted in one section. Six are separated from the lumen by

¹ *Hunterian Lectures on Traumatic Infection*, Edinburgh and London, 1896, p. 71, *et seq.*, Figs. 15, 16, and 17.

tubular glands; three project as far as the lumen of the appendix, into which, owing to the destruction of the lining epithelium and basement membrane, their minute lymph channels open. Most of the follicles possess no basilar lymph spaces; two or three have small irregular ones. The tubular glands are dilated, but their epithelial linings are perfect, except at their mouths, where they have been shed along with the epithelium of the lumen. Goblet cells are numerous. The lumen is not dilated and is of the usual trefoil shape. It

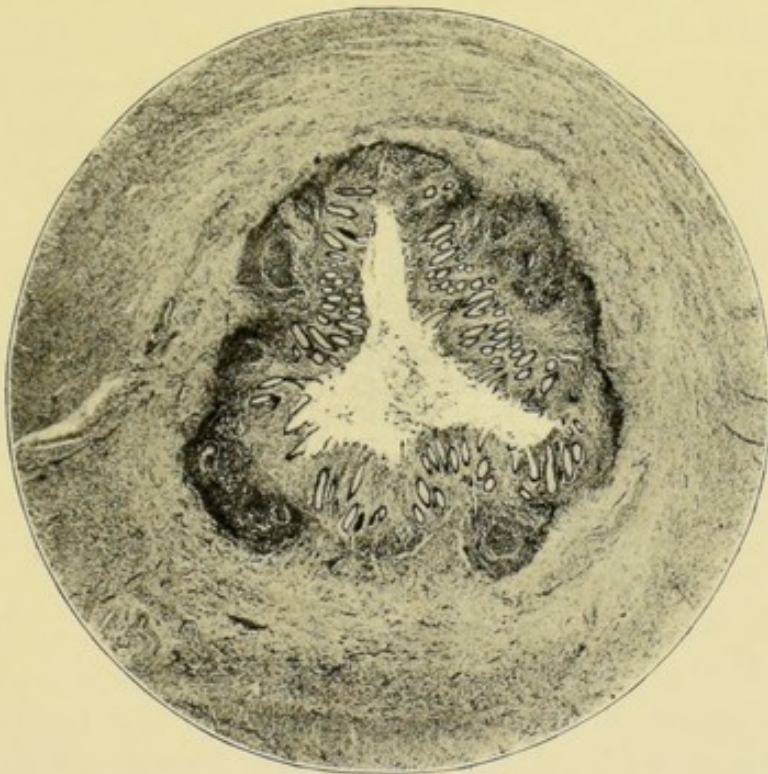


FIG. 47.—Appendicitis with a peri-appendicular and also a pelvic abscess. $\times 16$.

contains mucus, nuclei, detached epithelium, but no bacteria. Bacteria are also absent from the walls of the appendix. There are no signs of tubercle or of tubercle bacilli.

Thus the histological examination of this appendix shows, I think, that when it was removed it had ceased to be the cause of the grave clinical symptoms. These were evidently attributable, in the first place, to the abscess in Douglas's pouch, and, in the second, to the small abscess beneath the cæcum. The specimen does not, in my opinion, throw any clear light upon the mode of formation of either of those abscesses.

Evidence of perforation of the appendix was not obtained. Had the appendix been perforated the subcæcal abscess would, of course, have been at once explained. At the same time, the origin of the pelvic abscess would still have remained in doubt.

The pelvis is the commonest seat of an abscess that develops at a distance from the diseased appendix. But it is also to be remembered that pus may collect in the right hypochondrium and right flank in the space below the right lobe of the liver, as described by Morison. I have not met with an acute appendicular abscess in this region, but have had to open one which was chronic (Case 76, p. 253).

Mr. Robinson¹ has given an account of cases in which abscesses formed in that situation after the primary operation, and were emptied and drained by means of incisions made below the right costal margin.

In the acutest form of septic peritonitis with infection from a septic, gangrenous, or perforated appendix, the chief collection of septic fluid is around the appendix. But other foci are often opened in separating the coils of intestine (Case 79, p. 268). In judging how far this ought to be done, I am guided by the severity of the clinical symptoms, and by the character of the peritonitis. It may be advisable to separate intestines which are intensely inflamed, slightly glued together, and smeared over with septic lymph, as one seldom fails to find in their midst small collections of septic serum and pus. These fluids, together with scraps of the lymph, can be removed by swabbing and sponging. The sepsis can, moreover, be diminished by the abundant application of biniodide of mercury lotion, 1 in 1000 or 1 in 2000. On the other hand, it would be unreasonable to disturb the intestinal coils when the clinical symptoms have been of moderate severity, the abscess localised, and the contiguous peritoneum but slightly inflamed, inadherent, and smooth and shining.

In acute infective appendicitis, with or without perforation or gangrene, an early incision evacuates some evil-smelling serum and, perhaps, some thin starch-like pus from the vicinity of the appendix. Evidently the serum precedes the pus.

¹ "Some Complicated Cases of Peritonitis and their Surgical Treatment," *Lancet*, May 6, 1899, p. 1209.

The usual morphological characters of the pus in acute septic peritonitis are shown in the accompanying photograph (Fig. 48). The pus was obtained from the abdomen of a youth who died of septic peritonitis due to a gangrenous appendix.

Whenever I have inoculated culture media from the pus of appendicular suppuration, the bacillus coli communis has grown. But it does not follow that this was the only organism present, or that it was the most harmful. Indeed, the peritoneum seems able to resist considerable doses of colon bacillus,

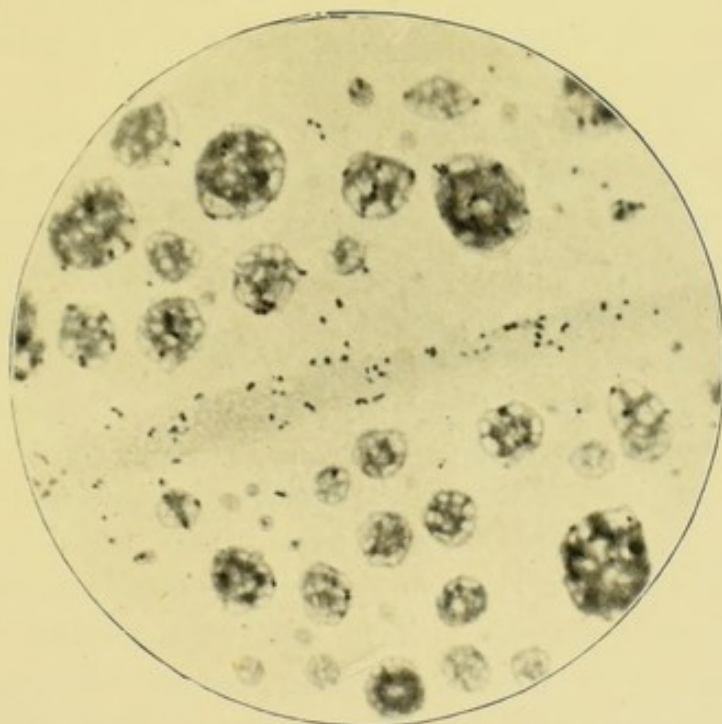


FIG. 48.—Pus from peritoneal cavity in diffuse septic peritonitis caused by appendicitis. The photograph contains numerous bacteria and small clumps of pus cells and coagulated albumen. $\times 1000$.

if we may judge from the impunity with which it is sometimes smeared with the pus from stinking abscesses (*e.g.* Case 52, p. 172).

Tavel and Lanz, in their admirable and much quoted monograph,¹ give a full account of the bacteria met with in the lumen of the appendix and in appendicular abscesses. These comprise many varieties of colon bacillus, encapsuled bacilli, cocci, diplococci, streptococci, staphylococci, pneumococci, and saccharomyces.

¹ *Ueber die Aetiologie der Peritonitis*, Leipzig, 1893.

The various varieties of colon bacillus possess two marked peculiarities. First, they play a great part in converting organic substances into fæculent material; and secondly, they produce offensive gases in large quantities. The colon bacillus is continuously forming gases within the intestines, and when their escape is prevented by mechanical, inflammatory, or paralytic obstruction, they accumulate and cause tympanites.

But the colon bacillus can also produce its ptomaines and gases outside the intestines, and, therefore, it is usual for appendicular abscesses to have a fæculent odour, and also to contain offensive gases.

In diffuse septic peritonitis, too, the peritoneal cavity often contains gas, although actual perforation has not occurred. I do not intend at present to enter upon the vast subject of the modes of causation of peritonitis, but merely remark that there is abundant evidence now to show that intestinal bacteria can escape through the intestinal and, I might add, appendicular walls, when they have undergone changes far short of perforation or of gangrene.

As I have said elsewhere, the colon bacillus is not always very virulent and does not, as a rule, invade the depths of the peritoneum. But, unfortunately, it is often associated with virulent pyogenic cocci. Two of these, the streptococcus pyogenes and the staphylococcus pyogenes aureus, are well known for their virulent properties. The streptococcus pyogenes was, I believe, concerned in the causation of portal pyæmia and hepatic abscess in one of my cases (Case 31, p. 119).

Tavel and Lanz, in fifty-nine cases, found streptococcus pure in three cases, and in combination in fifteen.

We have had various instances of the course pursued by acute septic peritonitis. It may end in suppuration which becomes localised and for a time quiescent (Case 52, p. 172). Or the septic inflammation, after forming an acute abscess, may continue to spread and become diffuse. In a small proportion of cases, however, the septic peritonitis is diffuse from the beginning, the limits of the disease cannot be defined, and if left alone, the patient soon succumbs to intestinal paralysis and general toxæmia.

The conversion of acute localised septic peritonitis into diffuse septic peritonitis, has certainly become rarer of late, because of the great improvements which have been made in the art of diagnosis; and also because the advantages of more expeditious surgical intervention are recognised. It is now not unusual to see cases of septic peritonitis recover which, but ten years ago, would have inevitably died. In acute localised septic peritonitis, the indications afforded by the pulse, temperature, vomiting, constipation, distension, pain, tenderness, and tumour are perfectly clear, unless masked by the administration of morphia.

It is very difficult, in surgical practice, to classify cases and say that in one the septic peritonitis was localised, that in another it had been localised but had afterwards become diffuse, and finally, that another had been diffuse from the beginning. But, I think, this is a correct way of representing the cases I have operated on since September, 1893. That date is taken, because I then began to keep a note of every operation and of its result. The infection in each case is known to have been derived from the appendix. Peritonitis caused by perforations of other parts of the alimentary tract and pelvic organs is excluded.

Acute localised septic peritonitis—

No. of cases, 14. Recovered, 14; died, 0.

Diffuse septic peritonitis—

No. of cases, 5. Recovered, 3; died, 2.

Doubtful whether still localised—

No. of cases, 6. Recovered, 3; died 3.

In diffuse septic peritonitis, M'Burney¹ records twenty-four cases with ten deaths.

It was a question whether it was worth while operating upon some of my cases. They had reached the stage graphically described by Professor White,² and presented "the typical picture of diffused peritonitis, the incessant restlessness, the greatly distended abdomen, tender everywhere to the slightest touch, dorsal decubitus, constant vomiting of small

¹ "The Treatment of the Diffuse Form of Septic Peritonitis occurring as a Result of Appendicitis" (*Med. Record*, N.Y., vol. xlvii. Mar. 30, 1895, p. 384, *et seq.*).

² *Lancet*, Feb. 16, 1895, p. 389, *et seq.*

mouthfuls without much effort, thoracic respiration, obstinate constipation, absence of intestinal sounds, and high fever, followed towards the end by subnormal temperature, cold sweats, and collapse." Professor White considers that these cases are absolutely hopeless when paralysis of the intestines has appeared, and he thinks it best to decline to operate. It is, however, hard to be sure that recovery may not ensue in those who are young, and endowed with strong vitality, and who, above all things, possess a healthy and vigorous heart. The last is all-important. I have elsewhere published cases of recovery under the most desperate circumstances.¹ The chances of success depend upon the care with which the operation is organised, and upon the rapidity with which it is performed. As a preliminary, the action of the heart should be stimulated by the subcutaneous administration of strychnine ($\frac{1}{50}$ gr.) before anæsthesia, and also by a nutrient enema containing an ounce of brandy. The limbs should be wrapped in flannel or sheets of cotton-wool. The temperature of the room or operation theatre should be raised to 75° F., and a hot-water bed or table should be provided. The administration of the anæsthetic requires great skill. Ether is unsatisfactory, owing to the abdominal distension. The A.C.E. mixture is, I believe, the safest and best, though rather slow in its action.

All instruments and sponges should be used out of warm lotion, temperature 105° F. A thermometer should be provided for the nurse, who ought to be made to use it. An irrigator should also be ready, or, if none be at hand, a large jug, to pour the lotion into the abdomen. The usual precautions must be taken to ensure asepsis. The abdomen having been opened, gas and pus are usually met with, and the latter should be immediately swabbed up with sponges, and washed away with abundance of hot lotion. The portions of septic lymph should also be sponged or pulled away. The inflamed peritoneum may ooze at this stage, but hot lotion (temperature

¹ "The Surgical Treatment of Diffuse Septic Peritonitis, with successful Cases" (*Med.-Chir. Trans.* vol. lxxviii. 1895).

Also "The Diagnosis and Treatment of General Septic Peritonitis" (*Clinical Journal*, April 1, 1896). Also "The Surgical Treatment of Acute Septic Peritonitis Localised and Diffused" (*Clinical Journal*, June 8, 1898).

105° F.) will arrest the bleeding. In searching for the appendix, more pus is usually met with amidst the coils of intestine, and should be rapidly washed away. In cases of this kind, the adhesions are of the slightest description. The appendix and its mesentery are usually too friable for elaborate treatment. Each should be tied with catgut and divided with scissors.

Sometimes, before this can be done, the distended intestines must be emptied of gas and feces. The gaseous contents easily escape through a puncture made with a small trochar and cannula (1.5 mm. diameter).

Should coils full of feces present themselves, those most distended must be withdrawn and opened longitudinally with knife or scissors at the side away from the mesentery. When all the gaseous and fecal distension has been relieved, the punctures and incisions should be closed with Lembert's sutures, and the intestines returned.

The remains of the pus and flakes of lymph are finally washed out of the abdomen with abundance of lotion. Attention must be directed in turn to each flank, to the iliac fossæ, to the root of the mesentery, and to the intestines. The abdominal cavity above the transverse mesocolon does not, as a rule, contain any pus.

Finally, a large rubber drain should be placed in Douglas's pouch and the wound sutured. These sutures only hold for a few days because the wound is almost certain to suppurate, but they serve to prevent extrusion of intestines during the vomiting.

After the operation is over, every effort should be made to prevent death from shock. Warmth must be maintained, and strychnine, brandy, or small doses (10 to 15 min.) of *Tr. Opii* administered. The latter should only be given when absolutely necessary for the relief of pain, and then, preferably, in a small nutrient enema, for there is always a risk of its aggravating the flatulent distension, which is the next great danger. This symptom is associated with intestinal paralysis, vomiting, and thirst, the treatment of which is mentioned elsewhere (Chap. XXI. p. 260).

Acute septic peritonitis is a deceptive and treacherous

disease. Before the end, the pain and vomiting may subside, and, owing to some form of septic intoxication, the patient may be cheerful and sanguine of recovery, he may even smile when spoken to, and answer with a strong voice; but the eyes, though sunken, are preternaturally bright, and the cheeks flushed. One glance at the abdomen, or one attempt to count the pulse, tells the inevitable end.

CHAPTER XV

CLINICAL SYMPTOMS OF APPENDICITIS

THE usual symptoms ascribed to appendicitis are pain in the right iliac fossa, constipation, abdominal distension, vomiting, rise of temperature, acceleration of the pulse and respiration. A tender place or a tumour, or rigidity of the abdominal muscles, may be discovered in the right iliac fossa.

But nearly always these symptoms belong, in reality, to the second phase of appendicitis in which the inflammatory process has had time to spread to the lymphatics, veins, peritoneum, and structures in the vicinity of the appendix. The first phase is that during which ulceration of the mucosa is spreading, strictures forming, and concretions growing.

During this phase, the diagnosis is often easy, but may be difficult, and only accomplished after the patient has been kept under the closest observation (Case 4, p. 40). As we have seen, the symptoms are obscure abdominal pains, settling at last in the iliac fossa, indigestion, flatulence, disorder of the bowels, constipation or diarrhoea, capricious appetite, inability to eat fruit or vegetables, unpleasant tastes in the mouth, odours in the nostrils, slight variations in the temperature, tenderness on pressure in the iliac fossa, slight muscular rigidity, tenderness in Douglas's pouch. At length, a classical attack of appendicitis supervenes and may eventuate in abscess, perforating ulcer, or gangrene and their sequelæ.

In the second phase, the clinical symptoms are much more emphatic. Grouped under the term "Perityphlitis" much has been written about them and, in accordance with some of the rules laid down, the earlier symptoms are often ignored. It

seems by some to be considered right to wait for perityphlitis, whereas, in many cases, it is a complication that ought never to be allowed to supervene.

The evidence upon which I base this opinion, is given in the chapters which deal with appendicitis with ulceration of the mucosa, and appendicitis with ulceration of the mucosa and concretions.

The rapidity with which pathological changes occur in the appendix is attended with correspondingly rapid clinical phenomena. For instance, gangrene of the appendix may occur in a few hours, and all the clinical phenomena may run their course in a few days.

Ulceration of the mucosa is a slower process, and is attended, during its earlier stages, with such slight symptoms that they are often overlooked by the unobservant. Ulceration, with a concretion, is usually attended with constant discomfort and occasional severe attacks of pain. At last, the appendicular symptoms become merged in those of perityphlitis. Cases with faecal concretion are slow in their earlier stages, because the growth of concretions is slow, and because the accompanying ulceration is chronic. The final ulceration, perforation, and gangrene are, of course, rapid. They supervene upon the stage of slow growth and ulceration, and are being precipitated by some unusual disturbance, such as exposure to cold (*e.g.* Case 81, p. 274).

Some cases of stenosis of the appendix are of still slower progress. The process of inflammation and cicatrisation takes a considerable time. Until the stricture of the appendix becomes impassable, the clinical symptoms may be slow in their evolution, but when, at last, occlusion is complete, the pent-up contents cause continuous and perhaps severe clinical phenomena. As I have already demonstrated, a good deal depends upon the nature of the pent-up contents.

I am inclined to think that pain is one of the earliest and most prominent symptoms of appendicitis.

We have to consider two kinds of pain. First, that which the patient can tell of; and second, that which the surgeon can elicit. Of course, the degree of pain described by the patient depends upon many circumstances, some of which are psychological.

At the commencement of the attack, the patient seldom locates the pain in the iliac fossa. As a rule, it is said to be felt all over the front of the abdomen, and especially about the umbilicus; and is referred to the peripheral distribution of the somatic and splanchnic nerves which enter into the formation of the solar plexus. In a few hours, perhaps, the acutest pain is felt in the region of the appendix. A gentleman, when first seen by Mr. Poulter, complained of pain about the umbilicus and in the region of the solar plexus. When seen a few hours afterwards, he had himself put a belladonna plaster over the appendix.

Not infrequently, pain is felt in the distribution of the anterior crural nerve, or in the spermatic cord and testicle, along the course of the genito-crural nerve. The testicle may retract.

A point beneath the right linea semilunaris, about on a level with the anterior superior spine of the ilium, is oftenest indicated as the most painful spot, and is the most tender on pressure. But I have found it unsafe to assume that the appendix will always be found beneath the spot which is said to be painful on pressure. A lady (Case 65, p. 219) had a tender place an inch above the outer half of Poupart's ligament, but the inflamed appendix was beneath the right rectus, about two inches from the umbilicus. A youth had great pain and tenderness beneath the lower part of the right rectus and in the recto-vesical pouch, whilst the acutely inflamed and perforated appendix lay external to the cæcum and right colon (Case 17, p. 81). When the inflamed appendix is in the pelvis, I have usually observed the pain referred to the umbilical region, and also elicited the greatest tenderness on pressure *per rectum*.¹ As a rule, acutely inflamed peritoneum is exquisitely tender, but that which lines the front of the abdomen is, to some degree, protected from direct pressure by the thickness of the subcutaneous and subperitoneal fat, and by the rigidity of the abdominal muscles. Very stout people may bear hard pressure upon the front of the abdomen,

¹ Bryant, *Annals of Surgery*, 1893, p. 178. "The pain, tenderness, and tumour in these cases are nearer to the median line in front, and rectal examination often discloses the presence of heat, induration, and abscess in the pelvis."

although suffering from general septic peritonitis (Case 79, p. 268). Therefore, in estimating the degree of tenderness and pain on pressure, the thickness of the abdominal wall has to be taken into consideration.

The tenderness is felt in the inflamed appendix, and also in the inflamed visceral and parietal peritoneum. When the appendix occupies the pelvic or extracæcal positions, the absence of a tender spot in the iliac fossa has been a frequent source of error. The peritoneum, too, may be inflamed at some distance from the appendix (Case 17, p. 81), and collections of pus may be separated from it by a considerable interval (Case 55, p. 180).

I have seen the pain located beneath the right eighth costal cartilage, so that an experienced surgeon diagnosed gall-stones (Case 37, p. 133).

In a young lady, the acute pain beneath the right costal margin, accompanied with vomiting, suggested a gastric or duodenal ulcer. I have also seen cases in which the pain was greatest along the upper half of the right linea semilunaris. In one of this kind, the lymphatics behind the right mesocolon were inflamed (Case 31, p. 119).

The extent of the abdominal wall which is painful on pressure, is a fairly accurate indication of the extent of inflamed peritoneum. The examination is easily bungled. The pressure should be made with the tip of the finger, and be light at the beginning and then gradually harder. The parts farthest from the appendix should be examined first, and the rectum never omitted. The statements of patients, as to the presence of pain, are to be accepted with extreme reserve, and only acted upon when corroborated by the other clinical signs. The neurotic easily imagine that they have got appendicitis. On the other hand, pain may be absent even when diffuse septic peritonitis is established. I saw a woman whose abdomen was soft and painless and which moved with respiration, although she died in a few hours of diffuse septic peritonitis caused by gangrene of the appendix.

Chronic appendicitis is accompanied with one of the most striking gestures of disease. When the patient, who is standing up, is asked whereabouts the pain is felt, the

trunk is slightly bent forwards and to the right, the face being turned in the same direction, and the flat of the hand is placed over the right iliac fossa. Sometimes the right thigh is at the same moment slightly flexed, adducted, and rotated inwards. These movements of the trunk and limb are instinctive. The question recalls the pain, and the attitude which gave most relief is instinctively resumed. The hand is held flat to cover as much as possible of the painful area. A strictly localised pain is indicated with the tip of the finger.

In appendicitis, the inflammation often spreads to the peritoneum of the iliac fossa, and may reach the iliac fascia and iliacus muscle. In a case of this description (Case 51, p. 171) the appendix was perforated, and lay in the iliac fossa, coiled upon itself and adherent to the small intestines, and surrounded by a chronic abscess. The peritoneum covering the iliacus and lower part of the abdominal wall was thickened and inflamed. Before the operation, the right thigh was flexed upon the abdomen, and any attempt at extension was resisted. The explanation is very simple. When the thigh is flexed, the crural arch and abdominal wall are relaxed. The fixity of the hip was probably due to actual inflammation of the iliacus muscle as well as of the iliac fascia and peritoneum. I have known the lameness and the fixation of the hip, in chronic appendicitis, delude the inexperienced and lead to the diagnosis of hip-joint disease. In acute appendicitis with perityphlitis and abdominal distension, both hips are usually flexed. Dr. Kelynack¹ refers to a case of appendicitis which was mistaken for "hysterical hip-joint disease," and says Gibney has recorded several cases in which hip disease was closely simulated.

Appendicitis may also simulate psoas abscess, because an appendicular abscess sometimes tracks into the right psoas muscle.² The absence of spinal rigidity or curvature should prevent this error. It is hardly necessary to add that the symptoms of iliac abscess, due to spinal caries, may also be closely simulated.

In chronic appendicitis, gurglings and *bauba rigma*

¹ *Loc. cit.* p. 154.

² Jacobson, *Operations in Surgery*, p. 804.

occur rather frequently in the neighbourhood of the cæcum. Whilst examining the cæcum, a curious gurgle is often heard or felt, and, at the operation, some dilatation of the cæcum is discovered. The patients, too, complain of colic and increased vermicular movements. But in acute perityphlitis the movements of the intestines are lessened or stopped by the inflammation of their serous covering. When that is acute and extensive, no movement can be seen, or heard, or felt. In thin subjects, the distended intestinal coils can be seen bulging the abdominal walls. In peritonitis, each bulge is motionless, and does not rise and fall even when sharply tapped with the finger. In distension due to mechanical obstruction, the bulgings appear and disappear as the intestines struggle to overcome the obstruction. This goes on until the muscular coats become exhausted, when stillness prevails. During this stage, a stimulus will sometimes excite fresh movements. But, at last, peritonitis ensues and all movement is abolished. A profound stillness accompanies the paralysis of peritonitis. Nothing can be heard with the stethoscope. In mechanical obstruction, a curious turmoil may be heard until exhaustion or peritonitis sets in.

When the abdominal viscera are inflamed and tender, the overlying muscles assume a protective rigidity. In appendicitis, this is seldom entirely absent, and is greatest when both the visceral and parietal peritoneum are inflamed. The rigid muscles protect the inflamed organ against pressure from without. Spasm is excited by rough and unskilful handling, so that sometimes an appendicular tumour of considerable size is overlooked. I have notes of two cases in which the muscular relaxation, caused by the anæsthetic, revealed a considerable tumour in the right iliac fossa. Before operating, I always feel the abdomen as soon as anæsthesia is established, and frequently discover a swelling which had hitherto been masked by the contracted muscles. In the majority of instances, the muscular rigidity is partial and, in appendicitis, is confined to the lower parts of the right internal and external oblique and transversalis muscles and to the right rectus abdominis. Even a small area of muscular

rigidity is of diagnostic value, because it helps to indicate the presence and situation of the inflamed organ. When a large area of the peritoneum is acutely inflamed, the whole abdomen may be motionless and rigid. Even the movements of the diaphragm are lessened or suppressed, so that respiration becomes purely thoracic. But too much is not to be inferred from the absence of this sign. I have recently seen the case of a woman who had a gangrenous appendix with diffuse septic peritonitis, but whose abdomen was soft and moved freely. Apparently, she suffered little pain even when pressure was applied to the abdomen.

In the slighter forms of appendicitis, such as those with ulceration of the mucosa, the muscular rigidity may be very circumscribed. Not infrequently, the outer edge of the contracted rectus abdominis feels peculiarly round, and rolls under the finger like a swollen appendix. I have known the inexperienced to be deceived by this, especially when they have ignored the golden rule and forgotten to examine both sides. The muscular fibres of the external oblique may also contract under the finger, and cause a sensation as of an elongated body resembling the appendix. This irritable contractility is not confined to one set of fibres, but may be felt upon the left side as well as upon the right. Muscular rigidity may be so great as almost to simulate the extreme hardness caused by fibrinous exudation. The latter, however, persists under the anæsthetic, and can therefore be avoided in making the incision (Case 83, p. 280).

CHAPTER XVI

CLINICAL SYMPTOMS—*Continued*

IN more than half the cases of appendicitis no tumour can be felt. In many instances of ulceration of the mucosa, of stenosis, or of kinking, the size of the appendix is little, if at all, increased and the peritoneum is not thickened. As a rule, no tumour exists in acute infective appendicitis with gangrene or perforating ulcer, or where both complications occur. Sometimes a tumour is present but cannot be felt on account of muscular rigidity, or because it is hidden away behind the cæcum or in the pelvis. In acute appendicitis with septic peritonitis and abscess, the abdominal distension usually suffices to hide the tumour. The discovery of a tumour in severe cases is rather favourable than otherwise, for it may indicate some attempt at localisation, or, at the least, it may help to confirm the diagnosis, and serve as a guide to the place for the incision. It is probably impossible to infer the exact nature of what is felt within the abdomen. The inferences drawn by Edebohls¹ from digital examinations in which the appendix was felt rolling under the finger, are apt to be fallacious. The tumour in the iliac fossa may consist of inflamed and thickened intestine, inflamed omentum, thickened peritoneum, fæces, or pus. The pus may be inside or outside the appendix, or the latter may be distended with mucus. Several of the above conditions may be coincident. The possibility that the tumour may be a malignant growth, or caused by tubercle or actinomycosis, has also to be borne

¹ "Diagnostic Palpation of the Appendix Vermiformis," *American Journal of Medical Science*, May 1894.

in mind. I have once mistaken the end of a conical, distended, and inflamed bladder for an appendicular tumour (Case 62, p. 213). After many mistakes, I am inclined to think that the appendix itself is seldom felt. In a recent case, a round tender cord could be felt rolling under the finger when pressed upon the pelvic brim. This was supposed to be the appendix, but that organ was to the right of, and behind the cæcum. The same fallacies prevail when the inflamed appendix is situated in the pelvis, and, in females, the ovaries and tubes become an additional source of fallacy. I have many times seen appendicitis mistaken for inflammation of the right ovary and tube.

Many appendicular tumours are immovable owing to adhesions and inflammatory exudation.

The presence of a tumour or collection of pus is often concealed by the muscular rigidity. In these circumstances, percussion may assist us. If the rigid and tender area be resonant, we may perhaps infer the absence of much inflammatory exudation or pus. Dulness, on the other hand, might indicate their presence. But it is to be remembered, that appendicular abscesses often contain gas, and also that feces may accumulate in the cæcum.

I have never used an exploring needle as an aid to the diagnosis of appendicular abscess. In most of the cases upon which I have operated, the needle must have been pushed through the cæcum or small intestines before it could have reached the abscess. I confess that I feel a repugnance to surgical procedures which are not guided by vision.

Generally speaking, appendicitis is attended with constipation. But exceptions to this rule are numerous, and looseness of the bowels or diarrhoea is often met with. Indeed, one can hardly generalise further than to say, that appendicitis is associated with some disorder of the digestion and of the action of the bowels.

Some degree of abdominal distension is seldom absent in appendicitis. Its degree is an indication of the gravity of the disease. In ulceration of the mucosa, stenosis, kinking, and conditions without much typhlitis or perityphlitis, it is probably accounted for by swelling and inflammation of the

ileo-cæcal valve, and of the intestine supplied by the ileo-cæcal arteries. But when there is any degree of inflammation of the serous covering of the cæcum, colon, and end of the ileum, those portions of the intestine become still. They are immobile, like an inflamed knee or hip, and cease to propel their gaseous and faecal contents, consequently, as the formation of gas by the intestinal bacteria is continuous, an accumulation soon takes place.

The extent of intestinal paralysis is mainly dependent upon the extent of the peritonitis. But, obviously, an obstruction limited to the vicinity of the ileo-cæcal valve may suffice to cause gases to accumulate in all the small intestines. As the late Greig Smith thought, the distended coils compress one another, and render the onward passage of gases and faeces additionally difficult.

Vomiting usually occurs once or twice at the commencement of an acute attack of appendicitis, and then ceases. First the contents of the stomach are ejected, then some mucus and gastric juice, and the latter may be mixed with bile. In neglected cases which have become complicated with septic peritonitis, the vomit may become stercoral. But, sometimes, the vomiting is so frequent and persistent as to suggest an acute mechanical intestinal obstruction. A young lady vomited for many hours during an acute attack of appendicitis, and, some days later, I removed an appendix which was ulcerated, and contained two concretions. She never vomited after the anæsthetic (Case 20, p. 90). A gentleman with appendicitis had persistent vomiting for forty-eight hours. In both of these cases, a mechanical obstruction was negatived by the natural escape of flatus. The method of controlling vomiting is described elsewhere.

The pulse, temperature, and respiration should be considered together. For instance, a high temperature, accompanied with rapid pulse and respiration, indicates an acute appendicitis and peritonitis. A high temperature with a normal pulse is probably transient, and of slight importance. On the other hand, a rapid pulse, accompanied with a low temperature, is often of grave import. On the whole, the pulse gives the clearest and truest information. At the beginning of

acute appendicitis, the pulse rate may suddenly rise to 120 or 130, and then fall at the rate of 10 or 15 beats in the twenty-four hours. A falling pulse betokens the subsidence of the acute inflammation. In estimating the frequency of the pulse, all the usual precautions should be taken. It is usually best to have it counted by the nurse during repose, and in the absence of the medical attendants. The hearts of nervous, excitable patients, especially of young females, beat rapidly under the influence of the emotions.

When the pulse rate suddenly quickens to 110 or 120, and does not fall, the appendicitis has probably resulted in perforation, gangrene, or acute abscess. In operations performed a few hours after the quickening of the pulse, I have many times found that the acutely inflamed appendix had recently perforated, and was surrounded by an area of acute septic peritonitis, with a small collection of pus.

In children, a quick pulse may not have the same significance as in adults. But in them the rate rapidly alters, so that a very few hours' delay will often tell whether it is increasing or diminishing.

I have many times seen the pulse fall as the appendicitis and peritonitis have subsided.

In the case which has already been described (Case 52, p. 172), the pulse was 116 and the temperature 100° F. at the beginning of the attack. Next day the rectal tumour was more exquisitely tender, the pulse was 120, the temperature 102° F., and, on the following day, the pulse was 130, and the temperature 101° F. After this the tenderness began to subside and, in five days, considerable pressure could be borne, the pulse had fallen to 84 and the temperature to normal. Although the attack had begun with a rigor, a perforation was not suspected. In removing the appendix, I found its tip surrounded by an abscess which contained about half an ounce of pus.

CASE 56.—About the same time, I saw a young lady, *æt.* fourteen years, whose case ran a similar course. The onset of the appendicitis was sudden, and on March 25, at 8.30 A.M., the pulse was 120, and an exquisitely tender swelling was felt in Douglas's pouch. The iliac fossa and

front of the abdomen were painless. At 9.30 P.M. the pulse had fallen to 109, and then to 100, although the temperature was 101° F. As the pulse fell, the rectal swelling became less and less tender. I suspect that perforation must have been very near at hand.

In adults with acute appendicitis, a pulse rate which exceeds 100 is a matter of concern. When called to see a doubtful case, I usually request the medical attendant to communicate with me when that limit is passed, especially if the increased rapidity is accompanied with an aggravation of the other local and general symptoms.

CASE 57.—Although acceleration of the pulse is such a constant and valuable sign in appendicitis and peritonitis, its presence is not invariable. I am indebted to Dr. Bagshawe for the notes of a case which I saw in the Great Northern Hospital. A man, aged sixty-two years, had had a sudden and violent pain in the abdomen, with vomiting and constipation. Five days later, the abdomen became much distended, the temperature was 97.8° F., and the pulse 108. Afterwards the temperature fell to 97° F., and the pulse to 88. He died suddenly ten days after the onset. The vermiform appendix was perforated, and the peritoneal cavity full of pus and lymph. A faecal concretion was found in the pus close to the perforation. The heart was hypertrophied, the aorta atheromatous, and the kidneys chronically inflamed.

In another case (Case 80, p. 272), serous fluid was removed from the general peritoneal cavity, and pus from the rectovesical pouch of a boy whose pulse at the time was 90.

When the heart has been beating at the rate of 120 to 130 per minute, for three or four days, it becomes exhausted and at length succumbs. This danger is to be taken into consideration in deciding the question of operation. Success is not very likely to crown the efforts of the surgeon when the heart has been allowed to become exhausted.

I have confined these brief remarks to the rate of the pulse, and have not referred to its quality. No doubt men of experience may draw conclusions of value from the quality of a pulse as well as from its rapidity; but as the latter can be

definitely and precisely counted, as an indication, it far outweighs the more subtle qualities.

The temperature is usually taken in the mouth or axilla. Probably a higher reading would be got in the rectum. In a case of bullet wound of the small intestines and of the duodenum, I found the temperature 98° F. in the mouth and axilla, whilst, in the rectum, it was 103° F.¹ There is nothing characteristic about the temperature chart of appendicitis, for it is such as is seen when any organ is acutely inflamed and invaded by bacteria. As I have just remarked, a sudden rise accompanied with a rigor may denote a rapid invasion of the peritoneum by pyogenic organisms. Perforation and gangrene of the appendix are often associated with rigors (Case 15, p. 75). The repetition of the rigors, with a persistently high temperature, may be due to portal pyæmia.

The pulse and respiration are a check upon inferences drawn from the temperature chart. A high temperature with rapid pulse and respiration indicates serious sepsis, whilst a high temperature with slow pulse and respiration is probably transient.

It is natural for more attention to be given to the temperature, during the attack of appendicitis, but I am convinced that a careful record of the temperature in the intervals between the attacks would lead to interesting revelations.

I have a partial record of the temperature of a young lady with chronic ulcerative appendicitis and faecal concretion. She said that for many months her temperature had fluctuated in an unaccountable manner, and the chart showed a daily fluctuation of a degree and a half of the Fahrenheit scale.

When we consider that in chronic ulcerative appendicitis, the mucous membrane, lymphoid tissue, and lymphatics are invaded by a variety of bacteria, surely we should expect to find one of the commonest effects of infection, namely, an evening rise of temperature.

The breathing is rapid during pain and fever, and also when the diaphragm is pushed up by abdominal distension.

¹ "The Surgical Treatment of Acute Septic Peritonitis," C. B. Lockwood, *Clinical Journal*, June 8, 1898, p. 127.

The number of respirations nearly always diminishes as the temperature and pulse fall, and after the abdominal distension has been relieved. If no diminution takes place, pneumonia or empyema is to be suspected.

The examination of the patient is incomplete without a digital examination of the rectum. When the appendix is in Douglas's pouch, the front of the abdomen is often painless. I have known this absence of pain lead to errors, which a rectal examination would have prevented. Nor can the extent of the peritonitis be gauged without a rectal examination. If the patient be placed upon the back or side, the finger can be passed with the greatest care and gentleness. Any rough or unskilful handling causes so much pain at the anal orifice, that tenderness in Douglas's or in the recto-vesical pouch cannot be discriminated.

If possible, the bladder should be emptied before the examination. A large collection of pus in the recto-vesical pouch feels like a distended bladder. When the pelvic peritoneum is inflamed, pressure on the lower end of the recto-uterine or recto-vesical pouch excites acute pain. Only the rectal wall intervenes between the peritoneum and the finger, elsewhere the subcutaneous fat and the abdominal muscles have to be reckoned with. Inflamed parietal peritoneum is exquisitely sensitive. When it is touched through the rectum, the patient usually shrinks and utters a shrill cry. In inflammation of the pelvic peritoneum, the act of micturition is accompanied with pain, as will be hereafter described. At times, the inflamed appendix can be felt *per rectum* (Case 78, p. 255), but a piece of inflamed omentum, or a peritoneal thickening, or fold, is easily mistaken for it. Small collections of pus in the recto-vesical or recto-uterine pouch are surrounded by exquisitely tender and thickened peritoneum, and fluctuation can seldom be elicited (Case 52, p. 172). It may be difficult or impossible to discriminate between an inflamed appendix and an inflamed Fallopian tube or ovary. I have often seen ovaritis diagnosed in mistake for appendicitis.

When a painful tumour is felt, *per rectum*, the examination ought to be repeated from time to time to learn what course

the disease is pursuing. The information gained in this way may prove of great importance.

The rectal examination may also reveal inflammation of the right broad ligament of the uterus (Case 69, p. 231).

A rectal examination under anæsthesia loses some of its value because the sensation of pain is abolished.

In the majority of females with appendicitis, a vaginal examination cannot be made. This is not a matter of importance, because the extent of peritoneum which can be reached *per vaginam* is quite small. In several instances, I have been unable to feel tender swellings through the vagina which were easily felt through the rectum.

A vaginal examination, however, is sometimes of great value. For instance, in a critical case of appendicitis with perforation and acute suppuration, it revealed an abscess in Douglas's pouch, which was opened and drained by an incision behind the neck of the uterus (Case 81, p. 274).

The act of micturition ought always to be inquired into. Not infrequently, the urine is retained and has to be drawn off. Sometimes, the act of micturition is attended with or followed by acute agony. This is caused by inflamed posterior and lateral false ligaments of the bladder becoming stretched as the viscus empties itself.

I have known children retain their urine for twelve or more hours for fear of the pain, and then shriek with agony during the act. As a rule, the pain is greatest towards the end of micturition.

This sign, together with the result of the rectal examination, is evidence of inflammation of the pelvic peritoneum, but not conclusive evidence that the inflamed appendix is in the pelvis. Once I erroneously concluded from the pain being in the recto-vesical pouch and over the bladder that, therefore, the appendix was in the pelvis, whilst, as the operation proved, it was situated outside the cæcum. When the rectal tumour is distinct and very tender, and the pain on micturition acute, a pelvic abscess is to be suspected.

In none of these cases had the inflammation spread through the wall of the bladder, though undoubtedly this may occur

CASE 58.—The symptoms of acute appendicitis, with perityphlitis, sometimes come to an abrupt conclusion. A boy aged nine years was admitted into the Great Northern Central Hospital under my care. I am much indebted to Dr. Bagshawe for a careful note of his case. On November 13, he complained for the first time of pain in the right iliac fossa and vomited the contents of his stomach. The pain was less until November 20, when it became very severe and he was admitted to the Hospital. A very tender mass was felt in the right iliac fossa and also through the rectum, high up on the right side. The abdominal wall was not rigid, except over the swelling, and it moved with respiration. His bowels had acted, but he had occasional vomiting after liquid food. He looked ill. On November 21, his temperature was 103.2° F., and the pulse 140. The temperature remained about 102° F., with a pulse rate of 120, until November 24, when I saw him, and decided to remove the appendix the next day. That night the temperature fell abruptly from 102.8° F. to 98° F., and the pulse from 124 to 100. The next day (November 25) the temperature fell to 96.2° F., and the pulse to 82. In cases with a history of this description, I have known pus escape into the bowels, and appear in the motions, but in this, in spite of careful watching, none was seen.

In critical cases, the signs of improvement may be quite trifling, but, nevertheless, enough to defer the operation until a more favourable time. For instance, a youth aged sixteen had appendicitis with a large hard mass in the right iliac fossa and a quantity of matted intestines in the recto-vesical pouch. Although the temperature ranged from 99° F. to 101° F. and the pulse was 116, improvement had begun because flatus was being passed more freely; the tongue was moist and beginning to clean at its edges, and he said he felt hungry. To my mind, the rapid pulse was the worst feature in his case, but thenceforth a continuous improvement set in.

CHAPTER XVII

DIFFICULTIES AND ERRORS IN DIAGNOSIS—COMPLICATIONS

IN such a complicated disease as appendicitis, errors in diagnosis are inevitable, and I have already referred to several. At times, the diagnosis can only be established by an exploratory operation. But in every case of supposed appendicitis, four questions are to be weighed and considered. First, is this appendicitis? Second, what kind of appendicitis is it? Third, what complications have supervened? Fourth, is it appendicitis only, or is it appendicitis complicating some other disease?

I have given instances showing how difficult it may be to discriminate between appendicitis and inflammation of the gall-bladder; also between appendicitis and calculous pyelitis (Case 37, p. 133). The frequency with which appendicitis is mistaken for ovaritis or salpingitis has also been mentioned (p. 26). Doubtless, the converse error is at times committed, and tubo-ovarian inflammations mistaken for appendicitis.¹

Whilst helping to explore an obscure abdominal swelling in the pelvis of a stout, middle-aged woman, a distended and inflamed appendix was discovered. Its presence had not been suspected and the tumour was supposed to be tubal or ovarian.

Mr. Harrison Cripps² says: "I have twice found the apex of an appendix at the very bottom of Douglas's pouch. In both of these cases, prior to the operation, the trouble

¹ "Tubo-ovarian Congestion simulating Appendicitis," John C. MacEvitt, *Brooklyn Med. Journ.*, April 1897. *Abst. B.M.J.*, Epitome, September 4, 1897.

² *Ovariectomy and Abdominal Surgery*, London, 1898, p. 254.

was diagnosed as an inflamed adherent ovary at the bottom of Douglas's pouch, and the real nature of the case only became evident after opening the abdomen and making prolonged and extensive dissection."

I have given several instances of appendicitis complicating other diseases. Perhaps, general tuberculous peritonitis ought to be put in the first place. But the mucous lining of the appendix may be involved in several of the diseases which attack the mucous lining of the intestines. Amongst these, are typhoid fever and ulcerative colitis. In ulcerative colitis, the presence of mucus and shreds of membrane in the stools, together with tenderness along the whole colon, would suggest caution. In a case of this kind, I declined to operate, although the appendix was thought to be inflamed, because the appendicular pain seemed slight in comparison with that in the colon, and because it seemed clear that, after the appendix had been removed, the diarrhoea, hæmorrhage, and separation of membrane would continue. But, in another case, the appendicular symptoms preponderated and a stenosed and distended appendix was excised with most beneficial results (Case 29, p. 115).

The danger of appendicitis being a complication of typhoid fever is by no means imaginary. Some years ago, I saw a young officer who appeared to have a typical attack of appendicitis. A small ovoid, tender tumour was felt in the right iliac fossa accompanied with sudden pain, constipation, and vomiting. The tumour gradually subsided, but, at the same time, it became apparent that the patient had developed typhoid fever of moderate severity. No operation was performed, and he made a good recovery.

Elsewhere a case is given in which the appendicitis did not precede but followed typhoid fever (Case 8, p. 54).

In some cases of acute infective appendicitis with septic peritonitis, acute obstruction may be a prominent feature. Under these circumstances, a mechanical cause is not infrequently diagnosed. Unless the case be seen from the beginning, it may be difficult or impossible to discriminate, because acute mechanical obstruction is, towards the end, complicated with peritonitis.

It is to be remembered that a mechanical obstruction may coexist with appendicitis.

I have elsewhere described (Case 64, p. 216) a case of appendicitis, with partial intestinal obstruction, in which the latter was caused by carcinoma of the ileo-cæcal valve.

The appendix was excised under the following circumstances:—

CASE 59.—A. B., aged sixteen, a schoolboy, had recently had a severe attack of influenza, followed by pneumonia and consolidation of the right lung, which had not yet cleared up. On March 21, he began to suffer pain throughout the abdomen. This was followed, on the 22nd, by constipation and vomiting. On the 23rd, an enema gave some relief and the vomiting was less. On the 24th, the constipation was absolute, with constant vomiting and great abdominal distension. When seen on the 24th, the abdomen was exceedingly tense, tympanic and motionless, and distended intestinal coils were distinctly visible. The abdomen was tender everywhere, including the recto-vesical pouch. The tenderness was greatest over the right iliac fossa, and most pain was felt there. The pulse was 90, but had been 120; the temperature was 99°, but had been 105° F. The diagnosis was general peritonitis with appendicitis. The obstruction rendered an operation imperative. An incision three inches long was made in the right linea semilunaris. The peritoneum was inflamed and its cavity contained a few ounces of yellow serum. The vermiform appendix was acutely inflamed and adherent to the iliac peritoneum. It began by running towards the right for about an inch, and then turned sharply to the left, and, after a course of an inch and a half, was acutely bent again towards the right. It was expanded beyond the second bend, and contained a faecal concretion about an inch long and a third of an inch in diameter. The part between the two bends was also dilated, and contained a similar concretion about half an inch long.

But although the inflammation of the appendix was recent, and the peritonitis extensive, they did not seem to account for the extreme distension. The incision was, therefore, enlarged and the abdomen explored. During this part of

the operation an adherent band of omentum was divided, but it did not seem to have caught the intestine.

Next, some enormously distended and purple coils of jejunum were found, withdrawn from the wound, and emptied of some quarts of liquid fæces. After this, the abdomen was explored, but no trace of a mechanical obstruction could be found. The appearance suggested a volvulus, but the mesentery was not twisted.

Thrombosis of the mesenteric veins was sought for, but not discovered.¹

The operation gave no real relief, the obstruction returned, and death ensued after the pulse had reached 170. The temperature remained subnormal.

On inquiry, a long-continued history of pain in the right iliac fossa, constipation, and "colic" was forthcoming.

It is not unimportant to remember that pneumonia sometimes begins with vomiting and abdominal pains, which simulate perforating gastric ulcer or appendicitis.

Two of my cases illustrate the part which the cæcum may play in appendicitis (Cases 9 and 82, pp. 56 and 277). In both of these, after the excision of the inflamed, ulcerated, and infected appendix, a recurrence of symptoms took place owing to fæcal accumulation within a capacious, elongated, pendent, and flaccid cæcum. Perhaps some would have considered them to have been suffering from stercoral typhlitis.

I have also met with two cases in which I thought that the primary disease was in the cæcum. In each the symptoms, course, and, unhappily, the end were the same.

CASE 60.—A delicate young woman, aged twenty-eight, had been laid up for three weeks with a dull pain in the right iliac fossa, accompanied with a high temperature. The bowels were constipated. An abscess developed in the right iliac fossa above the outer half of Poupart's ligament, and extended down the iliacus muscle into the thigh. The abscess was resonant on percussion, and was, not improbably, connected

¹ In Dr. Dunlop's case of thrombosis of the superior mesenteric veins there was no abdominal distension or tenderness, and some bloody fluid was passed *per rectum* (*Lancet*, June 23, 1900, p. 1800). I myself have recently operated upon a closely similar case.

with the cæcum. It was opened by an incision parallel to the outer half of Poupart's ligament. The pus which escaped was fæculent and, after a time, as had been expected, a fæcal fistula formed. After waiting nearly two years to see whether this would close, and after trying various operations which did not open the peritoneum, I was obliged at last to make a more determined effort. The abdomen was opened, the sinus excised, and an aperture in the posterior wall of the cæcum sutured. The operation was followed by symptoms of obstruction from which the patient died. These were supposed to have been caused by an acute attack of septic peritonitis. At the *post mortem* a cicatricial stricture of the ascending colon was discovered. The closure of the fæcal fistula had stopped the only passage for the fæces.

CASE 61.—In the second case, the patient was likewise a young woman, aged twenty-nine, who had been laid up for a few days with a pain in the right iliac fossa, and who had a high temperature. The abscess was supposed to be appendicular, but it was situated above the outer half of Poupart's ligament, and extended down the thigh in the course of the iliacus muscle. It was opened, and a fæcal fistula formed. After waiting a year, an attempt was made to excise the tract and suture the aperture without opening the peritoneal cavity. When this attempt had failed, the abdomen was opened, and a hole in the back of the cæcum closed with sutures. The vermiform appendix was adherent to the thickened iliac peritoneum and had to be removed. After progressing favourably for a time, this patient died of septic peritonitis.

In each of these unhappy cases the abscess differed from those caused by appendicitis. It had more the characters of an ordinary iliac abscess and, instead of extending inwards towards the pelvis or upwards, had made its way into the thigh. From the beginning, the opening into the cæcum was also suspected, and the likelihood of fæcal fistula pointed out. My experience of fæcal fistula on the front of the cæcum (Case 83, p. 280) and in the sigmoid flexure, has been very much more favourable.

The causation of the cæcal ulceration was never discovered, and I am reluctant to assume that it was stercoral.

In the first case, the family history of tubercle was rather strong, but no clear evidence could be obtained that the disease was tuberculous.

I have continued to watch for other instances of typhlitis without appendicitis, but hitherto unsuccessfully.

When an appendicular abscess is known to have burst into the cæcum, rectum, or bladder, the dangers of appendectomy must be largely increased. I declined to operate upon a young lady who had had a violent attack of appendicitis in India, with a clear history of rupture into the cæcum. The iliac fossa was tender on pressure, but there was no other evidence of chronic appendicitis. An operation, which would probably have opened the intestine, was obviously attended with the risk of septic peritonitis, and also with that of faecal fistula. Dr. Deaver¹ shows that in these cases the lumen of the diseased appendix either opens directly into the cæcum or by the intervention of an abscess cavity. In either case the caecal walls are in a most unfavourable condition for suturing.

¹ Appendicitis, 2nd Edition, Plates XX. and XXI.

CHAPTER XVIII

DIFFICULTIES AND ERRORS IN DIAGNOSIS—COMPLICATIONS— *Continued*

THE pain on micturition and the retention of urine, which sometimes complicate appendicitis, have been referred to and their clinical significance pointed out. I have also met with other urinary complications under these unusual and deceptive circumstances.

CASE 62.—X., aged twenty-three, was sent to me with an intimation that he had had two attacks of appendicitis. During the first he had had retention of urine, which was easily drawn off with a soft catheter, and found to contain blood. A fortnight later, he had severe abdominal pain, with a temperature ranging from 102° F. to 103° F. At the same time, a painful tumour was felt beneath the right linea semilunaris, in the position of the appendix. He vomited during this attack, was constipated, and the abdomen was distended. He said that eight months previously he had had a similar illness. When I saw him, he looked ill and had a temperature 101° F. and a pulse rate over 90. He said his appetite was very bad and that his bowels were constipated. The abdomen was slightly distended and tender everywhere below the umbilicus. An exceedingly tender ovoid tumour about 3 in. long and 2½ in. broad was felt beneath the right linea semilunaris. The abdominal wall over this tumour was rigid. *Per rectum* a distended bladder was felt. He passed, in my presence, half a pint of urine containing some muco-pus, albumen, and a trace of blood. The urine was passed freely and without pain. He also went the whole night without getting up to urinate.

I diagnosed appendicitis, inferring that the appendix was close to the bladder, and had caused some cystitis. The attacks of retention were also dependent upon the appendicitis.

As no change took place in his condition, I advised the removal of the appendix. Before anæsthesia, he passed ten ounces of urine, but the tumour remained unaltered. I found the peritoneum inflamed with some delicate thread-like adhesions; the appendix, lying on the back of the bladder, was engorged, hard, and inflamed, but not adherent. The tumour, which was felt under the right *linea semilunaris*, was not appendicular, but the apex of a conical bladder with thickened walls. A catheter drew off some turbid urine.

So far as the abdominal part of this operation was concerned, the after progress was quite uneventful, but the urinary organs soon began to give cause for the gravest anxiety.

At first, urine was passed frequently and was obviously septic. After a few doses of urotropin, the urine became acid, and the muco-pus disappeared. But after that the amount of albumen did not diminish, and amounted to 1.5 per cent, the urea being 1.5 per cent, with hardly any pus and a little blood.¹ Some staphylococci of doubtful nature were also found. The amount of urine secreted also became variable, and Dr. Norman Moore concurred with me in the opinion that the patient was suffering from acute nephritis. Three weeks later, almost complete suppression of urine supervened, and he died after passing some of a bloody tinge.

The coincidence of renal disease and appendicitis occurred in another instance, in which no operation was performed. The clinical symptoms, however, were quite clear, and there cannot be much doubt as to the correctness of the diagnosis.

CASE 63.—Miss X., aged twenty-three, was laid up for six weeks, at the age of eighteen, with "Perityphlitis." This was accompanied with retention of urine, which necessitated the use of the catheter.

In February, 1900, a second attack was diagnosed, accompanied with constipation, abdominal distension, a temperature which varied between 100° F. and 101° F., and a pulse which

¹ Dr. F. W. Andrewes kindly furnished this report.

rose to 100. Vomiting was absent. The urine had again to be drawn off with the catheter, but no pain was felt when the bladder was emptied. The right rectus abdominis was rigid, and there was a tender spot near the site of the right common iliac artery. On rectal examination, the right side of the pelvis was tender, and movements of the uterus were attended with pain. The region of the right iliac fossa was not tender, and the appendix was evidently in Douglas's pouch. She had previously been examined, under an anæsthetic, by a gynæcologist, who thought that the right ovary was inflamed.

The right kidney was movable and displaced, but was not tender on pressure.

The attack subsided, but a month later, severe pain was felt in the right lumbar region and the kidney was painful on pressure; in addition the urine was found to contain a large quantity of pus. An expert pathologist reported that this contained quantities of tubercle bacilli, but inoculation experiments failed to confirm this view. The family history of tubercle was, however, exceedingly strong.

With regard to this case, it is to be noted that Edebohls¹ has drawn attention to the coexistence of floating kidney and chronic appendicitis. Both are common diseases, and, therefore, might be expected to occasionally occur together.

During an acute attack of appendicitis a little girl (Case 52, p. 172) was known to have had pus and bacteria in the urine. The appendix was close to the fundus of the bladder, but no perforation was known to have taken place. Such a complication has been recorded, but is undoubtedly very rare.²

¹ *Centralblatt für Gynäkologie*, No. 40, 1898; *Abst. B.M.J.*, Epitome, March 4, 1899, p. 34.

² *E.g. Bull, New York Medical Journal*, 1875, vol. xviii. p. 248, mentions 66 cases of suppuration about the cæcum. Of these

28 opened externally	2 opened into bladder
15 ,, into cæcum	2 ,, ,, internal iliac artery
8 ,, ,, peritoneal cavity	1 chronic peritonitis
2 ,, ,, thorax	6 pyæmia.
2 ,, ,, rectum	

The pus from appendicular abscesses has been known to track in almost every direction, and also open into the great veins, uterus, vagina, and ureter. Many of these cases, however, belong to days when surgery was less prompt.

The following is an example of appendicitis, complicating another disease:—

CASE 64.—*Appendicitis complicating Carcinoma of the Ileo-Cæcal Valve.*—Towards the end of 1896, I saw, with Dr. Craig, a single lady, aged thirty-eight. Her history was as follows:—During the summer she had had a severe attack of appendicitis supposed to have been brought on by bicycling. After the attack subsided, she remained unwell and was advised by a well-known physician to have an operation performed if she had a recurrence. About November the second attack occurred, and, when I saw her, an ovoid tumour about three inches long and an inch and a half wide could be felt at the site of the vermiform appendix. The tumour was movable, hard, and painful on pressure. The small intestines were slightly distended, and their vermicular movements could be seen through the thin abdominal wall. Solid food increased the movements of the intestines and caused pain, especially in the right iliac fossa. On rectal examination, a hard mass could be felt high up on the right side of the pelvis. This was supposed to be related to the appendicitis.

It seemed clear to me and to others, that this lady had had two typical attacks of appendicitis. Dr. Craig raised the question of the possibility of malignant disease, because the patient had lost her mother and other near relatives from cancer of the breast. I did not myself think the tumour in the iliac fossa was a carcinoma. It felt like one of those masses which are so commonly caused by an ordinary attack of appendicitis. The clinical history of appendicitis was moreover perfectly clear, and, in addition, the patient's age was more in favour of appendicitis than of carcinoma. At the operation, the cæcum and ileum were drawn out of the abdomen. With some difficulty the appendix was found wrapped round the ileum. Its apex was adherent to the front of the mesentery. Thus the appendix overlay the anterior ileo-colic fold (Fig. 3, p. 15) which was present, and long enough to form a small ileo-colic fossa. The appendix was, with some difficulty, separated from the ileum and from the mesentery, and at least three inches of it removed. At its cæcal end, a considerable mass of hard tissue was felt in the wall of the

cæcum. I surmised that this was inflammatory, but removed a piece for histological examination. It proved to be columnar-celled carcinoma undergoing colloid change, and had probably begun in the ileo-cæcal valve. The patient soon recovered from this operation, and the abdominal pain and distension were relieved. The adherent vermiform appendix had evidently caused a partial obstruction of the ileum. About two months later, I performed enterectomy and removed the cæcum, about two inches of the ileum, and a portion of the mesentery, including an enlarged mesenteric gland. The growth was found at the site of the ileo-cæcal valve, having probably begun in that structure which, however, had disappeared. The ileum and the cæcum were united by circular enterorrhaphy by the Czerny-Lembert method. The tumour, which had been discovered *per rectum*, could not be felt through the abdominal incision. The patient made an excellent recovery from this operation and, for a time, experienced complete relief. Nine months later, however, symptoms of slight intestinal obstruction supervened. The rectum was almost occluded by a mass growing in the right side of the pelvis. There was also some suspicious induration at the site of the previous enterorrhaphy. The danger of intestinal obstruction was removed by the performance of inguinal colotomy; but, before proceeding with that, I examined the site of the former enterectomy through a small incision. As the junction looked narrow and felt hard, an anastomosis was formed between the ileum and the ascending colon, by the insertion of a Murphy's button. The patient soon rallied from this double operation and, after living in comfort for some months, ultimately died of the carcinoma.

The result of the histological examination of the appendix removed at the first operation is as follows. The base, as I have already said, is infiltrated with carcinoma of the columnar-celled variety and is undergoing colloid degeneration. The lumen of the appendix is a little larger than usual, and nearly filled with blood clot. This blood may have come from a small area of the mucosa which was ulcerated, but I think it is more likely that it came from the carcinoma. With the exception of the small ulcerated area, the epithelial lining of

the lumen is intact. The epithelium of the tubular glands is likewise perfect, but their lumens are dilated, and some contain a little mucus. The lymphoid follicles are clearly visible, but are small and not numerous—about three can be seen in one section. The submucous, muscular, and peritoneal coats are all infiltrated with inflammatory cells, as is also the meso-appendix, which contains numerous blood-vessels.

I should interpret these appearances as showing that the carcinoma had grown at the base of the appendix and caused an obstruction to the discharge of its mucous secretion. This accumulated, and caused the dilatation of the lumen and of the tubular glands. Then the pent-up mucus and its bacterial contents brought about an attack of appendicitis, which, owing to the increased vascularity caused by the cancerous growth, was accompanied with hæmorrhage.

When I reflect upon the case of this unfortunate lady, I am at a loss to know how an earlier diagnosis could have been made. It is, however, to be noted that, after the first attack of appendicitis, she continued ill, and the appendicular swelling underwent no alteration. The pelvic tumour is noteworthy, for it affords a clue to the course pursued by some of the appendicular lymphatics.

Dr. Kelynack, in his able monograph, has said that "primary cancer of the appendix may be said never to occur."¹ But Drs. Kelly and Deaver² have since given four instances, all of which were operated upon on the supposition that they were suffering from appendicitis.

Recently Dr. Rolleston has reported an undoubted case of primary carcinoma of the vermiform appendix.³ The patient had had four attacks of appendicitis, and the exact nature of the disease was not known until it was disclosed by the histological examination. It proved to be spheroidal-celled carcinoma beginning in the mucous membrane near the

¹ *The Pathology of the Vermiform Appendicitis*, London, 1893, p. 139.

² *Appendicitis*, 2nd Edition, p. 98, *et seq.*, Plate XIX. Also "Tumours of the Vermiform Appendix," Kelly, *Proceedings of the Pathological Society of Philadelphia*, vol. iii., n.s., No. 5, p. 109, *et seq.*

³ "A Case of Primary Carcinoma of the Vermiform Appendix," *Lancet*, July 19, 1900, p. 11, *et seq.*

apex of the appendix. Dr. Rolleston gives references to several additional cases.

Secondary malignant disease of the appendix is not so rare. I met with a nodule of malignant disease, quite unexpectedly, in the appendix of an old man who died of pyæmia, which had been caused by infection from ulceration of a malignant growth of the chest-wall.

It seems probable that some, who have recorded cases of carcinoma of the appendix, may have trusted to mere naked-eye evidence, which is quite unworthy of credence in a question of this kind.

I have seen inflammatory masses in the vermiform appendix which had the closest resemblance to carcinoma. In the following case the end of the appendix was occupied by a vascular growth which looked exactly like carcinoma; in addition the iliac glands were enlarged, and a hard mass filled the upper part of the right broad ligament, and was fixed to the wall of the pelvis:—

CASE 65.—*Appendicitis—Inflammatory Tumour of Appendix simulating Malignant Disease.*—The patient, a married woman aged thirty-seven, had had her first attack of appendicitis about Easter, 1895. It was accompanied by pain in the right iliac fossa, constipation, and fever. It had been diagnosed by a very capable physician. A second attack occurred in 1897. In August, 1899, a third and very violent attack occurred, and removal of the appendix was proposed. The last attack never quite subsided, and when I saw her in November, she had a temperature which was continuously raised (99.5° F.), and the pulse usually beat over 102 per minute. The bowels were constipated, with slight abdominal distension and nausea. Pressure in the right iliac fossa caused pain, and a tender swelling could be obscurely felt there. The result of the rectal examination was negative; the uterus was retroflexed and movable, but painful when moved. A year previously the interior of the uterus had been cleaned out with the curette.

The difficulties which surround the diagnosis of some cases of appendicitis were exemplified in this one. An able physician, who saw the patient during the second attack,

attributed her symptoms to pelvic inflammation. A mass of an inflammatory nature was afterwards met with in the right broad ligament. But this and other cases show that such pelvic inflammation may complicate appendicitis, and, therefore, its presence in a given case ought not necessarily to lead one to exclude appendicitis.

The abdomen was opened by an oblique incision parallel to the outer half of Poupart's ligament. Neither the cæcum nor the appendix lay beneath the incision, but both were situated higher up towards the umbilicus. Clearly the tender swelling, which was felt in the iliac fossa before the operation, could not have been the appendix. Some enlarged glands were seen along the iliac artery. When the finger was pushed into the pelvis, a good many small vascular adhesions were encountered. A hard swelling was felt projecting from the middle of the right side of the true pelvis into the broad ligament, towards the uterus. The right ovary and Fallopian tube could not be felt. The vermiform appendix was adherent to the cæcum, and its extremity was bulged out into a red and vascular tumour about an inch and a half long, and three-quarters of an inch in diameter. It was exceedingly vascular, and adhered so closely to the front of the cæcum that, when it had been removed, a gap in the peritoneum and muscular coats had to be sutured. The great omentum was adherent to this appendicular tumour. It is hardly necessary to remark that we had here a very close resemblance to a case of malignant disease,—a vascular adherent tumour of the appendix, enlarged iliac lymphatic glands, and a second tumour in the true pelvis. The microscope showed that the appendicular swelling was inflammatory.

Three weeks after the operation, when the wound was healed and the patient was thought to be convalescent, the temperature rose, and a violent neuralgic pain darted down the right thigh, in the distribution of the internal cutaneous and obturator nerves. This pain coincided with the period, and was followed by foetid uterine discharge. These symptoms subsided under treatment. The occurrence suggests that, as Clado has supposed to be possible, infection may have been carried from the septic uterus along the lymphatic channels to

the appendix. The intermediate broad ligament would thus be infected from the uterus and not from the appendix. The ultimate result of the operation was perfectly satisfactory.

Intussusception may simulate appendicitis. When the invagination is ileo-cæcal or in the end of the ileum, the tumour may be in the right iliac fossa or sufficiently near to it to bring appendicitis into the question.

CASE 66.—At St. Bartholomew's Hospital, a consultation was held upon a girl, aged eight years, who was suffering from intestinal obstruction of four days' duration. The vomiting was only occasional, the pain moderate, and the aspect good. No blood or mucus had been passed from the rectum, and there had been no tenesmus. The pulse was 120 and the temperature slightly raised. The abdomen was soft but did not move with respiration. A slightly movable tumour was felt in the right iliac fossa. Opinions were divided as to whether this was tuberculous or appendicular, but an operation brought to light a gangrenous intussusception. Had the case been seen earlier, it is possible that the diagnosis would have presented fewer difficulties.

I have also met with appendicitis under the following extraordinary circumstances:—

CASE 67.—Three months previously the patient, a strong working man, had had an abscess opened above the right anterior superior iliac spine. The cause of the abscess was unknown. A sinus remained and continued to discharge quantities of pus. Each night, his temperature rose to about 102° F., and he was obviously suffering from septic absorption. Some of his symptoms suggested the possibility of appendicular disease. I explored the sinus through a large incision. The peritoneum was not opened, but it was clear that the iliac fossa did not contain an inflamed appendix. The source of the pus remained uncertain. After some weeks of sepsis, the patient died, and, at the *post-mortem* examination, a perforating ulcer of the back of the middle part of the duodenum was discovered. The pus had tracked down behind the right colon, the vermiform appendix running upwards beneath the colon and adhering to it by inflammatory adhesions.

In some cases, plumbism seems to have been mistaken

for appendicitis, and laparotomy has been consequently performed.¹ Conversely, Dr. Le Gendre has shown that in lead colic a gangrenous appendix has been overlooked, with disastrous results.²

I have not met with appendicitis complicating pregnancy. The onset in pregnant women of severe appendicitis with abscess is usually followed by miscarriage and by a fatal ending.³ When we consider the communications which exist between the blood-vessels and lymphatics of the vermiform appendix and those of the right broad ligament, by means of the appendiculo-ovarian ligament, it would perhaps be rash to say that the relationship between appendicitis and pregnancy was merely due to casual coincidence. Possibly, the appendix may occasionally share in the enormously increased vascularity of the pregnant uterus and its appendages.

In recurrent appendicitis, the attacks are often coincident with the period. Probably this may be capable of a similar explanation. Mainly on account of this coincidence, I know of a case of appendicitis which was long thought to be one of ovaritis.

The vermiform appendix may be involved in abdominal actinomycosis, a disease which is perhaps commoner than is usually supposed. In the year 1899, I saw, at the same time, three cases of abdominal actinomycosis in the wards of St. Bartholomew's, and a fourth case was shortly after admitted. Actinomycosis, if unrecognised, may lead to grave errors in prognosis.

In three of the above cases, the disease was supposed to have begun in the vermiform process or in the cæcum;⁴ in the fourth, the origin was uncertain. Before the true nature

¹ Lord, *Journal of the American Medical Association*, April 15, 1899. Ref. *Lancet*, May 20, 1899, p. 1380.

² *Lancet*, July 15, 1899, p. 171.

³ Fowler, *Annals of Surgery*, 1894, p. 46. Vinay says abortion occurred thirteen times in thirty-two cases. Ten of the thirty-two cases ended fatally (*Lyon Médical*, tome lxxxvii., 1898, p. 9). The mortality would, however, I fear, prove much higher if all the fatal cases were published. I have just operated in a case of appendicitis complicated with hæmatosalpinx.

⁴ "Statistical Tables of the Patients under Treatment in the Wards of St. Bartholomew's Hospital during 1899," by T. Calvert, A. Garrod, and H. J. Waring, London, 1900, p. 157.

of the disease was discovered, three of the cases had been operated upon for supposed suppurative peritonitis. Ultimately, the characteristic nodules were found in the pus, and the iliac fossa and abdominal walls became full of very indurated tissue, which inflamed, suppurated, and left a chronic sinus.¹

A case which was under my observation whilst in charge of Mr. Butlin's wards improved, in a remarkable manner, under large doses of iodide of potassium, supplemented with occasional cleansing of the sinuses with Volkmann's spoon.

In addition to the diseases which have been mentioned as being likely to be mistaken for appendicitis, many others could be quoted from medical literature. We might include the perforating ulcers of the stomach, duodenum, and the rest of the alimentary tract, acute phlegmonous cholecystitis, gangrene of the gall-bladder, rupture of the gall-bladder, dropsy and empyema of gall-bladder, extra-uterine pregnancy, pelvic hæmatocele, suppurating ovarian cyst with twisted pedicle, movable kidney with twisted pedicle, internal strangulation of the intestines by volvulus, bands, and internal herniæ; and to these might be added indigestion, colic, and bilious attacks.²

I have recently operated upon a rather stout lady who, before the examination under an anæsthetic, seemed to be suffering from an acute attack of appendicitis with a localised collection of pus. But when the rigidity of the abdominal wall had disappeared a large tumour could be felt, mainly beneath the right rectus abdominis. It proved to be a suppurating ovarian cyst of the right side, with a rather broad pedicle. A careful vaginal examination had afforded no indication of its presence. The patient recovered.

Appendicitis may be complicated with phlebitis of the iliac and femoral veins.

CASE 68.—A lady, aged thirty-four, had reached the twelfth day of an attack of appendicitis, when she was seized

¹ Those who seek for further details of this disease are referred to *L'Actinomyose Humaine*, Poncet et Bérard, Paris, 1898, p. 296, *et seq.* These authors give full references to the literature of the subject.

² Deaver, *Annals of Surgery*, March 1898, p. 303, *et seq.*; and Fowler, *Annals of Surgery*, 1894, p. 155, *et seq.*

with a violent pain in the right thigh and an exacerbation of the fever. A tender cord could be felt along the course of the deep veins, and the foot and leg were œdematous.

The appendix, as we have seen, occasionally hangs over into Douglas's pouch and is, therefore, very close to the iliac veins, so that it is possible for the inflammation to spread from the appendix to the vein. But I doubt whether this often occurs. As a matter of fact, thrombosis of either leg is an occasional complication of appendicitis as well as of other inflammatory affections.

The prognosis of phlebitis and thrombosis is favourable, provided it is not complicated with septicæmia or pyæmia. The detachment of clots seems to be one of the chief dangers, and ought to be guarded against by prolonged rest and quiescence.

CHAPTER XIX

TREATMENT, EXPECTANT AND OPERATIVE

IF the acute stage of appendicitis be passed through, an operation may not be required, or, if required, can, as Mr. Treves has so well taught us, be done with greater safety during quiescence. When delay has been determined upon, the treatment consists in absolute rest in bed, enough opium to relieve the pain, a fluid and peptonised diet, and enemas to open the bowels. Absolute rest should also include the avoidance, as far as possible, of abdominal or rectal examinations.

The opium is best given by the rectum, and even adults are usually soothed by a small dose of from 10 to 20 minims in starch solution or in a nutrient enema. The opium may also be used by sprinkling the tincture upon hot stupes applied to the abdominal wall.¹

There is great diversity of opinion as to the use of purgatives in appendicitis. Dr. Maylard² has advocated the employment of saline aperients in the early stages of acute appendicitis. Copious warm soap and water enemas are first given, and if they do not succeed, hourly doses of sulphate of magnesia in hot water. My colleague, Mr. D'Arcy Power, has

¹ Fitz, in his well-known essay, says large doses may be required. He is also adverse to enemas. "A cathartic or a laxative may be demanded by the patient or friends, and an enema be thought desirable as a diagnostic aid. It is to be remembered that these may be the means of at once exciting a general peritonitis" (*Transactions of the Association of American Physicians*, vol. i., 1886, p. 130).

² *Glasgow Medical Journal*, March 1899, "Treatment, in the Early Stages, of Acute Appendicitis by Saline Aperients."

endorsed this method of treating simple appendicitis.¹ Unfortunately, with our present means of diagnosis, we cannot tell whether the constipation is due to ulcerative appendicitis, stenosis of the appendix with ulceration, mucocele, or empyema; or appendicitis with concretion, or with infection of appendicular walls, perforation, gangrene, abscess, and so forth. In addition, the constipation in some cases is caused by an actual mechanical obstruction (Case 64, p. 216). In many of them, a dose of sulphate of magnesia is not likely to do any good, and may do harm. But it is doubtful whether purgatives do as much harm as some suppose. If they act, they may do good. But sometimes they fail and only cause pain and distress, besides being a formidable complication when the operation is performed. I am, therefore, in the habit of relying upon enemas. The ordinary soap enema, combined with half an ounce of turpentine and half an ounce of castor oil, seldom fails. I can recall no case in which enemas have done harm beyond causing discomfort, or vomiting, or erythema.

If a purge be necessary, a dose of calomel (grs. iii.-v.) would be the safest.

It is better not to apply blisters or leeches to the abdominal wall. The subsequent condition of the skin increases the chances of suppuration, should an operation be performed. On the whole, warm applications to the abdominal wall seem to afford the best relief from pain. I have hardly any experience of the use of cold. It is well spoken of by some, but is rather a depressing remedy.

In chronic appendicitis, I have seen benefit follow small doses of salol in powder or β -naphthol. But, generally speaking, when we remember the pathological changes which may be proceeding within the appendix, any lengthened resort to such remedies is seldom justifiable. A patient, who seemed to have been benefited by salol, died of portal pyæmia. It is doubtful whether such feeble intestinal antiseptics can do much good.

I have seldom seen any permanent benefit result from applications to the abdomen. Sometimes warm fomentations, with

¹ *British Medical Journal*, Nov. 25, 1899, p. 1468, "The Prognosis and Modern Treatment of Appendicitis."

opium added, afford some degree of relief from pain. In cases in which the abdominal wall is red and exceedingly hard, owing to fibrinous effusion, the abstraction of blood by leeches, before pus is present, often relieves the pain. Incisions into the indurated abdomen are so dangerous that some procrastination may be justifiable (Case 83, p. 280).

On several occasions, I have judged it expedient to defer operating upon cases of acute appendicitis with acute localised peritonitis until daylight, and until the operation could be properly organised. Under these circumstances, a hypodermic injection of morphia has been permitted to relieve the severe paroxysms of pain. In the morning, the patient has both looked and felt better, and the pulse and temperature have fallen—conditions which might tempt some to defer the operation. I have, however, in some such instances, found the appendix acutely inflamed, perforated, and gangrenous, with extensive peritonitis.

In severe peritonitis, the acute onset may be followed by what Mr. Symonds¹ calls a "period of repose." The vomiting ceases and food may be retained; the pain subsides and a feeling of comfort is experienced. The administration of morphia or sedatives helps to bring about this deceptive calm. But, if attention be given to the pulse, temperature, and condition of the abdomen, the "period of repose" will seldom lull into false security.

In appendicitis, the question of operation is sure to arise. In gangrene, perforation, or infective appendicitis with septic peritonitis and acute abscess, an immediate decision is demanded; in ulceration, stenosis, and chronic abscess the dangers of delay are not so imminent. But, when the attacks have been severe, a short delay may be hazardous. On one occasion (Case 31, p. 119), a few weeks' delay ended in portal pyæmia. In another (Case 54, p. 177), the attacks of appendicitis had subsided and the patient was lying in bed awaiting convalescence. One afternoon, he was seized with violent pains and vomiting, the pulse accelerated, the temperature rose, and the abdomen distended. A perforated appendix was excised and

¹ "The Individual Value of the Symptoms in Perforative Peritonitis," C. J. Symonds, *British Medical Journal*, March 4, 1899, p. 520.

a quantity of fœtid pus washed out of the pelvis, and, after a terrible illness, the patient recovered.

The question of operation would cease to be difficult, if we could infer the pathological condition of the appendix and of the structures in its vicinity. There could be no doubt as to the propriety of excising an ulcerated appendix, or an ulcerated appendix with a concretion in its interior, or one which was full of pus or mucus, or which was perforated or gangrenous, with the attendant septic peritonitis and suppuration. At the present time, our knowledge does not justify a precise diagnosis in every case. But, nevertheless, progress is being made in this direction, and our inferences become more and more accurate as, in each instance, the morbid histology is ascertained and correlated with the clinical history.

The question of operation is especially difficult to decide in some of the slowly progressing cases of stenosis or of ulceration of the mucosa. The patient is so well after the subsidence of the acute symptoms, that an operation seems uncalled for. Under these circumstances, the chronically inflamed appendix is often overlooked because a rectal examination is not made. But, not infrequently, a rigorous examination shows that the appendix is tender between the attacks, and that the digestion and action of the bowels are unsatisfactory.

I have many times excised the appendix during quiescence, because the patient was about to reside where he would be out of the reach of surgical aid, and, almost invariably, the appendix has been more diseased than one had expected. On the other hand, when prompt surgical aid is obtainable, it may be justifiable to wait the course of events.

In cases of slight ulceration of the mucosa with bacterial invasion, characterised by symptoms of appendicular colic and culminating in attacks of appendicitis, the inconveniences and dangers of the condition exceed the risks of the operation; and this is also true in cases of stenosis, characterised by repeated sharp attacks of appendicitis with intervals of apparent recovery. In most of these, no tumour can be felt in the iliac fossa during the quiet interval, but deep pressure is attended with pain. The pelvic position of the appendix should be borne in mind.

In cases of chronic ulceration of the mucosa with bacterial invasion, characterised by severe attacks of appendicitis, by the presence of a painful tumour, and by persistence of the pain, alimentary disturbances, variable temperature, and ill-health, the propriety of an operation cannot be questioned. In this class concretions are often met with.

Empyema of the appendix is also accompanied with frequent attacks of appendicitis and, in the interval, with pain, increased temperature, anæmia, and alimentary disturbances. A hard and painful tumour may be felt (Case 46, p. 153), and an operation is necessary if perforation is to be avoided.

Mucocele of the appendix is also characterised by the presence of a hard and painful tumour, by frequent attacks of appendicitis of moderate intensity and duration, and by disorders of digestion. The temperature and pulse are not markedly disturbed during the attacks, and, with the exception of the pain and discomfort in the iliac fossa, the patient seems well in the interval. I doubt whether a mucocele is very dangerous, but it is sufficiently painful and troublesome to justify an operation. The after-progress of these cases seems to be particularly favourable.

In lymphangitis and lymphadenitis of the appendix, an operation is usually required on account of the severity and repetition of the attacks. I am, however, unable to discriminate clearly between this and the other severe forms of acute appendicitis.

The question of immediate operation may be difficult to decide during the first twenty-four or forty-eight hours of an acute attack of appendicitis, but it is always necessary to recognise that the patient's life is in peril, and that favourable symptoms may suddenly alter for the worse. In acute cases, the evolution of events should be watched from hour to hour; each clinical phenomenon weighed and considered, and an attempt made to gauge its pathological significance. The onset of appendicitis is usually sudden (Case 20, p. 90), and some of the severest kinds are ushered in by a rigor. The occurrence of a rigor is a sign of danger, as it indicates the presence of some of the more virulent pyogenic organisms.

The danger of operating during acute appendicitis has

probably been exaggerated. As a rule, only the cases with gangrene, perforation, acute abscess, and septic peritonitis are operated upon during the acute stage, and, in these, the death rate is necessarily higher. It is easy to confuse cause and effect, and attribute a fatal ending to the operation rather than to the disease.

It is obvious, that the time for operation must depend upon the estimate which is formed of the condition of the appendix and of the peritoneum. When, for instance, a perforation of the appendix has been diagnosed, it is irrational and dangerous to procrastinate. Mr. Treves¹ has said: "It may be laid down as a rough rule that the use of the knife will seldom be called for before the fifth day. Indeed, I would venture to think that surgical interference before the fifth day should not be undertaken except in the presence of emphatic symptoms. Indeed, the great majority of the operations for perityphlitis are performed after the first week." In my opinion, not even a "rough rule" ought to be laid down for the surgical treatment of appendicitis. Some cases of gangrene and of perforation run their course with frightful rapidity, and are soon beyond the reach of surgery. I myself have yet to regret having operated in appendicitis with acute symptoms.

But cases of appendicitis with superficial ulceration of the mucosa, stenosis, mucocele, chronic empyema, small concretions, and so forth, more often run a favourable course, and subside for a time. In such as these, it is undoubtedly better to operate during a period of quiescence. At the height of the attack, the shock of the operation is greater because the patient may have become debilitated by vomiting and a restricted dietary.

Moreover, when abdominal distension is present, the immediate and subsequent dangers are increased. The appendix may be harder to reach, and the distension may afterwards increase, and be difficult to overcome.

In addition, the inflamed peritoneum bleeds, and the usual landmarks are obscured. In spite of drainage, some of the blood may clot and decompose in the depths of the wound, leading to sapræmia (Case 55, p. 180).

¹ *Perityphlitis*, p. 56.

Owing to these difficulties the abdominal wound may have to be made longer, and there is a greater danger of ventral hernia. The dangers of ventral hernia are also increased, because the wound is more likely to suppurate. The wound may be infected whilst the inflamed appendix is being withdrawn, or it may become infected by the inflamed peritoneum, which will have bacteria in it for many days after the subsidence of the attack. The following case bears upon this point:—

CASE 69.—*Appendicitis with Interstitial Hæmorrhage—Perityphlitis, involving the Right Broad Ligament of the Uterus—Bacteria in the Peritoneal Exudation many Days after the Subsidence of the Attack.*—The patient was a robust young lady, aged eighteen years. Towards the end of 1897, I saw her in the midst of her second attack of appendicitis. She had a high temperature and rapid pulse,¹ abdominal distension, constipation, vomiting, and great pain in the right iliac fossa. The abdominal wall in the right iliac region was very rigid, and acutely painful on pressure. A tender ovoid tumour was afterwards felt at the site of the appendix. A curious doughy swelling could be felt *per rectum*, and this, I thought, was the right broad ligament inflamed and œdematous.

The attack of appendicitis subsided, and, after the lapse of a week, the rectal swelling had gradually disappeared. The vermiform appendix was removed in the usual way. It was most difficult to find, being hidden away beneath the cæcum, to which it was adherent, as well as to the peritoneum lining the iliac fossa. In removing the appendix, a small rent was made in the peritoneal and muscular coats of the cæcum, which required the application of a suture. The recently inflamed peritoneum bled a good deal, so a rubber drain was inserted. This was removed at the end of forty-eight hours, and a rapid recovery ensued, without any trace of suppuration.

Now, in this case, there can be no doubt as to the severity of the attacks, nor that they were accompanied with extensive and widespread perityphlitis. In the appendix, the following changes are found.

The peritoneal surface is rough and denuded of endo-

¹ I am writing from memory, and regret that I cannot be more precise.

thelium, and the subperitoneal tissue is thickened with inflammatory exudation and some old blood extravasation. The meso-appendix contains groups of inflammatory corpuscles, and its blood-vessels are abundant and rather large, and its lymph channels dilated. Many of the cellular interspaces contain old blood extravasation. The outer muscular coat is thin, the inner of about the usual thickness. The submucous tissue is very fibrous, with a considerable increase in the number and size of its blood-vessels. The lymphoid tissue has undergone no marked alteration. The muscularis mucosæ can be clearly seen at the base of the tubular glands, so that the lymphoid tissue cannot have been much inflamed. The lymph spaces are not dilated; indeed, they are rather smaller than usual. Some of the tubular glands contain a good many goblet cells, but most of them possess a complete epithelial lining. The epithelial lining of the lumen is intact for about two-thirds of its extent, whilst the remaining third has been shed, leaving the lymphoid tissue bare, and its lymph spaces open. The lumen contains detached epithelium, nucleated cells, pus cells, and a little mucus. Perhaps some of its original contents have escaped, but no bacteria can be found in what remains, nor can any be seen in the coats of the appendix, nor in the substance of the mesentery, the peritoneal surface of which has a little inflammatory exudation upon it. The cells of this are very granular, and presumably undergoing fatty degeneration prior to disappearance. Amidst this old exudation are a few bacilli, cocci, diplococci, and chains of from four to six cocci. Some bacilli, about the size and shape of tubercle bacilli, are also present, but, as they are chiefly on the surface, they may be adventitious.

This specimen affords much food for thought. I was surprised to find that such a severe attack had done such slight harm to the epithelial and lymphoid tissue of the appendix. We may next note that an acute inflammation of the appendix, like acute inflammations elsewhere, may be accompanied by intercellular hæmorrhage. But still more interesting is the undoubted persistence of bacteria in the degenerating lymph, ten days or a fortnight after the subsidence of the attack. We do not know whether these bacteria were

alive, but, when we consider the tenacity of life which some species display, it is probable that they were. That their pathogenic properties were slight, is proved by the result of the case.

It is usually considered that the operation of appendectomy may be undertaken a week after the subsidence of the acute symptoms. In most cases of superficial ulceration of the mucosa, stenosis, and mucocele, this will suffice, but the foregoing shows that when the peritoneum and pelvic contents are involved, the interval ought to be extended.

Delay is also desirable when the peritoneum is thickened with fibrinous effusion, as this renders the intestines difficult to recognise, and when they are wounded a faecal fistula is apt to form. This fibrinous effusion disappears in a remarkable manner, so that an operation which might previously have been difficult or impossible may become easy (Case 83, p. 280).

The removal of the appendix is usually considered to be justifiable after two attacks of appendicitis, as the recurrence is assumed to indicate some abiding cause. But, although this rule is in the main correct, it is not applicable to every case. For instance, one attack of appendicitis may leave a painful tumour in the right iliac fossa or in the pelvis. Should this not subside after rest, dieting, and medical treatment, then it is safer to remove the appendix. Furthermore, the assumption that a particular attack of appendicitis is the first, is apt to be erroneous. Careful inquiry will often reveal the possibility that the disease is of long standing, but that the previous attacks had been mistaken for colic, bilious attacks (whatever they may be), typhoid, renal colic, ovaritis, or peritonitis.

The careful preparation of the patient deprives the operation of much of its pain and discomfort. After appendectomy, flatulence is one of the commonest troubles. This can be limited by a light and nutritious diet for a few days before the operation, by stopping fruit and vegetables, and by thoroughly emptying the intestines with enemas. An attack of appendicitis is seldom brought on by enemas, but a purge given by the mouth sometimes precipitates one, and causes

delay. If, as is sometimes the case, aperients are being taken without inconvenience, they may be continued.

In addition, a warm bath may be given the evening before the operation, and the pubes, groin, thigh, and abdomen shaved. The cleansing and disinfection of the skin within the field of operation can be left until the following morning. The grease and sebaceous matter are extracted with soap and water and turpentine, and then a solution of biniodide of mercury in rectified or methylated spirit (1 in 500) is applied for not less than three minutes. The disinfected skin is protected with an antiseptic dressing until the operation. The above is usually the more convenient course to pursue, but in the case of ladies, children, or nervous subjects, the preparation and disinfection of the skin are postponed until anæsthesia is established. The spirit and biniodide of mercury lotion is such an efficient disinfectant, that this may be done with safety.

Four sponges are enough for the operation, and are prepared by the sulphurous acid method. A few sizes of twisted silk, 00, 2, and 4, are also sterilised by boiling for thirty minutes in water. For septic cases some biniodide catgut should be at hand.¹

Sterilised silkworm gut is used for closing the wound in the abdominal wall. No special instruments are required for an ordinary case—a knife, scissors, dissecting forceps, a dozen pair of pressure forceps, and a straight and a curved Hagedorn's needle will suffice. A pair of small retractors may be useful. All these instruments are sterilised by boiling for a quarter of an hour in washing-soda and water, a drachm to the pint, and are then put into carbolic lotion (1 in 60), until required for use. The ligatures and sutures are put into bowls of solution of carbolic acid of the same strength. Two flat dishes and half-a-dozen bowls are required for the instruments and sponges. They are sterilised by boiling in the same way as the instruments. Half-a-dozen towels should be sterilised by heat.

The hands of the operator and his assistant are disinfected

¹ For details see *Aseptic Surgery*, by C. B. Lockwood, London and Edinburgh, 2nd ed.

by trimming the nails as short as possible, washing and scrubbing in soap and water for three minutes, and immersion in spirit and biniodide of mercury lotion (1 in 500) for not less than two minutes by the clock.

Biniodide of mercury lotion (1 in 4000) is used throughout the operation, unless sepsis is met with, when its strength is increased.

At the completion of the operation the following dressing is applied. First, a layer of antiseptic gauze, then some alembroth wool, and next, an outside 8-fold Listerian dressing.¹ The latter is cut so as to fasten round the thigh and the pelvis with buckles and straps. It ought to reach about two inches above the umbilicus, and be made secure and air-tight by means of bandages and strapping. It is to be remembered that after the operation the patient may, whilst vomiting or straining, put the abdomen into violent action, or may pull off or displace the dressing whilst recovering from the anæsthetic. The outside dressing is practically the same as that which I use for the radical cure of inguinal hernia, but it is carried a little higher up the abdomen. I usually use the old-fashioned 5 per cent carbolic gauze, because it is so unirritating; but I have had equally good results with iodoform, sal alembroth, or double cyanide.

Before operating, an endeavour should always be made to diagnose the position of the appendix or of the appendicular abscess; and it is to be remembered that their positions may not coincide. Success, in this preliminary step, makes the operation shorter and simpler, and may save the general peritoneal cavity from contamination.

It is, of course, more easy to diagnose, by means of clinical signs, the position of the abscess, but that of the diseased vermiform appendix can seldom be thus inferred. In one case (Case 17, p. 81), the appendix was thought to be hanging into the pelvis, but it was found outside the cæcum and ascending colon. In another (Case 65, p. 219), it was supposed to have been felt in the iliac fossa, but was ultimately discovered beneath the rectus abdominis, not far from the

¹ Iodoform has seldom been used for the first dressing since we have learnt to disinfect the skin.

umbilicus. These difficulties are met by making a small incision two inches long, an inch above and parallel to the outer half of Poupart's ligament. The deep epigastric artery skirts the inner end of this incision.

In making the opening, M'Burney's¹ method is followed. The aponeurosis and muscular fibres of the external oblique muscle are split and pulled apart; afterwards, the fibres of the internal oblique and transversalis. These muscles are aponeurotic at the inner angle of the wound, and muscular at the outer. Some ascending branches of the deep circumflex iliac artery are met with between the internal oblique and transversalis, and, when cut, are apt to retract and continue to bleed, thus causing a hæmatoma, which is one of the commonest causes of suppuration. The remedy is obvious; the small vessels are, whenever possible, clamped before division, and tied forthwith. After the division of the fascia transversalis, the peritoneum is opened in the usual way, the possibility of adhesions between the parietal and visceral layers being borne in mind.

In simple cases, in which adhesions are absent or easily overcome, the appendix can usually be removed without further division of the abdominal walls. The cæcum is looked for and pulled out of the wound, with the appendix attached to it. But sometimes this cannot be done because of adhesions. The great omentum has a strange aptitude for adhering to the inflamed appendix, and to the parts around. The management of the omentum will be described in another section. But, at this stage of the operation, it can usually be detached with the finger and drawn from the wound. Not infrequently, it appears in view wrapped round the appendix, or its tip guides the finger towards that organ.

If these devices fail to discover the appendix, it should be felt for beneath the cæcum, and at the ileo-cæcal angle. A thoroughly well-educated sense of touch is required to recognise the difference between the appendix and the other inflamed structures. Should any doubt whatever arise, it is safer to enlarge the incision and proceed with the aid

¹ "The Incision made in the Abdominal Wall in Cases of Appendicitis, with a Description of a New Method of Operating," *Annals of Surgery*, vol. xx. p. 38, *et seq.*, 1894.

of vision. Usually the hard round outline of the inflamed appendix can be felt. In a recent case, however, the appendix was soft and flattened, hidden beneath to the right side of the cæcum, and most difficult to discover.

In the case of a young lady I could find neither the cæcum nor the appendix. The end of the ileum seemed to disappear beneath a layer of peritoneum which lined the iliac fossa. The incision was enlarged and the transverse colon traced to the hepatic flexure, which served as a guide to the right colon. The colon led downwards to a slight bulging behind the iliac peritoneum, and this proved to be caused by the cæcum with the inflamed and adherent appendix lying behind it. When difficulties like this arise, the advantages of the small oblique incision became apparent. If the appendix is adherent to the bladder, the broad ligament, ovary, or Fallopian tube, or is in Douglas's pouch, the cut can be prolonged inwards, and, if necessary, its outer end can be curved upwards. The deep epigastric artery and veins are cut through during the first step, but these vessels are easily secured.

The oblique incision was modified in a case in which the abscess was external to the cæcum and colon (Case 71, p. 249). It was departed from in others in which the abscess was in the pelvis. In these, the abdomen was opened through the linea alba (Case 83, p. 280), or at or through the outer edge of the rectus (Case 55, p. 180, and Case 80, p. 272). Once the appendix was removed through the scar of an old incision in the right linea semilunaris (Case 78, p. 255).

To lessen the risks of ventral hernia, it is advantageous on operating through the linea semilunaris, to adopt Mr. Bowlby's plan, and after dividing the front sheath of the rectus to pull the muscle inwards before dividing the hinder layers. When the operation is finished, the muscle falls into place and forms a barrier between the openings in its sheath, which are also closed with rows of buried sutures.

In operating through the linea alba, it is preferable, in order to diminish the risks of ventral hernia, to cut between the fibres of one of the recti rather than to pull the two muscles apart.

The meso-appendix and the other natural peritoneal folds have already been mentioned (p. 14). It is, of course, quite impossible to infer either their presence or absence. They are seldom such an embarrassment to the operator as inflammatory adhesions. The dangers and difficulties of the latter depend to a large extent upon his skill and experience. Their presence is often assumed when they do not exist.¹

It is often supposed, that because the attacks of appendicitis were severe, adhesions must have formed, and that they must be firm and extensive; an instance to the contrary might easily be adduced (*e.g.* Case 25, p. 106). The supposed presence of adhesions need never be a bar to an operation, as they are not as a rule very troublesome.

Thus, whilst severe attacks may not cause adhesions, I have, on the other hand, met with very troublesome ones after attacks of appendicitis which lasted for three days, but did not seem to be particularly severe (Case 24, p. 103).

Inflammatory adhesions may be either visceral or appendicular.

The visceral adhesions may mat the intestines and omentum together, and form a barrier which has to be overcome before the appendix can be reached. The appendicular adhesions may unite that organ to the cæcum, colon, ileum, great omentum, mesentery, rectum, ovary, Fallopian tubes, uterus, bladder, or iliac fossa. Adhesions to the liver, gall-bladder, and duodenum have been described but are rarely seen.

I have usually met with troublesome visceral and appendicular adhesions in cases in which a considerable tumour or induration was felt. In such an one (Case 7, p. 50), the operation took two hours and a quarter. When the barrier of omental and intestinal adhesions had been overcome, the appendix itself was easily separated.

The thin-walled ileum is often in danger of laceration during the separation of adhesions, and I have, on many occasions, had to suture rents which extended as deep as the mucous coat. These injuries heal exceedingly well after

¹ Deaver, who tabulates 200 cases, found adhesions in 12 per cent (*Annals of Surgery*, March 1898, p. 303, *et seq.*).

being brought together with Lembert's suture. The coats of the intestines ought to be carefully scrutinised after adhesions have been separated.

An abscess is occasionally met with in the midst of firm adhesions (Case 12, p. 64).

When a localised collection of pus is found, an attempt should be made to dam off the general peritoneal cavity with broad strips of antiseptic gauze. The pus is next removed with sponges. The abscess cavity is thoroughly swabbed with biniodide of mercury lotion (1 in 1000), and packed with sponges during the remaining steps of the operation. Great care is required to avoid washing pus into Douglas's pouch or into the flanks. Finally, an indiarubber drainage tube, $\frac{1}{3}$ to $\frac{1}{2}$ inch in diameter, is put into the cavity as far as its lowest limits. In very acute and septic cases, I reinforce the drainage tube with some strips of iodoform gauze. This prevents oozing of blood and aids the escape of septic fluids. Gauze drains and packing are, however, very painful to remove, and are, therefore, only used when absolutely necessary. I now use rubber tubes because they are less painful than glass, and less dangerous. I have known glass drainage tubes broken in the abdomen. In localised septic peritonitis, the wound does not always suppurate, and not infrequently the whole of it, except the drainage tube opening, heals by first intention.

During the acute stages of appendicitis, the omentum and intestines in the neighbourhood of the inflamed organs become glued together with fibrinous effusion.

This fibrinous effusion may form a considerable mass, and a large area of the abdomen may feel as hard as a board. Incisions into this indurated mass are liable to wound the cæcum or intestines, and ought, if possible, to be avoided. In a case of this kind (Case 83, p. 280), I began the search for pus with an incision over the locality of the appendix—where the abdominal wall felt extremely hard. The abdominal walls were inflamed and oedematous. The parietal peritoneum was half an inch thick and very vascular. An incision into it opened the cæcum. A fresh incision in the middle line evacuated the pus, and the patient recovered. The

wound in the cæcum was immediately sutured, but a faecal fistula formed. The intestinal walls were, doubtless, both inflamed and infected, so that sutures were likely to become septic. Six weeks afterwards, when an operation was done to close the opening, I found no adhesions.¹ Again, in operating upon a girl whose abdomen was exceedingly hard, about half an inch of inflamed peritoneum had to be cut through, but fortunately the pus was found without wounding the adherent intestines.

The cæcum, in another case, was opened in the endeavour to overcome very firm appendicular adhesions (Case 35, p. 129). The operation was done during the quiet stage, and, therefore, the intestinal wound at once healed.

In overcoming appendicular adhesions, the general surgical rule should be followed, and the operator work as close as possible to the adherent organ. The appendix usually separates quite easily when the muscular coats are reached. In cases of great difficulty, it might almost be sufficient to remove the mucous membrane.

Omental adhesions require the most careful management, otherwise an intra-abdominal hæmorrhage may occur. I make it a rule to transfix and tie each bit of omentum. It is also to be remembered that both ends of the cut omentum bleed; so that the bit of omentum which is left attached to the parietal peritoneum, to the cæcum, or to the pelvic organs, must also be transfixed and tied.

Inflamed omentum becomes very vascular, and the oozing of blood from it cannot always be controlled with ligatures. Hence, I have had to secure the omentum with a row of interlocking sutures, and to remove nearly the whole of it (Case 24, p. 103).

It is not necessary to excise inflamed omentum unless it is obviously septic. The accompanying microphotograph shows the characters of the inflamed peritoneum, and was taken from a section of the meso-appendix. The great omentum looks almost exactly like it. The serous membrane is infiltrated with groups of inflammatory cells grouped about the dilated

¹ "The Surgical Treatment of Diffuse Septic Peritonitis," C. B. Lockwood, *Med.-Chir. Trans.* vol. lxxviii. 1895.

blood-vessels, but no bacteria whatever could be found in the inflamed peritoneum. The recuperative powers of the peritoneum are most extraordinary. Great masses of fibrinous exudation disappear, and adhesions cease to exist. It is not, therefore, necessary to excise the great omentum whenever it is inflamed.

But in acute infective appendicitis, in gangrene of the appendix, or in perforation, the omentum may be widely in-

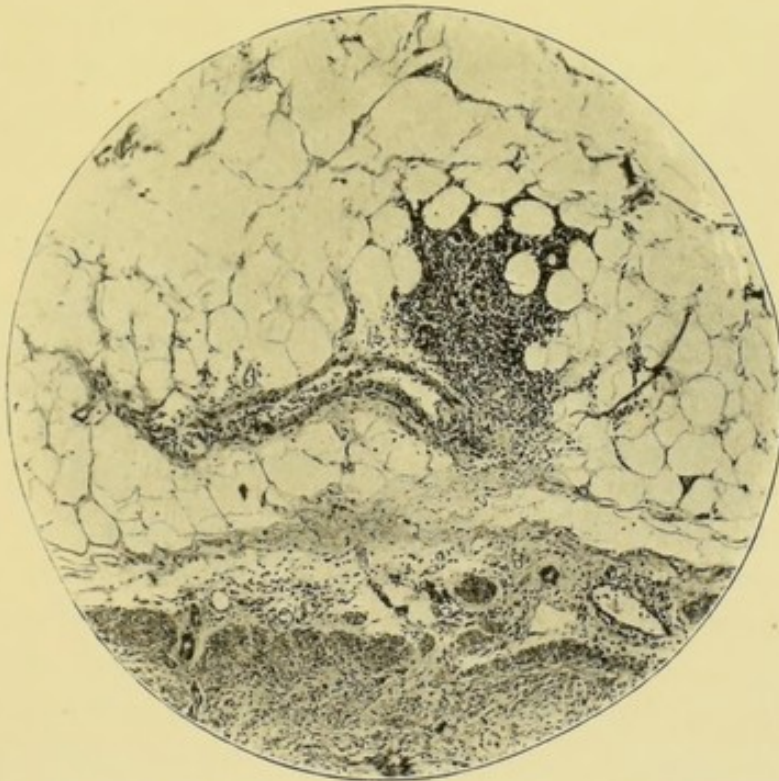


FIG. 49.—The inflamed peritoneum (meso-appendix) in appendicitis without suppuration. $\times 55$.

fested with bacteria. It does not follow, on that account, that special efforts should be made to remove it. Such efforts might open up fresh and uninfected areas of the peritoneum, or entail additional delay with its attendant shock. But when the circumstances are favourable, I think septic omentum ought to be excised.

The following case illustrates the septic condition of the omentum and the conditions under which it occurs.

CASE 70.—*Appendicitis with Perforation—Acute Localised Subcaecal Abscess—Bacteria in Walls of Appendix and in*

Inflamed Omentum.—W. D., a boy aged six years, was admitted into the Great Northern Central Hospital suffering from an acute attack of appendicitis. I am indebted to Dr. Bagshawe for the history of the illness. He was probably suffering from his first attack, which began about August 15, 1898, with diarrhœa and a severe pain in the abdomen. Constipation then ensued and the boy continued very ill until his admission on August 20. On that date, he was drowsy, as if under the influence of opium, his temperature was 100.4° F., and his pulse 120. A very tender swelling was felt in the right flank above the anterior superior spine of the ilium. The abdominal wall, in this region, did not move with respiration and was rigid. No tumour or tender spot could be felt *per rectum*.

An enema evacuated fœces and flatus. Fluid nourishment was taken without vomiting. On August 21, the temperature had risen to 101.8° , and the pulse was 116. On August 22, his general condition was the same, and I then saw him for the first time. The temperature was 100° F. and continuously high, the pulse had accelerated to 124. The boy did not look particularly ill; vomiting was absent, the abdomen was not much distended, and the bowels had acted. I was, however, impressed by three things: first, the acceleration of the pulse; second, the continuously high temperature; and, third, the exceedingly tender swelling in the upper and outer part of the right iliac fossa. These all pointed to an acute localised sepsis; probably an acutely inflamed appendix with a peri-appendicular abscess.

Guided by the painful swelling, the abdomen was opened by an oblique incision made an inch and a half further out than usual. Inflamed and adherent omentum was first encountered. A large portion was ligatured and excised; its histological characters will be presently described. No pus was seen until the cæcum was raised, when about two ounces of fetid pus escaped from a cavity which also contained the inflamed and perforated appendix. No concretion was discovered. The pus was thoroughly washed out with 1 in 1000 biniodide of mercury lotion, and the appendix removed in the usual way. A rubber drainage tube was placed in the outer

part of the wound, and the remainder was closed. The patient made an uninterrupted recovery, and was quite well three months afterwards.

The excised omentum is intensely inflamed, very vascular, and swollen. Its surface is covered with inflammatory exudation which consists of fibrin and nucleated corpuscles. Its substance is very cedematous, penetrated by dilated blood-vessels, and crowded with nucleated cells. The appearances

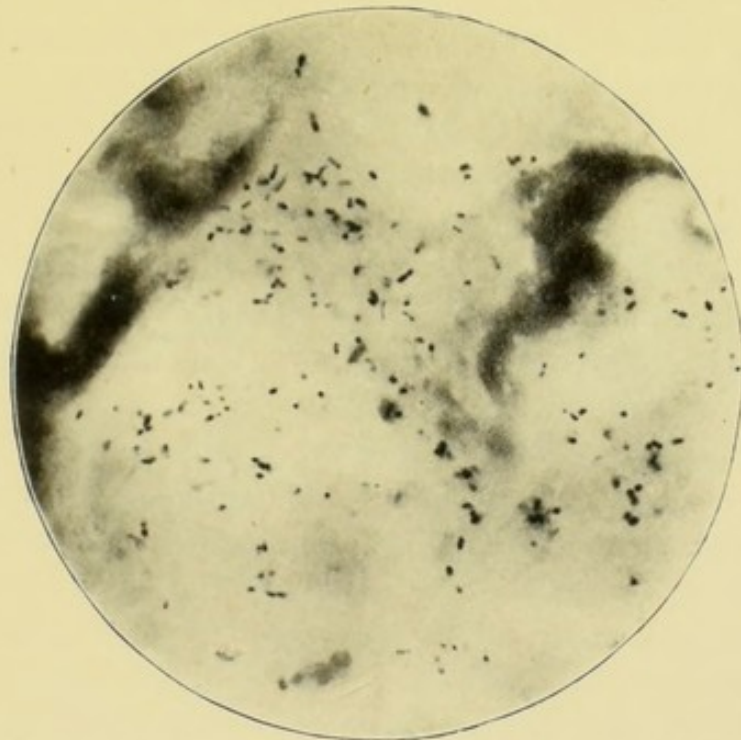


FIG. 50.—Inflamed omentum. $\times 1000$. Acute appendicitis with perforation and localised foetid abscess. The omentum was not involved in the abscess, but apart from it.

in hæmatoxylin stained sections are almost the same as in the microphotograph made from a case without suppuration (Fig. 49).

In specimens stained by Weigert's method, the lymph on the surface and the peritoneal covering of the omentum, for a depth of 1 mm., is full of cocci, diplococci, short chains of cocci and bacilli. The latter are by far the most numerous (Fig. 50). They vary in length from $.75 \mu$ to 2μ ; their usual width is $.5 \mu$. They doubtless belong to the groups of bacteria which are included in the terms *bacterium coli commune* or *bacillus coli communis*. These bacteria were numerous on the

surface of the omentum and probably absent from its depths. I have referred elsewhere¹ to this circumstance, and pointed out how it influences the curability of the peritonitis by operation (p. 168 *seq.*).

The intensity of the inflammation makes it difficult to identify the different coats of the appendix. They are all so infiltrated with inflammatory cells and fibrin, that even the muscle cells are difficult to see. The structure, however, is not so entirely obscured as in another case in which the perforation was associated with a concretion (Case 15, p. 75).

The peritoneal surface is covered with a layer of fibrinous exudation mixed with inflammatory cells. The subperitoneal tissue is full of dilated blood-vessels and similar inflammatory cells, which penetrate and almost entirely conceal the muscular coats. The submucous coat is also very vascular, and is replaced by fibrinous exudation and cell infiltration. In many of the blood-vessels throughout the appendix, the endothelial lining is in a state of proliferation.

No trace whatever of lining epithelium or of glands is seen, but some of the inflamed lymphoid tissue of the mucosa still remains. Thus, whilst all the coats are intensely inflamed, the stress of the inflammation has fallen upon the mucous and peritoneal coats. At one part of the circumference, the inflamed coats are almost perforated. This is due to ulceration of the mucosa and submucosa, and to purulent softening of the muscular and peritoneal coats.

The lumen contains quantities of bacteria in the midst of pus cells.

The whole thickness of the inflamed appendix is infected with cocci, diplococci, short chains of cocci, and bacilli. These possess the same morphological characters as those in the omentum, with the exception that the chains of cocci are longer and more numerous. The bacteria are most abundant in the submucosa and in the peritoneal exudation. The accompanying microphotograph is taken from the former. It gives a good idea of the numbers and characters of the bacteria (Fig. 51). It is a question whether some of them may not possess capsules.

¹ *Hunterian Lectures on Traumatic Infection*, p. 12, Fig. 3.

Tubercle bacilli were searched for, but none were found.

In this case it is clearly proved that bacteria abounded in the omentum, and at some distance from the pus. The abscess was localised beneath the cæcum, but the omentum was separated from it by the cæcum and some coils of the small intestines.

In removing the omentum, all the ligatures ought to transfix and interlock. Silk is the safest and best material, except when the omentum is septic. Then I use raw catgut

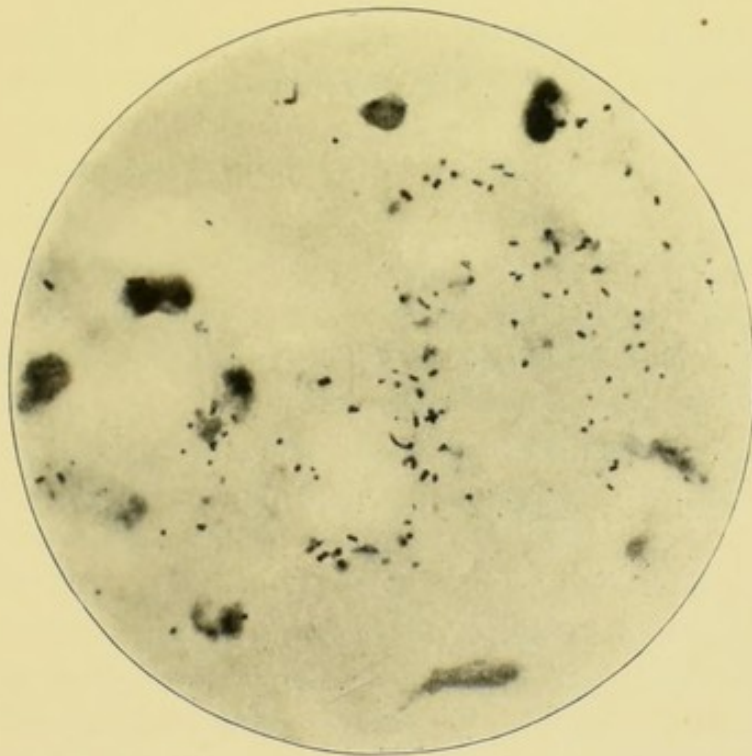


FIG. 51.—Acute appendicitis with perforation. Bacteria in appendicular walls. $\times 1000$.

which, after being scrubbed with soap and water and soaked in ether, has been kept for not less than seventy-two hours in 1 in 500 solution of biniodide of mercury in water.

Hæmorrhage from the meso-appendix is one of the dangers of the operation, but is easily avoided by securing that structure with sutures of thin silk. Each suture should transfix the meso-appendix and interlock with its neighbour. A small artery at the cæcal end of the appendix has usually to be secured with a special suture. In septic cases, I use biniodide catgut to secure the meso-appendix.

A pair of pressure forceps ought to be kept on the stump

of the meso-appendix, which should not be allowed to fall back into the iliac fossa until it is absolutely certain that its vessels are perfectly secured. I always carry some curved pressure forceps lest, owing to the presence of short attachments in the iliac fossa, the meso-appendix should be difficult to secure.

When the meso-appendix has been tied and divided, the appendix is amputated by the circular method. The peritoneum and muscular coats are divided, with a circular cut, half an inch from the cæcum, and are turned back as far as the cæcum. Until specimens had been microscopically examined, I was under the impression that only the peritoneum was turned back.¹ Next the appendix is held up and ligatured with 00 silk at its junction with the cæcum. Before the final cut is made, a pair of pressure forceps is applied to prevent the escape of septic contents from the lumen of the distal end. Finally, the mucous membrane is touched with a little liquefied carbolic acid, and the peritoneum and muscular coats brought over with a few points of Lembert's suture. After the amputation has been performed in this manner, no "stump" is left and, therefore, none can be invaginated into the cæcum. I have long taught that if a stump is left, the operation is incomplete.² For acute septic cases, I use biniodide catgut in amputating the appendix, as well as for the meso-appendix, the omentum, or the adhesions.

The ideal plan would be to close the wound with layer upon layer of buried silk sutures. This might allow the patients to resume their occupations sooner, and would diminish the risks of ventral hernia. But my own experience of buried silk sutures after appendectomy, has not been very satisfactory. On ten occasions, the small abdominal wound was closed with four layers of sutures. First, a layer in the peritoneum; secondly, a layer in the internal oblique

¹ Most surgeons seem to be under the impression that they turn back what is usually called "a cuff" of peritoneum, *e.g.* Mayo Robson, *Med. Soc. Trans.* vol. xx. 1897, p. 88.

² Dr. A. A. Warden, *Lancet*, Aug. 4, 1900, p. 328, "A Note on the Safest Method of Removal of the Appendix," seems to have somewhat erroneous ideas of the methods by which the appendix is excised.

and transversalis; thirdly, a layer in the aponeurosis of the external oblique; and fourthly, a row in the skin. Three of the ten cases, or thirty per cent, treated in this way, suppurated with extrusion of some, if not all, the sutures. Only six, out of a series of sixty similar wounds, closed with a single row of fishing-gut sutures, ended in suppuration, a proportion of ten per cent.¹ Even this compares badly with the percentage of suppuration after radical cure of hernia and nephrorrhaphy, in which large quantities of silk are likewise buried. I would attribute the sepsis to infection from the lumen of the appendix, whilst it is being cut across and pulled through the wound. As I have said elsewhere, the inflamed peritoneum may also be haunted by bacteria long after the subsidence of the attack.

Sutures of strong silkworm gut are, therefore, inserted at intervals of not more than half an inch apart. The two end sutures are placed a little beyond the limits of the incision, so as to give greater strength and closer apposition. Each loop includes a minute piece of peritoneum and of skin, perhaps an eighth of an inch of both, together with a considerable bulk of the muscles and aponeurosis.

I have observed that great care has to be taken to include all the layers, when the muscles and aponeurosis have been incised in the direction of their fibres, but too much importance need not be given to this objection.

I know of three of my own cases in which ventral hernia followed the removal of the appendix.²

In one a hæmatoma formed and the wound suppurated—the suppuration was very subacute and ceased in less than a month. I do not think, however, that the scar would have stretched if the patient, in spite of proper warnings, had not gone yachting and pulling at chains and ropes. The hernia was small and easily controlled, and is said to have caused no

¹ "The Organisation of Aseptic Operations and some of the Causes of Failure," by C. B. Lockwood, *B.M.J.*, Feb. 24, 1900, p. 420.

² Harrington (*Phil. Med. Journal*, June 1899, quoted by Tubby, *Appendicitis*, London, 1900, p. 91) examined 236 cases of appendicitis which had been operated on at the Massachusetts General Hospital by various surgeons, and for all varieties of appendicitis. He found 27 true hernias or 11½ per cent. Hernia was commonest after suppuration, packing, and drainage.

inconvenience. In the second case, the patient was obliged to return to military duty rather sooner than one could have wished.

In the third (Case 14, p. 69), an acute localised septic peritonitis, with abscess, was found and drained. The patient was provided with a belt, but this she omitted to wear during her laborious work of tailoring. The hernia, having very thin walls and being very prominent, prevented her from working. I had, therefore, to perform an operation for its cure.

The liability to ventral hernia is much greater when the wound suppurates. The statistics of radical cure of hernia bear out this statement. The wound is always in danger of infection when the appendix is removed, because the septic contents may escape when its interior is laid open. Of course, infection is unavoidable when a peri-appendicular abscess is met with, or when the appendix is perforated or gangrenous.

Before the wound is sutured, every particle of bleeding is stopped by ligaturing each little vessel with 00 twisted silk. Some branches of the deep circumflex iliac artery are cut between the muscular fibres of the internal oblique and transversalis; and some twigs of the deep and superficial epigastric arteries may be met with. If any of these are allowed to bleed, the muscular planes become infiltrated with blood and ill-adapted for repair. It is better to clamp the small vessels the moment they are cut, so as not to give them time to retract.

I have found it most undesirable to rely upon the fishing-gut sutures for stopping hæmorrhage from these muscular twigs; as it is sure to continue or recur when the patient vomits, and then a hæmatoma is apt to form and cause suppuration.

CHAPTER XX

INCOMPLETE OPERATIONS

I HAVE already referred to operations in which surgeons have failed to discover the appendix, and have, therefore, supposed it to have been absent. Under these circumstances a continuance of the symptoms is to be anticipated. At other times the density of the adhesions has prevented removal. But, in cases of appendicular abscess, the appendix is sometimes deliberately left behind. Two reasons are usually brought forward in defence of this practice: first, the danger of infecting fresh areas of the peritoneum in searching for the appendix; and second, that as the appendix is so much altered by the inflammation, it cannot be a source of future danger.

The line of practice usually followed is illustrated by the following:—

CASE 71.—*Appendicitis with Faecal Concretion—Perforation—Acute Localised Suppurative Peritonitis—Appendix not Excised.*—R. W., aged four, was seized on April 11, 1897, with a sudden pain in the abdomen and vomited several times. On the 13th, the temperature rose to 102° F. and the abdomen was distended. These symptoms subsided, but, on the 26th, the pain, vomiting, and abdominal distension returned, with acceleration of the pulse to 120, and a rise of temperature to 102° F., and then to 103° F. When I saw him on May 1, he was exceedingly ill, with a temperature of 103° F. and pulse 138. The bowels had not acted for five days, and no flatus had passed for thirty-six hours. Vomiting had been less frequent, but opium had been administered. The whole abdomen was slightly tender and did not move

with respiration. By far the most tender spot was situated above and behind the right anterior superior iliac spine, towards the outer side of the cæcum and colon. This part of the abdominal wall was particularly hard and rigid. On April 27, he had had some pain when the bladder was emptied, but I could feel no thickening or abscess *per rectum*, and the examination caused hardly any pain. I, therefore, inferred that the appendix was not in the pelvis, but towards the outer side of the cæcum and colon. It was almost certain that an acute, localised, appendicular abscess had formed. An incision was made an inch above and parallel to the front half of the iliac crest. In the front part of this incision, the general peritoneal cavity was opened for about an inch; in the outer part, an abscess could be felt. The general peritoneal cavity was shut off with a sponge, and the abscess opened with the finger. A quantity of foetid pus escaped, and then a faecal concretion $\frac{3}{4}$ in. long and $\frac{1}{2}$ in. diameter was felt and extracted. The appendix could neither be seen nor felt, and was, therefore, left alone. A large rubber drain was inserted. The whole operation lasted about twenty-five minutes. The child made an uneventful recovery. Especial attention had to be paid to the abdominal distension, which had been allowed to become rather extreme. Six hours after the operation, an enema of castor oil $\bar{\text{v}}\text{iss.}$, turpentine $\bar{\text{v}}\text{iss.}$, and gruel $\bar{\text{v}}\text{ii.}$ was given, and evacuated a quantity of feces and flatus.

Two years afterwards, the patient was exceedingly well and the appendix seemed perfectly quiescent.

CASE 72.—A similar operation was performed upon a medical man, *æt.* twenty-eight. On July 6, he was seized with a violent pain in the region of the cæcum. A purge caused an evacuation of the bowels, with much tenesmus. The next day, a painful tumour was felt in the right iliac fossa, and his temperature reached 102° F. Fluid nourishment was vomited. About mid-day on July 9, he seemed to be improving, his temperature was 99° F., and the pulse-rate 96. About five in the afternoon, the pain suddenly increased; he became rather collapsed, with increased abdominal distension, and the pulse ran up to 120, the vomiting becoming almost constant.

Soon after midnight, the abdomen was opened by the usual oblique incision; some serous fluid and about two ounces of fœtid pus escaped; a fœcal concretion was extracted, and the appendix was felt but could not be drawn into the wound, and was, therefore, left behind. Four years afterwards this gentleman was known to be quite well, and not to have suffered any return of the appendicitis.

How ought the clinical history of a case like this to be interpreted? During the earlier days, the appendix was acutely inflamed and ulcerated, the ulceration being deepest at the site of the concretion; the neighbouring peritoneum was also inflamed. The perforation took place when the pain increased and the patient became collapsed, and when there was a great increase in the pulse rate. The operation took place seven hours later, and by that time at least two ounces of pus had formed—a quantity well within the range of possibility.

When the acutely inflamed appendix is left, it may slough and appear in the wound, but such a fortunate ending is not very common.

CASE 73.—On September 30, 1897, at the request of Sir Thomas Smith, I operated upon a boy, aged eleven years, who was exceedingly ill with an acute attack of appendicitis. The attack had begun without apparent cause four days before, on September 26, and when I saw him his temperature was 102° F. and his pulse 120 to 124. The abdomen was distended, and there was constipation and vomiting. The abdominal wall was rigid over the right iliac fossa and the right flank. Great pain was complained of in both of those places, which were also exquisitely tender to the touch. A distinct induration could be felt above the outer half of Poupart's ligament, and I inferred that this indicated the situation of the pus. The result of the rectal examination was negative. The abdomen was opened by the usual oblique incision, which in this case corresponded to the induration. Some inflammatory œdema of the abdominal muscles was met with; and, when the inflamed peritoneum was opened, some serum escaped, but no pus was found in the iliac fossa. Guided by the rigidity, pain, and tenderness in the right flank, I pushed my finger in that direction, and evacuated about two ounces of fœtid pus

from an acute localised abscess situated at the outer side of the cæcum and colon. A concretion was sought for, but none was found. The vermiform appendix could not be felt. After the operation the boy began to amend, and the abscess cavity was gently washed out, every day, through a drainage tube. On October 8, two inches and a quarter of the appendix came away as a slough. No microscopical examination was made, so that a mistake may have been made, as in Mr. Sheild's case (*v. inf.*). A month later, the boy was up and about the ward. More than a year afterwards, I heard that he had remained quite well.

I have known a concretion to escape from the wound some days after an abscess around the appendix had been opened.

But the course of events is not always so smooth after the evacuation of an appendicular abscess, without the removal of the diseased appendix. My friend, Mr. Sheild, has given me the particulars of a case in which the symptoms recurred, and I have heard of many others which have not been published.

CASE 74.—On February 21, 1896, Mr. Sheild operated upon a gentleman, *æt.* thirty years, and evacuated a very large and fœtid abscess from the right iliac fossa. The illness had lasted a fortnight, and was accompanied with vomiting, abdominal distension, and increased temperature (102° F.). The appendix could not be seen or felt, and the critical condition of the patient forbade a prolonged search. A week after the operation, the discharge from the drainage tube was fæculent. Concretions and sloughs also escaped, and the appendix itself was thought to be amongst the latter. The patient recovered and seemed quite well for nearly four years, but then had two attacks of acute appendicitis. An indurated mass could be felt in the iliac fossa. Mr. Sheild opened the abdomen by a free incision in the right linea semilunaris, and traced the right colon down to the cæcum, which was firmly adherent to the old scar. With difficulty, the cæcum was turned out of the abdomen, together with a large, indurated, club-shaped appendix, imbedded in a mass of adhesions. The patient made a good recovery.

CASE 75.—When I held the office of Surgical Registrar to St. Bartholomew's Hospital, I performed a *post-mortem*

examination upon a woman aged twenty-six, whose history was as follows:—Five months previously she had had a severe attack of appendicitis which ended in suppuration. The abscess was opened in America, and it was said that the surgeon had found many intestinal adhesions, and had come to the conclusion that the appendix was not in the usual situation; at all events it was not removed. The wound never healed, but a sinus remained and discharged foetid pus. A severe and prolonged operation was performed with the idea of closing this sinus. It was traced far into the pelvis, and, at length, some sutures were inserted to close an opening which was supposed to lead into the intestine. Death ensued two days afterwards from general septic peritonitis.

At the necropsy I found the small intestines matted together by old as well as recent adhesions. The vermiform appendix was nearly five inches long and, after arising from the cæcum in the iliac fossa, hung over into Douglas's pouch. The end of the appendix was bulged out by a large faecal concretion, which could be seen through an ulcerated opening. The sinus ended at this perforation.

I also have notes of a case in which the late Mr. Marrant Baker opened an appendicular abscess, but did not remove the appendix. The patient ultimately died, and the appendix was, *post mortem*, found with a pin protruding from its interior through a perforation.

The following case made a deep impression on my mind:—

CASE 76.—Mr. R. was seized with violent abdominal pain after a long bicycle journey, during which he was exposed to a bitterly cold wind. Complete intestinal obstruction followed, with vomiting and abdominal distension. These symptoms were suddenly relieved, but the region of the appendix continued to be painful, and the temperature and pulse were raised. At the end of a fortnight, during which the temperature had ranged for some days betwixt 101° and 102° F., I opened a localised abscess beneath the lower part of the right linea semilunaris. The abscess cavity was gently explored with the finger, but neither the appendix nor a concretion was felt. Some months later, an abscess was opened beneath the left rectus abdominis. A few months after, I evacuated a huge

collection of stinking pus through an incision in the right loin. An abscess subsequently formed in the pelvis, and was opened by the side of the rectum. And, lastly, an abscess near the site of the first incision gave exit to a slough which my friend, Dr. Tanner, thought to be the appendix. The long and dreadful illness, borne with courage and fortitude, at length ended in recovery.

Another of the evils which may ensue, when the appendix is not completely removed at the operation, is shown by the following:—

CASE 77.—S. T., aged thirty-seven, a married woman with three children, was admitted into one of the medical wards of St. Bartholomew's Hospital with this history:—On January 16, whilst at work making buttons, she was seized with a sudden and severe pain in the left hypochondrium, and this was followed by pain in the right iliac fossa. In a short time vomiting began, and continued off and on during the night. On January 17, the bowels acted after liquorice powder, and the temperature was 101° F. and the pulse 112. The abdomen was slightly distended and moved with respiration, except over the right iliac fossa. In that region, pressure caused tenderness and resistance, but no tumour could be felt.

These symptoms continued, and each night the temperature rose to 102° F. and the pulse ranged from 100 to 104. When I first saw her, on January 29, the right iliac fossa was occupied by a hard and tender swelling, which ran upwards along the course of the colon. No fluctuation was felt, but the presence of pus was inferred from the persistently high temperature and pulse, and from the pain and tenderness in the tumour.

The usual oblique incision was made, and the general peritoneal cavity opened. By pushing up the thickened and inflamed cæcum, an abscess cavity, containing about half a pint of foetid pus, was opened, and a large soft concretion was found amidst the pus. The appendix was incorporated by inflammatory exudation with the under surface of the cæcum. Its outlines were difficult to see, and it bled very freely. I managed to remove what I judged to be two-thirds of its length, but was obliged to leave the rest for fear of causing a

faecal fistula. The abscess cavity was thoroughly swabbed out and drained with a large rubber drainage tube, and also with a piece of antiseptic gauze.

After the flatulent distension had been relieved with calomel and enemas, a speedy recovery ensued, but the site of the drainage tube refused to heal. On May 27, four months after the first operation, an anæsthetic was given and the sinus opened up. No concretion was found, nor could the stump of the appendix be discovered amidst the granulations. The sinus became smaller, but had not quite healed when the patient was last seen in October.

Unfortunately, the appendix was not histologically examined. I see no reason to suppose that it was actinomycotic.

The following is another case of persistent abscess and sinus following a failure to remove the appendix.

CASE 78.—*Appendicitis with Chronic Abscess in Douglas's Pouch and Septic Sinus—Removal of the Appendix—Death from Vomiting.*—A girl, aged ten years, had had four attacks of appendicitis. The first was in January, 1897, the second and third in May and October of the same year, and the last in April, 1898. An abscess formed during the last attack and was opened. The wound healed, and a subsequent attempt to remove the appendix failed on account of the formidable intestinal adhesions.

In October, 1898, after pain and fever, an abscess discharged through the lower end of the wound, and left a sinus which refused to heal. When the child was placed under my care, a scar, with a discharging sinus at its lower end, was seen in the right semilunar line. No tumour was found in the iliac fossa, but a tender irregular mass was felt through the right side of the rectum. Under an anæsthetic, a probe was passed about four inches down the sinus, and was felt, *per rectum*, in the midst of the tender swelling. It was clear that the septic sinus led to the diseased appendix, which was adherent to the right side of Douglas's pouch, a particularly dangerous position.

Evidently a severe operation was required for the removal of an appendix in Douglas's pouch, and the dangers of the

septic sinus had also to be considered. But, in addition, after the examination of the sinus, the child vomited continuously for three days, so that we looked forward with great apprehension to a second anaesthesia. The friends were duly warned, but the presence of the septic sinus seemed to necessitate an attempt.

On November 5, an anaesthetic was given, and the abdomen opened through the old incision in the right linea semilunaris. Adherent great omentum was first encountered, and, after it had been undone, the adherent small intestines. After a prolonged struggle, these adhesions were overcome, and the appendix detached from the right side of Douglas's pouch, where it lay over the external and internal iliac artery and vein. The appendicular adhesions were less firm than those of the omentum and intestines, a peculiarity which I have noticed on other occasions.

The appendix was inflamed, dilated, and perforated at its tip, which lay in a small abscess. It had twisted upon itself half an inch from its origin from the caecum, so that it was occluded at that point, just as if it had had a stricture. The wound was closed, after drainage had been thoroughly provided for with gauze and a rubber tube. Some blood was lost during this arduous operation, but on the following day the shock had nearly passed away. Her condition seemed favourable, with the exception of persistent vomiting, which, however, continued until November 10, when she died. The abdomen, which was but slightly tender, moved throughout, the bowels acted, and there was no distension. At the *post-mortem* examination, the peritoneum was rather red and inflamed, but without any fluid or pus. It seemed to me doubtful whether the peritonitis was sufficient to explain the fatal result.

The sections of the appendix are circular, with a diameter of a centimetre. The lumen is irregular in outline and dilated. It is more than half a centimetre across at its widest part. With the naked eye, it is easy to see that the mucosa, submucosa, and subperitoneal coats are twice as thick as usual. The microscopic examination shows that the peritoneal covering has lost its endothelium, that the basement membrane is thickened, and that the thickening of the subperitoneal tissue

is mainly caused by separation of its fibres by inflammatory effusion. Inflammatory cells are scattered throughout its meshes, and have collected into small groups which look like miliary abscesses; some of the groups are contained in small veins or lymphatics. The subperitoneal blood-vessels are dilated, full of blood, and rather more numerous than usual. In parts, the tissues are filled with fresh blood corpuscles extravasated during the operation.

The longitudinal muscular coat is thin and irregular, and is

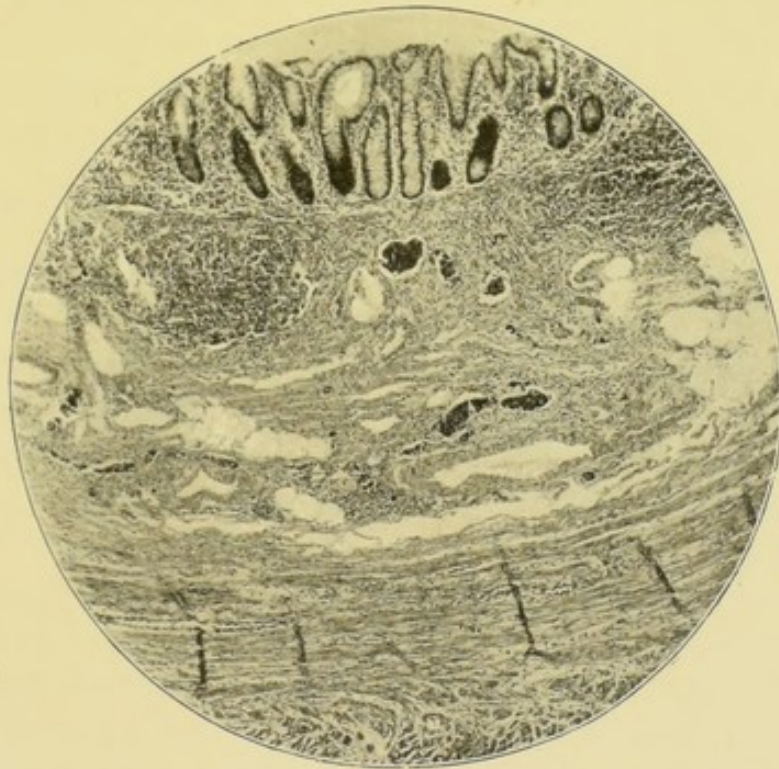

FIG. 52.¹—Appendicitis with perforation and abscess in Douglas's pouch. Removed during quiescence. $\times 40$. The œdema of the submucosa is well shown, also the small groups of inflammatory cells. The lumen is above.

absent at the meso-appendix. The circular muscular coat is rather thinner than usual, although its fibres are separated by inflammatory cells. The submucosa looks very loose, because its lymphatics and lymph spaces are dilated, as are also its blood-vessels. It contains groups of inflammatory corpuscles similar to those in the subperitoneal coat (Fig. 52). The mucosa contains numbers of lymphoid follicles, sixteen of

¹ This microphotograph has a certain resemblance to Deaver's drawing of acute interstitial appendicitis (*Appendicitis*, 2nd edition, Philadelphia and London, 1900, Plate VII.).

which were counted in one section. The mucosa also contains groups of inflammatory cells.

Some of the follicular lymph sinuses are dilated and surround the whole follicle. The tubular glands are dilated and contain many mucous cells. The epithelial lining of the lumen is present throughout the greater part of its extent. In some places, however, it is detached, opening some of the lymph canalicular system to the contents of the lumen. The lumen is half full of mucus, epithelium, and pus corpuscles, unmixed with bacteria. Specimens were stained for tubercle with a negative result.

The histological examination throws no clear light upon the cause of the perforation. The absence of ulceration and of bacterial contents excludes a concretion. The capacious lumen and the thinning of the muscular coats are consistent with the supposition that the perforation may have been caused by retention of contents, owing to occlusion at the twisted part. At all events, the appendix was an abiding danger so long as it remained in the abdomen. It is to be regretted that failure attended the first attempt which was made to remove it, because at that time the septic sinus had not formed.

It is clear, that no reliance can be placed on the statement that the violence of the appendicitis renders the appendix innocuous. Evidently, when left behind, it may (1) be in a state of acute sepsis; (2) contain a concretion or foreign body; (3) keep open a septic sinus; or (4), after being quiescent for a time, be capable of causing a fresh outburst of inflammation.

I cannot, therefore, agree with those who are content with the mere opening of the abscess. On the contrary, I believe that it is better for the patient to take the immediate risk of a determined attempt to excise the appendix;¹ but how far the attempt should be carried must depend upon the peculiarities of each case. Obviously, an operation which was unjustifiable in the case of a delicate child of four years of age and with

¹ The treatment of the appendix must vary with its condition and the state of the patient. It should always be removed, if possible (Jacobson, *The Operations of Surgery*, 3rd edition, p. 797). Lennander, too, is emphatic on this point (*Appendicitis*, Wien, 1895).

great distension (Case 71, p. 249), might be justifiable in the case of a vigorous adult.

Furthermore, my own observations lead me to believe that the dangers of infecting fresh areas of peritoneum are exaggerated.

Dr. Fowler says that of twenty-five cases in which the appendix was not removed, there were seventeen recoveries and eight deaths. Of the seventeen recoveries, two suffered in the course of the next two years from a subsequent attack, and one of these proved fatal.¹ I think it will ultimately be found that recurrence takes place in about 15 per cent of the cases of appendicitis, with suppuration, in which the abscess is opened and the appendix not removed.

¹ "Observations on Appendicitis," 5th part, *Annals of Surgery*, vol. xix. p. 569.

CHAPTER XXI

THE AFTER-TREATMENT OF APPENDECTOMY

THE following remarks on after-treatment are not intended to apply to ordinary simple cases of appendectomy, in which grave or serious complications hardly ever arise, provided no sepsis is introduced and all hæmorrhage is efficiently controlled. The greater obviously includes the less, and he, who understands the after-treatment of a serious case, can manage a mild one. By prompt and well-timed measures, some of the complications can be prevented or mitigated, whilst the fatality of others can be averted by surgical intervention. Judgment and courage are called for in the use of remedies, and fortitude, too, is needed when a second operation has to be undertaken under forbidding circumstances.

Unfortunately, all appendix operations are not simple, but some may be complicated with troublesome adhesions, abscesses, or various degrees of septic peritonitis; and may be followed by shock, vomiting, thirst, tympanites, constipation, peritonitis, abscess, and the other general complications of sepsis.

The details of the after-treatment are also important, because, of necessity, they have oftentimes to be carried out by others than the operator. A clear apprehension of the complications which are to be expected, and of the signs of their coming on, is better than a belief that they can be cured with drugs after they have become established.

The removal of the non-adherent appendix causes hardly any shock. In abdominal surgery some of the principal causes of shock are (*a*) prolonged anæsthesia; (*b*) abstraction of heat by exposure to the atmosphere, and by contact

with cold towels, lotions, sponges, and instruments; (*c*) violence applied to the abdominal viscera by their extrusion, by traction, squeezing, rough handling, or the application of cold or excessive heat; (*d*) pain and other nerve influences; (*e*) hæmorrhage.

When the operation is properly organised and skilfully performed most of these influences are eliminated. But sometimes formidable adhesions are encountered, and a long and determined struggle ensues before the appendix can be found and separated. The separation of the adhesions entails some hæmorrhage, which, although not profuse at any particular moment, may amount to a good deal in the aggregate.

The lotions and sponges ought to be heated to 105° F. when they reach the wound. To be sure of this, the nurse should be instructed to use a thermometer. I have seen considerable shock follow the introduction of a large quantity of very hot (temperature 112° F.) lotion into the peritoneal cavity.

Shock is met by warmth, enemata of brandy and hot water, subcutaneous injections of strychnine ($\frac{1}{50}$ gr.), and, when associated with much pain, by the administration of opium by the rectum, or even the subcutaneous injection of morphia ($\frac{1}{6}$ to $\frac{1}{3}$ gr.). In appendix cases, I have hitherto found such measures as these suffice, and have not had to resort to the infusion of saline solution into the veins.

Vomiting is particularly noxious because of the violence which it inflicts upon the freshly sutured abdominal wound, and upon the recently manipulated abdominal viscera. Sometimes, the vomiting is partly neurotic and under the patient's control. Therefore, before the operation is begun, the patient should be requested to exercise control.

Vomiting is one of the common complications of appendectomy. It is mainly caused by the anæsthetic, and as often by ether as by chloroform or A.C.E. The nature of the case and of the operation is not without influence. I have had none whatever after operations of moderate severity upon elderly people, and a good deal after severe operations upon delicate girls and women. It usually begins as soon as the patient is back in bed and is regaining consciousness. It has certainly been less troublesome, since we have had patients put back to

bed lying on the right side, so as to allow the buccal and pharyngeal mucus to run from the mouth. This position also tends to prevent blood or inflammatory effusion from leaving the right iliac fossa. In most cases, the vomiting may occur once, twice, or three times, and then cease. In such slight cases it is merely necessary to be very cautious when beginning to give nourishment. First, a teaspoonful of hot water is given, and this is followed in half an hour by a tablespoonful, and so on. Barley water, lemon water, weak tea, or peptonised milk and soda water may be given, if preferred. Milk as a nutriment is quite unnecessary, but very small quantities of peptonised milk and soda water are often retained when everything else is vomited. Ice is objectionable because it seems to increase the thirst.

I have known vomiting cease after the most varied remedies. A draught of very hot water, a cup of very hot tea, hot brandy and water, a drop of iodine in water (ostentatiously measured out), bicarbonate of soda in water. Washing the stomach out with a stomach tube has given relief, but is apt to be followed by faintness and exhaustion. It is always to be remembered that the heart may be called upon for some great effort, and that, therefore, its powers should not be squandered.

As a rule, the vomiting gradually subsides, the odour of the anæsthetic disappears, less mucus is brought up, and at longer intervals. But, sometimes, the vomiting and retching become persistent, and the character of the vomit alters. First, the mucus and gastric juice are mingled with bile from the duodenum, and, at last, a black grumous fluid is ejected. The quantity of this fluid is sometimes quite extraordinary.

The vomiting at this stage is probably due to intestinal obstruction. Flatus has not been passed, and the abdomen is distended and tympanitic. Under these circumstances, the ordinary drugs prescribed for vomiting are unavailing, and merely lead to waste of time and opportunity. The obstruction and tympanites must be attacked with courage and determination, and the vomiting ceases when, by means of calomel and enemas, the bowels have been relieved of flatus and fæces. After that, the pulse falls, the patient goes to sleep, and is in a fair way to recovery.

At the same time, the strength may be maintained by judicious rectal feeding. The services of a competent nurse are now indispensable. A skilful one can continue rectal feeding for days or weeks, whilst the unskilful speedily makes the rectum sore and intolerant.

The nutrient enema should be (1) liquid, (2) bland and unirritating, (3) easily absorbed, (4) peptonised, (5) nutritious. On the whole, peptonised milk fulfils these conditions the best.

The necessary quantity can easily be made with one of the peptonising powders or pancreatic fluids. The process is continued for twenty minutes. This makes the milk very unpalatable, but, under the circumstances, this is of no consequence.

The rectum is washed out with tepid water, and \bar{z} iii. or \bar{z} iv. of enema are gently run into the bowel by means of a soft catheter and a funnel. The latter is easily improvised out of the barrel of a \bar{z} iv. glass syringe.

The catheter should be about No. 10 to No. 12 size and very smooth, and it ought to be well lubricated with vaseline. If the anus be sore or very sensitive, a 5 per cent solution of cocaine is applied upon a pledget of wool before the use of the catheter. The rectum ought to be thoroughly washed out at least once in the twenty-four hours.

Enemas of equal parts of peptonised milk and peptonised meat essence, seem also to act well in sustaining the patient's pulse. Sometimes a teaspoonful or more of the very best old brandy may be added to each enema. When the rectum is intolerant, the addition of four or five minims of Tr. of opium may be required.

When the vomiting has subsided and nutriment can again be swallowed, then the enemas may be gradually discontinued. Roughly speaking, an adult does not gain strength unless at least two pints of nutritious fluid can be taken by the mouth in the twenty-four hours.

Thirst is sometimes very distressing after laparotomy, even when this has been simple and of short duration. If the tendency to vomit has ceased, the thirst is soon relieved with sips of hot water. But should that be ejected, then the

thirst can be relieved by slowly introducing a tepid solution of common salt and water (a teaspoonful of salt to a pint of water) into the rectum. The instruments required are a No. 12 Jaques' soft rubber catheter and the barrel of a glass syringe.

The amount which the rectum can retain and absorb varies, but is usually about half a pint. This form of enema is quite unirritating, and can be repeated every two or three hours, if necessary. After severe operations, such as those which last for over an hour, thirst is almost sure to occur. These cases are also especially liable to suffer from vomiting. It is, therefore, sometimes advisable not to run the risk of giving fluids by the mouth, but to resort at once to "rectal drinking."

Flatulence and flatulent distension or tympanites are almost inevitable sequels of abdominal operations. I have not the slightest doubt that, as Mr. Malcolm and others have pointed out, in the early days of abdominal surgery, many of those who were supposed to have died of septic peritonitis, died of flatulent distension ending in intestinal obstruction. Even at the present day, this complication is not always thoroughly understood. Those in charge of the case are apt to allow flatulent distension to become established, and then endeavour to overcome it with drugs. Clearly, prevention is better than cure. Its advent ought to be forestalled.

The causes of flatulence and flatulent distension are complicated, and the subject is one which is well worthy of further investigation and study. The main factors concerned are (*a*) the intestinal bacteria and intestinal contents; (*b*) the muscular and peritoneal coats of the intestines; (*c*) the muscular walls of the abdomen.

And, first, it ought to be recognised that the intestinal gases perpetually tend to increase. Perhaps some are swallowed and others separated from the blood, but the amount from these sources must be trivial compared with the quantity of gas produced by the intestinal bacteria. Of these gas-making bacteria, the colon bacillus is the chief. When colonies of colon bacillus grow in the depths of gelatine in culture tubes, each deep colony is crowned with little bubbles of gas. If

this is formed in such quantities under artificial conditions, what must be the aggregate volume of gas produced by the innumerable bacteria which inhabit the alimentary tract?

The gas is made by the bacteria whilst they are decomposing the intestinal contents into faecal material. One of the methods of preventing flatulence and flatulent distension is thus obvious. Care should be taken before the operation, by judicious purging, enemas, and dieting, to empty the bowels of their bacterial and faecal contents.

Castor oil is a safe and convenient purge, but, before it is administered, it is well to inquire whether aperients can be borne. Sometimes they cause great pain and discomfort, or may even precipitate an attack of appendicitis. If the patient is in the habit of taking some particular purgative, it is wise to continue its use, as from his own experience he will probably know what is best. If aperients cannot be taken, the bowels are cleared with enemas.

The diet should be carefully regulated for three or four days before the operation. Fruit, vegetables, and indigestible foods are to be eschewed.

In sudden and violent appendicitis, with perforation and gangrene, and acute septic peritonitis, the intestines may contain considerable faecal matter. This contingency is to be borne in mind, and calomel given as soon as the shock of the operation has passed away.

The muscular coats, in particular, and the peritoneal are concerned in the causation of flatulent distension. The muscular coats propel the faecal and gaseous contents of the intestines. They may fail to do so after appendectomy (*a*) because they are themselves inefficient or paralysed; (*b*) on account of localised or generalised peritonitis; (*c*) because of mechanical obstruction.

The muscular coats of the intestines may, in the old, atrophied, and debilitated, be deficient in quantity and quality. Such patients are, therefore, to be watched with care, and the distension combated with strychnine, alcohol, and stimulating enemas. The nervous system is also to be taken into account. The most marked tympanites, I ever saw, was in the case of a hemiplegic old lady.

The injudicious administration of morphia or of opium is a too common cause of paralysis of the intestinal muscle. This permits the flatus to accumulate in the paralysed coils of intestine, which become tightly distended and kinked, or obstructed by pressure upon one another, and thus intestinal obstruction is established. The symptoms of this paralytic flatulent obstruction can be distinguished from those associated with acute septic peritonitis. In both, the abdomen may be tightly distended, and there may be vomiting, and the non-passage of flatus or *fæces*. But, in paralytic flatulent distension, the pulse is but slightly quickened, and seldom reaches 100; the abdomen also is not very tender, and may move during respiration; the temperature, too, may not be raised. In peritonitis, the pulse is rapid and speedily runs up to 120 and to 140; the abdomen is exquisitely tender, still, and rigid. The temperature may be raised.

Some degree of peritonitis is always caused by the operation for the removal of the appendix. The character of the peritonitis mainly depends upon the nature of the disease for which the operation was performed. In cases of slight ulcerative appendicitis, without adhesions, in which the operation is performed quickly and gently, the peritonitis is so slight as to be barely appreciable, and flatus easily passes the ileo-cæcal valve, although the first passage is usually attended with pain.

When adhesions are met with, a more severe attack of localised peritonitis ensues. The peritoneal coverings of the cæcum and of the end of the ileum are especially inflamed. As is well known, the inflamed segment of bowel not only neither moves nor propels its *fæcal* and gaseous contents, but even acts as an obstruction to the propulsive efforts of the bowel above. The first passage of flatus through the inflamed segment of intestine, is nearly always attended with considerable and acute pain, like that which is felt during an attack of appendicitis. This pain may be looked for eighteen to twenty-four hours after the operation. Sometimes it is said to be very severe, and is attended with slight disturbance of the pulse or temperature. I have come to the conclusion that the ileo-cæcal valve being swollen and inflamed, becomes an additional obstacle to the passage of flatus. As I have

already said, the ileo-cæcal valve and the vermiform appendix are supplied by the same artery—the posterior ileo-cæcal—so that they have a close vascular relationship to one another. Operation may be undertaken for appendicitis, complicated with localised or generalised septic peritonitis. These are generally cut short by the removal of their cause, which may be an ulcerated and infected appendix, or one which is perforated or gangrenous, or both. Unfortunately the opposite may occur, and the septic peritonitis may receive an impetus and be made worse by the operation.

Septic peritonitis, whatever its extent, is almost sure to hinder the propulsive action of the intestinal muscle, and is, therefore, nearly always accompanied with flatulent distension, and, in its later stages, with intestinal obstruction. Exceptional cases occur in which diarrhœa is met with, but in my experience they are unusual.

Flatulent distension is also permitted by the state of the abdominal walls, and it is favoured by weakness and relaxation of the abdominal muscles. It is common in women with thin, flaccid, weak abdominal muscles.

The injury done to the abdominal walls by the operation, is another cause of flatulent distension. The bruising and laceration of the muscles render their action painful, and they cease to exert their wonted pressure upon the intestines. The presence of sutures has, at first, a similar effect, so that the expulsion of flatus by the abdominal muscles is, for a time, in abeyance.

In simple cases, the flatulence usually begins about eighteen or twenty-four hours after the operation, and is over within the next twenty-four. In some cases, relief is given by simply passing the rectal tube and leaving it in the rectum for half an hour at a time. The patient may, at the same time, be turned upon the right side. Should this fail, an enema of soap and water with half an ounce of castor oil and half an ounce of turpentine, usually succeeds. In addition, the enema of assafœtida of the British Pharmacopœia or the old-fashioned rue enema may be tried. These remedies seem very harmless. They may make the anus and rectum sore, or excite vomiting, or accelerate the heart for a little time. But should

enemas not succeed, then a purge must be given. Calomel is undoubtedly the quickest and most efficacious, and causes the least pain.¹ In cases complicated with abscess and septic peritonitis, the treatment of the flatulent distension may require some amount of courage and promptitude. I am convinced that prompt and repeated doses of calomel have often saved patients' lives. The prejudice which formerly existed against the use of purgatives in abdominal cases, has probably by this time ceased. The following illustrates their value.²

CASE 79.—The patient was a very stout and plethoric policeman aged forty-six. The illness began about forty-eight hours before the operation, with a violent pain in the abdomen. He vomited several times, and the abdomen became very tense and distended. The bowels ceased to act and no flatus or fæces passed. The temperature was $100\cdot6^{\circ}$ and the pulse 104, full and regular. The abdomen was moderately painful on pressure and rigid over the right iliac fossa, and the pain was said to have begun in that region. An incision was made through the right linea semilunaris. Pus and gas escaped. Several collections of pus were found amongst the coils of intestines. Each was thoroughly washed out with biniodide of mercury lotion, 1 in 1000, before any further search was made for the source of the infection, which was supposed to be the appendix. That organ was found amidst a collection of pus, and was acutely inflamed throughout, and gangrenous at its tip. The operation was completed in the usual way, a large rubber drainage tube being placed beneath the cæcum. The man took the anæsthetic badly, and his whole venous system was engorged. His alimentary tract, too, was full of flatus and fæces. Five grains of calomel were given, as soon as he came out of the anæsthesia, and the dose was repeated in two hours, as an evacuation had not occurred. In addition, enemas of thin gruel, with half an ounce of turpentine and half an ounce of castor oil, were administered. These measures caused a copious evacuation, and recovery ensued.

¹ I have observed great differences in the action of calomel. Some specimens do not act although given in 10-grain doses, whilst 5 grains are usually efficacious. It seems as though the cheaper and less pure samples of calomel acted the best.

² Given in *Practitioner*, April 1898, vol. lx. p. 397.

The efficiency of calomel is also illustrated by other cases, notably by Case 54, p. 177.

It is a question whether, in desperate cases, more drastic purgatives than calomel might not be justifiable. I have not yet resorted to croton oil.

When flatulent distension does not yield to drugs, an extension of the septic peritonitis, or the presence of an intra-abdominal abscess, is to be suspected. In a desperate case of this description, a large abscess in Douglas's pouch was opened *per vaginam* (Case 81, p. 274), and, in another, pus was found in the recto-vesical pouch (Case 80, p. 272).

I have seen my colleagues, Harrison Cripps, and Bruce Clarke, in desperate cases of flatulent distension, successfully establish a temporary opening in the cæcum or ileum. Hitherto, I have not been obliged to resort to this expedient after appendectomy. Flatulence is sometimes accompanied with eructation. This is relieved by some simple remedy such as peppermint, or oil of cajuput on sugar. Hiccough may be persistent. Small doses of nitro-glycerine in lozenges will sometimes cure this distressing complication.

Retention of urine is, for reasons which have been given (p. 205), rather common in cases of appendectomy. It ought, therefore, to be always kept in view and a catheter used when necessary. I once saw very distressing, but not fatal, consequences, follow from this condition having been overlooked. The pain, caused by the accumulation of urine, was attributed to peritonitis.

Appendectomy is not a painful operation. As a rule, the degree of pain is about equal to that of a moderate attack of appendicitis. I usually prescribe 10 or 15 minims of tincture of opium, in a small starch enema, to be given in case the pain is so severe as to render the patient restless. In at least a third of the cases, the anodyne is not required. Patients do not care for opium administered in enemas, and seldom crave for a second dose. It would be cruel to allow a patient to suffer excess of pain, but those who have no opium recover their appetites sooner and suffer less from flatulent distension.

Morphia is seldom required, and is so dangerous, as a routine treatment, that I forbid my house-surgeons to use it

without my permission. In one case (Case 37, p. 133) the gall-bladder and the kidney were explored before the appendix was excised. Four hours afterwards the patient was in great pain, with cold sweats, and a small and irregular pulse. After a sixth of a grain of morphia, he became warm and comfortable, with a good pulse and freedom from pain. When it is absolutely necessary to give morphia, it is better to give a small dose and repeat it, if necessary, than to give a large and dangerous dose which may not be required. The effects of morphia upon the nervous system and digestion are too well known to call for remark; its relation to flatulent distension of the abdomen has been mentioned.

In ordinary uncomplicated cases of appendicitis, the diet, the day after the operation, usually consists of a little tea and toast or soup and milk. The imbibition of fluids is, however, usually attended with flatulency, so that a more solid dietary is soon resumed. On the second or third day some fish may be given, then chicken, and afterwards a light diet without fruit or vegetables.

Sometimes a drainage tube is used to provide for the escape of the blood, which oozes from inflamed peritoneum or from minute adhesions. The drainage tube is usually supplemented with some gauze packing; and the bleeding ceases within twenty-four hours, when both the gauze and the drainage tube had better be removed. The gauze is liable to stick and cause great pain when withdrawn, and the drainage tube is a source of infection from the atmosphere. As a general rule, the drainage provided for blood should be removed within forty-eight hours. At first, pure blood escapes, then blood-stained serum, and, at last, colourless serum, which is an indication for taking out the tube.

When hæmorrhage is complicated with sepsis, as, for instance, in oozing from an abscess cavity, then the drainage is to be withdrawn with caution and by degrees. At the end of twenty-four hours, part of the gauze is removed; at the end of forty-eight, the remainder, and then the drainage tube is shortened and removed.

In acute abscess and in septic peritonitis, the immediate and thorough removal of septic fluid is all-important during the

first forty-eight hours. The action of the drainage tube has to be helped every four hours by gentle suction. I usually proceed as follows, always remembering that it is possible to force septic fluids amongst the intestinal coils. First, the tube is cautiously sucked out with a long thin rubber tube on the nozzle of a half-ounce glass syringe. This fluid is emptied into a glass for examination because the management of the drainage tube and the prognosis depend to some extent upon its characteristics. Second, the drainage tube is cautiously filled with biniodide of mercury lotion (1 in 4000) and then sucked out until no pus escapes. It ought to be turned round occasionally lest a bit of omentum, an epiploic appendix, or a part of the intestinal walls enter one of its apertures. It should also be pulled out a very little to prevent its lower edge pressing upon the rectum or intestine. But these accidents are unlikely to occur, if the tube is prepared by rounding its edge and making a single small oval aperture a third of an inch from its lower end.

The tube has usually to be emptied every four hours during the first twenty-four, and then every six hours, and so on. As soon as the quantity of pus diminishes, and it becomes thinner and odourless, the large drainage tube is taken out and a small one pushed gently to the bottom of the sinus. This can be shortened day by day, and at last removed. The removal of the drainage tube, whether inserted for the removal of blood or of pus, is almost invariably followed by a transient rise of temperature and acceleration of the pulse.

The pus, which is washed out, is sometimes horribly offensive. This may be due to a faecal fistula (Case 21, p. 93), but more often to the presence of the colon bacillus, the intestine being intact.

After having used glass tubes for some years, I have of late used rubber. They seem to cause less pain, and are free from any danger of breaking. Properly managed, they are efficient, and our results have been quite as good as with glass.

When the drainage tube is removed too early, the temperature and pulse begin to rise, the abdomen becomes distended and painful, vomiting and symptoms of intestinal obstruction

recur, and a painful tumour may be felt in Douglas's pouch. The following is a case in point.

CASE 80.—*Appendicitis with Gangrene of Part of Appendicular Wall and Septic Peritonitis—Return of Peritonitis after the Removal of the Drainage Tube—Recovery after a Second Operation.*—X., aged fourteen, a delicate boy, was seized at mid-day on April 6, with sudden and violent abdominal pain. The pain was worst on the right side. Vomiting began at 1 P.M., and became continuous. On April 7, his bowels acted. I saw him at 11 P.M. on that day; the temperature was 100.6° F. and the pulse 120. The abdomen was slightly distended, but moved with respiration. It was tender everywhere, but especially on the right side, where the rectus and oblique muscles were rigid. No tumour was felt in the iliac fossa, but *per rectum* the pelvic peritoneum was very tender, and a very painful tumour could be felt high up on the right. We inferred that this was caused by a perforated appendix lying in the rectovesical pouch. The abdominal trouble was complicated by very severe bronchitis.

There was a clear history of an attack of abdominal pain five months before. We came to the conclusion that this had been caused by an attack of appendicitis.

At 11 P.M. on April 7 (less than thirty-six hours after the commencement of the attack), in order to reach the appendix by the most direct way, the abdomen was opened by an incision through the outer edge of the right rectus. An acutely inflamed appendix with a patch of gangrene about its middle, was found beneath the ileum, hanging over the brim of the pelvis. A good deal of thin, slightly foetid pus surrounded the appendix and filled the upper part of the rectovesical pouch. After excision of the appendix, a rubber drain was pushed to the bottom of Douglas's pouch, and a strip of gauze was placed beneath the cæcum.

In spite of a severe attack of bronchitis, this patient made good progress towards recovery, and a small drainage tube, which had been used to replace the larger one, was removed. On April 17, he seemed very ill again with pain in the left side of the abdomen, and with a tender spot beneath the middle of the left rectus, which was slightly rigid. There was also

decided tenderness in the recto-vesical peritoneum. But the bowels had acted after enemas, and the temperature and pulse were normal. I diagnosed slight obstruction, due to matting of the intestines. On April 23, he seemed better, but, on the 24th, was very ill. The left side of the abdomen was dull and very tender. Under an anæsthetic, no collection of fluid could be felt. I opened the wound and pushed my finger into the left side of the abdomen. Some ounces of yellow serum escaped. I then explored the recto-vesical pouch, and found a little thin odourless pus. This was thoroughly washed out with biniodide of mercury lotion, and a long thin drainage tube put in, through a fresh incision in the lower part of the linea alba. Although this operation was followed by a fresh attack of bronchitis, he made a good recovery.

The morbid histology of the appendix was the same as that of another case (Case 16, p. 79), in which the clinical symptoms were similar. I do not, therefore, propose to describe the condition in detail. The peritoneal and muscular coats are intensely inflamed with dilated blood-vessels and lymphatics, and there is so much cell infiltration that their tissues are hidden. The submucosa is oedematous and packed with inflammatory cells. The lymphoid tissue of the mucosa is wanting, but, in some sections, parts of the epithelium of the lumen are seen, together with portions of five or six short and dilated tubular glands. Some of the epithelial cells are flattened. The lumen contains some granules, nuclei, pus cells, blood corpuscles, and occasionally short bacilli and cocci.

The evidences of infection are clear, although bacteria are not so numerous in the inflamed tissues as in many cases which ran a less violent course. Towards the lumen, the inflamed tissues contain cocci, diplococci, chains of four cocci, and encapsuled diplo-bacteria. It is hard to say whether these ought to be called cocci or bacilli. A few minute bacilli, single and in pairs, are also present.

The meso-appendix is also packed with inflammatory cells, and contains many dilated blood-vessels and lymphatics. The endothelial lining of some of the veins and lymphatics is proliferating.

In some sections, the continuity of the inflamed submucosa and peritoneum at the hiatus muscularis is clearly seen.

It is not uninteresting to speculate upon the causation of this very acute and dangerous attack of appendicitis. I confess that the histological examination affords hardly any clue to the conditions which preceded the attack. But when we recall that the patient had had an attack of appendicitis five months before, I think we may assume that the case was one of chronic ulceration of the mucosa with bacterial invasion, which ended in a sudden extension of infection and inflammation, and finally in gangrene.

I propose to give another case in which appendicitis was complicated with a large collection of fœtid pus in Douglas's pouch. If this formidable complication had not been discovered and evacuated, it would undoubtedly have cost the patient her life.

CASE 81.—*Acute Ulcerative Appendicitis, with Concretion, Perforation, and subsequent Formation of Abscess in Douglas's Pouch.*—The patient was a lady, æt. twenty-eight. On February 11, she was exposed to cold and wet, and on the 12th, during a long railway journey, was seized with most violent pain in the abdomen. As soon as she arrived in London, she went to bed, and I saw her on the night of February 14, with my friend, Dr. Leonard Mark. The bowels had acted on February 12, and flatus was being passed from time to time. The abdomen was distended, but moved with respiration. There was considerable tenderness over the cæcal region. No tumour could be felt but the abdominal wall was laden with fat. The uterus was movable but painful. The urine was passed with pain and difficulty. The temperature was 102° F. and the pulse 120. Food was vomited as soon as it was swallowed.

On the morning of the 15th, she had merely passed flatus after an enema. The tender area had increased, and now involved the right flank, the right iliac, inguinal, and hypogastric regions.

The abdomen was opened by an incision along the right linea semilunaris. Fœtid pus and gas escaped. Abscesses

were found all round the cæcum, along the right colon, and amongst the coils of the small intestines.

The acutely inflamed appendix was adherent to the end of the cæcum, and was perforated about an inch from its origin, the aperture being situated at the junction with the meso-appendix. The latter ran along the appendix nearly as far as its free extremity. A faecal concretion was found in the part beyond the ragged hole. I am not aware whether another concretion slipped out through the perforation whilst the appendix was being excised. Remembering the pain in the region of the uterus, and also the painful micturition, I passed my finger into Douglas's pouch, but did not meet with any pus. Two large drainage tubes were inserted, one beneath the cæcum, and the other along the inner side of the colon, where pus had been met with. On February 19, the temperature was normal, and the pulse 96. A little faecal discharge escaped from the wound. On February 25, the patient was not so well. She had a rigor, and there was pain on micturition. On February 28, the temperature was 103° F., and the pulse again 120. The abdomen was exceedingly fat, but the lower part was rather tender and resistant. *Per vaginam* a very tender spot was felt towards the left side of the roof of the vagina. Under an anæsthetic, a tense collection of fluid was felt in Douglas's pouch. A transverse incision behind the uterus evacuated at least a pint of most fœtid pus. A large drain was inserted, and also a quantity of gauze packing. In less than two months, both wounds were healed, with the exception of a stitch aperture, which afterwards closed.

This fortunately-ending case illustrates several points in the clinical history of appendicitis. The faecal concretion had existed for months or years, and along with it inflammation and ulceration of the mucosa. We afterwards learnt from the patient, a very intelligent woman, that for some months she had had pain and discomfort in the right iliac fossa. "When out walking she had sometimes to stop and press her hand upon her side." Her digestion also was bad, with unpleasant tastes in the mouth. The acute attack of appendicitis and the subsequent perforation were apparently brought about by a very usual cause, namely, exposure to cold. It is easy to imagine how cold, applied to

the surface of the body, increases the vascular engorgement of an already inflamed appendix. The operation calls for little remark. The faecal fistula was due to failure of the sutures, which closed the hole in the inflamed caecum. My experience of fistulae, which form in this way, is that they always close. Finally, as regards the pelvic abscess, the question arises as to whether I caused it myself, when I explored the pelvis with my finger, or whether it was caused, before the operation, by the spread of infection from the perforated appendix. A previous case (Case 55, p. 180) shows that the last may occur, although the appendix may not hang into the pelvis. I have elsewhere published¹ a case which shows that Douglas's pouch, or the recto-vesical pouch, is the part of the peritoneal cavity into which fluids of all kinds gravitate, even though they escape from openings close to the pylorus. In addition, there was reason to suspect the condition of Douglas's pouch before the operation. It is conceivable that the peritonitis which then existed may have ended in abscess. The finger was thoroughly washed in biniodide of mercury lotion, 1 in 2000, before it was thrust into the pelvis.

In acute cases, the formation of a faecal fistula in connection with the stump of the appendix (Case 81, p. 274), the front of the caecum (Case 83, p. 280), or the end of the ileum (Case 21, p. 93), does not seem an addition to the immediate dangers of the case. But so long as the faeces are fluid, the leakage may be considerable, and a source of great discomfort. Purges should, therefore, as far as possible, be avoided and enemata used to move the bowels.

The probability is that the fistula will gradually close, especially if the appendix has been removed. The fistulae, which develop in acute cases, seem different from those which follow subacute abscesses caused by perforation of the back of the caecum (Case 60, p. 210, and Case 61, p. 211).

The management of a faecal fistula is simple. By means of drainage or gauze packing, the external aperture should be kept well open until the deeper parts have cicatrised. If this be not attended to, some tracking of pus and faeces may occur.

¹ "Additional Cases of Perforating Ulcer of the Duodenum," *Med. Soc. Trans.*, vol. xviii. p. 88, London, 1895.

In ordinary cases the small abdominal wound is secured with six fishing-gut sutures. On the tenth day, four of these are removed, and the rest on the twelfth. Afterwards, the wound is protected with a little collodion dressing, or dry iodoform gauze.

Inasmuch as a strong scar is all-important, the patient is given three weeks in bed, three weeks on a couch, and six weeks' gentle exercise. During the second three weeks, he can lie about in the open air, or go for drives in an easy carriage. A light abdominal belt is also adjusted before the bed is left. When this is worn out, another is not required. At the end of the third week the patient can use an ordinary w.c., and the attendants are warned to see that the right thigh is raised during the act of defecation, and also that constipation and straining are avoided.

There is much diversity of opinion as to the need for an abdominal belt. But patients are often anxious about the abdominal wound, and think it is likely to burst; I am also unable to see what harm a light abdominal belt can do, especially if the pad exerts no harmful pressure on the wound.

After appendectomy, the diet and the action of the bowels require careful attention for about three months. Fruit and vegetables are to be cautiously resumed, and an action of the bowels secured every day by a gentle purgative or enema. I have already described a case (Case 9, p. 56) in which inattention to these matters caused an apparent relapse. The following is also a case in point:—

CASE 82.—*Appendicitis with Ulceration of Mucosa and Bacterial Invasion—Excision of Vermiform Appendix—Recurrence of Symptoms due to Faecal Accumulation in Capacious Floating Cæcum.*—C. W., æt. thirty-eight, a bank clerk, consulted me because of pain in the right iliac fossa with great abdominal discomfort, especially after food. He was very anxious, because his little son had nearly died of perforation of the appendix, due to a concretion. The case is mentioned elsewhere (Case 71, p. 249). The patient's history was as follows:—For at least three years, he had had an uncomfortable abdomen, and any slight indiscretion in diet brought on diarrhoea. Fruit and vegetables had to be especially avoided. He had recently

been a week in bed owing to pain in the right iliac region. When he got up, he had to use a bath chair, because walking was so painful. Whilst in bed, his bowels were constipated and he felt sick, but did not vomit. The pulse rate and body temperature were not recorded. He always referred his pain to M'Burney's point and firm pressure at that point increased it. No tumour was felt either through the abdominal wall or by rectal examination. He said he had had two similar attacks in his twenty-third and twenty-fourth years.

As the symptoms were not severe, I advised him to try the effects of a careful diet and salol powder. At the end of a fortnight, his condition was unchanged, and a week later, the appendix was removed through the usual incision.

The patient had a floating cæcum and, in consequence, the cæcum, end of ileum, and vermiform appendix were in the recto-vesical pouch. Inasmuch as the pain had been felt in the usual place, this position was unexpected.

Adhesions were absent, so that the cæcum and appendix were easily withdrawn from the pelvis and well out of the wound. The appendix was over 12 centimetres long. Near the cæcum it was 10 mm. in diameter, but tapered off to 5 mm. In the proximal part, the lumen was circular, and 3 mm. across; in the distal, it had dwindled until it was only 1 mm. across. The appendix was acutely bent upon itself an inch from the cæcum, and the part beyond the bend was exceedingly hard and swollen.

A short meso-appendix was tied, the whole appendix excised in the usual way, and the wound closed with buried silk sutures and fishing-gut. Recovery was uninterrupted.

The lumen of the excised appendix beyond the bend was very capacious and full of putty-like material.

The result of the histological examination is as follows:—The coats together are from 3 mm. to 3.5 mm. thick. Nearly the whole of this great increase is due to cedema of the submucosa, which varies from 1.5 to 2.5 mm. in thickness. The peritoneum and muscular coat are normal, with the exception of some dilation of blood-vessels and lymphatics. The blood-vessels of the cedematous submucosa are also dilated. The lymphatics and the spaces of the submucosa contain albuminous fluid.

The lymphoid follicles and lymphoid tissue of the mucosa are opaque, and the stroma hidden, owing to multiplication and swelling of the lymph corpuscles. The follicular sinuses are slightly dilated. The epithelium of the tubular glands is being shed. In some, it is lost at the mouth, and in others, it is lost throughout. The lining epithelium of the lumen is all destroyed, and the subjacent lymphoid tissue ulcerated.

The lumen is filled with nuclei of various sizes, some derived from the epithelium, and many from the ulcerating lymphoid tissue; there are also epithelial cells, pus cells, granules, fibres, and quantities of small ovoid bacilli in groups, pairs, short strings, longer bacilli in wavy leptothrix, comma-shaped bacilli, and occasional diplococci. These bacilli are acid-fast and retain fuchsin.

The purulent and bacterial contents of the lumen are penetrating the mucosa by the gaps left by the shedding of the epithelium of the tubular glands, and, in the same way, but not to the same extent, as in Fig. 13, p. 58. Also, in the distal sections especially, the purulent fluid and bacteria have infiltrated the mucosa as far as the base of the tubular glands, and, in places, almost as deep as the submucosa.

The immediate results of this operation were most satisfactory. The patient lost all his pain and discomfort, his appetite improved, and he could eat fruit and vegetables.

Fifteen months after the operation he returned in some alarm, because the old feelings of discomfort had returned, and were gradually getting worse. On inquiry, it appeared that his meals had been taken most irregularly and eaten rapidly; also, that he had neglected his bowels, and only allowed them to act at long and irregular intervals. I attributed his symptoms to fecal accumulation within the large floating cæcum. All the symptoms at once disappeared when the meals were properly regulated, and the bowels thoroughly emptied with an enema in the morning.

In one of my cases (Case 55, p. 180) an attack of acute intestinal obstruction, less than a year after I had operated for appendicitis, was caused by adhesions complicated by iliac and pelvic abscesses. In my experience, however, this is an exceedingly rare complication after the appendix has been excised. The

danger is greater when the appendix is not removed, because it, too, may form adhesions with other organs and become a strangulating band. This had occurred in a case upon which I operated for acute intestinal obstruction. Unfortunately the loop of intestine was either gangrenous or on the point of becoming so, and had to be excised. The patient seemed likely to recover until the junction gave way on the third day. The inflammatory adhesions of the peritoneum tend to disappear in a remarkable manner. This is shown by the following case, which also illustrates several additional points, and I have therefore quoted it at length:—

CASE 83.—The patient was a postman, aged twenty-five years.¹ His illness began suddenly, without premonitory symptoms, on June 3, 1894. He was seized with violent pains in the abdomen, his bowels ceased to act, and he had occasional vomiting. He was treated with opium and a liquid diet. I saw him on June 11 in the Great Northern Hospital. His temperature was 100·2° F., where it remained until the 13th, when it fell to 98·6° F. Throughout the rest of his illness, it never rose beyond 99·4° F. His pulse was 88, and never exceeded 96 per minute. He was exceedingly ill, with an anxious expression, and was suffering great pain. The abdomen was tense, and did not move with respiration. In the right iliac region, it was more distended than elsewhere, and there was an induration about the cæcum, with slight œdema and redness of the skin. It was obvious that he was suffering from typhlitis, and as I had seen similar cases recede, leeches were applied, and afterwards warm fomentations. During the 12th, 13th, and 14th the iliac swelling disappeared, but his condition became decidedly worse. The abdomen was more distended. The bowels did not act after the enemas, and it was questionable whether any flatus escaped. The pain was most severe in the lower abdomen, and was only relieved by opium. A tense fluctuating swelling was also felt in the recto-vesical pouch. As it was obvious that the patient would die, if unrelieved, on June 15, I opened the abdomen in the right linea semilunaris with the idea of finding the

¹ “The Surgical Treatment of Different Septic Peritonitis,” by C. B. Lockwood, *Medico-Chirurgical Transactions*, vol. lxxviii. 1895, p. 16.

vermiform appendix, and, if possible, of removing it, and afterwards exploring and emptying the fluid in the pelvis. The tissues through which I cut were inflamed, and the parietal peritoneum could not be recognised. A substance was found which was supposed to be it, but an incision led into the cæcum. At this situation, all the intestines were adherent, and they bled and were lacerated by the gentlest touch. The opening in the cæcum was, therefore, repaired with Lembert's sutures, and the abdominal wound was closed. A fresh incision was made in the *linea alba*. The peritoneum was thick and hard to recognise. In its interior, the intestines were found acutely inflamed and covered with flakes of lymph. The peritonitis could be traced much higher than the wound, and had no definite limits. No firm adhesions were met with, and the various coils easily parted before the finger. About two pints of purulent and stinking fluid had collected in the pelvis. The vermiform appendix could neither be seen nor felt; and, as there was much oozing of blood from the inflamed serous membrane, the man was in a precarious state, so the abdomen was thoroughly washed with some gallons of hot water, and a glass drainage-tube was inserted into Douglas's pouch. The intestines were distended, but I did not puncture them, because, after the evacuation of the purulent fluid from the pelvis, they seemed to have enough room. He soon rallied under the usual remedies, and flatus was passed, both by a long tube and then naturally. The discharge sucked from the drainage tube was purulent, but not feculent. On June 18, the glass tube was changed for one of india-rubber. The same night he again had a violent abdominal pain, with a fresh outburst of the peritonitis. His abdomen became distended again, but, fortunately, the wound in the cæcum gave way. A quantity of flatus and feces escaped, and his symptoms were gradually relieved. After this his bowels acted, although a good deal escaped by the fecal fistula. By the end of July, the median wound had nearly closed. On August 1, I closed the fecal fistula by dissecting the cæcum from the edges of the wound, and inverting the aperture with a double row of silk sutures. I was astonished on this occasion to find that the adhesions, which

before had been troublesome, had almost disappeared. Indeed, after the cæcum had been freed from the edges of the wound, it was easily drawn out, and many of the neighbouring coils of intestine came into view. They were unadherent, and looked quite healthy,—very different from their condition when seen six weeks before. As there was some purulent infiltration of the abdominal wall, the wound in it was not closed. The sinuses were opened, the whole dusted with iodoform, and packed with iodoform gauze. The fistula never leaked again, and the wound speedily healed by granulation, so that the patient was discharged on September 3.

INDEX

- Abscess — chronic appendicular, 171 ; hepatic, 120, 186 ; iliac and psoas, 195 ; in Douglas's pouch, 274 ; intra-peritoneal, 68 ; peri-appendicular, 64, 123 ; sub-diaphragmatic, 123
- Actinomycosis, abdominal, 222
- Adhesions, inflammatory — dangerous, 238 ; disappearance of, 280 ; treatment of, 240
- Age as a causation factor in atrophy of tissue, 47
- Appendectomy, probable cause of failure in some cases, 50 ; fatal cases, 77, 121
- Appendicitis, cases of. See "Cases."
- classification, pathological, of — with ulceration of the mucosa, *without* bacterial invasion, 35, 129, 131 ; *with* bacterial invasion, 36-73 ; with fecal concretions, 74-101 ; with stenosis and its complications, 102-131 ; with complete obliteration of the lumen, 133-139 ; with lymphadenitis and lymphangitis, 140 ; with tubercle, 151 ; with peritonitis, 166 ; with acute suppuration, 177
- clinical symptoms of, 191-206
- clinical and pathological — abscess, 64, 68, 123, 274 ; actinomycosis, 222 ; appendicular colic, 40, 43, 87 ; carcinoma of cæcum, 216 ; colitis, ulcerative, 208 ; empyema, 115, 153 ; fecal fistulæ, 93 ; kidney disease, 214 ; foreign body in lumen, 99 ; hæmorrhage, interstitial, 231 ; hæmatosalpinx, 222 ; hernia — inguinal, 99, retroperitoneal, 112, ventral, 69 ; lymphadenitis, 141, 146 ; lymphangitis, 141, 146 ; oedema of lymphatics, 148, of submucosa, 144 ; peritonitis, 34, 68, 79, 157, 170, 208 ; phlebitis of iliac and femoral veins, 223 ; pus in urine, 215 ; suppuration, acute, 177, 180 ; tubercle, 151 ; typhoid, 54, 208
- Appendicitis, complications of, anatomical, 34
- diagnosis of, 207
- definition of term, 1, 4 ; fulminating, 167 ; simulating ovaritis and salpingitis, 9, 222 ; streptococcic, 168 ; tuberculous, very rare, 151
- treatment of, expectant, 225 ; operative, 227 ; *do.*, after, 260
- Appendicular colic, objections to use of the term, 3 ; complicating appendicitis, 40, 43, 87
- Appendix, vermiform — anatomy and histology of, 7 ; colour and consistence, 7 ; dimensions, 7 ; surface-marking, 8 ; M'Burney's point, 8 ; origin and position, 9, 14 ; foetal type, 12 ; retroperitoneal hernia of, 13 ; mesentery and connections, 15 ; contradictory views with regard to muscular coats, 17 ; peritoneum and its continuity with submucosa, 19 ; hiatus muscularis, 19 ; muscular coats, 20 ; submucosa, 21 ; mucosa, 21 ; lymphoid follicles and lymphatics, 23 ; arterial supply, 27 ; veins, 30 ; nerves, 31
- condition during quiescence, 50, 54 ; never absent except as the result of disease, 7, 113 ; other structures simulating it, 50
- Atrophy of tissue, age-factor in, 47
- Bacillus, colon, some marked peculiarities of, 186
- Bacteria, invasion of, in appendicitis, 36 *et seq.* ; the cause of fecal concretions, 75, 78 ; some of unusual morphological appearance, 84
- BECK (Carol) on subphrenic abscess, 124

- Belt, abdominal, use of, after appendectomy, 277
- BERRY on appendix, 10 ; meso-appendix, 15
- BOWLBY'S operation for appendicitis, 237
- BRYANT on position of appendix, 9 ; on seat of pain, 193
- BULL'S definition of perityphlitis, 4 ; statistics of suppuration about the cæcum, 215
- Cæcum, foetal type of, 12 ; position of appendix in cases of floating cæcum, 11
- CALEY'S clinical statistics of appendicitis, 6
- Calomel, unequal action of, 268
- Carcinoma of the ileo-cæcal valve associated with appendicitis, 216
- Cases (author's) of appendicitis with ulceration of the mucosa *without* bacterial invasion, 35 ; *with* bacterial invasion, 36, 39 ; and appendicular colic, 40, 43 ; bacilli filling lumen, 46 ; invasion of appendicular walls after subsidence of acute symptoms, 50 ; following typhoid, 54 ; invasion by way of tubular glands, 56, 59, 61 ; peri-appendicular abscess, 64 ; acute septic peritonitis and intraperitoneal abscess, 68 ; perforation and acute suppurative peritonitis, subsequent ventral hernia, 69
- with faecal concretions and perforation, 75 ; perforation and gangrene, streptococcal peritonitis, 79 ; perforation and gangrene, 81 ; following peritonitis, 85 ; appendicular colic, 87 ; infection of peritoneum and meso-appendix, 90 ; perforation and gangrene, subsequent faecal fistulae, 93 ; cure after upwards of twenty attacks, 96 ; shot found in lumen, appendix in sac of inguinal hernia, 99
- with stenosis and dilatation of mucosa, 103 ; obliteration of lumen and cystic dilatation, 106 ; mucous cyst of appendix, 108, 111 ; empyema and retroperitoneal hernia, 112 ; empyema, 115 ; invasion beyond the stricture, 116 ; portal pyæmia, 119 ; abscess and portal pyæmia, 123 ; ulceration and invasion of appendicular walls, 125 ; recurrent after fifteen years, 128, after nine years, 129 ; superficial ulceration without bacterial invasion, 131
- with complete obliteration of lumen, 132, 135 ; mucosa destroyed after one attack, 136, after two attacks, 136
- Cases (author's) of appendicitis with lymphadenitis and lymphangitis, 141, 146 ; oedema of submucosa, 144 ; oedema and distension of lymphatics, 148
- of tuberculous appendicitis associated with tubercle of the lungs, trachea, and larynx, 151 ; with empyema, 153 ; with tubercle of cæcum and ileum, 156 ; with tuberculous peritonitis, 157
- presenting difficulties in diagnosis, 209, 211, 212, 216, 219, 221, 223
- Catarrh, histological evidences of, 2
- CLADO on the appendicular lymphatics and their passage into the pelvis, 25, 27 ; on course of infection, 220
- CLARKE (Bruce), treatment of flatulent distension during abdominal operations, 269
- Coats, muscular, histology of, 20
- COFFEY on the follicular sinus, 25
- Colic, appendicular, objections to use of term, 3 ; complicating appendicitis, 40, 43, 87
- renal or gall-stone, mistaken for appendicitis, 9
- Colitis, ulcerative, 208
- Concretion, long present without causing perforation, 98
- Concretions, faecal, and appendicitis, 74-101 ; not necessarily cause of ulceration, 87, 90
- Constipation associated with appendicitis, 46, 64
- CRIPPS (Harrison), two cases in which apex of appendix was found in Douglas's pouch, 207 ; treatment of flatulent distension during abdominal operations, 269
- CRUVEILHIER on arterial supply of appendix, 27
- Cysts, appendicular, 106, 108
- DANIEL, case of abscess bursting into peritoneal cavity, 171
- DEAVER on philology of term "appendicitis," 1 ; on appendicular abscess, 212 ; carcinoma, 218 ; inflammatory adhesions, 238
- Diagnosis, difficulties in, 171, 209-223
- Diet after appendectomy, importance of attention to, 277
- Diseases simulating appendicitis, 223
- Distension, abdominal, 46, 269
- DOUGLAS, pouch of, seat of pain, 9 ; abscess in, 274
- DUNLOP, case of thrombosis of mesenteric veins, 210
- DURAND on plica vascularis, 27

- EDEBOHLS on appendicitis complicating floating kidney, 215
 Empyema, occurrence of, 112, 115, 153
 Enemas, nutrient, indicated, 263
- Fistulae, faecal, after appendectomy, 93, 276
- FITZ on use of opium, 225
 Flatulence in abdominal operations, 264, 269
- FLETCHER (Morley) on contents of cysts, 108, 111
 Foreign body in appendix, 253; in lumen, 99; the focus of a faecal concretion, 75; causing hypertrophy, 101
 FOWLER on position of appendix in case of non-descent of caecum, 11; on appendicitis associated with pregnancy, 222; statistics of incomplete operations, 259
 Fulminating appendicitis, 167
- Gangrene, occurrence of, 79, 81, 93
 GERLACH, valve of, 11
 Gesture of patient when indicating seat of pain in chronic appendicitis, 194
 GIBNEY on cases of appendicitis simulating hip disease, 195
 Glands, tubular, bacterial invasion by way of, 56, 59, 61
- Hæmatosalpinx complicating appendicitis, 222
 Hæmorrhage, control of, 245, 248; occurrence of, 231
 Hæmorrhoids, appendicitis following operation for, 125
 HARRINGTON, statistics of hernia after appendectomy, 247
 HAWKINS on catarrhal appendicitis, 2; case in which a diseased appendix was diagnosed as healthy, 6; on position of appendix, 9; on muscular coats, 17; on bacterial invasion, 57; on formation of faecal concretions, 74; on natural cure of acute catarrhal appendicitis, 98, and of perityphlitis, 129
 HEATON on stenosis of the appendix, 128
 HENLE on arterial supply of appendix, 27
 Hernia, inguinal, 99; retroperitoneal, 13, 16, 112; strangulated into post-caecal pouch, 14; ventral, 69, 247
 Hiatus muscularis, histology of, 19
 Hips, flexion of, in acute appendicitis, 195
- Intussusception simulating appendicitis, 221
- JACOBSON on removal of appendix, 258
- KELLY on primary carcinoma of appendix, 218
 KELYNACK on appendix being invariably present in healthy subjects, 8; on case of appendicitis simulating hysterical hip disease, 195; on primary carcinoma of the appendix, 218
 Kidney disease, 214
 KLEIN on the follicular sinus, 25
 KRAUSE on arterial supply of appendix, 27
 KRUFFT on appendicular abscess, 172
- Leeches, indicated, 227
 LE GENDRE, case of plumbism in which gangrenous appendix was overlooked, 222
 LENNANDER on removal of appendix, 258
 Liver, abscess of, 120, 186
 Lumen of appendix, filled with bacilli, 46, 64; foreign body in, 99; obliterated, 106, 128, 133-139; process of obliteration, 68
 Lymphadenitis and appendicitis, 141, 146
 Lymphangitis and appendicitis, 141, 146
 Lymphatics, histology of, 23; distension of, 148
- M'BURNEY, point of, 8; case of obliteration of lumen, 136; statistics of operations for diffuse septic peritonitis, 187
 MACÉVITT on tubo-ovarian congestion simulating appendicitis, 207
 MALCOLM (J. D.) on flatulent distension in intestinal obstruction, 264
 MAYDL on subphrenic abscess, 124
 MAYLARD on use of purgatives, 225
 Mesentery, histology of, 15
 Meso-appendix, infection of, 90
 Micturition, painful, as a clinical symptom, 9, 205
 MORISON on appendicular abscess, 184
 Morphia masking symptoms, 76
 MORRIS (R. T.) on posterior ileo-caecal artery, 29
 MOULLIN (Mansell) on strangulated hernia into post-caecal pouch, 14
 Mucosa, histology of, 21; destruction of, 136, 138; dilatation of, 103; ulceration of, with bacterial invasion, 36-73, without, 35, 129, 131
- Nerves of the appendix, 31
 NIEMEYER on catarrh, 2

- Œdema of lymphatics, 148; of submucosa, 144
- Omentum, septic condition of, 241
- Operation for appendicitis—when indicated, 227; choice of time, 230; preparation of patient, 233; antiseptics, 234; method of incision, 236; incomplete cases, 250-259
for diffuse septic peritonitis, 188
- Opium—indicated, 35, 174; causing paralysis of intestinal muscle, 266; dangerous as a routine treatment, 270
- Ovaritis simulating appendicitis, 9, 222
- Pain—absent in some cases, 120, 123; a prominent symptom, 192
- Patient, preparation of, for operation, 233
- Perforation of appendix, 69, 75, 79, 81, 93
- Peritoneum, infection of, 90
- Peritonitis—complicating appendicitis, 34, 68, 79, 157, 166, 170, 208; followed by appendicitis, 85; recent advance in prognosis, 187; statistics of operations, 187
- Perityphlitis defined, 4; fatal effects of suppuration in, 129; case of, 214
- Phlebitis of iliac and femoral veins, 223
- PICQUART and FAWCETT on absence of appendix, 8
- Plumbism simulating appendicitis, 222
- Pneumonia, symptoms at onset, simulating those of appendicitis, 210
- PONCET and BÉRARD on actinomycosis, 223
- Pouch of Douglas, seat of pain, 9; abscess in, 274
- POWER (D'Arcy) on the use of purgatives, 225
- Pregnancy and appendicitis, 222
- Pulse-rate, abnormal, diagnostic significance of, 200
- Purgatives in appendicitis, 225, 268
- Pus in urine, 215
- Pyæmia, portal, 119; due to streptococcus pyogenes, 186
- QUAIN on arterial supply of appendix, 27
- Recovery, cases in which it is generally permanent, 161, 164
- Rectum, importance of digital examination of, 9, 102, 104
- Recurrence of appendicitis after fifteen years, 128, after nine years, 129; due to fecal accumulation in cæcum, 56
- Respiration, abnormal, diagnostic significance of, 203
- ROBINSON on appendicular abscess, 184
- ROBSON (Mayo) on removal of appendix, 246
- ROLLESTON on primary carcinoma of appendix, 218
- ROLLESTON and LOCKWOOD on anatomy of appendix, 7, 10
- Salpingitis simulated by appendicitis, 9
- SAPPEY on arterial supply of appendix, 27
- Sclerosis and appendicitis, 132
- Sections, method of preparing, 18
- SENN on appendicitis obliterans, 133
- Serum, anti-streptococcic, 170
- SHEILD, case of recurrence following incomplete operation, 252
- Shock following operation, 260
- Shot found in lumen, 99
- Sinus, follicular, 23
- SMITH (Greig) on intestinal obstruction, 200
- SMITH (Horton) on appendicitis complicating typhoid, 55
- Stenosis of appendix, 33, 102-131
- Streptococcic appendicitis, 168; peritonitis, 79
- Submucosa, histology of, 21; œdema of, 144
- Suppuration, acute, 177, 180
- Suppurative appendicitis, objections to use of term, 3
- SYMONDS on "period of repose" following peritonitis, 227
- Symptoms, clinical, of ulceration of mucosa, 40, 46; of appendicitis, 191
- TALAMON on appendicular colic, 3; clinical statistics of appendicitis, 6; valve of Gerlach, 11; formation of fecal concretions, 74
- TAVEL and LANZ on bacterial infection, 185, 186
- Temperature, abnormal, diagnostic significance of, 200
- Treatment of appendicitis, expectant, 225; operative, 227; after, 260
- TREVES on definition of perityphlitis, 4; valve of Gerlach, 11; fetal type of cæcum and appendix, 12; muscular coats of appendix, 17; appendicular cysts, 106, 110; pathological importance of cæcal fossæ, 114; natural process of cure in perityphlitis, 129; fatal effects of suppuration in perityphlitis, 167; choice of time for operation, 230

- Tubercle in association with appendicitis, 151-156, and with peritonitis, 157
- Tuberculous appendicitis, a correct nomenclature, 2
- Tumours, significance of their occurrence in appendicitis, 198
- TURNER on position of appendix, 9
- Typhoid in association with appendicitis, 54, 208
- Ulceration *with* bacterial invasion, 36-73; *without*, 35, 129, 131
- Urine, pus in, 215; retention of, after appendicitis, 47
- Uterus, retroflexion of, in appendicitis, 37
- Veins of the appendix, 30
- VINAY on appendicitis complicating pregnancy, 222
- Vomiting in appendectomy, 261
- Walls, appendicular, invaded by bacteria, 50, 125
- WARDEN on removal of appendix, 246
- WHITE on operation for diffuse septic peritonitis, 187, 188

THE END

