

**The Rectum : its diseases and developmental defects / by Sir Charles B. Ball.**

**Contributors**

Ball, Charles B. Sir, 1851-1916.  
University of Leeds. Library

**Publication/Creation**

London : Oxford University Press, 1908.

**Persistent URL**

<https://wellcomecollection.org/works/trqtq9f9>

**Provider**

Leeds University Archive

**License and attribution**

This material has been provided by This material has been provided by The University of Leeds Library. The original may be consulted at The University of Leeds Library. where the originals may be consulted.

Conditions of use: it is possible this item is protected by copyright and/or related rights. You are free to use this item in any way that is permitted by the copyright and related rights legislation that applies to your use. For other uses you need to obtain permission from the rights-holder(s).



Wellcome Collection  
183 Euston Road  
London NW1 2BE UK  
T +44 (0)20 7611 8722  
E [library@wellcomecollection.org](mailto:library@wellcomecollection.org)  
<https://wellcomecollection.org>



# THE RECTUM

ITS DISEASES & DEVELOPMENTAL DEFECTS

SIR CHARLES BALL

OXFORD MEDICAL  
PUBLICATIONS



*The University Library  
Leeds*



*Medical and Dental  
Library*





30106

004196399



**STORE**

WI 600

BAK



H  
407

SCHOOL OF MEDICINE  
UNIVERSITY OF LEEDS.

Hist. Store





OXFORD MEDICAL PUBLICATIONS

THE RECTUM

ITS DISEASES AND DEVELOPMENTAL DEFECTS




PROVINCIALE ARCHEOLOGICO



Digitized by the Internet Archive  
in 2015

<https://archive.org/details/b21519146>





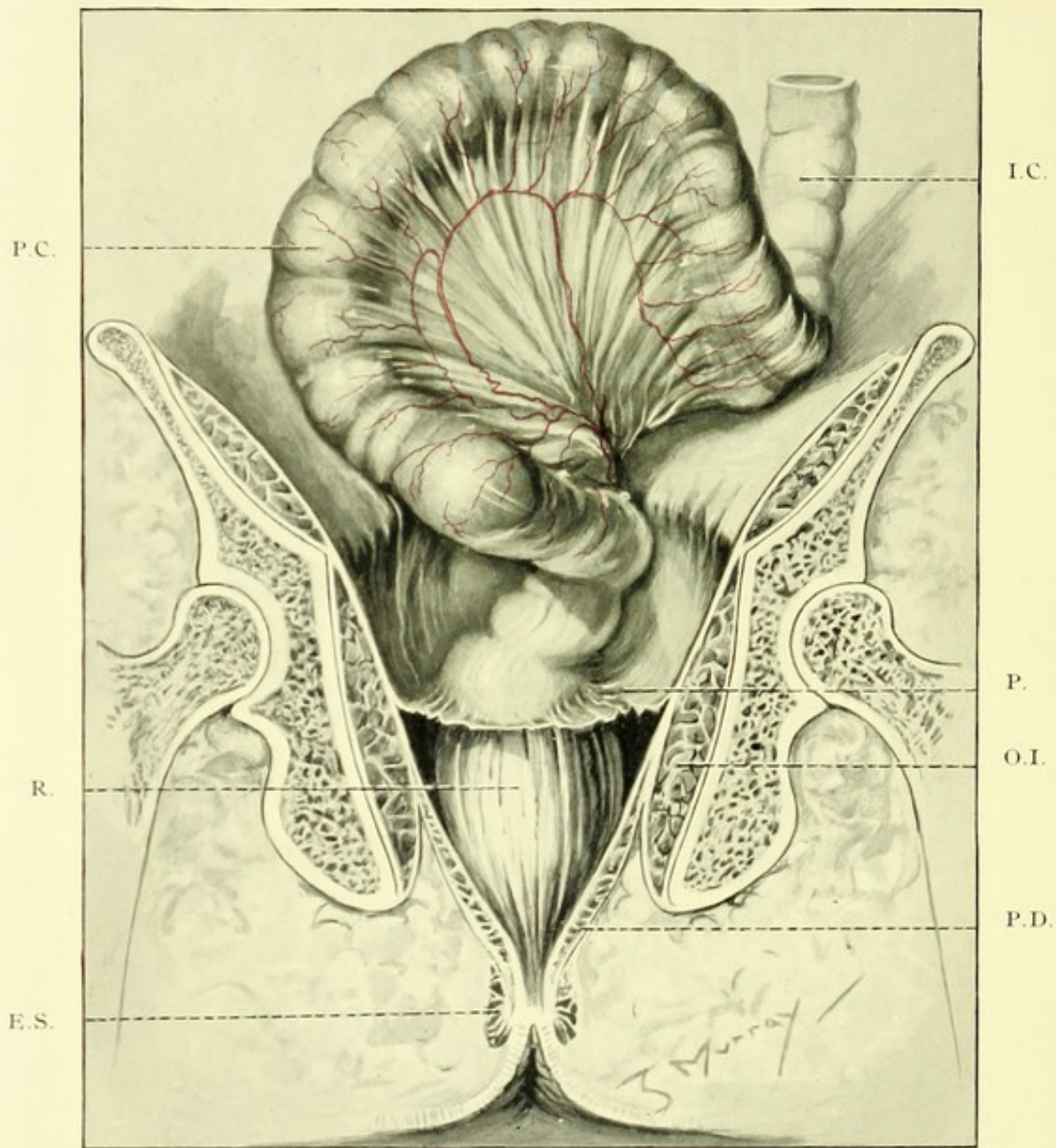


PLATE I.

THE PELVIC COLON AND RECTUM—FRONT VIEW.

The front of the pelvis, together with the genito-urinary organs, have been removed, exposing the anterior aspect of the rectum, showing its relations to the external sphincter, the pelvic diaphragm, and the peritoneum, also its continuity above with the pelvic colon. I.C. Iliac colon. P.C. Pelvic colon. R. Rectum. P. Peritoneum. O.I. Obturator internus muscle. P.D. Pelvic diaphragm. E.S. External Sphincter.

OXFORD MEDICAL PUBLICATIONS

# THE RECTUM

ITS DISEASES AND DEVELOPMENTAL DEFECTS

BY

SIR CHARLES B. BALL

M.Ch., F.R.C.S.I., Hon. F.R.C.S. Eng.

REGIUS PROFESSOR OF SURGERY IN THE UNIVERSITY OF DUBLIN

SURGEON TO SIR PATRICK DUN'S HOSPITAL

HON. SURGEON TO THE KING

LONDON

HENRY FROWDE  
OXFORD UNIVERSITY PRESS

HODDER & STOUGHTON  
WARWICK SQUARE, E.C.

1908



UNIVERSITY OF LEEDS  
MEDICAL LIBRARY.

OXFORD: HORACE HART  
PRINTER TO THE UNIVERSITY

603520

## PREFACE

A FORMER work, *The Rectum and Anus, their Diseases and Treatment*, was published in 1887, and a second edition in 1894. It is now out of date and withdrawn from circulation.

Instead of attempting to revise this work it appeared desirable to write a new book upon the same subject, but upon different lines.

The course of Lane Lectures on Diseases of the Rectum, delivered at San Francisco in 1902, and the Erasmus Wilson Lectures on Adenoma and Adeno-carcinoma of the Rectum, delivered at the Royal College of Surgeons, England, in 1903, suggested to the Author that a work founded mainly upon these lectures might possibly prove to be more acceptable than an attempt to produce a bulky monograph on the subject.

In order to carry out this idea, and at the same time to keep the work as concise as possible, it has been necessary to omit historical accounts of the evolution of modern treatment and the description of operations now obsolete, to avoid repetition of notes of cases of a similar kind; not to encumber it with a mass of more or less useless statistics, and while endeavouring to give full credit to others whose work is made use of, not to overweight the book with authorities.

An endeavour has been made to make the illustrations a feature of the work. Except a few which are purely diagrammatic, they are all taken from actual cases or specimens; the plan largely adopted in obtaining those of clinical cases, the stages of operations, &c., was to have stereoscopic photographs taken, and from these half-tone drawings were made. In this way the flatness of ordinary photographic reproductions is avoided



and the attention concentrated upon the more important details. With few exceptions these drawings have been made by Mr. James Murray of Edinburgh, to whom the Author's best thanks are due for the care and skill with which he carried out the work.

Minute pathology is illustrated by photo-micrographs which were taken specially for this work by Professor Alfred Scott, whose skill in such matters is so well known. The Author desires to thank him most heartily for the great trouble he has taken in producing them.

The reproduction of the illustrations has been excellently carried out by the publishers, and, as is not usually the case, the original drawings have lost but little of their artistic merit in the process.

The Author has received valuable help from so many in the preparation of the work, that it is impossible to thank all individually; he, however, appreciates very fully the great kindness shown to him. To Dr. Walter G. Smith he is especially grateful for his kindness in looking through the proofs as they issued from the press.

24 MERRION SQUARE, DUBLIN,

*September, 1908.*

## CONTENTS

CHAP.	PAGE
I. ANATOMY OF THE RECTUM AND ANUS . . . . .	1
II. DEVELOPMENTAL DEFECTS. EMBRYOLOGY OF RECTUM AND ANUS . . . . .	23
III. DEVELOPMENTAL DEFECTS. VARIETIES . . . . .	32
IV. DEVELOPMENTAL DEFECTS. TREATMENT . . . . .	52
V. DIAGNOSIS OF RECTAL DISEASE . . . . .	57
VI. INFECTIVE DISEASES . . . . .	62
VII. ULCERATION . . . . .	90
VIII. FISTULA . . . . .	94
IX. STRICTURE . . . . .	119
X. STRICTURE. TREATMENT . . . . .	140
XI. IRRITABLE ULCER OR FISSURE . . . . .	146
XII. PROLAPSE . . . . .	153
XIII. PILES . . . . .	174
XIV. EXTERNAL PILES . . . . .	180
XV. INTERNAL PILES . . . . .	187
XVI. BENIGN TUMOURS . . . . .	212
XVII. CANCER . . . . .	235
XVIII. CANCER. SYMPTOMS . . . . .	250
XIX. CANCER. TREATMENT . . . . .	257
XX. COLOTOMY . . . . .	290
XXI. FOREIGN BODIES . . . . .	305
XXII. INJURIES . . . . .	309
XXIII. NEUROSES . . . . .	313
XXIV. PRURITUS ANI . . . . .	319
XXV. DIVERTICULA . . . . .	326
INDEX . . . . .	329





## LIST OF ILLUSTRATIONS

PLATE

I.	The pelvic colon and rectum—front view . . . . .	<i>Frontispiece</i>
II.	Oblique frozen section through the pelvis at the level of the middle of the prostate gland . . . . .	<i>to face p. 19</i>
III.	The blood-vessels of the rectum . . . . .	,, 20
IV.	Schema of the relations of the anal veins to internal piles, founded on numerous dissections . . . . .	<i>to face p. 187</i>
V.	Adenoma which was attached by a broad strap-like pedicle (Mr. R. L. Swan's case) . . . . .	<i>to face p. 221</i>

FIG.

PAGE

1.	The rectum and anal canal in the male—Longitudinal section . . . . .	4
2.	The interior of the rectum . . . . .	6
3.	The normal anus . . . . .	8
4.	Vertical section through the lateral wall of the anal canal of a child aged three years . . . . .	9
5.	Muscles and nerves of the male pelvic outlet . . . . .	11
6.	Muscles of the male pelvic outlet—side view . . . . .	13
7.	The rectum seen from above in a male subject . . . . .	15
8.	The relations of the rectum to the female genital organs . . . . .	16
9.	Rectum hardened <i>in situ</i> with formalin and then dissected out . . . . .	17
10.	The rectum viewed from behind . . . . .	18
11.	The relations of the rectum to the male genito-urinary organs . . . . .	20
12.	Diagram of the intestinal canal of a very young human embryo . . . . .	25
13.	Vertical section of a human embryo of twelve somites (Wood Jones) . . . . .	27
14.	Vertical section of an older embryo (Wood Jones) . . . . .	27
15.	Vertical section of a still older embryo (Wood Jones) . . . . .	28
16.	Imperforate rectum (Wood Jones) . . . . .	28
17.	The development of the external genital organs, after models by Prof. Ecker . . . . .	30
18.	Imperforate rectum and anus, absence of external genital organs, and extroversion of the bladder . . . . .	33
19.	Specimen removed <i>post mortem</i> from the case illustrated in Fig. 18 . . . . .	34
20.	Mesial section of an imperforate rectum (Prof. A. F. Dixon). . . . .	35
21.	Dissection of an imperforate rectum . . . . .	35
22.	Diagram of imperforate rectum with outlet in the posterior portion of the male urethra . . . . .	36
23.	Dissection of an imperforate rectum with posterior urethral outlet . . . . .	36
24.	Diagram illustrating imperforate rectum with vesical outlet . . . . .	37



FIG.		PAGE
25.	Dissection of an imperforate rectum with vesical outlet . . . . .	37
26.	Dissection of an imperforate rectum with vaginal outlet (Prof. McWeeney's case)	38
27.	Imperforate rectum with spinal outlet (Mr. Wheeler's case) . . . . .	39
28.	Diagram of imperforate anal canal . . . . .	40
29.	Diagram of imperforate anal canal with vulvar outlet . . . . .	40
30.	Imperforate anal canal with vulvar outlet . . . . .	41
31.	Diagram of imperforate anal canal with sub-urethral outlet . . . . .	42
32.	Imperforate anal canal with sub-urethral outlet (Cruveilhier's case) . . . . .	43
33.	Imperforate anal canal, perineal outlet . . . . .	43
34.	Diagram showing anus well formed, but ending in a cul-de-sac . . . . .	45
35.	Anus divided into two openings by a lateral ridge . . . . .	46
36.	Prolongation of the perineal raphé back to the coccyx, dividing the anus into two openings . . . . .	46
37.	Diagram of imperforate anal canal, the anal depression opening into the vulva instead of into the rectum . . . . .	47
38.	Remnant of post-anal gut . . . . .	48
39.	Diverticulum from posterior surface of rectum—Persistent post-anal gut (Mr. Sinclair White's case) . . . . .	48
40.	Congenital sacro-coccygeal tumour (Mr. F. T. Heuston's case) . . . . .	49
41.	Congenital sacro-coccygeal tumour (another view of Mr. F. T. Heuston's case).	50
42.	Structure of congenital sacro-coccygeal tumour . . . . .	50
43.	Colotomy for imperforate rectum six months after operation . . . . .	53
44.	Rizzoli's operation for vulvar anus, first stage . . . . .	55
45.	Rizzoli's operation for vulvar anus, completed . . . . .	55
46.	Chronic inflammation of the rectum—proctitis . . . . .	65
47.	Inflammation of rectum—proctitis—with formation of abscesses in the sub- mucosa . . . . .	66
48.	Diagram of the relations of the anal canal and lower rectum . . . . .	67
49.	Diagram showing the positions of abscesses in relation to the rectum . . . . .	68
50.	Abscess of ischio-rectal fossa pointing beside the rectum . . . . .	70
51.	Correct line of incision for evacuating ischio-rectal abscess . . . . .	71
52.	Superficial ulcer of the mucous membrane in chronic dysentery . . . . .	75
53.	Tubercular deposit in sub-mucosa and muscular coat of intestine . . . . .	77
54.	Tubercular infiltration of the wall of the intestine . . . . .	78
55.	Section of tubercular ulcer of the rectum . . . . .	79
56.	Tubercular ulceration of the interior of the rectum . . . . .	80
57.	Tubercular ulceration of the anal canal . . . . .	80
58.	Tubercular ulceration of the skin surrounding the anus . . . . .	82
59.	Syphilis. Condylomata of the anus and surrounding skin . . . . .	85
60.	Spirochaete pallida from anal condyloma . . . . .	86
61.	Haemorrhoidal ulcer of the rectum . . . . .	90
62.	Follicular ulceration of the rectum . . . . .	91
63.	Ulceration of the anal sinuses in a man who died of Bright's disease . . . . .	92
64.	Diagram of complete rectal fistula . . . . .	96



## LIST OF ILLUSTRATIONS

xi

FIG.		PAGE
65.	Diagram of abscess and sinus of the superior pelvi-rectal space . . . . .	97
66.	Diagram indicating the ordinary forms of incomplete fistula . . . . .	98
67.	Multiple fistulae . . . . .	100
68.	Diagram of horseshoe fistula . . . . .	101
69.	Tubercular fistula . . . . .	104
70.	Operation for fistula, stage 1 . . . . .	108
71.	Operation for fistula, stage 2 . . . . .	109
72.	Operation for fistula, completed . . . . .	110
73.	Recto-rectal fistulae . . . . .	117
74.	Stricture of the anus . . . . .	126
75.	Stricture of the rectum, probably syphilitic . . . . .	127
76.	Diagram of Dieffenbach's procto-plastic operation for strictured anus . . . . .	144
77.	Sentinel pile at base of painful fissure . . . . .	147
78.	Painful fissure with sentinel pile at base . . . . .	147
79.	Diagram illustrating the varieties of prolapse of the rectum . . . . .	153
80.	Partial prolapse—mucous membrane only—of rectum . . . . .	154
81.	Complete prolapse of the rectum, showing concentric folds . . . . .	157
82.	Proctopexy and proctorraphy . . . . .	166
83.	Colopexy . . . . .	168
84.	Colopexy, further stage of operation illustrated in Fig. 83 . . . . .	169
85.	Diagram illustrating the method of fixing the colon to the peritoneum, iliac fascia and muscle in the operation of colopexy . . . . .	170
86.	Peters's operation for prolapse of the rectum . . . . .	171
87.	Intussusception caused by cancer of the ileo-caecal valve which was protruded through the anus . . . . .	172
88.	Section of intero-external pile . . . . .	179
89.	Single thrombosed external pile . . . . .	181
90.	Operation for thrombosed external pile . . . . .	184
91.	Prolapsed internal piles . . . . .	189
92.	Prolapsed, gangrenous internal piles . . . . .	192
93.	Fibrous tumour originating in a pile that had existed many years . . . . .	194
94.	Piles prolapsed by means of catch forceps . . . . .	202
95.	Operation for internal piles, stage 1 . . . . .	203
96.	Crushing clamp with parallel-acting blades . . . . .	204
97.	Operation for internal piles, stage 2 . . . . .	204
98.	Operation for internal piles, stage 3 . . . . .	205
99.	Operation for internal piles, stage 4 . . . . .	206
100.	Operation for internal piles, stage 5 . . . . .	207
101.	Adenoma protruded through the anus and attached by a long, narrow, round pedicle . . . . .	213
102.	Widely diffused adenomatous growths in the rectum (Mr. T. E. Gordon's case)	215
103.	Section of adenomatous disease of the rectum, from the case illustrated in Fig. 102 . . . . .	216
104.	Section from another portion of the specimen illustrated in Fig. 102 . . . . .	216



FIG.		PAGE
105.	Multiple adenomata of the rectum caused by the deposit of the ova of <i>Bilharzia haematobia</i> in the mucous membrane. (Dr. H. P. Keatinge's case) . . . . .	217
106.	Single adenoma of the rectum caused by the deposit of <i>Bilharzia haematobia</i> ova . . . . .	217
107.	Section of adenoma of the rectum containing numerous ova of <i>Bilharzia haematobia</i> . . . . .	218
108.	Section of <i>Bilharzia</i> disease of the rectum more highly magnified . . . . .	218
109.	Commencing adenoma of the rectum, from a case of prolapse . . . . .	219
110.	Simple adenoma found in connection with a typical adeno-carcinoma of the rectum . . . . .	219
111.	Multiple adenoma of the rectum prolapsed through the anus (Mr. R. L. Swan's case) . . . . .	220
112.	Rectal adenoma very finely split up . . . . .	221
113.	Section of adenoma of the rectum . . . . .	221
114.	Section of finely-split-up adenoma . . . . .	222
115.	Section of villous adenoma of the rectum . . . . .	222
116.	Simple villous adenoma found in connection with typical adeno-carcinoma of the rectum . . . . .	223
117.	Papillomatous warts (Villous tumour) of the lower portion of the anal canal in a male . . . . .	225
118.	Papillomatous warts of the anus in a female . . . . .	225
119.	Section of anal papilloma . . . . .	226
120.	Fibrous tumours of the rectum (Sir Kendal Franks's case) . . . . .	227
121.	Fibrous tumour originating in a pile that had existed many years . . . . .	228
122.	Mr. A. E. Barker's case of naevus of the rectum . . . . .	229
123.	Pedunculated Lymphoma springing from the mucous membrane of the rectum . . . . .	230
124.	Dermoid tumour attached to the coccyx (Mr. T. E. Gordon's case) . . . . .	232
125.	Well-marked coccygeal dimple . . . . .	233
126.	Tuberous adeno-carcinoma of the rectum . . . . .	238
127.	Atrophic adeno-carcinoma of the rectum . . . . .	239
128.	Section of the edge of a tuberous adeno-carcinoma of the rectum . . . . .	240
129.	Infiltration of the muscular coat of the rectum by glandular epithelium in a case of cancer . . . . .	241
130.	Infiltration of the muscular coat of the rectum by glandular epithelium in a case of cancer, more highly magnified . . . . .	241
131.	Cancer of lymphatic gland secondary to adeno-carcinoma of the rectum . . . . .	242
132.	Secondary cancer of the lung. The primary cancer was in the rectum . . . . .	242
133.	Simple adenoma found in connection with a typical adeno-carcinoma of the rectum . . . . .	243
134.	Simple villous adenoma found in connection with a typical adeno-carcinoma of the rectum . . . . .	243
135.	Mucoid degeneration of adeno-carcinoma of the rectum producing tight stricture . . . . .	244



## LIST OF ILLUSTRATIONS

xiii

FIG.		PAGE
136.	Section of mucoid degeneration of adeno-carcinoma of the rectum . . . . .	244
137.	Sarcoma of the anal canal and skin on the inside of the right thigh . . . . .	245
138.	Long tubular stricture caused by infiltration of the rectum with spindle-celled sarcoma . . . . .	246
139.	Spindle-celled sarcoma of the rectum . . . . .	246
140.	Melanotic sarcoma of the rectum . . . . .	247
141.	Section of melanotic sarcoma of the rectum . . . . .	248
142.	Adeno-carcinoma surrounding the entire circumference of the bowel and producing slight intussusception . . . . .	254
143.	Muscles and nerves of the male pelvic outlet . . . . .	261
144.	Complete, aseptic, perineal excision of the rectum with conservation of sphincteric control, stage 1 . . . . .	263
145.	Complete, aseptic, perineal excision of the rectum with conservation of sphincteric control, stage 2 . . . . .	265
146.	Complete, aseptic, perineal excision of the rectum with conservation of sphincteric control, stage 3 . . . . .	266
147.	Complete, aseptic, perineal excision of the rectum with conservation of sphincteric control, stage 4 . . . . .	268
148.	Partial, perineal excision of the rectum for a small nodule of cancer, stage 1 . . . . .	269
149.	Partial, perineal excision of the rectum for a small nodule of cancer, completed . . . . .	270
150.	Sacral excision of the rectum, stage 1 . . . . .	272
151.	Sacral excision of the rectum, stage 2 . . . . .	273
152.	Sacral excision of the rectum, stage 3 . . . . .	274
153.	Sacral excision of the rectum, stage 4 . . . . .	275
154.	Sacral excision of the rectum, completed . . . . .	276
155.	Vaginal excision of the rectum (Murphy), stage 1 . . . . .	278
156.	Vaginal excision of the rectum (Murphy), stage 2 . . . . .	279
157.	Vaginal excision of the rectum (Murphy), stage 3 . . . . .	280
158.	Vaginal excision of the rectum (Murphy), stage 4 . . . . .	281
159.	Vaginal excision of the rectum (Murphy), stage 5 . . . . .	282
160.	Vaginal excision of the rectum (Murphy), stage 6 . . . . .	283
161.	Abdominal excision of the rectum, stage 1 . . . . .	284
162.	Abdominal excision of the rectum, stage 2 . . . . .	285
163.	Abdominal excision of the rectum, stage 3 . . . . .	286
164.	Abdominal excision of the rectum, stage 4 . . . . .	286
165.	Abdominal excision of the rectum. Completion of the operation by colotomy when the meso-colon is not sufficiently long to admit of the bowel being brought out at the anus . . . . .	287
166.	Sacral anus six years after the entire rectum and anal canal had been removed for cancer . . . . .	288
167.	Colotomy . . . . .	293
168.	Colotomy. Method of suturing the colon to the abdominal wall, I . . . . .	293
169.	Colotomy. Method of suturing the colon to the abdominal wall, II . . . . .	294
170.	Colotomy. Method of suturing the colon to the abdominal wall, III . . . . .	294

## LIST OF ILLUSTRATIONS

FIG.		PAGE
171.	Colotomy. First stage of operation completed . . . . .	295
172.	A belt for use after colotomy . . . . .	300
173.	Villous condition of the mucous membrane of the colon in a case of colotomy of 30 years' duration . . . . .	301
174.	Method of removing the 'spur' by elastic pressure-necrosis, previous to closing a colotomy wound . . . . .	303
175.	Kurz needle . . . . .	303
176.	Apparatus for use after removal of the 'spur' in colotomy . . . . .	304
177.	Pruritus ani. The lines of incision in the operation for inveterate pruritus ani . . . . .	323
178.	Operation for inveterate pruritus ani . . . . .	323
179.	Inveterate pruritus ani. Area rendered anaesthetic by operation . . . . .	324
180.	Diverticulum from the posterior surface of the rectum (persistent post-anal gut) . . . . .	326
181.	False or acquired diverticula of the upper part of the rectum and pelvic colon	327



## CHAPTER I

### ANATOMY OF THE RECTUM AND ANUS

It appears desirable, at the outset, to briefly allude to some of the more salient features of the anatomy of the rectum, for, as in other regions of the body, a knowledge of local anatomy is essential as a preliminary to accurate examination and efficient surgical treatment. This is all the more necessary as recent methods of anatomical research, both by means of frozen sections and formalin-hardened bodies, have demonstrated that the descriptions given in the older textbooks are often inaccurate, and frequently, from a surgical standpoint, largely misleading; even the terms used are erroneous, as the *intestinum rectum* in man is anything but straight, having important flexions both in the antero-posterior and lateral planes, while the sigmoid flexure is quite unlike the Greek letter from which its name is derived.

Much has been done in the Dublin School of Anatomy by means of these recent methods to render the descriptions of the structure and relations of the lower bowel more accurate, and my thanks are due to Professor Cunningham, Professor A. F. Dixon, and Professor Edward H. Taylor for very valuable material placed at my disposal in this connection.

The portion of free intestine intervening between the descending colon and the rectum proper, formerly described as the sigmoid flexure, resembles more closely the Greek letter Omega, as pointed out by Treves in 1885, and that which was formerly designated as the first stage of the rectum, i. e. the portion completely surrounded by peritoneum and attached by a mesentery, resembles in structure and function the colon so closely, that it is best described in this connection, reserving the term 'rectum' for the termination of the bowel which is devoid of mesenteric attachment. Jonnesco uses the terms *iliac colon* and *pelvic colon* for those portions of the large intestine intervening between the descending colon and the rectum proper, and his description is so graphic and complete that anatomists are now adopting his nomenclature as the



most accurate means of describing this surgically important portion of the intestinal tract.

**Iliac colon** (Jonnesco) is a continuation of the descending colon, reaching from the iliac crest to the inner border of the Psoas tendon, where it passes into the pelvic colon. Like the descending colon, it is usually without a mesentery and uncovered by peritoneum for one-third to one-fourth of its circumference. A mesentery is somewhat rarely found in the adult, but in the embryo appears to be the rule, the intestine growing between the layers of peritoneum and separating them as development progresses until the mesentery is obliterated. The length of the iliac colon is usually five to six inches, although occasionally it may be reduced to three inches, or increased to ten. When distended it may touch the abdominal parietes in front, and is the portion of bowel which sometimes presents in the incision for laparo-colotomy; when this is the case it cannot, owing to absence of mesentery, be drawn out as a loop through the wound. It is well to remember when this happens that the free loop is to be felt for, lower down towards the pelvis, where the mesentery is usually long.

**Pelvic colon** (Jonnesco) is free and attached by a long meso-colon; it is continuous with two fixed portions of large intestine, the iliac colon above, and the rectum proper below. It usually terminates at the inner border of the third or fourth sacral vertebra. According to Professor Bermingham, the point is more frequently above than below the body of the third sacral vertebra; it is not clearly separated from the iliac colon above, except by the presence of a mesentery, but it is somewhat sharply differentiated from the rectum below by a circular furrow, which becomes much more distinct when the bowel is distended. As its name implies, the pelvic colon is usually found after death lying in the true pelvis; according to Jonnesco, this is its normal position in 92 per cent. of adults. In the infant it is usually in the abdomen, on account of the small size of the cavity of the pelvis. In the adult it may be pushed up into the abdominal cavity by its own distension, or by the enlargement of other pelvic viscera. As the pelvic colon lies loose, it is thrown into loops usually numbering three, although sometimes the number is reduced to two, or increased to four, these differences being due to the length of the gut itself and the length of its mesentery, both of which are subject to very considerable variation. The usual length of the mesentery, taken at its highest point, is four to six and a half inches, but it is sometimes



reduced to three inches or increased to over nine inches. The length of the mesentery of the pelvic colon has very important surgical bearings, notably in relation to excision of the rectum and to colotomy, while an unduly long mesentery favours the occurrence of intestinal obstruction by volvulus, which it is well known occurs most frequently in this segment of the intestine. The structure of the pelvic colon resembles the other portions of colon in the fact that the external longitudinal coat of muscular fibres is collected into the three longitudinal bands or taeniae, and that between these bands the characteristic sacculations of the large intestine are evident. Numerous appendices epiploicae are also present. As the rectum is approached the taeniae broaden out, and the anterior and postero-external tend to coalesce, the appendices epiploicae disappearing.

**The rectum** is most conveniently described as consisting of two portions, the upper or rectum proper, sometimes called the rectal pouch or ampulla, and the lower or anal canal. The rectum proper commences at the termination of the pelvic colon about the body of the third sacral vertebra; it passes down in a curve following the hollow of the sacrum and coccyx, until it perforates the pelvic diaphragm at a point about one and a half inches in front of, but below the tip of, the coccyx, resting on and supported by the pelvic diaphragm; in consequence of this curve the direction is at first downwards and backwards, then directly downwards, and lastly downwards and forwards, making an angle of  $45^{\circ}$  to  $60^{\circ}$  with the horizontal. As it passes into the anal canal it turns abruptly backwards, the two tubes being almost at right angles, a deep groove for the pubo-rectalis muscle marking the bend posteriorly. In front of the anal canal the anterior wall of the rectum forms a sort of pouch underneath the prostate in the male, and in the multiparous female this pouch is much more pronounced, owing to loss of support by the perineal body and general laxity of pelvic structures.

The length of the rectum proper is five to six inches, and its diameter is very variable, being about one inch at the upper portion and as much as three inches in the widest portion of the rectal ampulla. Besides the antero-posterior curves already alluded to, there are certain important lateral inflexions which appear to be more prominent in man, and probably are connected with his erect posture.

As the pelvic colon passes into the rectum the characteristic sacculations of the large intestine become fewer and more definite, so that in the



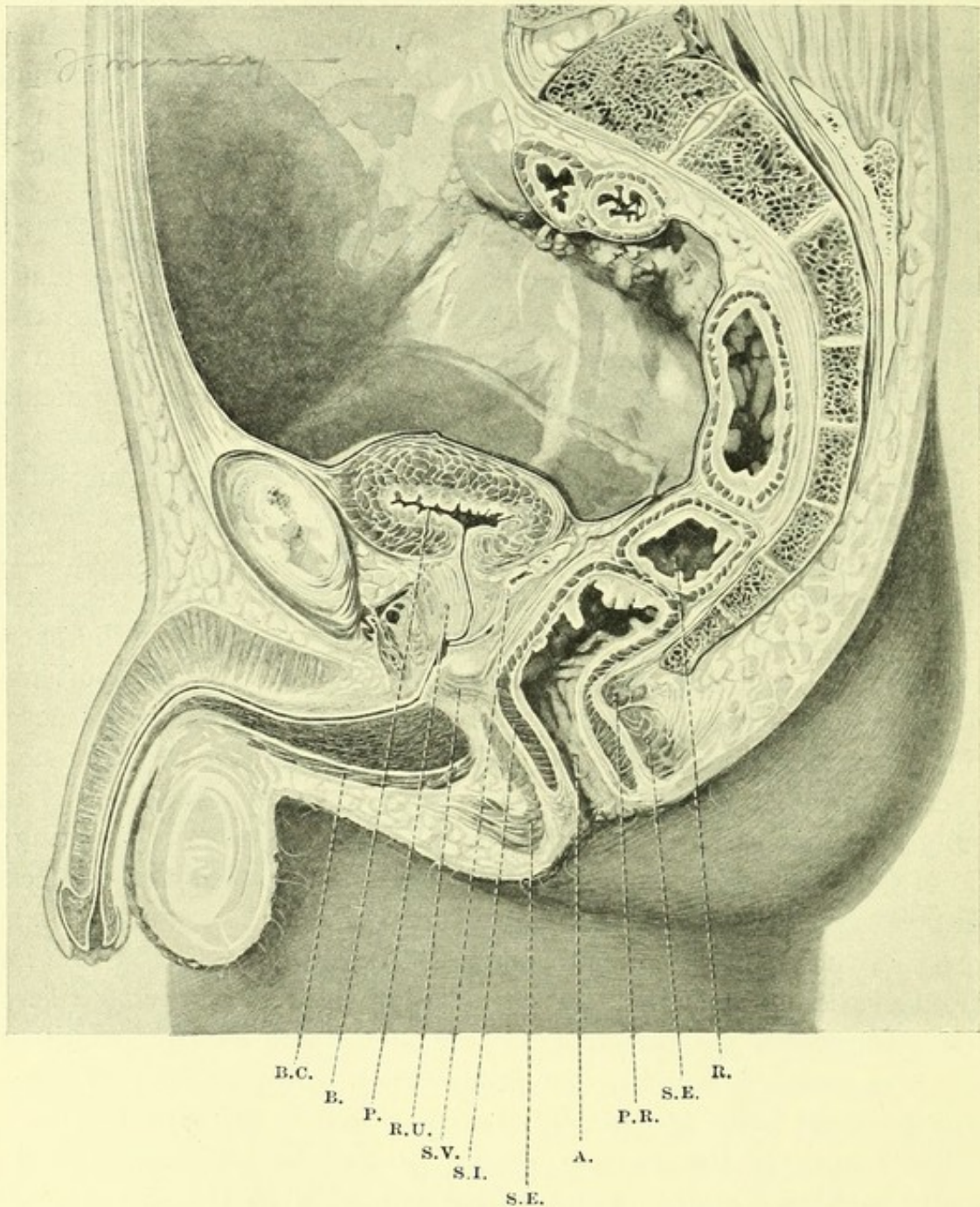


FIG. 1. The Rectum and Anal Canal in the Male.—Longitudinal section.

Section made by Professor A. F. Dixon of a formalin-hardened male pelvis. B.C. Bulbo-cavernosus muscle. B. Bladder. P. Prostate gland. R.U. Recto-urethralis muscle. S.V. Seminal vesicle with ejaculatory duct below. S.I. Internal sphincter muscle. S.E. External sphincter muscle. A. Anus. P.R. Pubo-rectalis muscle round which the rectum bends sharply to be continued into the anal canal. R. Rectum.



rectum they are comparatively large and follow a definite arrangement, three being usually described. Opposite each sacculation is a well-marked furrow formed by the bending inwards of all the coats of the bowel; these are very constant, and they cannot be completely effaced by distension of the intestine, as there is a permanent shortening of the external coat of the bowel at each inflexion. Each furrow corresponds with a ridge in the lumen of the bowel described as the rectal valves by Houston. These valves are arranged somewhat in a spiral manner in the rectum, occupying chiefly the lateral and anterior aspects of the bowel, but not going round the entire circumference; the normal arrangement is for the one nearest the anus to be placed on the left side, the next above to the right at the upper portion of the rectal ampulla, and the highest, of smaller size and more closely corresponding to the ridges in the colon, is placed again on the left side. Occasionally this arrangement is reversed, two of the valves being found on the right side and only one upon the left. The function of these valves is supposed to be to support the faecal mass from pressing upon the termination of the rectum until the normal impulse to evacuate the bowel takes place.

It has been suggested that habitual constipation may be due to too great prominence of these valves, and ingenious apparatus has been devised for producing pressure necrosis of them as a means of curing this constipation. This theory and the treatment based thereon appear to me to be quite erroneous, for, as was long ago pointed out by O'Beirne, the lower rectum is normally empty except immediately before defaecation, the mere passage of faeces into this portion of the bowel inciting the impulse to evacuate it, and one of the most fertile sources of habitual constipation is the neglect to obey this impulse when felt. As a result of this neglect the bowel becomes tolerant, so that the presence of faeces in the lower portion no longer produces the normal desire, the mass becomes hardened by absorption of the fluid portions, and obstinate constipation is the result. The truth of this statement can easily be demonstrated by digital examination, the healthy rectum being found empty, but the rectum habituated to constipation loaded, unless it is examined shortly after an evacuation.

There are, however, other points of surgical interest about these valves: in the first place, they are accountable for the great difficulty found in passing a tube or other instrument from the anus up into the colon, and in partial excision of the rectum the surgeon is often



enabled to bring down the amputated extremity of the gut to the normal position of the anus by stretching out these lateral inflexions of the rectum, assisted sometimes by a division of the superficial muscular fibres at the bases of the furrows corresponding to the rectal valves.

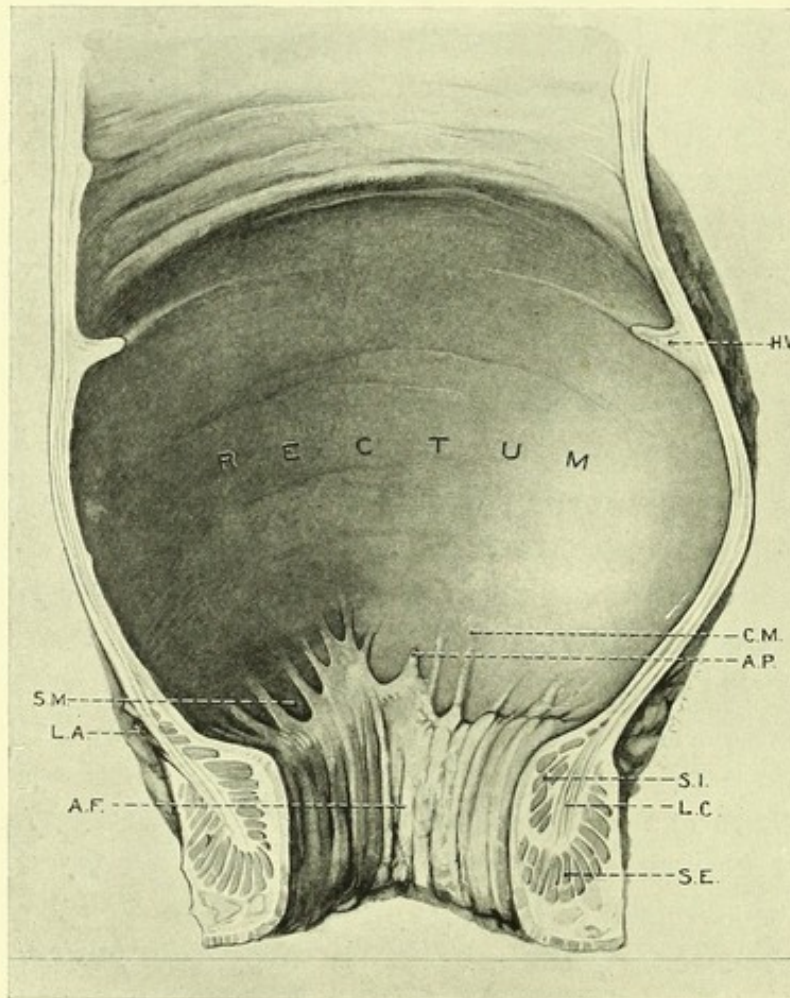


FIG. 2. The Interior of the Rectum.

Rectum removed from the body, hardened by distension with formalin solution, and opened by anterior vertical incision. S.M. Sinus of Morgagni. L.A. Levator ani. A.F. Anal folds. S.E. External sphincter muscle. L.C. Longitudinal muscular coat of bowel. S.I. Internal sphincter muscle. A.P. Anal papilla. C.M. Column of Morgagni. H.V. Lowest of Houston's valves.

**Anal canal.** That the anus is not merely an orifice, but that it is a passage of very appreciable length, was obvious to most thinking surgeons, but it is only since the introduction of frozen sections that it has been demonstrated as such a very definite canal anatomically.



Although elsewhere I have used the term in a different sense, I prefer now to adopt the original description given by Symington, who places the upper opening of the canal at the point where the bowel perforates the rectal diaphragm, the lower being the external orifice of the anus. The length of the anal canal is in the male a little over one inch, and in the female a little under one inch; in direction there is a marked contrast with the rectum, for as the lower portion of the rectum is directed downwards and forwards, the anal canal is directed downwards and backwards, so that the axes of the two canals are placed almost at right angles. The upper portion is covered by mucous membrane and the lower by scaly epithelium, the junction between these two being marked by an irregular line which is of considerable surgical importance, so that a somewhat detailed description of it is necessary, particularly as in most anatomical textbooks it is but briefly and inaccurately dealt with. The muco-cutaneous junction, instead of being an even white line as described by Hilton, is marked by numerous projections upwards of the true skin, sometimes attached by their bases and edges but leaving a free margin above, so forming true valves (the anal valves of Morgagni); at other times these projections are free at the edges as well as above, constituting little white papillae from one-eighth to even one-fourth of an inch in length, while again they are attached all round, merely forming pointed ridges of skin passing up towards the mucous membrane. It is impossible to give a description of a typical or even average arrangement, as no two rectums are alike. In the foetus or young child these structures are most distinct, as in the adult the arrangement is very frequently modified by piles or other changes which must be considered pathological; even in the most marked cases their number and distribution round the circumference of the anal canal are extremely variable, and, in rectums otherwise normal, valves and papillae may be entirely absent, while the ridges even may be but slightly marked. Above the junction the mucous membrane is thrown into vertical folds (the columns of Morgagni), and between these columns little pouches or sinuses are frequently to be observed. Like the anal valves, these columns and sinuses are extremely variable both as to number and prominence, so that no typical description can be given. The under surface of the anal valves is covered by scaly epithelium, and the upper by transitional epithelium which passes into the sinuses and to some extent up the furrows between the columns of Morgagni, while the true glandular tissue



of the mucous membrane extends down to a lower level upon the columns of Morgagni than elsewhere. Owing to the irregularity of this junction, it has received the name of pectinate line, which appears to be a suitable one. It seems to be probable that the pectinate line indicates the point of junction of the proctodaeum and hind-gut during development, and that the anal valves are vestigial remains of this junction; Mr. Bland Sutton attributes a like origin to the hymen in the female, and certainly

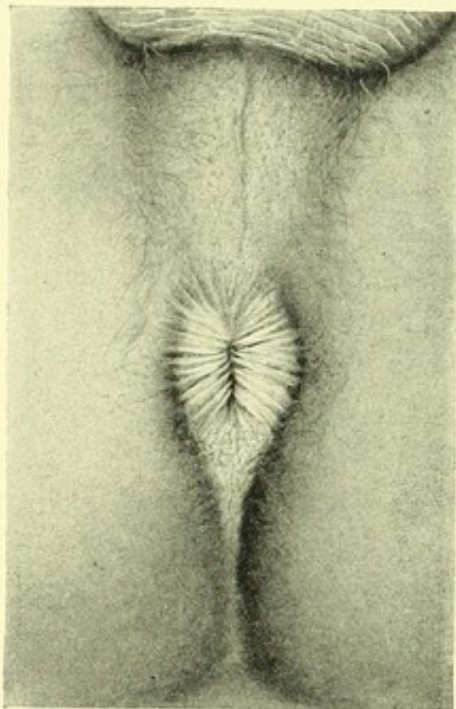


FIG. 3. The Normal Anus.

Appearance of normal anus when the thighs are flexed and abducted, and the nates separated. The radiating folds of skin seen under these circumstances become the vertical cutaneous folds of the lower portion of the anal canal when the nates are approximated.

the extreme variability of both these structures apparently tends to confirm this view as to their common origin. Below the pectinate line the skin of the anal canal is thrown into vertical folds similar to the columns of Morgagni in the upper portion; both of these are for the purpose of permitting dilatation of the anal canal for the passage of faeces: when the anus is inspected by separating the nates, these vertical folds appear as radiating ridges of thin skin. (Fig. 3.)

The musculature of the rectum may be conveniently divided into the intrinsic and extrinsic muscles, the former being a continuation of the layers found in other portions of the intestinal tube, but with certain important modifications. The latter, the levator ani, external sphincter, and the recto-urethralis muscle support the termination

of the bowel and are mainly responsible for the important sphincteric function.

**The intrinsic muscles.** The longitudinal coat of the bowel in the greater part of the colon is arranged in three characteristic bands or taeniae, leaving the internal muscular coat exposed between them, but as the descending colon is followed down it will be found that the postero-external comes to the front, and merges with the anterior taenia



to form a broad band, which in the lower portion of the pelvic colon occupies nearly the entire anterior aspect of the gut. The postero-internal taenia in like manner spreads out on the posterior aspect, so

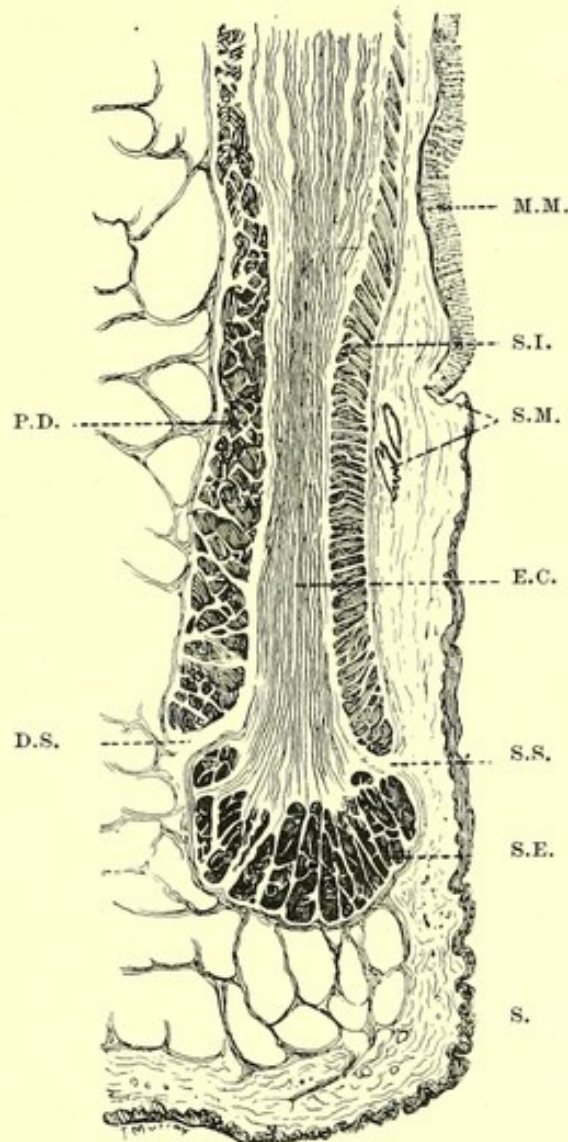


FIG. 4. Vertical section through the Lateral Wall of the Anal Canal of a Child aged 3 years.

M.M. Mucous membrane. S.I. Internal sphincter. S.M. Sinuses of Morgagni; the upper one is seen protected by an anal valve, in the lower one the incision has cut across dilatations of the sinus. E.C. External longitudinal muscular coat of the bowel. S.S. Space between the two sphincters. S.E. External sphincter muscle. S. Skin. D.S. Space between pelvic diaphragm and external sphincter. P.D. Pelvic diaphragm.

(Drawn from a microscopic section,  $\times 5$ .)

that in the lower portion of the pelvic colon the longitudinal fibres form a broad band in front and behind, surrounding the entire gut, with the exception of a narrow space upon each lateral aspect through which the



inner coat is protruded in several small sacculations. In the rectum proper the longitudinal fibres form a continuous band all round the intestine, although the layer is thicker anteriorly and posteriorly than it is upon the sides. As the anal canal is reached the longitudinal fibres become closely applied to the pelvic diaphragm, and pass in and are lost with some fibres of the latter muscles as an aponeurosis between the two sphincters. The circular fibres of the rectum in the greater part of its course resemble the same coat in other parts of the intestine, but as they come to surround the anal canal they gradually become thickened to form the so-called internal sphincter, which terminates somewhat abruptly at a point somewhat below the pectinate line, where it is separated from the external sphincter by the aponeurosis formed by the longitudinal coat, and by the pelvic diaphragm. It will thus be seen that the internal sphincter has a very definite lower margin, but above it merges in the internal circular coat of the bowel, of which it is only a part and with which it is probably also functionally related, the main sphincteric control being effected by the extrinsic muscles.

**The extrinsic muscles.** The rectum is attached to the pelvis by three important muscles—the levator ani, external sphincter, and the recto-urethralis. These muscles, which enter largely into the formation of the floor of the pelvis, are very complex, due in large measure, no doubt, to the fact that in animals provided with tails they have important functions to perform which are not required in man and in the higher apes; they have therefore in part become vestigial and in part modified in consequence of the erect position of man. Much has been done, especially by Holl (*Die Muskeln und Fascien des Beckenausganges*), Von Bardeleben (*Handbuch der Anatomie*, VII, Band 4: Jena, 1897), and Peter Thompson (*The Myology of the Pelvic Floor*, London, 1899), to elucidate this difficult subject, which has been further complicated by the number of names given by various authors to separate bands of muscular fibres. The following description, based largely on Thompson's work, appears to be the most definite.

**Levator Ani** is composed of three main portions—the ilio-coccygeus, pubo-coccygeus, and pubo-rectalis.

**Ilio-coccygeus**, although definitely attached to the ilium in many lower animals, in man takes origin from the spine of the ischium and from a portion of the obturator fascia, roughly indicated by a white line which extends in a curve from the spine of the ischium to the back of



the pubis. Although in older textbooks this white line is described as a tendinous origin of the levator ani, recent observations tend to show that but few, if any, of the muscular fibres are actually attached to it,

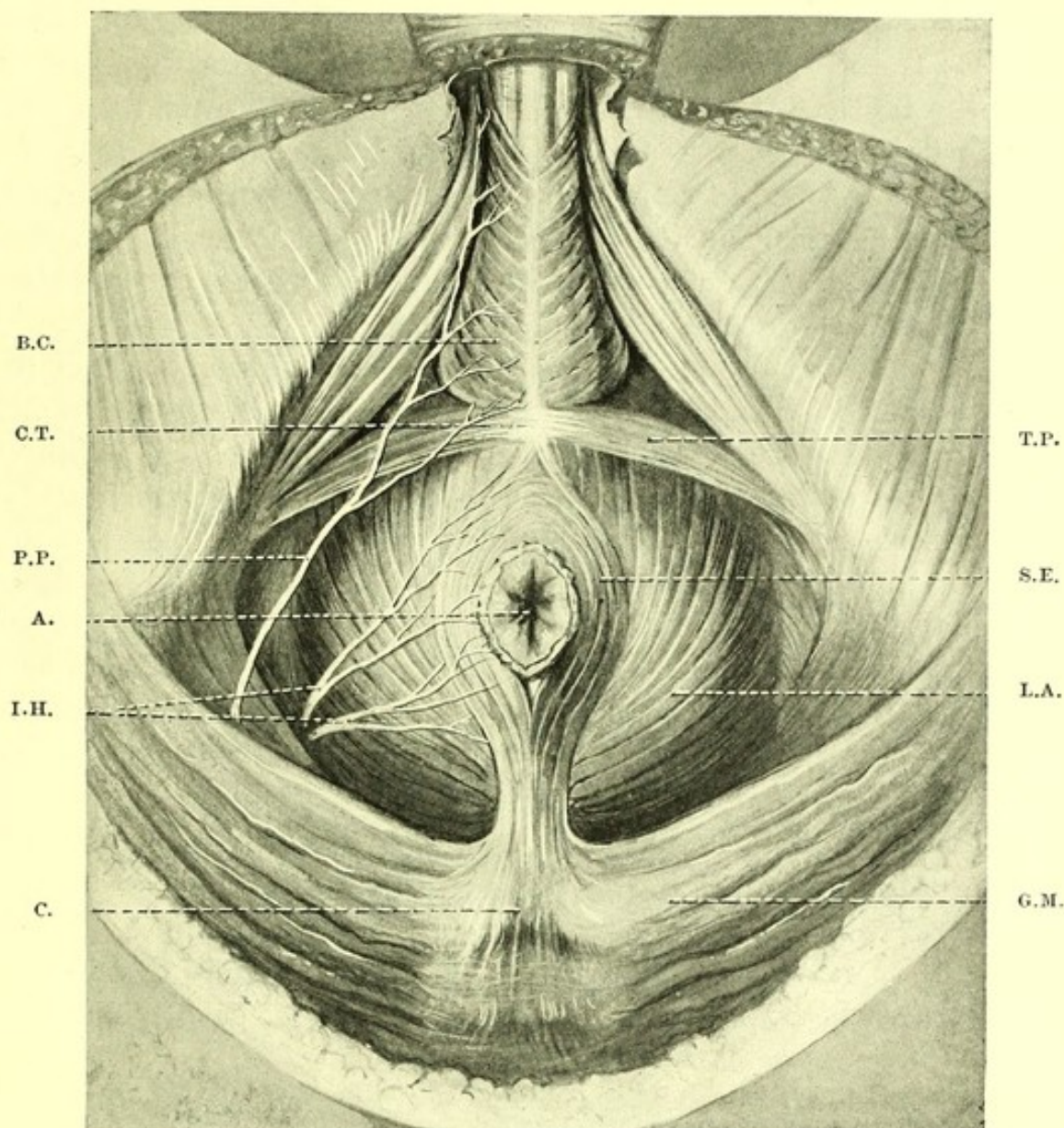


FIG. 5. Muscles and Nerves of the Male Pelvic Outlet.

T.P. Transversus perinei muscle. S.E. External sphincter muscle. L.A. Levator ani muscle. G.M. Gluteus maximus muscle. C. Coccyx. I.H. Inferior haemorrhoidal nerve. A. Anus. P.P. Posterior superficial perineal nerve. C.T. Central tendinous point of perineum. B.C. Bulbo-cavernosus muscle.

and that it is merely a thickening of the pelvic fascia. From this origin the ilio-coccygeus extends in a fan shape to be inserted into the side of the sacrum and coccyx; it is thin and in part membranous, and must be



regarded as a degenerated muscle whose primary function in connection with the tail is lost, but in virtue of its position it contributes to the formation of the pelvic floor. It has no direct relation to the rectum.

**Pubo-coccygeus** arises from the back of the pubis, and also from the obturator fascia, where usually its fibres blend with those of the ilio-coccygeus; from this origin the fibres pass almost horizontally back, overlapping the ilio-coccygeus, closely related to the rectum (and vagina), to be attached to the coccyx and ano-coccygeal ligament. A few of the anterior fibres descend in front of the rectum to the perineal body, while lateral fibres are continued down into the aponeurotic sheath which surrounds the anal canal, in which the longitudinal fibres of the external coat of the rectum terminate.

**Pubo-rectalis**, or sphincter recti, is the name given by Holl to an important band of fibres of the pubo-coccygeus, which, instead of being inserted into the coccyx and its ligamentous connections, is continuous with the fibres of the same muscle on the other side, forming a strong muscular cord round the lateral and posterior aspects of the upper opening of the anal canal. The fibres of the pubo-rectalis muscle arise from the back of the pubis on either side, under cover of the pubo-coccygeus, and pass between the layers of this muscle, with more or less interchange of fibres, to the back of the rectum, where they are continuous with the fibres of the same muscle on the other side. It is the most muscular portion of the levator ani, and when removed from a formalin-hardened body leaves a deep groove posteriorly where the rectum turns abruptly into the anal canal (see Fig. 11). According to Thompson, although traces of this muscle are found in some lower animals, it is only in the anthropoids that we find a muscular sling strongly developed for the first time, which in man has become evolved into such an important structure.

**External Sphincter** is described by Thompson in three divisions—(1) Subcutaneous, (2) Superficial, (3) Deep.

1. **Subcutaneous External Sphincter**, a delicate band of muscle surrounding the anal outlet immediately underneath the thin skin; it does not reach the coccyx posteriorly, and anteriorly it blends with the sphincter vaginae, or in the male is continued on to the scrotum; it is situated internal to the aponeurotic sheath formed by the longitudinal coat and the pubo-coccygeus.

Thompson considers that the subcutaneous external sphincter is



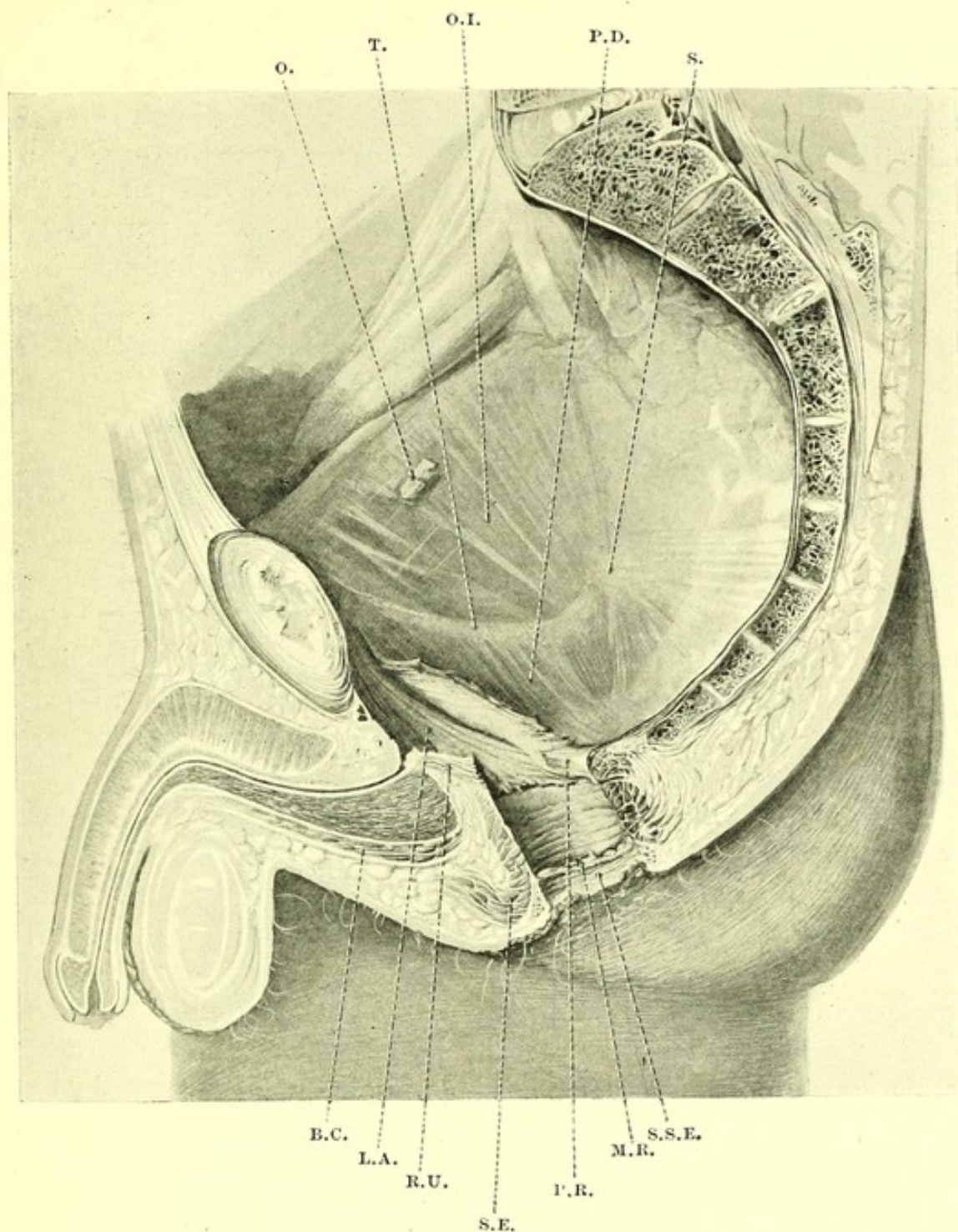


FIG. 6. Muscles of the Male Pelvic Outlet.—Side view.

The illustration is taken from the same section from which Fig. 1 was drawn, but the viscera have been removed by Professor A. F. Dixon to show the musculature of the pelvic outlet. *o.* Obturator vessels and nerve. *t.* White tendinous line from back of pubis to spine of ischium. *o.i.* Obturator internus muscle covered by thin fascia. *p.d.* Pelvic diaphragm. *s.* Spine of ischium. *b.c.* Bulbo-cavernosus muscle. *l.a.* Levator ani muscle, deep layer; the superficial layer, shown cut across above, has been reflected to expose the fibres of the pubo-rectalis muscle. *r.u.* Recto-urethralis muscle. *s.e.* External sphincter muscle. *p.r.* Pubo-rectalis muscle. *m.r.* Muscular coat of rectum cut across. *s.s.e.* Superficial fibres of external sphincter muscle.



a remnant of the panniculus carnosus, which is such an important muscle in some lower animals but in man is only elsewhere represented by the platysma and some of the facial muscles.

**2. Superficial External Sphincter** is sometimes called the coccygeal part of the external sphincter, as it is the only portion that is prolonged back to the coccyx. It surrounds the lower portion of the anal canal as an elliptical mass of muscle; in front it becomes in part tendinous at the central point of the perineum, some fibres are attached to the skin, while others are lost in the sphincter vaginae in the female, or the bulbo-cavernosus muscle in the male.

**3. Deep External Sphincter**, surrounds the anal canal as a muscular cylinder; its fibres behind are continuous, while in front they are in part continuous, while some extend into the transversus perinei, and by this means are attached to the ischium.

**Recto-urethralis** (Henle) is a definite muscular band by which the front of the bowel at the angle made by the sudden turn of the rectum into the anal canal is connected to the urethra; it lies between the two heads of origin of the pubo-rectalis muscle, and is a structure of some surgical importance in excision of the rectum and in perineal prostatectomy.

**Function of the rectal muscles.** During defaecation the levator ani and external sphincter muscles are relaxed, and the faecal mass is extruded by the involuntary muscular coats of the bowel assisted by the voluntary action of the abdominal muscles, the internal sphincter probably not acting as a sphincter at all, but co-operating in the peristaltic movement of the internal muscular coat of the intestine. When the mass is extruded the anterior portion of the upper opening of the anal canal is fixed by the recto-urethralis muscle, while the strong pubo-rectalis compresses the sides and draws the posterior portion of the opening towards the pubis. The various portions of the external sphincter then complete the evacuation and closure of the anal canal.

In addition to the attachments of the rectum to the bony skeleton by means of the extrinsic muscles alluded to, prolongations of the pelvic fascia are continued with the levator ani into the subcutaneous tissue of the anal canal, and form a fascial covering for the lower portion of the rectum; this visceral layer of pelvic fascia, although not well marked at the sides and in front, becomes posteriorly a more definite structure of some surgical importance, known as the **fascia propria of Waldeyer**.



This fascia is very loosely attached to the rectal pouch, so as to permit of the ready distension of the gut, and in the space which intervenes ramify the blood-vessels and lymphatics. Above, the fascia propria is lost in the subperitoneal tissue. In the operation for trans-sacral excision of the rectum, it is very essential to remember this fascia, as, if at an

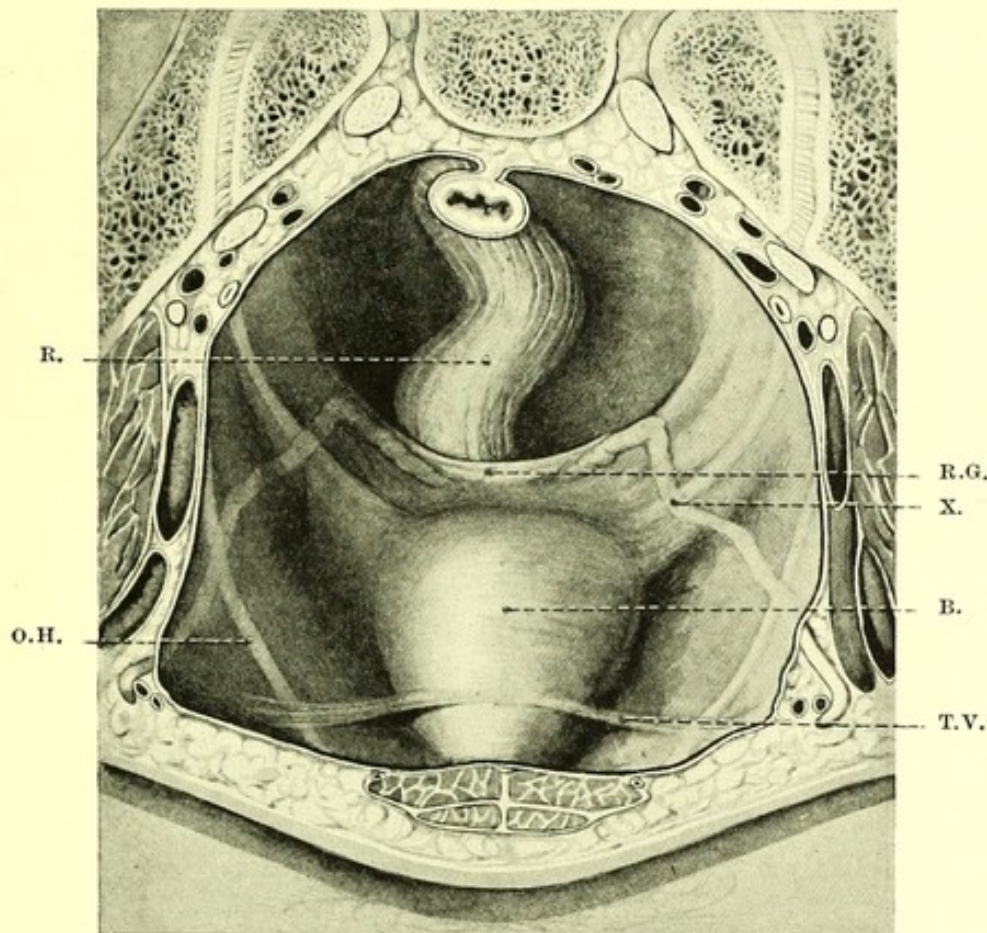


FIG. 7. The Rectum seen from above in a Male Subject.

The pelvis has been sawn across obliquely. R. Rectum. O.H. Obliterated hypogastric artery. R.G. Recto-genital fold of peritoneum. X. marks the point where the vas deferens crosses the ureter. B. Bladder. T.V. Transverse vesical folds.

early stage of the operation it is freely opened up, the separation of the gut will be greatly simplified.

The **ano-coccygeal ligament** is a rounded cord extending from the tip of the coccyx to the submucous tissue of the upper portion of the anal canal, and to which the fibres of the superficial external sphincter are intimately attached. Upon either side of the rectum, just underneath



the lateral reflexions of the peritoneum, are connective tissue attachments which are important from the fact that they carry the middle haemorrhoidal vessels: they are called the **lateral ligaments of the rectum**; they are readily recognized in excision of the rectum, and should be ligatured before they are cut.

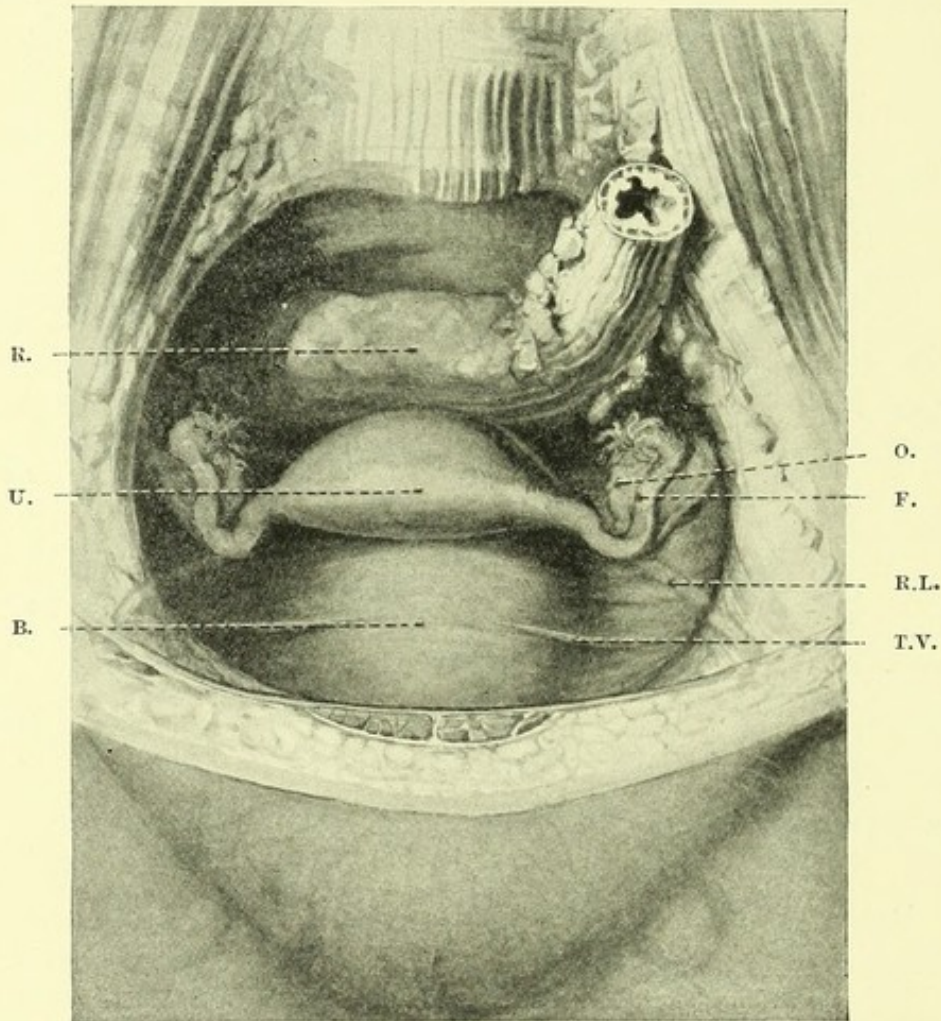


FIG. 8. The Relations of the Rectum to the Female Genital Organs.

R. Rectum. U. Uterus. B. Bladder. T.V. Transverse vesical folds. R.L. Round ligament of uterus. F. Fallopian tube. O. Ovary.

**Relation to peritoneum.** In the upper portion of the rectum proper, the peritoneum surrounds the entire circumference of the bowel with the exception of a small strip at the posterior aspect, and is as intimately adherent to the external coat as in other portions of the intestine; the portion uncovered by peritoneum broadens out as the tube

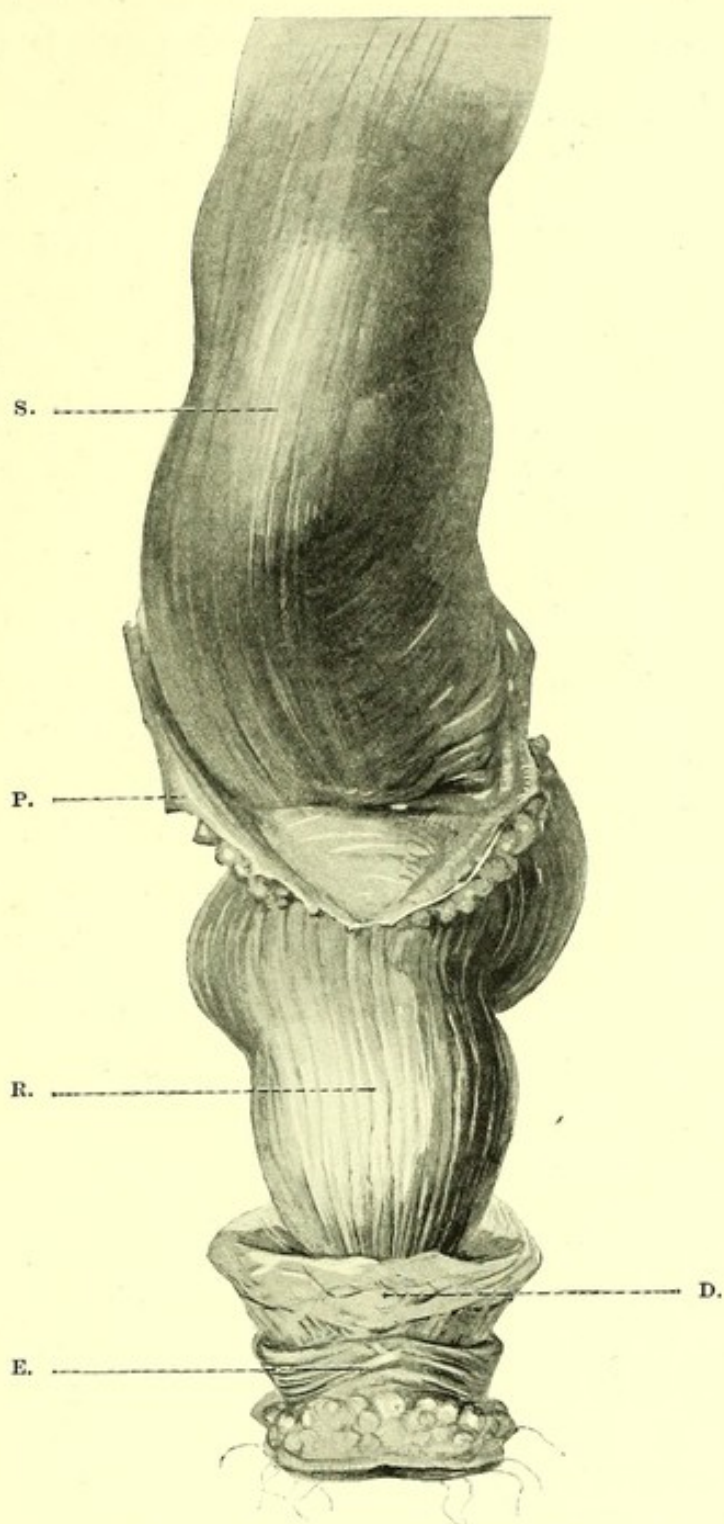


FIG. 9. Rectum hardened *in situ* with Formalin and then dissected out.

S. Sacral curve of rectum. P. Peritoneum cut at its reflexion from the bowel. R. Portion of rectum uncovered by peritoneum. D. Pelvic diaphragm. E. External sphincter.



is followed down the curve of the sacrum, till at the level of the lateral ligaments of the rectum the entire posterior surface is uncovered; the peritoneum sweeps over the lateral ligaments, leaving the sides un-

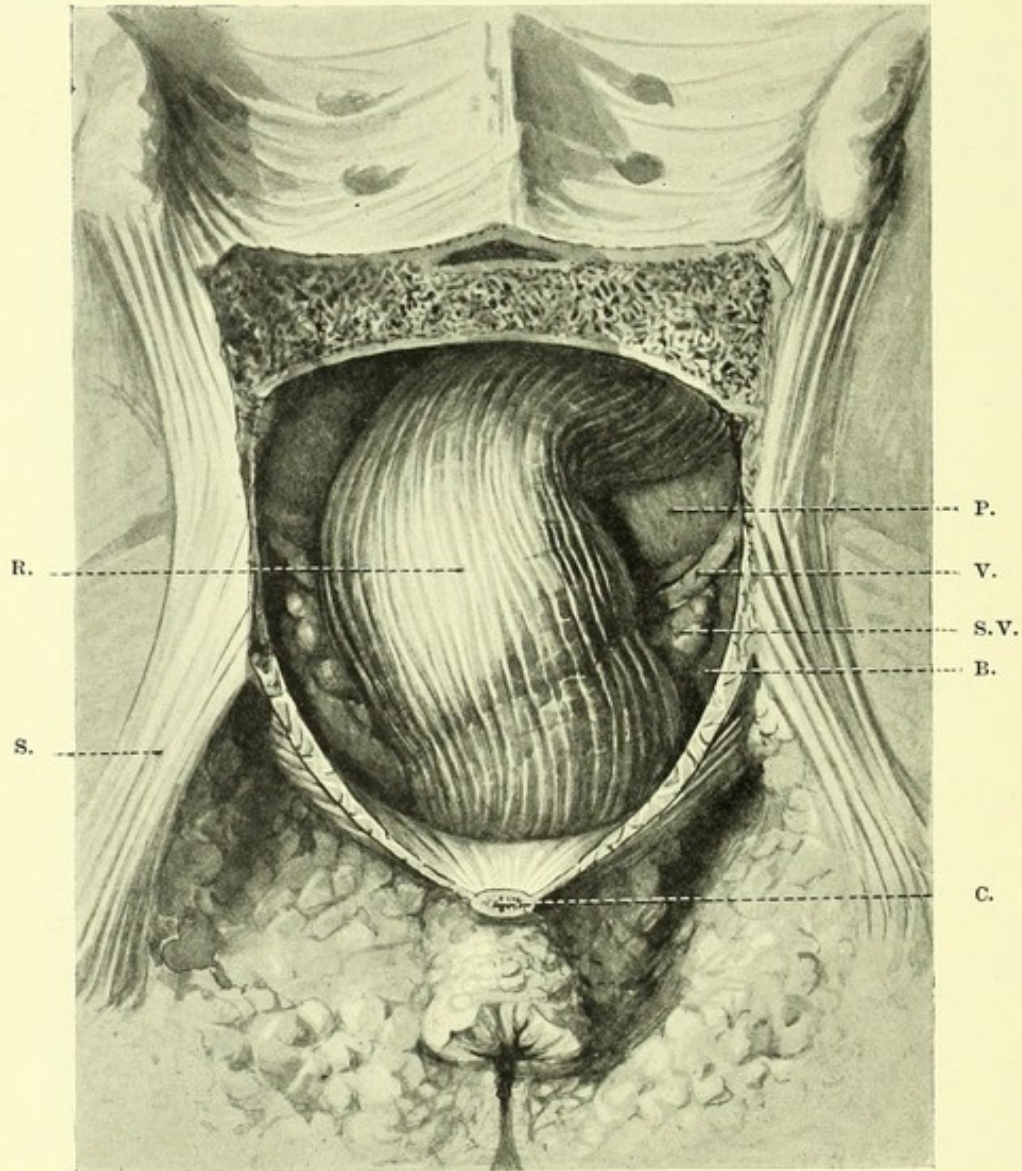


FIG. 10. The Rectum viewed from behind.

The soft parts have been removed from the back of the pelvis, the coccyx has been cut across and reflected together with the pelvic diaphragm, and the sacrum has been sawn across transversely. R. Rectum. s. Sacro-sciatic ligament. c. Coccyx cut across and reflected with pelvic diaphragm attached. B. Bladder. s.v. Seminal vesicle. v. Vas deferens. P. Peritoneum.

covered, but in front it descends lower, to curve upwards again upon the posterior wall of the vagina, or, in the male, the bladder, thus forming the pouch of Douglas. The immediate relation of the peritoneum to the





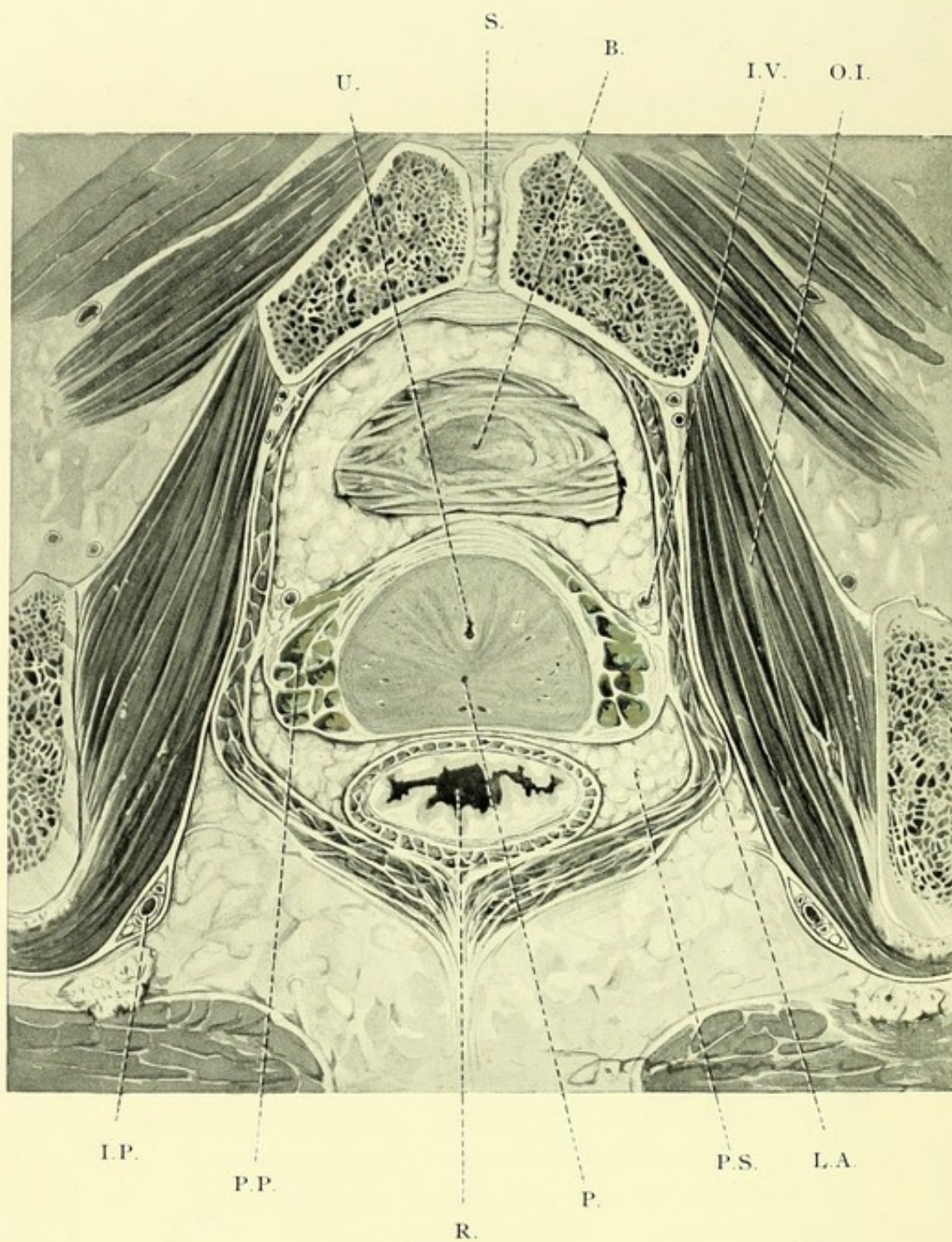


PLATE II.

OBLIQUE FROZEN SECTION THROUGH THE PELVIS AT THE LEVEL OF  
THE MIDDLE OF THE PROSTATE GLAND.

I.P. Internal pudic vessels and nerve. P.P. Prostatic plexus of veins  
R. Rectum. P. Prostate gland, the two common ejaculatory ducts are seen  
near the posterior surface. P.S. Perirectal space. This space, which is of con-  
siderable size to allow of distension of the rectum, has a smooth fascial boundary,  
and contains loose areolar tissue together with some fat. L.A. Levator ani  
muscle. O.I. Obturator internus muscle. I.V. Branch of inferior vesical  
artery. B. Bladder, a thin slice of the bladder has been taken off in the section  
showing an elliptical mucous surface in the centre surrounded by vesical muscle.  
S. Symphyseal pubis. U. Urethra passing through prostate gland.



rectum in the lower portion of Douglas's pouch is much less intimate than it is above, allowing free mobility of the rectum in distension. This is surgically very important, as the peritoneum can here be separated by a finger or handle of a knife from the rectum with the greatest ease, whereas above this is quite impossible. The lower portion of the rectal ampulla and the entire anal canal are not related to the peritoneum.

Amongst other relations of the rectum, it is well to remember that posteriorly it rests upon the hollow of the sacrum and coccyx, pyriformis muscle, and pelvic diaphragm, while anteriorly it is closely applied to the vagina in the female, and to the bladder, vesiculae seminales, vasa deferentia, prostate, and commencement of the urethra in the male, while laterally it is in relation to the loops of intestine which drop into the pelvis.

**Arteries of the rectum.** The abundant blood supply of the rectum is derived from several sources; two of these are single vessels, the superior haemorrhoidal and the middle sacral, while the two others, the middle and inferior haemorrhoidal, are symmetrical.

The largest and most important vessel is the **superior haemorrhoidal**, which is a continuation of the inferior mesenteric artery; this vessel passes down in the mesentery of the pelvic colon lying near its attachment. At the upper portion of the rectum it divides into two main branches right and left, these soon break up into a number of smaller branches, which anastomose freely round the circumference of the gut and then pass in through the muscular coats of the bowel to the submucous coat, where they end in a number of terminal branches which descend vertically (one being usually found in each of the columns of Morgagni) to the pectinate line; the entire mucous membrane is supplied by the superior haemorrhoidal artery, and its anastomosis with the middle and inferior haemorrhoidal arteries is not usually very free. The **middle haemorrhoidal artery** arises either direct from the internal iliac artery or as an axis with other branches of this artery; one passes on each side to the lateral aspect of the rectum in the lateral ligament and breaks up into a number of branches, which are distributed to the outer tunics of the bowel but not to the mucous membrane; it anastomoses freely with the inferior haemorrhoidal, but not so freely with the superior.

The **inferior or external haemorrhoidal** rises from the internal pudic, and passes across the ischio-rectal fossa to be distributed to the muscles and tissues of the anal canal, the cutaneous but not the mucous



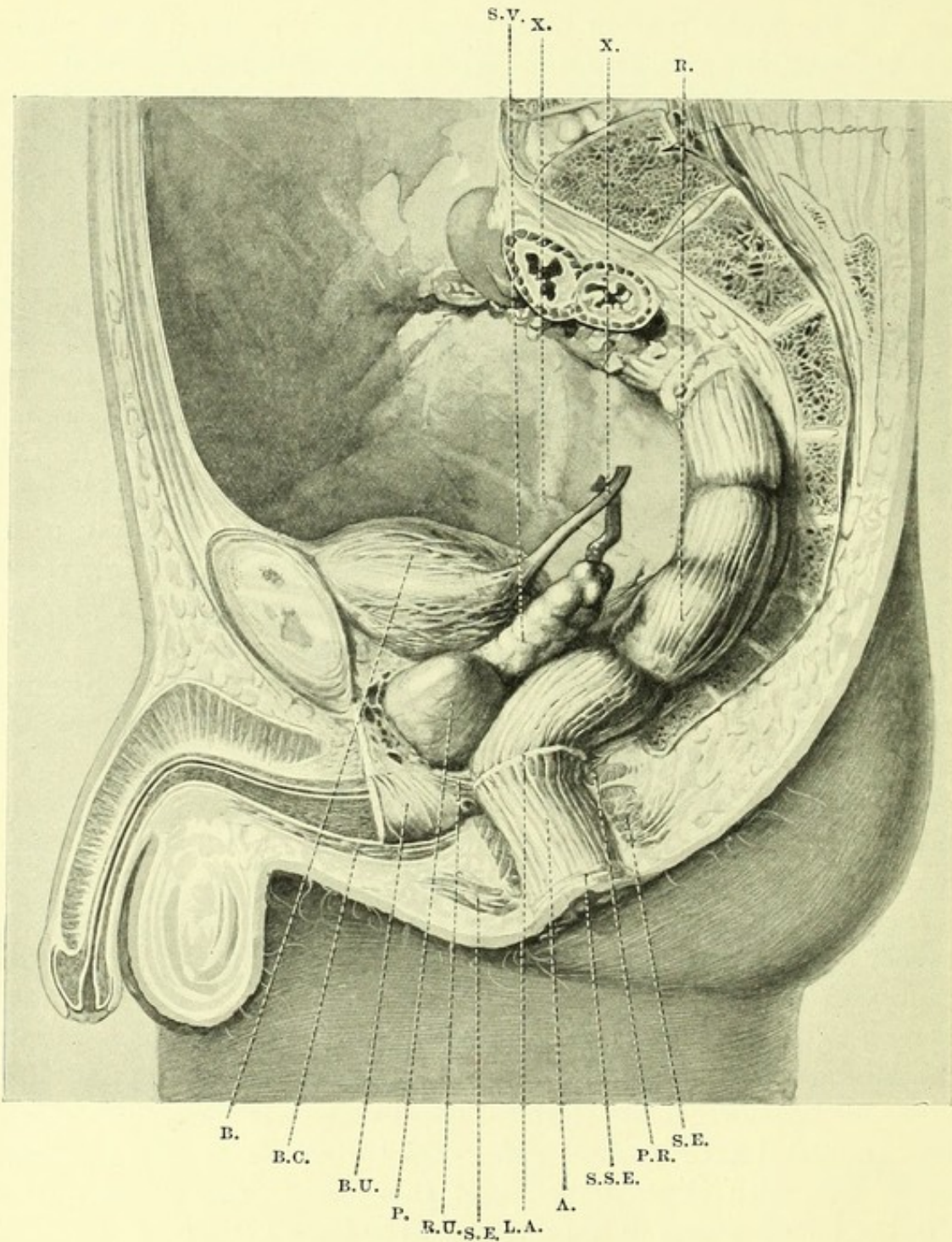


FIG. 11. The Relations of the Rectum to the Male Genito-Urinary Organs.

The illustration is taken from the same section from which Fig. 1 was drawn, the pelvic viscera have been dissected out of the left half of the body by Mr. McConnell and placed *in situ* on the section of the right side. B. Bladder. B.C. Bulbo-cavernosus muscle. B.U. Bulb of the urethra with covering muscle removed. P. Prostate gland. R.U. Recto-urethralis muscle. S.E. External sphincter muscle. L.A. Levator ani muscle cut across. A. Anal canal covered by some fibres of levator ani muscle. S.S.E. Superficial fibres of external sphincter muscle. P.R. Puborectalis muscle. R. Rectum. X. marks the point upon each side where the vas deferens crosses the ureter. S.V. Seminal vesicle.



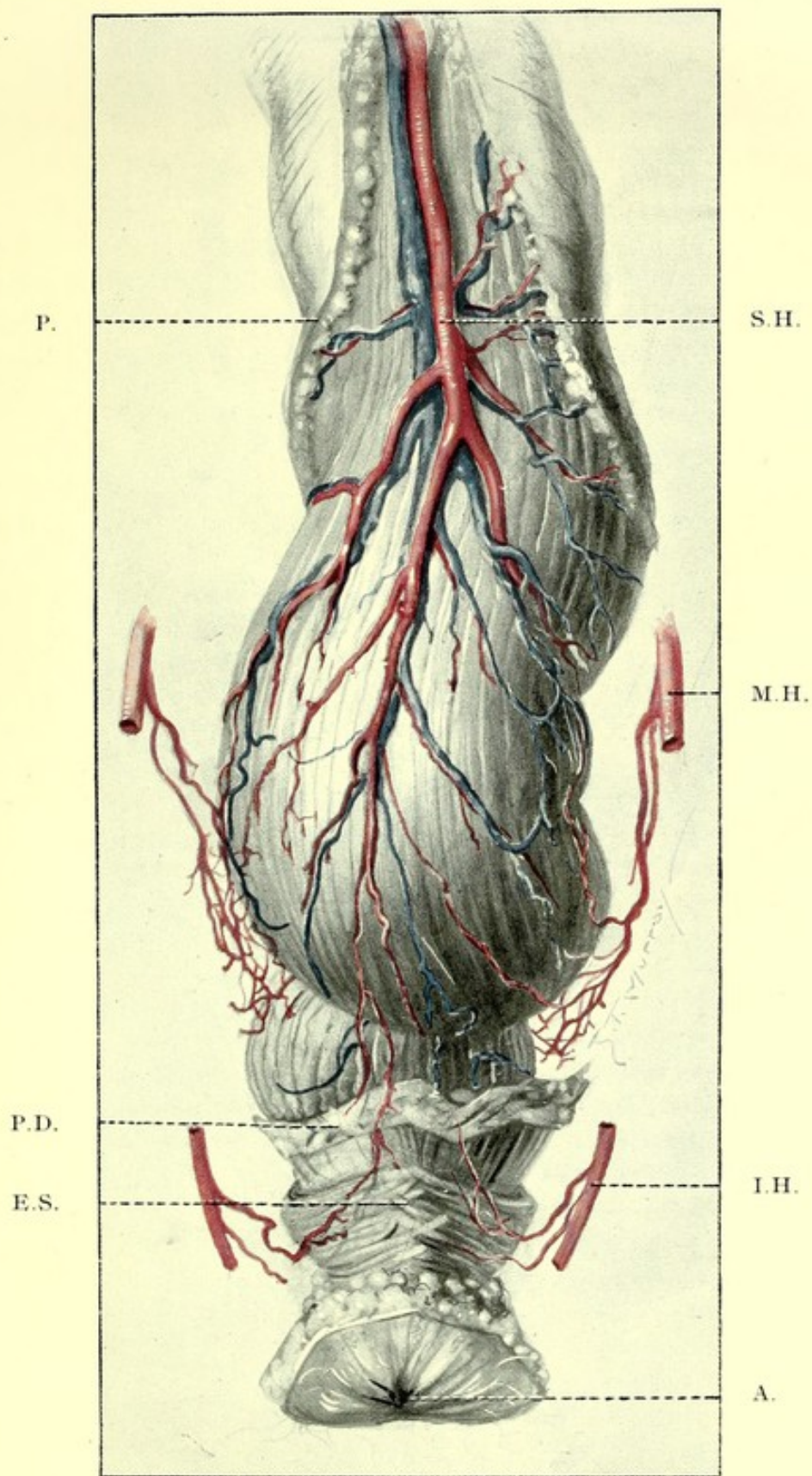


PLATE III.

THE BLOOD VESSELS OF THE RECTUM.

S.H. Superior hæmorrhoidal artery. M.H. Middle hæmorrhoidal artery.  
 I.H. Inferior hæmorrhoidal artery. A. Anus. E.S. External sphincter muscle.  
 P.D. Pelvic diaphragm. P. Cut edge of peritoneum.





portions of the interior of this canal receiving its blood supply from this source; it also supplies the skin round the margin of the anus. The midsacral artery also sends a small branch to the lower end of the rectum and anal canal.

**Veins of the rectum.** The veins of the rectum follow the arteries, but there is a very important difference between those accompanying the superior haemorrhoidal and the other arteries supplying the rectum, the superior haemorrhoidal veins being radicles of the portal system, while the others discharge their blood into the caval circulation, the neighbourhood of the anal canal being the portion of the body in which the two systems are most closely related. I have not, however, by injections been able to demonstrate the free anastomosis between the two systems which is described by some authors in this region.

The **superior haemorrhoidal veins** commence in the haemorrhoidal plexus, which is situated in the submucous and subcutaneous tissue of the anal canal. The veins are of considerable size, and present in the adult a number of ampullary dilatations which, however, must be considered pathological, for although pretty constant in the adult rectums of both sexes, they are not to be found in the young infant. The blood from this plexus collects into veins which pass up in the submucous tissue with the corresponding arteries to the rectal ampulla, where they perforate the muscular coats through circular openings; they then ascend upon the outside of the rectum, and finally join the inferior mesenteric vein and thence to the vena portae. Like the rest of the portal system, the superior haemorrhoidal veins are destitute of valves. The veins accompanying the middle haemorrhoidal arteries present no special features of interest.

The **inferior haemorrhoidal veins** receive the blood from the region of the anus, and, according to Konstantinowitch, there is one principal vein which surrounds the anus in a circular manner, receiving radiating branches from the interior of the anal canal which pass out in the radiating folds of skin which surround the external anal aperture, this circular vein discharges its blood into the external haemorrhoidal vein and thence into the caval circulation.

**Lymphatics.** The lymphatics of the rectum have been specially studied by Gerota. The network of lymph-vessels from the mucous membrane empties into a number of vessels which perforate the coats of the bowel and communicate with a number of small glands on the



posterior surface of the rectum lying close to the muscular coat, in the loose tissue between the rectum and the fascia propria, the lymphatic vessels from thence pass up with the superior haemorrhoidal vessels into the mesentery of the pelvic colon. The lymphatics from the skin of the anus pass up in the cleft between the scrotum and the thigh to the inguinal glands. The line of infection, therefore, in cancer of the rectum is first the small glands at the back of the rectum, and then the mesenteric glands; it is only in epithelioma of the skin-covered portion of the anal canal that primary enlargement of the inguinal glands is to be looked for.

**Nerves of the rectum.** The nerves of the interior of the rectum are similar to the sympathetic system of plexuses of the rest of the intestinal tube, but nerves of ordinary sensation are absent; this accounts for the freedom from pain experienced in early cases of cancer originating in the ampulla, and also for the fact that people have not infrequently perforated their own rectums by the careless introduction of enema pipes and other foreign bodies through the anus. The anal canal, on the contrary, especially about the pectinate line, is very largely endowed with nerves of sensation, and tactile corpuscles are numerous. These sensory nerves are branches of the sacral plexus. The levator ani and external sphincter are also supplied by branches from the sacral plexus, especially the third nerve; it is therefore of great importance to preserve this nerve in operations for excision of the rectum in order to retain sphincteric control.



## CHAPTER II

### DEVELOPMENTAL DEFECTS. EMBRYOLOGY OF RECTUM AND ANUS

THE large variety of forms in which Developmental Defects of the rectum and anus are met with are of considerable surgical importance, for the early recognition of the exact condition and efficient treatment of it will frequently be the means of saving life. In addition to their surgical interest the study of these malformations in the light of modern embryology is a most engrossing one, as even the most apparently complex defects are susceptible of explanation by errors in the process of development, while on the other hand their very existence in the human subject throws important light upon certain of the earliest periods of development which are so little known in the human species, although so well worked out in many lower animals.

In order, however, to obtain an intelligent understanding of this most interesting subject it will be necessary to allude very briefly to a few of the well ascertained embryological facts; it is only possible here to give the barest outline, and for those who wish to go further in the matter I would refer them to the systematic works on embryology.

Owing to the great difficulty of obtaining very early normal human embryos, much of the work has been done on lower animals, and although the details are somewhat different and more complicated the higher we ascend the animal scale, yet the practical identity of the main facts of embryology in all except the very lowest forms of animal life is one of the most astonishing facts in the book of Nature. In studying the embryology of higher animals certain stages are noticed in which the conditions are widely different from the adult state, structures appear for which the mature animal can have no use, only to disappear again in whole or part, or sometimes to be replaced in function by the development of entirely new organs. Upon what is known as the recapitulation theory, these developmental abortions receive a most interesting explanation. According to this theory, they are indications of the lines upon which



the evolution of the species has come down, and as Marshall puts it, 'the embryo during development builds up its own ancestral tree.' It is quite true that there are very wide gaps in the history thus afforded, but certain facts appear to be explicable on no other hypothesis, as for instance the whale-bone whale, which as an adult has no teeth in the ordinary sense, but as an embryo it has teeth which never cut through the gum, and disappear before birth, clearly indicating its descent from a toothed animal. The heart of any of the higher mammals is during a stage of development similar to that found in the adult fish, and the presence of gill-clefts indicates that some remote ancestors breathed by gills instead of lungs, while the presence of a yolk-sac and vitelline duct would indicate that we are descended from animals that laid eggs. To come to an example more nearly connected with the subject we are at present discussing, the early human embryo is provided with a tail, and a portion of the intestine, the post-anal gut which rapidly disappears, goes down into this tail. As Balfour has suggested, this indicates that some of our predecessors were provided with movable tails, with an anus at or near the extremity; this arrangement might have been attended with obvious convenience, but the position which a later evolution has chosen between the tubera ischii is one of greater safety for this important organ.

The embryological facts which it is necessary to understand in order to appreciate the explanation of the various malformations of the rectum are—

That the rectum proper is formed from the hind-gut of the embryo.

That, for a time, the hind-gut communicates with the allantois.

That for an extremely short period there is a communication between the hind-gut and the neural canal or groove (neurenteric canal).

That a pouch forms from the hind-gut, the post-allantoic gut, as the posterior extremity of the embryo develops.

That as the tail develops a prolongation of the gut grows down with it which rapidly disappears, the post-anal or tail-gut.

That part of the anal canal is formed by a depression in the outer layer of the embryo—anal depression—or proctodaeum, which opens into the hind-gut.

That the permanent opening of the genito-urinary tract is at its formation intimately associated with the proctodaeum.

That the bladder is formed from a portion of the allantois, with which the hind-gut for a time freely communicates.



That the uterus and vagina are formed independently of the intestine.

**The hind-gut.** If an early embryo is examined in longitudinal section, it will be seen that the endoblastic cavity in its interior can be divided into three portions—the fore-gut ending anteriorly in a cul-de-sac, the mouth developing and communicating with it subsequently; the mid-gut, that portion which communicates freely with the yolk-sac; and the hind-gut, all that portion of the endoblastic cavity behind the yolk-sac.

**Allantois** is the term applied to an epithelial lined cavity, partly in the body-stalk, and partly in the embryo. At a very early stage it is directly continuous with the hind-gut, no line of demarcation being observ-

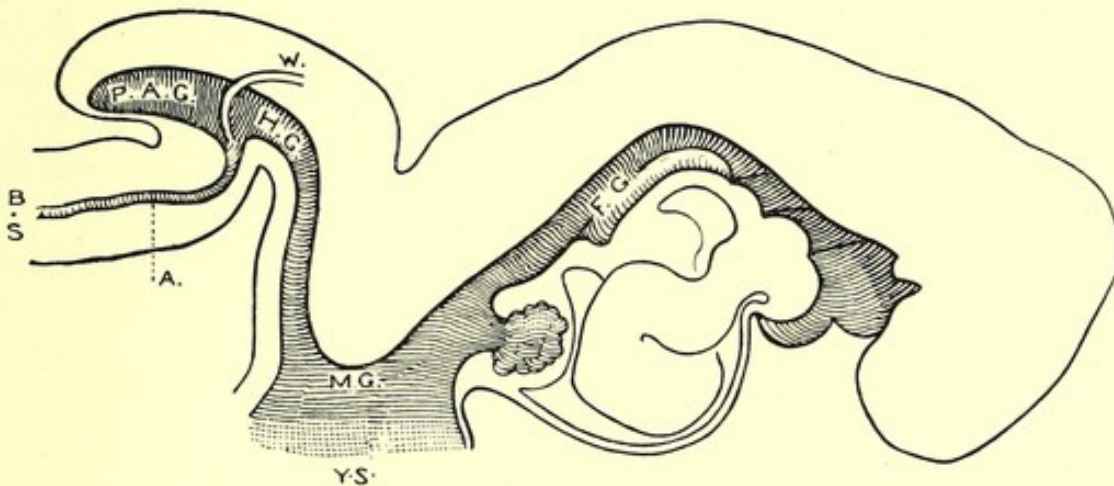


FIG. 12. Diagram of the Intestinal Canal of a very young Human Embryo.

F.G. Fore-gut. M.G. Mid-gut. H.G. Hind-gut. P.A.G. Post-allantoic gut. Y.S. Yolk-sac. B.S. Body-stalk. A. Allantois. W. Wolffian duct.

able, as development progresses it becomes normally completely shut off from the hind-gut. A portion of the intra-embryonic allantois forms the urinary bladder into which the ureters and urethra open, the remainder of the intra-embryonic portion being left as the obliterated urachus.

**Neurenteric canal.** In lower animals in which the earliest stages of development of the embryo can be easily investigated, a free communication between the enteric and neural canals is very constantly found, which becomes obliterated at a very early period, so early indeed that its existence in the human embryo has been seldom demonstrated. What the meaning of a neurenteric canal is it is hard to imagine. Although so constant a feature in comparative embryology, no adult form of animal is known in which it normally exists, but we shall see later



on its persistence explains a certain curious congenital malformation. The most plausible theory of its presence appears to be that of Sedgwick, that it is an excretory opening from the central canal of the developing nervous system, although no direct evidence in support of this theory is forthcoming.

**Post-allantoic gut** is the term applied by Wood Jones to a pouch which forms from the hind-gut as the posterior extremity of the embryo elongates, and which develops the rectal ampulla below the peritoneal reflexion. I am much indebted to him for the illustrations, and for a description of his observations which throw such important light on some of the common forms of malformation. His description is as follows. 'The first stage to be described in the development of the rectum is the condition found in the embryo of 12 somites. It is an embryological condition of great importance, for it gives the key-note to the whole of the further development, and furnishes the clue to the proper understanding of the malformations that occur in actual practice.

'In this embryo the state of things is very simple, for development has only reached that stage in which the body-stalk is the fixation point of the embryo, and is the direct continuation of the posterior end of its body. The outward appearance of the embryo at this stage is that of a little body tapering to a tail, the tail being fixed to the wall of the ovum, and constituting the body-stalk, and so its hind end forms a curve. The condition of the alimentary canal in this stage is likewise simple. From the large yolk-sac the hind-gut runs backwards into the body-stalk, where it becomes continuous with the allantois. There is no difference between hind-gut and allantois, and in the curving body-stalk they form a dilated chamber, which is curved into a "U-shaped bend". (Fig. 13.)

'The allantois is not then, at this stage, a ventral bud from the hind-gut, but is its direct continuation, and is only marked off from it by a thickening of the wall, serving to subdivide the terminal dilatation. There is no hind-gut posterior to the origin of the allantois, and this is an important fact.

'In the next stage, which is represented by many well-described embryos, a great change has taken place, for now the body-stalk ceases to be the posterior termination of the body of the embryo. The body-stalk becomes ultimately the umbilical cord of the foetus, and so, from being the direct continuation of the posterior end, it afterwards occupies a ventral and somewhat anterior position. This change naturally produces



great alterations in the condition of the cavities situated within the hind end. The altered position of the body-stalk is brought about by the rapid backward growth of the hind end of the embryo, and in order to follow the changes with any degree of clearness it is necessary to take two landmarks, (1) the posterior termination of the allantois, and (2) the concavity of the "U-shaped bend".

'The first landmark, in the 12-somite embryo, is situated at the posterior end of the body, and in the foetus is at the umbilicus. The second landmark is in the 12-somite embryo the posterior limit of the body cavity, and in the foetus is the bottom of the recto-vesical pouch. It is therefore seen that the relations of the parts in the 12-somite

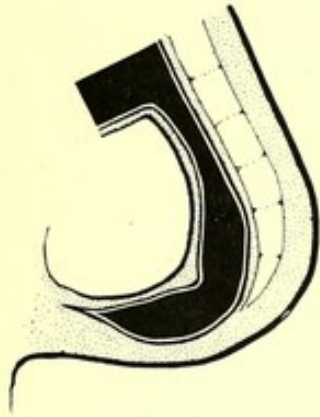

FIG. 13. Vertical section of a Human Embryo of 12-somites (Wood Jones).

The hind-gut is continuous with the allantois, and forms a U-shaped bend.

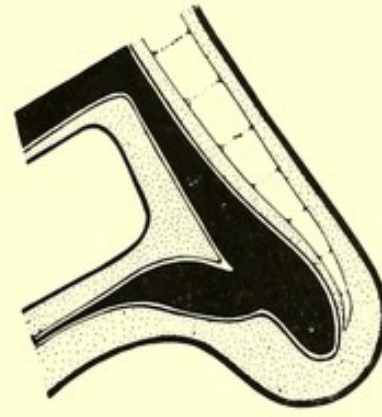

FIG. 14. Vertical section of an older Embryo (Wood Jones).

The post-allantoic gut is budding backwards in the growing hind end, and the allantois has become a ventral diverticulum.

embryo alter greatly with development, and it is necessary to follow the stages of the change.

'The growth at this period is a backward extension of the dorsal surface of the embryo, so that the posterior end shoots back past the body-stalk, and comes to extend free beyond it, and thus gives it its ventral position.

'The cavities within the hind end share in this change, and from the simple condition of the "U-shaped bend" the better recognized stage is brought about, in which the hind-gut extends posterior to the allantois, which thus becomes a ventral diverticulum from it. Now this backward growth of the hind-gut takes the form of a bud, which arises at the old junction with the allantois, and stretches backwards: I have called it the



“post-allantoic gut”, and it is in reality the growing hind-gut keeping pace with the growing hind end of the embryo. (Fig. 14.)

‘In the 12-somite embryo the connection between the allantois and the hind-gut is of necessity very small, and even at this stage there are distinct evidences of a separation of the two chambers, and this is increased with the backward budding of the “post-allantoic” gut. Ultimately the connection between the two is normally lost, partly by the infolding of the lateral walls, and partly by the rapid growth of the two portions of the “terminal dilatation”.

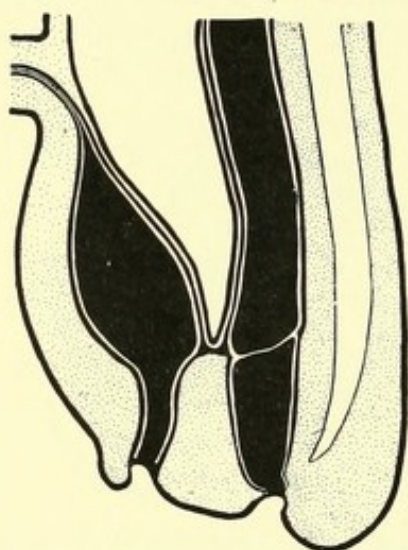


FIG. 15. Vertical section of a still older Embryo (Wood Jones).

The post-allantoic gut has met the proctodaeum, and has lost its connection with the allantois.

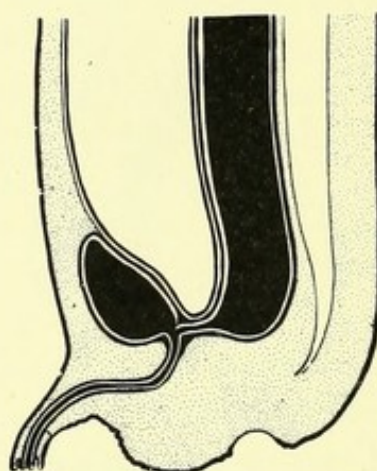


FIG. 16. Imperforate Rectum (Wood Jones).

The post-allantoic gut has failed to develop, and the communication with the allantois persists.

‘In this stage, therefore, we have a chamber—the post-allantoic gut, stretching backwards past the allantoic origin.

‘The next stage in the development of the rectum is the ingrowth of the proctodaeum, and its normal meeting with the lumen of the post-allantoic gut.’

**Post-anal or tail-gut.** As the tail grows out from the hind end of the embryo it draws with it a prolongation from the intestine, the tail-gut; even in mammals which are provided with long tails this prolongation extends to the extremity of the tail. It is extremely evanescent, disappearing under normal conditions at a very early period without leaving any permanent trace of its existence. Young and Robinson have



specially studied the development and morphology of the tail (*Brit. Med. Journ.*, 1904); they record the following interesting observation on the post-anal gut in certain mammalian embryos: 'Its existence is very transient, and its anterior and posterior parts remain for a time after its intermediate portion has entirely disappeared, indeed a solid cord of cells which represents the terminal portion of the post-anal portion of the gut continues to be formed by the undifferentiated tissue of the tail tip after the disappearance of the more anterior part of the tube has commenced.'

**Proctodaeum or anal depression** is the term applied to a little pit which appears early in the outer layer of the posterior end of the embryo, perforates the post-allantoic gut, and forms the permanent anal canal; its formation is so closely related with the formation of the genito-urinary outlet that they are best considered together.

If a human embryo of about five weeks is examined, the anal depression will be found in front of the tail, its edges being continued forwards as two ridges on either side, the external and internal genital folds; these unite in front, and between them is a little prominence, the genital tubercle, and the rôle played by these structures in further development has an important bearing on the study of congenital malformations. At this period there is no external differentiation of sex, and up to the tenth week the development is identical in both sexes, but from this on changes become apparent. In the male the genital tubercle elongates and forms the penis, the inner genital folds the urethra, and the outer folds the skin of the perineum, scrotum, and penis, the perineal raphé permanently marking this line of union. In the female the genital tubercle remains small and forms the clitoris, the inner genital folds the nymphæ, the opening into the vagina forming between them; the hymen, according to Bland Sutton, being the vestigial remains of this process. The outer genital folds form the skin of the perineum and the labia majora.

The actual development of the anal canal requires to be dealt with in a little more detail. The proctodaeum forms very early, and grows in towards the gut; as it grows the mesoblast is pushed aside until finally a membrane consisting of epiblastic and mesoblastic epithelium alone remains; this has been called the anal plate, or anal membrane; instead now of at once perforating, the anal plate becomes elongated into a cord of cells (Minot's *Embryology*, p. 190). This has been observed in the



embryo of the rabbit, sheep, and guinea-pig. As the tail becomes rolled round more towards the ventral aspect this cord of cells shortens until a membrane composed of two layers of epithelium again appears; this perforates and establishes the permanent opening. In the human embryo this opening takes place about the end of the fifth week, and

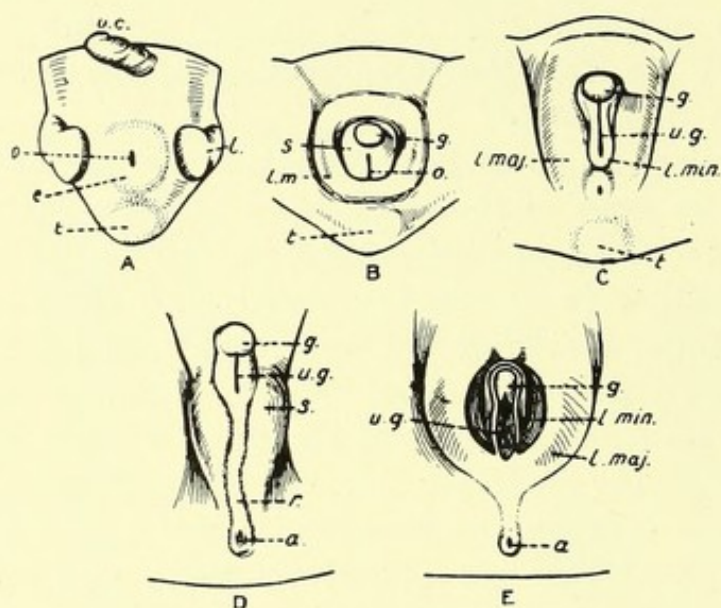


FIG. 17. The Development of the External Genital Organs, after models by Professor Ecker.

In the first stage, A, there is a single cloacal opening, *o*, surrounded by a circular ridge. In B this ridge has become differentiated into *g* the genital eminence, *s* the inner genital fold, and *l.m.* the outer genital fold. So far there is no external indication of the sex of the foetus. In C the female type is becoming apparent: the genital eminence is becoming the glans clitoridis, the inner genital folds the nymphae, the outer genital folds the labia majora, and the anus appears as a separate opening. E shows a more complete development of the female genitalia, the clitoris having decreased in size. In D the formation of the male genital organs is seen: the genital folds have joined in the middle line behind to form the scrotum and posterior urethra, the line of junction being marked by a prominent raphé; the anterior urethra has not yet completely closed, a slit marking the remains of the urogenital sinus. The penis is developing from the genital eminence. *a.* Anus. *o.* Cloacal opening. *g.* Genital eminence or glans. *l.m.* Outer genital fold. *l.* Lower limb. *l.maj.* Labium majus. *l.min.* Labium minus. *r.* Raphé. *s.* Inner genital fold in B, scrotum in D. *u.c.* Umbilical cord. *u.g.* Uro-genital sinus. *t.* tail.

the vestigial remains of the anal plate are to be found at the pectinate line as the anal valves (see p. 6).

**The bladder**, as has been already noticed, is formed from a portion of the intra-embryonic allantois, and has therefore during early embryonic life a free communication with the intestine; the recto-urethralis muscle, described by Henle, which comes to be of importance in perineal prosta-

tectomy and excision of the rectum, is, according to Wood Jones, probably the vestigial remnant of this communication.

**The uterus** is formed by a coalescence of the Müllerian ducts, which are formed quite independently of the intestine and are of epiblastic origin. The vagina, according to Wood Jones, is developed by the formation of a cord of cells in the indifferent tissue of the mesoblast, which subsequently becomes canalized.

Having now sketched in brief outline the more important points in the process of development of the rectum and anus, we are in a position to approach the study of the congenital malformations with a prospect of being able to classify the very varied conditions met with upon an embryological basis, indicating as far as possible how they have originated in the failure of certain steps in the developmental process, or sometimes in the persistence of conditions which should normally have become obliterated during development.



## CHAPTER III

### DEVELOPMENTAL DEFECTS. VARIETIES

ARREST or irregular development of—

- |                               |   |   |
|-------------------------------|---|---|
| 1. Hind-gut.                  | { | Absence of rectum and entire large intestine, with faecal outlet at umbilicus.  |
| 2. Post-allantoic gut.        | { | Imperforate rectum.<br>„ posterior urethral outlet.<br>„ vesical outlet.<br>„ vaginal or uterine outlet.<br>„ spinal outlet.  |
| 3. Proctodaeum.               | { | Imperforate anal canal.<br>„ vulvar outlet.<br>„ anterior urethral outlet.<br>„ perineal, scrotal, or sub-urethral outlet.<br>Anus well formed, but ending in cul-de-sac.<br>Irregular development of anal canal other than occlusion.<br>Uro-genital outlet in rectum. |
| Persistence of post-anal gut. | { | Remnant of post-anal gut as diverticulum.<br>„ „ as congenital tumour.  |

**1. Arrest or irregular development of hind-gut.** The hind-gut, as previously noted, is all that portion behind the communication with the yolk-sac, which eventually forms the entire large intestine and portion of the ileum. In the adult no indication of what was mid-gut normally remains, but its position is not infrequently marked by a congenital malformation, the diverticulum of Meckel, which is usually found in the ileum tolerably near its termination. If, then, the hind-gut has not developed, we find the rectum and other portions of the large intestine absent in whole or part, or rudimentary, and the small intestine ending in (1) a cul-de-sac, or (2) having an opening at the umbilicus from persistence of the vitelline duct. The case from which Figs. 18 and 19 are taken illustrates this condition. A child aged 3 months



was brought to Sir Patrick Dun's Hospital with imperforate rectum and anus, extroversion of the bladder and urachus to the umbilicus, and an opening between the ureters, through which faeces escaped freely, and through which the intestine prolapsed. The child was in a miserable state, and died shortly after admission, no operation having been attempted. At *post-mortem* examination it was found that the rectum, entire colon, meso-colon, and caecum were absent; the ileum, apparently normal,

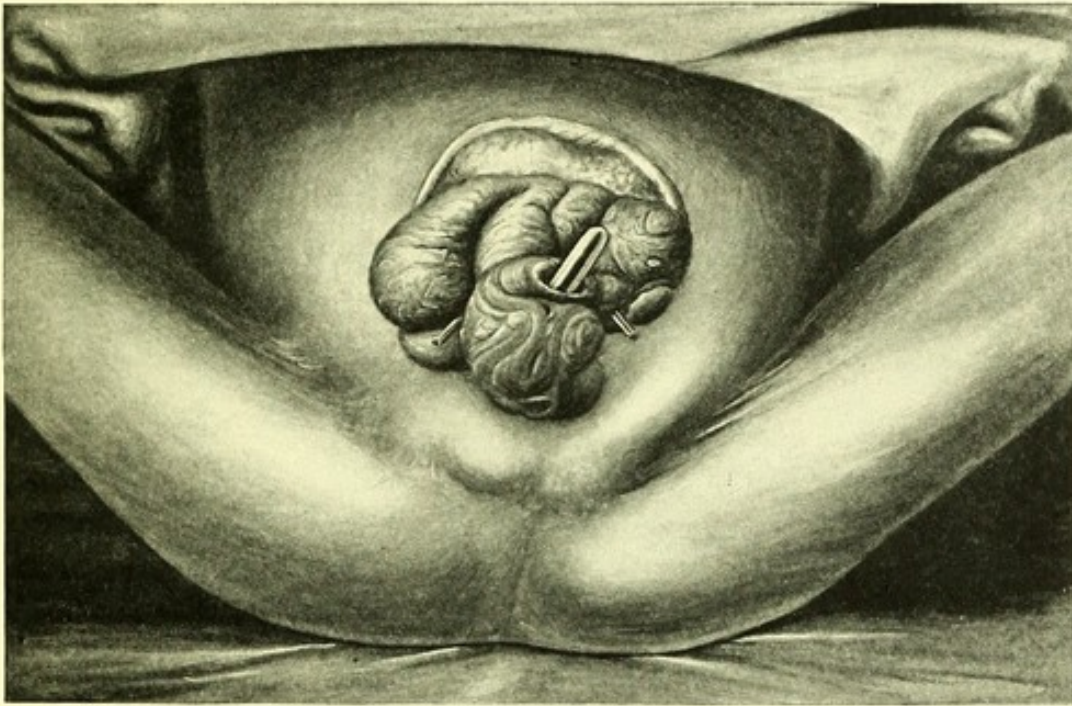


FIG. 18. Imperforate Rectum and Anus, Absence of External Genital Organs, and Extroversion of the Bladder.

The two small probes indicate the openings of the ureters on the exposed surface of the bladder. The large probe in the centre lies in an opening through which faeces escaped and through which several inches of intestine occasionally prolapsed.

(From a stereo-photograph of a child aged three months at Sir Patrick Dun's Hospital.)

opened through the extroversion, and was continued beyond the opening as a short contracted diverticulum like a vermiform appendix, the sole remnant of the hind-gut. Cases of this kind are usually associated with other developmental defects, and in the case described the liver and kidneys were also malformed. Even if born alive such children seldom survive long, and are beyond the scope of surgical treatment.

**2. Non-development of post-allantoic gut.** Imperforate rectum is one of the commonest forms of malformation met with in this region, and in a great majority of cases the termination of the bowel



as an open tube is in the same position, that is, on a level with the peritoneal reflexion (Figs. 20 and 21). Wood Jones considers that this is due to failure of the hind-gut to bud out as post-allantoic gut, and there is strong evidence in support of this contention: (1) the frequency with which this condition is associated with fistulous opening into the bladder or prostatic urethra (permanent allantoic opening); (2) when no fistula exists there is usually found a fibro-muscular cord in the same position; (3) there is often associated with imperforate rectum irregular development of the bony framework of the pelvis, of which the following have been recorded. The tubera ischii may be too close together, the coccyx

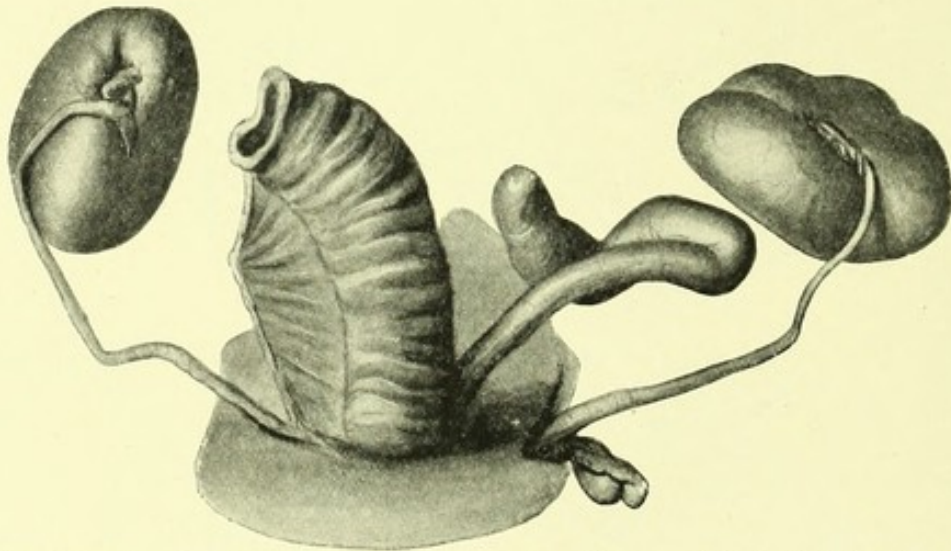


FIG. 19. Specimen removed *post mortem* from the case illustrated in Fig. 18.

The ileum, with a portion of mesentery attached, is seen entering the back of the bladder. The only remnant of the rest of the small, and of the entire large, intestine is a narrow cul-de-sac, like a vermiform appendix. The kidneys are malformed, but the ureters are normal.

absent, or the sacrum malformed, indicating abnormal growth of the hind end of the embryo, upon the proper development of which the production of the post-allantoic gut depends.

Imperforate rectum may be associated with imperforate anus, or the anal canal may be well formed but ending in a cul-de-sac, and where no adventitious opening exists complete intestinal obstruction is the result. If associated with imperforate anus this condition is usually recognized early, as the non-passage of faeces leads to inspection, and imperforate anus is readily detected; but if the anus appears to be normal the infant will probably be dosed with purgatives, and it is only when meteorism and faecal vomiting supervene that the existence of grave



intestinal obstruction is suspected. It is often then too late to save the infant's life by operation. In every case in which an infant's bowels have not moved during the first twenty-four hours of its life a careful examination should be made. If the anus appears to be normal, the introduction of a probe or the well-greased tip of the little finger will readily determine whether the anal canal is patent or a cul-de-sac. If

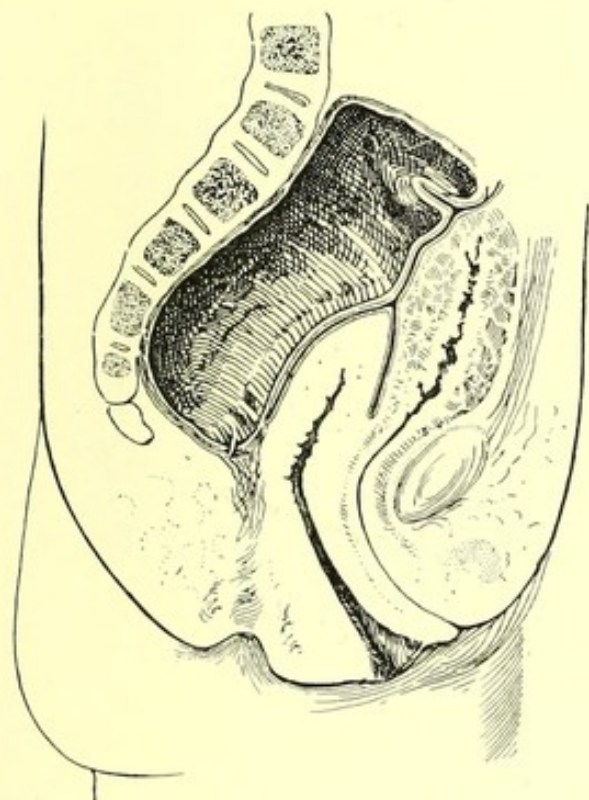


FIG. 20. Mesial section of an Imperforate Rectum.

The rectum terminates at the level of the cervix uteri; the anus is well developed.

(From a frozen section made by Professor A. F. Dixon.)

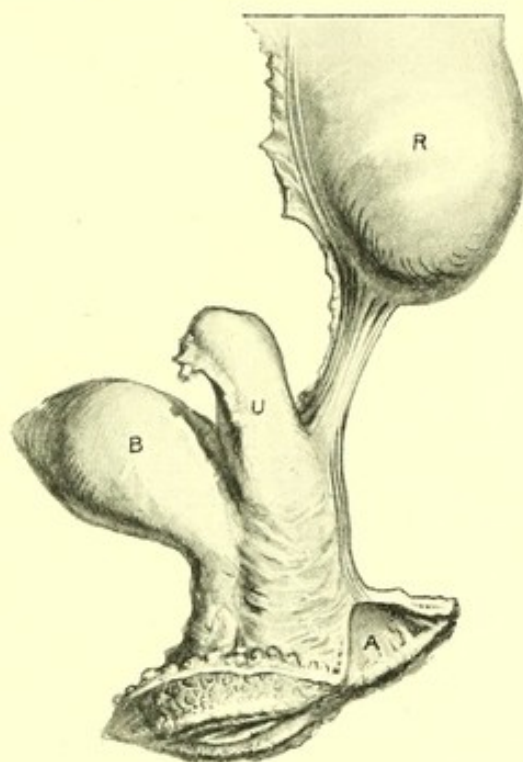


FIG. 21. Dissection of an Imperforate Rectum.

The rectum, R, ends in a pouch which is attached by a firm fibro-muscular cord to the back of the vagina at the level of the cervix uteri, and continued down to the apex of the anal depression, A. U. Uterus. B. Bladder.

(From a specimen in the Pathological Museum of Trinity College, Dublin.)

the distended rectum cannot be felt from the perineum, and if no impulse can be detected when the child cries, the case is probably one of imperforate rectum, and the diagnosis will be further confirmed if any of the abnormalities of the bony pelvis previously noted are present. The treatment of imperforate rectum is more conveniently considered, together with that of other forms of malformations, in a separate chapter (see p. 52).



**Imperforate rectum with posterior urethral outlet** is one of the varieties which has been frequently noted, but it appears to be quite useless to attempt to collect from published cases reliable statistics as to the relative frequency of the various forms of congenital malformation. Probably a considerable number of infants die annually from intestinal obstruction, the result of imperforate rectum, without the exact condition having been ascertained. If, however, this malformation is associated

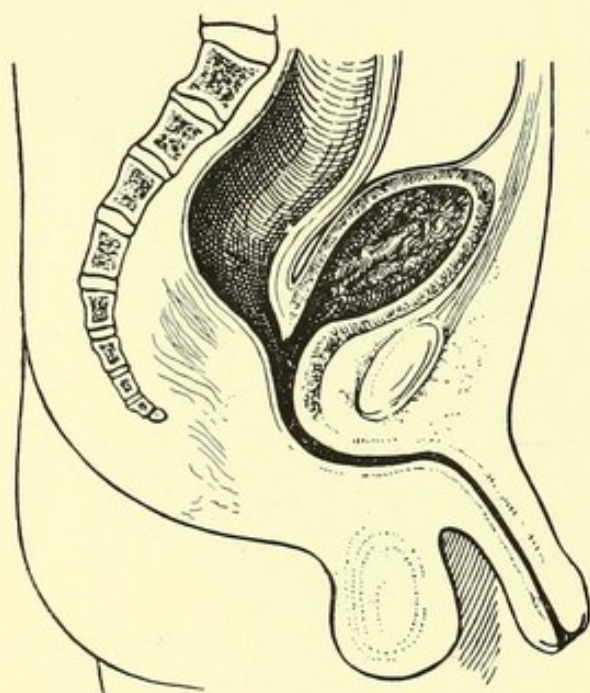


FIG. 22. Diagram of Imperforate Rectum with Outlet in the Posterior Portion of the Male Urethra.

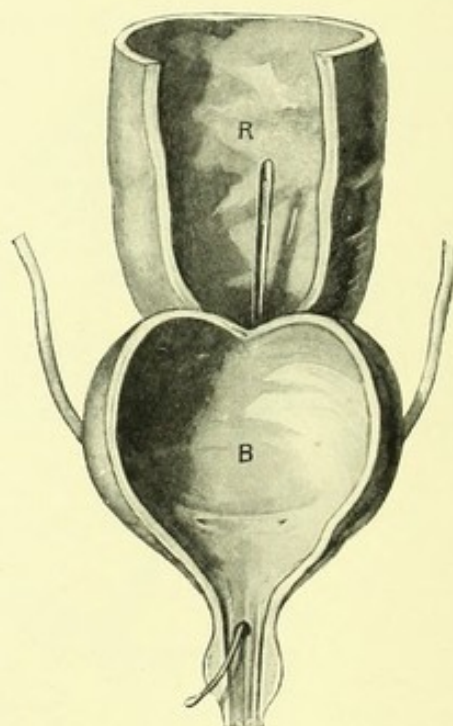


FIG. 23. Dissection of an Imperforate Rectum with Posterior Urethral Outlet.  
R. Rectum. B. Bladder. A probe indicates the passage from the rectum to the prostatic urethra.  
(From a specimen in the Pathological Museum of Trinity College, Dublin.)

with others where the condition is rendered obvious, such as in the one under consideration, by the fact of meconium passing per urethram, it is sure to attract notice, and the case is likely to be recorded. In like manner deductions drawn even from large statistics as to the percentage of children born with congenital malformations of the rectum are not alone useless, they are misleading.

The communication between the rectum and prostatic urethra, there can be little doubt, is due to the persistence of the communication which



exists in early embryonic life between the hind-gut and allantois; the opening is usually too small to permit of efficient faecal evacuation, but the escape of flatus and constant dribble of meconium per urethram clearly indicate the nature of the case and serve to delay the appearance of symptoms of intestinal obstruction.

**Imperforate rectum with vesical outlet.** This variety is in its origin similar to that last described—persistence of the allantoic

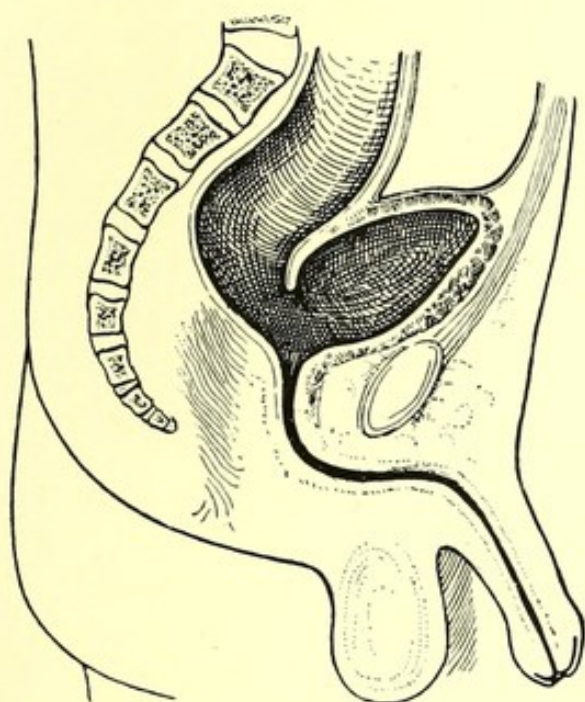


FIG. 24. Diagram illustrating Imperforate Rectum with Vesical Outlet.

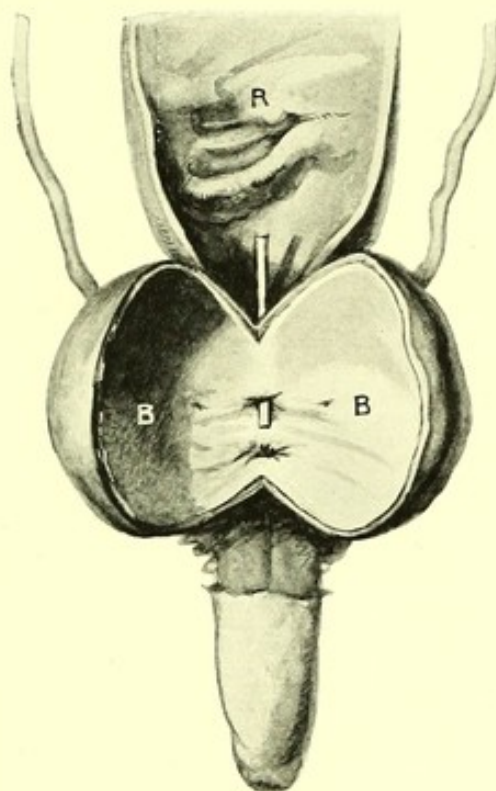


FIG. 25. Dissection of an Imperforate Rectum with Vesical Outlet.

The opening from the rectum, R, to the bladder, B, is indicated by a glass rod. The vesical orifice is situated between the two ureters.

(From a specimen in the Pathological Museum of Trinity College, Dublin.)

opening. Both bladder and prostatic urethra are of allantoic origin, and we have no knowledge of what determines the precise position of the opening. There is, however, one important clinical difference between the two: when the opening is in the prostatic urethra and is tolerably free there is a constant dribble of meconium from the urethra, but where the opening is in the bladder it becomes intimately mixed with



the urine, and voided with it. In the latter case also, if the opening is free enough to obviate intestinal obstruction, it is tolerably certain to soon start fatal disease of the kidneys, by ascending ureteritis.

**Imperforate rectum, with vaginal or uterine outlet.** The

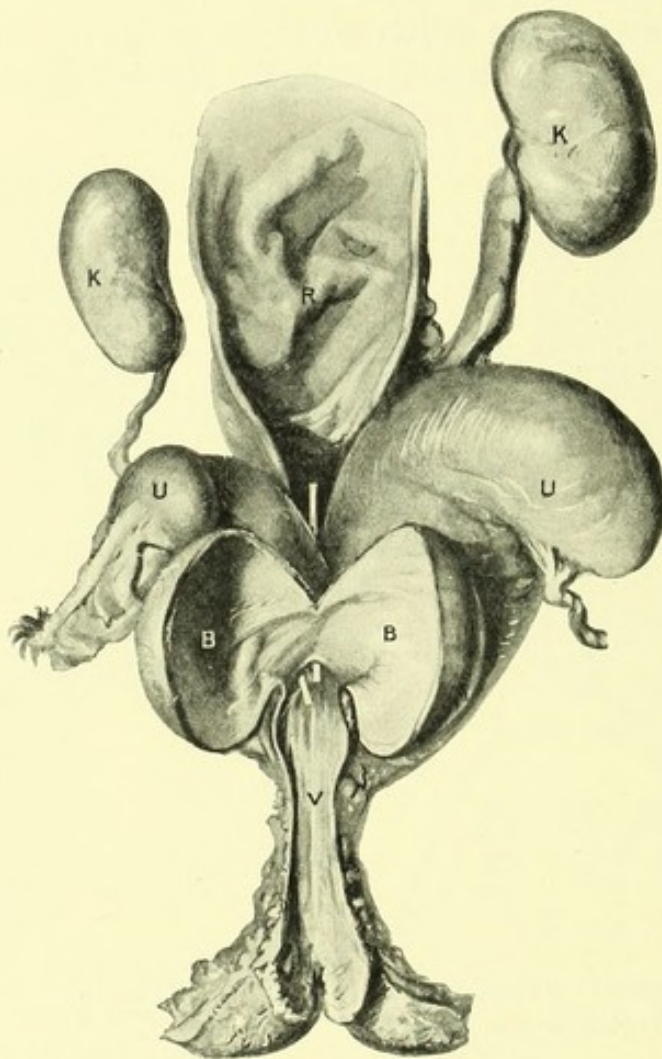


FIG. 26. Dissection of an Imperforate Rectum with Vaginal Outlet.

The rectum opens into the top of the vagina, indicated by central glass rod. The uterus is double, and each uterus receives the ureter of the corresponding side; neither of the ureters open into the bladder. The right uterus communicates with the vagina, indicated by the lateral glass rod, but the left uterus has no such communication; it, together with the ureter and the kidney on the same side, is in consequence much distended by retained urine. K. Kidney. R. Rectum. U. Uterus. B. Bladder. V. Vagina.

*(Drawn from a specimen kindly placed at the author's disposal by Professor E. J. McWeeney.)*

large proportion of cases recorded in literature as vaginal outlet, in connection with imperforate rectum, probably ought more accurately to be described as vulvar outlet, which is one of the commonest forms of



malformation met with. A congenital faecal outlet in the vagina proper is extremely rare, so much so, that its existence has been doubted by some authorities. When we consider the totally different embryological origin of the rectum and utero-vaginal tract, the rarity of a communication being found between them at birth becomes at once apparent. There can, however, be no doubt of its occasional existence. Dr. McWeeney kindly afforded me the opportunity of examining the case from which Fig. 26 is taken. It will be seen

that the rectum is imperforate, the uterus double, each ureter opens into the corresponding half of the bifid uterus, the bladder is a closed sac, without ureteral or urethral openings, and the rectum opens by a narrow tract into the top of the vagina, between each of the uteri. Dr. Klein showed me a somewhat similar case with double uterus, and an interesting case is recorded by Ahlfeld (*Die Missbildungen der Menschen*) in which a female, with anus and vulva normal, had a double vagina, one of which communicated with the rectum. A few other cases with double uterus and vaginal outlet to rectum are to be found in literature, which would appear to indicate that a want of coalescence between the Müllerian ducts to form the normal uterus is a frequent if not constant condition associated with true vaginal outlet to imperforate rectum.

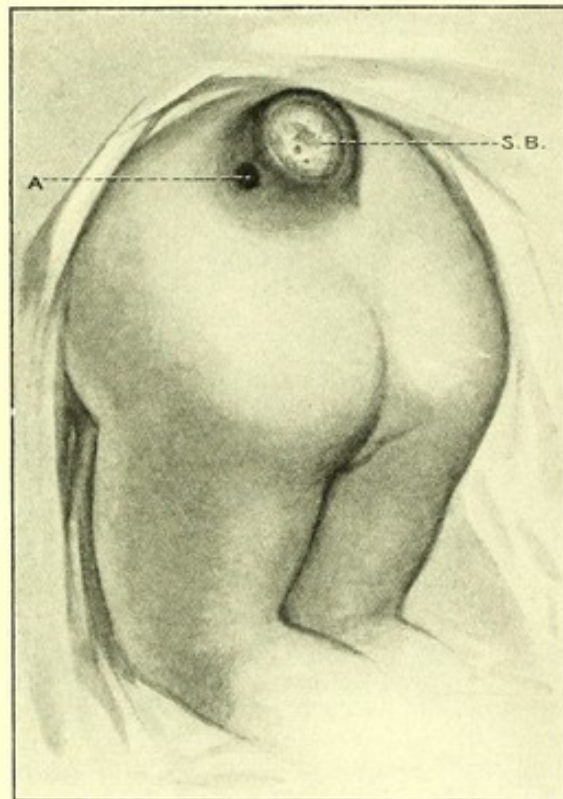


FIG. 27. Imperforate Rectum with Spinal Outlet.

The child had a large spina bifida, S.B., the surface of which was ulcerated. At the left side of the spina bifida there was an orifice, A, through which all the faeces passed. The anus was undeveloped. (From a drawing made from a patient under the care of the late Mr. W. I. de C. Wheeler.)

**Imperforate rectum, spinal outlet.** Among the recorded cases of congenital malformation are to be found a few in which it is stated that the outlet was through an aperture in the sacrum, but in none of them is much detail given. The late Mr. W. I. de C. Wheeler kindly



gave me a sketch (Fig. 27) of a case that occurred in his practice many years ago, in which a child with an imperforate rectum had also a spina bifida with an opening at the side of it through which faeces passed. The child lived a few months, but no *post-mortem* examination could be obtained. Such cases are susceptible of no other explanation than the persistence of a neurenteric canal, and are of extreme interest, as indicating that a purely embryonic structure which exists for such a short time may occasionally continue permanently.

3. Arrest or irregular development of proctodaeum. The

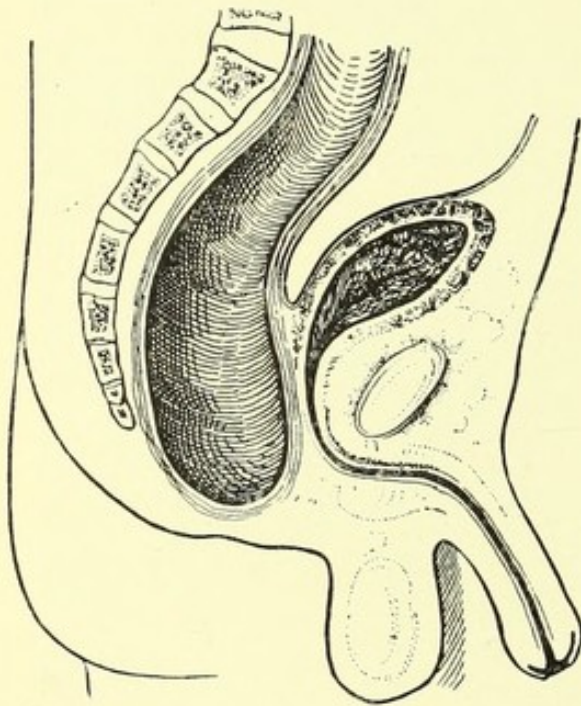


FIG. 28. Diagram of Imperforate Anal Canal.  
The post-allantoic gut is well developed, but the proctodaeal portion of the anal canal is undeveloped.

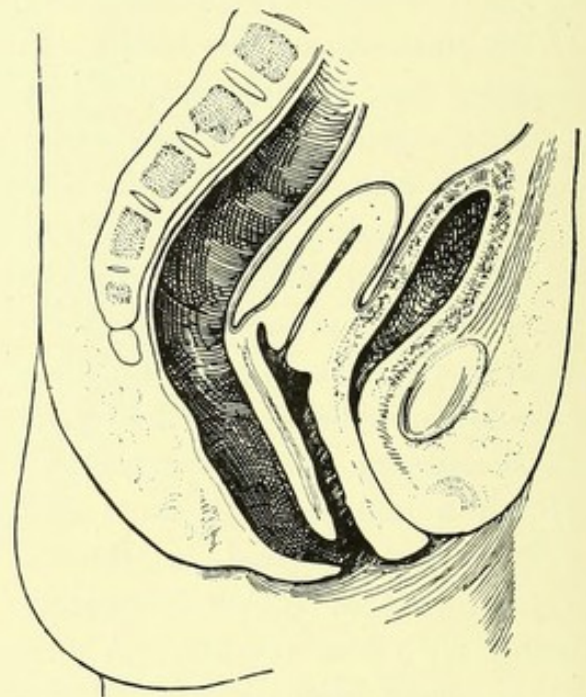


FIG. 29. Diagram of Imperforate Anal Canal with Vulvar Outlet.

proctodaeum forms the anal canal as far as the pectinate line, and where it is absent or fails to effect union with the hind-gut we have the condition known as imperforate anus, of which there are several varieties to be considered.

**Imperforate anal canal**, in its most complete form, indicates that the proctodaeum is quite undeveloped; in such cases we find no trace of anus, the median raphé of the perineum being continued back to the coccyx, or possibly the normal site of the anus is marked by a shallow depression, or a wart-like prominence. This condition is not infrequently



associated with imperforate rectum, while in other cases the post-allantoic gut has developed well, and formed a normal rectum, the proctodaeum alone being at fault. It is a matter of considerable importance to determine this point. If there is a normal rectum distended with meconium, it may form a prominence in the perineum which can be seen or felt, and an impulse may be detected when the child cries.

When considering the question of imperforate rectum we noted that, while in some cases the obstruction was complete, in others a faecal

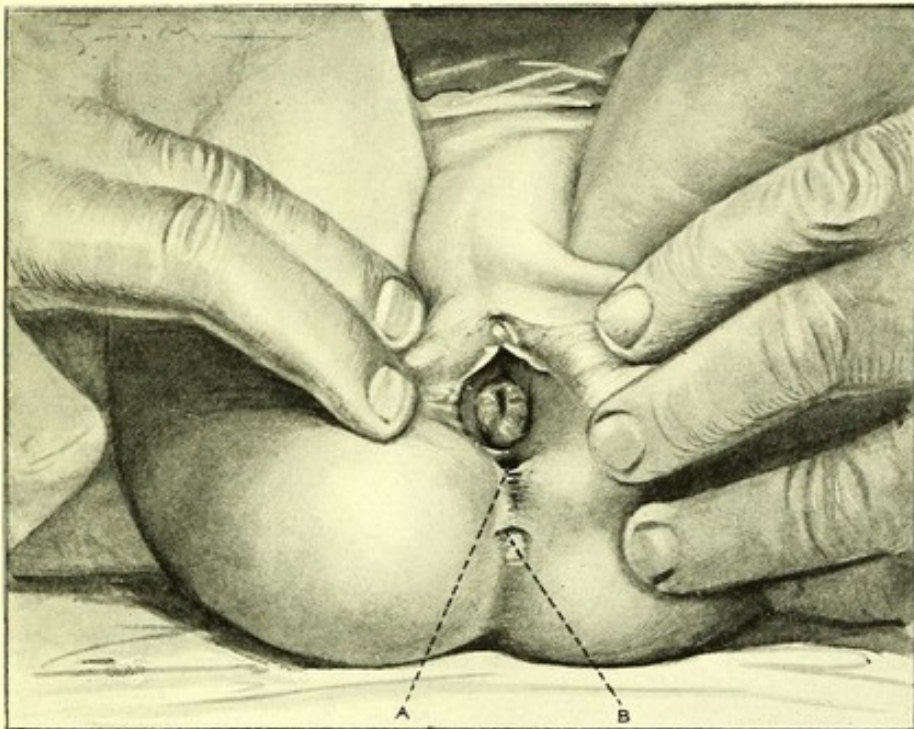


FIG. 30. Imperforate Anal Canal with Vulvar Outlet.

A. Abnormal opening of bowel. B. Normal situation of opening marked by a shallow dimple.  
(From a stereo-photograph of a case at Sir Patrick Dun's Hospital.)

outlet was provided, the more frequent of these being due to persistence of the allantoic opening. So in cases of imperforate anus we meet with cases of complete obstruction, while in others an outlet is provided. These, however, have no connection with the allantoic opening, but are to be explained by involvement of the end of the bowel in the genital folds which form the external genital organs. In these cases the outlet may be found in the vulva in the female, in the anterior urethra in the male, in the perineum, scrotum, or skin of the penis.

**Imperforate anal canal, vulvar outlet.** In the female the



genital folds coalesce to form the skin of the perineum, but remain separate as the labia majora and nymphae of the vulva, so that if they include posteriorly a prolongation of the rectum, the opening will be found in the vulva. This variety is in its method of production similar to the anterior urethral outlet in the male, the difference being due to the different development of the genital folds in the sexes.

Imperforate anus with vulvar outlet is one of the commonest forms of malformation met with, most of the cases described as vaginal opening being probably of this nature. It appears also to be relatively more frequent than other forms, from the fact that it is probably much the most usual one in which an abnormally placed anus may functionate quite efficiently. There are numbers of cases recorded (and I have had one in my own practice) in which women grew up, were married and had children, quite unaware that they suffered from any malformation, having perfect control over their vulvar anus.

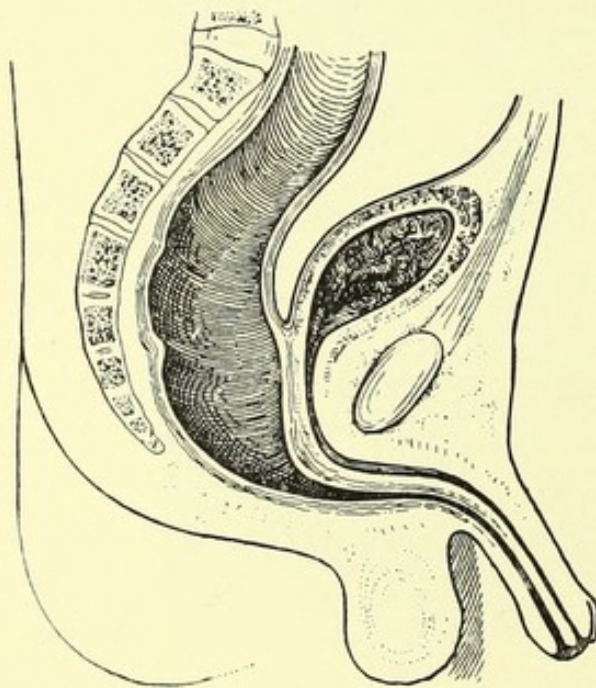


FIG. 31. Diagram of Imperforate Anal Canal with Sub-urethral Outlet.

**Imperforate anal canal, anterior urethral outlet.** In the male, if a prolongation from the termination of the rectum becomes enfolded in both genital folds, it is possible for an opening to exist in the anterior urethra

communicating with the rectum, and some such cases are described. In most, however, of the cases recorded of 'Atresia Ani Urethralis' the descriptions are so imperfect that it is difficult to distinguish whether the opening originated as a persistent allantoic opening or an inclusion by the genital folds. If the opening is in the prostatic urethra the former, and if in the anterior urethra the latter, is, I am sure, the true explanation. Clinically, one symptom is common to both, viz. the passage of flatus and dribbling of meconium from the urethra, but it ought usually to be possible to determine whether this symptom is associated with imperforate rectum or imperforate anus, and thus



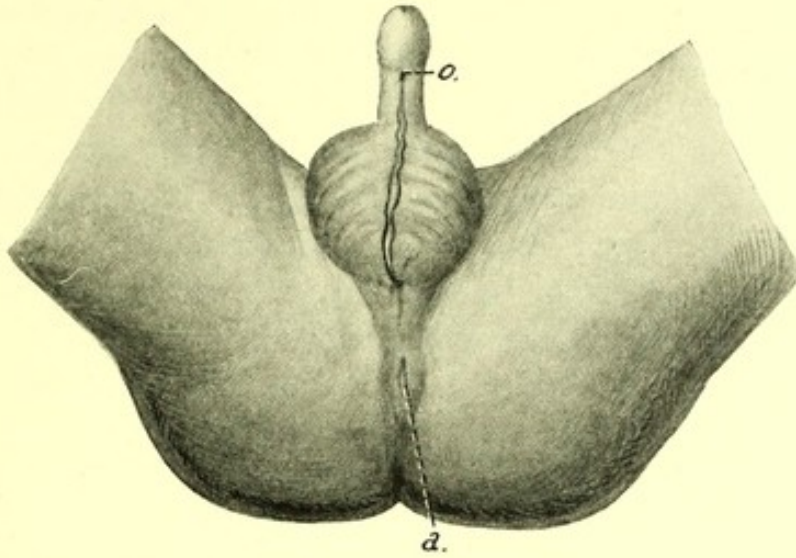


FIG. 32. Imperforate Anal Canal with Sub-urethral Outlet.

*o.* abnormal outlet of intestine situated under the prepuce. *a.* normal position of anus which was undeveloped. A subcutaneous track extends from the rectum to *o.*

(From Cruveilhier's plate.)

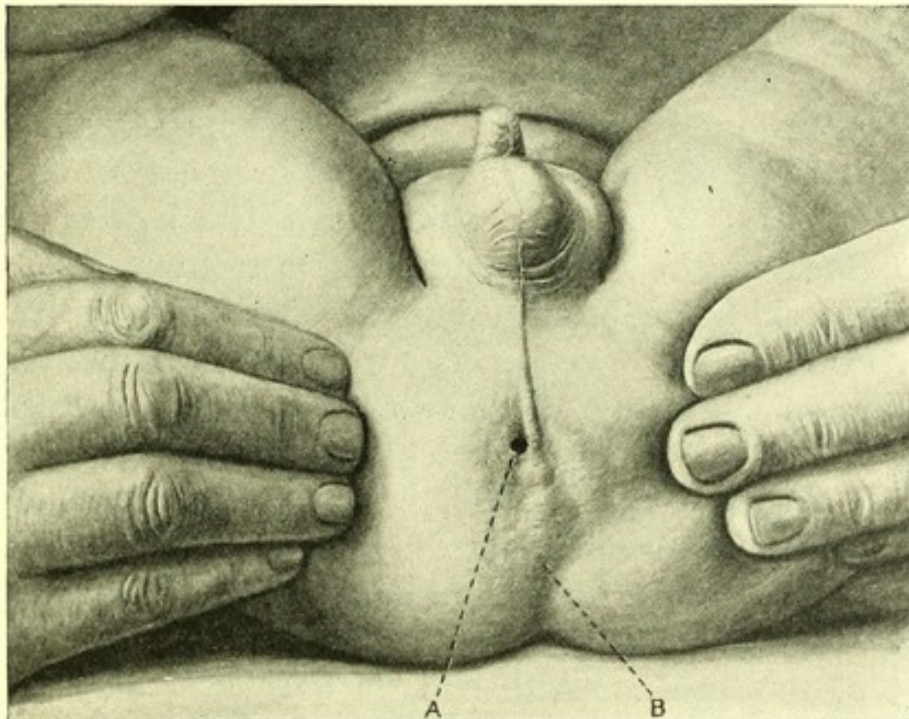


FIG. 33. Imperforate Anal Canal, Perineal Outlet.

The perineal raphé is continued over the normal site of the anus to B. The abnormal opening, A, is in front of the normal site, and to the right of the perineal raphé.

(From a stereo-photograph of a case at Sir Patrick Dun's Hospital.)



establish the position of the urethral opening. The opening is generally insufficient to provide for complete faecal evacuation.

**Imperforate anal canal with perineal, scrotal, or sub-urethral outlets.** Where a prolongation from the rectum is included between the external and internal genital folds, instead of being covered in by both, as in the previous cases, we may have the outlet in the perineum, margin of vulva, scrotum, or underneath the urethra in the penis. The classical case of this kind is the one described by Cruveilhier, where in a case of imperforate anus the rectum was continued as a narrow subcutaneous channel under the raphé of the perineum, over the scrotum, and up the penis to an orifice at the fraenum of the prepuce. Such complete cases as this have been rarely seen, but in a less degree they have been more frequently recorded. Fig. 33 is taken from a patient of mine where the median raphé was continued over the site of the normal anus, and the outlet was to the side of the raphé a short distance in front of its normal site.

It is probable that sometimes a prolongation from the rectum may be included in the genital folds without any outlet being provided, thus forming a diverticulum from the anal canal. The following case appears to be of this nature: I saw in 1886, in conjunction with my colleague Professor Finny, a medical man in this city, who, having suffered for some days from an intermittent fever, developed an inflammatory swelling at the root of the penis and deep in the scrotum. He told us he had suffered from some pain while the bowels were being moved, and asked me to delay examining the rectum till he was under ether. Upon making an incision into the swelling a gangrenous and abominably foetid abscess was opened, apparently in connection with the left crus penis. Passing my finger into the rectum, I was surprised to find a membranous stricture immediately within the anus, through which, however, the finger readily passed, and above it I could detect a diverticulum of the rectum passing off in the direction of the situation of the abscess. I forcibly dilated the anus and membranous stricture; subsequently faecal matter in small quantity passed from the wound at the root of the penis. Although he developed septic pneumonia and other symptoms of wound infection, he eventually, after a protracted and severe illness, made a good recovery. After the operation we were informed by his mother that he had been born imperforate, and was operated upon by the late Dr. Fleetwood Churchill. There was never



any mixture of faeces with the urine. He has since remained quite free from any trouble, and I believe the diverticulum has been obliterated by the inflammation, the process resembling an acute attack of appendicitis.

**Anus well formed, but ending in cul-de-sac.** The proctodaeum may develop a normal-looking anus which may be found to be imperforate at the level of the pectinate line; this condition is sometimes associated with imperforate rectum, but in others the rectum has been well developed, nothing but a membranous septum separating the two. This membrane may even be protruded through the anus when the infant makes violent straining efforts to pass faeces, in other cases the

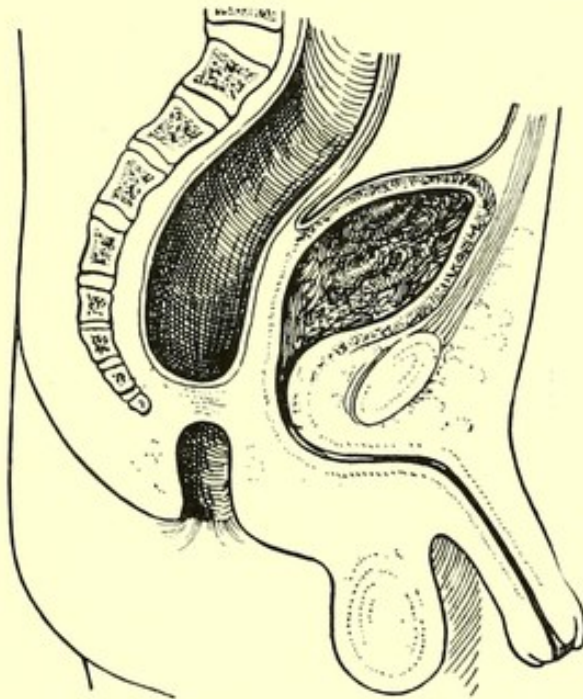


FIG. 34. Diagram showing Anus well formed but ending in a cul-de-sac.

anal canal may be conical, ending in a solid fibro-muscular cord attached to the rectum; this condition is interesting, and receives a possible explanation from the changes which the anal plate has been observed to undergo in certain animals before direct communication is established (see p. 29). In other instances the proctodaeum appears to have 'missed its way', passing up at the side of the rectum instead of directly opening it up. These observations conclusively show that the theory at one time advanced, that these malformations were the result of intra-uterine inflammatory adhesions, is untenable.



### Irregular development of anal canal other than occlusion.

The proctodaeal process may be so small that, although pervious, it does not form an efficient anal canal; in these cases we may thus have a congenital stricture which is probably more frequent than is usually thought

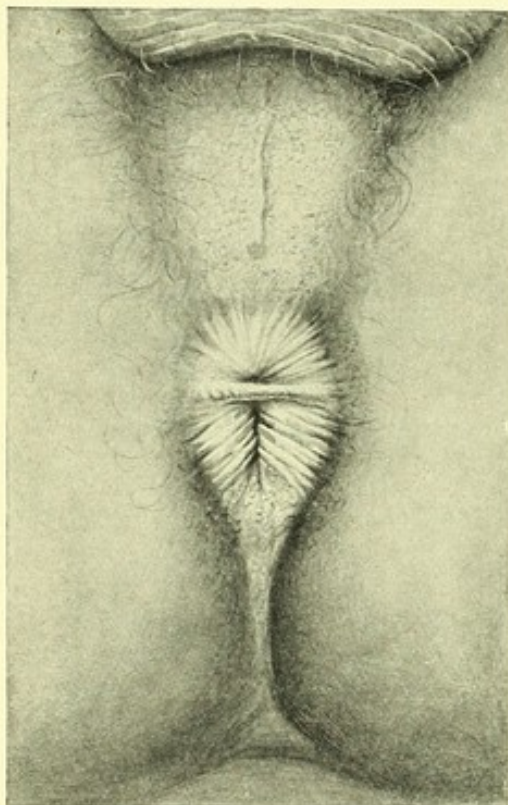


FIG. 35. Anus divided into two openings by a Lateral Ridge.

(From sketch of a case seen at Sir Patrick Dun's Hospital.)

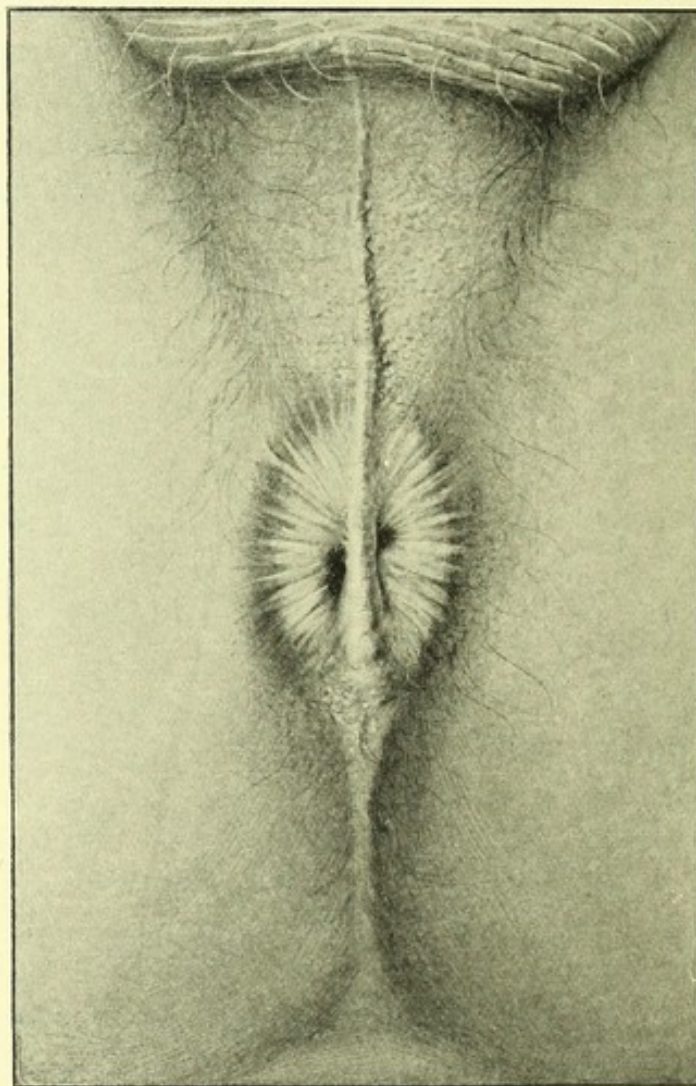


FIG. 36. Prolongation of the Perineal Raphé back to the Coccyx, dividing the Anus into two openings. The opening on the right side was the largest, and through it the faeces passed.

(From sketch of a case seen at Sir Patrick Dun's Hospital.)

to be the case. It may also develop more than a single opening; these openings may be placed laterally, the median raphe being continued as a cord across the anus, or a band may pass from side to side leaving



one opening in front of the other. When one of these openings is much larger than the other the case may be mistaken for fistula, but of course the fact that they are both completely lined with epithelium should settle the diagnosis. The anal depression, instead of normally opening into the rectum, may have an orifice in the vulva, the classical case of Amussat which he describes as a vaginal opening being probably of this nature.

**Uro-genital outlet in rectum.** We have seen that the outlet of the rectum in the genito-urinary tract, both in imperforate rectum and

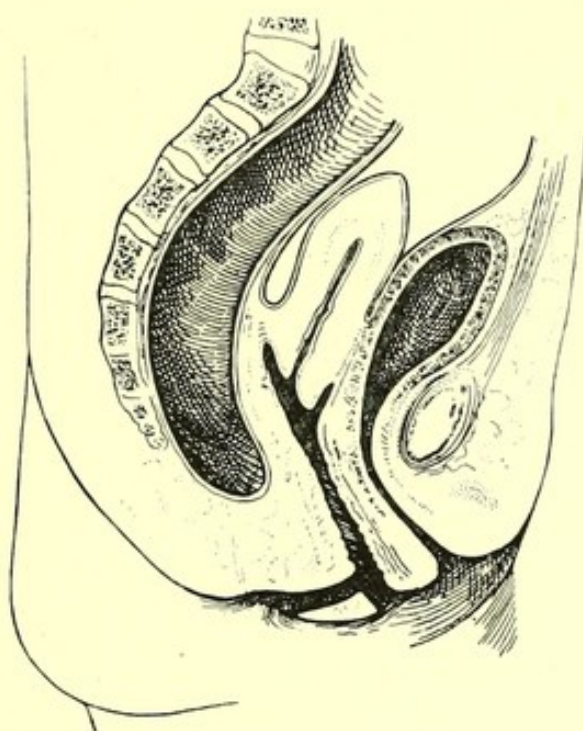


FIG. 37. Diagram of Imperforate Anal Canal, the Anal Depression opening into the Vulva instead of into the Rectum.

imperforate anus, is not infrequent, and the converse condition in which there is failure in development of the normal genito-urinary opening with an outlet in the rectum has been occasionally noted, but is extremely rare. Its embryological significance appears to be similar, and does not demand further consideration here.

**Remnant of post-anal gut** may appear as a **rectal diverticulum**. Fig. 38, taken from the rectum of a child aged 3 months, which was opened for anatomical purposes, shows a minute pit which is in all probability a remnant of a post-anal gut; it corresponds with the



attachment of the ano-coccygeal ligament, and suggests the possibility that this ligament is in reality a vestigial remnant of a post-anal gut.

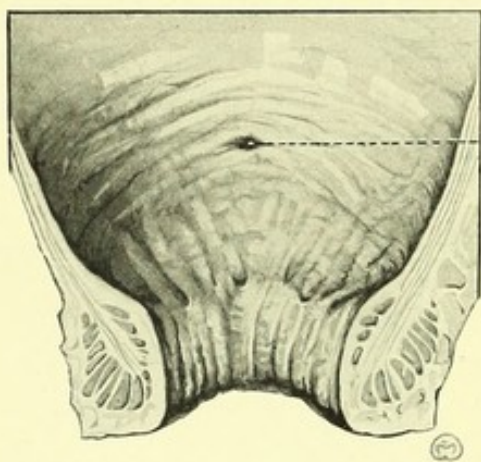


FIG. 38. Remnant of Post-anal Gut.

Found in the rectum of a child aged 3 months, which had been opened for anatomical purposes. P.A.G. Depression in posterior wall of rectum, vestigial remains of post-anal gut.

are occasionally met with in the sacro-coccygeal region of the new-born.

A more definite diverticulum having a like origin was exhibited by Mr. Sinclair White at the British Medical Association meeting at Leicester (*Brit. Med. Journal*, September 30, 1905), and I am indebted to him for a stereo-photograph from which Fig. 39 was made. The diverticulum resembles a vermiform appendix attached to the back of the rectum; it was found in a case of cancer of the rectum, but obviously is unconnected with that disease.

**Congenital tumour.** New growths sometimes of enormous size

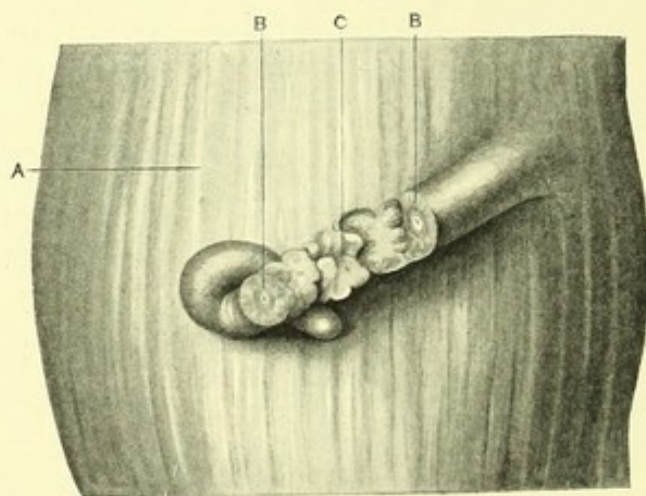


FIG. 39. Diverticulum from the Posterior Surface of the Rectum (persistent Post-anal Gut).

The central portion of the diverticulum has been cut away at B.B. for microscopical examination. The section removed shows the tissue, c, which attaches the proximal portion of the diverticulum to the wall of the rectum, A. The distal portion of the diverticulum is free and bent round upon itself. The structure is entirely below the peritoneal reflexion.

Microscopical examination of the section removed showed that all the coats of the bowel are present in the diverticulum, which has a narrow lumen. The interior of the rectum is occupied by a cancerous growth which is unconnected with the diverticulum.

(From stereo-photograph of a specimen exhibited at the British Medical Association Meeting at Leicester by Mr. Sinclair White.)



These tumours may present very varied characters, and pathologists have had much difficulty in coming to a conclusion as to their nature, from the fact that congenital growths in this region are probably of widely differing origin, some due to spina bifida in its various forms, some to dermoids and foetal inclusions, others have been supposed to originate in the coccygeal gland, while there is little doubt that a remnant of the post-

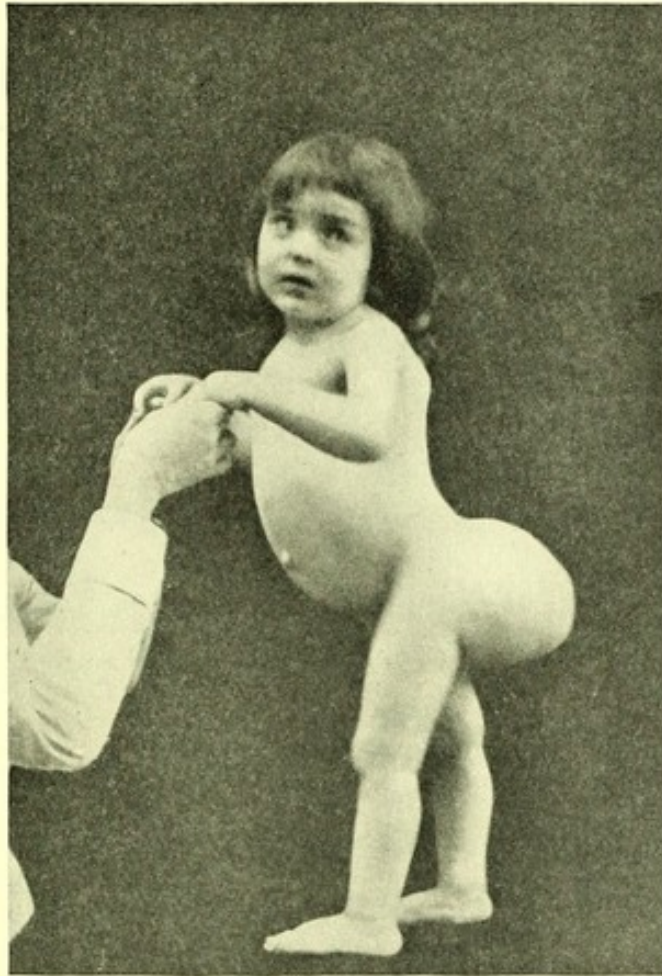

FIG. 40. A case of Congenital Sacro-coccygeal Tumour.

Under the care of Mr. F. T. Heuston, to whom the author is indebted for an opportunity of seeing the case and for the photographs here reproduced.

anal gut may be the origin of some of such tumours. It is with the latter alone that we are at present concerned.

The histological structure is very varied, but if in some portions of the tumour, at any rate, there is an irregular adenomatous arrangement of the cells suggesting their origin from mucous membrane, it is strong evidence in support of the theory that they have originated in the



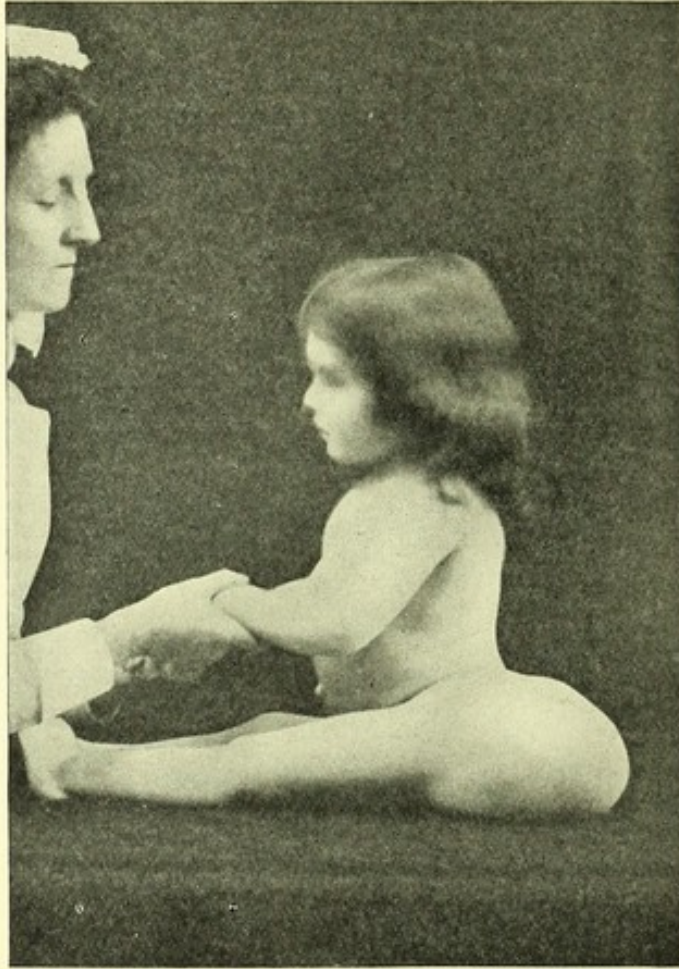

FIG. 41. Another view of Mr. Heuston's case of Congenital Sacro-coccygeal Tumour.

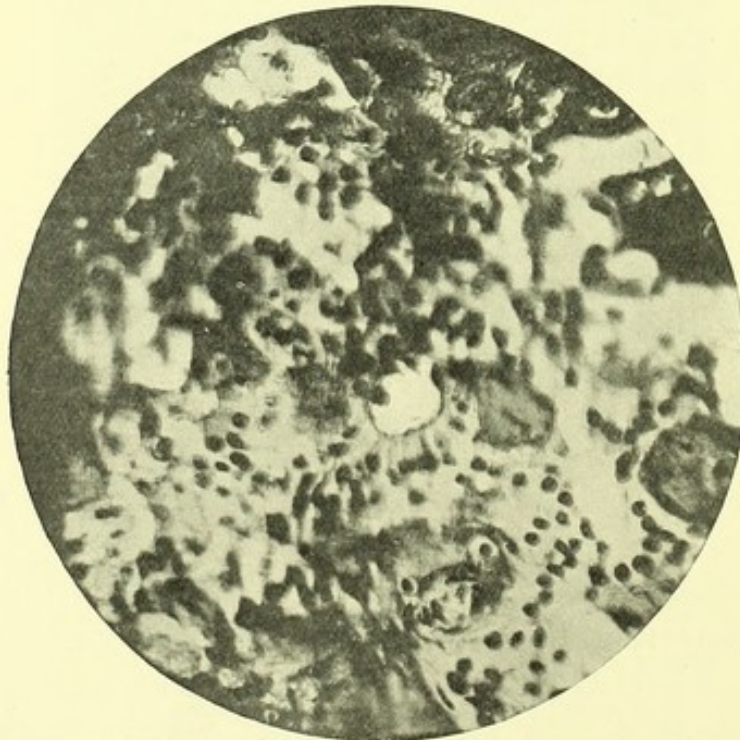


FIG. 42. Section of Congenital Sacro-coccygeal Tumour. The structure is indefinite, but in part shows an irregular adenomatous arrangement of the cells. (*Photo-micrograph*,  $\times 100$ .)



remnant of a post-anal gut. A curious and important fact about them is, that they are sometimes clinically malignant. In a case under my care some years ago, a tumour of this nature, of moderate size externally, but which pushed the rectum forwards, causing obstruction and retention of urine, was removed together with the coccyx and part of the sacrum. The child recovered well, but died some months afterwards, and at the *post-mortem* examination secondary metastatic tumours of like character with the primary growth were found in the liver and lungs (Fig. 42). Many of these tumours are so extensive even at birth that complete removal is impossible, and they tend to grow somewhat rapidly and soon prove fatal.

Cases are on record, especially amongst the older literature of congenital malformation, of instances in which there was an opening of the bowel at other places than those which have been dealt with, and of such conditions as multiple stenoses; the descriptions, however, are so vague, that it is impossible to classify them upon an embryological basis.



## CHAPTER IV

### DEVELOPMENTAL DEFECTS. TREATMENT

ALTHOUGH the forms met with are so various, it appears desirable to consider together all that are amenable to surgical treatment, and to try and formulate certain principles applicable to groups of cases.

In the first place it is essential to remember that the tissues of the new-born infant, especially the intestine, are very fragile and will not stand much handling, that good union may be expected in parts sutured together, provided they can be brought together without tension, and that the sutures are not tied too tightly, but anything like strain in bringing mucous membrane to skin or tight suturing is sure to end in failure.

Much depends upon the extent of intestinal obstruction—is it complete, is it partial, or is there an efficient abnormal opening? In the first case immediate operation is essential to save life, in the second it cannot well be long delayed, while in the third the surgeon may well wait until the child is older, and select his own time for carrying out a well-planned and deliberate operation.

**Where obstruction is complete,** the first question to decide is whether the case is one of imperforate anus or one of imperforate rectum. If a membranous diaphragm is found obstructing the anus, it is a simple matter to open and remove it. If the anus is completely imperforate, but bulging can be detected, or an impulse felt in the perineum when the child cries, longitudinal incision should be made in the middle line, the centre of which corresponds to the normal position of the anus, and the bowel sought for, opened, and, if possible, the mucous membrane should be brought to the skin margin of the wound and sutured there without tension. If, however, there is no evidence that the bowel is near the perineum, and that the case is one of imperforate rectum, it is not advisable to make deep search in the perineum by incision. In a large number of such cases failure to reach the bowel has been recorded, even where



excision of the coccyx has been undertaken as an aid to exploration, and when the distended bowel has been found, the difficulty of bringing it down so as to suture it satisfactorily to the skin has been insuperable. If the infant survives it will be with a fistulous track, rather than with a useful anus. I am satisfied that the right treatment in such cases is preliminary colotomy, by which the urgent symptoms of intestinal obstruction are overcome with the least amount of risk; subsequently,

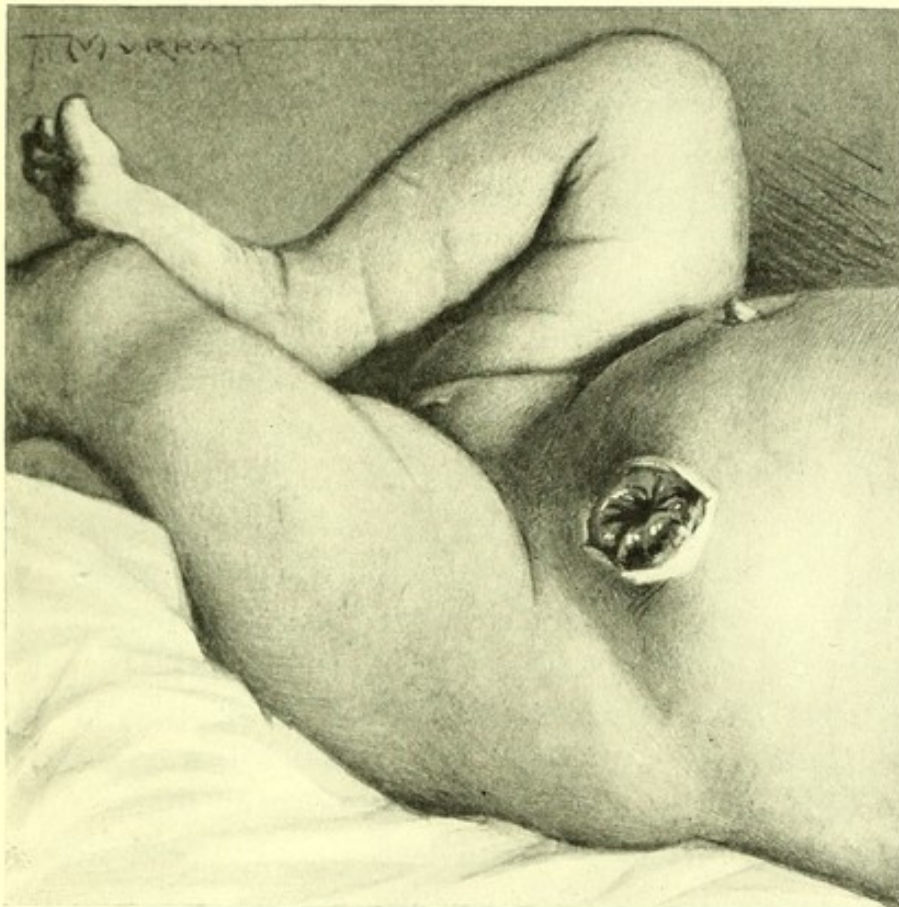


FIG. 43. Colotomy for Imperforate Rectum six months after operation.  
(From stereo-photograph of a case at Sir Patrick Dun's Hospital.)

when the child has gained strength, an attempt can be made to restore the normal anus with much better prospect of success. The following case, from which Fig. 43 is taken, illustrates a method which, although unsuccessful in this individual instance, appears to be based upon sound surgical principles. An infant with imperforate rectum came under my care at Sir Patrick Dun's Hospital; there was no evidence that the bowel came down close to the perineum, meteorism and faecal vomiting



were marked, there was no other faecal outlet present. The distended iliac colon was at once opened by abdominal incision. In consequence of the great distension, no attempt was made to determine the site of obstruction. Relief followed, and the child thrived, and at six months was otherwise healthy and well nourished. An attempt was now made to re-establish the normal outlet. The abdomen was again opened and the termination of the bowel was found at the usual site on a level with the peritoneal reflexion, the fundus of the bowel was freed by division of the peritoneum and the fibro-muscular cord of attachment, and an incision made in it of sufficient size to admit a  $\frac{3}{8}$ -inch rubber tube, which was carefully sutured by purse-string suture of fine catgut which included the wall of the bowel and the rubber of the tube. An opening was now made through the pelvic diaphragm and skin of the perineum at the normal site for the anus, care being taken to, as far as possible, separate and not cut the fibres of the sphincter muscle. The free end of the rubber tube was now brought out at the anus, and with a little additional freeing of the attachments of the bowel the rectum came down so as to allow it to be sutured to the skin without undue tension; unfortunately severe bacterium coli infection followed, from which the child died. I believe, however, that success may sometimes be expected from similar operations in the future, and that it is well worth the attempt, as the alternative is death, or the miserable condition of a persistent colotomy opening.

**Imperforate anus, with outlet in the anterior urethra, vulva, or skin of perineum, scrotum or penis,** is amenable to surgical treatment with every prospect of success; and in the case of vulvar anus especially, a considerable number of successful cases have been recorded, due no doubt to the fact already noted that vulvar anus is frequently sufficiently free to provide for efficient evacuation of the bowel, so that the grave complication of intestinal obstruction does not exist.

The best means of dealing with these cases is, as far as may be practicable, the method first, I believe, described by Rizzoli for vulvar anus, the idea being to dissect out the abnormal outlet with the tube leading to it, and transplant it to its normal position, the wound left being closed by sutures. In the case from which Fig. 30 is taken this was done with complete success, the following being the details of the operation. An incision is carried round the abnormal outlet and back in the middle line to the site of the normal anus, and the end of the



rectum with its adventitious tube exposed; in doing so care must be taken to separate as far as possible, and not divide, the fibres of the sphincter muscle; the outlet with its tube are now raised from their bed by dissection and brought back and sutured to the skin at the normal position, and the perineal and vulvar wounds closed by deep sutures, especial care being taken to unite the separated fibres of the sphincter muscle in front of the replanted anus. This operation, so suitable for competent vulvar anus, may require modification in the

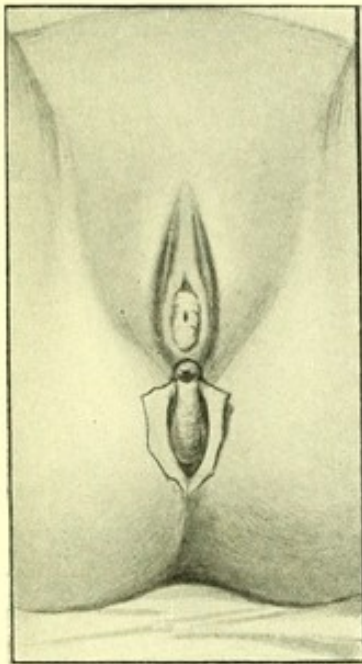


FIG. 44. Rizzoli's Operation for Vulvar Anus, first stage.

An incision is made surrounding the abnormal anus and continued back to the normal situation of the anus. Flaps of skin are raised and the termination of the gut dissected free so that it can be twisted back to its proper position.

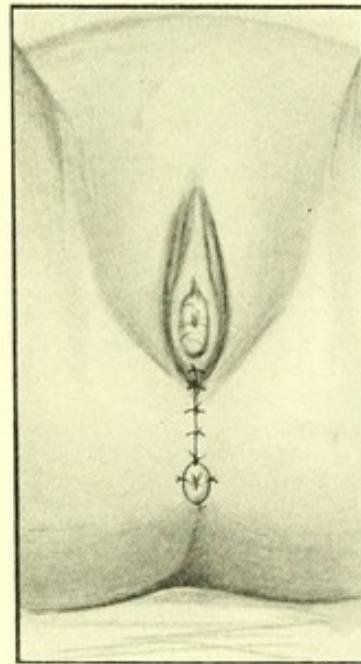


FIG. 45. Rizzoli's Operation for Vulvar Anus, completed.

The anus is transferred to its normal site and retained there by sutures. The perineal and vulvar wounds are closed by sutures.

other forms; if the adventitious tube is redundant, or is merely a fistulous track, it may require removal in order to form an efficient anus, and when the outlet is in the urethra, the mucous canal leading to it should be cut across, and the distal end closed by suture with inversion of the edges of mucous membrane.

**Imperforate rectum, with faecal outlet.** It is probable that the operation already described for imperforate rectum would be applicable



to those cases in which a faecal outlet is present in some of the other pelvic organs, the only difference being that it would be necessary to cut across the mucous canal leading to it from the rectal pouch, and close the distal end by sutures which inverted the mucous edges.

The general principles of treatment will of course require occasional modifications to meet the requirements of individual cases, but it does not appear to be necessary to go into further detail; congenital stricture, for instance, should be treated on lines laid down in considering the general subject of anal stenosis, and the other irregularities of development of the proctodaeum, such as double orifice, present no difficulty.



## CHAPTER V

### DIAGNOSIS OF RECTAL DISEASE

THE early diagnosis of rectal disease is attended in some instances with difficulty, partly from the fact that patients suffering from these diseases do not seek the advice of the surgeon until they have suffered for some time, when the severity of the pain, considerable loss of blood, or great difficulty in defaecation, overcome the repugnance to local examination. In other cases, more especially in commencing malignant disease, where early diagnosis is of such paramount importance, the subjective phenomena may not in the first instance point to the rectum as the seat of lesion.

It is essential, therefore, that the surgeon should pay particular attention to those symptoms which, although not directly pointing to disease of the lower bowel, are frequently caused by such condition, and when the statements of the patient render it probable that rectal disease exists, he should insist on a complete local examination. Amongst the more vague symptoms which should arouse the suspicions of the medical attendant we may enumerate the following: slight morning diarrhoea, which continues for a long time, alternating with attacks of constipation, flatulent dyspepsia, sense of weight about the pelvis, dull pain about the sacrum, with pain or oedema of the left leg. Progressive anaemia may be the result of abundant and frequently repeated hemorrhage from the rectum, which sometimes continues for a considerable time before it is noticed by the patient, the loss occurring painlessly at the time of defaecation. And, again, owing to the close sympathy between the uterus and adjacent mucous tract, disease of the latter may lead to the erroneous impression that the cause of the patient's suffering is to be found in the organs of generation. Similarly we sometimes find that irritability of the bladder is the symptom to which the patient directs special attention.

In order to elucidate the symptomatology as fully as possible, it is



well, in the first place, to let the patient describe his case in his own words, then, by a few well-directed but not leading questions, we may be able to complete the history. The questions to be asked may be usefully directed in reference to the following principal points:—

**Pain.** Inquire if the pain is severe or not; whether it is situated in the rectum or is complained of elsewhere; what is its relation to defaecation. Is it worse during evacuation, shortly afterwards, or is it independent of the act? Is itching, sense of fullness, or heat complained of?

**Protrusion.** Is there any swelling or protrusion at the anus? Does this occur only at defaecation, or does it appear at irregular times? Does it disappear spontaneously, can the patient return it, or is it constantly present?

**Bleeding.** Is there discharge of blood after defaecation, during defaecation, the blood being intimately mixed with the faeces, or does it occur independently of the act?

**Pus and Mucus.** Is the discharge foetid? Is it mixed with faeces? Does it occur only during, or after defaecation, or is it continuous?

**Faeces.** Is there diarrhoea or constipation? What is the consistence? Are they of normal size, tape-like, or lumpy?

Having now clearly obtained the subjective phenomena, we should, if there is a suspicion even of rectal disease, insist on a complete local examination. Under no circumstances is the attendant justified in prescribing without careful examination, although often he will be asked by his patient to prescribe something for 'the piles'. I have seen several cases of extensive malignant disease of the rectum, which had passed all hope of useful treatment and had been under the care of medical men who had rested satisfied with the statement of the sufferers that they were suffering from piles, and who had never made an examination.

Of some diseases the symptomatology is tolerably diagnostic; as, for instance, if the patient has severe pain continuing for some hours after defaecation, if the motions are small and tape-like, and if they are streaked on one side with bloody mucus, there is a very strong probability that there is a painful fissure present, but without examination we cannot possibly say that the fissure is the only rectal disease; indeed, in a considerable proportion of cases we find more than one pathological condition present.

**Examination.** If possible the patient should have the bowel



emptied by an enema immediately beforehand. In some cases this is absolutely essential; as, for instance, where it is necessary to use a speculum for the exploration of the higher portions of the mucous membrane.

**Position.** By far the most convenient position for ordinary examination is the dorsal, with the pelvis well raised on a gynaecological chair, the knees bent, and the thighs separated. If this is inconvenient, the patient may lie on the left side with the knees drawn up, or sometimes the knee-elbow position will afford greater facilities for examination. By separating the buttocks we obtain a good view of the anus and surrounding skin, pathological changes in which are easily noticed. By gently feeling the anal margin, we may be enabled to detect deep-seated hardness, which may be due to the presence of a fistula; tenderness at any part of the circumference will serve to direct our attention to that portion more particularly. By drawing open the anus and directing the patient to bear down, a good view will be obtained of the muco-cutaneous junction, the condition of sphincter as to laxity can be observed, and any discharge noted both as to quality and quantity, a full view of external and sometimes of internal piles being also thus obtained. By separating the radiating folds of the anus, we may be enabled to see the commencement of fissure, a small sentinel pile frequently serving to direct our attention to this lesion. The presence of fistulous openings and the more obvious anal diseases, together with the existence of oxyurides, may also be determined. A digital examination should now be instituted, and it is by this means that the most important information is to be obtained, the educated finger being able to recognize with certainty almost all varieties of rectal disease. In order, however, that the fullest information may be obtained, it is evident that familiarity with the normal parts is essential, the surgeon should bear distinctly in mind what he is about to look for, and prosecute his examination in a definite and systematic manner. Having filled the nail with soap, he should cover the finger well with some stiff lubricant; ordinary oil is not satisfactory. This may appear a small matter, but it makes the difference between little or considerable pain to the patient, and, as a result, passiveness or resistance to the examination. The thymol or eucalyptol jelly sold in collapsible metal tubes for obstetric purposes answer the purpose admirably, and, moreover, have the advantages of ready portability and asepticism.



The finger should be introduced by a gradual boring motion, with a direction, at first, slightly forwards. This should be carried out slowly, so as to give the sphincters time to relax; if attempted suddenly, spasm will to a certainty be induced. As the finger enters, the condition of the sphincter may be noted—i. e. whether it is relaxed, normal, or spasmodically contracted. A firm, long-continued resistance is very characteristic of spasm, the result of chronic irritation. The finger should be steadily passed up to the fullest extent, and by telling the patient to bear down forcibly, the rectum can be explored for a considerable distance. Malignant infiltration, or stricture, can be detected, if situated within reach. By sweeping the finger round the mucous membrane its condition can be noted; a general smoothness, and absence of the normal folds, indicating atony. Ulceration may be recognized, and the attachment of adenomata can be felt. In examining for adenomata it is of importance that the investigation should be conducted as directed, from above downwards, as otherwise the tumour may be pushed up out of reach, the pedicle, in these cases, being often of considerable length. Faecal accumulation in the rectal pouch is, of course, recognized without difficulty, and the condition of the surrounding contents of the pelvis should be noted. The finger is now partly withdrawn, passing the pulp round the entire circumference of the mucous membrane, the internal openings of fistulae and ulceration being carefully felt for. As the margin is approached internal piles may be perceived, but the fact should always be remembered that internal haemorrhoids, unless they have been previously thickened by inflammation, are extremely difficult to recognize by the touch; indeed, the surgeon is more likely to be deceived by the sensation conveyed to the finger by internal piles than by any other rectal disease. I have frequently seen cases in which these growths, although scarcely appreciable to the touch, were found, upon ocular examination after dilatation of the sphincter, to be of considerable size. This is, no doubt, due to the fact that they are so soft and movable that they resemble closely in feel the normal columns and folds of the mucous membrane. Where, however, they have been thickened, either by present inflammation or by the growth of connective tissue in them, no difficulty can be experienced in their detection.

Immediately inside the anus we may be able to feel the upper portion of a painful ulcer, and can sometimes recognize the fact that the extreme sensitiveness is confined to one portion of the surface. Before



withdrawing the finger the entire circumference of the anal canal should be examined by gently pinching each portion between the finger inside and the thumb outside. In this way slight indurations which may have previously escaped detection can sometimes be noticed.

**Bi-manual examination.** Much may be learned by bi-manual exploration that cannot be detected by the ordinary digital examination above described; and where symptoms suggest malignant or other high-lying disease that cannot be detected in the ordinary way, bi-manual examination should always be adopted before giving a positive diagnosis. For this purpose an anaesthetic may be necessary. With the patient in the dorsal position one or two fingers are to be introduced far into the rectum, and with the other hand deep pressure made into the pelvis above the pubis. In this way a cancerous mass can often be felt between the two hands, and its mobility, upper limit, and relations to other structures determined. Useful information can also be obtained as to the condition of the extra-rectal pelvic organs.

**Specula.** The great variety of specula which have been invented may be taken as an indication that their utility is limited. Personally, I have little reliance on their aid to diagnosis. It is by the sense of touch rather than by sight that disease of the interior of the rectum is best recognized. Some form of duck-bill speculum may occasionally be useful, Hegar's vaginal retractor answering all purposes, when it is desirable to see the lower portions of the rectal mucosa. For disease of the bowel higher up, tubular specula, rectoscope and colonoscope are sometimes used. I seldom employ them, and am somewhat sceptical as to the diagnosis and treatment of high-lying disease of the rectum which we hear of being effected by their means.

**Bougies** are of little use for diagnostic purposes, although often of service in the treatment of stricture which is within reach of the finger. The attempt to locate by a bougie a stricture too high to be felt with the finger is highly dangerous, and as Syme wrote many years ago, 'There is good reason to suspect the honesty of a man who pretends to enter a stricture which is beyond the reach of the finger.'

Introduction of the whole hand into the rectum has been occasionally employed for the purpose of diagnosis, but with improved methods of bi-manual examination and the trivial danger of modern exploratory laparotomy it must now be considered obsolete.



## CHAPTER VI

### INFECTIVE DISEASES

INFLAMMATION of the rectum (proctitis) or of the structures immediately surrounding this viscus (periproctitis) may be due either to toxic or bacterial causes. We are familiar with examples of toxic proctitis as a result of the ingestion of certain purgative medicines, which produce a burning and irritation in the lower rectum, and in some very susceptible persons even an acute catarrhal inflammation of the mucous membrane. Similarly in some individuals certain articles of food are capable of producing a like inflammation. Proctitis started in this way is usually of a trivial nature, seldom invading surrounding structures and usually subsiding rapidly when the cause of irritation has been removed.

Bacterial inflammation occurs here as elsewhere from direct infection, but, in considering this subject, we cannot fail to be struck with the power of resistance to infection possessed by the tissues of the anal canal. Cracks and abrasions of the delicate skin of the anus are very frequent, and these must of necessity be constantly soiled by intestinal contents, which as we know possess a very copious bacteriological flora, and although the infection of these abrasions sufficient to produce abscess must be considered common, yet it is not at all as common as might be expected, and the cases in which inflammation and abscess result probably only constitute a very small fraction per cent. of the abrasions soiled with faeces. Again, we know that the operations for the removal of internal piles are extremely rarely followed by serious septic complications, yet the wounds resulting from these operations are constantly subject to faecal infection. The contrast between these wounds and wounds which penetrate the rectum above the pelvic diaphragm is very marked indeed; the latter are highly susceptible to septic infection. If we take, for instance, excision of the rectum, we find that one of these cases seldom recovers without some suppuration occurring, while severe and frequently fatal sepsis occurs only too often, and we know that perforation



of the intestine into the peritoneal cavity, permitting extravasation of faeces, is rapidly followed by acute septic peritonitis.

In what does this relative immunity of the anal canal from septic infection, when wounded, consist? I am confident the true explanation lies in its anatomical structure. The muscles of the sphincteric zone are closely blended together, and there are no loose connective tissue interspaces in which serum or blood can collect, and along which septic processes so rapidly spread, consequently any infection that may take place remains superficial and drainage is perfect. Above the pelvic diaphragm these conditions are reversed, the rectum being surrounded by particularly loose areolar tissue, in which sepsis can run riot. The structure of the anal canal resembles in this respect that of the lips, and those of us who are old enough to remember the pre-antiseptic days will recollect how operations for hare-lip and epithelioma healed readily, while wounds which opened up loose areolar planes, as in the neck, were so frequently followed by profuse suppuration.

Infection of the rectum and surrounding structures may for clinical purposes be conveniently considered under the following headings: 1. Catarrhal inflammation. 2. Gonorrhoea. 3. Diphtheria. 4. Local suppuration. 5. Diffuse sepsis. 6. Gangrenous inflammation. 7. Dysentery. 8. Tuberculosis. 9. Syphilis. 10. Actinomycosis.

**1. Catarrhal inflammation.** Under this heading are included all those acute inflammations of the rectum attended by swelling of the mucous membrane with increased mucous, purulent, or sanious discharge, and as can readily be understood this condition may be due to many diverse causes; some, no doubt, are originated by toxic substances in the intestinal contents, while others are due to some of the many infective agencies capable of producing similar inflammation elsewhere. When very acute it presents many symptoms in common with amoebic dysentery, and the clinical difference is rather one of degree than kind. I shall, therefore, confine the term to those cases in which the inflammatory process is limited to the rectum, and in which the abdominal pain and constitutional symptoms of typical dysentery are absent. As such we not infrequently meet with cases, especially in children. The symptoms are great tenesmus, with the frequent passage of small quantities of bloody mucus, at first mixed with faeces, and then alone; at the same time there is vesical irritation, and general sense of heat and weight about the pelvis, resulting from the inflammation of the mucous and



submucous tissue; oedema is present, and occasionally, in consequence, a partial prolapse takes place, resembling the chemosis met with in acute inflammation of the conjunctiva (ectropion recti, Roser).

Catarrhal proctitis is in all respects analogous to the localised inflammation of other parts of the intestinal tube, such as gastro-duodenal catarrh, typhlitis, colitis, &c., and it may terminate in several ways. In the vast majority, the disease subsides completely in a few days, but it may, if severe, be accompanied by inflammation of the structures outside the rectum (periproctitis), which may eventuate in abscess and fistula. Or, again, the disease may merge into the chronic form, or be followed by ulceration more or less deep.

The frequency with which inflammation of the intestinal mucous membrane is accompanied with considerable bloody discharge has been noticed by Cohnheim (Leube, *Ziemssen's Cyclopaedia*, vol. vii, p. 363). He suggests that, from the fact that during the process of digestion the chyle vessels of the mesentery always contain red blood corpuscles, it may be inferred that the intestinal mucous membrane is one of the regions of the body where the passage of blood corpuscles through the walls of the vessels takes place with special facility.

Amongst the causes which give rise to this disease, epidemic influences are undoubtedly occasionally noticeable; this is especially observed in the catarrhal proctitis of children, the bacteriology of which, as far as I know, has not been satisfactorily elucidated.

2. **Gonorrhoea** of the rectum may produce a catarrhal proctitis, attended with a copious purulent discharge, the detection of the specific organism, the gonococcus, establishing the diagnosis. Inflammation of the rectum from this cause is decidedly rare, and when we consider that the anus in females must frequently be soiled with gonorrhoeal discharge, the rarity of cases in which this disease is proved to exist tends to indicate that the rectum is not very susceptible to gonorrhoeal infection.

**Chronic catarrhal proctitis.** Where acute catarrhal proctitis has merged into the chronic form, the symptoms become somewhat modified, the acute pain and tenderness give place to rather a sense of weight and fullness than actual pain. The discharge also becomes altered; instead of consisting of a tolerably intimate mixture of blood and mucus, as is found in the acute form, it becomes more purulent, and if blood is present it exists as streaks in the pus, which have evidently arisen from ulcerations of the mucous membrane rather than from a general oozing



from the inflamed surface. On inspection the mucous membrane appears more thickened and indurated (Fig. 46), and there is much proliferation of the sub-mucosa. Ulceration of the surface is also more frequent in the chronic form.

**Treatment of proctitis.** In dealing with acute proctitis the first essential is to evacuate the canal, and this should be accomplished by the administration of purgatives, not by enemas, owing to the pain that the latter occasion, and the danger which exists of spread-

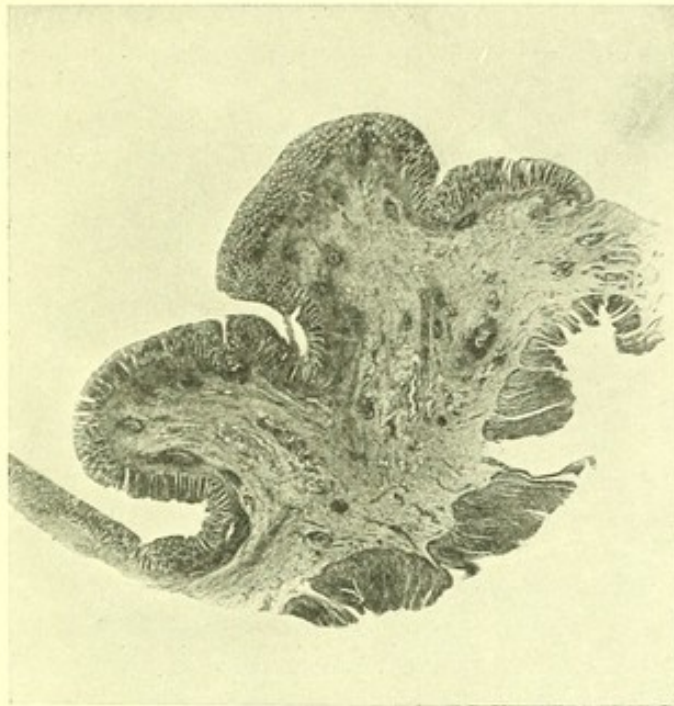


FIG. 46. Chronic Inflammation of the Rectum.—Proctitis.

There is considerable proliferation of the submucous tissue, which has thrown the mucous membrane into ridges.

(Photo-micrograph,  $\times 5$ .)

ing infection up the intestine. Calomel followed by some saline will usually prove most suitable, preferably sulphate of soda, or sulphate of magnesia in some form, such as the more potent mineral waters, or the effervescent sulphate of soda will be found an easily taken and satisfactory aperient. Powerful purgatives must be carefully avoided. Where it can be taken without much nausea, castor-oil will fulfil every requirement. Absolute rest in bed is essential, and the occasional use of a hot hip-bath will give relief. The diet should be carefully regulated; all food leaving a copious faecal residue is to be avoided, and during the



acute stage the patient should be restricted to milk, strong meat-soups, and eggs. If there is much tenesmus, injections of two ounces of mucilage of starch with a few drops of tincture of opium may be used, but as a rule it is better not to use opium or morphia to any great extent, as owing to its tendency to produce constipation the disease may be aggravated.

When inflammation of the rectum has become chronic, especially if it be due to gonorrhoea, thorough washing out of the rectum is indicated, followed by astringent irrigation by means of a double channel catheter, or, if this is not at hand, two large catheters introduced side by side will

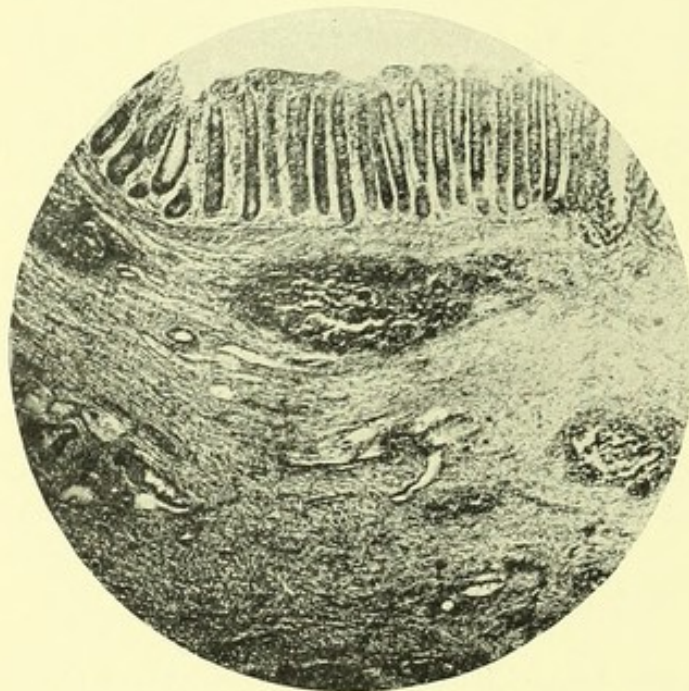


FIG. 47. Inflammation of the Rectum.—Proctitis, with Formation of Abscesses in the Sub-mucosa.

(Photo-micrograph,  $\times 20$ .)

answer the purpose quite well, through one of which the fluid is allowed to run in, while it flows out through to the other, without extending too far up the colon. A thorough swabbing of the inflamed mucous membrane with a 2 per cent. solution of silver nitrate, or with tincture of iodine, through a Kelly's proctoscope, is, however, probably the best treatment of all.

3. **Diphtheria** has occasionally been noticed in the rectum and anus, in conjunction with the same disease in its more usual situation. In other cases membranous proctitis simulating true diphtheria has been



observed, arising apparently primarily in this situation. Probably these cases are of the same nature as the membranous colitis sometimes arising in severe general sepsis, and as far as I know primary diphtheria of the rectum has not as yet been demonstrated bacteriologically.

4. **Local suppuration** occurs in various situations in connexion with the rectum, and when acute is usually the result of infection with the common pus-forming bacteria; when originating in the wall of the

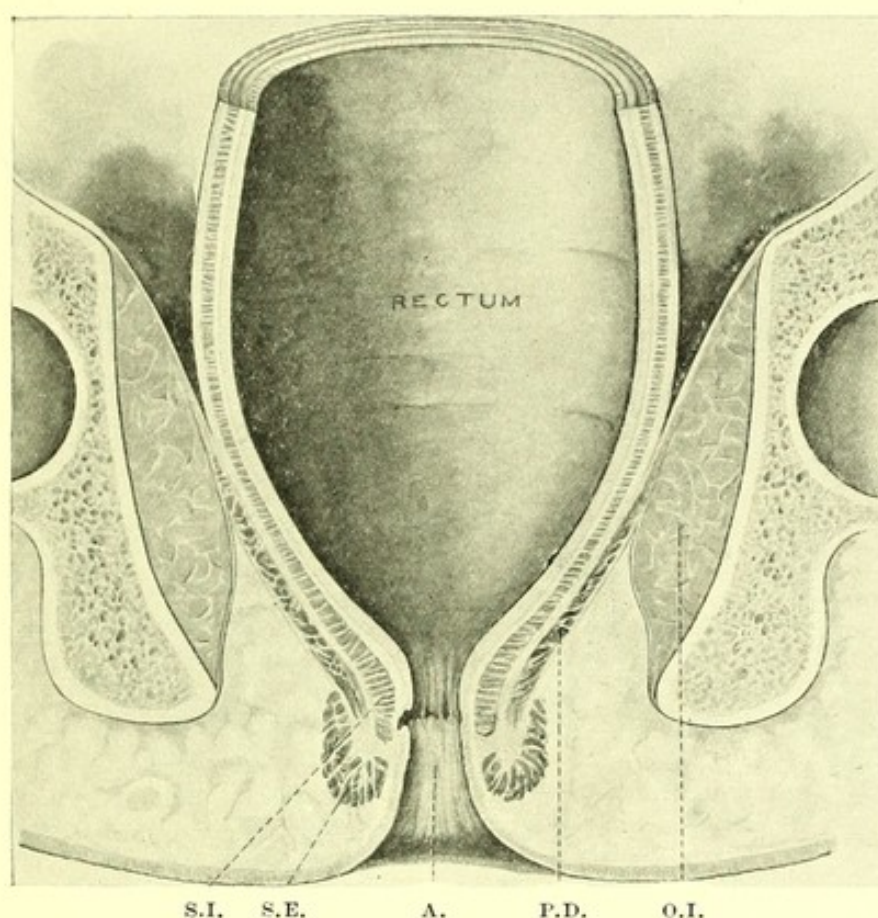


FIG. 48. Diagram of the Relations of the Anal Canal and Lower Rectum.

Drawn to scale from frozen sections. A. Anal canal. S.E. External sphincter muscle. S.I. Internal sphincter muscle. P.D. Pelvic diaphragm. O.I. Obturator internus muscle.

gut itself the usual position is in the sub-mucosa (Fig. 47). In this position it is decidedly rare, and cases such as that from which the photo-micrograph is taken are seldom met with; it was one of extensive inflammation of the rectum in which minute abscesses were found in the sub-mucosa. Much more common are abscesses outside the intestinal tunic, and we must recognize three positions (Fig. 49) in which these may



be present : (1) subcutaneous at the outlet of the anal canal ; (2) in the ischio-rectal fossa ; and (3) above the pelvic diaphragm in the superior pelvi-rectal space.

(1) **Subcutaneous abscess** at the outlet of the anal canal is usually the result of suppuration occurring in a thrombotic external pile, or possibly a furuncle. When in this situation the symptoms and treatment present no special points for consideration : incision, curetting, and

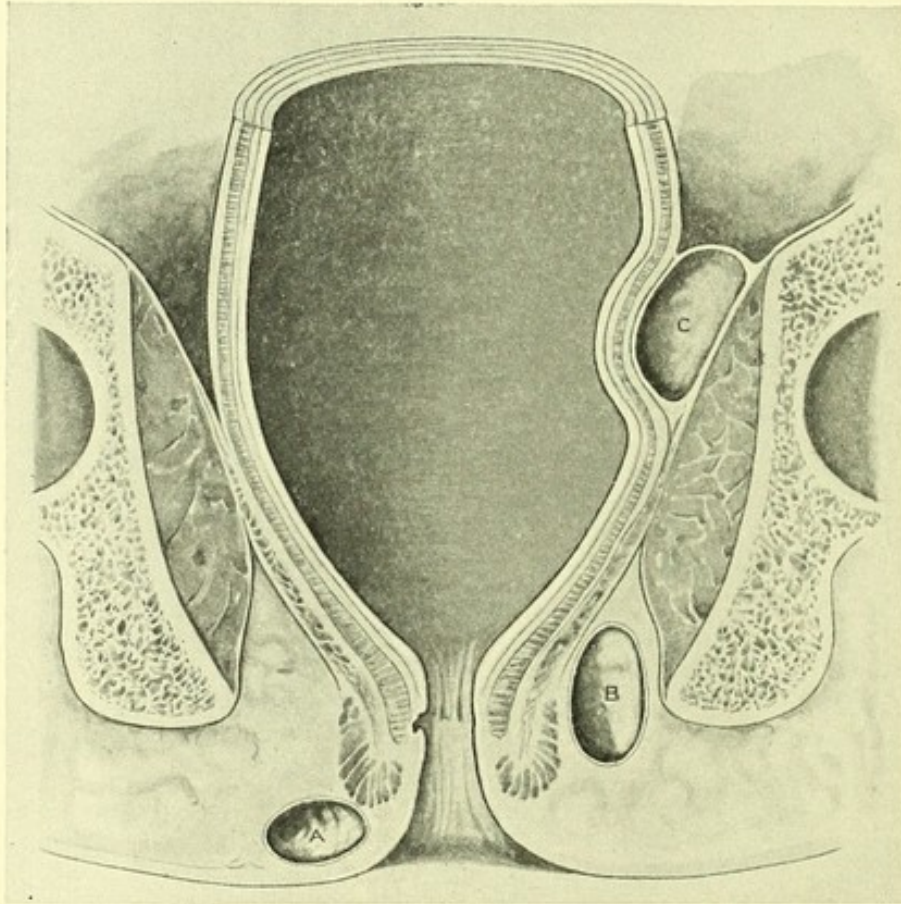


FIG. 49. Diagram showing the Positions of Abscesses in relation to the Rectum.

A. Marginal abscess. B. Ischio-rectal abscess. C. Abscess of the superior pelvi-rectal space.

packing with a shred of iodoform gauze, are all that is required, and it is seldom followed by fistula or other complication of importance.

(2) **Abscess in the ischio-rectal fossa** is in the majority of cases probably due to perforation of the rectal tunic, the result of traumatism or ulceration, the position of such perforation usually being at the pectinate line in one of the little anal pouches. It is well known that this is a frequent position for perforation to take place from injury by fragments of bone, pins, &c., which have been swallowed, and which



have passed along the intestinal tract without producing injury elsewhere, but owing to the abrupt narrowing of the bowel at the anal canal, and the direction of the little anal valves favouring the projection of foreign bodies into the anal pouches, puncture is frequently produced here. Even if the puncture does not extend in the first instance through the entire thickness of the bowel, the wound is apt to become infected, and suppuration once started tends to make its way through the muscular coat at the point where the levator ani and external longitudinal coat pass between the sphincters, and thus reach the ischio-rectal fossa, where the loose adipose tissue favours the rapid increase of an abscess; in this way the foreign body which originated the traumatism may be found in an ischio-rectal abscess outside the rectum altogether. I have found in these abscesses such foreign bodies as pins, pieces of bone, apple core, and even a small bird's feather, all of which had evidently penetrated from the rectum into the ischio-rectal fossa.

In addition to such obvious traumatism, an ulceration starting in one of the rectal sinuses may originate an ischio-rectal abscess; the majority of these are unquestionably tubercular and will be considered under that heading, but it is quite certain that acute staphylococcus abscess does sometimes start in this way.

Although it appears probable that the majority of acute ischio-rectal abscesses start from perforation of a rectal sinus, some cases certainly originate outside the rectum. Sometimes they start from a trivial abrasion of the skin of the anus, which becomes septic, and involving the lymphatics terminates in ischio-rectal abscess, in the same way that we so frequently see mammary abscess following chapped nipples; it is also possible that an acute inflammation of the mucous membrane without obvious ulceration may start an ischio-rectal abscess, as we see perineal abscess following urethral gonorrhoea.

The formation of acute ischio-rectal abscess is attended in the majority of cases with some fever, and the constitutional disturbance is generally out of all proportion to the local disease. The pain is severe, and is increased by defaecation. There is frequently irritability of the bladder, strangury or retention of urine being not uncommon symptoms. Its situation is most frequently on the lateral aspect of the anus, and it presents itself as a prominent, tense, red, and shining swelling, in which fluctuation is distinctly to be felt (Fig. 50). Where the abscess is due to perforation of one of the anal pouches the symptoms may not be so



severe, as the pus finds exit into the anal canal, forming an internal rectal sinus, but the tendency, nevertheless, is for the abscess to increase until an external opening also forms and complete fistula is produced.

Where the abscess originates in the ischio-rectal fossa it at first spreads in the loose adipose tissue, but, owing to the anatomical relations of this fossa, its extension upwards is limited by the intimate union

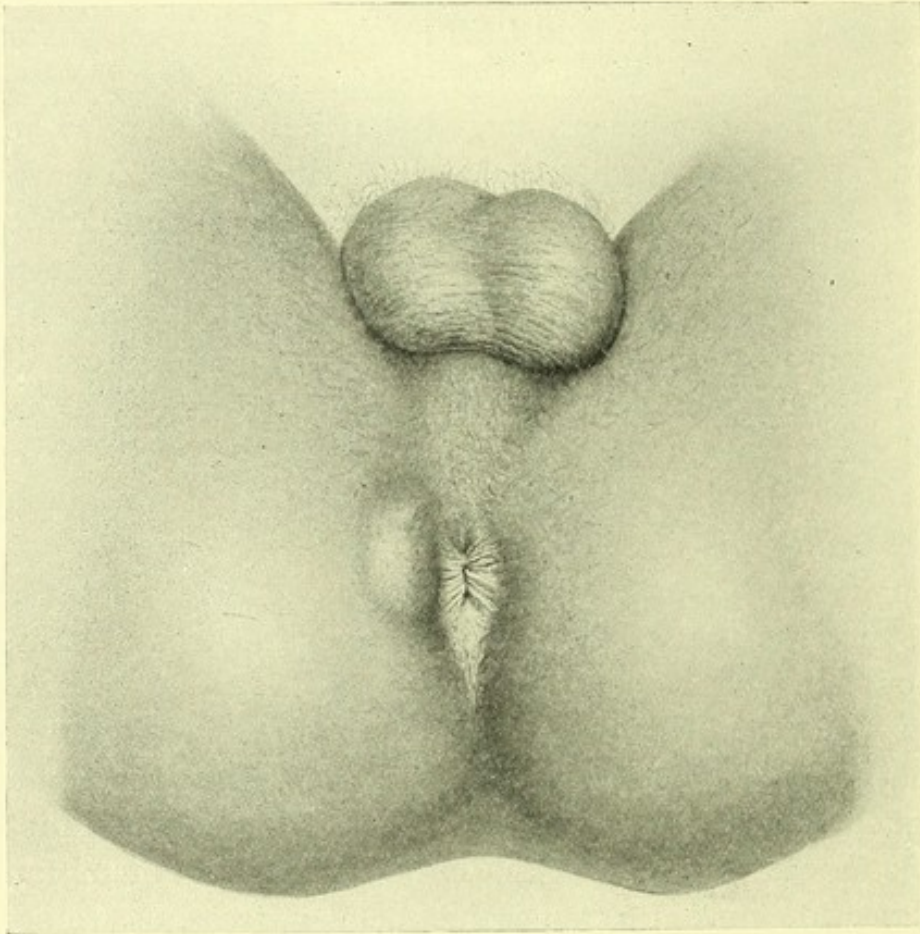


FIG. 50. Abscess of Ischio-rectal Fossa pointing beside the Rectum.  
(From stereo-photograph.)

of the obturator fascia on the outside to the anal fascia on the lower surface of the pelvic diaphragm, and the abscess becomes extremely tense, the severity of the constitutional symptoms being largely proportional to the degree of tenseness. The directions in which the abscess tends therefore to increase are (1) towards the skin, and (2) to follow the lower surface of the pelvic diaphragm covered by the anal fascia, which directly leads it through the muscular tunic of the anal canal between



the two sphincters (Fig. 48), and having reached the loose submucous coat of the bowel, tension is relieved and rapid expansion can take place. The point, however, at which perforation of the mucous membrane takes place is in the great majority of cases at the pectinate line immediately above that portion of the anal canal which is covered by scaly epithelium.

**Treatment** of ischio-rectal abscess should be prompt. It is better

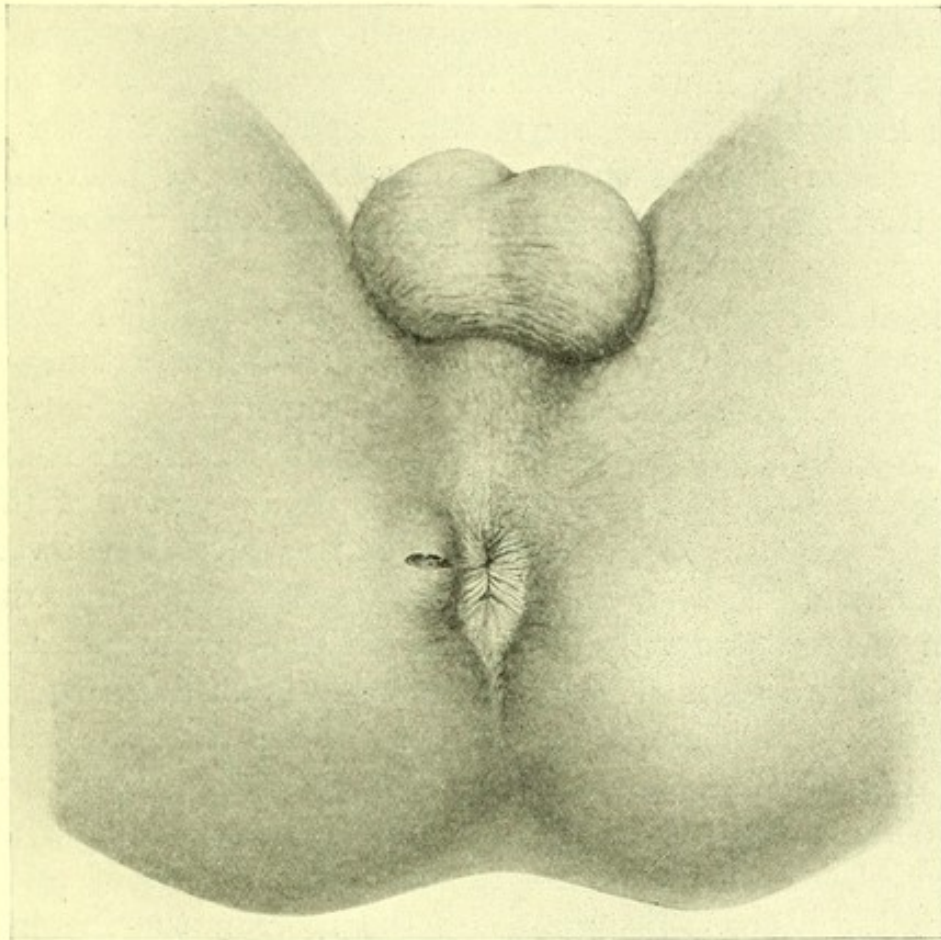


FIG. 51. Correct line of incision for evacuating Ischio-Rectal Abscess.  
(From stereo-photograph.)

to administer a general anaesthetic. If a prominent fluctuating point can be determined, this is best incised, an incision being made radiating from the anus. When the cavity has been thoroughly opened the interior should be carefully curetted, and if the abscess is multilocular the septa must be broken down, and every ramification of the abscess cavity opened up and cleaned; the surface may then be dusted with iodoform and packed lightly with gauze. If seen before fluctuation is



obvious it is usually easy to determine the focus of suppuration. With the index finger in the rectum the anal circumference can be gently pinched between the finger and thumb, and in this way even a small induration can be detected, which when incised will give exit to a few drops of pus; this minute cavity should be as thoroughly curetted as the more obvious abscess. The early treatment of ischio-rectal abscess is a matter of the greatest importance, as if it is early seen and efficiently dealt with the occurrence of fistula can usually be avoided.

5. **Diffuse sepsis** in connection with the rectum seldom originates spontaneously; it is, however, not infrequently the cause of death after operations involving the higher rectum. The clinical features of this condition are in many respects similar to those of puerperal sepsis, and, like that affection, may present themselves in various degrees of severity.

In the more serious cases, after a stage of incubation lasting a few days the patient is seized with rigors, quickly followed by general and considerable febrile disturbance, with high temperature and rapid pulse. Profuse perspirations occur at irregular intervals, causing the temperature to fall temporarily, pain is complained of in the region of the pelvis, and in many cases this rapidly increases and involves the lower portion of the abdomen. The patient lies on the back with legs drawn up, meteorism is present, vomiting occurs, and the face presents an aspect of great anxiety, a train of symptoms clearly indicating involvement of the peritoneal serous membrane. When this has occurred death, in the great majority of cases, soon terminates the patient's sufferings. Other symptoms indicating the septic state are sometimes to be met with, as an erysipelatous blush on the buttocks, the deposit of membranous patches on the mucous membrane of the rectum, the involvement of some of the synovial cavities or of the pleural and pericardial sacs, and the occurrence of metastatic abscesses in many parts of the body.

In the milder cases of septic proctitis the disease may be somewhat more limited in extent, and consist in a diffuse pelvic cellulitis, without involvement of the peritoneal cavity or evidence of septic manifestations in other parts of the body. This condition is analogous to the localised sepsis of the puerperal state, and, like it, may end in resolution, but much more frequently terminates in somewhat diffused suppuration. Pus formed in this way accumulates in considerable quantity in the loose areolar tissue situated between the recto-vesical fascia and the peri-



toneum, and may point near the anus, finding its way down posteriorly between the two pubo-coccygeus muscles, or it may escape through the sacro-sciatic notch, or, passing upwards, appear as an iliac abscess. In other cases suppuration appears in the pelvic lymphatic glands.

The treatment of these cases is eminently unsatisfactory; as, however, many of these cases are due to infection by streptococci, injections of antistreptococcic serum may be employed.

Improved methods of wound treatment have largely diminished the number of cases in which septic periproctitis follows even such severe operations as excision of the rectum, but unfortunately cases are still to be met with, the difficulties of obtaining a complete asepsis being obviously so much greater here than in other parts of the body, auto-infection from intestinal contents being difficult or impossible to prevent.

**6. Gangrenous inflammation.** Sepsis of a very violent character, attended with extensive necrosis of the soft tissues, is frequently attended with surgical emphysema, the product of infection by gas-forming bacteria. It is a very formidable disease, and may be attended with fatal result, or where recovery takes place there is a great destruction of tissue, with the consequent troubles attending the contraction of cicatrices. This disease may commence in the skin and rapidly spread to the underlying connective tissue, or the skin may be only secondarily affected, the deeper structures being first implicated. It is stated to occur more commonly amongst the well-to-do, who consume large quantities of animal food and drink too much alcohol, and is almost exclusively confined to the male sex. There is a livid tumefaction in the posterior portion of the perineum, attended with considerable pain. If the disease spreads deeply into the pelvis, pressure on the sacral plexus may give rise to reflected pain. Fever of a low type is present, with brown furred tongue, quick weak pulse, and in severe cases delirium supervenes. The skin covering the swelling sloughs generally at several points as in ordinary carbuncle, to which this disease bears great resemblance. As the cutaneous slough separates, masses of dark gangrenous tissue are brought into view, discharging an offensive ichorous fluid rather than normal pus. After separation of the gangrenous tissues a great chasm is left, which heals but slowly, and relapses, with extension of the disease, are common.

In other cases the disease commences in the rectum itself. I



recently saw a case in which a rapidly necrosing inflammation followed a trivial injury by an enema pipe, the destruction of tissue being chiefly confined to the intestinal tunic; it ended in the separation by sloughing of about five inches of the entire circumference of the bowel and the formation of a very intractable stricture.

The **treatment** should be prompt. Early and deep incisions must be made in lines radiating from the anus; frequent syringing with anti-septic solutions, followed by warm boric acid stupes, may be employed. At the same time the patient's strength must be supported by a liberal allowance of milk, strong beef-tea, eggs, &c., and the administration of alcohol is usually indicated.

In making the diagnosis of abscess in connection with the rectum, the surgeon must bear in mind that suppuration, symptomatic of other diseased structures, may be present in the posterior perineal region; this is especially the case with urinary abscess; gangrenous periproctitis resembles closely the widespread necrosing inflammation following extravasation of urine. Usually, of course, urinary extravasation commences in the anterior perineum, and the tendency is to spread forwards, but occasionally the posterior perineum becomes involved, and then an error in diagnosis might readily occur. It is also well to remember that abscess pointing beside the rectum may have its origin in the prostate, the female genital organs, or may be caused by disease of the bony pelvis, or spine.

7. **Dysentery.** True dysentery is properly considered in connection with diseases of the large intestine generally, and a full account of it would be out of place in the present work; there are, however, certain definite lesions to be found in the rectum, a description of which is necessary. Although civilian surgeons in this country have but little opportunity of seeing the earlier stages of this disease, cases of chronic dysentery and its sequelae not infrequently require treatment, especially amongst Anglo-Indians and others who have returned from tropical countries.

The changes in the intestinal tunics resulting from dysentery have been fully investigated, and are admirably described by Ziegler (*Special Pathological Anatomy*, p. 288). In recent cases the mucous membrane is highly congested and swollen, and generally beset with minute extravasations of blood. The epithelial surface is overlaid with a glairy blood-streaked mucus. This presently becomes more slimy and bloodstained,



and interspersed with flaky fibrinous shreds and films, which indicate the beginning of a superficial necrosis of the mucous membrane. Soon the necrosis is made sufficiently evident by the appearance of erosions and loss of substance.

In slighter cases the necrosis and loss of substance are, at first, merely superficial, but the deeper structures are successively attacked, and in severe cases the whole of the glandular layer of the mucous membrane at particular spots may perish. The necrotic tissue is reduced to a turbid mass, in which the structural elements and the nuclei of the

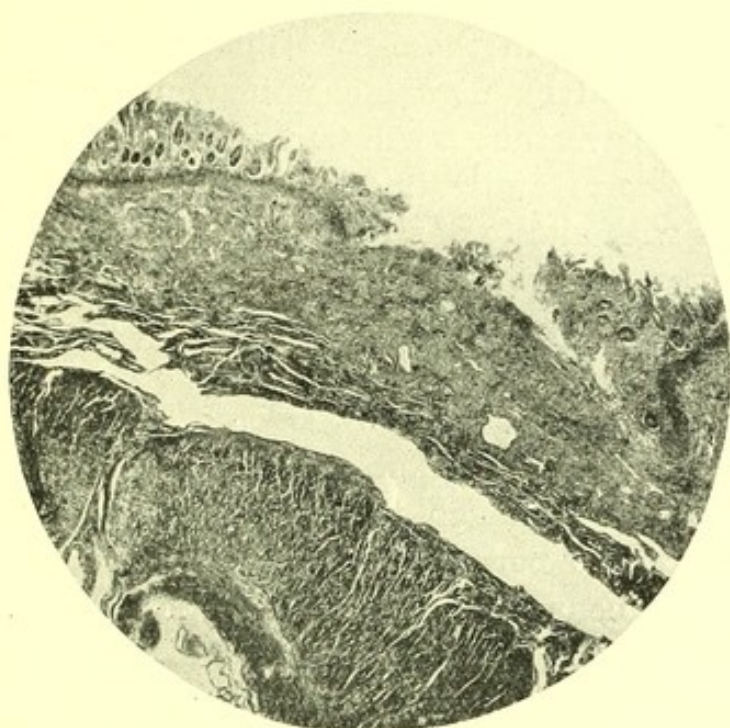

FIG. 52. Superficial Ulcer of the Mucous Membrane in Chronic Dysentery.

The ulceration is confined to the mucous membrane, and there is practically no infiltration of the deeper layers of the intestinal wall.

(*Photo-micrograph, × 22, of a section in the Pathological Department, Trinity College, Dublin.*)

cells soon cease to be recognizable. The parts which undergo necrosis seldom cover any great extent of surface, and are often confined to the prominent ridges and folds of the mucous membrane. These look dirty grey or black, while the intervening parts are still livid or dark red; in other cases the necrotic tissue takes the form of a flaky more or less adherent coating, or, more rarely, of broad, continuous sloughs. The underlying tissue is, in all cases, densely infiltrated with cells. The infiltration may extend through the entire thickness of the sub-mucosa,



and may at length invade the muscular layers. When the mucosa is removed open ulcers are of course left behind. These may vary in their depth and extent. Sometimes over a great part of the bowel the mucous membrane remains only in narrow strips or islands.

The disease may become arrested at any of the various stages of its course, and repair then begins. And when the ulceration has been deep, atrophic cicatrices may result. During this process of cicatrization a muco-purulent discharge takes place, constituting what has been called chronic dysentery, and it is in this stage that British surgeons most frequently meet with this disease in persons who have returned invalided from warmer countries. In these cases ulceration of the rectum can frequently be diagnosed by digital examination, or seen by means of a speculum, and the treatment will require much patience and care. Probably the best form of treatment is the careful swabbing of the ulcerated surfaces with nitrate of silver solution through a Kelly's proctoscope. The ulcerations are usually quite superficial, but of sufficient depth frequently to destroy the secreting surface of the mucous membrane, but not of sufficient depth to destroy the deeper structures. As the ulcers heal they are covered by smooth cicatrices in which the glandular epithelium is not regenerated. It is seldom, if ever, that the ulceration extends deep enough to produce, when healed, contraction sufficient to give rise to permanent stricture. It is probable that the many museum specimens of extensive ulceration and stricture labelled 'Dysenteric' are probably due to other causes, confusion having arisen from the fact that ulceration, from whatever cause arising, is characterized by clinical symptoms, the discharge of bloodstained pus, &c., suggestive of chronic dysentery.

8. **Tuberculosis.** Intestinal tuberculosis may exist as a primary disease, the bacilli being introduced in milk or other articles of diet, or it may be secondary to tuberculosis elsewhere, especially pulmonary phthisis. It is obvious that a person suffering from cavities in the lungs with abundant sputum must frequently swallow a large number of bacilli, and yet we see that intestinal tuberculosis is by no means a necessary sequela to advanced phthisis, many patients escaping from this complication. Koch suggests, as an explanation of this fact (*Mittheilungen aus dem Kaiserlichen Gesundheitsamte*, 2. Band), that the bacilli undergo digestion in the stomach, but that possibly the more resistant spores escape; as, however, these spores are of slow develop-



ment, the majority may escape with the faeces; it is only where some lesion of the intestine exists, or where they become accidentally lodged for some time in a portion of the intestine, that they have the opportunity of development. According to Gaffky (Koch, loc. cit., p. 34), the faeces of persons suffering from intestinal tuberculosis contain numbers of bacilli. He has drawn the following conclusions from a number of observations on this subject. In health, and in non-tubercular illness, no tubercle bacilli could be found in the faeces. In phthisis, where the sputum contains bacilli, none were found, except where symptoms of intestinal

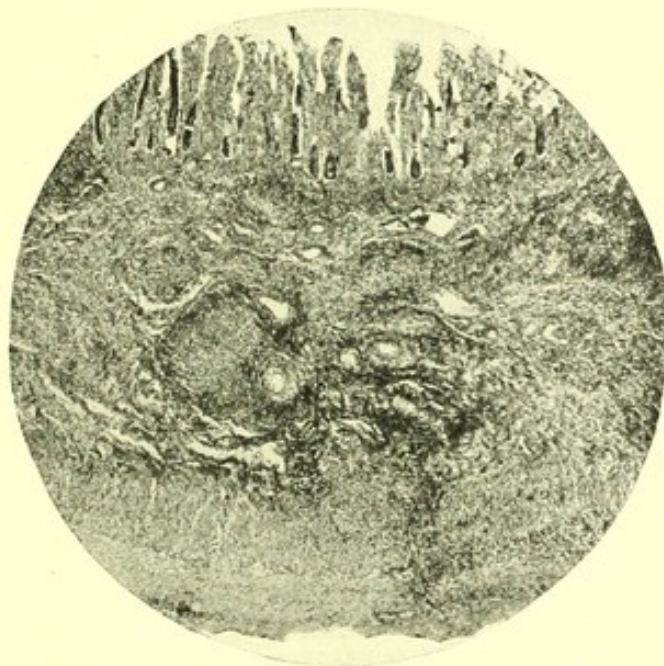


FIG. 53. Tubercular Deposit in Sub-mucosa and Muscular Coat of Intestine.  
(Photo-micrograph,  $\times 30$ .)

ulceration were present, and then they were abundant. He also found in faeces two other forms of bacilli, which were stained blue by Ehrlich's method, but they differed in shape from the tubercle bacillus.

Professor G. Sormani (*Annali Univ. di Medicina*, Aug., 1884, and *Lond. Med. Record*, March 16, 1885) has published some interesting experiments on the artificial digestion and other conditions influencing the life of these organisms. The stomach of a pig recently killed, and kept without food for forty hours before death, was the source of the gastric juice employed. Complete physiological digestion not only destroys the vitality of the bacillus of tubercle, but its form also. The



destruction of the bacillus is not among the first phenomena of digestion, rather among the last to happen; that is to say, these organisms are, among organized substances, the least easily attacked by the digestive juices. A digestion of too short duration, or of little activity from scarcity of gastric juice, or from insufficient acidity, does not attack the bacillus of tuberculosis, and in such case it maintains its virulence nearly unaltered. The knowledge of this, according to Sormani, helps to explain the frequent association of intestinal tuberculosis with pul-

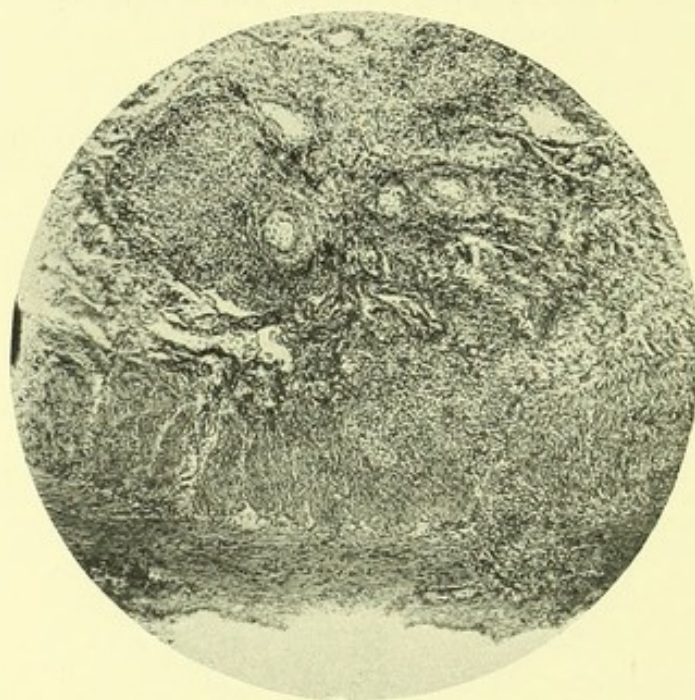

FIG. 54. Tubercular Infiltration of the Wall of the Intestine.

A more highly-magnified view of the section illustrated in Fig. 53. To the left-hand side of the photograph is seen a tubercular nodule in the submucous coat, and to the right-hand side and below the tubercular infiltration passing through both muscular coats of the bowel.

(*Photo-micrograph*,  $\times 63$ .)

monary phthisis. The stomach of the tubercular patients, little active, as a rule, from catarrh due to the fever, and possibly to the remedies, is of so weak digestive power that it readily allows these bacilli to pass unaltered, so that they may subsequently become foci of intestinal tuberculosis.

In the rectum the most usual site for the commencement of tuberculosis is in the anal sinuses; this is explained by the fact that these little pouches act as so many traps to catch the bacilli or their spores. Tubercular ulceration differs essentially from dysenteric ulceration, the



tendency of the former being to rapidly extend through the muscular tunic of the bowel, whereas the dysenteric ulcer, as we have seen, usually remains confined to the mucous membrane; this tendency to perforate explains the frequency of tubercular abscess in the ischio-rectal fossa. The bacilli, having found a resting-place in one of the anal pouches, form an ulcer which perforates usually between the levator ani and external sphincter, and thus an abscess starts in the ischio-rectal fossa; this burrows slowly, causing considerable undermining and thinning of the skin, and eventually opens, generally close to the anus, by one or more apertures forming a tubercular fistula. Tubercular abscess formed in this way is more chronic, and is attended with much less pain and

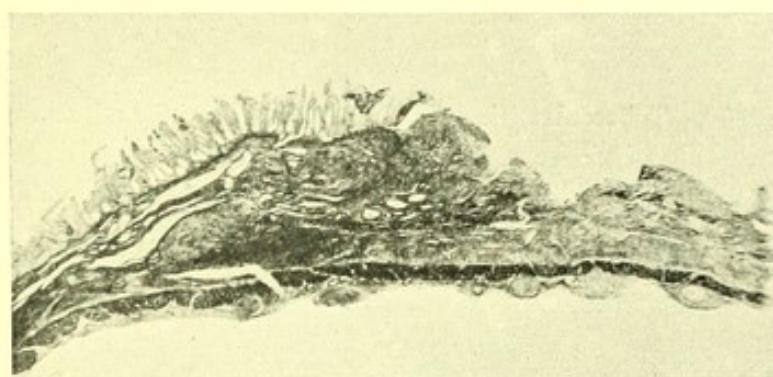


FIG. 55. Section of Tubercular Ulcer of Rectum.

The mucous and other bowel coats are normal on the extreme left-hand side of the figure. Tubercular infiltration of the sub-mucosa is seen in the middle, an open ulcer on the right, and tubercular nodules on the external coat.

(*Photo-micrograph*,  $\times 10$ .)

constitutional disturbance, than that caused by the other usual pus-forming cocci.

Tubercular ulcers of large size in the interior of the rectum are much less common than the small perforating ulcers originating there. They are to be diagnosed from syphilis, cancer, and chronic indolent ulcer; this can usually be done by noting the absence of much infiltration of the edges, and, as in other portions of the intestinal tube, bacilli are usually to be found in abundance in scrapings from the surface.

**Tuberculosis of skin.** In the lower segment of the anal canal and in the peri-anal skin tubercular ulceration is not infrequent; in the majority of cases this is associated with tubercular fistula. The ulcer is usually of moderate size, with much undermining of the edges, the



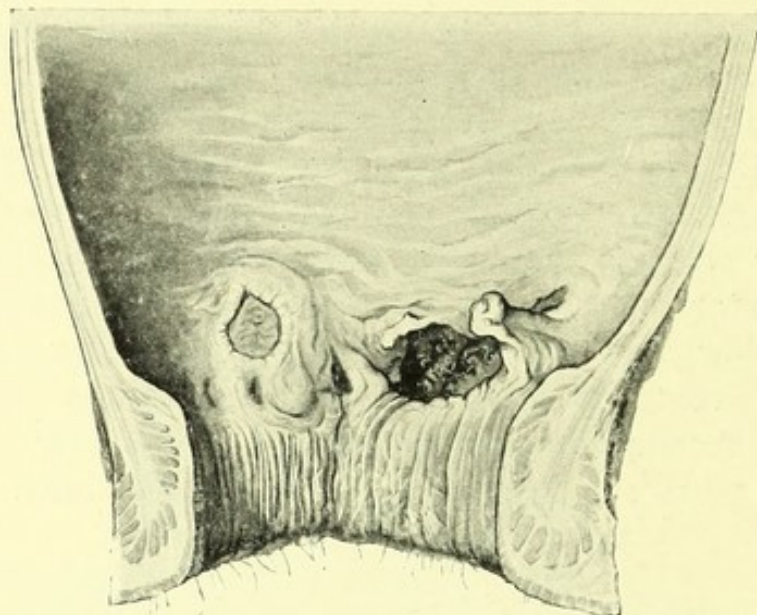


FIG. 56. Tubercular Ulceration of the Interior of the Rectum.

Originating in the anal sinuses. The ulcer on the left-hand side is surrounded with considerable infiltration of the sub-mucosa, the one on the right extends deeply into the muscular tunic of the rectum.

*(From a post-mortem specimen obtained at Sir Patrick Dun's Hospital.)*

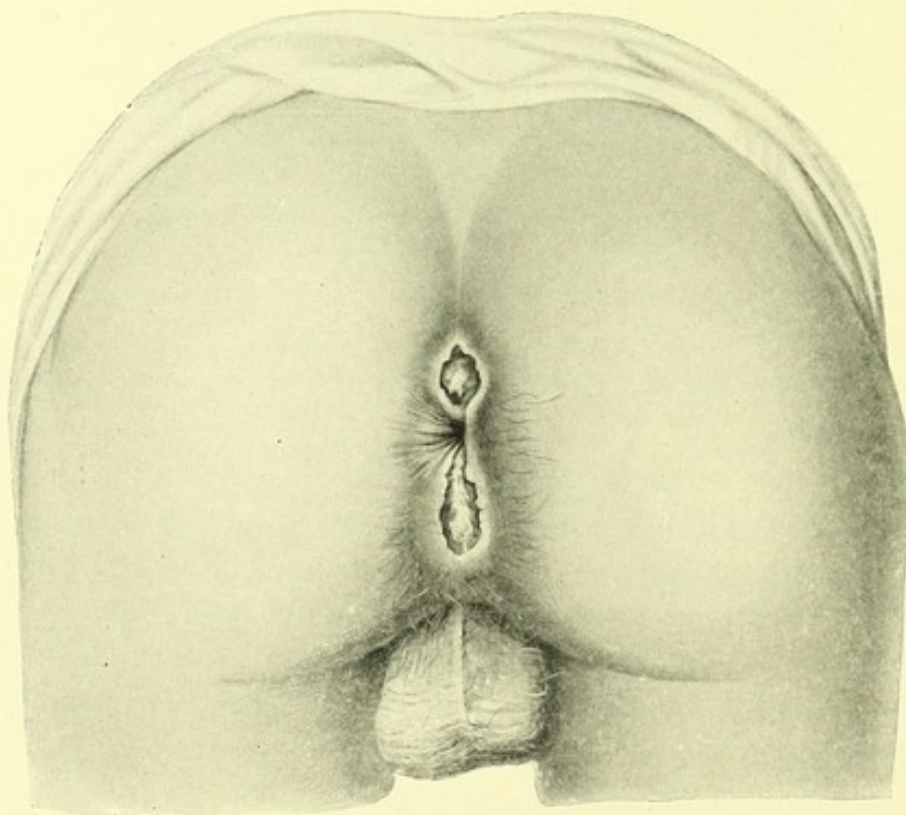


FIG. 57. Tubercular Ulceration of the Anal Canal.

*(From a sketch made of a patient aged 30 at Steevens' Hospital, under the care of the late Mr. Robert MacDonnell.)*



skin of which is much thinned and of a red or livid colour, and there is often more than one aperture in the skin. The surface of the ulcer is smooth, pale, and usually devoid of granulation; it secretes a moderate amount of thin pus; in the scrapings from these ulcers bacilli are apparently not so easily found as they are in the ulcers of the mucous membrane.

Extensive tubercular ulcer of the skin in the neighbourhood of the anus is not so frequently seen as the form above alluded to, but in rare instances a large portion or even the entire circumference of the cutaneous portion of the anal canal and surrounding skin may be destroyed, leaving a large ragged ulcer, widely exposing the musculature of the pelvic diaphragm, the termination of the bowel being marked by an irregular fringe of mucous membrane. Probably many of the cases described in older books, as cases of rodent ulcer and of L'Esthiomène, were of this nature.

As an example of the great ravages of this disease, the following case is given in a valuable paper by Dr. Angus McDonald (*Edinburgh Medical Journal*, April, 1884, p. 910).

'The case came under my notice after it reached an extreme degree of advancement; it had then lasted some six or eight years. The destruction of tissue was terrible in extent. I have reason to know that it is the same case as that referred to by Duncan, in 'Duncan and West', p. 656. Of it (at the time when he saw the case, which at least was a year before I was introduced to the patient) Dr. Duncan says, "A case to which I was called some years ago is, so far as I know, so unprecedented in the amount of destruction as to be worth describing. I only saw it once in consultation. The disease was at one time regarded as cancerous. The patient, aged about forty, had had the disease for at least five years, and she lived many years after my visit. While the disease was already extensive, she bore a child. On the hips, just beyond the ischial tuberosities, were long scars, thin and bluish, of healed ulcers. The entire ano-perineal region was gone, there being a hollow space as big as a foetal head. The urethra was entire, as well as the mucous membrane between it and the cervix uteri, which was healthy. Except the anterior portion of the vagina, no trace of it, or of the anus or rectum, was discoverable. Behind the cervix uteri the bowel opened by a tight aperture, just sufficient to admit a finger; when the faeces were hard she could keep herself clean, but only then. Although the extent of ulceration was severe, the patient was attending to her household duties." To this graphic description of the case I can fully subscribe, with this addition, that latterly the ulceration went still higher up into the pelvis, leaving



the bowel hanging loose for some distance from the upper level of ulceration, giving it the appearance of the torn sleeve of a coat. This patient lived two and a half years after the time referred to by Dr. Duncan, and died of exhaustion and diarrhoea. Notwithstanding this shocking amount and prolonged continuance of ulcerative action, there was no involvement of inguinal or other glands.'

In other cases tubercular ulceration in this neighbourhood assumes more the form of hypertrophic lupus with irregular nodular outline, ulcerated surfaces alternating with cicatrices, in which a large amount of new fibrous tissue is developed.

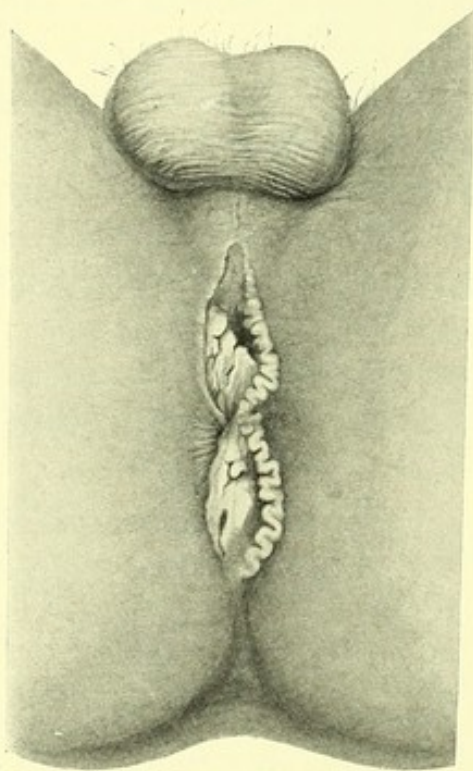


FIG. 58. Tubercular Ulcer of the Skin surrounding the Anus.

The edge is raised and on the left side shows a remarkable sinuous outline covered with pearly-white epidermis; dense white plaques of epithelium are seen on the surface of the ulcer.

(From a sketch made of a boy aged 16, at Sir Patrick Dun's Hospital.)

white epidermis, and between these plaques was a granulating surface. The discharge was very slight and the growth almost painless. I excised the entire mass and closed the gap by a shifting plastic operation, and recovery was complete. A microscopic examination of this case revealed abundant giant cells, but careful search failed to detect tubercle bacilli. I have not heard of any recurrence of the disease.

In a case which was under my care in Sir Patrick Dun's Hospital, 1890, the appearances were remarkable. The patient was a lad aged sixteen years, apparently in robust health, who stated that the ulceration had commenced two years previously. It extended up the anal canal, but did not encroach much on the mucous membrane; it extended out into the right buttock for about one inch and a half, and reached from the coccyx nearly to the scrotum. The whole ulcerated surface was raised about one-eighth of an inch above the surrounding structures, the margin was remarkably convoluted and tortuous, the edge being covered with pearly-white epidermis. Over the surface were large plaques of the same pearly-



**Treatment of tubercular ulceration** may be summed up shortly. As complete an extirpation as is possible is the indication. When complete excision can be practised, it is undoubtedly the best procedure, but the extent of the ulceration may be such that this is impracticable, or it may be placed so high in the rectum that its excision may be attended with considerable risk, or lastly, the ulceration may not have destroyed the power of continence, yet it may be so situated that a wide excision would necessarily have this undesirable result. Under all these conditions the right treatment is a thorough scraping with a sharp curette, and careful cauterization of the scraped surface with nitrate of silver, or other similar application. It is, however, often necessary to repeat this treatment, sometimes several times, but eventually a sound cicatrix may be obtained. The treatment of tubercular fistula will be dealt with later on.

**9. Syphilis.** From the fact that syphilis is credited with causing a large number of the cases of stricture met with in practice, considerable attention has been directed to the subject, and at all stages of this protean disease the anus and rectum may be the locality affected. Considerable looseness of description is, however, to be found in the accounts given by various authors, particularly in reference to the primary lesions met with. There can, however, be no doubt that both the chaneroid and true chancre have been met with not only at the anus, but in the interior of the rectum.

The discovery of the specific organism, by the late Dr. Schaudinn, now generally admitted as the cause of syphilis, will no doubt in the future tend to clear up much of the confusion which surrounds the subject of this disease in the rectum. In anal condylomata at any rate the *Spirochaete pallida* can be demonstrated without much difficulty (Fig. 60).

At the anus, especially in the female, the chaneroid is of common occurrence, and in this sex it may be the result of auto-inoculation from similar disease in the vulva, the discharge trickling down over the perineum, and so infecting any excoriations of the part that may be present, or it is quite possible that the accidental contact of the penis during coition may be the means of conveying infection. In the male, however, primary soft sore in the neighbourhood of the anus is exceedingly rare, and when present furnishes strong presumptive evidence of sodomy. According to Péan and Malassez (*Étude clinique sur les ulcérations anales*, Paris, 1872), nearly one-half of the superficial anal ulcera-



tions observed in females at the Lourcine, in 1868, were due to soft chancre, and according to Fournier (*Dict. de Méd. et Chirurg. Pract.*, art. Chancre, p. 72), one-ninth of the cases of chancroids in the female are situated at the anus, whereas in the male he met with only one case in four hundred and forty-five.

In position, these ulcers may be found on the skin in the immediate neighbourhood of the anus, or between the folds of the outlet, and extending over the border of the sphincter. They are mostly multiple, with sharply cut edges, in fact they in no way differ in appearance from the same form of ulceration met with in other parts of the body. When the ulcer extends over the margin, the pain is considerable, especially after defaecation, and bleeding is not uncommon. In rare instances extensive phagedaena may supervene and occasion considerable destruction of the parts; when this has been the case, or, indeed, when the chancres have been numerous and large, an anal stricture may be the result, but generally these sores heal without difficulty.

That chancroids may extend up into the cavity of the rectum has been put beyond doubt by the observations of Bumstead and Taylor (*Venereal Diseases*, Philadelphia, 1879), Van Buren (*Diseases of the Rectum*, London, 1881), and others, and there can be but little doubt that the much greater relative frequency of non-malignant stricture in the female is in a great measure due to this fact, although in all probability other causes are concerned in the production of the same result, for a further consideration of which the reader is referred to the chapter upon stricture.

That a primary soft sore may be found in the interior of the rectum without involvement of the anus has been denied by many authorities. The following case recorded by Neumann (*Allgem. Wien. med. Zeitung*, No. 49, 1881), from the very full and elaborate way in which it has been investigated, appears to set the matter at rest:—

‘Upon examination, a sharply cut sore, having the characters of a soft chancre, was found on the posterior wall of the rectum, about 4 cm. above the sphincter; the anus and genital organs were healthy. Inoculation of the discharge on the patient’s arm produced characteristic soft sores. The patient’s husband was then examined, and was found to have a soft sore on the margin of the prepuce. He admitted that he might have infected his wife directly. Subsequently two chancres appeared among the anal folds, presumably from secondary inoculation.’



The first and most important indication in the treatment of soft sore in this region is absolute cleanliness. The bowels should be kept somewhat free, by means of a saline aperient, and iodoform, or black-wash, used as a local dressing. Where the ulcer presents a spreading edge, cauterization with nitric acid is indicated, and, should the ulcer become chronic and assume the characters of irritable ulcer, division of the sphincter or forcible dilatation may be required.

**True chancre** at the anus is very rarely met with. This fact is accounted for by Péan and Malassez by the very slight disturbance to which the disease gives rise, so that the sufferers do not usually seek advice. True chancres here, as elsewhere, have a hard and raised outline, with indurated base, and might be mistaken for fissure, from which, however, they may be distinguished by the freedom from pain. In doubtful cases the diagnosis should be suspended, pending the appearance of secondary symptoms. Primary hard chancre within the rectum is even rarer still, and it is scarcely possible that it can occur in this situation except as a result of unnatural connection. Cases of it have, however, been put on record by Ricord, Fournier, and others.

Of all syphilitic diseases in the neighbourhood of the anus, **condylomata**, mucous patches, or moist papules are the most frequent. According to the statistics of Bassereau, condylomata were present in this situation in 110 out of 130 cases in the male, and in the female, if we except the vulva, the skin immediately surrounding the anal outlet is found to be the locality most affected.

It is not likely that typical condylomata could be mistaken for anything else, their appearance being so characteristic; the raised flattened surface, pearly-grey colour, and abominably foetid discharge, generally

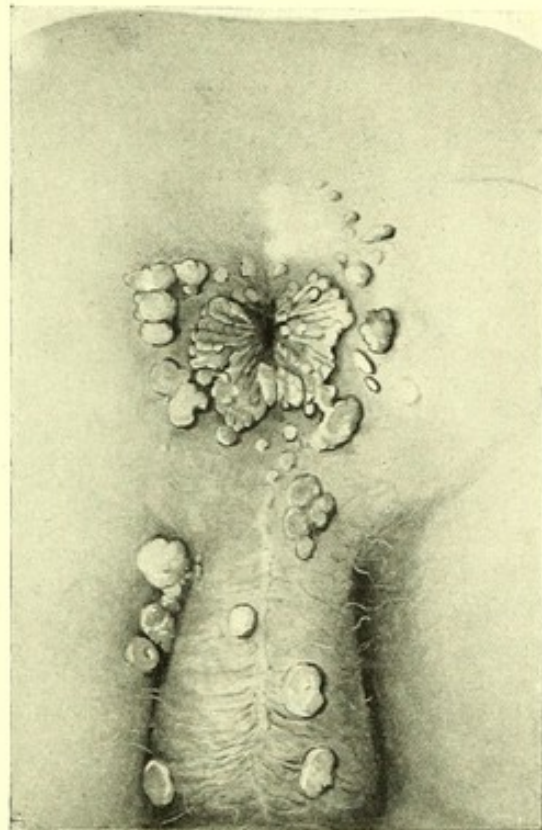


FIG. 59. Syphilis. Condylomata of the Anus and surrounding Skin.  
(From stereo-photograph.)



rendering the diagnosis easy. They are due to an inflammatory change in the epidermis and corium, especially the papillae, which swell up, owing to the infiltration with exudation cells and fluids, the epidermal covering becoming macerated and softened. Their growth is much fostered by inattention to cleanliness, and they have a great tendency to relapse. They sometimes undergo considerable increase in size by branching, and proliferation of the papillary structure. When this is

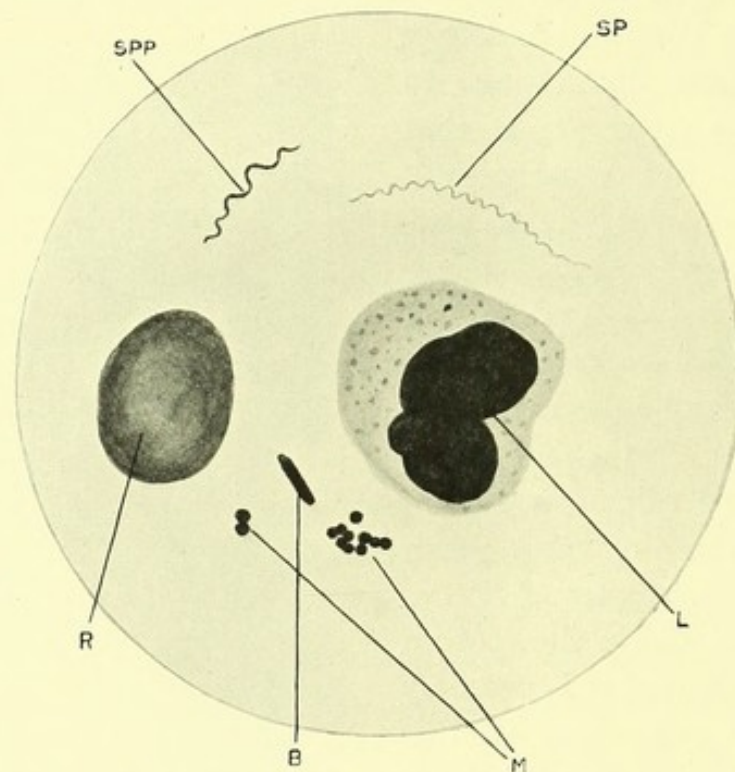


FIG. 60. *Spirochaete pallida* from Anal Condyloma.

S.P. *Spirochaete pallida*. S.P.P. *Spirochaete pseudo-pallida*. L. Leucocyte.  
R. Red blood corpuscle. B. Bacillus. M. Micrococci.

(Drawn with Camera lucida from smear preparation—Leishman's stain—by Dr. H. J. Wright, I.M.S.,  
House Surgeon, Sir Patrick Dun's Hospital.)

extensive they present a cauliflower-like appearance, or even a distinctly pedunculated wart may result. On the other hand, ulceration may take place, and irregular ulcers, called by the French writers 'rhagades', may be found. These are situated in the anal folds, and may be diagnosed from the ordinary fissures in this locality by being multiple, by having one or both edges elevated, and by being considerably less painful. After these ulcers are healed the elevated edges may persist as folds of hypertrophied skin, sometimes with a markedly crenated



border like a cock's comb. They are of a pale pink colour, soft, glistening, and moist. These appearances are so characteristic that even taken alone they are strong presumptive evidence of the presence of constitutional syphilis.

At the period of secondary syphilis, when numerous patches are commonly found on the fauces, similar patches are frequently found in the interior of the rectum, if looked for by means of a speculum, but apparently they do not give rise to any subjective symptoms.

It is well to remember that Kelsey and other American authorities confine the term 'condylomata' to the non-syphilitic hypertrophic folds of skin found round the anus resulting from piles.

**Gummata.** There is no part of the body, in which connective tissue is present, in which the gummatous deposit so characteristic of the later stages of syphilis may not be found, and we find that the lower bowel and anus prove to be no exception to this rule.

Cases of localised gumma in the rectum have been put on record by Leisol (*Archiv f. Dermatol. u. Syph.*, Wien, 1876), Mollière (op. cit.), Verneuil (quoted by Fournier, op. cit.), and Barduzzi (see Bumstead and Taylor, *Venereal Diseases*, p. 607). The most interesting case of this kind is, however, described by Zappula (*Arch. f. Dermat. u. Syph.*, Prag, pp. 62-90, 1871). The patient, a man of thirty-six years of age, had gonorrhoea, and an ulcer on the glans penis fifteen years before. Mercurial treatment was at once adopted, and no lesions of syphilis subsequently appeared. Fifteen years later he began to suffer from pains situated to the right side of the anus, and in the right tuberosity of the ischium, and very soon the symptoms of rectal stricture became developed, and so severe was the obstruction that a large faecal accumulation, which could be felt through the abdominal wall, formed. Upon digital examination, smooth, elastic elevations were recognized, which appeared to be enlarged folds of mucous membrane. At a distance of 4 cm. from the anus there was found a painless swelling, the size of a hazel nut, globular, smooth, and elastic. It was apparently situated under the mucous membrane, to which it was not attached. The diagnosis lay between syphilis and cancer, and as a complete cure resulted from the exhibition of iodide of potassium, the former diagnosis was established.

**Ano-rectal syphiloma.** Under this name Fournier has described (*Lésions Tertiaires de l'Anus et du Rectum*, Paris, 1875) a remarkable



specific infiltration of the rectal wall, which, as he states, begins in the submucous layers, the mucous membrane being only secondarily affected and at first free from ulceration. This disease, he has noted, is more common in females in the proportion of eight to one, and its usual situation is the rectal pouch, but the anus may be involved. The tendency of this infiltration is to undergo ulceration, or sometimes to end in cirrhotic contraction without any ulceration. What the exact pathology of this condition is does not appear to be settled. Fournier speaks of it as a hyperplastic proctitis, passing at a later stage into a fibro-sclerous condition, and it appears that it is more closely related to the diffused sclerotic changes which take place in the spinal cord, liver, and other organs during the later periods of syphilis, than that it is, as Van Buren describes it, an infiltrated form of gumma. It is to be diagnosed by the stiff, lumpy feel of the intestine, usually free from ulceration. Van Buren states that he has seen it entirely disappear under a mercurial course, but it is obvious that treatment, to be at all effectual, must be undertaken before the stage of cirrhotic contraction has set in.

In **congenital syphilis** the only common manifestation at the anus is the mucous patch, sometimes associated with radiating fissure-like ulcers. I have, however, met with one case of stricture in a child, aged ten years, who had well-marked 'Hutchinson's teeth' and interstitial keratitis, and, from the great infiltration and firm feel of the coats of the bowel, I have but little doubt that it was the result of a similar cirrhotic change to that described by Fournier, as resulting from the later stages of the acquired disease. Bodenhamer (*The Congenital Malformations of the Rectum and Anus*, p. 63, New York) alludes to inherited syphilis as an occasional cause of congenital stricture.

Trelat (*Progrès Médical*, p. 473, June 22, 1878) speaks of small superficial fistulae perforating the tabs of skin usually found in syphilitic disease. He says that they are all healed and dry within, like the holes for ear-rings, and are characteristic of syphilis. They have sharply cut orifices, and are found in cases of ano-rectal syphiloma.

During the later stages of syphilis a form of ulceration is not uncommon in the rectum, which may assume extensive proportions, and finally, by the contraction which takes place during its cicatrization, occasion stricture of the bowel.

These ulcers usually invade the anal canal, but may also extend for



a considerable distance up the rectum. Their outline is irregular; sometimes islands of unaffected mucous membrane are to be found, surrounded by an area in which the entire thickness of the mucous membrane has been destroyed, closely resembling the annular ulceration of the skin in typical syphilis. There is a considerable amount of new tissue to be felt, and if the ulceration has continued for any considerable time, narrowing of the bowel to some extent is almost certainly present.

Extensive **amyloid degeneration** of the rectum, in common with that of the rest of the intestinal tract, is frequent in old-standing cases of extensive syphilis, but this condition is not of much practical importance, as it gives rise to no symptoms of significance except diarrhoea, which is due to the extensive changes of the whole intestinal tube, rather than to any local disease of the lower bowel.

The **treatment** of syphilis of the rectum presents no peculiar features, the various manifestations demanding similar treatment to that employed for the corresponding lesions in other parts of the body.

10. **Actinomycosis**, when it occurs at the anus and surrounding skin, presents characters similar to those met with in other parts of the body—chronic inflammatory swelling covered with livid skin, numerous sinuses exuding pus in which the characteristic club-shaped bodies may sometimes be seen, or the typical fungus can be found by microscopic examination.

The infective diseases of the rectum above alluded to not infrequently lead to important changes which may remain after the specific character of the disease which gave rise to them has subsided, and which therefore necessarily require separate consideration, and of these the more important are ulcer, stricture, and fistula. Examples of all of these come under the surgeon's notice for treatment at a time when it may be quite impossible to determine the exact nature of the infective process which gave rise to them.



## CHAPTER VII

### ULCERATION

**Ulcerations of the rectum**, due to dysentery, tuberculosis, and syphilis, have been dealt with under their respective headings.

**Simple ulcer.** Following surgical operations, burns, or other forms of trauma, and following the separation of sloughs due to sepsis, a granulating surface similar to that met with in other parts of the body

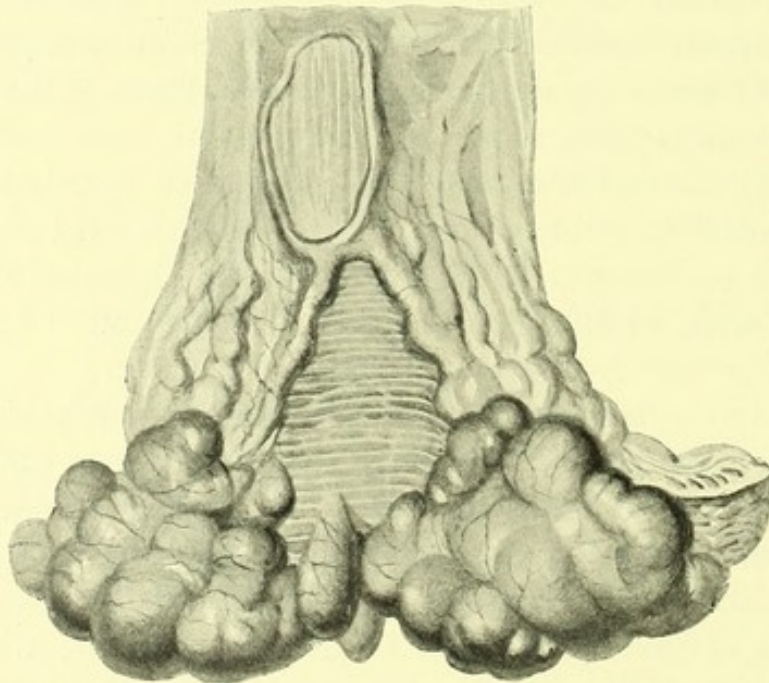


FIG. 61. Haemorrhoidal Ulcer of the Rectum.

Two chronic ulcers are seen with raised edges and marked varicosities of the haemorrhoidal veins.  
(From a painting in the Royal University of Ireland.)

may be met with. Usually, healing progresses smoothly, and cicatrization rapidly takes place, but occasionally the ulcer becomes indolent, the granulations disappear, the edges become thickened, and the characters that we are so familiar with in indolent ulcer on the leg develop. A special form of indolent ulcer has been named the haemorrhoidal ulcer,



associated with piles, and analogous to the varicose ulcer met with in the leg. It is certainly by no means a common condition, and judging by the rarity with which we meet indolent ulcer following operations for piles, it would appear that a varicose condition of the haemorrhoidal veins is much less operative in the causation of indolent ulcer than is a similar condition in the veins of the leg.

The treatment of indolent ulcer of the rectum is similar to that elsewhere; rubbing the surface with silver nitrate or copper sulphate may be all that is necessary, or if this fails, a thorough scraping with a sharp curette, rest in bed, and local cleanliness will usually suffice. If the destruction of tissue has been extensive, and especially if the whole circumference of the bowel has been implicated, the contraction of the cicatrix may be sufficient to produce stricture. In very extensive ulceration of the rectum, where all other means have failed, colotomy, as a temporary measure to afford physiological rest to the ulcer, is undoubtedly a sound plan of treatment, and has many times been employed with success. In a large indolent ulcer which had proved intractable for many years, I succeeded in getting sound healing in this way. The colotomy wound was subsequently easily closed.

**Follicular ulcer.** A form of multiple ulceration of the rectum and large intestine has been described under the above heading, the exact pathology of which appears to be obscure. The symptoms are those of chronic dysentery, and an examination with speculum reveals numerous small, circular, sharply cut ulcers, extending through the entire thickness of the mucous membrane. The condition is undoubtedly a very rare one. Probably the best form of

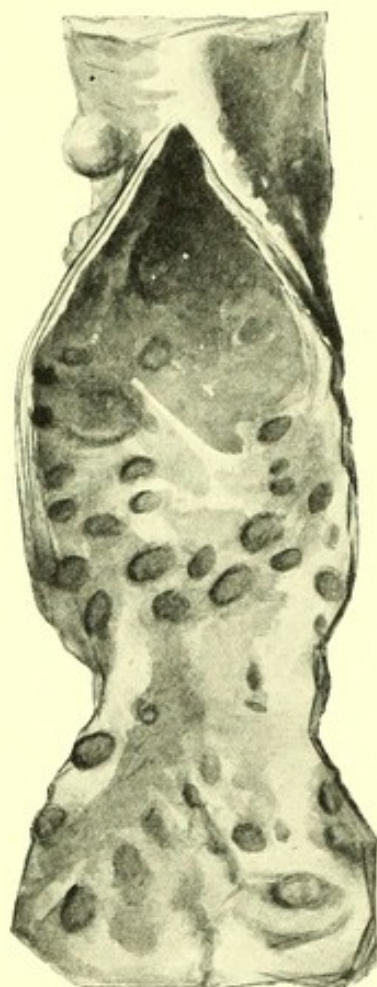


FIG. 62. Follicular Ulceration of the Rectum.

Numerous small, sharply cut ulcers are seen extending through the mucous membrane, and in some places smooth cicatrices caused by the healing of former similar ulcers.

(From a specimen in the Museum of the Royal College of Surgeons in Ireland.)



treatment is the direct application of silver nitrate, by means of the proctoscope.

**Ulcers in the sinuses of Morgagni.** As has already been pointed out, these little sinuses are a very frequent site for the origin of rectal tuberculosis. Occasionally, however, ulcers are met with here which are not tubercular, and which probably owe their origin to localised sepsis following injury, or the lodgement of foreign bodies. Unless they encroach on the sensitive area, they may give rise to only trivial symptoms, but there is always the possibility of sepsis passing through the floor of the ulcer and forming an ischio-rectal abscess.

The following case illustrates this condition. A man aged 60 was for several weeks in the medical wards of Sir Patrick Dun's Hospital,

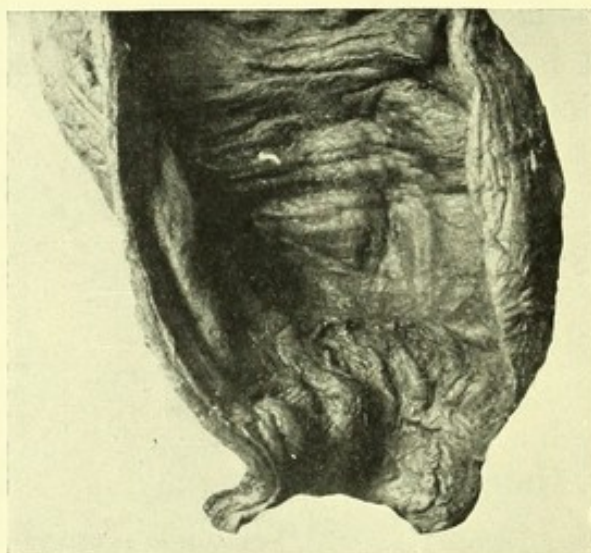


FIG. 63. Ulceration of the Anal Sinuses in a Man aged 60, who died of Bright's Disease.  
(Direct photograph from specimen.)

suffering from Bright's disease, from which he eventually died. During his stay in hospital he never complained of any uneasiness about the rectum, and, as there was no indication to excite suspicion, no rectal examination was made. I injected the vessels of the rectum for anatomical purposes, and on slitting up the bowel was surprised to find three well-marked ulcers immediately inside the external sphincter. On reference to the figure (Fig. 63) it will be observed that they had manifestly commenced in the little sinuses, two of which remained unaffected. None of these ulcers invaded the anal margin, with its numerous sensory



nerves, hence the complete absence of symptoms in this case, as contrasted with the extreme agony attending the ordinary irritable ulcer.

In connection with this case it may be well to inquire whether there is anything more than an accidental relation between ulceration in the lower bowel and disease of the kidneys. Bartels says degeneration of the blood-vessels of the intestinal mucous membrane is certainly a very common condition with amyloid disease of the kidney, and extensive ulceration, destructive of the mucous membrane, is by no means a rare consequence thereof. He considers that intestinal ulceration has a direct sequential relation to diseased kidney, and he states that follicular ulceration of the large intestine is not infrequently associated with amyloid changes. Dickinson also, in the Croonian Lecture for 1876, mentions intestinal ulceration as one of the rare complications of renal disease.

Irritable ulcer or fissure, owing to its special character, will be treated separately.



## CHAPTER VIII

### FISTULA

**Rectal fistulae** present themselves to our consideration in considerable variety, and from their great frequency, and the discomfort they produce, constitute a subject of great interest to the surgeon. It is, therefore, to be little wondered at that, in looking through the voluminous literature on this subject, the names of many of the great masters of surgical art are to be found.

The use of the term 'fistula' (a pipe), so common in general surgery, originated probably in the special variety now under consideration, and amongst the older surgeons the term was confined to those cases in which the tissues immediately surrounding the ulcerating track had become much indurated and thickened, the effects of long-continued inflammatory changes. Now, however, it is used in a broader sense, and is applied to any abnormal communication between a mucous canal and the external skin, or between two mucous surfaces, the term 'incomplete fistula' being sometimes used where the fistulous track has only one aperture, either mucous or cutaneous.

The exciting cause of rectal fistula may occasionally be a penetrating wound, but much more frequently it is the result of suppuration, any of the varieties of abscess commonly eventuating in this condition. Why an abscess situated in this region is more likely to become fistulous than abscesses situated in other parts of the body is a question of considerable interest, but the true explanation is not far to seek. In the first place, the looseness and free motion of the tissues in the ischio-rectal fossa tend to prevent rapid closure of an abscess cavity, in the same way that we see sinuses remaining for a long time unclosed in the axilla or female breast, and where a cutaneous opening alone exists this must be taken as the principal cause; but where there is a mucous aperture, a very much more potent influence is brought to bear, namely, the constant trickle of mucus and thin faeculent matter along the track of the fistula.



Of the complete muco-cutaneous fistulae connected with the rectum, the best practical division is according to the position of the internal opening, and we find there are three situations in which this opening may be found. In the first and most simple case the fistula is sub-cutaneous, the inner opening being situated superficial to the external sphincter, at the anal verge; to this alone should the term *fistula in ano* be confined. Next we may find the opening situated between the two sphincters; this is the most common variety. And, lastly, we have the fistula in which the opening into the rectum is situated above the pelvic diaphragm, traversing, therefore, the so-called 'superior pelvi-rectal space of Richet'.

The **superficial fistula** has its origin in a marginal abscess, and is generally very minute, and productive of little inconvenience; it may be altogether superficial, or extending through a few fibres of the external sphincter; as, however, it does not open directly into the cavity of the rectum, the escape of flatus and fluid faeces does not take place, consequently secondary suppuration is uncommon. So slight is the irritation, that occasionally we see the internal surface of the fistulous track cicatrize, and then it remains as an epidermis-lined tube, like the hole for an ear-ring, and ceases to give annoyance. These may sometimes be mistaken for congenital openings, the result of irregular development of the proctodaeum, but a history of previous suppuration should establish the diagnosis.

The ordinary form of **complete rectal fistula** is the result of abscess in the ischio-rectal fossa, either primary or secondary to changes in the rectal wall, and the position occupied by the internal opening is tolerably constant, being situated between the two sphincters at the pectinate line. The external opening is subject to more variety, but is generally within one inch from the anal verge, though occasionally at a considerably greater distance, as in the groin or thigh. The position of the internal opening in this variety is a subject of very considerable importance, as, unless acquainted with its usual situation, the surgeon may fail to find it, the reason for this being, that in most cases the mucous membrane of the bowel is separated from the muscular wall for a variable height above the orifice, so that the opening is not really at the highest point to which suppuration has extended, as one might be led to expect.

In a large majority of cases the internal opening will be found immediately above the pectinate line, and there are definite anatomical



reasons why this should be so. If the fistula is the result of primary suppuration in the ischio-rectal fossa, the abscess is prevented from extending upwards by the pelvic diaphragm with its fascial coverings, while its spread is directed by these structures between the sphincter muscles as the line of least resistance, and thus it perforates the muscular coats of the bowel just above the level of the pectinate line; similarly, if the suppuration commences as an ulceration in the interior of the rectum,

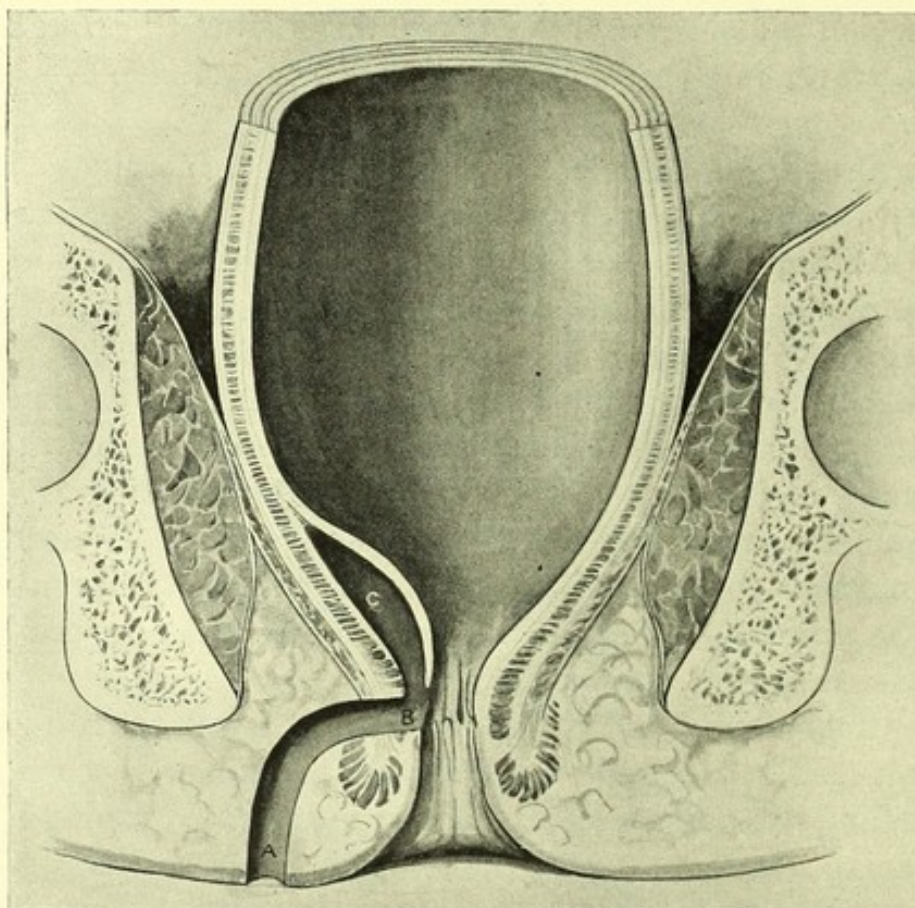


FIG. 64. Diagram of complete Rectal Fistula.

A. External opening. B. Internal opening. C. Separation of mucous from other coats of the rectum by suppuration.

the most common position for such ulcer to commence is in one of the little sinuses of Morgagni; the suppuration then follows the line of least resistance out into the ischio-rectal fossa below the pelvic diaphragm. Again, as the rectum is suddenly constricted at the upper opening of the anal canal, this region is more vulnerable to puncture by pins, fish-bones, and such-like foreign bodies, which, when swallowed, may make the



tour of the entire length of the intestinal canal in safety and perforate the wall of the bowel at this point.

When, however, the abscess originates above the levator ani muscle in the superior pelvi-rectal space, the pus may separate the rectum from its loose connections for a considerable distance upwards, extending round its entire circumference, and open into the lumen of the bowel at almost any point. In these cases of pelvi-rectal fistula originating above

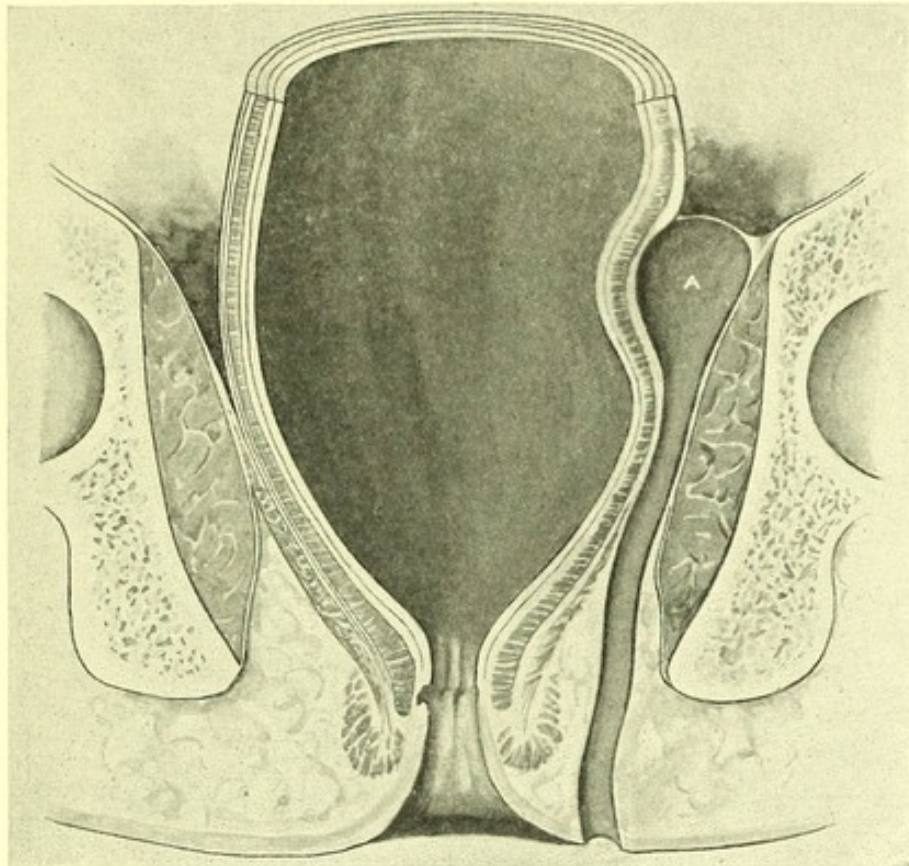


FIG. 65. Diagram of Abscess and Sinus of the Superior Pelvi-rectal Space.

A. marks the position of the abscess from which the sinus originated.

the pelvic diaphragm the cutaneous orifice is usually situated posteriorly, the abscess having passed between the posterior portions of the pelvic diaphragm, this structure being more easily penetrated by suppuration immediately behind the rectum than at any other portion of the circumference.

Of **incomplete fistulae** two varieties are described, to these the terms 'blind internal' and 'blind external' have been applied. These names are most confusing, and were it not that they have received the



sanction of long usage, would not be referred to here. In order to prevent misconception, it is necessary to state, however, that the blind internal fistula is that in which there is a mucous but no cutaneous opening, and the blind external fistula is merely a sinus with a cutaneous aperture, but no opening in the mucous membrane. Although this is the generally accepted way in which these terms are used, some authors reverse this arrangement. I have frequently found students transpose the names, a mistake which, considering the nomenclature, is scarcely to be wondered at. In the following pages the terms 'internal

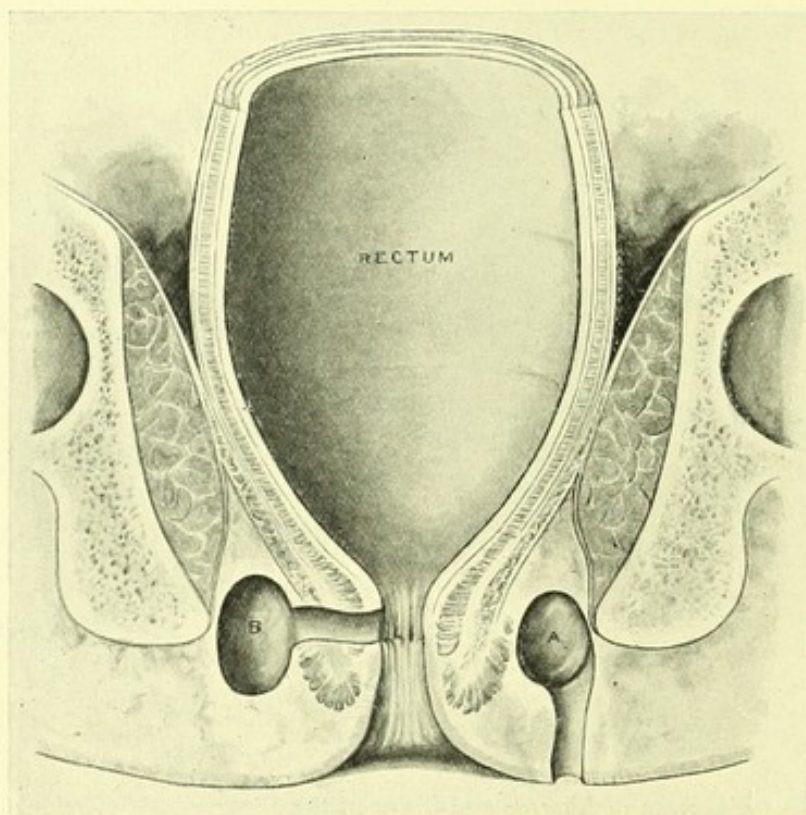


FIG. 66. Diagram indicating the ordinary forms of Incomplete Fistula.  
A. External rectal sinus. B. Internal rectal sinus.

and external rectal sinus' will be used, as more clearly indicating the conditions referred to.

**Internal rectal sinus** may, therefore, be defined as a suppurating track, communicating with the cavity of the rectum by means of an opening in the mucous membrane. Its origin may be due to similar causes to those which produce the complete fistula, and, indeed, it is frequently only the preliminary stage of the latter condition, an internal



rectal sinus, if left to Nature, sooner or later perforating the skin, and thus forming the complete fistula.

**External rectal sinus** is the result of an abscess which has commenced in the structures external to the rectum, not directly stercoral in its origin, which has broken or been opened externally, and which, from causes previously enumerated, is prevented from healing in the ordinary manner. The direction of the sinus may be towards the rectum, and sometimes ulceration will transform this also into a complete fistula, but in other cases the track leads away from the rectum into the upper portions of the ischio-rectal fossa. Owing to the difficulty which is experienced sometimes in detecting the internal opening of a complete fistula, the diagnosis of external rectal sinus has been more frequently assumed than its existence proved. The study of dissected specimens has, however, completely determined the existence of this condition, but it is very much rarer than the complete fistula.

The track of a fistula is seldom straight, and the calibre generally varies at different parts of its course. This irregularity is one of the most important reasons why difficulty is experienced in making a probe traverse the full extent of the fistulous channel. We sometimes find a sharp angle in the course, the cutaneous extremity at first leading away from the rectum, and then taking a sudden turn towards the bowel. This is probably due to the fact that the changed course is rendered necessary by the fistula following for some distance the direction of the levator ani muscle. And, again, it is common to find pouches, or diverticula, communicating with the main track. These diverticula sometimes become blocked up, forming foci of fresh suppuration which may perforate the skin at a distance from the original orifice, so that we sometimes meet with cases of fistula in which numerous external openings exist. I have seen in one case as many as twenty-two external openings, the whole of the buttock on both sides being riddled with fistulous tracks, a condition which has not inaptly been compared by Mr. Allingham to a miniature rabbit-warren. Increase in the number of internal openings is extremely rare, and it never exists to the same extent as is the case with the cutaneous orifices, but sometimes two or more openings may be recognized in the mucous membrane. In the case above mentioned, and in the one figured, only one internal opening was discoverable.

Of these **complex fistulae**, as they have been called by Hamilton,



one important variety remains for consideration, namely the 'horseshoe fistula'. In this the external and internal openings are on opposite

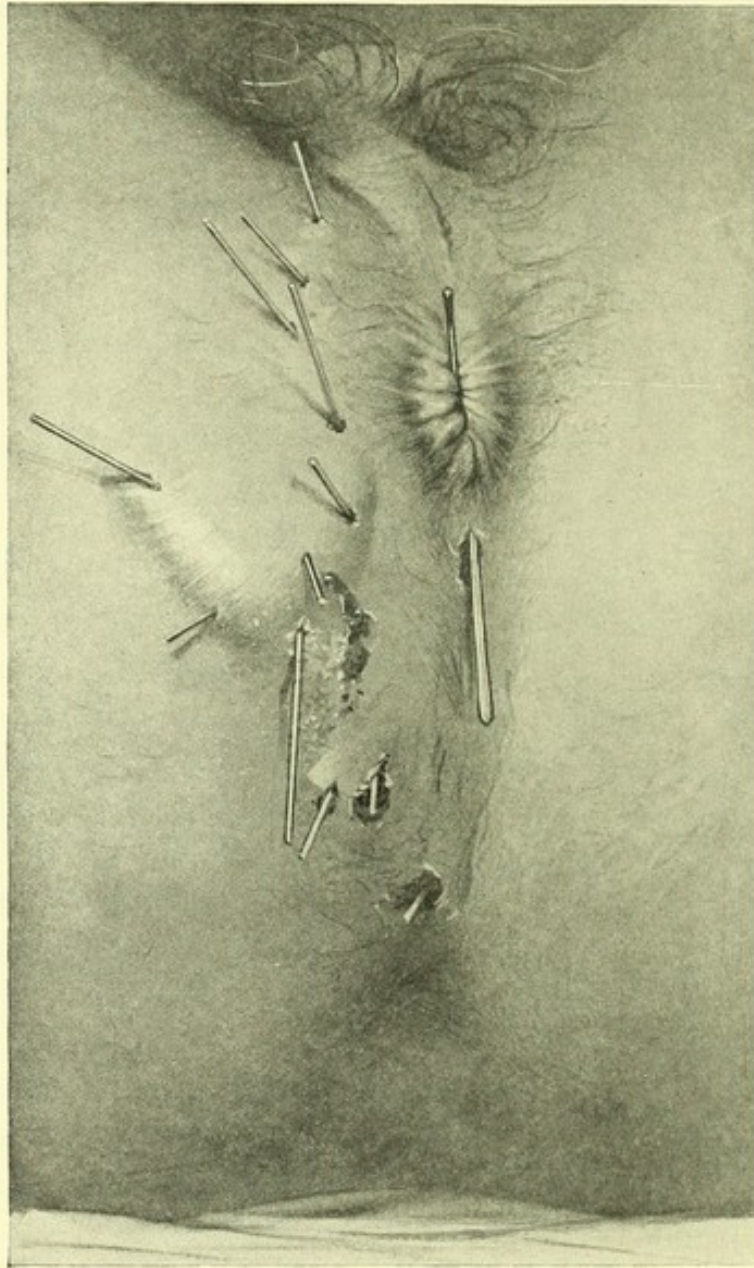


FIG. 67. Multiple Fistulae.

The large probe passes through one of the external openings, through the single internal opening and out at the anus. The other probes indicate numerous external openings, all of which communicate with the main track of the fistula.

*(From stereo-photograph of case at Sir Patrick Dun's Hospital.)*

sides, the track running round the margin of the anus subcutaneously; this may be due to abscesses starting in both ischio-rectal fossae simul-



taneously, or it may be the result of the burrowing of matter from an abscess in the first instance unilateral. It is to be recognized by the discovery of the external and internal apertures upon opposite sides, and by the induration which marks the path of the fistula.

Histologically considered, a fistula resembles in structure an indolent ulcer. Its surface is covered by unhealthy granulations in part, and in others granulations are wanting; frequently we see at the

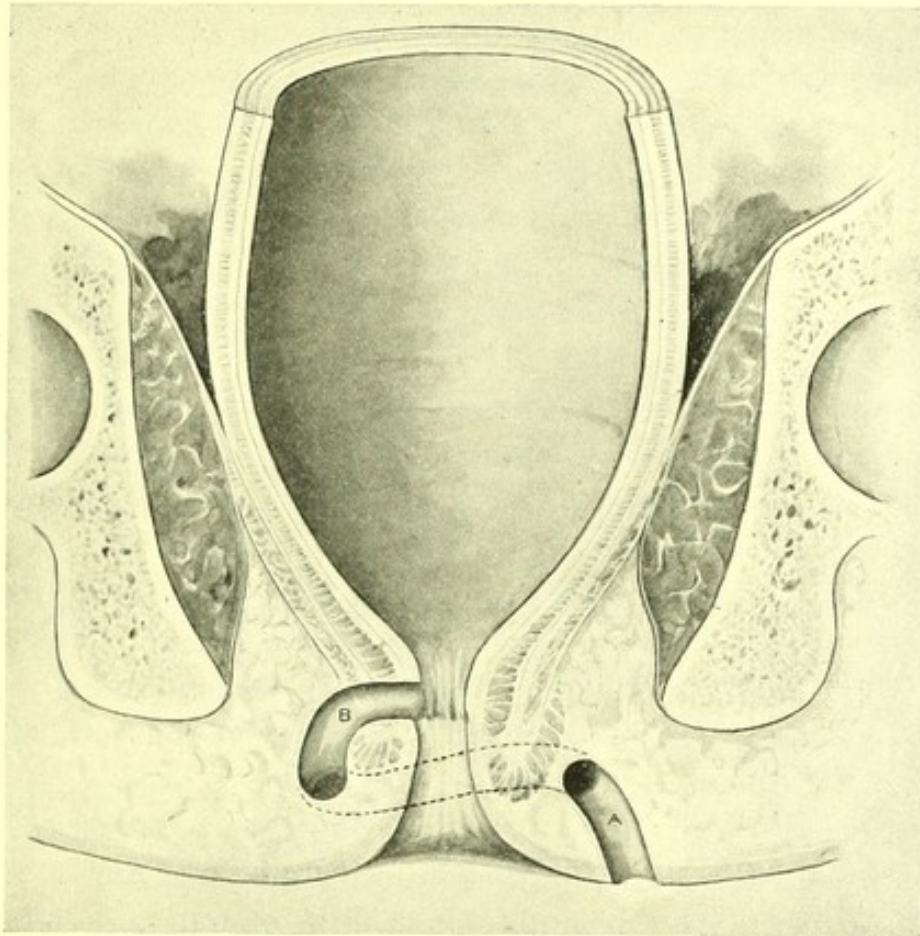


FIG. 68. Diagram of Horseshoe Fistula.

A. External opening. B. Internal opening. The dotted lines indicate the track of the fistula round half the circumference of the perianal tissues.

external orifice a flabby sentinel granulation protruding, which, when present, renders the opening much more obvious. Immediately surrounding the granulation is a layer of fibrous tissue, which is sometimes of extreme density, feeling almost of cartilaginous hardness. This is found only in fistulae of long standing, and is due to the proliferation of the connective tissue elements at the base of the granulations, in abortive



attempts at healing. The rapidity with which this hardness disappears when the fistula is healed is remarkable. The most marked example of this condition that ever came under my notice was in a man who had had fistula for fifteen years. He had a hard warty growth about one inch from the anus, and  $\frac{3}{4}$  inch in diameter, which was attended with but little discharge; from this point a hard ridge could be felt passing deeply. This wart was so firm and elevated that it suggested to more than one surgeon who saw it the idea that it was epitheliomatous; a probe, however, could readily be passed into the rectum, and simple incision sufficed to effect a permanent cure. I saw this patient a year after the operation, and the cicatrix was as soft and elastic as the neighbouring skin, no trace of the warty protrusion remaining. The older surgeons looked upon the thickening as a new growth, which it was necessary to remove. Hence arose the term of cutting *out* a fistula, and so freely was this done that in many cases incontinence of faeces was produced, and the patient was rendered much more miserable by the *cure* (!) of his fistula.

The symptoms of which fistulous patients complain vary according as to whether there is active suppuration going on or not. The abscess from which the fistula originates is, if acute, extremely painful, though frequently tubercular abscess occurs in this locality, in which case the initial pain may be slight. With a fistula fully established little pain is experienced, but considerable annoyance is occasioned by the soiling of the linen with discharge, which is generally accompanied with an unpleasant odour. There is generally some tenesmus, and the faeces may be stained with blood, &c.

A person suffering from fistula is always liable to attacks of secondary suppuration, due to blocking of the tube by small particles of faeces or exuberant growth of the granulations. This, of course, is attended with pain, until a new opening forms, or is made by the surgeon, or until, as sometimes happens, the passage of the original fistulous track becomes re-established. Fistula in some persons, more particularly those of a nervous temperament, produces an amount of depression and constitutional disturbance altogether out of proportion to the local disorder; their minds being impressed with a feeling of physical weakness, rendering them miserable and unhappy.

The diagnosis of fistula is generally attended with but little difficulty, although sometimes the small size of the external orifice renders it difficult of detection, and in others the great induration and prominence may give



rise (as in the case above detailed) to the suspicion of epithelioma. Cases of the latter kind show how important, as an aid to diagnosis, the positive detection of an internal opening may be.

A difficulty may possibly arise in determining whether a fistula is connected with the bowel or with the genito-urinary organs, but in the majority of cases no such difficulty should arise. Rectal fistulae usually open in the posterior perineum, while those in connection with the urethra open anteriorly; at any rate, a probe introduced into a fistula will show to which side of the perineal septum the track lies. This perineal septum is a very definite structure; it is seldom perforated by suppuration, so that it may be generally assumed that abscess posterior to it is associated with the rectum. In urinary fistulae the escape of urine along the track will serve to establish the diagnosis. The fistula of the superior pelvi-rectal space may be difficult to recognize. If the opening into the rectum can be found with the probe and finger in the bowel, or if faecal matter escapes at the orifice, the diagnosis is obvious, but under other circumstances it may be impossible to distinguish this form from sinus following suppuration in connection with other pelvic organs, or with diseased bone.

**Tubercular fistula.** Tuberculosis of the rectum has been dealt with elsewhere (p. 76). The tubercular ulcers which so frequently form in the rectal sinuses rapidly tend to perforate, and produce abscesses in the ischio-rectal fossa which ends in the production of fistula. It is a matter of importance to be able to recognize tubercular from other forms of fistula, and the characters are in many cases sufficiently distinct to enable the surgeon to make a positive diagnosis. Inquiry should first be made as to the nature of the preceding suppuration. Ischio-rectal abscess, the result of staphylococcus or streptococcus infection, is acute, and extremely painful, while that due to tuberculosis is more chronic and seldom attended with severe pain, so much so that the patient is sometimes unaware of its existence until rupture and the discharge of pus attracts his attention. The appearance of the fistula itself in typical cases is often characteristic: the external opening is large and irregular in shape, surrounded with dusky livid edges of thinned skin which are much undermined, the track of the fistula is wide, the internal opening patulous and easily detected by digital examination or by the passage of a probe. In a large majority of cases tubercular fistula coexists with, and is dependent on, pulmonary phthisis, so frequently is this the case that every patient with fistula, even if the local appearances are not



characteristic of tuberculosis, should be examined for disease of the lungs and the sputum, if any, examined for bacilli ; the microscopic examination of the discharge from the fistula is not to be depended on for diagnostic purposes.

**Should a patient with phthisis be operated on for fistula ?**

The answer to this question must depend on the individual characters of each case. If the patient is in an advanced stage of consumption, or if

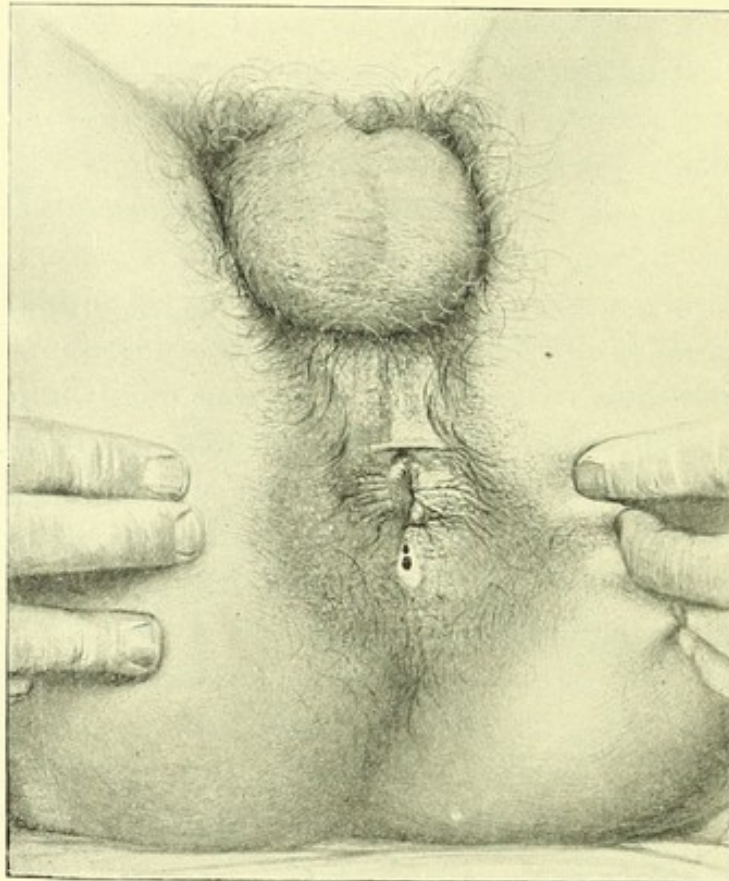


FIG. 69. Tubercular Fistula.

The double opening and thin edges, which are much undermined, indicate the tubercular origin of the fistula.

*(From stereo-photograph of case at Sir Patrick Dun's Hospital.)*

there is extensive ulceration of the rectum, wide ramifications of the fistulous tracks, and moderately extensive disease of the lungs, it is better not to operate, in all other cases operation should be recommended. The question of dealing with tuberculosis is essentially different from that of cancer, the latter should only be operated on when there is a reasonable probability of being able to completely remove the disease, but in tuber-



culosis it is well to eradicate every focus of infection that is possible, even if it is known that other foci must be left behind as inoperable; the fewer the centres of infection in the organism the greater the probability of its being able successfully to resist their inroad.

The **examination** of a fistulous patient is to be carried out in a methodical way. The best position is the dorsal, with legs drawn up and widely separated and the pelvis well raised so that a good view can be obtained of the anus and surrounding skin. If the external orifice is prominent, or if there is a sentinel granulation present, it will be obvious, but where small, and situated between folds of skin, pressure with the top of the finger will usually cause a little drop of matter to exude, and so demonstrate its position. Careful feeling with the finger will also frequently tell us the direction which the track takes; with the index finger in the rectum and thumb outside the tissues surrounding the anal canal can be gently pinched all round the circumference and any increased thickness due to inflammation surrounding the fistula detected. A probe should now be passed along the fistula, and in doing this considerable care is requisite, and the utmost gentleness should be observed, always remembering that the probe is to be directed by the channel it is passing through, and not forcibly by the hand of the surgeon. It is well to be provided with one of the flexible spiral metal probes, and also with a very fine silver probe, for the investigation of tortuous and very narrow fistulae; sometimes, also, by bending the point of the ordinary probe, it will be found to pass with greater facility. The probe having been passed, the finger should be introduced gently into the rectum, and it is a matter of importance that this should be subsequent to the passage of the probe, as if the finger is introduced into the rectum in the first instance, a spasm of the sphincter muscles is set up, which will greatly increase the difficulty of passing the probe. It will be frequently found that, as the top of the finger passes the sphincter muscle, the end of the probe is felt free in the cavity of the rectum, thus demonstrating the fact that the fistula is complete. In other cases the mucous membrane is felt to intervene between the tip of the finger and the probe, and the latter can be passed freely over a considerable surface, showing that the mucous membrane has been separated to a large extent from the muscular walls of the rectum. In these cases the internal opening generally exists, but it may be hard to find, the usual fault being that it is looked for too high up. Careful palpation with the pulp of the finger will sometimes, if the sense



of touch is delicate and has been educated, determine the orifice, while at others it may be brought into view by simply everting the mucous membrane of the anus. Should a doubt still exist as to the completeness of the fistula, injection of milk may be had recourse to, a speculum having previously been introduced into the rectum, when of course the appearance of milk in the bowel will set the question at rest; or a few drops of solution of hydrogen peroxide may be injected along the fistula, and if there is an internal orifice present, bubbles of oxygen gas will escape into the rectum. If none of these methods demonstrate the inner opening, the case must be looked upon as one of external rectal sinus, but when the fistulous track passes through the muscular wall and separates the mucous membrane from the outer coat, a mucous orifice may nearly always be found. Should this, however, not be the case, the failure will be of little moment practically, as the same plan of treatment applies to both. Where the entire substance of the rectal wall intervenes between the finger and probe, or where the probe is guided away from the rectum along the anal fascia to the upper portion of the ischio-rectal fossa, the case is one either of external rectal sinus or of fistula originating in the superior pelvi-rectal space. We must, therefore, in these cases go farther, and try and find the cause, such as diseased bone, &c.; and in the female a vaginal examination may show us a uterine or ovarian origin. Where there are numerous external openings it is necessary to carefully probe all these so as to determine whether they are all connected and the direction which they take. The upper limit of the separation of the mucous membrane should also be made out, and search should be made for more than one internal orifice, if such be present.

The diagnosis of internal rectal sinus is generally more difficult than the forms we have been considering. In this variety the faeces may be smeared with pus, or blood, and a boggy swelling felt at some portion of the anal circumference. If the internal orifice can be felt, or seen through a speculum, a bent probe may be introduced into it, and made to protrude beside the anus.

Having made the diagnosis of complete fistula, we must, before proceeding to treatment, satisfy ourselves as to the presence or absence of other important diseases, and, of these, changes in the rectum itself hold a first place. The coexistence of fistula with other pathological conditions in the lower bowel has been already alluded to, but I cannot



too fully impress on the junior practitioner the necessity of examining for stricture, malignant disease, haemorrhoidal and other tumours, in every case that comes under his notice.

Where the inconvenience produced by fistula is but slight there is sometimes considerable difficulty in getting a patient to consent to the treatment necessary for cure, but it may be taken as a general rule that the longer a fistula is left without being efficiently dealt with, the more tortuous and complicated it becomes, and the more difficult will any subsequent procedures be.

**Treatment of fistula.** Since Pott pointed out that the complete excision of a fistula was unnecessary, and that a simple incision converting the tracks of the fistula and the rectum into a single tube was all that was required, this treatment has been almost universally adopted, the attempt to close an established fistula by scraping, drainage tubes, and antiseptic dressings being so seldom successful that it is now usually discarded by surgeons. In order to effect this division several methods have been employed: 1. Passing a blunt-pointed director through the fistula, hooking out the end through the anus, and cutting through the tissues resting on the instrument, taking care to make the incision through the anal margin radially to that orifice, so that the divided edges are square and not bevelled, is at once the best and most simple method where a director can be passed through the fistula, and where the opening is low enough to admit of the point of the director being hooked out at the anus without undue force.

2. If the opening is too high, or if the structures are too indurated to admit of the protrusion of the probe at the anus, a blunt-pointed curved director may be passed along the fistula into the rectum, and the index finger of the left hand passed through the anus; a blunt-pointed knife is introduced along the director, which is then withdrawn. The probe point of the knife is to be pressed upon the pulp of the finger and both withdrawn with a sawing motion dividing the intervening structures. Special instruments for this purpose have been devised, but are quite unnecessary, while the methods of division by simple or elastic ligature, or by the Paquelin or galvanic cautery, are to be condemned.

3. In cases where the track is so tortuous or complicated that a probe will not pass into the rectum, or where no internal orifice exists, it is obvious that the above methods are unsuitable. In these cases the



direction of the track should be ascertained by passing a probe along it as far as possible. With a pair of scissors the fistula is now laid open as far as the end of the probe, and the edges of the incision caught in catch forceps and forcibly divaricated; it will be seen that the fistula is lined by granulation tissue. With a little care the probe can now be passed further along, although the direction may be quite different from

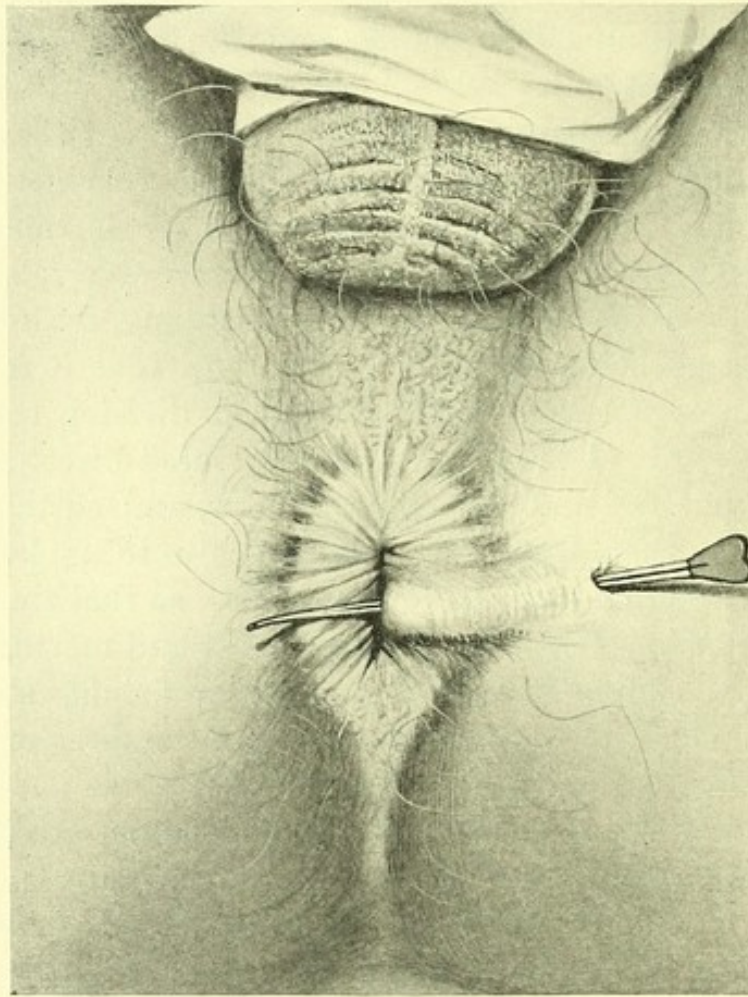


FIG. 70. Operation for Fistula, stage 1.

A director has been passed through the fistula, into the rectum, and out at the anus.

(From stereo-photograph taken during operation.)

the first portion laid open. The second portion is in like manner laid open with scissors, and so on until the probe passes into the rectum, or failing an internal opening until the entire fistula is explored. In tracking a difficult fistula, it is often a help to feel for the internal opening with the finger in the rectum; it can almost always be recognized by the practised hand, and a probe suitably bent can be passed from the internal



orifice for a sufficient distance along the track to afford important information as to its direction, or sometimes to be made appear in the external incision. A probe must be used with the utmost gentleness in these cases; the old method of forcing a probe or director into the rectum when no internal opening can be made out is unquestionably bad

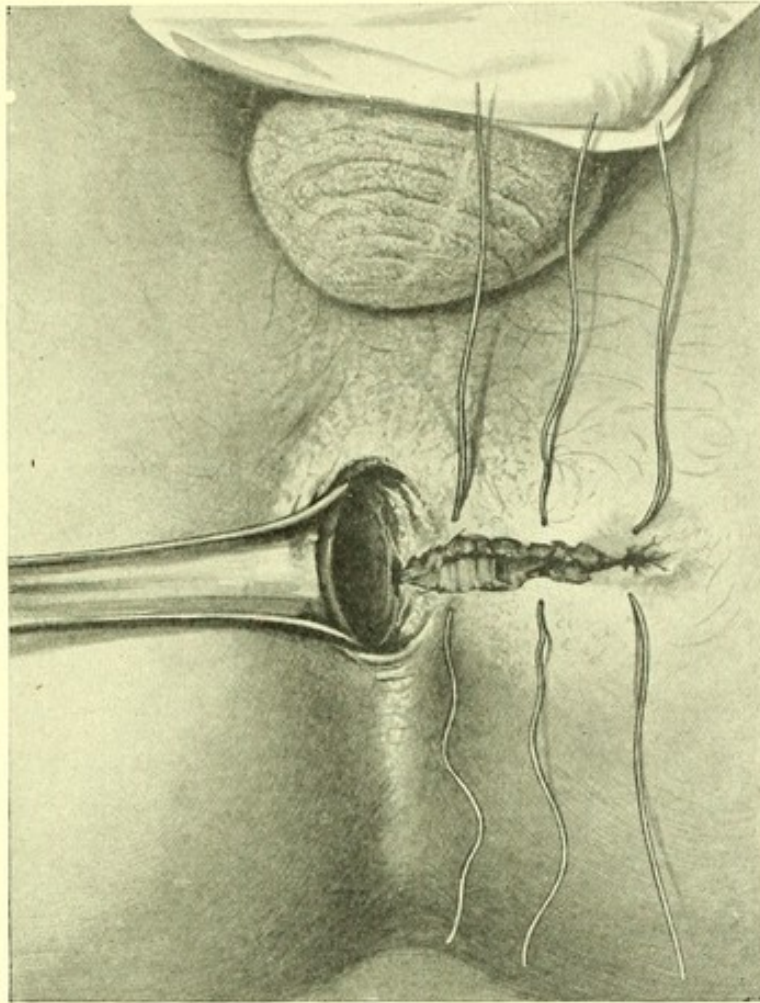


FIG. 71. Operation for Fistula, stage 2.

The fistula has been slit up. The granulation tissue scraped away. The track of the fistula disinfected with absolute phenol. Sutures have been passed underneath the fistulous track.

*(From stereo-photograph taken during operation.)*

surgery, and will in all probability end in failure to cure the fistula. Having now opened up the intervening tissues between the two orifices, it is necessary to follow any offshoots from the original track, or, if multiple external openings are present, to connect them with the primary incision. It is rare to find more than a single internal opening, but should others be present they are best dealt with in the same way.



The after-treatment formerly was to plug the wounds so formed and allow them to heal by granulation. This was a tedious process, occupying many weeks, and if the sphincter was at all deeply cut a certain amount of incontinence frequently formed a most distressing sequela. Although sporadic attempts to close fistulae wounds by suture had hitherto been

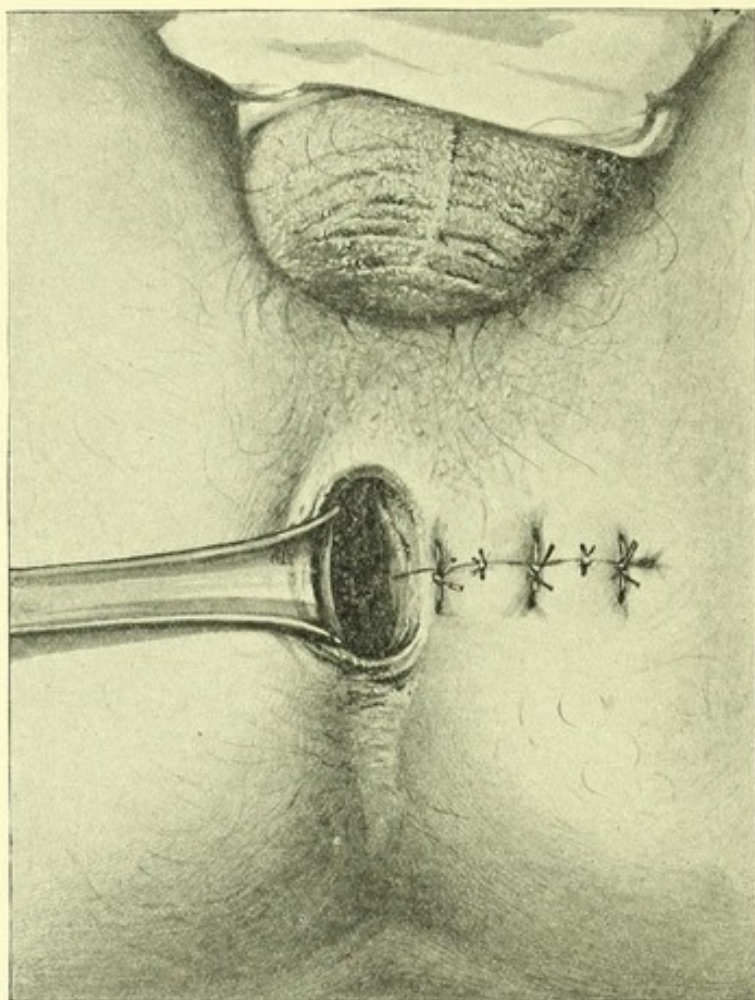


FIG. 72. Operation for Fistula, completed.

The deep sutures have been closed and two points of superficial suture added.  
(From stereo-photograph.)

recorded, it was an American surgeon, Dr. Stephen Smith, who first, in 1886, drew special attention to this subject, and since reading his article I have invariably attempted to obtain immediate closure except in extremely complicated cases, and of recent years have been almost invariably successful, but success is only to be obtained by thoroughness and careful attention to detail. In the first place all granulation tissue



possible is to be removed by the curette, exposing a firm connective tissue surface; this then is to be somewhat forcibly scrubbed with a gauze sponge, which will remove small portions of infected tissue that may have escaped the curette. The entire track is now to be carefully searched to make sure that no diverticulum has escaped notice, any doubtful pieces of tissue, including the margins of the external openings, are to be dissected away with forceps and knife, and the wound thoroughly disinfected. For this purpose the usual solutions of bichloride of mercury or carbolic acid are quite ineffectual; either liquid carbolic acid, formalin, or strong solution of iodine must be used, and applied by means of a small gauze mop to every crevice of the wound. Before attempting to proceed further the surgeon must sterilize his hands as thoroughly as possible, or, better still, put on fresh gloves, and then pass sutures, preferably of boiled fishing-gut, in the following way: the first is passed at one margin of the wound close to the anus, by a needle of sufficient curve to allow of its being passed above the internal opening, without perforating the wound surface. Having passed round well above the internal opening, it in like manner traverses the tissues outside the wound on the other side of the incision, and is made to perforate the skin at a point near the anus accurately corresponding to the point of entry upon the opposite side. It is somewhat difficult to pass this suture satisfactorily, and it is well to have several needles of different curves so that the most suitable one can be chosen for the individual case; if properly passed it will be found to completely surround the fistula, no portion of it being visible from the wound surface. In like manner three or four more deep sutures are to be passed at intervals, surrounding the entire depth of the wound. Before tying these sutures the skin margin is to be accurately approximated by superficial sutures, and then the deep sutures closed, commencing with the one nearest to the anus. If all goes well the wound will be soundly healed in a week, and all sutures can be removed, but up to that time a careful watch must be kept for suppuration. Upon the slightest trace of pus becoming visible along a suture, that suture should be removed, and if there is anything like general suppuration all sutures must be taken out, the newly healed wound opened up, plugged with iodoform gauze, and treated as if no sutures had been applied, and the wound irrigated and re-plugged every day. It will then gradually fill up, and heal by granulation. If a drop of pus exudes anywhere by pressure on the granulating



surface while the wound is healing it should be carefully searched with a probe, as possibly a minute offshoot from the original fistula may have escaped at the first operation, and if this is not slit up the case will not be cured. It will thus be seen that if it be possible to obtain immediate union many weeks of treatment are saved, and the restoration of sphincteric function is more complete. If sufficient care is taken the great majority of cases of fistula can be so closed. Where the wound becomes infected, and immediate union fails, we are in no worse position than if the attempt had not been made, indeed if, as is sometimes the case, suppuration remains limited to a portion of the wound, the outer portion may unite primarily, so that the time necessary for complete healing is considerably less than if the whole wound healed by granulation.

There is a general idea that operation on fistula is a trivial matter, not demanding much skill. This no doubt is the case in the most simple forms, but to effect complete cure in a complicated case is a difficult and tedious operation demanding the exercise of considerable patience and attention to minute details. It is only by thoroughness that one can hope to cure such a case at a single operation.

Treatment of internal rectal sinus can be carried out much in the same way as that already described, the only difference being that it is necessary to establish an external opening. For this purpose a bent probe should be introduced from the rectum into the sinus and cut down upon from the outside as near the anal margin as possible, or, if this is not practicable, the sinus should be steadied between finger and thumb and cut down on until the granulation tissue lining is exposed. The further treatment is then the same as in complete fistula.

Horseshoe fistula also is to be similarly treated. Starting at the external opening the fistula is to be followed and opened up round to the opposite side, where the internal opening is situated, and the sphincter then divided into the internal opening. The entire track is then to be cleaned, disinfected, and sutured up as in the ordinary type.

Fistula of the superior pelvi-rectal space, with an opening into the rectum above the pelvic diaphragm, is not very satisfactory to deal with. The operation must be conducted upon somewhat different lines, as it is necessary to provide drainage for fear of extravasation in the loose areolar tissue above the pelvic diaphragm. If the internal opening can be detected and a probe passed through into the rectum, the intervening tissues may be divided and the two tubes thrown into one; all granulation



tissue is removed with the curette, and the surface thoroughly disinfected. An attempt may now be made to suture the wall of the rectum from, and including, the internal opening to the margin of the anus, but the deeper part of the wound outside the rectum must be kept open by a drainage tube. It is not likely that union will take place under these circumstances, and if not, the wound must heal by granulation, and a certain amount of incontinence is almost sure to result.

Tubercular fistula is to be treated upon the same lines as the simple complete form, but may require more extensive removal of surrounding structures, especially of the thinned and overhanging skin.

**After-treatment of operation** when the fistula has been sutured demands but little attention if the wound continues to be aseptic. A firm pad kept in place by a perineal bandage relieves painful spasm of the levator ani. The bowels should be kept confined for four days. If, however, the wound suppurates and opens up, it will have to be dressed daily. After the bowels move the wound should be irrigated and lightly plugged with iodoform gauze, and a careful watch for any suppurating track discharging into it maintained. The process of healing by granulation is, as a rule, somewhat slow, and is liable to sudden arrest after it has hitherto progressed favourably. The causes of this delayed healing are many. In the first place, the frequent distension and soiling of the wound by the passage of faeces is, of course, impossible to obviate, but much may be done by ensuring a soft motion at regular intervals, at the same time taking care not to establish diarrhoea. Another important factor is the congestion of the lower portion of the rectum, so common in these cases. Where this congestion is considerable, healing is much retarded, the wound resembling a varicose ulcer of the leg, which is sometimes so difficult to heal. Precisely the same treatment will be found to apply to both, the most essential element of which is rest in the recumbent position; this, by relieving the vessels of the weight of the contained column of blood, materially assists the healing. After the first three or four days it is not necessary to keep the patient in bed, but the recumbent posture should be maintained on a couch for the greater part of the day, until cicatrization is completed. Stimulating applications will be found of great service in these sluggish cases which become indolent, such as balsam of Peru, or compound tincture of benzoin; sometimes lotions of zinc sulphate or ferrous sulphate will answer better. If not progressing satisfactorily, it is a good plan to vary



these applications, or more potent stimulants may be tried, such as red oxide of mercury, or nitrate of silver. When other means have failed, change of air, particularly to the seaside, will frequently cause these indolent sores to assume a healthy surface and rapidly heal. This is especially true of hospital patients sent to a convalescent home in the country.

If a nerve twig is exposed in the granulating surface, the ulcer will assume some of the characters of irritable ulcer; this condition demands thorough scraping with the curette.

Under the term **trichiasis recti**, Gross (*System of Surgery*, vol. ii, p. 602, sixth edition) has described a condition which retards healing of these wounds. It is, as the name implies, analogous to the trichiasis of the eyelid, the margins of skin becoming turned inwards. The hairs which grow in the neighbourhood of the anus are directed against the wound, and so a source of irritation is kept up. The treatment should consist in the removal of the cutaneous margins, or, where this is not considered advisable, careful epilation.

**Secondary suppuration** occurring in the proximity of the wound will of course delay the healing process, and the surgeon should always be on his guard for this complication. Any complaint from the patient of pain about the incision or any increase of the discharge, calls for the most minute examination of the part, and if any secondary focus of suppuration be found during the after-treatment, it should be opened up from the original wound without delay.

An unpleasant sequela to the operation for fistula is a certain amount of **incontinence of faeces** when fluid, or of flatus. This is happily now of rare occurrence, and only follows extensive operations, such as those required for the superior pelvi-rectal fistula, or where more than one division of the sphincter has been rendered necessary and when primary union fails. If it exists to any extent it is productive of great annoyance to the patient, possibly more than the original fistula, the cure proving worse than the disease. Something can be done to remedy this in mild cases, by the judicious use of the cautery. If the sharp point of Paquelin's thermo-cautery be applied to the cicatrix of the operation wound, contraction will follow, giving tone and increased power to the sphincter and decreasing the size of the anal outlet. In this way this troublesome complication can sometimes be relieved, but care is obviously necessary not to cauterize the anal margin to too great an extent, as an intractable form of stricture might be the result.



In more marked cases a plastic operation to reunite the separated surfaces of the divided sphincter may be called for and is sometimes quite successful.

Fistulous communications between the rectum and other mucous tracks (*fistulae bimucosae*) may be conveniently classified into four divisions: (1) in which some portion of the bladder or urethra is penetrated, (2) where the female genital organs are implicated, (3) where a fistulous channel is established between some other portion of the intestinal tract and the rectum, and (4) recto-rectal fistula.

(1) **Recto-vesical and recto-urethral fistulae** may result from a variety of causes, of which the following may be enumerated. Direct traumatism; this will most commonly result from, or be occasioned by, an accident attending some surgical operative proceeding. Formerly when the distended bladder was tapped through the rectum for the relief of retention of urine, fistulae of this kind sometimes resulted. Penetration of the vesical wall may also result from the forcible introduction of an enema pipe or other foreign body through the anus. Accidental injury of the rectum in perineal lithotomy or prostatectomy must be noted as an occasional cause.

Suppuration originating in the structures surrounding the rectum or urethra may, by opening both these mucous tracks, result in the formation of a fistulous communication; such is occasionally the case with prostatic abscess. Malignant disease, whether originating in the tissue of the rectum or in its immediate proximity, is undoubtedly the most frequent cause of an abnormal communication being established between these two organs. This subject, however, will be more fully considered in the chapter upon cancer.

Primary ulceration of the bladder of a non-malignant type must be admitted as a cause, though it is an extremely rare one, a few cases having been recorded in which urinary calculi escaped by this means into the rectum, and were discharged through the anus.

In the female, recto-vesical fistulae are, as might be anticipated from the anatomical relation, excessively infrequent; such cases have, however, been recorded.

The **symptoms** of this condition are extremely distressing. The escape of urine into the rectum causes excoriation of the anus and great irritability, but if the opening into the bladder is sufficiently large to permit the entrance of faeces, the suffering of the patient is usually



almost intolerably severe, cystitis followed by nephritis of an aggravated form being the inevitable result. I have, however, seen one case of the kind in which, although a small quantity of faeces passed into the cavity of the bladder, but little irritation was produced, the diagnosis of the condition being first made by the appearance of striped muscular fibre as a urinary sediment; this was accounted for by the escape from the bowel of small particles of incompletely digested meat.

The **treatment** of this condition must vary with the extent and nature of the fistulous communication. Where the size is moderate, and the surrounding tissues normal, an attempt should be made to close the opening by a plastic procedure, in the same way that vesico-vaginal fistula is closed, a large duck-bill speculum being introduced into the rectum, but where there has been very extensive destruction of the recto-vesical septum, or where the surrounding tissues are infiltrated, especially if that infiltration has the clinical features of malignancy, the proper course is undoubtedly to permanently divert the faecal current from the rectum by the establishment of an abdominal artificial anus.

Dittel (*London Medical Record*, p. 139, July 15, 1878) has advocated an exceedingly ingenious operation for the cure of recto-urethral fistulae in the male, the steps are as follows: A sound, having been introduced through the urethra, he makes a transverse incision in the perineum in front of the anus, and then carefully dissects between the rectum and urethra. When the fistula is met, it is divided, and the rectal and urethral orifices separately sutured. This operation would appear to promise excellent results, but as far as I can learn it has not been performed sufficiently often to justify conclusions as to its merits.

I have done this operation twice, once with excellent results; in the second a troublesome perineal urethral fistula followed, which was hard to close.

(2) Recto-vaginal fistulae are fully dealt with in gynaecological works, and do not demand further consideration here.

(3) **Fistulous communications between the rectum** and some other **portion of the intestinal tract** are extremely rare. Esmarch describes the formation of an anus preternaturalis in ano as a sequela to extensive prolapsus recti. Where the prolapse is considerable, a pouch of peritoneum descends through the anus at the anterior aspect of the protrusion, and in this pouch a knuckle of small intestine is not infre-



quently situated. If, now, this becomes sufficiently constricted to induce gangrene, a fistulous communication between the rectum and small intestine may be a possible result. An artificial anus so formed differs in no material respect from a similar condition elsewhere. If the discharge is light in colour and contains a large proportion of imperfectly-digested food, and if there is progressive marasmus, the probability is,

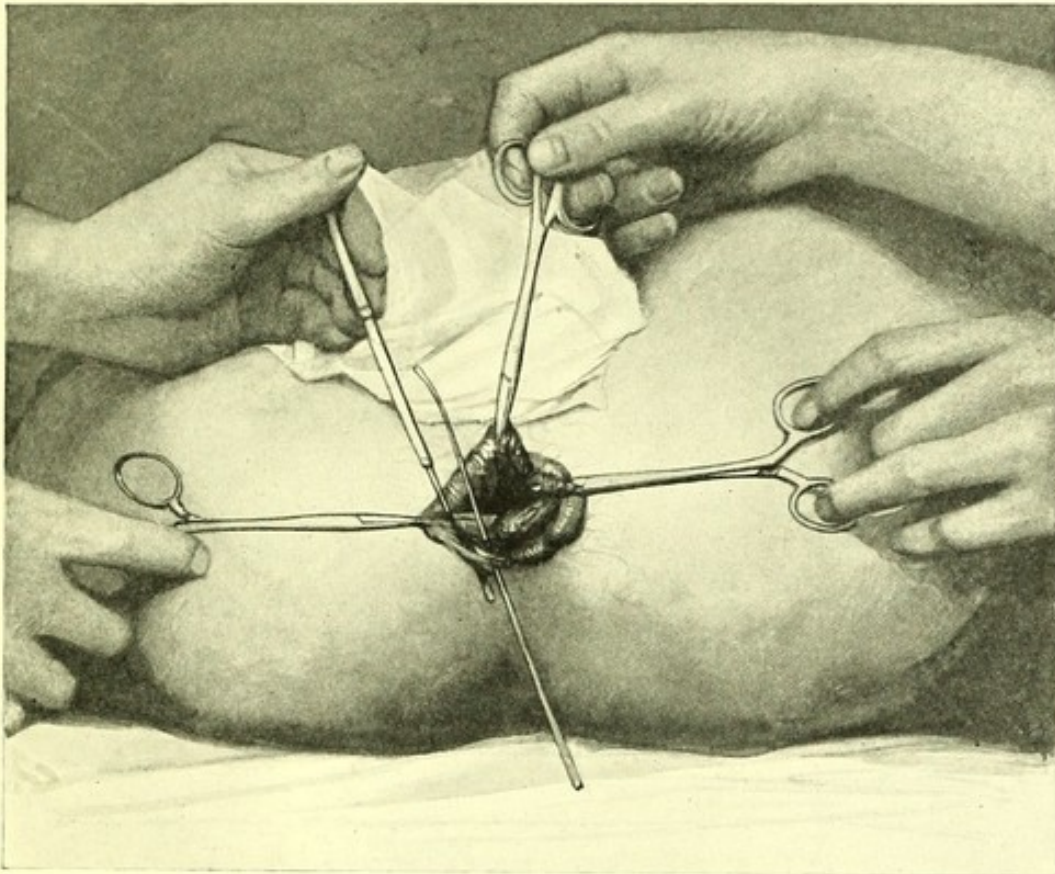


FIG. 73. Recto-rectal Fistulae.

Two short fistulae are indicated, one by a probe, the other by a blunt dissector; there was no cutaneous orifice. Cutting away the overlying bridges of mucous membrane completely cured the patient.

*(From a stereo-photograph of a case at Sir Patrick Dun's Hospital.)*

that the portion of small intestine implicated is high up, and consequently of a kind where, if unrelieved, a fatal termination must be looked for soon. An attempt should be made to cure it either by resection or lateral anastomosis of the intestine.

A few cases have been noted of communication having been formed between other parts of the intestine and the rectum. As a result of abscess due to appendicitis, fistulous communication between the vermi-



form appendix and rectum may be established; several such cases are recorded. I have had a case of this nature at Sir Patrick Dun's Hospital. A man aged 40 was admitted with symptoms of violent peritonitis, of which he died, and at the post-mortem it was found that the vermiform appendix was firmly adherent to, and communicated with, the upper portion of the rectum. An abscess had formed in the adhesions, which ruptured, and gave rise to the fatal peritonitis.

(4) **Recto-rectal fistulae.**—An abscess originating in the rectal sub-mucosa may fail to perforate the outer tunics of the bowel, but may open through the mucous membrane into the lumen of the rectum by more than one orifice, thus forming a true fistula bi-mucosa. Fig. 73 is from a stereoscopic photograph of a patient in whom two such fistulae were present. Division of the mucous membrane from one opening to the other, free use of the curette, followed by light plugging, sufficed to cure the patient.



## CHAPTER IX

### STRICTURE

JUDGED from a clinical standpoint, stricture of the rectum would include all those pathological changes which result in a more or less complete retardation of the passage of the faeces through this tube, but it will facilitate the consideration of the subject if at present we confine the term to those changes in the wall of the bowel and anal outlet which produce a narrowing of the lumen of the gut, reserving for future consideration those neoplastic growths which are characterized by the clinical features of malignancy, and also those instances of obstruction due to the pressure of structures outside the rectum. Of the true strictures, the most important are the cicatricial stenoses, which, of course, necessarily presuppose the existence of loss of substance, the result of ulceration, or direct traumatism. What the exact nature of this preliminary destruction of tissue was, it may be quite impossible to determine. Even where we have to deal with an open ulcer the diagnosis is beset with difficulty, and where, as in the present instance, we may have to deal only with the cicatricial contraction subsequent to this process, it is obvious that the difficulty is much enhanced.

Whether **spasmodic stricture**, due to a spastic contraction of the circular unstriped muscular fibres, ever is present, has been freely discussed by most of the authors on rectal surgery, and considerable differences of opinion are to be found in their works on the subject, but the majority of writers refuse to admit muscular spasm as a cause of temporary stricture, much less of permanent stricture.

Mr. Harrison Cripps, in his book, *Diseases of Rectum and Anus* (p. 205, London, 1884), brings forward strong evidence in favour of muscular spasm being an important factor in the etiology of rectal stricture. That a permanent condition of spastic contraction exists, he does not consider to be possible, but that long-continued irritation, by exciting frequent intermittent spasm, may terminate in shortening of the



muscular fibres, with increase of the connective tissue elements, he considers highly probable, and analogy furnishes us with numerous examples of similar changes, the result of long-continued irritation. Of these, the most familiar is the condition of the knee-joint, to which Mr. Barwell has applied the term 'contracture', where, as a result of pathological changes in the articulation, spasm of the muscles is first produced. And, finally, such a continued shortening of the hamstring muscles results, that the knee is permanently flexed, and the head of the tibia subluxated backwards. Many other examples could be quoted, if necessary. I have seen a case in which aggravated talipes equinus resulted from a patch of lupus extending under the tendo Achillis, causing atrophic shortening of the muscles of the calf, and we have frequent opportunities of witnessing the considerable contraction, with increase of tissue in the external sphincter ani, which may result from the long-continued irritation of a small painful fissure. It may be argued that all these are examples of contraction of voluntary muscular fibre, and that, consequently, no deductions can be with safety drawn from them, justifying the conclusion that like changes can take place in unstriped muscular fibre, but we know that oesophagismus may last for a very long time from a small ulcer or excoriation of the oesophagus, although it must be admitted that hitherto it has not been demonstrated that spasmodic stricture of this tube has occasioned permanent contraction, recognized after death. In the bladder, however, the presence of a calculus, or of ulceration without direct obstruction, will produce such an amount of thickening and contraction of the wall of the viscus, that after death it may be found impossible to dilate it to its normal proportions. Cripps does not rely upon analogy alone for supporting his argument, but brings forward the following instance of rectal ulceration with some tendency to stricture. He says:—

‘ I was puzzled about the case, for upon the first examination I found ulceration in the posterior part of the bowel, with an annular stricture situated two inches from the anus, which would barely admit the tip of the finger. The examination was extremely painful. Upon examining the same patient a few days later under an anaesthetic, the ulceration was present as before, but, to my surprise, there was scarcely any stricture, for the finger would pass readily into the bowel, with only a sense of being slightly gripped at the spot which previously would not admit the finger-tip. I had this patient under observation some time, and soon learnt that by introducing the finger somewhat roughly into the bowel, the sense of stricture was immediately produced, but by keeping



the finger gently in contact with the strictured part a feeling of gradual giving way was experienced, so that the finger would lie comparatively easy in the narrow part, where upon any rough movement it could be felt to be palpably and immediately grasped.'

Two years afterwards Mr. Cripps saw this patient again, and on examination, in the place of the yielding and comparatively soft stricture encountered previously, there now existed a firm, hard, totally unyielding fibrous contraction, narrowing the bowel to the smallest circumference. Since the publication of Mr. Cripps's views on this subject I have had an opportunity of seeing a case which, to my mind, strongly supports his ingenious theory of the causation of stricture. The case was one of fistula complicated with stricture. Upon making an examination it was found that the fistula communicated with the bowel by a large ulcerated opening on the coccygeal aspect of the gut, and immediately above this ulcer a tight annular stricture was to be felt, which barely admitted the tip of the finger; it gave the idea of being quite above, and unconnected with the ulcer. What the original cause of the ulcer was in this case I am not prepared to say, as it possessed at the time it first came under my observation no very distinctive features, but viewed in the light of Mr. Cripps's theory, I am of opinion that the following sequence of events occurred: the ulcer became established, and by the irritation thus set up a frequent peristaltic action of the muscular coat of the rectum was induced, tending to expel the source of irritation, and in time atrophic shortening of the overtaxed circular fibres of the muscular coat was produced, finally the ulcer by perforating the rectum gave origin to a suppurative proctitis, hence the fistula. In support of this view of this interesting case, I may allude to the fact, with which most surgeons are familiar, that a not uncommon symptom complained of by patients suffering from rectal ulceration is a forcing down and straining, as if there was something to be evacuated immediately after the bowel has been completely emptied, and at other times when it contains no faeces. This is undoubtedly due to the contractions of the tube above the source of irritation in their useless attempts to expel it.

In my opinion, the strongest support is lent to this theory (although this is not alluded to by Mr. Cripps) by the position of the internal opening of fistula when found in connection with stricture. Where a fistula forms in connection with a strictured urethra or other mucous tract, it is in nearly all instances found to open into the tube above the



seat of stenosis, but in the rectum this is not invariably the case. In a large number of instances (probably the majority) the internal openings of such fistulae are found below the stricture. That ulceration should occur leading to fistula in the dilated portion of gut above the narrowed part can be readily understood as being a direct result of the stricture, but how are we to account for the occurrence of fistula below? This has been a puzzle to many surgeons, and when reading Mr. Cripps's views on the pathology of stricture, it at once occurred to me that in it we had the true explanation of this fact, which may be thus briefly formulated. Ulcer of the rectum, by perforating, may produce a fistula, and at the same time may lead to a permanent contraction of the gut immediately above the seat of ulceration; so that the only relation existing between the fistula and the stricture is the fact that they have a common origin in the ulcer.

Granting, then, that some cases of stricture originate in long-continued spasm, the result of irritation, there remains a large number in which cicatricial contraction is the sole cause, and we may take as a type of this class those which originate in direct traumatism.

As will be seen in the chapter on syphilis, chancroids are of common occurrence at the anus, and are occasionally found in the rectum, and the question, what share they take in the aetiology of stricture, has been warmly discussed. It is quite impossible to come to any accurate conclusion from published statistics as to the relative importance of the various venereal diseases in the production of stricture. Some surgeons, as Gosselin ('Des rétrécissements syphilitiques du Rectum', *Arch. Gén. de Méd.*, tome iv, p. 667) and Mason (*Am. Journ. of Med. Science*, p. 22; 1873), would have us believe that it almost invariably results from chancroids, while, on the other hand, we find other authorities, such as Allingham and most English authors, discountenancing the views held by Gosselin and Mason, and not recognizing chancroids at all as a cause of stricture. Again, it would appear that some surgeons, having it impressed upon their minds that the most common cause of stricture is syphilis, are too apt to accept a syphilitic history on insufficient, or even no definite, evidence of this disease. The published statements vary so much, according to the views of the surgeon describing them, that the only conclusion we can arrive at, from a study of them, is that in many instances the origin of the disease is rather a matter of conjecture than a scientifically ascertained fact, but sufficient evidence is, I think, forth-



coming to establish the fact that primary soft chancre, phagedenic ulceration, gummatous ulceration, and cirrhotic changes of advanced constitutional syphilis, all have a share in the aetiology of stricture. It is, however, probable that a large majority of cases of stricture are due to advanced syphilis.

It must be remembered that it is often difficult and sometimes impossible to determine accurately what the initial cause of the ulceration which has produced the stricture may have been. Some surgeons consider gonorrhoea is a more fruitful source of rectal stricture than syphilis, but hitherto this theory has not been proved by detection of gonococci in the ulcerations associated with stricture; the tendency, however, of gonorrhoea to produce fibrosis renders it possible that further research may establish this theory.

**Dysentery** has been credited with being the cause of a considerable number of the examples of stricture which come under our notice, but we must remember that the symptoms of rectal ulcer, from whatever cause arising, are in many respects similar to the milder cases of true dysentery. If every case in which there is a muco-purulent and sanious discharge is called dysentery, then, indeed, the aetiological influence of this disease must be considered great, but if the term is restricted to true dysentery, we must admit that the number of cases which can be traced to this disease is small indeed.

**Tubercular ulceration** is by some stated to be an occasional, though it must be admitted a rare, cause of stricture. The fact that a considerable proportion of cases of rectal stricture eventually die of pulmonary phthisis would, however, tend to show that in all probability a larger number of cases have really commenced in rectal tuberculosis than has hitherto been recognized.

**Traumatic stricture.** Where injuries have been inflicted on the rectum, especially those which are attended with considerable loss of substance, or where extensive sloughing or long-continued suppuration has supervened, stricture is liable to occur; this is peculiarly the case where the entire thickness of the gut is destroyed throughout its circumference; on the contrary, where the mucous membrane alone is destroyed, or where the whole thickness of the bowel is destroyed in part of its circumference only, stricture will be a less probable result. On the other hand, in healthy individuals extensive wounds heal frequently without much contraction. This is notably the case in gunshot wounds.



I have had an opportunity of seeing two very remarkable cases of traumatic stricture. A medical man who suffered much from constipation, for which he treated himself with glycerine injections, by mistake one night injected strong hydrochloric acid; this was followed by extensive sloughing and the formation of a dense and tight stricture, which, however, responded well to dilatation by means of Hegar's dilators, and he has since been able to maintain the dilatation by the occasional passage of a bougie. The second case I saw while lecturing at San Francisco, and was kindly asked to operate on it. A young man was operated on for a railway smash in the country, where the surgeon had no skilled assistance; as the patient was much collapsed a hot saline enema was administered, but so hot that the rectum was extensively scalded, and apparently the entire rectum had sloughed in consequence. A very tight stricture resulted which had resisted prolonged attempts at dilatation aided by external incision. I excised the cicatricial tissue and brought down healthy bowel to the anus, and I was informed that the ultimate result was satisfactory.

As a result of operations for fistula, prolapse, and haemorrhoids, occasional instances of traumatic stricture are observed. Where the old operation of widely excising a fistula was resorted to, this complication must have frequently supervened, but where the modern operation is adopted, there is but little risk of such an occurrence. Similarly in the removal of piles, unless the submucous tissue is much encroached upon, or too much of the skin at the anal border removed, as has frequently happened when Whitehead's operation has been improperly performed, there need be little fear of stricture supervening. Where the actual cautery has been very freely used, or where nitric acid, or other powerful escharotics, have been extensively applied in the treatment of rectal disease, stricture has been known to follow.

A considerable number of cases of stricture have been met with after parturition, which are apparently due to that process; in some, no doubt, the direct pressure of the foetal head, by causing sloughing or inflammatory changes in the rectal wall, is the exciting cause, but probably in the majority of these cases the immediate cause is the contraction following local sepsis, ensuing as a complication of child-birth. In a case recorded by Whitehead, the long-continued wearing of a vaginal pessary appeared to be the exciting cause, and similar cases have been noticed by obstetric surgeons. It will be seen from the foregoing that



a very great variety of injuries may eventuate in stenosis of the lower bowel.

A consideration of a large number of statistics shows that females are attacked with rectal stricture more frequently than males, the proportion being about three to one. To what can this greater frequency of non-malignant stricture in the female be due? Various explanations have been given, but, to state the case broadly, the true explanation lies in the anatomical relationships of the lower bowel to the organs of generation in the female, in consequence of which secondary inoculation of the rectum from venereal disease of the genitals is more apt to take place than in the other sex, and also various displacements and diseases of the uterus are possibly competent to produce injurious effects, which of course are negatived in the male; the traumatism common in child-birth, too, no doubt tend to swell the number of cases.

In its **pathological anatomy**, stricture of the rectum must necessarily present numerous varieties of character, especially when we take into consideration the many diverse aetiological sources to which I have traced its possible occurrence. It may, in the first place, present differences in situation; thus, stricture may be situated at the anus, when it owes its origin to congenital narrowing, to too free a removal of external piles, or a liberal application of the cautery, and to the cicatricial contraction following the healing of chancreoids or other forms of ulceration. Fig. 74 represents a tight anal stricture, the result of extensive burns in a man who fell into a fire while in an epileptic fit. The protected position of the anus renders the occurrence of burns sufficient to cause anal stricture extremely rare. In by far the majority of cases, however, the locality affected is the rectal pouch, the lower orifice of the stricture being within three inches of the anus. In rarer instances the position is higher up at the junction of the sigmoid flexure with the rectum, and a few cases have been recorded where a double stricture has been present, one at the upper portion of the rectum and the other in the pouch. The cause of these multiple stenoses is stated in most of the cases to have been dysentery.

There is considerable variety to be found in the extent of stricture, the amount of intestine involved in the stenosis varying greatly. In some the contraction is distributed uniformly around the entire circumference of the gut, but only a very small portion of the tube is implicated. This form constitutes the so-called annular stricture of the rectum, and



probably those cases which have arisen from the permanent contraction of the circular muscular fibres, before alluded to, are of this nature. In such cases the intestine is sharply constricted, as if it had been included in a ligature, all the coats of the tube being contracted, and at the same time hypertrophied. In other instances we find that the contraction is due to puckering up, and protrusion into the lumen of the bowel, of one side more particularly of the intestinal tube: such cases are generally the result of cicatricial changes during the healing of an ulcer,

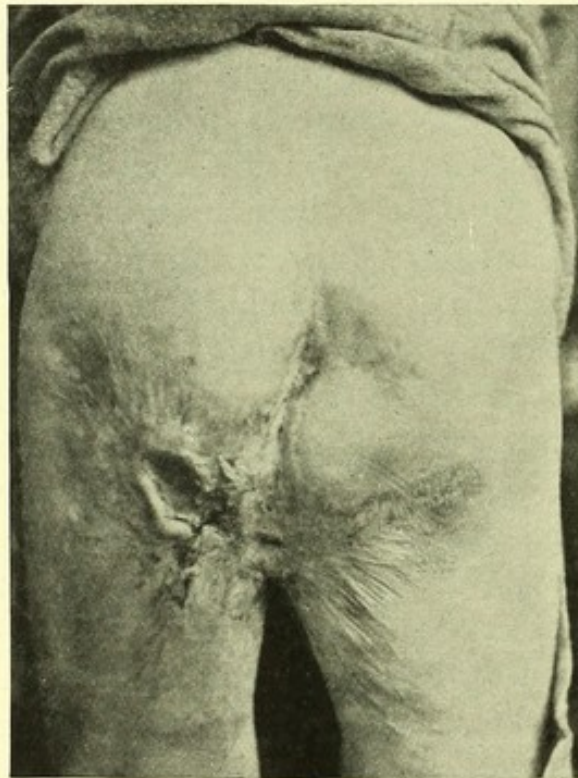


FIG. 74. Stricture of Anus.

The result of a severe burn in an epileptic who fell into the fire.

(*Reproduction of a photograph taken of a case at Sir Patrick Dun's Hospital.*)

and may be so sharply marked as to justify the term valvular strictures. We may recognize a third variety where a considerable length of the bowel is involved in the contraction, or where, by the increase in thickness of the rectal wall due to hypertrophic changes in the connective tissue elements, the lumen of the gut becomes narrowed, sometimes for a distance of several inches. These constitute the so-called tubular strictures.

It is but seldom that the surgeon has an opportunity of seeing the



*post-mortem* appearances of fibrous stricture of the rectum in its early stages. Indeed, the same may be said of the clinical phenomena, as it is only when some obstructive symptoms become developed that these patients usually seek medical aid.

Of the more extensive stenoses, however, the *post-mortem* appear-

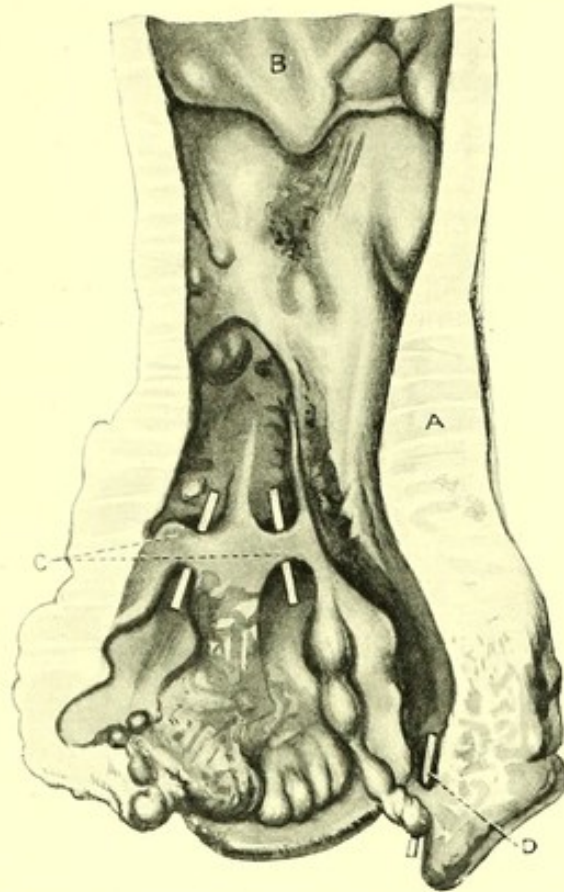


FIG. 75. Stricture of the Rectum, probably Syphilitic.

The lower portion of the rectum is extensively ulcerated, and the mucous membrane is in great part destroyed.

A. Tough fibrous tissue forming stricture. B. Healthy mucous membrane above the disease. C. Recto-rectal fistulae. D. Complete rectal fistula. Note the deepest ulceration and all the fistulae are below the most tightly strictured portion of the bowel.

(From a painting in the Royal University of Ireland.)

ances have been noted frequently, as this disease, although called non-malignant stricture, is one which frequently terminates fatally. From a review of the published reports of the morbid anatomy in such cases, it would appear that there is great thickening, as a rule, of all the coats of the bowel, the new tissue formed being extremely dense and hard (Fig. 75); hence the old term 'scirrho-contracted rectum', which was



applied very loosely before the characters of fibrous, as contrasted with malignant, stricture became clearly differentiated.

In microscopic section it will be seen that there is great hypertrophy of the connective tissue elements in all the coats. More particularly is this to be noted in the muscular coats, the fibres of which are separated and compressed by new connective tissue formations, and a considerable amount of hard adipose tissue is always also present.

Both above and below the strictured point considerable alterations are to be observed in the intestine. Below, we sometimes find polypoid excrescences, occasionally of a considerable degree of density. The mucous membrane is, in the majority of cases, ulcerated, or replaced by cicatricial tissue. In other cases, however, the mucous membrane remains unaltered, and, when this is the case, it may be taken as evidence of the extrinsic origin of the stricture. The glandular structure of the lining membrane is atrophic, and the openings of fistulae and internal rectal sinuses are not infrequently met with. These gross pathological changes so frequently met with are, in my opinion, a very strong confirmation of the opinion held by Mr. Cripps, as to the aetiology of stricture from spasm, which has already been discussed. By any other theory they appear to be quite inexplicable.

Of the changes which are to be observed in the bowel above the stricture, generally the most obvious is dilatation, and this may be present to a marked degree. The mucous membrane will frequently be found to have disappeared in patches, as a result of ulceration, and at the seat of these ulcers the wall of the rectum may be so thinned that rupture has taken place. If this perforation is above the peritoneal reflexion, extravasation of faeces and acute peritonitis will be the result, but if the opening takes place into the areolar tissue of the pelvis, then stercoral abscess is the result. This abscess may open in various places, resulting either in a complete muco-cutaneous fistula, which will then present the characters described under the head of fistula of the superior pelvi-rectal space, while at other times a fistula bi-mucosa will result, and of these the most common, in the female, is a communication between the rectum and vagina, the vaginal orifice being situated generally high up, close to the attachment of the vagina to the cervix uteri. In the male the fistulous track most frequently communicates with the bladder, causing then, in the majority of cases, extreme suffering, owing to the escape of faeces into the cavity of the bladder, a condition which is



one of those most urgently demanding the performance of colotomy. In some rare cases, however, the bladder appears to be tolerant of its abnormal contents. In one case which came under my notice the first condition which attracted attention was a peculiar deposit in the urine, the patient making no complaint of pain about the bladder or rectum. Upon microscopical examination, however, of the deposit some particles of striped muscular fibre were to be seen, which were evidently portions of undigested food which had escaped from the bowel, and a rectal examination revealed the presence of a strictured rectum.

Although the greater number of cases of recto-vesical fistula are to be found in the male subject the female is not exempt.

One of the most remarkable instances of fistula bimucosa is that recorded by Quain (*Diseases of Rectum*, p. 190, London, 1854) as having been found at the *post-mortem* examination of Talma, the eminent tragedian. The pelvis was filled with an enormous sac, formed by the upper part of the rectum largely dilated. When the sac was raised a circular narrowing of the gut was discovered, situated at a distance of six inches from the anus; this was proved upon closer examination to be wholly impervious. It was, in fact, a solid cord, but on the surface irregular, and having the appearance of a purse drawn tightly, and puckered with the strings tied around it. The great dilatation of the bowel at its lower end dipped down below the level of the stricture in the form of a dependent sac, in which was an opening about an inch in diameter, from which fluid had been diffused into the abdominal cavity. The rectum below the stricture was no more than the size of a child's intestine, and upon it, close to the stricture, was an ulcerated surface, with a narrow opening, to which the edges of the aperture above the stricture had been adherent. A new communication, but an imperfect one, had thus been established between the two parts of the gut, severed one from the other by the stricture. The adhesions had given way, doubtless in consequence of the violence of the expulsive efforts, and thus the contents of the bowel had escaped a short time before death. In this interesting case an effort had evidently been made by Nature to overcome the obstruction. In a case recorded by Wagstaffe (*Trans. Path. Soc. London*, vol. xx, p. 176) a somewhat similar condition was observed.

**Symptoms** of non-malignant stricture are generally in the earlier stages extremely vague. The most frequent are attacks of diarrhoea alternating with constipation, and where these have persisted for some



time the suspicions of the surgeon should be aroused, and a rectal examination instituted. The diarrhoea is generally slight, and is more noticeable in the morning; it is frequently associated with the discharge of small quantities of bloody mucus, and brown matter resembling coffee-grounds. This diarrhoea is due to catarrhal inflammation, caused by the irritation of retained faeces above the strictured point, the mucous discharge softening down the faecal accumulation and so allowing it to pass the stricture. When the bowel has been evacuated a period of constipation ensues, to be again followed by faecal accumulation and catarrhal discharge. As the case progresses the intervals of constipation become fewer, and the local irritation and discharge increase, unless, indeed, the case goes on to complete obstruction, which is not a very frequent occurrence, the patient generally becoming exhausted before this takes place. Associated with the diarrhoea there is a good deal of tenesmus in most instances, and pain, which is generally referred to a point above the symphysis pubis, or the middle of the sacrum, is common. Pain after food, and flatulence, are not so frequently complained of as when the constriction is situated higher up in the intestinal tube, and the same may be said of vomiting. This last is only to be observed as a very late symptom, and after long-continued obstruction, when it may occasionally become stercoraceous.

The symptoms, although at first mainly local, after a variable time produce a general impression on the system. The exhausting mucopurulent discharge, which is commonly derived from the altered surface of the dilated bowel above the stricture, more particularly when there is a large amount of ulceration, may produce hectic fever, or amyloid degeneration of internal organs, with which we are familiar as a result of protracted suppuration in other parts of the body, moreover, the possible occurrence of septic poisoning is always to be remembered. On the whole, the disease is of an essentially chronic character, and it may take many years to run its course. The most distressing symptom which a patient with well-developed stricture suffers from is the constant desire to go to stool, attended with colicky pains, but the attempt to defaecate is frequently without result. This is caused by the accumulation of faeces above the strictured part, and is only temporarily relieved by the spontaneous diarrhoea referred to, or by the action of purgatives. As the constriction becomes narrower meteorism becomes developed, the greatly dilated and full colon may be felt through the abdominal wall, the feeling



of doughy softness conveyed by faecal accumulations on palpation of the abdomen may be made out, or the outline of the large intestine may be indicated by dullness on percussion. Visible peristalsis is often a marked symptom; if the abdomen is watched it may be very obvious, a large and somewhat firm tumour being seen to slowly form, due to the strong contraction of the thickened muscle in the dilated intestinal wall above the obstruction, the tumour then gradually disappears, to re-form again after a more or less short interval. The patient is quite conscious of this occurrence, and will often describe it as 'a lump forming in my stomach'. It is frequently associated with a certain amount of cramp-like pain. Owing to the increased efforts to obtain an evacuation the suffering becomes intensified, till finally death results from exhaustion, unless it is hastened by some of the complications, such as peritonitis from perforation, or the supervention of sudden and complete obstruction.

Much has been written on the shape of the stools as indicating stricture, but the idea taught in most textbooks, that narrow or tape-like faeces are indications of the presence of a stricture, requires qualification. Such an appearance is often produced where no stricture is present, and, on the other hand, a well-formed motion may be passed by a person suffering from marked stenosis. In the case of stricture of the urethra, the twisted or forked stream of urine is not formed by the shape of the stricture, but by the collapsed meatus urinarius, the flow of urine not being sufficient to dilate fully this orifice. So also in the rectum, the margin of the anus gives the final form to the voided faeces. Where there is a contracted state of the anus, due to fissure or other cause, the faeces are passed in the form of narrow cylinders, or they may be flattened laterally. Where a stricture is situated at some distance from the anus it is quite possible that the mass may be re-formed in that portion of the rectum below the stricture, and so be passed of normal calibre. More frequently, however, the faeces are found in little masses of a spherical or ovoid shape, reminding one of the appearance of sheep or rabbit droppings, and this is to be explained by the relaxed condition of the termination of the bowel and sphincters being unable to compress the mass sufficiently to render it again of uniform consistence.

There can be no doubt, however, that in some cases the faecal mass is passed in narrow cylinders as a result of stricture, and Van Buren has given the true explanation of this condition (*Diseases of the Rectum and Anus*, p. 279). When a stricture is situated low down in the rectum,



it is during the violent efforts accompanying defaecation extruded through the anus far enough to give its final impress to solid matter passed under this extreme pressure; and Kelsey (*Diseases of the Rectum and Anus*, p. 189) records an interesting case in which he was able to observe the mechanism of an occurrence of this kind, which I give in his own words: 'The woman suffered from a stricture one inch above the anus, which was of sufficient calibre to admit the ends of two fingers easily. She had never noticed any deformity of the faeces. While under the influence of ether, and after the sphincter had been very thoroughly dilated, an O'Beirne's tube was passed through the rectum, which was empty, into the sigmoid flexure, which was full. After resting there a few moments it provoked a movement of the bowels. The stricture was instantly crowded down into view, appearing at the anus, and taking the place of the anus, which, owing to the complete dilatation, ceased to have any action, and was merely a patulous ring. Through the stricture there came a long tape-like evacuation, the mould which gave it its peculiar form being the stricture pressed to the surface of the perineum, and greatly lessened in calibre by folds of mucous membrane, which were crowded into it from above. While remarking to those present on the peculiar mechanism of its production, the straining ceased, the stricture rose, the mucous membrane was relaxed, and a passage of natural formation was the result. This alternation was repeated several times. At each effort the stricture was forced down to the anus, the membrane above it was crowded into it, so as greatly to lessen its calibre, and a flat passage was the result. When the effort was less violent there was still a passage, but the stricture having risen to its place, and not being so tightly filled with the mucous membrane, the passage was natural. The lesson to my own mind was this, that a stricture of large calibre might, as a result of straining, cause a passage of small size, and that, to get this peculiar shape, the stricture must be crowded down so as actually to take the place of the external sphincter, and be the last contracted orifice through which the soft substance is expressed.'

A very grave, but rather infrequent, termination to stricture is **complete obstruction**. After a stricture has continued for a long time, possibly many years, without affecting the general health to any great extent, the bowels being relieved sufficiently by the process before alluded to, the symptoms of complete obstruction may supervene, and it is a remarkable fact that the onset of this condition is not uncommonly



somewhat sudden. This abrupt complication may be due to one of two causes, either the impaction of a foreign body, or even an unusually hard mass of faeces in the narrowed gut, or as a result of an inflammatory oedema of the mucosa and sub-mucosa due to the irritation of retained and decomposing faeces.

Of the former variety the following is a well-marked instance. I was called to see a man aged 30 years, whom I found suffering from well-marked symptoms of obstruction of the rectum; the belly was tumid and tender, and he had vomiting, not, however, stercoraceous. There were frequent abortive attempts to defaecate, and I was informed that he had obtained no relief from the bowels for the past ten days. He stated that he had small-pox four years previously, which was followed by a discharge of matter from the rectum, and that since then he had suffered from alternating attacks of diarrhoea and constipation. Upon making a rectal examination a stricture was at once detected within one and a half inches from the margin of the anus. A hard substance could be felt projecting through the orifice of the stricture, and with considerable difficulty I removed it with a forceps. It proved to be a plum-stone. He assured me that it was over a year since he had swallowed it, as he had a distinct recollection of the fact of having done so. I treated the case with a limited incision and dilatation with bougies, and I afterwards heard that the patient remained in tolerably good health, although he still required the occasional introduction of a bougie.

It is a very remarkable fact how frequently fruit-stones have been found impacted in intestinal strictures, or collected in numbers in the pouch above them. A very interesting case of this kind is reported by Dr. Wickham Legg (*Path. Soc. Trans.*, vol. xxi, p. 171). A woman aged 28 had frequently before death vomited and voided by the rectum cherry-stones, and during life a tumour composed of them could be felt through the abdominal wall, giving to the hand a very peculiar sensation as they were rubbed together. At the *post-mortem* examination the ileo-caecal valve was found strictured, and in the intestine above there was nearly an imperial pint of fruit-stones. A number of similar instances are to be found recorded. In some cases, possibly, the mechanical irritation set up by the accumulation of stones may be looked upon as the cause, not the effect, of the stricture. Such, however, was evidently not the case in the instance I have brought forward. Besides cherry-stones, many other



hard and insoluble substances, as pieces of bone, apple-core, &c., have been found lodged in a stricture, and so constituting the determining cause of complete obstruction.

Inflammatory swelling as a cause of complete obstruction is more often met with in cases of malignant disease of the rectum than in cases of the ordinary stricture, but even in the latter it is sometimes observable, more particularly after the injudicious use of bougies.

One of the most serious complications that may arise during the course of stricture of the rectum is **peritonitis**. In this case we find inflammation of the peritoneum occurring either as an acute and general manifestation, the result of rupture of the intestine and extravasation of faeces, or as a more chronic and limited disease, the former not being an infrequent termination to years of suffering from rectal stricture. It may be due to spontaneous rupture of the attenuated and ulcerated wall of the bowel in the neighbourhood of the stricture during a violent effort at defaecation; or, at other times, we have to admit that the treatment adopted by the surgeon must be held to be directly responsible for the fatal perforation. There is, unfortunately, no lack of cases in which the point of a bougie, an enema pipe, or even the index finger of the surgeon, has penetrated through a diseased intestinal wall and permitted the extravasation of faeces to take place: this accident has occurred to the most accomplished surgeons, who, with a candour highly to be commended, have recorded their misfortunes, and so enabled us to learn a lesson that should ever be present with us when dealing with cases of this kind, to employ the utmost gentleness when examining or conducting the treatment of constriction of the rectum. When only the tip of the index finger can be insinuated into the aperture of a stricture, the temptation to force it through, so as to determine the length of the stricture, or to effect dilatation of it, is indeed strong, but it must be absolutely resisted, unless we wish to swell the already long list of mishaps which have occurred. The old saying, 'Meddlesome surgery is bad,' applies with more force to the disease under consideration, probably, than to any other surgical affection.

**Chronic and limited peritonitis.** As a result of the inflammation and ulceration of the rectum associated with stricture, the pelvic peritoneum may become involved, and bands of adhesion be found in consequence, without any perforation having taken place. It is not at all infrequent to find this condition on *post-mortem* examination of old-



standing cases of rectal stenosis. Thickening of the peritoneum, limited effusion, and bands of lymph being the most common appearances met with. In some cases the adhesions produce by their contraction an increased narrowing of the lumen of the bowel, the most common seat of which is at the junction of the pelvic colon and the rectum, so that the obstruction thus formed may be considerable. The symptoms of this complication are, however, seldom recognizable during the life of the patient, so that the treatment of it comes scarcely within the range of practical surgery. Where, however, it is suspected, it furnishes a strong additional argument for the relief of the irritation by colotomy.

**Abscess and fistula** complicate the case in a very large proportion of cases of rectal stricture, and they may be found in various situations. When occurring in the ischio-rectal fossa the communication between the bowel and the suppurating cavity is generally to be found below the seat of stricture, and when so placed it is, as I have before endeavoured to show, strong evidence that it has originated in an ulcer, which was also the exciting cause of the stricture. It is quite possible that these ischio-rectal abscesses may occasionally form as the result of infection, without any direct communication being established with the gut, in the same way that we find extra-articular abscesses occurring in the neighbourhood of a diseased joint. Where, however, they form as the result of perforation of the pouch above the stricture, they are usually situated above the levator ani and recto-vesical fascia, in the superior pelvi-rectal space. From this position they may penetrate in various directions, as into the vagina or bladder, or into the peritoneum; or the first place at which they become superficial may be in the iliac region, as happened in one case under my care. If they come down to the perineum, their most usual position is posterior to the anus, as the pelvic diaphragm more readily allows the passage of pus there than at any other part of the circumference. These fistulae are considered elsewhere (see page 97). When found in connection with stricture of the rectum their symptoms, when fully formed, are sufficiently obvious, so that the subject need not be further discussed.

Upon making an examination of a person affected with rectal stricture, it will generally be found that the anus is surrounded by **hypertrophied flaps of skin**, which no doubt owe their origin to the continued maceration and irritation of the parts by the acrid discharge.



**Haemorrhoids** are of common occurrence as a complication, and this is not to be wondered at when we consider the pressure that must be exercised on the branches of the haemorrhoidal veins in passing through a dense stricture.

It is also common to observe the openings of fistulae, and these are frequently multiple, but of all conditions **great relaxation of the anus** is the most noticeable, the finger readily passing through without any difficulty. This relaxed condition of the anus permits the involuntary escape of sanious muco-pus, which constitutes one of the most unpleasant subjective phenomena of stricture, and it also sometimes permits the extrusion of the stenosed portion of the bowel which has been already alluded to. True prolapse of the rectum is, however, an extremely rare complication of rectal stricture.

Upon introducing the finger into the rectum the stricture, if situated in its usual position in the rectal pouch, will be at once felt if it has encroached much upon the lumen of the bowel; but if the amount of contraction is slight, so that two or more fingers can be passed readily into it, it may be more difficult of detection: in these cases a thickening and hardness, or ulceration of, or outgrowths from, the mucous membrane will excite the suspicions of the surgeon. In this preliminary examination the whole under surface of the stricture should be carefully felt, relative involvement of the various portions of the circumference of the gut made out, and the existence and extent of ulceration or outgrowths determined. Where the entire circumference of the gut is tolerably uniformly contracted, and where the amount of induration of the tissues is considerable, the sensation conveyed to the finger resembles closely the feel of the os uteri when the finger is in the vagina; this likeness is occasionally further increased by the fact that the finger can be passed round the stricture, which appears to project down into the bowel, and is due to a limited intussusception following the violent expulsive efforts.

With the finger the lower limits of the stricture can be completely examined, but, unless the opening is sufficiently large to admit the passage of the finger through the stricture easily, the surgeon is unable to form an opinion of the length of bowel involved. For this purpose bulb-ended bougies, as recommended by Bushe, are necessary. They are best made of ivory or ebonite bulbs fastened on to a whalebone or readily flexible metal rods; they should be of various sizes. Having selected the



largest that will easily pass through the stricture, the instrument should be introduced through the contraction until the end is felt to be free in the bowel above. By gradually withdrawing it the surgeon will be able to recognize the moment it enters the superior opening of the stricture, and thus an estimate of the length of the stenosis can be arrived at. Where the stricture is situated beyond the reach of the finger great difficulties will be experienced in the diagnosis, indeed, it may be safely asserted that stricture of the upper portion of the rectum has been supposed to exist much more frequently than its existence has been demonstrated, even when the greatest care has been taken in the examination by accomplished surgeons. The diagnosis and treatment of non-existing strictures has been a favourite field of practice for charlatans; persons suffering from ordinary constipation being easily led to believe that their symptoms are due to mechanical obstruction. Kelsey (*Diseases of the Rectum and Anus*, p. 182) gives an amusing case of this kind. 'A lady went to consult a rectologist, for some reason or other which is not stated, and a sound was introduced into her anus. Her husband, learning this, rushed to the house of the scoundrel in a violent rage, and armed with a whip. Half an hour later he returned, disconsolate. He had found out that, like his wife, he had a stricture of the rectum, and, like her, he had submitted to catheterization.'

If the patient has symptoms which would lead us to suspect the presence of a stricture high up, such as diarrhoea alternating with constipation and paroxysmal colicky pain, great straining and pain while at stool, and the discharge of muco-pus or altered blood from the anus, and yet if under such circumstances no indication can be obtained by ordinary digital examination, the patient should be placed under ether, and an examination conducted in the lithotomy position. First of all the anus should be well stretched, and the bi-manual method adopted, with one hand pressing deeply down into the pelvis through the abdominal wall, and the index finger of the other hand passed as high as possible up the rectum. By this means we may be enabled to make the diagnosis; failing this an enema should be administered, and if this is at once returned without our being able to distend the colon it is strong evidence of obstruction. A careful examination with a bougie should now be instituted, but the information obtained by its use is open to several fallacies. In the first place, the point may impinge against the promontory of the sacrum, and so its further progress may be arrested,



or it may be caught in some of the folds of mucous membrane. This may generally be obviated by having the bougie hollow and perforated at the point like an O'Beirne's long tube, and made so that an enema apparatus can be attached. When, now, the point becomes arrested, some warm water can be thrown up, and so the loose folds of mucous membrane lifted off the end of the instrument. Another source of error is the bending of the bougie upon itself, so that a considerable length may be passed although a mechanical obstruction exists. Whenever the progress of the instrument becomes arrested, the direction of the end of the bougie should be altered and a fresh attempt made. The utmost gentleness should be observed, the surgeon always bearing in mind that the coats of the bowel may easily be perforated. The only unequivocal indication that the instrument is really in a stricture is the feeling that it is grasped, a sensation with which we are quite familiar in the catheterization of urethral stricture. Of course it is obvious, however, that before we can attach any importance to this symptom in rectal stricture the sphincter ani must have been temporarily rendered paralytic by hyper-distension, unless indeed it is so relaxed as a result of the disease as to render this preliminary step unnecessary. The only means left at our disposal for the further examination of the bowel high up is by abdominal section, which should at once be performed if the symptoms indicate a stricture which it is impossible to locate by the methods already alluded to.

The only points of diagnosis which remain for our consideration are the differentiation of benign stricture from malignant neoplasms on the one hand, and extra-rectal disease producing pressure upon the other; of the latter enlarged prostate gland is much the most common, the difficulty in obtaining an evacuation and the flattened faeces often causing prostatic hypertrophy to be mistaken for rectal stricture. It is generally easy to distinguish the obstruction due to this cause, or to the pressure of tumours, or by bands of adhesion, from non-malignant stricture, the sensation conveyed by the finger readily estimating whether the obstruction is situated in the rectal wall or not. The diagnosis between malignant and non-malignant disease, although in typical instances easy, is sometimes attended with very considerable difficulty, so that it may be impossible to arrive at a definite conclusion until the case has been kept under observation for some time, and its rate of progress carefully noted.



The following table illustrates the more important points of difference :—

## NON-MALIGNANT STRICTURE.

Essentially chronic, and not implicating the system for a long time. The orifice of the stricture feels as a hard ridge in the tissues of the bowel. Polypoid growths, if present, are felt to be attached to the mucous membrane.

Ulceration of mucous membrane may be present, but without any great induration of the edges.

The entire circumference of the bowel constricted unless the stricture is valvular.

Pain throughout the whole course, in direct proportion to the faecal obstruction, and only complained of during the efforts at defaecation.

Glands not involved.

There is usually evidence that ulceration has commenced at the anus and travelled upwards.

More common in females.

## MALIGNANT OBSTRUCTION.

Progress comparatively rapid and general cachexia soon produced.

Masses of new growth are to be felt either as flat plates between the mucous membrane and muscular tunic, or as distinct tumours encroaching on the lumen of the bowel.

Ulceration, when present, is evidently the result of the breaking down of the neoplasm, and the edges are much thickened and infiltrated.

One portion of the circumference generally more obviously involved.

In the advanced stages pain is frequently referred to the sensory distribution of some of the branches of the sacral plexus, due to direct implication of their trunks.

The sacral lymphatic glands can sometimes be felt through the rectum to be enlarged and hard.

Usually commences well above the anus.

Both sexes equally liable.



## CHAPTER X

### STRICTURE. TREATMENT

THE various plans of **treatment** which have from time to time been advocated for rectal stenosis may be conveniently classed under the following heads. (1) Dietetic and medicinal; (2) dilatation, (*a*) gradual, (*b*) sudden; (3) incision, (*a*) internal, (*b*) external; (4) excision; (5) colotomy; (6) electrolysis.

By attention to the **diet** a considerable amount may be done in the way of making life more endurable, and it is obvious only such food should be allowed as will leave a small faecal residue. First in importance stands milk, which should form a large portion of the patient's food, and strong soup, eggs, and meat, in moderation, also may be allowed. As most vegetables leave a considerable residue they should be but sparingly used, and such articles of food as oatmeal, brown bread, &c., should not be permitted. One objection to giving too unstimulating a dietary is that the faeces which are formed produce so little excitation of peristalsis that purgative medicines will, at the same time, be required in considerable quantity.

As to the **medicinal treatment** of stricture, it is obvious from the very nature of the case that the use of purgative medicines must constitute an important element of our practice, and that some discrimination must be exercised in our employment of such agents.

Of all aperients, the sulphates of soda and magnesia, as combined in some of the many mineral waters in the market, will be found to answer best. A sufficient dose should be taken early in the morning to ensure a free evacuation. Where the calls to stool are frequent, and where considerable straining exists, it is generally an indication of retention of faeces above the stricture, which are best dislodged by a copious enema of soap and water. Compound liquorice powder will often prove an



efficient aperient, or, where patients can take it without nausea, castor oil. Frequently, however, it will be found well to change the medicine employed, care being taken not to use any of the more irritating drugs, such as colocynth, &c., for they only tend to increase the tenesmus. Belladonna is highly spoken of by many authorities, and in some cases certainly tends to relieve spasm; it is best given in the form of a suppository containing a grain of the extract. This may be with advantage combined with five grains of iodoform, especially if there is an open ulcer present. Where the bowel is very irritable, marked benefit will result from the use of small starch and opium enemas, and where the catarrhal discharge is considerable, injections containing liquor of bismuth, or tincture of rhatany, will probably diminish the secretion. Where the disease is of unquestionable syphilitic origin, mercury or iodide of potassium may be tried, but these remedies can only prove useful in those cases of recent origin where syphilitic deposit or ulceration is progressing. It is manifestly useless to expect that where atrophic shortening of the muscular fibres, with cicatricial or cirrhotic contractions, has taken place, any good can possibly result. Indeed, it is probable that under these circumstances a positive injury will be inflicted by so-called specific treatment further lowering the already debilitated constitution.

Medicinal treatment, however, can only at best do little more than relieve symptoms, and for any permanent benefit we must look to some of the mechanical or surgical operative methods indicated in the above enumeration. Of these the first is **dilatation**. Where the obstruction is considerable, as is almost always the case when the patient comes under observation, an attempt may be made to dilate by means of bougies. In those cases in which there is no open sore, the careful use of bougies is of the greatest service, and although it cannot be said with certainty that a permanent cure can be effected (by which is understood that no further treatment will be rendered necessary), still a considerable amount of good can be done, and the space necessary for a free motion can be maintained by the occasional passage of a bougie. When a stricture of the urethra has been relieved by gradual dilatation, no surgeon will admit that the case has been completely cured, but by subsequent occasional catheterization the stricture can be prevented from contracting again to such a degree as to occasion serious symptoms. The same is true of a stricture of the rectum; when extensive ulceration is



present with the stricture, extreme caution is required, as the danger of rupture is a very real one, so that unless such cases respond easily to treatment with a bougie they are best dealt with by excision.

Much will depend on the form of bougie used. The so-called gum elastic instruments, which are made of plaited cord covered with varnish, and which have been in general use for many years, are unsuitable, as they do not long retain a smooth surface, and they are made unnecessarily long. Kelsey recommends the use of soft rubber bougies similar to those occasionally used for the urethra, and these answer the purpose admirably, as it is almost impossible that any injury could be inflicted by their use. The only drawback to them is that they are so soft that it may be found difficult to pass them into the orifice of the stricture. Bougies made with an olive-shaped bulb, mounted on a flexible whalebone stem, are largely used by some surgeons, but by far the best form are the dilators recommended by Hegar for dilating the cervix uteri, made of metal or vulcanite; the surface is smooth and the gradation of sizes very uniform and gradual, so that the circumference of any one is only very little greater than the next size smaller. In order to use them they should be warmed and well covered with vaseline, and a size selected which passes through the stricture quite easily; after resting a moment or two in the bowel it should be removed and immediately followed by the next size larger, and so on. It is, however, well not to attempt too much at one sitting, two or three sizes larger than the largest which can be passed without being gripped being quite sufficient. After an interval of two days the passage of bougies should be repeated, when it usually happens that two or three sizes larger than at the first sitting can be passed without difficulty. In this way a sufficient dilatation can usually be accomplished in a short time, but the passage of a full-sized bougie must be maintained for a long time afterwards, first at intervals of a few days, and afterwards at gradually increased periods. The secret of success is to use great gentleness, never to use force, and to be satisfied with doing a little at a time. When a bougie of moderate or large size is tightly gripped by the stricture the suction arising by its withdrawal may give the patient more pain than its introduction; this can readily be obviated by having the bougies perforated longitudinally so as to admit air into the rectum as they are withdrawn. Many other forms of bougies have their advocates; some are conical, others are capable of dilatation *in situ* by means of air, water, or by mechanical means, but none will be found



so safe and efficient as Hegar's dilators, the mechanical dilators being especially dangerous.

**Treatment by incision.** As in stricture of the urethra there are advocates for internal and external urethrotomy, so we find stricture of the rectum has been treated frequently by internal and external incision; the former is so dangerous from its liability to be followed by extravasation, and stercoral abscess or diffuse sepsis, that it has been now quite abandoned. External incision or linear proctotomy is a safer proceeding, as it permits of free drainage; it should never be considered in a case where efficient dilatation by Hegar's dilators is practicable, or in a case in which, although dilatation is not satisfactory, excision can be efficiently carried out; where, however, neither of these methods is indicated linear proctotomy may sometimes prove a useful substitute for colotomy.

The operation is best performed by making an incision from above the stricture directly backwards through the entire thickness of indurated tissue, through the anal canal sphincters and skin towards the tip of the coccyx. The wound is to be lightly plugged and allowed to heal by granulation. Even after this operation the stricture is apt to recur unless the lumen of the bowel is kept patent by the occasional passage of a bougie; a certain amount of incontinence of faeces is of course a necessary result of this operation.

**Excision** of the stricture has been performed several times for non-malignant stricture, and in suitable cases when simple dilatation fails has much to recommend it. It is preferable to linear proctotomy both as to the cure of stenosis and the ultimate control of the bowel, and also for the general comfort of the patient. The first case of a simple stricture I excised was one in which there was a doubt between malignant growth and simple stricture; the result was extremely good. Microscopic examination showed that the case was one of benign stricture. I have since adopted excision in several cases in which there was no question as to diagnosis, with equally good result. The method of operation differs in no respect from the perineal excision of rectal cancer.

**Electrolysis** has been recommended for the treatment of rectal stricture in the same way that it is used in stricture of the urethra. It is to me inconceivable that good results could possibly follow its use. If the current is strong enough to destroy tissue, injury may be done by



destroying tissues not intended, while even if the stricture itself is necrosed the healing after separation of the eschars will only add to the contraction. The supporters of this treatment would have us believe that a current of electricity passed through the contracted material of a stricture has some elective and alterative effect on it. I am convinced that if the electrodes had been passed without any current with the same assiduity, they would by their mechanical pressure have produced as good results.

**Colotomy.** Where none of the foregoing methods are applicable colotomy is a last resource ; it may become necessary under the following conditions : (1) where a long tubular stricture exists with much infiltration of surrounding strictures, as in some extensive cases of syphiloma,

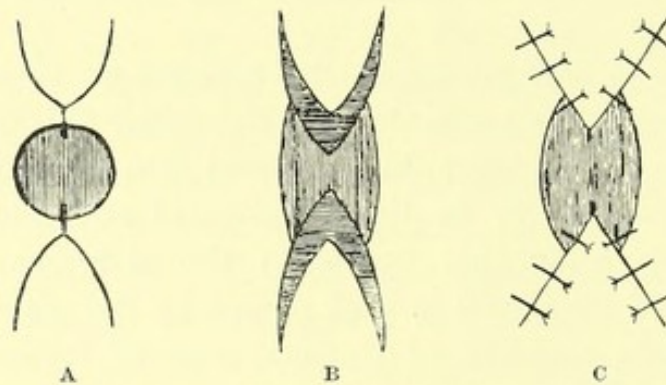


FIG. 76. Diagram of Dieffenbach's Proctoplastic Operation for Strictured Anus.

A. Vertical incisions are made through the front and back of the stricture and continued so as to outline V-shaped flaps of skin. B. Shows the flaps raised and the anus dilated. C. The flaps slid up into the anus and retained in position by sutures.

or following very widespread sloughing, the result of injury or sepsis ; (2) where extensive ulceration is present ; (3) where the peri-rectal structures and skin are penetrated by suppurating sinuses and fistulae. In the first class the colotomy must usually be definitive, but in the last two cases it may be possible to perform colotomy as a temporary measure, an attempt being subsequently made to heal up the ulcers or fistulae and to dilate the stricture. If this be practicable the colotomy wound can then be closed.

**Stricture of the anus** is most frequently the result of some operative interference, and can generally be treated by dilatation sufficiently to obviate any inconvenient obstruction, unless there is a great deal of dense cicatricial structure, in which case the proctoplastic



operation of Dieffenbach (Fig. 76) may be had recourse to. Vertical incisions are made through the contracted tissues, one anterior and the other posterior, and from the outer ends of each of these two primary incisions two radiating incisions are carried through the skin, thus forming an angular flap of integuments. This flap is dissected up, and its apex brought up to the inner extremity of the vertical incision, where it is retained by sutures. The incisions are in the shape of the letter Y, and the resulting cicatrix in the shape of the letter V. Cases requiring this operation are, however, of rare occurrence.



## CHAPTER XI

### IRRITABLE ULCER OR FISSURE

THERE are but few diseases which, while of very limited extent, produce such extreme misery to the patient, and none in which surgical treatment is attended with more certain success than in the affection under consideration.

The pain is due to the abundant supply of sensory nerves to the anal canal. The high degree of sensibility in this region is probably connected with the function of sphincteric control, for we find a similar abundant nervous supply in the sphincteric zone of the bladder. Any breach of surface, therefore, is liable to occasion a considerable degree of pain and produce reflex spasm of the sphincteric apparatus. The origin of the fissure is usually traumatic, from the passage of a hard solid motion, a congenital narrowing of the anus, when present, probably rendering such an occurrence more probable. Ulcers, the result of syphilis or other causes, when occurring in the sensitive zone, are painful, but seldom give rise to the typical symptoms of irritable ulcer.

The theory formerly held as to the cause of fissure and the reason why it did not heal like other simple cracks was that, once started by some slight traumatism, it was maintained by the spasm of the sphincters thereby produced, and thus a vicious circle was established, the more irritable the ulcer the worse the spasm, and the greater the spasm the more irritable the ulcer became. The treatment based on this theory was the partial or complete division of the sphincter muscle, or the forcible stretching of this muscle until its resistance was quite overcome, and the success which attended this line of treatment was taken as proving the truth of the theory upon which it was based.

Fourteen years ago I published a theory as to the cause of fissure (*The Rectum and Anus*, 2nd ed., p. 137) which has received considerable support from other surgeons, and a more extended personal experience has convinced me that in the vast majority of cases, at any rate, the real



explanation of the origin and maintenance of this painful affection is as follows. During the passage of a motion one of the little anal valves is

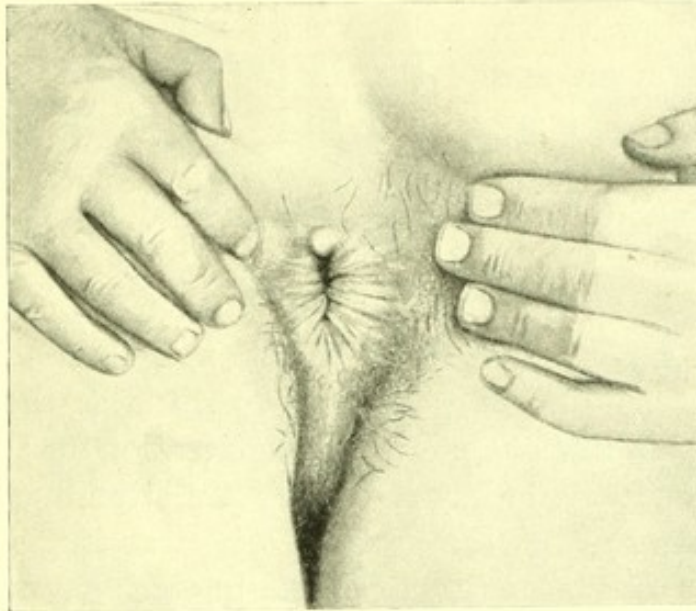

FIG. 77. Sentinel Pile at Base of Painful Fissure.

(From a stereo-photograph of a case at Sir Patrick Dun's Hospital.)

caught by some projection in the faecal mass and its lateral attachments torn. At each subsequent motion the little sore thus made is reopened,

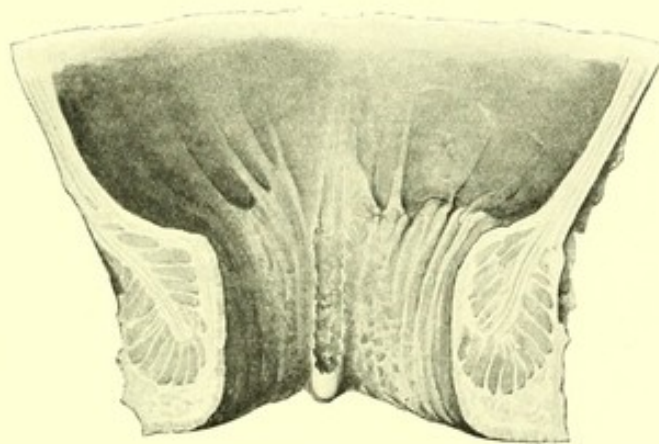


FIG. 78. Painful Fissure with Sentinel Pile at Base.

(From a specimen found post mortem.)

and possibly extended. The repeated interference with the attempts at healing ends in the production of an ulcer, and the torn-down valve becomes swollen and oedematous, constituting the so-called pile, or, as it



sometimes has been called, the 'sentinel pile' of the fissure. Most of us have experienced the little bits of skin torn down at the sides of the fingernails, popularly called 'torments', and how painful they are when dragged upon. Now the torn-down anal valve resembles closely this condition of the finger, except that in the former it is situated at the acutely sensitive anal margin, and subjected to the periodic strain of defaecation. It is therefore not to be wondered at that the pain should be so excessive as seriously to affect the general health and render life miserable.

The first case which directed my attention to the theory above detailed occurred many years ago. An otherwise healthy young woman consulted me complaining of very severe pain after the bowels moved. So great was the pain that she postponed defaecation for several days, with the result that she was quite incapacitated from attending to her duties for several hours after the bowels moved. She was in no way a neurotic subject, and I was convinced that her suffering was extremely acute.

Upon superficial examination nothing was to be seen, but the left side of the anus was extremely tender to the touch, and any attempt to introduce the finger was attended with such pain and spasm that I did not persist in it, but prescribed an aperient, and the following day dilated the anus under ether, when a small ulcer rather triangular in shape was clearly seen; the base of the triangle was below, and was formed of an oedematous little tag of cutaneous tissue, which I recognized as an anal valve. Catching this in a forceps and drawing it down tended to enlarge the ulcer, and the resemblance of this to the 'torments' on the finger at once suggested itself. Since then I have seen a large number of cases; in most of them the torn-down valve was hypertrophied and quite obvious, while in a few it was very small and had to be carefully looked for. In the same way we see very minute 'torments' at the side of the finger giving rise to a good deal of discomfort when pulled upon.

**Symptoms.** The subjective phenomena of irritable anal ulcer present a train of symptoms which are eminently characteristic, so that from them alone the diagnosis can be made with almost absolute certainty.

The pain is paroxysmal, and always associated with the act of defaecation. During the actual passage of the motion, however, it is not usually severe, but shortly afterwards it comes on with great intensity. It is a dull, gnawing, and extremely distressing sensation, situated immediately within the anus, and not infrequently associated with some



reflected pains. It lasts for many hours, completely incapacitating the sufferer from following his occupation, and necessitating the recumbent position while it lasts. It then subsides or entirely disappears, to be, however, reproduced in all its intensity when next the bowels move. The act of defaecation, is, therefore, postponed as long as possible, with the result that when the evacuation does take place the pain is greatly increased. As a result of the constant pain, the constipation, and the frequent resort to narcotics, constitutional symptoms of a severe type may develop, the countenance becomes careworn and sallow, the appetite is bad, and there is considerable emaciation, a train of symptoms which, in many respects, resembles the cachexia of malignant disease. The faeces are passed in a narrow cylinder, or sometimes they are flattened and tape-like, due to the incomplete relaxation of the sphincter during defaecation, and not infrequently a streak of bloody matter is to be seen on them.

If a patient comes to us complaining of severe pain lasting for some time after defaecation the presumption is strong that a fissure is present, no other rectal disease producing this characteristic distress. The disease is more common in females, and although more frequently met with in young adults, no age appears to be exempt, and it is not infrequently met with amongst old people.

Upon making an examination, the first thing that attracts our notice frequently is a small 'sentinel' pile, which is a torn-down and enlarged anal valve, immediately above which will be found the fissure. If no sentinel pile is obvious, it will be found that on passing the finger round the anus one part of the circumference is observed to be tender, and any attempt to introduce the finger gives a great deal of pain, and is violently resisted. Upon separating the anal folds the lower termination of the fissure can generally be seen, the base being red or grey, and the edges somewhat indurated. Above the anal margin the fissure is wider, so that it presents a club- or racquet-shaped appearance, but when the sphincter is fully dilated and the speculum introduced, the stretching of the lower part shows the whole as an elliptical or triangular ulcer.

Although usually solitary, sometimes we find them multiple. This is most frequently the case when they are of syphilitic origin.

In the light of the theory above indicated, the explanation of these symptoms is rendered obvious: every time the bowel moves the thickened and displaced anal valve is dragged upon, the little sore reopened and



irritated by faecal soiling; even when in rare instances the ulcer is due to syphilis or other cause than a torn-down anal valve, the passage of a motion opens up the sore and drags on its lower edge. The severe pain is thus started, and usually only subsides after the lapse of some hours, to be again set up in a similar manner the next time the bowels move, so that the ulcer does not get a chance of healing.

**Treatment.** In the more recent examples of this disease, and in those in which the origin is undoubtedly syphilitic, a cure can be sometimes accomplished by local applications, but in those which have existed for some time these means will, in all probability, prove ineffectual, and operative treatment is called for. There is not in the whole range of surgery any operation in which the surgeon can speak so positively as to the certainty of cure and freedom from risk, so that it is to be strongly recommended in all except the most trivial cases.

If the patient refuses to be operated on, or if the surgeon considers the case suitable for the milder measures, he should prescribe a purgative of sufficient strength to ensure one soft and easy evacuation daily. Immediately after the evacuation the anus should be well washed with soap and water, and, if possible, defaecation should take place at night, immediately before the patient goes to bed.

The introduction into the rectum of boric ointment by means of a rectal tube sometimes gives relief. The collapsible tubes in which ointments of various kinds are now often put up, to which an ebonite rectal tube can be screwed on, afford a convenient way of introducing ointment into the inside of the rectum.

The operations formerly advocated were first, complete division of the sphincter. This was subsequently modified by making the incision through the superficial fibres of the sphincter only. This again, in turn, gave way to simple hyper-distension of the muscle, until its resistance was overcome.

Until recently the operations above detailed have been universally employed, and undoubtedly the success attending them has been great. Adopting the theory as to causation I have above described, it is easy to explain how these (as I now believe unnecessary procedures) have afforded such complete relief to symptoms. First as to dilatation. When the anus is widely stretched by the fingers, beyond the limits of natural dilatation by the passage of a motion, the little valve is torn down beyond the extent to which it is torn in normal defaecation, consequently rest is



given to the ulcer and healing ensues, the subsequent defaecation not reopening the sore. In like manner spontaneous cure occasionally ensues by the valve being torn down to its full extent during repeated acts of defaecation, then the fissure heals and the valve remains a little cutaneous tag, like many external piles. In the 'torments' at the side of the finger, if the little piece of skin is forcibly torn down, although the process is painful, a cure results just in the same way that forcible dilatation cures an anal ulcer. Secondly, complete or partial division of the sphincter through the floor of the ulcer, if carried down through this tag, relaxes each side, so that the subsequent motions do not catch in it and reopen the wound. Most surgeons of experience in this subject have met with cases in which both dilatation and incision have failed, and the advice given by many writers to supplement the operation by the removal of the so-called pile, at the lower end of the ulcer, is undoubtedly sound. I would, however, go a step farther and say that the removal of this little tag is all that is necessary, and that neither forcible dilatation nor incision of the sphincter is called for.

What I recommend in these cases where the classic symptoms of painful fissure are present is as follows: Do not subject the patient to the pain of extended digital examination, much less occasion him the torture of passing a speculum, but, after having the bowels fully relieved by an efficient aperient, administer an anaesthetic, and dilate the anus with the fingers sufficiently to obtain a good view of the entire circumference at the muco-cutaneous junction, then, if the symptoms have been characteristic, a little ulcer will almost certainly be found, and at its lower extremity the torn-down anal valve sometimes greatly hypertrophied. All that is now necessary is to catch this in a forceps, and with a fine pair of scissors remove it by a V-shaped incision, with base towards the ulcer, so that nothing be left that can be caught by a passing faecal mass. If there is unhealthy granulation tissue in the ulcer, it should be removed with a sharp spoon. The cure will then be as immediate and certain as when the little 'torment' at the side of the finger-nail is shaved off level with the skin. It is advisable after this little operation to examine carefully all the other anal valves, and if any of them are likely from their size and projection to be torn down and so form other fissures, to snip them off with the scissors.

I have now operated in this way upon a large number of cases. In almost all the piece torn down by defaecation was found, although in some



it was small. In two of the cases, in addition to the treatment above detailed, I slightly incised the sphincter, as it was very rigid and contracted. This I did in deference to old tradition, and I now believe it was inflicting a useless although trivial injury on the patient. One of these cases had been twice operated on by other surgeons, once by incision, and once, I was informed, by the truly barbarous method of Maisonneuve, namely, gradually introducing the whole hand into the rectum, closing the fist, and then forcibly withdrawing it. What this heroic treatment failed to accomplish, the little operation of snipping away anal valves surely effected.

In conclusion I would wish to point out that the cases alone suitable for this operation are the painful or irritable fissures of the anus. These are not to be confounded with the superficial cracks of the anal skin common in eczema and some other conditions, nor with the superficial ulcers met with in syphilis. They must also be distinguished from ulcers entirely confined to the mucous membrane which do not produce the characteristic symptoms.



## CHAPTER XII

### PROLAPSE

By the term 'prolapsus', or 'procidencia recti', is understood the protrusion of a portion of the rectal wall through the anus. The old term 'prolapsus ani', which is to be found in many textbooks, is so obviously erroneous that it is best discontinued. Of prolapsus, adopting the classical description of Cruveilhier, we can recognize three distinct varieties, (1) where the mucous membrane alone protrudes (partial

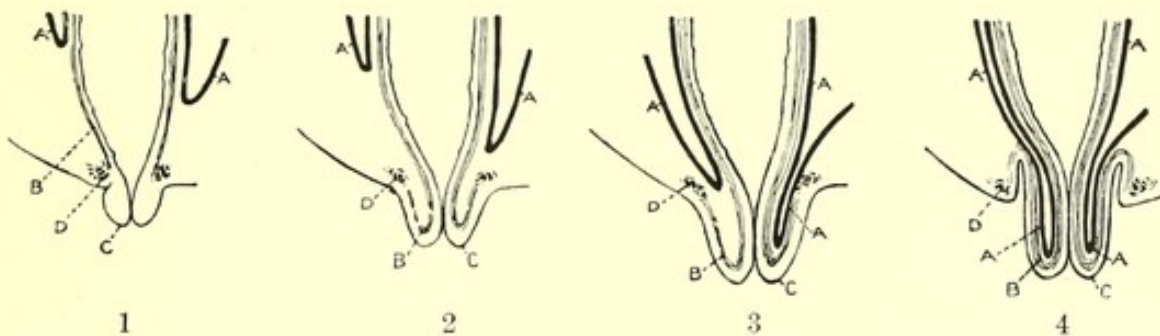


FIG. 79. Diagram illustrating the varieties of Prolapse of the Rectum.

1. Prolapse of mucous membrane only. 2. Prolapse of mucous membrane and muscular coats of rectum. 3. A more extensive form of the variety illustrated in No. 2, showing involvement of peritoneal pouch in the prolapse. 4. Intussusception protruded through the anus. A. Peritoneum. B. Muscular tunic of rectum. C. Mucous membrane. D. External sphincter.

prolapse), (2) where the entire thickness of the intestinal wall is included in the protrusion (complete prolapse), and (3) where there is invagination as well as prolapse, or, in other words, the external appearance of an intussusception.

**1. Partial Prolapse.** When the extruded mass consists of mucous membrane alone, the muscular coats of the intestine remaining *in situ*, the condition is spoken of as partial prolapse. This is of somewhat common occurrence, and is a very much less serious affection than either of the other varieties.



A slight protrusion of the mucosa can be produced voluntarily, and normally occurs during and immediately after defaecation. In some animals this is more especially noticeable than in the human subject, the horse being a familiar example.

We may conveniently group the causes of pathological prolapse of the mucosa under three heads, (1) that due to the effusion of inflammatory products in the lax tissue of the sub-mucosa, (2) where the

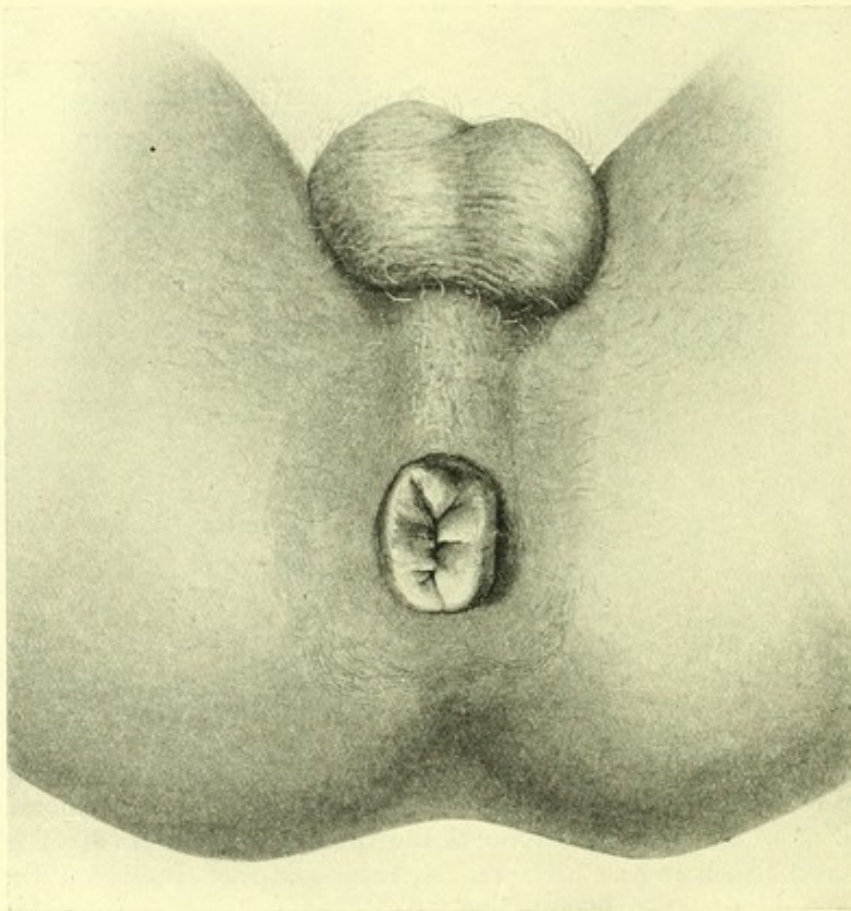


FIG. 80. Partial Prolapse—mucous membrane only—of Rectum.  
(From a stereo-photograph of a case at Sir Patrick Dun's Hospital.)

mucous membrane is dragged down by piles, polypi, or other neoplasms attached to it, and (3) where the folds of prolapsed membrane have been protruded by peristalsis, the muscular structures of the anus and perineum being relaxed.

In cases of catarrhal proctitis and dysentery, inflammatory exudations frequently cause the protrusion of bright red folds of mucous membrane from the anus, a condition which has by Roser not inaptly



been compared to the inflammatory ectropion of the ocular conjunctiva. Prolapse occasioned in this way is generally, in the first instance, of limited dimensions, but a prolapse once started has a tendency to increase in the same way that intussusceptions of other portions of the intestine are progressive. So that a prolapsus recti which has attained large dimensions may have been, in the first instance, due to a trivial inflammatory exudation in the rectal sub-mucosa.

The protrusion of folds of mucous membrane associated with the prolapse of internal piles is exceedingly common, but it seldom occurs to any great extent. This is probably due to the fact that the presence of the haemorrhoids has produced a certain amount of inflammatory thickening in the sub-mucosa, which renders the extensive separation of the mucosa improbable, and the prolapse will certainly disappear entirely if the piles are subjected to efficient surgical treatment.

The form of prolapse produced by adenoma is peculiar, and deserves some notice. In this form, instead of a broad fold of mucous membrane being protruded, a narrow funnel-shaped portion is drawn out, sometimes of upwards of two inches in length, and constituting the pedicle of the growth. This likewise gives rise to no trouble after the adenoma has been removed.

The most important cause in the production of this variety of prolapse is the occurrence of violent and long-continued expulsive efforts, especially if associated with a relaxed condition of the muscles around the anus, consequently we find prolapsus recti a common accompaniment of vesical calculus and phimosis in the child, of urethral stricture in the adult, and of enlarged prostate in the aged. Other cases are apparently due to the irritation of intestinal parasites, or of diarrhoea, while the custom, which is common amongst nurses, of leaving young children to sit on the chamber utensil for a long time after defaecation is completed undoubtedly tends to favour the production of prolapsus recti. Any disease which leads to great wasting and absorption of ischio-rectal fat and consequent want of support to the pelvic diaphragm is an undoubted predisposing cause; a large number of cases in childhood appear to have followed such debilitating diseases as measles, whooping cough, and rickets.

This is a disease which is very much more common at the extremes of life, the majority of cases being met with in young children and old people, its primary occurrence between the ages of 15 and 50



years being quite unusual. Most of the authors who have written on rectal disease enumerate as one of the causes of the greater prevalence of prolapse amongst children, the want of support to the lower bowel in consequence of the greater straightness of the sacrum. This, however, I think, cannot be considered an important aetiological factor. In old age the general relaxation and want of tone favours the formation of rectal prolapse.

**Symptoms of partial prolapse.** The diagnosis of this disease is easy, the protrusions of mucous membrane appearing as bright red folds, arranged with sulci between them, which radiate from the aperture (Fig. 80), whereas the sulci in complete prolapse are principally parallel to the anal margin of the bowel (Fig. 81), and, again, in partial prolapse the size of the tumour is usually of much more limited dimensions. The principal masses in partial prolapse are placed laterally, and on the surface of the prolapsed intestine superficial catarrhal ulcerations are frequently to be seen. At first the protrusion only occurs after defaecation, and is easily returnable; in more chronic cases, however, it becomes more difficult to replace, and may reappear independently of defaecation. The mucous membrane also becomes thickened, and the sub-mucosa infiltrated. A muco-purulent discharge is common, and anal bleeding to a slight extent often occurs. As has been elsewhere stated, the protrusion of internal piles is frequently associated with more or less prolapse of the mucous membrane, but this is a condition which ought always to be readily distinguished from the disease under consideration. Prolapsed haemorrhoids are more isolated tumours, and firmer to the feel than a mere flap of mucous membrane, and when of the venous variety the livid colour will serve to establish the diagnosis.

Of the **complications** of partial prolapse, the most important is inflammatory gangrene, which is an occasional termination, by means of which Nature sometimes effects a spontaneous cure of this disease, the gangrene being due to inflammatory stagnation, and not to the strangulation of the prolapse by the sphincters, indeed in these cases relaxation of the sphincters usually precedes the disease, and in cases of gangrene the finger can be readily passed into the rectum, showing that there is no strangulation by the muscles.

Spontaneous recovery may also sometimes result without the actual occurrence of gangrene, the prolapsed mucous membrane being injured either by the passage of a hard faecal mass or external agencies to such an extent that inflammation is set up sufficient to effect a permanent cure.



**Complete prolapse.** After partial prolapse has existed for some time, it may merge into the more serious form where all the tunics of the bowel are involved; probably, however, in a large proportion of cases complete prolapse commences from above, without there having been any preliminary partial prolapse of mucous membrane.

Several theories have been advanced to explain the occurrence of complete prolapse, and the whole subject has been ably dealt with in a recent paper by Lenormant (*Revue de Chirurgie*, Feb. & March, 1907). Accord-

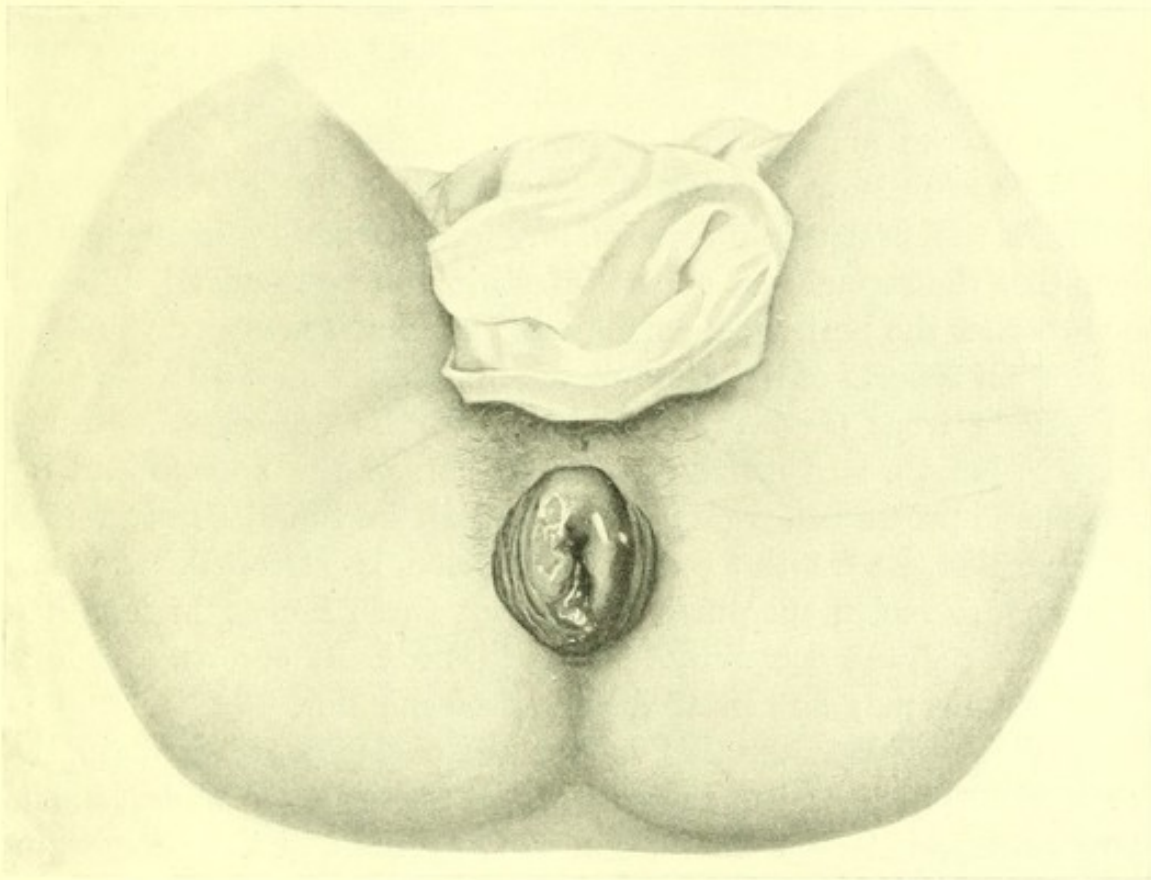


FIG. 81. Complete Prolapse of the Rectum, showing concentric folds.  
(From a stereo-photograph of a case at Sir Patrick Dun's Hospital.)

ing to Jeannel, elongation of the pelvic meso-colon is looked on as the principal preliminary factor in the production of complete prolapse, and this view is apparently supported by some experiments of Raynal in which it was not found possible to produce a complete prolapse on the cadaver until the pelvic meso-colon had been divided. Lenormant, on the contrary, thinks that the musculature of the pelvic diaphragm is the chief protection against prolapse, and that its undue relaxation is a necessary prelude to the occurrence of extensive protrusion. He cites in support of this



view the common experience in perineal excision of the rectum, that once the levator ani has been completely divided round its entire circumference the rectum can be drawn down without much difficulty. Zuckerkandl and others consider that a predisposing cause is an abnormally deep pouch of Douglas, into which a loop of small intestine drops; when this becomes distended with gas it causes a bulging of the anterior wall of the rectum, which may be so considerable that it is caught by the peristalsis of the rectal muscles and forced through the anus as a prolapse. Judging purely from clinical experience, which clearly shows that in a large proportion of cases prolapse is preceded by some enfeebling disease in childhood, or general wasting in old age, relaxation of the muscles and ligaments of the pelvic outlet must be considered a prominent predisposing factor.

When the protrusion reaches any considerable dimensions it is obvious that the serous coat of the intestine will be involved, and, owing to the fact that the peritoneal pouch descends much lower on the anterior than on other aspects of the rectum, the first appearance of a sac is to be looked for in front (Fig. 79). If, however, the prolapsus continues to increase in length, so that the upper portion of the rectum and pelvic colon become protruded, a peritoneal sac will be found surrounding the tumour, except where the pelvic meso-colon is attached. As a rule, where the protrusion measures more than three inches in length it is generally curved, the concavity looking towards the coccyx, and in very extreme cases it may be arranged in a spiral manner.

The diagnosis between this variety and prolapse with invagination is easily made, as in the latter the outer layer retires again within the anus, leaving a sulcus between the margin of the anus and the tumour, along the entire circumference of which a probe, or the finger, can be passed, while in the latter this sulcus does not exist, the outer layer of the prolapse being directly continuous with the anus. Complete prolapse may assume very great proportions, in rare instances the greater part, or even the entire length, of the colon may be protruded. In one case which came under my notice the whole large intestine was thus extruded. The patient was a child, aged 4 months. The prolapse was arranged in a spiral manner, making two and a half revolutions. The apex was formed by the caecum, the ileo-caecal valve being distinctly discernible, while the other end was continuous with the anus. The mucous membrane was in several places superficially ulcerated. The patient died of



peritonitis. From the history I received of this case, I have no doubt that it commenced as an ordinary prolapsus recti, which gradually increased in dimensions by successive portions of the colon becoming involved until the whole protruded. A similar result occurs from an ileo-caecal intussusception, the large intestine becoming invaginated from above downwards. In the latter case the first part to appear through the anus will be the ileo-caecal valve, while in the former it will make its appearance last. In cases of colic or rectal intussusception, which have secondarily involved the entire lower portion of great intestine down to the anus, it may be impossible to arrive at a conclusion as to whether the disease has originated as an ordinary prolapse, or as an intussusception higher up. The mass may also assume large proportions, even to the extent of hanging down between the thighs. This may be the case to such a degree that all attempts to return it within the abdominal cavity will prove abortive.

Prolapsus recti is generally unattended with severe pain, the mucous membrane, from a point immediately within the anal margin, being of low sensibility, but the constant mucous discharge, and the incontinence of faeces, which in severe cases is always more or less present, renders the patient very miserable.

The **complications** of complete prolapse are both important and serious, and they owe their chief gravity to the involvement of a peritoneal pouch brought down with the prolapse. In intussusception the invaginated peritoneum is usually soon the seat of a localized adhesive peritonitis which obliterates the sac, but this is not the case to the same extent in prolapsus recti, the protruded portion of peritoneum retaining its continuity with the general cavity. Into this peritoneal pouch a portion of intestine is apt to fall, constituting a hernia of a peculiar variety, which may be appropriately described under the term prolapsal hernia. It is usually the small intestine that is thus implicated, but the ovaries, bladder, and other viscera have occasionally been found similarly involved. In the first instance, the hernial tumour is to be looked for on the anterior aspect of the prolapse, in consequence of the peritoneum descending lower in front than behind. In aggravated cases, however, the small intestine may descend behind as well as in front. A hernia thus formed is to be recognized by the same signs that we are familiar with in the more usual seats of this disease, the tumour is usually tympanitic on percussion, and the sac can generally be emptied by



pressure, the enclosed portion of intestine being reduced into the abdominal cavity. The same changes which are observed in hernia generally have also been noted in this form. It may become irreducible by the formation of adhesions between the sac and the contained viscera, or strangulation may result from the constriction of the neck by inflammatory swelling. According to Esmarch, the formation of what he terms an 'anus preternaturalis in ano' has been known to occur as a result of this strangulation.

A very rare complication of complete prolapse is the spontaneous rupture of the entire rectal tunics, and the protrusion through the rent of a portion of the small intestine. In a very interesting paper by M. Quénu ('Des ruptures spontanées du rectum', *Revue de Chirurgie*, March 10, 1882), the whole subject of spontaneous rupture of the rectum is fully discussed, and the recorded cases of this rare injury collected. In all nine cases have been noted; and of these five are described tolerably completely, and in four out of the five an old and extensive prolapsus recti preceded the rupture. The immediate exciting cause in these cases was some violent muscular effort, as defaecation, vomiting, or lifting a heavy weight, and in all the protrusion of small intestine through the anus was followed by a reduction of the prolapsus recti. All the cases occurred in adults, only one was noted in the male subject, the others occurring in women. In none of the cases did the structures appear to present any macroscopic change, such as ulceration or inflammatory softening preceding the accident, but in the case which came under the personal observation of M. Quénu there was a considerable amount of inflammatory exudation to be seen under the microscope, although to the unaided eye the tunics appeared to be absolutely normal.

The position at which the rupture occurred varied from 1 to 5 inches from the anal margin, and the direction of the rent was transverse in some and longitudinal in others. The diagnosis is readily made, the escape of small intestine at the anus, with its smooth peritoneal covering and attached mesentery, being pathognomonic of the lesion. The prognosis is very bad, none of the recorded cases having recovered. The treatment adopted by Adelman is, however, based on sound surgical principles. Having failed to reduce the hernial protrusion by direct pressure, this surgeon performed laparotomy, and drew back the small intestine into the peritoneal cavity, and then, by pulling down, and so



reproducing, the prolapsus recti, he brought the rupture, which was situated at  $2\frac{1}{2}$  inches from the anus, into view, and carefully stitched it up. With the improved methods of dealing with peritoneal wounds now at our disposal, should the case be seen early enough, it is possible that success might attend a similar procedure.

An interesting case of spontaneous rupture without prolapse is referred to on p. 311.

In forming a **prognosis**, in any case of prolapse, it is well to bear in mind that in young children there is a strong tendency to spontaneous cure, and only mild measures will be necessary to assist nature, but where the disease exists to any extent in the aged, no such result can reasonably be looked for. At any age, if the prolapse is attended with much inflammatory thickening, and if it is of long duration, relief can scarcely be expected by any means short of surgical operation. In cases of extensive protrusion, with formation of a peritoneal sac, the danger to the patient's life is considerable, peritonitis not infrequently supervening as a result of sloughing, ulceration, or the inflammation or strangulation of a hernia.

**Treatment.** The first step which is usually required in the treatment of this disease is to effect reduction. Indeed, in many cases, it will be found that the unaided efforts of the patient will be sufficient to effect this when the prolapse is recent, or, in the case of young children, the mother will have returned the protrusion within the anus before the surgeon is called in. Where the disease has become chronic, or where the sub-mucosa has become distended with inflammatory effusion, considerable difficulty may be experienced in effecting reduction, and in a few very rare cases the hypertrophic changes may be so extensive that it may be quite impracticable to return the mass into the abdominal cavity.

In order to effect reduction in the child, the little patient should be laid across the knees, and gentle pressure of the whole mass of the tumour should be for some moments exercised, so as to reduce its bulk by the squeezing out of the contents of the bowel prolapsed, and of any fluid effusion in its tunics. After this, reduction should be proceeded with, efforts being made to return the more central parts first, and in the great majority of cases but little difficulty will be experienced. It will sometimes be found that the prolapse immediately reappears after the removal of the finger. In order to obviate this, Sir C. Bell has suggested an ingenious manœuvre. He advises a small piece of paper



to be twisted into the form of a hollow cone, in the way that paper bags are made. This is to be well greased on the inside, and the apex of the cone placed in the aperture of the prolapse. The index finger is then to be placed in the cone, and steady pressure kept up. As the paper advances it draws with it those portions of the prolapse which last came down, till finally the whole is reduced. The finger is now withdrawn, and the paper left *in situ*.

In the case of the adult similar means will usually be found sufficient, the most convenient position being with the patient resting on his hands and knees. Should any difficulty be experienced in effecting reduction, it is better at once to administer an anaesthetic, and to be prepared, if the case is severe and somewhat chronic, to operate for the radical cure at the same time. Reduction having been effected, it is necessary to apply some retaining apparatus, and the best evidence we can have of the difficulty of effectually keeping the prolapse up is the vast number of appliances which have been invented for the purpose. The best temporary means is to apply a pad of tenax, absorbent cotton, or some similar material to the anus, and then to strap the nates together with strips of strong rubber plaster.

In order to prevent the recurrence of the prolapse, great attention must be paid to regulation of the action of the bowels, and the usual sitting position during their evacuation should absolutely be interdicted, defaecation being effected either on a bed-pan, lying on the side, or in the erect position. It is also a useful plan for the patient to accustom himself to have the bowels moved the last thing before going to bed, so that he may at once lie down after the act. This is a good rule in many other rectal diseases, and with a little practice the habit can readily be acquired without discomfort. The anus should be well washed with cold water, solution of alum, or decoction of oak-bark. I am convinced it is a bad practice to use astringent injections, as, if they were strong enough to be of any practical utility, they are apt to produce tenesmus and straining, which will be productive of much more harm than any good they can accomplish. But a small enema of cold water will often prove of service.

It is obviously a matter of the greatest importance to arrive at a diagnosis as to the cause of the prolapse, and, when this is practicable, to direct treatment to the removal of that state, whatever it may be, but unfortunately, in a number of cases it is impossible to arrive at any



conclusion as to the cause, so that our treatment must be somewhat empirical. In the case of children, however, we should examine carefully for rectal adenoma, oxyurides in the rectum, phimosis, or for symptoms of vesical calculus. In certain cases it would appear that the exciting cause is an intestinal catarrh. Should any of these conditions be made out, it will usually be found that efficient treatment for their removal will prove sufficient to effect a cure of the prolapse. Where constipation is present, the bowels should be regulated by change of diet, and, if necessary, plain enemata, rather than by the administration of purgatives, which cannot fail to prove harmful. Any debilitating disease is to be appropriately treated.

In the adult, one of the most common causes for prolapse of moderate degree is the presence of internal piles, and the surgeon can promise the patient an absolute cure of the prolapse by efficient surgical treatment of the piles, the cicatrization following the removal of the haemorrhoids by any of the usual methods, detailed in the chapter on that subject, tending to produce an adhesion between the mucosa and the deeper layers of the rectal wall, and so preventing that free movement of the mucous coat which is essential to the formation of the prolapse in its earlier stages, and, again, the denser tissue of the cicatrix tends to prop up and stiffen the lower portions of the rectum. Where there are, in addition to the piles, many redundant folds of mucous membrane, they may be subjected to operation at the same time that the haemorrhoids are treated, portions being pinched up with a forceps and crushed, or cauterized, or if the ligature is preferred, the circle of mucous membrane may be divided into four or five segments with a scissors, and each portion separately ligatured. Such diseases of the urinary organs as stricture, or enlarged prostate, should receive appropriate treatment, and, where constipation is present, the bowels should be relieved in such a way as to prevent straining. Sufficient has, however, been said as to the importance of recognizing, and as far as possible removing, the cause of prolapsus recti, and in children these measures, in addition to the mild local treatment already indicated, will usually prove sufficient, the disease having a decided tendency to disappear as the patient approaches the age of puberty. In a few cases, however, in childhood, and in the majority of cases in the adult, something more will have to be done.

A great deal of ingenuity has been expended on the construction of pessaries and various forms of retentive bandages, but the best of



them are uncomfortable, dirty, and generally ineffectual, still, in decrepit old people upon whom it is undesirable to operate, a well-made pessary may sometimes be of use. The modern improved methods of operation give such good results that all other cases, where palliative means fail, should be strongly advised to submit to operation.

Subcutaneous injection of ergotin, strychnin, carbolic acid, and other fluids have been sometimes used, but the results have proved to be so unsatisfactory and inefficient that they are now practically given up. Cauterization by chemicals, such as nitric acid, or by heat, has been chiefly relied on until recent years, when improved methods of treatment have largely superseded it in cases of extensive prolapse; in slight and moderate cases, however, cauterization is often effectual. In very mild cases the application of chemical or actual cauterization at points over the surface prolapsed, sufficient to produce superficial sloughs, may, as the ulcers therefrom heal, so stiffen up the rectal tunics, that a cure will result. In more extensive cases the method of Van Buren is preferable: the prolapsed bowel is to be reduced and a large-sized duck-bill speculum introduced; three or four vertical lines of cauterization are now made with a Paquelin cautery, from points well inside the rectal ampulla down through the anal canal. The cauterization should extend through the entire thickness of the mucous membrane; the linear cicatrices which result from this operation tend to support the bowel and render further recurrence unlikely. It is important to remember that the bowel should be reduced before the cauterization is made, in order that the superficial portions of the eschar may correspond with the deeper tissues when in the normal position. After either method the recumbent position should be maintained and great care taken to prevent the occurrence of prolapse until healing of the ulcers is established.

Narrowing of the anus by circular cauterization, or by plastic operation, although recommended on high authority, is an unscientific and unsatisfactory way of dealing with prolapse, and the same must be said of the ingenious operation suggested by Thiersch (Louis Pique, *Bulletins et Mémoires de la Société de Chirurgie de Paris*, Jan. 1906). He passes a silver wire by means of a large curved needle first on one side, half round the circumference of the anal canal, and then on the other. Entering the needle at the retro-anal raphé  $1\frac{1}{2}$  cm. from the anal margin, it emerges at a point in the centre of the perineum  $1\frac{1}{2}$  cm. in front of the anus, care being taken to keep well outside the lumen of the anal



canal while passing the needle. The wire is then drawn through, and the point of the needle is subsequently reintroduced at the aperture of exit, passed round the other side of the anal canal and out at the aperture of entry, and the wire drawn through. By a little manipulation the loop of wire in front is drawn through the anterior aperture into the subcutaneous structures and the ends of the wire are twisted together and similarly sunk through the posterior aperture into the subcutaneous structures and both openings closed; there is thus established a completely buried silver-wire ring in the tissues surrounding the anal canal, the idea being that it may remain permanently, or be removed at a later period when sufficient inflammatory thickening has been produced to prevent undue relaxation of the peri-anal musculature. Platt (Tuttle, *Diseases of the Rectum*, p. 693) has suggested the use of kangaroo tendon instead of silver wire, and it certainly appears to be preferable. After passing it subcutaneously, he keeps the index finger in the anal canal while tying it, so as to estimate exactly the proper degree of tightness. This operation has not been much adopted and the results obtained are not very encouraging. The idea of maintaining a rigid metallic ring in the flexible musculature surrounding the faecal outlet does not appear to be based upon sound surgical principles, and in any case it is open to the objection which applies to other procedures noticed, that it is designed to prevent merely the protrusion through the anus, and not to prevent the commencement of the prolapse higher up the bowel at its point of origin. If a cistern is leaking we know that it is necessary to close the leak from the inside, and that attempts to do so from the outside will be ineffectual; similarly in the treatment of extensive prolapse the most scientific and effective method is from above, at the point of origin of the prolapse. It cannot of course be claimed that any surgical operation can completely restore the relaxed muscles and ligaments of the pelvic outlet; recent methods, however, show that as in nephropexy and hysteropexy, much may be done by fixation and suspension, and excellent results practically are obtained by fixation of the rectum or colon, either alone or in conjunction with myorrhaphy of the levator ani, and narrowing of the lumen of the rectal ampulla by rectoplicature.

Proctopexy is an operation designed to fix the extra-peritoneal portion of the rectum to the coccyx and perineal structures; it has been largely practised in France, since it was first advocated by G. Marchant.



The tip of the coccyx is removed and the pelvic diaphragm split down to the margin of the anus, exposing the posterior surface of the rectum ;

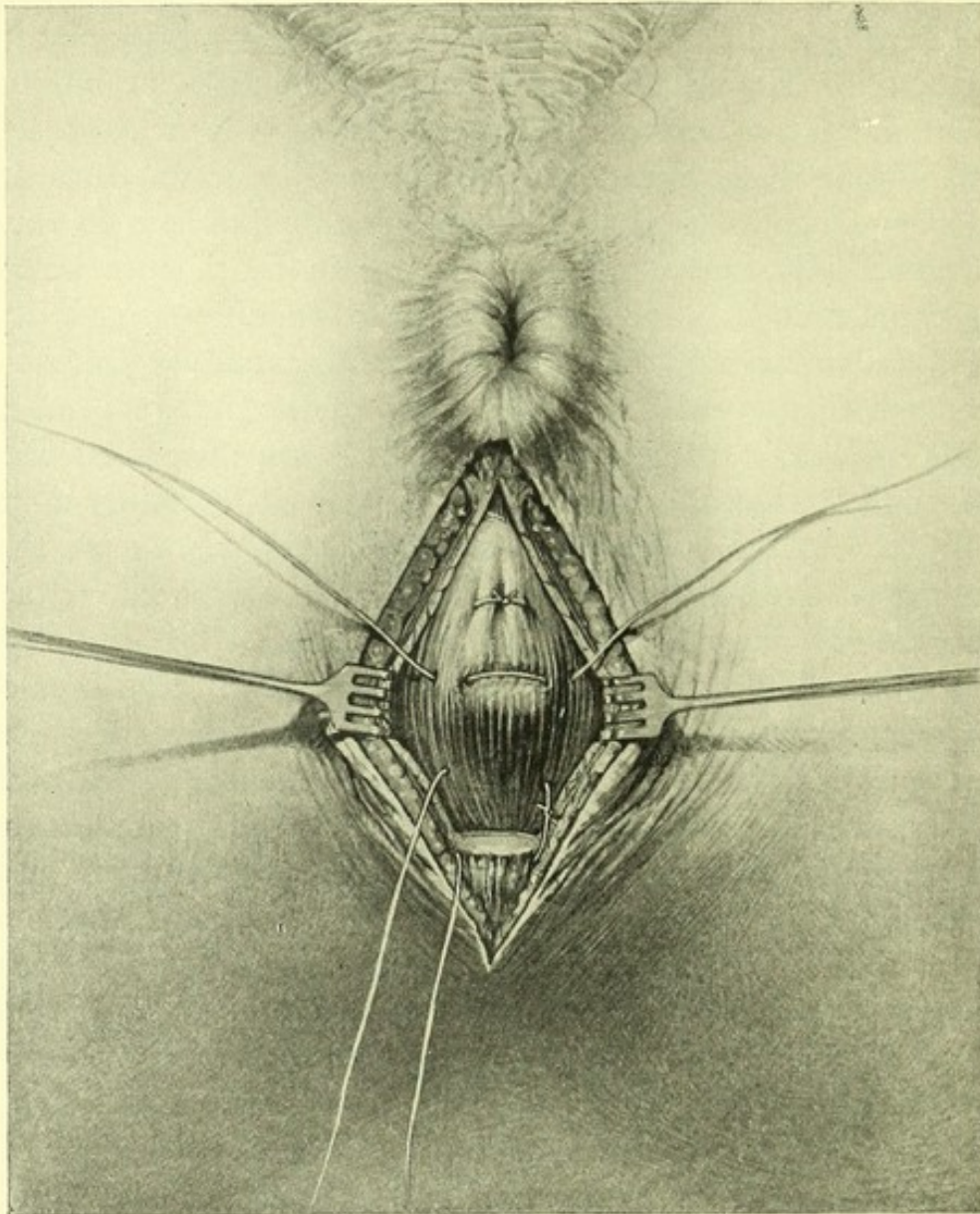


FIG. 82. Proctopexy and Proctorrhaphy.

The coccyx has been removed and the pelvic diaphragm split in the middle line to within half an inch of the anus. Sutures have been passed through the ligament on either side of the sacrum and through the muscular coat of the back of the rectum. The sutures are shown in position, one having been closed; these sutures fix the back of the rectum to the sacro-sciatic ligaments (proctopexy). The other sutures are shown passed in such a way, through the muscular coat of the rectum, that when closed they infold a longitudinal strip of bowel (proctorrhaphy).

*(From a stereo-photograph of operation done on a cadaver.)*

the prolapse is completely reduced and the bowel is sutured to the sacro-sciatic ligaments, taking care that the sutures pass only through



the muscular, and not the mucous, coats of the rectum; the pelvic diaphragm is then brought together by a series of buried sutures and the wound closed. Marchant and many other surgeons have supplemented this operation by the old suggestion of Verneuil to infold by suture the bowel wall (proctorrhaphy); this will have the effect of narrowing the lumen, if a series of sutures are placed so as to infold the rectal wall in the long axis of the rectum, or to shorten the length of the tube, if the sutures are placed so as to infold the rectum transversely. (Fig. 82.)

MM. Duval and Lenormant (*Revue de Chirurgie*, 1904, p. 728) have still further added to this operation by infolding the anterior surface of the rectum in a similar way through a separate incision in front of the anus, dividing the pelvic diaphragm in the middle line. The edges of the divided levator ani are subsequently brought together by buried sutures (myorrhaphy), passed, if necessary, in such a way as to tighten up the relaxed muscle.

A considerable amount of success has attended proctopexy in prolapse of moderate extent, but in severe cases recurrences have been frequent, so that it has now largely given place to colopexy, the operation of fixing the pelvic colon by laparotomy. The full history of this procedure, together with details of hitherto published cases, is fully given in an able article by Lenormant (*Revue de Chirurgie*, Feb. & March, 1907); according to him, priority is claimed for Jeannel, who in 1889 fixed the colon in a case of prolapse by means of colotomy; the artificial anus thus formed was subsequently closed and the prolapse remained definitely cured. Colopexy of course presupposes the reducibility of prolapse, irreducible prolapse being best treated by excision. In the majority of recorded cases, fixation has been made to the anterior abdominal wall. Lenormant, following Rotter, advocates fixation to the left postero-lateral wall of the pelvis as a better operation, as the position of the fixed colon more nearly approaches the normal, and it affords a fixed point of suspension; they also recommend that the surface selected for attachment of the colon should be denuded of peritoneum. These views I believe to be thoroughly sound, and although not previously published, I have since Feb. 1901 (before I had heard of Rotter's case) adopted a similar procedure.

Fixation to the front abdominal wall if combined with colotomy (colopexotomy) is of course not likely to stretch or give way, but where reliance has been placed on suture of the unopened intestine to the



peritoneum, or transversalis fascia alone, failure has been frequently recorded. Ayant (quoted by Lenormant) examined two dogs about three months after colopexy had been performed, and found the adhesions had stretched and become lax.

The operation which I first performed in 1901 and have since done

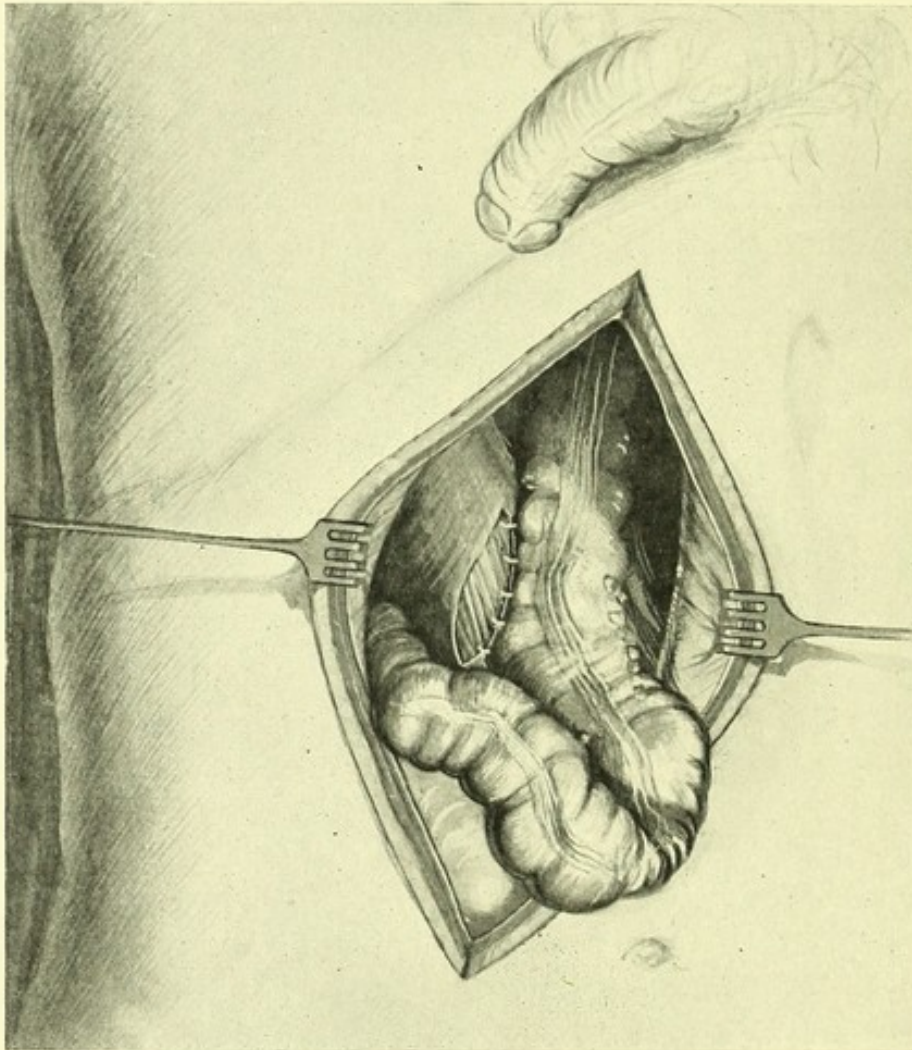


FIG. 83. Colopexy.

Body in high Trendelenberg position. Abdomen opened by splitting left rectus muscle. Incision through peritoneum exposing iliac fascia. Pelvic colon where it joins rectum pulled taut and applied to peritoneal incision. Internal edge of peritoneal incision sutured by five points of suture to serous coat of colon between its mesentery and postero-external taenia.

*(From a stereo-photograph of operation on a cadaver.)*

four times, differs slightly from that recommended by Lenormant and Rotter, but the main principle of fixing the pelvic colon to left posterior



aspect of the pelvis, and to a surface denuded of parietal peritoneum, is the same.

The patient is placed in a tolerably high Trendelenberg position, and the abdomen opened by vertical incision and splitting of the

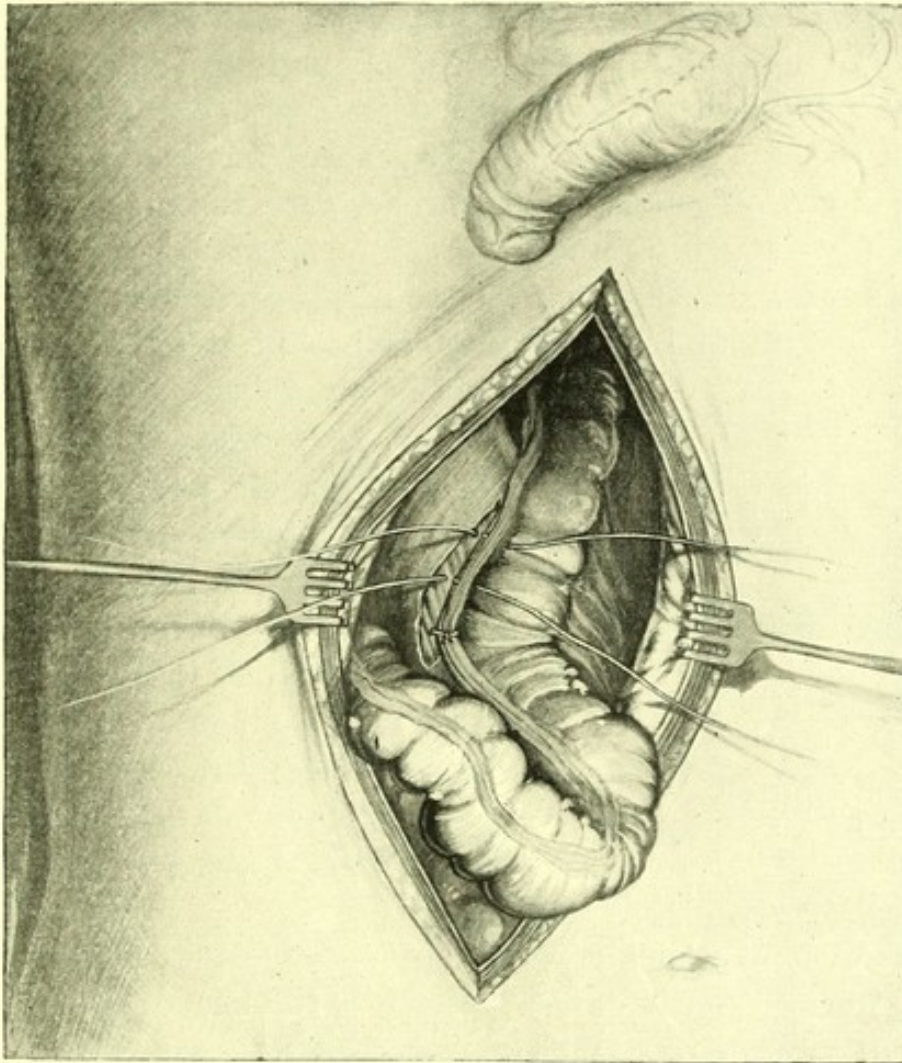


FIG. 84. Colopexy, further stage of operation illustrated in Fig. 83.

The postero-external taenia is fixed to the iliac fascia and underlying muscle by three points of suture, one of which is shown closed. The operation is to be completed by fixing the outer edge of the peritoneal incision to the serous coat of the colon external to the postero-external taenia.

*(From a stereo-photograph of operation on a cadaver.)*

left rectus muscle. The pelvic colon is drawn upon until the prolapse is quite reduced; a vertical incision  $2\frac{1}{2}$  inches long is now made through the pelvic peritoneum parallel to, but outside, the left ureter, and the cut edges of peritoneum raised from the iliac fascia. The pelvic



colon, held moderately taut, is now laid down over this incision, so that one of its longitudinal bands lies on the iliac fascia, and the portion which corresponds with the incision noted; the inner edge of the peritoneal incision is attached by a few points of fine suture to the peritoneal and muscular coat of the bowel between the mesenteric attachment and the longitudinal band at the place previously selected. Four sutures of thicker silk are now passed underneath the longitudinal band and through the iliac fascia and underlying muscle, deep enough to obtain a substantial hold; when the four sutures have been placed in position, they are tied, and the ends cut off short; in doing so, care should be taken not to tie them tightly enough to produce pressure necrosis. The outer edge of peritoneum is now attached by a few points of fine suture to the intestine outside the longitudinal band where it has been stitched to the iliac fascia. The abdomen is then closed in the usual way, in layers.

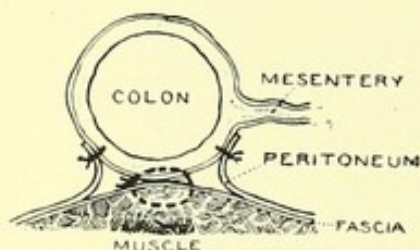


FIG. 85. Diagram illustrating the Method of Fixing the Colon to the Peritoneum, Iliac Fascia, and Muscle in the operation of Colopexy.

This operation provides for the firm and unyielding attachment of the pelvic colon to the fixed pelvic wall, and the length of bowel attached is sufficient to minimize the risk of kinking or the formation of a spur. Of the five cases in which I have performed this operation, one died suddenly of pulmonary thrombosis while sitting up ten days after operation, the

others have been completely cured.

In the case of women where prolapsus uteri is associated with prolapse of the rectum, fixing the rectum to the back of the uterus at the same time that hysteropexy is performed, has been done by several surgeons, while Bardenheuer and Wenzel (quoted by Lenormant), acting on the theory of Zuckerkandl, that an abnormally deep pouch of Douglas is a cause of prolapse, have endeavoured to obliterate this pouch by suture of the rectum to the posterior surface of the uterus.

Ludloff has suggested an operation to avoid risk of adhesions stretching, which would have the stability of a colopexotomy without the disadvantage of an external opening: he divides the pelvic colon across, closes the lower end by suture, and after traction fixes it between the layers of the abdominal muscles. The upper lumen is then implanted laterally in the lower portion of the pelvic colon. He demonstrated the



possibility of this operation upon dogs, and it has since been performed on man with complete success by Gangitano, after failure of two simple colopexies.

The pelvic colon has been twice resected by von Eiselberg for the cure of inveterate prolapse, and with a similar view Herzen and Rotter have made free lateral anastomosis between the two ends of the pelvic colon.

The most extensive operation hitherto recorded, according to Lenormant, is that published by La Nouene. In a case of prolapse of the rectum and entire large intestine, complicated with perforation near the caecum, the perforation was closed by suture, the ileum divided, the ascending and transverse colon fixed to the abdominal wall, the pelvic colon to the iliac fossa, and the ileum implanted in the pelvic colon. Recovery was complete, and ten months afterwards there was no evidence of recurrence.

Peters (*Brit. Med. Journal*, June 22, 1901) has suggested an operation for narrowing by infolding that portion of the rectum which is covered by peritoneum; it is based on the idea that prolapse originates as an intussusception, and its object is to narrow the lumen of the dilated part or intussusciens. After laparotomy and reduction of the prolapse, a series of sutures are so placed on the anterior surface of the rectum that when closed they will infold a furrow in the long axis of the bowel. As an addition to colopexy, this operation might be desirable where dilatation of the rectal ampulla was obvious; similarly, where there is marked relaxation of the perineal structures, colopexy may well be combined with myorrhaphy of the pelvic diaphragm, and infolding of the rectal wall where uncovered by peritoneum, behind the anus, and if necessary, also in front of the anus as suggested by Lenormant.

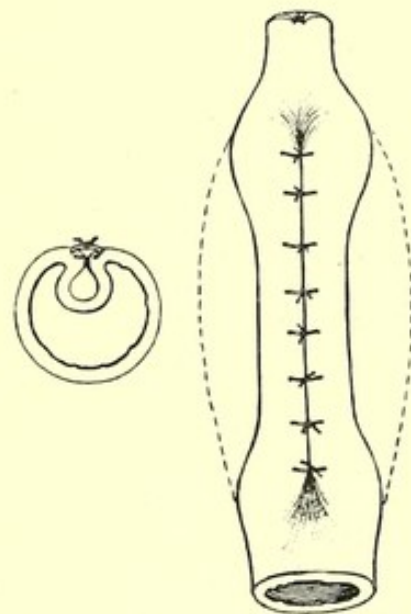


FIG. 86. Peters's Operation for Prolapse of the Rectum.

After laparotomy and reduction of the prolapse, a series of sutures are passed through the peritoneum covering the anterior surface of the rectum in such a way that when closed they will infold a longitudinal strip of bowel. The dotted line indicates the outline of the bowel before infolding, and the figure to the left shows in transverse section the effect of the infolding sutures.



**Excision of Prolapse.** Previous to the introduction of colopexy, excision of the entire prolapsed mass was occasionally had recourse to, in some cases with apparently good results. In one of my own cases an enormous prolapse, 12 inches long by 6 inches in diameter, was thus dealt with, the edge of the bowel and peritoneum being sutured to the margin of the anus, and the anal aperture narrowed by plastic operation to a reasonable size. A year subsequently there had been no recurrence of the prolapse, but the anus remained patulous and incontinence for loose motions existed. Excision must still be considered the proper

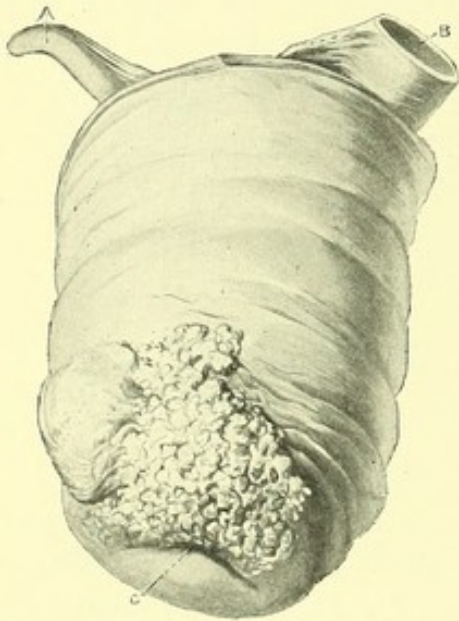


FIG. 87. Intussusception caused by Cancer of Ileo-caecal Valve, which was protruded through the Anus.

A. Vermiform appendix. B. Ileum with its divided mesentery. C. Ileo-caecal valve with cancerous mass.

(From a specimen removed by operation.)

operation for those rare cases of enormous prolapse which are irreducible, or in which there is extensive ulceration, gangrene, or spontaneous rupture of the gut.

**Third variety of prolapse** is when there is invagination and the appearance of an intussusception, either in the rectum or protruding at the anus. A full consideration of the interesting subject of intussusception is outside the scope of the present work, but there are a few points in connection with diagnosis and treatment which it is necessary to discuss. The important point to remember in diagnosing between an intussusception protruding through the anus, and an ordinary prolapse, is the presence of a sulcus between the anal margin and the prolapse. If this exists, it is obvious that the case

must be one of intussusception, and if with a finger or ordinary probe the bottom of the sulcus can be reached, it will indicate that the intussusception has taken place in the rectum. If, on the contrary, the starting-point of the invagination cannot be felt in this way, the case will be one of colic, or the more common form of ileo-caecal intussusception. Primary intussusception of the rectum is rare, most of the cases in which an intussusception is present in the rectum, or protruding at the anus, having originated higher up the intestinal tube. The starting-point of the invagination may



be a new growth, either simple adenoma or a malignant tumour, so that it is important to remember that a tumour felt in the rectum may in this way have originated at a distance from its present site. The following case will indicate this point. An old lady aged eighty suffered from complete intestinal obstruction; she stated that a lump had protruded from the anus three months previously, which she had herself put back and that it had not since recurred; digital examination revealed the presence of a malignant growth in the rectum freely movable, with a sulcus all round, the bottom of which could not be reached with the finger. After dilatation of the anus under an anaesthetic, the mass was easily made to protrude, and was removed by circular incision. When the peritoneum was opened the vermiform appendix appeared, it was then for the first time evident that the tumour had originated in the ileo-caecal valve, and formed the apex of an intussusception, which had traversed the entire length of the large intestine. The operation was completed by circular union of the ileum to the colon and return of the line of junction within the rectum; the patient twelve hours afterwards sat up suddenly in bed and fell back dead.

An intussusception in the rectum has been mistaken for a new growth; such a mistake ought not to occur, as the soft feel of the tumour, the presence of the sulcus around, between it and the rectal wall, and the recognition of the central opening in it, should establish the diagnosis with certainty.



## CHAPTER XIII

### PILES

**Piles** or haemorrhoids have been recognized from the earliest periods of surgical history, and constitute the commonest of all forms of rectal disease; so common are they that but few persons pass through life without having at some time suffered, it may be to only a slight degree, from this troublesome affection. The term is often used by the public in a very loose way to describe any disease of the rectum; thus we find patients consulting us for 'a touch of the piles', who are found upon examination to be suffering from extensive cancer, and again, pruritus is commonly described as 'itching piles'. The futility, therefore, of attempting to undertake the treatment of any rectal disease without thorough examination is sufficiently obvious.

The term piles appears to be more suitable than haemorrhoids, as the latter indicates the symptom of bleeding, which is by no means always present.

**Definition.** We may define piles as tumours primarily originating in dilatation and thrombosis of the veins of the anal canal and lower rectum.

**Aetiology.** When we come to inquire into the aetiology of this disease, we find that the causes of piles which have from time to time been given are indeed numerous, and that they are met with under almost all conditions of life (in the male and in the female, amongst the opulent and poor, the sedentary and active), so that we must look for one common cause as essential in the production of the same disease under such diverse circumstances. That common predisposing cause is, I feel sure, an anatomical one; and that the erect position occupied by man is the essential element is, I think, a plausible theory. As is well known, prolapse of the rectum is common in quadrupeds, but true piles, if they occur at all, must be extremely unusual.

It is desirable here to recall some of the important features of the



venous system of the anal canal (see p. 19). The radicles from which the superior haemorrhoidal vein arises form a plexus, which may be conveniently termed the anal plexus, surrounding the upper portion of the anal canal, i. e. that portion which is covered with mucous membrane. In the adult these veins are always found to be more or less varicose, usually ten or twelve distinct ampullary pouches being easily discernible surrounding the circumference of the bowel at this situation. That these pouches are pathological is proved by the fact that they are not to be found in the new-born child. The anal plexus discharges its blood into veins which run in the long axis of the rectum, in company with the terminal branches of the superior haemorrhoidal artery; these veins perforate the muscular coat of the bowel about one inch above the anal canal, and eventually discharge their contents into the portal vein. From the lower portion of the anal plexus, veins pass down in the radiating folds of skin which cover the lower portion of the anal canal to join a circular vein surrounding the anus (see Plate IV), which discharges its blood into the caval circulation *via* the inferior haemorrhoidal veins. Thrombosis of the veins of the anal plexus is the essential preliminary condition to the formation of internal piles, while, if the veins in the lower portion of the anal canal become thrombosed, external piles result.

Piles are unknown elsewhere than in the anal canal and lower rectum. How is it that they are not found in other portions of the intestinal tract? and why is it such an essentially human disease? The act of defaecation and the constrained position in which that act is carried out in man are probably the primary exciting causes. During the passage of a solid mass of faeces along the great intestine considerable pressure is exercised on the blood-vessels. In the colon this is rather salutary than otherwise, as the vessels are arranged, for the most part, at right angles to the axis of the bowel, so that the contraction of the tube empties the veins into the larger channels, but when the lower portion of the rectum is reached this is not the case. As previously mentioned, the vessels of the lower bowel are arranged parallel to the direction of the intestine, consequently the passage of the faecal bolus forces back the blood in the opposite direction to that in which it should flow in the veins. An illustration will make this more clear. If an elastic band is passed round the arm, and gradually rolled down towards the hand, the superficial veins below the point of constriction are rendered full and prominent. Now, a strictly analogous thing occurs during defaecation, with the exception



that the veins are to be found in the outer and compressing tunic, and it is the solid mass of faeces in the interior that moves on. The passage, therefore, of every hard and constipated motion subjects the veins of the anal plexus to a very considerable dilating strain, and consequently furnishes one of the most important, if not the principal, factor in the production of piles. When the abdominal muscles are called into forcible action, a considerable amount of pressure is brought to bear on the entire portal system of veins, and under ordinary circumstances the sphincters and levatores ani, acting simultaneously, equalize this pressure on the anal plexus, so that no dilating strain can be experienced, but when defaecation is taking place the anal muscles are relaxed, while the abdominal muscles are contracting forcibly, consequently there must be a strong tendency to regurgitation of blood into the rectal veins. All prolonged efforts of straining at stool are, therefore, to be avoided by persons with any tendency to piles, and at the same time the bowels should not be allowed to become too constipated, and food calculated to leave a hard faecal residue should be avoided.

As was long ago pointed out by Verneuil, the veins from the anal plexus to the superior haemorrhoidal vein pass through openings in the muscular coat of the bowel, so that at the time of defaecation the muscular contraction tends to render the current of blood through them liable to interruption. The tendency of the portal circulation to be obstructed in its passage through the liver also undoubtedly possesses some aetiological influence, but clinical experience does not confirm the view that it is of as much importance as was formerly believed to be the case, and it appears to be doubtful if the tributaries to the portal vein are as devoid of valves as they are usually described in anatomical textbooks.

**Sex.** Much has been written on the relative frequency of piles in the male and female sex, and very opposite opinions are to be found in the works of different authors on the subject. In my own practice I find the ratio is about five males to three females, but statistics are at all times apt to be misleading, and especially is this the case in the subject under consideration. Females, from natural delicacy, are apt to postpone consulting their medical attendant for a disease which occasions such slight annoyance as ordinary internal piles, unless they are strangulated or inflamed, and again, they are so accustomed to the menstrual flow, that they attribute but slight importance to a bloody discharge from a neighbouring organ. It very frequently happens that we find anaemic



women suffering from bleeding piles, who have either not noticed or paid little heed to the bloody discharge from the rectum until their attention has been directed to it by their medical attendant. In men, on the contrary, the discharge of blood generally attracts their attention, and they forthwith consult their doctor. There are several reasons why we should *a priori* expect piles to be more frequent in women than in men. In the first place, the pressure of a gravid uterus tends to produce dilatation of the veins of the haemorrhoidal plexus in the same way that it produces varicosities of the labial veins and those of the lower extremity generally, and, as a matter of fact, piles are extremely common, both during pregnancy and immediately after parturition. Another cause which must not be lost sight of is the habit which women undoubtedly have more than men of permitting their bowels to become habitually constipated, although this may be to a certain extent counterbalanced by the greater pelvic capacity which they possess. In women also, at the menopause, a discharge of blood from the rectum, frequently attended with the presence of haemorrhoidal tumour, is of common occurrence, and the pressure of a retroflected uterus, or of tumours connected with the ovaries or other pelvic viscera, may sometimes be admitted as a cause of this disease. On the other hand, men, as a rule, suffer more from the deleterious influences of excess in eating and drinking.

**Age.** Piles are essentially a disease of the middle period of life, their occurrence under the age of puberty being extremely uncommon, and when they do occur in children they are generally found to be formed of simply dilated veins. I have seen two cases (one in a child aged 6 years, and another in a child aged 8 years) in which there were single external piles manifestly due to varix, and similar cases have been noticed by other observers. In a case recorded by Mr. F. Ogston, junior (*Lancet*, May 12, 1886), the disease appeared to be congenital. Such cases are, however, more properly classed as cavernous naevi than true piles. The earliest age at which an internal pile has been noted, so far as my knowledge goes, is that recorded by Allingham (*Diseases of the Rectum*, p. 92 note, fourth edition): in a child aged 3 years he found three well-marked venous haemorrhoids. On the other hand, piles but seldom originate in old people, except as a result of paralysis of the sphincter muscle, either associated with general paralysis or from intrinsic relaxation. When this takes place, owing to the pressure on the portal system, from contraction of the abdominal muscles being unopposed



by the relaxed sphincter, varicosities in the anal plexus of veins are apt to occur.

**Heredity.** It is almost impossible to form an opinion as to the influence of heredity in a disease so widespread and common as piles. No doubt the habits of life which help to the formation of haemorrhoids are frequently inherited, and to this extent heredity may be admitted as a cause, but I do not think there is any evidence to justify us in attributing any great importance to it.

**Excessive eating** must be admitted as an important element in the formation of this disease, as, in addition to the general plethora which is induced, Niemeyer (*Pract. Med.*, vol. i, p. 586, 1871) has in detail pointed out that a general engorgement of the portal system of veins especially takes place during digestion, as evidenced by the temporary enlargement of the spleen during that time. This engorgement, when frequently repeated and carried to an abnormal extent, will produce a more permanent dilatation of the tributaries of the vena portae, and so the formation of piles may be originated. The increased bulk and frequently irritating nature of the faecal residue in those who eat inordinately contributes to this result.

A catarrhal condition of the mucous membrane, by the congestion which is produced, tends to the formation of piles. This catarrhal condition is frequently, to a great extent at any rate, caused by the habitual use of strong purgative medicines. Many persons are morbidly sensitive about the action of their bowels, and consume enormous quantities of medicine, with the result of keeping up a constant irritation of the mucous membrane. If the habit of getting the bowels to move once a day at a certain hour is cultivated, it can generally be acquired without the use of cathartics; and for persons with haemorrhoidal tendencies the best time is immediately before going to bed, as the subsequent rest in the recumbent position tends to relieve the congested mucous membrane.

**Pathology.** We have already defined piles to be tumours primarily originating in dilatation and thrombosis of the veins of the anal canal and lower rectum, and with the causes which lead to such dilatation we have dealt so far as they are at present known. Like varicose veins in other regions, especially the leg, and in the venous sinuses about the ear, phlebitis and thrombosis are of common occurrence. It is beyond the scope of the present work to discuss the complex question of venous thrombosis. Those interested in the subject will find a very able article



on the subject of thrombosis by Dr. Welch, of Baltimore, in Allbutt's *System of Medicine*, but there are certain points which it appears to be desirable to allude to in this connection. That some septic infection is the exciting cause of thrombosis appears to be probable, and the clinical experience that it is met with most commonly in those veins which, from their situation, are most exposed to infection, lends support to this view. From thrombi removed from piles cultivations of bacillus coli communis can generally be obtained, but whether this ubiquitous bacterium is the usual cause of the thrombosis cannot as yet be considered proved, but it appears to be likely that such is the case.

Although it is desirable to retain the classification of piles into external and internal for clinical reasons, their pathology is similar, the only difference being that external piles are covered by the skin and internal piles by the mucous membrane (Fig. 88). Until thrombosis takes place the venous dilatations give rise to no trouble, but once it occurs it is only in the most trivial cases that complete resolution takes place; recurrences are frequent, and new connective tissue formation takes place round the inflamed veins. Above the pectinate line the mucous membrane is vascular, and its surface granular, so that it bleeds upon the slightest abrasion. As time goes on the connective tissue formation becomes more apparent and the dilated and thrombosed veins less obvious, so that, in cases of old standing, we have formed the so-called cutaneous piles, which are merely connective tissue covered by skin in the lower portion of the anal canal, while internal piles tend to become soft fibromata in which dilated veins cease to be numerous (Fig. 93).

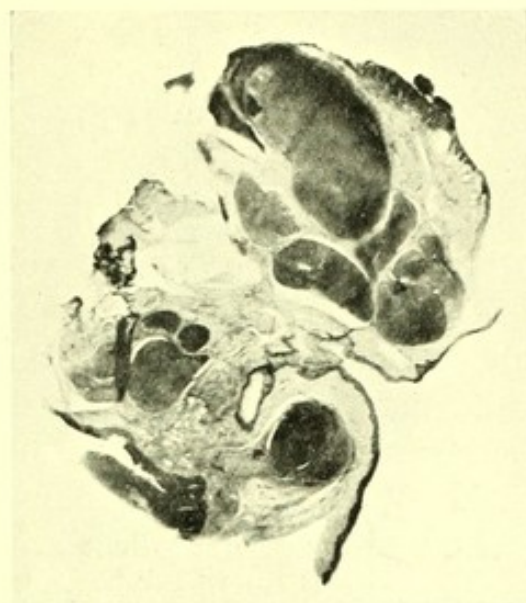

FIG. 88. Section of Intero-external Pile.

Upon the right-hand side of the illustration the upper half has a covering of mucous membrane, the lower half a covering of skin, between these there is a sulcus which corresponds to the pectinate line. The upper half is therefore internal pile, the lower, external pile. The structure of the interior of both portions is practically identical—loose areolar tissue with dilated thrombosed veins.

(Photo-micrograph,  $\times 4$ .)



## CHAPTER XIV

### EXTERNAL PILES

ACCORDING to the definition given in the last chapter, **External Piles** have their origin in dilatation and thrombosis of veins, situated in the lower zone of the anal canal, which is covered by skin and not by mucous membrane. As we have already seen, this situation is below the site at which the ring of dilated veins in the anal plexus is so constantly observed, and the only veins normally found in this region are the small communicating veins which run from the anal plexus to the circular vein which surrounds the anus. These veins are found in the radiating folds of skin at the anus, and are very small; they are more marked at the sides than in front and behind.

**Acute external piles** are caused by thrombosis of one or more of these communicating veins. The first symptom of acute external piles is a sharp smarting pain usually felt for the first time during defaecation, and a little shot-like swelling is felt at the anus which is tender to the touch. In the majority of instances this quite disappears in a few days, but in others it grows rapidly to the size of a pea or even a filbert-nut (Fig. 89), and is attended with a considerable amount of pain and constitutional disturbance, the tongue becomes furred, the febrile condition being out of proportion to the local cause. The skin in the neighbourhood becomes inflamed and swollen, spasmodic contraction of the levator ani and sphincters add much to the patient's suffering, this being peculiarly annoying just when the patient is falling asleep, the violent contractions and acute pain completely waking him up, and there is a sensation as if there was a foreign body in the rectum, producing tenesmus and painful straining. The symptoms are all aggravated by walking or by any sudden contraction of the diaphragm, as in coughing or sneezing, constipation is usually present, and when the bowels do move the pain at the time and for some time subsequently is much increased.

If an examination be made of a patient in this condition, one or



more livid tumours will be seen in the neighbourhood of the anus. These are acutely sensitive, and have a tense glistening surface, pressure fails to empty the blood out of the tumour, and it is obviously due to the formation of a firm coagulum. The sudden onset, rapid growth, and the fact that the pain is first felt during defaecation, has led many authors to conclude that the clots found in external piles are the result of extravasation, and that they are therefore extravascular. This, however, is not the case, as can readily be proved. When treated by incision, the little clot shells out, leaving a smoothly lined cavity the endothelial surface

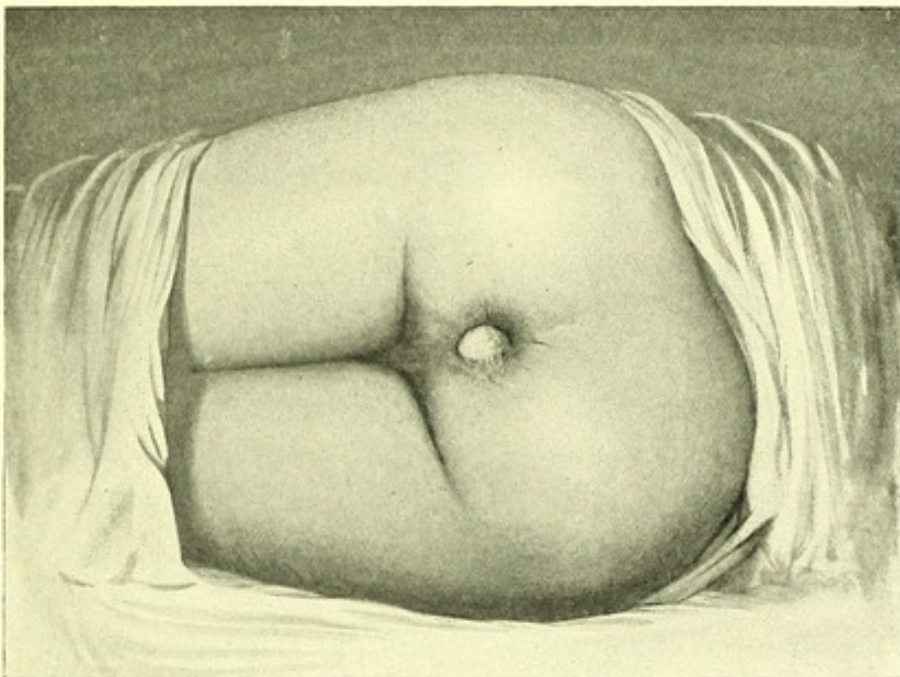


FIG. 89. Single Thrombosed External Pile.

A smooth, glistening tumour is seen on the right side of the anal margin. In the living, this appears of a livid purple colour from the blood clot in its interior.

*(From a stereo-photograph.)*

of which can be demonstrated. Extravasation of blood into the tissue surrounding the anus is extremely common as a result of forcible dilation as a preliminary to numerous rectal operations, yet we do not find external piles resulting from this procedure, but rather a diffused extravasation, resembling the familiar 'black eye', which disappears painlessly in a few days without the production of any localized tumour.

The rapid formation of a coagulum of sufficient size, in the interior of a vein, to dilate a very minute vein to the dimensions frequently met with in external piles is very remarkable, and difficult of explanation.



A section of a thrombosed pile shows the clot usually to be more or less laminated, so that its increase in size must be due to the deposit of successive layers, which of course presupposes the existence of a current of blood between the coagulum and the walls of the vessel as long as the former continues to enlarge. We know how slight the tension of the blood is in small veins, and how easily venous stasis is brought about by moderate pressure, yet we see the clot in a pile enlarging until it becomes so tense that pressure necrosis of the wall of the vessel and even of the overlying skin not unfrequently results. If an incision is made into one of these little tumours while actively enlarging, it turns out quite readily and is found not to be adherent to the dilated vessel, but little fluid blood comes from the vein, and all the symptoms rapidly subside. This rapid enlargement of a thrombus, without arresting the blood-stream while it is growing, is more noticeable in piles than in phlebitis of other veins in the body, and as far as I am aware has never received a satisfactory explanation.

The terminations of an acute thrombosed pile may be (1) **Resolution**, and when of small size this frequently happens, no trace of the thrombosed vein remaining. (2) **Gangrene**. As already mentioned, the tension may become so extreme that pressure necrosis of the vein and of the overlying skin may ensue, giving exit to the thrombus, a spontaneous cure thus resulting. (3) **Suppuration**. If the clot becomes infected with pus-cocci, suppuration may ensue ending sometimes in the formation of a marginal fistula. (4) **Cutaneous pile**. When complete resolution does not take place the clot becomes adherent to the vessel wall and organizes; this organized clot, together with some proliferation of the connective tissue around the pile, forms a permanent enlargement covered with skin and known as the cutaneous or fleshy pile. These may become somewhat pedunculated, being attached by a narrow neck, while more commonly they are found with a broad base of support, the hypertrophy of the skin being confined to the radiating folds that normally surround the anus. These little cutaneous excrescences are called by some of the American authors 'condylomata', and no little confusion has arisen in consequence, the latter term being in this country only applied to the soft mucous papilloma of unquestionable syphilitic origin.

Cutaneous piles are apt from local inflammatory causes to become oedematous; they then become much increased in size, smooth and shiny on the surface, and acutely painful. Amongst the direct exciting causes



of oedematous piles may be enumerated fissures or other breaches of the muco-cutaneous surface, or the eczematous inflammation which is not uncommon in this region. This inflammatory swelling usually subsides in a few days, leaving the pile somewhat permanently increased in size.

Although cutaneous piles most frequently arise from acute thrombosis, this is not by any means their only origin, any inflammatory condition of the anus may lead to a like result, especially secondary syphilis, while a form known as the sentinel pile indicates the presence of a painful fissure, and is due to the inflammatory enlargement of a torn-down anal valve (see p. 147).

A form of external pile, to which the term **Compound external pile** might suitably be applied, is not uncommon. It is usually of considerable size, about as large as a filbert, with smooth surface, and very prone to inflammation. If incised in the usual manner, it is found to consist principally of connective<sup>4</sup> tissue, and contains several thrombosed veins of considerable size, instead of one central cavity as in the common variety of venous pile. It is found in persons who have suffered from repeated attacks of inflamed external piles, and is almost always placed laterally, the long axis being antero-posterior.

While free from inflammation, external piles give rise to but trivial annoyance, which is caused by the mechanical inconvenience due to their size, but when inflammation supervenes, the pain becomes extremely severe, so that the strongest man may be thereby quite incapacitated for any active employment. Haemorrhage from external piles is an unusual occurrence, and when present is not generally severe. I have, however, several times seen it, and in each case its source could readily be determined, the blood being seen to flow from minute orifices in the pile. Reflex pains are commonly complained of, and the bladder participates in this reflex irritability, as evidenced by frequent micturition, or sometimes by retention.

A rare complication of piles is caused by the calcification of the enclosed thrombus, constituting the so-called phlebolith. Concretions so produced are to be recognized by their hardness to the touch, feeling like grains of shot or peas inside the dilated vein. In structure they correspond with similar concretions found more commonly in some of the larger varicose veins in other parts of the body, that is to say, the phleboliths consist, as might be expected, of the coagulated protein



compounds of the blood together with some insoluble calcium salts. When situated in the haemorrhoidal veins they may give rise to irritation, and are occasionally discharged spontaneously by the ulceration of the overlying skin.

The **treatment** of external piles is usually sufficiently simple. It may be divided into the palliative and radical; the latter of these is in nearly all cases preferable. If, however, the patient will not submit to the trivial operation necessary, recourse must be had to local applications. Of these **palliative treatments**, the best, probably, during the period

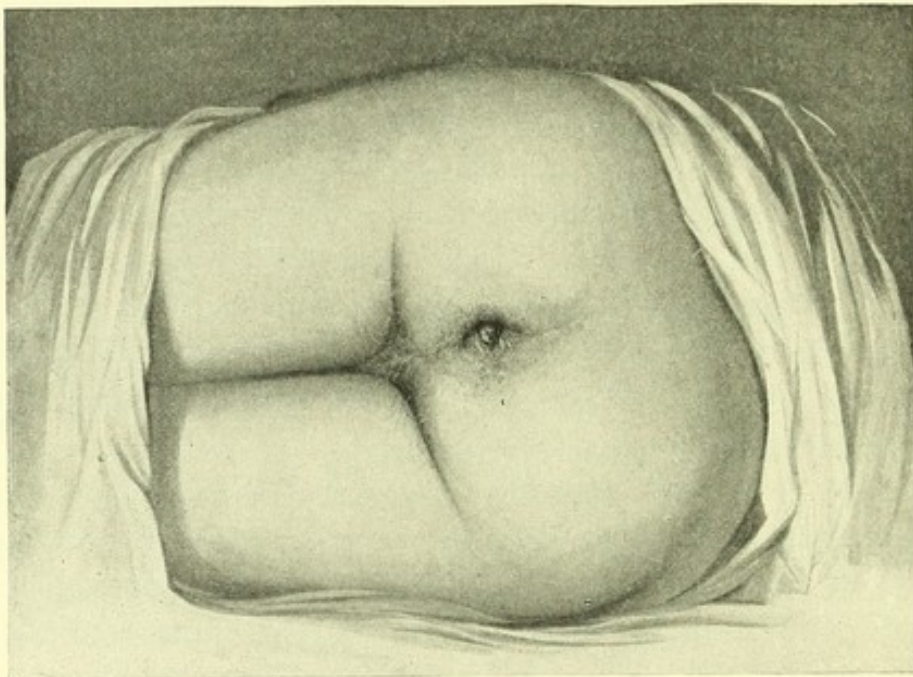


FIG. 90. Operation for External Thrombosed Pile.

Taken from the same case illustrated in Fig. 89, after a radial incision had been made in the pile. A dark-coloured blood-clot is seen protruding from the incision.

*(From a stereo-photograph.)*

of acute inflammation is the application of a mixture of extract of belladonna and glycerine smeared over the part, and followed by a warm stupe. At the same time the bowels should be freely cleared, and a light unstimulating diet, with rest in bed, prescribed. The inflammation will then usually subside in a few days, but it frequently leaves behind a thickened projection of skin ready at any time to again inflame on the slightest provocation, or, if suppuration occurs, the cure may be radical, but only at the cost of much unnecessary suffering.

The **radical cure** may be accomplished either by incision or



excision. The question whether these procedures should be carried out while there is inflammation present has been frequently discussed, many surgeons preferring to wait until the acute symptoms have subsided. This I believe to be quite unnecessary, only subjecting the patient to prolonged pain. It is but seldom that the surgeon is consulted about external piles except when they are inflamed, and the most certain and rapid way of giving relief is immediate operation. I have never seen the slightest ill effect follow operation under these circumstances.

**Simple incision** may be applied when the pile consists of a single inflamed, dilated, and thrombosed vein. It is only necessary to incise the tumour freely with a sharp bistoury, and turn out the little contained clot. Bleeding need not be apprehended; the cavity should be dusted with iodoform and the patient kept quiet for a day or two. The relief is usually immediate and complete; the sides of the cavity shrivel away, and the cure of the individual pile incised, at any rate, is permanent. Local anaesthesia is usually quite sufficient.

If the inflammation has commenced to subside, the thrombus will be found to have become adherent to the vein wall and cannot be enucleated so satisfactorily, and if the pile be of the variety which I have described as compound external, simple incision will not give relief, the clots cannot be turned out, and the tumour will not collapse. For these forms, therefore, and also for the cutaneous piles, excision is the proper remedy.

**Excision** undoubtedly is the form of treatment of most general applicability. If there are several tumours to be removed it is better to give the patient a general anaesthetic, as the pain is considerable, and in performing the operation the surgeon must be careful not to cut away the folds of skin about the anus too freely, else an anal stricture may be the unpleasant result. Only the distinct tumours should be dealt with, and of these only about two-thirds of each should be removed. The bases will then shrink, and all danger of stricture will be obviated. Simple oedematous folds of skin need not be interfered with, as they will quite subside when the source of irritation is removed. Haemorrhage after this operation, however performed, is usually trivial, and readily arrested by the firm pressure of a pad of gauze. Occasionally, however, when a large and fleshy pile has been removed, a small arterial branch may require a ligature. In the treatment of broad-based piles I have often found it a good plan to bring the cutaneous edges of the



wound together with a few points of catgut suture. By doing so healing will usually be much more rapid than if the surface is left to granulate. After the operation is completed the surface of the anus should be well dusted with iodoform, and an aseptic pad tolerably firmly applied, which will check any tendency to bleeding, and also diminish the painful spasm of the levatores ani, so troublesome after many rectal operations. The bowels should be kept confined for three days, when a mild aperient, followed if necessary by an enema, should be prescribed. It is better to confine the patient to bed until the wounds are closed, as the congestion caused by the erect position tends to interfere with the healing process. Sometimes there is some difficulty in getting the wounds to cicatrize well, unhealthy little ulcers forming. Indeed, I think that there is more difficulty in this way after the operation for external piles than there is after the removal of internal piles, even of greater size. Should the wound become sluggish, it may be painted with balsam of Peru, or compound tincture of benzoin; and in other cases lightly touching the ulcer with copper sulphate will frequently stimulate a healthy action.







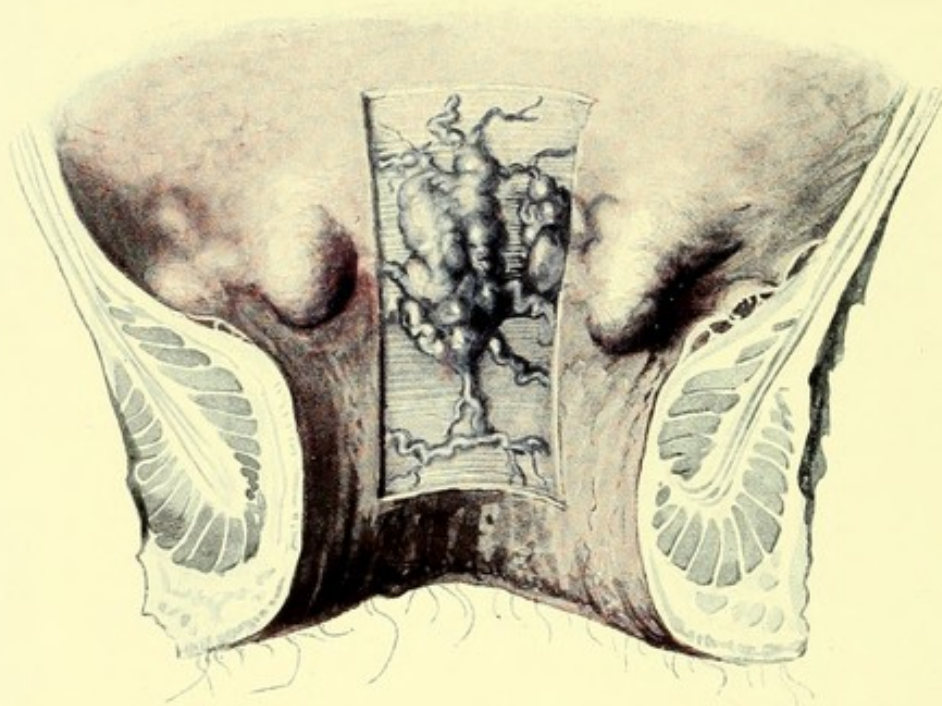


PLATE IV.

SCHEMA OF THE RELATION OF THE ANAL VEINS TO INTERNAL  
PILES, FOUNDED ON NUMEROUS DISSECTIONS.

In the centre a rectangular flap, partly of mucous membrane, and partly of the skin of the anal canal, is shown removed, exposing several varicose veins above, which constitute the bulk of the central pile. From the lower portion of the mass of varicose veins a small vein descends to join a vein which passes round the circumference of the anal canal underneath the skin. Upon each side of the raised portion of mucous membrane internal piles are seen. The incision for opening the anal canal and rectum traverses an internal pile, and shows blood clot in its interior exposed by the section.



## CHAPTER XV

### INTERNAL PILES

INTERNAL piles are those found in the upper zone of the anal canal, which is completely covered by mucous membrane ; they may exist alone, or in conjunction with external piles, when the condition is described as Intero-external.

As has already been stated, the pathology of internal and external piles is similar, the differences being due to their anatomical situation, upon which their relative clinical symptoms largely depend. The mucous membrane covering internal piles soon becomes granular, and its vascularity increased, so that **bleeding** is usually the first symptom to attract attention ; so constant is this symptom, that the terms 'bleeding' and 'internal' piles are practically synonymous. It is very rarely that the disease has existed for any time without this symptom being marked. It is at first only at stool that this loss of blood is occasionally noticed, the tender and highly vascular mucous membrane being bruised and lacerated by the passage of a hard faecal mass, the blood continuing to drip from the anus for some time after the rectum has been evacuated. As the disease progresses the bleeding becomes more frequent, till it occurs daily after each evacuation of the bowels, indeed, in extreme cases, it is not confined to the act of defaecation, but comes on at irregular times, without any apparent exciting cause. In this way a condition of the most profound anaemia may be induced, attended with pallid features, dizziness, and palpitation of the heart. It often happens, more especially in women, that these symptoms of anaemia have directed the attention of the medical attendant to a daily loss of blood from the rectum, which the patient has either not noticed, or not heeded.

The amount of blood which may be lost in this way is occasionally great, but the actual amount is usually much exaggerated by the patient, a little blood making a great show when distributed over clothing, or mixed with urine and faeces.



It is obviously necessary to distinguish between haemorrhage resulting from piles and bleeding coming from some other part of the intestinal tract, such, for instance, as the stomach or small intestine. When not very excessive the latter is altered in colour by the digestive action of the intestinal contents, being of a dark, or sometimes tar-like, appearance ; and it is, moreover, intimately mixed with the faeces. The blood from piles, on the contrary, is not mixed with the faeces, but has evidently escaped subsequently to the evacuation of the rectum, and if it has been exposed to the air for any time is of a bright red colour. The fact that it is usually seen by the surgeon some time after it has been passed has given rise to the belief that it is invariably of arterial origin, but venous blood, if exposed to the air, will become bright in colour, even after it has escaped from the body. And again, when a patient is examined with his piles prolapsed, the blood may be seen escaping in jets, leading to the belief that it is coming from a lacerated artery ; but it can readily be noticed that the jets are synchronous with the contractions of the abdominal muscles, during respiration or straining, it may therefore be taken that the bleeding from internal piles is almost invariably venous.

In cancer of the rectum bleeding is a frequent symptom, but the blood is intimately mixed with thin faeces and foetid mucus, so that it is not likely to be mistaken for the blood arising from piles.

**Prolapse.** Usually, after a few premonitory attacks of bleeding, the patient is conscious of a prolapse after defaecation. At first this reduces spontaneously, but after a time it is necessary to push it back within the sphincteric zone after the bowels are evacuated, and in cases of old standing the piles may prolapse independently of the bowels acting, while the patient is walking, or taking other exercise, and as this is frequently associated with bleeding, the annoyance produced is very great. When piles have been subject to prolapse for many years, bleeding usually ceases to be a prominent symptom, the piles having become changed into soft fibromata, which are much less vascular. The mucous membrane covering them loses its character, becomes white in colour, and upon microscopical examination is found to have lost its adenomatous tissue, and becomes similar to the skin of the lower zone of the anal canal.

It is essential for efficient treatment to understand the **mechanism of prolapse** of internal piles. It is but rarely that the base of an



internal pile becomes elongated into a pedicle of sufficient length to permit of the pile being protruded at the anus through the lower zone of the anal canal, as so constantly happens in the case of benign adenoma; what usually happens is, that the coverings of the entire anal canal become revolved. If an ordinary case of internal piles be examined while prolapsed, it will be seen (Fig. 91) that in the centre are several bright red swellings, obviously covered by mucous membrane, and that these are surrounded by a more or less irregular ridge, as obviously covered by thin skin, and not mucous membrane. This ridge was formerly described as a ring of external piles, but it is not so, it is simply the lower skin-covered zone of the anal canal, which has become turned inside out, and this can easily be demonstrated. If the prolapsed internal piles are reduced by gentle pressure, it will be seen that as they disappear within the sphincters the outer ring gradually unrolls, and the anus returns to its normal appearance. It must be remembered, however, that internal piles often co-exist with external piles, but this is a condition quite different from that above described; true external piles do not disappear from view when the prolapsed internal piles are reduced within the sphincters.

**Mucous discharge** is occasionally an annoying symptom of internal piles, but it is not at all so marked as in cases of adenomatous disease.

**Pain.** As the upper zone of the anal canal is comparatively insensitive pain is not usually much complained of in pure internal

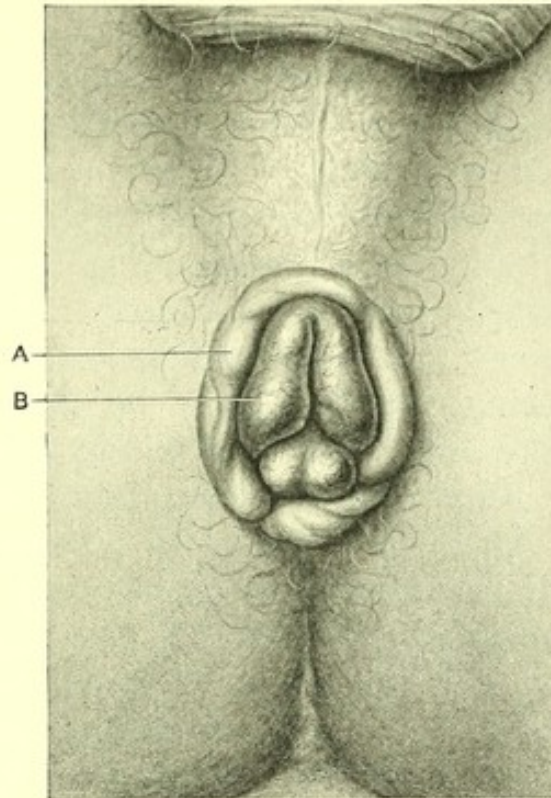


FIG. 91. Prolapsed Internal Piles.

In the centre is seen a group of internal piles, B, covered by a mucous membrane. This group of internal piles is surrounded by a ring, A, covered with the thin skin of the anal canal. The outer ring is formed by the prolapse of the internal piles causing revolution of the anal canal.

(From a drawing.)



piles. If pain is present to any extent as a symptom, it indicates that, either as a result of inflammation starting in the piles, or as a result of their strangulation by the sphincters, the lower zone of the anal canal has become secondarily involved, or that the piles are associated with some other disease, probably fissure.

**Diagnosis of internal piles.** A history of bleeding after the bowels move, attended with prolapse, which can be completely returned, but without much pain, suggests to the surgeon the probability of internal piles; before undertaking the case, however, he should insist upon a thorough local examination. If the case is of some duration there will probably be found thickening of the skin of the anus, with hypertrophy of the radiating folds, and if the patient is told to strain down, some of the internal piles covered by bright red mucous membrane will become apparent; if, however, the case is a more recent one, nothing abnormal may be noticed, unless the patient is examined immediately after the bowels move, or better still, after he has been for some minutes straining down over a pan of hot water, when the characteristic ring of revolved anal canal, with a bunch of piles in the centre, will become obvious. A careful digital examination should also be made, but it must be remembered that internal piles, even of large size, may not be detected by digital examination, unless they are inflamed, or have undergone fibroid change. Ordinary internal piles are indistinguishable to the touch from healthy mucous membrane, nevertheless, the examination is necessary to make sure that no other disease of the rectum co-exists, and although the piles themselves may not be palpable, the pulsation of somewhat large arteries, terminal branches of the superior haemorrhoidal artery, can often be detected, and if very marked, usually indicate that the piles are of considerable size and vascularity.

**The clinical relations and complications of internal piles.** From what has been already said on the aetiology of piles, it will be obvious that they are not infrequently symptoms of some remote and more important visceral disease, and the surgeon who looks at these cases with the eye of a specialist, and directs his treatment solely to the rectum, will be sure to be disappointed, while in some instances positive injury will be inflicted on his patient. Of the more important organic diseases with which piles may be associated, those of the heart and liver occupy the most prominent position, and it is incumbent on the



surgeon to carefully examine every patient with piles for any symptom of these affections. The surgeon may have great difficulty in deciding on what treatment to adopt for rectal haemorrhage from internal piles when they are associated with grave visceral lesions.

The discussion of this subject brings us to the oft-debated question, Is the bleeding from piles ever salutary, and if so, under what circumstances should it be allowed to continue unchecked? It is not to be wondered at that, during an age when the periodical loss of blood was considered essential even for the healthy, this spontaneous bleeding from the rectum was considered not to be in any sense prejudicial, but rather on the contrary a thing to be encouraged, and even, if possible, in some cases initiated. Now, however, all surgeons will agree that the loss of blood such as takes place from internal piles is a pathological condition which it is well to free the patient from as soon as possible, the only possible exception that I know being some few cases of cirrhosis of the liver, in which an occasional rectal haemorrhage tends to prevent the occurrence of ascites, and some middle-aged and very plethoric people, who, although they frequently have a slight bleeding, appear to remain otherwise in perfect health, and not to suffer in any way from symptoms of anaemia. In these cases the surgeon may well await the onset of indications that the loss of blood is ceasing to be well borne, before recommending any operation for radical cure, unless, indeed, the inconvenience (other than bleeding) is so great that operation may be demanded. Each case, therefore, must be judged on its own merits, and not treated according to any fixed rules.

The association of piles with uterine disease is not uncommon, and such cases are occasionally still further complicated by the presence of irritable bladder. In dealing with them we must always bear in mind the fact that uterine disease will frequently give rise to reflex pain in the rectum when no indication of disease is to be found in that organ, and, conversely, we not uncommonly see women who are being treated for supposed uterine disease, when the symptoms may be all referable to a small anal fissure or some other rectal disease.

**Strangulation and gangrene** of internal piles may arise from two quite distinct conditions. Either the piles may be extruded from the anus and caught by the sphincter, or inflammation may be started from the infection of some trivial abrasion, and gangrene may rapidly ensue. It becomes a matter of importance to determine which of these



conditions is present, as in some respects the treatment varies with the cause. The diagnosis is not difficult. If the congestion is produced by constriction of the sphincter, the history given will be that the patient had prolapse of the piles after defaecation, which probably occurred on

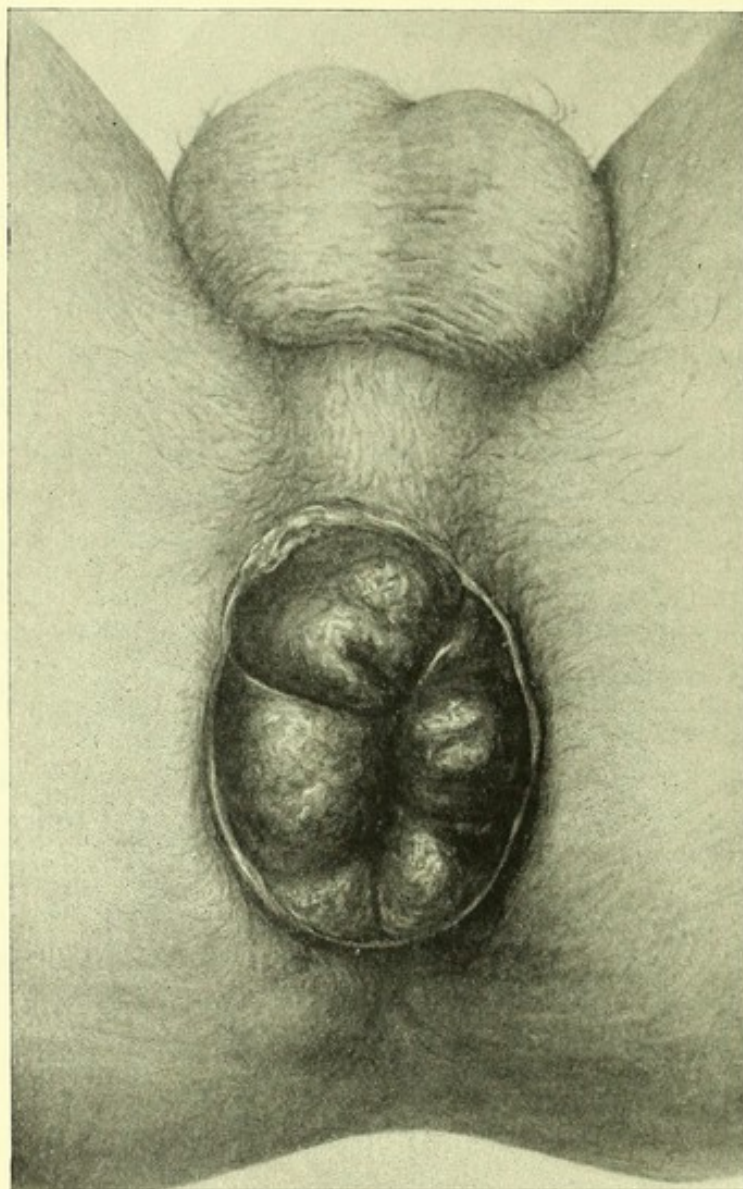


FIG. 92. Prolapsed, Gangrenous Internal Piles.

*(From a stereo-photograph of a case at Sir Patrick Dun's Hospital.)*

frequent previous occasions, when he was able to replace them himself. He, however, fails at last to reduce them, or they descend again immediately after they are replaced. They soon become swollen, and the pain becomes extreme, with considerable fever and other constitutional



disturbances. Upon inspection there will be found protruding from the anus one, or more frequently several, livid, tense tumours. (See Fig. 92.) Round the margin of the anus there is some slight inflammatory oedema. Any attempt to touch these piles produces the greatest pain; in fact, there are but few diseases in which the pain is of such a severe character as in the one under consideration. If the finger be passed into the rectum great resistance is experienced, and the forcibly contracting sphincter can be felt grasping the finger tightly. If left unreduced, these intensely congested piles rapidly pass into a state of gangrene, and are thrown off, eventually producing a spontaneous cure, which, however, is frequently incomplete, as the entire pile seldom dies, and the ragged portion which remains is likely to give trouble at some future time. Bleeding during the separation of the sloughing pile is not of uncommon occurrence.

The treatment to be adopted may be either temporary or radical. In the first instance, reduction of the piles within the sphincter should be attempted; and if the case is seen early, and is not complicated by much external inflammation, reduction can usually be readily effected. In order to accomplish this it is best to try and replace the most central portion first, by passing the finger into the rectum, and as it is withdrawn to force up the remainder of the prolapsed portion. It is, however, wiser to obtain the permission of the patient to perform the radical operation at once; and owing to the very severe pain usually attendant on this condition, there is seldom any difficulty about this.

Should piles be operated on during inflammation? is a question upon which considerable difference of opinion has been expressed. Those surgeons who oppose operation appear to me to base their objections purely upon theoretical grounds, no bad results, as far as I know, having been recorded, while, on the other hand, those surgeons who have made a practice of operating, express themselves favourably to it. My own practice, when called to a case of strangulated piles, is to recommend the immediate administration of an anaesthetic, dilatation of the sphincters, and the complete removal of all piles that can be seen, just as if the case was one uncomplicated by strangulation.

The history of a case of inflammatory strangulation of piles differs from that of one of acute strangulation, the result of nipping by the sphincter, and it is important to make the diagnosis. In the former the patient may be conscious of having abraded the anus during defaecation, and a day or two afterwards pain and throbbing in the rectum gradually



come on, rigors and febrile disturbance supervene, and there is great swelling and tumefaction about the anus. Upon examination the internal piles will be seen protruded, together with oedematous folds of mucous membrane; the external piles, if present, will also be tumid from inflammation, and swollen folds of skin will surround the anus. Often, as a result of inflammation, internal and external piles run into one another, the line of junction being only marked by a slight sulcus. If the finger be passed into the rectum, the sphincter will not be felt unduly

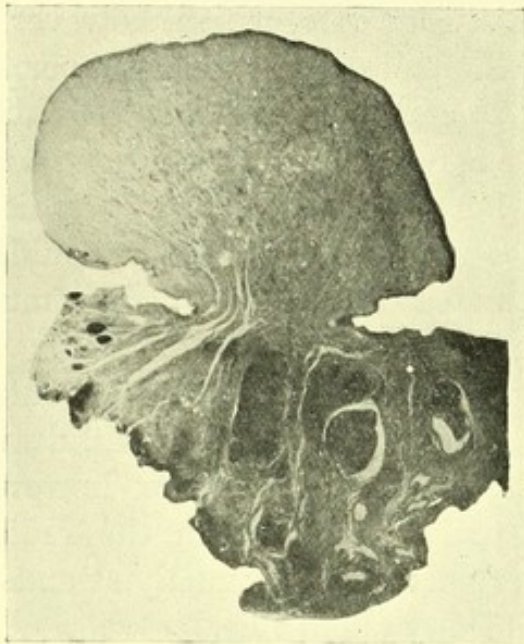


FIG. 93. Fibrous Tumour originating in a Pile that had existed many years.

In the lower portion, typical pile structure is seen; in the upper, a soft fibroma attached by a pedicle.

(From a photo-micrograph,  $\times 4$ .)

tense, the contrast with the condition of things in the previous case being most marked. If an attempt is made to reduce these inflamed piles within the anus, the most acute suffering will be induced, and the result will be quite futile. I have several times seen cases in which continued attempts had been made to reduce what really were inflamed external piles and oedematous folds of skin, or internal piles, which from the inflammation of the surrounding structures were quite irreducible, under the impression that the case was one of strangulation by the sphincter. The writings published on rectal disease do not, in my mind, attach sufficient importance to this subject, but I think that the truth of what I have

stated above will be evident to any surgeon of extended experience.

**Other benign tumours.** The transformation of internal piles into soft fibromata is elsewhere (p. 226) dealt with. True adenomata are but seldom found as a complication of internal piles.

**Fissure of the anus** is not an uncommon complication of internal piles, and when a patient complains of pain during and for some time subsequent to defaecation this may always be suspected, as internal piles produce only a sense of discomfort rather than real pain except when inflamed.



**Simple stricture and malignant neoplasms** are sometimes met with co-existing with piles, and it is necessary, of course, to determine whether this is the case by careful digital examination. Indeed, the complete rectal examination of every case of piles that presents itself should be the invariable rule.

The only other local affection likely to complicate piles is fistula, and usually there will not be much trouble about the diagnosis of this disease.

#### TREATMENT OF INTERNAL PILES

The treatment of internal piles may be classified into the palliative and radical. Unquestionably, in some cases, palliative treatment will be followed by complete immunity from further trouble, but where the piles are large, and attended with the formation of much new tissue, it can hardly be expected that anything short of some surgical operative procedure will effect a cure. There are two classes of cases in which the surgeon will confine himself to the medical treatment of the case, one, that in which he considers there is a fair chance of cure by such measures, and the other in which operation is declined by the patient, or is considered inexpedient on account of some complication, and in which, therefore, the surgeon has to confine himself to mere palliation. I think the recommendations of a surgeon to have the trivial operation necessary for complete cure, are more often neglected by the patient suffering from internal piles than any other surgical malady. This is partly due to the fact that the public are still imbued with the teaching of former days, that piles are beneficial, and believe that many ills and disabilities follow this trivial operation. Again, the pain suffered is not very considerable unless inflammation has supervened. There is no class of cases in which, with such slight risk to life, so much good can be done by operation, and patients who have suffered years of trouble and annoyance with piles are most grateful for the relief afforded by surgical treatment. What, then, are the indications or contra-indications for resorting to, or not resorting to, operation? I can point out some of them. If the case is an uncomplicated one of long standing, with large piles prolapsing after defaecation, and with considerable haemorrhage, radical treatment is clearly indicated; and, on the other hand, if the piles are associated with grave visceral disease, operation should not



be undertaken, unless the bleeding is so copious as to immediately threaten life.

Should piles be operated on during pregnancy? is a question that often arises, in consequence of a very common connection between the two, many pregnant women suffering great inconvenience and copious bleeding from this cause. Now, in order to answer this question, we must remember that the cause of the piles in this case is frequently due to the mechanical pressure of the gravid uterus, and that they will subside as soon as delivery takes place, and that owing to the close nervous relationship which exists between the uterus and rectum, any operation must occasion some risk of premature delivery. In this, as in many other cases, the indication for operation rests with the answer to the question, whether the loss of blood is making itself constitutionally felt to any great extent or not, if it is, the piles should certainly be operated on. I have on several occasions operated under these circumstances with the best results, and without curtailing the duration of pregnancy.

The most important indication to be fulfilled in the treatment by medical measures is the regulation of the bowels. If the bowels are allowed to become costive, the piles are liable to be excoriated during defaecation, and increase of bleeding and possible subsequent inflammation is the necessary result, whereas, if an easy and soft evacuation is secured each morning, a state of comparative comfort can be maintained.

Numerous purgative medicines have been especially recommended for persons suffering from piles. In a work of the present kind, of course, it would be impossible to enter upon a discussion of the comparative merits of all the numerous purgative drugs which have been advised in cases of the kind under discussion. The use of aloes is by many writers supposed to be contra-indicated in rectal disease, for what reason I do not know; on the contrary, I think a pill composed as follows the best for ordinary purposes:—

Ext. aloes . . . . .	gr.	$1\frac{1}{4}$
Ext. nucis vomicae . . . . .	”	$\frac{1}{2}$
Ext. belladonnae . . . . .	”	$\frac{1}{8}$

One or two for a dose as required.

If these pills are taken occasionally, and a dose of some of the well-known ordinary purgative mineral waters in the morning, motions of the



proper consistency will be ensured. If the pills alone are used, the dose will have to be augmented, and if the mineral water only is employed, it is apt to produce only a small fluid motion, after a time leaving some larger masses in the great intestine. When this occurs, it is, I think, the indication for the employment of pills containing aloes. In many cases, better, however, than any purgative medicine is the use of an enema, the employment of which is too much neglected in this country, most people, especially ladies, preferring to take any quantity of medicine to the use of this simple expedient.

After the bowels have been moved, the anus should be carefully washed with cold water. This is one of the most important conditions to fulfil in order to make the patient comfortable, and it is one of the most powerful means of checking the tendency to haemorrhage that we possess. Banks tells us (*Liverpool Med. Clin. Journal*, p. 293, July, 1886) of a method which a patient of his found out for himself, and it appears to be at once the most effectual, and has the advantage of being simple and always applicable. 'So soon as the bowel was evacuated, he remained perfectly still, emptied the pan of the water-closet, and keeping the rush of water on with his right hand, he threw it up with his left, on to the everted mucous membrane. By this means he thoroughly cleansed his piles, and, by the direct application of cold water to them, ensured contraction of their blood-vessels and their complete retraction. Carefully drying the parts with a soft towel (and not using paper), he then washed his hands, and was comfortable for the rest of the day.'

The diet should be regulated. All food tending to leave large faecal residue should be avoided, but the error most common is eating too great a quantity of food, rather than the quality, and all persons suffering from piles who are great eaters will derive great benefit from restricting their diet. Stimulants are better avoided, except under special conditions.

Various 'Pile cures', both internal and topical, are from time to time loudly proclaimed, not only by advertising quacks, but also by some who ought to know better, and certain remedies have their periods of fashion; formerly it was, confection of black pepper internally, with gall and opium ointment, topically; while, more recently, extract of hamamelis was the favourite remedy. It is just as reasonable to expect that these applications would amputate a diseased limb, as that they could remove piles of old standing, in which much new tissue has been formed; nevertheless, certain local applications are of considerable use for







1. Destruction of the vascular surface by chemical caustics or actual cautery.

2. Production of coagulation-necrosis in the interior of each pile by submucous injections, electrolysis, or igni-puncture, &c.

3. Removal of each separate pile by ligature, clamp, and cautery, crushing, or excision, either singly or in combination.

4. Complete excision of the entire pile-bearing area of mucous membrane.

1. **Destruction of vascular surface.** Strong nitric acid is the application most frequently used for this purpose, and for a certain class of cases it undoubtedly answers admirably, viz. the small bright-red naevoid pile, the object being to destroy the spongy and highly vascular mucous membrane covering this pile, and thus substitute for it a cicatrix. As its action is only quite superficial, it is manifestly unsuitable in cases where there is extensive new formation of tissue, and the attempt to treat such cases by means of nitric acid has brought the method into undeserved disrepute. In order to use it with success the rectum should be well cleared out by an enema, and the pile, if possible, protruded. If this cannot be done, a small speculum, preferably of silvered glass with a small aperture, should be introduced. The pile is now made to protrude into the aperture of the speculum, and fuming nitric acid spread over the surface with a glass rod or piece of stick. In doing this care should be taken to protect the skin of the anus from contact with the acid, or it may be protected by smearing with oil or vaseline. When sufficient acid has been applied, the surplus is neutralized by the application of chalk and water, or solution of carbonate of soda. If confined to the mucous membrane, the application of nitric acid is almost absolutely painless, but if any is allowed to escape over the delicate skin surrounding the anus, a very considerable amount of burning pain will result. The acid application usually requires to be repeated two or three times, at intervals of a week, before the cure is complete.

Other chemical caustics have been employed for a like purpose, or the actual cautery is sometimes used, but none of them answer the purpose better than fuming nitric acid, which has stood the test of such a long experience.

2. **Production of coagulation-necrosis** in the interior of each pile by means of submucous injections, electrolysis, igni-puncture, &c.

The treatment of piles by submucous injection has been largely



practised, in America especially, and the advantage claimed for it is, that it is comparatively painless, and does not necessitate the confinement of the patient to bed. Various fluids have been used, but carbolic acid of sufficient strength to produce coagulation necrosis, in the interior of the growth, is the one which usually is now employed. There are, however, serious objections to this form of treatment; it is by no means devoid of danger, extensive and serious venous thrombosis having been often produced, and it is impossible so to control the effect that the diseased structures are alone necrosed, while it is seldom that the destruction of the piles is so complete as to obviate the danger of recurrence of the symptoms. The other methods of producing coagulation-necrosis, although safer, are open to the same objection of incompleteness, the best of these methods, however, in my opinion, being electrolysis, and I occasionally employ it in cases of very small highly vascular piles, where the patient cannot afford the time, or will not submit to the trivial operation for complete removal.

The way of performing electrolysis is as follows: The piles, having been brought into view, a few drops of a 4 per cent. solution of eucain, or cocain, is injected into each pile that it is desired to treat, and after the lapse of a few minutes, four or five round sewing needles, mounted in a handle, are passed into the centre of the tumour, and connected with the negative pole of the battery, the other (positive) pole being applied by means of a wet sponge to the buttock. After a few minutes the surface of the pile will be seen to become white, and minute bubbles of hydrogen gas will be seen escaping round the needles. As soon as this is well marked the needles are withdrawn, and, if deemed necessary, re-introduced into another part of the same, or another pile. In a few days the piles shrivel up and disappear painlessly. If the positive pole is used the needles stick tightly in, and haemorrhage may result from their forcible withdrawal. It has, however, in order to avoid this inconvenience, been recommended, in the case of naevi, to use the positive pole first attached to the needles, and then, after a few minutes, to reverse the current for a short time previous to the withdrawal of the needles. I have not, however, found this plan satisfactory, and prefer to use the negative pole all through.

**3. The removal of each separate pile by ligature, clamp, and cautery, crushing, or excision, either singly or in combination.** The methods here grouped together constitute those which



are generally applicable to almost all cases of internal piles, which come under the notice of the surgeon for treatment, and no doubt, with any of them, the end in view, the complete removal of each separate pile can be accomplished with certainty, thoroughness, and at the most trivial risk. Some surgeons favour one, and some another, of these methods, and each of the methods has been modified into numerous sub-varieties. It does not appear to me to be profitable to devote much space to their discussion, they can all be found described at length in some of the larger text-books. During the past twenty years I have given a fair trial to each method advocated which promised a reasonably good result, and as a consequence have come very definitely to the conclusion that by far the best way of removing each separate pile is by a combination of ligature, crushing, and excision. I have operated many hundred times for the removal of piles in this way, to the exclusion of all other methods except a few cases treated as before detailed, by nitric acid or electrolysis, and still fewer in which complete excision of the pile-bearing area has been adopted; and although I have no doubt many of the other methods answer admirably, I am so convinced that this combination is the best, that it is the only one which I propose to deal with in detail.

**Preliminary preparation.** For at least two nights before the operation, the patient should take an efficient purgative, and the morning of the operation the large intestine should be thoroughly emptied by copious enemata.

**Operation.** The patient having been anaesthetized to full relaxation of voluntary muscles, is placed in lithotomy position, and the anus thoroughly dilated by the introduction of the two index fingers or thumbs, by means of which a strain is kept up upon the sphincters, until complete relaxation has taken place; this should be done carefully, so as to avoid laceration. The piles now become prolapsed and generally more tumid, owing to extravasation of blood into the sub-mucosa, the result of the stretching. An exact estimate is now to be made of the amount of tissue necessary to remove, and a haemostatic catch forceps applied to each pile, or piece of spongy mucous membrane, requiring removal (Fig. 94). Four or five pairs of forceps are thus usually applied, and allowed to hang down in a cluster, in this way there is no danger, when afterwards the parts become obscured by blood, of any of the smaller piles being overlooked or forgotten; taking up one of the catch forceps now, by gentle traction, the base of the enclosed pile is made prominent, and its lateral



attachments to the anal canal separated by snipping through with a scissors: much of the success of the operation depends upon how this dissection is carried out. As already pointed out (p. 189) prolapsed internal piles are surrounded by a ring, formed by revolution of the lower zone of the anal canal, and between this and the piles proper there is found an irregular sulcus, which corresponds to the pectinate line or mucocutaneous junction (Fig. 91). If the dissection of the lateral connections of the piles is commenced at the pectinate line, as is commonly recom-

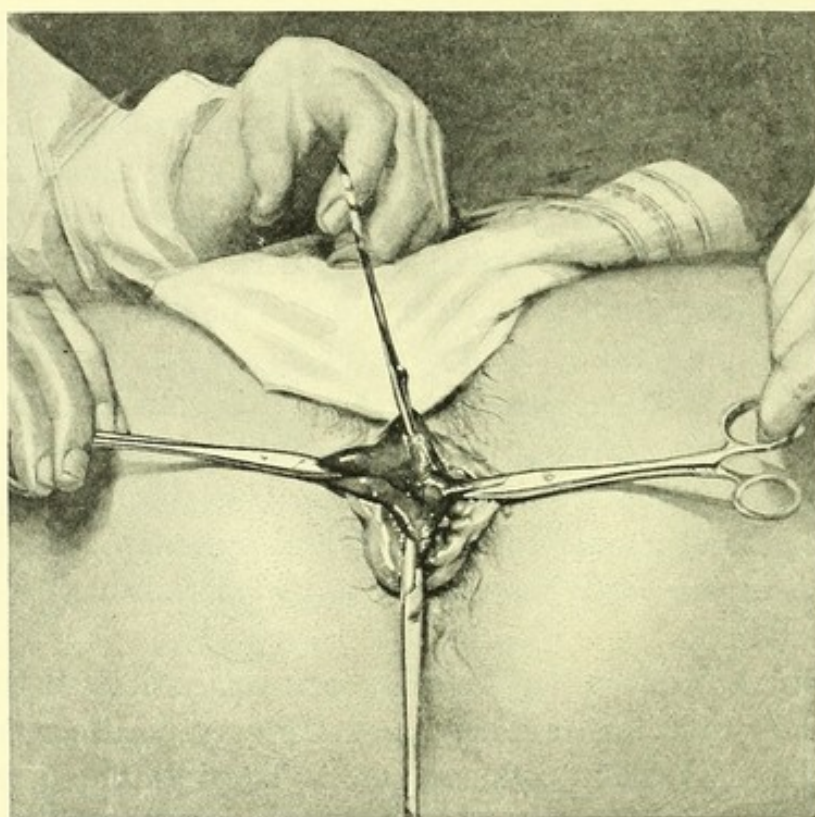


FIG. 94. Piles Prolapsed by means of Catch Forceps.

(From a stereo-photograph.)

mended, following the original description of Mr. Salmon, it will be found that although the revolution of the lower anal canal can be reduced at the completion of the operation, it is apt to recur the first time the bowels move, and become permanent in the shape of cutaneous tags (external piles), which give a good deal of annoyance and sometimes require a further operation for their removal. If, on the contrary, the dissection is commenced at the outer edge of this cutaneous ring, too much tissue will be removed, and possibly an anal stricture will result, or, when



healing has taken place, it will be found that a portion of mucous membrane has become permanently everted, which is a great discomfort to the patient from the moist mucous secretion which constantly soils the parts. It is obvious, therefore, that the proper position to commence the dissection is between these two lines. The best results are obtained by making a curved incision corresponding to the base of the pile being dealt with, taking care that the greatest convexity of the curve does not involve more than one-third of the cutaneous ring (Fig. 95), while the

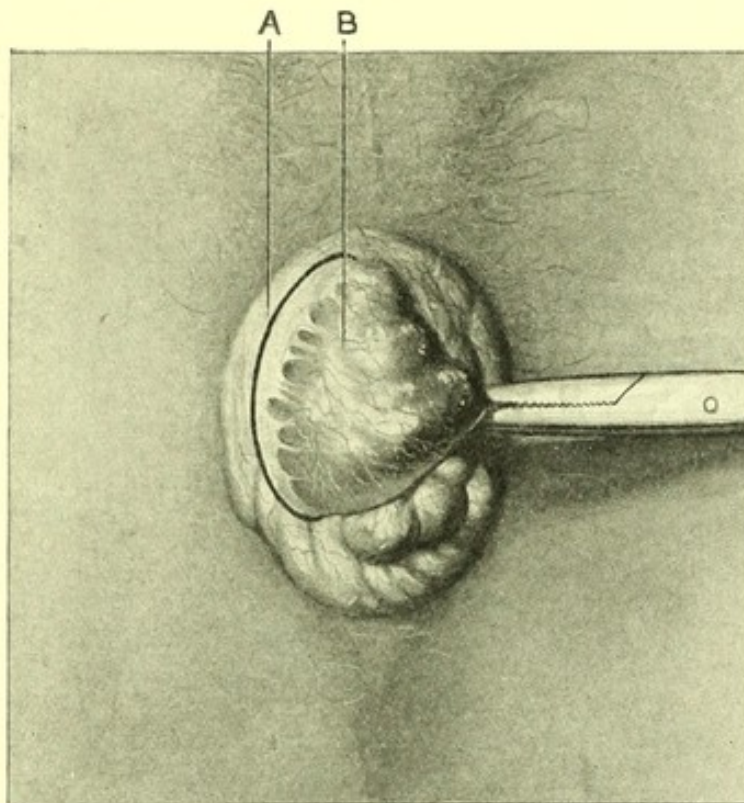


FIG. 95. Operation for Internal Piles, stage I.

The pile B to be dealt with is drawn down by catch forceps and the pectinate line exposed. An incision A is made round the base of the pile including about one-third of the skin of the revolved anal canal. The incision exposes, but does not involve, the fibres of the external sphincter muscle. The ends of the incision terminate in the mucous membrane at each side of the pile.

ends of the curved incision terminate in the mucous membrane at each side of the pile. By blunt dissection the pile is now separated from the external sphincter muscle, which is usually clearly visible and must on no account be injured; the dissection is carried up the anal canal until the pile remains attached above only by healthy mucous membrane with the vessels coming down into it; this mucous membrane pedicle is crushed



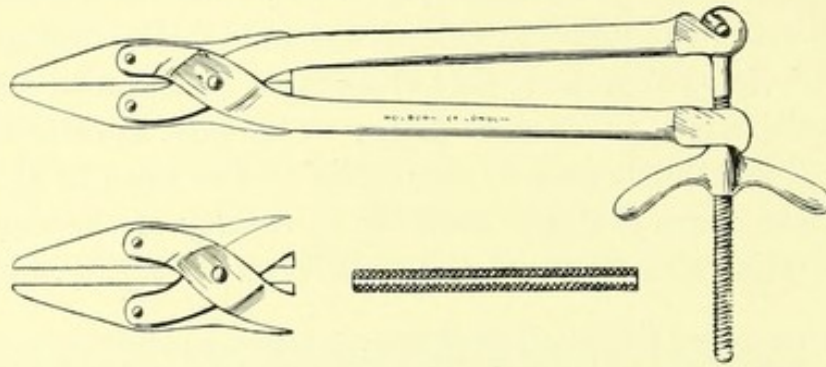


FIG. 96. Crushing Clamp with Parallel-acting Blades (Holborn Surgical Instrument Company).

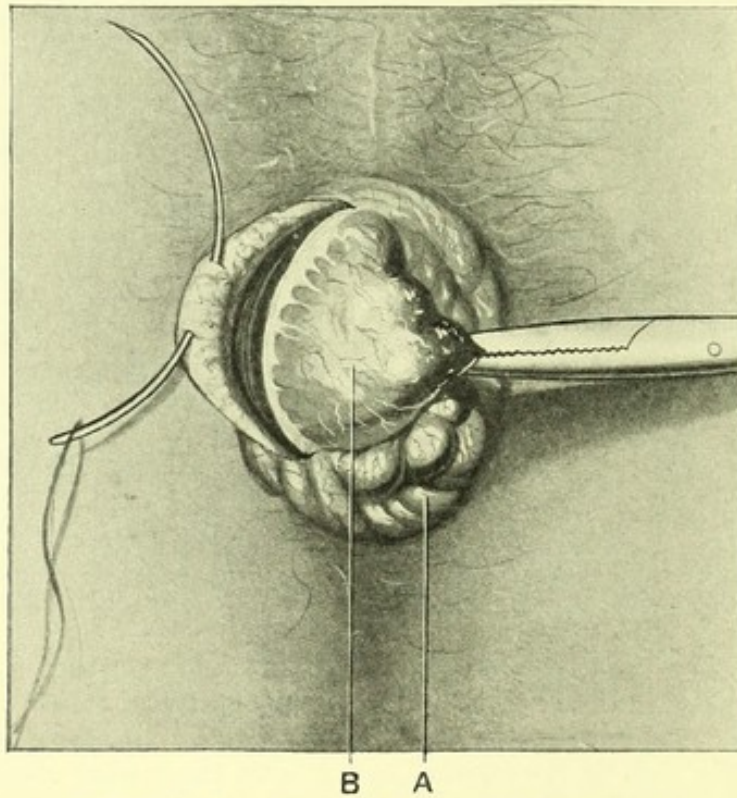


FIG. 97. Operation for Internal Piles, stage 2.

The flap marked by the incision, in Fig. 95, has been raised, exposing some fibres of the external sphincter muscle and a curved needle, carrying a silk ligature, passed on the subcutaneous aspect of the flap. A. Revolted anal canal. B. Pile.



in a powerful clamp: I prefer one with parallel closing blades (Fig. 96). The line of incision is carefully searched, and if any arteries are seen bleeding, they can be twisted. A curved needle armed with strong silk is now passed through the subcutaneous tissue, at a point corresponding to the greatest convexity of the incision (Fig. 97), and is next passed through the centre of the crushed mucous membrane forming the pedicle of the pile; this ligature is tied first on one side very tightly, thus strangulating one half of the already crushed pedicle (Fig. 98), and

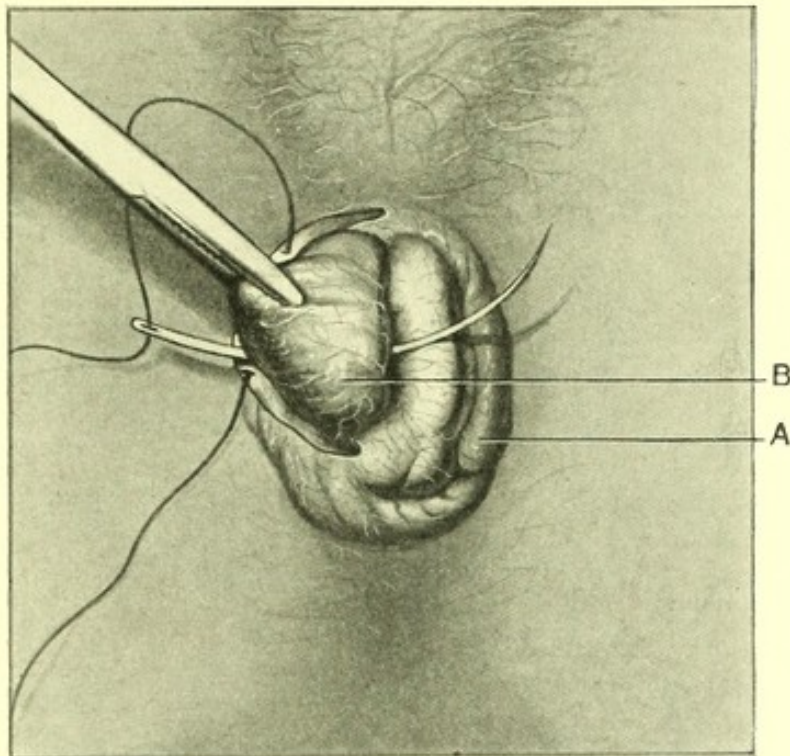


FIG. 98. Operation for Internal Piles, stage 3.

The base of the pile being transfixed by needle carrying ligature, which has previously been passed on the subcutaneous aspect of the flap. A. Revoluted anal canal. B. Pile.

the ends are then passed round and tied also very tightly on the other side, constricting the entire pedicle, including the half already tied (Fig. 99). The effect of this ligature is to control the larger blood-vessels going into the pile, while at the same time, owing to its having a subcutaneous hold on the revoluted skin of the anal canal, it returns this into place, and maintains it in position until union has taken place. The use of the crushing clamp is of importance in allowing more accurate application of the ligature and more certain haemostasis. The pile is now cut away in front of the ligature, but not close enough to endanger



slipping, and the remaining piles to which catch forceps were attached at the commencement of the operation treated in the way above described. In the illustrations of this method, for the sake of clearness, the treatment of only a single pile is indicated, but it is to be understood that all are to be treated in like manner.

4. **Complete excision of the entire pile-bearing area.** In 1882, Mr. Whitehead described an operation for complete excision, in which the entire circumference of mucous membrane constituting the

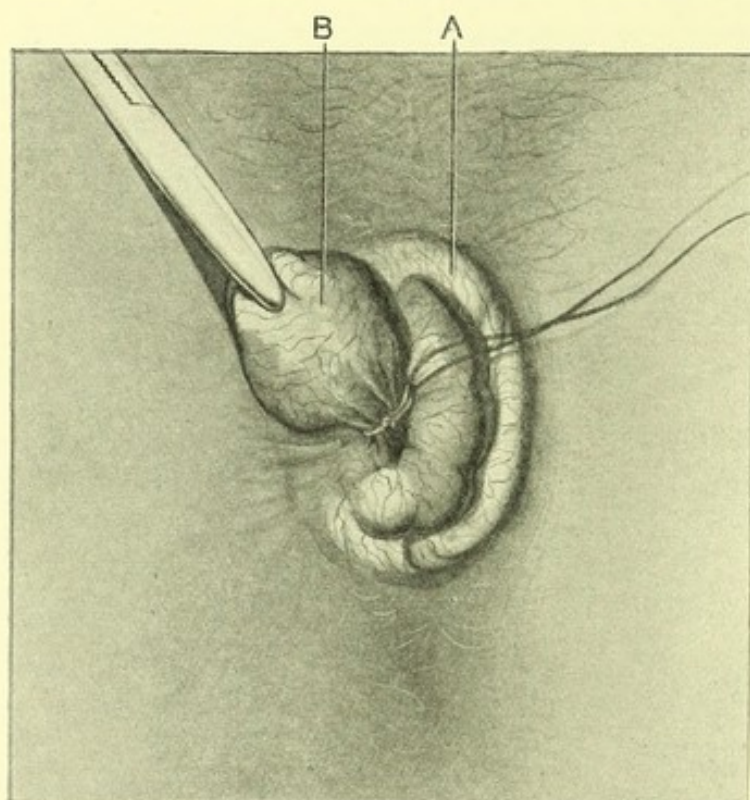


FIG. 99. Operation for Internal Piles, stage 4.

The ligature has been tied first round half the pile, then again tied round the entire base of the pile. A. Revolved anal canal. B. Pile.

pile-bearing area was removed, the divided mucous membrane above being sutured to the cut edge of the skin below. The thoroughness of this procedure rendered it attractive, and it was very largely adopted both in Europe and America, but a large number of cases, both of anal stricture and permanent eversion of mucous membrane, having resulted, the method has become largely discredited of late. From personal experience of a considerable number of cases treated in this way, I am satisfied that if the surgeon fully realizes that the cutaneous ring surrounding the piles



is only the revoluted lower portion of the anal canal, and avoids removal of more than its inner third, and if he avoids injury of the fibres of the external sphincter muscle, neither anal stricture nor permanent eversion of mucous membrane will result. It is, however, a more complicated and severe operation, and haemostasis is less complete than in the one which I have above described, and which will be found suitable for possibly 95 per cent. of the cases presenting themselves for treatment. There is a condition which we occasionally see in which Whitehead's operation

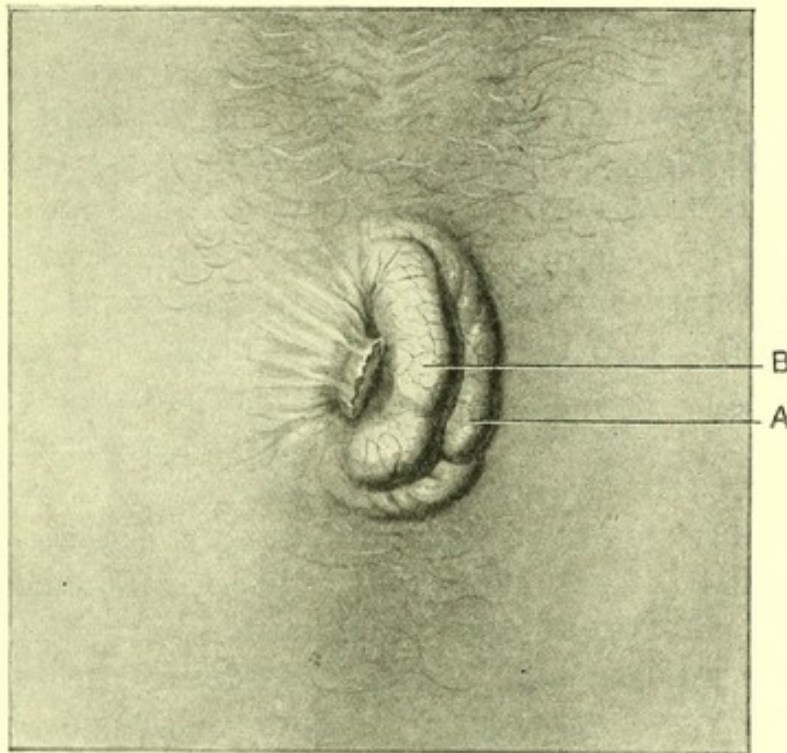


FIG. 100. Operation for Internal Piles, stage 5.

The pile cut away after being ligatured. It shows the way in which the flap of skin is drawn in and held in place by means of the subcutaneous ligature. A. Revoluted anal canal. B. Internal pile.

appears to be the most suitable, viz. when no distinct tumours are present, but the whole mucous membrane has become converted into a spongy, highly vascular mass; in these cases excision of the entire ring is still called for. It is performed as follows: The patient having been prepared as in the previous case and the anus thoroughly dilated, an incision is commenced in the cutaneous ring, but quite close to the pectinate line; a vertical incision is made from the commencement of this incision through the diseased mucous membrane and, circumferentially, round



the mucous membrane of the bowel above the disease. Only a small portion of the circumference above and below is divided at a time, any arteries severed are twisted and the cut edge of the mucous membrane above sutured to the skin below, before the next portion is incised, in this way the entire ring of diseased mucous membrane is removed. If we were able to always obtain primary union this would be an ideal operation, but unfortunately this is not the case; no matter what antiseptic precautions we take, soiling by intestinal contents almost always occurs to a sufficient extent to prevent primary union, although grave sepsis is fortunately extremely rare. The subsequent healing by granulation is much more rapid and satisfactory if vertical strips of mucous membrane remain intact, as is the case where the piles have been dealt with separately, than where the entire ring has been removed.

**The after-treatment** of cases in which piles have been removed by operation is a matter of importance. Once the surgeon is satisfied that bleeding is satisfactorily stopped, the stumps of the piles should be carefully reduced, and if the operation has been properly done, this can readily be accomplished, and the anus made to assume its normal appearance. A firm aseptic pad is applied to the anus and retained in position by a T-bandage.

Rest in bed for at least a week is necessary, and the bowels should be confined until the fourth day; usually there is no difficulty about this if the bowels have been thoroughly evacuated beforehand, as owing to fear of pain the patient naturally resists any inclination to defaecate, and the desire soon passes away, or, if the bowel is irritable, opiates may be indicated.

On the evening of the third day a purgative, preferably castor-oil, should be administered, and after the bowels move the anus should be thoroughly washed with solution of lysol or other antiseptic solution, and if any prolapse has taken place boric ointment should be applied and the prolapse carefully reduced. The thorough reduction of the ligatured stumps immediately after the operation, and subsequently, should prolapse recur when the bowels move, adds much to the comfort of the patient and the satisfactory result of the operation. After the first motion care must be taken to avoid constipation. The ligatures come away about the 8th-10th day, and the little ulcers left usually heal readily.

**Pain.** The amount of pain after operations for piles varies greatly; some patients scarcely experience any, while others obviously suffer



a good deal. When pain is severe, it is usually more or less paroxysmal, due to spasm of the pelvic diaphragm, coming on suddenly, especially as the patient is trying to go to sleep, and effectually waking him up; it can, however, readily be quieted by morphia.

**Bleeding.** Except for a slight oozing into the first antiseptic pad, bleeding should not occur if the directions above given are adhered to, but occasionally a bleeding vessel may have been overlooked and returned within the sphincter, or, from faulty tying, a ligature may slip, and considerable bleeding may take place. If the preliminary dilatation has been thorough this will show itself externally, but occasionally concealed haemorrhage may go on to a considerable extent, and a large quantity of blood collect in the rectum and colon; this will be indicated by pallor, restlessness, haemorrhagic pulse, and an intense desire to defaecate, which, if allowed to take place, will result in the expulsion of dark-coloured blood-clots. To attempt to plug the rectum under these circumstances, as is usually recommended, is excessively painful, seldom effectual, and often likely to tear open the wound, and so increase the bleeding; the proper treatment is to at once anaesthetize the patient again, wash out the blood clots from the rectum, and then, by drawing down the field of operation, the bleeding point can be seen and properly secured.

A slight amount of bleeding is often noticed the first few times the bowels move, which may be repeated until the wound is quite healed. It is well to caution the patient as to the possibility of this, as otherwise he may think that the operation has failed to relieve him of his most prominent symptom.

**Retention of urine,** especially in males, is of common occurrence after pile operations, and is often as much due to the difficulty experienced in passing water in the recumbent position as to any direct result of the operation. If the patient experiences difficulty he may be permitted to stand out of bed, which usually is all that is necessary, and I very rarely have to use a catheter now in these cases.

**Sepsis.** The extraordinary freedom of these wounds from serious septic complication is very remarkable, considering our inability to prevent soiling of the surface by intestinal contents. A wound infection sufficient to prevent primary union after excision of piles is undoubtedly the rule, but further complications such as extensive venous thrombosis, ischio-rectal abscess, diffuse periproctitis, and peritonitis, although noted by writers as possible, are so extremely rare, that the risk of their occur-



rence need not be seriously considered. Tetanus, which formerly was enumerated as one of the real dangers of pile operations, was, when it occurred, due probably always to external infection of the wound, and should never appear if modern aseptic methods are adopted.

**Delayed healing.** We occasionally see that the little ulcers left when the ligatures come away, instead of healing naturally, become indolent with raised edges. When this occurs, the patient must be kept in bed, efficient antiseptic cleanliness maintained, and the surface of the ulcer curetted or touched with silver nitrate, or copper sulphate, when it will generally heal without difficulty.

**Results.** The risk of operations for piles is probably as trivial as any operation in surgery, and the mortality, in good hands, is probably a small fraction of one per thousand, so that it cannot be taken into serious consideration when compared with the great comfort and improved health which follows a proper operation.

**Recurrence.** In order to prevent recurrence the operation must be thorough, but when this is the case recurrence is seldom seen, unless the piles have depended upon some permanent obstruction to the portal circulation, in which case no operation should have been undertaken. In the great majority of cases the cure is both absolute and complete. One interesting point I have frequently observed, and I have little doubt but that the observation is familiar to other surgeons: when a few small piles have been removed from an intensely congested rectum, with spongy mucous membrane, and when there is an opportunity afforded of seeing this case some months afterwards, it will usually be found that the mucous membrane has quite regained its normal condition, that its surface is smooth, and that the great congestion has disappeared. Now, it has always appeared to me that the mere removal of the mechanical irritation of a few small piles was not in itself sufficient to account for this change. Can it be that the formation of a cicatrix, necessarily following the removal of a pile, has any effect upon the rectal circulation? As is well known, the formation of a cicatrix in iridectomy, and other similar operations, has a very marked effect in lowering intra-ocular tension in cases of glaucoma. Many have been the explanations put forward to account for this result, and perhaps one of the most plausible is that of Exner (Schmidt und Graefe, *Handbuch*, 5. Band, p. 121), who has been able to show, by a series of carefully conducted injections, that direct communications between somewhat large arteries and veins are formed in the



stump of iridectomy wounds. Hitherto, I have not had an opportunity of examining pathologically cases of piles cured by operation, but when the undoubted fact is remembered that the presence of an operation cicatrix in the rectum does relieve congestion, it appears only reasonable to assume that a similar explanation to that given by Exner may be accepted in this case.



## CHAPTER XVI

### BENIGN TUMOURS

THE new growths met with in the rectum, which clinically are non-malignant, are of varied structure, some presenting somewhat special characters from their position, while others possess no features of importance to distinguish them from the same disease when met with in other parts of the body ; many of these growths are found attached to the wall of the intestine by a more or less narrow pedicle, the so-called 'polypus' of the rectum. This word, as used to express a tumour attached by a single more or less narrow pedicle, has always appeared to me to be one of those etymological conundrums which we so frequently meet with in medical history, and which it is high time to replace by a more exact nomenclature.

The most important class of the growths we are considering, from a surgical standpoint, and at the same time the most interesting, are the **adenomata**. By the word adenoma we understand a tumour which is largely composed of epithelial tissue similar to that formed in secreting glands, and when occurring in the intestinal tract the epithelial elements of the new growth correspond with those normally found in the follicles of the intestinal mucosa. If the epithelial proliferation is simply a surface development, even though it may produce a tumour of considerable dimensions projecting into the lumen of the bowel, we speak of it as a simple adenoma, and if, on the contrary, the epithelial development grows through its basement membrane, invades the sub-mucosa, infiltrates the muscular coat, and even the tissues outside the intestinal tunic, the case is one of infiltrating adenoma or adeno-carcinoma, which is the typical form of intestinal cancer, and is characterized by all the clinical evidence of malignancy.

Unlike haemorrhoids, which are confined to the rectum, adenomata, both the simple and infiltrating varieties, are found throughout the entire length of the intestinal tract, but are much more frequently met



with in the rectum. No doubt this is in part due to the greater facilities for diagnosis afforded by the lower bowel; but allowing fully for this consideration, it is certain that the actual frequency of occurrence of these growths in the rectum is much greater than it is in the other portions of the intestines.

There is a close analogy between the growth of adenomata of the

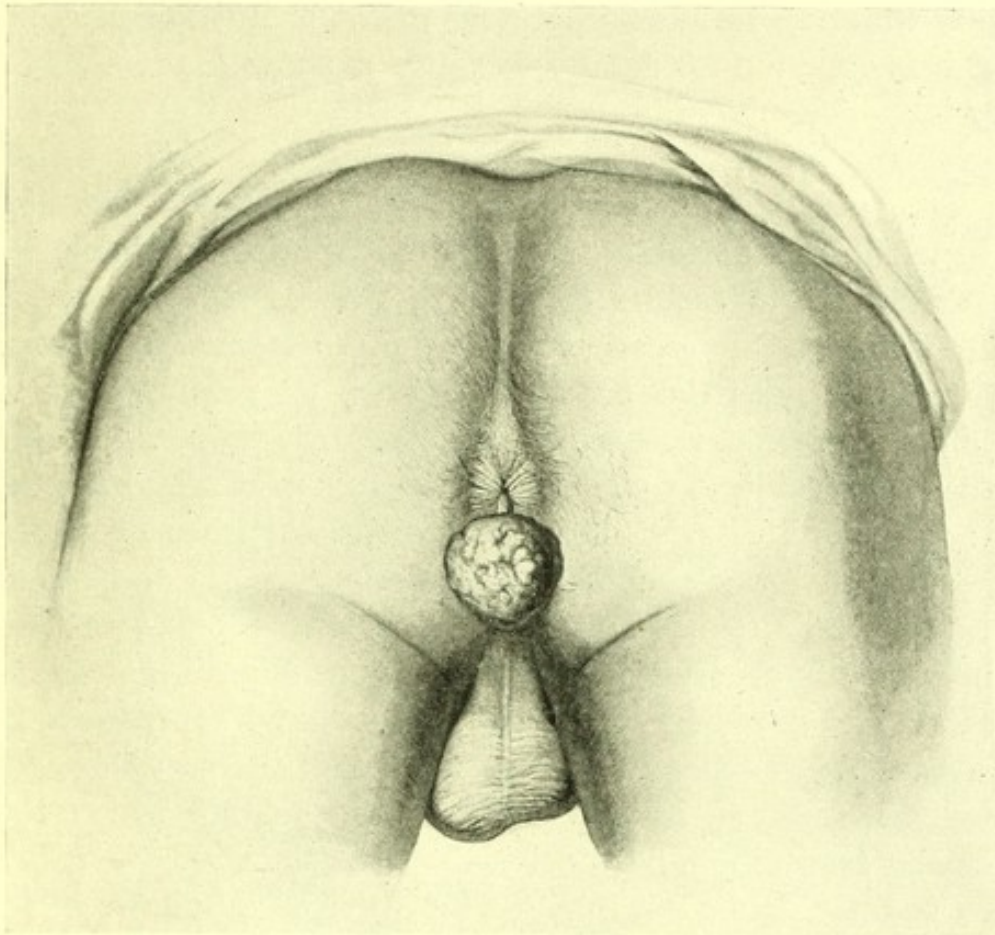


FIG. 101. Adenoma protruded through the Anus and attached by a long, narrow, round pedicle.

*(From a painting in the Museum of Trinity College, Dublin.)*

intestinal mucosa and cutaneous warts. The increase of the papillae of the skin and overgrowth of epithelium on the surface of a wart has its exact counterpart in the formation of a small adenoma; both occur more frequently in children, there is a tendency in both for the surface to be increased by tuberculation and fission. The tendency to become pedunculated, although more frequent in intestinal adenoma, is not uncommon in cutaneous papilloma, and as the cutaneous wart, after existing for



many years without apparent change, may spread into the deeper tissues and become a malignant epithelioma, so we find that cancer of the rectum may have been preceded for a long time by a purely benign adenomatous growth, particularly if the tumour is one of the sessile and non-pedunculated varieties of simple adenoma. Another point of resemblance between cutaneous warts and intestinal adenomata is that both are influenced by heredity; numerous instances are recorded of several members of the same family suffering from adenomatous growths in the rectum, and we know that it is common for cutaneous warts to show the result of similar hereditary influence.

The relation of simple to malignant adenoma is a question of great interest. Pathologists have from time to time thought that, from the way in which the protoplasm of the epithelial cells stains, from the presence or absence of goblet cells, from the fact that the epithelium lining the acini was disposed in one or more layers, and from other characters of the epithelial cells themselves, they have been able to discriminate between the benign and malignant forms. It, however, appears that none of these characters are sufficient alone to make the diagnosis: there is one, and only one, positive evidence of malignancy, and that is the perforation of the muscularis mucosae and the development of the epithelial elements in the deeper structures of the intestinal tunic; once this has occurred the growth of epithelium becomes rampant, it invades all structures in its neighbourhood, and reproduces itself in distant parts. What the explanation is of this increased growth, once the basement membrane is penetrated, is the enigma which the large army of cancer researchers have set themselves to solve.

There is little doubt but that the origin of certain cases of adenoma can be traced to local irritation. In cases of prolapsus recti in young children we often find small sessile adenomata on the exposed mucous membrane; these, which are quite too small to have had anything to say to the production of the prolapse, are in all probability caused by friction against the child's clothing. Upon the exposed mucous membrane of a colotomy wound, in like manner, we not infrequently can watch the development of similar growths. Again, in cases of cancer of the rectum attended with copious discharge we occasionally find adenomatous growths at a distance from and below the cancer, which are obviously confined entirely to the mucous membrane. In a case of widely diffused adenomatous growth of the rectum—which I saw with Mr. T. E. Gordon and



was the most extensive I have ever seen (Fig. 102)—a hair-ball, composed apparently of the patient's own hair which she had swallowed, was also present. The entire rectum was filled with an enormous mass of villous-like soft new growth, from which there was a very profuse mucous

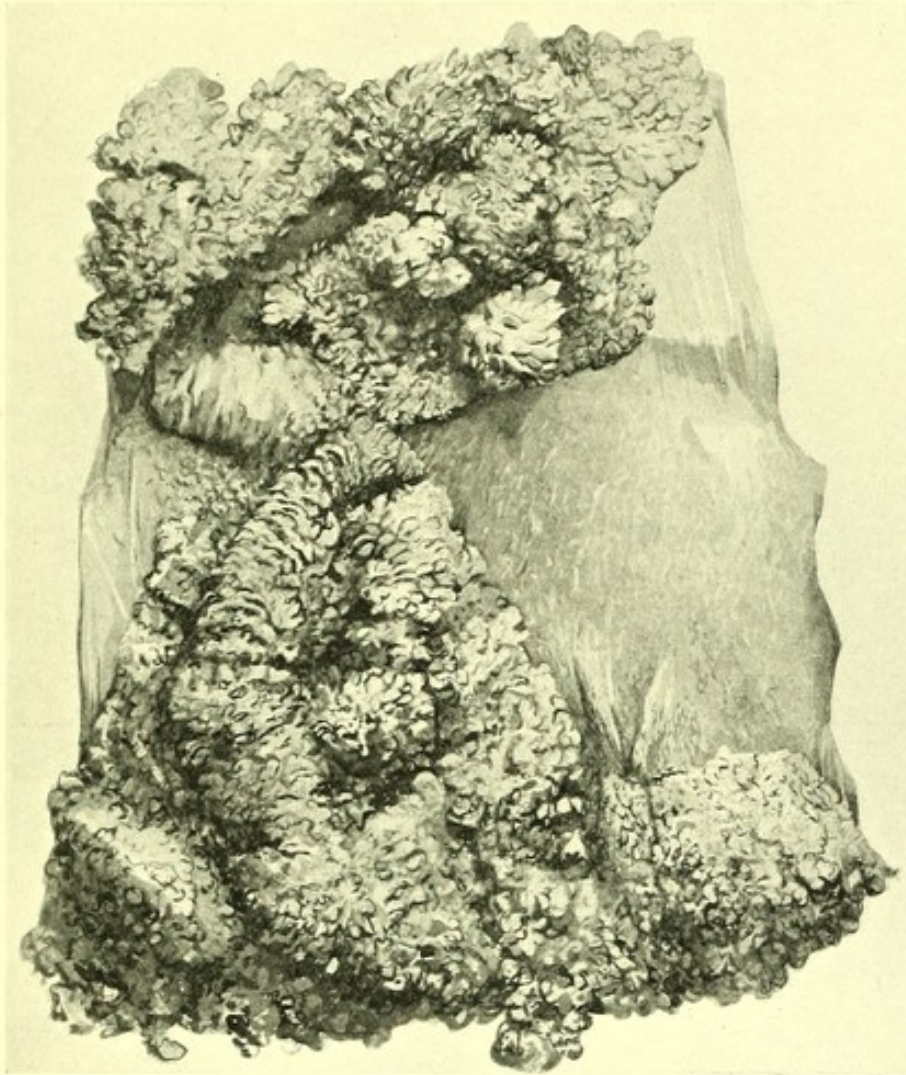


FIG. 102. Widely diffused Adenomatous Growths in the Rectum.

Probably caused by hair-ball. At one part the adenoma had infiltrated the muscular coat of the bowel, and become malignant.

*(From a specimen removed by excision of the rectum by Mr. T. E. Gordon, two-thirds natural size.)*

discharge, occasionally bloodstained. Excision of the rectum was performed, and it was found that almost the entire mucous membrane of the rectal ampulla was involved, and that at one portion, less than an inch in diameter, on the posterior aspect (Fig. 104), the growth had infiltrated the muscular coat of the bowel. A large mass of felted hair



was subsequently removed from the rectum above the line of excision. Three years afterwards the patient developed typical cancer.

Dr. Belleli, of Alexandria (*Progrès Méd.*, No. 30, 1885), in 1885 noted

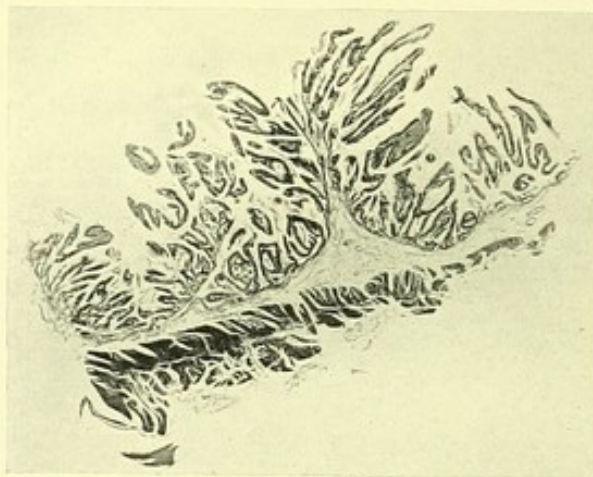


FIG. 103. Section of Adenomatous Disease of the Rectum, from the case illustrated in Fig. 102.

It is in this part purely benign in character, the disease not having penetrated the muscularis mucosae.

(*Photo-micrograph*,  $\times 4$ .)

the occurrence of adenomata of the rectum caused by the deposit of the ova of *Bilharzia haematobia* in the mucous membrane, and since then

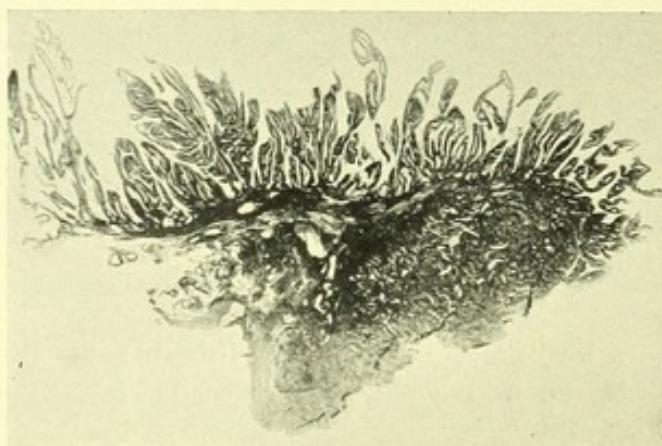


FIG. 104. Section from another portion of the specimen illustrated in Fig. 102.

The adenomatous tissue is here seen penetrating the deeper tunics of the bowel, indicating that it has at this point become malignant.

(*Photo-micrograph*,  $\times 4$ .)

the existence of bilharzia disease of the rectum has been fully recognized. In some lectures delivered by Frank Milton, M.R.C.S. (*Journal of Tropical*



*Medicine*, June and July, 1902), on bilharzia, the subject is fully dealt with ; he states that infection of the rectum is 'second only to the bladder in frequency of occurrence'.

I am much indebted to Dr. H. P. Keatinge, Director, Egyptian Government Medical School, Cairo, for kindly sending me two beautiful

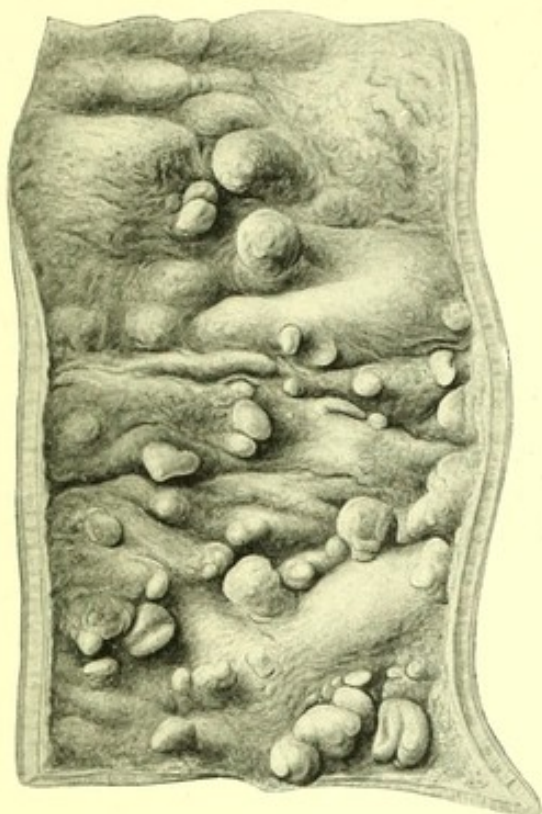

FIG. 105. Multiple Adenomata of the Rectum caused by the deposit of the Ova of *Bilharzia haematobia* in the Mucous Membrane.

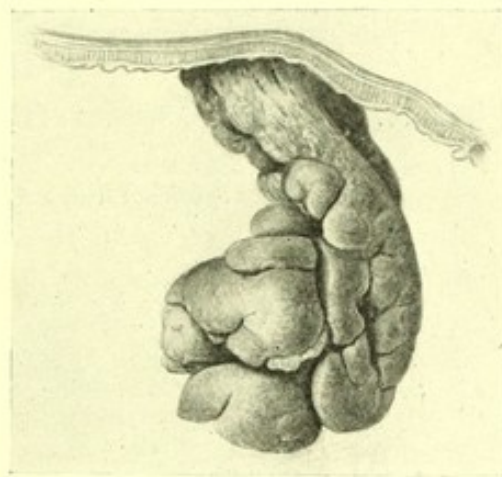


FIG. 106. Single Adenoma of Rectum caused by the deposit of *Bilharzia haematobia* Ova. *Natural size.*

(From specimens kindly sent to the author by Dr. H. P. Keatinge, Director, Egyptian Government Medical School, Cairo.)

specimens of bilharzial disease of the rectum from which Figs. 105-108 have been drawn.

It is probable that other intestinal parasites sometimes produce new growths in the wall of the intestine, and this possibly may be one of the reasons of the greater frequency of simple adenoma in childhood. A case of rectal tumour caused by *Oxyuris vermicularis* is recorded by M. A. Ruffer (*Brit. Med. Journal*, Jan. 26, 1901): at post-mortem examination of an Egyptian adult several small tumours were found in the



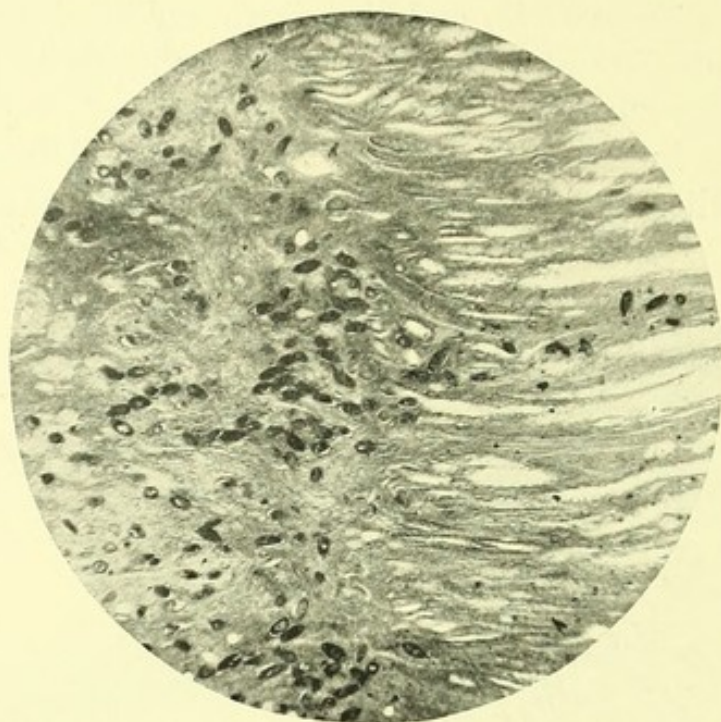


FIG. 107. Section of Adenoma of the Rectum containing numerous Ova of *Bilharzia haematobia*.

(From the specimen illustrated in Fig. 105. Photo-micrograph,  $\times 40$ .)

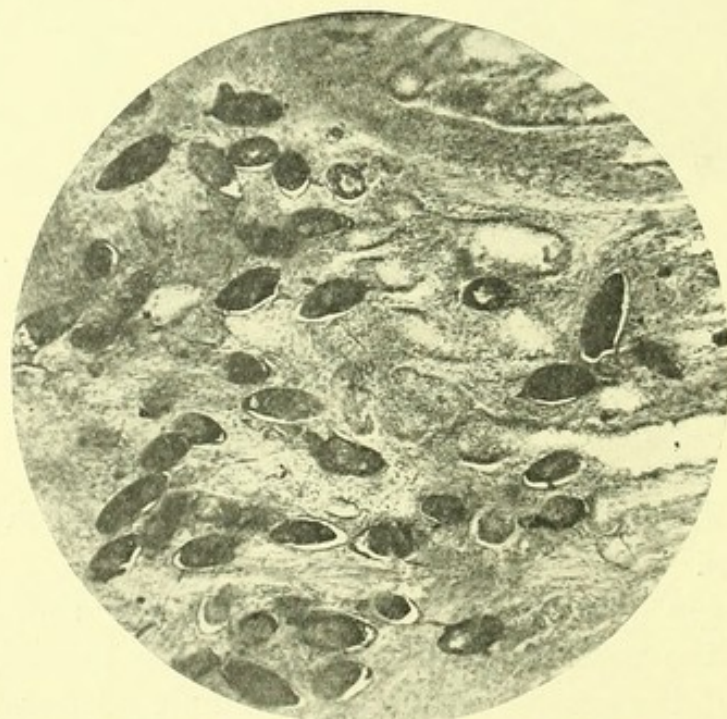

FIG. 108. Section of *Bilharzia* Disease of the Rectum.

The same section as that illustrated in Fig. 107, more highly magnified.

(Photo-micrograph,  $\times 200$ .)



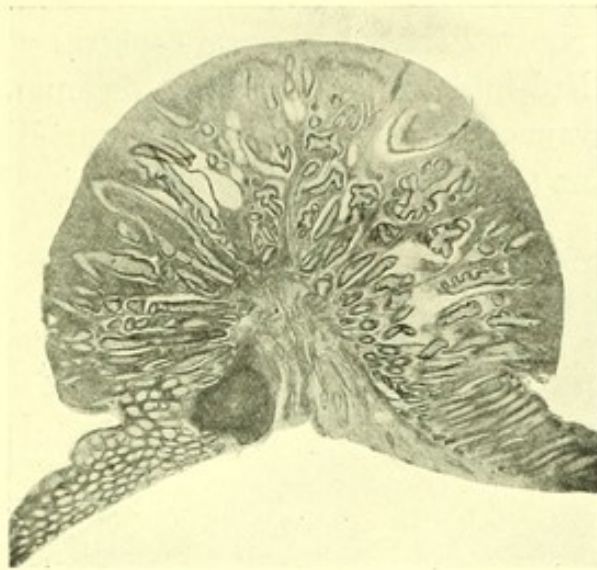


FIG. 109. Commencing Adenoma of the Rectum, from a case of Prolapse.

The adenoma was probably due to friction against the child's clothes. On the left-hand side of the illustration the healthy mucous membrane has been cut horizontally, and on the right vertically. The section also passes through a solitary lymph follicle.

(*Photo-micrograph*,  $\times 4$ .)

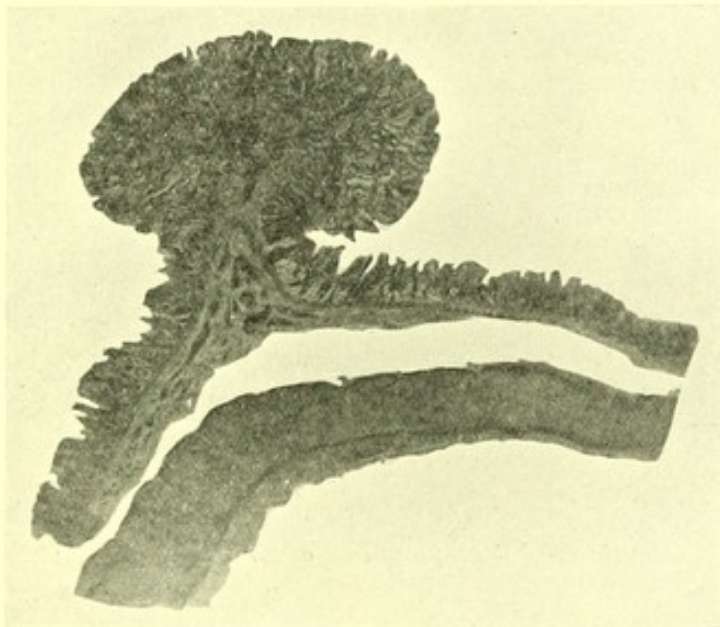


FIG. 110. Simple Adenoma found in connection with a Typical Adeno-carcinoma of the Rectum.

The benign character of the growth is indicated by the way the muscular coat has separated from the mucous coat in preparing the specimen.

(*Photo-micrograph*,  $\times 8$ .)



wall of the rectum, which were at first thought to be due to bilharzia, further examination showed that they were caused by the ova of *Oxyuris vermicularis*, which had undergone calcareous degeneration.

The first appearance of an adenoma is a wart-like projection from the mucous membrane (Fig. 109). If this is examined microscopically it

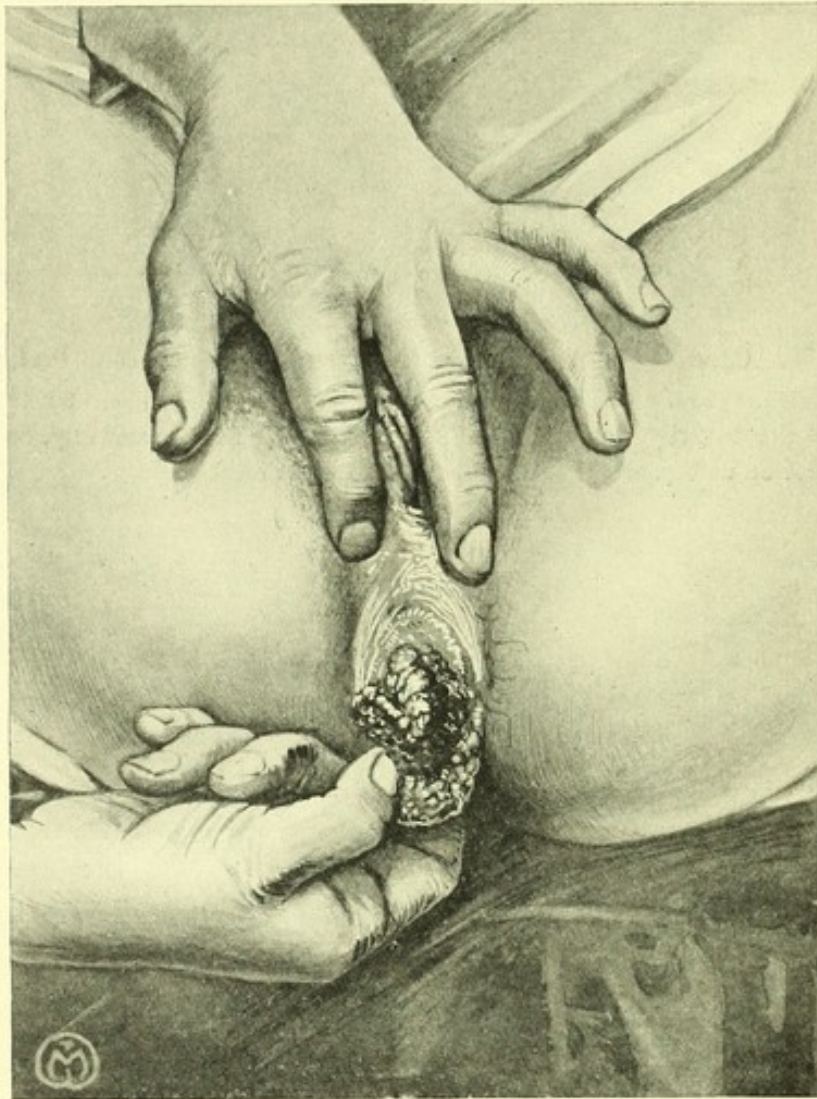


FIG. 111. Multiple Adenoma of the Rectum prolapsed through the Anus.  
(From stereo-photograph of case of Mr. R. L. Swan's.)

is found that the secreting follicles have become elongated and increased in number, and that the projection is caused by their being crowded together. This nodule soon becomes more prominent and rounded, while its base becomes narrowed into a pedicle producing the so-called 'polypus' of the rectum.









PLATE V.

ADENOMA WHICH WAS ATTACHED BY A BROAD STRAP-LIKE  
PEDICLE, IN A CASE SEEN WITH MR. R. L. SWAN.

From a painting of the growth made immediately after its  
removal. Natural size.



The pedicle once having formed tends to elongate, so that a growth which originated some distance up the rectum may eventually come to be extruded from the anus. This pedicle is sometimes thin and round (Fig. 101), while at others it is broad and strap-like (Plate V). It consists only of the mucous and submucous coats of the bowel with the vessels for the nutrition of the growth.

In the large majority of cases pedunculated adenomata are single, but occasionally they are multiple, and in rare instances large tracts of mucous membrane are completely covered with them. The shape of

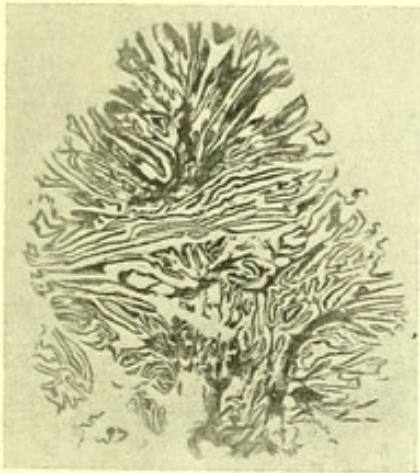


FIG. 112. Rectal Adenoma very finely split up.

(*Photo-micrograph*,  $\times 4$ .)

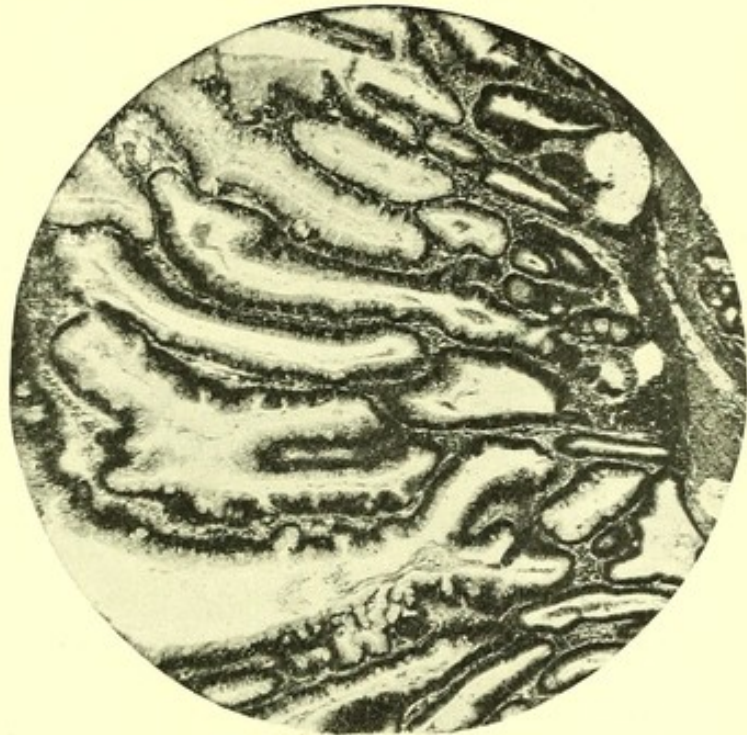

FIG. 113. Section of Adenoma of the Rectum.

(*Photo-micrograph*,  $\times 20$ .)

a simple adenoma is usually more or less globular, but it frequently manifests a tendency to increase its surface by tuberculation, while in others the surface area is still more largely increased by deep divisions; under [these circumstances these papillary adenomata become what has been usually described separately as villous tumours. An examination of a large number of specimens will show that there are all possible gradations between the simple ovoid, smooth-surfaced adenoma, and a villous tumour with a pile almost as fine as velvet. It is more accurate, therefore, to consider all these tumours as varieties of adenoma.



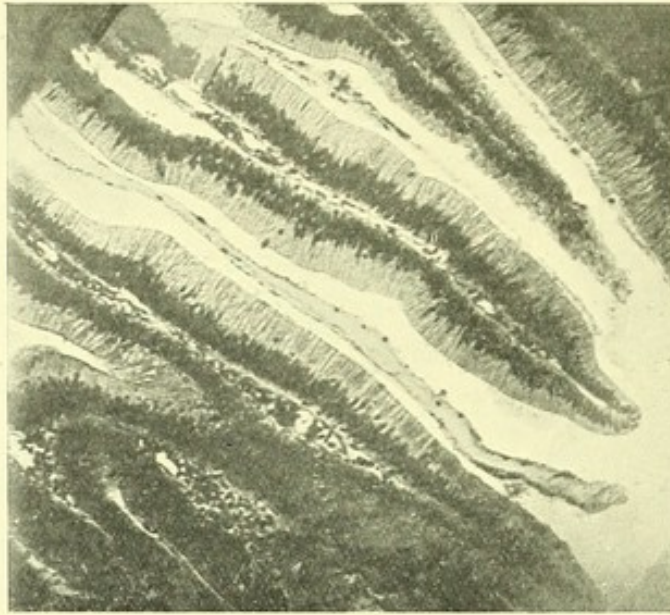


FIG. 114. Section of finely-split-up Adenoma.  
(*Photo-micrograph*,  $\times 100$ .)

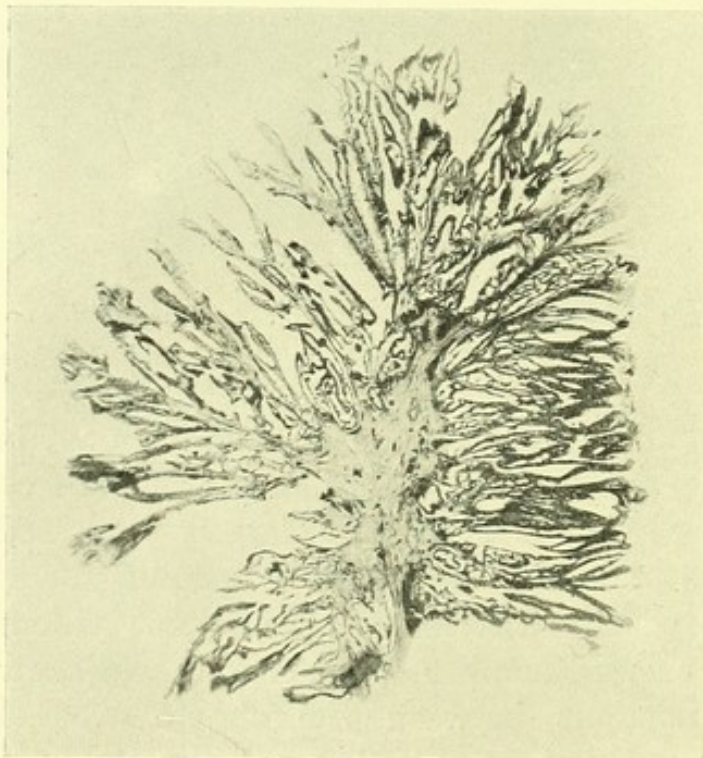


FIG. 115. Section of Villous Adenoma of the Rectum.  
(*Photo-micrograph*,  $\times 10$ .)



The symptoms of simple adenoma of the rectum, when of small size and not involving the sphincteric zone, are of a trivial character; when, however, the pedicle becomes sufficiently long to allow of the growth being protruded through the anus, it becomes congested, and the surface is liable to be abraded, bleeding is therefore a common symptom. It is a clinical maxim that haemorrhage from the rectum in young children always raises the suspicion of adenoma, as piles, which are the commonest cause of such bleeding in the adult, are rare in early life. Another symptom which is common where the adenomatous growth is extensive is the discharge of glairy mucus. In cases of villous adenomata this discharge may be very considerable, causing frequent desire to evacuate the bowel, the mucus even escaping almost continuously, causing much discomfort to the patient. This abundant formation of mucus is due to the great increase of secreting surface, and is remarkable as showing that the adenomatous tissue of the new growth remains functional. We occasionally meet with cases of considerable mucous discharge, highly alkaline, and producing much irritation of the anus and surrounding skin, in which it is impossible to detect by digital examination any adenomatous growth in the rectum; these cases may be explained by the presence higher up the bowel of adenomatous growths which are not within reach of the finger.

The mechanical effects produced by pressure of unusually large adenomata of the rectum occasionally give rise to important symptoms, such as intestinal obstruction and retention of urine; they have also been known seriously to obstruct parturition, but usually, except in embryonic adenoma, the size is so inconsiderable that pressure effects are trivial. In other instances, when situated some distance up the bowel, the continued peristaltic action evoked has caused intussusception.

Adenomata, sometimes of considerable size, occasionally undergo spontaneous cure. When the pedicle becomes long enough to permit of extrusion at the anus the retraction of the bowel after defaecation

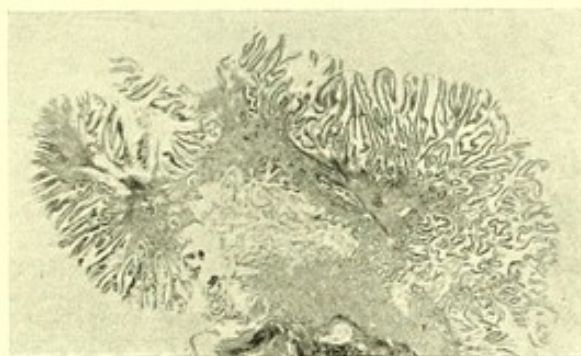

FIG. 116. Simple Villous Adenoma found in connection with Typical Adeno-carcinoma of the Rectum.

(Photo-micrograph,  $\times 4$ .)



may tear through the thin pedicle, but whether, like cutaneous warts, they disappear without any apparent cause we have no knowledge.

The **diagnosis** of this disease is usually easy, piles being the only other rectal disease liable to be mistaken for it. In the latter case the patient is usually older, the tumours multiple, attached lower down and by a broader base, the surface smooth and not so distinctly lobulated, and the mucous membrane of the termination of the lower bowel more congested and involved. In examining a patient digitally for suspected adenoma, it is well to follow the advice of Mollière, and pass the finger first up to its fullest extent, and then gradually to withdraw it, sweeping it round the entire rectal surface. In this way the pedicle will be hooked by the finger, and the growth found; if, however, the examination is conducted from below upwards the tumour may be pushed up out of reach.

**Treatment** of simple adenoma consists in the removal of the pedunculated forms after ligature of the pedicle, and when this is at all broad and strap-like it is a wise precaution to transfix and ligature it in sections. The sessile varieties, especially, if there is any tendency to infiltration of the deeper structures, are best excised. Where a considerable area is covered by villous growths they may be removed with the curette in the same way that venereal warts are so successfully treated.

Embryonic Adenomata are dealt with in the chapter on developmental defects (see p. 48).

**Papilloma.** Wart-like growths are occasionally found springing from the anal canal and surrounding skin, but do not arise from the mucous membrane. They sometimes grow to a considerable size. I have removed a mass of this kind, close on half a pound weight, from the anus of a woman. In appearance and histological structure they resemble the venereal warts on the prepuce in the male and vulva in female, and like them probably have their origin in the irritation of gonorrhoeal or other acrid discharge; for this reason, as might be expected, they are more commonly met with in women, but are occasionally seen in the male sex (Fig. 117). They are much split up, producing a cauliflower appearance, and exude a thin discharge which is abominably offensive.

**Treatment.** When of small size, merely keeping the parts dry and dusting with calomel will cause them to shrivel up and fall away, but it is usually quicker and more certain to snip them off with scissors, care being taken not to remove too much of the skin from the base, for fear of producing stricture. Bleeding is seldom of any consequence, and



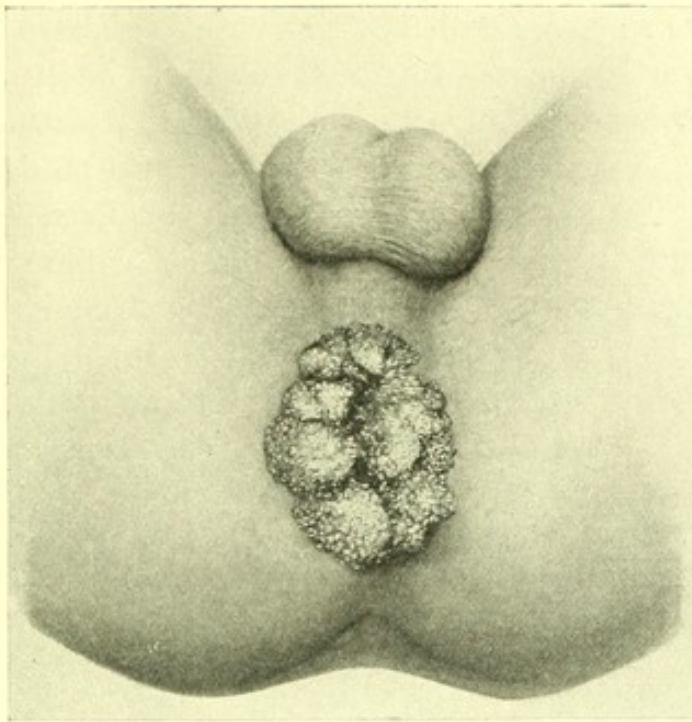


FIG. 117. Papillomatous Warts (Villous Tumour) of the Lower Portion of the Anal Canal in a Male.

The surface is covered with scaly epithelium.

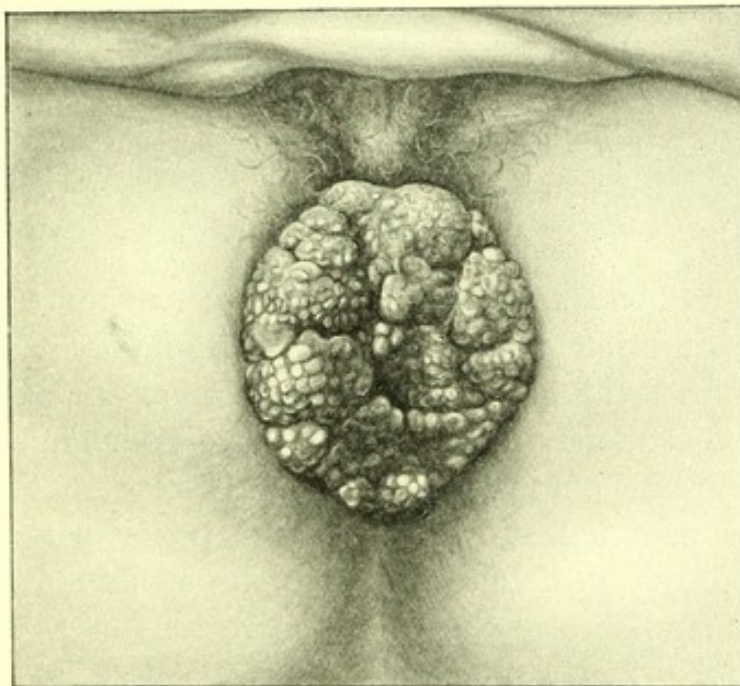


FIG. 118. Papillomatous Warts of the Anus in a Female.

(From stereo-photograph of a case at the Sir Patrick Dun's Hospital.)



the cure is complete if care is taken to keep the parts dry afterwards. They may also be removed satisfactorily with the sharp curette; it is an assistance often in these cases to freeze the warts with ether or anesthetic, they then break away easily with the curette, without injuring the underlying skin.

**Fibroma.** Tumours composed mainly of loose connective tissue are not infrequent in the rectum, and like the simple adenomata are often more or less pedunculated; they are usually associated with piles, and in a great majority of cases are directly formed from internal piles. If a series of cases of internal piles are examined it will be found that

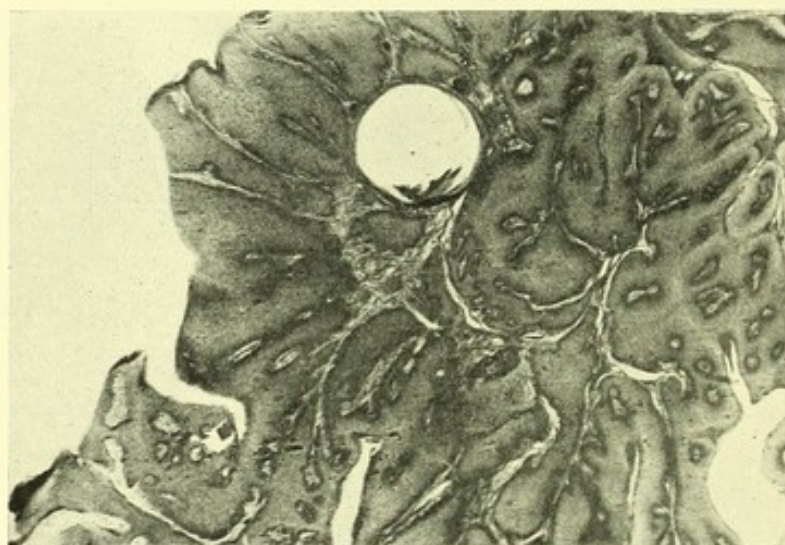


FIG. 119. Section of Anal Papilloma.

From the case illustrated in Fig. 122.

(Photo-micrograph,  $\times 42$ .)

fibroid change gradually takes place and becomes more marked in proportion to the duration of the disease, until finally the dilated veins entirely disappear, nothing but soft fibrous tissue remaining. When this has occurred the tendency is to become more pedunculated, or to form cylindrical worm-like outgrowths. Fig. 121 represents a well-marked example of the pedunculated form; in the upper portion is a fibrous tumour attached by a pedicle to ordinary pile structure; it was removed with four other similar growths from the rectum of a woman who had suffered from piles for twenty years. I have a series of pile sections taken from a large number of different cases, showing all gradations of this fibroid change by which an internal pile becomes a fibrous tumour.



The clinical evidence of this change is found in the colour and texture of the pile, both of which gradually become modified. Where piles have existed for a long time the bright red colour is lost, and when the fibroid change is complete they assume a yellowish-white appearance, the mucous membrane becoming more like skin, at the same time they become more solid to the touch. When once formed the tendency is

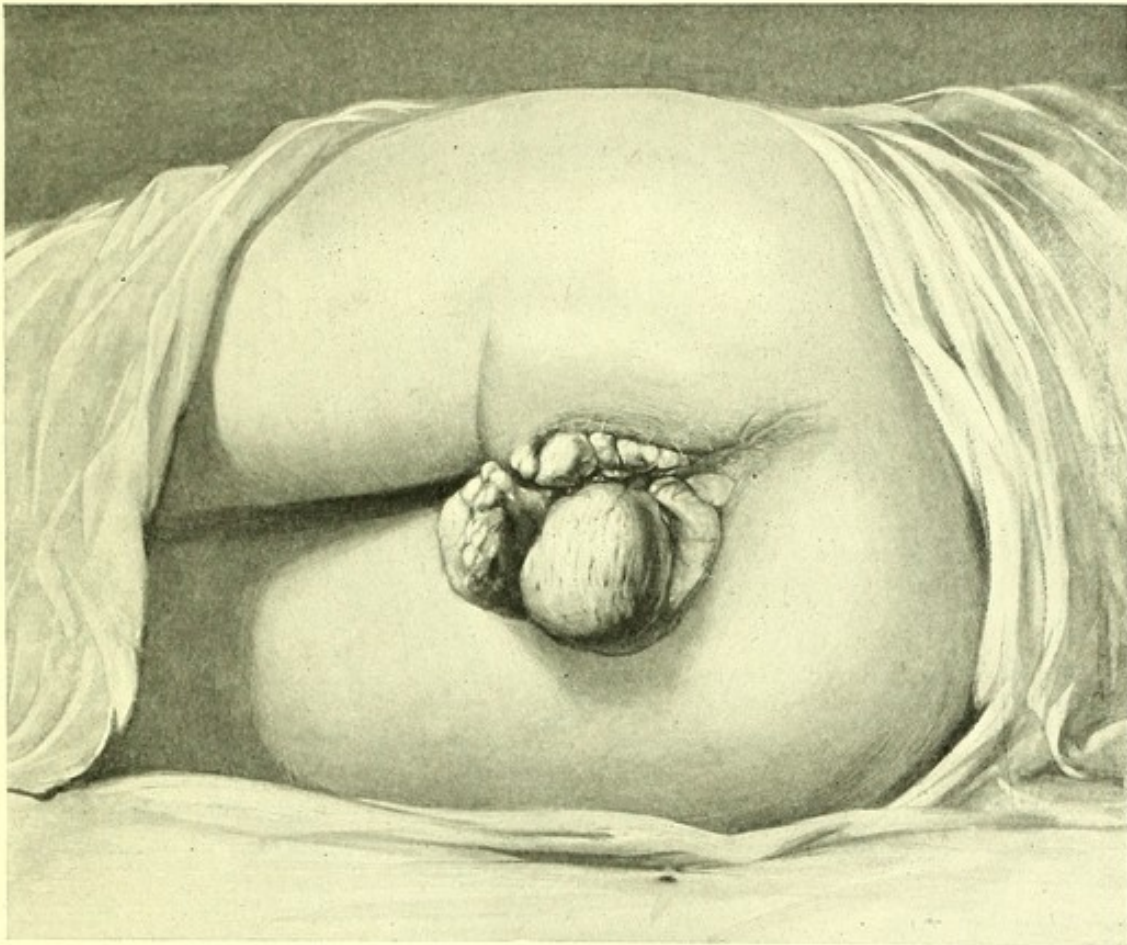


FIG. 120. Fibrous Tumours of the Rectum.  
(From photograph of case seen with Sir Kendal Franks.)

to slowly increase in size, and they sometimes after many years reach very considerable dimensions, as in the case (Fig. 120) which I saw in consultation with Sir Kendal Franks.

**Treatment.** The removal of soft fibrous tumours is to be carried out in the same way as internal piles, and owing to their diminished vascularity there is less trouble with haemorrhage.

**Fibro-myoma** in the rectum is rare, but when present it originates



in the musculature of the rectal tunic in the same way that similar tumours form in the uterus, and, like uterine fibro-myomata, they sometimes become pedunculated; they then hang loose in the lumen of the bowel, and have been recorded of considerable size. I removed one of these tumours from the posterior wall of the rectum; it was about the size of half a walnut, was sessile, and the mucous membrane was quite freely movable over the surface of it; in structure it resembled the familiar uterine fibro-myoma, and possibly was in an early stage of development and might eventually have become pedunculated as in

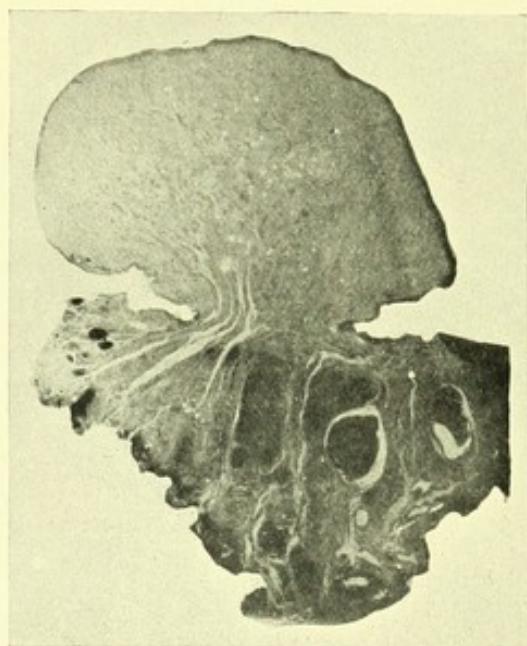


FIG. 121. Fibrous Tumour originating in a Pile that had existed many years.  
In the lower portion, typical pile structure is seen; in the upper, a soft fibroma  
attached by a pedicle.

(*Photo-micrograph*,  $\times 4$ .)

other recorded cases. The clinical diagnosis of such a case from sarcoma may be impossible, and I operated on the above case under the impression that it was of this nature, the free mobility of the mucous membrane over the tumour excluding the diagnosis of carcinoma.

**Angioma.** Vascular tumours of the rectum technically should include piles, but the characters of the latter are so special that it is convenient to consider this disease separately. In rare instances angiomas of the same character as naevi, and probably of congenital origin, are met with; a few such cases are recorded, but I have no personal experience of them: the most remarkable instance that I am



acquainted with is that described by Mr. Arthur Barker, *Medico-Chirurgical Transactions*, vol. lxvi. (Fig. 122.)

A healthy man, aged 45 years, stated that since boyhood he had difficulty in obtaining a motion when he was at all constipated, and that at these times there was bleeding from the bowel. Sometimes he remained free from these symptoms for several years at a time, his bowels as a rule being regular. A

careful examination of the wall of the bowel showed three shallow ulcers on the rectal mucous membrane, they were seated on some smooth longitudinal folds of the gut, of a yellowish colour, and suggesting a quantity of fat in the submucous tissue. The ulcers, though shallow, exuded continuously a considerable quantity of blood. Their base, however, presented a peculiar mottling of a purplish colour, as also did the surface of the irregular folds alluded to, the whole picture giving rise to the suspicion of a naevoid mass in the wall of the bowel. The statement of the patient that similar bleeding had occurred on and off since boyhood seemed to lend support to this view. The patient was afterwards admitted into University College Hospital, where the bleeding became of daily occurrence, and very copious, and, in spite of all treatment, he died of haemorrhage. At the *post-mortem* examination the wall of the rectum in its lower four and a half inches was found much thickened by a naevoid growth in its walls, which gave a purple colour to the mucous membrane. There were three or four prominent longitudinal folds, each three-quarters of an inch or more in width, the two largest being on the left side of the bowel. These were the folds felt during life, one of them just to the left of the middle line in front. Two ulcers, one of them about the size

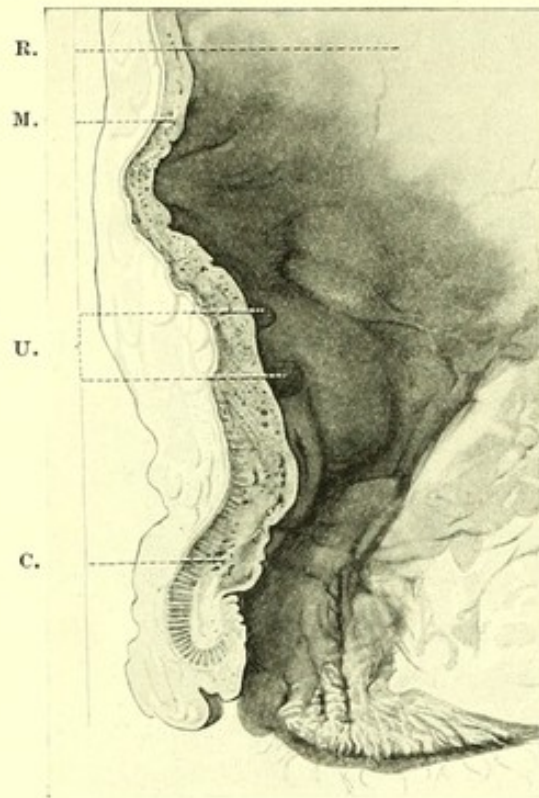

FIG. 122. Mr. A. E. Barker's case of Naevus of the Rectum.

R. Mucous surface of rectum. M. Cut edge of mucous membrane. U. Two ulcers upon the naevoid surface from which haemorrhage took place. c. Cavernous structure in section.



of a threepenny-piece, the other larger and somewhat irregular, were situated about two inches from the anus. The tumour everywhere presented the character of cavernous naevoid tissue.

**Lymphoma.**—Fig. 123 represents a section of a polypus, from a boy aged six, the subject of a prolapse of the rectum, at the apex of which two small growths, attached by short pedicles, were seen and removed. The general character resembled that of ordinary adenomata, but, upon minute examination, these were found to consist almost entirely of lymphoid tissue. Presumably they originated in the solitary glands of the mucous membrane. In the specimen illustrated apparently three of the solitary glands have grown together and greatly increased in size. They appear to have pushed their way through the mucous

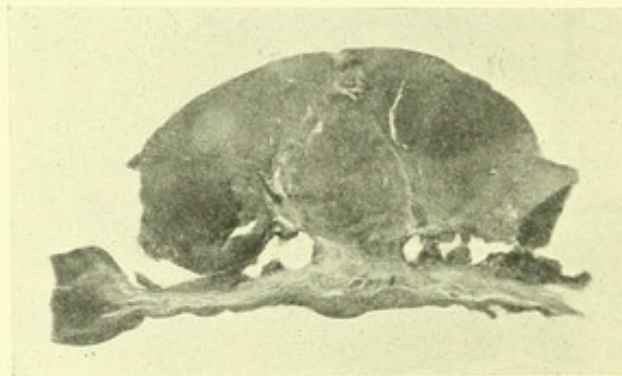


FIG. 123. Pedunculated Lymphoma, springing from the Mucous Membrane of the Rectum.

(Photo-micrograph,  $\times 4$ .)

membrane, small remnants of which may still be seen at several points in the section.

A few similar cases are met with in literature; possibly many have been overlooked, being mistaken for simple adenomata, to which they bear such a close resemblance.

**Lipoma** occurs in the interior of the rectum, as a more or less pedunculated growth, and a considerable number of cases have been described. Unless of a size sufficient to give rise to obstruction or prolapse, they do not appear to be characterized by any definite symptoms.

Cases are on record in which the tumours have been expelled by unaided efforts of the patient to defaecate. This, in all probability, is due to the fact that rotation of the pedicle has taken place, which causes rupture or strangulation. Virchow has shown that a similar rotation, and



final separation, sometimes takes place on the outside of the gut in the pedicles of fatty tumours, occurring in the appendices epiploicae, and he thus attempts to account for the occurrence of free lipomata in the peritoneal cavity. In some of the recorded cases the pedicles of rectal lipomata have been noticed to contain a tolerably large funnel-shaped process of peritoneum. This, taken with the fact that all the recorded cases appear to have descended from the sigmoid flexure, or upper part of the rectum, would possibly tend to show that these growths had originated in the appendices epiploicae, which had become inverted. Against this theory, however, is the fact that similar tumours are sometimes found in the small intestine. In colour they are described as being redder than the ordinary lipomata, but otherwise they present no characters different from the same growth occurring in other parts of the body.

The removal of these growths can be carried out in the same way as that of other pedunculated tumours, namely, by ligature and snipping off of the tumour. It is essential to remember how frequently there is a prolongation of peritoneum into the pedicle.

Fatty tumours under the skin surrounding the anus are similar to subcutaneous lipomata elsewhere.

**Teratomata and dermoid tumours.** Although tolerably commonly met with in the sacro-coccygeal region, and in the pelvis in connection with the genital organs, teratomata containing embryonic remains not normally met with at the hind end of the embryo, and therefore indicating foetal inclusion, have been but rarely described as occurring in the rectum proper. From the few recorded cases the two following remarkable instances may be quoted; the first is by Dr. Port (*Transactions of the Pathological Society*, vol. xxxi, p. 307, 1880). A girl, aged 16, had suffered for three months from painful straining and difficulty in obtaining an evacuation. A polypoid tumour of large size came partly out at the anus when the patient wanted to pass a motion, and a lock of long hair repeatedly made its appearance, and could only with difficulty be replaced. It was found that the tumour was attached to the rectal wall by two pedicles about three inches above the anal orifice. The tumour subsequently became completely extruded, when the pedicles were ligatured and the growth removed. It measured  $2\frac{1}{2}$  inches by 2 inches by  $1\frac{1}{2}$  inches, and the bulk of it was found to be made up of fibrous tissue, with numerous fat cells, and embedded



in it were two masses of bone, one hard and the other spongy. The coverings of the tumour showed all the characteristics of ordinary skin, i. e. epidermis, papillae, hair follicles, and sebaceous glands. The microscopical examination proved also the existence of numerous bundles of muscular fibres below the cutis. A canine tooth was observed growing from the tumour, near the pedicles.

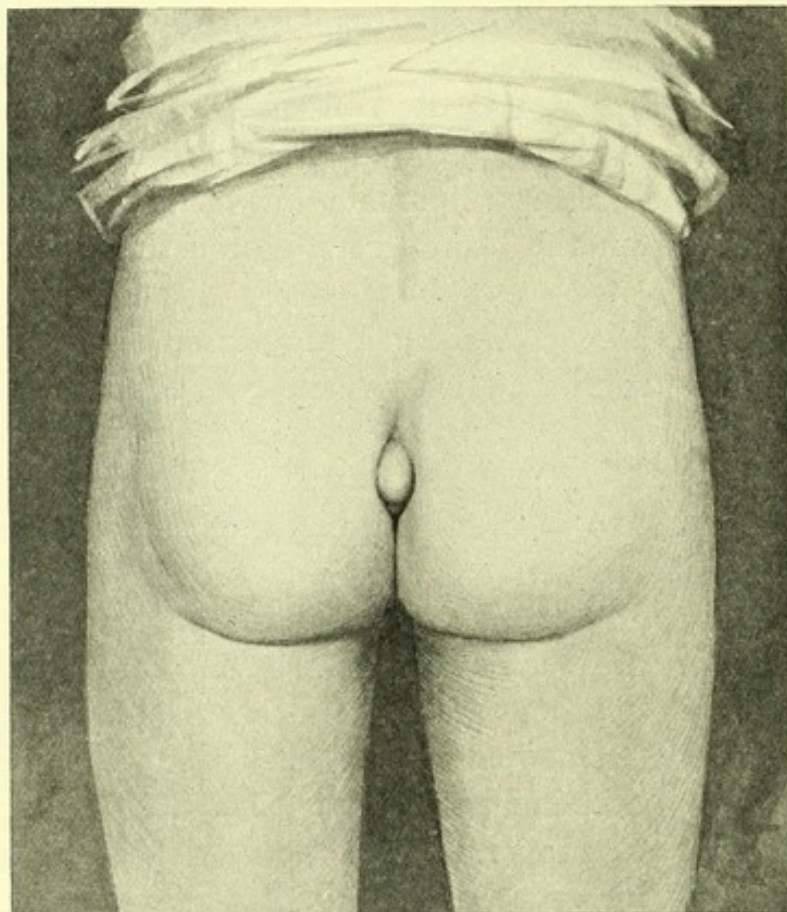


FIG. 124. Dermoid Tumour attached to the Coccyx.  
The result of inclusion of ectoderm, as the tail disappears.  
(From a stereo-photograph of a case under the care of Mr. T. E. Gordon.)

A somewhat similar case is described by Dr. Danzel (Langenbeck, *Archiv f. klin. Chirurg.*, p. 442, 1874). A woman, aged 25, complained of hairs protruding from the anus, which she pulled out when they became too long. They were found to spring from a polypoid growth about the size of a small apple, which was situated in the front of the rectum, about  $2\frac{1}{2}$  inches from the anal margin. The tumour was removed, and, besides the lock of hair, a tooth was found on the outside, and



microscopical examination demonstrated a bony capsule containing brain substance in the interior.

Dermoid cysts containing skin, hair, epithelial debris, with sebaceous matter, have been more frequently met with. The following case, which was under my care, is a good illustration of one of these tumours. A girl, who had some symptoms of rectal obstruction, was found to have in the left ischio-rectal fossa a tumour of considerable size ; it was closely related

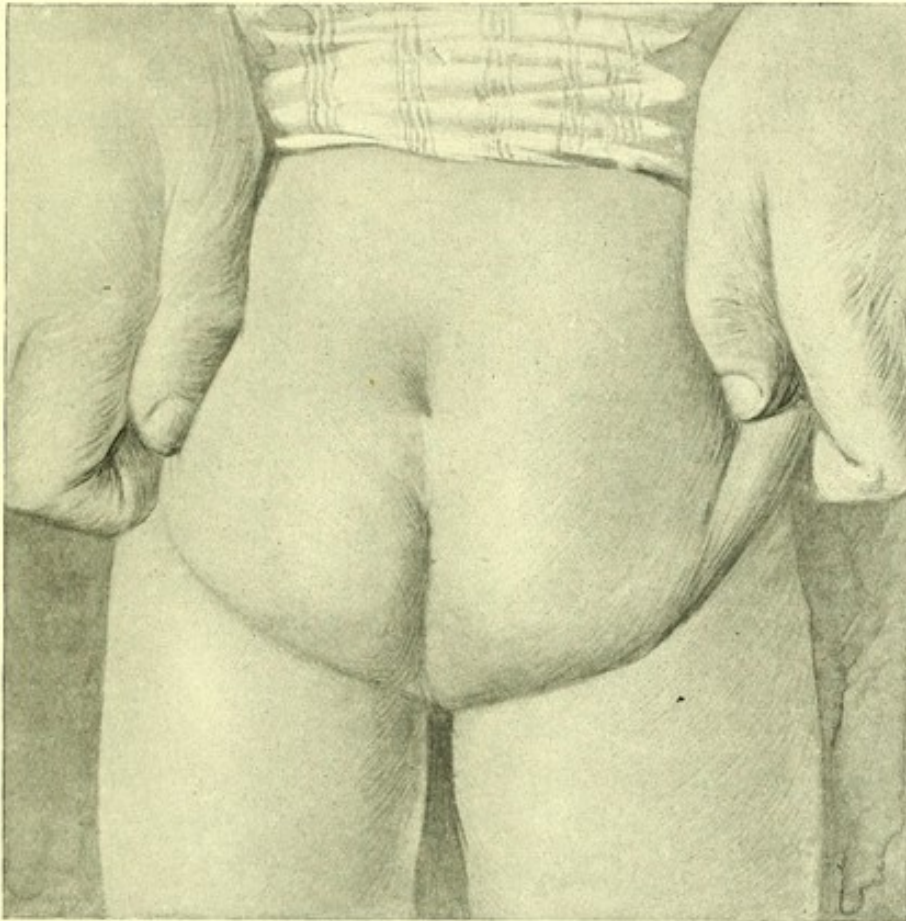


FIG. 125. Well-marked Coccygeal Dimple.

The result of hyper-involution of the tail.

(From a stereo-photograph taken of the brother of the case of dermoid tumour illustrated in Fig. 124.)

to the left side of the coccyx, and it invaded the recto-vaginal septum, compressing both canals against the walls of the pelvis and extending far into the pelvic cavity. It ruptured during removal, the contents being like bread-sauce, containing numerous hairs felted together. Difficulty was found in removing the higher ramifications of the cyst, and as a result a small sinus remained, which was only finally closed after it had been opened up and curetted several times.



The occurrence of a dermoid in this locality suggests that possibly the inclusion of epiblastic tissue from which it arose was produced at the time of the involution of the tail of the embryo, and it is probable that the coccygeal dimple which is so commonly met with is likewise caused by a hyper-involution of the embryonic tail. (Figs. 124, 125.)

**Atheromatous cysts** are sometimes met with in the skin surrounding the anus. They are usually of small size and of trivial importance.

Tumours containing **bone** and **cartilage** have been described. It is probable that they were associated with sarcomata, as is the case so often in connection with these tumours when found in other parts of the body.



## CHAPTER XVII

### CANCER

OF the various new growths which are found in the rectum, and which are clinically malignant, cylinder-celled epithelioma, or, as it is sometimes called, 'malignant infiltrating adenoma,' or adeno-carcinoma, is unquestionably the most common.

Subsequently we will discuss, as far as is at present possible, the pathological differences between the various forms of rectal tumour exhibiting malignancy, but as it is sometimes quite impossible to differentiate these varieties clinically, it will be convenient to retain the term 'cancer', using it in its broadest sense, as synonymous with all the forms of malignant tumour, whether histologically of epithelial or connective tissue origin. It is not necessary here to discuss the theories which have from time to time been put forward to explain the aetiology of cancer. Much has been written and said upon this subject, it still, however, remains an inscrutable mystery why it is that tissue in all respects apparently identical with normal epithelial structure should overstep its natural limits of growth and development, extend widely into neighbouring regions, appear as metastatic growths in other situations, break down and suppurate as a result of excessive and exuberant growth, recur after wide removal, and, lastly, produce that constitutional disturbance and rapidly-progressing marasmus known as the cancerous cachexia.

In order to arrive at some idea as to the frequency of rectal cancer, both relatively to the examples of the same disease in other parts of the body, and more particularly in other parts of the intestinal tract, it becomes necessary to consult large statistics. It is, however, quite useless to collect for this purpose a simple record of cases published in periodical literature, the returns of large hospitals alone affording reliable informa-



tion. From these it appears that of all cases of cancer about 4 per cent. are found in the rectum, and of cancer of the intestinal tract about 80 per cent. are found in the lower bowel.

The degree in which apparently similar forms of carcinoma exhibit the clinical features of malignancy varies notoriously with the situation in which the disease develops. Thus, for instance, epithelioma of the tongue is extremely malignant, whereas the same disease situated upon the lip is, at any rate in the early stages, one of the most benign of the unequivocal epitheliomata; similarly, epithelioma on the scrotum is very much more satisfactory to deal with than the same disease when occurring on the penis. Compared with other regions of the body, it would appear that the rectum is one in which the average intensity of the malignancy is not very great, the disease for a long time not passing the limits of the intestinal wall.

It is quite impossible to estimate accurately the duration of this disease, as the symptoms during the early stages are so slight that they may be scarcely sufficient to attract the attention of the patient. This will be a matter of familiar observation to all surgeons. It not infrequently happens that a patient comes to us complaining of some slight diarrhoea or other mild rectal trouble, and an examination unexpectedly reveals the fact that he is the victim of cancer so extensive that it must have obviously existed for a considerable period. And, again, the life of a patient is not infrequently sacrificed by the accidental complications of the disease, such as intestinal obstruction, or involvement of the bladder or ureters, rather than by the progressive marasmus, which is the usual mode of termination of cancer of other regions.

Probably two years is about the average duration of life from the time that the disease is first recognized in cases that have not been operated on.

Some authors state that as the result of their experience a greater number of males suffer from rectal carcinoma, while others assert that the opposite is the case. Large statistics, however, show that there is extremely little difference in the relative frequency.

Although essentially a disease of middle life and old age, rectal cancer has been met with many times under the age of 20 years. Personally I have seen three such cases at the ages of 16, 18, and 19 respectively, and, as noticed in other parts of the body, these cases of precocious cancer are usually furiously malignant.



**The pathology of cancer of the rectum and anus.** The older method of classification of tumours into benign and malignant, although of great practical utility, was soon found to be insufficient, for although the difference between typical varieties was sufficiently obvious, cases were met with on the borderland between the two which it was impossible to refer to either with certainty, and for these the class of semi-malignant tumours was introduced. Since the clinical classification has given place to the histological, it does not appear that the exact limitation of the groups is thereby rendered in some instances more definite, and this is notably the case in cancer of the rectum. The clinical differences between the simple adenoma, or mucous polypus of the rectum, and cylinder-celled cancer of that organ, are sufficiently obvious, the simple adenoma generally occurring in young persons, being attached by a long pedicle, not tending to recur after removal, or to affect the constitution. The cancer, on the other hand, is sessile, it tends to infiltrate deeper parts, to break down and ulcerate, to profoundly affect the constitution, to recur after removal, and to produce metastatic growths of similar character at a distance from the original site. Now when these growths are examined under the microscope they both consist essentially of the same tissue, namely the glandular structure of the mucous membrane, such as is normally found lining the Lieberkühn follicles of the intestine, the principal difference being that in the benign form there is a tendency to project into the lumen of the bowel, and to draw down a pedicle of normal mucous membrane, while in the cancer the wall of the intestine is from the very first infiltrated with the new formation. First, the muscularis mucosae becomes perforated, then the sub-mucosa invaded, and subsequently the muscular coat itself is infiltrated, so that the chief histological difference between these growths is really one of situation, and of relation to surrounding tissues, more than of structure. In cases, however, of somewhat rapid growth the cells become more irregular in shape, more crowded in the acini, and more embryonic in type, but this is not invariably the case.

**Varieties of malignant disease.** Of cancers originating within the rectum adeno-carcinoma or cylinder-celled epithelioma is the only form of carcinoma met with. When commencing in the lower segment of the anal canal it is of the usual scaly-celled epitheliomatous form found in skin cancer in other parts of the body, and sarcoma in some of its various forms is occasionally met with in the rectum, but it may be taken



that 95 per cent. of all cases of malignant disease in this region are adeno-carcinomata.

**Clinical types of carcinoma.** Clinically, adeno-carcinoma, as met with in the rectum, presents one of two tolerably distinct types: (1) (Fig. 126) Commences as a flat tubercle in the mucous and submucous tissue; it increases somewhat rapidly by exuberant growth at the margin, while the centre breaks down and forms a crateriform ulcer; it tends to spread round the circumference of the bowel somewhat more rapidly than it extends in the vertical direction, thus making an oval ulcer.

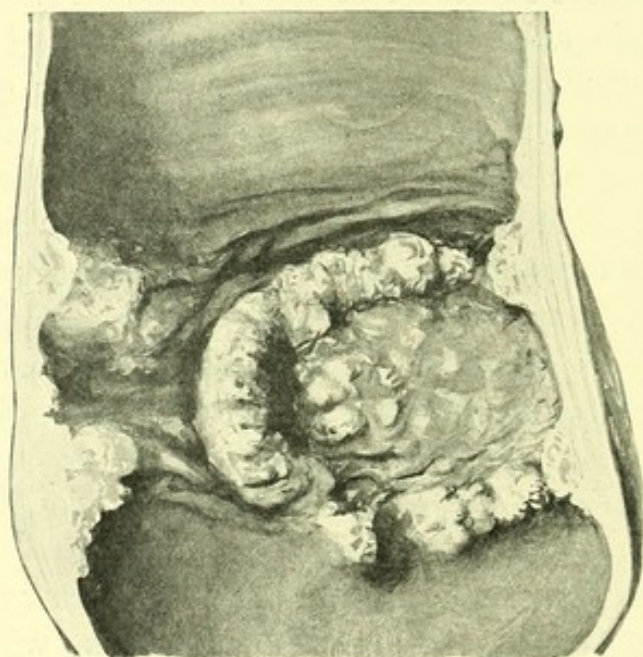


FIG. 126. Tuberos Adeno-carcinoma of the Rectum.

The growth has broken down into a crateriform ulcer in the centre and spread round almost the entire circumference of the bowel, but has not as yet extended to the peri-rectal tissues. The infiltration of the wall of the rectum is well seen where the bowel has been opened.

*(From a specimen removed by sacral operation.)*

Perforation of the muscular coat occurs early, with involvement of the surrounding structures and pelvic lymphatics, and the disease runs a somewhat rapid course. This is the form more commonly met with in comparatively young subjects. (2) (Fig. 127) Commences as a more superficial ulceration, and has not the exuberant edges met with in the other variety, the adenomatous tissue of the new growth is less in quantity and more atrophic, but there is a considerable formation of dense connective tissue surrounding the ulcerated surface, which tends to contract and narrow the lumen of the bowel, producing intestinal



obstruction, which indeed may be the first symptom to draw attention to the disease. This apparently is the schirro-contracted rectum of the older writers; it runs a much more chronic course, and is usually met with at a more advanced age than the first variety, but all grades between these two typical forms are often met with.

If a section be made of the growing edge of an adeno-carcinoma

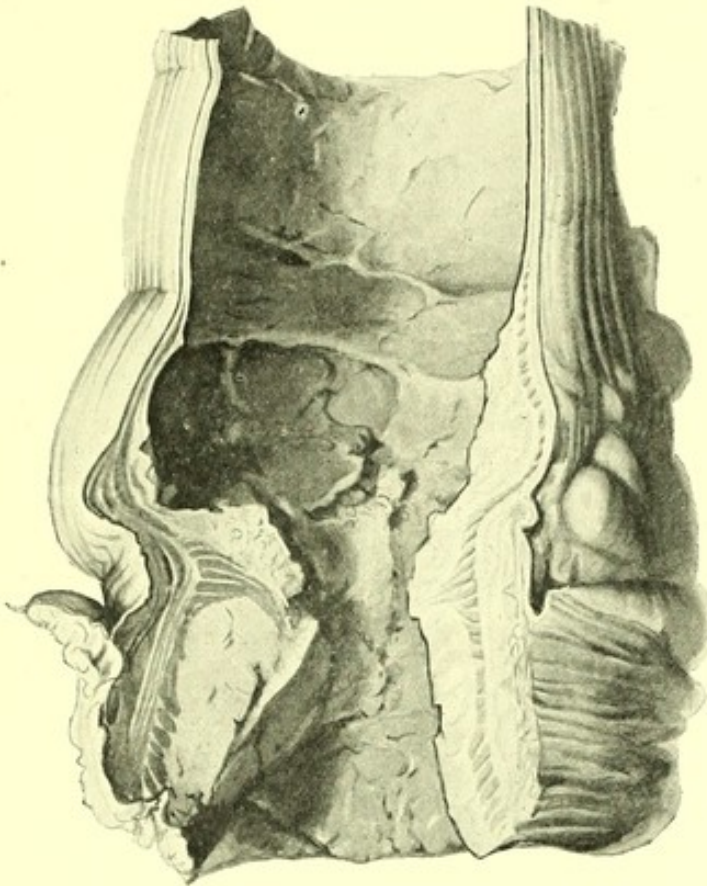


FIG. 127. Atrophic Adeno-carcinoma of the Rectum.

The disease produced a tight stricture. On the right-hand side of the illustration enlarged lymphatic glands are seen underneath the peritoneum.

*(From a specimen removed by sacral operation.)*

it will be found that there is a considerable proliferation of the mucous glands, that the adenomatous tissue breaks through the muscularis mucosae and spreads in the submucous tissue separating the bundles of muscular fibres, constituting the essential characteristics by which adeno-carcinoma is distinguished from the non-malignant form. It eventually perforates the entire thickness of the intestinal tunic and spreads in the tissues of the pelvis, any of which may become implicated in the growth.

The lymphatics soon become involved; first the glands at the back



of the rectum, then those along the great iliac vessels, the glands in the groin escaping involvement except where the skin of the anal canal is encroached upon, or at a late period where there is a widely diffused contamination of the lymphatic system. Next in order of frequency to the lymphatic system, metastatic growths are met with in the liver, and they occasionally have been observed in the lung and elsewhere, but wherever found they reproduce accurately the original type of disease—

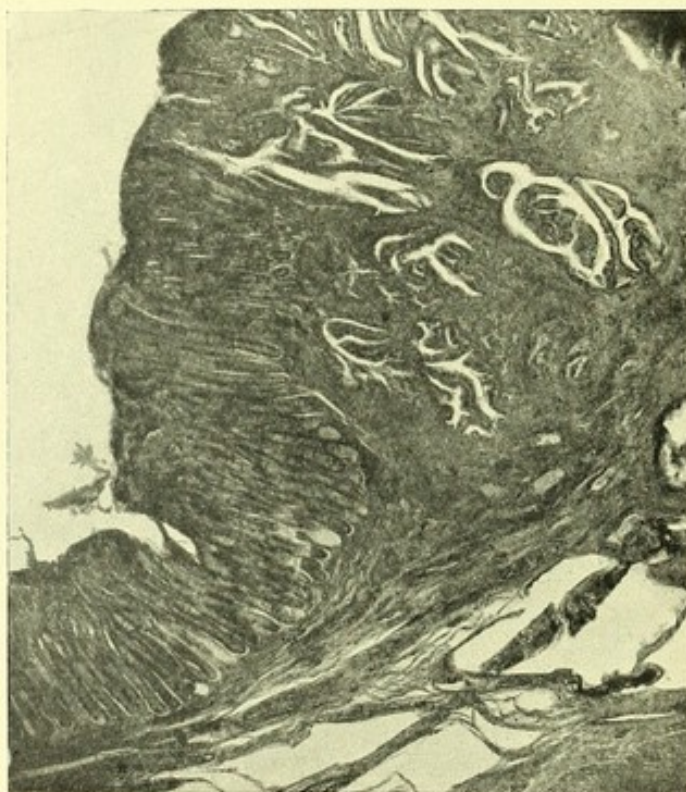

FIG. 128. Section of the edge of a Tuberos Adeno-carcinoma of the Rectum.

To the left-hand side of the section normal mucous membrane is seen. To the right, great proliferation of the gland tissue which has grown through the basement membrane into the submucosa.

(*Photo-micrograph, × 70.*)

namely, an arrangement of adenomatous tissue similar to that met with normally in the Lieberkühn follicles of the intestine.

Associated with adeno-carcinoma it is not uncommon to meet with polypoid growths which, from their pedunculated growth and freedom from involvement of the deeper structures, are essentially benign tumours; these may either be of the tuberculated character commonly found, or the tumour may be split up so as to be formed of a mass of



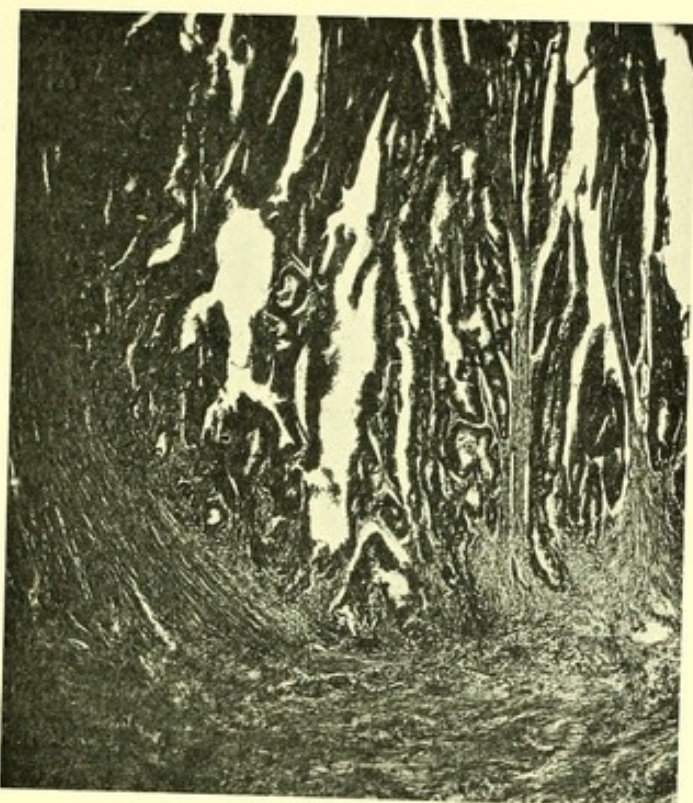


FIG. 129. Infiltration of the Muscular Coat of the Rectum by Glandular Epithelium in a case of Cancer.

(*Photo-micrograph, × 30.*)

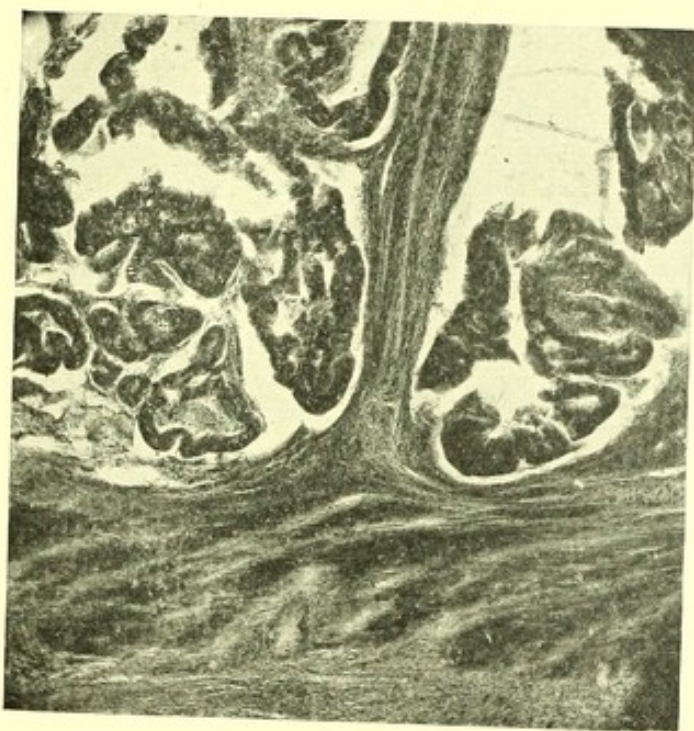


FIG. 130. Infiltration of the Muscular Coat of the Rectum by Glandular Epithelium in a case of Cancer, more highly magnified.

(*Photo-micrograph, × 100.*)



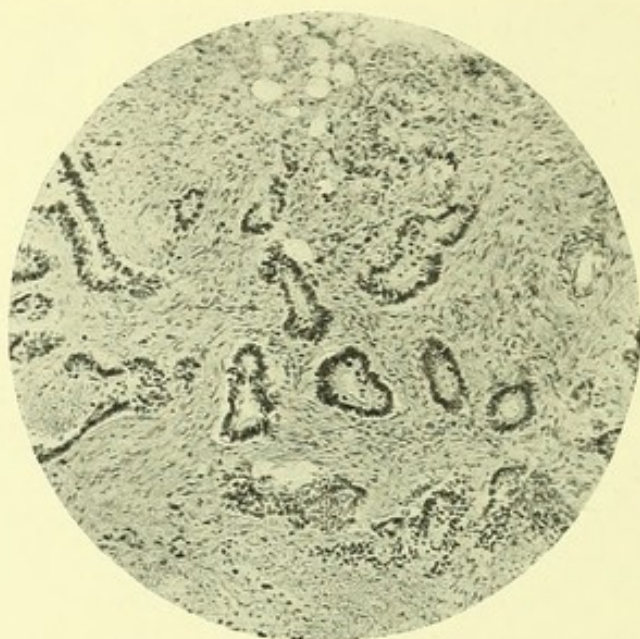

FIG. 131. Cancer of Lymphatic Gland secondary to Adeno-carcinoma of the Rectum.  
(*Photo-micrograph*,  $\times 30$ .)

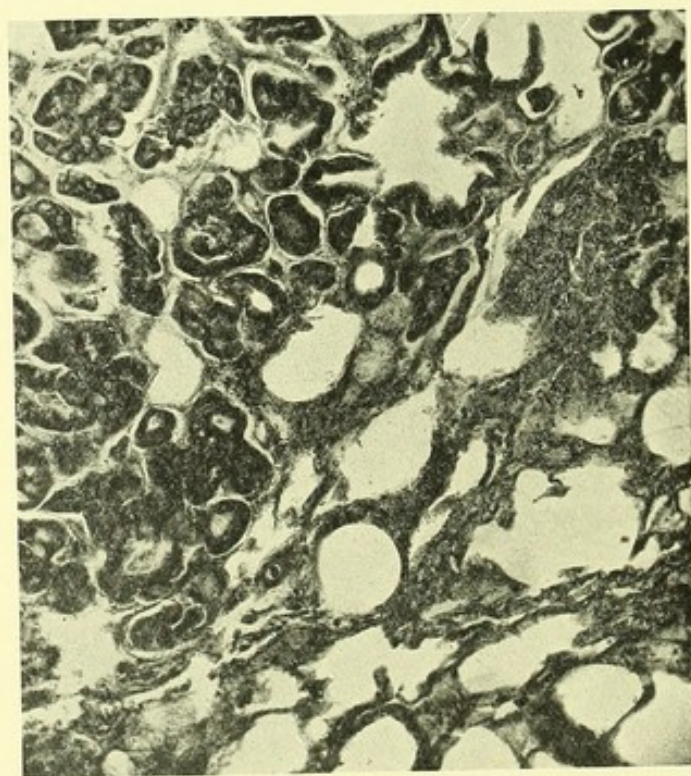


FIG. 132. Secondary Cancer of the Lung. The primary cancer was in the rectum.  
To the left above is seen the characteristic glandular epithelium of  
intestinal adeno-carcinoma.  
(*Photo-micrograph*,  $\times 100$ .)



filiform processes, the so-called villous growth. It appears probable that these neoplasms are the result of the direct irritation of the discharge from the cancerous ulcer.

A certain amount of mucoid degeneration which is not sufficient

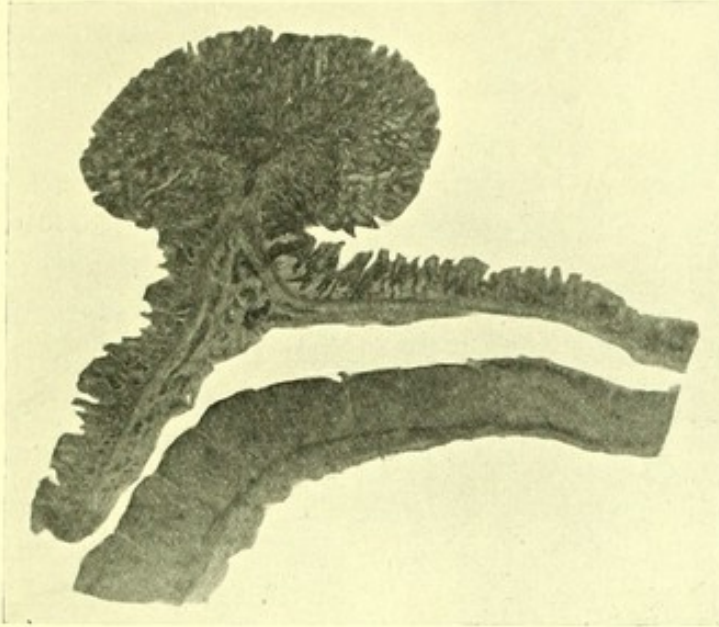


FIG. 133. Simple Adenoma found in connection with a typical Adeno-carcinoma of the Rectum.

The benign character of the growth is indicated by the way the muscular coat has separated from the mucous coat in preparing the specimen.

(*Photo-micrograph*,  $\times 8$ .)

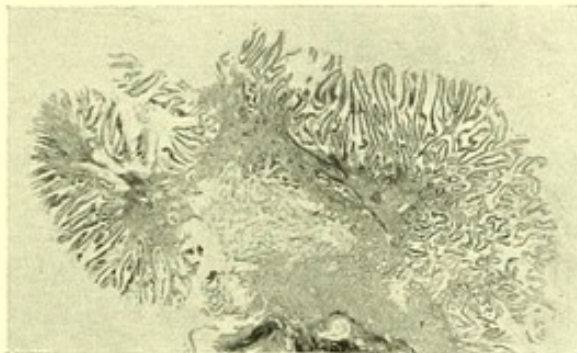


FIG. 134. Simple Villous Adenoma found in connection with typical Adeno-carcinoma of the Rectum.

(*Photo-micrograph*,  $\times 4$ .)

to produce well-marked clinical symptoms is frequently found in the histological examination of intestinal cancers, while in a small percentage of cases it will be found that adeno-carcinoma of the rectum has undergone mucoid degeneration, which is characterized by a somewhat wide



infiltration of the tissues by a smooth gelatinous material. Clinically the importance of this condition is that it is liable to be mistaken for tertiary syphilis, but the latter is usually characterized by much greater density and firmness to the touch, and it more frequently implicates the anal canal.

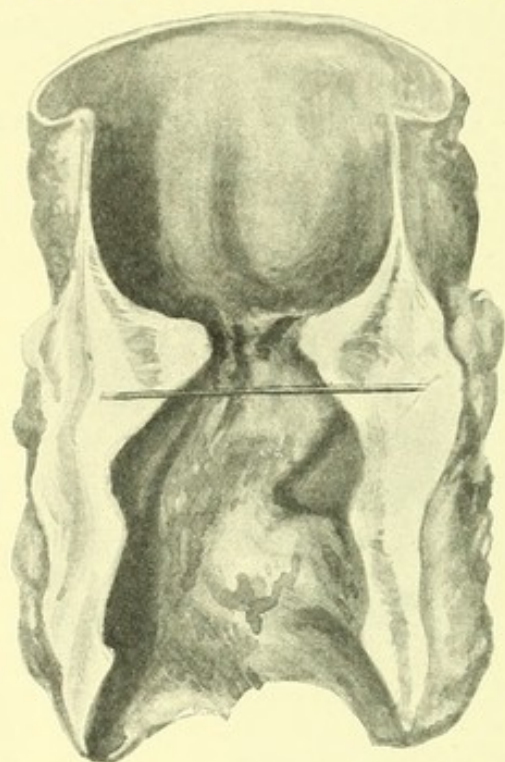


FIG. 135. Mucoid Degeneration of Adenocarcinoma of the Rectum producing tight Stricture.

The dilatation of the intestine above the stricture is well marked.

(From a specimen removed by sacral operation.)

I have had two well-marked cases of colloid or mucoid cancer under my care; the first (Fig. 135) formed a long tubular stricture of the rectum about 4 inches in length, all the coats of the bowel were widely infiltrated and the lower portion was ulcerated, the intestine above the stricture being greatly dilated. The growth was removed by sacral route, but the disease recurred a few months subsequently. The second occurred at the upper portion of a cicatrix following an operation for fistula; it

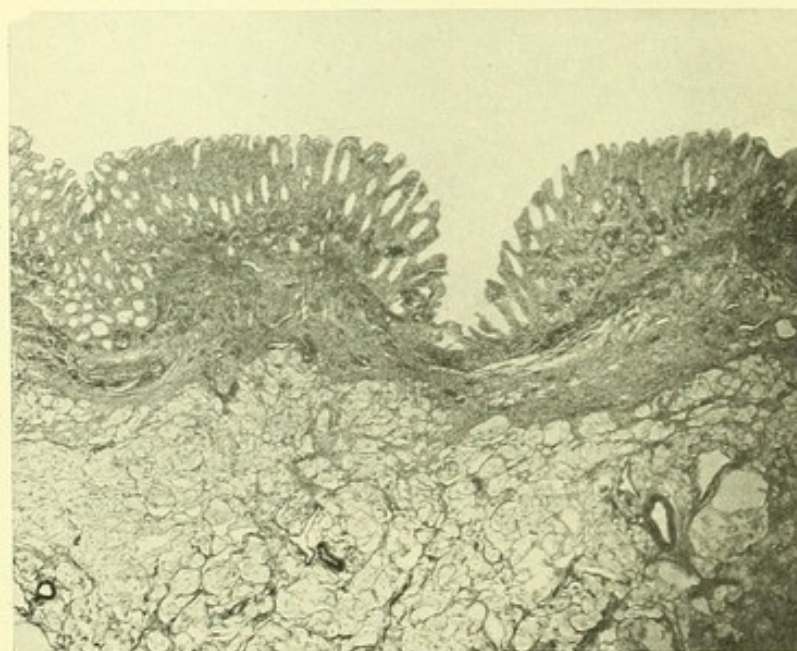


FIG. 136. Section of Mucoid Degeneration of Adenocarcinoma of the Rectum.  
(Photo-micrograph,  $\times 14$ .)



was readily removed and the patient was free from recurrence three years afterwards.

There can be no doubt that simple adenoma after existing for a considerable time may infiltrate the deeper structures and become cancerous (see p. 214).

**Sarcoma.** The second great class of malignant neoplasms, coming, in order of frequency, after the carcinomata, are those tumours the bulk

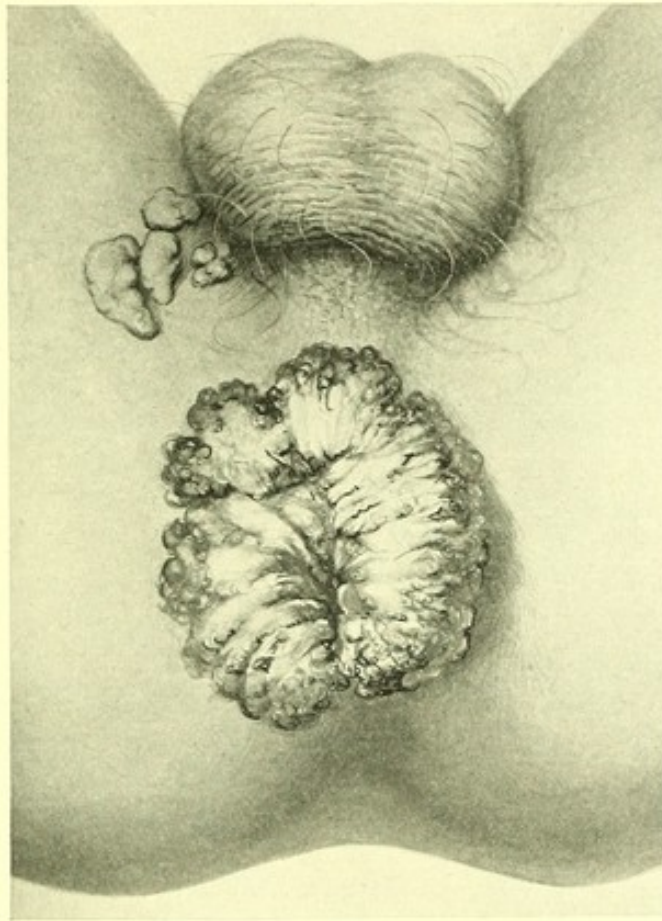


FIG. 137. Sarcoma of the Anal Canal and Skin on the inside of the Right Thigh.  
(*Drawn from a specimen in the Museum of the Royal College of Surgeons in Ireland.*)

of which is composed entirely of embryonic connective tissue, but sarcomata are rare in the intestinal tract.

In the Museum of the Royal College of Surgeons in Ireland are two very remarkable examples of sarcomatous growths. In the first (Fig. 137) there is projecting from the anus a large mass, which measures 5 inches by 4; it is much lobulated on the surface, presenting somewhat the appearance of an ordinary papilloma of this region. It differs,



however, in this, that the individual lobules are much larger, and the intervening depressions much shallower; a small group of secondary growths appears near the scrotum, in the skin of the thigh, and the disease extends up into the rectum for a distance of about 2 inches. There does not appear, however, to have been any obstruction, as the tube was quite pervious behind the growth. There is, unfortunately, no reliable history with this specimen. Dr. P. S. Abraham, the late curator

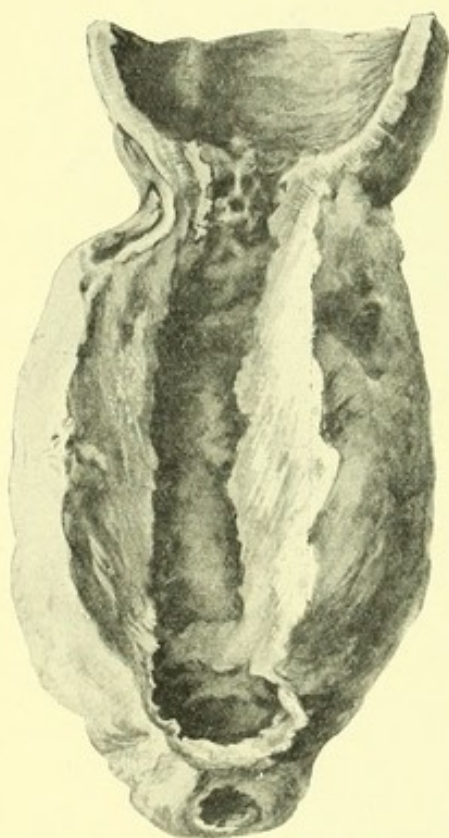

FIG. 138. Long Tubular Stricture caused by Infiltration of the Rectum with Spindle-celled Sarcoma.

(From a specimen in the Museum of the Royal College of Surgeons in Ireland.)

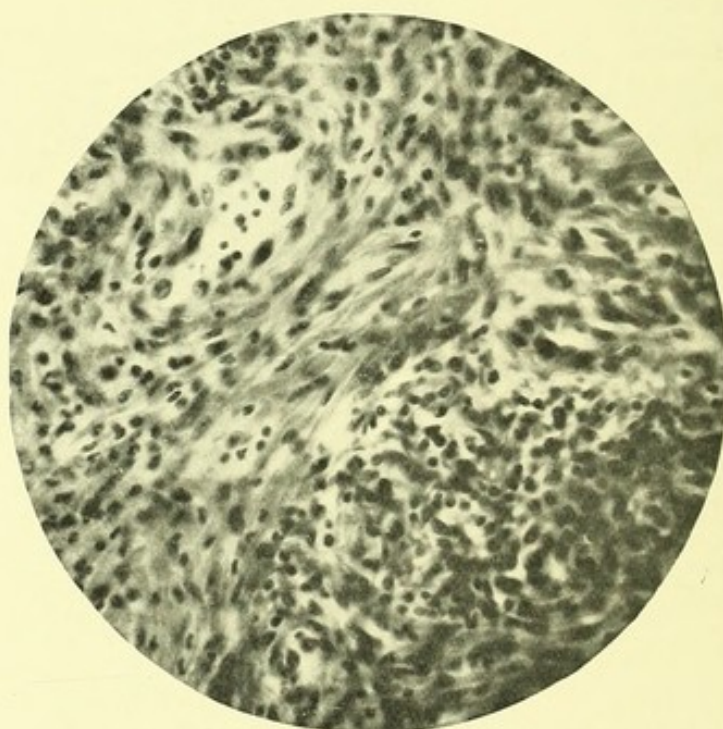


FIG. 139. Spindle-celled Sarcoma of the Rectum.  
(Photo-micrograph,  $\times 170$ .)

of the museum, kindly undertook a detailed examination, and he made microscopic sections from the mass inside the rectum, from the external growths, and from the secondary formations. In all of them the appearances were practically identical; there was no trace of proliferating mucous membrane, almost the entire of the sections consisting of small spindle cells, with but little fully developed connective tissue.

The second specimen is one in which a long tubular rectal stricture



exists, commencing about 1 inch inside the anus, and extending upwards for a distance of 5 inches. All the coats of the bowel appear to be lost in the growth which surrounds the intestine evenly, and which measures 1 inch in thickness at the middle portion. Above the neoplasm the intestine is widely dilated, showing very clearly that during life the degree of obstruction must have been considerable. Microscopic examination showed this also to be a case of spindle-celled sarcoma.

A third case was recently under my care. The clinical symptoms were those of adeno-carcinoma, and it was removed by the sacral route. It proved more extensive than was suspected, and I was not satisfied that its removal was quite complete. Recurrence took place within six months after operation. Except that it was much lighter in colour, the macroscopic appearances after removal were those of adeno-carcinoma, but microscopic examination showed it to be a typical sarcoma. (Fig. 139.)

Tumours of the type known as lympho-sarcoma have been occasionally described in various parts of the intestinal tract. In 1884 a case of this kind was under my care. A man aged 60 complained of difficulty in getting his bowels to move, and a tumour was felt in the hollow of the sacrum, apparently involving the outer rectal tunic, but the mucous membrane was freely movable over it. An attempt was made to remove it by incision of the posterior wall of the rectum, but it was not completely extirpated, as it was found to infiltrate widely the muscular coats of the rectum and surrounding structures. The patient died of septic peritonitis. At the *post mortem* the pelvic and lumbar lymph-glands were found much enlarged. Microscopic examination showed the case to be one of lympho-sarcoma.

**Melanotic sarcoma.** Primary intestinal melanosis is rare in the human subject, although, as long ago pointed out by Virchow, it is frequently met with in horses, especially white ones. The published

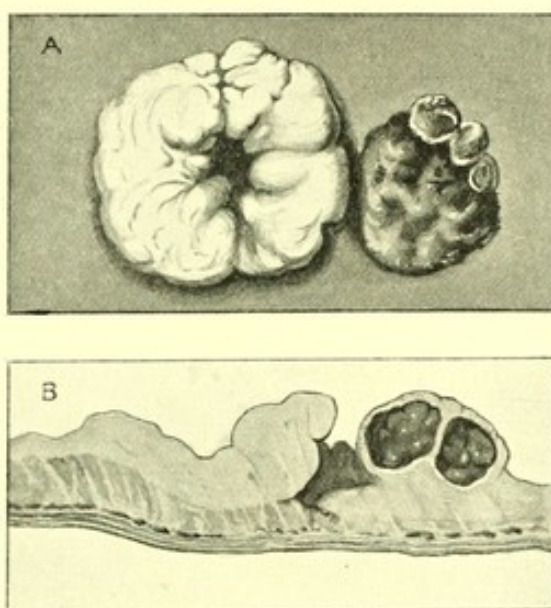


FIG. 140. Melanotic Sarcoma of the Rectum.  
(From a specimen removed by excision.)



records of cases of this disease in the human subject show that it more frequently occurs at the anus than within the rectum, and that it is usually actively malignant. In November, 1884 (*Transactions of the Royal Academy of Medicine*), I published a remarkable case of this disease. A female aged 60 complained of pain during defaecation, slight discharge of bloody mucus, and the protrusion of a 'lump' after the bowels moved, which had lately increased in size. Digital examination revealed the presence

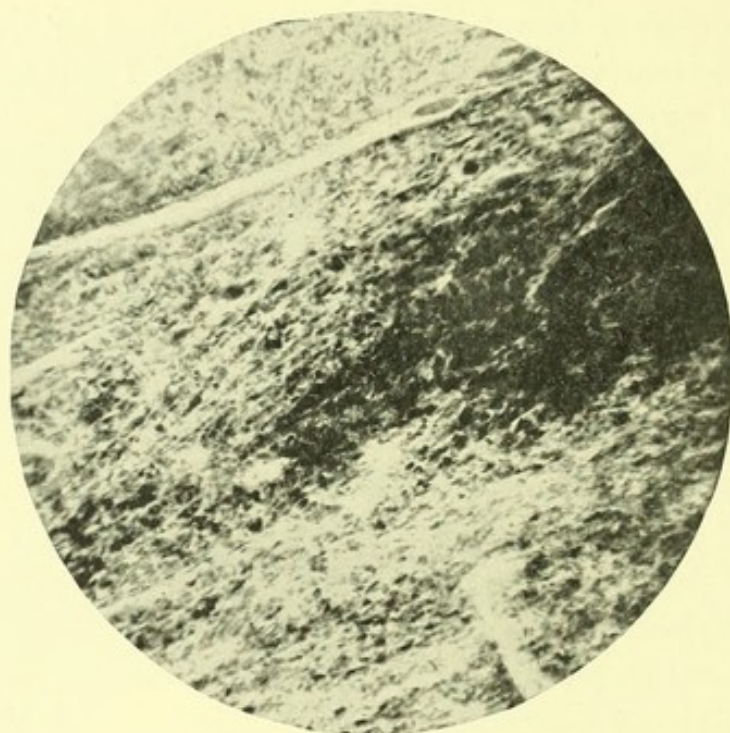


FIG. 141. Section of Melanotic Sarcoma of the Rectum.

From the case illustrated in Fig. 145.

(*Photo-micrograph*,  $\times 112$ .)

of three isolated tumours on the anterior aspect of the rectal pouch, all of them well above the anal canal. The anterior portion of the rectum with the three tumours was excised; they proved to be sarcomata, two of them being quite black from the deposit of melanotic pigment. Contrary to usual experience in multiple melanotic sarcomata elsewhere, there was no recurrence. The woman died ten years afterwards of acute pneumonia, without the slightest evidence of further appearance of tumours in the rectum or elsewhere.

Cancer of the anus is not very common. When originating in that portion which is covered by scaly epithelium, it is usually of the type



of epithelioma, found in cutaneous cancer elsewhere. It occasionally commences in the cicatrix of a previous surgical operation, and may then resemble the well-known warty epitheliomata of cicatrices found in other parts of the body.

True rodent ulcers probably occasionally attack the skin of the anal region, but the great majority of cases recorded formerly under this title were in all probability really tubercular (see p. 76).



## CHAPTER XVIII

### CANCER. SYMPTOMS

As in cancer of other parts of the body, **pain** is a prominent symptom at a certain period of the disease, but in the early stages it is in many instances exceedingly slight, usually while the disease remains confined to the interior of the rectum, and before the anus or the pelvic contents have been encroached upon. So trivial is the pain, that in some instances patients consult a surgeon on account of some slight discharge from the anus or sense of uneasiness in the rectum, and an examination reveals the fact that a very extensive neoplasm is present, which must have existed for months previously. I was consulted by a gentleman who complained of slight oedema of left arm, pain down right leg, with some loss of sensation over the area supplied by the anterior crural nerve. He never had diarrhoea, his bowels moved every day without pain, but on one or two occasions he had passed a little blood. He had a hard mass in the right iliac fossa, enlarged inguinal glands on the same side, and enlarged glands in the left axilla. He ridiculed the idea that he had anything wrong with his rectum. Nevertheless, I found upon making a digital examination that the whole pelvis was filled with a mass of rectal cancer. This freedom from pain is no doubt due, as Hilton has pointed out, to the characteristics of the upper part of the normal rectum—i. e. its great distensibility and little sensibility, conditions the physiological reason of which is obvious. In the immediate neighbourhood of the anus these conditions are reversed, and, as might be expected when this region is involved in the disease, the pain experienced is considerable. It will be within the experience of most surgeons to have met with cases of malignant disease of the rectum in which for months, or even years, trivial pain alone is complained of. Sooner or later, however, pain becomes a prominent symptom, and is frequently very intense. In



no locality, not even excepting the tongue, is the suffering sometimes more severe. The pain may be due to four distinct causes, and the character of the suffering in each case is quite distinct. (1) The disease may involve the anus, where owing to the abundance of cutaneous nerves and continued motion of the part, the pain will be severe. (2) As the cancer extends beyond the limits of the intestinal tube, the nerves of the sacral plexus may be encroached upon, which may result in violent neuralgia, or in painful cramps of the muscles of the lower extremity. It is well to bear this always in mind, as not infrequently an attack of (so-called) 'sciatica' has been the first indication of a cancerous rectum. (3) Obstruction, when situated in the rectum or lower part of the sigmoid flexure, is followed by a considerable amount of pain, which is always of a paroxysmal character, and associated with frequent efforts to defaecate. (4) Implication of the bladder will be of course associated with considerable suffering, especially if the disease has progressed so far as to form a fistula and permit the flow of faeces and flatus into the bladder, or of urine into the rectum.

**Bleeding** is a symptom which is seldom altogether absent, and on the other hand is not often severe. It commonly follows the passage of hardened faeces, and may be taken as an indication that ulceration has commenced. A certain amount of discharge also is a common result, frequently bloodstained and abominably foetid. At a later stage this discharge, mixed with thin faeces, comes away through the patulous anus, the relaxed sphincters having lost all power of control. The skin about the neighbourhood becomes excoriated, constituting by no means the least of the miseries to be endured by the sufferer.

**Diarrhoea** may alternate with constipation, or be continuously present, and is often the earliest symptom which attracts attention. Every case of diarrhoea, or so-called dysentery, which has become at all chronic, should be examined by the rectum, and in not a few the cause will be found to be a malignant growth. I have several times seen cases which had been treated for diarrhoea for considerable periods which owed their origin to this cause. The importance of making an early examination in these cases cannot be overestimated. Early diagnosis is of greater importance here probably than elsewhere, the great majority of cases not coming under the notice of the surgeon until the disease is so far advanced that the hope of successful operative treatment can no longer be entertained.



**Obstruction.** As has been before pointed out, narrowing of the intestinal tube, sufficient to retard the passage of faeces, may be due to two distinct causes in cancer, either the neoplasm may by its exuberant growth obstruct the calibre of the bowel, or in the more chronic form the cicatricial contraction may form a true stricture of the gut. In either case the symptoms will be similar.

Stricture of the rectum produces symptoms, in some respects, differing from those met with in obstruction of the intestine higher up. The continuous straining and tenesmus which is so marked in the former is less marked in the latter, while vomiting of faecal matter, which comes on tolerably soon when the small intestine is completely stenosed, may not appear for a very long time when the rectum is occluded. In some of the recorded cases complete obstruction was continuous for many weeks or even months before continuous and faecal vomiting supervened.

Cancerous obstruction, which may have existed for some time, may eventually give way, and an exit be established for faeces through the rectum again, or by an alternative route. In the first instance, the neoplasm may slough to such an extent that the bowel will become pervious again, or, ulceration of the bowel above the obstruction may lead to perforation and the formation of stercoral abscess, which may again open into the bowel below the cancer, thus affording a new, though not very efficient, route for the faeces.

Where an opening of sufficient size forms into the vagina, the more urgent symptoms of obstruction may be relieved, but the patient is left in a truly miserable state, but where the opening takes place into the bladder, no sufficient exit for faeces will be by this means provided, and the urgency of the obstruction will continue, while at the same time the other symptoms will be much aggravated. Ulceration opening into some of the pelvic viscera in this way may be due to breaking down of the neoplasm itself, or it may be due to the distension and irritation of faeces above the obstruction, the ulceration then being of a simple character. This form of stercoral ulceration may take place at a long distance above the seat of obstruction, several cases being recorded where the caecum has given way and produced a fatal peritonitis, in consequence of the dilatation due to obstruction of the rectum by cancer. At other times nature has attempted to overcome the obstruction by the formation of an artificial anus at some part of the cutaneous surface, but such cases are of extreme rarity, and likely only to give a very



inefficient relief to the obstructed gut. Smith (*Surgery of Rectum*, 1872) gives a case in which an extravasation in this way found its way into the hip-joint. Faecal abscess, the result of perforation, may form in the pelvis, escape into the buttock and assume very large proportions.

**Involvement of lymphatics.** The glands first affected, if the disease does not implicate the anus, will be the pelvic and lumbar systems. The former may possibly be felt through the walls of the rectum, and the latter occasionally by deep abdominal palpation.

When secondary tumours have formed in the liver, there may be indication of its increase in size, and possibly, if the abdominal wall be thin, the surface may feel irregular and knobby.

Oedema of either leg is a symptom occasionally present in the later stages, and is usually of grave import as indicating an involvement of the iliac vein in the disease. In common with all forms of cancer, the peculiar cachexia soon becomes obvious, and if haemorrhage has been at all abundant it comes on more rapidly. I think the sallow skin which is so characteristic is more marked in this form of cancer than in others. The onset of bladder implication is indicated by frequent and painful micturition, and fistula is of course soon rendered obvious after it has occurred, the passage of flatus *per urethram* sometimes being the first symptom noticed.

Secondary involvement of the ureter in rectal cancer produces a hydro-nephrosis, and if both ureters are involved complete suppression of urine will supervene.

**Digital examination.** Whenever the symptoms of rectal cancer exist at all, a complete digital examination should be made. In the majority of cases, within a short distance of the anus the surgeon will feel a hard nodular and irregular surface, which may surround the entire circumference of the bowel, or be more particularly confined to one side of it. When stricture exists, the tumour frequently is felt projecting into the lumen of the bowel, and conveying to the finger a sensation almost exactly resembling that of an irregular os uteri (Fig. 142). Should the finger not encounter anything abnormal, the patient should be made to stand up, and the digital examination should then be repeated, the patient at the same time being told to bear down. In this way a tumour which was not within reach by the ordinary method may occasionally be explored. Should nothing still be felt, and the symptoms clearly point to rectal disease, the patient should be etherized, and a careful



bi-manual examination instituted, with the patient in the lithotomy position; this method is also of use in determining the height to which neoplasms, that are easily recognizable below, extend upwards.

Kelly's proctoscope or colonoscope may also occasionally be of use in difficult high-lying cases, but the certainty of diagnosis by touch is, where at all possible, much to be preferred, as the view obtainable through any form of speculum is frequently misleading.

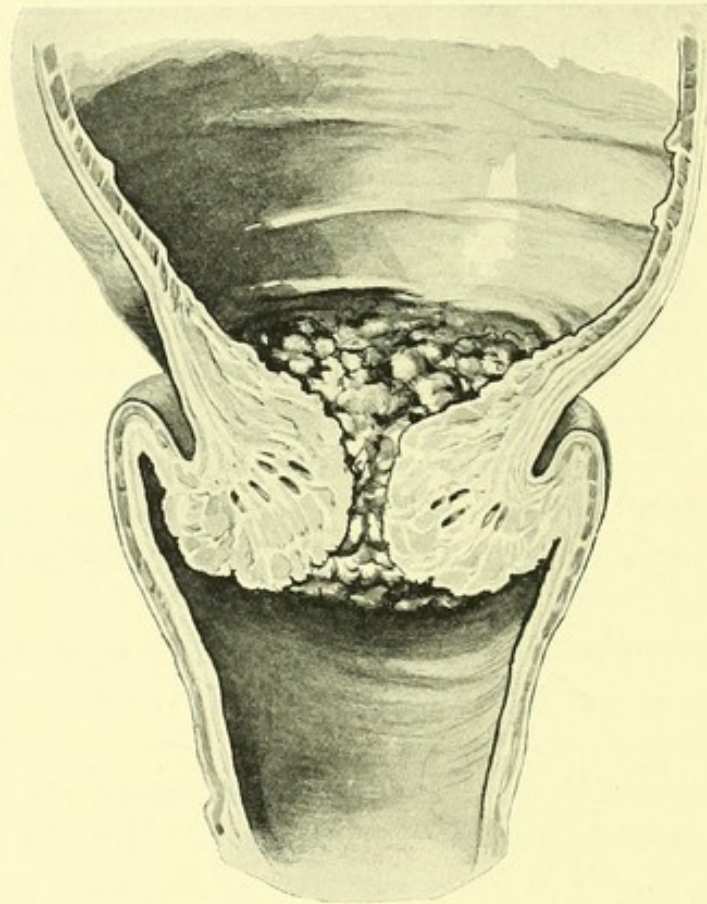


FIG. 142. Adeno-carcinoma surrounding the entire Circumference of the Bowel and producing slight Intussusception.

The bowel above the stricture is much dilated.

(From a specimen removed by sacral operation.)

The existence of malignant disease having been determined, it is essential, with a view to treatment, to determine the following points: First, the distance to which the disease extends upwards; this may be done with the finger alone, by the bi-manual method, or by a ball-ended probang. Secondly, the movability of the rectum upon the other pelvic structures is of use in estimating whether or not the



disease has spread past the limits of the intestinal tube. And, thirdly, a careful examination should be made to feel, if possible, any enlarged glands, which may sometimes be felt in the hollow of the sacrum through the rectal wall. In examining a case of this kind the greatest care should be employed, as in several recorded cases the attempt to pass a probang, or even a roughly made digital examination, has been followed by rupture into the peritoneal cavity.

In the female additional information may be gained by vaginal examination, the extent of the growth being sometimes easily determined through the recto-vaginal septum, while the fixity or freedom of the uterus is a point of great importance to make out.

**Diagnosis.** The firm irregular masses obviously implicating the mucous membrane when recognized by digital examination usually render the diagnosis of cancer of the rectum unequivocal, but occasionally difficulties may arise. When the mucous membrane is ulcerated the possibility of tubercular, syphilitic, or other non-cancerous conditions demands consideration, but in adeno-carcinoma the infiltration of the deeper tunics and the protuberant masses are more marked and easily recognizable. Multiple non-malignant adenomata might possibly also be mistaken for cancer, but here again the freedom of the outer coats of the bowel from infiltration ought to establish the diagnosis.

To distinguish between the malignant and non-malignant strictures is a matter of greater difficulty. In this the duration of symptoms will prove of much service, the onset and progress of the non-malignant being extremely slow. The sensation conveyed to the finger will also be different. The ordinary stricture is smoother, and more regular, and there is generally an absence of the nodular and protruding masses so characteristic of cancer. Again, in the malignant form there is usually a portion of tolerably healthy mucous membrane between the cancer and the anus, whereas in the non-malignant stricture the lower portion of the rectum is generally more or less implicated.

Tumours not involving the mucous membrane may be of two kinds, (1) originating in the muscular coats of the rectum, and (2) originating outside the rectum altogether, but compressing the bowel. If it is found that a tumour moves freely with the rectum in the pelvis, but that the mucous membrane over it is smooth and not involved, although possibly adherent to the growth, we are justified in positively stating that the case is not one of adeno-carcinoma; it may, however, be a sarcoma,



which will require similar treatment. Tumours originating outside the rectum and infiltrating the bowel wall can usually be diagnosed by their comparative immovability, or if entirely outside the bowel and only compressing the rectum the freedom of the entire thickness of the rectum can usually be detected. It is strange the mistakes that are sometimes made from want of familiarity with the details of digital examination. I have several times seen the fundus of a retroflected uterus, or even a normal cervix uteri, mistaken for a rectal tumour.

Secondary cancer of the rectum is usually due to involvement of the bowel by malignant disease originating in the uterus, or in the prostate gland; such cases do not require here any detailed consideration, they are usually quite inoperable.

The diagnosis between squamous epithelioma of the anus and papillomata is sufficiently easy, as in the latter the skin surrounding the tumour is not involved, the neoplasm being in some instances even pedunculated, whereas in the epithelioma there will be considerable infiltration of the true skin.



## CHAPTER XIX

### CANCER. TREATMENT

THE surgical treatment of cancer of the rectum has been much discussed of recent years; the literature of the subject is voluminous, and the published statistics of radical operation very considerable, relating both to immediate mortality and the question of recurrence.

Some enthusiastic surgeons have published results showing such low death-rate and frequent freedom from recurrence that they excite the envy of less fortunate operators, while others, discouraged by frequent failure and rapid recurrence, have apparently restricted the radical operation within very narrow limits indeed.

**Extirpation of the cancerous rectum** appears to have been performed first as far back as 1763, by Faget, but it is only within the last thirty years, largely due to the work of German surgeons, that excision has become generally adopted. A review of the experience gained during this period enables us to form a fair estimate of the possibilities and limits of the operation, and to define what may be termed the standard of surgical treatment at the present day; we can as yet only look forward to the time when that earnest band of men who are devoting their lives to cancer research will solve the problem of the cause of this terrible disease, and show us how its cure may be effected. Then possibly the hypodermic needle may be enabled to claim a greater success than can to-day be achieved by the most extensive surgical procedures, conducted with scrupulous attention to elaborate technique.

The more encouraging results obtained in recent years are due to many causes—early diagnosis, better selection of suitable cases, greater attention to the preparation of the patient, improved methods of operation and the details of operative technique.

The question of early diagnosis has already been dealt with.



**Selection of suitable cases.** Reckless operation on cases that are too advanced, in which the immediate risk is great and rapid recurrence, if the patient recovers the operation, certain, has done much to discredit operations in these cases, and published statistics, so often fallacious on surgical subjects, are possibly more misleading upon results of excision of cancer of the rectum than of almost any other surgical procedure. It is, however, certain that if adeno-carcinoma of the rectum is operated on early enough, before the peri-rectal tissues are much encroached upon, the results now attainable are admirable, both as regards immediate recovery and freedom from recurrence.

In my own practice three cases of excision of undoubted adeno-carcinoma of the rectum have remained well after periods over ten years, and one is alive and well fifteen years after operation.

In estimating the suitability of a case for operation, evidence of secondary infection either in the liver or deep abdominal lymph-glands must be carefully looked for, and next to this the most important point to pay attention to is the mobility of the mass in the pelvis, as estimated by digital examination. If freely movable the case may be considered favourable, as it is probable that the disease is as yet confined to the bowel tunics. A less degree of mobility indicates that the surrounding soft parts are to some extent involved, and it may in consequence be inferred that the difficulties of the operation will be much increased, and the danger of rapid recurrence so great, that if this evidence of involvement of soft parts is at all considerable, especially if the bladder, prostate gland, or uterus, are adherent to the tumour, radical operation is best declined. If the mass is quite fixed, indicating involvement of the bony pelvis, operation is contra-indicated.

**Preliminary preparation.** A thorough and intelligent preliminary preparation of the patient is of real importance. Four or five days before operation free purgation should be commenced, and continued till the day previous to operation, when a copious enema should suffice to completely empty the colon. The patient is to be well fed with food that will leave but little residue, and the night before operation a full opiate is to be administered to check peristalsis. Another enema may be given a couple of hours before operation, and when the patient is well under ether a thorough washing-out of the rectum and lower part of the colon with a 2 per cent. solution of lysol or other antiseptic solution should be employed. This preliminary preparation is quite essential, for it is



well known that the septicity of the intestinal contents increases the longer they are retained, and a thorough evacuation, carried out during several days previously, tends largely to diminish the risk of wound contamination in these cases. But it may not be possible to effect this thorough evacuation, large masses of scybala may block the colon above the seat of disease, or the stricture may be so tight that complete obstruction has supervened—these are cases in which a previous colotomy is clearly indicated. Some surgeons, indeed, recommend colotomy previous to all excisions of the rectum, but where the bowel can be efficiently evacuated I am satisfied that it is unnecessary and objectionable, as it causes delay and subjects the patient to a double operation. Where, however, complete evacuation is impossible without colotomy, it should be certainly undertaken as a preliminary, or, if obstruction is complete and attended with much meteorism, the method of intestinal drainage introduced by the late Mr. Greig Smith is probably preferable.

**Choice of operation.** Having determined that a given case of cancer of the rectum is suitable for removal, that is, that it is freely movable or at any rate only slightly invades the peri-rectal tissues, it is necessary to consider in the first place what route is the best adapted to the individual case, and this will largely depend upon the situation of the disease: (1) the growth may involve the anal canal only; (2) it may be situated low down in the rectal ampulla; and (3) it may originate high up above the peritoneal reflexion; it must, however, be remembered that the disease may be so extensive as to occupy situations 1 and 2 or 2 and 3, while in some rare cases the entire rectum including the anal canal may be implicated. The routes we have to select from are: (1) the perineal; (2) the sacral; (3) the vaginal; and (4) the abdominal.

**Perineal route.** Perineal excision, formerly the only method employed for the removal of rectal cancer, is now not so frequently undertaken. Poucet (Delore and Chalier, *Revue de Chirurgie*, May 10, 1907), however, believes that the perineal route, when associated with removal of the coccyx, is still the best in the great majority of cases, and he claims that more complete asepsis can be obtained by this method than by others; his technique is as follows:—

If there is any external growth it is removed by curette or cautery, a day or two before operation. Great attention is paid to cleansing the rectum and surrounding parts, peroxide of hydrogen being used to wash



out the bowel. The anus is closed by purse-string suture. A circular incision is carried round the anus, and one linear incision, starting from this, extends back to the base of the coccyx and another forward to the bulb of the urethra. The coccyx is removed after its musculature and ligamentous attachments have been scraped away. The pelvic diaphragm is split in the middle line, giving access to the posterior surface of the rectum; this is to be cleared from the hollow of the sacrum, care being taken to remove any lymphatic glands that are present. The levator ani is divided all round the anal canal and split in front to the vagina, or to the urethra in the male. The recto-urethralis muscle is divided, and separation of the rectum from the vagina in the female, or the prostate and bladder in the male, carefully carried out, great attention being paid to the control of bleeding. If the case is at all extensive the pouch of Douglas will have to be opened. A loop of pelvic colon can generally be drawn down, and by gentle traction on it where it joins the rectum the lateral ligaments and other attachments can be readily commanded and divided after ligation. This division of attachments should be carried out little by little, until the rectum comes down so far that its diseased portion can be brought well below the skin-level without undue tension. Every bleeding point not previously ligatured must now be attended to, the peritoneal opening closed by sero-serous sutures, the levator ani closed by myorrhaphy, retaining a healthy portion of the rectum or pelvic colon at the normal site of the anus, and the skin wound closed, securing the bowel by a few points of suture. The last step is to divide the rectum well above the disease between two catch forceps. Where it is possible to accomplish this successfully the diseased rectum is removed like a cyst without any faecal soiling of the wound.

The great advantages of this operation are free access to the rectum both behind and in front, with accurate haemostasis, but above all it can usually be done practically as an aseptic operation; it is not, however, so suitable for some high-lying cancers as some of the following methods. It has, as hitherto done, this serious drawback, a certainty of the loss of sphincteric control; we hear of cases recorded in which the sphincter has been retained in whole or in part, with the result that the patients have control, but a reference to Fig. 143 will show that circular division of the levator ani round the circumference of the rectum of necessity divides the nerves which supply the sphincteric



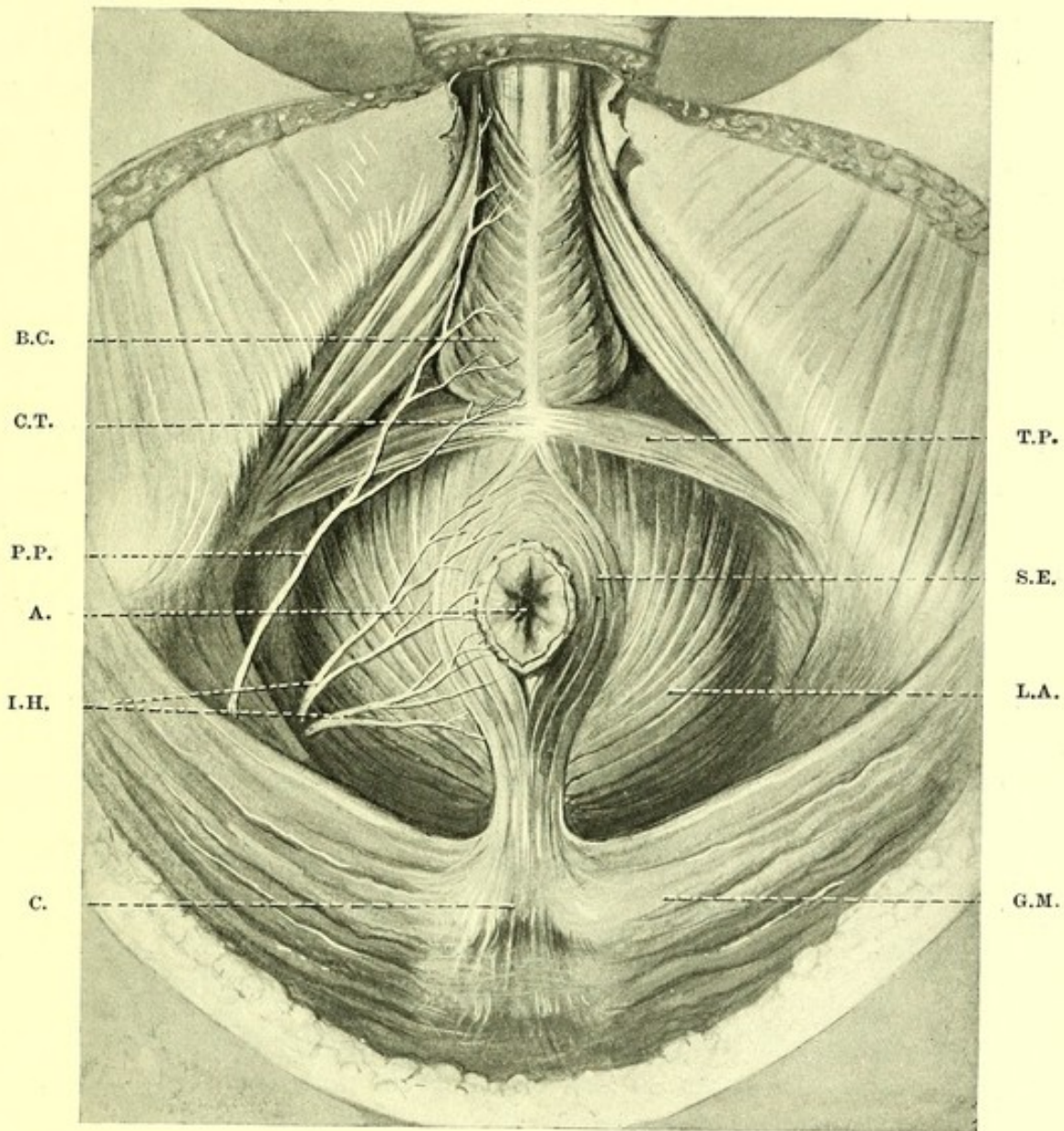


FIG. 143. Muscles and Nerves of the Male Pelvic Outlet.

T.P. Transversus perinei muscle. S.E. External sphincter muscle. L.A. Levator ani muscle. G.M. Gluteus maximus muscle. C. Coccyx. I.H. Inferior haemorrhoidal nerve. A. Anus. P.P. Posterior superficial perineal nerve. C.T. Central tendinous point of perineum. B.C. Bulbo-cavernosus muscle.



apparatus. It is manifestly useless to preserve a muscle the nervous supply of which is hopelessly severed, and any so-called control which patients operated on in this way may eventually obtain can be only of the same kind as that observed in some cases of colotomy, in which, after some weeks, evacuation of the bowel takes place at definite times, so that the patient is able to make the necessary preparations for it, and so avoid some of the misery of an involuntary evacuation, but it is not sphincteric control in the true sense of the word.

If it were possible to do the perineal operation in such a way that useful control of the bowel could be preserved, it would add very greatly to the value of this operation. Of course, where the disease extends so low that the anal canal is involved, no operation can possibly be devised which will retain efficient control, but where the disease is in the rectal ampulla it appears to be possible to retain the nervous supply to the sphincteric apparatus intact, and if the wound can be maintained aseptic, perfect restoration of function should be possible. Since reading the admirable paper by Delore and Charlier, above alluded to, I have worked out a method on the dead body, but of course, it is only by extended experience on the living, which has not yet been available, that the procedure must be judged; as, however, it appears to be so promising I give the details, which the accompanying illustrations will render clear. It is only suitable for those cases in which the entire anal canal is free from involvement by the cancer.

The rectum is to be very thoroughly cleansed by purgatives and enemata.

The best position of the patient is what is called in America the exaggerated lithotomy position: lying on the back with the thighs fully flexed and divaricated, and the pelvis raised above the level of the rest of the body to such an extent that the surface of the perineum assumes almost a horizontal position.

The anal canal and rectal ampulla are to be firmly plugged with gauze soaked with 1-500 mercuric iodide solution in spirit, and the area of operation, and the vagina in the female, disinfected with minute attention to detail, and rubber gloves subsequently put on.

A median incision is made from the central point of the perineum to the front of the anus, and from the back of the anus to the base of the coccyx. The coccyx is removed and the levator ani and external sphincter carefully split in the middle line as far as the anus, and the fascia propria



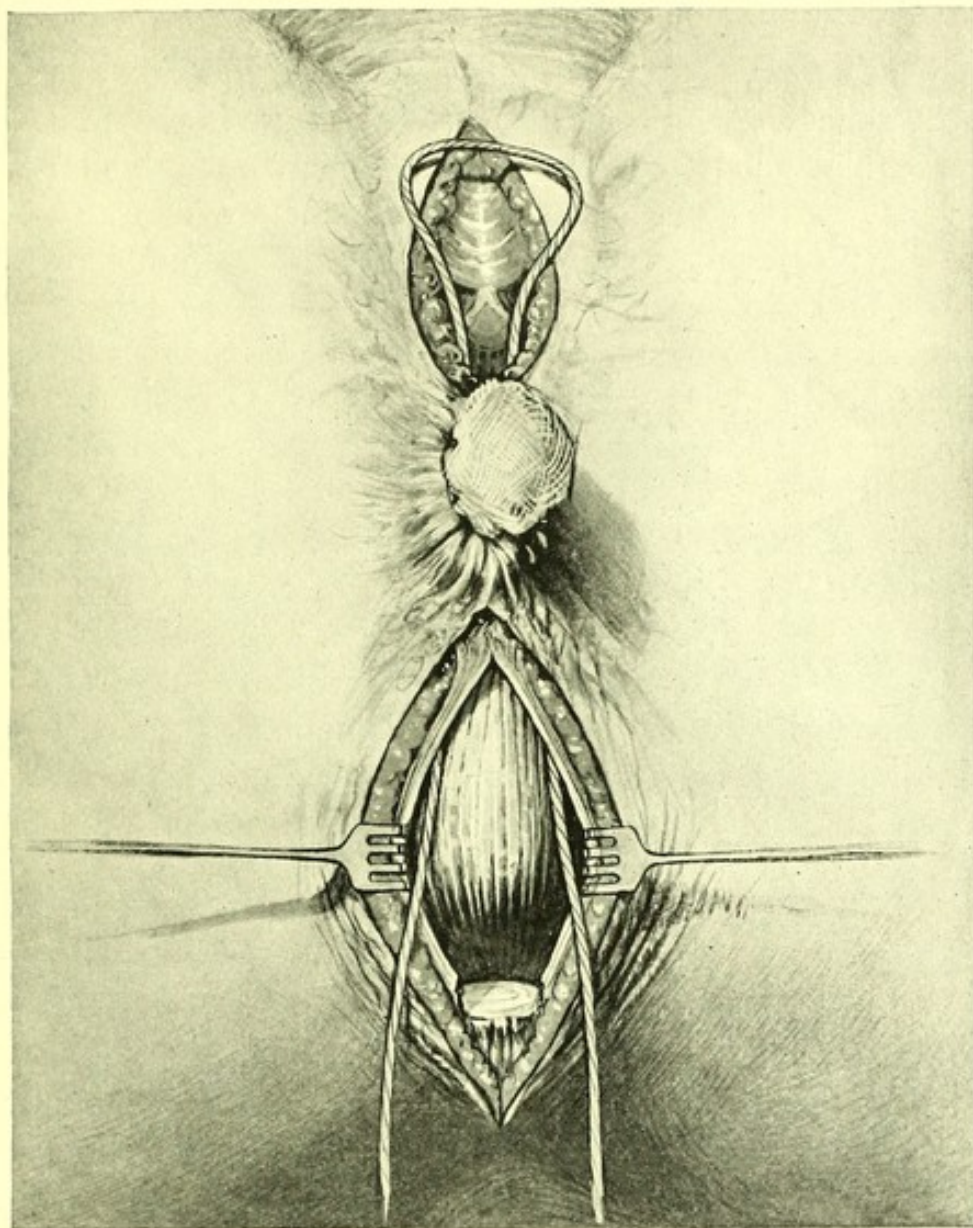


FIG. 144. Complete, Aseptic, Perineal Excision of the Rectum with Conservation of Sphincteric Control, stage 1.

The anal canal has been plugged with gauze moistened in mercuric biniiodide solution (1-500). An incision has been made from the base of the coccyx to the back of the anus, and from the front of the anus to the urethral bulb. The coccyx has been disarticulated and the levator ani and external sphincter muscles split to the back of the anus, and from the front of the anus to the central tendinous point of the perineum. A stout ligature has been, by means of these incisions, placed round the rectum above the insertion of the pelvic diaphragm.

*(From stereo-photograph of operation on the cadaver.)*



freely divided. In front the external sphincter, levator ani, and the recto-urethralis muscles are split from the anus to the central tendinous point of the perineum. It is now quite easy to pass a finger from one incision to the other, above the levator ani on either side of the rectum, in the superior pelvi-rectal space. A stout ligature is passed so as to surround the rectum above the insertion of the pelvic diaphragm (Fig. 144), and tied very tightly, so as to compress the rectum on the gauze plug. Tying on the plug renders the occlusion of the rectum by the ligature more perfect, and the cord is less likely to cut the bowel wall than if the gauze plug is not present. It is essential that the ligature should constrict the bowel about half an inch above the insertion of the pelvic diaphragm so as to allow of the subsequent circular division of the rectum. This can readily be ensured if one blade of a curved intestinal forceps is passed from the posterior to the anterior incision on each side of the rectum through the superior pelvi-rectal space, and the ligature tied underneath these blades. If this precaution is not taken the ligature tends to slip down into the angle between the rectum and pelvic diaphragm, and leaves insufficient room for the subsequent steps of the operation. The ligature having been securely tied, the posterior and anterior incisions are to be continued through the anal canal, and the rectum divided circularly above the insertion of the pelvic diaphragm. It is convenient to keep the blades of the forceps in position until this circular division of the rectum is complete, as they protect the ligature and indicate the angle between the rectum and levator ani where the division should be made.

Each lateral half of the anal canal and external sphincter—retaining its normal relations to the levator ani and its nervous supply intact—is now retracted, exposing very fully the rectum, ligatured on the gauze plug. (Fig. 145.)

In order to prevent possibility of the ligature slipping, or leakage through the plug, a few mattress sutures should be passed through the tissue of the gauze, the cut edge of the rectum, and the muscular coats of the bowel above the ligature, and tied, not too tightly. All ends of ligatures should be cut off closely to avoid the temptation of pulling on them in order to draw down the rectum. The separation of the rectum can now be accomplished with considerable ease, provided the cancer has not extended to any great extent into the peri-rectal tissues. By blunt dissection the bowel can be freed from the bladder in the male,



or the vagina in the female, and the reflexion of peritoneum freely exposed and opened, and if the pelvic meso-colon is long enough, a loop

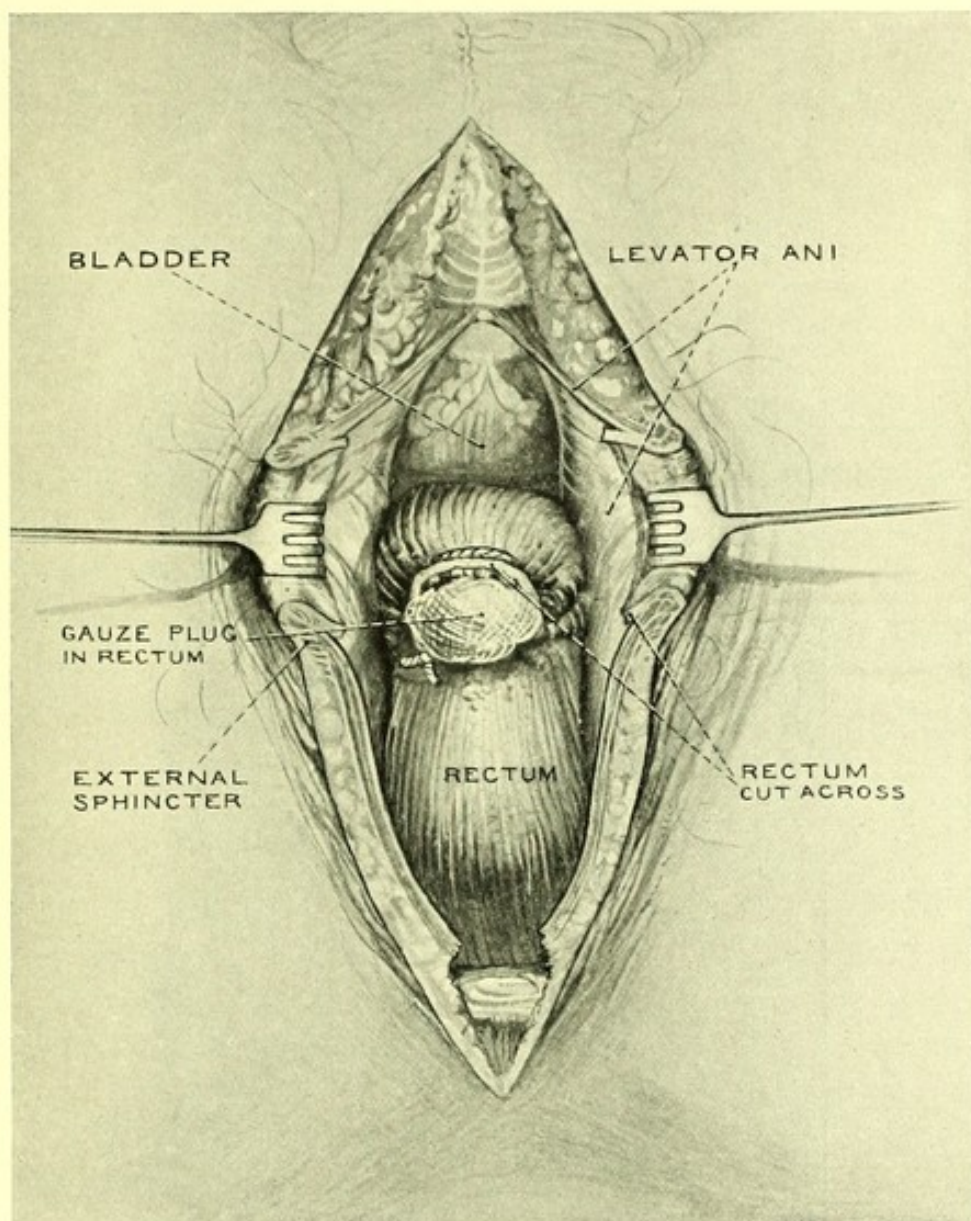


FIG. 145. Complete, Aseptic, Perineal Excision of the Rectum with Conservation of Sphincteric Control, stage 2.

The ligature has been tied tightly round the rectum, compressing it upon the gauze plug half an inch above the insertion of the pelvic diaphragm. Vertical incisions have been made in the anal canal in front and behind, and the rectum divided circumferentially just above the insertion of the pelvic diaphragm. Each half of the pelvic diaphragm and external sphincter muscle with its nervous supply intact has been drawn aside, giving free access to the rectum.

of pelvic colon drawn down, and the superior haemorrhoidal artery secured in its meso-colon. By gentle traction on this loop the lateral ligaments can be put on the stretch and divided, having been previously ligatured



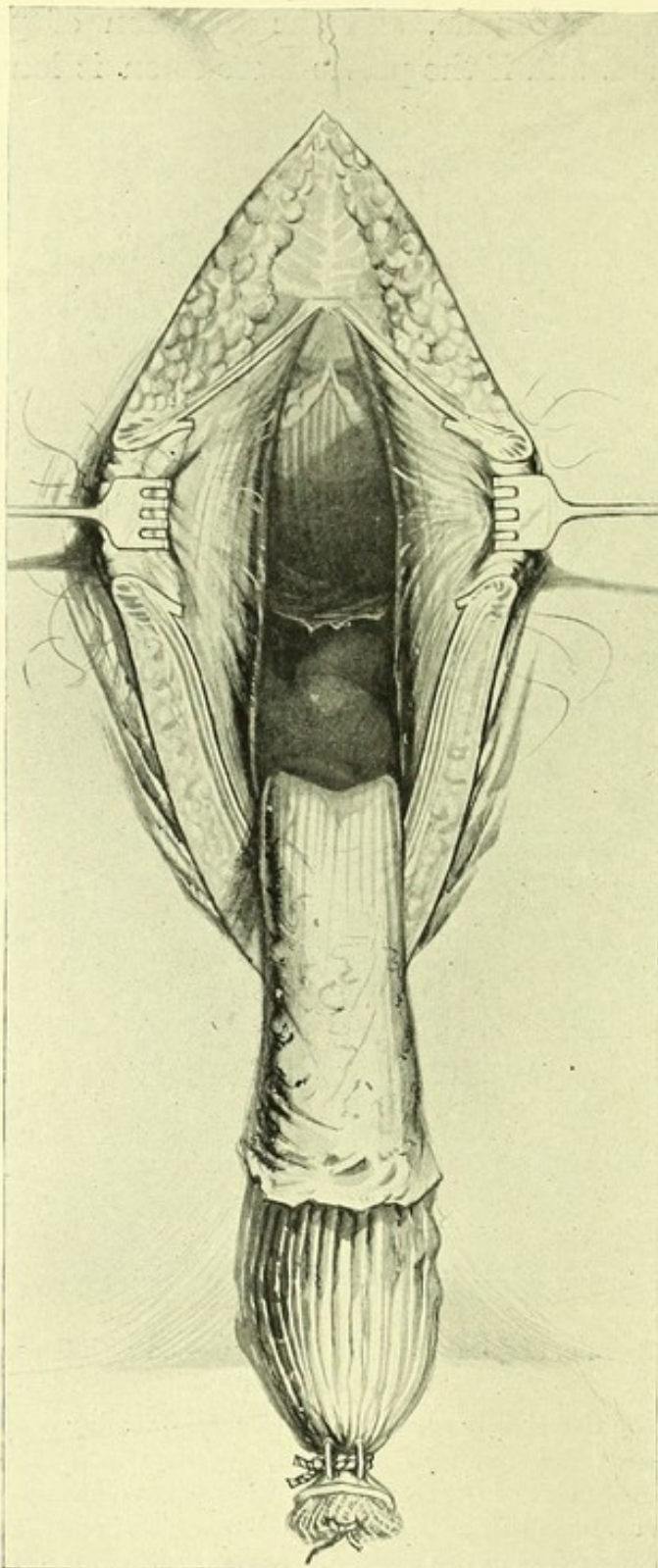


FIG. 146. Complete, Aseptic, Perineal Excision of the Rectum with Conservation of Sphincteric Control, stage 3.

Mattress sutures have been passed through the gauze plug and through the rectum above and below the ligature, to prevent slipping. The rectum has been separated from the bladder in front, the peritoneum opened in Douglas's pouch, and the bowel completely separated from its connections, so that it can be drawn down to such an extent that healthy intestine for two inches above the disease can be brought below the level of the perineum.



to control the middle haemorrhoidal arteries. All further attachments can be readily divided, and the lymphatic vessels and glands cleared with the rectum from the hollow of the sacrum. The entire rectum can now be drawn down below the level of the perineal skin (Fig. 146). The peritoneum may be sutured by sero-serous sutures, although it is doubtful whether this is always necessary. The pelvic diaphragm is restored by careful buried catgut sutures in the levatores ani and sphincter muscles, particular care being taken to suture accurately the posterior loop of the pubo-rectalis muscle (see p. 12). Space both in front and behind is left for drainage tubes, and the skin closed by suture, leaving the pelvic colon protruding at the anus. Finally, the pelvic colon is divided between two ligatures, the entire diseased rectum cut away, and the bowel retained in the anal canal by a few points of suture which do not penetrate the mucous coat. The ligature on the pelvic colon may be allowed to remain for a few days to avoid soiling the wound.

Although it might in some instances be possible to remove all obvious disease without opening the peritoneum, it is probably better to undertake complete extirpation.

If no loop of pelvic colon can be drawn sufficiently far down even after extensive separation of attachments—which cannot be considered probable—to permit of the operation being completed as above described, the bowel must be divided between ligatures as high as possible and the operation terminated by colotomy.

This operation appears to offer the following advantages :—

Freedom from soiling the wound.

Ease of separation of rectum from surrounding structures, without bruising, owing to the abundant room given by the anterior as well as posterior incisions.

Accurate haemostasis, as the superior and middle haemorrhoidal arteries can be ligatured before they are divided, and other vessels are readily accessible and easily controlled.

Retention of the normal relations of the sphincter and pelvic diaphragm to the anal canal, except for the anterior and posterior incisions.

Immunity from injury of the nerves involved in sphincteric control and reasonable prospect of avoiding incontinence of faeces.

Free removal of disease and of the lymphatic vessels and glands from the hollow of the sacrum.

I have done this operation only once upon the living, and found



it gave abundant room for manipulation. Unfortunately in this case while separating the rectum high up an extra-rectal stercoral abscess

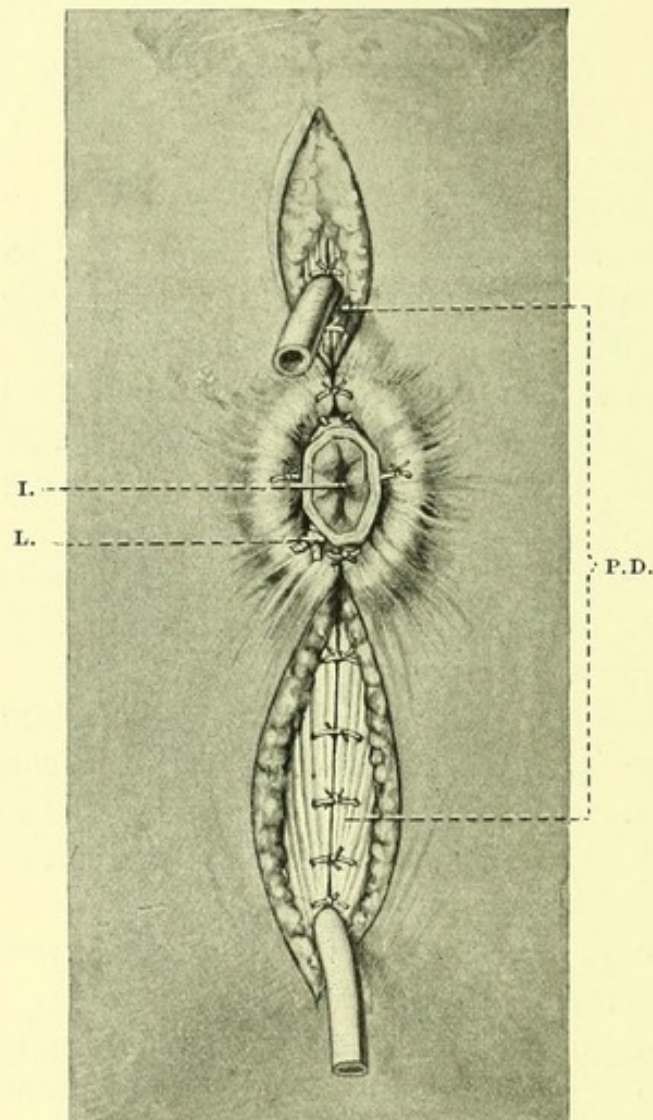


FIG. 147. Complete, Aseptic, Perineal Excision of the Rectum with Conservation of Sphincteric Control, stage 4.

The pelvic colon or rectum, as the case may be, has been divided between two ligatures well above the disease. The pelvic diaphragm has been restored by buried catgut sutures, leaving room for drainage tubes in front and behind. The ligatured bowel is retained at the anus by a few points of suture, and the anal canal closed by sutures. I. Intestine fixed in anal canal. L. Ligature round intestine. P.D. Pelvic diaphragm closed both in front and behind by buried sutures. Superficial sutures to close the skin wound are all that is necessary to complete the operation. The ligature round the intestine is left until adhesions form.

was opened, and some soiling of the wound, followed by local sepsis, supervened, preventing primary union. Ultimately a good result with



fair control was obtained. In a case operated on in this manner by my colleague, Professor E. Taylor, it was possible to preserve complete asepsis and primary union followed.

If only a portion of the circumference of the bowel is infiltrated, an

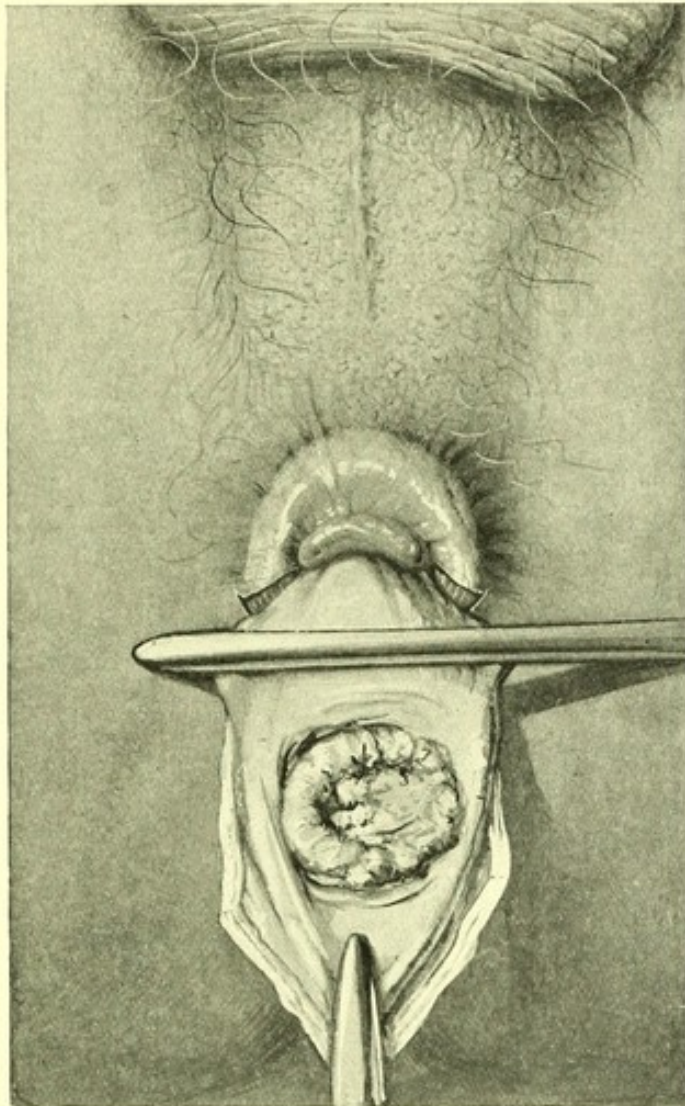


FIG. 148. Partial, Perineal Excision of the Rectum for a small Nodule of Cancer, stage 1.

An incision has been made round the portion of the circumference of the anus that corresponds with the growth. From each end of this incision vertical incisions have been made in the rectum marking out a flap which will leave a wide margin of healthy tissue all round the disease. The flap has been dissected free and drawn down. The base of the flap is controlled by a pair of pressure forceps.

incision is to be carried round that portion of the anus corresponding with the disease, and the levator ani divided to a similar extent. Vertical incisions are then to be made on either side, but well free of the growth,



and carried up the rectum to a point sufficiently above the cancer; the flap thus formed is to be freed from its connections, drawn down, and a clamp applied to the healthy tissue above. The diseased part is then cut away, any vessels bleeding are to be ligatured, and the cut end of mucous membrane attached to the skin by deep and superficial sutures.

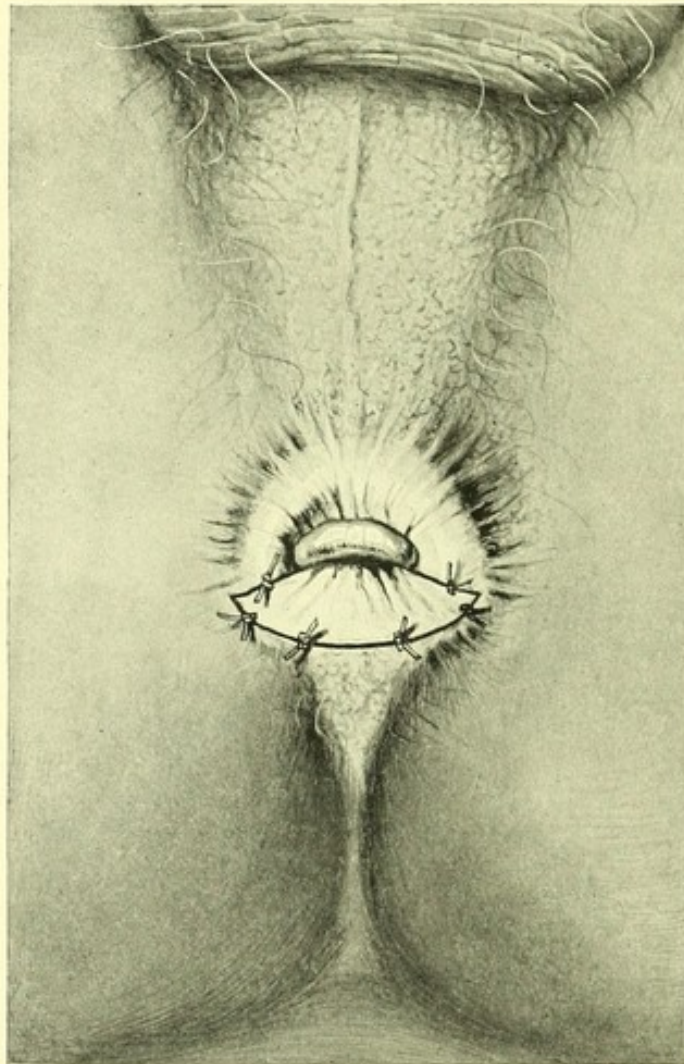


FIG. 149. Partial, Perineal Excision of the Rectum for a small Nodule of Cancer, completed.

The flap has been cut off where it had been controlled by the pressure forceps, and the operation completed by suture of the divided portion of the rectum to the anus.

In passing the deep sutures, care must be taken that they are passed not only through skin and rectal wall, but also under all the peri-rectal tissues, and in sufficient number to obliterate any cavity outside the rectum in which blood or serum may collect. This is a matter of high importance in the prevention of sepsis. The contrast between wounds of



the anal canal alone—such as pile and many fistula operations—and those wounds which penetrate the entire rectal tunic, and so open up the superior pelvi-rectal space, is very marked, sepsis to any serious extent being excessively rare after pile operations, but common after wounds, such as excision of the rectum, which open through the rectal wall above the pelvic diaphragm (see p. 62). It is therefore imperative to close the deeper portion of the wound efficiently by deep sutures, or if this is found to be impracticable, to ensure free drainage by means of tubes, iodoform gauze packing, or by leaving the wound freely open. These partial operations are, however, not very satisfactory.

In connection with perineal excision it is well to remember that in some rare instances it may be possible to prolapse the entire cancerous mass through the anus. This may be the case in single nodules occupying portions of the circumference of the bowel low down, and also when the disease completely surrounds the intestine, either rectum or colon, an intussusception may be induced which becomes long enough for the cancer to reach the anus. When it is possible thus to extrude the entire growth through the anus, excision can be very easily accomplished, the wound, carefully sutured, being returned within the anus. Such cases usually do well, as the fact that the disease can be protruded indicates that the peri-rectal tissues are not as yet involved.

**Sacral route.** In the early days of perineal excision by the older methods it became evident that they were unsuitable for cancers which extended a considerable distance up the rectum, it was therefore sought to obtain more room, first by posterior incision, then the coccyx was removed, and finally, by Kraske's sacral incision, a great impetus was given to the efficient treatment of extensive cases. Kraske's original incision has been much modified by other surgeons. The method which appears to be best is as follows.

The skin over the sacrum is to be cleansed antiseptically and an incision made from the middle of the sacrum to within about an inch of the anus. This exposes the fibrous coverings of the bone with the attached ligaments, and the connections of the levatores ani to the coccyx and to one another in the middle line. An incision is now made through the musculature below the tip of the coccyx, and with American pruning shears the ligaments—first on one side of the coccyx and then on the other—are severed, while a third section is carried transversely through the fifth sacral vertebra, and the triangle of bone thus separated from its



attachments is easily removed. This transverse division of the sacrum is practically that recommended by Bardenheuer, which I consider far the best line of section. When made through the fifth sacral vertebra sufficient room is usually secured, but a further bone section can readily be made if required. It is, however, of great importance to keep it as low as possible, so as to ensure the safety of the nervous supply of the sphincteric apparatus. The removal of the entire piece of bone is

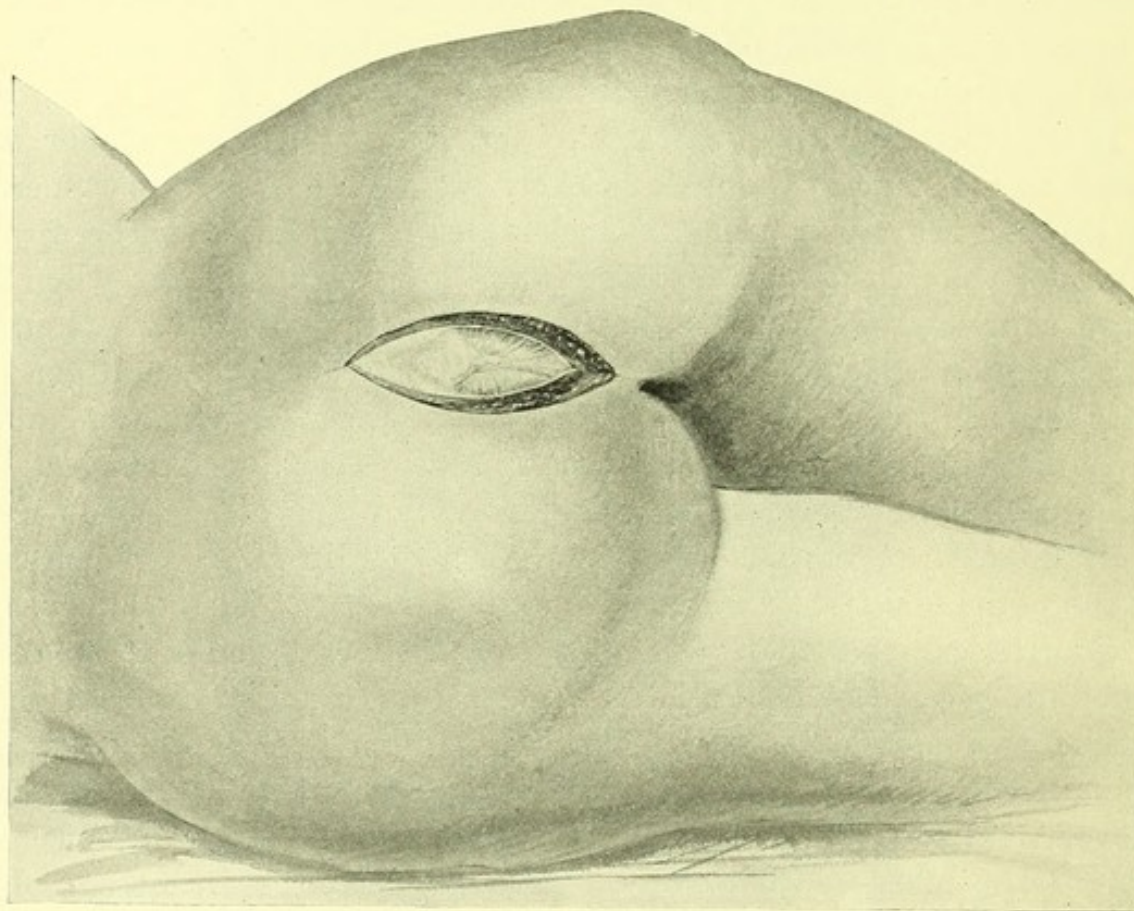


FIG. 150. Sacral Excision of the Rectum, stage 1.

Patient in semiprone position. A free incision has been made from the middle of the sacrum to the back of the anus, exposing the sacrum, coccyx, and pelvic diaphragm.

unattended with subsequent trouble, and is, I think, to be preferred to any of the osteoplastic operations which have been recommended. The American pruning shears, as used by gardeners, cut the bone cleanly without much bruising, and more rapidly than other instruments. The fascia propria is now cut through, the posterior surface of the rectum exposed, and a clean dissection made exposing the external muscular coat of the bowel, all connecting bands being divided between ligatures if likely



to contain any vessels of considerable size. It is sometimes easy and desirable, as suggested by my colleague Prof. E. Taylor, to open the peritoneum in front and on both sides early, and separate adhesions until a loop of bowel can be drawn out. The intestine is now crushed with a powerful clamp and divided between two ligatures above the disease, the cut mucous surface being disinfected with pure carbolic acid, or the actual cautery, and the diseased portion widely removed. At other

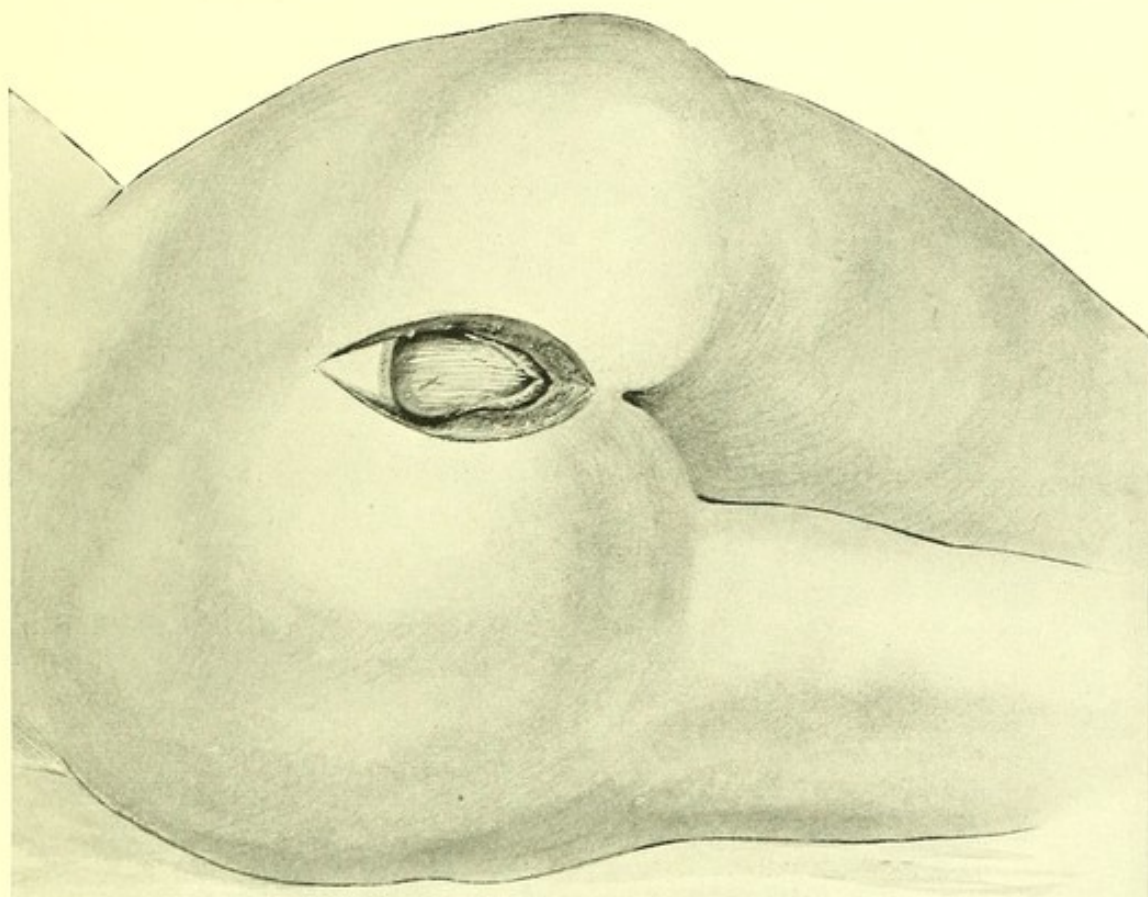


FIG. 151. Sacral Excision of the Rectum, stage 2.

The coccyx and last bone of the sacrum have been removed, exposing the back of the rectum.

times it is more convenient to divide the rectum in the first instance below the disease, while in a few cases I have found it necessary to make this preliminary division through the cancerous mass, removing both diseased ends subsequently.

We now have to decide whether the case is one in which a sacral anus should be made, an end-to-end resection be performed, or the lower portion completely removed without injuring the pelvic diaphragm



or sphincteric apparatus, and the upper portion brought out, and fixed at the normal anus. Formerly a very large proportion of cases were completed by the formation of a sacral anus, and in my own series several of the earlier cases were thus completed, although I now know that many of them were suitable for an operation that would possibly retain sphincteric control with an anus normally situated.

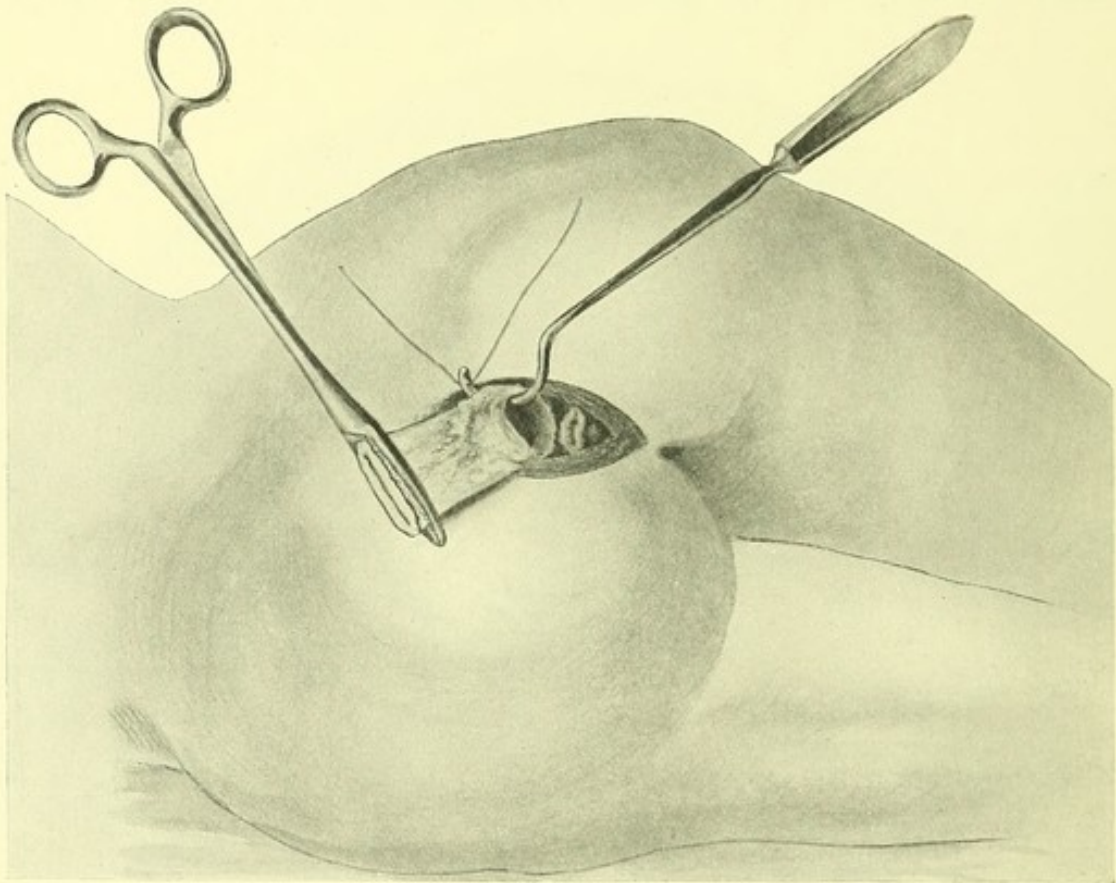


FIG. 152. Sacral Excision of the Rectum, stage 3.

The rectum has been divided below the disease and controlled by pressure forceps. The peritoneum has been opened in Douglas's pouch. The way to pass sutures so as to tie off the attachments of the upper portion of the rectum before dividing them with scissors is indicated.

I believe that a sacral anus is necessary only in a very small proportion of cases—namely, those in which the disease is extremely extensive and involves the anus to such an extent that it is impossible to retain the surrounding musculature in any useful condition, and also in those rare cases in which it is found impossible to free the upper segment sufficiently to bring it down for a resection or normally situated artificial anus. Should the case be considered one in which



a sacral anus is necessary, the upper segment is to be freed above the disease which is to be removed, making sure that the section traverses the bowel well free of infiltration. The free lumen is now to be brought out over the divided sacrum and sutured to the skin (Fig. 166).

A resection, with end-to-end junction, if a fair amount of healthy

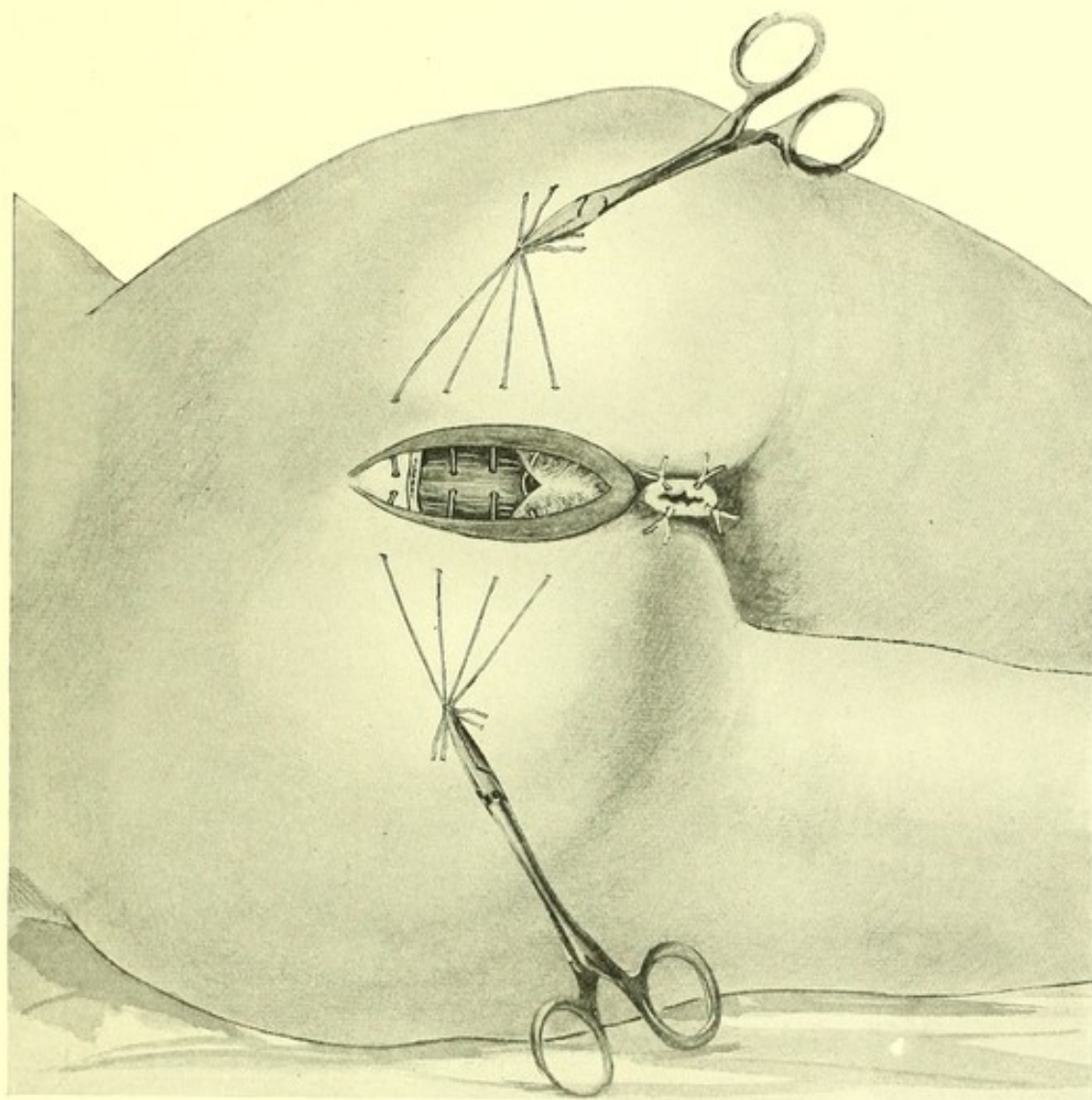


FIG. 153. Sacral Excision of the Rectum, stage 4.

The deep sutures have been placed in position. The upper one passes through the periosteum of the sacrum. The next two pick up small portions of the muscular coat of the rectum, and the lower one passes through the divided attachments of the levator ani muscle on each side. The upper lumen of the bowel is shown sutured to the anus.

bowel exists below the disease, may sometimes be a possibility, and in the rare cases in which it succeeds the result is very perfect. The con-



ditions under which this operation is performed are, however, extremely unfavourable for good union. In the first place, there is not a uniform covering of peritoneum, secondly, the solid faeces of the colon exercise a considerable tension upon the bond of union. To dilate the anus for the passage of faeces, even under normal conditions, necessitates a very considerable strain, and if, as is usually the case, the bowels are kept

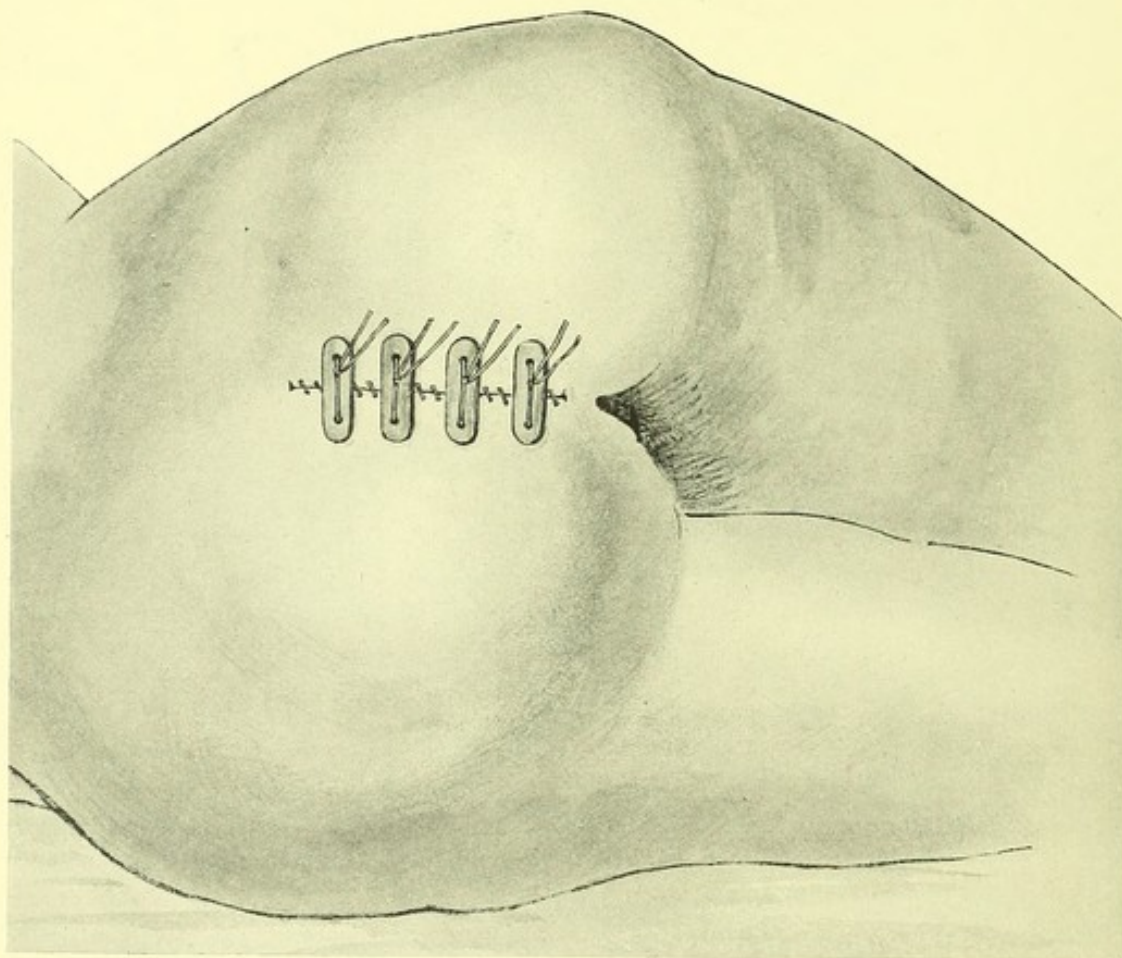


FIG. 154. Sacral Excision of the Rectum, completed.

The wound closed, the deep sutures tied over lead plates, the superficial parts brought together by continuous suture.

confined for many days after operation, the strain will be so great as almost certainly to tear through the new bond of union even if tolerably firm. It is well, therefore, if the surgeon attempts this method, to commence free saline purgation after the second day, and in this way as far as practicable to assimilate the case to that of the small intestine with its fluid contents, where we know the results of end-to-end junction



are so much better than they are in the colon. The method of junction may be by suture, decalcified bone ring, or Murphy button, at the discretion of the surgeon.

In three cases in which I attempted to get end-to-end junction a posterior fistula formed, and although a good result was finally obtained after closing of the fistula, I now think it better to suture only the front and sides of the bowel in the first instance, leaving the posterior portion open, and close this posterior opening by a subsequent plastic operation. In a case in which I adopted this method the line of union was more satisfactory.

The method which promises the best results in a very large majority of cases is undoubtedly that of Moulouquet (*Soc. de Méd. d'Amiens*, July, 1890). He dissects out the lower portion of bowel to the upper surface of the pelvic diaphragm, and the entire mucous membrane down to its junction with the scaly epithelium of the anal canal, but carefully preserves the entire sphincteric apparatus from injury, and then frees the upper end sufficiently to bring it out at the anus, without tension, and suture it there, thus making an artificial anus at the normal position, completely provided with an efficient sphincteric control. There is usually no great difficulty in freeing the upper portion sufficiently to bring it down to the anus, even where an extensive excision has taken place. It is a good plan to keep a ligature on the proximal end of the intestine for forty-eight hours, so as to permit some adhesions to take place before the wound becomes soiled with faeces. The danger of necrosis of the intestine is the one drawback to the employment of this method. In my own cases a small portion of the gut sloughed in two instances, but not sufficiently to prevent an excellent result from being eventually obtained. By this operation an opening directly external, controlled by an efficient sphincter, is obtained.

**Vaginal route.** As involvement of the recto-vaginal septum occurs early in many cases, excision of a portion of the posterior vaginal wall together with the cancer has been tolerably frequently practised, and in three cases under my own care this was done without difficulty, the vaginal wound being closed by sutures, but in my cases, although the operation was primarily successful, recurrence was rapid, and such must very frequently be the case where the peri-rectal tissues are so much invaded.

The excision of cancers confined to the rectal tunic by incision



through the healthy vagina appears to present a better prospect, and has been put in practice by many surgeons, especially by Murphy of Chicago, and in suitable cases it is no doubt a good method. I have only adopted this method on one occasion, and was much pleased with the free access it gave to the disease and the satisfactory result eventually obtained.

**Abdominal route.** Excision of the rectum from above appears

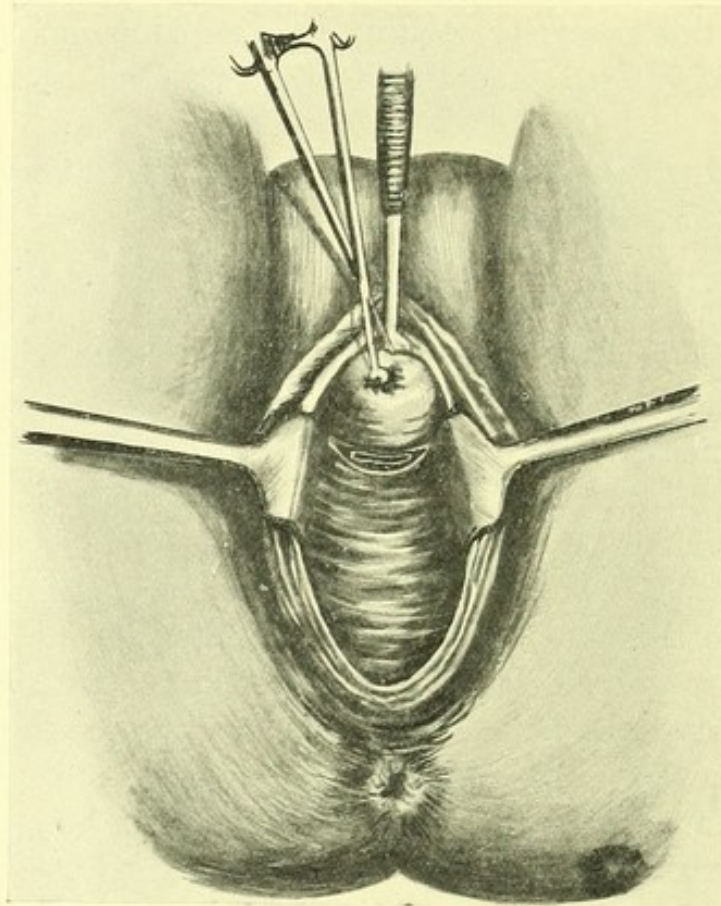


FIG. 155. Vaginal Excision of the Rectum, stage 1.

Patient in lithotomy position. The vagina is dilated with broad retractors. The cervix uteri drawn down, and the peritoneum opened in Douglas's pouch. For this and the following five illustrations the Author is indebted to Dr. Murphy of Chicago.

first to have been performed by Czerny in 1883, in a case in which he found the perineal route to be impracticable, and although its claims have been strongly advocated, especially by Quenu and Hartmann, it has not yet assumed a largely recognized position in surgery. The advantages are: (1) After the abdomen is open it is possible to estimate exactly the extent of disease, and the degree, if any, of lymphatic and peritoneal involvement, so that if the disease is found to be too extensive, the



operation can be terminated as an ordinary colotomy, or if this is considered to be unnecessary, the abdominal wound may be closed and the case allowed to run its course. (2) As the meso-colon is divided, the superior haemorrhoidal artery is secured, and also the two middle haemorrhoidal arteries at an early stage, so that the operation is almost bloodless. (3) A complete removal of the lymph-glands and ducts most likely to be involved is quite possible. (4) As the bowel is securely

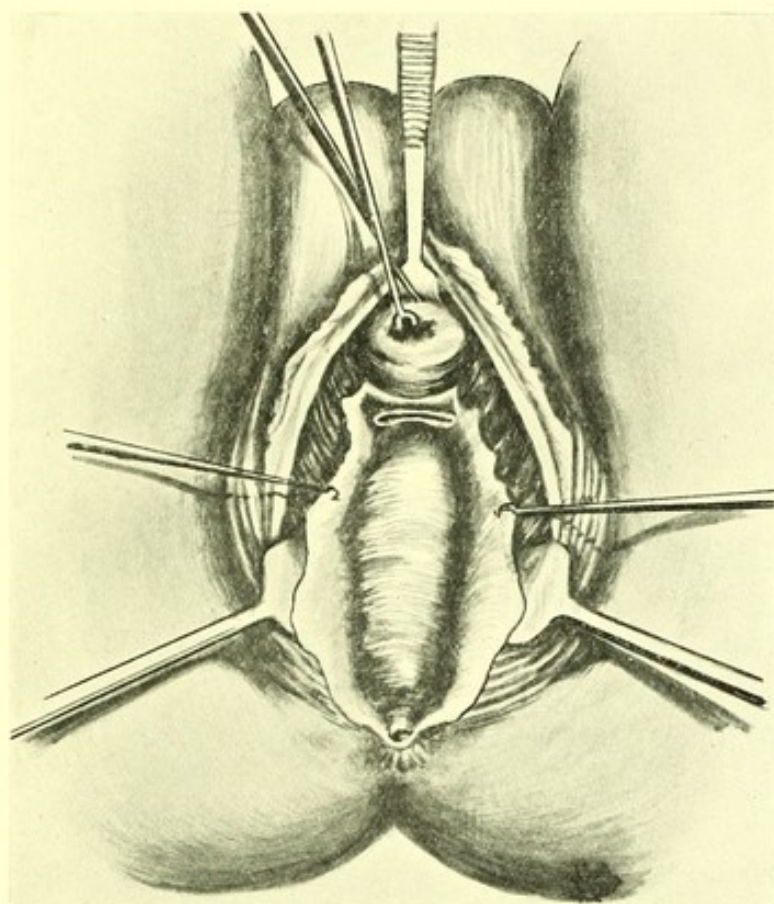


FIG. 156. Vaginal Excision of the Rectum, stage 2.  
Reflection of flaps of vaginal wall from the rectum (Murphy).

tied above, and possibly below the disease, wound-soiling from intestinal contents is reduced to a minimum.

These are very important advantages. Many cases which have been treated by trans-sacral incision would, I believe, have given a better result by this method, which has hitherto only been adopted in very extensive cancers of the rectum, and usually terminated by bringing out the divided colon either at the original abdominal wound or through



a separate incision in the iliac region. If it is necessary to terminate the case by a permanent colotomy, this must be considered a very serious objection, but I am convinced that it is possible to bring the divided colon down to, and fix it to, the anus in a large proportion of cases, without any wound whatever of the anal canal or pelvic diaphragm, and so obtain a perfect sphincteric control. The operation is best conducted as follows. The preliminary preparation having been

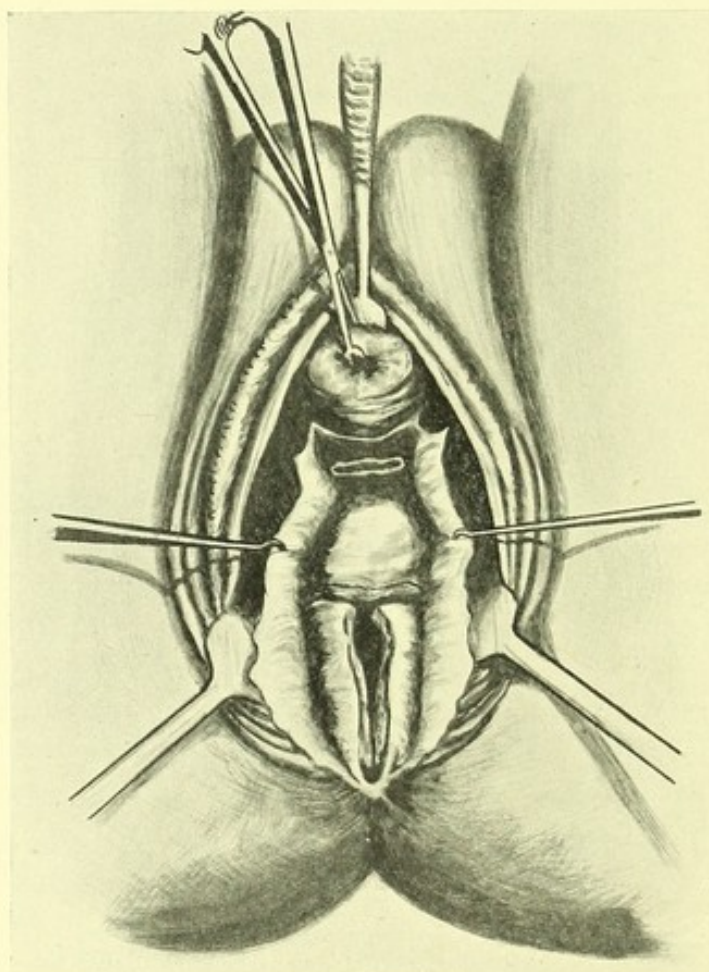


FIG. 157. Vaginal Excision of the Rectum, stage 3.

Rectum laid open and cut across below the site of disease (Murphy).

carried out as previously indicated, the patient is placed in the Trendelenberg position, as nearly vertical as possible, in order that the intestines may fall out of the pelvis and so give plenty of room (Fig. 161). The abdomen is opened by a long vertical incision, which separates the fibres of the left rectus muscle, and the extent of disease is determined. If movable, and the peritoneum free from infection, excision may be



proceeded with. A loop of pelvic colon is drawn out, and the point at which the meso-colon is longest determined. The average greatest length is about 6 inches, and, if found as long as this, the divided colon can be brought to the anus without undue tension. If, however, it proves to be considerably shorter than this limit, the case will probably have to be terminated by colotomy. The colon is ligatured, after crushing, firmly in two places, and divided, the cut ends being disinfected with pure carbolic acid and tied up in aseptic gauze. It will be observed that

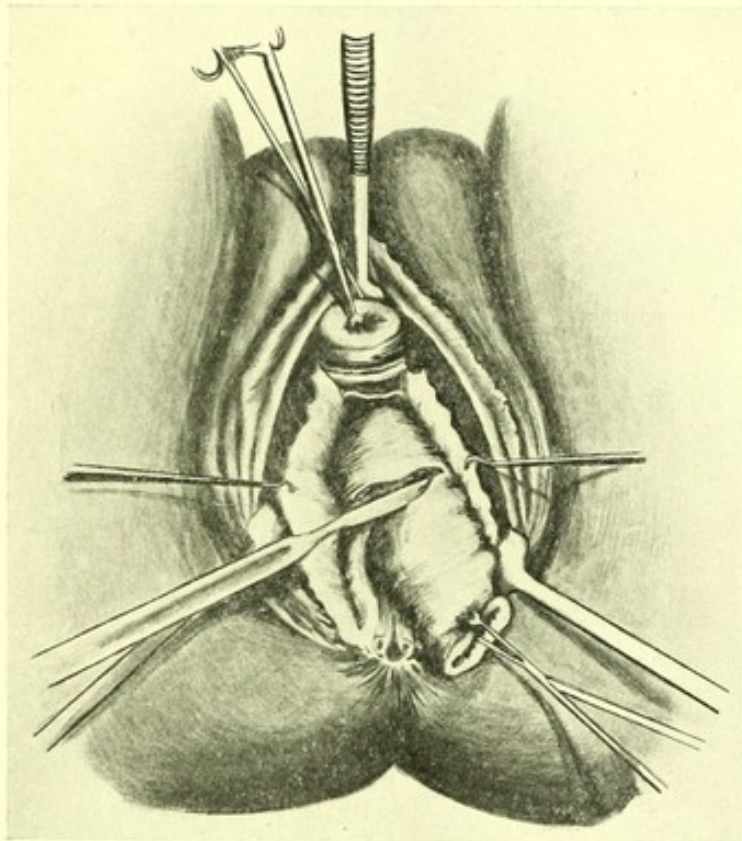


FIG. 158. Vaginal Excision of the Rectum, stage 4.  
Resection of portion of rectum involved in the disease (Murphy).

the point selected for division has no direct reference to the seat of disease, it is chosen so as to give as long a meso-colon as possible. The meso-colon is now divided between clamps down to its attachment, and if the Paquelin cautery is used, top-sewing of the divided edge is rendered unnecessary. The attachments of the lower portion are ligatured piece by piece, and divided until a point is reached at which the posterior surface of the rectum ceases to be covered by peritoneum; the superior haemorrhoidal artery will have been ligatured in the lower



portion of the meso-colon thus tied. The lateral ligaments are then tied with the peritoneum covering them and divided, these will include the middle haemorrhoidal artery upon each side. The peritoneum in front,

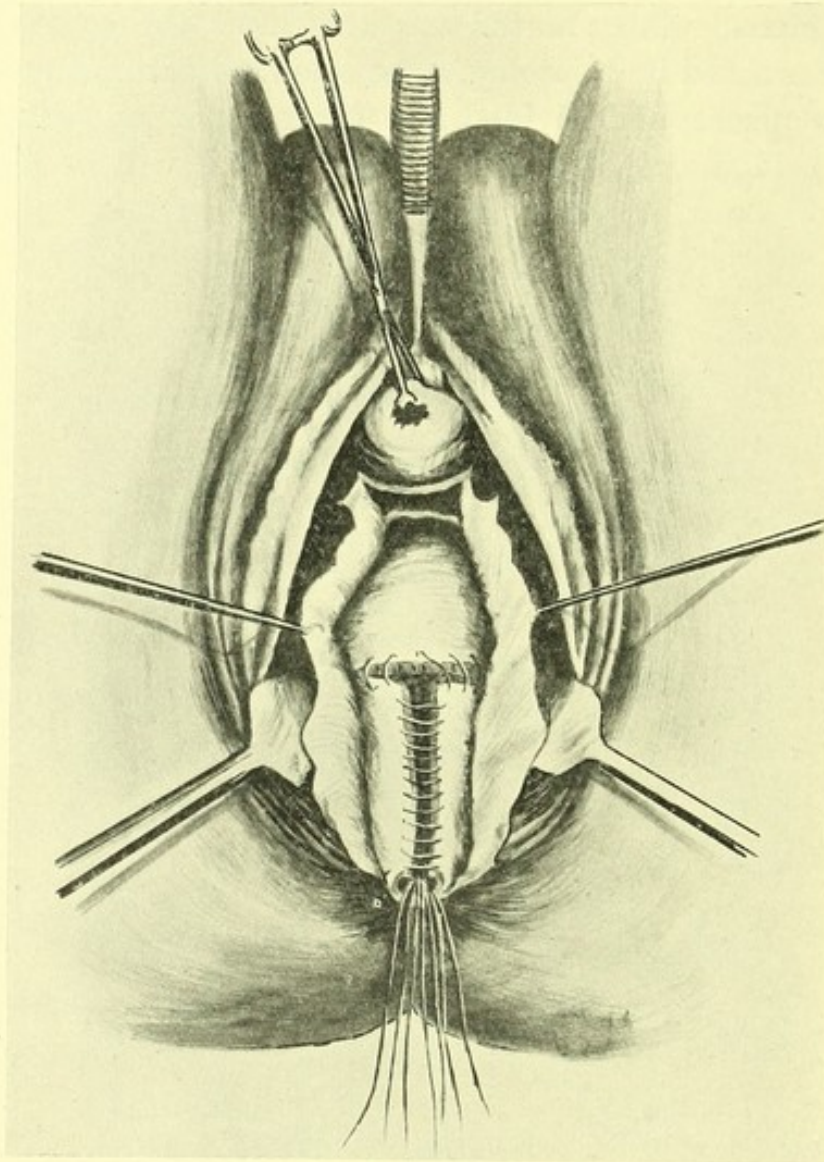


FIG. 159. Vaginal Excision of the Rectum, stage 5.

Restoration of the rectum by sutures tied on the inside of the bowel, the ends left long and protruding at the anus to give greater facility for removal (Murphy).

as it is reflected off the front of the rectum, is now divided, thus completing the separation of the peritoneum from the rectum.

By blunt dissection, the bowel can now be cleared down to the pelvic diaphragm, and, if possible, firmly ligatured below the seat of disease. An assistant should thoroughly wash out the anal canal and



rectum up to the point at which it is ligatured, after which it may be divided from above, but below the seat of ligature. The end of the colon is brought out at the anus and fixed there, after the mucous membrane of the lower segment has been dissected away after the method of Moulonguet. This appears preferable to any attempt at end-

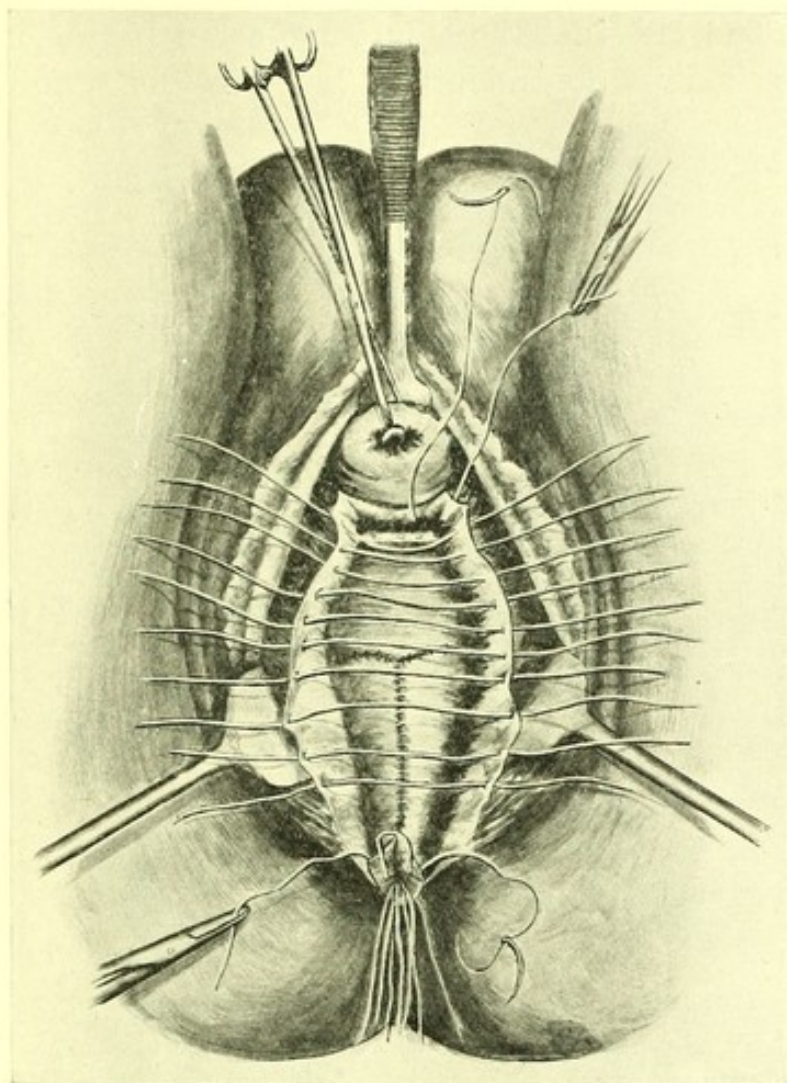


FIG. 160. Vaginal Excision of the Rectum, stage 6.

The incisions in the peritoneum and in the posterior vaginal wall being closed by suture (Murphy).

to-end junction, for reasons already given. If it is thought desirable to employ drainage, an incision for the insertion of a tube, or iodoform gauze, can be made through the pelvic diaphragm at the apex of the coccyx. In three cases of this operation I had no difficulty in bringing down the pelvic colon to the anus as above described. Where the meso-colon is too short, the operation has usually been completed by colotomy.



Kummell of Hamburg ('*Epitome of Current Medical Literature*,' *Brit. Med. Journal*, March 29, 1902) has demonstrated that when the meso-colon is too short to permit of the pelvic colon being brought down to the anus, the transverse colon may be divided in the neighbourhood of the splenic flexure, and its proximal end brought down to the anus, or joined end to end to the divided rectum, the distal end being inverted and sutured. The fact that the transverse colon has a larger marginal artery renders it less dependent on blood-vessels running into it at

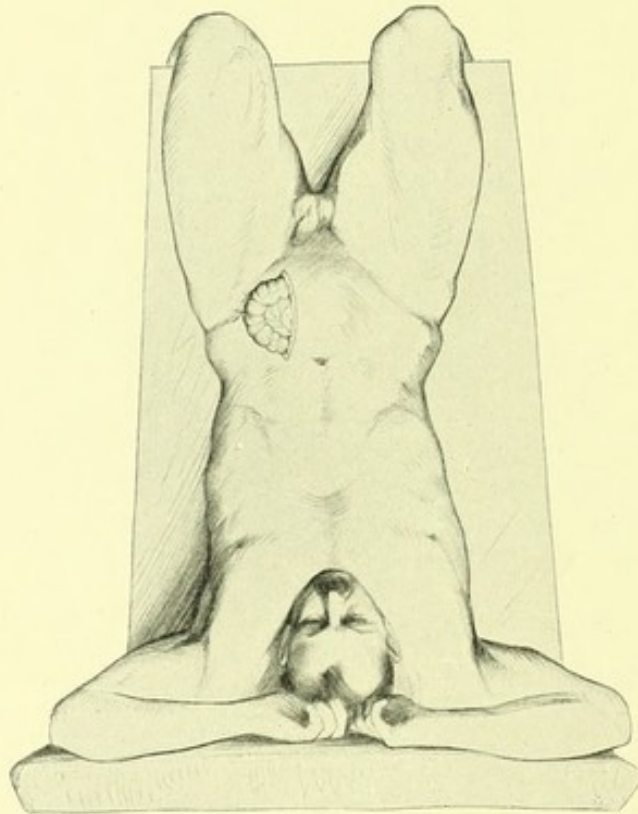


FIG. 161. Abdominal Excision of the Rectum, stage 1.

Patient in high Trendelenberg position. The summit of the loop of pelvic colon with the longest meso-colon drawn out at the abdominal wound and ligatured in two places.

right angles to its axis, and consequently the mesentery can be freely divided with less risk to the vitality of the bowel than is the case with the pelvic meso-colon. This suggestion appears to be well worth consideration in certain cases as an alternative to terminating the operation by artificial anus; it is of course necessary to fix the open lower end of the portion of colon thus interrupted to the abdominal wound, thus forming a colostomy, which although not acting as a faecal outlet must be attended with some mucous discharge.



Dr. Louisa Aldrick-Blake suggests (*Brit. Med. Journal*, Dec. 19, 1903) a combination of abdominal and perineal routes in which the abdominal wound is closed before the bowel is opened. With the patient in the Trendelenberg position the abdomen is opened and the limits of the disease determined, the reflexion of the peritoneum from the rectum is divided above the disease by a V-shaped incision, and the diseased rectum thoroughly mobilized down to the tip of the coccyx.

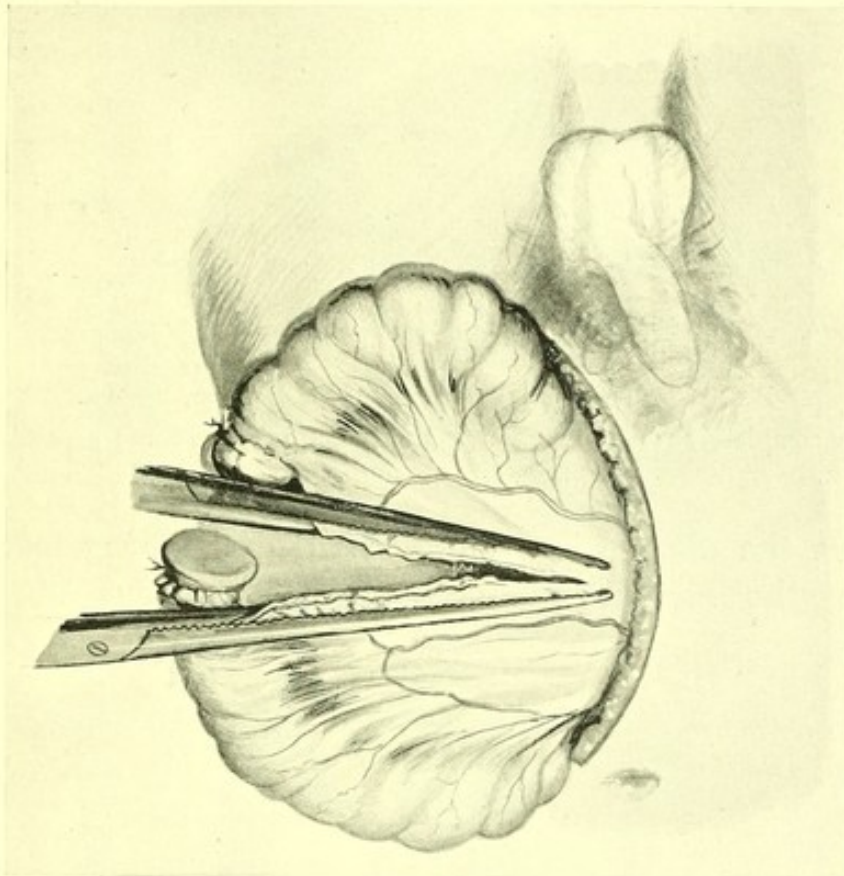


FIG. 162. Abdominal Excision of the Rectum, stage 2.

The colon has been cut across between two ligatures, and the ends tied up in sterilized gauze. The meso-colon has been divided, between clamp forceps, down to its attachment by means of a Paquelin cautery.

The peri-rectal tissue and glands in the hollow of the sacrum are detached with the bowel, the superior and two middle haemorrhoidal arteries ligatured and divided, and the pelvic meso-colon divided as far as may be necessary to allow a perfectly healthy portion of the pelvic colon to reach the anus without undue tension. A silk suture is then placed for the purpose of subsequent identification at the point at which it is intended to divide the bowel. The pelvic colon is now crowded



down into the pelvis, and the flap of peritoneum carefully sutured to the pelvic colon higher up and the abdominal wound closed. By perineal

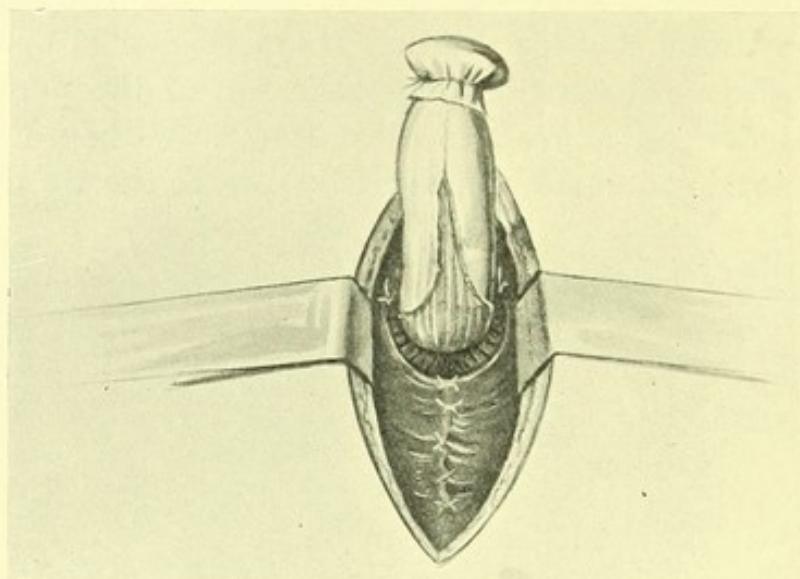


FIG. 163. Abdominal Excision of the Rectum, stage 3.

The rectum completely freed from its peritoneal attachments and separated down to the pelvic diaphragm.

incision now, the disease is again exposed and, owing to the previous mobilization, the rectum can easily be drawn out at the wound,

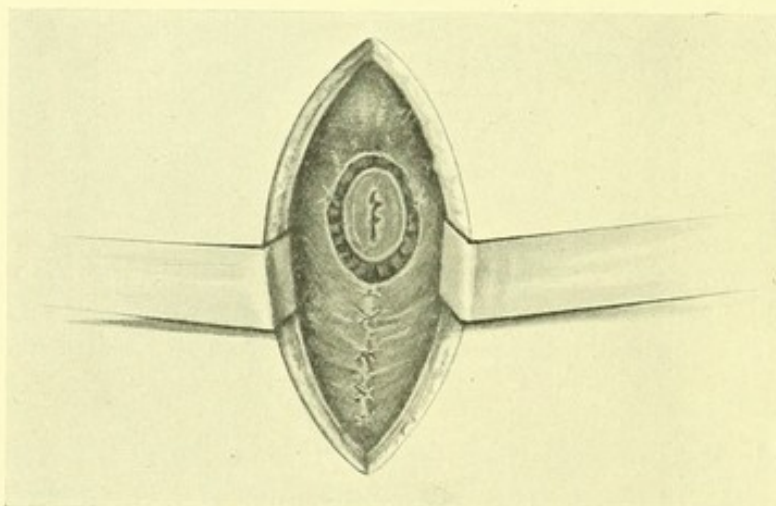


FIG. 164. Abdominal Excision of the Rectum, stage 4.

The rectum has been ligatured below the site of disease and cut across at its junction with the anal canal.

amputated at the point indicated by the silk suture, and the operation completed in the ordinary way.



**Results of operations for cancer.** To give statistics of the results of all cases of cancer operations appears to be useless, as they vary greatly in degree of severity. If very rigid selection of cases is employed and only the most favourable operated on, very good statistics both as to operation mortality and recurrence may be obtained; whereas the immediate mortality and rapid recurrence must be considerable when extensive operations are undertaken. Even with our most approved

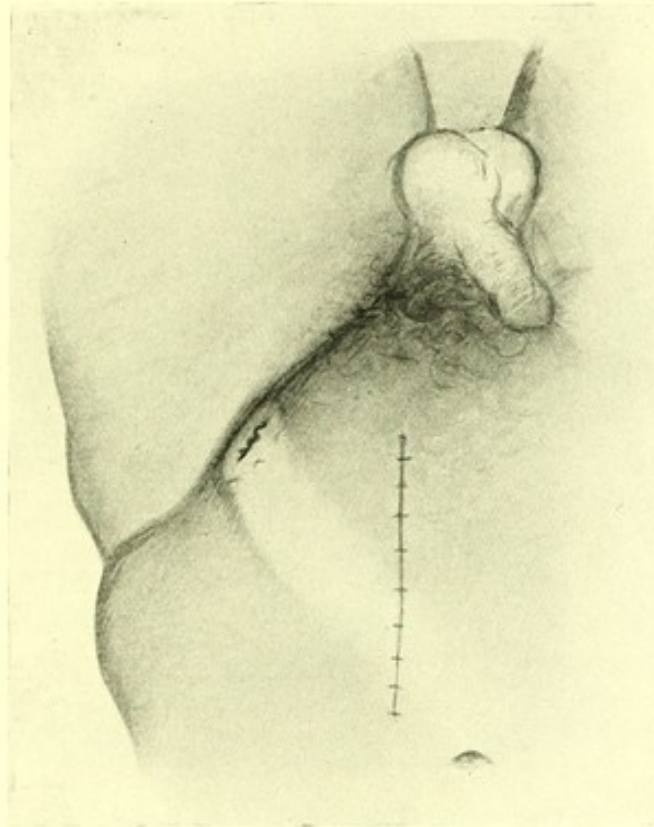


FIG. 165. Abdominal Excision of the Rectum.

Completion of the operation by colotomy when the meso-colon is not sufficiently long to admit of the bowel being brought out at the anus.

technique, stercoral fouling is to some extent almost always present, so that the dangers of sepsis cannot at all times be obviated. Much has, however, been done by preliminary preparation, and the use of clamps and ligatures, to reduce the extent of stercoral fouling within narrow limits, so that cases of severe sepsis are not now so frequently met with as they used to be.

It may, however, be broadly stated as a result of consideration of statistics published by reliable authorities, that in severe cases a mortality



death-rate of 10 per cent. must be considered good, but that the rate should not reach 20 per cent. As compared with other operations these rates must appear high, and they show that the operation is not lightly to be undertaken. Similarly, in regard to statistics of recurrence, these also vary according to the extent of disease. It may, however, be confidently asserted that the prospect of non-recurrence is good if the perirectal structures are not implicated, and bad if they are at all seriously involved.

**Palliative treatment of cancer of the rectum.** The medical

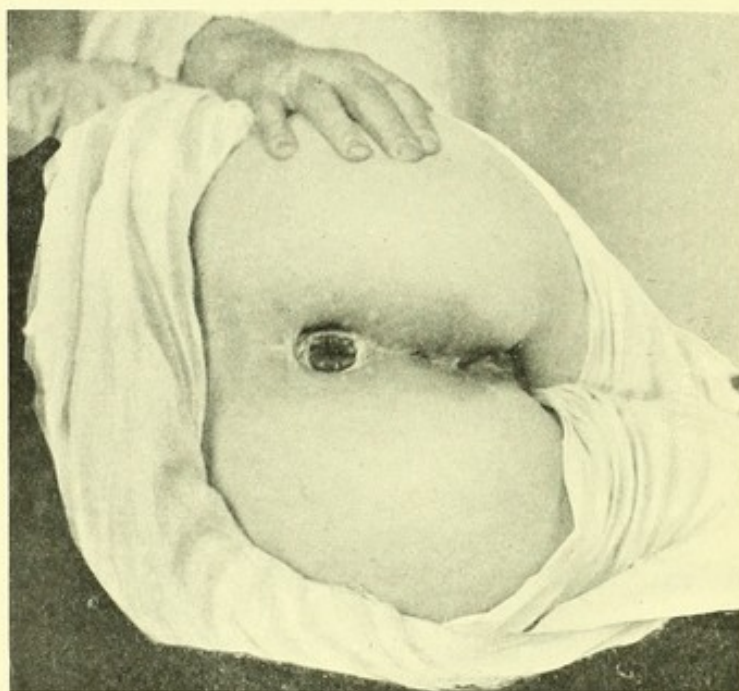


FIG. 166. Sacral Anus, six years after the entire Rectum and Anal Canal had been removed for Cancer.

*(Reproduction of photograph.)*

treatment of inoperable cancer of the rectum presents two chief points which must be borne in mind. First, to ensure that the bowels are kept sufficiently free to obviate the occurrence of faecal accumulation above the disease, and secondly, to supervise the use of morphia and other narcotics. In order to relieve pain, morphia, either hypodermically, in the form of suppositories, or internally, is frequently used somewhat recklessly, with the result that there is superadded to the miseries of the rectal cancer the mental suffering and total inability to bear physical pain of the morphia habit, so that, unless used with a very sparing hand,



opium, instead of rendering the remainder of life more comfortable, adds to its suffering.

The use of bougies, or any dilating instrument, is attended with extreme danger, several cases of fatal rupture having been induced by this means.

If the bowel is so much encroached upon that mechanical obstruction is impending, colotomy must be resorted to, but I am satisfied that the routine treatment by colotomy in all cases of cancer of the rectum unsuitable for radical operation is as unscientific as it is unnecessary; a large number of inoperable cases reach a fatal termination without obstruction becoming marked; such patients pass away in greater comfort than if they had been subjected to colotomy. The argument sometimes used, that by placing the diseased structures at physiological rest the progress is rendered less rapid, is an attractive one, but it is not borne out by practical experience.

On the other hand, where obstruction is threatened, colotomy should not be unduly delayed. Meteorism should not be allowed to become marked, and if possible the operation should be undertaken before large faecal masses form in the colon above the disease. We sometimes see the entire colon packed with scybala as large as billiard balls or even the closed fist, under these conditions even an extensive colotomy may fail in providing for their evacuation. When done in time, the risk of colotomy is trivial.

Formerly, while the death-rate after colotomy was considerable, alternatives were occasionally employed. (1) Clearing the obstruction by curetting away masses of cancer, and (2) linear proctotomy or posterior incision through the entire length of the obstructed bowel. As both these methods are less efficient and much more dangerous than colotomy, they may well be considered obsolete.



## CHAPTER XX

### COLOTOMY

WHEN the resources of modern surgery fail to save a diseased or shattered limb, amputation as a last resort becomes necessary to save life, so, in cases of rectal disease, direct treatment may be impracticable, and colotomy the only means at our disposal to obviate obstruction, and so relieve suffering and prolong life.

By the word 'colotomy' is meant, the making of an artificial outlet for faeces in the colon, the word 'colostomy' being sometimes used as a substitute—the association of a word meaning intestinal mouth, with an outlet instead of an inlet, being defended by the use of the term 'mouth of a river'. The former is, however, generally used and well understood, so it will be employed here.

As the object of this operation is to provide an alternative outlet for intestinal contents, through which more or less incontinence of faeces is a necessary result, it follows that the condition of the patient afterwards is by no means pleasant to himself or to those about him; it is therefore only to be undertaken when the indications are imperative, and after the patient has been fully told of the inevitable result of the operation. When obstruction is marked, patients suffer so much pain and distress that they generally gladly accept the conditions, and when the operation is successful in relieving urgent symptoms, are loud in their thanks for the relief obtained. A surgeon who fails to recommend colotomy in urgent cases is, in my mind as guilty of dereliction of duty as if he refused to sanction tracheotomy for the relief of a patient suffering from obstructed glottis.

It is necessary to clearly indicate the conditions calling for this operation, and they may be conveniently grouped under the following heads: (1) Developmental defects which cannot be relieved by perineal incision. (2) For the relief of distress attending recto-vesical fistula.



(3) For obstruction, the result of (a) pressure of tumours, (b) cancer of the bowel, (c) non-malignant strictures, which are of such an extent as to preclude perineal operation. (4) As a means of treating extensive ulceration and other conditions, by providing physiological rest to the part.

1. The question of colotomy in developmental defects of the rectum has been dealt with elsewhere (p. 52).

2. Cases of recto-vesical fistulae not amenable to direct treatment from the miserable conditions present, urgently demand relief by colotomy (p. 116).

3. The vast majority of cases in which colotomy is indicated are cases of cancerous obstruction of the rectum, in which radical operation is impracticable (see p. 289). In a few cases obstruction, the result of pressure from external tumours, or of stricture of syphilitic origin, may require like treatment.

4. Temporary colotomy has been done to allow physiological rest in cases of extensive ulceration of the rectum, and also for the cure of membranous colitis; such cases are, however, unusual.

**Site of operation.** Almost any portion of the large intestine, from the caecum to the pelvic colon, may be opened to form an artificial anus, but for disease of the rectum only two situations require consideration—the descending colon where it is in part uncovered by peritoneum, and the pelvic colon.

**Lumbar colotomy** was the operation almost always selected, except in cases of congenital malformation, until within the last twenty years, the advantage claimed for it being, that it was possible to open the colon by incision through the lumbar muscles, without injuring the peritoneum. Since, however, the peritoneum has ceased to be a source of anxiety to the surgeon, anterior, or laparo-colotomy, has come to be almost universally preferred. The objections to the lumbar operation are, that it does not give an opportunity of estimating the upper limits of disease; the wound is deeper, opening up inter-muscular spaces which are liable to infection from the septic contents of the bowel; difficulty is often experienced in finding an uncovered portion of the colon, and consequently the peritoneum may be opened—finally, the position of the artificial anus is inconvenient for the patient to attend to. The posterior operation had only one real advantage: in cases of obstruction with extreme meteorism, protrusion of dilated small intestine when the peritoneum was opened, was troublesome to deal with and difficult to replace; now,



however, the method of intestinal drainage recommended by the late Mr. Greig Smith obviates this serious complication. We must therefore consider the operation of lumbar colotomy obsolete; consequently, it is unnecessary to describe it.

**Anterior colotomy, or laparo-colotomy**, where the pelvic colon is opened, is now recognized as the proper operation for all cases of rectal disease requiring the formation of an artificial anus. It allows, if there is not much meteorism, a complete investigation of the upper limits of disease, which should always, if possible, be carried out. It occasionally enables the surgeon to substitute for colotomy the more radical operation of excision, while if excision be not possible, there is the certainty that the opening in the colon will be above the disease. The wound is not so deep, and there is less opening up of inter-muscular planes and consequently less fear of wound infection. Lastly, the artificial anus is more conveniently under the control of the patient.

The form of operation varies according as to whether, (1) the obstruction is not pronounced, so that the bowel can be thoroughly evacuated by purgatives and enemata before operation, and the abdomen is therefore not unduly distended. (2) There is chronic obstruction, the colon being loaded with large masses of scybala, which cannot be evacuated before operation, but the abdomen is not much distended with flatus. (3) The symptoms of obstruction are urgent, with an extreme degree of meteorism and probably faecal vomiting. (4) The operation is undertaken as a temporary measure with a view to its closure at a subsequent period.

In the above classification we may take the first as the one in which colotomy is most frequently demanded, and to which the typical operation is alone applicable. In these cases the symptoms of obstruction have been gradually developing, but have not as yet become complete, and no great distention of the bowel above the stricture has taken place.

The patient should undergo preparation for a few days previous to operation, by purgatives and the use of enemata. A vertical incision about 2 inches long is made over the outer portion of the left rectus abdominis muscle, the fibres of this muscle split by blunt dissection, and the peritoneum opened in the usual way; a finger should now be introduced into the pelvis, and the upper limits of the disease made out. If, as a result of this investigation, the removal of the disease by excision is considered to be impossible, the operation is proceeded with, a loop of pelvic colon is drawn out at the wound, the appendices



epiploicae and longitudinal bands serving to distinguish it from small intestine. If the loop first seized has not a sufficiently long pelvic meso-colon to allow it to be well drawn out through the wound, it should be

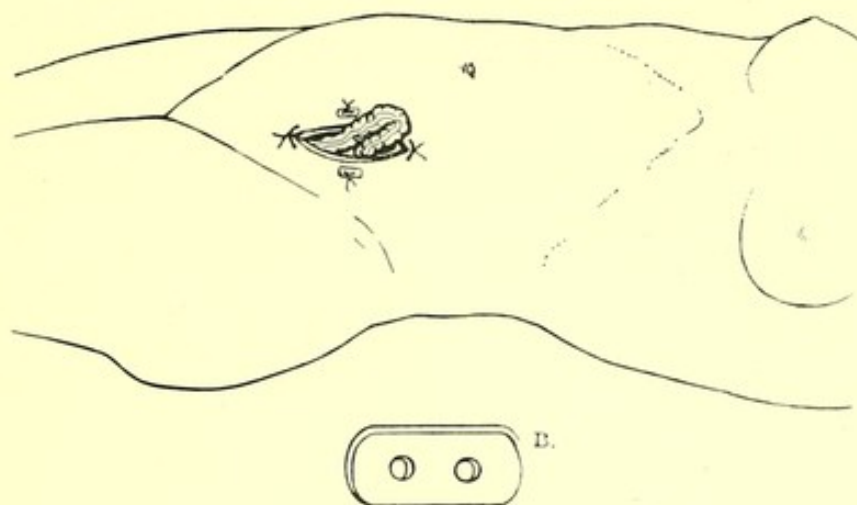


FIG. 167. Colotomy.

An incision has been made into the abdomen by splitting the fibres of the left rectus muscle, and a loop of pelvic colon with its meso-colon withdrawn. A retaining double suture has been passed through the entire thickness of the abdominal wall on each side, through the pelvic meso-colon, and tied over lead buttons B. The angles of the wound are closed by sutures, which also pass through the muscular coat of the intestine underneath a longitudinal band.

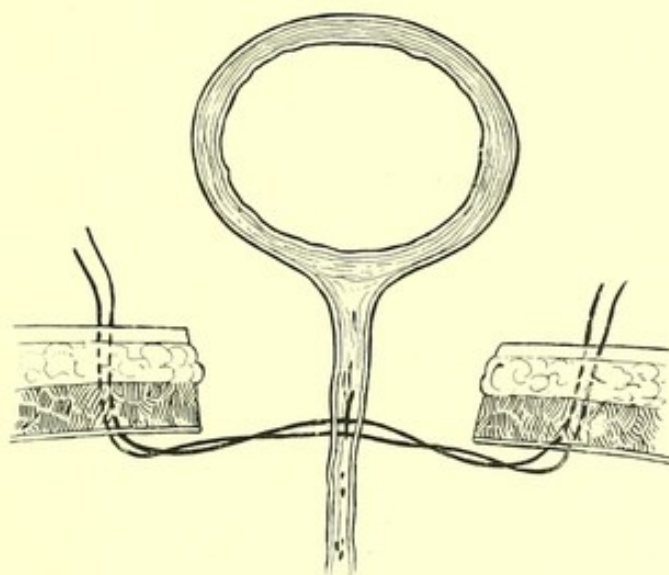


FIG. 168. Colotomy. Method of Suturing the Colon to the Abdominal Wall, I.

A double ligature has been passed through the abdominal wall and through the pelvic meso-colon.

replaced and a piece with longer meso-colon sought for. Occasionally, as a result of too short meso-colon or adhesions, it is impossible to draw out a full loop, so as to expose meso-colon above the level of the skin,



without undue tension, but this very rarely happens. It is desirable that a sufficient loop should be drawn out so that, when it is subsequently

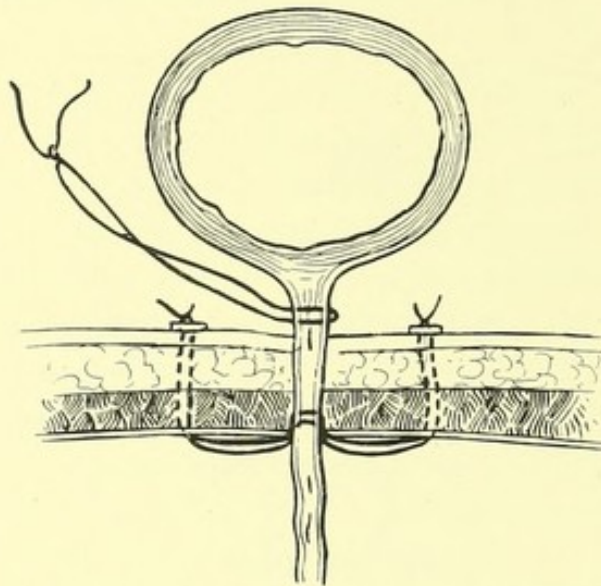


FIG. 169. Colotomy. Method of Suturing the Colon to the Abdominal Wall, II.

The double ligature is shown tied over lead buttons, and a ligature placed in position to control the arteries of the pelvic colon when the second stage of the operation is undertaken.

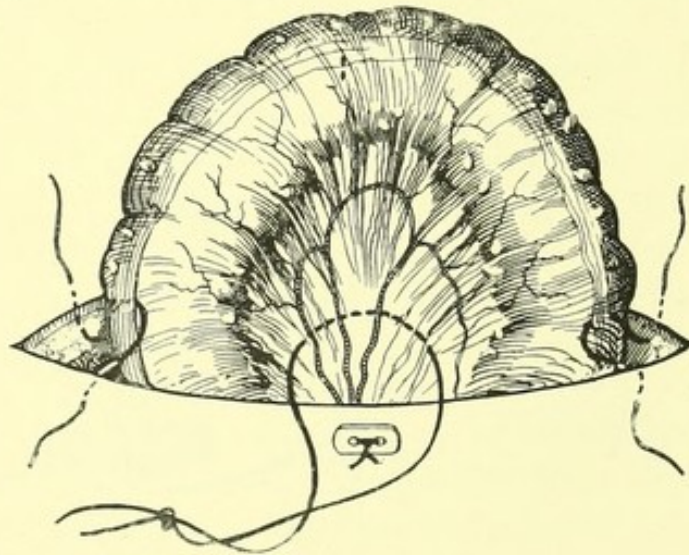


FIG. 170. Colotomy. Method of Suturing the Colon to the Abdominal Wall, III.

Lateral view, showing button suture closed, sutures placed at angles of wound through abdominal wall and under taenia of colon. A ligature is placed in position round the meso-colic vessels to be tied before the loop of intestine is cut off.

cut off level with the skin, the upper and lower openings of the bowel shall be distinct, and separate from one another like the openings of



a double-barrelled gun. The loop is now fixed in the wound, and several methods of doing this have been described; after trial of many of them I consider the following to be the best way. A large-sized full-curved needle is threaded with moderately thick silk and passed through the entire thickness of the abdominal wall, including peritoneum, about 1 inch from the middle of the wound upon one side, then through the pelvic meso-colon at a point where no large vessels are seen, and out through the entire thickness of the abdominal wall at a corresponding point on the opposite side of the wound. The needle is cut off, leaving a double strand of silk to form the suture, and each end of the double suture threaded through small lead buttons, each of which has two

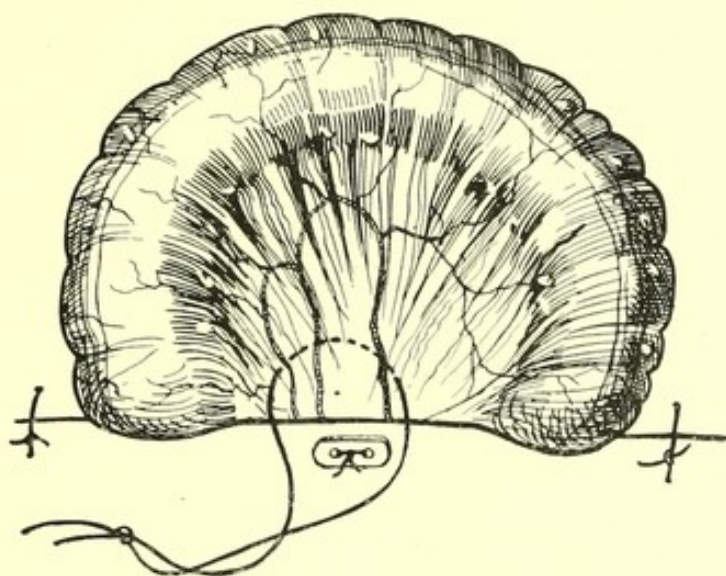


FIG. 171. Colotomy. First stage of operation completed.

holes in it; if these are not at hand common bone, or metal buttons such as are used by tailors, will answer quite as well, but buttons made of horn are not suitable, as they will not stand preliminary boiling. The double suture is tied over the button on each side of the wound, sufficiently tightly to keep the skin edge in close apposition to the bowel and meso-colon. A single suture is passed at each angle of the wound through the entire thickness of the abdominal wall and underneath a longitudinal band of muscle on the colon, but not including its mucous membrane. These sutures are quite sufficient to retain the loop of colon without risk of hernia of small intestine through the wound beside it, and if properly applied the skin margins and peritoneum covering bowel



should be evenly in contact all round. If there should be any irregularity, it is easily remedied by a few additional points of superficial suture.

It is customary to defer the opening of the bowel for a few days until it has contracted adhesions to the wound, and where the intestine has been well cleared out before operation, it is as well to follow this practice, although I am convinced that the risk of immediate opening has been much over-estimated. If it is decided to delay the opening, a piece of sterilized protective should be laid over the colon, because, if a dry gauze sponge is applied directly to it, so much lymph is exuded by the exposed peritoneum that it adheres somewhat tightly to the loose meshes of the gauze.

Delayed opening of the colon is usually undertaken on the third day, but may be done earlier if necessary, as the intestine becomes adherent to the wound in a few hours. Before opening, the wound surface, suture points, and surrounding skin, for a radius of several inches, should be washed with alcohol, dried, and saturated with balsam of Peru, which adheres closely and tends to prevent irritation from faecal soiling. The best method is to cut off the entire loop with its meso-colon flush with the skin, and for this purpose it is unnecessary to give an anaesthetic, as the bowel is quite insensitive, no pain being complained of if care is taken to prevent disturbance of the wound in the abdominal wall. Bleeding is usually smart, but it will be much diminished if at the preliminary operation a ligature has been applied to the meso-colon, so as to include all the vessels in it. This can be readily done by passing the ligature with a needle through the meso-colon close to the bowel on one side, just below the level of the point selected for the button suture, and bringing it back through the meso-colon close to the bowel on the other side. I have many times done this, leaving the ligature in position, but unclosed at the first operation, and tying it immediately before cutting the loop off.

When complete, both openings should appear distinct and separated from one another by the divided meso-colon, and on a level with the skin. The sutures may be removed on the eighth day. Loose absorbent dressings should be applied, and purgatives administered if there has been no motion twenty-four hours after the colon has been opened. The dressings must be removed when soiled with faeces, the wound and surrounding skin washed first with water, then with alcohol, and balsam of Peru again applied to prevent faecal irritation, and fresh absorbent dressing put on.



The method described is simple, rapid, and quite effectual. Some surgeons have, in the endeavour to still further simplify this operation, used less perfect methods of suturing, or even dispensed with sutures altogether, relying on a glass rod or probe passed through the meso-colon, and resting on the abdominal wall on either side of the incision, to retain the loop of gut. Such a method is highly dangerous, and has been attended with fatal consequences, hernia of the small intestine taking place beside the colon, while on the other hand, when not sufficiently secured by suture, the colon has slipped back into the abdominal cavity. If the directions above given are adhered to, neither of these accidents could possibly occur, provided the wound is not longer than 2 inches. If from extreme thickness of the abdominal wall it is necessary to make the incision longer than 2 inches, it would be wise, as an additional precaution, to pass a few points of interrupted suture through the skin and muscular coat of the bowel.

2. We occasionally meet with cases, usually of slow-growing cancer of the rectum, in which there is an accumulation of solid masses of faeces above the stricture, blocking the entire large intestine round to the caecum, but unattended by flatulent distension, and in which attempts to dislodge this accumulation through the stricture by purgatives and enemata are quite futile, so that the abdomen remains flaccid and the scybala are easily palpable through the abdominal wall. Such cases call for immediate colotomy. Even if the original cancer is of such a nature that its relief by excision may be possible, preliminary colotomy is indicated, as clearance out of the scybala is the first essential. In such cases it is more probable that no radical operation can be contemplated and a permanent artificial anus must be established, the operation required being of the same character as that already described, except that the opening should be made into the bowel at once, and the abdominal wound sufficiently large to avoid any constriction of the orifice.

After the colotomy is completed, attempts should at once be made by means of purgatives, the use of enemata through a stomach tube passed far up the large intestine from the colotomy opening, and of a scoop to evacuate the loaded bowel. These attempts may have to be repeated as other faecal masses come down to take the place of those already removed. In one case of this kind, although I removed enormous quantities in this way, the bowel never regained its tone, and the patient died. At the *post mortem* we found that only the pelvic and part of the



descending colon had been cleared; the rest of the large intestine was packed with masses as big as cricket-balls.

3. When the symptoms of intestinal obstruction are acute, the abdomen being tightly distended, and faecal vomiting possibly present, immediate operation is imperative, but, as is well known, laparotomy under these circumstances is attended with risk of protrusion of dilated small intestine to such an extent as to prevent useful investigation of the site of disease, and the protruded loops relieved of the support of the abdominal wall dilate still more, so that their return, unless they are evacuated, may be impossible. Under these conditions, intestinal drainage as introduced by the late Mr. Greig Smith is the right procedure. A small incision only large enough to admit the index finger is made into the peritoneum in the position above indicated. Immediately the opening is made the finger is introduced, which prevents protrusion. Dilated large intestine is now felt for; if this can be made to present at the incision, it is to be caught with catch forceps, and the parietal peritoneum sutured to the serous coat of the bowel all round the opening. The bowel is then to be opened by an incision large enough to insert a  $\frac{1}{2}$ -inch rubber tube, which is sutured with catgut to the intestine. If it is impossible to make large intestine to present at the incision, it is probably safer to make the opening in the nearest dilated loop of small intestine, than to enlarge the opening in search of the pelvic colon. In favourable cases there will be abundant discharge of flatus and faeces, the symptoms of obstruction are rapidly relieved, and the abdomen in a few days resumes its normal flaccid condition; the case can then be dealt with as may be required, by excision or colotomy. This little operation has been the means of saving many lives that would have been lost had a more extensive laparotomy been performed in the first instance. It can easily be done by means of local infiltration-anaesthesia. It is not even necessary to remove the patient from bed.

4. Temporary colotomy may occasionally be required as a preliminary to excision, where it is impossible to evacuate the bowel previous to operation; and possibly, in certain cases, to afford physiological rest to a diseased rectum. Under these circumstances an entire loop of intestine should not be drawn out at the wound, but a portion of the surface of pelvic colon opposite to its mesenteric attachment is sutured with catgut to the edges of peritoneum and transversalis fascia where they have been divided in the primary incision, but not to the



skin. After adhesions have formed in a few days, the colon can be opened by incision in its long axis. Colotomy thus formed can be closed, if required subsequently, by paring the edges and suture, but when a loop has been drawn out and cut off, a more extensive operation is necessary to close it (see p. 30).

**Prognosis.** It is quite useless to quote statistics of the result of colotomy as the cases vary so greatly. If the operation is done before obstruction is pronounced, the immediate risk is quite trivial, indicating that the inherent danger of colotomy when properly performed is almost negligible. If, on the contrary, the entire colon is packed with solid faeces, it may be impossible to procure efficient evacuation through an artificial anus, and death will ensue, or if the intestines are enormously distended with gas and fluid faeces due to bacterial changes in the contents, the result of obstruction, the bowel may be unable to recover its contractile power or death may result from septic absorption. A very copious flow, immediately the intestine is opened, of thin offensive faeces, frothy, like barm, from admixture with bubbles of gas, is a very unfavourable symptom, as indicating profound bacterial change in the intestinal contents.

The ultimate result of colotomy of course depends on the nature of the case for which it is employed. If for cancer of the rectum, the disease runs its course unchecked, and the idea that colotomy in an early stage of cancer of the rectum retards its growth by affording physiological rest to the part is, to say the least, problematical; if, on the contrary, colotomy has been performed for non-malignant disease which does not of itself influence vitality, there may be no limit to the time a patient may live with an artificial anus.

**After-treatment.** At first there may be no motion for some days after the gut is opened, and it is then necessary to give purgatives, after which the evacuations continue frequent, and the dressings have to be often changed. As time goes on, however, the intestine accommodates itself to the altered conditions. We often see cases that have but one normal evacuation each day, and the patients know when it is coming sufficiently long beforehand to make the necessary preparations, but have no power of controlling it. Such persons may have a tolerable existence, and may be able to get about and attend to business.

After the wound is healed, a belt with a rubber pad, having a pneumatic tube border, should be fitted on; a little tenax or other



deodorizing absorbent should be kept in the hollow of the pad, to prevent soiling of the clothes by the escape of mucus or thin faeces—or in other cases a truss with a metal plate controlled by a spring answers better.

Formerly trouble was occasioned by faeces passing the opening and getting into the lower portion of pelvic colon, and operations for the closure of the lower opening have been undertaken; but no trouble of this kind will ensue if the operation has been conducted as above described, the stump of meso-colon between the two openings forming an effectual 'spur' which will ensure the delivery of the faeces outside




FIG. 172. A Belt for use after Colotomy.

It is made of waterproof webbing, and is provided with a rubber pad with a pneumatic tube border. In the centre of the pad there is a pneumatic prominence to adjust to the colotomy opening and prevent prolapse of the bowel.

the body. It is an advantage to retain the lower opening, as it enables the rectum to be washed out periodically by means of a tube; this, especially in cancer cases, gives considerable relief to the patient.

**Prolapse and hernia** are somewhat frequent complications of colotomy. There is a tendency for prolapse of the colon to take place through the upper opening and more rarely through the lower. Much can be done to obviate the occurrence of prolapse at the original operation, if care is taken to select a high loop of pelvic colon and draw it out sufficiently far for the upper portion to be simply a straight tube from the attached iliac colon to the abdominal wound. Ventral hernia also is sometimes met with at either or both sides of the colotomy



opening; it is probably the result of making too large an incision in the abdominal wall. If the opening made is only just large enough to accommodate the loop of pelvic colon withdrawn, hernia is not likely to occur. Both these complications, when present, are best treated by using a colotomy truss instead of belt.

**Atrophic changes** in the lower segment occur as the result of disuse, the mucous membrane becomes thinner and paler in colour, and in a specimen preserved in the Hunterian Museum, no. 2591 (Fig. 173), taken from a case of colotomy of thirty years' standing, the mucous membrane had become villous. These changes have been cited in support of the theory that colotomy may inhibit the growth of cancer of the rectum; it is unsafe to argue that the adenomatous tissue of malignant disease is affected in the same way as normal tissues by disuse, and clinical experience certainly does not bear out this contention.

**Adenoma** of the exposed mucous membrane is sometimes seen (see p. 214); it is not of much surgical consequence.

**Closure of old-standing colotomy wounds.** It occasionally happens that colotomy has been performed with a view of establishing a permanent artificial anus, and that subsequent unexpected changes have restored the competency of the rectum to discharge its function; the question of closure of the colotomy wound then arises. Two such cases have been under my care, the first, an elderly man who had obstruction with a large cancerous(?) mass in the rectum which appeared to be too adherent to excise. Colotomy was performed; four years subsequently I found the disease in his rectum had disappeared, no discharge came from it except a little mucus, and a large rubber stomach tube could be passed from the lower colotomy wound to the anus, without encountering obstruction. Clearly, I had either made a mistaken




FIG. 173. Villous condition of the Mucous Membrane of the Colon in a case of Colotomy of 30 years' duration.

(Drawn from a photograph of a specimen in the Hunterian Museum.)



diagnosis, or the case was one of those excessively rare instances in which an unequivocal cancer disappears. He had not been under the care of a cancer quack, otherwise, no doubt, the 'cure' would have been loudly proclaimed. The second was a somewhat similar case. A medical man had been colotomized in New Zealand for what was stated to be cancer of his rectum six years previously. I was unable to detect any evidence of the cancer, and the passage of a stomach tube indicated no obstruction. In both of these cases I reverted to the old idea of producing a pressure necrosis of the 'spur' rather than adopting resection, and end-to-end or lateral anastomosis, for the following reasons. The records of excision of old-standing colotomies has hitherto not been satisfactory, and it did not appear to be safe to recall suddenly into activity a considerable portion of the bowel that had been for years functionless. By obliteration of the spur, however, it is possible gradually to restore the function of the lower segment, while the colotomy opening still remains open; then if the rectum functionates normally, the abdominal opening can be easily closed.

The following method was employed in both cases. With the thumb of the left hand in the upper opening, and the index finger in the lower, the walls of the intestine were pinched together, and the absence of a loop of small intestine between them determined. By means of a Kurz needle, a silk ligature was passed from one tube to the other about  $1\frac{1}{2}$  inches from each opening, and the ends drawn out at the respective orifices; a round rubber cord was drawn through by means of the silk ligature and the latter discarded; two narrow bands of aluminium  $1\frac{1}{2}$  inches long, with holes at each end, were threaded with the rubber cord which was tied as tightly as possible, the aluminium plates resting against the bowel wall in each portion. By this means an elastic pressure was obtained compressing the walls of the intestine together, after the manner of the enterotome of Dupuytren, but in a more certain, elastic, and less clumsy way. In both cases the rubber ligature cut through in about ten days, leaving a deep furrow connecting the two portions of intestine. A piece of rather stiff rubber tubing,  $\frac{3}{4}$ -inch in diameter and about 4 inches long, was obtained and the middle fastened by means of suture to the centre of a disk of thick sheet rubber of sufficient size to overlap the entire wound, a piece of round solid rubber intervening to separate them about 1 inch. One end of the tube was now introduced into the upper, and the other end into the lower portion of the



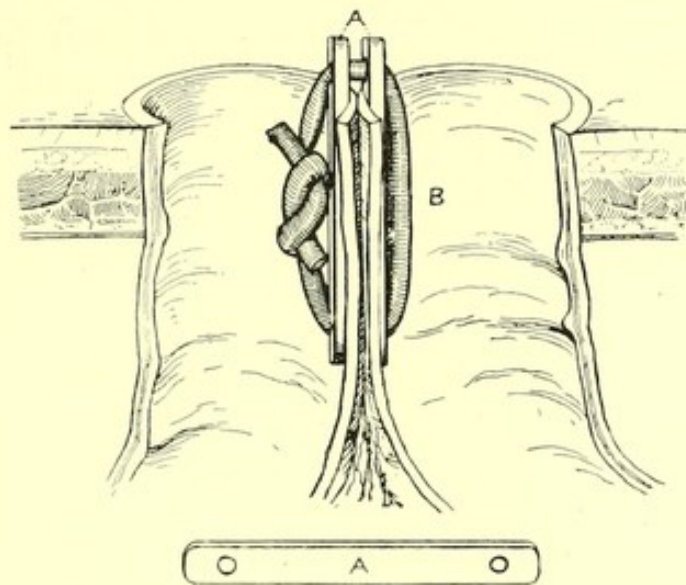


FIG. 174. Method of removing the 'spur' by Elastic Pressure-necrosis previous to closing a Colotomy Wound.

A rubber cord B is passed from one segment of the bowel to the other and tied over two aluminium plates A.

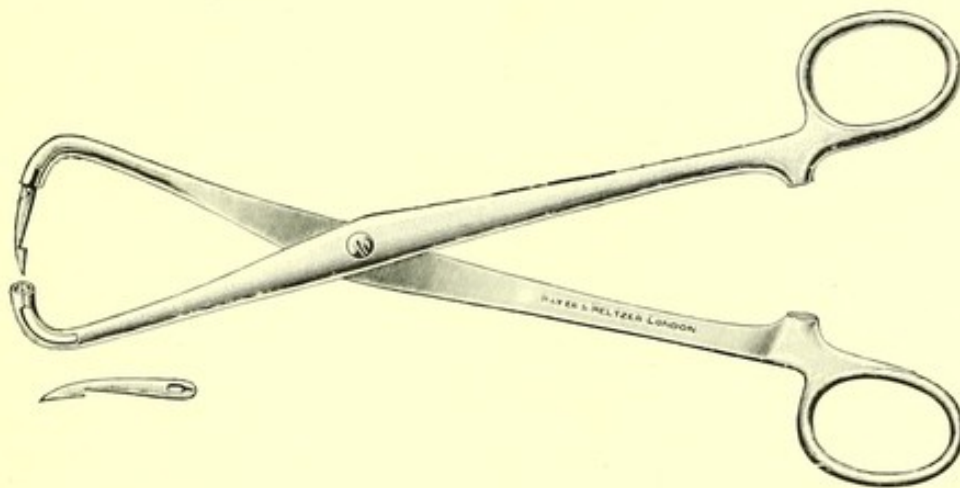


FIG. 175. Kurz Needle.

Used for passing a ligature from one portion of the colon to the other in the operation illustrated in Fig. 174.



colon, and the disk of rubber strapped down over the wound ; in this way the faecal contents were directed once again into the rectum, and its competency to discharge its functions estimated, while the colotomy was still available in case of emergency. In both the cases, normal

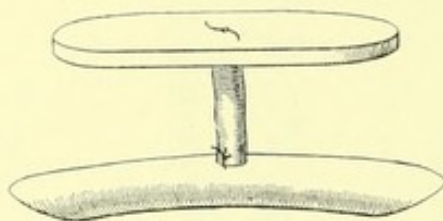


FIG. 176. Apparatus for use after Removal of the 'Spur' in Colotomy.

A thick rubber tube is attached by means of a piece of solid rubber cord to an oval flat piece of sheet rubber. The sheet rubber lies on the abdomen, and the tube passes from one section of the bowel to the other.

defaecation was resumed, the tube withdrawn, and the wound closed ; in the first case a pin-hole opening remained, but in the second, firm union took place. Some months afterwards an attempt was made to close the minute opening in the first case, but the patient, an old man with a weak heart, died somewhat suddenly.



## CHAPTER XXI

### FOREIGN BODIES

VERY various substances may reach the lower bowel, either by descending from other parts of the alimentary tract, or by being introduced through the anus. And concretions once started in the rectum may go on gradually increasing *in situ*.

Foreign bodies, which pass through the entire alimentary tract, are necessarily somewhat limited in size, yet it is astonishing what large and irregularly shaped articles can pass the ileocaecal valve. In a case recorded by Pilcher (*Lancet*, vol. i, p. 23, 1866), a woman suffering from melancholia swallowed a number of nails, pebbles, &c., in the hope of committing suicide, and subsequently, in the space of six weeks, passed by the rectum 300 grammes weight of various substances, including nineteen large pointed nails, a screw 7 centimetres long, numerous pieces of earthenware and glass, a piece of needle, two knitting-needles, a piece of whale-bone, &c.

Concretions found in the rectum may consist entirely of faecal matter, sometimes formed round a small foreign body as a nucleus, such as a chicken-bone, or the concretion may be formed of some unusual and indigestible substances swallowed, as the oat-hair concretions met with sometimes in Scotland, or as in a case recorded by Gross (vol. ii, p. 570), in which an enormous rectal concretion was composed largely of calcined magnesia.

**Foreign bodies introduced through anus.** According to Captain Hamilton (*A New Account of the East Indies*, London, 1708), at Balasore on the Bay of Bengal, it was the custom of the people there every morning after defaecation to put into the rectum a dried clay plug, which remained in position till the next morning, when it was removed to allow the bowels to move, a fresh one being subsequently employed. The plugs were found scattered about the ground in great numbers, and proved a puzzle to visitors till the custom was explained to them.



In some countries still the introduction of foreign bodies is adopted as a means of punishment.

The rectum has occasionally been made a hiding-place for jewels, &c., and, according to Poulet (*Foreign Bodies in Surgery*, vol. i, p. 222), convicts have been known to secrete instruments in the rectum for the purpose of assisting them in escaping from prison. He quotes a case reported by Closmadeuc, in which a young convict died of peritonitis, and at the post-mortem there was found in the transverse colon what is known as a *nécessaire*, which consists of a cylindrical box of wood, closed with a little wax; the pieces which it contains can be fitted one to another so as to serve as a file, saw, &c., the box serving for a handle. In the case alluded to the box was cylindro-conical, contained thirty different pieces, and was covered with a piece of sheep's omentum: it was 14 centimetres long, and weighed 650 grammes. It had been habitually introduced by the largest part, so as to be expelled during defaecation. An interesting feature in this case is the way in which the foreign body found its way up to the transverse colon. This was probably due to the conical shape.

As a result of accident, foreign bodies have sometimes slipped through the anus, and they have also occasionally been introduced for the purpose of checking a diarrhoea. These explanations are not infrequently made by persons who are ashamed to admit the real cause, namely, some perverted sexual impulse. It is astonishing the variety of articles which have been found in the lower bowel. It would, of course, be useless to recount them all, but the following are a few of those collected by Poulet—pieces of wood, snails, glass bottles, crockery, stones, tin-covers, preserve jars, pieces of soap, fork, handle of shovel, pepper-box, pig's tail, upholsterers' nails, ale glass, bottle of mushrooms, &c. The length of some of the foreign bodies found here is considerable. Velpeau (*Arch. Gén. de Méd.*, 4<sup>e</sup> série, tome xxi) removed an eau-de-cologne bottle over 11 inches long, while Laure (*Gazette Médicale de Lyon*, 1868) records a case in which a wooden club was withdrawn from the rectum of a man aged 60 years which measured 12½ inches; the upper end caused a projection in the right hypochondrium; the patient recovered. It is hard to imagine how such an article could be introduced so far without producing fatal mischief.

Foreign bodies introduced into the rectum may be expelled by natural effort, or they may be more or less tolerated for some time in the bowel, but usually such grave symptoms are soon developed that the



surgeon's aid has to be called in. A case is reported by Dr. Weigand (Schmidt's *Annalen*, vol. iv, p. 95, 1862) in which a piece of wood 5 inches long, the top of a pole which broke off in the rectum, was retained for thirty-one days, and then expelled by natural effort.

As a result of residence in the rectum a foreign body may become incrustated with earthy salts, as in a case recorded by Dr. Dahlenkamp (Heidelberg *klin. Annalen*, 1829), in which a piece of oak was removed from the rectum which had been there for ten years. It was covered over half its surface with a saline incrustation of a brilliant silvery appearance, which analysis showed to be phosphate of lime. When the foreign body has perforated the bladder, and remains *in situ* for any length of time, a deposit of calculous matter is likely to take place.

The removal of foreign bodies from the rectum may tax considerably the ingenuity of the surgeon. If the body is large and friable great care must be exercised. In the first place it is well to dilate the anus very thoroughly, when possibly the substance may be expelled naturally; if not, its removal must be attempted by the aid of forceps, &c.

If the foreign body is a bottle, and the neck presents, a strong forceps may be passed through the neck, widely divaricated, and used as a means of traction. If, however, as is more likely to be the case, the bottom of the bottle presents, greater difficulty will be experienced. In one case (Pollock, *Med. Press*, 1869) a champagne bottle was removed by perforating the bottom, and getting a wire hook in, a month after the foreign body had been introduced. Possibly the dental engine, armed with a corundum bit, might prove of service in similar cases.

Where other means fail, the abdomen should be opened, and the substance removed by manipulation, the anus being enlarged, if necessary, by an incision back to the coccyx. In other cases, where also other means fail, the body may be broken up by a cephalotribe, or other similar instrument; such treatment is, however, exceedingly dangerous, the laceration of the gut having been, in some instances, extreme. Cripps mentions a case from the practice of Burnett, in which a man introduced a jam-pot into his rectum; finding that it obstructed a motion he knocked the bottom, which was uppermost, out with a poker; this was followed by considerable haemorrhage, and prolapse of the bowel through the opening. The rest of the jam-pot was removed with very great difficulty by means of a craniotomy forceps six days later, and the patient eventually recovered.



In some cases the ingenious method of Lefort (Poulet, loc. cit.) may be had recourse to, i. e. of injecting soft plaster of Paris into a hollow article, such as an ale glass, and allowing it to harden before attempting removal. Care must be taken, if an upper opening exists, that the plaster does not escape above, so forming a concretion.

Where the foreign body is wood, or substance of similar density, the use of a gimlet or screw to fix the object, and assist in its withdrawal, may prove of service.

Where the body has prongs, like a fork or a hook, portion of which has perforated the bowel, the perforating part is to be carefully withdrawn from the mucous membrane, and protected with a forceps, a tube, or piece of cork during extraction. The famous case in which a pig's tail was extracted by Marchettis (Poulet, loc. cit., p. 260) illustrates the use of a little ingenuity in this way. A pig's tail, with the bristles cut short, had been introduced into the rectum of a woman. As soon as any attempt was made to pull it out the bristles caught in the mucous membrane. Marchettis selected a hollow reed, and first tying a string to the end of the tail, he slipped the tube up, and thus extracted the foreign body without difficulty.

Where the foreign body is made of metal wire, it may be divided by means of a cutting pliers, and so rendered more easy of extraction. An electro-magnet has been used for the removal of iron nails.

In cases where the foreign body has got up out of reach into the pelvic colon, it may be only possible to remove it by abdominal section. In this way Realli (*Gaz. Méd.*, July 1851) removed a piece of wood which was firmly impacted high up, and which resisted all attempts to extract it by the anus. Having opened the abdomen, he attempted to force it down from its position, but failing in this, incised the wall of the bowel, and successfully removed the foreign body. The patient recovered perfectly. In the *History of the American War* allusion is made to a case in which a stone introduced into the rectum perforated the peritoneal cavity, and was removed therefrom by abdominal section. A third case is detailed by Studsgaard (*Soc. de Chirurgie*, p. 662, 1878), in which a mushroom bottle,  $6\frac{1}{2}$  inches long, was introduced into the bowel. The introduction of the hand, after posterior division of the anus, failed in removal. Laparotomy was subsequently performed, and the bottle removed by incision of the great intestine, which was closed by Lembert's suture. The patient made a good recovery.



## CHAPTER XXII

### INJURIES

WOUNDS of the rectum may be the result of foreign bodies being forcibly thrust into or through the bowel, of injury inflicted during parturition, of perforation by fragments of bone or other hard substance which have passed through the alimentary tract, of gunshot injury, and of penetration by a fragment of broken pelvis, all of which would be classed under the head of lacerated and contused wounds. Cleanly incised wounds in this region are extremely unlikely to occur, except as the result of surgical operation, either intentionally done, as in the operation for fistula and other similar procedures, or unintentionally, as an accident of the operation of perineal lithotomy, or prostatectomy.

**Direct injury.** A number of cases have been recorded in which an enema tube has been forced through the healthy rectum, and the injection discharged either into the peritoneal cavity, or into the loose areolar tissue surrounding the bowel. So slight is the sensibility of the rectum a little way from the anus, that this accident has happened while the patient was giving himself an injection. Where the perforation occurs into the peritoneal cavity death has in a number of cases resulted, and where the areolar spaces of the pelvis are penetrated, diffuse suppuration, which is likely to prove fatal, is a probable result. Similarly, foreign bodies are sometimes forcibly thrust through the anus, and perforate the rectal wall above. There was in Sir Patrick Dun's Hospital a man with a recto-urethral fistula, under the care of my colleague, the late Professor Bennett, which resulted from the man being impaled by a pitchfork. While sliding down a hayrick, one prong passed through the anus, injuring the prostatic urethra, while the other passed up between his legs without doing any injury. An almost identical case is recorded by the late Mr. Tufnell, in the *Proceedings of the Pathological Society of Dublin* (vol. iv, part 2), in which one prong of a pitchfork penetrated the rectum, dividing the prostate gland in two. The patient died on the



fifth day. Mr. Prescott Hewett (*Trans. Path. Soc., London*, vol. i, p. 152) published the particulars of a perforating wound of the rectum, from a person falling upon the leg of a chair, which penetrated the anus. The result proved fatal. A similar case is related as occurring from a person falling on a stake fixed in the ground, in which the posterior wall of the bladder was much lacerated through the rectum. Recovery followed, urine being evacuated by the urethra after two months (Holmes, *System of Surgery*, vol. ii, p. 722, second edition). The late Sir William Stokes mentions a case (*Trans. Acad. Med., Ireland*, vol. i, p. 88) in which a lad fell on a long ironworker's tongs, one handle of which penetrated the anus, entered the bladder, and again perforating this viscus opened into the peritoneal cavity. He was brought to the Richmond Hospital in a state of profound collapse, and died shortly afterwards. These cases are interesting in showing how serious injuries might be inflicted upon the abdominal viscera without any cutaneous wound existing, and in the absence of any accurate history considerable difficulty might be found in making a diagnosis. A case is recorded by Birkett (Holmes's *System of Surgery*, loc. cit., p. 753) in which a patient suffering from rectal ulcer himself passed the tube of an enema syringe through the floor of the ulcer, opening up the loose areolar tissue of the pelvis. This was followed by emphysema of the entire lower part of the abdomen, and as this symptom has occurred in other cases, such as the apparently trivial operation of tapping the bladder through the rectum, it might prove useful in establishing a diagnosis in obscure cases.

There was recently a remarkable case of injury to the rectum in Sir Patrick Dun's Hospital under the late Prof. Bennett's care. The patient was caught in the perineum by a rapidly moving chain, which inflicted a severe lacerated wound in the region of the anus. When admitted, it was found that the lower end of the rectum was separated from its attachments round the greater part of its circumference, and projected at the bottom of a ragged cavity, the case somewhat resembling the dissection made for the purpose of amputating the rectum.

During **parturition** injury to the rectum sometimes occurs, the recto-vaginal septum being torn through more or less, in addition to complete rupture of the perineum, or even the septum has been known to give way without tear of the perineum, the child being born through the anus.

**Injuries by substances swallowed.** Owing to the sudden way



in which the rectal pouch narrows at the anal canal, substances which have thus far safely made the tour of the alimentary tract may become arrested, and possibly puncture the coats of the bowel and give rise to abscess and fistula. I removed the prong of a horn hair-comb which was transfixing the lower end of the rectum of a young man, and fish-bones, pins, and such-like substances are not infrequently found in a like situation. They give rise to a considerable amount of discomfort and pain during defaecation, and are easily recognized by digital examination and removed.

Gunshot wounds penetrating the pelvis and perforating the rectum are, according to the statistics of Army surgeons, less fatal than similar injuries through the abdomen above the pelvis; this is to be accounted for by the greater facilities for drainage.

A consideration of the histories of rectal injuries shows that where the wound is extensive, and consequently drainage free, the prognosis is tolerably good, whereas punctured wounds in which the conditions of free drainage are not found are apt to be followed by putrid emphysema, extravasation of faeces, diffuse inflammation, and other more serious septic complications.

The practical deduction from this is that treatment should be directed, where necessary, to affording as free drainage as possible by incision, outside the rectum if possible; but if this cannot satisfactorily be accomplished it may be necessary to incise the anal canal, and wall of the rectum; it is better to do this than run the risk of extravasation with its serious consequences.

Wounds of the recto-vaginal septum are fully dealt with in gynaecological works.

**Spontaneous rupture of the rectum.** In the majority of cases of so-called spontaneous rupture of the rectum, prolapse or some diseased condition of the bowel-wall preceded the perforation (see p. 161). An interesting case of spontaneous rupture of the rectum in an apparently strong and healthy man, aged 30, is put on record by Heinke (*La Semaine Médicale*, Sept. 12, 1906). While making a great effort to lift a piece of iron with the body bent forcibly forward, he experienced severe pain in the lower part of the abdomen; he vomited, and twenty hours afterwards, when admitted to hospital, he was in a state of profound collapse, the belly was distended and very sensitive, particularly in the lower portion. The abdomen was immediately opened, and exit given to



a large quantity of sero-purulent fluid mixed with caraway seeds, but no other obvious faecal matter was observed, the intestines were distended and inflamed. Evisceration failed to demonstrate a perforation, so the intestines were replaced in the abdomen and drainage adopted; death ensued in two days. At the *post mortem* examination a linear tear of the anterior surface of the rectum a little to the right side was found 17 cm. from the anus, through which the mucous membrane was somewhat everted; the tissues of the bowel-wall appeared to be quite healthy.

In this case the rupture apparently was solely the result of intra-abdominal strain during a violent effort.



## CHAPTER XXIII

### NEUROSES

**Rectal constipation.** During health the lower portion of the rectum is empty, except immediately preceding the act of defaecation, and the impulse to expel the faeces is caused by the descent of a mass of excrement into the rectal pouch. This fact, which was pointed out by O'Beirne (*New Views on the Process of Defaecation*, 1833) more than seventy years ago, although frequently doubted, is substantially true.

If the call to empty the bowel is not responded to at the time, the desire to a certain extent passes off, and when next the bowels move it will be found that what first passes is a hard mass, the more fluid parts having been absorbed by the rectum. Many of the cases of habitual constipation met with in practice owe their origin to a habit of neglecting the calls of nature. The rectal pouch soon becomes tolerant of the presence of faeces, the intervals between defaecation become longer and longer, and the habit of costiveness becomes more and more established. In adults, who are capable of taking a sufficient amount of exercise, and those in whom the health is good, the faecal mass is, sooner or later, expelled, but habits of irregularity in this respect once started are difficult to overcome. In some people the bowels are evacuated more than once daily, while in others there is only one stool in two or three days, and yet neither of these can be said to deviate from a condition of normal health. It is the irregularity in responding to the call that is a principal factor in the production of this form of constipation.

In elderly and debilitated people, in otherwise healthy adults, after some rectal operations, and occasionally in children, there may be incomplete defaecation, resulting in a gradually increasing accumulation in the rectal pouch, the true condition not being suspected, as the bowels occasionally act. After a time a catarrhal diarrhoea is produced by the irritation of the mass, and the patient is supposed frequently to be suffering from ordinary diarrhoea. This catarrhal discharge, which is



not inaptly compared by Cruveilhier to the overflow of an atonic bladder, may be sufficient to soften and break down the mass, thus permitting its expulsion, but, at other times, symptoms resembling acute obstruction of the bowel supervene. Active peristaltic motions take place, which are unable to expel the accumulation of faecal matter in the rectum, violent colic is often induced, with frequent straining and exhausting efforts to procure an evacuation, profuse sweats break out, the patient becomes cold, the pulse small and weak, and not infrequently vomiting occurs, in fact, the degree of collapse produced may be considerable. If an attempt is made to give an injection, it will be found that there is resistance to the introduction of the tube, and that it is almost impossible to force any fluid in. A digital examination will now reveal the fact that the bowel is blocked by a hardened mass of clay-like faeces, which must be broken up mechanically before the rectum can be emptied. For this purpose a lithotomy scoop, or the handle of a spoon, may be used to aid the finger, and as soon as a tube can be introduced copious injections of hot soap and water may with advantage be used to assist in the dislodgement. This operation is frequently a tedious, and at all times an unpleasant, proceeding, but the relief given is great, the amount of faeces got rid of being sometimes very great.

Besides the symptoms detailed, rectal constipation may give rise to other serious complications. Ulceration of the bowel, leading to perforation, may result at any part of the large intestine. Or extensive sloughing of the rectum may supervene, as in a very remarkable case that I saw many years ago, in consultation with Dr. Wright, of Dalkey. A widow aged 65 had what appeared to be an attack of inflamed piles, from which she had suffered before. She stated positively that the bowels had been quite regularly moved. She suffered from retention of urine, and swelling of the vulva came on, followed by diarrhoea. The skin of the buttocks became red, glazed, and erysipelatous-looking, and felt very tense, the inflammation being much more marked on the right side. The skin gave way finally, permitting the escape of a considerable quantity of faeces. Rectal examination now revealed the fact that the entire lower bowel was blocked with faeces. By careful breaking up of the mass, and copious enemata, Dr. Wright succeeded in evacuating what the nurse described as a 'bucketful' of faeces. When I saw the patient, at the right side of the bowel, about one and a half inches from the anus, the wall of the rectum had sloughed, leaving



an opening as large as a half-crown piece. There was a considerable quantity of faeces in the areolar space external to the bowel, and pressure with the finger extruded lumps of hard faeces as big as walnuts through the large fistulous opening in the right buttock, through which, indeed, almost all the faeces appeared to pass. Notwithstanding the age of the patient, and the gravity of the local manifestations, the constitutional symptoms were slight, and she made a good recovery. The fistulous track completely closed without any active surgical treatment, and she had no stricture or other inconvenience. This case shows very forcibly how insidious may be the onset of a grave rectal constipation.

Except during the paroxysmal efforts at expulsion, pain is not a prominent symptom, and when present is due to the pressure on the branches of the sacral plexus, thus we sometimes meet with cases of sciatica due solely to the pressure of an over-distended rectum.

Having once got rid of the accumulation, care must be taken to prevent its recurrence. This is best done by alterations in diet, by the use of purgatives, and enemata, and care to at once defaecate when faeces are felt to go down into the lower bowel. Variety in the way of food is of great importance, as if there is too great uniformity, diminished sensibility of the intestinal canal will be induced. The habitual use of coarse vegetable food, such as bread, oatmeal, and potatoes, induces chronic constipation, while these articles of diet will relieve the constipation which comes on in persons who habitually use too much animal food. Similarly, milk used as a principal article of diet may produce constipation, while with others it acts as a purgative. In the same way aperients must be used with the greatest discretion; if one form ceases to act it is better to change it for another than to increase the dose. But the best treatment of all, as it more nearly simulates the normal stimulus, is the daily use of a small enema. It has been frequently stated that the constant use of enemata leads to the production of rectal atony, but this objection, I feel sure, is chimerical. Probably the best way of all is to constantly change the kind of stimulus applied to the intestinal mucous membrane. Dr. Lee has suggested, that when a patient is trying to get rid of a rectal accumulation, much assistance may be derived from firmly pressing up with the fingers into each ischio-rectal fossa, by this means making the presenting mass more wedge-like and easy to pass.

There is a form of rectal atony met with in hysterical females and



hypochondriacal men, whose attention is morbidly fixed upon the evacuation of their bowels, and whose sole interest appears to be directed to the subject of defaecation. In illustration of this subject, I cannot do better than quote from the graphic pen of Dr. Weir Mitchell (*Diseases of the Nervous System*, London, 1881). 'If it happens to you in an evil hour to have one of these cases to treat, with the additional need to treat also the difficulties with which some tender mother surrounds such a case, you are much to be pitied. I recall such an example which I saw in consultation some years ago. It began with a spot of abdominal tenderness over the spleen. Pressure on this caused nausea and vertigo. Then we had convulsions, hysterics, coma, enormous polyuria, and at last constipation. The physician in charge gave this list of the drugs given in four days: night and morning on each day an ounce of castor oil, at midday and bed-time one drop of croton oil, three drops had been used in one day. The more drugs she took the more she demanded, and yet it was impossible to see that it gave her pain. Meanwhile for the nurse and mother the arrangement for each evacuation was the event of the day. A long stomach tube was carried six or seven inches up the bowel and half a pint of olive oil injected, then followed from one quart to three of flaxseed tea. During the use of the enema one person was occupied compressing the anal opening, so as to prevent the escape of fluid. This help was made necessary on account of the great relaxation of the sphincter, into which a thumb could be passed without any resistance which could be felt to arise from a muscular act. Meanwhile the patient, while insisting on the use of more water, was shrieking with pain. The whole affair took two to four hours, and the patient was, I thought, the least exhausted of those concerned. Sometimes their efforts gave rise to a stool, sometimes there was none for a week, and sometimes under the wild entreaties of the patient these trying scenes were repeated in the night, nurse and mother being aroused to assist. I endeavoured to get this girl out of the control of the family, but I did not succeed, and I believe that her hysteria is now firmly established.'

There is a form of atony of the sphincter which gives rise sometimes to a good deal of annoyance, in which it is impossible to expel just the last portion of faeces, so that there is difficulty in cleansing the parts after defaecation, and a tendency to have a slight escape of faeces during the day. This condition is not infrequently associated with



piles, but is sometimes independent of them. It is to be treated by small enemata or by copious ablutions with cold water after defaecation.

**Incontinence of faeces**, from paralysis of the sphincters, will result from any central lesion of the spinal cord, which destroys the function of the third and fourth sacral nerves; in such cases the power of controlling the escape of fluid faeces is completely lost, and the anus appears flaccid and patulous; a similar result may follow certain cerebral lesions, or be present in post-diphtheritic paralysis. Operative treatment with a view to narrow the patulous anus has sometimes been suggested, but is of course quite futile in cases of complete paralysis. Partial incontinence, the result of injury or certain surgical operations, is dealt with elsewhere (p. 114).

**Irritability of the rectum** is sometimes due to a catarrhal condition of the mucous membrane, while at others no such definite cause can be assigned, frequent desire to go to stool, usually at inconvenient times, being noticed. Of this condition many familiar examples will suggest themselves, indicating that when the mind is intensely occupied, chiefly by anxiety, the rectal reflexes may be abnormally high. It is common to hear of students going in for an examination having diarrhoea in the morning before it, and of persons having a desire to defaecate before a train starts, or when it stops at a station; and I know a surgeon who has always to retire to the water-closet immediately before undertaking any severe operation. This minor degree of irritable rectum is common enough, but in rare cases it may be so marked that it may materially affect a person's enjoyment of life, or even interfere with business, as in the case of a clergyman, recorded by Curling, in whom the desire usually came on just before commencing divine service. Cases of this kind are best treated by urging the patient to try and overcome the inclination, in which, with the exercise of a little moral control, they will usually prove successful.

**Neuralgia.** As in other parts of the body, pain of a more or less severe character may exist at the lower end of the bowel, without any discoverable cause. It is usually found in rather weak and hypochondriacal males and hysterical females. At other times pain referred to the anus and interior of the rectum may have its origin in an injury to the coccyx, constituting one of the symptoms of the so-called 'coccydynia'. These cases are to be treated in the same way that vague neuralgias of other



parts of the body are, but it must be admitted that for the most part they are exceedingly unsatisfactory cases to deal with.

**Morbid sensibility.** The third class is when there is a true hyperaesthesia of some particular spot, which frequently is associated with more or less spasm of the sphincters and levatores ani. These symptoms are usually all much aggravated by passing a motion, the pain afterwards being very severe. In the great majority of patients suffering from these symptoms, a definite cause will be found in the presence of a small irritable ulcer or painful fissure, but in a few no such obvious pathological condition is to be seen. If, however, the symptoms are really severe, the best treatment to adopt is forcible dilatation of the sphincter.



## CHAPTER XXIV

### PRURITUS ANI

PRURITUS ANI, or, as it has been not inaptly termed, painful itching of the anus, is a most distressing complaint when met with in an aggravated form, patients frequently stating that it is much more difficult to bear than acute pain, and that their lives are rendered absolutely miserable by it. As it may arise from a multiplicity of causes, it may tax considerably the powers of the surgeon to cure. It will, therefore, assist in the consideration of the subject if we discuss in detail the various diseases of which pruritus ani is a symptom.

At a recent meeting of the British Medical Association at Oxford an interesting discussion took place in the Section of Dermatology on the causation and treatment of pruritus ani. Any one reading that debate cannot fail to be struck with the enormous number of distinct diseased conditions to which this annoying symptom was attributed by the various speakers, and large as the number of supposed causes assigned were, the various plans of treatment advocated were still greater, all the resources, not only of the Pharmacopoeia, but of the extra Pharmacopoeia, being in turn favoured.

The conclusion which naturally presents itself from reading this discussion is that the aetiology of pruritus ani is in many cases indefinite. Of the many causes assigned few are obviously operative, while on the other hand the majority are purely speculative, also that the treatment is frequently eminently unsatisfactory.

Cases in which itching of the anus is the prominent symptom may be conveniently classed in three groups:—

1. Those due to parasites either animal or mycotic.
2. Those resulting from dermatitis of the cutaneous portion of the anal canal and surrounding skin.
3. Those in which the disease is essentially in the nerves supplying the affected area with sensation.



**Parasitic pruritus.** The presence of thread-worms (*Oxyuris vermicularis*) in the rectum is a cause of itching, especially in children, and occasionally in adults they give rise to irritation. In order to efficiently treat such cases it is essential to know the life-history of the worm. Heller has shown (Ziemssen's *Cyclopaedia*, vol. vii, p. 752) that these worms live principally in the caecum and lower part of the ileum, and that it is principally the females, when about to deposit eggs, that descend into the rectum. The diagnosis can be made sometimes by seeing the worms in the motion just passed, or in the anal folds of the skin, and if an injection of cold water is given while the itching is present, a number will probably be expelled. Heller's observation has most important bearing on our treatment in these cases of a very common and a very obstinate disease, as, if the caecum is the principal habitat of the parasite, it is manifestly useless to treat the rectum by small injections of lime-water, infusion of quassia, &c. The great difficulty in treatment is humorously alluded to by Bremser (quoted by Heller, loc. cit.): 'Just as these parasites are, on the one hand, to be counted among the most troublesome of all those that live at the expense of our bodies, so on the other do they, at the same time, belong to those which are the very hardest to exterminate. Their number is legion. And if, after we have slaughtered thousands, we lay our weapons aside for one moment, imagining ourselves safe from a fresh attack, new cohorts again advance with increased reinforcements. The faeces and intestinal mucus contained in the large intestine behind which they hide themselves serve them for a breastwork and parapet. If one attacks them from the front with anthelmintics, these become so weakened by the long march through the small intestine that the worms only laugh at them. If we attack them in the rear with heavy artillery the foreposts stationed in the rectum must certainly succumb, but the heaviest enema bombardment cannot reach those encamped in the caecum, and so long as ever so few remain behind in some hiding-place, they, from the amazing rapidity with which they are reproduced, soon again become a large army.' According to Heller no direct reproduction of these worms takes place in the intestine, but the eggs which pass out with the faeces must pass through the stomach, the action of the gastric juice being necessary to allow the worm to escape from the egg by softening the outer coat. He supposes that the eggs are conveyed to the mouth by the fingers after scratching, having frequently found the eggs under the nails of



persons suffering from oxyurides. This shows what an important item in both treatment and prophylaxis absolute cleanliness is. Heller considers free purgation the best form of treatment, and in aggravated cases the washing out of the entire large intestine by means of Hegar's monster clysters.

Tumours of the rectum have been described as the result of irritation produced by the ova of thread-worms (see p. 217).

Pediculi and scabies may possibly be the cause of pruritus ani, and if so their presence should be easily determined.

Eczema marginatum and intertrigo which have their natural habitat in the groins may spread along the perineum to the anus and give rise to pruritus, the treatment being attention to personal cleanliness and the use of an efficient parasiticide, probably the most efficient being a solution of mercuric iodide in alcohol (1-1000).

**Dermatitis.** In the second group are included cases classed under that protean generic term eczema. As in other parts of the body, great variety is to be observed in the intensity of the inflammation, the character of the local appearances, and the efficacy of treatment adopted; some cases yield to the simplest remedies, while others prove intractable to all usual therapeutic methods. It will generally be found that the most suitable applications to eczema of the anal region when acute and of the moist variety are those which are emollient and unirritating, while in the more chronic and in the dry variety highly stimulating applications, such as nitrate of silver, &c., are indicated. I have frequently found the best application to be an ammonia soap, which may easily be prepared by diluting linimentum ammoniac B.P. with olive oil as much as may be necessary; but no general treatment is invariably suitable, what cures one will make another, which as far as appearances go is identical, much worse, so that it is sometimes necessary to change the treatment very frequently until the necessities of the individual case are at last met. In the treatment of these cases it must always be remembered that the local trouble may be due to some more general disease, notably gout or diabetes.

Although the majority of cases of pruritus ani due to chronic dermatitis are curable, if sufficient care and time is devoted to their treatment, a few appear to defy all the usual forms of therapeutics, and may justly be termed inveterate.

**Nerve lesions.** The third group consists of those cases in which chronic intolerable itching is present, without obvious evidence of



dermatitis, although abrasions of the skin may be present, the result of scratching; there are, however, often present very definite trophic changes in the skin, notably white patches, due to loss of normal pigment, while sometimes the skin surrounding the anus is of a dull bluish-white colour with a smooth surface like parchment. There cannot be any doubt that their cause is some change in the sensory nerves of the affected area, but by calling them neuroses we do not advance the aetiology any further than when we similarly describe certain forms of trigeminal neuralgia, the intimate pathology of which is unknown, as neuroses. In some of these cases a condition of dermatitis is present at the commencement, which, however, may quite disappear, with no improvement, but rather an aggravation of the itching; in others no inflammatory state of the skin other than that produced by scratching is present. These cases are quite incurable by any form of external application or internal treatment, and their lot is a very miserable one, the intolerable itching keeping the patient awake at night and rendering life almost unbearable.

Pruritus is not infrequently associated with piles, which usually, however, are insignificant, being nothing more than hypertrophied anal folds of skin. They have frequently been removed under the impression that they cause the pruritus. My experience is that their removal tends rather to aggravate than relieve the itching, and that if the pruritus is cured the piles will probably cease to give trouble.

**Surgical treatment** of pruritus ani. Thorough dilatation of the anal canal has been frequently tried, but I have never seen any real benefit derived therefrom. Two other operations have been advocated, the cauterization of the skin affected down to the papillary layer with the benzolin cautery strongly advocated by the late Sir W. Mitchell Banks, and the complete removal by excision of the implicated skin. I have no personal experience of either of these methods, as they appeared to me both crude and unscientific.

Reasoning from the analogy of the satisfactory results obtained by the removal of the Gasserian ganglion in cases of extreme trigeminal neuralgia, it occurred to me that inveterate pruritus ani might be similarly treated by the excision of the posterior roots and ganglia of the third and fourth sacral nerves. As, however, I feared that possibly this might interfere with sphincteric control of the rectum, I determined to adopt in the first instance the more simple procedure of division of the sensory nerves going to the affected skin. This appears such



an obvious method that I feel sure it must have occurred to other surgeons, but I have not seen any cases published in which it has been carried out.

Pruritus ani never passes to the mucous membrane above the mucocutaneous junction, but is confined to that portion of the anal canal with cutaneous covering, and the skin in the immediate neighbourhood of the anus, especially those parts which are in contact in a position of rest.

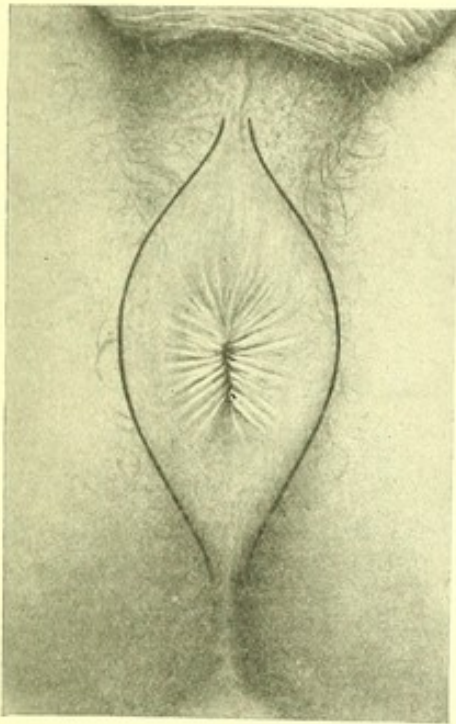


FIG. 177. Pruritus Ani.

The lines of incision in the operation for inveterate pruritus ani.

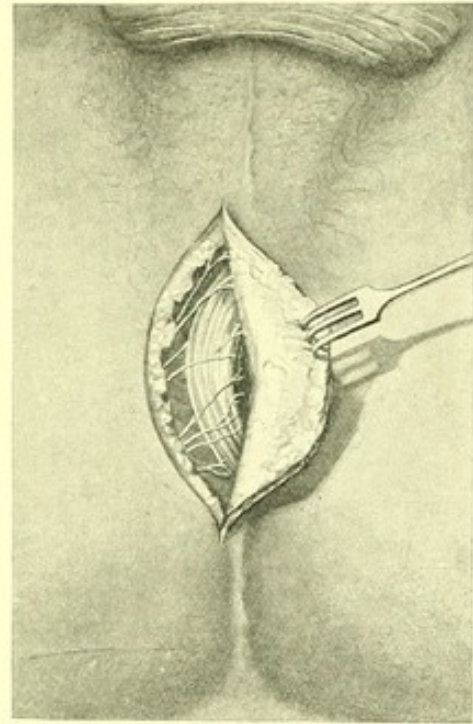


FIG. 178. Operation for Inveterate Pruritus Ani.

Method of dissecting the flaps and of dividing the terminal cutaneous nerve-twigs, which for the purpose of clearness are somewhat exaggerated in the drawing.

If, therefore, a typical case of pruritus ani is examined it will be found that the affected area implicates the lower portion of the anal canal and the surrounding skin, extending further in the middle line towards the coccyx behind, and along the perineum in front, than it does upon the sides, not infrequently involving the fourchette in the female. The implicated region is elliptical in shape, being twice as long in the antero-posterior direction as it is broad in the lateral, with the anal canal in the centre. It receives its sensory nerves from branches of the third and



fourth sacral nerves, which come down on the levator ani muscle and reach the skin by perforating the external sphincter muscle. The procedure about to be described is devised for the purpose of dividing all these nerve-twigs before they reach the skin of the affected area.

The skin having been cleansed as completely as possible, a curved incision is made on each side of the affected area (Fig. 177), enclosing the entire ellipse with the exception of a narrow neck in front and behind. These incisions are carried down to the sphincter muscle, and the flaps

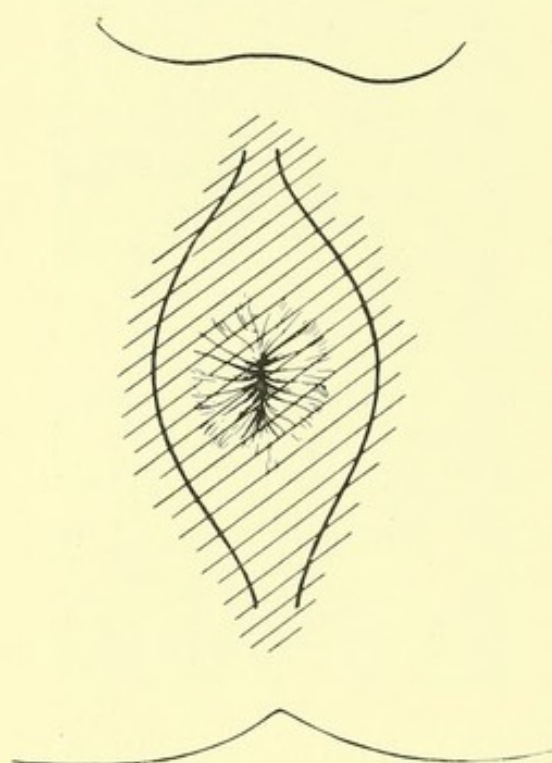


FIG. 179. Inveterate Pruritus Ani.

The oblique lines indicate the area which is rendered anaesthetic by the operation.

raised by careful dissection with scissors from the surface of the muscle, round its anal margin, and up the anal canal to above the muco-cutaneous junction, the dissection extending round the entire circumference, all connections with the subjacent tissues being divided (Fig. 178). The pedicles in front and behind are now undercut to a point well beyond the area of irritation, and the outer concave edges of the incision also undercut to a distance of at least a quarter of an inch free of the involved skin all round. Care must be taken to stop all bleeding, and the flaps should not be replaced until it is completely arrested, as the formation of a haematoma in the wound might compromise the vitality of the flaps. The flaps are finally replaced and retained by

sutures, a few intervals being left between them for drainage.

The immediate result of this operation is to render the entire ellipse included between the incision, the pedicles, and outer edges as far as they have been undercut, superficially anaesthetic (Fig. 179), and the itching is at once relieved.

The first case operated on in this manner occurred five years ago. Except for slight superficial vesication upon one side of the flap healing was rapid. Cutaneous sensation returned some months after the operation, but by this time the skin had become so altered that the pruritus



did not return, and the patient has not had a moment's trouble with itching since. His case had been an extremely severe one, of sixteen years' duration, and his life was so miserable that he threatened suicide if he could not be relieved.

I have now operated fourteen times by this method; in all of them the relief was immediate; in no case did the vitality of the flaps suffer, and in none of them has there been any return of pruritus in the area dealt with, even after the return of normal sensation. Two cases came back asking for treatment of small spots of irritation over the tip of the coccyx which had escaped the previous operation; both were dealt with by raising and replacing a small flap of skin which included the affected spot. On one occasion I have dealt similarly with a localized patch of pruritus with marked trophic changes in the front of the vulva with equally satisfactory results. Since the first note of this operation for pruritus ani was published (*Brit. Med. Journal*, Jan. 21, 1905) I have received information from several surgeons who have adopted it with uniformly satisfactory results.



## CHAPTER XXV

### DIVERTICULA

**Diverticula** of the intestine have been divided by Rokitansky into the true and false, the former being congenital, and consisting of the entire thickness of the intestinal wall, while the latter are probably acquired, and consist of hernia-like protrusions of the mucous membrane

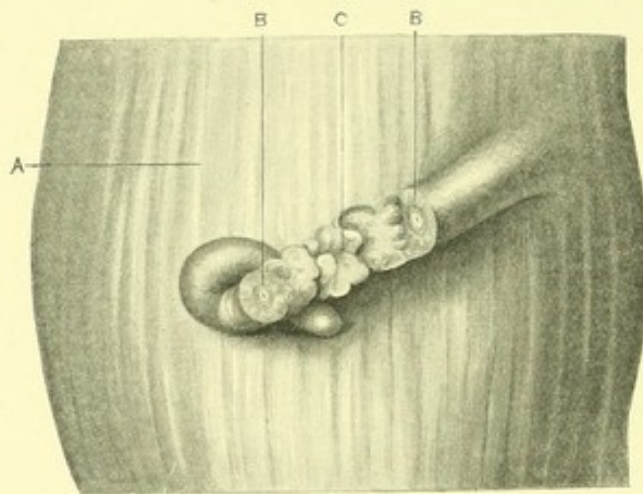


FIG. 180. Diverticulum from the Posterior Surface of the Rectum (Persistent Post-anal Gut).

The central portion of the diverticulum has been cut away at BB for microscopical examination. The section removed shows the tissue, c, which attaches the proximal portion of the diverticulum to the wall of the rectum, A. The distal portion of the diverticulum is free and bent round upon itself. The structure is entirely below the peritoneal reflexion.

Microscopical examination of the section removed showed that all the coats of the bowel are present in the diverticulum, which has a narrow lumen. The interior of the rectum is occupied by a cancerous growth which is unconnected with the diverticulum.

*(From stereo-photograph of a specimen exhibited at the British Medical Association Meeting at Leicester by Mr. Sinclair White.)*

between the bundles of muscular fibres, in this respect resembling the sacculation of the urinary bladder frequently found in obstructive disease of the urethra.

True, or congenital, diverticula of the rectum have been but seldom met with. When attached to the posterior surface they are probably explained by the presence of a persistent post-anal gut, as in the case Fig. 180, and when to the anterior portion, and subcutaneous, they are of proctodeal origin, due to inclusion by the uniting genital folds (p. 44).



Although so few cases of true diverticula of the rectum have been described, it is possible that they are not quite so rare as is thought; they are seldom sought for in *post-mortem* examinations, and even in anatomical dissection they might readily be overlooked. In the case referred to (p. 44), blocking and violent gangrenous inflammation led to the detection of a subcutaneous perineal diverticulum, and the case suggests the possibility that other instances of severe sepsis may have originated in the same way, in all respects similar to the cases of appendicitis in connection with the vermiform appendix with which we are now so familiar, but which were for such a long time not properly understood.

**False, or acquired, diverticula** are thus described by Rokitansky (*Pathological Anatomy*, Sydenham Society, vols. i and ii). They consist solely of mucous membrane and peritoneum. They occur throughout the entire course of the small and large intestine. They are found in considerable numbers: they occur from the size of a pea to that of a walnut in the shape of round, baggy pouches of the mucous membrane. They form, more especially in the colon, nipple-shaped appendages, which occasionally are grouped together in bunches. When occurring in the small intestine they are commonly developed on its concave side, and are, therefore, placed between the layers of the mesentery. When in the colon, faeces are retained in them, and sometimes dry up into hard concretions. The specimen represented by Fig. 181 was taken from the body of a woman who died of strangulated

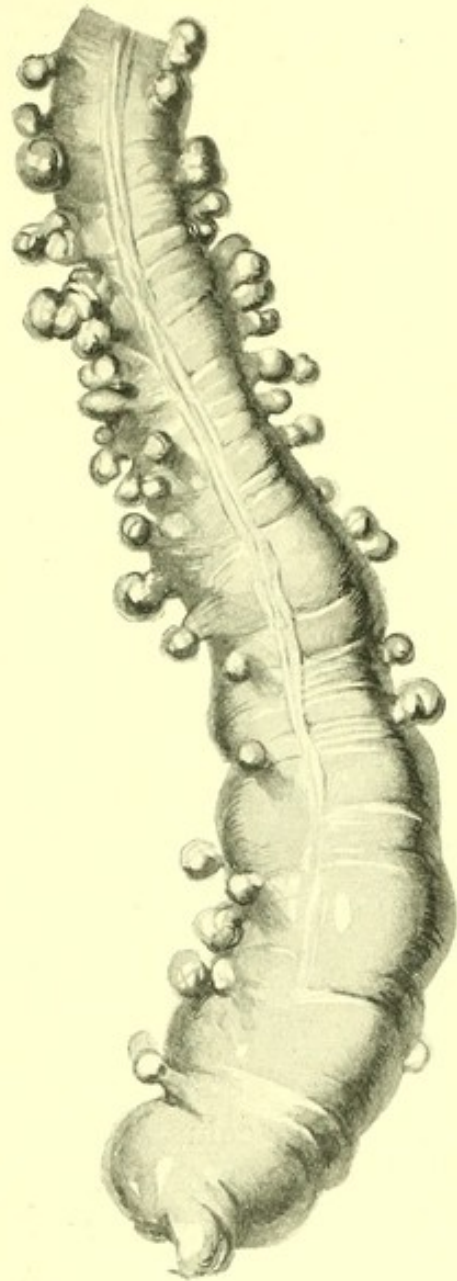


FIG. 181. False or Acquired Diverticula of the Upper Part of the Rectum and Pelvic Colon.

Numerous hernial protrusions of the mucous membrane through the muscular coat of the bowel are present; each of them contained a little pellet of hardened faeces.

(From a specimen found post mortem at Sir Patrick Dun's Hospital.)



hernia. The entire colon was closely studded with these little protrusions of mucous membrane, and they descended down into the rectum within two inches of the anal margin. Each of them contained a little hardened pellet of faeces. In none of them was there the slightest appearance of ulceration or other trouble, and they were in no way associated with the hernia, which had proved fatal. I have since seen two similar cases exhibited at the Dublin Biological Club, one by Mr. Lentaigne and the other by Dr. Bewley. As far as one can learn, they are seldom productive of symptoms during life, although from their appearance ulceration and perforation similar to what takes place in the vermiform appendix would seem a probable result. Cases are, however, recorded by Mr. Sydney Jones and Mr. C. Hawkins, in which false diverticula of the sigmoid flexure became attached to, and finally opened into, the bladder (*Lond. Path. Soc. Trans.*, vol. x, pp. 131 and 208). Dr. Platt records a case (*Lancet*, vol. i, p. 42, 1873) of a little girl, aged 9 years, who suffered from symptoms of intestinal obstruction. Upon making a digital examination, a soft elastic swelling was felt in the anterior wall of the rectum, and leading into this was an orifice which felt like the os uteri. The long tube could be passed up the rectum without difficulty. The child died, and it was found at the *post-mortem* that the small intestine was strictured, and the swelling in the rectum is described as a hernia of the bowel beneath the peritoneum. It is probable that it was a case of false diverticulum.

The disease described by Physick under the name of 'encysted rectum', and by Gross under the name of 'sacciform disease of the anus', consists in an enlargement of the sinuses of Morgagni, which are situated between the columns in the upper portion of the anal canal and protected by the anal valves. These, normally, are extremely small, but as age advances they occasionally become considerably dilated, so as to admit the tip of the finger. They may ulcerate in consequence of their becoming receptacles for little masses of faeces (see p. 92). This ulceration may be followed by suppuration, and may be attended with severe pain. Enlarged sinuses can be diagnosed by being hooked up with a strabismus hook or bent probe, and the treatment consists in snipping away the little anal valve in front of them, which will entirely obviate any danger of further accumulation. If they result in the formation of fistula, or painful fissure, suitable treatment for these conditions will have to be undertaken.



## INDEX

- Abscess, ischio-rectal, 68.  
 — sub-cutaneous, 68.  
 — sub-mucous, 66.  
 — superior pelvi-rectal, 68.  
 Actinomycosis of anus, 89.  
 Adelman, treatment of ruptured prolapse, 160.  
 Adeno-carcinoma, 235.  
 Adenoma, 211.  
 — analogy with cutaneous warts, 214.  
 — caused by hair ball, 215.  
 — caused by local irritation, 214.  
 — diagnosis, 224.  
 — heredity, 214.  
 — in relation to Adeno-carcinoma, 214.  
 — spontaneous cure of, 223.  
 — treatment, 224.  
 Ahlfeld, developmental defect, 39.  
 Aldrick-Blake, Dr. Louisa, excision of cancer, 285.  
 Allantois, 25.  
 Allingham, piles in early life, 117.  
 — stricture, 122.  
 American pruning-shears, 272.  
 Ampulla of rectum, 3.  
 Amyloid degeneration of rectum, 89.  
 Anal canal, 3.  
 Anal depression, 29.  
 Anal papilla, 7.  
 Anal valves, 7.  
 Anatomy of rectum, 1.  
 Ano-coccygeal ligament, 15.  
 Ano-rectal syphiloma, 87.  
 Anus, multiple opening of, 45.  
 Anus, warts of, 224.  
 Appendices epiploicae of colon, 3.  
 Arteries of rectum, 19.  
 Atheromatous cysts at the anus, 234.  
 Ayant, colopexy, 168.  
  
 Balfour, tail-gut, 24.  
 Banks, Sir Mitchell, treatment of piles, 197.  
 — pruritus ani, 322.  
 Bardeleben, anatomy of pelvic floor, 10.  
 Bardenheuer, treatment of prolapse, 170.  
 — excision of rectum, 228.  
 Barker, A., angioma of rectum, 228.  
 Bassereau, condylomata, 85.  
 Bell, Sir C., treatment of prolapse, 161.  
 Belleli, adenoma caused by Bilharzia ova, 216.  
 Benign tumours, 211.  
 Bennett, Prof. E. H., foreign bodies in rectum, 307.  
 — injury to rectum, 309.  
 Bermingham, Prof., anatomy of rectum, 2.  
  
 Bewley, Dr. H., false diverticula, 328.  
 Bilharzia haematobia, a cause of adenoma, 216.  
 Bland Sutton, development of hymen, 8.  
 Bodenhamer, inherited syphilis, 88.  
 Bone in rectal tumour, 234.  
 Bumstead and Taylor, syphilis of rectum, 84.  
 Burkett, injury of rectum, 310.  
  
 Cancer, 235.  
 — choice of operation, 259.  
 — clinical types, 238.  
 — colloid degeneration of, 244.  
 — duration of, 236.  
 — excision, 257.  
 — — abdominal route, 278.  
 — — aseptic with preservation of sphincteric control, 262.  
 — — end-to-end junction, 275.  
 — — partial perineal, 259.  
 — — perineal route, 259.  
 — — results, 287.  
 — — sacral route, 271.  
 — — vaginal route, 277.  
 — in early life, 236.  
 — involvement of lymphatics in, 239.  
 — mucoid degeneration of, 244.  
 — of anus, 248.  
 — palliative treatment of, 288.  
 — secondary growths in liver, 240.  
 — — in lung, 242.  
 — secondary to disease elsewhere, 256.  
 — statistics, 235.  
 — symptoms, 250.  
 — treatment, 257.  
 — variation in malignancy, 236.  
 Cartilage in rectal tumour, 234.  
 Catarrhal inflammation of rectum, 63.  
 Clamp for crushing piles, 202.  
 Closmadeuc, foreign body in rectum, 306.  
 Cohnheim, escape of blood into intestine, 64.  
 Colloid cancer, 244.  
 Colopexotomy, 167.  
 Colopexy, 167.  
 Colotomy, 290.  
 — after treatment, 299.  
 — anterior, 292.  
 — atrophic changes in bowel after, 301.  
 — belt for use after, 300.  
 — closure of the opening, 301.  
 — delayed opening of bowel, 296.  
 — in developmental defect, 53.  
 — lumbar, 291.  
 — prognosis in, 299.  
 — prolapse and hernia after, 300.



- Colotomy, temporary, 298.  
 Colostomy, 290.  
 Columns of Morgagni, 7.  
 Compound external pile, 183.  
 Congenital malformations, 23.  
 — sacro-coccygeal tumour, 49.  
 Cripps, Mr. Harrison, stricture, 119.  
 Cruveilhier, developmental defect, 43.  
 — varieties of prolapse, 153.  
 Cunningham, Prof. D. J., 1.  
 Curling, irritable rectum, 317.  
 Cylinder-celled epithelioma, 237.  
 Czerny, excision of the rectum, 278.
- Dahlenkamp, foreign body in rectum, 307.  
 Danzel, teratoma of rectum, 232.  
 Delore and Charlier, excision of cancer, 262.  
 Dental engine in removal of foreign bodies, 307.  
 Dermatitis of anus, 321.  
 Dermoid tumour of rectum, 231.  
 Developmental defects, 23.  
 — — treatment, 52.  
 Diagnosis of rectal disease, 56.  
 Dieffenbach, operation for stricture of the anus, 145.  
 Diphtheria of the rectum, 66.  
 Dittel, operation for fistula, 116.  
 Diverticula, 326.  
 Diverticulum, false or acquired, 327.  
 — true or congenital, 326.  
 Dixon, Prof. A. F., 1.  
 — imperforate rectum, 35.  
 Dupuytren, enterotome, 302.  
 Duval, treatment of prolapse, 167.  
 Dysenteric ulcer, 75.  
 Dysentery, 74.
- Ecker, Prof., development of genital organs, 30.  
 Eczema, 321.  
 — marginatum, 321.  
 Eiselberg, von, treatment of prolapse, 171.  
 Embryology of rectum, 23.  
 Encysted rectum, 328.  
 Esmarch, anus preternaturalis in ano, 160.  
 Exner, veins in cicatrix, 210.  
 External piles, 180.  
 External sphincter, 12.
- Faget, excision of cancer, 256.  
 Fascia propria. Waldeyer, 14.  
 Fibroma, 226.  
 Fissure of the anus, 146.  
 Fistula, 95.  
 — bi-mucosa, 115.  
 — complete rectal, 95.  
 — complex, 100.  
 — incomplete, 97.  
 — incontinence of faeces from, 114.  
 — multiple, 100.  
 — recto-rectal, 117.  
 — recto-urethral, 115.  
 — recto-vaginal, 116.  
 — recto-vesical, 115.
- Fistula, relation to phthisis, 104.  
 — secondary suppuration, 114.  
 — superficial, 93.  
 — treatment, 107.  
 — tubercular, 103.  
 Foreign bodies in rectum, 305.  
 Fournier, ano-rectal syphiloma, 87.  
 — syphilis of rectum, 84.  
 Franks, Sir Kendal, fibrous tumour of rectum, 227.  
 Function of rectal muscles, 14.
- Gaffky, intestinal tuberculosis, 77.  
 Gangitano, treatment of prolapse, 171.  
 Gangrene of rectum, 73.  
 Gerota, lymphatics of rectum, 21.  
 Gonorrhoea of rectum, 64.  
 Gordon, Mr. T. E., dermoid of coccyx, 232.  
 — adenoma of rectum, 215.  
 Goselin, stricture, 122.  
 Greig Smith, intestinal drainage, 298.  
 Gross, sacciform disease of rectum, 328.  
 — Trichiasis recti, 114.  
 Gummata of rectum, 86.  
 Gunshot wound of rectum, 311.
- Haemorrhoids (see Piles), 174.  
 Hair-ball a cause of adenoma, 215.  
 Hamilton, Capt., anal plugs, 305.  
 Hawkins, Mr. C., false diverticula, 328.  
 Heincke, rupture of rectum, 311.  
 Heller, *Oxyuris vermicularis*, 320.  
 Heuston, Mr. F. T., congenital sacro-coccygeal tumour, 49.  
 Hilton, white line, 7.  
 Hind-gut, 25.  
 Hole, anatomy of pelvic floor, 10.  
 Houston's valves, 5.
- Iliac colon, 1.  
 Ilio-coccygeus muscle, 10.  
 Imperforate anal canal, 40.  
 — — anterior urethral outlet, 42.  
 — — perineal outlet, 44.  
 — — scrotal outlet, 44.  
 — — sub-urethral outlet, 44.  
 — — vulvar outlet, 41.  
 Imperforate rectum, 33.  
 — posterior urethral outlet, 36.  
 — spinal outlet, 39.  
 — vaginal outlet, 38.  
 — vesical outlet, 37.
- Incontinence of faeces, 317.  
 Infective diseases of rectum, 62.  
 Injuries of the rectum, 309.  
 Injury of rectum by substances swallowed, 310.  
 Intussusception of rectum, 172.  
 Irritability of rectum, 317.  
 Irritable ulcer, 147.  
 — pathology, 147.  
 — treatment, 150.  
 Ischio-rectal abscess, 68.  
 Itching of the anus, 319.



- Jeannel, proctopexy, 167.  
 — prolapsus recti, 157.  
 Jonnesco, anatomy of rectum, 1.
- Keatinge, Dr. H. P., Bilharzia disease of rectum, 217.
- Kelly, proctoscope, 254.  
 Kelsey, stricture, 132.  
 — use of term condyloma, 86.  
 Klein, imperforate rectum, 39.  
 Koch, intestinal tuberculosis, 76.  
 Konstantinowitch, circular vein of anus, 21.  
 Kraske, excision of rectum, 271.  
 Kurz, needle for colotomy, 302.
- La Nouene, treatment of prolapse, 171.  
 Laparo-colotomy, 292.  
 Lateral ligaments of rectum, 19.  
 Laure, foreign body in rectum, 306.  
 Lee, rectal constipation, 315.  
 Lefort, removal of foreign body from rectum, 308.  
 Leisol, gumma of rectum, 86.  
 Lenormant, prolapsus recti, 157.  
 Lentaigne, Mr. J., false diverticula, 328.  
 Levator ani, 10.  
 Lipoma, 230.  
 Ludloff, treatment of prolapse, 170.  
 Lymphatics of rectum, 21.  
 Lymphoma, 229.  
 Lympho-sarcoma, 247.
- MacDonald, Dr. Angus, tubercular ulcer, 81.  
 MacDonnell, Dr. R., case of anal tuberculosis, 80.  
 McWeeney, Prof. E. J., imperforate rectum with vaginal outlet, 38.  
 Malignant disease, varieties, 237.  
 — infiltrating adenoma, 235.  
 Marchant, proctopexy, 165.  
 Marchettis, removal of foreign body from rectum, 308.  
 Marshall, development of rectum, 24.  
 Mason, stricture, 122.  
 Michel, diverticulum, 32.  
 Milton, F., Bilharzia disease, 216.  
 Minot, anal plate, 29.  
 Mollière, adenoma, 224.  
 Morgagni, anal valves, 7.  
 Moulouguet, excision of rectum, 277.  
 Mucoid cancer, 244.  
 Mucous discharge from rectum, 223.  
 Müllerian ducts, 31.  
 Multiple adenomata, 221.  
 Murphy, vaginal excision of rectum, 278.  
 — button, in excision of rectum, 277.  
 Muscles of rectum, 8.
- Nerves of rectum, 22.  
 Neumann, syphilis of rectum, 84.  
 Neuralgia of rectum, 317.  
 Neurenteric canal, 25.  
 Neuroses of rectum, 313.
- O'Beirne, defaecation, 313.  
 Ogston, F., Junior, piles in early life, 177.  
 Omega loop of colon, 1.  
 Oxyuris vermicularis, 320.  
 — — ova a cause of rectal tumour, 217.
- Painful fissure, 144.  
 Papilloma of anus, 224.  
 Péan and Malassez, syphilis of rectum, 83.  
 Pectinate line, 6.  
 Pelvic colon, 1.  
 Periproctitis, 62.  
 Peters, treatment of prolapse, 171.  
 Phlebolith in piles, 183.  
 Physick, encysted rectum, 328.  
 Pilcher, foreign body in rectum, 305.  
 Piles, 174.  
 — in early life, 177.  
 — pathology of, 178.  
 — external, 180.  
 — — acute thrombotic, 180.  
 — — compound, 183.  
 — — cutaneous, 182.  
 — — gangrenous, 182.  
 — — suppurating, 182.  
 — external treatment, 184.  
 — internal, 187.  
 — — complications of, 190.  
 — — diagnosis, 190.  
 — — gangrene of, 191.  
 — — relation to fibrous tumour, 194.  
 — — retention of urine in, 209.  
 — — strangulation of, 191.  
 — — symptoms, 187.  
 — — treatment, 195.
- Platt, false diverticula, 328.  
 — treatment of prolapse, 165.  
 Polypus, 211.  
 Port, teratoma of rectum, 231.  
 Post-allantoic gut, 26.  
 Post-anal gut, 28.  
 — persistence of, 47.  
 Poucet, excision of cancer, 259.  
 Poulet, foreign bodies in rectum, 306.  
 Precocious cancer, 236.  
 Prescott Hewett, injury of rectum, 310.  
 Procidencia recti, 153.  
 Proctitis, 62.  
 Proctodaeum, 29.  
 Proctopexy, 165.  
 Proctorraphy, 167.  
 Proctoscope, 254.  
 Prolapsal hernia, 159.  
 Prolapse, 153.  
 — complete, 157.  
 — complications, 159.  
 — diagnosis of, 156.  
 — excision of, 172.  
 — partial, 153.  
 — treatment, 161.  
 — varieties of, 153.  
 — with invagination, 172.
- Pruritus ani, 319.



- Pruritus ani, division of cutaneous nerves in, 322.  
 — eczematous, 321.  
 — from nerve lesions, 321.  
 — parasitic, 370.  
 — treatment of, 322.  
 — varieties, 319.  
 Pubo-coccygeus muscle, 12.  
 Pubo-rectalis muscle, 12.
- Quain, Fistula bi-mucosa, 129.  
 Quénu, spontaneous rupture of rectum, 160.  
 — and Hartmann, excision of rectum, 278.
- Raynal, prolapse, 157.  
 Realli, removal of foreign body, 308.  
 Recapitulation theory of development, 23.  
 Rectal constipation, 313.  
 — pouch, 3.  
 Recto-urethralis muscle, 14.  
 Rectum, anatomy of, 1.  
 — development of, 23.  
 Rhagades, 86.  
 Ricord, syphilis of anus, 85.  
 Rizzoli, operation for vulvar anus, 55.  
 Rodent ulcer of anus, 249.  
 Rokitansky, false diverticula, 327.  
 Ruffer, M. A., Oxyuris vermicularis causing tumour, 217.
- Sacciform disease of rectum, 328.  
 Sacral anus, 274.  
 Sacro-coccygeal tumour, congenital, 49.  
 Salmon, treatment of piles, 262.  
 Sarcoma of rectum, 245.  
 — melanotic, 247.  
 Schaudinn, Spirochaete pallida, 86.  
 Schirro-contracted rectum, 239.  
 Sedgwick, function of neurenteric canal, 26.  
 Sinus, external rectal, 99.  
 — internal rectal, 98.  
 Sormani, intestinal tuberculosis, 77.  
 Sphincter muscle, external, 12.  
 — — internal, 10.  
 Spirochaete pallida, 86.  
 Spontaneous rupture of rectum, 160.  
 Stokes, Sir W., injury to the rectum, 310.  
 Stricture, 119.  
 — complications, 132.  
 — of the anus, 125.  
 — pathology of, 125.  
 — spasmodic, 119.  
 — symptoms, 130.  
 — traumatic, 123.  
 — treatment, 140.  
 Studsgaard, foreign body in rectum, 308.  
 Swan, Mr. R. L., adenoma, 220.  
 Sydney Jones, false diverticula, 328.  
 Syphilis of rectum, 83.
- Taeniae of colon, 3.
- Tail-gut, 28.  
 Taylor, Prof. E. H., 1.  
 — excision of cancer, 269.  
 Teratoma of rectum, 231.  
 Thiersch, operation for prolapse, 164.  
 Thompson, P., anatomy of pelvic floor, 10.  
 Thread-worms, 320.  
 Trelat, syphilitic fistulae, 88.  
 Treves, Sir F., anatomy of colon, 1.  
 Trichiasis recti, 114.  
 Tubercular fistula, 103.  
 — ulcer of rectum, 79.  
 Tuberculosis of anus, 79.  
 — of rectum, 76.  
 Tufnell, J., injury to rectum, 309.  
 Tuttle, treatment of prolapse, 165.
- Ulcer, 90.  
 — diphtheritic, 66.  
 — follicular, 91.  
 — haemorrhoidal, 90.  
 — indolent, 91.  
 — malignant (see Cancer), 235.  
 — painful, 146.  
 — simple, 90.  
 — syphilitic, 83.  
 — tubercular, 79.  
 — uraemic, 92.  
 Uro-genital outlet in rectum, 47.
- Van Buren, stricture, 131.  
 — syphilis of rectum, 84.  
 Veins of rectum, 21.  
 Velpeau, foreign body in rectum, 306.  
 Verneuil, treatment of prolapse, 167.  
 — veins of rectum, 176.  
 Villous tumour of rectum, 221.  
 Virchow, melanotic sarcoma, 247.  
 — lipoma, 230.  
 Vitelline duct, persistence of, 32.
- Wagstaffe, fistula bi-mucosa, 129.  
 Waldeyer, fascia propria of rectum, 14.  
 Weigand, foreign body in rectum, 307.  
 Weir Mitchell, hysterical constipation, 316.  
 Welch, thrombosis of veins, 179.  
 Wenzel, treatment of prolapse, 170.  
 Wheeler, Mr. W. I., imperforate rectum, spinal outlet, 39.  
 Whitehead, operation for piles, 206.  
 Wickham Legg, fruit-stones in intestine, 133.  
 Wood Jones, post-allantoic gut, 26.  
 Wounds of rectum, 309.  
 — during parturition, 310.  
 Wright, H. J., Spirochaete pallida, 86.  
 Wright, W. M. A., sloughing of rectum, 314.
- Zappula, gumma of rectum, 86.  
 Ziegler, dysentery of rectum, 74.  
 Zuckerhandl, cause of prolapse, 158.



SOME NEW AND FORTHCOMING  
MEDICAL WORKS

Published by  
HENRY FROWDE  
and  
HODDER & STOUGHTON

Including some of the books formerly published by  
YOUNG J. PENTLAND

IN the choice of Authors and Subjects  
the publishers have had the advantage  
throughout of the advice and assistance  
of  
WILLIAM OSLER, M.D., F.R.S.  
Regius Professor of Medicine  
in the University of Oxford

OXFORD MEDICAL PUBLICATIONS

HENRY FROWDE  
Oxford University Press

HODDER & STOUGHTON  
20 Warwick Square, London, E.C.



# INDEX OF AUTHORS

	PAGE		PAGE
Abel, Rudolf, M.D. . . . .	17	Ferguson, J. Haig, M.D., F.R.C.P.E. . . . .	9
Abraham, Phineas S., M.D., F.R.C.S.I. . . . .	6	Fisher, J. H., M.B., F.R.C.S. . . . .	18
Adamson, H. G., M.D., M.R.C.P. . . . .	28	Foster, Michael G., M.D. . . . .	23
Affleck, J. O., M.D., F.R.C.P.E. . . . .	22	Fox, T. Colcott, M.B., F.R.C.P. . . . .	8
Anderson, the late Sir Thomas M'Call, M.D. . . . .	31	Freyer, P. J., M.D. . . . .	7
Andrewes, F. W., M.D. Oxon., F.R.C.P. . . . .	6	Frost, W. Adams, F.R.C.S. . . . .	19
Ashby, Henry, M.D., F.R.C.P. . . . .	22		
Atkinson, Stanley B., M.B., B.L. . . . .	6, 13	Gamee, Professor Arthur, <b>F.R.S.</b> . . . .	22
Auld, A. G. . . . .	22	Garrod, A. E., M.D. Oxon., F.R.C.P. . . . .	23
		Gaskell, W. H., M.D., <b>F.R.S.</b> . . . .	22
Ball, Professor Sir Charles, F.R.C.S. . . . .	4	Geddes, Patrick, F.R.S.E. . . . .	30
Bardswell, Noel D., M.D., M.R.C.P. . . . .	8, 12	Gee, S. J., M.D., F.R.C.P. . . . .	24
Barker, A. E., M.S., F.R.C.S. . . . .	7	Gibson, G. A., M.D., F.R.C.P.E. . . . .	15, 22, 23, 32
Barwell, Harold, M.B., F.R.C.S. . . . .	27	Gillespie, A. Lockhardt, M.D., F.R.C.P.E. . . . .	22
Behrens, Dr. W. J. . . . .	30	Godlee, R. J., M.S., F.R.C.S. . . . .	7
Berry, G. A., M.B., F.R.C.S.E. . . . .	19	Gordon, M. H., M.A., M.D. Oxon. . . . .	17
Berry, James, M.S., F.R.C.S. . . . .	7	Gotch, Professor, <b>F.R.S.</b> . . . .	22
Birmingham, the late Professor A., M.B. . . . .	20	Gow, W. J., M.D., F.R.C.P. . . . .	6
Bland-Sutton, J., F.R.C.S. . . . .	7	Gowers, Sir William, M.D., <b>F.R.S.</b> . . . .	22
Bloch, Ivan, M.D. . . . .	6	Graham, James, M.D. . . . .	32
Boldt, J., M.D. . . . .	18	Gray, A. A., F.R.S.E. . . . .	22
Boyd, F. D., M.D., F.R.C.P.E. . . . .	8, 23	Guthrie, L. G., M.D. Oxon., F.R.C.P. . . . .	10
Boyle, H. Edmund G., M.R.C.S. . . . .	29		
Bradford, J. Rose, M.D., <b>F.R.S.</b> . . . .	8, 22, 23	Hadley, W. J., M.D., F.R.C.P. . . . .	8
Broadbent, Walter, M.D., M.R.C.P. . . . .	16	Haldane, J. S., M.D., <b>F.R.S.</b> . . . .	23
Brockbank, E. M., M.D. . . . .	6, 12	Halliburton, Professor, <b>F.R.S.</b> . . . .	22
Bruce, Alexander, M.D., F.R.C.P.E. . . . .	22, 30	Hanke, Victor, M.D. . . . .	19
Bruce, J. Mitchell, M.D., F.R.C.P. . . . .	15, 22	Hare, Professor H. A., M.D. . . . .	23
Brunton, Sir Lauder, Bt., M.D., <b>F.R.S.</b> . . . .	8, 22	Harmer, W. D., M.C. Cantab., F.R.C.S. . . . .	7
Bryant, John Henry, M.D. . . . .	23	Harris, V. D., M.D., F.R.C.P. . . . .	22
Buchanan, R. J. M., M.D., F.R.C.P. . . . .	13	Haultain, F. W. N., M.D., F.R.C.P.E. . . . .	9
Burghard, F. F., M.S., F.R.C.S. . . . .	7	Hawkins, H. P., M.D., F.R.C.P. . . . .	8, 22
Butlin, H. T., M.S., F.R.C.S. . . . .	7	Hay, John, M.D., M.R.C.P. . . . .	13
		Haycraft, Professor, M.D., F.R.S.E. . . . .	22
Campbell, H., M.D., F.R.C.P. . . . .	8	Hepburn, Professor D. H., M.D. . . . .	20
Cash, J. T., M.D., <b>F.R.S.</b> . . . .	23	Hill, Professor Leonard, M.D., <b>F.R.S.</b> . . . .	22, 23
Cautley, E., M.D., F.R.C.P. . . . .	8	Hopkins, F. G., M.B., <b>F.R.S.</b> . . . .	23
Chapman, J. E., M.R.C.S. . . . .	8, 12	Houghton, Capt. J. W. H., R.A.M.C. . . . .	7
Cheyne, Sir W. Watson, Bt., <b>F.R.S.</b> . . . .	30	Howden, Professor R., M.B. . . . .	20
Clubbe, Charles P. B., M.R.C.S. . . . .	32	Hoyle, William E., F.R.S.E. . . . .	31
Coats, G., M.D., F.R.C.S. . . . .	19	Hutchinson, Jonathan, <b>F.R.S.</b> . . . .	6
Collins, E. Treacher, F.R.C.S. . . . .	18		
Colman, W. S., M.D., F.R.C.P. . . . .	22	Jamieson, W. Allan, M.D., F.R.C.P.E. . . . .	14, 22
Corner, E. M., M.C. Cantab., F.R.C.S. . . . .	11, 26		
Cowan, John M., M.D. . . . .	8	Kanthack, the late A. A., M.D., F.R.C.P. . . . .	22
Crocker, H. Radcliffe, M.D., F.R.C.P. . . . .	30	Keating, John M., M.D. . . . .	31
Cunningham, Professor D. J., M.D., <b>F.R.S.</b> . . . .	20	Kelynack, T. N., M.D., M.R.C.P. . . . .	32
Cushny, Professor A. R., M.D. . . . .	23	Keogh, Sir Alfred, K.C.B., D.G. . . . .	6, 25
		Ker, C. Buchanan, M.D., F.R.C.P. . . . .	8, 22
Daniels, C. W., M.B. . . . .	8	Kermission, Professor E. . . . .	13
Davidson, Andrew, M.D., F.R.C.P.E. . . . .	31		
Dixon, Professor A. F., M.B. . . . .	20	Lambkin, Col. F. J., R.A.M.C. . . . .	6
Dixon, Walter, M.D. . . . .	23	Langley, Professor J. N., <b>F.R.S.</b> . . . .	22
		Lawrence, T. W. P., F.R.C.S. . . . .	22
Edkins, J. S. . . . .	22	Lea, A. W. W., M.D., F.R.C.S. . . . .	14
Edmunds, Arthur, M.S., F.R.C.S. . . . .	12	Leech, the late D. J., M.D. . . . .	23
Edwards, F. Swinford, F.R.C.S. . . . .	7	Legg, T. P., F.R.C.S. . . . .	7
		Leishman, Lt.-Col. W. B., R.A.M.C. . . . .	6, 25

*All the works in this list may be ordered through any bookseller.  
Books issued at 7s. 6d. and over will be sent on approval for examination.*



# Index of Authors

3

	PAGE		PAGE
Leuckart, Professor Rudolf . . . . .	31	Robinson, Professor Arthur, M.D. . . . .	20
Lister, Right Hon. Lord, O.M., F.R.S. . . . .	4	Robson A. W. Mayo, F.R.C.S. . . . .	7
Lockwood, C. B., F.R.C.S. . . . .	7, 14, 24	Rogers, Leonard, I.M.S., F.R.C.S., F.R.C.P. . . . .	4
Long, Eli H., M.D. . . . .	16	Rowell, George, F.R.C.S. . . . .	23
Lucas, E. W. . . . .	23	Russell, S. Risien, M.D., F.R.C.P. . . . .	22
Luff, A. P., M.D., F.R.C.P. . . . .	8, 22	Russell, William, M.D., F.R.C.P.E. . . . .	22, 23
McBride, P., M.D., F.R.C.P.E. . . . .	15	Sanderson, the late Professor Sir Burdon, F.R.S. . . . .	22
McCann, F. J., M.D., F.R.C.S. . . . .	11	Sargent, Percy, M.B., F.R.C.S. . . . .	29
McCrae, Thomas, M.D., F.R.C.P. . . . .	5	Savage, G. H., M.D., F.R.C.P. . . . .	23
M'Kendrick, Professor, F.R.S. . . . .	22	Schäfer, Professor E. A., F.R.S. . . . .	22
Mackenzie, Hector, M.D., F.R.C.P. . . . .	22, 23	Sherrington, Professor, F.R.S. . . . .	22
Mackenzie, James, M.D., M.R.C.P. . . . .	4	Shillitoe, Arthur, F.R.C.S. . . . .	6
Makins, G. H., M.S., F.R.C.S. . . . .	7	Shoemaker, Professor J. V., M.D. . . . .	23
Manson, Sir Patrick, M.D., F.R.S. . . . .	8, 22	Smith, Professor W. G., M.D., F.R.C.P.I. . . . .	23
Marshall, C. Devereux, F.R.C.S. . . . .	6	Smith, W. Ramsay, M.B. . . . .	32
Marshall, Professor C. R., M.D. . . . .	23	Snell, Simeon, F.R.C.S.E. . . . .	32
Martin, Sidney, M.D., F.R.S. . . . .	22, 23, 31	Snowball, Thomas, M.B. . . . .	18
Mayou, M. Stephen, F.R.C.S. . . . .	7, 25	Solly, S. E., M.D. . . . .	23
Melville, Lt.-Col. C. H., R.A.M.C. . . . .	6, 25	Spencer, Major C. G., F.R.C.S., R.A.M.C. . . . .	26
Mercier, C. A., M.D., F.R.C.P., F.R.C.S. . . . .	6, 14	Spriggs, E. I., M.S., F.R.C.P. . . . .	8
Metchnikoff, Professor Elie . . . . .	6	Starling, Professor, F.R.S. . . . .	22
Miles, Alexander, M.D., F.R.C.S.E. . . . .	21	Stephenson, Sydney, F.R.C.S.E. . . . .	18
Milne, J. S., M.D. . . . .	16	Stiles, H. J., M.B., F.R.C.S.E. . . . .	7, 20, 30
Moore, B. . . . .	22	Still, G. F., M.D., F.R.C.P. . . . .	6, 16
Moore, Norman, M.D., F.R.C.P. . . . .	16	Stockman, Professor Ralph, M.D., F.R.S.E. . . . .	22, 23
Moore, Sir J. William, M.D., F.R.C.P. . . . .	22	Sutherland, G. A., M.D., F.R.C.P. . . . .	8, 27
Mott, F. W., M.D., F.R.S. . . . .	6, 22	Taylor, Frederick, M.D., F.R.C.P. . . . .	22
Mourilyan, E. P., Fleet-Surgeon, R.N. . . . .	6	Taylor, James, M.D., F.R.C.P. . . . .	8, 22
Moynihan, B. G. A., F.R.C.S. . . . .	7	Thomson, Alexis, M.D., F.R.C.S.E. . . . .	21
Muir, Robert, M.D., F.R.C.P.E. . . . .	17	Thomson, Professor Arthur . . . . .	20
Murphy, J. Keogh, M.C. Cantab., F.R.C.S. . . . .	6, 13, 25	Thomson, Professor J. Arthur . . . . .	23
Neuberger, Professor Max von, M.D. . . . .	16	Thomson, St. Clair, F.R.C.P. . . . .	6, 7
Newman, David, M.D. . . . .	7	Thorburn, William, F.R.C.S. . . . .	7
Norwell, J. Stewart, B.Sc. . . . .	32	Tirard, Professor Nestor, M.D., F.R.C.P. . . . .	23
Oliver, Professor Thomas, M.D., F.R.S.E. . . . .	22, 23	Tod, Hunter, M.D., F.R.C.S. . . . .	7, 26
Osler, Professor William, M.D., F.R.S. . . . .	5, 6	Turner, W. Aldren, M.D., F.R.C.P. . . . .	22
Owen, Edmund, M.S., F.R.C.S. . . . .	7	Tweedy, Ernest Hastings, F.R.C.P.I. . . . .	9
Parsons, J. Herbert, D.Sc., F.R.C.S. . . . .	18, 19	Waggett, E. B., M.B. . . . .	27
Pasteur, W., M.D., F.R.C.P. . . . .	22	Walker, J. W. Thomson, F.R.C.S. . . . .	7
Paterson, Professor A. M., M.D., M.R.C.S. . . . .	20	Wallace, Cuthbert S., M.B., F.R.C.S. . . . .	10
Paton, Professor Noel, F.R.S. . . . .	22	Waring, H. J., M.S., F.R.C.S. . . . .	21, 31
Payne, J. F., M.D. Oxon., F.R.C.P. . . . .	16	Washbourn, J. W., M.D., F.R.C.P. . . . .	23
Pembrey, M. S., M.D. Oxon. . . . .	22, 23	Waymouth Reid, Professor . . . . .	22
Philip, R. W., M.D., F.R.C.P. . . . .	22	West, C. Ernest, M.D. Oxon., F.R.C.S. . . . .	6
Phillips, John, M.D., F.R.C.P. . . . .	7	White, W. Hale, M.D., F.R.C.P. . . . .	8, 22, 23
Pinches, H. Irving, M.B. . . . .	11	Whitelocke, R. H. Anglin, F.R.C.S. . . . .	14
Playfair, Ernest, M.D., M.R.C.P. . . . .	16	Wild, R. B., M.D., F.R.C.P. . . . .	23
Pollock, Major C. E., R.A.M.C. . . . .	6, 25	Williamson, R. T., M.D., F.R.C.P. . . . .	14, 22
Poore, G. V., M.D. . . . .	23	Wood, G. E. Cartwright, M.D. . . . .	22
Power, D'Arcy, M.B. Oxon., F.R.C.S. . . . .	6	Woodhead, Professor German Sims, M.D., F.R.C.P.E. . . . .	17, 22
Poynton, F. J., M.D., F.R.C.P. . . . .	28	Wrench, G. T., M.D. . . . .	9
Rawling, Louis B., F.R.C.S. . . . .	7	Yetts, W. P., Surgeon, R.N. . . . .	6
Richards, W. H., Staff-Surgeon, R.N. . . . .	6	Young, Professor A. H., F.R.C.S. . . . .	20
Ritchie, James, M.D., B.Sc. . . . .	17		
Rivers, W. H. R., M.D., F.R.C.P. . . . .	22		

*All the works in this list may be ordered through any bookseller.  
Books issued at 7s. 6d. and over will be sent on approval for examination.*



## The Collected Writings of the Right Hon. Lord Lister, O.M., F.R.S.

In 2 volumes. Crown 4to.

VOLUME I.	VOLUME II.
Introductory Essay.	Part III. Antiseptic Surgery.
Part I. Physiology.	Part IV. Surgery.
Part II. Pathology and Bacteriology.	Part V. Addresses.
	<i>In the Press.</i>

Original  
Treatises

### The Rectum : Its Diseases and Developmental Defects

By SIR CHARLES BALL, F.R.C.S.I., F.R.C.S. (Hon.), Regius  
Professor of Surgery, University of Dublin, &c.

*Just published.* £1 10s. net.

A large work on the Surgery of the Rectum together with  
its Diseases and Developmental Defects. Illustrated by 5 colour  
Plates and 142 original Illustrations. Crown 4to.

### Heart Diseases

By JAMES MACKENZIE, M.D., M.R.C.P., author of *The Study of  
the Pulse.* *Just published.* £1 5s. net.

A very complete account of the author's long researches.  
Fully illustrated in one volume. Crown 4to.

### Fevers in the Tropics

Their Clinical and Microscopical Differentiation.

By LEONARD ROGERS, I.M.S., F.R.C.S., F.R.C.P., Professor of  
Pathology, University of Calcutta. Crown 4to. An illustrated  
Prospectus on application. *Just published.* £1 10s. net.

Fully illustrated by a coloured Plate, Drawings, and over 100  
Charts.

'It is a marvel of industry and represents the work of many years.'  
—**Indian Medical Gazette.**

'The appearance of this scholarly and exhaustive, yet most readable  
work on Tropical Fevers will be eagerly welcomed by every student  
of Tropical Medicine.'—**Journal of the Royal Army Medical Corps.**

'Contains the results of a mass of original work and personal investi-  
gations conducted with untiring energy. . . It will certainly take a very  
important place in the annals of Indian Medicine.'—**British Medical  
Journal.**

'Major Leonard Rogers has indeed produced a monumental work,  
the like of which has not appeared previously. . . what has previously  
been non-existent, namely, a complete, scientific, and thoroughly  
up-to-date monograph of the perplexing fevers of India. We have  
not perused with such pleasure any work on Medicine.'—**The Lancet.**

*The above works can be had on approval from any bookseller.*



## A System of Medicine

Systematic  
Works

By EMINENT AUTHORITIES in the United States, Canada, Great Britain, and the Continent, edited by WILLIAM OSLER, M.D., F.R.S., Regius Professor of Medicine in the University of Oxford; and THOMAS McCRAE, M.D., F.R.C.P. (Lond.), Associate Professor of Medicine, Johns Hopkins University, Baltimore. In seven octavo volumes of about 900 pages each, illustrated. Price to subscribers for the seven volumes, 24s. net each volume; to non-subscribers, single volumes 30s. net.

A Special Prospectus will be sent on application.

Professor Osler's 'System of Medicine' is undoubtedly one of the most important works ever undertaken in the literature of Medicine. With well recognized qualifications the Editors unite a wide literary knowledge and an acquaintance with the thinkers and writers of the present day. They have thus been able to collect an exceptional group of contributors who have dealt with the subject assigned to them in a manner specially suited to the needs of the Practitioner.

Of the seven volumes constituting the work, the first three volumes are already published, the fourth volume has just been issued, and the others will be published at intervals of about three months.

'We may express our high appreciation of the first volume.'—**British Medical Journal.**

'The work throughout is of the highest merit, and if the subsequent volumes maintain the same standard of excellence as those to which we have referred, there will be at the service of every practitioner one of the soundest and most complete reference books on Medicine ever published.'—**The Practitioner.**

'The system is sure to secure the favour of a large public.'—**The Lancet.**

'A credit alike to American Medicine and to the care and judgement of its distinguished Editor.'—**Edinburgh Medical Journal.**

'The work, without question, is going to prove a highly useful and authoritative record covering the whole field of Medicine.'—**The Hospital.**

*This work can be had on approval from any bookseller.*



Systematic  
Works

# A System of Syphilis

Edited by D'ARCY POWER, M.B. (Oxon.), F.R.C.S., and J. KEOGH MURPHY, M.C. (Cantab.), F.R.C.S.

This work is designed to be an exhaustive treatise on the subject of this disease and its various manifestations both ordinary and rare. Each volume is fully illustrated with original illustrations, many of them direct colour photographs, and is complete in itself. Price £2 2s. per vol. net, or to subscribers £10 10s. net the set complete in six volumes. Vol. I now ready. Vol. II in the Press; ready in the autumn.

Vol.

- |  |  |
|--|--|
| I. Introduction  | Jonathan Hutchinson, F.R.S.  |
| History  | Ivan Bloch, M.D.   |
| Microbiology   | Professor Elie Metchnikoff.  |
| General Pathology  | F. W. Andrewes, M.D. (Oxon.), F.R.C.P.   |
| Early Manifestations (Male)  | Colonel F. J. Lambkin, R.A.M.C.  |
| Early Manifestations (Female)  | A. Shillitoe, F.R.C.S.   |
| Congenital Syphilis  | G. F. Still, M.D., F.R.C.P.  |
| <i>With over 30 Colour Illustrations from direct colour photographs and many others in half tone.</i>  |  |
| 'In one respect the first volume is the most important medical publication of recent years. It is, we believe, the first attempt in the English language to present in an authoritative and comprehensive form the sum of knowledge of a single disease. We are at once struck with the fact that the editors have gone in nearly every case to the acknowledged living authority on the subject.'— <i>St. Bartholomew's Hospital Gazette.</i> |  |
| II. Surgery of Syphilis  | D'Arcy Power, M.B. (Oxon.), F.R.C.S.   |
| Syphilis in connexion with Obstetrics and Gynaecology  | W. J. Gow, M.D., F.R.C.P.  |
| Treatment of Syphilis  | Colonel Lambkin, R.A.M.C.  |
| An Outbreak of Syphilis in Virgin Soil   | Colonel Lambkin, R.A.M.C.  |
| III. Visceral Syphilis   | Professor William Osler, M.D., F.R.S.  |
| Syphilis in connexion with Life Insurance  | E. M. Brockbank, M.D., F.R.C.P.  |
| Mental Affections of Syphilis  | Charles A. Mercier, M.D. (Oxon.), F.R.C.P.   |
| Medico-legal Aspects of Syphilis   | Stanley B. Atkinson, M.B. (Cantab.).   |
| IV. Syphilis of the Nervous System   | F. W. Mott, M.D., F.R.S.   |
| V. Diseases of the Skin  | Phineas S. Abraham, M.D., F.R.C.S.I.   |
| The Eye  | Devereux Marshall, F.R.C.S.  |
| The Nose and Throat  | St. Clair Thomson, M.D., F.R.C.P.  |
| The Ear  | C. Ernest West, M.D. (Oxon.), F.R.C.S.   |
| VI. The Public Services—The Navy   | Fleet-Surgeon E. P. Mourilyan.   |
|  | Staff-Surgeon W. H. Richards. Surgeon W. P. Yetts.   |
| The Army   | Introduction by the Director-General of the Army Medical Service, Sir Alfred Keogh, K.C.B. Lieut.-Colonel Melville, R.A.M.C. Major C. E. Pollock, R.A.M.C. Lieut.-Colonel Leishman, R.A.M.C. |

*This work can be had on approval from any bookseller.*



# A System of Operative Surgery

Systematic  
Works

Edited by F. F. BURGHARD, M.S., F.R.C.S. This system will be fully representative of the present state of opinion as to Operative Surgery in the United Kingdom.

The work will be in four volumes. The first volume will be published in the autumn of 1908. The Entire System will be published before the end of 1909.

## List of Contributors

### VOLUME I.

- The Principles and Technique of Wound Treatment C. B. Lockwood.  
Local Analgesic Methods Capt. J. W. H. Houghton, R.A.M.C.  
Amputations, Excisions, Ligature of Arteries, Operations upon the Peripheral Nerves, Veins, Tendons, Muscles, Ligaments and Fasciae.  
Operations upon the Long Bones (excluding Tuberculosis) F. F. Burghard.  
Plastic Surgery T. P. Legg.

*This volume is arranged so that it can be used separately by students preparing for the higher surgical examinations.*

### VOLUME II.

- Operations upon the Thyroid James Berry.  
Hare Lip and Cleft Palate Edmund Owen.  
Operations upon the Tongue, Tonsils and Pharynx H. T. Butlin.  
Operations for Tuberculosis of Glands, Bones and Joints H. J. Stiles.  
Operations upon the Stomach and Spleen B. G. A. Moynihan.  
Operations upon the Intestines G. H. Makins.  
Hernia A. E. Barker.  
Operations upon the Rectum F. Swinford Edwards.  
Operations on the Bile Passages and the Pancreas A. W. Mayo Robson.

### VOLUME III.

- Operations on the Skull and Brain Louis B. Rawling.  
Operations upon the Spinal Cord William Thorburn.  
Thoracic Surgery R. J. Godlee.  
Operations upon the Kidney and Ureter David Newman.  
Operations for Vesical Calculus and upon the Prostate P. J. Freyer.  
Operations upon the Bladder and the Urethra J. W. Thomson Walker.  
Operations on the Male Genital Organs F. F. Burghard.

### VOLUME IV.

- Vaginal Gynaecological Surgery John Phillips.  
Abdominal Gynaecological Surgery J. Bland-Sutton.  
Ophthalmic Surgery M. S. Mayou.  
Aural Surgery Hunter Tod.  
Laryngeal Surgery W. Douglas Harmer.  
Nasal Surgery St. Clair Thomson.

*This work can be had on approval from any bookseller.*



Systematic  
Works**A System of Diet and Dietetics**

A single volume under the Editorship of Dr. G. A. SUTHERLAND, M.D., F.R.C.P. This book is designed to be a complete account of dietetics viewed both from the scientific and practical standpoint. Prospectus on application. Crown 4to.

*Just published.* £1 10s. net.

## CONTENTS.

- Introduction.—General Principles Sir Lauder Brunton, Bt., F.R.S.  
 The Diet of Prehistoric Times and the Evolution of the Present-day Diet Harry Campbell, M.S., F.R.C.P.  
 The Physiology of Digestion, Absorption and Nutrition, The Results of Experimental Diets in man and animals E. I. Spriggs, M.S., F.R.C.P.  
 Special Diets, Diet Cures, Patent and Proprietary Foods E. Cautley, M.D., F.R.C.P.  
 Rectal Alimentation F. D. Boyd, M.D., F.R.C.P.E.  
 The Rôle of Alcohol in Health and in Disease Harry Campbell, M.D., F.R.C.P.  
 Diet in General Diseases :  
   Fevers Claude Buchanan Ker, M.D., F.R.C.P.  
   Tuberculosis Noel Bardswell, M.D., M.R.C.P., and J. E. Chapman, M.R.C.S.  
   Gout, Rheumatism and Rheumatoid Arthritis A. P. Luff, M.D., F.R.C.P.  
   Diabetes J. Rose Bradford, F.R.S.  
   Obesity E. Cautley, M.D., F.R.C.P.  
 Diet in Diseases of Special Organs :  
   The Stomach and Bowels H. P. Hawkins, M.D. (Oxon.), F.R.C.P.  
   The Liver and Pancreas W. Hale White, M.D., F.R.C.P.  
   The Lungs G. A. Sutherland, M.D., F.R.C.P.  
   The Heart and Blood Vessels W. J. Hadley, M.D., F.R.C.P.  
   The Kidneys J. Rose Bradford, F.R.S.  
   The Nervous System James Taylor, M.D., F.R.C.P.  
   The Integumentary System T. Colcott Fox, M.B., F.R.C.P.  
   The Blood and Blood-forming Organs John M. Cowan, M.D.  
 Diet in Infancy and Childhood, Diet in Diseases of Children G. A. Sutherland, M.D., F.R.C.P.  
 Diet in the Diseases of Hot Climates { Sir Patrick Manson, F.R.S.  
   { C. W. Daniels, M.B.

*This work can be had on approval from any bookseller.*



## Rotunda Practical Midwifery

Obstetrics

By ERNEST HASTINGS TWEEDY, F.R.C.P.I., Master of the Rotunda Hospital (Dublin), President, Section of Obstetrics British Medical Association, 1907; and G. T. WRENCH, M.D., late Assistant Master. 162 Illustrations. Special Prospectus on application. *Just published.* 16s. net.

'The wonderful material afforded by the Rotunda Hospital Practice forms quite a unique basis for a work such as this, and when interpreted for us by such authorities as the writers of the present volume it affords a book of exceptional value and striking suggestiveness—full of sage advice and practical acute observation.'—*Edinburgh Medical Journal*.

'We are grateful . . . for an interesting and stimulating original work.'—*British Medical Journal*.

'The practical side which is struck in the first chapter is maintained throughout, and in all instances treatment is given clearly and minutely described. . . .'*The Hospital*.

'Any one who begins this book because he ought to, will finish it because he likes it. It is clear, practical, and delightfully written, and it is a wholly creditable fulfilment of its aim as an exposition of "Rotunda Practical Midwifery".'*Medical Chronicle*.

## Rotunda Midwifery for Nurses and Midwives

By G. T. WRENCH, M.D., late Assistant Master of the Rotunda Hospital. With a Preface by the Master of the Rotunda. Pp. 324. 114 original Illustrations. A Special Prospectus on application. 6s. net.

'The aim throughout has been to put before nurses and midwives the knowledge which they actually need as clearly and practically as possible. . . . The numerous, well-executed illustrations add greatly to the usefulness of this book, which we strongly recommend to nurses and midwives.'*Nursing Mirror*.

'Calculated to fulfil its purpose admirably—written with an evident enthusiasm.'*Edinburgh Medical Journal*.

'An admirable little book for its purpose, written in the simplest language. We can cordially recommend the book to all nurses.'*Journal of Obstetrics and Gynæcology*.

## Handbook of Obstetric Nursing

By F. W. N. HAULTAIN, M.D., F.R.C.P. (Edin.), and J. HAIG FERGUSON, M.D., F.R.C.P. (Edin.). **Fifth Edition.** Revised and Enlarged. Pp. 267. Figures 37. 5s.

*Formerly published by Young J. Pentland.*

'Full of concise, useful information.'*The Hospital*.

'The excellence of this handbook for nurses is attested by the fact that the present is the fifth edition.'*The Lancet*.

**Works costing 7s. 6d. or over can be had on approval from any bookseller.**



For the  
Prac-  
titioner

## Functional Nervous Disorders in Childhood

By LEONARD G. GUTHRIE, M.A., M.D. (Oxon.), F.R.C.P., Senior Physician to Paddington Green Children's Hospital; Physician to the Hospital for Paralysis and Epilepsy, Maida Vale, &c. Pp. 300. One Plate. Prospectus on application. **7s. 6d. net.**

'It is saying much to state that his sense of humour is commensurate with his erudition, and the combination of the two make many of his chapters delightful reading. We have nothing but commendation for his work, which well deserves the success it will assuredly attain.'—**British Medical Journal.**

'We have read no book upon this subject which can compare with Dr. Guthrie's work for charm of literary style, and comprehensiveness of survey. The book is so fascinating that one must needs choose some time of leisure for its perusal, for, when once opened, it is not easily laid aside. We think Dr. Guthrie's work is likely to take its place as a standard work on the subject, and to be one of the most popular of the Oxford Medical Publications.'—**Practitioner.**

'We wish this book might be placed in the hands of every practitioner who has to do with nervous and delicate children. It brings home forcibly the great importance of the careful and intelligent management of the neurotic child.'—**Detroit Medical Journal.**

## A Surgical Mono- graph Prostatic Enlargement

By CUTHBERT S. WALLACE, M.B., F.R.C.S., Assistant Surgeon to St. Thomas's Hospital, &c. Pp. 215, with 80 Illustrations and one coloured Plate. Prospectus on application. **12s. 6d. net.**

'The book is all that could be asked for on such a subject; it is careful, judicious, and complete. The printing is perfect and the illustrations have come out very well.'—**Lancet.**

'The invaluable experience of a surgeon who has both seen and does much on this branch of surgery.'—**St. Thomas's Hospital Gazette.**

'Mr. Wallace has done a piece of good work, and this book should enhance his reputation.'—**Edinburgh Medical Journal.**

*These works can be had on approval from any bookseller.*



## Operations of General Practice

For the  
Prac-  
titioner

By EDRED M. CORNER, M.C. (Cantab.), F.R.C.S., Assistant Surgeon to St. Thomas's Hospital; Senior Assistant Surgeon, Hospital for Sick Children, Great Ormond Street, &c.; and HENRY IRVING PINCHES, M.A., M.B. Pp. 296, Illustrations 170. **Second Edition.** Prospectus sent post free on application.

*Just published.* **15s. net.**

'Certain of a hearty welcome from every earnest practitioner.'—**Hospital.**

'There has been a want of a suitable work giving clear instructions for the operations which a general practitioner would be inclined to undertake. This want appears to us to be very well supplied by this book. It is large without being too big; it is clearly written, and gives just that amount of assistance which is likely to be needed.'—**Lancet.**

'By carefully following out the directions and studying the illustrations here given, the veriest novice ought to be enabled to acquit himself honourably.'—**Medical Chronicle.**

*Second Edition.*

'The very favourable impression we formed of the work less than a year ago has been quickly confirmed.'—**Hospital.**

'The excellence and utility of the book has been fully proved.'—**British Medical Journal.**

## Cancer of the Womb: Its Symptoms, Diagnosis, Prognosis, and Treatment

A Gynaecological  
Mono-  
graph

By FREDERICK J. McCANN, M.D., F.R.C.S., M.R.C.P., Physician to the Samaritan Hospital for Women, London; Lecturer on Gynaecology, Medical Graduates' College and Polyclinic, London. Fully illustrated. Pp. 172, Plates 46. Prospectus on application. **20s. net.**

'The work is illustrated throughout by original photographic plates, most of them showing the naked-eye and microscopic appearances very clearly. The book is one of very great merit; it will be read with interest both by the specialist and general practitioner as an authoritative exposition of the important subject with which it deals.'—**Edinburgh Medical Journal.**

'Will be read with interest as a well prepared summary of the author's investigations. There is much merit in the illustrations.'—**British Medical Journal.**

'The outstanding feature of the work is the wealth and beauty of the illustrations. . . . Dr. McCann has produced a valuable work which deserves to be widely known.'—**Practitioner.**

*These works can be had on approval from any bookseller.*



For the  
Prac-  
titioner

## Life Insurance and General Practice

By E. M. BROCKBANK, M.D., F.R.C.P., Assistant Physician, Manchester Royal Infirmary. 8vo, pp. 288. Prospectus on application. *Just published.* 7s. 6d. net.

'Should find a welcome place in any medical library, and is a worthy addition to the excellent series of medical publications to which it belongs.'—**Journal of the Royal Army Medical Corps.**

'The majority of medical men have, at one time or another, to act as medical examiner for insurance purposes, and, while the training of the modern medical man should render him quite competent for the task, yet there are differences between this kind of examination and that carried out for purposes of diagnosis, which make the advice of an expert of considerable value and assistance. It is just this kind of advice which Dr. Brockbank offers in his work on "Life Insurance and General Practice".'—**British Medical Journal.**

'After a careful perusal of this volume we can recommend it to our readers as a useful guide in the medical examination for life insurance in general practice.'—**Lancet.**

## Diets in Tuberculosis. Principles and Economics

By NOEL D. BARDSWELL, M.D., Medical Superintendent, King Edward VII's Sanatorium, Midhurst; and J. E. CHAPMAN, M.R.C.S. Pp. 183. *Just published.* 6s. net.

'Concisely written and practical from cover to cover—richly supplied with full menus and practical instructions for cooking, and deserves the highest praise.'—**British Medical Journal.**

'The most interesting chapter in the book on the comparative economy of the cheap foodstuffs is full of important practical hints. We cordially recommend the book.'—**Scottish Medical and Surgical Journal.**

'The authors have succeeded in producing an interesting treatise.'—**The Lancet.**

## Glandular Enlargements and other Surgical Diseases of the Lymphatic System

By ARTHUR EDMUNDS, M.S., F.R.C.S., Assistant Surgeon, Great Northern Central Hospital, &c. Pp. 236, with 19 Illustrations. *Just published.* 7s. 6d. net.

A practical account of diagnosis and treatment from the surgical point of view rather than a monograph.

*An Early Review.*

'Mr. Edmunds has given us a book which will be of great use to the practitioner and which gathers into small space practically the sum of our knowledge of the subject.'—**Glasgow Medical Journal.**

*All works costing 7s. 6d. and over can be had on approval from any bookseller.*



## The Law in General Medical Practice, or Clinical Jurisprudence

For the  
Prac-  
titioner

By STANLEY ATKINSON, M.B., B.L., Secretary of the Medico-legal Society, &c., &c. *Just published.* 7s. 6d. net.

A book for Practitioners—the legal pitfalls of daily practice

‘A useful little manual—deals with matters of the greatest importance to the general practitioner, about which, it is feared, many have but a limited knowledge: should be carefully read by all young practitioners. It need not take long to master its contents, and it is highly desirable that every practitioner should be acquainted with the Law relative to his or her profession.’—*British Medical Journal.*

## Clinical Methods of Examining the Heart

By JOHN HAY, M.D., M.R.C.P., Assistant Physician, Liverpool Royal Infirmary. *In the Press.*

A short handbook detailing the most modern methods of clinical examination as well as their significance. With a preface by Dr. Mackenzie.

## The Blood in Health and Disease

By R. J. M. BUCHANAN, M.D., F.R.C.P., Assistant Physician, Liverpool Royal Infirmary. *In the Press.*

Designed to be a short, practical account of the clinical features and treatment of diseases of the blood with a full account of microscopical features so far as they concern the practitioner—amply illustrated with 16 original colour Plates.

## Diseases of the Lungs

By R. J. M. BUCHANAN, M.D., F.R.C.P. *In preparation.*

Designed to follow the same practical lines.

## A Handbook of the Surgery of Children

By Professor E. KERMISSON, Paris. Translated by J. KEOGH MURPHY, M.C. (Cantab.), F.R.C.S. With additions by the Translator. *In the Press.*

*All works costing 7s. 6d. and over can be had on approval from any bookseller.*



For the  
Prac-  
titioner

## Diseases of the Spinal Cord

By R. T. WILLIAMSON, M.D., F.R.C.P., Assistant Physician,  
Manchester Royal Infirmary, &c. Crown 4to, pp. 420, Figures  
183. Prospectus on application. **15s. net.**

*Just published.*

A Textbook on diseases of this part of the Central Nervous System; the author gives the pathology so far as it is known up to the present date, and discusses the symptoms and treatment with care. The book is fully illustrated by 183 original Illustrations and Diagrams and 7 Plates.

*An Early Review.*

'May be regarded as able and authoritative. We offer our hearty thanks for this admirable volume.'—**Glasgow Medical Journal.**

## Criminal Responsibility

By CHARLES A. MERCIER, M.D. (Oxon.), F.R.C.P., F.R.C.S.  
8vo, cloth, pp. 232. **7s. 6d. net.**

## Sprains and Allied Injuries of Joints

By R. H. ANGLIN WHITELOCKE, F.R.C.S., Surgeon, Radcliffe  
Infirmary, Oxford. *In preparation.*

To be a full and practical treatise on the less severe injuries of the joints. Fully illustrated.

## Diseases of the Skin

By W. ALLAN JAMIESON, M.D., F.R.C.P. (Edin.), Extra Physi-  
cian for Diseases of the Skin, Edinburgh Royal Infirmary;  
Lecturer on Diseases of the Skin in the University of Edin-  
burgh. **Fourth Edition.** Revised and Enlarged. 8vo, cloth,  
pp. xx + 600, with 9 coloured Illustrations. **21s.**

A Manual for Students and Practitioners.

*Formerly published by Young J. Pentland.*

## Aseptic Surgery

By C. B. LOCKWOOD, F.R.C.S., Surgeon to St. Bartholomew's  
Hospital.

A new edition in preparation, brought completely up to date.

## Puerperal Infection

By ARNOLD W. W. LEA, M.D., F.R.C.S. *In preparation.*

*These works can be had on approval from any bookseller.*



## The Principles of Treatment and their Applications in Practical Medicine

For the  
Prac-  
titioner

By J. MITCHELL BRUCE, M.A., LL.D., M.D., F.R.C.P., Consulting Physician to Charing Cross Hospital and to the Hospital for Consumption, Brompton. 8vo, cloth, gilt top, pp. xviii + 614.  
**Third Impression.** **15s. net.**

*Formerly published by Young J. Pentland.*

'We have rarely perused a book with more satisfaction. . . . A Treatise of the nature was wanted, and practitioners and students will find it most valuable.'—**Lancet.**

'This work is not only remarkable in itself, but it is one sorely needed. . . . Every sentence is deserving of respect as the deliberate and well-founded opinion of a competent author.'—**British Medical Journal.**

'The book fills a long-felt want, and fills it admirably.'—**Medical News.**

## Diseases of the Heart and Aorta

By G. A. GIBSON, M.D., D.Sc., F.R.C.P. (Edin.), Physician to the Royal Infirmary; Consulting Physician to the Deaconess Hospital; Lecturer on Medicine at Minto House, and on Clinical Medicine at the Royal Infirmary, Edinburgh. 8vo, cloth, pp. xxiv + 932, with 210 Illustrations. **15s. net.**

*Formerly published by Young J. Pentland.*

## Diseases of the Throat, Nose and Ear

By P. M'BRIDE, M.D., F.R.C.P. (Edin.), Lecturer on the Diseases of the Ear and Throat in the University; Aural Surgeon and Laryngologist, Royal Infirmary, Edinburgh. **Third Edition**, thoroughly revised and partly rewritten. 8vo, cloth, pp. xviii + 744, with 48 coloured Illustrations from original Drawings. **25s.**

A Clinical Manual for Students and Practitioners.

*Formerly published by Young J. Pentland.*

'Still the best before the Medical Public.'—**Lancet.**

'As a guide for students and practitioners it may be safely pronounced absolutely reliable.'—**British Medical Journal.**

*These works can be had on approval from any bookseller.*



Historical  
Works**The History of Medicine**

By PROFESSOR MAX VON NEUBERGER, Professor of Medical History, University of Vienna. Translated by ERNEST PLAYFAIR, M.D., M.R.C.P. *In preparation.*

A large and complete work on the History of Medicine from the earliest times up to recent years.

**English Medicine in Anglo-Saxon Times**

By J. F. PAYNE, M.D. (Oxon.), F.R.C.P. 23 Illustrations, 8vo. **8s. 6d. net.**

**The History of the Study of Medicine in the British Isles**

By NORMAN MOORE, M.D. (Cantab.), F.R.C.P., Physician to St. Bartholomew's Hospital. Pp. 202, with 10 Illustrations. 8vo. **10s. 6d. net.**

**Surgical Instruments in Greek and Roman Times**

By J. S. MILNE, M.A., M.D. Pp. 187, with 54 Illustrations. 8vo. **14s. net.**

**The Writings of the late Sir Wm. Broadbent, F.R.S.**

Collected and edited by WALTER BROADBENT, M.D., M.R.C.P. Demy 8vo. Pp. 439. Illustrated. *Just published.* **15s. net.**

'At once a mass of clinical wisdom and observation, and a fitting memorial of a teacher whose personality exercised no small influence upon the medical thought of his generation.'—**British Medical Journal.**

New  
Works**Dental Materia Medica, Therapeutics and Prescription Writing**

By ELI H. LONG, M.D. Now ready. Cloth, pp. 298, with 18 Plates. **15s. net.**

'The coloured illustrations are really excellent, and we do not remember to have seen anything like them in any previous Materia Medica.'—**The General Practitioner.**

**Common Disorders and Diseases in Childhood**

By G. F. STILL, M.D., F.R.C.P., Professor of Diseases of Children, King's College; Physician to Out-patients, Hospital for Sick Children, Great Ormond Street, &c.

*In active preparation.*

*These works can be had on approval from any bookseller.*



## Practical Pathology

Works on  
Pathology

By GERMAN SIMS WOODHEAD, M.D., F.R.C.P. (Edin.), Professor of Pathology, University of Cambridge. Rewritten and brought up to date, with over 200 coloured Illustrations.

**Fourth Edition.** *In active preparation.*

A Manual for Students and Practitioners.

## Manual of Bacteriology

By ROBERT MUIR, M.D., F.R.C.P. (Edin.), Professor of Pathology, University of Glasgow; and JAMES RITCHIE, M.D., B.Sc., Superintendent, Research Laboratory, R.C.P., Edinburgh; formerly Professor of Pathology, University of Oxford. Crown 8vo, cloth, pp. xxiv + 605, with 171 Illustrations in the Text.

**Fourth Edition, thoroughly revised.** 10s. 6d. net.

‘Established for so many years as the **chief English Textbook** on Bacteriology for the Medical Student and Practitioner. . . . It would be difficult to find a work which so completely fulfils its purpose.’—**Lancet.**

‘The setting of this manual is beyond all praise; the book is of handy size, beautifully printed on fine paper and neatly bound.’—**Dublin Journal of Medical Science.**

*Formerly published by Young J. Pentland.*

## A Laboratory Handbook of Bacteriology

By Dr. RUDOLF ABEL, Medical Privy Councillor, Berlin. Translated by Dr. M. H. GORDON, M.A., M.D. (Oxon.), B.Sc.

**Tenth (German) Edition.** 5s. net.

‘A book the popularity of which in Germany is such that it has reached a tenth edition in ten years naturally arouses high expectations which are not likely to be dispelled by its perusal.

‘Justifies the claim advanced in his preface—to be clear and concise and to bring forward only reliable and fully proved methods of examination which are as simple as possible to undertake and to put into practice.

‘The book is bound in oilcloth so as to resist the dangers of the laboratory bench, and it is well printed and practically free from errors.

‘There is no doubt that this volume will be found in all laboratories, as it is full of useful and accurate information.’—**Lancet.**

‘We can assure the intending purchaser that he will find it thoroughly reliable.’—**British Medical Journal.**

‘There can be no doubt as to the great value of this book for everyone engaged in bacteriological work.’—**Journal of Royal Institute of Public Health.**

‘The success of the book is assured.’—**Montreal Medical Journal.**

*All works costing 7s. 6d. and over can be had on approval from any bookseller.*



Works on  
the Eye

## The Pathology of the Eye

By J. HERBERT PARSONS, B.S., D.Sc. (Lond.), F.R.C.S. (Eng.), Assistant Surgeon, Royal London (Moorfields) Ophthalmic Hospital; Assistant Surgeon, University College, London; Ophthalmic Surgeon, Hospital for Sick Children, Great Ormond Street. In Four volumes, with over 700 Illustrations. Royal 8vo, cloth. The Fourth and last volume just published. Separate Prospectus on application. **15s.** net each volume.

In four volumes. (Awarded the Nettleship Gold Medal of the Ophthalmological Society.)

'One of the most important contributions to ophthalmological literature that has hitherto appeared.'—**Lancet.**

'In every respect the greatest literary contribution that has ever been made to the Pathology of the Eye.'—**Annals of Ophthalmology.**

'Will long be read as *the* Text-book on Ocular Pathology.'—**British Medical Journal.**

## Ophthalmological Anatomy, with some Illustrative Cases

By J. HERBERT FISHER, M.B., B.S. (Lond.), F.R.C.S. Royal 8vo. Illustrated. Pp. 188. **7s. 6d.** net.

## Trachoma

By Dr. J. BOLDT. Translated by J. HERBERT PARSONS, D.Sc., F.R.C.S.; and THOMAS SNOWBALL, M.B., C.M., Burnley. With an Introductory Chapter by E. TREACHER COLLINS, F.R.C.S. Royal 8vo. **7s. 6d.** net.

## Epidemic Ophthalmia: Its Symptoms, Diagnosis, and Management

By SYDNEY STEPHENSON, F.R.C.S. (Edin.), Ophthalmic Surgeon, Evelina Hospital and N.E. Hospital for Children, London. 8vo, cloth, pp. xvi + 278. Illustrated with a coloured Plate and 25 Figures in the Text. **9s.** net.

*These works can be had on approval from any bookseller.*



## The Fundus Oculi, with an Ophthalmoscopic Atlas

Works on  
the Eye

Illustrating its Physiological and Pathological Conditions

By W. ADAMS FROST, F.R.C.S., late Ophthalmic Surgeon, St. George's Hospital; Consulting Ophthalmic Surgeon to the Royal Westminster Ophthalmic Hospital, London, &c. In one handsome 4to volume, extra cloth, gilt top, with 47 Plates, exhibiting 107 beautifully coloured Figures and numerous Engravings in the Text. **£3 3s. net.**

*Formerly published by Young J. Pentland.*

## The Treatment of Diseases of the Eye

By Dr. VICTOR HANKE. Translated by J. HERBERT PARSONS, B.S., D.Sc. (Lond.), F.R.C.S. (Eng.); and GEORGE COATS, M.D., F.R.C.S. (Eng.). Crown 8vo, cloth. **3s. 6d. net.**

## Manual of Practical Ophthalmology

By GEORGE A. BERRY, M.B., F.R.C.S. (Edin.), Senior Ophthalmic Surgeon, Edinburgh Royal Infirmary; Surgeon, Edinburgh Eye Dispensary; Ophthalmic Surgeon, Royal Hospital for Sick Children; Lecturer on Ophthalmology, University of Edinburgh. Crown 8vo, cloth, pp. xx + 570, with 223 Illustrations, mostly from original Drawings. **10s. 6d. net.**

*Formerly published by Young J. Pentland.*

'An eminently practical guide.'—**Medical Chronicle.**

'Dr. Berry has the knack of telling the practitioner exactly the kind of thing he wants to know, and often looks for in vain in the average text-book.'—**Liverpool Medico-Chirurgical Journal.**

'One on which reliance can be placed.'—**Lancet.**

## The Arris and Gale Lectures on the Neurology of Vision

By J. HERBERT PARSONS, B.S., D.Sc. (Lond.), F.R.C.S. (Eng.). Two coloured Plates and 22 Illustrations. Demy 8vo, paper. **2s. 6d. net.**

*All works costing 7s. 6d. and over can be had on approval from any bookseller.*



Students'  
Text-  
Books

## Manual of Practical Anatomy

Anatomy

By D. J. CUNNINGHAM, M.D., D.C.L. (Oxon.), F.R.S., Professor of Anatomy in the University of Edinburgh. **Just published. Fourth Edition**, thoroughly revised, with many new and additional Colour Illustrations. In 2 volumes, crown 8vo, cloth.

VOL. I. Upper and Lower Limb, Abdomen.

II. Thorax, Head and Neck.

Illustrated with 573 Engravings, many in colours. 10s. 6d. each net.

'Undoubtedly the best work of its kind in the English language and thoroughly deserves all the success it has gained.'—**Lancet**.

'Likely long to remain the favourite text-book of the dissecting room.'—**Australasian Medical Gazette**.

'Colours have been freely introduced into the figures, and the facility of reference to the various parts has therefore been greatly increased.'—**British Medical Journal**.

## Text-Book of Anatomy

Edited by D. J. CUNNINGHAM, M.D., F.R.S., Professor of Anatomy, University of Edinburgh. **Second and thoroughly Revised Edition.**

The Articles are contributed by—

Professor A. H. Young (Manchester)

Professor Arthur Robinson (Birmingham)

Professor Arthur Thomson (Oxford)

Professor D. H. Hepburn (Cardiff)

Harold J. Stiles, F.R.C.S. (Edinburgh)

Professor A. M. Paterson (Liverpool)

Professor R. Howden (Newcastle)

The late Professor A. Birmingham (Dublin)

Professor A. F. Dixon (Dublin), and

The Editor

In one volume, royal 8vo, cloth, pp. xxxvi + 1388, with 936 Engravings from original Drawings, many in colours. 31s. 6d. net.

The work is also published in four parts with separate indexes, at the same price, as follows—

Part I. Embryology, Bones and Joints. 6s. net.

II. Muscles. Nervous System. Special Sense Organs. 9s. net.

III. Vascular, Respiratory and Digestive Systems. 9s. net.

IV. Urinogenital System. Surface and Surgical Anatomy. 7s. 6d. net.

'We do not know any text-book of anatomy which is better adapted to meet the needs of students and practitioners of Medicine and Surgery.'—**British Medical Journal**.

'There is no better Manual on the subject in any language.'—**The Times**.

*The above were formerly published by Young J. Pentland.*

*These works can be had on approval from any bookseller.*



Students'  
Text-  
Books

## Manual of Surgery

Surgery  
Operative  
Surgery

By ALEXIS THOMSON, M.D., F.R.C.S. (Edin.), Assistant Surgeon, Edinburgh Royal Infirmary; Surgeon to the Deaconess' Hospital, Edinburgh; and ALEXANDER MILES, M.D., F.R.C.S. (Edin.), Assistant Surgeon, Edinburgh Royal Infirmary; Surgeon to Leith Hospital. Two volumes. Crown 8vo, cloth.

**Second Edition, revised and enlarged. 10s. 6d. each net.**

VOL. I. *General Surgery*, pp. xxiv + 808, with 313 Illustrations in the Text.

VOL. II. *Regional Surgery*, pp. xvi + 816, with 203 Illustrations in the Text.

Price 10s. 6d. each net.

'We think it the most useful surgical text-book for students we have recently seen.'—**Bristol Medico-Chirurgical Journal.**

'Quite at the head of books of its class. Everything being taken into consideration it is one of the best, if not the best, of the many text-books of Surgery for students to read.'—**Birmingham Medical Review.**

'For all ordinary purposes the best systematic English text-book on General Surgery.'—**Scottish Medical Journal.**

'The book is eminently practical and thoroughly up-to-date, while it is one of the most reliable and readable books the student or general practitioner could possess. We most cordially recommend the manual to the perusal of every student desirous of finding nicely expressed everything of importance in connexion with modern general surgery.'—**Dublin Journal of Medical Science.**

'The teaching throughout is in complete accord with the latest developments of Surgical Work.'—**British Medical Journal.**

## Manual of Operative Surgery

By H. J. WARING, M.S., B.Sc., F.R.C.S., Assistant Surgeon, Lecturer on Surgical Anatomy, and Demonstrator of Practical Surgery, St. Bartholomew's Hospital; Consulting Surgeon to the Metropolitan Hospital, London; Member of Board of Examiners, Royal College of Surgeons, England. Crown 8vo, cloth, pp. xxx + 645, with 472 Illustrations in the Text.

**Second Edition. 10s. 6d. net.**

'Admirably serves the purpose for which it has been written.'—**Liverpool Medico-Chirurgical Journal.**

'The book consists of 645 pages of good clear print with 472 well-drawn excellent illustrations, most of which are original . . . a well-written, convenient and useful work.'—**Medical Chronicle.**

'In the second edition Mr. Waring has, by careful revision of the original issue, and by the addition with the help of colleagues of many new sections, successfully maintained the practical utility of the work.'—**British Medical Journal.**

*The above were formerly published by Young J. Pentland.*

**These works can be had on approval from any bookseller.**



Students'  
Text-  
Books

## Text-Book of Medicine

Medicine  
Physio-  
logy

By BRITISH TEACHERS. Edited by G. A. GIBSON, M.D., D.Sc., F.R.C.P. (Edin.). Two volumes, royal 8vo, extra cloth, pp. xxiv + 824, and xx + 910, with 122 Illustrations. **15s. net.**

The list of Contributors is as follows:—

J. O. Affleck, F.R.C.P.	Herbert P. Hawkins, F.R.C.P.	W. Pasteur, F.R.C.P.
Henry Ashby, F.R.C.P.	W. Allan Jamieson, F.R.C.P.	R. W. Philip, F.R.C.P.
A. G. Auld	The late A. A. Kanthack, F.R.C.P.	S. Risien Russell, F.R.C.P.
John Rose Bradford, M.D., F.R.S.	Claude B. Ker, F.R.C.P.E.	William Russell, F.R.C.P.E. Ralph Stockman, F.R.C.P.E.
Alexander Bruce, F.R.C.P.E.	T. W. P. Lawrence, F.R.C.S.	Frederick Taylor, F.R.C.P.
J. Mitchell Bruce, F.R.C.P.	A. P. Luff, F.R.C.P.	James Taylor, F.R.C.P.
Sir Lauder Brunton, M.D., F.R.S.	Hector Mackenzie, F.R.C.P.	W. Aldren Turner, F.R.C.P.
W. S. Colman, F.R.C.P.	Sir Patrick Manson, M.D., F.R.S.	W. Hale White, F.R.C.P.
G. A. Gibson, F.R.C.P.E.	Sidney Martin, M.D., F.R.S.	R. T. Williamson, F.R.C.P.
A. Lockhardt Gillespie, F.R.C.P.E.	Sir John William Moore, F.R.C.P.I.	G. E. Cartwright Wood, M.D.
Sir William Gowers, M.D., F.R.S.	F. W. Mott, M.D., F.R.S.	Professor G. Sims Wood- head, F.R.C.P.E.
V. D. Harris, F.R.C.P.	Thomas Oliver	

*Formerly published by Young J. Pentland.*

## Text-Book of Physiology

By BRITISH PHYSIOLOGISTS. Edited by E. A. SCHÄFER, F.R.S., Professor of Physiology in the University of Edinburgh. Two volumes. Vol. I, royal 8vo, cloth, pp. xx + 1036, with 3 Plates and 93 Illustrations in the Text. Price **31s. 6d.** Vol. II, pp. xxiv + 1365, with 449 Illustrations in the Text. Price **42s.**

The list of Contributors is as follows:—

The late Professor Sir Burdon Sanderson, F.R.S.	M. S. Pembrey, M.D. Oxon. (Guy's)
Professor Arthur Gamgee, F.R.S. (Man- chester)	W. H. R. Rivers, M.D., F.R.C.P. (Cambridge)
Dr. Gaskell, F.R.S. (Cambridge)	Professor Waymouth Reid (Dundee)
Professor Gotch, F.R.S. (Oxford)	B. Moore (Charing Cross)
Professor Sherrington, F.R.S. (Liverpool)	F. G. Hopkins, F.R.S. (Cambridge)
Professor M'Kendrick, F.R.S. (Glasgow)	Professor Leonard Hill, F.R.S. (University College)
Professor Haliburton, F.R.S. (King's College)	J. S. Edkins (St. Bartholomew's)
Professor Haycraft, F.R.S.E. (Cardiff)	A. A. Gray (Glasgow)
Professor Starling, F.R.S. (University Coll.)	Professor Noel Paton, F.R.S. (Glasgow) and The Editor.
Professor J. N. Langley, F.R.S. (Cambridge)	

*Formerly published by Young J. Pentland.*

***These works can be had on approval from any bookseller.***



Students'  
Text-  
Books**Text-Book of Pharmacology & Therapeutics**

Edited by W. HALE WHITE, M.D., F.R.C.P., Physician and Lecturer on Medicine, Guy's Hospital, London. Royal 8vo, pp. x + 1040. **21s net.**

Thera-  
peutics  
Physical  
Diagnosis  
Zoology

The list of Contributors is as follows:—

John Rose Bradford, M.D., F.R.S.	Leonard Hill, M.D., F.R.S.	George Rowell, F.R.C.S.
J. H. Bryant, M.D.	F. G. Hopkins, F.R.S.	G. H. Savage, F.R.C.P.
J. T. Cash, M.D., F.R.S.	D. J. Leech, M.D.	J. V. Shoemaker, M.D.
A. R. Cushny, M.D.	Edward W. Lucas	Samuel E. Solly, M.D.
Walter Dixon, M.D.	Hector Mackenzie, F.R.C.P.	Walter George Smith, M.D.
Michael G. Foster, M.D.	C. R. Marshall, M.D.	Ralph Stockman, F.R.S.E.
A. E. Garrod, F.R.C.P.	Sidney Martin, M.D., F.R.S.	Nestor Tirard, F.R.C.P.
J. S. Haldane, M.D., F.R.S.	Thomas Oliver, F.R.S.E.	J. W. Washbourn, F.R.C.P.
Hobart Amory Hare, M.D.	M. S. Pembrey, M.D.	W. Hale White, F.R.C.P.
	G. V. Poore, M.D.	R. B. Wild, F.R.C.P.

*Formerly published by Young J. Pentland.*

**Physical Diagnosis****A Guide to Methods of Clinical Investigation**

By G. A. GIBSON, M.D., D.Sc., F.R.C.P. (Edin.), Physician, Edinburgh Royal Infirmary; Lecturer on the Principles and Practice of Medicine in the Edinburgh Medical School; and WILLIAM RUSSELL, M.D., F.R.C.P. (Edin.), Assistant Physician, Edinburgh Royal Infirmary, Lecturer on Pathology and Morbid Anatomy, School of Medicine, Edinburgh. Edited by FRANCIS D. BOYD, C.M.G., M.D., F.R.C.P. (Edin.), Assistant Physician, Royal Infirmary, Edinburgh. Crown 8vo, cloth, pp. xx + 448, with 144 Illustrations. **9s. net.**

**Third Edition, revised and enlarged.**

'Has always been a popular work with both students and practitioners. . . . This the third edition has been revised and in great part rewritten. . . . we have the greatest confidence in recommending this work as an embodiment of sound and up-to-date clinical teaching.'—**Glasgow Medical Journal.**

*Formerly published by Young J. Pentland.*

**Outlines of Zoology**

By J. ARTHUR THOMSON, M.A., Regius Professor of Natural History in the University of Aberdeen. Crown 8vo, cloth, pp. xx + 856, with 378 Illustrations in the Text. **12s. 6d. net.**

**Fourth Edition, revised and enlarged.**

'All parts of the book are of great merit.'—**British Medical Journal.**

'Though our author, to use an American term, "enthuses" his readers, he does not waste words over it.'—**Nature.**

*Formerly published by Young J. Pentland.*

**These works can be had on approval from any bookseller.**



For the  
Senior  
Student  
and Prac-  
titioner

## Auscultation and Percussion, with the other Methods of Physical Examination of the Chest

By SAMUEL JONES GEE, M.D., F.R.C.P., Honorary Physician to H.R.H. the Prince of Wales, Consulting Physician to St. Bartholomew's Hospital, &c. **Sixth Edition**, pp. 327. Prospectus on application. **5s. net.**

'It will remain at once the Standard Authority in the sphere in which it deals, and a striking illustration of the methods of a distinguished teacher of Clinical Medicine.'—**Lancet.**

## Medical Lectures and Clinical Aphorisms

By SAMUEL JONES GEE, M.D., F.R.C.P., Honorary Physician to H.R.H. the Prince of Wales, Consulting Physician to St. Bartholomew's Hospital, &c. **Third Edition**, pp. 327. **5s. net.**

'We have rarely read a professional-work with so much pleasure—beautiful but all too brief.'—**Hospital.**

'We believe that many of them will live to be quoted hereafter by reason of their truth and racy terseness—when most of the set lectures of the present day shall have sunk into oblivion.'—**British Medical Journal.**

## Clinical Lectures and Addresses on Surgery

By C. B. LOCKWOOD, F.R.C.S., Surgeon to St. Bartholomew's Hospital; late Hunterian Professor, Royal College of Surgeons, England; late Surgeon to the Great Northern Hospital. Pp. 274. Four coloured Plates. **Second Edition.** Illustrated. **5s. net.**

'Whatever Mr. Lockwood writes every thinking surgeon is compelled to read.'—**British Medical Journal.**

'It is a work which every student should read before beginning his practice in the wards, and we feel that the same student will in the after years of his own professional work read the book again with an even deeper appreciation of its real helpfulness.'—**The Medical Chronicle.**

*A Full Prospectus of these books will be sent on application.*



## Oxford Medical Manuals

Oxford  
Medical  
Manuals

Edited by J. KEOGH MURPHY, M.D., M.C. (Cantab.), F.R.C.S.  
Crown 8vo. 5s. net each volume. Postage 4d. extra.

All these volumes are complete in themselves and profusely illustrated wherever necessary; from time to time they will be revised and kept carefully up to date. They are designed to be thorough and simple, and practical in every detail.

'The recently published Oxford Medical Manuals are types which other publishers may take as models. The books which make up this series are excellently printed, on thick, not over-glazed paper, and in general the subject-matter of each manual is freshly and interestingly written. The volumes are of a handy size, crown octavo, attractively bound and well indexed.'—**Hospital.**

'The publishers of the new series of handbooks are to be congratulated on their enterprise, which is likely to be received with warm appreciation by the medical reading public.'—**Practitioner.**

## NEW OXFORD MEDICAL MANUAL

### Diseases of the Eye

By M. STEPHEN MAYOU, F.R.C.S., late Hunterian Professor, Assistant Surgeon and Pathologist Central London Ophthalmic Hospital, &c. With over 100 original Illustrations and 8 colour Plates. *Just published.* 5s. net.

A practical guide for Students and Practitioners.

### A Manual of Venereal Diseases

By Officers of the Royal Army Medical Corps

Introduction by Sir ALFRED KEOGH, K.C.B., Director-General of the Army Medical Service. Illustrated. 5s. net.

History. Methods of Prevention. COLONEL MELVILLE.

Bacteriology. LIEUT.-COLONEL W. B. LEISHMAN.

Treatment. MAJOR C. E. POLLOCK.

'We have seldom reviewed a work with more genuine satisfaction. . . . We can most heartily recommend this small work to all who are interested in the subject of venereal diseases.'—**Edinburgh Medical Journal.**

'Will be found useful both to the student and practitioner.'—**St. Bartholomew's Hospital Journal.**

*A Full Prospectus of the Oxford Medical Manuals will be sent post free on application.*



## Gunshot Wounds

By MAJOR C. G. SPENCER, F.R.C.S., R.A.M.C., Professor of Military Surgery, Royal Army Medical College. Fully illustrated. Practical and up to date. 40 Figures. *Just published.*  
5s. net.

## Diseases of the Male Generative Organs

By EDRED M. CORNER, M.C. (Cantab.), F.R.C.S., Assistant Surgeon, St. Thomas's Hospital; and Senior Assistant Surgeon, Great Ormond Street Hospital, &c. Pp. 279, Figures 38. Illustrated.  
5s. net.

'Mr. Corner has given a succinct, yet clear and thoroughly sound, summary of such information as may be useful to the student, and there is indeed much to be found in his short chapters which one will not find in ordinary text-books such as the average student reads for examination.'—**Hospital.**

'A very readable little book, sufficiently full to be of use for reference to the practitioner, and yet unburdened with anything that is not of practical value.'—**Dublin Journal of Medical Science.**

'Well worth reading, and will no doubt be duly appreciated both by surgeons and general practitioners.'—**British Medical Journal.**

'A small book, containing a great deal of information.'—**Practitioner.**

## SPECIAL SUBJECTS

### Diseases of the Ear

By HUNTER TOD, M.A., M.D. (Cantab.), F.R.C.S., Aural Surgeon to the London Hospital, and Lecturer on Aural Surgery at the London Hospital School. Pp. 317, 18 full-size Plates, 15 Figures.  
**Second Impression.** Illustrated. 5s. net.

'We consider that this work is one well adapted to supply the needs of the student and as a handbook of reference for the general practitioner.'—**Lancet.**

'Will certainly take its place among the very best and most up-to-date works on the subject.'—**Journal of Laryngology.**

'Like most of the other volumes in this excellent series, an admirable book, both for the practitioner and the student. It is short, to the point and clear.'—**Hospital.**

*A Full Prospectus of the Oxford Medical Manuals will be sent post free on application.*



## Diseases of the Nose

Oxford  
Medical  
Manuals

By E. B. WAGGETT, M.B. (Cantab.); Surgeon for the Throat and Ear Department of the Charing Cross Hospital; Surgeon, London Throat Hospital, and Throat and Ear Department, Great Northern Hospital. Pp. 282, 3 Plates, 89 Figures, all of which are original. Illustrated. **5s. net.**

'The book is short, concise, and above all, readable. The illustrations are original and are very good.'—**St. Bartholomew's Hospital Journal.**

'Like most "specialities" rhinology is considered by the average practitioner as a difficult subject. . . . To the majority, therefore, Mr. Waggett's little work will prove highly useful.'—**Hospital.**

'Mr. Waggett has written an eminently readable book which is no mean feat. . . . Will be of genuine value to the busy practitioner and we cordially recommend it to him.'—**Lancet.**

## Diseases of the Larynx

By HAROLD BARWELL, M.B. (Lond.), F.R.C.S. (Eng.); Surgeon for Diseases of the Throat, St. George's Hospital; Laryngologist, Mount Vernon Hospital for Diseases of the Chest, &c. Pp. 266, 12 Plates, 21 Illustrations, all original. **5s. net.**

'Without doubt this volume will prove of more use to the student and general practitioner than the majority of the more pretentious works dealing with the same subject.'—**Lancet.**

'Concise and practical, the rarer forms of disease and theoretical aspects of the subjects being treated of briefly.'—**New York Medical Journal.**

## Treatment of Disease in Children

By G. A. SUTHERLAND, M.D., F.R.C.P.; Physician, Paddington Green Children's Hospital, and North-Western Hospital; late President for Section on 'Diseases of Children,' British Medical Association. Pp. 311. **Second Impression.** **5s. net.**

'We commend it to those who require a small and trustworthy work on the management of sick children.'—**Lancet.**

'The maximum of information in the minimum of space.'—**Hospital.**

'Much to commend but little to criticise.'—**British Medical Journal.**

'A study of this volume will afford the reader many valuable hints which he will find of very great service in practice.'—**Medical Press.**

'A valuable record of experience and common sense in the treatment of disease, and may be warmly recommended to the Profession as a trustworthy guide.'—**British Journal of Children's Diseases.**

*A Full Prospectus of the Oxford Medical Manuals will be sent post free on application.*



## Heart Disease. Including Thoracic Aneurysm

By F. J. POYNTON, M.D., F.R.C.P., Assistant Physician to University College Hospital, and late Sub-Dean to the Medical Faculty of University College; Physician to Out-Patients, the Hospital for Sick Children, Great Ormond Street. Pp. 310, 17 Plates, 20 Illustrations. **5s. net.**

'The most noteworthy feature of the book is the large amount of information which it contains; in fact, a volume with the appearance of a small text-book strikes the reader as almost a treatise.

'From all points of view this volume may be recommended to the student as a good text-book.'—**Lancet.**

'The book is well written and will take its place as one of the best text-books on the study of disease of the heart.'—**Practitioner.**

'In this admirable and comprehensive text-book Dr. Poynton gives a summary of the most important forms of heart disease, together with the chief methods that are employed in their clinical investigation and treatment. Dr. Poynton's book may be cordially recommended to advanced students and to practitioners.'—**Medical Chronicle.**

## Skin Affections in Childhood

By H. G. ADAMSON, M.D., M.R.C.P., Physician for Diseases of the Skin, Paddington Green Children's Hospital; Senior Assistant to the Department for Diseases of the Skin, St. Bartholomew's Hospital. Pp. 287, 12 Plates. Illustrated.

**5s. net.**

'This volume calls for highest praise. The author has given a most lucid account of the common skin diseases of childhood, and excellent illustrations throw light upon the distribution and characteristics of many of the affections described.'—**Practitioner.**

'This is an excellent work and the author has made what is to many an uninteresting branch of medicine a distinctly attractive subject.'—**St. Bartholomew's Hospital Journal.**

'Sound in information and practical in teaching. Here we have the series at its very best.'—**Hospital.**

'The illustrations are excellent, and there is a useful list of formulæ appended.'—**Medical Press and Circular.**

*A Full Prospectus of the Oxford Medical Manuals will be sent post free on application.*



## Practical Anaesthetics

Oxford  
Medical  
Manuals

By H. EDMUND G. BOYLE, M.R.C.S., Assistant Anaesthetist to St. Bartholomew's Hospital and Demonstrator of Anaesthetics in the Medical School. Pp. 178, 11 Plates, 11 Figures. Illustrated. 5s. net.

'This little work forms no exception to an excellent series of hand-books. The production is very good and the matter to the point and eminently practical.'—**Edinburgh Medical Journal**.

'As a rule it is better for the student to avoid the larger books on Anaesthetics until he has studied the subject practically, but this book is pre-eminently one that he should buy and read carefully.'—**St. Bartholomew's Hospital Journal**.

'We advise all who either have to administer anaesthetics or who hope to do so, to purchase this little book, as it will give them many useful hints on the subject.'—**Medical Press**.

'The teaching is direct and concise; no words are wasted in imparting instruction.'—**Folia Therapeutica**.

## Surgical Emergencies

By PERCY SARGENT, M.B. (Cantab.), F.R.C.S. (Eng.); Assistant Surgeon, St. Thomas's Hospital; National Hospital for Paralysis and Epilepsy, Queen's Square; and Senior Assistant Surgeon, Victoria Hospital for Children. Pp. 256. **Second Impression**. 5s. net.

'Deals with the more common of the surgical conditions in which prompt action is needed. A dogmatic style is employed, which is best adapted for those who need help suddenly.'—**Lancet**.

'The terseness and dogmatic style of the work constitutes its value. . . . It is a book we can heartily recommend to the younger practitioner who may at any moment be brought face to face with a serious emergency. Such a man will find here a readily available help to supplement his inevitably limited personal experience.'—**Medical Chronicle**.

'A capital book, clear, concise, and suitably dogmatic . . . combine to make the reading of the book, apart from the excellence of the subject-matter, a pleasure.'—**Practitioner**.

*A Full Prospectus of the Oxford Medical Manuals will be sent post free on application.*



### Tuberculous Disease of the Bones and Joints

By Sir W. WATSON CHEYNE, Bt., F.R.S., F.R.C.S., Professor of Surgery, King's College, London. 8vo, cloth, pp. xvi + 374. Illustrated with numerous Wood Engravings throughout the Text. **14s. net.**

### The Treatment of Wounds, Ulcers, and Abscesses

By Sir W. WATSON CHEYNE, Bt., F.R.S., F.R.C.S., Professor of Surgery, King's College, London. **Second Edition.** Crown 8vo, cloth, pp. xvi + 197. **3s. 6d.**

### An Atlas of the Diseases of the Skin

By H. RADCLIFFE CROCKER, M.D., F.R.C.P., Physician to the Department for Diseases of the Skin, University College Hospital. In two large handsome folio volumes, half morocco, gilt tops, containing 96 Plates, exhibiting 238 Figures in colours from original Drawings, specially prepared for the work, with Descriptive Letterpress. **£18 18s. net.**

### Surface and Surgical Anatomy

By HAROLD J. STILES, M.B., F.R.C.S. (Edin.), Surgeon, Royal Edinburgh Hospital for Sick Children; Lecturer on Applied Anatomy, University of Edinburgh; **Second Edition**, thoroughly revised. Royal 8vo, cloth, pp. viii + 260, with 139 Wood Engravings, many printed in colours. (Forming Section IV of Cunningham's Text-Book of Anatomy.) **7s. 6d. net.**

### Illustrations of the Nerve Tracts in the Mid and Hind Brain and the Cranial Nerves arising therefrom

By ALEXANDER BRUCE, M.D., F.R.C.P. (Edin.), Lecturer on Medicine in the School of Medicine; Physician, Royal Infirmary, Edinburgh. Illustrated with a series of 27 coloured Plates from original Drawings, with Descriptive Letterpress, and 27 Engravings throughout the Text. Oblong 4to, cloth. **50s. net.**

### Text-Book of General Botany

By Dr. W. J. BEHRENS. Translation from the Second German Edition. Revised by PATRICK GEDDES, F.R.S.E., Professor of Botany in the University of Dundee. 8vo, cloth, pp. viii + 374, with 408 Illustrations, finely engraved on Wood, and 4 Analytical Tables. New Edition. **5s.**

*All works of 7s. 6d. and over in price can be had on approval from any bookseller.*



## Contributions to Clinical Medicine

By the late Sir THOMAS M'CALL ANDERSON, M.D., Professor of Medicine in the University of Glasgow ; Physician, Glasgow Western Infirmary. 8vo, cloth, pp. xii + 416, with 28 Illustrations. **10s. 6d. net.**

## Functional and Organic Diseases of the Stomach

By SIDNEY MARTIN, M.D., F.R.S., Physician, University College Hospital ; Professor of Pathology, University College Hospital. 8vo, pp. 506. **16s.**

## Diseases of the Liver, Gall Bladder, and Biliary System

### Their Pathology, Diagnosis, and Surgical Treatment

By H. J. WARING, M.S., F.R.C.S., Assistant Surgeon St. Bartholomew's Hospital, &c. **12s. 6d. net.**

## A New Pronouncing Dictionary of Medical Terms

By JOHN M. KEATING, M.D. New Impression. Large 8vo, cloth, pp. 818. **7s. 6d. net.**

## The Parasites of Man

By RUDOLF LEUCKART, late Professor of Zoology and Comparative Anatomy in the University of Leipsic. Translated by WILLIAM E. HOYLE, M.A. (Oxon.), F.R.S.E. Large 8vo, cloth, pp. xxviii + 772. Illustrated with 404 Engravings. **31s. 6d. net.**

## Hygiene and Diseases of Warm Climates in a Series of Articles by Eminent Authorities

Edited by ANDREW DAVIDSON, M.D., F.R.C.P. (Edin.). Royal 8vo, cloth, pp. xx + 1016. Illustrated with 7 full-page Plates and 97 Engravings throughout the Text. **15s. net.**

*All works of 7s. 6d. and over in price can be had on approval from any bookseller.*



### Hydatid Disease in its Clinical Aspects

By JAMES GRAHAM, M.A., M.D., Medical Superintendent, Prince Alfred Hospital, Sydney. 8vo, cloth, gilt top, pp. xii + 204, with 34 full-page coloured Plates. **16s. net.**

### The Nervous Affections of the Heart

By GEORGE ALEXANDER GIBSON, M.D., D.Sc., F.R.C.P. (Edin.), F.R.S.E., Physician to the Royal Infirmary, and Lecturer on Medicine and Clinical Medicine in the Medical School of the Royal Colleges, Edinburgh; Examiner in Medicine in the University of Oxford. **Second Edition.** 8vo, cloth, pp. x + 106, with 35 Illustrations. **5s. net.**

### The Diagnosis and Treatment of Intussusception

By CHARLES P. B. CLUBBE, M.R.C.S. 8vo, cloth, pp. xii + 92. **3s. 6d. net.**

### Practical Guide to the Examination of the Eye For Students

By SIMEON SNELL, F.R.C.S. (Edin.), Ophthalmic Surgeon, Sheffield General Infirmary. Crown 8vo, cloth, pp. xvi + 177 with 88 Illustrations. **5s.**

### Illustrations of Zoology. Invertebrates and Vertebrates

By WILLIAM RAMSAY SMITH, M.B., B.Sc., and J. STEWART NORWELL, B.Sc. **New and Cheaper Edition.** Crown 4to, extra cloth, gilt top, with 70 Plates, exhibiting over 400 Figures. **7s. 6d.**

---

## OXFORD MEDICAL PUBLICATIONS

HENRY FROWDE  
Oxford University Press

HODDER & STOUGHTON  
20 Warwick Square, London, E.C.



