

**Syphilis / by V. Cornil ; translated, with notes and additions, by J. Henry C. Simes and J. William White.**

**Contributors**

Cornil, V. 1837-1908.  
Simes, J. Henry Clay, 1841-1907.  
White, J. William 1850-1916.  
University of Leeds. Library

**Publication/Creation**

London : Kimpton, 1882.

**Persistent URL**

<https://wellcomecollection.org/works/j7ngn5r4>

**Provider**

Leeds University Archive

**License and attribution**


This material has been provided by This material has been provided by The University of Leeds Library. The original may be consulted at The University of Leeds Library. where the originals may be consulted.

This work has been identified as being free of known restrictions under copyright law, including all related and neighbouring rights and is being made available under the Creative Commons, Public Domain Mark.

You can copy, modify, distribute and perform the work, even for commercial purposes, without asking permission.

**wellcome  
collection**

Wellcome Collection  
183 Euston Road  
London NW1 2BE UK  
T +44 (0)20 7611 8722  
E [library@wellcomecollection.org](mailto:library@wellcomecollection.org)  
<https://wellcomecollection.org>



*The University Library  
Leeds*



*Medical and Dental  
Library*

**STORE**

~~STACK~~ ~~STACK~~

WC 160

COR



30106

004180351

1871  
1872

21-11-84

# SYPHILIS.

LEEDS & WEST-RIDING

MEDICO-SURGICAL SOCIETY

BY

V. CORNIL,

PROFESSOR IN THE FACULTY OF MEDICINE OF PARIS, AND PHYSICIAN TO THE  
LOURCINE HOSPITAL.

TRANSLATED, WITH NOTES AND ADDITIONS,

BY

J. HENRY C. SIMES, M.D.,

DEMONSTRATOR OF PATHOLOGICAL HISTOLOGY IN THE UNIVERSITY OF PENNSYLVANIA,  
AND ASSISTANT SURGEON TO THE EPISCOPAL HOSPITAL, PHILADELPHIA,

AND

<sup>and</sup>  
J. WILLIAM WHITE, M.D.,

LECTURER ON VENEREAL DISEASES, AND DEMONSTRATOR OF SURGERY IN THE UNIVERSITY OF  
PENNSYLVANIA, AND SURGEON TO THE PHILADELPHIA HOSPITAL.

WITH EIGHTY-FOUR ILLUSTRATIONS.

---

LONDON:  
HENRY KIMPTON, 82, HIGH HOLBORN.  
1882.

216118

RESEARCH SOCIETY  
MEMBERSHIP

7000

MEMBER OF THE SOCIETY OF AMERICAN HISTORIANS

MEMBER OF THE SOCIETY OF AMERICAN HISTORIANS

19

J. HENRY HARRIS

MEMBER OF THE SOCIETY OF AMERICAN HISTORIANS

19

WILLIAM HENRY HARRIS

MEMBER OF THE SOCIETY OF AMERICAN HISTORIANS

MEMBER OF THE SOCIETY OF AMERICAN HISTORIANS

603034

1900

MEMBER OF THE SOCIETY OF AMERICAN HISTORIANS

1900

## TRANSLATORS' PREFACE.

---

FEW departments of medical science are so well or so thoroughly represented in medical literature as that of syphilis, the best treatises upon which are, in our opinion, to be found in the English language. None of them, however, have so thoroughly considered the disease from its anatomical standpoint, as has M. Cornil in his "Leçons," a book which has been a genuine addition to our knowledge of syphilis. Its general aim and scope are set forth in the author's preface. Agreeing with him that the accurate diagnosis and rational treatment of the disease depend largely upon a knowledge of its morbid anatomy, we, therefore, offer no apology for presenting this translation to the profession, premising that it is intended to supplement and not to supplant the excellent works already alluded to.

It is published with the consent and approval of the author, who kindly made suggestions as to some of the additions which seemed to him required.

The form of lectures, which was adopted by M. Cornil, we have changed, for the sake of uniformity, into that of chapters, and we have omitted the two somewhat irrelevant clinical lectures of M. Bouchard, which were interpolated in the original text.

Our additions, which aggregate about one-third of the present volume, have been made chiefly with a view of supplying additional clinical information upon topics of importance. They will be found throughout the text inclosed in brackets [—].



The lithographic drawings of the original have been copied and engraved upon wood, and have been intercalated in the text.

We beg to thank Dr. James W. White, for the preparation of the note on syphilis of the teeth, and Dr. John S. Walker, for kind assistance in making the translation.

PHILADELPHIA, June, 1882.

surface. Add to this description of the minute details a knowledge of the evolution of the histological phenomena from the beginning to recovery, and it becomes easy to follow the chain of symptoms.

These lectures may, therefore, be said to form an elementary manual of syphilis, based upon a minute knowledge of anatomy.


This is, it seems to me, the only logical method by which syphilis may be studied or understood. If students undertake to compare symptoms without first understanding the details of their pathological anatomy, they almost invariably become perplexed and confused. They depend upon their memory rather than upon their judgment.

Pathological anatomy, as revealed at autopsies, is the fundamental basis of nosology and scientific medicine.

These are truths which are elementary and almost commonplace, but are none the less worth repeating, for, although they are generally admitted on principle, we do not always apply them in medical teaching.

V. CORNIL.

PARIS, December 25, 1878.



# CONTENTS.

## CHAPTER I.

### GENERAL CONSIDERATION OF SYPHILIS—CONTAGION AND INOCULATION— PERIOD OF INCUBATION.

	PAGE
Definition of syphilis . . . . .	17
Theory of syphilis . . . . .	18
Its periods . . . . .	28
Virus and infectious diseases . . . . .	28
Contagion and inoculation of syphilis . . . . .	32
Unicists and dualists . . . . .	33
Long duration of the inoculation . . . . .	36
Is syphilis constitutional before the appearance of the chancre? . . . . .	37
Excision of chancre . . . . .	38

## CHAPTER II.

### ANATOMICAL DESCRIPTION OF INFECTING CHANCRE.

Macroscopical description of chancre . . . . .	40
Incubation of chancre . . . . .	40
The fluid secreted upon the surface of the chancre . . . . .	44
The false membrane of the chancre . . . . .	45
Microscopical examination of chancre . . . . .	47
Lesions of the epidermic cells . . . . .	49
Lesions of the papillæ . . . . .	54
Lesions of the connective tissue . . . . .	55
Vascular sclerosis . . . . .	56
Lesions of nerves in chancre . . . . .	62
Lymphatic lesions of chancre . . . . .	65
Adenitis . . . . .	68
Cicatrix of chancre . . . . .	68

## CHAPTER III.

## SOFT CHANCRE—SYMPTOMS AND COMPARISONS OF THE TWO CHANCRES.

	PAGE
Pathological anatomy of soft chancre . . . . .	70
Similarity of the anatomical characters of infecting and simple chancre . . . . .	73
Comparison of infecting chancre with gumma, etc. . . . .	73
Symptoms of infecting chancre . . . . .	75
Induration . . . . .	77
Varieties . . . . .	77
Healing of chancre . . . . .	80
Seats of chancre . . . . .	82
Symptoms of soft chancre . . . . .	84
Relative frequency of soft and indurated chancre . . . . .	85
Mixed chancre . . . . .	86
Specific nature of chancroid . . . . .	87
Diagnosis of chancre . . . . .	91
Prognosis of chancre . . . . .	101
Treatment of chancre . . . . .	102

## CHAPTER IV.

LYMPHATIC GLANDS DURING THE PRIMARY AND SECONDARY PERIODS  
OF SYPHILIS—CLASSIFICATION OF SYPHILIDES—MUCOUS PATCHES.

Symptomatic and histological description of syphilitic lymphatic glands . . . . .	121
Scrofulous and syphilitic glands . . . . .	123
Syphilides, general characters of . . . . .	125
Classification of syphilides . . . . .	126
Syphilides, many forms of . . . . .	127
The copper color of syphilis . . . . .	129
Mucous patches . . . . .	129
Pathological anatomy and symptoms of mucous patches of the vulva . . . . .	131
Mucous patches of the tonsils . . . . .	133
Lesions of the closed follicles of the tonsils . . . . .	138
Extirpation of syphilitic tonsils . . . . .	138

## CHAPTER V.

## DESCRIPTION OF MUCOUS PATCHES CONTINUED—THEIR TREATMENT.

Mucous patches of the tongue . . . . .	140
Eroded mucous patches . . . . .	142
Mucous patches with indurated base . . . . .	142
Diphtheritic mucous patches . . . . .	143

LEEDS & WEST-RIDING  
MEDICO-CHIRURGICAL SOCIETY

AUTHOR'S PREFACE.

---

THESE lectures were delivered during the spring and summer months of 1878, in the Lourcine Hospital. Having occupied for three years a position on the medical staff of this institution for syphilitic females, I am desirous, before retiring from duty, to take advantage of the immense material which has here been at my disposal.

Through the valuable works of Ricord, Cullerier, Langlebert, Clerc, Bassereau, Diday, Virchow, as well as the more recent monographs of Rollet, Alfred Fournier, Lancereaux, Martin and Belhomme, Mauriac, Louis Jullien, and others, syphilography has been elevated into a veritable science. The discussions as to duality or unicuity of the syphilitic virus, syphilization, the contagiousness of secondary lesions, the effects of mercury, etc., have been almost exhaustive. We now possess many excellent books upon these subjects, and I may add, that in no country have they been more thoroughly studied than in France. The most recent publications show, however, that we are far from having a correct idea of the minute anatomy, or of the histological evolution of the various lesions of this disease, from the initial chancre to the gumma, including the mucous patch, the superficial and deep cutaneous syphilides, the osseous and visceral affections. I have endeavored to supply this deficiency, not only by relating, arranging, and interpreting what has been written, but also and chiefly by adding some new observations. The title which I have chosen has permitted me great latitude, but I have spoken almost exclusively of what I have myself seen and investigated. It is not my intention to publish a complete treatise, but only a series of lectures upon the essential points of syphilis, and particularly upon its general pathological anatomy. H. Leloir, interne at the hospital, has given me much assistance in recording the lectures and cases, for which service I beg to express my thanks.

I have especially endeavored to describe the histology and evolution of the several varieties of chancres, of cutaneous and mucous papules, pustules, and tubercles; of cutaneous and visceral gummata, etc. The continual progress made in technical microscopy, renders this study always new or open to re-examination or revision. It is a field in which there is still much to glean. My observations have almost always been made upon tissues removed during life, permitting me to examine at once the separate elements, and to place portions in preserving or hardening fluids before they had undergone the slightest cadaveric change. This is, in fact, the only method by which good preparations can be obtained. I have drawn with the camera-lucida the principal types of the different lesions; but the drawings, reproduced in a single color by lithography, give only an imperfect idea of what is seen under the microscope. Yet I can vouch for their general accuracy. In the first eight lithographic plates Messrs. Leuba and Nicolet have represented my drawings as faithfully as possible.

The original portion of my investigations consists in the histological descriptions. Therefore I could have limited this work to the small compass of a memoir, and, without doubt, would have also limited the number of my readers; since those who study the evolution of such lesions from pure scientific curiosity are few. Again, I would not have attained my principal object, which was to place before the students of this subject the symptoms and course of the several pathological manifestations, having regard especially to their precise anatomy and evolution, as seen under the microscope. Pathological histology alone is not attractive, and we should, therefore, whenever possible, demonstrate its utility, and its direct application to the study of symptoms.

As a simple illustration of the method I have followed, I may mention the syphilitic papule or pustule. I have studied first its complete anatomy; and then have described in detail all the changes that the epiderm, rete mucosum, papillæ, derm, and vessels undergo, and have thus learned how far they extend and in what they consist. Such a description, aided, if possible, by a microscopic demonstration, or at least by accurate drawings, would seem to be an excellent preparation for the study of symptoms, which will then be promptly recognized. We learn in this manner the changes going on beneath the epidermis in the different layers of the skin, and cease to regard the eruption simply as a pimple limited in a certain way by a colored

	PAGE
Hypertrophied mucous patches . . . . .	147
Transformation of mucous patches into vegetations . . . . .	149
Eczema with mucous patches . . . . .	150
Dermatitis with mucous patches . . . . .	151
Vulvitis with mucous patches . . . . .	151
Abscess of vulvo-vaginal glands . . . . .	152
Vaginitis with mucous patches . . . . .	153
Metritis with mucous patches . . . . .	153
Œdema with mucous patches . . . . .	154
Vegetations with mucous patches . . . . .	154
Diagnosis of mucous patches . . . . .	154
Treatment of mucous patches . . . . .	156
Excision of chancre, mucous patches, etc. . . . .	157

## CHAPTER VI.

## EARLY CUTANEOUS SYPHILIDES.

Syphilitic fever . . . . .	164
Neuralgia of syphilis . . . . .	165
Osseous and rheumatoid syphilitic pains . . . . .	165
Anæmia of syphilis . . . . .	165
Roseola . . . . .	166
Papular syphilide (small) . . . . .	168
Histology of superficial papule . . . . .	171
Papular syphilide (lenticular) . . . . .	172
Histology of lenticular papule . . . . .	173
Effusion of blood into papule . . . . .	177
Diagnosis of papule and psoriasis . . . . .	179
Onychia and alopecia . . . . .	182
Macular syphilide . . . . .	186

## CHAPTER VII.

VESICULAR, PUSTULAR, BULLOUS, GUMMOUS, AND TUBERCULAR  
SYPHILIDES.

Vesicular syphilides . . . . .	189
Pustular syphilides . . . . .	191
Acne . . . . .	192
Impetigo . . . . .	192
Superficial ecthyma . . . . .	193
Deep ecthyma . . . . .	193
Histology of papule . . . . .	194
Impetigo rodens . . . . .	200
Bullous syphilides . . . . .	200



	PAGE
Rupia . . . . .	200
Pemphigus . . . . .	201
Cutaneous gummata . . . . .	204
Obliteration of vessels . . . . .	208
Phlegmonous syphilides . . . . .	211
Tubercular syphilides . . . . .	212
Grave early syphilides . . . . .	214
General considerations as to syphilitic eruptions . . . . .	216
Importance of their anatomy and histology . . . . .	217
Clinical characteristics of syphilides . . . . .	219
Treatment of syphilides . . . . .	221

## CHAPTER VIII.

### TERTIARY LESIONS OF MUCOUS MEMBRANES—SYPHILIS OF THE MUSCLES.

Tertiary lesions of the genital mucous membranes . . . . .	224
Tertiary syphilis of the mouth . . . . .	226
Superficial or cortical glossitis . . . . .	226
Deep glossitis . . . . .	227
Desquamative glossitis . . . . .	229
Gumma of tongue . . . . .	230
Diagnosis of lingual psoriasis . . . . .	231
Smoker's patches . . . . .	231
Tubercular and epitheliomatous ulcers . . . . .	232
Epithelioma and gumma . . . . .	233
Gumma of soft palate . . . . .	233
Gumma of tonsils and pharynx . . . . .	237
Diagnosis from scrofulides . . . . .	238
Muscular syphilis . . . . .	239
Gumma of muscles and heart . . . . .	240

## CHAPTER IX.

### SYPHILIS OF THE BONES, TEETH, AND ARTICULATIONS.

Syphilitic osseous lesions . . . . .	245
Simple osteo-periostitis . . . . .	247
Osteophytes . . . . .	248
Exostoses . . . . .	248
Enostoses . . . . .	248
Development of bone . . . . .	248
Rarefying osteitis . . . . .	249
Gummous osteo-myelitis . . . . .	252

## CONTENTS.

xiii

	PAGE
Gummosus osteo-periostitis . . . . .	252
Vegetating and gummosus pachymeningitis . . . . .	253
Eburnation of bone . . . . .	256
Varieties of exostosis . . . . .	257
Symptoms of syphilitic osseous lesions . . . . .	260
Osseous lesions in syphilitic new-born children . . . . .	265
Syphilis of the teeth . . . . .	287
Syphilitic teno-synovitis and arthritis . . . . .	290
Syphilitic dactylitis . . . . .	293

## CHAPTER X.

## SYPHILIS OF THE NERVES AND NERVE CENTRES.

Lesions of the pia mater . . . . .	297
Lesions of the brain . . . . .	298
Large gumma of brain . . . . .	298
Small gumma of brain . . . . .	304
Syphilitic inflammation of arteries of brain . . . . .	305
Syphilitic phlebitis and lymphangitis . . . . .	313
Symptoms of cerebral syphilis . . . . .	314
Syphilitic epilepsy . . . . .	319
Syphilitic paralysis . . . . .	321
Syphilis of spinal cord . . . . .	327
Locomotor ataxia . . . . .	329
Diagnosis of cerebral syphilis . . . . .	342

## CHAPTER XI.

## SYPHILIS OF THE LIVER.

Hepatic syphilis . . . . .	352
Syphilitic jaundice of secondary period . . . . .	353
Syphilitic interstitial hepatitis . . . . .	354
Gumma of liver . . . . .	356
Congenital syphilis of liver . . . . .	369

## CHAPTER XII.

SYPHILITIC LESIONS OF THE DIGESTIVE CANAL AND OF THE  
RESPIRATORY APPARATUS.

Gumma, ulcerations, and stricture of the œsophagus . . . . .	373
Gumma and ulcers of stomach . . . . .	375
Syphilitic ulcers and stricture of anus and rectum . . . . .	377

	PAGE
Syphilitic lesions of larynx, trachea, and bronchi . . . . .	379
Syphilis of the lungs . . . . .	390
Gumma of the lungs . . . . .	391
Lesions of the lungs in congenital syphilis . . . . .	403

### CHAPTER XIII.

#### SYPHILITIC LESIONS OF THE SPLEEN, OF THE SUPRA-RENAL CAPSULES, OF THE LYMPHATIC GLANDS, AND OF THE GENITO-URINARY ORGANS.

Lesions of the spleen . . . . .	410
Lesions of the supra-renal capsules . . . . .	412
Tertiary lesions of the lymphatic glands . . . . .	413
Gumma of the epididymis . . . . .	415
Interstitial orchitis in the adult . . . . .	416
Interstitial orchitis in new-born children . . . . .	420
Gumma of the testicles . . . . .	422
Syphilitic ovarian lesions . . . . .	422
Syphilis of kidney . . . . .	423
Interstitial and gummous nephritis . . . . .	424
Amyloid degeneration of kidneys . . . . .	425
Albuminuria in syphilis . . . . .	425

### CHAPTER XIV.

#### TREATMENT OF SYPHILIS.

Mercurial medication . . . . .	431
Anti-mercurialists . . . . .	432
Absorption and elimination of mercury . . . . .	433
Mode of administration and different preparations of mercury . . . . .	434
Iodide of potassium . . . . .	440
Mode of administration and doses of iodide of potassium . . . . .	440
Treatment of syphilis . . . . .	441
 BIBLIOGRAPHY . . . . .	 449
 INDEX . . . . .	 455

## LIST OF ILLUSTRATIONS.

FIG.	PAGE
1. Schematic section of indurated chancre . . . . .	43
2. Elements from surface of chancre. $\times 300$ . . . . .	45
3. False membrane from chancre. $\times 200$ . . . . .	46
4. Indurated chancre. $\times 15$ . . . . .	48
5. Schematic drawing of epidermal changes . . . . .	50
6. Superficial layers of epidermis of chancre. $\times 150$ . . . . .	52
7. Superficial portion of a mucous patch. $\times 300$ . . . . .	54
8. Connective tissue of chancre. $\times 200$ . . . . .	56
9. Arteriole from chancre. $\times 100$ . . . . .	57
10. Arteriole from chancre. $\times 200$ . . . . .	58
11. Vein from chancre. $\times 120$ . . . . .	59
12. Vessels from chancre. $\times 200$ . . . . .	59
13. Nerve from chancre. $\times 200$ . . . . .	63
14. Indurated part of chancre . . . . .	67
15. Indurated part of chancre. $\times 250$ . . . . .	67
16. Soft chancre. $\times 20$ . . . . .	71
17. Schematic section of soft chancre . . . . .	71
18. Chancre showing suppuration in epidermis. $\times 150$ . . . . .	109
19. Chancre from nympha. $\times 6$ . . . . .	112
20. Cicatrix from chancre. $\times 8$ . . . . .	114
21. Cicatrix from chancre. $\times 8$ . . . . .	115
22. Chancre from prepuce. $\times 8$ . . . . .	116
23. Chancre from prepuce. $\times 15$ . . . . .	118
24. Mucous patch from tonsil. $\times 12$ . . . . .	134
25. Mucous patch from tonsil. $\times 150$ . . . . .	135
26. Mucous patch from tonsil. $\times 60$ . . . . .	136
27. Mucous patch from tonsil, eroded. $\times 60$ . . . . .	136
28. Superficial part of mucous patch. $\times 300$ . . . . .	137
29. Epithelial cells from diphtheritic membrane. $\times 250$ . . . . .	146
30. Hypertrophied vulvar mucous patch. $\times 100$ . . . . .	148
31. Syphilitic papule. $\times 80$ . . . . .	170
32. Syphilitic squamous papule. $\times 20$ . . . . .	173
33. Rete mucosum from syphilitic papule. $\times 250$ . . . . .	174
34. Syphilitic lenticular papule. $\times 100$ . . . . .	175
35. Syphilitic lenticular papule. $\times 300$ . . . . .	176
36. Syphilitic lenticular papule. $\times 250$ . . . . .	177
37. Hemorrhagic squamous papule. $\times 40$ . . . . .	178
38. Ecthymatous pustule. $\times 20$ . . . . .	195
39. Epidermis from ecthymatous pustule. $\times 250$ . . . . .	196
40. Rete mucosum from ecthymatous pustule. $\times 120$ . . . . .	197

FIG.	PAGE
41. Ulcerated part of pustule. $\times 120$	198
42. Pemphigus bulla. $\times 8$	202
43. Rete mucosum from pemphigus bulla. $\times 200$	203
44. Cutaneous gumma	206
45. Cutaneous gumma. $\times 8$	207
46. Capillaries and connective tissue of gumma. $\times 200$	208
47. Vein from gumma. $\times 200$	208
48. Vein from gumma, oblique section. $\times 200$	209
49. Cutaneous gumma	210
50. Cutaneous gumma. $\times 8$	210
51. Tertiary syphilide of tongue. $\times 10$	227
52. Syphilitic osteitis	250
53. Rarefying osteitis. $\times 500$	251
54. Gummous pachymeningitis. $\times 6$	253
55. Gumma of dura mater. $\times 40$	254
56. Absorption of bone by gumma	255
57. Syphilitic sclerosis. $\times 20$	256
58. Syphilitic necrosis of frontal bone	257
59. Exostosis of cranium. $\times 10$	258
60. Exostosis of cranium. $\times 12$	259
61. Osteophyte from syphilitic child. $\times 150$	271
62. Osseous trabecula of syphilitic osteophyte. $\times 250$	271
63. Syphilitic exostosis of cranium. $\times 12$	275
64. Syphilitic exostosis of cranium. $\times 6$	276
65. Cranial bone of congenital syphilis. $\times 15$	277
66. Cranial exostosis of child. $\times 6$	279
67. Syphilitic exostosis of child. $\times 100$	280
68. Syphilitic exostosis of child. $\times 70$	281
69. Normal incisor teeth	289
70. Syphilitic incisor teeth	289
71. Histology of cerebral gumma	300
72. A. Syphilitic disease of cerebral arteries. $\times 200$	306
72. B. Syphilitic disease of cerebral arteries. $\times 100$	306
73. Syphilitic gummata of the pons Varolii	347
74. Syphilitic gummata of the pons Varolii	348
75. Deformed syphilitic liver	354
76. Cicatrization of syphilitic liver	355
77. Gumma from liver	358
78. Gumma from liver $\times 250$	359
79. Gumma from liver. $\times 12$	361
80. Gumma from liver. $\times 150$	363
81. Biliary capillaries in new-formed connective tissue of cirrhosis	365
82. Syphilitic interstitial pneumonia. $\times 300$	405
83. Syphilitic testis. $\times 180$	418
84. Gumma of kidney. $\times 200$	424

# SYPHILIS.

## CHAPTER I.

### GENERAL CONSIDERATIONS OF SYPHILIS—CONTAGION AND INOCULATION—PERIOD OF INCUBATION.

Definition of syphilis—The nature of syphilis—Its periods—Its virus—Its relations to infectious diseases—Contagion and inoculation of syphilis—Unicists and dualists—Long duration of the incubation—Is syphilis constitutional before the appearance of the chancre?

DEFINITION OF SYPHILIS.—*Syphilis is an infectious, contagious, and inoculable disease, of slow evolution; it first manifests itself by an indurated or infecting chancre, afterwards by eruptions of the skin and mucous membranes, later by chronic inflammations of the cellulo-vascular tissue and bones, and finally by special productions in the form of small tumors or nodules which have received the name of gummata.*

[It may not be amiss to mention one or two modifications of this definition, which would be necessitated by the adoption of any one of the several plausible, but as yet unproven theories as to the essential nature of the disease. Mr. Jonathan Hutchinson, who classes syphilis with the fevers, smallpox, scarlatina, measles, etc., defines it as a "specific febrile disease of prolonged but definite stages, which is produced by contagion only, which has a period of incubation, a period of outbreak (known as primary symptoms), a period of efflorescence or exanthem (known as the secondary stage), and which, in exceptional cases, differs somewhat from its more short-lived congeners, by being followed by sequelæ, to which we give the name of tertiary symptoms."<sup>1</sup>

His arguments, in support of this position, may be summed up as follows :—

[<sup>1</sup> The London Lancet, Feb. 5, 1876.]

theory, or rather for the assumption, of a similarity in nature between syphilis and variola, scarlet fever, etc., distinctly claims this peculiarity of certain contagious diseases (*i. e.*, protection against re-infection), as proof of the correctness of his views. In a cursory examination of the question this allegation seems quite plausible. But the degree of protection afforded by an attack of syphilis against subsequent re-infection is by no means well settled. The published instances of re-infection of syphilis are much more numerous than of re-infection after the acute exanthemata, and when we consider the frequent epidemic prevalence, and the greater liability to infection through the atmosphere, through fomites, and through actual contact in the latter diseases, the contrast becomes so great as to cast reasonable doubt upon the claim of a protective influence for syphilis. What physician in his own experience has been able to record a dozen cases of the re-infection of variola—and yet Diday and Gascozen each report twenty cases of the re-infection of syphilis in their own experience. Kœbner reports nearly fifty cases. Follin, Bouley, Caspary, Hutchinson, Ricord, and others have also reported well-authenticated cases. We have easy access to more than a hundred published instances of the re-infection of syphilis, and *all quite accidental*. We have not, as far as I am aware, a single record of systematic, carefully-conducted experiments bearing on this point. Even the extensive experience of Prof. Boeck, in his so-called syphilitic inoculations, is valueless in this, as in almost every other respect. It is true that he demonstrated a tolerance of the integument to the influence of chancroidal virus through repeated inoculations, and falsely claimed it as a protection against the re-infection of syphilis; but the same sort of tolerance was subsequently established by inoculations with the tartrate of antimony. Admitting, however, that the occurrence of syphilis in an individual *does* protect against re-infection—this does not necessarily connect syphilis with the acute exanthemata any more than with contagious parotitis. It appears to me that the only valid deduction to be drawn from the apparent protection claimed after an attack of syphilis, is that this is *similar* in some respects to the protection afforded by the acute exanthemata under like conditions. But it has been shown that this protective property is *not* confined to the acute exanthemata; hence it cannot be claimed as establishing any necessary connection between syphilis and these diseases. When we are able to explain *why* the occurrence of smallpox or scarlet fever protects against re-infection, we may then, perhaps, be able to ascer-

tain why a similar protection is exercised in *mumps*, in *yellow fever*, and in *sypphilis*."

"A second infection may be followed by general effects as well as local. A large number of cases of this 'reinfectio sypphilitica,' first described by Zeissl, have been published."<sup>1</sup>

Another objection to the theory under consideration lies in the necessity which exists for the employment of the same treatment, or a modification of it, in the tertiary as in the secondary stage, it being now generally admitted that mercury in some form should be used, even in the most tardy symptoms. Mr. Hutchinson says that "mercury is the true vital and physiological antidote of the sypphilitic virus."<sup>2</sup> If this be true it would without doubt explain its beneficial action in the early stages of the disease, but would furnish no reason for its administration at a time when, according to Mr. Hutchinson himself, the "virus" has been eliminated.

A theory which attempts to reconcile these apparent contradictions, and has claims on the attention of syphilographers which have not been duly recognized, is one which attributes to infection through the lymphatic system, and to changes produced in that system most, if not all, of the symptoms of syphilis. Several distinguished observers have from time to time pronounced wholly or in part in its favor, but it has been coldly received by the profession at large, for the reason that it still lacks demonstrative proof. As, however, in our opinion it presents fewer inconsistencies than any of the other theories—all of which are also open to the same objection as to absence of decisive proof—we will endeavor to present it as briefly as is consistent with clearness.

The infecting body in syphilis, as far as we yet have been able to isolate it, is a degraded or diseased cell, resembling a white blood-corpusele, but much smaller, and corresponding to the bioplastic disease germ of Beale. It is a particle of normal protoplasm which has undergone degeneration, and has acquired the property of rapid proliferation, and of impressing its own peculiarities upon germinal matter wherever it comes in contact with it. This property is only what is seen and admitted to be the case in pus cells, in the transformation of embryonal cells into epithelium, and *vice versa*—the "epithelial infection" of Rindfleisch—and is an instance of the unexplained but well-recognized influence which all cells, and especially diseased cells,

<sup>1</sup> Bäumlér, Ziemssen's Cyclopædia, p. 70.

[<sup>2</sup> Discussion before the Hunterian Society of London, 1874.]



have upon those immediately adjoining them.<sup>1</sup> The cells of syphilis, therefore, chiefly affect the white blood- and lymph-corpuses, which they contaminate, and cause to take on rapid growth, arresting the former in their development into red blood-cells, and producing the so-called syphilitic anæmia or leucocythæmia.

These cells are found in every instance, and without exception, at the point of syphilitic inoculation, wherever that may be, and by their proliferation and accumulation constitute the induration of the infecting chancre. The characteristic *hardness* of this sore is due to the crowding together of these cells; its *dryness* to their involvement of the walls of the vessels, preventing transudation of serum; its abrupt limitation to the absence of any true inflammatory exudation, shading off into the neighboring tissues; its superficial scalliness, abrasion, or ulceration to the degree of its interference by pressure with the blood supply to the epidermic layer of the skin.

<sup>1</sup> "It is not yet possible to say, in any universal sense, with regard to the metabolic contagia, what is the essential constitution of 'contagious matter,' or what the intimate nature of the 'transforming power' which the particle of such matter exercises on the particles which it infects. As regards the question of the force, chemists, when they refer in general terms to the various acts which they designate acts of fermentation, allege that certain processes of change in certain sorts of organic matter induce characteristic changes in certain other sorts of organic matter, not by the common chemical way of double decomposition with reciprocally new combinations, but (so to speak) as a mere by-play or collateral vibration-effect of the chemical force which is in movement; and, though language can hardly be more vague than this for any scientific purpose, it expresses clearly enough the conviction of experts that a certain great force in nature lies beyond their power even of definite nomenclature, much more of exact identification and measurement."

"It must not be forgotten that, among immediate effects of contagion in the living body, are cases wherein the process (so far as we can yet see) is primarily not catalytic or disintegrative, but is, on the contrary, anaplastic or constructive. Thus when tubercle gives rise to tubercle, whether by secondary and tertiary infection in a single diseased body, or by infection from the sick to the healthy, each new tubercle which the contagion brings into being is a growth-product of the texture which bears it. And, similarly, when the innumerable varieties of cancerous tumor propagate themselves by contagion, each after its special type, in the bodies of the respective sufferers, it is growth, not disintegration, which we first see. It would seem that in those cases of anaplastic 'contact-influence' something far beyond the analogy of chemical fermentations must be involved; and, in view of some of them, the physiologist has to bethink himself of the analogy of that 'contact-influence' which becomes the mainspring of all normal growth and development when the ovum receives spermatic impregnation."—Contagion: Its Mode of Action. By John Simon, C.B., F.R.S. *British Med. Journal*, Dec. 20, 1879.

The period of primary incubation, or that intervening between the reception of the poison, and the development of the initial lesion, on an average three weeks, represents the time occupied in the proliferation of these cells at the point of deposit, and during this time the system at large is uncontaminated.

The period of secondary incubation, or that between the appearance of the sore, and the outbreak of constitutional symptoms, on an average six weeks, represents the slow passage of these diseased cells through the lymphatic channels and glands in which by their multiplication they cause enlargement and induration, thus giving rise to the glandular swellings invariably found in syphilis, and most easily observable in the inguinal, epitrochlear, and post-cervical regions, and in the tonsils, which are essentially lymphatics, their involvement explaining the early syphilitic sore throat. These two periods taken together constitute the "initiator period" of Otis.

It seems impossible, in the light of certain well-known facts, to deny that the syphilitic poison, whatever its character, gains access to the general circulation *chiefly* if not entirely by the lymphatics. Fournier, quoted by Bäumlér,<sup>1</sup> has reported observations which tend to sustain this view: "In the collection of the Hôpital de Lourcine there are three preparations of women who died of intercurrent diseases while affected with syphilitic sores on the vulva. In these preparations not only the inguinal glands are swollen, but there is a hyperplastic enlargement of a number of glands above Poupart's ligament. In the second case there occur in the fossa iliaca, along the bloodvessels, nine enlarged glands, arranged in three groups, one above the other, the uppermost at the origin of the hypogastric artery. The enlargement of the iliac glands had attained nearly the same degree as that of the inguinal glands, among which one or two on each of the three preparations were distinguished by their greater size as the ones first attacked." Among the reported cases of artificial inoculation of syphilitic poison there are two where, the inoculation having been made upon the chest, not only were the glands of the first group enlarged, but also those of the second and third order, an indurated lymphatic cord connecting them with each other.<sup>2</sup>

After their entrance into the blood, the diseased cells which, in accordance with the general properties of all cells, proliferate most rapidly when arrested or slowed in motion, on reaching the capillaries,

<sup>1</sup> Ziemssen's Cyclopædia, vol. iii. p. 122.

<sup>2</sup> Bidentkap, Wiener Med. Wochenschrift, 1865, Nos. 31-44.

probably affect their walls, and the sensory and vaso-motor nerves as soon as they have accumulated sufficiently to make pressure on them, thus producing the insensitiveness of the skin and the mottling of the surface (roseola) caused by the irregular dilatation of the capillaries.

In the papillæ of the skin, around the circumference of which the capillary vessels wind in corkscrew fashion, we have an increase of pressure, and retardation of the blood-current, conditions favorable, as has been said, to exudation and proliferation of cells. Therefore when these "syphilitic" cells carried in the general circulation reach the papillæ, they escape into their substance, and multiply there. If the lymphatics, running through the centre of the papillæ from apex to base, were capable of taking them up again, and returning them to the systemic circulation, no local symptoms would ensue, but as these vessels are themselves pressed upon, and more or less occluded, we have an accumulation of cells going on, until little hard tumors are produced, which even become apparent on the cutaneous surface (papular syphilide). The pressure of this exudation prevents the imbibition of nutriment by the epidermic layers which die and desiccate, and we have the papulo-squamous syphilide—greater pressure produces ulceration or pustulation of various degrees, and we have the corresponding pustular and ulcerative syphilides.

This period—that of "general infection and localized cell accumulation"—extends over six to eighteen months, when it often terminates spontaneously, or more certainly under treatment, the diseased cells having undergone fatty degeneration, and been absorbed and eliminated.

During this period, however, the lymph channels throughout the body have been more or less subject to continuous irritation or even to inflammation of a low degree, the well-known tendency of which is to cause the deposit of fibrous material which, by its presence and subsequent contraction, tends to damage and obstruct them. We therefore find at a period, that of "lymphatic obstruction," varying in its date of appearance from months to years after the primary lesion, that certain local symptoms occur, which are called tertiary, which consist chiefly of the formation of small tumors (gummata, nodes, etc.), or of the death of various tissues, produced by pressure (syphilitic necrosis and ulceration), and which are due to the accumulation at these points of the normal nutritive elements, which are always somewhat in excess of the demand, and which should properly

be taken up by the lymphatics and restored to the general circulation. It is believed, however, that at these localities the lymphatics have become occluded or at least crippled, and are unable to perform their function; hence the crowding together and heaping up of the nutritive elements into "nodes and gummata." The non-contagiousness and the absence of symmetry of these lesions, and their greater frequency and severity after a serious and prolonged secondary stage, are thus explained. Microscopically they are said to contain no element which is distinctive, or which differs from those found in the lymph spaces, except in a tendency to fatty degeneration or liquefaction due to pressure.

The action of mercury in relieving the early symptoms also becomes intelligible in the light of this theory, through its influence in hastening destructive metamorphosis, and bringing about fatty degeneration, and its general undoubted tendency to relieve tissues encumbered with superfluous material. Small doses most naturally first influence newly-formed, immature deposits, such as those due to syphilis, and hence the advantage of the modern treatment which avoids salivation, due to the toxic action of the drug on the *healthy* tissues, and depends upon moderate, long-continued doses.

The necessity for the use of iodide of potassium in the later stages, with or without mercury, also becomes apparent when it is remembered, that iodine is the most powerful diffusible stimulant of the function of absorption with which we are acquainted, and that it also has a certain and well-established value in hastening tissue change, especially in unhealthy formations.

The unfavorable criticisms of this attractive theory, as far as we know, have been chiefly directed against the lack of *positive* proof in its favor, but it seems to us that, if the various statements here set forth are in consonance with general physiological and pathological truths, the burden of proof rests with those who assert the existence of a virus. This theory cannot be said to disprove that some such specific poison exists, but it certainly seems to show that the conception of a virus is not necessary for a proper understanding of the symptoms of syphilis, and that all the manifestations of the active stages depend upon the presence and contagious properties of demonstrable cells, which may or may not be the carriers of some additional material which is as yet undiscovered.

Our *résumé* has necessarily been brief and imperfect, but for an admirable exposition of the theory, with confirmatory evidence of the

above assertions taken from recognized histological and pathological authorities, we refer the reader to the excellent work of Dr. Otis.<sup>1</sup>

A theory originally advanced by Küss, of Strasburg, and advocated by Bumstead and Taylor, is that syphilis is essentially a disease of the connective tissue; but it is difficult to see on what grounds they have arrived at this conclusion. Their description of the process of infection, in the main, corresponds with that which we have just epitomized. They say that the disease "originates in the secretions of active lesions and in the blood;" "these fluids, inserted beneath the integument, do not pass at once into the circulation, but cause a local cell increase," which "remains local until mature," and is "accompanied by marked indurated enlargement of neighboring lymphatics. Such being the fact, the presumption is that these new cells have, like those of cancer and sarcoma, passed into and infected the lymphatic ganglia. That here, owing to the profusion of lymphatic globules, which we know to be protoplasm, or living matter of the most active kind, this new tissue, or rather these new cells, undergoes great change, increasing in numbers according to the susceptibility of the patient. Having been thus proliferated, these cells are now taken into the blood either gradually or suddenly, and by it are carried over the body, chiefly, however, at first to the periphery, where they are deposited." Thus far they are certainly in exact accord with the believers in the lymphatic theory. They continue: "Being deposited in the connective tissue, they take root in this soil, which is peculiarly susceptible to the influence of the syphilitic diathesis. Here they luxuriate, and are still further developed, not attacking primarily other tissues." The fact that connective tissue, which is found everywhere in the body, is almost constantly involved in syphilis, is undoubted, but we should not be led into regarding the mere assertion that it is "peculiarly susceptible" as a scientific explanation of this fact.

Here, again, the previous theory seems to us the more satisfactory in its application to clinical symptoms, and, at least, quite as well grounded. The same authors—after stating that the majority of modern syphilographers regard the blood rather than the lymphatics as the vehicle of contagion, an assertion open to reasonable doubt, and after reiterating their own conclusion that "syphilis is a disease

[<sup>1</sup> Clinical Lectures on the Physiological Pathology and Treatment of Syphilis. By Fessenden N. Otis, M.D. New York: G. P. Putnam's Sons. 1881.]

of the connective tissue, and not primarily of the lymphatics or of the bloodvessels" — immediately add: "The secretions of syphilitic lesions are found to consist of a serous fluid containing numerous shining granules or molecules, which are masses of protoplasm or germinal matter, holding the contagious properties of syphilis. These microscopic bodies are probably taken into the circulation by the lymphatics and conveyed over the body. Possibly they are absorbed by the blood-corpuscles, or the latter are infected in some mysterious manner by these actively increasing morbid cells. The fact that serum alone does not convey the syphilitic poison goes to prove that the corpuscles hold the contagious material."

It is not evident how this proves that syphilis does not primarily attack the lymphatics or bloodvessels, which certainly cannot be regarded as simply affording passageway for the conveyance of the protoplasmic masses, and remaining unaffected by them. That this is not true is evident from the histology of the chancre, and from the most superficial observation of the early stage of the disease. The authors themselves state that they "have never met with a chancre not attended by induration of the neighboring lymphatic ganglia," and regard it as an even more constant and persistent symptom than induration of the base of the ulcer itself. They also state in regard to the accompanying "specific engorgement" of the lymphatic vessels, that it is "dependent upon changes in the walls of these vessels identical with those which occasion induration of the base of the chancre and of the ganglia." As to the bloodvessels, they say also that in the development of syphilitic tumors, "as well as of syphilitic papules and tubercles, the first morbid change is in the adventitia of the vessels."

It seems probable that in the light of our present knowledge, syphilis cannot be considered as *exclusively* a disease of either blood, lymphatics, or connective tissue, but rather as one involving commonly these and all other tissues, its symptoms in the early stages resulting from the absorption and proliferation of certain contagious immature cells or protoplasmic masses, and, in the latter or "tertiary" period, possibly from the accumulation at certain points of normal nutrient material and tissue-waste, which the thickened or obliterated lymphatics are unable to remove.

Upon any or all of these points, however, we deem it the part of wisdom to refrain from final judgment.]

The definition includes all the periods of the disease, which are four in number:—

First. Period of incubation.

Second. Period of primary symptoms (chancre and adenitis).

Third. Period of secondary symptoms (syphilides of the skin and mucous membranes, mucous patches, roseola, papules, pustules, etc.). This period may be very long, and last two, three, five, or more years.

Fourth. Period of tertiary symptoms (tuberculo-ulcerous syphilides, periostitis, osteitis, gummata, etc.). The duration of this period is unlimited.

This separation of syphilis into periods is, to a certain extent, artificial, since the bones and viscera may be attacked during the first months of the infection, as will be seen later. It corresponds, however, to the course of most cases, and is desirable for purposes of dogmatic description.

**VIRUS AND INFECTIOUS DISEASES.**—Syphilis has been defined as “an infectious, contagious, and inoculable disease,” therefore it may be placed alongside of the other infectious and contagious diseases, such as smallpox, glanders, farcy, malignant pustule, vaccine, etc.

The essential character of infectious diseases is that they are contagious and inoculable; that is, that a portion of the contents of a pustule or of any other lesion containing a liquid, inoculated by a puncture of the derm, reproduces a disease similar to that which has served for the inoculation—a disease which begins in the same manner and has the same evolution.

The inoculated pustule of smallpox causes the smallpox with its several phases of incubation, premonitory symptoms, eruption, and suppuration. Again, glanders, when inoculated, is manifested by glander ulcers and the generalization of glander nodules. Similarly, if the serous fluid of an infecting chancre be inoculated, there is seen at the point of inoculation, after a period of incubation, an infecting chancre, soon followed by secondary symptoms.

Infectious diseases, as above described, should be separated from infectious diseases which are transmitted at a distance by means of the surrounding media, especially by air and water, and which are not inoculable (cholera, typhus, etc.).

The infectious diseases are also distinguished from poisons by the fact that the latter, when introduced into the system, are, after a short time, eliminated, provided death does not occur. Poison is not con-

tagious from a sick to a well person, neither is it inoculable. Again, it is not hereditary, while the virus, which is only slowly and incompletely eliminated, is transmitted by inheritance under certain determined conditions.

To examine the question further, it should be asked, What is the cause of infectious diseases? In what does the virulence of the inoculable liquid or *virus* consist? What is the virus, and particularly the serous, transparent, colorless liquid, a drop of which is sufficient to affect the whole economy, causing a chancre at the place of inoculation, a chain of enlarged inguinal lymphatic glands, and all the subsequent symptoms of syphilis?

The several hypotheses advanced by the schools of vitalists served only to explain the material changes of liquids and tissues.

We find first the hypothesis of Ch. Robin, that the tissues and blood, or rather the nitrogenized materials of the tissues, are gradually modified in a special manner by the contact of the virulent liquid, from whence results a general infection of the whole economy. This is, however, only a hypothesis, since nothing proves that it occurs in this manner, and it is not known in what this modification of tissues consists.

Later, Chauveau, from his investigations with the virus of vaccine, demonstrated that in this virus the fluid part is not capable of being inoculated, and that the solid particles, viz., the minute granules contained in the fluid, are alone able to reproduce the vaccine disease, when inoculated upon a healthy person.

[The contagion of smallpox, the cattle-plague, and relapsing fever was claimed by Chauveau and Burdon-Sanderson to reside in a living germinal cell resembling a white blood-cell, but of less size, more active, more short-lived, and capable of general movement and proliferation. "Beale also claimed that another cell with similar properties and powers, and directly descended from degraded cell elements of human origin, was the starting point of syphilis."<sup>1</sup>]

The question has been considerably advanced by Pasteur, who revived the old conception of parasites, and by new investigations demonstrated the rôle played by ferments and vibriones in a number of infectious diseases. In purulent infection, septic infection, and malignant pustule, Pasteur has determined by several cultivations, and several successive inoculations, the variety of micrococci, which, when introduced into the system, are the cause of the existing symptoms.

[<sup>1</sup> Otis, op. cit.]



Taking this as a basis of analogy, are we able to say that syphilis is due to the reproduction and multiplication in the economy of parasites of the same order as the bacteria of malignant pustule or as the micrococci of septic infection? Certainly nothing is more seducing than this theory, but, on the other hand, there is nothing at present whatever to prove it. The difficulties surrounding the investigation into the possible existence of a special parasite for syphilis are to be considered.

When an experimenter, for example, has, with all the minute precautions recommended by Pasteur, taken the blood of an animal attacked with malignant pustule, and has so placed a drop of this blood as to favor the development of the micrococci, if he sees a number of micrococci produced in the culture fluid, and by inoculating a drop of this fluid he reproduces the malignant pustule in the inoculated animal, there are two complete and distinct series of experiments. In the first the parasite is isolated and developed; in the second we are assured that this parasite thus isolated and reproduced, after several successive cultures, is able to transmit the malignant pustule.

Are we able to reproduce these two series of experiments with syphilitic virus? No. And even if we suppose that there is a special parasite in this virus, and that this parasite can be isolated, we are not able to prove that it alone will develop syphilis. In fact, we do not know any kind of animal life that may be inoculated with success, and determine the manifestations of syphilis. We never advise nor practice experimental inoculation of syphilis upon man. Although the inoculation of soft chancre has succeeded, according to Auzias-Turenne, upon monkeys, that of infecting chancre has thus far determined nothing, and what we know in regard to the copulating disease of the horse, or the discharge and venereal ulcers of the dog, is not so convincing that we can, in the present state of science, consider these animals as having any disease analogous to venereal disease in man.

We are only able to present a hypothesis upon the subject of syphilitic virus; but that which best explains the facts, which best agrees by analogy with the known symptoms of diseases similar to syphilis, is certainly the hypothesis of parasites.

[The subject of the inoculation of syphilis upon some of the lower animals has been recently experimentally studied by Klebs.<sup>1</sup> The

[<sup>1</sup> Archiv für Experiment. Pathologie u. Pharmakologie, Band x. s. 161.]

methods employed by him were either to inoculate the animal with a portion of a fresh chancre or that of cultivation. From his investigations he found that, under certain conditions, syphilitic indurations are not infective, or, more probably, they have ceased to be so at the time of inoculation; and, as these show the same histological elements as those which do infect, it is concluded that the cells are not the carriers of the virus. Klebs believes that the various stages of development of a fungus correspond with the various grades of infectiveness; and this is corroborated by another observation of his, that the extirpated masses were more active when they had been preserved for some days in glass tubes prior to their insertion.

From his experiments Klebs draws the following conclusions:—

1. Syphilis in man can be communicated to animals by inoculating them with portions of the syphilitic new formations. But the course of the disease is not the same for each genus. With apes, the disease is quite the same as in man; rabbits have given other results, which, although less striking, nevertheless will not allow any mistake as to their similarity with the disease in man.

2. In syphilitic new formations in man certain low fungoid organisms are found, which develop into peculiar forms—helicomonads.

3. By the transference of these to selected animals, changes are inaugurated which correspond not only with those of genuine syphilis in man, but also with those of the inoculated syphilis of animals.

In a paper on the fungus of syphilis by Bermann,<sup>1</sup> of Baltimore, he describes fungoid growths and micrococci adhering to, and partly filling up, the lumina of most of the lymphatic vessels found in the initial sclerosis.

According to Bermann, the micrococci are principally to be seen in the lymphatics and usually about the valves. They are small, strongly refracting, spherical bodies. The bacteria, as described by Klebs, were only found in a few instances, and only in the arteries. The changes in the lymphatics were seen chiefly at some distance from the sclerosed part. Wherever the fungi were most abundant in the lymphatics, there it was also found that the greatest change had occurred in the appearance of the tissues. The nearer to the original lesion the more prevalent were the micrococci or sporangia, while at some distance from the induration the more highly developed forms were found.]

[<sup>1</sup> Archives of Med., Dec. 1880.]

Another general disease of slow evolution, terminating with nodular productions analogous to gummata, and closely related to syphilis, is tuberculosis, which, as Villemin has shown, is capable of being inoculated and reproduced in several species of animals.

The glanders of the horse, with its initial ulcer, with its multiple manifestations, and its special nodules, is also related to syphilis.

It is with these two general diseases that we can best compare syphilis; but, although there are between them some resemblances, there are also many differences.

The histological structure of tubercles and that of gummata are very similar, the small cells, the embryonal tissue composing them, the granulo-fatty and caseous degeneration, which is observed in their centre upon comparative microscopic examinations of thin sections of a gumma and a tubercle, often occasion some hesitation in forming an opinion as to the nature of any given specimen. These comparative characters of gummata and tubercles will again be referred to when the tertiary period of syphilis is described. But, although gummata and tubercle are closely related histologically, they are not to be confounded in a macroscopical examination. While tubercles are generally located in the lungs, in the large serous cavities, or upon the surface of mucous membranes (intestinal, genito-urinary, etc.), the gummata, on the contrary, are almost always seated in the sub-cutaneous and sub-mucous connective tissue, in the testicles, in the liver, in the bones, in the dura mater, etc. Again, gummata are generally larger tumors than the tubercles, and they are always surrounded by very dense fibrous tissue.

In regard to glanders, its morbid productions are especially met with in the nasal fossæ, the muscles, the air-passages, etc., in the form of miliary abscesses following subacute or chronic purulent infection.

From the above it is seen that our knowledge is very limited as regards the different varieties of virus; the syphilitic virus particularly being less understood than that of glanders, malignant pustule, etc., which may be inoculated upon different animals, and consequently may be subjected to systematic experiments.

CONTAGION AND INOCULATION OF SYPHILIS.—Although we know but little of the syphilitic virus, considered by itself, or may even deny its existence, we are at least able to study its effects when it is implanted by contagion or inoculation upon a person who never has had syphilis.

Syphilis most frequently has its origin in sexual connection, yet it quite often occurs from the contact of the buccal mucous membrane of a nursing child with the nipple of its nurse, or *vice versa*, or by the common use of the same drinking glasses, etc.; or midwives and physicians may be infected in practising the vaginal touch. It is the serum of a chancre or mucous patch which determines the disease; the result is always an infecting chancre.

At the present time it is not generally believed that syphilis follows a gonorrhœa, all of the several varieties of chancres, vegetations, or, in a word, it is not thought that every venereal symptom may be the precursor of syphilis. Nevertheless this theory of the transmission of syphilis from all of the lesions of venereal disease, this doctrine of the *identity* of gonorrhœa and chancres prevailed without opposition during several centuries. At the present time it is entirely abandoned. I began my studies as interne in 1861 with Gibert, a celebrated dermatologist of the St. Louis Hôpital. At that time the physicians of that hospital, Gibert, Cazenave, Devergie, all defended the theory of identity. Gibert, for example, taught that syphilis followed gonorrhœa, vegetations, soft chancre as well as hard, and mucous patches. For a long time, however, in the School of Midi, Ricord and Cullerier had separated the cause of gonorrhœa from that of chancre; but they made no distinction between simple and infecting chancre; they were *unicists*, they thought that syphilis would follow soft chancre as well as the indurated chancre, and that the only transmissible lesion was always the chancre, the mucous patches following the chancres not having the power to communicate syphilis.

It was only later that Bassereau, Clerc, Diday, Rollet, etc., demonstrated that simple or soft chancre was different from hard or infecting chancre, and that the latter only had the power of determining constitutional syphilis. This distinction, or rather this opposition of the two chancres, this *dualism*, for such is the name of the new doctrine, has been accepted by Ricord and his pupils, particularly by Fournier in his late most excellent publications.

To return to the contagion of infecting chancre: When a person is exposed to impure connection, the lesions do not immediately supervene; there occurs a period of from two to four weeks, an average of twenty-five days, before any symptoms appear, and frequently a longer time elapses—six weeks or two months.

This period of incubation, which precedes the appearance of the in-

durated chancre, was not recognized as long as the two chancres were confounded. Rollet, Fournier, Clerc, etc., have, however, in the last few years, by many observations, determined this incubative interval to be almost invariably present. Thus when sailors, after having been away from port for a month, or even for two months, have been known to develop chancres upon the genital organs, or when a similar lesion occurs in the case of a prisoner in Saint Lazare sixty days after her admittance (Aimé Martin), the observations are as conclusive as experimental inoculations. And when such inoculations have been made to prove the transmission of syphilis by secondary lesions, and by the blood, they have also demonstrated the long duration of the period of incubation. Innumerable observations, clinical and experimental, have shown that the period of incubation of the hard chancre averages from three to four weeks. This is characteristic only of infecting chancre, since, as has been previously mentioned, the inoculated simple chancre appears almost immediately, first as an area of redness, then as a small pustule, and thirdly as an ulcer.

Many inoculations have been made with the serum of mucous patches, with syphilitic pustules, with the blood of syphilitic patients, upon persons who have never had syphilis. These experiments we do not hesitate to condemn when they are made without the consent of the patient. Wallace in England, Vidal de Cassis in France, Waller in Prague, Auzias-Turenne, Gibert, Belhomme, etc., have inoculated the serum of mucous patches. Ricord for some time maintained that the chancre alone was inoculable, but he now admits his error.

The blood of syphilitic patients has been successfully inoculated by Waller, Viennois, and the anonymous writer of the Palatinate. Pellizzari inoculated three young medical students, of whom one only had syphilis.

Whenever an inoculation with the serum or pus of a secondary lesion or with the blood is successful, it produces a chancre preceded by a long period of incubation. The symptoms of syphilis are then developed in their regular evolution, and successively appear, beginning by the incubation and primary lesion, continuing with the eruptions of the secondary and tertiary periods.

The inoculations made by Diday render it probable that the tertiary lesions are not inoculable, and consequently not contagious.

From the above facts a few practical conclusions may be drawn:—Mucous patches and moist papules, by contagion, have the power of

causing a chancre and syphilis. Syphilis transmitted by a syphilitic nursing infant, suffering with mucous patches of the lips, is seen as a chancre upon the nipple of the nurse, provided the latter has never had syphilis. Again, syphilitic papules of the nipple of a syphilitic nurse occasion a chancre upon the lip of a healthy infant.

Secondary lesions of syphilis remain a long time. In the hospitals, female patients return during two, three, and even five years with mucous patches on the vulva; it is the same with mucous patches of the tongue, mouth, etc., with men. Syphilis may then be communicated by a syphilitic person during three, four, or five years after the beginning of the disease. In marrying, after contracting syphilis, there is danger of communicating the disease to the wife and of having syphilitic children. In hereditary syphilis the woman seems to occupy the most important place, and it is rare that a syphilitic father has a child affected with syphilis, if the mother remains healthy during marriage.

There are no reliable cases evincing the truth of syphilitic contagion by the spermatic fluid, or of inoculation by this liquid. The tears and saliva, obtained from syphilitic persons, have been inoculated upon healthy persons without producing the disease.

[There has been, as far as we know, not one trustworthy case of the transmission of syphilis by means of any of the normal secretions, even where the most careful and persistent attempts at inoculation have been made. The evidence as to its transmission by uterine discharges seems as yet to leave the matter open to doubt, though it is highly probable that a simple leucorrhœa, unaccompanied by secondary lesion of the uterus, is not capable of conveying syphilis.]

As the blood is undoubtedly contagious and inoculable, while the fluids of the various secretions do not possess these properties, it is very probable that the passage of the serum of the blood through the glandular membranes and cells arrests the contagious particles, and renders the secreted fluids harmless.

[If the theory of lymphatic absorption as stated above be correct, this becomes comprehensible. The syphilitic cells are said to influence only germinal matter, or white blood-corpuscles, and would therefore have no effect upon the formed material of the tears, milk, saliva, semen, etc., which not having been impressed by their contagious properties, would, of course, be harmless when inoculated. A further extension of this line of argument is of great interest in its application to other syphilitic phenomena. The law of Colles, for example, that

an apparently healthy mother, being delivered of a child which has derived syphilis from paternal influence, is able to suckle that child with impunity, although a healthy wet-nurse contracts syphilis from it, has never been controverted, and has always seemed more or less mysterious. It is possible, as the corpuscles do not pass over from one organism to the other, but are arrested by the "septum between the maternal and foetal vascular systems" (Kassowitz), that only such minute quantities of the poison are carried over as not to produce observable symptoms. We can understand by this view how a mother may appear to escape altogether, and yet give birth to a series of markedly syphilitic infants.]

Whatever may be the lesion or fluid which determines the transmission of syphilis, it appears that the result is always the same, and is an infecting chancre, preceded by a period of incubation.

PERIOD OF INCUBATION.—This period includes the interval elapsing between the inoculation and the appearance of the chancre.

Most writers believe that the absorption takes place immediately at the point of contamination, the virus being taken up by the lymphatic and blood circulation, and carried throughout the whole system, and that the infection of the entire economy is completed before the chancre appears.

Although it may be several weeks after impure connection before the chancre is seen at the part which has been inoculated, they believe that from the first day the patient has been infected with syphilis. Cusco goes even further, and maintains that it is possible to become syphilitic by absorption of the virus, without having a chancre. We are not of this opinion, and believe that, although, in many cases, especially with women, the initial chancre has not been detected, it is due to its being painless, small, or so situated as not to be seen—in a word, it has been overlooked.

Writers who maintain that the virus has been absorbed, and that it affects the whole system before the appearance of the chancre, advance in justification of their opinion the physiological experiments made by Renault with glanders. In 1848 Renault inoculated thirteen horses with glanders; all had the puncture cauterized with a hot iron at periods varying from one to twenty-four hours after the inoculation. All were affected with glanders.<sup>1</sup>

<sup>1</sup> Aimé Martin and Belhomme, *Traité de la Syphilis*, 2d edition, 1876, p. 51.

These experiments, however, cannot be considered to apply equally to syphilis.

The following experiment with tubercle was made by Cohnheim: A drop of liquid obtained from a tubercle was placed in the anterior chamber of the eye, behind the transparent cornea, in such a manner that day by day the result could be studied. The inoculated part remained without change for a week, but on the eighth day there suddenly occurred a congestion and protrusion of the cornea, and a new formation of tissue, analogous to tubercle, in the iris and in the membranes of the eye. In this case the period of incubation had been a period of rest for the virus, since it was only at the termination of a week, that the neighboring parts reacted and reproduced a similar tissue. This primary phenomenon was followed later by a formation of tubercles in the lungs and other organs.

During the period of incubation of syphilis, does the virus remain localized as in the experiment of Cohnheim, and consequently without danger as far as general infection is concerned?

We are not in possession of absolutely conclusive evidence upon this point, but it is highly probable that the syphilitic virus, inserted under the skin, remains there a certain length of time without any other action than gradually to change the cells which are in immediate relation with it, and slowly to prepare them for the hyperplasia which soon constitutes the chancre.

The chancre always appears at the primary contaminated point. If we suppose that the syphilitic virus is from the first carried everywhere in the economy, it is difficult to understand why there is not during one or two months, any other lesion elsewhere than at the point of entrance. The chancre, we reiterate, the primary lesion, is invariably met with in the part inoculated, never elsewhere; and secondarily, a gland is swollen after the appearance of the chancre, then several glands, and these glands for some time, as we know from our study of other diseases, arrest the diffusion or generalization of morbid products and tumors.

This conception of the innocuousness of the virus, at the beginning of the contamination, is, as we understand it, very important in a practical point of view. It would indicate that the destruction of the chancre, at the moment of its appearance, would prevent syphilis. Ribes in 1820, and Ricord in 1845, maintained with much force, that the cauterization or excision of chancre, practised soon enough, completely arrested further lesions.



But at the time Ricord advised cauterization of the chancre, he confounded the soft with the infecting chancre, and it is possible his success was only with soft chancres.

Auspitz and Paul Unna have since practised a number of excisions of chancres, in 33 cases, from which 10 for special reasons have been excluded. In 23 cases, 14 patients did not present any symptoms of general infection during a sufficiently prolonged period of observation. The remaining 9 cases were affected with constitutional syphilis.

When induration does not follow after excision, the patients do not have secondary lesions, even if the inguinal glands are swollen at the time of excision of the chancre. Again the secondary lesions seem to be delayed in patients who have submitted to excision of the primary lesion.

Auspitz and Unna advise excision of the chancre, when the induration has existed for a short time only, if the chancre is not accompanied with a painless swelling of the inguinal glands, and when the situation of the chancre permits its removal without difficulty.

These results of the excision of the indurated chancre should be remembered. They give support to the theory, that syphilis is not at once generalized in the system before any apparent manifestation. Yet, although this theory seems to agree best with the facts, we cannot in the present state of knowledge regard it as proved.

[Bumstead excised indurated chancres in 15 cases without once preventing the development of syphilis. Zeissl, Mauriac, and Isidor Neumann, in 17 additional cases had similar results. Kölliker, in a lecture on the excision of the *Initial Lesion of Syphilis*, published in the *Centralblatt für chirurgie*, No. 48, 1878, draws the following conclusions: 1. In certain cases, which at present cannot be designated with certainty, extirpation of the primary sore serves to prevent general contagion. 2. This may occur even when the glands in the neighborhood are indurated. 3. On the other hand, extirpation is often fruitless, no matter how early undertaken. 4. Even where excision does not prevent the occurrence of general symptoms, it modifies them and makes the course of the disease milder. He concludes by agreeing with Auspitz, that the initial indurated sore is not to be considered as a symptom of complete general infection.

Berkeley Hill thinks "it is wiser to assume that we cannot indicate any period at which syphilis is a local disease, which can be extirpated by local treatment." Hutchinson "finds it very diffi-

cult to believe that absorption of the syphilitic virus is so rapid, that there is no stage during which it remains limited to the seat of inoculation ; he prefers to act as if this stage comprised the first week or ten days after contagion." This would seem to conflict with his theory of the exanthematous nature of syphilis, as there is no evidence, whatever, that the diseases with which he classes it can be similarly aborted (see p. 19).

Van Buren and Keyes say that "the patient already has syphilis before his chancre appears." Jullien insists that, after the appearance of the chancre, "all cauterants, all attempts at absorption should be abandoned." Belhomme and Martin say "the chancre is the first manifestation of constitutional syphilis." Diday asserts that "it is not in the power of the physician to prevent by local medication or treatment the sequelæ of the chancre." Lee believes that after the chancre has appeared, local treatment is unavailing. Otis says the evidence does not seem "sufficient to warrant any positive claim to the prevention of general infection, by excision of the initial lesion of syphilis. The manner in which infection takes place (any moment after which might carry an infected or degraded cell into a lymph vessel, and there out of reach) would appear to render it, at the least, highly improbable that every infecting cell could be removed by removal of the initial lesion. The procedure is, however, in harmony with our view of the case." Mauriac believes that excision of the chancre is useless: 1. Because it does not prevent the reproduction of the primary sore ; 2. Because it does not prevent constitutional infection ; and 3. Because it does not diminish the subsequent severity of the disease.

It will thus be seen, that there is great difference of opinion among syphilographers upon this point, but that the weight of authority is against the *probability* of the abortion of syphilis by excising or otherwise destroying the chancre. Our own experiments in this direction are not yet sufficiently numerous to justify generalization ; but we may venture to say, that the results thus far obtained appear to favor the theory which regards chancre as a local development and not as necessarily a symptom of general syphilis.

Most authorities are agreed, however, that cauterization or excision of an abraded or absorbing surface soon after exposure, and before the development of the chancre, is strongly indicated, and has probably in several cases prevented constitutional infection.]



He suggests, that as the skill and accuracy of these observers are beyond question, this fact is in accord with the decreasing severity of syphilis, and with the circumstance now generally admitted that chancres of long incubation are apt to be followed by benign syphilis.

He adds the subjoined table, made up from a moderate number of cases, and intended to show the slight variations in the period of incubation due to differences in the source of original contagion, and also the general average duration of this period at the present day, and in his own experience :—

SOURCE OF INFECTION.	DURATION OF INCUBATION.			
	Maximum.	Minimum.	Average.	
Infecting chancre . . . . .	39 days.	15 days.	24 days.	} General average. 26 days.
Mucous patches . . . . .	30 "	10 "	27 "	
Pustular syphilide . . . . .	35 "	28 "	30 "	
Blood . . . . .	35 "	25 "	30 "	

Fournier mentions a case in which this period reached seventy-five days. In 37 out of 42 cases of experimental inoculation collected by Hill and Cooper, the incubation was stated with exactness, the extremes being ten and forty-six days, the most common periods twenty-five and twenty-eight days, and the average twenty-four days.

The longest period of incubation observed by Bumstead and Taylor was fifty days; the shortest they do not state—and this indeed has never been absolutely determined. Diday, however, has reported one case in which the interval between exposure and the development of the sore was twenty-four hours; Otis and Taylor each a similar one; Hammond one in which it was thirty-six hours; Le Fort several from three to seven days; Hardaway one in which it was seven days; Rollet one of nine days, etc.

We have several times seen *an ulcer* follow exposure to contagion within two or three days, succeeded in its turn by constitutional syphilis, but have never noticed characteristic induration develop earlier than the seventh day.

It is an excellent general rule for prognosis in cases of suspicious ulcers upon the genitals, to assume that, if an interval of ten days or more has elapsed between the last exposure to contagion, and the development of the sore, the latter is probably the initial lesion of syphilis.]

When the surface of a fully developed chancre is examined, there is constantly found a secretion of a transparent, thin, serous liquid, small in amount. The margins of the chancre, covered by layers of the superficial and deep epidermis, are directly continuous with the

neighboring cutaneous or mucous surfaces. Upon the labia majora, for example, the most common seat of chancre in the female, it is found in passing from the healthy skin to the eroded surface of the chancre, that the corneous layer of the epidermis, which passes over its margin, is a little thinned, and ceases at the beginning of the erosion, while the epidermic layers of the rete mucosum cover almost the entire surface of the chancre, at least, if there be no true ulceration. There is a gradual thinning of the epidermic layers from the periphery to the centre.

The ulceration, when it exists, is a simple cup-shaped depression; its surface is smooth, and the margins are not abrupt. At the centre of the chancre, and extending over a greater or less extent, there is found a kind of gray or yellowish-gray opaque false membrane, having very much the appearance of the false membrane of diphtheria. It may form a regular or irregular layer, or is at times distributed in small patches or islands. It is removed with difficulty, yet by scraping with a bistoury it may be separated, and then its close attachment can be appreciated; also its thickness, which is from a fifth to a fourth of a millimetre, sometimes more. Beneath the false membrane there is found a tissue which readily bleeds.

[A rare variety of the initial lesion of syphilis, is the diphtheroid chancre of Dr. Morrow, in which a large portion of the glans penis is covered with a glistening grayish-white coating of a leathery consistence, simulating, in all its characters, a diphtheritic exudation. Dr. Taylor regards this as a form of scaling or dry chancre, the syphilitic cells being developed in the superficial lesions of the glans. We have never seen this lesion.

Multiple chancres occasionally occur, and sometimes assume a herpetiform character. "They look like small round excoriations, of a deep-red, sometimes coppery hue, bleed readily and have a very slight induration of their bases, which often increases at a later period. From five to fourteen chancres may be observed upon the prepuce or glans. In their first stage, the diagnosis is difficult; but the absence of itching and burning, their dark color, and their chronicity are points which aid in distinguishing them from herpes. Another important feature is, that their surface is very smooth and shining. Moreover, induration of the inguinal ganglia is soon developed."<sup>1</sup> We have never seen these sores in so great numbers, nor

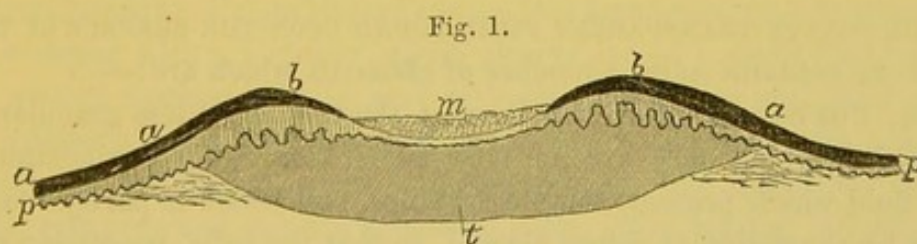
<sup>1</sup> Bumstead and Taylor, p. 450.

have we seen them remain distinct throughout their entire course. When they are very close to one another, as is usually the case, the induration at their bases is continuous, and the three or four sores can be lifted up together.

Mauriac describes a form of initial lesion as "infecting balano-posthitis." In this condition, "the mucous membrane of the prepuce is thickened, has a deep-red color, and is slightly excoriated, either partially or completely." In its early stage, this is exceedingly deceptive, the general inflammatory appearances leading almost invariably to the supposition that the case is one of simple balano-posthitis. The induration, which almost always exists, is broad and uneven, and not so strictly defined as in the chancre. If the prepuce be watched while the patient retract it, the indurated portion will be seen to offer resistance, and then to erect itself or stand upon its edge before it turns over. We have, however, in several instances, seen this precise condition not followed by constitutional symptoms. The prognosis, therefore, in such cases, should always be doubtful.]

When an entire chancre, with a more or less hard base, is examined, it is seen that it is not a depression, but, on the contrary, a papular prominence of the derm, for although its centre is depressed, and slightly cup-shaped, its borders are thicker and more prominent than the healthy skin with which they are continuous.

Thus, a diagram of a section of a chancre made vertical to the surface of the skin, gives us the following figure.



Schematic section of an indurated chancre. *a, b.* Corneous epidermis. *p.* Papillæ. *t.* Indurated tissue at the base of the chancre. *m.* False membrane.

The corneous layer of the epiderm *a* is continuous with the healthy part of the skin over the elevation formed by the margin of the chancre *b*, afterwards it is thinned, reaching the depressed centre. This depression is covered by the adherent false membrane *m*. The Malpighian layer, between the corneous layer and the papillæ *p*, is thickened at the margin of the chancre, and thinned or even lost in the centre of the excoriation under the false membrane. The papillary layer *p*,

presents, at the margin of the chancre, a thickness and elongation of the papillæ which are, however, thinned over the excoriation. Finally, the connective tissue of the derm is thickened and indurated throughout the region *t*.

If, instead of examining a vertical section, the chancre be examined from the surface, a circular area is observed, the centre of which is more or less excavated, the margins, formed by the elevation of the epidermic and papillary layers, being prominent. The epidermic layers gradually thinning from the healthy parts to the centre of the chancre form for it a border similar to a soft corn on the foot.

A chancre presents for examination the secretion found upon its surface, the epidermic layer and the false membrane covering it, and finally the lesions of the dermo-papillary indurated tissue.

The chancres which may best be studied, and those most usually observed, are generally seated upon the skin or near muco-cutaneous junctions—on the vulva, glans, prepuce, lips, tongue, etc.—that is upon a membrane analogous to the skin, covered with thick layers of pavement epithelium, and possessing a papillary chorion. Therefore the type of our description relates to a membrane, cutaneous or mucous, consisting of a papillary layer and an epithelial covering, the latter formed of a rete mucosum and a superficial epidermic or corneous layer. The pathological alterations of these different layers will be first described, and afterwards the lesions of the appendages of the skin, hair, glands, etc.

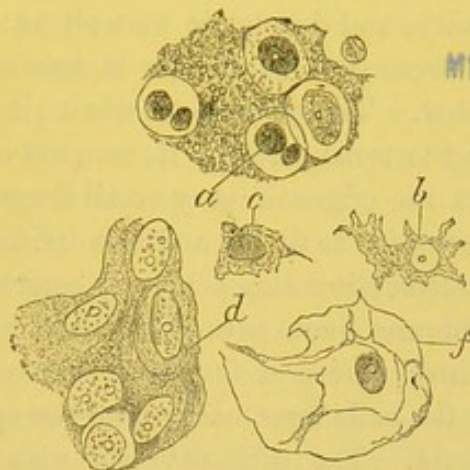
THE SCANTY TRANSPARENT FLUID FOUND UPON THE SURFACE OF THE CHANCRE contains quite a number of elements which are:—

1st. Pus corpuscles or lymph cells: these more or less granular or atrophied lymph cells are not very numerous. They are contained in a fluid which presents minute granules, and which is partly coagulated by the action of dilute alcohol, so that the cells, possessing one or two nuclei, and a clear protoplasm, are frequently surrounded by a granular substance, which latter appears more solid than the protoplasm, *a*, Fig. 2.

2d. Fine, albuminous, or fatty granules, having Brownian movements; very small spores separate or forming rows, rod-shaped bacteria, etc. These several productions, vegetable or vibriones, are especially numerous the day the patients come into the hospitals, before they have had a bath or previous to the lesions being treated with local medication.

3d. Corneous cells, *f*, Fig. 2, and cells of the rete mucosum, *d*, Fig. 2, undergoing destruction; they are not numerous: some of them are reduced to an elongated nucleus, more or less atrophied, which is surrounded by the very fine granular débris of the cellular mem-

Fig. 2.



Elements from the surface of a chancre. *a*. Pus corpuscles with amorphous granular matter surrounding them. *b*, *c*. Atrophying epidermic cells. *d*. Cells of the rete mucosum. *f*. Corneous cells.  $\times 300$ .

brane, so that the whole is moved by the movements of the fluid of the preparation, and presents an elongated, thin, shrunken nucleus, surrounded by irregular lines formed by an extremely fine collection of granules.

**DIPHThERITIC FALSE MEMBRANE.**—This membrane may be removed by scraping with a bistoury, which always causes a slight bleeding of the eroded surface. It is gray or yellow, saturated with fluid, and, by teasing a small fragment with needles, in water, we obtain a liquid containing cellular elements. These elements are numerous lymph cells, corneous and spinous epithelial cells. The teasing is done in a drop of water, or in diluted alcohol, after which we add a drop of picro-carminé in order better to see the minute details of the preparation. The lymph cells are seen with all their characteristics, some small, containing only a single nucleus, others larger, with their nuclei branching; occasionally they present amœboid movements. The separated and free epithelial cells in the fluid are sometimes those of the corneous layer, thin, atrophied, folded, with their nucleus elongated and shrunken; sometimes thicker cells with irregular prolongations and facets; sometimes spinous cells of the rete mucosum,

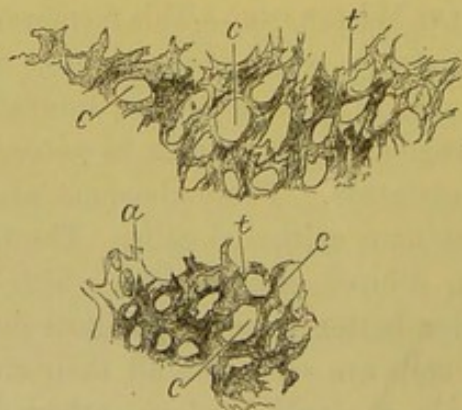


united or separate, with their oval nucleus. Also at times are found among these isolated elements large epidermic spherical cells, the colloid protoplasm of which takes the picro-carminic staining, and which are analogous to the cells found in the false membranes of diphtheritic angina.

When the false membrane is dissected with needles, it is found to be torn with difficulty, and is elastic as well as resisting. All its elements cannot be separated, even after it has macerated for some time in diluted alcohol. The membrane, when all the pus corpuscles and epidermic cells are removed from it, consists of a dense felt-like mass of fibrils. At the edges of very small fragments, obtained by teasing, the fibrils are seen to divide and sub-divide into short branching prolongations, resembling stag's horns; sometimes a microscopic fragment of the membrane shows several of these prolongations arising from a common centre, where is found an oval nucleus, and giving the impression that the cells have undergone the special alteration of pharyngeal diphtheria. The difficulty met with in isolating these filaments is such, that we cannot affirm the membrane to be entirely a product of the epidermic cells. The filaments are readily stained by carmine: lymph cells are frequently found in the meshes formed by their interlacing.

Figure 3 represents two fragments of false membrane obtained by teasing. There are seen the trabeculæ, which are quite thick, termi-

Fig. 3.



Fragments of false membrane from a chancre, obtained by teasing. *t.* Trabeculæ which form spaces, *c*, by interlacing, and terminate in dendritic filaments, and short prolongations resembling a stag's horn. *a.* Epithelial cell with numerous processes, it has retained its oval nucleus.  $\times 200$ .

nating by filaments of various shapes and in short processes. These trabeculæ have between them spaces, *c*, which often contain lymph

cells. At *a* is seen a cell with multiple prolongations which retains its oval nucleus.

A drop of crystallizable acetic acid, placed under the thin glass cover, immediately swells and dims the filaments, so that we see in their place a pale and transparent substance, in the midst of which exist oval and small nuclei becoming very distinct. This reticulated substance acts with acetic acid in the same manner as fibrin. Whatever may be the chemical nature of this membrane, and we are uncertain upon this point, it certainly has a great analogy to the diphtheritic false membrane of the pharynx and larynx.

[The diphtheritic membrane of chancre is described by Clerc (quoted by Bumstead) as "a kind of false membrane, presenting some resemblance to the diphtheritic patches which characterize certain forms of syphilitic symptoms affecting mucous membranes. It usually occupies only the centre of the chancre, its edges shade off into the reddish circumference, it is of a translucent slightly greenish and pultaceous appearance, unlike the dull or yellowish-gray membrane which covers the whole surface of a chancroid. Clerc believes that this diphtheritic layer is a *constant* feature of a chancre during the early stage of its existence." There can be no doubt of its great frequency, the reasons for which are here made evident by Cornil's excellent description of its anatomy.]

This completes the microscopical examination of the fluid and free elements upon the surface of the chancre, and also of the false membrane which covers it. We now pass to the detailed examination of preparations obtained by making thin sections of chancres which have been removed.

In order to obtain these preparations, the removed part, that is the entire chancre with the healthy skin or mucous membrane surrounding it, is placed either in alcohol or in osmic acid, in order to fix the elements, then it is macerated for twenty-four hours in picric acid or Müller's fluid, or bi-chromate of ammonium; then placed in a solution of gum, and finally in alcohol, until it is sufficiently hard. Thin sections are made, stained with picro-carmin and mounted in glycerine.

Sections, passing through the large axis of the chancre, show, with low power, the entire chancre.

Figure 4 represents a chancre removed from the labium majorum, and magnified fifteen diameters. In this figure, which is very correctly drawn by means of the camera lucida, it is seen that the two layers of

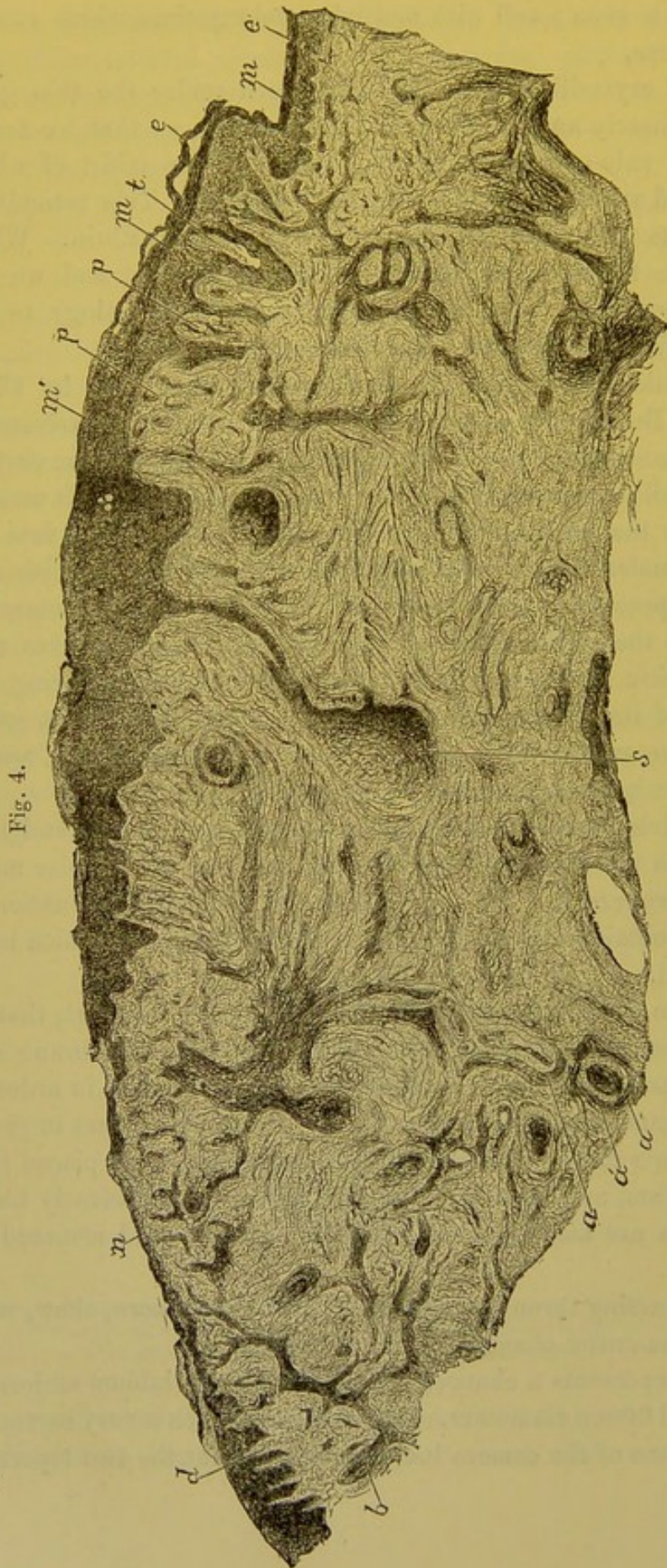


Fig. 4.

Section of an indurated chancre of the labium majorum. *e*. Corneous epidermis, which gradually becomes thinner from the margin to the centre of the chancre, where the epidermis, *n*, is very thin. *m*. Rete mucosum. *m'*. Thickened rete mucosum of the chancre. *p*, *d*. Hypertrophied papillae at the margin of the chancre. *a*. Section of a sclerosed artery. *a'*. Thickened connective tissue around arterioles. *t*. Hair passing out from the surface of the chancre. *b*. Section of a hair sheath. *s*. Sudorific gland. X 15.

the normal epiderm, *e*, over the healthy portion of the skin, is thickened at *m*, where the elevated margin of the chancre begins; at the same time the papillæ, *pp*, become very much elongated and thickened in the whole circumference of the chancre. In the central part of the chancre, at *n*, the epidermic layer is much thinned and reduced to the rete mucosum, but remains, however, as a distinct layer. At *d* the epidermic layers and swollen papillæ appear newly formed. All the connective tissue traversing this region between the smooth muscular fibres is sclerosed, and it is easily seen, even with this low power, that the coats of the arteries, *a a*, and all the vessels are enormously hypertrophied. In this preparation are very distinctly seen the hairs, *t, b*, and their glands; also the sudorific glands, *s*.

In every preparation of chancre there are observed, as constant lesions, changes in the cells of the epidermic covering, a papillary hypertrophy at the margins of the chancre, and in all the subjacent connective tissue an infiltration of the papillary network and of the derm by embryonic cells—an inflammation with exudation. The fixed connective-tissue cells, and the flat cells, between the fasciculi of fibres, are swollen and proliferating. The vascular coats, especially the tunica adventitia of the arterioles and venules, are inflamed and thickened. The fasciculi of fibres of the connective tissue are well preserved, perhaps even thickened, from which result the special induration and resistance of the derm.

The general disposition of all the lesions in a chancre having been described, we are now ready to study more minutely the modifications of each part. Close attention to all the histological details, notwithstanding their length, is necessary, to thoroughly comprehend the subject. If a knowledge of only its external characters be desired, it is sufficient to examine a chancre moulded in wax; but, in order to see what is beneath the surface, in order to study the lesions in detail, we must have recourse to histology.

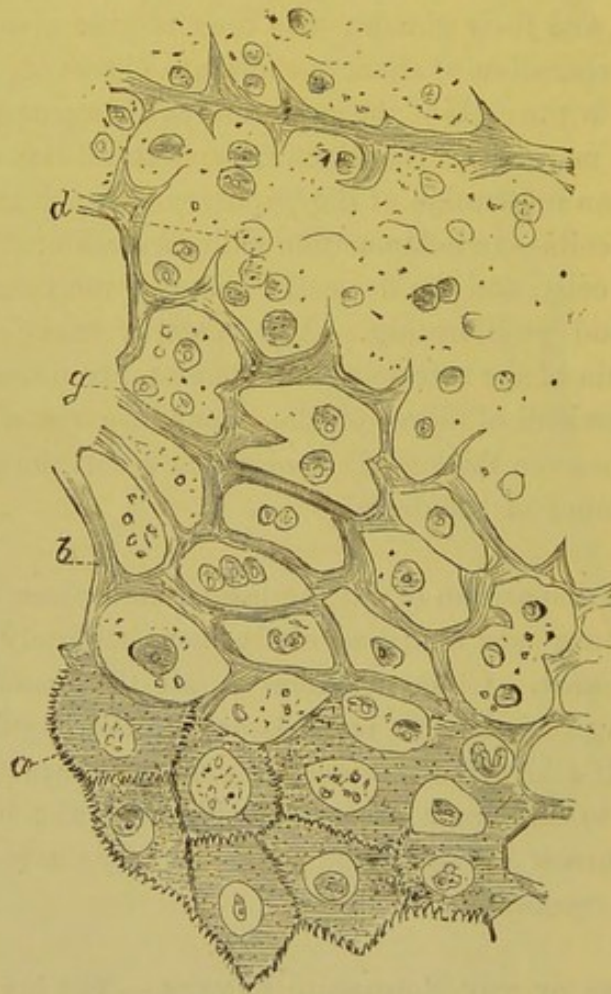
ALTERATIONS OF THE EPIDERMIC LAYERS.—The layers of the epidermis are three in number,—the corneous, the granular, or intermediate, and the Malpighian, or rete mucosum.

The superficial lamellæ of the corneous layer differ but little, or not at all, from the normal. They are simply elevated, and their layers are separated by the changes in the deeper corneous layers, where we frequently find cavities containing lymph cells, or an in-

filtration of lymph cells interposed between the rows of epidermic cells.

The cells of the deeper corneous layer, or of the granular layer, present a small cavity, which is hollowed around the nucleus of the cell, between the nucleus and the solid part of the cell (Fig. 5). The nucleus may be atrophied and flattened; the cavity formed in the middle of the cell contains, with the atrophied nucleus, a few granules; at other times the nucleus is large and budding, or the cavity may contain two or three round and granular nuclei.

Fig. 5.



Schematic drawing of the changes in the epidermis, after Leloir.

Very thin sections of the epidermis changed in this manner, sometimes show the cavities empty (*a*, Fig. 5); the nuclei having been washed out by the fluid used in preparing the specimen; and the nuclei are found at times lying across the trabeculæ, as occurs, for example, in preparations of cartilage.

When several neighboring cells undergo this lesion they are seen as a number of cavities, limited by a more or less thin border, which is the remains of their solid substance. Leloir, who was the first to describe, and explain this formation of cavities to the Society of Biology,<sup>1</sup> from some sections of syphilitic vegetations that we had examined together, has compared the appearance of the excavated epidermic cells to that of vegetable cells. The comparison is very just, and there exists a great resemblance between epidermic tissue changed in this way and vegetable tissue. The solid protoplasm of the cell forms the thin membrane of a cavity containing one or more round and granular elements (*b, g, Fig. 5*). Alongside of these cells are found larger cavities, containing a greater number of pus corpuscles (*d, Fig. 5*). This would lead to the belief that these larger cavities are the result of the opening of the excavated cells into one another. Indeed, quite often a reticulum is seen, formed by the cell walls, traversing a cavity filled with pus corpuscles; the reticulum and cavities are similar to those I had previously described in variolous pustules. From the walls of these cavities arise incomplete partitions, which are the remains of walls of smaller cellular cavities.

Figure 6 is a section of the corneous layer and rete mucosum in the proximity of a hair from the surface of an indurated chancre, magnified 150 diameters. The cells upon the surface at *a*, are raised and desquamating, at *b* they form a compact layer, beneath which we see numerous excavated corneous cells, *c*, and large cavities, *d*, filled with pus corpuscles. The net-work of trabeculæ, which separates these cavities, is formed by corneous cells, and the walls of excavated cells opening into one another. The corneous layer stops at *m*. Beneath this the granular layer presents a few cells, in which is seen a cavity around a nucleus at *p*. The rete mucosum, which is extremely thick, also shows excavated cells, *r*, and cavities filled with pus, *n*. Upon the surface of the corneous layer are seen, at *s*, a few nuclei and atrophied cells surrounded by a delicate net-work of fibrils and granules. At other parts of the surface of the chancre, are seen pus corpuscles dissociating and separating the layers of the corneous epidermis.

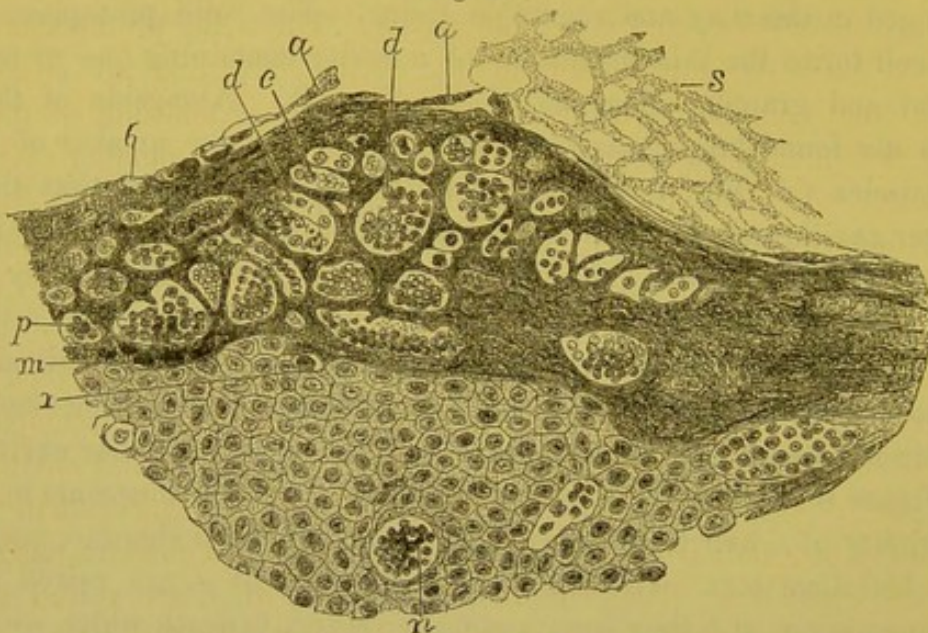
From this description, it is seen that the superficial and intermediate layers of the cutaneous epidermis, are, at the chancre, the seat of a true infiltration of lymph cells. It may also occur in the rete

<sup>1</sup> Gazette Médicale, Nos., 18 and 24, 1878.

mucosum, but in this region the excavated cells and collections of pus corpuscles are seldom seen, although, on the contrary, they are very frequently met with in the superficial layers.

This kind of inflammation of the epidermic cells is not peculiar to chancre; mucous patches, vegetations, and cutaneous syphilides usually present the same lesions when they are moist upon their surfaces, or when they are erosive or squamous.

Fig. 6.



Section of the superficial epidermic layers near a hair follicle upon the surface of an indurated chancre. *b*. Corneous epidermic layer. *a*. Cells which have become detached from the surface. *c*. Cavity excavated in a cell. *d*. Larger cavities filled with pus corpuscles. *r*. Cell of the granular layer, *m*, with a cavity in which exists the nucleus. In the rete mucosum, there also are seen cells with cavities, and small cavities, *n*, filled with pus corpuscles. Upon the surface of the chancre are seen, at *s*, atrophied and granular epidermic cells similar to those which are represented at *b*, Fig. 2.  $\times 150$ .

Similar lesions are also found in all inflammations of the skin. They are also notably found in tumors which include the derm, and which cause an irritation of the cutaneous surface. Further on, these lesions will be considered in connection with mucous patches and syphilides, in order to explain the process of desquamation and superficial erosion or scabby suppuration, without there being any notable loss of substance of the epidermic layers. But for the present, we will endeavor to ascertain how it is that pus corpuscles are met with in the epidermis.

There are two hypotheses: A. The corpuscles come from the vessels of the papillæ by emigration, pass between the cells of the rete mucosum, and collect in small groups in the different layers of

the epidermis. Many pathologists, indeed, think that superficial inflammations of the mucous membranes occur in this manner, and Auspitz and Unna, who have described these small collections of pus in the epidermic layers, where a chancre exists, do not hesitate to believe that the cells come from the papillary vessels, separate the epithelial cells, and form collections between them. According to these writers, the walls of the pus-containing-cavities, are simply formed of epidermic cells pushed aside and flattened by pressure.

This view of the process may also be sustained by what sometimes occurs in the indurated chancre, as pointed out by Ordóñez, viz., a slight escape of blood between the papillæ and rete mucosum, at which time there would also be an escape of white corpuscles, which would afterwards pass towards the exterior. On the other hand, in our preparations it was always found that the corneous layer was the seat of pus; that there were here numerous excavated cells, and cavities containing pus, while in the rete mucosum pus corpuscles were fewer in number and more seldom seen. It may be said, that the lymph cells pass out of the vessels, then readily into the rete mucosum, the cells of which are soft, and are afterwards pushed towards the cutaneous surface, accumulating in the corneous layer where the resistance is greater. The pus corpuscles are arrested under the epidermis penetrating it only with difficulty.

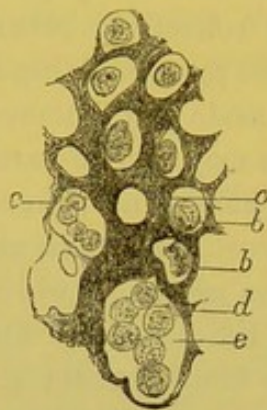
But, in every case, there should be found numerous lymph cells, between the cells of the rete mucosum, and this is precisely what does not take place. Again, when there exist small cavities filled with pus, there are always found alongside of them excavated epidermic cells, so that these two lesions appear to us the two phases of the same process.

Therefore, we are much inclined to admit the second hypothesis, *B*, that the pus corpuscles are formed in the excavated epidermic cells by division of the pre-existing nuclei and by an endogenous generation. The nutrient material comes from the blood plasma by imbibition, determining an exaggerated nutrition of the nucleus, which then divides; each division is surrounded by a small quantity of protoplasmic substance, which is also furnished by the blood plasma. Fig. 7 is a representation of this process, and is a very exact drawing from a preparation of a mucous patch situated on the tonsil. The thin section of the superficial layer of the epithelium shows a few cells which are excavated, forming cavities; those at *a* are empty; at *b*, they have a round nucleus; at *c*, a larger cavity containing several



spherical cells which are pus corpuscles. The substance between the cavities consists of the solid protoplasm of the cells, between which are even seen their indentations and the uniting substance.

Fig. 7.



Section from the superficial part of a mucous patch seated on the tonsil. *a.* Excavated epithelial cell. *b.* An excavated cell having a free nucleus in its centre. *c.* Excavated cell containing several pus corpuscles. *e.* Larger cavity with a projection. *d.* Similar projections formed by the destruction of the walls of the cells and transforming them into a single cavity.  $\times 300$ .

Without wishing to deny absolutely that the white corpuscles pass out of the vessels, and, not being able to penetrate the epidermic layers, are collected in groups in the corneous epidermis, we believe that the endogenous generation plays a no less important part in the phenomena that we have been describing.

It has previously been mentioned that at the margins of the chancre, and even upon the surface, in many cases, the rete mucosum was preserved and increased in thickness.

Ordônez, a very conscientious observer, whose scientific labors have prematurely terminated, has satisfactorily demonstrated the fact, that the epidermis is preserved and the rete mucosum thickened over a chancre.<sup>1</sup> He says the cells of the rete mucosum send out prolongations which penetrate between the papillæ. Auspitz and Unna also insist upon this new formation of cells of the rete mucosum, and upon their penetrating deeply into the papillary layer. We think it is more correct to say, that it is the papillæ of the derm, which in the chancre are constituted of embryonal tissue, infiltrated with young cells, which bud and elongate, while at the same time they are swollen by the formative inflammation of their tissue. From this swelling and hypertrophy of the papillæ, the cells of the rete mucosum, between the

<sup>1</sup> Martin and Belhomme, *Traité de la syphilis*.

primary elongated papillæ, are also elongated and extend more deeply than in their normal condition.

When the superficial layers of the corneous epidermis are detached and destroyed, in what is termed chancrous erosion, the rete mucosum is alone retained at the central portion. The cells of the rete mucosum may be partly or entirely disintegrated, and are now replaced by lymph cells or pus corpuscles, and by the false membrane which has been previously described. In a thin section made vertical to the surface, after hardening the chancre, this false membrane presents a homogeneous finely granular structure, separating the lymph cells. There are almost always found a few lamellæ of corneous cells, or cells of the rete mucosum in the false membrane upon the surface of the chancre.

LESIONS OF THE CONNECTIVE TISSUE.—The lesions of the dermo-papillary connective tissue are most important in the chancre, for this tissue appears to be affected very early; there is usually found, first, a papule—which is an elevation due to a thickening of the papillary layer.

Some twenty years ago C. Robin, after having examined indurated chancres, announced the results of his investigations, according to which the induration was formed almost entirely of fibro-plastic elements.<sup>1</sup> Later he gave a more detailed description, quoted in the lectures of Ricord on chancre.<sup>2</sup> According to Robin the indurated tissue consists of a framework of fibres of cellular tissue, and elastic fibres, between which are found an amorphous substance, fibro-plastic cells and nuclei, and lymph cells (*cytoblastions*). These terms will be explained further on. Virchow, some time after, published in several papers,<sup>3</sup> and in his book upon constitutional syphilis,<sup>4</sup> a description of chancre, which latter he considered as a hyperplasia of the cellular tissue, and which he anatomically compares to gummata of the tertiary period. In this work Virchow gives an anatomical description of gummata, and visceral syphilis, which has been the origin and foundation of all works since published upon this subject.

In order to study the indurated connective tissue at the base of a

<sup>1</sup> Mémoire présenté à l'Académie des sciences, séance du 2 Novembre, 1846.

<sup>2</sup> Leçons sur le chancre, recueillies et publiées par A. Fournier, p. 131.

<sup>3</sup> Virchow. Tageblatt der Naturforscher-Versammlung. Tübingen, 853, No. 6, p. 63. Virchow's Archiv, t. xv. p. 326.

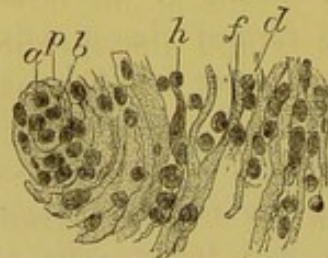
<sup>4</sup> La syphilis constitutionnelle, traduction de P. Picard, Paris, 1860.

chancre, it should first be examined in the fresh state, immediately after removal. Fragments of the tissue taken from the indurated base, and teased in diluted alcohol, show the fasciculi of the connective tissue, which are preserved intact, and the fibrils of which are united together; free cells are also observed in the fluid. These cells are small lymph cells possessing a single nucleus, and are very numerous (*cytoblastions* of Robin), or larger lymph cells, such as are met with in all inflammations. At the period of absorption of the chancre, many of these cells contain fine fatty granules. The other cellular elements are the flat or fixed cells of the connective tissue, the nuclei of which have become larger, while the protoplasm is granular and swollen (*fibro-plastic cells* of Robin).

In thin sections of the dermo-papillary tissue, the arrangement of the connective-tissue fibres and the cells interposed between them is very well seen.

Thus in Figure 8 is seen a capillary, *p*, the lumen of which contains lymph cells, *a*, and an endothelial cell, *b*. Around this capillary the fibres of the connective tissue, *f*, are separated by rows of lymph cells, *d*, and by a few fixed connective-tissue cells, *h*. In the tissue

Fig. 8.



Connective tissue of an indurated chancre. *a*. Capillary vessel with its wall, *p*, and an endothelial cell, *b*. *f*. Fibres of connective tissue separated by flat connective-tissue cells, *h*, and round lymph cells, *d*.  $\times 200$ .

of the papillæ, and in the superficial dermal tissue, the fibres are a little thickened, but in the deep connective tissue of the derm many fasciculi of its fibres have retained their normal size, and are also separated by small round cells, while the fixed connective-tissue cells are swollen. The adipose tissue also presents, in the deep layer of the skin, a new formation of elements, so that each adipose cell is transformed into a nest of small cells or is surrounded by these elements, as occurs in every inflammation of this tissue.

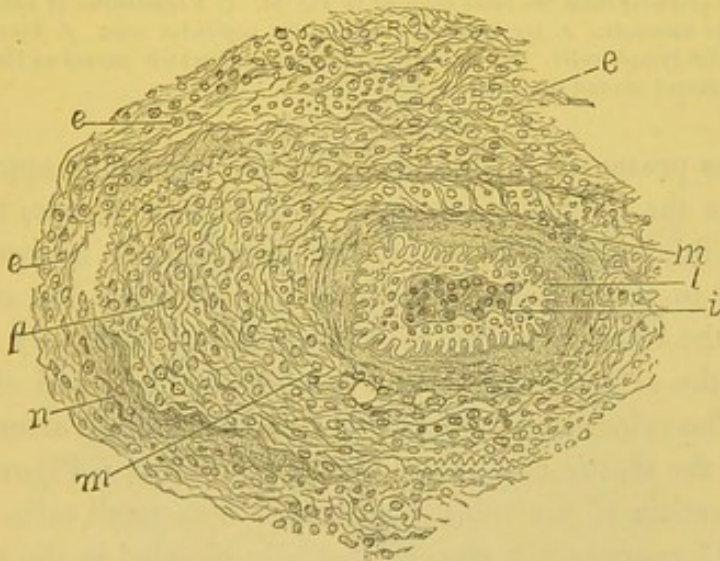
Besides these lesions, common to all inflammations of the skin, a special alteration is always met with in the indurated chancre, which

was first described some years ago in Germany; it is a *sclerosed inflammatory thickening of the coats of the arterial and venous vessels* occurring, particularly in their external coat or tunic adventitia.

The arterioles of the dermic tissue, for example, when transverse sections of them are examined, show a thickening of their coats two or three times greater than normal.

Figure 9 shows a section of an arteriole magnified 100 diameters. The internal coat—the part included between the internal elastic layer, *l*, and the lumen of the vessel, *i*—is a little thicker than normal. The lumen of the vessel is somewhat contracted, and filled with lymph cells, endothelial cells, and fibrine. The muscular coat—the part included between the letters *l* and *m*—is not hypertrophied. But all that part external to the middle coat, from *m* to *e*, is considerably increased in thickness and infiltrated with cells between the fibrils of the connective tissue. The neighboring connective tissue is also infiltrated, so that the whole vessel is surrounded by a considerable zone of inflammation.

Fig. 9.

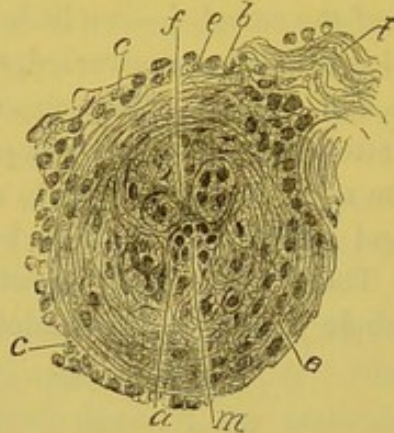


Section of a sclerosed arteriole from the base of an indurated chancre. *i*. Internal boundary of the internal membrane of the vessel; the lumen of the artery is filled with endothelial and lymph cells. The internal membrane, extending from *i* to *l*, contains round cells. *l*. Internal elastic tunic of the middle coat. *m*. Muscular layer. *p*. Much thickened connective tissue of the middle coat. *n*. Elastic fibres. *e, e*. Thickened connective tissue of the adventitia.  $\times 100$ .

Figure 10 represents a section of an arteriole, much smaller than the preceding, included in the indurated chancre, of which Figure 23 is an entire cut. In this figure, which is drawn with high power, the much contracted lumen is filled with an endothelial cell, *m*, and

some lymph cells, *a*. The elastic membrane, *f*, forms a circle around the lumen of the vessel, and sends prolongations of elastic fibres to the periphery. Between these fibres, the spaces contain round cells of new formation. We, therefore, find cells of new formation in the middle coat, *b*, in the external fibrous coat, *e*, and numerous round cells surrounding the latter.

Fig. 10.



Section of an arteriole from the same chancre as Fig. 23. *t*. A fasciculus of connective tissue alongside of the arteriole. *e*. Its external coat. *b*. Its muscular coat. *f*. Elastic fibres. *a*. Lumen filled with lymph cells. *m*. An endothelial cell over which passes an elastic fibre. *c*. Lymph cells situated around the external coat.  $\times 200$ .

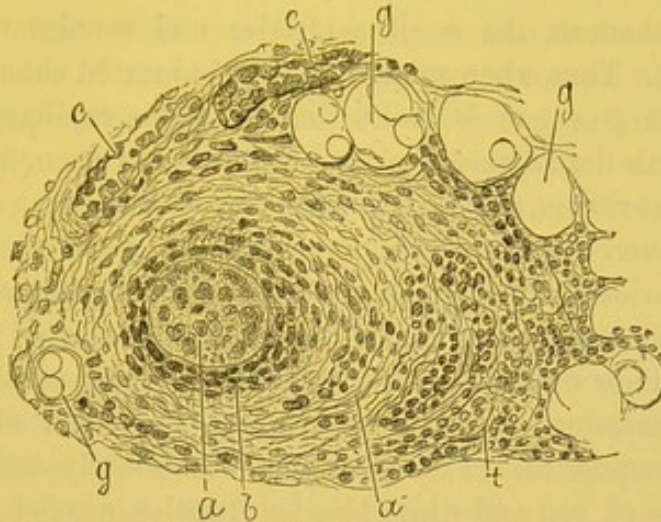
The veins present a similar modification, only more apparent, and more unlike the normal state, since normally, as a rule, the wall of the vein is thinner, and its calibre has the shape of an oval opening, when seen in transverse section. In a chancre, on the contrary, a section of the lumen of a vein is circular, its wall is greatly thickened, especially the external coat, and it has become thick and rigid as an artery. The veins are readily distinguished from the arteries by the absence of the elastic coat, which is represented at *l*, Figure 9. The tunica adventitia of the veins is infiltrated with small cells.

Figure 11 represents a section of a vein situated in the sub-dermic connective tissue of a chancre; it is seen that the calibre of the vein is round like that of an artery and its coats, particularly the tunica adventitia, are considerably thickened, and, together with the perivascular connective tissue, are infiltrated with round cells.

Figure 12, obtained from the chancre represented in Figure 23, is a very good example of inflammation of small veins. The four small vessels, which are here drawn magnified 200 diameters, possess very small circular openings filled with lymph cells. All the coats contain

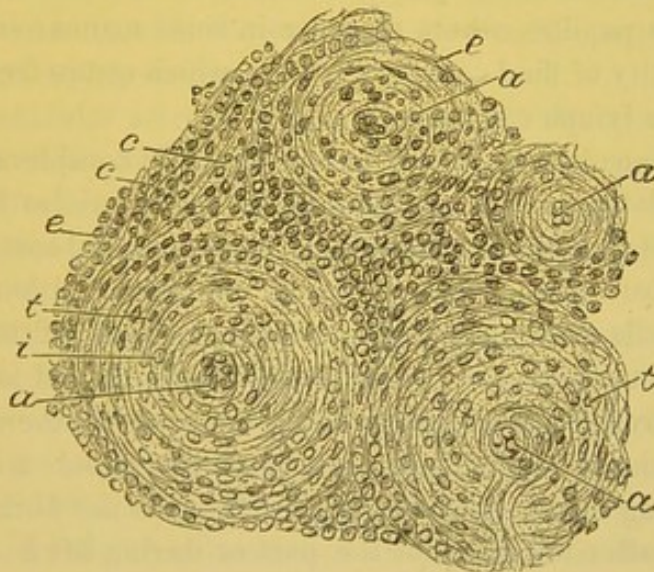
round or flat cells of new formation, and the peripheral tissue is infiltrated with numerous round cells.

Fig. 11.



Section of an inflamed vein within the indurated part of a chancre. *a*. Central lumen of the vein filled with lymph cells and fibrin. *b*. Middle coat. *t*. Connective tissue of the adventitia. *c*. Capillary vessels. *g, g*. Adipose vesicles.  $\times 120$ .

Fig. 12.



Section of several vessels in the indurated tissue of the chancre represented in Fig. 23. *a*. Lumen of vessels filled with lymph cells, endothelium, and considerably contracted, due to the thickness of their walls. *c*. Peripheral connective tissue of the vessels infiltrated with small round cells. *e*. External coat of the vessels. *t*. Muscular coat. *i*. Internal coat.  $\times 200$ .

In all the figures where are shown sections of an indurated chancre with low power, in Figures 4, 19, 20, 21, 22, and 23—whether the chancre is fully developed, as in Figure 4; ulcerated, as in Figures

19, 22, and 23; or cicatrized, as in Figures 20 and 21—it is always possible to see, even with very low power, from 6 to 12 diameters, the thickness of the walls of the vessels, and their inflammatory condition in the indurated portion of the chancre.

In every chancre, the small arterioles and venules undergo the same changes. Thus when preparations of indurated chancres are examined with a power of 50 to 80 diameters, the capillary vessels in connection with the adjacent sclerosed tissue are seen, increased in size by evident ridges, and surrounded by an accumulation of elements, such as are observed in chronic cirrhoses of the liver.

The capillaries of the papillæ, however, are frequently dilated beneath the false membrane, and at the central ulcerated part of the chancre, but their walls are not thickened. In these cases, when thin sections are examined, the capillaries are found filled with red and white blood-corpuscles. This dilatation occasionally coincides with extravasations of red and white blood-corpuscles around the vessels. It also accounts for the facility with which the surface of a chancre bleeds, when the false membrane which covers it is removed.

At those parts where the chancre is abraded or ulcerated, the papillæ are infiltrated with lymph cells, which become free upon the surface of the papillæ, where they are in some manner secreted with a small quantity of fluid containing fibrin, which comes from the blood, as do also the lymph cells.

In some chancres, the induration of which is considerable both in extent and density, the vessels—veins, and arterioles having their walls inflamed and thickened, especially their internal coats—are often completely obstructed, or nearly so, by an accumulation of swollen endothelial cells and lymph cells. When sections of them are examined, after the action of coagulating fluids employed to harden the specimen (chromic acid, Müller's fluid, or alcohol), there is seen in the transverse and longitudinal sections of the vessels a coagulum of fibrin inclosing round and endothelial cells. Is the fibrin coagulated immediately after the death of the part or during life? We do not know: what is certain, is that some vessels are in places completely filled by the coagulum. In the examinations of the chancre of Case V., we saw in almost all the vessels within the induration, cells filling their narrow lumen, and, in several, a fibrinous coagulum similar to that which is represented in Figures 46, 47, and 48, drawings made from a cutaneous gumma. These coagula are stained a very deep orange-red by picro-carminé. Whether the fibrin is coagulated before

or after death, it is certain, that the circulation has been arrested more or less completely in these inflamed vessels, and that the cellular elements of the region nourished by these vessels had to suffer in their nutrition.

This is, indeed, what takes place in these cases; and the round or lymph cells of those portions of the chancre, where the circulation is impeded or impossible, become granular, fatty, or caseous. We have only seen these lesions—complete obliteration of some of the vessels, caseous condition of the cells of the central part of the chancre—well marked in one instance, that of Case V. The seat of the chancre is important in explaining the inflammation of the internal coat of the vessels, and their obliteration. In Case V. the chancre had involved the fossa and prepuce; the irritation from stretching, which the small ulcerated chancre was subjected to during very frequent erections, and the tearing of the indurated tissue, which has resulted, have contributed to increase the local inflammation.

The sclerosed thickening of the arterioles and venules is important, not only anatomically, as an essential character of chancre, which is only very seldom found in mucous patches, and never in any other syphilide or nodule, with the exception of some gummata, but is also very important symptomatically.

It is this vascular sclerosis, in connection with the complete general preservation of the firm trabeculæ of the derm, with the normal state of most of the fasciculi of the connective tissue, and of the elastic tissue, that gives to the infecting chancre one of its essential clinical characters, the induration.

The induration is sometimes superficial, sometimes deep and superficial. This depends upon the arrangement of the vessels, which form on the skin two horizontal networks, one superficial beneath the papillæ, the other deeper, made up of larger vessels, at the base of the derm. When the sclerosis affects only the superficial vessels, we have a superficial induration. If the sclerosis has involved at the same time both the superficial and deep vascular networks, the intermediate branches being equally affected, we have a more extensive hard nodule, varying in thickness according to the region of the skin involved.

In the first case the induration is foliaceous or parchment-like; in the second it is ligneous, and gives the sensation of cartilage. Almost always the sclerosis is continued along the coats of the vessels further



than the induration itself, beyond the limits of which the vessels, whose walls are inflamed, are surrounded with normal connective tissue, while in the indurated portion this tissue is likewise inflamed.

[The especial involvement of the walls of the bloodvessels may be capable of explanation on the theory that the poison of syphilis particularly affects the white blood-cells, and is conveyed into the system largely, if not exclusively, by them,—a theory which there are many reasons for believing in, some of which have already been enumerated. The anæmia or leucocythæmia of the early stages, the apparent immunity of a mother bearing a syphilitic child, the absence of contagious property in the physiological secretions, are a few of many facts which seem to show that the action of syphilis, as far as the blood is concerned, is chiefly expended upon the corpuscular element, and especially upon the white blood-cells.]

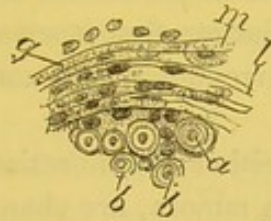
Now, in the vast majority of cases of syphilitic infection, the contaminating agent is more or less purulent and irritating in its character; and, after its introduction beneath the superficial epidermic layers, acts as a foreign body, and sets up, at least in a mild degree, the initial processes of inflammation. The slowing of the blood-current, the increase in number of the white blood-corpuscles, their adherence to the walls of the vessels, and their partial or complete penetration of the latter, are all conditions in every way favorable to the influence exerted upon them by syphilis, and which probably partially account for the peculiarly marked sclerosis, which is present in the vascular walls, chiefly in the small vessels, but also, it seems probable, to some extent in the lymphatics.]

This induration, and sclerosis of the arterial coats, this infiltration of the connective tissue with cells, are lesions which do not develop very rapidly, either in their period of formation and increase, or in their period of resolution. This fact, taken in connection with the intimate changes of the tissues involved, renders the long duration of a chancre, and the persistence of the indurated nodule when the induration is thick and considerable, not at all astonishing.

The nerve fasciculi which pass into the indurated tissue of a chancre, and which are surrounded by a connective tissue infiltrated with small round cells, are inflamed in their laminated sheaths, the connective tissue which accompanies the vessels between the nerve fibres in the interior of the fasciculi being also inflamed. Thus, in the examination of a chancre removed by Mauriac from Case V., I have been able to study transverse and longitudinal sections of nerve fasciculi. The

laminated sheath was separated; the flat cells between the laminæ were larger and more swollen than normal, or were replaced by numerous elongated, oval, and small cells. Figure 13 represents a part of a section of a fasciculus so altered; the laminæ, *m*, *l*, of the sheath, *g*, are separated by elongated or round cells, and between the nerve fibres, are seen small cells. The nerve fibres themselves, *b*, *b*, are normal, and their medullary substance and axis cylinders are not changed. In another examination of a chancre, which had been treated by osmic acid, immediately after its removal by Heurteloup, the nerve fibres were also normal. I should say, however, that in these examinations, I have not searched for the ultimate terminations of the nerves in the papillæ.

Fig. 13.



Part of a nerve fasciculus found in a chancre. *g*. Dissected laminated sheath, the laminæ of which, *m*, *l*, are separated by round or elongated cells. *a*, *b*, *b*. Transverse cuts of nerve fibres.  $\times 200$ .

The inflammation, the separation of the sheath of the nerve fasciculi by cells of new formation, in the tissue of the chancre, is not accompanied with pain. The chancre from Mauriac's patient, with whom the lesion was very intense, was absolutely painless. This neuritis without pain is a curious circumstance, and should be remembered.

[This absence of pain and of other subjective symptoms, which is one of the marked clinical characteristics, not only of the chancre but also of the cutaneous syphilides, is presumably due to the non-inflammatory character of the exudation which separates the nerve sheath from the fasciculi. As a result of a specific influence inciting certain cells to rapid growth and multiplication, it produces here, as elsewhere, the physical effects of an inflammatory transudation, but is almost always unaccompanied by the hyperæmia, the active vascular excitement, and the heat, pain, burning, or itching which accompany acute or well-developed inflammation. It would be interesting to note whether some such nerve disturbance, due to pressure, does not underlie the irregular capillary dilatations found in the erythema and

roseola of early syphilis, and soon followed (in the papular eruption) by visible and tangible evidences of exudative processes similar to those just described.]

In the preceding descriptions, generalities have been adhered to, which may be applied as well to the skin as to mucous membranes, and to the different regions which may be the seat of chancres; but there are a number of details to add concerning the changes of organs which may be included in the chancre, for example: hair, sebaceous glands, sudorific glands, mucous glands, etc. Not wishing to complicate the description, it may be said in a general manner that in all organs we observe a multiplication and hypertrophy, from excess of nutrition of their epithelial cells, and at the same time an infiltration of their peripheral connective tissue with young cells or lymph cells. Thus the ducts of the sudorific glands are increased in diameter, and their epithelial cells are larger than normal, while the periphery of the glandular ducts is surrounded by a zone of small cells pressed one against the other.

The sebaceous glands, either in connection with the hairs or separate, as occurs in the labia minora, are changed in the same manner. In some chancres, as for example, those of Case II., there are no sebaceous cells in the glands situated in the chancre (see Fig. 19). The lining and contents of these glands consist now of pavement epithelial cells and pus corpuscles. Again, the cells of the rete mucosum, which pass into the hair follicles, form thick layers, and contain excavated cells or nests of small round cells.

In regard to the hypertrophy, and increased nutrition of the epithelial cells of these different parts, from what occurs in the rete mucosum, and in the corneous layers of the epidermis, it may be concluded that the modifications of the epithelium are secondary to the sclerosis of the dermo-papillary tissue; the cells of the sudorific glands are swollen because the neighboring tissue is congested and inflamed; the fat disappears from the sebaceous glands on account of the inflammation; the cells of the rete mucosum are swollen with nutritive fluids, because the papillæ are inflamed and congested; the prolongations of the rete mucosum between the papillæ are longer than usual, because the papillæ are elongated and hypertrophied. During its period of development and acme, the chancre always occasions lesions of the surrounding parts, which consist of an œdematous swelling of the skin and a lymphangitis which connects it with

one or more lymphatic glands, the latter soon becoming tumefied; this lymphangitis and swelling of the glands are always present.<sup>1</sup>

A chancre of the prepuce and fossa glandis is always accompanied by a hard œdema of the prepuce, an inflammatory œdema similar to that of elephantiasis. A chancre of the labium majorum is also always followed by an œdema of that region. This inflammatory œdema, looking like that of erysipelas, with red lines upon the cutaneous surface, extends as far as the region of the groin. It is unilateral because the chancre is always situated only upon one of the labia majora.

When either the labium or the skin on the back of the penis is carefully felt, there are found hard sinuous cords, which may be followed as far as the inguinal glands. They are the inflamed lymph vessels. In men, upon the dorsal region of the penis, are frequently seen secondary ulcerations and enlargements of these perivascular indurations.

[<sup>1</sup> It would seem evident that in this assertion Cornil is in accord with the majority of syphilographers.

Berkeley Hill says that the involvement of the lymphatics in syphilis is certainly more often present than absent, and is due to "thickening of the walls of the vessels by proliferation of the cellular elements, and invasion or multiplication of leucocytes."

Van Buren and Keyes define syphilitic lymphatics as a "specific induration of the lymph vessels and surrounding cellular tissue"—"starting in the induration of the chancre."

Henry Lee says: "We have seen that the secretion of a primary sore is inoculable, so as to produce the specific induration only during its earliest stages; and it is during this same period that the action takes place which produces the specific affection of the lymphatic vessels."

Bumstead and Taylor, after making the assertion already quoted, that "specific engorgement of the lymphatics is dependent upon changes in the walls of those vessels identical with those which occasion induration of the base of the chancre and the ganglia," add that the distal extremities of these changed vessels are found "in the induration surrounding the chancre."

Elsewhere, however, they quote with apparent approval the researches of Auspitz and Unna above alluded to.

Von Biesiadecki, quoted by Bäumlner, found "the muscular fibres in the lymphatic vessels enlarged through the presence of numerous exudation cells; the adventitia was contracted, containing only a few of these cells; the vessels were in places plugged by coagula, or closed by a thickening and folding of the intima."

Many more authorities might be adduced, but these would appear to be sufficient to demonstrate the general belief in an involvement of the lymphatics in the early stages and in the sore itself.]

In the indurated portion of the primary chancre, the lymphatic vessels and spaces of the derm are filled and distended with lymph cells; the cellular tissue surrounding them is indurated and infiltrated with cellular elements. The same inflammatory change of the contents of the lymphatic vessels and peripheral connective tissue is extended along these vessels, on the back of the penis, and in the labia majora. When there is ulceration of a secondary indurated nodule upon the penis, the connective tissue is here thickened over a considerable extent, and the bloodvessels are sclerosed. This histological examination has been made by Verson from a secondary induration.<sup>1</sup>

[A description of the lymphatic vessels given by Auspitz and Unna<sup>2</sup> is in direct opposition to the above. They describe the walls of these vessels at the beginning of the process of induration as free from granulation cells, differing in this respect from the adventitia of the bloodvessels, and, therefore, readily distinguished from the veins. It is only when the surrounding connective tissue becomes infiltrated with young cells, that the walls of the lymphatics are affected. The gaping, oblong, round or oval openings, bounded by sharp edges, which are mostly empty, and are seen throughout the entire sclerosed portion, they consider to be enlarged lymph spaces.

A later article by Unna,<sup>3</sup> accompanied by a drawing, Fig. 14, shows a lymphatic vessel at *f*, the lumen of which is seen entirely free from any cellular obstruction.

In order to ascertain if possible which of these descriptions of the lymphatic vessels—that given by Auspitz and Unna, or that according to Cornil—is correct, a number of histological examinations of indurated chancres were made, from the results of which it would seem proper to infer that there is a certain amount of truth in both views, but that neither in their extreme should be adopted. Either to describe all the lymphatics in the indurated portion as empty spaces, or to say that they are all obstructed by corpuscles, we are convinced from our examinations would not be correct. But in sections of the diseased part, we find many openings such as represented in Fig. 14, at *f*, and which are empty lymphatics. This is more especially true of the preparations made from chancres hardened in alcohol, and colored with carmine. There is also seen such an appearance as represented

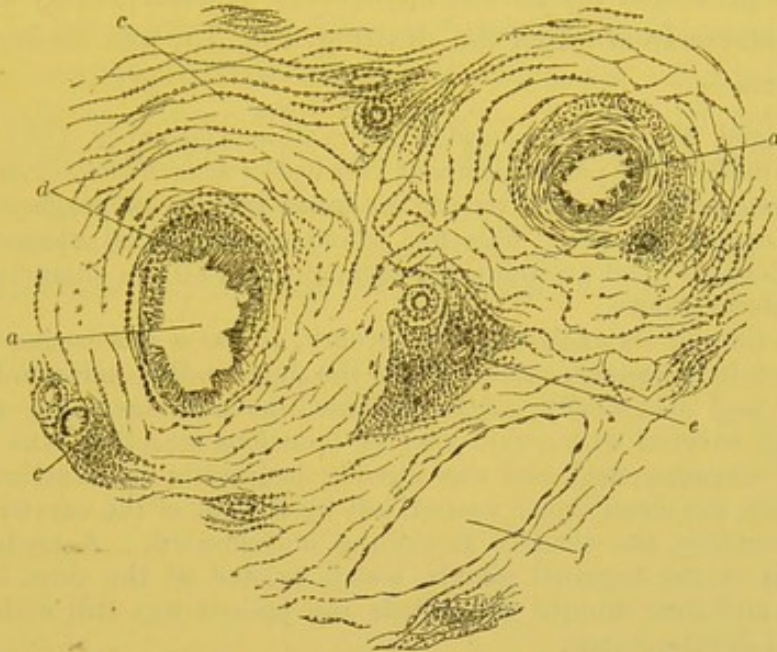
<sup>1</sup> Verson: In Virchow's Archiv für Path. Anat., vol. xlv. 1869.

<sup>2</sup> Vierteljahreschrift f. Derm. u. Syph., Wien, 1877, s. 160.

<sup>3</sup> Vierteljahreschrift f. Derm. u. Syph., Wien, 1878, s. 543.

in Fig. 15, *l*; more particularly in sections made by freezing the tissue, immediately after removal, by means of the freezing microtome

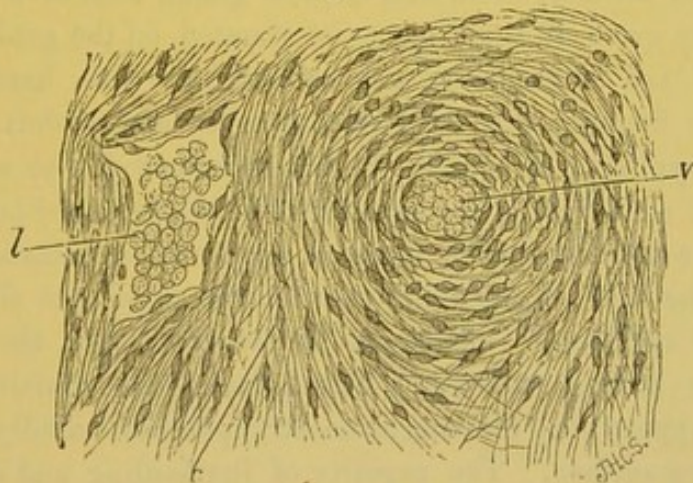
Fig. 14.



Section of the indurated portion of a chancre. *a*. Artery. *d*. Vein. *f*. Lymphatic.  
*c*. Connective tissue; and *e, e*, Vasa vasorum (Unna).

with the rhigoline spray, and then placing them in a solution of osmic acid and mounting them in glycerine. We have here at *l* a lymphatic,

Fig. 15.



Section from the indurated portion of a chancre. *v*. Vein. *l*. Lymphatic vessel, with lumen obstructed by lymph corpuscles. *c*. Connective tissue.  $\times 250$ .

which is very readily distinguished from the veins of the tissue; its lumen is seen almost filled with lymph corpuscles, but the surrounding connective tissue presents no abnormal appearance.

Our examinations seem to prove, therefore, that while some of the lymphatics may be empty, there are also found others obstructed by lymph corpuscles. The endothelial lining of the lymphatic vessels we found presented the normal appearance as described by Unna.

The chancre from which the drawing, Fig. 15, was made, was obtained from—

J. H., aged 28, who came under observation December, 1881. A few days previously, at a period of about two weeks after a suspicious connection, he had noticed a small papule on inner surface of prepuce just behind the corona glandis. This had taken on superficial ulceration, had become elevated upon an indurated base, and had all the characteristics of an indurated chancre.

At the time of its excision, in February, it was a saucer-shaped ulcer, a few lines in diameter, raised above the surrounding surface, having a distinctly and specifically indurated base, movable upon the subjacent tissue, was covered with a thin grayish tenacious secretion, was painless, definitely circumscribed, and was already beginning to cicatrize. After its excision, the clean linear wound, left by the cut of the curved scissors, healed promptly, the cicatrix remaining unindurated. A moderate engorgement of the inguinal glands, which existed at the time, has since subsided, and four months afterwards the patient was still without constitutional developments.

There was strong reason for suspecting the woman from whom he believed himself to have contracted the disease, but no examination could be obtained. Another patient with undoubted syphilis attributed his infection to her.]

With the chancre and with the secondary lymphangitis, there is always found an alteration, first of one gland, then of a number of glands in the groin, if the chancre be situated on the genital organs. The glands are as large as a hazel-nut, are oval, hard, and roll beneath the fingers; this enlargement of several glands is characteristic of syphilis; it should always be looked for to confirm the diagnosis of an infecting chancre, and will be described later.

When the chancre heals, there is simply a cicatrization and recovery. The loss of substance due to the erosion is slight. The papillæ are not usually destroyed by the ulceration, the epidermic layers only having suffered. The lymph cells contained in the papillæ disappear; the rete mucosum and epidermis rapidly form upon the papillary surface. The rapidity of the healing and of this new formation of layers of the epidermis is sometimes astonishing. A chancre or mucous patch, that has been seen to-day with a gray false membrane upon its surface, to-morrow will present a new epidermic layer. The cicatrix is far from being always visible, especially in the

case of chancres of the labia majora. This is, however, very variable. Thus there will be seen frequently coming to the hospitals nurses who have had a chancre of the breast. They still have copper-colored spots, but without induration, even when the date of the chancre is four or five years previous. When a chancre of the prepuce or fossa glandis is accompanied with intense induration, the latter may persist some months or a year after cicatrization. Upon the prepuce the cicatrix, which results from the healing of a chancre, is at times sunken or depressed as the ulcerated chancre itself. Here the chancre may have its seat at the bottom of the folds of the skin of the prepuce, and the erections may increase the ulceration.<sup>1</sup>

<sup>1</sup> The cases relative to the pathological anatomy and symptoms of indurated chancre are placed at the end of the third chapter.



LEEDS & WEST-RIDING  
MEDICO-CHIRURGICAL SOCIETY

### CHAPTER III.

#### SOFT CHANCRE—SYMPTOMS AND COMPARISONS OF THE TWO CHANCRES.

Pathological anatomy of soft chancre—Similarity of the anatomical characters of infecting and simple chancre—Comparison of infecting chancre with guma, lupus, etc.—Symptoms of infecting chancre—Its surface—Induration—Varieties—Healing of chancre—Its seat—Symptoms of soft chancre—Relative frequency of soft and indurated chancre—Mixed chancre—Diagnosis and treatment of chancre.

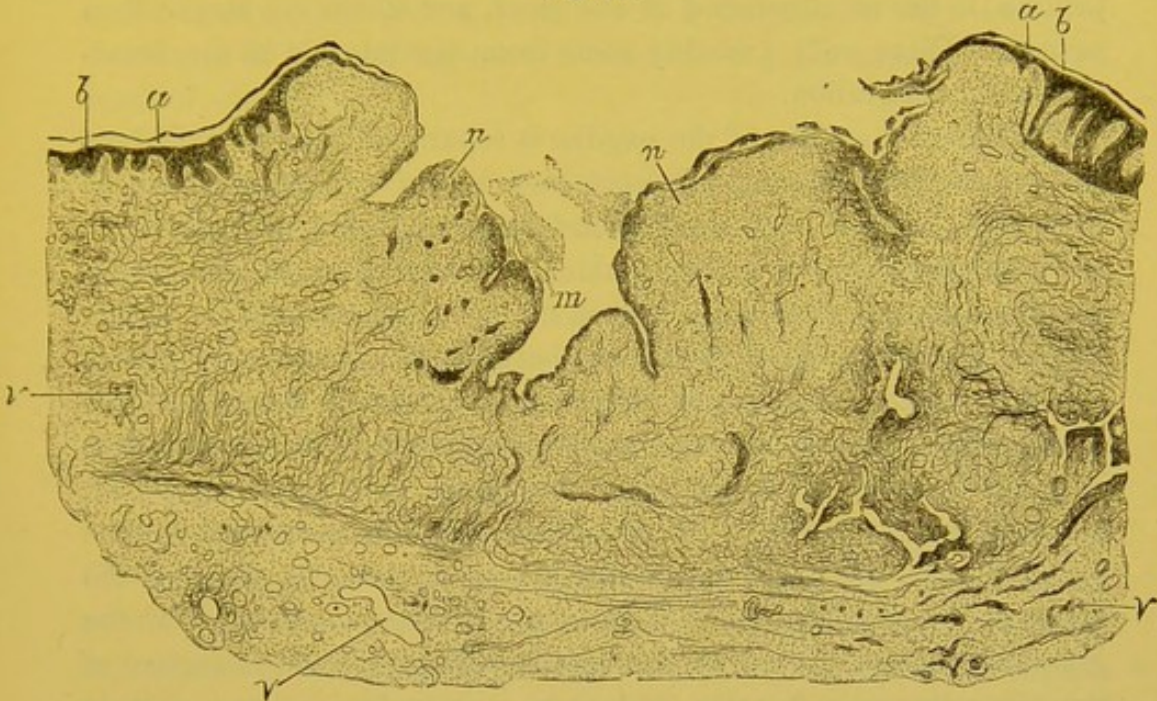
**PATHOLOGICAL ANATOMY OF SOFT CHANCRE** (simple, non-infecting chancre, chancroid).—In the case of a soft chancre, either produced by auto-inoculation, or contracted during sexual connection, there are observed from the first certain pathological phenomena.

The first day we see a small red point, which on the second day becomes an acuminate red papule, and is converted into a small pustule by the end of the second or third day, especially in a region where the skin is very delicate, as, for example, the internal surface of the thigh. The pustule very soon breaks, and beneath the lowest epidermic layers, we find a deep suppurating ulcer, which rapidly extends in circumference and depth. The chancrous ulceration reaches its acme during the first week, and is then seen with all its characteristics. It is a deep crater-like ulcer, its borders are perpendicular or undermined, its surface is granulating and irregular, formed of soft fleshy granulations and infiltrated with pus, of which there is an abundant secretion, and which gives it a grayish color. The serum upon the surface of an indurated chancre is small in amount and transparent.

A vertical section of this variety of chancre, made after hardening, and examined with low power, twenty diameters, gives a picture similar to Fig. 16. The corneous epidermis, *a*, and the rete mucosum, *b*, which cover the skin in the proximity and at the margin of the chancre, are abruptly arrested at the point where the ulceration begins. The irregular cavity of the chancre appears upon section as a notch, like a volcanic crater. The cavity of the chancre, *m*, is limited by fleshy granulations, *n*, the tissue of which is directly con-

tinuous with the tissue of the hypertrophied papillæ found at the border of the chancre.

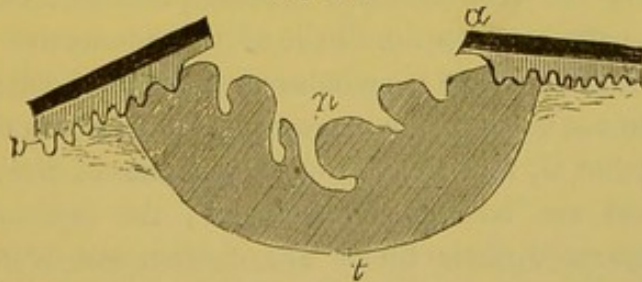
Fig. 16.



Section of a soft chancre. *a*. The epidermis, the rete mucosum, *b*, is abruptly arrested at the edge of an anfractuosity, *m*, which forms the loss of substance of the chancre. *n*. Granulations continuous with the papillary tissue. *v*. Vessels.  $\times 20$ .

The general appearance of a section of a soft chancre is seen in the accompanying diagram, Fig. 17.

Fig. 17.



Schematic section of a soft chancre. *a*. Corneous epidermis. *p*. Rete mucosum and papillæ, which are abruptly arrested at the ulcerated surface. *t*. Deep border of inflammation.

Passing to the details of alteration, there are found in the superficial layers of the epidermis, and in the rete mucosum, cells containing a cavity between the nucleus and substance of the cell, such as always exist when there is an inflammatory congestion of the cutaneous

papillæ, and which occur in all cutaneous inflammations or tumors, when they reach the surface of the integument.

Numerous lymph cells are found infiltrating the tissue of the papillæ, in the neighborhood of the ulcer, and which are larger than normal. These cells probably come from the interior of the blood-vessels by emigration.

The external surface of the papillæ is separated from the epidermic layers; in other words, the epidermic layers are loosened at the border of the ulcer from the inflamed and hypertrophied papillæ.

In all parts of the inflamed skin, in the remains of the dermo-papillary tissue, in the derm, and in the subcutaneous cellular tissue, there is an infiltration of round cells between the constituent elements of the connective tissue. As the ulcerated surface is approached, the lymph cells become more numerous. The tissue of the granulations is granular, without fibrils, since the fibres have been separated, softened, and destroyed. By this destruction of connective tissue the pus corpuscles are set free, forming a layer upon the surface of the granulations, which varies in thickness. It is this infiltration of the granulations, and the purulent secretion which give to the surface of the ulcer its grayish color, and some writers have compared it to diphtheria.

It is not intended, *à propos* of soft chancre, to give the histology of inflammation and suppuration of the derm and subcutaneous connective tissue; but two points must be alluded to: First, in the soft chancre, there is not a sclerosis of the vascular walls; we meet with nothing but what occurs in every common inflammation, that is, the external coat of the arterioles and venules presents a certain number of migrating cells between the fibrils of the connective tissue of the tunica adventitia, but there is no induration and thickening of the wall, and also we do not observe any narrowing of the calibre of the vessels. The second point is, that the fibrous trabeculæ of the derm of the region involved are not preserved intact; the fasciculi of fibrous tissue are separated, their fibrils are distinct one from another at points near to where there has been a loss of substance. The fibrils separated by the lymph cells are themselves destroyed by the softening and suppuration of the tissue. These changes, upon the surface of a simple chancre, result in the fibrous tissue losing its firmness and normal elasticity; its fibrous trabeculæ have a tendency to disappear. The lymph cells, which collect in great numbers in the

granulations and neighboring connective tissue, are large, turgid, and become free by softening the fibrils between which they are placed.

The absence of specific induration comparable to that of the indurated chancre, and also a tendency to a progressive destructive involvement of neighboring tissues, result from this anatomical arrangement of elements.

ANATOMICAL CHARACTERS OF INFECTING AND SIMPLE CHANCRES — If the histological lesions of infecting chancre are compared with those of simple chancre, it will be seen that there are differences which distinctly separate them. In the infecting chancre, there is the sclerotic thickening of the dermo-papillary tissue and of the walls of the vessels; the superficial epithelium and rete mucosum are partly preserved, even over the eroded or ulcerated surface; the scanty secretion contains a relatively small number of lymph cells.

In the simple chancre, on the contrary, there is a gaping crater-like opening, a result of the complete and rapid destruction of the superficial and deep layers of the epidermis, and from the progressive suppuration, a breaking down of the papillary and dermic layers; the papillæ, the connective tissue of the derm, and the sub-dermic tissue are transformed into a granulating tissue, in which the vessels are not sclerosed; the fibrous trabeculæ are separated and destroyed.

From this it will be seen, that between these two chancres, there is a distinct and complete difference; one being essentially a prominent papule, the other an ulcer; and if to their histological characters be added, the difference in the change occurring in the lymphatic glands, if it be recalled, that one occasions syphilis, while the other is a lesion purely local, it must be concluded that they are two very distinct diseases, which should not both be known by the name of chancre. It is not, however, absolutely necessary to change it, since its significance is so well understood.

INFECTING CHANCRE COMPARED WITH GUMMATA, LUPUS, ETC.— The structure of an infecting chancre should not be compared only with that of the soft chancre, but also with other cutaneous lesions that closely resemble it. It is rather with visceral gummata, as of the liver and testicles, or with the gummata and later syphilides of the skin and genital organs, that the comparison should be made. This Virchow has done. These lesions, indeed, present a like induration to that of chancre. It will be seen later, that certain mucous patches

of the labia majora and minora also have an eroded appearance, and are accompanied by an induration of the connective tissue, which is somewhat analogous to that previously described as occurring in the primary lesion of syphilis. In these cases the vessels may also be notably thickened and sclerosed.

The histological structures of infecting chancre have been compared with lupus as well as with syphilis. I have not recently examined lupus, and can only describe what has been lately given by Friedländer,<sup>1</sup> Lang,<sup>2</sup> Volkmann,<sup>3</sup> etc. In lupus there are found, besides the infiltration of the connective tissue with small cells, spherical collections of large cellular elements which do not correspond to the epithelial cells of the rete mucosum, but which are similar to the large cells that have been described as giant cells in tuberculosis.

Whatever may be the origin and nature of these "giant cells" of lupus, this disease has been associated with tuberculosis on account of its structure, and in some recent works, there is even a tendency to consider it as a manifestation of cutaneous tuberculosis. It is to be remembered, however, that giant cells, notwithstanding the opinion of Schüppel, and several other pathologists, do not belong exclusively to tuberculosis, since we also find them in scrofulous lymph glands, in inflammatory granulations of the skin (Jacobson, Heidenhain, Baumgarten), and in elephantiasis (Klebs). They are also met with in syphilis; as, for example, in cerebral syphilis (Heubner); in ulcerating syphilides (Bizzozero, Köster); in gummata of the testicles (Baumgarten); in syphilitic papules (Griffini).

Auspitz and Unna have not found giant cells in the infecting chancre; I have also examined several chancres, to ascertain if this variety of cells was present, but failed to find them; yet as previously mentioned, there is frequently an inflammation of the internal coat of the vessels, a swelling of the endothelial cells, and at the same time there is occasionally an almost complete obliteration of the vascular lumen by the endothelial and lymph cells united together by coagulated fibrin. We believe, moreover, that those cells which have been termed "giant cells," result primarily from an arrest of the blood circulation, followed by an accumulation of endothelial and

<sup>1</sup> Virchow's Archiv für path. Anatomie, t. lx.

<sup>2</sup> Vierteljahreschrift für Dermatologie und Syphilis, 1875.

<sup>3</sup> Berliner klin. Wochenschrift, 1875, No. 30.

lymph cells, which retain their vitality for a certain time in the midst of a fibrinous plasma.<sup>1</sup>

Giant cells will again be referred to *à propos* of other syphilitic lesions in which they are met with, and of the comparison of the indurated tissue of chancre with other syphilitic productions; *à propos* also of mucous patches and gummata. The tissue of hard chancre is very similar to that of cutaneous fibromata, fibro-sarcomata, and elephantiasis, but the arrangement and extent of the parts involved by these latter diseases establish a sufficient distinction between them.

SYMPTOMS OF INFECTING CHANCRE.—It has previously been stated that the incubation of an infecting chancre continues a long time before any symptom is manifest upon the skin. This period is not less than fifteen days to three weeks, averaging twenty-five days, and it may be prolonged to two months. [Hence in cases in which abrasion or tearing of the mucous or cutaneous surface has occurred during suspicious intercourse, it is not safe absolutely to deny the possibility of the development of syphilis until after the lapse of this latter interval. Perhaps it would be better, in view of the few rare, but undoubted cases of prolonged incubation which have been recorded, even to extend this period still further, see p. 41.]

What has been said of the anatomy and pathological histology of chancre, will aid us very much in understanding the symptomatology, since in all alterations of the skin analogous to those of chancre, the pathological anatomy and the symptoms are interdependent.

Chancre sometimes begins by a papule, that is, a thickening with a slight elevation of the papillary layer of the skin, such as occurs in chancres of the skin and nipple; sometimes by a superficial redness; sometimes by a scarcely visible excoriation or superficial erosion. As these initial modifications of the skin and mucous membrane are very slight, and painless (the indurated chancre is painless from its beginning to its termination), it follows that such chancres almost always are overlooked. The physician very seldom sees the beginning of a chancre, either in private practice—for it is seldom persons give that careful examination necessary to discover the lesion—or at the hospitals, where the men rarely present themselves when the chancre is in its initial stage; in a hospital for women it can readily be under-

<sup>1</sup> See a communication upon this subject, by Spiellmann, to the Society of Biology, 1878.

stood how it is that a chancre is never seen in its earliest period. With women, the chancre may be concealed in a fold or in a depression, so that the patient can only see it with difficulty, and, as she suffers no pain, it gives her no anxiety; these facts, together with her repugnance to consult a physician for any affection of the genital organs, explain very satisfactorily why, in hospitals for women, patients so seldom present themselves suffering with a typical and unquestionable chancre; they have had the lesion for some time; frequently the chancre is healed, and the patient presents secondary symptoms—mucous patches, roseola, papules, etc.

If the chancre has not begun by a papular elevation, there are most frequently found during the first days a certain degree of thickening of the chorium, and an erosion or ulceration upon its surface.

From the appearance of the surface of the chancre several varieties are recognized: the papular, erosive, desquamative, excoriated, and ulcerating. These several forms, which define themselves, and vary from the simple papular to the ulcerative, constitute a series, the differences in which are due chiefly to the different degrees of ulceration of the primary lesion. But it is seldom that an indurated chancre occasions a true and deep ulcer; more often, as has been demonstrated in studying the pathological histology of chancre, the epidermic layers and rete mucosum are preserved, and even increased in thickness at the margin of the erosion, at the same time that the papillary layer is also thickened, so that the chancre represents an elevated flat surface; the whole of the affected part of the derm being thicker than the surrounding normal skin. In erosions and excoriations it has been seen that the epidermic layers at the centre of the chancre were destroyed somewhat irregularly, but nevertheless there still remain a few epidermic islands or patches of the corneous epidermis, and laminae of dentated cells of the rete mucosum, forming a layer upon the surface of the excoriation varying in thickness.

Upon the surface of ulcerated chancres (Cases II., IV., and V.) the epithelium has entirely disappeared, and the superficial parts of the papillae, infiltrated with lymph cells, furnish a small quantity of pus which covers them. In two of the chancres situated upon the preputial fold, and especially in Case V., the ulcerated surface was funnel-shaped.

This, however, is a very unusual occurrence; on the contrary, the surface of the indurated chancre is generally but slightly excavated, and the excavation is more apparent than real, since the margins of

the ulcer are elevated, owing to the hypertrophy of the epidermic and papillary layers; the destruction of the most superficial layers of the epidermis occasions the excavation which is noticed.

If the surface of a chancre be carefully examined during its stage of perfect development, when the induration is beginning to increase—that is, at the end of the first or during the second week after its appearance—it is found that the slight depression is continuous without interruption, by an even and smooth surface, with the margin of the chancre which is covered by the epidermis. The thickened epidermis, at the margin of the chancre, is continuous on one side with the healthy epidermis of the skin surrounding it, and on the other side with the gradually thinning layers of the epidermis covering the chancre.

The surface of an eroded or excoriated chancre is smooth, as if varnished; we see islands of epidermis, and the parts are covered by the gray or yellowish false membrane previously described. The epidermic patches and false membrane are on the same level. Upon the surface of the lesion there is found a small quantity of a serous transparent fluid. If it be wiped with a cloth the surface remains intact; even if it be rubbed or scraped it continues smooth, glazed, and is soon again covered with a small quantity of transparent fluid.

The induration of a chancre occurs at the end of the first week, dating from its appearance. It may show itself only after fifteen days or three weeks from the beginning of the erosion, especially when it is of that rare form which will be described later—the mixed chancre.

The induration is progressively developed from the surface, that is from the papillary network, to the deep dermic and sub-dermic layers. The variations in thickness of the affected part give rise to several well-recognized degrees of induration.

*Parchment induration*, is that which gives to the fingers applied to the circumference of the chancre, the sensation of a piece of parchment forming the base of the erosion.

*Laminated induration*, is thinner and less distinct than the parchment variety, and gives to the fingers the sensation of a piece of paper.

*Nodular induration*, is that in which the base of the chancre is hard and thick, feeling between the fingers like a nodule of cartilage or wood; it is the most characteristic, but is seldom seen in women.

*Annular induration*, is that in which only the margins of the



chancre are indurated, and form a hard ring, the tissue in the centre retaining its normal elasticity.

The most readily recognized and the most characteristic chancre has the shape of a cup-like depression seated upon the indurated and elevated skin.

If the description of the histological alterations of the connective tissue and vessels beneath the chancre be recalled, it will explain the anatomical reasons for these several forms of induration. The laminated or parchment induration corresponds to a sclerosis limited to the papillæ of the derm and to the vascular network of the papillæ; deeper or nodular induration corresponds to a sclerosis of the dermic and sub-dermic connective tissue, and of the vascular network of these parts, which latter is much larger than the superficial network. Therefore, when there exists a lesion of large arterial and venous vessels, it is slower in forming and disappearing than a similar lesion of small vessels.

Indeed it is not to be expected, that an induration and thickening of the fibrous tissue of the external, middle, and internal coats of vessels would rapidly diminish. What is known of sclerosis in general leads us to suppose, *à priori*, that like lesions will be long in disappearing, and this is found to be the case, for traces of induration have been observed four or five years after the beginning of the chancre (Puche). Ricord has found remains of the induration ten and fifteen years subsequent to the primary lesion. [Biesiadecki attributes the persistence of the induration to a transformation of the newly deposited cells into connective tissue fibres.]

The induration and its extent are best appreciated by seizing the chancre, at its margin, between the thumb and finger, drawing it upwards, so that it may move upon the subcutaneous tissue, and then using slight pressure in a direction parallel to the surface of the chancre. By these means the resistance offered by the base of the chancre and the degree of its induration can be readily appreciated. This method of palpation is very easy in certain regions, but in other parts it is difficult to perform, especially in women; of course in some localities, as, for example, the os uteri, it is almost impossible.

The degree of induration varies very much according to the seat or region of the primary lesion, and also in accordance with the structure of the part. When occurring upon the glans penis, upon the internal surface, or mucous membrane of the prepuce, or in the fossa glandis, the chancre is generally very distinctly indurated; upon the

skin of the penis, and upon the general integuments, the induration is not so marked or so extensive. With women, the induration of the chancre is greater upon the labia majora than upon the labia minora and fourchette. The skin over the labia majora, which contains dense fibro-muscular tissue, is a better foundation for the induration than the very thin corium of the labia minora or fourchette. Upon the fourchette the chancre is almost always parchment-like, and the induration is quite difficult to recognize, owing to the formation of the part, and the difficulty experienced in seizing the chancre between the finger and thumb to elevate it.

[Ricord, in speaking of the induration of chancre, says, that its development and amount depend upon the lymphatic supply. Where the induration is greatest, there the lymphatics are more numerous; and that the induration consists in an inflammation of the capillary absorbents with effusion into the intervening tissue.<sup>1</sup> From our investigations of the indurated tissue of chancre, we cannot coincide with this view of Ricord's. In all the sections examined, which were taken from chancres having well-marked indurated bases, none presented any appreciable change in the surrounding connective tissue of the lymphatics, and their endothelial lining appeared unaltered. This is in accord with the examinations of Auspitz and Unna, who describe the lymphatics, within the indurated portion of a chancre, as free from any pathological changes. The opinion expressed by Cornil, that "the vascular sclerosis gives the infecting chancre one of its essential clinical characters—the induration"—is to us well sustained, and our examinations, all of which showed in an undoubted manner this modification of the arterial and venous systems, as described by him, incline us to accept his conclusions. It is possible, however, that the number, and position of the lymphatics of the affected part may exercise an influence upon the shape and amount of the induration, not, however, from a histological modification, but from functional properties. It would certainly seem that clinical observation and *normal* histology are in accord as to this point. Otis has called attention<sup>2</sup> to a clinical fact which he says he has often observed, namely, that "indurations of the initial lesion at the frænum and glans, posterior to the meatus, are uniformly small in extent. In the prepuce, on the contrary, where, according to the researches of Dr. Isidor Neumann, the lymphatics are much more deeply located,

[<sup>1</sup> Bumstead and Taylor, 1879. ]

[<sup>2</sup> Op. cit., p. 13.]

we find indurations more extensive. These vessels are represented as still more deeply seated in the base and body of the glans. These are also the known localities of occasional extensive indurations, while in the integument of the penis, where the lymphatic distribution is very superficial, forming loops near the apex of each papilla cutis, we have the most common occurrence of that thin induration which is termed the *parchment induration*.”]

In other regions, as the neck of the uterus, the induration is very difficult to appreciate, because first, as previously mentioned, a lesion limited to the neck of the uterus cannot be raised between the fingers; and, second, the fibro-muscular tissue of the neck is so rigid, that the hardness of the chancre could not be distinguished from the normal condition of the adjacent tissues.

The induration of an infecting chancre is not only very variable, but, in very rare cases, it may be absent, as admitted by all who have specially studied syphilis. Vidal has recently published two cases of this kind. Therefore it is not a positive and constant symptom, and, I believe, that induration is a symptom less important in infecting chancre, than the characters of the erosion, and the condition of the surface of the chancre, especially if, in addition to these, we take cognizance of the several indurated, painless, and hypertrophied lymphatic glands, the so-called *pleiade*.

The induration generally does not last longer than three or four weeks, and the chancre heals in five or six weeks; but the indurated nodule, if it were primarily large and cartilaginous, may persist and be still recognizable after four or five years, or according to Ricord, after fifteen years.

The healing of a chancre is very soon accomplished; the loss of substance is very little, almost nothing; it is only necessary that the papillary layer and the derm, neither of which has been destroyed, should rid themselves, either by the eliminative processes of ulceration or by absorption through the medium of the lymphatics, of the migrated cells which have infiltrated the part; the superficial epidermic layers then reform and become firm. As there is seldom an actual loss of substance—an ulceration—there is not found a true cicatricial tissue at the seat of the chancre, but simply a slight thickening of the skin, and a faint red or copper coloration which usually soon disappear; the coloration may persist for several weeks or longer, although it gradually becomes less distinct.

An indurated chancre may be transformed *in situ* into a mucous

patch, or may even form vegetations. This change, which has been well studied by Davasse and Deville, has played an important rôle in the discussions relating to the inoculation of secondary lesions. Ricord regarded the mucous patches, which were the origin of the contagion, as chancres transformed into mucous patches, and believed that the contagion was in reality due to the chancrous element. These discussions have to-day only a historical interest; their value has been already considered.

According to Fournier, three times in four the indurated chancre is single. In the fourth, where it is multiple, the chancres most frequently begin at the same time, and have simultaneously the same symptoms in reference to the induration, etc. The number of indurated chancres, which may exist at the same time, varies from three to four, but as many as nineteen have been reported by Fournier to have been present upon the genital organs of a syphilitic patient, all indurated and contemporary.

Multiple infecting chancres all begin at the same time, for the primary lesion of syphilis is not auto-inoculable, and therefore it has no tendency to be reproduced alongside of the primary sore, as is the case with soft chancre. This is a very important fact in reference to the course of this lesion, and will be considered *à propos* of the diagnosis of the two chancres. It will be seen that in obscure cases, the inoculation of the pus from the chancre upon the patient affected is one of the best means of arriving at a conclusion. If the inoculation determines a positive result, and occasions a soft chancre, it is certain the case is one of a simple chancre; if the inoculation fails, it may be concluded that the chancre under consideration is not a soft chancre.

[In our judgment, this statement is entirely too sweeping. Many authorities might be quoted to prove that the distinction thus claimed to exist between these sores is not by any means so absolute; but we must content ourselves with calling attention to the opinion of Mr. James R. Lane,<sup>1</sup> who, after either practising or witnessing seven thousand inoculations, writes as follows: "It is certainly not a fact that the hard sore is never inoculable on a syphilitic patient. With certain precautions it may undoubtedly be inoculated, and it will then produce a sore precisely similar in appearance and progress to a

[<sup>1</sup> Lectures on Syphilis, p. 32. London, 1881.]

soft chancre.<sup>1</sup> On the other hand, the inoculability of the soft sore has been much exaggerated. It is said that it is communicable to all persons and at all times, whether they have previously been the subjects of syphilis or not. This, again, is not the fact, for as I repeatedly witnessed, whenever there is any great depression of the vital powers, in tertiary syphilis, for instance, the difficulty of obtaining a positive result with any kind of matter is very great, though if the health can be made to improve the inoculations will succeed.”]

The appearances of an infecting chancre are varied; it may be more or less indurated, of moderate size or very extensive, single or multiple. Thus, between an erosion or slight abrasion situated upon a base scarcely parchment-like, that may readily be overlooked, to an ulceration with a nodular cartilaginous base of considerable size, as large as a quarter of a dollar, and accompanied by great oedema of the labia majora and minora, or of the prepuce, there are found several intermediate degrees. The infecting chancre may be very small (dwarf chancre of Fournier), or it may be very large, occurring in patches resembling herpes (herpetiform chancre of Dubuc).

The most frequent seat of chancres is the genital region; they are very seldom met with upon other parts of the body; this is especially true with men, less so in the case of women.

The most usual seat of chancres of the genital organs with men is the glans penis, the internal surface of the prepuce, and especially the fossa glandis and frænum. Three-fourths of all chancres are found in these localities. At times they are found upon the skin of the penis, at the meatus urinarius, upon the scrotum, upon the mucous membrane of the urethra, upon the groin. The existence of urethral chancres has complicated the discussions between unicists and dualists. The presence of an urethral chancre explains the transmission of syphilis by men who have apparently only suffered from a simple blennorrhagia, but have actually been the subjects of chancre, which was situated within the urethra and which occasioned the discharge.

With women, the labia majora are the most common seat of genital chancres; then follow the fourchette, the labia minora, the clitoris, the skin of the pubes or groin, the neck of the uterus, etc.

It is doubtful if an infecting chancre has in a single instance been found upon the vagina, and yet this canal is certainly the part most

[<sup>1</sup> In these cases it is inoculated after being irritated to free suppurative action, and the result is simply the effect of pus contagion. It may, however, in exceptional cases, produce a second typical hard sore.]

exposed to contagion. The cause of this immunity may possibly be found in the special structure of the vaginal mucous membrane, which is covered with thick layers of pavement epithelial cells. More probably, however, the entrance of the virus is rendered difficult by the absence of glandular orifices over its entire surface; the vaginal mucous membrane possessing papillæ and prominent villi, but no glands.

Extra-genital chancres, particularly those of the anus, are very much more common with women than with men. Yet all chancres of the anus with women do not indicate unnatural sexual relations: the anal orifice is so situated that in dorsal decubitus the fluids from the vulva flow over and often contaminate it.

[Anal chancres are usually seated at the margin of the anus, at the bottom of one of the radiating folds of skin produced by the contraction of the external sphincter. The ulceration is apt to follow the lines of these folds, and thus to assume an elongated or linear character. They are hard, and do not give rise to the painful symptoms of fissures of the anus. They have been observed as high as the upper margin of the internal sphincter, and it is probable that in those countries where the practice of sodomy prevails, they are not infrequent upon the walls of the rectum. Sauri-Ricardo records the case of a young woman who was infected by her husband during unnatural intercourse, and who subsequently developed dysenteric symptoms with a purulent discharge from the anus, then constitutional syphilis, and finally a stricture of the rectum.<sup>1</sup> In France, they occur in the proportion of one out of every one hundred and nineteen in men, and one in every twelve in women. They are certainly much rarer in this country. Attention has been called to the fact, that when confrontation is possible, the chancre of the anus will usually be found upon the same side of the body as that on the penis of the infecting person. Of course in chancres of the genitals, the reverse is true. This may be of importance from a medico-legal point of view.]

The seats of extra-genital chancres are the anus, mouth, lips, tongue, uvula, palatine arches, tonsils, cheek, nipple, etc.

A cephalic chancre is almost always infecting, but it must not be supposed that the skin of the head and face is not susceptible to invasion by a soft chancre. It has been inoculated upon these parts as readily as elsewhere. Soft chancre is rarely or scarcely ever seen

[<sup>1</sup> Jullien, p. 585.]

upon the lips or face, but this is probably due to the circumstance that it is more easily observed than infecting chancre, and is characterized by an ulcer so manifest that its presence causes more caution.

Infecting chancre, when occurring upon the skin, is covered by a scab; when partly upon the skin and moist mucous surface, as the lips, that portion upon the skin is covered by a scab, while that upon the mucous membrane presents the yellowish-gray false membrane previously described.

The infecting chancre is rare in the Lourcine Hospital. During the two and a half years that I have served in this hospital, I have seen only twenty indurated chancres; on account of its rarity many of my colleagues who have preceded me, as Cusco and Lancereaux, think that the chancre is not a necessary lesion of syphilis. Fournier, however, maintains the contrary, and reason and logic compel us to the conclusion that the syphilis of women does not differ from that of men, and that, as with men, there is invariably observed a chancre at the onset of the disease, a similar occurrence takes place with women, even although in certain cases, the chancre escapes notice.

**SYMPTOMS OF SOFT CHANCRE [CHANCROID].**—The symptoms of soft chancre will be briefly described. The details which have been given *à propos* of its anatomy need not be repeated. After having begun by a redness and a pustule or vesicle, or even by a small bulla which soon ruptures, it presents a crater-like and suppurating ulceration. This ulcer is painful and itching; the pus, which is secreted in large amount, is inoculable upon the patient himself, and auto-inoculation is always successful during the course of the chancroid. [This can hardly be accepted literally. Failures are by no means uncommon.] The patient frequently inoculates himself inadvertently or from uncleanness, so that the simple chancre is often multiple.

During the stage of acme, the chancroid has its margins loosened and undermined; the neighboring tissue is inflamed and doughy, and attacked with an œdematous inflammation, with redness of the skin but without any induration comparable to that of the infecting chancre.

When the lymphatic glands are affected, there may occur a true suppurating bubo, if the patient be broken down in health, or, if he has been negligent of treatment. In this case, an inguinal gland is swollen and becomes very large; the skin reddens upon its surface, and we soon feel a superficial fluctuation, due to pus formed in the cellulo-adipose tissue surrounding the gland. When this abscess is

opened, the gland in some cases suppurates, and there is formed an anfractuons cavity which secretes the sanious pus characteristic of simple chancre; the skin constituting its borders is red, inflamed, and separated from the tissue beneath.

These glandular abscesses, like the chancroid, sometimes become phagedenic. This is a formidable complication which occurs almost exclusively in soft chancre. It lasts a long time, occasions a loss of substance, destroys the tissues, and may even terminate fatally, if gangrene is very extensive.

Chancroid is variable in its duration, which is sometimes very short, especially if it has had careful treatment, lasting three, four, or five weeks; at other times it continues several months, and sometimes, if it is phagedenic, one or more years.

The chancroid, when healing, presents fleshy granulations, which grow from the bottom of the ulceration, reaching to the surface of the healthy skin, where they are soon covered by the epidermis. If the ulcer has been deep and extensive, a cicatricial tissue forms, which remains hard for some time, and which replaces the derm that has been destroyed. The place where the chancroid was situated is marked by a hard cicatrix, white upon the surface, irregular, and a little elevated or depressed relatively to the surrounding skin.

RELATIVE FREQUENCY OF INFECTING CHANCRE AND SIMPLE CHANCRE.—According to the statistics of the Hôpital du Midi, the soft chancre is seen much more seldom at the present time than it was some years ago. Thus, Puche, whose statistics were based upon the immense number of ten thousand chancres, found one indurated chancre to four simple chancres. Fournier and Cullerier (statistics of the Hôpital du Midi) give nearly an equal number of the two chancres. Clerc (statistics of Saint-Lazare) and Labarthe (from the cases of Simonnet), have found one indurated chancre to two soft chancres. The most recent analysis of cases by my friend and colleague Mauriac, of the Hôpital du Midi, has given him the opposite result, and it appears determined, according to him, that the soft chancre has decreased in frequency and tends to disappear. But the frequency of soft chancre varies very much in the different social conditions. For example, it is much more frequent than the infecting chancre among the old and depraved prostitutes, from the fact that these women have generally, some time previously, had a syphilitic chancre, and as they are syphilitic, they are not liable to a new infection of



the primary lesion, while they may be indefinitely affected with the soft chancre.

This lesion is also very frequently met with in the army, for the reason that soldiers generally are infected by the above class of women. Thus, according to the last statistics of the army in 1875, among 1000 soldiers who entered the hospital, there were 11 cases of soft chancre and 22 of syphilis; among 1000 who were admitted into the infirmary, there were 17 cases of soft chancre, 16 of syphilis, and 127 of urethritis. About two-thirds of those affected enter these institutions; therefore, if all who were attacked were admitted, it would give us 21 soft chancres and 28 infecting chancres among 1000 men. A proportion certainly very much below that of the syphilitic patients met with among the young rich and laboring classes of large cities.

**MIXED CHANCRE.**—There is a variety of chancre which is considered as possessing at the same time both the nature of an infecting chancre and that of a simple chancre.

It has been observed that a certain number of syphilitic infecting chancres, perhaps two or three in a hundred, may be inoculated upon the patient affected, and that the result of this inoculation is a soft chancre.

Again, Rollet and Laroyenne, of Lyons, have observed that by placing the pus of a soft chancre upon an infecting chancre, there results a special chancrous ulcer, the mixed chancre which Rollet considers a distinct variety. It is certain that a person affected with a mixed chancre communicates to a healthy person a similar lesion, that is, a chancre both infecting and ulcerating. These chancres have at the same time the characters of an infecting and simple chancre; the ulceration occurs very rapidly, and with the characters of a simple chancre; then from the fifteenth day to the third week, that is, after the long period of incubation of a syphilitic chancre, the base, until then soft, becomes indurated, the lymphatic glands become hard, and the secondary eruptions occur in the regular order of syphilis. I believe that the mixed chancre should be considered simply as two lesions developed at the same time upon the same patient, the result of the union of two viruses.

A mixed chancre is not *always* due to the contagion of a mixed chancre. Ricordi, Maziotti, and others, cite<sup>1</sup> cases of mixed chancre

<sup>1</sup> *Traité Pratique des Maladies Vénériennes*, de M. L. Jullien.

contracted by patients who had connection with women suffering at the same time with soft chancres and mucous patches. Frequently a person already affected with an indurated chancre, has connection with another person affected with a soft chancre, and grafts a soft upon a hard chancre. The contrary occurs very seldom, that is, the grafting of syphilitic chancre upon a soft chancre, owing to the abundant suppuration and pain of the soft chancre. Finally, mucous patches, upon which the pus of a soft chancre has been deposited during connection, may ulcerate and present all the characters of a simple ulcerating chancre or mixed chancre.

*Vaccino-syphilitic mixed chancre* is caused by the inoculation of vaccine virus contaminated with syphilitic virus; it runs the same course as the preceding, the vaccine pustule appearing first and developing normally, then fifteen or twenty days after the inoculation, the indurated papule of syphilitic chancre showing itself.

[There are many syphilographers who believe that the chancroid is a form of the initial lesion of syphilis, and that it is not followed by constitutional symptoms in the majority of cases, because the suppurative action which accompanies it favors the elimination of the poison. Others deny its specificity in toto, and attribute it to the contagion of pus, which may or may not contain, as an accident, the germs of syphilis, the ulcerative process in such cases overshadowing or altogether preventing the new cell-growth which gives to the true chancre its clinical peculiarities. Still others, and probably the majority, believe with the author, that the chancroid is a distinct disease depending for its transmission and development upon the existence of a virus which, under proper circumstances, produces the chancroid and nothing else, just as the poisons of smallpox and glanders produce only, and invariably, those affections. In other words, they believe it to be a "*specific*" disease.

Some of the arguments which are employed by those who deny specific character to the chancroid are as follows:—

1. The chancroid has no period of incubation, the pustule or ulcer appearing within a few hours of inoculation, or after about the interval which would be required for the manifestation of the irritant properties of any foreign body inserted beneath the skin. In no other specific disease is incubation entirely absent, though it may vary from three days in scarlatina, or twenty-five days in syphilis, to two years in hydrophobia.

2. The occurrence of chancroidal disease in any individual affords

no protection against a second attack, as is almost invariably the case in the specific diseases.

If it be urged in answer to these objections, that the chancroid as a *local*, contagious, specific disease is not strictly comparable with the exanthemata and those ailments which affect the system at large, it should be remembered that in that event it would be necessary to regard it as an isolated disease constituting a distinct class, and without congeners, a possible but improbable condition.

3. Sores in all respects resembling chancroids, have been produced on different parts of the body by inoculation with the contents of acne pustules.

4. All rapidly forming ulcers tend to assume the appearance said to be characteristic of the chancroid. This is especially the case in the tissue of the glans penis, which by reason of the thinness of its fibrous envelope, the delicacy of its trabeculæ, and the spaces necessitated for purposes of erection, breaks down easily under the ulcerative process. The direction of the connective tissue fibres composing the trabeculæ, and along which tissue all inflammation extends most readily, explains the undermined appearance of the edges of the sore, its other characteristics being simply those of active suppuration.

5. Extra-genital chancroids are very rare, and chancroids upon the skin of the penis are much less common than those upon the glans; nineteen-twentieths occurring in the latter situation; they are also very rarely found in the vagina;<sup>1</sup> yet all these parts are exposed with great frequency to contagion from chancroidal sores. This seems a sufficient answer to the assertion that if chancroids were due to pus contagion they would be much more commonly found upon the fingers of surgeons, etc.

6. Ulcers found upon the glans penis after the relief of a phimosis complicated with balanitis are often instances of the truth of the above statement, being usually indistinguishable from chancroid.

7. Many competent observers are of the opinion that they have seen syphilis follow a sore having all the characteristics of the chancroid from its appearance to its cicatrization. This is said to be especially the case in chancroids at the base of the penis.

The testimony in this respect is too clear and direct, and the ability

<sup>1</sup> Cornil calls attention (p. 82) to this point in speaking of the absence of infecting chancre from the same region, and adds yet "this canal is certainly the part most exposed to contagion."

of the witnesses too far above question to permit of reasonable doubt that this is a clinical fact.

To say that in such cases, especially when they occur in men, a chancre has existed, but has been overlooked, is to impugn the accuracy or the diagnostic powers of some of the most careful and most distinguished syphilographers of the day. When it is admitted that these cases are occasionally seen, they are variously explained. Those who believe that the chancroid is a sore produced by the virus of syphilis, assert that its appearance and general harmlessness are due, as has been said, to the accompanying suppuration, the eliminative action of which protects the constitution. They appeal to analogy in support of this position, citing the well-known differences in reaction to irritants in different constitutions; the bullet which becomes encysted in one individual, remaining harmless in another, etc. etc. Their opponents, the dualists, claim that these cases are instances of what they call the "mixed sore," by which they mean that the two poisons, the chancroidal and the syphilitic, have been implanted simultaneously, and run independently of each other their respective courses.

The objections to this latter view are, that it is entirely hypothetical, that it involves a belief in the frequency of an accident which from its very nature would be an exceedingly rare one, and that such a process, pathologically considered, is without parallel.

When vaccino-syphilis is adduced as an example of the implantation of two poisons at the same time, it is replied, that in all the recorded cases the vaccine pustule has run its usual course, developed, matured, and desiccated, and that *then* the chancre has appeared, after its usual period of incubation, and with all its ordinary characteristics.

8. Confrontation, which undoubtedly shows that in the majority of cases the hard sore is derived from the hard sore, and the chancroid from the chancroid, is no more an argument for dualism than for the form of unicism which recognizing only one specific poison, the syphilitic, attributes the production of the soft sore to pus contagion. If the chancroid depends on the irritating effect of pus, you would of course expect to find a suppurating sore in the individual from whom the disease was derived.

On the other hand, every surgeon of experience must have met with some exceptions to the general rule: must have seen for example cases in which chancroidal sores resulted from intercourse with persons having the primary or secondary lesions of syphilis, particu-

larly when they were suppurating freely, or were acquired, in rare cases, from women in whom no lesion of either sort was discoverable, but simply a purulent vaginitis or endometritis. These cases are difficult to explain on the dualistic theory, except by supposing that they are instances of mistaken diagnosis. On the theory of pus contagion of course their significance is evident.

9. Repeated inoculations from the chancroid show progressive enfeeblement of the power of inoculation. This is not observed in the specific diseases: vaccine lymph may be handed almost indefinitely from individual to individual, losing little or nothing of its protective power. It is observed, however, in inoculation from ordinary pustules, and was remarked many times during the experiments on "syphilization" made in various countries.

10. Inoculation with the secretion of a hard sore, *which has been irritated so as to secrete pus*, will produce a sore in no wise distinguishable from the chancroid (Clerc's chancroid), and reinoculable through a lengthened series in the same way. It can hardly be claimed that the chancroidal "virus" has been generated by this irritation, and yet if some chancroids originate in this way, by pus contagion, why not all chancroids?

11. Phagedæna supervening upon a syphilitic sore, has been experimentally shown<sup>1</sup> to be transmissible by inoculation, and seems in such cases to have superseded the syphilis which did not manifest itself. We have recently recorded two cases of this character.<sup>2</sup> This would appear to be an example of intensely irritant and destructive properties accidentally acquired by pus, and of which the chancroid is only a milder manifestation.

On the other hand, it is said that:—

1st. The chancroid is always the result of abrasion or inoculation of the secretion of a chancroid, and has a distinct individuality differing from other forms of ulceration.

2d. That the bubo accompanying one out of every three cases of chancroid, is peculiar and characteristic.

3d. That if inflammatory products can produce chancroids, the latter would be much more frequent on the hands of surgeons, nurses, and others who are exposed to daily contact with pus.

4th. That, admitting the existence of specific characteristics in the

<sup>1</sup> Lectures on Syphilis.—Lane.

<sup>2</sup> Apparent protection from syphilis afforded by phagedæna, Medical News, Feb. 25, 1882.

sore, some corresponding quality must be conceded to the pus, and that—

5th. To suppose that this is every now and then generated *de novo*, is to claim that the operation of the laws of nature and disease may now and then be arrested or upset.

6th. That chancroids are never followed by syphilis, and that in those instances in which it has been thought that this was the case, the sore was of the mixed variety, or an infecting chancre has existed and had been overlooked, or the diagnosis was wrong, the peculiar characteristics of the infecting sore not having been recognized.

7th. That the successful treatment of the chancroid requires the employment of some painful cauterant to arrest the spread of the ulceration, which it does by destroying the virus.

We are of course aware that this is by no means an exhaustive statement of the opposing views held on this subject, but have thought it proper to call attention to these differences of opinion. We do not presume, however, to decide a question upon which so many eminent authorities differ. It is chiefly important in its relation to prognosis, as regards which it is proper to say that the effect of an implicit reliance on the dualistic theory will often be found productive of error.

“It is unsafe to predict confidently that any venereal ulcer, even a soft sore attended with suppurating bubo, will entail no further consequences. There is a strong probability that an indurated sore will prove infecting: and there is a probability, though not nearly so strong, that a soft suppurating sore will not, but exceptions to both these general rules will be met with, and there is really no absolute proof of the infecting nature of any given sore, but the fact of infection itself.”<sup>1</sup>]

DIAGNOSIS OF CHANCRE.—Infecting chancre should be distinguished from simple chancre. This diagnosis, usually not difficult, is determined by the characters that have been described. The onset, the period of incubation, and the general appearance, are different. The infecting chancre is painless and almost constantly indurated, it is generally single, and is accompanied by induration of several inguinal glands. Soft chancre is often multiple, is painful, and is complicated with suppurating bubo.

<sup>1</sup> Lectures on Syphilis.—Jas. S. Lane, London, 1881, p. 23.

Among the other lesions which may be confounded with infecting chancre is herpes, which it is difficult at times to diagnose both with men and women, as it is frequently confluent, forming numerous groups invading the entire vulva, and often occasions an œdematous swelling of the labia majora and minora. Herpes, however, is more liable to be mistaken for mucous patches than for chancre, although some multiple chancres very closely resemble this affection (Dubuc); but these chancres are generally indurated. Again, herpes is at first vesicular, occurs in groups, which are regularly arranged, and when ulcerated, still keep the same arrangement. Finally, herpes, is attended with itching, heals in less than a week with simple lotions, and does not occasion adenitis.

The difficulty sometimes experienced in distinguishing a mucous patch, with raised and hard base and ulcerated surface, from a chancre, will be considered more fully after the former lesion has been studied.

At times there are seen tertiary syphilides of the glans or vulva, with a hard tuberculous or gummous base, and an ulcerated surface, and it is often very difficult, almost impossible, to differentiate them from the initial chancre. If it should be determined that the patient is already syphilitic, we must distinguish between a return of an indurated chancre, and a late syphilide. Here, it is to be apprehended, that doctrinal prejudices are liable to influence opinion. Pathologists who believe that syphilis once contracted remains during life, can scarcely admit the extinction of the virus, which is proved by a return of an infecting chancre. Again, on the other side, the anatomical and clinical characters of indurated chancres compared with a papulo-tubercular tertiary ulcer are the same, so that, at the present time, from our knowledge of the disease, most writers on this subject consider these supposed returns of chancres as tertiary syphilides.

The possibility of the development of a simple furuncle upon the mons veneris, penis, or glans, is not to be forgotten. These small furuncles probably arise from some local irritation and pursue the same course as elsewhere. They are situated upon a hard base, and consist of slight elevations, the summit of which soon becomes whitish as suppuration takes place.

There are also œdemas of the prepuce or vulva, following coitus or labor. These are readily recognized, but sometimes they are accompanied by an abscess of the prepuce, or quite frequently in women by an abscess of the vulvo-vaginal gland. An abscess of this

gland may also be complicated by an indurated or a soft chancre upon its suppurating surface. This, however, is very rare, but its possibility should be remembered when such abscesses refuse for a long time to cicatrize.

Ulcers due to arsenic and copper, also epitheliomatous and elephantiac ulcers, should not be forgotten when making a diagnosis.

[The diagnosis of chancre is a matter of such great practical importance, that it may be well, even at the risk of repetition, to enter into it somewhat fully. In doing so we shall follow closely the paper of Ch. Mauriac, which is the best *résumé* of this subject with which we are acquainted:—

1. In dealing with *lesions apparently non-venereal in their origin and character*, we should consider carefully the following points:—

*a.* The anatomical situation and the course of the lesion. Among those particularly to be viewed with suspicion may be mentioned herpetiform erosions of the lips, papules on the tip of the tongue, squamous or “scabby” ulcerations of the skin, scratches which obstinately refuse to heal, chronic inflammations at the tip of the fingers resembling felons, etc.

*b.* Indolence, absence of suppurative tendencies and persistence in spite of treatment, are negative signs which should lead us to believe that any cutaneous or mucous lesion is not of a simple nature.

*c.* If the morbid products are slight, rather serous than purulent, tend to form into crusts, or to assume a pseudo-membranous form upon an eroded surface, syphilis should be suspected.

*d.* The consistence of the base upon which the lesion is situated is one of the most important diagnostic points, and should always be carefully investigated. If, upon palpation, instead of the usual inflammatory swelling and thickening, shading off into the surrounding tissue, we meet with a cartilaginous, elastic, sharply circumscribed resistance, we may immediately suspect very strongly that we are dealing with a syphilitic growth, although even this symptom cannot be considered as infallible.

*e.* If the lymphatics of the groin become slightly swollen and painful and progress no further, or if these symptoms occurring in a single gland subside spontaneously, it is probable that they are due to a sympathetic adenitis, such as follows many irritations of the skin or mucous membrane. If, on the contrary, they steadily augment in size and hardness, are almost painless, and constitute a chain of little tumors including several or all the inguinal glands, it may be con-



sidered strong presumptive evidence of specific disease, though even yet not conclusive.

In addition to these points, the history of the case must carefully be inquired into—the probabilities of infection, in regard to which we should not be misled by the beliefs of the patient, and the period of incubation—which, when it can clearly be established, is of great value.

Confrontation will often, not invariably, decide the matter, but, in this country at least, is rarely obtainable.

Difficulties of diagnosis are greatest during the first week or ten days, and steadily diminish with the age of the lesion, which, if syphilitic, is almost certain to assume in time definite character. The chief points among those mentioned are the period of incubation, the presence or absence of induration, and the condition of the nearest lymphatic glands. If, however, all of these seem to point to syphilis, the experienced observer will still refrain from giving a positive opinion, no symptom or group of symptoms being absolutely conclusive as to the specific character of any given primary lesion, certainty only being attained by the development of some of those general or constitutional phenomena which in from six to eight weeks follow the infecting chancre.

2. The *region occupied by a chancre* may cause errors or difficulties in diagnosis.

a. In the cephalic region, chancres of the hairy scalp, of the supra-orbital prominences, and of the chin and cheeks are the most deceptive. They always assume an ecthymatous form, and are so concealed by the hair on the head that it is impossible to judge of the character of their surface. In all such cases the hair must be carefully shaved, and if we then find that we are dealing with an ulceration, lacking the ordinary characteristics of ecthyma, and glazed, flat, or even elevated, our suspicions should be aroused, and after eight or ten days will usually be confirmed, if the sore is chancrous, by the development of induration and of neighboring lymphatic enlargement.

Razor-cuts on the chin, cheeks, or lips, which, after having healed, re-open and become covered with a crust, should on *à priori* grounds be suspected. This is equally true of pseudo-furuncles, acneiform pustules, cracks around the circumference of the nostrils, etc., which persist without giving rise to pain, and become bloody, incrustated, and surrounded by an area of subinflammatory, œdematous swelling. We should then carefully examine each day the preauricular, parotidian and submaxillary lymphatic glands.

A sty which behaves in an unaccustomed manner or is accompanied by hyperplasia of the lid, or a conjunctivitis which becomes localized and causes an isolated swelling, should be attentively watched.

In the neighborhood of the mouth, errors of diagnosis should be less frequent than in other portions of the cephalic region, because it has been shown so extremely often that the lips, tongue, and fauces are frequently brought in contact with syphilitic discharges and constitute one of the principal channels of infection. Here, however, as elsewhere, the chancre assumes at the very outset the appearance of ordinary lesions. Thus, upon the lips, the chap, crack, or fissure often found in the median line, the little aphthous erosions, herpetic ulcerations, and cigar or cigarette burns, simulate very closely the characters of the initial lesion, and, as the latter will almost invariably be attributed by patients to some such ordinary cause, may give rise to serious error.

At the end of the first week, however, the specific characters of labial chancre are usually so distinct as to render diagnosis easy.

In several instances, two of which have come under our own observation, these chancres have been mistaken for epithelioma and have been excised. The diagnostic differences may be indicated as follows:—

LABIAL CHANCRE.	EPITHELIOMA.
No marked differences between the sexes.	Twenty times more common in males than in females.
The ulcer may involve either lip.	Almost invariably situated upon the lower lip.
Occurs at any age.	Rarely occurs before middle life.
Patient often strong and robust.	Patient usually in impaired health.
Is insensitive.	Sharp, burning, lancinating pains.
Regular in outline, smooth surface, elevated.	Irregular in outline, ragged, filled with fungous granulations, bleeding easily.
Indurated and <i>sharply circumscribed</i> base.	Induration less cartilaginous, unequal, not clearly circumscribed, and more extensive.
Evolution of sore usually occupies a few weeks at the most.	Sore may be many months in developing after its first appearance.
Glandular involvement follows closely on appearance of sore.	Glands are not implicated for three or four months, often not until later.
No marked odor from secretion of sore.	Odor often extremely offensive.
History of exposure to syphilitic inoculation often obtainable.	Frequently no such history.
Heals rapidly, or disappears under mercurial treatment.	Not affected or rendered worse by such treatment.

While there is a possibility of error in diagnosis between a chancre and an epitheliomatous ulcer when a macroscopical examination alone is made, there is, on the contrary, no such apprehension when a microscopical examination of the lesions is instituted. The histological structure and arrangement are so very distinct and unlike in these lesions that a mistake cannot well occur. In the epithelioma we have the ingrowing of the interpapillary layers of epithelial cells, the branching or budding outgrowths from the sebaceous glands, which constitute the very characteristic epitheliomatous pegs, and the formation of the cell-nests or pearls upon these pegs, which are all so strikingly different, when contrasted with the histological composition of a chancre, that no doubt as to diagnosis remains.

Upon the sides of the tongue ulcerations, produced by the continual contact of that organ with rough and carious teeth, have been mistaken for chancres. This error should be guarded against, but is not so serious in its results as the failure to recognize the peculiar lesion when it is situated at the point of the tongue, the possibility of its communication to innocent people being, in such cases, an element of unusual importance. In the first five or six days it is impossible to diagnose it, but if the original little inflamed papule enlarges and extends, becoming elevated above the surrounding parts, if its epithelial covering drops off, and its surface becomes diphtheritic; if superficial cauterization with crayons of nitrate of silver, which so rapidly cure the common small painful papule of the tongue, have no effect upon it, there is a strong presumption that it is a chancre. This will be confirmed later by the appearance of submaxillary glandular enlargement and induration of the sore.

In the sloughing, phagedenic form (of which Mauriac has seen one case), it could hardly be confounded with cancer, certainly with nothing else except the later syphilides, and these will be considered later.

Of all the chancres of the cephalic region, however, that of the tonsils, or the isthmus of the fauces, presents the greatest diagnostic difficulties, on account of the effacement of its characteristics by the surrounding inflammation.

If in a case of prolonged sore throat there be an appearance resembling a single mucous patch, and if there be no history of antecedent syphilitic poisoning, it becomes probable that the trouble is chancrous, and this probability is greatly increased if any induration can be felt by palpation with one finger in the pharynx and another

external to its walls ; if enlargement of the glands above the angle of the jaw occurs ; or, of course, if the patient confesses to having been peculiarly exposed to contamination.

The sore is much more common in this region in females than in males, Mackenzie noting the fact that out of seven cases of primary syphilide of the tonsils which he had met with, six were women.

*b.* Superior and inferior extremities. Chancres of the hands are often seated at the margin of the nail, and closely resemble simple whitlows. They may be diagnosed by their long duration, their abrupt limitation, the hardness of the tissues around and beneath them, and the consecutive engorgement of the epitrochlear ganglion.

Upon the dorsal face of the phalanges the initial lesion at first simulates an inflamed papule or a boil, but is less painful, discharges no "core," and is elevated, not excavated.

The anterior face of the forearm in both sexes, the anterior surface of the thigh in men, and the posterior surface in women, are the parts most exposed to contagion.

The chancre of vaccino-syphilis occurs after the evolution of the vaccine sore. It can only be confounded with the ulcerations described by Blot under the name of "vaccinal phagedenism" which are rounded with abrupt borders and indurated bases, and are often accompanied with engorgement of the axillary lymphatic glands. The diagnosis from appearances is difficult, but may be made by noticing the fact that these sores run an acute course, and are readily cured by poultices or emollient applications, which, of course, have no effect on chancre.

*c.* Upon the trunk the mammary and hypogastric regions are those most frequently involved. In the former locality the initial lesion is most likely to be mistaken for eczematous excoriations, fissures, and small furuncular or papillary tumors. The diagnosis rests upon the presence of the characteristic induration, elevation, etc., and upon the poly-ganglionic axillary enlargement. In cases where syphilis has been transmitted during suckling, confrontation is almost invariably possible, and furnishes the most satisfactory guide.

Chancres of the hypogastrium are generally large and ulcerating, and are most liable to be mistaken for chancroids.

*d.* Genital organs. The diagnosis of sores situated in this locality, is chiefly between chancre, chancroid, and herpetic ulceration. The diagnostic table given below expresses the main points of difference.

INITIAL LESION OF SYPHILIS.	LOCAL VENEREAL ULCER.	HERPETIC ULCERATION.
<i>Origin—</i> Due to contagion from a chancre, a syphilitic lesion, or blood, or pus from a person having syphilis.	Usually due to contact with pus from a similar sore, or to accidental inoculation of the secretion of a chancre upon a person already affected with syphilis; more rarely to the irritation of pus from other sources.	Mechanical irritation; friction, as in sexual intercourse; chemical irritation, as of acrid discharges; uncleanliness. Occasionally follows cold or fever; may be a neurosis.
<i>Incubation—</i> Not less than ten days; often three weeks; very rarely six to eight weeks.	None.	None.
<i>Situation—</i> Most frequent upon the genitals. Often seen on the hands, nipples, lips, etc.	Almost always upon the glans penis or prepuce; rare upon other portions of the genitals; scarcely ever seen elsewhere.	Glans penis and inner layer of prepuce.
<i>Commencement—</i> Begins as an erosion, papule, tubercle, or ulcer. May remain without ulceration through its entire course.	Begins as a pustule or ulcer.	Begins as a group of vesicles, which may coalesce or may ulcerate singly.
<i>Number—</i> Single or simultaneously multiple; occasionally but rarely successively multiple.	Often multiple, frequently by auto-inoculation.	Multiple, apt to be confluent.
<i>Shape—</i> Round, oval, or symmetrically irregular.	Round, oval, or unsymmetrically irregular with border described by segments of large circles.	Irregular, edges serrated or described by segments of small circles.
<i>Depth—</i> Usually superficial—cup-shaped or saucer-shaped—or may be elevated.	Hollow, excavated, or "punched out."	Superficial.
<i>Surface—</i> Smooth, shining, red, glazed; diphtheritic membrane or scab.	Rough, uneven, "worm-eaten," warty, whitish-grayish, pultaceous.	Same as local ulcer, but more superficial.

INITIAL LESION OF SYPHILIS.	LOCAL VENEREAL ULCER.	HERPETIC ULCERATION.
<i>Secretion—</i>		
Scanty, serous, auto-inoculable with great difficulty, producing either a chancroidal sore or in rare cases a second sore like the first.	Abundant, purulent. Readily auto-inoculated.	Moderate secretion, auto-inoculated with difficulty.
<i>Induration—</i>		
Almost always present; firm, cartilaginous, or parchment-like; circumscribed, terminating abruptly; movable upon subjacent parts; skin not adherent; usually persistent: disappears under specific treatment.	Only exceptionally present, may be caused by caustics or other irritants, or by simple inflammation; boggy, inelastic, shades off into surrounding parts to which it is adherent; disappears soon after cicatrization.	Same as local ulcer.
<i>Sensibility—</i>		
Very little or no pain.	Painful.	Painful.
<i>Course—</i>		
Usually regularly progressive towards health, the sore often healing spontaneously. Phagedena uncommon. Second attack also very rare.	Irregular, may cicatrize rapidly or may extend, taking on phagedenic action. No protection against a second attack.	May spread in exceptional cases, by the appearance of successive crops of vesicles. Usually heals promptly under mild local treatment. Likely to recur, especially in uncleanly patients with long foreskins.
<i>Histology—</i>		
A new cell-growth. Very little destruction of tissue.	An ulceration with more or less loss of substance.	Originally an elevation of the epidermis in spots by an effusion of serum.
<i>Bubo—</i>		
Constant, painless, multiple.	In one-third of the cases; painful, inflammatory, single.	Rare. When it does occur painful, single, inflammatory.
<i>Prognosis—</i>		
Good locally; constitutional syphilis will follow in the great majority of cases, but in a few may not appear, or may be prevented by treatment.	More serious locally on account of loss of tissue; occasional refusal to heal and possibility of phagedena. Very rarely is followed by syphilis.	Always good if the diagnosis be absolute. Should be guarded when there is the least doubt as to the herpetic character of the affection.
<i>Treatment—</i>		
Excision when seen early, other local treatment ineffective.	Local treatment curative.	Local.

Chancres of the meatus are more often syphilitic than simple in their character. In the former case, they are attended with little or no ulceration, are confined to one lip of the meatus, are accompanied by the usual induration and glandular involvement, and are often, indeed usually, not discovered by the patient, who imagines he has a gonorrhœa. Chancroid of the meatus is irregular in shape, ulcerated, involves both lips, is painful, and does not have the characteristic induration.

The diagnosis between infecting urethral chancre and gonorrhœa may be tabulated as follows :—

INFECTING URETHRAL CHANCRE.	GONORRHŒA.
Incubation almost invariably more than ten days.	Incubation almost invariably under ten days, or more properly absent altogether.
Always occupies the meatus, certainly never posterior to the fossa navicularis.	Beginning at or near the meatus soon extends backward, involving the deeper region of the urethra.
One lip of meatus, red, swollen, everted. Induration characteristic.	Both lips of meatus affected. Œdema or ordinary inflammatory hardness.
Discharge slight, serous, or sero-sanguinolent.	Discharge abundant, purulent, or mucopurulent.
Ardor urinæ if present, only felt at extreme orifice of urethra.	Felt for some distance back.
Chordee and vesical symptoms absent.	Usually present in a greater or less degree.
Uninfluenced by anti-blennorrhagics and injections; rapidly disappears under mercurial treatment.	The reverse is true.

The small hard tumors which occasionally appear or may be felt along the under surface of the penis during an attack of gonorrhœa, and which are due to inflammation and enlargement of the follicles, should not be confused with chancre. They usually feel like grains of sand or small peas directly beneath the skin, are situated *behind* the fossa navicularis, have no characteristic induration, and subside spontaneously or go on to suppuration.

When phimosis exists, the diagnosis between sub-preputial chancres and chancroidal, herpetic, or balanitic ulcerations is often one of great difficulty. It should be founded on the following considerations :—

SUB-PREPUTIAL CHANCRE.	SUB-PREPUTIAL ULCERATION (NOT SYPHILITIC).
The incubation is that of chancres, ten to twenty-one days—or more.	The interval between the exposure and the subsequent ulceration, swelling, etc., is much shorter.
If the site of the original trouble can be felt or can be described by the patient, it will be found to be single.	Several points of ulceration, abrasion, or pustulation, will usually be found or described.
Inflammatory phenomena comparatively slight.	Inflammatory phenomena, heat, pain, redness, swelling, very marked.
Swelling, hard, dry, indurated characteristically.	Swelling œdematous, sero-purulent, like that of phlegmonous erysipelas.
The discharge from the preputial orifice is moderate, thin, serous or bloody, not readily inoculable.	Discharge profuse, purulent, usually very irritating, and apt to be inoculable both accidentally and experimentally.
The margins of the preputial orifice are not markedly inflamed or ulcerated.	Almost invariably ulcerated.
At some point the induration can probably be isolated from the surrounding tissues, and raised and felt between the thumb and finger.	This is usually not possible, no distinct dividing line existing.
Syphilitic buboes are invariably present.	Buboes, if present at all, are of an inflammatory character.

The diagnosis between a new indurated chancre and an ulceration occupying the site of an old chancre, the induration of which has never entirely disappeared—"relapsing chancre"—is extremely difficult, and unless a clear history of the case can be obtained, is impossible.

The latter cases are often reported as instances of a second syphilitic infection.

The opinion must be based upon the presence or absence of a syphilitic history and the circumstances of the exposure, incubation, etc. The possible effect of local irritation on an old indurated mass, should always be taken into account.

The *prognosis* of syphilitic chancre considered as a local affection depends chiefly upon the seat of the lesion. A chancre of the conjunctiva may give rise to a grave ophthalmia; a chancre of the tongue or of the fauces may, through interference with mastication, deglutition, and digestion, cause great general debility.

As regards the genital organs, however, the prognosis is almost uniformly favorable. Phagedenic or gangrenous processes are rare, ulceration even is usually very slight, or, if seemingly extensive, is apt to be at the expense of the neoplasm and not of the normal tissues.



The relation between the constitutional disease of which the chancre is the precursor, and the sore itself is a question of great interest.

It may be at once acknowledged, however, that our information upon this point is deficient. We are able neither to predict the form of local lesion from the character of the source of infection, nor, on the other hand, can we, with any accuracy, forecast the constitutional condition which will result from any given sore. The varieties of the chancre in form, extent, etc., depend more upon local causes or upon the idiosyncrasies of the patient, than upon any special source or peculiarity of the virus.

Every syphilographer of experience, has seen the most widely differing forms of initial lesion derived from the same individual.

Mauriac mentions a case in point:—

Two men contracted syphilis from the same woman. In one, after an incubation of a month, a large, markedly indurated chancre appeared, and persisted for six weeks; the other, at the end of five weeks, had a very small, scarcely indurated chancrous erosion which disappeared in two weeks.

The same diversity exists in the forms of constitutional disease arising from a given focus of infection.

It is probably safe to say, that a rapidly ulcerating and unusually extensive or obstinate chancre, indicates a grave form of early syphilis, but as the first secondary symptoms and the chancre are nearly contemporaneous, their apparent relation may be simply the effect upon them both of a general constitutional condition.

The amount of glandular implication is also an entirely unreliable guide, and presents all sorts of variable phenomena.

It may be said in conclusion of this question of prognosis, that while “primary syphilis permits us to anticipate to a certain limited extent the character of the early secondary developments, it furnishes no reliable basis for opinion as to the visceral and other affections of the later periods.”]

**TREATMENT OF CHANCRE.**—The treatment of indurated chancre is very simple; it tends naturally to recovery, as a local lesion. There is but little to be done except to apply suitable lotions or ointments, or to isolate the sore by means of charpie. Should extirpation of the chancre be performed? The statistics given by Auspitz and Unna are very favorable, as has been shown in Chapter I.; they give the hope that the entire removal of a chancre, at its beginning, will pre-

vent syphilitic infection. Therefore, the operation may be undertaken, if the chancre is situated in an accessible region, and one which will admit of interference; for example, the labia, or the free portion of the prepuce.

The question whether anti-syphilitic treatment should be immediately begun when the presence of an indurated chancre is recognized, has been answered differently by different writers. Several authors, and particularly Diday, do not give mercury during the course of the chancre, waiting until the secondary symptoms make their appearance before instituting mercurial medication.

It appears certain that mercurial treatment during the period of acme of chancre does not stop the evolution of syphilis nor prevent secondary symptoms; yet the regular administration of mercury during the period of the chancre, or after its cicatrization, may retard the appearance of these symptoms. Since these eruptions occur, as they do, at the end of the second month from the first appearance of the chancre, or in three or five months even when mercury has been administered, it seems to many physicians unimportant. Some prefer not to give mercury, permitting the disease to take a natural course. In the hospital of Lourcine, when the women are admitted with a chancre, it has generally begun to cicatrize; they almost always present secondary symptoms, mucous patches, or beginning roseola, so that mercurial treatment is immediately begun. The administration of mercury will be more fully described when the general antisiphilitic treatment is considered.

Although the treatment of indurated chancre is not very important, it is different with soft chancre, which has a great tendency to extend and inoculate the patient. It also frequently occasions suppurating buboes, and even goes on to phagedenic ulceration, therefore it is necessary to destroy it as soon as recognized. It may be cauterized with the actual cautery, with nitric or sulphuric acid, with Vienna paste, etc. The caustic preferred by Ricord and many others, is carbo-sulphuric paste, consisting of powdered charcoal made into a paste with sulphuric acid. It has the advantage of forming a black scab when placed upon the chancrous ulcer, and remaining until the granulations beneath become healthy, so that when the scab falls off the chancre is seen in a healing condition.

If cauterization be refused by the patient, we advise rest to prevent suppuration of the bubo, and apply astringent washes, or dust the ulcer with powdered iodoform.

[It has been for many years the almost universal custom to cauterize freely all soft or suppurating venereal ulcers, *i. e.*, all sores diagnosed as chancroids, whether situated on the genital regions or elsewhere. This plan of treatment was adopted avowedly because the sore being attributed to the action of a specific virus, it was thought necessary absolutely to destroy that virus before any healthy reparative action could take place. Manifestly if the chancroid be regarded as an inflammatory ulcer, resulting from pus contagion, it is no more requisite to use painful cauterants in its treatment, than it would be in a case of ulceration following a burn or scald. On the other hand, it may be said that if the theory of specificity be assumed to be true, there are yet reasons<sup>1</sup> for believing that during the past twenty years the chancroid has been so modified in character and tendencies as no longer to require the active measures instituted by our predecessors.

Experiments have shown that after repeated inoculations, chancroids lose all their virulence, and that it even becomes impossible to transmit them in this manner, the same fact being true as regards the inoculation of other purulent secretions. During the last half century it is possible that chancroids have undergone this progressive enfeeblement while being handed from person to person—a process similar to experimental inoculation—and that they have consequently become much milder in type.

Leaving aside, however, these theoretical considerations, the practical question, that which most concerns both the physician and the patient, is, as in every other case of disease, what is at once the speediest and the safest method of cure?

The objections to cauterization, which have been well set forth by Dr. Greenough, in the paper already mentioned, are as follows:—

First. The pain to which it gives rise, and which to many patients is almost unbearable.

Second. The inflammatory action which follows, and which often in the case of the male, produces enough œdema and swelling to cause phimosis, and thus to conceal the sore and prevent the proper application of remedies.

Third. The subsequent effusion of lymph which is apt to cause an induration closely resembling that of the true chancre, and thus to greatly obscure the diagnosis.

<sup>1</sup> On the Treatment of Chancroid, by F. B. Greenough, M.D., Boston Med. and Surg. Jour., Jan. 11, 1877.

Fourth. The occurrence of sympathetic buboes, which are much more likely to complicate the case if the additional powerful irritation of cauterization be added to that of the original disease.

Admitting then that these are valid objections to the use of the cautery, it remains simply to inquire whether there are advantages numerous or important enough to outweigh them, the question thus becoming one to be settled largely by clinical observation.

During five years—since the spring of 1877—we have seen and treated in the venereal dispensary of the University Hospital, in the venereal wards of the Philadelphia Hospital, and in private practice, a large number of chancroidal ulcers, and during that time have only used cauterization under certain exceptional circumstances presently to be mentioned. The favorite application, but not on account of any supposed specific action, has been iodoform in powder, ointment or ethereal solution; the general rule has been followed of meeting indications—that is, of using sedative lotions, lead-water, or lead-water and laudanum, or sulphate of zinc and opium, in the acutely inflamed painful sores, and of using stimulating washes—sulphate of copper, strong zinc solutions, nitrate of silver, etc.—upon indolent, pale and flabby ulcers. Special indications having been met, iodoform generally completed the cure. As compared with the former methods of treatment, we are confident that, while avoiding, to a great extent, the complications above mentioned, we, at the same time, noticeably shortened the period required for healing. The unreliability of hospital cases, which of course make the bulk of the statistics, and which disappear long before entire recovery, prevents us from giving exact figures, but it would be safe to say that the average time of cure did not exceed ten days or two weeks. In a few cases in which after four or five days' treatment no tendency to reparative action is observable it becomes necessary to employ a cauterant, and fuming nitric acid or bromine should be thoroughly applied to the surface of the ulcer with the idea of destroying the unhealthy granulations and surrounding them with a layer of plastic lymph which at once resists further ulcerative action, and furnishes a basis for new growth. Special formulæ for lotions, powders, and ointments may be found in all manuals and text-books on these subjects.

The local treatment of infecting chancre is of very little importance except as regards the question of excision. Healing will take place in the great majority of cases under any emollient application, or without any if only cleanliness be observed.

Cauterization, except in a few instances to be mentioned, is worse than useless in cases without gangrenous or phagedenic tendencies, because, on the one hand, it retards rather than hastens cicatrization, and, on the other, is manifestly inferior to excision as an abortive method.

We feel no hesitation in saying that the evidence in favor of this latter procedure is sufficiently conclusive to warrant its adoption in most instances.

No other plan of treatment results in so speedy a return to local health. If the chancre be picked up with a pair of vulsellum forceps, and removed by a sweep of the knife or by means of curved scissors, the wound will usually heal within two or three days, and without complication.

The statistics in reference to its influence upon the subsequent development of the disease have already been given, but we may add that the opinion deduced from them has been greatly strengthened by our personal experience. For a few months we have excised most of the typical infecting chancres which have come under our notice, and which have been favorably situated for the operation. In the majority of cases, some fifteen or twenty in number, syphilis has followed, but in a few it seems probable that constitutional disease has been prevented. As most of them are unavoidably open to the doubt as to accuracy of diagnosis, so often urged against this form of proof, we do not give them in detail, although ourselves convinced of the great probability that they would have been followed by syphilis if uninterfered with. In two cases, however, we have had an opportunity of confirming the diagnosis by confrontation, and found that the sores had been derived from women with active syphilis, in both cases with mucous patches. In one of the male patients there was slight glandular involvement, which has since subsided; in the other no glandular trouble was discoverable. In both the ordinary time of development of constitutional syphilis has long since passed, and no sign of general syphilis has manifested itself.

Unless some hitherto unnoticed and untoward results should follow this little operation, it seems proper to us to employ it in all cases except those where an unusually deep induration occupies the tissues of the glans itself. In these, which are not very common fortunately, it may fairly be doubted whether the probabilities of protection are sufficient to compensate for the pain and the deformity resulting from excision. In such cases, or in those where the patient for any reason

refuses the more radical operation, cauterization may be employed, but with greatly diminished chances of benefit. Nitric or sulphuric acid should always be used for this purpose, and should be freely applied and pressed into all the interstices of the sore.

The reasons for and against the mercurial treatment of chancre will be given in the chapter on the treatment of syphilis.]



The ulceration of the left nymphæ has not changed its appearance, and is still a little indurated. The erosions upon the internal surface are not changed, and the nymphæ continues œdematous.

The inguinal glands have slightly increased in size.

26th. The wound continues to heal.

The ulceration of the left labium minorum is completely covered with a whitish, adherent coating, composed of epithelial cells and leucocytes; the surface beneath this false membrane is bleeding.

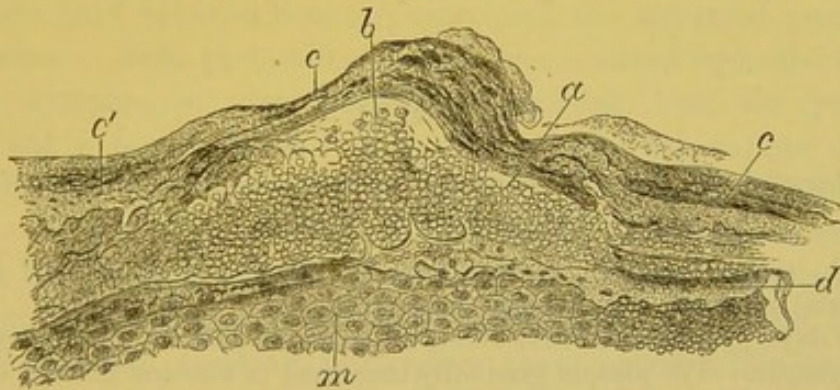
29th. Mucous patches are observed upon both thighs.

June 6th. The wound of the right labium is entirely healed, and has a brownish color. The labium is still swollen. The ulcerations of the nymphæ and the mucous patches upon the thighs have disappeared.

The patient left the hospital on the 18th of June in the same condition.

*Histological Examination of the Chancre.*—The piece was hardened in Müller's fluid, gum, and alcohol. Fig. 4 is a drawing of an entire section of this chancre, enlarged 15 diameters. The papillæ are hypertrophied, and the epidermic layers increased in thickness at the margins of the chancre, *p* and *d*. This thickening of the epidermic layers and the inflammation of their cells were very distinct, even upon the surface of the chancre and near its borders, especially where the hairs emerge. In Fig. 6 we have drawn a section of the superficial layers of the epidermis upon the chancre near its border, where

Fig. 18.



Section from the surface of an indurated chancre, showing the suppuration in the epidermis. *a*. Layer of pus-corporuscles interposed between the superficial corneous lamina, *c*, and a lamina of deep corneous cells, *d*. At *c'* are seen the corneous cells having their nuclei atrophied. *b*. Isolated pus-corporuscles. *m*. Cells of the rete mucosum.  $\times 150$ .

a hair follicle exists. This drawing, magnified 150 diameters, shows the suppurating foci in the corneous cells of the epidermis; the formation of small excavated cavities in these cells, as at *c*; the small islands of pus-corporuscles, *d*, limited on all sides by epidermic cells. The larger cavities have changed the corneous epidermis into a



reticulum with large meshes, formed of corneous cells, filled with pus.

Upon other parts of the surface of the chancre we see pus-corpuses arranged in groups, which are interposed between the corneous epidermic layers. Thus Fig. 18 shows a layer of round corpuscles placed between the laminae, *c* and *d*, of the superficial epidermis.

The rete mucosum presents similar lesions, particularly in the epithelial sheath of a hair represented in Fig. 6. Here are seen excavated cells, *c*, and small cavities filled with pus, *n*.

The epithelial layer at the centre of the ulcerated chancre was thinned and mixed with pus. At this point the papillae form a layer in which they are each a little increased in size. The lesions of the connective tissue, the infiltration of lymph-cells, the inflammatory thickening of the cells are readily seen.

In the region in which the sudorific glands are found, in the tissue of new formation of the chancre, they are scarcely changed. The peripheral connective tissue especially is inflamed, and forms around the segments of their convolutions a border of small round cells. Here, also, the epithelial cells are a little enlarged, and the ducts larger than normal. Upon transverse section, the lumen of the ducts, lined with epithelial cells, frequently presents in its interior round cells, which are only the desquamated, free peripheral cells.

## CASE II.

### *Indurated Chancre of labium minorum—Excision—Histological examination of chancre.*

E. B., seamstress, æt. 19, until now has always enjoyed good health. No special personal or hereditary history.

Five days previous she first observed a small painful pimple upon the right nympha. The pimple gradually increased in size and finally changed into a superficial ulcer. She bathed it frequently, but it did not disappear, and she entered the hospital—St. Clement ward, June 26th, 1878.

At the free border of the inferior half of the right nympha, upon its internal surface, is found a small superficial round ulcer, about eight millimetres in diameter. This slightly excavated erosion is covered with a brownish closely-adherent scab. The margins and base of the chancre are distinctly indurated, and have a cartilaginous feel, seeming to be a centimetre thick.

The right nympha is very œdematous, but the induration is very easily distinguished from the surrounding tissue.

In the right inguinal fold, are found two glands as large as small hazelnuts, which are very hard, and roll beneath the finger.

Two or three small glands are felt in the left groin. The other glands, the skin and mucous membranes are normal. No fever.

29th. The inferior half of the labium minorum, upon which is located the indurated chancre, was removed with a bistoury.

July 1st. The portion remaining is greatly œdematous, but we are not able to trace the slightest evidence of specific induration. The wound is suppurating profusely.

2d. Condition the same. Suppuration increased, the wound tends to granulate and cicatrize. Right inguinal glands diminished in size. Ordered liquor of Van Swieten.

3d. The wound whitish, the new-formed granulation tissue is infiltrated with pus; beneath the wound, the connective tissue is œdematous, but not more so than upon the day of operation.

5th. The wound is clean, discharging very little pus, smooth, and the adjacent connective tissue very much less œdematous, softer.

7th. The wound is covered by an epidermic layer. The adjacent connective tissue still presents some hardness, which in a few days gradually disappeared, as did the surrounding œdema.

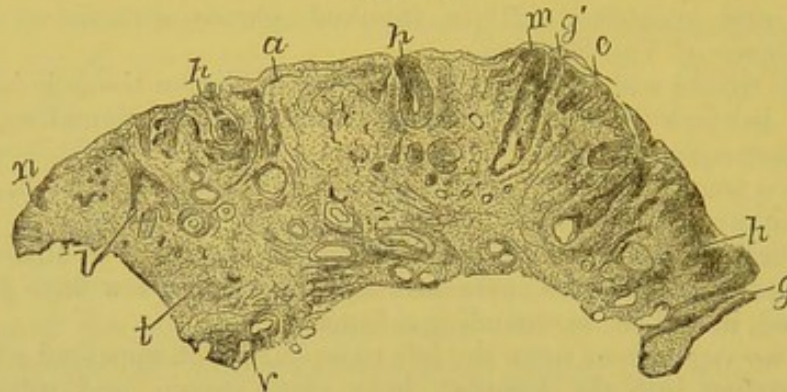
23d. Two vegetations upon the left nympha, which appeared a few days after admission into the hospital, have since grown, and were to-day excised. As yet there are no secondary symptoms.

*Histological Examination of the Chancre.*—The piece removed was placed in alcohol, then, the same day, in picric acid, and afterwards in gum and alcohol.

Figure 19 is a drawing of a section through the large axis of the chancre made vertical to its surface, magnified six diameters. The prominent part between *m* and *n* represents the ulcerated portion of the chancre. This part, as mentioned, was situated upon the border of the nympha, so that the section includes both the primary ulcer, and a portion of the internal and external surface of the labium. The epithelial covering, *n*, of the internal surface of the nympha, in the neighborhood of the chancre, is very thick and the papillæ are very long. The normal epithelial covering tapers and stops at *m*. The surface of the chancre from *m* to *n* has lost its normal epithelial covering, in its place there exists a thin layer, *a*, formed of pus corpuscles and epithelial cells. These elements cannot be seen with low power. The papillæ do not form an elevation upon the surface of the chancre; their extremities give origin to a small quantity of pus, which dries and forms a thin layer. At the margin of the chancre, *n*, the normal epidermis remains, and the papillæ are hypertrophied. From the drawing, it is seen that there is very little loss of substance. A layer of pus corpuscles and epithelial cells replaces the normal epidermic layers, and beneath this layer, the papillæ infiltrated with lymph cells separate the elements. The

tissue of the chancre forms an indurated mass, and is composed of an infiltration of round cellular elements between the fasciculi of connective tissue; the walls of the vessels, arteries and veins, are thickened by the formation of new cells. The tunica adventitia is especially changed.

Fig. 19.



Section of an indurated chancre of the labium minorum. *n*. Normal epidermis at the margin of the chancre. *e*. Rete mucosum. *a*. Ulcerated part; the epidermis is lost from *m* to *n*. *g*. Normal sebaceous gland. *g'*. Sebaceous gland in which there still exist some sebaceous cells. *h, h*. Sebaceous glands situated in the ulcerated part of the chancre, and which do not contain sebaceous cells. *l*. Cul-de sac of an inflamed sebaceous gland. *t*. Indurated connective tissue. *v*. Vessels.  $\times 6$ .

In this chancre there are all the elements for a complete study of lesions of sebaceous glands. In the labia minora these glands are very numerous, and in each preparation we find several in the various stages of alteration. We are able even with low power, as in Figure 19, to see the changes that occur in the sebaceous glands. Here the glands distant from the chancre, and outside of the inflamed and indurated tissue are normal; they are seen to possess a single lining of pavement cells; the excretory canal and acini present a distinct centre filled with normal sebaceous cells. In the gland, *g*, at the margin of the chancre, the sebaceous cells are not distinct as in the deep acini, and the lumen of the duct is filled with pavement cells. The sebaceous glands, *h, h*, and *l*, which are in the inflamed tissue, do not contain any distinct, fatty sebaceous cells, but are filled with newly formed pavement epithelial cells. When an inflamed and a normal gland are compared under higher power, in the former it is found that the sebaceous cells are gradually crowded to the centre of the ducts, and the acini are filled by a development of pavement cells; in those parts most altered, at the centre of the chancre, there are no sebaceous cells: the pavement cells of the ducts and acini frequently show a cavity between the nucleus and protoplasm of the

cell, and there are often round cells, pus corpuscles, or lymph cells in the interior of the glands, alongside of the epithelial cells or in the cavities which they have formed. It is particularly in that part of the glandular duct nearest to the suppurating surface, that these round cells are met with. The lesions of the sebaceous glands are secondary to the inflammation of the connective tissue.

## CASE III.

*Indurated chancre of the right labium minorum—Mucous patches.*

M. B., chambermaid, æt. 21, admitted into the Lourcine Saint-Clement Ward, May 9, 1878. No special personal or hereditary history. She first noticed her disease four days previous to entering the hospital.

*Present Condition.*—Considerable œdema of the right labium, also of the nymphæ of the same side; upon the internal surface of the latter we find a festooned gray ulcer, bulging at the centre; at the periphery, the depression from the loss of the epithelial covering is very slight.

Upon the inferior part of the right nymphæ, and upon its free border is found an irregular ulcer, extending towards its internal surface. The margin of the ulcer consists of a whitish covering of epithelial cells, thinning towards the eroded surface. This surface is yellowish-gray, and when wiped is immediately again covered with a clear serous fluid. The base of the ulcer is indurated, almost fibrous in nature.

Upon the external surface of the labium on each side of the fourchette, are seen ulcerated mucous patches. The radiating folds of the anus are hypertrophied, and there are found here a few mucous patches.

A single, very hard, and very large gland is situated in the right groin; in the left groin are seen two small indurated glands. The skin and buccal mucous membrane are healthy. Cervical lymphatic glands normal. Ordered Van Swieten's solution.

*Histological Examination of the Surface of the Chancre and of the False Membrane.*—The grayish false membrane covering the surface of the ulcer was removed by scraping. Microscopical examination showed it to consist of:—

1st. Epithelial cells isolated or in various sized patches, Fig. 2 (see page 44). Several of these cells have arborescent prolongations resembling deer horns, as in the false membranes of diphtheria, Fig. 3 (see page 44). We also find spherical epithelial cells varying in age and size.

2d. Pus corpuscles provided with one or several nuclei; various sized granules; numerous vibriones; collections of small spores.

May 20th. The chancrous erosion has entirely disappeared, but the induration has increased. The œdema of the right labium majorum has very much diminished.

26th. Extension of the mucous papules upon the labia majora.

June 8th. The patient left the hospital with the mucous papules of the labia majora gradually disappearing.

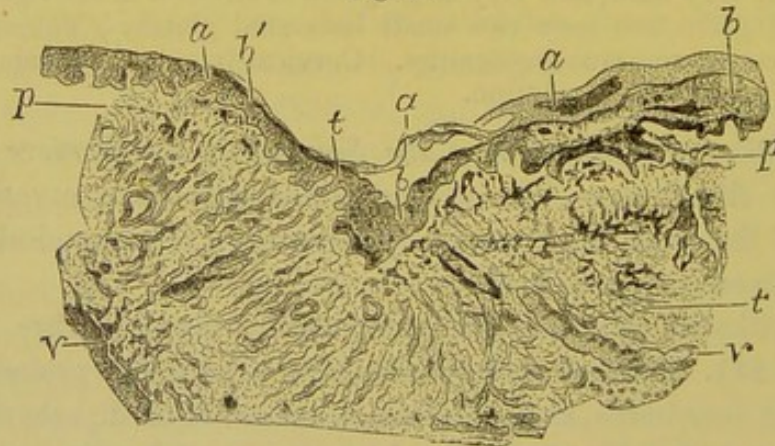
#### CASE IV.

##### *Histological examination of an indurated chancre of the prepuce.*

During the month of June, 1878, my colleague, Dr. Mauriac, sent me, for examination, an indurated chancre of the prepuce, which he had removed with a part of the prepuce from a patient in the Hôpital du Midi. The chancre had existed some three weeks, extending transversely around the prepuce like the segment of a ring. The part first attacked was cicatrized, while that which remained, about one-half, still suppurated. The chancre measured in its greatest diameter about two and a half centimetres. The cicatrized portion was covered with normal epithelium and depressed; the ulcerated part was covered with a thin grayish layer nearly even with the neighboring normal skin. Beneath the ulcerated and cicatrized part was felt a characteristic woody induration. The piece was hardened in Müller's fluid gum and alcohol.

The prepuce, and especially its cutaneous portion, is certainly as to structure the most simple region, which may be the seat of a chancre, since here there are only connective tissue, vessels, nerves, and an epidermic covering. Therefore this case and the following may be

Fig. 20.



Cicatrix from a portion of the chancre, Fig. 22. *a.* Corneous epidermis. *b.* Rete mucosum. *p.* Papillæ. *t.* Very hard cicatricial connective tissue. *v.* *v.* Vessels with extremely thick walls.  $\times 8$ .

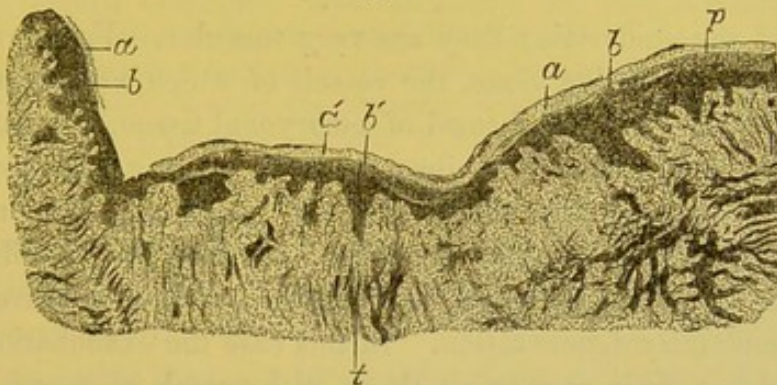
regarded as types of the pathological anatomy of chancre divested of all foreign elements.

Preparations made vertical to the cutaneous surface show us the following conditions:—

1st. In the oldest part of the chancre, completely cicatrized, there is a point where the cicatrix is a little sunken, so that, upon section, Fig. 20, the cicatrix has the shape of an obtuse angle. The surface of the cicatrized chancre presents its two layers of epidermis, the corneous and mucous layers. The superficial epidermis, *a*, is partly separated at the summit of the angle. The rete mucosum, *b*, is quite thick, but irregular. We see in this drawing, magnified eight diameters, the rete mucosum, *b*, very thick at the angle of the cicatrix which it fills up, and also at the points where the papillæ are large as seen to the left of the drawing. The papillæ are also very irregular, but larger than normal; they are, however, mostly deprived of the embryonal cells which infiltrate them during the acme of the chancre. The connective tissue of the derm is fasciculated and dense, contains many round or flat cells, and its vessels, *v*, are extremely thick.

2d. Fig. 21 shows cicatrization of the chancre in a part where it is more extensive than in the preceding. The corneous layer of the

Fig. 21.



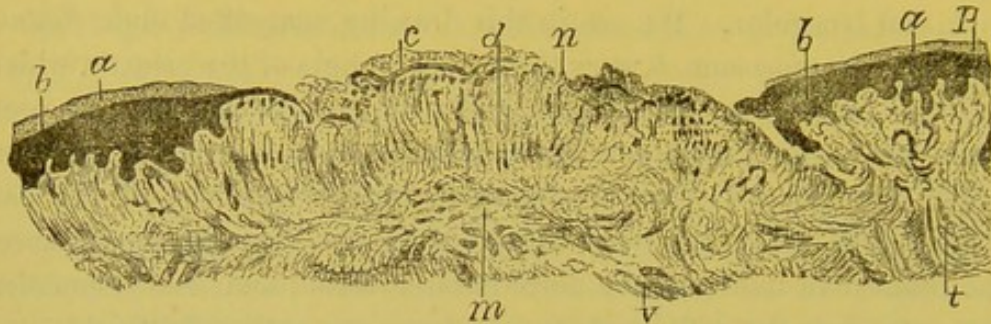
Cicatrized portion of the chancre, Fig. 22. *a*. Corneous epidermis. *b*. Rete mucosum. *a'*, Epidermis, and *b'*, rete mucosum of the cicatrized part. *p*. Papillæ. *t*. Indurated connective tissue.  $\times 8$ .

epidermis, *a*, *a'*, is very thick; the rete mucosum, *b*, around the chancre and upon its surface, is also thickened. The margin of the chancre presents the rete mucosum extremely thick at *b*; where the ulceration of the chancre exists, the papillæ are visible and large, also irregular. This irregularity and hypertrophy of the papillæ are manifestly due to the circumstance, that they have been affected during the suppurating period of the chancre, and that they have developed during the healing period.

3d. Fig. 22 represents the ulcerated part of the healing chancre. In the central part of the figure, for about eight or nine millimetres, the epidermis and rete mucosum are lost. These two layers, *a* and *b*,

which are seen at the side of the ulcerated part, terminate by tapering at the edge of the ulceration. They are replaced by a layer of pus corpuscles, mixed with epithelium, *c*. The papillæ, which are exposed, budding, and larger than normal, fill up the space left by

Fig. 22.



Section of an indurated and ulcerated chancre of the prepuce. *a*. Corneous epidermis. *b*. Rete mucosum arrested at the ulcerated portion of the chancre; at this part are seen, at *c*, either pus corpuscles or a false membrane. The papillæ, *d*, possess vessels, *n*. *t*. Indurated connective tissue. *m*. Subpapillary indurated tissue of the chancre. *v*. Deep indurated vessels and tissue of the derm.  $\times 8$ .

the loss of the epidermis; they are very vascular. From an examination of these papillæ alone, the vessels of which are permeable to the blood, and which are formed of embryonal tissue, we are able to say that we have a wound in the process of healing, and not undergoing destruction or elimination. In the latter case, the circulation would not be so perfect, and the cells infiltrating the papillary connective tissue would be modified in their nutrition or have undergone granulo-fatty degeneration. In this case the examination of the papillæ shows their connective tissue with vessels of new formation which are very numerous, seen even with low power, eight diameters, as represented in Fig. 22.

The deep connective tissue is fasciculated, infiltrated with numerous cells and thickened.

We may now ask the cause of the deep, angular, V-shaped cicatrization, seen in a section of the old part of the chancre. If we refer to Fig. 20, it appears to us that there certainly is a loss of substance of the dermo-papillary tissue at this point. The proof is, that a large arteriole comes nearly to the surface of the corium; the shape of the loss of substance is singular, also its depression. We believe the cause of this angular depression is due to the exaggeration of the normal folds of the prepuce, and the localization of the chancrous ulcer at the bottom of one of these folds.

## CASE V.

*Infecting chancre of the border of the prepuce, removal on the 30th day of its existence—Histological examination of the chancre.*

M. L. H., æt. 25, commercial business, ward 8, No. 14 (service of Mauriac). After two months' continence, the patient had connection twice, with an interval of eight days, with a girl in the Latin quarter. Forty days later, the 1st of August, he observed a small pimple situated upon the edge of the prepuce. Gradually this pimple enlarged, particularly on the mucous side, the preputial orifice contracted, and in about ten days complete phimosis occurred.

This chancre began about the first week in June, 1878; *it was painless from its beginning until removed by circumcision.* Very simple applications had been employed. Adenitis was multiple and bi-lateral. *There was no inflammation of the preputial mucous membrane, nor any other complication.*

The chancre was excised on the 13th of July, twenty or twenty-five days after its appearance. There was considerable hemorrhage from several arterioles, which was difficult to arrest on account of the vessels being in the midst of the sclerosed tissue. Union was not immediate, owing to frequent erections. But the wound has been healthy, and pursued the same course as in a non-syphilitic patient.

July 31st. The first spots of erythematous roseola make their appearance (about forty-five days after the primary lesion). No disturbance of the general health. Extensive adenitis of the inguinal region. Beginning cervical adenitis.

*Histological Examination of the Chancre.*—Dr. Mauriac, physician at the Hôpital du Midi, sent us for examination, July 13th, a chancre of the prepuce, which was removed by circumcising the patient. This chancre is seated upon the free border of the prepuce, presents a very deep depression, a cone with a sharp angle, at the centre of the lesion. The chancrous connective tissue is extremely hard and dense, woody, and has the shape of a slightly flattened spheroid. The indurated part measures not less than 12 millimetres in its greatest diameter.

The piece was examined after hardening in Müller's fluid, alcohol, and gum.

Sections passing through the middle of the chancre show it separated into two halves by a distinct space, of an infundibular form, or very sharp angle, which penetrates deeply into the tissue of the chancre. The surface of the margin of the chancre is covered with a thick epidermis, which tapers towards the infundibular part.

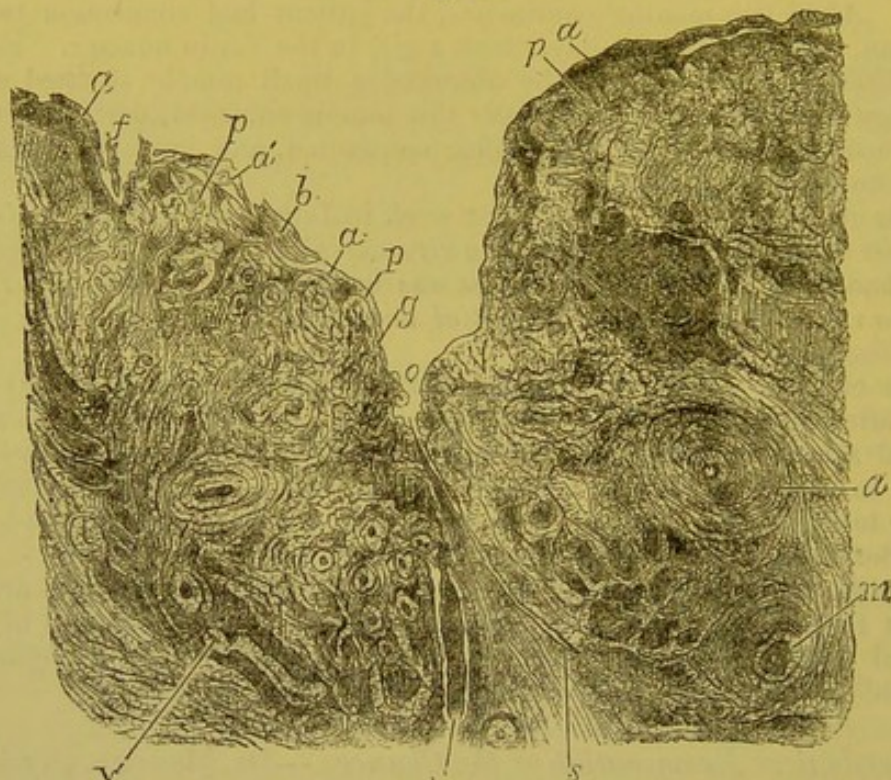
Where the part is most contracted the epidermis ceases, and the connective tissue, which forms the margin of the loss of substance,



contains a few round or lymph-cells, which are mostly granular, fatty, large, and possess one or more nuclei.

Fig. 23 is a drawing of this chancre, magnified 15 diameters, the tissue of which is divided into two parts by an infundibular depression,

Fig. 23.



Section of a highly indurated chancre of the prepuce during the state of acme and full development, ulcerated and seated at the bottom of a cutaneous fold. (Removed by Mauriac.) *a*. Superficial epithelium, which is very thick, and separated at *a'* from the rete mucosum, *b*. The epithelial layers cease at *g*, the opening of the infundibulum, *o*. The depression *o* is analogous to *f*, which latter is lined with its normal epithelial layers, while from *g* to *p* the loss of substance from the surface of the chancre is limited by a tissue infiltrated with cells. Throughout the indurated tissue represented in this figure, the walls of the vessels are extremely thick and inflamed: as at *v*, *v'*, *m*, *d*; *s*, cleft of the caseous central part.  $\times 15$ .

*o'*. The superficial epidermic layers cease at *g*. The walls of the vessels, *v*, *v'*, *m*, *d*, are seen, with this low power, to be very thick. At *s* is seen an opening or slit in the central part of the indurated tissue, the cells of which have undergone caseous degeneration.

At the bottom of the fissure, the chancrous tissue presents an opening which increases its length, and is in the direction of the connective-tissue fibres; it seems artificial, probably because the indurated tissue had been stretched during the erections, perhaps also because it has been forcibly pressed between the fingers after the excision of the chancre to ascertain the presence of induration.

Beneath the epidermis, the papillæ included in the chancre are hypertrophied, very vascular, and infiltrated with small round cells.

The tissue of the derm is much inflamed, and filled with round cellular elements, still the fasciculi of fibres of the connective tissue can be distinguished; these fasciculi, however, appear compressed by the cellular infiltration at the centre, beneath, and at the sides of the loss of substance of the chancre. The cells are here mostly granulo-fatty.

Throughout the indurated part, the vessels are altered in various degrees. The vessels of the papillæ are simply filled with blood, and surrounded by a few round cells, but the deep arterioles and venules, in all the indurated region, have their walls thickened by the formation of cells between their external and middle coats. The internal coat is always very much less affected than the external or middle coats.

The vessels—arteries, veins, and capillaries—of the central part of the chancre, almost all have the lumen obliterated; for example, the transverse sections of capillaries present collections of lymph-cells, which fill them; longitudinal and transverse sections of arteries show large endothelial cells joined together with lymph-cells and coagulated fibrin. This coagulum, which is not always adherent to the internal coat, is also seen in longitudinal cuts of arterioles. The veins show a similar lesion. The calibre of these vessels is contracted at the same time that their walls are thickened. Figure 12 (see page 59) is a drawing of a section of four small veins, magnified 200 diameters. Their lumen, *a*, is very narrow and filled with lymph and endothelial cells, which form a mass in the centre. The walls have considerable thickness relative to their lumen; some round or oval cells are disseminated in the internal coat, *i*, in the muscular coat, *t*, and in the external coat, *e*, which latter is limited by connective tissue, *c*, filled with round cells.

Figure 10 (see page 58) represents a section of an arteriole, magnified 200 diameters, which shows similar alterations of its coats. The elastic membrane, *f*, is seen in immediate contact with the endothelial and lymph-cells, filling the lumen of the vessels. Cells of new formation exist between the fasciculi of the elastic membrane and outside of them, between the elastic membrane and muscular coat. The external coat, *e*, is little changed at this point, but it and the fasciculi of the neighboring connective tissue are separated by an accumulation of lymph-cells, *c*. At those points where the obliteration of the vessels is more or less complete, the lymph-cells are granular and fatty. In a word,

there is here primarily an interference with the circulation of the blood, and secondarily a fatty degeneration of the cells.

In this preparation are found several fasciculi of nerve-fibres; these fasciculi are cut transversely and longitudinally. In the transverse cuts, the neurilemma, or, better, the sheath of the primitive fasciculi of the nerve-fibres, is dissociated by fusiform cells, that is, the flat cells of the connective tissue swollen by the peripheral inflammation, Fig. 13 (see page 63). The sheath is separated into several thin laminae, *m*, by fusiform and small round cells, *a*. The nerve-fibres, *b*, of the fasciculi are normal; but, even within the fasciculi are seen hypertrophied cells of the connective tissue, and sheath of Schwann, or round cells. This inflammatory lesion of the nerves is certainly secondary to the specific inflammation of the connective tissue of the derm. It is singular, that this change of nerve fasciculi did not occasion pain.

We see, from the above, that this chancre of the prepuce was in the period of caseous or fatty transformation of its elements, at the centre of the small tumor. This period coincides with the partial obliteration of the vessels. The condition of the nerves shows that the inflammation involves all the tissues and all parts included in the induration.

In regard to the shape of the loss of substance, characterized by a very deep infundibulum, it is occasioned by the normal arrangement of the part. The prepuce, at its free border, presents depressions and ridges, which are unfolded during erection. In these depressions and ridges the papillae and rete mucosum have the same arrangement as upon the normal skin. The chancre was evidently developed at the bottom of one of these depressions; it had caused an hypertrophy of the epithelial and dermo-papillary layers, so that the depression seemed still deeper. If the chancre had not been interfered with, and had healed, it would have presented a cicatrix having the form of that represented in Fig. 20 (see page 114).

## CHAPTER IV.

## LYMPHATIC GLANDS DURING THE PRIMARY AND SECONDARY PERIODS OF SYPHILIS—CLASSIFICATION OF SYPHILIDES—MUCOUS PATCHES.

Symptomatic and histological description of syphilitic lymphatic glands at the beginning of syphilis—Glands at the same time scrofulous and syphilitic—Syphilides—Their general characters—Classification—Their many forms—Their copper color—Mucous patches—Pathological anatomy and symptoms of mucous patches of the vulva—Mucous patches of the tonsils—Lesions of the closed follicles of the tonsils—Extirpation of syphilitic tonsils.

ALMOST at the same time that the chancre becomes indurated, the lymphatic glands, connected with it by means of the lymphatic vessels, become hypertrophied.

*Syphilitic Glands.*—The gland or glands nearest to an infecting chancre become enlarged and hard; they roll readily beneath the skin and the subcutaneous connective tissue which surrounds them; they are remarkably painless, and do not suppurate. These clinical characters, which have been previously mentioned, are constant. They are found in the groin when the chancre is upon the genital organs or anus; at the angle of the jaw when the chancre is upon the lips; in the axilla when the chancre is upon the nipple.

The glands of the groin, in connection with a chancre upon the genital organs, are successively involved, the gland first affected being the most inferior of the group upon the diseased side; for example, if the chancre be single and seated upon one of the labia majora, the nearest gland of the same side is first implicated, later the glands of the opposite side. [When the chancre is situated at one side of the frænum it is not uncommon to find the buboes in the opposite groin, a certain amount of decussation occurring between the lymphatics of the former region.] The inguinal glands now form a mass, like a string of beads, in which they are all hypertrophied, but are distinct one from another, the skin remaining healthy.

About a month and a half after the beginning of this affection of the glands nearest to the chancre, all the glands of the economy are successively invaded. At least all those which are

visible; they appear a little inflamed before or at the same time with the eruption of the cutaneous syphilides. I do not doubt but that the glands concealed in front of the sacral, lumbar, and dorsal vertebræ undergo a similar change. [It was so found in a case reported and figured by Jullien, as far as the lumbar and iliac glands were concerned.] The subcutaneous glands affected by syphilis are the cervical, maxillary, occipital, etc.

In what does the glandular lesion anatomically consist? It is characterized by Virchow as a simple hyperplasia, but this word is very vague, and it is necessary to examine the lesion in all its details before pronouncing upon it.

I have several times had an opportunity to examine syphilitic lymphatic glands in the fresh condition, immediately after they had been removed by operation. The normal structure of lymphatic glands consists of a fibrous capsule which gives off trabeculæ which accompany the vessels as far as the hilus; of a delicate reticulated tissue forming islands or follicles in the cortical portion; and of a reticulated tissue with larger meshes enveloping the former and leaving sinuses around the follicles. The afferent lymphatic vessels enter at the surface of the gland, form the sinuses and reticulated tissue with large meshes, and again form vessels which pass out at the hilus as efferent vessels.

In syphilitic lymphatic glands, the follicles of the delicate reticulated tissue are hypertrophied, and occasion small lobulated projections upon their surface when the capsule is removed. Again, if a section of a gland is made in its greatest diameter, there is seen a lobulated appearance due to the same cause; the fibrous capsule is not very notably thickened, and does not adhere to the neighboring connective tissue.

If the cut surface of one of these affected glands be scraped, and the scraping examined microscopically, there are found lymph-cells of ordinary size, and swollen cells possessing a large nucleus or several nuclei. Among the swollen cells, there are always some which present in their interior several red blood-corpuscles. There may be as many as eight to ten blood-corpuscles in a single cell. When there exist several nuclei in a large hypertrophied cell, there is always one which is much larger than the others and oval, while the other nuclei are round and small.

These swollen cells are seated in the peri-follicular lymph sinuses, but they are also sometimes found in the delicate reticulated tissue.

The fibrils of the reticulated tissue are not changed. The connective tissue of the fibrous trabeculæ, extending from the capsule to the hilus, is generally a little thicker than normal. It is this thickening of the trabeculæ, joined with the swelling of the delicate reticulated tissue of the follicles; and the increase of the number of elements in the lymph sinuses which occasions the lobulated condition above mentioned. These are the changes which essentially constitute the special inflammation of glands during the period of acme of the primary lesion, and also during the period of the secondary lesions. Lesions identical to these are found occurring in the closed follicles of syphilitic tonsils.

Such are the most frequent changes of these glands, which remain more or less hypertrophied, not only during the active period of the secondary lesions, but frequently after the syphilides have disappeared.

In certain cases, which are not very rare in hospitals especially devoted to syphilis, children, or young girls and women are met with who are anæmic and lymphatic, their glands presenting what Ricord calls a scrofulosis of syphilis, that is, the lymphatic glands of the neck or groin become very much enlarged, as large as a pigeon's egg, or even larger.

When in a syphilitic patient the lymphatic glands present this great enlargement, they are identical with strumous glands, a histological description of which has been published by me in the *Journal de l'Anatomie* of Robin, 1878. This description need not be repeated here; it is sufficient, in order to characterize these syphilitic and strumous glands, to mention that the fibrous capsule is extremely thick, and gives off thick fibrous trabeculæ which divide the gland into small islands. The trabeculæ forming the reticulated tissue have their fibres soft and swollen, and enclose large cells with oval nuclei, and granular or granulo-fatty protoplasm. The sclerosis of the capsule is such that in removing the gland, part of the surrounding tissue is removed with it, since this tissue is also connected with the gland, and likewise sclerosed. These strumous glands are also characterized by their union one to another by means of the sclerosed tissue which surrounds them, and they thus form a single mass frequently adhering to the skin.

[The following table will serve to contrast the buboes and lymphangitis characteristic of the two chief forms of venereal sores.<sup>1</sup>

<sup>1</sup> It is based on one contained in the excellent work of Van Buren and Keyes.

## SYPHILITIC BUBO.

Always accompanies or follows infecting chancre.

Several glands involved, making a group or chain of small, movable glands in one, or often in both groins.

Appears soon after chancre.

Slight enlargement.

Cartilaginous induration.

No inflammatory symptoms.

Glands freely movable.

Skin normal—not adherent.

Painless.

Indolent, slow.

Terminates by resolution, rarely by suppuration.

No marked tendency to phagedena.

No local treatment effective.

Mercurial treatment hastens resolution.

## INFLAMMATORY BUBO.

Occurs once in three cases of chancroid; occasionally, but more rarely in herpetic or balanitic ulceration.

One gland implicated, rarely bi-lateral.

No definite time of appearance.

Great enlargement.

Inflammatory hardness.

Always present.

Gland fixed (peri-adenitis).

Skin red, adherent.

Painful.

Runs an acute course.

Usually suppurates, rarely undergoes resolution.

Phagedena not very uncommon.

Local treatment required.

Mercury has no influence upon the condition.

## SYPHILITIC LYMPHITIS.

Lymphatic vessels feel hard, like the vas deferens; size of a knitting kneedle.

Painless to touch.

No pain on erection.

Skin normal.

Terminates by resolution.

Treatment unnecessary and ineffective.

## INFLAMMATORY LYMPHITIS.

Same, but less hardness.

Painful.

Erection gives rise to pain.

Skin red over inflamed vessel.

Resolution or suppuration.

Local treatment of great use.

It is interesting to observe in relation to the bubo following the indurated chancre, that in these rare cases in which extensive suppuration or phagedenic action occurs, the system at large often escapes contamination. Two cases<sup>1</sup> of this character have recently come under our notice; in both of them, the primary sores having all the characteristics of the initial lesion, the inguinal glands breaking down, however, before the appearance of the earliest syphilide. In both immunity from constitutional trouble was complete. The same important fact has been noticed by Fournier and Ricord to be true as regards the relation of bubo to the phagedenic initial sore, the latter form of chancre not being followed by the inguinal enlargement which, as has been said, is so nearly constant.

The bearing of these facts upon the doctrines of syphilis and

<sup>1</sup> Medical News, Feb. 25, 1882.

chancre is evident. They are altogether inexplicable on the theory, that the chancre is a symptom of constitutional syphilis, but if the theory of lymphatic absorption and the local character of the initial lesion be accepted, it becomes highly probable that such complete destructive action as occurs in the case of phagedena, would result in the death or elimination of all the virus and the consequent protection of the system. This same view would also seem to give strength to those syphilographers who are still believers in the essentially syphilitic character of the chancreoid, and who attribute its general innocuousness to the eliminative action of the pus which it secretes.

Occasionally extreme adenopathy occurs during the later stages of syphilis as a result usually of gummous infiltration, and if it affects the inguinal glands, and happens to be coincident with an ulceration of the genitals, it may be mistaken for chancreoid or sympathetic bubo. The treatment proper for the latter affections would of course be more than useless in this case, which requires for its cure the vigorous use of mixed treatment. The history of the case should be carefully inquired into, and if there be ground for reasonable doubt as to the character of the enlargement, specific treatment should be tentatively employed.

In the absence of such treatment the condition may remain unchanged, or the skin may soften and ulcerate, and the disease assume the appearance of a pustulo-crustaceous syphilide, which would of course be recognized very promptly.<sup>1]</sup>

SYPHILIDES; THEIR GENERAL CHARACTERS; THEIR CLASSIFICATION. — Constitutional syphilis exists when an indurated genital chancre is followed by a painless, hard swelling of the inguinal glands. The change in syphilis, of the lymphatic glands, is so characteristic that from it alone the diagnosis of syphilis is possible, especially when

[<sup>1</sup> A case of this character, in which no syphilitic history was obtainable, but which subsequently developed well-marked syphilodermata was reported by Dr. F. R. Sturgis, in the *Boston Medical and Surgical Journal*, February 3, 1881. Dr. L. Duncan Buckley, in *The American Specialist*, January 1, 1881, reports a case of enormous double cervical adenopathy occurring eleven months after infection, and coincident with a papulo-syphiloderm. The condition here was probably similar, but the syphilitic history, the presence of the eruption, and the situation of the enlargement made the diagnosis easy. It can readily be understood that, in such cases, when the glands of the groin are attacked, and the patient either ignorantly or wilfully denies previous syphilis, the recognition of the true condition may be extremely difficult.]



the cervical, maxillary, and other lymphatic glands are invaded as well as those in the inguinal region.

The eruptions of the skin and mucous membranes soon make their appearance, and constitute the first manifestations of the secondary stage of syphilis.

Syphilides usually appear about the forty-fifth day after the beginning of the infecting chancre, sometimes sooner, at other times later, even two or two and a half months from the date of the chancre. They are seldom as late as three or four months, yet they have occurred even after five months have elapsed. The mercurial treatment, given during the existence of the chancre, has been accused of causing this retardation of syphilides, but it must not be forgotten that the evolution of the disease is very variable.

Very often the eruptive lesions of the skin and mucous membranes begin at the moment the chancre is healed and cicatrized.

The different classifications of writers on syphilides are all partly correct, but contain many defects; it is difficult, however, to make a perfect classification, because there are many conditions to be considered, such as the date of attack, the gravity of the disease with different patients, the different anatomical lesions, etc. A complete classification, which would include all these conditions, would be too complicated.

Most writers have based their classification, as Willan, upon the anatomical alterations of the skin; in which are included, at the same time, the order of their appearance and evolution, for cutaneous and mucous syphilides are more superficial when they are more recent, and grow deeper as they grow older. Thus the syphilides of the first period of secondary lesions affect only the papillary surface and epidermic layers. These are, according to the anatomical classification, erythemata or superficial spots, as roseola; limited, slight, and temporary inflammations of the papillary and epidermic layers, as papules. The older syphilides, on the contrary, belonging to the later secondary period, appear as pustules or tubercles, which affect the deep dermic and sub-dermic layers in connection with the papillary network and epidermis; they are destructive, and are followed by cicatrices. Therefore the anatomical classification will be retained, as it indicates with sufficient exactness the successive evolutions of syphilides from the surface to the deep parts of the skin; the sequence of the deep lesions, followed by ulcerations and cicatrices upon the superficial and benign lesions.

The following is the classification we have adopted:—

- |   |   |   |
|---|---|---|
| 1st. Erythematous syphilides (roseola). | { | Diffused ;<br>Macular ;<br>Papular.   |
| 2d. Papular Syphilides.                 | { | Small papules. — (Papular or papulo-granular syphilide) ;<br>Miliary syphilide ;<br>Conical, lichen-like syphilide ;<br>Large papules.—Patches of papulo-lenticular syphilide ;<br>Papulo-tuberculous ;<br>Papulo-squamous. |
| 3d. Vesicular syphilides.               | { | Varicelliform ;<br>Eczemiform ;<br>Herpetiform.   |
| 4th. Pustular syphilides.               | { | Acneiform ;<br>Impetiginous ;<br>Ecthymatous (sometimes superficial and precocious, sometimes late and ulcerated)—ulcerous ecthyma.   |
| 5th. Bullous syphilides.                | { | Pemphigus ;<br>Rupia.   |
| 6th. Gummous and tubercular syphilides. |   |   |

In this classification there is indicated the gradual passage of the superficial lesions of the early period of secondary symptoms, the roseola and the papules, into the deeper and later lesions of the second period, such as ecthyma, and finally into the rupia, tubercles, and gummata of the third period.

This transition is so insensible that some writers place the deep ecthymata, rupia and the ulcero-crustaceous syphilides, with the tertiary lesions of syphilis, while others, as Fournier, admit as tertiary syphilis only gummata ; this distinction has no positive value.

Syphilides of the first period are almost always polymorphous, that is, the eruptions present at the same time the different varieties of roseola, papules, small pustules or scabby papules, and mucous papules. In ordinary eczema or impetigo of a strumous nature, we

have the same elementary lesion of the skin, and the same appearance of all the regions affected; but, on the contrary, there are found in syphilis varied elementary lesions, spots of erythema alongside of papules and vesico-pustules, and other lesions modified according to their location. If a number of syphilitic patients are examined, there will generally be found several who, together with an erythematous roseola, either beginning, or terminating, or replaced by pigmented spots, will show some papules of roseola upon the chest, or larger and more prominent disseminated papules upon the arms, palms of the hands, and back of the neck; vesico-pustules or small, scabby papules upon the scalp; partly scaly and partly mucous papules at the angles of the lips or eyelids, or a variety of mucous patches upon the vulva and in the mouth.

In other cases, there will be seen a papular syphilide in a somewhat chronic state; the papules when upon the skin of the limbs appear dry, their epidermis desquamating, or when upon the scalp appearing as scabby pustules with a yellowish exudation, consisting of epidermic laminae, and of sebaceous and pus cells; the same papules, if seated upon the nipple, are large and scabby; beneath the scab, which is only an exudation containing pus corpuscles mixed with dry epidermic cells, there is a serous or puriform oozing. In those regions where the skin is in folds, as upon a dependant mammary gland, the papule instead of being dry, is moist: upon the palm of the hand, where the epidermis is corneous and thick, the epidermic layers over the papule form hard scales, which have incorrectly been compared with psoriasis (*psoriasis palmaris*). The epidermic layer falling off from these palmar papules leaves a smooth deep copper-red surface, covered by the rete mucosum and a few of the cells of the corneous layer. The most superficial epidermic cells, lost over the surface of the papule, form an elevated border around its circumference.

This polymorphous condition, in relation to the seat of the lesions, is more apparent than real, as will be shown when the pathological histology of the several syphilides is studied; but it should be remembered that the variation in appearance, and the blending together of the elementary lesions are among the best diagnostic characters of the general semeiology of syphilides. It is the same with syphilides of a later period, the elementary lesions being so seldom isolated, that it is difficult to decide whether to place a given eruption among the pustules or bullæ, among the tubercles or gummata. There are frequently seen syphilides which involve all the layers of the

derm and epiderm, and they are given compound names, as papulo-vesicular, papulo-pustular, tuberculo-pustular, etc., names which define themselves.

The cutaneous syphilides have, for the most part, as a common character, a special coloration, which is said to resemble that of copper or the pinkish-yellow color of ham; this coloration is owing particularly to extravasations of red blood-corpuscles; as the spots are disappearing they become yellow, greenish-yellow, gray, following the tints of blood pigment in a superficial ecchymosis. The spots or papules for a time remain of a whitish color, but even when they have entirely disappeared, the surrounding skin is still a little pigmented (pigmentary syphilide, vitiligo).

This special hue of syphilides is marked in the eruptions of the first period; the ulcerous and scabby syphilides, on the contrary, frequently present at their border a pale color, which is not at all characteristic. The copper color is not seen in lesions of the mucous membranes.

Another distinctive character of syphilides, except diffused erythematous roseola, is that they all have a regularly round shape, whether isolated or in groups. They form small circles, figures of 8, etc.

Finally, the lymphatic glands are always affected in the region invaded by the eruptions, and the action of mercury upon these eruptions is to cause their rapid disappearance.

Syphilides are divided into cutaneous syphilides and syphilides of the mucous membranes, the latter including mucous patches of the secondary period, and some of the ulcerous syphilides of the tertiary period.

Such are the general characters of syphilides. They will now be studied in detail. The histological changes which constitute the transformation of a papule into a vesico-pustule, or of a tubercle into a gumma, will be especially explained, so that the appearance of lesions may be well understood, and an examination of the surface of these eruptions will indicate the changes which have taken place in all the deeper layers of the skin.

**MUCOUS PATCHES; THEIR DIFFERENT TYPES.**—A mucous patch is of itself positive evidence of the existence of constitutional syphilis. Moreover, it is, of all syphilitic lesions, the one which most frequently returns; it constantly reappears with any new outbreak of a cutaneous syphilide. It is easily cured, or rather made to disappear from

the mucous membranes, but it recurs quite as readily. Patients leave the hospital cured of mucous patches at the end of a month's treatment, but they soon return with a relapse, and this is often repeated during two or three years, sometimes longer.

In very young girls who are hospital patients, mucous patches of the vulva are not so difficult to cure or so apt to return as in adult women. This is explained by the less active state of the organs, due to the absence of any genital function, and of menstruation; but the duration of mucous patches of the lips or throat in children is equally as long as in older persons. Thus, in cases of congenital or acquired syphilis in infants, mucous patches of the mouth are seen to return during a period of four or five years.

The several types of mucous patches are:—

1st. *Small papules*.—This variety occurs most frequently with papular roseola, or with cutaneous eruptions of small size, as miliary cutaneous papules and syphilitic acne; these papules, which are seated upon the vulva and labia majora, with the exception of their size, present exactly the same characters as the following.

2d. *Large papular patches*.—These are the most frequent of all: their shape is generally round and regular. Those situated upon the skin are to be distinguished from those upon the mucous membranes. The former are always characterized by a papule, a regular thickening of the superficial layers of the skin, which forms an elevation representing a segment of a sphere. Their surface is red, smooth, polished, and moist; at times they present a very superficial erosion, an elimination of the most superficial layers of the corneous epidermis. Upon the mucous membrane of the labia minora and of the vulva, the surface of the more or less prominent papule is whitish, owing to an imbibition of fluids, and to changes in the epithelial layers. Mucous patches of the lips, tonsils, etc., present the same whitish-gray color and opacity of their superficial layers, as do those of the labia minora.

3d. *Eroded mucous patches* are only an ulcerated state of the preceding.

4th. *Mucous patches with indurated base*.—In hospitals, patients are often met with, who have mucous patches situated on labia which are inflamed and œdematous from the irritation of a recent chancre; these mucous patches, which are sometimes ulcerated, and the bases of which are indurated, rest upon a tissue already altered, and would be very difficult to distinguish from a chancre, if other

mucous patches were not frequent upon the vulva or elsewhere, or if only one of the patches were indurated.

5th. *Diphtheritic mucous patches.*

6th. *Hypertrophied papules.*

7th. *Vegetating papules.*—Even as the chancre may be occasionally, though rarely, changed into a mucous patch, so may a mucous patch be transformed into vegetations.

Before describing the pathological anatomy and symptoms of the several varieties of these lesions, their most common seats should be pointed out. These are first, in the order of their frequency, the genital organs and region of the anus. But their location varies according to the sex. While with women mucous patches of the labia and of the vulva are almost constant in syphilis, with men, on the contrary, they are not very frequently met with on the prepuce or glans, the most common seats being the scrotum and anus. With women the anus is also frequently the seat of mucous patches, which occur in the radiating folds of this region, and occasion a tumefaction of the surrounding skin.

The frequency of mucous patches upon the lips, tonsils, tongue, arches of the palate, eyelids, etc., is about the same in both sexes. Mucous patches of the breasts and umbilicus are observed almost exclusively in women; they are, however, much more rare than the preceding. Upon the neck of the uterus, mucous patches are very frequently seen.

The special form of mucous patches when they are seated at the commissures of the lips and eyelids has been previously mentioned; upon the skin side they present a small elevation, often scabby, and upon the mucous side a white patch.

[Desprès records five cases in which vegetative mucous patches occupied the external auditory meatus; they caused a moderate amount of offensive discharge, and were covered at their most external portion by a grayish crust. He believes they appear by preference in patients who have previously had otorrhœa. He has also observed mucous patches upon the concha, in the perforation of the lobule, upon the vocal chords, on the caruncle of the eye and the conjunctiva, and in the umbilicus.]

PATHOLOGICAL ANATOMY AND SYMPTOMS OF MUCOUS PATCHES.—We may begin with the flat papule (moist papule) of the skin or labia

majora. Nothing is more simple than its structure. If a thin section made through its greatest diameter be examined, it will be found that it is formed of a regular, imbricated thickening of all the superficial layers of the skin, corneous epidermis, granular layer, rete mucosum, papillæ, and derm.

The epidermic layers are seen gradually to increase in thickness from the normal skin to the summit of the papule, and then again to diminish; the normal papillæ, at the border of the papule, progressively enlarge until at the central part of the papule they are two or three times their natural size. The rete mucosum penetrates between the hypertrophied papillæ, as far as their base by epithelial prolongations, separating one papilla from another. These appearances of mucous patches may be seen with low power.

In studying preparations with high power, we find that the cells of the corneous epidermis and rete mucosum undergo the same lesions that have been described *à propos* of chancre: *i. e.*, an excavated state of the corneous cells, with atrophy of their nuclei—conditions comparable to vegetable cells—and desquamation of the most superficial epidermis. In some of these cells, which have been transformed so as to include small cavities, or which have united to form large cavities, several pus corpuscles are often seen.

The desquamation of the corneous cells, and the presence of fluid and pus corpuscles in the interior of such of the corneous cells as may remain, or in the rete mucosum covering the papillary layer, fully explain the smooth and moist state of the surface of mucous patches.

The cells of the rete mucosum sometimes show an analogous lesion—the formation of a cavity between the nucleus and substance of the cell—but it is particularly in the superficial layers that this alteration is observed.

When a cutaneous mucous patch of the labium majorum, for example, is slightly ulcerated, but still has a smooth, moist, red or pink surface, it means simply that the superficial corneous layer of the epidermis has entirely disappeared; there is then seen at the periphery of the patch a thin border which is the limit of the normal epidermis; the surface of the ulcerated patch is covered by the thick and transparent granular layer and hypertrophied rete mucosum.

Beneath the latter—the rete mucosum—the hypertrophied papillæ present an embryonal state of their vessels, a swelling of their endothelial cells, and an infiltration of round cells between the fibres of their external coat. The connective tissue presents the same infiltra-

tion of lymph cells between its fibres. There is always in the papillæ, and surrounding connective tissue of the derm, a true inflammation, which is evident from the tumefaction of the fixed cells, and the presence of round migratory cells or proliferated cells.

Such are the histological lesions of simple mucous patches of the vulva, whether small, miliary, and conical, or large, flat, and lenticular, when located upon the skin of the labia majora or upon the mucous membrane of the nymphæ. In the very soft moist part of the labium majorum the mucous patches, instead of being red and polished, are partly eroded, and appear covered with small, whitish granules, which resemble starch-grains moistened with water, or look like moist filtering paper. The most opaque points are simply collections of epidermic cells softened by the imbibed fluids, and many of which have been changed so as to enclose a small cavity; a few of these cavities contain one or more pus corpuscles. Whatever may be their seat or their appearance, remember that the regular thickening of the papules is due always to the inflammatory hypertrophy of the dermic and epidermic layers. Therefore it is not astonishing to find, in a confluent and persistent eruption of mucous patches of the labia a considerable inflammatory thickening of the derm. In many cases the skin is hard, thick, and of a deep red color.

Mucous patches of the arches of the palate, the palate, and the tonsils, also of the tongue and lips, are slightly elevated, with a regular surface, oval or circular in shape, gray or whitish in color, and have the opaline appearance of mucous membrane which has been touched with nitrate of silver. This surface is smooth, and the white color gives the impression that the opacity of the part is in the most superficial layers of the pavement epithelium.

Such patches are preceded by a redness of the palate and arches, and they are, almost always, accompanied by a hypertrophy of the tonsils. Several writers, particularly Aimé Martin, think that the hypertrophy of the tonsils is primary, and the mucous patch secondary. We have examined a number of women and children in regard to this point, and have several times positively seen the mucous patch begin before there was any tonsillary hypertrophy. Yet this hypertrophy is very common, and may be primary, which is easily explained, since the whole organ may be considered as a lymphatic gland, and it undergoes the same lesion that all lymphatic glands experience (see p. 23).

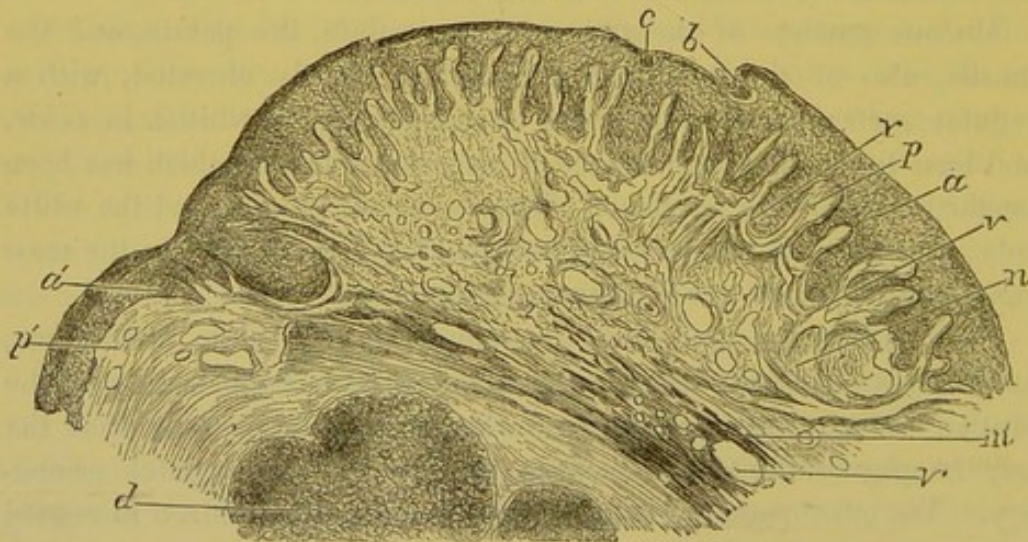
When one of these hypertrophied tonsils covered with opaline mu-



cous patches is removed, and thin sections are made of it, after hardening, there are found exactly the same changes as described in the vulvar papule. Upon all parts of a tonsil, which is the seat of a papule, there are seen the same thickening and the same inflammation of the epithelial layers of the papillary network and of the derm. The entire section, made vertical to the surface, forms a regular curve; the papillæ are two or three times longer than normal; the epithelial layers penetrate between and separate them; the most superficial layers of the epithelium show excavated cells with atrophied nuclei, or containing several nuclei or pus corpuscles. There are, in this superficial layer of the epithelium, small nests filled with pus corpuscles, true minute abscesses, containing four, ten, or even a hundred or more pus corpuscles.

These small abscesses frequently open upon the surface of the mucous membrane, and form cup-like cavities which contain pus corpuscles. This lesion cannot be considered an erosion of the patch, since the surface, to the unaided eye, is perfectly smooth, regular, and elevated, instead of ulcerated. The surface, although smooth, is moist, oozing, and discharges broken-down cells; the cavities in the

Fig. 24.



Mucous patch from the tonsil. *a*. Thick epithelial layer of the swollen mucous patch. *a'*. Normal epithelial layer. *b*. Cavity filled with pus cells, excavated in the superficial layer of epithelium, and opened upon its free surface. *c*. Cavity also containing pus in the epidermic layer. *p*. Hypertrophied papillæ of the mucous patch. *p'*. Normal papillæ. *n*. Thickened connective tissue of the mucous patch. *v*. Vessels going to the papillæ. *d*. Closed follicles. *m'*. Deep connective tissue with its vessels, *v'*.  $\times 12$ .

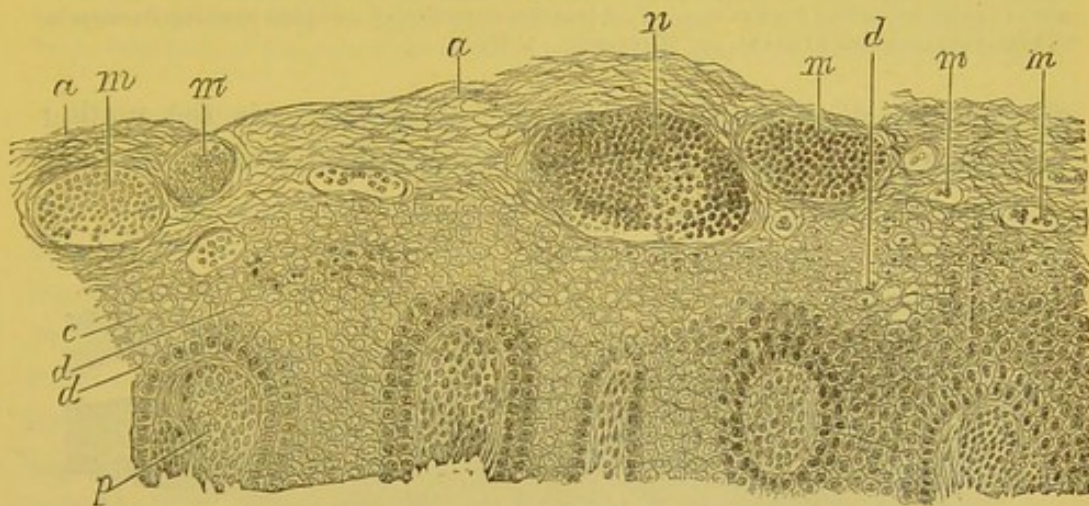
epithelial layer contain a little fluid, also pus corpuscles, inclosed either in the cellular cavities, or in small microscopic abscesses, to be

later described. In all mucous patches of the vulva and pharynx, there is a flow of fluid from the capillary vessels towards the free surface of the membrane, which carries off the pus corpuscles seated in the layers of epithelium.

Fig. 24 is a drawing of a section of a mucous patch of the tonsil, magnified 12 diameters, in which the relative thickness of all the parts constituting the mucous membrane can be seen. The epithelial layers, *a*, the papillæ, *p*, and connective tissue, *n*, are all swollen. At *b* there exists a small cavity which opens upon the surface, and contains pus corpuscles, not visible with this power.

In Fig. 25, magnified 150 diameters, is seen a number of cavities filled with pus corpuscles, varying in size, *m*, *m'*, *n*, which are all situated upon the surface of the mucous membrane. In this case,

Fig. 25.



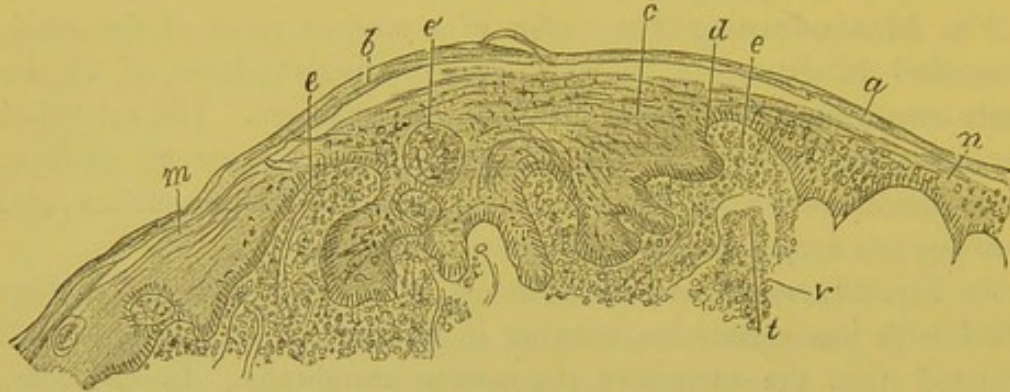
Mucous patch of the tonsil. *a*. Superficial epidermis. *m, m*. Cavities formed in the epidermis, and filled with pus corpuscles. *n*. Large cavity of the same nature situated near the surface of the patch. *c*. Cells of the rete mucosum, many of which present cavities between their nucleus and the substance of the cell. *d*. One of these cellular cavities. *p*. Papillæ.  $\times 150$ .

the cells of the rete mucosum, *c*, are mostly excavated, forming cavities, seen even with this power.

Figures 26 and 27 also represent mucous patches of the tonsil, magnified 60 diameters. In Fig. 26 the epithelial layers are very thick, the papillæ are also thickened and elongated. In Fig. 27 the superficial layer of the epidermis presents several small abscesses similar to those represented in Fig. 25. But in Fig. 27 the epithelial cells are partly disintegrated, and the patch is in places ulcerated.

Figure 28 is a drawing magnified 300 diameters, of a part of the epithelial surface of a mucous patch of the tonsil, showing the details

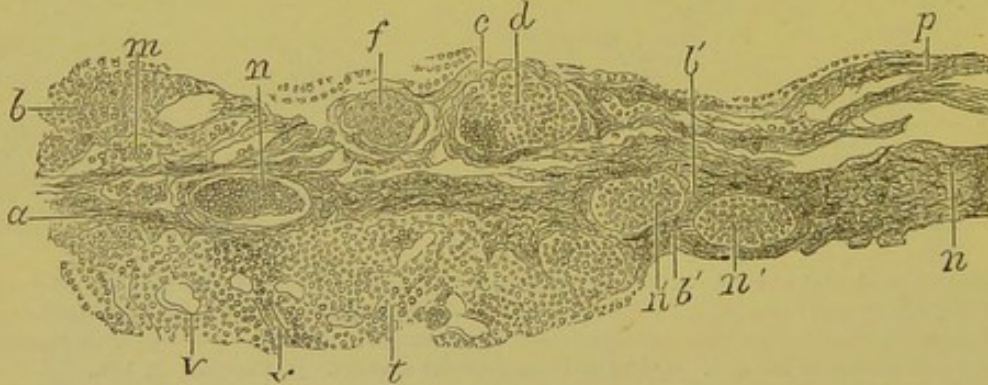
Fig. 26.



Section of a mucous patch of the tonsil. *a*. Superficial epidermis. *b*. Elevated part of the superficial epidermis. *c*. Rete mucosum, of which the cylindrical cells, *d*, cover the much hypertrophied papillæ, *e*, *e*, *e'*. The mucous epidermis is very thick over the entire region of the mucous patch extending from *m* to *n*. *e'*. A transverse section of a papilla showing its vessels. *t*. Embryonal connective tissue. *v*. Its vessels.  $\times 60$ .

of structure of the cellular cavities. Between some the uniting cement is seen, *d*. A few possess an atrophied nucleus in their

Fig. 27.



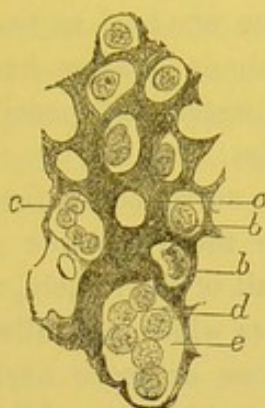
Section of an eroded mucous patch of the tonsil. *m*. False membrane, consisting of pus corpuscles and fibrin upon the surface of the patch. *d*. A small abscess limited by the superficial epidermic cells, *c*. *f*. A small abscess of which the pus corpuscles are granular. *n*, *n'*. Abscess of the same kind limited upon all sides by layers of epidermic cells. *a*, *b'*, *n*. Rete mucosum. *p*. Elevated superficial epidermic layer. *t*. Hyperplastic connective tissue. *v*. Vessels.  $\times 60$ .

cavity, *b*; others are empty, *a*; others, *c*, *e*, contain several round cellular elements.

The existence of these superficial cellular cavities, these small intra-epithelial abscesses, so remarkable and curious, and also of the analogous but less marked and less frequent change in the cells of the rete mucosum near the papillæ, readily accounts for the opacity,

for the whitish color, and for the imbibition of fluid by the epithelial layers which cover the mucous patches.

Fig. 28.



Section from the superficial part of a mucous patch seated on the tonsil. *a*. Excavated epithelial cell. *b*. An excavated cell having a free nucleus in its centre. *c*. Excavated cell containing several pus corpuscles. *e*. Larger cavity with a projection. *d*. Similar projections formed by the destruction of the walls of the cells and transforming them into a single cavity.  $\times 300$ .

We believe that these small abscesses or collections of pus cells come primarily from lesions of the epithelial cells. These cells first show a small amount of effused fluid in a cavity around their nucleus; at a given moment one or more pus corpuscles take the place of the nucleus in the cavity; later several cavities open one into the other, constituting collections of pus, which vary in size. The walls of the small abscesses are formed of one or more layers of epidermic cells flattened by pressure. It is also probable that the lymph cells passing out of the capillary vessels infiltrate between the cells of the epithelial covering, and collect together so as to form small abscesses.

Whatever this process may be, there is in the mucous patches of the tonsils an example of imperceptible suppuration occurring upon the surface of a mucous membrane, without any loss of the epithelial covering. Instead of being injured and destroyed, the superficial epithelium is thickened, and so also is the rete mucosum. Analogous changes take place in a number of cutaneous eruptions, as will be seen.

Beneath the epithelium, and between their prolongations, the papillæ present dilated vessels having embryonal walls; these vessels, like the papillæ, are elongated; the tissue of the mucous corium shows the same change of its vessels which are dilated and full of blood. Between the fibres of the connective tissue, there are also found a

certain number of round migratory cells. The walls of the arteries and veins are not sclerosed.

The closed follicles of the tonsil are seen, in a section, as large, regular circles, separated from one another by bands of connective tissue. They measure from one-half to two or three millimetres in diameter. Preparations obtained after hardening in alcohol, then placed for a few hours in water, and pencilled, show very distinctly the reticulum of the follicles.

In the connective tissue surrounding the follicles, there are seen clefts or canals which are the lymphatic spaces filled with round cells. At the external limit of the follicle, there also exist clefts or peri-follicular lymph sinuses which are filled with lymph cells, and large cells provided with one or more nuclei, and which contain in their interior red blood-corpuscles, resembling exactly the large multinuclear cells inclosing red blood-corpuscles, which were described as present in the lymphatic glands. In the reticular tissue are found the ordinary lymph cells, and a few of the preceding large cells. The fibrils of the reticular tissue do not present any change.

When the anfractuositities of the tonsil are cut transversely, the follicles, at the surface of the depressions, are seen covered with a thin layer of connective tissue which is lined by a stratified pavement epithelium. Papillæ are not always present upon that portion of pharyngeal mucous membrane which sinks into the depressions of the tonsil.

Mucous patches of the tonsils may ulcerate like those of the genital organs, or sometimes become diphtheritic.

A noticeable clinical symptom of syphilitic tonsils is their frequent insensibility. Many patients never complain of the throat, but when it is examined, the tonsils are found very large, and covered with opaline patches, and the palate and arches are also similarly affected. If the patient's attention be directed to this region, he alludes only to a little uneasiness and inconvenience from the hypertrophied tonsils.

The insensibility of the throat seen frequently in nervous young girls should be remembered as a possible explanation of their lack of sensitiveness, but it is certain that mucous patches, like all syphilitic eruptions, occasion little, if any, pain. If women complain to you of an acute sensation of pruriginous pain when they are affected with mucous patches of the vulva, thighs, and region of the anus, it is especially due to the irritated condition of the skin, which is red, and excoriated by the profuse oozing, in a word by an eczema intertrigo.

In the pharynx, the congestion of the palate, arches, and gums around the wisdom teeth, frequently occasions some pain, but the mucous patches of the tonsils or of the anterior arches are not at all, or but slightly painful.

We have frequently removed tonsils which were hypertrophied, and covered with mucous patches. It was owing to their hypertrophy that we excised them. The wounds caused by their ablation, with the tonsillitome, healed exactly as those which follow the removal of simple hypertrophied tonsils.

## CHAPTER V.

## DESCRIPTION OF MUCOUS PATCHES CONTINUED—THEIR TREATMENT.

Mucous patches of the tongue—Shaven state of their surface—Eroded mucous patches—Mucous patches with indurated base—Diphtheritic mucous patches—Hypertrophied mucous patches—Transformation of mucous patches into vegetations—Complications of mucous patches—Vulvitis, vaginitis, metritis, œdema, vegetations—Diagnosis of mucous patches—Treatment—Is it advisable to excise chancres and mucous patches, syphilitic tonsils, etc. ?

MUCOUS PATCHES OF THE TONGUE.—There are several varieties, two of which depend upon the seat of the lesion :—

1st. Mucous patches of the point and edge of the tongue developed upon the fungiform papillæ, which resemble mucous patches of the lips in so far as they are from their beginning covered by an opaline epithelial pellicle. They have not, however, a regular surface, but are more or less uneven, owing to the elevations of the fungiform papillæ. The patches, at the border of the tongue, frequently have ridges running parallel with the organ. Sometimes they are a little depressed ; sometimes their surface is very irregular, with ridges, folds, and depressions. When the lesion has returned, which is a frequent occurrence on the tongue, either with smokers, or with patients who have bad teeth in contact with the mucous patches at the edge of the tongue, the base of the patch is a little indurated and inflamed. Frequently, in similar cases, there is also seen a fissured state of the whole organ, characterized by irregular furrows varying in depth, and limiting segments of the mucous membrane ; this, however, is not characteristic of syphilis, it is met with in other lesions, is even seen in the normal state, and occasions no suffering.

2d. Mucous patches of the middle and posterior region of the tongue, seated upon a tissue provided with filiform and fungiform papillæ. These patches have a special shape. First, the fungiform papillæ of the lingual V may be attacked and form separately, by their tumefaction and by extension over the surface, a mucous patch. We have seen the large fungiform papilla, found at the angle of the

V, present such a degree of swelling and extension, that it alone formed a mucous patch with a smooth and regular surface. Upon the median or back portion of the tongue, there are frequently seen round or oval mucous patches, the large axis directed usually from before backwards, their surface smooth, and having a shaven appearance. This appearance is most striking, as they are surrounded with the long, projecting, filiform papillæ, which exist in this locality. Fournier, who insists upon this shaven appearance of the papillæ, asks the cause. I have not made any histological examinations, as a portion of the tongue cannot be removed as readily as a piece of the prepuce, but I believe this is not necessary to explain the anatomical structure of these patches. This appearance of the tongue deprived of papillæ at the points occupied by syphilitic lesions of the primary period is also seen in tertiary syphilides in patches on the tongue. Further on will be found reports on the microscopical examination of a case (see Chapter VIII.), in which the corneous prolongations of the filiform papillæ have disappeared. The filiform papillæ upon the back of the tongue present sharp, long projections composed of corneous imbricated cells, the lowest cells implanted upon a small, slightly elevated papilla. The corneous epithelial portions often measure a half to one millimetre in length, without including the algæ which grow upon them, are lost upon the surface of the mucous patches, and leave a smooth surface, covered simply by the stratified layers of the rete mucosum. The whole patch appears smoother and more depressed, owing to the surrounding corneous prolongations of the filiform papillæ being preserved, and increased in length by the lingual inflammation, so that it may be compared to a mowed circle in a meadow of grass. It is not surprising that the superficial corneous epidermis desquamates upon the back of the tongue, since it is incessantly rubbed by the passage of food and drink, and by the movements of speaking. It is, moreover, the same phenomenon that is seen elsewhere, upon the smooth surface of papules of the labia majora, tonsils, etc. Although a mucous patch upon the back of the tongue appears shaven, because it is surrounded with filiform papillæ, it is, nevertheless, certain that there is an inflammatory tumefaction of the connective tissue of the filiform papillæ upon its surface, and a true thickening of the corium, which we can determine by palpation. This variety has been minutely described since it seems to be an exception to the rule, in order to show that the essential phenomena of mucous patches are everywhere the same.



Mucous patches of the superior and inferior surface of the epiglottis may occur at the same time with those upon the tonsils and posterior walls of the pharynx. They are said by some writers to be very rare. I myself have no opinion upon this subject, not having specially observed them.<sup>1</sup>

3d. *Eroded Mucous Patches*.—The word eroded, as applied to chancres and papules, is not well defined, but usually indicates complete falling off of the corneous epithelium, the granular layer and rete mucosum remaining. Consequently, in order fully to understand this term, which is admitted by most writers, I accept as a definition of eroded, a falling off of the corneous layers of the epidermis. This desquamation occurs in the normal state, but then the cells or layers disappear separately, while in erosions the entire superficial or corneous epidermic layers fall off at the same time. The loss of the superficial covering is, in the case of syphilitic papules, more apparent on account of the layers at the periphery of the papule being thicker than normal. This erosion is a very frequent lesion. The retained rete mucosum forms a transparent varnish-like layer upon the surface of a papule, which, when it is located upon the skin of the labium majorum, for example, appears red, shining, glossy, and moist.

4th. *Mucous Patches with Indurated Base*.—In this category are placed the mucous patches which are seated upon a part changed by the presence of a previous chancre, and which is still œdematous and sclerosed. For example, when a chancre, seated upon the labium majorum is in process of recovery, the labia and nymphæ are still frequently hard, swollen, sclerosed; in a word, affected with inflammatory œdema. Moreover, the bloodvessels are sclerosed, not only at the point of the chancre, but all around it; and, as has also been mentioned, the lymphatic vessels are engorged throughout their entire course, from the chancre to the lymphatic glands. The inflammatory induration of these latter also constitutes an impediment to the circulation of the lymph, in the region between them and the chancre, and the lymph cells pass out between the fibres of the connective tissue. This condition explains the persistence of the œdema of the labia upon the side of the primary induration. Mucous patches occurring upon such an altered part, frequently behave in a special manner.

The base of the mucous patch, the papillary tissue, and the derm are thicker and broader than in a region where the skin is healthy.

[<sup>1</sup> Mackenzie describes them as not infrequent.]

If these patches ulcerate, the surfaces are excavated or cup-shaped. The surface of the ulcer at its centre has the epidermic layers and rete mucosum almost entirely destroyed, and covered by a yellowish-gray false membrane; by palpation between the finger and thumb it is possible to recognize an induration, which is not so hard or so characteristic as that of typical chancre. But the indurated chancre with women does not always have the induration so distinct as observed upon the prepuce with men. Therefore, if we could imagine a single one of these ulcerated papules having an indurated base, it would be very difficult, if not impossible, to diagnose from a primary chancre. But such a case never occurs.

When this lesion is observed, it is always accompanied with a more or less confluent eruption of vulvar mucous patches. These patches are usually symmetrical, and are in contact with others upon the opposite lip, so that if it were not known that syphilides were not auto-inoculable, it would be thought that they were the result of contact. Patients sometimes confess that they have had a previous lesion, a chancre. In addition, the enlarged lymphatic glands and a roseola, or characteristic cutaneous papules will be observed.

It is particularly by this grouping of symptoms that such mucous patches can be diagnosticated from infecting chancres. These two lesions are also very much alike in women, in regard to their anatomical structure and objective symptoms, especially in cases similar to the above. I have had occasion to examine, histologically, mucous patches seated upon a labium previously indurated by a cicatrizing chancre, and I have seen a deep infiltration of the derm with lymph-cells interposed between the fibrous fasciculi, and an inflammation of the external coat of the arterioles and veins, comparable to the same lesions of the vessels at the base of a chancre.

5th. *Diphtheritic Mucous Patches*.—This variety of mucous patches is frequently met with among women, and a good description is given by Aimé Martin from cases seen at Saint Lazare Hospital.<sup>1</sup> Clinically they are entirely distinct from true diphtheria, in that they cause syphilis by inoculation and contact, while pharyngeal or laryngeal diphtheria occasions only true diphtheria, diphtheritic angina, and croup. They differ also anatomically, for I have never found the special parasites of true diphtheria, the spherical bodies of Bolderew;<sup>2</sup>

<sup>1</sup> Union Médicale, August, 1861.

<sup>2</sup> In the false membrane of true diphtheria, a disease which it is difficult not to consider as due to micrococci, are found large, oval, or spherical bodies, a little

but in every other respect the false membranes of mucous patches are exactly similar to those of pharyngeal diphtheria.

One or more ulcerated mucous patches of the labium minorum, for example, may present, instead of their epithelial covering, a whitish or gray, sometimes yellowish false membrane, which is opaque and adherent. It is removed with difficulty, and is somewhat elastic; its removal causes the surface of the patch to bleed. It is reformed in a few hours after removal. Having remained a varying period of time, three or four days, if carefully treated, the epidermis forms beneath it, and it does not reappear.

A fragment of the false membrane, placed in a drop of water or diluted alcohol, shows cells readily separated by teasing, which are pus corpuscles and epidermic cells. The latter are seen with an atrophied, elongated, and granular nucleus, or with a small cavity filled with fine granules in place of the nucleus. The protoplasm of the cell is at times thin, fibrillated, or finely granular, sometimes cavernous, thick, with many facets and numerous prolongations.

The framework of the false membrane is very difficult to separate, since it is composed of a felt-like mass of dense fibrils, having an elasticity which makes it difficult to dissociate them. This false membrane has been examined by Chas. Robin and A. Martin, who consider it to consist of filamentous fibrin and pus corpuscles. So that according to them the false membrane has the same anatomical composition as that of diphtheria of the pharynx and larynx. There are certainly in this membrane filaments of fibrin; but we also find, at the edges of dissociated fragments, branching prolongations, and epidermic cells undergoing the change that has been described *à propos* of the false membrane of chancres. In the spaces excavated either in the middle of the epidermic cells or between their prolongations are found pus corpuscles.

Such is the false membrane studied after removal and teasing, but it should also be studied in its relation with the neighboring parts. This I have done from a labium minorum which I removed, hardened, and made thin sections of. The sections included the whole thickness of the removed labium; the papillæ at the border of the mucous patch were longer than those upon the simply inflamed tissue of the part;

larger than the cells, which contain micrococci or small rod-shaped bacteria. [Prof. H. C. Wood and Dr. H. F. Formad, in their recent investigations upon diphtheritic membrane, have demonstrated the above spherical bodies to be the white blood-corpuscles containing micrococci.]

and the epithelial layers at the margin of the patch were very notably thickened, as was also the rete mucosum. The prolongations of the rete mucosum, between the papillæ, were seen much elongated. The epidermic layers of the detached portion, which stopped at the eroded border of the patch, formed irregular stratifications.

In preparations stained with picro carmine the corneous layers were yellow, the rete mucosum was orange-red, and the connective tissue took only the carmine.

At the point where the erosion and false membrane began, the corneous layer had given away and the rete mucosum was dissociated by pus corpuscles.

Over all parts of the patch covered by the diphtheritic membrane, the latter had about the thickness of the epithelial layer, so that upon a superficial examination, with low power, this latter layer appeared to be preserved; and, further, to complete this resemblance, the superficial part of the false membrane presented a thin layer which was stained yellow by the picro-carmine, as was the corneous epidermis.

With a low power, however, a slight depression at the junction of the false membrane with the normal epithelial layers was seen; but the papillæ under the false membrane presented a different arrangement. Instead of being united to the cells of the rete mucosum, which was recognized by its prolongations, the papillæ were free beneath the false membrane; they were not so firmly united to it as they were to the normal rete mucosum. These papillæ were swollen, flattened, and lower at the ulcerated part in the centre of the patch.

Studied with high power, the most superficial part of the false membrane, in a section vertical to the surface, that which was colored yellow by the picro-carmine, was found to consist of longitudinal layers in which were seen a few atrophying corneous and flat cells; but the greater part of this portion was composed of delicate spores of roundish microscopic algæ which projected from the surface of the membrané.

Beneath this layer were found pus corpuscles, and in some places these corpuscles were situated in a reticulum of delicate fibrils of fibrin. Finally, most of the deep layers of the false membrane consisted of round cells or pus corpuscles with an interlacing of branching fibrils, and a few recognizable epithelial cells, as previously mentioned. In contact with the papillæ, and beneath the false membrane, was seen a granular substance, semifluid, containing many lymph cells.

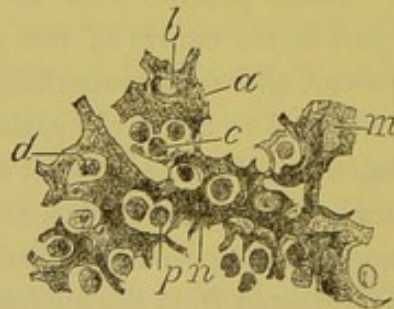
The connective tissue of a mucous patch, in a case examined, was very much altered, and infiltrated with lymph cells between the fas-

ciculi of the connective tissue, and around the vessels, extending two or three millimetres below the papillary network. The external coat of the arterioles and venules was much thickened by numerous cellular elements. In this case the chancre, lately cicatrized, was seated upon the labium majorum, and near to the diphtheritic mucous patch. From its close proximity to the nympha, the œdema as well as the perivascular inflammation of this region may be accounted for. The diphtheritic mucous patch had developed upon a tissue changed by a previous chancre.

In the case of the diphtheritic mucous patch which served for the preceding description, I removed the labium minorum upon which it was situated, and which was much swollen, and affected with inflammatory œdema, such as is frequently seen in similar cases.

Mucous patches of the vulva are not the only ones which may be covered by a diphtheritic false membrane. It may occur upon the lips, cheeks, throat. The mucous patches represented in Figs. 26 and 27 (see page 136) present a remarkable type of small foci of suppuration situated in the superficial layers (see *d, f*, Fig. 27); upon the ulcerated surface of one is an adherent gray layer. This false membrane, examined in sections made vertical to the surface, shows epithelial cells which may be considered as types of the branching degeneration of epithelium in diphtheria. Figure 29, magnified 250

Fig. 29.



Changed epithelial cells of the false membrane from the mucous patch represented in Figs. 26 and 27. *a*. Cell with multiple and ramifying prolongations and empty cavity, *b*. A cavity containing several pus corpuscles, *c*. *d*. An excavated cavity in a cell containing a pus corpuscle. *p*. Pus corpuscles lying between the cells. *m*. A cell with branching prolongations. *n*. A very large elongated and branching cell.  $\times 250$ .

diameters, shows some of these changed epithelial cells. They have multiple and irregular prolongations, and are pierced with holes filled with one or more pus corpuscles. Thus the cell, *a*, shows an empty cavity, *b*, and a cavity, *c*, which contains several pus corpuscles; at *d* is seen a cavity in one of these cells containing a pus

corpuscle. Pus corpuscles are seen between the branching prolongations of the cells as well as in the excavated cavities of the cells. From this drawing it is seen that the corpuscles have passed between the cells, and lodged there in such a manner as to cause simply an indentation; at other points there is a complete small cavity which contains a single corpuscle, or a cavity containing several, or even an opening piercing the cell containing one or more corpuscles. It is probable that the same changes take place as in intense inflammation, but the processes of the cells conceal the alterations of the nuclei, and the excavated cavities around the nucleus, which we have previously described, as occurring in cutaneous syphilides.

Returning again to mucous patches of the vulva and the accompanying inflammation:—

The labia minora are generally œdematous and irregular, their surface resembling goose-flesh, the skin of an orange, or the first stage of elephantiasis; it is a little transparent and contains fluid. This condition of the skin is due to a hypertrophy of the papillæ of the derm, which are elongated, and saturated with fluid; the epithelial layers of the rete mucosum are also thickened, and finally the connective tissue of the derm has its vessels greatly distended, while the fixed cells of the connective tissue, between the fasciculi of fibres, are swollen. There are also some migrated cells between the fasciculi.

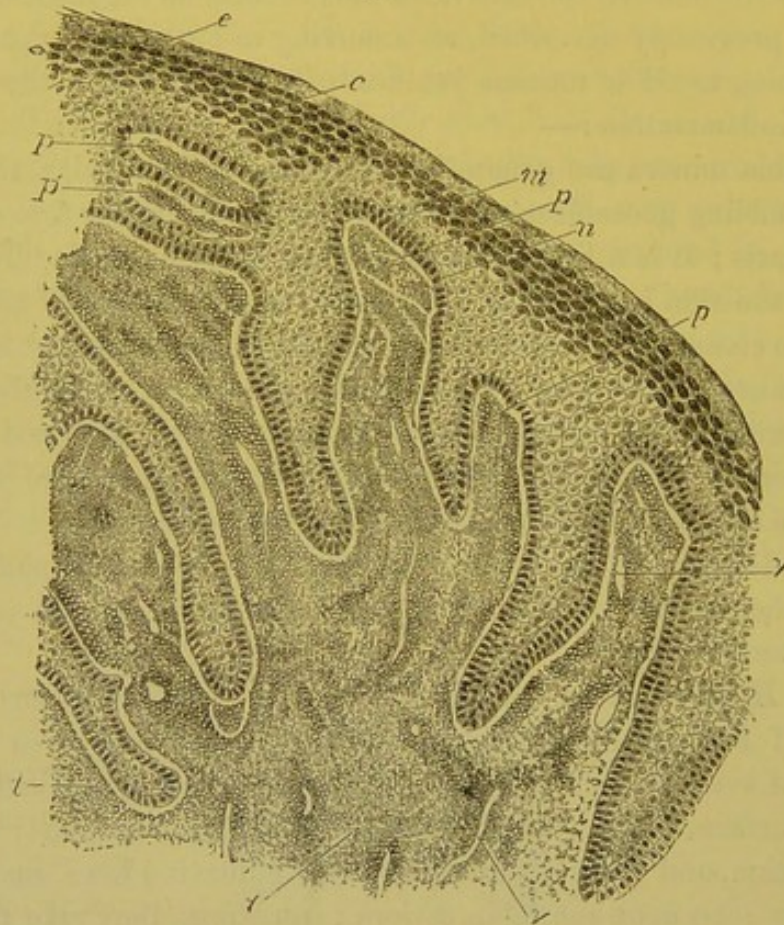
This œdema is not the only complication which accompanies mucous patches of the vulva. There are others, the details of which will be described later.

6th. *Hypertrophied Mucous Patches* (papulo-hypertrophied patches of Fournier).—Upon the vulva are occasionally seen mucous papules of every degree from those scarcely elevated, and with a red, shining surface, to hypertrophied papules, having a regularly increasing elevation, and lying upon a raised and indurated base, such as are frequently seen upon the labia majora; sometimes they take the form of swollen, soft, and gray patches, saturated with juice, irregular and fungoid upon the surface, and projecting one to three millimetres or more. This type is characterized by large papules, so confluent at times that they almost touch, and forming a continuous and irregular layer from the pubes to the buttocks, involving the labia and nymphæ, the inguinal folds, the upper part of the thighs, and surrounding the anus; they are accompanied by a considerable sanious oozing and exhale a heavy, repulsive odor. In the Lourcine Hospital are seen many such cases, but they must be examined when admitted, in order to see

them in their full development, since they rapidly change under hygienic and medical care. When it is seen how easily they may be prevented by cleanliness and bathing, the heedless neglect of themselves shown by some of these women is simply astounding.

The histological examination of these patches shows the same lesions as simple mucous patches, but in a higher degree. The papillæ are much longer; the vessels of the papillæ are elongated, and their walls are embryonal; the tissue of the papillæ contains numerous round

Fig. 30.



Part of a hypertrophied vulvar mucous patch. *e*. Corneous epidermis. *c*. Granular layer. *m*. Rete mucosum. *n*. Layer of cylindrical cells of the rete mucosum. *p*. Elongated and hypertrophied papillæ infiltrated with lymph cells. *p'*. Transverse section of papillæ. *v, v*. Vessels of papillæ. *t, t*. Inflamed dermo-papillary connective tissue.  $\times 100$ .

cells entangled in its meshes. The layers of the rete mucosum, the granular layer and the superficial epidermis are very much thickened. All the epithelial and epidermal layers are in place: the most superficial cells desquamate, and are found in the fluid which permeates through all the layers.

Figure 30 represents a part of one of these mucous patches magni-

fied 100 diameters. The papillæ, *p*, are seen traversed by the vessels *v*, *v*, and very rich in round cells, which extend into the connective tissue of the derm *t*. These papillæ are capped by a very thick epidermis regularly arranged. In this specimen, the intermediary layer formed by the granular cells, *c*, is composed of three or four layers of cells, and is consequently thicker than normal. In the superficial layers we frequently find, in these mucous patches, excavated cells, which resemble vegetable cells, or even small foci of pus corpuscles, surrounded by the corneous layers and opening upon the surface of the patch.

When these hypertrophied mucous patches are examined in their entirety, it is seen that their surface has not so regular a curve as that of the simple mucous patches. The length of the papillæ forming them varies, some being much longer than others, and, therefore, the surface of the patch is uneven and nodular.

These hypertrophied mucous patches are not only met with upon the genital organs, which, however, is their most frequent location, but are seen very often in the throat and on the tongue.

7th. *Mucous Patches transformed into Vegetations*.—When the nodules of mucous patches increase, and their papillæ become much elongated, and covered with thickened layers of epithelium, and when these papillæ are separated into groups and nodules, true syphilitic papillomata or cauliflower vegetations are formed. Between these and hypertrophied mucous patches, there is no difference in regard to origin or to the course of the lesions; the condition of the papillæ, of the connective tissue, and of the epidermic cells, is the same in both. With the cauliflower vegetations, there is only a greater segmentation of the patch into several small secondary nodules or buds, due to the separation of the groups of papillæ, which are separately capped by the covering epithelium.

This variety does not need a special description. Papillomata are not always of syphilitic origin when found upon the genital organs. They are frequently met with during non-syphilitic vaginitis, and with the symptomatic vaginal discharges of pregnancy.

Fournier describes a variety of mucous patches under the name of ulcerous patches, but, from his description, these are later lesions, and they will be referred to after the later syphilides have been described.

[In *résumé*, it may be said that the histological structure of mucous patches consists in a thickening of the epidermic layers and an increase in the size of the papillæ of the skin by a development of the



elements entering into their structure. This increase in size of the papillæ causes a corresponding increase in the length of the interpapillary prolongations of cells of the rete mucosum. The cells of the epidermis undergo a change in their structure, which results in the formation of cavities in their protoplasm; there also occurs a division of their nuclei, and, finally, the development of small microscopic abscesses, which uniting one with another constitute foci of suppuration. The bloodvessels of the papillæ are distended with blood. The tissue of the derm is found proliferating, but there is seldom observed that change which corresponds to the sclerosis of the vascular walls, such as exists in the chancre. Ulceration of the mucous patch may occur, and also the formation of a diphtheritic membrane upon the ulcer; these changes in no way differ from similar lesions occurring elsewhere.

These are the essential histological changes taking place in the development of mucous patches; for the more minute details due to situation, duration, etc., a study of the several varieties, as previously given, is necessary.

The mucous patches that have been considered form a very characteristic group, but one lacking in homogeneity, for some are more superficial, more benign, and more easily cured, others are deeper and more difficult to heal. Some are simply eroded upon the surface, others ulcerated and covered with a diphtheritic false membrane. Finally, some are but slightly elevated, while others are exuberant and hypertrophied. Notwithstanding this diversity in their appearance and course, I think it is impossible to mistake them or to confound them with other lesions.

COMPLICATIONS OF MUCOUS PATCHES.—The complications observed in connection with mucous patches in women are eczema, dermatitis, vulvitis, inflammation of the glands of the vulva, œdema of the vulva or of the labia majora, urethritis, vaginitis, inflammation and hypertrophy of the neck of the uterus and vegetations.

ECZEMA.—The most common complication is eczematous oozing, *eczema intertrigo*, which affects all the region of the labia majora, anus, and upper part of the thighs. This is accompanied by redness of the skin and by excoriations, which are often seen as fissures, especially at the region of the anus, are sometimes very painful, and itch intensely.

Small vesicles of eczema are frequently met with upon the skin

near mucous patches, especially upon the buttocks and thighs. This complication is not very important, and is due to the irritation of the fluids coming from the vagina and vulva, and to the oozing from the mucous patches; it occasions a more or less acute smarting pain.

Upon a vulva so changed, the erosions proper of the mucous patches are difficult to see; but by the gentle application of a solution of nitrate of silver, the circular or oval erosions of the patches immediately assume a whitish hue, owing to the saturation of their epithelium with fluid, which is rendered opaque by the deposit of silver.

DERMATITIS.—The skin of the labia majora, when it is the seat of mucous patches, during the first secondary period, or of a late eruption of confluent mucous patches, is indurated and thickened in a remarkable manner. It is then deep-red in color, and so thick and hard in its entire extent that sometimes, if we attempt to fold and raise it between the fingers, it offers a resistance almost as great as if it were a piece of paste-board.

It should be remembered, that mucous patches are not only a lesion of the epidermis or a papillary hypertrophy, but the whole of the deep layers of the derm and their surroundings are inflamed, and are the seat of an infiltration of lymph cells. When papules and cutaneous pustules are described, it will be seen that the lesions are much deeper than an examination with the unaided eye would lead us to suppose.

VULVITIS.—An inflammation of the vulva almost always accompanies mucous patches of the genitals, and is easily explained; the region of the papule is red, swollen, moist, and oozing, discharging even from the internal surface of the labia minora and vaginal entrance an opaque, creamy fluid. This fluid, very abundant with unclean women, consists of a mixture of the vaginal secretion, the secretion from the epithelial surface of the nymphæ, and especially the secretion from the sebaceous and vulvo-vaginal glands. The internal surface of the labia minora is generally red; the remains of the hymen are almost always swollen and of a bright-red color. The urethral and vaginal orifices are in a similar condition. The folds of mucous membrane forming the remains of the hymen and the upper part of the urethral opening are frequently the seat of red or pale irregular elevations, resembling vegetations; these elevations are covered by very thick layers of the epidermis.

The sebaceous glands of the labia minora are enlarged, and at their orifice is seen a small, opaque, white concretion, which may be forced out by pressure; it measures about half a millimetre in length, and consists of epithelial cells. The vulvo-vaginal glands are frequently swollen, so that they are easily felt, attaining the size of a cherry-stone or more. By pressure a turbid, mucous fluid, which contains numerous pus corpuscles and filaments of mucus, may be made to flow from their ducts. When the inflammation is very intense a few drops of this fluid are discharged from the duct, even in cases in which there is no abscess of the vulvo-vaginal glands; the discharge is due to a limited suppuration of the connective tissue surrounding the gland.

The vulvitis which accompanies vaginitis in non-syphilitic patients, frequently occasions small red erosions, round or oval in form, and upon the surface of which a desquamation of the most superficial epithelium occurs. These erosions are frequently bright-red in color, and measure from two to eight millimetres in diameter, are painful, vary from two to six in number, and are seated within the labia majora between their base and the hymen. They do not cause a thickening of the corium, and the connective tissue of the mucous membrane is pliant and normal, which facts distinguish them from mucous patches. These very superficial erosions are especially found in the folds between the hymen and nymphæ, while mucous patches are found upon the labia.

In the Lourcine Hospital there are frequent opportunities to study vulvitis in its most simple form, as in the children from Saint-Therese ward, there is usually no accompanying vaginitis; the redness, discharge, inflammation of the sebaceous and mucous glands, and erosions are the same as with girls arrived at puberty. In children, where the hymen is generally intact, this membrane, during vulvitis, is very red and swollen.

ABSCESSSES OF THE VULVO-VAGINAL GLANDS, which are very common in consequence of venereal excess, especially during menstruation, are also met with as a complication of mucous patches. In this case the labia of one side are swollen, œdematous, and deformed by an enlargement situated at the inferior part of the vulva. Fluctuation is readily felt beneath the skin, distended by the purulent fluid, and by puncture a considerable quantity of pus mixed with blood is discharged.

The mucous glands which are seated below the urethra, in the vestibule, may also be inflamed, and form a small cup-shaped ulcer about one and a half millimetres in diameter, whose margin is usually covered by normal mucous membrane.

VAGINITIS, characterized by considerable swelling, redness, purulent, and thick vaginal catarrh, hypertrophy, and redness of the villi and folds of the vagina, is seen in connection with syphilis and mucous patches. The vaginal entrance is contracted, and the introduction of the speculum is very painful.

Besides this vaginitis, which may occur independent of syphilis, there is always found, in syphilis, a certain degree of inflammation of the vagina, which is less intense, less red, and accompanied by a vaginal leucorrhœa. Mucous patches do not occur upon the vagina. The vaginitis is due to a neighboring inflammation caused by confluent mucous patches which exist upon the vulva, and to the changes which take place at the neck of the uterus.

The neck of the uterus presents very often, if not always, superficial or deep lesions during the secondary stage of syphilis. Quite frequently mucous patches, at first opaline, afterwards eroded, appear upon the os uteri, one or two in number, or form groups. The parts of the os, where the patches are situated, lose their epithelium and are transformed into ulcers. Very often, when mucous patches have not been observed, there is a slight erosion of the orifice of the os, a muco-purulent catarrh of the neck, and a hypertrophy of the entire organ, the neck especially becoming large and hard. This inflammation, and this fibro-muscular hypertrophy of the neck are certainly not always caused by syphilis. But if the neck of the uterus in young girls affected with simple vaginitis, who have never had children or miscarriages, be compared with that of girls, of the same age, who are suffering with syphilis, it is at once very evident that the syphilitic patients have the neck of the uterus enlarged and affected with a catarrhal inflammation; while it is small and normal in simple vaginitis. The only lesion observed in the latter is the redness of the vaginal mucous membrane continued over the os uteri. It may therefore be rationally concluded that the inflammation of the neck is sometimes directly due to syphilis, as are vulvitis and vaginitis, without necessarily the presence of mucous patches upon the neck.

VEGETATIONS occur very frequently as a complication of mucous patches, occasioned by the profuse discharge of the latter. They are seen in every variety from the cock's-comb to large vascular polypi implanted upon the hymen and around the urethral orifice, or from the small, villi-like, and soft elevations, scarcely visible to the unaided eye, found upon the internal surfaces of the labia minora, to the enormous cauliflower vegetations, as large as a walnut, or larger, located upon the labia majora, the entire vulva, and the region of the anus.

These vegetations are painful, particularly at their base and in the surrounding skin, their summit being very little or not at all sensitive. According to Leloir, no nerve fibres or axis cylinders are found in these formations.

ŒDEMA of the labia is seldom met with, except in the cases that have been previously mentioned. I have lately seen, however, a patient who had an œdema of the labia, occasioned by excessive coition with a man whose penis was abnormally large.

With men, mucous patches are complicated with œdema of the prepuce, vegetations, and, at times, blennorrhœa.

DIAGNOSIS OF MUCOUS PATCHES.—It is almost impossible to mistake a mucous patch after a number have been seen. They are formed upon a papule, that is, an inflammatory swelling of the corium and papillæ; the connective tissue is consequently thickened; their surface is oozing, and the epidermis or superficial epithelium, which covers them, is saturated or desquamated. Thus, upon the labia majora and minora there are seen, if the epithelium be simply saturated, whitish patches or small points, which resemble moist or pulpy paper, and consist of epidermic cells or excavated, changed superficial epithelium; upon a mucous membrane, as the lips or palate, the epithelium is whitish, opaline, resembling a surface which has been touched with nitrate of silver.

The mucous patch of the labia majora, if eroded, has a surface which is red and smooth after the superficial epithelium has desquamated; the shape of the patch is always circular, or regularly oval, and the derm is thickened upon its surface. Mucous patches of the neck of the uterus are readily recognized by their opaline surface and grouping. When they are ulcerated, the opaline appearance can generally be seen at their margins. If the entire patch be ulcerated, one may

hesitate between a simple ulcer of the neck and a syphilitic ulceration. The hypertrophied papules are very characteristic. The papules of the vulva and labia majora, even when in process of healing, are very distinct; as the epidermis forms the derm remains a little papular, and their surface is dull red.

THE DISEASES OF THE VULVA with which mucous patches may be confounded are, first, herpes. It has previously been mentioned, *à propos* of the diagnosis of chancre, that herpes of the vulva is sometimes characterized by an extremely confluent eruption of vesicles which rupture and become small erosions. Successive herpetic eruptions may occur, causing swelling of the labia majora and minora, and the entire vulva may thus become covered with small ulcers, which may last from eight to fifteen days, and are very apt to be mistaken for mucous patches. When a vesicle of herpes ruptures, and the raised epithelium has been thrown off, there remains a small erosion or superficial ulceration having the diameter of the vesicle—two to three millimetres. When several vesicles are close together they unite and form a single ulcer with festooned edges. But these ulcers, or erosions, do not rest upon a papular base over a swollen derm, which is sufficient to distinguish them from mucous patches. Again, in making a thorough examination of the patient, if there are successive eruptions, as in Case VI., there are seen recent and perfect vesicles alongside of old erosions. Although the vulva may be much inflamed, moist and covered with a purulent serum, and although the labia minora and majora may be œdematous, the inguinal glands are neither swollen nor hard. Herpes recovers of itself; the erosions which have succeeded the vesicles become small, cicatricial, white, or pigmented spots. The cicatrices soon disappear, and the skin, at the seat of the eruption, for a time remains pigmented.

In mucous patches the papules are much larger and more prominent, even when they are ulcerated; they have a base which is formed of the derm infiltrated with cells and swollen, which is not the case in herpes. Again, the lymphatic glands in connection with mucous patches are always indurated.

An indurated chancre is not liable to be confounded with a mucous patch, even with an indurated base (see page 142), because the patches are always multiple upon the vulva.

A soft chancre is also different from a mucous patch, in so far as it destroys the derm and forms a deep ulcer. It is true, when it is

healing, it granulates, and is even with the surrounding skin; but if there be any doubt inoculation will remove it.

Elephantiasis is not liable to be mistaken for mucous patches, since it is a deep lesion of long duration, a tumor, a true myxoma or a fibroma, and if there be any doubt, the continuation of the swelling in elephantiasis, compared with the rapid recovery of mucous patches, soon removes all uncertainty.

Mucous patches of the neck of the uterus are to be distinguished from herpes of this region, which, according to some writers, occasionally occurs. But herpes of the neck is met with only in connection with herpes of the vulva, so that this error may easily be avoided.

Mucous patches of the vulva, mouth, throat, etc., although local lesions, always indicate a syphilitic contamination of the whole system. Their course, their duration, and their prognosis, considered as local lesions, vary according to their seat and the age of the syphilis. Many recover simply by rest and cleanliness, as for example, in the first eruption of mucous patches upon the vulva, but they frequently return *in loco*. Mucous patches of the tongue and throat are more tenacious, but when the attack of syphilis is not very intense, they are readily healed. In some patients, especially with smokers, patches of the mouth and throat are incurable, internal treatment being powerless.

With several of our patients, we have seen the mucous patches of the tongue, fauces, and tonsils obstinately return during several years. We have also had women to return to the hospital for two or three years, at various periods, to be treated for these lesions.

TREATMENT OF MUCOUS PATCHES.—The mucous patches of the vulva, as they are seen in the Lourcine Hospital in their perfection, upon patients at the time of their entering the wards, vegetating, hypertrophied, or enormously confluent, covering the labia minora and majora, the inguinal folds, perineum, and anal region, and occasioning an inflammatory hypertrophy of the skin of these parts, are rapidly improved by rest, mercury, and cleanliness. Fournier advises simply a dressing of a simple powder or ointment. [Calomel or oxide of zinc in powder, either separately or combined in equal proportions, will usually be a sufficient dressing, if the parts be kept free from discharge, and separated by a piece of soft lint frequently changed.] We have obtained benefit from a slight cauterization with nitrate of silver, in addition to the internal treatment and local applications.

The vulvar symptoms soon disappear, the exuberant patches subside, the skin becomes pliant, and at the end of two or three weeks, three-fourths of the disease has vanished. The patches still remain a little papular; later they are entirely effaced, and leave only a red colored spot, which in time disappears without leaving a cicatrix.

Mercurial treatment is, without doubt, very efficient in causing this prompt recovery, but it by no means prevents a relapse, and a new eruption may occur in a few months.

Mucous patches of the mouth, lips, tongue, and throat, although not so exuberant as those of the vulva, are generally more difficult to heal. Fournier advises cauterization with acid nitrate of mercury, as he does not think mercurial treatment sufficient. If this caustic be employed, it should be used with every precaution, since a single application, carelessly made, may be followed by mercurial poisoning.

For the mucous patches of the second and third year of syphilis, seated upon the tongue or throat, vegetating, elevated, hypertrophied, and of long duration, covered with corneous or white layers, or for those patches which are but little elevated, but are accompanied by a sclerosis of the connective tissue of the mucous membrane, it is necessary to use a more energetic caustic, which will penetrate deeper than the nitrate of silver. We have several times, with success, employed acetic acid, which penetrates into the layers of inflamed connective tissue beneath the epithelium.

THE EXPEDIENCY OF SURGICAL OPERATIONS DURING SECONDARY SYPHILIS.—Excision of indurated chancres, of mucous patches of the labia majora and minora, removal of the tonsils, etc., have frequently been mentioned throughout the preceding chapters. Yet many eminent surgeons, especially Verneuil, are opposed to any operation during a disease as general as syphilis. The blood, the liquids and solids of the economy are impregnated with the syphilitic virus, and it should be asked, if there is, or if there is not, danger in submitting the patients in such a condition to surgical interference? if the wounds which result from such operations are not peculiarly unfavorable? etc. In regard to the danger or safety of operations upon patients affected with syphilis, I can say from my own practice, and that of all the physicians and surgeons connected with the Lourcine Hospital, that there is no possible objection to the performance of these minor operations upon patients who present an eruption of the secondary period. The indurated chancres of the labia which I have removed;



those that my colleagues Horteloup and Mauriac have operated upon ; tonsils that I have excised ; similar operations by Anger ; excisions of mucous patches of the labia minora, numerous operations upon enormous vegetations that we have frequently made, and removal of lymphatic glands have always been followed by a healthy wound. If the tissue were œdematous or indurated, union by the first intention did not take place, suppuration occurred and lasted a few days, but that was all, and there was observed neither separation nor abnormal redness of the edges of the wound. I mention these cases in order that there may be no hesitation to perform a small operation which may benefit the patient.

In a thesis by Petit,<sup>1</sup> written at the suggestion of Prof. Verneuil, the danger of such operations is considered. He has collected a number of cases published by different writers, and those observed by himself, from which he concludes that traumatic lesions may present a peculiar appearance, and follow an abnormal course with syphilitic patients.

First, however, we must exclude from these cases those which were reported previous to the period when the distinction between indurated and soft chancres was not recognized. For example, the observation of Cazenave, that with some patients, affected with syphilis, leech-bites are transformed into round ulcerated chancres. It is evident this has reference to soft chancres, since infecting chancres are not auto-inoculable (see p. 81).

The syphilitic eruptions which follow the application of croton oil, cantharides, or the reception of an injury, are also of but little value, since these eruptions frequently occur several times during the secondary stage, and their appearance may be only a coincidence.

As regards those difficult operations which are far from always succeeding, under any circumstances, as the auto-plastic, should we consider their failure, in syphilitic patients, to be due to the presence of syphilis ?

Ricord,<sup>2</sup> who certainly has had much experience, maintained that these operations upon syphilitic patients followed the same course as with non-syphilitic, provided that the wounds were not contaminated with the virulent pus. He evidently here refers to the pus of soft chancres.

<sup>1</sup> De la syphilis dans ses rapports avec le traumatisme. Henri Petit. Paris, 1875.

<sup>2</sup> Bulletin de la Société de chirurgie, t. ii., 1851-52.

Among the cases reported in support of Petit's thesis we cannot admit those of old gummata, which were opened and treated as abscesses, and did not heal. Here the iodide of potassium is as powerful as the knife is useless.

It is true, at times, that auto-plastic operations do not generally succeed, when we operate upon tissues which are inflamed even in a slight degree, or modified by cicatrices of chancres, by tubercles, or by syphilitic gummata. But there are cases of recovery, especially if the precaution of previously administering mercury and iodine has been taken.

Although a number of doubtful cases are excluded from the thesis of Petit, there yet remain some where syphilis has certainly been the cause of failure of the operation, and where injuries have occasioned secondary lesions. These cases derive most of their value from the circumstance that they have been observed by Verneuil. We are much more disposed to admit injuries as an efficient cause of some tertiary syphilitic manifestations, as we have frequently observed striking examples in osseous lesions (see Chapter IX.).

Major operations may be undertaken after a prolonged treatment with iodide of potassium and mercury. For the minor operations, such as are performed in the Lourcine Hospital, we may repeat, that we have never seen them followed by an accident, and that they seem to us entirely safe.

## CASE VI.

*Successive eruptions of herpes upon the genital organs.*

I. I., æt. 41, storekeeper, entered the hospital June 21, 1877, Saint Clement ward, No. 4.

This woman felt during the night of June 17th or 18th two small pimples in the perineal region, between the fourchette and anus.

She had attended to her work on the 17th, walking very much, and carrying merchandise upon her back and arms. On the 18th she continued her work. The 19th she was unable to go to the dispensary; she had fever, which continued during the night of the 20th and 21st.

On the 21st she went to the Pitié, from where she was sent to the Lourcine, as having syphilis.

The day after her admission we observed, disseminated, numerous and very superficial erosions, some without order, others grouped upon the labia majora and minora, and in the inguinal region. The vulva is swollen and red; there is a profuse oozing of sero-purulent fluid from the erosions. The patient has also had an abundant vaginal discharge during the past two weeks. Menstruation has ceased for twenty-one months. She has very seldom had sexual connection. During last month she remained four nights with a man about 48 to 50 years old.

Examination shows a large inguinal hernia of the right side. The glands of this region are not indurated or enlarged. She denies ever having had any affection of the vulva.

We ordered for treatment frequent washing and powdered starch.

On the 23d we find, besides the above-mentioned erosions, four or five small vesicles, which have developed since her admission, and are situated outside of the left labium majorum. These vesicles are as characteristically herpetic as possible: they are acuminate, transparent, as large as a large pin-head, and when pricked with a needle, discharge a transparent, clear fluid.

The patient suffered very much from the eruption during the first few days in the hospital, she was unable to sleep, the pain was smarting and burning, and she could not touch the parts without causing pain.

The erosions of the vulva, and the last eruption of herpes, continued to ooze for some days.

June 30th. The patient is better, but the erosions still exist; the vulva is less tender and not so much inflamed.

July 6th. Continues to improve, all the erosions have healed and are replaced by small round or irregular white spots; the skin surrounding these spots is slightly pigmented.

July 12th. Leaves the hospital recovered. The duration of the eruption being about fifteen days.

## CASE VII.

*Mucous patches on the tonsils ; removal of the tonsil.*

C. L., æt. 18, admitted into the hospital April 5, 1878, Saint Clement ward, bed No. 28.

No special personal or hereditary history. Two years previous she had mucous patches upon the vulva, for which she was treated in this hospital.

Her health has been good until the present time ; fifteen days previous to her admission, she saw mucous patches again appear upon the labia minora ; these ulcers becoming painful, she decided to enter the hospital.

*Present Condition.*—We find upon the internal surface of the labia majora six patches : four upon the right labium and two upon the left. These ulcerated patches are large, indurated at their base, and gray in color. One of these patches upon the right labium is deeply eroded, yellowish in color, the base much indurated, and might easily be mistaken for an infecting chancre.

Five or six non-ulcerated mucous patches at the anus.

Four or five indurated glands, as large as hazel-nuts, in the right and left inguinal folds.

Ulcerated mucous patches upon the left tonsil and internal surface of the lips.

*Treatment.*—Van Swieten's solution. Solution of nitrate of silver applied to the patches.

After twenty-five days of treatment, the patient left the hospital. The mucous patches had disappeared.

June 23d. Again entered the hospital. The mucous patches of the vulva and anus have reappeared, and have become large and vegetating.

The tonsils are hypertrophied, covered with large, opaline, but not ulcerated, mucous patches. Mucous patches upon the right anterior arch.

The left tonsil was removed with the tonsillitome on June 4th.

Prescribed as before. Emollient gargle. Cauterization with nitrate of silver.

June 18th. The wound caused by removing the left tonsil is perfectly healed. We cannot find upon it any trace of a mucous patch. On the contrary, the patches upon the right tonsil are scarcely diminished.

June 28th. More mucous patches in the throat. Two or three eroded mucous patches at the base of the tongue. The mucous patches upon the vulva and anus tend to disappear.

**HISTOLOGICAL EXAMINATION OF THE TONSIL.**—The removed tonsil is the seat of an opaline, non-ulcerated, smooth, oval mucous patch, measuring nearly a centimetre in diameter. A section of the hardened tonsil, passing through the long axis of the mucous patch, shows that the epithelial layers are increased, that the papillæ are elongated, and that the connective tissue is the seat of numerous dilated vessels. Figure 24 (see page 134) is a drawing of this patch seen with low power. Upon the epithelial surface we see a small indentation, *b*, and an indistinct point, *c* ; the former is a small superficial open abscess,

the latter a small abscess still imprisoned in the layers of the superficial epithelium. Figure 25 (see page 135) is the same section magnified 150 diameters; the changes of the epithelium and rete mucosum are shown. The small abscesses, *m*, *m'*, *n*, are seen situated in the most superficial layers of epithelium, and finally open upon the surface. The deeper epithelial cells, those between the papillæ, are mostly excavated, and a few contain pus corpuscles in their interior.

Figure 28 (see page 137) is a drawing with very high power, showing the excavated state of the cells and the beginning of the formation of small abscesses. It is very evident that the pus corpuscles are within the cells, or in a cavity in the centre of the cell, taking the place of the nuclei. The indentations which remain indicate the edges of cells.

All the dermo-papillary layers of the mucous membrane are simultaneously inflamed.

The papillæ present a small cell infiltration, which also extends between the fasciculi of the deeper connective tissue. The vessels are enlarged and filled with blood. Still deeper the closed follicles of the tonsil are very much larger than normal. Fig. 24 (see page 134) shows at *d* a portion of one of these follicles. The trabeculæ of the reticulum are normal, but the contents of the peri-follicular sinuses, of the afferent lymphatic vessels, and the meshes of the delicate reticular tissue are changed. These cavities are filled with lymph cells, some of which, especially in the peri-follicular sinuses, show a proliferation of their nucleus, and also contain in their protoplasm red blood-corpuscles.

## CASE VIII.

### *Indurated mucous patches resembling chancres.*

J. B., æt. 20, polisher, admitted into the hospital May 23d, 1878, Saint Clement ward, bed No. 32.

No special or hereditary history. Five months previous she had a few pimples upon the vulva; these had never entirely disappeared.

*Present Condition.*—Festooned, copper-colored erosion with a whitish epithelial border, situated upon the glans clitoridis.

Similar but smaller erosions upon the fourchette.

The left labium minorum is much swollen. It presents at its free border and upon its internal surface an irregular ulceration, about an inch in diameter. This erosion is somewhat convex, its bottom red (color of ham), shining, scarcely moist; its edges are covered by a slight whitish swelling, consisting of macerated epithelial cells and leucocytes. The margins and base of this erosion are indurated. If the beginning and history of this lesion were not known, it might very easily be mistaken for an indurated and eroded chancre.

Upon the left buttock, near the anus, is found a swelling a little more than an inch in diameter, formed of vegetating mucous patches. Four or five indurated glands, the size of hazel-nuts, are felt in each groin. Mucous patches are seen upon the tonsils and anterior arches of the palate. A large mastoid gland on the left side, and enlarged glands in both sub-clavicular triangles are observed. There is no roseola.

Ordered Van Swieten's solution.

The swollen and indurated portion of the nympha upon which is situated the chancrous-like erosion was removed with the knife.

The histological examination of this mucous patch served us in great part for the description of ulcerated mucous patches of the genital organs.

June 4th. The wound resulting from the excision is completely cicatrized, and the cicatrix is imperceptible. The vulva has become more regular since the removal of the nympha.

June 19th. The patient left the hospital. The excision of the nympha has been followed by very rapid cicatrization, and has occasioned no accident.

## CASE IX.

### *Mucous patches with indurated base.*

R. L., æt. 22, burnisher, entered the hospital June 6th, 1878, Saint Clement ward, bed No. 2.

No special personal or hereditary history. Six months previous she had an "excoriation" upon the right labium majorum. The physician whom she consulted, told her it was the result of an accouchement.

Since this time her health has been good, but some time ago she saw upon the vulva some mucous patches, which have ulcerated.

*Present Condition.*—There is an elongated, somewhat depressed, but very distinct cicatrix at the inferior extremity of the right labium in the fold formed between it and the nympha. At this point a manifest ligneous induration is easily felt. The labium is red and swollen. Both labia minora are covered, upon their internal surfaces, with ulcerated mucous patches. Another patch exists at the superior extremity of the right labium majorum. These mucous patches lie upon a tissue distinctly indurated, readily distinguished from the surrounding tissue. The surface of the patches is covered by a grayish, adherent false membrane.

In both groins are five or six glands, as large as hazel-nuts.

The trunk, nape of the neck, and internal surface of the thighs are covered with yellowish papules which have existed about three weeks.

Mucous patches are seen upon the tonsils and anterior arches of the palate, particularly the right.

Large gland in right mastoid region; a few indurated glands in the sub-clavicular triangles.

Ordered Van Swieten's solution. Application of a solution of nitrate of silver to the patches.

June 12th. The mucous patches have almost entirely disappeared.

June 21st. The patient left the hospital. The mucous and cutaneous lesions have completely disappeared.

## CHAPTER VI.

## EARLY CUTANEOUS SYPHILIDES.

Syphilitic fever—Neuralgia—Osteocopic and rheumatoid pains—Anæmia—Diffused, macular, and papular roseola—Differences of the eruption depending upon its location—Papular syphilide—Histology of the acute and superficial papule—Lenticular papular syphilide—Histological description—Effusion of blood into the papules—Diagnosis from simple psoriasis—Differences of the papular syphilide depending upon its location—Onychia and alopecia—Macular syphilide.

EARLY cutaneous syphilides appear a short time after, before, or at the same time with the mucous patches. The secondary stage of syphilis presents, during the two, three, or four years of its duration, successive crops of mucous patches and cutaneous eruptions. The syphilides are divided into early and late: the former generally confluent and superficial, the latter usually more localized, deeper, and tending to ulcerate.

After the cicatrization of the chancre, and whilst the mucous membranes are affected with moist papules, when the skin is covered with disseminated eruptions from the top of the head to the soles of the feet, when all the lymphatic glands are swollen, it is of course evident that the entire economy is infected: the blood is poisoned and syphilis is fully developed.

Very often, at the beginning of the eruption or a few days previous, patients complain of a special fever, *syphilitic fever*. Women, particularly the young and anæmic, enfeebled by living in the city, by overwork or dissipation, are more frequently attacked than men. The symptoms of syphilitic fever are paroxysms occurring at evening or during the night, which are rather more marked by the warm than cold stage, followed by an elevation of the internal temperature and increase of the pulse. The axillary temperature seldom reaches  $39^{\circ}$  C. ( $102.2^{\circ}$  F.); it remains between  $38^{\circ}$  C. ( $100.4^{\circ}$  F.) and  $38.5^{\circ}$  C. ( $101.3^{\circ}$  F.). The general phenomena, the malaise, the anorexia, and collapse, are very much less marked than in intermittent fever. The tongue is normal, and the appetite is generally unaffected, some-

times there is even boulimia. These symptoms are never so regular as in intermittent fever; the stages of chill, heat, and sweating do not follow in any regular order; the chills are frequently absent, and they are by no means amenable to treatment by sulphate of quinia. This special fever is very variable in duration, and is either limited to one or two paroxysms for each eruption of the cutaneous lesion, or, on the contrary, continues eight to ten days or even several weeks. According to the statistics of Fournier, one-third of the patients of the Lourcine Hospital suffer with syphilitic fever during the secondary period. From my experience, it is very much less frequent. It is true, I have not specially sought for this symptom, and it may have escaped my notice, since I only saw the patients during the morning.

The other general symptoms which accompany syphilitic cutaneous lesions are the neuralgic pains of various parts, frontal, occipital, intercostal; the nervous phenomena, hyperæsthesia, anæsthesia, or analgesia. These latter nervous symptoms occur only in women, and are connected with hysteria. Neuralgia and osteocopic or rheumatoid pains, connected with the bones, during the period of early lesions, should be regarded as lesions of the periosteum, articulations, fibrous tissues, and bones themselves. We have had opportunities to verify the occurrence of periostitis and osteitis in the secondary stage, and Mauriac has published some cases of periostoses appearing at the beginning of this period.

Anæmia also plays an important rôle in this stage of syphilis. It appears to be decided, from the counting of red blood-corpuscles by Wilbouchewitch, made at the Hôpital du Midi, that the number of red blood-corpuscles progressively diminishes during syphilis, and that the employment of mercury stops this diminution. This will again be referred to when studying the action of mercury. The number of red corpuscles contained in a cubic millimetre of blood, in the normal state, is from 4,260,000 to 6,447,000. In the syphilitic patients examined by Wilbouchewitch the average number was 4,321,000 red blood-corpuscles in a cubic millimetre. Important causes of this anæmia are the extensive congestions and inflammations of the skin; the oozing and suppurating eruptions of the genital organs, and with women the profuse leucorrhœa, which often exerts such debilitating influence; the neck of the uterus, whether the seat of mucous patches or not, being generally congested and affected with catarrh. The anæmia is manifested by a feeling of weakness, by unfitness for work, by fatigue following the least exercise, etc.



In Chapter IV. (see page 127) there is given a classification of cutaneous syphilides. The varieties are numerous, but this need not be discouraging, since most frequently the different elementary lesions are present upon the same patient, and their intermingling, in connection with the characteristic appearance of the chief eruption, and of the accompanying lesions, such as enlarged lymphatic glands and mucous patches, prevents any mistake in diagnosis.

Take, for example, a patient who offers a type of early syphilitic eruption: she presents upon the neck, chest, arms, and thighs, a diffused macular eruption, papular upon the inferior part of the trunk and forearms, while upon the palms of the hands are seen small papules, upon the surface of which the epidermis is desquamating or absent; around the alæ of the nose, upon the scalp, forehead, and nape of the neck there exist a few small scabby papules, and upon the scalp true pustules with brown scabs. Upon the back, as far as the loins, the roseola and the papules, by their number and diversity of color, give the appearance of a trout skin, the former, the roseola, varying from a pink tinge to the color of ham, the latter, the papules being red and copper color. Add to these eruptions the enlarged lymphatic glands of the neck, nucha, and groins, the mucous patches of the vulva, mouth, lips, and tonsils, and it gives a perfect picture of an early syphilitic eruption, such as is frequently met with.

1st. ERYTHEMATOUS SYPHILIDE; ROSEOLA.—This eruption presents three varieties: diffused, macular, and papular roseola.

Diffused roseola is characterized by a pinkish marbling of the skin, by pink lines, by diffused and very superficial red spots, which at the beginning of the roseola disappear upon pressure, and resemble very much the redness of the chest and shoulders caused by exposure to the air. This syphilitic roseola, although it lasts but a short time, is followed by yellowish or grayish spots, due to the presence of the coloring matter of the blood in the rete mucosum of the skin, and these spots do not disappear upon pressure.

Macular roseola is characterized by pink or red spots, round or lenticular, with borders sometimes quite distinct, more frequently poorly defined and irregular. These spots, which are at first not ham-colored and disappear completely upon pressure, soon present an ecchymotic yellowish tint not effaced by pressure, which is a characteristic feature. They are seated, like diffused roseola, upon the neck, front of the chest, shoulders, arms, abdomen, thighs, and

legs, in a word, over almost the entire body. The face is not always affected, but the eruption is quite often seen upon the forehead and around the mouth. The spots as they disappear become yellowish, or greenish-yellow, or gray, resembling small ecchymotic stains.

These rubeola-like spots may become very irregular in form, circular, crescentic, etc.

In papular roseola, the spots are similar in form and color to the preceding, but are more regular, and do not entirely disappear upon pressure. Papular roseola constitutes a variety intermediate between erythematous syphilides and papular syphilides; it frequently occurs together with these two other varieties, and often appears shortly after the first eruption.

While the lesions of diffused and macular roseola consist simply of a superficial congestion of a limited vascular territory of the skin, accompanied by an extravasation of a few red blood-corpuscles, and of their coloring material, the lesion of papular roseola is more intense, the papillary layer is a little thickened, which occasions the slight elevations that form the elementary lesion, and the bloodvessels are not entirely emptied by pressure.

Papular roseola (*roseola urticans* of Fournier) generally coexists with macular roseola, and occurs mostly upon the epigastric region, abdomen, back, and thighs. Its coppery-red or brown color is very characteristic.

Upon the palms of the hands, the papules undergo a modification, due to the thickness of the corneous epidermis, the most superficial layers of which fall off and expose the smooth surface of the papule. The epidermis is arrested at their border, and forms here a thin, horny, hard epidermic ring.

The erythematous syphilide is of all the syphilides the most frequent and most constant; it is the first manifestation of syphilis upon the skin, the appearance of spots and papules being secondary. It may be very slight and transient, so much so, that the patient has not perceived it; or, on the contrary, it may be very intense, extending over the entire body; it then becomes papular, and remains one, two, or three months.

With syphilitic erythema, there are almost always found small, scabby papules or vesico-pustules upon the scalp, upon the face, at those points mostly selected by the syphilides, the forehead, around the alæ of the nose and mouth, and upon the chin. The apparent variations of the eruption, depending upon its situation, are due to the

different structure of the parts. For example, in the case of the scalp, the large amount of sebaceous fluid, which in the normal state is secreted around the hairs, under the irritation of syphilis, becomes thickened and transformed into brown scabs. The transformation of a pimple of papular roseola into an oozing papule or a mucous patch, at the mouth or vulva, is a similar phenomenon.

There also frequently exist at the same time with the roseolar eruption, one or more large, flat, lenticular papules upon the posterior part of the neck, upon the shoulders, or upon the forehead.

Nothing is more simple than to diagnose an eruption of syphilitic roseola: simple roseola, the roseola caused by copaiba, by exposure to the atmosphere, by measles, by bites of insects, etc., are readily distinguished from it, if the patient be examined with care, if enlarged lymphatic glands and mucous patches are looked for, and finally if the special coloration of the papules which almost always attend the erythema of syphilis be remembered.

2d. PAPULAR SYPHILIDE.—There are two varieties of the papular syphilide: one *with small papules*, and one *with large papules*.

The first variety has received the name of papular, lichen-like, miliary, conical, or papulo-granular syphilide. These different terms correspond to the different appearances of the papules, which are small, flat, or conical superficial elevations. The color of these papules is a very characteristic, yellowish or copper hue, depending upon the intensity of the syphilis. However, when the eruption is conical and pointed at the summit, and when it begins to be altered by mercurial treatment, it is pale, having the color of the skin. The pointed papules are especially seated upon the face, on the chin, around the alæ of the nose, where they are always characteristic, being mingled with papular roseola; there are also sometimes small acne pustules at the summit of some papules. The papules gradually disappear and leave small, miliary, gray, ecchymotic spots.

The elevation of the skin is due to a thickening of the papillæ and epidermic layers; but at the summit of the papule and over all the surface forming it, the most superficial layers of the corneous epidermis have desquamated, while those at the margin of the papule are continuous with the normal skin of the periphery. The circular line where the epidermis is arrested forms a ring or narrow border, very characteristic of the papules of syphilis (border of Biett).

I have been able to remove and preserve, from an autopsy made

some years ago, small and slightly elevated syphilitic papules, existing at the same time with roseola. It should be known where they were situated during life, and they must be marked in some manner in order to recognize them after death, since those papules, which during life are partly effaced by pressure, are scarcely recognizable after death, when their small vessels are less engorged with blood, the modified epidermic layers are less transparent, and the elevation which forms the papule is smaller or may even be imperceptible.

The microscopic examination of these papules shows very distinctly the evidences of inflammation, and even an inflammation much deeper than would at first be supposed.

Examinations of thin sections of the skin at the seat of the papules show the surface of the papule to be slightly elevated. The superficial epidermis is here sometimes increased in thickness, sometimes it has partly desquamated, the most superficial layers of cells being deficient.

The epidermic layers around the elevated part of the papule deprived of its superficial epidermis, are preserved in their entirety.

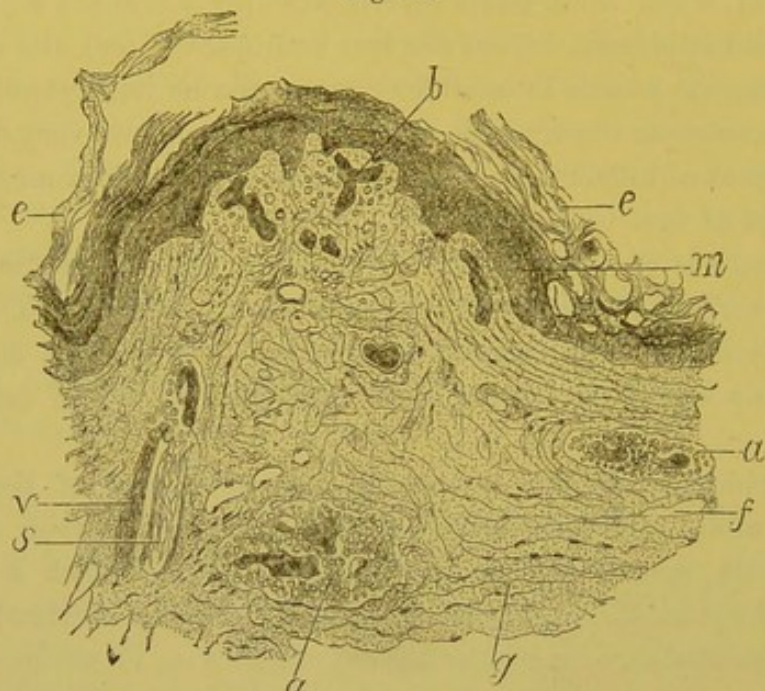
Figure 31, magnified 80 diameters, is a drawing which shows the superficial epidermis, *e, e*, arrested at the base of the elevated papule, and the pointed summit of the papule presents on its surface a layer of corneous epidermis reduced to half its thickness. The Malpighian layer is a little thickened. If, instead of examining a section vertical to the surface, the surface of the whole papule be examined, the epidermic border, preserved around the papule, is seen to form an elevated circle, the border of Bielt.

Beneath the rete mucosum are found the papillary vessels, *b*, filled with blood. These vessels are not, as Rindfleisch says, entirely emptied of blood by the pressure of the cutaneous muscles which contract after death. The capillary vessels, *v*, which surround the sudorific glands, as well as the vessels of the derm, are also filled with blood. The connective tissue of the papillæ is normal; sometimes around the capillary vessels we observe numerous effused lymph cells in the peripheral connective tissue.

In the deeper connective tissue, the ducts and lobules of the sudorific glands, and all the vessels of the derm beneath the papule, are surrounded by a more or less thick zone of lymph cells which have passed out of the vessels, and have collected along their course, separating the fasciculi of fibres of the connective tissue.

In Figure 31 are seen islands of lymph cells, relatively large collections surrounding the bloodvessels at *a, a*. The fasciculi of fibres of the connective tissue show in this drawing their arrangement and normal interlacing; they are not in any way changed; between them,

Fig. 31.



A syphilitic papule of the first period of the secondary lesions. *e*. Superficial epidermis. *m*. Rete mucosum. *b*. Vessels of the papillæ. *v*. Vessels of a sudorific gland. *s*. *a*. Spaces filled with pus around the vessels. *f*. Lymphatic cleft. *g*. Fasciculi of fibres of connective tissue separated by normal cells.  $\times 80$ .

and on their surface, the flat connective-tissue cells are not at all swollen, and there are no interposed lymph cells. The migration of white blood-corpuscles is then very limited, confined to the area around the bloodvessels. There occurs here a very slight pathological change which does not involve the fixed cells of the connective tissue, which does not modify the appearance of the fasciculi of fibres, and in which the lymph cells escaped out of the vessels remain localized. But it is noticeable that this inflammation, although not intense, is not limited only to the superficial layers of the skin, or to the papillæ. It extends deeper into the dermic layers as far as the region of the lobules of the sudorific glands and of the subcutaneous celluloadipose tissue.

In this lesion the connective tissue of the derm is not changed, but retains its proper elasticity, and is swollen only by the vascular congestion, and by the effusion of cells around the vessels. Therefore it

can readily be understood that pressure with the finger, in forcing back the blood contained in the vessels, partly causes the redness and tumefaction to disappear, but these symptoms reappear as soon as the pressure is removed.

The red color does not, however, *completely* disappear under pressure, and there is frequently seen a yellow color or ecchymosis that pressure does not modify at all. This phenomenon is due to the circumstance that some red blood-corpuscles have passed out of the vessels with the white corpuscles. The coloring matter of the red corpuscles impregnates the tissue of the papillæ, and gives to syphilides their copper or yellow color; later, this coloring matter is partly taken up, in the form of pigment, by the cells of the rete mucosum, which carry it to the surface of the skin, where it is eliminated. During all the time that this elimination continues there is a superficial pigmented coloration of the skin, which will be studied under the name of pigmented syphilide, but which is rather the pigmentation that follows superficial syphilides.

These changes I found in a case of small and acute syphilitic papules, which I examined after death. The cases where the opportunity occurs of removing after death a piece of skin for a similar examination are very rare, and I have not had the opportunity of making a histological examination of small pointed papules; but by connecting the preceding examination with what is already known of moist papules, and with what has been said of large lenticular papules, the anatomy of small conical papules may, without assuming too much, be inferred. They should, in every way, be similar to those already described, with this difference, that the papillary layer is thicker, and that this thickening is caused by a more intense inflammation of the connective tissue of the papillæ, such as is met with in the large papules. It also would seem, without doubt, that the papules of papular roseola are of an exactly similar constitution to the small papules, the histology of which has been given.

The pointed papules remain a varying length of time; they usually disappear in three or four weeks, when mercurial treatment has been employed; at other times they continue longer—two and three months. During recovery they sink, their copper color disappears and becomes dirty-gray, they leave no trace, or only a pigmented tint, which also disappears in time.

These papules are modified according to their location; the mucous patches corresponding to this variety may be small and acuminated;

upon the scalp we have small pustules or papules covered with a yellowish or brown scab; upon the palmar surface of the hands the papules are covered with hard epidermic scales, or they are depressed and surrounded by a corneous epidermis.

The second variety of papular syphilides is characterized by large papules, having a diameter of from a half-inch to an inch, or even larger. Willan names it papulo-tuberculous syphilide; Fournier, papulo-lenticular; Bazin, lenticular mucous patches of the skin, and papulo-squamous syphilide.

All these terms are justified by the appearance of the eruption. At its beginning a pimple is noticed with regular edges and pink surface, which soon assumes the characteristic copper color, and upon which the most superficial layers of the epidermis are desquamating; at the periphery of the papule the desquamation is arrested, and here is seen the epidermic border which has so frequently been described. The surface of the papule is now smooth and uniform, also very regularly circular. It corresponds to Bazin's description of mucous patches of the skin. These papules or cutaneous patches frequently occur with roseola, with mucous patches of the genital organs, and are disseminated over the back of the neck, forehead, back, and abdomen.

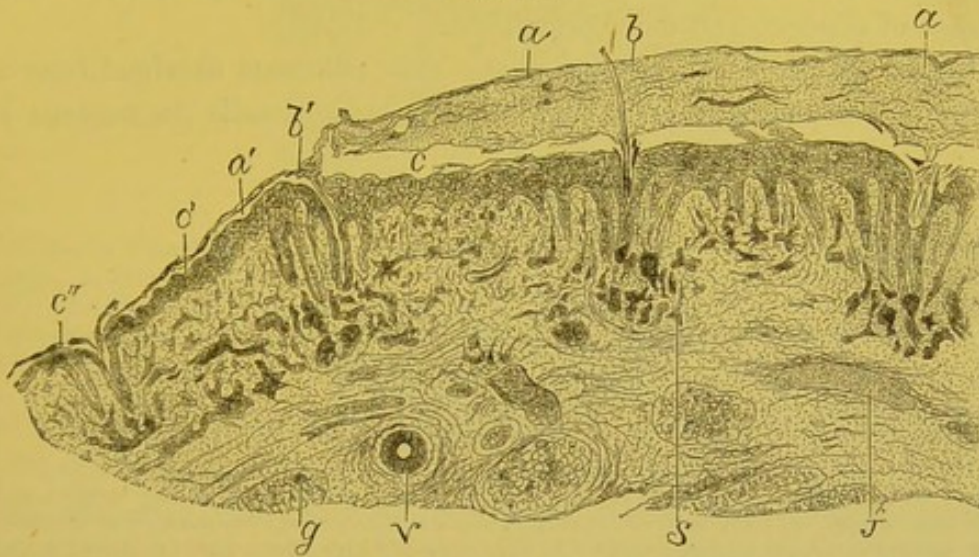
In the papular eruptions generalized over the entire body, the papules enlarge and thicken in such a manner that the skin where they are situated is so thick as to warrant the term papulo-tuberculous given to them by Willan; they unite together and form large bands, for example, upon the forehead—*corona veneris*; or circles, which surround the mouth and the alæ of the nose; they also form large circles upon the shoulders, neck, and trunk, and extend over the surface of the limbs. Often, during the period of acme, they are covered with thick, grayish scales, which may be removed in irregular fragments by scratching; this form is termed *papulo-squamous*. Their color is always very distinct, intense, deep copper-red; when they are at the height of their development upon the inferior extremities, they are sometimes the color of venous blood, especially when these parts are varicose. I have seen a pregnant woman with the eruption seated upon her legs, which were in a varicose condition; it had the color of venous blood shading to black, which was seen beneath the thick squamous scales covering the papules. During recovery, particularly under the influence of mercury, which frequently acts with great rapidity, their color becomes less intense, passes to a bright yellow, to ham color, then to dirty-gray, while at the same time they diminish in

size, and the desquamation ceases. They disappear without leaving any trace except a pigmented spot, which persists for a variable time.

I have removed and preserved, from different autopsies, several very distinct types of large syphilitic papules of the skin, both squamous and non-squamous, and am therefore able to give a complete anatomical description of them.

Figure 32 is a drawing of a squamous papule, magnified 20 diameters, being a section made vertical to the surface of the skin.

Fig. 32.



Half of a syphilitic squamous lenticular papule. *a*. Considerable thickening of the superficial layers of the corneous epidermis upon the papule. *a'*. The same layer of the neighboring cutaneous region appearing normal. *c*. Rete mucosum. *c'*, *c''*. The same layer continued upon the normal skin. *b*, *b'*. Hairs with their sheaths and sebaceous glands, *s*. *g*. Fat lobules modified by inflammation. *v*. Artery. *f*. Small vein filled with blood.  $\times 20$ .

The elevation of the papule forms the arc of a large circle. All the layers of the skin—epidermis, rete mucosum, papillary layer, and derm—present a thickness which begins at the border of the papule, where these layers are continuous with the normal skin. The greatest thickness is seen at the centre of the papule.

The corneous layer of the epidermis, *a*, is four or five times thicker than normal; with preparations stained by picro-carminé, this layer, formed of adherent scales, is colored bright yellow, yet between the stratifications are seen red and delicate lines running parallel to the surface.

The superficial corneous epidermis may be easily detached, and separated from the subjacent deep layers to which it is always united by prolongations of the corneous layers, which penetrate into the



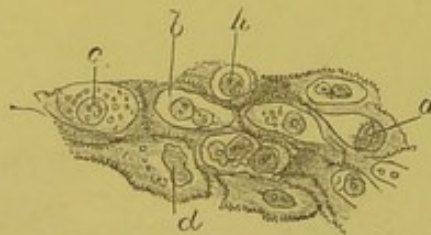
rete mucosum at the points where the hair, sebaceous and sudorific glands are located. Arches are thus formed which join the corneous layer to the rete mucosum.

The second epidermic layer, connected with the derm, consists of corneous cells of the deep layer, of the intermediate granular layer, and of the rete mucosum, *c*. The latter is very manifestly thickened, two or three times more than normal.

The cells of the granular layer and the dentated cells of the rete mucosum frequently present an excavated state of their protoplasm, the nature of which has been previously mentioned, *à propos* of chancre and mucous patches.

Figure 33 represents a part of the rete mucosum obtained from a section of a papule; in the dentated or spinous cells the nucleus is

Fig. 33.



Rete mucosum, the cells of which are excavated and proliferating at the location of a syphilitic papule. *a*. Excavated cell having its nucleus flattened against the wall of its cavity. *b*. Excavated cell containing two nuclei. *h*. Excavated cell with a large round nucleus. *c*. Cell containing some fat granules around the nucleus. *d*. A cell in which the nucleus is in the process of dividing. The crenated edges of the cellular partitions are very distinct.  $\times 250$ .

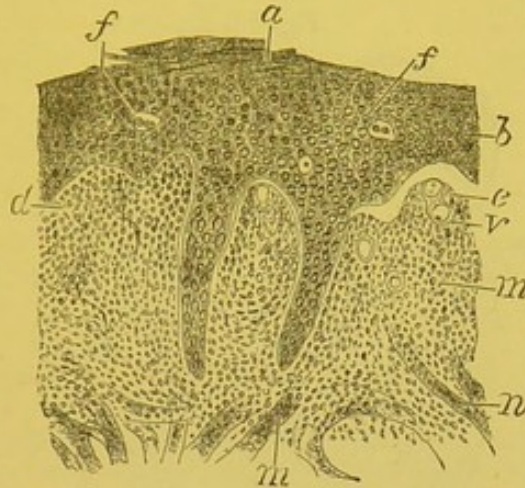
surrounded by a cavity, *h*. In the cavity represented at *a*, the nucleus is connected to the wall of the cavity; at *c* the nucleus is large and surrounded by fine fatty granules; at *d* the nucleus is seen dividing.

The prolongations of the rete mucosum which penetrate between the papillæ are longer than normal, while the papillæ themselves are elongated and hypertrophied.

Figure 34 shows very accurately this mutual penetration of the hypertrophied papillæ, *c*, into the rete mucosum, *b*, and the elongation of the epithelial prolongations, *m*, that the rete mucosum sends between the papillæ. These prolongations are very long, and the epithelial cells have proliferated on account of the inflammatory elongation of the papillæ. In this drawing, magnified 100 diameters, are seen the layers of corneous cells which still cover the granular layer of the rete mucosum.

The papillæ, *c*, are greatly changed by the chronic inflammation. Their fundamental substance is infiltrated with small round or lymph

Fig. 34.



Section of a lenticular papule, the scales formed by the superficial epidermis having desquamated. *a*. Corneous epidermic cells. *f*. Excavated cells of the rete mucosum, *b*. *m*. Prolongation of the rete mucosum between the papillæ, *d*. At *c* is seen a papilla which is separated from the rete mucosum and contains a dilated vessel, *v*. *n*. Fasciculi of smooth cutaneous muscle.  $\times 100$ .

cells and cells of the tumefied connective tissue. The fibrils of the connective tissue are separated by cellular elements. It is not, as in the preceding case, only an effusion of lymph cells alongside of the vessels, but the cells have penetrated everywhere in the papillæ between the fibres of the connective tissue. The papillary vessels are dilated and filled with blood.

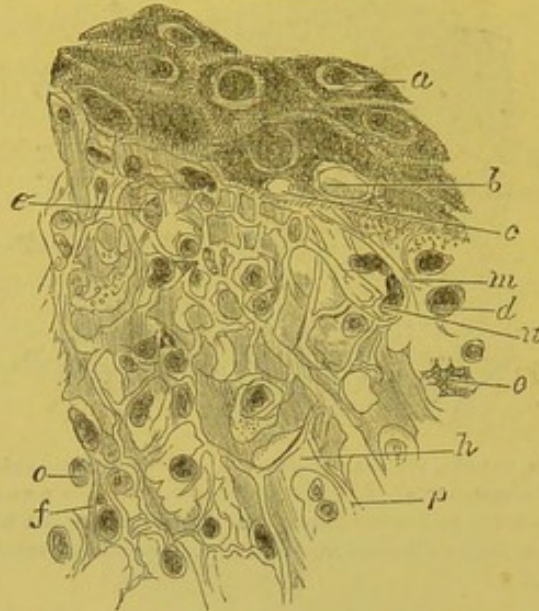
In order to study more completely the histological details of cutaneous papules, I have removed, with the consent of the patient, a portion of a large squamous papule. Figures 35 and 36 are drawn with high power from a section made after hardening the removed portion. They show the inflamed papillæ and the layers of the rete mucosum which immediately cover them.

In Figure 35, which is a drawing magnified 300 diameters, the papillary connective tissue exhibits cells interposed between its fibres, and excavated cells in the rete mucosum. Thus is seen at *b* an oval cavity excavated in a cell of the rete mucosum, and in the same cell another cavity, *c*. The fasciculi of fibres of the connective tissue, *p*, and the elastic fibres, *h*, form in the papillæ a network which becomes gradually finer as the epithelial cells are approached. In these meshes we find the flat swollen cells of the connective tissue, *e*, *e'*, and the lymph cells, *o*, round or more or less irregular. These

latter cells are often applied against the fibrils, as the cell *n* to the fibre *m*. Many of the small spaces are empty, owing to the cells having dropped out in preparing the section.

Fig. 35.

LEEDS & WESTRIDING  
MEDICO-CHIRURGICAL SOCIETY



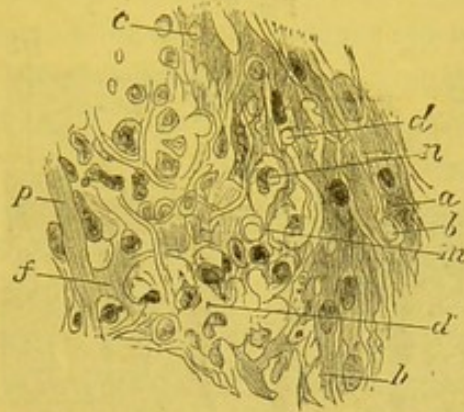
Section of a papulo-squamous lenticular papule of the skin (removed during life). *a*. Cells of the rete mucosum. *b*. Excavated cavity around the nucleus, the latter having disappeared in a cell of the rete mucosum. *c*. Smaller cavity of the same nature. *d*. Lymph cell. *e*. Flat cell of the connective tissue. *n*. Lymph cell flattened upon a fibre. *o*. Round lymph cell. *e'*. Flat connective-tissue cell. *h*. Elastic fibril. *m*. Elastic fibres. *f*. The same. *p*. Fasciculus of connective tissue.  $\times 300$ .

Figure 36 is a drawing magnified 250 diameters, showing a portion of an inflamed papilla with the cells of the rete mucosum covering it. The fasciculi of connective tissue, *f*, and the elastic fibrils, *p*, form a network with irregular meshes in which are found lymph cells of various shapes, some flattened against the fasciculi, some round and others oval, etc. The cells of the rete mucosum, *a*, present numerous round or oval openings, *b*, *c*, *d*, which contain either the nucleus of the cell or a round cell. There are also seen the prolongations, *h*, *m*, that the cells of the rete mucosum send into the papillary tissue. Between these prolongations the papillary tissue shows cells of new formation: for example, the cell *n* is seen lodged between the prolongations from the cell *m* of the rete mucosum.

In the large papules, there is not only an inflammation of the papillæ and the superficial corium; but the entire derm, and with it the subcutaneous cellulo-adipose tissue is inflamed in a like manner. In the derm, the fibres of the connective tissue are separated by

round cells arranged in rows or by the fixed swollen cells of the connective tissue. More deeply it is found that the adipose cells of the

Fig. 36.



Section of a papulo-squamous lenticular papule of the skin. *a*. Spinous cells of the rete mucosum. *b*, *d*, *c*. Openings which perforate these cells, or which separate them. *m*, *h*. Prolongations from the cells into the papillary tissue. *d'*. Lymph cells situated between the delicate fibrils and fasciculi. *n*. Lymph cells placed between the prolongations of the cells of the rete mucosum.  $\times 250$ .

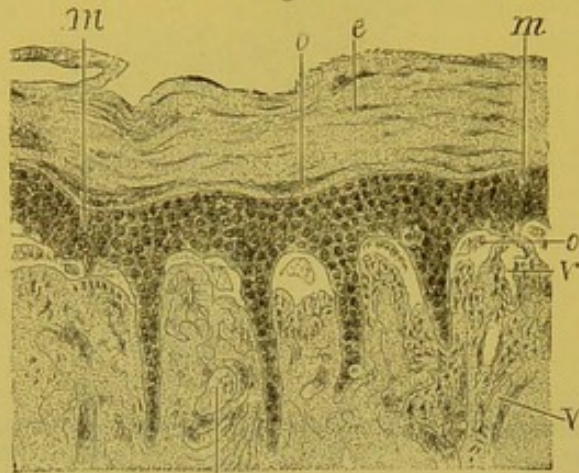
subcutaneous cellular tissue are inflamed; each adipose vesicle is surrounded by a circular row of lymph cells, and the fat is absorbed; the entire fat lobule is transformed into islands of embryonal connective tissue, the fat having disappeared.

The alterations of the epidermis and derm, in the large cutaneous papules, are seen very closely to resemble the modifications which occur in the epithelial covering of the corium of mucous membranes affected with syphilitic papules. The same changes may be traced in both, differing only on account of the difference in structure of the skin and mucous membranes. But there are also other dissimilarities.

In most of the preparations of cutaneous papules, there are seen a few papillæ which have a tendency to separate from the rete mucosum. In sections there exists a distinct cleft between the summit of the papilla and the rete mucosum. These spaces are not empty during life, but are filled with blood plasma, numerous red blood-corpuscles, and a few white blood-corpuscles. In Figure 34 (see page 175), the papillæ, *c*, are seen separated from the rete mucosum: in a papule which I have seen, there was an effusion of blood interposed between the papillæ and rete mucosum. This is represented in Figure 37. As each papilla is covered by the cap formed by the rete mucosum *m*, and its inter-papillary prolongations *m'*, there result as many small, limited, and circumscribed effusions of blood, *o*, as there are papillæ.

Yet the rete mucosum was in places completely raised by the blood, so that its prolongations and the superficial portion of the ducts of the sudorific glands were separated from the papillæ.

Fig. 37.



Hemorrhagic squamous papule. *e*. Corneous epidermis forming thick scales. *m, m'*. Rete mucosum sending epithelial prolongations between the papillæ. *o*. Spaces filled with blood situated between the papillæ and rete mucosum. *v*. Dilated vessels at the summit of the papillæ. *v', v'*. Bloodvessels much dilated and filled with blood at the base of the papillæ.  $\times 40$ .

It is very important to recognize these effusions of blood in syphilitic eruptions. They account for the special copper coloration of the eruptions, as well as for the various secondary tints which are seen during their recovery, and which are exactly the tints of ecchymoses and infiltrations of the skin by the blood pigment.

These bloody effusions are a manifestation of the alteration of the blood in syphilis—of the diminution of the corpuscles. The blood more easily passes through the walls of the vessels; the latter are, however, dilated, and their walls are changed in the inflamed papillæ. In preparations of hemorrhagic syphilitic papules, the vessels are always found dilated, and their walls thinned at the summit of the papillæ.

These syphilitic papules, covered with thick and superficial layers of corneous epidermis, that is, with scales, are termed papulo-squamous syphilides. They are generally very obstinate, since the thick layers of the epidermis repose upon the thickened and chronically inflamed derm.

But in the majority of lenticular papular syphilides, the superficial layer of the epidermis, that which is raised up in Fig. 32 (see page 173) has fallen off, and the surface of the papule is copper-red in color, smooth, and surrounded by a very distinct border, which belongs to

the superficial epidermis of the neighboring normal skin, and forms a circular margin to the papule. This variety of cutaneous papules, Fournier names eroded papules, but they scarcely merit the name, since we really have not a complete erosion. In the papules that I have examined, the whole of the corneous epidermis has not been absent; there always remained a notable layer which adhered to the granular layer and to the rete mucosum.

But the amount of corneous epidermis which remains is very small, since this layer and the rete mucosum, by their transparency, permit a view of the papillæ traversed by vessels filled with blood, so that the red color due to the inflammatory and ecchymotic congestion of the papillary network is very distinct. The term eroded papule may be retained, provided the anatomical change it corresponds to be not forgotten.

The term squamous papule or papulo-squamous syphilide, which corresponds to a very characteristic group, should also be retained. The squamous syphilides have frequently been named syphilitic psoriasis. The use of this compound word is not to be recommended, since the radical psoriasis represents a very distinct idiopathic cutaneous disease, which has little in common with syphilis.

Although there is, between the papule of psoriasis and the syphilitic papule, considerable analogy, if not absolute identity, as regards the chronic inflammation of the skin, and the inflammatory hypertrophy of the papillæ, yet the scales of psoriasis are, on the contrary, quite different from those of syphilis. The former, those of psoriasis, are bright, and of a silver white appearance when removed by scratching with the nail; they are seen as small, thin scales, easily detached, and the different stratifications have the same brilliant and mica-like aspect. This is not the case with the squamous syphilide; the scales in this lesion are more adherent, more granular, grayer, more of a dirty gray color, and their stratification is by no means regular; they have not the silvery appearance of psoriasis. Finally, the syphilide has not the same topographical distribution as psoriasis. The latter has for its most frequent seats the elbow and knee, the extensor cutaneous surfaces of the limbs, while the syphilide is found upon the face, neck, trunk, anterior surfaces of the limbs, and inferior part of the thorax and abdomen.

The name psoriasis has also been given to the squamous papules, covered with or deprived of their epidermic layers, which are situated upon the palms of the hands and soles of the feet. This is called palmar

or plantar psoriasis. This name is not advisable, since the papules are modified simply on account of their seat, and the structure of the skin of the hands and feet. Here the corneous epidermis attains considerable thickness and resistance; it forms a layer which at times measures a millimetre in thickness and is dense and hard like parchment. Thus it offers more or less resistance to the development of the papules, especially at their beginning. These papules for some time remain flat and depressed, on account of the thick epidermic covering, and their elevation is but slightly or not at all appreciable. Later, however, the epidermis covering the papule is raised, cracked, and partly or completely eliminated, or it forms hard and irregular stratifications. The thick and corneous scales which cover the papule, have given the lesion the name of psoriasis. And as true psoriasis seldom or never occurs upon the palm of the hands or sole of the feet, while these regions are a favorite seat for syphilides, it can be said that palmar or plantar psoriasis is generally syphilitic. Hardy and Bazin, however, admit a variety of non-syphilitic palmar psoriasis.

The different cases of syphilitic palmar psoriasis that one meets with could not usually be mistaken; at first they are seldom covered by epidermic scales; generally the corneous layer of the epidermis has fallen from their surface, and it is arrested at the circumference of the papule, constituting a narrow border, frequently separated from the subjacent skin. This margin or border of Bielt is formed by a thick epidermis, which is directly continuous with the normal skin at the periphery of the papule. The papule is red, smooth, dry, and upon palpation its surface is found firm, owing to the thick papillary layer being covered by the rete mucosum and an appreciable layer of the corneous epidermis. Such papules are positively characteristic of syphilis.

For the treatment of the severe forms of papulo-squamous syphilides of the hand, those in which very thick callous-like masses are found in consequence of the epidermic accumulations and the induration of the derm, we have several times employed gloves made of India-rubber, which have the property of softening the epidermis, causing the scales to desquamate, and rendering the derm more pliable. This local treatment is difficult to carry out, and in order to be active, should be combined with mercurial medication.

Although the papular syphilide is thus modified beneath the hard epidermis of the palms of the hands and soles of the feet, it presents

changes quite the opposite when situated upon regions where the skin is delicate and moist. Thus, in the flexures of the limbs, the folds of the elbow, of the groin, etc., every degree from squamous or dry papule to moist papule or mucous patch is met with. In those regions where two skin surfaces are in contact, this transformation of the dry into moist papule always occurs, for example, at the umbilicus, mammæ, axillæ, etc. These metamorphoses are readily accounted for. The lesions are the same in all cases: there are pus corpuscles in the desiccated lamellæ, as upon the surface of the mucous patch; the epidermic layers are dissociated, and their cells separated, if they come in contact with a fluid; they are solidified and remain in place, if they are exposed to the air. Thus far in the description of papules, the phenomena which occur in the hair follicles, sebaceous and sudorific glands have been omitted. The rôle played by these structures in the limited inflammations, which constitute the syphilides, is not so important as that of the papillæ and epidermic layers, although it may be said that the follicles and glands undergo the same alterations as the connective tissue and epidermic cells. The epidermic cells of the sheaths of the hairs are modified in the same manner as the cells of the rete mucosum; the connective tissue and the vessels which surround the sudorific glands experience changes similar to those which affect the connective tissue and vessels of the derm. The epithelial cells of the sudorific glands are swollen as in all cutaneous inflammations: the cells of the sebaceous glands are also in a state of hyperplasia, and their fat is diminished. These are lesions which occur in these structures during the course of any inflammatory processes. Therefore it is well not to accept certain descriptions of syphilides in which it is stated that a papule, a vesicle, or a pustule has its origin around a hair, and that the hair is found in the centre of a fully developed papule. This description of the importance of the hair follicle in syphilitic eruptions is found in Bassereau's book, otherwise one of the best monographs upon syphilides; it also occurs in Neumann's work, etc.

In regard to the bloodvessels which are found in the papillæ and in the derm at the base of papules, it has been mentioned that the capillaries were frequently dilated, and that their walls were changed, as in all inflammations, in such a manner as to permit the passage of the red and white blood-corpuscles through them. But the large, deep vessels of the derm and subcutaneous tissue never have their walls indurated and thickened, as occurs at the base of a chancre.



[The essential histological changes, which enter into the formation of a syphilitic papule, are a hypertrophy of the papillæ of the skin, an increase in the number of epithelial layers which form the epidermis, and a proliferation of the cells of the rete mucosum. The bloodvessels are congested, and there occurs an extravasation of the blood elements into the tissue of the derm, which gives the characteristic coloration to the lesion. Cavities are formed, and the nuclei divided in the cells of the epidermis. Desquamation of the superficial layers of the skin is one of the features of the papule. The changes are not limited to the papillæ and superficial corium, but in some varieties the inflammatory process extends to the subcutaneous adipose tissue, and an infiltration of the fibrillar connective tissue of the entire derm with embryonal cells is present. There is seen no vascular sclerosis comparable to that met with in the chancre. These changes are modified by situation, duration, etc., and will be found fully described under their appropriate headings.]

The *diagnosis* of a large papular syphilide is never very difficult. If the special color of syphilitic eruptions be remembered, if the arrangement and modifications of the papules according to their seats be recalled, if the palms of the hands and soles of the feet be examined, also the palmar surface of the fingers and plantar surface of the toes, where the same syphilides so frequently are seen, if the lymphatic glands are palpated, and the mucous membrane examined, there need be no hesitation or error in diagnosis. The papular syphilide is the most characteristic of all, and the most common after roseola. Its duration is relative to its intensity, but it is seldom that a syphilide with large papules continues less than two months, and frequently it remains three, four, or five months, especially if mercurial treatment has not been employed at all, or too timidly. There is no form of medical treatment in which the curative power of a remedy is so evident and so admirable, as in the use of mercury in cutaneous syphilides, and particularly in the severe forms of papulo-squamous eruption.

ONYCHIA AND ALOPECIA.—With syphilitic papules and at the same time with secondary syphilides, there occur two lesions allied to the lesions of the epidermis; they are the changes of the nails and hairs.

*Onychia* is a disease of the nails which results from the anatomical structure of the matrix of the nail, and of the peri- and sub-ungual

papillo-epidermic tissue. There are described two varieties—the dry and the moist.

The dry variety of onychia generally accompanies the papular and papulo-squamous eruptions situated upon the fingers and toes. At the same time that the palmar or plantar papules appear, the ends of the fingers or toes are attacked by papules, which pass around their extremities; they are also seated at the roots, edges, and under the nails.

Onychia is very variable in intensity. Sometimes the nail is slit, cracked, and readily broken; it is dry and separated from the skin, so that a probe may be introduced between the nail and skin.

When the papules exist at the unguis matrix, there is a swelling and an elevation of the skin at this region, and the formation of the epidermic layers of the nail is very much interfered with. At times there is an irregular thickening of the nail, by hard scabs, which are stratified and occasion a dense irregular elevation of a gray or opaque unguis mass, somewhat difficult to separate; sometimes these masses are divided by deep transverse furrows. When the lesion is disappearing, and the papules are effaced and lose their color, the nail reforms beneath the preceding layer, and when the latter falls off, under it is observed a transparent regular nail which permits the pink color of the papillary vascular network to be seen.

These forms of onychia, due to papules of the nail and its root, are very common, the same patient being affected with them upon most of the toes and fingers; or they are limited to one or two fingers or toes. Upon the toes they may be accompanied with a certain amount of oozing, and here is often seen, especially upon the great toe with persons who have their shoes too small, the painful inflammatory lesion of in-growing toe nail.

The moist variety of onychia occurs with vesiculo-pustular or pustular syphilides. Sometimes true whitlow is met with, that is, a little pus forms beneath the epidermis of the unguis matrix, a suppuration or oozing into the lateral furrow of the nail. The suppuration, the nutritive changes of the nail, the inflammatory granulations of the skin of the nail, all constitute a small group of symptoms which terminate in a destruction of the nail, and necessitate rest, poultices, and afterwards some simple dressing.<sup>1</sup>

[<sup>1</sup> Julien describes several forms of syphilitic onychia, but calls especial attention to the entire absence of pain, which he says characterizes all of them, the patient in some cases only becoming aware of the affection upon discovering the loss of one or more nails.]

Partial or complete *alopecia* of the scalp is a result of squamous or scabby papules, which are sometimes found here in great numbers. The falling out of the hair is also observed without our having seen any eruption upon the scalp, perhaps without any eruption having occurred. This alopecia, which supervenes during the secondary period of syphilis, and generally in the first year, is not permanent. The hair grows again as after typhoid fever, but it is often dull, brittle, and dry, although quite abundant. The scalp alone is not affected, the beard may also be lost as well as the hair of the genital region; this, however, seldom occurs.

Besides this early alopecia, many authors describe an alopecia which occurs late in the disease, and comes on gradually without the occurrence of any antecedent eruptions of the scalp. Fournier does not admit this kind of syphilitic baldness. He says "syphilis has never caused bald heads."

[Fournier makes the following division of those cases of alopecia, which are not connected with evident and unmistakable lesions of the scalp:—

1. Senile alopecia:—

This is usually a consequence of age, but may begin early in life. Its causes are various and are but little understood. It is not known why it affects men so much more frequently than women, nor why it sometimes occurs in individuals in the most vigorous health and under the best hygienic condition, nor why certain families are especially liable to it. It is often associated with gout, may follow all kinds of excesses, mental or physical, and has been produced by intense grief or anxiety. It has these distinguishing characters: *a*, it is slow and progressive, occupying months and years in its course; *b*, it is confined to a definite circumscribed region, the vertex and the antero-superior part of the cranium, respecting the lateral and posterior parts; *c*, it is absolutely symmetrical, affecting both sides exactly alike.

2. Cachectic alopecia:—

This may occur during any severe illness or chronic, deep-seated malady, such as cancer, diabetes, tuberculosis, etc. It is general, disseminated, attacks all the scalp at the same time, and leaves the remaining hairs, dull, dry, pulverulent, "like the hairs of a corpse."

3. The alopecia of convalescence:—

Many grave diseases are followed by alopecia immediately upon their subsidence. Typhoid fever, erysipelas, pneumonia, all the ex-

anthemata, when intense, are apt to cause a general falling out of the hair. This may happen in women after a normal labor, and with no concurrent disease whatever. This form of alopecia is produced by the disturbance of nutrition during the course of the disease, and is recognized by : *a*, the rapidity with which it supervenes upon the fever or other ailment which caused it ; *b*, its general and irregular distribution ; *c*, its moderation, the worst cases stopping short of complete baldness ; *d*, its temporary and reparable character.

#### 4. Syphilitic alopecia :—

Syphilis often gives rise to alopecia. It is not a delayed manifestation, but supervenes usually three, four, or six months after infection. Ordinarily, it follows the first signs of secondary symptoms, toward the third or fourth month, although sometimes when treatment is postponed it is delayed until the first or second year, at which time it is a symptom of ulcerative syphilides ; cachectic alopecia may occur at any period of syphilis. Occasionally appearing as a consequence of papular syphilide of the scalp, secondary alopecia in the great majority of cases is unconnected with any such lesion. It may occur in any of the forms of the disease, whether benign or malignant ; but still it is most usually met with in grave secondary syphilis accompanied by asthenic symptoms, emaciation, and general debility. The fall of the hair takes place without any inflammation, pain, or itching, and occurs indiscriminately at any part of the head, sometimes merely thinning the hair, and at others forming irregular islets of baldness. Generally both forms may be observed on the same head. The extent to which it proceeds varies greatly, from being scarcely perceptible to the falling off of the hair by handfuls or to the partial, and even in very rare cases to the entire, denudation of the cranium. The hair, too, loses its brilliancy, and becomes dry and dull. The duration of this form of alopecia is temporary, and after from one to six months the hairs are invariably reproduced, so that it may be laid down as an axiom that persistent and general alopecia is never of a syphilitic origin. Syphilitic alopecia may extend to the hairs of the rest of the body, causing the fall of the eyelashes, the eyebrows, and the hair of the pubes, etc. Alopecia of the eyebrows is not uncommon, especially in women, sometimes merely thinning them, and at others removing them in spots or islets, so that perhaps a third of the eyebrow may be wanting. Nothing is more characteristic than this broken arch, which is an almost pathognomonic sign of syphilis. The eyelashes are less frequently lost. Genital alope-

cia is pretty frequent, especially in women, and occasionally the hairs of the armpits and the rest of the body fall. But in all these cases the alopecia is only temporary, and after a certain time disappears. There is no special medication for syphilitic alopecia, all local applications being useless, and cutting the hair or shaving the head does not induce more rapid reproduction of the hair. The mercurial treatment is the exclusive and efficacious remedy, aided, if required, by iron, quinine, etc. Popular prejudice attributes the baldness, which is really the effect of syphilis, to the action of mercury; but under the influence of this a bald head becomes re-covered with hair.<sup>1]</sup>

3d. MACULAR SYPHILIDE.—The macular syphilide is generally admitted as a special variety of the syphilides; it has been described by Monneret, and especially by Hardy. We believe, however, that such cases are due to traces, more or less permanent, of pigment, left in the skin after the fading of previous syphilides, such as the erythematous, squamous, or vesico-pustular.

Following roseola there will always be seen a brown spot, which becomes yellow or slightly tinted with brown, leaves a dirty-gray coloration, and remains for a long time. A similar discoloration is observed to follow papular and vesiculo-papular eruptions.

In all these cases, the inflammatory congestion of the papillæ occasions an extravasation, a diapedesis of red and white blood-corpuscles. The coloring matter of the blood is transformed into granular pigment, which is deposited in the papillæ, and which is taken up by the cells of the rete mucosum. Later, as the deep layers of the epidermis approach the surface, through the physiological powers of the formation of new cells, the pigmented cells pass into the corneous epidermis.

Patients who have had roseola, almost constantly present, after they have recovered, spots of pigment or portions of the skin irregularly colored, being alternately white and pigmented. The neck is most frequently or more apparently affected, because it is exposed, and to the pigmentation, due to the effect of light, is added the pigmentation resulting from the changes in the papillary layer. But other regions of the body may be affected in the same manner, and show for

[<sup>1</sup> Dr. Thomas Barlow reports (*The Lancet*, August 25th, 1877) a case of alopecia occurring in congenital syphilis, and from his observation of this and other cases, concludes, that if in a very young infant there be more or less extensive baldness, followed by desquamation of the scalp, and especially if one or both eyebrows be bare, there should be a strong suspicion of congenital syphilis.]

a long time pigmented spots consecutive to a roseola. There may also occur, at the seat of the healing papule, a coloration of a whiter hue than that of the surrounding skin. The papule consists of an infiltration of the papillæ with cells of new formations, a true inflammation. The inflammatory lesion is followed by a reaction in the papillæ after recovery; the connective tissue may, as in cicatricial tissue, become more fibrous, and its vessels diminish in size, which occasions the white color of some papules, and causes the surrounding skin to appear more pigmented than normal. The origin of this pigmentation, secondary to syphilides, is perfectly understood; it is constant, and continues a varying length of time according to the intensity of the case. Now, if the physician finds, in a patient who has had syphilis, a dirty, irregular pigmentation upon the neck, and the patient (it is almost always a woman who presents this lesion) denies ever having had a cutaneous eruption, should her statements be considered as true? Are not patients frequently seen who are affected with a roseola, of the presence of which they are entirely ignorant? This fact alone suffices to render doubtful the existence of a macular syphilide, as a distinct syphilide or special eruption.

The pigmentation of the skin in syphilis is, however, of frequent occurrence, and it is one of the most marked symptoms of the disease. It is generally observed upon the exposed parts of the skin; neck, forehead, chin, commissure of the lip; but it may also, in exceptional instances, be observed upon the internal surface of the thighs, upon the abdomen, in fact, upon those parts where syphilitic eruptions most frequently occur.

In a pigmented skin there is seen a considerable amount of pigment, which is deposited in the cells of the rete mucosum. It is in this layer that the skin of the negro is most pigmented. The pigment is also disseminated in some of the cells of the corneous epidermis, even in the most superficial cells or those which are about to be thrown off.

Mercurial treatment has no effect whatever upon the lesion. It may be modified by favoring the renewal of the deep epidermic layers, and the desquamation of the superficial cells, as, for example, by employing douches and vapor baths.

[The true character of the rounded, permanent spots, inclosing, as in the meshes of a net, patches of paler skin, which constitute the so-called eruption, has not been finally determined. Hardy, Fournier, Drysdale, Atkinson, Duhring, and others regard it as a distinct manifestation of syphilis; Fox believes it to be of syphilitic

origin, and due, like vitiligo, rather to deficient coloring matter in portions of the brown spots than to an actual increase of pigment; Taylor thinks there is a remote and obscure connection between the lesion and the syphilitic diathesis, and that it is not a sequel of hyperæmia; Hill inclines to the view that it is a variety of leucoderma, the consequence of defective nutrition; and Keyes asserts that it almost invariably follows a syphilitic roseola; Drs. White and Pollard deny its syphilitic origin altogether, and Dr. Bulkley suggests,<sup>1</sup> that the theory that it only follows other skin eruptions may be due to the occasional occurrence of cases in which an ulcerating or tubercular syphilide has followed chloasma, and has caused a partial absorption of the pigment, producing spots resembling those of the pigmentary syphilide. The facts that it is uninfluenced by specific treatment; that it occurs in a region of the body notably free from syphilitic manifestations (Fournier found it on the sides of the neck in twenty-nine out of thirty cases); that it, or an eruption undistinguishable from it, is found in patients with chronic renal diseases, and in others with no history of syphilis; that while it runs a chronic course it is yet unattended with new cell-growth or with desquamation, and thus differs in its course and its appearance from all other syphilides,—seem to us to render it extremely probable that it is usually a sequel of those skin affections not necessarily syphilitic, but is oftener associated with syphilis than with other diseases, on account of the extreme frequency of the former malady.]

[<sup>1</sup> Archives of Dermatology, October, 1878.]

## CHAPTER VII.

## VESICULAR, PUSTULAR, BULLOUS, GUMMOUS, AND TUBERCULAR SYPHILIDES.

Vesicular syphilides, their histology and varieties—Pustular syphilides, acne, impetigo, superficial ecthyma—Deep ecthyma, its anatomy and histology, its diagnosis—Impetigo rodens—Bullæ, rupia, pemphigus—Syphilitic pemphigus of new-born children—Cutaneous gummata, their anatomy and histology—Obliteration of vessels—Tubercular syphilides—Syphilides immediately following the chancre, but grave in character—General review of syphilitic eruptions—The importance of anatomy and histology in their study—Treatment of syphilides.

THE erythematous and papular syphilides which have been described, are by far the most frequent as well as the least grave of the cutaneous lesions of syphilis. In order to complete the group of early, superficial, and mild eruptions, it is necessary to consider the vesiculo-pustular class of syphilides.

4th. VESICULAR SYPHILIDES.—This is a very rare form of skin eruption. Bassereau, in the excellent monograph in which he has analyzed all the cutaneous manifestations of syphilis, has recorded only twelve personal observations of vesicular syphilides, while during the same time, he noticed 153 erythematous, and 50 papular syphilides; the proportion of the latter being, to judge from our own experience, entirely too small. The cases of vesicular disease observed by Bassereau are far from being uniform in their characteristics, since he has divided them into four varieties. 1. A varicelliform syphilide; 2. An eczematous vesicular syphilide; 3. An herpetiform syphilide; and 4. A vesicular syphilide with a papular base. These groups are not admitted by all authors. Thus the syphilide in the form of varicella, characterized by vesicles disseminated over the trunk, face, and limbs, closely resembles, after a short duration, the eruption of varioloid, and after becoming pustular, may, at any given moment, be mistaken for an ecthyma. The eczematous syphilide is found sometimes with discrete vesicles,



sometimes with patches like moist or oozing eczema. It is possible that these appearances may be produced by imitative local troubles or by internal causes other than syphilis. There are often seen in syphilitic patients eczematous vesicles and patches on the surface of the thigh, in the femoral folds, in parts irritated by the discharge from mucous patches or of a leucorrhœa, and which cannot be pronounced truly specific in their character.

Another important fact in regard not only to these eruptions, but also to the early and superficial pustular eruptions, is, that the vesicle or pustule rests most frequently upon a papular base, or at least upon a copper-colored spot, so that the characteristic lesion of the skin in such cases is a roseolous spot or a papular elevation having the color, the density, and the distribution of the syphilitic eruption. This characterizes not only the fourth group of Bassereau, but also, the herpetiform syphilide in groups of phlyctenoid herpes or of herpes circinata; and likewise the pustules of syphilitic acne and impetigo.

The vesiculo-pustular syphilides, like all syphilitic eruptions, do not differ materially from analogous eruptions due to other causes. I have not had an opportunity of examining *post mortem* sections of the entire skin containing vesicles and small pustules caused by syphilis. But what has been seen in examining the contained liquid, the superficial or epidermic portions and the network of the pustule, compared with what has been observed in the vesicles of varicella and of variola, and in the pustules of the deeper forms of ecthyma, explains quite sufficiently the histology of these formations.

The vesicle is an elevation of the most superficial layers of the epidermis by a yellow liquid which contains a large number of lymph cells, and which soon becomes a little turbid and then puriform; the liquid contents dry upon the surface and form a small crust, which, when it is thrown off, is replaced by other crusts, or by scales, until finally there remains only a papillary elevation which soon disappears. The seat of the liquid effusion is in the corneous and granular layers of the epidermis, that is, above the rete mucosum. It is contained within walls formed of epithelial cells and in cavities which are the result of the opening of excavated cells. Below this modified corneous epidermis, the seat of the effusion, the epithelial cells of the rete Malpighii are also altered, and have become excavated. If the inflammation grows more intense, and extends in size and depth, if the vesicle, more prominent and voluminous in consequence of the larger quantity of liquid, becomes a vesico-pustule or a

pustule, the rete mucosum is involved in its totality, and even the papillary layer of the corium becomes infiltrated with pus.

The progress of the inflammation seems to be from the surface of the epidermis towards the corium, but in reality the inflammatory exudation occurs in the opposite direction, as both the effused liquid, and a portion of the lymph cells, which accumulate primarily in the superficial epidermis, are evidently the result of an intense congestion of the vessels of the papillary layer of the skin.

A phenomenon occurs here analogous to that which is observed upon the skin, and especially upon the surface of a tonsil affected with ulcerating mucous patches. If the vesico-pustule is not disturbed in its evolution by scratching, or by any other mechanical agent, the liquid exudes in very minute quantities upon its surface, and collects in crusts consisting of a mixture of desiccated pus and epidermic cells. These crusts gradually thicken by the addition of new quantities of liquid exudation; they are partially shed, and reproduced until they finally fall off, leaving a new and solid epidermis upon the surface.

If the Malpighian layer has been but little altered, or has remained almost intact, there will be neither depression nor cicatrix at the site of the previous eruption, but merely a stain or macule. If the rete mucosum has, however, been destroyed by suppuration, it is reproduced, and there is then no apparent cicatrix. But if, while this layer has undergone disintegration, the papillæ themselves have been markedly inflamed, infiltrated with cells which are poured out upon the surface of the pustule under the crust, and have been partially broken down by the suppurative process, then we find a very superficial cicatrix, stained if blood has been effused in the papillary layer, colorless if no such effusion has taken place. This latter condition prevails in certain superficial ecthymatous pustules, in which the cicatrices resemble closely those of varioloid or variola.

5th. PUSTULAR SYPHILIDES.—The pustular syphilide is found in the form of acne, of impetigo, or of ecthyma. Syphilitic acne is always early and superficial. Impetigo and ecthyma may also occur in the first stages and without any element of gravity, but in other cases, where they appear very early, may be of serious import, as in the malignant syphilis of Bazin and Dubuc; during the later eruptions they assume a still more serious aspect, and tend to rapid extension both in depth and superficial area, resulting in pustulo-crustaceous ulcers,

of long duration and of extent corresponding to the amount of suppuration and the tendency to confluence of the lesions, which are often accompanied by symptoms of general cachexia, and in exceptional cases even terminate in death.

*Syphilitic acne* is, at least, as much a papule as a pustule in its structure and evolution. It forms a conical projection of the same size as a miliary or granular papule. Upon the top of this copper-colored papule appears a very slight epidermic elevation, caused by an extremely small quantity of serous effusion, which rapidly becomes turbid and purulent.

The pustule is of short continuance, and is soon replaced by a little crust and then by scales. The papule disappears, and there remains only a grayish or ecchymotic stain, without cicatrix. This eruption appears in successive crops upon the face, the shoulders, the trunk, and thighs, in which latter situation the pustules are often confluent. There are generally at least as many papules or papulo-squamous spots as well-formed pustules, the papular elevation remaining after all traces of the pustule have disappeared from its summit. It is an eruption of the early stages, and behaves like the papular syphilide. It is distinguished from *acne vulgaris* by its distribution—for it especially affects the belly and thighs, while *acne vulgaris* is found only upon the face and shoulders—by its copper color, and its greater dryness, and by the absence of white permanent cicatrices.

*Syphilitic impetigo* appears, like scrofulous impetigo, in the form of little pustules, covered by yellow, gray, or brown crusts, and resembling isolated pimples, or as patches formed by the union of many pustules. The pustulo-crustaceous form is commonly found upon the scalp at the same time that a syphilitic roseola or mucous patches have invaded the general integumental surface. Bassereau notes 106 cases in which impetigo of the scalp occurred together with erythematous and papular syphilides.

The impetigo may, however, appear as the predominant eruption, the scalp, face, and forehead being the points of election. The reason for the transformation of an erythematous or papular syphilide into the pustulo-crustaceous form upon the face and scalp is found in the normal anatomy of these parts, and in the abundance of sebaceous glands with which they are supplied. These glands, especially large and numerous in the region of the soft down upon the cheek, and of the hairy scalp, when involved in the inflammatory action, produce a papule; upon the cutaneous surface their secretion is modified, and

consists then of a sebaceous liquid, more or less intermingled with blood-corpuscles. As a result, there is seen either a well-formed pustule, a sebaceous concretion, or a crust upon the surface of the papule.

Usually, and particularly when the pustules are discrete, they are seated upon a reddish, copper-colored patch or papule. When the eruption is confluent, it covers large surfaces with scabs, which have the light yellow color found in impetigo due to scrofula, and, indeed, the diagnosis between these two affections would be difficult if we were not guided in the syphilide by the copper-colored stain, and the cicatrix which follows the loss of the crust.

*Superficial ecthyma* is characterized by a large pustule, sometimes umbilicated, and then covered with a moderately thick dark crust. It leaves behind it ecchymotic stains. Its usual seat is upon the inferior extremities.

To these two varieties of superficial pustules must now be added the deep forms of impetigo and ecthyma, occurring during the tertiary period. In 1874, at an autopsy in a case of syphilis at the Charité, I had an opportunity of studying many large, deep ulcerating ecthymatous pustules in all their details, and was consequently enabled to give a complete histological description of them. This description will serve as typical, not only of the deep ecthymas, but also of the graver forms of impetigo, "impetigo rodens," and of rupia, for these three eruptions form a natural group among the pustulo-crustaceous syphilides, and even although they differ in certain respects in their early stages, they are identical in their progress and in their anatomical formation; and they attack the different epidermic and dermic layers in the same manner. They belong also to the same stage of syphilis, and are of about equal gravity.

*Deep ecthyma* at first appears as a collection of pus under a large elevation of superficial epidermis, as occurs in the variety already described. The pustule is regularly circular; the liquid contents soon thicken by evaporation from the surface, and constitute a crust which increases by the addition of successive layers as the suppuration beneath continues. These crusts in superimposed strata, clay-colored, greenish, or brown in hue, imbricated like the shell of an oyster, dry, hard, and resistant, are met with in impetigo rodens and in rupia, having the same configuration, and immediately suggesting syphilis. Under this crust which continues to enlarge and thicken, and forms a covering like the segment of a sphere, the pustule itself extends in breadth and depth. The crust overlaps the border of the

ulcer, or, when the latter is the larger, is set within it like a watch-crystal in its case. When it falls off there is disclosed an ulceration involving the papillæ, or extending even deeper into the skin. These pustules, with a diameter of one, two, or three centimetres, are sometimes spread singly over a large portion of the body, most frequently the inferior extremities; in other cases they are grouped in the form of circles or crescents.

When a thin section of such a lesion is examined with low power, there is first seen the superficial epidermis, or rather the epidermis modified and transformed into a crust, that is, into a mixture of epidermis and lymph cells. This layer, when examined in portions which have been kept in Müller's fluid, is not coherent, and is easily broken in making sections, or in transferring the preparation from one liquid to another.

Figure 38 represents the edge, and a portion of the surface of one of these pustules, magnified twenty diameters; the epidermic crust covering the pustules is absent from *m* to *m'*, but from *m* to *t*, in all the portion *e, e*, it is in place, and is continuous at *t*, with the neighboring skin. At the edge of the pustule, in the region included between *d* and *t*, the epidermic layers are in place, and are infiltrated with pus; the layer *n*, which appears under a low power as a network with fine meshes, belongs to the corneous stratum. The layer *d* represents the rete mucosum.

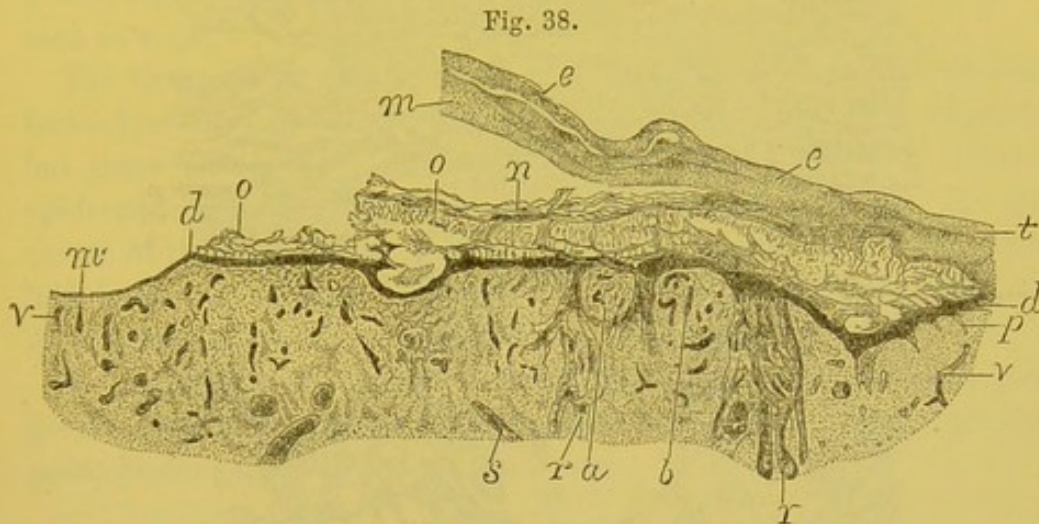
Passing from the edge of the pustule towards its centre, the cells belonging to the rete mucosum form a thin stratum, *m*, and then disappear, leaving the papillæ uncovered and suppurating. The papillary layer is easily discernible, and the papillæ, *a, b*, are larger than in health near the margins of the pustule, but near the centre they have run together, their extremities are no longer distinguished, and they form a uniform layer, from the free surface of which exudes the lymph cells with which they are filled. In the figure, *r, r* represent the epidermic prolongations which surround the hair follicles, and penetrate the acini of the sebaceous glands; the bloodvessels, *v, v*, are much dilated and congested.

The pustule studied in detail and with high power shows that the decaying crust is chiefly formed of pus corpuscles and epidermic cells; the best means of studying it is by removing a portion from its surface during the life of the patient.

The changes undergone by the epidermis in the region included

between *n* and *d*, Fig. 38, which is the Malpighian layer devoid of crust, are reproduced, magnified 250 diameters, in Fig. 39.

In the first layer are found cavities, *c*, filled with pus cells, the thin walls of which are made up of flattened corneous cells. These cavi-

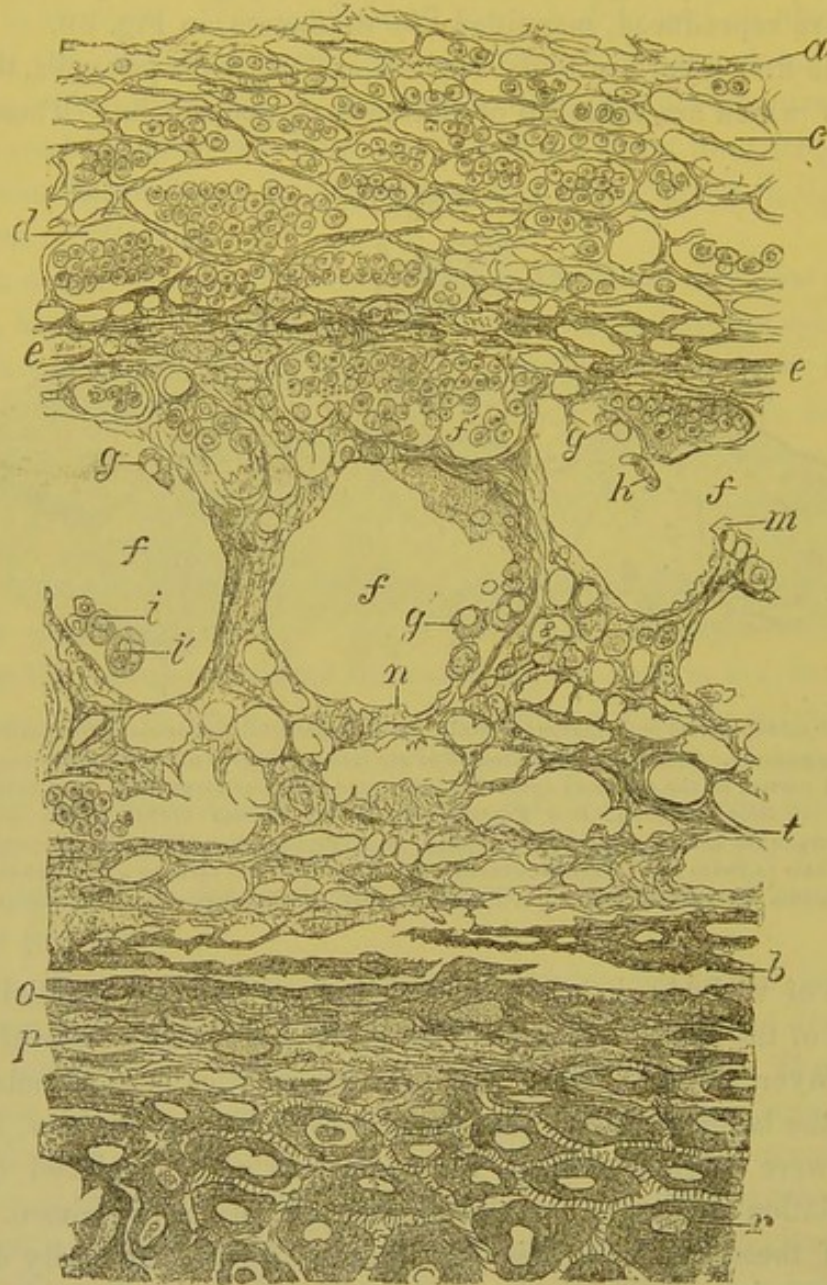


A part of a deep-seated ecthymatous pustule. *e, e*. Superficial epidermis corresponding to the scab of the pustule. This layer has fallen off at *m*; it is continuous at *t* with the normal epidermis. *n*. A portion of the corneous epidermis infiltrated with pus corpuscles. *o*. Cavities filled with pus. *d*. Rete mucosum. *a, b*. Papillæ seen in Fig. 40 with higher power. *p*. Papillæ placed between the normal and changed papillæ. *r, r*. Prolongation of the rete mucosum belonging to the hair follicles and sebaceous glands. *m'*. Ulcerated part forming a flat surface and covered with a thin layer of flat cells. *v, v*. Dilated vessels. *s*. Fasciculi of smooth muscular fibres.  $\times 20$ .

ties are of variable size, and have their long diameter parallel to the surface of the skin. Upon examining the smaller cavities of the subjacent layer, *e*, it is evident that they are cavities in epidermic cells. Below the layer of cells, *e*, is formed a zone of large cavities, *f, f, f*, which were originally filled with free pus cells displaced by the manipulation necessary for the preparation of the specimen. The walls of these large cavities are likewise formed by easily demonstrable corneous cells, some of which are detached, and appear in profile as at *h*, or in full view as at *g*, and the latter often contain a small empty cavity, and have crenated or indented edges. These walls often show notches as at *f'*, and irregular branching processes, as is the case in all suppurations occurring amidst epidermic cells.

There also are found, besides lymph and pus cells of the usual dimensions, some large cells containing two nuclei, *i*, or many nuclei, and even some cells containing red blood-corpuscles, *i'*. Then comes another layer, *t*, in which are seen ramifying cells excavated with small cavities containing pus; larger cavities are also observed.

Fig. 39.



Section of epidermic layers at the margin of an ulcerated ecthymatous pustule. Part of Fig. 38 seen with higher power. *a*. Surface of the corneous epithellum, the cells of which form a limiting reticulum of the cavities, *c*, filled with pus corpuscles. *d*. Larger cavities. *e, e'*. Layers of corneous cells with smaller cavities. *f, f, f'*. Large cavities having lost their pus corpuscles. *f'*. One of these large cavities containing pus corpuscles. *h*. Free cells *g, g*. Free cells excavated by a cavity. *g'*. One of these cells excavated and crenated. *i*. A free cell containing two nuclei. *i''*. A free cell containing blood-corpuscles. *m*. Excavated cell forming a part of the partition of a large cavity. *n*. Projections having their origin from a cell which forms the wall. *t*. Layers of corneous cells more or less excavated with cavities. *b*. Layer of cells with indentations (spines). The rete mucosum extends from *b* to *r*. *o*. Cells of the granular layer. *p*. One of these cells excavated with an oval cavity, the nucleus of which has disappeared. Many cells of the rete mucosum, *r*, for example, are excavated by a cavity at the position of their nucleus.  $\times 250$ .

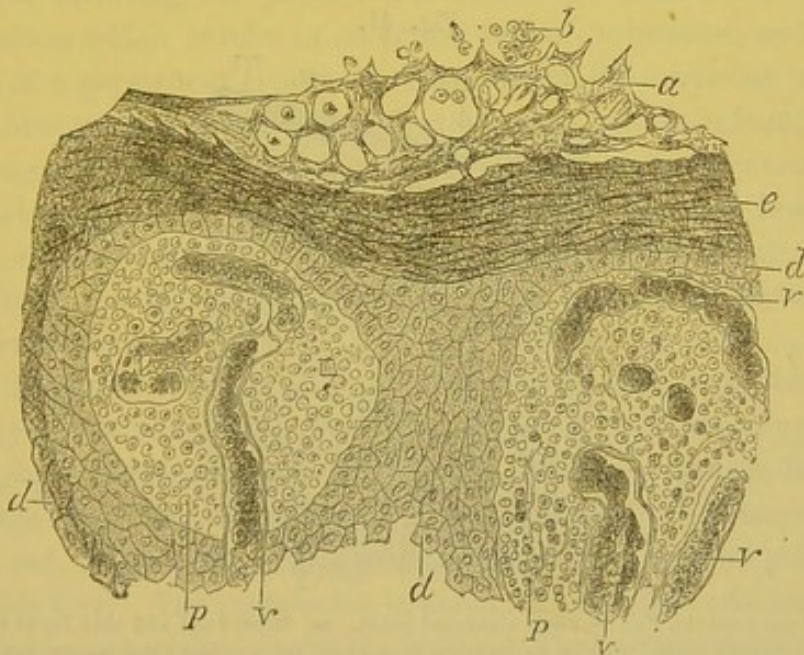
Finally comes the layers of large spinous cells, either separated or united to one another. The granular structure presents a certain

regularity, and the nuclei of the cells are sometimes preserved, as at *o*, and sometimes absent and the cells excavated with a cavity, as at *p*. The spinous cells of the rete mucosum, *r*, are large, and almost invariably have a cavity around the nucleus, which latter is often atrophied, replaced by granules, or absent. A part of a papilla may be seen at *s*.

The figure under consideration is an example of one of the various forms presented by the altered epidermis at the edge of a pustule; but these successive cavities filled with pus, and layers of altered epidermic cells, are very variable in their configuration. At the centre of the pustule the epidermis is destroyed, and the papillæ are laid bare, having upon their surface nothing but the pus, which, in drying, forms the imbricated layers of the crust of ecthyma.

The papillæ at the margin of the pustule are hypertrophied, congested, with dilated vessels, and separated from one another by interposed prolongations of the rete mucosum.

Fig. 40.



Section of the rete mucosum and of the papillæ of the deep-seated ecthymatous pustule represented in Fig. 38. The two papillæ *p*, *p'* are those figured at *a* and *b* in Fig. 38. *a*. Cavities formed in the corneous epidermis, and filled with pus corpuscles. *e*. Flattened epidermic cells. *d*. Cells of the rete mucosum which form a thin layer upon the surface of the papillæ *p* and *p'*, and which penetrate between them at *d'*. *v*, *v*. Dilated vessels of the papillæ filled with blood; the connective tissue of these papillæ is transformed into true small abscesses containing a semi-fluid granular substance, some red and white blood-corpuscles.  $\times 120$ .

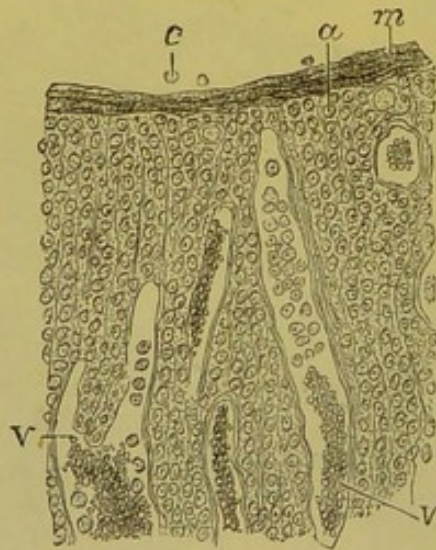
Figure 40 shows under a power of 120 diameters the two papillæ figured at *a* and *b* in Figure 38. Beneath the corneous layer in



which are seen cavities filled with pus *b*, the rete mucosum forms a moderately thick stratum which sends in at *d*, *d'*, prolongations belonging to the sebaceous glands. The papillæ *p*, *p'*, thus limited by the epidermic cells resemble small abscesses. Their normal fibrous tissue has been destroyed, and only lymph and red blood-cells are seen in their interior. The capillaries *v*, *v*, which here form terminal loops, are enormously dilated.

Figure 41 shows the condition of the cutaneous papillæ converted into a uniform layer at a point near the centre of a pustule, as at *m*, Figure 38. There still remain some flat cells upon the surface of the inflamed connective tissue. The elevation of each papilla is no longer recognizable. The delicate fibres of this tissue are separated by a large quantity of pus cells, and the capillary vessels are much increased in size. In the centre of this pustule the papillary layer is no longer covered by the flat cells of the epidermis, and the lymph cells which infiltrate it are poured out directly upon the suppurating surface.

Fig. 41.



Section of the pustule, Fig. 38, at an ulcerated point. *m*. Superficial and thin layer formed by flattened epidermic cells. *c*. Pus corpuscles free upon the surface; the connective tissue is filled with lymph cells. *v*, *v*. Vessels containing red blood-corpuscles and lymph cells. The capillary vessels are much dilated.  $\times 120$ .

The deep layers of the skin are altered in the same manner as the papillæ, that is, there is a large exudation of lymph cells around the vessels, between the fibrillæ and fasciculi of the elastic and connective tissues, around the fasciculi of smooth muscular fibre, in the lobules of fat—in brief—extending very deeply.

Thus it is found, that the suppuration in ecthyma is of long duration, attended with free formation of pus, and followed by an indelible cicatrix, due to the papillæ and the derm proper having been destroyed. The fibrous cicatricial tissue which repairs the pustule forms a slight depression, in the neighborhood of which the skin is at first stained and ecchymotic, subsequently white.

[The histology of syphilitic vesicles or pustules does not differ from similar lesions due to other causes. The process of their development is essentially an inflammatory one. The proliferation of the elements constituting the skin results in the formation of a papule. Upon the surface of this papule there is exuded above the rete mucosum, in the corneous layer, a yellow fluid containing lymph corpuscles, thus giving rise to the vesicle. An increase in the cellular elements of the fluid of the vesicle renders it purulent and develops a pustule. The pustule ruptures and its desiccated contents with the thrown-off epidermic cells constitute the scab. These changes may be limited to the corneous and Malpighian layers of the skin, or may extend deeper into the derm, involving the papillæ and connective tissue, a true ulcerative process which results in an actual loss of substance, and the formation of a permanent cicatrix. The cells of the corneous layer and rete mucosum present the modifications met with in inflammation of the integument—an excavated condition of their protoplasm around the nuclei, formation of cavities, division of nuclei and development of foci of suppuration. Other minute changes depending upon the intensity of the disease, its duration, and location, are described under the several varieties.]

The diagnosis of deep ecthyma does not depend, as is the case in so many of the superficial syphilitic eruptions, upon the copper color. This sign, so distinct in erythematous and papular eruptions, fails here. The edge of the ulceration, which looks as though it had been punched out, is red, if there be much inflammation—or it may be pale—or of a pinkish hue. The same color is noticeable in other pustular syphilides and in ulcerating syphilitic bullæ. These ecthymatous ulcerations consequently do not materially differ in respect to color from the scrofulous and cachectic forms of the same malady. If the local lesion only were considered, the diagnosis between deep syphilitic ecthyma and scrofulous ecthyma would frequently be very difficult. The latter ulceration is often deep and with perpendicular borders, as in the syphilides; the crusts, however, in syphilis, are drier, darker, and more imbricated, the cachectic lesion suppurating earlier and more freely,

consequently permitting of less adhesion of the crusts. This is not an invariable distinction, as in certain cases syphilitic ulcerations are attended with the formation of large quantities of pus. When the eruption is distributed upon the face and body as well as upon the limbs, the diagnosis of syphilis should be made, as the ecthyma due to scrofula is observed only upon the inferior extremities. It should be remembered, also, that syphilitic ecthyma appears usually in subjects previously enfeebled or placed under bad hygienic conditions, and is itself, by reason of the amount of suppuration when the pustules are numerous, a serious source of exhaustion.

The history and concomitant symptoms almost always lead to a recognition of the disease, as it is a persistent eruption, lasting for months, or even for a year, and often reappearing with all its original characteristics.

It necessitates a guarded prognosis on account of its persistence, and of the continual suppuration caused by it, especially when it is wide-spread.

It is formidable also, because it indicates a grave form of syphilis, particularly when it appears soon after the initial lesion.

*Impetigo rodens*.—All that has been said relative to deep ecthyma applies equally to the grave ulcerative and suppurative forms of impetigo.

6th. BULLOUS SYPHILIDES.—These consist of two varieties, rupia and pemphigus.

*Rupia* manifests itself at first by large elevations of the epidermis, filled with a clear or blood-stained serum, soon becoming turbid and purulent. The bulla bursts, allows some of the liquid to escape, and as it desiccates is covered with a crust, which dries, accumulates new layers, and becomes imbricated, as in the variety of ecthyma just described.

*Rupia* is, of all the syphilides, the one attended with the largest, thickest, darkest, and most characteristic crusts, as it is also the one presenting the most extensive ulcerations. Under these crusts, the papillary layer and the entire derm are undergoing suppuration, as in the last two eruptions considered.

Deep ecthyma, ulcerative impetigo, and syphilitic rupia have many points of resemblance, are of the same significance, and appear as the last manifestations of the secondary, or as symptoms of the tertiary period. This distinction is somewhat arbitrary, the pustulo-crusta-

ceous syphilide being sometimes assigned to the second and sometimes to the third stage of syphilis.

Although these different pustules or ulcerating bullæ generally appear in the two or three years following the chancre, they may show themselves five years or twelve years after the beginning of syphilis, and then it would be natural to place them in the tertiary stage.

The *pemphigus* of adults is never syphilitic. Three or four cases have been recorded in which pemphigus in adults was believed to be syphilitic, but these did not differ in any respect from ordinary pemphigus, so that as a syphilitic eruption it is at least so rare, that we need not here consider it.

This is not true, however, of the *pemphigus of new-born children*, which has some importance in the pathology of infantile syphilis.

The question of the specificity or non-specificity of this disease received great attention at the Academie de Médecine, in 1851, Cazeaux, at that time, maintaining that pemphigus had no relation to syphilis, while Dubois endeavored to demonstrate the existence of such a relation. One series of observers regard pemphigus as simply a sign of cachexia (Trousseau, Lassègue, Gibert, Diday, Bazin); others look upon it as a manifestation of hereditary syphilis (Cazeaux, Danyau, Bouchut, Vidal, Ollivier, Ranvier, and Parrot); still others, as Ricord and Gubler, believe it to be sometimes the result of cachexia, sometimes a symptom of syphilis, and with these observers, we coincide. One or many bullæ of pemphigus are frequently seen at birth upon children whose parents were never affected with syphilis, and in whom the symptom is of no gravity. On the other hand, we often see at the Lourcine Hospital, children born prematurely or at full term, with pemphigus either fully developed at the moment of birth or appearing a few days afterwards, and who commonly die with syphilitic cachexia, the sad heritage derived from their maternal parents.

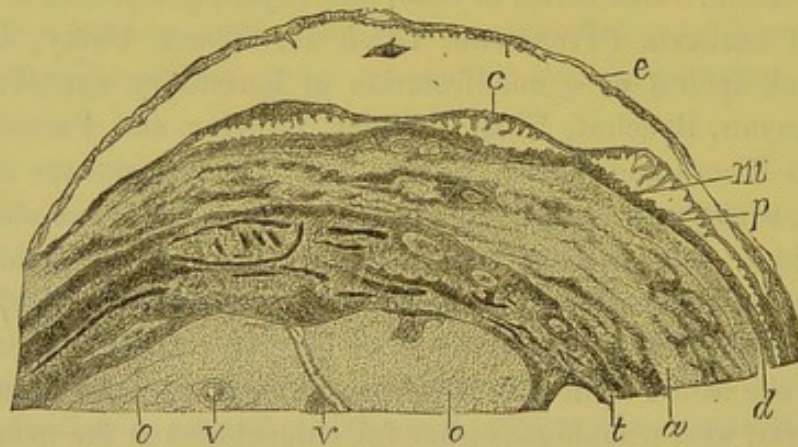
Syphilitic pemphigus is characterized by an elevation of the epidermis containing clear or blood-stained serum; the bullæ are more or less prominent, have a diameter of five to eight millimetres or of a centimetre, and are usually seated upon the palms of the hands, the soles of the feet, the anterior aspect of the forearm, and the palmar and plantar surfaces of the fingers and toes. I have recently made an autopsy upon a child, still-born a little before full term, whose mother had been under observation for nearly eight months. She

contracted syphilis at the time she became pregnant, and on her admission was affected with mucous patches. The child, which had not moved for five or six days before the accouchement, was a little macerated, and presented on the soles and palms some very characteristic bullæ of pemphigus. The epidermis was raised, and the papillæ congested in the region of the bullæ.

I examined many of these after first hardening them, and found two elevations of the two layers of epidermis placed one above the other. The corneous layer was separated from the rete Malpighii by a very large amount of liquid, while between the latter and the papillæ was found a smaller quantity. This is represented in Fig. 42, under a power of eight diameters. The bulla was about one centimetre in diameter, and covered the plantar surface of the great toe.

The distended superficial epidermis *e* formed a large circle; between it and the rete mucosum there was a liquid containing a few red blood-corpuscles and some lymph cells. The rete mucosum *c* is detached at places, and raised in such a manner that at *m* are seen its

Fig. 42.

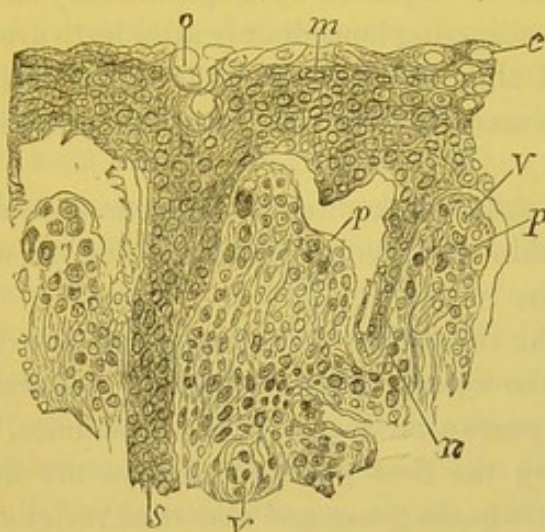


Pemphigus bulla from a new-born syphilitic child. The superficial epidermic layer *e* is elevated by a fluid exuded between it and the rete mucosum. The rete mucosum *c* is also partly raised, so that there exists a space filled with fluid between it and the papillæ, *p*. The epithelial prolongations and the ducts of the sudorific glands *m*, placed between the papillæ, and which run between them into the derm, are broken and suspended from the rete mucosum. *d*. Derm. *a*. Fibrous and muscular layers. *t*. Tendons and fibrous tissue. *o*. Cartilage of ossification of the first phalanx. *v*. Vessels.  $\times 8$ .

inter-papillary prolongations, and the ducts of the sudoriferous glands which have been drawn out with it, and have escaped from the derm. The same sanguinolent liquid exists between the rete mucosum and the papillæ *p*. Beneath the papillæ are seen the corium *d*, the adipose tissue and the sheath of the tendons *t*, and the epiphyseal cartilage of the first phalanx *o*.

Figure 43 shows in detail the lesion of the Malpighian and papillary layers, enlarged 200 diameters. The latter largely consists, as in a new-born child, of embryonic tissue; the rete mucosum presents an excavated condition of certain of its cells *c*; from *o* to *s* is seen a sudoriferous gland; *n* is an inter-papillary prolongation of the rete mucosum. The separation of the epidermis into two layers is at the granular layer. My opinion as to the true character of this case is corroborated by the fact, that the liver showed a lesion peculiar to hereditary syphilis—an interstitial hepatitis.

Fig. 43.



Section of the rete mucosum and papillæ from the same case of pemphigus as Fig. 42. *o*. Orifice of a sudorific gland. *m*. Cells of the rete mucosum, some of which are excavated *c*. *p*. Papillæ. *v*. Their vessels. *n*. Prolongations of the rete mucosum between the papillæ.  $\times 200$ .

Syphilitic pemphigus of the new-born is an eruption of great importance, as it is usually the first symptom of hereditary syphilis. It is, therefore, of moment to be able to diagnose it accurately. It may be recognized by its seat, which is usually the palms of the hands, the soles of the feet, the anterior surface of the forearm, the wrists, etc. It is essentially less a bulla than a papule, which may be understood from its anatomy. The swollen papillæ and congested distended vessels indicate a superficial inflammation of the true skin. If the epidermic layers are raised, it is due chiefly to their slight resistance, their delicacy, and their previous immersion in the amniotic fluid, *i. e.*, to conditions which are peculiar to the skin shortly after birth.

As an anatomical lesion, therefore, the pemphigus of infantile syphilis belongs rather with the papular than with the bullous eruptions; and should be classed with the roseola and papules of early

syphilis. It is in fact contemporary with the first cutaneous or mucous manifestations of syphilis; it almost always precedes them, but is closely followed if not accompanied by roseola and cutaneous or mucous papules. These last do not differ in children from those in the adult.

The macular and papular roseolas have, however, during the first days of life an intensely yellow hue, which is due to the fact that the skin of new-born children is congested, red, ecchymotic (Parrot); but the flat papules, and the mucous patches of the buttocks, lips, etc., resemble precisely the same lesions in the adult. Infantile pemphigus may be accompanied by a specific coryza.

The syphilides occurring immediately after birth are never deep, and the pemphigus of children is described in this chapter simply to conform to the elementary anatomical sequence of the lesions of the skin.

7th. GUMMOUS AND TUBERCULAR SYPHILIDES.—In the tubercles and gummata of the skin are seen the latest and deepest manifestations of cutaneous syphilis.

Gummata of the skin make their appearance at extremely variable intervals, after the contraction of syphilis; sometimes very late—twenty or thirty years after the chancre—sometimes, on the contrary, very early, during the first year, or even in the first four or five months; this occurs in the grave and abnormal varieties of the disease; most frequently they develop three or four years after the chancre.

The favorite localities are the face, scalp, shoulders, neck, arms, thighs, and legs, but they may occur in any region of the body.

For the present, only those affecting the subcutaneous connective tissue will be considered, but the submucous tissues are very frequently attacked, especially those of the cheeks, lips, tongue, soft palate, etc.

Cutaneous gummata are inflammatory tumors of the subcutaneous tissue—the cellulo-adipose connective tissue—which terminate by discharging externally; they cause a loss of substance to great depths, more considerable in extent at the bottom than at the cutaneous orifice, the disintegrated tissue being slowly thrown off like the core of a furuncle.

In the development of a gumma, there are four periods, which include the processes of formation, softening, ulceration, and reparation. The first period is of long duration, and as the tumor is painless, the patient usually discovers it by chance, as a rounded or slightly flat-

tened nodule seated deeply beneath the skin, which latter is slightly raised. The nodule is movable in the subcutaneous tissue, is hard, consistent, and gives rise to no subjective symptoms, unless it happens to include a nerve filament or trunk. Gummata upon the radial and ulnar nerves have been observed to excite pain analogous to that of neuromata.

The tumor grows slowly, little by little, until it acquires a volume varying from one centimetre in diameter to that of a hen's or even of a turkey's egg. These enormous gummata are exceptional, and our description is meant to apply to those ordinarily met with, having a diameter of from half to three-quarters of an inch.

The skin over the surface of the gumma is not usually changed, but remains normal, until suppuration begins. After a time the little tumor softens, becomes doughy, and then fluctuating, as a kind of liquefaction of its solid substance takes place. Soon the skin reddens, grows thin at the most prominent point of the gumma, and is finally perforated. The small, circular opening thus formed gives exit at first only to a very small quantity of purulent or gummy liquid; an open gumma not resembling in the least a discharging abscess.

The gumma does not at once empty itself when it is opened. The inflamed connective tissue remains in place adhering by its deeper portions to the subcutaneous cellular tissue; this latter is gradually thrown off in the form of small sloughs, shreds, and filaments, which are discharged with the purulent liquid derived from the walls of the cavity, the base and long diameter of which are much larger than the outlet. The walls of the cavity are quite resistant. The connective tissue and the epidermis covering the gumma, and constituting the superficial wall of the gummous cavern, do not become thin, but preserve a certain degree of hardness. The grayish and sloughing tissue from the bottom of the gumma is, however, gradually thrown off with the sero-purulent liquid secreted by the walls of the cavity, and when elimination is complete the period of reparation commences.

Granulations forming at the bottom soon fill the cavity, the solution of continuity is repaired, and cicatrization takes place; these processes often occur with astonishing rapidity, when compared with those of the previous periods. The resulting cicatrix is depressed, often adherent to the deeper tissues or to the bone itself, if the gumma has been situated above a superficial bone, and in this case there are seen surface irregularities, due to old periostitis or to periostosis in the neighborhood of the gumma. Over the surface of the cicatrix,



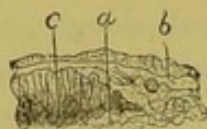
which is regularly circular, the skin is white and normal or pigmented around its circumference. Sometimes a number of gummata unite to form a more or less considerable group, each of them opening by a distinct orifice; there may also be many openings in the skin over a single gumma if the latter be very voluminous.

ANATOMY AND HISTOLOGY OF GUMMATA. — The structure of these connective-tissue lesions has been carefully studied by all pathologists, as the most characteristic production of syphilis, whether found in the skin or in one of the internal organs, as the liver. When the microscope was first applied to the study of tumors, Lebert, Verneuil, and Robin determined that there were no special cellular elements in the syphilitic gummata. Virchow and Lancereaux have given excellent descriptions of them, as has also Ch. Robin.<sup>1</sup>

When a section of the skin covering a gumma in its first stage is examined with a low power, it is found that it is slightly elevated by the accumulation beneath it, but the superficial coverings, the epidermis, and papillary layer, are absolutely intact.

Figures 44 and 45 have been drawn from a preparation made by Chambard of a gumma in this stage; in figure 44, as seen with the

Fig. 44.



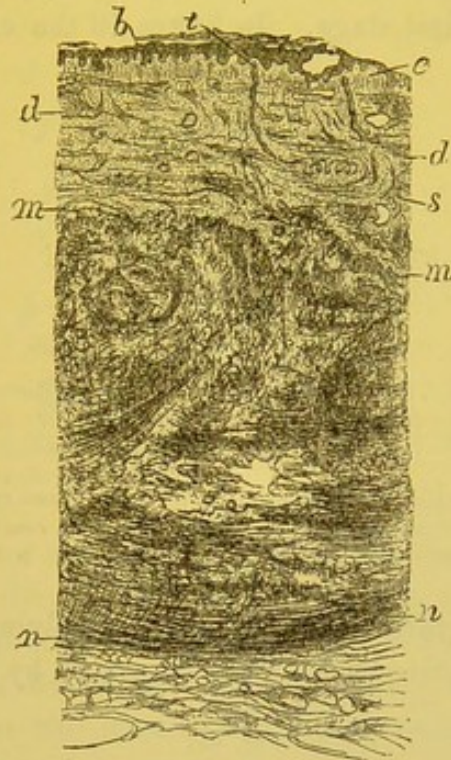
Section of the skin including half of a gumma, not magnified; *b*, skin surface; *c*, *d*, new tissue of the gumma.

naked eye; in figure 45, magnified eight diameters, showing the mass of gummous tissue, and its situation in relation to different portions of the skin. It is evident that the rete mucosum *b*, and the papillæ *c*, are not thickened; the dermal tissue *d* is normal, and the sudoriferous glands *t*, *s* are not involved by the new formation. The most deeply seated glomerules of the sweat glands may, however, be attacked. The new growth commences in the adipose lobules of the derm, and invades all its deeper portions as well as the loose subcutaneous cellulo-adipose tissue. The growth is, at this period, distinctly limited, although it gradually merges into the healthy tissue.

<sup>1</sup> Van Oordt, *Des Tumeurs gummeuse*, Thèse de Paris, 1859.

If a gumma be examined with a higher power, passing from the healthy skin towards its central and deeper parts, it is seen that at the margin the bundles of connective tissue fibres are separated by rows of round cells; the ducts of the glomerules of the several glands are

Fig. 45.



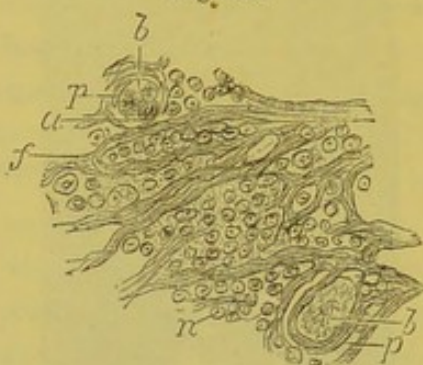
Part of Fig. 44, with higher power, situated between *c* and *d*. *b*. Epidermic layers. *c*. Papillæ. *d*. Connective tissue. *t*. Opening and duct of a sudorific gland, the glomerule of which is seen at *s*. All this superficial portion of the skin is normal or slightly inflamed. The tissue of the gumma, which is only a very intense inflammation of the cellulo-adipose, and subcutaneous cellular tissue, extends from *m* to *n*.  $\times 8$ .

surrounded by similar cells, and the islets of adipose tissue are equally involved. More deeply the bundles of fibres are isolated by masses of cells, arranged around them with some regularity. The fasciculi of connective tissue are easily recognized by their transparency, and the red color imparted to them by picro-carminé. The vessels are also isolated and surrounded by the same cells. The elastic fibres are not modified.

All the pre-existing cellulo-vascular tissue is thus infiltrated, and crowded with cells, the enormous quantity of which strangles the normal tissue elements, and impairs the circulation. In the interior of the capillaries and venules, there is seen an accumulation of round cells, and of detached and swollen endothelial cells; their lumen also

frequently shows granular or fibrillar coagulations of fibrin, which envelop the preceding elements, and the entire contents of the vessel are then seen colored red or orange-red, and with much more intensity of hue than the tissue simply infiltrated with cells. There are at intervals actual changes in the smaller vessels. Figures 46, 47, and 48 show the alterations of the connective tissue, and of the vessels in a gumma in the first stage. In figure 46 the capillaries are filled

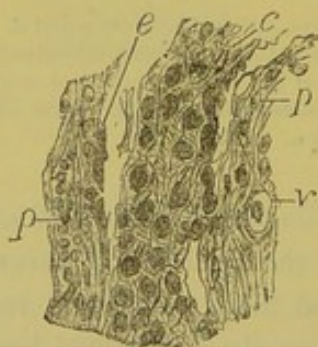
Fig. 46.



Connective tissue and capillaries of a gumma. *p, p.* Walls of two capillaries, which are filled with endothelial cells. *a.* Pus corpuscles and fibrin, forming a coagulum. *b, b.* Fasciculi and fibres of connective tissue, which are separated by round cells *n.*  $\times 200$ .

by a coagulum *b, b*, formed of endothelial and lymph cells and fibrin. The fibres of connective tissue *f* are separated by round cells *n*.

Fig. 47.



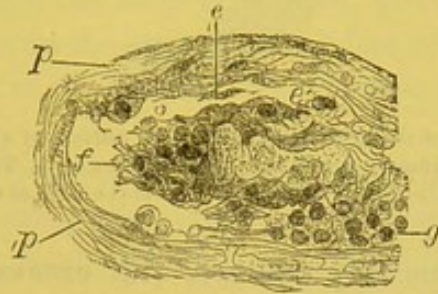
Longitudinal section of a small vein in a gumma: the wall *p, p.* of the vessel is formed of connective tissue, the fasciculi of which are separated by round cells. Its internal coat is lined with flat endothelial cells *e.* The lumen of the vessel is filled with a fibrinous coagulum *c,* entangling lymph cells.  $\times 200$ .

Figure 47 is a longitudinal section of a small vein, the wall of which *p* is formed of a tissue infiltrated with round cells. At its internal portion there are some endothelial cells *e,* and the interior of the vessel is filled with a fibrinous coagulum *c,* surrounding the lymph cells.

Figure 48 represents an oblique section of a vein obliterated in the same manner. The coagulum shows lymph cells and filaments of fibrin.

These coagula are occasioned—as is true in all intense and destructive inflammations—by a modification of the vascular wall. This

Fig. 48.



Oblique section of a vein in a gumma, obliterated as in Fig. 47. *p, p.* Walls of the vessel. *e.* Parietal endothelial cells. *e'*. Endothelial cell situated upon the surface of a fibrinous coagulum, which entangles endothelial cells and pus corpuscles. *f.* Free filaments of fibrin. *g.* Collection of lymph cells in the vessel.  $\times 200$ .

permits the escape of the corpuscles; the endothelial cells swell; the circulation is interfered with; the lymph cells are arrested in their movement; and there is at first obstruction of the vascular canal and then coagulation of the fibrin. These coagula are rarely visible in gummata, except at the moment when the mortification which precedes the elimination of the neoplasm occurs.

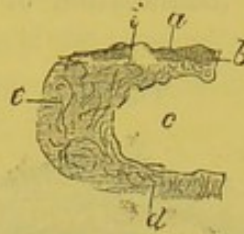
In the second period, or that of softening, the cellular elements become granulo-fatty, the bundles of connective-tissue fibres separate, the elements, at first compressed between resisting fibres, are more easily displaced, becoming more mobile, and the tumor grows less dense. At this time the superficial layers of the skin are infiltrated with the same cellular elements, and are finally perforated.

Figure 49 represents a naked-eye drawing of a preparation made by Chambard of an open gumma, in which the loss of substance has been considerable, and has left an empty cavity, the gummous tissue having been completely evacuated. Half of this cavity is represented at *c*; the walls, *b*, are formed by the superficial layer of the skin, *a*, by the corium, *e*, and by the subcutaneous connective tissue, *d*.

Figure 50 shows, with an enlargement of 8 diameters, that portion of the skin included between *a* and *b* in Figure 49. The rete mucosum, *a*, is considerably enlarged, and sends between the lengthened papillæ long epithelial prolongations, *d*; all the connective tissue

of the derm, *c*, is inflamed. In the portion *b*, and in all the region adjoining the perforation, the cells of the rete mucosum have under-

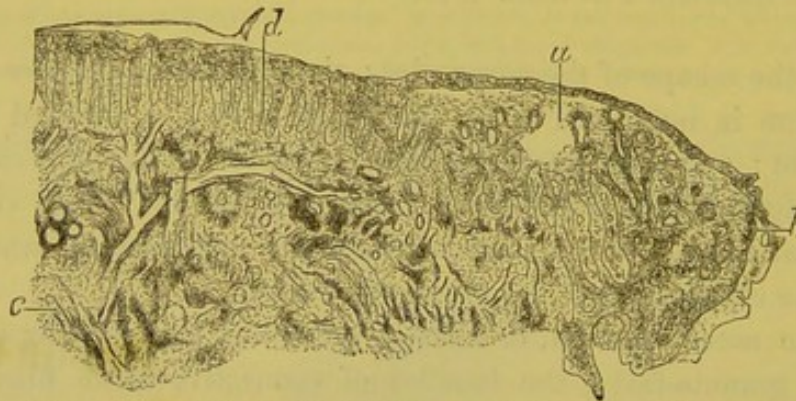
Fig. 49.



Section of half a gumma of the skin, natural size. *a*. Surface of skin. *c*. Empty cavity occupied by the soft part of the gumma which has been eliminated. *e*. Tissue of the derm. *d*. Deep portion of the derm and subcutaneous tissue which form the wall of the gummous cavity.

gone marked inflammatory changes, with excavated cavities in the cells which may be seen under a higher power. All the superficial

Fig. 50.



Represents that portion of Fig. 49 included between the letters *a* and *b*. *a*. Much thickened rete mucosum of the cutaneous surface near the opening in the skin of the gumma. The skin is arrested at *b*. *d*. Rete mucosum extending between the much elongated papillae of the inflamed skin above the gumma.  $\times 8$ .

portion of the derm and of the epiderm has then been acutely inflamed before the perforation occurs. That having taken place, the fluid and solid portions of the gumma are gradually discharged; the superficial wall not breaking down, but remaining *in situ* over the open cavity. This phenomenon is easy of explanation: the wall from *b* to *e*, Fig. 49, is composed of the derm of the inflamed skin, and is quite sufficiently resistant, as in all sclerosed connective tissue, to preserve its form.

The evacuation of the gummous tissue goes on very slowly; it may last a month or even two months after the opening in the skin has

taken place. The condition is very analogous to that in the interior of a furuncle, the core or slough in both cases being formed of bundles of connective tissue more or less disintegrated and filled with large numbers of cells. It is exuded in filamentous particles mixed with the fluid discharge.

The inferior wall of the cavity adheres for a long time to the gum-mous tissue, since it is composed of exactly the same structure, and, even after the slough has been eliminated, there may still be seen, in the tissue which forms the bottom of the loss of substance, numerous obliterated vessels in the midst of a connective tissue infiltrated with cells.

The process of reparation consists simply in the embryonic connective tissue becoming granulation tissue, growing from the surface of the cavity, and usually filling it with rapidity.

The diagnosis of these tumors is easy; they should not be mistaken for fatty tumors, sarcoma, fibroma, or cancer; there might, however, be some doubt between a gumma of the heart and a tumor of another nature in the same region.

Gummata which are open or about to open are very characteristic; they are distinguished from cold or scrofulous abscesses by the fluctuation and the thicker and more abundant pus of the latter. The walls and base of a gumma are hard and resistant, while the skin surrounding a cold abscess is more flaccid, and is apt to be discolored. The cicatrices are often different, scrofulous scars being more frequently irregular or honey-combed. The prognosis of gummata is not grave when they are few in number, do not come prematurely, and are not of excessive size. Their appearance, three or four months after the chancre, almost invariably indicates a grave abnormal syphilis.

[PHLEGMONOUS SYPHILIDES.—Occasionally, and especially in children, gummata soften with such rapidity as to bear a close resemblance to ordinary furuncles. Lancereaux quotes cases of subcutaneous tumors which softened or ulcerated with extraordinary speed, and Bäumler refers to cutaneous gummata in infants with hereditary syphilis, which have been described by Rinecker as *syphilis nodosa*, and anatomically examined by Virchow and Förster. They were precisely like the furuncles of poorly nourished children, but their contents did not consist of a "core" of cellular tissue or pus, but of a muco-

purulent fluid, which contained chiefly granular detritus. The diagnosis was made by the other signs of syphilis present.

Dr. Thomas Barlow has reported<sup>1</sup> a case of numerous furuncular swellings occurring in a child of ten weeks, and distributed over the greater portion of the body. They ran an acute course, rapidly suppurated and discharged pus, and before treatment was commenced were followed by extensive ulceration. Doses of one grain of gray powder three times daily, followed by mercurial inunction, rapidly caused their disappearance, as well as that of enlargements of the inguinal glands, the spleen, the liver, etc. Dr. Barlow believes that these were not ordinary furuncles, as they had no inflamed areola and discharged no core; they were not the "scrofulides phlegmoneuses" of Hardy, as they were much more acute, discharged laudable pus, and healed more rapidly; they were not ordinary gummata, as at no time was there any hard nodular mass to be felt, there was active suppuration, not gradual breaking down, and there was never any re-absorption even under treatment.

For these reasons he prefers to describe the eruption as a "phlegmonous syphilide," or a "syphilitic phlegmon," rather than as subcutaneous gummata.

Subsequently Mr. Frederick Taylor gave details of two similar cases, occurring in children aged thirteen weeks and four months respectively, and running a precisely parallel course. He calls attention to an article by M. Bouchut,<sup>2</sup> in which multiple abscesses of cellular tissue in undoubtedly syphilitic infants are said to appear as "small hard nodules in the subcutaneous tissue, which soften and fluctuate but do not burst for perhaps two or three months; the pus is small in quantity, of a yellowish sanious character, and the opening remains livid and fistulous for some time prior to closing." This description would, however, appear to apply very accurately to ordinary gummata, but the cases of Barlow and Taylor, as well as others of the same character, which have been reported, were entirely different.]

**TUBERCULAR SYPHILIDES.**—Syphilitic tubercles and gummata have numerous and striking analogies. They appear at the same stage of syphilis, are of the same clinical import, and are caused by the same pathological changes; the chief distinction being that the tubercles are more superficial, only involve the derm, do not extend into

[<sup>1</sup> The London Lancet, Dec. 1876.    <sup>2</sup> Gazette des Hôpitaux, Aug. 1, 1876.]

the subcutaneous tissue and give rise to a less abundant cellular infiltration.

Tubercular syphilides represent deep and enormously swollen papules, and are intermediate pathologically between the papule and the gumma.

They appear as single, flattened pimples, attended with an induration of the entire skin, from the superficial epidermis to the deepest layer of the derm; they are sometimes isolated, sometimes in groups, and may be scanty or may invade the greater part of the body. Their favorite seat is upon the face, at the mucous outlets, upon the nose, ears, forehead, back, neck, and inferior extremities, especially the legs.

There are two varieties, the dry and the ulcerating. Fournier has described them under the name of gummata of the skin, and he is correct in so far that their essential histological lesion is the same as that of the gummata—so that the latter might appropriately be called deep tubercles of the connective tissue.

The *dry tubercular syphilide* is usually copper-colored like the papules; the groups of thick flattened tubercles form segments of circles or complete rings; they are covered with thick scales, almost crusts, although there may be no ulceration of the skin, and healing may occur with the production of a white or pigmented cicatrix without any ulcerative process having taken place. The phenomena of deep infiltration by round cells, and of partial destruction of connective tissue, and its transformation into cicatricial tissue, which take place openly when ulceration has occurred, may likewise be accomplished beneath a skin which is intact or simply inflamed. It can easily be understood that such a process is one of long duration.

The *ulcerative tubercular syphilides* are more grave on account of the abundant suppuration caused by them. They may be isolated, but are usually in groups, and often extend over considerable portions of the skin. I have examined microscopically a patch of syphilitic tubercles, and have found the entire derm packed with round cells, and the papillæ hypertrophied and budding. Their surface was covered with epithelial cells and pus corpuscles. The cells of the rete mucosum and corneous layers of the epidermis showed the lesions which have been dwelt upon in considering mucous patches—excavations, branching prolongations, etc.

[The histology of gummata and tubercles consists in the formation of embryonal cells, which, in the former, the gummata, occupy a po-



sition deep in the derm, infiltrating the subcutaneous, connective and adipose tissues, and in some instances even involving the deeper structures, bone, cartilage, etc. The tubercles are the same in their histological structure, but are limited more particularly to the skin, implicating the derm alone, and not affecting the subcutaneous tissue. This infiltration, together with the part involved, undergoes retrograde metamorphosis, and is finally discharged as a slough. The bloodvessels included in the new formation are, at a certain time, obliterated by a coagulum in their lumen, which consists of lymph and endothelial cells and fibrin.]

Tubercles, particularly those of the face, are often so prominent, have such a marked wine-red or violet color, and so thicken the entire skin of the visage that the eruption has been called leontiasis. The ears may even be deformed as in erysipelas.

These tubercles give rise by their ulceration to extensive loss of substance, occurring at first at separate points, but uniting and following the circinate form of the eruption. The ulcerations are deep and abrupt, with red, inflamed, sometimes much hypertrophied edges, and occur in thickened and indurated skin, infiltrated with small cells. This form of tubercular syphilide often assumes a perforating character, penetrates the nasal septum and alæ, the lip or the ear, or involving the bridge of the nose, occasions the necrosis and loss of bone or cartilage which not infrequently cause a depression or falling in of that organ.

[The disease for which an ulcerating tubercular syphilide is most likely to be mistaken is lupus vulgaris, which is a cellular new growth resulting in various papular or tubercular patches which are usually followed by ulceration. It has no relation with syphilis, and should be carefully distinguished from it, as the treatment beneficial in one case is useless or absolutely harmful in the other. The main diagnostic points may be tabulated as follows:—

TUBERCULAR SYPHILIDE.	LUPUS VULGARIS.
Occurs chiefly among adults.	Occurs commonly in young persons.
Considerable infiltration of skin.	Not so marked.
Tubercles opaque, and of a deep brownish-red color.	Tubercles often translucent and lighter in color.
The characteristic ulcer produced in a month or two.	The same amount of ulceration would require several months or even years for its development.
Ulcers usually distinct.	Ulcers apt to be confluent.

TUBERCULAR SYPHILIDE.	LUPUS VULGARIS.
Ulcers deep and extensive.	More superficial and involving smaller area.
Ulcers small, circular, punched out.	No regular form, nor perpendicular edges.
Secretion copious, sometimes offensive.	Secretion slight, inoffensive.
Crusts bulky, greenish.	Crusts thin and dark colored.
Scales irregular in shape and attachment.	Scales arranged more regularly, attached in the centre, and loosened at the edges.
Cicatrices soft, white, circular.	Cicatrices distorted, irregular, puckered.
History and concomitant symptoms of syphilis.	No such history except as a coincidence.
Local treatment ineffective. Internal specific treatment effects a cure.	Eruption disappears only under very active local treatment.]

When either these tubercles or gummata or deep ulcerating pustular lesions are seated in the neighborhood of bones, as in the subcutaneous tissue of the scalp, or over the sternum, tibia, ulna, etc., it often happens that the periosteum is altered in the same manner as the skin.

There are still to be considered those grave eruptions which, whether primarily pustular, ulcero-crustaceous, tubercular, or gum-mous, give rise by their confluence to the enormous serpiginous ulcers of the lower extremities, back, shoulders, etc., which are occasionally seen in hospital wards.

These syphilides are of extreme and dangerous importance on account of the depth of the ulceration, the extent of the affected region, the free suppuration, the difficulty of cure, the tendency to relapse, and the cachexiæ of the patients; they usually occur at a period remote from that of infection, and are rare as compared with the whole number of infected persons.

Although this is the general rule, there are yet numerous exceptions. As has already been mentioned, the lesions of syphilis do not always succeed one another in entire accord with the artificial division into distinct periods, which is made and followed for convenience in study and description. The very first symptoms of syphilis may be deep, generalized, pustular or ulcerating eruptions, which have been variously named, but which are none other than those just described, only following immediately after the chancre instead of being separated from it by an interval of many years.

Such eruptions are usually more widely distributed than the late

syphilides, and they occur at a time when all the glands are involved in the general infection incident to the onset of syphilis; ordinarily when these same symptoms appear, the lymphatic glands are no longer either indurated or hypertrophied. The general symptoms, fever, prostration, osteocopic pains, etc., are much more intense than usual.

These early grave syphilides—or the “syphilides d’emblée”—are divided by Bazin into two varieties: 1st, a vesiculo-pustular form characterized by rupial bullæ or ecthymatous pustules, which spread rapidly, suppurate profusely, and are covered by thick yellowish or brownish crusts; this lesion, owing to the abundance of the suppuration, conjoined with involvement of so large an extent of cutaneous surface, may of itself produce profound cachexia and death, and such cases have been observed and recorded; 2d, there is a gangrenous, ulcerating, tubercular variety, in which the eruption is complicated by mortification affecting the centre of the ulcer, and causing great loss of substance. [Hardy says that this is due to an endo-arteritis, which completely obliterates the vessels. He reports cases of this character, and has made preparations demonstrating the affections of the arteries.] The sloughs are separated by the suppurative process; 3d, Dubois has described in addition a malignant, ulcerating tubercular variety in which very deep serpiginous ulcers occur, and are rebellious to treatment.

Between these syphilides of excessive gravity, and the successive eruptions or the single eruption of an erythematous or papular syphilide, which may be observed in light cases of the disease, and which often constitute the entire symptoms, there exist numerous intermediate conditions. Thus eruptions of large lenticular papules, or of thick papulo-squamous patches, are often seen to follow closely upon the primary lesion, and resist treatment for six months or a year. Such cases seem to connect the mild or common form of syphilis with the grave or malignant disease.

#### GENERAL CONSIDERATIONS REGARDING SYPHILITIC ERUPTION.—

In the last two chapters all the syphilitic cutaneous eruptions have been described, and it is seen that, with the exception of the “syphilides d’emblée” which do not conform to the general rule, they are deep, grave, and also more localized in direct proportion to their age.

The lesions of the skin in syphilis do not differ markedly, as regards the anatomical changes, from the same lesions observed in

papules, pustules, bullæ, etc., due to other constitutional conditions or to local irritants.

The lesions which have been described, do not permit, from a histological point of view, an explanation of the assumption of a particular form, the involvement of a certain region, or the symmetrical or irregular distribution of any special eruption. In this as in all other diseases, we are compelled to stop short of a knowledge of the original or essential cause. We may accumulate facts, study them in all their details, and discover anatomical and physiological reasons for the phenomena observed with the naked eye. Possibly with new and more nearly perfect methods further advances will be made; possibly, also material lesions or functional disorders of nerves will be found to explain the regular and symmetrical distribution of some of the eruptions. It is, however, essential that we should not conceal the unavoidable limit of our knowledge, or ignore that which now escapes our best efforts and methods.

The study of minute histology, practised with high powers, teaches that the phenomena which are most general and are common to the greatest number of cutaneous eruptions—the modifications of nutrition, of cell proliferation, of the migration of cells—are nearly identical, except in intensity, whether observed in papules, vesicles, pustules, or tubercles. These dissimilar eruptions, whether syphilitic or due to other causes, do not differ among themselves when studied under high powers, so much as one would on *à priori* grounds be led to suppose. It is not, however, the microscopic examination which determines the nature of eruptions. As Edmond Langlebert has said: In cutaneous pathology as in natural history, it is the form and not the intimate structure of tissues which constitutes the species.

Upon this point, I am entirely of his opinion, but it does not follow that we should not seek to discover with the aid of instruments more delicate and precise than the unassisted eye, the form and course of these eruptions which it has been thought important to study carefully under low powers. In this manner it is possible to determine exactly the changes in form and relation of the different layers of the skin; the precise limit of the lesions not only upon the surface, but also in depth; the pathological modification of each of the constituent parts, the epidermic layers, glands, papillæ, derm, etc.; the seat and the nature of abnormal growths; or in a word we are thus enabled to give a precise description of each of the elementary cutaneous lesions

from its onset to its acme, and, again, to the termination of the reparative period.

This sort of descriptive anatomy is not only more exact, but, also, simpler and more satisfactory than that which confines itself to the surface. As the study of symptoms and the investigations of pathology intermingle in these cases, the best methods at our disposal should of course be carefully employed, and it may be added, that it is as impossible to teach cutaneous pathology as any other branch of pathology, without beginning with an anatomical description of lesions as examined microscopically. The diagnosis of these elementary lesions is the basis of the broad distinction between diseases.

The histological study of the modification undergone by isolated and individual elements in cutaneous eruptions, is no less useful from another standpoint. While an examination under a low power shows the differences which separate a given species from one allied to it—as, for example, a papule from a pustule—and makes them better known in all their details, at the same time the analysis of the modifications of nutrition, and the emigration of cells shows the strong resemblances between species nosologically distinct, and the universality of the pathological laws which govern them. For example, the formation of peri-nuclear cavities in cells, the division of the nuclei, the formation of round cells or of pus corpuscles, is the same in the investing epithelium whether it covers a papule, a pustule, a mucous patch, or some form of tumor near the cutaneous surface. In the same manner the formation of small abscesses or islets of pus corpuscles in the superficial layers of the epidermis is identical in all its main features in a chancre, a mucous patch, a syphilitic or variolous pustule.

Again, the transudation of white blood-cells and their infiltration between the fasciculi of connective-tissue fibres is the same in the hard chancre, the soft chancre, the papule, and the pustule. It is the evolution, the more or less intense degree of inflammation, the topographic distribution of the lesions which determine the species. The more the elementary lesions of nutrition are studied with high powers, the more we find ourselves occupied with phenomena of general pathology applicable to a great number of different conditions. The manner in which cells are affected by very dissimilar maladies is in fact very limited and but slightly variable. The study of these general phenomena is, however, essential to a philosophic conception of the pathology of the disease in question.

It has been shown how the process by virtue of which a mucous patch exudes a transparent liquid filled with round cells, is the same as that which causes the exfoliation of the superficial epidermis, and the formation of scales in a dry papule, and in a higher degree of intensity, or a more advanced stage produces the suppuration of an acne pustule or the ulceration of an ecthyma. Other modifications of the same process have been considered, as the suppuration which occurs in certain cases under crusts, or even without the loss of the Malpighian, or corneous layers of the epidermis. These examples could be indefinitely multiplied by contrasting the lesions of diphtheria, and the formation of false membranes with those of mucous patches, by showing the analogy between the connective-tissue inflammation in papules, and that which occurs in pustules, etc., but it would invoke needless repetition. The principles have been fully set forth—the corollaries are almost self-evident.

[The *clinical* characteristics of the group of cutaneous syphilides may be stated as follows:—

1. General or constitutional symptoms are usually absent, with the exception of the syphilitic fever which precedes or accompanies the early eruptions.

2. Additional evidences of syphilis will usually be found, and should carefully be searched for. The chancre, its cicatrix or its induration, the buboes, sore throat, baldness, mucous patches, etc., if an early eruption be in question; osteocopic pains, nodes, and other bone lesions in the later stages.

3. The eruptions, especially the early ones, are apt to be polymorphous, or to present at the same time a variety of forms of cutaneous lesion, macules, papules, and pustules, being usually intermingled. This is due to the chronic, slow evolution of the disease which permits of the development of new symptoms during the gradual fading of previous ones.

4. The patches of eruption are apt to have a rounded or crescentic form, due to the anatomical arrangement of the cutaneous capillaries, and when seated upon the extremities occupy the side of flexion, the anterior surface of the forearm, the palm of the hand, the sole of the foot, etc.

5. The characteristic color of the syphilitic eruptions is a yellowish-red, usually described as “coppery.” Its peculiar dusky tint is due to the absence of the active hyperæmia and arterial excitement which usually exist in the non-specific eruptions, the color of syphilides

being the result of slow changes in the coloring matter of the blood which has exuded under pressure, and not the accompaniment of acute inflammation.

6. There is an absence of pain and itching which is very distinctive, and which is also due to the non-inflammatory character of the eruption. It is quite common to find patients who were not aware of the presence of an extensive syphiloderm until their attention was directed to it by the surgeon.

7. The early eruptions are contagious, superficial, general, and symmetrical, indicating by these characters the involvement of the blood, to which they are due.

8. The later eruptions are not contagious, are irregular in distribution, extend to the cutis vera, or beneath it into the connective tissue, and are described as local lesions or sequelæ following the acute or secondary stage, and due either to relapses in parts previously diseased, or to new growths resulting from changes effected by syphilis.

9. The early eruptions are frequently scaly, the pressure of the cell proliferation, which is always present, cutting off the supply of nutriment to the superficial epidermic layers, which accordingly dry, desiccate, and are exfoliated.

10. The scales are whitish, superficial, and usually not adherent, there being no plastic or inflammatory exudation to fasten them to the subjacent part.

11. The later eruptions have thick irregular or imbricated crusts, often occur in groups, and leave scars even if no ulceration has occurred.

12. Ulcers resulting from the breaking down of syphilitic deposits have rough abrupt edges, are irregularly crescentic or circular in shape, covered with an unhealthy greenish-yellow secretion, and, as a rule, are painless.

13. The cicatrices caused by syphilis are at first pigmented, then whitish, shining, rounded or radiating and depressed below the level of the surrounding surface—they often show very small apertures, the sites of pre-existing follicles.

14. The therapeutic test in all very doubtful cases is an extremely valuable one, although it should be necessary to resort to it only in extremely exceptional instances. The amenability of nearly all the cutaneous symptoms to well-directed specific treatment often renders this test very conclusive.]

TREATMENT OF SYPHILIDES.—The beneficial and often surprising action of mercury in syphilodermata is shown in an undeniable manner. The employment of this remedy, which may be administered in pills of the protiodide, as the bichloride in Van Swieten's solution, in Sedillot's pills, by inunctions, vapor baths, or hypodermic injections in doses proportioned to the extent and gravity of the symptoms, is unquestionably indicated by the clinical evidence. Under its use, for example, the blood-red or copper color of the papular eruption becomes lighter, and gradually disappears, as do also the small tumors themselves, leaving behind them only a discoloration. Nothing in therapeutics is more apparent than this action. If, in an obstinate papular or pustular syphilide, mercury be given in sufficient quantity to produce mild salivation, the disappearance of an eruption which had, perhaps, lasted for months, is often brought about in a week or ten days. No one denies this fact, but it is asked—what is the advantage of administering mercury in the benign and self-curable cases of syphilis? In such cases Diday does not employ this drug, which he reserves for obstinate and severe syphilides. Desprès, faithful to his conviction that the syphilitic virus should be permitted to eliminate itself uninterruptedly by means of the cutaneous eruptions, which, he thinks, should no more be interfered with than those of scarlet fever or smallpox, gives nothing except possibly some ferruginous tonic.

It should first be decided whether it is good practice to treat the secondary symptoms of syphilis with mercury—not only as regards the immediate results, which are excellent beyond question, but also in relation to the tertiary symptoms, which are the most to be dreaded; will they be hastened or delayed, will they be graver and more numerous, or more benign and rarer, if mercury be administered during the secondary stage? These are the vital questions.

Jullien has endeavored to reply to them in a statistical essay<sup>1</sup> prepared with great care, and based upon numerous observations: 1, in cases mercurialized upon the appearance of the chancre; 2, in cases treated during the secondary epoch; and, 3, in cases treated expectantly, and allowed to proceed to their natural evolution. The tertiary symptoms were the least severe in the last class, and the most extensive in the second.

<sup>1</sup> Louis Jullien, *Reserches statistiques sur l'étiologie de la Syphilis tertiare*. Paris, 1874.



What is the value of this conclusion from statistics? If it be admitted as it stands, and especially if Diday's assertion, that the grave lesions are more frequent in individuals put under the influence of mercury upon the appearance of the initial lesion be accepted, it is evident that mercury should not be prescribed. It must be remembered, however, that Jullien has derived his statistics from observations upon patients who were admitted to the hospital to be treated for tertiary symptoms, and has divided them into three series. Even if we should admit the general rule that patients who had been mercurialized during the secondary stage developed the most severe tertiary lesions, we would still wish, before drawing any conclusions, to know the proportion of cases in which any tertiary symptoms appeared in those not treated at all. That is, we would ask if there were not a greater number of patients treated during the secondary stage, who escaped the tertiary period absolutely and altogether, than there were among those not treated; or, in other words, does not treatment during the early stages *usually* effectually prevent later developments?<sup>1</sup>

Jullien has collected 208 cases of tertiary syphilis; 59 of which had been without treatment, and 149 mercurialized; but it is unquestionable that careful inquiry results in assigning many more cases of tertiary phenomena to the category of natural or untreated syphilis than to the class of those who have taken mercury, although the latter includes the large majority of all syphilitics. If it be considered as proven that syphilis after treatment with mercury only rarely gives rise to tertiary symptoms, it undoubtedly becomes necessary invariably to give mercury during the secondary stage, even at the risk of having exceptionally some graver lesion than if the disease had been allowed to develop naturally.

In the wards of the Lourcine Hospital we give mercury in small doses during the light secondary syphilides, a pill of half a grain of the protiodide or a teaspoonful of Van Swieten's solution in milk, for syphilides of average intensity, and double that, with or without inunctions in the graver forms, stopping before salivation is produced. We do not give mercury as a prophylactic, because we are not persuaded that it prevents the return of the syphilides. When we are

<sup>1</sup> In his excellent *Traité pratique des Maladies vénériennes*, Jullien is not so positive as in his statistical researches, and does not pretend to regard his theory as incontestably established.

dealing with grave precocious syphilides, or with tertiary syphilides, pustular or tubercular, we associate with the mercury the iodide of potassium, or give the iodide internally and the mercury by inunction.

The local treatment of the grave syphilides consists in lotions of corrosive sublimate, and of the pustular, crustaceous or ulcerative tubercular forms in dressings of the mercurial plaster or with iodoform.

[The treatment of the cutaneous manifestations of syphilis usually adopted in this country is in the main that recommended by the author, but so far as we know, the majority of syphilographers here prefer to administer mercury in small *continuous* doses extending over eighteen months to two years. (See Chapter XIV.) The arguments of Jullien, based upon hospital cases which have already developed tertiary syphilis, are such manifest examples of the *post hoc ergo propter hoc* method of reasoning that they do not seem worthy of serious refutation. If this were required, however, it would be found in a paper of Fournier,<sup>1</sup> who has recorded forty-seven cases of tertiary syphilitic epilepsy, of which forty-five went through the secondary stage with exceptionally few and mild symptoms, *i. e.*, they were cases in which mercurial treatment was employed not at all, or for but short periods, as recommended by Diday<sup>2</sup> and Jullien.<sup>3</sup> We believe that no recognized authority in America, at the present day, teaches that the proper administration of mercury during the secondary stage increases one iota the patient's liability to tertiary symptoms. On the contrary, there is every reason on both clinical and theoretical grounds to feel confident that such mercurial treatment vastly diminishes the probability of subsequent difficulty.

The local treatment of the syphilodermata is of secondary importance, but should not be entirely neglected. The papular and scaly syphilides, especially those of the palms and soles, should be stimulated by the use of oleate of mercury, or ointment of the nitrate or red oxide of mercury; ulcers should be cleansed carefully and dressed with similar ointments or with iodoform or calomel; the scabs of rupia should be softened with oil or poultices; serpiginous or phagedenic ulcers should be stimulated or cauterized, etc. etc.]

[<sup>1</sup> De l'épilepsie syphilitique tertiare. Le Progrès Médical, Dec. 18, 1875.

<sup>2</sup> Maladies Vénériennes et cutanées, p. 266.

<sup>3</sup> Maladies Vénériennes, p. 633.]

## CHAPTER VIII.

## TERTIARY LESIONS OF THE MUCOUS MEMBRANES—SYPHILIS OF THE MUSCLES.

Tertiary lesions of the genital mucous membranes—Tertiary lesions of the mouth—Superficial or cortical glossitis—Deep glossitis—Gummata of the tongue—Diagnosis of lingual psoriasis, smokers' patches, tubercular and epitheliomatous ulcers—Gummata of soft palate, tonsils, and posterior wall of pharynx—Diagnosis from the scrofulides—Muscular syphilis—Contraction of the biceps—Gummata of the muscles in general, and particularly of the heart.

THE *tertiary lesions of the mucous membranes* are often the contemporaries of the late cutaneous syphilides, and present numerous analogies with the latter in their location and their anatomical formation.

They are characterized by tubercular growths invading the inferior portion of the mucous membrane or extending beyond it, and by gummata precisely similar to those just described. They are always or nearly always ulcerative, but are not covered by crusts, owing to the facility with which the accumulated secretions, purulent and epithelial, are detached from the surface continually bathed in mucus. Thus, in cases where upon the skin there would be a scab, upon the mucous membrane there is found an ulcer discharging pus more or less freely.

Like the deep syphilodermata, they are usually limited and localized, for, as the disease grows older, its formations, instead of being extended and superficial, select their favorite locality, and deeply involve and destroy its tissues.

The mucous membranes usually affected by tertiary lesions are those of the genital region in both sexes, of the tongue, uvula, soft palate, isthmus and posterior wall of pharynx, the tonsils, pillars of the fauces, and posterior nares.

TERTIARY LESIONS OF THE MUCOUS MEMBRANE OF THE GENITAL ORGANS.—In the male these are seated upon the glans, the frænum, the reflected portion of the prepuce, and at the external meatus; in

the female upon the labia majora and minora, the urethral orifice, the clitoris, the entrance of the vagina, the neck of the uterus, and the anus.

They consist of ulcerations due to tubercles or gummata.

Upon the glans their progress is the same as in the elementary lesions of the skin, and they often appear around its circumference as small, painless, excavated, suppurating ulcers, more or less deep and indurated at the base. The patients believe that they have contracted a chancre, and if they have previously had a chancre, and constitutional syphilis, which they will almost invariably describe, one may be led to believe that a return of the initial lesion or a case of second infection is under observation. An interesting fact, and one upon which Fournier lays great stress, is that this tertiary lesion frequently occupies the site of the original chancre.

It is difficult to diagnose such an ulcer from an indurated chancre merely by the local signs, but the information communicated by the patient will usually resolve all doubts. It is also sometimes quite difficult to distinguish it from a soft chancre, but auto-inoculation will determine this point. Tertiary ulcerations of the glans appear on the average about five to eight years after the infecting chancre.

Gummata of the glans are sometimes seen in the form of pea- or bean-shaped nodes which break down into ulcers, sometimes as diffused hard patches which likewise ulcerate.

These gummata should not be confounded with furuncles, which, as Mauriac has shown, may occupy the same seat, but run their course much more rapidly. The orifice of the urethral canal may be involved in tubercular ulceration, and the skin of the penis sometimes contains true gummous tumors.

There is a lesion of the cavernous body which is worthy of mention, and which may be either syphilitic or traumatic. This consists in the presence in its substance of small, hard, painless, unilateral, fibrous tumors, which may partially atrophy under the influence of iodide of potassium if they are due to syphilis; they also produce during erection a curvation or bending—chordee—of the penis, owing to their non-participation in the general tumefaction of the erectile tissue.

Tertiary ulcerations of the vulva have generally a rounded form—oval or circular; they affect a greater extent of surface than the corresponding condition in the male, which accords with the greater extent of the vulvar mucous membrane as compared with that of the

glans, and with the more considerable development of the mucous patches of the vulva compared with the same lesions in the male. Their usual seat is in the fourchette or upon the labia, where they often assume the shape of the segment of a circle.

The neck of the uterus is frequently attacked by ulcerating tubercular syphilides, but the ulcers do not differ noticeably from other deep ulcerations occupying the same region, and due to non-specific causes. Limited or diffused gummata of the vulva, of the labia minora, and of the clitoris have been observed. Fournier denies the existence of gummata of the neck of the uterus.

**TERTIARY SYPHILIS OF THE MOUTH.**—The affinity of syphilis for the buccal mucous membrane is well known. The tubercles and gummata which frequently occur there are of different aspect according as they are seated upon the tongue or the palate.

Tertiary glossitis is usually easy of recognition, owing to the facility with which the tongue can be inspected and palpated, as well as to the subjective symptoms—the difficulties in mastication and articulation—which call early attention to it. Following Fournier, who has published an excellent monograph upon this subject, we may divide it into a sclerotic glossitis, which may be superficial, deep, or even generalized, and into a gummous glossitis, which may also be either superficial or deep, submucous or muscular.

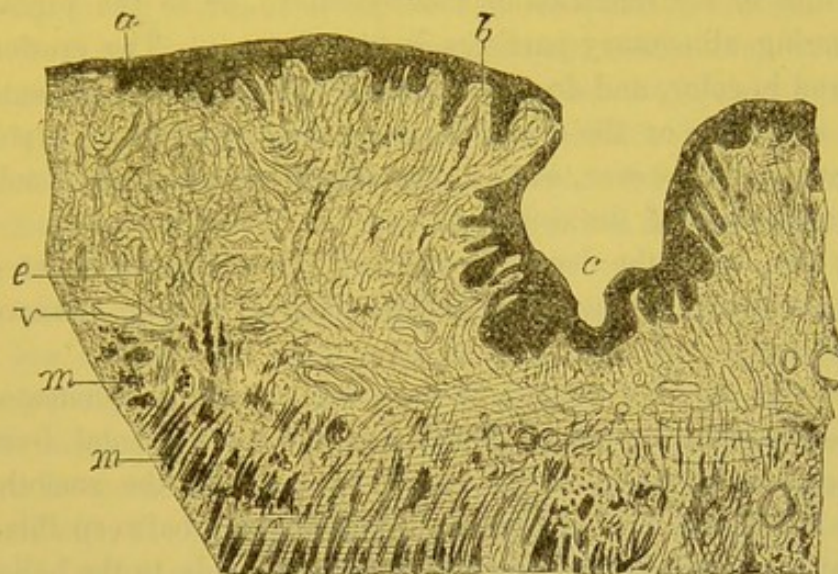
**SUPERFICIAL OR CORTICAL GLOSSITIS** consists in a circumscribed oval or circular thickening of the submucous cellular tissue, or else it is found in extensive patches.

This thickening is due to an infiltration of cellular elements into the fibrous tissue between the lingual muscles and their epithelial investment. It produces a greater or less number of indurations which may be easily recognized by digital palpation, and the surface of which is smooth, of a cherry or dusky-red color, dry, glossy, and neither eroded nor ulcerated.

Figure 51 shows a section of a preparation of this variety of tertiary glossitis seen under a low power. The papillæ do not form separate elevations showing themselves on the surface by a sinuous line of epithelium. The epithelial surface is, on the contrary, uniform, or is depressed at the seat of the fissures. Below this layer the papillæ, *b*, are few, isolated, and nearly normal, the only observable anatomical modification being the absence of the epithelial element

of the filiform papillæ which should exist upon the dorsum of the tongue. It is to this circumstance that we find the explanation of the smoothness of the surface of the tongue, which is not due to the destruction of the papillæ, as claimed by Fournier, since the papillary

Fig. 51.



Section of a tertiary syphilide of the tongue. *a*. Epithelial covering. *b*. Papillæ of the tongue. *c*. Deep furrow. *e*. Thickened connective tissue. *v*. Vessel. *m, m*. Fasciculi of muscular fibres of the tongue.  $\times 10$ .

fibrous tissue has undergone no change; but it results from a detachment of the corneous layer of the epithelium, particularly on the surface of the filiform papillæ, leaving the remainder of the epithelial covering remarkably smooth. The papillæ buried beneath this layer are not defined upon the surface by corresponding elevations. The connective tissue between the epithelium and the muscle, *m*, is much thickened by infiltration with small cells, as occurs in all chronic inflammations of this sort. The numerous vessels traversing the connective tissue are not notably affected. This superficial glossitis comes on with slowness, and often persists for years.

DEEP GLOSSITIS (lobular glossitis, lingual cirrhosis) attacks the muscular as well as the mucous layers of the tongue, and causes a greater or less swelling of the entire organ, which not only thickens it from below upwards, but enlarges it in its transverse diameter, and causes a rough, lobular, or mammillated condition of its surface. The lobules are separated from one another by depressions or fissures from one to three millimetres in depth, and are distributed with more or

less regularity, usually over the median portion of the tongue. They may, however, occupy its border. The mucous membrane is always smooth, even, and of a deep red hue.<sup>1</sup>

These two forms of glossitis, the deep and the superficial, may be accompanied by erosions, or even actual ulceration, of mechanical origin, due to the irritation of tobacco-smoke, or to the presence of decomposing alimentary particles in the fissures. The erosions are bright-red in color, and do not present the deeper hues, the extensive loss of substance or the sloughing base characteristic of syphilides. Gummata may, however, at any time supervene as an advanced stage or a complication of the condition.

Most frequently the deep glossitis and the lobular condition of the tongue are found in the region of the lingual V (the circumvallate papillæ).

When this sclerotic glossitis is not complicated with gummata there is no deep ulceration, but simply erosion due to accidental irritation. Fournier lays stress upon the deep-red color and the smooth, even surface of the mucous membrane. The analogy between this lesion and that found to exist in superficial glossitis leads to the belief that the filiform papillæ are simply deprived of their superficial corneous epithelium, and that the enlarged papillæ, which are thickened by the presence of newly-formed cells, are buried beneath the general epithelial layer.

Fournier has recorded a case of widely spread sclerotic glossitis, in which the whole tongue was measurably hypertrophied. This

[<sup>1</sup> Dr. Ch. Mauriac has published an interesting account of this affection (see review in *Le Progrès Médical*, 1877, No. 45, p. 853), which is rather rare, and not very well known. It is in character similar to syphilitic sarcocele, and consists of a sclerotic inflammation of the fibrous partitions separating the delicate muscular fasciculi of the organ. The affection begins always on the dorsal surface, at first being superficial, and then invading the deeper tissues. It is more frequently met in men than in women, and perhaps has some connection with the use of alcohol and tobacco. There appears to be a hypertrophic and an atrophic period. In the former the enlarged, hard, and painful tongue presents on the dorsal aspect hollow furrows filled with macerated epithelium. There are noticed large papillæ, and often ulcerations, at the points where the tongue touches the teeth, or in the bottom of the above-mentioned furrows. The second stage is that of retraction of the new tissue, and then there occurs a deep antero-posterior fissure, with several irregular fissures. Finally, as atrophy progresses the organ becomes smooth and shining, is divided into little lobules, and gives the sensation of a tongue made of wood. Specific treatment is seemingly of some service in the early stages, but is entirely useless when the disease is advanced.]

hypertrophy of the fibro-muscular tissue being separated into two equal parts upon the dorsum by the much depressed median longitudinal fissure.

[Parrot has called attention<sup>1</sup> to a syphilitic affection of the tongue, usually hereditary, which he calls "desquamative," and which begins at the tip of the organ or along its edges as a small, whitish, rounded patch about an eighth of an inch in diameter, and covered with thickened epithelium. Soon afterwards, the epithelium is shed in the centre of the patch, and it then appears as a whitish ring surrounding a red spot. Many of these circles then appear and by coalescence form irregularly curved lines, the concavity of which is generally directed forward.

A portion of the tongue is usually left unaffected, but before one patch has disappeared another begins, so that the disease may last for long periods.

The diagnosis is made upon the following considerations: The disease is essentially one of childhood; it occurs from one to ten years of age, the period when congenital syphilis is most active; it is associated with other specific symptoms (the writer found them in 28 out of 31 cases); it has many points of resemblance to cutaneous syphilis, as it appears in patches, with concentric edges, desquamates, returns in successive crops, etc.

In scarlatina, the tongue is rapidly and entirely denuded of epithelium, and is of an intense red; in thrush the desquamation does not take place in zones, and the microscope reveals the spores of the parasite; aphthæ do not usually extend beyond their first limits. Psoriasis, mucous patches, etc., are rarely or never found on the tongues of young children.

Parrot thinks the tongue is the seat of this disease instead of other portions of the buccal cavity on account of its rich blood-supply and physiological activity, "conditions which favor diathetic manifestations."

Martin, who examined microscopic sections of three tongues, found swollen and thickened epithelium; the cells of the Malpighian layer undergoing active proliferation, the papillæ and adjacent portions of the derm filled with lymph corpuscles. He believes the corium to be the tissue primarily affected, and thinks the symptoms which have been described are consecutive.

The treatment should be systemic, and is very efficacious.]

[<sup>1</sup> Le Progrès Médical, No. 11, 1881.]



GUMMATA OF THE TONGUE are sometimes mucous, sometimes sub-mucous, or muscular in their origin.

The mucous gummata are of the size of a pea or a cherry-stone, single or multiple, and often in groups. They begin as small, hard tumors beneath the epithelium, and their softening, their discharge through a small aperture, their excavated appearance and characteristic base do not differ from those of other gummata; this is also true of their duration and of their mode of healing.

The deep or muscular gummata are larger; they are seated in the lingual muscle, extending often into the submucous connective tissue, and may occupy either the lateral or median aspects of the tongue, or may affect its tip, its base, or its edges. They reach the size of a hazel-nut, and are either single or in groups of from two to six, or even more. They open by what is at first a very narrow, scarcely visible channel, which enlarges or extends in the direction of the muscular fibres; the gumma ulcerates in the same manner as when situated beneath the skin. Naturally the tongue is tumefied in proportion to the size of the gummata, and of their tendency to confluence. Fournier has recorded in his *Mémoires* three gummata seated upon the tongue of a patient of Horteloup, and each of which was the size of an almond with its long diameter directed longitudinally.

In those rare instances in which the gummata are extremely voluminous and confluent, there is prolapsus of the tongue, dribbling of saliva, impossibility of mastication, etc. Cloquet cites a case, believed at first by several physicians to be one of cancer, in which the tongue protruded from the mouth, and hung three inches below the chin. Under mercurial treatment a complete cure resulted in a little more than two years.

Another rare form results in serpiginous ulceration of the tongue.

The duration of these conditions when abandoned to themselves is indefinite; but when treated by mercury and iodide of potassium, or by the latter alone, they often disappear with surprising rapidity, though relapses may occur in after years.

In all of these affections of the tongue it is rare to find enlarged cervical or submaxillary lymphatic glands, which have resulted from the lingual lesions, and the same is true of gummata or of deep ulceration of the pharynx.

The differential diagnosis of syphilitic diseases of the tongue is one of some importance, especially in regard to non-syphilitic affections which simulate them. It would not be a matter of great moment if

a superficial sclerotic glossitis were mistaken for a case of chronic mucous patches. The latter, as previously mentioned, are variable in appearance. At first superficial, seated possibly on the edges of the tongue, where they are opaline, and often slightly ulcerated, or perhaps on the dorsum, where they are large and smooth, they may, particularly in smokers, be prolonged for months or years, and show decided induration of the base. In such cases there is but little real difference between these and a sclerotic glossitis.

Other lesions, however, it is much more important to recognize.

*a. Psoriasis of the tongue* closely resembles mucous patches and superficial glossitis, both in its pathological anatomy and in the lesions produced in the dermo-papillary layer, as it causes a chronic inflammation with thickening of the mucous corium.

This thickening, however, is less marked and less indurated, and the modifications of the epithelium which is shed are very distinctive. The surface of the mucous membrane in psoriasis is neither smooth nor red, but is covered with thick layers of epithelial cells which form a whitish glazing. This coating of desquamated epithelium infiltrated with fluid assumes irregular forms, and often extends over a large portion of the dorsum of the tongue.

The name of psoriasis given to this disease in France, would lead to error if it caused the belief that its external appearance at all resembled that of cutaneous psoriasis. This latter affection is a protracted, and in certain cases almost incurable disease. It may be only the first stage of epithelioma, and result in that ulcerating cancer of the tongue which is so rapidly fatal; or it may develop into patches of superficial epithelioma, such as Trélat has removed with apparent success.

In any case an examination of the layers of desquamated epithelium in psoriasis will render the diagnosis certain.

*b. The opaline patches* of tobacco-smokers, very superficial lesions without induration of the mucous corium, are more likely to be confounded with mucous patches than with tertiary glossitis. They generally consist of grayish, non-ulcerated spots, upon the internal surface of the cheeks or upon the mucous membrane at the corners of the mouth where the point of the cigar acts as an irritant. This superficial stomatitis is always aggravated by a bad condition of the teeth, it not being at all rare to see chronic inflammation of the side of the tongue where it comes in contact with the irregular edges of carious teeth.

c. It should not be forgotten that even a normal tongue in persons who do not smoke sometimes presents deep fissures, irregularly divided clefts, and elongated papillæ, and these appearances are exaggerated by the slightest inflammation.

d. Any superficial glossitis, no matter from what cause, occasions papillary hypertrophy, and an enlargement of the region situated between the depressions, that is, it gives rise to the formation of small nipple-like elevations, separated by well-marked clefts.

Gummata of the tongue may be mistaken only for tubercular ulcers or for epitheliomata.

e. *Tubercular ulcers* are of greater or less depth, their edges are often excavated, and their bases are usually irregular and of grayish color. It would be difficult, if not impossible, to make a diagnosis from the character of the ulcer alone. The sides and edges of ulcerating tubercles often show, however, a few small yellow points with opaque centres which are tubercular granulations undergoing caseous degeneration. These latter are finally thrown off by ulceration, and Trélat has very properly dwelt upon their clinical characteristics, as they are never seen in syphilis. In other cases, the tubercular ulcers present vegetations or exuberant granulations with their usual appearances.

The evolution of tubercles of the tongue is entirely different from that of gummata. The gumma begins as a single mass, submucous or muscular in situation, opening after a time by a narrow contracted passage, ulcerating, and discharging like a furuncle, and having a sloughing base. The tubercles, on the contrary, begin on the surface of the mucous membrane, as small prominent opaque nodules. By the union of many of these, a large irregular ulcer is formed, slower in its destructive evolution than a gumma. As it extends in depth, there are successive eruptions of tubercles, too minute to be detected with the naked eye, and situated between the muscular fibres. The ulcer has jagged edges, and usually suppurates less than the gumma. In cases of doubt, the chest should be carefully examined, as pulmonary tuberculosis almost always exists at the same time.

f. *Lingual epithelioma* may always be detected by microscopic examination of the fragments of tissue or of the grumous liquid resulting from the cancerous ulceration, large pavement cells and epidermic nests being always found. In addition, the epithelioma never becomes stationary or recedes, that of the tongue being especially grave and

rapid, often running its course and terminating in death in a year or eighteen months.

[The diagnosis between ulcerating epithelioma of the tongue and ulcerating gumma of the tongue has been tabulated by Fournier as follows:—

EPITHELIOMA.	GUMMA.
Chiefly affects persons between 50 and 70 years of age.	Is apt to occur at an earlier period of life.
Often a history of cancer in near relatives or ancestors.	No such history as a rule.
No history of syphilis.	Such history almost always obtainable.
The appearance which has just been described as "lingual psoriasis" usually precedes the cancerous disease.	Nothing which resembles this has been seen.
Is generally single and confined to one side.	May be multiple and bilateral.
Is sometimes found on the under surface of the tongue.	Never seen except upon the dorsum or side of the tongue.
Begins as a hard swelling upon the surface of the organ and ulcerates rapidly and superficially, <i>i. e.</i> , it is a tumor with ulceration.	Begins as a nodule beneath the surface, and then opens like a furuncle, leaving a hollow deep ulcer.
No cavity resembling that of an abscess.	An excavation like an abscess cavity.
Surface bleeds when touched, or spontaneously.	Ulcer covered by an irregular slough which does not bleed.
Edges turned outwards, with the border elevated, irregular.	Edges abrupt, perpendicular, "punched out," sharply defined.
Secretion profuse, offensive, irritating.	Secretion moderate, not so apt to be offensive.
Lancinating pain often darting towards the ear (said by Anger to be pathognomonic).	Painless or nearly so.
Great disturbance of deglutition, mastication, speech, etc.	Tongue much more mobile; functional troubles not so marked.
General cachexia supervenes.	No cachexia.
Microscopic examination shows the characteristic ingrowing of the inter-papillary epithelium, the large squamous cells, pearly bodies, and other histological peculiarities of epithelioma.	The microscope shows an infiltration of the part by embryonal cells in various stages of granular degeneration.
Submaxillary glands affected.	Glands not involved.
Specific treatment useless or harmful.	Specific treatment curative.]

GUMMATA OF THE SOFT PALATE, or of the palatine arch, have a special physiognomy, and usually result in a perforation of the palatine bones, causing a communication between the oral and nasal cavities. These gummata are slow and insidious in their onset. The

patient experiences no pain or discomfort, and rarely at this period consults a physician. If the parts be then examined, the soft palate is seen red, thickened, and either nodular in its entirety or at one point. The induration and thickening may be felt with the finger.

If the patient be asked to utter sounds requiring for their production the assistance of the soft palate—*ah*, for example—whilst the throat is being examined, it will be seen that the palate is elevated incompletely or not at all. The muscular membranous fold is in fact rendered almost completely immovable by an infiltration involving not only the mucous membrane, but also the muscle itself. Indeed, it is not to be supposed that a gumma of about one centimetre in diameter, and rounded in shape, should affect only the mucous membrane, and not the muscles in a membrane so thin as the soft palate. This general implication of the palatal tissues always takes place, and often to such an extent that the anterior or oral layer of mucous membrane, and the posterior layer, or that continuous with the nasal passages, are affected at the same time.

This immobility of the palate is a valuable symptom, and taken in conjunction with the induration, the thickening, and the prominence often presented by the gumma itself, permits of an early diagnosis, which it is especially important to make as soon as possible, in order to avoid perforation. If the patient be left without treatment, the gumma ulcerates and discharges, and if it be of the kind above mentioned, involving both the anterior and posterior mucous surface, complete perforation of the palate will follow with great rapidity, often taking place in a single day or night. As a result of the perforation, a number of worse symptoms appear—difficulty in respiration, nasal utterance, alteration in speech, return of liquids and of solid food through the nose during efforts at deglutition, etc. When the lesion is seated in the palatine arch, the opening of the gumma is not at once followed by all these symptoms, on account of the resistance of the bony plate. This latter is, however, thin, and is soon affected by an osteo-periostitis, which is set up, and although perforation occurs later, the communication which is finally opened between the mouth and the nose is no less grave, as it is almost always irremediable.

A gumma of the soft palate does not invariably give rise to perforation, especially if mixed treatment be at once commenced. It may affect only the anterior or posterior part of the palate; and then it will cicatrize after a time without noticeably interfering with the functions of the palate. There may even be a small but complete per-

foration at the moment of the evacuation of the gumma, which will entirely heal. We may cite in illustration the case of one of our old patients who returns to the hospital from time to time, and who a year or so ago had gumma of the left side of the soft palate, near the uvula. After the evacuation of the gumma, a grooved director could be passed through a minute opening in the palate. This is now closed; there still remains, however, a slight loss of substance, an inflamed infundibular depression at the site of the gumma, but no true perforation. A complete perforation, if it be very small, is not always followed by persistent symptoms, nor does it interfere with deglutition; patients accustoming themselves to swallow in such a manner that the alimentary bolus passes the isthmus of the fauces without returning by the nose. In the greatest number of cases the perforation, and the damage occasioned by gummata of the soft palate, and the palatine arch, occasion incurable functional disorders, snuffling, dysphagia, etc., and necessitate the use of the obturators and prothetic apparatus.

The uvula may be destroyed by a gumma or by deep tertiary ulcerations, or the palate may be torn in two by muscular contraction, after there has been considerable loss of substance, producing what Fournier calls the palatal curtains. Gummata of the palatine arch are yet more formidable on account of their accompanying osseous lesions, the loss of fragments of the superior maxillary, the sphenoid, the turbinate, the nasal bones, etc., for tertiary syphilis of the palate may extend to a more or less considerable portion of the neighboring tissues.

The falling in of the bony septum of the nose causes those hideous depressions of that organ so common in a more or less pronounced degree in tertiary syphilis. The grave forms of these syphilitic lesions of the nasal fossæ, and the palate, the loss of substance, the osteitis and necrosis of the bones of the face, the continual suppuration, the relapse or the spreading of syphilitic gummata and ulcers, the immense perforation, opening communication between the nose and mouth, and their train of anatomical and functional consequences, are without doubt the most disgusting as well as the most tedious results of syphilis.<sup>1</sup>

[<sup>1</sup> In the *Vierteljahrsschrift für Der Dermatologie und Syphilis*, Band iv. Heft 1 and 2, Schuster and Sänger recommend the use of the scraping spoon for the removal of syphilitic growths of the nasal cavity, to prevent falling in, and to arrest the disease process. Even perforation of the palate by scraping is at times the lesser

The syphilitic lesions of the palate may generally be diagnosed with facility, particularly if it has been possible to observe their evolution. For instance, there will be no room for doubt, if the early period and the period of softening of a palatal gumma have been witnessed. But it is not so easy when patients present themselves for the first time with extensive destruction of the mucous surfaces, or with oro-nasal fistulæ. Lupus, which may be readily distinguished at its commencement, or when one of its characteristic forms exists upon the face, may attack and perforate the palate, and may in this region be undistinguishable from syphilis. Th. Williams has described a perforating ulcer with all the characteristics of a gummous ulcer, but it seems highly probable that his cases were really of a syphilitic nature, and that his observations were upon persons who either wilfully denied having had syphilis, or who were not aware that they had it, or else were young subjects with late manifestations of hereditary syphilis.

In making the diagnosis it is also necessary to remember that the soft palate is occasionally though rarely attacked with tuberculosis. I have examined one case observed by Bernutz; Hanot has published the histological examination of an analogous case contributed by Isambert. Spiellmann has collected and analyzed in his thesis all the cases of this affection published in France or elsewhere. The pathological history of tuberculosis of the palate is not yet sufficiently investigated to furnish the material for an exact diagnosis.

of two evils. Artificial illumination should be used. Pathologically the conditions vary. There may be—1, simple syphilitic infiltration, the mucous membrane not hypertrophied, with or without alteration of the glands, capillaries, or epithelium; 2, the same, with hypertrophy of the mucous membrane and constriction of the dilated capillaries, by means of cell-growth; 3, more severe infiltration of the mucous membrane, passing into syphiloma; 4, syphilomata of the mucous membrane or condylomata. The subjacent bones and cartilages may show either necrosis with exfoliation, destructive inflammation, without loss of the mucous membrane, or plastic osteitis, with the production of spindle-cells and connective tissue, passing into bony formations.

The practical points are these: 1. Ulceration of the mucous membrane which has been held by writers to be the sole cause of ulceration of the bone and cartilage of the nose, is not invariably present. That membrane may remain uninjured while the subjacent tissues undergo changes like those of the tibia or frontal bone. 2. A healthy mucous membrane may be caused to ulcerate by mechanical interference, and then this ulceration may extend to the bones, or the disease in subjacent bones pass over to the injured membrane.]

TERTIARY SYPHILIS OF THE TONSILS AND OF THE POSTERIOR WALL OF THE PHARYNX.—These parts are sometimes attacked by tuberculo-ulcerous and gummous syphilides, which, under these circumstances, do not differ from the same lesions in other situations. The posterior orifices of the nasal fossæ, the posterior wall of the palate, the circumference of the Eustachian tube, which are even more frequently affected than the tonsils or the pharynx itself, should be examined with a rhinoscope whenever there is a suspicion of syphilis in chronic throat troubles. Fournier, in order to examine the posterior surface of the velum, seizes it with the fingers and simply elevates it, but to inspect it properly it is often necessary to employ a mirror.

The posterior wall of the pharynx, although not a frequent or favorite seat of syphilitic manifestations, may be attacked by gummous neoplasms developed between the basilar process and the mucous membrane, and which attain a considerable volume. Of this character was an enormous tumor which was taken at first for cancer, operated upon by Blandin, and then returning was believed to be incurable. The patient was sent in this condition to Bicêtre, where Maisonneuve, by means of iodide of potassium, effected a complete cure.

The loss of substance, and the vegetating ulceration which follows are very considerable, and often extend to the upper part of the pharynx. Under these circumstances adhesion may take place between the granulating surface of the pharyngeal wall, and the posterior face of the palate which approach each other during inspiration. The pharynx is then divided into two cavities, the superior communicating with the nasal fossæ, and situated above the raised and adherent velum, the inferior lying beneath it and opening into the mouth. If the velum has not undergone perforation, respiration can take place only through the mouth. Almost all such cases are due to syphilis. Julius Paul, of Breslau, has collated 30 instances of adhesion of the velum to the pharynx, in 26 of which the patients were syphilitic.

In almost all these grave cases of tertiary syphilis, the bones are altered by osteitis and necrosis, and sequestra are formed which must be thrown off. These are derived not only from the facial bones and those which make the septa of the nose, but also from the basilar process of the occipital, and from the inferior maxillary. Gummous osteitis, developed under such circumstances, may likewise, through the medium of the ethmoid, the sphenoid, and the basilar process,



reach the interior surface of the cranium. These cases of syphilis of the pharynx should be diagnosed from scrofulous affections of the mucous membrane.

Direct examination of the lesion does not always furnish sufficient information, and to obtain the necessary data, the information derived from the history of the patient, and from the evolution of the disease must also be considered.

The seat of the disease is an important diagnostic point: it has been shown that the tongue and the velum were attacked almost exclusively by syphilis, and rarely by scrofula. This is not true of the tonsils, and pharyngeal wall, which are said to be frequently invaded by deep scrofulides.

It is necessary, however, in this connection, to make a very comprehensive reservation. The scrofulides of mucous membranes, and particularly those of the pharynx, have thus far been but little studied from an anatomico-pathological point of view. If the observations upon pharyngeal scrofula made at autopsies, and with the microscope during recent years, be carefully examined, as Spiellmann has done, it will be seen that they almost uniformly disclose an undoubted *tuberculosis* of the mucous membrane.

In the examples published by Friedlander, O. Weber, Hanot, Letulle, etc., and in those which I have myself observed, there were found giant cells, tubercular nodules, or a tuberculous infiltration of the mucous membrane or granulo-fatty degeneration of the cell elements, etc. In the thesis of Looten, entitled *Scrofulides of the Mucous Membrane*, which is in some respects incomplete, all the lesions accepted as tubercular by this author, intestinal tuberculosis, for example, are included under the general head of scrofulides; he might with just as much reason reverse the proposition, and regard all scrofulous lesions as appertaining to and depending upon tuberculosis, but we prefer to wait until pathological anatomy and histology have been able to determine the exact nature of these changes. There can be little doubt that careful study will greatly enlarge the domain of tuberculosis by assigning to it as a causative agency many throat affections, and numerous alterations in the tonsils and posterior pharyngeal wall, and that almost nothing definite of what has been known as malignant scrofulosis will remain, lupus and the present scrofulide of the mucous membrane both being regarded as tubercular manifestations.

This work, however, is yet to be done, but we feel sure that it will

develop special indications which will enable us to distinguish between syphilitic and tubercular ulcerations, or neoplasms. An example of recent improvement in diagnosis resulting in this manner, is seen in the signs of tuberculous ulceration of the tongue; the little granulations with caseous centres, pointed out by Trélat, being pathognomonic. It is more than probable that the same sort of symptoms which may be recognized during life, will be found to be characteristic of pharyngeal tuberculosis.

However this may be, in the actual state of our knowledge at present, the diagnosis between tertiary syphilis of the throat, and the grave scrofulides of the mucous membrane rests upon the following points: 1. Tertiary syphilides develop only in persons who have had previous syphilitic symptoms. 2. They begin by deep neoplasms—gummata. 3. They run a more acute course than the scrofulides. 4. They yield to treatment by mercury and iodide of potassium, this therapeutic test being the most conclusive.

It will be seen, therefore, that the diagnostic differences are very uncertain, the antecedent being often difficult to determine, as the patient frequently belongs to the class of congenital syphilitics who are ignorant of their disease. Further, it is but rarely that we have an opportunity of observing the period of gummous infiltration, and, as far as the acuteness of the disease is concerned, although some gummata progress very rapidly to cure, there are cases of syphilis of the pharynx, which run an interminable course. It follows, then, that in all doubtful cases of deep pharyngeal ulceration it is necessary to try the mixed treatment. This plan has been adopted with much success by Horand, surgeon to the Lyons hospitals.

SYPHILIS OF MUSCLES.—Muscular syphilis is not very common; it may manifest itself by contraction, which at first appears to be idiopathic, as it is not accompanied by tumors, or changes in size, or lesions which are apparent during life; in other cases gummata develop in the interior of the muscles.

*Syphilitic contraction of muscles* is chiefly an affection of the muscles of the arm, and more particularly of the biceps. It appears about six months to a year after the chancre. The first symptom is a stiffness of the elbow—an interfeucé with complete extension of that articulation, and if force be applied the contracted tense biceps may be felt resisting the movement. Gradually extension becomes more and more limited, and the forearm remains flexed upon

the arm, at an angle varying from a large obtuse angle to one quite acute.

The movements of the joint are henceforth much restricted, but those included within the limits of the angle of extension are executed with facility. The cause is, however, no trouble in the joint, but an unconquerable contraction of the biceps which produces an acute pain whenever forced extension is attempted. Whenever the biceps muscles and its tendon are carefully palpated no tumors or inequalities of surface are discoverable; if it be examined during forced extension it is found prominent, and resembling a tightly drawn cord, the tendon particularly being hard and tense. When it is palpated while performing its function its contraction can be felt, and it may even be less hard than the corresponding muscle during analogous contraction.

Relatively very little is known regarding the lesions of the muscular fibres in these cases, as they are not grave, and usually result in cure at the end of some months, although they may extend over one or several years. Virchow<sup>1</sup> says that these contractions are due to calcareous degenerations of the muscular tissue, analogous to those which are produced by traumatic or rheumatic inflammation. There is developed in the midst of the interstitial tissue of the muscular fibres a connective-tissue formation, which hardens, and after having caused atrophy of the primitive muscular fibrillæ finally destroys them. I know of no recent histological examination of these cases.

[It has been denied that this affection has any essential relation to syphilis, and it has been attributed to rheumatism, to traumatism, and to other causes. The weight of evidence is, however, in favor of its syphilitic origin; nine out of ten cases observed by Mauriac had a distinct history of syphilis, and were accompanied by unmistakable eruptions, chiefly papular and papulo-squamous. He believes it to be a subacute myositis. In every one of six cases, reported by Notta, syphilitic symptoms were present. In none of them was there any association with rheumatism.]

*Gummata of muscles* have a much more important pathological significance than these simple contractions. They consist of tumors, often of considerable size, which may discharge externally, may give rise in various ways to serious results, and may even invade the cardiac mus-

<sup>1</sup> Syphilis constitutionelle, trad. de P. Picard, p. 105, and Archiv für Path. Anatomie, vol. iv. p. 271.

cles. The tongue appears to be of all the muscles the one most frequently affected, but among the external muscles the long muscles of the limbs, and those of the sides and nape of the neck are oftenest involved. Murchison has recorded a case of gumma of the diaphragm.

Muscles attacked by gummous growths exhibit at first an ill-defined puffiness or swelling, which becomes harder, larger, and usually changes the shape of the muscle within the diseased area; it grows longitudinally in the direction of the muscular fibres, and is preceded or accompanied by radiating pains, loss of movement, and sometimes by muscular contraction. If it be not too large, and the muscle which it occupies be easy of reach, a lateral motion of the tumor may readily be made.

At this stage it consists, according to Virchow, of granulation tissue, that is, of a large accumulation of small cells which infiltrate the connective tissue and the tissue surrounding the muscular fasciculi. This lesion is of a whitish or reddish-white color, becoming yellowish when the cellular elements, of which it is composed, have undergone early caseous degeneration, a very common occurrence. The growth is not very distinctly limited or defined, and it is distributed in striæ, which follow the direction of the fibrous and muscular fasciculi.

Although this description is not entirely satisfactory, inasmuch as it omits all mention of the condition of the muscular fibres themselves, and of the state of the vessels, yet it is not difficult to recognize that these lesions are identical with those of the subcutaneous gummata and with gummata of the liver and of other organs.

These gummata are usually five or ten centimetres in their long diameter, sometimes even much larger. Virchow describes a specimen, contained in his collection, in which the tumor, seated in the *dorsalis longus*, extended from the second to the eighth dorsal vertebra, and laterally from the heads of the ribs to their angles. Le Dentu has reported a case of gumma of the *gastrocnemius*, which measured fourteen centimetres in length. These gummata often involve the tendons at their point of insertion, and are then apt to produce periostitis.

If the tumor be left without treatment, and the muscle involved be superficial, it may suppurate and be evacuated in the usual manner. The skin reddens, inflames, and becomes adherent to the muscle. A perforation occurs, and permits of the gradual discharge of a thin, muco-purulent, sometimes bloody liquid. The destruction of the dis-

eased tissue then proceeds by the methods already described. When the gumma is entirely evacuated, reparation and cicatrization take place, but are slow and tedious.

[Bouisson<sup>1</sup> divides the progress of these tumors into three stages: one of a local and circumscribed swelling due to plastic effusion; then a moderate degree of softening and inflammation of the neighboring muscular fasciculi; finally, organization of the deposit into fibrous tissue or even into cartilaginous or osseous material. He asserts that in the second stage they may suppurate, and in this seems to agree with Cornil. Hill and Cooper also state that "if left to themselves they slowly enlarge, or soften at the centre, and by ulceration and absorption may communicate with the surface forming a ragged suppurating cavity."<sup>2</sup> Lancereaux and Mauriac deny the possibility of suppuration, and consider its absence an important point in diagnosis. They do not make any distinction between gummata of the deep and those of the superficial muscles.]

The most interesting and important study connected with muscular gummata is that relating to their effect upon the muscles of the heart. Ricord has published and illustrated, in his iconography of syphilitic diseases, a case of cardiac gummata; Lebert has also recorded one in his treatise on pathological anatomy; Virchow has observed the third, and has given a detailed description of it in his work on constitutional syphilis, collating all the known facts in regard to the disease, and adding two cases observed by himself; Lancereaux has collected nine cases. Thus the existence of gummata of the heart, a disease which it at first seemed should be considered fabulous, is today one of the most conclusively demonstrated results of constitutional syphilis.

Gummosus tumors in this situation are sometimes diffuse, sometimes circumscribed, generally of a yellow color, and are dry and caseous. They may be seated in the wall of either the right or left ventricle, in the inter-ventricular septum or in the musculi papillares of the left side, which are then found to have undergone a fibrous transformation. They are often accompanied by an endocarditis or a fibrous thickening of the endocardium, with prominent vegetations upon its surface.

In Virchow's case, the microscopic examination showed that the

[<sup>1</sup> Bumstead and Taylor, *op. cit.*, p. 667.]

[<sup>2</sup> *Op. cit.*, p. 333.]

small cells which constituted the larger portion of the gummata were situated around the muscular fasciculi and in the endocardial fibrous tissue. In the yellowish portions of the tumor, these cells had undergone a granulo-fatty degeneration. The muscular fibres were either fatty-degenerated or simply granular with their striæ preserved; they had disappeared altogether at some points, where they were deprived of their nutrition by the abundance and crowding together of cellular elements. There are many unsettled points which should be studied in this relation with our most recent and improved methods of investigation.

It is at any rate beyond dispute that syphilis may involve the cardiac as well as any or all of the other muscles. In no case of gumma of the heart was there softening or evacuation of the morbid products, which were simply dry and caseous, whilst there were fibrous induration and chronic sclerotic inflammation of the surrounding tissue. These neoplasms have, therefore, as in the case of the other deep muscles, no marked tendency to soften or discharge. The breaking down of tissue, suppuration and death by sloughing in muscular gummata characterize only those affecting the superficial muscles.

There is found in this distinction between the gummata of deep muscles leading to peripheral sclerosis, and to cheesy degeneration, and those of superficial muscles, suppurating and discharging, the key to the processes which occur in all the organs infiltrated with syphilitic nodules. Intestinal gummata, for example, suppurate, and are eliminated like the latter or like those of the subcutaneous connective tissue. Gummata of the liver or kidneys, on the contrary, become caseous at the centre, are surrounded by thick fibrous tissue, do not suppurate, and remain stationary without any tendency to elimination, just as do the cardiac gummata.

The gravity of gummous tumors of the cardiac muscles is of course evident, not, however, that any very striking symptoms are observable during life; there may be an increased impulse, palpitation, uneasiness and slight pain in the region of the heart, a little œdema or oppression; but these are symptoms common to many other diseases; upon auscultation a low bruit or a soft blowing sound may be heard with the first sound and at the apex.

The lesions are, however, none the less incompatible with life, and usually soon cause sudden death.

[In a rare case reported by Dr. Mannino, the diagnosis was made

during life.<sup>1</sup> A patient who had contracted syphilis eight years previously, and who had an unmistakable pustulo-crustaceous syphilide, complained of attacks of dyspnoea of increasing frequency and severity. He became weak, and developed cough. The cheeks, lips, and tip of the nose were blue; the great veins of the neck were prominent and turgid, while arterial pulsation was very weak. The skin of the trunk and neck was mottled, and the radial pulse imperceptible. The hands were cold. The heart's impulse was diffused, and the exact situation of the apex-beat could not be defined. The pulsation was visible also in the epigastrium to the left of the sternal line. The area of cardiac dulness was not increased, the lowest limit being the fifth intercostal space. At the apex, the first sound was obscure, and accompanied by a very weak blowing murmur. At the base and at the second right intercostal space, the *bruit* was somewhat louder, and the second sound weak, but clear; but the *bruit* was much more distinct at the epigastrium than in any other situation. The percussion sound was normal over the anterior part of the chest; but the posterior thoracic parietes were oedematous. Slight mucous *râles* were audible in places; elsewhere, the respiratory murmur was normal.

From these various symptoms it was diagnosed, first, that the right side of the heart was chiefly at fault, because the *bruit* was more distinct at the base and towards the right than at the apex, and still more distinct in the epigastrium; secondly, that the disease was not in the valves, but in the muscular structure of the heart, because of the rarity of primary disease of the right side of the heart, the normal area of dulness, and the peculiar and very feeble way in which the heart contracted, together with the great increase of tension in the venous system and the emptiness of the arteries.

Death occurred suddenly soon afterwards, and the autopsy revealed patches of fibrous induration on both ventricles and syphilitic myositis of the muscoli papillares. The case seems worth detailing here on account of the infrequency with which the diagnosis is made during life and confirmed by autopsy.]

[<sup>1</sup> The British Medical Journal, April 15, 1882.]

## CHAPTER IX.

## SYPHILIS OF THE BONES, TEETH, AND ARTICULATIONS.

Syphilitic osseous lesions, their gravity, frequency, etiology, and varieties— Simple osteo-periostitis—Osteophytes—Epiphyseal and parenchymatous exostoses—Enostoses—Rarefying osteitis—Gummous osteo-myelitis and osteo-periostitis—Vegetating and gummous external pachymeningitis—Eburnation of bone—Varieties of exostoses—Symptoms of syphilitic osseous lesions—Lesions of the bones in syphilitic new-born children—Histological description—Symptoms—Nutritive interference due to congenital syphilis or to other causes which may affect dental development—Effects of syphilis on first dentition—Stomatitis, its relation to dentition—Syphilitic teeth—Syphilitic inflammation of the gums—Syphilitic teno-synovitis and arthritis.

AMONG the most important and most common effects of syphilis are the osseous lesions, which occur during the later manifestations of the disease, and which are in many cases of exceeding gravity. Both in adults and in children affected with hereditary syphilis, the order, the seat of the lesions, and even the anatomical condition of the diseased bones are so characteristic that the diagnosis of syphilis is rendered easy. This has been especially pointed out by Parrot, who asserts that hereditary syphilis invariably occasions interference with the nutrition and development of bones.

Osseous syphilis is met with during any of the periods of the malady. It has already been observed, while discussing the early appearance of tubercles or gummata or deep pustulo-crustaceous syphilides in the grave forms of the disease, that the distinction into secondary and tertiary periods was neither constant nor positive, and that the reputed tertiary cutaneous phenomena may appear in the first year or even in the first six months following the initial lesion. Later it will be seen that the viscera also furnish exceptions to the rule, and that hereditary infantile syphilis is apparently in direct opposition to this classification into secondary and tertiary periods. Indeed, in syphilitic new-born children or fœtuses, the superficial lesions of the skin, which belong to the first period of syphilis, may be present at the same time with those lesions of the bones and viscera which are placed among



the tertiary symptoms. Again, with adults the tendons, the synovial membranes, the periosteum and the bones are sometimes affected during the first months succeeding the primary lesion. Mauriac, who has collected a number of early syphilitic affections of the periosteum and osseous tissue, has seen periostoses and large cranial nodes, due to a specific inflammation of the periosteum and bones, appear a few weeks after the beginning of the infecting chancre, before the first cutaneous eruptions, even before the roseola (see page 264).

I am fully of the opinion, that the osteocopes, many of the neuralgic pains, and the pains in the joints and sheaths of the tendons are due to material alterations of those parts. In connection with Ranvier I have several times seen convincing proof that this is the case with the bones. During the epidemic of cholera in 1865 and 1866 we examined the bones of patients who had died suddenly with this disease, while suffering with the secondary lesions of syphilis, and we found an osteitis characterized by an embryonic and gelatinous state of the inflamed medulla.

The cases of syphilitic osteitis and osteo-periostitis, developed in adults during the secondary period are less grave than those observed later, which are accompanied, not only by sub-periosteal and osseous gummata, but also by condensing osteitis and necrosis. Patients may recover if they are soon enough submitted to treatment with iodide of potassium and mercury, the lesions even disappearing without leaving any trace; but the bones attacked during the late period of syphilis more often retain permanent traces of the periostitis and osteitis in the form of exostoses and hyperostoses.

The determining cause, in tertiary as in secondary syphilis, of the osseous lesion and of its seat, is generally some form of traumatism, which is usually slight, but frequently repeated at the same point. It is owing to this circumstance that the superficial bones, those immediately beneath the skin, as the frontal bone, the clavicle, sternum, radius, tibia, etc., are the most frequent seats of the disease. Only the etiology of the osseous lesions with adults is here referred to. In cases of infantile syphilis, traumatism is not the determining cause; the active development of the bones sufficiently explains the seat of syphilis. In adults, however, it is very probably true, as Virchow has said, that the majority, if not all, of the osseous lesions have their origin in contusions, and that osseous syphilis may thus be regarded as a specific inflammation, localized at points which are predisposed to the

action of irritating agents. Thus it is, that syphilitic periostoses and exostoses are noticeably associated with various occupations. For example, syphilitic swellings of the periosteum of the clavicle are seen upon porters who daily carry heavy weights upon their back by means of straps which pass over the shoulder. A fencing master will have syphilitic lesions of the sternum and ribs, points where he is constantly receiving strokes from his pupils. As regards the cranial bones and the tibia, which are undoubtedly those most frequently affected with syphilis, they are also those most exposed to traumatism.

The lesions of the bones from an anatomical view are very numerous, varying from simple periostitis and osteitis to gummata; their final consequences also vary from the development of exostoses to the formation of sequestræ in pus cavities.

The following lesions may be successively described:—

1. *Simple osteo-periostitis.*
2. *Rarefying osteitis.*
3. *Intense rarefying osteo-myelitis or gummous osteo-periostitis.*

Then the consecutive lesions of these different states, which are: *Formative osteitis* or *eburnation*, the *exostoses*, the *necroses*, and the *sequestræ*, and finally the *osseous lesions of infantile syphilis*.

1. *Syphilitic osteo-periostitis* does not differ materially from ordinary osteo-periostitis. Limited to the superficial layers of the bone, and the periosteum, it most frequently occurs at the end of the secondary or in the tertiary period, attacking the tibia, clavicle, sternum, bones of the head, etc.

Beneath the periosteum, between it and the bone, there collect numerous round cells, analogous to those of embryonal marrow. At the same time the deep layers of the periosteum are inflamed, and contain cells interposed between the fasciculi of fibres. The neighboring connective tissue of the periosteum generally presents a slight inflammatory œdema, so that the tumor, situated between the skin and bone, is due both to the swelling of the periosteum and to the inflammatory œdema of the subcutaneous connective tissue. The surface of the bone beneath the periosteum has the openings of the Haversian canals enlarged, and filled with marrow, which is either red and embryonal, or is gray and gelatinous, consisting of the round cells of the medulla. The fat has disappeared from these changed canals.

This form of mild osteo-periostitis may disappear and leave no trace, even when it is quite deep, and in a flat bone, as the sternum, ribs, or cranium. It is accompanied with an embryonal condition of the marrow of the whole bone.

When the osseous disease has continued for a long time, the round cells under the periosteum nearest to the surface of the bone, act as osteoblasts during the period of ossification, and form bone by the same series of changes as are observed in ossification by the periosteum.

The osseous trabeculæ which first appear in pathological ossification upon the external surface of the diaphyses under the periosteum are named osteophytes. Owing to their very slight attachment to the surface of the old bone, they are detached with the periosteum, and adhere to the under surface of this membrane when it is separated from the bone. In proportion as the osseous tissue is formed between the periosteum and bone, these osteophytes become more compact, and united to the original bone; they are now called periostoses or exostoses. Their shape is very variable. Sometimes they project, and the exostosis seems to be superadded to the bone as a tumor or as the epiphysis of a long bone, and they are named *epiphyseal exostoses*. Elsewhere, in osseous tissue which has been the seat of an osteitis, new osseous lamellæ are formed upon the surface of the Haversian canals, and then there is an eburnation, a condensation of the bone in consequence of the new formation of lamellæ, which are added to those pre-existing. This is condensing or formative osteitis; the eburnation of the bone, and the exuberant formation of lamellæ may be termed *parenchymatous exostosis*.

These varieties of new osseous formations consecutive to osteitis and periostitis—osteophytes, epiphyseal exostoses, parenchymatous exostoses, enostoses, eburnation of bone, etc., constitute the secondary lesions common to all forms of syphilitic osteitis.

In order that the histological changes which take place in bone during syphilis may be better understood, a short account of the essential histological structure and development of bone is here given.

The structure of bones is simple; they are formed of a calcareous framework consisting of systems of osseous lamellæ, which contain bone cells arranged regularly around the Haversian canals. The latter contain in the normal state the nutritive vessels of the bone and the bone medulla. Normal medulla is formed of small round

cells similar to lymph cells, larger cells with one or more oval nuclei, and small drops of fat. The stroma of the medulla is mostly formed by vessels, and some very delicate and sparse fibrillæ of connective tissue.

The osteoblasts or bone cells, contained in the osseous lamellæ, are small cells within cavities, which latter communicate by numerous canaliculi with the Haversian system.

The development and ossification of bone is accomplished by two distinct processes, according to whether it is developed from cartilage or from periosteum.

In the former case, the cartilage cells are arranged in longitudinal rows, which are transformed into canals, and soon traversed by a capillary loop accompanied with embryonal cells, which have their origin from a proliferation of the cartilage cells. These cells are applied against the wall of the canals, becoming the osteoblasts, and are flattened by mutual pressure. They are surrounded with calcareous substance and form the osteoblasts, in the midst of a layer of osseous substance, which is deposited against the wall of the canal excavated in the cartilage. This is the origin of a Haversian canal.

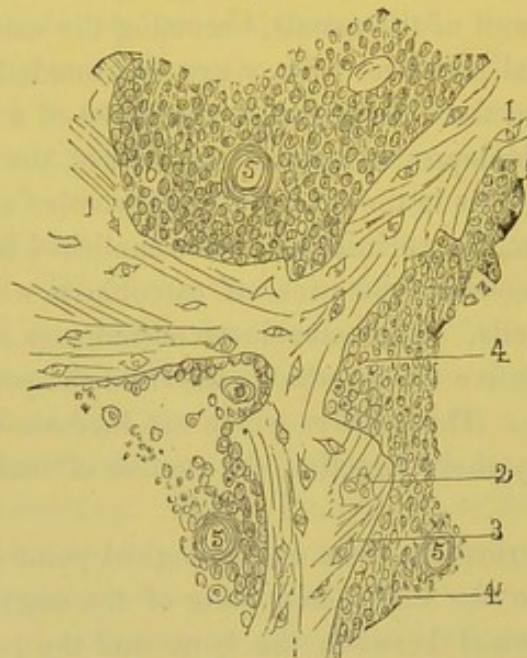
Ossification from the periosteum is accomplished in a similar manner by the calcareous incrustation of osteoblasts which are derived from embryonal cells. The osteoblasts accompany Sharpey's fibres, fibres of the connective tissue, which pass from the periosteum into the ossifying cartilage. These fibres which are incrustated with calcareous salts determine by their direction the course of ossification beneath the periosteum.

Simple osteo-periostitis, from a histological point of view, consists only in a return to the embryonal state of the marrow of the bone, and of the cells found between the bone and the periosteum. The disappearance of the fat from the interior of the Haversian canals, and the presence of numerous small round cells, give to inflamed bone the same structure as that of developing bone, and, therefore, it is not remarkable that the newly formed medulla cells have the same properties as these elements possess during early life. They are applied to the walls of the Haversian canals, and to the surface of the bone beneath the periosteum, becoming the osteoblasts, and assisting in the new formation of osseous lamellæ. These lamellæ constitute the exostoses.

2. When the inflammation is more intense there occurs a *rarefying osteitis*. The sub-periosteal inflammation extends into the Haversian

canals; the sub-periosteal tissue and the osseous marrow contain numerous small cells with transuded red blood-corpuscles. These elements are free, with a small amount of granular intercellular substance. When this variety of inflammation is still more intense, the abundant proliferation of cells is soon accompanied with a lesion of the osseous tissue. This tissue is softened, eroded, and destroyed at points upon the internal surface of the Haversian canals. A microscopic examination of thin, stained, and decalcified sections shows the vascular canals enlarged; the osseous trabeculæ forming the framework, instead of being regular and having even margins, are notched and present oval or irregular indentations, 1, Figure 52. These notches are filled with round, small

Fig. 52.



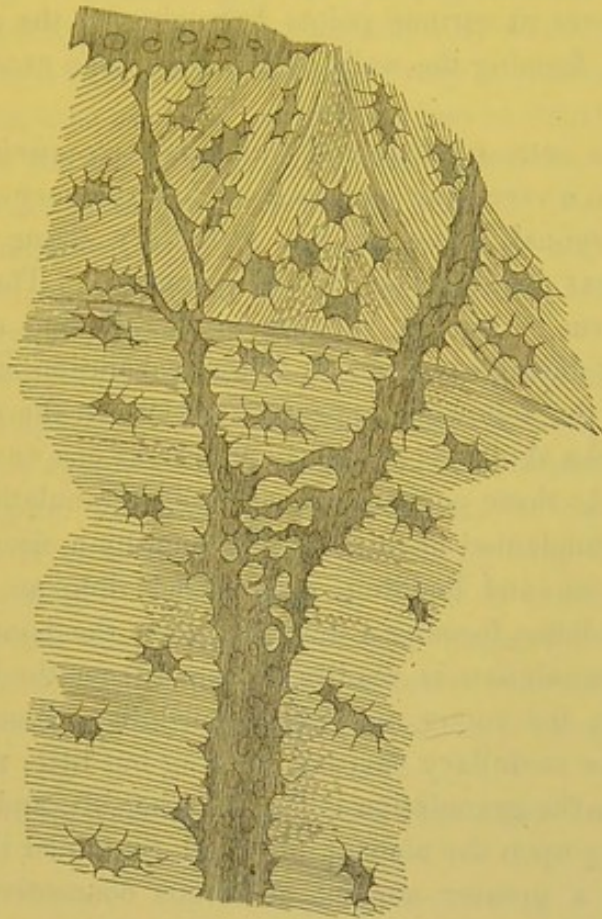Syphilitic osteitis.—1. Osseous trabeculæ with serrated and notched margins, in which are seen bone lacunæ containing one or several nuclei, 2; 4, medullary tissue; 5, vessels, the lumen of which is open. In the upper part of the figure the cells are atrophied and becoming caseous.

cells, and occasionally with one or two large giant or multinuclear cells shown in Figures 55 and 56 (see pages 254 and 255). The destruction of the osseous lamellæ, by the elements of inflamed marrow, is often so great that all the Haversian canals present notches and loss of substance to a varying extent. Some of the trabeculæ may be so changed that a communication is made from one Haversian canal to another (Fig. 53). The osseous tissue is, therefore, replaced more or less completely by the inflamed marrow. The original bone is eroded or almost destroyed. This lesion, which is observed so fre-

quently in diseases of the phalanges and short bones, is named *spina-ventosa*. It is frequently a result of syphilis.

When under the influence of appropriate treatment by iodide of potassium and mercury, or following the natural course of the malady,

[Fig. 53.]



Rarefying osteitis. Canaliculization of the osseous tissue.  $\times 500$ . (Volkmann.)

the inflammation ceases, and the disease retrogrades, there is seen a reparation of the diseased and partially destroyed bone. The same embryonal cells of the inflamed marrow which, when they were exuberant and free, assisted in the erosion of the bone, and the formation of notches and cavities in the lamellæ, are now less numerous, and are regularly applied to the walls of the Haversian canals; they have become osteoblasts possessing the property of forming new osseous lamellæ. There result new lamellæ with new osteoblasts, and these form several series parallel one with another or follow the irregular arrangement of the Haversian canals. This exuberent formation of new osseous lamellæ may constitute beneath the periosteum

exostoses of varying size, and in the bone a parenchymatous hyperostosis or an eburnation.

A large section made from dried bone by means of a saw, and taken from a part which was first affected with a rarefying osteo-myelitis, and in which at a later period reparation had ensued by a new formation of osseous lamellæ, shows very distinctly the changed and interrupted layers at various points belonging to the old bone, and the new layers, forming the walls of the Haversian canals.

3. *Gummous osteo-myelitis* and *gummous osteo-periostitis* are nothing more than a rarefying osteitis in which the very abundant subperiosteal embryonal tissue or the medullary tissue assumes the arrangement that is observed in the gummata. The lesions are seen in the form of tumors, varying in size, having a tendency to become caseous during some period of their evolution, and presenting at the autopsy the following appearances: When the pericranium is removed from the skull, it is found to adhere at one or several places to the bone. At these points is seen a fleshy granulation as large as a pea or bean, implanted upon the periosteum by a circular base; its surface is uneven and budding, and extends into an irregular depression in the bone, forming a union between the bone and pericranium. The granulation is readily detached from the bone in which it is imbedded; the young and friable medullary tissue, which connects it with the medullary cavities, offering but little resistance.

Upon section the granulation is found to be soft, and red, pink, or gray, depending upon the amount of blood contained in the vessels; when there is a greater amount of fibrous connective tissue in its structure, it is firmer. It usually presents an attempt at organization, being traversed by numerous vessels and fibres of connective tissue. If it be of long duration, it is yellow and opaque, and its centre or the greater part of the mass is caseous. It is a nodule of embryonal tissue, formed beneath the periosteum, and in the enlarged Haversian canals, with destruction of the osseous trabeculæ by an osteo-myelitis—a granulation transformed into a gumma, with a tendency to caseous degeneration of its constituent elements.

Gumma of bone is thus merely an intense and circumscribed osteo-periostitis, with destruction of the osseous lamellæ by a rarefying osteitis. It is the localization and form of the lesion that give it its distinctive characters.

Several gummous nodules are frequently connected together upon

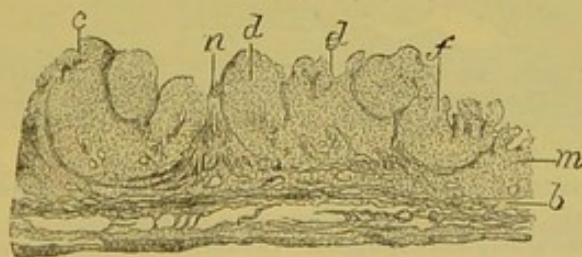
a common base in the pericranium. But at the same time there is almost always an analogous change developed between the dura mater and the skull. When the formation upon the dura mater corresponds to that upon the pericranium, complete perforation of the bone soon occurs. There may also be perforation of one or the other layers of the cranium by an isolated gumma. The granulations of periostitis or gummous pachymeningitis, accompanied by a loss of substance of the bone due to a rarefying osteitis, are very common.

At the same time that the periosteum and external surface of the dura mater are the seat of these very decided lesions, the internal surface of the latter membrane is often the seat of false membranes of varying thickness, traversed by embryonal vessels and infiltrated with blood. Indeed, there may be seen in such cases a true internal hemorrhagic pachymeningitis.

The most remarkable example of this variety of lesions occurred in a case of Bouillard's. The patient, a boy sixteen years old, had successively the symptoms of typhoid fever, acute phthisis, and tuberculous meningitis. At the autopsy the cranium was found pierced like a sieve with numerous vegetations arising from the pericranium, and especially from the dura mater. Those of the latter were quite large, and formed small dark-red tumors or vegetations situated in the perforations of the cranium. Their structure consisted of a soft, red, vascular embryonal tissue, sometimes caseous and opaque in the centre of the largest.

Figure 54 represents a section of the dura mater and several of the

Fig. 54.



Section of a gummous pachymeningitis. The dura mater presents an inflammatory condition with a new formation on its internal layer, *b*, which is continuous with the gummous nodules, *c*, *d*, *e*, *f*. These latter are separated by fibrous tissue, *n*. The nodules were situated in cavities excavated in the osseous tissue which had been in great part absorbed.  $\times 6$ .

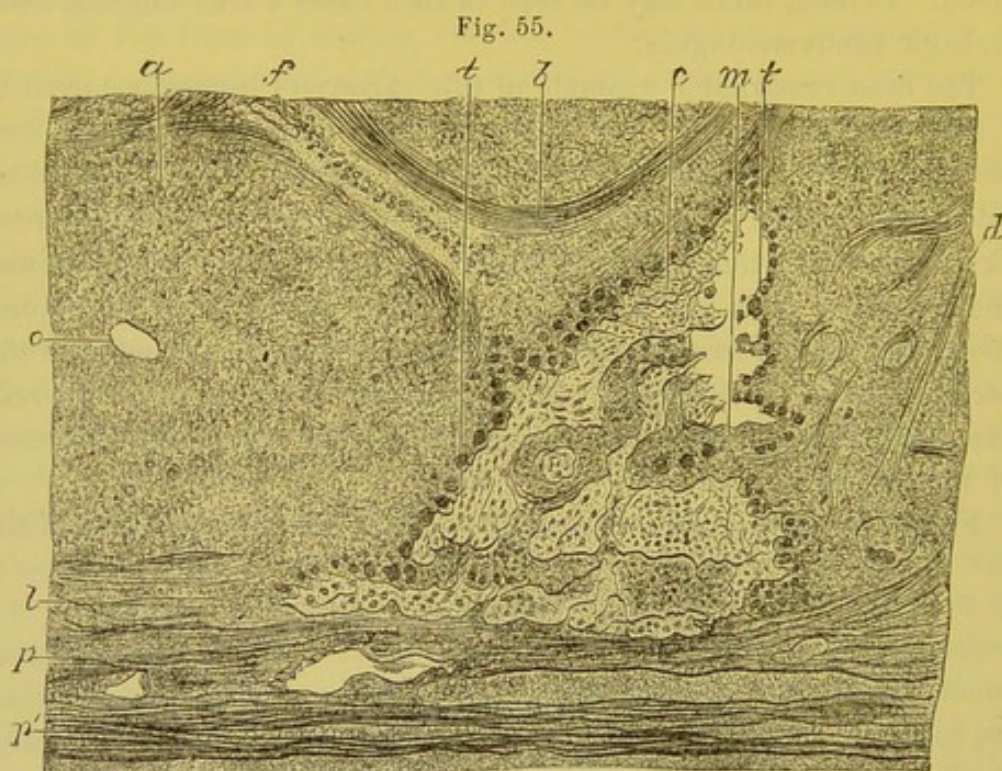
gummous granulations, *c*, *d*, *e*, *f*, which are connected to the external layer of this membrane, *b*. The granulations are separated from one another by bands of fibrous tissue.



Examined with higher power, the gummous granulations are seen to consist of a tissue made up of very delicate fibrillæ, between which are placed round nucleated cells; the protoplasm is small in amount. The reticulated arrangement of the fibrillar tissue was well shown in a pencilled section of a fresh piece.

Between the adherent granulations there was seen connective tissue, *n*. In several preparations there were found between the granulations the remains of osseous tissue, which had not been completely absorbed.

Figure 55 shows a group of these osseous lamellæ. The inferior horizontal lamella, *l*, in contact with the internal membrane, *p*, of the dura mater represents the internal table of the skull. It is continuous

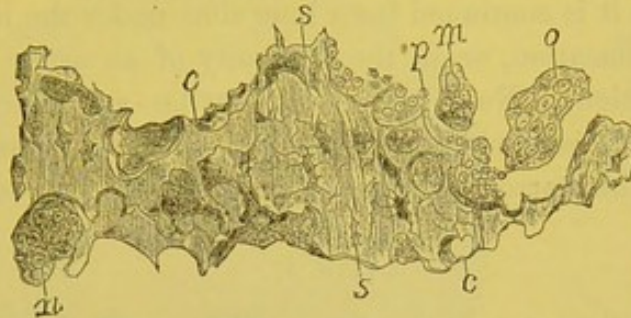


This figure shows a portion of the dura mater represented in Fig. 54 *p*, *p'*. Layers of fibrous tissue of the dura mater, from which the gummous nodules have their origin. One of the latter, *a*, is separated from the neighboring nodule by a zone of fibrous tissue, in which are seen some laminae of osseous tissue undergoing absorption. The horizontal osseous laminae, *l*, represent the remains of the internal table of the cranial bone, others are vertical or oblique. The laminae are irregular upon their surface, and around them is seen embryonal tissue containing numerous large cells (myeloplaxes, giant cells), *t*, *t*. *o*. Centre of a gummous nodule where is seen a large vessel. *f*, *d*. Fasciculi of fibrous tissue.  $\times 40$ .

with a system of oblique and horizontal lamellæ. These latter, situated between the granulation, *a*, on their left, and another on their right, are entirely surrounded by embryonal medullary tissue, which contain many large myeloplaxes (giant cells), *t*.

Fig. 56 represents a fragment of these lamellæ undergoing absorption. It shows the small notches, *c*. These lamellæ are, in some manner, eaten away, eroded by the numerous medullary cells, *p*, and by the giant cells, *o*, *m*, *n*, which are attached to their surface. In each notch are seen cells varying in size.

Fig. 56.



A fragment of osseous tissue undergoing absorption, situated between gummous nodules. *c*. notches upon the surface of the laminae; the anfractuosités and notches are all filled with large giant cells, *o*, *n*, or smaller giant cells, *m*, or round cells of the marrow, *p*. *s*. Osseous corpuscles.

When a small gummous tumor of the periosteum has excavated a cavity in the bone, and the inflammatory process ceases, the new formation becomes caseous and atrophied, the peripheral osteitis and periostitis disappear, and a partial renewal of bone may take place. The cavity is not completely filled, but the osteophytes, developed beneath the pericranium at the margin of the cavity, project as new-formed osseous tissue. The formative osteitis, extending some distance into the bone, causes an eburnation.

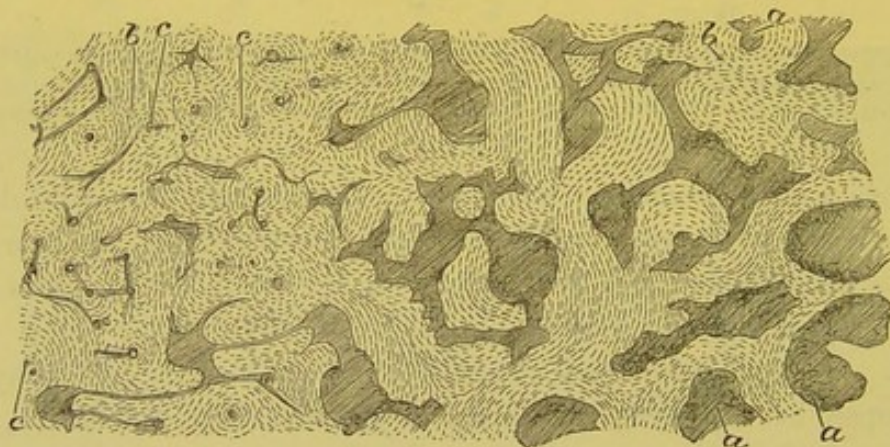
The appearance presented by the cranium in consequence of the superficial gummata varies. Most frequently there is an osseous cicatrix, a depression which Virchow has wrongly named dry caries. This depression is surrounded by osteophytes, or even by a circle of exostosis, while the bone is, for some extent, eburnated. If the cranial bone is completely perforated by a gumma, the loss of substance is not filled by new osseous tissue and there is formed only a fibrous cicatrix.

The process of periostitis and of the varieties of osteitis, including gummous osteitis, is the same for all the bones of the body; therefore, the above description of the changes as they are seen in the cranium are equally applicable to all bones. The bones of the skull, the sternum, the ribs, the clavicles, and the tibia are the favorite seats of the disease.

4. In describing simple osteitis and rarefying osteitis, the method was mentioned by which the osseous trabeculæ are increased in thickness when the osteitis ceased to be an acute inflammation. The cellular elements of the embryonal marrow were frequently seen to attach themselves to the surface of the vascular walls, and to act as osteoblasts in order to form new osseous lamellæ.

The *eburnation* or *sclerosis* of bone is often the result of the above process, when it is continued for a long time under the influence of a subacute inflammation, or in the proximity of an acute inflammation of long duration. New layers of lamellæ are added to the old ones, and the Haversian canals through which the vessels pass, are narrowed. This narrowing may be so great, that in some cases the

[Fig. 57.]



Syphilitic sclerosis of the frontal bone. *a.* Medullary spaces of the diploë. *c.* The same spaces much narrowed. *b.* Bony substance.  $\times 20$ . (Cornil and Ranvier.)

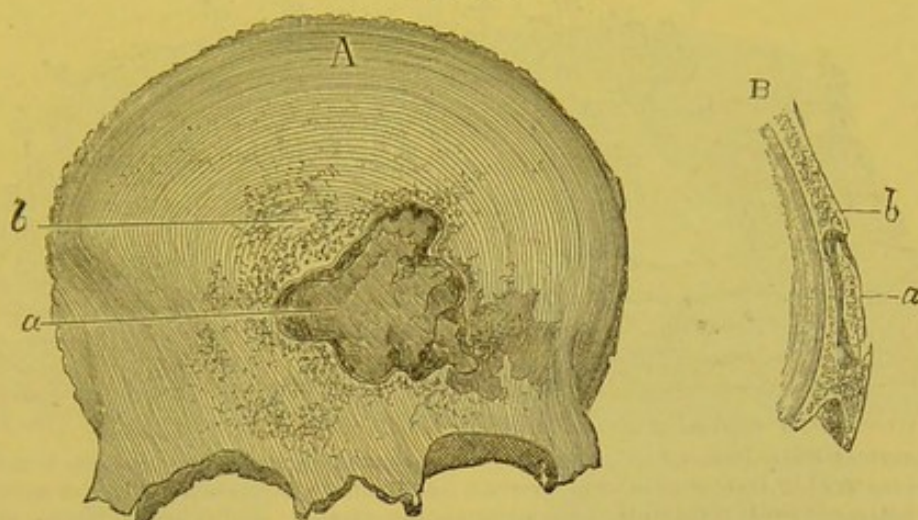circulation of the blood is impossible, and the primary canal is at times obliterated (Figure 57). The regions of bone in which the circulation is arrested are deprived of their nutrition, and necrosis results.

The bones of the cranium may be eburnated in their greater part without the slightest indication of necrosis; but in other cases in the neighborhood of and beneath suppurating periosteal gummata which have been of long duration, necrosis results from the contraction and obliteration of the Haversian canals.

Figure 58 is the frontal bone from a syphilitic patient, in which the middle portion presents a sequestrum, half the thickness of the old bone; it is eburnated, surrounded by pus, and encased as a watch glass in a frame formed by osteophytes, which are developed from

the normal bone. When a portion of necrosed bone is separated from the healthy or changed bone, there occurs a rarefying osteitis between the dead and living parts, which terminates in a complete separation. But at the same time suppurating granulations project

Fig. 58.



Syphilitic necrosis of the frontal bone. A.—Anterior surface of the frontal bone. *a*. Necrosed part. *b*. Region of the bone which is the seat of osteophytes. B.—Section of the frontal bone passing through the centre of the diseased part. *a*. Section of the necrosed part. *b*. Portion of the bone which overlies the necrosed portion.

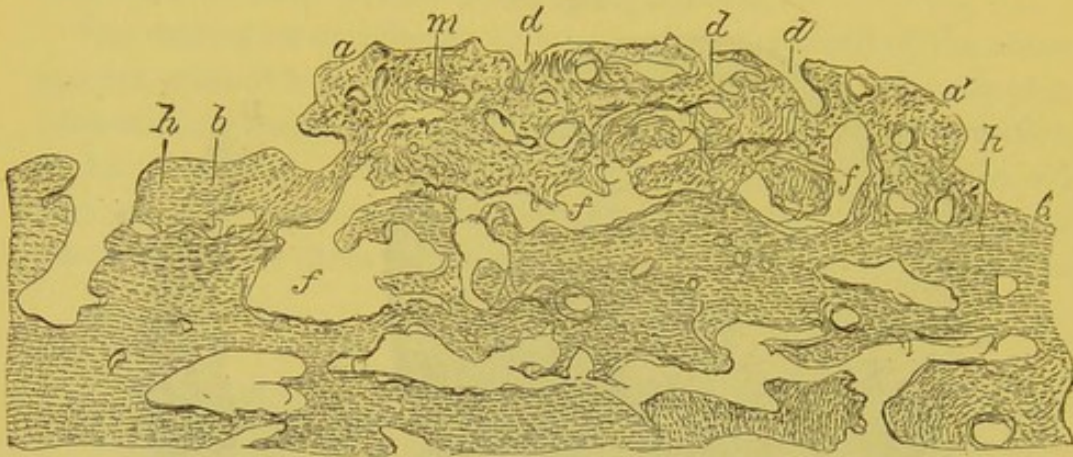
from the medullary cavities of the living bone, which push off the sequestrum. At the margins of this solution of continuity there is produced a slight inflammation with the formation of osteophytes, and the sequestrum is held in position.

A microscopic examination of a sequestrum shows that the Haversian canals are almost completely filled by osseous layers, or, at least so contracted, that the circulation of the blood is impossible.

5. *Exostoses* are met with in several varieties. A very common exostosis of the cranium is a medullary exostosis. Figure 59. It is connected to the surface of the bone, extending from *a* to *b*. The surface of the old bone, *b, b'*, shows at *c* a Haversian canal of large diameter; the Haversian canals, *f, f*, situated at the base of the new formation, between it and the old bone, are large, and filled with embryonal marrow. The osseous trabeculæ of the exostosis are very irregularly arranged. The Haversian canals, *d, d, d*, are perpendicular and oblique to the surface of the old bone, and open to admit the vessels of the periosteum; the others, *m*, form a transverse net-

work which unites the vessels coming from the periosteum with the large canals, *f, f*, proceeding from the old bone at the base of the exostosis. The superficial lamellæ of the old bone, *h, h*, are noticeable from their regular parallel arrangement.

Fig. 59.



Exostosis of the cranium of an adult. The sub-periosteal surface of the exostosis is limited by osseous laminae from *a* to *a'*. The external laminae of the diploë extend from *b* to *b'*. *c*. Canal enlarged by inflammation upon the surface of the cranium. *h, h*. External lamina of the diploë which is easily recognized by the direction of its parallel lamellæ, and by its bone corpuscles forming irregular series. *f, f*. Large medullary lacunæ placed between the old bone and the exostosis. *d, d, d*. Openings of Haversian canals of the new bone through which enter the periosteal vessels. *m*. Section of a small Haversian canal of the exostosis.  $\times 10$ .

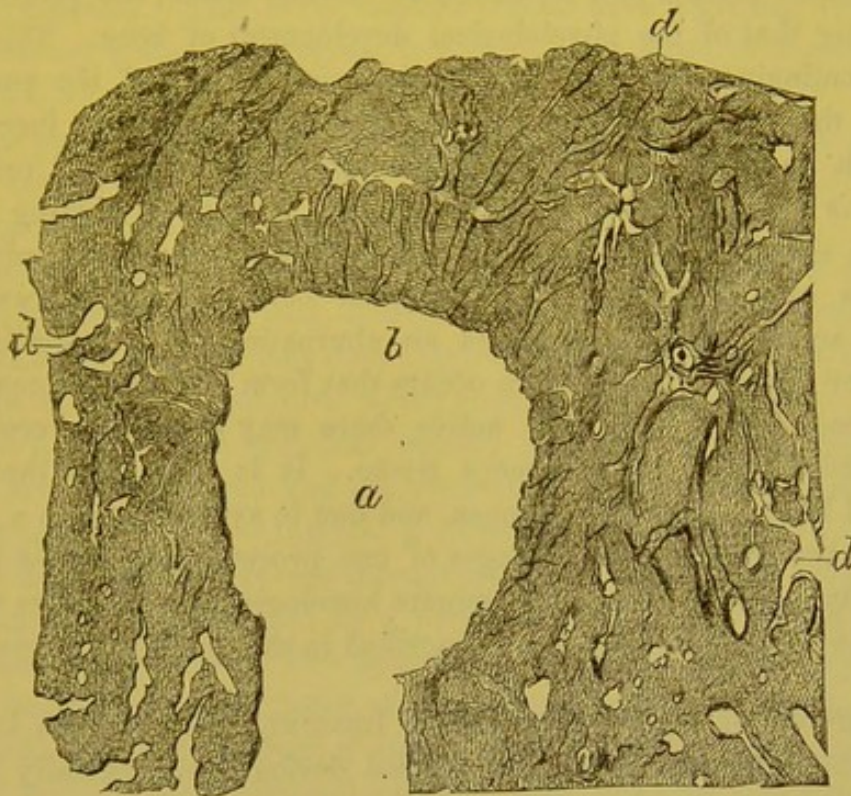
The direction of the Haversian canals in exostoses is at times quite regular. In preparations made from enormous exostoses of the parietal and occipital bones of a child which died of congenital syphilis, the very large Haversian canals were seen filled with embryonal marrow, and arranged perpendicularly or a little obliquely to the old bone. These large canals gave off narrow, lateral, and horizontal prolongations. The direction of the Haversian canals determines the direction of the osseous lamellæ, which are more or less regularly concentric to them.

When the exostoses, which at the beginning consist of spongy osseous tissue, have existed for a long time, they grow denser, in consequence of the formation of new osseous layers in the interior of the Haversian canals, and become compact or even eburnated.

Syphilitic exostoses of the cranium are generally less prominent than those of the extremities. They are, however, sometimes very large and projecting. Figure 60 is taken from one of the latter. *a*, A large medullary cavity excavated in its centre. From this cavity radiate small Haversian canals, *b*, which divide and form arches that

enlarge and anastomose at the surface of the exostosis, *d*. Here they were naturally in contact with the periosteal medulla. This exostosis consisted of compact osseous tissue, and resembled a fragment of a long bone with its medullary canal.

Fig. 60.



Prominent exostosis of the cranium. *a*. Central medullary cavity of the exostosis. *b*. The medullary canals of the new osseous tissue which emanate from the central cavity; they are small and are perpendicular to the surface of the cavity. *d*. Larger canals situated under the periosteum upon the surface of the exostosis.  $\times 12$ .

[The histological changes of the osseous tissue, as met with in the various forms of syphilitic lesions of the bones, are not to any great extent different from similar lesions due to other causes. In *osteoperiostitis* is seen a proliferation of the cells of the periosteum and of the cells within the Haversian canals or the medullary elements of the bone, which causes an increase in the size of these canals, the marrow itself becoming embryonic in nature. A continuation of this same process in a more intense degree results in an absorption of the osseous tissue, an enlargement of the Haversian canals, an increase in the amount of embryonal marrow, or, in brief, a *rarefying osteitis*, which in syphilis constitutes a gumma; that is, a gumma of bone is a localized intense osteo-periostitis, in which there is a destruc-

tion of the osseous trabeculæ by the formation of granulation or embryonal tissue, which later undergoes retrograde metamorphosis and absorption. The bone in which the gumma or rarefying osteitis has been developed, after the absorption of the gummous tissue, takes on reparative action, and there occurs a *formative osteitis*, in which there takes place a new formation of osseous tissue, the process resembling that of the physiological development of bone. This process continuing there results a condensing osteitis of the part, in which the laminæ surrounding the Haversian canals are increased to such an extent as finally to obliterate their lumen and cause a *sclerosis* or *eburnation* of the bone. An *exostosis* is nothing more than a slow formative osteitis, which results in the gradual addition of new osseous layers to the original bone; if the process becomes active, there is produced an eburnation of the new-formed bone, or if very intense, there occurs that form of osteitis known as rarefying, and if still more active there may even be a complete destruction of the new osseous tissue. It is thus seen that the several lesions occurring in bones, and due to syphilis, are, to a great extent, the continuation or stages of one process which varies in its intensity and its results. The minute histological modifications which occur in these lesions are fully described in the preceding pages.]

**SYMPTOMS OF SYPHILITIC OSSEOUS LESIONS.**—The osseous lesions of syphilis are not always recognized during life, especially those of gummata of the dura mater, affecting the internal layer of the cranial bones without causing a periostosis of the pericranium. But, in ordinary cases, when subcutaneous bones are involved, the symptoms are well marked.

The essential symptoms of syphilitic osteo-periostitis are pain and swelling. The pain is peculiar in that it is more intense during the night than the day, and so acute at times that it gives rise to the same sensation as when the bone is violently struck, the pain being excruciating, tearing, or starting. It prevents sleep, and by its persistence may become of considerable gravity. After two or three days' treatment with iodide of potassium it is usually relieved, and often entirely removed. This is certainly a most remarkable therapeutic phenomenon, as the pain not only disappears, but also the swelling due to the syphilitic neoplasm.

The osteocopic pains and the osteitis of the first period of secondary lesions are frequently limited to the regions where the tendons and

articular ligaments are joined to the extremities of bones, the wrist, elbow, knee, etc. These rheumatoid pains have evidently as an anatomical cause the periostitis and the temporary inflammation of fibrous tissue and tendons in connection with the periosteum. At other times the pain is connected with the periostitis and osteitis of the tertiary period. The early osseous lesions have a greater tendency to recovery under appropriate treatment than those of the tertiary period.

The pain occasioned by the osteo-periostitis of syphilis is always very acute when iodide of potassium is not administered. The slightest touch of the tumor causes most exquisite suffering. Osteo-periostitis of the sternum and ribs is accompanied with a circumscribed area of great pain, and interference with respiration. The lesions of the sternum may cause oppression, præcordial pain, and disturbances of the circulation, which simulate cardiac disease.

The symptoms of syphilitic osteitis are very variable, depending upon the bone affected and its connections. A general description is not possible. For example, a neuralgia due to compression of a nerve fibre, where it passes through an osseous canal, has no analogy with motor lesions caused by a paralysis of the motor nerve of the eyeballs or eyelids. The symptoms of course differ very much with the variations in form of the lesions which, it has been explained, may extend from a simple swelling of the periosteum and bone, to the suppuration and necrosis with fistulous tracts met with in intense gummous osteo-periostitis.

The most simple and most frequent cases are those of osteo-periosteal tumors of the superficial bones, the tibia, clavicle, sternum, frontal bone, etc. The nodular swelling, the single or multiple nodes, varying in size, and the special pain, are all characteristic. In passing the finger, for example, over the anterior spine of the diseased tibia, and over its inner surface, there are felt irregularities, flattened elevations, nodes, more or less numerous, having the doughy consistence of periostitis, or giving the sensation of osseous tissue according to the age of the lesion. The tibia may be double its normal size. By this examination the sensibility of the surface of the bone is also ascertained, mere contact sometimes causing great pain. Pain upon firm pressure or percussion of the bone may be elicited during the long period of transformation of osteo-periostitis into osteo-periostosis or into complete ossification of the inflamed



tissue, which may take several years. This pain occurs spontaneously during the early part of the night after retiring.

The periostoses of the clavicle are readily seen on account of the position of the bone, and most frequently are oval in shape with their long axes parallel to the bone. These tumors at times extend into the tendon of the sterno-cleido-mastoid muscle by a gummous infiltration.

The osteo-periostites of the anterior surface of the sternum and of the bones of the cranium, when recent, generally have the form of flattened tumors, varying in size and appearing as the segment of a sphere. They are then elastic to the touch, and may disappear, if iodide of potassium be given. Later, when osseous formations are developed around their circumference, they feel hard at the margins, while their central part is relatively soft. Upon the surface of the flat bones, which are exposed to external traumatism, an intense inflammation may be developed, terminating in the formation of pus beneath the periosteum. These purulent collections discharge their contents through the inflamed skin upon the surface. This is always a serious complication, for when suppuration takes place from an osseous surface, there may occur rarefying osteitis, and an elimination of bone fragments through the fistulous openings. Suppuration in bone is slow in its progress towards recovery; it may give rise to necrosis following eburnation of large fragments, peripheral exostoses, etc. Such lesions do not occur without greatly impairing the constitution, while the disease may, from its local effects, cause very grave functional disturbances.

Syphilitic inflammations and gummata of the periosteum and bones of the sternum are easily recognized. Tumors upon the anterior surface of this bone, which are small, hard, or elastic, and bone-like at their margins or throughout, may be considered to be syphilitic. But when there is an osseous lesion, accompanied with suppuration and a cutaneous fistula, through which porous fragments of bone are discharged, there is a doubt between syphilis and scrofulous osteitis, or rather tuberculosis of the sternum accompanied with osteitis and caries. Tuberculosis of the sternum is not a rare disease. In doubtful cases the previous history of the patient, the condition of the lungs, and the action of iodide of potassium will aid the diagnosis.

[As regards bones in general the differences between syphilitic and tuberculous inflammations may be stated as follows:—

SYPHILITIC OSTEITIS.	TUBERCULOUS OSTEITIS.
Syphilitic osteitis occurs in persons in varying physical conditions.	Osteitis of tuberculosis in persons who have other symptoms of this disease.
Begins most frequently in the periosteum.	Begins in the medulla.
Tends to the formation of new bone, or to necrosis.	Tends to disintegration of the parts.
Is often unaccompanied with suppuration.	Generally terminates in the formation of pus.
Does not involve neighboring articulations.	Apt to do so.
Frequent in bones of the cranium.	Almost never found in this situation.
Histologically consists of a relatively large mass of granulation tissue.	Made up of a varying number of tubercle granulations, and surrounded by isolated granules.
In the majority of cases can be cured, or at least arrested, if taken in time, by judicious specific treatment.	[We know of nothing which materially affects the course of this disease.]

It is frequently very difficult to make a positive diagnosis between gummata and osseous changes of the flat bones of the cranium. The lesions of the dura mater, and internal table of the skull are not here referred to, not being accessible to direct examination, but only those of the external table and pericranium. The difficulties are greater than with the sternum; the scalp is thicker, the bones are not so distinctly felt, they normally present many irregularities, and frequently upon the scalp of syphilitic patients there are ulcerous syphilides of the tertiary period, so that swellings which belong to the skin may be attributed to the periosteum and bone. Under such circumstances it is therefore necessary to examine the surface of the bone very carefully, sliding the scalp on the periosteum, and feeling for painful points. If the scalp be adherent to the surface of the bone, it is almost positive evidence that a periostitis exists, and if at this point there be a node, it is certainly either a gumma of the periosteum, if elastic, or a periostosis, if it be bony.

Syphilitic gummata and vegetations of the dura mater, and lesions of the internal table of the cranial bones cannot be recognized by physical signs, but their existence should always be suspected when changes of the pericranium and of the external layers of the bone are present. The functional symptoms of gummata of the dura mater are intense and persisting headache, and exaggerated pain when the cranium is percussed, symptoms which appertain, it is true, also to periosteal gummata; in the former, however, the pain is deeper and more intense. Frequently in these cases, the memory is weakened, the intelligence is dull, and the patient is in a more or less complete

state of stupidity. Epileptiform convulsions, vertigo, loss of consciousness, paralysis, limited to the arm, to the leg, sometimes incomplete hemiplegia and coma, indicating cerebral compression, terminate the patient's life.

Nothing is more variable than the intensity of the syphilitic lesions of the periosteum and bones, which in this respect resemble all the other manifestations of the disease. In some cases, for example, there is only a small sub-periosteal gumma of the tibia, which, treated early, completely disappears, or leaves a scarcely appreciable hyperostosis. In other cases, on the contrary, there are large prominent gummata, accompanied with intense inflammation of the skin, continual suppuration, necrosis of a portion of the bone and sequestræ which are thrown off, leaving large cavities. To this class belong numerous cases of syphilis of the cranial bones and lesions of the cervical vertebræ, tumors of the latter simulating retro-pharyngeal abscesses. Numerous observations might also be cited of diffused sub-periosteal gummata, in which the bones of the face are involved, and which are accompanied with fistulæ, necroses, and perforations, so that the visage becomes hideous and repulsive.

[The following conclusions, by Mauriac, in regard to the early syphilitic affections of the osseous system, have been frequently demonstrated to be in the main correct; we think them worthy of translation and insertion:—

1. Pericranial periostitis is often the first manifestations of syphilis. Sometimes it occurs a few days after the infecting chancre, and even before the secondary lesions.

*a.* It is exclusively seated in the periosteum of the cranium, and if a hyperæmic or inflammatory lesion of the osseous tissue exists, it is secondary, and remains subordinate to the periostitis.

*b.* Pericranial periostitis is the result of a true inflammatory process, an irritative or active process, as indicated by its acute symptoms and rapid course.

*c.* This variety of cranial tumors, when a result of acquired syphilis in the adult, has a tendency to resolution, either spontaneously or by appropriate treatment. The swelling readily disappears without leaving any trace.

*d.* In the hereditary syphilis of children, the cause of such pericranial tumors is an early irritative condition, and they disappear by suppurative or necrobiotic changes.

*e.* Pericranial tumors are the seat of fixed pain and the point of origin of radiating neuralgic pains.

*f.* The tumors may be discrete or confluent, and usually are located on the anterior half of the cranium. Their duration varies from four to six weeks, when not submitted to treatment. Under proper medication they disappear sooner.

2. Periostitis of the ribs, costal cartilages, and sternum may occur at the beginning of syphilis.

*a.* This sterno-chondro-costal periostitis, like the pericranial periostitis, is inflammatory and curable, and may be the cause of fixed and radiating neuralgic pains.

*b.* The tumors caused by it play an important rôle as painful foci in the dyspnœa which sometimes accompanies the first symptoms of syphilis. This syphilitic asthma has, however, many other causes.

3. Periostoses and exostoses may develop at the other parts of the osseous system during the early period of constitutional syphilis.

*a.* The period of incubation of these osseous lesions, dating from the appearance of the infecting chancre, varies from thirty to one hundred and twenty days.

*b.* They may appear several days before the eruption of the secondary cutaneous or mucous lesions. They occur spontaneously without the intervention of any exciting cause.

*c.* They seem to result from a form of syphilitic infection, in which the virus is unusually active as compared with the resistant power of the organism contaminated.

*d.* Periostoses of the tibia are the most frequent.

4. Among the inhabitants of tropical countries the osseous lesions are more common and more grave in hereditary than in acquired syphilis.

5. Early periostoses, in acquired syphilis, generally disappear by resolution, and are discharged by a more or less acute inflammatory process. The tumors of the limbs are usually less irritating than those of the pericranium.

*a.* They may recover spontaneously, but they disappear very much more rapidly under mercury and iodine with local antiphlogistic treatment.

*b.* They complicate the prognosis of syphilis, although they are often associated only with mild lesions in other organs, and do not necessarily indicate a malignant local process, or serious general constitutional tendency.<sup>1]</sup>

LESIONS OF THE BONES IN SYPHILIS OF NEW-BORN CHILDREN.—Hereditary syphilis affecting the bones of new-born children, is with-

[<sup>1</sup> Gazette des Hôpitaux, 1872.]

out doubt, one of the most interesting subjects connected with this disease. Ranvier communicated to the Society of Biology, in 1865,<sup>1</sup> the curious fact of the retarded ossification, and of the separation of the epiphyses in the case of a syphilitic infant who died a month after its birth. All the epiphyses were either completely detached from the diaphyses, or very slightly adherent; the proliferation of cartilage was normal, but ossification was slow, and the bone-cells did not appear within a centimetre of the line of apparent ossification, whereas in the normal condition they are found a millimetre distant from this line. This observation of Ranvier contained the germs of the history of hereditary syphilis of the bones. Wegner published on this subject, in 1870, an important *mémoire* (see page 282). Later, Parrot first brought to light, in France, in a series of communications to the Anatomical Society, and to the Society of Biology, and in his lectures on diseases of childhood, all that relates to syphilitic diseases of the bony skeleton.

In these lesions of the bones, as in the majority of organic changes observed to follow syphilis in cases of new-born children, the variations in the manner of the development of the tissues cannot receive their true signification unless the phases of normal development are well understood. And as the diseased tissues which are examined sometimes exactly resemble an earlier phase of development of these same parts, therefore, in order to study well the histological changes of an organ in hereditary syphilis, it is necessary to compare it with the different types which it presents from month to month in its regular development.

The variations from physiological ossification which are observed in syphilis, have some resemblance to rachitis, or to the diseases of badly nourished children.

When Parrot,<sup>2</sup> in 1873, brought before the Anatomical Society the long bones of new-born syphilitic children, and showed upon longitudinal sections of these bones the layers of ossification between the epiphyses and the diaphyses manifestly modified, I made the remark that these lesions were like those of rachitis. Ranvier also failed to see anything more than is seen in rickets, and we inquired what were the differential characteristics in like cases between syphilis and rachitis. Parrot has since endeavored, in

<sup>1</sup> *Comptes-rendus de la Société de Biologie*, 1865, p. 39.

<sup>2</sup> *Société Anatomique*, 1873, p. 92.

a series of publications, to elaborate this diagnosis,<sup>1</sup> and has extended and completed his first descriptions. He has studied not only the long bones, but also, and in a special manner, the flat bones of the cranium; and he rightly regards the nodes and the exostoses of the frontal and parietal as entirely characteristic of infantile syphilis. Parrot has brought together, in this chapter on infantile syphilis, a great quantity of material, but he has not yet published a systematic histological description comprising all the facts he has observed.

*Long Bones.*—The investigations of G. Wegner, and the first researches of Parrot, refer to the long bones.

Wegner has divided the phenomena which take place between the diaphysis and the epiphysis into three stages:—

In the first, the zone of calcified cartilage which separates the hyaline cartilage of the epiphysis from the new bony diaphysis is very much thicker than in the normal condition. The calcareous incrustation is considerable, and there has been an arrest of the normal production of bone. This layer of incrustated cartilage is brittle and honey-combed.

In the second stage, which is but an exaggeration of the calcification of the cartilage, there is found fibrous tissue in the medullary canals of the cartilage; the ossification of the intermediary cartilaginous substance is premature; there exists, besides, an atrophic and fatty-degeneration of the cartilage cells.

In the third stage, the cartilage thus changed is incapable of living; it is separated from the diaphysis by a soft or grayish layer of granulation tissue. This tissue, which is attributed by Wegner to an inflammation of the bone following necrosis of the cartilage, and to a formation of embryonic tissue (medullization and gelatinous transformation of Parrot), is so soft that the epiphysis and the diaphysis are torn apart by the movements of the child.

As a result there occurs a detachment of the epiphysis. The periosteum is inflamed, and is, as well as the perichondrium, thickened

<sup>1</sup> Parrot, Société de biologie, Séance du 1 Juin, 1872. Société anatomique, 1873, p. 92. Présentation d'os provenant d'un enfant syphilitique—Même recueil, 1873, p. 392. Syphilis et rachitis des enfants nouveau-nés—Même recueil, 1873, p. 248. Les lésions osseuses de la syphilis héréditaire et le rachitis—Archives de physiologie, 1876. Revue mensuelle de médecine et de chirurgie, 1877, p. 665. Le Progrès médical. Leçons sur la pathologie de la première enfance, numero du 6 Juillet, 1878. Congrès de l'Association Française pour l'avancement des sciences, 1877.

to quite a large extent, and a new formation of bone is observed beneath the latter.

[Veraguth<sup>1</sup> has recently investigated the changes due to inherited syphilis, which affect the growing extremities of the bones, and lead to the separation of the epiphyses. According to him, the first step in the pathological process is the occurrence, under the influence of the virus in the blood of the syphilitic child, of an excessive formation of vessels in the cartilage, and a corresponding overgrowth of the cellular elements. The change is greatest in the proliferating zone, and soon assumes a distinctly inflammatory character. *Pari passu* with this productive activity of the cells a retrograde process occurs in the intercellular tissue. The cementing substance between the fibrillæ becomes softened, or, as it were, dissolved, and the solidity of the cartilage is lessened in consequence, especially in the proliferating layer, in which the parallel arrangement of the fibres renders the effect of the change in the interfibrillar material the greater, and ultimately permits the occurrence of the parallel fissures which then extend through to the perichondrium. The cells increase in number by proliferation, and to them are added numerous lymphoid elements which wander in from adjacent vessels. Several observers have described a transformation of the medulla of the bone into granulation tissue, and the growth of this tissue into the fissures in the cartilage. This was not present in his case; many of the vascular canals of the cartilage contiguous to the growing papillæ of the medulla contained spindle-shaped and angular cells, but not in sufficient abundance to suggest an actual ingrowth of the medulla, so that the latter must clearly be regarded as an after-effect, the result of the fissuring, and not its cause. Some morbid changes were found in the bone itself, but these were of a degenerative character—fatty-degeneration of the cells of the medulla, deficiency of osteoblasts, and abundance of giant cells—and are to be regarded as secondary to the affection of the cartilage, which is thus a primary syphilitic chondritis.]

The division of hereditary syphilis of the bones into stages and periods, according to Parrot, is about the same as that of Wegner; but Parrot insists upon new osteophytic formations, and he gives to them the greatest significance. His general conception of the evolution of the disease is also different. The following, according to a *Mémoire* inserted in 1876 in the Archives of Physiology, is the division adopted by him from an analysis of fifty cases.

[<sup>1</sup> Archiv für Path. Anat., reviewed in the Lancet, June 11, 1881.]

In the first stage, the bones are heavier than in the normal state; dense osteophytic formations envelop the diaphysis of the long bones, and especially their inferior extremities. These osteophytes are characterized by fibrous and osseous trabeculæ, generally perpendicular to the surface of the bone. The *chondro-calcareous* layer, that is, the *layer of ossification of the cartilage*, is much thicker than normal, irregular, papillary.

In the second stage, the new bony layers are more porous; a gelatinous degeneration affects the epiphyseal cartilage, and the spongy bones at a point where they are in contact; the epiphyses tend to separate from the diaphyses. There is a solution of continuity more or less complete between the epiphysis and the bone, which results in a syphilitic pseudo-paralysis, curvatures, abnormal twistings, and preternatural mobility of the bones, with loss of the power of locomotion.

In the third stage, the osteophytes become medullated, their bony canals enlarge, and are filled with marrow, especially the canals or intermediary channels between the surface of the diaphysis and the osteophytes. The inferior extremities of the long bones, especially the inferior extremity of the humerus, increase in size by the formation of several layers of osteophytes.

In the fourth stage, the spongy tissue approaches nearer to the character it presents in rachitis.

From this *résumé*, which is given from the description made by the naked eye by Parrot, it is seen that he admits, from the beginning of the lesion, the existence of osteophytes, which, assuredly, are the most characteristic formations of infantile syphilis. The osteophytes, which are most frequently observed, in the lesions of the long bones, are seated at the inferior extremity of the humerus. He concludes by saying,<sup>1</sup> that there is at first "*periostogenesis*," a formation of osseous tissue from the periosteum, then "*chondro-calcosis*," a calcareous incrustation of cartilage, with subsequent gelatinous transformation and softening of the bone. The lesion, primarily distinctly syphilitic, becomes later more and more similar to rachitis.

The histological examination of the lesions of the long bones at the line of ossification has been minutely made by Wegner. The ossifying cartilage contains longer rows of proliferating cells than in the usual conditions, but, at the same time, the fundamental substance of the cartilage is incrustated with calcareous salts. The cartilage, calci-

<sup>1</sup> *Revue mensuelle*, 1877.



fied and thickened in an abnormal manner, is excavated by canals, which contain, with the vessels, a large quantity of fibroid connective tissue. There is also formed an osteoid tissue, so that where, in the normal state, there should be nothing but cartilaginous tissue, there may exist osseous trabeculæ.

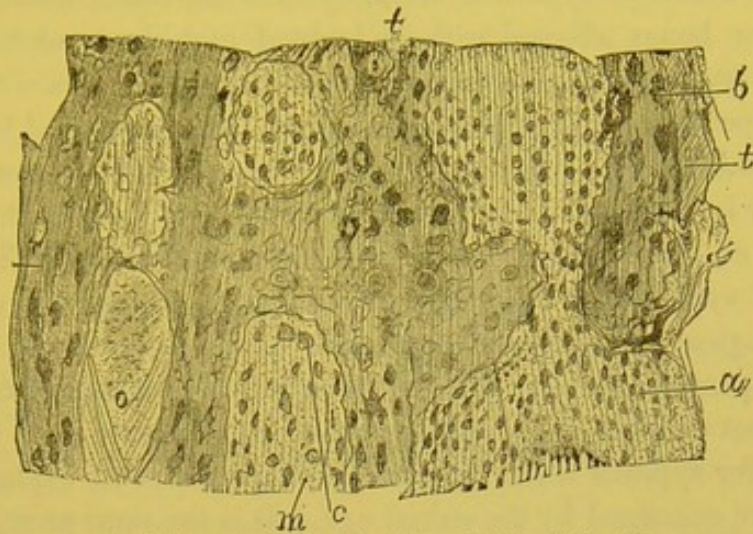
The portion of cartilage which remains incrustated with calcareous salts desiccates; the cartilage cells atrophy and become granulo-fatty. This portion, deprived of life, acts as an irritant body, excites around it an inflammation of the normal vascular tissues, and in particular an osteo-myelitis of the contiguous portion of the diaphysis. As a result of this osteo-myelitis the formation of a large amount of embryonic marrow takes place; the ossifying cartilage is then separated from the osseous tissue of the diaphysis by a soft, pink-colored, or gray layer, consisting of embryonic marrow analogous to granulation tissue, and in direct continuity with the marrow of the bone. This marrow is formed of a fibrillar substance infiltrated with round and fusiform cells. When the round cells are very numerous, the intercellular substance becomes liquid; and then the granulations are converted into a puriform fluid. Separation of the epiphyses is the immediate consequence of this state of the bone.

Parrot and Coÿne have given<sup>1</sup> a histological description of the osteophytes of the long bones of an infant six weeks old. These osteophytes, according to Parrot and Coÿne, present large elliptical spaces, their long axes parallel with the diaphysis. The narrow osseous trabeculæ anastomose in regular networks. The spaces limited by the trabeculæ contain a fibrillar tissue with a small number of ovoid nuclei, a few vessels and fatty granules. The osseous corpuscles of the trabeculæ are less uniform than those of the healthy portions; they are larger and less regular in their arrangement. We have in many cases verified the exactness of this description, and notably in the osteophytes of the tibia of an infant three months old. Figure 61 shows the osseous trabeculæ, *t, t*, parallel with one another and with the long axis of the diaphysis; they are united by short transverse trabeculæ, leaving between them the spaces *m*. The osseous corpuscles of these bony trabeculæ are very irregular, and placed without order; furthermore parallel osseous lamellæ are not seen as in normal bone. Nevertheless these trabeculæ are solid, and contain quite a large quantity of calcareous salts.

Figure 62 is a reproduction under a higher power (250 diameters)

<sup>1</sup> Société anatomique, March, 1873, p. 248.

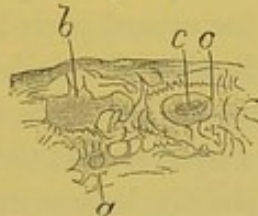
Fig. 61.



Osteophyte or new osteoid tissue from the tibia of a syphilitic child. The osseous trabeculae, *t*, containing the bone corpuscles, *b*, have between them spaces, *m*, filled with fibrils of fibrous tissue, oval and small cells, *a*, larger round cells, *c*, and fine fatty granules, *o*.  $\times 150$ .

of the osteoblasts or bone cells of Figure 61 ; it shows the difference in appearance and size existing between the bone-cells *b*, *a*, and *o*. But that which is most abnormal in these new osseous formations, is

Fig. 62.



A portion of an osseous trabecula from the same preparation as Fig. 61. The bone corpuscles, *a*, *b*, *o*, are very irregular both in shape and size ; *o* and *a* contain each a cell and its nucleus.  $\times 250$ .

the presence of fibrous tissue in the place of medullary tissue. This fibrous tissue is but slightly vascular, and is characterized by delicate fibrillae arranged generally in a parallel or concentric manner ; they are continuous with the osseous trabeculae which they penetrate. This tissue contains cells which are sometimes atrophied or withered, as at *a*, Figure 62 ; others round and larger as at *c* ; or again in place of cells there are found nothing but fine fatty granules situated in fibrillar tissue, as at *o*. At other times there are seen at the margins of the osseous trabeculae large cells spread out or flattened against the trabeculae and about to become osteoblasts. The irregular ossification takes place here entirely from the periosteum and from the fibrous tissue growing from it, and will be studied in connection with exostoses of the flat bones.

This structure of syphilitic osteophytes is not characteristic of the disease, for bones affected with undoubted rachitis or osteo-malacia, present a stage in which thick layers of osteoid tissue are found beneath the periosteum, the osseous trabeculæ being separated by fibrous tissue containing cells and occupying the place of the marrow.

Neither is it a matter of surprise that analogies exist in the minute structure of these lesions having such different origins. The entire history of syphilis furnishes us with analogous facts; for example, the histological processes in a pustule of simple ecthyma and in a syphilitic pustule do not differ, although the elementary cutaneous lesion is not evolved in the same manner; it may, however, easily be mistaken for syphilis when the general character of its evolution, and its form are examined by the naked eye. It is the same as regards the bones; the minute changes taking place in the ossifying cartilage may be the same in syphilis and in rachitis, but the beginning, the progress, and the termination are different.

The *anatomical diagnosis* between the lesions of infantile syphilis, and those of rachitis rests upon the following facts: In the first stage of syphilis there is observed an exuberance of calcification of the ossifying cartilage, and there exist peri-diaphyitic osteophytes which do not occur in rachitis. In the second period of rachitis a spongy tissue is formed with considerable decalcification of the bones; in syphilitic bones, on the contrary, there are osteophytes and a medullary softening between the diaphysis and the epiphysis, an epiphyseal separation. Later the syphilitic lesions resemble those of rachitis, and according to Parrot syphilitic bones become rachitic.<sup>1</sup>

[The chief points of clinical difference between the bone-diseases due to rickets and those of syphilitic origin may be tabulated as follows:—

SYPHILIS OF THE BONES.	RICKETS.
Swellings show themselves very soon after birth.	Rarely before six months; generally still later.
Preceded by snuffles, coryza, and cutaneous and mucous lesions.	No such prodromata.
Cachexia absent or moderate.	Cachexia marked.

[<sup>1</sup> At the debate at the recent Congress, the value of M. Parrot's researches on the early osseous lesions of syphilis was frankly acknowledged, but his contention that all rickets is the outcome of syphilis received only a single supporter. It is unquestionable that syphilitic children may become rickety, but the flaw in M. Parrot's reasoning is that he cannot absolutely exclude factors which are known in non-syphilitic children to have induced rickets. See *Lancet*, Sept. 17, 1881.]

SYPHILIS OF THE BONES.	RICKETS.
Circumscribed tumors on frontal and parietal bones, rarely on occiput.	Cranial bones thinned in spots, usually upon the occiput; thickened at sutures.
Ribs not markedly affected; swellings irregular.	All or nearly all involved; extremities symmetrically enlarged.
Disease of ribs when existent not ordinarily coincident with that of other bones.	Nearly always so.
Fontanelles close at usual period.	Closure delayed.
Other syphilitic symptoms present; enlargement of phalanges, metatarsal bones, etc.	Syphilitic symptoms absent.
There is an exaggerated calcification which causes necrosis of the new-formed tissue, and a consecutive inflammation, which terminates in the separation of the epiphyses.	There is formed a soft and non-calcified osteoid tissue.
Accompanied by synovitis, sinuses, cutaneous ulcers, etc.	Little external or surrounding involvement.
Generally disappears by resolution without leaving any permanent change.	Usually leaves some bending of shaft and distortion of the neighboring joint.
Specific treatment useful.	Of no benefit.]

We have now set forth our present knowledge of the anatomy of the long bones in infantile syphilis, taken from published works, and from a few personal observations; but it must not be thought that this pathological anatomy is complete; far from it. Since the works of Ranvier, Wagner, Waldeyer and Köbner,<sup>1</sup> Parrot, Poucet,<sup>2</sup> etc., have separated these lesions from those of rachitis, with which they were unquestionably confounded, it will be necessary to recommence the study of the lesions of rachitis, eliminating carefully all children suspected of syphilis. It is only by this means that we can arrive at an accurate differentiation of syphilis from rachitis.

The *symptoms* observed during life regarding the long bones, consist, according to Parrot, in a thickening affecting the inferior extremity of the humerus, or the internal surface of the tibia, and perceptible to the touch; or there are found at the middle of one or of several of

<sup>1</sup> Waldeyer and Köbner, Beiträge zur Kenntniss der hereditären Knochen-Syphilis, Virchow's Archiv, t. lv. p. 367, 1872. (See page 285.)

<sup>2</sup> Poucet has presented to the Société Anatomique (1874, p. 118 of Proceedings), nine cases of osseous lesions in syphilitic children. Twice there was separation of the epiphyses of all the long bones. Twice there was very evident rachitis.

the extremities, hard, olive-shaped nodes, corresponding to a formation of callus following a fracture of some of the lamellæ of the diaphysis. There may even exist a complete fracture in the continuity of a limb. Analogous nodes are also perceptible at the angles of the ribs and at the line of the chondro-costal-articulations. These tumefactions, like the incurvatures and flexions of the limbs, are symptomatically the same as those of rachitis. At a more advanced period, when the diaphysis of the bone is separated by a soft, inflammatory medullary tissue from the epiphysis, there is observed what Parrot has called the pseudo-syphilitic-paralysis, allied to that due to the separation of the epiphysis; the children have no power of movement, the motion of the diaphysis upon the epiphysis can be felt, and there is also deformity. The formation of callus in such cases is very tardy, not to say exceptional.

[The diagnosis between the syphilitic inflammations resulting in separation of the epiphyses and those due to non-specific causes may be made by attention to the following points:—<sup>1</sup>

SYPHILITIC OSTEO-PERIOSTITIS.	NON-SPECIFIC OSTEO-PERIOSTITIS.
Occurs in infants under three months of age.	No instance of its occurrence in children under one year of age.
History of syphilis in child and its parents.	No history of syphilis; sometimes a history of traumatism.
Implication of other bones.	Usually confined to one bone.
Coincident with the development of the shaft of the bone.	Coexists with the ossification of the epiphyses.
Other lesions of syphilis, nodes, skin eruptions, etc.	No such symptoms.
All these symptoms mild.	Pain, redness, and swelling severe.
Disease sharply localized.	Involves neighboring parts.
Lymphatics of limb unaffected.	Lymphangitis present.
Beneficial effect of specific treatment if given early.	No such effect.]

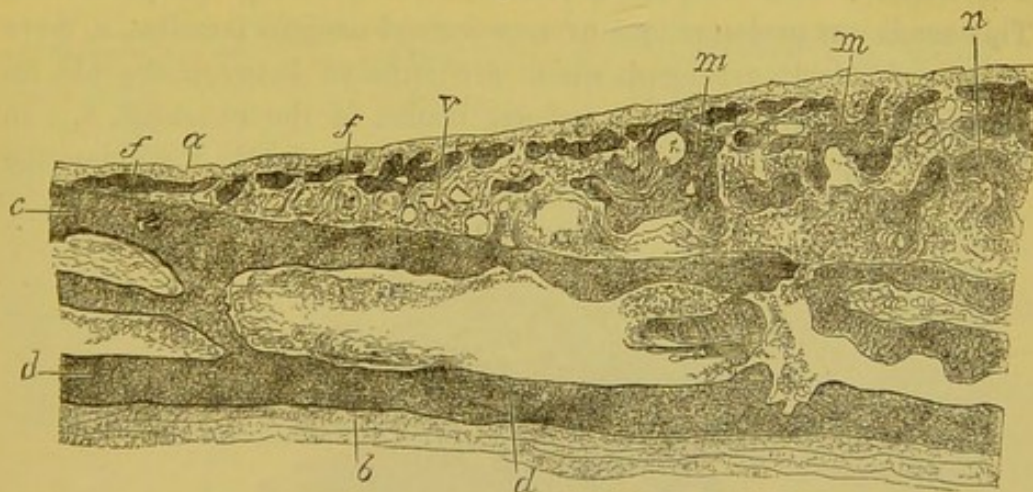
*Flat Bones.*—The most characteristic lesions of infantile syphilis affecting the bones are those of the bones of the cranium, described by Parrot. In a skullcap taken from a syphilitic child about two years of age, upon whom Th. Anger recently made the post-mortem; there were seen upon the frontal, the parietal, and the occipital bones

<sup>1</sup> This table, as well as the preceding one, has been compiled chiefly from Taylor's Syphilitic Lesions of the Osseous System in Infants and Young Children, which contains more information on this important class of diseases than any other work with which we are familiar.

flattened bony projections, the circumference of which were regularly circular, and the surface presented in each instance was a segment of a sphere of large size and varying thickness. Their color and their density at once indicated them to be exostoses. But the superficial lamellæ and the trabeculæ, which formed these tumors, were composed of a bony tissue less resisting, less brittle, softer than the osseous tissue of the adult. The thickness of these exostoses was considerable in their prominent central part, reaching three or four millimetres or even more. They diminished in thickness gradually towards the edge, which passed insensibly into the normal bony surface. The periosteum was generally thickened at the surface of the exostoses, and adhered to them in such a manner that its fibres remained attached when we endeavored to remove it. At the surface of the exostosis there were vascular apertures which transmitted the fibrous tissue of the periosteum and the vessels of the osseous canals.

If with the naked eye a section made perpendicular to the surface of these exostoses be examined, the arrangement of the new-formed lamellæ with those of the old bone can be compared. Thus in the most simple case of exostosis, such as is represented in Figure 63, under a power of 12 diameters, we have a cranial bone of an infant

Fig. 63.



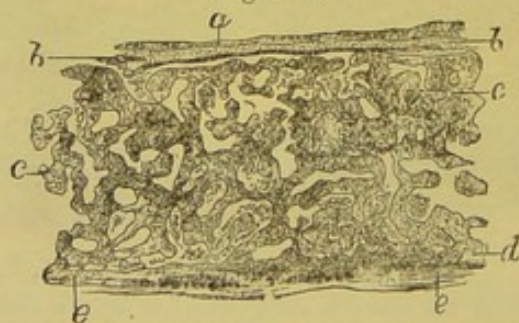
Syphilitic exostosis of the cranium from a child three months old. The internal, *d*, and external, *c*, osseous laminae of the cranium are surmounted by new osseous laminae, which are situated immediately beneath the periosteum, and are separated from the external laminae below by a very sharp angle; *m*, *m*, osseous laminae which connect the superficial laminae of the exostosis with the external laminae of the bone; *n*, vascular fibrous tissue which fills the medullary cavities.  $\times 12$ .

of three months: the two osseous lamellæ of the diploë, the internal table, *d*, and the external table, *c*, are separated by a medullary

space. At the edge of the exostosis, a thin new osseous lamina, *f*, a product of the periosteum is separated from the external table at an acute angle. Between the external table and the new-formed lamellæ the sub-periosteal connective tissue and the vessels penetrate obliquely. In proportion as the centre of the exostosis is approached, the new osseous laminae, *f*, *f*, *m*, are further separated from the external table, and the prominence of the tumor increases. There exist between these two osseous laminae medullary spaces, *n*, filled with fibrous and very vascular marrow; the new-formed osseous lamellæ, *m*, *m*, directed obliquely, parallel, or horizontally, to the osseous surface, without regular order, are placed between the external lamina of the diploë, and the periosteum, which latter is elevated by them. The figure shows this, and also the section of the vessels, *v*, of the fibrous marrow. This latter tissue consists of fibrillar connective tissue containing a large number of round and elongated cells. The vessels pass through the middle of this tissue. In this case the old osseous laminae are normal and the marrow contained in the old medullary spaces is simply embryonic and not fibrous marrow. It is a typical case of recent and very simple cranial exostosis.

Figure 64 represents, under a very low power (6 diameters), a section of this same exostosis through its most prominent portion. The internal table of the old bone, *d*, is the only one preserved. This sends out prolongations or new-formed osseous lamellæ, *c*, more or less regularly arranged, which are situated between the old internal lamina, *d*, and the superficial lamina of the exostosis, *b*. In this central portion of the exostosis, which is evidently the older, the

Fig. 64.



Section of the thickest part of Figure 63. *a*, periosteum; *b*, external lamina of the exostosis; *c*, dura mater; *d*, internal lamina of the cranial bone. The laminae, *c*, arranged more or less regularly, are, as well as the laminae *b*, of new formations.  $\times 6$ .

system of the new-formed osseous lamellæ is united with the old lamellæ in such a manner as to form a flat bone with a system of

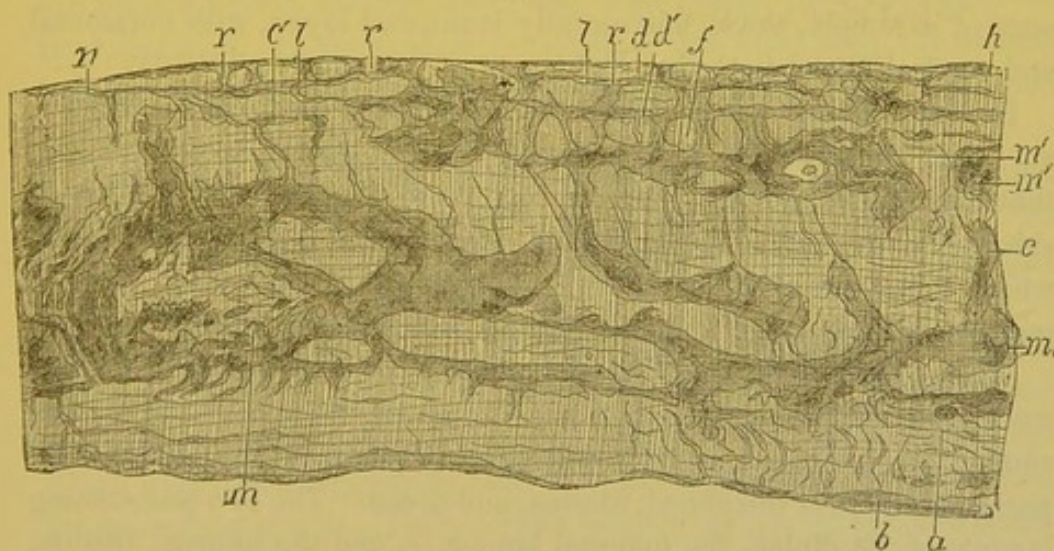
complex lamellæ. This exostosis presents the structure of a thick, flat bone limited on each of its surfaces by an osseous lamella.

Examination of older exostoses from the cranium of a syphilitic child two years of age, showed that the lesion had become more complicated, more difficult to analyze. In sections vertical to the surface of the bone, there are seen in the region near the periphery of the exostosis, thin lamellæ parallel to the surface and superposed; in the thicker central region there is a series of lamellæ most frequently placed without any particular order, except under the pericranium, where they are always found small, thin, and parallel with the surface of the bone.

In these thicker parts the most remarkable feature is the large medullary canals, full of red marrow, and directed perpendicularly to the surface of the bone, which enter the bone at the periosteum, and divide into horizontal branches. As in the preceding case, it is generally easy to recognize the two tables of old bone, which are situated at the inferior part of the section; the entire exostosis is peripheral, and is beneath the pericranium.

Figure 65, which was drawn under a power of fifteen diameters, represents the edge of one of these exostoses. The section, which is

Fig. 65.



Section of a cranial bone of a child two years old, affected with congenital syphilis. The section passes vertically through the periphery of the exostosis. The canals of the diploë, *m, m*, are very large. *a*. Internal lamina. *c*. External lamina of the diploë. *b*. Part of the internal lamina nearest to the dura mater. *m', m'*. Large medullary canals interposed between the old bone and the exostosis. The exostosis is located between the letters *h* and *m'*. This exostosis is somewhat laminated, and divided into parallel lamellæ, which run in the direction of the surface of the bone, and are separated by horizontal Haversian canals, *l, l*, which anastomose with each other and communicate with the vessels of the periosteum by vertical canals, *r, r, r*. The direction of the osseous lamellæ is regular only in the external table *c*.  $\times 15$ .



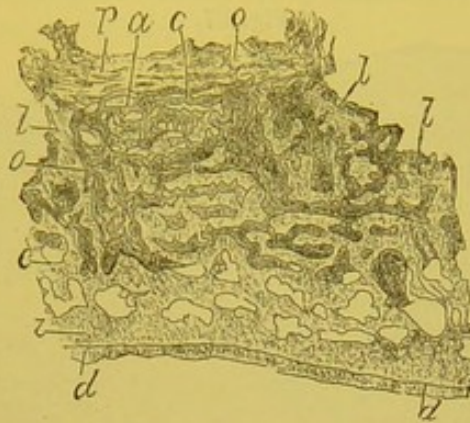
perpendicular to the surface of the cranium, shows the commencement of the exostosis. In the almost normal portion of the cranium, which is to the left of the figure, are seen the two tables of the diploë. The external table is the only one of which the osseous lamellæ have preserved in part their regular direction parallel to the surface of the bone; the internal lamina shows, on the contrary, even with this low power, a stratified condition of the different layers, the appearance of which is almost fibrous, and which are traversed by numerous capillary vessels. The zone, *b*, of this lamina is directly in contact with the dura mater. The new osseous layers, superadded to the external lamina, extend from *a* to *h*. The lamina, *n*, is superimposed upon the external table; it is thin and pierced with vascular openings, *r*. Beneath it the most superficial portion of the external lamina is equally vascularized, and further on it resembles a new osseous formation. As the thick portion of the exostosis is approached there is seen a new osseous lamina, *d*, which rests upon the other two, then a third, *h*, and so on. The vessels, *l*, from the periosteum, pass with the fibrous tissue between these horizontal laminæ which they separate, and run in a direction parallel to the surface. These canals are narrow, and are united by the vertical anastomosis, *rr*. Owing to this arrangement the new-formed osseous lamellæ at the edge of the exostosis have the appearance of a simple, thick, horizontally laminated layer, with horizontal and vertical osseous canals.

In this drawing it is seen that the pre-existing medullary canals, *m*, *m*, which separate the two tables of the diploë, are very large, and that their edges are irregular. From these large canals arise on all sides very numerous osseous canals, especially in the internal lamina, which is traversed by capillary vessels. The state of the osseous marrow in these large and small canals will be later referred to.

When, instead of studying the periphery of the exostoses, their most prominent central portions are examined, there is found a more complex arrangement, as shown under a low power in Figure 66. The pericranium, *p*, is thickened, fibrous, and dense. The two pre-existing laminæ of the diploë, the external lamina, *e*, and the internal lamina, *i*, are still recognizable; this last has preserved its relations with the dura-mater, *d*. But the external lamina is divided into a series of horizontal and vertical lamellæ, separated by large medullary spaces, lamellæ which are continuous with the new-formed lamellæ of the periosteum, and which occupy the upper two-thirds of the section. Beneath the periosteum, there exist very thin and generally hori-

zontal osseous lamellæ, *a, c, l*, separated by narrow vascular canals, and pierced by vertical blood-channels. In this cut the large medul-

Fig. 66.



Section of a thickened part of an exostosis of the cranium from a child two years old. *p*. Pericranium. *d*. Dura mater. *i*. Internal lamina. *e*. External lamina. *l*. Vertical lamina. *a, c*. Very thin sub-periosteal laminae. *o, o*. Large vertical medullary canals.  $\times 6$ .

lary canals are seen containing embryonal marrow, *o, o*. These canals run perpendicularly from the periosteum, conveying the vessels as far as the external table of the diploë, and sending off laterally horizontal divisions into the neighboring medullary canals. These large canals are limited by the osseous trabeculæ, which latter have the same vertical direction. In the cranial exostosis, as has been seen, the osseous lamellæ run in every direction, following the direction of the blood-vessels.

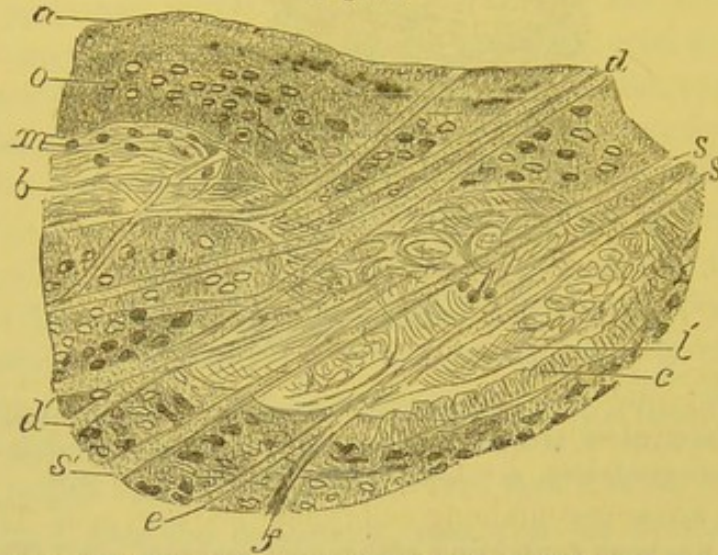
They differ from the exostoses of the adult in that they present very often, if not always, a fibrous condition of the contents of the medullary spaces, comparable to that which is found in the syphilitic osteophytes of the long bones.

Figure 67 represents osseous lamellæ situated under the periosteum, and constituting a part of one of these exostoses. The osseous tissue is traversed by Sharpey's fibres, or fibres of connective tissue, *d, s, s*, which pass from one osseous lamella to a neighboring one in crossing the medullary spaces. Thus the two fasciculi of fibres, *s, s*, completely cross the medullary cavity, *b*. In crossing it, they send fibrillar prolongations, which anastomose with the fibrillæ which fill the medullary cavity.

These fibrillæ are inserted upon the osseous lamellæ, and pass into the interior of the bone, and into the small fissures represented at *c*. The medullary canal, *b*, does not contain, in this preparation, any free

cells. The fasciculi of fibres only present between them some elongated and atrophied cells, *m*, at *b*. The osseous corpuscles are quite regular in their form.

Fig. 67.



Transverse section of an exostosis near the periosteum from a child two years old. *a*. Osseous lamina beneath the periosteum. *o*. Osseous corpuscles. *b*, *b'*. Medullary canals filled with a very dense fibrous tissue traversed by Sharpey's fibres, *d*, *d'*, *s*, *s'*, *e*, *f*. The very thick fibres, *s*, divide into fibrils, and are connected to the fibrils which fill the space left between the osseous lamellæ. Sharpey's fibres are seen to pass from one lamella to the other. *m*. Elongated and shrunken connective-tissue corpuscles. *c*. Small openings in the osseous lamella which contain fibrils crossing from the medullary cavity.  $\times 100$ .

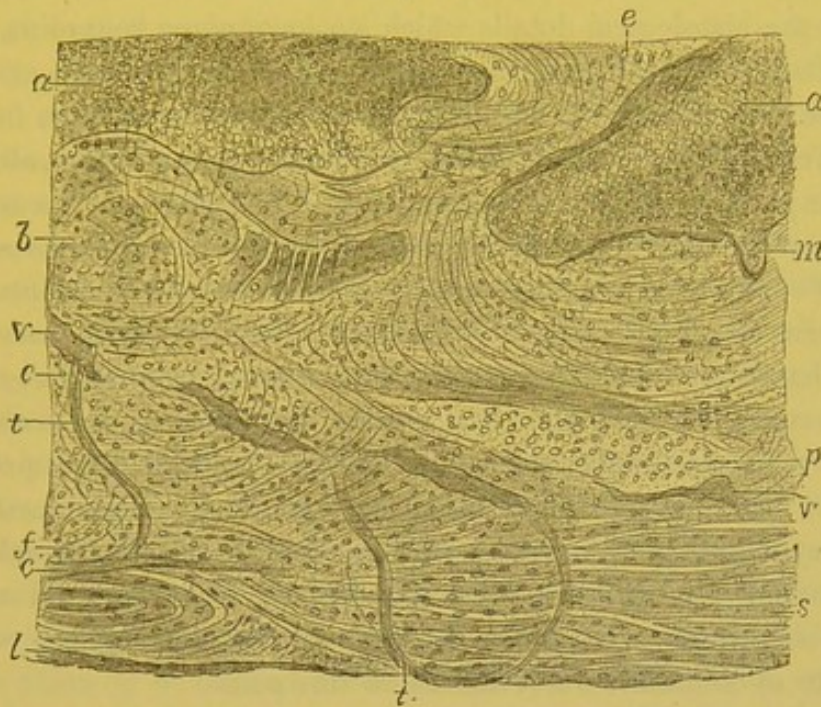
This figure represents a most intense degree of the fibrous condition of bone marrow. Very few bloodvessels are found here. But between this condition and the normal marrow, a number of intermediate varieties may be observed.

Syphilitic exostoses of the cranium in new-born children are very rich in the fibres of Sharpey and in fibrous tissue. The new osseous lamellæ are traversed by it in every direction, and, most frequently, without any regular order. It follows from this that the ossification of the exostoses is from the periosteum, both in the long bones of the limbs, and in the flat bones of the cranium, and that, furthermore, the more or less intense, interrupted, and renewed inflammation which prevents the ossification is not of a nature to accompany a regular osteogenesis.

In order to demonstrate this irregularity of the direction of the osseous lamellæ and of Sharpey's fibres, a portion of the internal osseous lamina of the diploë, at the surface of an exostosis of the cranium from the patient of Th. Anger is shown in Figure 68. In this figure

are seen large medullary spaces, *a, a*, filled with embryonic marrow. The internal lamina of the diploë, extending from *b* to *l*, presents everywhere bundles of Sharpey's fibres, some of which are parallel with one another, others intercrossed; they unite with each other, sepa-

Fig. 68.



Section of the internal lamina of a cranial bone from an exostosis of a child two years old. *a, a*. Large medullary canals filled with foetal marrow. The internal lamina extends from *b* to *l*. The osseous trabecula, *e*, unites the internal lamina with the system of other laminae of the bone. The internal lamina is traversed by Sharpey's fibres, the direction of which is more or less irregular, forming parallel and intersecting bands. These fibres are quite large at *c* and *s*, in all that portion of the external lamina which is nearest to the dura mater from *f* to *l*. *v*. Vessels which traverse the fibro-osseous lamina and send capillaries, *t, t*, to the dura mater. The bone corpuscles, *o*, are seen cut longitudinally and transversely; they vary in size; for example, those in the island *p* are large. At *m* is seen a notch due to a rarefying osteitis.  $\times 70$ .

rate from each other, and are arranged concentrically. Their direction determines the arrangement of the osseous corpuscles, *o*. In that portion of the lamina which borders on the dura mater, from *s* to *l*, the fibres of Sharpey are very large and very distinct. This portion of the bone is *probably* of new formation, for the fibres are all of the same age, and they differ as regards appearance from the rest of the fibres of the lamina. In this portion of the bone, as in the entire exostosis, the vessels, *v*, and the capillaries, *t*, come from the periosteum and from the dura mater, and penetrate the medullary canals after having passed through the osseous tissue. Furthermore, and it is an important fact, the bone marrow, contained in the large

medullary lacunæ, is embryonic, composed of round cells. In addition to this inflammatory state of the marrow, there are seen along the canals notches, *m*, filled with cells, and the osseous lamellæ at their surface are eroded, which indicates a partial inflammation of the exostosis—a rarefying osteitis, even in the tissue of the exostosis itself.

After the histological details which we have given regarding a few of the facts concerning the syphilitic exostoses of young children, which we have observed, we must not suppose that we are familiar with the entire history of the development of these exostoses, although we might perhaps be excused for so doing if, in addition to these facts, we remember and rely upon our knowledge of physiological ossification. We may safely believe that these exostoses are developed from the periosteum of both long and flat bones, like the normal bone itself, but we have not yet followed this development in its entirety. As to the manner of termination and cure of exostoses of those children who live to become adults, science is still less advanced. It is probable that after a certain number of inflammatory attacks, characterized by the embryonic state of the marrow contained in the bony canals, and by a partial absorption of the lamellæ, the process terminates in definite ossification with a normal state of the marrow, but we are not aware of authentic observations on this point.

The above description applies entirely to cases of congenital syphilis, that is, to those where syphilis has been evolved and has affected the bones at the same time that physiological ossification is going on. It is perhaps useless to remark that later, when ossification is completed, hereditary syphilis, which may, as we know, show itself tardily, affects the bones as does acquired syphilis.

A very exhaustive memoir upon the histology of the bones of syphilitic children by H. Wegner,<sup>1</sup> made from a great number of autopsies at the Charité Hospital of Berlin, is here given in abstract. Three stages of alteration of the long bones are recognized:—

*1st stage.*—While in the normal state the boundary of the hyaline cartilage is distinctly marked by a line which indicates the direct transformation of the cartilaginous tissue into a spongy tissue, the unaided eye being unable to distinguish a spongio-calcareous layer; in new-born syphilitic children, on the contrary, the bones are seen to

<sup>1</sup> Ueber hereditäre Knochen Syphilis bei jungen Kindern, Archiv f. patholog. Anatomie und Physiologie, t. L. p. 305, 1870.

have a spongio-calcareous layer interposed between the bone and cartilage, measuring two millimetres in thickness. This layer is limited on each side by a straight or undulating line. A microscopic examination shows that this lamina is only a zone of calcifying cartilaginous tissue more extensive than in the normal condition. The cartilage also presents collections of proliferating cartilage cells, which are larger than in the normal state.

There is, at the same time, a very active proliferation of the cartilage, a large calcareous incrustation, and an arrest of ossification. This abnormal layer is somewhat brittle and friable, and has a honey-combed appearance.

*2d stage.*—The changes are more distinct and extensive; the calcareous infiltration is irregular, and may reach four millimetres in thickness. Upon the side of the cartilage this layer is prolonged by papilla-like calcareous trabeculæ, which are frequently united at their extremities.

The layer of hyaline cartilage nearest the bone presents here, as in rachitis, a bluish appearance, and is almost diffuent. The trabeculæ of cartilage are proliferating, the cells are close together, and the intercellular substance is very small in amount. The vessels are surrounded by a large amount of fibrous connective tissue. At several points there is developed from the fibrillar tissue which surrounds the vessels, and from the cartilaginous tissue which forms the wall of the vascular canals, an osteoid substance, which later becomes true osseous tissue. Thus there is found in the interior of the cartilaginous canals, where there should only be cartilaginous tissue, trabeculæ of true osseous tissue, which, in a longitudinal section, may be followed into the thick spongioid layer, and into the osseous tissue of the diaphysis.

At the same time that this osteoid tissue is formed there is also seen around the vascular canals of the cartilage a calcareous incrustation of the cartilaginous substance and of the cells. This incrustation is much more advanced in the vascular parts, that is, nearer the bone, and is much less marked as the hyaline cartilage is approached. The calcareous walls of the vascular canals present a papilla-like appearance, the papillæ arising from the bone and terminating by free extremities in the hyaline cartilages, or they are united to neighboring papillæ. The perichondrium is calcified, and develops beneath it true osseous substance, which is an abnormal condition. The second stage is then characterized by an exaggeration of the changes found in the

first stage; proliferation of the cartilaginous trabeculæ, abundant calcification of the cartilage, too early and irregular ossification of the intercellular substance of the cartilage, a stationary state of the normal formation of bone from the epiphyseal cartilage.

*3d stage.*—To the preceding changes of the cartilage is added a thickening of the periosteum and perichondrium at the extremities of the long bones and at the junction of the ribs with the costal cartilages. Again, at the union of the epiphysis with the diaphysis, the line of calcareous cartilage, homogeneous and hard to the touch, but still friable, is limited by a reddish-gray or yellowish layer of purulent appearance. The medullary tissue of the diaphysis is grayer than normal. In consequence of the formation of this soft, almost liquid layer, between the epiphysis and diaphysis, the two segments of bone are separated; they may slide one on the other; the two fragments are only united by the thickened periosteum, and are completely separated when this membrane is divided.

Upon microscopic examination, the intermediary layer between the epiphysis and diaphysis shows, when it is of a gray-pink color, a very vascular granulation tissue, formed of round and fusiform cells. When this layer presents a purulent aspect, it consists of pus cells with a fluid intercellular substance and granulation tissue.

Beneath this semifluid layer the cartilage is seen very decidedly in a condition of calcareous infiltration. There is no proliferation of cartilage cells, but, on the contrary, a calcification and caseation of these cells. After decalcifying this cartilaginous tissue, the nuclei are found shrivelled amidst fine fatty granules.

To repeat, there are retardation of ossification, calcareous incrustation of the cartilage, want of nutrition, atrophy and fatty-degeneration of the cells of the cartilage, which form between the epiphysis and diaphysis a necrosed mass that irritates the living bone. The inflammation of the bone, the osteo-myelitis, which here results, occasions a separation of the epiphyses. There is frequently found an inflammation of the periosteum of the entire diaphysis.

This syphilitic affection of bones begins during foetal life, and generally involves several long bones at a time. In the order of frequency, they are the inferior extremity of the femur, the inferior extremity of the humerus, the epiphyses of the bones of the forearm, the superior epiphyses of the tibia, femur, and fibula, and, finally, the superior extremity of the humerus. The bones in which growth is most rapid are those most predisposed to the malady.

The description of the disease and its seat resembles the evolution of rachitis. Nevertheless it differs in its macroscopic and microscopic examination.

While in rachitis there is a soft and non-calcified osteoid tissue, in this disease, on the contrary, the exaggerated calcification is the cause of the necrosis of the new formed tissue and of the consecutive inflammation which terminates in the separation of the epiphyses. This affection should be classed in the group of degenerative inflammations.

Waldeyer and Köbner<sup>1</sup> have confirmed the histological investigations of Wegner. Their conclusions are based upon twelve cases. According to these authors, the alterations are always seen by the microscope when they are scarcely visible to the unaided eye. Lesions of the bones of the cranium and cranial gummous periostitis were more seldom found by them. Instead, however, of considering with Wegner that all the phenomena which occur between the diaphysis and epiphysis are due to an osteo-chondritis, Waldeyer and Köbner believe them to arise from a formation of syphilitic granulations, or, in other terms, of a gummous tissue. They compare the soft tissue between the cartilage and bone which separates the epiphyses to embryonal tissue. The necrobiotic changes which follow at a later period, the vascular lesions, and atrophy of the cells are compared by them to the modifications occurring in syphilomata. From studying the method of ossification along the cartilaginous trabeculæ, they conclude that the irregular ossification and the few and irregular osseous cells may be developed from the granular fusiform cells which are met with in the canals of the cartilage. Osteoblasts are not here seen regularly arranged in contact with the wall of the canals, as in normal ossification.

Waldeyer and Köbner believe that rachitis supervenes later as a result of osseous syphilis.

The *symptoms* of cranial syphilitic exostoses of new-born children have been recently described, for the first time, by Parrot, who regards them as an incontestable proof of syphilis. We cannot do better than quote his excellent description.<sup>2</sup>

“ On passing the hand over the child’s head, inequalities are felt,

<sup>1</sup> Beiträge zur Kenntniss der hereditäre Knochen Syphilis, Virchow’s Archiv, t. lv. p. 367.

<sup>2</sup> Leçons sur les maladies du premier âge. Progrès Médicale, No. du 6 Juillet, 1878.



the exact situation and configuration of which may be recognized by a more careful examination. They are flattened elevations, spread out, as it were, of variable prominence and extent, at first not very large, and of a perfectly circular contour, sometimes increasing in size without changing shape, but more frequently elongated in one or two directions. They are hard, and if it were not for their prominence, we should imagine we were touching healthy portions of the cranium. It is only in rare cases, when the pressure which we exert on their surfaces is considerable, that they appear to be endowed with a certain elasticity. They have four seats of predilection, the only ones which interest us clinically, viz., the two frontal and the two parietal, in the neighborhood of the bregma. Ordinarily they are symmetrically placed in regard to the frontal and sagittal sutures, but sometimes they are found either entirely in front of or behind the coronal suture, or very unequally developed upon the right and the left.

“These differences, however, do not diminish the importance of these prominences; it is sufficient to verify in one the characters that have just been considered to prove its syphilitic origin.

“This alteration may attack all the peri-bregmatic bones, or only a few.

“In the first case, the four elevations are separated one from the other, by ridges which are deep in proportion to the height of the prominences. They correspond to the sagittal and medio-frontal sutures, and to the coronal suture. Generally, when the patient is old enough, the position of the bregmatic membrane, completely ossified, is marked by a fifth projection hard and lozenge-shaped, appearing as if set in between the four others, and circumscribed by furrows, which seem to result from the duplication, at this point, of the two inter-fronto-parietal grooves.

“In some cases the posterior prominences are very extensive, very prominent, separated by a deep groove, and give to the regions they occupy a certain resemblance to the organs termed *nates* by the Latins; it is on account of this that I call the crania altered in this way *natiforme*.

“No matter how slight some of these lesions may be, it suffices to pass the hand over the cranial surface to recognize them; and they may frequently be seen even at a distance.”

[These cranial bosses are often found in children who are at the same time syphilitic and rickety, but this does not diminish their clinical significance, which, as Paul has shown, is almost pathognomonic.]

[SYPHILIS OF THE TEETH.<sup>1</sup>—In considering the conditions of the teeth pathognomonic of syphilis in the infant, the distinction must necessarily be made between those which are the effect of heredity and those which are merely congenital, as when the disease is acquired by the mother during gestation, and the child affected in utero, or when the latter is poisoned in its passage through the maternal soft parts.

The term "germ infection," or "sperm infection," has been suggested by Mr. Jonathan Hutchinson to signify infection of the child through the mother or father respectively, as a consequence of their blood-contamination by the elements of syphilis at the time of impregnation.

In congenital syphilis the interference with all the developmental processes is likely to produce irregularity as to eruption and position of the teeth; incongruity of size, individually and relatively; a soft and friable dentine; an opaque and chalky enamel, deficient in quantity and irregularly deposited; and a consequent proneness to decay. It is doubtful, however, if there are any signs absolutely diagnostic of syphilis in the teeth of the first dentition. The evidences of a check in development by interruption of nutrition during their formative stage may depend upon other causes, and are of diagnostic significance only when associated with other and more reliable expressions of the disease. Certainly the indications of hereditary syphilis, which in the permanent set are generally recognized as characteristic, are never met with in the first dentition. Malformed teeth, early erupted and early lost, are frequently associated with evidences of syphilis in the child, and result, doubtless, from stomatitis due to that disease. The effects, however, do not differ materially from those produced by stomatitis from any other cause.

The exemption of the teeth of the first dentition from the evidences of hereditary syphilis has been attributed to the fact that their calcification commences in utero, at a time when specific inflammations are not so likely to take place. Mr. Cartwright argues that the teeth, like the hair, being dermal appendages, and these superficial structures being most affected in secondary syphilis, the specific poison which lies latent in them during intra-uterine life may develop, at a later period, in organs formed from these structures.

Cachexia, independent of specificity, may account for early, late, or defective first dentition, as well as for various abnormalities in the teeth of the second dentition. Stomatitis, whether from syphilis,

[<sup>1</sup> The note on syphilis of the teeth has been furnished by Dr. J. W. White.]

mercury, or from whatever cause, is likely to register itself in badly organized teeth. The appearances characteristic of syphilis may also and frequently do exist conjointly with defective dental structures associated with and depending upon rickets, scrofula, mercurial poisoning, gout, rheumatism, etc. Horizontal furrows across the teeth are not pathognomonic of syphilis, but are due generally to some interruption of nutrition during their developmental period—such as is caused by the eruptive fevers, convulsions, etc. The so-called mercurial teeth are apt to be seamed horizontally, to be irregular in form, craggy, and honeycombed, and of an unhealthy, dirty yellow color, with wide spaces between them, the teeth seeming too small or too few to properly fill the jaw. In these teeth there is also apt to be a deficiency of enamel, which is particularly noticeable in the sixth-year molars and especially on their cusps.

All malformed, defective, or irregularly aligned teeth are, therefore, not to be regarded as indicative of a syphilitic taint, and great injustice may readily be done by want of discrimination.

The association of mercurial with syphilitic teeth is naturally of common occurrence, but enough cases with definite histories have been observed to make the association recognizable.

Nor are the special signs on the teeth which are considered as demonstrative of syphilitic taint to be found in all cases where known facts might justify the expectation, nor even in all the children of the same parents. Observation indicates that the special signs are likely to be most marked in the eldest, and least so in the youngest child. The special abnormality is valuable as a diagnostic sign when it is present, but its absence does not prove anything. It depends, doubtless, upon inflammation of the alveolar processes; but as the disease may have run its course without this special inflammation having been developed, the teeth may present no indications of syphilis. There appears a tendency in each case of syphilitic heredity to some special form of degeneration, implicating some one class of structures, the serous, the connective, the vascular, or osseous tissues, the mucous surfaces, or the glandular system. The predisposition is probably due to diathesis, existing cachexia, or special environment.

It may be worth while to note, as a clinical fact, that the dental peculiarities generally acknowledged as of syphilitic origin are very uniformly associated with interstitial keratitis.

The characteristic syphilitic deformity in the permanent denture, consists of a peculiar evidence of stunted development, especially of

the upper central incisors ; sometimes of the canines and of the sixth-year molars. In the latter, there is a dwarfing of the cusps, showing that the interference was during the deposit of the first formed portion of dentine.

In the incisors, however, are to be found those special pathognomonic indications which Mr. Hutchinson considers so reliable that he calls these the "test" teeth, and challenges the production of a single case of these "syphilitic teeth" without syphilitic antecedents. Hereditary syphilis, doubtless, affects to a greater or less extent all the teeth, but not so uniformly or so characteristically as to afford decisive evidence of the taint. When, however, the unmistakable evidence of syphilis is shown in the central incisors of the upper jaw, the other teeth are likely to be smaller than normal, stumpy in appearance, irregularly set in the arch, with spaces between them, and to have a stained, dirty appearance.

The special pathognomonic sign in the incisors is a want of normal width of the cutting edges, so that, instead of being broader there than at any other portion, they are narrowed, rounded, and have a peculiar crescentic edge, the surface of which is inclined upward and forward, instead of backward, as in normal teeth. Besides this crescentic edge, they are likely to be dwarfed in size, to stand apart and to converge toward each other. The cuts illustrate (Fig. 69) a pair of

Fig. 69.

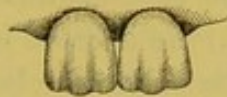

Fig. 70.



incisors showing, somewhat exaggerated, the serrations of the cutting edge which are frequently found in recently erupted normal teeth, and (Fig. 70) a pair of characteristic syphilitic incisors. It is this narrowing and rounding of these teeth, and the crescentic form of the cutting edges, together with the modification of the adjoining teeth—also narrowed and rounded—which gives the appearance likened by Mr. Hutchinson to a row of pegs stuck in the gums. As these teeth frequently project but half the normal distance from the gum, the simile of a row of pegs is descriptive. This appearance must not be confounded with the saw-like edges—serrations—of the incisors when newly erupted—a condition which is entirely normal.

The points of the crescentic edges and the points of the adjoining

teeth are generally worn away between the ages of twenty and thirty, so that the teeth resemble those of an old person, as though worn by long service, the denture appearing at thirty years of age like that of one sixty years old.

In acquired syphilis inflammation of the gums is occasionally met with, but not accompanied with such free salivary secretion as when the peculiar effects of mercury are exhibited in like inflammation; the gums swell and ulcerate, exposing the necks of the teeth, and unless counteracted, the disease involves the walls of the alveoli, causing loosening of the teeth, and ultimately necrosis of the jaw. It is exceptional, however, for the disease to reach the alveolar processes of the upper jaw unless led thereto by some local irritant, and still more rare to find such effects on the lower jaw without some predisposing local condition.

Nodes upon the periodontium, abscesses at the roots of teeth not decayed, and syphilitic periodontitis are among the occasional evidences of syphilitic infection.]

ALTERATIONS OF THE TENDONS AND SYNOVIAL MEMBRANES IN SYPHILIS.—The tendons, especially the large tendons, the tendo Achillis, the tendo patellæ, the tendinous attachment of the sterno-cleido-mastoid muscle, the flexor and extensor tendons of the fingers, etc., may be the seat of diffused or circumscribed gummata, of a fibrous thickening of a syphilitic nature. The synovial bursæ, and in particular the patellar, more rarely those of the semi-tendinosus, of the tuberosity of the tibia, of the olecranon, etc., are affected in the same manner (Verneuil, Keyes). The wall of the serous sac becomes the seat of a chronic inflammation, which affects the fibrous tissue, and which thickens it; there may also be gummata situated in the peripheral connective tissue. At the same time there is observed more or less abundant effusion into the serous cavity.

This lesion begins and progresses slowly, most frequently following contusions. It is generally mild, unless a gumma of the cellular tissue makes its appearance in the skin, and causes an ulcer, which communicates deeply with the synovial sac.

[“ Syphilitic bursitis attacks the tendinous bursæ more frequently in women, in contradistinction to gonorrhœal bursitis, which affects most the opposite sex. Usually there is a pre-existing gouty or rheumatic taint.<sup>1</sup> The subcutaneous bursæ, however, seem to be

[<sup>1</sup> Mauriac, Edin. Med. Journal, vol. xxi. pp. 275-448.]

equally affected in both sexes, although as traumatisms sometimes act as exciting causes, this equality may be more apparent than real, since men are more exposed to such accidents than women."<sup>1</sup>

"*Diagnosis.*—Syphilitic bursal diseases occur most frequently during the tertiary period, although occasionally during secondary syphilis, and their recognition must depend on a careful consideration of the following abstract of diagnostic points given by Fournier, since there is often no incontestable sign of syphilis detectable.

"1. The history of a primary lesion. 2. The comparative frequency with which such diseases occur in syphilitics, especially in women. 3. The association of bursal troubles with other secondary manifestations or gummata in the tertiary period. 4. The presence perhaps of undoubted specific lesions elsewhere. 5. Symmetry of the lesions, although this is not at all absolute. 6. The development of the disease contemporaneously with other lesions, and subject to the general evolution of the diathesis. 7. The absence of any other assignable cause. 8. The failure of ordinary measures and the prompt response to specific treatment."

Nancrede describes a subacute form of syphilitic bursitis, which is excessively rare, and occurs during the beginning of the secondary period. The pain is a marked symptom, and is increased by pressure or movement. The amount of effusion is small, and crepitation is felt when the tendon moves over the bursa. It lasts about a week, and may terminate in the chronic form, which is peculiar to the secondary period, and occurs much more frequently than the former. Its development is slow, from seven to ten months. The local symptoms do not differ from those of any other chronic bursal enlargement. The melon-seed bodies found in ordinary bursitis are not met with in that due to syphilis.

*Gummata* of the bursæ are seen more often than the forms of specific bursitis above described. They present symptoms which do not differ from those of gummata occurring elsewhere, viz., stages of formation, of softening, and, if permitted to take a natural course, of ulceration. They develop very slowly; the situation of the tumor corresponds to that of a normal bursa; its size is never very large, seldom exceeding that of a hen's egg, but from irritation it may be temporarily enlarged; the pain is slight, or entirely absent; its consistence is firm, elastic, and non-fluctuating. The skin may be unchanged, but is generally

[<sup>1</sup> Chouet, De la syphilis dans les Bourses Séreuses, Paris, 1874.]

dark-red in color, and frequently ulcerated; the ulcer has sharp-cut edges, a grayish base, and discharges a sanious fluid. The diagnosis depends essentially upon a specific history, the inherent characters of the lesion, and the beneficial effect of anti-syphilitic treatment.<sup>1]</sup>

The articulations are sometimes affected with chronic arthritis of a syphilitic nature, to which Richet has called attention in his excellent memoir on white swellings. The arthritis is not generally primary, but follows syphilitic alterations of the tendons or ligaments of the bones, or of the cellular tissue, which is contained in the folds of the synovial membrane. We have seen several specimens of these arthropaties, but we never have had occasion to examine them anatomically.

Autopsies showing the affection are uncommon, for none are mentioned in the memoir of Richet, nor in the thesis of Voisin on the same subject; indeed, we know of but one, the very important autopsy reported by Lancereaux. There existed in the right knee a yellowish-gray mass, elastic, of a gummous nature, four centimetres in thickness, occupying a portion of the tendo patellæ, the fatty cushion situated behind the synovial bursa and all the fibrous tissues inserted about the tibia. A lesion of the same nature, but less extensive, was seen in a similar situation in the left knee. Besides these characteristic gummous formations, there were also synovial effusion, inflammatory thickening of the synovial membrane and erosion of the cartilages. It is difficult to say what the anatomical alterations of the joint have been in cases which end in recovery. But as palpation of the articulation of the knee, which is the most frequent seat of this arthritis, renders perceptible soft masses, elastic or indurated points, or even hard borders at the sides of the patellar ligaments, or in the synovial folds, we can imagine that the synovial membrane is affected in such cases by fibrous or gummous neoplasms.

After the knee, which is the most frequent seat of syphilitic arthritis, come the elbow-joint, hip, instep, shoulder, wrist, and inferior maxilla. Arthritis is generally confined to a single joint, but it may show itself in both knees.

The symptoms consist in a tumefaction of the articulation in consequence of an inflammatory effusion into the synovial membrane. Thus, for example, the knee is swollen, and there is detected a moderately

[<sup>1</sup> Abstract from article on "Syphilitic Affections of the Bursæ." International Encyclopædia of Surgery, vol. ii.]

large quantity of liquid. Palpation gives the sensation of an elastic puffiness, less liquid than in hydrarthrosis, and a sensation approaching that experienced in the palpation of a white swelling. Sometimes indurated points or nodes can be felt. The pain is ordinarily slight, often is greater at night than in the daytime; movement of the limb is generally difficult or impossible.

The diagnosis usually cannot be made without taking into consideration the syphilitic antecedents and contemporary manifestations. There would assuredly be ground for considerable doubt in a great number of cases between a white swelling and a syphilitic affection. The employment of the iodide of potassium will then serve as a criterion in a difficult case when we suspect syphilis, whether in an adult or in a child.

Syphilitic arthritis of ordinary intensity is rapidly benefited and cured by the iodide of potassium.

[SYPHILITIC DACTYLITIS occurs at various periods of the disease, and in two varieties. One of these appears usually in the late secondary stage, and involves chiefly the periosteum and the fibrous and integumentary tissues surrounding a joint, usually a metacarpo- or metatarso-phalangeal articulation, involving a phalanx, and is characterized by slow, almost painless, swelling and discoloration of the affected member. This is due to a gummous infiltration, which, upon subsiding, leaves the finger or toe temporarily stiff, but not permanently disabled.

The second form is a specific osteo-myelitis with accompanying inflammation of the periosteum, and appears from five to fifteen years after the infection with syphilis. It is chiefly limited to these structures, the integument being but seldom involved; erosion of the neighboring articular cartilages often takes place; all the ligaments and the capsule of the articulation become thickened, and its function is frequently entirely lost.

The absence of acute inflammatory symptoms in the subcutaneous variety of dactylitis enables us to diagnose it from paronychia, whitlow, and gout. Rheumatoid arthritis begins in the joints, is associated with other symptoms, deformity of the fingers comes in early in the disease, and the sheaths of the tendons are involved.

The second variety might be taken for enchondroma or exostosis, but these swellings involve only a limited portion of the bone,



increase very slowly, and present dense, circumscribed tumors.<sup>1</sup> Dr. Taylor<sup>2</sup> thus indicates the rules for prognosis :—

“The *prognosis* of this affection of the fingers and toes depends entirely upon the accuracy of the diagnosis, and to a certain extent upon the period at which it is recognized, and in the event of its being correct, and as a consequence an appropriate treatment being instituted, it may be stated to be good, for the final impairment of the members is not so great as to cause utter uselessness. But if the origin of the lesion is not recognized, the chronic enlargement of the bone, the chronic hydrarthrosis with crepitation, or the latter symptom combined with chronic capsular thickening, might lead the unwary surgeon to pronounce an unfavorable prognosis, and perhaps to institute unnecessary operative procedure. The *treatment* is that of late syphilis, the use of iodide of potassium either alone or combined with a mercurial. The combination always answers best in

[<sup>1</sup> Mr. Deakin, in the Indian Medical Gazette, May 1, 1878, tabulates the diagnostic points somewhat as below :—

Syphilitic dactylitis.	Enchondroma.	Exostosis.	Strumous disease of bone.
Phalanges; metacarpal bones and neighboring articulations.	Metacarpal bones and phalanges. ..	Junction of shaft and epiphysis, points of muscular attachment. Dorsal surface last phalanx great toe. ..	Carpus and tarsus.
Affects the compact tissue (shaft of bone); periosteum; connective tissue. ..	Usually within substance of bone which encases growth. ..	Often with ossification of epiphyseal cartilage. ..	Cancellous tissue and synovial membrane.
Occurs as a rule during adult life. ..	Adolescence, during growth of bone. ..	Adolescence. ..	Childhood.
Skin thickened enchondromatous like, or red, tense, glistening, tendency to ulcerate.	Not involved. ..	Not involved. ..	Not affected in early stage.
Roundish, diffused swelling. ..	Clearly circumscribed, not involving joint.	Clearly defined, broad and flat, or pedunculated. ..	Uniform enlargement of articular ends.
Varying from hard to soft. ..	Usually firm. ..	Hard. ..	Soft, doughy.
Pain not severe, often less on pressure, worst at night. ..	Painless. ..	Painless, unless nerve involved. ..	Slight; wanting at first.
If tertiary, rarely symmetrical. ..	Often symmetrical.	Often symmetrical.	.....
Tends to suppurate. ..	To ossify. ..	To eburnate. ..	To suppurate.
Runs a rather acute course. ..	Usually chronic. ..	Chronic. ..	Chronic.
Accompanied by specific cachexia. ..	General health good; no syphilis. ..	General health good.	Strumous diathesis (i. e., a tendency to suppurative inflammations).
Single or few in number. ..	Multiple. ..	Single. ..	.....
Rapidly improved, if not dispersed, by specific treatment. ..	Not affected. ..	Not affected, as a rule.	Mercurials, as a rule, injurious.]

<sup>2</sup> On Dactylitis Syphilitica, New York, 1871.

cases where there is a coexistence of tegumentary lesions, but when these are strictly osseous and ligamentous, our chief reliance is upon the iodide, and we can, if that is inefficient, add the mercury. When the parts are very much distended, a minute incision may be necessary." ]

## CASE X.

*Syphilitic arthritis.*

F. A., æt, 35, seamstress, admitted to the Lourcine Hospital July 11, 1878, bed No. 4. Syphilis seemed to have begun with this woman, in February, 1869, by a very intense sore throat, followed by an eruption of large mucous patches on the lips. The latter continued two months. About April, 1870, there appeared upon the genital organs an eruption of confluent, very painful mucous patches, with considerable œdema of the labia majora. At this time the patient entered the hospital, under the care of Péan. Besides these patches, she then had an eruption of large papules upon the trunk, legs, arms, and palmar surfaces of the hands. She remained six months in the hospital, and was given pills of protiodide of mercury, sulphur baths, quinine, and iron. When she left, the papules had partly disappeared, and the mucous patches were entirely cured.

For two months the patient remained well, after this, she felt in the bones of the legs and thighs extremely sharp pains, especially at night, occasioning much loss of sleep. No similar pain in the clavicles, head, or arms; no headache. She again entered the hospital. At this time she had the itch. Upon the legs, buttocks, and thighs were also seen large red, painful pustules; these were cauterized with nitrate of silver. The eruption secreted a very profuse amount of serum; she now remained nine months in the hospital, and left entirely recovered.

During the three following years the patient remained well with the exception of an eruption of psoriasis upon the palms of the hands, the elbows, and knees. There was also an entire loss of hair from the whole body. That of the scalp had partly returned, but elsewhere it had not reappeared. During her several sojourns in the hospital, mercurial treatment had been employed.

*Present condition, 1878.* The face is pale, the skin elsewhere not colored, the emaciation considerable. There is some gastric disturbance. Pulse frequent. Appetite almost lost. General feebleness. Intense headache. Some vertigo. The predominant phenomenon is a very acute pain in the knees which renders walking difficult; this symptom has been present for the past two months.

The left knee is larger than the right. There is no change in the color of the skin. Upon the external surface of the articulation on the left side, there is seen a very appreciable swelling, especially when the knee is bent. By pressure there is felt a soft resistance, somewhat fluctuating, which appears due not only to fluid in the joint, but also to fungosities (fungous growths). On the right side the fluctuation is more evident, the movement of the patella is better felt. Flexion of the knees is painful; even when quiet the pain is acute. There are seen some exostoses on the tibia and ulna. No other syphilitic manifestations are present. The patient was ordered iodide of potassium.

August 5th. The left knee is of the same size as the right; but the skin is wrinkled. The patella is here more movable than the right. There still remains a little fluid.

The patient left the hospital recovered in September.

## CHAPTER X.

## SYPHILIS OF THE NERVES AND NERVE CENTRES.

Lesions of the pia mater—Inflammation and gummata—Lesions of the brain—  
 Large gummata—Their pathological anatomy—Symptoms and diagnosis—  
 —Their seat—Small gummata—Their relation to the vessels—Syphilitic in-  
 flammation of the arteries of the brain—Syphilitic lesions of arteries—Sym-  
 ptoms of cerebral syphilis—Syphilis of the spinal cord—Locomotor ataxy—  
 Diagnosis and prognosis of cerebral syphilis.

IN treating of the vegetations and gummata which are developed on the external or periosteal surface of the dura mater, it was mentioned that they frequently coexist with pseudo-membranous patches upon its internal surface. There are a certain number of recognized symptoms which are probably due to the presence of gummata upon the internal surface of the dura mater. Of all the cerebral and spinal membranes the dura mater is the one which is most frequently the seat of tertiary syphilis, chiefly owing to its intimate connection with the cranial bones, which are so often affected with this disease, and towards which it bears the relation of a periosteal lining. The symptoms produced by inflammation and by gummata of the dura mater are often mistaken for those of chronic osteitis, or of gummata of the cranial bones, and as the internal surface of this membrane, in contact with the pia mater and with the surface of the brain, is frequently attacked at the same time, it follows that this complication manifests itself by various cerebral symptoms; intense cephalalgia, trembling, dulness, intellectual torpor, loss of memory, and coma.

Besides these peri-encephalic lesions, the pia mater and even the brain substance and spinal cord may be the seat of sclerosis or of gummata.

The pia mater presents two varieties of lesions:—

1st. *A chronic inflammation*, followed by fibrous thickening and by adhesions to the surface of the brain. Cases have been recorded in which this fibrous thickening of the pia mater has been very widespread, producing a manifest compression of the nerves, and a sclerotic condition of the walls of the vessels within the membrane.

2d. *Gummata*, lesions much more characteristic than the foregoing. Lancereaux has seen in the pia mater, situated beneath the bone, a tumor the size of a cherry-stone, and which was hard, dry, slightly vascular, grayish in color at its periphery, and yellow in the centre. The gummata of the pia mater should not be mistaken for tubercles of this membrane, for the latter seldom or never attain so great a size.

LESIONS OF THE BRAIN.—Gummata of the brain and their anatomical results have been admirably described by Virchow in his work on constitutional syphilis, and in his lectures on tumors.

The works of Lagneau, Zambaco, Gros, and Lancereaux contain a large number of observations upon nervous syphilis.

Cerebral gummata may be found in two forms:—

1st. As large gummous masses developed upon the surface of the brain, within the convolutions, and in the gray substance or encroaching upon the white substance, and usually attacking the base, the cerebral peduncles, the pons Varolii, and the optic tract. These tumors, which are ultimately associated with the brain substance are generally multiple and of various dimensions. They are also found upon the cerebellum and upon the superior surface of the cerebrum.

2d. In the form of smaller nodules accompanying the cerebral arteries, and in particular the sylvian (middle cerebral) arteries.

These two varieties of syphilitic lesions do not differ materially in a histological point of view, as regards their structure; but their evolution is slightly different, and the last are generally accompanied by endarteritis, which results in a limited anæmic softening of the brain. In these cases the symptoms of arteritis are predominant. An account of the syphilitic alterations of the cerebral arteries will be given in its proper place.

A.—*Large gummata* of the brain surface possess perfectly distinct characteristics when examined by the naked eye. The two figures, (Nos. 73 and 74) which refer to a case of Coÿne and Lépine,<sup>1</sup> from the clinic of Prof. Sée, represent two flattened tumors, one of two, the other of three centimetres in diameter, both upon the right inferior aspect of the pons, and two other tumors resting upon the optic tract of the left side. These tumors, which are situated on the surface of the ner-

<sup>1</sup> Coÿne, Contributions to the Study of Cerebral Syphilis. Journal of "Connaissances Médicales," 1878, Nos. 17, 18, and 20.

vous substance, penetrate deeply into the nervous tissue, as is shown in Fig. 74, which represents a section of the pons at the seat of one of them. These tumors, which are precisely of the same nature as those observed by Charcot and Gombault,<sup>1</sup> and by Lancereaux,<sup>2</sup> in another series of analogous observations—present generally a dentate border, the projections of which extend between the fasciculi of the nerve fibres. The surface of these tumors presents two zones, a peripheral one, semi-transparent, without color, or pinkish and vascular; the other, which is large in size and central in situation, is opaque, yellowish-gray, dry, and hard. The surface of the tumor is at times slightly prominent, in other cases somewhat depressed. This last condition is due to atrophic degeneration of the cells at the central point. The lesion taken in its entirety constitutes a considerable mass, denser than the surrounding tissue, and forming a tumor which, in its development, can be recognized by the naked eye as well as by microscopic examination. These formations are hard, solid, and of a density analogous to that of the cerebral sclerosis sometimes found associated with the brain atrophy of crétins and idiots. In the sclerotic condition, however, the morbid tissue retains the shape of the convolutions, while here we have isolated tumors.

The pia mater is usually adherent to these tumors by an inflammatory fibrous tissue, and it is generally thickened at their summits. The microscopic examination of the tumors reveals numerous round cells of new formation, such as have already been considered in treating of the gummata of the skin and periosteum, and a structural formation analogous to that of these gummata, but modified by the nature of the tissue in which they are developed.

The peripheral zone, which passes imperceptibly into the normal nervous tissue, presents, in fresh specimens, or after maceration during two or three days in weak chromic acid solution, the elements of the neuroglia, and round or embryonic cells.

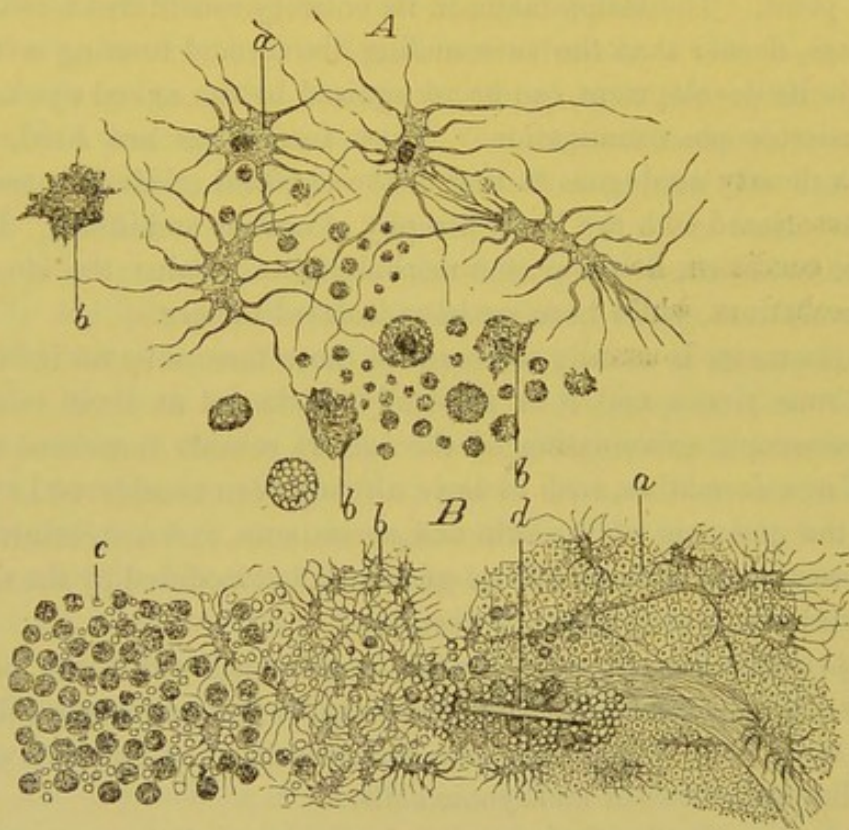
Thin sections made after complete hardening and staining with carmine, mounted in Canada balsam, show, especially at the periphery of the gumma, numerous sections of normal nerve-fibres. In these prepared specimens, as well as in those examined in the fresh state, the cellular elements, just as in the cases of Charcot and Gombault,

<sup>1</sup> Charcot and Gombault, Notes on a Case of Disseminated Lesions of the Nerve Centres in a Syphilitic. Archives of Physiology, 1873.

<sup>2</sup> Lancereaux, Theoretical and Practical Treatise on Syphilis, p. 350.

as well as in those of Coÿne and Lépine, assumed the form of stellate bodies described by Jastrowitch (spider-shaped cells). These cells contain a large nucleus, and a certain quantity of protoplasm, which continues into the extremities of the cell through the branching, rigid, refracting, prolongations, which are scarcely stained by carmine. Alongside of these cells others are found which have an oval nucleus, and a granular protoplasm without prolongations. There also exist a number of small round cells. These elements are situated in the midst of the reticulated tissue of the neuroglia. The round and oval cells are often collected together in groups (Fig. 71).

[Fig. 71.]



Syphilitic lesion of the nerve centres. *A*. Elements from *B*. *a*. Branched cells (spider-shaped cells) much enlarged, belonging to the neuroglia. *b*. The same elements granulo-fatty. *B*. Portion of a thin section through a small syphilitic nodule in the cortex of the brain. *a*. External zone nearly normal, in which enlarged stellate cells are scattered among the nerve fibres. *b*. Middle zone, almost exclusively constituted by large branched cells, mingled with a few round cells. *d*. Bloodvessel, partly covered by a mass of granular cells. *e*. Central portion of nodule, consisting of round granular cells. (Charcot and Gombault.) ]

From the preparations of Coÿne it was found that the bloodvessels were often surrounded by these small cells, situated in the lymphatic sheath which envelops them—but there was neither contraction nor

vascular obliteration by arteritis or by phlebitis. The spider-shaped cells, which should be considered as hypertrophied normal cells of the neuroglia, were numerous at the periphery of the transparent zone; they were entirely absent in the central opaque part of the tumor. These cells, which Charcot and Gombault considered characteristic of syphilitic gummata of the brain, Coÿne does not believe to be constant, for in a solitary gumma of considerable size, attacking the cerebellum, and which he studied with Peltier, there were no ramifying cells. Coÿne considers their presence as being due to their previous existence in the normal state in the region affected by the gumma, both in his own cases and in those of Charcot and Gombault.

In the central opaque and yellow part of the tumor only round and oval cells are found, more or less granular and atrophied, which form comparatively regular groups. These cells are not now seen forming a sheath around the vessels. The primitive structure of the nervous tissue is completely modified, very little remaining either of the reticulated tissue, the lymphatic sheaths, or of the nerve fibres. The vessels are generally slightly compressed owing to the large number of cells surrounding them. In the two cases of Coÿne, and in that of Charcot and Gombault, there was neither endarteritis nor fibrinous coagulation within the vessels. In other cases, there may be observed around the tumor a change in the cerebral substance, characterized by softness, by vascularity, by the presence of an opaque fluid, and when examined microscopically by a number of granular corpuscles. In the centre of the gumma, when it is of long standing, there may be found a cheesy condition, which, when examined histologically, is seen to consist of small round bodies, composed of minute acicular crystals of fat. But even at this stage, the central part of the gumma retains a certain degree of hardness.

The cerebral gumma is, therefore, characterized by two zones: one peripheral, in which are found nerve fibres, reticulated tissue, swollen and sometimes branching cells of the neuroglia, and a great abundance of small cells among the preceding elements and in the peri-vascular lymphatic sheaths; the other central, in which the numerous cells of new formation, crowded one against the other, and compressing the vessels, have destroyed all the elements of the nervous tissue, and are themselves undergoing a granulo-fatty atrophy.

The diagnosis of gummata of the central nervous tissue may be made by their known characteristics as revealed both to the naked eye and under the microscope. They are tumors or neoplasms



formed in the normal tissue with which they incorporate themselves, and which they partially destroy in their process of formation.

It is, from cerebral tumors, and particularly from tubercle, that the diagnosis should be made. It would be difficult to confound, for example, a superficial gumma with a sclerotic patch; the pinkish, grayish, semi-transparent tissue of the sclerotic patch is of the same color in the centre as at the circumference, and its appearance is that of organized fibrous tissue, and not of a neoplasm undergoing cheesy degeneration. The distinction between gummata and sarcomata is generally very easy.

We do not refer to angiolithic sarcoma, so easily recognized by its large flat cells, and by its vessels incrustated with calcareous salts; nor to sarcomata which are confined to the surface of the nervous tissue by a stroma of cellular tissue. Certain gliomata connected with the cerebral substance, and merging into it in an imperceptible manner, may give rise to difficulties, especially if their centres are cheesy.

But these tumors are single; furthermore, their structure, the reticulated tissue, the elongated connective-tissue cells, or the oval cells, are of the same shape; the ease with which these elements are torn apart; the softness and uniformity of the tissue, which is throughout very vascular, furnish well-marked differences. The thin embryonic walls of the vessels which traverse them; the fatty-degeneration of some of their cells, which are often filled with fatty granules, but are not atrophied; the absence of cohesion, and the mucoid condition of their older tissue, make them easily recognizable. The serious, but never insuperable difficulty of diagnosis is the distinction of gummata and large tubercles of the brain. The large cerebral tubercle appears to the naked eye as a single spherical tumor, or as numerous tumors of which the centre is yellow, often firm, the periphery gray and semi-transparent. But the opaque and dry portion, now and then fissured, or softened, is always more extensive than the central portion of the gumma. The circumference of the tubercle is more regular than that of the gumma; the tubercle does not send radiated and irregular prolongations into the neighboring cerebral tissue. Sometimes about the circumference of the cerebral tubercle are seen small miliary, semi-transparent tubercles, which are themselves spherical, and which blend with the semi-transparent gray surface of the large tubercle. In a great number of cases the tubercle is cheesy in its entirety, yet preserves its form; this is never

seen in gummata. Lastly, there may exist, rarely, it is true, very fine miliary tubercles of the pia mater, at the base of the brain, in the fissure of Sylvius, at the same time with large cerebral tubercles, and then the diagnosis is very simple. If these characters, drawn from naked-eye examinations, prove insufficient, the microscope will always overcome the difficulty. All the vessels in the opaque part of the tubercle are obliterated at their entrance into the opaque zone. In all this region giant cells are observed. On the contrary, in nearly all the recorded cases of large cerebral gummata, the vessels in the opaque part were patulous. It can very well be conceived by analogy with what has been seen in the skin, in gummata, and in the chancre, that there may at times be vascular obliterations. But this is a very rare condition, and altogether exceptional in gummata, while, on the contrary, it is constant and uniform in the cheesy portion of the cerebral tubercles.

The seat of these gummous tumors which attain the size of a walnut is at the base of the brain, near the pituitary body, on the surface of the pons, upon the peduncles of the cerebrum, and those of the cerebellum, upon the optic tracts, upon the anterior lobes, and on the surface of the frontal convolutions—which explains the aphasia often met with in these cases. They are also met with in the ventricles; on the surface of the cerebellum; at the points of origin or emergence of the cranial nerves, the optic nerve, the oculo-motor, the pathetic, the trifacial, the facial, the auditory, etc. These nerves whether directly invaded by the neoplasm, affected as a result of lesions at their points of origin, or surrounded and compressed at their exit from the brain by the thickened and inflamed membranes, the dura mater or the pia mater, especially at the orifices of the bony outlets, are very often altered in syphilis. The paralysis and the pain which result will be considered further on.

The possibility of gummata ultimately becoming softened and absorbed, leaving after them a cicatrix, or one of those small cysts so common in the brain, the walls of which are formed by a loose or fibroid connective tissue, and which contain a liquid analogous to that of white softening—cysts which are generally surrounded by softened or yellow cerebral tissue and filled with granular corpuscles—is a question difficult to determine. In the great number of cases collected by Gros and Lancereaux there were found small areas of softening, small calcareous and soft caseous masses, cerebral lacunæ corresponding to the cicatrices of softening, or cysts varying in size

and occupying the superficial or deep regions of the brain. These lesions are often coincident with gummata or vegetations of the dura mater, with syphilitic alterations of the bones of the cranium, and with gummata of the liver.

I have met with many of these small areas of softening which were consequent upon well-established syphilitic lesions of the dura mater and of the cranium. But these changes, which are often evidently of syphilitic origin, do not have the anatomical characters of syphilis; and although it can be imagined that a gumma, in an advanced stage of its retrograde evolution, may form a small soft mass undergoing fatty-degeneration, and surrounded by inflamed and softened cerebral tissue, it is, however, more difficult to admit the gummous origin of the lacunæ or of cysts. These last, indeed, appear to me to depend altogether upon chronic inflammatory lesions of the cerebral arteries connected with syphilis.

*B.*—Sometimes small syphilitic gummata, the size of which varies from that of a hemp-seed to that of a bean, are developed in the connective tissue of the pia mater about the cerebral arteries at the point where they pass between the convolutions. The arteries of the base and the middle cerebral arteries in particular are the chosen seats of these small tumors just as they are the seats by predilection of the miliary granulations of tuberculous meningitis. But the tubercular granulations of the meninges possess in their development, in the lesion of the sheaths of the microscopic arterioles, and in the obstruction of these small vessels, characters entirely distinctive.

The small gummata which are now in question are situated in the tissue of the pia mater; they surround the arteries which pass alongside of them and which are more or less compressed by a sclerotic inflammatory tissue; they partially penetrate the substance of the neighboring convolutions. The arteries are in such cases very much changed—attacked with chronic arteritis, with thrombosis, with a thickening of their coats, particularly their internal coats, in such a way that the circulation of the blood, hindered at first by the contraction of the calibre of the artery, becomes afterwards impossible. More or less considerable softening of the cerebral lobes follows, especially of the frontal lobe, or there are small areas of softening which in their further evolution leave in their places lacunæ, cicatrices, and small serous cysts. In cases of this kind, where there exist areas of softening of the brain of a variable extent, there also

exists a fibrous thickening of the meninges which accompanies the vessels. The vascular lesions are of great importance in these cases of small gummata and circumscribed syphilitic inflammations of the pia mater, for the areas of softening and the symptoms noted are the result of arterial thrombosis. The alterations which take place in the vessels should be examined with care. They have been studied by Heubner, who has made 164 autopsies of the brains of syphilitic subjects. There were 68 cases of gummata in which the condition of the vessels was not stated, and 44 cases of these tumors where the alteration of the vessels was mentioned. In 36 observations of meningitis and encephalitis, the vessels were mentioned but twice. He noticed 16 cases of vascular lesions without alteration of nerve-substance.

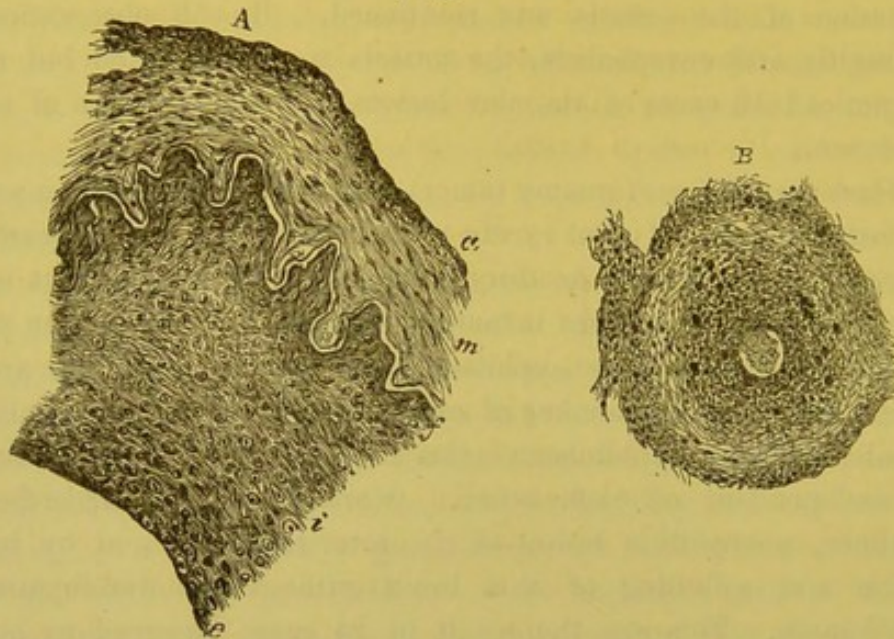
When a *syphilome* (gummy tumor) comes in contact with an artery, the latter occasionally but rarely remains intact, or it is mechanically altered by compression or thrombosis, or its walls take part in the change and are themselves inflamed; the specific arteritis then passes beyond the limit of the syphilome and extends along the arterial walls. In a certain number of cases the arterial lesions peculiar to syphilis and the syphilomata exist together in the same brain, but are independent of each other. More frequently, according to Heubner, a syphilitic lesion of the arteries is followed by inflammation and softening of the brain without the development of syphilomata. This was the result in 24 cases observed by him or by other authors.

Heubner describes syphilitic arteritis as altogether special and characteristic. He has given its pathological histology in detail; the following is a *résumé*: At the commencement there is observed, on the internal surface of the artery, a formation of new endothelial cells which are arranged in superimposed layers, some flattened, others fusiform or round. This proliferation fills the openings and depressions of the fenestrated membrane in such a manner that the surface of the artery becomes smooth and regular instead of being uneven. As a result, the fenestrated membrane, which, in its normal condition, is, in the arterioles of the brain, in immediate contact with the endothelium, is separated from it by a layer of newly-formed cells.

This process begins at the internal surface of the vessel, and is due to the direct and irritating action of the syphilitic blood. This zone of proliferation by increasing the thickness of the internal membrane

of the artery, reduces its calibre or at least diminishes its dilatability and elasticity under the influence of the blood. Inflammation going on, the endothelial layer is raised up at one point by the multiplication of the cells, and forms a lateral projecting vegetation into the lumen of the vessel, which by reducing the calibre of the vessel, may be the starting point of a thrombosis, or at least of a cerebral ischæmia. Heubner lays stress upon these characteristics of syphilitic

[Fig. 72.]



Syphilitic disease of cerebral arteries. *A.* Segment of middle cerebral artery, transverse section. *i.* Thickened inner coat. *e.* Endothelium. *f.* Membrana fenestrata. *m.* Muscular coat. *a.* Adventitia  $\times 200$  reduced one-half.

*B.* Small artery of pia mater, transverse section, showing thickened inner coat, diminished lumen of vessel, and considerable infiltration of adventitia. The cavity of the vessel is occupied by a clot.  $\times 100$ , reduced one-half. (Green.)

arteritis, and believes the formation of a single lateral projection of the internal membrane a pathological symptom appertaining especially to this form of arteritis.

The further consideration of the pathological histology of these facts will not be taken up, as they appear to us inadmissible until they are confirmed by additional evidence. For instance, Heubner believes that in the layer of newly-formed cells which is interposed between the arterial endothelium and the old fenestrated membrane, there are formed a new fenestrated membrane and new muscular fibres; he compares this new formation to a neoplasm reproducing the structure of arteries (an *artérioma*). It seems to us, on the contrary,

*à priori*, more rational to admit that the newly-formed cells have separated the fibres and the elastic laminae by passing between the laminae of the old elastic membrane, and that the same process takes place in the muscular layer. Later the arteritis, which has commenced in the internal membrane extends to the external coat of the artery; the vasa vasorum dilate, and there is formed about them a collection of round cells, which come from the blood by diapedesis. Whilst, according to Heubner, the newly-formed cells of the internal membrane are due to a proliferation of endothelial cells, the round cells which infiltrate all the external coats of the artery come, by diapedesis, from the blood contained in the small nutrient vessels of the artery. The external coat becomes inflamed, it is filled with lymph cells, and the inflammation is caused by the action of the syphilitic virus contained in the blood of the vasa vasorum.

[During the discussion at the London Pathological Society, in 1877, different opinions were expressed as to the character of the changes in the internal wall. In the opinion of some they resembled atheroma, or were due to organization of a peripheral thrombus, while others thought that they arose by a peculiar growth from the endothelium, and the interlaminar cells of the intima, producing a vascular structure, corresponding with other syphilitic new growths; in short, a form of syphilitic endarteritis.

According to Dr. Gowers, Heubner disclaimed any idea of there being any specific character in the structure of the growth itself. The description given by Heubner of syphilitic arteritis, is precisely the same as that given by Wilks and Moxon of "semi-cartilaginous thickening of arteries;" but the latter believed that the condition which they described was in no way connected with syphilis. It would seem, therefore, that the influence of the syphilitic dyscrasia was shown more in the degree to which the change was carried, than in the kind of change; and that more significance was to be attached to the nodular thickenings of the outer wall than to the endarterial changes.]

These pathological modifications occur with rapidity, and attain their maximum in the space of a few months. They may, however, remain stationary without notable change during several years. Heubner, and Lancereaux, who has followed him in the study of this process, maintain that the fatty-degeneration, so common in atheroma, and in senile arteritis, is not observed in syphilis. Yet, when the disease has lasted for a long time, there is a considerable diminution

of the calibre of the vessels which are transformed into tubes, or even into fibrous tracts, and sometimes portions of them are found which have undergone calcareous degeneration. Heubner compares this syphilitic arterial lesion with chronic endarteritis, and claims to have established marked differences between these two processes. The age of the subjects is not the same; the first attacks the old only, the second syphilitic subjects of all ages, during the secondary and tertiary periods. The commencement by the endothelium, in syphilis, differs from the beginning of atheroma, which begins simultaneously in the external and internal tunics. Atheroma has its seat in the aorta and in the large arteries, while syphilis has a marked preference for the small arteries, especially for the arterioles of the brain.

[Other writers give, with great confidence, the diagnostic points between syphilitic arteritis and atheroma. Lancereaux believes that this difference can be recognized, clinically, chiefly by the occurrence of symptoms of thrombosis in young subjects without evidence of disease in other arteries. He also bases his diagnosis upon the knowledge that the subject is syphilitic; the fact that atheroma is developed especially in the large vessels—aortic, splenic, mesenteric, and renal arteries—whilst in syphilitic arteritis the changes are chiefly found in the arteries of the brain; upon the frequency with which young subjects are attacked; and upon a certain symmetry in the development of the lesions.

It does not seem to us, however, that these differences are sufficiently uniform to warrant a diagnosis during life. When, however, the clinical and pathological distinctions are considered jointly, the separation of the two diseases becomes more evident; they have been stated<sup>1</sup> as follows:—

The syphilitic change is speedily developed, a few months being sufficient to cause great thickening of the coat and consequent narrowing of the lumen. The exact rate of progress of atheroma is not known, but it is certainly slow, and probably requires years for its development in most cases.

The syphilitic process from the first causes narrowing of the artery, while in atheroma the vessel is widened very early.<sup>2</sup>

[<sup>1</sup> Hill and Cooper, *op. cit.*, p. 199.]

[<sup>2</sup> "Atheroma is at first attended with a narrowing of the calibre of the vessel, in proportion to the thickness in which it is deposited. . . . A later consequence of the disease is dilatation of the vessel." Mr. Moore, in *Holmes's System of Surgery*, Am. ed., vol. ii. p. 307.]

The development of the syphilitic change is a more localized affection, indeed it may be limited to a short length of only a single vessel, and usually only the smaller arteries of a single organ or locality are affected. In atheroma the larger arteries are first diseased.

The site of the commencement of the morbid change is different in atheroma; this may be well seen in an artery, such as the basilar, where the fenestrated layer is well developed. Atheroma begins by the production of nuclei in the gaps of the fenestrated membrane, which collect between it and the endothelium. But from the first these nuclei, and afterwards the cells produced around them, are surrounded by a plentiful protoplasm of striated appearance. In short, the first effect of atheroma is to multiply the layers of elastic membrane. Thus a marked distinction is evident at once between the earliest development of atheroma and that of the syphilitic change. In the latter the new formation is cellular during all its early development, and the intercellular substance is only small in amount.

Another clear distinction is the rapid fatty-degeneration in atheroma of these new layers of cells and intercellular substance, by which the artery is soon beset with patches of rigid whitish material, consisting partly of fat and partly of calcified granules, of which the appearance is well known.

The relation of syphilitic arteritis to aneurism is one of the most interesting surgical questions of the day, but is yet *sub judice*. On the one hand, we have the statistics of Welsh, who, in 53 cases of aortic pouching or sacculation, 34 of which developed into aneurism, found 66 per cent. of syphilis; and we have, also, the testimony of Fournier, Russell, Lancereaux, Heubner, Chvostek, and others, who have reported cases of aneurism associated with extensive syphilitic disease elsewhere. The great frequency of syphilis detracts much, however, from the value of these observations, as it would hardly be difficult in this manner to prove a relation between syphilis and any other ailment that might be selected. In opposition, too, we have the evidence of Agnew, who, in twelve years' experience in the venereal wards of the Philadelphia Hospital, which are exceedingly rich in cases of advanced syphilis, did not meet with a single aneurism. To this we may add our own experience, extending now over nine years, nor have we seen or heard of such cases in the service of our colleagues.

The conclusions which we are warranted in drawing in regard to the entire subject of the relations of syphilis to arterial disease



were well expressed<sup>1</sup> at the time of the discussion in the London Pathological Society in 1877: 1. That certain changes have been found in the vessels affecting both the external and internal coats, occurring in patients who have contracted syphilis, and who have, moreover, died at a comparatively early age from disease which in most of the cases was the direct result of the arterial lesion. 2. That in many of the specimens examined the arterial lesion appeared to be of a gummous nature, consisting of a small celled growth and a delicate fibrillar stroma, while in other instances the disease appeared to arise from a form of chronic interstitial arteritis that could not be regarded as of a specific nature. 3. That one great point for future consideration will be whether these changes which are now regarded as specific have been observed in the bodies of patients who had undoubtedly never contracted this disease. Two or three such instances would throw much doubt upon the syphilitic nature of these lesions, while many such instances would upset the syphilitic theory altogether. 4. That it is desirable to collect and record cases where patients who have suffered from syphilis have prematurely died from a cerebral or any other affection resulting from arterial disease, inasmuch as a large number of such cases would establish syphilis as an important factor in the causation of such disease, even were the new growth frequently found to be identical with interstitial inflammation set up by other causes. 5. That, moreover, we should make the strictest inquiry into the history of patients suffering from aortic and other forms of aneurism, in order to see whether there is any foundation for the belief that aneurism occurs with much greater frequency in the subjects of syphilis than in non-syphilitics.

The majority of these questions may still be considered as not absolutely decided, but are certainly of undiminished interest and importance.]

The very decided opinions of Heubner are cited because his memoir is the result of much careful study, and because his anatomical examinations and his drawings are those of an histologist; but, nevertheless, we do not insist upon the adoption of his views. That the cells of the endothelium of the arteries are modified by the syphilitic virus circulating with the blood is possible, but in that case the change would be more frequent during the secondary period, and the lesion would be generalized. The vessels attacked by endarteritis

[<sup>1</sup> Medical Press and Circular, March 21, 1877.]

and peri-arteritis in syphilis have not the same tendency to fatty-degeneration as in atheroma, or in the senile condition of the arteries. This is perfectly true; in fact in atheroma fatty-degeneration of the internal membrane is primary; it must not be thought, however, that the yellow points which are found upon the internal membrane of the aorta are rare in young subjects; they are, on the contrary, very common in the cases of soldiers who die in the service (Ranvier). Age is not then one of the most important conditions.

Syphilis, or more correctly, syphilitic affections of the viscera, are accompanied with endarteritis and peri-arteritis which do not have a marked tendency to fatty-degeneration. But is this a reason that arterial lesions of this kind should appertain especially to syphilis? We do not think so. We find, in fact, in every chronic phlegmon, in every chronic sclerotic inflammation of connective tissue, secondary lesions of the arterioles absolutely like those which Heubner describes, and which belong to ordinary arteritis. It is essentially what one would obtain artificially by placing a ligature loosely around an arteriole.

[The order of frequency in which the tissues of the vessels are involved by inflammatory changes is usually believed to be determined chiefly by the character of the exciting cause. When internal or idiopathic disease such as gout, rheumatism, or syphilis, gives rise to arteritis, the tunica intima is first affected, though the disease may travel outwards involving successively the middle and external coats, and even the peri-vascular connective tissue. If the arteritis has a traumatic origin, however, the disease will be more likely to advance in the opposite direction.

Thus Agnew<sup>1</sup> says: The earliest evidence of the external form of the disease, that most commonly encountered by the surgeon, is hyperæmia of the nutrient vessels of the cellular tissue of the artery and its sheath, followed by a fibrinous and cell transudation. Should the inflammatory distension of the capillaries continue, a similar infiltration will extend to the middle coat, the effect of which will be to involve the tunica intima, producing endo-arteritis. Partly from the swelling and partly from the spasm of the muscular walls of the vessel excited under irritation of the vascular nerves, and thereby diminishing the canal of the artery, the inner coat is thrown into plications, and its nutrition seriously disturbed. The walls of the vessel

[<sup>1</sup> Surgery, vol. i. p. 531.]

thus filled with the products of inflammation may undergo several important structural alterations.]

Among cases of arteritis there are some which have a slighter tendency to fatty-degeneration than others; for example, the cases of arteritis due to rheumatism or to alcoholism possess to a less degree areas of cheesy degeneration than those due to senile atheroma; the chronic inflammations of the arterioles of the kidneys in interstitial nephritis, those of the vessels of the liver in cirrhosis, have almost no tendency to granulo-fatty degeneration. This anatomical characteristic *is not of itself peculiar to syphilis*. Nearly all cases of arteritis commence at the internal membrane. It is well, therefore, from these considerations, that we should be cautious before accepting the infallibility of the histological lesions described by Heubner in the cerebral arteries of syphilitics; we shall regard them, until more ample proofs are given us, as entering into ordinary chronic arteritis, and we wait new confirmative testimony before we admit that the arterial lesions are primary in cerebral syphilis, and independent of all inflammation and of all syphilitic neoplasms.

That which relates to the syphilitic diseases of arteries can be summed up by saying that, while this agency is very evident and very important as regards symptoms, for cerebral softening is a consequence of their obstructive effects, no entirely satisfactory explanation of their origin has yet been given. Most frequently the first change is due to the existence of small gummata seated around the arteries, but we have seen gummous nodules commencing in their external coat. Many writers even admit that the neoplasm can begin from the cells of their internal coat. Of this number is Dr. Celso Pellizari, who has recorded a case which may serve as a type of the rarity of the gummata under consideration.<sup>1</sup> The case was one of a patient who died with multiple cerebral symptoms, and who presented at the autopsy the following lesions: A syphilitic hepatitis, lesions of the dura mater, attachments of the brain to the cribriform plate of the ethmoid bone, a softening of the right hemisphere, a contraction of the middle cerebral and basilar arteries with organized thrombi and gummous nodules from the size of a pin's head to that of a bean, extending the entire length of the former vessels. In the examination of this artery Vincenzo Brigidi found together with a vegetating endar-

<sup>1</sup> Celso Pellizari, *Dellà sifilide cérebrale, ein partico lare delle lesioni arteriose da sifilide nel cervello.*

teritis an amyloid degeneration of the walls. Gummata and endarteritis with thrombosis were the cause of softening.

[It is generally believed that the veins are not at all or but slightly affected in late constitutional syphilis, and little is known as regards the diseases of the lymphatics during that period. Mr. Hutchinson has called attention<sup>1</sup> to the very few cases of syphilitic phlebitis which have been recorded, and yet he says most surgeons are familiar with the fact that inflammations around varices and even about healthy veins, are not infrequent in the subjects of syphilis.

He continues: "I think, also, that I have seen several cases in which the thrombosis and phlebitis were attended by other conditions sufficiently peculiar to justify a belief that they were of specific origin. In some, there has been great excess of inflammation, a large, hard mass forming in the cellular tissue and threatening to slough, much as subcutaneous gummata often do. These cases are much benefited by the iodide of potassium, so far as prevention of sloughing is concerned, but the thrombotic plugging remains. I am not aware that any specimens have been produced showing syphilitic disease of the cerebral veins. As regards the lymphatic trunks, I believe that they are liable to disease just as the arteries are, and that it results in similar conditions of plugging and its consequences. In a clinical lecture, published some months ago, I detailed several cases in which one lower extremity became greatly swollen, and remained for a long time in a state of solid œdema, there being, in some, reason to believe that the lymphatic trunks were inflamed, whilst in all there was a history of syphilis. In one remarkable case, I had treated the gentleman many years before for syphilitic paralysis of the fifth nerve. In him, a large network of cord-like lymphatic trunks could be felt over the lower part of his abdomen, one thigh being greatly swollen. There was no gland disease—and I am not speaking now of affections of the glands, but of the trunks. It would be very interesting, should opportunity for microscopic examination occur, to ascertain how far in this condition the changes in the walls of the lymphatics are similar to those seen in the arteries."

The possible frequent involvement of the lymphatics in the tertiary stage is interesting also in connection with the theory of syphilis which attributes the phenomena of that stage to obstruction of the lymphatic vessels. (See pp. 24, 25.)

[<sup>1</sup> British Medical Journal, February 10, 1877.]

Dr. Otis quotes<sup>1</sup> a single case as the only one he was able, after much research, to discover, in which symptoms referable to lymphatic occlusion were actually proved, upon post-mortem examination, to depend upon that condition. Even here, however, no examination had been made of the walls of the vessels, and the cause of their obstruction remained undetermined.]

The syphilitic alterations of the spinal meninges and of the spinal cord are analogous to those of the brain; but the cases that can be attributed to syphilis are very rare. The lesions of the meninges are nearly always secondary to those of the vertebræ. As to those concerning the spinal marrow itself, there are in the cases of adults but a very small number of incontestable observations. In the case reported by Charcot and Gombault, the patient presented, at the superior region of the dorsal marrow, on the left side, on a level with the 3d pair of dorsal nerves, a hard swelling, a protuberance occupying nearly a centimetre, in which were found fasciculi of fibres with stellate and round cells arranged along the vessels. The nervous substance was here replaced by a gummous neoplasm. The roots of the corresponding spinal nerve were altered at this point, and the pia mater and arachnoid were thickened.

*A propos* of this fact, Charcot, in examining the published cases of syphilitic lesions of the spinal cord, finds but three which are beyond criticism; two reported by Lancereaux, and one credited to Moxon.

When a syphilitic tumor is situated in a portion of the spinal cord, a secondary degeneration is found; thus in the case of Charcot and Gombault, the left anterior column was changed beneath the gummous swelling, and the right posterior column was degenerated above it. In hereditary syphilis of new-born children, Lancereaux and Potain have published cases of diffuse induration of the spinal cord in its entire length.

\*SYMPTOMS OF CEREBRAL SYPHILIS.—The symptoms depending upon the different alterations of the meninges, of the brain, and of the vessels, which have just been considered, differ, it is needless to say, according to the region of the brain which is affected by them. It is desirable that we should be able to diagnose the seat of the malady by the analysis of the symptoms, and we shall doubtless, at some future time, definitely effect these localizations; this is, however, impossible at the present time with the known facts of cerebral syphilis. We should remember that the lesions of the dura mater, of

[<sup>1</sup> Op. cit., p. 52.]

the pia mater, and often those of the cranial bones, coincide with gummata or more or less extended softening, in such a manner that multiple manifestations have to be contended with. Despite these difficulties, the progress of these encephalopathies, a certain number of characteristics which appertain to them, and, in doubtful cases, the antecedents of the patients and trial of the iodide treatment will ordinarily indicate their nature.

The most common, but not constant, initial phenomenon is cephalalgia, which is frontal, occipital, or parietal, very intense, piercing in many cases, often worse during the night, and accompanied frequently by vertigo and mental dulness. This pain is at times intolerable, so much so, that the patients become as if insane, or, on the contrary, they may be plunged into a stupor resembling coma. The cephalalgia may last for a long time with more or less intensity before any other symptom shows itself. If syphilis has been suspected from the antecedents of the patient, and iodide of potassium has been given with the result of lessening the pain or causing it to cease, the diagnosis is assured. During the cephalalgia, the patients often experience a diminution of their intellectual faculties—an unaccustomed inactivity—impossibility of transacting business, or of making the most simple calculations, forgetfulness of certain words, or of their actions of the day before, an alarming loss of memory, etc. Different forms of paralysis supervene. They commence nearly always, by being very limited, and are perceived either in loss of movement or sensation. The nerves at the base of the cranium are those the most frequently attacked. The paralysis of muscles supplied by the common oculo-motor nerve produces, for example, external strabismus, diplopia, impossibility of raising the eyeball, relaxation of the levator palpebræ superioris, blepharoptosis, mydriasis by relaxation of the ciliary muscle, with moderate dilatation and immobility of the pupil.

Paralysis of the superior oblique of the eye, the only muscle which is dependent upon the pathetic nerve, will lead to a diplopia. The diminution of the sense of taste, and even its complete abolition, the loss of the sense of smell, the diminution or the loss of hearing have been noted in connection with lesions of the bones, of the meninges, of the brain, or of the nerves of special sense. The disturbances of vision are exceedingly variable, and depend upon the seat of the lesion—whether it is localized in the optic tracts before their intercrossing, at the optic chiasm, or upon the optic nerves in their intra-

osseous canals. Subjective symptoms are observed, such as muscæ volitantes, circles of fire, etc., the sight of only a portion of objects, an incomplete or total loss of vision. These phenomena are benefited and very frequently cured at their commencement by the iodide of potassium. The partial paralysis sometimes first shows itself in a limb—in the lower extremity of one side for example, and after a certain interval is followed by transient or permanent amelioration, if the iodide of potassium employed in time has produced its curative action; if the lesion, instead of being checked, continues its progress, complete hemiplegia may supervene. This is generally progressive, slow at the commencement, with incomplete aphasia, especially if the paralysis be on the right side.

[In an elaborate memoir founded on a careful study of seven cases of early syphilitic affections of the nerve centres, Mauriac arrived at the following conclusions, most of which have been accepted by both syphilographers and neurologists:—

1st. Syphilis may attack the nerve centres at a period not far removed from the date of infection.

*a.* The early, "precocious," cerebro-spinal syphilitic diseases appear during the period of greatest activity of syphilis, *i. e.*, during the first two or three years.

*b.* They are the most frequent visceral complications of this stage.

*c.* They are also the most dangerous, and their gravity has no relation to their date of appearance, the earliest being as formidable as those which supervene later.

2d. They may take any of the forms of disease which are produced at any time by the effects of syphilis upon the nervous system.<sup>1</sup>

*a.* There are, however, some symptoms which seem to predominate, the most frequent of all being complete hemiplegia.

*b.* Right hemiplegia complicated with aphasia is the most common.

*c.* The paralytic outnumber the convulsive or epileptic forms.

*d.* They are characterized by an absence of systemization.

*e.* They affect the spine much less frequently than the brain.<sup>2</sup>

[<sup>1</sup> R. W. Taylor has recorded (*The Journal of Nervous and Mental Diseases*, Jan. 1876) several interesting cases of early cerebral syphilis. In one of them hemiplegia appeared in the fifth month after infection; the others were characterized by subacute meningitis, which also developed within the first year.]

[<sup>2</sup> Homolle gives (*Le Progrès Méd.*, Jan. 1, 1876) a case of subacute myelomeningitis with paraplegia occurring at the end of the second year of syphilis. The autopsy revealed softening of the lower portion of the cord and a thickening of the arterial coats. The vessels, however, were pervious. Dr. Keyes, in commenting

3d. Hyperplasias of the pia mater and the cortical layer of the brain, may be either circumscribed or diffused, but are usually of the former variety, and together with characteristic alterations of the sylvian arteries and consecutive softening of the brain substance constitute the special lesions of these diseases.

4th. In the majority of these cases the initial lesion and the subsequent mucous and cutaneous symptoms have been mild.

a. The general development of the constitutional disease is not prevented or retarded by the occurrence of these nervous affections.

b. The treatment is the same as would be proper at the particular stage of the disease at which the nervous phenomena appear, modified as to dose, combination with other agents, etc., only by the special symptoms of the case in question.]

These cases of hemiplegia are not accompanied, like those of copious hemorrhages, or of apoplectiform softening, by a total loss of consciousness. Patients preserve, on the contrary, to a great extent their consciousness, as is the case in certain forms of cerebral softening, and the paralysis affects only the power of motion.<sup>1</sup>

The paralytic phenomena which have just been considered, or one of them, preceded by cephalalgia, terminating in convulsions, or in a comatose condition and death, constitute a common form of syphilitic cerebral disease (paralytic form of Lancereaux). But in other observations, only hebetude and the paralysis of the insane are observed during the entire duration of the malady. In other cases it is aphasia which predominates, the impossibility of finding other expressions than one or more words, coexisting with a certain relative intelligence, sometimes even with the possibility of writing. Aphasia is at times intermittent, returning by exacerbations, with a gradual or sudden weakening of the motor power of the right side (Mauriac). This aphasia is connected with gummata occupying, as in the case of Bour-

on this case, remarks that this form of syphilitic spinal disease differs pathologically from tertiary disease of the same region; in the latter there is always either gummy tumor, sclerosis or disease of the bony canal, with or without meningitis or arterial lesions.]

[<sup>1</sup> Buzzard has recorded (*The Lancet*, June 7, 1879) several cases of "prolonged somnolence," associated with hemiplegia, and resulting in recovery. The condition was simply one of stupor and drowsiness, from which the patient could be readily aroused. Heubner attributes this somnolency to the narrowing of a number of arteries, in consequence of which there is congestion and defective oxidation, and accounts for the temporary recoveries by the possibility of the nervous substance becoming gradually accommodated to the change of vascular tension.]



ceret and Cossy, the posterior part of the second and third frontal convolutions, or with the limited softenings following gummata and thromboses of the middle cerebral arteries. Finally, along with several other phenomena connected with the intelligence or the power of motion, convulsive symptoms often predominate—veritable attacks of epilepsy characterized by facial grimaces, twisting of the neck, clonic convulsions, and biting of the tongue. However, these epileptiform attacks, which follow syphilis, and from which the patient has never suffered during infancy, do not present the same characteristics as idiopathic epilepsy. The initial cry is rare, the convulsions are often limited. The loss of consciousness is not always absolute; intelligence is lost gradually, and the attacks leave after them lethargy and incomplete paralysis, which end by becoming absolute. In place of convulsive attacks a simple trembling has been noted.

[Charcot believes partial syphilitic epilepsies to be among the most common developments of cerebral syphilis. He describes as follows<sup>1</sup> the characteristic symptoms of the disease:—

Partial epilepsy, whether of syphilitic origin or not, generally commences by convulsive movements of the face or arms on one side of the body. An attack commencing in the lower extremity must, therefore, be regarded as exceptional. In some cases, moreover, the disease assumes the appearance of ordinary epilepsy, for the patient suddenly falls down in an unconscious state, followed by convulsions, which are more or less general in character. The imminence of the latter is constantly indicated by severe headache, confined to a limited spot on the side of the head. The pain quickly extends to the face and neck on the same side; but there are exceptions to this general rule.

Another point to be noted is that the attacks very frequently set in towards evening. The manner of attack, and the succession of convulsive symptoms, are conformable to the rules established by Dr. Hughlings Jackson. That distinguished physician has observed that when the convulsive movements of partial epilepsy, commencing in the arm, tend to become more general, they attack the face before they extend to the leg. If the irregular movements have commenced in the face, the disease extends to the upper extremity first, and then to the legs. Lastly, if it be the lower extremity which is first attacked, the disorder of motor power is seen in the arm first, and then in the face.

[<sup>1</sup> Medical News and Library, April, 1877.]

Circumscribed gummous inflammation of the pia mater appears to be the pathological condition most frequently connected with partial syphilitic epilepsy. This has been pointed out by Todd, Echeverria, Lancereaux, and some other writers. It is, however, certain that several other forms of cerebral disease may be determined by this same gummous meningitis. The variations, as we have good reason to believe, depend on the points of cerebral surface attacked. If we accept the theory founded on recent investigations, the gummous patches in partial syphilitic epilepsy should be found on, or very near to, the ascending frontal or parietal convolutions. This has not yet been established by actual observation, but Prof. Charcot feels confident that the proof is only delayed. So long as the disease has not become inveterate—so long, in a word, as there are intervals of freedom from attack, we are entitled to conclude that the cerebral substance has not been disorganized by the gummous inflammation of the meninges.

From a record of 274 cases of epileptiform seizures of an undoubted syphilitic origin, Dr. Thomas Stretch Dowse summarizes his observations very briefly as follows:<sup>1</sup> The age of the patient is an important guide. Should a man or a woman be attacked by epilepsy between thirty and forty years of age, without any hereditary predisposition, or a previous seizure, then a syphilitic cause may be apprehended. And, apart from this, if between the attacks there is some degree of mental derangement, our basis for a diagnosis is greatly simplified, and it is even more so if there be a paresis more or less profound, localized, or unilateral, but generally passing off after the epileptiform seizure. The reflex processes are rarely if ever completely absent. The iris may contract under the influence of a strong light; the lids close when the conjunctiva is tickled, and a state of semi-consciousness, rather than profound coma, is a prominent feature from first to last.

The stages of the attack are ill-defined, and merge one into the other. The universal tonic spasm, with thotonism, rarely presents itself. Pallor, rather than cyanosis, is the facial exponent, and the duration of the fit is protracted to many hours, with intervals of wandering, delirium, and excitement. Foaming at the mouth is less prominent than a profuse flow of saliva, and all sorts of cries are associated with the seizure; but they are rarely so exalted as Romberg expresses it, "shrill and terrifying to man and beast."

[<sup>1</sup> The Practitioner, March, 1877.]

And, lastly, in reference to albumen in the urine. Considerable attention has been given to this point, but it has not been found in any but a few of the cases; but epileptoid seizures, associated with albuminoid syphilis, and a plentiful secretion of phosphatic albuminous urine are not uncommon.

M. Fournier says:<sup>1</sup> 1. Every case of epilepsy appearing for the first time in an adult subject of known syphilitic antecedents should be attacked with specific treatment. 2. Every case of epilepsy happening under the same conditions in a person of uncertain or denied syphilitic antecedents, should still at least, if not plainly explicable by some other cause, be submitted empirically to specific treatment. In obeying these two precepts marvellous successes may be sometimes obtained.

It is denied, and it seems to us with great justice, that syphilis ever causes epilepsy without first producing some structural alteration, the most frequent lesion being chronic meningitis.

Gowers asserts,<sup>2</sup> that although attacks of syphilitic epilepsy closely resemble those of idiopathic epilepsy, they may be distinguished: 1, by the age of the patient; they usually commence after twenty-five years of age, and, therefore, at a period of life at which epilepsy less commonly begins; 2, by the persistent headache which commonly precedes their occurrence, and exists during the whole of the intervals between, and not merely after the attacks; 3, by the frequent association of optic neuritis; 4, by the coincidence of paralytic symptoms; and, 5, by the association of early, and often progressive, mental disturbance.

We have seen during the last year three cases of syphilitic epilepsy, occurring in one case twelve months, in another eighteen months, and in the third two years after the contraction of the disease. The most interesting point which was common to all these was the development very early in the secondary period, as the most prominent and annoying symptom, of severe headaches. These yielded after some time to vigorous specific treatment, but returned at short intervals and on slight provocation. In one of these cases, the patient was confined to bed with a headache, which lasted for nearly ten days, was agonizing at night, yielded only to large doses of morphia, and only very slowly subsided under active mixed

[<sup>1</sup> L'Union Médicale, 1876.]

[<sup>2</sup> Hill and Cooper, *op. cit.*, p. 221.]

treatment. The temperature varied from 100° F. to 102° F.; the tongue was dry, furred, and cracked, and the condition was decidedly typhoid in its character. No sensorial or other cerebral disturbance was noticed, and no convulsions recurred. The early appearance of obstinate headache may probably be considered an indication that the special dangers which the patient has to run in the future are those connected with some of the developments of cerebral syphilis.]

There exist observations on cerebral syphilis in which the symptoms have approached very nearly to general paralysis.

[It is very important in many cases of suspected cerebral syphilis, associated with symptoms of insanity, to distinguish between the non-specific general paralysis of the insane and the paralysis not infrequently found in the later stages of syphilis. The importance of making the diagnosis, if possible, rests upon the influence which it will exert in both prognosis and treatment, the syphilitic affection being often relieved, or apparently cured, by the employment of mercury and the iodides, while the other affection is incurable. Dr. W. G. Mickle in a paper upon cases of this character thus details the points by which he believes syphilitic paralysis may be recognized:—

“ 1. Distinct history or symptoms of syphilis. 2. Preceding cranial pains, nocturnal and intense. 3. Exaltation less marked, less persistent, and perhaps less associated with general maniacal restlessness and excitement than in most cases of general paralysis. 4. Sometimes by such complications as palsies of one or several cranial nerves, or hemiplegia, paraplegia, etc., having the character and course of syphilitic palsies. 5. The greater frequency of optic neuritis, early amaurosis, deafness, local anæsthesia, vertigo, or local rigid contraction. 6. The affection of articulation is paralytic rather than paretic, and usually speech is not accompanied by any facial or labial tremors. 7. By cerebral or spinal meningitis, or pachymeningitis. 8. By the variety of the motor and sensory symptoms, their capricious association or succession, and transitory character, and by the absence of the general progressive muscular paresis of the other disease. 9. By the effect of anti-syphilitic treatment.”<sup>1</sup> Dr. Mickle also states that in general paralysis the faradic contractility of the muscles of the

[<sup>1</sup> British and Foreign Med-Chir. Review, July and Oct. 1876, April, 1877. Abstract by Dr. E. C. Seguin.]

extremities becomes considerably and progressively lessened, while in syphilitic cases it is normal, or not much impaired.<sup>1</sup>

Dr. C. R. Drysdale<sup>2</sup> believes that general paralysis of the insane is never caused by syphilis, although he recognizes the existence of syphilitic insanity in the form of mania, melancholia, or dementia.

He adds: "It is true, perhaps, that many patients with general paralysis have had syphilis. Mendel speaks of ninety cases out of one hundred and seventy-six; but there are many reasons why it is difficult to admit that there is any relation of cause and effect in these two diseases. General paralysis has very marked characters; it is almost confined to the male sex, scarcely ever seen before the age of thirty-five, and, in the male, it almost always affects the middle classes, whilst, in women, it almost always is seen amongst the poor. Syphilis has no preference for either age or sex, and when the cranium of a patient with cerebral syphilis is opened, we never find (as in the general paralytic invariably is the case) generalized meningitis. Cerebral syphilis presents special lesions. The affection of the cranium in general paralysis never goes beyond the meninges; whilst in the case of gummy tumor commencing in the meninges, it will extend and attack either the dura mater, the bones, or the cerebral pulp itself. If it has lasted long, we cannot say where it began.

[<sup>1</sup> A table compiled from a lecture on insanity, by Dr. E. C. Seguin (Hospital Gazette and Archives of Clinical Surgery, September 12, 1878), contrasts the two diseases as follows:—

GENERAL PARALYSIS OF THE INSANE.	SYPHILITIC GENERAL PARALYSIS.
Prodromic stage.	Absent.
Exalted notions, numerous and varied, and relatively exalted according to position in life.	Rare or absent.
Speech is tremulous and jerky.	Speech is thick.
Tremor of hands and lips.	Absent as a rule.
Preservation of strength.	Paresis or actual paralysis.
Pupils are apt to be contracted.	Apt to be open or wide.
No involvement of cranial nerves.	Palsy of the third or of other cranial nerves.
No headache.	Headache nocturnal.
Transient aphasic attacks.	More serious aphasic attacks.
Spontaneous remissions.	Progressive, except under treatment.
Abnormal cravings or appetites.	None.
Satyriasis.	Diminished virility.
Elevation of temperature.	Usually none.
Irritation and incoördination, usually without true paralysis.	Actual paralysis.]

[<sup>2</sup> A paper read before the British Medical Association, 1880.]

“Treatment again is of great service in many cases of cerebral syphilis, sometimes restoring apparently hopeless cases. When general paralysis exists, all treatment is unavailing. Specifics have no power at all against a meningitis, which, if it were syphilitic, would surely be affected by them.

“Many cases, too, are on record, where syphilis has coexisted with general paralysis of the insane. In such cases specific treatment can remove an exostosis, or a paralysis of the motores oculi, or a gummy tumor in the palate; but it leaves the other affection untouched.”

Hence his conclusion is that syphilis has nothing to do with the general paralysis of the insane.

M. Ball<sup>1</sup> gives a *résumé* of Fournier's views on insanity attending syphilis, which, according to that observer, presents itself either as a syphilitic dementia, as mania, or as general pseudo-paralysis.

In syphilitic dementia, the patient's temperament undergoes a radical change. His intelligence is clouded and his conduct strange. He becomes moody and taciturn. Labor is fatiguing and intolerable. His memory fails, though judgment often remains. Loss of memory may either be sudden or complete, or gradual and imperfect. The patient becomes careless as to his personal appearance, and very irritable. This condition may be designated as a precocious senility of the mind, differing from senile dementia, however, in being curable.

Syphilitic mania may be suddenly developed or present prodromal symptoms. The latter, when present, consist in a peculiar excitement, feverish activity, and in unusual loquacity. These prodromata terminate in delirium, which may manifest itself in several forms. Sometimes it is active and attended by complete insomnia. The patient becomes destructive, and suicidal tendencies show themselves. The delirium assumes the form of hypochondriasis or syphiliphobia. The patient believes himself persecuted. The delirium is impulsive.

General syphilitic paralysis. This variety of the disease begins with mental hebetude and with incoherencies of speech. The speech may become embarrassed, and stuttering, and local paralyzes, particularly those of the eye, soon follow. The diagnosis is based upon the concomitant symptoms, as headache, alopecia, and gummata, but particularly upon partial paralyzes. Strabismus is another valuable diagnostic symptom.

[<sup>1</sup> *Annal. et Bull. de la Soc. de Médecine*, July, 1881.]

The prognosis is favorable if the case receives prompt treatment, although the disease sometimes terminates fatally. The treatment must be energetic and thorough. At the beginning the mixed treatment is indicated: 5 grms. (75 gr.), at least, of the iodide of potassium should be exhibited daily, and inunctions also employed. If mercury is not well tolerated, recourse may be had to the chloride of gold.]

After a rapid survey of these syphilitic encephalopathies, it is seen that this is a malady which has not a constant and regular *form*, and of which no one symptom is invariably present. In one case they nearly all will be found united, as in the observation of Coÿne and Lépine, given on page 344; in another case, no other symptom but cephalalgia will present itself, as in the case of Peltier and Coÿne (see page 350), where sudden death took place without any other phenomenon than pain. Nevertheless, in this last case there was a gumma the size of a small walnut in the cerebellum.

[Althaus has observed<sup>1</sup> syphilitic affections of the nervous system most frequently in persons between twenty and thirty years of age; he regards as predisposing causes the neuropathic diathesis, hereditary tendencies, excessive mental strain, sexual excess, injuries, depressing emotions, and incomplete treatment.<sup>2</sup> He divides these affections into three forms:—

1. A congestive or hyperæmic form—characterized, when allowed to go on, by the general symptoms of paralysis of the insane, followed by aphasia, hemiplegia, paraplegia, etc.

In some cases the cervical sympathetic nerve has been found in a state of degeneration, and it is probable that disease of the superior ganglion of this nerve may have an important influence in the production of the repeated attacks of hyperæmia.

2. A cerebral tumor—a gumma, either hard or soft. There are then, nocturnal headache, sleeplessness, epileptiform attacks—which are the most prominent symptoms, the various phenomena produced by involvement of the cerebral nerves, etc.

3. Disease of the arteries—when this involves the basal sphere of

[<sup>1</sup> Medical Times and Gazette, Nov. 10, 1877.]

[<sup>2</sup> Dr. Dowse believes that there are two prime factors which tend to induce syphilis to expend itself upon the brain and nervous system, the first being hereditary predisposition; the second, previous inflammatory changes due to excesses, exhausting diseases, or traumatism. The Medical Press and Circular, Feb. 27, 1878.]

cerebral nutrition, comprising the vertebral, basilar, and carotid arteries, the circle of Willis, etc., in which there is little anastomosis, the result of occlusion of the vessels is some form of necrobiosis, red, yellow, or white softening followed by hemiplegia.

In the cortical sphere, plugging of the vessels is not so directly dangerous, as the peripheral parts may still be supplied with blood by anastomosis from the pia mater. Still the sudden establishment of collateral circulation by increasing the vascular pressure often gives rise to the temporary apoplectic seizures which are so common in this form of syphilis.<sup>1</sup>

Heubner<sup>2</sup> also divides cerebral syphilis into three distinct clinical groups, which, however, have certain symptoms in common, the most frequent of which are headache and sleeplessness.

Of the three fundamental types which he lays down, the first consists in physical disturbances, with epilepsy, incomplete paralysis, and a final comatose condition, usually of short duration.

This epileptic form is in nearly all cases found to be due to a gum-mous growth in the pia mater of the convexity of one of the cerebral hemispheres, either limited and superficial, or involving more or less of the cortex, and forming a distinct tumor. Out of twenty-six cases observed by Heubner, where the morbid process was of this form, epi-

[<sup>1</sup> Dr. C. C. Gray (Proceedings of Med. Soc. of County of Kings, April, '79) thus alludes to these points: "The morbid changes are of two kinds. There may be diffuse infiltration or tumors of the dura mater and subarachnoid spaces, implicating the surrounding structures in their growth; or there may exist disease of the arteries at the base of the brain. The arterial degenerations are of the arteries composing the circle of Willis, and especially the internal carotids and their branches. The specific deposit begins between the inner coat of the vessel and the endothelium, narrowing the calibre of the blood-channel, or even absolutely obstructing it. The lesions are thus manifold in their consequences. The new formations and the infiltrations are irritative to the membranes and the nervous structures beneath, or they may be destructive to the gray matter of the convolutions, by causing the death of cells upon whose existence the function of the part depends; whilst the constriction or occlusion of the vessels diminishes or cuts off the aliment of the tissues, and correspondingly devitalizes them. Interference with the blood-current in the internal carotids and their offshoots, the chosen site of specific arterial alteration, is peculiarly disastrous; since the middle cerebral or Sylvian arteries, springing directly from the internal carotids, supply the corpora striata and optic thalami with branches which are terminal, so that there is no anastomosing and collateral circulation at hand to relieve these basal ganglia of the evils attendant upon a blockade of the blood-supply through their sole nutrient vessels."]

[<sup>2</sup> Ziemssen, Cyclopædia of Medicine, vol. xii.]



leptic or convulsive attacks occurred twenty times; whilst in nineteen other cases, where the growth was limited to the white substance or the base of the brain, this symptom was found only twice. Similar observations were made by Jaksch, and these records entirely agree with the experience of Wilks, Hughlings Jackson, and others.

The second form described by Heubner is the apoplectic, characterized by "genuine apoplectic attacks, with succeeding hemiplegia, in connection with peculiar somnolent conditions occurring in often-repeated episodes, frequently phenomena of unilateral irritation, and generally at the same time paralysis of the cerebral nerves." The symptoms vary greatly in character and degree.

It is in this form that the peculiar affection of the cerebral arteries, leading to their more or less complete obstruction, is found, and upon this change appear to depend the apoplectic attacks and the hemiplegia.

The third form described by Heubner resembles very closely ordinary general paralysis of the insane. It differs, however, in the comparative infrequency with which delusions of exaltation are observed, and in the fact that exacerbations in the psychical symptoms often coincide with the outbreak of fresh syphilitic eruptions, or other local affections of bones, throat, nose, etc. Later on, transient and irregular paralyzes are observed, which come and go in a very rapid manner. Still the distinction from some cases of paralytic dementia is not easy to define.

Mr. Hutchinson says:<sup>1</sup> The occlusion of an artery and subsequent softening of brain-substance are one thing; a gumma of the dura mater is another. They are different in their symptoms, course, and progress under treatment. If a man be hemiplegic from softening of the corpus striatum consequent on arterial occlusion, there is but little hope that he may recover, however vigorously the iodide be pushed. It may prevent further arterial disease, but can not repair the brain. In cases of gumma, the hopefulness of treatment is, on the other hand, indefinite, and the triumphs of the remedy are matters of everyday experience. In many cases, too, the differential diagnosis can be made with fair accuracy. If we say that we recognize three forms of cerebral disease—one in which the symptoms result from arterial occlusion, one from the irritation of gummata, and one from periosteal thickening—we may assume that sudden attacks of paraly-

[<sup>1</sup> Medical Times and Gazette, Feb. 17, 1877.]

sis denote the one, that the second has all the symptoms common to cases of tumor, and that the severe pain and headache go with the last. To each of the three conditions a group of special symptoms might easily be assigned. We are surely advanced past the stage when it was necessary to mention all the symptoms which occur severally in each, as if all were to be expected in the condition known as "cerebral syphilis." No doubt in some cases all three lesions are present together, and in many two of them; but this ought not to prevent us from trying to discriminate, when, as is the case in most instances, discrimination is practicable.

He is not sure that we shall not be obliged, as knowledge advances, to admit yet a fourth group of cases—those namely, in which the symptoms are those rather of progressive and slow atrophy than of new growth or inflammation. He suspects that there are such cases, and that they are far less amenable to treatment than any of the others.

A further consideration of this most interesting subject would lead us beyond the scope of the present volume, but the constantly increasing importance which is being given to syphilis as a factor in the production of cerebral disease has led us to supplement the description of the author with those of the foregoing distinguished authorities.]

A word should be said regarding the symptoms which correspond to the syphilitic lesions of the spinal cord. If only authentic observations, and those in which the autopsy has confirmed the nature of the disease are considered, there is but little to do; but there are recorded, however, a certain number of paraplegic cases which have been improved or even cured by the iodide of potassium, in which, of course, anatomical confirmation was wanting. The phenomena observed in lesions of the spinal cord are, in the first place, pain more or less intensified, a rachialgitis limited to the diseased part of the marrow or extended in a circle, and a paralysis of the inferior extremities, of the bladder, or the superior extremities, according to the seat of the lesion.

[The syphilitic affections of the spinal cord are much more rare than the corresponding diseases of the brain and cranial nerves, and but few post-mortem examinations have been recorded. Circumscribed gummata of the cord are not so common as a diffused gummous infiltration of the meninges and lymphatic spaces.

Althaus writes:<sup>1</sup> Where the membranes grow together with the

[<sup>1</sup> Medical Times and Gazette, Nov. 10, 1877.]

periosteum of vertebræ and the surface of the cord, there are generally proliferation of the neuroglia and wasting of the white columns. Some cases, in which the symptoms of acute ascending spinal paralysis are observed during life, seem to be owing to hyperæmia simply, as no real structural alterations of the cord have been discovered.

In this latter case the symptoms generally commence at an early period—viz., in the first year,—and are accompanied by the usual early manifestations of constitutional syphilis. The first symptom is sudden paraplegia, with incontinence of urine and fæces. There is no pain in the spine, and no anæsthesia of the limbs. Decubitus soon becomes developed, and the patient dies within a few weeks from the beginning of these symptoms.

More frequently, however, paralysis comes on in the later periods of the disease, after many other symptoms have existed for a long time. There is muddy pallor of the skin, and a disagreeable smell about the patient, who is generally feeble and in a state of constant *malaise*. He experiences pain at different points of the spine, which is increased by pressure; and also pain, pins and needles, numbness and stiffness, in the lower extremities. These symptoms come and go, and then there is all of a sudden an attack of paraplegia or hemiplegia. Where the seat of the disease is in the lower portion of the dorsal cord, there is also paralysis of the sphincters. If the case is not well treated, the paralysis remains stationary, and ultimately decubitus is developed, followed shortly by a fatal result. By proper treatment, however, the patient may get well in a very short time.

Where the cervical spine is affected, matters are more serious. There are then not only paraplegia and paralysis of the sphincters, but also of the thoracic and abdominal muscles, the upper extremities, and the diaphragm. Asphyxia from paralysis of the phrenic nerve, or from pneumonia, generally carries the patient off in a short time, unless, as we have seen it, the remedy proves stronger than the disease. But in cases of this class we cannot look forward to perfect recovery, as the posterior columns of the cord generally become disorganized beyond thorough repair, and a state resembling locomotor ataxia may remain for life.

When growths do occur, they usually involve the membranes, although they may come from the substance of the cord.

Acute and chronic myelitis, meningitis, either with or without ver-

tebral disease, and sclerosis may also result from syphilis. The symptoms of the former do not differ from those of the ordinary idiopathic diseases; those of the latter will be presently considered.]

Fournier has recently pointed out a number of syphilitics affected with locomotor ataxia, and he has described syphilitic locomotor ataxia.

[Of the many disputed points which, a quarter of a century ago, engaged the attention of the profession, but which the progress of medical science, and especially the increased frequency and exactitude of pathological research, have effectually disposed of or reconciled, none are of greater interest than those relating to that most distressing and intractable of maladies, locomotor ataxia. The differing or opposing views which then existed, have been gradually subjected to a process of critical analysis, by means of which much that was doubtful or entirely false as regards the site and character of the essential lesion and the interpretation of the various symptoms has been rejected, the disease has become capable of accurate definition and classification, and its recognition by the general practitioner in one of its several stages is now a matter of daily occurrence.

With its symptoms and pathology we need not long delay. The constant presence, as the specific lesion of the malady, of a hyperplasia of the neuroglia of the posterior columns of the spinal cord, followed by atrophy and degeneration of the nerve elements or, in other words, of spinal sclerosis, most marked below, but often advancing gradually until the brain is reached, is now universally admitted. The symptoms, first of irritation of the posterior or sensory spinal nerves, the fatigue after moderate exertion, rheumatic or neuralgic pains, abnormal sexual impulses, vesical irritability, cutaneous hyperæsthesia, etc., followed by those of temporary or permanent paralyses of sensation, absence of the patellar reflex, anæsthesia of the skin, impotence, incontinence of urine, amaurosis and deafness, and finally by the characteristic loss of muscular co-ordination without paralysis, the staggering, uncertain gait, the inability to maintain equilibrium, the dependence upon the sense of sight for recognition of position, all these are, as has been said, well-recognized evidences of the disease. Their association with and relation to the sclerotic condition are also so unmistakable in the light of our present knowledge of the physiology of the cord that they require no comment.

The possible causes which may produce the sclerosis, and to which it has been assigned, are very numerous, the principal being heredi-

tary tendency, previous spinal shock, injury, or inflammation, over-exertion, rheumatism, gout, exposure to cold or wet, sexual excess, alcoholism, scrofula, and syphilis.

It may be said, however, that, with possibly one exception, no such definite association has yet been shown to exist between locomotor ataxia and any of these conditions as to furnish satisfactory reasons for considering them as usually related, or as to supply reliable indications for treatment.

The views taken by most authors as to the probable cause and termination of any particular case are exceedingly grave and discouraging, but they nearly all agree in making an important exception in favor of ataxia of syphilitic origin.

This is, of course, what might be expected from the well-known amenability of syphilitic lesions to properly directed treatment, whenever such treatment is applied before actual destruction or disintegration of tissue has taken place.

It would thus seem that the point of chief importance in the future study of locomotor ataxia, that which overshadows all others in its practical value, is the relation of this disease to syphilis. In its non-specific varieties it is admitted by the majority of authors to be but little if at all benefited by treatment, while, on the other hand, those cases in which the association with syphilis has been so distinct as to lead to the employment of specific treatment have been found to do well.

If, therefore, it can be shown that in the *majority* of cases ataxia is of syphilitic origin, and that the spinal changes upon which it depends are due to previous syphilis, the influence of the application of these facts to prognosis and to treatment becomes evident.

Here, however, excellent authorities differ, and we feel that the subject is of sufficient importance to justify an extended *résumé* of the various opinions.

In an article on Syphilis and Locomotor Ataxia, by W. R. Gowers,<sup>1</sup> he refers to a paper read at the Bath meeting of the British Medical Association, in which he had expressed the opinion that syphilis must be regarded as a cause of locomotor ataxia in one-half of the cases of that disease, and brought forward evidence in support of this assertion. During his investigations he had observed thirty-three cases of this disease. Of these cases, eighteen had a distinct history of constitu-

[<sup>1</sup> London Lancet, Jan. 15, 1881.]

tional syphilis, fifteen having had both primary sore and secondary symptoms, three secondary symptoms alone, the primary sore not having been recognized; five other patients had had the primary lesion, but no secondary symptoms. The remaining ten cases presented no history of a sore or constitutional symptoms. One of the latter had had a non-syphilitic rash, and five had suffered from gonorrhœa.

From further considerations, Dr. Gowers concludes that at least 50 per cent. of the cases of ataxia must be regarded as having syphilis for their essential cause. It may not, he thinks, have been the only cause of the disease; for example, sex possibly has some influence, "but the teaching of these facts, as far as they go, is that one-half of the patients with ataxia would not have this disease if they had not, at some previous period, suffered from syphilis."

In regard to the histological lesion, Dr. Gowers says: "The lesion in locomotor ataxia is, however, very different from those which are ordinarily caused by syphilis. It is a degeneration limited to a system of structure, and contrasts with the random distribution of ordinary syphilitic processes . . . and I can corroborate the statement of Westphal, that in cases which succeed syphilis, the lesion is precisely similar to that found in other cases. But theoretical considerations of this character must yield to facts. We know too little of any morbid agency thus to limit its possible operation to certain forms of effect, with which we happen to be familiar. Indeed, a study of the morbid changes which are universally admitted to be due to syphilis might make us hesitate in exclusions. In the falling of the hair after syphilis we have a change which no one hesitates to ascribe to syphilis, but which is very unlike its other consequences, and might almost be described as a true "degeneration of a system of structure."

"Other forms of degenerative diseases of the spinal cord, which occasionally follow syphilis, may also have a causal relation to it. It seems that one effect of constitutional syphilis may be to induce a neuropathic state in which certain degenerative diseases of the nervous system readily occur."

Erb, of Germany, has recently published<sup>1</sup> some important facts regarding the relation of syphilis to locomotor ataxia. They corroborate his previously published statements, and agree with the above views of Dr. Gowers. In one hundred consecutive cases of locomotor

[<sup>1</sup> Centralblatt für Med. Wissenschaften, London Lancet, 1881.]

ataxia, only twelve presented no history of a chancre or secondary syphilis. In seventeen cases the interval between the first symptoms of ataxia and the primary lesion was between three and five years; between six and ten years in thirty-seven cases; between eleven and twenty years in twenty-four cases, and more than twenty years in ten cases. To ascertain the truth of the objection that the large percentage of cases of ataxia with preceding venereal sores, or with constitutional syphilis, is due simply to the frequency of the latter, an investigation of the history of four hundred patients over twenty-five years of age, who were under treatment for diseases which were not suspected to have any relation to syphilis, was made by Erb. He found a history of chancre only, in 11 per cent.; a history of secondary syphilis, in 12 per cent.; while among the ataxic patients, taken from the same social class, the proportion was no less than 88 per cent. These figures, Erb thinks, justify the assumption that there must be an etiological connection between syphilis and locomotor ataxia.

According to Rosenthal, locomotor ataxia at times develops after syphilis and as a result of it.

Grasset, from whose work we have abstracted the following, gives<sup>1</sup> the views of the most recent writers in regard to locomotor ataxia and syphilis. He says: Fournier<sup>2</sup> has forcibly called attention to syphilitic locomotor ataxia, which has no characteristic symptoms, but presents those of common ataxia.

Although the lesion is not characteristic, it is at least similar to the usual lesions (sclerosis) of syphilis. The disease occurs too frequently in old syphilitics to be a mere coincident. Thus, in 30 ataxic patients, Fournier found 24 times a previous syphilitic history; Féréol 5 times in 11 cases; Siredey 6 times in 10 cases. The non-success of anti-syphilitic treatment is due to the circumstance that its administration is begun too late, but that it frequently succeeds the following cases attest.

Duchenne had, in 1858, drawn attention to the frequency of syphilis in progressive locomotor ataxia; then Greppo<sup>3</sup> reported a case of ataxia of the inferior extremities cured by anti-syphilitic treatment; still later Moore<sup>4</sup> published a similar case which recov-

[<sup>1</sup> *Traité pratique des Maladies du système nerveux*, Paris, 1881.]

[<sup>2</sup> *Anal. in Rév. des Sci. méd.*, ix. p. 228.]

[<sup>3</sup> *Gaz. Méd. de Lyon*, Aug. 1859.]

[<sup>4</sup> *Dublin Quart. Journ.*, 1866.]

ered after the use of iodide of potassium; Dreschfeld<sup>1</sup> speaks of an ataxic patient affected with syphilis and cured almost completely by the same remedy. Later appears the work of Fournier of which we have spoken, and, finally, Drysdale<sup>2</sup> has in a recent work confirmed this etiology. Like Fournier, he has seen this malady, said to be incurable, arrested and cured by the administration of iodide of potassium in large doses. Wiltshire and Bloxam strongly support his opinion. The latter has witnessed, at the Charing-Cross Hospital, several definite recoveries of locomotor ataxia. Albert Reder<sup>3</sup> has recorded, under the name of *tabes syphilitica*, the radical recovery by specific treatment of a syphilitic patient who had contracted his syphilis fourteen years previously. He presented only symptoms of disordered sensation and slight want of co-ordination of the inferior extremities.

Finally, Caizergues,<sup>4</sup> from whom the above references are taken, has published three new cases of syphilitic locomotor ataxia. In one, the beginning of the disease was manifested by motor symptoms; in another by symptoms of pain; and in the third by head and ocular symptoms.

Chauvet has denied the existence of *tabes syphilitica*. He believes, that syphilis never causes the development of a primary sclerosis of the posterior columns, but Grasset does not agree with him.

That syphilis produces diffused lesions in the brain, does not prove that it may not develop systematic lesions of the spinal cord.

Grasset has recently made an autopsy of one of the patients whose cases are reported by Caizergues in his thesis; the syphilitic etiology was manifest; the symptoms of locomotor ataxia complete in the inferior extremities; there were besides some symptoms of general paralysis (ambitious delirium). He found, at the autopsy, in the brain diffused lesions of meningo-encephalitis, and in the spinal cord very remarkable systematic lesions, which, below the brachial enlargement, occupied the entire space between the posterior cornua, and above the enlargement was limited to the columns of Goll.<sup>5</sup>

Here the clinical demonstrations should outweigh the evidences of pathological anatomy.

[<sup>1</sup> The Practitioner, 1875.]

[<sup>2</sup> Med. Soc. London, April, 1877.]

[<sup>3</sup> Vierteljahrs., 1874, p. 29.]

[<sup>4</sup> Des myelites syphilitiques, Cases IV., V., and VI., p. 72.]

[<sup>5</sup> See the communication by Estorc upon this case to the Congrès de Reims, Aug. 1880.]



The posterior columns may also be secondarily affected. Broadbent has remarked the frequency of this lesion. Homolle and Charcot have seen them distinctly changed in consequence of a diffused myelitis.

The columns of Goll may also be affected under the same circumstances. Homolle reports a curious and unique example from an anatomical point. There were clinically neither ataxia nor tendency to move backwards. Moore has seen a case of ataxia with a tendency to backward movement, in which a lesion of Goll's columns may be supposed, from analogy with Pierret's case, which we have elsewhere referred to.

Finally, we meet with some ataxias, certain forms of general spinal paralysis; Caizergues cites an example.<sup>1</sup>

Dr. Julius Althaus, in a paper published in the *London Lancet*,<sup>2</sup> analyzed a thousand consecutive cases of nervous diseases which came under his care in private practice; his object was to ascertain the part played by syphilis as a causative agent. Among these cases there were found thirty-two cases of locomotor ataxia. In twenty-nine of these thirty-two cases there was a history of syphilis; twenty-eight had had secondary symptoms; one had a soft chancre and bubo, but no secondary lesions. Thus giving the enormous percentage of 90.6 in favor of the syphilitic origin of tabes dorsalis.

Dr. Althaus then says: "An overwhelming numerical testimony is thus clearly exhibited in favor of the view that tabes is habitually preceded—I do not say produced—by syphilis. But the real question at issue is whether syphilis is the originator of ataxia or merely an accidental concomitant of it. . . . Other considerations, however, serve to show that ataxia is a disease, *per se*, which occurs without any syphilitic taint whatever, but which may, like so many other diseases, be imitated by syphilis under certain circumstances."

"1st. Tabes has unquestionably existed in Europe long before the first appearance of syphilis in this quarter of the globe."

"2d. Numerous cases of ataxia are on record, more especially as having occurred in women, where no syphilitic affection had preceded it."

"3d. Ataxia is not a common or inevitable consequence of syphilis, as, for instance, roseola or sore throat, but only appears to become

[<sup>1</sup> Des myelites syphilitiques, Case VII., p. 81.]

[<sup>2</sup> Note on the relations between syphilis and locomotor ataxia. Sept. 17, 1881.]

developed in the syphilitic, if they have neurotic constitutions, and if other causes, such as accidents, excesses, and the influence of wet and cold, etc., have also been active."

"4th. Treatment by iodide of potassium, even if used perseveringly and in large doses, is only exceptionally useful, even in cases with a pronounced syphilitic history, while the exhibition of nitrate of silver, ergot, the continuous galvanic current, nerve-stretching, and general remedial measures, which have the tendency to improve the condition of the central nervous system, but which have no influence on the syphilitic diathesis, are frequently productive of beneficial results."

"5th. The same disease, sclerosis, occurs in the lateral columns of the spinal cord, more particularly in young women who have never been exposed to venereal infection."

"6th. Syphilis may, however, imitate ataxia (to use an expression of Mr. Jonathan Hutchinson), just as it imitates iritis, lupus, rodent ulcer, and other diseases. Clinically the symptoms of syphilitic and non-syphilitic tabes appear to be identical. That ataxia should be so frequently associated with syphilis is probably owing, first, to the fact that syphilis, like masturbation and other excesses and irregularities, deteriorates the nutrition and power of resistance of the central nervous system; and second, more particularly to the specific tendency of the syphilitic virus, to lead to low forms of local inflammation, which, when once established, are apt to spread in certain definite paths. Where this kind of inflammation attacks the posterior root zones of the spinal cord, it will produce the clinical aspect of locomotor ataxia, being aided in its development and further progress by the natural tendency of spinal disease to invade minute symmetrical and homologous, anatomical, and histological portions of the organ."

Dr. Voigt<sup>1</sup> gives a list of 43 typical cases of tabes in male adults; 29, or 67 per cent., had had primary syphilis, and had undergone specific treatment; 8 presented no secondary symptoms. Of the remaining 14 cases of the 43, only 9 gave positive negative histories in regard to syphilis. In none was the cause of the disease referred to sexual excesses. Dr. Voigt here remarks, that locomotor ataxia occurs least often at that age when sexual excess is most common, and when the nervous system is least resistant. A comparison between syphilitic and non-syphilitic cases of ataxia is made: 1st. Age of occurrence. In both the maximum is from thirty to fifty years. 2d. First symp-

<sup>1</sup> Berliner Klinische Wochenschrift, 1881.

toms. In both most patients complain first of the lightning pains. 3d. Other symptoms. These are very similar, any difference depending upon the small number observed. Therefore, from a careful comparison of these points we find no distinct differences between syphilitic and non-syphilitic cases, and it is manifest that, so far as these cases prove, syphilis does not in *tabes* act as a specific disease-producing influence, but as a general influence, disturbing, perhaps, the nutrition of the organism generally, or of the nervous system particularly. In regard to the anti-syphilitic treatment of the disease, Dr. Voigt's results were not favorable, and therefore against the theory of syphilis being the cause of the affection.

While the statistics given point to a causal connection between syphilis and locomotor ataxia, Dr. Voigt does not think the question is more than *sub judice*.

Among those who do not consider syphilis as a cause of locomotor ataxia, we have several German writers, whose opinion, from their great prominence as investigators in nervous diseases, must not be overlooked. Westphal,<sup>1</sup> for example, in his study of this disease, found, in seventy-five cases of locomotor ataxia, only 18½ per cent. who gave a primary sore, and 14½ per cent. who suffered from secondary symptoms. Remak<sup>2</sup> found, in fifty-two cases, a history of syphilis only in one-quarter, and the statistics of Bernhardt,<sup>3</sup> which contain thirty-seven cases, give the same proportion.

Jullien<sup>4</sup> says, that, from a pathologico-anatomical point of view, he does not believe syphilis to have any direct influence in the etiology of *tabes dorsalis*. But from a clinical examination of this disease, he arrives at different conclusions. In the first place, syphilis is met with in nearly two-thirds of the cases, as antecedent to locomotor ataxia, and although syphilis is itself usually the result of debauchery, and precedes, in a great number of cases, a disease which is a frequent consequence of venereal excess, this coincidence, it must be admitted, affords much material for consideration. In the second place, ataxia is seen to develop at the same time, and to follow the same fluctuations as other lesions evidently syphilitic. Finally, with these patients, we are sometimes able, rarely it is true, to arrest the fatal course of the disease by means of the iodide of potassium or mercury.

[<sup>1</sup> Berlin Klin. Wochenschrift, 1880.

<sup>2</sup> Ibid.

<sup>3</sup> Ibid.]

[<sup>4</sup> Maladies Vénériennes, pp. 980, 981.]

In conclusion, Jullien says: There is complete disparity between the information furnished by pathological anatomy, and that obtained clinically, when both are impartially considered. We, therefore, withhold our judgment, until further investigations have more satisfactorily elucidated the subject.

Bumstead and Taylor<sup>1</sup> do not consider syphilis as a cause of locomotor ataxia, the latter being a lesion limited to the posterior columns of the spinal cord; while, according to these writers, the syphilitic lesions always originate in investing structures, and subsequently invade the cord. In regard to the similarity of symptoms, they say, the staggering gait, lack of co-ordination, darting pain and muscular spasms, caused by syphilis, may suggest locomotor ataxia; but the slow, definite progress of the latter affection, compared with the irregular grouping and uncertain course of syphilitic symptoms, renders the distinction clear.

Authorities upon both sides might still further be multiplied, but we shall now only be able to allude to the views of M. Alfred Fournier which he has recently expressed at great length with his customary accuracy and clearness of observation and induction.<sup>2</sup>

Having first stated that in his opinion, which he has arrived at after mature reflection, the existence of ataxia of syphilitic origin must be considered a demonstrated truth, he reviews as follows the objections which have been urged against this view. The existence of syphilitic ataxia is denied:—

1st. Because it has no peculiar symptoms. This he admits to be positively true. But he does not consider it a serious argument against the syphilitic nature of certain cases of tabes, for to require peculiar symptoms in order to admit the specificity of a morbid manifestation, will be to take from syphilis many symptoms which are by unanimous consent and well-known evidence duly accepted as pertaining to it. Syphilitic paraplegia does not present any special, still less any pathognomonic symptoms; in fact, it has not a single symptom peculiar to itself. This is also true of syphilitic epilepsy and of syphilitic hemiplegia. Indeed, cerebral syphilis, considered as a whole, after careful study, could not be said to furnish any symptoms which were not found in encephalopathies of another nature.

There are no peculiar symptoms claimed for syphilitic cirrhosis of

[<sup>1</sup> Venereal Diseases, Bumstead and Taylor, 1879.]

[<sup>2</sup> *Annales de Dermatologie et de Syphiligraphie*, 25 Janvier, 1882.]

the liver, for syphilitic nephritis, and for many other syphilitic visceral affections, why then for syphilitic ataxia?

Furthermore, ataxia may be said to be the clinical expression of the lesion of a system—of a portion of the spinal cord. Now, the lesion of this medullary portion can only disturb or destroy the physiological functions vested in this part of the spinal cord. It cannot give to this portion new functions which reveal the disturbance by some extraordinary and special symptom. As a medullary system, either injured by this or by that, by syphilis or by some other morbid influence, it always evinces its lesions in the same manner. Therefore, the posterior columns, injured by syphilis, occasion functional disturbances as they would if injured by any other cause, and it is for this reason that syphilitic ataxia has no known peculiar symptoms, which distinguish it from ataxies of other natures.

2d. Syphilitic tabes has no peculiar lesion. This he also admits as true. But is there, he asks, in pathological anatomy, an element or even a process which may be considered as belonging exclusively to syphilis?

The anatomical changes occurring in tertiary syphilis, primarily consist in cellular hyperplasias, which terminate, in their ultimate evolution, either in sclerosis or gummata. Now sclerosis is a very common lesion, and may originate from various causes. It is a process almost as common as inflammation. As clinicians and surgeons we consider gummata as lesions peculiar to syphilis. But the histologists, better judges than we upon this question of the specific nature of morbid tissues, refuse to recognize in the gumma anything special, peculiar, or exclusively belonging to syphilis, which may, therefore, be said to have no pathognomonic lesion, which permits the investigator, even armed with the microscope, to positively affirm, the anatomical presence of syphilis.

Scleroses, as has been so frequently repeated, are at any rate among the chief anatomical modifications produced by syphilis; why, then, should we expect syphilis to occasion in the spinal cord something different from that which it produces elsewhere?

If syphilitic tabes has for its lesion a sclerosis, it is an evidence in favor of our doctrine, since there is here an analogy which connects tabes with other syphilitic manifestations.

3d. Syphilis does not determine tabes, because it is not its nature to produce systemic lesions. Fournier does not admit the conclusions that are drawn from the systemic character of tabes, nor the anti-

systemic tendencies of syphilis. He thinks that in reference to their requirements, it is more correct to submit the alleged "laws" of the disease to observations, and if the observation demonstrates the existence of a syphilitic tabes, to accept the fact, even in spite of apparent contradiction of a principle. The existence or non-existence of a tabes, having its origin in syphilis, is to be determined exclusively from clinical investigations, and not from general conceptions of transcendental medicine.

It is true, that in most cases syphilis does not present systemic lesions, but exceptions to this law may be cited. With some patients the diathesis attacks and follows with marked preference, this or that organic system, for example, the skin or osseous system. Again, in secondary syphilis, the lesions are peculiar to the mucous membrane and lymphatic system.

In regard to the ataxia, is it, whatever may be its origin, an exclusively localized lesion of the posterior columns of the spinal cord, as certain of our profession think?

Almost invariably, it affects not only the posterior columns, but also the corresponding meninges. Again, it frequently invades other portions of the cord, the posterior cornua, the posterior fasciculi of the lateral columns. Further, if the posterior columns of the spinal cord are alone affected in tabes, what anatomical reason can be given for the paralysis of the cranial nerves? Finally, there are frequently associated with tabes some cerebral symptom, congestive icterus, epilepsy, aphasia, hemiplegia, intellectual disturbances, general pseudo-paralysis, general true paralysis, etc.

For these reasons, Fournier concludes that locomotor ataxia is not a strictly local disease, it is generalized and, although a clinical entity, cannot be defined by reference merely to the lesion of the posterior column.

4th. Tabes observed in persons affected with syphilis is not a syphilitic tabes, because it is not benefited by the ordinary treatment of syphilis. In answer to this objection Fournier asserts, from his personal experience, that mercury and iodine sometimes exert a decided therapeutic influence in syphilitic tabes. Several other authors have obtained results similar to him, and indeed, some were more fortunate, since they speak of recoveries, which notwithstanding all his efforts, he has never obtained. He attributes this failure to the following facts:—

a. In almost all cases, specific treatment is only begun at a period

when the disease is more or less advanced, generally a long time after its onset.

*b.* Before the appearance of its characteristic symptom—want of muscular co-ordination—tabes may exist as a complete and irremediable lesion in the posterior columns of the spinal cord. Pathological anatomy describes true ataxia as a destruction of the spinal cord, atrophy or beginning atrophy of the posterior columns, or, in other words, as due to lesions of an irremediable nature. Now, our specific agents have not the power to cure what is incurable, and cannot repair what does not exist. No one, even the most ardent partisan of mercury and iodine, has ever claimed for these remedies the power of creating anew anatomical parts already destroyed.

5th. Tabes of syphilitic patients has no connection with syphilis, except as a coincident occurrence. To this Fournier says, here is not a clinical question, but one of simple good sense. Recent statistics demonstrate the existence of syphilis in cases of locomotor ataxia in a proportion of from 70 to 91 per cent., an average of about 80 cases in every 100. Fournier himself, in 103 cases of undoubted tabes, found an undeniable previous history of syphilis in 94.

These statistics, which show the extraordinary frequency of a previous syphilitic history in tabes, furnish, in his opinion, peremptory reason for connecting tabes and syphilis, as effect and cause.

Having thus replied to the objections, he proceeds to state the following reasons for believing that the *great majority* of cases of locomotor ataxia are of distinctly syphilitic origin:—

1. The significant frequency, already mentioned, with which the diseases are found to be associated.

2. The almost exclusive development of ataxia in the tertiary period of syphilis; out of 85 cases of ataxia observed in syphilitic subjects, in 81 the disease developed in the fourth year of the syphilis, in 3 in the third year, and in only 1 in the last month of the second year.

This extraordinary regularity in the date of its occurrence, is inexplicable on the theory that it is derived from some cause independent of syphilis, the association with the latter disease being merely an accidental one. If that were the case, it is difficult to conceive why it should not at least occasionally be met with in the secondary or primary stages.

On the other hand, its appearance at that epoch is conformable with the general system of evolution of syphilis, which does not, as a

rule, produce its visceral complications for some years after the primary contamination.

3. The frequent similarity or identity of ataxic symptoms with those long known to be characteristic of syphilis, as, for example, paralysis of the cranial nerves, and even of the same pairs. the optic and oculo-motor; hemiplegias, epileptiform and aphasic attacks, etc.; progressive general paralysis, a not uncommon sequel of ataxia, is also a frequent and incontestable symptom of syphilis.

4. The beneficial influence exercised by specific treatment, which he claims to have used in many of his cases with the result of dissipating isolated symptoms, arresting or "immobilizing" the disease, and in some cases causing its complete and permanent disappearance.

5. The coincident development during the course of the ataxia of undoubted syphilitic symptoms, among which he mentions various ulcerative syphilides, gummata, exostoses, necroses, caries, etc.

6. The impossibility, in many cases, of finding any other imaginable cause for the production of the disease.

This review of the testimony as to the relation between syphilis and locomotor ataxia, cannot be said to supply positive and conclusive evidence of their etiological connection, but would certainly lead to the belief that there is something more than mere coincidence in the frequency with which the two diseases are associated. That syphilis gives rise to locomotor ataxia, in the same sense that lead poisoning causes muscular paralysis, may not yet be demonstrated; but that it acts as a predisposing or excitant element, so affecting or altering the nervous system that the cause or causes, whatever they may be, of locomotor ataxia, are free or more liable to produce the malady, seems to us beyond question. Therefore, although not quite prepared to accept the positive opinion of Dowes,<sup>1</sup> that locomotor ataxia is, with very few exceptions, due to syphilis, we may unhesitatingly, in the light of our present knowledge, coincide with Erb, in believing that the results of investigation justify us in concluding that there must be some not very indefinite etiological connection between syphilis and locomotor ataxia.

As to treatment, this opinion would naturally lead us to the following conclusions:—

In every case of ataxia, careful and minute search should be made for evidences of antecedent syphilis, either acquired or inherited.

[<sup>1</sup> The Medical Press and Circular, November, 1880.]



If this be found to have existed, the patient should be placed at once upon vigorous specific treatment, and should be directed to continue it through long periods.

If only a fair presumption of previous syphilis exist, the same treatment should be employed, as it would, at the most, be useless, not hurtful.

If the disease be recognized in its earliest stages, and found to be associated with syphilis, and treated in this manner, a prognosis may safely be given of a more favorable character than at present seems justifiable in any other variety or under any other mode of treatment.

Finally, the best prophylactic treatment of locomotor ataxia would consist in the thorough and long-continued use of specifics during the different stages of syphilis, even in the absence of characteristic symptoms.]

The force of Fournier's assertion, that syphilis is met with in two-thirds of the cases of locomotor ataxia, is weakened by the fact that in these cases there are merely the symptoms of common locomotor ataxia, showing that syphilis had modified neither the symptoms nor the lesion of the disease in question. It would seem, therefore, to be only a very remote predisposing cause. Want of coördination is, in itself, not a syphilitic symptom. Diseases directly caused by syphilis are always impressed with its own anatomical peculiarities, but in ataxia we find neither special inflammatory product nor gumma. Ataxia with syphilitic antecedents is the same anatomically as that which attacks the non-syphilitic, consequently we cannot admit the direct action of the virus.

The *diagnosis* of cerebral syphilis is based less upon the symptoms taken singly or in groups than upon the progress of the affection and upon the therapeutic action of iodide of potassium. An intense cephalalgia of long duration, which is cured, or benefited by the iodide, but relapses, which is accompanied by intellectual troubles, loss of memory, hebetude, slight paralysis limited to the muscles of the face or to the muscles of the eye, then a paralysis very slow in progress ending in hemiplegia, aphasia, and epileptiform convulsions, such are the varied symptoms upon which the diagnosis is established. These symptoms are slow in showing themselves, and they grow more intense very gradually. At their commencement they are benefited or cured by the iodide of potassium. Each one of them presents some characteristic peculiar to syphilis in such a way that recognition of the cause is possible

in the great majority of cases. The diagnosis from apoplexy and from softening is generally easy. The sudden onset of an attack with absolute loss of consciousness and complete hemiplegia excludes the idea of syphilis, for with the latter the commencement of paralysis is slow and progressive, and complete loss of consciousness is rare. It is more easy to confuse it with chronic softening; but in syphilis there are the violence of the cephalalgia, the possibility of improvement under the treatment by iodide of potassium, the epileptiform convulsions, and especially the presence of old or concurrent syphilitic lesions. Cerebral tumors are easily confounded with syphilis, but the age at which they are noticed will render the consideration of cerebral tubercles unnecessary, as they are an affection of infancy. Sarcomata might be mistaken for gummata; however, they are exceedingly rare, and the symptoms which govern them are progressive, without its being possible to benefit them by the iodide treatment. The prognosis is very grave. According to the statistics of Ligneau, who collected 147 cases, a fatal termination ensued in two-fifths of the cases, that is to say, 57 times. It is true that 7 of these cases succumbed to an intercurrent disease, which reduced the number of deaths to about one-third.

## CASE XI.

*Cerebral syphilis; Apoplectiform phenomena.*

By Drs. Lépine and Coÿne.

S. C., age 42 years, admitted to the charity hospital December 2d, 1873; bed No. 22, Saint Charles ward, under the care of Professor G. See.

The patient was brought to the hospital on account of acute and very grave cerebral symptoms, which rendered his clinical examination difficult and incomplete upon several points.

*Previous history.*—He is tall and well formed. When young was a soldier, and for some years past has been employed by the minister of the interior in the prison service. In the latter position his duties were very laborious, and he obtained but little sleep during the night. He has always been very temperate, never drinking alcohol to excess. His wife and brother-in-law were not aware of his ever having had syphilis; but they knew that he had for a long time taken iodide of potassium, and that, separated from his wife during the war, he had at that time a urethral discharge. In 1871, four days after very laborious extra duty, during which he had remained wet all night, he was seized with violent pains in the lower part of the back, accompanied with a sensation of cold in the lower extremities. Eight to ten days after the occurrence of these pains, his legs began to give way and to tremble; walking was possible, but difficult; he staggered, and his knees bent under him. A physician, who saw him at this time, applied a blister to the lumbar region, and endeavored to promote sweating. The day after the application of the blister, there occurred retention of urine. For this complication he entered the Necker Hospital, under Dr. Guyon. When he arrived at the hospital, he was able to ascend the stairs, notwithstanding the feebleness of his legs. During this time the patient had not felt any weakness in the arms, his mental faculties were not impaired, and vision was not perceptibly interfered with. His wife believed she had noticed a little deviation of his mouth, but the information upon this point was not very precise.

The patient remained two months in the Necker Hospital, under Dr. Guyon's care, who determined the existence of a stricture, and ordered iodide of potassium and pills, the name of which could not be ascertained. During his stay in the hospital the feebleness of the legs continued; at the time he left he began to walk, and in two months his improvement was such that he again began work; but he never regained his former strength, and was soon fatigued.

From this time until a month ago, his health was not bad, but he complained of weakness, extreme lassitude of the muscles, and espe-

cially of violent headache, which was more severe during the evening and night.

A month previous he began to complain of his left knee; he had some difficulty in bending it. Five days later he came to Paris, after a very difficult journey, and he experienced a sensation of continual cold in the lumbar region and in the left leg. These sensations continuing, a physician ordered cold douches and stimulating frictions. The first douche seemed to cause a certain reaction; but the following day, in leaving the hospital, where he had been to receive the second douche, he experienced some peculiar phenomena. Vision was disturbed, there was vertigo, he walked like a drunken man; then his left leg became suddenly cold and stiff; the arm of the same side was also similarly affected, and he finally fell. He was taken home, and it was found that the left arm and leg were paralyzed, and the tongue was affected. During the same day, the left arm, although feeble, ceased to be completely paralyzed; the patient could move it. This also occurred in the left leg during the same evening. The next day the patient was so far recovered that he could walk with the aid of a cane.

During the night from Sunday to Monday he was disturbed, and complained of violent suffering in the head. Talking was yet easy. At 6 o'clock in the morning he lost his speech, and the right side was completely paralyzed. He remained in this condition during the whole day, and the following morning, December 2d, was brought to the hospital.

*Present State.*—The right side is completely paralyzed; the skin of the arm of this side is warm; the patient cannot close the hand; the paralysis of the arm is accompanied by contracture; the fingers are closed on the palm of the hand.

Sensibility, although much lessened, is still present. The thigh and left leg are warm to the touch; they are in a most complete state of paralysis without contracture; their insensibility is almost absolute. The arm and left hand have some power. The patient can move this member and close the hand with considerable force. Sensibility is preserved.

The intelligence is relatively clear; he can understand what is said to him, and endeavors to reply, but his speech is not distinct.

December 3d to January 9th. The patient remained in the same condition. He complained of violent attacks of headache. The right paralyzed side showed a tendency to contract; more marked in the superior than in the inferior extremity. The existence of a left hemiopia is determined; the inferior part of the retina is paralyzed; there was no examination of the eye-ground.

The patient gradually lost strength, and died January 9th.

*Autopsy.*—January 10, 1874. The lungs are emphysematous at the apex and at their anterior borders; a little congested posteriorly. The spleen is larger and softer than normal. The kidneys are small, but normal. The liver presents nothing special. The cranium is normal on the exterior; its thickness is as usually found; the internal surface of the skull-cap and of the base of the cranium present nothing abnormal; there are no exostoses or carious points. The dura mater is normal.

The convex surface of the encephalon shows nothing special; the vessels are congested, but there is no subarachnoid œdema, nor any change of color or consistence or arrangement of the visible parts of the convolutions of this region. The base of the encephalon, on the contrary, pre-

sents important lesions seated upon the inferior surface of the pons and in the left lateral part of the great transverse or cerebral fissure of Bichat.

*Pons Varolii.*—Upon the inferior and anterior surface of the pons, in its right half, two gray-pink patches or gummata with a more opaque centre are seen. These two patches are situated, the one anterior, Fig. 73, *m*, *p*, and near the anterior border of the pons, the other posterior, *n*. They are both depressed at their centre, and have very much the external appearance of disseminated sclerosis, modified only at their central part by the addition of a new character. The posterior patch is the smaller; it lies transversely and is situated 6 mm. anterior to the posterior border of the pons. It measures 2 cent. in its large transverse axis, and 5 mm. in its antero-posterior diameter. Its internal extremity passes a little over the median line, and is hidden by the trunk of the basilar artery. The anterior and inferior cerebral artery and the trunk of the sixth pair of nerves cross it. Its periphery is jagged, and extends between the fasciculi of fibres as gray-pink lines. It is not distinctly defined in its limits. Its centre is depressed and covered by a thin layer of gray-pink transparent tissue, through which is seen a deeper layer formed by an opaque tissue which is also irregular in its external outline.

The anterior patch occupies almost the whole extent of the right half of the pons; it begins where the fifth pair of nerves emerge, and terminates in the fissure which contains the basilar artery. This patch, much larger in every way than the preceding one, is more depressed at its centre, resembling a cicatricial contraction. Its color is similar to the other, gray-pink with a brown tint. At its periphery, *p*, it has a moist and almost gelatinous appearance. In its centre, the aspect is modified by a more opaque appearance, and the nucleus, *m*, which causes this appearance, is more distinct than in the posterior patch.

The arteries forming the circle of Willis are healthy; the basilar artery only at its middle part presents two small tumors, large as millet-seeds, and pedunculated. This artery is also thickened in its external coat, and shows manifest traces of periarteritis, especially near the above-described patches.

The pia mater and arachnoid are thickened and opaque over the right half of the pons. They are adherent to the superficial portion of the patches, and cannot be detached without removing a part of the morbid tissue to which they are connected.

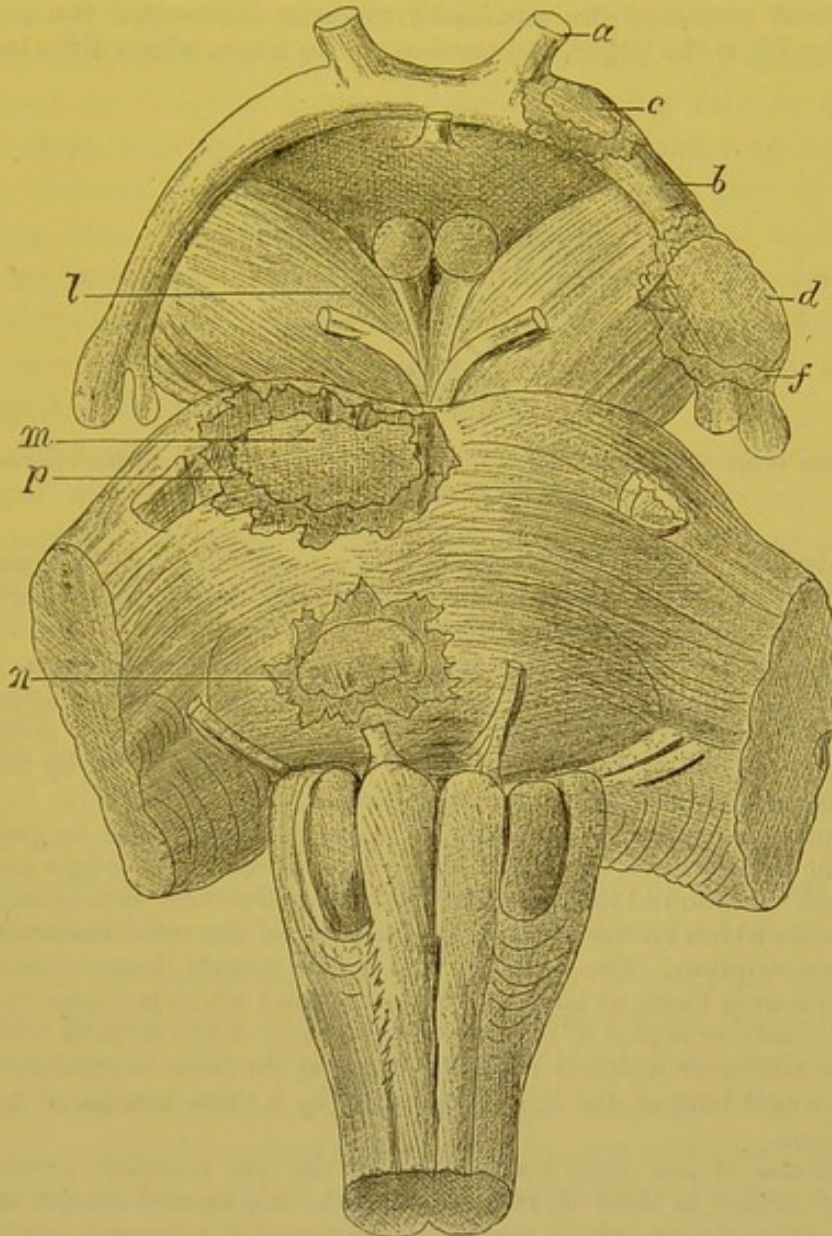
Besides these two patches which have been described, there are also seen changes of the same nature at the left optic tract, the curve of the hippocampus, and the left cerebral peduncle, where it is covered by the optic tract.

In separating the right sphenoidal lobe and the inferior and external lip of the great transverse or cerebral fissure of Bichat, where the optic tract crosses the cerebral peduncle, there was found a small gray-pink patch, which involved only a very superficial lamella of the peduncle, *l*. At the same region of the left side, there exists quite a large patch, which involves the left optic tract, the cerebral peduncle, and encroaches upon the curve of the hippocampus, *d*, *f*. At this point the optic tract is swollen to at least twice its normal size. The patch is deeply imbedded in the cerebral peduncle.

The pia mater is thus thickened and adherent. The periphery, *f*, has

a gray-pink color, and gelatinous appearance. The central part is more opaque, and corresponds to a central nucleus, *d*.

Fig. 73.



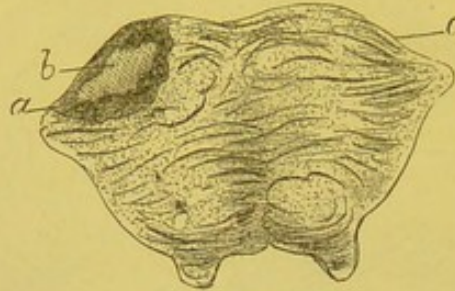
Syphilitic gummata of the pons Varolii. *a*. Left optic nerve: *c*. Anterior tumor upon the left optic tract. *b*. Left optic tract *d*. Posterior tumor of the left optic tract (internal zone). *f*. External zone of same tumor. *m, p*. Anterior tumor of pons. *n*. Posterior tumor of pons. *l*. Tumor of right cerebral peduncle.

More anteriorly, and near the optic chiasm, the same left optic tract presents, in its external half, an enlargement corresponding to a gray patch, oval in shape, with its long axis antero-posterior, *c*. The external appearances of these two patches correspond manifestly to the formations situated in the central portion, and are the same as those described for the patches of the pons.

The left optic nerve is healthy, the central artery of the papilla is normal, none of its branches being atrophied or obstructed. The centre of the papilla is a little depressed, its borders above and outside are not distinct, and at this part it has a yellowish-gray tint.

A vertical section of the patches of the pons shows that the anterior patch, Fig. 74, is the larger, and consists of two zones, which differ in color

Fig. 74.



*a, b.* Anterior tumor of the pons seen in transverse section. *a.* Pinkish-gray external zone, *b.* Whitish-opaque internal zone.

and consistence. The central is formed of a nucleus *b*, with irregular and serrated border; it is yellow-gray, opaque, and dense; it appears dry, although the vessels are not obliterated.

The enveloping tissue, *a*, is gray-pink, softer, almost gelatinous, moist, and traversed by a considerable number of bloodvessels. This tissue, and that of the centre, resemble that presented by a section of a gumma of certain organs. The remaining tissue of the pons not invaded by the neoplasm does not present any apparent lesion.

An antero-posterior cut made from below upwards, so as to pass outside of the left optic tract, permits the deep relations of the larger patch to be studied. It is found that it extends into the peduncular expansion, as far as the parts which correspond to the junction of the optic thalamus with the corpus striatum. The upper surface of the morbid tissue is connected with a softening focus, as large as an almond, and which occupies the interior and posterior region of the lenticular nucleus of the striated body, and the white substance which is beneath. So that the focus is separated from the sphenoidal horn of the lateral ventricle by a thick lamella of healthy nerve tissue.

The tumor of the optic tract, and also the one anterior, present the same appearance as those of the pons, they have a central opaque nucleus and a peripheral part, which resembles the tissue of sclerosed patches.

The spinal cord and canal do not present any apparent lesions. Transverse cuts were made at different points of the cord, in order to study the columns and gray substance, but nothing pathological was observed.

**HISTOLOGICAL EXAMINATION.**—After hardening in chromic acid solution, an examination shows that all the patches were of a similar nature. The two zones—peripheral and central—are rendered more distinct. In the external zone, the different elements are seen by teasing a portion of the tissue. There are found cells, which, when

viewed in certain directions, are fusiform, but when isolated are oval and nucleated; they are furnished, especially at their two extremities, with branched, rigid, and very refracting prolongations, which are scarcely colored by the carmine, while the nucleus and body of the cell are deeply stained. These cells resemble very much the cells described by Golgi as spider-like cells, differing only in having a larger body, and prolongations which are larger and less branching. These elements are very numerous in the external part of the enveloping zone. Besides these cells there are found others oval, granular, and containing a large granular nucleus; they are poorly colored by the carmine, and resemble the preceding cells, except that they have no prolongations. Finally are seen small nuclei, very abundant, and deeply stained by the carmine.

In the central part of the patch no spider-like or branching cells are met with; they are replaced by numerous oval and granular cells, and by numerous nuclei. But both these elements are more shrivelled, more granular, and more slightly colored with the carmine than in the external zone.

By examining thin sections, stained with carmine, two very distinct zones are seen, which differ, however, only in some insignificant details. At the extreme periphery, between the nerve fibres, the axis cylinders of which are colored, there exist numerous spider-like cells, which are here larger and more numerous than in those parts of the section which consist of the healthy portion of the pons. This increase in number and size of these cells is continued some distance outside of the peripheral zone, which latter is characterized by the presence of true nests of these cells. Besides these branching cells, there are found oval and granular cells without prolongations, which are collected in groups, and owing to the intensity of the carmine staining, appear as reddish spots. Finally, are seen numerous round embryonal nuclei, pressed one against another. Passing from the periphery towards the internal part of the first zone, there is observed a gradual decrease in the number of the several elements. On the outside are the spider-like cells, in the internal half are the nuclei and oval cells.

The nuclei are very abundant around the bloodvessels, where they form true sheaths. But it is noticed that, notwithstanding their number, they do not narrow or change the lumen of the vessels. Wherever they are found in the new formation, they all have the same appearance; those at the centre, as well as those at the peri-



phery, are equally stained by carmine. Between the oval cells numerous rows of these nuclei are seen.

At the central part of the patch, it is seen, with a low power, that the staining has been very irregular in its distribution. With higher power, it is found that all the lighter colored zone is formed by a few oval cells, and especially by small nuclei, which are shrivelled, compressed one against another, and traversed by bloodvessels, around which are not seen any lymphatic sheaths, and which are a little compressed in consequence of the sinking in of the nuclear elements. But the walls of these vessels are not altered; they are not obstructed either by the formation of clots or by endarteritis.

The embryonal elements which have been described form a uniform surface upon section; no part is more changed, more shrivelled than another; the elements found at a distance from the vessels are as little colored and shrivelled as those which are contiguous to the walls of these vessels. At the periphery of this central zone is seen a more marked predominance of embryonal elements and nuclei, than of the other varieties of cells which are met with in the external zone.

This description, made from sections of the pons, corresponds accurately to those made from the optic tract.

Sections of the spinal cord and medulla oblongata showed no indication of any pathological change.

## CASE XII.

### *Syphilitic tumor of the cerebellum; Sudden death.*

By Drs. Peltier and Coÿne.

X., æt. 37, eighteen months previously was seized with violent pains in the head, on the left side, posteriorly. These pains were most severe during the night. She was treated in the Necker Hospital with the iodide of potassium, and recovered in two months. After a period of eight months, there again occurred the same symptoms, which received the same treatment, and were followed by recovery. In October, she was admitted into the Pitié Hospital for similar lesions: no manifestations of syphilis were found. Treatment was begun, when on October 18th, at 6 o'clock P. M., the patient was suddenly seized with a paroxysm of pain. She raised herself in bed, gave a cry, and fell back dead.

*Autopsy.*—The viscera presented nothing special which could explain death, nor did they show any indications of previous disease. In examining the brain, an oval tumor, the size of a small walnut, was found, situated in the posterior and internal part of the greater circumference of the left hemisphere of the cerebellum. One end of the tumor extended as

far as the middle lobe and inferior vermiform process. It was completely covered by the cortex of the cerebellum, and was only recognized by a change in the tissue, which had a pinkish-gray or pink tint, and by the induration which it produced. Surrounding the tumor was seen a very thin layer where the nerve tissue was soft, almost gelatinous. At its inferior part, it pushed the inferior vermiform process into the fourth ventricle and pressed upon the left restiform body, which latter was deformed from pressure.

A vertical section made through its long axis, demonstrated two parts: 1st. An exterior zone or capsule, having a pink color; 2d. A central portion, which represented the nucleus, and was separated from the cortical layer by a yellowish lardaceous zone, while in the centre the color was uniformly yellow; here the tissue was dry, friable, and without points of softening. In the centre of the section were seen two or three vessels of medium size.

HISTOLOGICAL EXAMINATION.—Upon teasing a fresh portion of the new formation, there were found small, round, bright, and transparent nuclei, all of the same size, measuring about .006 mm. in diameter. The examination of a thin section, made after hardening the tumor, showed these nuclei especially at the periphery; they were collected into a zone which surrounded the central mass, and which measured from three to four millimetres in thickness. These nuclei were deeply and rapidly stained by carmine; at points where they have collected, there were found numerous young vessels with thin walls and a relatively large lumen. Upon some of these vessels were seen accumulations of nuclei filling the lymph sheaths. None of the vessels were obliterated. In the central part, the tumor changed a little. There were found in that situation the products of granulo-fatty degeneration. The nuclei which were here seen, were less colored by the carmine, irregular in shape, and therefore, less distinct. The vessels in this portion of the section, had thickened walls, and their lymph sheaths were distended with numerous nuclei. The walls of the vessels contained a greater number of fusiform cells than in the normal state, and in some their lumen was narrowed, in consequence of the development of a slight proliferating endarteritis; but there were no coagula in their interior nor any complete vascular obliterations.

## CHAPTER XI.

## SYPHILIS OF THE LIVER.

Hepatic syphilis—Syphilitic jaundice of the secondary period—Syphilitic interstitial hepatitis—Gummata of the liver—Their structure—Their symptoms—Congenital syphilis of the liver.

SYPHILIS OF THE LIVER.—Of all the internal organs, the liver is most frequently affected with syphilis; either during the secondary or tertiary periods, or in infantile syphilis. The more or less characteristic lesions of this organ have been known for a long time, viz. congestions of the liver, simple interstitial hepatitis, and gummata.

Professor Gubler described, in 1853, symptomatic phenomena due to alterations in the liver which he had observed during the secondary period of syphilis, and since that time, further observations have been made by Luton and Foville, Martel, Lancereaux, Fournier, and Lacombe.

During the first months which follow the chancre, and about the beginning of the secondary lesions, there is sometimes a heaviness in the hepatic region; when the organ is pressed pain is complained of; percussion demonstrates an increase in size. At the same time, there is jaundice, which is not permanent, and is similar to a slight catarrhal jaundice. This icterus is characterized by a coloring of the conjunctiva, of the urine, and of the skin; it is generally accompanied with a loss of appetite, gastric disturbance, sometimes fever, and almost always uneasiness, lumbago, and headache. Its duration is short, not continuing more than twenty days. The cause is probably a congestion of the liver or a compression of the bile ducts by the perivertebral and hepatic lymphatic glands.

It is not truly known whether this icterus is due to syphilis or not, no autopsies having been made during the affection; nor is it known if the liver presents any lesions. Fournier says, "the existence of a form of syphilitic icterus has been universally accepted, although no anatomical lesions have been demonstrated."

Icterus occurs during the secondary period but very seldom, not more than twenty cases having been reported, an extremely small proportion if the great number of syphilitic patients be considered. Professor Hardy, who has been a long time connected with the St. Louis Hospital, has never seen a convincing case. I have seen two cases of icterus in syphilitic patients, but I hesitate very much to ascribe them to the syphilis. There is now in my wards of the Lourcine Hospital, a patient with icterus, but she is in the fifth month of pregnancy, and during this condition, icterus due to modifications of the liver is not unfrequent. Again, this girl is employed in a brewery, therefore, most likely not a model of sobriety, and many cases of icterus are due to excess in drinking followed by indigestion.

Before deciding that a case of icterus is due to syphilis, it is necessary to be certain that some other sufficient cause may not be acting. Two cases reported as syphilitic icterus occurred in pregnant women.

Icterus observed during the secondary period, disappears soon and spontaneously. Fournier, however, lost one of his cases; there was no autopsy. Several autopsies of syphilitic women who died with icterus have, however, been made. One by Charcot, one by Fagge, and one by Andrew; the last two are quoted by Lacombe. These three patients succumbed to a grave icterus, with lesions which the microscope demonstrated to be acute yellow atrophy of the liver, and which have no relation to syphilis. The changes which properly belong to syphilis, consist in a new formation of lymph cells at the diseased parts, in an inflammation affecting especially the connective tissue, and infiltrating it with small round cells; or in true neoplasms, gummata. In acute yellow atrophy of the liver, on the contrary, there are atrophy and destruction of the hepatic cells, without any marked inflammation of the connective tissue.

Lesions of the liver, during the tertiary period of syphilis in the adult, are quite frequent. There are three special varieties which may exist alone or combined, and which are:—

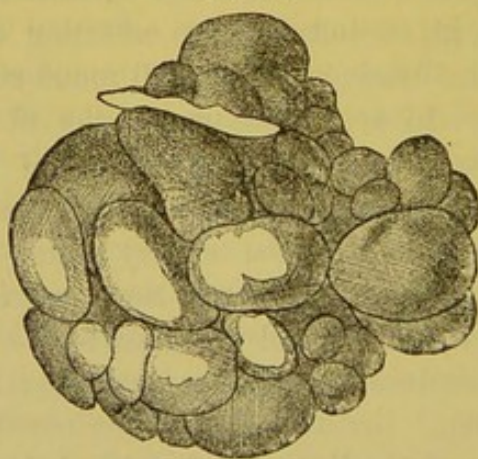
1st. Chronic interstitial hepatitis or cirrhosis; 2d, gummata; 3d, amyloid degeneration.

Of these diseases of the liver, the first two belong to syphilis; but the third cannot be regarded simply as a syphilitic lesion. The latter is more the consequence of a cachexia due to prolonged suppurations, which in some cases, it is true, belong to syphilitic manifestations, but the amyloid degeneration itself cannot be considered as forming one

of the characteristic neoplasms of syphilis. In the liver, as in other organs, the gummata alone are positively characteristic of syphilis; for even if the interstitial hepatitis presents, in its arrangement, in the shape of the organ and in the cicatrices, an appearance which is ordinarily attributed to syphilis, this does not constitute a positive distinction, but may be due to a simple interstitial inflammation.

1st. *Syphilitic interstitial hepatitis*, or cirrhosis, is general or local. When general, which is seldom the case, and recent, it cannot be diagnosed from simple or alcoholic cirrhosis. At the beginning of the lesion, it consists of a new formation of embryonal connective tissue, which somewhat regularly surrounds the hepatic acini, and later becomes dense fibrous tissue. Generally the disease consists in the local formation of fibrous tissue; the capsule of Glisson is thickened in places, especially where the ligaments are inserted; there are developed between the liver and neighboring parts, the diaphragm, kidneys, and transverse colon, adhesions which become fibrous, forming bands. The connective tissue of new formation which accompanies the vessels and capsule of Glisson, instead of forming an envelope to each acinus, as in alcoholic cirrhosis, is localized around large portions of the liver, in such a manner that the organ is lobulated, divided into round or irregular lobes, which are separated and project from the surface, and very much resembles the kidney of young animals. These lobules are separated by depressions, at the bottom

Fig. 75.



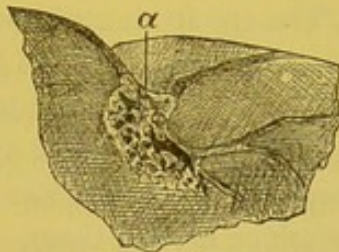
Liver deformed and lobulated by syphilitic cicatrices. (Frerichs.)

of which the capsule of Glisson is found thickened. The whole liver is deformed; the left lobe is generally drawn towards the right, and has become spherical. (Fig. 75.) At times the left lobe is com-

pletely separated from the right by a deep depression; the inferior border of the liver, instead of forming a regular line, is divided by deep vertical grooves and is bossellated. In other cases there are only found a few depressed cicatrices on the surface of the liver, and a fibrous thickening of the capsule over the cicatrices.

Cases in which cicatrices of the capsule are found associated with lobules and considerable deformity of the liver in syphilitic subjects are very numerous. The special works upon the diseases of the liver by Frerichs, Budd, and Murchison, mention many instances, and Lancereaux, who has observed them often, considers their presence of great value in the anatomical diagnosis of syphilis. (Fig. 76.)

Fig. 76.



Section of a syphilitic liver at the point of cicatrization. (Frerichs.)

Cicatrices and depressions of the liver are met with in other affections than syphilis; for example, shrivelled hydatid cysts, but in these there is always found the débris of the hydatids or cysts containing their special products. Depressions of another character are sometimes confounded with those due to syphilitic hepatitis; those arising from tight lacing, or compression of the liver by the ribs in senile deformity of the thorax. The thickening and the cicatricial depressions due to corsets, are found only upon the anterior surface of the liver, which is divided by a white, depressed, horizontal line, due to a fibrous thickening of the capsule, with vertical ridges.

The local cirrhoses due to syphilis, are readily recognized by palpation during life. The nodules and projections, separated from one another by deep depressions, and situated at the inferior border of the liver, are easily felt. The liver often notably projects at the border of the ribs, which renders this method of examination easy. The left lobe of the liver is frequently, in this disease, separated from the right by a deep furrow, which can be felt without difficulty, and the lobe appears hypertrophied and spherical.

These signs in connection with cutaneous cicatrices, syphilides,

syphilitic lesions of the bones, and other organs, would indicate a syphilitic hepatitis.

Nodules of a syphilitic liver need not be mistaken for those of cancer or other tumors, since the former are indolent and stationary, while the latter have a rapid growth.

The symptoms of general syphilitic cirrhosis are the same as those of simple cirrhosis; they are loss of appetite, wasting, ascites, etc.

[Hill says that the contraction of the liver excited by syphilis is distinguished from non-syphilitic contraction by the following characters: The cirrhosis produced by drunkenness, though uneven, is finely nodulated, whence the name, hob-nail liver. The capsule, though often much thickened, is seldom adherent; in syphilis the viscus is drawn into uneven masses by strong bands, and peritoneal adhesions are generally present. The induration of the nutmeg liver accompanying morbus cordis, is also distinguished by its general evenness from syphilitic cirrhosis. The gummy nodules differ from tubercles by their larger size, by their being located along the course of the streaks of fibrous tissue, and by the absence of translucent miliary tubercles, or gray granulations around them.

In *cancer*, peritoneal adhesions are unusual, the liver is enlarged rather than diminished, and the circumscribed cancerous masses scattered through the liver have no obvious connection with the fibrous structure.]

*Gummata* of the liver are most often found at the same points as the depressed cicatrices above mentioned. They are met with at the bottom of the depressions upon the surface of the organ, where a band unites the liver to the diaphragm, at the point of insertion of the suspensory ligament or in the depression which separates the right lobe from the left. Such a depression upon the surface of the liver presents a hard thickening of the capsule of Glisson. If the liver is deeply incised at this part, there are seen one or more small gummous tumors, which on section show a very dense fibrous transparent peripheral zone, and at the centre a homogeneous, caseous, yellow, opaque part; they are fibrous, resisting, elastic, and have a characteristic hardness so that they cannot be torn by the finger nail. These tumors are irregular at their borders; their surface on section is limited by an angular line; they are not a perfect circle. Sometimes they are in groups of four, five, or more, and the liver contains a varying number of such groups, or only a single group is met with.

They are generally small, varying in size from that of a pea to that of a walnut, seldom larger than the latter.

The seat of these gummata at the bottom of a cicatricial depression, beneath a fibrous induration of the capsule of Glisson, is so uniform that when a cicatricial depression is observed without a gumma, it is supposed that the latter has existed and has been absorbed. It is not at all improbable, that a gumma of the liver may be completely absorbed, and leave as a result a fibrous cicatrix. From the course taken by gummata of the testicles, of the skin, etc., this conclusion as to their consequences in the liver is justifiable. But although the several phases of caseous degeneration, and this degeneration itself, are seen in the liver, there is yet no positive evidence of the atrophy and disappearance of the caseous portion; this can only be surmised.

A liver affected with gummata is generally misshapen and lobulated, with cicatrices on its surface, and with fibrous bands which connect it with the diaphragm. The following description of gummata is not absolutely identical with that of gummata of the skin or brain, the details of structure differing according to the organ affected, although the essential phenomena are the same. The general features of these growths as compared with those peculiar to each tissue will thereby be elucidated.

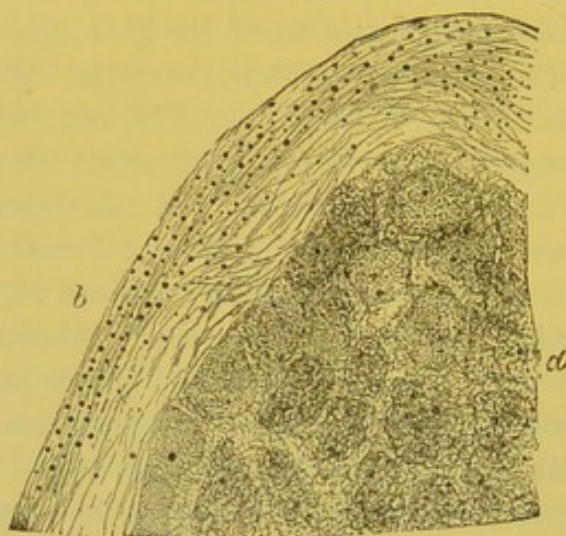
When a single gumma is examined with the naked eye, there are seen either beneath the capsule of Glisson thickened at this point, or in the tissue of the liver, three distinct zones; these are: the central portion of the tumor which is yellow or grayish-yellow, opaque, and cheesy; the semi-transparent fibrous capsule which surrounds it, and a zone formed by the ochre-yellow or reddish tissue of the liver.

This last is irregularly traversed by fibrous prolongations which extend from the preceding zone, penetrate the hepatic tissue, surround the neighboring lobules, and become continuous with the connective tissue accompanying the peri-lobular vessels. If a thin section of a gumma be examined under a low power in such a way as to display the different zones, the central cheesy portion is seen to be composed of a homogeneous tissue, finely granular, arranged at times in the form of small islets placed beside one another. This part, which to the naked eye occupies all the opaque and yellow centre, is limited at its periphery by an opaque band, black by direct light and under a low power, on account of the large quantity of fatty granules. This disposition of the caseous gumma and its fibrous capsule to form in islets is represented in Fig. 77. When a higher power is em-



ployed, the central portion is seen to be formed of small, round, granular, and atrophied cells arranged in small islets in the midst of a fundamental fibrillar substance; the cells in the centre of each islet being more atrophied, and more granular than those of the peri-

Fig. 77.



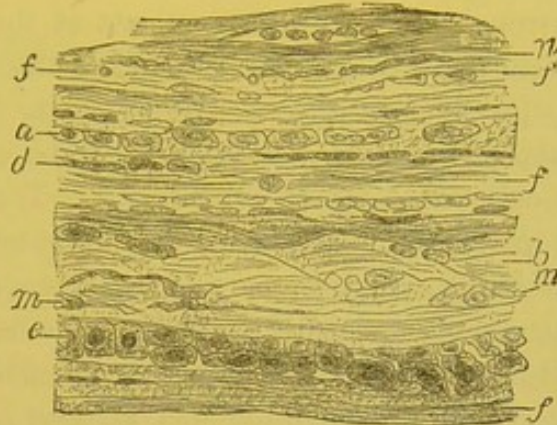
Portion of a gumma of the liver seen with low power. *a*. Central part of the gumma showing the arrangement into small islands. *b*. Connective tissue which forms the fibrous capsule of the gumma.

phery. The exterior and circular border, opaque under a low power, shows spaces limited by fibres of connective tissue, lymph spaces, which are filled with round cells containing minute fatty granules, or simply with large fatty granules.

It is in this zone surrounding the caseous portion of the gumma that the products of absorption of the cheesy elements of all the central mass accumulate before passing into the lymphatic vessels which carry them into the general circulation. Around this cheesy mass the semitransparent fibrous tissue, forming, as it were, a capsule, is composed of connective tissue in different conditions, depending upon whether the gumma is recent and growing, or old and undergoing cicatricial atrophy. In the first case, the fibres of connective tissue are thinner, less dense, and are separated by numerous round or embryonic cells. When it is older, the connective tissue predominates, and the cells are fewer; instead of being round, they become spindle-shaped, and they finally present the aspect of flat connective-tissue corpuscles interposed between the bundles of fibres. Thus, in a case of old gumma that I have examined, the bundles of fibres, *f, f*, Fig. 78, were parallel to one another and to the surface of the cheesy

portion, and they were separated by flat cells, *a*, *d*, *n*, which are seen in front and in profile. The zone exterior to the gumma is formed by prolongations of the preceding tissue which penetrate between the neighboring hepatic lobules. The bands of tissue which

Fig. 78.



Section of the peripheral fibrous tissue at the caseous portion of an old gumma of the liver. *f*, *f*. Fasciculi of fibrous tissue, flat, and parallel to the circumference of the caseous portion of the gumma. *c*. Capillary with its endothelium. *b*. Fibrous fasciculus cut obliquely, and separated by connective-tissue cells. *m*, *a*. Flat connective-tissue cells seen upon the surface and in profile. *d*, *n*. Flat connective-tissue cells seen in profile.  $\times 250$ .

thus surround the hepatic *islets* to a limited extent are formed by embryonic or by dense fibrous tissue, and contain more or less cells which may be round or flattened, according to the intensity and stage of the process. These are exactly the same lesions which are observed in the different forms of cirrhosis. This case was one of extremely localized cirrhosis.

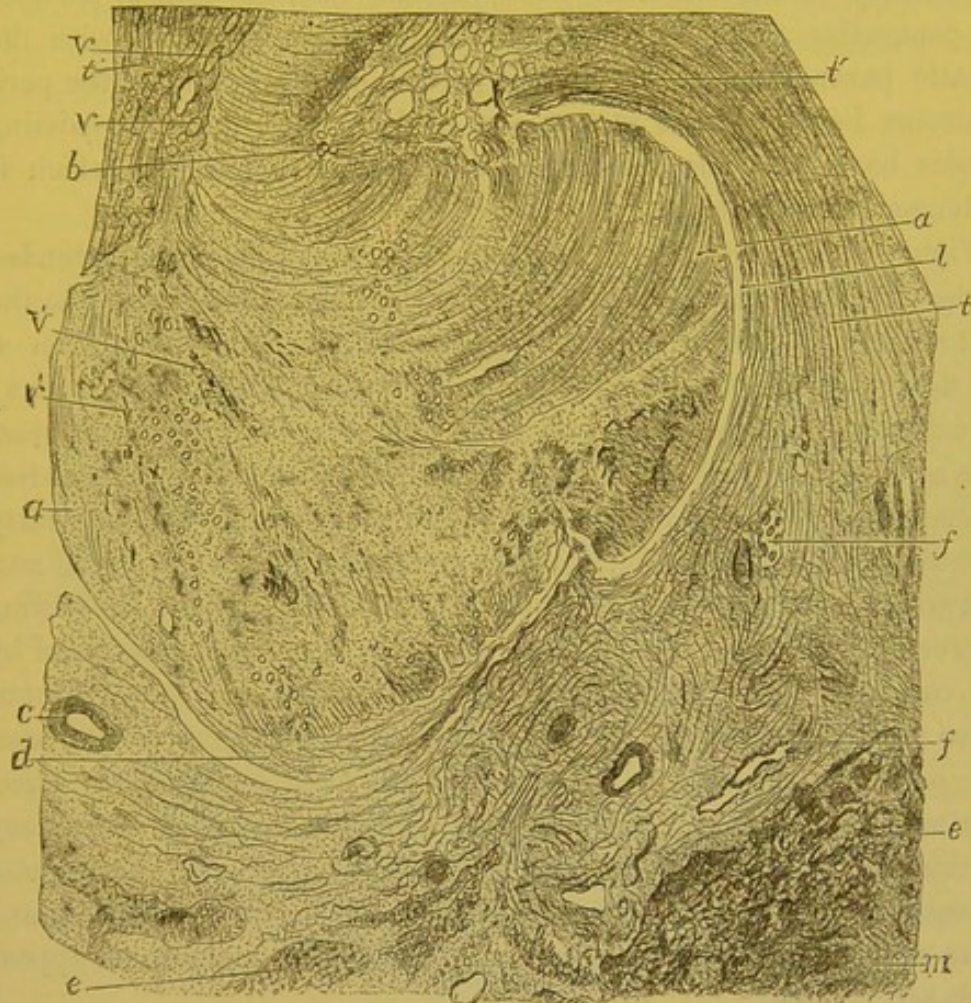
Such are the general facts, but they present variations according to particular cases, and it may be well, in order to comprehend them, to enter into the details. I have never met with a well-marked commencing gumma of the liver, but I have studied one which had reached its stationary period and was beginning to undergo cheesy degeneration at the centre. In this case the gummous nodule was single and quite large. Its central mass was formed of embryonic tissue, with very numerous cells in contact with one another and arranged in small islets, the central cells of which were more atrophied than those of the periphery. The greater portion of the vessels of this part undergoing cheesy degeneration were still permeable to the blood. Some among them, however, were completely filled with lymph cells glued together by fibrine. But in the peripheral zone, which was more embryonic than fibrous, the bloodvessels were nearly

all obliterated. In the specimens, colored by picro-carminé, and examined under a low power, they appeared as circular sections or as elongated figures more highly colored than the surrounding tissue, and of the red orange color of picro-carminé. The coagula were formed by the fibrine, by the lymph cells, and by the swollen endothelial cells. I had previously observed vascular obliteration in a case of very numerous and very large gummata of the liver in active development, which Lancereaux had studied at the Hôtel-Dieu, in 1863, in the service of Guéneau de Mussy. In the histological examination of these gummata, the vessels of the caseous portion were found to be obliterated by the lymph cells. These coagula and these incomplete vascular obliterations—for in gummata a certain number of vessels remain patulous—are apparently due to the intensity of the inflammation, and to the extreme number of the small round cells, and it is evident that they exercise considerable influence in producing the cheesy degeneration and atrophy of the centre of the gumma. They can be compared very properly with those which existed in gummata of the subcutaneous cellular tissue in the case of Chambard which we have recently noticed. If we now compare that which takes place in the skin with that which occurs in the liver, we can distinguish a marked resemblance between these two lesions, excluding, of course, the difference in details resulting from the unlike structure of the tissues involved. The central portion, crowded with round cells, is eliminated in the case of the skin, because the cutaneous surface is inflamed and destroyed, opening for it a passage, while the hepatic gumma is confined in its fibrous envelope without being able to escape, and its elements, ceasing to live, atrophy and become caseous. In gummata of the skin, the newly-formed cells are interposed between the bundles and fibres of pre-existing connective tissue. In the liver, the arrangement in acini, the regularity of the connective tissue and of the vessels which form the spherical islets composed of regular meshes, determine the arrangement of the cells into small spherical collections. Nevertheless this disposition is not constant; it is not found in old and atrophic gummata. In the older gummata, the fibrous tissue is in excess of the cellular element, not only in the peripheral zone, but also in the cheesy centre. This explains the characteristic fact that the centre is very hard, very fibrous, and in no wise softened in old gummata, while the contrary is the case with tubercles. Furthermore, in old gummata, the circulation of the blood is re-established not only in the peripheral part,

but also in the centre of the gumma. This circulation is far from being active, but the small number of vessels which are found in the centre of the gumma are permeable.

Figure 79 represents a section of an old gumma under a low power (12 diameters). The central mass, *a*, was united by a prolongation,

Fig. 79.



Section of an old gumma of the liver. *a, a*. Central caseous tissue of the gumma. *v', v'*. Its vessels. *l*. Boundary between the central portion and fibrous zone; this line of demarcation is marked in places by an opening or cleft. *t, t*. Connective tissue of the fibrous zone which entirely surrounds the central part. *v, v*. Small vessels of this zone. *c*. An arteriole of the fibrous zone. *f, f*. Quite large biliary vessels included in the fibrous zone. *t'*. Fasciculi of connective-tissue fibres running parallel with the surface of the caseous part. At *b* and *d* the fasciculi of fibres of the fibrous zone penetrate into the central caseous part. *e, e*. Tissue of hepatic cells interrupted by bands of fibrous tissue, *m, m*.  $\times 12$ .

*p*, with another portion of the same tumor equally cheesy. There is not a trace of the arrangement into small islets that we found in other cases. The tissue of the centre of the gumma shows even with this low power a peculiar structure; the fasciculi of fibres of connective

tissue of which it is formed are manifestly continuous at *b*, and at *d*, with the fibres, *t'*, of the peripheral fibrous zone, *t*. Small vessels, *v, v*, are seen in the central zone. The vessels, *v*, of the peripheral zone are the larger. Between the central zone and the tissue which surrounds it there exists at certain points, like at *l*, a cleft or slit, with a difference in coloring as well as in structure. The peripheral zone, *t, t*, is very broad, and much more vascular than the central portion. Its connective tissue is continuous by irregular bands, *m*, with the hepatic parenchyma, *e, e*. In this portion of the specimen the perigummosus hepatic tissue is not arranged in islets; the pre-existing lobules have been compressed, and changed in their shape, which is no longer recognizable.

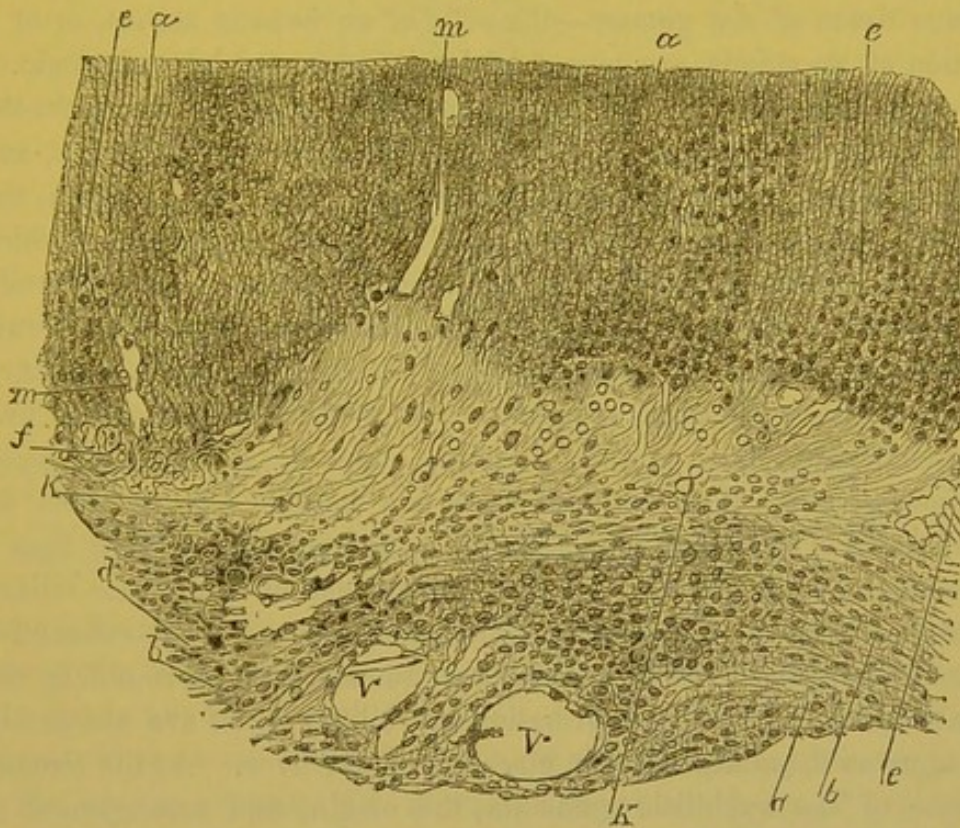
Figure 80, drawn under a higher power (150 diameters), intended to show how the bundles of fibres from the fibrous zone pass into the caseous one, is part of point *b* of Figure 79. The upper portion of the figure, *a, a*, belongs to the central cheesy tissue of the gumma; it consists of slender parallel fibres having between them round granular cells, pale, atrophied, and poorly stained with carmine. All this caseous portion is slightly opaque, due to the many very minute fatty granules. It is easily distinguished from the clearer peripheral portion which is formed by the fibres of connective tissue, *d*, showing between them round, fusiform, or flat cells, *b*, very well colored by the carmine. The continuity of the fibres of the peripheral fibrous layer with those of the cheesy portion is very evident in the cut. The peripheral fibres, the bundles of which have a concentric direction to the gumma, bend upon themselves at the margin of the cheesy portion, and penetrate it obliquely or at a right angle. At their point of entrance into the cheesy portion their fibrillæ are separated, and there are very fine granules between them which make them appear dark and opaque.

In old gummata, at the internal limit of the fibrous capsule, between it and the degenerated portion, there always exist clear spaces more or less regular, empty, or containing granules, or small oil-drops, or fat crystals, *e, f*. In this same zone are found, between the fibres, small crystalline masses or small transparent refracting spherical bodies, which are not stained by the carmine, and which, according to Malassez, are colored red by purpurine.

The bloodvessels of the cheesy portion of old gummata at one time present themselves in the form of empty furrows, at another, they are filled with red blood-corpuscles. They are small, and their walls

are thin. On the contrary, the peripheral vessels of the fibrous envelope are very large, and the circulation is active within them. Sometimes these latter vessels present, as in hepatic cirrhosis, a very pronounced chronic inflammatory thickening of their walls. Nevertheless, it is unquestionable, that in the early stage of a syphilitic neoplasm, the vessels of the affected hepatic region had a like structure. In the neoplasm, at its commencement, they were also modified in the same manner by inflammation, that is to say, their thickened walls presented a number of newly-formed cells.

Fig. 80.



Section of an old gumma of the liver, including caseous part and peripheral zone. *a*. Fibrous tissue of the caseous portion, the fibres of which are thin and parallel; it is directly continuous with the fibrils of the peripheral connective tissue, *b*. The cells, *c*, situated between the fibrils of the caseous tissue, are pale and granular, while the living cells, *d*, found in the peripheral fibrous tissue, are well stained by the carmine. *m*. Empty vessel. *m'*. Cleft in the caseous tissue. *e, f*. Spaces situated at the margin of the caseous portion, and containing crystals of fat *k*. Small round and refracting bodies at the edge of the caseous part. *v, v*. Bloodvessels  $\times 150$ .

At a certain moment, in consequence of this inflammation of the wall, and of the peripheral tissue, partial vascular obstructions occur, followed by a cheesy state of the central portions of the gumma. Some of these obstructed vessels become permeable or an incomplete

collateral circulation is subsequently set up, by the small vascular branches which were not obstructed in the first instance. In the peripheral portion of the gumma which has not been the seat of obstructions, the vessels are well developed on account of the abundance of new and organized connective tissue, which tissue supplies the nutritive elements and enables them to increase in size. This is the explanation of the difference which exists between the vessels of the central portion and those of the peripheral zone of the gumma.

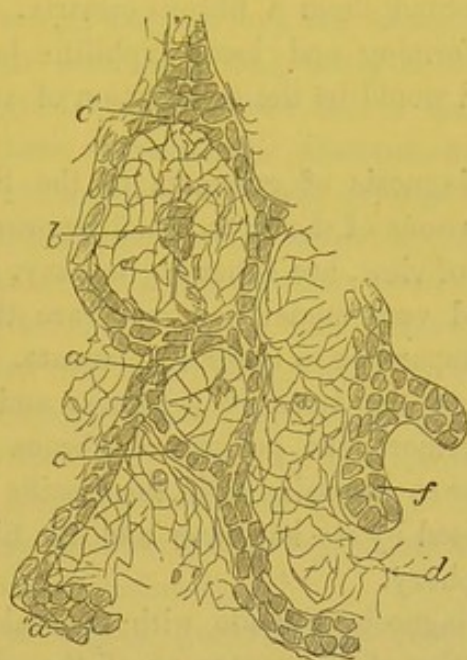
In regard to the modifications of the proper elements of the liver, the hepatic cells, and the biliary ducts included in the peripheral fibrous tissue of the gumma—the cells of an hepatic acinus, or of a portion of an acinus, are seen completely separated by embryonic or old connective tissue. The hepatic cells are separated one from the other by connective tissue, infiltrated with round or flat cells, and forming bands of greater or less thickness. In recent gummata, the hepatic acini or lobules which are involved in the inflammation which affects the tissues in the neighborhood of the gumma are uniformly surrounded, and sometimes separated by embryonic tissue as occurs in recent cirrhosis. The lesions of the bloodvessels and the biliary vessels are then the same as in cirrhosis; all the bloodvessels at first have embryonic walls, and are dilatable under the influence of blood pressure; later, their walls thicken and become very dense. In many cases of syphilitic gummata (in three cases out of five that I have recently examined), I found a new formation of delicate biliary canals, more or less numerous, in the embryonic or adult connective tissue forming the exterior zone of the gumma, and surrounding the hepatic acini. These new formations of biliary ducts are absolutely the same as those described in cirrhosis of the liver. At the circumference of the syphilitic gummata, the origin, and arrangement of these canals are, as in cirrhosis, in direct relation with the inflammation of the connective tissue and with the amount of the latter present.

In the peripheral fibrous tissue of old gummata, the form of the hepatic acini is more or less unrecognizable. Thus in Figure 79, the hepatic tissue, *e*, formed by the hepatic cells, is traversed by the thick bands of connective tissue, *m, m*, which accompany the branches of the portal veins. In the other peripheral portions of the same gumma, these bands are regularly arranged around the lobules.

In the fibrous envelope which is connected with the cheesy portion are often found large biliary vessels filled with cylindrical cells and

bile. It is possible that a large biliary vessel traversed this region prior to the formation of the syphilome. But the number of such vessels which are always found in this zone of newly formed tissue, would certainly indicate that the pre-existing biliary canals have be-

[Fig. 81.]



Network of biliary canaliculi in the newly-formed connective tissue of cirrhosis. *f*. Interlobular biliary canal. *c*. Very small canaliculus communicating with other canaliculi, also minute and lined with cells placed end to end. These canaliculi empty into larger canal *a*, *c'*, *a''*. *d*. Connective-tissue corpuscle.  $\times 300$ . (Cornil and Ranvier.)

come inflamed, and have remained dilated as a result of the formation of the neoplasm. In Figure 79, the letters *f, f* point out large bile canals filled with cylindrical cells. The power used is too low in this cut to show the cells of these ducts or the capillary biliary ducts.

The ultimate termination of these tumors, which are of great frequency, is, that after a period of augmentation and of maturity they become caseous at their centre. Then the lymphatic vessels or spaces of the peripheral connective tissue absorb the liquids and the fatty particles which are derived from the breaking down and fatty-degeneration of the gumma. The cheesy portion evidently atrophies and is compressed by the connective tissue which forms its capsule. This atrophy and contraction continue for years, and the tumor finally forms a small mass in which fibrous tissue predominates. Having reached this stage, the gumma may be completely transformed into cicatricial fibrous tissue, without any vestige of the several layers



which formed it, and without leaving any trace of a pre-existing tumor. This view seems probable, even if not entirely demonstrated. There are found very small atrophied fibrous gummata, and, reasoning by analogy, I am disposed to believe that, like the gummata which have the same structure as those of the liver, and which are seated in parts accessible to sight, they may heal in course of years, and simply leave behind them a fibrous cicatrix. According to this hypothesis, the deforming and local syphilitic hepatitis which has just been considered would be the termination of such gummous neoplasms.

The anatomical diagnosis of gummata of the liver is very easy. Tuberculous granulations of the liver, which approach nearest to it in a histological point of view, are generally miliary, scarcely visible to the naked eye, and very numerous; it is rare that hepatic tubercles attain a size comparable to those of gummata. When this occurs the central portion of the tubercle is cheesy and soft, puriform or calcareous. Furthermore, the peripheral fibrous zone is never, in tubercle, so dense or so extensive as in the specific tumor. A gumma may also be recognized by its hardness and its fibrous elasticity at the centre and periphery.

The anatomical diagnosis is made with the naked eye, for if we examine a small portion of the centre or of the circumference of a tubercle, and compare it with a similar portion of a gumma well prepared and under a high power, we cannot, ordinarily distinguish positively between them. The larger portion of the anatomical lesions, whether they are seated in the skin and are apparent, or hidden in the depths of internal organs, are characterized more especially by their form and their general arrangement rather than by the histological phenomena which occur in the tissues. The other tumors which appear in the liver, such as cancer, sarcoma, epithelioma with cylindrical cells, etc., have no analogous structure with the syphilomes.

[Dr. Wilks, long ago, described three varieties of the syphilitic liver, and in some respects his description is fully as accurate as it could be made at the present day.

The first of his varieties was that in which the whole liver has become infiltrated by a new fibrous tissue, producing a uniform and general hardening; the second, in which the presence of the new material in the course of the portal vessels has produced a contraction like that of cirrhosis; and the third, and most striking form, where the organ is pervaded by distinct nodules of the new formation. The

*first* variety has mostly been observed in children who have died of hereditary syphilis, the organ being large and intensely hard, all natural structure having disappeared to the naked eye, and the microscope showing the organ pervaded throughout by the adventitious material. The *second* form is constantly seen in those bodies which are tainted by syphilis, and is often found associated with the lardaceous degeneration. It may go on, like alcoholic cirrhosis, to produce dropsy, as was seen in a man lately in the hospital, and who required to be tapped several times before his death. The *third* form shows the most characteristic changes, and those which are generally pointed out as evidence of the presence of syphilis. Here are seen distinct nodules scattered through the substance of the organ, sometimes as small as peas, and at other times as large as walnuts. These after a time become dried up, and then form tolerably circumscribed masses; but the neighboring tissue is often infiltrated, and then they send out long processes into the neighboring hepatic tissue. When near the surface they shrink up the tissue, causing deep cicatrices, so that we may constantly meet with a liver much altered in shape, or apparently lobulated, from the effects of syphilis which had occurred several years previously.]

The *symptoms* of hepatic gummata are very variable. When a small number or even one alone exists, as we have frequently seen to be the case, and there is no accompanying extensive interstitial hepatitis, the symptoms are not marked, or simply contribute their part to the syphilitic cachexia in relation with other disseminated lesions.

If the gummata are numerous, forming tumors made up of several smaller ones, disseminated throughout the liver, if they are attended with irregularities on the surface of the organ, and a generalized interstitial hepatitis of the whole gland, there are then multiple and very grave symptoms. Between these two extremes, there are many intermediate conditions.

In the most severe cases, the liver is enlarged at the commencement, and sometimes there is jaundice. Palpation reveals the liver extending beyond the false ribs and nodular. In some rare cases, where it was possible to follow the evolution of the malady from its commencement, the liver diminished in volume, and the jaundice disappeared, but at the end of an uncertain period, there ensued a chronic interstitial hepatitis with dropsy, want of appetite, vomiting, swelling of the spleen, diarrhoea, hemorrhages, in a word, all the symptoms of cirrhosis. Palpation of the liver discovers the nodules,

the depressions, the marked irregularities of the anterior surface, and of the free edge of the liver, the tumefaction of its right lobe, etc. Brouardel has reported in his clinical lectures of 1874, delivered at the "Charity" Hospital, a very remarkable case of hepatic syphilis that he had watched during a number of years. The patient after having had gummata of the bones, syphilitic laryngitis, etc., presented a transient jaundice with a considerable tumefaction of the liver. He died three years after from dropsy, and with all the signs of syphilitic cirrhosis with diminution of the volume of the liver.<sup>1</sup> Pain in the hepatic region is rare.

[The following case is reported by Dr. L. Goldstein.<sup>2</sup> The patient, forty-three years old, had been infected with syphilis about twenty years previously, and four years ago had had rheumatic pains in the shoulders, and pain in the right side. Recently he had had icterus and swelling of the feet. He was anæmic, and thin, with dirty yellowish tinge of the skin; but there was no glandular swelling, no syphilitic eruption, and no prominence or tumor of the liver; indeed, this organ was apparently smaller than normal. After a time hæmatemesis occurred, and the stools contained blood. The spleen was not enlarged. Ascites developed, and after a violent attack of hæmatemesis he died, eighteen days from the first loss of blood. In the right lobe of the liver was a wedge-shaped mass of connective tissue, measuring three inches long by two inches broad, and from one to two inches thick; scattered through this were numerous cheesy nodules of various sizes, bounded by dense fibrous bands. From the wedge-shaped mass stout bands of fibrous tissue stretched downwards between the larger branches of the portal vessels. The whole surface of the liver was deeply marked and deformed by cicatricial contractions, and the cut surface was finely nodular, with a finer or coarser network of irregular fibrous bands. Microscopically these bands were rich in nuclei, though many presented fatty-degeneration of the new tissue. The cheesy nodules consisted of a finely granular detritus. The liver itself was small, with an adherent capsule; it was not lardaceous. The spleen and kidneys were congested, but otherwise normal.]

Such are the principal symptoms of gummata, which, by their number and their volume, produce compression of the branches of the portal vein, irritation or compression of the biliary ducts, and which, accompanied or not by a generalized interstitial hepatitis, produce

<sup>1</sup> Journal des Connaissances Médicales, 1874, p. 83.

<sup>2</sup> Berliner Klinische Wochenschrift, May 8, 1876.]

the same symptoms as simple cirrhosis. But the most common symptoms of hepatic syphilis are those of local interstitial syphilitic hepatitis, which have already been described. Very often it is impossible to recognize a single physical or functional sign when the neoplasm is small, or when there are but one or two gummous formations in the entire liver.

The diagnosis, in cases of ascites, with irregularities of the surface and free border of the liver, and with symptoms of cirrhosis, is based upon the knowledge of the syphilitic antecedents and upon the coincidence of late tertiary symptoms (exostoses, or ulcerating cutaneous or mucous syphilides). Lancereaux mentions also, as do Hérard and Leudet, cases of hepatic syphilis with albuminuria and Bright's disease. It is probable that this albuminuria is generally dependent upon an amyloid degeneration of the kidneys. Individuals affected with cirrhosis, due to alcoholism, usually present symptoms of the latter disease. Chronic tuberculous peritonitis might be mistaken for a syphilitic hepatitis.

The prognosis is very variable. It is certain that it is possible to live, and not experience the slightest symptom, with a single gumma of the size of a small pea; while, on the contrary, with the liver filled with gummata, and affected at the same time with an extended interstitial hepatitis, death would undoubtedly result. Nevertheless, in very grave cases, when there are syphilitic lesions to deal with, we must not despair of saving our patients. Lancereaux reports several examples of ascites, accompanied with cachexia, coming on in patients who had had tertiary syphilis, and who were completely cured by the iodide treatment, puncture, and the application of mercurial ointment on the abdomen.

A few words will suffice for the interstitial hepatitis of syphilitic origin, complicated with amyloid degeneration of the vessels and cells of the liver. This lesion, which is extremely rare, follows the same course, in regard to symptoms, as a simple cirrhosis; the amyloid degeneration which succeeds in such cases to prolonged suppurations of syphilitic origin is itself a cause of the cachexia, for the glycogenic function of the liver is destroyed in consequence of the degeneration of the cells.

CONGENITAL SYPHILIS OF THE LIVER.—Gubler gave in 1852 a very good macroscopic description of the anatomical condition of the livers of new-born syphilitic children. The liver is always larger

than in the normal condition. Its surface often presents thickenings of the capsule of Glisson; the hepatic tissue is harder, more elastic than normal; it rebounds when a piece is dropped upon the table; it presents the yellow color and the semitransparence of flint. Furthermore, Gubler has described small white granulations, which he compares to grains of wheat, and which are scattered throughout the parenchyma. The histological examination shows that these small granulations are formed by an accumulation of embryonic cells in the spaces which separate the hepatic acini. Ranvier and I had frequent occasion, about twelve years ago, to examine such cases of hepatic syphilis. The hepatic acini, in the normal state, are in contact except at the prismatic spaces which are formed by their union—spaces in which the capsule of Glisson forms an envelope to the afferent portal vessels of the lobule. It is in these spaces that the round lymph cells form and collect into small nodules representing microscopic gummata. The cells at the centre of the new formation are sometimes granular. This neoplasm is seated about the ramifications of the portal veins, which in consequence also present thickened walls with newly-formed cells in their external tunics. The small granules above mentioned are not always visible to the naked eye, and in their place are only seen, about the perilobular capillaries of the portal vein, an excessive number of embryonic cells. I have seen this condition many times in new-born children who have died in this hospital, and in the still-born before term. But in all these cases we must be careful not to take for a pathological condition a normal state of the connective tissue peculiar to the age of the embryo we examine. The connective tissue is embryonic, and consists of small round cells in the fœtus and in the new-born infant. It is necessary in these examinations to have for comparison a series of preparations of each organ corresponding with the age of the fœtus or new-born infant.

Independently of these lesions peculiar to the liver of new-born syphilitic children, there are found in very young children affected with hereditary syphilis true gummata of the liver, resembling those of the adult in size, form, and structure (Prévost, Lancereaux, etc.).

The symptoms of hepatic syphilis in new-born children are null, or they are identical with those of local and general troubles so often observed in children who have poor or insufficient nourishment (athrepsia of Parrot). The only physical sign which properly belongs to hepatic syphilis is, when it exists at all, increase in the size of the liver.

## [CASE XIII.]

*Syphilitic enlargement of liver.*By Mr. Hutchinson.<sup>1</sup>

Mr. Hutchinson has described some cases of syphilitic enlargement of the liver in the following words: "In several cases I have witnessed in young persons, the subjects of hereditary taint, great hepatic enlargement which has subsequently wholly disappeared. It is difficult to believe that there is any kind of gummous growth in such cases, and we are obliged rather to fall back upon the hypothesis of mere vascular turgescence. This turgescence may possibly in its turn be due to some disease in the nervous system. I well recollect a lad whose case illustrated what I am saying. He had on more than one occasion such enlargement of the liver that it hung below his navel, and was easily visible as a swelling when he lay on his back in bed. I had had him under observation for many years. He had nodes on almost all his long bones; and his mother, and several of his brothers and sisters, had suffered most severely from syphilis. At length he died. At the post-mortem the liver was found natural, and, excepting some patches of slight thickening of the capsule, showed no changes. . . . It seems clear, however, that among the unexpected incidents of constitutional syphilis we meet occasionally with general enlargement of such viscera as the spleen and liver, independent of any of the conditions of new growth, and which we recognize as specific and capable of spontaneous resolution."

The following case was apparently an example of this condition:—

B. B., aged twelve, was admitted to the London Hospital on October 26, 1876, suffering from enlargement of the liver.

*Previous History.*—He has always been delicate. Four years ago he was laid up for some weeks with "gatherings" in various parts of his body. A cicatrix, the result of one of these abscesses, is to be seen in the left groin. The enlargement of the liver has been noticed for several months, and remains stationary.

*Family History.*—His mother is dead. His father is a dissipated, drunken fellow. He had one brother and one sister; they both died young.

*Condition on Admission.*—He is small for his age. The forehead is square; the nose shrunken; the teeth somewhat peg-shaped. The nose used to be sore, and it "mattered" for a long time. There is a small cicatrix at the left angle of the mouth. The corneæ are clear. There are no nodes. He is thin and pale; the tongue is clean; the appetite good. The abdomen is very large-looking in its upper half. On palpation the swelling is found to be due to an enlargement of the liver. The inferior

[<sup>1</sup> Medical Times and Gazette, December 22, 1877.]

border is sharp and well defined; it reaches the umbilicus. Superiorly the liver dulness extends as high as the fourth rib. To the left it can be traced to a point drawn downwards in the line of the left nipple. The surface is quite smooth; the organ seems uniformly enlarged, and can be freely handled without causing any uneasiness. The spleen is also enlarged; its anterior border can be grasped between the finger and thumb when pressure is made with the other hand from behind. The blood is quite normal. The other organs are healthy.

The *treatment* consisted in the application of the tincture of iodine and of the biniodide of mercury ointment externally; the administration of the syrup of the iodide of iron, iodide of potassium, and cod-liver oil internally, together with a generous diet.

*Progress of the Case.*—The patient's general condition quickly improved. The enlargement of the liver decreased somewhat; at the time of his discharge (December 28, 1876) the inferior border was an inch above the umbilicus. The lad has been under observation since his discharge. The liver enlargement still continues, but is less than at the time of his discharge.

Mr. Hutchinson was at first doubtful whether the liver and splenic enlargement might not be "waxy." The healthy condition of the urine, the absence of diarrhœa, and the improvement under treatment, were against this supposition. The evidence of hereditary syphilis was not, perhaps, so strong as it might have been; still it was sufficient to justify the diagnosis.]

## CHAPTER XII.

SYPHILITIC LESIONS OF THE DIGESTIVE CANAL AND OF THE  
RESPIRATORY APPARATUS.

Œsophagus—Gummata, ulcerations and stricture—Gummata and ulcers of the stomach—Syphilitic ulcers and stricture of the anus and rectum—Syphilitic lesions of the larynx, trachea, and bronchi—Syphilis of lung—Gummata—Lesions of the lungs in congenital syphilis.

SYPHILIS OF THE DIGESTIVE CANAL.—Tertiary syphilides and gummata of the different regions of the mouth and pharynx have previously been described. The œsophagus, intestines, and rectum may be affected with tertiary syphilis.

The œsophagus is a passage for the rapid transit of food, and its pathology is not extensive; it is very seldom the seat of syphilis. There are, however, some undoubted cases of a syphilitic nature reported, as that by Follin, in which the patient suffered with dysphagia from stricture of the œsophagus, and who recovered under internal anti-syphilitic treatment alone. Virchow reports an autopsy, in which there were, besides a contracting ulcer, gummous tumors in a state of yellow, fatty metamorphosis, giving origin to the ulceration.<sup>1</sup> West found at the autopsy of a syphilitic woman, a dilatation of the superior part of the œsophagus below which the tube was very narrow and its walls indurated.

[The grounds which West gives for considering the above case as of syphilitic origin, are as follows: "The fact of stricture of the œsophagus in this case was perfectly patent, and it remains to consider whether any course, other than that to which I have referred it, can have produced this lesion. Certainly, no positive proof of the primary sore can be advanced, but the secondary symptoms extending over a long series of years, are distinctly marked; and in how very many cases do we find persons in the class of life of this girl, denying that they have ever had sores, when their effects are but too

<sup>1</sup> This case of gummata of the œsophagus, reported by Virchow, without histological details, is the only one we know of.



plainly visible in the scarred skin, the ulcerated throat, and the carious ossa frontis and tibia of the sufferer. Such a sore, no doubt, existed at some period of her career, and its probable site was manifested in the post-mortem examination, by a cicatrix, near the lower part of the vagina. We have no account of the swallowing of any caustic or irritating fluid, so that we cannot attribute the stricture to that cause. But we find a patient gradually exhibiting the symptoms of well-marked syphilitic cachexia, and also experiencing frequent ulceration of the fauces and pharynx. At first, slight dysphagia alone led to the suspicion that there was narrowing of the œsophageal canal; but, with its persistence and tendency to become worse, the suspicion became augmented, until at last, all doubt was removed, on an attempt being made to pass a small-sized bougie. . . . . The presence of numerous recent cicatrices clearly indicated that ulceration had existed in the walls of the œsophagus. The deposit in the submucous tissue was fibrous; it was exactly similar in nature to that which is so well described by Dr. Wilks as characteristic of syphilitic ulceration, and could not, under any supposition, be referred either to cancerous or tuberculous degeneration."

"The description referred to, which Dr. Wilks has given of syphilitic ulcer, is as follows: 'When a syphilitic ulcer is examined after death, it may generally, I think, be told . . . . by the adventitious fibrous deposit or lymph, which is formed in the tissue; and thus, besides the ulceration, you find the adjacent parts much thickened and indurated.'

"A case of syphilitic stricture of the œsophagus has been placed on record by Dr. Maury, of Philadelphia, in which recourse was had to gastrotomy, after it had become impossible for the smallest quantity of food, solid or liquid, to enter the stomach, and the finest bougie could not be got through the constricted portion of the tube. Before the operation, the patient had been kept alive for several weeks by the aid of nutritive enemata, and was reduced, of course, to a state of extreme emaciation. He died of exhaustion fourteen hours after the performance of the operation. The post-mortem examination displayed a very tight stricture, free from all evidence of cancerous disease: it was situated just above the cardiac orifice. The patient's syphilitic antecedents in this case were unequivocal, and Dr. Maury had not the least doubt that the lesion was of this nature.'"¹]

[¹ Pathology of the Œsophagus, by John F. Knott.]

Gummata of the œsophagus cannot be compared, in regard to their frequency, with those of the pharynx or liver. When simply more or less distinct cicatrices are met with, or a flat ulcer, as in another case of Virchow's, or a stricture consecutive to cicatricial fibrous bands, or a stricture above which there is an ampullar dilatation, we should be certain that they are not due to some inflammatory or accidental cause, and they should occur in a person evidently syphilitic before we venture to assert their connection with syphilis.

Syphilitic disease of the stomach is also very infrequent, and lesions of this organ should be carefully examined before being attributed to a specific cause.

Some four years ago, during the service of Woillez, at the Charité, I made an autopsy of a woman who had gummata of the liver and stomach. The mucous membrane of the stomach showed, along the small curvature and in the proximity of the pylorus, flattened, reddish tumors, one five centimetres in diameter, another three, and one two centimetres; the mucous membrane was intact, but thin and adherent on the surface of the tumors. Upon section, the thickened and indurated submucous connective tissue measured eight to twelve millimetres, and could be easily distinguished from the muscular layer beneath. The pylorus was contracted; the lymphatic glands, situated at the small curvature of the stomach, were hypertrophied and indurated; there was also found upon the peritoneal surface of the stomach a white, hard, and radiating cicatrix. Upon microscopic examination, the glandular layer of the stomach, at the location of the small tumors, showed small villous or papillomatous projections, due to hypertrophy of the connective tissue which surrounded the glands. These latter were separated by thick fibrous connective tissue; their excretory canal was contracted, sometimes obliterated by the connective tissue; although the deep acini of the glands were nearly normal, they were seen at one to one and a half millimetres from the surface of the mucous membrane, in the form of agglomerated circular sections having the normal diameter of the terminal acini of the glands. The latter contained a few cubical and small epithelial cells which did not constitute a complete lining, but the terminal dilatations were, however, completely lined by cylindrical cells with their large ends turned towards their wall, and their small ends towards the lumen of the gland which contained a mucous fluid.

The submucous connective tissue, which constituted the elevation of

the new formation, was compact, dense, felt-like, and traversed by vessels permeable to blood. It consisted of fasciculi of connective tissue, between which were numerous round, small, or oval embryonal cells. These cells were at times collected in small islands.

The much-thickened muscular layers of the stomach were composed of fasciculi of smooth fibres, separated by bands of fibrous tissue containing many embryonal cells. The sub-peritoneal connective tissue presented a new formation of similar cells.

In this case there were flat, reddish gummata of the stomach, situated beneath the glandular layer of the mucous membrane, and the nature of which was also confirmed by the presence of a gumma in the liver.

The patient had experienced much gastric pain, and digestion, which was at first difficult, afterwards became impossible. She died of pulmonary complications, with vomiting, and with swelling of the bronchial and lymphatic glands. The change in these structures will be later referred to.

It is very seldom, in the whole length of the digestive canal, from the œsophagus to the rectum, that we meet with the tertiary lesions of syphilis in the form of true gummous tumors, or as prominent and non-ulcerated new formations. Besides the cases that I have observed, I know only of those reported by Klebs, where there were gummata of the intestines, in one of which they were prominent, and the mucous membrane was intact; the others were ulcerated. The case which Virchow reports, in his work on the Pathology of Tumors, is very clear in regard to the existence of syphilitic ulcerations. It occurred in a woman treated in the Berlin Charity Hospital, during a period of six years, for the cutaneous and osseous lesions of tertiary syphilis; the bones of the nose had disappeared, and the autopsy showed gummata of the tibiæ, frontal and parietal bones. There existed extensive cicatrices on the soft palate and pharynx, also an internal hemorrhagic pachymeningitis with hyperostoses of the bones of the cranium. The rectum was the seat of ulcerations, some covered with recent diphtheric membrane, others having cicatrized; in the jejunum were found three large cicatrices corresponding to scattered small white tumors upon the serous membrane; in the ileum were seen two small ulcers which had not produced caseous deposits. The lungs and pleuræ presented lesions which will be spoken of later.

More frequently syphilitic lesions of the stomach and intestines, as observed after death, consist only of ulcers or fibrous cicatrices.

Ulcers of the stomach have been reported and connected with syphilis during the last few years by Engel, Fioupe, Lancereaux, Kaposi, etc. But if there be simply an ulcer or a cicatrix which follows it, even if there exist undoubted syphilitic antecedents, it is difficult to decide upon their nature. The cicatrices which follow a simple ulcer of the stomach due to any other cause, to bad food, or to swallowing corrosive liquids, cannot be certainly distinguished from similar lesions due to syphilis. It is true that simple ulcers of the stomach have, in certain cases, a characteristic appearance, the loss of substance presents a distinctly cut edge, and it is cone shape or cut in steps, corresponding to a section of the several layers of the stomach wall; but this arrangement is not always found, and these ulcers present numerous variations. Pathological anatomy, which permits us to positively distinguish the ulcers due to tumors, epithelioma, carcinoma, lymphoma, etc., does not give us certain information touching the anatomical diagnosis between simple ulcer and syphilitic ulcer, when the gummous neoplasm has disappeared by ulceration.

This anatomical diagnosis is yet more difficult in the mucous membrane of the large and small intestines, since here syphilitic ulceration is liable to be confounded with tuberculous ulcers, with the cicatrices of typhoid fever, with the ulcers of dysentery, and with any tumor—cancerous, leucæmic, etc.—that may ulcerate.

It should not be forgotten that pulmonary phthisis and tuberculosis of the intestine very frequently accompany syphilis, and that ulcerations connected with an amyloid state of the intestinal vessels may be the consequence of prolonged syphilitic suppuration.

It is necessary, in each particular case, to make a careful differential anatomical diagnosis, and even then syphilis cannot be positively affirmed if there be not a gummous new formation.

It is unnecessary to add that syphilitic ulcers of the stomach and intestines do not present any special symptom by which their nature may be recognized during life.

Anti-syphilitic treatment seems to have succeeded in some cases of gastric and intestinal troubles that have been referred to syphilis.

The difficulties that have been mentioned in regard to the diagnosis of syphilitic ulcers of the stomach and intestines are also applicable to the ulcers occurring at the inferior part of the rectum. Here they are always accompanied with narrowing, and are generally designated as *syphilitic strictures of the rectum*.

The nature of these ulcerations is as yet not universally agreed upon.

Gosselin, who has given an excellent description of them, attributes them to an inflammation of the rectum provoked by the presence of chancres in the anus; he does not consider them of a syphilitic nature. Lancereaux and Leudet regard them as not having any direct connection with syphilis, but believe that they may occur secondary to any venereal lesion of the vulva and anus (vulvitis, mucous patches, erosions, etc.). Desprès looks upon them as a consequence of phagedenic chancres and mucous patches of this region. The fact that they are met with almost exclusively in women, and that anti-syphilitic treatment has no effect upon these ulcers and strictures, testifies against their syphilitic nature. According to Virchow, it is impossible, by the examination of a portion of these ulcers and of strictures of the rectum, to decide whether they are the result of syphilis or of chronic dysentery; the location only may furnish positive information, for syphilitic ulcers are found at or near the anus or in the rectal ampulla, while dysenteric ulcers frequently exist along the entire large intestine. It may be added that, although venereal ulcers of the rectum are always accompanied with stricture, it is not the case with those of dysentery; the latter may even cause a dilatation of the rectum with rigid thickening of its walls. Guérin, Verneuil, and Panas regard the former as undoubtedly syphilitic. Fournier does not hesitate to connect them with syphilis, and describes them under the name of ano-rectal syphiloma. Mollière and Jullien also regard them as being syphilitic. (See page 83.)

Although it may be very difficult, if not impossible, to determine whether these ulcers are simply primary venereal lesions or syphilitic lesions of the secondary period, or gummata, there is no doubt that they frequently occur in syphilitic women.

The ulceration accompanied with stricture is situated in the lower half of the rectum, about five to six centimetres from the anus, seldom nine or more centimetres high (five times in fifty-eight cases, Perret). Sometimes it extends to the skin of the buttocks around the anus. The ulcer presents a red surface, covered with a thick muco-pus; the constituent parts of the mucous membrane, the glands, and epithelial covering have disappeared, and are replaced by a granulating embryonic tissue. According to Malassez, the most constricted and least dilatable part is not, as generally described, a cicatricial tissue, but a tissue exactly similar to that of granulations, consisting of young elements, and but slightly resisting. He also describes the inferior and older parts as made up of fibrous fasciculi

of new formation, surrounded by embryonal cells as in cicatrices. The fasciculi of the muscular layer are separated by these cells infiltrated between them; there are even collections of round cells which form miliary abscesses, the latter giving origin to fistulæ.

In exceptional cases the stricture may extend quite high, and is often complicated with fistulæ.

There are few affections in which the lesions are as painful, as long continued, and at times as serious, as they are in this disease. The symptoms of syphilitic stricture of the rectum do not differ from those of stricture of the rectum in general. During my service of three years in the Lourcine Hospital, I have only met with two cases. These occurred in women who had had a series of syphilitic manifestations. In one of the patients the stricture was so extensive that there was almost complete retention of the fæces, and it was with difficulty that a urethral sound could be passed through it. The patient had a passage from the bowels only every five days or at longer intervals, and the region of the anus was riddled with fistulæ. In the majority of cases the surgeon is as powerless as the physician, and the patient dies from stercoraceous retention or from peritonitis.

Treatment by mercurials and iodine has no effect whatever upon the strictures.

SYPHILIS OF THE RESPIRATORY APPARATUS.—The *larynx* is undoubtedly the part of the respiratory tract most frequently attacked by syphilis, and particularly by tertiary syphilis. The most frequent seat is the epiglottis. By laryngoscopic examination, the evolution of gummata of this organ can be followed. They begin by one or several small tumors beneath the mucous membrane, which open and present thick and undermined edges, the ulceration subsequently extending deeper, and often accompanied with perichondritis. These gummata are generally not hard and indurated, but, according to Virchow, consist of a soft, whitish, medullary tissue, very rich in embryonal cells. The vocal cords and interior of the larynx are also frequently ulcerated, the mucous membrane covering them is destroyed, and its connective tissue infiltrated with embryonal cells.

[It is asserted<sup>1</sup> that there is a peculiar serrated appearance of these ulcerations, when present upon the epiglottis, due to the histological structure of this organ. In the normal condition the glands of the

[<sup>1</sup> By Dr. Seiler.]

mucous membrane of the epiglottis are found to penetrate its cartilage, so that the ulcerative process of the disease, during its course, first destroys the softer tissues, thus leaving a honeycombed or irregularly serrated edge, formed by the more dense cartilaginous tissue. The same process takes place in tuberculous ulceration, with some slight modification. True tuberculous ulcers are, however, very seldom met with on the epiglottis. As a distinguishing point between laryngeal ulcers due to syphilis and those due to tuberculosis, it may be mentioned that the former are generally more or less symmetrical both as to position and shape, while the latter, the tuberculous, are more frequently unilateral.]

The anatomical changes of these deep ulcerations and inflammations are the same as those occurring in tuberculous laryngeal ulcerations, that is, œdema of the glottis, perichondritis, partial necrosis of the cartilages, abscesses and suppuration in the neck, cutaneous fistulæ, etc. When the disease is not so extended, but is limited to granulating ulcerations of the inflamed connective tissue of the mucous membrane, there are formed papillary vegetations and small irregular polypi.

If the patient recovers under appropriate treatment, there is danger of having cicatricial contractions of the mucous membrane, deviation of the epiglottis, or a laryngeal stricture.

Syphilis may then be symptomatically diagnosed by the signs of chronic laryngitis, the hoarseness, aphonia, fits of coughing, and paroxysms of suffocation. The latter are at times so intense, sudden, and grave, that recourse to tracheotomy is necessary.

[The larynx may be invaded during the earliest stages of syphilis, which, beginning in the pharynx or on the epiglottis, may affect any portion of its cavity: According to Klemm,<sup>1</sup> this form of syphilitic disease is not so rare as is usually supposed. But the symptoms, especially at first, are so slight as easily to escape notice. In the earlier stage the epiglottis is reddened, swollen, and beset around the edge with small ulcers, the borders of which are sharply defined, and whose surface is covered with a dirty coating. Already, even in this stage, this affection resists treatment. Of the severer forms two are to be distinguished: first, the *hypertrophic* or chronic inflammatory form, in which the epiglottis, or a part of it, is changed to a thick, firm lump, which may be confounded with acute non-syphilitic pro-

[<sup>1</sup> Centralblatt f. Chirurgie, 1878, p. 386. Philadelphia Medical Times, Aug. 31, 1878.]

cesses; second, the *ulcerative* form. This latter is more frequent. Here we find deep ulcers on the epiglottis, with thick, protuberant borders. Beginning usually at the edge, they consume a portion irregularly, and may eat away the whole epiglottis. The process may last for years, may involve the glottis, and lead to stenosis of the latter. At this point, however, infiltration and swelling are often found without ulceration, which is important in the diagnosis between this form of disease and tuberculosis. In the course of time, in syphilitic cases, certain characteristic crumplings and contractions form in the epiglottis. Pain on swallowing is among the most noteworthy symptoms. Painfulness to the touch, however, is not noticed. In this respect the syphilitic disease differs from the tuberculous affection, where the epiglottis is very sensitive to the touch. Syphilis of the epiglottis appears only some years after the initial lesion. It seems to occur more frequently among women than among men. It is remarkable that in these cases, even where the entire epiglottis has been lost, the patient can swallow without difficulty, and experiences no particular irritability of the glottis. Carcinoma and tuberculosis are alone to be distinguished from syphilis of the epiglottis, and here outside manifestations, history, etc., come into play, as local differences often cannot be made out. Treatment is both local and general. The disease is apt to be chronic. Klemm gives notes of seven cases.

Mr. Whistler,<sup>1</sup> as a result of observations made upon eighty-eight cases, groups the lesions found in syphilis of the larynx, as follows:—

1. Catarrhal congestions, simulating those arising from ordinary causes.
2. Congestions accompanied by diffuse redness and swelling.
3. Mucous patches of various types.
4. More chronic inflammation with redness, thickening, and ulceration.

The catarrhal congestions are, for the most part, superficial in character, and occur during the period of general eruptions, that is, during the first two years. Increased redness is their chief feature. This color varies in intensity and in tone. It is bright-red when acute, more dusky when chronic, but it certainly has not a coppery hue. From being unequally distributed it gives to the membrane a mottled appearance. The epiglottis is redder than usual. The mu-

[<sup>1</sup> Medical Times and Gazette, Sept. 21st–28th, 1878.]



cous membrane is no longer so transparent, and the yellowish hue of the normal epiglottis is lost, while tortuous vessels are seen running over its surface. In some cases the vocal cords are chiefly affected. Sometimes they are pinkish and dingy-looking, at others deeper-red and dry. They may be merely streaked with a few red lines, or the mucous membrane is occasionally eroded. With this, there is a want of proper tension, with defective approximation, and this leads to alteration of voice. All that these patients suffer from, as a rule, is hoarseness. Occasionally one meets with intense redness of the interior of the larynx, with swelling of the ventricular bands and arytenoids, accompanied by pain and cough. When such complications arise, they are generally due to some cause other than the syphilitic poison, such as, for instance, either cold, or excesses in drinking or smoking, or constant use of the voice. Mr. Whistler has seen many such cases; they resembled the acute catarrhs, and were relieved by somewhat the same measures. Confinement to a warm room, the inhalation of vapor medicated with benzoin and tincture of tolu, at intervals of two or three hours, will reduce any urgent symptoms more quickly than mercury would do without these aids. They should, therefore, be always added to the constitutional treatment in all such cases, for it is more than ever important that laryngeal inflammation be reduced as quickly as possible when it occurs in a syphilitic person.

In the second class of cases, the redness is equally diffused over the affected surface, like an erysipelatous blush or an erythema. No small vessels are seen running over the surface. Together with this, there is swelling; or maybe puffiness would better express the condition, as though there were a slight amount of œdema associated with it. This is most striking on the epiglottis. Its edges are rounded and cord-like, instead of being thin and sharply defined. From this it has a peculiar fleshy look when contrasted with the delicate tint of the normal epiglottis. Sometimes this redness extends over the whole mucous surface of the larynx. When, on the other hand, it is limited to certain parts—and this is more apt to be the case—the line of separation is well defined. The color in the earliest stages is rosy and somewhat opalescent-looking, gradually shading into a deeper-red. The intensity of the color may vary in different parts. In some cases it is somewhat patchy or spotted, like the condition spoken of already as laryngeal roseola.

The essential points which, according to Whistler, distinguish these

syphilitic catarrhs from others associated with diffuse redness and swelling, are these—

1. The redness is often more limited in its distribution, and it is not so bright. It is often rosy in the earlier stages, becoming darker in cases of longer standing. It is not vivid unless accidentally inflamed.

2. They are accompanied by general puffiness instead of great swelling.

3. There are no very acute subjective symptoms.

But none of these signs or symptoms will justify you in *absolutely* pronouncing the case syphilitic, if they are the only ones you have to go by. The history of the case and the other constitutional manifestations will usually guide you to a correct diagnosis.

The mucous patches of the third class are often opalescent, slightly elevated, the size of a large pin's head, looking like a nitrate of silver stain, and often situated on the epiglottis and the arytenoidean folds.

In other cases they are more markedly papular, vegetative, or ulcerated. Though differing from each other in various ways, they possess one common characteristic which is, that they are all primarily more or less papular. This seems to distinguish them from superficial ulcers or lesions associated with ordinary catarrhs. When they ulcerate, the ulcers are more regular in outline. They are more distinctly circular and isolated than those associated with ordinary catarrhal laryngitis, which have more the type of general erosion with no well-marked outline.

The form of laryngeal affection belonging to this class which Whistler, Mackenzie, Gerhard, and Roth, Vogler, Türck, Czermak, Seidel, and Desprès, describe as condylomata, are not admitted as such by Waldenburg, Isambert, Lewin, Fräikel, and others. Very recently Dr. Semon states,<sup>1</sup> that his experiences with regard to this question are entirely negative, and that in a large number of cases of early syphilitic laryngeal affections which he has seen, he has never been able, though paying special attention to the affection under consideration, to detect any projection or new formation to which, judging from the appearance of analogous tumors, seen on other mucous membranes or on the skin, he would be inclined to give the name "condylomata."

[<sup>1</sup> The Lancet, April 8, 1882.]

He considers the question as not yet ripe for decision.

Gougenheim finds,<sup>1</sup> in the earlier stages, ulcerative erosions seated on infiltrated surfaces, or, more rarely, on circumscribed papules, and occasionally pin-head sized whitish bodies supposed to be mucous patches.

In the fourth class you have ulcers appearing at a later stage of the disease; deep, with ragged edges, irregular in shape, multiple, surrounded by inflammatory thickenings, and occasionally, though not often, leading to perichondritis and necrosis of the cartilages.

Mr. Whistler thus describes<sup>2</sup> the diagnostic points which distinguish this affection from chronic glandular and from phthisical laryngitis:—

Chronic glandular laryngitis, although it is associated with deep redness and thickening of the mucous membrane, may be distinguished by the enlarged, prominent papillæ on the surface; sometimes there are small follicular abscesses containing muco-pus or pus, and presenting themselves as yellowish-red or yellow eminences. These, at times, are converted into follicular ulcerations. These ulcers, however, are quite superficial, and never lead to the destructive changes that are found in syphilis. Moreover, this condition of the larynx is almost invariably associated with a similar affection of the pharynx.

It will be, however, a far more important question to solve, whether the case be one of phthisis or syphilis.

In tubercular laryngitis the congestion in the earlier stages is more limited, so that, instead of the dusky redness of syphilis, there are redness and swelling, and especially œdema, of the arytenoids, or redness of the vocal cords, while there will be anæmia amounting often to extreme pallor in other parts. The mucous membrane, when ulcerated, instead of being dry, is bathed with purulent mucus. In both affections there is thickening, but in phthisis there is a greater tendency to softening, and the ulceration is more general. It often commences in the ventricular bands. It is formed of many small ulcers running into one another and creeping over the surface. These ulcers secrete freely, and are paler in color than the syphilitic ones. Their course is more rapid, and progressive destruction rather than chronicity serves also to separate them from syphilitic ulcers of the larynx.

[<sup>1</sup> Centralblatt für Chirurgie, 1881, p. 214.]

[<sup>2</sup> The Lancet, Nov. 9, 1878.]

In syphilis the voice is hoarse, in phthisis more feeble or whispering; in the latter the concomitant signs of pulmonary disease are generally, though not invariably, recognizable.

Moure compares<sup>1</sup> the early stages of laryngeal phthisis with secondary syphilis, and the ulcerative stage of laryngeal phthisis with tertiary syphilis. In the secondary period of syphilitic laryngitis the voice may be normal or hoarse; in the tertiary rarely aphonic, but always hoarse. In early tuberculosis the voice is husky, and there may sometimes be aphonia; in the ulcerative stage aphonia is always present. In secondary syphilis there is no cough; it is also rare in the tertiary stage, but is very frequent in the ulcerative period of laryngeal phthisis. There is no expectoration in secondary syphilis; but it is present, and may be blood-stained and purulent, in the tertiary. In commencing laryngeal phthisis it is mucoid, and in the ulcerative period muco-purulent. The pain is nocturnal in syphilis. The cervical and submaxillary glands usually swell in syphilis, whereas in tuberculosis they do not enlarge, but often atrophy. Both affections show hyperæmia of the mucous membrane; in phthisis it affects the arytenoid region, and is roseate in color; in syphilis it affects the front part or the free edge of the vocal cords, and in color is dark-red. The mucous patches of syphilis project above the mucous membrane, are depressed at their centres, and are surrounded by inflammatory redness. Tuberculous erosions, though gray, like the mucous patches, differ, in not projecting above the level of the mucous membrane; their edges are confused and irregular.

Gummata are apt to be mistaken for tubercles, and syphilitic for tuberculous ulceration. Gummata are large and yellow, and cause projections under the mucous membrane; tubercles are gray, opaline, and small, and give a granular appearance to the mucous membrane. Gummata affect chiefly the epiglottis, the glottic portion of the larynx, and the trachea; tubercles appear most often on the subglottic portion of the arytenoid cartilages. The ulcers in syphilis are solitary or few in number, their edges are hardened and cut perpendicularly; in tuberculosis they are oval or round, with dentated edges, often covered with fleshy granulations or polypoid vegetations. Both ulcerations affect the epiglottis, but differ in their mode of evolution. In phthisis they proceed from below upward, and from the periphery to the centre; in syphilis the process is reversed. The affection can always

[<sup>1</sup> *Annales des Maladies de l'Oreille et du Larynx*, Feb. 1880.]

be arrested in syphilis; this is impossible in tuberculosis, especially if the ulcerative stage has been reached.

Gougenheim<sup>1</sup> believes that hoarseness only occurs when the true vocal cords are involved in inflammation or ulceration, thinks this is rare, and that, therefore, disturbance of phonation is exceedingly uncommon, and the affection, in its early stage at least, is frequently overlooked.

In a case reported by Dr. Poore,<sup>2</sup> although the cough and emaciation gave an impression of phthisis, the diagnosis was made by the appearance of the epiglottis, which was ulcerated, thickened, and infiltrated, and by the absence of special pulmonary disease.

Iodide of potassium, in large doses, produced a rapid disappearance of both laryngeal and lung symptoms.

This ulceration of the epiglottis is usually the accompaniment of a still later or tertiary stage of syphilis than the ulceration just described, and which is characterized, by Whistler, as belonging to the "earlier and intermediate periods."

Mackenzie writes:<sup>3</sup> The ulcers may form three or four years after inoculation, but they sometimes occur twenty, thirty, forty, and even fifty years after the date of infection without the occurrence of intermediate symptoms, and when, indeed the primary cause may have even been altogether forgotten. Their effect is to produce great loss of substance, and the consequent changes in the form of the epiglottis and other parts of the larynx are very remarkable. The ulcers may form in any region of the larynx, but the epiglottis is the part most frequently affected—one of the most common conditions consisting of general thickening of the valve, with ulceration of the central portion or lateral edge. The upper surface is more often attacked than the under surface. Under these circumstances great dysphagia is usually experienced, but when the ulcers are healed, swallowing can generally be effected without trouble, even though nearly the whole of the valve is destroyed. When the walls of the pharynx are also ulcerated, there is danger of the edges of the epiglottis uniting with them. This condition gives rise to one of the most dangerous forms of dysphagia, as well as to serious dyspnoea. The ulcerative process frequently destroys the mucous and submucous tissues to a very considerable extent, and sometimes attacks the muscles,

[<sup>1</sup> *Op. cit.*]

[<sup>2</sup> *The Lancet*, Jan. 10, 1880.]

[<sup>3</sup> *Syphilis of the Larynx.*]

perichondrium, and cartilage. It is often associated with œdema, and is also not unfrequently followed by the formation of false excrescences, which are most apt to occur on the inter-arytenoid fold and the anterior surface of the posterior wall of the larynx, but are occasionally seen on the vocal cords.

The diagnosis of *tertiary* ulcers of the larynx from those of phthisis and cancer may be tabulated as follows:—

SYPHILIS.	PHTHISIS.	CANCER.
Development of ulcer acute, occupying only a few days.	Development slow; follows throat symptoms, by several months.	Intermediate in time; appearance of ulcers in a few weeks.
Considerable irregular inflammatory, or œdematous swelling.	Uniform, pale swelling, looking like an infiltration.	Nodular excrescences and acute inflammation of neighboring mucous membrane.
Epiglottis affected, if at all, on upper surface.	Lower surface.	No uniformity.
Ulcer, solitary; rarely more than two.	Numerous.	Solitary.
Proceeds from centre to periphery, or from above downwards.	The reverse is true.	Irregular in their course.
Deep, round, or oval.	Generally round.	Irregular in shape.
Diameter of 1 to 1½ centimetres.	2 or 3 millimetres.	2 or 3 centimetres.
No cachexia—	Phthisical appearance.	Cachexia.
Treatment usually highly beneficial.	Treatment has but very moderate effect.	No effect.

Among the most serious and alarming results of laryngeal syphilis is the gradual stenosis which occurs as a consequence of vegetations, gummy tumors, cicatricial contraction, etc. Krishaber, who has written an elaborate paper<sup>1</sup> upon this subject, arrives at the following conclusion:—

(1) The syphilitic laryngostenoses show themselves at the most varying periods after infection. (2) Their late appearance is not always, but frequently a proof of the presence of an advanced stage of syphilis. (3) The lesions which produce laryngeal contraction in syphilis are different, according to the sudden or slow appearance of respiratory troubles. (4) Sudden narrowing is almost always due to œdema, which accompanies the different specific manifestations; slow narrowing is most frequently the consequence of a hypertrophic

[<sup>1</sup> Gazette Hebdomadaire, 1878, 45, 47. London Medical Record, Jan. 15, 1879.]

or luxuriant inflammation ; sometimes it is due to cicatricial narrowing, and least frequently to the formation of an osseous tumor. (5) The respiratory accidents are the graver the closer the lesions are found to the tracheal region. Tracheal lesions are most frequently fatal. (6) The slow form may be complicated by œdema, and suddenly take an acute course. This complication is infrequent. (7) The acute form may be successfully and quickly fought by specific treatment, and surgical intervention may be avoided even in cases of apparently imminent asphyxia. (8) The specific treatment must begin with very high doses, and must be continued in gradually diminishing intensity, even after the cessation of the respiratory troubles, in order to avoid recurrence. (9) The slow form gives way to the treatment more reluctantly the more insidious and prolonged has been its invasion. (10) It is arrested sometimes spontaneously, and then tracheotomy is not called for; it never undergoes a spontaneous retrogressive metamorphosis. (11) If there be, in consequence of cicatricial narrowing, any tendency to obliteration of the larynx, this will take place whatever may be done; the opening of the air passages, and the uninterrupted wearing of the canula, are imperiously demanded in such cases. (12) The merit of mechanical dilatation of the larynx has not as yet been determined. (13) Syphilitic vegetations of the larynx may be destroyed or removed like other non-specific laryngeal growths. (14) The differential diagnosis between simple and syphilitic vegetations is easy, but there are difficulties regarding the differential diagnosis of syphilitic, tuberculous, and carcinomatous neoplasms. (15) In all forms of syphilitic stenosis cough is rare, and pain little marked. (16) Conservation of the voice is compatible with gravity of the evil. (17) Except in case of growths, local treatment is useless. (18) In most cases the choice of treatment will be between specific medicine and tracheotomy.]

The treatment which most frequently succeeds in laryngeal lesions is the iodide treatment, especially if the disease be seen at its beginning. Cauterizations with nitrate of silver or chromic acid (Isambert) aid recovery. Tracheotomy, as a last resort against the paroxysms of suffocation which threaten life, succeeds, perhaps, more often than in other affections where this operation is indicated. According to the statistics of published cases collected by Trélat tracheotomy succeeded 76 times in 100 cases. Unfortunately the operation does not prevent a relapse or return of the lesion. Thom-

son has four times successfully performed tracheotomy on an old man in the space of four years.

[In conclusion, we may append the following notes as to the treatment of syphilitic laryngitis, taken from a review of M. Isambert's work on that subject: 'The general treatment should consist in protiodide of mercury in pills ( $\frac{1}{4}$  to  $\frac{1}{3}$  gr. ter die), or bichloride in solution. Should the affection have passed the secondary stage, iodide of potassium may be employed, or, in stubborn cases, the "mixed treatment." Tonics, iron, quinine, etc., are usually called for. The patient should carefully avoid catching cold, and should also avoid the use of tobacco and alcoholic liquors. Complete repose on the part of the organ itself is absolutely essential. The local treatment is of great importance. In the early stages, when we have only congestion or superficial ulceration, insufflations of powdered tannin, alum, nitrate of silver, or, better still, spray of carbolic acid solution, or solutions of alum, acetic acid, sulphate of zinc, etc. When the laryngoscope shows ulceration, the local treatment should be more precise and energetic. Cauterizations at the seat of ulceration may be practised, by means of a small sponge moistened with tincture of iodine, solution of nitrate of silver, of sulphate of copper, 1 to 30; of alum, 2 to 30; of sulphate of zinc, 1 to 100. These substances are preferably to be dissolved in pure glycerine. The crayon of nitrate of silver or sulphate of copper may also be employed. Experience has shown that excessive inflammation and œdema of the glottis are not to be feared with this treatment. M. Isambert has obtained excellent results in rebellious cases by the use of chromic acid 1 to 8 and 1 to 5, which modifies the pathological tissues advantageously. When necrosis of the cartilages sets in, a practised surgeon may sometimes succeed in preventing extension of the injury by cauterizing the diseased points by means of the galvanic cautery. Dr. V. Masson, in his thesis (Paris, 1875), has given the indications for tracheotomy with great exactitude. The surgeon may be called upon to perform this operation on account of asphyxia from œdema of the glottis, gummy tumor, or vegetations obliterating the air passages, abscess, inflammatory swelling, or obstruction by loosened portions of necrosed cartilage.

When asphyxia comes on progressively, Isambert recommends cau-

[<sup>1</sup> M. H. Duret in *L'Année Méd.*, No. 10, 1877, *Philadelphia Medical Times*, Dec. 22, 1877.]



terizations by chromic acid (1 to 3), thus crisping the swollen tissues, giving access to the air, and sometimes influencing the disease favorably at the same time. He reports two cases cured in this way. The patient must, however, be carefully watched, and if relief is not gained it will be necessary to operate. When the progress of asphyxia is sudden, tracheotomy is to be performed at once, even when the patient is *in extremis*.]

The *trachea* and *larger bronchi* present lesions analogous to those met with in the larynx, but they are not so frequent; they are mostly seated at the superior and inferior extremities of the trachea. As in the larynx, the new formations are formed of small nodules in the mucous membrane, similar to the large lingual papillæ, they ulcerate, and in healing cicatricial bands of fibrous tissue are formed, which contract the tracheal tube transversely, or diminish its length.

The most authentic cases of this class are those reported by Worthington, Moissenet, Virchow, Wilks, and Lancereaux. Syphilitic lesions of the trachea, anatomically, very closely resemble tuberculous ulcerations; but they differ at their beginning by the nature of the initial neoplasm, by the formation of cicatricial tissue, and by the tendency to stenosis of the tracheal tube.

The symptoms of syphilitic trachitis are those of chronic trachitis, to which are added, if there be cicatricial or inflammatory contraction, dyspnoea, suffocation, whistling, noisy and even wheezing respiration.

The history of *syphilis of the lung* is as yet not well understood, although it was pointed out by the old writers long before the anatomical and clinical discoveries of Laennec. But when Morton, Sauvage, etc., describe venereal, *i. e.*, blennorrhagic, and syphilitic phthisis, it simply means that these diseases have had some influence on the causes, more or less distant, which have determined phthisis. At the present time we are more particular, and it is not enough that syphilis is admitted as a predisposing or determining cause of one of the most common chronic diseases, pulmonary phthisis, to entitle the phthisis to be called syphilitic. Again, it is not enough that pulmonary tubercles, or one of the numerous anatomical forms of tuberculosis of the lung, be met with at the autopsy of a subject having previously had or still presenting syphilitic lesions, in order to attribute the pulmonary lesion to syphilis. Indeed, in the Lourcine Hospital women are often seen, who have tuberculous symp-

toms before having had the lesions of the beginning of syphilis; syphilis and tuberculosis may exist at the same time; a previous syphilis does not prevent phthisis from developing later. In order that the syphilitic lesions of the lungs may correspond to the same changes which occur in the other viscera, there should be found in them either an inflammation of special character, affecting especially the connective tissue, chronic and sclerosed in nature, or else gummous new formations. The macroscopic and microscopic anatomy should be carefully examined and give characteristic results; clinically the course, seat, and dissemination of the morbid products should be explained or recognized by special symptoms.

In collecting cases of pulmonary syphilis, those which have not been examined post mortem must be omitted, since there may be present a more or less chronic broncho-pneumonia, or a very slightly confluent manifestation of tubercles terminating for a time in recovery, or any other lesion of the bronchi and lungs.

Infantile syphilis of the lung is well understood, and since the works of Depaul, Lorain and Robin, Virchow, etc., it is admitted without question. I have had the opportunity of examining, with Ranvier, a typical case. But as yet, for the adult lung, accurate information is wanting.

Virchow, in his book on constitutional syphilis, remains in doubt, but in his work on tumors, he is more explicit, although somewhat cautious. He does not wish to deny all cases which have been reported as gummata of the lungs. However, it must be acknowledged that the anatomical diagnosis of gumma of the lung from the various forms of the tuberculous lesions is very difficult, particularly if the published reports are relied upon. During November, 1861, I showed to the Anatomical Society a specimen of lungs which presented two small hard tumors, covered by a callous thickening of the pleura, by an envelope of indurated lung tissue, and at their centre composed of very dense fibrous nodules, one of the tumors being a little softened. The syphilitic patient from whom these lungs were taken, had also ulcerative laryngitis and gummata of the testicles. I consider this lesion of the lungs as syphilitic, but must admit that the anatomical appearances are doubtful, since there are frequently found at the apices of the lungs analogous fibrous masses, often softened at their centre, and which are in no way connected with syphilis. Virchow reports the autopsy of a syphilitic woman, in which the pleura and lungs presented tumors varying in size from a pea to a walnut, homo-

geneous, yellow, denser, and more resisting than are tuberculous and caseous pneumonic nodules of the lungs, but he has found similar lesions in tuberculosis. This microscopic examination, made in 1862, has not been again repeated with the care that the science of to-day calls for.

In a case reported by Maunoir,<sup>1</sup> where syphilis was very evident, the pulmonary formations, considered as gummata, were examined by Malassez, who found, at their central part, fibrous tissue and degenerated small cells. External to the fibrous tissue arranged in concentric layers, there existed, in the peripheral portions, a zone of proliferating tissue with the connective-tissue cells pressed together and intact. The vessels were nearly all obliterated, and appeared as the so-called giant-cells. This case is very evidently one of syphilis, although large fibrous tubercles are met with in the lungs, and although vascular obliteration occurs in tuberculosis as well as in syphilis. In another case reported by Maunoury,<sup>2</sup> the history was not obtained; the patient had albuminuria; at the autopsy tumors were found in the liver, pleura, and lungs, and were considered to be gummata, but there is no report of a microscopic examination.

In another case presented to the Anatomical Society, by Cüffer, a man treated by Gosselin, for a suppurating gumma of the thigh, died with a pulmonary complication, characterized by pleurisy, and by nodules or masses, varying in size, situated at the base of the upper, and lower lobes of the left lung, and in the middle and lower lobes of the right lung. The nodules appeared like the lobules of the lung in their arrangement, and resembled the lobules in pneumonia; upon section they were grayish in color, and were somewhat rounded in shape, but they were whiter and harder than pneumonic lobules. A microscopical examination was made by Coÿne and myself; we found the external portion made up of catarrhal and purulent pneumonia, but in other places were found numerous small, nucleated cells, collected together as in syphilitic gumma. In the same patient, there was a recent, very characteristic gumma of the kidney.

The preceding cases appear to relate to gummata of the lungs, but from their anatomical histories, it is certainly difficult to decide upon the existence of gumma in these organs. Notwithstanding the contrary opinion of Lancereaux and Landrieux, I believe that the study of

<sup>1</sup> Anatomical Society, 1875.

<sup>2</sup> Anatomical Society, 1876.

gummata of the lung, from an anatomical and histological point, is not sufficiently advanced to enable us positively to affirm their existence.

In new investigations upon this subject, it must not be forgotten that the lungs act towards tumors in a manner different from most other tissues and organs. When an inflammation or a tumor, sarcoma, carcinoma, etc., is developed in the lung, the alveolar cavities of this organ are filled with the cells of new formation. In a carcinoma of the lung, the cells of the neoplasm are at first only situated in the interior of the alveoli. It is the same with acute pneumonia in which the fibro-elastic tissue of the alveolar walls is not changed, while the alveolar cavities are filled with cells. In tubercular granulations of the pulmonary lobule, the small cells of the neoplasm first fill the alveoli. The alveoli act then as the inter-fascicular spaces of the connective tissue. This would indicate that it is the same in syphilis, that the alveoli of the lung are primarily filled with small cells, and that the new formation of connective tissue takes place later, the pulmonary fibrous framework of the invaded region becoming thickened and forming a sac for the gumma. These are, however, only hypotheses.

It is not at all probable that the cicatrices found upon the surface of the adult lungs are in any way characteristic of syphilis, since they are frequently observed in old persons, and their origin is more likely to have been caseous tubercles, surrounded by fibrous tissue, or a localized interstitial pneumonia.

[While the relation of syphilis to pulmonary disease is, as yet, like its relation to various nervous affections, somewhat indeterminate, there is certainly sufficient evidence to warrant a belief in the existence of syphilitic disease of the lung—although it may be admitted that we have not learned how to distinguish with absolute certainty either the histological changes or the clinical symptoms which belong to it.

Perhaps the most valuable contributions to our knowledge of this subject were made during the discussion on visceral syphilis, which took place in the London Pathological Society in 1877, and the result of this, together with the views of Fournier, Rollet, and a few others, include nearly everything trustworthy as regards pulmonary syphilis with which we are acquainted.

The great frequency and extreme gravity of both syphilis and phthisis render the question as to their relation in the highest degree important, so that, although we believe after careful investigation,

that it is at present impossible to arrive at any entirely satisfactory conclusion, it seems desirable to review briefly what is certainly known in regard to syphilitic lung disease, and to state the views of the most prominent writers on the subject.

There are, first,<sup>1</sup> certain well-authenticated cases in which a gummous infiltration or growth in the thoracic wall, commencing in muscle or periosteum, has invaded, first the pleura and then the lung, penetrating to a certain depth into its substance. (See p. 408, Case XIV.) Secondly, there are cases in which there is syphilitic disease of the larynx and trachea, extending downwards along the bronchi and their divisions, and then entering the lung, producing probably more or less affection of the alveolar structure. In this class of cases there is the additional element of the secondary results, due to narrowing of the bronchi, imperfect expansion of the lung, and the retention of bronchial secretion. Thirdly, there are well-authenticated cases of gummata of large size in the lung, presenting characters similar to those in other organs. Fourthly, there is the disease of the lung peculiar to infancy, described by Virchow and F. Weber nearly thirty years ago, and named by them "white hepatization," which has been shown to be of syphilitic origin, and variously termed "epithelioma of the lung," "epithelial induration," and "syphilitic pneumonia," by later writers. This change, which is found in newly-born children, or during the first few months of extra-uterine life, consists in a diffuse syphilitic growth of highly vascular character, commencing in the peribronchial or perivascular fibrous tissue, and thence invading the alveolar septa, gradually obliterating the alveoli. There is in these cases a very remarkable persistence of overgrown epithelium in the alveoli.

We have, then, sufficient evidence to warrant a belief in the existence of syphilitic disease of the lung, and there remain the questions of what other forms it may assume in the adult, and what are its relations to pulmonary phthisis. It has been suggested that a form analogous to the white hepatization of the newly-born might exist in the adult. Bearing in mind, however, the structural difference between the foetal or infantile lung and the fully-developed adult lung, we might anticipate that a great difference would be observed in the process in the two cases. In the infant lung, the highly cellular character and the ready reversion to the embryonic type of structure would naturally lead to an exuberance of growth and rapid diffusion

[<sup>1</sup> The Lancet, March, 1877.]

of the morbid process, which could not occur in the more fibrous and less cellular lung of the adult. Hence a slower growth, a more fibrous character, and a more limited extent of disease would probably be found in the adult. Such, indeed, seems to be the case, and the majority of the specimens of syphilitic lungs exhibited at the Pathological Society, in 1877, appeared to come under this class.<sup>1</sup>

It appears fair to say that syphilis and fibroid diseases of the lung have some distinct association; whether of cause and effect, or whether simply as a modification of ordinary tubercular or catarrhal processes can hardly yet be determined.

In reference to this form of fibroid phthisis, Dr. Goodhart, who does not believe that it is possible to distinguish histologically the changes due to tubercle or any other form of growth from those resulting from syphilis, asserts that its characteristics are yet quite distinct to the eye. He adds:<sup>2</sup> This fibroid disease of the lung is a disease which is prominently fibrous, and not tubercular; it shows no softening or caseous change, nor alveoli stuffed with catarrhal cells, nor peribronchial tubercles; it attacks the base or root of the lung in great part, and not the apex; it is associated in most cases with peculiar puckerings of the pleura, and it leads to gangrene, and not to molecular or cheesy changes. It differs from chronic pneumonia and that state of solidity which ensues after contraction of the lung from old pleurisy, in that it is less evenly distributed and generally less widely spread over the lobe than they; it is nodular rather than diffused, and it is symmetrical, and not unilateral. And then it differs from miners' phthisis in wanting the extreme amount of dilatation of the tubes, and in possessing more solidity from greater growth. Many of the patches of disease look, it is true, not unlike red hepatization or gray; but they are much more tough, generally less granular looking, and often somewhat translucent. It is also usually associated with syphilitic lesions of other viscera. These are the points which make one think that there is a fibroid form of lung disease dependent upon syphilis; and, if so, it is a point of importance with regard to treatment.

No one would deny, however, that this fibroid disease of the lung is quite different from the other forms met with in phthisical subjects, such as tubercular deposits in the apex of the lung, chronic catarrhal or pneumonic phthisis, and acute tuberculosis. The point in dispute

[<sup>1</sup> The Lancet, March 10, 1877.]

[<sup>2</sup> British Medical Journal, February 10, 1877.]

is whether the fibroid indurations of the lung found in connection with syphilis differ in any respect from fibroid induration, originating in other causes, and whether the puckering of the pleura, the narrowing of the bronchi, the vascularity of the diseased tissue, etc., are, as alleged, indicative of their specific character. Now, fibroid phthisis is by no means a common form of that disease, and yet it is totally distinct in its morbid appearance and clinical history from the other forms of phthisis. "It is clearly possible, therefore, by carefully recording most of the cases and post-mortem examinations of fibroid degeneration of the lung that come under observation, to settle pretty accurately the relation which the fibroid affection bears to syphilis, to show whether the distinctions above specified are well-grounded ones, or whether the combination of the local and constitutional affections is not after all a mere coincidence, there being no causal connection between them."<sup>1</sup>

We are not aware that a sufficient number of cases have been recorded and compared to determine this point, although, as has been said, the evidence seems to point conclusively to an association between syphilis and fibroid phthisis.

Fournier thinks there are five anatomical points of distinction between syphilitic gumma and tubercle.

"1. Situation: Tubercle involves upper part of both lungs: gumma one lung, and may be limited to a portion."

"2. Number: Gummata are few as a rule: solitary tubercles sooner or later become confluent."

"3. Gummata are larger than tubercles, never miliary in form."

"4. Color: Gummata are always white or yellow, never transparent like miliary tubercle."

"5. Consistence: Until softening takes place the gumma is of more equal consistence than tubercle, and if it softens, does not break down wholly, owing to the capsule. The microscope shows no difference of structure.

Syphilitic lesions of the lungs develop very insidiously, and may have reached a decided development while yet the symptoms are obscure. The symptoms are slight trouble in respiration, mild cough, often dry, and if expectoration exists, it is scanty, and of catarrhal kind. The physical signs are absent unless a circumscribed patch is superficially situated, when the respiration will be

[<sup>1</sup> The Medical Press and Circular, April 4, 1877.]

weak and rough. Later the symptoms become more marked, the dyspnoea increases, but never becomes very intense; the cough grows more severe and spasmodic; expectoration abundant, yellow, mucopurulent, even purulent; and hæmoptysis may occur. Fournier does not think, as many do, that the last symptom is less frequent in syphilitic than in ordinary phthisis, but admits that the amount expectorated is less. When the lesions are developed, the general condition and symptoms are similar to ordinary phthisis, being those of gradual decay. Usually the course is less rapid than in tuberculosis, but it may become rapid and severe if other organs are coincidentally involved. Fournier recognizes three varieties of this trouble; the latent, in which the lesions are circumscribed, cause no symptoms, and are not detected until after death. In the second variety there is some slight trouble with the breathing. The general condition is not altered, and the patient does not fall away. The signs are those of limited induration, or a cavity. The third is a severe form, presenting all the features of well-developed consumption. The prognosis depends on the extent of the lesions, and on their amenability to treatment. It has been found, on post-mortem examination, that gummous masses have undergone natural involution. Fournier admits that the diagnosis is difficult. He calls attention to the fact, that a remarkable tolerance of the disease may sometimes be seen, in which event, the patient retains his flesh and strength to a considerable degree. This should lead to suspicion of syphilis. Another point of distinction is its slow evolution, whereas it is more rapid in tuberculosis. Fournier says that a similar tolerance is observed in scrofulous persons also. The treatment consists of large doses of the iodide of potassium, and inunctions of mercurial ointment with tonics, etc. Local remedies may be applied to the chest.

His paper ends with the following conclusions: "1. Tertiary syphilis can produce in the lungs, lesions, which either locally or by reacting on the general symptoms simulate pulmonary phthisis."

"2. These lesions are often amenable to specific treatment. However grave and important they may appear, they are far from being beyond the resources of art."

"3. Consequently when a case of pulmonary lesion presents itself, it is important, unless the existence of tuberculosis can be made out quite certainly, to ascertain if the lesion can be traced to syphilis. It is necessary, that is, to remember that syphilis is a possible cause of phthisis.



“4. When syphilis is suspected to be the cause, the primary indication is to prescribe specific treatment, which has been known to produce gratifying results.

“In this connection, it may be of interest to briefly present the views of a German observer<sup>1</sup> as they stand in striking comparison with those of Fournier. Rollet thinks that the symptoms of syphilis of the lungs are more or less pronounced dyspnœa, even an orthopnœa, besides heaviness and oppression at the chest on deep inspiration, possibly with a sharp pain. The cough is generally dry, particularly in the early stages of syphilis, and sometimes accompanied with bloody sputum. Percussion reveals oftentimes a sharply defined round or irregular space of dulness, mostly in the middle thoracic region on either side, particularly in the anterior and lateral portions. Rollet thinks that Grandier's statement, that in twenty-seven cases the syphilitic affection of the lung was seated in the right middle lobe, needs further confirmation before conclusions can be drawn. He thinks that the fact that the upper lobes generally remain unaffected in syphilis has much importance. Auscultation shows, in early stages, absent or lessened breath-sound, and later on the usual symptoms of phthisis. The history of the case is of the greatest importance, and coexisting syphilitic lesions, the absence of a tendency to phthisis, and an improvement under anti-syphilitic treatment, are points of value in diagnosis.<sup>2</sup>

Prof. Schnitzler lays<sup>3</sup> particular stress on the relations of pulmonary syphilis to specific affections of the larynx, on the simultaneous appearance of the lesions, and the confirmation of syphilis of the lungs through coexisting disease of the larynx. Among the earliest symptoms, Prof. Schnitzler designates the sensation of weight and pressure in the chest, irritation in the throat, and paroxysmal cough. The latter is attended with more or less expectoration, of a catarrhal or purulent nature, which at times becomes distinctly tinged with blood. Hæmoptysis is not a very rare manifestation. Dyspnœa and asthmatic attacks and pain in the larynx are usually present; aphonia and dysphagia are rarely absent. Percussion yields a dull note over the middle or lower lobe, and the ear detects indistinct bronchial breathing and moist râles. The attending fever is usually of an intermittent or remittent character while the disease is progressing, but the constitution of the patient is never so severely involved

[<sup>1</sup> Rollet, *Lungen Syphilis*, Wien. Med. Presse.] [<sup>2</sup> *Annals of Dermatology*.]

[<sup>3</sup> *Pulmonary Syphilis and its Relations to Phthisis*, Wiener Med. Presse, Oct. 1879.]

as in cases of phthisis. Even in persons very much reduced, syphilitic affections of the lungs are curable. Pulmonary syphilis makes its appearance in the form of circumscribed infiltration (nodules), or diffuse exudations. In the latter condition, the lung presents firmer texture, greater weight, and smooth surface. The section of the affected lobe presents a grayish-red or yellow color, and yields a slight serous flow on pressure. The bronchial glands are usually considerably tumefied. The circumscribed infiltrations occur more frequently in adults, and generally a number of nodules, rarely more than ten, are found varying in size from a hazelnut to an egg. When the gummata commence to break down vomicæ are left, which when they are closed with granulations leave large contracted cicatrices. As a rule, syphilitic lesions of the lungs appear from two to five years after the infection, in rare cases even ten and twenty elapse before the supervention of lung trouble. While the affections described belong almost entirely to the tertiary stage of syphilis, Prof. Schnitzler calls attention to an earlier disease of the lungs, which appears as a specific bronchial catarrh. The author finds that specific laryngitis is often accompanied by catarrhal symptoms in the large and small bronchi, even within the first two months after infection, which disappear only in consequence of an anti-syphilitic treatment. It is believed that many cases of asthma, which yield so readily to the iodide of potassium, depend upon syphilitic bronchitis and secondary glandular enlargements. For the differential diagnosis of pulmonary syphilis, it is of the greatest importance to establish specific antecedents, and the immunity of the family from phthisis. The seat of the lesion alone is not conclusive, for syphilis may be localized in the apices.

Professor Gamberini, of Bologna, has recently discussed<sup>1</sup> at some length the subject of pulmonary syphilis. Besides relating two cases of his own which were thought to be instances of early syphilitic affection of the lung, the author quotes fully a number of cases recently reported by other observers.

The following are the general conclusions at which Gamberini has arrived after a careful study of his own cases and those of others. The existence of a simple inflammatory syphilitic pneumonia may be admitted, but is not yet conclusively proved. The occurrence of a gummous form of disease of the lung is established beyond doubt. True pulmonary tuberculosis may be associated with syphilis, but it

[<sup>1</sup> *Giornale Italiano delle Mal. Vener. etc.*; *British Medical Journal*, Jan. 1, 1881.]

always preserves its own pathological characters. To distinguish between the syphilitic and tubercular forms of lung affection, the author proposes for the former the title of "consumptive pulmonary syphilis." The influence of specific treatment is, at the present time, the best therapeutic means of diagnosis between tubercular and syphilitic disease of the lung. The author agrees with Schnitzler that pulmonary disease as a consequence of late general syphilis, or even of acute secondary syphilis, is not a rare occurrence. Laryngeal lesions often precede or accompany syphilitic pulmonary affections. This has been proved by the observations of Schnitzler, who, indeed, affirms that the diagnosis of syphilitic lung disease may be made by means of the laryngoscope alone. The symptoms of syphilis of the lung are generally those of pneumonic phthisis, from which, during life, there may be no certain means of distinguishing it; even after death, the distinction cannot always be made between gumma and tubercle, especially when the gummous nodules are in a state of caseation, or are infiltrated. It must be noted that syphiloma most usually spares the apex, whereas tubercle most frequently attacks that portion of the lung. This, however, is not constant, as has been shown by Fournier. The course of pulmonary syphilis is commonly slow and apyretic, which is not usually the case in tubercular phthisis. Syphilis also is accustomed to attack only one lung, and one part of the lung. This tendency to localization is considered by the author to be a very important point in the diagnosis of pulmonary syphilis, whether the lung be attacked at an early or at a late stage of the disease.

According to Dr. Frederick Robinson,<sup>1</sup> who differs markedly in some respects from the preceding writers, there are two distinct forms of lung affection which should be considered as syphilitic. In the first, and less frequent, the greater part of the organ is involved, and the disease appears primarily at the base, extending to the entire lung posteriorly, as well as anteriorly to the apex. The other, and more common, class is that in which the disease is limited to one or both apices. In either case, the patient has passed through the stage of secondary syphilis, and the constitution is left free from any outward manifestation of such disease. "As regards the former condition, I admit there is little if any difference to be observed between it and ordinary chronic pneumonia. It has seemed to me that the

[<sup>1</sup> Notes on Syphilitic Phthisis, London Lancet, May 5, 1877.]

lung is more extensively involved than in the latter affection, and that premonitory symptoms, local and general, are less apparent. There is little if any pyrexia, but slight rise in temperature, dyspnœa only on exertion, and no sputa. The organ is found to be in a state of consolidation more or less extensive, and remains so for a long indefinite period. Ultimately recovery takes place."

"In the second and more frequent form of the disease, the individual presents himself with symptoms which, at the first glance, appear to be those of ordinary chronic tuberculosis in the first stage, affecting one or both apices. Closer investigation, however, will detect some points of divergence. These are—

"1. The physique. The ordinary characteristics of a phthisical subject are wanting. The chest is well developed, and body fairly nourished.

"2. The absence of constitutional irritation of a severe character. The thermometer rises but little above the normal standard. There is freedom from night perspiration, diarrhœa, and irritating cough.

"3. The dulness on percussion is less pronounced, and less definable in extent; it more frequently affects *both* apices, and simultaneously.

"4. The characteristics of tubercular sputa in the earliest stage are wanting. The patient is pallid, complexion waxy, and his appearance generally indicative of cachexia. On auscultation, loud, harsh inspiration, with expiratory murmur of the same character, is detected, or else tubular breathing if the case be more advanced. Vocal resonance, more or less distinct, is always present. The pulse is frequent, but not so rapid, perhaps, as in ordinary phthisis. There may be no sputa, or else a little frothy mucus is hawked up from the throat rather than expectorated.

"As regards the greater prevalence or otherwise of hæmoptysis I am not yet in a position to offer a decided opinion."

These views of Dr. Robinson are accepted in the main by Dr. Reginald E. Thompson, in a paper on *Syphilitic Phthisis*,<sup>1</sup> in which the physical signs are more fully given; he is inclined to believe "that syphilitic phthisis is not so rare a disease as it is now supposed to be, and many a patient may be saved from what appears to be at first sight a dangerous malady by treatment with appropriate remedies." In a later paper<sup>2</sup> he describes the symptoms as "marked dyspnœa after exer-

<sup>1</sup> London Lancet, Sept. 15, 1877.

<sup>2</sup> British Medical Journal, Aug. 28, 1880.

tion, slight hæmoptysis, and expectoration, which was sometimes abundant. The physical signs were dulness on percussion, and a peculiar alveolar rustle resembling the sound produced by the rumpling of wall paper, together with bronchial breathing and bronchophony. These were accompanied by cachexia and other evidences of syphilis."

Jullien<sup>1</sup> says: "The following characters should lead one to suspect the syphilitic origin of a pulmonary lesion: 1st, localization of the lesion elsewhere than at the apices, at a definite point and only in one lung; 2d, slow course, much slower than tuberculosis; 3d, persistence of general good health until a very late period of the disease; 4th, good results from the employment of mercury and iodide of potassium; rapid recovery of lesions which are incurable, if they have any other origin than syphilis; 5th, previous or contemporary venereal lesions, cutaneous gummata, exostoses, perforations of the palate, hemiplegia, sarcocele; 7th, the age of the patient is generally more advanced than in tuberculous phthisis."

The most recent as well as the most extensive series of observations on syphilis of the lung have been published by Dr. Paneritius, of Berlin,<sup>2</sup> who reports one hundred and ten cases of the disease. His conclusions have been thus described:<sup>3</sup>—

In contending for the comparative frequency of syphilitic affections of the respiratory system, he does not profess to have discovered an unusual number of syphilitic patients who had gummous nodules (or cavities resulting therefrom) in their lungs. On the other hand, the syphilitic affection of the lung, which he wishes to emphasize, is an interstitial pneumonia, an induration of the connective tissue following the track of the bronchial and pulmonary arteries for a certain distance from the hilus of the organ into its interior. It is essentially an affection of the middle region of the lung, and the affection is not one of the air-cells, but solely of the supporting connective tissue of the organ. The physical signs are found mostly in the interval between the base of the scapula and the vertebral column; they are nothing uncommon, being more or less diminished percussion resonance, weakened respiratory murmur, and especially weakened or altogether absent expiratory murmur, and these variously extended or added to in intensity.

[<sup>1</sup> *Maladies Vénériennes*, p. 908.]

[<sup>2</sup> *Lungen-Syphilis*, Berlin, 1881, pp. 295.]

[<sup>3</sup> *The British Medical Journal*, Feb. 4, 1882.]

Clinically the disease begins with first an active stage, in which the patient, often with the appearance of blooming health and feeling well in general, complains that there is, especially on exertion, a certain feeling of weight in one side of the chest (usually the right), with difficult respiration, and not seldom dyspnœa in the evening. After a time, these subjective indications become more intense; the dyspnœa while walking is marked, there is a dry cough, and sometimes in the evening some slight asthmatic attacks. A true pulmonary catarrh, without fever, may follow, the dyspnœa may become more intense, and there may be, with the cough, slight pains referred to the middle portion of the affected lung. These hardly distinctive symptoms are gradually increased, so that the respiration becomes wheezing, the asthmatic attacks come on oftener and last longer, and there is general disorder of the digestion, with a feeling of weight in the hypochondria. If the practitioner be on the lookout, he will hardly ever fail to find, in this first stage of the pulmonary affection, the usual indications of constitutional syphilis in the skin, the mucous membranes, the bones, etc. There may be also, rheumatic and nervous symptoms, sleeplessness, and blood disorders, such as chlorosis. In the second—the destructive or passive—stage, there are more or less fever, purulent expectoration, even hæmoptysis, very severe and frequent asthmatic attacks, general disorders of the digestion and of the secretions, loss of strength, cachectic appearance, and, as the disease progresses, all the various indications of pulmonary phthisis may show themselves. Of those symptoms, the author especially dwells upon dyspnœa, asthma, hæmoptysis, and the characters of the sputa.

In a number of cases anti-syphilitic treatment led to a rapid reduction of the symptoms and a permanent restoration to health.

We believe that the foregoing abstracts represent the best professional thought on this important subject, about which, it is evident, much has yet to be learned before it can be removed entirely from the region of doubt and conjecture.]

Although there still exists some doubt concerning the syphilitic alterations, the specific pneumonia and gummata of the adult lung, there is no uncertainty as to the occurrence of these lesions in the fœtus.

In the syphilitic fœtus born before term, in the syphilitic child born dead at full term, and in the syphilitic children who live a few days, there are found, at the autopsy, in the lungs, nodules or small

tumors, usually superficial, sometimes deep, hard, isolated or in groups, pink, gray, or red in color, with scattered whitish or yellowish points. Their size varies from a lentil or pea to a small walnut. Upon section, their form is seen to be spherical or lobular, and throughout they present the same small whitish points. These nodules are scarcely prominent, and represent simply a part of the lung, more or less considerable, in a state of special lobular hepatization. At other times, instead of spherical islands, there is an invasion of a greater extent of a lobe of the lung, or an entire lobe may be involved. The dense altered part usually sinks immediately when placed in water; it is colorless, gray or white, both upon its surface and on section. The cut surface is level and smooth. The pleura is always affected—thickened and inflamed.

Virchow has given this condition the name of *pneumonia alba*, white hepatization. The histological description has been given by Virchow, Förster, Robin, and Lorain. Depaul has described its gross appearances.

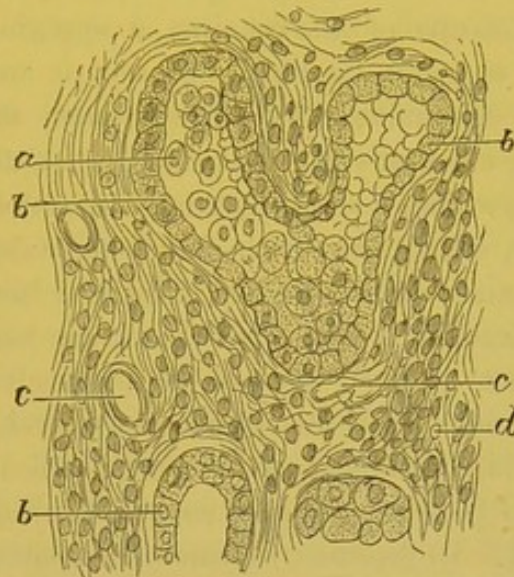
The isolated nodules present the same structure as the more extended regions of white hepatization. The walls of the alveoli, the tissue which surrounds the bronchi and vessels, are thickened, and contain round embryonal or fusiform cells. The contents of the alveoli are formed by layers of pavement or cubical cells arranged one upon the other; sometimes they form epithelial pearls—therefore the name epithelioma given by Robin and Lorain. In the centre of the alveoli, the more or less rounded cells are found filled with fatty granules. The bronchi, which are lined with cylindrical ciliated epithelium, and which have their walls thickened, contain in their interior an accumulation of cylindrical and round cells. The central part of the nodules, where the circulation is interfered with by the numerous cells, may undergo a dry caseous degeneration, or may soften and give origin to a small quantity of puriform fluid.

The parts affected with a more extended hepatization have a similar structure, but they do not always present a very marked or regular thickening of the alveolar walls. Förster, who has well described this thickening of the pulmonary fibrous framework, asks if it should be considered characteristic of syphilis, since he has met with it under other conditions. Parrot<sup>1</sup> thinks that all cases of infantile pneumonia, where Förster has met with this lesion, should be considered as syphilitic. It is very probable that this is true.

<sup>1</sup> Progrès Medical, Aug. 24, 1878.

[“In the lungs, an interstitial syphilitic pneumonia may be diffused or circumscribed. This lesion of the lung has received different names. Lorain and Robin called it epithelioma of the lung; it is the white hepatization of Virchow, which other authors regard as gumma. It is seen in new-born children, and up to the age of ten or twelve years. To a certain degree its characters approach the structure of the lung of the embryo. In syphilitic pneumonia the inter-

Fig. 82.



Transverse section of a hepatized nodule of syphilitic interstitial pneumonia, from a new-born child. *d*. Proliferating connective tissue of the lung. *b*. Pavement cells arranged around the alveoli. *a*. Free spherical cells in the alveoli. *c*. Vessels.  $\times 300$ . (Cornil and Ranvier.)

lobular connective tissue enters into proliferation and presents a large quantity of embryonal cells; the alveolar walls are thick while the narrow alveoli are lined, and even filled by epithelial cells, which are of the pavement form in contact with the walls, round in the centre of the alveoli. As the process progresses the epithelial cells become fatty, degenerated, and subsequently broken down and absorbed, while the embryonal inter-alveolar tissue rapidly organizes into fibrous tissue. Thus results a small fibrous tumor. In this tissue a gumma may ultimately develop.” Fig. 82.<sup>1</sup>]

With differences of aspect easily understood, due to the dissemination or generalization of the lesion, or to the vascularity at the time of death, the same pathological modifications are always observed. In some cases there is a tendency in certain parts to an exuberant

[<sup>1</sup> Cornil and Ranvier's Pathological Histology. Shakespeare and Simes, Am. Ed., 1880.]



formation of round cells, and the hepatization is rich in juices; again there may exist many epithelial cells, in the bronchi and alveoli, often in a state of granular degeneration, and then the hepatization is opaque, with numerous white points or islands, and it is dry. Virchow has seen true gummata in similar lungs.

It is impossible to confound this syphilitic pneumonia with tuberculosis. Tubercle granulations are never congenital. Virchow, however, as a rare exception, has seen one case.

At an autopsy made with Anger upon a child two years old, we found, besides exostosis of the cranium, a syphilitic lesion of the lungs. The patient, since its birth, had almost constantly a cough and suffered with bronchitis. In different parts of the lungs—the base of the lobes, especially the sharp borders of the superior lobes—we found, together with a slight pleurisy without effusion, indurated hepatized nodules, which from their gray-pink color were very distinctly seen in contrast with the much congested lung. These lobes were slightly prominent, as always occurs in lobular pneumonia. Upon their surface, and on section were seen small points, and opaque whitish lines. Their cut surface was level, resisting; upon scraping, a little fluid was obtained, and they sank in water.

Examination of the hepatized part showed the lesions of a chronic lobular pneumonia. In the most chronic pneumonic parts, the alveoli were completely filled by cellular elements, which varied according to the part of the alveolus examined. Immediately in contact with the fibro-vascular wall, we found one or two layers of swollen pavement cells applied against the wall, their transverse diameter being greater than their vertical. In the interior of the alveolus there were large round granulo-fatty cells, and large round cells containing several granular nuclei. The alveolar walls were thick, but contained very few fusiform and no embryonal cells. The very abundant vascular network upon the surface, and in the alveolar walls of the affected portions of the lung, contained but little blood.

Those parts of the lung which appeared to be more recently changed presented in their alveolar walls numerous capillary vessels filled with blood. The walls were also lined by pavement cells, but instead of finding only round cells in their interior, we saw collections of prismatic cells situated in the centre of the alveoli; these cells, with agglomerations of analogous cells, extended into and filled the bronchi. The latter were distended by prismatic or cylindrical swollen cells pressed against one another. The internal surfaces of both the small and larger bronchi were lined with cylindrical ciliated cells

arranged in several layers, the oldest filling the calibre of the tube. Around the bronchioles and vessels there was seen a considerable amount of fibrous connective tissue, and the fasciculi were separated by flat cells.

The miliary gray points, situated in the midst of the pink hepatized tissue, were, to the unaided eye, colorless, owing to a less quantity of blood contained in the vessels of the alveolar walls. These were evidently the most chronic portions of the alteration.

Around the changed lobules, the pulmonary tissue was much congested, and the vessels of the alveolar walls were distended with blood.

These are lesions which certainly should be connected with syphilis. The child was manifestly syphilitic; since its birth it had had successive eruptions of cutaneous syphilides, mucous patches, and cough; the bones of the cranium were covered with exostoses; it died of syphilitic cachexia with a pulmonary lesion, which had no connection with tuberculosis, and which could not be connected with a simple broncho-pneumonia. It is true, the connective tissue of the lung did not present any manifest inflammatory thickening, but I do not hesitate, however, to consider the case one of syphilitic pneumonia.

The pathological anatomy of pneumonia, due to hereditary syphilis, is as yet incomplete. It is necessary to have determined the exact state of the alveolar walls of the lung, and the structure of the fibrous tissues which compose them, during intra-uterine life and early childhood, in order to make comparisons with pathological changes which take place in the pulmonary framework.

In one case of hereditary syphilis, in which there existed a special broncho-pneumonia, I found a very curious lesion of the elastic fibres. They were brittle, and broke into small fragments like filaments of glass. I have since searched for this same lesion in simple broncho-pneumonia, and in some cases which were connected with syphilitic pneumonia, but was not successful in finding it.

The symptoms of syphilitic pneumonia are very variable; newborn children, affected with the variety described by Depaul, die asphyxiated a few days after birth. Those who live longer are attacked with broncho-pneumonia, which presents the same symptoms as simple broncho-pneumonia.

The lesions of the thymus gland, usually described with infantile syphilis of the respiratory organs, have not, according to the most recent investigations upon this subject, the value formerly attributed to them by Paul Dubois.

## CASE XIV.

*Syphilitic disease of the pleura and lung.*<sup>1</sup>

In a carefully reported case of undoubted syphilitic disease of the right lung, Dr. Wm. Pepper and Dr. W. H. Warder found the following physical signs, the pulmonary affection having shown itself ten months previously, coincidentally with the development of a late ulcerating syphilitic. It began as a bronchitis with congestion of the right lung, followed by hectic, night sweats, etc.

The respiratory movement over the lower part of the right lung was restricted, while that of the left lung was exaggerated. The heart's impulse was displaced towards the left, the apex-beat being in the line of the nipple. Resonance was good everywhere except over an area semicircular in shape, which extended on the lateral aspect of the chest, from the liver-dulness below up to the line of the nipple, sloping downwards both in front and behind. Over this area there was absolute dulness on percussion. Auscultation over this space gave only very feeble, scarcely audible bronchial breathing, without rales. There was also almost complete absence of vocal fremitus and of vocal resonance. There were a few crackling rales in the lung tissue immediately adjoining this area of flatness. Elsewhere the respiratory murmur was normal.

Marked improvement occurred under specific treatment, but the patient relapsed and died six months later. At the autopsy a large mass was found, presenting the general contour of the lung, dense yellowish-gray, of a firm, fleshy consistence, intersected by fibrinous trabeculæ, but containing no trace of pulmonary structure.

In the centre of the lower lobe a cavity of considerable size filled with shreds of tissue and pus, lined by a shaggy wall, existed. The size of the cavity was at least two and one-half inches in diameter. The division between the lower and middle lobes was only in part demonstrated. Through the lower and middle lobes the morbid tissue formed a uniform mass. In the upper lobe, the lung substance was replaced by an aggregation of firm nodules of varying size. In a few places there were nodular formations on the exterior of the pleura, or at least a uniform fibrinous membrane could be dissected up; and in a few places, especially on the upper lobe, it brought with it nodules springing from the pulmonary surface. The mediastinum was filled with diseased glands; the external surface of the heart was occupied by growths similar to that of the lung; the left kidney contained a gummous growth; and nodules of varying size were found in the subcutaneous tissue of the abdominal and thoracic walls.

The Committee on Morbid Growths, to whom the specimens were submitted, reported as follows: "A microscopic examination of a thin section taken from the mass which occupies the position of the right lung shows

<sup>1</sup> Transactions of the Pathological Society of Philadelphia, 1878.

it to consist almost entirely of a dense fibrillar connective tissue. The bloodvessels, which are few in number, are surrounded by an infiltration of indifferent cells. One of the small nodules taken from the left lung, upon examination, is found to consist of a similar tissue in an earlier stage of development. The alveolar spaces in the proximity of the nodule are seen to have their walls thickened by fibrillar connective tissue. The cells lining the alveoli are in a state of proliferation."

In this case there had been, many years previously, a pleuro-pneumonia, with emphysema of the right side. This, however, can hardly be considered to militate against the syphilitic character of the case, but probably only affords an indication of the well-known tendency of syphilis to involve by preference parts previously diseased.]

LEEDS & WEST-RIDING  
MEDICO-CHIRURGICAL SOCIETY

### CHAPTER XIII.

#### SYPHILITIC LESIONS OF THE SPLEEN, OF THE SUPRA-RENAL CAPSULES, OF THE LYMPHATIC GLANDS AND OF THE GENITO-URINARY ORGANS.

Lesions of the spleen and supra-renal capsules in hereditary syphilis—Tertiary lesions of the lymphatic glands—Gummous tumors of the epididymis during the secondary period—Interstitial orchitis in the adult—Interstitial orchitis in new-born children—Gumma of the testicle—Syphilitic ovarian lesions—Albuminous nephritis during the secondary period—Interstitial nephritis and gummous nephritis—Amyloid degeneration.

**SYPHILIS OF THE SPLEEN.**—The spleen is always hypertrophied in hereditary syphilis; the capsule is thickened and inflamed, and the splenic tissue is harder than normal. But the modifications of the parenchyma, which correspond to this state, are not yet known.

[In a paper read before the Royal Medical and Chirurgical Society in 1867, Dr. Gee established the following propositions: In about half the cases of congenital syphilis the spleen is enlarged so that it can be felt during life. In about one-quarter the enlargement is really great; sometimes, in addition to enlargement of the spleen, there is enlargement of the liver and the lymphatics; the majority of cases of great enlargement die. The degree of the splenic enlargement may be taken as an index of the severity of the cachexia, with this qualification, that the spleen does not diminish *pari passu*, but remains, it may be for years, more or less enlarged, a monument of what the cachexia has been. Sometimes an enlarged spleen is the only sign of an active syphilitic cachexia. In two post-mortem cases the enlargement seemed to be a simple hypertrophy; in one of them there was considerable thickening of the capsule.

In commenting upon these facts, Dr. Barlow states<sup>1</sup> that the diminution in the size of the liver under treatment begins to take place before the diminution in size of the spleen, but adds, that in cases of slight enlargement the improvement in the latter organ keeps pace with, or, at all events, only lies a little behind the other symptoms.

[<sup>1</sup> The British Medical Journal, Jan. 20, 1877.]

In one case which he saw post-mortem, there was simply "slight enlargement with hardness," there was no reaction with iodine, and there were no gummata. He continues: "If one regards, with Mr. Hutchinson, congenital syphilis as one of the exanthemata, this enlargement might at first seem to have some affinity with the enlargement of the spleen in typhoid fever. But the spleen in typhoid fever is generally, not always, an enlargement with softening; and, moreover, so far as I know, it does not remain permanently after the subsidence of fever." Mr. W. J. Tyson has reported a case<sup>1</sup> of a child born of syphilitic parents, in whom, at two years of age, the spleen extended in a downward direction for three and a half inches, reaching the crest of the ilium; in front it approached closely to the umbilicus. The liver was not enlarged, and there was no albumen present in the urine. He ordered mercury with chalk, one grain every morning and evening; and one grain of iodide of potassium with ten minims of syrup of iodide of iron to an ounce of water, three times a day. Sixteen months later the spleen had become imperceptible, and three years afterwards the child was in excellent health.]

It is probable that the spleen is also more or less hypertrophied in secondary syphilis of the adult, but as a constant symptom this is not so well established.

[Syphilis of the spleen during the secondary period is said to be due to hyperæmia, and later to depend in many cases upon an interstitial hyperplasia, causing induration and fibrous contraction of the trabecular tissue where it takes place.<sup>2</sup>]

Gummata of the spleen are very infrequent.

[E. Wagner has very accurately described the gummata found in the spleen. "The number of the tumors designated by this observer as syphilomas is various, and generally inversely proportioned to their size. They are always sharply circumscribed, generally round or roundish, seldom irregular, sometimes very small—most frequently one-half to one line, rarely one to one and a half inches in diameter. Recent syphilomas are grayish-red, homogeneous, somewhat dry, tough, almost cheesy. The surrounding splenic tissue is somewhat compressed, the remainder usually somewhat harder." "Oppolzer, Frerichs, and Lancereaux consider the splenic tumor as a usual

[<sup>1</sup> The Lancet, October 23, 1880.]

[<sup>2</sup> Hill and Cooper, op. cit., p. 165.]

accompaniment of syphilis of the liver."<sup>1</sup> In twenty-two autopsies upon persons dying with well-marked syphilitic lesions, Dr. Greenfield found gummata of the spleen in three cases, in one recent, in the other two old and caseous.<sup>2</sup>

Amyloid degeneration of the spleen is frequently found in connection with a syphilitic cachexia, and it is considered by many writers as having its origin in the latter affection. In a collection of one hundred and fifty-two cases of amyloid degeneration of the spleen, Fehr found thirty-four which suffered with constitutional syphilis. But, with Cornil, we are inclined to consider the amyloid degeneration as a consequence of a cachexia, produced by prolonged exhaustive suppurative discharges, and not as a manifestation of syphilitic disease.]

Splenic infarctions or the indurated nodules which follow infarctions must not be mistaken for gummata. It is very probable that certain thickenings of the capsule are due to syphilis; but they are so often met with in old persons, that they cannot be regarded as characteristic.

[Anti-syphilitic treatment administered during the early period of gummata of the spleen offers a possibility of recovery, but this is greatly lessened when the lesion has become chronic.]

**SYPHILIS OF THE SUPRA-RENAL CAPSULES.**—The supra-renal capsules have been seen by Virchow in a state of fatty-degeneration during the tertiary period of syphilis. But this is a lesion which does not necessarily depend upon syphilis.

A special alteration connected with hereditary syphilis is observed in new-born children. It affects both the capsule and parenchyma of the organ (Ollivier, Ranvier, and Parrot). The capsule is inflamed and thickened. A section, examined microscopically, shows a new formation of embryonal elements, arranged in layers or round masses between the fibrous fasciculi. In the parenchyma are seen small spots or semi-transparent nodules, which consist of embryonal cells, similar to those found in the liver of the same patients.

**SYPHILITIC LYMPHATIC GLANDS OF THE TERTIARY PERIOD.**—During the tertiary period of syphilis the lymphatic glands are not so frequently affected as during the stage of the chancre or the early cutaneous

[<sup>1</sup> Mosler, Diseases of the Spleen; Ziemssen's Cyclopædia of Medicine, Am. ed.]

[<sup>2</sup> The British Medical Journal, Jan. 20, 1877.]

eruptions (see page 121 *et seq.*). The "pleiades ganglionnaires" of the first period of syphilis are gradually removed; they remain for one or more years larger and harder than normal; but, finally, they return to their usual size. When the deeper lesions supervene, such as tuberculous or gummous syphilides of the skin and mucous membranes, the lymphatic glands, in the proximity of the ulcerations, are very seldom hypertrophied or inflamed anew.

In visceral syphilis of the liver, of the digestive organs, and of the lungs, the lymphatic glands may be implicated. Thus, in the case previously mentioned apropos of gummata of the stomach, there was, besides the gummata of the stomach and liver, an adenitis which extended to the lymphatic glands situated in front of the cœliac axis, along the superior border of the pancreas, in the neighborhood of the pylorus, and around the bronchi. These glands were white, swollen, and indurated; upon section their surface exuded small drops of a puriform fluid. This fluid, examined in the fresh state, contained round lymph cells, somewhat granular, and numerous large swollen endothelial cells provided with an oval nucleus, or several nuclei.

These glands, hardened in Müller's fluid, gum, and alcohol, and examined with the microscope, show that all the peri-glandular and capsular lymphatic vessels, the lymph paths, the peri-follicular sinuses, and all the cavernous tissue of the glands were filled, and very much distended with large spherical cells, which were epithelioid in type, derived from the lymph cells, and from the swollen endothelium which lines the cavities and lymph paths. At the centre of the gland, especially after removing the free cellular elements from the section with pencilling, there were seen large alveolar spaces, which represented sections of the afferent lymph canals. The reticulated tissue of the cavernous substance also presented very large meshes filled with these cells. The lymph canals at the centre of the gland, after pencilling to remove the free cells which fill them, were seen much enlarged; the lymph sinuses with their partitions and the meshes of the lymph cavernous tissue appeared empty, or partly filled with cells.

Where, upon a section, an island of delicate reticulated tissue was found, there were seen around it immense meshes of cavernous tissue, and the sinuses and lymph paths were irregularly distended. These cavities, more or less empty of their contents, showed in places the large, swollen, granular endothelial cells, possessing one or more oval



nuclei, also lymph cells. The granular protoplasm of the large cells was sometimes spherical, sometimes elongated, occasionally flat, and frequently sent off angular prolongations. The cells were also often irregularly pavement with blunt borders, due to mutual pressure.

There was here a catarrhal inflammation of all the lymph paths within the gland, an inflammation secondary to the same lesion of the afferent lymph vessels, and having for its origin the syphilitic lesions of the liver and stomach. It is certain, that there is in such cases an inflammation of the internal lining of the lymph paths, and that the large swollen cells which fill them have not been simply transported, but have formed within the gland, either from the endothelial cells or from the lymph cells.

This is a variety of medullary syphilitic adenitis, in which the lymph paths and sinuses, that is, all the cavernous substance, are the seat of a chronic inflammation, which may be termed catarrhal, in contrast to sclerosis, or cirrhotic inflammation, which is characterized by an increase of the connective tissue framework. This adenitis is the result of the chronic inflammation of the lymphatic vessels.

At the autopsy of a syphilitic child two years old, the bronchi were found surrounded by large, very vascular, and indurated lymphatic glands. The glands had not undergone caseous degeneration, nor were any opaque points visible to the unaided eye, which could separate them from strumous or tuberculous lymphatic glands.

The histological examination of these glands, after hardening in alcohol and picric acid, showed a large amount of fasciculi of transparent fibrous tissue, easily stained with picro-carmin, similar to those reported in several cases of chronic adenitis and especially in tuberculosis. The thick fasciculi of fibrous tissue were arranged like those around bloodvessels.<sup>1</sup> In this case, in consequence of a chronic inflammation of the lymphatic glands, caused by a specific inflammation of the lung, there resulted a fibrous thickening of the framework of the gland.

In another class of cases, not very frequent, however, gummata are found in the lymphatic glands. Verneuil reports a case of gummata of the lymphatic glands of the inguinal region, in which the patient suddenly died from hemorrhage, due to ulceration of the

<sup>1</sup> The Lesions of the Lymphatic Glands, by V. Cornil, *Journal de l'Anatomie de Robin*, 1878.

femoral vein. Gonnet<sup>1</sup> has collected in his thesis the cases of gummata of the deep and superficial lymphatic glands.

[Amyloid degeneration of the lymphatic glands has been met with in the later period of syphilis, as pointed out by Virchow.]

**SYPHILIS OF THE TESTICLES.**—Syphilitic lesions of the testicles consist in gummous nodules of the epididymis, which supervene at the end of the secondary period, and later in orchitis, which may be either interstitial or gummous. There is also a syphilitic interstitial orchitis of new born children.<sup>2</sup>

**GUMMATA OF THE EPIDIDYMIS.**—Towards the termination of the secondary lesions of syphilis, a period varying from four months to a year after the beginning of the chancre, there is occasionally observed upon the epididymis a limited induration, generally at its head. The small tumor, varying in size from a bean to a walnut or larger, is connected to the testicle, is hard, indolent, and may easily be overlooked. More rarely it is situated upon the body of the epididymis, and the spermatic cord has been seen swollen. It is uni- or bilateral. There is no accompanying affection of the tunica vaginalis, or of the skin.

The tumor very soon disappears under treatment by mercury and iodide of potassium.

<sup>1</sup> Gonnet, *Essai clinique sur l'adénopathie tertiaire*. See also Humbert, *Thèse d'agrégation sur les néoplasmes des ganglions*, 1878.

<sup>2</sup> The sarcocele of the French school may be a thickening of the tunica albuginea, with the formation of new fibrous tissue between the seminiferous tubules, which gradually causes the absorption of these last and takes their place. This is the sclerous sarcocele of Fournier, the interstitial orchitis of Cornil and Ranvier, the diffuse orchitis of Lancereaux, or the syphilitic albuginitis of Ricord. It is the most common manifestation of syphilis in the testicle, and causes atrophy of this organ unless arrested by treatment. The other form is the gumma proper, a plastic product accompanied by thickening of the tunica albuginea and hyperplasia of the fibrous septa. The gumma may be circumscribed, and of the size of a walnut, or may infiltrate the testicular tissue spreading along the septa. M. Reynier reports two cases of the first variety, and refers to two others, one by West the other by Huber. He makes a distinction between superficial gummata, suppurating speedily, causing ulceration, and yielding to treatment, so that the intact seminiferous substance may regain its functions, and deep gummata, generally parenchymatous, rarely suppurating, of slow progress, possibly causing fungous masses when opening exteriorly, and yielding to treatment after the testicle has been reduced to a shell and its functions destroyed. Fungoid formation does not necessarily follow suppuration.—*Boston Med. and Surg. Journ.*, Oct. 23, 1879, Dr. E. Wigglesworth.]

The nature of these gummata is determined, not only by the previous history of the patient, but also from the fact that they have not followed a gonorrhœa, and that they promptly disappear under specific treatment.

There has as yet been no histological examination of these tumors. They are supposed to consist of a gummous formation, an infiltration of the cellular tissue with small round cells. Since the presence of these tumors does not stop the secretion of the spermatic fluid, nor the ejaculation of this secretion containing normal spermatozoids, it has been concluded that they are situated in the peripheral connective tissue of the ducts of the epididymis, and not in the ducts themselves.

[This form of epididymitis was first described by Dron, some twenty years ago. It may be recognized by its association with early syphilitic symptoms, by its comparative indolence and painlessness, its situation in the globus major instead of the globus minor, and its rapid disappearance under constitutional treatment.

It should not be confounded with the little fibromata which occasionally occur in this region.

Bassereau, Rollet, Lancereaux, and Fournier have reported cases. It is very rare for the affection to spread beyond the globus major, although in a few instances it has involved the whole epididymis.

Hill has seen<sup>1</sup> two cases in which it appeared at the first outbreak of the cutaneous symptoms, and before the primary sore had healed, but usually it occurs about three and a half months after infection. In the later stages the epididymis is affected only when the testicle itself is diseased. Greenfield reports<sup>2</sup> one case in which at an autopsy a small gumma was found in the epididymis, but does not give any details. The case is presumably the only one of the sort thus far recorded.]

INTERSTITIAL ORCHITIS.—Interstitial orchitis of the adult, in acquired syphilis, belongs, like gummous orchitis, to the period of the later tertiary lesions. It seldom occurs before the third year. It is uni- or bilateral. The testicle is the seat of an inflammatory thickening of all its connective tissue—a chronic interstitial inflammation. The epididymis is seldom affected; if it be involved, it is its head that is changed.

At the beginning of interstitial orchitis, the gland is larger than

[<sup>1</sup> Op. cit., p. 291.]

[<sup>2</sup> The British Medical Journal, Jan. 20, 1877.]

normal, its oval shape is retained, and the enlargement is not very marked. If the disease be permitted to take a natural course, the gland gradually atrophies, still remaining indurated. There is frequently a notable effusion into the tunica vaginalis, which is inflamed.

When a syphilitic testicle has been removed by the surgeon, or when it is examined after death, there is seen an inflammation of the visceral layer of the tunica vaginalis, together with a thickening or roughness, due to small indurated projections which involve the tunica albuginea.

A section of the testicle through its long axis, shows the fibrous partitions, which run from the body of Highmore, thickened and dense. The entire organ is more indurated than normal. The seminal tubes cannot be drawn out, as in a healthy gland, on account of their attachment to the new-formed connective tissue. The cut surface is gray or pink at the beginning of the disease; later, when the testicle is atrophied, it has a fibrous appearance.

Section of the tunica albuginea shows the membrane to be irregularly thickened, measuring from one to five millimetres. Its very dense tissue passes into the projecting granulations upon its surface. The fibrous trabeculæ which traverse the gland have also undergone the same change.

The distribution of the interstitial inflammation in the parenchyma of the testicle is not uniform; there are seen points of fibrous tissue in the regions where the inflammation is most intense.

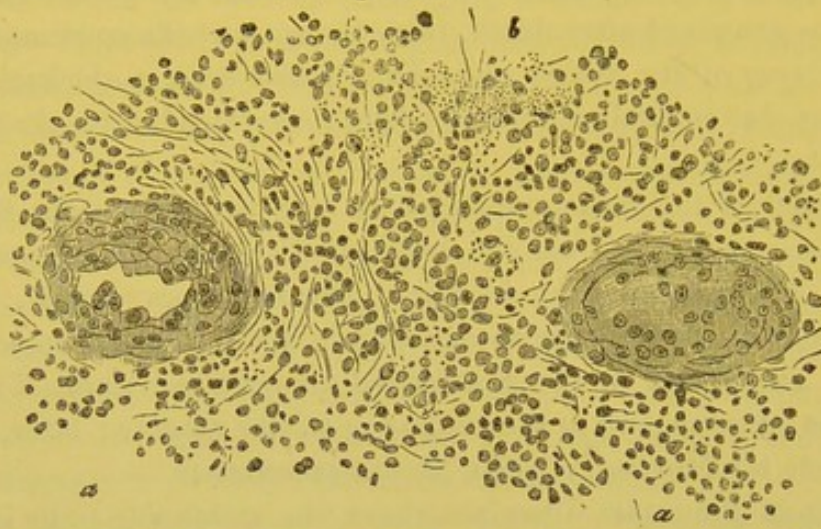
A section examined with the microscope, after hardening and staining with picro-carmin, presents, with a low power, the seminal tubes separated by large bands of fibrous tissue infiltrated with round cells. If the lesion is at the stage of acme, the thickened connective tissue has the characters of embryonal tissue. The wall of the seminal ducts is thicker than normal; instead of showing, between the layers which compose it, the flat cells of connective tissue, it contains swollen or round cells. The loose connective tissue surrounding the ducts, formed of fasciculi of fibres, is infiltrated with numerous round cells, a true embryonal transformation, which also affects the wall of the vessels.

The epithelial cells lining the seminal ducts, at the same time become granulo-fatty, round, and fill the lumen of the ducts (Fig. 83).

In proportion as the thickening from the growth of embryonal connective tissue becomes more marked, the compressed ducts are atrophied.

When the lesion is seen in a more advanced stage, the connective tissue, still relatively very thick, becomes fibrous and dense; the seminal ducts are contracted and the gland progressively atrophies.

[Fig. 83.]



Syphilitic testis. *a.* Tubuli seminiferi. *b.* A part of the round cell growth beginning to undergo fatty-degeneration.  $\times 180$ . (Erichsen.)]

The microscopical examination of a section of interstitial atrophied orchitis, demonstrated the slender seminal ducts, isolated in the midst of a compact fibrous tissue, the latter possessing a few flat, round, or oval cells. The ducts themselves contained some granulo-fatty cells, their walls were very thin, but still retained their characteristics.

The symptoms of interstitial orchitis are insidious; the patient does not always observe them at the beginning, there is not any local suffering, but only a dull pain in the lumbar region, and this is sometimes absent. The disease may begin in one or in both testicles at the same time; after having affected one, it may later invade the other.

The skin of the scrotum is normal, one or both of the testicles are increased in size, a tumor is observed which is often due to a slight effusion into the tunica vaginalis with the hypertrophy of the gland. The epididymis is seldom swollen. Ricord formerly believed that the epididymis and cord were never implicated, but later observations have shown that both these parts of the spermatic passage may at times present nodules of considerable size.

Upon careful palpation of the testicle there may be noticed the elastic resistance of the tunica albuginea, the thickening, the unevenness, the small, hard granulations upon the surface of the organ, all peculiarities which are valuable aids to diagnosis.

These physical signs vary according to the age of the lesion while the gland is hypertrophying; in a few years an incurable fibrous atrophy follows, and, as a consequence, the function of the testicle is lost, there is no formation of spermatozoa, and impotency results. The latter is to be distinguished from sterility. Fournier maintains that patients who have the testicles indurated, and completely atrophied from an interstitial orchitis, may still have sexual connection. This, however, does not agree with the general opinion, which is, that syphilitic orchitis destroys the capability of erection.

Syphilitic orchitis is to be diagnosed from tuberculosis of the testicle. The latter disease frequently extends along the spermatic cord, and terminates by suppuration with the formation of fistulous tracts; this does not occur in syphilitic orchitis. Sarcocoele, carcinoma, sarcoma, and cystic tumors are always unilateral, their size is relatively much larger, and their progressive rapid evolution is very different from that of syphilitic orchitis.

A syphilitic testicle, when not submitted to treatment, slowly but surely progresses to a fatal atrophy and functional loss of the organ. But, on the contrary, under the combined influence of iodide of potassium, and mercurial frictions upon the scrotum, the disease is almost always arrested and the testicle retains its function. To accomplish this the treatment must be applied during the first stage of the disease.

[The following table<sup>1</sup> clearly presents the main points of difference between encephaloid carcinoma, tubercle, and syphilis of the testicle.

SYPHILITIC ORCHITIS.	ENCEPHALOID CARCINOMA OF TESTICLE.	TUBERCULAR ORCHITIS.
Syphilitic history.	No history of any special condition.	Tubercular history.
Usually occurs at 25 or 30 years of age.	Any age.	Not often seen after thirty.
Begins in the testicle.	Begins in the body of the organ.	Begins in the epididymis.
Is situated primarily in the connective tissue.	Begins by the deposit of small nodules in the seminiferous tubules.	Exists primarily in the tubules.
Tendency to fibrous development.	Tends to formation of patches of softened, white, pultaceous material.	Tends to fatty, caseous, or purulent degeneration.

[<sup>1</sup> Founded on one in Agnew's Surgery, vol. ii. p. 590.]

SYPHILITIC ORCHITIS.	ENCEPHALOID CARCINOMA OF TESTICLE.	TUBERCULAR ORCHITIS.
Slow in its progress.	Rapid in its course.	Slow in its progress.
Skin of the scrotum rarely involved.	Skin of the scrotum finally involved.	Skin involved only just before the formation of abscess.
Ulceration or suppuration rare.	Ulceration and fungus common.	Suppuration common.
Fistulæ uncommon.	Fistulæ common.	Fistulæ common.
A feeling of great weight, with only such pain as results from dragging on the cord.	Pain severe and lancinating in advanced stages.	Little pain.
Tumor very hard; uniform.	Soft and fluctuating.	At first hard, knotty, irregular.
Skin of scrotum purplish and unaffected.	Network of large veins over surface of tumor.	Skin congested, but otherwise unaffected.
Of moderate size; rarely exceeds twice its normal diameter.	Attains great size.	Of moderate size.
Painless on pressure.	Painless on pressure.	Painful on pressure.
Both testicles often affected.	Generally only one testicle affected.	Often both testicles affected.
Fungus rare.	Fungus always present in advanced stages.	Fungus common.
No discharge or bleeding.	Bleeds freely; offensive discharge.	Not so apt to bleed; discharge not so offensive.
Lasts many years.	Rarely extends beyond 20 months.	Lasts several years.
Curable.	Fatal.	Generally incurable.
No involvement of inguinal glands as a rule.	Inguinal, iliac, and lumbar glands, and cord affected.	Usually no inflammation of glands.]

INTERSTITIAL ORCHITIS OF NEW-BORN CHILDREN.—In connection with Coÿne, a few years ago, I had the opportunity of examining the testicles of a child three years old, affected with hereditary syphilis. The seminal ducts were found separated by numerous round or fusiform cells.

Parrot and Hutinel have especially studied syphilitic testicles in new-born children. Hutinel's investigations are based upon ten cases. The testicles are slightly enlarged, and harder than normal, the scrotum is pendent, the epididymis is normal, the lesions of the tunica albuginea are very slight, and at times there is found a little exudate upon the tunica vaginalis, a few lymph cells in a reticulum of fibrin.

Both testicles are similarly changed, and more uniformly altered

than with the adult, or the interstitial orchitis may be unilateral and very irregularly distributed.

The lesion consists in small collections of round embryonal cells, resembling lymph cells, arranged in the connective tissue around the arterioles which come from the tunica albuginea. These islands of embryonal tissue are arranged similarly to those met with in the livers of new-born syphilitic children, and may be described as small gummata. The lesion is accompanied by a more or less marked diffused interstitial orchitis. Or there is only seen a thickening from the new formation of small round cells of the connective tissue of the testicle. The seminal ducts are all surrounded with these cells, and the gland undergoes a very notable hypertrophy. The cells within the ducts become granulo-fatty and atrophied. The ducts are also atrophied. These changes very closely resemble those found in a syphilitic testicle of an adult. It must not, however, be forgotten, that the testicle of a new-born child, in the normal state, contains embryonal tissue and not fibrous connective tissue. Therefore, in order to study a syphilitic testicle of a new-born child, or any of the lesions of hereditary syphilis, the normal appearances of these organs, according to the age of the child, must be known.

The symptoms of this affection are the hypertrophy, the weight, and the general or nodular induration of the testicles. Children suffering with this disease, usually die early from involvement of some important organ.

[Henoch reports<sup>1</sup> seven cases of disease of the testicles accompanying infantile syphilis, these being enlarged, hard, and inelastic, and frequently nodulated. The children were from three months to two and one half years of age, and the diseased condition usually improved under the use of mercury. In the case of one child, aged two and one-half years, the general appearances had vanished after thirty inunctions of fifteen grains each of mercurial ointment. The swelling of the testicles did not disappear, and the child dying three months later of measles with diarrhoea, the autopsy showed both testicles still very large and indurated. Microscopical examination proved extensive interstitial hypertrophy of the connective tissue, most strongly developed in the corpus Highmori. No gummata were found.

This case, like a case of Desprès, goes to prove that when fibroid new formation is already present as the result of inflammation, no

[<sup>1</sup> Schmidt's Jahrbuch. Bd. 178, No. 4.]



diminution of the size of the testicle need be expected to result from the use of mercury. The process in question represents an interstitial orchitis and epididymitis, and may be classified with the similar conditions, occurring in cases of hereditary syphilis, in the liver and in the cortical substance of the kidneys.<sup>1]</sup>

**GUMMOUS ORCHITIS.**—Gummos orchitis is only a more advanced stage of interstitial orchitis. The cells of new formation are localized as small tumors, seated at the surface of the gland, near the tunica albuginea, which is also often involved, and in the body of Highmore. They are seldom found in the connective tissue, which surrounds the epididymis and spermatic cord. They are always accompanied by an interstitial orchitis, and peri-orchitis, in which the inflamed tunica vaginalis is the seat either of an effusion, or of bands which unite the visceral and parietal layers. Their number, size, and grouping are variable. Like all gummata, they are characterized macroscopically by their fibrous induration, and central caseous degeneration; microscopically they do not differ in structure from gummata found elsewhere.

The symptoms and diagnosis of gummos orchitis are the same as those of interstitial orchitis, except that the nodules and irregularities upon the surface of the tunica albuginea are more apparent.

Gummata of the testicle, like interstitial orchitis, do not tend to suppuration, which distinguishes them from tuberculosis. Rollet, however, has seen gummata complicated with ulcerative inflammation of the skin of the scrotum, and with hernia, or fungus of the substance of the testicle.

Both testicles are most generally affected in syphilis, while only one of these organs is diseased in cancer, sarcoma, enchondroma, etc.

The prognosis is the same as in interstitial orchitis, and their treatment does not differ from that of this lesion. Castration is recommended as a remedy.

**SYPHILIS OF THE OVARIES AND FALLOPIAN TUBES.**—Lécorché and Lancereaux have described three cases of fibrous thickening of the ovary. But to me these cases seem very doubtful. Fibrous thickenings, or even small fibrous tumors of the ovary found *post-mortem*, and still more so the tumors felt by palpating the abdomen,

[<sup>1</sup> Dr. E. Wigglesworth in Bost. Med. and Surg. Journ., vol. xxiii., 1879.]

or through the vagina, are of doubtful syphilitic origin. In old women the ovaries are shrivelled, and become very hard; they contain fibrous nodules due to the final transformation of the corpora lutea, and may also present a myxomatous or calcareous degeneration.

Bouchard and Lépine have reported a case of salpingitis, with the development of soft, reddish tumors, and grayish granulations in the Fallopian tube.

**SYPHILIS OF THE KIDNEYS.**—These glands may be affected, either during the secondary or tertiary period of syphilis.

During the first months which succeed the infection, it has several times been observed that an intense and temporary acute albuminuria was present. Perroud, of Lyon, has noticed two cases: the first, in an old man, where the albuminuria had probably been favored by a senile change of the renal arterioles; the second, in a young girl, who had previously been exposed to cold, which may have been partly the cause of the albuminuria.

Lancereaux reports three cases of albuminuria following the secondary period of syphilis.<sup>1</sup> Two were a long time under mercurial treatment, and it is possible that the mercury was the cause rather than the syphilis. The amount of urine passed was small.

[Dr. Drysdale, of London, is inclined to believe that after the brain and liver, the kidneys were most frequently of all the internal organs affected with syphilitic inflammation and neoplasms. Although most writers on albuminuria did not admit syphilis as a cause, he is from personal observation convinced that many cases of that disease in adults are due to this often unsuspected agency. The morbid anatomy of syphilitic albuminuria may consist of diffuse inflammation of the cellular elements of the kidney, which, as in the case of syphilitic cirrhosis of the liver, spinal cord, etc., leads to destruction of the secreting cells, and ultimately to fatty-degeneration of the organ. The disease usually commences insidiously, is accompanied by anasarca, and may end in death from asthenia, or in coma. The diagnosis is made out by the history of the case, and is often quite clear; but even when the history is indistinct, assistance may be gained by noticing whether there are any scars on the liver after death. No matter what treatment had been employed, Dr. Drysdale found that, in certain cases of syphilis, a fatal termination occurred by the in-

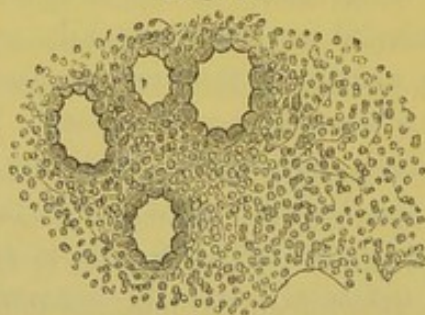
<sup>1</sup> La Syphilis, 2d edition, page 153.

sidious commencement of nephritis, usually far on in the disease, but occasionally arising precociously, or within a year after infection. The latter was, however, very rare. His experience was that the iodide of potassium sometimes was useful in these cases; and that the prognosis was generally very bad.<sup>1</sup>]

The renal lesions of tertiary syphilis consist in gummous formations and amyloid degeneration of the vessels.

Syphilitic gummata of the kidney are infrequent. In 1864 I obtained a kidney which contained twenty-one of these tumors in its cortical substance. It occurred in an old woman, who during life suffered with albuminuria and anasarca.<sup>2</sup> The liver was riddled with characteristic gummous neoplasms. The kidneys showed an amyloid degeneration of the vessels and a parenchymatous nephritis. The gummata did not differ from these new formations found elsewhere. Three zones were discernible: 1st, a peripheral inflammatory zone in which the connective tissue infiltrated with small cells separated the uriniferous tubules, the glomeruli, and vessels of the kidney; 2d, a middle zone in which the connective tissue predominated, but where the glomeruli and some tubules were seen separated from one another and filled with the neoplasm; 3d, in the centre the fibrous tissue containing small, atrophied, and granular cells; here were still recognized atrophied and fibrous glomeruli. To the unaided eye, the centre of

[Fig. 84.



The peripheral portion of a gummous growth in the kidney, showing the small-celled granulation tissue in the intertubular tissue.  $\times 200$ . (Green)]

the gummata were yellow, while at the periphery they appeared gray, and in contact with the renal parenchyma they were more or less congested.

In connection with Coÿne I had the opportunity of examining a

[<sup>1</sup> The British Medical Journal, Aug. 23, 1879.]

<sup>2</sup> Cornil, Thèse de doctorat sur les lésions anatomiques du rein dans l'albuminurie, page 50, 1864.

similar case, in which there was only one gumma ; it was large, homogeneous, and gray.

Tügnel, Lancereaux, Lallier, Axel Key, and others have reported analogous cases.

Simple interstitial nephritis without gummous formations, and cicatrices upon the surface of the kidney, have been observed by Lancereaux, and reported by him as due to syphilis.

The symptoms in connection with this lesion are the cachexia and albuminuria with their usual phenomena. But although the albuminuria may depend upon the syphilis, it cannot be certainly determined from the symptoms alone which one of the renal lesions is present, viz., amyloid degeneration, interstitial nephritis, parenchymatous nephritis or gummata.

Albuminuria occurring in tertiary syphilis rapidly causes an incurable cachexia.

[The best and most comprehensive article upon this subject recently published, with which we are familiar, is one by Barthèlemy, entitled *Some Remarks upon Visceral Syphilis and especially upon Renal Syphilis*,<sup>1</sup> in which he gives a *résumé* of the discussion which took place in the Clinical Society of London, January, 1880, and also adds several cases relating to nephritis of specific origin which came under his own observation.

In the course of the above discussion, Dr. Coupland reports two cases of hereditary syphilis. The first, a girl 13 years old, who presented in a marked degree the signs of inherited disease. At the time of her admittance into the hospital she was suffering with renal dropsy, and in the right side of the abdominal cavity was a very evident hard and irregular tumor, connected with the liver. She died after remaining in the hospital three months. At the autopsy, two large gummous tumors were found in the liver. The spleen was enlarged and indurated, but not amyloid in nature. The kidneys presented the lesions of parenchymatous nephritis.

The second case, a girl 18 years of age, was one of a family of thirteen children ; seven had died young, and there had been two abortions. There was no history of infantile syphilis, nor was there any trace of hereditary disease. Her health was good until she was 15 years of age, when a periosteal tumor developed near the knee. This was followed by other nodes upon the anterior part of the leg

[<sup>1</sup> *Annals de Derm. et de Syph.*, April, 1881.]

and forearm, and two years later there occurred necrosis of the frontal bone. She died from nephritis and a phlegmon of the right leg, consecutive to a suppurating gummous tumor of the tibia. At the autopsy, numerous gummous tumors of the osseous system were found. The liver contained in its substance a small gumma. The spleen was enlarged, but not amyloid. The kidneys were changed as in the first case—parenchymatous nephritis.

Hutchinson remarked that lesions similar to the above are frequently met with in early syphilis in the adult, and that he had seen a number of cases during their life, but had the opportunity of making an autopsy only in four or five. These patients were generally endowed with great vital powers, but, if death resulted from syphilis, it was usually due to a nephritis.

Barlow is of the opinion that patients attacked with congenital syphilis are very susceptible to or are predisposed to nephritis.

Mahomed, on the contrary, believes that most cases of nephritis due to syphilis are primarily cases of amyloid degeneration. He had in several instances seen cases of granular contracted kidney associated with amyloid degeneration in syphilitic patients.

In concluding, Coupland said he was convinced that patients suffering for a long time with syphilis have a great predisposition to be affected with and to die from parenchymatous nephritis.

Barthèlemy believes that patients who have contracted syphilis are more frequently affected with syphilitic nephritis than is generally supposed, and that the renal lesions may occur during the secondary as well as the tertiary period. These lesions are parenchymatous, interstitial, and amyloid. They are always grave, and frequently terminate in the death of the patient; but they are not necessarily fatal, and under specific treatment may recover.

The following cases are given by Barthèlemy :—

CASE I.—E. B., aged 31 years, ironer, admitted into hospital on Nov. 26, 1879.

*Previous History.*—Typhoid fever when 6 years old, neuralgic pains when menstruating; general health good.

Infecting chancre in June, 1879. In August, general eruption of papulo-squamous syphilide. From September she has suffered very much with headache, both day and night.

Alopecia of scalp and eyebrows.

For five months, that is, since one month after the appearance of the chancre, the patient has noticed a swelling of the face, which has never disappeared.

*Present Condition.*—Headache very violent; patient cannot sleep; great thirst and poor appetite. Frequent urination; obliged to get up during the night to pass water. Subject to nocturnal delirium. Large amount of albumen in urine. The face is swollen. Vision imperfect for the past five months. Papulo-eroded syphilide of the vulva. Enlarged lymphatic glands in both groins.

January 3, 1880. Renal symptoms continue (headache, feebleness, trembling, paleness, swelling of face, albuminuria).

January 7th. Headache progressively disappeared; also the œdema of the face. There remains some paleness. Strength returning. Delirium ceased.

January 15th. The patient left the hospital. She is evidently convalescent, but not recovered from her syphilis or nephritis. She has no swelling of the face, but is still pale; no headache, but some imperfect vision. The albuminuria is still present.

Barthèlemy, in commenting upon this case, says it is a demonstration of the early appearance of albuminuria in syphilis, and he does not think there is any proof of the albuminuria being a simple coincidence, giving the following reasons: First, that the patient worked only at ironing clothes, and was not exposed to wet or damp. Second, that she had not taken cold. And, finally, that she had neither the habits nor symptoms of an alcohol drinker.

CASE II. is the history of a patient in whom, previous to the contraction of syphilis, albumen had appeared in the urine. The albuminuria, which evidently was not of specific origin, was not at all influenced by anti-syphilitic treatment.

CASE III.—A., three years before entering the hospital, had contracted syphilis. At the time she presented herself for treatment she had mucous patches in the throat and upon the vulva, continual frontal headache and vertigo. *No albumen in the urine.* After three months of anti-syphilitic treatment she left the hospital recovered. Four months later there was swelling of the thighs with pain, which soon involved the whole lower extremities.

There was no cardiac disease, or any pain in the renal region. In a few days the headache returned, œdema of face and genitals was also added to the other symptoms. Dyspnœa was very intense. An examination of the urine, which she passed in large amount, showed albumen to be present in considerable quantity (22 grammes in a litre).

During the treatment, which was continued for seven months, and was chiefly anti-syphilitic, the patient had suffered with a large abscess, situated upon the right buttock. At the time she left the hospital an examination of her urine showed only a very slight trace of albumen, nitric acid causing only an insignificant cloudiness, and her general health was such as to lead to the conclusion that complete recovery was to be expected.

This case Barthélemy considers interesting, as it demonstrates the gravity of nephritis in syphilitic patients, the recovery of the kidney affection under specific treatment, and of itself warrants, in his opinion, the conclusion that the renal disease was of a specific character.

CASE IV.—C., age 55 years, jeweller, entered the hospital April 2d, 1877. At 18 years of age he had a discharge from the urethra which lasted three months. This was treated with anti-blenorrhagics as usual. The patient had never noticed the presence of a chancre; his general health remained good.

In 1867, without any appreciable cause, he was attacked with violent neuralgic pains, which continued day and night, but were more severe in the head during the night; they lasted about two years.

In 1869 the patient noticed upon the forehead, above the left eyebrow, a tumor, which rapidly increased to half the size of a walnut. The tumor was soft and fluctuating, and in a few days discharged a serous fluid. Soon after, alongside of the preceding tumor, another tumor, which ran the same course, was perceived. Within a month the entire scalp was covered with an eruption, especially in the occipital region, where it was confluent. After the evolution of these small tumors there remained deep cicatrices. With the eruption of the tumors the headache disappeared, and the patient had several years of good health.

In January, 1877, he was attacked with violent pain in the left arm, more severe during the night. A month later an exostosis appeared upon the left humerus. In March pain was felt in the left buttock and groin, resembling that in the arm. At the same time the left femur at the upper third increased in size.

In this condition C. was first admitted into the hospital, May, 1877. There is no doubt that he was suffering with syphilis, although he was ignorant of the fact, and had not been under treatment for this malady. He left the hospital in October, 1877, and remained in good health until March, 1880, when there rapidly appeared several symptoms, such as general weakness, inability to make the slightest exertion, tendency to sleep, sadness, inactivity, etc. His mind acted slowly, conversation was incoherent, memory failing, was always cold, even in May. There was no fever and his appetite was not good. He suffered no pain except headache, which was continual day and night. There were sometimes painful cramps in the legs, especially at night. Vertigo; no paralysis. No difficulty in speaking. No œdema. Finally, there occurred slight swelling of the face, and an examination of the urine showed the presence of a considerable amount of albumen. He died comatose a few days after re-entering the hospital.

*Autopsy.*—The left pleural cavity contained about forty ounces of clear fluid. The left lung was compressed, otherwise healthy. The right lung much congested. Heart normal in size; mitral valve thickened and atheromatous, but competent.

*Cranium.*—The scalp was removed with difficulty, the skin was thin, adherent to the bone and changed into a nodular tissue. The posterior third of the second frontal convolution had upon it a marked depression, forming a cavity, half as large as an almond, covered by a layer of the pia

mater, which was not thickened. In the cavity of the depression there was neither inflammatory product nor new formation. The arteries at the base of the brain were not atheromatous. The remainder of the brain was normal.

*Abdomen.*—Spleen normal, liver slightly fatty-degenerated.

*Kidneys.*—The capsule was easily removed. Upon the surface of the cortical substance were seen numerous hard, yellow-white lenticular nodules, indicating a marked granulo-fatty-degeneration. The change was more evident in the left kidney, which was also smaller than the right. The organ macroscopically resembled very much a cirrhotic liver; the surface was yellow, mammillated, and wrinkled. Upon section the fatty-degeneration was more evident. The entire cortex was white and much thickened, and its separation from the medullary part was very indistinct. There was no trace of caseous foci or gummata.

A microscopic examination was made by Dr. Balzer. Sections of the kidney were treated with picro-carmin and also methylaniline. The latter reagent showed the presence of advanced amyloid degeneration. The capsule of the glomerules was thickened, fibrous; some of the latter were wholly converted into fibrous tissue. The fibrous tissue throughout the entire organ was very much increased. These changes were indicative of interstitial nephritis.

The modifications found in the uriniferous tubules were well marked. The tubules were compressed, atrophied, and in places difficult to recognize. Their epithelial lining was granular and disintegrating. The centre of the tubules was occupied by refracting masses, as described by Cornil, granular corpuscles and free fat granules. These changes, in connection with those previously described, demonstrated the presence of several pathological processes, amyloid degeneration, interstitial nephritis, and parenchymatous nephritis.

In review of this case Barthèlemey observes that there was evidently an unusual form of nephritis, in which the early symptoms escaped notice, and that it is evident from the many and profound lesions which existed that it had been of long duration.

No explanation of the occurrence of the disease, could be elicited from the patient when minutely questioned. Prolonged suppuration or tuberculosis were not present to account for the amyloid degeneration. This latter, however, is one of the results of syphilis, and in default of other causes may not the syphilis, which was neglected and which had so seriously implicated the skin and bones, be considered an immediate agent? The case to him appears as one of nephritis due to or constituting a tertiary lesion.

Barthèlemey has not personally met with any cases of syphilis of the primary period, in which albuminuria was present. Cases, however, have been reported by Perraud and Lancereaux. Nephritis of the secondary period, on the contrary, is not of unusual occurrence. Nearly all writers on syphilis, from Boyer to Fournier, Lancereaux,



Cornil, Guiol, Brouardel, and Descout, have seen and reported cases of this affection.

The conclusions arrived at by Barthèlemy, from his study of the subject, are the following:—

Nephritis is one of the complications of all the periods of syphilis, even in the acquired form.

It is always a grave lesion, at times curable, not only in the adult, when a consequence of acquired syphilis, but also in children affected with the hereditary form. It has, with the other lesions of specific origin, the common character of gravity in proportion to the age of the syphilis; the length of time during which antisyphilitic treatment has been employed has also its influence upon prognosis.

Children affected with hereditary syphilis may either die early with lesions which may be referred to the kidneys, or they may recover in spite of those lesions.

In cases of nephritis in adults it is advisable to ascertain if there is a specific origin for the renal lesion, either acquired or hereditary.]

## CHAPTER XIV.

## TREATMENT OF SYPHILIS.

Mercurial medication—The anti-mercurialists—The absorption and elimination of mercury—Mode of administration and its different preparations in the treatment of syphilis—Iodide of potassium—Manner of administration and doses.

IN the course of this work the principal manifestations of syphilis and the requisite treatment thereof have been considered. The therapeutic indications in the case of infecting chancres, mucous patches, superficial and deep cutaneous syphilides, and the tertiary phenomena have been so fully treated of that it is necessary now merely to recall in a general way the most rational course of therapeutics to be pursued.

It has been shown that the first two stages of syphilis are amenable to treatment by mercury—the third stage to that by iodide of potassium. Physicians sometimes prescribe the iodide at the very outset of the disease, or they may employ the mixed treatment, and although it is necessary to take into account the regimen, the administration of tonics, etc., it will always be found that mercury and the iodide of potassium, used as above mentioned, form the basis of all special therapeutic treatment. It will be proper in this place to inquire into the use of these two remedies.

A. MERCURIAL MEDICATION.—Mercury was employed as a remedy in syphilis at the close of the fifteenth and at the commencement of the sixteenth century, at a time when this malady established itself in Europe with a violence of which we happily at this time have no conception.

At that period mercury was given in the form of ointments, plasters, or fumigations. The evils arising from its administration, often given over to charlatans, became worse than the disease itself. The very large doses of mercury given thus by means of friction, baths, and sweatings led to salivation, ulcers of the mouth, to the breaking

and falling out of the teeth, to cachexias and palsies. The introduction of guaiacum and of the sudorifics, which were advanced as sovereign remedies in the cure of syphilis, was hailed as a deliverance. From this time the physicians divided themselves into Mercurialists (Vigo, Fracastor, Massa, Botal, and Rondelet), and Anti-mercurialists (Torella, Fernel, Fallope, etc.). Shortly afterwards mercury was used internally, at times in the form of the red oxide, at others as the deutoxide, or in pills of metallic mercury—the latter form, according to accounts of the times, being taken by Francis I. The employment of mercury was still, however, nearly always pushed to the production of salivation.

Nevertheless at the commencement of the eighteenth century, Chicoyneau, and the school of Montpellier, substituted for salivation—now considered useless—more moderate doses with a prolonged course of medication, called the method of elimination. In our time, Broussais and his followers, Deruelles, Devergie the elder, and others, considering syphilis as a collection of non-specific inflammatory lesions, treated it by bleeding and by attention to the diet.

Fergusson, Thompson, etc., also treated their patients, in England, without mercury. It is necessary to count among the anti-mercurialists the partisans of syphilization, Auzias-Turenne and Spérino, who, seeking a sort of vaccination for syphilis, believed they could cure it, and place a patient beyond the reach of its poison by inoculating him with the pus from a simple chancre. The well-established dualism of chancroid and syphilis has terminated these attempts.

Murphy (1839), in England, Joseph Hermann (1855), and Lorimer, in Vienna, endeavored to show that mercury was the sole cause of the secondary and tertiary phenomena of syphilis. Kletzinsky having proved that the use of iodide of potassium tended to eliminate mercury from the system, Melsens argued from this that iodide of potassium acts in the third stage of syphilis merely because it drives out the mercury, the cause of all the evil. Kussmaul (1866) and Virchow by a long study of the histological effects on the one hand of mercurialism, and on the other of constitutional syphilis, had no difficulty in proving that there is no analogy between these phenomena.

At the present time the number of anti-mercurialists is very small, our esteemed colleague, M. Desprès, being, we believe, the only representative of this doctrine in France. M. Desprès regards the tertiary productions, especially the gummata, as traces of chronic inflamma-

tions, similar to those resulting from purulent infection, and he denies that they possess any specific quality. According to him, syphilis should not be obstructed in its onward course any more than an eruptive fever should, and he confines his treatment to the giving of tonics to sustain the strength of his patients.

Although the ultra anti-mercurialists have nearly disappeared, many of the syphilographers, Diday, Lancereaux, Jullien, etc., enlightened by the normal progress of syphilis, by no means give mercury in every case, and they can thus be classed with the moderate mercurialists in comparison with Fournier, who invariably employs this drug, and continues its use after all phenomena have disappeared.

*Absorption and Elimination.*—The usual avenues by which mercury effects its entrance into the system are the skin, the respiratory passages, the alimentary canal, and the subcutaneous cellular tissue, according as we employ friction with mercurial ointment, baths, fumigations, soluble preparations—as Van Swieten's solution—pills of the protiodide or biniodide, or hypodermic injections. By cutaneous friction or by fumigation mercury may be made to penetrate the skin, where it is found in a fine metallic granular condition in the epidermis. Gübler and Neumann state that mercury reaches the sweat glands and the hair follicles. Rindfleisch, and more recently Fleischer, have, however, failed to find it either in these glands or in the rete mucosum. It is certain that by means of friction mercury may be absorbed, and will enter the blood independently of the vapor which is taken up by the pulmonary surfaces. Does it penetrate the skin as a chloride under the influence of the sweat (Müller), or simply as a vapor, as is held by Rabuteau? The experiments of V. Regnaud and of M. Merget, on the volatilization of mercury at all temperatures, and on the quickness of the separation of its molecules, tend to support this latter theory. Mercury is unquestionably volatilized and disintegrated when it is incorporated with the fats in ointments.

According to M. Mialhe, mercury taken into the stomach is invariably transformed into the bichloride, by the hydrochloric acid of the gastric juice, and is absorbed in this form in combination with the albuminoid substances of the plasma. M. Rabuteau, on the contrary, holds that the salts of mercury are reduced in the stomach or in the blood, giving metallic mercury as the result. For example, the bichloride decomposes into the chloride of sodium, and mercury is

precipitated. The protiodide is transformed first into mercury and the biniodide. This is still further changed by giving an iodide (of sodium?), which is found in the urine.

While considering the manner in which mercury is absorbed by the skin, and the mucous membrane of the digestive tract, it should be borne in mind that the entrance of mercury into the blood is very rapidly and easily accomplished; and that absorption takes place with still greater certainty and rapidity by way of the respiratory passages, and by means of subcutaneous injections.

There is not only this uncertainty regarding its precise condition at the time of absorption, but we are even less well informed as to the manner in which mercury is retained in the organs, and as to the combinations it forms with the cellular elements and fluids of the body. It is known that the glands, the liver, the kidneys, and other organs, such as the brain, store it up in part, and that at the same time there is a process of elimination going on through the urinary, salivary, cutaneous, mammary, and other secretions. The elimination through the milk, which contains an appreciable quantity, acting through the nurse to whom it has been given, has been put to good use in the treatment of infants affected with hereditary syphilis. The kidneys are, however, the principal organs through which mercury is eliminated. The iodides, the bromides, and the alkaline chlorates aid this process of elimination by favoring the formation of double salts. For example, the iodide of potassium is eliminated in the form of a double iodide of mercury and potassium. The same is the case with the chlorate of potassium, which is, as is well known, a useful remedy when it becomes necessary to combat the toxical effects of mercury, which is then eliminated in the form of a double chloride of mercury and potassium.

Mercury remains in the system for some time after it has been continuously employed for a long period. It has been found in the viscera many months, and even a year after mercurial treatment had been suspended.

*Physiological Action.*—The action of mercury upon healthy organisms varies according to the dose and the manner in which it is given. When the ordinary therapeutic dose is employed,<sup>1</sup> patients placed

<sup>1</sup> It may be given in the dose of from three-quarters to one and a half grains of the protiodide, in the form of pills; or from  $\frac{1}{2}$  to  $\frac{1}{4}$  grain of the biniodide, in compound syrup of the biniodide; or in the form of Van Swieten's solution, in the dose of from  $\frac{1}{2}$  to  $\frac{1}{4}$  grain of the bichloride of mercury; or as the pills of Sedillot.

under this treatment rarely experience any toxic symptoms, even if the medication be carried on continuously for several weeks. Sometimes, however, the bichloride of mercury is badly supported by the stomach; at times it nauseates and even produces vomiting; and it is for this reason that it is generally given in milk or sweetened water. Pills of the protiodide frequently cause pain in the stomach, or diarrhœa, and to guard against these accidents, opium is often incorporated with them.

What is the result of this treatment?

According to M. Rabuteau, mercury in these small doses, acts in the same manner as arsenic, as an arrester of destructive metamorphosis. Rabuteau, in experiments upon himself, has shown quite a notable diminution in the quantity of urea secreted during the 24 hours. But these experiments, we think, require repetition and confirmation. The examination of the blood has produced very variable, and even opposite results. Thus, while Bretonneau, Trousseau, etc. speak of a remarkable fluidity of the blood, and of the want of its coagulability, Lemaire and Gélis conclude from experiments made under the supervision of Bouillaud, that the mercurial treatment augments the plasticity of the blood.

It has already been noticed (page 165) that mercurial treatment moderates the diminution of the number of red blood-corpuscles, caused by syphilis, and at first even stops it; but at the end of a certain period, notwithstanding the administration of mercury, or on account of it, the number of red corpuscles diminish. The experiments made by Wilbouchewitch, at the hospital du Midi, have been repeated by Keyes in America. This author concludes that mercury given in small doses, even for a long period, increases the number of red corpuscles, and that it acts as a tonic in augmenting the weight of the body, even in the case of non-syphilitics; but, on the contrary, given to excess, it diminishes the number of red corpuscles.

When mercury is given in large doses, it has been demonstrated by the researches of Gübler, confirmed by those of Wilbouchewitch, that the number of red corpuscles diminishes very rapidly. According to Hallopeau, who has recently published a very complete monograph on the physiological and therapeutical action of mercury (*Thèse d'agrégation*, 1878), the inflammations, the increased secretion, and the disorders of nutrition observed in mercurial poisoning, are probably due to two causes: 1st. To the presence in the blood of an oxide of mercury, in a soluble combination with the albumen and

chloride of sodium. 2d. To the rapid destruction of the red blood-corpuseles.

When mercury is given in a still larger dose, or when it is employed in a manner which renders its absorption very rapid, such as by mercurial friction, fumigation, calomel in divided doses, touching mucous surfaces or sores by the acid nitrate of mercury, etc., stomatitis and salivation rapidly follow, but are symptoms not sought after in these days, it being now believed that the dangers of these conditions, which are in many cases of extreme gravity, sometimes even resulting in rapid death, are totally disproportionate to the advantages derived therefrom.

Trifling examples of mercurial poisoning are, however, frequently seen from time to time, such as a redness or swelling of the gums, a moderate thickening of the tongue, a little increase of salivary secretion, or, in other words, slight salivation. In a more advanced stage the gums are swollen, and there are noticed whitish patches, due to the saturation and to the desquamation of the superficial layers of the epithelium, ulcerations of the gums and of the internal surfaces of the cheeks, with excessive salivation, breaking off of the teeth, swelling and thickening of the tongue, glossitis, and fetid breath.

To illustrate the grave character of this symptom in certain cases, it is not necessary to go back to the ravages of mercury during the fifteenth and sixteenth centuries, of which Jean de Vigo, Ulrich de Hutton, etc. have left us a description. I myself, on one occasion, during my residence at the Saint Louis Hospital, assisted at the cauterization of a series of cases of lupus by acid nitrate of mercury. The next day, all the unfortunate subjects were affected with stomatitis, and two of the number died within a few days from its effects. The antidote, which is quite efficient, but which should be employed before the stomatitis has become intense, is the chlorate of potassium, which is given in solution in doses of from sixty grains to one hundred and fifty grains a day. It is necessary merely to allude to *chronic* mercurial poisoning, as in the case of workmen employed in the silvering of mirrors, and as is still seen among the miners of Almaden. The cachexias, palsies, convulsions, nervous affections, albuminuria, and aneurisms which are observed under these conditions never present themselves in a syphilitic undergoing proper treatment.

While studying the general action of mercury upon the composition of the blood, and its effect upon the excretions, a few words should be said in relation to its local action, and its power as a parasiticide.

In contact with the skin, it often produces an artificial vesicular eruption. It rapidly kills pediculi and their eggs, as well as the eggs of all insects and inferior organisms, and all cutaneous vegetable parasites. Finally, the local cauterant action of mercury is of great service in many forms of ulcers and inflammations, whether of syphilitic origin or not. The general effect of mercury having thus briefly been considered, its action in syphilis must be investigated. Of the beneficial effect of this action there can be no doubt; it causes the disappearance of cutaneous syphilides, which, if left to themselves, would be very persistent; it retards the return of such eruptions; and in a great number of cases puts off indefinitely the appearance of tertiary symptoms.

Is its general action debilitating or *denutritive*? Does it act, for example, like venesection or fasting? It is true that the recent experiments which have been cited prove that the therapeutic dose of mercury is not denutritive. Should it be then considered as a tonic, or as an arrester of destructive metamorphosis? Must we say that mercury diminishes the intensity of the circulation and the nutrition in syphilitic neoplasms? Shall it be admitted, according to Julien, that it favors absorption by stimulating the lymphatics? We are not at present in possession of sufficient information to enable us to answer these questions definitely. To say that mercury is the antidote of syphilis, would be to express a fact without being able to explain it; nothing more is explained when it is termed a specific. If its action is looked upon as that of a parasiticide in syphilis, according to the views taken by Hallepeau, it will have to be admitted that the malady is due to parasitic micrococci, which is probable but is not yet demonstrated. It will be wise for the time being simply to be governed by the results of empirical observation.

In this hospital the initial stage of infecting chancre is rarely seen. It has already been observed that the benefit derived from the use of mercury at the *onset* of chancre has not been shown, and that according to the statistics of Diday its use in such cases would be injurious.

The indubitable beneficial action of mercurial preparations in syphilis is best seen in cases of the secondary phenomena, and especially of widespread papular syphilides, or of ulcerating crustaceous or severe early syphilides. We administer it in varied doses, according to the extent and gravity of the eruptions. In the deep cutaneous syphilides, which indicate the passage from the secondary to the ter-



tiary stage, we employ the iodide of potassium with it. The most satisfactory preparation is the protiodide, in the dose of from  $\frac{3}{4}$  to 1 grain, and Van Swieten's solution in the dose of from one to two teaspoonfuls daily. Against stubborn syphilides we employ frictions of the Neapolitan ointment<sup>1</sup> in the dose of from  $\mathfrak{zj}$  to  $\mathfrak{z}iiss$  daily. The absorption of this is very rapid, especially when it is rubbed on the skin in regions where it is the thinnest, or where the temperature is the greatest, such as the axilla, the groin, and the popliteal space. Every second day this inunction is employed, alternating with a simple or sulphur bath. Patients should then be well watched, for stomatitis is apt to make its appearance very rapidly in some cases.

We possess in the baths of the bichloride of mercury and in fumigations very active means of treatment. Frictions and baths of the bichloride are very useful when the stomach is unable to bear mercury. They can be employed in the cases of young children suffering from hereditary syphilis, especially when the digestive functions are impaired. In the cases of children at the Saint Thérèse—children suffering with acquired or hereditary syphilis, whose ages varied from 2 to 15 years—we employed most frequently Van Swieten's solution in milk in a dose proportioned to the age of the little girls.

We have very frequently in our service pregnant women who are syphilitic. When syphilis has shown itself a little before conception, or at the same time, or within the first two or three months of pregnancy, these women generally abort if the disease be permitted to take its natural course; on the other hand, if mercury be used methodically, in moderate doses, but continued for some time, the patients usually carry their children to the end of their term, and the child is born well and free from syphilis. We have treated in the St. Clement ward, during the greater part of their pregnancy, syphilitic women who have been confined, and whose children, nursed by them, are healthy.

Within the past twenty years, in addition to the remedies already mentioned, hypodermic injection has been employed. Hebra, Hunter, Scarenzio, Lewin, Aimé Martin, Liégeois, Dron, and Diday have used it with success. Of all the different methods of giving mercury this is assuredly the one by which a certain determined dose can most readily be made to enter the system, and which causes the most immediate modifications in the syphilides. This method is

[<sup>1</sup> Ung. hydrarg. U. S. P.]

largely employed in many large special hospitals, especially at Milan, at Vienna, and at Stockholm. Injections were made by Liégeois twice daily, using a very weak solution; he introduced but  $\frac{1}{5}$ th to  $\frac{1}{8}$ th of a grain at each puncture. Stronger injections, such as Lewin employed, were only given at intervals of two days. Injections should be made in regions rich in connective tissue, and poorly supplied by vessels and nerves, such as the back, the buttocks, the scapular region, or the external aspect of the arm, etc. The inconvenience attending this form of injections is that at times they cause considerable pain, and are very apt to give rise to small subcutaneous abscesses, all the salts of mercury, especially the biniodide, being irritants. To guard against these accidents it is necessary to take the precaution to introduce the needle sufficiently deep into the subcutaneous connective tissue, and not to insert it twice in the same place, or very near a former puncture. Furthermore, it is also well to use at once a systematic method of massage over the small swelling caused by the injection. Bergh, of Stockholm (oral report), has never had any bad symptoms or abscesses caused by these hypodermic injections, because he has always resorted to massage in every case.

At this hospital we give mercury in small doses in such a manner as to avoid salivation, and continue it during the presence of all the symptoms of which this remedy tends to diminish the intensity and shorten the duration. We do not advise its administration when the syphilides have disappeared. We thus class ourselves among the moderate mercurialists, such as Diday, Lancereaux, etc.

The specialists who regard mercury as the antidote for syphilis give it at the beginning of a chancre, and continue its systematic use for a number of years independent of the slight character or even of the total absence of the earlier symptoms, in order to guard against or prevent their later appearance.

Fournier proceeds by successive treatments: he gives mercury for a period of two months, then he desists for a month or more in its use; this period passed, he again takes up the mercurial treatment, independently of what has occurred in the meanwhile, and continues it during six weeks or two months. After which, the patient is given a rest of three months when the treatment is again renewed during six or eight weeks, and so on, care being taken to allow an interval of rest after each period of medication.

B. IODIDE OF POTASSIUM.—The employment of the iodide of potassium in the later stage of syphilis is one of the great therapeutical dis-

coveries of our time. Biett gave the iodide of mercury to syphilitics in his cases at the Saint Louis Hospital, but the good results might be credited to the mercury as well as the iodide.

Wallace, in 1834, experimented at the Gervis Street Hospital, in Dublin, with the iodide of potassium, and the publication of the results obtained by him and by Ricord, Trousseau, and the greater number of syphilographers soon brought the remedy into common use.

The iodide of potassium is given internally and in solution; it is doubtful whether it is absorbed when applied to the skin in the form of ointments; it may be to a very slight degree, but from the stomach it certainly passes immediately into the fluids of the economy. It is eliminated by the urine, the saliva, the nasal mucus, the milk, the tears, and the sweat. The duration of the process of elimination depends upon the amount taken; thus a dose of fifteen grains would be eliminated in three days, and a dose of one hundred and fifty grains in ten days (Rabuteau). Unlike mercury, iodide of potassium never remains for any length of time in the economy after its use has been suspended.

Wallace gave the iodide of potassium in doses of thirty grains. In the dose of from fifteen to thirty grains, which we use ordinarily in the lesions of the tertiary stage, the iodide generally causes coryza and lachrymation, due to its elimination by the saliva and the tears. If its use be continued, patients become accustomed to it. Evil results from its use must be rare; we have never observed any. Rabuteau considers that symptoms of gastritis are sometimes due to impurities of the iodide—containing iodates. The acid of the stomach then sets free the metallic iodine, and as a result the stomach is irritated and vomiting occurs.

The majority of authors look upon the iodide as a resolvent, which acts by producing a process of non-assimilation, causing loss of flesh, diminishing the size of the glands, the breasts, the thyroid body, the testicles. On the contrary, the experiments made by Rabuteau upon himself show that during this treatment the quantity of urea secreted is greatly diminished. There are instances on record, which show that individuals have grown fat while taking as much as six pounds of the iodide of potassium in six years. However contrary these opinions may seem, and however ignorant we may be as regards its mode of action, its efficacy in proper cases is undoubted, especially in the deep syphilides of the skin and mucous surfaces, gummata, osteo-periostitis,

and the tertiary visceral lesions. The manner of giving the iodide is very simple. When it is well tolerated, it can be taken at any hour of the day. A solution is made containing fifteen grains to the teaspoonful, which is taken in half a glass of water, or it may be mixed with a syrup of orange, which conceals the saltish taste. It is given most frequently in doses of from fifteen to thirty grains daily, but it can be taken without inconvenience, in doses of sixty and seventy-five grains, and even one hundred and twenty or one hundred and fifty grains when severe symptoms present themselves. As the iodide is eliminated rapidly, it is necessary to give the same dose daily, until its curative effect has been produced.

[We believe that a careful and impartial review of the testimony as to the results of the mercurial and non-mercurial treatment of syphilis will prove convincingly the far superior efficacy of the former method. Without denying that certain cases of syphilis do well without any treatment, or with simple attention to hygiene, diet, etc., or even while admitting that in the majority of instances at the present day the disease tends to a spontaneous cure, it may still be considered as well established that, without detriment to health, the probability of that cure can be increased, and the duration of the active stage of the malady lessened, by a careful administration of some form of mercury. We are also of the opinion that similar though not quite so conclusive evidence exists in favor of a continuous, as opposed to an intermittent, plan of treatment, although various circumstances may render the latter desirable. The reasons which have been advanced for the employment of mercury in syphilis are—

1. The clinical evidence of its usefulness in the control of early symptoms and the prevention of later developments.

2. Its "tonic" action, which, by counteracting the anæmic tendencies of syphilis, lessens the severity of the disease.

3. Its action as a physiological antidote to the syphilitic poison which it destroys.

4. Its properties as a promoter of destructive metamorphosis, and fatty degeneration, through which it renders possible the absorption and removal of the new cells which are everywhere found to cause the secondary symptoms.

The first reason is one which will be admitted by the large majority of persons having any familiarity with the management of cases of syphilis, and is of itself sufficient to justify the use of the drug.

The second cannot be considered as so unquestionably proved. The careful observations of Dr. Keyes and others have established beyond a doubt the fact that, under the influence of mercury, the number of red blood-corpuscles in a syphilitic, which have notably diminished, will be brought up to their original normal proportion or will even exceed it. This, however, does not demonstrate a true tonic action on the part of the medicine, but may be explained in other ways. Then, too, if the usefulness of mercury depended solely upon this property, iron and other well-known tonics should be of marked if not equal efficacy, whereas it is certain that, while they are of great use as adjuvants in treatment, they have comparatively no control over the symptoms or course of the disease. It is unquestionable that the influence of small doses of mercury is beneficent in some forms of struma, in certain lung affections, in chronic joint troubles, and other cases in which the general health is depressed, but it does not follow that it does good in such cases by a tonic, or still less by a specific antidotal action. The instances mentioned, and most others in which this remedy has been found of value, are associated with impaired nutrition and assimilation, with imperfect action of the lymphatics in removing tissue-waste, with the occurrence of plastic exudation, or with other conditions in which the anti-plastic, the so-called "alterative" action of mercury better explains its beneficial effects than any mere tonic property; and this brings us to a consideration of the fourth theory which has been advanced in explanation of the action of mercury in syphilis.

This view, which has several times been alluded to in the preceding pages, attributes the early symptoms of syphilis to the presence and rapid multiplication everywhere throughout the body of a degraded cell, a disease-germ or particle of germinal matter, which, at the site of inoculation, produces the induration of the chancre; in the inguinal lymphatics the syphilitic buboes; in the walls of the cutaneous capillaries causes the irregular dilatation characteristic of the roseola; in the papillary layer of the skin the little tumors of the papular syphilide, etc. etc.

The well-known property of the white blood-cells of absorbing into their substance foreign bodies which come into contact with them favors the idea that they are the chief agents by which these new cells find their way into the recesses of the organism. It is not essential to this theory that the existence of a distinct syphilitic virus be denied; nor is it necessarily inconsistent with the fungoid theory

of syphilis. The cells which are microscopically demonstrable, and which certainly exist and multiply in the manner described, may or may not be merely the carriers of some subtle poison, but, for the purposes of study, it is asserted that they may be considered as the only visible and tangible source of syphilis. Their effect, then, on the white blood-cell is to impart to it their own properties of rapid growth and immature decay, and to arrest its further progress and development into the red blood-cell. This explains the anæmic condition of the blood in this stage of syphilis.

Now it appears evident that whatever would hasten the degeneration of these newly formed cells, and so favor their absorption by the lymphatics and bloodvessels would aid materially in the disappearance of the symptoms, and would at the same time, by diminishing the sources of contamination of the white blood-cells, relatively increase the number of the red corpuscles and so produce the apparent tonic effect. This degeneration will take place in most cases sooner or later under the influence of pressure from overcrowding of cell elements, and it is for this reason that syphilis has been said to tend to a spontaneous cure; but a drug which favors fatty degeneration and hastens destructive metamorphosis would on *à priori* grounds be expected to exert a good influence, and diminish the duration of the disease.

The armamentarium of the physician furnishes no remedy the power of which in this direction is at all comparable to that of mercury, which has been employed for many years to meet precisely these indications. Therefore, it is said, mercury does good in syphilis by facilitating the removal of the cell-growths which cause the various phenomena of the disease.

Moreover, according to this view *small* doses of mercury only are needed, because newly formed and immature tissues have markedly less resistant power than have normal structures, to oppose to any force or agency brought to bear upon them. Numerous illustrations of this rule in general pathology establish its truth.

Hence, before the physiological effect of mercurial preparations is attained, before they induce unhealthy changes in the normal tissues as shown by salivation, emaciation, etc., they are enabled to produce their beneficial results by aiding in the removal of these comparatively feeble and easily influenced new deposits.

No one of these theories can be considered as in every respect satisfactory, but we incline to the last one as offering an explanation

based chiefly upon known physiological laws, and as dispensing with vague assertions as to "specific," "antidotal," and other influences.<sup>1</sup>

As to the beneficial influence of the iodides in the later stages, a therapeutic fact established beyond all possibility of contradiction, a similar diversity of opinion as to their mode of action prevails. A tonic effect is again, but with less plausibility, claimed as one of the causes of the curative power of these preparations. The views held as to their *modus operandi* will depend upon the particular theory of the tertiary stage which is adopted. Their powerful and almost invariable effects cannot be very clearly accounted for if we regard the tertiary symptoms as relapses of diseased parts affected during the secondary stage, or as outbreaks of poison stored up or encysted in various localities, either upon the "tonic" or the "antidotal" theory. If, however, the tertiary phenomena are due, as is asserted by Dr. Otis, to a crippled condition of the lymphatics which permits of an abnormal accumulation of the nutritive waste of the body resulting in tumors, nodes, gummata, etc., which produce further results—ulceration, caries, necrosis, etc.—simply by their pressure effects, it becomes evident that a stimulus directed to the lymphatic system to enable it properly to fulfil its function would be a great desideratum, and the well-known absorbent properties of the iodides would thus furnish a reasonable explanation of their action.

However this may be, the clinical evidence, as in the case of mercury, is quite sufficient to justify the employment of these drugs, and it now only remains to indicate the proper methods of administering them, which may be epitomized as follows, beginning with the appearance of the initial lesion:—

1. Do not employ mercurial treatment until either by confrontation or by the development of constitutional symptoms the diagnosis of syphilis is assured. Mercury always retards the appearance of the secondary symptoms, and sometimes prevents it altogether. As no venereal sore can with absolute certainty be pronounced syphilitic it is unwise to add an element of uncertainty to the case by delaying indefinitely the outbreak of unmistakable symptoms. There is sufficient evidence to prove that the subsequent course of the case is not materially affected by this delay.

2. When the time has arrived for the administration of mercury it

[<sup>1</sup> For a full exposition of it we refer the reader to the work of Dr. Otis already quoted from.]

is well to explain to your patient the necessity for long-continued treatment, and to point out the risks of neglect.

Having done this, we believe that, in the majority of cases, the most satisfactory method of giving the drug will be by the mouth, the preparation to be preferred being the protiodide of mercury in pill form, in the dose of  $\frac{1}{4}$  to  $\frac{1}{2}$  of a grain, three or four times daily.

R.—Hydrarg. iodid. vir. gr. xx.

Confect. rosæ, q. s.

M. et ft. pil. no. lx.

S.—One pill four times daily.

If these should disagree with the stomach, and produce dyspeptic symptoms, or should give rise to colicky pains and diarrhœa, from  $\frac{1}{20}$  to  $\frac{1}{12}$  gr. of opium may with advantage be added to each pill.

At the same time a saturated solution of chlorate of potassium should be given as a mouth-wash, to be used twice daily, as a prophylactic against salivation.

3. To ascertain the proper dose of the drug in each individual case the rule of Dr. Keyes is a very good one: Continue gradually to increase the dose until slight tenderness of the gums or of the posterior molars is noticed. Then diminish it one-half, and you will be able to administer it indefinitely with no unpleasant results.

4. If the preparation selected agrees with the patient, and controls the symptoms, and if there are no intercurrent complications, pursue this treatment continuously for eighteen months.

If, however, the protiodide gives rise to persistent bowel trouble, as it does in a small number of cases, substitute for it the bichloride in solution, or in combination with a tonic—

R.—Hydrarg. chlorid. corros. gr. iss.

Tinct. cinchonæ co. fʒiv.

M. S.—Teaspoonful in water after meals.

In some cases of irritable stomach, or when it becomes desirable to intensify the mercurial influence, inunctions may be used. Half a drachm of the ten per cent. oleate of mercury, or a drachm of mercurial ointment rubbed into different portions of the cutaneous surface once daily, may be employed for a short time. The uncleanliness of the procedure, and the almost certain eczematous irritation of the skin which it produces, render it unsuitable for long-continued use.

Vapor baths of mercury may be taken in various ways, the simplest being the volatilization by means of an alcohol lamp of a drachm of calomel, the apparatus being placed beneath a chair upon which the



patient sits, a blanket extending from his shoulders to the ground, serving to retain the fumes in contact with his body.

5. By whatever method or methods the mercurial influence is kept up, the dose should be temporarily raised whenever new symptoms make their appearance, and, after they have vanished, should again be dropped to the standard dose for the particular patient.

6. The local treatment of symptoms is of secondary importance, and altogether subservient to the constitutional treatment. It may, however, be useful as an adjuvant. Mucous patches should be treated with sulphate of copper or nitrate of silver if on mucous membranes; when on cutaneous surfaces they should be dusted with powder of starch and calomel, or of calomel and lycopodium.

The scaly and tubercular syphilides will be benefited by the application of a salve consisting of equal parts of citrine ointment and cosmoline—

R.—Ung. hydrarg. nitrat.,  
Cosmolin. aa ʒij.

or by ammoniated mercury and cosmoline, two drachms to the ounce, or by any other stimulating and absorbent ointment.

Ulcers may be dressed with iodoform, or, when sluggish, touched with acid nitrate of mercury.

Enlarged glands may be painted with iodine or let alone; they rarely run on to suppuration.

7. At the end of eighteen months small doses of iodide of potassium should be added to the mercurial, and this "mixed treatment" should be persevered in for six months longer. If during this period any symptom of syphilis makes its appearance, the six months of mixed treatment should be dated from that time. In other words, some such formula as this—

R.—Hydrarg. biniodid. gr. jss.  
Potass. iodid. ʒij.  
Syr. sarsaparil. co.  
Aquæ, aa fʒiij.

M. et S.—Dessertspoonful in water after each meal—

should be administered for the last six months of the two years after the outbreak of the disease, or should be recommenced and continued for six months if any symptoms appear later. Great care should be taken to give the mixture largely diluted, and so to vary it as to do away as far as possible with any irritation of the intestinal tract.

In obstinate tertiary conditions the dose of the iodide may with

impunity be run up to twenty, thirty, or even sixty grains four times daily. If this be done, the cases which refuse to come under its control will be very rare.

8. At the end of two years the patient should be kept under observation for another full year, and if during that time no symptoms are developed he may consider himself as in all probability cured. If such symptoms do appear, however, he should recommence treatment, and should continue it for at least six months after their subsidence.]

The first part of the report deals with the general situation of the country and the progress of the war. It is followed by a detailed account of the military operations and the results of the campaigns. The author then discusses the political and economic conditions of the country and the measures taken by the government to deal with the crisis. The report concludes with a summary of the findings and recommendations for the future.

The second part of the report contains a list of the names of the officers and soldiers who were killed in action during the war. This list is followed by a list of the names of the officers and soldiers who were wounded and the names of the officers and soldiers who were captured. The list also includes the names of the officers and soldiers who were missing and the names of the officers and soldiers who were discharged.

The third part of the report contains a list of the names of the officers and soldiers who were promoted during the war. This list is followed by a list of the names of the officers and soldiers who were awarded medals and the names of the officers and soldiers who were awarded decorations. The list also includes the names of the officers and soldiers who were awarded honors and the names of the officers and soldiers who were awarded titles.

The fourth part of the report contains a list of the names of the officers and soldiers who were promoted during the war. This list is followed by a list of the names of the officers and soldiers who were awarded medals and the names of the officers and soldiers who were awarded decorations. The list also includes the names of the officers and soldiers who were awarded honors and the names of the officers and soldiers who were awarded titles.

The fifth part of the report contains a list of the names of the officers and soldiers who were promoted during the war. This list is followed by a list of the names of the officers and soldiers who were awarded medals and the names of the officers and soldiers who were awarded decorations. The list also includes the names of the officers and soldiers who were awarded honors and the names of the officers and soldiers who were awarded titles.

The sixth part of the report contains a list of the names of the officers and soldiers who were promoted during the war. This list is followed by a list of the names of the officers and soldiers who were awarded medals and the names of the officers and soldiers who were awarded decorations. The list also includes the names of the officers and soldiers who were awarded honors and the names of the officers and soldiers who were awarded titles.

The seventh part of the report contains a list of the names of the officers and soldiers who were promoted during the war. This list is followed by a list of the names of the officers and soldiers who were awarded medals and the names of the officers and soldiers who were awarded decorations. The list also includes the names of the officers and soldiers who were awarded honors and the names of the officers and soldiers who were awarded titles.

## BIBLIOGRAPHY.

### SYPHILIS.

- John Hunter. A Treatise on the Venereal Disease. London, 1876.
- Ph. Ricord. Traité des maladies vénériennes, recherches critiques et expérimentales sur l'inoculation. Paris, 1838.
- Lettres sur la syphilis. Paris, 1856, 2d édition.
- Clinique iconographique de l'hôpital des vénériens, in folio. Paris, 1851.
- Cazenave. Annales des maladies de la peau et de la syphilis. Paris, 1844-1852.
- Maisonneuve et Montanier. Traité pratique des maladies vénériennes. Paris, 1853.
- Diday. Exposition critique et pratique des nouvelles doctrines sur la syphilis. Paris, 1858.
- Histoire naturelle de la syphilis. Paris, 1863.
- Vidal de Cassis. Traité des maladies vénériennes. Paris, 2d édition, 1855.
- Rollet. Recherches cliniques et expérimentales sur la syphilis. Paris, 1861.
- Melchior Robert. Nouveau traité des maladies vénériennes. Paris, 1861, 2d édition.
- Alph. Guérin. Maladies des organes génitaux de la femme. Paris, 1864.
- L. Belhomme et Aimé Martin. Traité pratique et élémentaire de pathologie syphilitique et vénériennes. Paris, 1876, 2d édition.
- Davasse. La syphilis, ses formes, son unité. Paris, 1865.
- Ph. Ricord. Leçons sur la chancre, publiées par Alph. Fournier. 2d édition, 1860.
- Cusco. Leçons cliniques sur la syphilis. "Gazette des hôpitaux," 1862.
- E. Langlebert. Traité théorique et pratique des maladies vénériennes. Paris, 1864.
- Cullerier. Précis iconographique des maladies vénériennes.
- Virchow. La syphilis constitutionnelle. Traduit en français par J. P. Picard, 1860.
- Pathologie des tumeurs, traduit en français par P. Aronsohn.
- Bassereau. Traité des maladies de la peau symptomatiques de la syphilis. Paris, 1852.
- Després. Traité thérapeutique et pratique de la syphilis. Paris, 1872.
- Lancereaux. Traité historique et pratique de la syphilis. Paris, 1873, 2d édition.
- A. Fournier. Leçons sur la syphilis étudiée plus particulièrement chez la femme. Paris, 1873.
- Leçons sur la syphilis tertiaire, 1875.

## CHANCRE.

- Boys de Loury et Costilhes. Chancres observés à l'hôpital Saint Lazare. "Gazette médicale," p. 369, 1845.—Mémoires sur les chancres chez la femme. "Gazette médicale," 1847, p. 274.
- Auzais-Turenne. Inoculation de la syphilis aux animaux. "Gazette médicale" de Paris, 1850-1851; et traité de la syphilisation, 1878.
- Clerc. Du chancroïde syphilitique. "Moniteur des hôpitaux," 1854.—Réponse au mémoire de M. Cullerier. Paris, 1855.
- Dron. Du double virus syphilitique. Thèse de Paris, 1856.
- Fournier. Recherches sur la contagion du chancre. Paris, 1857.—Etude sur le chancre céphalique, 1858.—Diagnostic général du chancre syphilitique. "Union médicale," Août, 1871.—Etude sur l'induration syphilitique primitive. "Archives de médecine," 1867, t. ii. p. 503.—Pseudo-chancre des sujets syphilitiques, 1868, t. i. p. 642.
- Nadaud des Islets. Inoculation du chancre mou à la région céphalique. Thèse, Paris, 1858.
- Diday. Observations de chancres de la bouche. "Annales de dermatologie," t. iv., 1872.
- E. Langlebert. De l'accident primitif produit par la contagion physiologique artificielle des accidents secondaires de la syphilis. "Moniteur des hôpitaux," 1859.
- Rollet. Etude sur le chancre produit par la contagion de la syphilis secondaire, et spécialement du chancre du mamelon et de la bouche. "Archives de médecine," Février, 1859.—Article chancre du "Dictionnaire encyclopédique."
- Laroyenne. Etudes expérimentales sur la chancre, dans "Annuaire de la syphilis," par Diday et Rollet. Lyon, 1859.
- Baerensprung. Mittheilungen aus der Abtheilung und Klinik für syphilitische Krankheiten. Berlin, 1860; et "Charité Annalen," t. iv. p. 16.
- Alph. Guérin. Du chancre induré. "Gazette des hôpitaux," 1867.
- Melchior Robert. Quelques considérations sur l'auto-inoculabilité du chancre infectant, et sur le chancre dit mixte.
- Aimé Martin. De l'accident primitif de la syphilis constitutionnelle. Thèse, 1863.
- L. Lefort. Recherches sur quelques points de l'histoire clinique des maladies vénériennes. "Gazette hebdomadaire," Juin, 1869.
- Labarthe. Le chancre simple. Thèse, 1872.
- Vidal. La syphilis constitutionnelle ayant pour accident initial le chancre mou. "Union médicale," 1872.
- Schwartz. Etudes sur le chancre du col utérin. Thèse, Paris, 1873.
- Mauriac. Rareté actuelle du chancre simple. Paris, 1876.
- A. Ricordi. L'ulcero misto, etc. "Annali universali d'omodi," Avril, 1866.—Nuovo tributo allo studio del l'ulcero misto. "Giornale italiano della malattie venereæ e della pella," t. ii., 1867.

- Dubuc. Variété clinique du chancre syphilitique.—Du chancre syphilitique multiple herpétiforme. "Annales de dermatologie et de syphilographie," t. v. p. 241.
- Louis Jullien. Traité des maladies vénériennes. Paris, 1879.

## SYPHILIDES.

- M. Devergie. Clinique de la maladie syphilitique, enrichie d'observations communiquées par MM. Cullerier oncle, Cullerier neveu, Bard, Gama et Desruelles, avec atlas colorie. Paris, 1826.
- Cazenave. Traité des syphilides. Paris, 1843.
- E. Bazin. Leçons sur la syphilis et les syphilides. Paris, 1866.
- Hardy. Leçons sur la maladies de la peau. Paris, 1860. 1st édition par Moy-sant. 2d édition par Lefevre, 1863.
- Bassereau. Traité des affections de la peau symptomatiques de la syphilis. 1852.
- Schweich. Etudes sur la classification des syphilides. Thèse, 1869.
- Dubuc. Des syphilides malignes précoces. Thèse de Paris, 1864.
- Profeta. Sull'i dermatosi sifilitiche. Palerme, 1876.
- Vajda. Beiträge zur Anatomie der syphilitischen Papel der Geschlechtstheile. "Stricker's Jahrbuch," 1876, p. 309.
- Moriz Kaposi. Die Syphilis der Haut und der angrenzenden Schleimhaut, mit Tafeln in Chromolithographie, ausgeführt von Carl Heitzmann. Wien, 1873.
- Cazenave. Syphilis tuberculeuse. "Annales des maladies de la peau," 1850, p. 100.
- Chausit. Diagnostic de la syphilis tertiaire. "Gazette des hôpitaux," 1863, p. 203.
- Diday. Pathologie de la syphilis tertiaire. "Gazette des hôpitaux," 1863, p. 70.
- A. Fournier. Gommes du tissu cellulaire. "Progrès Médical," 1874, p. 309. Leçons sur la syphilis tertiaire, 1875.

## TERTIARY GLOSSITIS AND PHARYNGITIS.

- A. Fournier. Des glossites tertiaires, glossites scléreuses, glossites gommeuses; avec trois planches en chromo-lithographie. Paris, 1877. Leçons sur la syphilis tertiaire.
- Hugonneau. Étude clinique sur la glossite interstitielle syphilitique. Thèse, Paris, 1876.
- Gustave Simon. Des glossites gommeuses. Thèse de Paris, 1877.
- Mauriac. De la syphilose pharyngo-nasale. Paris, 1877.
- Looten. Des scrofulides des muqueuses. Thèse d'agrégation, 1878.
- Spiellmann. De la tuberculose de la muqueuse digestive. Thèse d'agrégation, 1878.

- Julius Paul. De l'adhérence du voile du palais, etc. "Archives de médecine," 1865, vol. ii.  
 Chaboux. Lésions de la région naso-pharyngienne que l'on doit rattacher à la syphilis. Thèse de Paris, 1875.

#### SYPHILIS OF THE MUSCLES.

- Notta. Mémoires sur la rétraction musculaire syphilitique. "Archives de médecine," 1850, p. 434.  
 Virchow. Syphilis constitutionnelle, p. 105 et suivantes.  
 Bouissan. "Gazette médicale de Paris," 1846, Juillet et Août; et Tribut à la chirurgie, 1858, t. 1.  
 Ricord. Clinique iconographique, pl. xxix.  
 Lebert. Traité d'anatomie pathologique, t. i. pl. lxxviii. fig. 5.  
 Mauriac. Leçons sur les myopathies syphilitiques. G. Masson, 1878.  
 Le Dentu. "Gazette des hôpitaux," 1875.  
 Lancereaux. Traité historique et pratique de la syphilis, p. 295.  
 E. Wagner. Das Syphilom des Herzens und der Gefässe. "Arch. der Heilkunde," 1866, p. 518.

#### SYPHILITIC DISEASES OF THE BONES.

- Virchow. La syphilis constitutionnelle. Paris, 1860.  
 Ranvier. Comptes-rendus de la Société de biologie, 1865.  
 Cornil and Ranvier. Manual of Histology. Am. ed., by Shakespeare and Simes.  
 Hutchinson. Syphilitic Lesions of the Bones of the Cranium. "Lancet," 1872.  
 Mauriac. Affections syphilitiques précoces du système osseux. 1873.  
 Moscowitz. Thèse de Paris, 1874.  
 Rémy. Nécrose syphilitique du pariétal; abcès du cerveau consécutif. "Soc. anat.," 1874.  
 Barié. Carie syphilitique du rocher. "Soc. anat.," 1874.

#### SYPHILITIC DISEASES OF THE TENDONS AND SEROUS CAVITIES.

- Richet. Mémoire sur les tumeurs blanches. "Mem. de l'Académie de médecine," 1853.  
 Voisin. Thèse de Paris, 1875.  
 Verneuil. Hydropisie des gaines tendineuse dans la syphilis. "Gazette hebdomadaire," 1866, p. 609.—Lésions syphilitiques tertiaires des bourses sous-cutanées et tendineuses. "Gazette hebdomadaire," 1873.  
 Moreau. Affections syphilitiques des bourses séreuses. Thèse, 1873.  
 L. Keyes. Syphilis as affecting the Bursa. "American Journal of the Medical Sciences," 1876.  
 Siry. Observations de tumeurs syphilitiques des muscles sterno-mastoïdiens. "Progrès médical," 1875.  
 Sabail. Tumeurs syphilitiques des tendons et des aponévroses. Thèse de Paris, 1876.

## SYPHILIS OF THE ŒSOPHAGUS.

- Follin. Des rétrécissements de l'œsophage. Paris, 1853.  
 James West. "Dublin Quarterly," Feb., p. 86, Aug., p. 29, 1860.  
 Virchow. Pathologie des tumeurs, t. ii. p. 408.

## SYPHILIS OF THE STOMACH, INTESTINE, AND RECTUM.

- Cullerier. De l'entérite syphilitique. "Union médicale," 1854.  
 Ern. Müller. Ueber das Auftreten der constitutionellen Syphilis im Darmkanale. Inaugural-dissertation. Erlangen, 1858.  
 Gosselin. "Archives de médecine," 1854.  
 Delens. Article rectum du "Dict. encyclop. des sciences médicales."  
 Leudet. Mémoire sur les lésions de la syphilis viscérale. "Moniteur des sciences," 1860.  
 Desprès. Chancre phagédénique du rectum. "Archives de médecine," 1868.  
 A. Fournier. Lésions tertiaires de l'anus et du rectum. Leçons recueillies par Porak, 1875.

## SYPHILIS OF THE LARYNX.

- Worthington. Syphilitic Tracheitis. "Med. and Surg. Trans.," London, 1842.  
 Moissenet. Rétrécissement cicatriciel de la trachée. "Union médicale," p. 510, 1878.

## SYPHILIS OF THE LUNGS.

- Lagneau. Maladies pulmonaires causées ou influencées par la syphilis.  
 Pihan-Dufeillay. Rapport à la Société anat. sur des présentations de M. V. Cornil; Nov. 1861.  
 Landrieux. Thèse de Paris, 1872.  
 Fournier. De la phthisie syphilitique. "Gazette hebdomadaire," 1875.  
 Maunoir et Malassez. "Soc. anat. et Progrès médical," 1875.  
 Mannoury. "Soc. anat. et Progrès médical," 1876, p. 420.  
 Cüffer. "Soc. anat.," 1874, p. 844.  
 Depaul. "Soc. anat.," 1873, et "Académie de médecine," 1873.  
 Parrot. Syphilis héréditaire. "Progrès médical," 1874.

## SYPHILIS OF THE TESTICLES.

- Dron. De l'épididymite syphilitique. "Archives générales de médecine," 1863, t. ii. pp. 513 et 724.  
 Fournier. Du sarcocèle syphilitique et de l'épididymite secondaire. "Mouvement médical," 1874.  
 Curling. Disease of the Testicles.  
 Vidal. Testicule vénérien. "Annales des maladies de la peau," de Cazenave, t. ii. 1845.



- Virchow. La syphilis constitutionnelle.  
 Fournier. Du sarcocèle syphilitique. "Annales de dermatologie et de syph.," 1875.  
 North. "Med. Times and Gazette," 1862, vol. i. p. 403.  
 Thomas Bryant. "Med. Times and Gazette," 1863, vol. ii. p. 614.  
 Hennig. "Jahrbuch für Kinderkrankheiten," 1872.  
 Lewin. "Berlin. klin. Wochenschrift," 13 year, 1876.  
 Hutinel. Lésions syphilitiques du testicule. "Revue mensuelle de méd. et de chirurg.," 1878, p. 107.

#### SYPHILIS OF THE KIDNEYS.

- Frerichs. Die Brightsche Nierenkrankheiten und deren Behandlung. Braunschweig, 1871.  
 Cornil. Mémoire sur les lésions du rein dans l'albuminurie, 1864, p. 50.  
 Tüngel. "Klinische Mittheilungen von der Medicinischen Abtheilung des allg. Krankenhauses," Hamburg, 1861.  
 Raymond, Mal. de Bright chez un syphilitique. "Progrès médical," 1864, p. 248.  
 Axel Key. Altérations des reins dans la syphilis. "France médical," Janvier, 1878.  
 Barthélemy. Quelques considérations sur la syphilis viscérale, et particulièrement sur la syphilis renale. "Annales Derm. et de la Syph.," April, 1881.

- 
- [Hill and Cooper, Syphilis and Local Contagious Disorders, 1881.  
 Van Buren and Keyes, Genito-Urinary Diseases with Syphilis, 1877.  
 Bumstead and Taylor, Venereal Diseases, 1879.  
 Holmes's System of Surgery. Article, "Syphilis," by Henry Lee.  
 Agnew's Surgery.  
 Ashhurst's Surgery.  
 Ziemssen, Cyclopædia of Medicine, vol. iii.  
 Diday et Doyon, Maladies vénériennes et cutanées, 1876.  
 Jullien, Maladies vénériennes, 1879.  
 Belhomme et Martin, Traité de la syphilis, 1876  
 Otis, Physiological Pathology and Treatment of Syphilis, 1881.  
 Taylor, Bone Syphilis in Children, 1875.  
 Lane, Lectures on Syphilis, 1881.]

INDEX.

- A**BSCESS of vulvo-vaginal glands, 152  
Absorption and elimination of mercury, 433  
Acne, syphilitic, 192  
Adenitis, syphilitic, 121  
Albuminuria, syphilitic, 425  
Alopecia, 184  
Althaus, cerebral syphilis, 324  
    locomotor ataxia, 334  
    syphilis of spinal cord, 327  
Amyloid degeneration of spleen, 412  
Anæmia, syphilitic, 165  
Anal chancre, 83  
Aneurism and syphilitic arteritis, 309  
Animals, syphilis in, 30  
Annular induration, 77  
Arterial sclerosis in chancre, 57  
Arteritis, syphilitic, 305  
Arthritis, syphilitic, 292  
Articulations, syphilitic lesions of, 292  
Author's preface, v  
Auto-inoculation of chancre, 81
- B**ALANO-POSTHITIS, infecting, 43  
Bermann, micrococci of syphilis, 31  
Bibliography, 449  
Bielt, border of, 169  
Blood-corpuses in syphilis, 165  
Blood of syphilitic patient, inoculation of, 34  
Bone, development of, 248  
    gumma of, 252  
    lesions in new-born syphilitic children, 265  
    syphilis of, 215  
    symptoms of, 260  
    syphilitic eburnation of, 256  
    syphilitic sclerosis of, 256  
Border of Bielt, 169  
Brain, syphilitic lesions of, 298  
Bronchi, syphilis of, 390  
Bubo, inflammatory, 124  
    syphilitic, 124  
Bullous syphilides, 200  
Bumstead and Taylor, locomotor ataxia, 337  
Bursa, gumma of, 291  
Bursitis, syphilitic, 290
- C**ACHECTIC alopecia, 184  
Case of cerebral syphilis, 344  
    chancre of labium, 108, 110, 113  
    chancre of prepuce, 114, 117  
    herpes of genitals, 160  
    indurated mucous patches, 162  
    mucous patches of tonsils, 161  
    syphilitic arthritis, 296  
    syphilitic disease of pleura and lung, 408  
    syphilitic enlargement of liver, 371  
    tumor of cerebellum, 350  
Causes of infectious diseases, 29  
Cerebral gumma, large, 298  
    small, 304  
    syphilis, diagnosis of, 342  
    symptoms of, 314  
Chancre, anal, 83  
Chancre and chancroid, relative frequency of, 85  
Chancre, auto-inoculation of, 81  
    arterial sclerosis in, 57  
    cicatrix of, 68  
    compared with chancroid, 73  
    with gumma, 73  
    with lupus, 74  
connective-tissue lesions of, 55  
diagnosis of, 91  
diphtheritic membrane of, 45  
diphtheroid, 42  
dry, 42  
epidermic layers of, 49  
excision of, 38, 106  
extra-genital, 83  
healing of, 80  
histology of, 47  
incubation period of, 33, 36, 40  
induration of, 61  
lymphatic vessels in, 65  
lymphangitis of, 65  
macroscopical description of, 40  
microscopic description of, 47  
mixed, 86  
multiple, 42  
nerve lesions in, 62  
œdema of, 65  
of labium, case, 108, 110, 113  
of prepuce, case, 114, 117

## Chancre—

- of throat, 96
  - of tongue, 96
  - pain of, 63
  - pathological anatomy of, 40
  - prognosis of, 101
  - scaling, 42
  - seat of, 82
  - sebaceous glands in, 64
  - secretion of, 44
  - sudorific glands in, 64
  - symptoms of, 75
  - transformation of, into mucous patch, 80
  - treatment of, 102
  - vaccino-syphilitic, 87
  - venous sclerosis, 58
- Chancroid, histology of, 70
- pathological anatomy of, 70
  - specific nature of, 87
  - symptoms of, 84
- Characteristics of syphilides, 125
- Charcot, syphilitic epilepsy, 318
- Chauveau, vaccine virus, 29
- Children, cranial exostoses of, symptoms of, 285
- Cicatrices, syphilitic, of liver, 354
- Cicatrix of chancre, 68
- Cirrhosis, lingual, 227
- of liver, syphilitic, 354
- Classification of syphilides, 126
- Clinical characters of syphilides, 219
- Cohnheim, inoculation of tubercle, 37
- Color of syphilides, 129
- Comparison of tubercle and gumma, 32
- Complications of mucous patches, 150
- Congenital syphilis of liver, 369
- Connective-tissue lesions of chancre, 55
- Connective-tissue theory of syphilis, 26
- Considerations regarding syphilitic eruptions, 216
- Contagion and inoculation of syphilis, 32
- Contagion, Simon on, 22
- Contents, table of, ix
- Contraction of muscles, syphilitic, 239
- Convalescent alopecia, 184
- Corona veneris, 172
- Cranial exostoses in children, symptoms of, 285
- Cutaneous gumma, 204
- syphilides, early, 164
- Cytoblastions of Robin, 55

**D**ACTYLITIS, syphilitic, 293

- Definition of syphilis, 17
- Dermatitis of mucous patches, 151
- Desquamative glossitis, 229
- Development of bone, 248
- Diagnosis of cerebral gumma, 301

  - of cerebral syphilis, 342
  - of chancre, 91

## Diagnosis—

- of mucous patches, 154
  - of osseous syphilis, 261
  - of syphilitic ecthyma, 199
  - of syphilitic orchitis, 419
  - of syphilitic papule, 182
- Digestive canal, syphilis of, 373
- Diphtheritic membrane of chancre, 45
- mucous patches, 143
- Diphtheroid chancre, 42
- Dowse, syphilitic epilepsy, 319
- Dry chancre, 42
- syphilitic onychia, 182
  - tubercular syphilide, 213
- Drysdale, syphilitic paralysis, 322
- Dualism, theory of, 33

- E**ARLY cutaneous syphilides, 164
- Eburnation of bone, syphilitic, 256
- Ecthyma, syphilitic, 193
- Eczema of mucous patches, 150
- Elements in secretion of chancre, 44
- Enostoses, 248
- Epidermic layers of chancre, 49
- pus formation, 52
- Epididymis, gumma of, 415
- Epilepsy, syphilitic, 319
- Epithelioma and gumma of tongue, 232
- and labial chancre, 95
  - of lung, 404
- Erb, locomotor ataxia, 331
- Eroded mucous patches, 142
- Eruptions, syphilitic, 216
- Erythema, syphilitic, 167
- Erythematous syphilides, 166
- Exanthemata and syphilis, 18
- Excision of chancre, 38, 106
- of syphilitic tonsil, 138
- Exostoses, 257
- cranial, in children, symptoms of, 285
- Extra-genital chancre, 83

**F**ALLOPIAN tubes, syphilis of, 422

- Fever, syphilitic, 164
- Fibro-plastic cells of Robin, 56
- Formation of pus in epidermis, 52
- Fournier, locomotor ataxia and syphilis, 337
- syphilis of lung, 396
  - syphilitic epilepsy, 320
  - syphilitic paralysis, 322
- Fumigation, mercurial, 438

**G**AMBERINI, syphilis of lung, 398

- General character of syphilides, 125
- Genital organs, tertiary lesions of, 224
- Giant cells, 74
- Glanders and syphilis, 32

- Glands, vulvo-vaginal, abscess of, 152
- Glossitis, deep, 227  
desquamative, 229  
superficial, 226
- Gowers, locomotor ataxia, 330  
syphilitic epilepsy, 320
- Grasset, locomotor ataxia, 332
- Gumma and epithelioma of tongue, 232  
cerebral, histology of, 299  
  large, 298  
  small, 304  
histology of, 206, 213  
of bone, 252  
of bursa, 291  
of epididymis, 415  
of heart, 242  
of kidney, 424  
of liver, 356  
  symptoms of, 367  
of muscle, 240  
of œsophagus, 375  
of pharynx, 237  
of pia mater, 298  
of skin, 204  
of soft palate, 233  
of spleen, 411  
of stomach, 375  
of testicle, 422  
of tongue, 230
- Gummosis and tuberculous syphilides, 204  
osteomyelitis, 252  
pachymeningitis, 253
- Gums, syphilitic inflammation of, 290
- H** HEALING of chancre, 80  
Heart, gumma of, 242  
Hepatic syphilis, 352  
Hepatitis, interstitial syphilitic, 354  
Hereditary syphilis of bone, 265  
  of liver, 369  
  of lung, 403  
Herpes of genitals, case, 160  
Heubner, syphilitic arteritis, 305  
Histological lesions of bone in new-born syphilitic children, 269, 275  
Histology of chancre, 47  
  of chancroid, 70  
  of diphtheritic membrane, 46  
  of gumma, 206, 213  
  of gumma of brain, 299  
  of gumma of liver, 357  
  of macular syphilide, 187  
  of mucous patches, 131  
  of pemphigus, 202  
  of syphilitic arteritis, 305  
  of syphilitic lymphatic glands, 122  
  of syphilitic osseous lesions, 259  
  of syphilitic osseous lesions, Wegner, 282  
  of syphilitic papule, 169, 182  
  of syphilitic pneumonia in child, 405
- Histology—  
  of syphilitic pustule, 194, 199  
  of syphilitic tubercles, 213  
  of vesicular syphilide, 190
- Hutchinson, definition of syphilis, 17  
  theory of syphilis, 18
- Hypertrophied mucous patches, 147
- Hypodermic injections of hydrarg. bichlor. 438
- I**CTERUS, syphilitic, 352  
  Identity of venereal lesions, 33
- Illustrations, list of, xv
- Impetigo rodens, syphilitic, 200
- Impetigo, syphilitic, 192
- Incubation period of chancre, 33, 36, 40  
  of syphilis, 33, 36, 40
- Indurated base, mucous patches, 142
- Induration and lymphatics, 79  
  annular, 77  
  appearance of, 77  
  laminated, 77  
  nodular, 77  
  of chancre, 61  
  parchment, 77
- Infecting balano-posthitis, 43
- Infectious diseases and virus, 28  
  diseases, causes of, 29
- Inflammation of arteries, syphilitic, 305  
  of gums, syphilitic, 290  
  of lymphatics, syphilitic, 313  
  of pia mater, syphilitic, 297  
  of veins, syphilitic, 313
- Inflammatory bubo, 124
- Inoculation and contagion of syphilis, 32  
  of blood of syphilitic patient, 34  
  of normal secretions, 35  
  of serum of mucous patch, 34  
  of tertiary lesions, 34  
  of tubercle, Cohnheim, 37
- Interstitial syphilitic orchitis, 416
- Intestines, syphilis of, 376
- Inunction, mercurial, 438
- Iodide of potassium medication, 440
- J** OINTS, syphilitic lesions of, 292  
  Jullien, locomotor ataxia, 336  
  syphilis of lung, 402
- K** IDNEYS, gumma of, 424  
  syphilis of, 423
- Klebs, syphilis in lower animals, 30
- Krishaber, syphilis of larynx, 387
- L** ABIAL chancre and epithelioma, 95  
  Laminated induration, 77
- Larynx, syphilis of, 379  
  treatment of, 388

- Lesions of connective tissue in chancre, 55  
 of nerves in chancre, 62  
 Lingual cirrhosis, syphilitic, 227  
 List of illustrations, xv  
 Liver, congenital syphilis of, 369  
 gumma of, 356  
 syphilis of, 352  
 syphilitic cirrhosis of, 354  
 Lobular glossitis, 227  
 Localization of syphilitic virus, 37  
 Locomotor ataxia, 329  
 Lung, syphilis of, 390  
 in new-born child, 403  
 Lupus and syphilitic tubercle, 214  
 Lymphangitis of chancre, 65  
 syphilitic, 124, 313  
 Lymphatic glands, syphilitic, 121  
 tertiary lesions of, 412  
 Lymphatic theory of syphilis, 21  
 Lymphatic vessels and induration, 79  
 in chancre, 65
- MACKENZIE**, syphilis of larynx, 386  
 Macroscopical description of chancre, 40  
 Macular syphilide, 186  
 Mauriac, cerebral syphilis, 316  
 infecting balanoposthitis, 43  
 Mercurial bath, 438  
 fumigation, 438  
 hypodermic injections, 438  
 inunction, 438  
 medication, 431  
 Mercury, absorption and elimination of, 433  
 physiological action of, 434  
 Metritis of mucous patches, 153  
 Mickle, syphilitic paralysis, 321  
 Micrococci of syphilis, 31  
 Microscopic description of chancre, 47  
 Mixed chancre, 86  
 Moist syphilitic onychia, 182  
 Morrow, diphtheroid chancre, 42  
 Mouth, tertiary lesions of, 226  
 Mucous membranes, tertiary lesions of, 224  
 Mucous patches, 129  
 and vulvar diseases, 155  
 complications of, 150  
 dermatitis of, 151  
 diagnosis of, 154  
 diphtheritic, 143  
 eczema of, 150  
 eroded, 142  
 histology of, 131  
 hypertrophied, 147  
 indurated base, 142  
 inoculation of serum of, 34  
 metritis of, 153  
 œdema of, 147
- Mucous patches—  
 of tongue, 140  
 of tonsil, 133  
 of vulva, 131  
 pathological anatomy of, 131  
 seats of, 131  
 shaven, 141  
 treatment of, 156  
 vaginitis of, 153  
 varieties of, 130  
 vegetating, 149, 154  
 vulvitis of, 151  
 Multiple chancre, 42  
 Muscles, gumma of, 240  
 syphilis of, 239  
 syphilitic contraction of, 239
- NEAPOLITAN** ointment, 438  
 Nerve lesions in chancre, 62  
 Nerves and nerve centres, syphilis of, 297  
 Neuralgia of syphilis, 165  
 New-born children, pemphigus of, 201  
 syphilitic lesions of bones in, 265  
 Nodosa, syphilis, 211  
 Nodular induration, 77  
 Normal secretions, inoculation of, 35
- ŒDEMA** of chancre, 65  
 of mucous patches, 147  
 Œsophagus, syphilis of, 373  
 Onychia, syphilitic, 182  
 Operations, surgical, during secondary syphilis, 157  
 Orchitis, gummous, 422  
 syphilitic, 416  
 syphilitic in new-born children, 420  
 Origin of syphilis, 33  
 Osseous lesions in new-born syphilitic children, 265  
 syphilis, 245  
 Osteitis, rarefying, 249  
 Osteo-myelitis, gummous, 252  
 Osteo-periostitis, syphilitic, 247  
 Osteophytes, 248  
 Otis, reinfection of syphilis, 19  
 Ovary, syphilis of, 422
- PACHYMEMINGITIS**, gummous, 253  
 Paget, residual abscesses of, 18  
 Pain of chancre, 63  
 Palate, gumma of, 233  
 Pancreatitis, syphilis of lung, 402  
 Papilloma, syphilitic, 149  
 Papular syphilides, 168  
 Papulo squamous syphilide, 172  
 Paralysis, syphilitic, 321  
 Parasitic theory of syphilis, 29  
 Parchment induration, 77

- Parrot, syphilitic lesions of bone in new-born children, 266
- Pasteur, theory of parasites, 29
- Patches, mucous, 129  
tobacco smokers', 231
- Pathological anatomy of chancre, 40  
of chancroid, 70  
of mucous patches, 131
- Pemphigus, histology of, 202  
of new-born children, 201  
syphilitic, 201
- Period of incubation of syphilis, 33, 36, 40
- Periods of syphilis, 28
- Pharynx, tertiary lesions of, 237
- Phlebitis, syphilitic, 313
- Phlegmonous syphilides, 211
- Physiological action of mercury, 434
- Pia mater, gumma of, 298  
syphilitic inflammation of, 297
- Pigmentation of skin in syphilis, 187
- Pneumonia alba, 404
- Preface, author's, v  
translators', iii
- Prognosis of chancre, 101
- Psoriasis and syphilitic papule, 179  
of tongue, 231
- Pus formations, epidermic, 52
- Pustular syphilide, 191
- R**AREFYING OSTEITIS, 249
- Rectum, syphilitic stricture of, 377
- Reinfection of syphilis, Otis, 19
- Relative frequency of chancre and chancroid, 85
- Residual abscess of Paget, 18
- Respiratory apparatus, syphilis of, 379
- Rickets and syphilis of bones, 272
- Robin, theory of virus, 29
- Robinson, syphilis of lung, 400
- Rollet, syphilis of lung, 398
- Roseola, syphilitic, 166
- Roseola urticans, 167
- Rupia, syphilitic, 200
- S**ARCOCELE, 415
- Scaling chancre, 42
- Schnitzler, syphilis of lung, 398
- Sclerosis, arterial, in chancre, 57  
syphilitic, of bone, 256  
venous, in chancre, 58
- Sclerotic glossitis, 228
- Scrofulosis of syphilis, 123
- Seat of cerebral gumma, 303  
of chancre, 82
- Seats of mucous patches, 131
- Sebaceous glands in chancre, 64
- Secretion of chancre, elements in, 44
- Seguin, syphilitic paralysis, 322
- Senile alopecia, 184
- Serpiginous syphilitic ulcer, 215
- Shaven mucous patches, 141
- Simon on contagion, 22
- Skin, gumma of, 204  
pigmentation of in syphilis, 187
- Smallpox, virus of, 29
- Smokers' patches, 231
- Soft chancre, description of, 70
- Solution, Van Swieten's, 108
- Specific nature of chancroid, 87
- Spinal cord, syphilis of, 327
- Spleen, amyloid degeneration of, 412  
gumma of, 411  
syphilis of, 410
- Stomach, syphilis of, 375
- Stricture of œsophagus, syphilitic, 373  
of rectum, syphilitic, 377
- Sudorific glands in chancre, 64
- Supra renal capsules, syphilis of, 412
- Surgical operations during secondary syphilis, 157
- Symptoms of cerebral syphilis, 314  
of chancre, 75  
of chancroid, 84  
of cranial exostoses in children, 285  
of gumma of liver, 367  
of syphilitic orchitis, 418  
of syphilitic osseous lesion, 260  
of syphilitic pneumonia in child, 405
- Syphilides, bullous, 200  
classification of, 126  
clinical characters of, 219  
color of, 129  
d'emblée, 216  
early cutaneous, 164  
erythematous, 166  
general characters of, 125  
macular, 186  
papular, 168  
papulo-squamous, 172  
phlegmonous, 211  
pustular, 191  
treatment of, 221  
tubercular, 212  
vesicular, 189
- Syphilis and exanthemata, 18  
and glanders, 32  
and locomotor ataxia, 329  
blood-corpuscles in, 165  
cerebral, diagnosis of, 342  
symptoms of, 314  
congenital, of liver, 369  
connective-tissue theory of, 26  
contagion and inoculation of, 32  
definition of, 17  
Hutchinson's definition of, 17  
incubative period of, 33, 36, 40  
in lower animals, 30  
lymphatic theory of, 21  
micrococci of, 31  
neuralgia of, 165  
nodosa, 211

## Syphilis—

- of bone, 245
  - of bones and rickets, 272
  - of bronchi, 390
  - of digestive canal, 373
  - of Fallopian tube, 422
  - of intestines, 376
  - of kidney, 423
  - of larynx, 379
  - of liver, 352
  - of lung, 390
    - in fœtus, 403
  - of muscles, 239
  - of nerves and nerve centres, 297
  - of œsophagus, 373
  - of ovary, 422
  - of respiratory apparatus, 379
  - of spinal cord, 327
  - of spleen, 410
  - of stomach, 375
  - of supra-renal capsules, 412
  - of teeth, 287
  - of testicle, 415
  - of trachea, 390
  - origin of, 33
  - osseous, diagnosis of, 261
  - parasitic theory of, 29
  - periods of, 28
  - secondary, surgical operations during, 157
  - theory of, Hutchinson's, 18
  - transmission of, 35
  - treatment of, 431, 443
- Syphilitic acne, 192
- adenitis, 121
  - albuminuria, 425
  - alopecia, 184, 185
  - anæmia, 165
  - and tuberculous osteitis, 263
  - arteritis, 305
    - and aneurism, 309
  - arthritis, 292
  - bubo, 124
  - bursitis, 290
  - cirrhosis of liver, 354
  - contraction of muscles, 239
  - dactylitis, 293
  - eburnation of bone, 256
  - ecthyma, 193
    - diagnosis of, 199
  - epilepsy, 319
  - eruptions, considerations of, 216
  - erythema, 167
  - fever, 164
  - glossitis, 226
  - icterus, 352
  - impetigo, 192
  - impetigo rodens, 200
  - inflammation of gums, 290
    - of pia mater, 297
  - interstitial hepatitis, 354
  - lesions of articulations, 292

## Syphilitic lesions—


- of bones in new-born children, 265
- of brain, 298
- of joints, 292
- lymphangitis, 313
- lymphatic glands, 121
  - histology of, 122
- lymphitis, 124
- onychchia, 182
- orchitis, 416
  - in new-born children, 420
- osseous lesions, histology of, 259
  - symptoms of, 260
- osteitis, 249
- osteo-periostitis, 247
  - in children, 274
- papilloma, 149
- papule and psoriasis, 179
- papule, diagnosis of, 182
  - histology of, 169
  - treatment of, 180
- paralysis, 321
- pemphigus, 200
- phlebitis, 313
- pigmentation of skin, 187
- pneumonia in child, 403
- pustule, histology of, 194, 199
- roseola, 166
- rupia, 200
- sclerosis of bone, 256
- serpiginous ulcer, 215
- stricture of rectum, 377
- tonsil, excision of, 138
- tubercle and lupus, 214
- tubercle, histology of, 213

## TABLE of contents, ix

- Taylor, dry chancre, 42
- Teeth, syphilis of, 287
- Tertiary lesions, inoculation of, 34
  - of genital organs, 224
  - of lymphatic glands, 412
  - of mouth, 226
  - of mucous membranes, 224
  - of pharynx, 237
  - of tonsils, 237
  - of vulva, 225
- Testicle, gumma of, 422
  - syphilis of, 415
- Theory of dualism, 33
  - of unicism, 33
- Throat, chancre of, 96
- Tobacco smokers' patches, 231
- Tongue, chancre of, 96
  - gumma of, 230
  - mucous patches of, 140
  - psoriasis of, 231
  - tubercular ulcers of, 232
- Tonsil, mucous patches of, 133
  - syphilitic, excision of, 138

- Tonsil—  
 tertiary lesions of, 237  
 Trachea, syphilis of, 390  
 Transformation of chancre into mucous patch, 80  
 Translators' preface, iii  
 Transmission of syphilis, 35  
 Treatment, iodide of potassium, 440  
   mercurial, 431  
   of chancre, 102  
   of mucous patches, 156  
   of syphilides, 221  
   of syphilis, 431, 441  
   of syphilis of larynx, 388  
   of syphilitic papule, 180  
 Tubercle and gumma, comparison of, 32  
 Tubercle, inoculation of, Cohnheim, 37  
 Tubercular syphilides, 212  
   ulcers of tongue, 232  
 Tuberculous and syphilitic osteitis, 263
- U**LCKER, syphilitic serpiginous, 215  
 Ulcerative tubercular syphilide, 213  
 Unicism, theory of, 33  
 Urticans, roseola, 167
- V**ACCINO-SYPHILITIC chancre, 87  
 Vaginitis of mucous patches, 153
- Van Swieten's solution, 108  
 Varieties of mucous patches, 130  
 Vascular sclerosis in chancre, 57  
 Vegetating mucous patches, 149, 154  
 Veins, syphilitic inflammation of, 313  
 Venereal lesions, identity of, 33  
 Venous sclerosis in chancre, 58  
 Veraguth, syphilitic lesions of bone in new-born children, 268  
 Vesicular syphilides, 189  
 Virus and infectious diseases, 28  
   of smallpox, 29  
   syphilitic, localization of, 37  
   theory of, Robin, 29  
   vaccine, Chauveau, 29  
 Voigt, locomotor ataxia, 335  
 Vulva, mucous patches of, 131  
   tertiary lesions of, 225  
 Vulvar diseases and mucous patches, 155  
 Vulvitis of mucous patches, 151  
 Vulvo-vaginal glands, abscess of, 152
- W**EGNER, histology of syphilitic osseous lesions, 282  
 Whistler, syphilis of larynx, 381  
 White hepatization of lung, 404





London, 1882.

A  
LIST OF WORKS  
IN  
MEDICINE & SURGERY

PUBLISHED BY

HENRY KIMPTON.

LONDON: 82, HIGH HOLBORN, W.C.

*N.B.—Henry Kimpton supplies all his publications, and  
with few exceptions, those of other Publishers at a  
discount of 25 per cent. for cash WITH ORDER.*

HENRY KIMPTON'S  
Recent Publications.

ROBERTS BARTHOLOW, A.M., M.D., LL.D.

*Professor of Materia Medica and General Therapeutics in the  
Jefferson Medical College of Philadelphia, &c.*

**Medical Electricity; a Practical Treatise**  
on the applications of ELECTRICITY to MEDICINE  
and SURGERY, 8vo, 96 illustrations, 7s 6d 1881

"This treatise by Dr. Bartholow is intended as a text-book for students, but is meant also to aid the practitioner in his daily work. It probably fulfils the writer's intention better than any of the numerous handbooks which have hitherto appeared."—*Edinburgh Medical Journal*, February, 1882.

"As a guide to the employment of electricity in medicine and surgery, indeed, the volume is a very valuable contribution to our literature, and we welcome it as likely to be of considerable service to the profession."—*Medical News*, April 28, 1882.

---

W. SYMINGTON BROWN, M.D.

*Member of the Gynaecological Society of Boston, Fellow of the Mass.  
Medical Society, etc.*

**A Clinical Handbook on the Diseases of**  
WOMEN. 8vo, 10s 1882

---

SAMUEL BENTON, L.R.C.P., LOND.,  
M.R.C.S. AND L.M. (ENG.)

**Nurses and Nursing; and why are there  
not more Good Nurses?** 1s 1877

---

V. CORNIL.

*Professor to the Faculty of Medicine of Paris, and Physician  
to the Lourcine Hospital.*

**Syphilis; its Morbid Anatomy, Diagnosis  
AND TREATMENT.** Translated with notes and ad-  
ditions, by J. HENRY C. SIMES, M.D., Demonstrator  
of Pathological Histology in the University of  
Pennsylvania, and J. WILLIAM WHITE, M.D., Lec-  
turer on Venereal Diseases and Demonstrator of  
Surgery in the University of Pennsylvania. In one  
handsome octavo volume of about 450 pages, with  
90 *very elaborate illustrations.* 18s 1882

In the preparation of this volume it has been the object of the author to elucidate the symptoms and course of syphilis by a study of the changes undergone by the various tissues during its evolution, and in this way to furnish an accurate and reliable basis for the recognition and treatment of the disease. In availing himself of his unequalled opportunities for the prosecution of these investigations, he has, at the same time, made such free and judicious use of the labors of others and has so combined the histological and symptomatic elements of the malady, that he has produced a work at once scientific and practical, and one which is without exact parallel in the literature of syphilis.

The translators have edited this work as well as translated it. Many recent advances have been incorporated, and in order to adapt it thoroughly to the wants of the practitioner, much space has been given to the clinical symptoms and therapeutical management of the disease.

---

FREEMAN J. BUMSTEAD, M.D.

*Professor of Venereal Diseases at the College of Physicians and Surgeons, New York, etc., etc.*

**The Pathology and Treatment of Venereal DISEASES.** Revised and largely re-written with the co-operation of R. W. TAYLOR, M.D., of New York. Fourth Edition, in one Large and Handsome Octavo Volume of 835 pages, *with 138 illustrations*, 25s  
1880

"Bumstead's work is already classic, and hardly requires reviewing. This edition is well up to date, and everywhere bears marks of careful and erudite preparation.....Must take first rank among the works in the English language on Venereal Diseases."—*Lancet*, July 31st, 1880.

"It is one of the best general treatises on Venereal Diseases with which we are acquainted, and is especially to be recommended as an admirable guide to the treatment of Syphilis."—*Practitioner*, March, 1880.

CORNIL AND RANVIER.

**Cornil and Ranvier's Manual of Pathological Histology.** Translated with Notes and Additions, by E. O. SHAKESPEARE, M.D., Pathologist and Ophthalmic Surgeon to Phila. Hospital; and HENRY C. SIMES, M.D., Demonstrator of Pathological Histology at the Univ. of Pa. Large 8vo, 700 pages, *with over 300 illustrations*, 25s 1880

"Their book is not a collection of the work of others, but has been written in the laboratory beside the microscope. It bears the marks of personal knowledge and investigation upon every page, controlled by and controlling the work of others.....In short, its translation has made it the best work in pathology attainable in our language; one that every student certainly ought to have."—*Archives of Medicine*, April, 1880.

"This will be found an exceedingly interesting valuable work by all who are engaged in the study of or take an interest in histology—normal or morbid. The material which was utilized in its preparation was derived from autopsies and operations in the hospitals of Paris, which are so very rich in it. Nothing was taken for granted but everything verified by microscopical investigation by the authors themselves in their own laboratories assisted by their pupils. As an aid to microscopists in their investigations it will be found invaluable—in fact, the very best which we are acquainted."—"*Cincinnati Medical News*," February, 1880.

AUSTIN FLINT, M.D.

**A Treatise on the Principles and Practice  
OF MEDICINE.** Revised and Largely Re-written.  
Fifth Edition, large 8vo, 25s 1881

"We cannot conclude this notice without expressing our admiration of this volume, which is certainly one of the standard text-books on medicine, and we may safely affirm that, taken altogether, it exhibits a fuller and wider acquaintance with recent pathological inquiry than any similar work with which we are acquainted, whilst at the same time it shows its author to be possessed of the rare faculties of clear exposition, thoughtful discrimination, and sound judgment."—*The Lancet*, July 3, 1881.

"Has never been surpassed as a text-book for students, and a book of ready reference for practitioners."—*N. Y. Medical Record*.

"A well-known writer and lecturer on medicine recently expressed to the writer of this notice an opinion in the highest degree complimentary of the admirable treatise of Dr. FLINT; and in eulogising it he described it accurately as 'readable and reliable.' No text-book is more calculated to enchain the interest of the student, and none better classifies the multitudinous subjects included in it. It has already so far won its way in England that no inconsiderable number of men use it alone in the study of pure medicine; and we can say of it that it is in every way adapted to serve not only as a complete guide to the subjects of examination, but also as an ample instructor in the science and practice of medicine. The style of Dr. FLINT is always polished and engaging; but if we may do so, we would especially commend Chapter VI., on Diseases of the Nerves, as an example of the way in which a difficult subject can be presented to ensure that it should be fully understood. The whole work, however, abounds in perspicuous explanation, and is a most admirable text-book of medicine."—*Medical News*.

SAMUEL W. GROSS, A.M., M.D.

*Lecturer on Venereal and Genito-Urinary Diseases in the  
Jefferson Medical College of Philadelphia, etc.*

**A Practical Treatise on Impotence, Sterility,  
AND ALLIED DISORDERS of the MALE SEXUAL  
ORGANS.** 8vo, 174 pages, with 16 illustrations,  
7s 6d 1881

"Dr. Gross is a forcible and interesting writer, and he here presents, in an attractive style, very much valuable information. The question of Impotence and its numerous causes is exhaustively discussed. So also are Sterility, Spermatorrhœa, and Prostatorrhœa. This is an unusually valuable book, and must be read by every would-be thorough physician."—*American Specialist*, October, 1881.

---

EDWARD D. HALL, M.D.

**The Metric Dose Book;** giving the minimum and maximum Doses of old and new Drugs by the Gramme System. Also, containing a Table of the Metric System as applied to Medicine, and a Therapeutical Synopsis of the principal new Drugs.  
1s 6d 1881

---

GEORGE JONES, F.C.S.

**A Chemical Vade Mecum;** FOR MEDICAL STUDENTS. Intended as a refresher to the memory upon the more important facts in Chemical Science.  
2s 6d 1881

---

JOHN M. KEATING, M.D.

*Lecturer on the Diseases of Children at the University of  
Penna., etc., etc.*

**The Mother's Guide in the Management  
AND FEEDING OF INFANTS.** 3s 6d 1881

"On the whole this is a good book. There is the ring of common sense in the remarks about the employment of a wet nurse, about the proper food for a nursing mother, about the tonic effect of a bath, about the perambulator versus the nurse's arms, and on many other subjects concerning which the critic might say, "surely this is obvious," but which experience teaches us are exactly the things needed to be insisted upon with the rich as well as the poor. The chapter on the subject of Cow's Milk is excellent. Dr. KEATING has well stated the difficulties and dangers which beset the subject. On the question of condensed milk, as on others he speaks evidently from the result of personal knowledge."—*Lancet*, January 28, 1882.

"Grave objections exist against the mothers' books in ordinary circulation, and hence we hail with genuine pleasure the appearance of a volume which, in a small compass, includes all that a woman need know concerning the management, treatment, and feeding of infants. But Dr. KEATING has accomplished even more than this, for many a young practitioner will find in this unpretending little handbook a fund of information of the most valuable kind to assist him in successfully passing that trying ordeal of experience—a mother's questions regarding her child."—*Medical News*, December 9, 1881.

KILNER.

**Kilner's Compendium of Modern Pharmacy  
AND DRUGGIST'S FORMULARY.**

Shows at a glance how to manufacture over three Hundred Elixirs, Saccharated Extracts, Tinctures, Fluid Extracts, Specific Medicines, Emulsions, Syrups for Soda Fountains, Medicated Syrups, Medicated Wines, Solutions, Flavoring Extracts, Medicated Waters, Mineral Waters, Perfumery and Toilet Articles, Pills, Liniments, Powders, Cold Cream, Explosive Prescriptions, Hair Oils, Pomades, Tooth Powders, Hair Dyes and Tonics, Toilet Soaps, Farrier's Prescriptions, Mouth Washes, and Poisons and their Antidotes; together with Tables of Metric Weights and Measures; and Miscellaneous Information Indispensable to Druggists. 28s

1882

"No Chemist can afford to be without this admirable work."—*Medical News.*

A. F. A. KING, M.D.

*Professor of Obstetrics and Diseases of Women and Children in the Medical Department of the Columbia University, Washington, etc., and in the University of Vermont, etc., etc.*

**A Manual of Obstetrics.** Small 8vo, with 58 illustrations, 8s

1882

"No more useful Student's work on the subject exists in the English Language."—*Medical News.*

SAMUEL O. L. POTTER, A.M., M.D.

*President of the Milwaukee Academy of Medicine, etc.*

**An Index of Comparative Therapeutics.**

With Tables of Differential Diagnosis, a Pronouncing Dose-List in the Genitive Case, a List of Medicines used in Homœopathic Practice, Memoranda concerning Clinical Thermometry, Incompatibility of Medicines, Ethics, Obstetrics, Poisons, Anæsthetics, Fees, Asphyxia, Urinary Examinations, Homœopathic Pharmacology, and Nomenclature, etc., etc. Second edition, 12mo, 6s 6d

1882



## ELIAS LONGLEY.

**Student's Pocket Medical Lexicon;** Giving the correct Pronunciation and Definition of all Words and Terms in general use in Medicine, and the collateral Sciences; with an Appendix, containing a list of Poisons and their Antidotes, Abbreviations used in Prescriptions, and a Metric Scale of Doses. 12mo, 4s 1882

"This is a very compact and complete little dictionary, and will be found useful for references, not only as to meanings, but for correct pronunciations."

"An invaluable pocket companion."—*Medical News.*

A. HUTCHINSON SMEE, M.R.C.L.,  
F.C.S., F.S.S.

**Milk in Health and Disease.** 2s 6d.

T. GAILLARD THOMAS, M.D.

*Professor of Diseases of Women in the College of Physicians and Surgeons, New York.*

**A Practical Treatise on the Diseases of WOMEN.** Fifth Edition, Enlarged and thoroughly Revised, royal 8vo, 806 pages, containing 266 illustrations, 25s 1880

"The alterations and additions which have been made are both numerous and important."

"The attraction and permanent value of this book lie in the clearness and truth of the clinical descriptions of disease, the fertility of the author in therapeutic resources, and the fulness with which the details of treatment are described, the definite character of the teaching, and last, but not least, the evident candour which pervades it."—*Medical Times and Gazette*, July 30, 1881.

"We cannot pretend to make a critical examination of Dr. Thomas's great work in this place, nor, indeed, is it called for. It is incomparably the most valuable, because the most practical, treatise on Gynæcology in the English language, and to students especially, who, above all things, require explicit directions how to work, it is an invaluable adjuvant to clinical observations."—*Medical News.*

---

A. A. SADGROVE, M.P.S.

**A Chart of Materia Medica and Therapeutics;** containing everything mentioned in the British Pharmacopœia of 1867, alphabetically arranged for the use of Students. 1s

---

JOHN B. ROBERTS, A.M., M.D.

*Lecturer on Anatomy and on Operative Surgery in Philadelphia School of Anatomy, Demonstrator of Anatomy in the Philadelphia Dental College, Recorder of the Philadelphia Academy of Surgery, etc., etc.*

**The Compend of Anatomy;** for use in the Dissecting Room and in preparing for examinations. Crown 8vo, 4s 6d 1882

"As a student's *vade mecum* of anatomy, it is probably the best that has been published."—*Cincinnati Lancet and Clinic*.

"A useful work for minor examinations in Anatomy."—*Medical News*.

---

TOM ROBINSON, M.D.

*Physician to St. John's Hospital for Diseases of the Skin.*

**On Baldness and Greyness;** their Etiology, Pathology, and Treatment. Small 8vo, 2s 6d 1882

"The result of a large experience."—*Chemist & Druggist, Aug., 1882.*

---

TOM ROBINSON, M.D.

*Physician to St. John's Hospital for Skin Diseases.*

*Read before the Harveian Society.*

**Nocturnal Incontinence of Urine.** 1s 1880

W. J. WALSHAM, M.B., F.R.C.S.

*Demonstrator of Anatomy and Operative Surgery at  
St. Bartholomew's Hospital, etc.*

**A Handbook of Surgical Pathology;** for  
the use of Students in the Museum of St. Bartho-  
lomew's Hospital. 8vo, 10s 6d 1878

~~~~~

\* \* HENRY KIMPTON arranges with the leading  
publishing firms in America for the sale of his publica-  
tions in that country. Terms are made in the interests  
of Authors, either for sending a number of copies of their  
works to the United States, or having them reprinted  
there, as may be most advantageous.

---



---

## HENRY KIMPTON

*Having purchased the stock of the following Stan-  
dard Works is enabled to offer them at the  
low prices affixed for cash nett.*

PROFESSOR R. OWEN'S

**Odontography**, or a Treatise on the Comparative  
Anatomy of the Teeth, their Physical relations,  
Mode of Development, and Microscopic Structure  
in the Vertebrate Animals. One vol. text, and  
Atlas, containing 168 beautiful plates, (pub £5 5s),  
half bound morocco, new, £2 1840—45

Only a few copies of this splendid work remain and it will never  
be re-printed.

COOKE ON CANCER.

**On Cancer;** its Allies and Counterfeits by THOMAS WEEDEN COOKE, Surgeon to the Cancer Hospital  
*Twelve coloured plates, 8vo, cloth, new, pub. a*  
12s 6d, for 3s 6d 1865

ERICHSEN ON CONCUSSION OF THE SPINE.

**On Concussion of the Spine, Nervous Shock** and other Obscure Injuries of the Nervous System, in their Clinical and Medico-Legal Aspects. Thick crown 8vo, *cloth, new, pub. at 10s 6d, for 4s* 1875

ELLIS'S DISSECTOR.

**Demonstrations of Anatomy;** being a Guide to the Knowledge of the Human Body by Dissection. By G. VINER ELLIS. 8th edition, *with 248 engravings, cr. 8vo, cloth, new, pub. at 12s 6d, for 7s* 1878

ALFRED HAVILAND, M.R.C.S.E., &c.

**Phthisis in Females in England and Wales.** Map 3 ft. 3 in. by 2 ft. 6 in., coloured, (the Geographical Distribution of.) 1s 1d post free.

ALFRED HAVILAND, M.R.C.S.E., &c.

**Cancer in Females in England and Wales.** Same size and price as above.

# The Medical News,

A Weekly Journal of the  
Medical Sciences.

**ONE PENNY.**

*ANNUAL SUBSCRIPTION, 6s. 6d. POST FREE.*

CONTAINS

NOTES AND LEADERETTES;  
ORIGINAL ARTICLES ON MEDICINE,  
SURGERY, &c.; LEADING ARTICLES;  
MEDICAL NEWS; PASS LISTS;  
APPOINTMENTS, VACANCIES, &c.;  
COLLEGIATE & CLINICAL NEWS  
METROPOLITAN AND PROVINCIAL;  
EXAMINATION QUESTIONS; REVIEWS. &c.

SUPPLEMENTARY PLATES

Illustrating Original Articles, are frequently issued.

---

NOW READY, Vol. I. of the

*MEDICAL NEWS,*

WITH INDEX, TITLE-PAGE, &c., COMPLETE.

*Bound in cloth, price 3s. 6d. nett; if by post, 4s.*

CONTENTS: The Essential Features of Diseases of Children, by C. E. ARMAND SEMPLE, M.B., M.R.C.S.—The Essential Features of the Diseases of the Nervous System, by DAVID DRUMMOND, M.A., M.D.—On Case Taking, and the Examination of Patients, by W. R. WILLIAMS, F.R.C.S.—Notes on Physiology, by W. ROBINSON, M.B.—And Numerous Papers, by Dr. MILNER FOTHERGILL, DR. JAMES PALFREY, DR. COUPLAND, DR. MEARS, MESSRS. HOWLETT, F.R.C.S., GOYDER, L.R.C.P., PORRITT, L.R.C.P., etc., etc.





1104  
-<sup>a</sup><sub>n</sub> 18)



