

Post mortems and morbid anatomy.

Contributors

Shennan, Theodore.
University of Leeds. Library

Publication/Creation

London : Constable, 1912.

Persistent URL

<https://wellcomecollection.org/works/npgk9ctx>

Provider

Leeds University Archive

License and attribution

This material has been provided by This material has been provided by The University of Leeds Library. The original may be consulted at The University of Leeds Library. where the originals may be consulted.

Conditions of use: it is possible this item is protected by copyright and/or related rights. You are free to use this item in any way that is permitted by the copyright and related rights legislation that applies to your use. For other uses you need to obtain permission from the rights-holder(s).



Wellcome Collection
183 Euston Road
London NW1 2BE UK
T +44 (0)20 7611 8722
E library@wellcomecollection.org
<https://wellcomecollection.org>



E/n

*The University Library
Leeds*



*Medical and Dental
Library*

Stack
Q2 35
SHE



30106

004090816

K
316UNIVERSITY OF LEEDS MEDICAL AND
DENTAL LIBRARY

Author SHENNAN, T.

Brief title Post mortems and morbid
anatomy.

Ed. and Date 1912

Class mark Stock QZ 35 SHE Acc. No. 605456

This book is due for return on the last date shown below.

CANCELLED



POST MORTEMS
AND
MORBID ANATOMY



POST MORTEMS AND MORBID ANATOMY

By

THEODORE SHENNAN M.D. F.R.C.S. Edin.

Pathologist to the Royal Infirmary, Edinburgh; Lecturer on Pathology and Bacteriology in the
School of Medicine of the Royal Colleges, Surgeons' Hall, Edinburgh; *formerly*
Conservator of the Museum of the Royal College of Surgeons of Edinburgh;
Examiner in Pathology and Bacteriology in the University of St.
Andrews, Pathologist to the Royal Hospital
for Sick Children, Edinburgh, etc


LONDON

CONSTABLE AND COMPANY LIMITED

10 ORANGE STREET LEICESTER SQUARE W.C.

1912

BUTLER & TANNER,
THE SELWOOD PRINTING WORKS,
FROME, AND LONDON.



605456

To my old Friend, and former Chief,
CHARLES W. CATHCART, F.R.C.S.



PREFACE

ALL will admit that it is exceptional for a student of medicine to carry with him into practice a knowledge of *post-mortem* technique and of Morbid Anatomy sufficient to enable him to conduct a *post-mortem* examination creditably, and to present a reasonably correct report of the abnormal conditions encountered during it. Through lack of this knowledge, many practitioners fail not only to elucidate the true nature of obscure clinical cases, but also to contribute to the sum of medical science.

Further, teachers of Pathology find that it is more difficult to convey a clear picture of the naked-eye appearances of diseased organs than of General Pathology or of Pathological Histology.

While this volume has been written primarily with the object of assisting Students, Practitioners, and Teachers of Pathology, it is hoped that the Laboratory worker, the practising Pathologist, and the Investigator of pathological problems will also find in it something of value suited to their several needs.

Although particular attention is paid to Morbid Anatomy as studied in the *post-mortem* room, the Microscopical and Bacteriological aspects of disease have also been discussed, seeing that a knowledge of these is essential for a clear comprehension of the naked-eye appearances. Diseases of the Blood are not specially considered, because, in the *post-mortem* room, one has to deal rather with their results, as seen in the organs and in the bone-marrow.

The arrangement of the subject-matter necessarily corresponds, for the most part, to the order in which a *post-mortem* examination is conducted.

Although the influence of Edinburgh teaching will be apparent, I have endeavoured to present, so far as is possible, an independent view of pathological changes, in the light of my own experience during the last sixteen years, not only in Edinburgh, but also at other Schools, both at home and abroad. Therefore, the views on any debateable subject must be taken as expressing my own opinions, and not as representing the teaching which prevails in any one School.

I have, however, made free use of such Manuals as Orth's *Pathologisch-anatomische Diagnostik*, Kaufmann's *Lehrbuch der speciellen Pathologie*, Ziegler's *Lehrbuch*, Adami's *General Pathology*, and the *post mortem* Manuals of Létulle, Chiari, Nauwerck, and others. The *Catalogue of the Museum of the Royal College of Surgeons of Edinburgh*, Volumes I and II, by Mr.

C. W. Cathcart, and Volume III by myself, has furnished many of the descriptions.

The Illustrations, without exception, represent naked-eye appearances, and are all original. For the most part, they have been taken from specimens in my own collection. Others have been taken from specimens in the Museum of the Royal College of Surgeons of Edinburgh, and, for permission to use them, I have to tender my thanks to the Museum Committee of that College. Personal friends have furnished the remainder, and these are acknowledged in each case. The photographs, with two exceptions, were taken either by Mr. Albert Norman, or by myself.

To render the book more generally useful, I have added an Appendix, containing Tables of Equivalent Imperial and Metrical Measurements of Weight, Length, and Capacity ; and, in addition, the Laboratory Methods of more general utility, both for Preserving tissues in their Natural Colours, and for preparing Microscopical Sections. To assist those who desire to amplify the descriptions, and to carry their investigations further, I have compiled a Bibliography of the more important original papers which appeared from January 1908 to August 1911, in the principal medical journals published in this country, in North America, in France, and Germany.

For much helpful and friendly criticism I have to thank Mr. Cathcart, Mr. Stiles, Professor Muir, Drs. Carnegie Dickson, A. M. Drennan, J. S. Fraser, Harvey Pirie, W. T. Ritchie, Henry Wade, B. P. Watson, and D. P. D. Wilkie. Finally, my thanks are due to my publishers, Messrs. Constable and Co., for much kindly consideration.

T. S.

ROYAL INFIRMARY,
EDINBURGH,
January, 1912.

CONTENTS

CHAPTER I	PAGE
THE POST-MORTEM EXAMINATION	1
CHAPTER II	
THE EXTERNAL EXAMINATION OF THE DEAD BODY	12
CHAPTER III	
THE EXAMINATION OF THE INTERIOR OF THE BODY	29
CHAPTER IV	
THE THORACIC CONTENTS	38
CHAPTER V	
THE PERICARDIUM AND HEART: THE CORONARY ARTERIES	49
CHAPTER VI	
DISEASES OF BLOOD-VESSELS	90
CHAPTER VII	
EMBOLISM AND INFARCTION	104
CHAPTER VIII	
RESPIRATORY TRACT AND LUNGS: PLEURAE: THORACIC WALLS	111
CHAPTER IX	
THYROID: MOUTH: PHARYNX: OESOPHAGUS	156
CHAPTER X	
THE ABDOMEN—PERITONEUM: STOMACH	168
CHAPTER XI	
THE ABDOMEN (<i>continued</i>)—INTESTINES: PANCREAS	195

	PAGE
CHAPTER XII	
THE ABDOMEN (<i>continued</i>)—LIVER: GALL-BLADDER	225
CHAPTER XIII	
THE ABDOMEN (<i>continued</i>)—SPLEEN	263
CHAPTER XIV	
THE ABDOMEN (<i>continued</i>)—KIDNEYS AND URINARY BLADDER: SUPRA-RENALS	275
CHAPTER XV	
REPRODUCTIVE ORGANS: MAMMA	324
CHAPTER XVI	
LYMPHATIC GLANDS AND BONE MARROW	348
CHAPTER XVII	
THE CENTRAL NERVOUS SYSTEM: CALVARIUM: PERIPHERAL NERVES	354
CHAPTER XVIII	
THE NASAL CAVITIES AND ACCESSORY SINUSES: THE MIDDLE AND INTERNAL EARS: THE ORBIT	397
CHAPTER XIX	
BONES: JOINTS: MUSCLES.	405
CHAPTER XX	
POST-MORTEM CHANGES PRODUCED BY POISONS	423
APPENDIX	443
BIBLIOGRAPHY—JAN. 1908 TO AUG. 1911	459
INDEX	477

LIST OF ILLUSTRATIONS

FIG.	PAGE
1. Author's Cones for measuring the diameters of orifices	2
2. Adapted Calipers	3
3. Method of sewing up skin incision	10
4. Elephantiasis, lower extremity	28
5. Vitreous degeneration (Zenker's)	30
6, 7. Author's method of opening the body in children	33, 34
8. Lymphosarcoma of mediastinum invading the lung	40
9. Embolism of pulmonary artery	44
10. Acute fibrinous pericarditis, <i>Cor villosum</i>	50
11. Tuberculous pericarditis, with effusion	53
12. Lines of incisions for opening the Cavities of the Heart	54
13. Distribution of coronary arteries	57
14. Fossa ovalis with two large apertures	60
15. Patent septum ventriculorum	61
16. Obliteration of tricuspid orifice	62
17. Congenital abnormality of great vessels	62
18. Fatty infiltration of wall of right ventricle	63
19. "Globular" heart	64
20. Brown atrophy of heart	65
21. Dilatation of left ventricle	67
22. Fatty degeneration of myocardium, "Thrush-breast" mottling	70
23. Infarction of left ventricle, with rupture	71
24. Infarction of left ventricle; Myomalacia	71
25. Chronic fibroid myocarditis	73
26. Chronic aneurysm of heart	74
27. Syphilitic gummata of myocardium	75
28. Portions of heart to be removed for examination of primitive muscle	76
29. Acute vegetative endocarditis	79
30. Chronic endocarditis of mitral valve	80
31. Stenosis: mitral, aortic, and tricuspid openings	81
32. Aneurysm of sinus of Valsalva, extending into septum	81
33. Ulcerative endocarditis of aortic valve	82
34. Ulcerative endocarditis of mitral valve	83
35. Ante-mortem thrombosis in left auricular appendix	85
36. "Ball-thrombus" in left auricle	86
37. Agonal thrombus	87
38. Pedunculated polyp of heart	88
39. Angioma, with phleboliths	90
40. Fatty degeneration of endothelium and intima, aorta	91
41. Senile calcification of media of arteries	92
42. Atheroma of descending aorta	93
43. Aneurysm of aorta which ruptured into superior vena cava	97
44. Aneurysm of aorta, which ruptured into trachea	98
45. Dissecting aneurysm, aorta	99

FIG.		PAGE
46.	Aneurysm of vein	100
47.	Gummatous aortitis	101
48.	Lipaemia in diabetes	107
49.	Oedema of larynx	112
50.	Tuberculous ulceration of larynx	114
51.	Syphilitic ulceration of larynx	115
52.	Necrosis of pharynx and larynx, in chloroma	116
53.	Bronchiectasis	119
54.	Method of incising lungs (diagrams)	121
55.	Emphysema, vesicular	126
56.	Infarction of lung	129
57.	Acute lobar pneumonia, grey hepatization	132
58.	Carnification of lung	133
59.	Acute broncho-pneumonia, child	134
60.	Acute broncho-pneumonia, adult	135
61.	Acute lobular pneumonia	136
62.	Pyæmic abscesses of lung	137
63.	Anthraxis, Lung	139
64.	Silicosis, Lung	140
65.	Lung ; miliary tuberculosis, blood-spread	142
66.	Lung ; lymphatic miliary tuberculosis	143
67.	Tuberculous broncho-pneumonia, child	145
68.	Tuberculous broncho-pneumonia, with excavation ; adult	146
69.	" Healed " tuberculosis of lung	147
70.	Fibroid tuberculosis of lung	148
71.	Syphilitic interstitial pneumonia	149
72.	Acute fibrinous pleurisy	151
73.	Calcification of pleuritic adhesions	152
74.	Empyema	153
75.	Syphilis of naso-pharynx	165
76.	Squamous epithelioma of oesophagus	167
77.	General adherent tuberculous peritonitis	172
78.	Tuberculous peritonitis, miliary	173
79.	Diaphragmatic hernia, rupture	176
80.	Hour-glass contraction of stomach	177
81.	Contraction of stomach, due to rigor mortis	178
82.	Congenital stenosis at Vater's ampulla	179
83.	Peptic ulceration, stomach	182
84.	Healed gastric ulcer	183
85.	Haemorrhagic erosions, stomach	184
86.	" Lymphomatous " nodules, stomach	188
87.	Malignant adenoma, stomach	189
88.	Encephaloid cancer, stomach	190
89.	Scirrhus cancer, stomach	191
90.	Colloid cancer, stomach	192
91.	Colloid cancer, omentum	193
92.	Sarcoma, stomach	194
93, 94.	Hernia within lesser sac	198, 199
95.	Intussusception, small intestine	200
96.	Meckel's diverticulum, ileum	202
97.	False diverticula, large intestine ; faecal concretions	203
98.	Bilharziosis, rectum	206
99.	Malignant adenoma, small intestine	208
100.	Malignant adenoma, rectum	209
101.	Sarcoma, jejunum	210
102.	Infarction of small intestine	211
103.	Follicular enteritis	214

FIG.	PAGE
104. Fibrinous enteritis	215
105. Dysenteric ulceration, large intestine	216
106. Tuberculous ulceration, ileum	217
107. Typhoid ulceration of intestine	219
108. Syphilitic ulceration of rectum	220
109. Haemorrhagic pancreatitis with fat necrosis in omentum	221
110. Dilatation of pancreatic duct, caused by cancer of head of pancreas	223
111. "Red" infarction of liver	230
112. True infarction of liver	230
113. Waxy (amyloid) degeneration of liver	234
114. Focal necroses, liver	235
115. Chronic venous congestion, liver	236
116. Chronic venous congestion liver; advanced	237
117. Portal pyaemia	239
118. Tropical abscess, liver	241
119. Actinomycotic abscesses, liver	242
120. Syphilitic gumma, liver; waxy (amyloid) degeneration	243
121. Lymphadenoma, liver	245
122. Coarse cirrhosis, liver	248
123. Primary sarcoma, liver	253
124. Secondary melanotic sarcoma, liver	254
125. Secondary encephaloid cancer, liver	255
126. Secondary scirrhus cancer, liver	255
127. Secondary malignant adenoma, liver	256
128. Secondary chorionepithelioma, liver	257
129. Gall-stones	260
130. Sago-waxy and diffuse waxy (amyloid) spleen	265
131. Atrophy, spleen	266
132. Infarction, spleen	270
133. Leucocythaemia and Chronic venous congestion, spleen	271
134. Lymphadenoma, spleen	273
135. Horse-shoe kidney	283
136. Congenital cystic kidney	284
137. Arteriosclerotic kidney	287
138. Cloudy swelling, kidney	289
139. Waxy (amyloid) degeneration, kidney	292
140. Argyria, kidney	295
141. Infarction, kidney	297
142. Pyaemic abscesses, kidney	299
143. Disseminated suppurative pyelo-nephritis	300
144. Chronic tuberculosis (scrofulous) kidney	301
145. Acute glomerular nephritis	304
146. Subacute parenchymatous nephritis; large, coarsely mottled	306
147. Chronic parenchymatous nephritis; surface	308
148. Chronic parenchymatous nephritis; section	309
149. Leucocythaemia, kidney	311
150. Malignant hypernephroma, kidney	313
151. Malignant hypernephroma, kidney	313
152. Hydronephrosis	315
153. Villous papilloma, urinary bladder	319
154. Urinary calculi	320
155. Supra-renals in Addison's disease	322
156. Uterus bicornis.	325
157. Procidentia uteri	326
158. Pyometra	326
159. Myoma, body of uterus	328
160. Myoma, cervix uteri	329

FIG.		PAGE
161.	Columnar-celled cancer of cervix uteri	330
162.	Squamous epithelioma of cervix uteri	330
163.	Hydatid mole	331
164.	Chorionepithelioma	332
165.	Compound cystic ovarian tumour	333
166.	Papilliferous cystic ovarian tumour	334
167.	Dermoid cyst of ovary	334
168.	Tuberculosis, testicle	339
169.	Syphilitic disease, testicle	339
170.	Lymphadenoma, lymphatic glands	349
171.	Calcareous plates, arachnoid mater of spinal cord	358
172.	Intra-dural sarcoma, cord	358
173.	Tuberculous nodules in spinal cord	359
174.	Gumma, spinal cord	359
175.	Syringomyelia	360
176.	Calvarium, showing hyperostosis from syphilitic pachymeningitis	367
177.	Do. magnified	368
178.	Osteitis deformans, calvarium	370
179.	"Corona veneris"	371
180.	Acute leptothrix meningitis	379
181.	Gummatous lepto-meningitis	381
182.	Porencephaly	383
183.	Cerebral haemorrhage, unilateral	385
184.	Pontine haemorrhage	386
185.	Bilateral cerebral haemorrhage	387
186.	Cerebral softening	388
187.	Acute suppurative encephalitis; Abscess of brain	389
188.	Chronic internal hydrocephalus	390
189.	Glioma of brain, surface	391
190.	Glioma of brain, section	392
191.	Ponto-cerebellar angle tumour	393
192.	Perithelioma of fourth ventricle	394
193.	Cystic epithelioma of infundibulum of pituitary body.	395
194.	Teratoma (embryoma) of brain	396
195.	Base of skull, illustrating methods of exposing nasal and orbital cavities ; and middle and internal ears	398
196.	Upper surface of petrous pyramid ; the middle and internal ears exposed	403
197.	Acute suppurative osteo-myelitis ; tibia	406
198.	Brodie's abscess, tibia	407
199.	Syphilitic node, femur	409
200.	Chondroma, leg	413
201.	Central sarcoma (myeloid) tibia.	414
202.	Tuberculous arthritis	418
203.	Arthritis deformans, hypertrophied synovial fringes	419
204.	Arthritis deformans, changes in bones of hip-joint	420
205.	Lipoma	422
206.	Fibroma	422
207.	Exsiccator, adapted to economize embedding reagents	451

COLOURED PLATES

- PLATE I. Fig. 1. Acute lobar pneumonia, red hepatization.
Fig. 2. Late acute glomerular nephritis.
Fig. 3. Chronic interstitial nephritis.
Fig. 4. Subacute atrophy of liver.

- PLATE II. Fig. 1. Leucoblastic reaction in bone marrow.
Fig. 2. Erythroblastic bone marrow.
Fig. 3. Bone marrow in chloroma, child.
Fig. 4. Exhausted, gelatinous, bone marrow.
Fig. 5. Spleno-medullary leucocythaemia, bone marrow, pigmentation.
Fig. 6. Lymphatic leucocythaemia, bone marrow.

- PLATE III. Diagrammatic representation of longitudinal section of crus, pons and medulla, showing approximate position of the nuclei of the cranial nerves.
- A. Transverse section at level of third nucleus.
 - B. Transverse section of pons at level of fifth nucleus.
 - C. Transverse section at lower end of pons.
 - D. Transverse section through olivary body.



CHAPTER I

THE POST-MORTEM EXAMINATION

GENERAL CONSIDERATIONS

Instruments and Accessories required.—Those marked with an asterisk are usually considered essential.

Instruments.—*One strong Cartilage Knife. *One or more strong Scalpels, with large handles. *One probe-pointed straight Bistoury. One probe-pointed curved Bistoury. *One Hamilton's Brain Knife or ordinary Amputation Knife, *never* double-edged; "Catlins" are of doubtful advantage, and the double edge carries with it the risk of injury to the operator. *One pair strong Dissecting Scissors, one blade blunt-pointed. *One pair blunt-pointed Bowel Scissors; these may be of Guy's Hospital pattern. *Chisel—Macewen's or preferably Littlejohn's. *Cutting Bone Forceps, angled. *Saw, with curved point; for some purposes a movable back is useful, but care should be taken that this fits well. Metacarpal Saw, ~~or~~ Ferguson's Saw. *Two pairs large Dissecting Forceps. "Lion" Forceps. Forceps with broad "bite" for stripping dura, e.g., Thornton's T-shaped Cyst Forceps. Channelled Probe. *Long Probe of medium thickness. *Periosteum Elevator. Mallet. *Needles, half-curved or serpentine, prismatic on section, with the lateral edges blunted,—4-5 in. (10-12 cm.) long. *Strong Cord or "Dutch Twine." *Steel Measuring Tape—inches and centimetres. Calipers—inches and centimetres. Cones for measuring *circumferences* of orifices— $\frac{1}{2}$ inch or 1 cm. to 8 inches or 20 cm. Balance and Weights—ounces or grammes. *Measuring Glass for fluids—ounces or cubic centimetres. Syringe with nozzles of various sizes. *Sponges or Absorbent Wool.

Chain-Hooks and Retractors with sharp points should not be used; they can be dispensed with, and they are liable to injure the operator. Coronets and adjustable metal Skull-rests, Spine-wrenches, Retractors, Rib-shears (St. Thomas's Hospital pattern is the strongest made) and Double Spinal Saws are not essential though they may be included in a Hospital Instrument case.

Hints with regard to Instruments.—The fitted post-mortem cases supplied by instrument makers contain all instruments that are required for most examinations. The following, for example, make a useful set:—Cartilage-Knife, Brain-Knife, Chisel and Saw, with one handle adjustable to all; probe-pointed straight or curved Bistoury, large and small Scalpel, Dissecting Scissors, one blade blunt-pointed; Dissecting Forceps; Bone-Forceps, needles and twine.

Knives.—The Cartilage and Brain Knives which I now use at the Edinburgh Royal Infirmary are wider and thinner in the blade than usual, so that continual grinding and re-sharpening do not give them too much of a wedge-shape. The width supplies the necessary strength and weight.

In the pathological departments of hospitals it is necessary to stock several of each kind of knives, scissors and forceps.

Bowel-scissors are usually included in the list of essential instruments. The hook at the end of one blade is of very doubtful value, and it is better removed as in the Guy's Hospital pattern. In place of bowel-scissors, ordinary strong blunt-pointed scissors, which may be angled, may be employed.

All scissors should have accurately fitted joints and well-ground sharp blades.

Scissors with short narrow blades, one or both sharp-pointed, are useful for opening up small vessels or ducts, and the spinal dura mater.

The saw should have the distal end curved and the teeth should be "set" well out, so that it does not jamb in the saw cut. An ordinary carpenter's saw

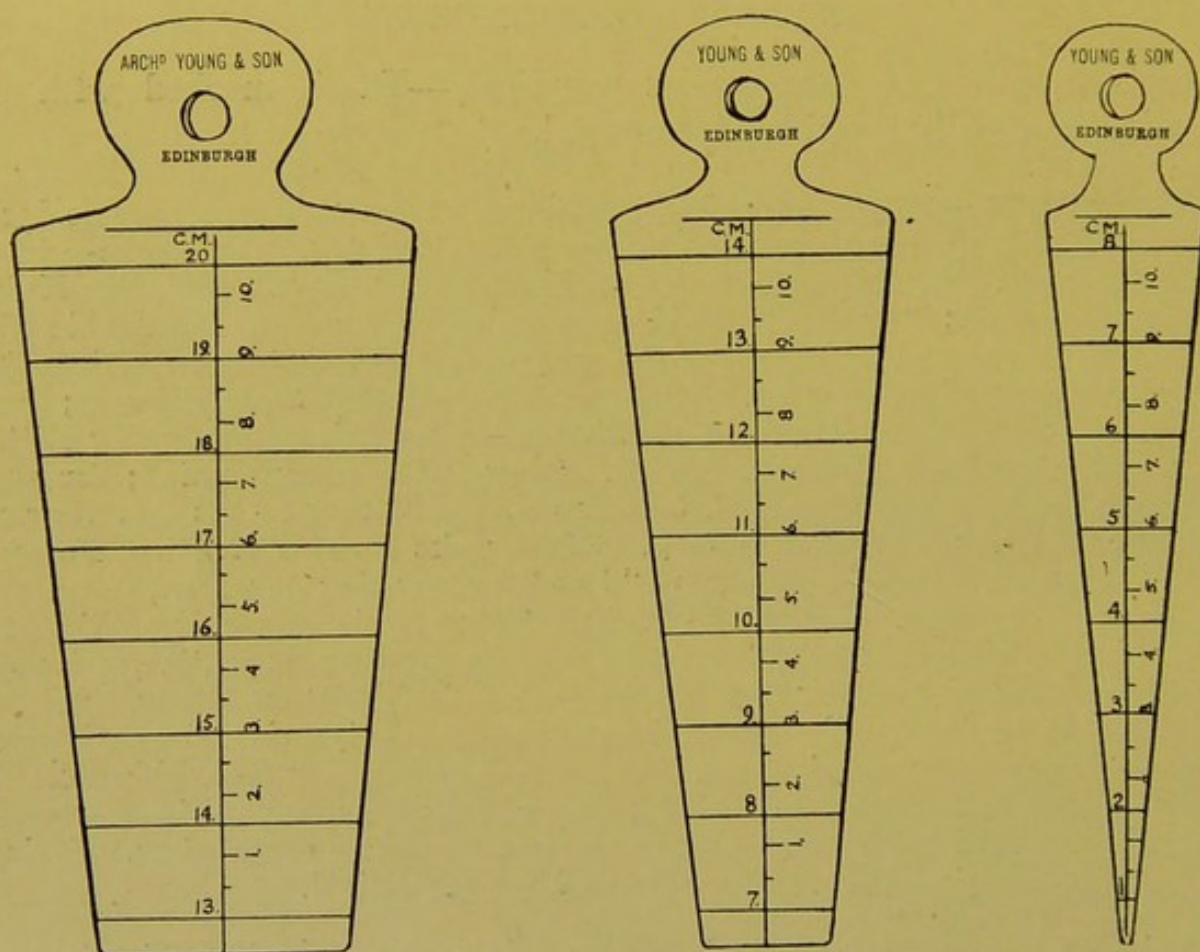


FIG. 1.—Author's Cones for taking circumferential measurements. ($\times \frac{1}{2}$.)

may be substituted for that usually supplied, and for some purposes its weight is of advantage.

The mallet is usually made of box-wood or other hard wood—a croquet mallet with the handle cut short makes an excellent substitute—but a steel mallet or hammer with a lead face is preferable.

The Cones used in the Edinburgh Royal Infirmary were made for the author six years ago. The inclination of the sides is such that the lines indicating the circumferential measurements in centimetres are separated by intervals of 1.5 cm. A longitudinal line graduated in sub-divisions of centimetres is also marked on the surface so that the depth of funnel-shaped apertures can be measured as well as the circumference (Fig. 1).

The Calipers figured were adapted for the author so as to take accurate internal as well as external measurements (Fig. 2).

All instruments and accessories should be kept scrupulously clean, and in perfect condition. Those used in septic cases should be sterilized so as to prevent risk of infecting the operator on a subsequent occasion.

All the other instruments are figured in Instrument Makers' Catalogues.

Accessories. The Post-mortem Room.—The post-mortem room should be a commodious, well-lighted, well-ventilated apartment. The windows should be large and low in the wall; a roof-light is also an advantage. The windows should be placed so that bright, direct sunshine is excluded.

Good Ventilation is most important. Numerous air inlets should be distributed so as to furnish a plentiful supply of air, which in winter should be led over heating coils. Some form of air-extracting apparatus should be a *sine quâ non*, and the best is the electric fan, which should be placed in the roof, or on one wall of the theatre, or may be connected by air shafts with gratings in the operating table itself, so as to create currents of air which will carry bad odours away from the operators, and also from spectators. No doubt in time in hospitals, ozone-manufacturing machines will be fitted up to destroy all such emanations. After a prolonged trial I have found these machines to be highly satisfactory for this purpose.

The *walls* and *floor* should have a smooth impermeable surface—of cement, glazed tiles or similar materials—so that they may be regularly washed down and flushed out with a stream of water from the hose. Materials like linoleum, wood, or the substance called "lithic" are quite unsuited for flooring a post-mortem theatre—at least in the operating area.

Water Supply.—A plentiful supply of water should be available, delivered through a flexible hose pipe of sufficient length to reach any part of the floor or walls. This should have an adjustable nozzle of simple but strong construction delivering a jet or spray of water at will. Similar but shorter pipes may be furnished under each operating table, with taps within easy reach of the operator or his assistant.

Additional Appliances.—In well-appointed Pathological Departments connected with hospitals the following additional appliances should be available. Some of the details make for the comfort of the operator, but the more




FIG. 2.—Calipers. Upper pointers adapted for taking internal measurements. ($\times \frac{1}{2}$.)

important are designed to secure accuracy in the records and to increase the scientific value of the data obtained.

Appliances.—The *Operating Table*, of slate, white marble, or white glazed fire-clay should measure approximately 7 ft. 6 in. (225 cm.) by 24 in. (60 cm.) and should stand about 32 to 34 in. (80 to 85 cm.) from the floor. It is convenient to have longitudinal and transverse scales marked on the surface, so that the height of the body and its width across the shoulders may be readily ascertained. The surface should slope slightly from the raised margin downwards towards a drain placed in the centre or towards the foot of the table. The opening of the drain is closed by a removable grating, and the fluids pass either directly into the drains, or into a pail in which they are disinfected before being poured into the drains. In some hospitals all drains from the post-mortem room lead into a cess-pool where disinfection can be accomplished.

The *Sink* should be of a convenient height. Rose taps, well raised above the sink, should have double or treble joints, or a ball-and-socket joint, so that the spray of water can, if desired, be directed all over the surface of the sink; the "rose" of the tap being about 8 or 9 in. (20–23 cm.) above the surface of the sink. No rubber tubing should be used in these fixtures. Taps with conical nozzles should be fixed in the end of the sink farthest from the drain, for the purpose of washing out hollow organs. All taps should be controlled by levers or push buttons on the floor.

A thick plate-glass or earthenware slab upon which organs may be cut up should be fitted up in connexion with the sink and its surface adjusted so that fluids flow from it into the sink.

Weighing the Body and Organs.—In order that measurements and weights of organs may be of the highest value in determining the normal or abnormal, they should be taken in relation to the height and weight of the individual. It should be remembered that measurements which would be normal in a large body would not necessarily be normal in a small one, even though they happened to agree with the so-called normal standards. As a matter of fact, we are not yet in possession of a sufficient number of measurements of organs, compiled with reference to the size and weight of the whole individual, to enable us to be sure of what the normal standards are in the two sexes, and at different ages.

For obtaining the body weight it is easy to fit up a weighing machine with a platform to receive the carrying board upon which the body is conveyed from the mortuary to the operating room. The weight of the carrying board is ascertained previously and marked upon it, so that, by deducting that weight from the total, the weight of the body is readily determined.

Still more convenient appliances are available by which the body can be weighed as it lies upon the trolley or upon the operating table.

For weighing the organs some form of beam-balance should be used. Spring balances tend to diminish in accuracy with constant use.

The weights and measurements used should belong to the metric system, by which comparisons and relations are more readily calculated than in the Imperial system. (*See Comparative Tables in Appendix.*)

Post-mortem Examinations in Private Houses.—Most of the accessories above mentioned are not available in private, but substitutes for those which are essential can readily be contrived.

A table, or tables, of suitable height can usually be obtained. Failing these the lid of the coffin may be utilized. Frequently the bed on which the body rests is alone available, or it may be necessary to examine the body upon the floor. The surfaces are protected by laying plenty of newspapers or a water-proof sheet over them, and arranging the coverings protecting table or bed so

that any overflow of fluids may be caught in a pail, or other receptacle, standing upon the floor. The body may be examined as it lies in the coffin. Several layers of newspapers are laid upon the sides of the coffin, and cotton wool or clean rags are packed at the sides of the body, in the flexures and behind the shoulders. If the head has to be examined it is almost essential to remove the body from the coffin.

Clean old rags or sheeting torn up serve as *swabs*.

A plentiful supply of cold water is required with at least two basins; a small bowl, or other dish, for scooping out fluids; a bottle of lysol or sanitas should be obtained, and the position of the bath-room or water-closet ascertained.

Before the operator removes his coat or opens his bag, all these points should be attended to, and none of the more immediate preparations made until the relatives have finally left the room. If a relative insist on his right to be present during the examination in spite of advice to the contrary, tendered in a sympathetic and friendly fashion, care should be taken to make the ordeal as light as possible for him. It is, however, much better, from every point of view, to have none but assistants present, so that everything may be tidied up, the operator have his coat on, and all trace of the post-mortem obliterated or hidden before relatives are again admitted. Particular care should be taken to remove all traces of blood from the tables or dishes used.

Precautions to be observed previous to and during the Progress of Post-mortem Examinations.—(a) **The Operator.**—The clothes should be protected by an apron, with bib, water-proofed with rubber or “pegamoid.” Good rubber water-proofing¹ is better than “pegamoid,” and in my experience wears longer, its surface being less liable to crack. The apron should be marked so that the same surface is always worn next to the clothing. An “overall” with short sleeves, the latter drawn sufficiently tight to keep up the shirt sleeves, may be worn in addition over the apron. The overall should fasten at the back with tapes.

Many pathologists wear rubber goloshes or boots in the post-mortem room.

Care of the Hands: Infections.—In opening the cavities and examining the organs after death, the operator frequently comes in contact with tissues and fluids of infective nature so that certain precautions are necessary to prevent serious consequences to his own health. He must allow himself the utmost consideration in this respect; and, after all, there is no reason why he should take risks which the surgeon, in operating upon the living patient, is sometimes called upon to face. All such risks can, in point of fact, be eliminated so far as is humanly possible.

Infection, necessarily, takes place almost solely through the skin of the hand and *forearm*. Therefore, before undertaking any post-mortem examination it is an imperative duty to examine these parts carefully, so as to detect the presence of *recent* cuts, scratches, or abrasions. These, as well as furuncles, or other minute pustules; erosions of the skin, “hang-nails”—i.e. small tears in the surface of the skin at the base of the nails—

¹ “Batiste.”

should contra-indicate any participation either in the operation itself or in the handling of the organs after removal, unless the hands are protected with rubber gloves.

Doubtless a considerable degree of immunity is conferred by the constant practice of post-mortems—particularly against *staphylococci* and *streptococci*—but this should not be relied on to protect the operator if there be visible breaks of continuity in the skin surface.

The pathologist frequently notices that he is more liable to local infections after his return from a holiday, when he is, presumably, in the enjoyment of perfect health, and at such a time he should be all the more careful to employ all means for preventing infection.

Minute wounds, pricks and cracks in the skin, which cannot be detected by the unaided eye, may be rendered evident by laving the hands in a weak watery solution of ammonia, acetic acid or formalin. Létulle employs successive baths of permanganate of potass and bisulphite of soda for a similar purpose. Harvey Littlejohn uses a mixture of methylated spirits and turpentine for detection of lesions and for protection of the hands.

If the post-mortem examination must be conducted in spite of the presence of lesions of the skin, “non-slip” gloves should be worn, or the lesions should be sealed up with “flexile collodion” or with a solution of celloidin in equal parts of alcohol and ether, a few filaments of cotton wool being incorporated to make the protective layer more tough and resistant. “Flexile collodion” will not adhere to a moist surface, and in any case the tendency of such applications to separate or crack must be borne in mind. A more satisfactory application, which adheres better than all other similar preparations, is the “Antiseptic Skin” introduced by Mr. Alexander, Dispenser to the Edinburgh Royal Infirmary. This is comparable to a proprietary article which has had a great vogue of recent years. The formula for Mr. Alexander’s preparation is as follows:—

Celloidin	10 grms.
Amyl acetate	6 c.c.
Acetone	to	120 c.c.

If no lesions are found it is nevertheless wise to anoint the hands and forearms with aseptic vaseline, taking care that the grooves surrounding the nails are filled up. All superfluous vaseline should be wiped off the palms of the hands so that a firm grasp of instruments is assured.

The nails should be cut short.

During the course of the operation, care must be taken that no blood or discharges are allowed to dry upon the surface of the skin, even when protective applications have been used. This is guarded against by *laving* the hands and forearms *frequently* in *cold* running water. This practice is of great importance, and must always be borne in mind. If a tap be not available, as may happen when operating in private, a basin of cold

water, which may contain some lysol or other antiseptic, should be placed within easy reach for the same purpose.

Gloves.—When the case is manifestly septic, and if the operator suspects that his skin surface is not perfect, or if experience demonstrates that his skin is very susceptible to irritation, he should wear a pair of impervious rubber gauntlets, concerning the internal asepticity of which there is no room for doubt. They must be regarded as introducing another risk because the minutest aperture in them will admit dangerous fluids, which will be retained in contact with the skin, soaking into it, and thus greatly multiplying the chances of infection. Apart from this, it should be remembered that gloves retain the normal excretions of the skin, and acting in a manner like a poultice, may occasionally provoke the development of small pustules without any infection occurring from without. A further drawback to the employment of gloves, if they are at all thick, is that they interfere with the flexion of the fingers and lessen delicacy of touch, which is such an important guide in all operative procedures. Yet, in spite of all these disadvantages, gloves, or rather gauntlets, are frequently of great use to the pathologist, and, provided common-sense precautions be taken, need cause little anxiety. In my own department I insist upon the use of non-slip gloves. Before use, French chalk, with which a few drops of clove oil may be incorporated in bulk, should be dusted into them, and over the skin surfaces.

The care of the gloves should be made a personal consideration. After use, all blood and discharges should be washed off at once in cold running water, and the gloves placed for a *short* time in a suitable antiseptic solution, then dried, powdered, and kept under cover. Some varieties of gloves on the market may be sterilized with moist heat.

Treatment of Wounds.—If, by misadventure, the hands or arms be pricked or cut during a post-mortem examination, the operation should be stopped at once; the wound encouraged to bleed under *cold* running water, or after preliminary cleansing it may be sucked thoroughly, washed with a strong antiseptic, touched with bromine, or painted with tincture of iodine, and a "soak" of carbolic or sublimate applied. As an alternative the permanganate of potassium and sodium bi-sulphite solutions may be employed. It is probably more rational *not* to seal the wound with a collodion preparation. If a substitute be available he should complete the examination under supervision of the pathologist. If the operator is obliged to continue the operation he should protect the hands with rubber gloves.

These simple measures in the majority of cases prevent any serious consequences.

If in spite of all precautions a furuncle develop, the following procedure will be found of value. Taking a small quantity of liquefied carbolic acid on the point of a needle, or bistoury or match sharpened to a point, this point should be pressed down into the centre of the suppurating focus, passing

deeper as the anaesthetic effect of the carbolic acid becomes pronounced. A second droplet should be applied to ensure, if possible, the destruction of the focus. In most cases, this early treatment is successful in averting danger. If the inflammation proceed, the sufferer should at once place himself under the care of a surgeon.

Infection may, however, be avoided by a little preliminary care in examination of the skin, and by insisting on the rule, that *under no circumstances should blood or discharges be allowed to dry on the surface of the hands or arms, particularly the latter.*

(b) **Precautions as to Knives and other cutting instruments.**—All knives should be sharp. Blunt knives require greater pressure, and this may cause them to slip, or the hand to slip from the haft on to the blade, with the attendant dangers. The sharper the knife the less frequent the accidents. The handles of the knives should be relatively large so as to afford a firm grip. Needles also should be of fair size. If needles are prismatic on section the lateral margins should be blunted before using.

An experienced pathologist always cuts *away from*, never *towards* his other hand, or those of an assistant, and when he lays down the knife he places it at some distance from the field of operation, with the cutting edge turned away from him.

In dividing bone, the operator should avoid producing ragged edges, all cuts being made with a sharp saw, rather than with bone-forceps. In some parts of the body the latter instrument may sometimes have to be used, for example, in dividing the ribs and the laminae of the vertebrae, and if the instrument be sharp, a clean cut is usually obtainable. The existence of divided bone should be borne in mind, and care be taken that spicules do not scratch the skin. For example, in the case of the ribs, the skin should be folded over the cut ends, when the hand is passed into the pleural cavities. For the same reason, extra care is to be exercised when examining or seeking for fractures.

One can indicate only the chief dangers to be guarded against. The operator's common-sense should enable him to avoid others.

(c) **The Operation.**—While most of the points of technical importance in the conduction of the post-mortem examination will be referred to in their proper places, some generally applicable hints may be mentioned here.

In all cases, even in those apparently of small importance, *system* and *cleanliness* should be insisted on. The *light* should be the best procurable, preferably daylight. With artificial light, however good, it is often impossible to distinguish variations in colour which are readily appreciable in daylight. For example, bile pigmentation becomes less evident.

All unnecessary *disfigurement* should be sedulously avoided. The face should always be respected unless under very exceptional circumstances.

The *incisions* in the skin should be as few as possible, and their extent

strictly limited to the requirements of the individual case. They should be made perpendicular to the surface, because, if this be done, the edges of the wound, in sewing up the body, can be accurately co-adapted without tags or hacks. Where the skin is thin, and the subcutaneous fat scanty, care should be taken not to "button-hole" it from the under surface while reflecting it. Long, bold, sweeping cuts should be the rule, made with the belly of the knife rather than with the point, the blade being drawn through rather than pressed into the tissues.

The organs should be preserved in their natural relationships until no further information can be gained by preservation of such relationships.

Firm adhesions uniting important structures should not be severed until their relationships and extent have been determined. In breaking up such adhesions great force should never be employed, because the organs involved may give way more readily than the adhesions, with the result that the true pathological picture may be lost.

In examining any organ in detail, as few incisions as possible are to be made in it, consonant with the attainment of the information desired; and, in the first instance at least, these incisions should not pass right through the organ, so that, if necessary, the different slices may be replaced readily in their natural mutual relationship. Blood or other fluids which veil the outer or cut surfaces should be removed by passing the blade of the knife gently over the surface. Washing with water may remove delicate lymph deposits, may wash out blood from congested surfaces, or may prevent correct appreciation of the degree of oedema if this be present, and will prevent the microscopical detection of glycogen in the superficial parts of sections of organs or malignant tumours.

The order of examination should be *Inspection*—size, symmetry, colour, etc.; *Palpation*—consistence—uniform or irregular, normal or abnormal; *Smell*. In handling an organ one should be as gentle as possible; for example, rough handling may rupture gastric or intestinal ulcers, producing apparent perforations, or apparent ruptures may be produced in a softened, fatty, friable heart muscle or in a fatty liver.

Histological and Bacteriological Investigations.—Bottles with fixing solutions, tubes of culture media, or sterilized plugged test-tubes or pipettes, platinum needles, clean slides and cover-glasses should be at hand to receive tissues or fluids for microscopic examination. It must be remembered, however, that the importance of data obtained by bacteriological examination of material obtained at a *sectio* decreases proportionately with the time that has elapsed since the death of the individual, because saprophytic and putrefactive bacteria soon penetrate throughout the body. This is particularly the case in the trunk, the head and extremities escaping decomposition for a longer period. Of necessity, the results will also vary with the weather, decomposition being delayed in cold, and accelerated in warm weather. If circumstances be at all favourable, the sooner after death tissues and fluids are taken for histological, cytological or bacteriological investigations, the more satisfactory may one expect the results to be.

Refrigerating chambers should form a part of mortuaries in connexion with large hospitals, so that the decomposition of the bodies is prevented.

(d) **Restoration of the Body.**—After the operation is over the body has to be restored, so far as is possible, to its former condition and appearance. The cavities have to be swabbed out, all visible fluid being removed; firm plugs of non-absorbent cotton wool should be inserted so as to prevent escape of fluids from the mouth and other natural orifices; the organs replaced, with the exception of parts reserved for further investigation, and the skin incisions sewn up. Sawdust, absorbent wool or newspapers may be used to compensate for the loss of fluids or gases from the cavities, and to fill out the skin to its natural contour.

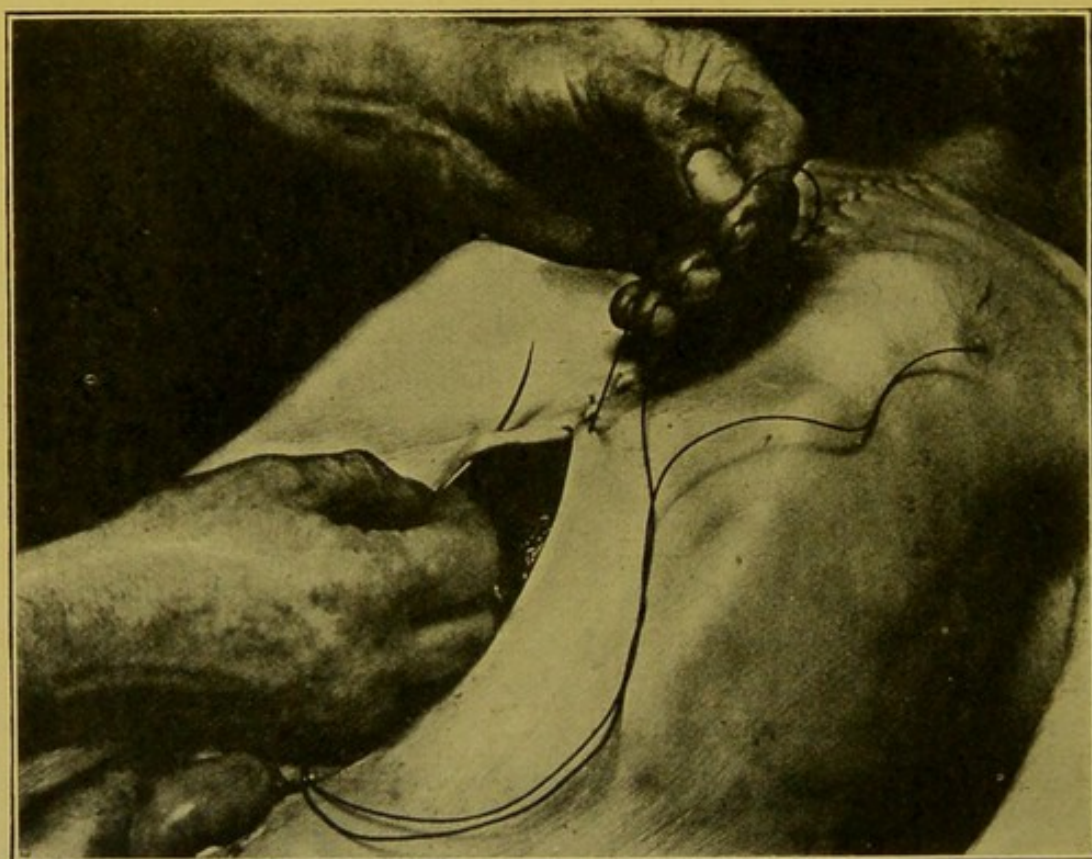


FIG. 3.—Method of sewing up skin incision.

The edges of the skin incisions are now co-apted, the glovers' or blanket stitch being employed. In this procedure, the needle is passed always from within outwards, the slack of the twine being drawn tight with the left hand between each stitch. This ensures that the edges fit closely, so as to prevent subsequent soiling of the grave-clothes or other coverings of the body with fluids oozing through the wound. The stitches should not be more than half an inch apart (1 cm.) and each puncture should be midway between two in the opposite lip of the wound (Fig. 3).

Subsequently every trace of blood or discharge should be removed from the body and its vicinity. This should be a special care in private post-mortem examinations, and moreover in such cases, unpleasant odours should be removed by opening the windows, or masked by burning some ground coffee in the room. As an alternative, sanitas, pinol, or some other aromatic liquid may be sprayed about the room.

(e) **Cleansing the Hands after Operation.**—On completion of the post-mortem examination, the hands *and arms* are to be subjected to prolonged washing in *cold* running water, until every visible trace of blood or discharge is removed. A soft sterilized rag, or piece of cotton-wool, may be used to assist this end. Nail-brushes must be avoided, as they are apt, even when sterilized, to abrade the skin, particularly round about the nails, and they even may rub in infective material. After this preliminary cleansing, the parts are to be thoroughly washed with soap and water, which may now be moderately warm. They are then rinsed thoroughly in cold running water, soaked in 1:100 Lysol, 1:40 Carbolic Acid, or 1:1000 to 1:2000 Corrosive Sublimate or in 1:500 Biniodide of Mercury solution in spirit, rinsed in clean cold water, and finally wiped dry.

As deodorising agents, sanitas, pinol, alcohol—with or without camphor—or other suitable medium may be employed.

As an emollient application I find the Lanolin cream of the Edinburgh Royal Infirmary Pharmacopoeia very satisfactory.¹

¹ I am indebted to the Infirmary dispenser, Mr. Alexander, for the formula. It is as follows:—

Hydrous Wool Fat	4 oz.
Glycerin	4 oz.
Distilled Water	4 oz.
Hard Soap	1½ drm.
French Oil of Roses	½ drm.

Dissolve the soap in the distilled water with the aid of heat, and add the glycerin. Rub down the wool fat in a warm mortar, and gradually incorporate the glycerin soap solution, stirring constantly until quite cold. Finally add the perfume. Mix, and pass through washed muslin gauze.

CHAPTER II

THE EXTERNAL EXAMINATION OF THE DEAD BODY

The Signs of Death.—On rare occasions a body retains such a life-like appearance, that the possibility that death has not really taken place may enter the mind of the observer. The questions of *apparent death* and *premature burial* are ever present to the lay mind, and although no case of alleged premature burial in which a physician has been in attendance during the illness of the individual has withstood investigation, the physician must be able to take such steps and give such proofs of death as will satisfy the anxious relatives, particularly in cases in which the vital activities have been suspended suddenly and the previous condition of the individual has given no hint of an immediately fatal event.

Brouardel's Lectures on *Death and Sudden Death* may be consulted for a full discussion of this subject. Only the essentials will be mentioned here.

Difficulty arises only in the period of time immediately following death. Later on, signs appear which remove all difficulty in deciding that death has taken place.

The most evident signs are complete stoppage of respiration and circulation. These are positive signs when they can be absolutely determined, but occasionally trouble may arise. For example, although no pulse can be felt at the wrist, the heart may still be beating feebly. If auscultation be resorted to, the heart may be beating too feebly to produce audible sounds, and it is not impossible that in the condition of nerve tension which prevails at such a time, the observer may mistake his own heart sounds for those of the individual under examination. This is avoided if the listener feel his own pulse at the same time. He then finds that the beats he hears and his own pulsations are synchronous. It is well to intermit the auscultation.

Hypodermic injection of ether or strychnine produces no change.

The surface of the skin usually becomes pale and yellowish. The life-like colour of the cheeks and lips may be preserved in cases of poisoning by carbon monoxide, and also occasionally in death from other causes. If the arteries be injected with formalin for preservation of the body, a most life-like pink tinge is imparted to the skin-surface.

The temperature gradually falls after death, more slowly in warm weather, and if the body be covered with non-conducting materials such as blankets.

In some infective diseases, in some lesions of the central nervous system—e.g. haemorrhage into the caudate nucleus, etc.—and in certain abdominal conditions, the temperature frequently continues to rise after death for a short time.

The eyeball usually loses its tension soon after death; it may remain tense in the drowned. The pupil dilates primarily, then contracts, sometimes unequally, and is usually found of medium size. The cornea rapidly becomes sunken and dim.

The prominent parts of the face—nose, malar prominences and chin,—become “sharp” or “peaked” from draining away of tissue-fluids and blood.

Reflexes are abolished. There is no response to strong stimulation, e.g. ammonia placed near the nostrils (Brouardel); pricking; pinching; electricity; though it must be remembered that pricking and pinching may provoke no reflex in hysteria or catalepsy.

Incisions fail to cause bleeding. Exceptions may be met with, e.g. apparent bleeding may occur in extreme cyanosis, or when at a later period development of gases in the trunk expresses blood from the trunk into the extremities.

If a ligature be tied round a finger, no distal congestion and swelling take place, and if the blood be expressed from the nail matrix it does not return. If the hand be held up against a strong light no pink colour is visible where the fingers touch. The skin loses its elasticity and transparency.

Post-mortem lividity, due to the action of gravitation in causing the blood, which remains for a long time fluid in the capillaries, to seek the dependent parts, is constant and may occur very early. It is most marked in conditions in which coagulation of the blood is delayed, for example in asphyxia, and in certain acute infective conditions. Hypostasis may be present before death in extreme heart failure. It may be delayed in death from haemorrhage, etc.

Post-mortem lividity may be of a rose-red colour in hydrocyanic acid poisoning, and sometimes in carbon monoxide poisoning.

Many other signs of death are available, but the more reliable have been mentioned.

Individual signs may be wanting, but application of simple tests such as those mentioned will enable the physician in practically every case to give a decided opinion.

THE POST-MORTEM EXAMINATION

Clinical Facts available for the Guidance of the Operator.—While occasionally, for example in some medico-legal cases, the operator has no information as to the previous history of the case, he is usually furnished with a more or less complete statement of the events which marked the fatal

illness, or in a case of accident, of the circumstances under which death took place. Such information should be welcomed, and is of great value in indicating the probable seat of important pathological changes, and, as a result, is of use in directing the preliminary preparations, the order in which the cavities and organs should be examined, and also indicates where special care has to be exercised. The pathologist must not, however, indulge too much in prophecy, particularly if the practised clinician, in spite of all the aids now available under the category of physical diagnosis, has been unable to form any decided opinion as to the cause of death. He is wiser to marshal, in his mind, all the possible explanations of the physical signs observed during life, so that if one of these fail, he may proceed to another, without losing his own respect, or that of his friend, the physician.

The pathologist's business is not so much to correct the medical attendant as to assist him in finding out the true nature of the disease which has caused death. Tact is frequently a very essential qualification of the pathologist.

The special points to be observed in making medico-legal post-mortem examinations will be referred to in a subsequent chapter (p. 423).

The Record of the Case.—It is advisable in all cases, particularly in those in which medico-legal investigations may follow, to have some one to take manuscript notes as the changes are described and dictated by the operator. If the recording of the facts of the case be delayed until the examination is completed, the operator is apt to forget important details, if he have no notes to guide him taken during the course of the post-mortem.

In all cases, the record should commence with the name and age of the individual; the dates of death and post-mortem: temperature of the room: and the name of the medical attendant.

If possible, the number of hours which have elapsed between death and the post-mortem examination should be ascertained. This, as well as the atmospheric temperature prevailing, are of importance in connexion with the onset and disappearance of post-mortem rigidity. The operator should avoid interpreting, as pathological, changes resulting from post-mortem decomposition.

The Examination of the Exterior of the Body.—The external examination of the body may reveal important indications of disease, therefore this must be conducted with care. It does not necessarily occupy much time. The natural method of progression is from the General to the Local and Particular.

After removing the coverings of the body, the operator proceeds with a **General Survey** of it.

Position and Attitude.—The body usually lies supine, with the arms close to the sides, or flexed at the elbows, the forearms in pronation and the palms of the hands resting upon the trunk, the lower limbs extended and

close together. Any departure from this position is very noticeable, and may give important indication of pathological changes present in the body—for example, Pott's curvature of the spine, kyphosis, fractures of the long bones or other gross lesions.

Apparent Age.—This may not correspond with the actual age of the individual, and the difference may give indications as to whether he has “worn well.” In premature old age, for example, we should expect to find arterial degenerations and their results.

General State of Nutrition.—**Corpulence** may suggest alcoholism, or some forms of heart disease. It should be distinguished from oedema with ascites, from abdominal or pelvic tumours, and from general or localized subcutaneous emphysema which has developed before or after death. Sometimes the whole head and trunk, and to a lesser extent, the extremities, are swollen from emphysema, not “surgical,” due to escape of air from the lungs or air-passages, but resulting from post-mortem evolution of gases (*Bac. aërogenes capsulatus*). In mechanical injury,—for example, crushes of the thorax, with rupture of the lungs and extensive fracturing of the ribs,—air may escape into the subcutaneous tissues of the thorax and neck.

Adiposis may be extreme, so that the fat hangs in ridges and folds upon the trunk, neck, and extremities. During life, it may have been associated with pain, a condition possibly related to *molluscum fibrosum*. Dercum names this condition *Adiposis dolorosa*. (See also Surface examination of Thorax, p. 23; of Abdomen, p. 24; and Diseases of the Pituitary Body, p. 394.)

Emaciation.—General emaciation suggests malignant growth, particularly affecting the oesophagus and producing stricture of that tube; extensive tuberculosis; starvation; or in the infant, congenital syphilis. It is not constantly present in atrophic cirrhosis of the liver. General emaciation is occasionally met with in long-continued paralysis and idiocy. Emaciation may be due to loss of fat, or concurrent atrophy of muscles. It is sometimes due more to the latter than to the former, as in one case of acute exophthalmic goitre I examined, in which the body, apparently much emaciated, possessed a layer of subcutaneous fat, half an inch in thickness, over the retracted abdomen.

Œdema (Anasarca) produces a puffy pallor of the skin, pitting on pressure, most extreme in nephritis but also occurring in obstructive or congenital heart disease, chlorosis, and other diseases in which there is either obstruction of the venous and lymphatic return, or toxæmias producing either local or general transudation. Œdema is readily distinguished from subcutaneous emphysema by the absence of “crackling” on palpation. In *myxoedema* the surface is pale, dry and puffy, but pitting is not so readily produced as in anasarca; the hair, moreover, is scanty all over the body.

The **Muscularity** should be noted—whether good, moderate or poor.

Symmetry.—Proportion of head to body, large in hydrocephalus, sporadic cretinism, acromegaly, osteitis deformans; small in microcephalic

idiots; unequal development of limbs—infantile paralysis, progressive muscular atrophy, hypertrophy or atrophy of one or both limbs of one side—the latter, for example, in hemiplegia, and in poliomyelitis anterior; atrophy of separate groups of muscles from localized nerve lesions; deformities or losses, the result of disease or of operation; contractures in diseases of the central nervous system; distortions due to rickets, or to osteomalacia, and other changes in the symmetry and normal proportions of the parts of the body. See *Gigantism* (p. 395), *Acromegaly* (pp. 395, 412), *Achondroplasia* (p. 412), *Rickets* (p. 409), *Osteomalacia* (p. 410), *Osteitis deformans* (pp. 370, 411), *Leontiasis ossea* (p. 412), *Infantile spinal paralysis* (p. 362), *Sporadic and Endemic Cretinism* (p. 157), *Myxoedema* (p. 157), *Syringomyelia* (pp. 360, 420), and *Locomotor ataxia* (pp. 363, 420).

Colour.—In the dead body, the colour of the skin varies, being pale and yellowish or greyish in the upper parts, and pink, or more often purplish and livid, in the dependent parts. This dark discoloration becomes patchy in distribution as it passes upwards, over the lateral aspects of the trunk and limbs. It may be marked on the head, face and neck in asphyxia, or where some thoracic condition—pneumonia, pleurisy, congenital heart disease, mediastinal tumour or œdema, aneurysm, or even some myocardial lesion such as fatty degeneration, myocarditis, obstruction of the coronary artery and its results—has interfered with the circulation of aërated blood through the upper part of the body. This is better termed “cyanosis.” If the head has not been supported after death, or if it has been dependent, lividity will be marked, especially in its posterior parts. *Post-mortem lividity* results from the influence of gravity upon the blood which remains fluid for a long time in the capillaries. It is not seen over bony points—scapulae, spinous processes, iliac crests and sacrum—owing to compression of the superficial tissues between these structures and the surface upon which the body lies. Lividity can be abolished by pressing the thumb upon the skin, and if the position of the body be altered, the parts which are now dependent become livid, e.g. the face, when, for example, the body is turned over to remove the spinal cord from behind. After decomposition has set in, the haemoglobin diffuses out from the vessels into the tissues and stains them, so that the discoloration does not alter with the position of the body.

Patches of lividity, “cadaveric sugillations,” have to be distinguished from bruises inflicted before death. If incisions be made into the latter, the blood is found not only in the vessels, but diffused through the tissues, which also show signs of mechanical injury. (This alteration also at times occurs in the tissues beneath bed-sores.) The tissues, moreover, may be pulpy, so that the examining finger may be passed readily in all directions through the subcutaneous and even through the deeper tissues.

Related to post-mortem diffusion of haemoglobin is the condition seen in deaths from acute and severe septicaemias, in which haemolysis has

2 occurred. In such cases, the haemoglobin diffuses out at a very early date after death, so that a superficial pink network marks the position of the subcutaneous veins. The change may be universal or confined to the neck and the upper parts of the trunk. It warns the pathologist to take special precautions to avoid infection.

The skin is *darkened*—"mulatto-coloured"—in Addison's disease and "bronzed diabetes"—in the former, particularly in parts normally exposed and in the flexures; the mucous membranes of mouth and vagina share in the dark discoloration. In *pellagra* discoloration may also occur.

The cutaneous pigment is lessened uniformly in albinism, in which also pigment may be absent in the hair and irides. In *leucoderma* (cf. *pityriasis*) and *anaesthetic leprosy* it is absent in patches.

In *Argyria*—Argyrosis—the skin of the head and neck, and of the hands, may have a peculiar grey, earthy, or "unearthly" (Adami) colour, resulting from the deposit of metallic silver at the extreme surface of the corium, immediately underneath the epithelium. Nowadays this condition is seen very rarely. I have encountered only one case in fifteen years.

In *Melanosia*—late stages of generalized malignant melanotic new-growth—the pigmentation may be diffused over the whole surface. In *Chlorosis* the skin has a waxy pallor, almost translucent because of the general anasarca; the body is well-nourished. In *Pernicious Anaemia*, and in the *cachexia* of malignant disease, especially carcinoma, the colour of the surface varies from a yellow to a brownish colour, approximating to that of Addison's disease, and there is a varying degree of emaciation. In *Septicaemias*, toxic jaundice may be present. The yellow discoloration is, however, not usually so deep as in obstructive jaundice from malignant disease, or from gall-stones.

Goose-skin or "*Cutis anserina*"—the roughness caused by the contraction of the *arrectores pilorum*—is usually confined to the drowned, and is a local manifestation of rigor mortis (*q.v.* p. 18.). It is of short duration.

Tattoo-marks, and pigmentations of inflammatory origin, or resulting from the occupation of the individual, should be noted.

"Parchment" patches on the cutaneous surface indicate where plasters, fly-blisters, or hot poultices have been applied to the skin shortly before death. These patches are smooth, brownish, sometimes depressed, hard, and their margins are sharply circumscribed.

The position, general appearance and probable causation, of sinuses, fistulae, ulcers and scars should be carefully noted. New-growths may occur, e.g. naevi and molluscum fibrosum. The former—Angioma—may be extensive; in the latter soft, rounded or flap-like prominences of greatly varying size may be scattered in profusion over the whole body. They usually develop in connexion with a cutaneous nerve.

Blisters and vesicles are not always or necessarily ante-mortem manifestations. The distinguishing mark of an ante-mortem blister is the

accompanying congested areola. The serum is also highly albuminous, as contrasted with the more watery contents of the post-mortem manifestation. Vesicles, containing gas, may arise during rapid decomposition and may be seen on gangrenous parts of the body even before the death of the individual.

Cutaneous eruptions, unless accompanied by crusts (*echthyma*, *rupia*) or by formation of pustules or vesicles, usually fade rapidly after death, unless haemorrhage has taken place into the patches, e.g. in purpura, *lymphatic leucocythaemia*, *phtheiriasis* (bites of arachnida).

The skin may be dry, darkened and scaly in *tuberculosis*, *pityriasis*, etc. It may be thickened, e.g. the stratum corneum in *ichthyosis* and *psoriasis*, the corium in *scleroderma* ("hide-bound disease"). Cancer may spread diffusely in the skin, producing great thickening and rigidity of it—*cancer en cuirasse*. Fortunately, this is rare now, thanks to the earlier detection and removal of the primary growth.

In *Mycosis fungoides*, there is great thickening in patches. An offensive thick discharge escapes between the nodosities. It is possibly of sarcomatous nature and is sometimes, in default of exact knowledge, referred to a position mid-way between the granulomata and the sarcomata.

Decomposition sets in early in warm weather, and also in infants and in cases which have shown marked debility. An early evidence of it is the greenish discoloration which is so commonly seen in the anterior abdominal wall. It appears here very early if a suppurative peritonitis have caused death, and, in fact, its appearance in any part of the surface at an unusually early stage, may be taken to indicate a subjacent collection of pus. The colour is produced by the action of sulphuretted hydrogen (H_2S) and sulphide of ammonium $[(NH_4)_2S]$, produced during decomposition, upon iron-containing pigments of the blood and muscles.

Under certain circumstances—death by drowning, certain abdominal conditions and particularly in very corpulent persons—a great development of **gas** may take place, chiefly produced by putrefactive bacteria, which penetrate the tissues from the intestines. The gas distends the cavities, produces subcutaneous emphysema and causes what Brouardel has termed the "posthumous circulation." This may be seen in warm weather in from twenty-four to thirty hours after death. The development of the gases drives the blood to the peripheral parts, so that wounds of the surface may bleed. The blood, later, decomposes, and its haemoglobin diffuses into the already swollen tissues, colouring them of a dusky reddish-brown tint, which the unwary may translate as evidence of ante-mortem cyanosis. In such parts the observer will be assisted by the early separation of the superficial layers of epithelium. This usually indicates that death has occurred several days previously.

As decomposition sets in, post-mortem rigidity becomes abolished.

Post-Mortem Rigidity—Rigor Mortis.—Rigor mortis is practically constant in adults. Occasionally in adults and in infants, particularly in

presence of great emaciation, it may be very slight and evanescent.

Careful observers have stated that rigidity does not follow death from carbon monoxide (charcoal fumes) poisoning, or from lightning stroke, but equally careful observers have found it present in such cases. It may not be evident, or it passes off quickly in cases where the muscles have been exhausted by repeated convulsions, e.g. in death from moderate doses of strychnine, or in tetanus.

The muscles contract strongly during the production of rigidity. This is noticeable in the skeletal muscles generally, but becomes of importance when it occurs in hollow organs, such as the heart and stomach, in the former giving the impression of death during systole of the ventricles, such as might be expected to occur in digitalis, strychnia or strophanthus poisoning; in the latter (stomach) causing irregular contractions of the muscular walls, simulating the so-called idiopathic hour-glass contraction of that organ, or pyloric stenosis (*see* p. 178). It may be stated at once that the ventricles are as frequently found relaxed in death apparently due to the poisons mentioned, the actual condition depending on the time which has elapsed after death, and that in the case of the stomach, it can be forcibly distended with water or air so that the true state of matters in that organ can be determined. True hour-glass stomach in the majority of cases is caused by the contraction of the scar-tissue in a chronic gastric ulcer.

The rigidity first appears in the muscles of the head, neck, and upper extremities, and in that order, and then proceeds from above downwards to those of the trunk and lower extremities. Its time of onset varies greatly, but speaking generally it appears from three to six hours after death.

In persons dying suddenly from injury to the cervical spinal cord, rigidity may occur immediately, e.g. on the battlefield. It also occurs very early in poisoning with large doses of strychnia, in tetanus, in fatigue, in septic conditions, and also in cancer, in pulmonary and abdominal tuberculosis—in fact, in individuals who have died after long-continued, exhausting diseases. When, however, it occurs thus early, it also, as a rule, disappears soon. It occurs late in sunstroke. The most extreme rigidity I have encountered was in a muscular adult male who died from meningeal anthrax. Before death numerous convulsions, almost tetanic in nature, had occurred.

Rigor mortis passes off in the order in which it has appeared, and its disappearance marks the advent of decomposition. It must be remembered that forcible extension of the limbs, for example, abolishes the rigidity, unless in the early stages of its onset when its development is incomplete, and also that rupture of muscle fibres or bundles may take place during its development, or when it is abolished by forcible extension. Careless lifting or manipulation of the body, before the post-mortem examination has begun, may suffice to produce flaccidity of the arms or neck, giving the impression that rigidity has passed off.

Under ordinary circumstances rigor mortis begins to pass off in from twenty-four to forty-eight hours. It remains longer in those who have been struck down while in good health, and in cases in which decomposition is delayed or prevented.

The cause of the rigidity is usually stated to be the coagulation of the albuminous plasma of the muscle fibres with formation of "myosin," but this does not explain the accompanying contraction. It is not known if changes in chemical reaction have anything to do with it, or if the nervous system has any controlling influence in preventing this coagulation.

In hemiplegia the paralysed side becomes rigid sooner than the other, but the rigor mortis passes off early and then the paralysed side is more flaccid than the other.

Detailed External Examination.—After a general survey, such as has been indicated, has been completed, a more *detailed* examination of the surface and of the cavities immediately opening upon it should be undertaken.

This must proceed in strict order from the head to the feet, the anterior surfaces being first examined, then the lateral and posterior surfaces. The stricter the method of procedure, the less risk there is of missing important points. In this sectional examination one may insist at this early stage on the necessity to *remember the orifices opening on the skin surface*.

Head.—The head is enlarged in *hydrocephalus* (p. 390), *acromegaly* (p. 412), *leontiasis ossea*, *osteitis deformans* of Paget (p. 370).

In rare cases, enlargement of the calvarium is the result of malignant growth, osteo-sarcoma. The enlargement in this case occurs usually in early life, and in contour it is irregular.

The cranium may be small—*microcephaly* (p. 383),—in idiots, from premature closure of the sutures. One side may be atrophied along with facial hemiatrophy. Local depressions may be the result of fracture, trephining or of atrophy or hypoplasia of cerebral tissue (*porencephaly*) (p. 383).

The *Scalp* may show loss of hair, either general—ordinary baldness—or that due to myxoedema (p. 157) or syphilis; or the loss may be localized in patches—neurotrophic or organismal, e.g. *alopecia areata*, and ringworm. In alopecia the cause may be neurotrophic, or, according to Sabouraud, organismal. In it the hair is practically completely lost in the area affected. In ringworm (*tinea tonsurans*) the hairs are short and stubbly, and brittle owing to the growth of the *microsporon* in the hair follicles and in the hair itself.

Favus is recognized by its characteristic yellow "cups."

The hair may be densely matted, in those who have abjured the use of soap and water, and have allowed *arachnida* to develop on the scalp unchecked. These produce weeping inflammations of the skin, and the exudations in combination with the dirt present bind the hair into a mass sometimes half an inch in thickness, in which I have found long-buried

hairpins during the attempt at hygienic cleansing and disinfection. This condition includes *plica polonica*.

The surface of the scalp may not be uniformly symmetrical. Part of it may be raised, oedematous, soft, and pit deeply on pressure. This results from haemorrhage or suppuration into its substance, or beneath it, and suggests as probable causes, mechanical injury to the scalp or bone, or erysipelas.

Abnormal prominences may result also from congenital malformation, or new-growths—multiple *encapsulated adenomata*, sebaceous cysts or “*wens*”, *dermoid cysts*, usually in the middle line; cutaneous *myomata* and other solid benign tumours; *malignant sebaceous tumours*, and *squamous epitheliomata*;—or from *herniation* of the brain through faults in the cranium, or through trephine openings. Of the tumours, the sebaceous cyst is distinguished by its pultaceous grey contents, the dermoid cyst by its smooth inner surface—which, however, may present the appearance of sodden skin—and its white, greasy contents. Benign adenomata are usually multiple, are easily shelled out, and on section have a greyish, almost uniform, surface, which on close examination shows a delicate stroma. Malignant sebaceous tumours are characterized by fungation and deep ulceration; squamous epitheliomata are more or less flattened, with low, overhanging, “rolled” edges, and ulcerated centres. Secondary sarcomata present as rounded low elevations under the skin. Similar thickenings may develop in chloroma. In all cases microscopical examination is advisable to confirm the diagnosis.

The scalp may present depressions over old fractures, or where the bone has been removed by operation (trephining) or disease (tertiary syphilis). It is usually adherent over such areas. Recent depressed fractures are usually masked by swelling due to haemorrhage or oedema.

In infants, the scalp is usually depressed over the fontanelles. A prominence of the fontanelles indicates increased intracranial pressure, due to meningitis, tumour, or hydrocephalus. In congenital syphilis the bony margins of the anterior fontanelle may be thickened and rounded. This is the result of formation of “bosses” of new bone from the outer table. The thickening also extends along the line of the sagittal and inter-frontal sutures.—(Parrot’s nodes or bosses.)

All cuts and bruises found in this region should be carefully examined, and it should be remembered that the impact of a heavy, blunt instrument upon the head may produce a comparatively clean-cut wound, simulating an incised wound. The position of all wounds should be accurately ascertained, as possibly having a relation to lacerations or haemorrhages found subsequently in the brain or its membranes.

The **Face** is next examined in a similar systematic manner. The features may be asymmetrical in hemiplegia. One side may be dwarfed—facial hemiatrophy or rather hypoplasia,—from some intracranial injury sustained most probably at birth.

The face may be oedematous in heart and kidney disease or in early trichinosis, in local inflammation, or from pressure upon cervical veins.

Tumours may occur on the surface, for example, *rodent ulcer* on the temples, or cheeks; *xanthoma* or *xanthelasma tuberosum*, a peculiar yellow flattened or nodular growth, usually on the eyelids, and occasionally accompanying jaundice or diabetes; *epithelioma* on the lips, or cheeks; *dermoid cysts* along the lines of closure of the branchial clefts, i.e., in a line from the bridge of the nose along the temples to the external auditory meatus, or on either side of the nose.

The antrum of Highmore may be distended by *sarcomata*, or by *cysts* or *solid adenomata*. *Osteoma* or *osteo-sarcoma* may develop in connexion with the nasal bones or with the ethmoid, causing striking deformity in that region. *Lipoma* may develop in the temporal regions. Laterally, *keloids* may develop from the lobe of the ear, starting, for example, in the hole pierced for ear-rings, and mixed tumours of the parotid may cause great swelling in the neighbourhood of the angle of the jaw. *Odontoma* and *sarcoma* may occur in the body of the lower jaw, and *chondroma* or *osteoma* near its angle.

Abnormal prominences may be of inflammatory origin—*erysipelas*, *parotitis* ("mumps"). *Naevi* and pigmented moles are occasionally found disfiguring the face, and in marasmic children localized gangrene of the cheek (*Cancrum oris*, "*Noma*") is observed in rare cases.

Another rare condition is lymphangiomatous swelling of the lips—*macrocheilia*.

Lupus causes superficial scarring of the face usually in the neighbourhood of the nose (*L. erythematosus*), or may cause extensive destruction of these parts (*L. exulcerans*). *L. erythematosus* is probably non-tuberculous.

Acquired *syphilis* in severe cases causes destruction of the nasal septum and palate, so that the nose becomes depressed, but there is not such extensive destruction of the soft parts, as a rule. In congenital syphilis the nasal bones especially and their supports are destroyed so that the bridge of the nose is markedly depressed.

Tertiary syphilis may produce extensive, slow necrosis of the frontal bones—"corona Veneris" (p. 371)—or gummata may develop anywhere in the face, and on breaking down, produce deep ulcers. Similarly *actinomycosis* may cause deep ulceration, and also prominent nodules of granulation tissue. The pus is greyish, thick, glairy and contains minute yellow granules composed of the matted streptothrix.

Haemorrhage from the nose or mouth indicates local injury, fracture involving the anterior fossa and sphenoid bone, or rupture of an aneurysm into the trachea or oesophagus. Frothy bloody fluid escaping from the nose and mouth may come from the lungs in extreme congestion of these organs. Development of gases in the intestine after death, presses up the diaphragm and increases the flow. Haemorrhage, or escape of cerebro-

spinal fluid, from the ear depends on fracture of the petrous portion of the temporal bone. Pus escaping from the ear indicates suppurative otitis media, and directs attention to the possible presence of abscess of the temporo-sphenoidal lobe or cerebellum, or thrombosis of the lateral sinus. The external ear may be distended with blood, "*haematoma auris*" as the result of direct injury, or in certain forms of insanity.

The Eyeballs are pushed forwards in *exophthalmic goitre*, and by growths developing in the orbit—*sarcoma*, *chloroma*. Haemorrhage under the bulbar conjunctiva suggests local injury to the soft parts, or fracture involving the walls of the orbital cavity. It is occasionally seen in death from asphyxia. One or both eyes may be wanting, or atrophied. *Molluscum contagiosum* may occur about the eyebrows.

Parchment-like patches and excoriations on the lips should be carefully examined, as giving indication of poisoning by strong acids, alkalies or other corrosives. Herpes may occur on the lips, particularly the upper one, in cases of pneumonia, and may give a hint of the presence of that disease.

The mouth should be opened, and injuries or anomalies of the lips, alveolar margins, teeth, gums, palate and tongue noted, e.g. hare-lip, cleft palate, etc.

Neck.—The position of parts must be carefully noted, so as to detect the presence of Pott's Disease of the cervical column, or fracture.

Diffuse lipoma may be found, and in the middle line the prominence of the enlarged thyroid in *goitre*, and laterally of enlarged glands—tuberculosis, lymphadenoma, lymphatic leukaemia, or secondary malignant disease—should be carefully distinguished. Extensive ulceration, scarring of tuberculous origin—lupus or caseating glands—may be found especially on the lateral aspects of the neck. Scars may also result from burns or operative procedures. Congenital cysts or fistulae may be found, due to defective closure of branchial clefts. Supernumerary auricles may occasionally be found on the lateral aspect of the neck.

Thorax.—Alterations in shape are of especial importance, e.g. the long, narrow chest of tuberculosis; the rounded "barrel-shaped" chest of chronic bronchitis and emphysema; the "pigeon breast" resulting from early rickets, or in cases in which during early life there has been severe bronchitis or other obstruction to respiration, so that the sides of the thoracic cage are drawn inwards in the neighbourhood of the costo-chondral articulations. Prominence or concavity of part or whole of the sternum and costal cartilages, may be due to rickets or result from the occupation of the individual, or is congenital ("funnel-breast"). Widening of the lower part of the thorax may be caused by distension of the abdomen or by enlargement of the liver or spleen. In children suffering from rickets the characteristic enlargement of the costo-chondral articulations ("rickety rosary") may be seen and felt.

Aneurysms of the arch of the aorta may project forwards through the sternum. The bone is absorbed, but the cartilage persists.

In females the mammae should be carefully examined, for hypertrophy or atrophy—a mamma may be enlarged from suppuration in its substance or behind it—for tumours, cystic or solid, benign or malignant. These rarely reach the post-mortem room. Occasionally, however, one meets with recurrence of mammary cancer in the scar or in the surrounding pectoral region or in the axillary glands. Diffuse carcinomatous infiltration of the skin of the thorax (*cancer en cuirasse*) following mammary cancer, is rare, and is accompanied by oedema of the corresponding arm. It is still less common to find diffuse emphysematous gangrene. Several cases have been reported following injection of normal salt solution into the sub-mammary tissues. From a case of this nature, I isolated the *Bac. aërogenes capsulatus* of Welch. The instruments had been used three or four months earlier in a case in which gangrene had occurred.

The presence of supernumerary mammae or nipples should be noted.

If any punctured wounds exist, their position should be carefully noted, a probe passed along their course, and retained there during the subsequent opening of the thorax.

Examination of the Surface of the Abdomen.—In young children the abdomen is wider above than below owing to the relatively large size of the liver; in the adult female it is wider below, owing to the relatively great width of the iliac bones.

The skin should be examined for the presence of silvery scars—*striae gravidarum* or *striae albicantes*—resulting from the stretching of the skin which occurs in pregnancy or obesity, and also for localized pigmentations, for example, *pityriasis versicolor*, in which scurfy brown patches develop, from the action of the *Microsporon furfur*. The *linea nigra* of pregnancy appears as a brown streak in the middle line below the umbilicus. The greenish discoloration of the abdominal parietes, which indicates commencing decomposition, has been referred to already (p. 18).

In severe anaemias, in which during life arsenic has been administered to excess, the skin of the lower part of the abdomen may be of a dark brown, almost black, colour.

Increase in the Size of the Abdomen.—*Uniform* general prominence of the abdomen points either to thickening of the walls (fat) or to excess of fluid within its cavity. In corpulence, the walls may fall away towards the flanks, and the umbilicus is usually deeply recessed. When ascites accompanies corpulence, the anterior wall remains projected upwards (forwards), the abdomen on transverse section being more or less rounded, and the umbilicus is levelled up or even prominent.

When ascites is present without increased deposit of fat, the skin is tensely stretched and glossy, the general contour of the abdomen rounded, the ribs pushed upwards and the lower part of the thorax widened. The umbilicus is flattened or projects. If the condition is due to obstruction

of the portal circulation, the veins coursing over the surface are prominent and dilated (collateral circulation).

A similar appearance with, however, irregular resistance, is found in generalized abdominal tuberculosis in children. In such a case, the contrast between the enlarged abdomen and the other emaciated parts of the body is very marked. In addition, the greenish colour of decomposition appears very early, particularly if loculi of pus have formed.

When fluid is accompanied by gas —“*tympanites*”—the walls are tightly stretched and the skin glossy. This occurs usually when perforation of some part of the alimentary tract has taken place.

Irregular enlargement of the whole abdomen may suggest new-growths, for example, large multiple cystic ovarian tumours, fibroids of the uterus, or extensive malignant tumours of these organs. Localized enlargements may be due to enlargement of the liver—infiltrations, hypertrophic cirrhosis, new-growths, cysts, or abscesses; dilatation of the stomach, colon or sigmoid (iliac and pelvic colons), from obstruction; idiopathic dilatations of the colon—Hirschsprung's disease; enlargement of the spleen—splenic anaemia, myelogenous leucocythaemia, malaria; enlargement of the kidneys—congenital cystic kidney, hydro- or pyo-nephrosis, hypernephroma, etc.; massive enlargement of lymphatic glands, chiefly retroperitoneal; abdominal aneurysm with, possibly, rupture behind the peritoneum; pregnancy or distended bladder. Intussusception does not, as a rule, give much indication of its presence, and large scybalous masses in the colon are more easily felt than seen. Prominences localized to the various potential apertures, umbilicus, inguinal canals, etc., would suggest herniae.

In any of the above the coincident occurrence of ascites, or an extreme degree of the morbid process itself, may so increase the distension of the abdomen that this is practically uniform.

All abnormal prominences should be palpated.

The abdominal parietes are *retracted* in actual starvation, and in pathological changes so interfering with alimentation and assimilation as to cause an extreme degree of emaciation. In adults, marked emaciation with retracted abdomen usually indicates obstruction of the oesophagus from cancerous stricture or from congenital or cicatricial stenosis.

General emaciation of the body, with distension of the abdomen, occasionally most marked above the umbilicus, is found in advanced pulmonary phthisis, with associated fatty liver, and abdominal tuberculosis in the adult, or in tuberculous peritonitis and tabes mesenterica in the young.

The *Umbilicus* in the adult is situated on a transverse plane which passes a little below the level of the highest point of the crest of the ilium. It is a little lower than this in infants and in extremely fat individuals. Normally, it is moderately recessed, more so in the infant than in the adult. It is more recessed than normal in adiposity, and in extreme anasarca; it is flattened in pregnancy, tympanites, and a moderate grade of ascites, unless

these conditions are accompanied by adiposity or oedema ; it projects in marked ascites. Rarely, congenital tumours and cysts give rise to localized swellings in this situation, and herniation of part of the abdominal contents may take place at the umbilicus. Umbilical faecal fistulae are rare and usually indicate a communication with the small intestine by way of a Meckel's diverticulum. It is even less common in the post-mortem room to meet with a patent urachus communicating with the urinary bladder. In cases of death with jaundice occurring shortly after birth, and in tetanus of new-born infants, the stump of the umbilical cord should be submitted to careful bacteriological examination.

The situation, dimensions, and condition of incised or lacerated wounds should be carefully noted, as to age, sound healing, stretching with possible herniation, presence of suppuration between the lips of the wound, or along the tracks of the stitches ; and microscopic films should be made and culture media inoculated, particularly when peritonitis is present. The result of bacteriological investigations may give important indications as to the source of the infection of the peritoneum.

Passing to the *Lower Parts of the Abdomen*, and *Perineum*, the inguinal region is to be examined for presence of herniae or enlarged lymphatic glands, and the consistence of the latter. In the male, the penis is to be examined for evidence of urethral discharge, balanitis, phimosis, paraphimosis, circumcision, papilloma, epithelioma, soft or hard chancres, or scars of these chancres upon glans or prepuce, condylomata, adhesions between glans and prepuce, gangrene from phagedena or from embolism. I have examined a case of gangrene of the lower extremities and penis following embolism of the abdominal aorta.

Congenital abnormalities are not common. These may be, extroversion or ectopia of the bladder ; defects in the urethra—epispadias, hypospadias ; hypoplasia or hyperplasia of the penis. Hyperplasia of the penis in the young, with premature puberty, may be associated with tumours of the supra-renal. Other abnormalities may occur, such as, separation of the scrotum into two lateral parts, with a deep cleft between ; this may be associated with an extreme degree of hypospadias—pseudo-hermaphroditism ; undescended testicle, the hypoplastic organ either lying at some point along the line of descent, or being retained within the abdomen. Enlargement of the scrotum results from hernia, orchitis, tumour or gumma of testis ; also from tuberculosis of the epididymis, hydrocele, oedema, and elephantiasis.

In the female, one may find evidence of inflammation of urethra or vagina, with purulent discharge ; enlargement of labia majora or minora ; inflammation or tumour of Bartholin's gland ; elephantiasis, true or false ; venereal warts ; fibroma of labia ; oedema ; condylomata on apposed surfaces ; gummatous or epitheliomatous ulceration about vulva or anus ; prolapse of uterus. (*See Chap. XV. p. 324.*)

In the perineum, in addition to the diseases already referred to, fistulae may open, cystic tumours may develop, and at the anus there may be haemorrhoids, or prolapse of the rectum.

Excessive pigmentation of the skin is seen in Addison's disease, but pigmentation may be extreme, almost to a deep sepia colour, in the absence of any disease of the supra-renals.

The *Posterior Surface of the Abdomen* should be examined at the same time as that of the thorax. One looks for any pathological alteration in the vertebrae, for example displacements or deformities of the varieties described, pp. 23, 154; enlargement or atrophy of the erector spinae; spina bifida, evident or occult; soft projections at the sides of the vertebrae suggesting sarcoma, or psoas abscess pointing behind. After any long-standing disease, and frequently in cases in which there have been severe lesions of the spinal cord, bed-sores may be present over the sacrum. Bed-sores are usually associated with inflammatory and necrotic changes in the subjacent parts.

Over the trunk generally, wounds of whatever nature—operative or otherwise—should be examined carefully, as to condition, age, and asepsis.

The Extremities.—A rapid survey of the extremities usually suffices. The shoulders and upper extremities are first examined, and then the lower extremities. They may present a great variety of pathological conditions, but one especially looks for evidence of injury, scars, losses of parts, fractures—recent or old—dislocations, ankyloses, the distortions of rickets or osteomalacia, bruises, lacerated or incised wounds, ulcers, abscesses, enlarged glands and bursae, aneurysms, varicosities, tumours—fibroma, neurofibroma, osteoma, chondroma and chondrosarcoma, other sarcomata and squamous epithelioma. Sarcomata occur perhaps oftener above and including the upper epiphyses of radius, ulna and tibia, whereas carcinomata occur more commonly below these levels. Further, one looks for tuberculosis of the joints and atrophy of the muscles moving them, and for contractures.

In rare cases ossification of the muscles occurs—riders' bone—in the adductors of the thigh, for example, and still less commonly cases occur of generalized ossification of the muscles—"ossified man," "myositis ossificans."

Localized *Gangrene* may be present. Raynaud's disease consists in symmetrical gangrene localized to the tips of the fingers and toes, depending on local anaemia from vaso-motor constriction of the arteries of supply. There need be no evident discoloration, but simply loss of substance and scarring, with rounding off of the tips of the digits. Similar changes may result from poisoning with ergot of rye. Arterial sclerosis is usually present as well in such conditions.

Ordinary *Dry gangrene* of the extremities is readily recognized. It may be symmetrical and more often affects the lower than the upper limbs. The skin is dry, shrivelled, dark in colour, and a sharp line of demarcation

separates the gangrenous from the healthy tissues. There is little odour of putrefaction. The arteries should be examined specially.

In *Moist gangrene* the limb is swollen, vesicles may be present on the surface, which is pale or shows pink, livid, black or greenish patches. There is no distinct line limiting the condition. The fluids escaping may be offensive. The veins should be examined specially and the fluids investigated by bacteriological methods.

A whole limb or part of it may be atrophied, e.g. in hemiplegia and in diseases of the joints. The hands and feet may be enlarged out of all proportion in *acromegaly* (p. 412). In *elephantiasis* great and irregular enlargement of a limb occurs from blocking of the lymphatics by the adult filariae

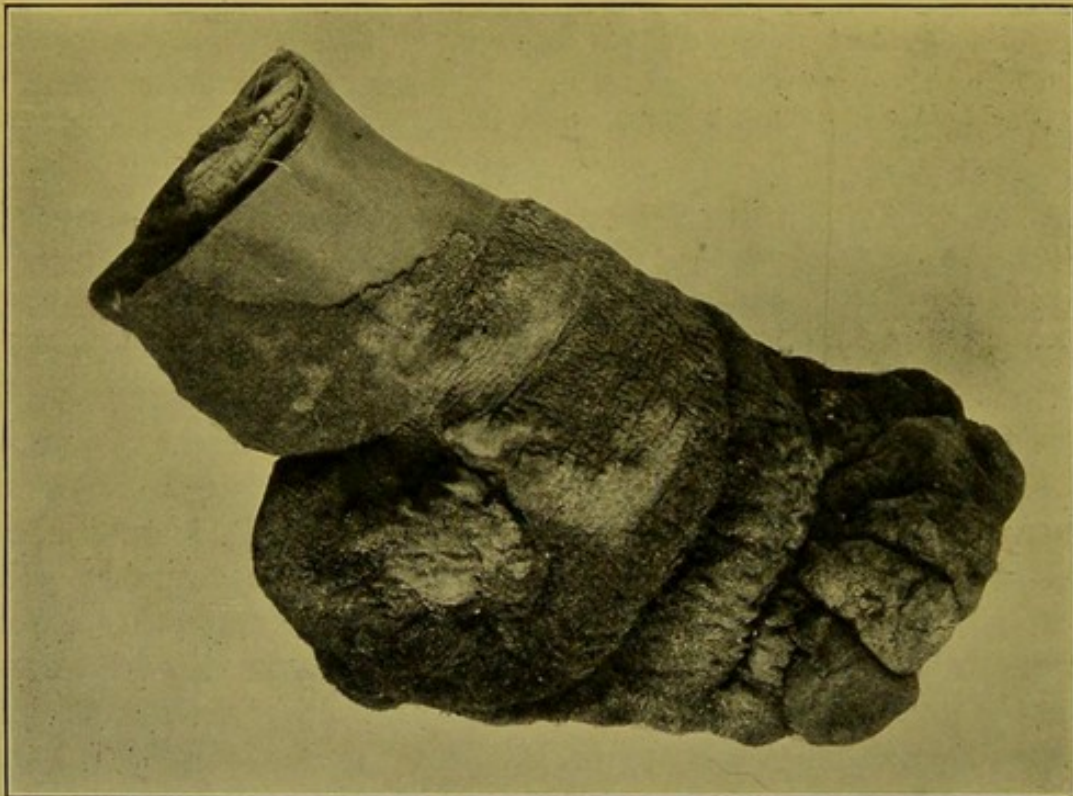

FIG. 4.—Elephantiasis of foot and leg. (\times circ. $\frac{1}{3}$.)

(Mus. R.C.S. Ed.)

(Fig. 4). Single hands or feet or individual digits may undergo hypertrophy or elephantoid change.

The tibia and skin in front of it may show important evidence of old syphilis. The tibia may present raised, smooth, osseous "nodes," and the skin may show dark pigmented scars of old syphilitic ulcers or the rounded, slightly depressed, polished, thin scars of rupia. It must be remembered that the skin in this region may be diffusely pigmented in old people and in others who have been in the habit of sitting close to a blazing fire.

A survey of the surface as indicated above, though it takes some time to describe, need not occupy much time in practice, and constantly gives valuable clues and indications, which direct the pathologist in his subsequent examination of the body cavities.

CHAPTER III

THE EXAMINATION OF THE INTERIOR OF THE BODY

THE OPENING OF THE CAVITIES

THE order adopted may be—Head, Thorax, Abdomen, but no absolute rule can be laid down, though it is usual to examine the thorax and abdomen before the head. If the brain is to be examined at an early stage, I usually open the thorax as well, so as to determine the amount of distension of the chambers of the heart and of the thoracic venous and arterial trunks, before severing the cerebral vessels. Many writers consider this procedure unnecessary.

It is sometimes convenient to begin with a cavity to which special attention has been directed during life, and in which the existence of important pathological changes is suspected. The order taken here will be—Thorax, Abdomen, Head.

In ordinary cases, both the thorax and abdomen are opened by a median incision, commencing above at the body of the hyoid bone, passing to one side of the umbilicus and terminating at the pubic symphysis. If permission be given for examination of thorax or abdomen only, the median skin incision should be limited accordingly, and a transverse incision made at the level of the xiphisternum, or about an inch (2 cm.) below or above it, to allow of the reflexion of the superficial soft parts.

Preliminary Skin Incision and Reflexion of Soft Parts.—The operator stands at the right side of the body, under the shoulders of which a wooden block or other support is placed so as to extend the head and tilt the chin upwards. The primary incision, as described above, is made with the cartilage knife, which should be held in a full, firm grip. The operator should keep his elbow rigid so that all movement of the arm takes place from the shoulder. The incision should pass through the skin and superficial fat only; the operator then dissects downwards just below the xiphisternum until he reaches the extra-peritoneal fat. Before actually opening the peritoneal cavity, it is well, at this stage—particularly in cases of abdominal distension, in which one suspects that gases have escaped into or developed in the peritoneal cavity—to pour some water into the wound and puncture the peritoneum through this so that any escape of gas may be detected at once even though in small quantity. If the distension, on the contrary, be the result of general peritonitis or ascites, fluid will escape on puncturing the peritoneum, turbid in the former condition, clear and translucent in the latter.

The opening may now be enlarged until through it the anterior surface of the liver becomes visible. The index and middle fingers of the left hand are

then inserted into it in full supination. These fingers, pointing downwards towards the pubes, are employed to draw the abdominal wall well forwards, while the knife, inserted between them, and followed by them, prolongs the incision downwards to the symphysis, thus opening up the whole cavity. In order to give more room at the lower part of the opening, the recti may be divided from their under surfaces just above their attachment to the pubic bones.

To expose the thoracic cage, the upper part of the edges of the abdominal incision are now each in turn pulled strongly outwards, and the superficial soft parts are cleared away from the costal margins; then, progressing upwards in a similar fashion, the soft parts are pulled away from the thorax and separated from it with long sweeping cuts of the knife. The thoracic walls and clavicles should be exposed as far out as the anterior limits of the axilla. In emaciated subjects, great care should be taken to avoid "button-holing" the skin.

In clearing the costal margins the suspensory ligament of the liver is divided along with the obliterated umbilical vein.

While carrying out these procedures, note should be taken of the thickness and consistence of the skin, the amount of subcutaneous fat—*panniculus adiposus*—the presence, degree, and extent of subcutaneous oedema or emphysema; and the colour and condition of the muscles. Normal fat is of a canary yellow colour. In certain wasting diseases, if it be not practically absent, it darkens in colour or may have a greyish tint. In subcutaneous oedema—*anasarca*—it is pale and translucent; and a watery fluid escapes from the cut surface. Muscle is normally of a purplish-brown

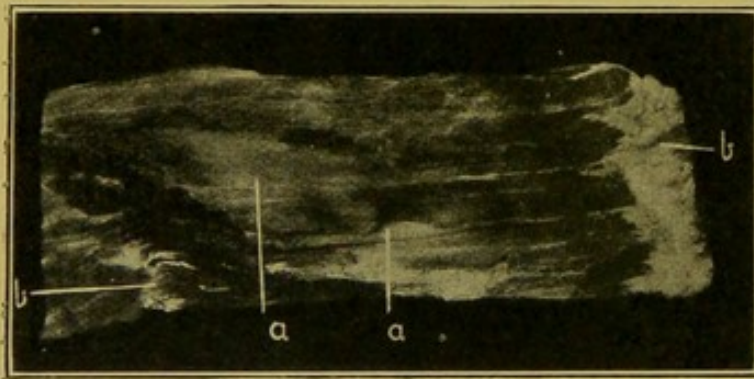


FIG. 5.—Zenker's vitreous degeneration of striped muscle; rectus abdominalis. ($\times \frac{2}{3}$.)

(a) Affected portions; (b) transverse fibrous bands in muscle.

colour; it becomes opaque, pale and bleached in the neighbourhood of acute septic conditions, and if, in addition, it is breaking down, a creamy fluid of a colour somewhat like that of anchovy sauce may be scraped from its cut surface. In general toxaemias, and particularly in typhoid or enteric fever, pallor appears in patches, e.g. in the upper parts of the recti abdominales;

this results from coagulation and fragmentation of the muscle fibres—the so-called "vitreous degeneration" of Zenker; it is as though the colour has been washed out in patches. The patches are glassy and somewhat translucent (Fig. 5). In anaemia the muscles generally are pale and are often atrophied; in chronic diseases, and in old age, the muscles are dry and of a dark brown colour. Muscles may be the seat of fatty change, either a fatty infiltration, the fat separating up the bundles, or fatty degeneration, the muscle becoming yellowish or orange in colour. In carbon-monoxide poisoning, the muscles are of a light pink or red colour,

this forming one of the appearances characteristic of that form of gas-poisoning.

The position and extent of collections of *pus* should be carefully noted, and, if possible, one should determine whether these are confined to the muscles, or represent extensions from suppurations originating nearer the surface (in connexion with the ribs, or axilla), or within the thoracic or abdominal cavities, or whether they have developed in relation to ligatures or stitches.

The *Mammæ* in the female may next be investigated by incising them from the under surfaces of the reflected flaps of the soft tissues. The presence of diffuse fibrous changes—chronic interstitial Mastitis, or, more correctly, Mammitis (*Masta*, nipple)—should be determined. In this condition, the mamma is converted into a firm, white fibrous plate sometimes with small retention cysts. One must not forget that carcinoma may develop in mammae which have undergone this transformation. In addition, one should look for localized tumour formations—fibroma, fibro-adenoma, adenoma, papillomatous cysts, and the various sarcomatous and carcinomatous tumours. Milk and hæmorrhagic cysts, tuberculous sinuses and abscesses may occasionally be found post-mortem. The presence of changes in the *nipple*, e.g. the flattened spongy enlargement of Paget's Disease, and the retraction which takes place in scirrhus cancer, and also possibly in chronic interstitial inflammations should be noted. (*See also* p. 345.)

Portions of tissue or of tumours taken for microscopical examination should not exceed 3 or 4 millimetres in thickness, and should be placed at once in suitable fixing solutions. (*See Appendix.*)

Pathological Changes in Thoracic Walls.—The exposed thoracic walls should be examined in detail before proceeding further. The alterations in shape which the thorax may undergo are of importance, for example, the changes occurring in rickets, in osteo-malacia, in curvatures of the spine, in chronic bronchitis, in aneurysm of the arch of aorta; and also the widening of the lower part of the thoracic cage resulting from enlargement of the liver or from distension of the abdomen.

Sternum.—The sternum may be congenitally absent, in whole or part, and in very rare cases it is so deficient that the heart projects. Fractures of the sternum, not always appreciable from the skin surface, are now evident. In their neighbourhood, the soft parts are infiltrated with blood, and by pressing upon the lower end of the bone, the fracture is rendered more evident. The junction between the manubrium and gladiolus sterni may present a distinct angle with the convexity forward, the projection exceeding the normal, e.g. in emphysema of the lungs. In extreme cases, this angling may simulate a fracture of the bone. The xiphisternum may be set at almost a right angle to the gladiolus, so that its tip projects forwards. The bone may be softened from infiltration with new-growth, e.g. cancer, secondary to a mammary tumour; or a rounded, fibrous, compressible,

evidently hollow, swelling may project through it, this being an aneurysm of the thoracic aorta which has brought about erosion of the sternum by pressure. The pressure absorption caused by the aneurysm does not to any extent affect the costal cartilages because these are non-vascular structures, and incapable of being absorbed unless they become vascularized.

Costal Cartilages.—These are occasionally fractured in cases in which great compressing force has been applied to the chest; but, more usually, as a result of such accidents they separate from their attachments to sternum or ribs. “Beading,” “Rickety Rosary”—due to enlargement of the costo-chondral articulations, can now be distinguished easily, and the deformities at these articulations found in various conditions—e.g. rickets, osteo-malacia—are more evident.

The position of fractures of the anterior portions of the ribs, and the nature and position of any abnormality of the clavicles, should also be noted. If the existence of **pneumothorax** be suspected, its presence may be detected in the following manner before opening the thorax. A square is dissected out from the soft parts between the cartilages close to the sternum, so that the parietal pleura is exposed, and the hollow filled with water; the pleura is then punctured. Air, if present, reveals itself by the escape of bubbles through the water.

The *Axillae* should be opened up, and the condition of their contents—glands and vessels—ascertained.

It is advisable at this stage to note the general position and relationships of the abdominal organs, as these may be disturbed during the opening of the thorax.

Methods of Opening the Thorax.—The thorax may be opened either along a line passing just within the outer ends of the rib cartilages, or by dividing the ribs in a line corresponding to the anterior border of the axilla; both methods will be described, but the former is recommended as preferable in the majority of cases.

A third alternative method for use in young children will also be described.

Ordinary Method of opening the Thorax.—If the rib cartilages be not extensively calcified they should be divided with a “cartilage” knife near their articulations with the ribs, in an oblique line passing downwards and outwards from the second rib to the costal margin. In carrying out this procedure the knife should be held with its long axis at an angle of about 30° to the horizon, so that after cutting through one cartilage, it falls upon that immediately below. This prevents the knife from passing deeply into the thorax and injuring its contents. The edge of the knife should be directed outwards so as to cut through the cartilages obliquely—the object being, that, when the hand is subsequently passed into the pleural cavities no sharp angle is left which might abrade the skin. The operator then passes to the head of the body and cuts through the cartilage of the first rib *from below upwards and outwards*, until the knife is stopped by the clavicle. If the first cartilage be calcified it should be divided with the bone-

forceps. The necessity for outward direction of this cut will be manifest if one remember the shape of the manubrium sterni.

Resuming his original station, the pathologist pulls upwards the lower left cartilages with his left hand, and cuts through the anterior attachments of the diaphragm, repeating the procedure upon the other side; then still raising the sternum and keeping the knife close to its under surface, he frees it wholly from the mediastinal structures. This separation should take place readily; strong adhesion to subjacent structures indicates pathological change in these, e.g. inflammation—adherent mediastino-pericarditis—malignant tumour, aneurysm.

The sterno-clavicular articulations are now opened *from behind* and the sternum separated from the clavicles by dividing the ligaments connecting these bones, care being taken not to injure the large subjacent vessels. For the separation of the sternum from the clavicles the bone-forceps should not be required, because, quite apart from the clumsiness of such a procedure and lack of anatomical knowledge it reveals, ragged edges and spicules of bone are left, which are highly dangerous to the hands of the operator during subsequent manipulations. While it is easier to open the capsules of the joints from behind when these are put upon the stretch in pulling the sternum upwards, the joints may alternatively be opened from their anterior surfaces; but it is not then so easy to avoid injury to the venous trunks which are immediately subjacent.

Second Method of Opening the Thorax.

—If the rib cartilages be extensively or wholly calcified, the *second* alternative

method of opening the chest may be employed. In carrying out this the ribs are *sawn* through in the anterior axillary line. The sternum is then separated from the clavicles, or the clavicles may simply be cut through with the saw in the same line as the ribs. After removing the sternum and the portions of the ribs attached to it, and before investigating the pleural cavities or removing the thoracic contents, the skin and soft parts should be inverted over the cut ends of the ribs so as to protect the hands.

Third Method of Opening the Thorax, which may be employed in young children (Figs. 6 and 7).

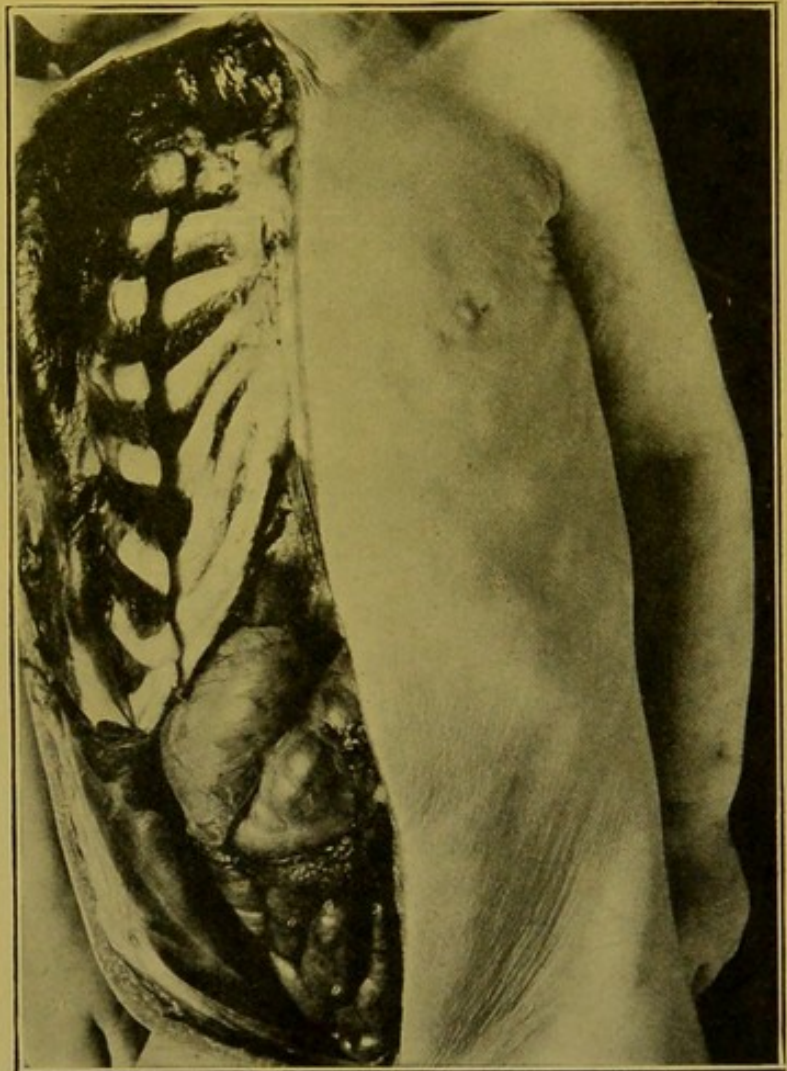


FIG. 6.—Author's method of opening the body in young children.

The preliminary incisions and clearing the soft parts off one side of the thorax.

In young children in whom accurate replacement of the anterior portion of the thoracic wall is difficult, I have devised the following method of opening the chest. It is simple and has much to recommend it. The customary median skin incision may be employed, or an incision corresponding to the line along which the cartilages on the right side of the body are divided. If the former be used then the soft parts have to be cleared off from the cartilages on the right side only. These are divided in the ordinary manner and the subjacent mediastinal soft parts separated from the sternum from below upwards and towards the left side. The right sterno-clavicular joint is next separated and the man-

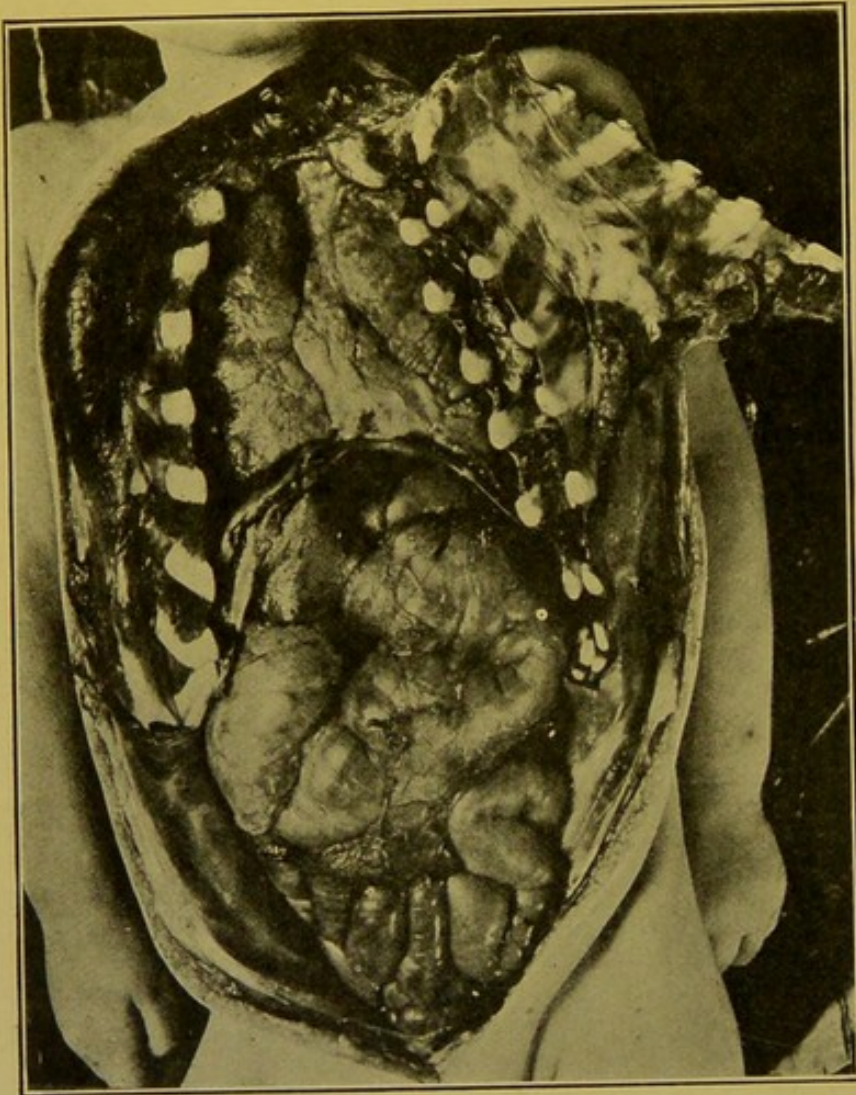


FIG. 7.—Author's method of opening the body in young children.

The sternum turned over to one side; thorax and abdomen laid open.

brium completely freed from the mediastinal structures. Still raising this "lid," as it were, one makes a hinge for it by cutting obliquely through the left rib cartilages and the left sterno-clavicular joint in the usual line, but *from the under surface*, the skin and soft parts over the cartilages being left uninjured. Quite as free access to the thorax is obtained by this method as by the one ordinarily employed, with the great advantage that the opening is easily and securely closed when the *sectio* is completed. It is difficult, otherwise, to prevent falling in of the sternum in young children.

The thoracic and abdominal organs are now exposed.

Calcification of Costal Cartilages.—This alteration in the cartilages is frequently found, particularly affecting the

first, fifth and sixth cartilages. In old age, all the cartilages may be calcified. Calcification is indicated by the increased resistance offered to the knife in passing through the cartilages, and bone-forceps may be required to divide them. On section the calcareous deposit appears as opaque, yellowish particles and areas on the cut surface. Occasionally, along with the calcification, patches of vascularization may be found. These are soft, spongy areas either near the surface or near the articulations to the sternum or rib. True ossification has been observed frequently.

The Removal of the Viscera.—Before proceeding to detail the method of conducting the examination of the interior of the body, and the data by which the pathological appearances encountered during its course may be recognized, it may be well to indicate in outline the order which I have adopted in the Royal Infirmary, Edinburgh, for removing the viscera from the thorax and abdomen, and which I recommend as fulfilling best the conditions already laid down.

The organs are removed in groups :—

- (1) Small intestine, with, or without
- (2) Large intestine.
- (3) Stomach and duodenum with liver, bile ducts throughout their whole length, pancreas, spleen and mesentery.
- (4) Kidneys with supra-renals and ureters.
- (5) Thoracic contents along with the cervical soft structures, the aorta in its whole length, inferior vena cava, crura of the diaphragm with solar plexus and receptaculum chyli.
- (6) Pelvic organs, which in certain cases may be removed in continuity with large intestine (2), and kidneys (4).

After making the preliminary mesial incision from thyroid cartilage to pubic symphysis and opening up the thoracic and abdominal cavities, the thoracic organs are examined *in situ*, and in certain cases of sudden death the cavities of the heart and pulmonary artery are opened up. Then before doing more in this cavity the abdominal organs are removed in a certain order after being thoroughly examined in their natural positions.

1 In the first instance the mesenteric glands are palpated and incised, special attention being directed to those in the ileo-caecal angle and leading up from that point towards the root of the mesentery. Those round the greater curvature of the stomach, in the lesser curvature and in the hilum of the liver may be examined at the same time. The appendix also should be investigated.

The small intestine is now separated from its mesenteric attachment, to within three inches of the ileo-caecal valve, and divided at either end between ligatures. Then the large intestine is separated down as far as the upper end of the rectum where it may be either divided or kept in continuity with the rectum and removed later along with the pelvic contents.

The spleen may be removed at this stage or along with the stomach and accessory organs. Now working from below upwards, the duodenum, pancreas, liver and stomach are freed—the right supra-renal being peeled off from the under surface of the liver with the fingers—and this group is separated by dividing the oesophagus as it passes through the diaphragm. A ligature may be placed upon the oesophagus before dividing it. In cases in which it is essential to examine minutely the mesenteric arteries, the intestinal tract should be removed in a mass along with stomach, liver,

spleen, etc., and abdominal aorta, from which it can readily be detached later.

Then the knife is carried vertically downwards to the inner side of the supra-renals between these and the crura of the diaphragm, and the kidneys are freed, beginning with the left one. After the ureters have been stripped down as far as the brim of the pelvis they may be slit up with scissors and their contents and condition of their lining membrane ascertained. If they present no marked abnormality they may be divided at once and the kidneys with ureters and supra-renals removed from the body. Then the pelvic contents are scooped out in one mass along with, or separated from, the large intestine. In the abdominal cavity there now remain only the crura of the diaphragm with solar plexus and receptaculum chyli, the aorta and inferior vena cava, which are to be removed along with the thoracic contents.

A block being placed underneath the shoulders, the knife is passed upwards underneath the skin of the neck, through the floor of the mouth and carried round on either side close to the rami of the lower jaw bones. The index finger of the left hand being passed up from below, the tongue can be drawn down into the incision, and then the soft palate and the pharynx separated with the knife right up to the base of the skull. The cervical structures are now stripped off completely from the vertebrae as far out as the transverse processes. Continuing downwards, the whole of the soft tissues as far out as the first rib are separated. Then while pulling upon the cervical structures one separates the thoracic contents from the vertebrae with a few touches of the knife, and proceeding in the same way removes the structures remaining in the abdomen down as far as the brim of the pelvis (*see also* p. 46).

The organs are now examined in detail in any order which may be desired.

I usually commence by placing the thoracic organs on their anterior surface, slitting up oesophagus, larynx, trachea and main bronchi, and aorta. If desired the thoracic duct can be dissected out along its entire length, commencing in the thoracic region where it lies in the angle between the oesophagus and aorta. Then the lungs are separated from the heart and trachea, and the heart examined in detail, along with the great vessels which remain in continuity with it. Thereafter the examination of the lungs follows the usual course.

In the abdomen the first group examined is that comprising the stomach, liver, duodenum and pancreas. The duodenum is opened up in its second part and the patency of the common bile duct is determined by a "milking" pressure downwards along that structure as it lies in the gastro-hepatic omentum. Pressure should *not* be made upon the gall-bladder, as the pressure exerted is always too great, and readily dislodges plugs of mucus which may be blocking the orifice of the common bile duct. Thereafter the liver is separated by cutting through the gastro-hepatic omentum.

The examination of the individual abdominal organs takes the usual course.

The only objection to the above method of conducting the examination is that the oesophagus is divided, but if, before removing the stomach, the finger be passed up along the oesophagus on the left side, any gross abnormality will be detected and then the stomach may be retained in continuity with the thoracic organs. An advantage which the method presents is that the aorta, and, what is also important, the thoracic duct, are preserved throughout their whole length.

CHAPTER IV

THE THORACIC CONTENTS

EXAMINATION IN SITU

THE normal lungs, in absence of pleuritic adhesions, collapse to a certain extent when the chest is opened, and so retract from the pericardium and the structures in the superior mediastinum. Hence, if the anterior margins of the lungs are found closely approximated or superimposed, one must conclude that pathological changes exist, such as pleuritic adhesions or hypertrophic emphysema with, possibly, chronic bronchitis or consolidation of the lungs, provided that the lungs are not floated forwards by accumulation of fluid within the pleural spaces.

THE MEDIASTINUM

Thymus.—In young children, the *Thymus Gland* is a prominent structure at the thoracic inlet. It is a bi-lobed, elongated organ of a pale salmon colour, the lobes thick and narrow above, and more or less expanded below over the surface of the pericardium. The lobes separate a little above, and usually extend up as far as the lower extremities of the lateral lobes of the thyroid. The distance to which the gland extends downwards varies greatly in different individuals. In the young it does not usually reach far beyond the first part of the gladiolus sterni, but it may reach the level of the fourth costal cartilages.

Normally, its thickness does not exceed one-quarter of an inch—7 or 8 mm.—and its width is usually about one inch or an inch and a half—2·5 to 3 cm. Each half is more voluminous about its mid-point, where it is closely approximated to its fellow of the opposite side. This point corresponds nearly to the plane of the thoracic inlet. The size of the organ varies even in health, but if it exceed the measurements given, it may be considered abnormal. At birth it weighs about half an ounce—15 gm. It increases in size up to the second year of life, weighing then about three-quarters of an ounce—20 to 25 gm. Kaufmann considers these weights excessive. Thereafter it does not show much alteration until puberty, and then gradually atrophies until about the twenty-fifth year it has almost disappeared, although microscopical traces of the organ, which has undergone fatty change, can still be made out. Rarely the thymus persists throughout life.

In poorly nourished children the thymus may be atrophied. A more important condition is hyperplasia, which has been blamed for causing sudden death both in infants and in older children, and even, in rare cases, in adults. Two explanations of the sudden death are usually given. The first—mechanical pressure upon the trachea, particularly if the enlargement

be accompanied by increase in size of the neighbouring lymphatic glands ; further the enlarged thymus may cause spasmodic closure of the glottis—so-called “Thymic Asthma”—through pressure, either upon the vagus or upon the recurrent laryngeal nerve. The second—that, in such cases, death is due to the condition of Status Lymphaticus, in which there is swelling of spleen and lymphatic tissues, in addition to the hyperplasia of the thymus. Many deaths explained as due to status lymphaticus—*Thymus-Tod*—have occurred in the course of treatment by therapeutic sera. Recent investigations have demonstrated that these deaths may be a direct result of anaphylaxis.

Occasionally in leucocythaemia and in lymphadenoma, the thymus is greatly enlarged. Haemorrhage may occur into it, e.g. in children who have died asphyxiated, and also occasionally in congenital syphilitics. Suppuration has been described, e.g. in congenital syphilitics, but the appearances may in reality be due to alterations, non-purulent, occurring in Hassall's corpuscles. Occasionally tuberculosis affects the thymus, either in the form of caseation or as miliary tuberculosis.

The **Large Venous Trunks** may be distended, or may be the seat of thrombosis. The cause of these vascular changes should be looked for in the pressure upon the superior vena cava or innominate vein of malignant growths, aneurysms, enlarged glands of tuberculosis, lymphadenoma or lymphatic leucocythaemia. Failing these, the cause of *thrombosis* may be suppuration in the parotid, or *venous distension* may be caused by inflammatory oedema in the mediastinum, or by heart failure or valvular disease, or by rupture of an aneurysm of the aorta into the superior vena cava.

New-growths of the mediastinum may be either *primary*, as is most common, or *secondary*.

Of the *primary* mediastinal tumours, *Lymphosarcoma* is the most common. This tumour may originate either in the thymus gland or in the lymphatic glands themselves. If developing from the former the tumour is more uniform on the cut surface, infiltrating and enclosing the large vessels and the trachea, and when examined microscopically, contains areas resembling Hassall's corpuscles. When developing from the lymphatic glands the growth is more nodular, and in the centre of the primary nodules, small pigmented patches, corresponding to the original lymphatic glands, may be seen (Fig. 8).

Occasionally *teratomata* (Embryomata) may be found in the mediastinum. These may form large nodular, more or less solid, tumours, or firm, thick-walled irregular cysts.

Carcinomata, usually of the colloid variety, may develop in the walls of the bronchi, originating in the mucous glands in that situation. Of secondary tumours, carcinomata are more common than sarcomata.

Aneurysms behind the manubrium sterni and the upper part of the

gladiolus, develop from the ascending aorta, and especially from its junction with the transverse part of the arch. If higher up in the thoracic inlet, they may develop from the innominate artery. Tuberculous

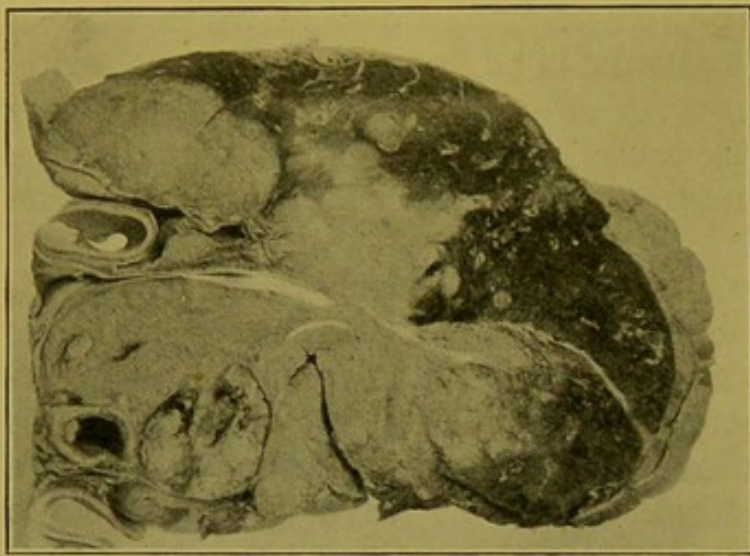


FIG. 8.—Lymphosarcoma of mediastinum invading lung.
(\times circ. $\frac{2}{3}$.)

glands may form large, irregular masses adhering to surrounding structures. The most common morbid changes, however, are seen in connexion with the pericardium and heart.

The Pericardium.—Normally a little loose, areolar tissue with a modicum of fat intervenes between the pericardium and the posterior surface of the sternum. The pericardium, normally, is thin, translucent, and not visibly

congested. The parietal layer blends above with the adventitia of the great vessels behind the manubrium sterni, and the sac extends downwards, forming a triangle, the base of which extends obliquely across the sternum in a line a little below the junction of gladiolus with xiphisternum. Examples of congenital absence or defect of the pericardial sac are so rare that they need not be considered.

The areolar tissue in front of the pericardium may be infiltrated with pus or oedematous fluid. The fat may be increased in amount, or fibrous changes may have occurred, binding pericardium to sternum—"chronic adherent mediastino-pericarditis." The surface of the pericardium may be thickened, rendering it more or less opaque, or it may be infiltrated with tuberculous nodules,—miliary, caseating, or fibrous—or with sarcomatous new-growth. Any marked increase in the vascularity of the parietal pericardium suggests the presence of inflammation internally, or it may be simply a part of a general chronic venous hyperaemia.

The lymphatic gland, placed just at the attachment of the diaphragm in front, may be greatly enlarged, usually from tuberculosis.

The Pleurae.—After this preliminary examination of the structures in and near the middle line, the condition of the *Pleural Cavities* should be investigated. After first looking into the cavities to detect any obvious abnormality, the hand should be passed into each in turn, commencing with that on the left side. In this way, one determines the presence of adhesions, their extent and probable age. If fluid be present, its character should be carefully noted,—whether clear, serous and straw-coloured, blood-stained, turbid, milky, containing suspended flakes of lymph, or definitely

purulent. Fluid does not always indicate pleurisy. It may be of dropsical nature, and one must not forget that a large quantity may collect in the pleural cavities during the last hours of life, and this in spite of repeated recent tapplings. Sometimes, dropsical fluids ('hydrothorax') contain a few flakes of lymph, but when lymph is present in any large amount, particularly if floating in a turbid fluid, the condition is inflammatory, and a layer—possibly scanty, more often distinct—of fibrinous exudate will be found on some part of the pleural surface.—In cases in which bacteriological investigations are essential, cultures should be made at once, before contamination occurs, and also some of the fluid should be collected in a sterilized test-tube or a Pasteur's pipette, for microscopical examination.—In *empyema*, the fluid is distinctly purulent, and may be putrid and evil-smelling. This may be associated with bronchiectasis, excavation, or gangrene of the lungs, with or without perforation of the visceral pleura.

In tuberculosis, or in localized empyema, the exudation may be thick, flocculent or caseous. When air has escaped into the pleural cavity, e.g. from the lung (pneumothorax) the anterior parts of both parietal and visceral layers of the pleura are usually dry and parchment-like. Haemorrhagic lymph with blood-stained fluid may indicate a very severe acute infection of the pleura, but is frequently found in tuberculous pleurisies; in malignant growths—sarcoma, for example—of the pleurae; in infarction of the lung; as a result of mechanical injury; or in cases of death from asphyxia, e.g. in carbonic acid poisoning. In cases of asphyxia or metallic poisoning, there are usually minute haemorrhages underneath the pleura. The presence of large quantities of blood, with soft, recent clots (haemothorax) points, in the great majority of cases, to rupture of an aneurysm into the pleura, provided it be not due to mechanical injury of the thoracic walls, heart, or great vessels.

In adults it is the exception to find the pleural cavities completely free from adhesions. The *ligamentum latum pulmonis*—that reflexion of the pleura passing from the posterior surface of each root to the posterior wall of the thorax—must not be mistaken for an adhesion in that situation. It is best marked on the right side.

If a pleurisy be limited to the diaphragmatic surface on the right side, it may be secondary to perihepatitis, or to abscess or other inflammatory condition in the liver. If on the left side only, one should look for perisplenitis, peritonitis in relation to a gastric ulcer, or to gastric carcinoma, or it may even be associated with aneurysm of the descending thoracic aorta or disease of the oesophagus.

A more detailed examination of the pleural surface, including the interlobar surfaces, may be delayed until the lungs are removed from the thorax.

The Pericardium should now be opened, and the heart and great vessels examined *in situ*.

THE PERICARDIUM

The outer surface of the pericardium has already been examined along with the other mediastinal structures while they lay in their natural position within the body (p. 40).

The cavity of the pericardium may be distended from enlargement of the heart, but the greatest increase in size occurs in the presence of effusion into its cavity, e.g.—in pericarditis, particularly, in my experience, when this is of tuberculous nature. The enlarged pericardium may be closely apposed to the thoracic wall as far out as the mid-axillary line. The left lung is compressed and pushed upwards and backwards in the thorax, the right lung being affected to a lesser extent.

To Open the Pericardium.—The most prominent part of the sac is pinched up with dissecting forceps, or between the left thumb and forefinger, and a small opening made into it. If the presence of pericarditis be suspected, the outer surface of the sac should be seared before making this opening, media inoculated direct from the fluid, and films made from it for microscopic examination; or, if preferred, a portion of the fluid may be withdrawn into sterilized pipettes or test-tubes for subsequent investigation in the laboratory.

The pericardium is then opened up obliquely from base to apex of the heart, and if more room is required a second incision may be made from the middle of the primary one towards the right lower angle of the pericardium.

In opening the Pericardium and examining its interior, care should be taken to avoid rupturing delicate adhesions which may exist between the surfaces, particularly over the apex of the left ventricle. If the sac contain blood the parts should be handled with great care and the source of the haemorrhage determined before removing the heart. *For the appearances presented in Pericarditis, see p. 50.*

Haemopericardium.—Blood may escape into the pericardium by rupture, e.g. of one of the large vessels or of a cavity of the heart itself, or, it may escape in multiple minute quantities from the embryonic vessels which develop during the organization of the exudate in pericarditis. In the former case the clotted blood forms a thick jelly-like layer which conceals and compresses the heart. In the latter, the blood is intimately mixed with the exudate.

In rupture of the heart or puncture of its walls the aperture may be very small, and when rupture has occurred particular care must be exercised in the examination, because extreme degenerative changes of the myocardium usually exist, and rough handling may readily enlarge the aperture or cause fresh lacerations, especially in the neighbourhood of the inferior vena cava. Blood is also usually present when the pericardium is invaded by malignant new-growth, but it may come from the acute haemorrhagic pericarditis which usually accompanies that condition. The exudate may be haemorrhagic in certain blood diseases with a tendency to bleeding. In recent and subacute tuberculous pericarditis the effusion is usually haemorrhagic.

Hydropericardium.—Under normal conditions the pericardial sac contains a small quantity—a quarter to one ounce (5–30 c.cm.)—of clear straw-coloured serous fluid. The amount may be greatly increased in certain cardiac and renal conditions without recognizable pathological alteration of the serous membrane, but the greatest accumulation takes place in connexion with chronic (recurrent) pericarditis, particularly if of tuberculous nature (see Fig. 11, p. 53).

Pneumopericardium is a very rare condition, of which I have never seen an example. It may be connected with gangrene of the lung, malignant ulceration of the oesophagus, gastric ulceration with perforation of the central tendon of the diaphragm, abscess of the liver, communicating with stomach and pericardium. It may be produced by growth of gas-producing micro-organisms, notably the *Bacillus aërogenes capsulatus* of Welch. The surfaces anteriorly are usually dull, darkened in colour, dry and parchment-like.

Examination of the Heart and of the great Vessels as they lie in position in the Body.—In cases of extreme enlargement of the heart within the pericardium, the heart should be carefully examined *in situ*, and measurements taken before opening any large vessel in the neck or head, and before removing the lungs.

The topographical relationships of the heart should also be compared with those ascertained during life.

The following measurements may be taken:—

- (a) Base to apex. Normally about 5 in. (12.5 cm.) in the adult.
- (b) Greatest width, parallel to auriculo-ventricular groove. Normally $3\frac{1}{2}$ to 4 in. (9–10 cm.).
- (c) Greatest antero-posterior thickness. Normally about $2\frac{1}{2}$ in. (6.5 cm.).
- (d) Circumference, at the auriculo-ventricular groove, $9\frac{1}{2}$ in. (24–25 cm.).
- (e) Base of ventricles anteriorly, to corresponding point posteriorly, along the line of the septum, over the apex, $7\frac{1}{2}$ in. (19 cm.).

The corresponding measurements in the *largest* human heart I have examined were: (a) $7\frac{1}{2}$ in. (19 cm.); (b) 8 in. (20.4 cm.); (c) $4\frac{3}{8}$ in. (12.4 cm.); (d) $19\frac{1}{2}$ in. (50 cm.); (e) 12 in. (30.5 cm.). Weight after emptying, 51 oz. (1445 gm.). In an *atrophied* adult heart the corresponding measurements were: (a) 4.2 in. (10.5 cm.); (b) 2.6 in. (6.7 cm.); (c) $2\frac{1}{8}$ in. (5.5 cm.); (d) 6.4 in. (16.2 cm.); (e) $5\frac{7}{8}$ in. (15 cm.); weight, $6\frac{1}{2}$ oz. (184.25 gm.).

While for convenience these measurements are given, it must be remembered that they can be regarded as only approximate. It is not always realized how much the size of the heart and other organs varies with the size and age of the individual. Therefore in referring to tables of measurements and weights due allowance should be made for variation within physiological limits.

As the heart lies *in situ* unopened one can better appreciate the degree of dilatation of individual chambers of the heart, and the relative size of auricles and ventricles, or of the chambers on the right and left sides of the heart. Great dilatation of the right ventricle widens the heart, making

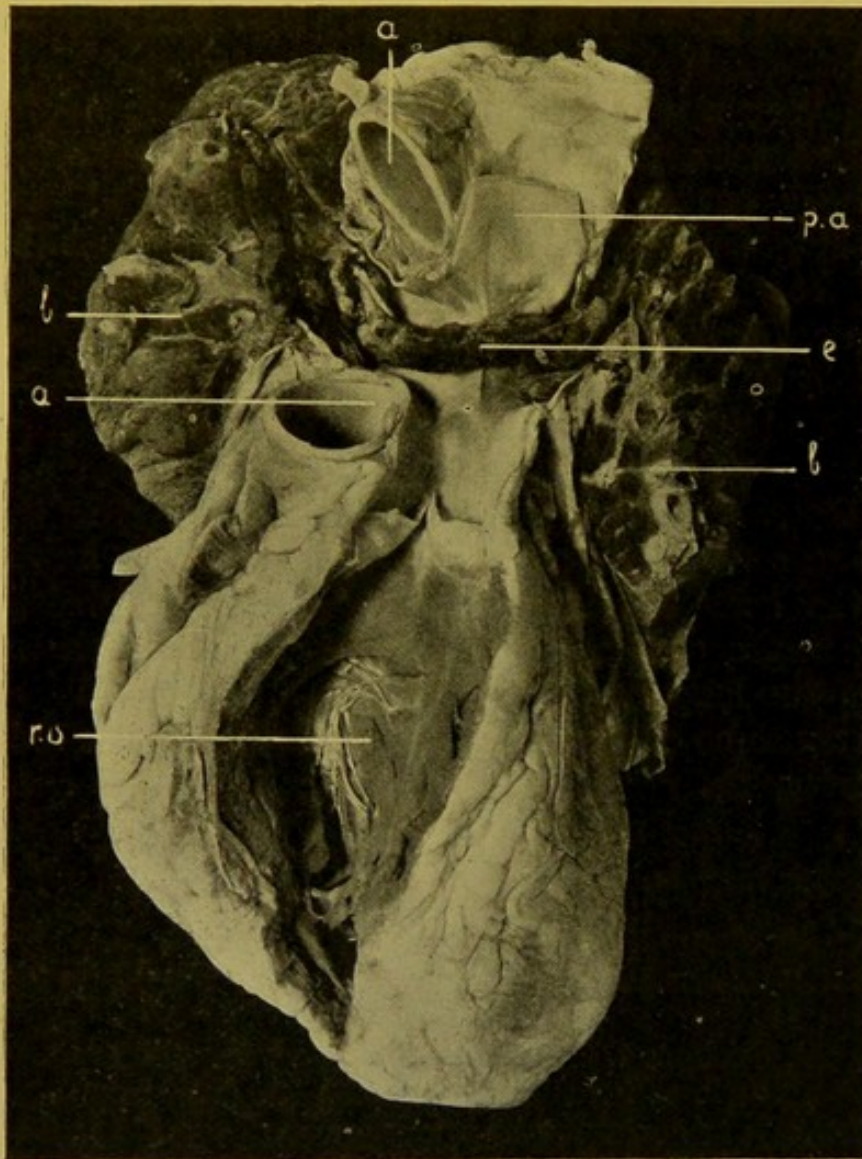


FIG. 9.—Embolism of pulmonary artery. (\times circ. $\frac{1}{2}$.)

(e) The embolus, a portion of elongated thrombus from varicose vein of lower extremity; (a) aorta; (p.a.) pulmonary artery; (r.v.) right ventricle; (l.) lung.

it more or less quadrilateral (*Cor quadratum*). Dilatation and hypertrophy of the left ventricle extends the apex and exaggerates the conical shape of the heart (*Cor bovinum*). General dilatation of all the cavities produces the "globular" heart.

The cardiac veins and sinuses should also be examined at this stage. The only opportunity one has of appreciating the degree of dilatation of these sinuses is before any veins are divided, and the best view is obtained by gently tilting the heart forwards out of the pericardium so that its posterior surface becomes visible. The more fluid the blood, the greater is the distension of the veins.

The amount of epicardial fat should be noted. (*See Fatty Loading and Fatty Infiltration*, p. 63.)

It is always advisable, and in cases of sudden death essential, to examine the **pulmonary artery**, **aorta**, and large **venous trunks** in the superior mediastinum and thoracic inlet. They should be slit up longitudinally to determine the nature and condition of their contents. This is especially important if death has occurred suddenly in an individual who has been confined to bed perhaps only for a short time, and in whom embolism is suspected. The arteries should be opened up with as little manipulation

of the parts as possible, seeing that emboli, having been impacted immediately before death, are readily displaced.

The embolus is generally a detached portion of a thrombus which has developed in varicose veins of the lower extremity, or in dilated veins of the pelvis, and although it is a cylinder of much smaller diameter than the pulmonary artery which it blocks, it accomplishes this end by becoming folded upon itself (Fig. 9, p. 44).

The cavities of the heart itself may be opened *in situ*, but I do not consider this absolutely essential, and even if it be omitted the omission leaves few possibilities of error, particularly if the thoracic viscera be removed *en masse* as I recommend. Still, even if this procedure be not followed, with ordinary care the heart can be removed from the thorax without producing artificial lesions.

It is of the greatest importance to note the appearance of the blood which escapes when the great vessels are opened. If it be fluid and of a dark colour when the examination takes place shortly after death—12 to 24 hours—one should suspect the action of toxic agencies, and pay special attention to the search for the source of the toxaemia. In the majority of cases these toxaemias are of bacterial origin. It should be remembered, however, that in gaseous poisonings the blood is also usually fluid and dark in colour. A common example of this is furnished in death from poisoning with carbonic acid gas.

When there has been much rapid blood destruction the endothelial lining of heart and blood-vessels is stained with haemoglobin at an early period after death. Ordinarily this staining does not begin until the onset of decomposition.

REMOVAL OF THE CERVICAL AND THORACIC VISCERA

In the majority of cases the better procedure is to remove heart and lungs *en bloc* along with the larynx, trachea, oesophagus, other soft structures in the neck, the tongue and floor of the mouth; but as in many cases it is more convenient to remove the organs separately, *both* the alternative methods of operating will be described.

A. Removal en bloc.—A block is placed under the shoulders, to raise the upper part of the thorax and to extend the chin. The skin of the neck is reflected from the anterior and lateral surfaces and freed from the tissues forming the floor of the mouth right up to the lower jaw-bones, the skin incision already made being extended upwards if necessary for a short distance. In the majority of cases it is not necessary to prolong the incision to the tip of the chin, and this should be avoided if possible, as the under surface of the chin is generally left exposed on dressing the body and the upper end of the incision is left visible unless in addition a bandage be passed under it and over the vertex of the skull. A strong, narrow-bladed bistoury is passed upwards under the skin, which is kept on the stretch, behind the symphysis menti and passed round the inner surface of the lower maxilla separating the floor of the mouth from its bony attachments. The

tip of the tongue is brought down through the opening thus made, and traction exerted upon it, while an assistant keeps the skin incision well open and the head strongly extended. The knife can now be passed upwards through the soft palate, so as to separate this from the hard palate. The knife is then carried round on either side, separating the pillars of the fauces along with the tonsils, and backwards until stopped by the transverse processes of the upper cervical vertebrae. The structures in front of the neck, including the air and food passages, thyroid, the structures in the carotid sheath and the lymphatic glands in the neighbourhood, are now dissected from the vertebrae, from the thoracic inlet right up to the base of the skull and then the remaining attachments to this are divided. The mass thus separated comprises, in addition to the structures already named, the submaxillary and sublingual glands, the lymphatic glands in the digastric triangle and those behind the pharynx. The retropharyngeal lymphatic glands may show occasionally the first signs of invasion by tuberculosis from the naso-pharynx or tonsils. In fact, all structures in front of the prevertebral layer of the deep cervical fascia are removed in this dissection.

The cervical sympathetic may be removed along with the cervical tissues. This generally happens. It lies immediately posterior to the carotid sheath, but with care in dissecting up that structure, it may be left behind entire to be removed later if desired.

At the thoracic inlet, wing-like expansions including the subclavian vessels and cords of the brachial plexus, are separated. On the left side care should be taken to remove the thoracic duct as it arches forwards over the summit of the pleura to enter the subclavian vein at its junction with the internal jugular. In dissecting this part away the knife should not be carried too close to the neck of the first rib, upon which the inferior cervical sympathetic ganglion lies, unless the cervical sympathetic has already been separated along with the other cervical structures; it is well in this case to remove the inferior ganglion as well. Before going further—particularly in medico-legal cases—the base of the tongue and the epiglottis may be examined; and the oesophagus and trachea slit up to exclude the pressure of any abnormality or of a foreign body.

Attention is now directed to the thoracic contents. If firm adhesions exist in the pleural cavities, the *parietal* pleura should be stripped up from the ribs with the fingers, until the sides of the vertebral bodies are reached. If, however, the adhesions are readily separable, the lungs are tilted forwards, first on the left then on the right side, and the pleura divided along a line corresponding to the articulations of the ribs with the vertebrae. Before making this cut the finger should be passed along the oesophagus and aorta, to ascertain whether new-growth or aneurysm be present. If the latter, it may be advisable to remove lungs and heart separately, so as to determine more readily whether portions of the vertebrae or thoracic wall should be removed along with the aorta, etc., and if not, to ascertain which vertebrae are involved. Exerting traction upon the freed cervical structures, one can now strip the whole of the thoracic contents away from the vertebrae, a few touches of the knife being necessary to divide intercostal vessels, etc.

In accordance with the method which I advocate as the best for removing the thoracic and abdominal organs (pp. 35, 36), the abdominal contents have already been removed, leaving the diaphragm with its crura, upon which lie the solar plexus and the receptaculum chyli, the abdominal aorta and the inferior vena cava. These are now stripped off from the vertebrae along with the thoracic contents, so that aorta and thoracic duct are preserved entire for examination.

While following this plan as a general rule, the operator must be ready to modify the procedure to suit individual cases. For example, in tumour, stricture,

etc., of the oesophagus, it may be preferable to retain that structure in continuity with the stomach, the lungs and heart being separated firstly and the remaining thoracic structures with those in the neck being removed along with the abdominal organs.

B. Alternative Method (not recommended as a routine procedure).—If the organs are to be removed separately it is immaterial whether heart or lungs are removed first. In most cases, it is easier to remove the heart first and then the lungs.

Tilting the heart out of the pericardium—lifting it by the ventricles, or, if the cavities have been opened, with the left forefinger and thumb inserted respectively into the left and right ventricles—one draws it *gently* upwards, and in succession divides the inferior vena cava, the left and right pulmonary veins, the superior vena cava, the pulmonary artery and the aorta, the last two as they pass through the pericardium, so as to leave 1–1½ in. (2.5–3 cm.) of these vessels above the valves. If pericarditis be present, it is better to remove the pericardium along with the heart and cut through the pulmonary vessels and aorta outside the sac. The appearance of the blood which escapes when the vessels are divided, should be noted (*see* p. 45).

The left, and then the right, lung are in turn tilted forwards and the remainder of their roots divided from behind. The cervical structures, with the structures in the superior mediastinum, the aorta, oesophagus and thoracic duct, may be removed subsequently, the same precautions being observed as in the former method of removal. If the aorta show aneurysmal dilatation, it is better either to remove the thoracic contents in one mass, or first to remove the lungs carefully, and then remove the heart in continuity with the aorta and great vessels, trachea and oesophagus.

If the aneurysm affect the descending aorta one may proceed as already indicated, removing heart and right lung and retaining left lung, or separating it as the requirements of the case indicate. In some cases it may be desirable to retain the oesophagus in continuity with the stomach.

The great advantage of the first method is that it conforms to the rule that all organs should be preserved in their natural relationships as long as possible.

After gaining any information from examination of the organs in relation to each other, they are separated, and the subsequent examination follows the same lines in both cases.

After removal of the contents, the thoracic walls should be carefully examined, for fracture, new-growth, or disease of bone, and the presence and nature of curvatures of the spine ascertained.

Examination of the Thoracic Organs after removal from the Body.—The whole mass is first placed on its anterior surface and in turn the pharynx and oesophagus, trachea with bronchi, and aorta are slit up longitudinally. The incision in the bronchi should be carried well into the root of the lungs and in the case of the left bronchus this can be done without necessarily cutting across the aorta. At this stage also, the thoracic duct in its upper part, where it lies in the angle between the aorta and oesophagus, can be dissected out. It is more easily isolated when it can be followed throughout its entire length.

Separation of the Heart.—After a general examination of the thoracic organs, the lungs may be separated from the heart and mediastinal structures. The

mass is placed upon its posterior surface and a long-bladed knife is inserted from behind in the angle between the left lung and the mediastinal structures. The knife is brought forward with a sawing motion dividing the bronchi and pulmonary vessels as close as possible to the root of the lung.

A similar procedure is carried out on the other side, leaving the aorta, pulmonary artery, venous trunks, oesophagus, trachea and main bronchi in their normal relationships and still in continuity with the pericardium and heart.

The arch of the aorta may now be opened up by continuing the incision which has been made in the descending aorta along the convexity of the arch, either passing in front of the roots of the great vessels or passing through these and slitting them up. It should then be carried down the ascending part of the aorta in the direction of the tip of the right auricular appendix to within about one inch of the aortic opening, so as to permit of that being viewed along with the inner surface of the aorta.

The heart may now be separated from the mass by dividing the great vessels just within the pericardium, or the pericardium may be retained in connexion with the heart.

CHAPTER V

THE PERICARDIUM AND HEART

THE CORONARY ARTERIES

For the Examination *in situ* of the Pericardium, Heart, and Great Vessels, *see* preceding Chapter.

DISEASES OF THE PERICARDIUM

New-growths of Heart and Pericardium.—Primary tumours are very rare. Over a dozen cases have been collected by Wolbach in which rhabdomyoma occurred as multiple rounded tumours throughout the myocardium. All cases were under four years of age, and half of the number had associated extensive nodose sclerosis of the brain.

Secondary tumours are less infrequent. The most common is the sarcoma (lymphosarcoma) extending from the mediastinum, and occasionally spreading to the wall of the right auricle, sometimes even attacking the right ventricle, passing through its walls and forming rounded or lobulated projections within the heart. Secondary sarcoma may replace the myocardium in the anterior parts of both ventricles and extend deeply into the septum. It may also be metastatic, and the heart be covered and infiltrated with innumerable small nodules of the new-growth. Secondary nodules of melanotic sarcoma may vary greatly in degree of pigmentation.

Encephaloid and scirrhus cancers also may invade the pericardium and penetrate the walls of the heart. These tumours usually cause great thickening of the visceral pericardium, which is pale, grey, or creamy. They have to be distinguished from chronic tuberculous pericarditis, and other granulomatous new-growths of the pericardium and heart. Widespread malignant tumours are usually accompanied by an acute haemorrhagic pericarditis. Occasionally, carcinomata form thin opaque layers on the epicardium, which have to be distinguished by microscopic examination from ordinary milk spots. Small cysts lined with cubical cells may develop as a result of proliferation of the endothelial cells.

PERICARDITIS

The appearances presented by pericarditis have already been noted if the heart has been examined *in situ*. When the heart is removed and isolated the changes can be more minutely examined.

At a very early stage the surface is simply congested and retains its smooth and glistening character. Soon the congestion increases, particularly at the base of the heart, and in the neighbourhood of the auriculo-ventricular groove. The surface becomes dim from swelling of the endothelium, and

a coagulable fluid exudes, from which a layer of fibrin is deposited. This tends to spread rapidly over the whole surface. The exudate may be thin, with honey-comb markings, or thick and shaggy with villous projections (*Cor villosum*, *hispidum*, *tomentosum*) (Fig. 10). It may form closely aggregated warty excrescences, or a series of parallel ridges, e.g. over the right ventricle. It may present Laennec's "bread-and-butter appearance." This simile is not inapt, the surfaces somewhat resembling that produced by separating two pieces of bread and butter which have been pressed together.

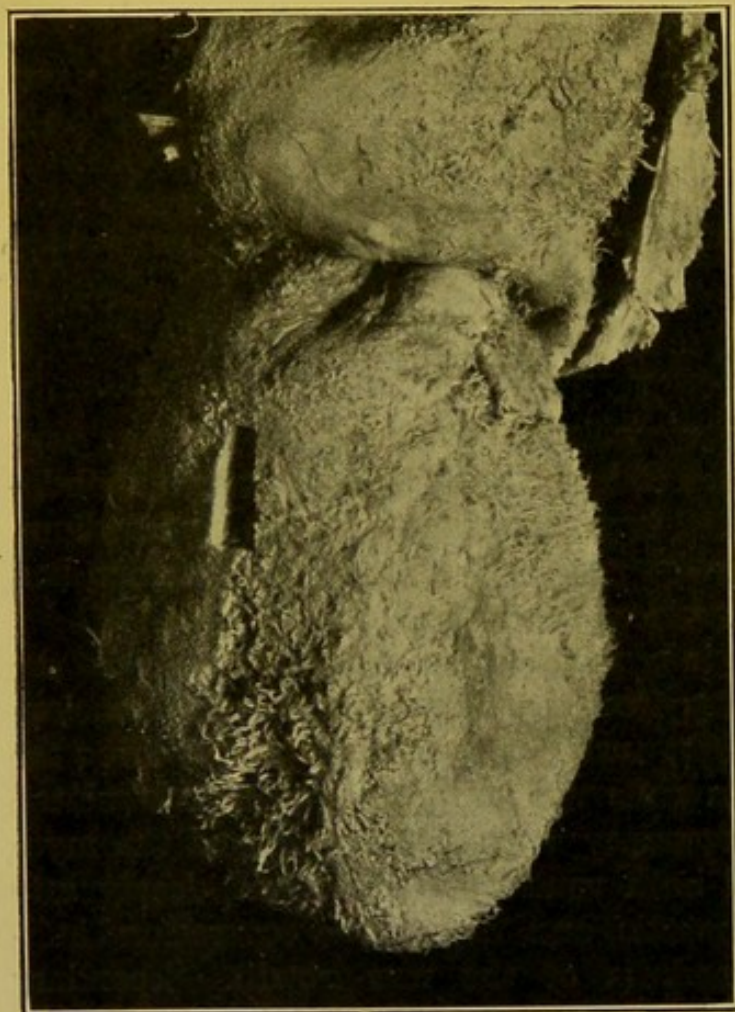


FIG. 10.—Acute fibrinous pericarditis (*Cor villosum*).
Parietal pericardium turned upwards. ($\times \frac{1}{2}$.)

In the early stages the layer of fibrin can be readily removed leaving a smooth, usually moderately congested surface. From the congested

vessels of the pericardium newly formed embryonic vessels arise and pass into the exudate. To the naked eye the surface becomes dull, and numerous minute bright red points project upon it. When the vessels have passed into the exudate, more difficulty is experienced in removing the lymph completely from the pericardium, and when separating it, one can see extremely delicate threads, corresponding to the embryonic vessels, passing across the angle of reflexion. Accompanying these vessels young connective tissue cells pass into the fibrin, and from these, fibrous connective tissue develops—primarily along the vessels—gradually replacing the fibrinous

layer. When this formation of connective tissue, "organization," is advanced the exudate cannot be removed completely from the pericardium, and if the "organization" be still more advanced, it may be impossible to tear across the adhesions, or to remove the layer from the surface of the heart, without injuring the heart itself.

Haemorrhagic Pericarditis.—Haemorrhagic exudation occurs in the course of very severe infections, in tuberculous infections, in invasion of the pericardium and heart by malignant tumours, and in haemorrhagic diatheses—purpura, scorbutus, etc.

Putrid Pericarditis is rare and results from infection of the pericardium from gangrenous processes in the neighbourhood, or from extension into it of ulceration of the oesophagus or stomach.

Recurrent Pericarditis.—This may present different appearances. Fibrinous pericarditis may be seen in presence of old adhesions, fibrinous exudate filling up the intervening spaces; or recent layers of fibrin may cover deeper layers of vascularized exudate in which organization is well advanced, being separated by a fairly well-marked red line of demarcation. This condition has a chronic course clinically.

Fully Organized and Adherent Pericarditis.—Organized pericarditis may be evidenced either by general or more often by localized thickening of the pericardium, or by adhesions connecting its two surfaces.

(a) Localized inflammatory—milky—thickenings are most often seen over the right auricle, but also frequently over the right ventricle. They are much less common over the left auricle and ventricle. The surface of the thickening may be smooth, or it may be irregular, nodulated, or crossed by parallel ridges. These thickenings may be accompanied by ridges and bridges crossing the angle of reflexion of the pericardium from the great vessels, or passing between the right auricular appendix and neighbouring parts.

The term "milk spots" more usually refers to the localized smooth patches of fibrous thickening covered with endothelium which occur commonly on the outer surface of the right ventricle. Their margins are sometimes thin and delicate, gradually passing off into the pericardium—"friction spots"—sometimes abrupt and undermined, forming occasionally an incomplete bridge between adjacent spots on the surface—old pericarditis.

These milky areas are sometimes localized to the lines of the coronary vessels, either outlining them or lying in spots over them. The vessels underneath may show nodose thickenings, or degenerative changes may be found, especially in the media.

(b) **Adherent Pericarditis.**—It is rare to find universal adhesion of the surfaces. More often the adhesions are in the form of bands of considerable length and width, allowing the heart a certain amount of freedom within the pericardium, or they may be more delicate and shorter but more uniformly spread over the surfaces. Generalized delicate adhesions may be accom-

panied by coarser and stronger adhesions which have formed in the neighbourhood of the septum ventriculorum.

General adherent pericarditis, particularly if associated with an increased amount of fibrous tissue in the mediastinum causing adhesion of the pericardium to the thoracic wall—chronic adherent mediastino-pericarditis—brings about hypertrophy and dilatation of the heart and consequent general venous hyperaemia, which may be accompanied by dropsy.

In old adhesions calcification may take place, particularly in the neighbourhood of the auriculo-ventricular groove, or it may form thick plates like oyster-shells, practically covering the whole surface, and interfering greatly with the movements of the heart. Calcification may extend into the myocardium.

Tuberculous Pericarditis.—Tuberculosis of the pericardium is, in my experience, a comparatively rare disease and only a small percentage of the cases of acute pericarditis I have investigated have proved to be of tuberculous origin. Manifestations of tuberculosis when they occur in the pericardium are usually distinct. The disease may occur as (a) *miliary tuberculosis*, metastatic by way of the blood stream, or spreading directly from the mediastinum, from the pleura, from the lung, or less commonly from the abdomen. Accompanying fibrinous exudate upon the surfaces may veil the tubercles to a certain extent. It may be in the form of (b) *chronic tuberculous pericarditis*, in which both surfaces of pericardium are greatly thickened, covered with a thick, fibrinous deposit, and frequently widely separated from each other by turbid, in many cases haemorrhagic, fluid. In tuberculosis a larger amount of fluid may collect within the sac than in any other disease, and in two cases examined by me, it amounted to between 45 and 50 ounces (Fig. 11). In my experience, the presence of fluid is not invariable. Whether fluid be present in excess, in small amount, or absent, the pericardium is greatly thickened, from *recurrent* inflammation, organized in its deeper layers and showing here numerous creamy tubercles. The surface is covered with a thick, shaggy and irregular layer of more recent exudate. The thickening may be nodular, with tags and irregular processes. Bands of more or less vascular adhesions may form, particularly at the base of the heart. Between the adhesions, pockets may form containing fibrinous lymph.

Suppurative Pericarditis.—In suppurative pericarditis the contents of the pericardium may be creamy and of a greenish-yellow colour. Commonly a fibrino-purulent exudate covers the surfaces. The condition may be secondary to mediastinal suppuration or to disease of the lungs or ribs, or to empyema. Frequently, however, it is metastatic and occurs in pyaemia. In such cases one can frequently make out a patch of necrosis on the surface of the pericardium, which draws attention to subjacent suppuration, or there may be haemorrhagic raised patches on the surface of the left ventricle indicating the presence of pyaemic abscesses in the

myocardium. In the metastatic form the primary focus of suppuration may be comparatively slight and localized, e.g. a small superficial abscess of the skin, or suppuration in the tonsil.

Etiology of Pericarditis.—The most common cause is acute rheumatism, but pericarditis may occur in other acute infective diseases such as pneumonia, scarlet fever, typhoid, measles, cholera, small-pox. Apart from these conditions, however, it occurs commonly in cases of chronic nephritis and

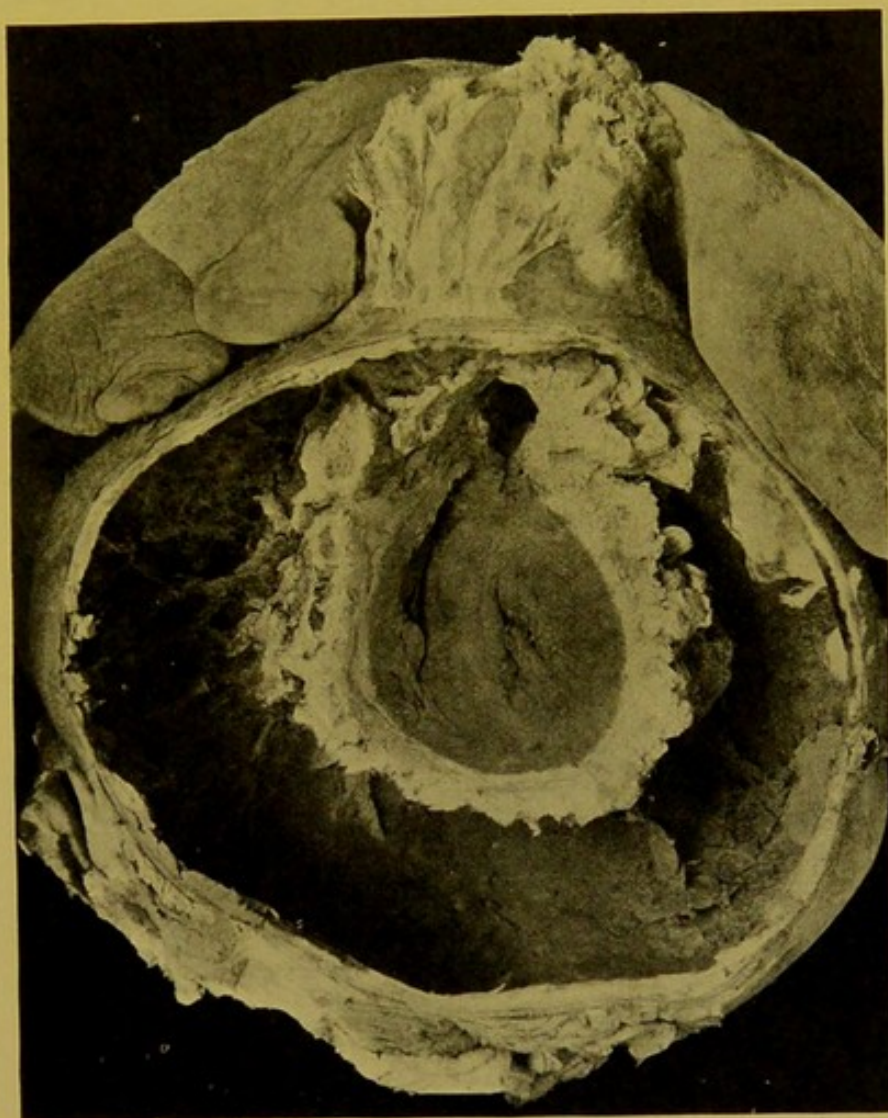


FIG. 11.—Recurrent tuberculous pericarditis, with effusion, 50 oz. ($\times \frac{1}{2}$.) Lungs pressed upwards and outwards. (Dr. Byrom Bramwell's case.)

alcoholism, these conditions no doubt acting as predisposing causes, reducing the resistance of the individual affected to the attacks of bacteria.

Bacteriology of Pericarditis.—Many bacteria have been found in association with pericarditis, probably having an etiological relationship in most cases, e.g., Staphylococcus (aureus, albus, citreus), Streptococcus pyogenes, Pneumococcus, Meningococcus, bacilli of the colon group, Bacillus pyocyaneus, Friedländer's bacillus, the influenza bacillus. In a case of purulent pericarditis in an infant, the bacillus pyocyaneus was the only organism

I was able to separate. In another case in an adult, the pericarditis apparently resulted by spread from aphthous ulceration of mouth, pharynx and oesophagus, the immediate cause being a streptococcus. The special variety caused by the tubercle bacillus has been considered separately.

Haemopericardium, *see* p. 42.

Hydropericardium, *see* p. 43.

Pneumopericardium, *see* p. 43.

Method of Examining the Heart after Removal.—The heart has been investigated already to a certain extent as it lay in position in the body.

The chambers should now be examined individually in the order in which the blood flows through them. (Fig. 12.)

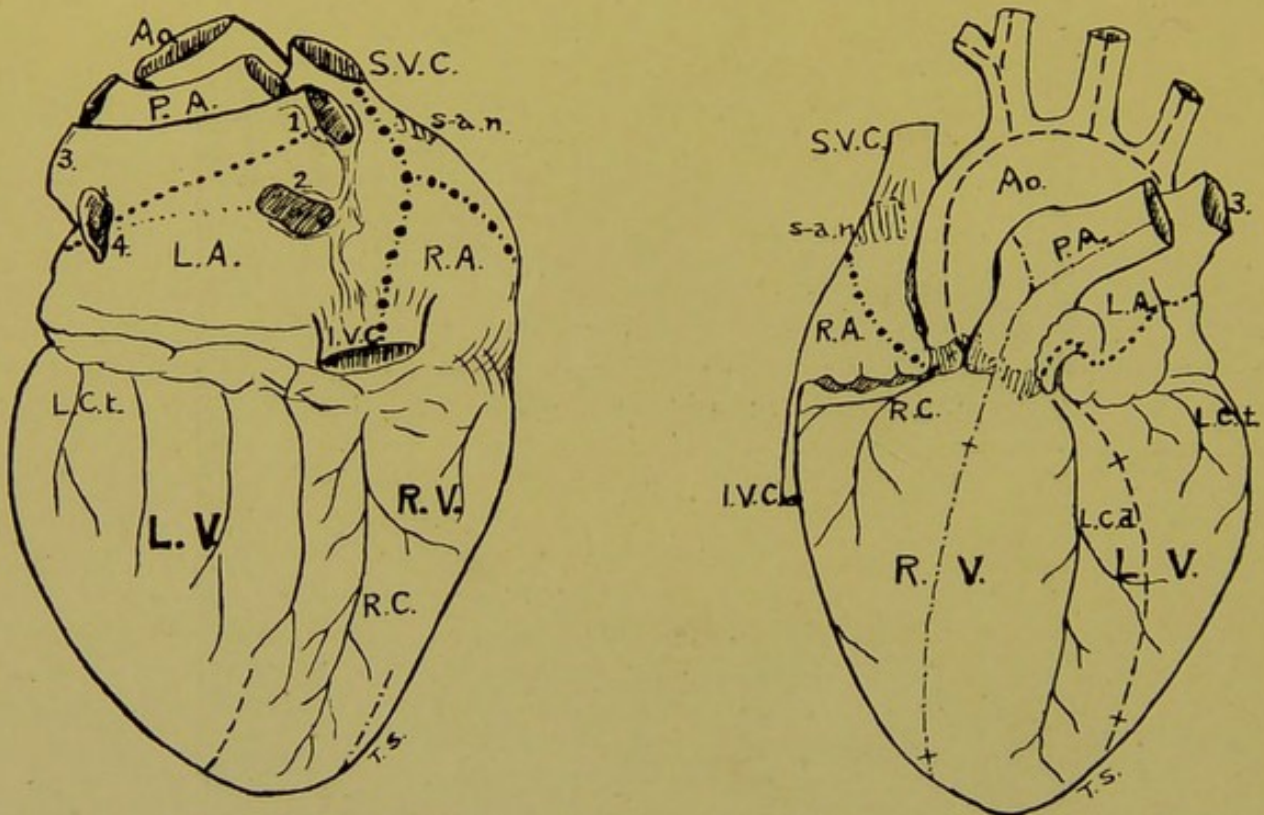


FIG. 12.—Lines of incisions for opening the Cavities of the Heart.

(*r.a.*, *l.a.*) Right and left auricles; (*r.v.*, *l.v.*) right and left ventricles; (*ao.*) aorta; (*p.a.*) pulmonary artery, valves indicated; (*s.v.c.*) superior vena cava; (*i.v.c.*) inferior vena cava; (*r.c.*) right coronary; (*l.c.d.*) left coronary, descending branch; (*l.c.t.*) do., transverse branch; (1, 2, 3, 4) orifices of pulmonary veins; (*s.a.n.*) portion of wall of right auricle to be removed for investigation of sino-auricular node.

To open the cavity of the **Right Auricle** the heart is placed on its anterior surface and a probe-pointed bistoury or scissors passed from the inferior to the superior vena cava, and the wall between these openings laid open. From the centre of this incision a second oblique cut may be made into the auricular appendix. These incisions should lay open the whole of the cavity. Musculi pectinati are seen in the appendix and also on the outer side of the auricle. After investigating the conditions present and after examining the tricuspid opening and valve from the auricular aspect, the heart should be placed on its posterior surface

and an incision made through the wall of the **right ventricle** parallel to the septum, and—in the adult—about one finger's breadth from it. This cut is extended upwards and downwards to an extent sufficient to allow of a general examination of the interior of the ventricle after clearing out any clots present. The "moderator" band has usually to be cut across in making this incision. The forefinger should now be passed up gently into the *conus pulmonalis*, clots withdrawn, and the undefended spot palpated, to detect any patency. Then the competence of the **pulmonary valve** to water should be tested. The artery is divided transversely just below its bifurcation and held about 4 in. (10 cm.) beneath a tap of water, the heart being supported so that any stretching of the orifice is avoided and so that the plane of the latter is kept strictly horizontal. It matters little how the heart is supported, whether by the margins of the cut artery or by the heart itself at the level of the auriculo-ventricular groove, so long as the cusps come into accurate apposition, and this can be assured by looking down into the artery while carrying out the test. If water be retained, the artery is "competent to the water test." The previous opening of the ventricle is, of course, essential to allow any water which passes through the valve to flow away. The circumference of the opening should be measured by means of cones passed from the ventricle (normally, 8.5 to 9.1 cm.).

There is no satisfactory method of testing the competence of the auriculo-ventricular valves *post mortem*.

The incision in the wall of the ventricle is now extended upwards between two of the cusps of the pulmonary valve, preferably between the two anterior ones; or it may pass close to the septum between the right anterior and posterior cusps. The cavity of the right ventricle is in this way completely exposed. (In addition some authorities open up the tricuspid orifice by continuing the incision connecting the *venae cavae* downwards into the ventricle, passing between the marginal (outer) and septal segments of the valve. This procedure is seldom necessary, or indeed desirable.)

The segments of the **tricuspid** can now be examined from the ventricular aspect and the cone circumference taken, the cones being passed from the auricle. (Normally 12.9 to 13.7 cm.) Thereafter the examination of the right ventricle is completed, the degree of dilatation or hypertrophy is determined, and the presence of pathological changes in the myocardium noted.

The ventricle in the adult measures about three and a half inches (8 to 9 cm.) in length internally, from pulmonary orifice to apex. The thickness of its walls varies from one-sixth to one-quarter of an inch (5 to 7 mm.) at a point a short distance below the auriculo-ventricular groove, to one-eighth of an inch (3 mm.) at the extreme apex. The septum ventriculorum should not show any marked bulging into the cavity, and if this be present, it indicates hypertrophy of the left ventricle. The normal colour of the myocardium is like that of an ordinary muscle, but its texture is closer.

Left Side of the Heart. Left Auricle.—The heart being placed on its anterior surface, an incision is made through the wall of the auricle joining the orifices of the upper or lower right and the lower left pulmonary veins, and then passing on in the same line into the appendix. This incision opens up the whole of the cavity, which, as in the case of the right auricle, is to be examined for the presence of hypertrophy and other myocardial changes, dilatation, thickening of the mural endocardium and thrombosis.

The wall of the left auricle is normally thicker—averaging 2–3 mm. ($\frac{1}{10}$ – $\frac{1}{8}$ in.)—than that of the right auricle, and the mural endocardium is thicker and more opaque than that lining the right auricle. The walls of the cavity present fewer irregularities than those of the right auricle, there being only

a few pectinate muscles at the entrance to the appendix, and within the appendix.

Mitral Opening.—In order to examine the valve satisfactorily the left ventricle should be opened from the front. This is done by making an incision through the walls parallel to the septum ventriculorum and less than a finger's breadth from it. This incision should be carried upwards into the angle between the descending and transverse branch of the left coronary artery, and downwards if necessary beyond the apex on to the posterior wall. The mitral opening with its valve should be examined firstly from above, the heart being supported by the margins of the opening in the wall of the left auricle. Afterwards it should be examined from the ventricular aspect, and thus without actually touching the valve a considerable amount of information is obtained. The forefinger should then be passed down gently through the opening so as to determine the presence of acute or chronic endocarditis, of stenosis or dilatation of the opening or other pathological condition. The circumference of the opening should be taken at this stage, the cones being passed in the direction of the blood stream, i.e. from the auricle. (Normally 9.7 to 11.1 cm.) The normal opening admits two fingers. If a more minute investigation of the segments be required the openings in the auricle and ventricle may be joined by an incision passing through the appendix and through the anterior angle of the mitral opening. This is not always necessary, however.

The cavity of the *left ventricle* can be examined through the incision already made in its walls, which is usually sufficient to give all access required, particularly if the mitral opening have been laid open completely.

Aortic Opening.—The competence of the valve to water is first tested in a manner similar to that already adopted in the case of the pulmonary valve, all blood-clot being first removed from between the cusps. In estimating the competence of the valve it should be remembered that in making the longitudinal incision through the wall of the left ventricle some of the larger branches of the left coronary artery may have been divided, and the water may slowly drain away through these. Hence while conducting the test the aorta should be cut short enough to allow of inspection of the cusps, so that if competent they can be seen to be ballooned out by the water and to come into accurate apposition. If the valve is to be preserved intact, a probe-pointed bistoury is passed downwards along the internal surface of the aorta towards the angle between the right auricular appendix and the ventricular wall. The instrument usually passes directly into the right coronary artery and this vessel is slit open along with the aorta above it. In a similar manner the left coronary is opened up along with the wall of the aorta on that side. If, in making this incision, the knife be kept directed a little backwards, one avoids injuring the pulmonary artery to any important extent. In order to ensure this, the pulmonary artery may be dissected off the aorta before proceeding to open up the left coronary artery. The aortic valve with the sinuses of Valsalva is now exposed.

If on examining the aortic valve from above it is found that no recent endocarditis is present, the forefinger may be passed upwards from the ventricle into the opening to palpate the aortic sinus and valve segments. The cone circumference should then be taken. (Normal 7.3 to 8.2 cm.)

If it be desired to expose the valve more completely and if no advantage is to be gained by preserving the pulmonary artery, a straight probe-pointed knife should be passed up into the aorta and carried outwards through the wall between two of the cusps, the two being chosen which will best permit the incision already made on the left ventricle to continue as directly as possible upwards into the aorta and join the incision already made in the latter. In

making this incision care should be taken to avoid injuring the pulmonary artery and the mitral valve. This is the procedure to be recommended as it gives good access.

Left Ventricle.—The normal internal measurement of the left ventricle is similar to that of the right ventricle, but the walls are thicker, varying from one-half to five-eighths of an inch (1 to 1.5 cm.) opposite the base of the anterior papillary muscle, and from one-sixth to one-quarter of an inch (0.5 cm.) at the apex. The consistence of the muscle is usually firmer than that on the right side.

Coronary Arteries.—The right coronary artery is usually larger than the left and supplies the greater part of the wall of the right ventricle, the right auricle and greater part of the left auricle.

The left coronary artery supplies the greater part of the outer wall of the left ventricle, the anterior two-thirds of the septum ventriculorum (by a special septal branch), a small portion of the right ventricle near the septum in front (Fig. 13), and the lower part of the left auricle. The *descending* branch is the one which is most commonly the seat of disease and it should always be examined carefully. These vessels may be slit up with a narrow probe-pointed bistoury or with a pair of scissors having a narrow blunt-pointed lower blade. If extensive chronic

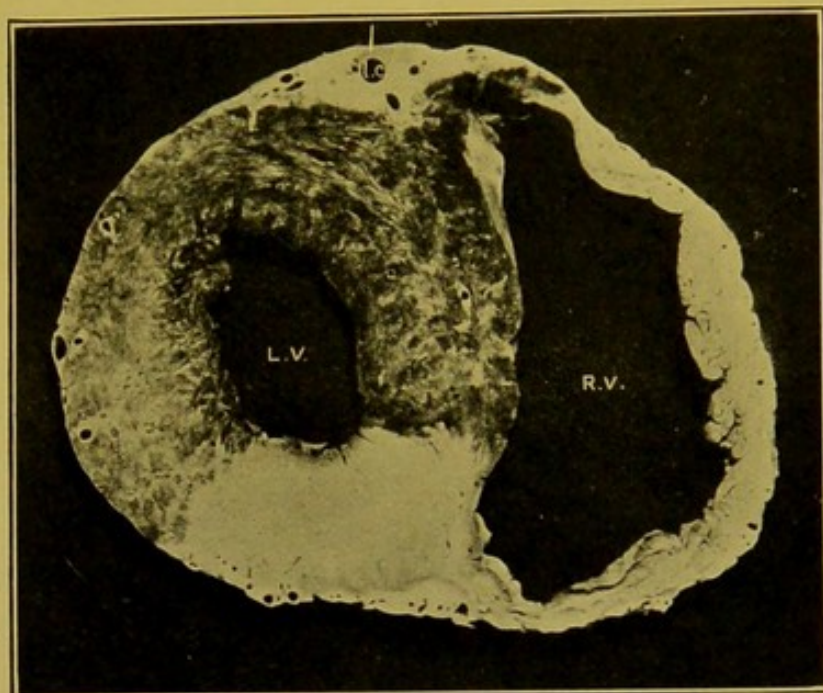


FIG. 13.—Transverse section of ventricles; left coronary (l.c.) injected to show its distribution. (\times circ. $\frac{3}{4}$.)
(l.v.) Left ventricle; (r.v.) right ventricle.

myocarditis or infarction of the heart muscle be present it is better to investigate the artery concerned by making numerous transverse cuts across its course.

The Cardiac Ganglia.—Dissection of these ganglia is so rarely required for the purpose of microscopic examination that the reader may be referred to textbooks on anatomy for information as to their position, etc.

Weight of the Heart.—After the examination of the heart is completed the organ should be weighed, i.e. after all blood and blood clots have been removed and the pericardial sac and mediastinal structures separated. In 356 adult females, I found that the average weight of the heart was 12 oz. or 340 gm., and in 584 males the average weight was 13 $\frac{4}{5}$ oz. or 390 gm. These weights are greater than those given by most other authors, who agree more or less in stating the average weight for the female to be 9 oz., or about 220 gm., and in the male 11 oz. or about 315 gm. The weight necessarily varies with the size of the individual, and due allowance should be made before concluding that the heart is either heavier or lighter than normal.

The extremes of the weights of adult hearts I have measured have been 6½ oz. (184·25 grm.) and 51 oz. (1445 grm.).

The measurements of the **Orifices** of the heart may be considered at this point. For many years the cones introduced by D. J. Hamilton were used in the post-mortem examinations in the Royal Infirmary, Edinburgh. These were graduated so as to indicate the size of the diameters of the orifices in inches. The following table is that which was used by him and by most of his successors.

TABLE I.
DIAMETERS OF ORIFICES IN INCHES.

Tricuspid	1·5-1·8
Pulmonary	1·1-1·2
Mitral	1·2-1·4
Aortic	0·9-1·0

The writer, with the view of arriving at more accurate observations than was possible by the use of the diameter measurements, introduced cones graduated to measure the circumference of the openings, and the second table gives Hamilton's figures converted into the metrical system and also the corresponding circumferential measurements calculated from them.

Circumferential measurements have been long in use in Continental schools, and their employment is now becoming general.

TABLE II.

	Diameters.		Circumferences.
	ins.	cm.	
Tricuspid	1·5 to 1·8	3·8 to 4·7	4·5 to 5·5 11·4 to 14·0
Pulmonary	1·1 to 1·2	2·8 to 3·0	3·4 to 3·7 8·6 to 9·5
Mitral	1·2 to 1·4	3·0 to 3·5	3·7 to 4·4 9·5 to 11·0
Aortic	0·9 to 1·0	2·3 to 2·5	2·8 to 3·2 7·2 to 8·0

To compare with these, a third table showing actual averages obtained by measuring the circumferences of a large number of orifices with the writer's cones is given, which will be seen to correspond fairly closely to those worked out from Hamilton's table.

TABLE III.

	FEMALE.		MALE.	
	No. of Cases.	Average.	No. of Cases.	Average.
Tricuspid	173	12.9 cm.	278	13.7 cm.
Pulmonary	123	8.5 cm.	238	9.1 cm.
Mitral	159	9.7 cm.	307	11.1 cm.
Aortic	108	7.3 cm.	211	8.2 cm.

The size of the auriculo-ventricular openings may be gauged roughly with the fingers. Thus, the adult mitral orifice usually admits two fingers, and the tricuspid three fingers. This method should not be allowed to replace the more accurate method of measurement by graduated cones or other instruments. Its untrustworthy character can best be demonstrated by giving a few examples from reports on post-mortem examinations made by the *same* individual over several months. The actual cone measurements were also taken. It was found that "two fingers" corresponded to circumferences of from 9.5 to 12.5 cm.; "three fingers" from 11.5 to 15.5 cm.; "four fingers" and "five fingers" from 13 to 18 cm.

DISEASES OF THE HEART.

CONGENITAL ABNORMALITIES

The heart is *absent* in the rare acardiac fetuses. It may be *rotated*, or lie mainly on the right side, **dextrocardia**. Dextrocardia also includes the cases in which the cavities of the heart are transposed. The heart may lie outside the thorax, projecting through a defect in the sternum, **ectopia cordis**. These abnormalities occur so rarely that they only require mention.

Bifid Ventricle.—Occasionally, particularly in the young, an antero-posterior groove is seen crossing the apex of the heart in the line of the ventricular septum. This condition as usually encountered is of no importance.

Defects.—(1) In the *Septa*. (2) At the *Orifices*. (3) In the *Vessels*.

One should think of these defects, now to be described, as being etiologically related, in the majority of cases, to foetal endocarditis of the pulmonary valve, and its results both at that opening and in the infundibulum leading to it (*conus pulmonalis*).

(1) DEFECTS IN THE SEPTA.

(a) **Patent Foramen Ovale.**—In otherwise normal hearts a valved aperture is frequently found in the anterior part of the *fossa ovalis* in the auricular septum. It is stated that this modified opening can be found in from 30 to 50 per cent. of hearts examined in the post-mortem room. My own experience goes to support the lower percentage as the more accurate. So long as the pressure on the two sides of the septum remains normal, the valved opening is kept closed. Any increase in pressure on the right side tends to open it and allow of direct communication between the auricles. (See also *Crossed Embolism*, p. 106.)

The term "patency" of the foramen ovale is reserved for conditions in

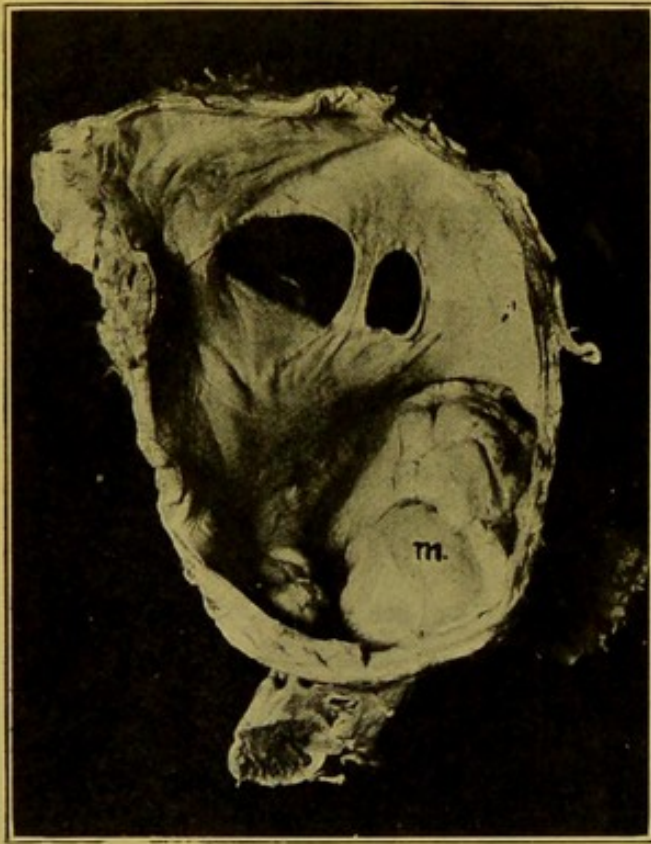


FIG. 14.—Large fossa ovalis, showing two large apertures. (\times circ. $\frac{3}{4}$.)

(m) Mitral valve, ballooned upwards. (Mus. R.C.S. Ed.)

which there is a direct opening in the fossa which allows of free and constant communication between the auricles. The openings may be multiple and may correspond in extreme cases to practically the whole extent of the fossa (Fig. 14). In other cases the opening in the fossa may be accompanied by other defects in the septum, outside the fossa, or the foramen may be closed, and these other defects be present. These conditions are usually associated with some other congenital abnormality of the heart, most frequently with narrowing of the pulmonary artery or stenosis of its orifice, and (or) patency of the ductus arteriosus. With it also is frequently associated a defect in the upper part of the ventricular septum.

(b) **Defects in the Ventricular Septum.**—The ventricular septum is completely absent in the three-chambered (tricelcian) heart. This condition is rare. It is not necessarily incompatible with existence, there being a tricelcian heart in the Museum of the University of Durham School of Medicine which was taken from an individual who died at the age of 19 years and 8 months. This is, however, exceptional. There are two examples of the condition in the Museum of the Royal College of Surgeons of Edinburgh, both from young individuals. In all three specimens, as well as in another case I examined, there is practically no trace of septum. Otherwise the conditions vary. The foramen ovale may

be either open or closed. The aorta and pulmonary artery either arise from the common ventricle, retaining their normal position, or they may be transposed.

Lesser defects in the septum ventriculorum are more frequently met with, the commonest being a **patency** of the undefended spot, limited to the *pars membranacea septi*, or involving in addition portions of the septum in front of or behind that area (Fig. 15). In two cases I have seen patency of the septum in front of the *pars membranacea*. There may be no indication of this defect during life, except vague systolic murmurs which cannot be definitely localized. In one case I found the *pars membranacea* closed, but aneurysmal, the concavity being towards the left ventricle.

(2) DEFECTS AT THE ORIFICES.

Occasionally the aortic valve has two segments, or four segments, instead of the normal three, excluding any apparent duplication, or adhesion resulting from endocarditis. Similarly the tricuspid valve may possess four cusps, but these peculiarities are not of pathological importance.

The valves most commonly affected by congenital disease are those upon the right side of the heart, and especially the **pulmonary valve**, this being the valve which is only exceptionally affected in the course of endocarditis in the adult. Stenosis of the orifice is its most common congenital alteration. The *conus pulmonalis* also may be greatly narrowed. Associated with this condition there may be patency of the foramen ovale, of the ductus arteriosus, and also defective closure of the ventricular septum. In cases in which the pulmonary artery is stenosed and the ductus arteriosus very small, the bronchial arteries may enlarge to assist in supplying blood to the pulmonary circulation.

In a well-developed young man of twenty years of age I found an enormously hypertrophied and dilated right ventricle associated with fusiform dilatation ($1\frac{1}{2}$ in.—4 cm.—in diameter) of the pulmonary artery, patent ductus arteriosus, slight fenestration of the fossa ovalis, and narrowing of the aorta in its ascending and transverse parts.

Tricuspid Opening.—This opening may be stenosed as a result of foetal endocarditis. Obliteration of the opening must be extremely rare. The Museum of the Royal College of Surgeons, Edinburgh, contains a heart which was taken from a child four years of age, in which the tricuspid opening is completely closed, the right ventricle is so small that it could have

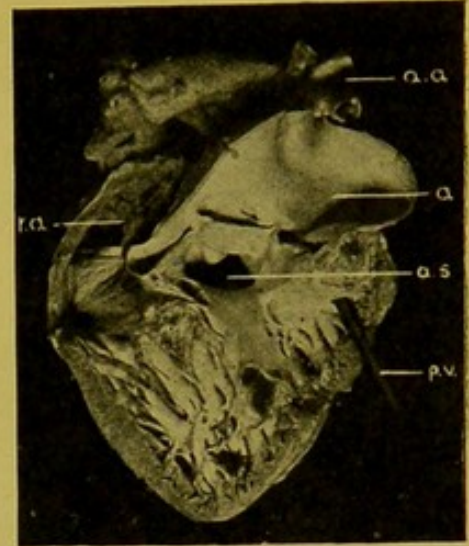


FIG. 15.—Patent septum ventriculorum, in heart of child. ($\times \frac{1}{2}$.)

(a.s.) Aperture in septum; (a) aorta; (a.a.) arch of aorta, with great vessels; (r.a.) right auricle; (p.v.) pointer in stenosed pulmonary valve.
(Mus. R.C.S. Ed.)

admitted only a drop or two of blood, and the pulmonary artery is so minute that its origin could not at first be discovered. The foramen ovale is open and there is an aperture in the septum ventriculorum in the usual position; the ductus arteriosus is almost closed. (Fig. 16.)

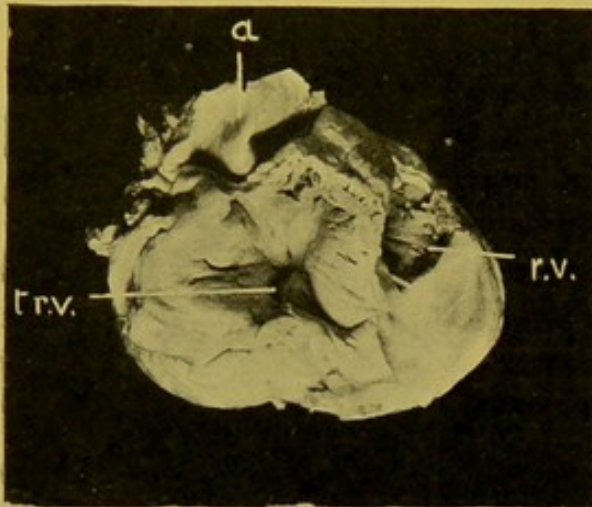


FIG. 16.—Obliteration of tricuspid (t.r.v.)
($\times \frac{2}{3}$.)
(r.v.) Right ventricle; (a) aorta. (Mus. R.C.S., Ed.)

(3) ABNORMALITIES OF VESSELS.

The number of pulmonary veins may vary. This is unimportant.

The aorta may be of very small size, a condition first described by Virchow as associated with chlorosis. This may be accompanied by hypoplasia of the heart. The individual as a whole may be poorly developed, there may be defects in the external genitals.

It is exceedingly rare to find the aorta and pulmonary artery transposed.

The aorta may arise from both ventricles, i.e. the opening is above the aperture in the septum ventriculorum. In such cases the pulmonary artery is usually stenosed.

In the heart of an infant—which was first described by Sir John Struthers, who presented the specimen to the Museum of the Royal College of Surgeons, Edinburgh—in addition to other abnormalities the great vessels are quite abnormal, the result of defective development of the arch of the aorta. The anterior trunk corresponds in its origin to the pulmonary artery. From its posterior wall, about half an inch above its origin, two vessels arise and pass to the lung. The main vessel passes on for a short distance and gives off the left subclavian artery. Thereafter it takes the place of the latter part of the normal transverse and descending portions of the thoracic aorta. A smaller posterior trunk arises above the opening in the septum ventriculorum, from both ventricles, and divides into the innominate artery and left common carotid. In this case there had been evidently a complete interruption of the arch of the aorta between the

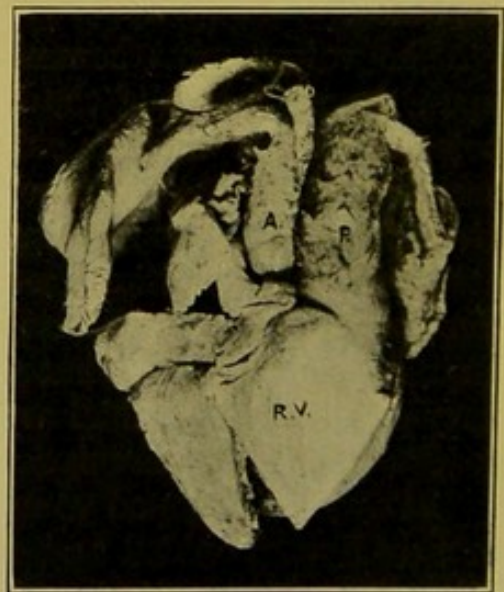

FIG. 17.—Congenital heart disease.
(\times circ. $\frac{2}{3}$.)

(a) Aorta; (p) pulmonary artery; (r.v.) right ventricle. The lungs are seen to either side, at the upper part of the illustration.

(Mus. R.C.S., Ed.)

left common carotid and left subclavian arteries. The larger vessel corresponds to the pulmonary artery which had supplied blood by way of a greatly dilated ductus arteriosus to the third part of the aortic arch, and descending aorta (Fig. 17).

ACQUIRED ABNORMALITIES

Increase of the Epicardial Fat.

In the normal heart there is always a certain amount of fat along the auriculo-ventricular groove, along the line of the septum ventriculorum and along the branches of the coronary vessels as they ramify over the surface. The fat serves to support and protect these vessels during the action of the heart.

In **Fatty Loading** (Adiposity, Lipomatosis) the epicardial fat is increased in amount and spreads beyond its normal limits over the surface of the heart. The increased deposit occurs more especially on the right side, but even in the case of the left ventricle there may be a thick deposit over the apex amounting to half an inch (12 mm.) in thickness. Fatty loading of the heart usually accompanies greatly increased deposit elsewhere (general adiposity), though this association is by no means invariable. In simple fatty loading, the layer of fat, as seen on the cut surface of the walls of the ventricles, is sharply demarcated from the myocardium (*see* Fig. 38, p. 88).

Fatty Infiltration is generally associated with fatty loading, but the actual increase in the amount of fat need not be very great. The important character distinguishing fatty loading from fatty infiltration is, as the name implies, a penetration of the fat in the latter condition between the muscle bundles and individual fibres.

The slightest grades of infiltration appear to the unaided eye as a blurring of the sharp line of demarcation which normally separates epicardial fat from myocardium. In advanced cases the fat may penetrate the wall of the ventricle and appear on the inner surface as yellow spots and streaks. Frequently, however, these sub-endocardial collections of fat are found independently of and unconnected with the fat on the outer surface. (Fig. 18.)

Fatty infiltration is best seen at the apex of the right ventricle anteriorly. It seldom affects the left ventricle.

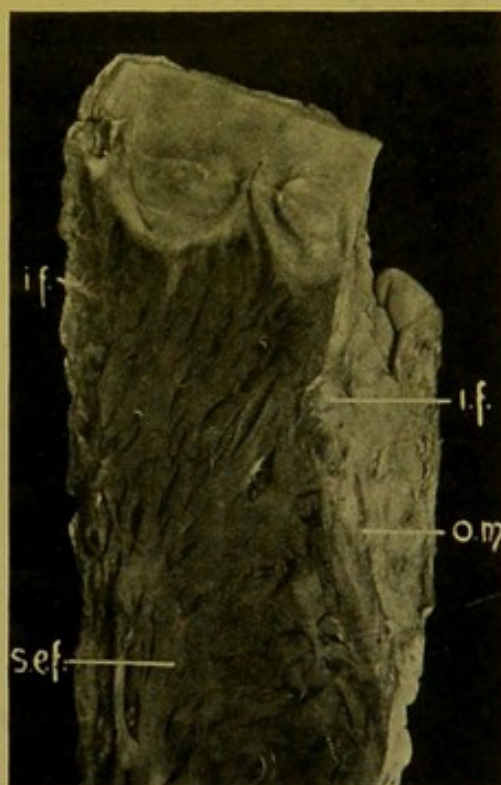

FIG. 18.—Fatty infiltration of the wall of right ventricle. (\times circ. $\frac{1}{2}$.)

(i.f.) Infiltrating fat; (s.e.f.) sub-endocardial fat; (o.m.) outer limits of myocardium.

Decrease of the Epicardial Fat.

Serous or Dropsical Degeneration of the epicardial fat is commonly met with in old age and in emaciated individuals, for example, in those who have long suffered from malignant tumours or from pulmonary tuberculosis. The heart is atrophied; the epicardium loose and wrinkled, lying in folds over the heart. The sub-epicardial fat has disappeared, and

is replaced by a serous fluid which is very easily recognized, distending the loose folds of the epicardium, particularly near the apex of the heart and near the auriculo-ventricular grooves. (See Fig. 20.)

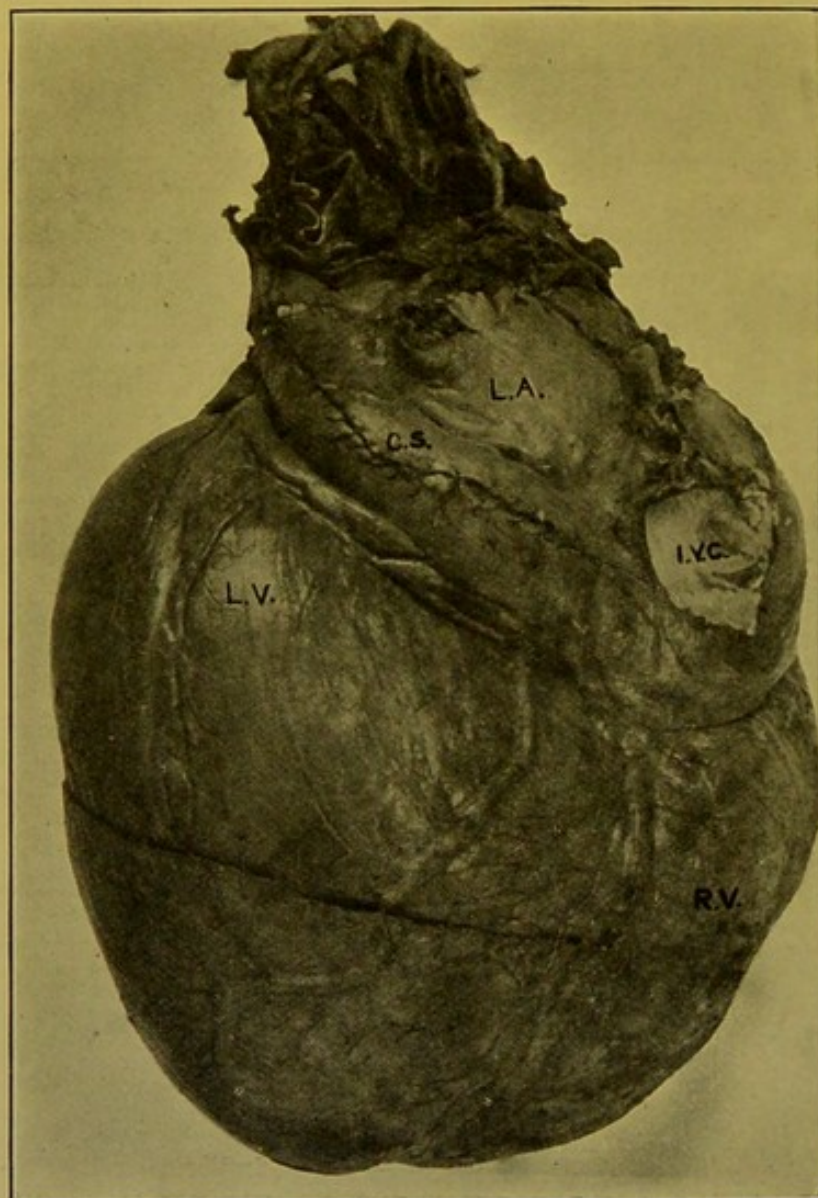

FIG. 19.—“Globular” Heart. (\times circ. $\frac{1}{3}$.)
(l.a.) Left auricle; (l.v.) left ventricle; (r.v.) right ventricle; (i.v.c.) inf. vena cava; (c.s.) coronary venous sinus.

ALTERATIONS IN THE SIZE OF THE HEART

A. Affecting the whole heart—

- (1) Enlargement.
- (2) Diminution.

B. Affecting individual chambers—

- (1) Enlargement.
- (2) Diminution.

A. (1) **General Enlargement** of the heart may result from dilatation of all the cavities. This may be the result of interference with its nutrition or of chronic mediastino-pericarditis with adhesions to the sternum, but more com-

monly it is the result of valvular disease, notably of mitral stenosis associated with similar though less marked changes in aortic and (or) tricuspid valves.

General dilatation also occurs when there is mitral incompetence associated with tricuspid incompetence. Other combinations of lesions also may bring about a similar condition. General dilatation with incompetence of the valves may be associated with hyperplasia of the aorta. The largest

heart—"globular heart"—which I have examined, measuring $7\frac{1}{2}$ inches (19 cm.) from base to apex, and 8 inches (20 cm.) transversely, had dilated and incompetent tricuspid and mitral valves, and comparatively normal pulmonary and aortic valves. The circumference of the aorta lessened in size rapidly from 3 inches (7.5 cm.) at the origin of the vessel, to 1.4 inches (3.5 cm.), at the end of the arch. After emptying, the heart weighed 51 oz. (1445 gm.). (Fig. 19.)

A. (2) General Decrease.—The common example of general diminution in the size of the heart is Brown Atrophy of the heart muscle ("pigmentary degeneration"). It is impossible to mistake an atrophied heart for a child's heart if the relative proportions of the ventricles and the great vessels be taken into account. In the atrophied heart the size of the vessels does not diminish to any extent, so that the alteration in proportion is very striking. (Fig. 20.)

The myocardium is distinctly brown, of a burnt sienna or almost Vandyke brown colour, and the contrast between it and the pallor of the great vessels and epicardial fat is very striking. The walls may be thin, and the cavities diminished in size; there is serous or dropsical degeneration of the sub-epicardial fat, with looseness and wrinkling of the epicardium, which also usually shows some thickening. The coronary arteries and their branches are distinctly tortuous, this appearance affording one of the distinguishing characters of atrophy of the heart muscle.

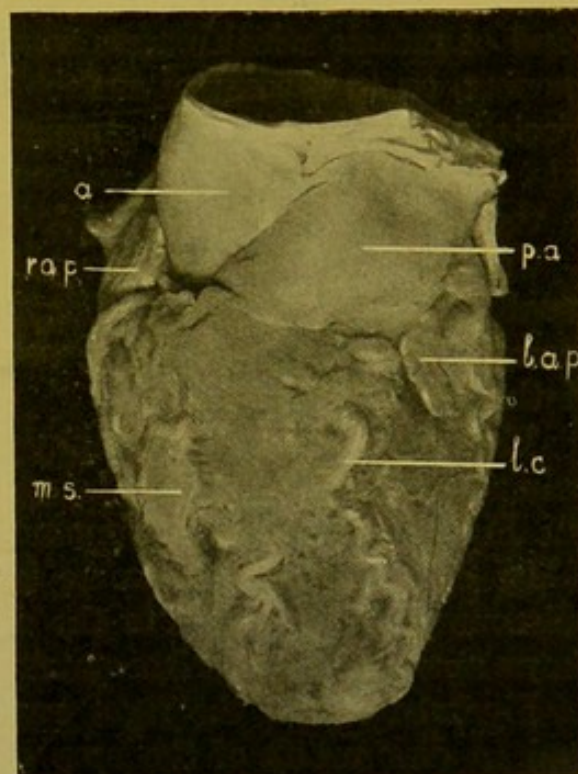


FIG. 20.—Brown atrophy of heart.
(\times circ. $\frac{2}{3}$.)

(a) Aorta; (p.a.) pulmonary artery; (r.a.p.) right auricular appendix; (l.a.p.) left do.; (l.c.) descending branch of left coronary; (m.s.) small "milk spot."

B. (1) Localized Enlargement of the Heart, affecting individual cavities.—The **Right Auricle** is always dilated if death has been due immediately to heart failure. Dilatation is frequently associated with a similar change in the right ventricle, though it is found frequently without other distinct evidences of cardiac disease, and simply indicates heart failure. The appendix shares in the dilatation. The walls are thin and the cavity enlarged. The special indication of dilatation of the cavity is the separation of the muscular bundles in its outer wall and in the appendix, so that in the intervals the epicardium comes in contact with the endocardium, and the dark plum-coloured post-mortem clot is seen through these thin parts of the wall. The coronary sinus may be greatly distended, particularly in

long-standing dilatation of the right auricle following chronic valvular disease on the left side of the heart.

Right Ventricle.—In dilating, the cavity tends to widen rather than to elongate; and in hypertrophy, the walls may increase in thickness so as, in extreme cases, to measure $\frac{5}{8}$ inch (1.5 cm.) near the base, and $\frac{3}{8}$ inch (1 cm.) at the apex.

The normal internal measurement may not be greatly exceeded even in a heart which is partly dilated. In one case of extreme dilatation I found an internal measurement of 5 inches (12.5 cm.).

If hypertrophy accompanies the dilatation, the wall—including the columnae—becomes thicker and of firmer consistence than normal, a broad band of muscle which passes from the posterior wall, below the tricuspid opening, on to the septal surface below the pulmonary opening, becoming specially prominent. The septum in extreme cases bulges towards the left side. Hypertrophy is not so frequently associated with fibroid change as in the case of the left ventricle.

The colour of the hypertrophied muscle is paler than normal. This is usually partly anaemic. A slight degree of fatty degeneration may be present, though it is seldom so evident to the unaided eye as in the case of the left ventricle.

The cause of the hypertrophy and dilatation is some obstruction in the pulmonary circulation, this being most often secondary to mitral stenosis (see Fig. 30, p. 80) or incompetence.

In cases in which chronic hyperaemia of the lungs is extreme, the pulmonary artery shares in the dilatation and thickening, and frequently shows upon its inner surface patches of fatty change or even atheroma.

Hypertrophy of the right ventricle is also found in conditions which lead to diminution of the area of distribution of the pulmonary artery, e.g. in emphysema; chronic interstitial pneumonia; bronchitis; also in presence of pleuritic adhesions; in anthracosis with shrinking of the bronchial glands, leading to narrowing of the bronchial and pulmonary vessels, especially the veins; and, finally, it may be caused, apparently, by curvatures of the spine, especially kypho-scoliosis.

In a condition such as pulmonary tuberculosis, in which the nourishment of the heart muscle may be defective, increased resistance in the pulmonary circulation does not always lead to hypertrophy. For the development of hypertrophy a plentiful supply of nutrition is essential. In the diagnosis of hypertrophy, special stress should be laid upon the *increased consistence* of the heart muscle, seeing that, if dilatation be extreme, the actual transverse measurement of the cut surface of the wall may not exceed the normal.

In dilatation without hypertrophy the wall may be extremely thin, about 1 mm. at the apex, or an apparently thick wall may be composed chiefly of epicardial fat, this not necessarily infiltrating the muscle.

Left Auricle.—The greatest dilatation of the left auricle occurs in mitral stenosis. It is usually accompanied by hypertrophy. The thickness of the walls may become nearly double the normal, i.e. they measure 4 or 6 mm. (about $\frac{3}{16}$ inch) instead of 2 or 3 mm. (about $\frac{1}{16}$ inch). Great dilatation also occurs in mitral incompetence. Degenerative or fibroid changes may be found in the muscle.

Left Ventricle.—The greatest *dilatation* occurs as a consequence of degenerative changes in the myocardium brought about by disease of the coronary arteries. This cause may be associated with some obstruction or with incompetence at the aortic opening (Fig. 21). Rapid dilatation also follows rupture or perforation of the aortic cusps, or obstruction of the coronary arteries.

Dilatation may result moreover from recent toxic or inflammatory changes in the heart muscle, or from failure of compensation, whatever the cause may be, and from diffuse fatty degeneration, e.g. in alcoholics.

The ventricle is dilated in aortic incompetence, particularly when associated with atheroma of the aorta and disease of the coronary arteries. The dilatation may also result from extensive fibroid changes in interstitial myocarditis. In extreme dilatation the internal measurement, from base to apex, may reach 5 inches (12·5 cm.), but usually it does not exceed 4 inches (9·5 to 10 cm.).

For partial enlargements of individual cavities, see **Aneurysm of the Heart** (p. 74).

Hypertrophy of the left ventricle with or without dilatation results from aortic stenosis, from adherent pericarditis, and from general increase in blood pressure, such as accompanies chronic disease of the kidneys, or arterial sclerosis. Marked hypertrophy of the left ventricle, as seen best in chronic Bright's disease with increase of arterial blood pressure, is readily detected before opening up the heart, by the firm consistence of the walls of this cavity. The septum bulges towards the right side.

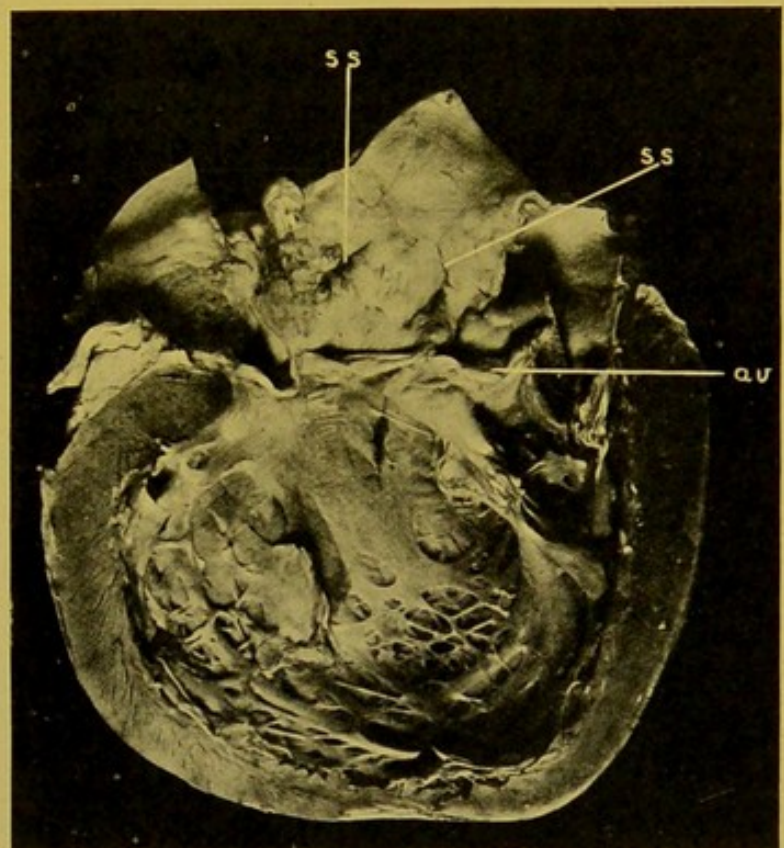


FIG. 21.—Dilatation of left ventricle. (\times circ. $\frac{1}{2}$.)
(a.v.) Aortic valve, with incompetent tongue-shaped cusps; (s.s.) syphilitic scars in aorta.

When associated with dilatation (excentric hypertrophy), it constitutes the "bovine heart"—*Cor bovinum*—in which the left ventricle occupies more of the anterior surface of the heart than normal. In the hypertrophied muscle one constantly finds small spots of fibrous change (*see* Fig. 13, p. 57), and microscopically there is usually evidence of fatty degeneration.

It must not be forgotten that rigor mortis causes the heart to contract firmly, producing an apparent thickening and increase of consistence often erroneously called "concentric" hypertrophy. Therefore the thickness of the wall must be considered in relation to the internal measurement of the ventricles.

The best way to demonstrate hypertrophy is to cut right across both ventricles in a plane parallel to the base, about the position of the base of the anterior papillary muscle.

Under the microscope individual fibres are thickened and their nuclei enlarged. Some authorities claim to have demonstrated hyperplasia as well.

In hypertrophy, the wall may measure 1 in. to $1\frac{1}{8}$ in. (2.5 cm. to 3 cm.), opposite the base of the anterior papillary muscle, and $\frac{5}{8}$ inch (15 mm.) at the apex, but even in a greatly hypertrophied heart, the thickness at the extreme apex may not be much increased.

B. (2) Localized Diminution in the Size of the Heart.—Apart from alterations in size resulting from congenital disease, to which reference has already been made (pp. 59–62), the best example of this diminution in size of individual cavities is the atrophy of the left ventricle associated with extreme mitral stenosis (*see* Fig. 30, p. 80). If, however, the mitral stenosis be complicated by the presence of aortic stenosis, or of greatly increased arterial blood pressure, hypertrophy of the left ventricle develops, provided the left coronary artery be able to furnish an adequate supply of blood to the myocardium.

DISEASES OF THE MYOCARDIUM

Normally the heart muscle has a colour like that of voluntary muscle, but it is of a closer texture, and of purpler, more livid ("blae," *Scottice*) tint.

In **Cloudy Swelling** the heart muscle becomes paler in colour, particularly in patches in the vicinity of the endocardium. When associated with congestion of the walls, pink or reddish blotches are seen on the cut surface. For confirmation microscopically, portions of the muscle may be fixed in Zenker's solution, corrosive sublimate, or alcohol, sections cut with the freezing microtome and mounted stained or unstained in an aqueous medium. The cells are swollen, finely granular, and their nuclei obscured. The granularity disappears when the section is treated with weak acetic acid.

Cloudy swelling occurs in acute toxic conditions, particularly with high temperature. (*See also* Acute Myocarditis, p. 72.)

Fragmentation and Segmentation of the Heart Muscle.—The muscle, especially of the papillary muscles and septum, is bleached, somewhat opaque, pale and greyish-brown in colour. Under the microscope the fibres are ruptured transversely (fragmentation) or the cement substance has given way (segmentation). This is possibly at times an agonal or even post-mortem (*rigor mortis*) change, caused by irregular contractions of the fibres. It occurs frequently in septic and toxic cases, in Bright's disease and in *sudden death*. In some of the cases observed by me, rigor mortis has been well-marked.

Some believe the condition to indicate the onset of early decomposition, but I think this may be excluded, as the change is found before decomposition can occur.

Zenker's degeneration of the muscle, and *amyloid degeneration* of the connective tissue may occur.

Fatty Degeneration of the Heart Muscle.—Fatty degeneration of the heart muscle occurs in two forms: (1) diffuse and (2) mottled ("thrush-breast").

The (1) "Diffuse" form occurs most typically in the hearts of chronic alcoholics and is best seen in the ventricular septum. It is also found in general wasting diseases, in some cases of chlorosis, or in individuals who have been confined to bed for a long time. In this condition the muscle is faded, of a somewhat light brownish colour. If chronic venous congestion be present, the muscle is dark brown in colour. On cutting into the papillary muscles or removing a slice from the left side of the septum ventriculorum, the muscle is found to be of close texture and frequently shows a somewhat indefinite, slightly yellowish, streaking. The surface looks smooth and greasy. Microscopically the greater number of fibres in the section are crowded with minute globules of oil. This condition is often associated with obstructive disease of the coronaries, but in alcoholics the coronary arteries may be quite healthy. To the experienced observer this variety of fatty degeneration is quite as characteristic as the more easily distinguished mottled variety.

(2) "Thrush-breast" mottling. — (Synonyms: "Tigroid" marking, "tabby cat" striation, "sentry-box" marking, "lightning" marking.) The mottlings or flecks of fatty degeneration are usually best seen in the papillary muscles of the left ventricle, but in well-marked cases the whole of the wall of the left ventricle, especially near the endocardium, is altered. The condition may also be fairly extensive in the wall of the right ventricle, but usually the left ventricle is more affected than the right. To the naked eye the muscle is beset with numerous transverse, parallel, zig-zag lines of a pale greyish-yellow colour, and about 1 mm. in width, between which are the remains of apparently healthy heart muscle (Fig. 22). Microscopically, minute droplets of oil are found in patches made up of portions of adjacent fibres, while the intervening portions and patches are healthy. In both

forms the heart is generally flabby and friable, but fatty hearts are not all necessarily friable.

Pigmentation of the Heart Muscle.—The heart muscle fibre normally contains a little pigment at the poles of the nuclei and this increases in amount in old age and in exhausting diseases. In well-marked cases the pathological pigment extends for a considerable distance along the axis of the muscle fibre. The pigment is of a light yellow colour. It is probably related to the lipochromes, as it is rendered more evident microscopically when sections are treated with *sudan* or *scharlach*, but its nature is not yet finally determined. The pigmentation is usually associated with atrophy of the muscle fibres.

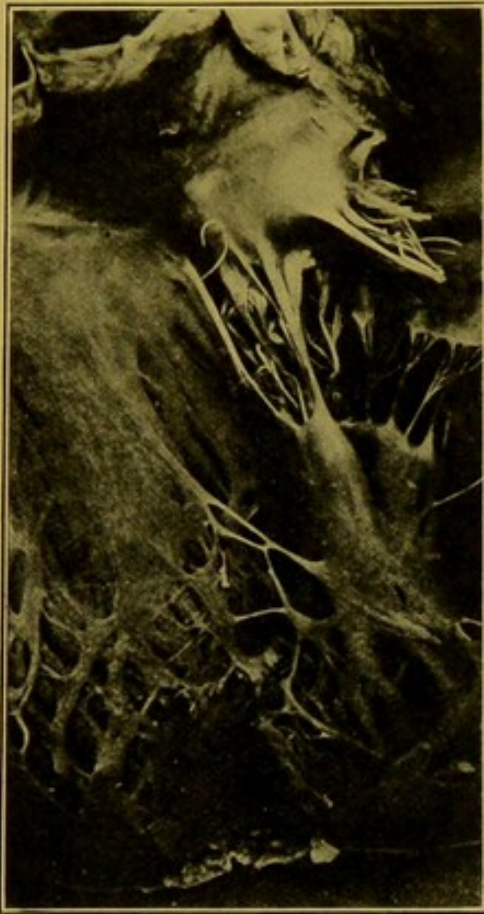

FIG. 22.—Portion of wall of left ventricle, with papillary muscle, showing fatty degeneration of the myocardium.—“Thrush - breast” type. (\times circ. $\frac{1}{3}$.)

Infarction of the Heart Muscle.—“**Myomalacia Cordis.**” Infarction of the heart muscle follows obstruction of a branch of the coronary artery.

The coronary arteries are not strict “end-arteries.” They possess arterial anastomoses along the interventricular grooves, over the apex, and over the great vessels at the base.

Infarction is practically confined to the wall of the left ventricle. The coronary artery may be the seat of proliferative end-arteritis or of atheroma and the immediate cause of the infarction is a complete block of one of its branches, due to thrombosis,

or, less commonly, to embolism. Block of a coronary vessel itself or of one of its main branches usually results either in immediate death, or in rapid necrosis of a large portion of the wall and early death from rupture of the heart (Fig. 23).

When a small branch is affected the area supplied undergoes anaemic necrosis. It becomes of a yellowish-brown colour, contrasting sharply with the neighbouring purplish-brown heart muscle. If the patch become infiltrated with blood it is of a darker colour than the healthy heart muscle. (Fig. 24.) The dead muscle swells up, undergoing coagulation necrosis.

Under the microscope the nuclei of the affected fibres fail to stain; the fibres are swollen and glassy and tend to retain nuclear stains *diffusely*. In the early stages the swollen muscle fibres may be separated by red blood corpuscles. At a later stage these patches become surrounded and

isolated by young granulation tissue, which, if the patch be small enough, gradually replaces it. In some cases the myocardium near the apex of the left ventricle may show numerous pale fibrous spots which have replaced small areas of necrosis. If the areas be of some little size, or if they be very numerous in one part of the wall, that part may dilate rapidly or slowly, depending upon the amount of damage to the muscle, producing either an acute or a chronic aneurysm of the heart. (See p. 74.)

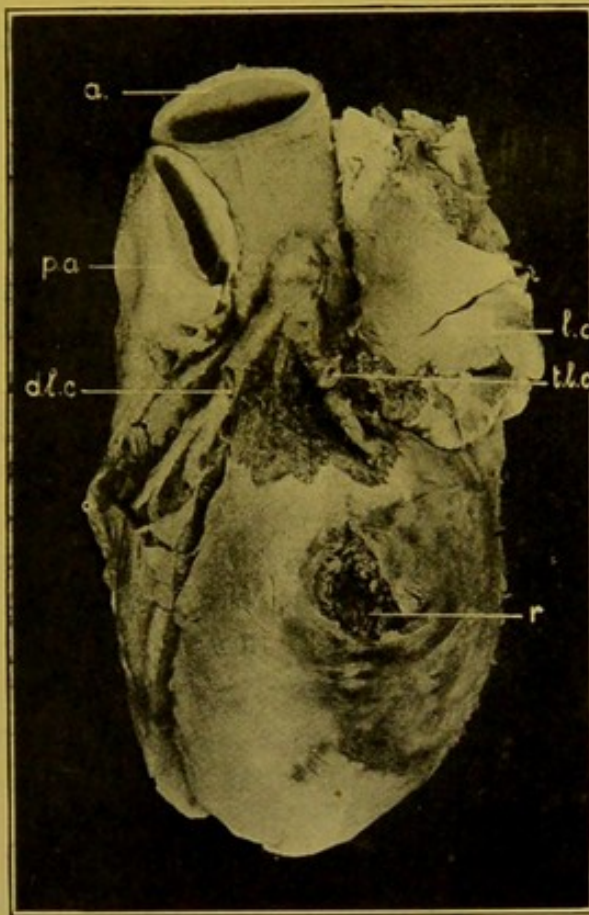


FIG. 23.—Infarction of left ventricle, with rupture (r.). (\times circ. $\frac{1}{2}$.)

(t.l.c.) Atheromatous transverse branch of left coronary, obliterated by recent thrombosis; (d.l.c.) descending branch, left coronary; (a) aorta; (p.a.) pulmonary artery; (l.a.) left auricle.

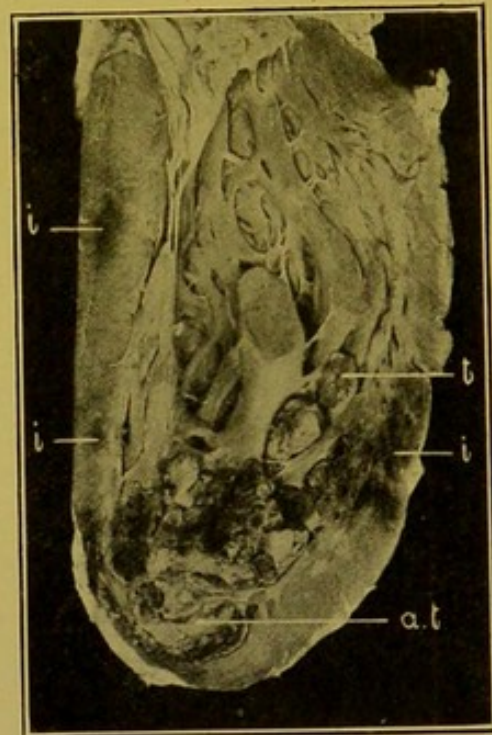


FIG. 24.—Myomalacia cordis. (\times circ. $\frac{3}{5}$.)

(i) Haemorrhagic infarcts; (a.t.) cardiac aneurysm, containing ante-mortem thrombus; (t) thrombus projecting between columnae carnae.

Sub-endocardial haemorrhage occurs especially as a result of severe toxæmias, either bacterial or chemical, e.g. phosphorus; or gas-poisoning; also in acute leucocythaemia and in cases in which there have been extensive burns of the skin. Small petechial haemorrhages occur commonly in asphyxia. They are seen chiefly on the left side of the ventricular septum, and on the papillary muscles. In several cases I have seen haemorrhages into the cusps of the arterial valves, in one case associated with acute valvular endocarditis.

MYOCARDITIS

In **Acute (Parenchymatous) myocarditis** the muscle is generally of a dull greyish-brown colour and typically shows some reddish mottling. Minute greyish necrotic patches may also be visible. The muscle is flabby and friable, and is imperfectly contracted. Under the microscope many fibres appear cloudy or even hyaline, and vacuoles may be seen within them; the nuclei of the muscle fibres may be swollen and vesicular. The interstitial tissue, particularly near the vessels, is infiltrated with nucleated cells—lymphocytes and polymorphs—and sometimes in addition with red blood corpuscles. The condition is common as a sequel of pericarditis or endocarditis, affecting a layer at the surface of the heart. The generalized form occurs in acute infections and toxaemias, e.g. small-pox, typhoid, puerperal fever, diphtheria, influenza, etc.

Acute suppurative myocarditis is the most important variety of acute **interstitial** inflammation of the heart. (Synonym: Abscess of the heart.) This condition is never primary. It may spread from the mediastinum, but is more commonly one of the phenomena seen in pyaemia, being caused by impaction of septic emboli from the systemic veins, or from the left side of the heart. The condition especially affects the left ventricle. In the myocardium and under the epicardium small haemorrhagic areas are seen. These are usually arranged along the line of the coronary arteries. They are seldom in large numbers, and in the centre of each area there is a suppurative focus, which may or may not be visible to the unaided eye. In the case of the larger areas the central part is of a pale greyish-brown colour; it is seldom yellow, as the pus is mixed with broken-down muscle fibres, blood and pigment.

Microscopically, in the centre there is some breaking down of the heart muscle so that a small cavity is formed containing fragments of tissue, leucocytes and bacteria, usually cocci. The neighbouring muscle shows cloudy swelling and necrosis with sometimes some fatty degeneration. There is infiltration with leucocytes. The condition may extend to the surface and cause pericarditis, or less commonly endocarditis. Suppurative myocarditis is associated especially with suppurative disease of bone. In rare cases the abscesses are of large size; in such cases one should exclude actinomycosis.

Bacteriology.—The bacteria found may be *Staphylococci*, *Streptococci*, occasionally *Pneumococci* and less commonly other organisms such as *Gonococci*.

In rheumatic myocarditis Aschoff and Tawara have recently described scattered collections of leucocytes along the course of the vessels, not proceeding to suppuration.

Chronic Interstitial Myocarditis.—This is a condition in which small

elliptical patches of myocardium are replaced by bluish-white, pearly areas of fibrous connective tissue. These may result from different forms of acute myocarditis; they may be secondary to endocarditis or pericarditis, or even to abscess of the wall, but they are associated most characteristically with disease of the coronary arteries, which brings about anaemic necrosis of the heart muscle in minute patches, which are afterwards replaced by fibrous tissue (*see* description of Infarction of the Heart, p. 70).

Necrosis may be rapid or gradual. The scar tissue is reddish at first, rather soft, retracted, and gradually becomes grey-red or brown, and then white.

In cases occurring in advanced life, the coronary arteries usually show chronic thickening, sclerosis or atheroma. In young individuals they may show syphilitic (proliferative) endarteritis. These conditions may affect both the larger branches and the minute branches within the muscle.

In syphilis, again, arterial changes may not be marked, but there may be a toxic action upon the muscle fibres as the first effect. As these gradually degenerate and disappear, connective tissue is formed to take their place. This is laid down especially along the lines of the vessels. (*See* Syphilis of the Heart, p. 74.)

Results.—If the patches be minute and scattered, no important result follows.

When under the endocardium, chronic myocarditis may lead to thickening of it and commonly to thrombosis over the affected area. Occasionally it brings about stenosis of the "sub-aortic sinus." Fibrous changes in the tips of the papillary muscles and columnae carnae are common. It should be remembered that some of the apparently fibrous columnae carnae are in reality branches of the auriculo-ventricular bundle ("false tendons," Tawara).

If the patches be very numerous, closely clustered under the endocardium, forming a more or less thick and more or less uniform, pale fibrous-looking layer in that situation, the cavity as a whole tends to dilate (Fig. 25). If the condition be localized, it causes an aneurysm of the heart-wall. The condition of the branch of the coronary artery supplying the affected

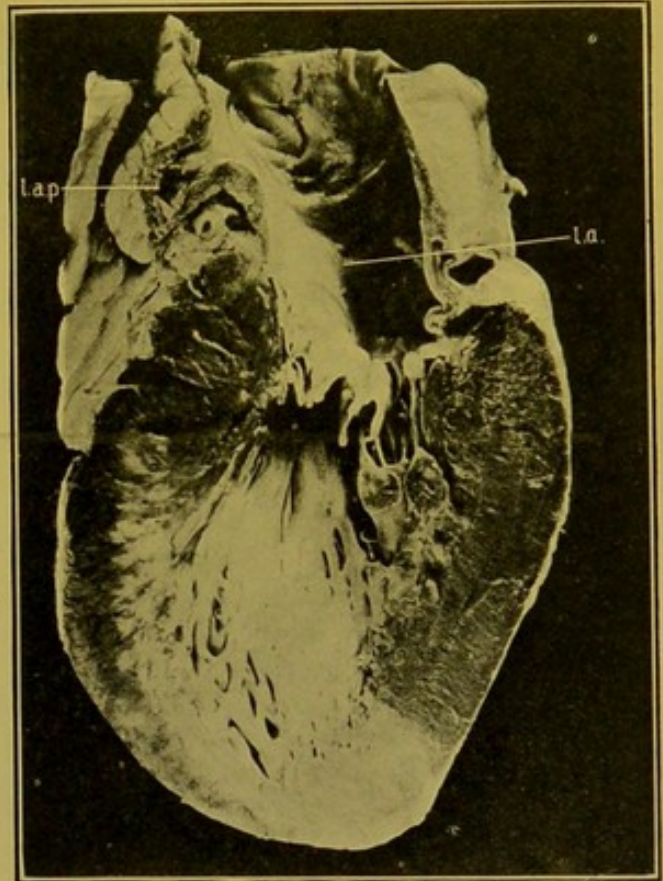


FIG. 25.—Chronic fibroid myocarditis.
(\times circ. $\frac{2}{3}$.)

The white portions of left ventricle are fibrous. (*l.a.*) Left auricle; (*l.a.p.*) left auricular appendix.

area should be carefully investigated, by making numerous transverse incisions across its course.

Aneurysm of the Heart Wall.—Local aneurysmal dilatation of the heart wall is the result of some obstructive change in a branch or branches of the coronary arteries. This may be of rapid development, due to thrombosis or embolism, and lead to softening of the heart muscle with rapid dilatation of the affected area and rupture,—Acute aneurysm. (See Fig. 23, p. 71.) More often it is the result of chronic endarteritis leading to chronic fibroid myocarditis. The affected area gradually dilates, and in the wall of the fully

developed aneurysm the muscle may practically disappear. As a rule, the hollow is filled up with laminated thrombus. These "chronic" aneurysms occur most commonly near the apex of the left ventricle anteriorly. They may also occur at the lower part of the septum and at other parts of the walls of the left ventricle, less commonly on the posterior wall of the right ventricle. Chronic aneurysms rarely proceed to rupture. (Fig. 26.)

I have once seen an aneurysmal dilatation of the *pars membranacea septi* projecting towards the right ventricle, stretching over it the septal cusp of the tricuspid valve.

Granulomata of the Heart.—

Tuberculosis rarely attacks the myocardium. Miliary tuberculosis has been described.

Caseous tuberculous nodules are

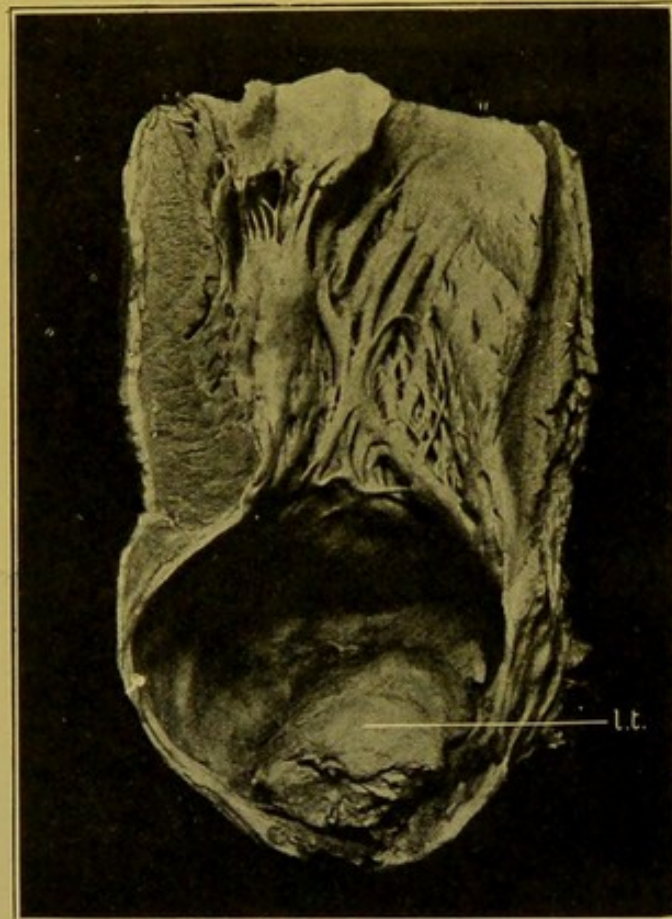

FIG. 26.—Chronic aneurysm at apex of left ventricle. (\times circ. $\frac{2}{3}$.)

(l.t.) Laminated thrombus within aneurysm. (Mus. R.C.S. Ed.)

occasionally found in the young, in the walls of the ventricles, especially of the left one. The nodules are firm with central caseation and may break down and soften. In one case, I found tuberculous abscesses at the root of the heart, in relation to the commencement of the great vessels.

Syphilis of the Heart.—Chronic myocarditis, secondary to proliferative endarteritis of the coronary arteries has already been mentioned. In this condition, small pale areas of connective tissue are seen replacing the muscle. Microscopically these are composed of fibrous tissue which may be well-formed towards the centre of the patch, but younger and more

cellular at the edge, where extension is taking place. Clumps of muscle fibres and single fibres are seen in various stages of atrophy in the midst of the fibrous tissue, which seems to be spreading along the vessels.

Gummata of the Heart Muscle.—In one heart which I examined, presenting this condition, the surface of the right auricle and ventricle presented an uneven, nodular surface, and on the outer wall of the ventricle beneath the pericardium there were flattened fleshy bodies possessing a granulomatous structure, and showing the type of caseation regarded as characteristic of tertiary syphilis (Fig. 27). In another case the gummata were at an earlier stage, dark red, soft, and gelatinous (*see* Fig. 44, p. 98). In a third case the gumma was situated in the ventricular septum and involved the auriculo-ventricular bundle, causing "heart-block."

Many of these diseases of the myocardium, particularly when chronic, also affect the walls of the auricles, and these should be examined at the same time as the walls of the ventricles.

Rupture of Papillary Muscles.—In a few cases in which I have observed this condition, it resulted either from fatty changes in the muscle, e.g. in the old, or was associated with ulcerative endocarditis and rupture of the chordae tendineae.

The Primitive Muscular Tissue of the Heart.—Of late years much research has been directed towards the elucidation of the phenomena of "heart-block" and other pathological conditions, dependent on lesions of the primitive muscle tissue of the heart.

In the routine examination of the heart muscle, special attention should be directed to the neighbourhood of the *pars membranacea septi*, and to its relation to fibrous and calcareous thickenings in the upper part of the muscular septum and in the ring of attachment of the anterior mitral segment.

For the following description of the primitive tissue and its lesions I am obliged to Dr. W. T. Ritchie.

EXAMINATION OF THE PRIMITIVE TISSUE OF THE HEART.

Three portions of tissue should be removed for examination by serial sections:—1. That portion of the wall of the right auricle and of the superior vena cava lying between the latter and the right auricular appendix. This

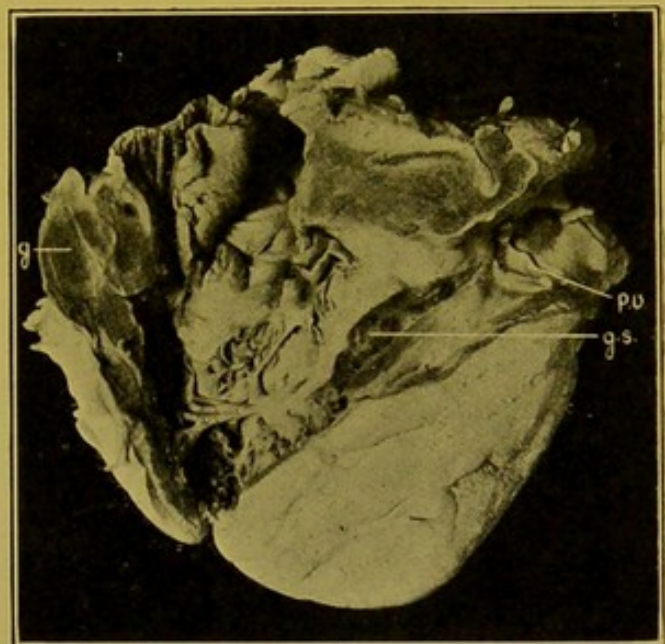


FIG. 27.—Syphilitic gummata of myocardium; right ventricle. (\times circ. $\frac{1}{2}$.)

(g) Gumma; (g.s.) gumma in septum, with V-shaped portion removed; (p.v.) pulmonary valve. (Mus. R.C.S. Ed.)

contains the sino-auricular node (see Fig. 12, *s.a.n.*, p. 54). 2. A portion of the cardiac septum extending backwards to the mouth of the coronary sinus and forwards so as to include the *pars membranacea septi* and the attachment of the septal cusp of the tricuspid valve. This portion of tissue contains the auriculo-ventricular node, the auriculo-ventricular bundle and its two main branches. In order to demonstrate these structures to best advantage, this portion of tissue should be cut in a plane corresponding to the free margins of the aortic cusps (Fig. 28). 3. A portion of the ventricular wall close above the base of the anterior papillary muscle of the left ventricle. The Purkinje fibres will be found in the subendocardial tissue.

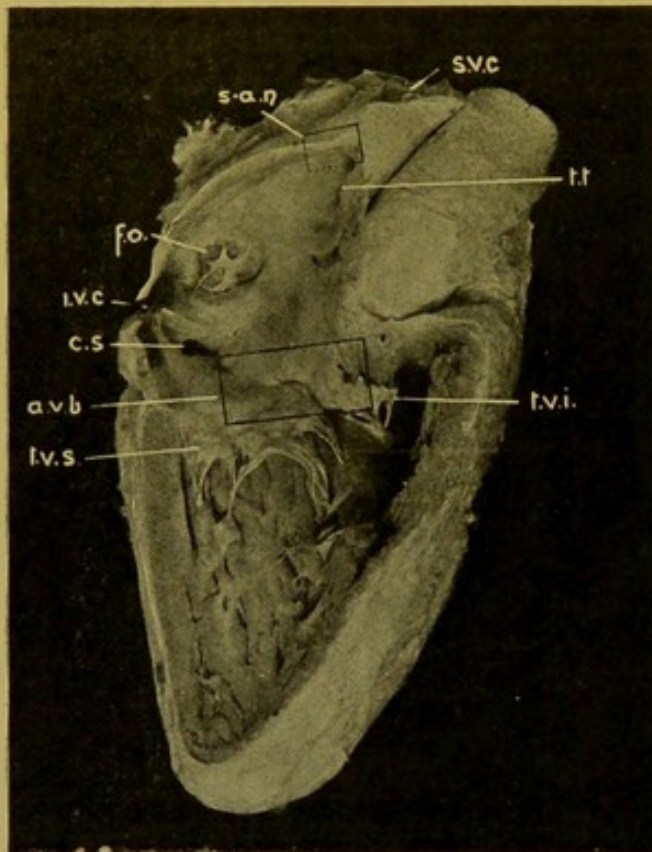


FIG. 28.—Portions of heart to be removed to investigate its primitive muscle tissue. Right auricle and ventricle opened. ($\times \frac{1}{2}$.)

(*a.v.b.*) Block containing auriculo-ventricular bundle. (*s.a.n.*) block containing sino-auricular node; (*s.v.c.*) superior vena cava; (*f.o.*) fossa ovalis; (*i.v.c.*) inferior vena cava; (*c.s.*) coronary sinus; (*t.v.s.*) septal cusp of tricuspid; (*t.v.i.*) infundibular cusp of tricuspid; (*t.t.*) taenia terminalis.

The sino-auricular node, the site of origin of the normal stimuli for the heart's contraction, is a narrow club-shaped or spindle-shaped band of tissue lying in the groove between the superior vena cava and the right auricular appendix. It consists of an irregular reticulum of slender muscle fibres, with faint striation, of nerve ganglia and of nerve fibres. In cases of perpetual arrhythmia, the sino-auricular node has been found to be the seat of chronic inflammatory changes.

The auriculo-ventricular node lies in the inter-auricular septum in front of the mouth of the coronary sinus and above the line of attachment of the septal cusp of the tricuspid valve. In structure, the node is similar to the sino-auricular node. From the anterior end of the auriculo-ventricular

node the auriculo-ventricular bundle passes forwards, and usually obliquely from right to left, through the central fibrous body, and then passes forwards in the *pars membranacea septi* near its lower border, at the anterior, or deepest part of which the bundle bifurcates. The left branch passes downwards and spreads out in a fan-like fashion beneath the endocardium on the left side of the ventricular septum. The right branch passes downwards either beneath the endocardium of the right ventricle or buried within the musculature of the septum. The terminal fibres of the bundle

gradually assume the characters of Purkinje fibres and are widely distributed in the subendocardial tissue of both ventricles, some passing across the cavity of the ventricle to the papillary muscles as "false tendons" (see p. 73).

The proximity of the bundle to the anterior cusp of the mitral valve and to the right-posterior cusp of the aortic valve renders it liable to be involved when there is ulcerative endocarditis. Fibrous overgrowth and calcareous deposits in the bundle are not uncommon, and the bundle may also be destroyed by gummata, and by tumours of the septum of the heart. In cases of complete and permanent heart-block, the lesion will be found completely severing the continuity of the bundle.

KEITH & FLACK, *The Lancet*, 1906, ii. 359; *Journ. of Anat. and Physiol.*, 1907, xli. Third Series, vol. ii. 172.

TAWARA, *Das Reizleitungssystem des Säugetierherzens*, Jena, 1906.

MÖNCKEBERG, *Untersuchungen über das Atrioventrikulärbündel im Herzen*, Jena, 1908. *Herzschwäche und plötzlicher Herztod als Folge von Erkrankungen des Atrioventrikulärsystems. Ergebnisse d. allg. Pathol. u. path. Anat. d. Menschen u. d. Tiere* (Lubarsch & Ostertag), Jena, 1910, xiv. I. Abt. S. 594.

KEITH. *A System of Medicine* (Allbutt & Rolleston), London, 1909, vi. 132.

DISEASES OF THE ENDOCARDIUM

In considering diseases of the endocardium we must consider it both as it covers the walls of the cavities—the **mural endocardium**—and in its duplications which form the **valves** at the various orifices of the heart.

Under normal conditions, the endocardium of the right auricle is thin and transparent over the greater part of the wall, so that the subjacent muscle is plainly visible. The endocardium of the left auricle is thicker and more opaque. General diffuse opacity of the endocardium of the right auricle is always abnormal.

Thickening of the **mural endocardium** very commonly accompanies thickening of the segments of the valves. It is best seen in the left auricle and in the left ventricle; in the latter, particularly on the septal wall. Occasionally in the "sub-aortic sinus" it may lead to contraction, and I have seen localized thickenings and projections in this situation either in the form of ring-like ridges extending on to the aortic cusp of the mitral, or forming little valve-like pockets in the "sinus."

Diffuse thickening of the endocardium is not of importance unless it be associated with chronic interstitial myocarditis which then has to be regarded as the more important condition. The columnae carnae may become atrophied, but I would again observe that all fibrous-looking bands and tendinous ridges in the body of the left ventricle are not necessarily atrophied columnae carnae. In some cases they may be branches of the auriculo-ventricular bundle of His.

VALVULAR ENDOCARDITIS

Except during foetal life valvular endocarditis is usually limited to the left side of the heart. When the pulmonary or tricuspid valves are affected with endocarditis in the adult, they may show any of the varieties of the disease that are met with in the mitral and the aortic valves, so that one may consider the subject of endocarditis generally, as it affects these two valves.

It is very exceptional to find the pulmonary valve affected, even when the other three valves show extreme changes. Endocarditis of the tricuspid valve is not quite so rare, and this valve may be affected simultaneously with the mitral and aortic valves. The mitral valve is more commonly affected than the aortic valve.

In "**Simple**" **Valvular Endocarditis** there is a deposit of vegetations on that surface of the valve upon which the blood impinges as it passes through the heart, i.e., upon the auricular surfaces of the mitral or tricuspid valves, and upon the ventricular surfaces of the aortic or pulmonary valve. This deposit takes place in the first place along the "*lines of contact*" of the segments. In the case of the auriculo-ventricular valves this line is a short distance above the free margins of the segments, the narrow area intervening between it and the free margin forming a ribbon-like surface which comes closely into apposition with a similar surface upon the corresponding segment or segments, thus completely closing the orifice and producing, as it were, a tight joint.

In the case of the arterial valves, the three semilunar cusps come into mutual contact at their corpora Arantii only, and in endocarditis the vegetations are first deposited over that common meeting point. Adjacent cusps come into contact along the *bases* of the lunulae, the surfaces of the thin expansions composing the lunulae of adjacent cusps lying against each other and accurately closing the aperture. The lunulae may show fenestrations but these are not necessarily abnormal.

Acute Vegetative Endocarditis.—Along the lines of contact the endothelial cells, which become swollen and softened in toxaemic conditions, are readily rubbed off by the friction of the segments against each other. Upon this surface denuded of endothelium, blood-platelets adhere, and by gradual accretion form the vegetations. At their bases of attachment these seldom exceed 1 to 2 mm. in width, and they project for a similar distance. The vegetations form a line or festoon, not at the extreme margin of the segments, but a little within the free margin (Fig. 29), unless the segments have been thickened as a result of a previous old endocarditis, when the vegetations may be laid down, in some parts at all events, at the extreme margins of the cusps. Vegetations are composed chiefly of altered blood-platelets, with a small proportion of fibrin, and on their surface a thin layer of fibrin entangling leucocytes may

sometimes be seen. Vegetations become organized from the valves, leucocytes and proliferated connective tissue (fibroblasts) and endothelial cells passing into the thrombus, and later, small blood-vessels appearing and penetrating for a certain distance. As a result of this organization the projections may disappear completely, but it is extremely common to find nodular thickenings, at the margins of the mitral cusps, or in the neighbourhood of the corpora Arantii in the case of the aortic segments, which have evidently persisted from an old endocarditis. The true nature of these nodular thickenings in the case of the auriculo-ventricular valves is verified by coincident thickening of the chordae, and fibrous alteration in the tips of the papillary muscles. It is important to note these additional points, seeing that slight nodular thickenings may persist from foetal life. Oedematous thickenings are also not uncommon. The no-

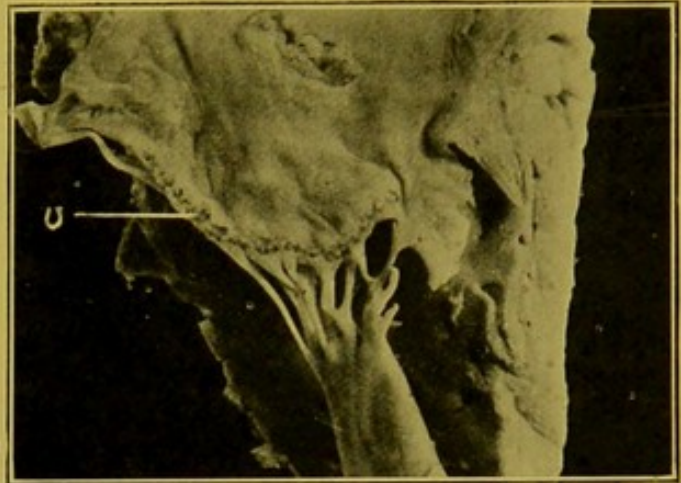


FIG. 29.—Acute vegetative endocarditis of auriculo-ventricular valve (v). (\times circ. $\frac{3}{4}$.)

dular thickening of old endocarditis, which is seen in the situations mentioned above, has to be distinguished carefully from the fibrous thickening which is very commonly found at the *attached* margins and to some extent throughout the body of the valve segments in cases in which there has been high arterial blood pressure. This is frequently found in athletes—even in adolescents—and in those whose work has necessitated great muscular effort. The thickening may be associated in the case of the arterial valves with dilatation of the sinuses of Valsalva and in the case of the auriculo-ventricular valves—especially the mitral—with fatty degeneration or atheroma of the cusps.

In **chronic endocarditis** of the **mitral valve** the chordae tendineae are usually thickened and *may* be shortened. They are often longer than normal. A constant feature is the extension of the fibrous alteration into the tips of the papillary muscles, and even into the substance of these structures. The vegetations may extend up into the angles between the segments, and thus will be produced what is actually, as a result of subsequent vascularization of the vegetations, lines of granulation tissue, which tend to grow together and fill up the angles with organized fibrous tissue firmly connecting the two segments along their margins, thus narrowing the orifice.

The inflammation in severe cases extends throughout the segments so that the segments tend to become shortened, contracted and thickened. The shape of the valve is altered so that it now forms a shallow saucer-shaped diaphragm with a crescentic opening placed towards its outer part,

the concavity of the crescent directed inwards ("button-hole" mitral), see Fig. 31.

The chordae may coalesce so as to form a thick curtain which makes the surface of the segments continuous with that of the papillary muscles. On the ventricular aspect of these "curtains" ridges corresponding to some of the old chordae are seen. The curtains may coalesce at their margins so that the valve assumes the shape of a flattened funnel (Fig. 30).

The greatly thickened fibrous tissue becomes of cartilaginous consistence and may be the seat of extensive calcareous deposit. Frequently this calcareous deposit is exposed on the auricular surface of the segments,

and covered with a little recent thrombus. It may extend beyond the ring of attachment of the valve and invade or press upon the auriculo-ventricular bundle of His, which passes close to the base of the anterior segment. This is one of the pathological changes which brings about the condition of "heart block."

While it is readily understood how stenosis of the mitral orifice is produced, it will also be understood that if the thickening of the segments be extreme, so that the margins of the opening are rendered extremely rigid, regurgitation of the blood will take place during systole, and stenosis and incompetence will co-exist.

Results in Heart and General Circulation. — Stenosis of the

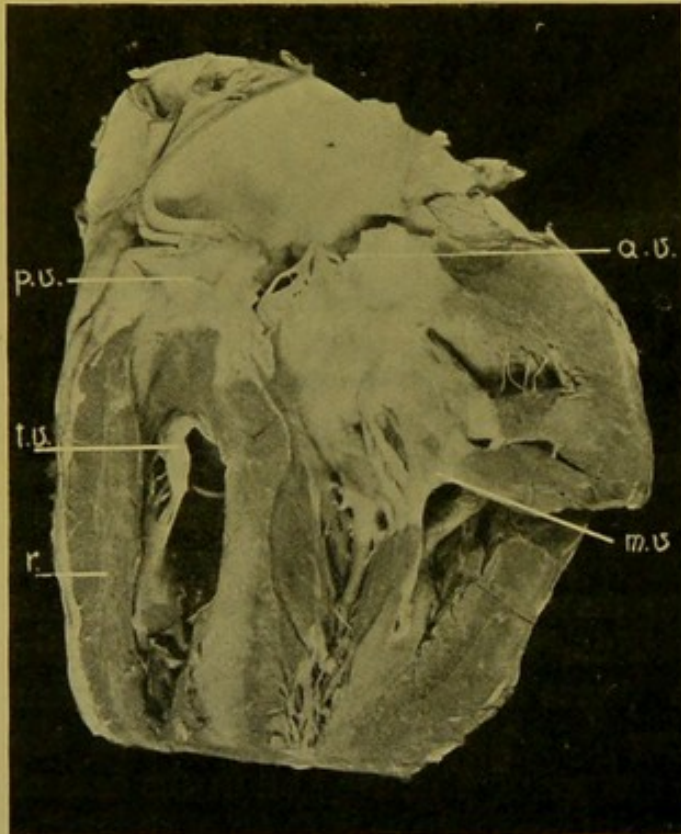


FIG. 30.—Chronic endocarditis of mitral valve, with stenosis. Hypertrophy of right ventricle. (m.v.) Mitral valve; (r.) wall of right ventricle; (t.v.) tricuspid valve; (p.v.) pulmonary valve; (a.v.) aortic valve. (× circ. $\frac{2}{3}$.)

mitral valve is characteristically associated with atrophy of the left ventricle, with dilatation and hypertrophy of the left auricle, with chronic venous hyperaemia in the pulmonary circulation, and later with dilatation and hypertrophy of the right side of the heart. If the left ventricle in such cases be hypertrophied, or hypertrophied and dilated, this is either the result of accompanying aortic stenosis or incompetence, or, if the aortic valve be approximately healthy, the hypertrophy is related to some cause outside the heart such as chronic disease of the kidneys, either accompanied by or dependent on arterial sclerosis.

The greater number of the foregoing remarks on the pathology of endo-

carditis apply also to the arterial valves—aortic and pulmonary—but certain points peculiar to these may be referred to.

Aortic and Pulmonary Endocarditis.—While endocarditis of the pulmonary valve is extremely rare, when it does occur it presents characters similar in all respects to those of aortic endocarditis, so that a separate description is not required.

The general phenomena of endocarditis at the aortic orifice are the same as those occurring at the mitral orifice, any difference depending upon anatomical peculiarities.

The vegetations are deposited upon the ventricular surface of the corpora Arantii, or in addition, in festoons along the bases of the lunulae. They may extend on adjacent cusps so as to meet in the angle be-

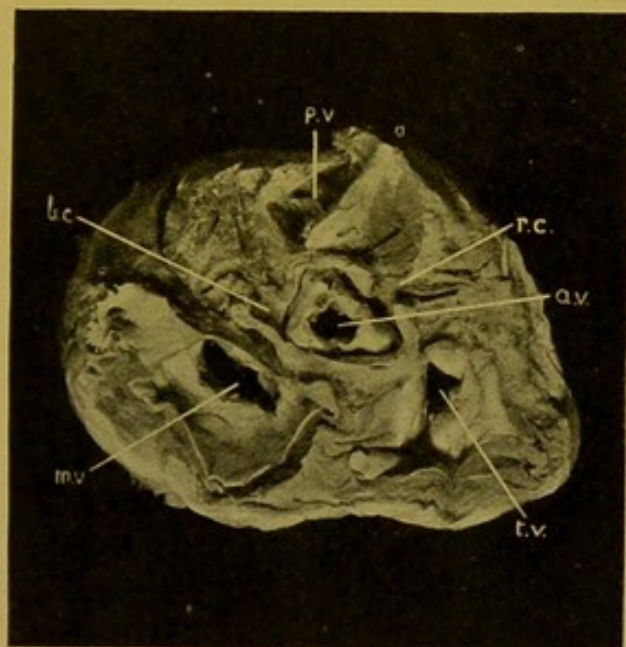


FIG. 31.—Chronic valvular endocarditis, with stenosis at mitral, aortic, and tricuspid openings. Pulmonary valve (*p.v.*) unaffected. ($\times \frac{2}{3}$.)

(*m.v.*) Mitral valve; (*a.v.*) aortic valve; (*t.v.*) tricuspid valve; (*l.c.*) left coronary artery; (*r.c.*) right coronary artery.

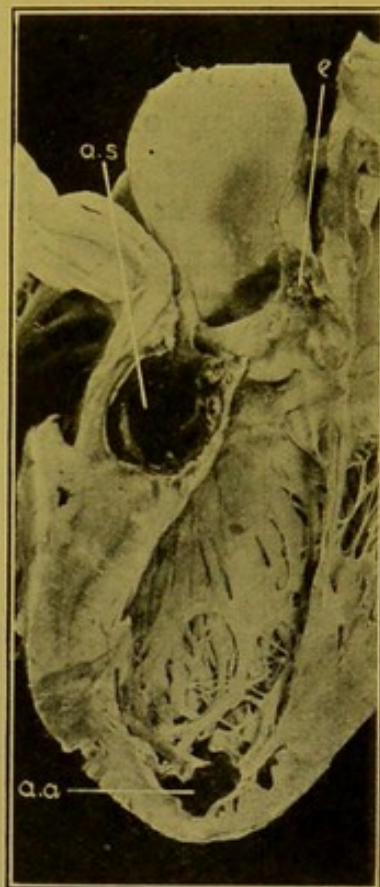

FIG. 32.—Aneurysm behind aortic cusp, extending into ventricular septum (*a.s.*). ($\times \frac{1}{2}$.)

(*e.*) Endocarditis in angle between two cusps; (*a.a.*) small aneurysm at apex of left ventricle.

tween them, and just as in the case of the mitral and tricuspid valves, the cusps may become adherent in one, two, or all of the angles.

The adhesion may be so moderate in extent that appreciable stenosis does not result.

When adhesion occurs in all three angles it may bring about fusion of the cusps so that the altered valve forms a diaphragm across the opening with a small, more or less triangular, opening in its centre. All degrees and modifications occur, depending on the amount of contraction of the cusps, the extent of adhesions, the degree of fibrous thickening and cal-

careous deposit, with consequent rigidity of the valve, allowing of regurgitation—Incompetence associated with stenosis. (Fig. 31.)

Aneurysmal hollows may form in thickened cusps, or in the adhesions between them, large enough to admit the tip of the forefinger. When this occurs, the relation of the hollow to the ventricular septum, ventricle or auricle should be noted, as aneurysm of a sinus of Valsalva may extend into the septum ventriculorum (Fig. 32).

Incompetence of a valve may be brought about by a "giving" of its ring of attachment and of the supporting muscle; or it may be due to rigidity of the cusps in chronic endocarditis as already explained (p. 80; *see also* p. 84).

Another contributory cause of incompetence must also be mentioned. In at least four cases, mostly of syphilitic nature, I have found flattening and thickening of the aortic cusps and lengthening of their free margins. The cusps were more or less tongue-shaped, and had flapped backwards and forwards in the current of blood, *see* Fig. 21, p. 67.

No sharp line of demarcation either as to etiology or morbid anatomy can be drawn between the so-called *simple* endocarditis and the *ulcerative* or *malignant* variety. The difference is one of degree, and the interval between them is filled up by the varieties of endocarditis which come under the term "*redundant*." It is convenient to consider these severer forms of endocarditis separately. Some of their results have already been considered along with those of "simple" endocarditis.

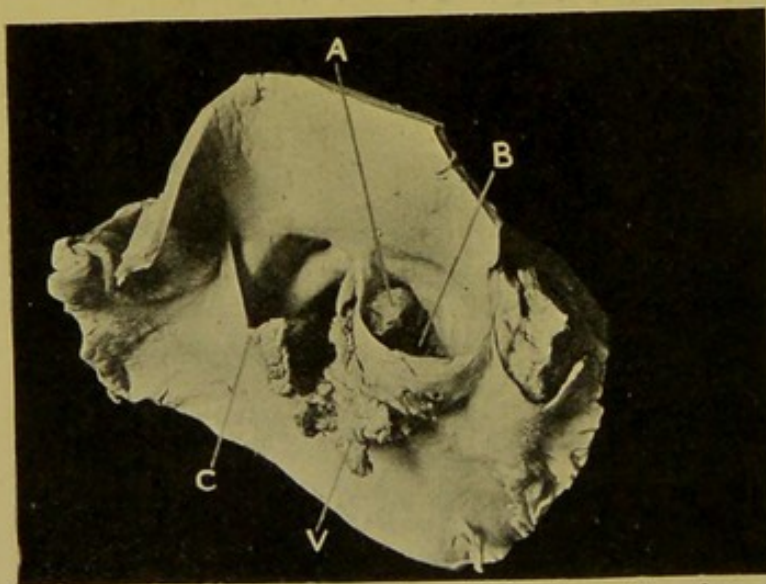


FIG. 33.—Ulcerative endocarditis of aortic valve.
($\times \frac{2}{3}$.)

(A) Opening which has formed between adjacent sinuses of Valsalva; (B) opening into aneurysmal dilatation which ruptured into conus pulmonalis; (C) part of ruptured cusp, edge of rupture covered with granulations; (V) other part of cusp, elongated by deposit of vegetations. (Mus. R.C.S. Ed.)

as can be determined with the naked eye, but, particularly in the case of the valves on the left side of the heart, one has to go only a short distance before meeting with the varieties included under the term "*ulcerative*" endocarditis. "Redundant" endocarditis may proceed to breaking down and ulceration.

In "**Redundant**" **Endocarditis** the vegetations are more extensive or thicker than in simple endocarditis, e.g. in the case of the arterial valves they may extend over the ventricular surfaces of the cusps and even on to the mural endocardium. In the auriculo-ventricular valves they may form flattened polypoid or tongue-shaped processes (up to 1 cm. in length) attached near the margins of the segments. These redundant vegetations may show no tendency to break down, at least so far

Ulcerative Endocarditis.—In ulcerative or malignant endocarditis changes occur similar to those described under the heading of redundant endocarditis, but in addition there are the results of what is practically abscess-formation and breaking down or ulceration of the valve segments. The inflammatory processes are necessarily more active and wide-spread than in the so-called simple endocarditis and the segment becomes infiltrated, softened, and bulges in an aneurysmal fashion. Sooner or later the weakened part gives way and leaves either a ragged opening which extends to the free margin of the segment, or an aperture or perforation in the segment. The margins of the opening in either case are usually covered with infective vegetations (Fig. 33). If the

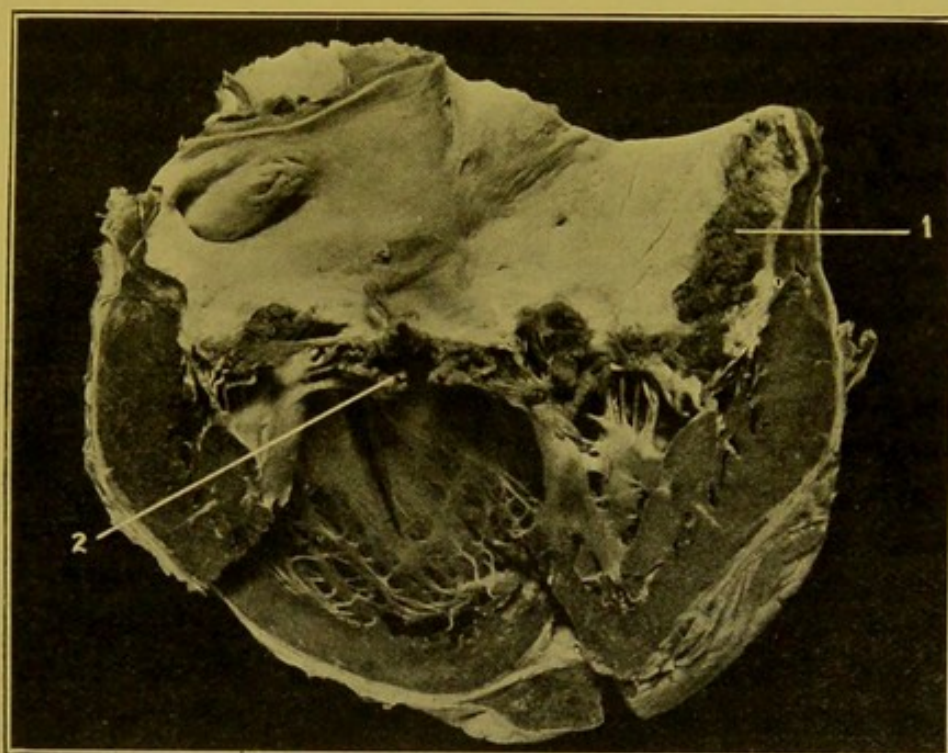


FIG. 34.—Ulcerative endocarditis of mitral valve. (\times circ. $\frac{1}{2}$.)
(1) Mural endocarditis, right auricle; (2) ruptured chorda covered with vegetations.

defect extend to the free margin of the cusp as in the case of the aortic valve, the free portions of the cusp become elongated by deposit of blood-platelet thrombus until in extreme cases they may form long whip-like processes more than an inch (2.5 cm.) in length. These float backwards and forwards in the blood stream and where they strike against the ventricular endocardium below, and the intima of the aorta above, they cause in the former case acute endocarditis, and in the latter local acute aortitis with the result that an acute aneurysm develops, the interior of which is covered with vegetations.

In the case of the mitral cusps the ulcerative endocarditis extends to the chordae, which soften and may rupture (Fig. 34), causing very marked incompetence in the valve with severe dyspnoea during life. (See also

*Ulcerative
whip-like
vegetations
&
acute
endocarditis
of mitral
valve
causing
Aortic
T. infert
Endoc*

*Heart
filari
cabin*

*valv
valv*

Rupture of Papillary Muscles, p. 75). If healing take place the subsequent thickening and retraction of the cusps are necessarily greater than in the case of a less severe—"simple"—endocarditis. Calcification is also marked.

Chronic aneurysms of the cusps tend to develop as a result of the severe forms of endocarditis. These are most commonly seen on the mitral segments, particularly the anterior one. They project towards the auricle, forming rounded or polypoid prominences on the auricular surface of the valve, their orifices being visible on the ventricular aspect. Their walls may consist simply of the thickened portion of the segment or they may be lined with recent vegetations, and may be perforated at their most prominent points, vegetations projecting through the openings towards the auricle.

Apart from the valvular incompetence produced by acute ulcerative endocarditis, a very serious result is the breaking down and carrying away in the blood stream of fragments of the infective vegetations, which act as septic emboli and produce pyaemia in the systemic arterial circulation.

* Acute Endocarditis is generally associated with acute changes in the myocardium.

Bacteriology.—In all cases of endocarditis in which the post-mortem is conducted within a few hours after death, an attempt should be made to cultivate the organisms present in the vegetations. In *simple* endocarditis the diplococcus described by Poynton and Paine—*Diplococcus rheumaticus* (*Streptococcus faecalis*)—should be sought for. The tendency at the present day seems to be to pay a little more attention to this micro-organism as an etiological factor, but important authorities refuse to allow that it is of any etiological importance. The great bulk of the cases of acute simple endocarditis occur as a complication of acute articular rheumatism; and, as pointed out by Beattie, in these cases it is important to make cultivations from the inflamed synovial fringes in the affected joints, as well as from the local cardiac lesions. Tonsillitis also frequently precedes the disease.

In ulcerative endocarditis any association with lobar pneumonia, or localized empyema, or with any of the acute zymotic diseases should be noted. The blood and vegetations should be investigated for the presence of *pneumococci*, for the ordinary pus cocci—*streptococci*, *staphylococci*—*gonococci*, influenza bacilli and many others, some indication being given by the nature of the preceding or accompanying disease.

THE CAVITIES OF THE HEART

After opening up the cavities the amount and condition of the blood clot still remaining should be noted. If the blood has been fluid the cavities are now empty. If clots persist within it, the time of their formation—whether ante-mortem or post-mortem—should be determined.

The Characteristics of Ante-mortem Thrombi and of Post-mortem Clots.—

Thrombosis means the coagulation of blood within the cavities of the heart or within the blood-vessels during life. The necessary factors are, a slowing of the current and some pathological change in the endothelial lining—either roughening of it or removal of it. In the latter case, the sub-endothelial connective tissue is exposed. To such surfaces blood-platelets readily adhere, particularly if the current be slow, and the thrombus increases in size usually by deposition of white corpuscles and formation of fibrin, which at a later stage may show vascularization and organization. Hence, ante-mortem thrombi are *all* more or less *adherent* to the wall of heart or vessels, and this has to be looked upon as their principal distinguishing characteristic.

Ante-mortem Thrombi are usually pale, and of a greyish or pale-fawn colour. In the heart they are usually polypoid (Laennec), projecting in the auricles from the appendices (Fig. 35) or between the muscoli pectinati, and in the ventricles between the columnae carneae. Occasionally a thrombus projecting from the auricular appendix increases in size until it fills the cavity of the auricle. Thrombosis occasionally begins behind the outer auriculo-ventricular valve segments, and, in these cases the subjacent myocardium should be examined for pathological changes. In all these situations, slowing of the current is an important factor in the causation. Aneurysms of the heart always contain laminated thrombus. (See Fig. 26, p. 74.)

Ball or Globular Thrombi lying free in the cavities form exceptions to the general rule that ante-mortem thrombi are always adherent to the wall. Such thrombi have probably been adherent at an earlier stage in their formation, and, on becoming free, being too large to pass onwards through the valvular openings, which in such cases are much stenosed, have become in course of time still larger from deposit of laminated thrombus. Globular thrombi are not common. They are found most often in the left auricle, but may also occur within the ventricles.

A very good example of globular thrombus associated with marked stenosis of the mitral orifice is preserved in the Museum of the Royal College of Surgeons, Edinburgh. It was described by William Wood, a Fellow of the College, in the *Edinburgh Medical Journal*, 1814, No. 10, p. 50. It has been referred to as the first case described, but Mr. Wood in this paper

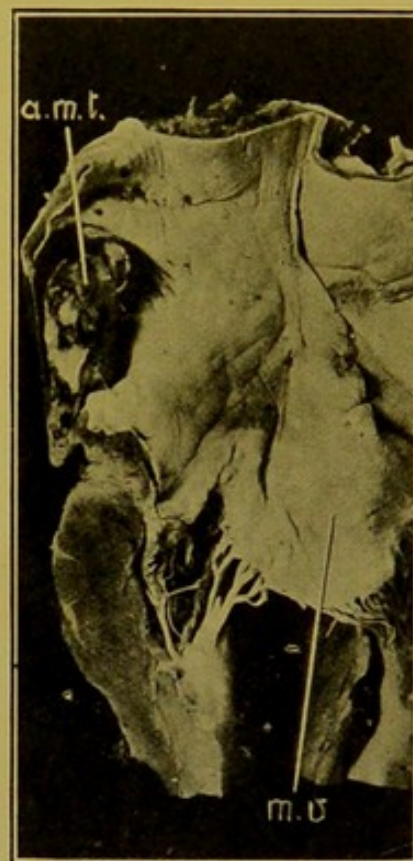

FIG. 35. — Ante-mortem thrombus in left auricular appendix (a.m.t.). (\times circ. $\frac{2}{3}$.)
(m.v.) Anterior mitral segment.

refers to other published cases. The patient was a girl of fifteen years of age who had suffered from great dyspnoea for three years before her death. No special symptoms were referable to the presence of the thrombus, which was accompanied by two other smaller thrombi. It was rather more than $1\frac{1}{2}$ in. in diameter, its surface was smooth and polished and had a singularly dotted appearance (Fig. 36).

Cardiac thrombi, when of any size, are usually fluid in the centre. This is the result of softening, which may be "simple"—i.e. no bacteria can be detected, either by cultivation or by microscopic examination. If, on the contrary, pyogenic organisms can be demonstrated, the softening

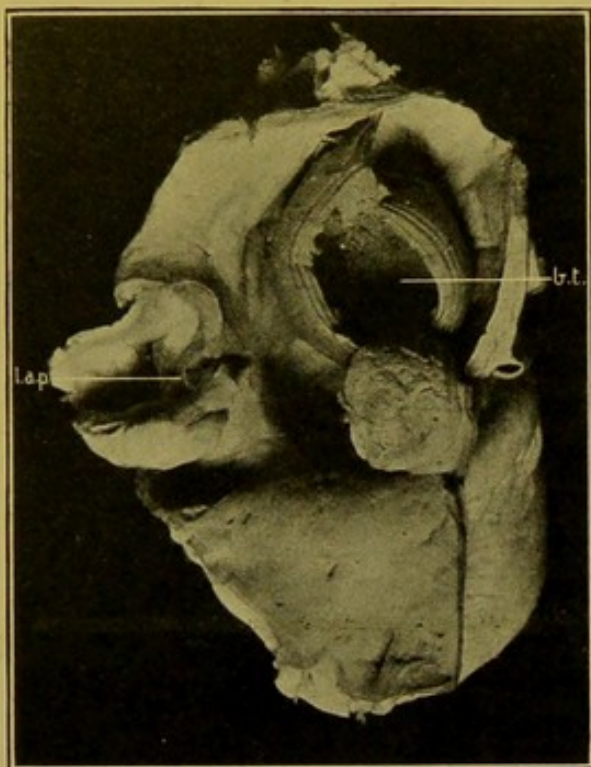


FIG. 36.—"Ball thrombus" in left auricle.
(\times circ. $\frac{1}{2}$.)

(b.t.) Thrombus; (l.a.p.) left auricular appendix.
(Mus. R.C.S. Ed.).

is termed "puriform." Fragments of thrombi, or of vegetations upon the valves—blood-platelet thrombi—may be carried off in the blood stream and act as "emboli." Those from the right side of the heart become impacted in branches of the pulmonary artery, whereas those from the left side are caught in the systemic circulation. Occasionally, separated fragments of ante-mortem thrombi are found in the cavities of the heart entangled in post-mortem clots.

Post-mortem Clots.—Various though the appearances of the post-mortem clots may be, they all have this character in common, that they do *not* adhere at all to the walls of the cavity in which they form. Some authorities include with them the "agony" or "agonal" thrombus.

Typical post-mortem clots are readily turned out of the cavities of the heart when these are opened. The blood may have simply coagulated after death and forms a soft cast of the cavity; or the red corpuscles have had time to settle down to the lower (posterior) part of the cavity and a "buffy" layer develops in the upper part. Some fibrin is present in this layer and in it also is found the greater number of the white corpuscles. The presence of fibrin gives it a firmer consistence than the red layer underneath which closely resembles black-currant jelly, both in appearance and consistence. Post-mortem clots, however, may be pale and watery (oedematous clots). In cases of leucocythaemia the clot is also pale, and may be of a lemon-yellow colour, and if separation of the corpuscular elements have taken place the proportion of the pale upper part is greater than in the

ordinary blood clot. Again, in cases of lipaemia, for example, in certain forms of diabetes, the excess of fat may lie in a thick layer in the upper part of the clot. This appearance, however, is not at all common, even in diabetes.

Post-mortem clots may show apparent adhesion if the tougher parts become entangled between the chordae tendineae, or columnae carnae, and this is very frequently mistaken for the adhesion characteristic of true ante-mortem thrombosis.

“Agony” or “Agonal” Thrombi.

—At the very end of life when the circulation is at a very low ebb, particularly in diseases such as lobar pneumonia, in which the coagulability of the blood is increased, and in cases in which death has been a slow process, a firm, stringy, tough, pale-yellow thrombus forms in the cavities, particularly on the right side of the heart. When it forms on the left side it is usually less extensive. The thrombosis commences usually in the auricular appendix, or behind the segments of the auriculo-ventricular valve or between the columnae at the apex of the ventricle. The thrombus may completely fill the cavity of the right ventricle, and extend upwards into the pulmonary artery, in well-marked cases forming a cast of this vessel and its branches, even to the finest ramifications (Fig. 37). Where it passes through the arterial opening it bears projections, corresponding in shape, though not in size, to the sinuses of Valsalva. This variety of thrombus is often termed “ante-

mortem stringy thrombus,” though, considering the period of its formation, and the circumstances under which it develops, it should be classed rather with the post-mortem clots. It is pale throughout, firm, and can be split up longitudinally. It is sometimes so entangled amongst the columnae, or the chordae, that the heart can be suspended by it. There is no true adhesion, however, and no organization as a rule.

At times, all varieties of thrombi and clot may be present together.

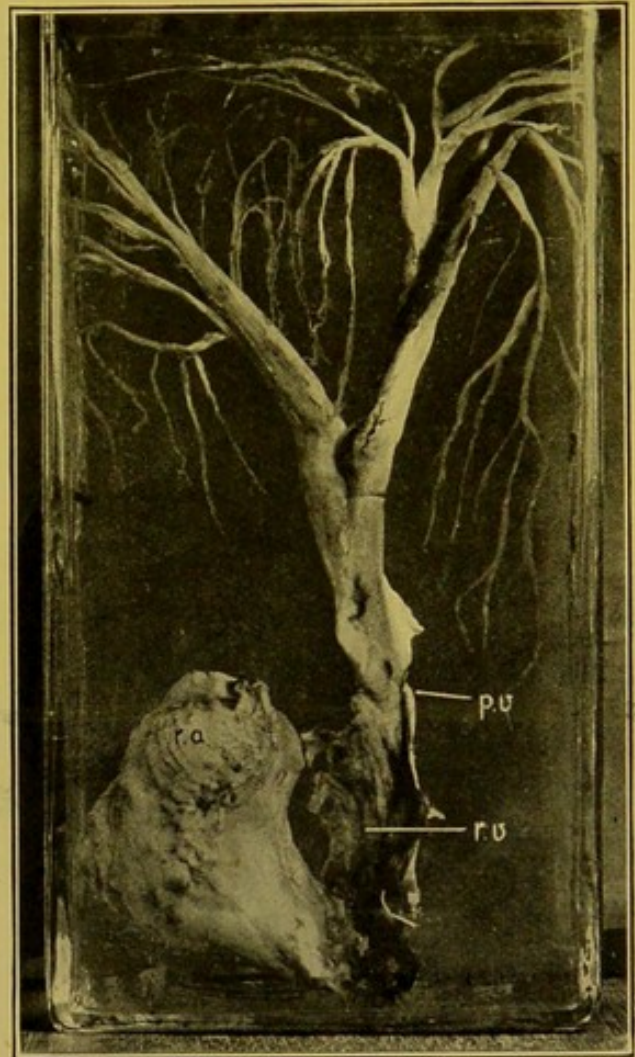


FIG. 37.—Agonal thrombus. ($\times \frac{1}{2}$.)

(*r.a.*) Portion from right auricle; (*r.v.*) portion from right ventricle; (*p.v.*) constriction corresponding to position of pulmonary valve.

—(From Dr. J. D. Comrie's collection.)

It must not be forgotten that red ante-mortem thrombi may form in systemic or pulmonary veins, and they are not necessarily adherent to the walls, but they will always be found in relation to, and formed upon, occluding pale, laminated, adherent thrombi. If a pale, firm thrombus is found loose in an artery—that is, excluding the “agonal” thrombus—it has almost certainly been transferred from its site of origin somewhere in the venous circulation. (*See Embolism, p. 104.*)

Pedunculated Polyps of the Heart.—These structures are organized

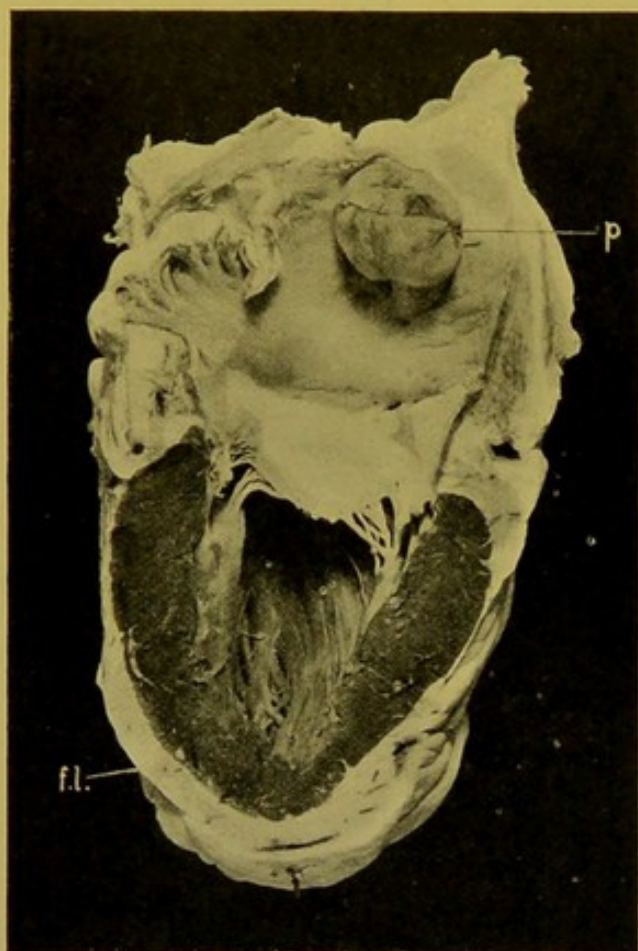


FIG. 38.—Pedunculated polyp of heart.
(\times circ. $\frac{1}{2}$.)

(p.) Polyp in left auricle; (fl.) fatty loading over left ventricle.

formations, in most cases springing from the wall of the left auricle, usually near the fossa ovalis (Fig. 38). The pedicle is sometimes narrow, sometimes broad. They are firm or gelatinous, elastic, ovoid or pear-shaped formations, in some instances hanging down into the left ventricle with a constriction corresponding to the mitral orifice. The surface is usually glistening, smooth, and covered with a distinct membrane which often resembles the endocardium. They may present calcified, fatty or pigmented patches, and upon the surface there may be irregular knobs and depressions. In colour they are yellowish-grey, dark red or brownish-red, the colour often varying in different parts of the polyp. These polyps are more or less organized, the organization in some being little marked, in others so advanced that their structure resembles that of a fibroma or myxoma.

It has been suggested that they may be related to varicose veins which may develop near the posterior border of the fossa ovalis. Some are evidently partly organized thrombi attached to diseased patches of the heart wall. (Welch.) They have to be distinguished from the ordinary globular or polypoid thrombi.

DISEASES OF THE CORONARY ARTERIES

For Anatomy, see page 57.

Diseases.—The orifice of the arteries may be partly or completely blocked by atheroma of the aorta. This is looked upon as specially characteristic

of the syphilitic form of that disease. In adults the coronary arteries themselves are very commonly the seat of **atheroma**. Both vessels may be affected, but usually the condition is more marked in the left coronary artery, particularly in its descending branch.

In rare cases the vessels may be completely occluded by thrombosis.

Syphilitic endarteritis (productive or obliterating endarteritis) is not so frequently seen. For final diagnosis the microscope is necessary in many instances.

The relationship of the foregoing conditions to infarction of the heart muscle (myomalacia cordis), chronic interstitial myocarditis, aneurysm of the heart wall, diffuse fatty degeneration with dilatation of the cavities, should be determined.

The coronary arteries are very rarely the seat of **aneurysmal dilatation**. The aneurysm is of small size and usually ruptures into the pericardium, occasionally into the pulmonary artery.

Spontaneous rupture of the artery is exceedingly rare.

In hypertrophy of the heart the coronaries are as a rule healthy or approximately so. Létulle notes that hypertrophy of the heart may develop even if the coronary arteries are blocked.

CHAPTER VI

DISEASES OF BLOOD-VESSELS

(See also Diseases of Coronary Arteries, p. 88.)

Mechanical Injuries.—Rupture of arteries may occur under varied circumstances, but they come under the notice of the pathologist chiefly in connexion with fractures or dislocations of bones and joints, as in the cases of the popliteal, brachial and middle meningeal arteries. Occasionally, pressure of fragments of bone in badly united fractures may bring about formation of false aneurysms, e.g. in the case of the popliteal artery.

Tumours of the Blood-Vessels.—**Angioma.**—The common variety of angioma as occurring in the sub-cutaneous tissues forms a more or less

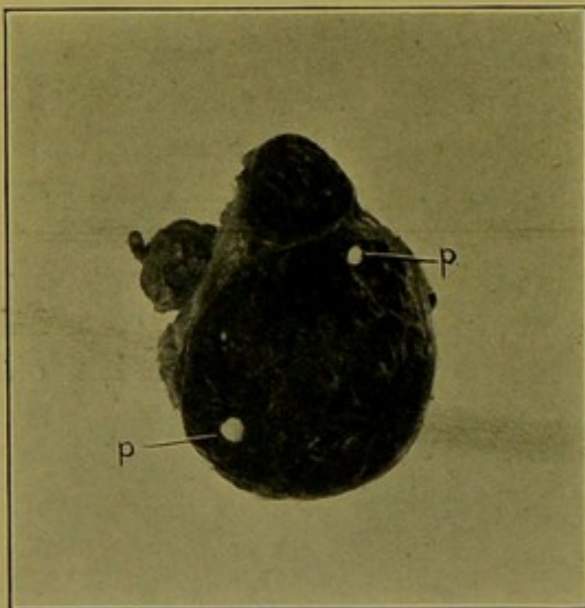


FIG. 39.—Angioma, almost natural size, with phleboliths (*p.*).

rounded or flattened dark reddish-purple mass. The cut surface is spongy, particularly when some of the blood has escaped, and in the substance of the tumour numerous hard pearl-like shotty nodules may be seen. These are calcified thrombi—phleboliths (Fig. 39).

Congenital angiomas may cause great deformity, for example in the hands of infants. They are also found in the form of diffuse subcutaneous naevi in various parts of the body.

For **Cavernous Angioma** *v. Liver*, p. 252.

Atrophy of the arteries may occur in chronic anaemia, and general marasmus, or in atrophy of individual

organs. After amputation of a limb the main artery becomes abruptly narrowed and in the stump may be converted into a fibrous cord.

In **Hypertrophy** of arteries the vessels elongate, become tortuous and their walls thickened. This is seen in the uterine artery during pregnancy, or in the renal artery supplying a kidney which is hypertrophied to compensate for atrophy of its fellow.

Degenerations.—**Cloudy Swelling** of the endothelium is very common in conditions which cause high temperatures, and in certain poisonings.

Fatty degeneration of the endothelium is very common and is due in many cases to the action of toxins, or in other cases to mal-nutrition. In the aorta the condition is constantly mistaken for nodular atheroma. It is commonly found in the first part of that vessel just above the valves, but it may also be found in the descending aorta and in the great vessels. In the pulmonary artery it is not uncommon. The endothelial cells, and the sub-endothelial connective tissue cells of the intima are affected.

To the naked eye the change appears as delicate yellow streaks and spots usually projecting slightly upon, and irregularly scattered over, the surface of the intima (Fig. 40). It may proceed to superficial erosion, a rough surface being left upon which thrombosis may occur. These erosions are chiefly met with in young individuals and are found in some cases of tuberculous excavation of the lungs.

In the middle-sized and smaller arteries fatty degeneration may affect the muscle fibres of the *media*, e.g. in phosphorus and alcoholic poisoning. In this situation it is often associated with calcareous deposit. In minute arterioles and in capillaries it chiefly affects the endothelial cells, being evident in these firstly in the neighbourhood of the nuclei. It is one of the important causes of capillary haemorrhage in the aged.

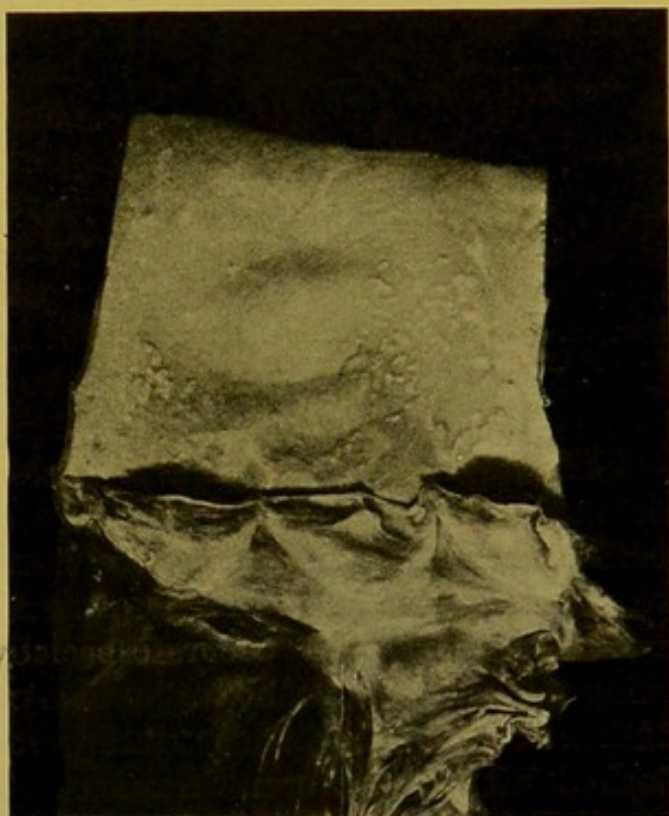

FIG. 40.—Fatty degeneration of endothelium and intima; aorta. (\times circ. $\frac{3}{4}$.)

Calcification.—(1) Calcification associated with atheroma and arterial sclerosis will be noted later.

(2) In old age, calcification frequently occurs, the deposit taking place chiefly in the *media* of the medium-sized vessels. The muscle fibres are first affected, probably previously undergoing fatty degeneration. To the naked eye, the calcareous deposit is seen to form closely apposed rings and segments of rings encircling the vessels (Fig. 41). In parts, the deposit may form a continuous calcareous tube ("pipe-stem" arteries). The condition is also found in the cerebral vessels in some forms of insanity. Thrombosis readily occurs in such arteries. This condition is often associated with nodular atheroma in the aorta or even in the same vessel.

Waxy or Amyloid Degeneration commences in the small arterioles just before they break up into the capillary network. The connective tissue of

the media is first affected and then the condition extends to the connective tissue of the intima. Occasionally the adventitia is affected. In larger arteries the intima may be affected primarily. This change is best demonstrated in microscopic sections by staining with methyl violet.

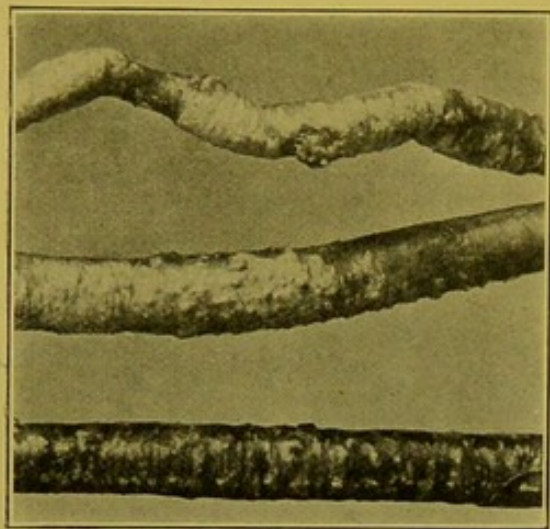


FIG. 41.—Senile calcification of media of large arteries. (\times circ. $\frac{1}{2}$.)
(Mus. R.C.S. Ed.)

“**Endarteritis**” or simply “**Arteritis**.” (A) **Acute Endarteritis**.—This condition is sometimes put down to traumatism, but usually it results from the action of specific poisons and infections, spreading locally or generally.

The characteristic appearances are best seen in the aorta, though here the condition is rare. Rounded, somewhat gelatinous patches of a greyish colour develop on the inner surface. These become pink, but possibly this is a post-mortem change due to absorption of haemoglobin. On the patches, e.g. in the presence of infective endocarditis, deposit of fibrin may take place.

Microscopically, the intima is thickened and infiltrated with leucocytes. The media also is infiltrated and the vasa vasorum are dilated. Frequently there is necrosis of the connective tissue cells of the intima. The changes are essentially the same as those found in inflammation elsewhere.

Suppurative Arteritis occurs especially in the neighbourhood of suppurating wounds. It usually begins as a peri-arteritis, the adventitia becoming infiltrated with pus which gradually extends inwards. The lumen becomes blocked with a puriform thrombus. The condition may also develop as the result of septic embolism; and in this case, as a result of acute inflammation of the wall of the vessel, an acute embolic aneurysm may result. This happens most frequently in the arteries of the limbs, though I have seen it also in a branch of the superior mesenteric artery. The patient—a young woman—died from rupture of the aneurysm, and haemorrhage into the peritoneal cavity.

(B) **Chronic Endarteritis**.—It is a question whether this name is permissible for a condition in which there are none of the characteristic signs of inflammation, the change being rather of the nature of strain hypertrophy followed by degenerative changes. Two forms may be described which are usually known under the names of **Atheroma** and **Arterial Sclerosis**.

Seeing that the etiology of the two conditions may be similar, most authors speak of them together as the *nodular* and *sclerous* varieties of *arterial sclerosis*. I shall describe them as separate conditions, as, in my opinion, this method of dealing with the subject tends to a better comprehension of the pathological changes.

(a) **Endarteritis deformans.** (Synonym—**Atheroma.**)—This is a condition in which irregular fibrous thickening of the intima occurs, the thickening showing a constant tendency to undergo degeneration. The causes may present great variety, amongst the most important being the action of toxins, chemical or bacterial, e.g. alcohol, and syphilis; some writers include gout and lead-poisoning.

Whenever it is met with at ages below forty or fifty, a syphilitic origin should be suspected.

The change depends upon excessive strain upon an area of the wall the nutrition of which is defective. The primary change is usually a "giving" of the media, the media having undergone degenerative changes as a result of obliterative endarteritis of the vasa vasorum. Local dilatation of the vessel takes place and the intima becomes compensatorily thickened to fill up the hollow and to afford a resistance equal to that of the rest of the wall of the vessel. In the aorta, the patches appear to the naked eye as more or less circular areas, raised *post mortem*, somewhat translucent at first and of a pinkish-grey colour, the margins usually gently sloped. They are usually multiple. (Fig. 42.)

As the strain continues the deeper parts of the thickening, i.e. the parts farthest removed from their nutritive supply—whether from the vasa vasorum or from the lumen of the vessel—undergo degenerative changes, firstly, as a rule, hyaline and fatty, the latter change causing a yellow opacity to develop in the centre of the patch. As this extends throughout the patch, it produces a soft pulpy or porridgy mass which gives the name "atheroma" to the condition. This stage may go on to calcareous deposit, or calcification may follow directly upon the hyaline degeneration. A calcareous plate is produced which either is localized to the deeper part of the patch or involves the whole of it, in the latter case being covered with endothelium only. The plates may be extremely dense, very similar to dense bone, and are more or less curved, showing the original curve of the wall. They may be found at any part of the aorta, but especially at its commencement, in the transverse part, and in the abdominal aorta, where the calcareous deposit may occasionally reach a thickness of one-quarter of an inch, and present a curious coralline aspect.

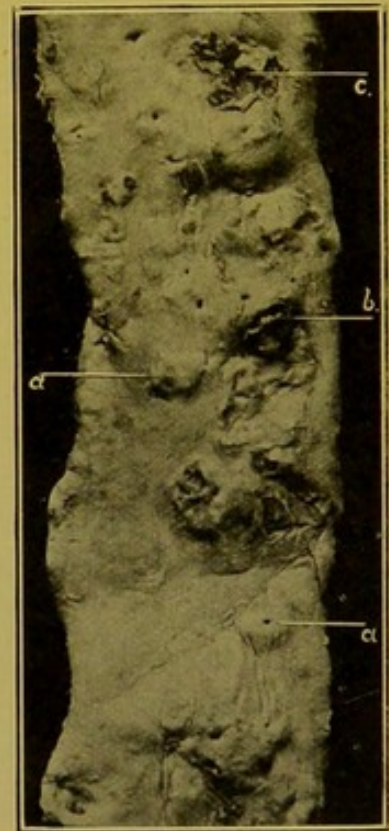


FIG. 42.—Atheroma of descending aorta. (\times circ. $\frac{1}{2}$.)

(a) Early patches, which in this case were especially localized to origins of intercostal arteries; (b) patch breaking down, ready to be discharged into blood-stream; (c) atheromatous ulcer.

The position of the patches is determined by the amount of strain to which the vessel has been subjected. For example, in the aorta they occur just above the aortic valves; on the convexity of the arch; at the origin of the great vessels; at the junction of the first and second parts of the aorta; where the aorta passes through the diaphragm; and surrounding the origins of the intercostal and lumbar arteries.

In the early stages the microscope reveals new-formation, in the intima, of fibrous tissue in laminae. Soon the cells between the laminae undergo fatty degeneration, appearing as narrow spindle-shaped collections of oil droplets with the nuclei of the cells in the central part. Later, the laminae undergo similar degeneration, which may be preceded by hyaline degeneration. In complete degeneration the deeper softened parts are made up of irregularly clustered oil droplets, fatty acids, cholesterolin crystals and fragments of broken-down tissue; no nuclear stain is taken. The degenerating patch may invade the inner layers of the muscular coat.

As a rule, there is no cellular infiltration or vascularization of the intima, just as in arterial sclerosis. Whenever in a condition apparently atheromatous, vessels can be seen in intimal thickenings, a syphilitic origin may be suspected, or the thickening may represent the remains of an organized thrombus. In this case haemosiderin pigment may be seen in the new tissue.

The muscular coat is frequently thinned at the part corresponding to the centre of the patch, but this is not always evident, though there is always some fatty degeneration of the muscle fibres. Usually, some of the vasa vasorum are almost obliterated, particularly in cases of syphilitic origin, and their outer coats are infiltrated with lymphocytes. As these vasa are followed up through the media they are frequently seen to be surrounded by cellular connective tissue which is developing at the expense of the media.

The *endothelium* lining the vessel is usually unaffected.

Such is the appearance as found in the aorta and larger trunks.

In *smaller vessels*, such as the coronary arteries, the basal arteries, especially these entering into the formation of the circle of Willis, the cerebral arteries, and less commonly the renal arteries, the patches present the appearance of whitish or yellowish nodules, which are very frequently calcified. The thickening is not symmetrical, thus altering the shape of the lumen.

The microscopical examination is guided by the position of the elastic lamina, to the inner side of which the thickening takes place, and the pathological changes correspond almost exactly to those described in the case of the aorta.

Further Results of Atheroma.—(1) In the aorta, thrombosis is common, the fibrinous deposit upon the patch being usually thin; in rare cases, large oval masses of thrombus may form. Smaller vessels may become blocked by thrombosis.

(2) In the aorta the patch may soften and its contents be discharged into the blood stream, or calcareous plates may be dislodged, in either case an "atheromatous ulcer" being left. The detached materials act as emboli and occasionally produce embolic aneurysms. The blood may dissect its way through the base of an atheromatous ulcer, penetrating either to the exterior of the vessel or working its way back into the channel,—⁽³⁾ "Dissecting Aneurysm." (See also p. 99.)

(3) In the larger vessels atheroma is the commonest cause of aneurysm.

(4) The interference with the lumen of smaller arteries causes local anaemia and gives rise to atrophic or degenerative changes in the parts supplied.

(5) The increase in the rigidity of the vessels gives rise to hypertrophy of the left ventricle.

(6) **Arterial Sclerosis.**—"Arteriosclerosis." This is a condition of thickening of the arterial wall which may occur independently of syphilis or of atheroma. It may be looked upon as an indication of ageing of the vessel, more or less physiological in old age, but when occurring below the age of forty or fifty it is distinctly pathological. The change primarily affects the media. At first, it may be of the nature of a hypertrophy to compensate for dilatation, but sooner or later a fibrous overgrowth occurs in the media, and subsequent to or possibly simultaneously with this, the intima undergoes great and regular hypertrophy, the endothelium taking no part in the change.

Though the fibrous thickening is especially seen in the intima and media, it usually also affects the outer coat to some extent. The typical pulpy change of atheroma is absent. Calcareous deposit is frequently seen in patches in the media and even in the outer layers of the intima. In several cases in the aged I have seen invasion of the media by granulation tissue, in which there was formation of true cartilage and bone, e.g. in the posterior tibial artery.

The walls are more rigid than normal, the medium-sized and smaller vessels tending to remain open when cut across. The aorta in such cases may show no atheromatous change, or be affected only to a moderate degree. In the smaller vessels, particularly in the limbs, thrombosis may occur with dry gangrene as a result. A change similar to this, but especially affecting the intima is found in the neighbourhood of chronic interstitial inflammations, e.g. of the lung, and also in obliteration of vessels after ligature. The closure of the ductus arteriosus is brought about by a similar mechanism.

ANEURYSM

An aneurysm is a localized persistent dilatation of the wall of the heart or of a blood-vessel, resulting from the giving way of the middle coat. In most cases it is associated with atheroma, but this may be absent. It may occur (1) in any of the severe infections, in which a patch of mes-arteritis

may lead to localized weakening of the wall; (2) in various intoxications, such as alcoholic, lead and tobacco poisoning, and as a result of endogenous poisonings, as in gout, diabetes and Bright's disease. External injury may determine a rupture of the aorta with formation of a dissecting aneurysm.

True aneurysms are those in which the sac is formed of one or more of the coats of the vessel. If the wall of the sac communicating with the vessel consists of other tissues, it is termed a *false* aneurysm. True aneurysms may be *fusiform*, *cylindrical* or *diffuse*—the stretched media being demonstrable in patches in their walls—or it may be *sacculated*, forming a projection on one side of an artery more or less sharply marked off from the lumen of the vessel. In sacculated aneurysms, all the coats of the vessel can be distinguished near the communication with the artery, the media first disappearing and then the intima. The greater part of the wall is thus composed of adventitia which undergoes fibrous thickening. The whole of the area of the sac devoid of intima is lined and filled with laminated thrombus.

If an aneurysm impinges upon a bone, e.g. in pressure upon the vertebrae, the wall is completely wanting over the exposed surface of the bone.

Organization of the thrombus in an aneurysm does not usually occur. It may occasionally take place in small sacculated or fusiform aneurysms.

The tendency of an aneurysm is to increase in size, and when it comes in contact with *hard* structures, such as bone or cartilage, it causes erosion of these. This is more evident in a vascular tissue, such as bone, than in cartilage, which has to be vascularized before it can be absorbed.

Frequently a secondary false aneurysm intervenes between the parent sac and the structure pressed upon. When it presses upon soft structures, such as *mucous* membranes, e.g. of trachea or of any part of the alimentary tract, it firstly causes catarrh of the surface and an oozing of blood into the hollow viscus. Later, it interferes with the blood supply of the area more intimately pressed upon, and causes necrosis and rupture. When an aneurysm presses upon *serous* membranes, e.g. pleura, adhesions form through which blood may escape slowly into the lung. The *skin* is very resistant to pressure. It seldom gives way unless ulceration takes place or unless its nutrition is interfered with to such an extent that necrosis occurs over the projecting part of the aneurysm.

Effect upon the Heart.—Apart from the direct effects of aneurysm occurring in the first part of the aorta, the work of the heart is usually increased, so that as a rule the left ventricle is hypertrophied. Frequently, however, even in presence of large aneurysms of the aorta, I have seen the left ventricle of normal thickness or even atrophied.

Common Situations of Aneurysms.—In order of frequency the vessels affected are—thoracic aorta, popliteal artery, femoral artery, abdominal aorta—especially in the neighbourhood of the coeliac axis and the origin

of the mesenteric arteries—carotid, subclavian, innominate, axillary and iliac arteries. Other vessels are much less commonly affected, e.g. the splenic artery, the coronaries, the bronchial arteries,—even affecting intrapulmonary branches,—hepatic artery, gluteal artery, cerebral arteries—of which, in my experience, the anterior cerebral is most frequently affected—and the superior mesenteric artery or its branches.

Aneurysms of Thoracic Aorta. —

Aneurysms of the ascending aorta may press upon the coronary artery, and may rupture into the pericardium, pleura, trachea, lung, oesophagus, superior vena cava, pulmonary artery, right auricle, right ventricle, or externally. Aneurysm of the arch may involve the great vessels, may cause paralysis of the glottis by pressure upon the recurrent laryngeal nerve, may press upon or rupture into the trachea and bronchi, particularly the left bronchus. It may project forwards or backwards—being usually associated with a secondary false aneurysm—and penetrate the sternum, or project above it in the neck, or to either side of it, forming rounded prominences like mammae. Aneurysms of the arch may rupture into the left bronchus, oesophagus, lung or pleura and rarely into the pericardium. The rupture is usually of small size and occurs underneath the mass of the thrombus. (Figs. 43 and 44.)

Aneurysms of the abdominal aorta develop mostly in the region of the coeliac axis and at the origin of the mesenteric arteries. They may rupture behind the peritoneum, forming a huge false sac, or into the peritoneum, into small or large intestines, into the left pleura and lung, posterior mediastinum, inferior vena cava, or into the pelvis of the kidney. They may give rise to no symptoms during life.

Aneurysms of the popliteal artery may cause absorption of the femur and tibia.

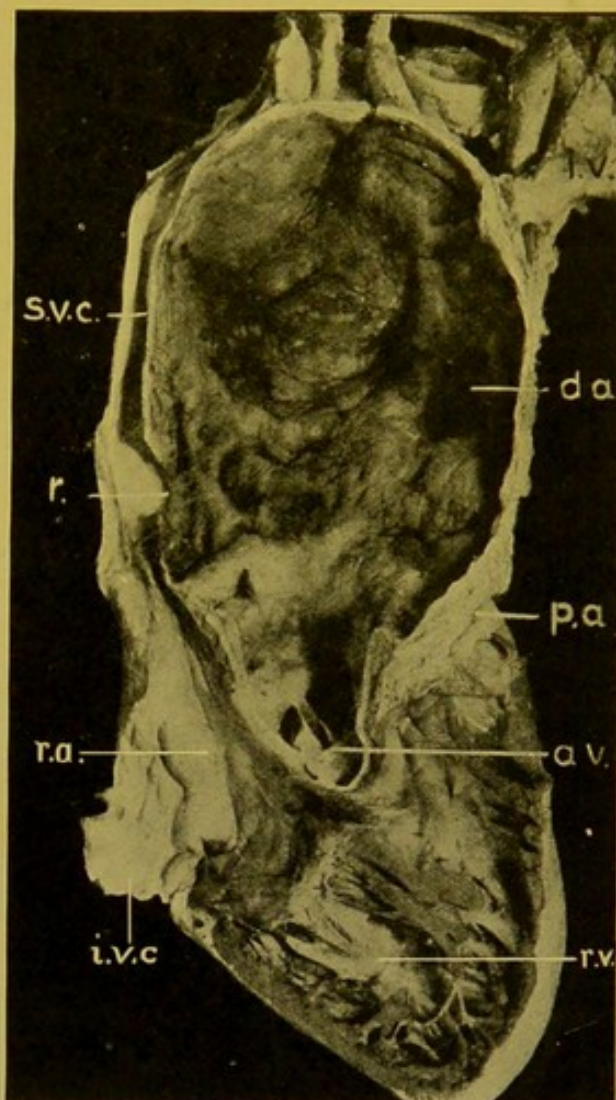


FIG. 43.—Aneurysm of ascending and transverse parts of aorta, which ruptured into superior vena cava. Many syphilitic scars seen on inner surface of aneurysm. (\times circ. $\frac{1}{3}$.)

(d.a.) Commencement of descending aorta, opening out of aneurysm; (s.v.c.) superior vena cava; (r.) rupture; (a.v.) aortic valve; (r.a.) right auricle; (i.v.c.) inf. vena cava; (r.v.) right ventricle; (p.a.) commencement of pulmonary artery; (i.v.) obliterated innominate vein.

Other less common varieties of aneurysm.—**Cirroid aneurysm** occurs especially in the face and scalp. The vessel is dilated, tortuous, elongated.

The **racemose aneurysm** is similar to the cirroid but the branches of the artery also are affected.

An **embolic aneurysm** is a localized dilatation of a vessel which may be otherwise comparatively healthy. It results from mechanical injury, from impaction of a calcareous atheromatous plate, or it is produced by the action of a septic

embolus, causing local inflammation and weakening of the wall, sometimes proceeding to rupture.

Hernial Aneurysm.—

This is seldom seen except in branches of the pulmonary artery on the walls of tuberculous cavities, or within persisting septa traversing them. The caseous change invades the adventitia and media, causes absorption or destruction of these, and then the intima bulges through the defect in the wall. If rupture occurs, the resulting haemorrhage may be fatal.

Miliary Aneurysms.—

These are spindle-shaped or rounded swellings, from a small pin's head to a millet seed in size, which occur especially upon the small cerebral arterioles. Microscopic examination may be required for their detection. They are most common on the middle cerebral, especially on its branches to the basal ganglia. They are also found on the branches

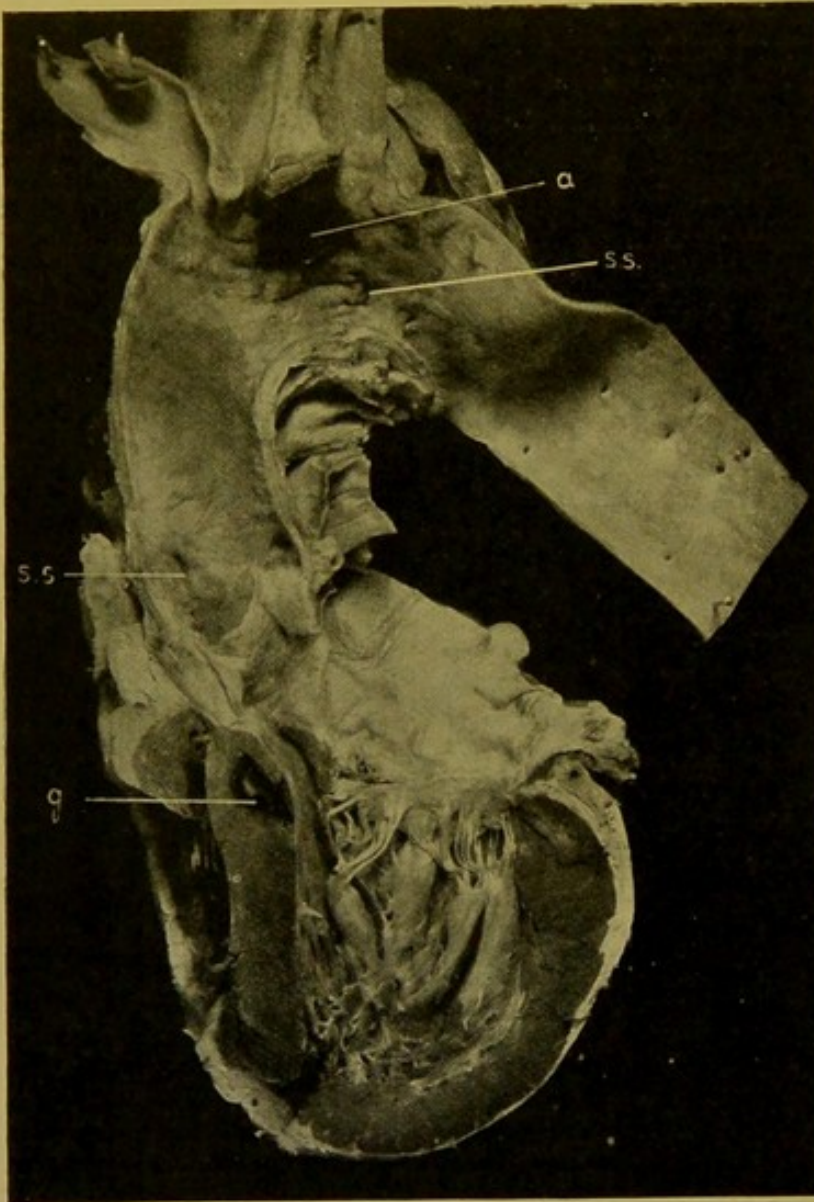


FIG. 44.—Saccular aneurysm of transverse part of aorta, which ruptured into trachea. (\times circ. $\frac{1}{2}$.)

(a) Aneurysm; (s.s.) syphilitic scars; (g) recent gumma in ventricular septum.

of the basilar artery and in other parts of the brain. They are best seen in central haemorrhages by washing away the blood clot and cerebral substance with a jet of water. This exposes small dark swellings upon minute vessels. When the vessels are examined microscopically, little of the original structure of the wall can be made out. The muscular coat may disappear completely, and a fibrous wall consisting of thickened adventitia

and intima is left. Some authors consider that these aneurysms originate from an inflammation of the adventitia, others, that they commence with fatty degeneration of the intima. As in other aneurysms, the determining cause of the dilatation is the degeneration of the media. In cerebral haemorrhage in children, they are sometimes found, originating occasionally as a result of septic embolism.

Dissecting Aneurysms are comparatively rare. They usually result from rupture of the intima during great strain. The blood passes into the wall, and along the media separating up the coats. (Fig. 45.) It may pass back into the vessel, the new channel after a time becoming lined with endothelium, or it may extend rapidly to the adventitia and rupture on the outer surface. In the aorta rupture of the intima takes place most commonly a short distance above the valves and the blood may pass in the wall right down to the bifurcation of the abdominal aorta, separating the intima completely from the outer coat. Usually, however, it does not extend so far. In at least five cases I have found no atheromatous change, the intima evidently rupturing as a result of disease of the media.

In the Museum of the Royal College of Surgeons, Edinburgh, there is a preparation of the heart of a child, four years of age, who died suddenly from rupture of the pulmonary artery into the pericardium. The outer coats of the vessel show microscopic changes similar to those in dissecting aneurysm of the adult.

In a case—male, sixty-three years of age—from which the preparation is preserved in the same museum, a similar mechanism had brought about a separation of the inner coats of the external iliac and femoral arteries on the right side with resultant obstruction of the vessel lower down, which had caused gangrene of the extremity.

Dissecting aneurysm also occurs in smaller vessels forming a rounded or oval thickening of their walls.

Arterio-venous Aneurysm. —(1) *Varicose aneurysm*, in which a saccular aneurysm opens into a vein.

(2) *Aneurysmal Varix*, in which a direct communication forms between an artery and vein, so that blood flows from the artery into the vein without the intervention of a sac.

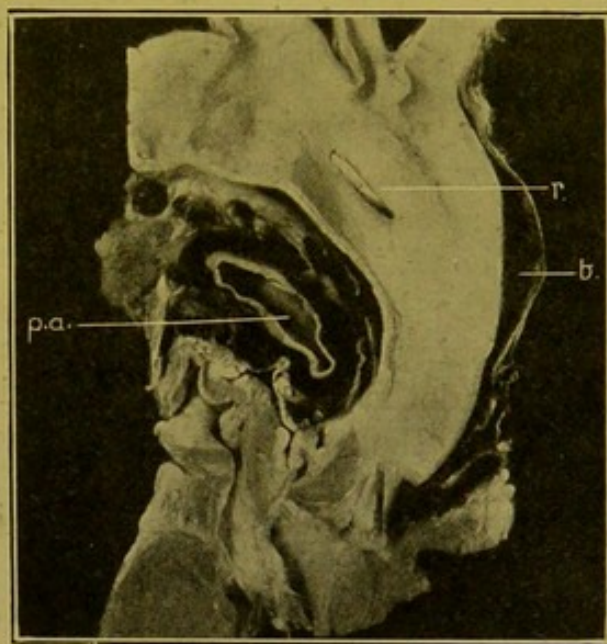


FIG. 45.—Dissecting aneurysm, aorta; opened from behind. (\times circ. $\frac{1}{3}$.)

(r) Rod in rupture in anterior wall; (b) blood dissecting up the coats of the aorta; (p.a.) pulmonary artery, surrounded by blood.

Aneurysm of Veins.—In addition to the dilatation of veins known as the ordinary *varix* or *varicose veins*, definite aneurysms may form upon these vessels. I have seen an aneurysm three-quarters of an inch in diameter upon the saphena vein, the vessel being thickened and contracted above and below the aneurysm, and in another specimen obtained from the dissecting room, an aneurysm was found below a valve, in a smaller vessel. It was about the size of a large pea (Fig. 46).

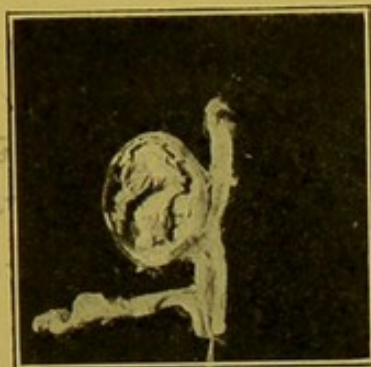

FIG. 46.—Aneurysm of vein.
($\times \frac{1}{2}$.) (Mus. R.C.S. Ed.)

Syphilitic Disease of Blood-Vessels.—The commonest condition found in syphilis is an arteritis which may commence either in the intima (syphilitic endarteritis, proliferative endarteritis), or in the adventitia (syphilitic periarteritis), the latter developing especially in the neighbourhood of gummata. This form is also seen in the vessels in syphilitic meningitis. The disease may affect

a number of arteries simultaneously. It seems to have a special proclivity for attacking the arteries at the base of the brain, but it also occurs in the coronary arteries of the heart.

The condition produces firm greyish-white nodules in the wall which narrow the lumen or nearly obliterate it. Microscopically, the special distinguishing characters of this form of endarteritis are: (1) proliferation of the endothelium; (2) proliferation of the sub-endothelial connective tissue cells, the new cells being rounded, spindle-shaped, or branching, and arranged loosely and irregularly. Those near the elastic lamina are often arranged perpendicularly to that structure. (3) In arteries this cellular tissue is vascularized by penetration inwards of vessels from the vasa vasorum; this does not occur in the case of arterioles. The intima is practically converted into a layer of granulation tissue. The elastic lamina may be thickened, granular, or split up. On either side of it there may be small collections of lymphoid cells. The media is always more or less infiltrated with lymphocytes and young connective-tissue cells (mes-arteritis). The adventitia is greatly thickened, of loose structure and infiltrated with similar cells. Small gummata may form in the adventitia. There is a great tendency to thrombosis, and organization of the thrombus from the altered intima completely closes the vessel. Even without thrombosis, however, the condition may go on to obliteration of the artery, the vessel contracting into a fibrous cord. In the heart, the most important result is local anaemia and necrosis (myomalacia) which may go on to rupture of its walls, or to a patchy chronic fibroid change.

In the aorta, changes similar to those described tend to obliterate the vasa vasorum in patches. As a result of this there is a tendency for proliferative changes to spread into the media, leading to more or less extensive degeneration of the media. Probably following this, localized gelatinous-looking raised plaques of a greyish-white colour form in the intima very

similar to those which form in atheroma. These, however, do not usually undergo such extreme degenerative changes as occur in that condition, but may become vascularized, and finally connective tissue is formed which tends to retract and produce scar-like—frequently pigmented—depressions on the surface. This condition occurs especially in individuals under the age of thirty or forty, and usually attacks the commencement of the aorta, but is also found at other parts of that vessel, e.g. the arch and the abdominal aorta. (See Figs. 21, p. 67, and 44, p. 98.)

Rare cases may be met with, in which extreme gummatous thickening of the media and intima takes place, as in one case I examined, in which, in parts, the arch of the aorta reached a thickness of one-third to half an inch. The thickening extended into and led to obliteration of the lumens of the great vessels (Fig. 47). It was characterized by an excessive formation of large epithelioid cells and giant cells. The spirochaete of syphilis can be demonstrated in this condition.

Tuberculous Arteritis especially affects the medium-sized and smaller arteries and arterioles, e.g. the cerebral arteries, the lobular branches of the pulmonary artery and the renal arteries. In tuberculous meningitis the condition starts in

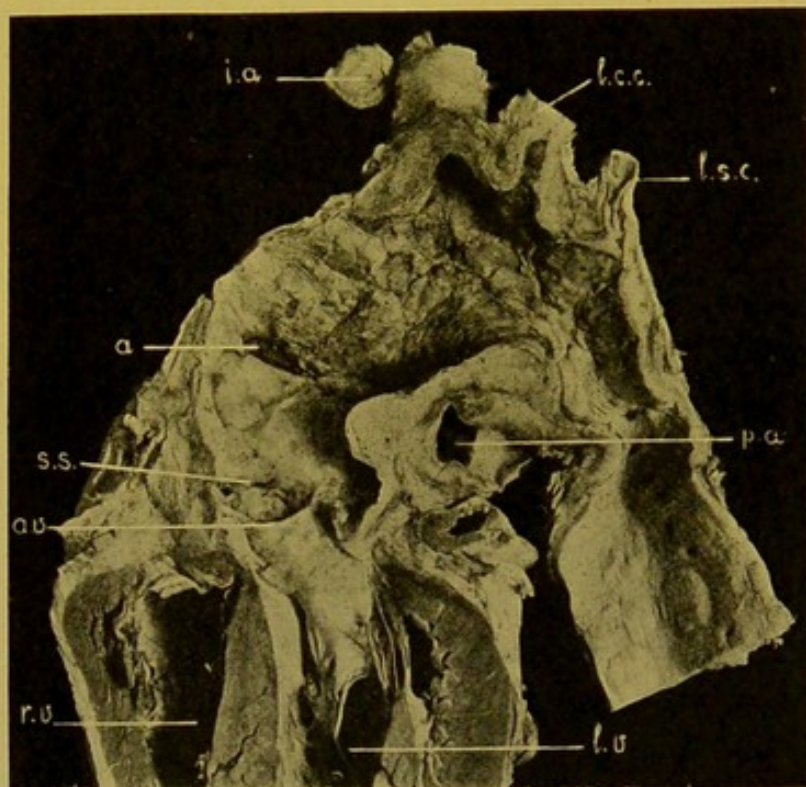


FIG. 47.—Gummatous aortitis. ($\times \frac{1}{2}$.)

(*r.v.*, *l.v.*) Right and left ventricles; (*a.v.*) aortic valve; (*s.s.*) syphilitic scar; (*a*) aneurysm; (*p.a.*) pulmonary artery; (*i.a.*) innominate artery, a portion cut off and placed so as to show almost complete obliteration; (*l.c.c.*) left common carotid completely obliterated; (*l.s.c.*) left subclavian, stenosed.

most cases in the perivascular lymphatic sheath and proceeds from without inwards, invading the middle and inner coats successively. In the lungs it occurs, for example, where an artery and a bronchus alone remain, in the process of excavation. As a result of the invasion from without of the coats, irritation and proliferation of the inner coat may occur, leading to thrombosis and occlusion of the vessel, or the affected part of the wall may soften, and a hernial aneurysm result which may rupture and cause a fatal haemorrhage. In the kidneys it occurs especially in miliary tuberculosis, in the course of the radiating arteries. As a result, tracts of caseating material form which are sometimes of conical shape like infarcts.

Periarteritis is chiefly important as a syphilitic process, e.g. in the vessels of the pia mater. Different forms of it may occur, for example,—

(1) A form characterized by diffuse infiltration of the outer coat with rounded cells, occurring comparatively early in the course of the disease.

(2) A similar change, with in addition a tendency to the formation of nodules which may proceed to caseation and formation of gummata. Gummata look like small yellow berries on the artery.

(3) **Nodose Periarteritis.** (Synonyms: **Periarteritis nodosa multiplex, Polyarteritis nodosa.**)—This is a rare condition in which small rounded nodules form upon the arteries especially of the heart and kidneys, mesentery, liver, abdominal organs, omentum and peritoneum. For a long time the condition has been recognized as probably *not* of syphilitic nature, but as almost certainly due to some other infective process. As a result of changes in the adventitia and a spread of these inwards to the muscular coat, degenerative changes occur in that coat. The internal elastic lamina gives way; a local aneurysmal dilatation occurs, with local thrombosis and proliferative changes in the persisting coats of the vessel. The condition may run its course in from six to twelve weeks.

Changes Occurring after Ligature of Vessels.—The intima and media are usually ruptured and retract. This retraction assisted by local thrombosis occludes the lumen, and the permanent closure is completed by organization of the thrombus, with proliferation and thickening of the intima as far as the nearest collateral. Support is also obtained from the cicatricial tissue which forms in the neighbourhood.

DISEASES OF VEINS

Varicose Veins.—Varicose veins are found very commonly in the lower extremity; in the haemorrhoidal plexus; in the spermatic (pampiniform) plexus—especially on the left side, causing *varicocele*—and prostatic plexus in man; and in the utero-vaginal and vesical plexuses of women. In other parts of the body the varices are less prominent, e.g. at the lower end of the oesophagus (*see* Cirrhosis of the liver, p. 250). A dilatation depends upon weakening of the wall or upon mechanical obstruction of the circulation which increases the pressure in the veins. In the early stages there may be simply dilatation, thinning of the wall and incompetence of the valves. Later on, there is evident atrophy of the media with formation of fibrous tissue in all the coats. This is usually associated with chronic periphlebitis, and now the veins are with difficulty dissected from the surrounding tissues.

Following upon the varicosity of the veins, e.g. in the lower extremity, the skin becomes thinned. In very chronic cases fibrous tissue forms in the skin and subcutaneous tissue, and frequently ulceration occurs—varicose ulcers. The bone underneath may be thickened.

Acute Phlebitis or Endophlebitis.—The intima is roughened, nodular, covered with thrombus which may close the lumen. Organization proceeds, accompanied by thickening and induration of the walls and of the surrounding tissue. *Endo*

Infective or Suppurative Phlebitis may arise in the neighbourhood of suppurative processes, the inflammation extending inwards, causing endophlebitis and thrombosis. This checks the progress of the disease for a time until the thrombus becomes infected and breaks down, bringing about embolism with pyaemia, or extension of the thrombosis. Examples of this are found commonly in the lateral sinus and jugular veins, also in the uterine veins in puerperal fever, the thrombus extending upwards into the inferior vena cava. *Infect*
or
Supp
exten
endo
+
throm
lateral
sin
jug

The condition used to be very common in the veins of the arm, when venesection was in fashion.

Welch has noticed a nodular, sometimes a more diffuse, accumulation of lymphoid and endothelioid cells beneath the endothelium of veins (less frequently of arteries) in enteric fever, diphtheria, variola, and other infective diseases. This may lead to thrombosis.

Chronic Endophlebitis is common in areas the seat of chronic inflammation. It commences as a fibrous thickening of the outer coat, the process extending inwards, narrowing or obliterating the lumen. This is found in the liver, lung and kidneys and also in systemic veins which are varicose, e.g. the saphena. In these the media may become broken up and replaced to a great extent by fibrous tissue. Some authors consider that the condition really begins as a lymphangitis of the adventitia. *Chro*

Tuberculosis of the Intima of Veins, especially of the pulmonary veins, is of great importance in connexion with general miliary tuberculosis; the breaking down of the nodules into the circulation accounting for the great numbers of bacilli necessary to set up that condition.

Lymphadenoma.—In one case I found a spread of lymphadenomatous tissue into the wall of the inferior vena cava, causing a localized greyish-white, rounded swelling with smooth surface.

Phleboliths.—Rounded masses, resulting from the calcification of thrombi, and usually of a whitish colour and general pearly appearance, are seen in angiomata (*see* Fig. 39, p. 90) or in the spleen. They can be found probably most frequently—at least, so far as my own experience goes—in the prostatic plexus of veins, in elderly individuals. Thrombosis is also common in this plexus.

CHAPTER VII

EMBOLISM

EMBOLISM is the name given to the transport from one part of the circulation and impaction in another part of some substance (*Embolus*) which does not mix homogeneously with the blood.

Nature of Emboli.—Emboli are most commonly composed of either firm or soft semi-fluid fragments of thrombi, but they may also consist of vegetations (platelet thrombi) from the heart valves or portions of the valves themselves, cells from the liver, spleen or bone-marrow, placental cells, pigment, fat, fragments of atheromatous plates, or broken-down débris from atheromatous patches, air, foreign bodies of various kinds, or bacteria. Embolism of portions of tumours (sarcoma or carcinoma) is a very important factor in the malignancy of these growths, seeing that the cells, possessing as they do the faculty of reproduction, may produce secondary tumours or metastatic new-growths similar to the parent tumour, when they are carried off and impacted in other parts of the body. Other transported cells, for example those of the liver, spleen or bone-marrow, not possessing this faculty, remain sessile until in course of time they degenerate and disappear. Cells of placental origin undergo a similar fate unless they are in reality derived from a chorionepithelioma, when they tend to reproduce that tumour.

When emboli are minute, and *bland* or non-infective, they circulate until they are absorbed.

The result is different when they are infective, their dissemination usually causing a septicaemia or pyaemia.

As a general rule, capillary embolism is of little importance, unless the emboli be septic. Such emboli can most easily be demonstrated in the glomerular capillaries of the kidney.

Source of Emboli.—In most cases emboli are carried in the direction of the blood-stream, hence emboli impacted in the pulmonary artery or its branches come from the systemic veins, right heart or the pulmonary artery between its origin and the site of impaction; emboli in the portal vein from its radicles, e.g. from thrombosis, usually septic, occurring in connexion with the alimentary canal, appendix, pancreas or spleen; emboli in the systemic arteries from the pulmonary veins, left heart or some part

of the aorta or arteries between the heart and the site of impaction of the embolus.

In some cases the source may be detected readily. Emboli may, for example, be derived from thrombi in the right auricular appendix, and emboli of such derivation are the commonest cause of pulmonary apoplexy. They may also be detached thrombi from uterine veins, displaced during injudicious movement of the patient after delivery. They may be portions broken off from a propagated thrombus projecting from an occluded vein into an important trunk in which the blood flow is still active, or from a thrombus occurring in veins of the extremities or pelvis, particularly when these are varicose. Such emboli, in the great majority of cases, become impacted in the lung.

Embolism in the systemic arteries is most often the result of detachment of "vegetations" (*platelet thrombi*) from the mitral and aortic valves, especially the former. The source may also be found in thrombosis in the left auricular appendix, at the apex of the left ventricle, or upon atheromatous patches on the inner surface of the aorta.

Frequently it is difficult or impossible to detect the source, particularly if this be some peripheral venous thrombosis, which has given few or no indications of its presence and especially if the entire thrombus has been dislodged.

The distance travelled by emboli depends upon their size. Embolism never occurs in the cavities of the heart, and never in veins unless in the case of the rare retrograde embolism.

A soft embolus may be broken up by striking on the angle between two branches of a vessel, and the fragments, being carried on further, cause multiple obstruction, the results of which may be similar to those following obstruction of the larger vessel. A soft embolus, again, on impaction, tends to accommodate itself to the shape of the vessel, and plug it completely, whereas a hard embolus may not cause complete obstruction until secondary thrombosis has occurred at the site of impaction.

Elongated emboli are usually caught on a bifurcation and at first may leave the branches partly open. They may subsequently slip to one or other side so as to block one branch completely, or the obstruction may be rendered complete by the occurrence of thrombosis. Elongated narrow emboli, again, may become doubled up so as to block a much larger vessel than that from which they were dislodged. In this way a main branch of the pulmonary artery may be completely occluded (*see Fig. 9, p. 44*).

The results of embolism, if non-infective, are not so evident in the skeletal systemic circulation as in the internal organs, because, in the former, e.g. in the extremities, there is usually free collateral circulation. Infective emboli, however, may produce metastatic abscesses wherever they are arrested, and in the arteries of the extremities may cause inflammatory softening of the walls and acute aneurysmal dilatation.

Atypical or Aberrant Embolism.—1. **Crossed or Paradoxical Embolism.**—

This is brought about by the passage of emboli from the systemic venous system into the systemic arteries without traversing the pulmonary circulation. It occurs in cases in which the Foramen Ovale is not completely closed, but remains as a valved opening, the lips of which remain closely apposed, until a dislocation of the relation between the blood-pressure in right and left auricles occurs. When the pressure is increased on the right side and diminished on the left, the septum bulges towards the left, and the opening is widened, thus allowing of the passage of an embolus directly from the right into the left auricle. Such an explanation would account for some cases of tumour metastasis without implication of the lungs, though it must be remembered that the pulmonary capillaries are the widest in the body (Zahn), and may allow cells to pass which will subsequently be caught in the systemic capillaries.

2. **Retrograde Embolism.**—This occurs in rare cases in which the circulation is much disturbed and a backward current produced, for example in tricuspid incompetence with heart failure or when intra-thoracic pressure is greatly increased (Greenfield). Instances of retrograde embolism are to be found in the plugging of the hepatic vein in cases in which the primary thrombosis has occurred in the ovarian vein (Arnold), inferior vena cava, or right auricle. Again, abscesses or metastatic tumour-growth may occur in the liver, following suppuration or tumour-growth (sarcoma) in relation to the systemic venous circulation, without the lungs being infected. Here again, one has to exclude cases in which the particles may have been small enough to pass the pulmonary capillaries. Retrograde embolism may occur at other parts of the circulation. For example, I have seen a fragment, detached from the thrombus within an aneurysm of the arch of the aorta, which had been carried backwards and had lodged in the orifice of the left coronary artery, causing sudden death.

Diagnosis from Thrombi.—A recent embolus lies loosely in the vessel, unless subsequent thrombosis has occurred. An ante-mortem thrombus is always more or less adherent. The wall of the vessel is healthy or practically so at the site of embolism; whereas it always shows some alteration, and is sometimes markedly diseased at the site of thrombosis. An adherent plug which rides a bifurcation may usually be looked upon as primarily an embolus. In the veins and heart, thrombosis may occur, but never embolism, unless this be retrograde. In the arteries of the lung, intestines, kidneys and spleen, and in the basal arteries of the brain, thrombosis is rare, whereas embolism is less common than thrombosis in the cerebral arteries and in the coronary arteries of the heart.

Air Embolism.—This occurs rarely in the course of operations involving the great veins at the root of the neck, and cases have been described in which air has entered the uterine veins after delivery. To air embolism, also, have been ascribed fatal results in caisson-workers and in divers.

The air, in the first-mentioned cases, is churned up with the blood in the heart, and blocks the pulmonary capillaries. If this condition be suspected, the pericardium after being opened to a limited extent, should be filled with water, through which the right ventricle should be punctured; the escaping air is then readily detected.

In reality air embolism is a very rare condition, most of the cases in which air, or rather gases, have been found in the circulatory system or in the organs, being dependent upon the action of gas-producing bacilli.

Fat Embolism.—This is the commonest variety of embolism, occurring in fractures of bone, particularly when the fatty marrow is greatly increased, and also as the result of *trauma*, mechanical or otherwise, of any organ or tissue containing fat. Hence, as may be surmised, its frequency is no criterion of its importance.

Fatal results are believed occasionally to follow fat embolism in the pulmonary or cerebral capillaries, after mechanical injuries and in diabetes mellitus.

The fat is most easily demonstrated in the pulmonary capillaries and in the glomerular tufts in the kidney.

Fat may be present in great quantity in the blood in death from chloroform poisoning, the amount in some cases being exceeded only by that present in certain cases of diabetes mellitus with lipaemia (Fig. 48).

Emboli consisting of fragments of **atheromatous plates** are said to cause aneurysm by mechanical injury of the vessel-wall, but this fact has not been completely verified.

In malaria, **pigment** may be found in considerable amount in the brain capillaries, either free or contained within cells. Malarial coma has been ascribed to blocking of the capillaries by this pigment.

The **Results of Embolism** depend on:—

1. The nature of the embolus.
2. The condition of the circulation.
3. The nature of the tissues.

1. The influence of the **nature** of the embolus has already been discussed sufficiently.

2. **Condition of the circulation** at the site of impaction, particularly with reference to the available collateral circulation or anastomoses.

(a) Where a **free** collateral arterial circulation is present, temporary anaemia follows primarily in the area supplied. Then the collaterals dilate, become elongated and tortuous. The converse takes place when the circulation is slowed; hence the local vessels more directly affected by the block become narrower, shorter, straighter and their walls thinner. The distal circulation is wholly restored, after a time, by way of the collaterals.




FIG. 48.—Lipaemia in diabetes. Blood in test-tube.

Elements separated:
(1) Fat; (2) serum; (3) leucocytes, chiefly; (4) red blood corpuscles.

(b) Where there is **imperfect** or less free collateral circulation.—The best example of this is the superior mesenteric artery, in which, fortunately, embolism is of rare occurrence. This artery communicates freely with the coeliac axis above and with the inferior mesenteric artery below, but the area it supplies is of immense size, comprising the jejunum, ileum, ascending colon and half of the transverse colon. From this circumstance alone one can readily recognize that when the main artery is blocked some time must elapse, even under favourable circumstances, before the circulation can be restored in the central part of the area. The difficulties are increased by the persistent contraction of the musculature of the bowel which occurs directly the vessel is occluded, and prolongs the anaemia. When, at last, relaxation takes place, the anaemia gives place to venous engorgement and—as the nutrition of the vessels has been impaired—haemorrhage occurs into the mucosa and sub-mucosa, i.e. a condition of *infarction*. A similar contraction of the muscle in the capsule and trabeculae of the spleen follows immediately on occlusion of the splenic artery or one of its branches.

These conditions can be produced experimentally by ligature of the superior mesenteric or splenic arteries.

(c) Where there is **no** collateral arterial circulation, or practically none, and adjacent “end-arteries” communicate with each other only through their capillaries.—Arteries conforming to the third class occur in the kidney (interlobular), spleen, heart, retina, lungs (particularly the branches of the pulmonary artery distributed to the free margins of the lobes and to their more superficial parts), liver and central nervous system (particularly the arteries to the basal ganglia, and to the grey matter of the spinal cord).

Some include the superior mesenteric and cerebral arteries amongst the end-arteries.

Finally, by multiple embolism, or by disease of collaterals preventing these from compensating for obstruction of the main trunk, a vessel which, if conditions were normal, would come under the first or second class, becomes reduced to the status of an end-artery and the results are such as follow block of an end-artery.

3. **The Nature of the Tissues.**—This is a very important factor in determining the results of block of the artery supplying the part. Some tissues, for example lung and connective tissues, are more resistant than others, and may preserve their vitality until the circulation is restored, others, for example brain tissue and glandular epithelium, are more delicate and die rapidly when their nutrition is cut off even for a short time.

The ultimate results of embolism may be summarized thus:—

1. Formation of a collateral circulation.
2. Aneurysm—rarely, except when the embolus is infective.
3. Infarction, which may be non-septic or septic.
4. Necrosis and gangrene.

The special result which will now be discussed is *Infarction* following impaction of a *bland* embolus.

Infarction.—In infarction, the preliminary local anaemia tends to be succeeded by an access of blood which “stuffs” full (*infarcio*, I stuff in) the area affected. The degree of “stuffing,” however, varies according to the nature of the tissue affected, so that infarcts are divided into haemorrhagic, white or pale, and mixed.

1. **Haemorrhagic Infarction.**—This may occur in spleen, intestine, lungs and heart. The name indicates that the tissue affected becomes filled with blood.

Observations made by Cohn, Litten, Vulpian, Greenfield and others, have demonstrated that the blood in haemorrhagic infarction passes in through the capillary anastomoses from neighbouring arteries. It flows into abnormal capillaries, capillaries which have suffered loss of nutrition and whose walls are more permeable than normal. Accordingly the blood readily escapes by diapedesis into the tissues and fills them up. The engorgement is intensified by the thrombosis which soon develops in the vein leading from the part. Usually the tissues affected die.

2. **Pale or White Infarct.**—Under these terms are included infarcts which are pale from the commencement and never become haemorrhagic. They have to be carefully distinguished from “decolorized” infarcts, which are haemorrhagic infarcts in which the blood pigment has been altered and in part absorbed.

In pale infarcts necrotic changes take place very early and other changes occur which prevent penetration of the area by the blood, so that the part remains anaemic. They occur most characteristically in the brain.

3. **Mixed Infarcts.**—These are pale infarcts which are haemorrhagic at the periphery, where the blood has penetrated for a short distance. Some think that mixed infarction is the commonest result of embolism of an end-artery. The most characteristic examples of these are seen in the kidney and occasionally in the spleen.

Changes Occurring in Infarcts.—The infarcted area soon dies and then it excites reactive phenomena in the surrounding tissue which aim at absorbing or removing it, or isolating it by formation of a wall of connective tissue.

In the infarct itself decolorization takes place, the red corpuscles being carried off by phagocytes or more commonly breaking up *in situ*, the haemoglobin being altered into haemosiderin or haematoidin, or becoming transformed into colourless albuminates which are absorbed. At an early stage phagocytes containing blood-pigment can be detected in the surrounding tissue. Leucocytes may not be very prominent, but sometimes they penetrate the infarct, forming a pale zone surrounding the grey necrotic centre. This can be seen especially in infarction of the kidney, even in cases which result from apparently bland embolism. This is only a tem-

porary phenomenon, the leucocytes being engaged in removing the dead tissue, and in time it becomes over-shadowed by the formation of vascular granulation tissue which separates the living from the dead tissue. The subsequent changes, resulting in the formation of dense scar-tissue replacing or surrounding the remains of the infarct, are very similar to those which occur in vascularization and organization of a thrombus (p. 85), or of an inflammatory exudate (p. 50), and have already been fully described in connexion with these conditions. (*See also* Pleurisy, p. 152.)

The scar-tissue retracts forming localized pits, or long, sometimes branching, grooves on the surface of the organ, which persist throughout life and can readily be detected years afterwards at the post-mortem examination.

Infarcts of different ages are frequently found in the same organ, e.g. spleen or kidney, indicating the recurrence of embolism.

The foregoing description applies to cases in which the emboli have been "bland." When the infarct follows impaction of an infective embolus, to the purely physical results of the impaction have to be superadded results due to the special characters and actions of the organisms present. For example, when these are pyogenic cocci, suppuration of the infarct rapidly takes place.

CHAPTER VIII

RESPIRATORY TRACT AND LUNGS—PLEURAE— THORACIC WALLS

The *nasal cavities* and *accessory sinuses* are best examined from above, after removal of the brain. (See Chap. XVIII. p. 397.)

LARYNX

The mucous membrane of the larynx is covered with ciliated epithelium, except over the true vocal cords, over the margins of the false cords and on the under surface of the epiglottis. It is richly supplied with lymphoid cells, which in some places, e.g. on the posterior surface of the epiglottis and in the sinuses of Morgagni, may be collected into follicles.

Congenital Defects and Malformations are unimportant.

Stenosis.—Narrowing of the larynx may be due to pressure from without, but more commonly follows disease of the larynx, e.g. tumours, membranous inflammation or swelling of the mucous membrane, or contraction of cicatrices, the last condition being due usually to syphilis, or to lupus. The glottis may be narrowed as a result of paralysis of its muscles or of spastic contraction of them, such as occurs in laryngismus stridulus. Stenosis may be congenital, and accompanied by a similar condition at the junction of pharynx and oesophagus. The epiglottis may be folded upon itself.

Disturbances of Circulation and Inflammations.—(1) **Active hyperaemia.**—The congestion in this condition disappears very soon after death, because of retraction of the elastic tissue of the mucous membrane.

(2) **Chronic venous hyperaemia.**—In chronic congestion the mucous membrane is purple and swollen. The condition is the result of heart or lung disease or results from the pressure of tumours locally or upon the laryngeal veins.

(3) **Petechial haemorrhages** may be found in asphyxia, in scurvy, in haemophilia and in various severe intoxications and infections.

(4) **Oedema of the Larynx** (Syn.: "Oedema of the glottis") is characterized by an infiltration of the submucous tissue with serous fluid, which produces soft translucent, or firmer opaque swellings. It affects principally the posterior surface of the epiglottis, the aryteno-epiglottic folds, the tissues covering the arytenoid cartilages, and the false cords. The condition may be inflammatory or non-inflammatory; in the former the swellings are opaque, and in the latter they are translucent.

{ inflammatory — opaque
non-inflammatory — translucent

1. (a) **Acute inflammatory oedema.**—Here the oedema may be the result of local traumatism; swallowing of boiling water; presence of irritating foreign bodies; or it accompanies acute catarrh, or ulceration. It may follow inflammation in the neighbourhood, e.g. pharyngitis, tonsillitis,

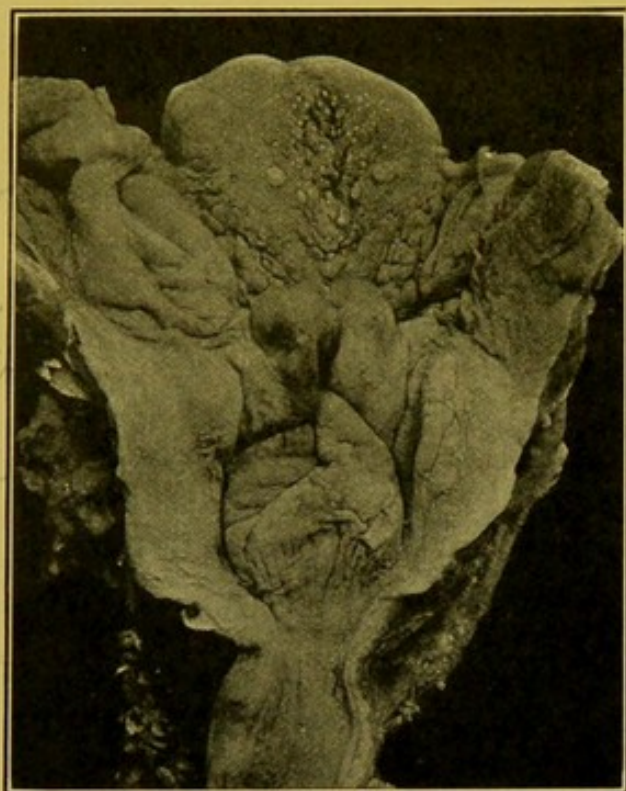


FIG. 49.—Oedema of Larynx viewed from behind. (\times circ. $\frac{1}{2}$.)

Pillars of fauces, epiglottis, aryteno-epiglottic folds, and inter-arytenoid folds affected. Lymphoid nodules at base of tongue swollen.

parotitis, caries of the vertebrae with retro-pharyngeal abscess, erysipelas. It may occur independently of neighbouring inflammation, as in a case in which I found that the condition was caused by the *pneumococcus*; the larynx was completely obstructed. It may occur in severe infective diseases and in diphtheria.

(b) **Chronic inflammatory oedema** is usually partial, and is never so extreme as in the case of acute inflammation.

2. **Non-inflammatory oedema** may occur in the course of Bright's disease; in the presence of heart or lung disease; in cirrhosis of the liver; as a result of the pressure of tumours, of enlarged glands, or of aneurysms, upon the cervical veins. It may be of angioneurotic origin, occurring principally in women, and

associated with a similar condition in the pharynx and on the skin surface. Occasionally it follows the administration of potassium iodide and here the oedema is usually subglottic.

Acute Laryngitis.—In acute catarrh the congestion tends to lessen after death, but otherwise the appearances are similar to those found in catarrh elsewhere. There is a great tendency to ulceration or superficial erosion of the vocal cords, of the inter-arytenoid folds and of the anterior commissure.

The condition may be induced by the most varied kinds of irritants,—chemical, thermal, or mechanical. It may occur in most of the acute specific diseases, especially measles, scarlet fever, influenza, small-pox, typhoid; while rheumatism, gout, tuberculosis and syphilis may be predisposing factors.

Chronic Laryngitis.—The secretion is scanty, the mucous membrane is reddened and may be hypertrophied and rough. The thickening is the result of cellular infiltration along with connective tissue hyperplasia. Occasionally, papillomatous growths are produced. Small retention cysts

may form in the mucous glands of the larynx and trachea, appearing as small clear projecting spots which have to be distinguished from miliary tubercles. The epithelium may be lost or may be replaced by squamous epithelium with formation of a thick stratum corneum. This thickening forms bluish or milk-white patches and is specially evident over the ventricular bands or on the vocal cords; similar changes occur in the trachea.

Membranous Inflammations of the Larynx.—These are sometimes divided into the “croupous,” in which a superficial fibrinous membrane is produced, and the “diphtheritic,” in which the superficial portions of the mucous membrane are necrotic and form the deeper layers of the membrane. The former is easily separated from the surface, the latter on separation leaves a rough, ulcerated surface. Membranous laryngitis, while occurring especially in diphtheria, may occur in the course of other infective diseases, e.g. small-pox, scarlet fever, measles, or typhoid. It rarely occurs in the course of pyaemia and pneumonia. The action of irritating gases, e.g. ammonia, and the action of corrosives or of hot steam may also induce a membranous inflammation. Occasionally, in children, thick membranes develop in which the *pneumococcus* is the only organism demonstrable.

Suppuration in the Larynx.—In suppurative laryngitis the mucous membrane and submucous coat are infiltrated. This may go on to abscess formation and perichondritis. It occurs as a result of mechanical injury, ulcerative laryngitis and extension of other severe inflammations from the neighbourhood.

Perichondritis.—In perichondritis the perichondrium is separated from the cartilages by purulent infiltration. (Fig. 50, 2.) It occurs especially as a complication of ulcerative processes—tuberculous, syphilitic—and less commonly in typhoid fever, pyaemia and small-pox. The arytenoid cartilages are most frequently affected, then the cricoid by direct extension, then the thyroid. They become necrosed and are cast off. The pus usually forms fistulous openings within the larynx, through which portions of the cartilages may project. In rare cases the pus makes its way to the skin surface or into the oesophagus. The collections of pus in the larynx may be of such a size as to cause suffocation.

Tuberculosis of the Larynx (Syn.: “Laryngeal phthisis.”).—This condition is rarely primary. It is generally secondary to pulmonary tuberculosis. The condition is usually characterized by infiltration, irregular thickening and ulceration, over the epiglottis, aryteno-epiglottic folds, arytenoids and inter-arytenoid folds. It may begin at any part, even upon the true vocal cords. Small grey, or yellow tubercles may occasionally be seen, but this stage must be very brief as usually the first lesions to be detected are small localized or more generalized superficial ulcers or erosions which have resulted from the breaking down of tubercles. These ulcers coalesce and produce a worm-eaten appearance of the mucous membrane. The epithelium and submucous tissue are destroyed and then the condition

from early appearance of gran. Later Epithelium & submucous
tissue destroyed & necrosis of cartilages & bony larynx &

Epiglottis
AE to
Larynx
Arytenoids
Small
yellow
tubercles
or ulcers

extends to the perichondrium, bringing about necrosis of the cartilages. The arytenoid cartilages are most often affected and tuberculous ulcers are most commonly found at their bases. On the inter-arytenoid folds nodular polypoid granulomatous excrescences may develop, often concealing an ulcer. In rare cases there is deep ulceration on the posterior surface of the epiglottis. Under the microscope the ulcers are lined with caseous material, and giant-celled tubercles are found in the deeper layers.

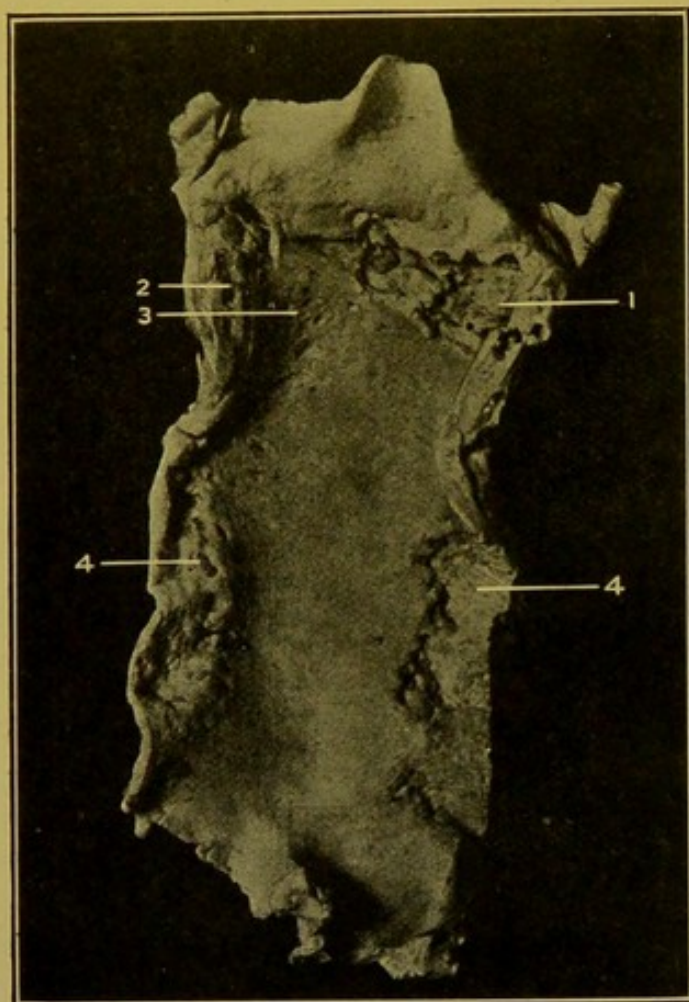


FIG. 50.—Tuberculous Ulceration of Larynx and Trachea, viewed from behind. (\times circ. $\frac{2}{3}$.)

(1) Ulcer in larynx, involving whole of true cords; (2) Suppuration round cartilage; (3) Erosions in lower part of larynx; (4) Ulcers on posterior wall of trachea. (Mus. R.C.S. Ed.)

Lupus of the Larynx.—This condition is found in 3–8 per cent. of those affected with lupus. It is most common in young women under the age of twenty. In the early stages the condition is characterized by local tumefaction. In course of time smooth, hard, pink nodules appear, varying in size from that of a pin's head to that of a split pea, particularly at the margins of the epiglottis. They extend over both surfaces of the epiglottis, and tend to soften, undergoing very slight ulceration. The aryteno-epiglottic folds may be thickened and indurated, and an irregular nodular thickening may extend over the inner surface of the larynx as far down as the sinus of Morgagni. The ulcers are never covered with a layer of pus. Healing is followed by cicatrization, which may lead to stenosis of the larynx.

Syphilis of the Larynx.—(1)

Inherited.—In the first years of life the disease usually appears

as laryngeal catarrh or as one of the milder forms of secondary syphilis. If it become manifest at puberty the lesions are usually of tertiary type.

In the case of a male, æt. 18, suffering from congenital syphilis, the mucous membrane of the larynx and the upper part of the trachea was covered with superficial stellate scars. The lower part of the trachea was finely nodular, and at its lower end there was some ulceration.

(2) **Acquired.**—The lesions are somewhat loosely placed among the secondary and tertiary manifestations of the disease. Of the earlier lesions

simple catarrh and mucous papules or patches may develop. In the later, tertiary, stages one meets with infiltration and ulceration, gummata, or fibroid change. The ulcers are usually deep, with sharply cut, thickened margins, and the destructive change may extend to the perichondrium and cause necrosis of the cartilages. Microscopically there is increase of cellular connective tissue beneath the mucous membrane and surrounding the cartilages. Healing may take place with marked cicatrization and adhesions. There may be extreme stenosis and deformity. The upper part of the larynx, particularly the epiglottis, shows the greatest amount of destruction, but other parts, e.g. the arytenoid cartilages and the vocal cords, may also be attacked. The cords may be united more or less by membranous bands. The ulceration and cicatrization frequently involves in addition the base of the tongue, and pharynx (p. 165).

Lesions in Typhoid Fever.—

The lesions in the larynx in this disease may be of the nature of catarrh, erosion, or deep ulceration. These are chiefly met with at the margins of the epiglottis and this cartilage may be destroyed. In other cases the lymphoid tissue is especially affected, so that there is diffuse or circumscribed swelling. The mucous membrane may be congested or an exudate may form upon its surface. Sometimes small nodules composed of necrotic epithelium infiltrated with bacteria and leucocytes develop on the surface.

In **glanders** small cellular nodules form in the submucous coat; these seldom ulcerate.

In **chloroma** and **acute lymphatic leucocythaemia** the tip of the epiglottis may become necrotic, and the cartilage projects. This accompanies great infiltration of the lymphoid tissue in the neighbourhood,—lingual and faucial tonsils. These also may become necrotic (Fig. 52).

In **leprosy** small granulomatous nodules develop similar to those of syphilis and lupus. They may ulcerate, and, if they heal, the healing is accompanied by cicatrization.

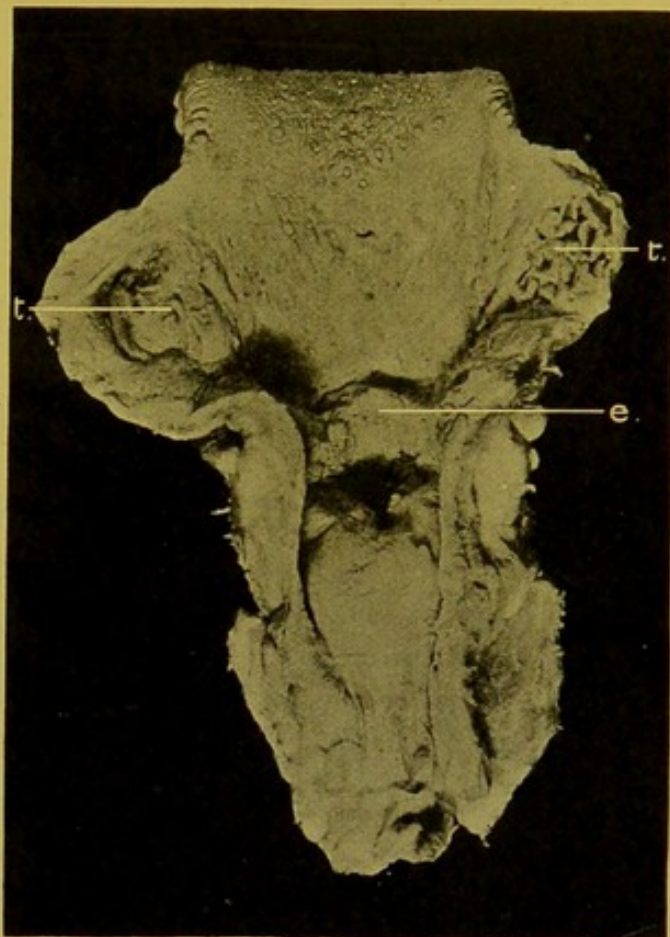


FIG. 51.—Syphilitic Ulceration of Larynx, viewed from behind. (\times circ. $\frac{1}{2}$.)

Great destruction of epiglottis (e), and scarring over ary-epiglottidean folds. Tonsils (t) show much scar-formation. (Mus. R.C.S. Ed.)

Tumours of the Larynx.—Tumours of all kinds are rare, but of those which occur, the more common forms are the *papilloma* and the *squamous epithelioma*. *Papillomata* form small red outgrowths which may be sessile, for example on the vocal cords, or multiple, and, especially in children, may cover a large area of the inner wall of the larynx. *Mucous polypi* may be found projecting from the sinuses of Morgagni.

Malignant tumours. *Sarcomata* are rare. They may be round-celled, spindle-celled, lympho-sarcoma or giant-celled sarcoma. The round-celled sarcomata are soft and undergo early degeneration. Spindle-celled

sarcomata are round or nodular and tough. They grow very slowly. Other forms are extremely rare. *Squamous epithelioma* may develop upon the vocal cords, or extend from the tongue or pharynx, causing deep excavation and destruction of the larynx, the remaining parts being swollen and ulcerated. *Columnar-celled cancer* is very rare.

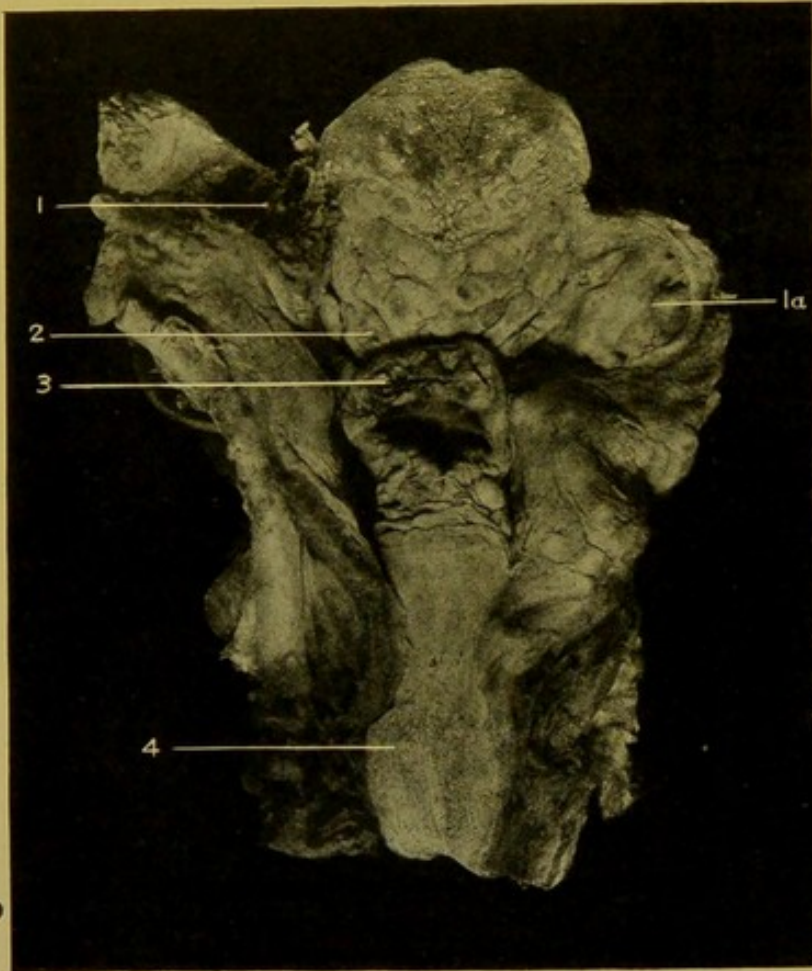


FIG. 52.—Larynx, etc., in Chloroma in Adult. (\times circ. $\frac{1}{2}$.)

(1) Left tonsil, gangrenous; (1a) right tonsil greatly enlarged; (2) lingual tonsil, some of the nodules undergoing central necrosis; (3) swelling and necrosis of soft tissues covering epiglottis, cartilage projecting; (4) nodules in wall of oesophagus.

TRACHEA

Congenital malformations of the trachea alone, or in association with malformations of the oesophagus, are so rare that a full consideration is not necessary.

Fistulae may be found representing remains of the branchial clefts.

Occasionally **lateral diverticula** are found in the trachea. These are lined with mucous membrane, which may be covered with ciliated epithelium.

Inflammation.—**Acute Catarrh** of the trachea produces changes very similar to those occurring in the larynx, or in the larger bronchi, and thus no special description of the condition is required. In **chronic catarrh**, sometimes minute clear retention cysts project on the surface. These may be mistaken for miliary tubercles. In chronic catarrh there may be small patches of metaplasia, squamous epithelium replacing the normal

ciliated epithelium. In **diphtheria** of the trachea, the membrane is usually easily separable, the reason being that the trachea is lined by ciliated epithelium placed upon a basement membrane.

Ulcerations.—**Tuberculous ulceration** is found more frequently at either end of the trachea than in the central part, and, if in the central part, more frequently on the posterior wall than on the lateral or the anterior walls. The ulcers may be deeply excavated and possess thick infiltrated margins (see Fig. 50, 4, p. 114). **Syphilitic ulceration** is found chiefly near the bifurcation and more frequently associated with laryngeal syphilis than with bronchial syphilis. Stenosis may result.

Local destruction, with perforation of the wall of the trachea, may result from extension of malignant tumours of the thyroid or oesophagus, but cancer of the oesophagus more frequently perforates the left bronchus. An aneurysm may cause destruction of the wall by pressure, and it may rupture just above the bifurcation, or into the *left* bronchus. Softened lymphatic glands may ulcerate through the walls of the trachea or main bronchi. In one case I examined, a gland in breaking down had formed a communication between the *right* bronchus and the pulmonary artery; death occurred suddenly from haemorrhage.

Stenosis of the Trachea.—This may result from scar-formation or granulo-matous growths internally, or from pressure, from the outside, of enlarged glands, of an enlarged thyroid, of tumours in the neighbourhood—especially of the thymus and the oesophagus, or from the pressure of aneurysms.

Tumours of the trachea are extremely rare.

BRONCHI

The larger bronchi are lined by stratified ciliated epithelium, the medium-sized bronchi by simple ciliated epithelium, and the small terminal bronchi by non-ciliated cubical epithelium. The terminal bronchi open out into three to five infundibula or alveolar passages which are wider than the terminal bronchi. The hemispherical vesicles project on the walls of the infundibula. The infundibulum with its vesicles form an acinus, and nine to fifteen acini form a lobule. The left bronchial vein opens into the vena azygos minor superior, the right vein into the vena azygos major.

Acute Bronchitis.—In acute bronchitis, the mucous membrane is congested and oedematous. The secretion varies in nature and consistence. It may be thin or thick, mucous, sero-mucous, muco-purulent or purulent. The mucus is secreted in excess by the glands in the wall of the bronchus or develops in the superficial layer (or ciliated columnar cells) of the mucous membrane, whereas the serous and purulent exudates are products of the inflammation—the fluid and cells passing through the mucous membrane. Microscopically, the two superficial layers, and sometimes even the deepest layer of epithelial cells, are cast off, except in the grooves or hollows of the mucous membrane or in the mouths of the ducts. In these there are always, in *acute* bronchitis, representatives of all three layers. The lumen contains

globules of mucus, red blood corpuscles, polymorphs and cast-off epithelium. The basement membrane is greatly thickened and indented on its under surface by vessels and cells. The submucous tissue is greatly congested, infiltrated and oedematous.

At a slightly later stage proliferative changes may be found. The inflammatory changes do not usually attack the muscularis mucosae or, except for the catarrhal condition of the mucous glands, the wall of the bronchus outside of that structure.

In **Chronic Bronchitis** the mucous membrane may be hypertrophied or atrophied. In the former case the mucous membrane is thickened, velvety and of a purplish or purplish-grey colour. The surface may be granular, and polypoid excrescences have been described. These I have never seen. In the atrophic form the mucous membrane is thin, glistening, smooth, and often streaked with longitudinal and transverse grey ridges. The surface is usually covered with viscid muco-purulent fluid. In both cases the walls of the bronchi are evidently thickened, or at least stiffened, by infiltration and newly formed connective tissue, so that they tend to project above the cut surface of the lung. Microscopically, the epithelium either may be represented by its deeper layers only, or it may be almost completely lost, a few small rounded cells being seen here and there on the surface of the basement membrane, which is much thickened. The inner fibrous coat is thickened irregularly, whence results the striation seen with the naked eye. The blood-vessels are much dilated, and there is great infiltration of leucocytes round about them. The muscularis mucosae is infiltrated with cells and separated up by oedema, the result being that the bronchus tends to dilate. The outer fibrous coat also shows changes. It is infiltrated with leucocytes and shows proliferation of its connective tissue—*peribronchitis*—which may be so considerable in degree as to lead to marked thickening. In very advanced cases, in which chronic peribronchitis is extreme, the cartilages tend to undergo metaplasia into fibrous tissue.

The mucous glands are either over-distended with mucus or show an enormous accumulation of leucocytes.

In the chronic bronchitis accompanying heart disease the secretion is more watery than in the local variety, and there is very intense venous congestion of the inner fibrous coat so that it is of a deep purplish colour. The epithelium is almost entirely shed and the secretion is thin and frothy. Chronic bronchitis is constantly associated with vesicular emphysema and often with bronchiectasis, and is frequently accompanied by atheroma of the pulmonary artery. When fibrous peribronchitis is extreme, interstitial fibrosis may extend throughout the lung.

Croupous or Plastic Bronchitis.—Membranes may develop upon the walls of the bronchi in many severe infections, particularly in diphtheria and pneumonia. They are, in rare cases, found in pulmonary tuberculosis, erysipelas, typhoid, small-pox, scarlet fever, articular rheumatism and pem-

phigus. The membrane in true plastic bronchitis is firmer and tougher than that formed in the above-mentioned diseases; it is whitish, laminated and is mainly composed of fibrin. It occurs especially in young males, and extends in the smaller bronchi and their ramifications, forming a tree-like cast. The etiology of this condition is unknown.

Bronchiectasis.—Bronchiectasis indicates the dilatation of a bronchus. The condition is in most cases chronic, and chronic bronchitis is always present. Dilatation of the terminal bronchi may occur independently of dilatation of the larger bronchi. The dilatation may be regular (cylindrical), or fusiform, globular, sacculated or varicose (moniliform). The dilatation is most extreme in fibrotic lungs. It is not constantly found in emphysema, but when it does occur the dilatations are either fusiform or globular, affecting single tubes, or cylindrical, affecting groups of them. One lung or both may be affected. Bronchiectatic cavities have to be distinguished from tuberculous cavities, particularly when they form near the apex of the lung.

Usually, the pleura is not thickened over a bronchiectatic cavity. The bronchus opens by more gradual transition into the cavity in the case of bronchiectasis, and mucous membrane can be demonstrated over the whole surface of the cavity, unless ulceration has occurred. The walls are more regular, thinner, smoother and more translucent. The contents are purulent, sanguineo-purulent or putrid. Calcareous concretions may be present. The walls are swollen and congested, if the cavity remains free from accumulations; they are congested and atrophied when there is much accumulation; and ulceration and gangrene may occur when there has been prolonged retention.

The surrounding tissue may be either collapsed from pressure, consolidated from chronic pneumonia, or emphysematous, or normal.

Conditions of other organs.—The right side of the heart in extreme cases is dilated. Waxy or amyloid disease may occur in the liver or kidney. Secondary abscesses may occur in the brain. There is clubbing of the fingers from the long-standing venous congestion.

The principal causes are chronic bronchitis and accumulation of secretions within the bronchi. It may be associated with, and to a certain extent dependent on, collapse. The immediate cause in many cases is a plugging or obstruction of the bronchus. The resulting dilatation may be either

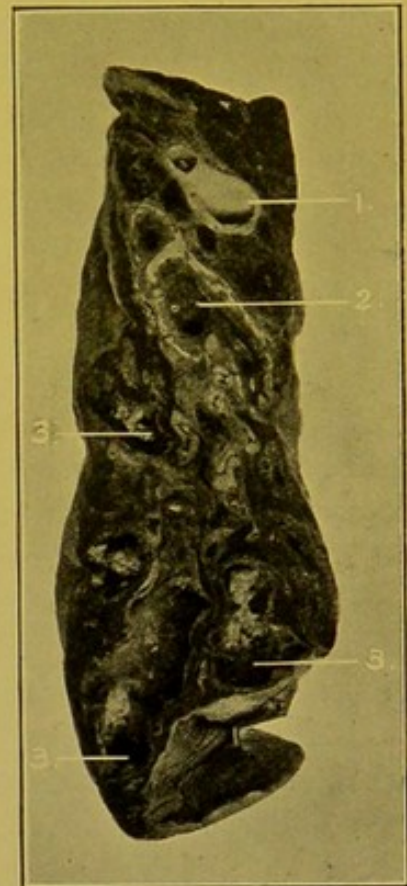

FIG. 53.—Bronchiectasis, lower lobe of lung. (\times circ. $\frac{1}{2}$.)

(1) Pulmonary artery; (2) bronchus; (3) dilated bronchi.

*Dilatation
chronic
always
regular
fusiform
globular
not at
emphysema
One or
lung
Pleura
usual
thick
over c
Walls
regular
thinner
smooth
bron
Content
putrid
or
Calo
Ulcer
&
gang*

proximal or distal; in the latter case, the tubes are dilated by the inspiratory traction exerted by the chest wall. In chronic interstitial pneumonia and peribronchitis the traction of the fibrous bands pulling from a fixed point—the chest wall, to which the lung is closely apposed by atmospheric pressure—tends to dilate the bronchus weakened by chronic bronchitis.

Acute bronchiectasis or **bronchiolectasis** accompanies most often bronchitis, measles, or whooping-cough. The lungs are packed with small thin-walled air-containing cysts, each with a smooth lining membrane.

Putrid Bronchitis or Gangrenous Bronchitis.—The mucous membrane is covered with a greyish-yellow layer and is itself brownish-red, thickened and loose. The condition is generally localized, sometimes affecting both lungs. The affected bronchi are usually dilated. It is seldom primary, frequently secondary, and the surrounding lung also may be inflamed.

Tuberculous Bronchitis occurs frequently in the course of pulmonary tuberculosis. The tubercles develop in the walls of the larger bronchi, and by breaking down form ulcers. This condition may follow pulmonary excavation, or it may be due to an extension from tuberculous glands. Tuberculous broncho-pneumonia in its earlier stages belongs to this type of bronchitis. The lung tissue connected may collapse or become tuberculous. (*See also Lymphatic Tuberculosis of Lung*, p. 143.)

Syphilis of the main bronchi usually leads to scar-formation and stenosis.

Narrowing of the Bronchi is brought about by—

(1) Changes in the wall, by scar-formation in relation to tuberculous glands; by scars of syphilis, by tumour-formation, by inflammatory swelling of the mucous membrane in the case of the smaller bronchi.

(2) Blocking of the lumen by secretion or membrane, by formation of caseous masses, by foreign bodies.

(3) Pressure from without of enlarged glands, of inflammation round about the glands, of aneurysms.

The result of a complete block is collapse of the vesicular lung tissue connected with the bronchus; incomplete obstruction results in emphysema.

Foreign Bodies in the Bronchi.—These more often occur in the right bronchus than in the left, the right being wider and its axis lying more in line with that of the trachea than does that of the left bronchus.

DISEASES OF THE LUNG SUBSTANCE

The *malpositions* and *malformations* of the lungs are seldom of much importance pathologically. The right lung may have only two lobes or one lobe: the lobes may be imperfectly separated, or the lung may possess four lobes instead of the normal three. The left lung occasionally possesses three lobes.

Weight of the Lungs.—In a series of cases examined in the Pathological Department of the Edinburgh Royal Infirmary, I found the following to be the average weights of the right and left lungs.

Left Lung.—In 452 adult females the average weight of the left lung was 1 lb. 3 ozs. or 538 gm., and in 760 adult males, 1 lb. 10 ozs. or 708 gm.

Right Lung.—In 453 females the average weight of the right lung was 1 lb. 4 ozs. or 566 gm., and in 748 males, 1 lb. 12 ozs. or 764 gm.

These figures probably slightly overstate the normal weight of these organs.

Method of Examining the Lungs.—After completing a general examination of the thoracic organs while they are still in continuity, the lungs may be separated from the heart. This is done by dividing the structures composing their roots close to the lungs. The left lung should be examined first, as in the case of all double organs. Before incising the lungs the presence, and, if present, the nature and stage of organization of pleurisy should be ascertained. Then the glands at the root should be incised, and the bronchi and vessels at the root slit up into the lung substance, and the condition of all these structures carefully noted.

A general survey should be made of the *surface* of the lung as to volume, size of the whole lung, relative size of the lobes, increased consistence—local or general, presence of emphysema or collapse, colour, distribution and amount of extraneous pigment, presence of scars at the apex or at other parts of the surface, presence of adhesions or thickenings of the pleura. If the parietal pleura has been removed along with the lungs, lines of yellow fat which mark out the former relationship of that layer to the intercostal spaces will be seen traversing the surface from behind forwards and downwards. In pneumothorax as well as in extreme emphysema a portion of the pleural surface may be dry and parchment-like.

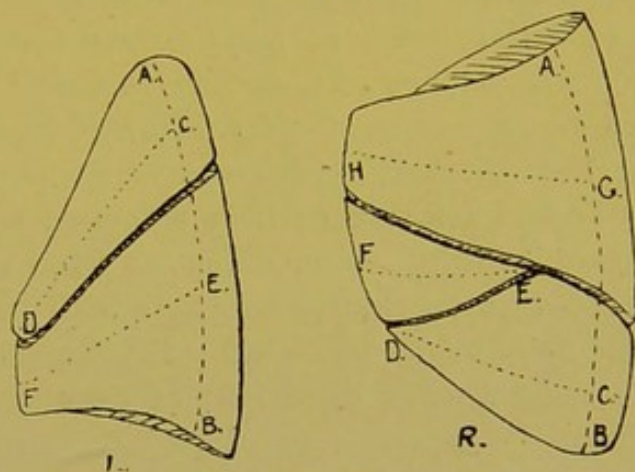


FIG. 54.—Diagrams showing lines of incisions for opening up the lungs.

(L) Left. (R) Right (see text).

Method of incising the Lung and Details as to its Examination.—The **Left lung** is placed on a slab upon its inner surface with the apex away from the operator.

It is steadied with the left hand, the index finger being placed between the lobes, and then with one sweep of a long-bladed knife the organ is incised from the outer lateral aspect inwards towards the root—Fig. 54, L, A to B—the two halves of the organ remaining attached to each other by the structures at the root as by a hinge. Thereafter the anterior parts of the lobes may be incised from C to D and from E to F. Subsidiary sections may be made as the nature of the case demands, hinges of connecting tissue being left between the sections.

Right lung.—To incise the right lung it should be placed upon its inner surface with the apex proximal and the root towards the left of the operator. As in the case of the left lung a section is made from A to B, and to open up the anterior parts of the lobe and the middle lobe subsidiary oblique sections are made from C to D, E to F and G to H. (See Fig. 54, R.)

EXAMINATION OF THE LUNGS

General Considerations.—The points to be investigated in the lung are its colour, air-content, consistence, friability, consolidation, the nature of fluid escaping from the bronchi and cut surfaces, and the nature of abnormal cavities.

(1) **Colour.**—In the child the lungs are of a uniform pink colour throughout, provided pneumonic consolidation be absent. On the outer surface the lobules can be easily distinguished by the mosaic markings on the surface formed by the junction of the interlobular septa with the deep layer of the pleura. In the healthy adult, at all events under civilized conditions, the pink colour is concealed by a varying degree of carbon pigmentation. The carbon is deposited in the lymphatics of the deep layer of the pleura, thus outlining the polygonal lobules and emphasizing the tessellated or mosaic appearance of the pleural surface. On the cut surface, it is distinct along the septa and surrounding the bronchi and large vessels.

All patches of new fibrous tissue formed as the result of inflammatory changes, or from the irritation of foreign particles, tend to become impregnated with carbon pigment. Such pigmented fibrous tissue is constantly found in relation to healed foci of tuberculosis, but it is also met with in chronic fibroid tuberculosis, and in the pneumoconioses (dust diseases). An exception to this rule is met with in certain forms of syphilitic interstitial pneumonia, in which the new fibrous tissue may be unpigmented.

The blue-black colour of carbon pigmentation is readily distinguished from the sepia colour of secondary melanotic tumours.

In extreme anaemias the lungs are pale and grey, apparently devoid of blood except posteriorly where hypostasis increases the amount of blood present and produces a reddish-brown colour. A bright red or pink colour is found in the lungs in poisoning with carbon monoxide, or with sulphuric acid.

Even in lungs which are practically healthy, the blood tends to gravitate after death to the posterior parts (hypostasis).

Gangrenous areas are either grey or black and the peculiar, penetrating, offensive odour reveals the nature of the condition. All collapsed areas become of a dull purplish colour unless there is carbon pigmentation, which gives them a slaty-grey colour.

(2) **Air Content.**—If the lung contain air it will float in water. Any part which is completely consolidated or airless will sink. If a part containing air be compressed, a frothy fluid—serum or blood mixed with air—escapes and the lung may crepitate between the fingers. The amount of air is increased in emphysema and it is lessened or lost altogether in oedema, haemorrhage, collapse, and consolidation from whatever cause—inflammation, infarction, or new-growth.

(3) **Consistence, Friability, etc.**—In pneumonic consolidation and in

infarction, loss of air is associated with increased friability, whereas in collapse it is associated with increased toughness of the parts affected.

These changes can best be appreciated by palpation. The normal lung collapses like a sponge when compressed, and, like a sponge, does not break down, it simply parts with the air contained. By gentle compression between the fingers and thumb and by passing the fingers over the pleural or cut surfaces any variation in consistence is readily detected. In a consolidated lung *friability* indicates exudative consolidation of recent or comparatively recent date. If the thumb be pressed into the solid part, this breaks down—"gives"—before it. The method of applying the pressure is important. The pulp, *not* the tip, of the thumb should be applied to the cut surface *gently* and with gradually increasing pressure. If the lung gives way, exudation is present, if not, the thumb squeezes out blood, and other fluids mixed with air, until it meets the surface supporting the organ, or the opposing fingers, with empty collapsed lung alone intervening. This point is important because in extreme oedema—particularly the so-called "solid" oedema—the *tip* of the thumb can be driven readily through the lung, and in consequence an erroneous diagnosis of pneumonia may be given. Naturally, if oedema accompanies pneumonia special care has to be exercised, the amount of air escaping and the specific gravity of the part as tested in water becoming important aids.

Collapse and also increase of fibrous tissue—the latter, for example, in the various forms of interstitial pneumonia, and in late chronic venous congestion—increase the consistence and toughness of the lung.

(4) **Fluids escaping from the Cut Surface.**—In chronic venous congestion and in emphysema, unless oedema co-exist, the cut surface is dry and harsh.

In oedema, a watery, more or less blood-stained, more or less frothy, fluid escapes, which scarcely stains the fingers.

In oedema, accompanying chronic venous congestion, the fluid is brownish, containing haematogenous pigment.

In hypostatic congestion, and in haemorrhage with collapse, almost unmixed venous blood escapes.

In grey hepatization a certain amount of a fluid containing minute light grey particles—the plugs from the vesicles—can be scraped from the cut surface. In resolution the fluid is brownish, more plentiful and contains similar granules. If the pneumonia has gone on to suppuration, slimy pus-like fluid lies upon the cut surface, and can be scraped off in considerable amount. Since in this condition there are usually necrotic and haemorrhagic areas, some blood is usually commingled.

In coal miners' lung, the fluid escaping contains numerous particles of carbon, so that it stains the fingers a grey colour, and if the incised lung be placed on a white surface, e.g. a porcelain plate, a dark grey fluid collects round about it. This is seldom absolutely "inky," as is commonly described.

In gangrene the fluid may be watery, brown or black, and is very offensive.

(5) **Excavation.**—This has already been in part considered when describing the changes met with in bronchiectasis (p. 119). The character of the excavations in tuberculosis of the lungs will be fully considered later (pp. 144–146).

DISEASES OF THE LUNG SUBSTANCE

ALTERATIONS IN THE AMOUNT OF AIR PRESENT IN THE LUNG.

(a) **Collapse and Atelectasis.**—These terms are commonly used as synonymous, although the term “collapse” should be reserved for the airless condition of a lung which has *formerly* been distended and functioning, whereas “atelectasis,” strictly speaking, indicates that the vesicular tissue has *never* been distended with air. The terms will be employed with the above meanings.

Atelectasis is met with only in infants. The lung retains its foetal aspect and condition. It is small, purplish, flabby and tough. On section it has to be distinguished from pneumonic consolidation, in which the lung, or the affected portion of the lung, is increased in volume, altered in colour, firm in consistence and friable. In both conditions the lung, or the portions of it affected, sinks if placed in water. In medico-legal examinations of apparently still-born children it is well before removing the lungs to place a ligature tightly round the trachea to exclude all possibility of entrance of air into the lungs during the operative manipulations. It is also necessary to exclude in such cases the action upon an atelectatic lung of anaërobic gas-producing bacteria. On opening up the bronchi these may contain mucus, meconium or amniotic fluid.

If the condition be partial, a portion of the lung is small, unexpanded, dark in colour and recessed below the general surface. Such portions are with difficulty distinguished from the localized patches of collapse found in young children accompanying bronchitis and broncho-pneumonia, but can be distinguished microscopically by the prominence of the endothelium lining the vesicles.

Collapse.—(a) *Collapse from compression.*—Occasionally the whole organ is collapsed as the result of the presence of collections of fluid or gas within the pleural cavity; the pressure of tumours, of aneurysms, or of a dilated heart; pressure upwards of abdominal tumours, particularly when these affect the liver; pressure upwards of collections of fluid in the peritoneal cavity or of gas within the hollow abdominal organs or within the peritoneum.

The collapsed portions of lung vary in appearance and colour, the variation depending upon the amount of carbon pigment present and upon the degree of congestion of the part, so that collapsed areas may be anaemic, or dark purple. If carbon be present they are greyish-brown or slaty. The collapse may be superficial or may involve the greater part of a lobe.

The lower lobes are more often involved than the upper lobes. In extreme cases, if no pleuritic adhesions exist, the whole lung may collapse against the bodies of the vertebrae.

(b) *Collapse following bronchitis*.—In this variety, the bronchus or bronchiole leading to the part becomes blocked by swelling of its mucous membrane and by exudation into its lumen. The air in the vesicles served by the bronchus becomes absorbed. The area is usually hyperaemic from venous congestion and purplish in colour. On section the area is of a pyramidal shape corresponding to the lobules or groups of lobules affected. In the immediate neighbourhood, the lung is emphysematous.

Emphysema.—Emphysema is divided into two varieties:—*vesicular* and *interstitial*.

Vesicular emphysema may be either of acute or of chronic development.

(a) In *acute* emphysema the lung becomes over-distended with air without much atrophy of the walls of the vesicles. The condition may be total or partial, and is a result of violent expiratory efforts. It occurs in alcoholism, in asphyxia, and in asthma. It is common in whooping-cough and in acute bronchitis, particularly in children, in whom it is often accompanied by collapse and broncho-pneumonia.

(b) *Chronic* emphysema may present different aspects.

(1) The whole lung may be universally increased in volume as a result of the continued forced expiratory efforts in chronic bronchitis or in individuals whose occupation necessitates continued forced expiration, or it may result from a weakening of the elasticity of the lung.

This variety is the so-called *substantial* or *hypertrophic* emphysema of authors. The lung does not collapse on opening the chest.

The thorax is increased in all its diameters, and rounded on cross-section—"barrel chest." The extrinsic muscles of expiration are hypertrophied—sterno-mastoids, scaleni, etc.

(2) Emphysema may be *compensatory* ("vicarious"), as a result of destruction of a part of the lung, e.g. by tuberculosis. Similar emphysematous areas are found in the immediate neighbourhood of all non-functionating portions of the lung, whatever the cause of the loss of function may be.

(3) *Senile* or *Atrophic Emphysema*.—The lung collapses on opening the chest, provided no adhesions exist. The organ is usually dark in colour, and the emphysema results from an atrophy and degeneration of the fibrous and elastic elements in the walls of the infundibula or alveoli. The thorax is usually lessened in size.

In ordinary chronic emphysema the margins of the lung become translucent, and frequently clear bullae, often of considerable size, develop at the extreme margins. The emphysematous portions are usually empty, except for air, unless pneumonia be present, though at times small concretions, of a nature related to that of "corpora amylacea" may be found within the cavities. The condition begins usually at the anterior borders of the

pyramidal
shape
hyperaemic
congestion
emphysema
interstitial

Acute
alcoholism
asthma
whooping-cough
acute

Chronic
Substantial
Hypertrophic
Barrel chest
sterno-mastoids
scaleni

Compensatory
T.B.

Senile
collapse
dark

Bullae
concretions

upper lobes, particularly in the long, tongue-shaped process of the upper left lobe, to which the name "lingula" is given. It is found commonly at the apex, along the anterior margins of the lobes (Fig. 55), and along the free edges of the base. The emphysematous portions are pink, the carbon pigment having disappeared.




FIG. 55.—Vesicular Emphysema of lung.—Section. (\times circ. $\frac{1}{2}$.)

The atrophy of the inter-vesicular walls and septa is the characteristic change. The infundibula dilate, the vesicles on their wall flatten out, the network of capillaries becomes separated up, and the cells filling up the interstices undergo fatty degeneration and disappear along with the supporting elastic and fibrous tissue. In this way appreciable gaps form in the walls, and these soon enlarge, allowing free communication between the infundibula. The stretched capillaries and lymphatics become impervious and finally give way.

The muscularis of the bronchi may be hypertrophied, but in older cases it is usually atrophied so that the bronchi also undergo dilatation.

The principal result is an interference with the pulmonary circulation leading to hypertrophy and dilatation of the right ventricle.

Interstitial Emphysema.—In cases in which the air-pressure is greatly increased in the alveoli, the air may escape into the lymphatics of the interlobular septa, forming clear elongated vesicles separating up the lobules and groups of lobules.

Causes.—Bronchitis and broncho-pneumonia, accompanied by violent coughing. It may develop in still-born children, as a result of too energetic attempts at insufflation.

Sites.—The parts most often affected are the anterior margins of the upper lobes. The inflated areas are usually sub-pleural. The air may pass towards the root of the lung; into the mediastinum; or it may even become subcutaneous.

These vesicles can readily be produced at the post-mortem examination by employment of too great force in removing the lungs.

CIRCULATORY CHANGES IN THE LUNGS.

Anæmia.—When anæmic, the lungs are light grey or dark grey in colour, the intensity of the colour depending upon the amount of carbon pigment present. The condition may be general, or it may be localized to one part of the lung, and then is caused by pressure from without, or by emphysema, or by collapse of the area. The surrounding lung tissue may show a collateral hyperæmia.

Hyperæmia, Congestion of the Lungs.

Active (inflammatory) hyperæmia is described upon page 130 as forming

the first stage of Lobar Pneumonia. This condition may also be caused by inhalation of irritating gases, or by exposure to extremes of heat or cold.

Passive Hyperæmia, Venous Congestion, may be of rapid or of slow development. The former is found in the lungs of individuals who have died of failure of the heart, and also may result from pulmonary thrombosis. The lungs are voluminous, and full of dark blood, which escapes in large amount from the cut surface. Petechial or more diffuse hæmorrhages may be found under the pleura.

Chronic venous congestion results most often from mitral stenosis or incompetence, but it may also be caused by weakness on the right side, or by interference with the propelling power of the heart, caused by chronic adherent mediastino-pericarditis, or by fibroid myocarditis. The congestion is most extreme when due to mitral incompetence. When caused by mitral stenosis, infarction of the lungs is a common additional result.

In the earlier stages the cut surface of the lungs is reddish, and the consistence is increased (*red induration*). Later, the colour deepens and becomes distinctly brownish, or purplish-brown, and the consistence increases still more (*brown induration*). Usually some patches of the lung are browner than others, and in them the consistence is so increased that the vesicles do not collapse, and their walls are plainly visible. The surface is drier than normal, unless oedema co-exist. The walls of the pulmonary vessels are thickened, and small patches of atheroma may be seen on the intima of the pulmonary artery.

Microscopically, the capillaries are *thickened*, dilated, and elongated so that they project into the air spaces. Frequently small hæmorrhages occur from them. The endothelial cells become swollen and catarrhal, and free cells can always be seen within the vesicles, crowded with carbon particles and altered blood-pigment (hæmosiderin), especially in the more indurated parts of the lung, and particularly in the vicinity of the septa and pleural surface. In later stages, there is increase of fibrous tissue and pigment in the walls of the vesicles.

The right ventricle is dilated and hypertrophied.

Hypostatic Congestion.—In the lungs, after death, the blood gravitates to the dependent posterior parts of the lungs. During life if the action of the heart and of the respiratory muscles is very weak, the blood tends to collect in the capillaries and veins in the basal portions of the lungs, or in the posterior parts, if the individual be confined to bed. The affected parts are dark purple, and contain less air than normal. Oedema is often associated with the congestion. Reaction of a low inflammatory type may occur, with escape of catarrhal cells and leucocytes, and formation of fibrin in the vesicles (Hypostatic pneumonia).

Oedema of the lungs usually accompanies venous congestion, though this may be absent. The watery fluid escapes from the capillaries into the vesicles and into the interstitial tissues. Oedema is most often caused by heart failure, but it also occurs during toxæmias. In subacute and chronic nephritis, oedema is constantly seen, particularly in the upper lobes of the left lung. In very marked cases the lungs are voluminous, sometimes translucent, and if congestion be present the lungs may appear to be consolidated and friable, so as to simulate the consolidation of lobar pneumonia. If, however, pressure be applied as indicated on page 123, this so-called "solid oedema"

can be readily distinguished. The watery fluid which escapes does not stain the fingers to any extent.

RESULTS OF ALTERATIONS IN THE CIRCULATION.

Haemorrhage into Lungs or Bronchi.—Bleeding takes place when ulceration extends through the elastic membrane of trachea or bronchi, e.g. in pulmonary tuberculosis, in bronchiectasis, or it follows pressure of an aneurysm, or invasion of the air passages by malignant growth. The largest haemorrhages occur when an aneurysm of the aorta ruptures into the trachea or left bronchus. In one case I found a communication between the right bronchus and the pulmonary artery resulting from the breaking down—suppuration—of a lymphatic gland; there was no evidence of tuberculosis.

Small bleedings or oozings may take place in acute catarrh of the upper air passages, in chronic venous congestion and hypostasis of the lung, in infarction, in malignant growth, in early tuberculosis, in syphilis of the lung, as a result of the action of some poisons, and in some acute infective diseases such as scarlet fever, small-pox, anthrax, or plague.

Larger haemorrhages from the lung may follow the rupture of hernial aneurysms upon the walls of tuberculous cavities.

It is rare to meet with ulceration into a vessel in acute tuberculous caseation. Lesions in the central nervous system, particularly in the pons and medulla, associated with interference with the respiratory function, are sometimes accompanied by haemorrhages into the lungs, as well as into the stomach, oesophagus, and liver.

Pulmonary haemorrhage occurs also in haemophilia; in scurvy; in presence of animal parasites such as *Distoma pulmonale* (*Paragonimus Westermani*), hydatids of *T. echinococcus*, as a result of mechanical injury or of low atmospheric pressure, and also sometimes vicariously, e.g. in suppressed menstruation. Bronchial anthrax is characteristically accompanied by haemorrhagic effusion into the walls of the bronchi, and along the interlobular septa. Haemorrhage into the mediastinum without evident gross lesion of blood-vessels should always suggest a severe bacterial infection, as by *Bac. anthracis* or *Pneumococcus*.

Minute multiple haemorrhages occur in the lung as a result of multiple embolism, particularly if the emboli be septic, but a similar condition follows fat embolism in some cases. These haemorrhages may be regarded as of the nature of minute infarcts. Aspirated blood usually gravitates to the lower lobes, and fills the central parts of the lobules.

Pulmonary haemorrhages, whether large or small—as distinguished from haemorrhagic infarcts—are characterized by their ill-defined margins, and by the fact that they occur not only under the pleura but also fairly uniformly throughout the lung.

Pulmonary Infarction.—In pulmonary infarction localized areas of the lung, near its surface as a rule, and more often in the lower than in the upper

lobes, become filled with blood. They are usually of a wedge-shape, with the base to the pleura. The condition follows embolism of medium-sized or smaller branches of the pulmonary artery, less commonly venous thrombosis. (See *Embolism*, p. 104.)

The blood filling the infarcted area comes either from the collaterals of the pulmonary artery, from communication between the bronchial and pulmonary arteries, or from the peri-bronchial, subpleural, interlobular or bronchial veins.

Obstruction of the main artery is followed in most cases by instant death (see Fig. 9, p. 44); closure of small branches near the root of the lung does not lead to infarction on account of the free collateral circulation.

In the majority of cases a predisposing condition exists, such as interference with the pulmonary circulation by chronic venous hyperaemia. This most commonly results from mitral stenosis or incompetence, and infarction occurs more frequently in association with mitral stenosis than with incompetence of that valve. The influence of the blocking of the artery of supply is assisted, most probably, by patchy stases and thromboses, particularly in the peripheral parts of the area but also within it. When the blood enters the part after the preliminary anaemia it distends the capillaries as a result of these multiple blocks, and penetrates the walls, doubtless because of interference with their nutrition and consequent degenerative changes.

Infarction may also follow septic embolism in the absence of chronic venous hyperaemia, partly, no doubt, by development of septic thrombi in the capillaries and veins, but also by degeneration of the walls of the capillaries caused by the toxin. Some authors suggest that infarcts may form without previous embolism, when numerous thrombi are produced in an area of the lung as the result of the action of toxic substances. In such cases the resulting area of haemorrhagic infiltration is circumscribed.

Infarcted areas project on the pleural surface as a result of partial retraction of the surrounding vesicular lung tissue. At an early stage, a pleuritic exudate forms. The infarct is usually found in the haemorrhagic stage, and on section it is of a dark purple or purplish-brown colour, uniform,

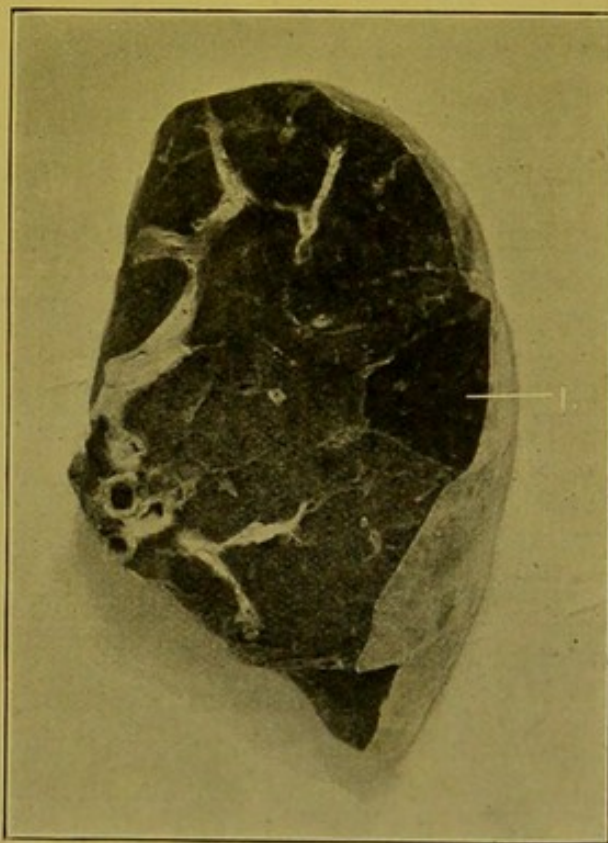


FIG. 56.—Infarct of Lung, upper lobe.
(\times circ. $\frac{2}{3}$.)

(1) Infarct with margins sharply demarcated by interlobular septa.

smooth, with a sharply-marked margin corresponding to the septum limiting the affected group of lobules (Fig. 56). At the apex of the wedge the blocked artery accompanying the bronchus supplying the area can usually be made out easily.

Occasionally infarcts are seen at a later stage when alterations have taken place in the blood pigment, and sometimes a line of granulation tissue or a limiting zone of suppuration separates the area from the more healthy tissue. One seldom meets with scars which one can diagnose as organized infarcts. Many small infarcts can undergo absorption, leaving simply increased pigmentation of the part and thickening of the walls of the infundibula and vesicles, but the connexion of these with a pre-existing infarct is difficult or almost impossible to prove. Sometimes infarcted areas undergo purulent softening or gangrene, and may cause empyema.

Under the microscope the infarcted areas, if examined at an early stage, are crowded with red blood corpuscles, with a few leucocytes and a varying proportion of catarrhal cells depending upon the degree of the pre-existing chronic hyperaemia. The nuclei in the walls of the vesicles may still retain their staining power. If they are examined at a later stage the area is usually necrotic, the nuclei have lost their staining power, but the outlines of the vesicles with the capillaries contained in them can usually be distinguished for a considerable time.

Inflammation of the Lung.

PNEUMONIA

In pneumonia the infective agent may penetrate the lung by way of the bronchi, by way of the blood-vessels or lymphatics, or as a result of traumatism. Inflammation may be wide-spread, affecting the whole or the greater part of a lobe ("**lobar pneumonia**"), or it may be localized, in areas either few in numbers, or scattered throughout the whole lung. These are in *most* cases—apart from certain tuberculous infections—related to the bronchi and are termed "**broncho-pneumonia**," or "**peribronchial pneumonia**" or "**lobular pneumonia**."

(a) **Lobar pneumonia.** (Synonyms: "Fibrinous" pneumonia, "croupous" pneumonia, "exudative" pneumonia.)—In this variety of pneumonia the changes are analogous to those occurring in inflammation of a serous surface, the difference in the course and results depending solely upon the fact that the exudation takes place into cavities. The analogy is similar to that between an ulcer of the skin surface and an abscess of the deeper tissues.

The process is usually divided into several stages: (1) **Congestion**; (2) **Consolidation** or **Hepatization** including (a) Red Hepatization, and (b) Grey Hepatization; and (3) **Resolution**.

(1) In the first stage, which may last from twelve to twenty-four hours, the lobe becomes somewhat voluminous. On section it is of a dark red colour, and on compression between the thumb and fingers, frothy coagulable fluid mixed with blood escapes. The lung still contains air, but its friability is

Dark red. Frothy bloody fluid on surface contains air.

Dark red. More friable & thinner perhaps.

But surface is so much

increased. Microscopically, there is acute congestion of the walls of the vesicles and infundibula, and when suitably fixed, the vesicles contain granular coagulated albuminous material with escaped red blood corpuscles, a few leucocytes and desquamated endothelial cells. Some fibrin threads are usually found at this stage in some of the alveoli.

(2) Following this stage, consolidation becomes complete, the lung airless and still more voluminous. In the earlier stages of hepatization, that termed "**Red Hepatization**," which usually develops from the second to the fourth day, the lung on section is of a dull red colour, sometimes with a purplish tinge. Its consistence is increased and its friability is extreme. The cut surface may be somewhat granular because of the retraction of the elastic tissue in the walls of the vesicles, thus rendering prominent the plugs contained within them. If the surface be mottled with deposits of carbon, it presents an appearance which has been likened to that of red granite. Recent pleurisy may be present. (See Pl. I, Fig. 1.)

Under the microscope the congestion of the walls of the vesicles is still marked, but the vesicles are filled with a close fibrin network which is attached to the walls, and communicates with similar plugs in neighbouring alveoli through pores in the walls. In the meshes of the network there red blood corpuscles are scattered, singly or in small groups, also polymorphonuclear leucocytes and large mononuclear phagocytic cells, mostly derived from the endothelium lining the vesicles, but in some instances, doubtless, emigrated from the blood-stream. At this stage the fibrin threads are glassy, continuous and refractile. By employment of suitable staining methods, *pneumococci* can be detected—in smallest numbers where there is most fibrin, in greatest numbers where there are most leucocytes, e.g. in the bronchi and infundibula.

This stage goes on to the later or "**Grey Hepatization**" stage, in which to the naked eye the affected part is of a pale pinkish-grey colour. This stage lasts from the fourth to the eighth day. Fibrinous pleurisy and acute bronchitis are always present. The cut surface is finely granular, and from it a thin fluid containing greyish or greyish-yellow granules—the loosened plugs—can be scraped away. In mounted preparations a layer of these granules collects at the bottom of the jar. The lung is voluminous and increased in weight (Fig. 57). More recent—red—stages of extending inflammation may be found in the upper parts of the affected lobe or of the lung. The branches of the pulmonary artery may be full of agonal thrombus.

Under the microscope the congestion has lessened, the fibrin is granular for the most part and the red blood corpuscles have disappeared. The nucleated cells, particularly the polymorphs, have increased in number; the plugs have retracted from the walls of the vesicles. These phenomena may be regarded as evidence of an attempt at resolution.

(3) Hepatization is succeeded by "**Resolution**" in which absorption of the exudate takes place. This usually becomes well marked about the eighth or ninth day.

9th day Resolution - Greenish-brown fluid on pressure
Still 4-6th

The affected area may be still of a greyish-yellow colour, or vascularity may have returned so that it is of a dirty brown colour. From the cut surface a thin, or creamy greyish-brown fluid, containing granular remains of the plugs, can be scraped away.

The infiltrated lung is still soft and friable because of changes in the elastic tissue.

Under the microscope the vesicles contain remains of fibrin, leucocytes and mononuclear phagocytes which have ingested particles of broken-down cells and granular fibrin. Air has now re-entered the lung. When resolution is delayed, evidence of partial organization of the plugs may be found.

Another appearance frequently met with, particularly in alcoholics and diabetics, is what appears to be an extreme grade of Grey Hepatization in which as a consequence of increased exudation and, particularly, infiltration with leucocytes, the volume of the lung is greatly increased, so that it may weigh 5 or 6 lbs. (2,200 to 2,700 gm.). The lung is pressed against the thoracic wall so that its surface shows imprints of the ribs. The cut surface is of a yellowish or greyish-yellow colour, and anaemic. The exudate fills the vesicles and compresses the vessels, bringing about interference with nutrition so that necrotic changes commonly result. It is frequently accompanied by scattered haemorrhages into the substance of the lung, and in more extreme cases a slimy, creamy, pus-like fluid exudes on the cut

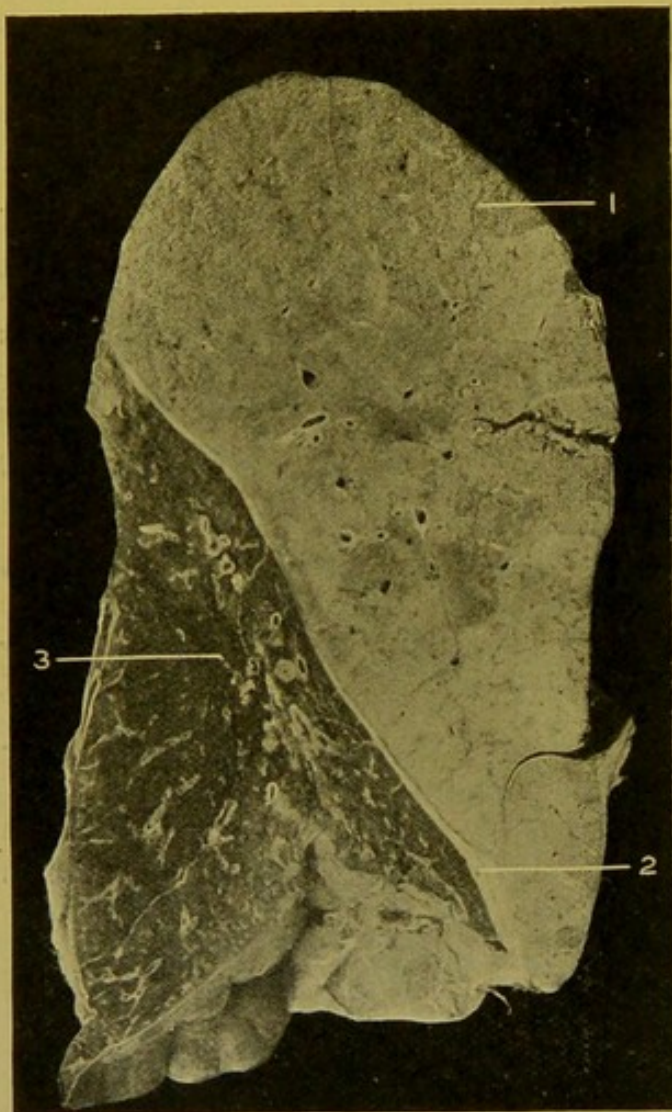


FIG. 57.—Acute Lobar Pneumonia. Grey Hepatization. (\times circ. $\frac{1}{2}$.)

(1) Hepatized lung; (2) adhesion between lobes; (3) partly collapsed lower lobe.

surface. This is the so-called "suppuration" of the lung.

Microscopically, there is a great increase in the number of leucocytes both in the vesicles and in the veins and capillaries.

It is questionable whether recovery ever takes place from this condition.

General Results of Lobar Pneumonia.—(1) Complete resolution with return to the normal, with, at most, permanent thickening of the walls of the infundibula and vesicles.

(2) Suppuration, necrosis or gangrene of the lung, generally assisted in causation by secondary infections. These results frequently follow in alcoholics, but gangrene may be induced by previously existing bronchiectasis or putrid bronchitis.

(3) Rarely the inflammation may become chronic, and bring about "Carnification" of the lung, in which the exudate becomes organized and the walls of the vesicles become thickened from formation of young connective tissue. The affected portion becomes tough and of a fleshy, light brownish-pink colour, and contracts. The carbon pigment disappears, in part, or completely. The bronchi dilate, and usually adhesions form between the pleural surfaces (Fig. 58). The vesicles may contain an increased number of catarrhal cells. Leucocytes are usually conspicuous by their absence at this stage.

(4) Calcification of the plugs is extremely rare. I have seen one case only. The lungs were pigmented, firm in consistence, and felt as if full of sand.

In pneumonia the lymphatics and the root glands are usually full of material derived from the consolidated parts of the lung, and in the early stages the glands are congested and oedematous.

Bacteriology of Pneumonia.—In a great number of cases of fibrinous pneumonia practically pure cultures of the *pneumococcus* may be recovered from the lung—upon Pfeiffer's blood agar, or agar containing fresh serum, e.g. ovarian, ascitic, hydrocele fluid, etc.

In lobar pneumonias caused by the *diplobacillus* of Friedländer the exudate tends to be slimy in the early stages and to contain more swollen catarrhal endothelial cells, and, in later stages, many vacuolated leucocytes. The cut surface is usually smoother and more uniform than in the pneumococcal cases.

In influenzal pneumonias the *pneumococcus* often accompanies the influenza bacillus, and the distribution of the consolidation is often irregular, tending to present a more or less lobular character, while, in addition, there may be purulent exudation into the bronchi, and acute interstitial changes.

Acute (Simple) Broncho-Pneumonia and Lobular Pneumonia.—(a) **Broncho-pneumonia** in its narrower sense, meaning by the term, extension of inflammation from the bronchiole to the vesicles served by it, is the form which

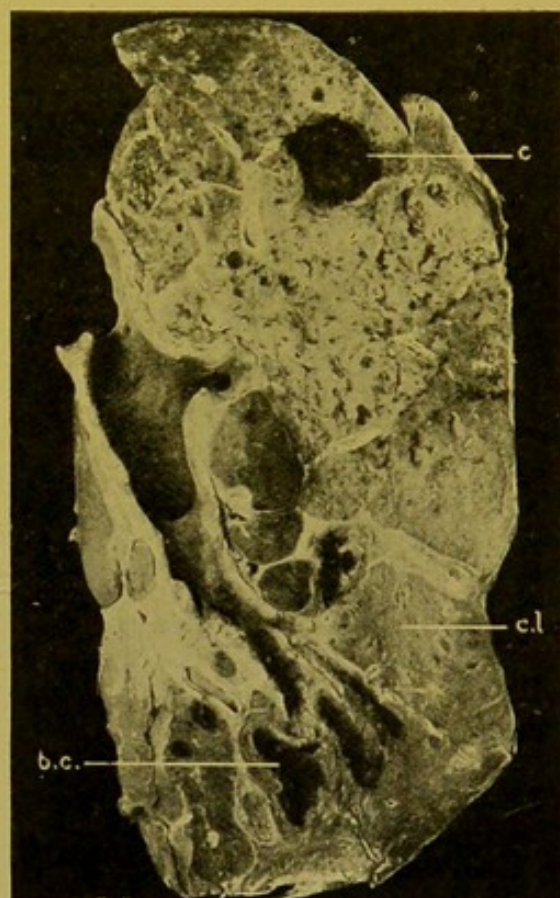


FIG. 58.—Carnification of Lung.
(\times circ. $\frac{1}{2}$.)

(c.l.) Carnified lung; (b.c.) bronchiectatic cavity;
(c.) cavity full of blood-clot.

pneumonia constantly takes in infancy, but it is also met with at the other extreme of life.

(1) In infancy it is usually secondary to bronchitis of the larger tubes or to a bronchiolitis occurring in the course of acute specific infections, particularly whooping-cough and measles. It may follow extensive burns of the surface and less commonly it complicates diphtheria, scarlet fever, and acute 'inflammatory' conditions of the gastro-intestinal tract, e.g. the acute dysentery of childhood.

The condition is essentially catarrhal in nature. It begins as a bronchiolitis with plugging of the lumen with exudate. This exudate contains detached epithelium, leucocytes, catarrhal endothelial cells, granular debris, and in the smallest branches the cubical epithelium tends to remain

within the lumen separated from the walls at parts by cellular exudate. The walls are greatly thickened through infiltration, congestion, and oedema. This is simply "capillary bronchitis" which in both adults and children causes intense dyspnoea — "suffocative bronchitis." The inflammation gradually extends out in the walls of the adjacent infundibula and vesicles, the congestion being more apparent at the periphery of the affected area, while nearer the centre the infiltration tends to mask the congestion. It also extends to the vesicles, in which numerous catarrhal endothelial cells and leucocytes are seen. Small haemorrhages may also occur. The proportion of polymorphs to catarrhal cells varies in different vesicles and in different cases. In some vesicles there is formation of fibrin.

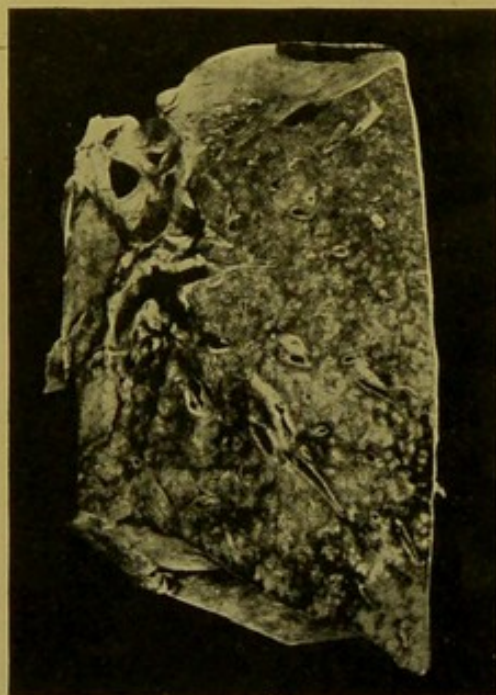

FIG. 59.—Acute "Simple" Broncho-pneumonia in a Child.—Lower lobe. See description in text. ($\times \frac{3}{4}$.)

The central plug in the bronchiole at a later stage undergoes fatty degeneration and becomes liquefied.

A knowledge of the microscopic appearances assists comprehension of the *naked eye* characters. The whole lobule or only the central part of it may be affected. The affected patch is of a grey colour passing at its margin rapidly into a red zone of consolidated congested lung tissue. A little later the central part becomes yellow from increasing infiltration with leucocytes, and from softening. It is surrounded by a grey zone and this again by a zone of congested tissue. The intervening pulmonary tissue is congested and still vesicular, or may be consolidated (Fibrino-catarrhal pneumonia). These nodules are not of large size; they may be of the size of a pin's head if the areas be cut transversely, or they may show branch-

ing, the stems and branches being at the most about 2 mm. in diameter. Collapse and emphysema are constant accompaniments, bringing about a marbling of both pleural and cut surfaces. The condition is not usually associated with pleurisy. (Fig. 59.)

(2) Another form of **Broncho-Pneumonia**, which seldom occurs in children but is found not uncommonly in older individuals, results from inhalation of septic or foreign material ("aspiration," "inhalation," "vagus," pneumonia). The whole lung is congested, and firm areas can be felt both on the surface and in its substance. The condition especially attacks the lower lobes, and more often the left than the right lung.

"Hypostatic" pneumonia is usually of this type.

Most commonly such pneumonias follow operative procedures in the mouth and upper air passages, or septic inflammations, ulceration and malignant growths in these situations, or paralysis of the vagus.

On section, on the congested surface there are seen prominent areas varying in size from that of a split pea to that of a hazel-nut or even larger. These are usually paler in colour than the general surface. They may be of a greyish-red, or distinctly grey colour, or of a yellowish-grey colour, depending upon the degree of infiltration and exudation. They have ill-defined margins. In the central parts pus can usually be expressed from the bronchi. On palpation they are distinctly friable. In general appearance they resemble small patches of fibrinous pneumonia. (Fig. 60.)

(b) **Lobular Pneumonia**.—In another form especially occurring in adults the appearances are similar to those found in ordinary lobar pneumonia, but the consolidation is limited to single lobules, or more commonly, to groups of lobules. The affected areas are sharply marked off from the surrounding vesicular lung tissue by a margin which corresponds to the

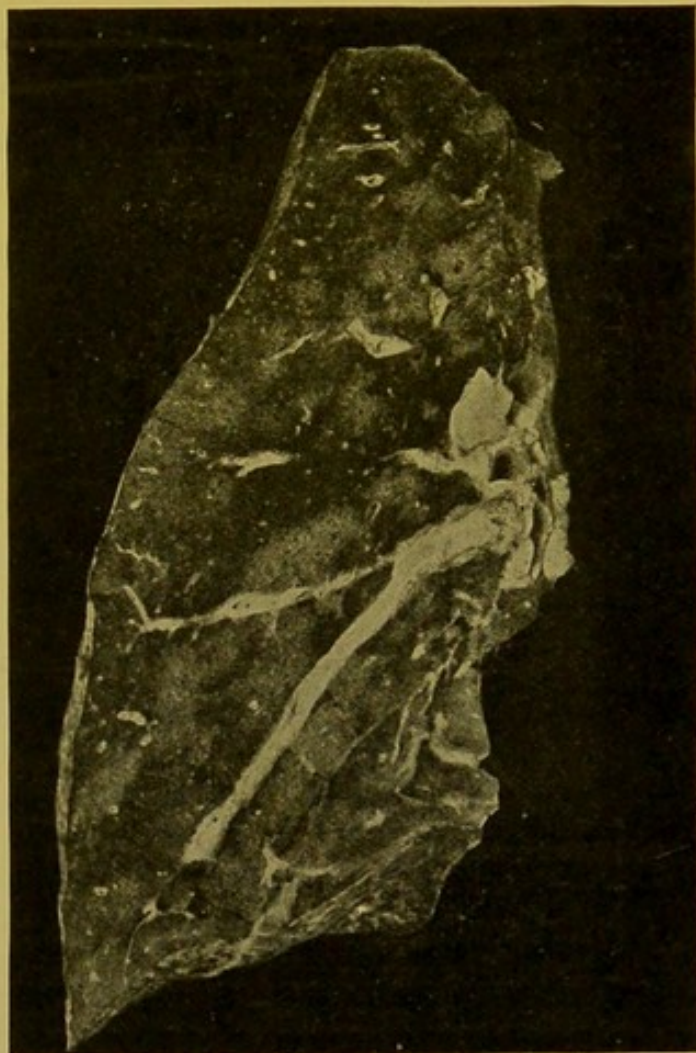


FIG. 60.—Acute broncho-pneumonia, Adult.
(\times circ. $\frac{3}{8}$.)

The pale patches, with ill-defined outlines, were consolidated areas.

"aspiration"
"inhalation"
"vagus"
adult
all lung
congested
firm
can be felt

Prominent
areas
paler than
surface
grey
grey
yellow
depending
infiltration
pus
pus
central

adult
like
but
lobes
sharp
giving more
appearance

interlobular septa, giving a mosaic appearance to the pleural and cut surfaces, which characterizes the condition even when consolidation is extensive. There are always some intervening functioning lobules. The condition has been termed "pseudo-lobar" pneumonia (Fig. 61). The infective agents are similar to those of lobar pneumonia and the microscopic appearances also correspond.

Bronchitis may occur as a secondary manifestation and pleurisy may develop over the superficial nodules.

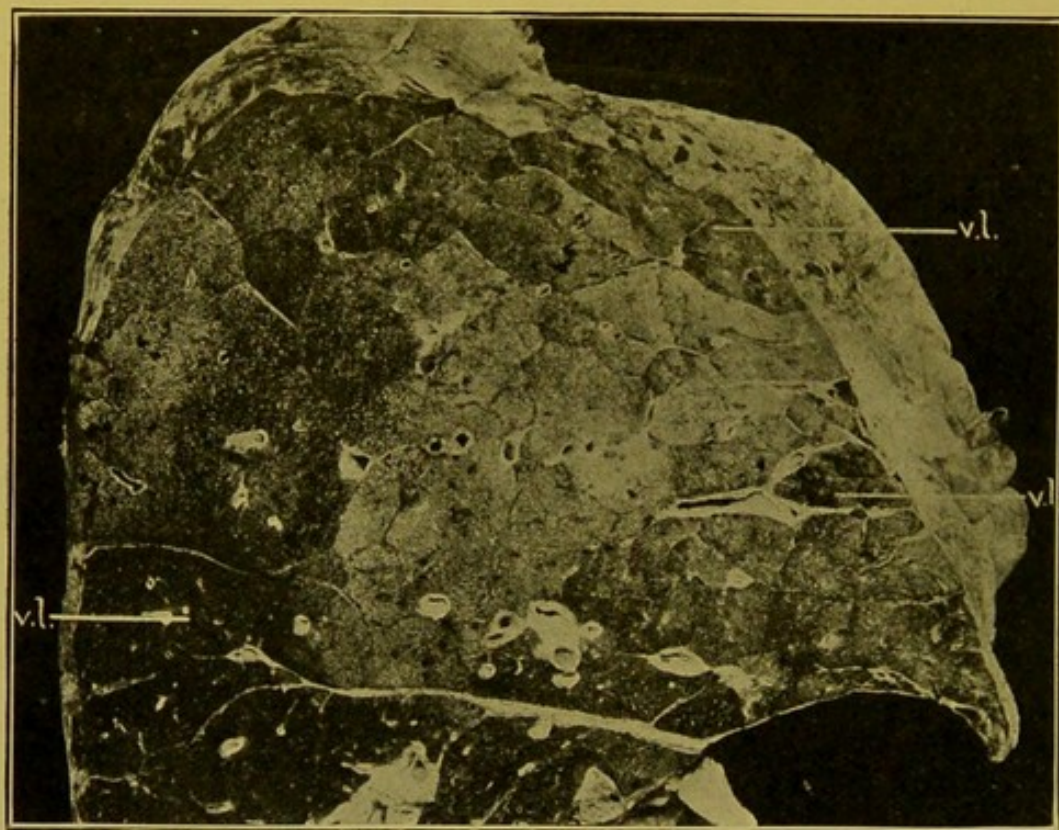


FIG. 61.—Lobular Pneumonia—Upper Lobe. (\times circ. $\frac{2}{3}$.)

(v.l.) Lobules still vesicular. The paler patches, limited sharply by the interlobular septa, are consolidated.

Septic Pneumonias.—These include the conditions already described as septic broncho-pneumonia and "suppurating" lobar pneumonia, but other conditions which come under this heading are, abscess-formation in pyaemia, aspergillary pneumonycosis, and suppuration following punctures and other wounds of the lung communicating with the surface.

Abscesses may occur as a part of a general pyaemia, resulting from impaction in the lungs of septic emboli from suppurative lesions of the bones, parotid, or scalp, and may occur as a sequel of any septic inflammation affecting the systemic venous circulation. They follow dissemination of the ordinary pyogenic bacteria, but are also occasionally produced by the streptotricheae and, in rare instances, by aspergilli, particularly *aspergillus fumigatus*. (See Fig. 62.)

In a case of streptothrix infection I examined, the lesions suggested acute tuberculosis, but the congestion surrounding the small cavities and

the vascularity of their walls hinted at another causation. In streptothrix infections these abscesses are usually scattered in great numbers throughout the lungs; in aspergillary mycosis, they are usually in smaller numbers and more localized to the superficial parts of the lungs. They contain brownish, grumous material.

In well-marked **Septic Broncho-Pneumonia** large areas of the lung may be consolidated. The areas are more or less homogeneous, greyish-red in colour, and at the periphery there may be a zone of deep congestion and haemorrhage. In the central part the tissue is breaking down into irregular abscess cavities which communicate with bronchi. In other cases the appearances resemble those of simple broncho-pneumonia, but the patches are usually larger, projecting slightly on the pleural surface, and on the cut surface they are breaking down in the central parts, the cavities frequently coalescing to form irregular abscess cavities which, like those of the former variety, communicate with the bronchi. In the intervening lung tissue the vesicles contain catarrhal cells and large numbers of polymorphs. Some fibrin also is frequently present.

Gangrene of the Lungs.—As already indicated, patches of gangrene develop in the course of lobar and of lobular pneumonia probably as the result of a mixed infection. Gangrene may follow direct or indirect mechanical injuries of the lungs. Infarcts may become gangrenous. Diffuse gangrene may result from the spread of infection from a septic or putrid bronchitis to the lung parenchyma, or it may be caused by the aspiration of septic material, such as particles of food, necrotic portions of malignant tumours, or secretions from ulcers of the upper air passages and mouth, portions of carious teeth, or portions of broken-down bronchial or root glands. The *aspiration pneumonia*, induced in this manner, affects particularly the lower and middle lobes of the lungs, and the process soon spreads to the surrounding lung tissue. In the early stages, the gangrenous patch is a greyish-green to dark greyish-brown evil-smelling area, which later becomes more fluid, and lies as an irregular slough in a space, the walls of which are covered with gangrenous shreds. Microscopically, fragments of lung tissue, elastic fibres—though these tend to be dissolved up—blood pigment, oil droplets,

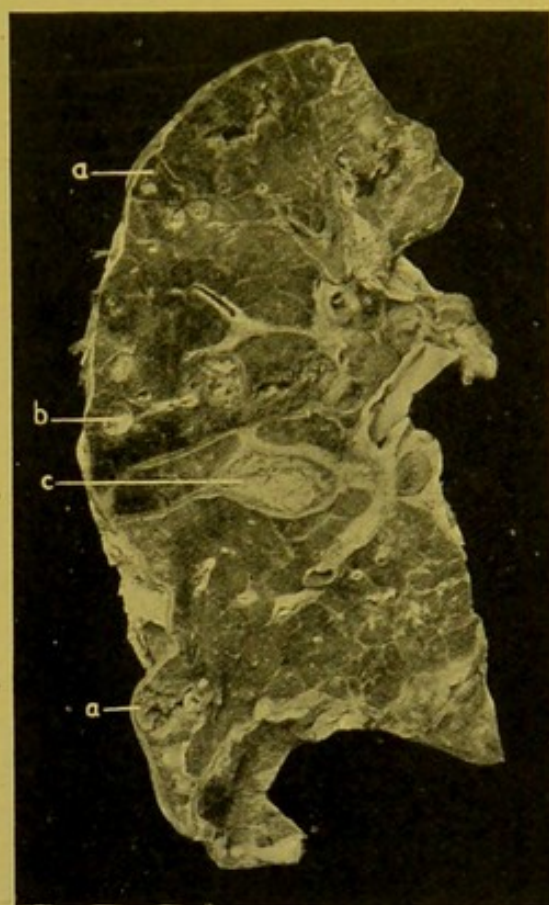


FIG. 62.—Pyæmic Abscesses of Lung.
(\times circ. $\frac{2}{3}$.)

(a.b.) abscesses; (c.) collection of purulent lymph between the lobes.

consolidation of lung
stomach
& down
red
congestion
at periphery
& haemorrhage
irregular
cavities
of central
parts

early
greyish green
to grey
Microscopic
fragments
elastic fibres
blood pigment
oil droplets
fat

and fatty acid crystals are found. The surrounding lung is consolidated. Many varieties of bacteria may be found, e.g. any of the pyogenic cocci, influenza bacilli, spirochaetes, fusiform bacilli, leptothrix forms, etc. Aspergillary forms are said to be associated especially with gangrene occurring in the course of diabetes.

Circumscribed gangrene may result from septic embolism.

Gangrene may be combined with abscess-formation, and very commonly accompanying them there is pleurisy, or occasionally, pneumo-thorax.

Pulmonary Anthrax. (*Wool-sorters' disease, rag-pickers' disease.*)—Infection takes place by the inhalation of dust containing the spores of the anthrax bacillus. The disease begins usually at the lower end of the trachea or in the main bronchi, as a congested hæmorrhagic area on which, occasionally, necrotic spots (*malignant pustules*), are found. The hæmorrhagic infiltration extends outwards through the wall, and then spreads to the mediastinum and along the interlobular septa. The mediastinal tissues and glands show very characteristic oedema and hæmorrhagic effusion. The pleural cavities generally contain serous or sero-sanguinolent effusion. The bacteria are present in great numbers in the exudate within the bronchi, and in all the hæmorrhagic areas. At a later stage the organisms penetrate to the blood-stream.

Pneumonic Plague.—Pneumonic plague may develop as a primary confluent lobular pneumonia; or as an aspiration pneumonia, the infective material being inhaled from degenerating areas in the mouth or pharynx. Multiple foci may be found especially in the lower lobes; these may result from metastasis by way of the blood-stream. The foci undergo necrosis at an early stage, and in the scanty exudate the plague bacilli are found in great numbers. Other bacteria may be associated with the plague bacillus in causing extensive hæmorrhagic and necrotic changes in the lungs.

INTERSTITIAL PNEUMONIA

This is a condition, or group of conditions, in which the connective tissue increases in the deep layer of the pleura, in the septa, in the outer coats of blood-vessels and bronchi, and in the walls of the vesicles. Occasionally **acute** interstitial pneumonia occurs in man, accompanied by exudative changes in the vesicular tissue, and resembles closely the pleuro-pneumonia of cattle. Usually the condition is **chronic**, and results from long-continued irritation. The irritant may enter (*a*) by the air-passages—dust and other foreign particles—*pneumoconiosis*; (*b*) by the blood- or lymph-vessels—tubercle, syphilis, etc.; or (*c*) the condition may follow previous inflammation of the lung or pleura.

The increase of connective tissue is common to all the varieties of interstitial pneumonia, although in the pneumoconioses it especially affects the interlobular septa and the deep layer of the pleura, whereas in the forms due to the action of organismal toxines, the outer coats of the blood-vessels

and bronchi and the walls of the vesicles are more especially affected. In all forms the connective tissue encroaches upon the vesicles tending to cause obliteration of these, and the endothelium of the more severely affected vesicles undergoes a remarkable alteration. It proliferates, the resulting cubical cells forming a layer or layers on the inner surface of the vesicle closely resembling that lining the alveoli of secreting glands. The intervening vesicular tissue becomes emphysematous. Bronchiectasis is common.

I. PNEUMOCONIOSES OR DUST-PNEUMONIAS.

(a) **Anthracosis** (Coal Miners' lung).—In all individuals who have lived under civilized conditions the lungs are impregnated to a greater or less extent with carbon pigment. The term "anthracosis" is applied especially to conditions in which this deposit of carbon pigment is extreme and in which the whole of the lung is of a dense sooty black or coal-black colour. Dense pigmentation may, however, be found in the lungs of individuals who have never entered a coal mine, and in such cases it is often associated with chronic tuberculosis, or other forms of chronic interstitial pneumonia. The pigment lies primarily in the pulmonary lymphatics, in the walls of the vesicles, in the interlobular septa, in the deep layer of the pleura, in the lymphatics surrounding the bronchi and blood-vessels and it is in greatest concentration in the root glands. The inner coats of the bronchi and blood-vessels and the superficial layer of the pleura are completely, or practically completely, free from pigment. The outer surface of the lung is covered with a filmy grey layer which may be compared to the "bloom" on the surface of a grape. This appearance results from the presence of the thin unpigmented layer of superficial pleura. In exceptional cases the pigment is found in adhesions between the pleural surfaces and even in the lymphatics of the parietal pleura, in the

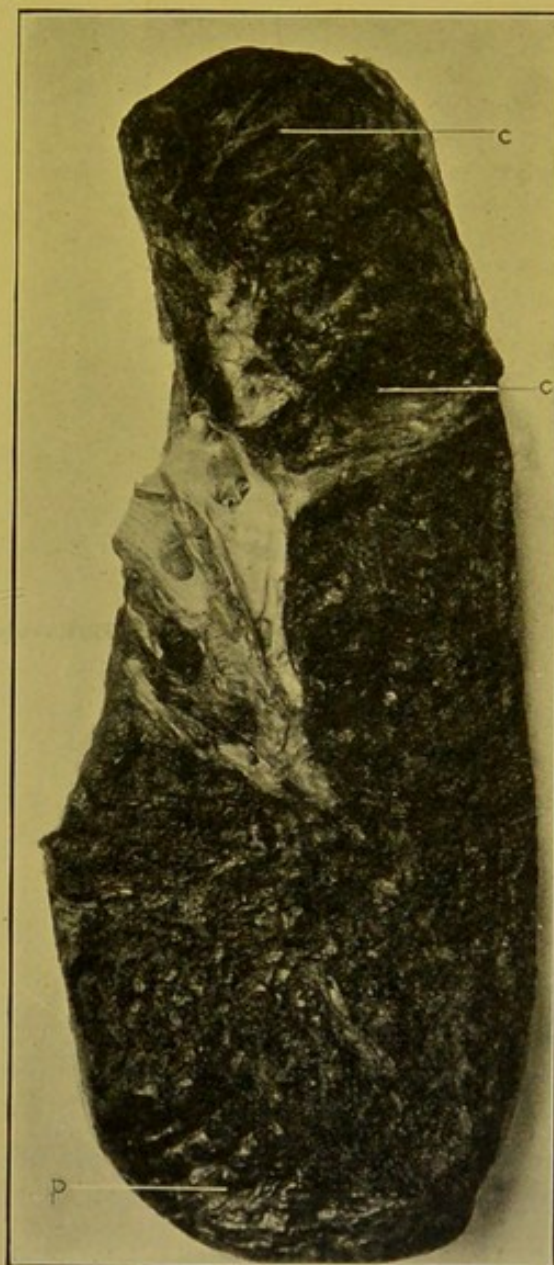

FIG. 63.—Anthracosis. Section of the lung from which the condition was described by Gregory and Christison. (*Ed. Med. Jl.*, 1831, cix., 389.) (\times circ. $\frac{3}{8}$.)

(c.) Cavity in upper lobe; (p.) diaphragmatic pleura. (Mus. R.C.S. Ed.)

connective tissue of the mediastinum, in the lymphatic glands in the hilum of the liver, and also in the spleen.

On section, in long-standing cases, there is thickening of the interlobular septa and to a less extent of the deep layer of the pleura. The connective tissue round about the bronchi and vessels shows moderate thickening and sometimes, particularly near the root of the lung, large areas of almost solid, deeply pigmented lung tissue are met with. This extreme fibrous formation is usually associated with additional tuberculous infection. From the cut surface a greyish-red fluid escapes, the red colour depending upon admixture with blood. The fluid is seldom inky black in colour. Tuberculous excavation may be associated with anthracosis. (See Fig. 63.)

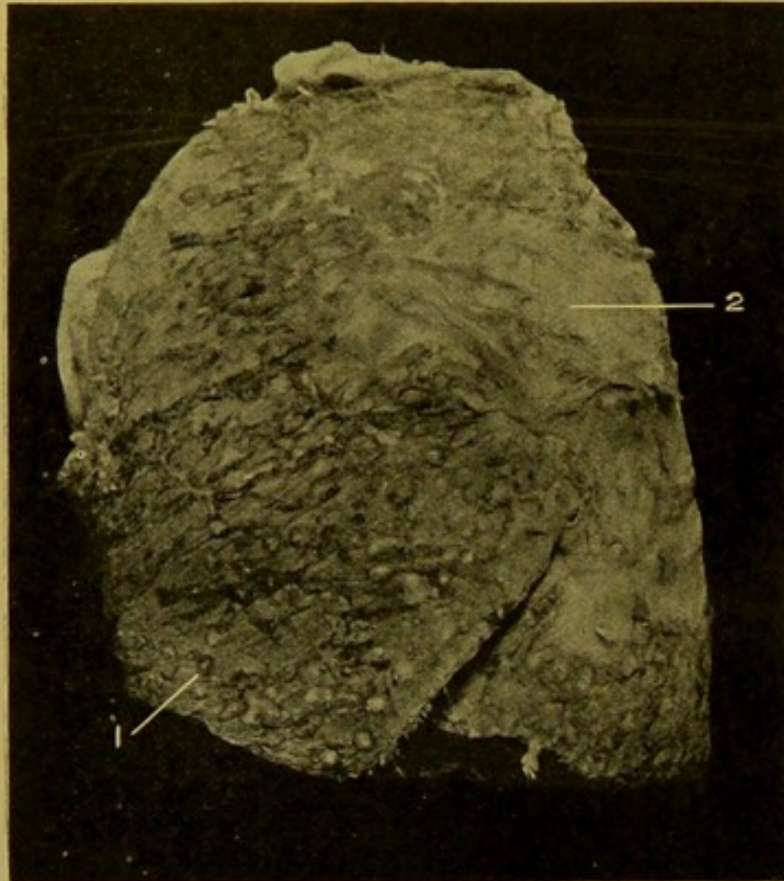


FIG. 64.—Silicosis, outer surface of Left Lung. (\times circ. $\frac{1}{2}$.)
Showing (1) typical nodules, and (2) scar-formation over surface.
(Mus. R.C.S. Ed.)

Under the microscope the pigment is seen in the deep layer of the pleura, in the thickened septa, and outer walls of the bronchi and blood-vessels. Pigmented catarrhal cells are always to be seen within the vesicles. The other changes are those common to all chronic interstitial pneumonias (p. 137).

(b) **Silicosis** (Stone Masons' Lung: "*Chalicosis*," "*Lithosis*").—This form of interstitial pneumonia occurs especially in workers in *hard* sand-

stone. The interstitial pneumonia of clay-workers, of needle-grinders, and of ganister workers is probably of the same nature. In needle-grinders, particles of the stone rather than the particles of iron cause the irritation. Generally speaking the distribution of the fibrous tissue is similar to that found in interstitial pneumonias generally, but in addition the fibrous tissue tends in a special manner to be aggregated in rounded fibrous nodules, or groups of such nodules bound together by fibrous tissue and sometimes forming a dense mass of almost stony hardness traversing the lung on a level with the root. Within these solid areas the individual nodules may be of a dark grey colour and surrounded firstly by a pale fibrous zone, and this again by a black zone of carbon deposit. These nodules when they

abut on the pleura are hemispherical, developing at the junction of the interlobular septa with the deep layer of the pleura. The pleura over them is thickened and frequently scar-like processes radiate from them over the surface, and local adhesions commonly form between the pleural surfaces. (See Fig. 64.)

On section the nodules are of a varying depth of grey and are surrounded by a zone of carbon pigmentation.

Under the microscope the fibrous tissue is arranged in concentric rings enclosing between them particles of siliceous material which are of a grey colour as a result of their refractile nature. They are readily distinguished from the opaque-black particles of carbon in the looser fibrous tissue at the periphery. Moreover, the fibrous tissue in the central parts is practically non-cellular, while that at the periphery is infiltrated with cells. The other changes are those common to all chronic interstitial pneumonias. If tuberculosis has attacked the lung in silicosis, and excavation has occurred, particles of the stony material may be expectorated in the sputum. These are the so-called "lung stones," or lung calculi ("pneumoliths").

(c) **Siderosis.**—The chronic interstitial pneumonia of those who inhale iron dust or iron oxide, e.g. mirror-makers, is of a more diffuse character than the varieties already described, the lung not being distorted in any way and the increase of connective tissue being more regular. The lung is of a rust colour throughout.

II. The interstitial pneumonias, in which the irritant is spread by blood-vessels or lymphatics, include the interstitial pneumonias of *tuberculosis* (pp. 147 and 148), and *syphilis* (p. 148), and the less common inflammations produced by *glanders* (p. 149) and *leprosy* (p. 149).

III. **Interstitial Pneumonia secondary to inflammation of the lung or pleura.**—This may be taken to include the condition known as *Carnification*, though there is organization of the exudate in the vesicles, as well as thickening of the walls, and of the interlobular septa. (See p. 133.) More commonly the outer walls of the bronchi and blood-vessels are greatly thickened, and dense, frequently unpigmented, scar-tissue forms along the septa. This apparently may spread either from the root, or from the pleura (pleurogenous). The presence of old thickening of the pleura, or of old adhesions, distinguishes pleurogenous interstitial pneumonia from that due to syphilis in which no pleuritic adhesions or thickenings may be present.

TUBERCULOSIS OF THE LUNG

The tubercle bacillus produces different anatomical changes in the lungs, depending on the one hand upon the virulence of the organism, and on the other upon the resistance of the soil. When the virulence is high or the soil weak, we find acute miliary tuberculosis, acute broncho-pneumonia with caseation, and accompanied, in young and old, by rapid excavation. When the virulence is low or the soil more resistant, the pathological changes

tend to be more chronic, accompanied by slow caseation, slow excavation and a tendency to development of fibrous connective tissue with encapsulation of the focus. Encapsulation indicates an attempt at healing, and is more commonly seen in adult or aged individuals than in the young.

The tubercle bacillus may invade the lung tissue along three channels.

(1) It may be inhaled, either from the outer air, or from a tuberculous caseating focus which has ulcerated into the **air channels**. The resulting lesion is therefore comparatively coarse in distribution, corresponding to the branching of the bronchus or bronchi affected.

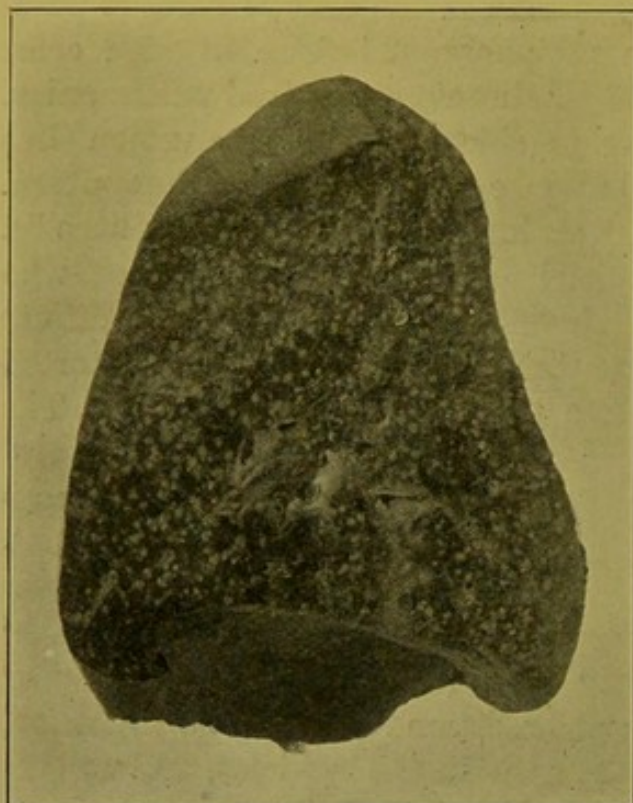


FIG. 65.—Miliary Tuberculosis of Lung, lower lobe. (\times circ. $\frac{2}{3}$.)

Blood-spread. Crowded minute rounded tuberculous nodules.

(2) The bacillus may enter by the **blood-vessels**, for example, when a tuberculous focus or gland breaks down into the pulmonary artery, or when bacilli from a focus elsewhere in the body reach the venous circulation either directly, or by way of the thoracic duct. The bacilli or caseous material containing these act as emboli which are caught in the capillaries and there set up tuberculosis. In this case the disease presents a fine distribution—miliary tuberculosis—and may bear no special relation to the bronchi.

(3) The organisms may spread along the **lymphatics** and this also brings about a fine distribution of miliary tubercles limited to the lines of the lymphatics, i.e. along the septa, in the adventitia of the bronchi and large vessels, and in the deep layer of the pleura.

As the second and third forms are the simplest, they will be described firstly.

Acute Miliary Tuberculosis of the Lung—Embolic or Metastatic.—This is, in most cases, part of a generalized tuberculosis, and while it is occasionally found in adults it occurs more characteristically in the young. The whole lung from apex to base, on surface and on section, is beset with grey or yellow miliary tubercles which have no special relationship either to bronchioles or vessels, or to septa. These are minute, solid, *rounded* bodies, about 1 to 2 mm. in diameter. They may be most numerous in the upper lobe. The intervening lung is vesicular and congested. The central part of each minute nodule may show commencing softening. The lung is more

voluminous than normal, and does not collapse when the chest is opened. (Fig. 65.)

Microscopically, the process commences with swelling and proliferation of the endothelium of the capillaries in the walls of the vesicles, of the neighbouring endothelium lining the vesicles, and of the connective tissue cells in their walls. The resulting mass of large mononuclear cells projects into, and soon fills, the neighbouring air vesicles. Giant-cells also may develop, but these are not essential, and in the more acute cases they are scanty. In the nodules, crowds of tubercle bacilli may be demonstrated by employment of suitable staining methods—e.g., Ziehl-Neelsen's Carbol-fuchsin method (p. 452).

If the patient live long enough, the nodule may caseate and extend to the air channels, leading to development of tuberculous broncho-pneumonia. Usually, however, before this occurs the individual dies of concurrent meningitis.

Source.—One should always look for a primary degenerating focus from which dissemination has taken place. This may be found in the lung itself, more frequently in a root gland, or in an abdominal gland, or intestinal ulcers. Foci may be found in the wall of a pulmonary vessel. These appear on the intima as small raised patches, of the size of a hemp-seed or split pea.

Lymphatic form of Miliary Tuberculosis of the Lung.—In this variety the infection spreads from a tuberculous focus within the lung or in a root-gland, or in the pleura. The tuberculosis tends to be more localized, forming lines and clusters of grey or caseating tubercles, often aggregated round a spot of pigment, corresponding to the lymphatic in an interlobular septum, or surrounding a bronchus—peribronchial tuberculosis—or blood-vessel. (Fig. 66.) This condition constantly accompanies tuberculous broncho-pneumonia with

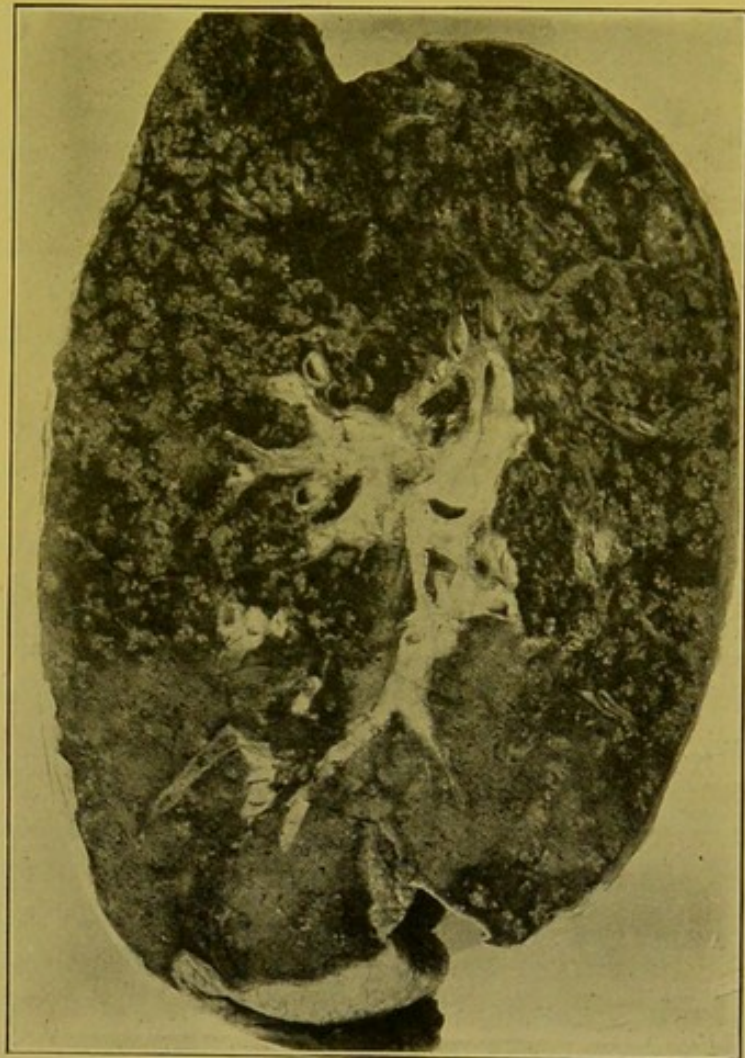

FIG. 66.—Lymphatic spread of Tuberculosis in Adult Lung (see text). (\times circ. $\frac{2}{3}$.)

The basal parts are almost free from tuberculosis.

micro
1. bull
2. bull
3. bull
4. bull
5. bull
6. bull
7. bull
8. bull
9. bull
10. bull

nodule
caseat
ext. to
vesicles
↓
T. B. Br
Pneumo

excavation. The condition may be either acute or chronic, and, in either case, the tubercles are seen in the situation of the lymphatics. More commonly it is of more chronic course than the other variety of miliary tuberculosis and, microscopically, a large proportion of the tubercles contain well-marked giant-cells. Lymphatic tubercles in the walls of the bronchi may extend, so that the whole wall becomes caseous, or it may extend more directly inwards and cause tuberculous bronchitis which may go on to tuberculous broncho-pneumonia. The more chronic the tubercle, the greater the amount of pigmented fibrous tissue surrounding it. It is found in its most chronic form in chronic interstitial tuberculosis of the lung.

Tuberculous Broncho-pneumonia.—This is the condition which is commonly meant when one speaks of "*acute pulmonary tuberculosis*," "*galloping consumption*," "*acute phthisis pulmonalis*." "*Phthisis*," being more strictly a clinical term, will not be employed in describing these pathological changes. Tuberculous broncho-pneumonia corresponds to simple broncho-pneumonia in distribution, but a form is also met with in which there is extensive and rapid caseation of large areas of the lung, corresponding more to the pseudo-lobar type of pneumonia—"confluent" lobular pneumonia.

The condition is usually the result of inhalation of air containing tubercle bacilli; or of the discharge from tuberculous root-glands, or less commonly from laryngeal ulcers or from other tuberculous processes in the upper air-passages; or it is secondary to lymphatic peri-bronchial tuberculosis. It is characterized by the formation of firm caseous nodules of a creamy colour in relation to the terminal bronchioles. At the surface these are conical, with their bases to the pleura. In cases pursuing a favourable course the nodules become encapsuled by fibrous tissue and rendered innocuous—a process of healing—whereas in advancing cases, even in infants a few weeks or months old, the areas spread more or less rapidly, fresh tubercles develop at their periphery or along the lymphatics, and as the central parts become more and more a-vascular and deprived of nourishment, they break down. Seeing that this destruction involves the bronchi connected with the nodules, the broken-down tissue passes into the air passages, and is either expectorated, or is distributed further along the bronchial tree, setting up fresh foci of broncho-pneumonic tuberculosis, particularly in the lower parts of the lungs. The portions of lung intervening between the tuberculous nodules show catarrhal changes.

The larger bronchi may show tuberculous ulceration, or the caseous process may extend rapidly at the surface of the lung, and cause either empyema or pneumothorax. If the infective sputum be swallowed, ulceration of the Peyer's patches of the small intestine usually results, with or without tuberculosis of the mesenteric glands.

The appearances met with *post mortem* vary in the very young individual and in the adult. In the *former* the lung remains voluminous, and on passing the hand into the peural, which in some cases is covered with recent exudate,

firm masses are felt within the lung as if this contained large numbers of swanshot.

On section the creamy nodules stand out above the surface, the intervening vesicular tissue retracting. There may be no special localization, although in lungs containing large numbers of the nodules, these tend to be somewhat more aggregated in the apical portions of the lung. (Fig. 67.) Excavation is usually absent, at least below the age of five to eight years, but I have seen cavities of some standing in infants a few weeks old.

In *adults* the condition is usually more or less limited to the neighbourhood of the apices of the lobes; excavation is the rule, and the appearances presented are somewhat as follows:—The cavities may be near the apex of one or both lobes, and more often in the left lung. Extension takes place downwards so that the more recent changes are nearer the base. At the extreme base the lung is congested and may display on its cut surface a few scattered grey tubercles, lymphatic tubercles or miliary tuberculous broncho-pneumonia. At a slightly higher level these are more numerous and gathered into racemose clusters; occasionally yellow caseating tubercles appear among them. Still higher, the prevailing type is the yellow caseating tubercle resulting from a close aggregation of grey tubercles; these interfering with the nutrition of the central part of the nodule so that this caseates. The caseating centre corresponds to the bronchiole or infundibulum. Above this the yellow tubercles coalesce to form larger, creamy-coloured nodules raised above the pleural and cut surfaces and corresponding in size to lobules or groups of lobules. Near the surface these are irregularly conical with the base towards the pleura. A little higher up the central excavation is more distinct and the liquefied material is being discharged through the bronchus. The bronchus becomes ulcerated away and its walls practically continuous with the walls of the cavity, which contains thick caseous pus. The walls are necrotic, irregular, formed of yellow caseous material which gradually extends. Neighbouring cavities may coalesce. If this caseation and coalescence be very rapid, portions

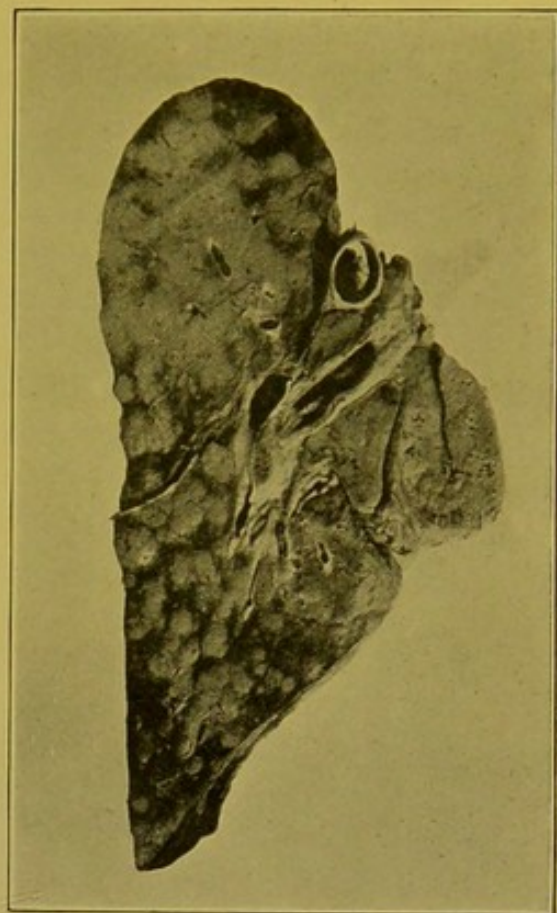


FIG. 67.—Tuberculous Broncho-pneumonia in a Child. (\times circ. $\frac{3}{4}$.)

Nodules more crowded near apex than in lower lobe. Enlarged caseous root-glands. (Mus. R.C.S. Ed.)

Nodule
Inverted
shaped
yellow
caseous
material
Cavity
creamy
yellow
grey
Angel

of the lung may become necrosed, forming a slough which lies in the cavity. With the opposite tendency to heal, the caseous material is cast off, the walls are covered with purulent material and become lined with a somewhat imperfect granulation tissue, containing giant-celled tubercles. This gives the walls a smoother character, which becomes more and more pronounced as organization proceeds. (See Fig. 68.)

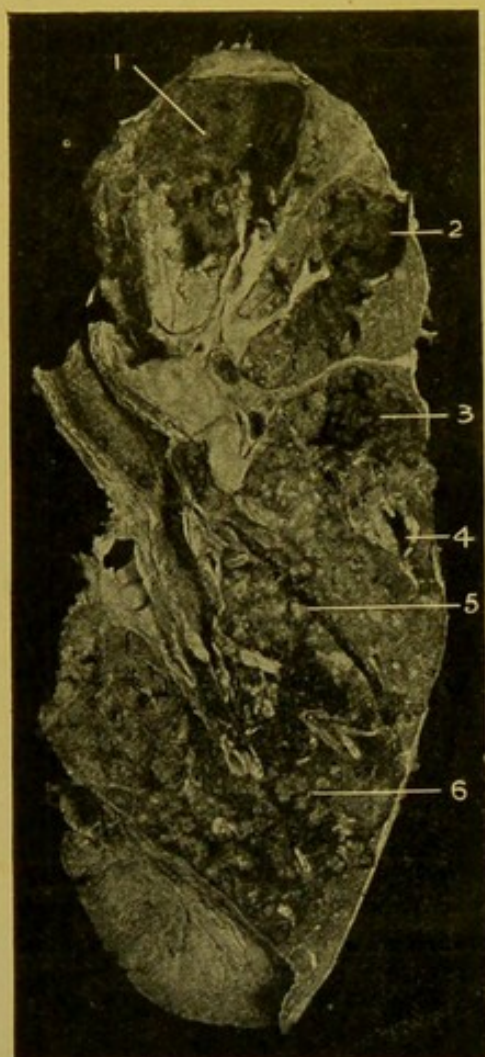


FIG. 68.—Tuberculosis of the Lung, with Excavation, in Adult.

(\times circ. $\frac{1}{2}$.)

(1) Old cavity with thickened pleura over it; (2) and (3) recent cavities; (4) recent cavity almost filled with soft caseous material; (5) caseating broncho-pneumonic nodule; (6) early tubercles, some broncho-pneumonic, many lymphatic.—(From Dr. Drennan's Collection.)

Over these older cavities, which are usually situated near the apex of the lobe, the pleura is almost invariably thickened and adherent. They have to be distinguished from bronchiectatic cavities which constantly accompany old tuberculous cavities (see p. 119).

It will be evident from the foregoing description that lymphatic spread of tuberculosis is constantly associated with broncho-pneumonic tuberculosis.

Sometimes old chalky or calcareous or fibrous tubercles or contracting cavities surrounded by dense pigmented fibrous tissue are found near the apex, or at other parts of the lobe. (Fig. 69.) Usually, but not invariably, one or more caseous glands are found at the root of the lung. If these be present and there exist no distinctly older tuberculosis in the lung, one has to consider the possibility of the glandular rather than the pulmonary tuberculosis being the primary condition. In children this is very frequently the case.

Microscopical Appearances of Tuberculous Broncho-Pneumonia. — Typically, the histological appearances in the early stages resemble those of a simple broncho-pneumonia. It is a question whether the condition may not commence as a simple broncho-pneumonia which later becomes infected

with the tubercle bacillus, or, as is more likely and certainly more generally accepted, is tuberculous from the first. The changes are very similar to those described in the simple form—plugging of the bronchiole with exudation, peribronchiolitis, spread to the infundibular passage and to the alveoli. One distinguishing character is that catarrhal cells derived from the alveolar endothelium are more numerous than leucocytes and they tend as they degenerate to adhere more to each other and to the wall of the

vesicle, particularly on the side nearest the bronchiole. Giant-cells are not commonly found in rapidly advancing cases. As caseation progresses the interior of the nodule assumes a homogenous appearance, the outlines of the vesicles and of the occluded bronchiole or infundibulum being made out with difficulty, all nuclear staining power being lost. Outside the nodule the walls of the vesicles are infiltrated and congested, and the vesicles contain well-marked and separate catarrhal cells. Bacilli can usually be found, particularly in the neighbourhood of the proliferating cells. In slowly-advancing tuberculous broncho-pneumonia there is always a tendency at parts towards formation of fibrous tissue in the parts surrounding the nodule.

Bacteriology.—Occasionally pure cultures of the tubercle bacillus can be recovered from the caseous material, but usually, particularly where there is excavation, there is a mixed infection, e.g. with the *staphylococcus pyogenes aureus* or *albus*, *streptococci*, *micrococcus tetragenus*, *bacillus mucosus capsulatus*, *pneumococcus*, etc. These tend to make the process more destructive by setting up acute inflammatory processes, and much more malignant, clinically, by exciting hectic fever.

Caseo-fibroid Tuberculosis.—This somewhat chronic variety of tuberculosis usually begins at the apices. Portions of the lung are undergoing fibroid induration, with carbon pigmentation, i.e., attempted organization or interstitial pneumonia. These are separated up by slowly caseating broncho-pneumonic tubercles and lymphatic tubercles. The pleura over the areas is in most cases greatly thickened and the neighbouring portions of the lung tend to become collapsed. The endothelium of the collapsed vesicles proliferates to form a layer of cubical cells which remain attached to the walls and resemble closely the cells of a secreting gland. The older parts are riddled with cavities. The neighbouring more healthy parts of the lung are usually the seat of compensatory emphysema and bronchiectasis.

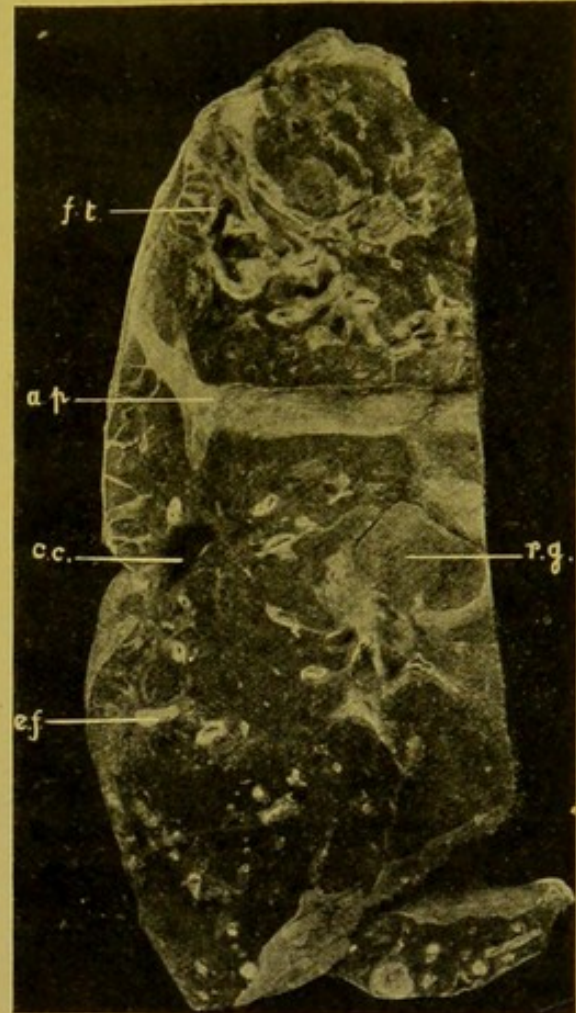


FIG. 69.—Healed Tuberculosis of the Lung. (\times circ. $\frac{1}{2}$.)

(f.t.) Great increase of fibrous tissue, with smooth-walled cavities, partly bronchiectatic; (a.p.) old adhesions between lobes; (c.c.) contracted cavity, with pigmented fibrous wall; (e.f.) area of pigmented scar-tissue, with radiating bands of similar tissue, and a dry cheesy focus in the midst of the area; (r.g.) enlarged caseous root-gland.

Chronic Fibroid Tuberculosis.—This is a tuberculosis of slow progress associated with very slow caseation and softening, and great tendency to formation of fibrous tissue encapsulating the tubercles. Both lungs are affected to a greater or less extent.

The lung, or the part of it affected, usually towards the apex, is dense, collapsed, much less vesicular than normal, and covered with dense firm pleuritic adhesions. Numerous old cavities may be seen, many tuberculous, probably most bronchiectatic, but excavation may not be a prominent feature. (Fig. 70.)

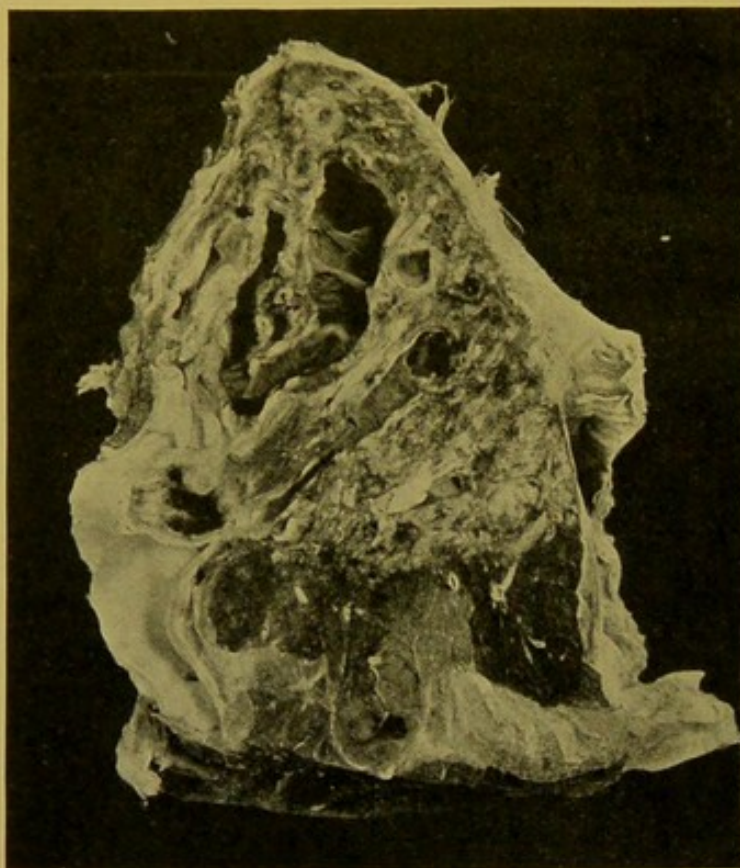


FIG. 70.—Chronic Fibroid Tuberculosis, at apex.
(\times circ. $\frac{3}{4}$.)

Dense fibrous induration surrounding dilated bronchi. In lower part specimen is vesicular. Adherent pleurisy over indurated area.

SYPHILIS OF THE LUNG

Manifestations of syphilis are not commonly met with in the lung. When they do occur, they mostly belong to the tertiary class.

Gummata may be found, and they are more often seen in children with congenital syphilis than in adults with acquired syphilis. They form greyish-red or light grey, semi-translucent nodes, varying in size from that of a pea to that of a hazel-nut.

At a later stage they become more opaque and white in the centre; they may break down and form small vomicae. In adults the grey nodes may closely resemble tuberculous caseous areas. They may show little surrounding scar-tissue. Microscopical examination is of great assistance in determining their nature.

Diffuse interstitial pneumonia is much more common as evidence of syphilis, both in the congenital and acquired forms of the disease. In congenital syphilis the fibrous tissue is very cellular and vascular, compact in texture, and the vesicles may be represented by a few duct-like or acinous-like spaces. The endothelium is proliferating and cubical. The walls of the vessels are thickened, particularly the adventitia, and to the naked eye the lung, as a whole or in patches, may be anaemic—"white hepatization." In the acquired form, in adults, there is more localized formation of fibrous tissue, less cellular than in the congenital disease, in bands intersecting the

lung in all directions, especially in the lower lobes near the base and towards its outer part. These are continuous with the deep layer of the pleura, and in retracting draw in the pleura, producing deep scars on the surface of the lung (Fig. 71). There may be no manifest thickening of the pleura itself. In rare cases, gummata or remains of gummata may be found in these bands.

In **Glanders**, small greyish or yellowish nodules may form in the lung. These vary in size from that of a millet-seed, to that of a pea. More often diffuse purulent infiltration or localized abscesses are found.

In **Leprosy**, the lungs are frequently affected. The lesions resemble some forms of chronic tuberculosis, particularly the caseo-fibroid type.

In **Actinomycosis**, nodules of granulation tissue, containing in their midst clumps of the fungus, may occur. Small or large cavities — abscesses — may develop, or nodules encapsulated by fibrous tissue. (See also p. 137.)

Parasites of the Lung.

Hydatid Cysts are the most common. (See also p. 128.)

Tumours of the Lung

are in most cases secondary.

Lymphosarcoma may spread into the lung from the root-glands or mediastinum.

Round-celled or *spindle-celled sarcoma*, *melanotic sarcoma* and other varieties of sarcoma, including very rarely *myeloid sarcoma*, spread to the lungs by metastasis by way of the blood-stream.

All varieties of *carcinoma* may form secondary growths in the lung.

Occasionally primary colloid cancer develops in connexion with the mucous glands of the bronchi, and rarely primary *endothelioma* is found either developing in connexion with the bronchi, or more often from the lining of the vesicles. I have seen three of these tumours. They are of a grey colour, and in general appearance may resemble confluent tuberculous broncho-pneumonia.

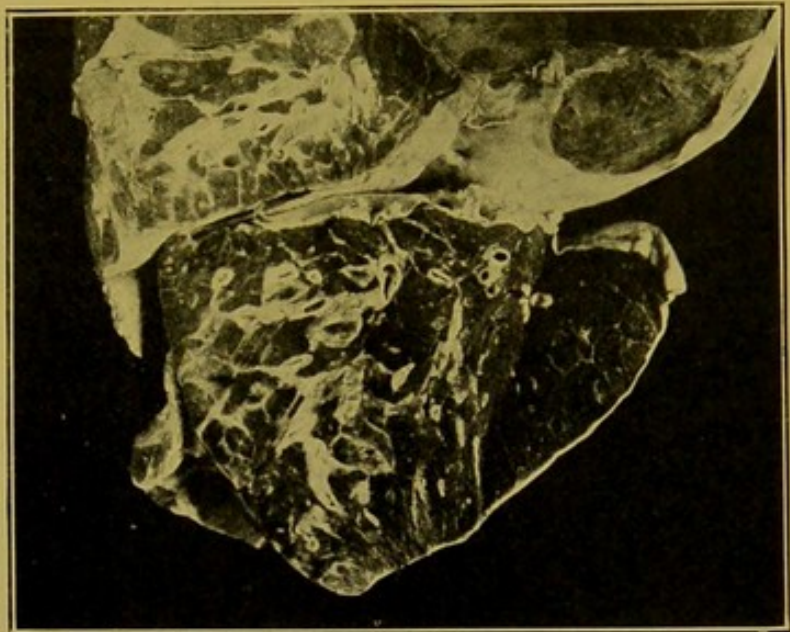


FIG. 71.—Syphilitic interstitial pneumonia in lower lobe, and in lower part of upper lobe. (\times circ. $\frac{1}{2}$.)

DISEASES OF THE PLEURA

As a rule, in health, the pleural cavities are dry. There is, however, a constant flow to and from the cavity by way of the lymphatics. A varying amount of serous fluid may collect during a prolonged death agony, and in heart or kidney

disease there may be a rapid and great accumulation during the last few hours of life.

Hydrothorax.—In hydrothorax, a large amount of serum transudes into the pleural sacs, there being no inflammation of the pleura. It occurs as a part of general dropsy; in individuals dying from heart disease; and in certain forms of asphyxiation. If general adhesions exist, these become soaked with the serous fluid and assume a gelatinous aspect. If the adhesions are localized the fluid collects in loculi. If no adhesions exist and if the accumulation is great, the lung is compressed inwards and backwards against the vertebral column.

In long-standing hydrothorax, the pleura becomes opaque and thickened.

The explanation formerly given of hydrothorax was that it is a result of pressure upon the azygos veins, which drain the pleura of fluid supposed to transude from vessels in the parietal pleura. More recently, however, it has been suggested with more reason that the fluid comes from the visceral pleura and that it accumulates as a result of pressure upon the pulmonary and bronchial veins as they leave the lung, on the right side by dilatation of the auricle, and, on the left side, by dilatation of the left auricle and left ventricle.

Pneumothorax.—Pneumothorax is the term applied to the presence of air in the pleural cavity.

It seldom results from the rupture of emphysematous lung tissue. It occurs more often as a sequel of rapid extension to the pleura of tuberculous or gangrenous cavities or of abscesses. It may also follow punctured wounds of the chest wall, rupture of cancerous ulcers of the oesophagus, or extension of gastric ulcers through the diaphragm.

On perforation taking place, the lung immediately collapses, the extent of collapse depending upon the presence or absence of pleuritic adhesions. At the *post mortem* examination it may be difficult to discover the actual perforation, because (1) it may be very small, or (2) if the condition have lasted some days, the opening may be covered over with lymph. Often, however, particularly in the case of abscess of the lung, the opening may be larger and easily distinguished. A purulent pleurisy may result.

Haemothorax.—Pure blood collects in the pleural cavity as a result of mechanical injury to the chest wall—e.g. punctured wounds, fractures of the ribs,—or it may escape from an aneurysm. On examination of such a case, a large amount of blood clot is found in the deeper parts of the cavity, and above the clot there is a large amount of separated serum.

The term "haemothorax" should be reserved for the effusion of pure blood into the pleural cavity. In many cases, however, blood is mingled with pleural effusions. For example, in ordinary pleurisy, haemorrhage may result from rupture of newly-formed embryonic vessels. It is also found in the transudates associated with heart disease, particularly in presence of pulmonary infarcts. It is found in haemorrhagic pleurisies, these being usually of a grave nature and associated particularly with tuberculous infections, but also with malignant growth or with other new-formations of the pleura, e.g. lymphadenoma. It may also occur in scurvy and in severe infective diseases such as small-pox.

Petechial haemorrhages, which may be scattered over the posterior surface of the lung or collected in larger areas, are found under the pleura in death from asphyxia or when coma has been long-standing. This condition is associated with great venous congestion of the lung or with hypostasis. Petechial haemorrhages are also found in severe infective conditions, in puerperal fever, and in metallic poisonings.

Chylous and Chyliform Effusions.—In these conditions an opalescent or milky fluid collects within the pleural cavities. (1) The fluid may be of the

nature of chyle and result from rupture or obstruction of the thoracic duct.

(2) The fluid may contain no chyle and, as in a case coming under the author's observation, the material causing the opalescence may be of the nature of globulin. No appreciable sedimentation occurred even after the fluid had stood for four years. (*See also Chylous Ascites*, p. 169.)

PLEURISY

While pleurisy can occasionally be met with as a *primary* condition, caused, e.g., by the *pneumococcus*, it is usually *secondary* to disease of the lungs, disease of the glands at the root of the lungs, or inflammation in the neighbourhood, e.g. of the thoracic walls, pericardium, peritoneum, or mediastinum. Pleurisy may occur in the course of acute rheumatism, of Bright's disease, or of septicaemia. It may follow mechanical injury of the chest wall.

Though the inflammation is actually excited by organisms, exposure to cold frequently plays an important predisposing part, probably by lowering resistance and thus favouring invasion by bacteria. Most pleurisies are caused by one of three organisms, the *tubercle bacillus*, the *pneumococcus*, or a *streptococcus*. *Staphylococci* also have been found. The first named is regarded as the commonest cause of pleurisy with effusion. The *pneumococcus* is found in serous as well as in purulent pleurisies following pneumonia, but this organism is also found in serous effusions which are not secondary to pneumonia.

Pleurisy may be secondary to infarction of the lung, and it may even occur in the course of a gonococcal infection.

Males are more frequently affected than females.

Acute Fibrinous Pleurisy.—Fibrinous pleurisy with a minimal amount of serous fluid is usually termed "*dry*" pleurisy. Pleurisy if accompanied by a large amount of serous fluid is termed "*moist*" pleurisy or pleurisy

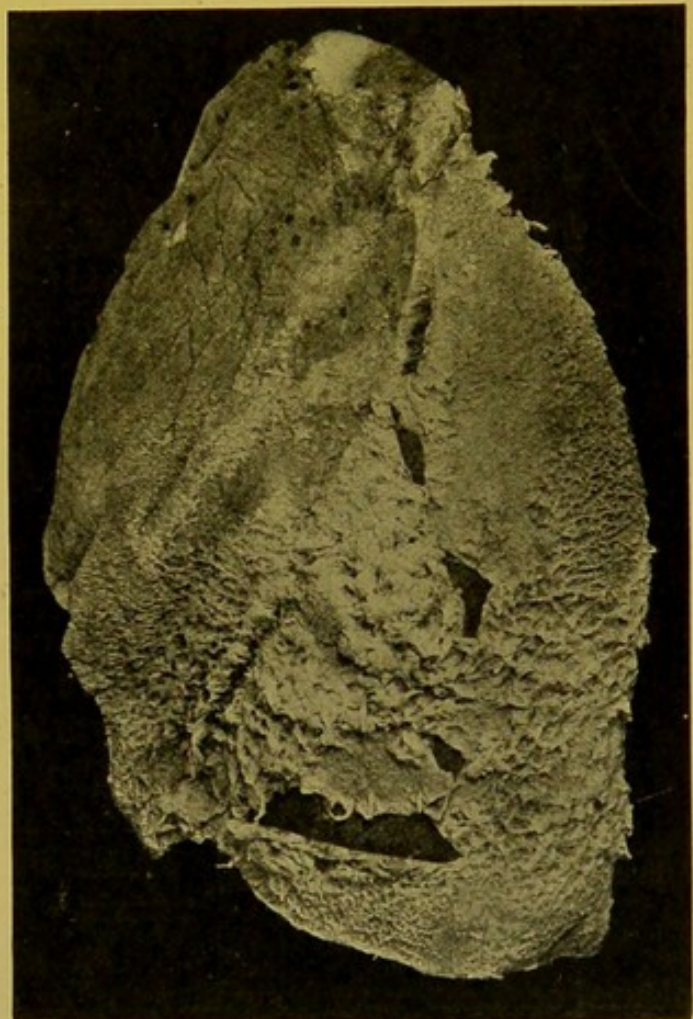


FIG. 72.—Acute Fibrinous Pleurisy. (\times circ. $\frac{1}{2}$.)

Early stage, in which exudate is easily stripped from the pleura.—(From Dr. J. D. Comrie's Collection.)

with effusion. The effusion is the result of the blocking, with fibrinous plugs, of the lymphatics which drain the pleura. The surface becomes covered with a rough layer of lymph of varying thickness. The amount is usually greatest and of fibrino-purulent character when the inflammation results from pneumococcal infection (Fig. 72).

In the earliest stages the surface becomes congested. A little later the pleura loses its smooth, glistening appearance, as a result of swelling and desquamation of its endothelium. This stage is followed by the deposit of lymph upon the surface. In the early stages—twenty-four to forty-eight hours—this can be removed readily, leaving a comparatively smooth con-




FIG. 73.—Calcification of Pleuritic Adhesions—macerated. (\times circ. $\frac{1}{2}$.)

(Mus. R.C.S. Ed.)

gested surface. A little later—two to three days—on removal, a dull granular congested surface is left, the granularity being due to projection of minute vascular loops. At a still later date—three to five days—vessels have passed into the fibrinous layer, so that on clearing this off, delicate filaments are seen crossing the angle of reflexion. Still later, as organization progresses, the exudation cannot be completely removed and the deeper parts of the exudate are seen to be vascular. When organization is complete the newly formed inflammatory tissue cannot be removed without injury to the lung substance.

Haemorrhagic exudation, if unassociated with mechanical injury or with malignant new-growth, is most often caused by the tubercle bacillus, but in some cases, microscopical demonstration of tubercles or of tubercle bacilli is necessary to complete the diagnosis.

In completely organized pleuritis the pleural surfaces may be adherent, or a more or less thick, white, fibrous plate may form on the surface of the lung. This may become of almost cartilaginous density and consistence. Sometimes an extensive, flat, calcareous or bony plate forms in the adhesions (Fig. 73). In all cases in which the adhesions between the pleural surfaces exceed a thickness of about 1 mm. ($\frac{1}{25}$ in.) other underlying conditions should be suspected, such as tuberculosis, or new-growth, e.g. secondary cancer or primary endothelioma.

The pleura is always thickened, sometimes to a very considerable extent, over old superficial tuberculous cavities, and usually in such circumstances its two surfaces are adherent. This affords one point of diagnosis between

old tuberculous cavities and bronchiectatic cavities over which usually the pleura shows no special thickening (see p. 119).

Fibrous adhesions are found most commonly over the apical parts of the lungs, along the posterior surfaces, and on the diaphragmatic surfaces. The presence of well-marked diaphragmatic adhesions directs attention to a possible original extension of inflammation from the peritoneum.

Empyema or Purulent Pleurisy may be a sequel of other forms of pleurisy, or may be purulent from the commencement. It may be localized or general (Fig. 74). It may develop by direct spread from lobar pneumonia, septic pneumonia, abscess, septic infarction, gangrene, tuberculous excavation of the lung, or bronchiectasis. It may follow suppurative conditions in the abdominal cavity—peritonitis, abscess of liver or spleen, appendicitis, or retro-peritoneal abscess. In several cases I have seen it follow perforation of a gastric ulcer through the diaphragm.

The exciting cause is always bacterial—*pneumococcus*, *streptococcus*, occasionally the tubercle bacillus,—although in cases following rupture of a tuberculous cavity into the pleura the *pneumococcus* or a *streptococcus* may be the actual causal agent. In empyemas secondary to abdominal suppurations the organisms which have caused these will be found. In putrid empyemas, *leptothrix* forms have often been found, usually along with other organisms.

The *Micrococcus tetragenus*, *Bacillus pyocyaneus* and *streptothrix* forms have also been isolated in a few cases of empyema.

The pus may rupture into a bronchus, or pass downwards behind the diaphragm and peritoneum.

The Pleura in Tuberculosis.—A thick, caseo-fibrinous deposit with yellow tubercles in the deeper organizing parts of a chronic pleurisy betokens its tuberculous nature. Similar changes may be found in the pericardium. To the naked eye tuberculous pleurisy may have no distinctive character, but they are frequently haemorrhagic.

In acute generalized tuberculosis, grey miliary tubercles may be found over the whole pleural surface, especially between the lobes and on the diaphragmatic aspect.

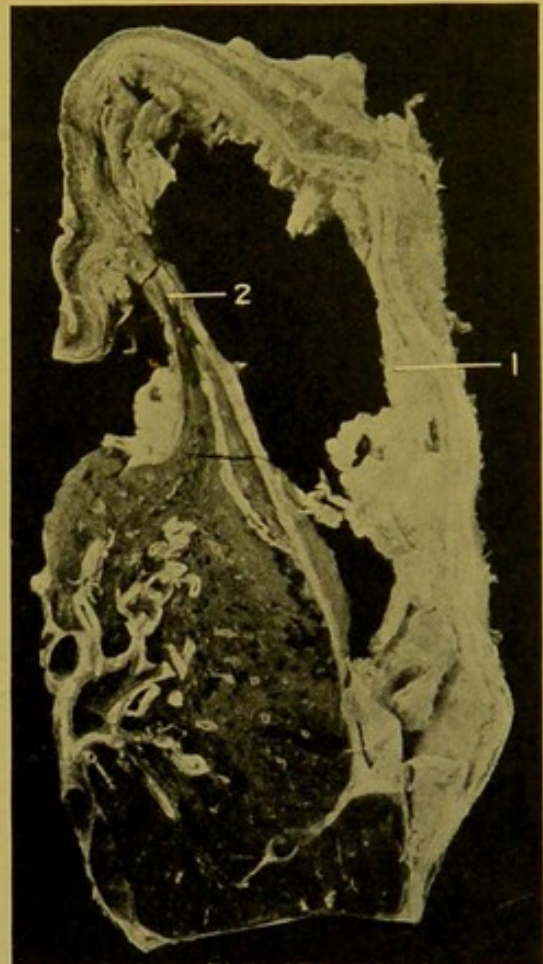


FIG. 74.—Empyema of Pleura.
(\times circ. $\frac{1}{2}$.)

Greatly thickened visceral and parietal layers, with thick exudate (1) on surface; (2) adhesion between surfaces. Lung shows considerable collapse.

Tuberculosis may spread locally from caseous root-glands, or from a superficial tuberculous focus in the lung. Occasionally the tubercles are large, yellow and fibrous, with thin raised edges, resembling in some degree the "*perlsucht*" of cattle. When on the parietal pleura, these are sometimes confined to the parts of it lying over the intercostal spaces.

The pleura is frequently infected from the abdomen, the bacilli passing through the diaphragm.

Tubercles have to be distinguished from minute areas of chronic fibrous thickening of the pleura—1 to 2 mm. in diameter—which are sometimes found in relation to the junctions of interlobular septa with pleura, and more often over the upper than over the lower half of the lung.

Occasionally air escapes into the interlobular lymphatics and, by dilating these, appears under the pleura as small white raised spots between the lobules. Examination with a lens discloses their real nature. These are produced, usually, by a too forcible removal of the lung from the thorax.

The fibrous nodules found in *silicosis*—"stone-masons' lung"—are easily differentiated from those of tuberculosis. If on the surface, they are flattened or hemispherical; their diameter is seldom less than 2 mm., and it may reach 5 mm. ($\frac{1}{16}$ to $\frac{3}{16}$ of an inch). Their structure is characteristic. The central part is white or light grey, the periphery is dark grey or black (*see p. 140*).

THE THORACIC WALLS

DISTORTIONS OF THE THORAX RESULTING FROM SPINAL CURVATURE

These can be examined most conveniently after removal of the thoracic contents.

Lateral curvature (Scoliosis, Gr. *σκολιός* = crooked or twisted) produces asymmetry. Along with the lateral deviation, a rotation of the vertebrae occurs round a centre which is near the tips of their spinous processes. The result is that the bodies of the vertebrae may be considerably displaced although the line of the spinous processes remains almost straight. The ribs also are displaced in a manner depending on the direction of the spinal curve. Even under physiological conditions there may be slight bending of the thoracic vertebrae towards the right. In pathological scoliosis, this bend is increased, its convexity being towards the left. The ribs project in the concavity, and the angles of those on the side corresponding to the convexity become more acute, so that that side of the chest becomes flattened. In consequence the angles project posteriorly on the right side, and with this the right scapula becomes more prominent. The angles on the opposite side are flattened, but anteriorly the curve near the costo-chondral articulations become sharper, so that the mammary region on that side projects. Put in another way, one oblique diameter (that from the left mammary region to the right scapular region) is increased, and the other is diminished. A compensatory curve to the opposite side forms in the lumbar region.

Lateral curvature results from rickets, osteomalacia, osteitis deformans, senile atrophy, obliquity of pelvis in morbus coxae. It may result from the falling in of the ribs following empyema, and it is usually present in Friedreich's Ataxia. Lateral curvature which has resulted from faulty attitude is almost confined to females.

In very severe cases of scoliosis the dorsal spines project backwards—kypho-scoliosis—the trunk is shortened, and the costal margin is approximated to the iliac crest.

Kyphosis (Gr. *κυφός* = a hump) is the name given to a general projection backwards of the cervico-dorsal spine or part of it. The normal curve with its concavity anterior, becomes more pronounced, so that the back becomes "rounded" or even in severe cases, a "hump" is produced. The latter condition is, however, usually associated with lateral curvature.

It occurs chiefly in children and in old people. It may be due to muscular atrophy, or occurs in "barrel-chest," in which the lungs are the seat of chronic bronchitis and emphysema. The stoop may be the result of bad habit, or may even be due to myopia.

In otherwise well-developed individuals the thorax may be abnormally narrow. This may be associated with the aortic hypoplasia of Virchow.

In **Angular Curvature** (Pott's), the spine is bent at a sharp angle. The condition depends on injury or disease—tuberculosis or syphilitic caries—of the bodies of the vertebrae, and, although commonest in the dorsal region, it may occur at other parts of the spine. The bodies of the vertebrae are destroyed whereas the neural arches remain unaffected. In this condition one should look for pus in relation to the part affected. In long-standing cases the active process may be arrested and the bodies of the affected vertebrae become ankylosed.

Lordosis (Gr. *λορδός* = bent forwards) is the name given to an incurvation of the spine in the lumbar region, compensatory to Kyphosis, or the result of change in the direction of the sacrum—more horizontal than normal—in rickety pelvis. It is also constantly seen in ankylosis and in congenital dislocation of the hip-joint. It is included here for comparison with the other distortions of the spine.

CHAPTER IX

THYROID, MOUTH, PHARYNX, OESOPHAGUS

DISEASES OF THE THYROID

Normal Measurements.—Lateral Lobes : length, 5–6 cm. ; width, 2–5 cm. ; thickness, 1·5–2 cm. Isthmus : width, 0·7–2 cm.

Anomalies.—Total absence is associated with sporadic cretinism. One or both lateral lobes, or the isthmus may be absent ; the pyramidal lobe may persist. The isthmus may pass behind the trachea.

Accessory thyroids may be found in various situations :—root of tongue, larynx, behind trachea, on aorta, along the line of the thyro-glossal duct. Cysts lined with ciliated epithelium, and having lymphoid tissue in their walls, are occasionally encountered near the foramen caecum.

Atrophy is normal in old age, with increase of fibrous stroma, sclerosis of arteries and general shrinking.

Hypoplasia : *see* Cretinism, p. 157.

Permanent Enlargements.—**Goitre, Struma, Bronchocele: Graves' disease, Basedow's disease,** etc.

Vascular Goitre.—The dilatation of the arteries and veins, present during life, is not usually appreciable after death. Cavernous angioma may form.

Parenchymatous Goitre. — Hyperplastic. The organ is brownish-red, or liver-coloured, and more or less glassy on section. Microscopically there is increase of secreting tissue, many spaces being filled with cubical or low columnar cells, arranged round a lumen ; others lined with cubical cells and containing a varying amount of colloid material, or in many cases a more fluid material of protein nature, sometimes mucin, sometimes albumin. In **Nodular—adenomatous—Goitre**, rounded masses of gland tissue are found, separated by fibrous septa from the surrounding glandular substance.

In **Exophthalmic Goitre**, proliferation of the epithelial cells is a prominent feature (Greenfield), closely apposed spaces being filled with cubical cells, or lined with low or high cylindrical cells, and showing many papillomatous ingrowths into the lumens ; colloid is scanty, mucin more common. The stroma shows diffuse round-celled infiltration. The blood-vessels are dilated. To the naked eye the cut surface is more or less homogeneous, and duller than normal.

In **Colloid or Gelatinous Goitre, or Cystic Bronchocele**, the colloid is

greatly increased, dilating both new and old vesicles, the size of which varies from that of a pin's head to that of a pea. The lymph-vessels do not contain colloid (Müller), and obstruction of these may cause the condition. If haemorrhage has taken place into the cysts, the contents are brownish.

Fibrous Goître.—The increase of connective issue partly obscures the epithelial proliferation. The fibrous tissue frequently shows hyaline degeneration, with calcification, or, rarely, bone-formation. The parenchyma to a great extent disappears. Amyloid degeneration of the vessels may occur, but it is not common.

Results of Goître.—Compression of the trachea, or of important vessels and nerves. A goître may grow round the trachea or oesophagus.

The thymus gland may be enlarged concurrently.

Myxoedema.—This condition is caused by atrophy of the thyroid, or destruction of it by tumours, or interference with its internal secretion. Diminution in size may be masked by increase of connective tissue. The disease is characterized by excessive formation of mucin in the deeper layers of the skin and mucous membranes, and also by formation of soft fat in these situations.

Cretinism.—(a) **Sporadic.**—The gland usually cannot be found. The thyroid may be represented by small cysts, or by fibrous nodules. Atrophy is less common. (b) **Endemic.**—Goître may be present, but in most cases increase of connective tissue, and diminution of the vesicles with absence of colloid are the outstanding features. The thymus and pituitary glands have been found enlarged in some cases. The growth of the long bones at the epiphyseal cartilages is arrested.

The skull in sporadic cases is sometimes dolichocephalic, and the anterior fontanelles remain open for a long time. In the endemic form it is brachycephalic.

Malignant Goître.—**Epithelial tumours** form nodular masses, of the size of a hen's egg up to that of a child's head, and are surrounded by thyroid tissue. They are usually adeno-carcinomatous in type, and some of them form colloid. Squamous epithelioma is rare. They occur in one or both lobes and have a great tendency to metastatise, especially to the medulla of bones.

Sarcomata,—round or spindle-celled, mixed-celled, giant-celled,—angio-sarcoma, alveolar sarcoma, osteo-sarcoma, and chondro-sarcoma, occur, forming nodular tumours, mostly affecting one lobe, rarely both lobes. On section they are smooth, whitish or greyish, or red if full of blood. Their consistence varies with the proportion of cells present; striped muscle fibres are occasionally found. They metastatise both by the blood, and by the lymph-channels.

Acute inflammation of the thyroid is met with occasionally, for example in septicaemia and pyaemia, typhoid and rheumatic fevers, and following diphtheria.

The **Parathyroids** are small, elongated ovoid, slightly flattened bodies of a pale pink colour, with a smooth, glistening surface over which a few branching vessels ramify. They are soft and inelastic. Some are of a yellow colour. Their average length is 6–8 mm.; their width, 3 mm.; and their thickness, 1–2 mm. The number may vary from three to seven; the average number is four.

One is almost constantly on the posterior surface of the oesophagus or pharynx; the others may be placed—(1) at or near the junction of the middle and inferior thirds of the lateral lobe of the thyroid, near its posterior border, in loose tissue between the branches of the inferior thyroid artery, or (2) at or near the junction of the upper and middle thirds, near the same border; or (3) near the lower pole of the lobe.

DISEASES OF THE LIPS AND MOUTH

Congenital Anomalies. (*See also Macrocheilia, Macroglossia, p. 160.*)

The most important anomalies are *Clefts* in the sagittal plane affecting the lips, jaws, hard palate, soft palate, uvula, at any part of the arch formed by these structures, or affecting the whole arch.

Acquired fissures of the palate are usually of syphilitic origin.

Inflammations.—Suppuration of the lips may be *acute*, following operations and injuries, or resulting from infection of “cracks” of the surface; or *chronic*, affecting especially the upper lip, and occurring mostly in strumous and scrofulous children.

Stomatitis.—(1) **Vesicular or Pustular Stomatitis.**—Vesicles first appear; these leave erosions, which may go on to deeper ulceration. The parts affected are the tip and sides of the tongue, the lips and the cheeks. The condition sometimes resembles that found in foot-and-mouth disease of cattle.

(2) **Aphthous Stomatitis.**—Opaque, greyish or yellowish patches form, surrounded by a red border; they may disappear in a few days, leaving sharply defined erosions. They occur on the tongue, lips, cheeks, rarely on the palate and fauces, in badly nourished children, especially during teething; also in women during menstruation, pregnancy, the puerperium, and accompanying severe anaemias. The nature of the condition is not well understood.

(3) **Parasitic Stomatitis.** (Syn. “Thrush,” Soorerkrankung.)—It is characterized by catarrh associated with growth of a fungus, probably *oidium albicans*, within and between the epithelial cells. White adherent patches, which tend to coalesce, develop upon the dorsum of the tongue, on the cheeks or palate, and also, occasionally, on the inner surfaces of pharynx and stomach, etc.

(4) **Ulcerative stomatitis** is usually acute, in most cases commencing over the alveolar margins, which become red and swollen. The condition

may go on to necrosis and softening, and may spread, causing extensive destruction in the mouth. It attacks badly nourished individuals, and those suffering from tuberculosis or other exhausting disease, such as typhoid, diabetes, or scurvy (haemorrhagic ulceration). It may follow metallic poisoning—mercury, phosphorus (tends to go on to suppurative periodontitis and necrosis of the jaw-bones), and copper.

(5) **Suppuration** may occur in the *gums*, in connexion with carious teeth, and also in the *tongue*, developing in connexion with wounds or ulcers of it, or complicating infective disease, or occurring in the course of Bright's disease, or in the presence of foreign bodies. The tongue may be diffusely infiltrated and swollen, hard, showing the imprints of the teeth at its margins, or the suppuration may be localized—abscess of the tongue.

(6) **Gangrenous stomatitis.** (Syn. Noma. Cancrum oris.)—This may follow measles, scarlet fever, or typhoid fever. It may be preceded by ulcerative stomatitis, or originate independently. A livid swelling is seen on the mucous membrane near the angle of the mouth or over the gums. This becomes dark, almost black in colour; goes on to gangrene; becomes soft, pulpy and foetid, and the cheek undergoes perforation. Many micro-organisms, including diphtheroid bacilli, have been described as connected with the disease. The most important, etiologically, seem to be spirochaetes and fusiform bacilli.

(7) **Chronic Stomatitis and Glossitis.**—This condition is also described under the names *leukoplakia oris et linguae*, *hyperkeratosis*, *hairy tongue*, *ichthyosis*, *smokers' patches*, *psoriasis linguae et buccalis*, terms which indicate the increase which commonly occurs in the horny layer.

Greyish or bluish-white patches develop, which may be slightly raised, and may cover practically the whole surface of the mouth.

It is caused by the long-continued action of irritants.

It is more common in males, especially in syphilitics and in excessive smokers.

Oral Syphilis. — *Primary* manifestations may form on the lips, on the tip of the tongue, or on the tonsils.

Condylomata may be found on the lips, cheeks, or tongue.

Tertiary manifestations are the most important. Gummata may develop in the sub-mucous layers or deep in the substance of the tongue or in other parts. On the dorsum of the tongue they form tuberos masses. They may form also in the soft palate, in the soft parts covering the hard palate, in the fauces, tonsils, pharynx and naso-pharynx. They are rare in other parts. Gummata usually break down to form deep ulcers, with yellow necrotic bases, and, frequently, undermined edges. Results.—The palate may become perforated; retracting scars, with ridges and bridges may form in the pharynx and naso-pharynx; and deep furrows and ulcers may remain on the surface of the tongue.

Oral Tuberculosis is usually associated with tuberculosis of the face,

or lungs, or larynx. The tonsils may be primarily affected; the tongue, palate and pharynx usually secondarily.

The tuberculous ulcer of the tongue frequently has a papillomatous fringe at its margins.

Lupus of the mouth extends from a similar condition of the face, and is characterized by the formation of red nodules which break down and ulcerate. Scarring of the surface generally results.

The lesions of **Leprosy** of the mouth are identical with those which occur upon the skin surface.

Actinomycosis in man usually affects the gums, the mucous membrane of the cheeks, and the tongue. Gumma-like tumours form, or suppuration takes place—the pus being glairy and containing yellowish granules of the fungus. Rarely, in man, sarcoma-like osteomyelitis of the jaw develops; more often it causes chronic periostitis with suppuration and formation of fistulae to the surface. The disease may extend widely, to the neck, vertebrae, or even to the skull and cerebral membranes. In the tongue one finds chronic abscesses or localized fibrous nodules.

Pigmentation of the mucous membrane occurs in Addison's disease and in Argyria.

In **Acute Lymphatic Leucocythaemia** the gums, lingual tonsils, and faucial tonsils are swollen, pale and of a greenish colour. Necrosis may follow, leading to deep, putrid, ulceration (*see* Fig. 52 (1), p. 116).

Macrocheilia and **Macroglossia** are conditions arising from dilatation of the lymphatic spaces and vessels of, respectively, the lips and tongue. In this rare disease, the parts are greatly swollen. It is due to a blockage, probably congenital, of the lymphatics draining the parts.

Cysts of the mouth. *Ranula*,—sublingual or parotid. Sublingual *dermoids*; *thyroglossal* cysts, near the foramen caecum, at the root of the tongue (p. 156); *dental* cysts, cysts of the jaws, developing from the tooth follicles; *adenocystoma*.

Other **Tumours** of the mouth.—*Haemangioma* and *lymphangioma* may be found as small soft projections upon the tongue. The most common malignant tumour is *squamous epithelioma*, developing in the lips, at the sides of the tongue, on the gums, or on the cheeks. *Adenomata* rarely develop from mucous glands, either in the lips or under the tongue. I have met with one example only, a malignant tumour, developing from the mucous glands in the latter situation.

Sarcoma of the mouth is rare. Round and spindle-celled sarcomata may be found in the gums and jaws, but seldom elsewhere.

Malignant Epulides of the jaws are of the structure of fibro-sarcoma, or spindle-celled sarcoma, usually containing multinucleated giant-cells in addition, particularly in the deeper parts. They grow from periosteum or from bone-marrow.

Some forms of epulis are apparently of non-malignant nature. At all events the tissue composing them appears to be simple fibrous tissue.

DISEASES OF THE PAROTID

Acute (primary) parotitis—syn: “Mumps”—may be epidemic or sporadic. It is infective and attacks children and young adults. Bacilli and streptococci have been isolated. The disease begins as a catarrh of the duct, accompanied by inflammation of the interstitial tissue of the gland. It more often affects the left than the right gland. Complications occur especially in young adults, e.g. swelling of the testis, mamma, or ovary.

Acute suppurative parotitis (secondary Parotitis) either follows oral inflammation or ulceration, or occurs in the course of infective diseases, e.g., pyaemia, typhoid, diphtheria, etc., or is secondary to inflammatory foci elsewhere in the body. *Staphylococci* (*aureus* or *citreus*), and *streptococci* are most frequently found. On section, numerous greenish-yellow points are seen, corresponding to pus in the acini and ducts; the suppuration spreads also in the interstitial tissue. Complications—phlebitis, septic thrombosis of the jugular veins, extending upwards and downwards—may cause death by pyaemia.

Tuberculosis, syphilis (gummata) and *actinomycosis* may affect the parotid.

Tumours.—Mixed tumours occur—most commonly a mixture of chondroma, myxoma, and endothelioma, originating probably from remnants of branchial or ear cartilages; also chondro-myxo-sarcoma. Chondroma and fibroma are less common. Occasionally primary carcinoma develops, composed of large cells often with bloated nuclei and clear protoplasm, or of smaller cells resembling those of a hypernephroma.

Ludwig's Angina, Cynanche, is a very acute inflammation, frequently with suppuration, of the floor of the mouth, and upper lateral parts of the neck, which may lead to general sepsis, or to death from oedema of the larynx. The inflammation originates about the submaxillary gland. The tissues may undergo necrosis.

DISEASES OF THE PHARYNX

The mass of soft tissues removed from the neck, including all the structures in front of the vertebrae, and still connected with the thoracic organs (*see p. 45*), is placed upon a slab with the posterior surface upwards. The central part corresponds to the posterior wall of the pharynx composed of constrictor muscles. The **Retro-Pharyngeal lymphatic glands**, if enlarged, may be readily found upon this surface, one on either side, in a plane crossing the upper part of the tonsils or passing a little above the tips of the great Cornua of the Hyoid bone. If they are not distinctly enlarged, they may easily be missed. They lessen in size with increasing age. These glands receive the lymphatics from the posterior part of the nasal cavities and the upper part of the naso-pharynx. The enlargement may be of tuberculous nature or the result of an acute infection, which sometimes causes localized sup-

uration, producing one of the varieties of Retro-Pharyngeal abscess. Tuberculosis does not attack them so frequently as the upper glands of the jugular chains, which receive the lymphatics more directly from the tonsils.

If the whole of the tissues down to the vertebrae and to their transverse processes has been removed, the superior cervical sympathetic ganglion will be found a little further out, lying close behind the upper part of the internal carotid artery. The ganglion is about 3 cm. in length, about 5–6 mm. wide and about 2 mm. in thickness. It is somewhat fusiform, of firmer consistence and of a paler greyish-pink colour than the lymphatic glands lying close to its outer side. It is usually cut across below its upper extremity, but its identification may be completed by demonstrating its continuity below with the white, fibrous-looking sympathetic cord, which is about 1 mm. in diameter. Continuing to dissect this downwards, the middle ganglion, causing only moderate thickening of the cord, will be laid bare. Normally, this lies opposite the sixth cervical vertebra. In most cases, unless special care has been taken, the inferior cervical sympathetic ganglion is left in the body. It lies upon and usually bends over the neck of the first rib, to which it is bound down. It is often fused with the first thoracic ganglion. The inferior cervical ganglion is thicker, wider and shorter than the superior ganglion, and can be easily found in the following manner. The forefinger of the left hand should follow the inner (upper) margin of the first rib until it rests upon the soft structures covering its neck. With the knife kept close to the bone, all the soft parts not only in front of but also above and below the anterior half of the neck of the rib should be removed. On palpating these after removal, the firm resistant ganglion is easily recognized, and it is a very simple matter to dissect it free. The vertebral artery lying in front of it may be removed along with it.

Resuming the examination of the posterior wall of the pharynx, the carotid sheath may now be opened, and the vessels and vagus nerve lying in it examined.

The **cervical glands** lying along the sheath should be carefully examined, sections being made through them, and the presence of tuberculosis or of lymphadenomatous enlargement, or the enlargement found in lymphatic leucocythaemia should be noted. In tuberculosis the glands may show caseation—frequently old, the infection sometimes not progressing further in the body; or the caseation may be active, or the glands may be simply of soft consistence, somewhat greyish in colour, and on the cut surface showing little yellowish prominences. In lymphadenoma the glands are usually firm, fibrous-looking, or of a patchy, greyish-pink colour. In leucocythaemia the glands are rather soft and of a pale greyish-pink or greyish-salmon colour.

Retro-Pharyngeal Abscess. — In retro-pharyngeal abscess, the pus collects in the space between the pharynx and the anterior surface of the vertebrae. This condition may result (firstly) from suppuration in connexion with the retro-pharyngeal glands, secondary to affections of the nasal cavities or of the pharynx, e.g. in scarlet fever, diphtheria, typhoid, and occasionally following direct infection through the mucosa; (secondly) from caries of the upper cervical vertebrae, mostly of tuberculous nature, but occasionally the result of actinomycosis, tumour-growth or fracture; (thirdly) from suppuration of the middle ear; (fourthly) from mechanical

injuries, e.g. from foreign bodies, such as fish-bones or sharp spicules of bone, or (fifthly) from scalds or from the action of corrosives.

In very rare cases, chronic sinuses are met with in this region, apparently secondary to disease at the base of the skull.

The pharynx may now be slit up in the middle line as far down as the cricoid cartilage, at the level of which it joins the oesophagus. The soft palate with uvula, the pillars of the fauces with the tonsils lying between them, the base of the tongue, and the laryngeal opening are now to be examined.

The presence of oedema, congestion, false membrane, or catarrhal exudate, is to be noted. These conditions are usually the result of acute infections or of the action of corrosives. They may follow the swallowing of boiling liquids. The congestion present during life sometimes remains, after death, in acute, but particularly in chronic inflammation and in chronic venous hyperaemia of the part, e.g. in individuals who have been excessive smokers or of alcoholic habit. In such, the parts may not only be congested but also may show slight brownish pigmentation. In **acute inflammation** the surfaces may be covered with muco-purulent or purulent secretion. **Erosions**—so-called “Catarrhal Ulcers”—may be found, or **vesicular eruptions** may persist, i.e. in small-pox, in herpes, and even occasionally in pemphigus. In **Diphtheria** the parts are more or less completely covered with a greyish false membrane. This is usually separable over the soft palate and fauces and more adherent over the tonsils, and it may extend downwards over the epiglottis into the larynx. It is sometimes difficult to distinguish diphtheria of the tonsil from **lacunar** (follicular) **tonsillitis**. In the latter condition the tonsils are enlarged and their crypts filled up with yellowish, or greyish-yellow, masses, made up of mucus, separated epithelium, fatty material, pus corpuscles and bacteria. These masses project from the crypts, and may, by coalescing with each other, simulate the false membrane of a true diphtheria. If no membrane be present, transverse sections should be made through the tonsils, so as to detect the presence of plugs in their crypts, or inflammatory changes in their substance. Occasionally, the surface of the tonsils is so thickened by chronic inflammation, or by infiltration with leucocytes, as to simulate a membranous exudate.

Acute inflammations may indicate infection in rubeola, measles or scarlet fever, and occasionally in these infections, as also in small-pox, and dysentery there may be localized necrosis, simulating false membranes.

Ulceration of the surface of the tonsils may follow separation of false membranes or of localized patches of necrosis. Ulceration of the tonsils is occasionally found in the course of typhoid fever.

In the ordinary variety of **Tonsillitis**, the gland becomes greatly enlarged, so as to narrow—sometimes to a great extent—the opening of the fauces. The mucous membrane is red and swollen and the surface covered with mucous or muco-purulent secretion, sometimes blood-stained, sometimes

whitish from the presence of cast-off epithelial cells. It may be associated with suppuration in the neighbouring tissues. It may follow diphtheria, but more often follows a simple lacunal tonsillitis. The swelling is due to great cellular infiltration and to formation of abscesses internally. These may be multiple or confluent, and at times cause destruction of the whole tonsil.

While it is customary for the abscess to rupture on the free surface, the pus may instead penetrate behind the pharynx and form a retro-pharyngeal abscess, or it may extend downwards in the neck and produce mediastinitis or pleurisy; more locally, it may lead to oedema of the larynx. One of the most serious consequences which may follow is a production of *septic thrombi* in the neighbouring veins with subsequent pyaemia. Hence, in cases of so-called *Cryptogenic Pyaemia*, the tonsils and their beds should always be carefully examined.

Chronic Inflammation of the Pharynx. — Chronic inflammations result either in hypertrophy or in atrophy of the parts. In the palate and pharynx, chronic catarrh is met with most frequently amongst drunkards, amongst excessive smokers and people who have had to speak or sing in an impure atmosphere or in the open. In *hypertrophic catarrh* the reddened mucous membrane shows thickened ridges, particularly on the posterior wall of the pharynx, or small pink nodules project on that surface (*granular pharyngitis*). These nodules and ridges result from swelling of the follicles, or of the mucous glands, and in particular from infiltration of the mucous membrane. The **Adenoid vegetations**, found in young children in the upper part of the pharynx, are of somewhat similar structure. In *atrophic catarrh* connective tissue is developed in the mucous membrane, and its contraction makes the latter thin and smooth, and causes atrophy of the follicles and mucous glands. Frequently, enlarged veins are seen on the surface of the thin mucous membrane and occasionally cysts may be found.

Chronic inflammation of the tonsil and pharyngeal tonsils may also be hypertrophic or atrophic, and the pathological changes are on the whole similar to those already described as affecting the palate and pharynx, the hypertrophic form occurring most frequently in children, particularly if they tend to be scrofulous. The lymphoid tissue is especially increased and the crypts are compressed to a corresponding degree.

Accompanying these hyperplasias of the lymphatic tissue of the pharynx, the lymphoid tissue at the base of the tongue—the so-called “*Lingual Tonsil*”—may also be swollen (see *Chloroma* and *Acute Lymphatic Leucocythaemia*, p. 115). In cases in which adenoid vegetations are present it is well to remember that these may be associated with a latent tuberculosis of the tonsil. **Tuberculosis of the tonsils** may be primary or secondary, the latter, for example, occurring in many cases of pulmonary tuberculosis with excavation. The varieties of tuberculosis found may be either the

disseminated grey or yellow tubercles, or caseating tubercles with a varying amount of fibrous tissue formation, according to the stage of the process.

Lupus occasionally attacks the pharynx, having extended directly from the face. In the early stages reddish, raised nodules appear which later break down and ulcerate. It may lead to scar-formation and deformities resembling those of syphilis, but they tend to be more symmetrically distributed than in that disease.

Syphilis of the Pharynx and Nasopharynx.—Although primary and secondary manifestations are occasionally met with in this situation, one more often sees the results of the tertiary form of the disease. These are by no means commonly seen in the post-mortem room, and may be in the form of gum-mata, with, at times, deep ulceration; of scars causing great deformity; or of narrow, band-like bridges and adhesions between different parts (Fig. 75). The uvula may be almost separated or may remain as a small fibrous projection from the soft palate (see Fig. 51, p. 115).

Actinomycosis of the tonsils, with resulting cervical abscess, seldom occurs. In such cases the slimy nature of the pus with the presence of the small, yellowish granules of the ray-fungus, will direct attention to the real nature of the disease.

Tumours of this part are not common. *Fibroma* and *fibro-sarcoma* usually develop from the base of the skull. *Lipoma*, *chondroma*, *angioma* and *papilloma* have been found.

Congenital tumours occur infrequently in the region of the nose and pharynx.

Occasionally, persistent fistulae are found in the lateral walls of the pharynx, representing incompletely closed branchial clefts.

The most important tumour found in this situation is *squamous epithelioma*, usually extending backwards to the pharynx from the tongue. It may also extend upwards from the larynx, and occasionally may commence in the sinus pyriformis, or in the tonsil. Other malignant tumours, such as *sarcoma* or *lymphosarcoma*, are of great rarity.

At the junction of pharynx with oesophagus some interesting conditions may be found. This, for example, is a common site of origin of *epithelioma*, and here also *stenosis*—congenital or acquired—may occur and may lead to formation of **Diverticula**. These are herniations of the mucous

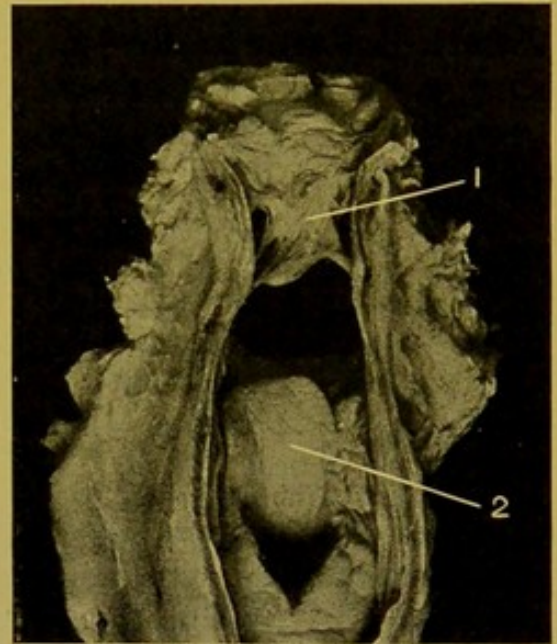


FIG. 75.—Syphilitic scarring and adhesions in Nasopharynx. (\times circ. $\frac{1}{2}$.)

(1) Uvula, bound by adhesions to wall of nasopharynx; (2) epiglottis.—(Mus. R.C.S. Ed.)

Syph
etc

membrane of the pharynx through imperfections in the other coats, the projection being more or less bulbous or pear-shaped, and extending usually downwards behind the upper part of the oesophagus. **Lateral Diverticula** occurring in this situation are very rare and represent persistent branchial fistulae. These have to be distinguished from **Traction Diverticula** which occur more often in the oesophagus and result from contractions and scar-formation round tuberculous glands. They may be lateral or even anterior.

Decubital Necrosis of the Pharynx.—This is occasionally found in old people, or in individuals who have lain for a long time in a comatose, or semi-comatose, condition. It is due to pressure backwards of the cricoid cartilage upon the wall of the pharynx. The pressure produces small rounded areas of necrosis, on separation of which ulcers are left in the middle line on both anterior and posterior walls of the pharynx.

DISEASES OF THE OESOPHAGUS

In considering pathological changes in the oesophagus it is well to remember that it is poor in blood- and lymph-vessels and possesses few mucous glands; moreover, the epithelium covering it is thick. Hence hyperaemia is rarely prominent except in the passive form, in which the veins at the lower end of the oesophagus become varicose as a consequence, particularly, of cirrhosis of the liver. Varices are seen occasionally at the upper part of the oesophagus also.

The oesophagus in the adult measures $9\frac{1}{2}$ inches (about 25 cm.) in length. It is narrowed normally, firstly, at its commencement; secondly, about $2\frac{1}{2}$ inches (6–7 cm.) lower down, at the point where, in the foetus, a diverticulum passes off to form the lungs; and, thirdly, where it passes through the diaphragm. It is important to remember these three situations, because they are the common sites at which malignant tumours of the oesophagus develop.

Deformities of the oesophagus are more commonly acquired than congenital. **Stenosis** may result (1) from compression from without, by an enlarged thyroid, by tumours of the lymphatic glands, by mediastinal sarcoma or aneurysm. It is most extreme when the tube is encircled by a new-growth, e.g. mediastinal sarcoma. (2) It may be due to obstruction of its lumen by impaction of foreign bodies, or by polypi or cancers of its wall; (3) the narrowing may be due to alteration in the wall itself by cicatrices, remaining after recovery from the destructive action of corrosives, or of boiling water, or the stricture may be of cancerous nature. The tube is dilated if the stenosis affects the lower portion or the cardiac orifice of the stomach.

Traction Diverticula are generally found on the anterior aspect of the oesophagus, most commonly just below the level of the bifurcation of the trachea. The narrow and funnel-shaped projection should be carefully followed out, and the scar-tissue surrounding a shrunken bronchial gland demonstrated at its apex.

Peptic, or Round, Ulcers, analogous to those found in the stomach, are

occasionally met with in the lower 2 or 3 inches of the oesophagus (5–7 cm.). Post-mortem digestion may cause destruction of the posterior wall, particularly in young children. The distinguishing characters of this change will be described in connexion with a similar change found in the stomach.

In addition to the causes of perforation of the oesophagus already referred to—such as cancerous ulceration, peptic ulceration—perforation may result from ulceration following the action of corrosives; from ulceration at the apices of traction diverticula; from extension of neighbouring suppurative processes, or from the pressure of an aneurysm.

Tumours of the Oesophagus.—Non-malignant tumours—polypi, papillomata, adenomata, myomata and lipomata are rare. Of the malignant tumours—the squamous-celled carcinoma is by far the most common (Fig. 76), though occasionally medullary cancer and cylindrical-celled cancer may occur, the last two sometimes extending upwards from the cardiac region of the stomach. Cancer of the oesophagus has a tendency to surround the tube and cause stenosis. More rarely it is insular. The sites of predilection have already been referred to. These are (first) the upper end; (second) where the oesophagus is crossed by the left bronchus, and (third) where the oesophagus passes through the diaphragm. The last two situations are the most common sites. The lymphatic glands in the vicinity are affected at an early stage, and metastases are found in the liver and also in the lungs. Pedunculated Rhabdomyomata are rare.

Parasites.—An uncommon parasite is the *Oidium Albicans*, the cause of aphthae. This condition always arises by extension from a similar condition in the mouth. It is found in weakly children, and also occasionally in pregnant women. The condition is important, in that infection may take place through the ulcers which result, and may lead to pericarditis, pleurisy or mediastinitis.

For Action of Corrosives on the mucous membrane of mouth, pharynx and oesophagus, see Chapter on *Poisons*, p. 423.

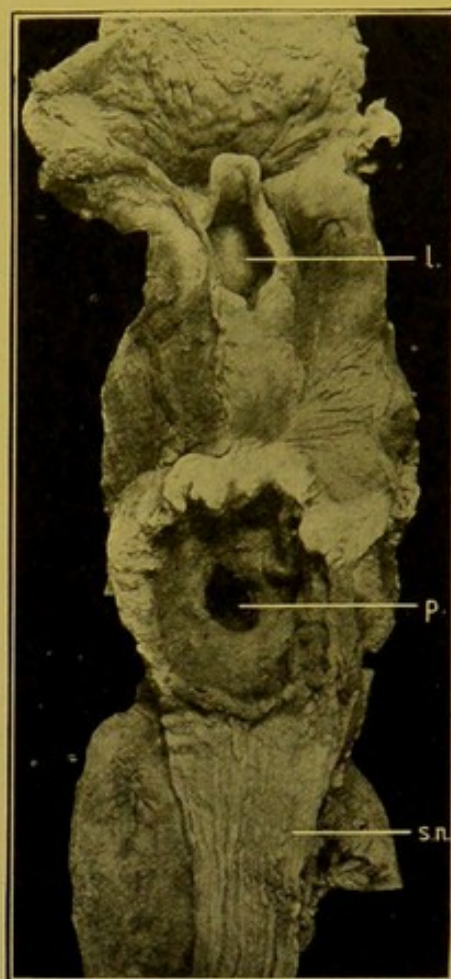


FIG. 76.—Squamous Epithelioma of Oesophagus, ulcerating into trachea. (\times circ. $\frac{1}{2}$.)

(l.) larynx; (p.) perforation; (s.n.) secondary nodules in sub-mucous coat.—(From Dr. J. D. Comrie's Collection.)

CHAPTER X

THE ABDOMEN

THE method of opening the abdomen has already been described on p. 29.

THE PERITONEUM

Anatomical.—The normal peritoneum forms a smooth, glistening layer which covers the abdominal organs and assists in retaining them in position with relation to each other and to the abdominal wall. All these organs are really outside the peritoneum with the exception of the ovary, the posterior surface of which is covered by germinal epithelium. The peritoneum consists of a layer of flattened endothelial cells supported by a framework of connective and elastic tissue in which is an extremely rich and close vascular network through which direct absorption of fluid takes place. Numerous large sub-endothelial lymph channels, through which fluids and cells are conveyed away from the peritoneal cavity, are found over the surface of the diaphragm. Free and direct lymphatic communication also exists between the peritoneum and the thoracic serous cavities. Under normal conditions the peritoneal cavity—so-called—contains a small quantity of a lubricating serous fluid.

Extra-peritoneal Haemorrhage occasionally takes place into the anterior wall. This results usually from direct mechanical injury; it may follow operative procedures; or is the result of toxic action upon the vessel-walls. The local infiltration into the surfaces of recent incised wounds is usually of little importance or interest, but in rare cases in operations about the liver, gall-bladder or common bile duct, when on account of old adhesions difficulty has been experienced in reaching or manipulating the parts, the operator may inadvertently injure vessels in the suspensory ligament of the liver, and extensive haemorrhage may take place into its substance, tearing it up and subsequently making its way into the peritoneal cavity.

Retro-peritoneal haemorrhage is more common, arising from mechanical injuries to liver, to structures in the gastro-hepatic omentum, to pancreas or to kidneys; from rupture of abdominal aneurysms; from fracture of the bony pelvis; from injury of bladder, or of the urethra behind the triangular ligament, the last being in most cases associated with fracture of the pubic arch.

Extra-peritoneal Suppuration may be found *anteriorly*, in connexion with stitch abscesses or with other lesions. In such cases a bacteriological examination may give some indication of the origin of the infection, and of its relationship to an accompanying peritonitis. Suppuration *behind* the

peritoneum may be perinephric and may have spread from suppuration of the kidney. It may also follow suppuration in the pancreas, in the liver, in a retro-caecal appendix, in the iliac bone, in the sacro-iliac synchondrosis, or it may follow psoas abscess. In the pelvic region, pus may form between the layers of the broad ligament; round about the rectum; in relation to the prostate; or it may penetrate the acetabulum, having originated in the hip-joint. Occasionally, pus forms in and around the retro-peritoneal glands. The pus in most of these instances collects in the lumbar and iliac regions, and in the pelvis.

The fluid contents of the peritoneum may be increased from (a) transudation—*ascites*; (b) from inflammatory exudation—*peritonitis*; or (c) from escape of the contents of the alimentary canal.

Ascites.—The fluid is watery and frequently holds in suspension flakes of fibrinous lymph. It is less albuminous than blood serum, its specific gravity varying from 1,003 to 1,014. It contains few cells, these being desquamated, fatty, or necrotic endothelium, or leucocytes, many of which contain oil droplets.

Causation.—(1) Obstruction to drainage, e.g. portal cirrhosis—this is denied by some authors; obstructive heart and lung disease; direct obstruction of the thoracic duct or of its tributaries; rupture of the receptaculum chyli or of its radicles. (2) Chronic toxæmias—Bright's disease of the kidneys, chlorosis, syphilis, cachexia of cancer; (3) disease of the peritoneum—tuberculosis or cancer—tumours of the ovary. When associated with malignant tumours the fluid is usually haemorrhagic and contains tumour-cells the characters of which may enable a diagnosis to be made during life.

Quinke describes an "idiopathic" ascites, occurring at puberty in girls.

Where old adhesions exist, the ascites may be loculated.

Chylous and Chyliform Ascites is caused by rupture of the thoracic duct or its radicles or from obstruction of these by tumour-growth, filariae, or chronic inflammatory changes in or around the duct, its radicles, or in the mesenteric or retro-peritoneal lymph-glands. In true chylous ascites the fluid is watery, milky or opalescent, with a yellowish tint, and fat can be separated by shaking up the fluid with ether, the milkiness disappearing to a greater or less extent; whereas in chyliform or lactescent ascites, in which the fat is in minimal amount and the suspension consists principally of globulin, it does not clear up when treated with ether, but when treated with equal parts of a saturated aqueous solution of ammonium sulphate and allowed to stand over night, the globulin is precipitated and the fluid becomes clear.

Ascitic fluid is pink or wine-coloured if there have been escape of blood in small quantities, e.g. in tuberculous peritonitis, in malignant tumour-growth of peritoneum or ovary, or after repeated paracentesis. It is yellow or greenish-yellow if jaundice accompany the ascites.

In long-continued ascites the peritoneum becomes thickened and opaque, sometimes with nodular elevations, best marked over the liver and spleen, or with filamentous fibrous adhesions between the organs or between the parietal and visceral layers of peritoneum. These thickenings may be pigmented, grey or black, if old inflammatory changes or chronic venous hyperaemia have existed for a lengthened period.

Blood escapes into the peritoneum as a result of mechanical injury to some part of the abdominal wall, or abdominal organs, e.g. in fractures of the pelvis or of the lower ribs, in rupture of the liver or spleen; when an operation has been recently performed; in rupture of a tubal pregnancy or from the mouth of the Fallopian tube; in rupture of a pregnant uterus; in rupture of a corpus luteum; in tuberculosis and cancer of the peritoneum; in rupture of aneurysms, in tears of the suspensory ligament of the liver or of the gastro-hepatic omentum.

Acute Peritonitis.—In acute peritonitis the appearances vary greatly. The abdomen is usually distended and tympanitic. On opening the cavity the coils of small intestine, and, it may be, a considerable length of large intestine, are distended with gas. This is due to paralysis of the muscular coats, and may be present in apparently moderate grades of the inflammation. Nevertheless, in very acute infections, or at a very early stage, distension may be absent. The omentum is congested, often retracted, and may be covered with patches of yellowish lymph.

In so-called “Dry” peritonitis the serous surface loses its lustre, is dull, congested, and at parts is covered with a fibrinous or fibrino-purulent exudate. The congestion is best seen along the lines bounding the surfaces of contact of adjacent coils, and the exudate collects on those portions of the serous coat which share in the formation of the more or less prismatic (potential) space left between three or four adjacent coils, i.e. along the lines and areas of least pressure. In cases in which the fluid exudate is more abundant, the congestion becomes more diffused, and the layer of lymph more generalized.

The fluid may be serous, turbid with flakes of lymph in suspension, sero-purulent, or definitely purulent. If pus has formed, it tends to gravitate towards the posterior parts,—flanks or pelvis. The fluid may be yellow from presence of bile, pink or reddish-brown from presence of blood, dull yellow or light brown with faecal odour in perforation of ileum or colon. In cases following rupture of gastric or duodenal ulcers the half-digested stomach contents and sometimes “coffee-grounds” may be recognizable in the peritoneal cavity.

Peritonitis may be localized by recent or older plastic adhesions to the neighbourhood of the focus of origin. Anatomically, it may be localized to the area above the transverse meso-colon, or to one or other side of the mesentery of the small intestine. The lesser sac may escape when the main cavity of the peritoneum is affected, and *vice versâ*. Death may

be caused by rapid dissemination from a previously localized peritonitis.

Healthy plastic adhesions round about an operative anastomosis should not be mistaken for peritonitic exudate ; they are greyish, localized, and the vascular reaction is also localized and of moderate degree.

Channels of infection in Peritonitis.—(A) Through the abdominal parietes :—lacerated, punctured or incised wounds ; extension through the diaphragm from pericarditis, pleurisy, or mediastinal inflammation ; extension from disease of the hip-joint.

(B) Extension from inflammatory foci in the abdominal walls :—osteomyelitis of ribs, pelvic bones, or vertebrae.

(C) Infection from hollow abdominal organs :—

(1) With perforation :—gastric, duodenal, or intestinal ulceration, typhoid, tuberculous, follicular, catarrhal, malignant ; separation of sloughs, e.g. in intussusception ; rupture in impacted hernia ; rupture of a gangrenous appendix ; rupture of an extra-uterine gestation, of the uterus, or of the urinary bladder ; ulceration of the gall-bladder from the pressure of gall-stone ; ulceration at the tip of a Meckel's diverticulum.

(2) Without actual perforation :—in acute inflammation, particularly with suppuration or necrosis, of some part of the alimentary tract ; in infarction of the intestine ; in septic embolism, volvulus, cystitis, cholecystitis, ureteritis and pyelitis, appendicitis, salpingitis, puerperal metritis or endometritis.

(D) Extension from inflammation of solid organs :—e.g. of pancreas, ovary, liver, spleen, kidney, supra-renals, or lymphatic glands.

In both male and female the most common cause of peritonitis is appendicitis. Eustace Smith describes a rheumatic variety of peritonitis.

Bacteria which have been found in peritonitis :—*Bacillus coli communis* and *Bacillus lactis aërogenes*, *Bacillus pyocyaneus*. Less frequently *Pneumococcus*, which may produce an abundant fibrino-purulent exudate ; *Bacillus typhosus* ; *Bacillus influenzae* ; *Gonococcus*, usually from salpingitis ; *Bacillus aërogenes capsulatus* ; *Streptococci*, seldom further identified, but I have found *S. pyogenes*, *S. faecalis*, occasionally even *S. salivarius* ; *Staphylococci*, *aureus*, and more often *albus*.

In perforative peritonitis, anaërobic organisms should be sought for. In appendix cases, bacilli of the colon group are often associated with streptococci.

It may be taken for granted that a bacteriological examination, to be trustworthy, should be undertaken within at most three or four hours after death.

Chronic Peritonitis.—The commonest evidence of chronic peritonitis is the presence of stringy fibrous adhesions between adjacent surfaces of the membrane. For example, these commonly occur between the upper surfaces of the liver and spleen, and the diaphragm ; between various portions of

the intestinal tract—caecum, hepatic or splenic flexures—and the abdominal parietes or the abdominal organs. It is extremely rare to find adhesions over the stomach on either surface, either anteriorly or posteriorly and, if present in the latter situation, they usually indicate the presence of a chronic gastric ulcer or of malignant growth. Localized adhesions are not uncommon within the female pelvis, binding down not only the uterus

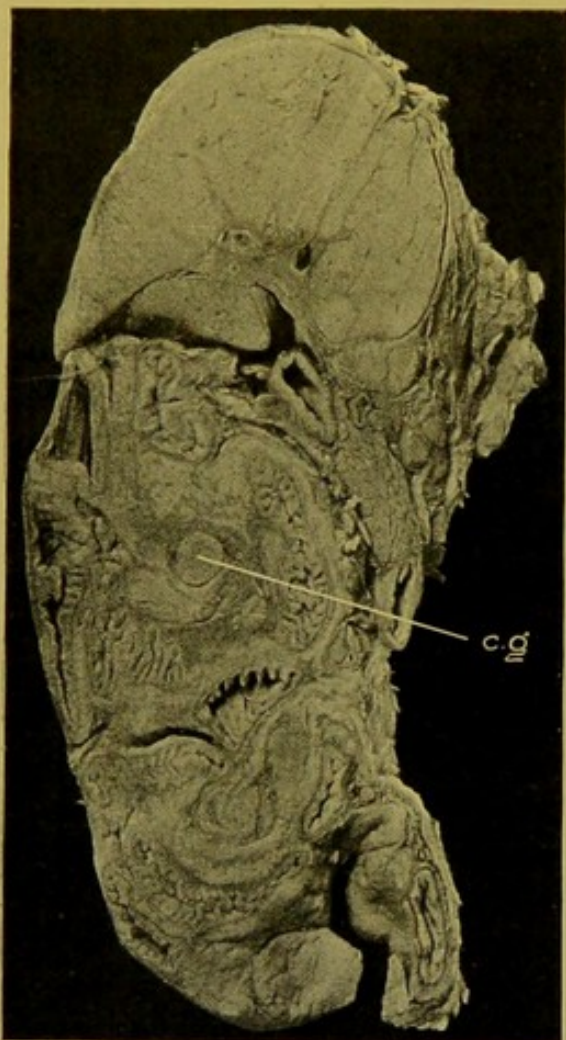


FIG. 77.—Generalized Tuberculous Peritonitis, in child. (\times circ. $\frac{1}{2}$.)

Mesial, sagittal section through abdominal contents; (c.g.) caseous gland.

and appendages to the walls, but also fixing down coils of intestine within the pouch of Douglas. Adhesions may also be localized to the region of the appendix.

While in the *adult* chronic peritonitis is more commonly localized as just described, in some cases it is more diffused throughout the cavity. Diffuse general chronic adhesive peritonitis is, however, best seen in the *young*, and is most often the result of a tuberculous infection. The coils of the intestine and the solid abdominal organs are bound together into one mass which is attached to the walls (Fig. 77). Within the adhesions caseous glands and caseous exudate are enclosed, and at times one finds, in addition, foci of suppuration from which sinuses may pass to the skin surface. Chronic peritonitis may also assume the form of a general opaque thickening of the peritoneum, adhesions being absent or localized to certain situations—for example, over the liver or spleen, or in the region of the gall-bladder. This variety of peritonitis is associated with shrinking of the mesenteries and

omenta and with accumulation of fluid within the peritoneal cavity—*ascites*. Occasionally on the surface of the liver and spleen the peritoneum is extremely thickened, the thickening forming either a flat disc which may be $\frac{3}{4}$ in. in thickness in its centre, or button-like or knob-like elevations. In either case the thickening is composed of dense laminated fibrous tissue, “lamellar fibroma.” Chronic inflammatory change in and around the lymphatic trunks may be associated with chronic peritonitis and leads to obstruction of these channels, so that chylous fluid collects in the peritoneal cavity—*chylous ascites*. In rare cases one finds thin-walled transparent cysts with gaseous contents, either sessile or pedunculated, attached to

mesentery or serous coat of intestine. These appear to be in most cases developed in connexion with lymphatics—indeed, some of them appear to be of the nature of cystic lymphangiomata. (See “Gas-cysts,” in Bibliography.)

Tuberculous Peritonitis. (1) **Miliary Tuberculosis.**—This may be limited to the serous aspects of tuberculous ulcers of the intestine, or may be generalized, the tubercles being scattered over both visceral and parietal surfaces of the peritoneum. Both conditions are frequently associated with fibrinous exudation—in the one case localized to the bases of the ulcers, in the other generalized (Fig. 78). The common variety of chronic tuberculous peritonitis occurring in children has already been described, but another manifestation of tuberculosis is seen in the contraction and thickening of the great omentum which comes to form a thick firm ridge passing more or less completely across the abdomen about the level of the umbilicus. Tubercles of the peritoneum may be white, opaque, fibrous, and sometimes may extend to a diameter of 3 or 4 mm. This form of tuberculosis is often found to be due to infection with the bovine tubercle bacillus—“*Perlsucht*.” One has to distinguish this form from miliary carcinoma of the peritoneum, the nodules of which are usually of a yellowish tint and surrounded by a narrow zone of congestion.

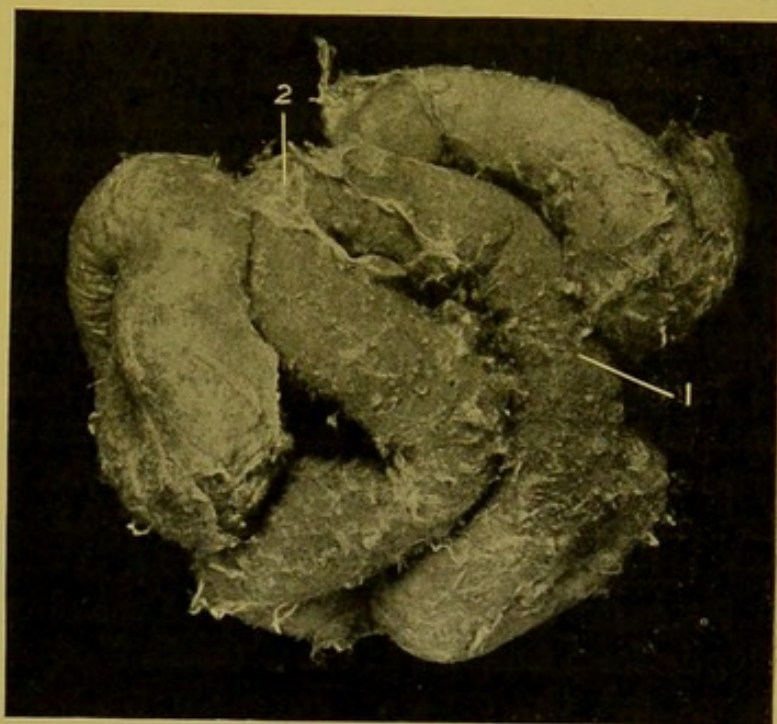


FIG. 78.—Tuberculous Peritonitis. (\times circ. $\frac{1}{2}$.)
Generalized miliary tubercles, with fibrinous exudation.

EXAMINATION OF THE OUTER SURFACE OF THE INTESTINE.

It is usually easy to diagnose *tuberculous ulcers* from the serous aspect. From this aspect the ulcer appears as an oval, purplish or dark grey patch on the surface opposite to the mesenteric attachment, and having its longer axis usually transverse to that of the bowel. On this dark ground the tubercles in the sub-serous lymphatics—yellow towards the centre of the patch, greyer and smaller (younger) farther out—are distinct. There is occasionally some local fibrous thickening of the peritoneum. If the tubercles cause obstruction of the lymphatic vessels, these become distended with chyle and stand out as white arborisations, radiating out from the

*to B. in
trans
to the*

mesenteric attachment of the intestine over the affected area. *Ulcers of other kinds* are visible from the serous aspect only when they extend very deeply into the walls of the intestine, and then small dull grey or yellowish-grey patches of necrosis may be seen. These seldom exceed 5 or 6 mm. in diameter ($\frac{1}{5}$ or $\frac{1}{6}$ in.). In typhoid fever, occasionally small granulomata may develop upon the serous aspect of the ulcers.

True ante-mortem perforations are seldom of large size; they are surrounded by a narrow necrotic rim, and there is local acute peritonitis. If the perforation have taken place while peristalsis was still going on, liquid faeces mixed with inflammatory exudate will be found in the peritoneal cavity. Occasionally rupture of the thin base of an ulcer may take place after death, for example, during the manipulation of the bowel by the pathologist, but in this case the indications of acute peritonitis are absent.

Sometimes pus may collect in small pockets of the peritoneum shut off by adherent coils of intestine. These may be recent or of some standing, and in the latter case the coils surrounding the collection may become perforated from *without inwards*. The direction taken by the ulcerative process from within or from without, is indicated by the wider extent of the ulceration in the earlier affected coat, mucous membrane, or peritoneum respectively.

In *rupture* of the intestine from violence or in perforation by bullet-wounds or stabs, there is escape of the contents, retraction of the muscular coats and eversion of the mucous membrane, which in complete separation of the intestinal tube, may be turned back over the outer surface for a quarter to a third of an inch (7 to 10 mm.).

Tumours of the Peritoneum.—Secondary *cancer* or *sarcoma* spread directly from tumours of the abdominal organs, or they may be scattered throughout the cavity. Favourite spots for their development are the attachment of the mesentery, the omentum, the recto-vesical or Douglas' pouch. The pelvic organs may be matted together and concealed by malignant growths of the ovary, uterus or rectum. Occasionally rupture of papilliferous cysts of the par-oöphoron occurs, and as a result the whole peritoneum may be covered over with small papillomata.

In *colloid cancer* the whole abdominal contents are sometimes matted together by a gluey mass of new-growth. In most cases, however, of secondary colloid cancer of the peritoneum, the omentum is especially affected, and it becomes densely infiltrated and thickened (see p. 193 and Fig. 91).

Parasites.—Hydatids of *Taenia echinococcus* may invade the peritoneum, e.g. from rupture into it of hydatids of the liver, and the cysts may be found in any part of the cavity, but chiefly in the omentum and in the pelvis. In extremely rare cases *ascarides* have been found in the peritoneal cavity, having worked their way through the substance of the liver from the bile-ducts.

THE STOMACH

Removal of the Stomach.—If the post-mortem be conducted according to the plan outlined on pp. 35, 36, the stomach will be removed along with the liver, spleen, duodenum and pancreas. For details *see* p. 226.

Anatomical Points.—The adult stomach when distended measures 10 to 11 in. (25 to 27.5 cm.) in length; its width measures from $3\frac{1}{4}$ to 6 in. (8–15 cm.); its capacity varies from 9 oz. to 59 oz., and averages 35 to 40 oz. or about 1 litre. Its shape is like that of a pear or calabash.

In the new-born child the stomach is hardly as large as a small hen-egg, and its capacity is about 1 ounce (28 cm.). Its shape corresponds pretty closely to that of the adult, and the cardiac end is well developed. Frequently the pyloric portion is found much contracted.

The pylorus, when the stomach is empty, lies in the middle line. Its average position, however, is a little to the right of the mesial plane, and its axis lies on a transverse plane which passes midway between the top of the sternum and the pubic crest (Addison).

As the stomach fills up, the lesser curvature tends to become wider, so that the pylorus recedes an inch or more from the middle line. The greater curvature of the stomach crosses the middle line about a finger's breadth above the umbilicus, or about half-way between the inferior border of the liver and the umbilicus.

The upper (anterior) surface of the stomach is in contact with the diaphragm towards the left, with the left lobe of the liver above, and with the anterior abdominal wall in front. Its lower (posterior) surface is in relation to the lesser sac of the peritoneum and lies against the posterior part of the diaphragm, the spleen, left kidney with supra-renal, anterior surface of pancreas, transverse mesocolon and transverse colon.

Structure of Wall.—The *serous* and *sub-serous* coats call for no special attention. The internal—oblique—*muscular* layer does not extend into the pyloric part of the stomach. The middle muscular layer is thickened at the pylorus to form the pyloric sphincter. The *mucous membrane* is thickest (2 mm.) in the pyloric region and thinnest over the fundus. At the cardiac orifice it is overhung by that of the oesophagus, so that pathological thickening is recognized by the levels of both corresponding or by the gastric mucous membrane projecting over that of the oesophagus.

When the stomach is contracted, the longitudinal folds of the mucous membrane become exaggerated (*see* Fig. 81, p. 178). These folds, due to contraction, can be readily abolished by stretching the wall mechanically, or by distending the stomach with water. The surface of the mucous membrane, especially in the pyloric portion, is marked out in minute, slightly raised polygonal areas—“*areae gastricae*” (*see Changes in Chronic Gastric Catarrh*). *See* Fig. 83, p. 182.

At the pylorus the glands (zymogenic) project into the submucous coat, the muscularis mucosae being defective there (*cf.* Brunner's glands in duodenum).

In the interstitial tissue, particularly in the pyloric region, there is usually a considerable amount of lymphoid tissue. This may be collected into follicles, the bases of which are embedded in the sub-mucous coat.

Blood-Vessels.—The arterioles supplying the wall break up into fine capillaries at the bases of the glands. These capillaries empty into a superficial plexus of relatively large venous capillaries which encircle the mouths of the glands. From this plexus, venous radicles pass down through the mucous membrane to join the veins of the submucous coat.

The *lymphatics* of the mucous membrane are irregularly dilated, and pass to valved lymphatics in the submucous coat, and thence to the sub-serous lymphatics.

EXAMINATION OF STOMACH FROM EXTERIOR.

Alterations in Position.—Rarely the stomach is transposed (*situs inversus*). It may be herniated through a congenital opening or traumatic rupture in diaphragm (Fig. 79), or through the umbilicus. The stomach may retain its foetal vertical position, or in women this alteration in position

may be due to tight-lacing. When this is the cause the pyloric part lies at an acute angle to the vertical portion.

Other alterations in shape are best considered with the changes in the walls which cause these.

Changes in the Serous Coat.—The serous surface is normally of a light grey or grey-fawn colour, and it is almost opaque. Fibrous thickening of the serous coat—**Perigastritis chronica**—may be a part of a general peritonitis, or more often is localized over the sites of ulcers or tumours. Adhesions may form to the liver, diaphragm, transverse colon, spleen, diaphragm, or omentum.

Acute perigastritis (peritonitis) may be

a part of a general peritonitis, or may be localized to the neighbourhood of perforations or of operation wounds. Reactive peritonitis may be absent where death has quickly followed a rapid perforation, for example, caused by the corrosive poisons.

Changes in the Wall.—**Dilatation—Gastrectasis.** Displacement of the

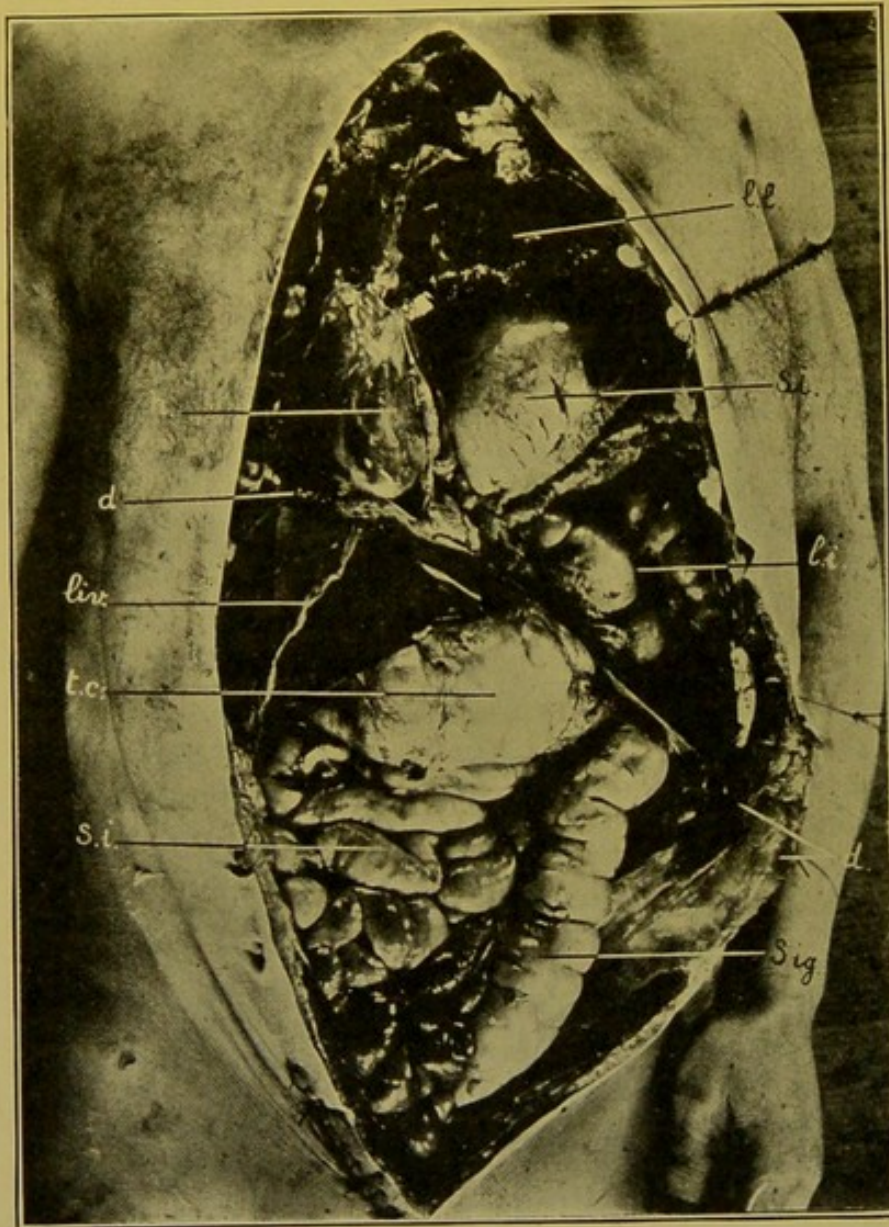


FIG. 79.—Traumatic Diaphragmatic Hernia.

(l.l.) Left lung; (h.) heart; (d.) diaphragm; (St.) stomach; (l.i.) portion of colon, above diaphragm; (liv.) liver; (t.c.) transverse colon, distended; (s.i.) small intestine; (Sig.) sigmoid.

pylorus—Gastroptosis. In most cases dilatation is due to obstruction at the pylorus, in the duodenum, or in the upper part of the jejunum. It may also be due to paralysis of the muscular coat, and distension with gas.

Specific causes.—Dilatation may result from (1) *Stenosis of the pylorus*, from contraction of the scar of a chronic ulcer, from tumour-growth infiltrating the pylorus and causing contraction or associated with fungation into the lumen; from abnormal position, or from pressure of adhesions; from congenital stenosis in which a hypertrophy of the muscular coat occurs, with which may be associated hypertrophy of the muscularis mucosae, and enlargement of Brunner's glands.

(2) *Congenital stenosis* in the vicinity of the bile papilla in the duodenum; tumour-growth in the wall of the duodenum or in the head of the pancreas; *duodenal ulceration*.

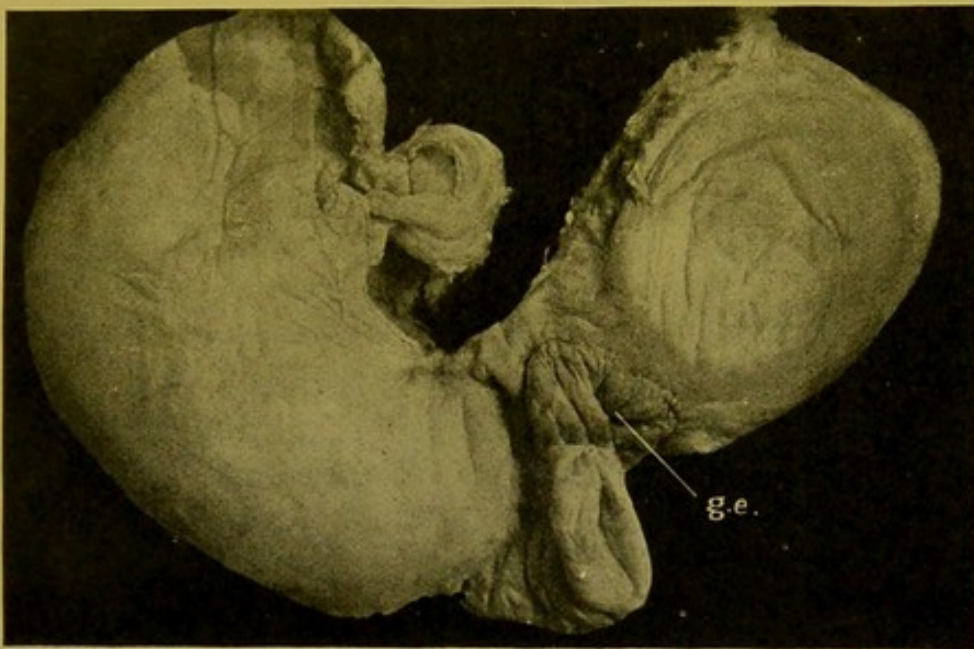


FIG. 80.—Hour-glass Contraction of Stomach, following ulceration.
Gastro-enterostomy (g.e.) had been carried out.

(3) Pressure on the duodenum, near its junction with the jejunum, by the mesentery containing the superior mesenteric artery.

(4) Contraction of ulcers—tuberculous, etc.—near the upper end of the jejunum.

(5) So-called idiopathic, relatively acute, dilatation of the stomach, is due to over-filling of the stomach, fermentation of its contents, with finally paralysis of its muscular coat. Defects may form in the muscular coat.

(6) It may result in some cases of chronic catarrh with paralysis resulting from changes in the solar plexus.

The wall of the greatly dilated stomach is usually thin; the surface of the mucous membrane is smooth, and may be atrophied. The pylorus descends a little and moves outwards 1 to 3 in. (2.5–7 cm.) from the middle line, the hepato-duodenal ligament being elongated. The greater curvature

is relatively much more displaced than the lesser curvature, and it may reach the brim of the true pelvis.

Diminution in the size of the Stomach.—The stomach lessens in size—(1) if its functions are in abeyance, through interference with the supply of food; for example, in actual starvation or caused by contraction of oesophagus or of cardiac orifice; in general cachexias; from malignant ulceration, or from pressure from without of an aneurysm, or tumour. (2) From contraction of scar-tissue in the walls of the stomach, or from contraction following chronic gastric catarrh or chronic peritonitis. (3) The greatest degree of diminution results from the contraction of an infiltrating cancer of the wall, when the cavity may be so small as to admit only the index finger.

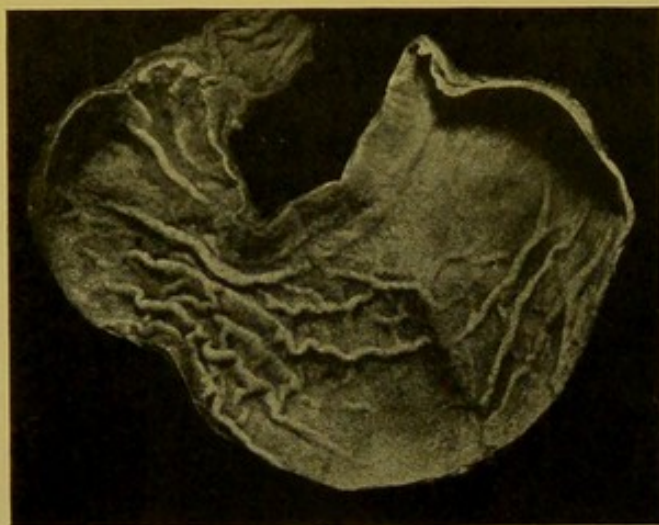

FIG. 81.—Stomach showing contraction due to *rigor mortis*, simulating hour-glass contraction. (\times circ. $\frac{2}{3}$.)

“Hour-glass” Stomach.—This condition is not uncommon in the lower animals as a natural condition, but in man in the great majority of cases it is the result of cicatrization following ulceration. It may also be caused by contraction of a bridle outside—adhesive peritonitis. The constriction is usually near the middle of the stomach, so that it is divided into two intercommunicating sacs, corresponding to its cardiac and pyloric portions. The former is usually dilated (Fig. 80).

The condition is frequently simulated by the contraction of the muscular coat in *rigor mortis*, but in this case the apparent constriction can be removed by distending the stomach with water or by traction upon the walls (Fig. 81).

Hour-glass stomach has also to be distinguished from a rare condition in which, accompanying dilatation of the stomach, the duodenum is greatly distended down to the level of *Vater's ampulla*—the bile papilla—as a result of congenital stenosis in this position. On examining the anatomical relationships of the parts, however, the common bile-duct is found to pass downwards behind the second dilatation, and no ulceration or pathological thickening of the wall is found at the constriction between the two sacs (Fig. 82). See also p. 201.

Method of Opening the Stomach.—The position of tumours, ulcers, operation wounds, will determine the line along which the stomach should be opened. In many cases preliminary fixation by gentle distension with formalin is useful for preserving the relationships of parts, and the actual shape of ulcers and tumours, particularly if the latter are of soft consistence.

In ordinary cases a good deal of latitude may be allowed, the actual line of the incision being of little moment.

Létulle advises that the incision should pass along the greater curvature anterior to the attachment of the omentum until the pyloric portion of the stomach is reached, and should then pass upwards on the anterior (upper) surface as to pass through the pylorus in the middle of its anterior surface.

Contents of the Stomach.—In medico-legal cases the contents should be preserved for subsequent investigation. (*See chapter on Poisons, p. 424.*)

The contents should be examined with due regard to the condition of the mucous membrane, e.g. gastric catarrh, ulceration, tumour-growth (haemorrhage), post-mortem digestion.

Gas may be produced by fermentation of the contents of the stomach, or may consist of air which has been swallowed. The latter is of importance

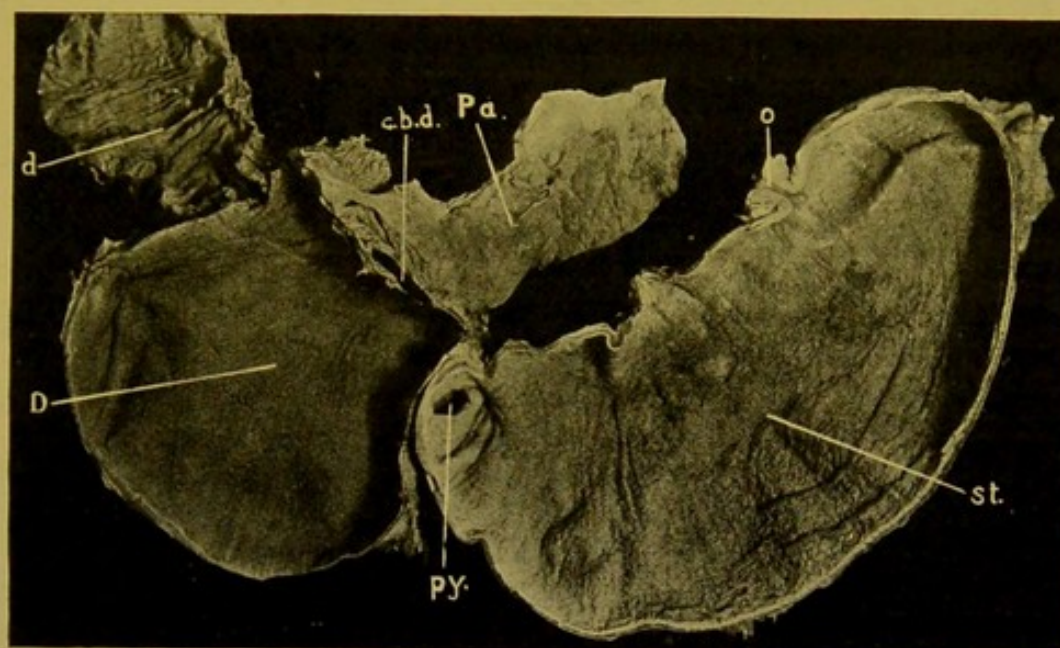


FIG. 82.—Congenital Stenosis at Vater's Ampulla. (\times circ. $\frac{1}{4}$.)

The stenosis is seen between the dilated upper part of the duodenum (*D.*) and the lower part (*d.*), which is of normal size. (*st.*) Stomach; (*o.*) oesophageal opening; (*py.*) pylorus; (*Pa.*) pancreas; (*c.b.d.*) rod in common bile-duct.

only in newly born children as showing that they have lived for a time, particularly if along with this the absence of distension of the lungs indicates that they have not breathed (Orth).

The usual contents consist of food materials, semi-digested or undigested. In young children, whitish masses of curdled milk are frequently found. In adults, fat balls may be found, and very rarely masses of hair, pieces of paper, etc.

Blood may be derived from the stomach itself or may have been swallowed.

If in large amount it has usually come from the wall of the stomach, from rupture of a large vessel, but sometimes even in the case of large collections no gross lesion can be found, and either a general oozing from the surface, or bleeding from multiple small haemorrhagic erosions, has to

be blamed. In all cases in which no distinct source can be found in the body of the stomach, and particularly if the liver be the seat of coarse cirrhosis, the venous plexus at the lower end of the oesophagus should be carefully examined. A small erosion in this situation may suffice to cause a gross haemorrhage.

If the blood be partly digested, in the form of a fluid containing in suspension small brown particles like coffee-grounds, the bleeding has been chronic, and has come from small vessels, for example, upon the surfaces of peptic or malignant ulcers.

If the blood be mixed with mucus, it has oozed from the general surface, which has been hyperaemic either from inflammation, or following cirrhosis of the liver, or obstructive heart or lung disease. (See p. 184.)

If the blood be fresh, mixed with air and frothy, it has been swallowed, and the original site of the haemorrhage has to be sought in some part of the air-passages.

Bile pigment gives a yellow or greenish-yellow colour to the stomach contents.

Parasites.—Animal parasites are seldom found.

Vegetable parasites are common—Fungi, bacteria—leptothrix forms, yeasts and sarcinae. In necrotic parts of tumours, spirochaetes and fusiform bacilli may be present, and can be demonstrated by silver-staining methods.

Examination of the Mucous Membrane.—**Post-mortem Digestion—Gastro-malacia**, is a softening and destruction of the wall of the stomach progressing from within outwards, and resulting from the action upon it of the acid gastric juice present at death. It occurs most typically in young children whose stomachs contain milk. The action is most marked towards the cardiac end in the part to which, in the prone position of the body, the contents gravitate. The mucous membrane alone may be digested away, or the action extends to the deeper coats until the wall is perforated. In the wall surrounding the opening the thickness of the tissues gradually lessens until at the margin a delicate ragged fringe is left representing remains of sub-serous and serous coats. The most important feature is a negative one—there is no peritonitis. As a result of the digestion, the coats become soft, swollen, translucent, and easily separated as a gelatinous or pulpy mass, which will be greyish or yellowish if the walls have been anaemic, or brownish if they have been congested.

Some degree of softening may occur whenever the contents are highly acid, and thus in some forms of poisoning this change may accompany the special changes due directly to the corrosive action of the poison.

Post-mortem digestion has to be distinguished from peptic ulceration. It may extend to neighbouring organs, to pleura or pericardium, to oesophagus, or even to lungs. In this way stomach contents have been known to reach the air passages after death.

After death, gas-forming bacteria may produce *emphysema* of the

stomach walls which become vesicular and crackle on stroking with the finger.

In cases in which chronic venous hyperaemia, or chronic gastric catarrh has existed, the sulphur compounds produced during decomposition may make the mucous membrane dark green or black, from the action upon the blood pigment,—haemosiderin,—deposited in the walls in such conditions. The haemoglobin also tends to diffuse from the vessels so as to produce a brownish network over the inner surface which is all the more distinct if the mucous membrane has been removed by post-mortem digestion.

Peptic Ulceration of the Stomach (syn. : Round, or Perforating, Gastric Ulcer).—This occurs most commonly in females, but the only predisposing cause proved so far is chlorosis. Welch found that 40 per cent. of his cases were males and 60 per cent. females, and noted that in females, gastric ulcers were more common than duodenal, whereas the contrary was the case in males.

The exciting cause is some disturbance of circulation leading to necrosis or devitalization of the mucous membrane, so that it can be digested by the gastric juice. In the case of duodenal ulcers, a small branch passing to its upper anterior quadrant just outside the pylorus, from the gastroduodenal, or cystic artery is affected (Wilkie). In normal conditions it is supposed that auto-digestion is prevented by the alkalinity of the blood circulating in the walls of the stomach.

Many factors have been assigned as exciting causes, and our information is still unsatisfactory in this respect. Amongst explanations usually given are embolism or thrombosis of the gastric vessels ; but the former can only be of serious moment when the embolus is septic. The following also are assigned as possible factors in the causation :—local anaemia, due to spasm of individual arterioles ; venous stasis in severe vomiting ; mechanical pressure from tight-lacing ; haemorrhagic extravasation into mucosa and submucosa ; mechanical injury ; gastric catarrh ; alterations in the blood, for example, in haemoglobinuria, malaria or chlorosis. It is commonly believed that extensive burns of the skin surface are constantly followed by formation of ulcers of the pylorus and duodenum, presumably due to thrombosis, or embolism, or to localized haemorrhagic extravasation.

The ulcer had sharply cut, abrupt, "punched-out," margins. The deeper coats are usually less extensively affected than the mucous membrane so that the ulcer may be funnel-shaped, or have terraced walls. The axis of the funnel is not always perpendicular to the surface of the mucous membrane, but corresponds to the axis of the arteriole supplying the part. Occasionally the mucous membrane overhangs the ulcer, in consequence of the more extensive digestion of the submucous coat. (Fig. 83.) The margins show no thickening, and inflammatory and necrotic changes are practically wanting, except when perforation has taken place. The opening may

be in the centre of a small necrotic area. In all cases in which perforation has taken place during life the serous coat shows evidences of peritonitis.

The ulcers are most commonly encountered on the posterior (lower) wall, close to the lesser curvature, and in the pyloric region of the stomach. They are less common on the anterior wall. In the duodenum they occur most commonly in the first part, in its upper anterior quadrant. They are seldom larger in diameter than $\frac{5}{8}$ in., or about 15 mm.

Results.—Healing with cicatrization (Fig. 84); haemorrhage from ulceration into a large vessel, e.g. coronary gastric arteries, splenic vessels; peritonitis

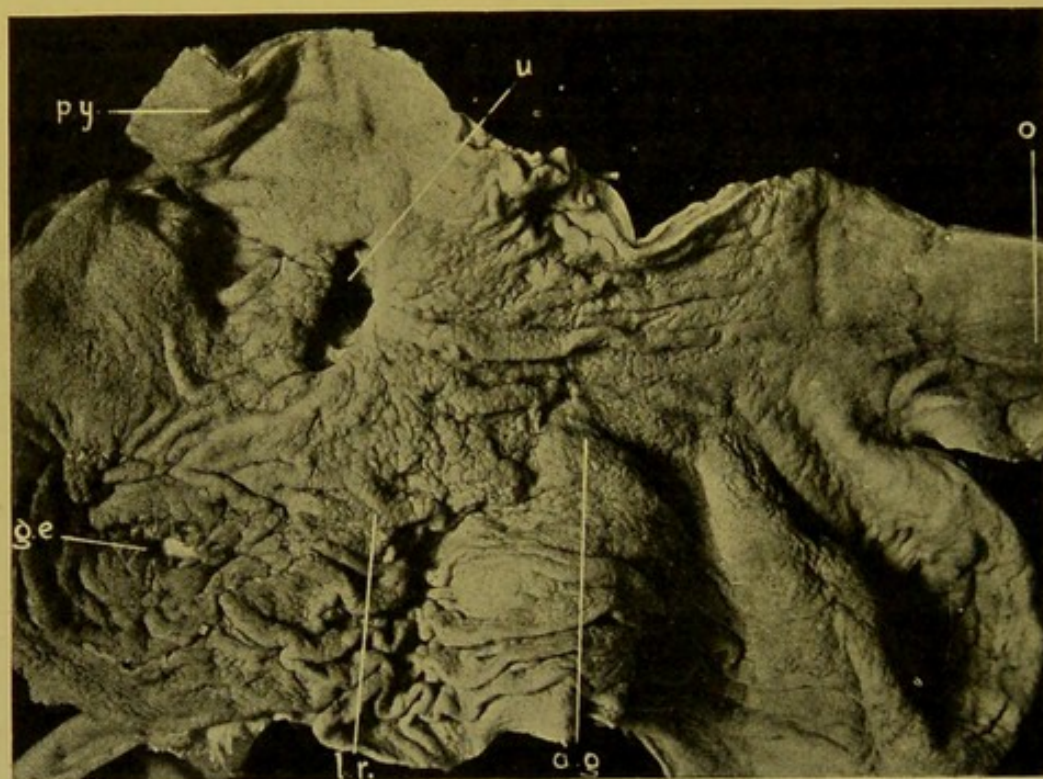


FIG. 83.—Gastric ulcer (*u*) on lesser curvature, near pylorus (*py*). (\times circ. $\frac{1}{2}$.)

The stomach also shows chronic gastric catarrh. (*o.*) Oesophagus; (*l.r.*) thickened longitudinal ridges of mucous membrane; (*a.g.*) areae gastricae; (*g.e.*) gastro-enterostomy opening.

from perforation, with escape of stomach contents; fatal general peritonitis is most likely to follow perforation of an ulcer situated on the anterior wall of the stomach. A subphrenic abscess may result, which may extend downward in the flanks, or make its way through the diaphragm to the pericardium or more often to the left pleura and lung. In the lung, in addition to the localized destruction of tissue, a septic broncho-pneumonia usually develops. The suppuration may penetrate the gall-bladder, the colon, or even extend to the skin surface. When the ulcer is situated upon the posterior wall, adhesions readily form to neighbouring organs and tissues, e.g. pancreas, liver and posterior abdominal wall. The ulceration may penetrate to the pericardium or pleura, or if adhesions form, the extension may take place into the liver, pancreas and even lung, the tissues of

which then form the base of the ulcer. Ulcers which have cicatrized may extend at a later date.

The foregoing description applies to the round or perforating gastric ulcer when it is seen at a comparatively early stage.

Frequently, however, the post-mortem is conducted after the patient has suffered for a long time from recurrent attacks and has died from haemorrhage. In such a case a deeply extending ulcer with indurated and thickened margins and base is found, surrounding which much cicatricial contraction may have occurred, leading to localized diminution of the cavity of the stomach, or to

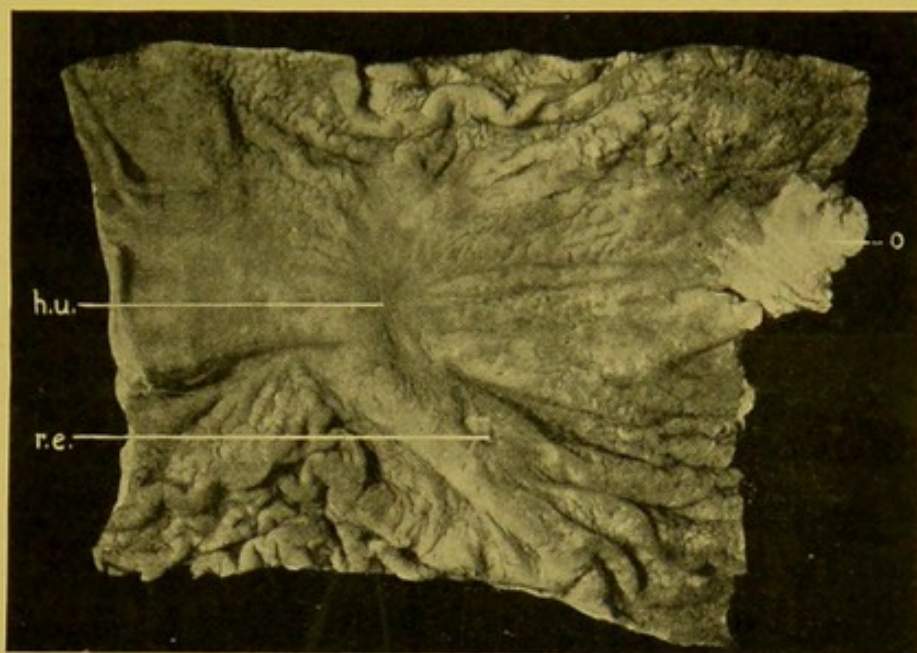


FIG. 84.—Healed gastric ulcer (*h.u.*). (\times circ. $\frac{2}{3}$.)
(*r.e.*) Recent erosion; (*o.*) lower end of oesophagus.—(From Dr. J. D. Comrie's Collection.)

marked stenosis of its pyloric portion with resulting dilatation of the organ above the situation of the ulcer. To this variety of ulcer the term *chronic gastric ulcer* may fitly be attached.

The ulcer may be of large size, the diameter at times being as great as $1\frac{1}{2}$ in. (3 to 4 cm.). The base is firm, indurated, and may be formed by adjacent structures to which the serous surface has become adherent, but this is not invariable. The base is most commonly formed by pancreas, less frequently by liver. In the former case the splenic artery or vein may be ulcerated into. The margins are greatly thickened, indurated from proliferation of connective tissue, and bands of cicatricial tissue radiate from it. Chronic ulcers may be accompanied by recent peptic ulcers, and malignant tumours may develop in their margins.

The extension may depend on persistent anaemia, increased acidity, or wrong feeding.

Peptic ulcers may heal with formation of flat scars. (Fig. 84.)

If a large vessel has been opened into, an attempt should be made to inject the main trunk to demonstrate the exact situation of the opening. The arteries most frequently perforated are the coronary artery, the gastro-epiploic, the splenic, or their branches, and the various arteries which supply the pancreas.

Hyperaemia of the Stomach.—I have already referred to the vascular supply of the gastric mucous membrane (p. 175). Bearing the anatomical facts in mind, it will readily be understood that acute arterial hyperaemia will be less evident at the post-mortem examination, and of a more diffuse pink character, than the hyperaemia of venous origin. Frequently, indeed, no evidence of arterial hyperaemia remains after death, whereas evidences of venous hyperaemia persist to a greater or less degree.

Venous Hyperaemia.—Venous hyperaemia may result from obstructive heart or lung disease, but is most marked when it follows hepatic cirrhosis. The walls of the stomach are usually distinctly thickened, the thickening especially affecting the mucous and sub-mucous coats. The inner surface is dark brown or purplish-brown in colour, and there is always evidence

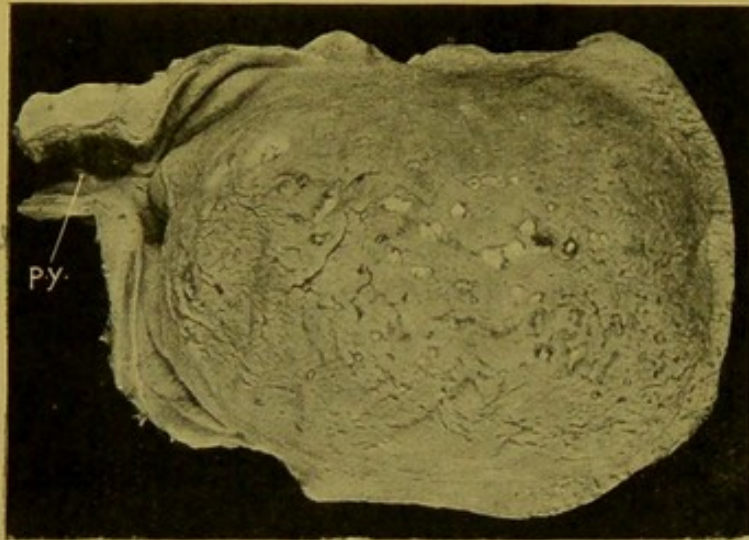


FIG. 85.—Haemorrhagic Erosions in pyloric portion of stomach. (\times circ. $\frac{1}{2}$.)

(py.) Pylorus. (From Dr. Drennan's Collection.)

of the presence of chronic gastric catarrh. Covering the surface there is a layer of blood-stained turbid mucus. Frequently haemorrhages, usually of small size, occur in the mucous membrane, particularly along the summits of the ridges, and, over these, haemorrhagic erosions may form. If the stomach contain a large amount of blood, the lower end of the oesophagus should always be carefully examined for the presence of varicose veins from which

the haemorrhage may have taken place. In long-standing cases of venous hyperaemia the mucous membrane may be of a slaty-grey colour, particularly towards its pyloric end. This is due to alteration of the blood pigment which is deposited in the mucous membrane.

Haemorrhagic Erosions have already been referred to in considering the sources whence haemorrhage may occur into the cavity of the stomach (see p. 179).

They take the form of small *superficial* losses of substance or minute ulcers, usually about 2 mm. ($\frac{1}{16}$ in.) in diameter, in the bases of which are seen small dark brown or black spots—the extravasated blood. They are usually rounded, with abrupt margins; occasionally they are elongated and may coalesce to form larger erosions, which may attain a diameter of 1 cm. ($\frac{3}{8}$ in.) or even more. They may be scattered all over the inner surface of the stomach, or may be localized to the pyloric portion, or to the summits of the ridges of the mucous membrane, or to the lesser curvature.

The haemorrhages interfere with the nutrition of the superjacent mucous membrane, which in consequence undergoes digestion. Sometimes the digestive process removes the extravasated blood as well as the necrotic tissue, and then the erosion is pale in colour throughout (Fig. 85). The primary *haemorrhages* frequently occur in hyperaemias of the stomach resulting from obstructive disease of the lung, heart or liver, or from repeated vomiting. In the last condition the constant contractions of the muscular coats cause a hyperaemia which is most extreme in the folds of mucous membrane.

They may also result from certain vasomotor changes; in the haemorrhagic diatheses, purpura, haemophilia, etc.; in place of, or during, menstruation; in many poisonings, whether the poison has formed within the body, as in uraemia or icterus, or has been introduced from without, e.g. phosphorus, arsenic, corrosive sublimate, acids or alkalies. They appear occasionally to result from embolism in endocarditis or in pneumococcus septicaemia, though this is denied by some authorities, and in such infections the condition seems rather to be due to thrombosis. In one case I examined, the superficial veins were thrombosed and contained numerous organisms, principally streptococci. The gastric and intestinal haemorrhages which sometimes follow operations, particularly upon the abdominal organs, may in some cases be explained on the grounds indicated above. (*See also* p. 210.)

Haemorrhagic erosions are probably related in causation to the peptic ulcer of the stomach. They are often associated with a moderate amount of bleeding into the cavity; occasionally they give rise to fatal haemorrhage.

Atrophy, Degenerations, etc.—**Simple Atrophy** of the stomach wall is met with in general marasmus. The wall is thin, almost translucent and the cavity may be dilated.

Fatty Degeneration occurs in the cells of the glands in parenchymatous gastritis and in the muscular coat in dilatation of the organ.

Well-marked **Waxy or Amyloid Change** is rarely found in the wall of the stomach, and before testing for its presence it is necessary to wash off all mucus and blood from the surface.

INFLAMMATIONS OF THE STOMACH.

Acute Gastric Catarrh.—In the majority of cases, acute gastric catarrh is caused by the ingestion of irritating substances. It may also follow the action of toxins conveyed to the stomach by way of the blood-stream, and occasionally it arises by extension from inflammation in the neighbourhood.

Its presence is often recognized with difficulty, particularly if the post-mortem examination has been delayed.

If the organ be examined soon after death, the mucous membrane is swollen, diffusely congested, and may show numerous minute haemorrhages. The surface is covered with tough, tenacious, glassy, often reddish mucus, which may be turbid from the presence of degenerated epithelial cells and leucocytes. The cylindrical epithelium lining the ducts of the glands

undergoes mucoid degeneration, with formation of numerous goblet-cells. Sometimes the cells become detached. Frequently there is catarrh of the deeper parts of the glands, or the cells become cloudy, granular or fatty. These changes render the mucous membrane somewhat opaque to the naked eye. The interstitial tissue shows marked cellular infiltration, and the blood-vessels are dilated. The sub-mucous coat is congested, infiltrated, and oedematous. The finer microscopical appearances described as occurring in the glands are very frequently lost as the result of post-mortem digestion or putrefactive changes.

Chronic Gastric Catarrh.—This may follow the acute condition, or it may be chronic from the outset. It is characterized by atrophy of the secreting structures, increase of the interstitial tissue, and, in some cases, by a tendency to the formation of retention cysts in the glands. The increase of connective tissue is especially evidenced by the projection of the mucous membrane in thick ridges, knobs, or even polypoid excrescences—*polyposis ventriculi*. In the earlier stages there is some hypertrophy of the epithelium of the glands, and this, along with the changes occurring in the interstitial tissue, causes obstruction of the ducts and consequent distension of the glands. These retention cysts are never large, are seldom prominent, and are especially seen in the polypoid outgrowths. Later on, the new connective tissue contracts and causes atrophy of the secreting structures, affecting even the deeper parts of the mucous membrane. When the increase of connective tissue affects to a marked degree the sub-mucous coat, it may lead to contraction of the organ. In the most common variety of gastric catarrh, that which is found most typically in chronic alcoholics, the thickened mucous membrane forms firm longitudinal ridges, which are most prominent in the body of the organ. These ridges are sometimes simulated in the contraction of the stomach due to rigor mortis, but cannot be flattened out by traction. (Fig. 81, p. 178.) Near the pylorus the ridges give place to an irregular fine mammillation of the mucous membrane (*État mamelonné*). This is due to increased prominence of the “*areae gastricae*” (see Fig. 83, p. 182). The mucous membrane, especially in the pyloric region, is slate-coloured, grey, or reddish-grey, or if accompanied by chronic venous hyperaemia it is of a dark brown or purplish-brown colour.

The surface is covered with soft greyish masses of mucus. The muscular coats may either be thickened or, when there is extensive formation of connective tissue, it may be atrophied. Chronic gastric catarrh may occur both independently and accompanying tumours and ulcers of the wall. At the pyloric end, the thickening of the wall is often great, and may depend chiefly upon a thickening of the muscular coats. The appearance may thus closely resemble that of the contracting scirrhus of the pylorus. Even under the microscope some difficulty may be experienced in differentiating the two conditions, seeing that in a contracting scirrhus the epithelial cells may be very scanty and atrophied. (See pp. 191, 193.)

Phlegmonous Gastritis.—Suppurative changes are rarely met with in the stomach, and when they do occur they principally affect the sub-mucous coat. The condition may be *diffuse*, causing great thickening of the wall, especially near the pyloric end. The walls are softened, with low, spongy projections on the inner surface, and on section the sub-mucous coat is of a distinct yellow colour from infiltration with pus. The suppuration is usually confined to the stomach, but it may extend to the duodenum, or even to the oesophagus. The condition may also be *circumscribed*, and localized abscesses form in the wall. These may be of large size. Small perforations of the mucous membrane may occur, through which the pus escapes into the cavity of the stomach.

The condition may be associated with peptic or malignant ulceration, or corrosion of the wall, and it also occurs in severe pyaemic infections, particularly when induced by streptococci. The suppuration may extend through the wall and cause peritonitis. In two cases examined by the author, the progress of the disease had been very rapid.

Accompanying these changes secondary abscesses may appear in the liver or throughout the organs.

Membranous Gastritis.—This condition is extremely rare, and is more frequently met with in children than in adults. The surface of the mucous membrane is covered with white, or greyish, or yellow, or even brown membrane, which usually is most apparent along the swollen ridges of the mucous membrane. It is usually firmly adherent and the subjacent tissues are swollen, reddened, and sometimes show haemorrhages. There may be accompanying membranous inflammation of the pharynx, larynx, oesophagus, and the condition may also attack the intestine. The membrane may consist wholly of fibrinous exudate, or, just as in the case of the true diphtheritic membranes, it may, in its deeper parts, be made up of the necrotic superficial layers of the mucous membrane. In the latter variety, the inflammatory changes in the deeper layers of the mucous membrane are much more intense than in the former. In childhood, it most frequently follows diphtheria, but it also occurs during pyaemia, in scarlet fever, measles, cholera infantum and small-pox, and occasionally it is found in children dying of tuberculosis. In adults, the disease is secondary to various acute infective conditions, and it is also found in pulmonary tuberculosis.

The actual nature of the condition has not yet been determined.

Other Inflammatory Conditions of the Mucous Membrane.—Infection of the gastric mucous membrane with *Anthrax bacilli* is an extremely rare occurrence. It causes single or multiple congested and oedematous swellings, each with a necrotic centre.

The stomach is rarely affected in **Tuberculosis** unless upon its serous surface, which is occasionally affected along with other parts of the peritoneal surface. If ulcers are produced on the mucous membrane, these are usually small, irregular, undermined, with caseous nodules in their bases. They may result from the swallowing of sputum rich in tubercle bacilli or from a blood-spread of the infec-

tion. In **Typhoid Fever**, the lymph follicles of the stomach wall may become swollen, infiltrated, and undergo ulceration along with the lymphoid collections in the intestinal wall.

Syphilis.—Gummata are very rarely found as localized, hard, smooth, yellow thickenings of the sub-mucous coat, over which ulcers may develop. These changes may occur both in acquired and in congenital syphilis.

Lymphomatous nodules may very rarely be found in the stomach. In this condition, which may really be of the nature of lympho-sarcoma, the raised soft nodules, about one-eighth to three-quarters of an inch in diameter, form in the wall of the stomach probably in connexion with the lymph follicles. (Fig. 86.) These may ulcerate in the centre, forming small irregular erosions with thick, soft, necrotic bases.

In **Lymphatic Leucocythaemia**, large ulcers may form near the lesser curvature,

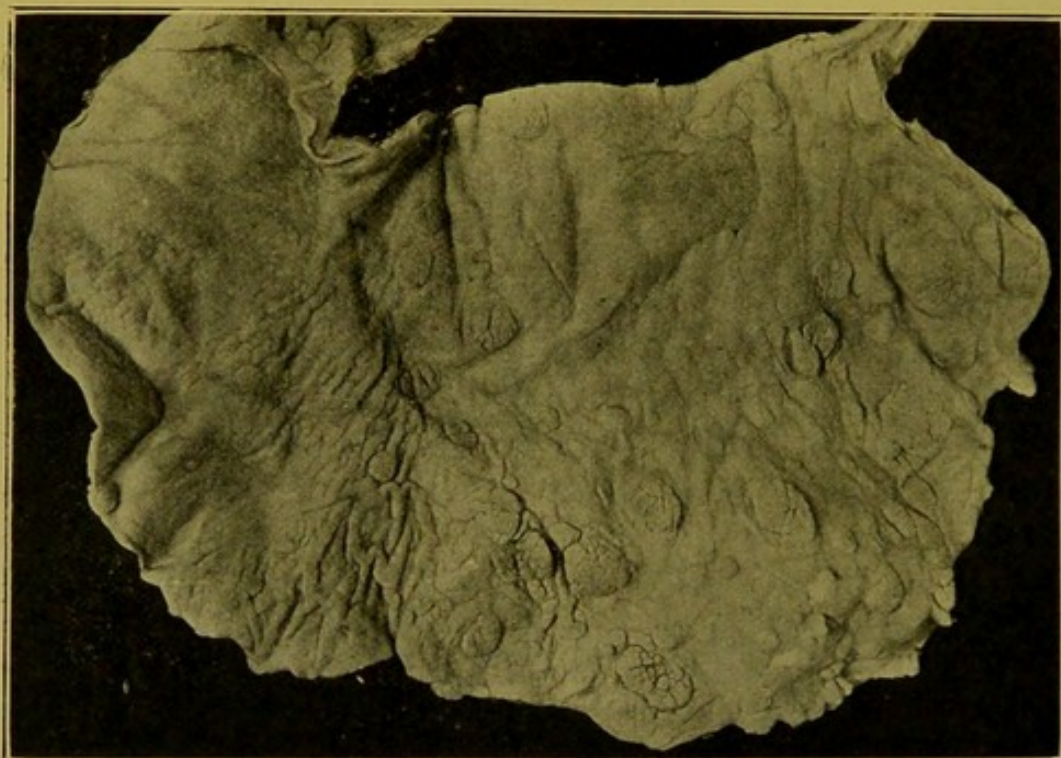

FIG. 86.—Lymphomatous nodules on inner surface of stomach. (\times circ. $\frac{1}{2}$.)

usually on the posterior surface. Their edges are thickened, soft, frequently worm-eaten, and the ulcer itself may penetrate to the muscular coats.

Bilharziosis.—Occasionally the stomach wall is invaded in this disease, and pedunculated cystic formations containing large numbers of more or less typical ova are found.

TUMOURS OF THE STOMACH.

Non-Malignant Tumours are rarely met with. Occasionally glandular **Polypi** are found at the cardiac end; the greater number of polypi, however, form on a basis of hypertrophic (chronic) gastric catarrh. These are seldom of large size; they may be multiple; they are of a greyish-white colour and may show numerous minute cysts. They are sometimes associated with carcinoma.

Fibromata, **myomata**, and **fibro-myomata** are occasionally found as localized greyish thickenings of the wall. **Neuro-fibromata** are extremely rare, but may be multiple and scattered throughout the walls of the stomach and intestines. Other rare tumours are **angioma** and **aberrant pancreas**.

Malignant Tumours are more often met with in the stomach than in any other part of the body, particularly after middle life. They are more frequently of carcinomatous than of sarcomatous nature. They are usually primary.

Carcinoma of the stomach develops most frequently at the pyloric end of the stomach and along the lesser curvature. Next in frequency it attacks the cardiac orifice, or occurs as a diffuse infiltration of the wall, and occasionally is localized in the fundus. When in the last situation, there may be little beyond the resulting haemorrhage to indicate its presence during life.

Extension takes place most readily along the sub-mucous coat.

Carcinoma seldom attacks the greater curvature. It may develop in connexion with old gastric ulcers, and may be accompanied by chronic gastric catarrh.

The lymphatic glands most commonly affected secondarily are those in the lesser curvature (coeliac), and then the portal. Extension may take place to the thoracic glands, and lungs, and to the liver.

The varieties found are : (1) the *malignant adenoma*, (2) the *encephaloid cancer*, (3) the *scirrhus cancer*, (4) the *colloid cancer*—which is essentially one of the first three forms, but the growth shows so constantly and consistently the colloid transformation, that a separate, distinguishing name has to be applied to it—and, rarely (5) the *squamous epithelioma*.

Characters of these tumours as seen by the naked eye.

1. **Malignant Adenoma** (syn.: Columnar-celled Carcinoma, Cylindrical-celled or Tubular Cancer, Adeno-carcinoma).—This tumour develops from the cylindrical cells of the ducts of the glands. (Fig. 87.)

The peripheral part of the growth usually rises rather abruptly from the mucous membrane. In the neighbourhood there may be small secondary

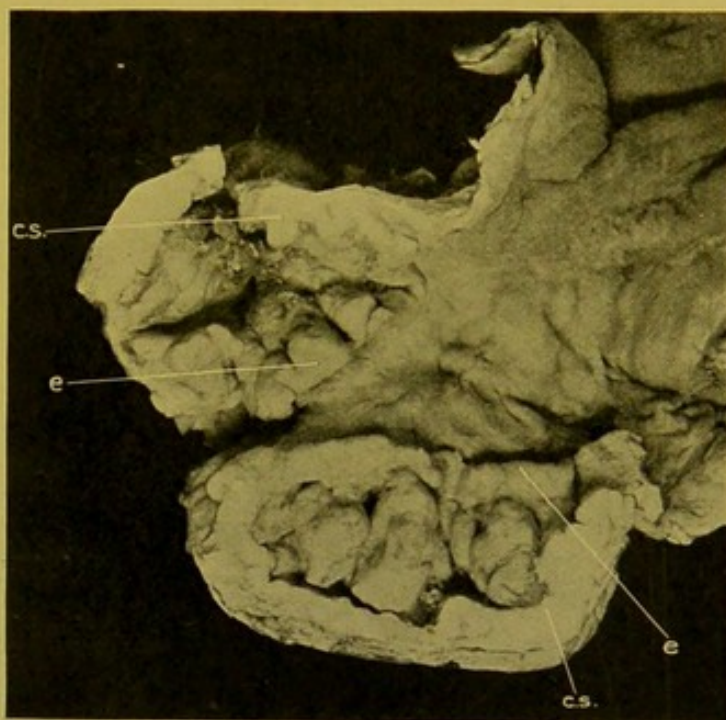


FIG. 87.—Malignant Adenoma just within Pylorus.
(\times circ. $\frac{1}{2}$.)
(c.s.) Cut surface of the tumour; (e.) raised everted margin.

tumours. The parent tumour seldom exceeds $\frac{1}{2}$ in., or about 1 cm., in thickness, and it is usually thinner than this towards the margins. Its consistence is soft, its margins spongy and may overhang the mucous membrane. Its central part is invariably ulcerated, with evidence of old or recent haemorrhage. The older haemorrhages form dark sepia-coloured or black patches, the blood having been altered by digestion, or by post-mortem changes. The wall is infiltrated with new-growth, and adhesions, as a rule, form at an early stage to neighbouring structures and organs. The lymphatic glands in the vicinity are usually affected, and metastasis soon takes place to the liver and other organs.

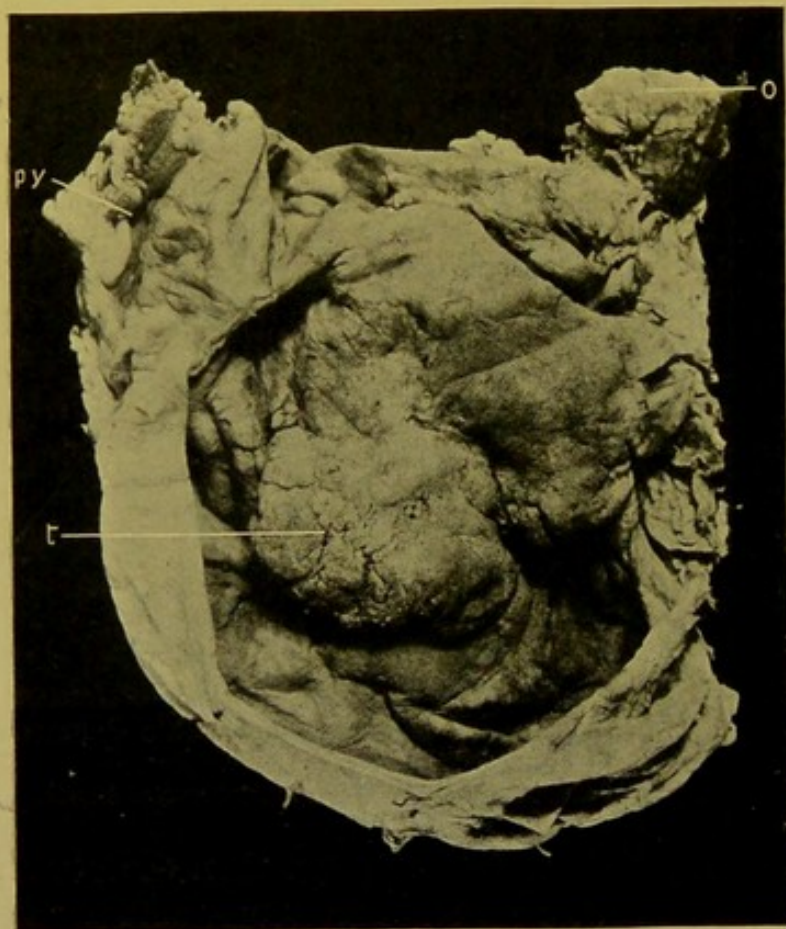


FIG. 88.—Encephaloid Cancer of the body of the Stomach. (\times circ. $\frac{1}{2}$.)

(o.) Oesophageal opening; (py.) pylorus; (t.) tumour.

This is the most common cancer of the stomach, and in my experience may occur at any part of the wall. According to some authors it especially affects the pyloric half. The cancers occurring in the body of the organ and at the cardiac orifice are most frequently of this nature. The so-called "Islet cancers" of the body of the stomach are either malignant adenomas or encephaloid cancers.

2. Encephaloid Cancer

(syn.: Medullary Cancer, Soft Cancer, Spheroidal-celled Cancer, Carcinoma globocellulare).—This cancer somewhat resembles the malignant adenoma. It is usually, however, softer, more spongy (Fig. 88). Its

margin is usually thicker and rises abruptly $\frac{1}{2}$ to $\frac{3}{4}$ in. (1 to 3 cm.) from the mucous membrane, which may show practically no thickening. The fungating character, along with the great tendency to ulceration in the central parts, and to necrosis with formation of sloughs and the resulting haemorrhage, may be regarded as characteristic of the growth. In my experience it occurs most often in the fundus, or near the cardiac orifice.

Metastasis readily takes place to the liver and to lymphatic glands.

Encephaloid cancer may extend throughout the whole wall of the stomach, and then the inner surface is covered with soft, rounded, knobby

projections which are apt to ulcerate readily but not deeply, and, as already indicated, haemorrhage is common.

3. **Scirrhus Cancer** (syn. : Hard Cancer, "Scirrhus").—The appearance of this growth is very characteristic.

The wall, at the site of the tumour, may be 1 in. (2.5 cm.) in thickness, but the average thickness is about $\frac{1}{2}$ in. or a little more (1 to 1.5 cm.). All of the coats show pathological change. The mucous membrane forms a greyish-white layer, about 2 to 3 mm. thick. Underneath this the sub-mucous coat is seen as a paler, more opaque, layer, which may measure from $\frac{1}{5}$ in. (5 mm.) to $\frac{1}{3}$ in. (10 mm.) in thickness. Even more character-

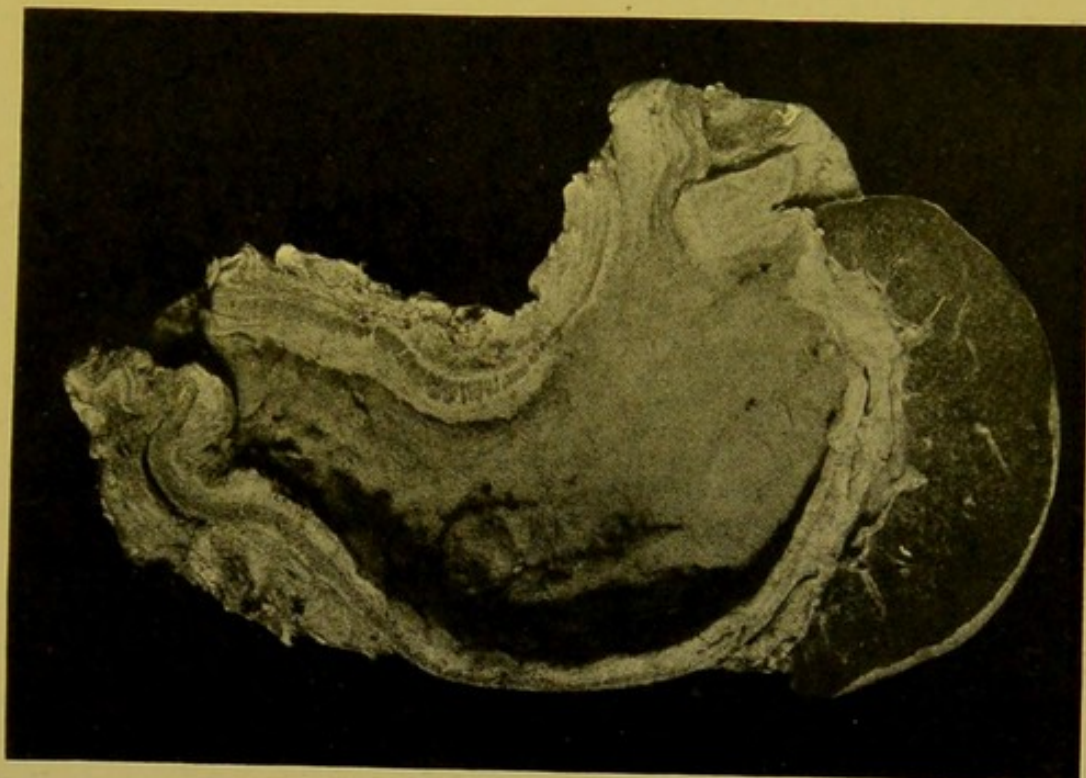


FIG. 89.—Scirrhus Cancer of Stomach, affecting pyloric portion. (\times circ. $\frac{1}{2}$.)

istic than these is the thickened, brownish, muscular coat, which may vary in thickness from $\frac{1}{5}$ to $\frac{1}{3}$ in. (5 to 10 mm.) and is usually broken up into blocks by white lines, or wedge-shaped processes of new-growth, which pass down into it from the sub-mucous coat. The sub-serous coat participates to a moderate extent in the thickening. The serous surface is slightly nodular as a rule, but adhesions may not form to neighbouring structures. (Fig. 89.) The tumour cells do not readily become disseminated.

These appearances indicate that the tumour develops most in the sub-mucous coat. The hypertrophy of the muscular coat is a secondary manifestation. The tumour is of very firm consistence, consequent on the large proportion of connective tissue present.

Scirrhus most commonly affects the pyloric region and orifice, but it may extend thence throughout the whole of the stomach. Its plentiful

Scirrhus
 $\frac{1}{2}$ " - 1
all coats
are affected
m. m. -
to
sub-muc
palpable
 $\frac{1}{3}$ "
muscle -
 $\frac{1}{3}$ " broken
sub-serous
serous -
affected
may be nod
& may be
adhesion

develops
sub-muc
hypertro
of muscular
coat is a
firm

*spastic
stenosis*
*adom
erative
ulcerate
& deep*
fibrous stroma tends to contract and thus lessens the size of the pylorus—stenosis—with consequent dilatation of the stomach, but if it be diffused the resulting contraction may so diminish the cavity of the organ that it can only admit the index finger. Such extreme contraction is not common. Even in the diffused form of the tumour, ulceration seldom occurs on the mucous surface, and when it does occur it is neither extensive nor deep. The inner surface is covered with rounded elevations and elongated ridges, distantly resembling the appearances found in chronic gastric catarrh, from which it has to be distinguished. It must be differentiated also from pyloric hypertrophy, and chronic peptic ulceration.

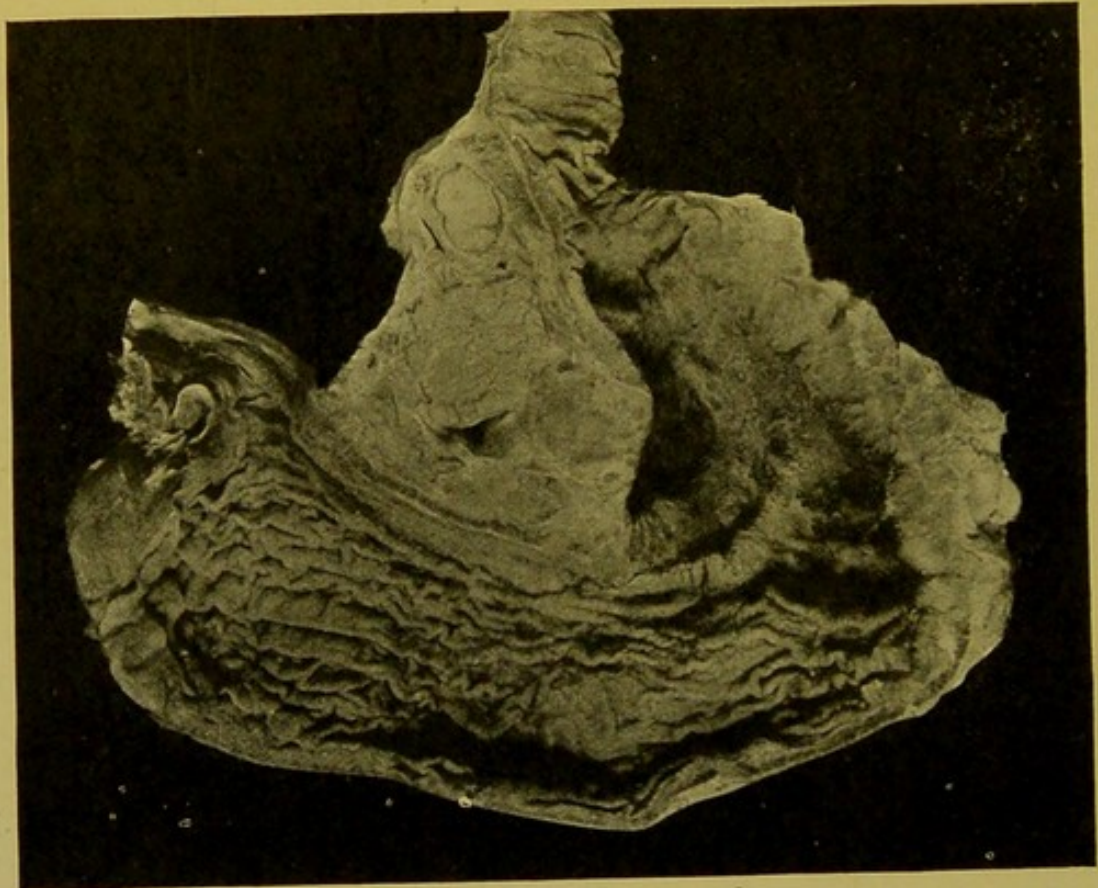


FIG. 90.—Colloid Cancer of Stomach, affecting cardiac end. (\times circ. $\frac{1}{2}$.)

*colloid
dubious
as a
pure
infiltration
part is
translucent
showed great
as. gives
cutaneous
low material
be deep
evolution*
4. **Colloid Cancer** (syn.: Carcinoma Mucosum v. Gelatinosum).—This cancer appears either in the form of nodular tumours or as a diffuse infiltration of the walls. The part affected is translucent, greatly thickened, of fair consistence, and on pressure gelatinous yellowish material can be removed from the surface, which is at times deeply ulcerated (Fig. 90). On section of the wall the distinction between the various coats is lost to a great extent, or completely. On close inspection, a less translucent network of connective tissue can be distinguished, and the gelatinous material is seen to lie in the meshes of that network. It might be compared to a close-meshed sponge which has been soaked in melted gelatine and then allowed to harden. The tumour soon extends to the peritoneum, which may throughout be

thickened and matted together. The omentum undergoes characteristic changes, becoming shortened, thickened, and converted into a mass of new-growth of a pink colour, which in shape has not inaptly been compared to that of a cock's comb (Fig. 91). The secondary growths usually do not possess the translucency of the primary tumour.

5. **Squamous Epithelioma** occurs but rarely in the stomach and ordinarily develops at the cardiac orifice. It possesses the same general characters as does the malignant adenoma. Occasionally it develops at the pylorus or in the duodenum as an implantation cancer.

Microscopical characters of the above varieties of carcinoma:—

1. **The Malignant Adenoma** is composed of more or less irregular, atypical, gland tubules which possess no basement membrane, and which invade all the coats of the stomach. In the more malignant varieties the cells tend to lose their cylindrical shape. An adenoma of the alimentary tract becomes malignant as soon as it penetrates the muscularis mucosae. In the normal stomach some of the pyloric glands penetrate to the submucous coat, the muscularis mucosae being deficient there, and in the duodenum Brunner's glands lie in the submucous coat, but these are the only situations where a mistake is likely to be made, and if the regular character of the normal tubules, along with the fact that they possess a basement layer, be recognized, there is no room for error in diagnosis.

2. **Encephaloid Cancer** develops in the first instance as a tubular cancer, but soon the alveoli become filled with solid masses of relatively small, rapidly proliferating, cells, which are usually rounded or may be polygonal from mutual compression. In the fully developed encephaloid cancer the cells predominate over the fibrous stroma.

3. Microscopically the appearance characterizing **Scirrhus Cancer** is the large proportion of fibrous tissue forming the stroma. It predominates greatly over the amount of cells present in its meshes. The epithelial cells are closely aggregated and angular, and form narrow columns lying in the flattened alveoli. They are usually atrophied and degenerated, and in older parts of the tumour may almost completely disappear, so that the condition may present difficulties in diagnosis from a chronic inflammatory process, or a simple hypertrophy of the wall. Occasionally the scirrhus

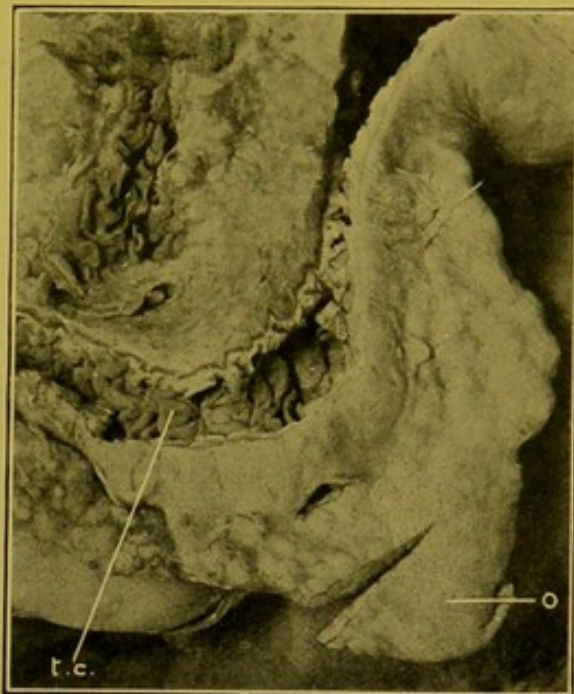


FIG. 91.—Colloid Cancer of Omentum.
(\times circ. $\frac{1}{2}$.)

(t.c.) Transverse colon, opened from behind; (o.) omentum, with an incision into it.

cancer has the characters of a tubular cancer, in which the stroma is unusually developed.

4. The microscopical appearance of **Colloid Cancer** depends upon the age of the tumour. In the early stages the alveoli contain proliferated epithelial cells which display a varying degree of degeneration, their protoplasm containing clear droplets of colloid which gradually increase in size until they flatten the nucleus and push it to one side of the cell. The cell

then ruptures and sets free the colloid which coalesces with similar droplets from other cells to form the gelatinous mass visible to the unaided eye. In the midst of this the nuclei remain distinguishable for a time, but in the latest stages they may completely disappear, so that the meshes contain nothing apparent under the microscope but a mass of streaky, homogeneous material.

5. The rare **Squamous Epithelioma** is recognized by the fact that its cells possess "prickles," and are aggregated in columns, in the centre of which cell-nests may be found.

The characters of these tumours when affecting other parts of the alimentary canal are identical with those described above.

Sarcomata seldom attack the stomach, and are amongst the tumours which are least frequently encountered in the post-mortem room. They may be primary or secondary.

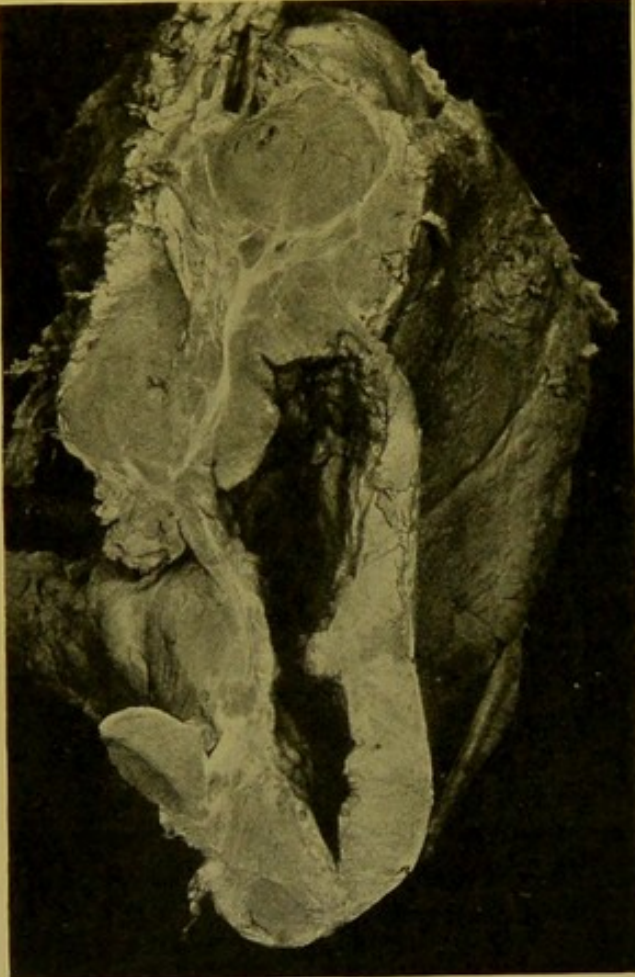


FIG. 92.—Sarcoma of Stomach. Lymphatic glands, infiltrated with the new-growth, are seen near the upper part of the illustration.
(\times circ. $\frac{1}{2}$.) (Mus. R.C.S. Edin.)

Round-celled Sarcomata are less uncommon than other varieties of sarcoma. They occur as rather soft new-growths, causing extreme thickening of the viscus, particularly of its pyloric third. (Fig. 92.) They may spread to the duodenum or to the oesophagus. Microscopically the part affected is densely infiltrated with small, deeply staining, round cells.

Spindle-celled Sarcomata form rounded or oval circumscribed tumours in the wall near the greater curvature. They may reach an enormous size—up to 12 lb. (5.4 kgm.)—and they may undergo cystic degeneration.

Myxosarcomata and **Angiosarcomata** of the stomach are extremely rare.

Lymphosarcomata may spread to the stomach from the lymphatic glands in the vicinity.

CHAPTER XI

THE ABDOMEN (*continued*)

INTESTINE AND PANCREAS

THE INTESTINE

As a general rule, unless formalin has been injected, a diameter—*post mortem*—at any portion of the small intestine exceeding $1\frac{1}{4}$ in., or at the outside $1\frac{1}{2}$ in. (3 to 4 cm.) is to be considered as a pathological dilatation. In formalin-injected bodies the diameters are usually greatly diminished. As a rule the jejunum is wider than the ileum. One must remember that the duodenum possesses no mesentery and that the lower end of the ileum usually lies in the pelvis, from which it passes upwards to join the large intestine.

Duodenum. Irregular transverse ridges or folds—*valvulae conniventes, plicae circulares*—begin to appear in the mucous membrane about an inch or two beyond the pylorus, and these gradually become longer, more regular, and more numerous as one passes down to the jejunum. On the inner aspect of the descending portion, about its middle, but often lower, and even occasionally at the commencement of the third part, is the bile papilla, protected by a prominent hood-like fold of mucous membrane. Nearly an inch higher up is a second smaller papilla, the *caruncula minor* of Santorini. Occasionally the glands of Brünner can be distinguished in the first part of the duodenum as small, rounded or flattened masses of a greyish colour measuring about the size of a pin's head, embedded in the submucous coat.

The third part of the duodenum descends to a comparatively low level in the abdomen, its lower border reaching the fourth lumbar vertebra, i.e. a little below the level of the umbilicus, and from this point it ascends a little to join the jejunum. The **Jejunum** is characterized internally by its prominent and numerous *valvulae conniventes*. Its walls are usually thicker and more vascular than those of the ileum, and Peyer's patches when present are small and rounded.

In the **Ileum** there are fewer well-marked folds of the mucous membrane, though in some cases the *valvulae* persist to within 2 or 3 feet of the ileo-caecal valve. The *Peyer's patches* are numerous, large and distinct, placed opposite to the mesenteric attachment of the bowel, on its inner surface. They are elongated, their long axes corresponding with that of the bowel. Numerous smaller collections—*lymph follicles*—can be distinguished as greyish white spots, about the size of a pin's head or millet seed, lying underneath the mucous membrane. They are larger in the large intestine—particularly in the caecum—than in the small intestine, and more prominent in the child than in the adult. They are most easily seen when the intestinal wall is thin, for example in marasmus, however caused. They are commonly termed "*Solitary Glands.*"

Blood Supply of Intestine.—The superior mesenteric artery supplies jejunum, ileum, caecum, and ascending colon, and greater part of transverse colon, i.e. that portion of the intestine corresponding to the mid-gut of the embryo. It com-

municates above with the pancreatico-duodenal, which supplies the lower part of the duodenum, and below with the inferior mesenteric artery which supplies the lower part of the large intestine and anastomoses with the inferior haemorrhoidal vessels at the lower end of the rectum. The first vessel named—superior mesenteric—is important in relation to infarction of the intestine.

The **Mesentery** measures 6 or 7 in. (15 to 19 cm.) from its root to its attachment to the intestine. The lymphatic glands contained between its layers become affected in local diseased conditions of the intestine, but those near its root may be affected also in general toxæmias or infections.

The **Large Intestine** forms less than one-fifth of the whole intestinal canal. The caecum is the widest part, and from this point it gradually lessens in size down to the anus. The caecum when full is from $2\frac{1}{2}$ to 3 in. in diameter (6 to 8 cm.); the descending colon from 1 to $1\frac{1}{2}$ in. in diameter (2.5 to 4 cm.).

The **Appendix caeci**, or **vermiform process**, the root of which is readily found by following backwards one of the longitudinal bands of the colon, extends from the posterior part of the caecum, either downwards and inwards to hang over the brim of the true pelvis, or inwards and upwards in the direction of the umbilicus, or it may pass directly upwards behind the ascending colon. It possesses a mesentery. Its length may vary from $\frac{3}{4}$ in. (1.8 cm.) to 9 in. (23 cm.). Its average length is about $3\frac{1}{2}$ in. (9.2 cm.) and its average thickness about $\frac{1}{4}$ in. (6 mm.) (Berry). Its lumen is of variable size, and is frequently occluded. This condition is by no means always to be considered pathological. Total occlusion is found in three or four per cent. of all bodies. Partial occlusion is present in twenty-five per cent. of all cases, and in more than half of those over sixty years old, whereas it is unknown in the child (Birmingham). The submucous coat is almost wholly occupied by lymphoid nodules. These tend to atrophy in old age.

The **Caecum** as a rule is completely covered by peritoneum. The **Ascending Colon**, uncovered by peritoneum posteriorly, lies in contact from below upwards with iliacus muscle, quadratus lumborum, and lower part of right kidney. Hence, suppuration arising in connexion with a retrocaecal appendix, or with caecum or ascending colon, may burrow upwards in the lateral lumbar regions so as to produce a subphrenic collection of pus which may invade the liver or penetrate to the right pleura. The **Iliac Colon** is fixed down in the hollow of the ilium. The **Pelvic Colon**, which comprises the lower end of what was formerly termed the sigmoid flexure, along with the upper part of the rectum, forms a large loop which is accommodated within the pelvic cavity.

Malpositions (*Situs inversus*) and **Displacements**.—Sometimes the whole of the abdominal contents are transposed, accompanying a similar displacement of the thoracic organs. Occasionally the intestine alone is transposed and sometimes the colon alone. The caecum and ascending colon occasionally are furnished with a mesentery, which may permit of abnormal displacements and even volvulus.

Hernia.—Most herniations occur at parts of the abdominal walls, through which, in course of development, vessels, nerves or canals have passed, or where channels which have served their function remain open abnormally.

A full description of the method of development of hernias, and the structures involved in them is unnecessary in this place.

If the presence of a hernia be suspected or if it be discovered in the course

of the examination, care should be exercised to retain the organs and parts involved in their proper relationships until all the facts have been ascertained. A useful procedure is to pass a suture through the neck of the sack and the structures entering it, so that if removal of the sac and its contents be desired later for the purpose of making a permanent preparation, its dissection may be undertaken with fair prospects of retaining everything in its natural relative position.

The herniated parts may comprise: (1) Part of omentum or intestine, including vermiform process. (2) Organs—ovary, spleen, gall-bladder, uterus, even when pregnant, extra-uterine gestations, stomach, liver. (3) Portions of organs—e.g. of liver, stomach, ureters rarely, or diverticula of urinary bladder. In pseudo-hermaphrodites, the uterus, tubes, and ovaries may be found in the sac (Kaufmann).

Hernias may be: (a) *external*, forming a projection appreciable under the cutaneous surface; or (b) *internal*.

(A) **External Hernias.** (1) **Oblique and Direct Inguinal**,—entering the external and internal abdominal rings respectively, and passing superficial to Poupart's ligament, over the spine of the pubes. Practically all or any portion of the abdominal contents may pass into an inguinal hernia, but most often portions of omentum, or of intestinal tract.

(2) **Femoral or crural**,—entering the most internal compartment underneath Poupart's ligament (crural canal), and passing external to the spine of the pubes, thereafter passing upwards over Poupart's ligament, on to the abdominal wall. This variety is most common in women.

The contents may consist of a coil of intestine, or a portion of the circumference of the wall only—Littre's or Richter's hernia—a portion of omentum, occasionally the appendix, ovary, tube, gall-bladder or part of a lobulated liver.

(3) **Obturator**,—passing through the obturator canal. This may be bilateral. Only a portion of the wall of the bowel may be involved (Littre's or Richter's hernia); on rare occasions, a tube or ovary passes into the sac.

(4) **Sciatic**,—passing above or below the ischial spine, also known as "gluteal," as it presents in that region.

(5) **Perineal**,—passing through a defect in the pelvic floor.

(6) **Umbilical**.—Herniation may be due to congenital weakness, and is most liable to occur during the first year of life before the opening is firmly closed. The greater part of the abdominal contents may escape ("eventration"). It also may occur in multiparae in whom frequent pregnancies have weakened the puckered scar which normally closes the orifice.

Tumours are occasionally found in umbilical hernias.

(7) **Abdominal**,—passing through the linea alba. These result from stretching of the linea alba from repeated pregnancies, or from the giving of the scar of a laparotomy wound.

(B) **Internal Hernias.** (1) **Diaphragmatic.**—A sac of peritoneum may cover the hernia, or the sac is wanting, and the escape takes place through a rupture or defect in the diaphragm. The defect may be large. It may be in the central tendon permitting herniation into the pericardium, or lateral, giving rise to hernias into the pleural cavities. The weak part may be at the oesophageal opening, and occasionally a large congenital defect exists on the left side behind the diaphragm.

In severe crushes the diaphragm may be ruptured and a large portion of the abdominal contents may escape into the pleural cavity (*see* Fig. 79, p. 174).

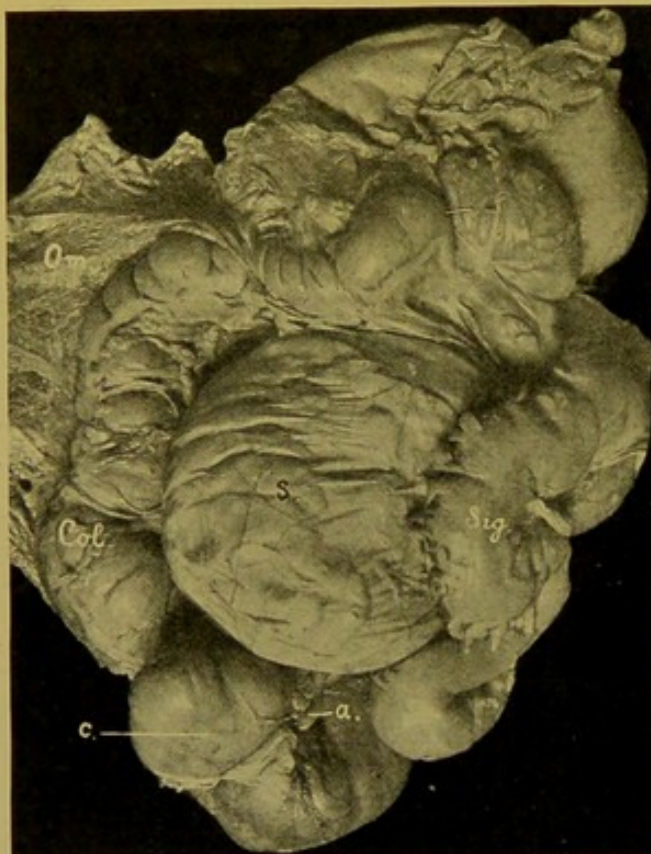


FIG. 93.—Herniation of Small Intestine into Lesser Sac. (\times circ. $\frac{1}{4}$.)

Sac (s.) in position; (o.) omentum turned upwards; (Col.) ascending colon; (c.) caecum; (a.) appendix; (sig.) sigmoid flexure.

(2) Into the **lesser sac** of the peritoneum. The whole of the small intestine or less frequently part of the large intestine may enter through the Foramen of Winslow (Figs. 93, 94). Occasionally a loop of small intestine enters the lesser sac through a defect in the transverse meso-colon.

(3) Herniations may also take place through defects in the mesentery or through loops formed in chronic peritonitis by adhesion of the tip of the appendix vermiformis, or of one or more of the appendices epiploicae, or of Meckel's diverticulum, to the neighbouring surface of peritoneum.

(4) Failing these, the various peritoneal pouches must be examined, e.g. duodeno-jejunal, sigmoid, or peri-caecal.

When the hernia has been located, the condition of the sac, if one be present, and of the neighbouring structures must be ascertained, e.g. as to acute or chronic peritonitis; the position, nature, and relations of the opening through which the hernia has passed; the condition of the herniated part—peritonitis, turgescence, haemorrhagic infiltration, necrosis, gangrene, perforation; and also the possible relation of the hernia to thrombosis of veins, embolism, septic inflammations or hepatic abscesses.

Finally, in cases in which during life there have been indications of obscure obstruction of the bowel, difficulty may be met in finding the actual cause of the incarceration, and as reduction may take place easily after

death, during manipulation of the parts, great care must be exercised during the search.

Intussusception or Invagination.—Intussusception is the telescoping of a portion of the bowel into the bowel immediately below it, and its incarceration there. The lower part of the bowel forms the sheath or *intussusci-piens*, and the entering bowel forms the *intussusceptum* or *invaginate*. The first entering part usually remains at the apex of the intussusceptum, and increase takes place at the expense of the sheath. There are thus three layers of bowel, the outer and middle having their mucous surfaces apposed, and the middle and inner layers having their serous surfaces next one another. The mesentery with its vessels is drawn in between the middle and inner layers and from the pull thus exerted upon the intussusceptum the latter tends to become concave towards the mesentery, and the opening at its apex is also drawn towards the concavity. The thin-walled mesenteric veins entering the invaginated part are naturally occluded by the pressure sooner than the arteries, so that the intussusceptum becomes swollen, oedematous and through infiltration with blood becomes purplish or dark brown in colour. Later, the mucous membrane becomes necrotic, greyish and opaque—"infarction"—and ulcers may form, or the included part may become gangrenous and slough, particularly near its apex (Fig. 95).

Results.—Under favourable conditions adhesion takes place between the apposed peritoneal surfaces of the middle and outer layers, and, the necrotic invaginate separating and being passed *per rectum*, a natural cure takes place, leaving a ring-shaped scar, which may contract and at a later period cause stenosis or atresia of the bowel, with dilatation and muscular hypertrophy of the walls above the constriction. The slough may consist of as much as 12 ft. of bowel. Separation of the slough may take place very slowly.

The bowel may become evaginated. This probably frequently occurs in the abdominal colics of infancy. The condition may become

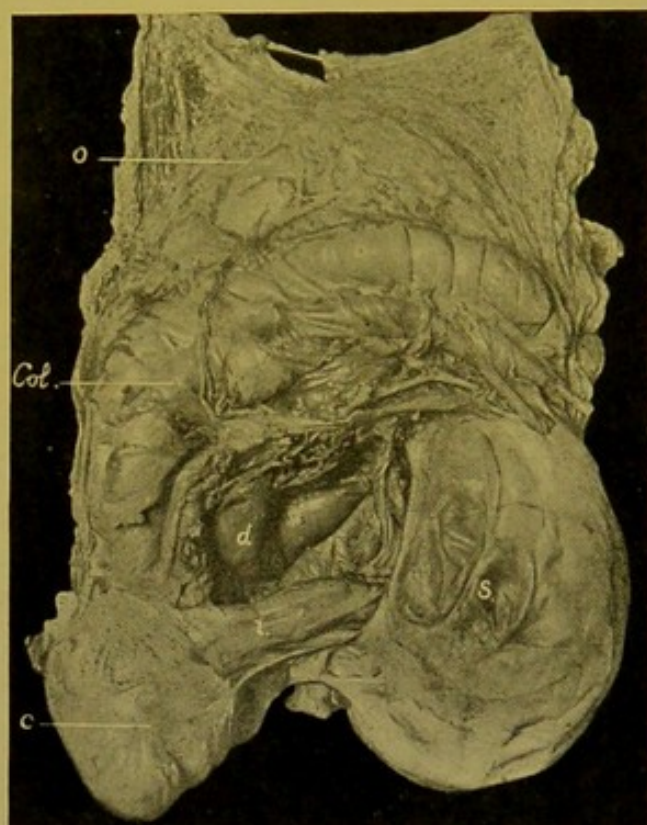


FIG. 94.—Herniation of Small Intestine into Lesser Sac. (\times circ. $\frac{1}{4}$.)

Sac (s.) turned towards left side so as to show its opening; (d) lower part of duodenum; (i.) lower end of ileum emerging from sac; (o.) omentum; (col.) colon; (c.) caecum.

chronic, the swelling diminishing and the lumen becoming once more pervious.

The bowel may separate before firm adhesions have formed, and then death takes place from acute peritonitis resulting from escape of the contents

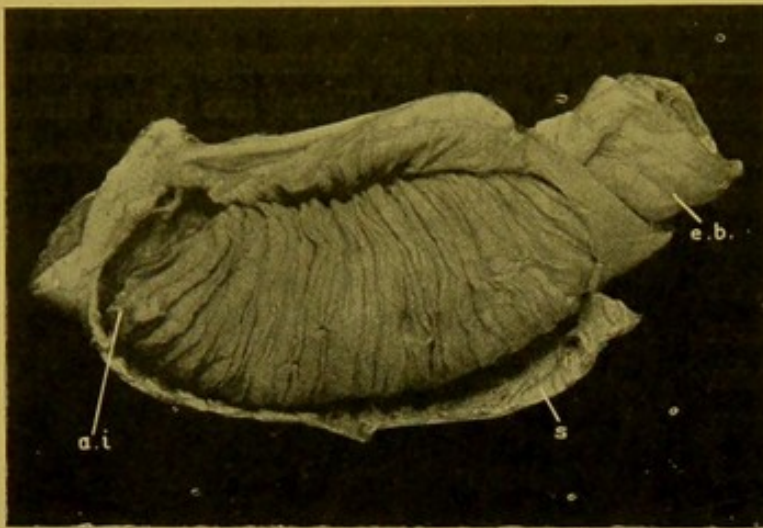


Fig. 95.—Intussusception. (\times circ. $\frac{1}{2}$.)
(a.i.) Apex of intussusception; (s.) sheath; (e.b.) entering bowel.
(Mus. R.C.S. Edin.)

of the bowel. In the dilated bowel above, catarrhal ulcers may form, perforate and give rise to acute peritonitis.

Varieties of Intussusception.

—(1) Small intestine into small intestine; (2) small intestine into large intestine; (3) large intestine into large intestine.

The most common form is the ileo-caecal, in which the ileo-caecal ring remains at the apex of the intussusceptum. In other cases the

valve retains its position, and the ileum passes into the colon.

Causation.—Intussusception is caused by irregular peristalsis, or, it may be, absence of peristalsis, in a short length of intestine which then becomes drawn into an actively peristaltic part below, or pushed into it by peristalsis above.

Sometimes a polypus of the mucous membrane becomes engaged in a part of the bowel in active peristalsis, and pulls down with it the part of the wall to which it is attached. This initiates the process of invagination, which, once begun, tends to continue.

Agonal Intussusceptions.—These are found commonly in young children who have died quickly, and result from the irregular peristalsis which occurs during the agony or even after death. They are readily distinguished from true intussusceptions, as they can easily be evaginated; there is no hyperaemia or adhesion, and the invagination may be upwards as well as downwards. They are occasionally found in young adults.

Prolapse of Rectum.—This condition depends on relaxation of the sphincter following chronic catarrh. An essential is atrophy and looseness of the tissue surrounding the rectum such as occurs chiefly in old people. The immediate cause is the pressing-down in difficult defaecation and urination.

In **Prolapsus Ani**, only the mucous membrane and submucous tissue of the rectum project.

Volvulus.—A twisting most frequently affecting the sigmoid flexure—iliac and pelvic colons. The twist is usually in the axis of the whole coil,

less frequently in the long axis of the intestine. Volvulus occurs more readily when the base of the meso-sigmoid has become narrowed as a result of chronic fibrous peritonitis.

A similar condition may occur on the right side, if the caecum and ascending colon possess a mesentery.

Torsion of the omentum may also occur.

Appearances presented by a necrotic coil of intestine.—The coil is usually more distended than the neighbouring portions of the bowel. The walls are dark, of a dirty purplish-brown, dark grey, or black colour; the surface has lost its lustre, and may be granular; it may be covered with a fibrinous or fibrino-purulent exudate.

Acquired Changes in the Lumen. Stenosis and Atresia.—Obstruction may be brought about by—

(1) Obstruction of the lumen by foreign bodies in the lumen; scybalous masses; gall-stones; intestinal calculi; tumours.

(2) Changes in walls, e.g. congenital atresia or stenosis; contracting scars; tumours of walls; valvular kinks of intestine; accidental fixation of a loop to operation wound causing kinking; changes—as in intussusception.

(3) Pressure from outside: contracting adhesions; pressure of tumours which may also infiltrate the wall; incarceration—as in hernia—in openings in the abdominal wall or in fissures in mesentery, omentum, or mesocolon.

The portion of intestine above the constriction is usually dilated, hypertrophied, and full of pea-soup-like contents. That below is contracted and empty. For further results of obstruction, see *Catarrhal Ulceration*, p. 213.

Dilatation of Lumen. (A) **Localized Dilatations.**—(1) Rarely as a result of congenital stenosis at the position of the bile papilla, the duodenum above this point becomes greatly dilated and the muscular coats hypertrophied. The condition simulates closely hour-glass contraction of the stomach. On closer examination, however, the common bile duct is found passing down behind the dilated duodenum, and no appearance of contracting gastric ulceration or inflammatory thickening is found at the site of constriction (see Fig. 82, p. 177).

The stenosis at the papilla may be only 5 to 10 mm. in diameter. Below this point the bowel may be of almost normal diameter but has thin walls.

(2) Occasionally, particularly in old people, a small diverticulum forms in the neighbourhood of the bile-papilla. It is composed of mucous membrane alone, and is directed towards the head of the pancreas. Traction diverticula composed of all the coats of the bowel are sometimes found in this situation.

(3) Multiple **false diverticula** of small size, admitting the tip of the index or little fingers, sometimes form at the mesenteric attachment of the small intestine, and may project between the layers of the mesentery. They occur (v. Hanseman) where the mesenteric veins penetrate the wall. Contraction of a scar in the mesentery may produce traction diverticula in this

situation, and aberrant pancreatic nodules may be found at the apex of similar protrusions. The first described consist of mucous membrane and submucosa.

Meckel's Diverticulum—congenital, true, diverticulum. This is a short, wide, hollow protrusion, like the finger of a glove, which springs from the convex surface of the ileum usually in its lower part. It represents a partially persistent omphalo-mesenteric duct. Some authors state that it may be found in 2 per cent. of bodies examined, but in the experience of most pathologists it is much less common than this would indicate. (Fig. 96.)

Its axis is placed slightly obliquely to that of the ileum. It is usually about $2\frac{1}{2}$ to 3 in. (6 to 8 cm.) in length, and occurs from 20 in. (45 cm.) to 2 ft. (60 cm.), above the ileo-caecal valve. Its position may vary from 6 in. (15 cm.) to 12 ft. (360 cm.) from the valve. In diameter it usually

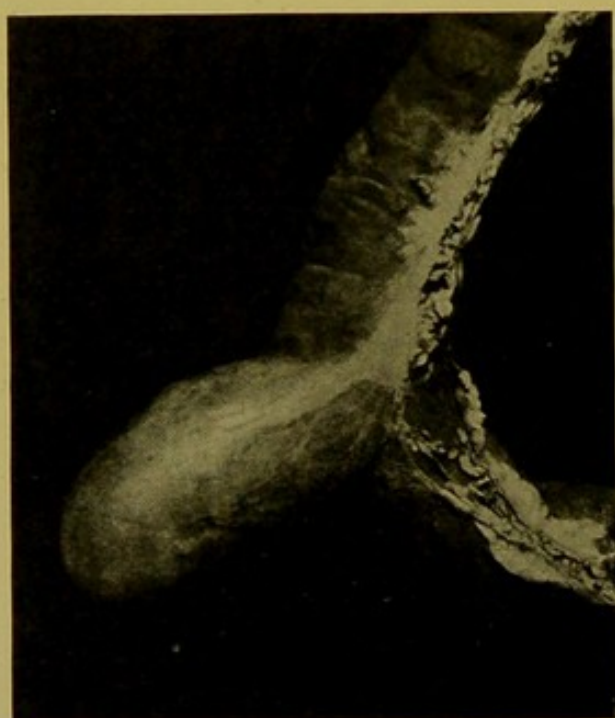


FIG. 96.—Meckel's Diverticulum.
(\times circ. $\frac{1}{2}$.)

equals that of the bowel from which it springs. In most instances its extremity is free, but its apex may be connected with the umbilicus by a fibrous cord, containing the omphalo-mesenteric vessels. On this cord or, at the umbilicus, portions of the duct may persist as cysts, and if the communication with the bowel be occluded, one large cyst may form (*enterocyst*). If all connexions of such cysts with the intestine have disappeared, it may be difficult to recognize their true nature. From remnants of mucous membrane in the umbilicus, adenomata may develop. These are seen almost only in young individuals.

Meckel's diverticula usually give rise to no important pathological changes, but they may be the seat of the different varieties of ulceration that are found in the intestine. Thus perforation may occur, or localized peritonitis may cause adhesion of the tip to some part of the parietal or visceral peritoneum, thus producing a loop or bridge under which herniation of a portion of intestine may take place.

The apex may be the seat of an aberrant pancreas.

False Diverticula of the large intestine depend usually on distension of the normal sacculations, or they may consist of projections of mucosa and submucosa through defects in the internal muscular coat. They may project into appendices epiploicae. They usually contain scybalous masses, or intestinal concretions. (Fig. 97.) In some cases they result from gaseous

distension of the bowel. By pressure the scybalous masses or intestinal concretions may cause ulceration, with consequent perforation and fatal peritonitis.

(B) **Diffuse Dilatations** occur most commonly above parts at which the bowel is abnormally constricted. The contents undergo putrefactive fermentation, this being especially marked in the case of the small intestine. At first the musculature hypertrophies, but later it becomes paralysed, and then the stagnation and gas-production develop to a dangerous extent, leading to extensive ulceration. If perforation take place the opening is usually small, and purulent or faeculent peritonitis results.

Thrombosis may also occur in the veins with portal embolism and hepatic suppuration as possible results.

Hirschsprung's Disease is the name given to an enormous dilatation of the colon, especially involving the sigmoid flexure, occurring usually in boys. The walls are greatly thickened and adhesions may form between the serous surfaces. The condition has been put down to a congenital dilatation and hypertrophy of the colon,—whence the name *megacolon congenitum*,—or to formation of a valve-like kink at the lower end of the sigmoid.

Congenital Malformations of the Intestine.—Large or total defects are incompatible with life, the latter for example occurring only in acardiac fetuses. Small defects are not so rare, e.g. the appendix is occasionally wanting (Fawcett, Schridde).

Congenital Stenosis and Atresia.—At times such stenoses are multiple. One of the most remarkable examples of congenital stenosis occurs at the entrance of the bile-duct into the duodenum (pp. 178, 201, and Fig. 82, p. 179). The most practically important, as well as the most common forms of congenital atresia, occur in connexion with the rectum and anus.

Atresia Recti and Atresia Ani—Imperforate anus. The anus alone may be imperforate, or the anus is formed and the rectum incomplete, or neither may be developed. The blind extremity of the rectum may communicate by a fistulous opening with the bladder: with the prostatic or penile urethra: with the skin surface behind the root of the penis, or on the surface of the scrotum, or in the perineum behind the scrotum, or in the position of the anus. In the female it may communicate with the vagina. These malformations are of necessity

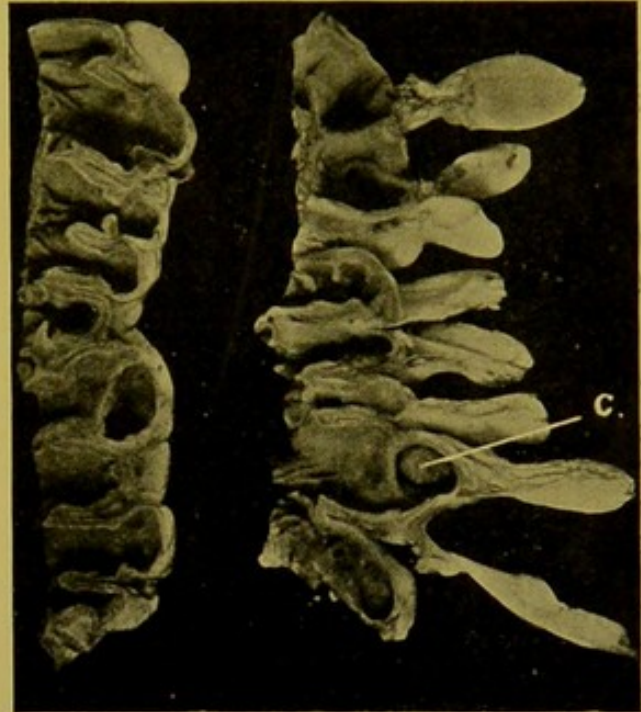


FIG. 97.—Diverticula in large Intestine.
(\times circ. $\frac{1}{2}$.)

(c.) Faecal concretion in diverticulum, which is at base of an epiploic appendage.

found only in the newly-born and for their full demonstration it is necessary to remove in a mass the whole of the contents of the pelvis along with the superficial structures in the perineal region from pubes to coccyx.

Before proceeding to remove the intestine one should examine both surfaces of the *mesentery* and note the pressure of scars or diffuse thickenings of peritoneum ; general thickening of mesentery, whether due to fat, or to diffuse new-growth, e.g. lympho-sarcoma extending from retro-peritoneal glands ; shortening of mesentery, as in tuberculosis ; enlargement of mesenteric glands, especially those in the ileo-caecal angle, and the nature of the enlargement as determined by incision.

REMOVAL OF INTESTINE.

It is immaterial whether the small intestine be separated from below upwards or from above downwards ; the latter is easier.

The mesentery should be divided close to the intestine.

On reaching the duodeno-jejunal junction the bowel is cut across between ligatures. After separating the whole of the small intestine it may be removed in continuity with the colon, or it may be divided a few inches from the ileo-caecal opening *beneath* a ligature passed round the ileum. A ligature is not absolutely necessary on the lower end as regurgitation seldom takes place through the ileo-caecal opening.

Removal of the Large Intestine.—The caecum with appendix is raised and the peritoneum on either side of it divided ; then pulling on it gently, a few touches of the knife will suffice to free the ascending colon, more care being requisite where it lies upon the second part of the duodenum and right kidney. Freeing the hepatic flexure presents little difficulty unless this be drawn up and fixed to the liver or gall-bladder by old peritonitic adhesions. In the case of the transverse colon the omentum may first be removed and then the way is clear to separate this part of the colon by dividing its meso-colon. The greatest difficulty is met with at the splenic flexure, as this is sunk deeply in the left hypochondrium, and is frequently more or less fixed by adhesions. There is some danger of rupturing the bowel by too great traction, and the knife may injure the stomach, spleen, or pancreas. The separation of the descending colon, iliac and pelvic colons is easily accomplished, the mesentery of the last being divided, as in the case of the small intestine, close to the bowel. The rectum may now be divided between ligatures, thus permitting the large intestine to be removed from the abdomen. The whole pelvic contents are best removed along with the urinary organs, but there are no great objections to removing the contents of the pelvis along with the large intestine in cases other than hydro-nephrosis, pyonephrosis, pyelonephritis and cystitis, tuberculosis of the urinary tract, and the like, where it is almost essential to preserve the urinary tract in continuity.

EXAMINATION OF THE INTERIOR OF THE INTESTINE.

It is a common practice to wash out the intestine with a stream of water previous to opening it. This practice is of doubtful expediency, seeing that the relationship of the contents to the part in which they lie is lost ; and moreover it almost completely stultifies any conclusions, for example, as to presence or absence of animal parasites. If lavage be practised, no unnecessary force of water should be employed, and the contents as they escape should be closely

scrutinized, being preferably allowed to fall, in the first place at least, into an enamelled pail or other similar receptacle, so as to permit of further examination, if this be deemed necessary.

The usual method of opening the intestine is to slit up the small intestine along its attachment to the mesentery, and the large intestine along one of the longitudinal—outer—bands of muscle. The ligatures on the small intestine are removed, and the larger blade of the intestinal scissors is inserted along the mesenteric attachment. Then keeping the blades of the scissors apart at an acute angle and fixed, the intestine is rapidly drawn over the lower blade towards the operator. If the intestine have been properly removed—i.e. if it have been completely separated from its mesentery—the scissors will not diverge from the line of the mesenteric attachment and the bowel will be completely and easily laid open. While this is being accomplished the escaping contents should be carefully scrutinized, and their nature noted.

Another method which is especially applicable in children is to evert the bowel completely. A portion is first carefully everted—as in turning back the cuff of a sleeve—and then, holding the everted part with the left thumb and forefinger, a jet of water is directed into the hollow thus made between the everted and entering portions of the intestine. The jet of water tends to push in the free intestine, the action of the water being assisted by paying in the rest of the intestine with the right hand. The mucous membrane thus becomes the outer coat, and the serous coat lines the tube. This procedure can be applied only in the case of the small intestine.

In the case of the large intestine the bowel cannot readily be drawn over the blade of the scissors, and these have to be employed in the usual manner to cut along one of the longitudinal muscular bands.

Commencing at the upper part the opened intestine is then slowly drawn between the ring and middle, and over the index finger of the left hand, the mucous surface being uppermost, and the whole of it carefully examined along with the contents which still cling to it.

A disadvantage in this method is that the faeces stain the fingers and there is some difficulty subsequently in removing completely the unpleasant clinging odour, but this will be obviated if the operator wear rubber gloves.

Contents of the Intestine.—Under normal conditions the small intestine has fluid or semi-fluid contents, and the large intestine semi-solid contents. The contents of the small intestine should not be so offensive as those of the lower bowel, in which decomposition has taken place. Both should be of a brown colour from bile-staining, and they should be easily removed from the mucous surface, leaving this practically clean.

In obstructive jaundice the contents are typically dirty grey in colour, like moist pipe-clay (clayey stools); if haemorrhage has taken place into the bowel, the normal contents are more or less mixed with blood, and their colour may vary from a reddish-brown, through a dirty greyish-brown to black (melaena). The source of the blood is often made out with difficulty. The colour of melaena has to be distinguished from that of meconium in newly born infants, which has a greenish tinge. **Meconium** is made up, microscopically, of roundish or oval, homogeneous green granules and globules—“meconium bodies”—which vary greatly in size

(2-40 m.), and when treated with nitric acid become of a dirty blue colour. They are probably masses of cast-off intestinal epithelium stained with bile. In addition there is a great quantity of granular detritus, oil droplets, cholesterin crystals and intestinal epithelium (Orth).

Fat may be collected in whitish or bile-stained balls, or in droplets. The fat in the faeces is especially increased in diseases of the pancreas or obstruction of its ducts.

Bile-stained clumps of *casein* are frequently found in cases which have had a milk diet during life.

Mucus is very commonly increased in amount. It may form a tenacious layer on the mucous membrane, tinged by admixture with bile or faeces, or grey and turbid from the presence of cast-off epithelial cells, or leucocytes. Scybalous masses are usually covered with yellowish mucus, and in mucous colitis the mucus becomes massed so as at times to form long cylinders which are not unlike intestinal worms or collections of fibrinous exudate. (See *Mucous Colitis*, p. 213.)

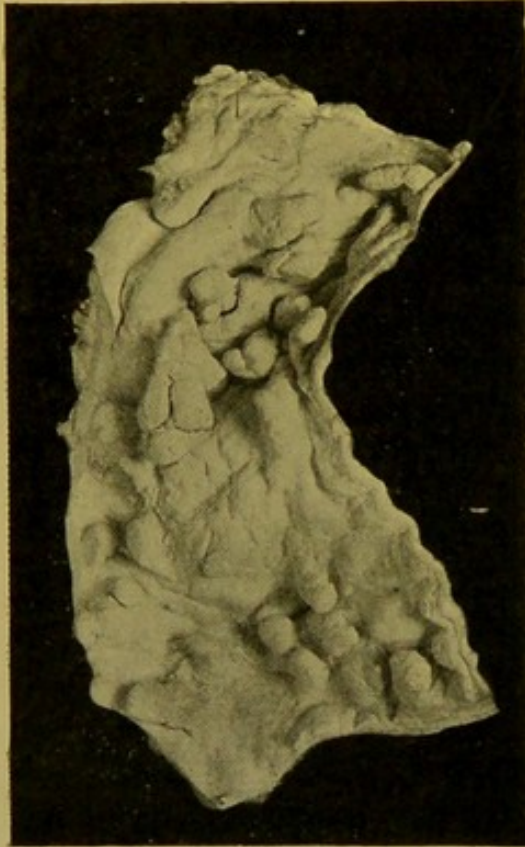


FIG. 98.—Bilharziosis of Rectum.
(\times circ. $\frac{1}{2}$.)

The polypoid excrescences are well seen.

In dysenteric enteritis, grey sheets and shreds of necrotic mucous membrane become separated. These are readily recognized when floated out in water (p. 215).

Intestinal concretions (enteroliths) may be composed of various substances, such as phosphates or lime salts, undigested vegetable material, hair, substances given in treatment of disease, such as magnesia, chalk, shellac, etc.

Animal Parasites of the Intestinal Tract.

—**Protozoa.**—*Amaeba* or *Entamaeba coli*, *Amaeba* or *Entamaeba histolytica*, *Cercomonas intestinalis*, *Trichomonas intestinalis*, *Balantidium coli*.

Metazoa.—**Trematoda** are seldom found in the intestine. *Distoma hepaticum* (*fasciola hepatica*) may be found in the faeces, "grape-skins." In the rectum the irritation of the ova of *Schistosomum haematobium* (*Bilharzia haematobia*) may give rise to polypoid and papillomatous outgrowths of the mucous membrane (Fig. 98). The ova of trematodes are found in the faeces more often than the parent worms.

Cestoda are more common inhabitants of the intestinal tract, though I have seldom met with them during a *post mortem* examination. *Taenia solium*, the "pork tape-worm," is comparatively rare in Britain. *Taenia saginata*, (*inermis*, *mediocanellata*), the "beef tape-worm," occurs more

often. *Dibothriocephalus latus* occurs but rarely, in the southern and eastern parts of England. It is not uncommonly encountered in Switzerland, Sweden, North Germany and Japan.

Nematoda.—These are less uncommon. The *Ascaris lumbricoides* lives in the upper part of the small intestine; *Ascaris mystax* is occasionally found in children; *Oxyuris vermicularis*, the ordinary "thread" or "seat-worm" inhabits the caecum and travels down the colon; *Ankylostoma duodenale*, the "hook-worm," has its habitat in the jejunum; *Trichocephalus dispar* is the commonest intestinal parasite, and lives in the caecum; the adult *Trichina spiralis* comes to maturity and gives birth to its numerous embryos in the intestine; the *Anguillula stercoralis* is an unimportant intestinal parasite.

INVESTIGATION OF THE WALL OF THE INTESTINE.

General Considerations.—Thickening of the wall may be localized or diffuse. In bodies which have been injected with formalin for purposes of preservation, the walls may be much contracted, thickened and firm, and the intestine shortened.

Natural thickening may be due to old peritonitis, and the small intestine may be shortened to half its normal length, but this is rare. These thickenings of serous or muscular coats are usually more or less localized, for example in the neighbourhood of chronic ulcerations—particularly in the large intestine—or above stenoses of some standing.

Thickening of the mucous and sub-mucous coats is more common, and is usually diffuse. This thickening may be due to oedema. If proliferative inflammatory changes have caused the thickening, the coats are more or less opaque and greyish in colour. If the wall be diffusely thickened and pale, waxy or amyloid change should be suspected, and iodine solution applied to the mucous surface.

The normal folds may be increased in size and new folds may make their appearance in the lower part of the ileum. If the villi are opaque and visible to the unaided eye, this is sufficient proof that they are considerably enlarged.

The lymph follicles are seldom very apparent to the unaided eye. When they are enlarged they become prominent and easily recognizable, measuring one, two or more millimetres in diameter.

Old hyperaemias are indicated by a slaty colour, either punctate when the villi have been affected or diffuse when the congestion has been extensive in mucosa and submucosa. Minute white points may be seen in the upper parts of the jejunum or ileum, resulting from retention of chyle in the lymphatics of the villi. A reddish-brown discoloration of the muscular coats suggests the rare pigmentation found in haemochromatosis.

Tumours of the Intestine.—Although many varieties of non-malignant tumours may occur in the intestine, few of them are of much practical importance and they are of very rare occurrence. *Myoma*, *fibroma*, *lipoma*, and *adenomyoma* have been found, but apart from their tendency to become polypoid and cause invagination of the wall, they are not of much importance. True tumours rarely occur in the jejunum or ileum.

The *adenomatous polypus* of the rectum may form a rounded or oval projection on the mucous surface or be represented by innumerable small finger-like processes covering a large area, the whole mass sometimes attaining a thickness of $\frac{1}{2}$ to $\frac{3}{4}$ in. (12 to 20 mm.). Microscopically the new-growth resembles in structure the mucous membrane of the rectum, with cystic dilatation of the tubules, and at its base it is limited by *muscularis mucosae*.

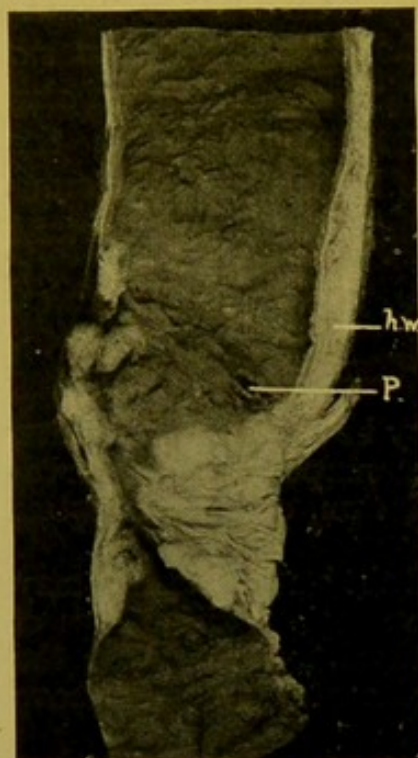


FIG. 99. — Malignant Adenoma of Small Intestine. Malignant Stricture. (\times circ. $\frac{2}{3}$.)

(h.w.) Hypertrophied wall of bowel above the stricture; (p.) perforation immediately above stricture.

Malignant epithelial tumours occasionally develop in the duodenum in the neighbourhood of the bile-papilla, the variety usually met being the *malignant adenoma* ("columnar-celled cancer"). They are only occasionally found in the jejunum or ileum (Fig. 99), but are common in the large intestine affecting especially the rectum (Fig. 100), sigmoid flexure, and less commonly other parts of the colon, particularly at the ileo-caecal opening and at the flexures. The amount of interstitial tissue may vary, so that both soft and hard—scirrhus—varieties occur. *Spheroidal-celled carcinoma*—encephaloid and scirrhus, occur less frequently, and *colloid cancers* are not uncommonly met with, particularly in the rectum. I have seen the last variety in two cases in young children under twelve years of age.

At the anus, and in the lower end of the rectum, *squamous epithelioma* may develop.

Carcinoma of the appendix is rare; I have seen one case of scirrhus cancer of this process in a young adult female. Hartmann states that primary columnar-celled carcinoma of the appendix is not uncommon between the ages of twenty and thirty years.

Carcinomata of the intestine have the same general characters as are seen in similar tumours of the stomach, in connexion with which their characters are detailed (*see pp. 189 to 194*). In the intestine they may involve only part of the circumference, or, particularly in the hard contracting varieties, whether containing solid or tubular collections of epithelial cells, they may surround the lumen, and cause stenosis with its usual consequences above the stricture—dilatation, hypertrophy, ulceration (catarrhal, stercoral), perforation, and it may be fatal peritonitis.

Metastasis may take place to peritoneum, liver, retro-peritoneal glands, etc. Occasionally there is no metastasis.

Secondary metastatic carcinomata of the intestine are rare, and when they occur they affect the mucous membrane of duodenum and jejunum

rather than the lower parts of the tract. In these cases the primary tumours are most commonly located in the stomach. *Primary Sarcomata* of the intestine are very rare. They form raised, circumscribed, soft, greyish masses with smooth or deeply ulcerated surface. The usual variety is the *lympho-sarcoma*, and this has to be distinguished from the tumour-like thickenings which may form in the lymphoid collections of the intestine in lymphatic leucocythaemia, and even in rare cases of lymphadenoma. Microscopic examination may be required to distinguish them from the softer carcinomata. (See Fig. 101.)

Secondary metastatic sarcomata of the intestine are more often seen, particularly of the melanotic variety. The nodules develop in the submucous, muscular or serous coats. They are also found in the appendices epiploicae, and at the attachment of the mesentery to the intestine.

CIRCULATORY CHANGES IN THE INTESTINES.

The walls of the intestine are normally greyish-white or yellowish-grey in colour, with portions, usually the dependent coils, showing hypostatic congestion. On the inner surface there is usually some congestion round about the lymph follicles and Peyer's Patches, and in the valvulae conniventes.

Active hyperaemia usually disappears after death, except in such conditions as cholera asiatica.

In **chronic passive hyperaemia**, the walls are purplish or brownish in colour, and thickened, this change being due in some cases to hypertrophy of, or fibrous tissue increase in, the muscular coats, as well as to oedema.

In **oedema**, accompanying both active and passive hyperaemia, the mucous and submucous coats are swollen and translucent, and the coats separate easily. This is best seen in cases of acute peritonitis, in which in

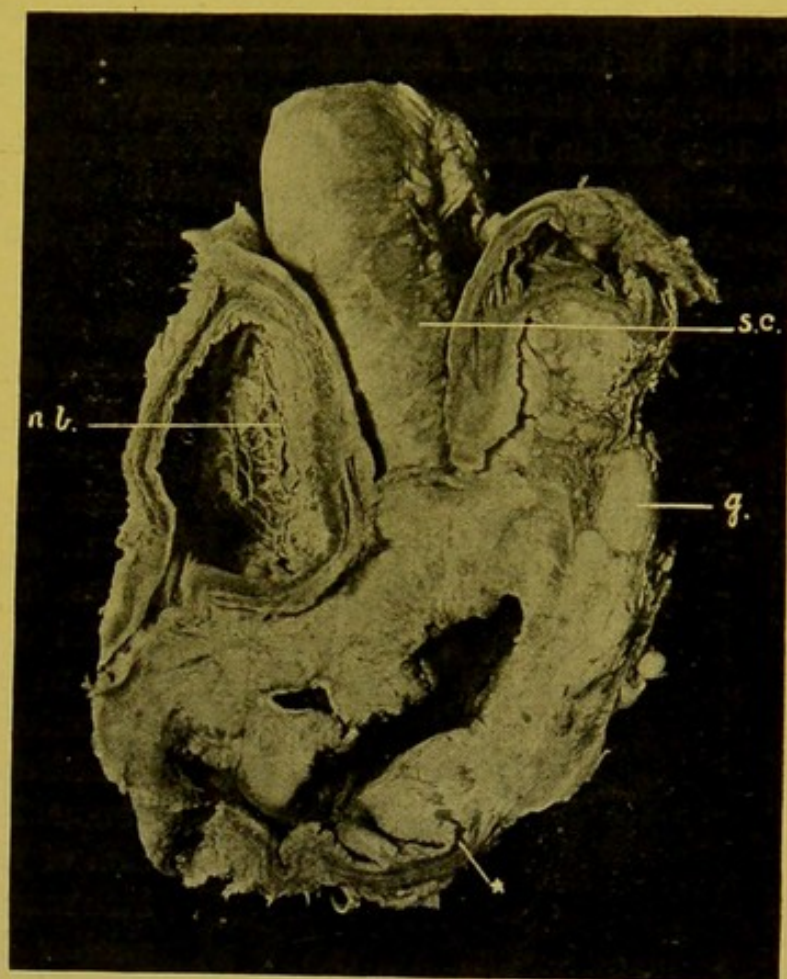


FIG. 100.—Malignant Adenoma of Rectum. (\times circ. $\frac{1}{2}$.)

The star * indicates the muscular coat where it is being broken up by the infiltrating new-growth. (h.b.) Hypertrophied urinary bladder; (s.c.) secondary nodules of cancer on peritoneum; (g.) infiltrated lymphatic glands.

detaching the intestine from its mesentery, care has to be taken to avoid exerting too great traction upon the bowel, as the walls readily give way.

Embolism and Thrombosis. Infarction.—For arterial supply, *see* p. 195.

Although the superior mesenteric artery communicates with the pancreaticoduodenal artery above, and with the inferior mesenteric artery below, by means of arterial anastomoses, and is not, in Cohnheim's sense, strictly an end-artery, yet functionally it enters this category. From the nature of the branching of the artery, embolism of the smaller branches, immediately supplying the intestinal wall, cannot cause infarction, but block of several of the larger branches or the main vessel itself is required to bring about that condition.

While infarction is typically brought about by embolism of the superior

mesenteric artery, the embolus being derived from thrombi in the left heart, vegetative endocarditis of mitral or aortic valves, or from thrombi formed upon atheromatous patches in the aorta, it may also occur in presence of portal venous hyperaemia, and then is due to thrombosis of the portal or mesenteric veins. Moreover, analogous conditions arise in the more local acute venous hyperaemia following obstruction of the mesenteric veins in hernia, intussusception, or volvulus, in which similar haemorrhagic infiltration and necrosis of the bowel may occur.

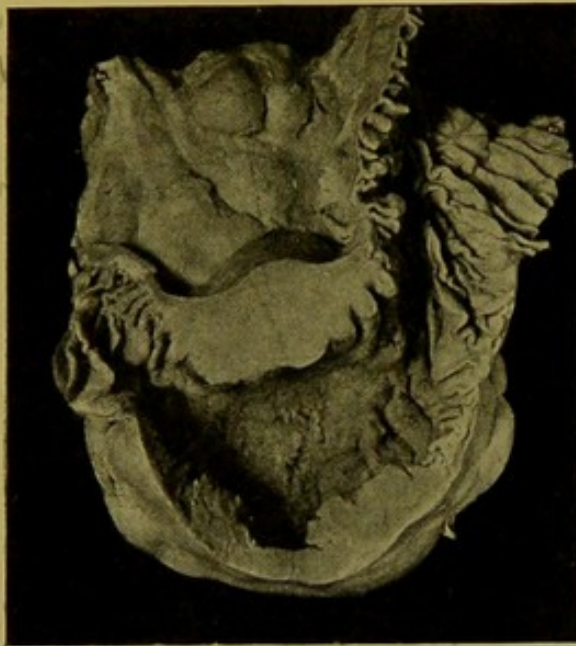

FIG. 101.—Round-celled Sarcoma of Jejunum. (\times circ. $\frac{1}{2}$.)

The tumour forms a thick, soft swelling of the wall of the bowel. Several infiltrated glands are seen in the mesentery.

The infarcted area after preliminary contraction becomes dilated, dark purple, or purplish-brown in colour, the serous surface loses its lustre, and signs of peritonitis may develop (Fig.

102). On opening the bowel, the contents are haemorrhagic and slimy, and the mucous membrane is dull, infiltrated with blood, brownish and opaque, evidently becoming necrotic. In localized infarcted areas—internal or reduced external hernias, intussusception, volvulus—perforation may occur with consequent generalized acute peritonitis.

Punctiform haemorrhages may occur in the wall of the intestine, in both active and passive hyperaemia. They may be localized to the margins and bases of ulcers—tuberculous, typhoid, dysenteric, or malignant. In cases of ulcerative endocarditis, with multiple fine embolism, small haemorrhages may also result. Associated with these there may be formation of small peptic or embolic ulcers, or erosions, from which haemorrhage

take place, or small embolic abscesses may develop, surrounded by a haemorrhagic zone (Orth).

Punctiform haemorrhages may also occur in leucocythaemias, in scorbutus and purpura, in septic diseases, in severe burns of the surface, in waxy or amyloid degeneration, especially of the large intestine. In purpuric conditions the haemorrhages and subsequent erosion and necrosis may be extensive. Larger haemorrhages may occur as the result of the action of various poisons—sulphuric acid, phosphorus, arsenic, mercury, and many others; in dysentery and typhoid; in cirrhosis of the liver; from mechanical action of foreign bodies; and in gross injuries of the bowel.

In poisonings and toxæmias, the haemorrhage may be very evident in the upper part of the intestine, then an unaffected and normal-looking part may intervene, followed by another portion, usually commencing towards the lower end of the ileum,

which again shows gross haemorrhage. It is difficult satisfactorily to account for this anomalous distribution of the haemorrhagic areas.

In newly-born infants haemorrhage may take place from the stomach and duodenum.

The blood may be in the form of "coffee-grounds" in the upper part of the intestine, but more often it is red, and mixed with the intestinal contents; lower down it is usually purplish-brown, coagulated, and partly altered, or black and tarry (Melaena). The tarry faeces of melaena have to be distinguished from the dark grey or black discoloration of the intestinal contents, produced by bismuth or iron preparations administered during life.

Lymphatic varices, according to Létulle, are specially seen in the serous and sub-serous coats as white spots and lines, particularly in the duodenum and jejunum in cases of chronic nephritis. I have frequently noted this relationship.

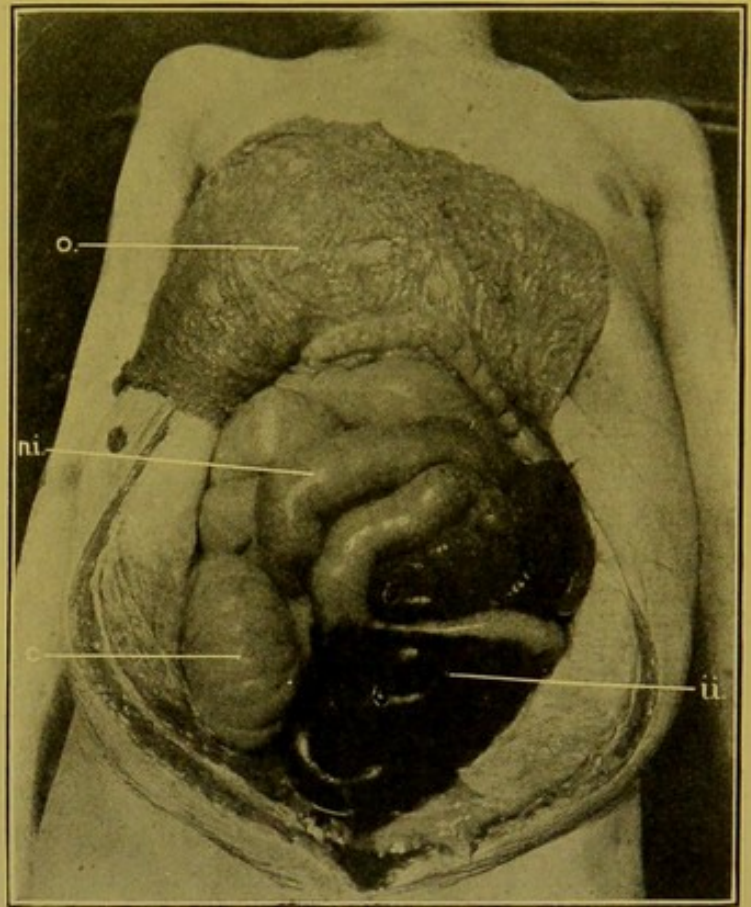


FIG. 102.—Infarction of Small Intestine in adult female.

(o) Omentum, turned up over thorax; (n.i.) jejunum above infarct, distended; (i.i.) infarcted intestine; (c) caecum.

Degenerative Changes in Intestine.—Apart from the *atrophy* accompanying chronic inflammatory changes in the wall, Jürgens describes an idiopathic progressive gastro-intestinal atrophy, in which a granular fatty degeneration is found in the muscular coats, vessels and nerves. It is seen best in the large intestine as whitish-grey spots and streaks in the longitudinal bundles.

In children marasmic from actual starvation, from congenital syphilis, or from wasting diseases, and also in marasmic adults, the walls of the intestine may be atrophied and almost transparent. A similar change, affecting especially the mucous membrane, has been described in so-called pernicious anaemia, but authors of repute consider that the appearances can be accounted for by post-mortem changes.

In chronic peritonitis, pulmonary tuberculosis, in alcoholics, and in the aged, *fatty degeneration* frequently occurs in the muscular coats of the intestine.

Pigmentation (melanin, Rosenfeld) may accompany atrophy of the muscular coats in alcoholics; and with similar changes in liver, pancreas, and lymphatic glands forms one of the characters of the rare condition *haemochromatosis*. The liver is usually cirrhotic. v. Recklinghausen is of opinion that the pigment is "iron-free haemofuscin."

Waxy or *amyloid degeneration* develops in the intestine at a later stage than in the glandular organs. The walls become pale, in colour like old ivory, and have a peculiar semi-translucent, waxy appearance. The iodine reaction produces, in the small intestine, an appearance like that of brown velvet, from the villi being early affected; and in the large intestine a more diffuse discoloration. The lymph follicles may be unaffected and stand out as light yellow spots. This degeneration most frequently occurs in severe pulmonary tuberculosis and in tertiary syphilis. It may at times be detected in the bowel, when it is not evident in the solid organs.

INFLAMMATION OF THE INTESTINE (ENTERITIS).

Under the term Enteritis are usually included all those inflammatory changes in which the wall is attacked from within—*Colitis*, *duodenitis* or *duodenal catarrh*, *catarrh* of *jejunum* and *ileum*—*jejunitis*, *ileitis*—*typhlitis*, *appendicitis* (See Addendum, p. 224), *sigmoiditis*, *proctitis*.

Although these different names are applied to inflammation of the various sections of the tract, the process must be looked on as similar in all cases, and the various descriptive names given to the inflammatory condition, e.g. *catarrhal*, *desquamative*, *croupous*, *dysenteric*, *ulcerative*, indicate a varying severity of the inflammatory process, or, as in the case of *follicular enteritis*, indicate that in some cases special structures may be affected. The changes are similar to those found in gastritis.

Acute Catarrhal Enteritis.—In this, the common form of enteritis, the

mucosa and submucosa are congested, thickened, soft, loose, oedematous, and often muddy from infiltration with cells. The secretion of mucus is increased and this covers the surface in a tenacious layer. The mucus is clear, or greyish and turbid from presence of leucocytes and cast-off epithelium—possibly partly a post-mortem change; it may be stained with bile or mingled with the contents of the bowel. In rare cases the secretion is purulent or muco-purulent.

Desquamation is marked in the large intestine, particularly in the summer diarrhoea of infants.—It must not be forgotten that in some of these cases, particularly in very young children, little macroscopic evidence may remain, apart from congestion of the folds of mucous membrane in the lower part of the large intestine.—The desquamation may produce flat erosions (*catarrhal, stercoral, erosions*), and these may extend more deeply (*catarrhal ulcers*) or go on to more severe forms of ulcerative enteritis, or to widespread necrosis (p. 216).

The lymphoid collections—solitary glands and Peyer's patches—are usually enlarged. Normally these are more prominent in children than in adults.

Chronic Catarrhal Enteritis is common in adults accompanying the venous hyperaemia resulting from obstructive heart, lung, or liver disease. The parts affected are thickened and usually show a brownish or greyish (slaty) discoloration, and are covered with mucus.

Proliferative changes are found in the connective tissue, bringing about thickening of the mucous and submucous coats. This rarely produces the mammillations and polypoid projections so commonly seen in chronic gastric catarrh, and when these occur they are generally limited to areas of the mucous membrane in the neighbourhood of chronic tuberculous and dysenteric ulcers, particularly the latter.

The proliferated interstitial tissue at a later period tends to contract, and the mucous membrane then becomes atrophied, thin, firm, pigmented, the glands disappearing to a great extent, or in rare cases becoming cystic. In the small intestine the villi may disappear. The muscular coats may undergo fatty degeneration.

Mucous Colitis, Enteritis mucosa chronica.—In this disease mucus appears in the faeces in rope-like masses, often closely resembling tape-worms or ascarides, or masses of fibrin. If treated with acetic acid, mucus becomes opaque, whereas fibrin swells up and becomes transparent.

The condition depends on great production of mucus which unites to form a membranous layer, and this, when cast off from the surface, becomes twisted together in a long cylinder.

It may occur in hysteria and neurasthenia.

Suppurative enteritis is extremely rare. The mucosa and submucosa become infiltrated with pus; the mucous membrane undergoes necrosis and ulceration. In anthrax particularly, localized abscesses may form,

and, in pyaemia, multiple small embolic abscesses may be found, going on to formation of erosions and small ulcers from which serious haemorrhage may take place.

Follicular Enteritis.—Apart from the inflammations of the intestinal lymph collections which are so characteristic of typhoid fever and tuberculous infection, these structures—solitary glands and Peyer's patches—are also attacked in dysentery, in diphtheria and cholera, and also in less severe infections.

In some cases the solitary glands are specially affected, in others the Peyer's patches, in others both of these structures.

The follicles become swollen and translucent, or if proliferation occur, they are greyish and prominent. This change may go on to suppuration

and necrosis, with formation of the *follicular ulcer*. This is small, rounded, with a sharp-cut margin, and may be surrounded by a zone of hyperaemia (Fig. 103). The destructive changes tend to spread, to a varying extent, especially in the submucosa, so that the margins of the ulcer become undermined. Neighbouring ulcers may coalesce so as to form irregular sinuous ulcers with overhanging processes and bridges of mucous membrane. This type of pathological change is best seen in dysenteric ulceration of the large

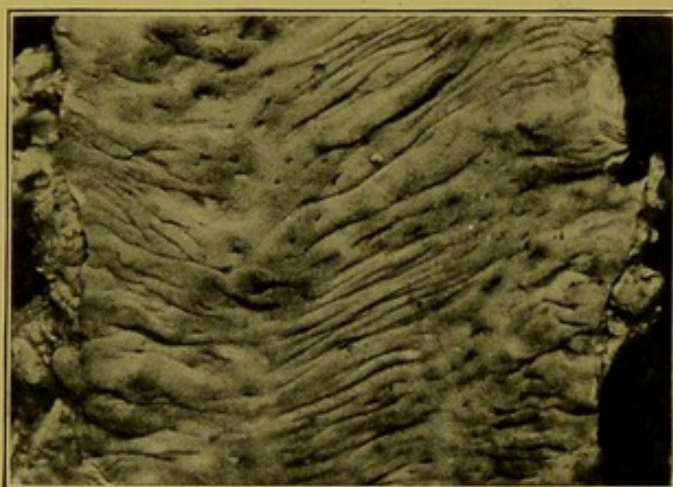


FIG. 103.—Follicular Ulceration of the Large Intestine, early stage. (\times circ. $\frac{2}{3}$.)

There are numerous pin's-head-sized losses of substance. One larger irregular ulcer near upper left-hand corner of figure.

intestine. If such ulcers be examined microscopically there may be little trace of acute suppuration, but the neighbouring tissue is infiltrated with small round cells (lymphocytes). These ulcers may heal and the epithelium be renewed to a great extent; the hollows remaining may contain plugs of mucus. Occasionally submucous cysts may develop. Scars may form, and pigmented projections may persist in the neighbourhood.

SPECIAL FORMS OF ENTERITIS.

In **Dysentery**, catarrhal changes may alone be evident, but the disease is more commonly associated with destructive and desquamative changes or with the formation of follicular abscesses and ulcers.

The enteritis is localized characteristically to the large intestine, especially attacking the mucous membrane along the areas corresponding to the longitudinal muscular bands, and particularly in those portions of the colon where the faeces tend to stagnate, e.g. in the caecum and at the flexures.

Again, the changes increase in severity as one passes down the colon. If the small intestine be affected, it shows only congestion and swelling, or at the most, in addition, superficial destruction only.

The early changes are similar to those already described as occurring in catarrhal enteritis, but in addition marked hyperaemia and even haemorrhagic extravasations are evident. On the mucous surface an exudate of fibrin may form—*croupous enteritis*, *dysentery crouposa* (cf. Fig. 104), or the membrane as in true diphtheria of the fauces includes also a varying thickness of mucous membrane, and even of submucous coat. This layer becomes necrotic, losing all power of taking nuclear stains in microscopic specimens, and is crowded with bacteria, many of them saprophytic. On separation, the membranes are passed in the faeces, and the bases of the ulcers remaining are usually formed by the transverse muscular coat, which by this time has undergone considerable thickening (Fig. 105). Perforation seldom occurs, but it may do so and cause a fatal peritonitis.

The mucous membrane between the ulcers is greatly swollen, hyperaemic, extensively undermined, and may later become attacked by the ulcerative process.

By alteration of the blood effused into the walls, these take a diffuse slaty colour.

The ulcers may cicatrize and then one finds a slaty surface with scattered areas of uneven scar-tissue, with darker-coloured, frequently almost black, polypoid projections of persisting mucous membrane. The deeper coats are thickened.

Just as in the more common forms of enteritis sometimes the general mucous membrane and sometimes the lymphoid collections are specially affected, so in dysentery in addition to the common variety just described, another rare variety is described, in which the fibrino-necrotic change affects particularly the mucous membrane over the lymph follicles. The processes follow an analogous course, with the result that follicular ulcers develop, which differ from those already described in that the inflammatory and necrotic process spreads from the surface. The ulcer is open, with flattened

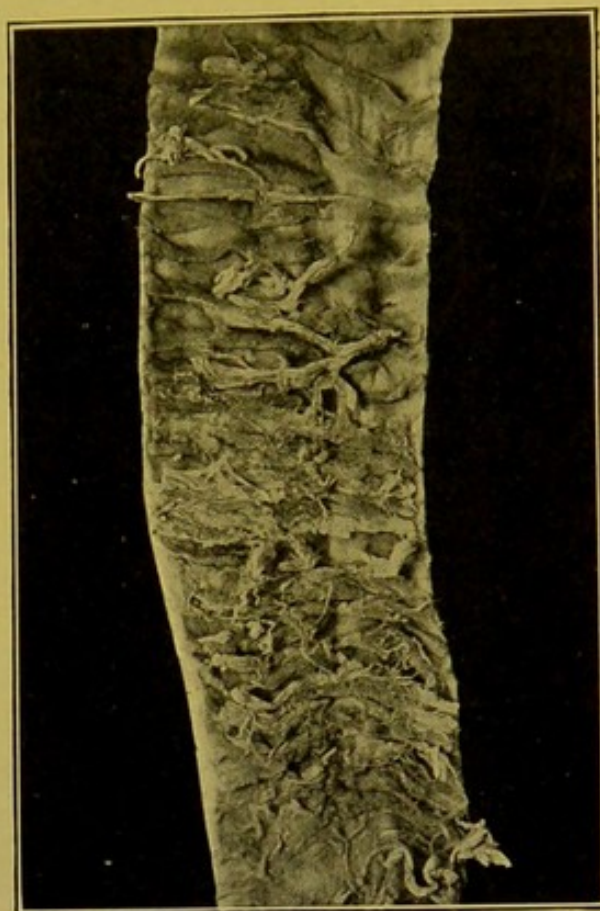


FIG. 104.—Fibrinous (Croupous) Enteritis.
(\times circ. $\frac{1}{2}$.)

Portion of Jejunum, showing surface covered with fibrinous exudate.

edges, the mucous membrane covering the follicle being completely destroyed. Dysenteric ulceration may extend to the Appendix.

While these changes are specially characteristic of dysentery it must not be forgotten that analogous fibrinous and necrotic changes occur in stagnation of faeces (coprostasis), at the flexures and in the rectum; in cholera, especially in the small intestine; in puerperal disease, in both small and large intestines; less commonly in typhoid, small-pox, pyaemia; from the action of certain chemical substances, e.g. corrosive sublimate, arsenic, bismuth; in uraemia, etc. Probably in these cases the toxins and inorganic poisons induce a change in the mucous membrane predisposing it

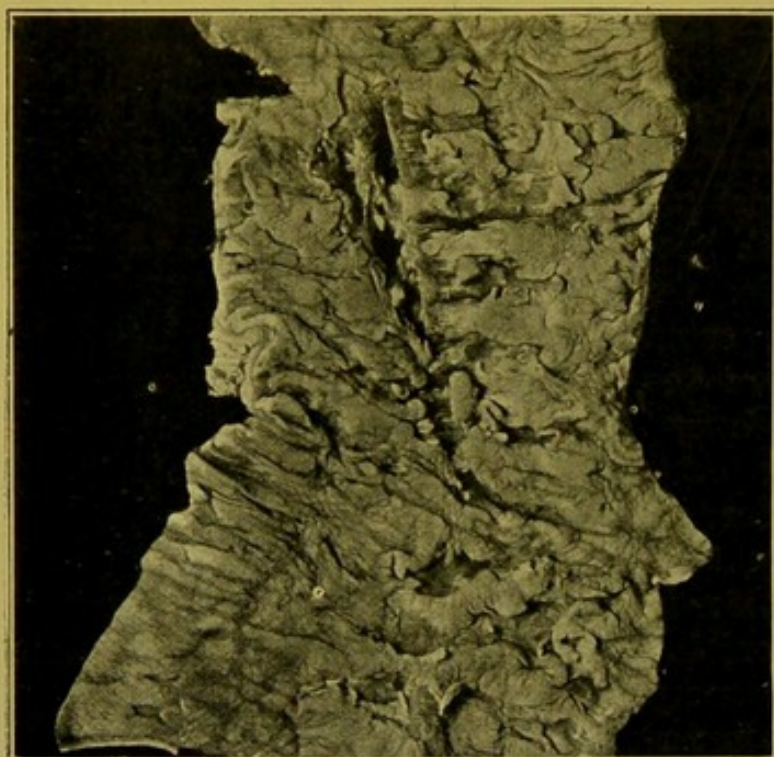

FIG. 105.—Dysenteric Ulceration of Large Intestine.
(\times circ. $\frac{2}{3}$.)

The irregular ulcers, with undermined edges, and bases formed by the transverse, inner, muscular coat, are easily made out.

to the action of organisms already present in the bowel or introduced from without. Orth thinks that in the intoxications the predisposing cause may be thrombosis of the smaller vessels.

Tuberculous Ulceration.

—This form of ulceration from preference attacks the lymph follicles, especially the Peyer's patches in the ileum. The severity of the process generally lessens as one passes from the ileo-caecal valve upwards and downwards in the intestine, but in very severe cases ulcers may develop from duodeno-jejunal junction to rectum.

I have found old cicatrizing tuberculous ulcers encircling the jejunum at its upper part, in a case presenting during life the symptoms of congenital pyloric stenosis; and in another case, in an adult, the whole of the small intestine showed at intervals ring-shaped stenoses, between which the bowel was dilated in a fusiform manner.

Usually, however, the ulcers are limited to the lower Peyer's patches in the ileum, and as an immediate consequence, the mesenteric glands in the ileo-caecal angle and those leading up from this region to the root of the mesentery, are most often found tuberculous.

The reason for this localization of the ulcers to the Peyer's patches is the tendency for bacteria to be taken up by leucocytes and carried through the Peyer's patches to the lymphatics, and thence to the glands in the mesentery.

The condition is most commonly the result of swallowing infective sputa from tuberculous excavation of the lungs, but is frequently, particularly in children, the result of swallowing of tubercle bacilli from without, which either (1) after being inhaled, have become entangled in the tracheal and bronchial mucus, which has then been swallowed, or (2) have been ingested directly in articles of food, such as milk.

All stages of the process may be found post-mortem, from the yellow caseous tubercle, with or without satellite grey tubercles, through the single, oval or rounded ulcer, to the large sinuous ulcer formed by confluence of two or more single ulcers. In the great majority of cases the process is active, so that in the margins and bases of the ulcers, caseous tubercles are seen, and in the tuberculous granulation tissue farther out, giant-cell systems or collections of proliferated epithelioid cells are prominent features. This granulation tissue causes thickening of the margins and bases, which are also usually eroded and irregular. In the neighbourhood, patchy congestion, haemorrhages and hypertrophy of the mucous membrane may be seen. Usually the whole of the Peyer's patch is not affected, because, from the fact that the tubercles spread along the lymphatics which encircle the bowel as they pass to the mesentery, the ulceration usually extends in the same direction, i.e. at right angles to the long axis of the bowel. (Fig. 106, 1.) In rare cases when the whole or major part of the patch is attacked by several ulcers which coalesce, the long axis of the resulting ulcer may lie parallel to that of the bowel.

The mucous membrane is not usually so much affected as the deeper coats, particularly the submucosa, so that it may persist to some extent and overhang the ulcer. In chronic ulcers this is not so evident.

The tubercles are best seen on the serous surface (Fig. 106, 2), which in some cases also shows fibrous thickening, or adhesion to adjacent coils or to the omentum.

Though the ulcers are usually more or less oval, and situated on the surface of the bowel opposite to its mesenteric attachment, in cases of long standing they may completely encircle the lumen.

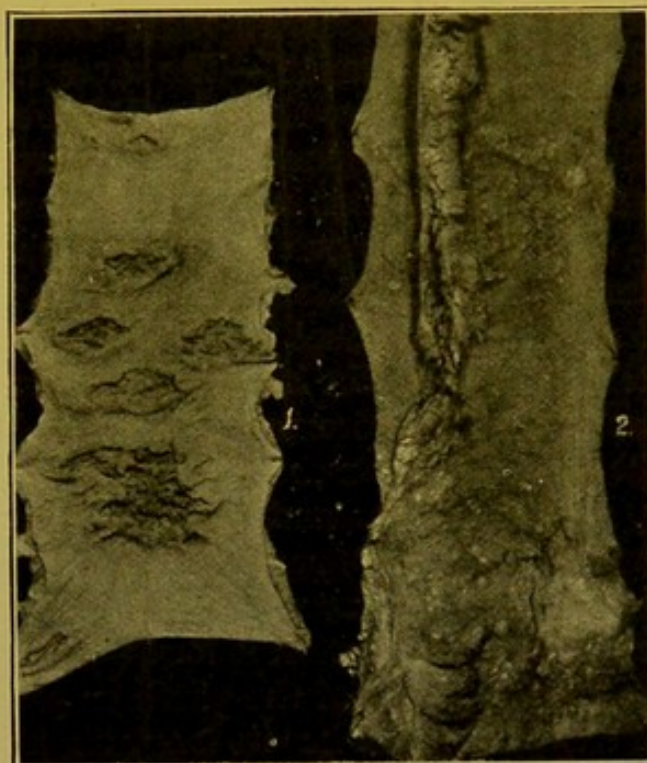


FIG. 106.—Tuberculous Ulceration of Ileum.
(\times circ. $\frac{1}{2}$.)

(1) Mucous surface; (2) serous surface, showing the tubercles clustered over the base of the ulcers, and spreading along the lymphatics towards the mesentery.

When tuberculous ulcers heal they cause cicatrization, and may lead to stenosis. The healing is usually incomplete. The area is pigmented.

Perforation may occur in early ulcers with rapid caseation and softening, but also, apparently, it may result from rapid necrotic changes, of small superficial extent, occurring in the bases of more chronic ulcers. The perforation may lead (1) to acute peritonitis, or (2) if adhesions exist between adjacent loops of intestine, may result in a *fistula bimucosa*, through which the loops intercommunicate, or (3) to a localized abscess between adjacent loops, limited by adhesions.

Tuberculous ulcers of the jejunum or colon or appendix are closely analogous in structure to those of the ileum.

Typhoid Ulceration.—The ulceration of the intestine in typhoid fever is usually limited to the lower Peyer's patches, sometimes the lowest patch, and the solitary glands in the surrounding wall, or it may affect all the lymphoid collections in both small and large intestines, and in the appendix.

The disease is one of those which cause a special reaction in lymphoid tissue. The initial congestion, oedema, infiltration and proliferation affect the whole individual Peyer's patch or solitary gland, i.e. not only the follicles but also the interfollicular tissue, hence the surface of the thickened patch in time becomes levelled up ("like a garden bed"). Catarrhal changes are seen in the intervening congested mucous membrane.

As the oedema and infiltration increase, the blood supply of the central part of the Peyer's patch or solitary gland becomes cut off and it dies. A slough, greenish-brown or dark brown in colour from bile-staining, forms, and when it separates, it leaves an ulcer with overhanging margins, which retains the shape of the patch or gland. Hence the typical typhoid ulcer of a Peyer's patch has its long axis placed longitudinally in the bowel.

The infiltration is at its height at the beginning of the second week of the disease. The sloughs form towards the end of the second and beginning of the third week; they separate during the course of the third week, and by the fourth week the congestion and swelling of the margins are lessening; the ulcers are "clean," with the transverse muscular coat forming their bases (Fig. 107). The overhanging mucous membrane tends to adhere to the surface of the ulcer, which heals over without cicatrization, and at a later stage may show regeneration of mucous membrane. Finally the only trace of the ulcer is a smooth, slightly slaty, area on the mucous surface opposite the mesenteric attachment.

Films or sections made from the infiltrated patches may be stained to show the organisms. Their detection is assisted by the circumstance that, though of themselves they stain poorly and are Gram-negative, they usually lie in large clumps, which are recognized with considerable ease.

Perforation may take place if the cellular infiltration and necrosis advance deeper than usual into the muscular coats, not depending directly upon the separation of the sloughs, but on a subsequent circumscribed necrosis of the serosa which readily ruptures.

Haemorrhage occurs commonly, during the process of separation of the slough; hence usually during the third week of the disease.

The *mesenteric glands* show changes very similar to those described in the Peyer's patches, though sloughing is not so evident. They are much enlarged, soft on section, of a light grey colour mottled with pink patches.

Syphilitic Ulceration of Intestine.—In *congenital syphilis*, one may see multiple hard flat swellings or ulcers, especially of gummatous nature, with dense callous margins and similar bases. The ulcers resemble closely those of tuberculous origin. They may cause stenosis, or may perforate and cause peritonitis.

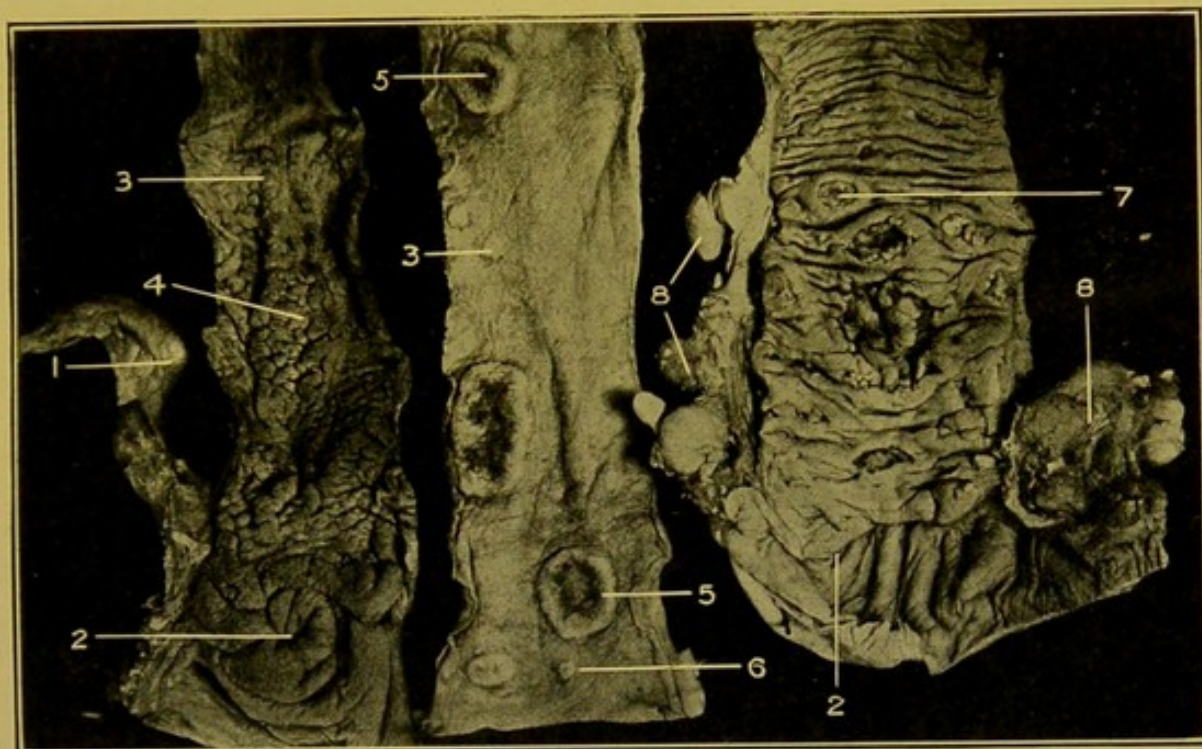


FIG. 107.—The Intestinal Lesions in Typhoid Fever. (\times circ. $\frac{1}{2}$.)

(1) Appendix; (2) ileo-caecal valve; (3) swollen solitary glands; (4) swollen Peyer's patch, early stage; (5) swollen Peyer's patch, later, beginning to slough in centre; (6) solitary gland, with central necrosis; (7) several Peyer's patches with slough separated—typhoid ulcer,—the base of which is formed by inner muscular coat; (8) swollen lymphatic glands.

In *acquired syphilis* the rectum is specially affected. Gummata form in the mucous or submucous coats and breaking down they produce ulcers, in the base of which the inner muscular coat is seen, as in those found in congenital syphilis. They tend at times to surround the rectum, and from their cicatrization may cause stenosis. Their smooth firm surface distinguishes them from carcinomatous ulcers. Their raised margins are sharp. They may affect the whole of the lower part of the rectum or even extend higher, and are separated from the healthy mucous membrane above by a sharp indented margin (Fig. 108). The outer coats, and the peri-rectal tissue are often greatly thickened. The anus may be free from inflammation, but the mucous membrane may be prolapsed and polypoid, with haemorrhoids.

Gonorrhoea may also attack the rectum.

The last two diseases occur almost exclusively in women.

DISEASES OF THE PANCREAS

Congenital Anomalies are rare; they accompany defective development of the intestinal tract.

Accessory Pancreases—rounded flat masses, of the size of a linseed up to an inch in diameter—are occasionally found in the walls of the stomach, duodenum, or jejunum. They are found rarely in the neighbourhood of the umbilicus. They may develop in the tip of a Meckel's diverticulum, or may themselves be the cause of a traction diverticulum of the intestine. Pancreatic tissue may be found in association with small myomata of the walls of the alimentary tract.

I have seen one case in which an extension of pancreatic tissue formed a complete ring—about $\frac{3}{4}$ in. (12 cm.) in width,—encircling the second part of the duodenum. It caused no constriction. In other reported cases stenosis has been produced. (For Congenital stenosis of the duodenum, see p. 178.)

Haemorrhage into the pancreas may result from traumatism, rupture of atheromatous arteries, thrombosis of vessels, chronic venous congestion, and rarely from embolism. It may occur also in various metallic and narcotic poisonings, and in the haemor-

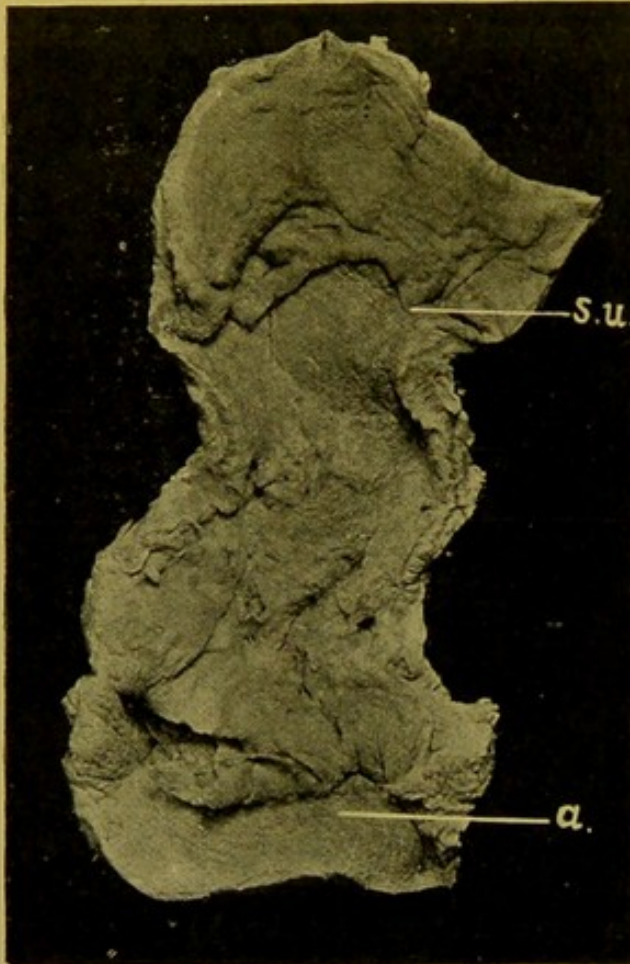

FIG. 108.—Syphilitic Ulcer of Rectum. (\times circ. $\frac{1}{2}$.)
(s.u.) Upper edge of ulcer; (a.) anus.

rhagic diatheses. In most cases it accompanies pancreatitis. The haemorrhages may be small or large, within the organ or surrounding it. The lesser sac may contain blood-stained fluid.

Pancreatitis.—No hard and fast lines can be drawn between the *acute pancreatitis*, *acute haemorrhagic pancreatitis*, *haemorrhagic necrosis*, and *gangrenous pancreatitis* of authors. They all represent stages of one pathological process, and all are associated with fat necrosis.

Naked eye appearances.—In the early stages the organ is enlarged throughout, or especially at the head end. It is fairly firm, and yellowish in colour with pink spots scattered over the surface. Haemorrhage commonly takes place, and upon its extent depend the appearances presented. Hence the surface may be mottled, red haemorrhagic patches alternating with grey

or yellow areas. Opaque spots of fat necrosis are constantly seen in the substance of the pancreas. In more extensive haemorrhages, the affected parts are dark brown or even slate-coloured, and in addition blood infiltrates the surrounding tissues, particularly near the head. It also extends into the root of the mesentery, and even lower in the abdomen, behind the peritoneum. Necrosis of the parenchyma of the organ is a constant feature in advanced cases (Fig. 109).

If gangrene follow, dark greyish or brownish-grey friable areas appear, with surrounding haemorrhage. In extreme cases the whole organ may form a sloughy shreddy mass.

In later stages peritonitis develops, particularly in the lesser sac, which may be filled with offensive pus and necrotic tissue; this may be discharged into the intestine. Thrombosis of the splenic vein is a frequent sequel.

Microscopically, the only changes seen in slight cases may be some infiltration of the septa, with swelling and granularity of the secreting cells. In more severe cases the leucocyte infiltration is more marked, and red blood corpuscles and fibrin may be seen in addition. The cells of the parenchyma are necrotic, their nuclei failing to stain in microscopic sections.

Fat Necrosis is a constant feature. The lobules of fat undergo degenerative changes converting them into opaque, yellow or whitish, chalky material. Polygonal areas of fat necrosis are found within the pancreas, in the neighbouring fat, extending throughout the omentum, in the extra-peritoneal fat, and even in the fat in front of the pericardium. (See Fig. 109.)

The necrotic changes are caused by the *trypsin* and the fat necrosis by the *fat-splitting ferment* of the pancreas. The fat is split into fatty acids and glycerines. Soon the fatty acids combine with calcium salts to produce hard calcareous nodules. If recovery take place, the areas of fat necrosis may be absorbed, leaving cysts in their place.

Causes of pancreatitis. Traumatism, the organ being crushed against the vertebral column; rupture of arteries; acute infections; impaction

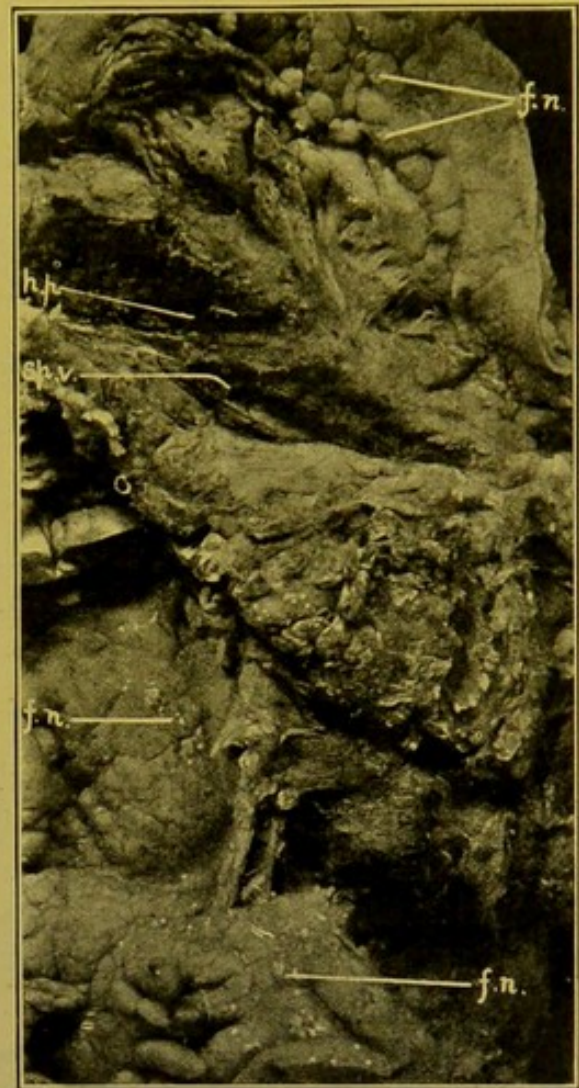


FIG. 109.—Acute haemorrhagic Pancreatitis (*h.p.*), with Fat Necrosis (*f.n.*) in fat in neighbourhood. (\times circ. $\frac{1}{3}$)

(*Sp. v.*) Splenic vein. (Mus. R.C.S. Edin.)

of calculi in Vater's ampulla, possibly with regurgitation of bile into the pancreatic duct. The actual determining cause is probably invasion by pathogenic bacteria by way of the ducts, blood-vessels, or lymphatics, or by direct spread. In some cases of gastro-duodenal catarrh, the inflammation apparently spreads to the pancreas from the duodenum. Pancreatitis is more common in males than females.

Extensive necrosis of the pancreas may occur without visible signs of inflammation. One has to assume self-digestion of the organ giving rise to the haemorrhage and other changes, some special condition being present bringing about conversion of the inert trypsinogen into active trypsin, e.g. entrance of enterokinase into the ducts.

Acute Suppurative Pancreatitis.—The pancreas is enlarged and the surrounding tissue is indurated. In colour it is greyish or dirty brown. The suppuration may be diffuse, but more commonly is localized, for example in the head of the gland. Often the suppuration is round about, rather than within the pancreas, and necrosis of its parenchyma is usually present.

Suppuration occurs in the liver secondarily more often than in the other forms of pancreatitis. The abscesses of the pancreas may discharge into the stomach, duodenum, or lesser sac, or the pus may burrow downwards in the flanks.

Suppuration may be associated with occlusion of the duct by gall-stones or pancreatic calculi, or by carcinoma. It rarely runs an acute course; it may last for weeks or months. Pyogenic cocci, *Bacillus coli communis*, *Bacillus proteus*, or *Pneumococcus* may be found.

Chronic Interstitial Pancreatitis.—Causation. It may occur in syphilis, both congenital and acquired; in the former the fibrous change being diffuse, in the latter localized, forming scar-like processes.

It may result from chronic catarrh; from obstruction of the duct by calculi, pancreatic or biliary; in carcinoma of the head or body of the organ, or of the duodenum. It may be secondary to cirrhosis of the liver, but in alcoholism the pancreas may be affected alone. A partial fibrosis occurs in the bases of chronic gastric ulcers which have penetrated to the pancreas.

The fibrosis may be either interlobular or intralobular (Opie).

1. Interlobular.—The organ is enlarged, dense, the lobulation accentuated, the connective tissue replacing the parenchyma to a great extent. The Islets of Langerhans may persist unaltered in the midst of the fibrous tissue. There are many plasma cells and eosinophils.

2. Intralobular.—This variety is less common. The organ is small and firm, the connective tissue increased and infiltrated with fat. The Islets of Langerhans are separated from the parenchyma by areas of connective tissue, and in their interior there is also increase of connective tissue. This form may be associated with diabetes mellitus, and one form is found in the later stages of von Recklinghausen's haemochromatosis.

Pancreatic calculi are usually white, composed of carbonate and phosphate of calcium, and at times contain cholesterine. They may resemble grains of sand or be as large as walnuts. They occur singly, or in great numbers.

Results:—Moniliform or cylindrical dilatation of the duct; sclerosis of the organ, usually interlobular. The Islets of Langerhans may escape, or undergo hypertrophy. Occasionally fistulae form to the stomach, duodenum, or peritoneum. There may be associated carcinoma.

Cysts of the Pancreas.—Most cysts described as pancreatic develop in the neighbourhood and involve the pancreas later.

Retention usually causes beaded dilatation of the duct (Fig. 110).

Some pancreatic cysts may be of the nature of cyst-adenoma—proliferous cysts. Congenital cysts are extremely rare, and associated with a similar development in the liver and kidneys. They are of very small size.

Pseudo-cysts are more common, following necrotic changes in the organ, and may contain bloody fluid. The inner surface is smooth, but possesses no lining membrane. The fluid may be under considerable tension.

Lipomatosis.—In this condition there is replacement of the interlobular and intralobular connective tissue by fat. The parenchyma tends to disappear. In moderate degree it is common after the age of forty.

Tuberculosis.—In generalized tuberculosis, miliary tubercles form in the pancreas just as in other organs. Yellow tubercles or caseous masses are rarely found.

Syphilis.—The pancreas is frequently affected in congenital syphilis. The special change found is formation of connective tissue along the vessels, which are the seat of periarteritis. The Islets of Langerhans may be little affected.

In acquired syphilis, gummata or fibrous scar-tissue develops.

Degenerations attack the Islets of Langerhans more severely than the rest of the parenchyma.

Opie describes hyaline degeneration (epithelial-hyaline) of the Islets. Fatty degeneration affects all parts of the parenchyma, and a moderate degree is not abnormal over forty years of age. Amyloid or waxy degeneration occurs as in other organs. Focal necrosis may be found in the parenchyma.

The Pancreas in Diabetes.—While it is generally admitted that diabetes may occur without pathological changes in the pancreas, in very many cases important alterations are found in it, chiefly chronic intralobular pancreatitis, with invasion of the Islets of Langerhans. In diabetes associated with advanced interlobular fibrosis, Opie has found hyaline degeneration of the Islets. In bronzed diabetes, sclerosis is associated with deposit

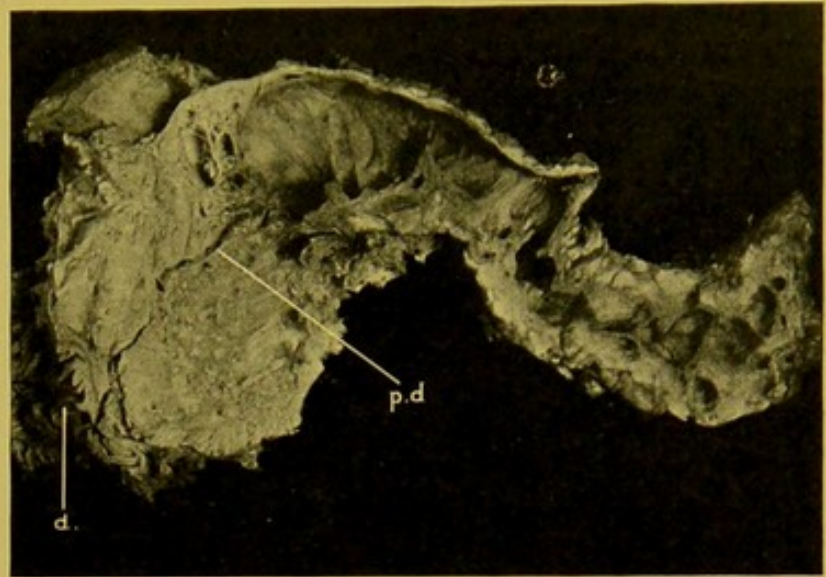


FIG. 110.—Cancer of head of Pancreas, obstructing the main duct (*p.d.*), and causing dilatation of the duct throughout the remainder of the organ, which is atrophied. (*d.*) Duodenum, second part. (\times circ. $\frac{1}{2}$.)

of pigment. Carcinoma, haemorrhagic necrosis, or simple atrophy of the organ are found in some cases of diabetes.

Tumours of the Pancreas.—The more important tumours are the *carcinomata*. They may develop at any part, but most often occur in the head (see Fig. 110). Scirrhus cancer is the usual type. Columnar-celled cancer is rare, as is also encephaloid cancer. Metastatic secondary growths in the liver are usually of small size. Multiple papillary *cystadenomata* have been described, with metastasis to the lymphatic glands and to the lungs.

If carcinoma of the stomach or of duodenum be present in addition to carcinoma of the pancreas, the former is usually primary; but if a carcinoma of the gall-bladder accompany carcinoma of the pancreas, it is difficult to determine which is the primary tumour.

Sarcomata rarely develop in the pancreas. The affected organ may not be greatly enlarged; it is almost homogeneous, whitish; the stroma and acini are invaded by the cells. Lymphosarcoma of the glands in the neighbourhood may invade the pancreas, and suppurative changes may follow, both in the tumour and in the pancreas.

ADDENDUM; APPENDIX VERMIFORMIS. (See pp. 171, 196, 203, 208, 212.)

Typhlitis and Appendicitis.—Primary **Typhlitis** is a rare condition. It results most often from stagnation of the faeces within the Caecum, with consequent stercoral ulceration, or from some other local irritation, such as the presence of animal parasites. Typhlitis and perityphlitis are more commonly secondary to appendicitis.

Catarrh of the Vermiform Appendix is not uncommon. Recurrent catarrh, particularly if the proximal part of the appendix be stenosed as the result of former inflammation, may lead to the formation of *concretions* within the lumen. These may consist of inspissated mucus, or desquamated epithelium, infiltrated with earthy salts. More often they are soft and composed of faeces which contain a larger proportion of bacteria than elsewhere. *Foreign bodies* and *animal parasites* are extremely rare.

Inflammation of the appendix (**Appendicitis**, Epityphlitis) follows invasion of its walls by bacteria through defects in the epithelial lining. The gland tubules are usually first affected, and then the submucous coat, including the lymph follicles. The process soon extends through the wall to the serous covering; fibrin is deposited upon the inner surface and within the deeper tissues. Possibly the pressure of a concretion, or the distal distension following stenosis, may assist in causing *necrosis* and *gangrene* of the walls, but these factors are not essential, seeing that the severe acute inflammation which occurs is of itself sufficient to bring about these results. The inflammation is often *suppurative*. **Portal Pyaemia** (p. 239) follows the septic thrombo-phlebitis which may result in the appendicular veins. *Peritonitis* (Peri-appendicitis, **Perityphlitis**), either with or without perforation of the walls, is a usual sequel, and this may be localized or general. Pus from a retro-caecal appendix (see p. 196) may extend upwards in the flank behind the liver and may invade that organ from the surface.

The most common causal **bacteria** are *bac. coli communis* and *streptococci*; but all the other *pyogenic cocci* (including the *pneumococcus*), *bac. lactis aërogenes*, *bac. proteus*, and many others may also be found.

In **actinomycosis**, thick walled abscesses or granulomatous swellings may form in the appendix.

CHAPTER XII

THE ABDOMEN (*continued*)

THE LIVER

Anatomical Points and Relationships.—In the right mammary line the liver extends up to the level of the lower border of the fifth rib; and in the mesial plane of the body, to that of the sixth chondro-sternal articulations. The oblique lower border crosses the mesial plane almost midway between the tip of the ensiform cartilage and the umbilicus. The fundus of the gall-bladder presents near the angle between the outer edge of the rectus and the costal margin.

The *size* of the liver varies a little in health; its average transverse diameter is about 9 to 11 in., or 22 to 28 cm.; its antero-posterior diameter 7 to 8 in., or 17 to 20 cm.; and its thickness from above downwards 3 to $3\frac{1}{2}$ in. or 7 to 9 cm.

In the adult, the right lobe is about four times the bulk of the left, whereas in the infant the lobes approximate in size, the right lobe being about twice the size of the left and the liver as a whole larger in proportion to the size of the body.

The *weight* of the liver is usually given as 54 oz.—1,620 gm. in the male, varying from 50 to 58 oz.—circ. 1,420 to 1,649 gm.; in the female, as about 45 oz.—1,275 gm. with variations in health from 40 to 50 oz.—circ. 1,140 to 1,420 gm. In 687 adult males, I found the average weight of the liver to be 63 oz. or 1,764 gm.; and in 444 females, it was $51\frac{1}{2}$ oz. or 1,460 gm. The average in these 1,131 adults was 58 oz. or 1,645 gm. *small from*

In the adult, the liver is about one-fortieth of the body weight, and in the infant it is about one-twentieth of the weight of the whole body. The *capsule* is thin, smooth, shining, translucent, permitting the fine lobular mottling to be seen. The *lobules* measure in diameter about $\frac{1}{20}$ to $\frac{1}{15}$ in. (2 to 3 mm.).

The visceral—under—surface of the liver rests upon the following structures:—the pyloric end of the stomach, the first part of the duodenum, the hepatic flexure and commencement of the transverse part of the colon, the upper half of the right kidney and supra-renal.

The **Gall-bladder** is about 3 in. (8 cm.) in length, and its greatest transverse diameter measures from 1 in. to $1\frac{1}{4}$ in. (25 to 30 mm.). Its capacity is about 1 to $1\frac{1}{2}$ fluid oz. (circ. 25 to 40 cm.).

Bile-ducts.—The *hepatic duct* is about 1 to $1\frac{1}{4}$ in. in length (25 to 30 mm.). Just outside the portal fissure it is joined at an acute angle by the *cystic duct*. The *common bile-duct* in its upper part lies close to the free border of the gastro-hepatic omentum, in front of the foramen of Winslow, with the hepatic artery to its left, and the portal vein behind. The length of the common duct is about 3 in. (7 to 8 cm.). The upper portion is of variable size, but is usually about $\frac{1}{4}$ in. (6 to 7 mm.) in diameter; the lower part—which is embedded in the head of the

pancreas, and then passes obliquely through the wall of the duodenum in company with the pancreatic duct—narrows abruptly to about $\frac{1}{16}$ in. (2 mm.) in diameter. This portion varies greatly in length. The mucous membrane of gall-bladder and bile-ducts has a honeycombed appearance.

Removal of the Liver, Stomach, Duodenum, etc.—It is best to remove the liver in one mass along with the stomach and spleen, duodenum and pancreas, and then after examining these in their normal relationships to each other, to proceed to separate up the organs and examine them individually.

In the first place, the diaphragm should be separated from the ribs and posterior wall; then the spleen, carrying with it the fundus of the stomach and tail of the pancreas, should be pulled forwards out of the body, and separated from the structures on the posterior wall of the abdomen, leaving in position the left kidney and supra-renal. Passing to the other side of the body, one should tilt up the right lobe of the liver and separate it from the posterior wall as far inwards as the sides of the vertebrae, special care being exercised in freeing the right supra-renal from its under surface. Then the upper end of jejunum and the duodenum along with the head of the pancreas are stripped up from the aorta and vena cava, and from the anterior surface of the right kidney, the superior mesenteric artery and coeliac axis being divided close to their origins. The diaphragmatic attachments of the pericardium are then separated, and, finally, by cutting across the crura of the diaphragm along with the oesophagus, the whole mass is set free, and can be lifted out of the body.

Examination of Liver and Bile-ducts.—The mass separated as described above, is placed upon its posterior surface, the liver turned next to the operator with its anterior margin tilted up so as to display the under surface with the gall-bladder and structures in relation to the hilum.

The condition of the **Common Bile-duct** is first investigated.

An incision is made through the outer wall of the second part of the duodenum, and this being held open with the fingers of the left hand so as to expose the region of the bile papilla, the forefinger of the right hand should be passed behind the gastro-hepatic omentum and the thumb gently pressed from above downwards along the line of the common bile-duct, careful watch being kept in the meantime upon the papilla to detect any escape of bile. If bile escape under these conditions, one may conclude that the common bile-duct was patent during life. The procedure generally followed is to exert pressure upon the gall-bladder, but this is not to be recommended, as the force thus exerted may be sufficient to expel bile past a gall-stone or to dislodge catarrhal exudate which has been sufficiently adherent during life to block the lower end of the duct. The patency of the common bile-duct having been determined, gentle pressure may now be applied to the fundus of the gall-bladder, so as to ascertain whether the cystic duct is pervious. The bile-ducts may then be opened up as far up as the hilum of the liver. The easiest way to accomplish this is to rotate the mass so that the liver is farthest from the operator and to place the forefinger of the left hand behind the gastro-hepatic omentum so as to render the latter tense. Then an incision is made close to the margin of the omentum, and at right angles to it, and extended into the omentum until the common bile-duct—easily recognizable from its yellowish-brown colour—comes into view. With a probe-pointed bistoury the duct is slit up right into the duodenum and similarly the hepatic duct, with its radicles, and the cystic duct, are in turn laid open. It will facilitate the opening up of the cystic duct if traction be exerted upon the gall-bladder, so as to straighten out the duct to some extent. If obstruction exist at any point in these passages the portion above the block is deeply stained with bile, whereas the part below the block may show either no discoloration at all, or this may be slight in degree.

The **Gall-Bladder** is to be opened and the nature of the escaping bile as to thickness, colour, visciduity, presence of small masses of inspissated bile or of the various forms of gall-stones should be carefully noted. The bile when smeared on a white surface is usually of a dark golden-brown colour. Its appearance, however, varies greatly from a watery orange-coloured fluid to a deep greenish-brown almost black tarry fluid. In certain catarrhal conditions of the bile-ducts with obstruction to the outflow of bile, the gall-bladder may contain only a small amount of colourless or straw-coloured mucus.

The other structures in the gastro-hepatic omentum—portal vein, hepatic artery and lymphatic glands—having been investigated, the Liver may be separated from the other organs. Before examining it further its *weight* should be ascertained. (See p. 225.)

In order to demonstrate structural changes within the liver a series of antero-posterior cuts should be made into the organ with a large-bladed knife. These, in the first place at least, should not extend completely through the organ, the different slices still remaining attached below. Sometimes a view of the interior, sufficient to display all important changes, is obtained by making one transverse coronal section across the organ.

Displacements of Liver. (1) **Congenital.**—The liver may be displaced, along with a general transposition of the organs, the left lobe being the larger, and bearing the gall-bladder—(*Situs inversus*).

(2) **Acquired.**—The liver may be displaced by pressure from above or from below. Although the liver may be displaced as a whole in consequence of increase in the volume of either thoracic or abdominal contents, the common displacements are rather of the nature of a rotation or tilting round the transverse or the antero-posterior axes, or may be due to a combination of these two rotations. Moreover, in cases in which the liver is displaced as a whole (*total hepatoptosis*), some tilting or rotation accompanies the total displacement. Again, in cases in which during life a definite downward displacement of the organ has taken place, this may not be apparent at the *post mortem* examination, because distension of the bowel with gas may push it up as a whole, or tilt it up to its normal position, a position to which, in any case, it tends to return on the prone position being assumed. In such cases, however, there is usually some indication in the abdomen that the relative position of the organs has been altered during life, e.g. the pylorus may be displaced downwards and the gastro-hepatic omentum elongated. In such livers there is usually in addition a transverse depression corresponding to the level of the waist. The term *Partial Hepatoptosis* is applied to conditions in which a portion of the liver, usually of the right lobe, descends lower than normal in the abdomen. This prolongation downwards may be external to the gall-bladder or may carry the gall-bladder upon it, or it may be lobed and attached to the liver only by a broad band of connective tissue. Very rarely a large downward prolongation, which consists largely of an angiomatous transformation of the liver substance, is found in the same situation.

The first three forms of prolongation are included under the term *Reidel's lobe*. The main mass of the organ is usually distorted and tilted.

Grooves on the surface of the Liver. (1) **Antero-posterior.**—These are seen not uncommonly, passing across the upper surface of the right lobe, and are seldom more than a quarter to a third of an inch in depth. They may be found at all ages; bands of the diaphragm may occupy them, and may have assisted in their causation.

In some cases doubtless they are due to mechanical pressure.

(2) In infants, particularly those in whom a rickety rosary is well-marked, oblique grooves on the surface of the liver result from the pressure of the ribs. When occurring in adults these are said to be due, in some cases, to tight-lacing, but I believe that they can rarely be put down to this cause.

(3) Not uncommonly, a wide transverse groove or depression is found passing across the right lobe of the liver, just over the position of the gall-bladder. This is the true atrophic groove resulting from pressure. The capsule is always thickened over the part affected, and the subjacent liver substance is atrophied. The atrophy is most marked over the position of the gall-bladder, where a deep notch may form in the anterior margin of the liver.

These transverse grooves result in women commonly from tight-lacing, but are found also in working men who have worn a rigid leathern belt.

Portions of normal or lobed livers may pass into umbilical hernias, or into the thorax through congenital or acquired defects in the diaphragm. These acquired defects result usually from mechanical rupture of the diaphragm.

General consideration of the pathological changes which may affect the liver.

Alterations in Shape. (1) **Congenital.**—Some degree of foetal lobulation may persist. One or other lobe may be partly or wholly wanting, the remaining lobe usually undergoing compensatory hypertrophy.

(2) **Acquired.**—The local atrophy due to tight-lacing may be accompanied by great distortion of the liver.

Tertiary syphilis may cause great deformity of the liver, and in cirrhosis great irregularity of the surface results.

Reidel's lobes have been mentioned already (p. 227), as forming in connexion with the right lobe, and occasionally tongue-shaped projections are found projecting from the left lobe, either forwards or backwards.

Alterations in Size. (1) **Enlargement.** (a) *Uniform.*—The liver is uniformly enlarged in the venous congestions; in leucocythaemia; in parenchymatous swelling; in waxy disease; in fatty infiltration, whether this be of a moderate degree, or extreme as seen in the typical alcoholic—"soakers"—liver; and in hypertrophic or monolobular cirrhosis. In some cases of multiple metastatic cancer, and of primary sarcoma, the liver may be fairly uniformly enlarged, and may weigh as much as 19 or 20 lbs.

(b) *Partial or Irregular.*—One lobe may be hypertrophied, if the other lobe has undergone atrophy from any cause. Irregular enlargements

are brought about by presence of large foci of suppuration; masses of new-growth, or cysts, e.g. hydatid cyst of *Taenia echinococcus*.

(2) **Diminution.** (a) *Uniform.*—The liver is uniformly diminished in size, and usually deeply pigmented, in general marasmus, from whatever cause—starvation, stenosis of oesophagus, old age, etc. The diminution may be slight or extreme in acute yellow atrophy; and is generally considerable in sub-acute atrophy. In advanced cases of common cirrhosis the liver is diminished in size.

(b) *Partial or Irregular Diminution.*—Atrophy of one lobe may occur and this may be accompanied by compensatory enlargement of the other. Local loss of substance may occur in tertiary syphilis, in acute and subacute atrophy, in cirrhosis, particularly when originating in the capsule. The loss of substance resulting from long-continued mechanical pressure has already been noted.

A liver, which is considerably diminished in size, may yet retain approximately its normal weight.

Weight must be distinguished from Specific Gravity. For example, an alcoholic fatty liver may weigh 6 or 7 lb. (3,000 gm.), yet its specific gravity be very much below that of a normal liver.

Changes in Colour.—The liver is normally of a dark purplish-brown colour, somewhat like that of blocks of chocolate. This colour should be uniform both on the outer and cut surfaces. The under surface of the liver is frequently of a dark bluish-grey or indigo colour. This is especially seen in livers in which there has been deposit of iron, and results from the action upon this iron of the sulphides which develop rapidly after death in the large intestine and diffuse readily from it.

Bile-pigment diffuses into the walls of the gall-bladder after death, and stains the adjacent structures.

It is unnecessary at present to consider the various pathological changes in the colour of the liver, seeing that these are fully described in connexion with the different diseases in which they occur.

(See *Changes in Liver in Anaemia* (p. 237), *Cloudy Swelling* (p. 231), *Fatty Infiltration* (p. 232), *Fatty Degeneration* (p. 231) and other degenerations, *Jaundice* (256), *Venous Hyperaemia* (p. 236), *Acute and Subacute Atrophy* (p. 245), *Cirrhosis* (p. 247), *Haemochromatosis* (p. 238), *Carcinoma* and *Sarcoma* (p. 253), etc.)

Metallic pigmentations are seldom encountered. In a case of Argylia, which I examined, the liver cells contained no metallic silver, and the amount of deposit in the connective tissues and in the walls of the blood-vessels was so small as to be scarcely appreciable, even with high powers of the microscope.

In young children, pale, anaemic or fatty patches of a pale yellow colour are frequently found underneath the capsule, apparently caused by pressure, and, occasionally, similar yellow areas, the so-called **anaemic** or **white infarcts** of the liver, are found in the adult. In the adult, particularly

when the liver contains numerous metastatic nodules, the liver substance between the nodules and the capsule becomes of a dark-brown colour from infiltration with blood. This condition is sometimes included under infarction of the liver—

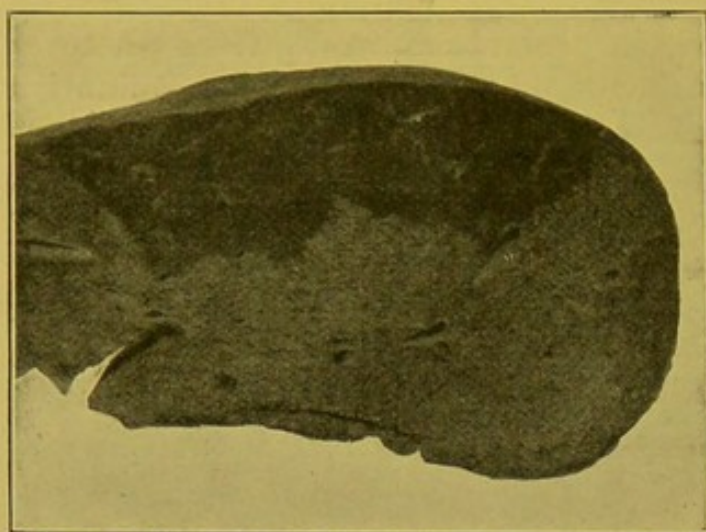


FIG. 111.—Red (False) Infarction of Liver.
(\times circ. $\frac{1}{2}$.)

“red infarction”—and some of the changes found, e.g. obstruction of the portal vein and hepatic artery are such as would be necessary to cause that condition. (Fig. 111.) In these areas the capillaries are distended with blood; and the liver cells may be pigmented and atrophied. True infarction of the liver, apart from the condition just mentioned, is

an extremely rare condition (Fig. 112).

In deaths from puerperal eclampsia, the liver may be pale as a whole, and show numerous more or less extensive extravasations of blood underneath the capsule, or in the substance of the organ, particularly near the coronary ligament. Associated with such haemorrhages, areas of necrosis are sometimes found. Similar appearances are found in newly born children who die in convulsions, or are born of eclamptic mothers.

All necrotic tissue within the liver tends to become bile-stained.

Alterations in Consistence.

—The normal liver, when removed from the body, and placed upon a flat surface, flattens out; the dome-like curve of its parietal surface becomes greatly lessened, and the general concavity of the visceral surface, with its numerous secondary depressions which lodge portions of the adjacent organs, is almost completely flattened out. Any softening of the organ tends to accentuate this flattening, whereas any increase in consistence tends to prevent it.

The consistence is uniformly increased in waxy or amyloid degeneration of the liver, which, when very marked, may preserve the liver in its original

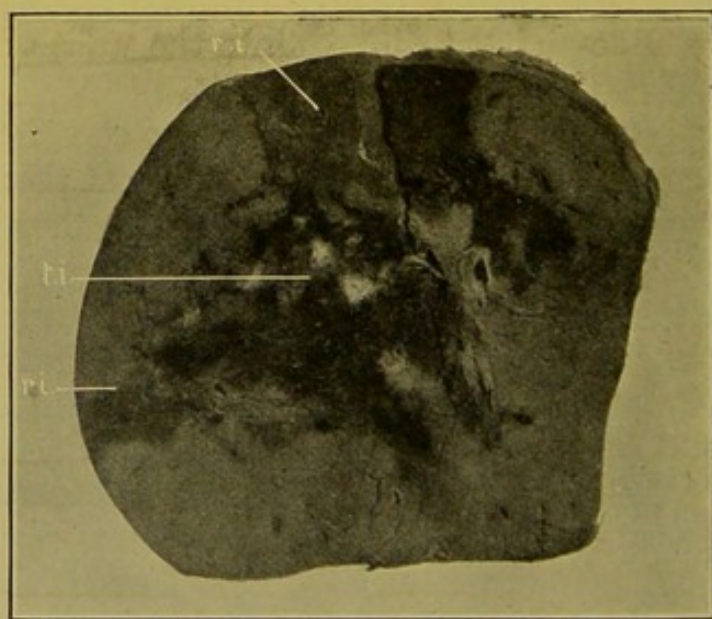


FIG. 112.—True Infarction of the Liver (*t.i.*).
(\times circ. $\frac{1}{2}$.)

(*r.i.*) “Red” infarction, between true infarct and the capsule.

shape. In interstitial hepatitis, whether multilobular, monolobular or intralobular, the consistence is also increased, but never to the same degree and never with the same loss of flexibility as in the case of waxy degeneration. In metastatic malignant growths, the enlargement is usually accompanied by an increase in consistence. The consistence is **increased locally** in areas in which large primary or secondary growths are infiltrating the organ, particularly in scirrhus cancer, and to a less degree in the case of other large secondary growths.

The consistence is **uniformly diminished**, in fatty degeneration and extreme infiltration, the **friability** being also increased if the fatty degeneration be marked. Decomposition also causes softening of the organ.

Local softening is especially found in presence of suppurations, cystic formations, and in the breaking down of new-growths.

DEGENERATIONS AND INFILTRATIONS OF THE LIVER.

Cloudy Swelling (syn. : Parenchymatous inflammation).—This is one of the most commonly found pathological changes. It follows the action of toxic substances within the body, particularly when associated with high temperatures. Under such conditions, the eliminating organs, e.g. liver and kidneys, and highly organized tissues like the heart muscle and ganglionic cells, are especially affected.

The liver is increased in size, its capsule tense, and its colour paler than normal both on its outer and cut surface. The cut surface is often in addition dull and opaque as though hot water had been poured over it. In other cases the cut surface presents an appearance as though covered with a translucent film. To the naked eye, the peripheral parts of the lobules may be marked out as paler grey circles. The lobules are enlarged as a result of swelling of the liver cells in the peripheral zone. The intra-lobular capillaries are thus compressed; hence the pallor is in part due to the actual changes in the liver cells, and in part to the diminution in the amount of blood within the liver. Under the microscope the liver cells in the peripheral parts of the lobules are swollen, rounded, and tend to lose their trabecular arrangement. The nuclei may stain normally or more often they take the stain faintly, or not at all. The protoplasm is finely granular, the granulations being most probably in the first instance due to infiltration with albuminous granules—alkali albumen—resulting from the breaking down of protein material elsewhere in the body. Later the cytoplasm shares in the degenerative changes. In the early stage the granularity can be completely removed by application of weak acetic acid or a weak alkali. Cloudy swelling may be associated with fatty degeneration of the cell, or proceed to that condition.

Fatty Degeneration of the Liver.—Fatty degeneration may occur in the course of severe toxæmias, and usually in such conditions is a sequel of cloudy swelling, particularly where inflammatory changes are associated

with the toxaemia, e.g. in pyaemia and septicaemia, in typhoid fever, etc. In such cases the change affects specially the *outer part* of the lobule.

(2) It is a common pathological change in chlorosis, anaemia from loss of blood, and pernicious anaemia. In these conditions the degeneration is usually *central* in the lobule.

(3) It is a constant result in recent poisoning by phosphorus, arsenic, antimony, chloroform, chloral, alcohol, iodoform, carbon monoxide, etc. In these cases, particularly in the first two, the changes are *diffused* throughout the lobule, and the droplets are of large size, resembling those seen in fatty infiltration.

In the early stages, the size of the liver may be increased; later, it diminishes, and the capsule becomes wrinkled and dull. The consistence is soft and doughy; the organ may be pulpy and is very friable, so that it is readily torn during removal. The colour varies from a dull purplish-brown or almost roan-brown to an orange or bright yellow colour, the colour also depending upon the relation between the amount of fatty change and the amount of blood present in the capillaries. In anaemic conditions the colour may be clayey. In conditions such as pernicious anaemia, in which there is also a deposit of altered blood pigment in the liver cells, the liver is of a brick-yellow colour, and if jaundice be present, it is of a dark greenish-yellow colour.

Under the microscope the nuclei stain well in the early stages, and the fat is deposited in fine droplets, which tend to be arranged along the margins of the trabeculae. Thus, in the early stages the condition is, in part at least, rather of the nature of an infiltration than a degeneration, the fat being derived from fat-depôts elsewhere in the body. In the later stages, when the cell itself becomes affected, the nucleus loses its staining power, and the cell tends to break down to a fatty detritus composed of albuminous granules and oil droplets.

Fatty Infiltration of the Liver.—Fatty infiltration of the liver depends upon excessive deposit of fat, and upon insufficient removal, the latter resulting from influences which interfere with its oxidation.

The liver differs from all other organs and tissues of the body in that the connective tissue cells are not infiltrated, but the liver cells themselves.

Fatty infiltration is the commonest change found in the liver in chronic alcoholics, the reason probably being that alcohol, being in itself a food product more easily oxidized than fat, interferes with the oxidation of the fat so that this becomes stored up in the liver.

The essential feature is that the fat is derived from without, and does not necessarily involve degeneration of the cell, though its presence usually impairs the function of the cell, and the process may end in degeneration.

To the naked eye the liver is enlarged, sometimes very greatly; in extreme cases its weight may reach 6 or 7 lb. (3,000–3,500 gm.). Its specific gravity, however, is much diminished.

The changes in colour vary with the degree of the infiltration. In *moderate* degrees the fat is deposited in the peripheral zone of the lobule, and this is marked out as a grey or greyish-yellow circle enclosing a brown spot which corresponds to the more central part of the lobule, the brown colour being deeper if chronic venous congestion co-exist. To chronic venous congestion accompanied by fatty infiltration, the name "nutmeg liver" is commonly applied. In more *extensive* infiltration the liver cells throughout the lobule are distended with fat, and compress the intra-lobular capillaries so that the amount of blood in the liver is diminished. The lobule is much enlarged, and the whole liver may be of a bright canary-yellow colour; soft, doughy in consistence, bulging on the cut surface and friable. A greasy fluid can be scraped from the cut surface.

Under the microscope minute globules appear, clear and colourless, with a dark outline. They accumulate, run together to form a larger globule, distending the cell, which forms a thin ring surrounding it. The nucleus, which still stains well, is pushed to one side, thus producing the typical signet-ring appearance of the cell infiltrated with fat.

In fatty infiltration of the liver there is usually no jaundice or ascites and the bile is thin and watery.

Livers which have undergone fatty infiltration are very liable to traumatic rupture, from comparatively slight causes.

Reactions for Fat.—The fats deposited are compounds of oleïn, palmitin and stearin. Osmic acid, which is used to demonstrate fat, stains the oleïn series; sudan and scharlach stain all three series, hence the two last reagents indicate an apparently greater deposit of fat than osmic acid and are to be preferred for its demonstration. They are employed in saturated solution in 70 per cent. alcohol, and being more readily soluble in oils than in alcohol, are quickly taken up from the alcoholic solution by the oil droplets. For mounting sections stained after this manner, glycerine or dextrin media should be employed. For Lorrain Smith's methods, see Appendix.

Waxy or Amyloid Degeneration or Infiltration.—This change occurs specially in the course of diseases which bring about cachexial conditions, such as chronic tuberculosis, with caseation, breaking down, and long continued discharge; long-standing suppurations, especially of bones and joints. It also occurs in the tertiary stage of syphilis, in chronic rheumatism, in malaria and in dysentery. It is occasionally found without any recognizable cause. The change affects solely the connective tissues and basement membranes.

The liver is enlarged, weighing sometimes as much as 10, 14 or 16 lb. (5 to 8 kgm.). In consistence it is firm and elastic and the deposit of waxy material tends to preserve the shape of the organ, so that, when removed from the body, it does not flatten out when placed upon a surface. It is enlarged in all its diameters, and the anterior margin, though still angular, is blunter than normal. In colour it is pale, having a general purplish-

grey colour on the cut surface, or, when the condition is extreme, it may resemble flint both in colour and translucency (*see* Fig. 119). On this surface there may be small yellowish opaque flecks and spots indicating fatty change.

The lobules are greatly enlarged, and in those which are cut transversely, a translucent ring is seen corresponding to the position of the intermediate zone (Fig. 113). On application of a solution of iodine (iodine 1 part, potassium iodide 2 parts, water 100 parts), the ring becomes of a deep brown colour, the tissue within the ring assuming a yellowish colour, which is also seen between the rings, in the tissue corresponding to the outer zones of adjacent

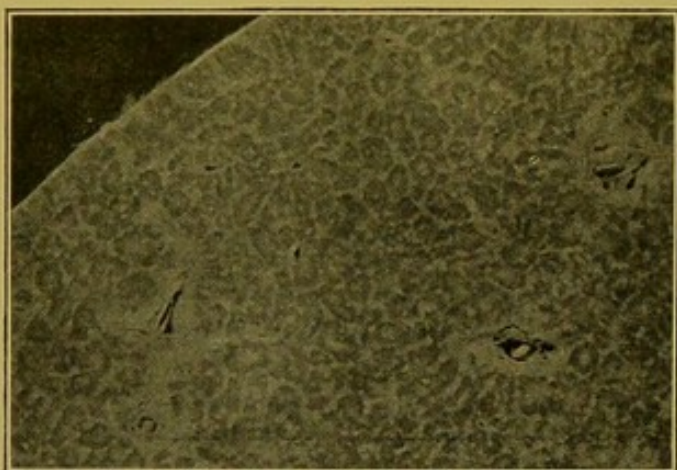


FIG. 113.—Waxy, Amyloid Liver.

Cut surface unstained, magnified about $2\frac{1}{2}$ times, to demonstrate the waxy ring or oval area corresponding to the intermediate zone of the lobule.

lobules and the portal spaces. Sometimes the waxy change is concentrated in certain parts of the liver, translucent areas being thus produced, in which even atrophied liver cells are very scanty. These areas at times occur independently, but they may also develop in close relationship to syphilitic gummata. In syphilis, the distribution of the waxy change in the liver is sometimes quite irregular.

Under the microscope the waxy material is laid down between the capillaries and the

columns of liver cells in the intermediate zone of the lobule. It compresses both capillaries and liver cells, and causes atrophy of the latter, so that in late stages they are represented by pigmented granular material only. The condition tends to extend towards the periphery of the lobule rather than towards the central part. In the portal spaces, the basement membrane of the bile-ducts, the connective tissue in the media and intima of the hepatic artery, the wall of the portal vein, and small patches of the connective tissue surrounding these structures may also show the waxy transformation.

Focal Necroses.—Minute opaque dull grey-brown areas of necrosis are frequently observed in the liver in cases of severe infection. They are most commonly seen in typhoid fever, but they are also found in septicaemia and in scarlet fever, and are well-marked in cases of puerperal eclampsia. They are best seen on the cut surface, above which, as a rule, they do not project. They vary in size from the hardly visible up to the size of a hemp seed, and are frequently of polygonal shape (Fig. 114).

Under the microscope, the cells in the area have lost their nuclear stain. Later they tend to disintegrate and leucocytes collect round about the area.

Characteristically bacteria are absent, at least they can seldom be demonstrated.

There is no unanimity of opinion as to their cause. They may result from the local action of bacterial toxins, from local thrombosis which may follow disorganization of the endothelium of the capillaries following the action of a toxine, or as a sequel to embolism of phagocytic endothelial cells from the spleen or intestine, or of placental cells in cases of puerperal eclampsia. Adami is inclined to support the opinion that the capillary thrombi which bring about the necrosis are the result of a primary haemolysis.

Congestions of the Liver.—In congestion of the liver there is an increase of blood within the organ, resulting either from an increased inflow of blood through the portal vein, or a decreased outflow through the hepatic vein; the former constituting acute or active congestion, the latter including the passive congestions which are usually chronic.

Active congestion is usually the result of gastro-intestinal congestion and catarrh, and, particularly in tropical climates, it may be the result of infective conditions, e.g. malaria, dysentery, and intermittent fever. It is said to occur in suppressed menstruation. The *post mortem* changes are seldom well-marked. The liver is enlarged and uniformly dark purple in colour. On section, a large amount of blood escapes from the cut surface. There is no special localization of the congestion to the central part of the lobule as in the case of chronic venous hyperaemia. Microscopically, the walls of the dilated vessels are not thickened, and some accompanying parenchymatous degeneration is usually found.

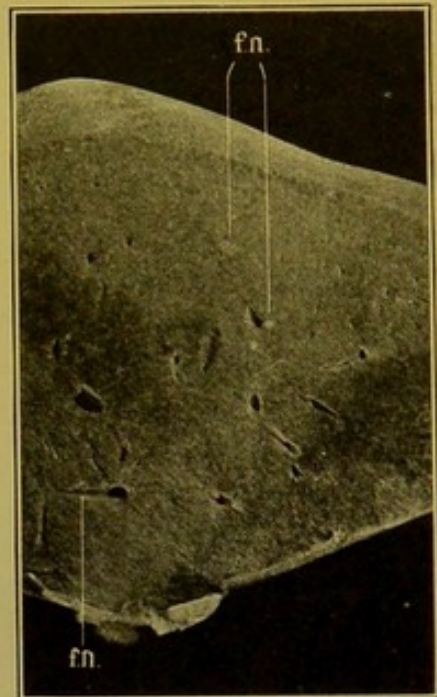


FIG. 114.—Focal Necroses of Liver (*fn.*). (\times circ. $\frac{3}{5}$.)

(2) **Passive Congestion** is a much more common condition. It may be acute or chronic; the latter being more common. Chronic congestion is also known as **chronic venous hyperaemia**, "cyanotic atrophy," "nutmeg" liver. The immediate cause is some obstruction to the outflow of blood from the liver, resulting from disease of the heart or lungs. It results particularly from valvular disease of the heart and from incompetence of the valves rather than stenosis. The congestion is most marked when tricuspid incompetence is associated with mitral incompetence. Adherent pericarditis, by interfering with the propelling power of the heart, may be an additional factor in its causation. In some cases the primary cause is found in obstruction within the pulmonary circulation, such as is produced by chronic interstitial pneumonia, or chronic bronchitis with emphysema. Acute venous congestion is caused by rapid failure of the right heart.

The changes produced are similar to those described under active congestion, but the central zone of the lobule is more deeply congested than the peripheral zone.

In early stages, the liver as a rule is enlarged, and the capsule tense. In later stages, it is diminished in size, and the capsule wrinkled. In estimating the size of the liver, it should be remembered that some of the blood drains away from the liver after death, by the action of gravitation. Thus the size of the separated liver may not bear a true relationship to the size it

presented during life.

The surface of the organ may be irregular, closely resembling the appearance met with in some varieties of cirrhosis of the liver, for which the condition is frequently mistaken by the inexperienced. The superficial irregularity is usually less coarse than in cirrhosis, and its distribution is, as a rule, more regular. On section, the appearances vary with the stage of the condition. A large amount of blood flows away from the cut surface. The walls of the hepatic vein, which are normally thin and translucent, are rendered opaque through fibrous




FIG. 115.—“Nutmeg” Liver; chronic venous hyperaemia, with some fatty infiltration at periphery of lobules. (\times circ. $\frac{2}{3}$.)

thickening, and the lumen is also distinctly increased. In the earlier stages, each lobule is marked out by a central, purplish-brown or dark brown spot, which is produced by the overfilling of the central vein and the capillaries in the central part of the lobule. This spot is surrounded by a dull greyish-brown to mustard-yellow zone, corresponding to the outer portion of the lobule, in the cells of which there is usually some fatty infiltration, on the degree of which the colour depends (Fig. 115). Later on, the dark spots tend to coalesce, as the liver-columns disappear under the pressure of the capillaries, which continue to dilate, and in the late stages of the process, it may be difficult to distinguish individual lobules.

In these late stages also, yellowish nodules, which may reach the diameter of about a sixth of an inch, are seen on the cut surface, and may project upon it (Fig. 116). These consist of fatty liver cells, chiefly in relation to the sub-lobular veins, and represent attempts at regeneration of the organ. In the advanced stages, new fibrous tissue forms along the interlobular fissures, and in the portal spaces, rendering the organ tougher than normal, so that it somewhat resembles the cirrhotic liver, from which however it is readily distinguished by its dark colour.

Microscopically, the central vein and the capillaries in the central part of the lobule are dilated, the dilatation lessening as one passes outwards in the lobule. It is important to note as distinguishing chronic hyperaemia from acute hyperaemia that the walls of the central vein and of the affected capillaries are distinctly thickened, the walls of the latter forming a more easily distinguishable and more continuous layer than in the normal condition. Between the capillary wall and the liver cell a clear narrow space can always be seen in well-marked cases. The liver cells may have completely disappeared in the central part of the lobule, and in any case the width of the column, normally exceeding that of the capillary (as 3:2), is diminished. Characteristically, there is increase of yellowish-brown pigment, usually described as haematoidin, in these cells; this can be made out readily by examination of unstained microscopic sections.

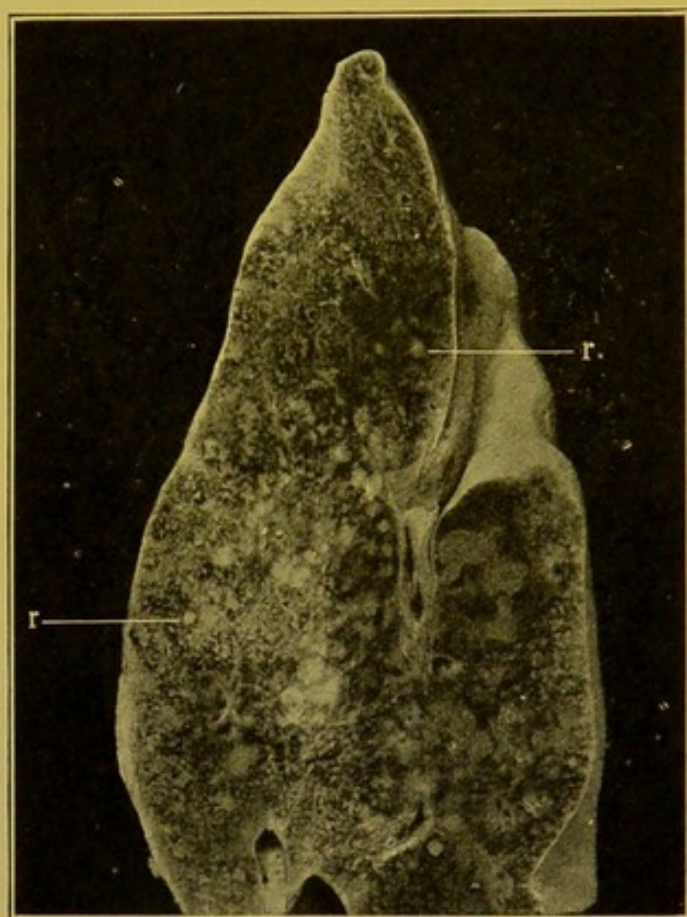


FIG. 116.—Advanced Chronic Venous Hyperaemia, showing areas of regeneration (r.) of liver tissue. (\times circ. $\frac{2}{3}$.)

In advanced stages of chronic venous congestion one usually finds, in addition, results of obstruction to the portal circulation, such as chronic venous congestion of the alimentary tract, pancreas, and spleen. Ascites also may be present.

Changes in the Liver in Anaemia.—As a type of the changes occurring in the liver in severe forms of anaemia, those met with in cases of so-called *Pernicious Anaemia* may be described.

The liver may be slightly diminished in size, of a yellow-ochre colour

or of a light brick-yellow colour. On section, similar colour changes are evident, and on close inspection the brick or ochre colour is seen to be most marked in the outer parts of individual lobules. Frequently the liver near to its visceral surface is of a dark slate-grey colour, and on close inspection this discoloration is seen to affect the parts of the lobule, which, in areas nearer the parietal surface of the organ, are of an ochre colour. This discoloration is due to the action of sulphides—ammonium sulphide and sulphuretted hydrogen—which have diffused from the large intestine—upon the deposit of haemosiderin pigment which produces the yellowish-brown discoloration described. This action can be imitated by applying a solution of ammonium sulphide to the cut surface of the organ, upon which the iron containing parts will become of a dark grey or black colour (Quinke's test). Another test readily applied is Perl's Prussian Blue Reaction. Before applying this test the surface of the organ should be thoroughly washed with water to remove excess of blood. A 10 to 20 per cent. aqueous solution of *ferrocyanide of potassium* is poured upon the surface, and allowed to act for a few minutes. This is followed by the application of a 5 per cent. aqueous solution of *hydrochloric acid*. The latter bleaches the surface, and then gradually a greenish colour develops in the affected parts, which rapidly intensifies to a deep blue. These reactions may also be employed successfully to demonstrate haemosiderin in microscopic sections. Under the microscope the pigment is seen to be deposited in the first place near the nuclei of the cells in the peripheral zone of the lobule, and as the deposit increases it forms an irregular line running up the centre of the column of liver cells. Some pigment is also found in the endothelial cells of the capillaries. Accompanying the pigment—haemosiderin—which displays this reaction, there is usually, in addition, a lighter yellow pigment—haemofuscin—which does not give the reactions of haemosiderin.

Pigmentation of a nature similar to that met with in the severe anaemias, is found also in other conditions, particularly in the rare disease known as **Haemochromatosis**. This disease apparently depends upon great destruction of red corpuscles in the portal area. Most of the glands of the body are of a deep reddish-brown colour. The discoloration of the liver is intense. Granules of haemosiderin and haemofuscin are found in the secreting cells and endothelium of the liver and pancreas, also in connective tissues, in smooth muscle fibres of the alimentary tract and of the vascular system and genito-urinary passages, and in lymph-glands. Bronzing of the skin is not a constant feature of the disease. The parenchymia cells and endothelial cells of various organs also take up red blood corpuscles. In late stages, cirrhosis of the liver and pancreas develops. In the pancreas this fibrosis is usually intralobular, and sometimes is associated with fibrous transformation of the Islets of Langerhans, and with glycosuria—"Bronzed Diabetes."

The exact nature of Haemofuscin is not yet determined. Some authorities regard it as a derivative of haemoglobin, similar in constitution to

haemosiderin, but not giving the reactions of that body, the iron contained being still in too close combination; others look upon it as a product of protein metabolism. It corresponds in some respects to the class of melanine pigments, and in others to the lipochromes.

Suppuration in the Liver.—(1) In **General pyaemia** the infective emboli are conveyed to the liver by way of the hepatic artery. The abscesses may be scattered throughout the liver or may be to a large extent superficial. In some cases wedge-shaped necrotic infarcts form in this situation. This form of suppuration is frequently associated with ulcerative endocarditis, which may form the original focus from which dissemination has taken place, or the primary suppuration may occur in the head or in the extremities.

(2) **Portal Pyaemia** commonly results from the impaction in branches

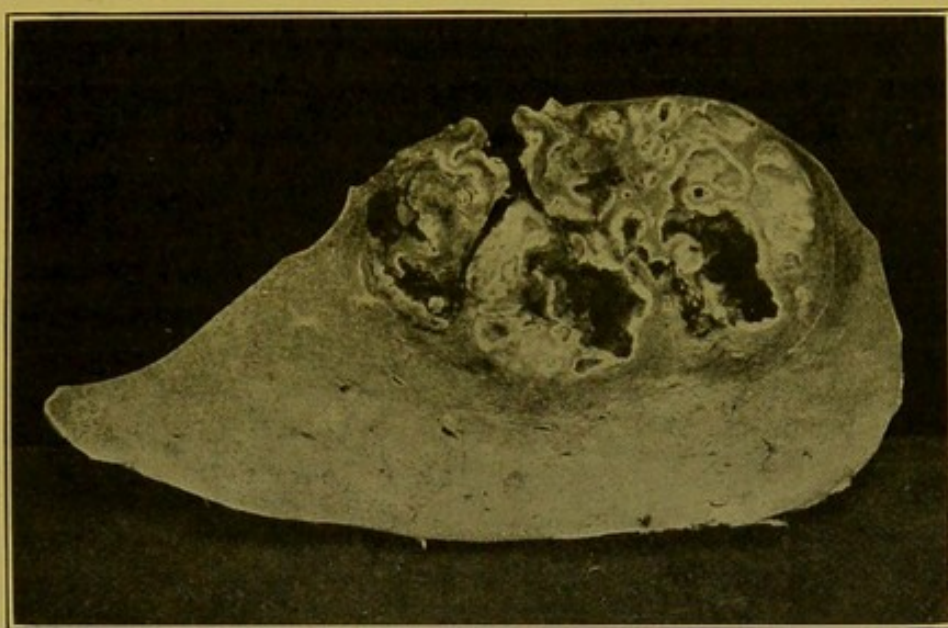


FIG. 117.—Liver; Portal Pyaemia. (\times circ. $\frac{1}{3}$.)

The pus had been in part evacuated. The operation opening is seen in the upper part of the illustration.

of the portal vein of infective emboli originating in some part of the portal system. The condition is sometimes termed *suppurative pylephlebitis*, because the infection may originate an inflammation of the wall of the larger branches of the portal vein, or of the main trunk itself, accompanied by septic thrombosis, and from this the septic process passes outwards along the branches of the portal vein. This thrombosis does not always occur, if the emboli be of small size, and pass directly to the smaller branches of the portal vein. The difference, however, is simply one of degree.

The resulting suppuration takes the form of multiple abscesses which may be localized to one lobe of the liver, especially the right lobe, or to one portion of it. (Fig. 117.) In the early stages, the abscesses show a certain amount of branching, but, later, the smaller abscesses tend to coalesce. Even then at the outer parts of the affected area smaller foci are seen, diminishing

as one passes outwards in the liver. In the larger abscesses the walls are usually irregular, with remains of necrotic trabeculae projecting into the cavity. The walls are of a light yellow colour, and they are surrounded by dull-brown condensed liver tissue. At a later stage, in favourable cases, the yellow necrotic layer is replaced by granulation tissue, which as time goes on, becomes more and more organized to scar tissue.

The liver as a whole is enlarged. The portal vein, if the seat of septic thrombosis, may be distended with offensive pus. This may be limited by thrombosis, or as in one case I examined, every radicle of the portal vein throughout the abdomen may be filled with greenish-yellow pus. In the same case, the mouth of the splenic vein was blocked by thrombosis. Frequently the septic thrombosis extends into the hepatic vein, and may be followed by embolism in the lungs.

Microscopically the ordinary appearances of septic thrombosis are seen in the branches of the portal vein accompanied by infiltration and exudation in the connective tissue of the portal space. The liver cells are at first pushed aside, but soon the infiltration extends into the lobule, and degeneration of the liver cells takes place.

In a large number of cases, the *original focus* of the suppuration is situated in or around the appendix vermiformis. Portal pyaemia may also follow severe inflammations of the stomach and intestine, particularly if accompanied by ulceration; or it may follow peritoneal or retroperitoneal suppuration. In the newly born, suppuration may extend from the umbilicus, along the umbilical vein.

Bacteriology. — The organisms found most commonly belong to the *colon* group, but the ordinary pyogenic cocci are also frequently found, particularly *staphylococci* and *streptococci*.

(3) **Suppurative Cholangitis** most frequently follows formation of gall-stones and their impaction in the ducts, or blocking of the ducts by cancer or rarely by parasites which have penetrated to the ducts, and died there. It may be secondary to severe intestinal inflammation, particularly dysenteric or typhoid ulceration. It also occurs as a complication of influenza. The bile ducts are distended with bile-stained pus and their walls may be rough and incrustated. The resulting suppuration, seeing that it primarily follows the distribution of the portal spaces, has a branching character. At a later stage it may come to resemble the suppuration in portal pyaemia. Nevertheless, in the less affected parts of the liver, bile-stained lines of suppuration can be seen localized to the portal spaces. The organism most frequently found is the *bacillus coli communis*. Cholangitis is frequently associated with endocarditis.

(4) Occasionally sub-phrenic or perinephric abscesses may invade the liver directly, causing localized suppuration of its substance.

(5) Abscesses following retrograde embolism in the hepatic vein may produce large abscesses similar to those already described. It is said to

occur especially as a sequel to suppuration in the meningeal sinuses, and in the brain itself.

(6) Large localized abscesses occur more commonly in tropical countries, though they may also result from the coalescence of abscesses in portal pyaemia. The true **Tropical Abscess** is frequently solitary or may be accompanied by two or three other large abscesses (Fig. 118). It most frequently develops in the right lobe, and is a common sequel of endemic dysentery. In general appearance it corresponds to the large abscesses already described, and in the necrotic, irregular walls the *entamaeba histolytica* is usually found. It is still, however, a question how far the *entamaeba* is alone responsible for the abscess-formation. The exciting cause is conveyed to the liver, according to some authorities, by way of the portal vein or bile-ducts. Other authorities are of opinion that the *entamaeba* may migrate across the peritoneum (Herringham). Alcoholism and malaria are predisposing factors.

The appearance of the pus depends upon the amount of blood and necrotic liver tissue contained in it. Usually it is of a brownish-pink colour and has been compared to anchovy sauce. If the pus be evacuated by operation, *entamaebae* are seldom found in the first pus removed, but in that covering the dressings after some days they are found more constantly. The pus may point in different directions and may open near the umbilicus, or into the intestinal canal.

When it opens into the peritoneal cavity, a fatal peritonitis usually results. The abscess may perforate the diaphragm and the pus be discharged through a bronchus. If sinuses have formed to the surface or through the lung the *entamaeba* is also to be found in their walls. In cases which survive, connective tissue forms in the wall of the abscess. This contracts and finally a comparatively small cavity or a fibrous scar, in which calcification may occur, may alone be left to mark the site of the suppuration.

(7) Suppuration may occur in connexion with dead hydatid cysts of the

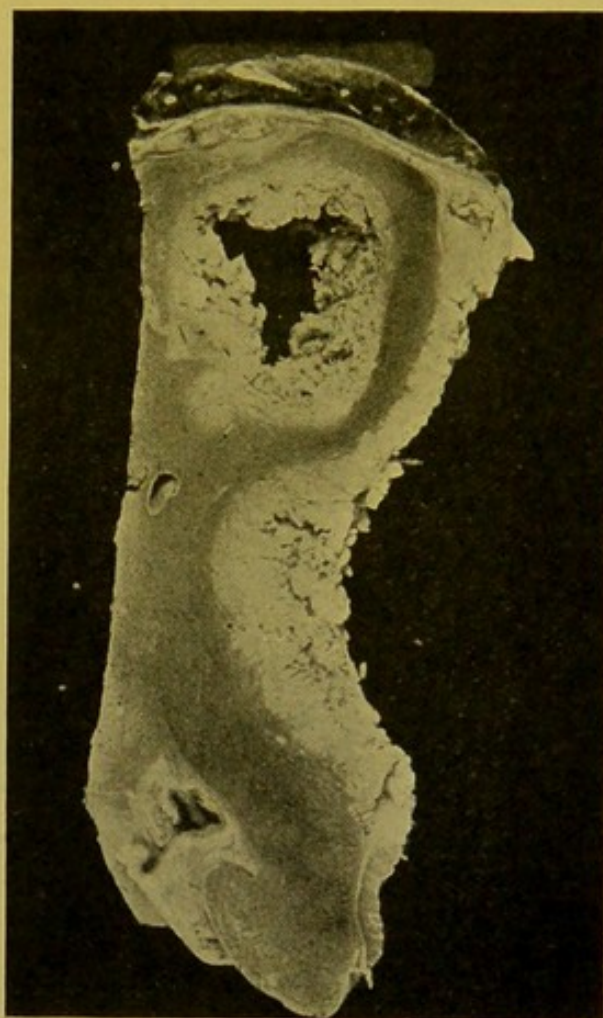

FIG. 118.—Tropical Abscess of Liver.
(\times circ. $\frac{1}{2}$.)

Portion of Liver, showing a complete section through one abscess and part of the wall of a larger one. Small portion of right lung at upper end of specimen. Adherent pleurisy and perihepatitis.

liver. In this form of abscess the walls are usually firm, composed of condensed liver tissue, lined by necrotic tissue or incrustated with salts, and within this is a mass of pulpy, opaque material of pinkish colour. The collapsed ectocysts may still persist, or, if these disappear, the hooklets of the degenerated scolices can always be found on microscopic examination, and give indication of the nature of the suppuration.

(8) In **actinomycosis**, irregular intercommunicating abscesses form. These may be localized to one part of the liver as in the case of suppuration in

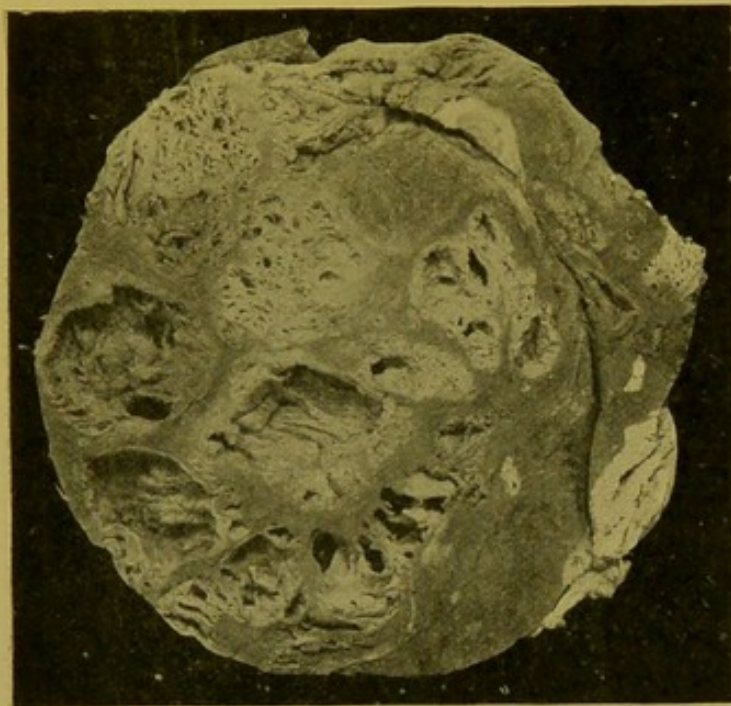


FIG. 119.—Actinomycotic Abscesses of Liver.
(\times circ. $\frac{1}{2}$.)

portal pyaemia, the closely set abscesses being separated up by a sponge-work of persisting liver tissue. The pus is usually somewhat slimy and contains yellow mustard-coloured granules of the ray-fungus. In general characters, origin and distribution, the abscesses correspond to those developing in portal pyaemia. (Fig. 119.)

Infection takes place from the intestines or by the bloodstream following invasion of the air passages.

Tuberculosis of the Liver.

—(1) Miliary tubercles, grey or caseating, develop in the

connective tissue of the portal space, whence they extend into the lobule. Occasionally they develop in connexion with smaller bile-ducts, and then may be bile-stained. (2) Larger caseating tubercles are sometimes found in the liver, particularly in children. The central part is frequently softened, and usually bile-stained. They are occasionally of considerable size. (3) Tuberculosis sometimes attacks the larger bile-ducts, causing ulceration of their walls.

Leprosy.—In leprosy, foci may be found within the portal spaces, sometimes extending to the peripheral zone of the lobule. The nodules contain large endothelioid cells, many of which are crowded with the characteristic bacilli.

Syphilis of the Liver.—(1) In the acquired form of the disease the most important hepatic changes occur in the tertiary stage. The chief lesion is the *gumma*, which in the adult is practically always accompanied by extensive interstitial changes, usually taking the form of fibrous scars radiating throughout the organ. Early gummata are of a reddish-grey colour and rather soft. They consist primarily of granulation tissue containing large

numbers of endothelioid and lymphoid cells, and similar cellular tissue spreads irregularly in the surrounding liver tissue. In later stages gummata are characterized by necrotic and fatty changes, and they are surrounded by dense, often hyaline, scar-like, connective tissue. The greyish-yellow colour of the caseating gumma, its dryness, toughness and elastic consistence, distinguish it from caseating tuberculous masses, and from true neoplasms. Gummata (Fig. 120) may be single or multiple, varying in size from that of a pea to that of a Tangerine orange, and occasionally they attain even a larger size. They may occur at any part of the organ—either close under the capsule or deep, in the midst of scar-tissue, but are perhaps most frequently found in the neighbourhood of the suspensory ligament. Calcification may occur, or softening may take place, presumably through secondary infection, and an abscess may result. The final result depends

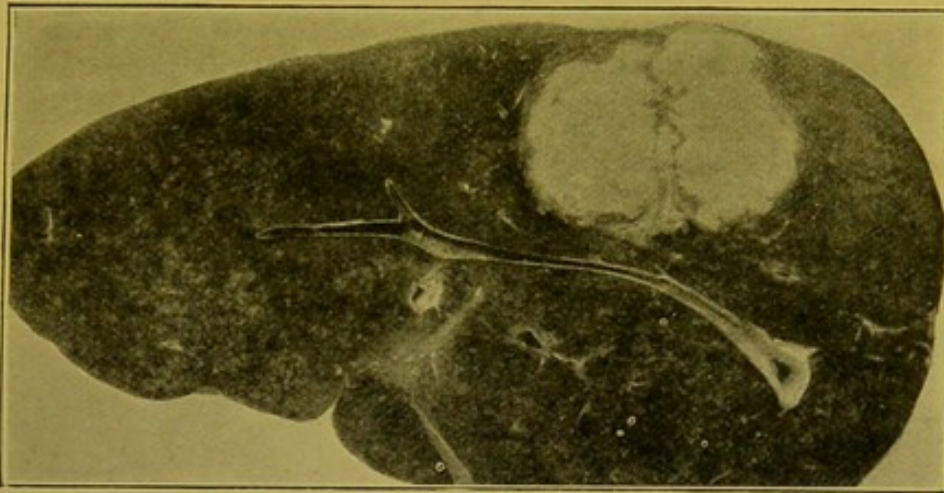


FIG. 120.—Syphilitic Gumma of Liver, near the upper surface of the right lobe. (\times circ. $\frac{1}{2}$.)

The liver showed extreme waxy (amyloid) transformation.

upon the number, size, and position of the gummata. There may be only a few puckered scars on the surface, with some localized thickening of the peritoneum. In severe cases, the liver may be greatly deformed. It is traversed in all directions by broad bands of fibrous tissue which surround large masses of liver tissue, which, by contraction of the fibrous bands, come to form rounded projections on the surface (*Hepar lobatum*). These sometimes even become polypoid. In the fibrous bands within the organ dry, old, gummatus masses may be found. The arterioles and even branches of the portal vein within the scar-tissue frequently show proliferation of the intima and endothelium, and occasionally thrombosis. The capsule of the organ usually shows some thickening and almost invariably fibrous adhesions to the surrounding parts, particularly to the diaphragm.

The fibrous bands resemble very closely those found in coarse cirrhosis; they contain a large proportion of elastic tissue; large numbers of bile-duct structures may be found. Usually lymphocytes and plasma-cells are present

in considerable numbers. The liver tissue away from the scars may show little change, but usually distinct fatty change is found in the immediate neighbourhood of the scars and of gummata, and very frequently waxy (amyloid) change, either throughout the organ or localized to one part of it, for example, in the neighbourhood of gummata. A diffuse intralobular cirrhosis or fibrosis seldom develops. In some cases coarse cirrhosis is closely simulated, and in others a portion of the liver may escape practically completely. Jaundice does not occur; the spleen, however, may be greatly enlarged.

(2) **Inherited Syphilis.**—(a) As met with in children, the principal change is of the nature of a diffuse small-celled infiltration which extends throughout the whole, or the greater part, of the organ. These cells result from proliferation of the endothelium of the intralobular capillaries, of the lymphatics and of the connective tissue cells. The lobular arrangement may be lost. In the part affected, individual liver cells and small groups of liver cells become surrounded by young connective tissue. The liver cells proliferate, and many show atrophy and granular degeneration. In many cases miliary gummata are also found. These closely resemble miliary tubercles, presenting the appearance of minute grey or yellow spots. They consist of small collections of large cells surrounded by an irregular zone of small lymphoid cells. At an early period the central part becomes necrosed and more or less homogeneous. Miliary gummata are generally placed close to the portal spaces.

The organ may be slightly enlarged. It is indurated, heavy, smooth on the outer and cut surfaces. It is usually of a yellowish-grey colour, the more healthy parts of the liver retaining a pink colour.

Occasionally the liver is of a grass-green colour, and jaundice frequently co-exists. Ascites is not common.

The *Treponema pallidum* can be demonstrated in large numbers by Levaditi's method of silver-impregnation, or in scrapings from the fresh liver by Burri's Indian-Ink method. (See p. 452.)

(b) **Delayed inherited Syphilis.**—The manifestations of this condition appear later in life, but as a rule under twenty years of age. The individual is often ill-developed and other evidences of syphilis can usually be found, e.g. disease of the cornea, alteration in the shape of the teeth (Hutchinson's teeth) and disease of bone. The changes in the liver resemble some of those found in acquired syphilis, the organ showing the deformity from gummata and scar-formation characteristic of that form of the disease. Perihepatitis is frequently found.

The Liver in Leucocythaemia.—The liver is usually enlarged, pale, and shows the usual characters of the anaemic liver. In the lymphatic form, greyish, firm nodules, composed chiefly of lymphoid cells, may develop in relation to the portal spaces. Under the microscope, the changes are such as occur in the severe anaemias, and in addition, the portal spaces are

infiltrated with the cells characteristic of the variety of the disease, and the blood-vessels, also, contain large numbers of these cells.

The Liver in Lymphadenoma.—The liver may show few changes, or it may be enlarged with numerous small grey nodules with ill-defined margins, both under the capsule and throughout its substance. These vary in size from minute granules to the size of a hemp seed, and at times, large firm white masses may develop in relation to the larger portal spaces, especially in the neighbourhood of the hilum (Fig. 121). These may show patches of necrosis. Under the microscope, small cellular areas, composed of endothelioid cells with many characteristic "lymphadenoma cells" containing convoluted nuclei, may be seen developing in the portal spaces and extending thence

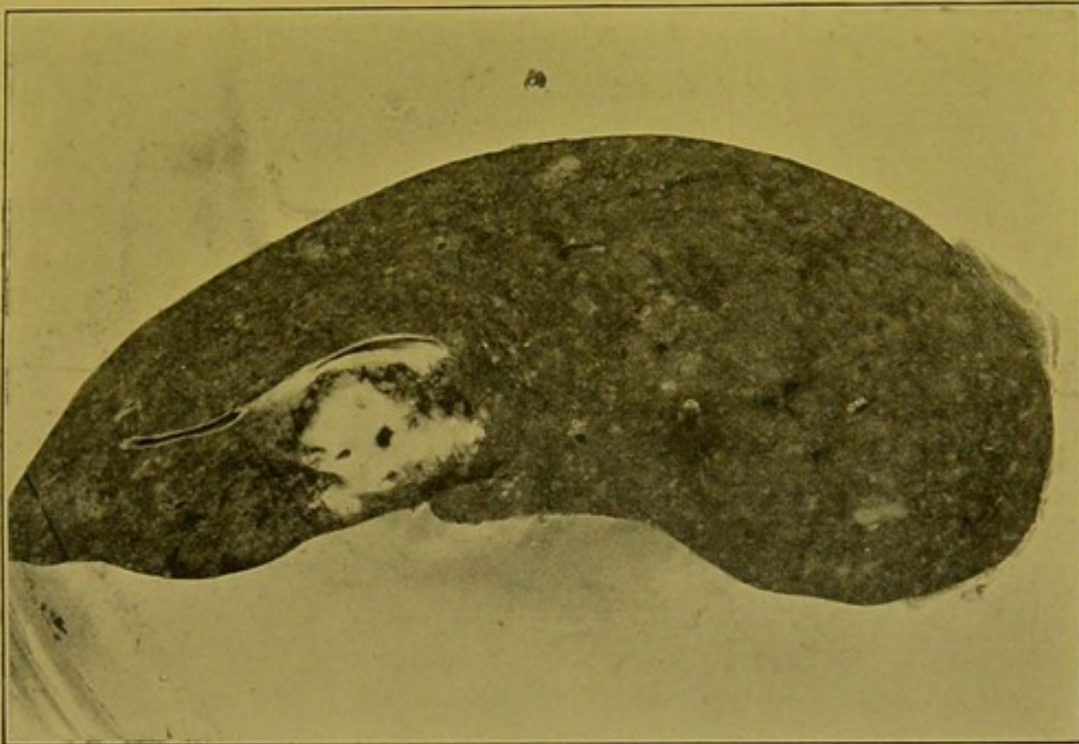


FIG. 121.—Liver in Lymphadenoma; section. (\times circ. $\frac{1}{2}$.)
Multiple minute lymphadenoma nodules, and one large mass, comparable to "suet" bodies in spleen.

into the liver substance. In one case investigated by me, the liver, in addition, was the seat of changes resembling those which occur in acute yellow atrophy, the degenerative and regenerative changes being especially evident near the surface of the organ.

Acute Yellow Atrophy of the Liver.—This is one of the rarest of diseases, and most probably results from the action upon the liver of toxic substances conveyed by the portal or arterial blood. It forms one of the varieties of malignant jaundice. In its etiology the influence of sex is undoubted, females greatly preponderating among those attacked. Fifty per cent. of the cases occur between twenty and thirty years, but no age is exempt from it. Occasionally it is found in individuals below the age of ten years.

In women the disease develops especially in connexion with pregnancy, generally commencing about the mid-point, or directly after labour.

In the majority of cases it attacks those who are of robust constitution, but may follow wound sepsis, erysipelas, or puerperal fever; there need be no definite relation to syphilis or to alcoholism. It may be superadded to other diseases of the liver, e.g. lymphadenoma.

The changes somewhat resemble those resulting in phosphorus poisoning, but clear distinctions can be drawn between the two conditions. (*See Phosphorus Poisoning*, p. 436.)

Great diminution in the size of the liver is a characteristic feature; the organ may be reduced to one-third or even to one-fourth of its normal bulk. This diminution is not invariable. The liver is soft, but its friability is not increased. The capsule is wrinkled. The surface is usually of a dark greenish-yellow or orange colour, with, occasionally, scattered patches of a red colour. Haemorrhages may be seen under the capsule and throughout the organ. The yellow colour predominates in acute recent cases, whereas in relatively older cases the red colour predominates. The yellow patches represent portions in which the liver cells, though degenerating and necrotic, still persist. In some cases the organ is of a yellowish-green colour throughout, with scattered pale yellow spots and blotches. If the cut surface be exposed to the air, particularly in warm weather, a whitish shimmering layer of leucin and tyrosin may form upon it. These products of the disintegration of albumen are found in other toxic poisonings, notably in phosphorus poisoning.

Under the microscope the portal spaces appear to be more numerous than normal, owing to the shrinking of the liver tissue. In the yellow parts the affected liver cells have lost all power of taking nuclear stains; they are swollen, granular, their margins irregular, and later they break down. Fatty changes may be present in the cells, but necrotic changes predominate. In sections stained with *sudan* or with *scharlach*, the fat has to be distinguished from coarse granules of bilirubin or the common brown liver pigment, the colour of which may be intensified by the use of these reagents. (*See also Protagon*, p. 290.) There is great cellular infiltration in the portal spaces and the number of bile-duct structures is increased, these evidently corresponding to the finer intra-lobular ducts which have been rendered apparent by the destruction of the liver cells which advances from the periphery of the lobule towards its centre. The yellow colour depends chiefly upon the bilirubin present.

Part of the organ may escape.

The *kidneys*, *heart*, and skeletal *muscles* frequently undergo fatty degeneration, but never to an extreme degree. The *spleen* is enlarged, softened, and diffuent. Haemorrhages are commonly found on all the serous surfaces. Leucin and tyrosin can be demonstrated in the urine.

In some cases the changes are less acute, and the individual lives longer. In such cases, which may be classed under the **sub-acute liver atrophies**, evidences of regeneration are well marked and the liver is divided up into brownish-pink—"old-rose"-coloured—areas and greenish-yellow areas, the

latter resembling in many respects an invading tumour-growth (Plate I, Fig. 4). The pink portions closely resemble, to the naked eye, normal liver tissue, but, as a matter of fact, these portions present the most extreme changes. They are composed of very cellular and vascular connective tissue in which are numerous mononuclear cells and fibroblasts with a varying proportion of polymorphs. Crowding this tissue are numerous branching bile-duct structures, many of them being in part made up of small polygonal cells, and frequently containing in their centres plugs of bile. They can be seen close up to the persisting portal veins. In addition, fine oil droplets and granules of pigment can be made out within some of the cells lying in the connective tissue. The yellow portions possess some general resemblance to liver tissue, but there is no distinct and regular separation up into lobules. Where portal spaces can be distinguished, these are extremely cellular at their periphery, the cellular parts replacing the liver tissue. The greenish-yellow colour of these parts of the liver seems to be due to a great extent to the presence of inspissated bile in the columns of cells. Fatty change, if present, is limited to small irregular areas.

All degrees of transition between sub-acute atrophy and coarse cirrhosis of the liver may be encountered. A feature which assists the recognition of the former condition is the presence of jaundice. The clinical history also indicates a shorter duration of ill-health.

Chronic Interstitial Hepatitis, or Cirrhosis.—These terms are applied to a group of pathological changes occurring within the liver, in which an increase of fibrous connective tissue takes place, either between or within the lobules, accompanied by or preceded by necrotic or degenerative changes, and in late stages proceeding to regenerative changes in the parenchyma of the organ.

The distribution of the fibrous tissue varies with the cause, and also probably depends upon the channels by which the (causal) noxious substances have been conveyed to the liver.

Three main types of cirrhosis are distinguished, (a) Coarse or multilobular, (b) Fine or monolobular, and (c) Intralobular or intercellular.

(a) **Coarse or Multilobular Cirrhosis.**—This variety is also shown as polylobular, atrophic or common cirrhosis; gin drinkers' liver; brandy drinkers' liver, "hob-nail" liver. It was first described by Laennec and thus is sometimes termed *Laennec's Cirrhosis*.

The cause of the condition is some toxine of chemical or bacterial origin which is elaborated in, and conveyed from, the alimentary tract, which is the seat of chronic catarrh. It is probably not the direct result of bacterial action in the liver itself, the discovery of bacilli of the colon group in the liver in cases of cirrhosis suggesting *post mortem* invasion. Some of the names applied to the condition indicate that abuse of alcohol—more in the form of spirits than of beer—is one of the most frequent causes of the catarrh of the alimentary canal which usually precedes the changes in the liver, but other

irritants may also induce this condition. The more constant *direct* effect of alcohol is to produce the enlarged fatty liver. The most extremely cirrhotic liver I possess was removed from the body of a strict teetotaler who was afflicted with flatulent dyspepsia, for the relief of which he took daily an infusion of a teaspoonful of black pepper. At the present time this liver measures 7 in. (17.5 cm.) from side to side, $4\frac{1}{2}$ in. (10.6 cm.) from before backwards and 1.6 in. (4 cm.) in thickness. It weighs $14\frac{1}{10}$ ozs. (400 gm.) (Fig. 122).

Cirrhosis may follow attacks of scarlet fever, diphtheria, typhoid,

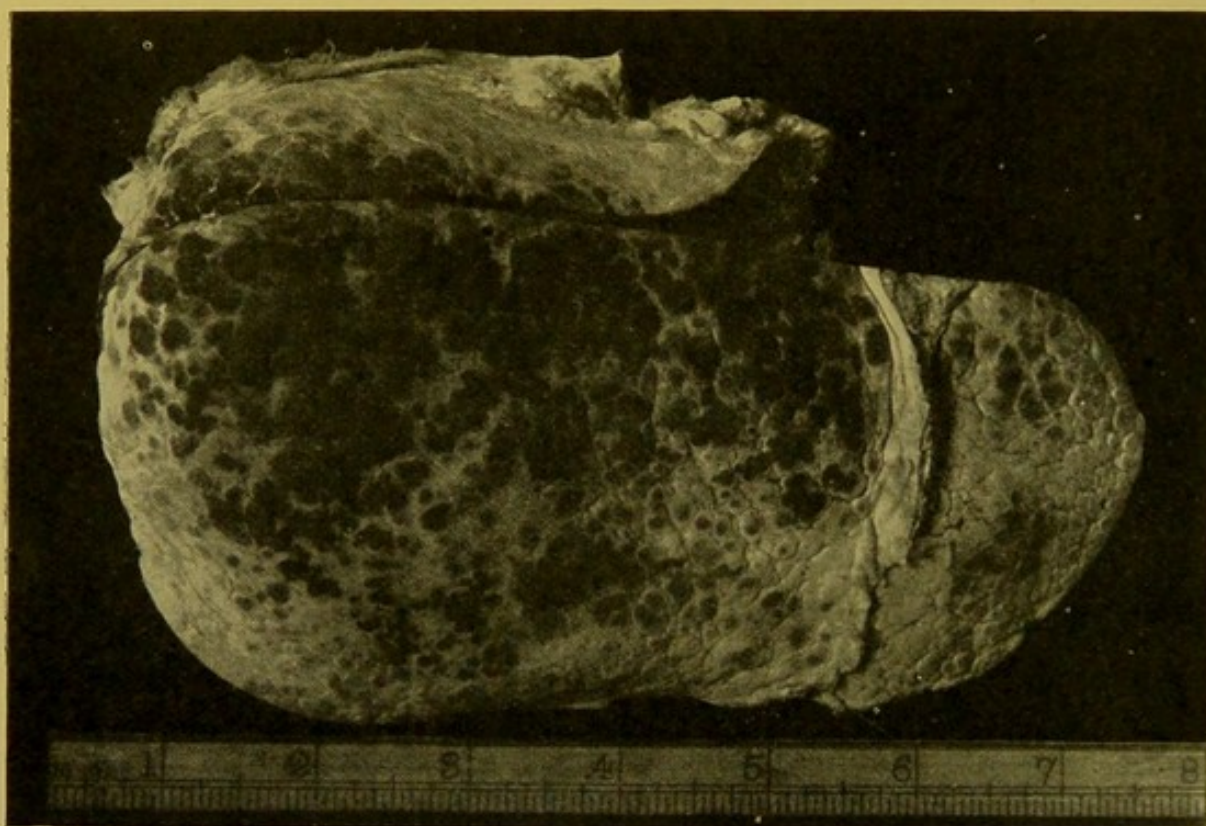

FIG. 122.—Coarse Cirrhosis of Liver.

Case described in text. A portion of the suspensory ligament is still in position, on the upper surface of the liver. Many of the prominences appear dark in colour owing to accidental drying of the surface. The scale indicates inches.

and in some cases the cause appears to be tuberculosis, syphilis or malaria. In malarial cases, it is not easy to exclude the action of alcohol or syphilis.

The condition is more common in males than in females, and usually develops at ages from forty-five to fifty years.

The weight of the cirrhotic liver may approximate to or even exceed the normal, but in most cases it is diminished.

The view generally accepted has been that the formation of the fibrous tissue is the primary change, and that in consequence of the spread of this in the liver, the parenchyma undergoes atrophic and degenerative changes.

As the result of recent investigations there seems no reason to doubt that, in the early stages of common cirrhosis, infiltrative changes and proliferation of connective tissues may be distinct, though of moderate

intensity, before any clear evidence is obtainable of degeneration of the parenchyma, but in many quarters the views enunciated by MacCallum and later by Gourievitch are gaining ground. These authors believe that the primary change is of the nature of degeneration or necrosis of liver cells, and that the formation of connective tissue is compensatory. A great deal of evidence can be brought forward in support of this explanation. It also brings cirrhosis into etiological relationship with the acute and subacute liver atrophies. Other authorities of weight (e.g. Kaufmann) admit that both degenerative and regenerative changes may be present in the liver, but they believe that these are concomitant results of the same noxious influences.

In common cirrhosis the fibrous tissue appears to develop along the medium-sized branches of the portal vein, and it forms a coarse network, the meshes of which contain areas of persisting or regenerated parenchyma.

One cannot draw a hard and fast line between coarse and fine cirrhosis.

The connective tissue network passes right up to the capsule, with the under surface of which it is continuous. Rounded masses of liver tissue, in part at least the result of regeneration, project as small dome-like elevations, which vary in size from $\frac{1}{16}$ in. (2 mm.) to $\frac{1}{4}$ or even $\frac{1}{3}$ in. (6 to 10 mm.) in diameter. The capsule over these is usually tightly stretched, and thinner than in the depressions, where it is continuous with the network which passes throughout the organ. The anterior margin of the liver is more rounded than normal. The left lobe may be more affected than the right, and the change may be less marked in the Spigelian lobe than in the rest of the organ. The shape may become very irregular.

On the cut surface, the liver parenchyma appears in the form of yellow, or occasionally bile-stained, rounded or oval areas, embedded in the greyish-pink fibrous tissue. Laennec derived the name "Cirrhosis" from the yellow colour of these nodules.

Under the microscope, the connective tissue forms thick, dense bands, which, if actively developing, are infiltrated with cells and contain large blood spaces, the latter connected with the hepatic artery, and also, it is stated, with the portal vein. Through these an amount of blood may reach the organ sufficient to compensate in some degree for the diminution in the volume of blood conveyed to it through the portal vein. Towards the margins of the fibrous bands the connective tissue is invariably cellular and in some parts merges into the liver tissue. Elastic tissue is always increased in common cirrhosis, as compared with hypertrophic biliary cirrhosis. Sometimes, but by no means invariably, there is an increase of bile-duct structures which some authorities of repute still hold to be of new-formation from the persisting liver cells. The old idea that these are simply pre-existing intralobular bile-ducts which have been rendered evident by the disappearance of the liver cells, is again gaining ground. If this be actually so, it is necessary to conclude with Milne that their lining cells

have become swollen and hypertrophied. They are, however, so numerous in some cases that it is difficult to credit the statement that they are never of new-formation.

The small bile-ducts also may become obstructed, so that some of the nodules are deeply bile-stained. Kretz states that in half of the cases haemosiderin pigment is present in considerable amount in the connective tissue network, and in the liver cells. Proliferative changes are very constantly seen. This proliferation is generally by amitosis, but frequently in the large hypertrophied liver cells, beautiful mitoses can be seen. In proliferating areas the newly formed cells are clear, non-granular, and are not arranged in regular columns. In some cases the nodular masses of regenerated liver tissue resemble adenomata—nodular hyperplasia—and not infrequently transitions to primary carcinoma are found. (See p. 253.)

The interference with the flow of blood through the branches of the portal vein results in back-pressure and chronic venous hyperaemia throughout the portal system, usually accompanied by ascites. The obstruction also leads to dilatation of the radicles of the portal vein which communicate with the systemic venous circulation, e.g. along the round ligament with the epigastric veins; at the lower end of the oesophagus, with the azygos vein; and at the lower end of the rectum, with the haemorrhoidal veins.

A further important result of the chronic venous hyperaemia, induced throughout the portal venous system, is the frequent occurrence of haemorrhage into the stomach, either by an oozing from the surface, or from erosions which form along the thickened ridges of mucous membrane, or over the varicose veins which develop at the lower end of the oesophagus.

Accompanying cirrhosis one frequently finds thickening of the peritoneum, either generalized or localized to the surface of the liver or spleen. If this be of tuberculous nature, the ascitic fluid is haemorrhagic.

Jaundice is usually absent.

In **Pigmentary Cirrhosis**, a large amount of haemosiderin and haemofuscin is found in the connective tissue network and in the liver cells. (See *Haemochromatosis*, p. 238.)

(b) **Monolobular Cirrhosis**.—The varieties of interstitial hepatitis which are included under this category are of somewhat rare occurrence, and are usually divided into two classes: (1) Hypertrophic Biliary Cirrhosis, and (2) Obstructive Biliary Cirrhosis.

(1) **Hanot's Hypertrophic Biliary Cirrhosis**.—In this condition the liver undergoes progressive enlargement, and its weight may reach 5 to 10 pounds (10 to 20 kgm.).

The capsule is smooth, or may be slightly wrinkled, resembling the surface of morocco leather. The organ is usually deeply bile-stained, the tint varying in intensity. The consistence is moderately increased. On section

the network of fibrous tissue may be so fine, that it is not appreciable to the naked eye. In some cases it can be distinguished because of its retraction, the lobules standing out on the cut surface, separated by a shallow network of the retracted tissue.

Under the microscope the newly developed connective tissue forms a close, delicate or thick, network enclosing individual lobules, and also sometimes single cells or small groups of cells. It also passes into the lobules along the columns of liver cells. The connective tissue, if it be actively developing, is cellular, and contains large blood spaces. It also contains numerous bile-duct structures, particularly in the part corresponding to the original position of the periphery of the lobule, and these form a characteristic feature of the microscopic picture. Their lining epithelium is frequently proliferated so as to form club-shaped masses of small cells. Elastic tissue is not so plentiful as in the case of common cirrhosis.

Greenish collections of inspissated bile obstruct the small bile-channels, are contained within the liver-cells and endothelium of the capillaries, and even at times project into the capillaries. At times the jaundice is less marked and fatty changes are evident in the parenchyma. There may also be increase of brown pigment in the cells.

Hanot stated that the liver cells may show comparatively little change, and looked on this as characteristic of the condition, but too great stress should not be laid upon the absence of degenerative changes.

Etiology.—There is no proved relationship to alcoholism, syphilis, or malaria. Hanot was of opinion that the condition commences in an *ascending* inflammation of the smaller bile-ducts, but Rolleston, apparently with greater reason, blames a general infection, with a resulting *descending* cholangitis. The larger bile-ducts, characteristically, show little change, and there is no catarrh of the duodenum. The jaundice results from the blocking of the smaller bile-ducts from thickening of their epithelium, desquamation, and formation of plugs of inspissated mucus. Histologically, the primary change is probably of the nature of degeneration and necrosis in the peripheral part of the lobule, followed by secondary formation of fibrous tissue.

The spleen is greatly enlarged, and, microscopically, the Malpighian bodies undergo hyperplasia, or are the seat of fibrous transformation.

The pancreas is not increased in weight or size, but may show very intimate fibrosis of embryonic type, spreading outwards along the ducts.

The faeces usually show some bile-pigmentation.

Ascites may be completely absent.

Numerous transitions may be encountered between this form of cirrhosis and the common, atrophic cirrhosis. Characteristic examples of the condition occur between the ages of twenty and thirty years. It is rarely met with after forty years of age. Both forms are more common in males than in females.

(2) **Obstructive Biliary Cirrhosis.**—This form of cirrhosis may occur at any age. It is the result of obstruction of the larger bile-ducts, usually outside the liver, by gall-stones, by congenital stenosis or obliteration, or by the pressure exerted upon them by tumours or, occasionally, by enlarged glands.

The larger bile-ducts are dilated, containing dark viscid bile. Frequently fibrous perihepatitis is a prominent feature.

The liver is greatly enlarged in the early stages and smooth both on the capsular and cut surfaces. In later stages, it tends to contract and irregular prominences form upon the surface. In consistence it is firmer than the liver the seat of Hanot's cirrhosis. The colour is a deep green from bile staining, and coarse, often nodular, fibrous bands compose a network passing throughout the liver.

The changes found in the small bile-ducts are similar to those occurring in Hanot's cirrhosis, and in addition, the larger ducts are greatly dilated, but this is not invariable. There is fibrous thickening of their walls.

The cause of the cholangitis of the smaller ducts is almost certainly an ascending infection.

The *spleen* undergoes no characteristic alteration, unless the cirrhosis of the liver be of multilobular type.

In the early stages of the process, small necrotic areas are sometimes seen at the periphery of the lobules, followed by infiltration of the connective tissue in the portal spaces, which may go on to abscess-formation or may simply precede the formation of new connective tissue.

(c) **Intercellular or Intralobular Cirrhosis.**—In the forms of cirrhosis of the liver already described, it has been seen that connective tissue may invade the lobule, as well as encircle it, but intercellular or intralobular cirrhosis is found most characteristically and most widespread in the livers of children who have died with the manifestations of congenital syphilis, and it has been described already along with the other changes which are produced in the liver by syphilis, whether acquired or congenital (pp. 242 to 244).

Tumours of the Liver.—(a) *Non-malignant tumours* are rare. The most common is the **Cavernous Angioma** or **Cavernoma**. It is of a dark purplish-brown colour, and on its cut surface a delicate reticulum can be made out. It is seldom more than a quarter to a third of an inch in diameter; more or less rounded in the substance of the organ, and hemispherical if subcapsular. It may be single or multiple. It occurs chiefly in old people. The non-malignant Adenoma is with difficulty distinguished from the nodular hyperplasia found in cirrhosis, in subacute atrophy, and in cyanotic atrophy. Except in cirrhosis, hyperplastic nodules have ill-defined margins; occasionally they are rosette-shaped. Adenomata may develop from liver cells or from bile-ducts, and their microscopical characters vary accordingly. They are soft, encapsuled, and vary greatly in size. In colour they may be light brown, greyish-pink, or yellow. They are found most often in connexion

with cirrhosis. Transitions to carcinoma are common. **Cysts** occur most frequently singly and under the capsule. They are thin-walled, with fibrous-looking ridges over their inner surface. They contain bile-stained mucus, or clear watery fluid. In origin they depend upon developmental anomalies of the bile-ducts. Usually they are lined with flattened epithelium. Occasionally multiple cysts are found accompanying cystic changes in the kidneys and (or) pancreas.

(b) *Malignant tumours* are more common, especially carcinoma. **Primary Sarcoma** is rarely encountered. It may occur as a single mass, or as numerous masses causing great enlargement of the organ. Round-celled and spindle-celled sarcoma, and angiosarcoma may be found. They show numerous haemorrhages and necrotic areas, and accordingly are generally of a reddish-brown colour. (Fig. 123.) **Secondary Sarcoma** is less uncommon, and practically all varieties may occur. The most common variety is the *melanotic sarcoma*, which forms either large sooty-black masses, causing distortion of the liver; or nodules of the size of a pea or cherry are scattered throughout the liver, increasing its size more or less uniformly; or the liver is full of closely set, minute metastases, so that its cut surface looks as if covered with grains of black pepper (Fig. 124). The primary tumour may have developed in connexion with the choroid of the eye, or from a pigmented mole.

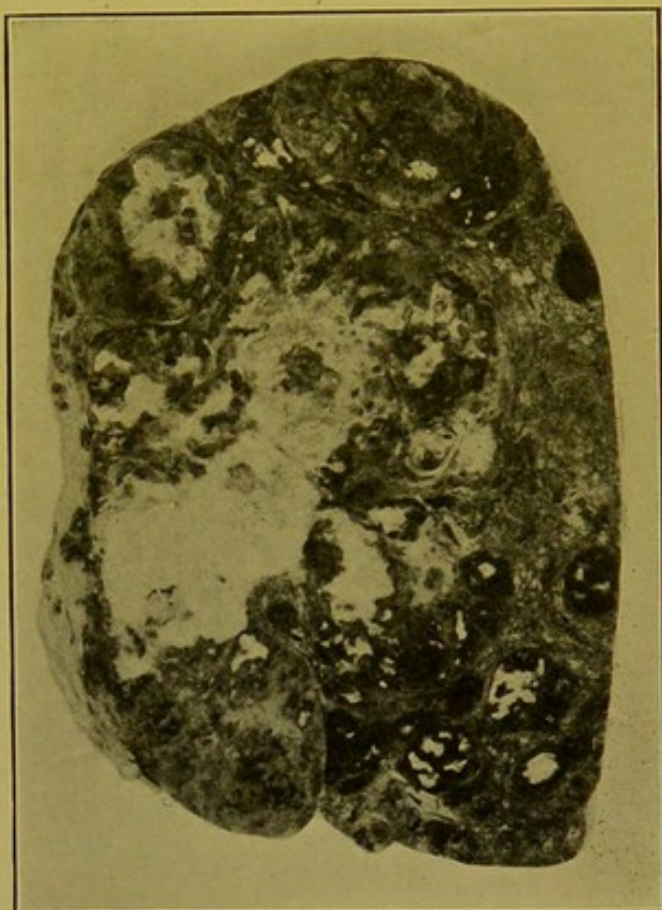


FIG. 123.—Primary Sarcoma of Liver.

(\times circ. $\frac{1}{3}$.)

Large—pale—areas of necrosis. Dark areas indicate haemorrhagic infiltration.

Primary Malignant Epithelial Tumours occur more frequently, and may develop both in otherwise normal livers and in cirrhotic livers. The greater number of primary carcinomas may be grouped under the *liver-celled type* of cancer and the remainder under the *bile-duct cancer*. The former are composed of masses of large cells possessing a trabecular arrangement somewhat resembling that of normal liver cells, though the trabeculae are usually thicker, composed of a greater number of layers of cells, and are more irregular, not being arranged in lobules. In the bile-duct cancers, the development tends to follow the lines of the portal spaces, thus giving an irregularly branched character to the growth, which also forms nodules, sometimes hard,

1 Liver al Type masses large with a arrange irregular no lobes

2 Bile follows line of portal

sometimes soft, which press aside the liver tissue. In these the cells are generally columnar or cubical, and tend to be arranged in tubules, having thus the characters of the *columnar-celled cancer*.

Occasionally primary cancer is of the type of the *encephaloid cancer*. Usually one large, soft, spongy mass develops, sometimes with surrounding local metastases. It bulges on the cut surface, and the displaced, condensed, liver tissue forms a sort of false capsule. A radiating scanty reticulum can be distinguished. The tumour is of a greyish-pink, sometimes of a dull opaque white colour, and always shows degenerative changes and softening in its central part (see Fig. 125).




FIG. 124.—Melanotic Sarcoma of Liver. (\times circ. $\frac{2}{3}$.)
Crowded minute metastases.

Scirrhus cancer is also found, but less frequently. The nodules are pale greyish, and of firm consistence. They undergo less evident degeneration than other varieties of malignant growth in the liver. Subcapsular nodules become deeply umbilicated (see Fig. 126) as a result of the contraction of their plentiful connective tissue stroma. An apparently primary scirrhus cancer may have extended to the liver directly from the gall-bladder.

Metastatic or Secondary Cancers may be of columnar-celled or encephaloid or scirrhus type, but most are of the first type. They are secondary to primary tumours of the stomach, duodenum, pancreas, intestine or prostate. *Squamous epithelioma* may be secondary to a tumour of the oesophagus; scirrhus and other cancers of the mamma may extend to the liver by way of the suspensory ligament.

Secondary encephaloid (Fig. 125) and *scirrhus* (Fig. 126) cancers

possess characters similar to those already described as distinguishing the corresponding primary tumours of the liver. In *secondary columnar-*

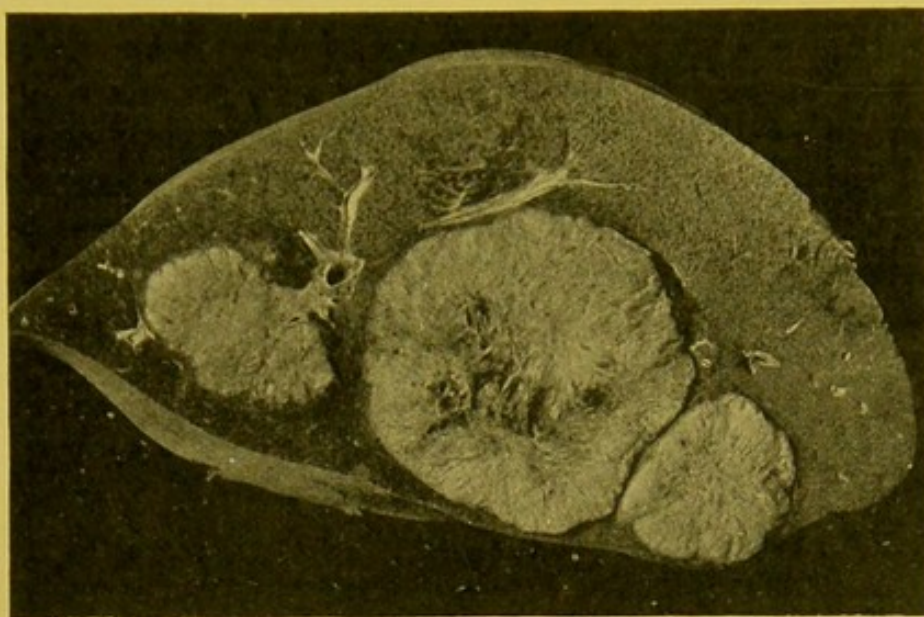


FIG. 125.—Secondary Encephaloid Cancer of Liver. (\times circ. $\frac{2}{3}$.)
Nodules, spongy, soft, projecting on cut surface; radiating reticulum, central necrosis.

celled cancer—malignant adenoma—the nodules are as a rule very numerous, involving the greater part of the liver, causing massive enlargement, so that it may extend below the level of the umbilicus. The surface also

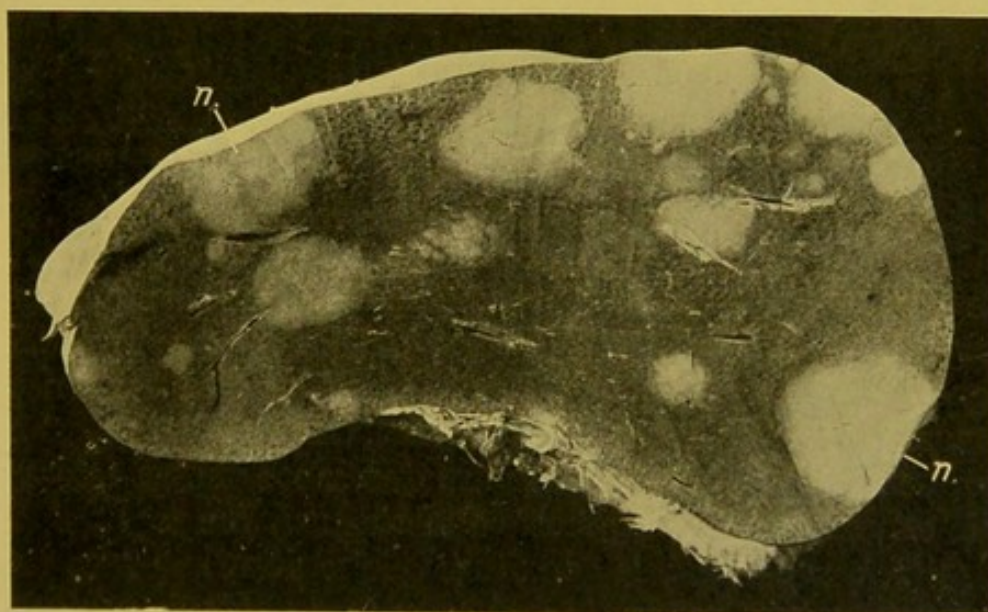


FIG. 126.—Secondary Scirrhus Cancer of the Liver. (\times circ. $\frac{1}{2}$.)
(n.) Nodules of new-growth, showing no tendency to break down, but retracting so as to produce umbilication on the surface of the organ.

is nodular, the nodules being usually umbilicated, as a result of central degeneration and softening (Fig. 127). On section their margins bulge a little upon the surface, and are sometimes distinctly crenated. They are of a

general greyish-pink colour and show numerous spots of haemorrhage throughout. In the centre they are yellow from fatty degeneration and necrosis. The liver tissue between is frequently deeply bile-stained, furnishing a marked colour contrast. Between neighbouring nodules, and between nodules and the capsule of the organ, one commonly sees the so-called "red infarcts" of the liver (p. 230). Both in primary and in secondary cancer, but particularly in the former, the growth tends to invade the radicles of the hepatic vein. If this occurs, a cancerous thrombus usually forms, from which metastasis may take place to the lungs. Frequently, however, though the hepatic vein is invaded in primary liver-celled cancer, this metastasis does not take place.

Chorionepithelioma and **Hypernephroma** may also form secondary growths in the liver. The nodules of the former may closely resemble the softer

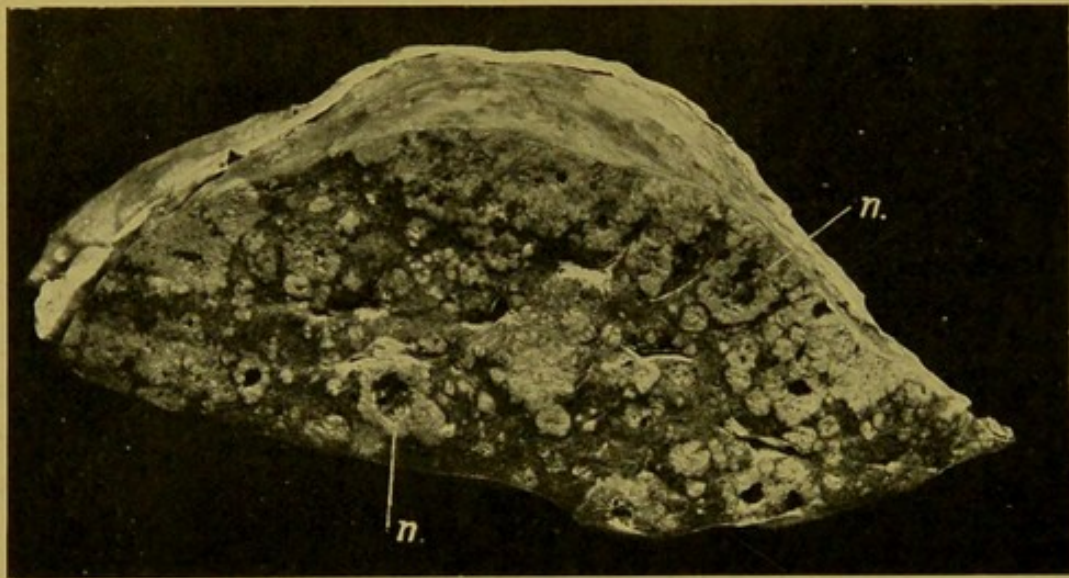


FIG. 127.—Secondary Columnar-celled Cancer of the Liver; antero-posterior section. ($\times \frac{1}{2}$.)

(n.) Larger nodules of new-growth, breaking down in the centre.

haemorrhagic sarcomata, being reddish-brown, and containing areas of haemorrhage, or, if haemorrhage be not evident, they may resemble the more opaque encephaloid cancers. (Fig. 128.) Secondary hypernephromata resemble more the secondary columnar-celled cancers, but are of somewhat firmer consistence and in some cases are of a more yellow colour; usually microscopic examination is required to distinguish them.

Jaundice (*Icterus*).—In this condition bile is absorbed into the general circulation, and stains the tissues and secretions. All tissues are affected, but particularly the ordinary connective tissues. The cartilages, the cornea, the brain, nerve tissue and the lungs are relatively unaffected. The tears are said to be invariably free from pigment, and in obstructive jaundice the faeces are generally of a light grey colour—like moist pipe-clay—from absence of bile. Depending upon the intensity and duration of the condition, the tint of the tissues, particularly of the skin, varies in colour from a pale

yellow to a dark brownish-green. The causes of jaundice are generally divided into (1) the simple *obstructive* and (2) the *toxic* or *infective*, but it must be remembered that in the latter group the jaundice is really *obstructive*, because in these cases the small capillary bile-ducts become obstructed by inspissated bile.

(4) **Obstructive Jaundice.**—This is caused by obstruction of the larger bile-ducts at any part of their course down to the opening of the common bile-duct into the duodenum, from congenital absence or narrowing, or from spasmodic stricture. A common cause is catarrh of the ducts, extending upwards from the stomach and duodenum; not only because of the thickening of the walls which this condition produces, but also because the

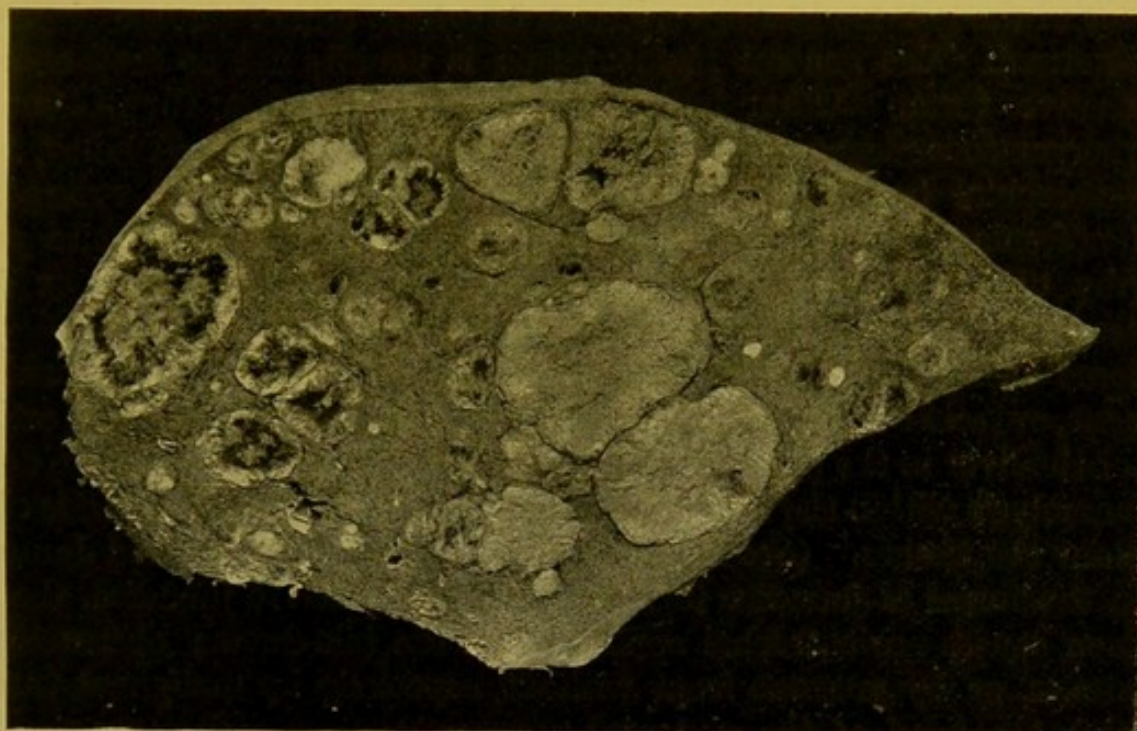


FIG. 128.—Secondary Chorioneplithelioma of Liver. (\times circ. $\frac{3}{8}$.)

The paler nodules resemble nodules of secondary encephaloid cancer; the darker, haemorrhagic nodules more those of non-pigmented sarcomata.

inspissated mucus along with the desquamated epithelium forms a plug which blocks up the narrow lower end of the common bile-duct. The obstruction may also be caused by new-growths or gall-stones or animal parasites *within* the ducts; by pressure *from without* of enlarged lymphatic glands in the gastro-hepatic omentum or surrounding the head of the pancreas; by pressure of tumours of the duodenum or pancreas, or of aneurysms of the hepatic artery or coeliac axis (both rare). Finally, cicatricial contraction resulting from old inflammation in connexion with the gall-bladder, or gastro-hepatic omentum, may bring about *obstruction* of the main bile-ducts.

The result in all cases is stagnation of bile in the bile-ducts with dilatation of these and absorption of the bile into the lymphatics. From these

it is conveyed by way of the thoracic duct to the general circulation. A great increase in the intensity of pigmentation may result from the action of the bile-acids in causing haemolysis, the haemoglobin set free being transformed into bile in excess in the liver.

Recent investigations would indicate that a large proportion of the bile, possibly the bulk of it, passes direct into the capillaries of the lobule. This has not yet been confirmed.

(B) **Toxic Jaundice.**—This is secondary to extensive breaking down of the red blood corpuscles in the circulation, with the result that the liver cells become overloaded with bile-pigment. The bile is discharged in a concentrated form which tends to obstruct the capillary bile-ducts.

In toxic jaundice the faeces may be bile-stained and the bile which is present in the gall-bladder is very dark in colour, and of thicker consistence than normal. The general pigmentation is usually not so deep as in the obstructive form. Other indications of toxæmia are found, such as parenchymatous degeneration of specialized tissues—liver, kidney, heart, etc.—petechial haemorrhages in the serous membranes, and enlargement with softening of the spleen. The jaundice occurring in acute yellow atrophy of the liver, phosphorus poisoning, and Icterus gravis or Weil's disease is probably of similar nature.

Some authors are of opinion that discoloration of the tissues with bile pigment, or rather with urobilin, can occur without any immediate participation of the liver in the process. They claim that the pigment can be derived by haemolysis within the vessels and that the pigment thus formed is able to discolour the tissues. (See Bibliography for Acholuric Familial Jaundice.)

In the forms of jaundice included under obstructive jaundice, the most common causes are catarrhal conditions of the bile-ducts; obstruction by gall-stones, or by pressure from without, especially by malignant tumours affecting the head of the pancreas.

Animal Parasites of Liver.—Hydatids of *Taenia echinococcus*; Ova of *Schistosomum Japonicum*; *Ascarides*, in the bile-ducts; *Cysticercus cellulosae*; *Distoma hepaticum* and *Psorosperms* (very rare); *Pentastomum denticulatum*.

THE GALL-BLADDER.

Oedema of the walls of the gall-bladder is common in chronic venous hyperæmia affecting the portal circulation.

Cholecystitis.—*Acute catarrh* in general characters resembles catarrh of other mucous membranes. *Chronic catarrh* is usually associated with dilatation of the gall-bladder, and thinning of its walls. In rare cases polypoid thickenings of the mucous membrane develop.

The more severe inflammations most frequently accompany cholelithiasis, or in very rare cases result from the presence of animal parasites. Occasionally they are caused by severe infective conditions, such as typhoid fever.

In *Suppuration* of the gall-bladder—*Empyema* of the gall-bladder—the cystic duct is usually obstructed, often by calculi, and the bladder may be greatly distended. In other cases the pus infiltrates the walls. Necrosis is common, with

ulceration as a sequel. This may lead to perforation, and bring about a general peritonitis, or a localized suppurative peritonitis which may become sub-phrenic.

Chronic productive inflammation leads to great thickening and contraction of the gall-bladder. The thickened walls may undergo calcification or ossification. Peritonic adhesions usually form to omentum, large intestine or duodenum.

Tuberculosis of the gall-bladder is extremely rare.

In *Typhoid fever*, the bacilli often persist in the contents of the gall-bladder, and also in its walls, leading to diffuse infiltration, at times accompanied by ulceration. See p. 262.

Tumours.—The important tumours are of malignant nature, and for the most part carcinomata. They are often associated—possibly etiologically—with the presence of calculi. They originate either at the neck or at the fundus, and may grow either diffusely or in nodules. They may extend directly into the liver or along its surface. The more common varieties are the *columnar-celled*, the *scirrhus* and the *colloid* cancers. The columnar-celled cancer usually forms large whitish masses, which spread to the liver, and break down at an early stage in their central, older, parts, so that on section they show an irregular ulcerated cavity, frequently containing gall-stones. Metastasis takes place to lymphatic glands, peritoneum, etc.

Scirrhus cancer grows more diffusely. It is of firmer consistence, and may simulate chronic inflammatory thickening. The peritoneum may show diffuse infiltration, and the tumour may spread directly into the liver, or along its surface.

Colloid cancer is not so common as the other varieties. The whole wall of the gall-bladder shows diffuse thickening, and the peritoneum may be extensively invaded.

Squamous epithelioma is very rare, and may develop by metaplasia of the epithelium of the mucous lining.

Tumours of the **main bile ducts** outside the liver are of rare occurrence. They are often of *scirrhus* type, and lead to stenosis of the ducts.

Gall-stones.—As in the case of other true calculi, gall-stones possess a nucleus, which is essential to their formation. This nucleus is always rich in bile pigment combined with calcium, and it may consist of pigment-calcium, flakes of mucus, collections of epithelial cells, particles of fibrin, clumps of bacteria, especially *bacillus coli communis* and *bacillus typhosus*. In very rare instances the nucleus may be a fragment of an animal parasite or other foreign body.

Varieties of Gall-stones (see Fig. 129).—(1) The Common Gall-stone.—In this variety the body of the calculus is made up of a radiating mass of cholesterine crystals, with an admixture of a certain amount of bile pigment—bilirubin calcium, biliverdin calcium, and bilihumin calcium—and some bile acids. These are bound together by mucus, along with margarate, stearate and palmitate of calcium. On the surface of this nucleus, which is of a dark brown colour, cholesterine is deposited in concentric apparently almost homogeneous porcellaneous laminae, which are white or of various shades of brown to black or dark greenish-brown, the colour depending upon the amount of bilirubin and biliverdin present; hence the surface of the stone may be of a pale yellow colour, or brown, depending upon which lamina is outermost. Calcium carbonate may be deposited on the surface, forming a hard opaque

chalky-white layer. Calcium carbonate may also be found in small nodules throughout the calculus, particularly in presence of biliverdin calcium. Common gall-stones may contain traces of iron, copper, manganese, phosphates, etc.

This variety of gall-stone may occur singly, or in small numbers, or be present in thousands. When the number is small, the individual calculi are usually of considerable size, and of more or less uniform bulk. If occurring singly, or if from two to four in number, they may completely fill the gall bladder, which is tightly contracted upon them. They measure most commonly about one quarter to half an inch in diameter (5 to 15 mm). They

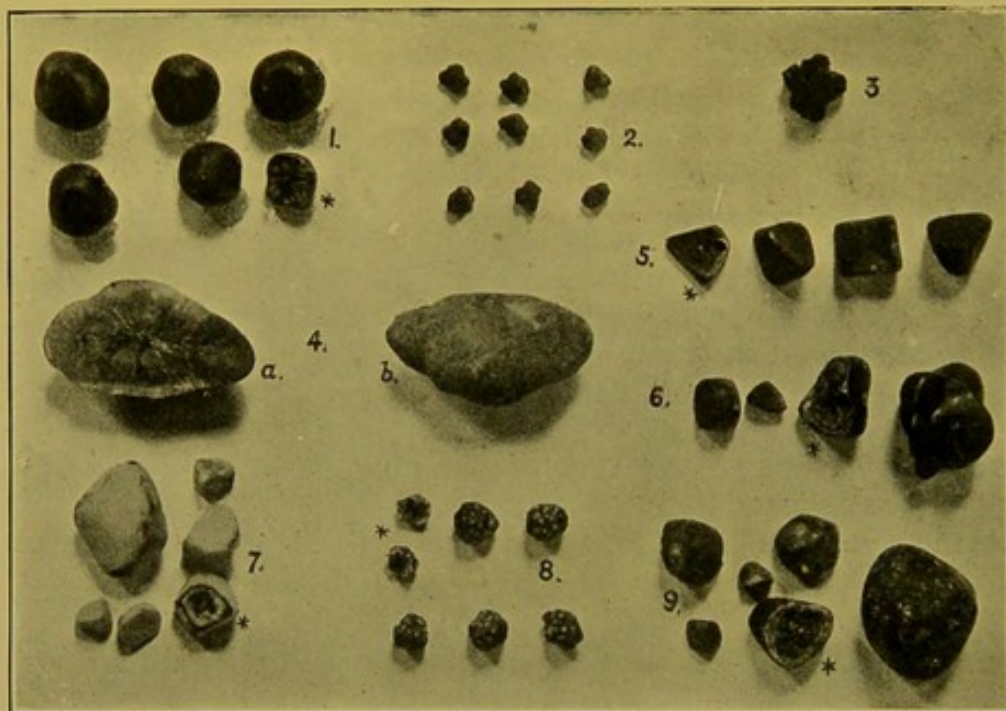


FIG. 129.—Gall-Stones. (\times circ. $\frac{3}{4}$.)

(1, 5, 6, 7, 9) Various examples of calculi, showing different shapes, and varying proportions of cholesterine and pigment. One calculus* in each set cut across to display structure. (4) Almost pure cholesterine calculus (a) section, showing radiating arrangement of crystals, (b) surface. (2, 3) Bilirubin-calcium calculi. (8) Mulberry-like, composite calculi.

may be angular or tetrahedral or barrel-shaped, and the apposed surfaces of multiple calculi are faceted. The free surfaces are usually slightly rough or nodular. The faceted appearance results rather from mutual compression than from attrition. This can be proved by making a section across the gall-stone, when the laminae will be seen to follow more or less closely the outline of the cut surface. When in large numbers, the majority of the calculi are of very small size, almost like gravel. Generally the gall-bladder contains some bile in addition to the calculi, but at times bile is absent and the calculi lie embedded in tough mucus.

In consistence, mixed cholesterine-pigment calculi are usually soft and friable, and when crushed between the fingers feel greasy. The proportion of cholesterine varies from 25 to about 90 per cent.

Chemical Reactions of Cholesterine.—If a solution of iodine be applied,

followed by concentrated sulphuric acid, a blue colour develops. Cholesterine dissolves in boiling alcohol and in ether. The presence of calcium carbonate may be detected by testing with a weak mineral acid. Gmelin's test for the presence of bile pigment consists in the addition of a small quantity of (old) nitric acid, yellow with nitrous acid; if bile be present a play of colours is produced, beginning with green and passing through blue and violet to red and lastly to yellow.

(2) **Pure Cholesterine Calculi.**—These are not common; they occur usually singly, but two or three may be present. They are pale yellow in colour, waxy, translucent, oval in shape, with a slightly nodular surface which feels greasy. On section the calculus is composed of radiating, glistening crystals of cholesterine, which are bound together by a certain amount of organic and inorganic material; the nucleus may contain very little pigment.

Rarely, cholesterine gravel is met with, as a fine, soft, granular accumulation of what Naunyn regards as amorphous cholesterine. Very rarely one may encounter soft, pulpy concretions of cholesterine, or the so-called carious gall-stones, which have been rendered friable by the action of the bile, or of bacteria, upon them.

(3) **Bilirubin Calcium Calculi** are found more commonly than the last variety. They are of a dark brown, almost black, colour, in shape irregular; sometimes they are like the mulberry; their numbers may vary from four or six to twenty or even more. They are usually of uniform size, from an eighth to a quarter of an inch (3 to 8 mm.) in diameter, and they appear as if they had all been formed in the same mould. They are regularly irregular.

These calculi consist of bilirubin calcium without cholesterine, or with only traces of that substance. They crumble easily between the fingers, particularly when dry, and to preserve them they should be kept in a weak aqueous solution of formalin.

Small concretions of bilirubin calcium may be found in great numbers within the intra-hepatic bile-ducts. They are more or less rounded or oval.

(4) **Calculi formed of calcium carbonate** occur extremely rarely in man. They are small, smooth, chalky-white, hard and heavy.

Etiology of Gall-stones.—In Europeans of all ages coming to the post-mortem room, from five to twelve per cent. have gall-stones. In most cases examined, the gall-stones have not caused symptoms of sufficient importance to draw attention to them during life, and thus it may be said that they are frequently "latent." They occur more commonly in females than in males, anything causing stagnation of bile predisposing to their formation; hence they are found chiefly after middle life, and in those who have deficient nitrogenous diet and who have little exercise, or who wear tight clothing.

Cholesterine is a normal constituent of the bile, and is a product of the mucus-secreting cells of the gall-bladder and bile-ducts. It is increased more particularly in catarrhal conditions, and the longer the bile remains in

the gall-bladder, the more cholesterine does it contain. It is formed along with fats and soaps in the dissociation of cholesteryl oleate. An important factor in the etiology of gall-stones is the action of bacteria. Normally the bile is aseptic, but certain organisms, particularly the *bacillus coli communis* and the typhoid bacillus, can gain access, under conditions favourable to their dissemination from the bowel, and these give rise to the catarrhal conditions which are essential. Both these organisms have been separated from the bile, and they have also been found in the nuclei of calculi. In *Typhoid carriers* the typhoid bacillus commonly settles down in the walls of the bile-ducts, hence it is almost impossible to render the bile again sterile even by the use of suitable vaccines. So long as they remain, and this may be for many years, the individual is a possible source of infection to others. Adami found that bacterial cultivations from the fluid in the gall-bladder were usually successful if, instead of being clear, thin layers of the fluid contained more or less pigmented flocculi.

Another factor is obstruction of the bile-ducts, for example, closure of the cystic duct by the pressure of tumours, or of scar-tissue in the walls, and in children obstruction may be caused by a kink or twist in the wall.

Local effects of Gall-stones.—When the cystic duct is obstructed, the bile is gradually absorbed and the fluid within the gall-bladder comes to consist of colourless or straw-coloured mucus.

In the presence of gall-stones the wall of the gall-bladder may be smooth, thickened, or show irregular pouchings. Pressure of the calculi on the walls causes atrophy of the mucous membrane, or superficial loss of substance. At times deeper ulceration occurs and this may destroy the whole of the mucous membrane. Occasionally the walls become necrotic, and this is associated with localized or generalized suppuration. The formation of retracting scar-tissue may cause the bladder to contract closely round the calculi, or, if the calculi have been extruded, this contraction may go on until the cavity is practically or completely obliterated, and the gall-bladder is represented by a small mass of dense fibrous tissue, in which calcareous deposit may take place. When the progress of the ulceration is *slow*, adhesions tend to form to adjacent structures, and through these, a passage may form along which the calculus may pass. Thus gall-stones may pass to the cutaneous surface in the neighbourhood of the umbilicus, to the duodenum, to the colon, or less commonly to the stomach, ileum, urinary passages, pleurae, and even occasionally they penetrate the portal vein. Gall-stones of large size, after penetrating to the duodenum, may, in their progress down the intestine, cause obstruction at the lower end of the ileum. If the ulceration of the gall-bladder progress *rapidly*, perforation of the wall may take place with fatal peritonitis as a result.

CHAPTER XIII

THE ABDOMEN (*continued*)

THE SPLEEN

(For Method of Removal, see p. 226).

Anatomy and Relationships.—The posterior and upper part of the spleen comes within an inch and a half of the middle line. Its long axis is oblique from above downwards and outwards. In length it is about 5 in. (11–14 cm.), in width about 3 in. (7–8 cm.), and about 1 in. (2.5–3 cm.) thick, in the adult. The normal weight is usually given as 5–8 oz. (150–250 gm.; Kaufmann, 90–120 gm.). In 1,325 adults I found the average weight to be 176 gm. or nearly 6½ oz. In 802 males the average weight was 185.4 gm. or nearly 6½ oz., and in 523 females, 159.5 gm. or nearly 5½ oz. The upper end is usually slightly thicker than the lower, but the shape varies considerably so that this cannot be looked upon as a constant character. The outer surface lies against the diaphragm. The visceral surface is in relation to the stomach, kidney and splenic flexure of the colon; and the end of the tail of the pancreas usually touches it in the neighbourhood of the hilum. The notches on the anterior margin vary in number; usually there are two, but there may be six or seven. The posterior border near its lower end may also be deeply notched, and deep transverse fissures are sometimes seen crossing the outer surface.

Small separate masses of splenic tissue—accessory spleens, “splenunculi,” or “splenicula”—are frequently met with in the neighbourhood, especially just below and in front of the main organ, e.g. in the great omentum, occasionally close to the hilum of the spleen, or between the layers of the costo-colic fold (suspensory ligament). Usually they are not more than one to three in number, but as many as thirty or forty have been found. They are subject to the same pathological alterations as the main organ.

Lymphatic vessels are present in the deep layers of the capsule and communicate along the trabeculae with the lymphatics in the adventitia of the arteries.

Normally the capsule is thin and smooth, but at the post-mortem it is not found so tensely stretched as are the capsules of the kidney and liver. This is no doubt due to the retraction which takes place after death, owing to the fact that unstriped muscular tissue is present in considerable amount in the splenic capsule and to a lesser extent in the trabeculae, which, however, are richer in elastic tissue. The capsule is sufficiently transparent to allow the colour of the organ to be distinguished. On section, the organ is of a brownish-purple colour, the depth of the brownish tint depending upon the amount of blood pigment present in the organ, hence the adult organ is browner than that of the child, as a rule. On the cut surface, the trabeculae appear as thin white or greyish lines and the Malpighian bodies as minute pale grey or yellowish spots about 1 mm. in diameter. They do not usually project above the general surface.

Congenital Anomalies.—In bodies otherwise normal, absence of the spleen is an excessively rare occurrence. The organ has been found to be wanting in monsters and in association with congenital heart disease.

The spleen may be transferred to the right side, either without displacement of the other organs or accompanied by complete transposition.

Acquired Displacements—The spleen may pass into a congenital or traumatic diaphragmatic hernia, or into an umbilical hernia.

Wandering Spleen.—This is very rare. The organ is pushed up during pregnancy, and in presence of abdominal tumours; it is pushed downwards as a result of tight-lacing, and, if the displacement be accompanied by increase of weight, the supporting ligaments are stretched and the gastrosplenic omentum with its vessels is elongated. The veins are liable to be kinked or twisted and, as a result, the organ increases in size from engorgement, or if the artery is blocked the organ may atrophy.

Instances have occurred in which the organ has descended into the pelvis.

Changes in the Capsule.—**Acute Perisplenitis.**—See *Peritonitis* (p. 170) and *Suppuration* in connexion with spleen (p. 271).

Chronic Perisplenitis.—In the adult it is extremely common to find the capsule thickened, and the thickening is very often associated with adhesions to the diaphragm or to the neighbouring organs. The perisplenitis may be the result either of changes within the organ or of peritoneal inflammation. It has even been put down to friction. It may follow abscess-formation, infarction, chronic splenitis, or it may be the result of local inflammations, which have extended from the pleura.

Small spots of thickening, which have to be distinguished from tubercles, may be scattered over the surface, or more commonly there is a more or less general thickening of the capsule, on the surface of which rounded flat depressions are sometimes seen. The thickening may be irregular, in localized patches which may form button-like elevations above the surface, or it may take the form of more diffuse laminated fibrous thickenings. This fibrous tissue is extremely dense and may resemble cartilage. It constitutes the so-called “flat,” or “lamellar” or “corneal” fibroma of the spleen (see Fig. 131, p. 266). The fibrous layer is usually thickest towards its central part, where in some cases it forms a conical mass, which encroaches on the splenic tissue, and may reach a thickness of $\frac{1}{2}$ to $\frac{3}{4}$ in. (1 to 2 cm.). Such extreme thickening, however, is exceptional. Calcareous deposit may take place in the fibrous tissue and frequently adhesions form between the spleen and the adjacent organs.

Degenerations and Infiltrations.

Waxy, Amyloid or Lardaceous Degeneration. Waxy degeneration is encountered in the spleen more frequently than in any other organ and is produced by conditions which favour its occurrence in the liver and kidney (*q.v.* pp. 233 and 291).

It appears in two forms in the spleen: (a) "Sago" Waxy, and (b) "Diffuse" Waxy (Fig. 130).

(a) "Sago" Waxy Spleen (syn.: Amyloid Disease of the Follicles). In this variety the Malpighian bodies are principally affected, so that the cut surface is covered with numerous rounded greyish or flint-coloured translucent bodies, like incompletely cooked grains of sago, i.e., grains which have still a small white opaque centre. This opaque centre corresponds to the central artery of the Malpighian body, which along with the immediately adjoining portion of its lymphadenoid sheath remains unaffected in the typical sago waxy spleen. The waxy nature of these bodies is brought out very clearly by application of a solution of iodine. Frequently a narrow congested zone is found surrounding the Malpighian bodies, or the pulp may be anaemic. The organ is moderately increased in size and its consistence firmer than natural.

Under the microscope (methyl-violet stain) the waxy change affects the reticulum of the Malpighian body and the connective tissue supporting the walls of its capillaries.

Within the close glassy network produced, a few lymphoid cells persist. The arteries also are frequently waxy.

(b) "Diffuse" Waxy Spleen. ("Bacony," "lardaceous" spleen.) In the early stages this change is usually recognized with difficulty. When it is well-marked the organ is distinctly increased in size. It is firm in consistence, tough, and the margins may be rounded; the capsule is tense and often thinner than normal. Both its weight and its specific gravity are increased. Frequently perisplenic adhesions co-exist. On section the surface is smooth, wax-like, of a dark brownish flint colour. The edges of the cut surface remain sharp. The Malpighian bodies may not be visible; the trabeculae usually stand out distinctly. On application of iodine solution, the whole surface becomes of a deep brown colour and on this, in typical

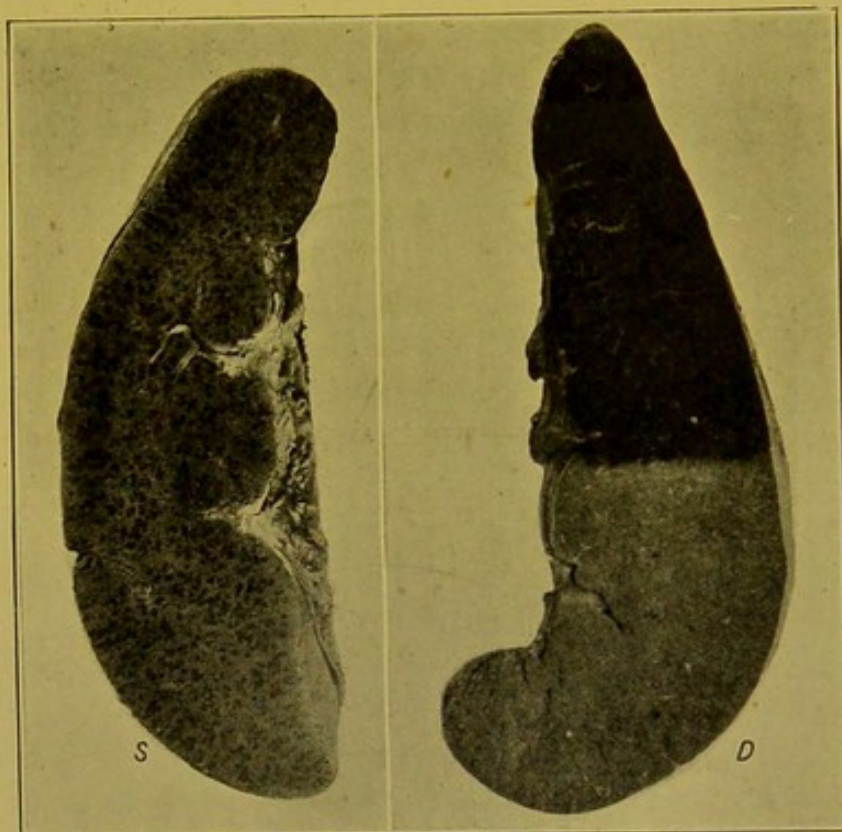


FIG. 130.—Waxy, Amyloid Degeneration of the Spleen.
(\times circ. $\frac{2}{3}$.)

(S.) Sago waxy form; (D.) Diffuse waxy form. In the latter a solution of iodine has been applied to half of the organ, causing a dark colouration.

cases, the Malpighian bodies may be picked out as minute opaque spots of a lighter colour than the remainder of the surface.

Under the microscope the waxy change is seen to affect the walls of the sinuses and the connective tissue between these, the endothelial cells and lymphoid cells being unaffected. The central artery of the Malpighian body and the reticulum in the immediate neighbourhood also show the waxy change.

When the two changes, sago and diffuse waxy, are conjoined, as is usually the case, the organ shows greater enlargement than when either occurs separately, and in extreme cases it may have the appearance and consistence of a mass of bees' wax. In these mixed cases usually either the sago waxy or diffuse waxy change predominates. The arteries and veins passing throughout the organ in the mixed form and in the diffuse waxy spleen are affected.

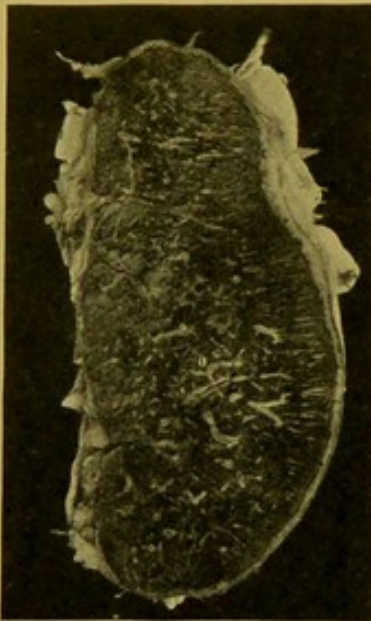

FIG. 131.—Atrophied Spleen; section. (\times circ. $\frac{3}{4}$.)

Trabeculae and vessels prominent because of atrophy of pulp. Greatly thickened capsule at upper and outer part. "Lamellar fibroma" over which adhesions have formed.

Fatty Degeneration is occasionally found in the Malpighian bodies, in septicaemia and pyaemia, but is generally of little importance as compared with fatty degeneration in other organs.

Hyaline Degeneration is very commonly found in the intima of the central artery of the Malpighian body, in acute infective conditions generally, and in chronic general arterial disease. In acute infections it occurs particularly in diphtheria and in scarlet fever, and is associated with acute softening of the organ. The more chronic form is frequently associated with chronic kidney disease.

Atrophy of the Spleen.—Simple atrophy of the spleen is found commonly in old people, and in younger individuals after long-standing chronic disease. The Malpighian bodies become small; the pulp is distinctly diminished and, as a result, the trabeculae and fibrous tissue are prominent and relatively increased (Fig. 131). The organ is small and tough; the capsule wrinkled and thickened; the weight decreased. On section the surface is somewhat dry; the organ is distinctly paler than normal and of a light brown or greyish-brown to rust colour. The pigment is distinctly increased if the atrophy is associated with the presence of a disease characterized by haemolysis. The thickened trabeculae stand out on the cut surface. The arteries are usually sclerosed. In cases in which death has occurred from inflammatory and toxic changes, an atrophied spleen becomes slightly enlarged and softened, but it still retains its pale brownish colour. Under the microscope the pigment is contained within fixed and free phagocytic cells.

In certain diseases in which the spleen is enlarged, e.g. lymphadenoma,

splenic anaemia, "waxy" disease, etc., the Malpighian bodies and pulp are atrophied, so that even though enlarged the organ is functionally atrophied.

Pigmentation of the Spleen.—Normally the spleen contains a certain amount of altered **blood pigment**, but in all diseases associated with blood destruction, e.g. the severe anaemias, leucocythaemia, chronic malaria, intermittent fever, in passive congestion and in exhausting diseases associated with great cachexia, the pigment is increased.

To the naked eye, the cut surface is of a distinctly brownish tint which varies in intensity. On application of the Prussian blue test (potassium ferrocyanide and hydrochloric acid, *see* p. 238) the organ becomes of a deep blue colour, or perhaps more often greenish or greenish-black, depending upon the amount of iron-containing pigment present.

Under the microscope the pigment is contained especially within large phagocytic cells, some at least of which are derived from the endothelial cells of the sinuses, within which they may be seen attached to the walls or lying free within the lumen, others of which are leucocytes, derived from the blood-stream. Haematogenous pigment is also increased in infarction, after typhoid fever, and in syphilis.

In **haemoglobinaemia** the organ is enlarged, reddish-brown or chocolate-brown, the pigment being seen both within cells and lying free. In *chronic malaria* the organ may be very dark in colour from deposit of **melanin**.

Jaundice.—In *icterus neonatorum* one occasionally finds bilirubin crystals. At the post-mortem the colour of the organ is brown or reddish-brown. In jaundice in the adult there is usually a diffuse olive-brown bile-staining.

Carbon pigment is sometimes found in the adventitia of the arteries, round the periphery of the Malpighian bodies and along the trabeculae, usually within phagocytic cells. It is found in cases of extreme emphysema of the lungs and when carbon pigment has escaped from lymphatic glands into the lymph vessels or blood-vessels. It may be sufficiently plentiful to produce black streaks and points visible to the naked eye.

Post-Mortem Discoloration is commonly found at the lower part of the organ where it lies in contact with the splenic flexure of the colon. A dark greenish or black colour is produced as a result of the action of sulphides—sulphuretted hydrogen and ammonium sulphide—upon the iron-containing derivatives of haemoglobin contained within the spleen.

Vascular Changes in the Spleen.

(1) **Acute Congestion** or **acute softening** of the spleen—*acute splenitis*. This condition occurs especially in acute infective diseases and also in diseases associated with haemolysis. This change is one of those most commonly met with in the post-mortem room. In some infective diseases the condition may not be present, e.g. in typhoid fever, in which softening may not take place, but proliferative changes may be

found in the endothelial cells lining the sinuses. Softening may also be absent in some cases of pneumonia. The appearances vary greatly. Although during life the organ may be firm from engorgement, and the capsule tense, so that it may rupture from a very slight injury, after death, in typical cases, softening is usually extreme, so that the organ is readily lacerated during removal, particularly in the young.

The colour depends altogether upon the degree of congestion and oedema of the organ and upon the relative proportion of nucleated cells and red blood corpuscles. When the congestion is very marked, as is frequently the case in the early stages, the pulp is of a somewhat deep red colour, whereas, in later stages, when large numbers of leucocytes and proliferated endothelial cells are present in the sinuses and infiltrate the splenic substance, the pulp is pale greyish-pink in colour.

The condition of the Malpighian bodies also varies. They are sometimes not visible, the swelling of the pulp being the principal change present. In other cases they are greatly enlarged, pale, slightly greyish or yellowish in colour, and stand out prominently on the cut surface. Between these two extremes, all grades of enlargement are met with. An attempt has been made to associate the special alterations in the Malpighian body with a micro-organismal invasion of the spleen, and this is no doubt frequently the case. In conditions of acute septicaemia, e.g., in typhoid and scarlet fevers; in ulcerative endocarditis, malaria, trypanosomiasis, recurrent fever, etc., the Malpighian bodies are usually enlarged, but this is not constantly the case. In diphtheria—in which the constitutional effects are regarded as due to the toxæmia,—the same condition is sometimes found, while in many acute diseases both Malpighian bodies and pulp are greatly swollen.

In the toxæmias, according to the same authorities, the pulp is specially affected. An analogy may be drawn between the spleen and the kidney, all of the blood conveying either bacteria or toxins having to pass through the Malpighian body before reaching the splenic pulp, just as in the kidney the blood has to pass through the glomerular tuft before reaching the inter-tubular plexus from which toxins are excreted by the epithelium of the tubules. Thus, just as toxins, being concentrated in the tubules of the kidney, have a special tendency to induce changes in the parenchyma, so toxins as they lie longer in contact with the walls of the splenic sinuses than with the vessels of the Malpighian bodies, may be able to produce a greater effect upon the pulp than upon the Malpighian bodies.

Naked Eye Appearances.—When the organ is held between the finger and thumb with the cut surface uppermost, and slight pressure is exerted, the softened pulp wells up and flows off the surface—"diffluent spleen"—and if this surface be held under a gentle stream of water the pulp can be readily washed away, leaving the trabeculae standing out distinctly. This is not invariably the case in acute congestion of the spleen.

Under the microscope, the Malpighian bodies, when enlarged, frequently

show hyaline degeneration of the intima of the central arteries and an increase of the cells within the lymphadenoid sheath. According to Muir, the new cells are larger and more basophil than ordinary lymphoid cells, and are specially aggregated round the periphery of the follicles. The splenic pulp and sinuses are densely packed with red blood corpuscles, and in some spleens, which are pale to the naked eye, the sinuses contain large numbers of phagocytic (to bacteria and red blood corpuscles) leucocytes and large proliferated endothelial cells. Large cells like myelocytes, in which the nuclei may be proliferated, may also be present. They are said to occur particularly in typhoid fever. The endothelial cells lining the sinuses are also swollen and project into the spaces. In certain cases bacteria can be demonstrated in sections.

(2) **Chronic Venous Congestion of the Spleen.**—Chronic venous congestion of the spleen occurs especially as a result of hepatic cirrhosis, but is also found in conditions of back pressure in the liver, such as extreme chronic venous congestion, the result of cardiac or pulmonary disease. It also occurs in the presence of obstruction to splenic and portal veins by thrombosis, or of pressure upon these veins of a cancer of the head of the pancreas, of enlarged glands, or of tumours of the liver. In some cases, when associated with cirrhosis of the liver, one has to consider the possibility of the splenic condition being coincident with, or even prior to, the alteration in the liver, another factor—of toxic nature—being present and causing the enlargement of the spleen.

The organ is enlarged and its consistence is usually increased so that it becomes firm and elastic. It is thicker than normal; the capsule is thickened and the organ cuts crisply; the cut surface remains flat and its margins remain more or less sharp (*see* Fig. 133 *b*, p. 271).

Typically, the organ is of a deep plum colour with, in the later stages, a distinct brownish tinge. The Malpighian bodies may not be visible and the splenic pulp, unless there be a terminal acute congestion, cannot be washed away under a stream of water. The increased firmness of the organ depends on the thickening of the trabeculae and of the reticulum of the pulp.

Acute and chronic congestions of the spleen can be distinguished more easily by the naked eye than by the microscopic appearances.

Under the microscope the sinuses are greatly dilated and their walls distinct; the connective tissue between them is increased and infiltrated with red blood corpuscles. The endothelium lining the sinuses is prominent and contains altered blood pigment, which is also seen within phagocytic cells lying free within the sinuses and in the tissue separating the sinuses. The dilated sinuses are most easily distinguished in the immediate neighbourhood of the trabeculae and underneath the capsule of the organ. The Malpighian bodies may be unaltered or show slight fibrous change. In later stages the contraction of the hyperplastic connective tissue may bring about *cyanotic atrophy*.

Focal Necroses occur in the spleen, especially during the course of typhoid fever, less commonly in scarlet fever, diphtheria, pneumonia, etc. They are evidences of very acute infection, in some cases indicating the actual presence of bacteria, and resulting from local intense action of their toxines. They may be visible to the naked eye as small greyish points, or they may require the microscope for their detection. For microscopic characters, see description of the similar change in the liver (p. 234).

Infarction of the Spleen.—The typical infarct of the spleen is of haemorrhagic nature, but occasionally it may be pale from the outset. The branches of the splenic artery are typical endarteries and the local anaemia, caused

by their obstruction through embolism, is prolonged by the coincident contraction of the muscular tissue in the capsule and in the trabeculae, in that portion of the organ corresponding to the distribution of the artery. Infarction, however, is not only caused by embolism but also by thrombosis occurring particularly in such diseases as leucocythaemia, typhoid fever and rarely in polycythaemia with cyanosis. Occasionally it is caused by thrombosis of the splenic vein.

The infarct is typically of the shape of a blunt cone, with the base to the outer surface, and it may extend right across the organ. The affected area in the early stage is usually of a deep purple colour, though this colour may be confined to the peripheral part, the central area being of a reddish-grey colour. Such areas can be felt as well as seen before the organ is incised. The base of a recent infarct is raised above the general capsular surface and may be the seat of acute peritonitis, with fibrinous

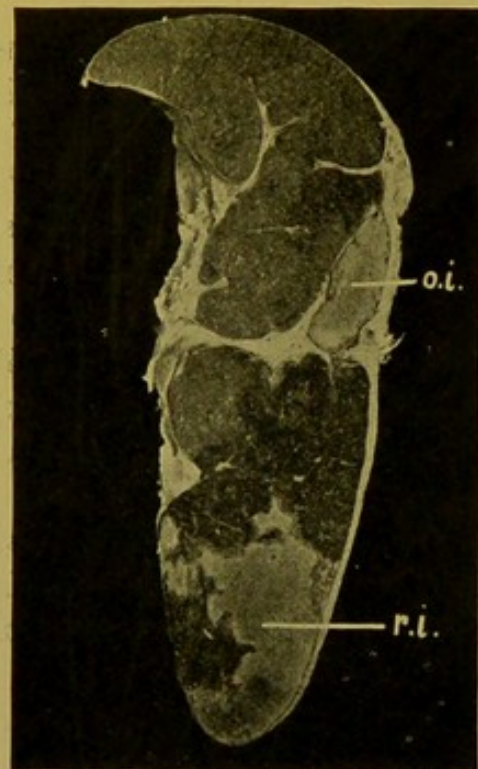


FIG. 132.—Infarction of Spleen: section. ($\times \frac{1}{2}$.)

(*r.i.*) recent decolorized infarct; (*o.i.*) old infarct surrounded by contracting scar-tissue. Remainder of organ shows enlargement and prominence of Malpighian bodies, from acute congestion.

deposit. In later stages, when decolorization is taking place, the colour passes from a dirty greyish-brown to a light yellowish-grey, and at the periphery a narrow yellow zone appears in which fatty changes are taking place. (Fig. 132.)

Frequently infarcts are found which are of a greyish-brown colour and project on the convex surface suggesting both from the naked eye and microscopic appearances as well as from the characters of associated infarcts in other organs, an early stage of infarction rather than a stage of decolorization.

Under the microscope the tissue in the affected area loses its power of

taking the nuclear stains. The Malpighian bodies persist longest. The tissue undergoes coagulative necrosis.

Organizing infarcts are characterized by the formation of a narrow zone of young vascular connective tissue which surrounds them and causes a retraction of the capsule. Old infarcts may be represented by narrow grey scars passing across the organ from a deep funnel-shaped depression on the surface—these have to be distinguished from syphilitic scars — or by larger conical areas of scar-tissue enclosing small masses of yellow necrotic tissue, the remains of the infarcted areas. Occasionally calcification takes place either throughout the necrotic area or at its periphery, producing a more or less calcareous or gritty mass surrounded by fibrous tissue.

Septic Infarcts in their general appearance, in the early stage, resemble the ordinary haemorrhagic infarcts, but soon they tend to break down and soften so that a cavity is formed close under the capsule containing brownish-grey softened necrotic tissue or full of greyish or anchovy-sauce-like pus, composed in great part of broken-down splenic tissue. Occasionally the fluid resembles ordinary pus. The spaces resulting are surrounded by a zone of congestion.

Phleboliths. — Occasionally within the spleen small, irregularly rounded, yellow, calcareous masses are found which may reach one-third of an inch in diameter. These are probably calcified thrombi, occurring in varices on the veins. Similar collections may be produced by encystment of *Pentastomum denticulatum*.

The Spleen in Leucocythaemia.—The spleen is specially affected in cases of myelogenous leucocythaemia, although in some cases of lymphatic leucocythaemia also the organ may be considerably enlarged. In the former

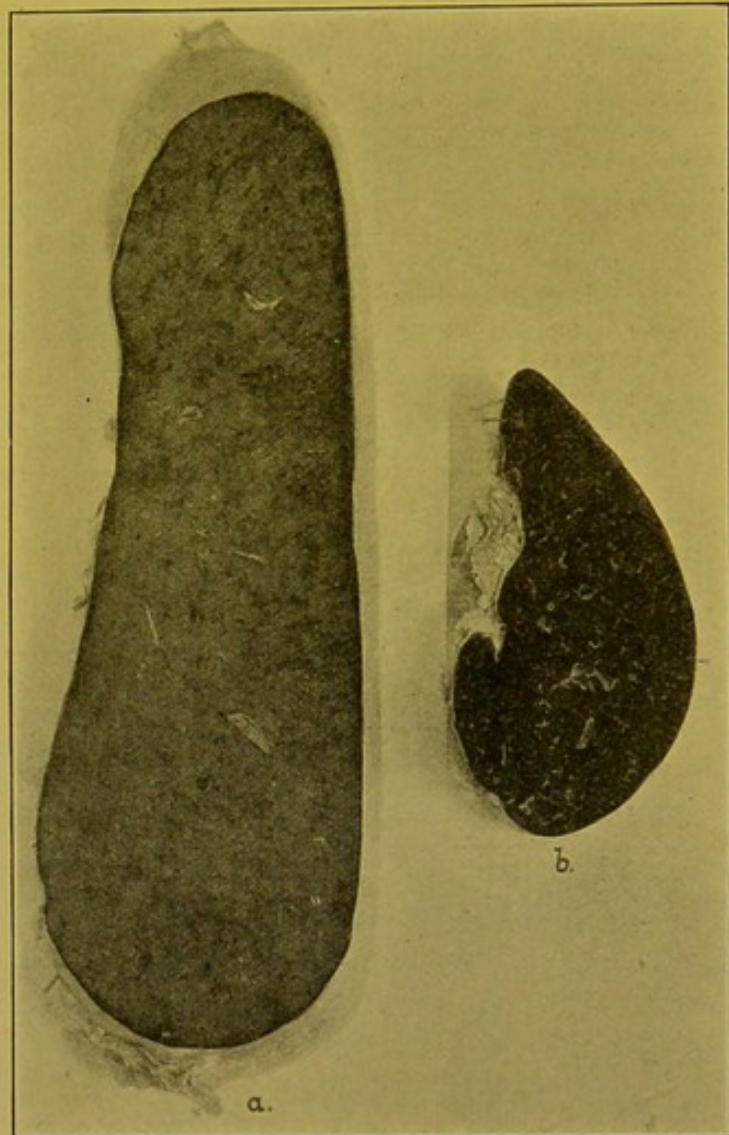


FIG. 133.

(a.) Section of Spleen in Myelogenous Leucocythaemia; great enlargement and pallor. (b.) Chronic venous hyperaemia of Spleen—section; organ moderately enlarged. Photographed with *a* to indicate size of the leucocythaemic spleen. (\times circ. $\frac{2}{3}$.)

the organ is greatly enlarged in all its diameters, measuring 10 to 12 in., or more, in length, with a corresponding increase in thickness and width (Fig. 133). It may extend across to the right side of the abdomen. The capsule is thickened and, in long-standing cases, fibrous perisplenitis is usually present, forming a thick layer on the surface. In some cases fibrous adhesions may form to the diaphragm and adjacent organs. When cut into, the colour is paler than normal, bleached looking, of a brownish-pink colour, with a grey tinge, which varies in intensity. The colour has been aptly compared to that of a slice of "pounded" beef-steak. It may be mottled with yellowish or brownish areas. The consistence is relatively soft in the early stages, but as the interstitial tissue undergoes hyperplasia the organ becomes firmer. Frequently there are haemorrhages underneath the capsule and throughout the organ. In some cases the follicles are most affected, and they may become greatly swollen, even to the size of peas. The older the condition, the more prominent do the whitish bands of connective tissue become. Infarcts may be present as a result of thrombosis, and in some cases sago-waxy degeneration accompanies the change. This enlargement has to be distinguished from the enlargement of Banti's disease, of lymphadenoma, of kala-azar and of malaria, in the last of which probably the most extreme enlargement of the organ is found.

Under the microscope the fibrous stroma is usually thickened from cellular hyperplasia with, in later stages, fibrous over-growth accompanied by proliferation of the endothelial cells of the sinuses. The Malpighian bodies may show great increase of the adenoid reticulum. The endothelial cells both fixed and free display phagocytosis and the sinuses contain large cells like myelocytes along with which nucleated red cells are usually found.

In **lymphatic leucocythaemia** the spleen may, or may not, be enlarged. If enlarged, the enlargement, as a rule, is not so enormous as in the case of spleno-medullary leucocythaemia. Small haemorrhages are seen, especially under the capsule. Under the microscope there is a great aggregation of lymphocytes in the sinuses and between them. Accompanying these changes there are other important alterations in the lymphatic glands (p. 350), in the bone marrow (p. 353), and in the liver and kidneys (*q.v.*, pp. 244 and 310).

The Spleen in Lymphadenoma.—The appearance of the spleen in this disease varies. It is usually considerably enlarged and the enlargement is uniform. The consistence is increased. On the surface, the capsule is usually slightly thickened and adhesions are usually absent. Darker projecting areas corresponding to the bases of infarcts are not uncommonly met with. On section the organ may be simply congested, and of a somewhat brownish-red colour, or in addition the Malpighian bodies may be prominent. In well-marked cases these are distinctly, though somewhat irregularly, enlarged and they project on the cut surface. In the early stages they are of a greyish colour, frequently with a pink periphery. As the nodules

enlarge they are seen to be intersected, at least at their outer margins, with pink streaks indicating that the outer layers at least are visibly vascular, thus distinguishing them from the nodules in chronic tuberculosis, which are non-vascular throughout. In other cases, which are rather more rare than the form just described, the cut surface shows thick branching processes and nodules of a pale grey or greyish-pink colour with a certain degree of translucency. These have been compared to lumps of suet. Along with these larger nodules numerous other smaller nodules are scattered irregularly over the cut surface (Fig. 134). In one case I examined the organ was greatly enlarged, the greater number of the Malpighian bodies moderately increased in size and each surrounded by a brownish zone, the pulp between being congested.

Under the microscope, the change consists characteristically of a proliferation of the endothelioid cells and reticulum of the Malpighian bodies, in the later stages the proliferated fibrous tissue reticulum displacing to a great extent the cellular elements. Lymphocytes are present in but small numbers in the later stages. Surrounding the enlarged Malpighian body there is a zone of pigmentation, the pigment being contained for the most part within large phagocytic cells. The pulp may not be greatly affected, though it is pushed aside in the enlargement of the Malpighian bodies. The fibrous transformation may extend in some cases to the reticulum of the pulp.

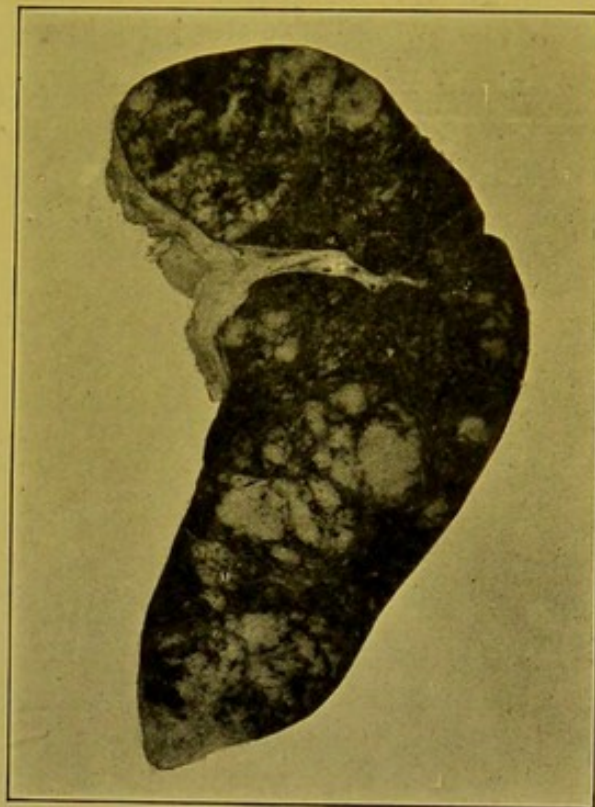


FIG. 134.—Spleen in Lymphadenoma.
(\times circ. $\frac{3}{8}$.)

The pale areas are the so-called "Suet bodies"—greatly enlarged, altered Malpighian bodies.

The Spleen in Tuberculosis.—Infection is almost invariably secondary.

(a) **Acute miliary tuberculosis** constantly affects the spleen in generalized tuberculosis, disseminated by way of the blood-stream. The organ may be enlarged, and slightly softened. The cut surface is of a dark red colour, and upon it are seen separate grey or yellowish minute tubercles, of the size of a millet seed (miliary), or smaller (sub-miliary). These may be discrete and few in numbers, or they may crowd the whole surface. They project slightly above the cut surface, this character distinguishing them from healthy Malpighian bodies which are cut through on the level of the surface.

(b) **Subacute and Chronic Tubercles** are larger than the acute tubercles, and are caseated. In size they may vary from that of a hemp-seed to that

of a pea, and surrounding them may be seen smaller satellite grey tubercles. When occurring in children, they may be regarded as strongly suggesting that the nature of the infection is bovine. This manifestation of tuberculosis in the spleen is not common.

Tumours of the Spleen.—Neither primary nor secondary tumours of the spleen are common. Primary fibroma, chondroma, osteoma, lymphangioma, and haemangioma have been recorded. Of the secondary tumours, sarcomata occur less infrequently than carcinomata. Of the sarcomata, the most common varieties are the round-celled forms, especially melanotic sarcoma. I have seen but few secondary carcinomata, and most of these have extended directly into the spleen from the fundus of the stomach.

Animal Parasites.—The most frequent are the *hydatids* of *Taenia echinococcus*. *Cysticercus cellulosae* and *Pentastomum denticulatum* are very rare.

The great enlargement of the spleen in kala-azar and in malaria has been referred to already (p. 272). The parasites are most readily detected in stained films.

CHAPTER XIV

THE ABDOMEN (*continued*)

THE KIDNEYS AND SUPRA-RENAL CAPSULES

The Removal of the Kidneys and Supra-renal Capsules.—If the other abdominal viscera have been removed in accordance with the method recommended on pages 35, 36, the kidneys with their supra-renal capsules and ureters remain *in situ*, along with the bladder and other structures in the pelvis. Two vertical incisions are made on either side of the vertebral column, internal to the supra-renal capsules and upper parts of the kidneys. The kidneys and supra-renals, along with the fatty and areolar tissue embedding them, are separated, the arteries and veins being divided and the ureters stripped down to the brim of the pelvis. —Occasionally it may be convenient to remove the kidneys with the portion of aorta from which their arteries spring.—The ureters may be slit up with scissors at this stage, or, before separating the kidneys, they may be dissected out as they pass over the sacro-iliac synchondrosis, and slit up.

The peritoneum passing over the brim of the true pelvis is now divided, and the pelvic organs and vessels separated from the walls by the free use of the knife until one reaches the coccyx behind and the lower limit of the pubic arch in front. The organs are then pressed first to one side and then to the other, while the firm connexions with the perineum and the walls of the orifices opening upon it are cut through towards the mesial plane, completely freeing the organs. In completing the removal one may prefer to cut through the deeper perineal attachments from the perineum. To do this the lower extremities are widely separated; a deep oval incision is made so as to enclose the perineal orifices, then a long-bladed knife is passed upwards and outwards through the incision so that its point rests against the walls of the pelvis. Then, with one sweep of the knife carried right round the pelvis, the remaining attachments of its contents can be divided.

If one wish to remove the kidneys and supra-renals without disturbing the other abdominal organs, the whole mass of the small intestine should be pulled over to the opposite side of the abdomen and a vertical incision made through the peritoneum along the outer side of the colon. On stripping up the peritoneum along with the colon towards the mesial plane, the kidneys and supra-renal capsules are exposed.

The right supra-renal is usually closely apposed to the under surface of the liver, and it has to be dissected off with care.

The right kidney is usually thicker and shorter than the left, and the upper end of each kidney is a little more bulky than the lower. The right kidney is a little lower in the body than the left, and the right kidney almost invariably contains more blood than the left, so that it appears slightly congested when compared with the left.

How to determine the side to which a kidney belongs, after its removal from the body.—If the supra-renal has been removed with the corresponding kidney

it will indicate the upper end, and as it usually overlaps a little on the anterior surface it will also indicate whether the kidney is right or left. The direction of the ureter is of additional assistance.

If the supra-renal has been separated from the kidney, one has recourse to other anatomical indications. The left kidney has very constantly a transverse prominence crossing the middle of its anterior surface. If this ridge be not prominent, one has to fall back on the direction of the ureter and the relative position of artery, vein and ureter at the hilum—normally vein, artery, ureter, from before backwards.

There is no very dependable way of indicating the side to which a separated *supra-renal* belongs. Its shape—right, triangular; left, crescentic—is of assistance, but the shape may vary.

EXAMINATION OF THE KIDNEYS.

Measurements.—According to Orth, the *combined* weight of the kidneys after removal of the capsule and the connective tissue in their hilum, is, in the newly born, 23 gm.; at the end of the first year 62 gm. ($2\frac{1}{2}$ oz.); in the adult male 320 gm. ($11\frac{1}{4}$ oz.); in the adult female 293 gm. ($10\frac{1}{2}$ oz.). He gives the proportion to body weight as 1 to 200, but according to Henle the proportion is as 1 to 240.

In a large number of autopsies of adults I found that the average weights of the kidneys *with their capsules* were as follows:—

Males.—849 cases. Left Kidney, 182 gm. ($6\frac{1}{2}$ oz.). Right, 812 cases, 181 gm. ($6\frac{2}{5}$ oz.).

Females.—512 cases. Left Kidney, 152.5 gm. ($5\frac{2}{5}$ oz.). Right, 480 cases, 151 gm. ($5\frac{2}{5}$ oz.).

Taking both together, the left kidney averaged $\frac{1}{289}$, and the right kidney $\frac{1}{304}$ of the body weight. The total average was $\frac{1}{298}$.

The average length of the kidney is $4\frac{1}{2}$ in. (11–12 cm.), its width about 2 in. (5–6 cm.), and its thickness about $1\frac{1}{4}$ in. (3–4 cm.).

The kidney is embedded in a layer of fat of varying thickness. This is sometimes termed its *fatty capsule*, but the term “capsule” is usually applied to the smooth, translucent, fibrous layer, which is closely applied to the kidney, and is removed along with it. Usually some fat remains attached in the hilum of the organ, being more adherent there than over the general surface. The fatty capsule is adherent and increased in thickness in chronic interstitial and atrophic changes in the kidney.

The surface of the kidney is marked out into areas by shallow grooves which represent the deep sulci which, in the foetus, separate up the organ into lobes. These have to be distinguished from the scars of old infarcts.

Normally, the *fibrous capsule* is more or less translucent; a few delicate stellate veins can be seen radiating over its surface; it can be stripped off the kidney readily, leaving a smooth surface. This capsule consists really of two layers, the outer composed of dense fibrous tissue, and the deeper, which is closely applied to the surface of the kidney, containing some unstriated muscle which in some kidneys, particularly in the young, may form a well-marked layer. The deeper layer is frequently left attached to the kidney when the fibrous capsule is stripped off. Some unstriated muscle passes down along the vessels and is especially grouped round about the “arches” of the renal vessels.

Occasionally small, opaque, flattened, patches of supra-renal tissue of a yellowish or yellowish-brown or ochre colour are seen underneath the capsule or between its layers.

Appearance on Section.—(1) **Cortex.** It is very difficult to convey an accurate idea of the normal *colour* of the cortex, seeing that it changes quickly when exposed to the air, losing chiefly the bluish-grey tint which modifies the ordinary somewhat brownish-pink or salmon colour. The papillary parts of the medulla are normally of about the same tint as the cortex, though the greyish tint is usually less evident. The boundary or intermediate layer is usually of a purplish-red colour, but this is readily modified by slight changes in the width of the tubular parts.

In the adult, the cortex *measures* about one-fifth of an inch (5–6 mm.) in width, this being about one-third to two-fifths of the width of the medulla. Usually, but not invariably, the inter-pyramidal cortex is a little wider than the sub-capsular cortex, but the width of the former varies so much and depends so much upon the plane of section that no hard and fast rule can be given as to its relative thickness.

On close examination of the cortex in a good light, particularly with the aid of a lens, it is seen to be made up of narrow lines and columns arranged perpendicularly to the surface. These are alternately red and pinkish-grey, the latter being the wider. The red lines correspond to the interlobular vessels and rows of glomeruli. Immediately surrounding and embedding these two structures and slightly wider under the capsule than in the deeper part of the cortex, is the “*labyrinth*” which contains practically the whole of the secreting part of the renal tubules. The labyrinth comprises practically the whole of the *grey column* in the superficial parts of the cortex close to the capsule, and the margins of it in the deeper parts, the central portion in the latter situation corresponding to the *medullary rays*, which contain almost exclusively collecting tubules and parts of the loops of Henle. These are continuous with pale streaks which pass down through the intermediate or boundary layer of the medulla, and which separate the prominent red lines of that layer which are formed by the grouped straight vessels of the medulla.

The grey columns in the cortex when looked at with a lens are distinctly translucent, and one can see vessels, etc., which are a little distance beneath the cut surface. This translucency is lost whenever the light is refracted by oil droplets within the epithelium, or obstructed by the fine granular deposit in cloudy swelling or catarrh, or the opaque coarser deposits in other conditions. Hence opacity of the grey columns, particularly if associated with increased width, invariably indicates pathological change in the tubules of the kidney. This opacity usually affects the labyrinth more than the medullary ray, so that, in the grey columns, one can frequently distinguish an opaque edge and a more or less translucent central part continuous with the “ray” passing down into the medulla.

Medulla.—The boundary layer or intermediate layer of the medulla, “base of the pyramid,” as already indicated, is composed of alternate light and dark streaks corresponding to tubules—loop tubules, and larger collecting tubules—and straight vessels, respectively. These streaks become more commingled in the papillary part, which is thus of a lighter colour and more uniformly and finely striated.

The Renal Pelvis is usually separated from the inter-pyramidal kidney substance by a small amount of yellow fat. The tips of the pyramids covered only with mucous membrane project into the calyces. The mucous membrane of the pelvis

as a whole is smooth, glistening and of a bluish-white or grey-white colour. Its vessels should not be appreciable to the naked eye.

Renal Vessels.—On the cut surface, the larger branches of the renal artery and vein are visible between the pyramids, and a few small branches are seen between the cortex and medulla. Normal arteries collapse on section.

General Consideration of Pathological Changes met with in the Kidney.—

The cortex is in general more affected by pathological changes than the medulla, and very frequently, particularly in conditions involving narrowing or atrophy of the cortex, the sub-capsular cortex appears to be more affected than the inter-pyramidal cortex. Parenchymatous changes are usually more distinct in the deeper parts of the superficial cortex than in the layers immediately underneath the capsule.

The kidney is **increased in size** in all acute and sub-acute inflammations; in leucocythaemia; in waxy or amyloid degeneration; in congenital cystic kidney; in most new-growths; in compensation for absence, hypoplasia, atrophy or loss of its fellow. It appears to be **enlarged** in hydronephrosis, and pyonephrosis, though its substance is actually reduced. It is **diminished** in size in hypoplasia, in atrophy, in loss of function, and in late stages of chronic nephritis. Atrophy may be compensated for by increase of the peripelvic fat, or by dilatation of the renal pelvis.

The fibrous **capsule** is thickened and adherent in most cases in which there is increase of fibrous tissue in the kidney, especially along the interlobular veins, and on being stripped off, it tears away with it small portions of the substance of the kidney, but, if it be oedematous, it leaves its deeper layers attached to the kidney. The capsule can be stripped off more readily than normal, in most forms of acute nephritis, and also when decomposition has set in.

The sub-capsular **cortex** is **widened** in all acute and sub-acute inflammations of the kidney; in cellular infiltrations; in waxy degeneration, unless this be associated with extreme cirrhosis of the organ. It is **narrowed** to a greater or lesser degree in all forms of chronic nephritis with atrophy, and in cases in which the renal pelvis is greatly distended. The cortex becomes **pale** if the tubules are swollen and press upon the intertubular plexus and glomeruli, and also if numerous glomeruli are thrombosed, degenerated, or necrotic. Pallor with **opacity** indicates granularity, or necrosis, or fatty change in the epithelium of the tubules. A deep **dusky-red colour** points to greatly increased vascularity, particularly if this has been of long duration. In congestions, the vessels of the mucous membrane of the renal pelvis share in the engorgement. Deposits of altered blood pigment impart to the cortex a brownish tint, which is best seen if anaemia co-exist. The colour of the cortex deepens and approximates to that of the base of the pyramid in typical cases of chronic interstitial nephritis and in arterio-sclerotic atrophy.

In uncomplicated **vascular changes**, the red lines representing the inter-

lobular vessels and glomeruli remain regular and parallel to the grey lines of the tubular parts. They become irregular, and distorted in all varieties of chronic nephritis, particularly in interstitial nephritis, and also in arterio-sclerotic atrophy.

Vessels can be made out in the cortex only when thickened, and sclerotic.

Petechial haemorrhages are seldom found in the cortex apart from acute general pyaemia, though they occur sometimes in acute nephritis, and constantly in one form of sub-acute parenchymatous nephritis. Occasionally, in acute nephritis, particularly about a week to ten days after the onset, the enlarged congested glomeruli and sheaves of dilated straight vessels may simulate petechial haemorrhages, and are often mistaken for these. Diffuse haemorrhages occur in infarction and in lymphatic leucocythaemia.

A moderate degree of **decomposition** is shown by a slaty or indigo discoloration of the parts of the kidneys closely apposed to the large intestine. In more advanced decomposition the whole cortex becomes of a uniform pink, or later, of a greyish-green, or if iron be present, of an indigo or almost black colour.

Other changes in colour will be considered when dealing with pathological deposits in the kidney.

The normal kidney when held horizontally by the middle between the thumb and forefinger tends to dip slightly at its upper and lower ends. This tendency is increased if the **consistence** be lessened, so that the kidney, when held in this manner, forms an arc of a circle. If the consistence be increased, in addition to the increased firmness and elasticity detected by palpation, the kidney usually retains its shape even when held by one end. The consistence is lessened especially in the acute inflammations and is most marked if decomposition has supervened. In atrophic conditions, particularly if there be increase of the interstitial connective tissue the consistence is increased. This is by no means invariable. It is also increased in chronic venous congestion and in practically all forms of waxy change.

As already indicated, pathological changes are never so well-marked in the medulla as in the cortex, and some of the principal changes affecting the **medulla** have already been referred to when considering those of the cortex. The more extreme the changes occurring in the course of chronic nephritis the more does the colour of the cortex approximate to that of the medulla and the less distinct does the line separating these two areas become. The medulla is seldom affected primarily, and when this occurs it generally indicates a condition secondary to inflammation of the pelvis of the kidney.

The **peri-pelvic fat** may be increased in amount and this may be regarded as of compensatory formation. Its development may be sufficient to cause the kidney as a whole to retain its normal size, although on section the kidney substance itself may be greatly atrophied.

Tissue of the nature of haematoblastic bone marrow has been found in the peri-pelvic fat.

General Consideration of Microscopical Changes.—In the normal kidney glomeruli are usually absent from the immediately sub-capsular part of the cortex, and, the existence of atrophic changes in the cortex may be assumed when no tubules intervene between them and the capsule.

In the normal glomerulus there is a hardly appreciable amount of connective tissue between the loops. The size of the glomerulus may be diminished as a result of back pressure in the tubules; also in atrophy, when diminution of size is usually associated with a loss of nuclear staining, and more or less loss of patency of the capillaries. The glomerulus is increased in size in waxy (amyloid) change; also when it is infiltrated with cells, and when there is proliferation of the connective tissue between the loops and of the endothelium of the capillaries.

The glomerular space normally is very narrow and empty. It may be dilated from back pressure in the tubules. It may contain blood, homogeneous or granular albuminous material, leucocytes, or cells cast off from the surface of the tuft, or from the Bowman's capsule. These may undergo degeneration. In sub-acute but also in chronic nephritis a certain amount of organization takes place following on these proliferative and exudative changes.

Bowman's capsule may become thickened both in acute and chronic nephritis. In acute nephritis it may become swollen and hyaline, and surrounding it there may be great infiltration with small round cells (lymphoid) and polymorphs, particularly in the neighbourhood of the afferent arteriole. In sub-acute and chronic forms of interstitial nephritis, Bowman's capsule undergoes thickening from formation of concentrically arranged fibrous connective tissue. This last change is of importance in distinguishing atrophies following nephritis from the atrophy resulting from primary arterial sclerosis.

The principal degenerative changes affecting the **Interlobular Vessels** and the afferent arterioles are either of the nature of hyaline or of waxy change. Sections of arteriosclerotic atrophy of the kidney afford the most easily accessible examples of sclerosis of the smaller arteries. Proliferative end-arteritis of the afferent arterioles, often associated with infiltration of the vessel wall, is frequently followed by similar changes in the glomerulus, bringing about obstruction of its capillaries.

Under normal conditions the capillaries of the **intertubular plexus** are scarcely visible, a few triangular chinks only being seen between the tubules. Whenever this plexus forms a distinct feature in the microscopic field, the kidney is congested.

The alterations which the **tubules** may undergo vary greatly both in kind and in intensity. One should bear in mind that the renal epithelium may undergo post-mortem changes very rapidly.

The pathological changes affecting the secreting parenchyma are the following: (a) degenerations, (b) desquamation and proliferation, (c) pigmentation, (d) dilatation of tubules, (e) atrophy, (f) hypertrophy and hyperplasia, and (g) formation of casts. Several of these changes may be conjoined.

(a) *Degenerative changes* include granular and cloudy changes, ballooning of the cell, fatty change, necrosis and calcification. All these alterations may be met with in the course of acute parenchymatous nephritis.

(b) *Desquamation*.—The cell, either still retaining its power of taking nuclear stains, or in various stages of degeneration and necrosis, becomes separated from the basement membrane. In the collecting tubules particularly, they may proliferate (*v.* parenchymatous and consecutive nephritis, pp. 304 and 299).

(c) *Pigmentation*.—Pigment is deposited firstly in the neighbourhood of the nuclei of the cells. The pigment may vary greatly in nature; met-haemoglobin, and haemosiderin and haemofuscin, derivatives of haemoglobin are the most common. Silver (Argyria) is usually deposited rather in the basement membrane than in the cells.

(d) *Dilatation*—generally associated with flattening of the epithelium—indicates more or less chronic parenchymatous changes.

(e) *Atrophy*.—The tubules become duct-like, and their cells very small and rounded, few in number and in many tubules they may disappear altogether.

(f) *Hypertrophy* and *hyperplasia*.—The cells are proliferated, columnar, closely set, sometimes with infoldings of the layer. This is best seen in chronic parenchymatous nephritis.

(g) *Casts*.—These generally indicate presence of nephritis. They are best seen within the medulla.

The Interstitial Tissue.—The kidney in its cortical part contains an extremely small amount of interstitial tissue, this being appreciable only along the interlobular vessels, particularly near the bases of the pyramids, and immediately under the capsule. Increase of connective tissue is especially liable to take place round the veins as they rise from the capsule, and this accounts for the abnormal adhesion of the capsule, which is found in the presence of chronic interstitial changes. Connective tissue may also be increased diffusely. If it is made out easily between the tubules of the *cortex*, it is increased in amount.

In acute parenchymatous nephritis the tubules may be separated by oedematous fluid with either very slight cellular infiltration or none at all. In acute interstitial inflammation the cellular infiltration is usually marked.

For infiltration of the cortex in leucocythaemia and allied conditions; in syphilis; and in localized and metastatic infective conditions, *see* later, pp. 310; 305; 300; 299.

In the *medulla*, changes in the interstitial tissue are usually less readily

distinguished, but in chronic conditions one frequently meets with hyaline swelling, waxy degeneration, and oedema of the interstitial connective tissue.

DISEASES OF THE KIDNEYS

Displaced Kidneys.—The right kidney is more frequently displaced as the result of *acquired* pathological changes; the left kidney more frequently as the result of *congenital* conditions. This is by no means invariable, as I have found the right kidney, in a male, lying over the position of the sacro-iliac joint. It had lost its normal bean-shape, was more or less elliptical, and the ureter emerged from its anterior surface. In another case, also in a male, the right kidney lay in the middle line, at the brim of the pelvis. In both cases the supra-renal was in its normal position. Both of these cases were exceptional in being apparently of congenital nature. Occasionally the kidneys descend into the pelvis.

Movable kidneys include both those which are abnormally movable in their natural positions, and also those which, on account of the extension of the peritoneum on to their posterior surfaces, have a more or less marked mesentery—mesonephron. These are termed **floating** kidneys. In addition to possessing a great range of movement, they occasionally may become twisted upon themselves or tilted so as to cause obstruction to the ureters or to the vessels. In multiparae, abnormal mobility of the kidneys behind the peritoneum is not uncommonly found from the loosening of their connexions, consequent upon pregnancy. This result may also be due to absorption of the fatty bed in which the kidney lies, or may be due to diminished support afforded by the abdominal organs and walls.

Other Congenital Anomalies. Aplasia.—Bilateral aplasia of the kidneys is very rare and is incompatible with life.

Unilateral Aplasia.—One kidney, usually the left, may be completely wanting. This may be associated with malformation of the genital apparatus on the same side. The corresponding ureter may also be wanting or it may be present as a thin-walled tube, blind at its upper extremity. The other kidney in such cases is hypertrophied, so as to carry on the function of the two organs.

Hypoplasia.—One or both kidneys may be under-developed. **Bilateral hypoplasia** is usually, but not necessarily, incompatible with life, but in any case the individual seldom reaches adult life, and is as a whole poorly developed. All the organs share in the hypoplasia. The kidneys, in such cases, are somewhat similar to those met with in atrophic conditions, being small, pale and somewhat irregular and lobed. They are smooth on the surface; the capsule is thin and strips easily and cleanly.

Unilateral hypoplasia.—In one case, an adult male, I found two pea-sized thin-walled cysts representing the left kidney. These lay low in the lumbar region and to them rudimentary vessels and ureters were

attached. The supra-renal body was of normal size and in its usual position. The right kidney was of double the normal size.

Fused Kidneys.

In the "**Horse-Shoe**" Kidney, the kidneys approximate at their *lower* ends and are joined together at that point either by renal substance or by a band of dense fibrous tissue. The former is the more common variety. The conjoined organs are generally placed lower in the abdomen than usual, so that the bridge may pass across the middle line as low as the last lumbar vertebra. The pelvis and ureters are separate and the ureters pass downwards in front of the bridge (Fig. 135). In very rare cases the bridge forms between the middle or the upper parts of the kidneys.

Other forms of coalesced kidneys may be found. I have seen a single kidney on the right side more than twice the normal size, of a crescentic shape with the convexity inwards, the lower end lying across the middle line in the mid-lumbar region, possessing two ureters which emerged from the concavity of the organ. In other cases, a form intermediate in shape between the crescent and

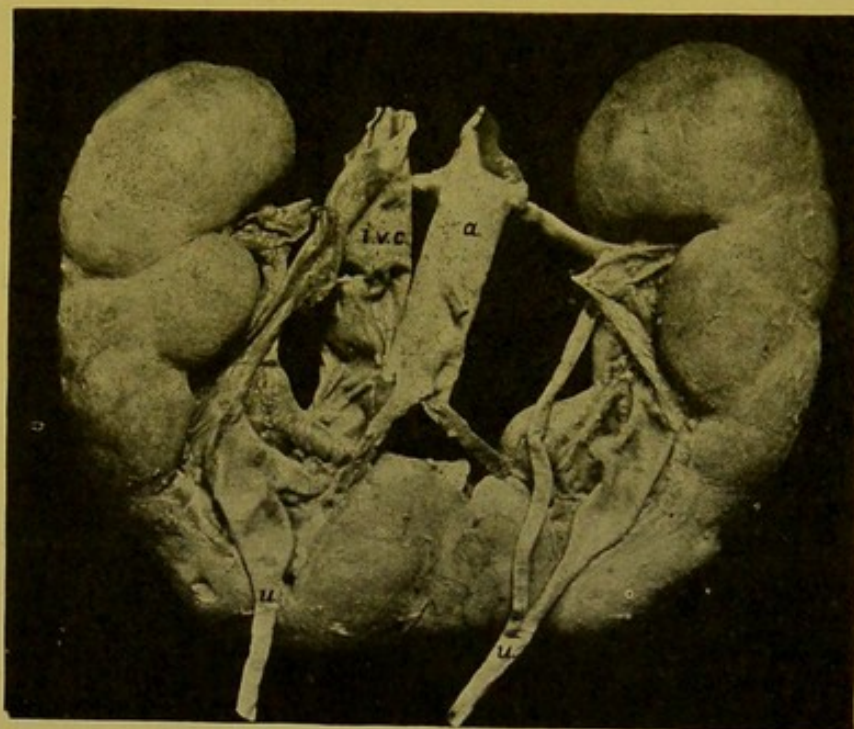


FIG. 135.—Horse-shoe Kidney. (\times circ. $\frac{1}{2}$.)

(a.) Aorta; (i.v.c.) inferior vena cava; (u.) ureter—double in upper part, on left side—passing down in front of bridge. (From Dr. Drennan's Collection.)

the "horse-shoe" may be found, the free ends of the structure being thicker than its central part. Such a mass may possess two pelves with two ureters or with one ureter common to both pelves.

The kidney on one side may be in **duplicate**. This is very rare. A much more common condition is "**multiple pelvis**," in which the pelvis is divided up into a number of segments which join the ureter within the hilum of the organ. The **Ureter** itself may be double, either throughout its whole course and possess two openings into the bladder, or the two tubes may coalesce at any level in the lower part of its course. These conditions while interesting anatomically are of no importance from a pathological point of view.

Kinks or twists at the junction of the ureter with the renal pelvis may cause unilateral or bilateral hydronephrosis, or atrophy. The ureters

may open abnormally below, e.g. into the vesiculae seminales, urethra, or, in the female, into the vagina or uterus.

Foetal Lobulation of the Kidney.—In this condition the kidney remains separated up into lobules by deep *regular* grooves and sulci. Its sole importance is that it may possibly be mistaken for the deformity produced by the scars of old infarcts or of syphilis, or the localized atrophy in the arterio-sclerotic, atrophied kidneys.

Congenital Cystic Kidney.—Both kidneys are usually affected in this

condition. They are usually enlarged, the enlargement being at times sufficient to cause obstruction at birth. Occasionally, however, they are not greatly increased in size. The substance of the kidney, both cortex and medulla, but especially the former, is converted into a mass of thin-walled cysts (Fig. 136). The inner surface of these is smooth and glistening. They contain either a watery fluid or an albuminous fluid which coagulates on fixation. The colour of the contents is brownish, yellowish, blue, or purple, depending upon the occurrence of haemorrhage into the cyst and alteration of the blood pigment. Similar cystic changes may be found in the liver and in the pancreas.

The condition is also found in extra-uterine life, and in a considerable number of cases I have met with it in individuals between the ages of forty and fifty-two. In these cases the disease must

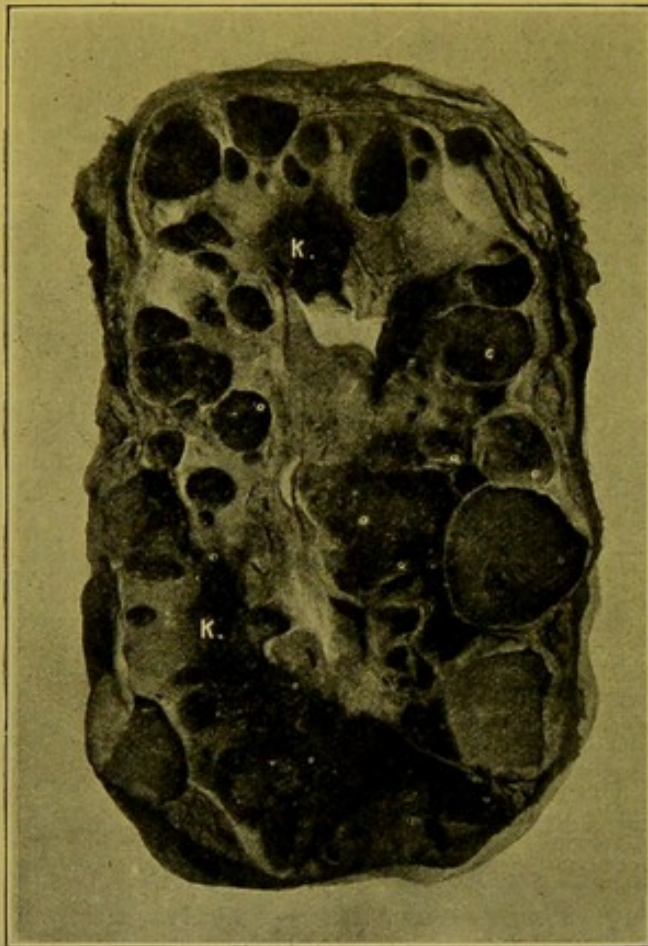


FIG. 136.—Congenital Cystic Kidney. (\times circ. $\frac{1}{3}$.)

Small areas of functioning kidney substance (*k*) still persist between the cysts, in the upper half of the specimen, and in the lower part, to the left.

develop gradually during life. I have observed a considerable number of kidneys which apparently showed earlier stages of the condition. Usually some remains of kidney substance can be recognized between the cysts, even in extremely cystic organs. The kidneys may measure 10 to 12 in. (25–30 cm.), or even more in length; 4 to 5 in. (10–12.5 cm.) in width; and up to 3½ in. (9 cm.) in thickness. The weight may reach over 1,200 gm.

Different explanations are given of the etiology of this condition. (*a*) The cysts are of the nature of retention cysts, the cysts developing by dilatation of the tubules and glomerular spaces, in such cases the obstruc-

tion being possibly due to some inflammation in the pyramid; (b) it originates in a primary interstitial nephritis; (c) it is the result of an error in development, the lower portions of the tubules failing to coalesce with the upper. This explanation is regarded as of questionable value. (d) The condition is of a nature similar to that of the multilocular cystic adenoma, the cysts developing from atypical glandular tissue.

ACQUIRED PATHOLOGICAL CHANGES IN THE KIDNEY

Before proceeding to consider the individual diseases which affect the kidney, it is well to emphasize the fact that it is often difficult, sometimes impossible, to correlate clinical signs and symptoms with definite anatomical alterations, seeing that there is a great amount of variation in both of these. An additional fact, the importance of which is brought home to the pathologist more and more, the greater his experience of morbid anatomy, is that one of the chief difficulties in differentiating between the varieties of renal disease is the great frequency with which intermediate or mixed forms of these diseases occur. It has been principally with a view to assisting in the diagnosis of individual diseased conditions which may occur either alone or in combination with others, that the consideration of the separate diseases of the kidney has been preceded by a general consideration of the more important pathological changes, both macroscopic and microscopic, which may affect the organ. The importance of this will be realized most in considering the more chronic conditions, which, either as separate entities, or more usually in combination, are included under the term "granular kidney," a term which of itself conveys no information as to the actual histological changes which have occurred within the kidney. A granular kidney may be large or small, pale or dark, coarsely or finely granular; it may result from chronic interstitial or chronic parenchymatous or arteriosclerotic changes; or it may be the latest stage of cyanotic induration (chronic venous congestion).

Atrophy.—The various forms of atrophy of the kidney cannot be differentiated sharply from each other. Most of them result directly from changes in the vascular supply of the organ or, indirectly, from alterations in the renal pelvis or ureters. Atrophy, therefore, may be *senile*, *arteriosclerotic*, or may result from *calculous pyelitis*, either with or without dilatation of the pelvis with fluid.

(1) **Senile Atrophy.**—Possibly in some cases of *senile atrophy* the change may commence in the glomeruli, these becoming atrophic and hyaline, and the tubule in connexion with it subsequently undergoing atrophic changes, the arterial change being inconsiderable.

(2) In most cases, however, atrophy follows upon a primary sclerosis of the arteries (**Arteriosclerotic atrophy**). The vessels affected may either be main branches or interlobular branches, or even individual afferent

arterioles. The sclerosis is frequently localized to these arterioles in the moderately atrophied kidneys of old age, in which it may produce an alteration which is inappreciable to the naked eye, yet can be readily recognized under the microscope.

Seeing that the histological changes are very similar, whether a large or a small artery be affected, the difference simply depending upon the number of glomeruli and tubules affected, one description may suffice for all.

The artery is thickened, and sclerosed. The intima, but also the media, especially in the case of the larger vessels, may show an increase in bulk, the increase of the media depending either upon hypertrophy of the muscular tissue alone, or this is conjoined with increase of the connective tissue intervening between the muscle fibres. The adventitia usually shares in the thickening. — **Atheroma** (*endarteritis deformans*) is in my experience rarely seen in the main renal artery or its branches within the kidney.—The result of this **arterial sclerosis** is that the blood supply of the glomerulus is interfered with. The capillaries become thickened, and hyaline; they lose their nuclei and finally become impervious. In late stages the glomerulus is represented by a homogeneous, hyaline or finely granular clump. As a result of the changes in the glomerulus, the epithelium covering it, and later, that lining the Bowman's capsule, degenerates. The capsule contracts closely upon the clump and becomes adherent to it. In typical cases the Bowman's capsule is not thickened, and there is no formation of a surrounding zone of fibrous tissue as is the case in chronic interstitial nephritis. The atrophied glomerulus may be the seat of calcareous deposit. The tubules in connexion with the affected glomeruli diminish in size, their epithelium being represented by a few deeply staining cells lying irregularly in the lumen, or this may be empty. Immediately adjacent tubules may become dilated and their epithelium may hypertrophy, or the neighbouring glomeruli and tubules may be absolutely normal. When a number of adjacent glomeruli are affected they tend to approximate to one another and the intervening connective tissue appears to be increased in amount. While undoubtedly within a given area of kidney substance there is an increased proportion of connective tissue, this may be due *in great measure* to the atrophy of the secreting tissue rather than to an actual increase of the connective tissue. The part may be infiltrated with lymphocytes.

While the preceding description no doubt gives a correct picture of the microscopical changes found in a case of true Arteriosclerotic Atrophy of the kidney, one must remember that in most cases of atrophy resulting from arterial sclerosis there is accompanying or subsequent true chronic interstitial change, with an *actual* increase in the amount of connective tissue between the tubules. In these cases, it is often impossible to decide which process has been the earlier in onset.

Naked-Eye Changes (Fig. 137).—If only a few of the afferent arterioles, glomeruli and tubules in relation to them be affected, there may be little or

nothing to indicate the change to the naked eye. If the condition be more widespread, the kidney is usually diminished in size, but this is not invariable, particularly in the senile condition where diminution may be but slight. In *typical* cases the capsule is *not* thickened. It is still translucent and either can be separated readily or shows only a little more adhesion than normal, the degree of adhesion depending upon the degree of associated chronic inter-

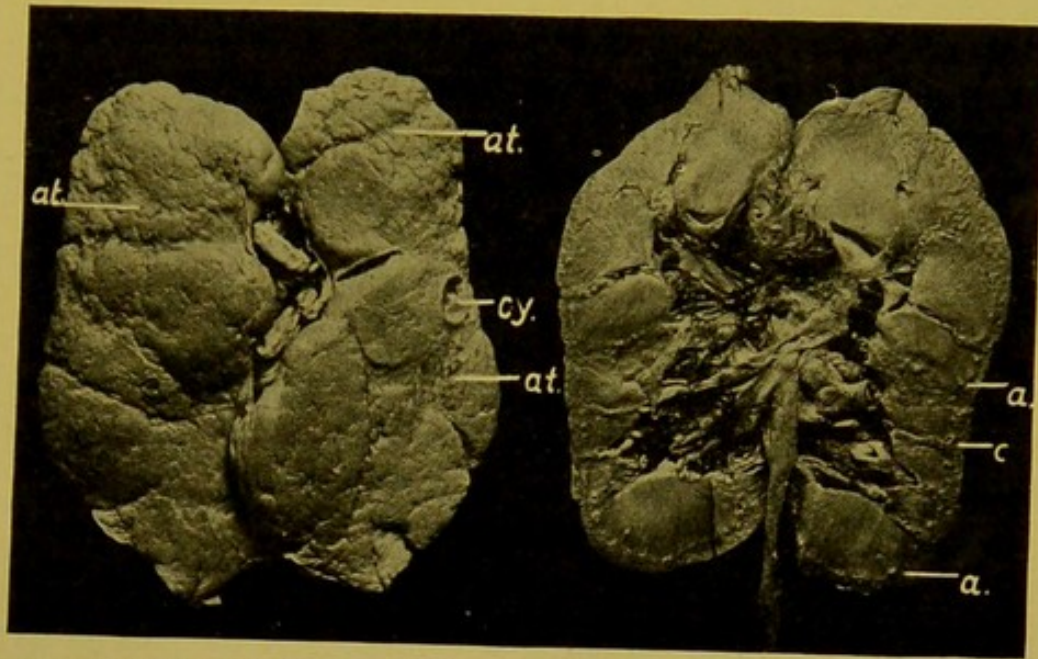


FIG. 137.—Arteriosclerotic Atrophy of Kidney. Outer and Cut Surfaces of the same Kidney, (\times circ. $\frac{3}{4}$.)

Atrophied areas (*at.*); cyst (*cy.*); thickened arteries (*a.*), projecting on cut surface; cortex (*c.*) narrow, but fairly well demarcated from medulla. The peripelvic fat is increased. (Mus. R.C.S., Edin.)

stitial change. The surface of the kidney is usually granular, but the distribution of the granularity is not uniform, some portions of the surface being more depressed than others; similarly the granularity is finer in some parts of the kidney than at others. The colour of the surface is of a dark reddish-brown or brick colour, a distinctly purplish or violet tint disappearing quickly on exposure to the air. The granulations are usually paler than the intervening tissue, and may be of a greyish or even yellowish-grey tint. They represent the least altered portions of the cortex. On section, one is struck with the diminution in the width of the kidney substance, both cortex and medulla being involved, but particularly the former, and, secondly, with the increase of the peri-pelvic fat, which is a very prominent feature in the condition. The appearances on the cut surface depend again upon the distribution of the change. In some cases portions of the cortex may be extremely atrophied, are darker in colour than the rest of the kidney, and resemble the flattened scars which result from extensive infarction, though without the haematogenous pigmentation which remains in that condition. They have to be distinguished also from the flattened scars which are sometimes seen in syphilis of the kidney and occur in *young* adults.

In other cases the greater part of the cortex may be affected, and diminished in width, but still *distinctly demarcated* from the medulla. One of the most important features is the thickening of the arteries, the larger of which are easily seen as thick-walled tubes which remain open on the cut surface. Smaller arteries are seen in the cortex pursuing a somewhat irregular or tortuous course towards the surface. In some, the tubular character can be made out, but others present the appearance of greyish-white, fibrous-looking, streaks. The vascular markings are less regular than normal. Small cysts may be seen near the surface, but these are more characteristically met with if other changes, either parenchymatous or interstitial, have supervened. Atrophied or calcified glomeruli appear as pale greyish or opaque yellow points on the cut surface.

(3) The atrophy resulting from calculous pyelitis and from great dilatation of the renal pelvis will be considered along with these diseases (p. 314). At present it will suffice to state that the atrophy primarily affects the pyramids.

With the atrophies may also be included the shrunk kidneys of chronic parenchymatous nephritis (p. 308), chronic interstitial nephritis (p. 309), and the late stages of chronic venous hyperaemia (p. 296).

Hypertrophy of the Kidney.—One kidney becomes hypertrophied compensatorily when the other has been put out of action from any cause. Similarly when a *portion* of one kidney has become atrophied or has been destroyed, e.g. by infarction, hypertrophy may take place in the remaining portion. In such cases it is stated that no actual increase of glomeruli or tubules takes place, such a hyperplasia being possible only in compensation for true aplasia, i.e. congenitally. In hypertrophy, the glomeruli and tubules may become increased in size and the epithelium of the latter undergo enlargement and proliferation.

DEGENERATIONS AND INFILTRATIONS OF THE KIDNEY.

(1) **Cloudy Swelling.**—The etiology of this condition has been sufficiently explained when considering cloudy swelling of the liver (p. 231). It is extremely common, occurring in all conditions in which toxins are being eliminated by the kidneys, and thus it forms the *earliest stage* of all parenchymatous inflammations of the organ. Many cases, apparently to the naked eye, of simple cloudy swelling, show marked degeneration, necrosis, or catarrh of the epithelium when examined microscopically.

Naked-Eye Appearances.—The kidney is moderately enlarged, the capsule tense and separates easily unless old interstitial nephritis be present. The organ is pale, thicker than normal and the stellate veins may be prominent. On section the cortex is widened and bulges. As a whole it is pale grey or greyish-white, the labyrinth being affected chiefly. The glomeruli may appear as minute pink dots. The pallor of the cortex contrasts with the engorgement of the medulla and a sharp line of demarcation separates the two areas (Fig. 138).

Under the microscope the epithelial cells lining the *secreting* tubules become swollen, and in consequence the tubules increase in diameter. The nuclei of many cells fail to stain, so that the affected tubules appear pale as contrasted with the glomeruli, the collecting tubules and the interstitial tissue, the cells of which may be normal or practically so, and stain in a normal fashion. The swollen cells are more clearly demarcated from their neighbours than usual, and project in a conical fashion into the lumen, until on cross-section the tips of the cells almost meet. The lumen in consequence becomes stellate. A little later the lumen may become dilated from obstruction lower down, and then its stellate shape is more easily recognized. If the change proceed, the granular albuminous material within the cells collects in blebs or vesicles in the projecting parts of the cells, which then break down into the dilated lumen, in which the blebs lie in close apposition, producing the appearance of a mesh-work. The lumen may also contain albuminous granules or coagulated albumen. When all this material has passed downwards with the urine or is absorbed, the tubules remain lined by truncated columnar cells which gradually resume their normal appearance. The condition may go on to fatty degeneration of the cells or to necrosis, or the cells may become catarrhal. Catarrh may be taken to indicate nephritis. For *Micro-chemical Reactions in Cloudy Swelling*, see Liver (p. 231).

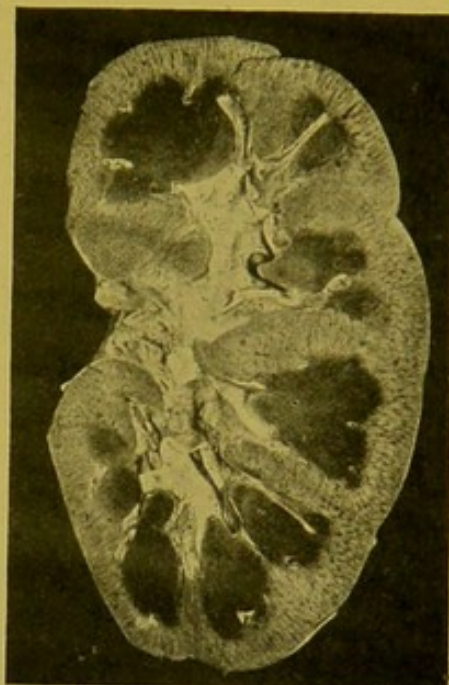


FIG. 138.—Cloudy Swelling of Kidney. ($\times \frac{1}{2}$.)

Cortex pale, and widened, due especially to swelling of tubular portions; sharply demarcated from medulla, which is deeply congested.

Fatty Change in the Kidney.—This may succeed cloudy swelling or result from interference with metabolism, as in pernicious anaemia, infarction, chronic venous hyperaemia, etc., or it may be the result of the action of chemical—e.g. chloroform, etc.—or bacterial toxins. In some cases there is infiltration with fat, the fat being brought from other parts of the body, whereas in others the fatty change is associated with degeneration of the cell. Very commonly the two conditions co-exist.

Naked-Eye Appearances of Fatty Change.—Occasionally, e.g. in the case of some chemical intoxications, such as phosphorus poisoning, there may be no special indication of the presence of fatty change beyond appearances indistinguishable from those of cloudy swelling.

Usually, however, fat gives some indication of its presence. If the whole cortex be affected it is of a dirty-white, more or less *opaque*, colour, the interlobular vessels and glomeruli being made out with some difficulty.

The tubular areas are swollen both in the cortex and in the bases of the pyramids, presenting the appearance of grey streaks passing down from the cortex into the medulla. This appearance generally indicates a severe acute parenchymatous change (catarrhal nephritis) with fatty or necrotic epithelium. More commonly the change is localized, and small *opaque* grey and yellow spots and streaks are seen in the cortex, giving it a patchy or mottled aspect. These changes are usually best seen in the deeper parts of the cortex. In cases of extreme anaemia, e.g. in pernicious anaemia, the whole kidney is pale and on the cut surface yellowish or pale brown opaque spots and streaks are seen, the brownish tint depending upon an accompanying deposit of altered blood pigment. In advanced waxy kidneys, in which advanced parenchymatous changes are also present, opaque spots representing fatty tubules stand out very distinctly on the grey translucent surface (see Fig. 139, p. 292).

Under the microscope, infiltrating fat can generally be distinguished from the fat accompanying local degeneration. In the former the droplets of oil are usually deposited at the base of the cell, which may remain attached to the basement membrane, and the nucleus retains its staining power. In typical degeneration the cell may be swollen or shrunken, the oil droplets being usually small, distributed irregularly throughout the cell, and the nucleus either fails to stain with proper intensity or remains unstained. The cell tends to be detached easily from its basement membrane and at a later stage breaks down. It is then represented by a clump of cytoplasmic granules with oil droplets of varying size. When the proximal convoluted tubules are affected, few of these degenerated cells can pass through the loop tubules of Henle and the fat has to be removed by absorption, hence, in suitably stained sections, lines and streaks of oil droplets can be seen in the lymphatics and tissue spaces in the interstitial tissue and in the capsule. This so-called fatty degeneration not only attacks the epithelium of the tubules but also that of the glomerular tuft and Bowman's capsule (e.g. in pregnancy). In phosphorus poisoning the epithelium of the straight tubules especially may be affected. It is common also to find fatty change of the endothelium of the capillaries, both of the tuft and interlobular plexus.

For *Micro-chemical Reactions for Fat*, see under Liver (p. 233).

Protagon.—The opaque grey opacity described above may be produced by a deposit of refractile globules of the lipoid substance "protagon" within the epithelium of the tubules or in the interlobular tissue spaces. This substance may be a precursor of fat and is easily mistaken for it. It has similar micro-chemical reactions, but can readily be distinguished under the microscope by its refractile character. In acute yellow atrophy I have seen appearances in the kidney corresponding with this description. Aschoff and Adami pointed out that some of the fatty material in chronic nephritis corresponds in its reactions to **myelin**.

Waxy Degeneration or Infiltration of the Kidney (syn.: "Amyloid," "Lardaceous" disease).—The etiology is the same as in the case of the

liver, but in some cases—e.g. in chronic nephritis—the kidney may be affected exclusively, or, of the other organs, the spleen alone may show waxy change. The aspect of the waxy kidney may vary greatly.

The slightest degree produces no alteration recognizable to the naked eye, e.g. when accompanying chronic glomerular and interstitial changes.

In well-marked cases the principal points on which the diagnosis depends are : (1) the general translucency of the kidney substance, most evident at the margins of the cut surface. (2) The pallor of the papillary part of the medulla and the diminished congestion of the boundary layer of the medulla, until in general tone it may approximate to that of the cortex, always, however, preserving its striated appearance. (N.B.—Nos. 1 and 2 may be simulated by oedema of the organ.) (3) In advanced waxy disease the glomeruli are enlarged and stand out as pinkish-grey translucent spots. Application of solution of iodine causes the waxy tissue to assume a deep vandyke brown colour, always, but not with strict accuracy, compared to that of mahogany.

Varieties of Waxy Change in the Kidney. — (1) The so-called “Simple” waxy degeneration may not show much change to the naked eye, e.g. in children with chronic tuberculous abscesses, etc., unconnected with the kidney. Sometimes there is a slight increase of consistence and there may be a certain amount of irregular patchy pallor.

Microscopically, the change though moderate is distinct, portions of the afferent arterioles, the glomerular capillaries, the interlobular arteries and the arteriolae rectae being affected.

(2) The **Large Pale Waxy or Amyloid Kidney** occurs particularly in the course of long-standing tuberculosis and syphilis, but by no means in all such cases. Frequently there is in addition a mixed infection. Nevertheless, in many cases of syphilis the degeneration occurs without ulceration or evidence of mixed infection. The etiology of amyloid degeneration is not wholly understood, as in apparently similar cases its incidence varies in different countries and even in different parts of the same country.

This is the most characteristic form of waxy degeneration of the kidney, and some of the most striking examples of it are to be found in cases of tertiary syphilis. Waxy degeneration is almost invariably accompanied by parenchymatous degeneration, or by interstitial change (especially in syphilis), or by a combination of these changes.

The organ is greatly enlarged; it may weigh 10 to 12 ozs. (300–350 gm.). It is of firm consistence, the surface often slightly irregular and pitted as the result of localized atrophic changes. The capsule is tense, seldom thickened, and usually strips off fairly easily; its deeper layers may be adherent. The outer surface is pale, greyish, and may be mottled with small opaque areas of fatty change or calcareous deposit. The stellate veins may be prominent. On the cut surface there is general pallor; the cortex is greatly increased in width; it may measure double

the normal. It is of a general yellowish-grey colour with a slight pink tinge, and patches of a pinker colour are scattered over the surface. A somewhat similar appearance is met with in some cases of lymphatic leucocythaemia, but in these there is no increased translucency. Fatty areas appear as opaque irregular yellowish-white spots which stand out clearly against the grey translucent background (Fig. 139). The enlarged glomeruli may be visible as darker grey translucent spots. The medulla is paler than

normal, but still its boundary layer is the reddest part of the kidney and shows alternate pink and grey streaks. Its relative increase in width is not so great as that of the cortex. The tips of the pyramids are pale and anaemic.

Under the microscope the waxy change is found to affect the afferent arterioles, the glomerular capillaries, the interlobular arteries and the vasa recta. The basement membrane of Bowman's capsule and of the tubules may be but slightly affected. The epithelium of the tuft and of the tubules may show little alteration, or may be fatty and catarrhal. Some authorities believe that these constantly associated parenchymatous and interstitial changes may be secondary to the waxy change in the arterioles and glomeruli.

(3) **Cirrhotic Waxy Kidney.**—The kidney in this condition is smaller than in the other varieties, but it is seldom diminished to the size of the ordinary shrunken kidney, whether arteriosclerotic, chronic parenchymatous or chronic interstitial. Generally speaking, it presents most of the characters of the cirrhotic shrunken kidney with those of the waxy change superadded.

Possibly in some cases this may be a further stage of the large waxy kidney, developing in a way similar to that suggested by some authors in the case of the shrunken kidney of chronic parenchymatous or of chronic interstitial nephritis.

In the cirrhotic waxy kidney the pallor even of the boundary zone of the medulla may be extreme, so that it is only very slightly pinker than the cortex, and the line of demarcation between the cortex and medulla is lost. The outer surface is irregular, somewhat nodular; the capsule may strip easily or, as is more usual, leaves its deeper layers attached to the kidney.

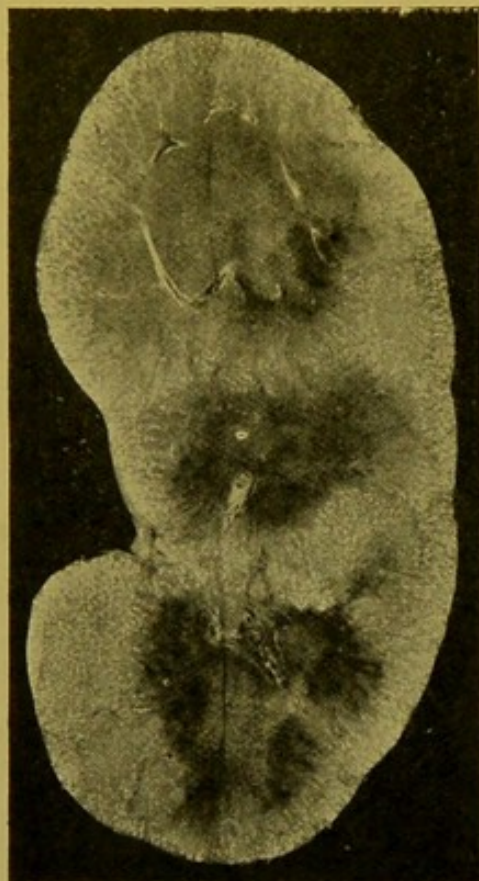


FIG. 139.—Waxy—Amyloid—Degeneration of Kidney, accompanied by diffuse interstitial and parenchymatous changes. ($\times \frac{1}{2}$.)

The translucent aspect of the organ is well represented. The opaque white points indicate fatty change in the tubules.

The microscopical changes are more extreme in this variety than in the others. The glomeruli form waxy clumps closely approximated to each other; and the interlobular arteries, the afferent and efferent arterioles, the basement membrane of Bowman's capsule and of the tubules are extremely waxy. The interstitial tissue itself, which is increased diffusely, may show little or no waxy change. Some of the tubules are atrophied, others are dilated and lined by flattened epithelium.

In some cases of waxy disease of the kidneys the change may chiefly affect the straight vessels of the medulla. In advanced cases the connective tissue of the medulla may be homogeneous and glassy and show a diffuse waxy reaction with methyl-violet. It is said that this occurs especially in cases of congenital syphilis.

In all the varieties of waxy kidney, but especially in the last two, colloid casts (so-called "waxy" casts) are found in many tubules both in cortex and medulla. These, when treated with iodine, become yellow, and when stained with methyl-violet they take a purplish colour intermediate between the blue-violet of the non-waxy tissue and the rose-pink of the waxy material.

Thrombosis is apt to occur in the renal veins, in presence of extreme waxy degeneration of the kidney.

Hyaline Degeneration in the Kidney produces no alteration appreciable to the naked eye. It occurs in the course of acute inflammations and from the action of acute toxins, especially that of diphtheria, but it is also found in general arterial sclerosis. The capillaries of the glomeruli sometimes individually, sometimes collectively, become thickened and homogeneous. The capillaries may be thrombosed or blocked by embolism. The afferent arterioles also are frequently affected, the intima undergoing degeneration.

The hyaline degeneration which occurs in atrophic and functionless glomeruli has already been referred to when considering arteriosclerotic atrophy of the kidney (p. 286).

Other Infiltrations and Deposits in the Kidney.—(1) **Altered blood pigment—Haemosiderin and Haemofuscin.** For the nature of these pigments, see Liver in Anaemia (p. 237).

The kidney as a whole is pale, and on section the tubular parts in the cortex are marked out as pale ochre-coloured lines and spots. On application of the Prussian blue test, these areas become of a deep greenish-blue colour. Under the microscope the golden-yellow granules of pigment are seen to be deposited in the cells of the secreting tubules, in the first place at their bases, round the nuclei. They are also found in the epithelium of the tuft, in the endothelium of the capillaries, and even in the lumen of the tubules. If the Prussian blue test be applied to microscopic sections the haemosiderin granules take a deep blue or greenish-blue colour, the haemofuscin granules retaining their yellow colour.

Haemoglobin, or more often **met-haemoglobin**, is deposited in the kidney

in poisoning with certain fungi, with potassium chlorate, and also in black-water fever. The kidneys are increased in size and have a distinct brownish colour. The pyramids may be streaked and spotted over with brown pigment and the cortex also is affected. Under the microscope, homogeneous reddish-brown or brownish clumps and hollow cylinders are found within the tubules. These are seen well in the convoluted tubules. Ordinary hyaline casts may also be seen.

Bile-pigment.—In the jaundice of newly-born infants bilirubin accompanied by uric acid or urates may be deposited in streaks radiating outwards from the tips of the pyramids. Microscopically, the deposit appears as an amorphous or granular yellowish mass or as acicular or rhombic crystals. It is deposited chiefly in the medulla, in the lumens of the tubules, in the epithelium, in the walls of the blood-vessels, and in the interstitial tissue.

In the jaundice of adults the epithelium throughout the kidney may be bile-stained. Sometimes granules appear in the epithelium, and these may be cast off into the tubules and agglomerated to form casts. The epithelium may be fatty or necrotic. Dark green streaks are seen in the medulla.

Uric Acid Deposit.—Uric acid along with the urates of sodium and ammonium are found chiefly in the pyramids in newly-born children. They form irregular, dark, brittle, cylinders made up of dark yellow or dark brown granules. It was formerly thought that these uric acid deposits or so-called “uric acid infarets” occurred only in infants who had breathed, but this is not invariably the case.

In adults, urates are deposited as opaque whitish streaks in the medulla, sometimes being localized to the tips of the pyramids, but the deposit also takes place in the cortex, for example in the atrophied “gouty” kidney. A similar deposit is seen frequently in leucocythaemia. Under the microscope acicular crystals chiefly of sodium urate, or minute rounded concretions are seen within the tubules, in the epithelium, and in the interstitial tissue. The tissue itself is frequently necrotic. Larger collections of the deposit may be found in the pelvis of the kidney, as terra-cotta coloured spheres of small size, or larger irregular masses.

Calcareous Deposits.—Calcium phosphate and calcium carbonate are deposited as white streaks in the pyramids radiating outwards from their tips, and also in atrophied glomeruli, and in necrotic epithelium. Under the microscope, fine granules which stain with haematein are seen in the interstitial tissue and in the epithelium and lumen of the tubules. In the glomeruli they cause a granular opacity. In poisoning with corrosive sublimate, a constant appearance is the deposit of calcareous salts in granules in the necrotic and detached epithelium, particularly of the *ascending part* of Henle’s loop.

Deposit of Silver—“Argyria.”—The kidney as a whole is of a grey colour,

and on close examination this colour is found to be produced by a great number of slaty grey points which are the pigmented glomeruli, but there is also a more diffuse greyish discoloration of the surface. (Fig. 140.) Grey streaks may be seen in the medulla. Under the microscope, minute black granules of metallic silver are seen in the walls of the glomerular capillaries between the epithelium and endothelium. A few granules may be seen within the cells themselves. A deposit also takes place in the basement membrane of Bowman's capsule and of the tubules, and to a much smaller extent in the walls of the vessels and in the interstitial tissue.




FIG. 140.—Argyria, Kidney. (\times circ $\frac{2}{3}$.)
The minute points in cortex are pigmented glomeruli.

CIRCULATORY CHANGES OTHER THAN THOSE PRIMARILY INFLAMMATORY

Passive Congestion.—(1) **Acute Passive Congestion** may readily develop as a result of local obstruction to the renal vessels or to the inferior vena cava, or as a result of failure of the right heart. It causes engorgement of the kidney and infarction may be associated. The organ is not greatly enlarged, and its consistence is not increased. On the cut surface the congestion is most marked at the extreme base of the pyramids. The degree of congestion of the cortex depends upon the amount of parenchymatous swelling accompanying. The tips of the pyramids may be comparatively pale, probably from oedema (cf. waxy or amyloid degeneration of kidney, p. 291). The congested parts are of a dark purple colour as contrasted with the deep purplish-brown of chronic congestion. Under the microscope the appearances on the whole are similar to those of the chronic condition, but the walls of the capillaries are not thickened. Haemorrhages may take place into the glomerular spaces and tubules, and into the interstitial tissue.

(2) **Chronic Passive Hyperaemia, or Chronic Venous Congestion** is a usual accompaniment of long-standing cardiac disease—incompetence or stenosis of mitral and (or) tricuspid valves; adherent pericardium or pleura; chronic mediastino-pericarditis; chronic myocarditis;—or of obstruction to the pulmonary circulation, such as may be caused by chronic bronchitis with emphysema or by chronic interstitial pneumonia.

The kidney is usually enlarged, weighing up to 8 or 9 oz. It is of firm consistence, and the stellate veins on the surface are engorged; the capsule

is usually slightly thickened, and slightly but distinctly adherent, so that it frequently strips in layers. On section, the kidney is of a general dark purplish-brown colour which rapidly changes, on exposure, to a deep reddish-brown. In typical cases the width of the cortex is uniformly increased. The interlobular vessels and glomeruli are easily distinguished as red lines and dots arranged in regular rows perpendicular to the surface, and separated by brownish-grey tubular areas. When cloudy swelling or fatty change is present, as in some long-standing cardiac cases, the colour of the tubular areas of the cortex is lighter and may even be yellowish and opaque. The straight vessels of the medulla are very prominent and are of a brighter reddish-brown tint than the rest of the surface. The engorgement also attacks the papillary parts of the medulla more diffusely and is distinct in the mucous membrane of the pelvis.

Under the microscope the glomeruli are enlarged, distending the Bowman's capsules; their capillaries are very distinct and their walls are thickened. The capillaries of the intertubular plexus show similar changes. The interlobular veins are dilated and may be tortuous. The straight vessels in the medulla are widened, forming very prominent features in the microscopic field. The epithelium of the tubules may be fatty. Haemorrhage commonly takes place into the glomerular space, into the tubules and occasionally into the interstitial tissue. The tubules may contain hyaline casts or coagulated albumen. Granules of altered blood pigment are seen in the epithelium and endothelium and also in the connective tissue. The connective tissue is increased along the interlobular vessels, in the glomeruli, in the capsule, and to a less extent between the tubules. This increase along with the general engorgement of the vessels causes the increased consistence of the organ.

In late stages the kidney may shrink and become nodular on the surface, forming one of the varieties of contracted granular kidney.—“Cyanotic Atrophy.”

Thrombosis may occur in the renal veins in advanced waxy disease. It may follow infarction of the organ or may extend into the renal veins from the inferior vena cava. This extension of a thrombus in the inferior vena cava may affect the renal vein on the right side sooner than that on the left, the latter usually joining the inferior vena cava at a slightly higher level. Thrombosis may also occur in the renal arteries following embolism or following local arteritis, e.g. of tuberculous nature. In marasmic infants, or in those born of eclamptic mothers, thrombosis may take place in the renal vein and give rise to infarction of the whole renal substance.

Embolism of the kidney occurs most frequently in the course of acute endocarditis, particularly if this be of the ulcerative variety, or it may follow thrombosis in the left auricular appendix or in the left ventricle either at its apex or behind the outer mitral segment, or rarely from thrombosis in the aorta, upon atheromatous patches. Retrograde embolism is also

occasionally met with in the renal veins. The principal result which follows embolism is infarction and, if the emboli be septic, abscesses usually develop. Metastatic suppuration will be considered along with the other suppurative inflammations of the kidney (*see* p. 298).

Infarction.—The arteries in the substance of the kidney are true “end arteries” and communicate with each other only by way of capillary anastomoses. When the artery is blocked by impaction of an embolus, the area supplied by the artery becomes anaemic and before the blood can penetrate from the neighbouring areas the renal epithelium, which is very easily affected by loss of nutrition, dies. It undergoes coagulative necrosis, imbibing water and swelling up. As a result the tubules also swell and by their mutual compression prevent the entrance of blood. The interstitial tissue and glomeruli being composed of more resistant tissue, persist longer.

Some authorities state that the renal infarct is always primarily haemorrhagic, but if the area affected be of any size, this is questionable.

Naked-Eye Appearances.—The central grey, or “wash-leather”-like portion of the infarct is generally confined to the cortex. Surrounding this there is a haemorrhagic area wider in some cases than in others, and always wider on the side next to the hilum, i.e. internally, than elsewhere. The blood passes in, not only from the surrounding areas of kidney substance but also from the capsular vessels, so that in some instances a thin red layer is seen under the capsule. Sometimes a narrow zone—of leucocyte infiltration—is seen between the greyish necrotic centre and the haemorrhagic periphery (*see* Fig. 141, *ll.*). This is of an opaque grey or light yellowish-grey colour. In later stages a brighter yellow zone, which results from fatty degeneration, is sometimes seen near the periphery of the infarct. The infarct as a whole is of a pyramidal shape, the base towards the capsule, and at its apex the obstructed arteriole can readily be distinguished, usually accompanied by the vein, which is the seat of a secondary thrombosis. Whilst infarcts of the kidney are usually of this mixed type, they are sometimes, particularly when of small size and superficial, haemorrhagic throughout. This is frequently seen, e.g. in septic embolism.

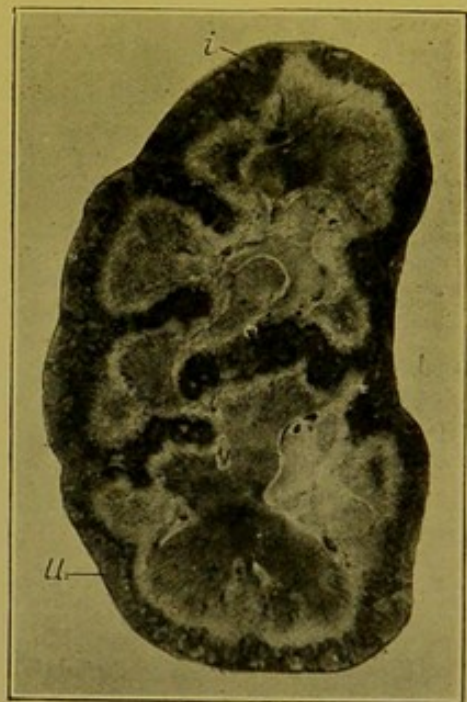


FIG. 141.—Necrosis of Renal Cortex: Multiple Infarction. (\times circ. $\frac{1}{2}$.)

Small separate infarct (*i.*); (*ll.*) infarct showing dark haemorrhagic zone, and pale line of infiltrating leucocytes between it and the grey necrotic central part.

Infarcts of the kidney are usually single; when of moderate size they are localized to the cortex (*see* Fig. 143), but, when larger, they may involve the whole thickness of the kidney substance. They may, however, be

multiple, and then the whole cortex including the interpyramidal cortex is beset with infarcts, the deepest layers of the cortex alone escaping (Fig. 141). Both kidneys may show this condition. The amount of haemorrhagic infiltration varies in multiple infarcts so that the cortex as a whole may be of a dark purplish-brown colour with dirty grey triangular patches scattered over the cut surface, or the cortex may be comparatively pale and the necrotic areas are the more prominent features.

Under the microscope, throughout the whole infarcted area the epithelium of the tubules fails to take the nuclear stain, with the exception of a few tubules at the extreme periphery. In the central pale part the only nuclei seen are those of invading leucocytes or of the cells of the interstitial tissue. Occasionally a few nuclei are seen in the glomeruli. Colloid droplets form within the epithelium of the affected tubules and collect within their lumens, which may also contain fibrin in small amount. Further out, if there has been marked infiltration with leucocytes, these are closely massed, separating up the tubules and also penetrating them. In the haemorrhagic areas the effused blood separates up the tubules and also penetrates into their lumens.

Subsequent Changes.—The central part of the infarct gradually breaks down, undergoes fatty change, and is absorbed. If this be complete, the infarcted area is replaced by pigmented scar-tissue which is very cellular and which is crowded with small atrophied glomeruli which usually contain a few nuclei, and with small atrophied duct-like tubules, which sometimes resemble the bile-duct structures found in cirrhosis of the liver. These atrophied glomeruli and tubules contrast sharply in size and structure with the corresponding healthy structures in the immediate vicinity. The contraction of the scar-tissue causes a deep, abrupt, often funnel-shaped depression on the surface, in which the capsule is adherent (see Fig. 146, i., p. 306). This has to be distinguished, firstly, from the grooves in persistent foetal lobulation, which are regular and separate up more or less uniform areas of healthy kidney substance, and in which the capsule is not adherent, and, secondly, from the scar-tissue resulting from inflammatory changes, particularly in syphilis of the kidney, in which the scar-tissue is pale and greyish, and in which there is no deposit of altered blood pigment such as occurs in the scars of old infarcts.

Suppuration in the Kidney.—Abscesses may be either (1) *Metastatic*—the pyogenic organisms being conveyed to the kidney in the blood-stream, or (2) they may develop as a result of *Direct* infection from the renal pelvis, the bacteria invading the kidney by way of the collecting tubules (see *Pyelitis* and *Cystitis*, pp. 316, 318). In the former, the infecting agents are most frequently the pyogenic cocci; in the latter they are more often bacilli, particularly those belonging to the *Bacillus coli communis* group.

(1) **Metastatic Suppuration.**—**Pyaemic Abscesses.**—This form of suppuration results from embolism, most commonly in cases of ulcerative endocar-

ditis of the mitral and aortic valves, but it also may follow septic thrombosis in the left auricular appendix or in the left ventricle.

The naked-eye appearances may vary. Typically, both kidneys, though not always to the same extent, show numerous yellow spots underneath the capsule, usually surrounded by red areolae. These spots may project slightly upon the surface. Frequently the yellow centre is absent, and only small haemorrhagic areas, triangular on section (i.e. minute infarcts), are seen under the capsule. The organ is always enlarged, usually of soft consistence, and the capsule can be stripped off easily.

On section, small abscesses, and yellowish spots and streaks are seen in the cortex, in most instances surrounded by a congested areola. In the medulla, the suppurating areas form more elongated streaks possessing the same general characters as the more rounded areas in the cortex. Sometimes the yellow centre may still remain firm, yellow and caseous-looking; usually, however, it is softened, and broken down into pus. The kidney as a whole shows acute, diffuse, inflammatory changes.

Under the microscope, in the early stages one can usually recognize the septic embolus in the centre of each affected area. On employment of suitable staining methods—e.g. Gram's method, thionin blue—the organisms contained in, and often forming the bulk of the embolus can be readily demonstrated. Even with haematoxylin stains, the plug is frequently sufficiently stained to be recognizable as of mycotic nature. The bacterial mass is surrounded by a zone of coagulative necrosis and this again by an extensive area of leucocytic infiltration. The embolus is found either within

the interlobular arteries, the afferent arterioles, or, in the glomerular capillaries. Occasionally small emboli may penetrate to the intertubular plexus. In the medulla the emboli may be found in the straight vessels but also in the tubules, the organisms having penetrated the walls of the glomerular capillaries and passed down the tubules either in the form of bacterial masses, or attached to renal casts. Being caught in Henle's loop they set up the suppurative process. The abscesses may coalesce and form large softened, necrotic areas surrounded by extensive infiltration.

(2) **Ascending Suppuration** (syn.: Consecutive Nephritis; Disseminated Suppurative Pyelo-nephritis, "Surgical" Kidney).—This form of suppura-

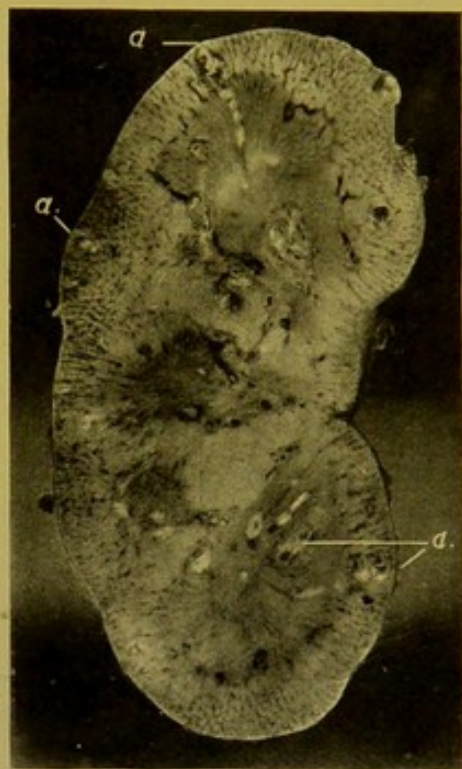

FIG. 142.—Pyaemic Abscesses in Kidney. (\times circ $\frac{1}{2}$.)

Section showing *separate*, more or less rounded abscesses in cortex, each surrounded by a zone of congestion; also more elongated abscesses in medulla. The accompanying acute parenchymatous changes are distinctly shown, particularly at the upper and lower ends of the kidney.

tion may be either bilateral or unilateral. It first affects the medulla, and the yellow *clustered* streaks of suppuration radiate out from the tips of the pyramids following the course of the collecting tubules. These streaks, which may have an irregular club-shape, extend in some instances right up to the capsule, and in advanced stages the appearances may be very similar to those of metastatic suppuration. The abscesses are frequently confluent and sometimes branching. Sometimes on the surface of the pyramid necrosis takes place. The abscesses in the cortex may be very extensive. They may have a rounded form, and are surrounded by a zone of very marked congestion and infiltration. The pus in the elongated medullary

abscesses may be of a *greyish*-yellow colour from admixture with catarrhal, fatty or necrotic epithelium. The tissues in the immediate neighbourhood may be soft and necrotic and the whole kidney rapidly tends to become of a greyish colour. After death decomposition sets in very rapidly in the affected kidneys.

Under the microscope, in the early stages the collecting tubules are packed with degenerating catarrhal cells and pus corpuscles. Leucocytes infiltrate the interstitial tissue.

While this form of suppuration usually originates in a septic cystitis, it may also occur as a sequel of calculous pyelitis, the organisms, which cause the suppuration, spreading from the intestine by way of the blood or lymph-channels to the renal pelvis, and thence spreading up into the kidney. The abscesses may break through into the pelvis of the kidney and in some cases they originate a general pyaemia.

Tuberculosis of the Kidney. (a) Acute.

Acute tuberculosis is, as a rule, part of a generalized tuberculosis, the dissemination of the bacilli taking place through the blood-stream. The tubercles which in any case are scanty, at least to the naked eye, are found chiefly in the cortex where they appear as minute grey nodules under the capsule or along the interlobular vessels. Under the microscope, giant-cell tubercles are recognizable, frequently in clusters, and usually in or near the Malpighian bodies. There is great endothelial and epithelial proliferation in the immediate neighbourhood, and giant-cells are usually well-formed, unless the process be relatively acute, and then the necrotic change is more rapid and the formation of giant-cells is less perfect or wanting altogether. According to Orth, when tubercles

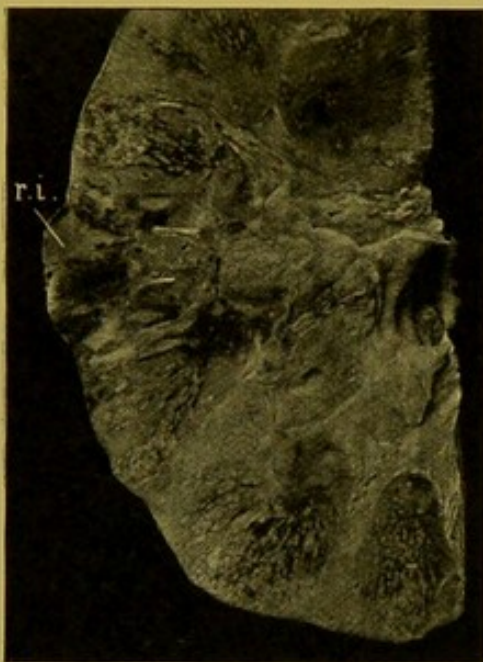

FIG. 143.—Disseminated Suppurative Pyelo-nephritis. "Consecutive Nephritis." Clustered lines of suppuration, radiating outwards from the tips of the pyramids. (\times circ. $\frac{3}{8}$.)

The condition was secondary to a septic cystitis and pyelitis. A recent infarct (*r.i.*) opposite the hilum, projecting on the surface—on left side of figure.

are found in the medulla they have usually an elongated shape and often bacilli can be demonstrated within the tubules. He considers that here one has to do with bacilli which have escaped through the glomerular tuft and set up typical changes in the tubule lower down.

(b) **Chronic Tuberculosis. The "Scrofulous" Kidney** (Fig. 144).—In this variety the organisms may attack the kidney either from above through the blood-stream, or from below by an extension upwards from a tuberculosis of epididymis, seminal vesicles, prostate or bladder. In the former case after changes similar to those described in the miliary tubercle, but more localized, the process extends by formation of satellite nodules so that a caseous area develops which breaks down into the pelvis, leaving an irregular cavity lined by caseous material. The process then extends over the pelvic mucous membrane and gradually erodes it. Later it extends down the ureter, which may become blocked by the cast-off caseous material so that both ureter and pelvis become dilated. From the orifice of the ureter it proceeds over the mucous membrane of the bladder, and may attack the ureter of the other side and then travel upwards to the other kidney. Further, extension may take place beyond the bladder to the prostate, seminal vesicles or to the epididymis. In such cases various stages of the process may be met with. One kidney may be disorganized to a considerable extent, while the other escapes completely, and when both are attacked one always shows a greater extension of the process than the other.

In the second form, in which extension takes place from below—from tuberculosis of epididymis, seminal vesicles, or prostate—somewhat similar changes are found and usually the kidneys are more or less uniformly affected. The process usually commences as a tuberculous ulceration of the mucous membrane covering the pyramids, which gradually extends into the medulla, the older parts breaking down and being cast off into the pelvis. This form is, however, less common than the other. The scrofulous kidney has to be distinguished from the kidney in hydronephrosis and in pyonephrosis, particularly the former of these. In the scrofulous kidney the surface of the pelvis and the cavities opening upon it are lined with a thin layer of yellow caseous material, and in advanced cases there is no healthy mucous membrane left, whereas, in hydronephrosis, however great the dilatation, the cavities are always lined with smooth mucous membrane. In the extreme distension which sometimes occurs in pyonephrosis, the distinction is not always easy, as the surfaces of the dilated calyces may

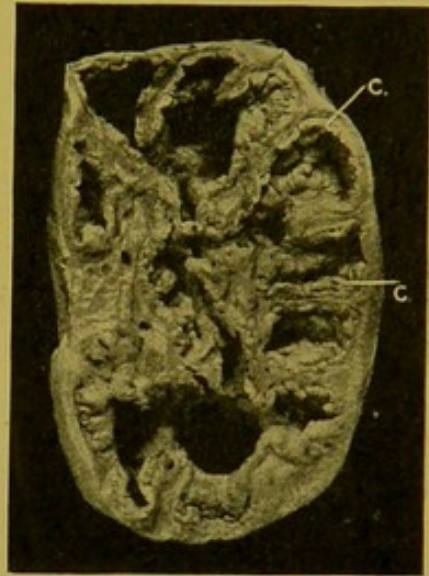


FIG. 144.—Scrofulous Kidney.
(\times circ. $\frac{1}{2}$.)

Spaces communicating with renal pelvis, lined with caseous material (c.)
(Mus. R.C.S. Edin.)

be covered with granular material which may simulate the deposit in the tuberculous kidney. The regular character of the dilatation, however, gives usually sufficient indication of the non-tuberculous nature of the process. In pyonephrosis, again, chronic suppurative foci in the atrophied renal substance in which the pus has become inspissated, may simulate foci of tuberculosis, but they can be readily distinguished under the microscope.

Syphilis of the Kidney.—It is rare to meet with well-marked evidences of syphilitic disease of the kidney. In one form there may be multiple foci of infiltration and formation of fibrous tissue. This may sometimes form a greyish-white area somewhat resembling the scar of an old infarct, but without any of the altered blood pigment which can always be detected in old infarcts.

Gummata are rarely seen. When present they are of small size, and seldom numerous. The most common result in the kidney from syphilitic infection is waxy or amyloid degeneration, and this may take the form of the large pale waxy kidney, in which the waxy change is usually accompanied by interstitial or parenchymatous changes. In congenital syphilis, induration and contraction of the kidney sometimes occurs. In such cases the fibrous tissue formation is frequently localized to the pyramids, where also waxy degeneration may be demonstrable (*see also Acute Interstitial Nephritis*, p. 305).

Actinomycosis of the Kidney.—In this disease granulomatous, tumour-like masses may form, and these may be mistaken for nodules of sarcoma.

NON-SUPPURATIVE INFLAMMATIONS OF THE KIDNEY

These include the different alterations in the kidney substance which are included under the term **Nephritis** or **Bright's Disease**, though the latter term is sometimes extended so as to include the waxy (amyloid) kidney. Nephritis includes a number of different acute and chronic conditions, which many authorities decline to class with the inflammations proper. They cannot be sharply differentiated from each other and although, for a proper comprehension of the changes found, certain definite varieties must be described, it should not therefore be assumed that these definite types occur invariably, or even commonly, in actual practice. So intimate is the relationship between the constituent parts of the kidney that it is hardly conceivable, for example, that the excretory apparatus can be affected long without involving the interstitial frame-work and blood-vessels, or *vice versa*. Moreover, the changes, whether affecting the parenchyma or the blood-vessels or the interstitial tissue, are seldom uniformly distributed, or of a uniform age throughout the kidney. Hence, although the changes will be described under the headings of *Acute*, *Intermediate* or *Sub-acute*, and *Chronic*, it must be remembered that one may meet with all these stages in the same kidney, and that frequently, shortly before death, a more

acute interstitial or parenchymatous inflammation may supervene in a kidney the seat of a long-standing nephritis. Again, circulatory disturbances are very readily induced in the kidney, and hypostasis or anaemia or a hyperaemia developing rapidly, through loss of compensation of the heart, may radically alter the whole appearance of the kidney, so that the characters presented at the post-mortem examination may not correspond accurately with those which have been present during life. So far as is possible, however, these and other sources of error will be indicated and guarded against in the descriptions of the various changes.

A disadvantage under which the pathologist labours is that usually the examination is not conducted until some time has elapsed after death, and during this period obscure changes may occur which may simulate the changes described in parenchymatous nephritis.

NEPHRITIS.

Nephritis generally affects both kidneys, as the toxic substances which cause the inflammation are conveyed in the blood-stream, but nevertheless both kidneys may not show the same degree of alteration. It may be assumed that the toxins which cause acute nephritis are more active than the more slowly acting toxins which bring about the local changes in chronic nephritis. Moreover there seems to be a difference in the action of different toxins so that some, possibly those of most active nature, affect especially the glomeruli as they are passing through it, and others possibly less active, or at least more dilute, become concentrated in the epithelium in the course of excretion, and for this reason exert their influence chiefly upon the tubules. In other cases, the interstitial tissue is especially affected, and in others the minute arteries first show the result of the morbid process. Therefore in individual cases nephritis may begin either in the *glomeruli*, or in the *tubules*, or in the *interstitial tissue*, and although very soon the remaining components of the renal tissue become affected, yet as these initial changes tend to predominate they give the name to the process.

Acute Glomerular Nephritis.—This condition is rare as a pure condition. The best example of it is seen following scarlet fever. It is usually associated with parenchymatous changes, and also with acute interstitial changes, these being the result of the action of the same toxine. (Fig. 145.) The organ is enlarged, the capsule strips readily. The outer surface is of a greyish-red colour; the stellate veins may be prominent. On the cut surface the cortex is widened and may be congested, but more often it is pale greyish-pink or even almost fawn coloured, the glomeruli standing out, particularly on oblique illumination, as small reddish-brown points (Plate I, Fig. 2). Small haemorrhages may be present in the cortex. The boundary zone of the medulla is deeply congested and haemorrhages may be found here also, but this congestion soon lessens. At a later stage the swelling of the

cortex becomes greater and in from three to five weeks after the onset the interpyramidal cortex may be greatly swollen. The cortex tends to become more opaque and of a greyish-white colour, and yellowish spots may be seen indicating fatty change in the tubules. The Malpighian bodies become pale grey or greyish-yellow.

Under the microscope the early stages are seen to affect the glomeruli chiefly. At first, these are congested and there is escape of red blood corpuscles between the capillaries of the tuft and into the glomerular space. The capillaries become swollen and hyaline and the afferent arterioles undergo similar changes particularly affecting the intima, the result being a narrowing of the lumen. Great infiltration of leucocytes takes place into the outer coats of the afferent arterioles, and within the glomerulus and the glomerular space. There is also proliferation of the endothelium of the capillaries and of the capsular epithelium. The result is that the glomeruli become to a great extent impervious. These changes may be extreme in some glomeruli, less marked in others, and some glomeruli may escape almost altogether. Coagulated albumen may be present in the glomerular space and in the tubules, in addition to the corpuscular elements. Later, from the action of the toxine assisted by the less efficient flushing of the tubules, caused by the blocking of the glomerular capillaries, the epithelium of the tubules undergoes cloudy swelling which may go on to catarrh, fatty degeneration or necrosis.

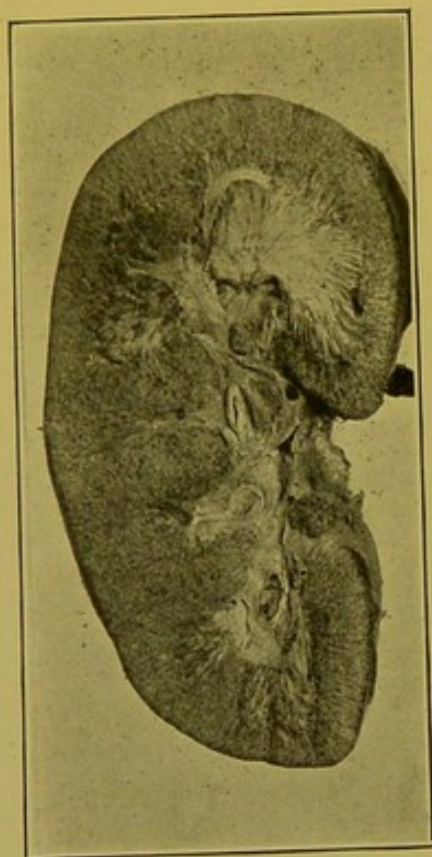


FIG. 145.—Glomerulo-tubular Nephritis in a child, post-scarlatinal. (\times circ. $\frac{1}{3}$.)

Glomeruli distinct; bases of pyramids paler than normal. Microscopically, early proliferative changes in glomerulus, and in glomerular space; infiltration round about glomerulus. (Mus. R.C.S. Edin.)

Acute Parenchymatous Nephritis (syn.: "Tubal," "Desquamative," "Catarrhal" Nephritis).

Naked-Eye Appearances.—The organ is enlarged, thickened; the capsule is tense and strips very easily, so that it may be left behind in the body if it have been incised during removal. The stellate veins are prominent. On section the organ is of a dusky greyish-red colour throughout, and its surface may be speckled with small red spots, the congested glomeruli.

The cortex is widened, it wells up on the cut surface and is sharply demarcated from the medulla, the boundary layer of which is always deeply congested. The tips of the pyramids are also congested, but not so deeply, and the vessels of the pelvic mucous membrane are engorged. At a later stage—that commonly seen in the post-mortem room—as the swelling of the tubules increases and as interstitial changes supervene, the cortex

becomes pale or blotchy and opaque, parts becoming yellowish from fatty degeneration, and greyish-yellow streaks pass down into the medulla between the straight vessels. There may be distinction between the labyrinth and the medullary rays, the former showing greyish opacity, whereas the latter may be translucent and oedematous.

Microscopically, the principal change is found in the *tubules*, the secreting parts of these being affected chiefly, although in later stages the collecting tubules may also participate in the process. The epithelium shows firstly cloudy swelling and granularity, particularly in the proximal and distal convoluted tubules and the ascending portions of the loop tubules of Henle. This is followed by changes, which vary according to the nature and concentration of the toxine, e.g. some toxines especially produce catarrh, in which the cells proliferate and become free in the lumen; other toxines produce necrosis. At an early stage, whatever be the nature of the toxine, the cells become separated from their basement membrane, whence the name "*Desquamative Nephritis*." The tubules become filled with degenerated or degenerating cells, some of which still retain some power of taking the nuclear stains, but most are granular, fatty or necrotic. Along with these one usually finds granular debris of cells, coagulated albumen, frequently blood corpuscles and fibrin. In the early stages the *glomeruli* may be normal or congested. Later the congestion becomes lessened as a result of back pressure in the tubules and from swelling of the cells lining Bowman's capsule and covering the tuft. At a still later stage there may be slight proliferation of the cells lining Bowman's capsule. In the *interstitial tissue*, in the early stages, there is marked oedema which may be accompanied by congestion. Later this tissue may show proliferation of nuclei, and here and there infiltration with lymphoid cells.

Acute Interstitial Nephritis is comparatively rare as an independent condition. The kidney becomes enlarged, sometimes to a marked degree, the cortex greyish-white or greyish-red and somewhat uniform, the distinction between the medullary rays and the labyrinth being lost to a great extent. The medulla is deeply congested. Under the microscope there is a great accumulation of mononuclear cells—lymphocytes, leucocytes and plasma cells—between the tubules of the cortex, round the stellate veins and round the interlobular veins. This infiltration may form a thick layer on the outer surface of the Bowman's capsule, which itself may be hyaline. In *syphilis* in young adults this is sometimes a characteristic appearance, the glomerulus showing little alteration or none at all. These changes vary in degree in different parts of the kidney. Tubular changes may be absent or slight or, later, various degenerative changes may supervene. The subsequent changes are not well understood, but it is believed that fibrous tissue may develop in the infiltrated parts so that many glomeruli atrophy and the tubules become fatty and collapse. The kidney at this stage is small, indurated and contracted.

Both in interstitial and in parenchymatous nephritis there are changes which may represent an intermediate stage between the acute and chronic varieties, or may be independent and of comparatively slow development—sub-acute or chronic—from the outset. For convenience, the term “sub-acute” is retained, though it is a bad term and does not always correctly indicate the nature of the changes which are taking place, particularly in the parenchymatous form in which, even after chronicity is well-established, the kidney may not be diminished in size. In the intermediate stages both chronic and acute changes are found in the kidney, and the organ is always increased in size. Bearing in mind these provisos and disadvantages we may proceed to describe the changes included under the terms “sub-acute” or “intermediate.”

Sub-acute Parenchymatous Nephritis.—This term is applied to the later stages of acute nephritis, i.e. occurring three weeks and upwards from the onset of the disease; or to a nephritis which is sub-acute, or more or less

chronic, from the outset. The organ is always enlarged, weighing up to 8 or 10 oz.; the capsule is tense, but not adherent; the stellate veins are dilated. The cortex may present one of two appearances. (1) It may be pale, much widened and greyish with opaque yellow spots indicating fatty degeneration, which is always found at this stage of parenchymatous nephritis. This is one of the forms of the common “large pale kidney” of authors, a form which is closely simulated by the large pale waxy kidney,—but which does not possess the partial translucency of that form of kidney disease,—and also at times by the early sub-acute interstitial kidney.

(2) In addition to the changes described in the first variety, the outer and cut surfaces may be mottled over with somewhat coarse haemorrhagic points. This variety has been termed the “large pale, coarsely mottled kidney” (Fig. 146). From the clinical

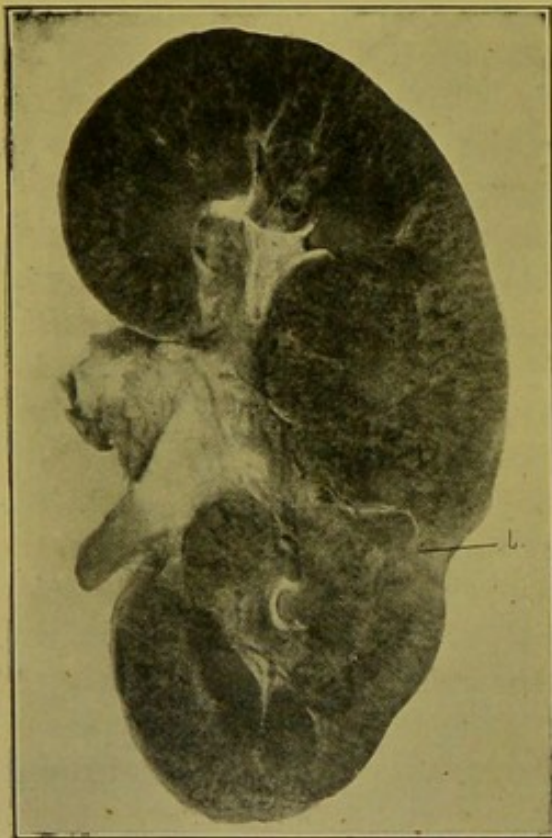


FIG. 146.—Sub-acute Parenchymatous Nephritis, with Haemorrhagic mottling. ($\times \frac{1}{2}$.)

“Large coarsely-mottled kidney.” (i.) Scar of infarct.

standpoint these varieties differ in that in the former case albuminuria is persistent and, in the latter, blood appears repeatedly in the urine. In both varieties the medulla is red and congested. Under the microscope the glomeruli may appear absolutely normal, but very frequently they

show proliferation and desquamation of the epithelium of Bowman's capsule and blood may be found in the glomerular space. The convoluted tubules show very marked changes which may be looked upon as succeeding those described in acute parenchymatous nephritis. The cells are fatty, and typically their apices are broken down, so that the cells are squat, stumpy, or flattened, lining the dilated tubules. They may be detached and cohere within the lumens as epithelial casts. In addition the tubules may contain hyaline, granular and fatty casts and in the haemorrhagic form, blood is seen within the tubules and may form haemorrhagic casts. Regenerative proliferation of cells is also seen at some parts. The connective tissue may be slightly increased, here and there showing cellular accumulations.

Sub-acute Interstitial Nephritis.—This form is sometimes termed the enlarged granular kidney or the "large pale finely mottled" kidney.

It may develop as a result of glomerular nephritis or glomerulo-interstitial nephritis, particularly if post-scarlatinal. It may also be sub-acute, slowly developing from the first.

The kidney is enlarged in all its diameters. It is also distinctly firmer than normal and more elastic. As the changes commence in the deeper layers of the superficial cortex, there is no adhesion of the capsule in the early stages, and no granularity of the surface. In later stages the capsule is distinctly thickened and adherent, so that it either strips incompletely, leaving a thin layer attached to the kidney, or as it is removed it carries with it granular portions of kidney substance. The superficial cortex may be of about the normal thickness. The deep cortex apparently escapes to a certain extent, in the earlier stages, and is usually wider than the superficial. The cut surface of the cortex is of a distinct greyish-pink or reddish-grey colour with uniform fine mottlings of a darker purplish colour, and usually some small retention cysts are observed. The medulla may appear more or less normal, but the boundary layer is usually somewhat paler than usual, its colour approximating to that of the cortex.

Under the microscope the most important changes are found in the *glomeruli*. The epithelium of the Bowman's capsule proliferates and is retained within the glomerular space, forming on section a crescentic layer of flattened spindle-shaped cells, the thickest part of the crescent being opposite the point of entrance of the afferent arteriole. At a later stage connective tissue is laid down between these cells. The glomerular capillaries may become separated up, and at a later stage the tuft becomes obliterated and hyaline from contraction upon it of the newly formed connective tissue. Some glomeruli show proliferative changes leading to increase of fibrous tissue within them. Many glomeruli remain normal. The *Bowman's capsule* also undergoes characteristic changes. It becomes thickened and may be split up into layers, and outside it a zone of fibrous connective tissue develops. Connective tissue also forms along the stellate veins, and as

this increases in extent, a wedge-shaped area of connective tissue spreads downwards from the capsule along the interlobular vein to meet the apex of another small wedge, the base of which is at the junction of cortex and medulla. Within the area of connective tissue thus formed the tubules and glomeruli are atrophied, and between neighbouring areas the tubules become dilated, containing colloid and other forms of casts, and showing changes which are characteristic of sub-acute or chronic parenchymatous nephritis. In other forms the connective tissue formation is more diffuse, and in this form the connective tissue may be more or less uniformly increased throughout the cortex.

As a result of contraction of the connective tissue along the interlobular vessels, the cortex is drawn in so that the surface becomes granular, the granules representing the more healthy renal tissue, the depressions between them indicating the portions in which the change is more advanced. In addition to this the arteries are always affected; the thickening of the intima may almost occlude the smaller vessels; the media is also usually thickened. In the medulla the increase of the interstitial connective tissue is also evident, and in this situation the connective tissue may undergo hyaline degeneration.

One result of the various changes described is that the left ventricle of the heart is hypertrophied.

The term "Diffuse Nephritis" is frequently applied when all the elements are affected,—glomeruli, tubules and interstitial tissue.

CHRONIC NEPHRITIS.

(1) **Chronic Parenchymatous Nephritis.**—This may possibly be the latest stage of the acute and sub-acute forms, and the microscopic appearances may correspond with those just described under the heading of sub-acute parenchymatous nephritis. Occasionally, however, a **contracted chronic parenchymatous nephritis** is met with, but not very often, probably because death supervenes before this stage can be reached. In some cases, from clinical

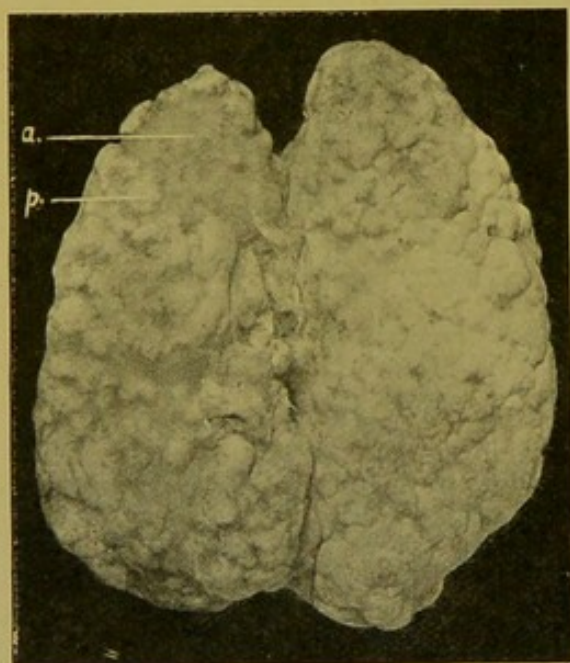


FIG. 147.—Contracted Chronic Parenchymatous Nephritis. (\times circ. $\frac{3}{4}$.)

(a.) Atrophied areas; (p.) parts showing well-marked chronic parenchymatous changes, with also proliferation in glomerular tufts and spaces. Arterial changes not marked. Proliferation of epithelium in some tubules.

evidence, it is not possible to assume that the earlier stages described have actually preceded this one. Probably it is not yet known how the condition originates in some cases. The contracted chronic parenchymatous kidney is one of the small pale kidneys (Figs. 147, 148). In extreme

cases it may weigh only $1\frac{1}{2}$ oz. The kidney is pale and on its surface there may be large rounded smooth projections. The capsule is usually slightly adherent and moderately thickened. Between the rounded projections the cortex is greatly diminished and may measure only 1 or 2 mm. in thickness. The medulla whilst narrower than normal does not undergo a proportionate diminution. The cut surface is throughout pale and of a dirty yellow colour, particularly in the portions corresponding to the projections, in which the parenchymatous changes are most manifest. Cysts also may be present.

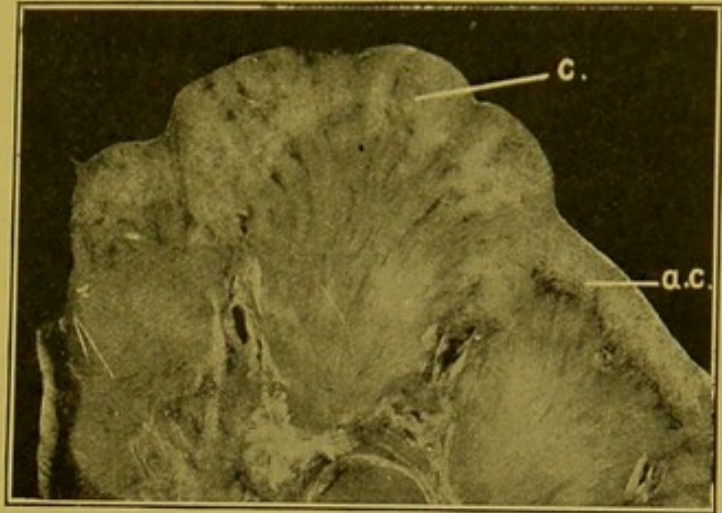


FIG. 148.—Chronic Parenchymatous Nephritis, Contracted. ($\times 2\frac{1}{2}$.)
(c.) Relatively swollen cortex; (a.c.) atrophied cortex. Vessels are not much thickened.

On microscopic examination, in the projecting area many tubules are dilated, lined with flattened epithelium; others are filled with catarrhal, fatty and disintegrating epithelium; others, again, contain regenerating epithelium. In the thinner parts of the cortex degeneration is much more marked and the tubules are atrophied, collapsed; their epithelium has disappeared in great measure, and the cells which remain are degenerating and fatty. Many tubules have disappeared completely. As a result of this disappearance of the tubules the glomeruli lie very close together. Arterial sclerosis is not very prominent. In uncomplicated cases there may be little actual increase of connective tissue, so that a "granular" surface does not invariably point to formation of fibrous tissue. Usually, however, further changes have supervened and many of the glomeruli show proliferation of the cells within them and of the epithelium covering them, and also formation of fibrous tissue. Later, they may again be separated up by interstitial new-formation of fibrous connective tissue.

(2) **Chronic Interstitial Nephritis.**—Cirrhosis of the kidney. In very numerous cases it is impossible to distinguish this condition from the late arterio-sclerotic, atrophic, kidney (p. 286), and many authors decline to recognize these forms of chronic kidney disease as distinct entities. Occasionally, however, forms occur which it is permissible to classify as chronic interstitial nephritis. The organ is much reduced in size, weighing $2\frac{1}{2}$ oz. or even less. The colour usually closely resembles that of the sub-acute interstitial nephritis (p. 307), but it may be of a brick-red colour throughout, unless parenchymatous fatty changes are present and then it is mottled with yellow. One of the most characteristic features is the great thickening and the firm adhesion of the capsule, but

this unfortunately is not an invariable feature. On removing the capsule, in typical cases it carries with it granular portions of kidney substance and leaves a granular surface resembling that of morocco leather. This granularity is due, as in the sub-acute interstitial form, to the contraction of the fibrous tissue which forms along the interlobular vessels. The cortex throughout is diminished and it may measure only 1 mm. in width. The interpyramidal cortex is diminished to a lesser extent. Cysts are almost constantly present, but they may be of microscopic size. The line separating cortex from medulla is usually irregular and indistinct. The medulla is diminished in width and, as in arteriosclerotic atrophy, there may be increase of the peripelvic fat. The arterioles are always thick-walled and prominent, though they may not form such an outstanding feature as in arteriosclerotic atrophy. (Plate I, Fig. 3.) Under the microscope the appearances resemble those described in sub-acute interstitial nephritis, but the connective tissue is more prominent, more fully developed, and generally more diffuse. Within it numerous collections of lymphoid cells are seen, resembling those found in scar-tissue elsewhere. The glomeruli and tubules enclosed by the fibrous tissue undergo changes similar to those already described in the sub-acute form, whereas between the fibrous areas, in the portions corresponding to the raised granules, the tubes are dilated, many cystic, and lined with flattened epithelium; this may be wanting in many tubules. Some of the tubules, particularly those near the surface, are filled with colloid material. In some cases the diminution in the size of the kidney is not so marked, the capsule may be thickened but can be removed more easily than described, and the line of demarcation between cortex and medulla may be fairly distinct. In such cases a microscopical examination is necessary to determine the real nature of the condition. In cases in which parenchymatous degeneration is prominent, it may be difficult to determine whether the parenchymatous change has been primary or secondary.

All the chronic forms of Bright's disease lead to thickening of blood-vessels and hypertrophy of the heart with a tendency to increase of the amount of urine. The individual is very liable to inflammations of the serous membranes and to cerebral haemorrhage.

The Kidney in Leucocythaemia and Chloroma.—The kidneys may simply show changes resulting from the anaemia which usually accompanies Leucocythaemia, such as fatty change and deposit of altered blood pigment. But in some cases the infiltration with cells is so great that the organ is greatly enlarged, and on section mottled with greyish-yellow patches, which may be so large as to simulate masses of sarcomatous new-growth. The organ may also appear glassy, somewhat resembling the waxy kidney. In some cases, as in that illustrated, numerous diffuse haemorrhages may be seen under the capsule and throughout the organ. Under the microscope the tubules are widely separated by masses of cells of a type corresponding to the variety of the disease. These alterations, in my experience, are

more often seen in cases of lymphatic leucocythaemia, than in the myelogenous form. (See Fig. 149.)

In **Chloroma**, which most authorities now regard as related to acute lymphatic leucocythaemia, distinct nodules composed of the infiltrating cells are seen. In one case I investigated, that of a child, these nodules were of a bright grass-green colour; and in another case, that of an adult male, they closely simulated nodules of secondary lymphosarcoma.

Tumours of the Kidney.—Primary non-malignant tumours are seldom encountered. Amongst these may be mentioned the *Adenoma* which forms soft white or yellowish nodules varying in size from that of a millet seed to that of a walnut. It possesses a distinct connective tissue capsule. Microscopically, some adenomata are of alveolar structure, others are tubular. In the small number which I have seen, the alveoli were filled with papillary ingrowths (papillary adenoma). This would appear to be a fairly common feature. Frequently cysts develop, sometimes small, sometimes of considerable size (cystic adenoma).

Fibromata are frequently seen as small rounded nodules varying from a pin's head size to about a quarter of an inch in diameter. They are white, uniform, elastic, and tend to project a little above the cut surface. They occur most frequently in the medulla at the junction of the intermediate zone with the papillary part. Under the microscope their margins are often not well-defined, the cellular fibrous tissue of which they are composed gradually fading off into the interstitial connective tissue of the organ. Tubules have been observed within them, particularly near the margins.

Fibromyoma and *angioma* are rarely met with. I have seen only one *lipoma*; it was of the size of a pea, and was embedded in the cortex.

Primary Carcinoma of the kidneys develops from the epithelium of the tubules, and while sometimes the microscopical structure retains some semblance of renal structure, it usually soon becomes very atypical. It is always unilateral; it is either soft or hard, localized and sharply separated from the kidney substance, or it may infiltrate the substance of the kidney diffusely. In such cases the kidney may be greatly enlarged. Carcinomata are met with relatively frequently in children, though they may occur at all ages. Degenerative changes occur at an early stage, e.g., fatty degenera-

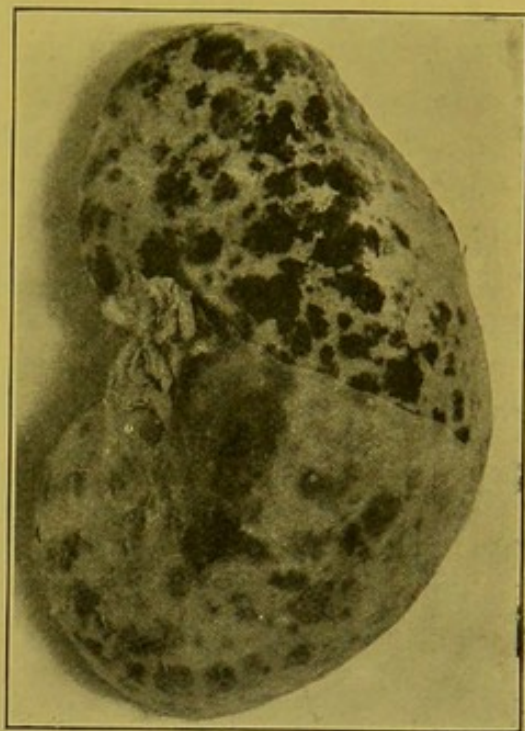


FIG. 149.—Kidney in Leucocythaemia (outer surface). (\times circ. $\frac{1}{2}$.)

Capsule in part removed, to show better the haemorrhages in the substance of the organ.

tion and necrosis, haemorrhage, calcification, mucous degeneration and cystic degeneration. **Secondary** nodules of **Carcinoma** are seldom found in the kidney and when they occur they usually develop in the cortex. They correspond with the primary growth in their naked-eye and microscopic characters.

Primary Sarcomata are also rare and are chiefly found in young children, though they are seen occasionally in adults. They may be of large size and have the characters of any of the cellular forms of sarcoma. Many of them are mixed tumours containing young embryonic striped muscle fibres, —*rhabdomyosarcoma*. In children these tumours may be of relatively enormous size and may fill the abdomen. They develop quickly; they are soft in consistence, and white or pink in colour. They may be very vascular and haemorrhagic; softened areas are commonly seen. Numerous aberrant forms are met with, some of them containing adenomatous tissue or tissue which cannot be distinguished in structure from that of the endotheliomata or peritheliomata.

Secondary Sarcomata are also rare, and they usually form rounded, sometimes multiple, nodules.

Tumours developing from inclusion of **supra-renal substance**, "**Grawitz' tumours**," are not infrequently met with in the kidney, and many tumours described as adenomata, carcinomata, sarcomata, endotheliomata or peritheliomata may be in reality of this derivation. Their malignancy may be very slight or it may be great. Their appearance may vary between wide limits. The typical **supra-renal tumour** or **hypernephroma**, or "supra-renal rest" tumour, forms usually a well-defined mass, varying from the size of a pea to that of a child's head, and composed of numerous irregular or somewhat rounded nodules and masses separated by connective tissue trabeculae. Degenerative changes occur readily and sometimes a great part of the tumour is of a dirty grey colour, softened and cystic. In the less altered portions, opaque areas of a sulphur-yellow or ochre-yellow colour can always be made out. This is very characteristic, and results from the attempt to reproduce the pigment and fat, characteristically found in the supra-renal body. Under the microscope the less malignant forms are made up of closely packed polygonal cells which are separated up into alveolar areas and columns by thin-walled blood-vessels. These cells when examined in sections cut with the freezing microtome contain large numbers of small fat globules, and when examined in paraffin sections they are clear and transparent, the nucleus being surrounded by clear spaces in the cytoplasm from which the fat has been dissolved out. The more malignant forms of hypernephroma may closely resemble sarcomata, and to the naked eye may be dark reddish-brown in colour, of soft consistence and showing less defined encapsulation than the less malignant forms. They may, for example, project into the renal pelvis, and, as in two cases I examined, the tumour may invade the vein, and extend into the vena cava,

filling it up as far as the opening into the right auricle. Necrosis readily takes place (see Figs. 150 and 151). Under the microscope these tumours have an appearance difficult to distinguish on the one hand from adenomatous cancer, and on the other hand from malignant perithelioma. The alveoli are lined with rounded and cubical cells, each with a dome-like projection into the lumen. These are clear and contain fat. The stroma is practically composed of thin-walled vessels. The spaces contain fluid, granular debris, and a few red blood corpuscles may also be present.

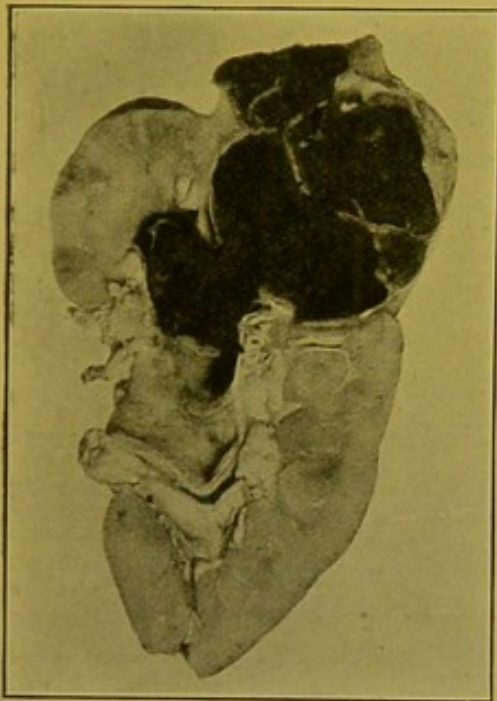


FIG. 150.—Malignant Hypernephroma (Perithelioma), penetrating Pelvis of Kidney. ($\times \frac{1}{2}$.)

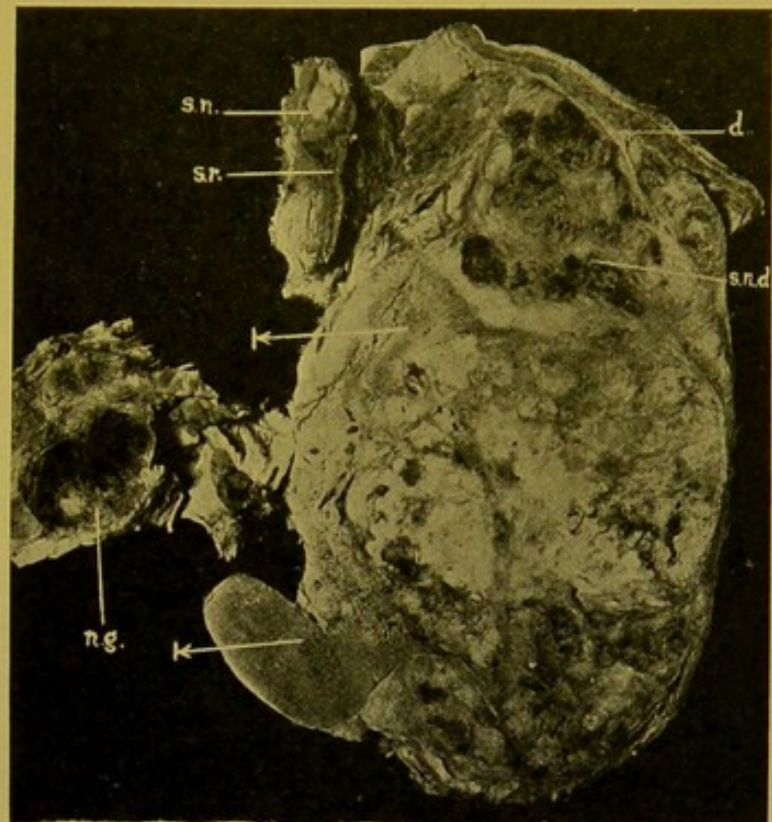


FIG. 151.—Malignant Hypernephroma of Kidney. ($\times \frac{1}{2}$.)

The arrows indicate persisting renal tissue. (d.) Diaphragm, infiltrated; (s.r.) supra-renal; (s.n.) secondary nodule; (s.n.d.) secondary growth between kidney and diaphragm; (n.g.) infiltrated lymphatic gland.

Parasites of the Kidney.—*Echinococcus Cysts*. These are rare. The characteristic ectocyst is easily recognized. The cysts may rupture into the pelvis of the kidney or they may suppurate and in rare cases may originate a pyaemia.

Ova of *Bilharzia haematobia*—*Schistosomum haematobium*—may be found in great numbers in the mucous membranes of the pelvis, of the ureters, and of the urinary bladder. They may give rise to inflammation and ulceration, and in the bladder to polypoid outgrowths, or the sole evidence of their presence may be raised rough, haemorrhagic areas at the base of the bladder. When examined under the microscope these are crowded with ova. The typical ova with terminal spines escape in the urine, and are frequently found embedded in small blood-clots.

Filaria sanguinis. The adult filariae may be situated in the lymphatics of the renal pelvis and of the abdomen and give rise to great dilatation of these vessels, which brings about chyluria. This may be accompanied by intermittent haematuria.

Cysticercus cellulosae and *Pentastomum denticulatum* occur but seldom and are not of great importance.

Eustrongylus gigas, the largest human filaria, has been found coiled up in the renal pelvis.

DISEASES OF THE PELVIS OF THE KIDNEY.

Hydronephrosis.—In this condition there is dilatation of the pelvis of the kidney, resulting from obstruction to the outflow of the urine. The obstruction must not be absolute otherwise the function of the kidney is completely abolished, and atrophy of the organ, without dilatation of its pelvis, takes place.

Hydronephrosis may be either *unilateral* or *bilateral*.

(a) **Unilateral Hydronephrosis** may be due to (1) obstruction of the ureter at any part of its course by a calculus. In scrofulous kidneys the dilatation is brought about by the obstruction of the ureter, caused by the cast-off caseous material. (See p. 301.)

(2) Primary changes in the wall of the ureter are rarely found as causes of unilateral hydronephrosis, with the occasional exception of contracting scar-tissue. This may be associated with S-shaped kinks of the ureter immediately below the renal pelvis.

(3) Pressure from without of tumours, scybalous masses in the colon, malignant tumours of the bladder, or, in the female, pelvic tumours, may cause unilateral dilatation.

(b) **Bilateral Hydronephrosis.**—In most cases of bilateral hydronephrosis, at least in the male, the obstruction has its position in front of the bladder. Thus, hypertrophy or tumour of the prostate, stricture of the urethra (Fig. 152), or, in children, phimosi, are the commonest causes. Amongst other less common causes of obstruction may be mentioned congenital bilateral narrowing or kinking at the junction of renal pelvis with ureter; tortuosity of the ureters; tumours of the pelvis pressing upon both ureters; pressure of the enlarged uterus in pregnancy; hypertrophy of the bladder causing pressure upon the lower end of the ureters as they pass through its wall; calculus in the bladder.

Depending upon the position of the obstruction, the whole urinary passages may be dilated or only the pelvis of the kidney, with or without an accompanying dilatation of the ureter. The walls of the dilated portions—except in the case of dilatation of the scrofulous pelvis and ureter—are always smooth and glistening. In long-standing cases they become pearly, and fibrous-looking; in early cases they remain translucent.

Secondary Changes in the Kidney.—The calyces undergo the greatest

distension and as a result the pyramids become flattened and later hollowed out. The kidney substance itself becomes atrophied, the tubules being chiefly affected, the glomeruli frequently persisting for a long time. In many advanced cases the kidney may be represented by a thin fibrous-looking cyst-wall in which to the naked eye apparently no renal tissue remains.

The kidney in such cases presents a microscopic structure resembling that of advanced arteriosclerotic atrophy accompanied by chronic interstitial nephritis. The glomeruli show all stages of atrophy and degeneration, and some are surrounded by a zone of fibrous tissue. They are closely massed together as the result of the extreme atrophy of the tubules, which are represented by small duct-like, sometimes empty, spaces. Both arteries and veins are greatly thickened.

Pyonephrosis.—Pyonephrosis may be looked upon as somewhat analogous to hydronephrosis, differing from it in that pus takes the place of the watery fluid. The varieties and position of

the obstruction may be similar to those found in hydronephrosis. The infection spreads upwards in the stagnating urine from a septic inflammation of the bladder or prostate, or is conveyed to it from the intestine by way of the lymphatics or blood-vessels. The pus is frequently offensive and of a greyish-yellow colour. In old-standing cases, a granular calcareous deposit may take place upon the wall, thus simulating to some extent the caseous deposit in scrofulous kidney. A common sequel is secondary or consecutive suppurative nephritis—disseminated suppurative pyelo-nephritis (p. 299). Suppuration may extend further and attack the perinephric fat in which widely-spreading abscesses may be found.

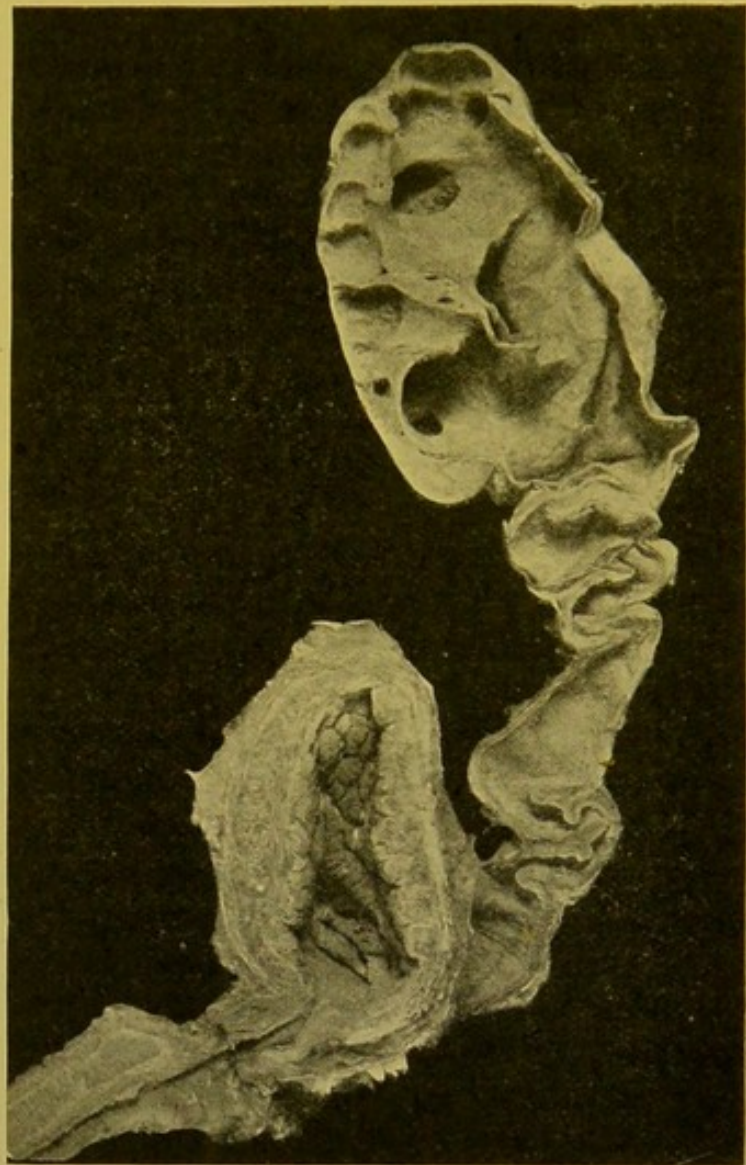


FIG. 152.—Hydronephrosis (double). ($\times \frac{1}{4}$.)

Dilatation of ureter; hypertrophy of bladder; stricture of urethra; perineal (operation) opening into membranous urethra.

Pyelitis and Ureteritis.—Inflammation of the pelvis of the kidney and the ureters. The non-suppurative inflammations may be due to the presence of parasites, e.g. *Filaria sanguinis*, and the ova of *Bilharzia haematobia* (*Schistosomum haematobium*) and *Eustrongylus gigas*.

They may also originate in the presence of calculi, lying either in the renal pelvis or in the ureter. Most inflammations of the pelvis, however, are caused either by infection from below by *bacillus coli communis*, pus cocci, including the *gonococcus*, or from above by organisms escaping from suppurative conditions of the kidney. In rare cases, the infective agent may be conveyed directly by the blood-stream.

Catarrhal inflammations occur not uncommonly in infective diseases such as typhoid fever, scarlet fever, small-pox, pyaemia, or cholera. The process may be purulent or associated with formation of a fibrino-necrotic membrane on the surface of the pelvis. These are especially produced by the *bacillus coli communis* and by pus cocci. According to Ziegler the *bacillus proteus vulgaris* also can cause such inflammations. In the slightest degrees of inflammation the contents of the pelvis are muddy or creamy, and of a greyish colour; the mucous membrane is congested and numerous haemorrhages into its substance are seen. In the more severe inflammations the surface becomes more irregular, loses its glistening character, and dull greyish patches like moist wash-leather are seen on the surface. Upon these there may be greyish, granular, deposits of phosphates.

Pus in the renal pelvis has to be distinguished from fluid rendered turbid with phosphates. This may closely simulate it.

Calculous Pyelitis or Nephrolithiasis.—The commonest calculus found in the renal pelvis is composed of uric acid, or urates. It usually contains in addition phosphates, carbonates, or oxalate of lime. The shape of the calculus corresponds to that of the branching pelvis; it frequently resembles in general appearance a piece of coral, with its irregular projections. Small calculi are common. These may be solitary or multiple, and may be of any size from that of a Brazil nut down to fine gravel. The mucous membrane shows inflammatory changes usually of a chronic catarrhal nature. In addition to uratic calculi one sees occasionally small yellowish-brown concretions attached to the papillae, and usually accompanied by uratic deposits in the tips of the pyramids. These are found not only in the very young but also in adults, and especially in gouty conditions.

Calculous pyelitis is generally unilateral. It may bring about hydronephrosis or pyonephrosis, or the calculi may cause ulceration of the wall of the pelvis. They occasionally escape into the intestine, or ulcerate through from the ureter into the bladder. The pus which may form in relation to calculi may penetrate the walls of the pelvis and produce an offensive purulent perinephritis.

Tuberculosis of the renal pelvis has already been referred to in considering the scrofulous kidney. Occasionally the surface is covered with miliary

tubercles. These have to be distinguished from the minute cysts which develop in some chronic inflammatory conditions.

Renal Haemorrhage and Haematuria.—Haemorrhage may occur in any part of the kidney and at any part of the urinary tract. In the kidney it is frequently seen in the superficial layers of the cortex, or between the capsule and the cortex; in the glomerular spaces and tubules; round about the straight vessels and extending along them. Apart from the haemorrhage resulting from mechanical injury, haemorrhage is especially apt to occur in the course of intense inflammations, e.g. in such diseases as scarlet fever, diphtheria, and septicaemia. It also occurs in leucocythaemia, pernicious anaemia, haemophilia, purpura, scurvy and malaria. The haemorrhages are usually of small size.

Local Diseased Conditions of the Urinary Tract in which Haematuria occurs.—

(1) **Kidney.** Mechanical injury; acute nephritis (particularly glomerular); sub-acute parenchymatous nephritis (large, with coarse mottlings); cirrhotic Bright's disease; infarction; nephritis from poisons, e.g. carbolic acid, turpentine, cantharides; carcinoma and sarcoma; angioma, usually occurring on the surface of the pyramids; tuberculosis (scrofulous kidney); calculous pyelitis; Bilharzia haematobia (*Schistosomum*); varicose veins of the renal pelvis.

(2) **Bladder.** Acute cystitis; varicose veins; tuberculous ulceration; villous papilloma; Bilharzia; carcinoma; calculi, particularly when composed of oxalate of lime.

(3) **Prostate.** Presence of tuberculosis or malignant tumours.

(4) **Urethra.** Mechanical injury, impaction of a calculus, and acute inflammations (gonorrhoea).

Haemoglobinuria.—In this condition haemoglobin, or more often met-haemoglobin, appears in the urine, giving it a uniform dark brown colour. It may be paroxysmal, after sudden chills and sometimes in the course of Raynaud's disease. It also occurs in certain poisonings, as by potassium chlorate, carbolic acid, or pyrogallie acid. It is found in severe infections which may at the same time produce toxic jaundice.

DISEASES OF THE URINARY BLADDER.

Anatomical.—To find the orifices of the urethra from the interior of the bladder, one should first look for the transverse ridge which crosses the surface a short distance behind the urethral orifice. At the extremities of this ridge the two slit-like openings of the ureters will be found.

On the posterior surface at the base the ureters are placed farthest out, then, in the male, come the vasa deferentia and vesiculae seminales. The last two structures intervene between the bladder and the anterior wall of the rectum.

Malformations of Bladder.—The bladder is formed from the portion of allantois which becomes shut off within the abdomen. Normally the obliterated portion of this persists as a fibrous cord connecting the apex of the bladder to the umbilicus. The allantois may persist in the form of thin-walled cysts, which may either be shut off completely or may extend upwards as far as the umbilicus,

or may communicate below with the bladder. In rare cases the allantois persists as an elongated bladder extending from the umbilicus to the urethra and sometimes this is patent at its upper end.

The anterior wall of the abdomen may be deficient in front of the bladder so that the anterior wall of the bladder projects—*Ectopia vesicae*—or, in addition, the anterior wall of the bladder may be defective so that the posterior wall of the bladder, with the ureteral orifices, presents at the opening—*Extroversio vesicae*. Accompanying this anterior defect, or occurring independently, there may be a defect in the upper wall of the urethra—*Epispadias*. Deficiency of the lower wall of the urethra—*Hypospadias*—which is sometimes associated with ‘*bifid scrotum*,’ is also occasionally met with as an independent malformation (*see also p. 26*).

Diverticula of the Bladder usually consist of mucous membrane herniated between the muscular bands. They occur most often near the ureteral orifices, particularly on the left side, on the posterior wall above the inter-ureteric ridge, and at the apex. They are either of congenital origin, or occur as a result of increased pressure within the bladder. Encysted calculi may be found within these diverticula.

Disorders of circulation—passive hyperaemia, varicosity of the superficial veins in the trigone, thrombosis;—**haemorrhages**, either occurring in intense hyperaemias or, more frequently, in the presence of tumours, both non-malignant and malignant, in calculous disease, and in mechanical injury, which most frequently is the result of fracture of the pelvis; and **oedema** of the mucous membrane, present no peculiarity when occurring in the bladder and need no special description.

Inflammation of Urinary Bladder.—**Cystitis** practically always results from changes occurring in the urine contained within the bladder. In the majority of cases infection is direct, e.g. in catheterization, the organisms being conveyed upon the catheter from the urethra, or infection may take place by direct extension from the urethra, prostate, or from the pelves of the kidneys and ureters.

Occasionally inflammation spreads through the wall from adjacent organs, or from a periproctitis. The organisms found may be of many varieties, but those most commonly found are the *bacillus coli communis*, *bacillus proteus*, typhoid bacillus, pus cocci, *gonococcus* and various organisms which can produce fermentation of the urine. The urine may be acid when passed, and quickly becomes ammoniacal from the action of the *micrococcus ureae*. In other cases ammoniacal decomposition takes place within the bladder.

In **acute catarrhal cystitis**, the mucous membrane is mottled with red points, made up of congested vessels and haemorrhages. The congestion is usually most marked at the summits of the ridges. The epithelium is swollen and desquamated. The urine contains pus corpuscles and numerous bacteria. In **chronic catarrhal cystitis**, the wall is thickened from infiltration of the submucous coat, and from hypertrophy of the muscle bundles, which is frequently accompanied by increase of the intermuscular connective tissue. The hypertrophy usually results from obstruction to the outflow of urine caused by enlargement of the prostate or stricture of the urethra.

In paralytic cases, e.g. in diseases of the lumbar cord, the wall of the bladder is distended and thin.

At the post-mortem examination, the mucous membrane is frequently of a dark purple, sometimes slaty or almost black, colour. These colour changes are due to haemorrhage into the wall and the subsequent alteration of the blood pigment. A slaty colour in most cases denotes chronicity, though similar changes may be brought about by decomposition. The surface may be covered with a muco-purulent layer, or on the ridges there may be a distinct fibrino-necrotic membranous layer, the so-called **croupous** or **diphtheritic cystitis**. The membrane, as in true diphtheria, involves the superficial layers of the wall, which are necrotic. Necrosis may extend more deeply and more widely, so that the term **necrotic** or **gangrenous cystitis** may be applied. Frequently ulceration also may be seen on the surface.

Upon the surfaces altered in these various ways there is usually a greyish or chalky deposit of phosphates. In some chronic cases cysts or granular nodules of lymphoid tissue develop on the surface. In **purulent** and **putrid cystitis** the necrotic changes are most marked. The surface is covered with pus which may also infiltrate the wall and extend to the surrounding connective tissue or even induce a localized peritonitis. These serious necrotic changes are most evident in cases in which the urine has escaped into the wall of the bladder, and extended in the peri-vesical connective tissue.

Tuberculosis of the bladder has already been referred to sufficiently in describing tuberculosis of the kidney and ureters (p. 301). In this condition the urine is muddy and often contains blood. In uncomplicated cases the urine has an acid reaction.

Tumours of the Bladder.—A great variety of tumours, both non-malignant and malignant, may occur in the bladder, but the two important forms are **villous papilloma** and **carcinoma**. The latter is frequently covered with papillary processes, and some forms of it are with difficulty distinguished from the ordinary villous papilloma.

Villous papilloma occurs as a spongy tuft with delicate outgrowths, usually situated at the base of the bladder (Fig. 153). The papillomatous

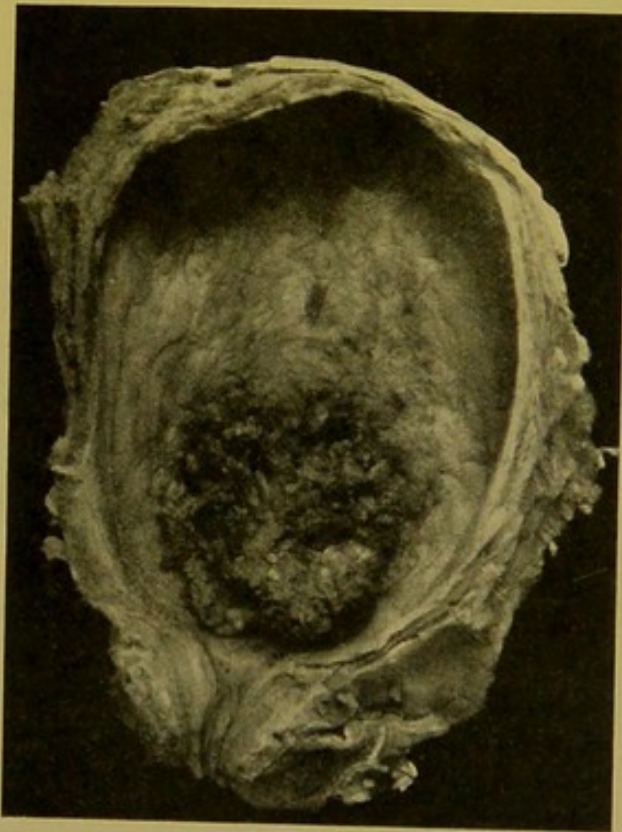


FIG. 153.—Villous Papilloma of Urinary Bladder. ($\times \frac{2}{3}$.)

projections are composed of an extremely delicate, cellular and oedematous connective tissue core, in which are numerous thin-walled blood-vessels. This is covered with multiple layers of more or less rounded or polygonal cells. The epithelial layers separate very readily from the core and thus haemorrhages are very frequent.

Carcinomata, chiefly of the *columnar-celled* and *squamous* types, are not uncommon in the bladder. They are either primary, or extend from the neighbouring organs, especially the uterus. They readily undergo degeneration; haemorrhage also occurs easily. Less commonly *encephaloid cancer* occurs as multiple nodules, and in rare cases *colloid cancer* is met with.

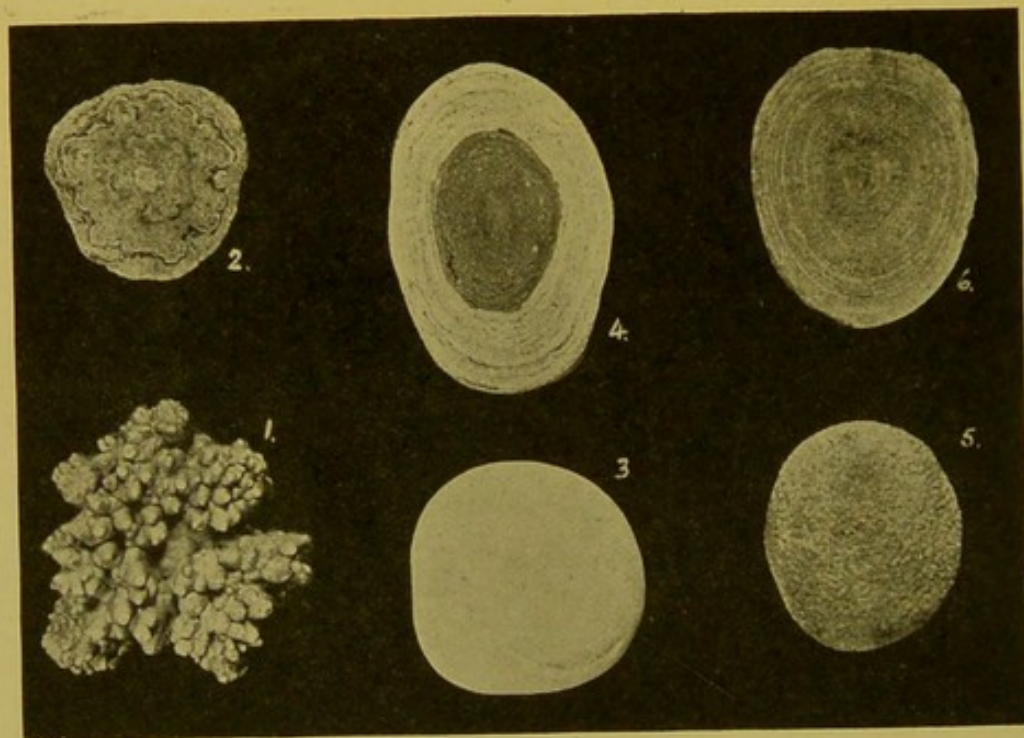


FIG. 154.—Vesical Calculi. (\times circ. $\frac{2}{3}$.)

(1) Mulberry calculus—oxalate of lime; (2) oxalate of lime centre—urate covering; (3) phosphatic calculus; (4) urate centre, phosphate covering; (5) uratic calculus; (6) urate calculus, cut surface. (Mus. R.C.S., Edin.)

Vesical Calculi (Fig. 154).—Vesical calculi are very rarely met with in the post-mortem room. They are generally of the same varieties as those met with in the renal pelvis. Undoubtedly many of them when of small size pass from the renal pelvis to the bladder where they gradually increase in size. They may, however, originate in the bladder in the presence of any foreign body or during the course of a cystitis. They are usually solitary but may be multiple and may reach a large size. The most common calculi are composed of *uric acid* and the urates, or of *phosphates* and *oxalate of lime*, and mixed stones containing any two of these or all three are frequently found. The **urate stone** is smooth or slightly granular on the surface, the granularity seldom exceeding that found on the surface of an orange. The colour is pale brown or reddish-brown, the consistence is hard and the stone is not very friable. On section it is made up of concentrically arranged layers. **Phosphatic calculi**, composed chiefly of calcium phosphate and ammonio-magnesium phosphate (triple phosphate), are chalky, of a dirty white colour and friable. The more phosphate they contain the softer is their consistence. Phosphates may be

deposited on the surface of a uratic or oxalate core. They are rarely pure. The deposit takes place in alkaline urine. **Oxalate of Lime Calculi** are very hard, warty or mulberry-like on the surface, or covered with limpet-like conical projections. They are usually coloured dark brown to black by the altered blood pigment which they contain. On section the layers have frequently a stellate arrangement. They may have a urate core or are covered with urates, or with phosphates. Calculi of **cystin** or **carbonate of lime** are rarely met with. The former are of somewhat firm consistence and have a bluish or greenish colour; the latter are hard, and of a white colour.

DISEASES OF THE SUPRA-RENAL BODIES

Usually the left supra-renal is of crescentic shape; the right supra-renal of a triangular shape. The left is thicker than the right, and on section triradiate. The weight of the supra-renals varies from 4.5 to 7.5 gm.

Even if the corresponding kidney be congenitally displaced, or atrophied or hypoplastic, the supra-renal usually retains its normal position and size.

Hyperplasia is associated with excessive growth of the sexual organs, and also in certain cases of chronic kidney disease with hypertrophy of the left ventricle, but an etiological relationship is not yet determined.

Waxy or Amyloid Degeneration is not infrequent, accompanying a similar alteration in other organs. The organ may be moderately enlarged; it is firm, of a pale grey colour, and translucency is never marked. The portions affected are the vessels and connective tissue of the cortex, but occasionally the medulla is affected, either alone or along with the cortex.

Suppuration is rare.

Miliary Tuberculosis may be found, but chronic tuberculosis is more common. It is usually secondary; rarely primary, and the supra-renal may be the only organ in the body showing evidence of tuberculosis. The disease begins in the medulla of one or both supra-renals, and is most often of the caseo-fibroid type. The organ may be as large as a hen's egg, and its substance wholly or almost wholly converted into yellow, tough, dry, caseous nodules, surrounded by greyish scar tissue. The central part may become softened or calcified.

Syphilis.—Single or multiple small gummata, or diffuse fibrosis may be found, both in congenital and in acquired syphilis.

Addison's Disease.—This disease depends upon inadequacy or diminution of the chromaffin cells of the medulla, possibly associated with mechanical or toxæmic irritation of the sympathetic. The local change in the supra-renal is most often caseo-fibroid tuberculosis. In some cases the supra-renal undergoes simple atrophy, the semilunar ganglia being healthy. It may be the seat of chronic inflammation resulting in atrophy, or of malignant disease or of hæmorrhage. Lesions may also be discovered in the semilunar ganglia and sympathetic nerves. The first two lesions of the supra-renal are the most common. In addition to the local lesions in Addison's disease, the lymphoid follicles of the alimentary tract are hypertrophied; the spleen is enlarged and softened, the thymus may persist, and the heart is usually atrophied.

The pigment is generally regarded as *melanin*, and, in the mucous membranes, is deposited chiefly in the cells of the corium.

Haemorrhage takes place into the supra-renals in the haemorrhagic diatheses; in leucocythaemia; as a result of mechanical injury—fracture of the spine, rupture of liver or of spleen, injury during birth. In infancy it may follow thrombosis of the veins. It occurs also in chronic venous hyperaemia; in toxic or infective

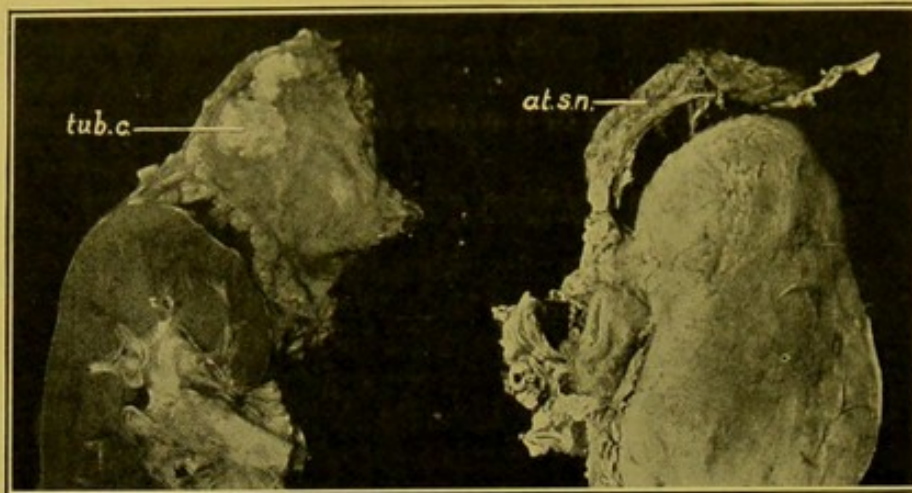


FIG. 155.—Addison's Disease.

Supra-renal and upper part of kidney, from two different cases of Addison's disease—showing in the one supra renal, caseo-fibroid change (*tub. c.*); and in the other, atrophy (*at. s.n.*). (\times circ. $\frac{1}{2}$.)

diseases, often associated with septic embolism. In many cases the cause is obscure.

Tumours of the Supra-renal. (*a*) **Non-malignant.**—Single or multiple nodules may form in the cortex, projecting on the surface and displacing but not invading the medulla. They are more or less rounded, of a sulphur-yellow colour, and may be mistaken for tuberculous nodules. The larger masses (adenomata) are usually unilateral. They may reach a considerable size, though more commonly they do not exceed the size of a cherry. In structure they resemble the *zona fasciculata*. They rarely contain much connective tissue. Occasionally pigmented adenomata arise from the *zona reticularis*. Adenomatous tumours of the medulla are rare; some have been described as sarcomata or gliomata.

Tumours frequently arise in accessory supra-renals or **Supra-renal "Rests."** These "rests" may be found in the neighbouring tissues, in the mesentery, in the broad ligament, on the ovarian or spermatic vessels, in the vaginal walls, in the inguinal canal and even in the epididymis. They may be embedded in the kidneys, the liver, or the head of the pancreas. The tumours arising from them are composed of cortex only or of cortex and medulla, and most of them present the characteristic ochre-colour of supra-renal tissue. They may be of large size, especially in the kidney. They are encapsulated, may remain latent for a long period and then may become malignant, taking on rapid growth.

Cysts of the supra-renal are rare. They may result from softening of adenomatous nodules, or from absorption of a haemorrhage. Occasionally they are of lymphatic origin.

Other non-malignant tumours are very rare, fibroma, fibromyoma, angioma, ganglionic neuroma, glioma.

Malignant tumours.—No sharp line of demarcation can be drawn between the malignant and the non-malignant hypernephromata. The primary tumours probably more often develop in cortex (mesoblastic) than in medulla (neuro-ectodermic). Tumours of the cortex may be *sarcomata*, *endotheliomata* or *peritheliomata*. Histologically, they resemble carcinomata, or may present that appearance at one part, and resemble sarcomata at another. The cells are clear, containing glycogen and fat. They may have an alveolar arrangement. If growth be active, the cells become atypical, spindle-shaped, or giant-cells with huge nuclei appear, and all alveolar arrangement may be lost. Then they resemble sarcomata, but on careful examination areas are found retaining the characters of supra-renal tissue. They may be of great size, up to 9 lb. in weight, and infiltrate the surrounding tissues and organs—liver and kidneys. Metastasis takes place to lung, liver, kidneys, pleura, lymphatic glands, skin, bone, and exceptionally to nervous system and heart. (*See Figs. 150 and 151, p. 313.*)

Malignant tumours of the medulla are described as glio-sarcomata rather than carcinomata. The medulla is of neuro-ectodermic origin.

Secondary malignant tumours are not infrequently found in the supra-renal. I have found both supra-renals infiltrated with mucoid cancer, secondary to a tumour of the mucous glands of the tongue. Both supra-renals were of the size of a Tangerine orange.

CHAPTER XV

REPRODUCTIVE ORGANS: MAMMA

FEMALE REPRODUCTIVE ORGANS

VULVA

Atrophy—Kraurosis vulvae—affects especially the labia and the vestibule. In the early stages the surface becomes smooth and pale, with small subcutaneous haemorrhages. Later, the tissues become dry, rigid, and white. The vaginal orifice may become rigid and contracted.

Hypertrophy.—The labia minora may hang down beyond the labia majora, as red bulbous swellings. The labia majora become greatly enlarged in **Elephantiasis**, sometimes forming huge sacs reaching to the knees—"Hottentot apron." In *Spurious Elephantiasis* the swelling is firmer and is caused by overgrowth of fibrous tissue; the surface is nodular.

Haematoma vulvae.—Haemorrhage into the labia may occur from rupture of varicose veins.

Hernias may descend into the labia majora alongside of or within the *processus vaginalis* of Nuck.

Specific Warts—condyloma acuminatum—may form large cauliflower masses covering the whole outer surfaces of both labia majora, or may be localized to a part of these. Frequently a large mass of warts springs from a comparatively small base.

Gonorrhoea causes inflammation of the vulva, vaginal glands and surrounding tissues; also urethritis, and swelling, oedema and ulceration of the labia. The vagina is more rarely affected. It may also cause abscess of Bartholin's glands.

Condylomata develop on the outer surfaces of the labia majora and on the adjacent surfaces of skin. They form soft, greyish, flat, raised patches.

Ulceration of the vulva may be gangrenous in children (*Noma*), and in adults, or may be malignant. Old tertiary ulcers may assume a malignant character.

Pseudo-hermaphrodites are usually males, with hypoplasia of the external genitals, and hypospadias; with splitting of the scrotum, or a deep recess in its anterior part.

Less commonly they are females, with hyperplasia of the clitoris, atresia vaginae, and adhesions of the labia simulating a scrotum.

Abscess of Bartholin's gland, if the duct alone be affected, is usually super-

ficial, small and bilateral; if involving the gland itself, it is deeper, larger and generally unilateral.

UTERUS

Malformations.—The uterus may remain *foetal*, i.e. the body is small, the cervix longer and thicker; or it is incompletely developed—*infantile*. Often the other reproductive organs, particularly the ovaries and the mammae, are hypoplastic, and incapable of functioning. Occasionally the whole individual remains undeveloped, and of child-like aspect.

The uterus may be absent, or the whole or one half may be rudimentary.

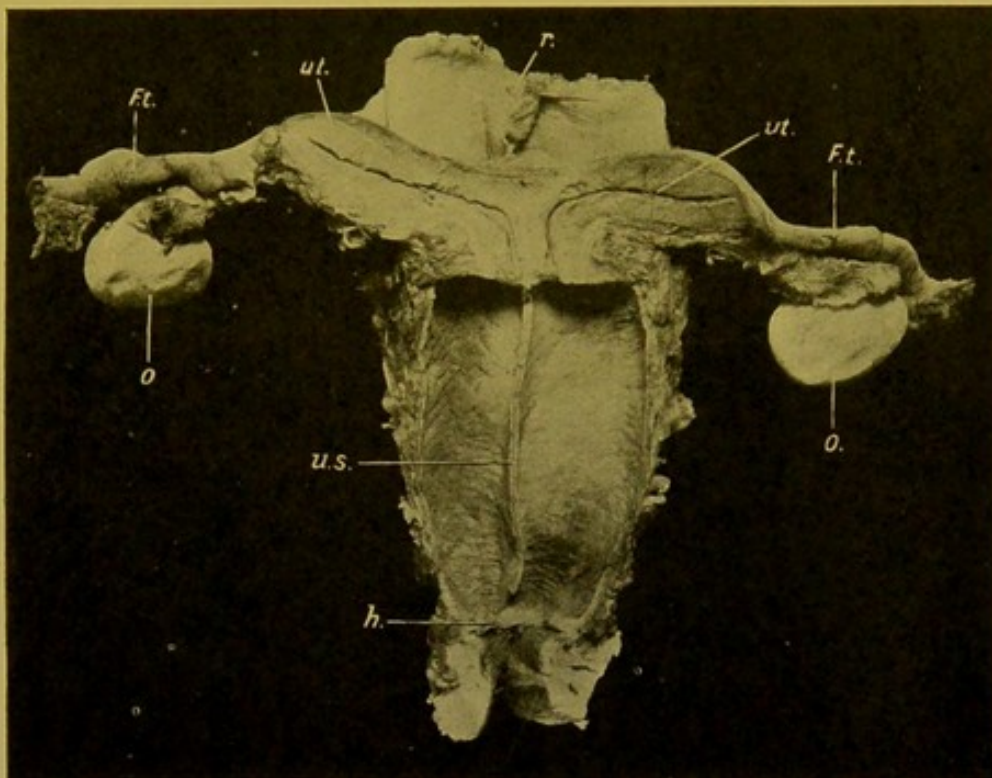


FIG. 156.—Uterus bicornis. (\times circ. $\frac{1}{2}$.)

(ut. ut.) Separate uterine cavities; (F.t.) Fallopian tubes; (o.) ovaries; (u.s.) septum in vagina, continuous with septum in cervix uteri; (h.) hymen; (r.) rectum.

Double Uterus is caused by a failure of the two lateral halves to unite. This failure may be :—

(a) *Complete*, the cavities being separate throughout, and the vagina also double.

(1) Uteri completely separate, *Uterus didelphys*.

(2) Uteri united below, divided above, the cavities separate, *Uterus bicornis* (Fig. 156).

(3) Uteri apparently completely united externally, separated internally by a septum, *Uterus septus*.

(b) The uterine cavity may be *incompletely* divided; the vagina single. The uterus is either horned, *U. bicornis v. arcuatus*; or apparently normal exter-

nally, but the upper part of the cavity is divided by a septum, *U. subseptus*.

Displacements.—**Prolapse**, i.e., partial descent of the uterus.

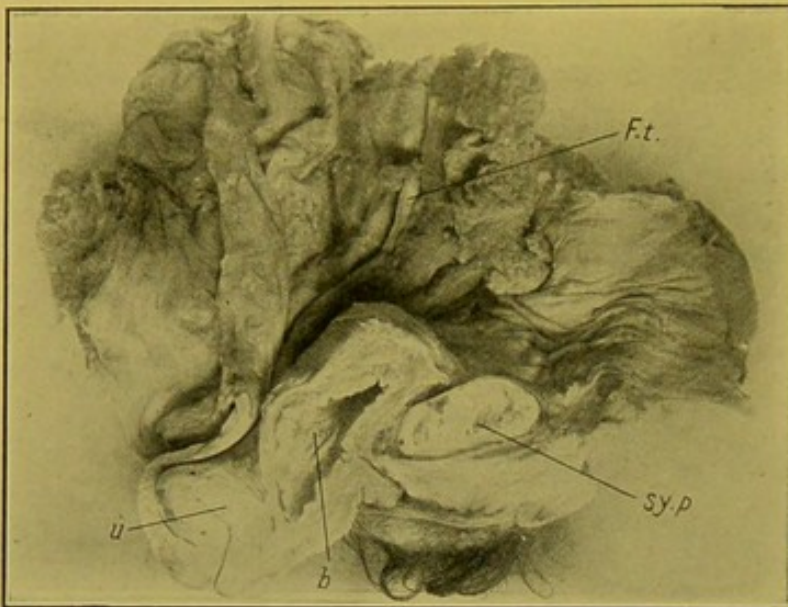


FIG. 157.—Procidentia uteri; complete descent.
(\times circ. $\frac{1}{3}$.)

(u.) Uterus; (b.) bladder; (sy. p.) symphysis pubis; (F.t.) left Fallopian tube. (Mus. R.C.S. Edin.)

- (2) The whole of the fundus may be inverted into the cavity of the cervix.
- (3) Inversion of one wall may take place.
- (4) The uterus may be turned inside out (commonest variety).

Hypoplasia and **Atrophy** are rare. The latter may be due to super-involution.

Hypertrophy.—Apart from the hypertrophy occurring in pregnancy, the uterus may become hypertrophied in presence of new-growths in its substance or in its interior, e.g. fibroids (see Fig. 159, p. 328). It may also result from chronic endometritis. Hypertrophy of the cervix occurs in prolapse.

Dilatation of the non-pregnant uterus is generally caused by obstruction of the cervix by chronic inflammation or by malignant growth. If it contain a watery fluid, the dilatation is called *hydrometra*; if pus, *pyometra* (Fig. 158); if blood, *haematometra*; if lochia, *lochiometra*. The pus may be offensive and undergo decomposition, with the production of gas, *physometra*.

Inflammatory Changes.—**Cervical Erosions** may present different aspects.

The common erosion is formed by an extension of the canal epithelium and glands on to the vaginal aspect of the cervix, replacing the normal

Procidentia, i.e., complete descent and escape from the body, with eversion of the vaginal walls. This must be distinguished from elongation of the cervix. The bladder comes down with the anterior vaginal wall, *cystocele*; the rectum may come down with the posterior wall, *rectocele* (Fig. 157).

Inversion is an accident of delivery; it may be partial or complete.

- (1) A portion of the fundus may be inverted.

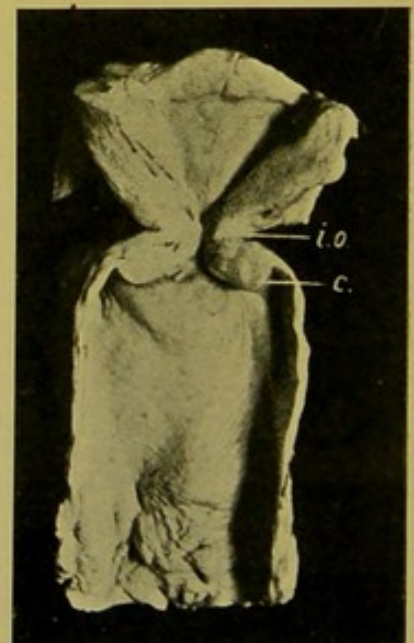


FIG. 158.—Pyometra, gonococcal.
(\times circ. $\frac{1}{2}$.)

(i.o.) Internal os; (c.) cervix.
(Mus. R.C.S. Edin.)

squamous epithelium. This produces rounded, often confluent areas, with congested surfaces.

These surfaces may be flat, or raised into papillary projections, the so-called "papillary erosions."

In the process of healing, the mouths of the glands may become obstructed, and small retention cysts are produced—"ovula Nabothii."

Occasionally the epithelium becomes cast off, and a surface covered with granulation tissue—an ulcer—is left.

Endometritis.—The most important **acute** inflammations occur during the puerperium.

(1) They are often originated by mechanical injuries—e.g., from the head of the infant, or in the course of instrumental labours—with subsequent infection.

The inner surface is covered with a soft, greyish or brownish (from haemorrhage) offensive layer. The inflammation may extend deeply in the wall, particularly in the cervical portion of the uterus, where necrosis may lead to perforation and fatal cellulitis or peritonitis.

(2) If there be no preceding mechanical injury, septic infection of the endometrium is generally limited to the placental site, on which small or large areas of greyish-yellow necrosis develop.—Sloughs have to be distinguished from remains of decidua, which are usually soft and easily detached.—The remainder of the mucous membrane is swollen, congested and oedematous. Septic thrombosis usually follows in the uterine veins, with subsequent pulmonary embolism. The lymphatics also may be affected and form large swellings with smooth inner walls, filled with pus. These may be well seen under the peritoneum surrounding the commencement of the Fallopian tubes.

The bacteria concerned are most often *streptococci*, alone, or associated with *staphylococcus aureus*, or *albus*.

Chronic Endometritis.—Usually leucocytic infiltration is wanting, and the changes are characterized by hyperplastic, hypertrophic, or atrophic changes in the glands. The interstitial tissue may become very cellular, of loose texture, and oedematous; the vessels thin-walled and dilated; so that it is frequently difficult to exclude the possibility that the changes are of sarcomatous nature.

In chronic endometritis the mucous membrane becomes uniformly thickened, extremely vascular, or polypoid outgrowths develop, with cystic dilatation of the glands.

Microscopically, **hypertrophic glandular endometritis** is characterized by great increase in the number of the glands, which retain their cylindrical structure; the epithelium is columnar, regular, and closely set upon a distinct basement layer.

In **hyperplastic glandular endometritis**, the gland tubules are increased in size, dilated, tortuous, with great thickening of the epithelium, which

shows infoldings, and projections into the lumen. A distinct basement layer can be distinguished in the wall of every tube.

Occasionally, gland tubules, having the characters of one or other of these varieties, can be seen within the muscular wall. This always warrants a strong suspicion of malignancy.

Endometritis with Atrophy is common in old women. The glands are degenerated or have disappeared; the connective tissue is more fibrous, and the walls of the vessels are thickened. There may be patches of squamous epithelium on the surface of the mucous membrane, which is smooth and pale.

Tuberculosis may attack the endometrium of the body of the uterus.

(1) In **Miliary tuberculosis** the mucous membrane is congested, moderately thickened, and grey or yellow tubercles are scattered over it.

(2) **Tuberculous Endometritis with caseation.** In early stages the mucous membrane is soft, reddened, thickened, with numerous tubercles; later these increase in size and numbers, and caseate. The surface becomes covered with friable, yellow, opaque material, and this change spreads for a varying distance into the wall.

Deep ulcers may result, or

the condition remains superficial, and the uterus becomes filled with soft caseous material. At a late stage the tuberculosis spreads down to the cervix and vagina.

Syphilis is rarely seen. Primary and secondary manifestations may occur on the vaginal surface of the cervix.

Tumours of the Uterus.—The **Fibroid**—fibromyoma, leiomyoma—is the most common. The more fibrous the tumour, the harder, paler, and more fibrillated is its aspect; the more muscular fibres it contains, the softer it is. The colour of the latter approximates more to that of the

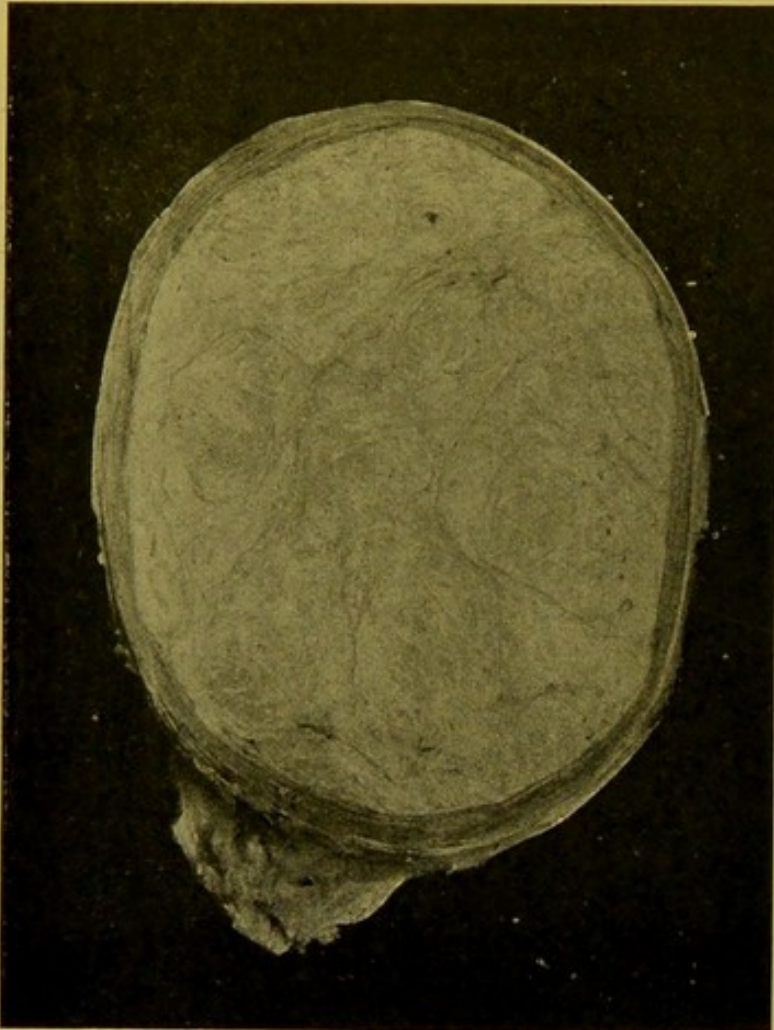

FIG. 159.—Fibromyoma of Body of Uterus. ($\times \frac{2}{3}$.)

Myoma (paler) in centre of section, surrounded by layer of uterine muscle (darker); fasciculation well shown.

uterine muscle than that of the former. It is often indistinctly encapsulated.

The typical fibroid is a rounded tumour, with distinct capsule. It is of close texture, and on section is composed of smaller, rounded, fibrillated masses which are bound together by intervening tissue of similar nature (Fig. 159). It is pale grey in colour, with a pinkish tinge. The uterus is often enlarged and mis-shapen, particularly when numerous tumours are present, but if the tumour be small and single, there may be little externally to indicate its presence. Fibroids may be *intramural*, in the substance of the wall; *sub-serous*, projecting under the peritoneum or even pedunculated; or *sub-mucous*. The last may also become pedunculated, and then form one of the varieties of *uterine polypus*. Fibroids occur both in the body of the uterus and in the cervix (Fig. 160), possessing similar characters in both situations. They may undergo cystic or myxomatous degeneration. Calcareous salts may be deposited either at the periphery or throughout the tumour ("womb-stone"). They may become septic and undergo necrosis. Rarely adenomatous cysts are seen in them, and some fibroids are full of large blood spaces. Fibroids which take on rapid growth, and sarcomatous aspect, have probably been sarcomatous from the outset. **Broad ligament fibroids** may be extruded uterine fibroids, or fibroids may develop from the muscular fibres which exist under the peritoneal investment of the broad ligament. Similarly fibroids may develop in the **round ligament** or in the **ovary**, but they are rare in these situations.

Uterine polypi.—(1) *Extruded submucous fibroids*. These may become covered with squamous epithelium in place of the ordinary columnar epithelium, or they may undergo ulceration and sloughing. (2) *Mucous polypi* develop from the uterine or from the cervical mucous membrane. They are more common in the latter situation. They are pedunculated adenomatous growths. With uterine polypi are also usually included remains of decidua, or chorion—*placental polypi*; and the *malignant polypi*, which are pedunculated portions of cancers or sarcomata.

Malignant Tumours.—**Carcinomata** are more common in the cervix than in the body of the uterus.

In the cervix superficial and deep forms occur. The latter may be in the form of a nodule under the intact mucous membrane; the

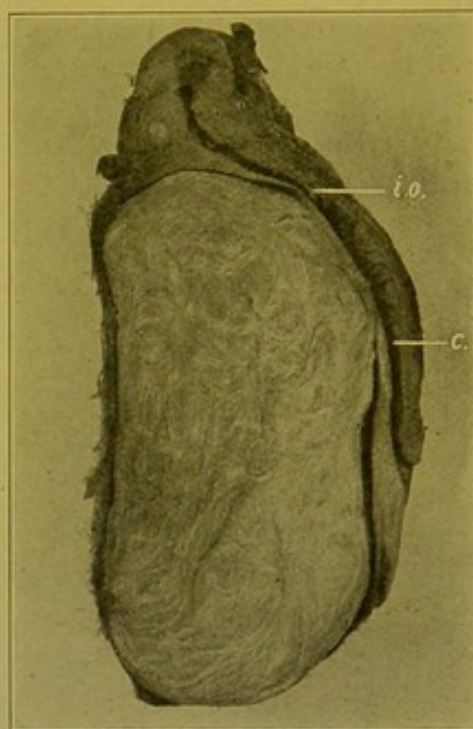


FIG. 160.—Cervical Fibroid.

(c.) Cervix uteri; (i.o.) os internum uteri.
(× circ. $\frac{2}{3}$.) (Mus. R.C.S. Edin.)

type is usually *columnar-celled carcinoma*, less commonly *encephaloid carcinoma*.

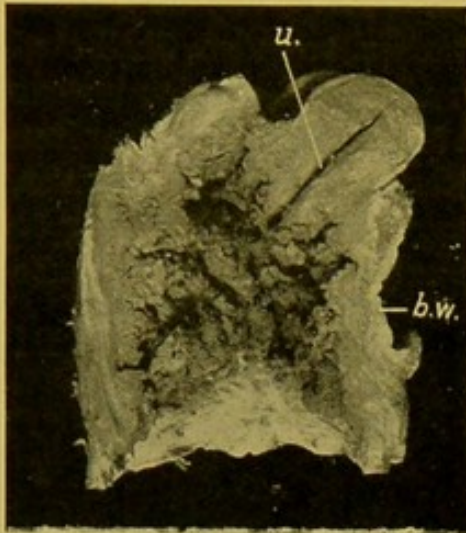


FIG. 161. — Columnar - celled Cancer of Cervix Uteri, invading vagina, rectum and bladder. (\times circ. $\frac{3}{8}$.)
(u.) Cavity of uterus; (b.w.) bladder wall.
(Mus. R.C.S. Edin.)

The superficial variety appears as a soft, spongy thickening of the mucous membrane, which increases rapidly, distending the cervix. It breaks down, forming a funnel-shaped excavation lined with shaggy, necrotic new-growth (Fig. 161). It tends to spread in all directions, and the excavation may extend to the rectum and bladder. Microscopically this tumour is a *columnar-celled carcinoma*.

Squamous Epithelioma (Fig. 162) grows from the vaginal portion of the cervix, and tends to extend downwards, forming sometimes a large fungous mass in the vagina. It may, however, also spread upwards towards the uterus, and to the adjoining structures. Microscopically, cell-nests occur only in small numbers.

Cancer of the Body of the Uterus is most commonly of adenomatous type. One variety grows diffusely, affecting the whole mucous membrane, which soon becomes rough, ulcerated, or covered with nodules of new-growth. It soon infiltrates the walls, and spreads to the peritoneal surface, giving this a nodular aspect. It seldom extends to the cervix.

Another variety has a great tendency to form characteristic polypoid outgrowths. These are composed of a delicate fibrous core, covered with large columnar or polygonal epithelial cells.

Sarcoma of the uterus is rare. It may be round-celled, mixed-celled, or spindle-celled. It forms a soft, spongy, greyish mass, which is brown if haemorrhage has occurred. It may practically replace the uterus, and may reach the size of an adult head or be even larger. It undergoes necrosis readily.

PLACENTA

In the early ovum, haemorrhage may occur, chiefly in connexion with abortion.

If such an ovum be retained, it is called a *haemorrhagic mole*; if the blood

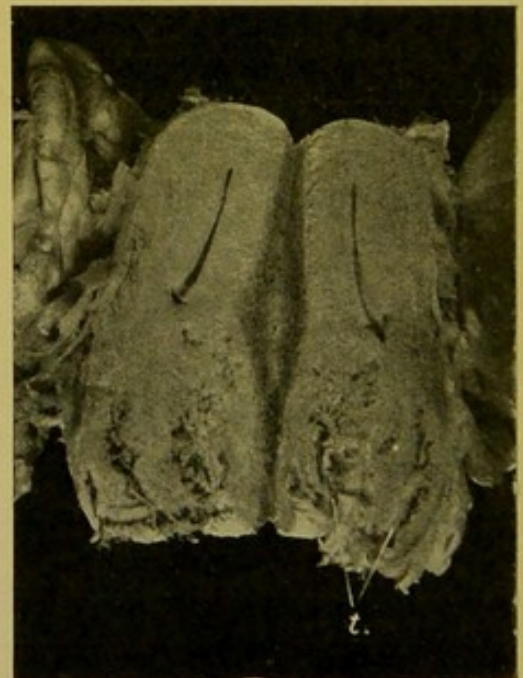

FIG. 162. — Squamous Epithelioma of the Cervix Uteri. The uterus laid open longitudinally. (\times circ. $\frac{1}{2}$.)

The tumour (t.) is extending in both lips of the cervix. (Mus. R.C.S. Edin.)

be partly decolorized, brownish in colour, and becoming organized, it is called a **fleshy mole**.

In the **placenta**, thrombosis in the intervillous spaces gives rise to yellowish or grey areas, generally termed **infarcts**.

Distinct evidence of **tuberculous invasion** is occasionally seen in the placenta, and in **syphilitic** women, *spirochaete pallida* has been demonstrated in the placenta. Gummata may develop.

Hydatid Mole.—The chorionic villi become hypertrophied irregularly and thickened; they become oedematous and undergo cystic degeneration, the central parts disappearing and being replaced by fluid. There is always an excessive proliferation of the epithelial coverings—Langhan's layer and the syncytium—and these eat more deeply than normal into the decidua, uterine wall and blood-vessels.

The uterus after an abortion is found to be filled with small clear or opalescent pedunculated thin-walled sacs, resembling white currants (Fig. 163); or if the pregnancy have gone on for a longer period, the placental site is covered with a thick yellowish mass, composed to a great extent of small cysts. In most cases the foetus has disappeared. Cases in which hydatid moles have been found, have to be watched carefully as they may develop chorionepithelioma.

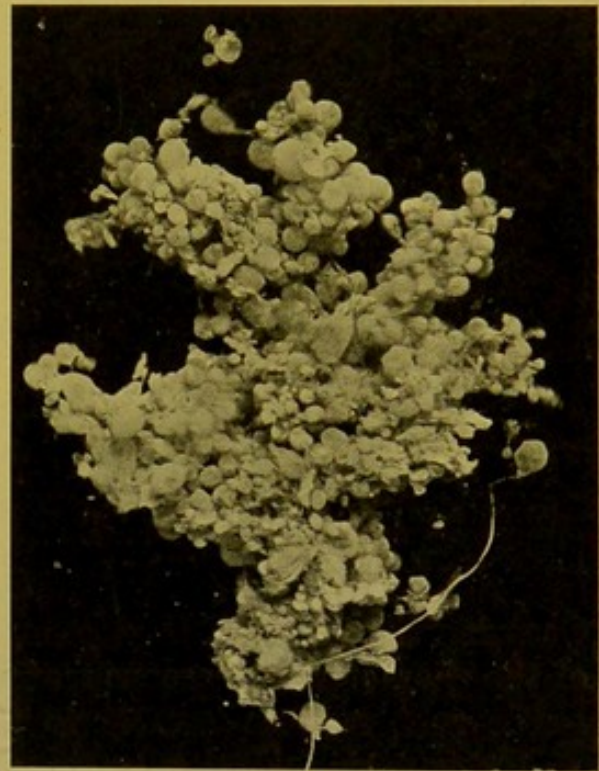


FIG. 163.—Hydatid Mole. (\times circ. $\frac{1}{2}$.)
Numerous thin-walled, bladder-like structures.

Chorionepithelioma.—Like hydatid mole, chorionepithelioma develops during or after a pregnancy marked by numerous severe hæmorrhages. At the placental site—hence usually near the fundus, and extending on either anterior or posterior wall—there is a soft, fleshy, hæmorrhagic, degenerating growth, which projects into the cavity, and infiltrates the walls deeply (Fig. 164). It penetrates the venous sinuses, and forms metastases readily and at an early stage, principally to the lungs and vagina, but also occasionally to other organs, such as the liver, kidney, and Fallopian tube. Microscopically, the growth consists chiefly of greatly and irregularly proliferated Langhan's layer and syncytium, with a large amount of intervening fibrinous coagulum.

FALLOPIAN TUBES

The **Hydatids of Morgagni** are small pedunculated transparent cysts attached to the fimbriae; they develop from the duct of Müller, and are

lined with ciliated columnar epithelium. They have to be distinguished from pedunculated cysts of the parovarium, which are derived from relics of the Wolffian body, and are lined with cubical epithelium.

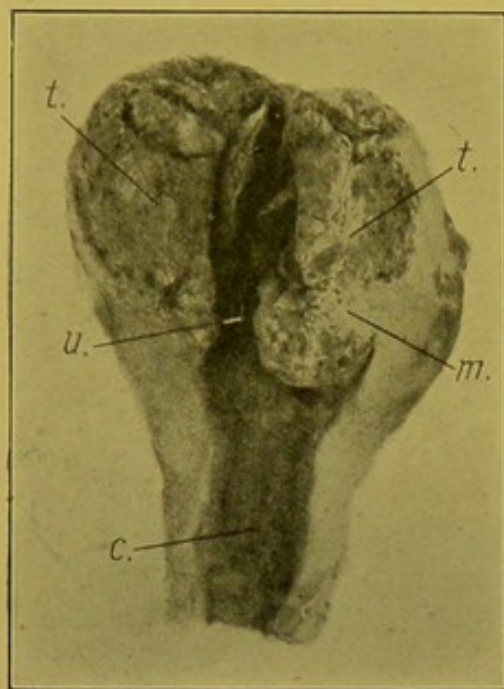


FIG. 164.—Chorionepithelioma.

(t.) Tumour; (m.) persisting muscle;
(u.) uterine cavity; (c.) cavity of cervix.
(Kindly lent by Prof. J. H. Teacher.)

Salpingitis.—The principal causes are *gonorrhoea* and *tuberculosis*.

Gonococcal Salpingitis.—The tubes are greatly thickened, tortuous, often bound down by peritonic adhesions; the folds of the mucous membrane are thickened, oedematous and infiltrated. This stage may go on to **Pyosalpinx**, with or without closure of the ostium. The distended tube nearly always has a typical “retort” shape owing to the non-dilatation of the isthmie portion. The folds—*plicae*—may be destroyed and the tube become simply an elongated abscess cavity lined with granulation tissue. This may organize further to fibrous tissue and the pus be replaced by watery fluid.

Tuberculous Salpingitis.—The changes are closely analogous to those already described as occurring in tuberculosis of the uterus.

Occasionally, in mixed infections, the tubes become filled with pus, instead of the characteristic caseous material. The dilatation may be extreme, the cystic tube reaching nearly to the umbilicus.

Hydrosalpinx.—The tube is greatly dilated with watery fluid. This may result from catarrhal inflammation, or be the late stage of a pyosalpinx. The dilated tube may be continuous with a cyst of the ovary—*tubo-ovarian cyst*.

Tumours.—*Villous papilloma*, *fibroma*, rarely *myoma*. *Carcinomata* are often of papillomatous type, resembling those which may occur in the urinary bladder.

Tubal Gestation.—A dilated part of the tube is filled with blood or blood-clot. Death may be due to rupture into the peritoneum and gross haemorrhage. The foetus may be found *in situ*, surrounded by the membranes. Chorionic villi can always be detected microscopically.

OVARIES

Age Changes.—The ovaries shrink, the *tunica albuginea* becomes thickened and pearly; the surface irregular, wrinkled or dimpled; the organ fibrous; the follicles disappear. Similar changes may be seen on the surface of ovaries which are still fertile.

Changes in the Graafian Follicles.—In some cases the Graafian follicles ripen, but fail to rupture, in which case they remain as small cystic spaces situated round the periphery of the ovary, giving rise to the so-called **Cystic Ovary**.

Changes in the Corpora Lutea. (1) *Cystic*. The walls of the cyst are bright yellow; it contains albuminous fluid.

(2) *Fibrous* corpora lutea have tough, semi-opaque walls, with characteristic wavy outlines. A cavity may persist in the centre. The vessels in the neighbourhood are thickened.

(3) *Calcified* corpora lutea are irregular, and nodular.

Abscess of the Ovary.—Separate small abscesses may form, or the whole ovary may become enlarged, soft, and sloughy. Accompanying this change, there is usually haemorrhagic and purulent infiltration in the uterus, tubes and broad ligament.

Tuberculosis is rare. It may either be miliary or caseating.

Tumours of Ovary.—**Simple cysts** are usually single and smooth-walled. They are dilated Graafian follicles.

Multilocular Cyst-adenoma.—This tumour develops in the oöphoron proper, i.e. in the part of the ovary farthest removed from the hilum. It is made up of numerous loculi, which vary greatly in size (Fig. 165). These are filled with a thick gluey albuminous fluid, containing pseudo-mucin. They are lined with columnar epithelium. The specific gravity of the fluid varies from 1,010 to 1,030; addition of acetic acid does not produce a precipitate. The tumours may be bilateral. In presence of jaundice the fluid becomes deeply bile-stained.

Papillary Cystadenoma develops from the par-oöphoron, i.e. the part at the hilum of the ovary. It is multilocular, like the last tumour, but in addition papillary processes project from the walls into the cysts. The papillomata may perforate the walls and project upon the outer surface (Fig. 166). If these become broken off, they may become implanted upon the peritoneum throughout the abdomen. Sometimes the processes increase in size, thickness and density, and come to fill the cysts completely. The fluid contained within the cysts is of low specific gravity. The tumours

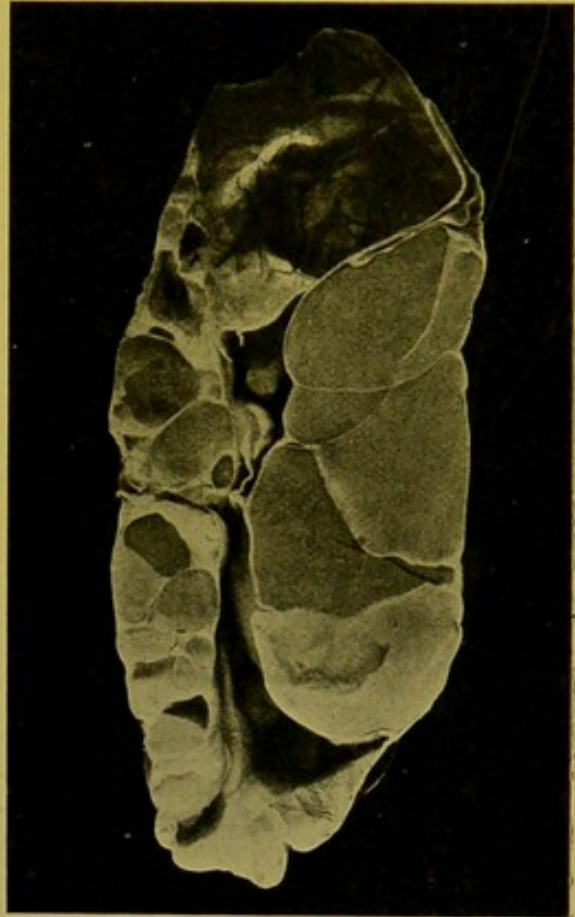


FIG. 165.—Compound Cystic Ovarian Tumour. *Cystoma glandulare ovarii*. ($\times \frac{1}{2}$.)

Many of the cysts still retain their gelatinous contents.

rarely reach the size of the multilocular cystadenomata. They are often malignant.

The most important change which may occur in connexion with ovarian cysts is **Torsion of the pedicle.**

This brings about what is practically infarction of the cyst, with haemorrhagic infiltration into it. The cyst may rupture, or it may give rise to peritonitis. I have examined cases of this nature which had presented the features of a ruptured extra-uterine gestation, or of aneurysm of the abdominal aorta, with haemorrhage into the peritoneal cavity.

Malignant Cysts.—It is difficult to distinguish these from the non-malignant cystic tumours without microscopic examination, and even then, several portions should be examined, seeing that the malignant transformation may be localized to one part of the tumour. They are frequently bilateral; they are soft, readily break down,

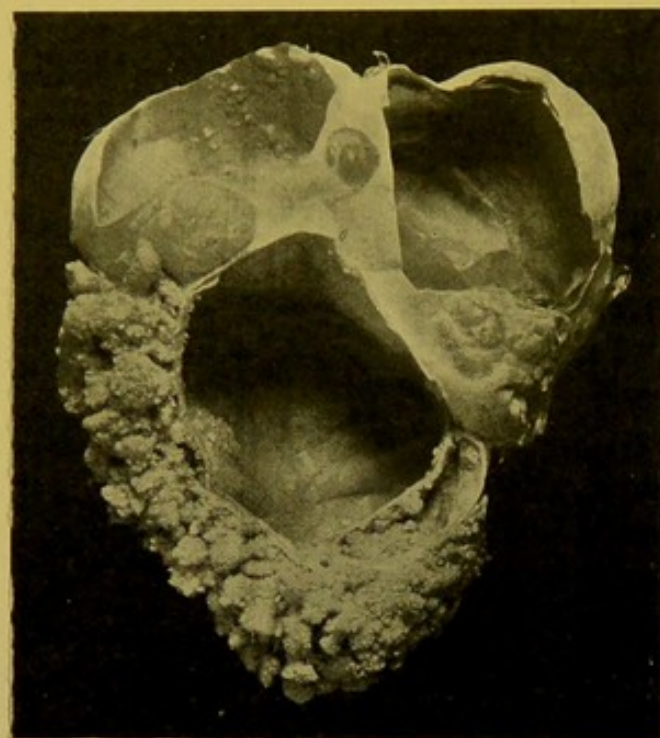


FIG. 166.—Compound Papilliferous Cyst of the Ovary. (\times circ. $\frac{2}{3}$.)

Most of the papillomata project on the outer surface.
(Mus. R.C.S. Edin.)

bleed easily, and at an early stage form metastases.

Dermoid Cysts develop in the ovary generally as the result of the inclusion of a twin ovum. They may form more or less simple cysts, the inner wall of which is composed of sodden skin. They contain a pultaceous, greasy, opaque substance, in which degenerated epithelium, cholesterine, and fatty acids are present. Very commonly long hair, coiled up in masses, is also contained within the cysts. Other cysts are more fully representative of the structures of the foetus, and their walls are thicker, containing bone, often with teeth projecting on its free surface, hence representing jaw-bones (Fig. 167, *tt.*); also glandular structures, cartilage, muscle, and other tissues.

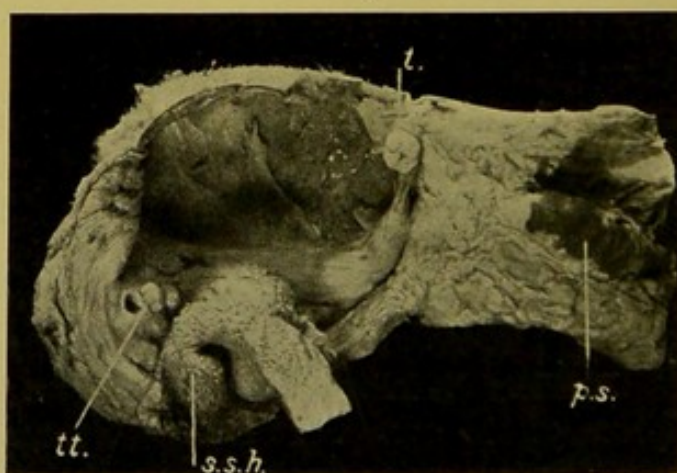


FIG. 167.—Dermoid Cyst of Ovary. (\times circ. $\frac{1}{2}$.)

(*s.s.h.*) Sodden skin, with scanty hairs; (*tt.*) teeth, set in a bony mass in the wall of the cyst; (*p.s.*) pigmented skin.
(Mus. R.C.S. Edin.)

Other Tumours of the Ovary.—*Fibroma* and *myoma* occur but rarely. *Endothelioma* may be found. *Sarcomata* are rare ; both ovaries are affected ; the varieties occurring are the round- and spindle-celled. *Carcinomata* are usually secondary.

REPRODUCTIVE ORGANS IN THE MALE

The method of removing these organs is that described for the removal of the contents of the pelvis (p. 275), but slightly modified if the testicles and penis are to be removed in continuity with the pelvic organs.

In the first place, the inguinal canals are laid open, and the **spermatic cord** isolated as far downwards as the pubic crest. Then with the forefinger of the left hand, the testicles, each in turn, are pushed upwards out of the scrotum, and pressure being kept up, a few touches of the knife set them free from all their connexions. To remove the **penis** in continuity with the bladder, the pubic arch should be divided with the saw, about an inch to either side of the symphysis, care being taken not to injure the structures lying behind the bone. The penis, or the portion of it to be removed, is dissected out of the skin covering it, and from the scrotal tissues, as far back as possible. An alternative method is to dissect the penis out of its cutaneous covering and then to separate it from the pubic arch, keeping the knife close to the bone in dissecting away the corpora cavernosa, the triangular ligament, the prostatic plexus, etc. This method is not so easy to practise as to describe, particularly if there be inflammatory changes and scar-formation in relation to the membranous urethra. The pelvic organs are subsequently removed in the usual manner.

Examination of Penis, Urethra and Prostate.—The **urethra** may be opened up firstly, and then the incision extended into the bladder, or the ordinary anterior, mesial incision may be made into the bladder, and then with a probe-pointed bistoury, passed from the bladder into the urethra, the penis is laid open along the septum between the corpora cavernosa.

Transverse incisions should be made across the **prostate**, and after isolating the **vasa deferentia** as they pass downwards over the posterior wall of the bladder, and the **vesiculæ seminales** as they lie upon the posterior wall internal to the vasa, these structures may be examined by means of numerous transverse incisions. One should not forget to examine the **prostatic plexus** of veins, as these are frequently the seat of *thrombosis*, and emboli may be derived from them. Further, *phleboliths* are more commonly found in this plexus than elsewhere in the body.

Diseases of the Penis.—Malformations of the urethra have already been referred to (p. 318). In rare cases the penis is **wanting**, this accompanying other defects of the genital apparatus. More commonly it is mal-developed and of **small size** ; this is often associated with hypospadias or epispadias. Occasionally in boys the penis is **hypertrophied**, the external organs of adult type, and the sexual functions precocious. This condition is frequently associated with new-growths of the supra-renals.

The orifice of the prepuce may be so small that it cannot be drawn back over the glans, and the anterior portion elongated—**phimosis** : this difficulty in retracting the prepuce may be due to inflammatory changes—**inflammatory phimosis**. When the prepuce has been retracted and cannot be again drawn forwards, the condition is **paraphimosis**. When associated with

severe inflammatory congestion and engorgement of the parts, paraphimosis may lead to great swelling and necrosis of the glans penis.

Inflammations.—**Posthitis**—inflammation of the prepuce—and **Balanitis**—inflammation of the glans, are often conjoined—**Balano-posthitis**. The commonest cause is gonorrhoea.

Syphilis.—The manifestations of the disease may be of the primary stage—**hard chancres** on the corona, usually in the vicinity of the frœnum, or upon the prepuce; of the second stage—**condyloma latum**; or of the third stage—**gummata** or **fibrous induration** of the corpora cavernosa or glans. One sees frequently at *post mortems* pale, thin, slightly recessed scars on the glans or prepuce, which indicate an old venereal infection.

Tuberculosis is rare in this situation. Tubercles may be found in the peri-urethral tissue in uro-genital tuberculosis.

Necrotic and **gangrenous** changes, especially affecting the skin of the penis and the glans, may follow **soft chancres**, or inflammatory paraphimosis, or erysipelas. **Soft chancres** occur upon the corona chiefly, and the neighbouring parts of the prepuce.

Tumours.—**Specific Warts**—**condyloma acuminatum**—may occur both on the prepuce and on the glans. The most important tumour is the **Squamous Epithelioma**, which attacks the prepuce or (and) glans. It may transform the prepuce into a large warty mass which readily undergoes ulceration. Epithelioma attacks the glans firstly in the region of the corona. Fungation and ulceration are prominent features. I have several times seen epithelioma causing great enlargement of the glans, and containing numerous elongated spaces from which creamy or pultaceous material, consisting chiefly of degenerated epithelial cells, could be expressed.

Concretions may form between the glans and the prepuce, and **cutaneous horns** may develop in this situation.

SCROTUM

Malformations—see with *Epispadias* and *Hypospadias* (pp. 26, 318).

Oedema may be extreme in cardiac and renal disease.

Fibrous tumours may occur, but the important tumour is the **Squamous Epithelioma**, which develops upon the lower part of the skin surface. This is the form which “chimney-sweeps’” cancer assumes. No doubt the irritation of the soot is a determining factor. It also occurs in this situation in workers in paraffin or tar.

Elephantiasis.—The scrotum becomes extremely enlarged, and on its anterior and upper surface a depression indicates the position of the penis. On section it is composed of extremely oedematous fibrous tissue, in which the testicle is deeply embedded. Search may be made for *adult filariae* in the lymphatics near the pubic attachment of the scrotum. **Spurious elephantiasis** is occasionally seen; the scrotum undergoes inflammatory enlargement and oedema as the result of chronic septic inflammation, and

in appearance the enlargement resembles a soft fibrous tumour. **Guinea-worms** may be encysted in the tissues of the scrotum.

PROSTATE

Acute Prostatitis is frequently secondary to urethritis or to other inflammations in the neighbourhood, or it may be determined by mechanical injury, such as forcible catheterization with formation of false passages. The inflammation may be catarrhal, affecting the ducts, or interstitial, causing great infiltration and swelling of the organ. **Suppuration** is a common sequel. The suppuration may occur in the substance of the gland, extending firstly round the ducts. The abscesses which develop may occupy the whole of the prostate, and communicate with the urethra or rectum, or may extend into the walls of the bladder and sub-peritoneal tissue. Suppuration may also occur round about the prostate, extending from the neighbourhood, or from septic thrombosis in the prostatic venous plexus.

In **Chronic Prostatitis**, the organ is soft and brownish; the glands dilated, containing a milky fluid.

Tuberculosis is most often secondary to tuberculosis of the neighbouring parts of the genito-urinary apparatus. Grey tubercles or larger caseous masses form in the organ. These may break down to form cavities communicating with the urethra, or sinuses develop opening upon the surface of the perineum.

In old age, laminated **Concretions** develop within the dilated glands. They may be of microscopic size, or are visible to the naked eye, and brown to black in colour. They are seldom larger than millet seeds. The larger concretions tend to undergo calcification—*prostatic calculi*. The smaller have the appearance and reactions of *corpora amylacea*. They are probably, in part at least, composed of inspissated mucus.

Hypertrophy and Hyperplasia.—Enlargement commonly sets in about the fortieth year, having as a main cause chronic gonococcal inflammation. The lateral portions—"lobes"—ordinarily increase in size, compressing the urethra laterally. In great enlargement the part behind the urethra, usually called the "third" or "middle" lobe, may be so enlarged as to form a bulbous projection into the bladder, and obstruct the urethra. In the **fibrous** variety, in which the fibrous and muscular tissues are increased, the hypertrophied prostate is fairly uniformly increased in size, and on section it shows some fasciculation. When the **glandular** portions of the organ are increased, the surface of the organ is more nodular, and on section numerous irregularly rounded masses project upon the surface. Similar appearances, in rare instances, are due to the presence of fibromata or myomata.

Malignant tumours of the prostate are rare. They are more often primary than secondary. **Carcinoma** is commoner than **sarcoma**. Any variety of carcinoma may occur. They show a great tendency to form metastases

in bones, even when the primary tumour is of small size. They are often with difficulty distinguished from glandular hypertrophy, as they may show little apparent local spread, and do not readily undergo necrotic changes. *Squamous epithelioma* has been reported.

Sarcomata are rare. They may be of large size. The varieties occurring are the round-celled, spindle-celled, angio-sarcoma, myxo-sarcoma, and lympho-sarcoma.

EPIDIDYMIS AND TESTIS

Abnormalities.—One or both testicles may be *absent*. When both are absent the whole body remains child-like; the larynx particularly is small. Absence of one testicle is compensated for by hypertrophy of the other. Congenital *hypoplasia* accompanied by mal-development of the vasa is not uncommon; it occurs in cretins, and in congenital syphilitics.

• **Undescended Testicle—Cryptorchism.**—Both testicles may be retained within the abdomen, or in the inguinal canal. When incompletely descended the testicles may become the seat of inflammatory changes or of new-growth.

Occasionally the testicle is **inverted** in the scrotum, so that the epididymis is anterior, and the *globus major* lowermost.

Inflammation.—**Orchitis**—inflammation of the testis—and **Epididymitis**—inflammation of the epididymis—result most often from extension of infection by way of the vasa deferentia from the urethra, prostate, or urinary bladder. The epididymis is first attacked, and the inflammation spreads later to the testis. The commonest cause is Gonorrhoea. In *gonococcal epididymitis*, the tubules show catarrhal changes and are invaded by leucocytes. The tubules may dilate and form abscesses. *Traumatic epididymitis* is characterized by serous and cellular exudation, which is often haemorrhagic. Orchitis may result also from infection by way of the blood-vessels, in pyaemia, parotitis, small-pox, scarlet fever, typhoid fever, and syphilis. The usual exciting agents are *streptococci*, and *staphylococci*. Foci of suppuration develop in the interstitial tissue, and also in the walls of the tubules. In epididymitis also the infective agent may be blood-borne.

Acute inflammations may resolve completely or go on to suppuration both in the tubules and in the interstitial tissue. Abscesses may open upon the skin surface and produce fungous protrusions. Suppuration usually results in formation of dense scar-tissue. White streaks and areas of fibrous tissue traverse the testis, or nodular thickening of epididymis and testis develop. Retention cysts may form both in epididymis and testis—*galactocoele* and *spermatocele*—these terms being applied according as the cysts contain a fluid like milk, or like spermatic fluid. The cysts in the epididymis may be of large size. The testis may atrophy. The vasa may become obliterated or cystic. In inflammations of the epididymis the tunica vaginalis is invariably affected; in orchitis it may escape, or at least be less severely involved.

Tuberculosis commonly attacks the testicle (Fig. 168). It is often localized to the epididymis, the testis being only slightly affected or not at all. This is due to the fact that the disease is usually part of a uro-genital tuberculosis, which, in extending, necessarily attacks the epididymis before reaching the testis. The disease generally commences in the lining membrane and walls of the tubules. On section, the epididymis contains loculi with caseous walls, and softened caseous contents. These loculi may be surrounded by tuberculous granulation tissue, or by fibrous scar-tissue. In **Generalized Tuberculosis** in boys, the testis is first attacked and grey tubercles develop; these soon increase in size, and coalesce, forming large yellow tubercles. The tubercles spread chiefly in the interstitial tissue, but also in the walls of the tubules.

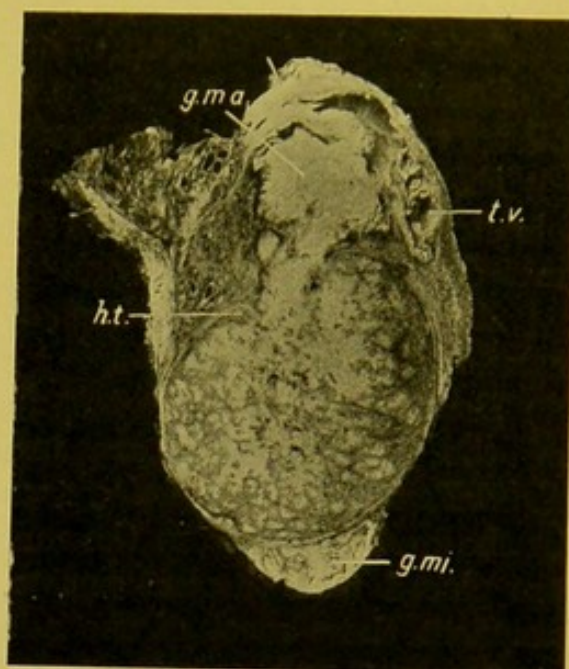


FIG. 168.—Tuberculosis of Testicle.
(\times circ. $\frac{3}{5}$.)

(*g.ma.*) Globus major of Epididymis, caseous; (*g.mi.*) globus minor, also caseating; (*t.v.*) tunica vaginalis testis, almost obliterated; (*ht.*) hilum testis, from which tubercles are invading the testis. (Mus. R.C.S. Edin.)

In contrast to tuberculosis, **Syphilis** tends to attack the testis rather than the epididymis. It may be affected in congenital syphilis, but typical **syphilitic orchitis** occurs especially in the later stages of the acquired form of the disease. Two main varieties can be distinguished—a *fibrous* and a *gummatous*.

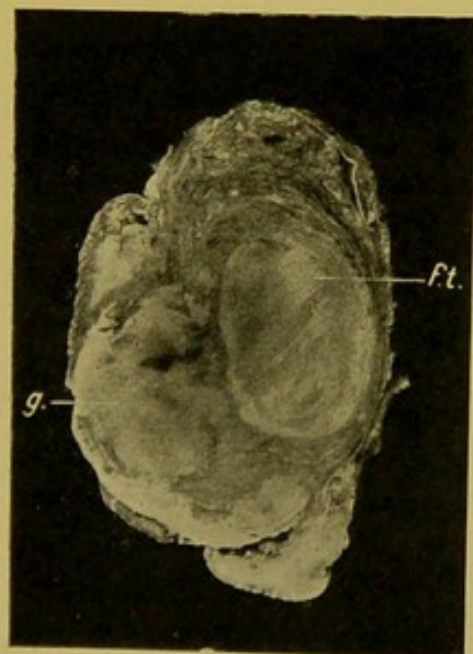


FIG. 169.—Syphilitic Testis.
(\times circ. $\frac{3}{5}$.)

(*f.t.*) Fibrous tissue in testis; (*g.*) gumma, protruding through an opening in the skin. (Mus. R.C.S. Edin.)

(a) In the former there is abundant development of white, dense, scar-like, fibrous connective tissue, which forms streaks and patches covering the cut surface, with intervening greyish testicular tissue (Fig. 169, *f.t.*). The organ is usually smaller than normal and of firm consistence. (b) Gummata appear as firm, yellowish, caseous masses, with irregular projecting angles at the periphery, embedded in firm pearly fibrous connective tissue, in which, microscopically, cellular infiltration and thickened arteries—proliferative endarteritis—can be seen. The organ is enlarged. The tunica vaginalis may be obliterated. The gumma may break down, and a fungous protrusion—the sloughing

gumma—may project through an opening in the scrotum (Fig. 169, *g.*).

Occasionally one sees gummata at an earlier stage. They are then soft and of a dirty greyish-brown colour.

Leprosy and **actinomycosis** may attack the testicle.

Cysts of the testicle are unimportant, unless occurring in tumours.

Tumours of the testicle are comparatively rare. They may occur at all ages. Frequently they are mixed.

Fibroma, *myxoma*, *myoma*—particularly *rhabdomyoma*, which may completely replace the testis—are very rare. *Chondroma* usually occurs as a mixed tumour. Supra-renal “rests” may be found in the epididymis.

Adenoma and *Cystadenoma* are usually mixed tumours, containing cartilage, muscle fibres, etc.

Dermoid Cysts of the testis are rare as compared with similar tumours of the ovary. They are usually of comparatively simple structure. *Solid Teratomata*, on the contrary, occur more frequently in the testis than in the ovary, and from the multiplicity of tissues that they contain, they are placed with the **embryomata**. Some authorities, e.g. Wilms, include amongst these most of the mixed tumours of the testis.

Sarcomata are mostly mixed tumours, but *round-celled* and *spindle-celled sarcomata* may occur. The latter are tough, often nodular on the surface, and may contain giant-cells and striped muscle fibres. *Angiosarcoma*, *fibro-sarcoma*, and *melanotic sarcoma* may occur. They may be cystic.

Carcinomata may be solid or cystic. The solid forms are usually soft, uniform, greyish or yellowish, and bulge on the cut surface. They are most often of *encephaloid* type, small-celled, and consequently with difficulty distinguished from round-celled sarcoma.

Tumours with the structure of *Chorionepithelioma* have been found in the testis, developing probably from foetal inclusions.

TUNICA VAGINALIS TESTIS

Hydrocele.—In *acute* cases the fluid is clear, serous, and may contain some leucocytes and red blood corpuscles. In *chronic* hydrocele the fluid is clear, straw-coloured, rich in albumen and fibrinogen; leucocytes are scanty. The tunica may be thinner than normal. In very chronic cases the walls are greatly indurated and thickened, and sometimes of cartilaginous density. Calcification may occur.

Haematocoele.—Haemorrhage may take place into a hydrocele, or may occur independently of hydrocele, arising from injury, or in the haemorrhagic diatheses. The contents may be of a chocolate colour.

Suppuration in the tunica vaginalis in most cases follows suppuration of the epididymis or testis. Less commonly it is haematogenous. The same applies to **Tuberculosis** of the tunica. In both diseases sinuses may form to the skin surface.

SPERMATIC CORD, VASA DEFERENTIA, AND SEMINAL VESICLES

The seminal vesicles may be absent on one or both sides, or may be fused together. Unilateral atrophy follows atrophy of the corresponding testicle; in one case of this kind I examined, the prostate did not share in the atrophy.

Inflammations of the vesicles (**Spermatocystitis**), and of the vasa deferentia are of rare occurrence; they may be *catarrhal*, *purulent*, *caseous*, and, in the vesicles, *haemorrhagic*. The inflammation usually spreads from the urethra or from the epididymis. The commonest cause is gonorrhoea. **Strictures** may develop in the vasa so that cystic dilatation of the epididymis may result; in spermatocystitis, the vesicles may be extremely distended with pus. If of tuberculous nature—also usually an extension from other parts of the genito-urinary system—tubercles develop in the inner layers of the mucous membrane, increase in size, coalesce, and caseate. The lumen becomes filled and distended with caseous material cast off from the surface. The process extends deeply into the wall, which becomes greatly thickened from formation of dense fibrous tissue in its outer coats.

The **spermatic cord** may show great **oedema**; or its veins may be dilated and varicose—**varicocele**. This disease is commonest in early adult life and affects chiefly the left spermatic vein.

THE MAMMARY GLANDS

Malformations.—Rarely one mamma, most often the right, may be absent. The nipple or the whole breast may be abnormally small.

Increase in the number of the nipples—**polythelia**—or of the mammae—**polymastia**—is sometimes seen. Supernumerary nipples may be situated upon a single mamma, or be connected with accessory mammae. Accessory mammae, which may secrete milk, may occur to the outer side of and above the normal gland, or to the inner side and below it, the latter situation being the commoner. They may develop at a distance from the mammae, e.g. in the axilla, upon the back, on the thigh, and even on the labium majus. The condition is met with in both sexes, and is explained as a reversion to ancestral conditions. Tumours may develop in accessory mammae,—*adenoma* or *carcinoma*.

Hypertrophy.—In lactation the mammae may undergo extreme hypertrophy; they usually return to the normal size on cessation of lactation. A more important condition is **Diffuse Hypertrophy**, which is seen occasionally in young girls about puberty. It is due to a diffuse fibrous overgrowth, or to an increase of the glandular tissue; the subcutaneous fat may disappear. Enlargement of the mammae may be due to hyperplasia of the fatty tissue. Enlargement of the male breast, usually bilateral,—and sometimes accompanied by anomalies of the genital apparatus, e.g. atrophy of the testes,—is termed **Gynecomastia**.

Inflammation.—Inflammation of the **nipple** is often associated with crevices and small ulcers on the surface; inflammation of the **areola** commences in the sebaceous glands. These inflammations may go on to local abscess-formation, or may extend down the ducts to the breast itself.

Inflammation of the Mamma almost always follows inflammation of the nipple or results from infection by way of the ducts. In rare instances the infective agent is blood-borne, e.g. in pyaemia occurring during the puerperium.

(1) **Acute parenchymatous mastitis** occurs usually in connexion with lactation, though a form of it may occur in infancy, or about the time of the first menstruation. In these cases suppuration rarely follows.

The ordinary form may especially affect the ducts, or attack individual lobules, chiefly those in the outer and lower quadrant of the mamma. At a later stage it may become diffuse, affecting the whole gland and interstitial tissue. The inflammation may resolve, or go on to suppuration. Numerous small abscesses develop, which tend to coalesce. The pus may burrow in various directions, even to the pleura. Fistulae may form to the skin surface. They may communicate with the milk ducts and give rise to *milk fistulae*. The actual infective agents are most often *staphylococci*.

Acute interstitial mastitis is most often caused by *streptococci*. The infection passes from the nipple to the lymphatics outside the ducts, and thence to the deeper interglandular tissues. These become oedematous and infiltrated with cells. The gland may be affected secondarily. The inflammation may resolve or go on to suppuration and wide destruction of the gland. The abscess may extend to the subcutaneous tissue in front of the mamma, or to the tissues behind the mamma, between it and the muscles—retro-mammary abscess. It may rupture on the skin surface or into a duct (rare); milk fistulae may form; general sepsis or chronic mastitis may result.

In **Chronic Mastitis** indurative changes occur, as a rule, in small sections of the mamma, but frequently the whole mamma is involved. It may lead to shrinking and atrophy of the individual lobules, or of the whole mamma. Sometimes the indurated mamma increases in size. Chronic mastitis is often associated with formation of cysts, sometimes small and sometimes large, often multiple, the contents of which may be watery, mucous, creamy, butter-like, or cheesy. Under the microscope fibrous tissue replaces the interlobular fat, and surrounds and separates individual lobules, the original nature of which is indicated by the presence of ducts. Some fat cells still persist in the midst of the new fibrous tissue. Various forms of tumour may develop in these shrunken mammae—*adenoma*, *carcinoma*, or *sarcoma*.

Actinomycosis may attack the mamma, sometimes extending from an infection of the lung and pleura.

Tuberculosis is not commonly found to attack the mamma. Single or multiple, small or large foci may form in the connective tissue round the terminal ducts. These go on to caseation and softening. The nodules may simulate tumour-formation. Fistulae may form as in other forms of mastitis. In more deeply situated forms, one should look for caries of the ribs, or tuberculosis of the axillary glands.

In **Syphilis** primary chancres and secondary lesions are not uncommon. The nipples and areolae and the skin surfaces under pendulous breasts are principally affected. Gummata also occur in the mammae, both in congenital and acquired syphilis. Syphilitic lesions may simulate those of tuberculosis and carcinoma.

TUMOURS OF THE MAMMA.

Tumours consisting of the connective tissues alone are infrequently encountered—*fibroma*, *myxoma*, *myoma*, *haemangioma*, *chondroma*, or *osteoma*.

Fibromata may be single or multiple (see Fig. 206, p. 422). Occasionally tumours composed apparently solely of fibrous tissue reach the size of the adult head. They are distinctly encapsulated. Pieces should be taken from several parts of such tumours for microscopic examination, so as to exclude the possibility of their being of sarcomatous nature. Pure **Myxomata** are very rare; they may be pedunculated. **Chondromata** are of slow growth, and usually are mixed tumours, containing sarcomatous or bony elements. **Angiomata** may be present at birth, or appear soon afterwards; they develop in the fibrous stroma, or in the fat.

Sarcomata, excluding sarcomatous transformations of other tumours, are rare, forming about 2 per cent. of all tumours of the mamma (Rodman). The majority of those in the Museum of the Royal College of Surgeons, Edinburgh, are **Spindle-celled Sarcomata**. These are usually circumscribed tumours but without distinct encapsulation, soft, bulging on the cut surface, pink or greyish in colour, and show a delicate fasciculation. They may reach a large size, and occur in both sexes. **Round-celled sarcomata** are usually of large size, soft, degenerating, and fungating. **Mixed-celled Sarcomata** are very rare; the only one I have examined was of the size of a duck's egg, and its naked-eye characters resembled those of the spindle-celled sarcomata. **Melanotic tumours** are rare. They may exist for many years without troubling the patient, and then enlarge rapidly. They show a great tendency to recur, nodules developing throughout the mamma and invading the underlying muscle. It is often difficult in the case of the mamma to determine whether pigmented tumours are sarcomatous or carcinomatous. **Giant-celled Sarcomata** are extremely rare. Fibro-adenomata may undergo sarcomatous transformation with disappearance of their epithelial cells.

Fibro-epithelial Tumours.—Pure **Adenomata**, in which the glandular tissue predominates, are very rare; the Museum of the Royal College of Surgeons of Edinburgh possesses only one example. They may be small or reach the size of a large duck's egg. They are encapsulated; the nipple and skin can be moved freely over them. The cut surface shows delicate branching lines of fibrous tissue, enclosing the soft greyish or pinkish glandular tissue. Microscopically, they are composed of closely-set tubules,

Round
degenerating
fungating
mixed

Melanotic
Benign
sclerosing

Giant

lined with columnar epithelium, and separated from each other by a small amount of fibrous connective tissue.

Fibro-adenomata are more common. There are two main types, (1) the *pericanalicular*, and (2) the *intracanalicular*.

In both forms the tumour is rounded or oval, rarely larger than a hen's egg; firm, distinctly encapsulated and apparently unconnected with mammary gland. They develop usually in the fourth decade of life, though they may occur earlier in life. They are situated superficially in the mamma, rarely deeply. Both mammae may be affected. On section, the *pericanalicular* adenoma presents the general characters of a fibroma, with, in addition, numerous raised whiter points, corresponding to the glandular parts; the *intracanalicular adenoma*, at the first glance, closely resembles the fibroma, but on stretching the cut surface, numerous fine branching fissures appear, round which the connective tissue is arranged.

Microscopically, the *pericanalicular adenoma* consists of fibrous tissue arranged in thick bands, encircling tubules lined with columnar epithelium; in the immediate vicinity of the tubules the fibrous tissue is of loose texture and may be myxomatous; the *intracanalicular adenoma* consists at base of spaces lined with cubical epithelium, and surrounded by fibrous tissue. From this, papillary or polypoid or branching leaf-like processes grow into the space, pushing in before them the epithelial lining, so that the cavity becomes extremely irregular, the surfaces apposed, and it looks like a branching narrow band of closely set, small, epithelial cells, with at parts interspaces, representing the original lumen. The ingrowths are invariably of looser texture than the surrounding fibrous tissue, and are frequently myxomatous—fibro-myxo-adenoma—or even sarcomatous.

Cysts.—I have already referred to the cystic changes in chronic mastitis (p. 342). In rare cases one or both mammae become converted into a mass of small cysts, which give a nodular aspect to the mamma (Reclus). Occasionally the cysts are larger. Some regard this condition as an extreme development of cysts in connexion with chronic interstitial mastitis, while others regard it as a new-growth—**polycystoma**. Similar appearances develop in the course of involution of the active gland—**Involution, Retention, cysts**. They are usually of the size of peas, and contain serous or gelatinous material of a brownish or greenish colour, or they contain milky or caseous material. Large single cysts caused by obstruction to the escape of milk are called **Galactoceles**—milk-cysts or butter-cysts. **Haemorrhagic Cysts** are rare. They may have smooth walls, outside which is a layer of vascular young connective tissue, which, in parts, extends to the inner surface, and gives rise to the haemorrhage. In other cases haemorrhage into retention cysts is caused by mechanical injury.

Cystic New-growths also occur—**Cystomata**. Of these the **Dermoid cyst** is extremely rare. Retention cysts may develop as a result of the formation of papillomata in the ducts—**Duct papillomata**. The ingrowths are vas-

cular, and bleed readily into the cyst, so that a brownish fluid escapes through the ducts. These cysts are situated immediately under the nipple. They may be accompanied by chronic mastitis. Related to these is the **Papillary Cystadenoma**, or **papilliferous cyst**, in which the papillary processes fill the cyst. They closely resemble the papillary cystadenoma of the ovary.

Malignant Epithelial Tumours.—These may be preceded by **Paget's Disease of the Nipple**. In this disease the patient, usually between forty and sixty years of age, suffers, during many years, from eczema of the nipple and areola. This may at last lead to a mushroom-like swelling of the nipple. The surface is irregular, nodular, congested, moist and excoriated—*papillary dermatitis*. The change may extend to the skin outside the areola. Later the nipple becomes ulcerated, the ulcer having the characters of **squamous epithelioma**. Microscopically, in the earlier stages, in addition to signs of chronic inflammation of the corium and infiltration and vacuolation of the epithelium ("Paget cells"), the deepest layers of the epithelium—particularly of that lining the orifices of the ducts—proliferate, with formation of irregular, polymorphic, deeply staining cells. These come to form a layer which separates the superficial epithelium, which is then cast off. The condition is not easily recognized as cancerous in the early stages. The new-growth spreads down the ducts into the mamma. I have seen Paget's disease associated with a scirrhous of the mamma.

The commonest tumour of the mamma is the **Scirrhous Cancer**, which some regard as an atrophying stage of the Encephaloid cancer. **Scirrhous** may involve the part of the mamma immediately subjacent to the nipple, or it may be situated farther out in the breast. It extends along the ducts, causing retraction of the nipple—unless a cyst in the duct region keeps this projected—and also extends to the skin along the suspensory ligaments of Cooper, which retract, causing dimpling of the surface. The skin may be widely infiltrated and thickened, and this malignant infiltration along with the firm oedema brought about by the obstruction of the lymphatics by the spread of the growth into them, causes the condition known as "**cuirass cancer**." The skin may show nodular excrescences. On section, the main growth is to the naked eye circumscribed, very hard, "stony," and creaks on being cut. The cut surface is pale greyish-pink and presents white and yellowish points in the central part, corresponding to collections of epithelial cells which are degenerating. This appearance is usually compared to that of the cut surface of an unripe pear. Scirrhous may also develop in the male breast.

Microscopically, the fibrous tissue forms a close network, the meshes of which contain more or less degenerated, angular cells. At the growing margin of the tumour the meshes are larger and the cells contained are more distinct, polygonal, and stain better, so that this part may resemble portions of some encephaloid cancers.

Encephaloid, Medullary, Cancer.—The growth is usually of larger size

than the scirrhous ; soft, greyish, or greyish-pink ; it bulges on section, and shows a delicate stroma on the surface. It may project under or through the skin ; it may ulcerate and fungate. Microscopically, a fine, wide-meshed stroma is filled with small or large epithelial cells, many of which show mitoses. These cells are rounded or polygonal from mutual pressure. Necrosis of the central cells is very common.

Spheroidal-celled tumours in which the proportion of stroma and cells is almost equal are sometimes called "**Simple cancers.**"

I have seen one mammary tumour which seemed to correspond to **Billroth's Myeloid Alveolar Carcinoma**. It was situated under the nipple ; of the size of a duck's egg ; ulcerated on the surface. Microscopically, the firmer parts showed well the characters of a duct cancer (*see below*), but the softer parts were composed of very large and numerous multinucleated epithelial cells, lying amongst large mononucleated cells which varied in shape and size. There was no intercellular substance.

Colloid Cancer (syn. : Mucoid cancer).—The tumour may be localized or infiltrate the mamma widely. The degenerated parts are soft, greyish, translucent. The microscopical characters correspond with those of colloid cancer of the stomach (*q.v.* p. 192).

A tumour to which the unfortunate name **Duct Cancer** is still sometimes applied is a somewhat rare, slowly growing tumour, less malignant than the ordinary mammary cancers. It begins in the duct region, and extends thence, pushing up the nipple and areola, over which there may be ulceration. It is seldom larger than a walnut, and is usually circumscribed. It may become pedunculated. Microscopically, it is acinous, composed of large tubules and spaces, lined with columnar cells, which are undergoing great hyperplasia, so that the epithelium projects into the spaces in papillae and irregularly branching or convoluted columns. It always, in some part, preserves its tubular arrangement. These appearances are very characteristic. This tumour corresponds to the **Adeno-carcinoma** of **Halsted**. It does not involve the axillary glands. It may be pedunculated.

Dissemination of Mammary Cancer.—The lymphatics of the breast drain chiefly into the deep fascial (retro-mammary, or pectoral) lymphatic plexus, and thence indirectly into the axillary glands. As soon as the lymphatic glands are obstructed, a reflux lymph-stream must pass across the middle line to the opposite axillary glands, upwards to the cervical and downwards to the inguinal glands. Other lymphatics follow the perforating branches of the internal mammary artery, and empty into the glands of the anterior mediastinum, and others follow the intercostals towards the spine. Lymphatics also pass upwards over the clavicle to the supra-clavicular glands. Other lymphatics perforate the pectoralis major and run in the fascia on its deep surface to open into the glands at the apex of the axilla. Free anastomosis exists between the intra-mammary lymphatics and those of the subcutaneous tissue and skin, the anastomosis

taking place through the medium of the ligaments of Cooper and the peripheral processes of the corpus mammae, which become continuous with the inter-lobular septa of the fatty superficial fascia. From the deep fascia, invasion extends downwards in the sheath of the rectus, down the lymphatics permeating the muscle, along those of the suspensory ligament, and along those under the peritoneum. Hence the abdominal organs may be secondarily affected in mammary cancer, as well as the pleurae, the mediastinal glands and the opposite axillary glands (Stiles and Handley).

CHAPTER XVI

LYMPHATIC GLANDS AND BONE MARROW

LYMPHATIC GLANDS

Simple Atrophy occurs in old age and in the advanced stages of wasting diseases. The glands may disappear, e.g. in the mesentery, or may be replaced by fibrous connective tissue or by fat. The lymph follicles in the mucous membranes also share in the atrophy. In **Waxy Degeneration**, the glands become enlarged, firm, grey and translucent; microscopically, the reticulum, trabeculae, and blood-vessels are especially affected. The causes may be similar to those of waxy degeneration in other tissues, or *local* waxy degeneration may occur in glands draining an area in which there is chronic tuberculosis or chronic suppuration. **Hyaline degeneration** may occur in the glands in tuberculosis.

Pigmentation.—The sinuses of lymphatic glands in the neighbourhood of haemorrhages become filled with red blood corpuscles, both free and contained within endothelial cells. The haemosiderin found in later stages occupies the same position as that taken by other pigments, including carbon, i.e. in the endothelial cells within the sinuses and lining their walls, and in the follicles and reticulum. Excess of pigment leads to development of fibrous connective tissue, and this results in induration and shrinking.

Acute Inflammation—Lymphadenitis.—The most common cause is the action of bacteria and their toxins. The gland swells up; on section it is soft and moist. It becomes of a greyish-pink to a dark-red colour. The vessels are greatly dilated and inflammatory exudate collects in the sinuses. Later it assumes a general greyish colour, and minute more opaque points of *necrosis* may appear, or *suppuration* may result with formation of yellowish-white or greenish-yellow softened foci. The surrounding tissue is oedematous and infiltrated. The exudate within the sinuses is at first fluid, but soon proliferation and catarrh of the endothelial cells lining the sinuses set in. Many of these cells are phagocytic. In addition, the sinuses contain red blood corpuscles, polymorphs and lymphocytes. In very intense inflammation, e.g. in *anthrax*, the exudate is fibrinous or haemorrhagic.

In suppurative lymphadenitis, the pus may break through the capsule of the gland.

Chronic Inflammation results from the slow action of bacteria such as the tubercle bacillus; or in syphilis; or from the irritation of dust or siliceous

particles. The gland becomes enlarged and indurated as a result of the formation of dense fibrous tissue, which replaces the parenchyma. In **Tuberculosis**, grey tubercles form firstly in the follicles and in the septa. If the action proceed slowly, there is great proliferation of the endothelial and endothelioid cells, and at a later stage giant-cells usually make their appearance. The lymphoid tissue is displaced and as a rule caseation takes place. The caseous foci coalesce and at last the whole gland may be converted into a cheesy mass. In some cases the progress is very slow, with excessive large-celled proliferation, which replaces to a great extent the lymphoid tissue. This condition may persist for many years without going on to caseation—twenty-eight years in one case I examined. The *Cervical* glands are **infected** by way of the tonsils or pharyngeal tonsils, with or without local ulceration or caseation. The *Bronchial* glands are occasionally involved by extension from the cervical glands, but more commonly the infective agent gains access through the bronchial walls, or the gland tuberculosis is secondary to tuberculosis of the lungs, or to tuberculosis of the abdominal glands. The *Mesenteric* glands may be affected in tuberculous ulceration of the intestine, or the organisms may pass to these glands through the wall of the intestine, without causing any lesion in the Peyer's patches, or extension may take place to the abdominal glands from the thoracic glands. Tuberculosis of glands in other situations may be secondary to tuberculosis of the skin.

The increased density of the "indolent" or "hard" bubo of **Syphilis** is due essentially to great accumulation of lymphocytes within the gland, though sometimes it is caused by a large-celled hyperplasia, such as occurs sometimes in chronic tuberculous lymphadenitis. The density may persist, but usually it disappears gradually. Occasionally gummatous caseation is seen in lymphatic glands.

Lymphadenoma (Hodgkin's Disease).—The changes in the lymphatic glands are in all essentials similar to those occurring in the spleen (*q.v.*, p. 272). Caseation does not occur, but streaks of fatty degeneration are usually seen on the cut surface. In the abdomen, the enlarged glands may form a nodular mass in front of the vertebrae, measuring $2\frac{1}{2}$ to 3 in. in thickness. In some cases of lymphadenoma the glands are not greatly enlarged. Tuberculosis may accompany lymphadenoma.

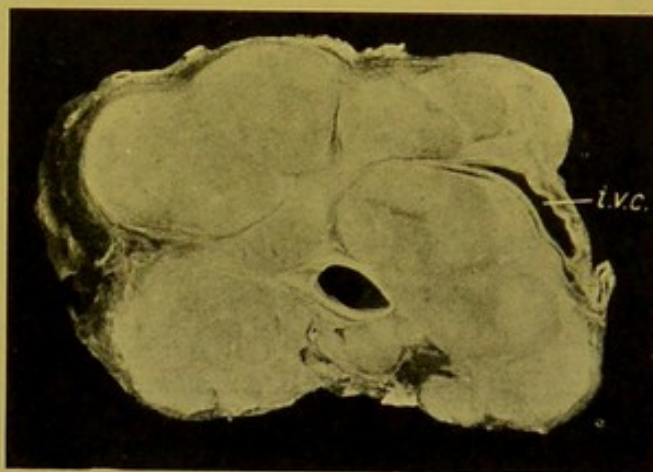


FIG. 170.—Lymphadenoma. Enlarged pre-vertebral glands. (\times circ. $\frac{1}{2}$.)
(i.v.c.) Inferior vena cava. The other vessel in the middle line is the aorta.

Leucocythaemia.—Enlargement, caused by accumulation of leucocytes within the glands, occurs especially in the lymphatic variety of the disease, but it may also occur in the spleno-medullary form. In the former, I have seen abdominal glands of the size of a duck's egg. The glands are softened, of a grey or greyish-pink colour on section, with occasional small haemorrhagic areas. The substance wells up when cut across. Tuberculosis may also accompany leucocythaemia.

Tumours of lymphatic glands. The common primary tumour is *Lymphosarcoma*, which usually attacks the mediastinal or retro-peritoneal glands. The growth soon breaks through the capsule and infiltrates the neighbouring tissues; in the thorax, extending into the lungs along the vessels and bronchi (see Fig. 8, p. 40), and in the abdomen causing great thickening of the mesentery, and involving most of the glands in the cavity.

Endothelioma may also occur.

In *Chloroma*, the microscopical appearances are very similar to those of lymphosarcoma. To the naked eye, the enlarged glands may have a greenish hue.

In *Secondary Carcinoma* involving glands, the peripheral sinuses are usually first affected.

Animal Parasites.—*Trichina* embryos; *hydatids*; adult *filariae*, coiled up in the dilated sinuses.

THE BONE MARROW

Method of Removal and Examination.—The bones usually examined are the ribs and one of the long bones of the extremities. It is not safe to rely upon the appearances presented by the marrow within the short bones of the digits, as the changes may not correspond to those occurring in the bone marrow of the long bones. If the cavities of the thorax and abdomen are fully opened up, a thin slice may be removed from the anterior part of the bodies of the vertebrae in order to demonstrate the changes occurring in cancellous bone.

The Ribs.—A rib is isolated and divided with bone-forceps about four inches behind the costo-chondral articulation. It is then compressed with the bone-forceps so as to squeeze out the marrow from the cut end. The drop of marrow is allowed to fall on to a small piece of paper, which passes with it through the fixing and hardening and embedding processes (Muir). The best fixative is a saturated solution of corrosive sublimate. A solution of formalin in absolute alcohol—1 part of the former to 9 parts of the latter—also gives good results. At the same time thin films should be made upon glass slides or upon thin cover glasses, and without drying, plunged into the corrosive sublimate solution. After fixation they may be preserved in methylated spirit, but to give the best results they should be stained within twenty-four hours. The stains commonly employed are eosin and methylene blue; eosin and haematein or haematoxylin (see Appendix).

The Long Bones—Humerus or Femur.—In adults the red marrow is confined to the cancellous tissue at the ends of the long bones, and the shaft is filled with yellow fatty marrow. In the latter part reactive and other changes are best demonstrated. The part removed should be the upper half of the shaft, and, if there be no contra-indication, it is advantageous to remove as well the head of the bone. Such a preparation when split up shows to the best advantage the

changes both in the cancellous bone and in the shaft. Usually, however, the femur is cut across just below the trochanter minor.

The Humerus.—Working from the incision already made for the removal of the thoracic organs, the operator dissects the head of the humerus free from its capsule and the surrounding muscles. It is then pushed upwards and the soft parts cleared away from the shaft, which is divided about its mid-point.

The Femur.—An incision is made over the upper half of the bone and the soft parts cleared away from the bone. It is then sawn through about its mid-point. The upper portion is pulled forwards into the wound, and its remaining attachments separated as far up as the neck. The bone is then cut across below the trochanter minor.

A further useful procedure is to scoop out, with a straight bistoury, a cylinder of marrow from the portion of the shaft remaining in the body. This can be used for making films, and should then be placed in a fixing solution (*see above*).

The portion of bone removed may be sawn up longitudinally, or split up, so as to demonstrate the state of the marrow; or it may be placed for twenty-four hours—not longer—in formalin solution (*see Appendix*) before being split up. The halves of the bone are placed in formalin fixing fluid, if it be desired to preserve the colour; and, if not, the marrow is scooped out and placed in the fixing fluids already mentioned—corrosive sublimate or Formalin-Alcohol.

Films prepared as described are required to demonstrate in a clear manner the characters of the cells of the marrow. If fixing media be not available when the films are made, these may be allowed to dry slowly in the air. As soon as possible they should be fixed in formalin vapour or in pure methylic alcohol (acetone-free). They may then be stained with eosin and methylene blue, or by Leishman's method. To demonstrate the erythroblasts and erythrocytes (red blood corpuscles), however, it is almost essential to use alcoholic eosin, so one must not expect to obtain such fully informative preparations when Leishman's method is used.

The marrow may be removed by a simpler method. After exposing the shaft of the bone, this is split up longitudinally with a broad carpenters' chisel, the marrow scooped out and the portions of bone replaced in position.

To make good the loss of a portion of the shaft, a piece of wood (e.g. broom-handle), about 2 inches longer than the bone removed, is prepared, and the ends cut into the form of a narrow-angled cone with blunt apex. A hollow is scooped out in the upper portion of the bone, and the piece of wood driven up into it until it holds firmly; then, tilting up the part of the shaft remaining below, the lower end of the stick is inserted into the medullary cavity, into which it is forced when the limb is straightened. This procedure is usually sufficient to restore the rigidity of the limb.

Appearances of the Bone Marrow.—The rib marrow, and that in the cancellous ends of the long bones, is "red"—functionating; the marrow in the shafts of the long bones—except in very young children—is "yellow," "resting," practically non-functionating marrow. When the marrow is called on to furnish an increased supply of red and white blood corpuscles to the blood, the red marrow is unable to cope with the demand, and the yellow marrow assists it. It does this by undergoing transformation into red marrow; in other words, the yellow marrow "reacts." Hence, the changes occurring in the yellow marrow, seeing that all stages of the transformation can be demonstrated, are more distinctive, and less difficult to

explain than those occurring in the marrow of cancellous bones and in rib marrow, in which, to a great extent, they represent an intensification of changes going on under normal conditions.

Excluding degenerative and pigmentary changes, there are only two outstanding varieties of transformation in the reacting marrow. These are : (1) the leucoblastic, and (2) the erythroblastic.

(1) The **leucoblastic reaction** is that commonly occurring during the course of acute infective conditions, and in the earlier stages of toxæmias. It also generally precedes an erythroblastic reaction, and this for two reasons : firstly, because after large *haemorrhages* the leucocytes are restored very rapidly ; and secondly, because the destruction of red blood corpuscles which renders necessary the erythroblastic reaction, and which brings about the clinical picture of a *severe anaemia*, can only be caused by the action of a toxin, to which the first response of the marrow is a leucoblastic reaction.

The yellow marrow becomes replaced by active, red—more correctly “pink”—marrow. The transformation advances from the ends of the shaft towards the centre, and from the peripheral layers, inwards (Pl. II, Fig. 1). In long continued infections the whole marrow may be transformed. In recovery, the marrow resumes its resting, non-functionating character. If the infection or toxin be not overcome, the transformed marrow becomes “exhausted” ; it becomes brownish in colour, and may become somewhat translucent from gelatinous degeneration ; or an erythroblastic reaction may become evident, in which a deeper, more uniform red colour replaces the pink of the leucoblastic marrow. Further, in late stages the bony trabeculae traversing the peripheral layers of the marrow tend to undergo absorption.

Microscopical Characters.—In leucoblastic marrow the vessels are dilated, and round about them the number of the myelocytes is greatly increased. These are large more or less rounded cells, with granular protoplasm, the granules corresponding in their staining reactions to those characterizing the different varieties of leucocytes. They have large oval nuclei, which stain faintly with methylene blue and other basic stains. In addition, fully developed leucocytes are numerous and also clusters of normoblasts close to the vessels, with excentric, pyknotic nuclei, and homogeneous protoplasm, staining deeply with alcoholic eosin. Fully developed red blood corpuscles are seen in large numbers.

The extreme conditions occurring in the marrow in the *leucocythaemias*, particularly the spleno-medullary variety, may be looked on as evidence of excessive leucoblastic reaction, in which the marrow not only resumes its active character, but reverts to a more primitive condition. The changes must develop in response to some toxæmia, the nature of which is still obscure.

In *Myelogenous Leucocythaemia*, the myelocytes, and their mother-cells,

"myeloblasts,"—of smaller size, and with some difficulty distinguished from lymphocytes and from normoblasts,—crowd the marrow, rendering the other cells less conspicuous. The marrow is of a greyish-pink, patchy colour (lymphoid), and may be brownish from pigmentation (see Pl. II, Fig. 5). In one case of this disease I found the outer layers of the femoral marrow of a slightly greenish colour.

In *Lymphatic Leucocythaemia* (see Pl. II, Fig. 6), in which the marrow is densely infiltrated with cells of the lymphocyte class, the appearance of the marrow may vary greatly. It may resemble an ordinary reacting leucoblastic marrow, the reacting parts being however of a lighter, greyer colour; the change may be more uniform, and of a distinctly grey colour, or of a greyish-yellow colour, like that of pus; whence the name "pyoid marrow" applied to it. In some cases whitish nodules are seen in the midst of the altered marrow, representing tumour-like aggregations of cells. In chloroma, which occupies a position intermediate between lymphatic leucocythaemia and sarcomatous new-growth, I have found the whole marrow of a dirty, greyish-green colour (see Pl. II, Fig. 3). The case was that of a young boy. In a case in an adult male, the microscopical characters of which corresponded to those found in chloroma, the femoral marrow was semi-translucent, dark reddish-brown, with brighter red patches, and embedded in it were numerous pale greyish-yellow tumour-like nodules. The brown colour was due to deposit of haematogenous pigment; there was some erythroblastic reaction, and some commencing gelatinous degeneration.

(2) The **erythroblastic reaction** occurs especially when there has been great destruction or loss of red blood corpuscles. It is characterized by a more distinctly red or purplish-red transformation of the yellow marrow (see Pl. II, Fig. 2). In late stages it becomes brownish from deposit of altered pigment derived from the broken-down red blood corpuscles. In extreme cases, e.g. in pernicious anaemia, the marrow becomes more fluid than the leucoblastic marrow, and the bony trabeculae are almost completely absorbed, so that the inner surface of the shaft becomes more or less smooth, and a cylinder of altered marrow can be easily removed. As already explained, the changes occurring in very chronic septicaemias come to resemble very closely those occurring in the more severe anaemias, and the reasons for this have also been given.

In **Leucopenia**, reaction may be practically non-existent, or slight and imperfect; or the marrow is of a darker yellow colour than normal marrow, with a greyish tint, and translucent (see Pl. II, Fig. 4). This is the *gelatinous degeneration* of the marrow which is seen typically in old age. In old age, and in some other analogous conditions, the fat in the rib marrow may be increased in amount. Microscopically, gelatinous degeneration is shown by the deposit of streaky concentric lines of mucoid material in the periphery of the fat cells, gradually replacing these completely.

CHAPTER XVII

THE CENTRAL NERVOUS SYSTEM

In cases in which both brain and spinal cord are to be examined, the cord should be removed firstly, for then one can be sure of separating it from the medulla by an accurately transverse cut, and thus preserving the upper segments of the cord in a suitable condition for subsequently investigating degenerations of tracts, if this be required.

THE SPINAL CORD

Anatomical.—In the adult, the spinal cord occupies the upper two-thirds of the vertebral canal, extending from the foramen magnum to the lower border of the body of the first lumbar vertebra, or the upper border of the second lumbar body, where it ends in the *filum terminale*. In the infant at birth, it extends as low as the body of the third lumbar vertebra.

The length of the cord in the adult varies from about 17 in. (43 cm.) in the female, to about 18 in. (45 cm.) in the male.

In the cervical region it is flattened from before backwards; in the dorsal region the transverse is only slightly greater than the antero-posterior diameter; whereas in the lumbar and sacral regions these diameters are practically equal, so that on cross-section the cord is rounded. The ganglia on the posterior roots lie within the inter-vertebral foramina, except in the sacral region, where they lie just within the vertebral canal. They are all outside the main sheath (*theca*) of the dura mater, though covered by extensions from it.

Removal of Spinal Cord.—The cord is usually removed from behind. In cases of exceptional importance, the vertebral canal may be opened up throughout its whole extent from occiput to coccyx; but in the majority of cases it is sufficient to expose the cord and the cauda equina as low as the level of the fourth lumbar spinous process. This corresponds to the point at which a line joining the highest points of the iliac crests would cross the middle line.

For the essentials of the method to be described I am indebted to the late Dr. Alexander Bruce, of Edinburgh. In order to make some of the details clear, the description has been somewhat elaborated.

Employing this method I have removed the cord as far down as the fourth lumbar vertebra in slightly under two minutes and a half from the first incision. Such rapidity is seldom necessary, and the operation is usually carried out more leisurely, particularly if the ganglia are to be removed in continuity with the cord.

The body is placed face downwards, with the head hanging over the end of the table, and steadied in that position by an assistant. A block is placed under the dorso-lumbar region so as to raise that part, and thus lessen the natural curves of the spine.

Standing on the right side of the body, facing the feet—i.e. with his right

side next to the body—the operator places his left hand flat upon the right posterior surface of the thorax of the body, and presses firmly outwards so as to drag the skin over towards that side. Then, keeping up the tension, and commencing over the sacrum, with one comprehensive and forcible sweep of the “cartilage” knife, he cuts down immediately to the proximal side of the spinous processes, simultaneously making the skin incision and clearing away the whole mass of the *erector spinae* from its attachments, as far out as the articular processes, and as far up as the occiput. In actual practice it will be found that when the knife has once penetrated to the bones, the results desired will be easily effected by holding it a little obliquely, both as regards the mesial plane of the body and the surface of the table, so that while the middle of the blade is making the skin incision, its belly and point are clearing the sides of the spinous processes and the laminae. One or two rapid additional touches may be required to clear the laminae sufficiently. A thin layer of muscle remains attached to the lateral aspects of the spinous processes.

Passing to the other side of the body a similar procedure is adopted, the knife, however, cutting from above downwards, the traction of the soft parts to this side in its turn enabling the original skin incision to be utilized.

In making these incisions in the soft parts one should note any extravasation of blood into the muscles, which generally indicates mechanical injury to soft parts or to spine, but which also may be produced by convulsive contractions of the muscles, for example, in tetanus. *Sarcomata*, developing in connexion with the vertebrae, may also be disclosed. These are rounded or lobulated, usually of a deep pink colour, approximating in depth of tint to that of the neighbouring muscle.

The laminae are next sawn through, beginning in the dorsal region.

The line which the saw cut follows depends on the varying width of the vertebral canal, narrowest in the upper dorsal regions, widest in the cervical and sacral regions, and of intermediate width in the lumbar region of the spine. The laminae should be divided just internal to the articular processes. This point is easily found in the *cervical* region, being indicated by a shallow groove at the outer end of the laminae. The saw-cut should incline slightly outwards. In the *dorsal* region, the articular processes are not easily felt from behind, and the saw-cut should be made at the deepest point of the lateral vertebral groove from which the *erector spinae* and its prolongations have been displaced, and in an almost vertical plane. In the *lumbar* region the articular processes are easily felt. The blade of the saw should rest against their inner surfaces, and the plane of the cut should be vertical, or may incline a little outwards. The laminae in this region are thicker than in other parts of the spine. If the sacral canal has to be opened, the saw should follow a line just internal to, or in the line of, the rudimentary articular processes of the sacral vertebrae; or if these be not sufficiently marked the saw-cuts should converge until, at the lower end of the sacrum, they are just half as far apart as they were at the lumbo-sacral articulation.

In all regions, the bone should be cut through completely, greatest care being taken in the dorsal region where the space existing between the cord (*dura*) and the wall of the vertebral canal is smaller than in the other regions of the canal. Cutting bone-forceps are used to divide the laminae of the upper cervical vertebrae.

The interspinous ligaments and ligamenta flava are now divided between two vertebrae in the mid-dorsal region. They may be separated with the cutting

bone-forceps, and the same instrument may be used to lever up the spinous processes immediately above.

The upper dorsal spinous processes are now grasped with lion-forceps, and if the operation has been carried out properly, the whole posterior wall of the upper part of the vertebral canal can be detached with a strong pull. If the laminae have not been sawn through completely, the cutting bone-forceps are used first on one side and then on the other, to complete the separation. A similar procedure lays bare the lower part of the spinal cord and cauda equina, within its sheath of dura mater.

The importance of a preliminary thorough use of the saw will be at once appreciated.

Before proceeding to remove the cord, all projecting spicules of bone should be removed with the cutting bone-forceps, with which also more access may be gained if necessary. The wider the opening the easier it is to remove the cord without injury.

The foregoing description applies to the normal and approximately normal spine. Difficulties are multiplied in pathological curvatures, particularly in lateral curvature and in pseudo-hypertrophic muscular paralysis, especially if there be a high degree of subcutaneous oedema. For such conditions, no definite rules of procedure can be given, and the operator has to apply the general principles indicated above, modified by his knowledge of the alterations in position and shape of the bones. For example, in lateral curvature, the plane in which the spinous processes lie will guide him in making the saw-cuts.

EXAMINATION OF THE VERTEBRAL COLUMN, AND THE CORD, *in situ*.

Normally, some loose, dark-coloured fat is found on the posterior surface of the dura, especially in the dorsal region, and a plexus of veins ramifies over this surface.

The Vertebral Column may show *abnormalities in shape*, e.g. lateral or antero-posterior curvatures or angling; or, *fracture-dislocations*, which are easily detected, evidence of their presence having been given already by the haemorrhagic infiltration of the muscles in the vicinity. The displacement of the vertebrae is not always evident on first examination, but abnormal mobility is revealed by careful manipulation.

The vertebral bodies may be the seat of *new-growth*; or *caries* or *periostitis* may develop, and pus, originating from such conditions, may penetrate the canal. When tuberculous caries of the bodies exists, tuberculous granulation tissue is frequently seen on the outer surface of the dura mater spinalis.

If *haemorrhage* has taken place into the canal, its source should, if possible, be determined.

Tumours may be found, as purplish-brown, soft, rounded masses, projecting into the canal, destroying or softening the bones, and compressing the cord to a greater or lesser extent. Hydatids of *Taenia echinococcus* are also occasionally found.

Dura Mater.—Normally, the dura mater is semi-translucent, though always thicker than that within the skull. It can be pinched up with dis-

secting forceps. If thickened it becomes more rigid and opaque. If pus be present beneath it, it may assume a yellowish or greyish-green colour; if blood, it may be dark purplish in colour. At parts, it may appear flattened, indicating possibly localized softening from myelitis or crushing. A more diffused flattening may indicate presence of syringomyelia.

Uniform, regular distension indicates meningitis; a localized smooth enlargement may point to presence of tumours, tuberculous or gummatous nodules, or localized syringomyelia, and is present in some cases of acute myelitis.

Removal of the Cord from the Vertebral Canal.—The cord is removed with least risk of injury, if retained within its dura mater.

A curved probe-pointed bistoury is passed *downwards* along each lateral aspect of the dura mater, so as to divide the nerve roots. Then one pinches up a fold of dura mater at its lower end with a trustworthy and strong pair of dissecting forceps, cuts it across along with the cauda equina and raises it out of the canal. Keeping up extension so as to avoid all bending and kinking of the cord, one now divides, with a to-and-fro movement of the knife, the loose connective tissue between the dura and the posterior common ligament.

The greatest difficulty will be experienced at the upper end of the canal, where the dura is fixed to the margin of the foramen magnum. If the connective tissue which attaches the dura somewhat firmly to the posterior common ligament in this situation be thoroughly divided, the attachment of the dura to the margin of the foramen magnum may, for the present purpose, be disregarded. With a sharp knife the dura with the cord contained is divided, transversely to the long axis of the body, just below the foramen magnum. This section passes through the uppermost cervical segment of the cord.

Any escape of pus, or other abnormal fluid, or excess of clear fluid escaping during removal of the cord should be noted. Normally, about half an ounce (15 c.cm.) of clear, limpid cerebro-spinal fluid escapes when the dura is opened in the lumbar region.

In this, the customary method of removal, most if not all of the spinal ganglia are usually left *in situ*. If the ganglia be required for subsequent investigation, for example, in conditions associated with vaso-motor circulatory disturbances or in ascending or descending degenerations, or for some other special purpose, they are best removed in continuity with the cord. This is assisted by the presence of the stout sheath-like prolongations of dura mater which cover the spinal nerves.

1. With a probe-pointed bistoury the ganglia may be dissected out from the intervertebral foramina without disturbing the bones further. If the transverse processes of the vertebrae are removed with the cutting bone-forceps, the dissection is rendered more easy.

2. They may be dissected out after removal of the spinal cord. In this case, tubes containing fixing solutions, into which the ganglia may be placed as removed, should be prepared and labelled beforehand so as to prevent confusion.

3. In cases in which accurate localization of lesions in the lumbar cord and conus medullaris is essential, it is advisable to open up the vertebral canal completely, and dissect out the dura mater complete along with the lower nerve roots which lie outside of it, and in continuity with their ganglia. On subsequently slitting up the dura, the individual lumbar and sacral roots can be followed up to the corresponding segments of the cord, with which they should be kept in direct continuity until the limits of these segments are accurately defined.

After removing the cord, it is placed on its anterior surface upon a *flat* support, and the dura slit up along the middle line posteriorly by means of small-bladed scissors. These should be inserted more or less parallel to the surface of the cord, so as to avoid cutting into it. While carrying out this procedure, one should note the presence of thickening of the dura—hypertrophic pachymeningitis; of subdural pus, or blood; of adhesions of dura to arachnoid; of opaque, cartilaginous-like or bony plates in the arachnoid (Fig. 171); of sub-arachnoid infiltration with pus; or of intradural tumours (see Fig. 172). Any abnormal thickening of the arachnoid veils the cord. Thickening may be uniform or patchy. Granular thickening of the pia-arachnoid indicates tuberculous or syphilitic meningitis, particularly if accompanied by delicate adhesions to the dura mater, or, in the former case, by greenish-grey exudation.

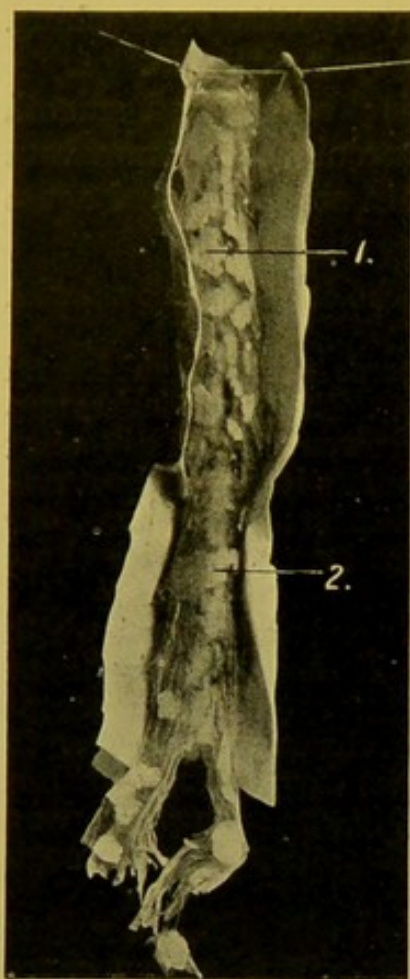

FIG. 171.—Calcareous plates (1. 2.) in arachnoid mater of spinal cord. (\times circ. $\frac{1}{2}$.)

The cord is then turned over and the membranes on the anterior surface treated in a similar fashion.

The tip of the little finger may now be passed gently along the surface of the cord. The consistence may be *lessened*—myelitis, or syringomyelia, the latter of which may affect only one or two segments, although the hollowing out of the cord is usually much more extensive; or the

consistence may be *increased*—sclerosis. The lateral halves should be compared as to symmetry.

If the cord is to be preserved for further microscopical investigation, it should be cut into lengths of 3 or 4 in. (8 to 10 cm.) by transverse incisions which leave the dura intact. These should be made just below the points of entrance of the posterior nerve roots, the cuts being made from this aspect, because the posterior roots, being larger than the corresponding anterior roots—except in the case of the first cervical—can be defined more readily than these. Any doubt as to the surface of the cord under examination is set at rest by distinguishing the anterior fissure and the anterior horns of grey matter upon the cut surface, at the cervical end, or by noting that the posterior roots of any segment are closer to each other than the corresponding anterior roots.

The cord may now be suspended or laid flat in 5 to 10 per cent. solution of commercial “formalin” in normal saline (0.85 per cent. sodium chloride), or

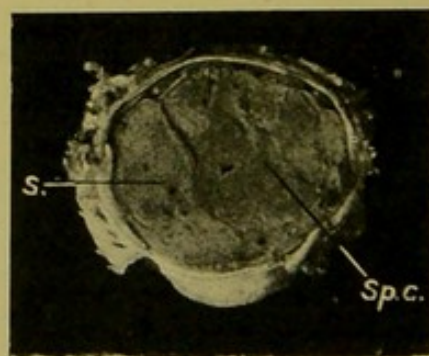


FIG. 172.—Intradural round-celled Sarcoma (s.); (sp.c.) spinal cord. (\times circ. 2.)

(Kindly lent by Dr. W. T. Ritchie.)

in the fixing solutions used in Pick's, Jores', or Kaiserling's methods for preserving the natural colour of organs (*see* Appendix).

Formalin penetrates rapidly, and its employment does not preclude transference to bichromate media at a later date. If alcohol or sublimate fixation be essential, small portions of the cord should be placed at once in these media. The cord should not be preserved permanently in formalin if a complicated microscopical investigation is to be carried out subsequently, but after fixation is complete, portions should be transferred to bichromate solutions (Müller) for Weigert-Pal staining, and the remainder may be preserved in weak spirit,—40 to 50 per cent.

EXAMINATION OF THE SPINAL CORD.

When sections are made across the fresh cord, there should be sharp distinction of white from grey matter. The cut surfaces should be almost flat; marked bulging and welling up of the substance usually indicates acute softening. This may also, however, be due to post-mortem change. Pathological softening may be due to myelitis

(p. 362). Softening is usually localized to one portion of the cord, and does not always affect the whole width of the cord. The softened cord is usually milk-white in colour.

Haemorrhages visible to the naked eye rarely met occur in the spinal cord.

If on section of the cord it collapses, because of the escape of clear fluid from a longitudinal hollowing out of the grey matter, the condition is **syringomyelia**, and before further sections are made the cord should be fixed in formalin.

Areas of **degeneration** may be visible on section as more opaque, or even creamy spots, and areas of **sclerosis** may be seen as somewhat grey spots, rather more translucent than the rest of the cord, but they are seldom clearly distinguishable in the fresh cord. Sclerotic and atrophic patches may appear a little retracted on section. **Gummata** and **tuberculous caseous nodules** form well-defined firm areas on the cut surface, usually more or less opaque in the centre with a greyish more translucent margin. In the neighbourhood of such masses

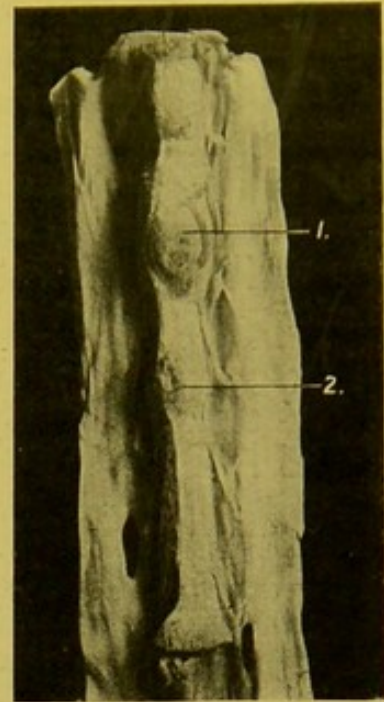


FIG. 173.—Tuberculous Tumours of spinal cord (1, 2). (\times circ. $\frac{1}{2}$.)

(Mus. R.C.S. Edin.)

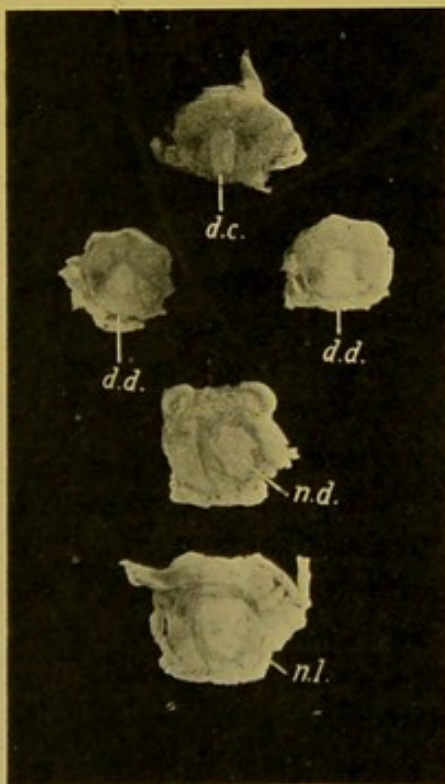


FIG. 174.—Caseous Mass (gumma) in upper lumbar cord (*n.l.*); extending into lower dorsal cord (*n.d.*). (\times circ. $\frac{1}{2}$.)

(*d.d.*) Ascending degeneration in posterior columns in dorsal region; (*d.c.*) degeneration in postero-internal tract in lower cervical region.

small rounded *herniations* of white matter may be seen along the lines of attachment of the nerve roots. (See Figs. 173, 174.)

Syringomyelia is a condition in which there is a hollowing out of the grey matter of the spinal cord (Fig. 175). When the cord is cut across, a clear watery fluid escapes from the cavity. Syringomyelia is found most commonly in the cervical and upper dorsal regions of the cord, but it may extend throughout the whole length of the cord, and even into the medulla and pons. The cavity may be single or multiple. It may be cylindrical, of small size, or large, stretching the remains of the cord over it in a thin layer. More often it is irregular or even chink-like, involving both sides of the cord, though not usually symmetrically. The cavity is situated most com-

monly behind the central canal, in the grey matter, or in one or both of the posterior horns. Occasionally spaces are found in the white matter. The central canal may communicate with the cavity, or may form part of its wall.

The wall is composed of neuroglia tissue, dense near the cavity, of looser texture as it passes outwards to become gradually lost in the surrounding tissue. There is usually no lining membrane; if the cavity be partly lined with cylindrical epithelium, this indicates that the central canal enters into its formation in that particular situation.

Etiology.—The following explanations have been suggested: (1) Syringomyelia is the result of a developmental defect; (2) it is due to a proliferation of neuroglia, of spontaneous or of inflammatory origin, with subsequent degeneration and softening of the central part; (3) it results from a degenerative softening of the spinal cord, probably following circulatory changes, e.g., thrombosis; (4) it results from actual destruction of the grey matter by haemorrhage; and (5) it is of bacterial origin, the bacterial invasion setting up the neuroglial proliferation, which is followed by degenerative softening.

The second explanation is that most favoured.

Haematomyelia—haemorrhage into the cord—is not a common condition. A large proportion of the cases are due to mechanical injury, such as partial dislocation with recoil (Thorburn). If it be associated with myelitis, it is often impossible to determine which has been the primary lesion. Haemorrhage may take place into a pre-existing cavity. Minute haemorrhages, which are of small importance, may occur in acute infections, in tetanus, and in asphyxia. When the haemorrhage is primary it may extend locally and transversely, forming a *rounded* or *oval* focus; or it may extend *longitudinally*, along the grey matter, particularly in the posterior horns. The

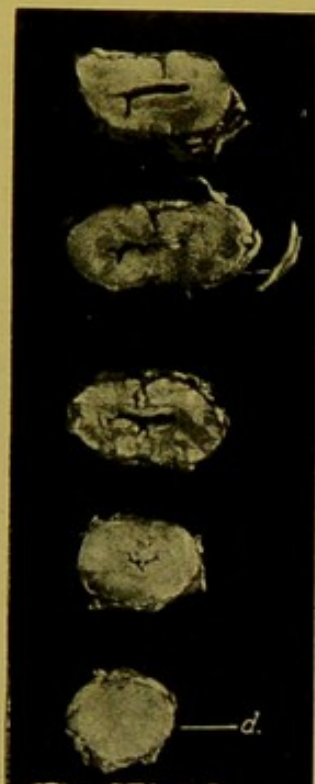

FIG. 175.—Syringomyelia, affecting cervical spinal cord.

It also extended into the medulla oblongata. (d.) An upper dorsal segment. (About natural size.)

latter variety, on absorption, may leave a cavity (*see Etiology of Syringomyelia*).

When the escape of blood has taken place shortly before death, the blood-clot is sharply demarcated from the white surrounding cord; if a few days have elapsed, the surrounding cord is softened and yellow; if a long time has elapsed, and the haemorrhage has been local and of small size, it is represented by a small pigmented patch, in which, under the microscope, crystals or granules of altered blood-pigment can be distinguished, but if the haemorrhage has been extensive, tearing up the grey matter, a longitudinal hollow may be left, as already stated.

On the outer surface the spinal cord may present nothing abnormal, or it may be thickened and its consistence increased locally, or it may be flattened and softer than normal. Occasionally the blood makes its way to the surface of the cord.

Spina bifida.—This rare condition presents usually the aspect of a more or less ovoid, soft, fluctuating swelling in the middle line in the sacral region and, much less commonly, in the cervical region of the body. It is associated with defects in the vertebral arches in these regions, which are normally the last to be closed in by formation of bony laminae. This swelling is covered with skin which, in the case of small sacs, may be concealed by a thick growth of hair—*Spina bifida occulta*. A pad of fat, along with some muscle, may intervene between the sac and the skin.

In some cases, the skin is defective over the summit of the swelling; its place being taken by a smooth scar-like expansion of dura mater. The sac itself varies in structure. It may consist of meninges alone, the cord and nerve roots lying in the usual position within the vertebral canal (posterior meningocele). The sac may, in exceptional cases, project anteriorly (anterior meningocele). The flattened nerve roots may be spread out over the inner surface of the sac (meningo-myelocele) or the sac may result from a localized dilatation of the central canal of the cord, and be covered with the nerve roots and meninges (syringo-myelocele).

Spina bifida may be associated with congenital hydrocephalus, or with club-foot.

Patency of the original medullary groove (*Rachischisis totalis* or *partialis*) is very rare. (*See Encephalocele*, p. 368.)

Spinal Leptomeningitis.—It is unnecessary to consider at length the various forms of meningitis of the cord, as these frequently spread from the cerebral membranes, and in their causation, course, and characters correspond more or less closely with the varieties affecting the cerebral membranes. The possible relation of meningitis to local conditions, e.g. pleurisy, neuritis, bed-sores, carbuncle of the back, should be borne in mind.

Meningitis is usually more evident over the upper and lower ends of the cord or over both regions than it is in the dorsal region.

In **tuberculous meningitis** the arachnoid is finely granular, and delicate

adhesions exist between it and the dura mater. It is seldom easy to recognize distinct grey tubercles.

In sporadic cases of **cerebro-spinal meningitis** (Weichselbaum) the inflammation may be localized to the spinal cord.

Syphilitic meningitis especially affects the lumbar region of the cord—though I have seen it extending all along the cord. There is great thickening and infiltration of the pia arachnoid. Microscopically the membranes and nerve roots are greatly infiltrated with cells, chiefly lymphocytes; the adventitia of the vessels is greatly thickened and cellular (periarteritis),—the thickening due partly to infiltration with leucocytes, partly to proliferation of the endothelial cells with formation occasionally of multi-nucleated giant-cells. The media also may be infiltrated and in a few of the vessels distinct proliferative endarteritis is present with thrombosis. The condition, though rare, is important in that it brings about compression of the cord, and the infiltration of the nerve roots leads to degeneration of these and secondary degenerations in the cord. The cord may also show local softening. (For further information on *Serous Meningitis*, see Bibliography.)

Acute poliomyelitis, or **acute infantile spinal paralysis**, is a condition in which the grey matter of the anterior horns is predominantly affected. It occurs in epidemics or sporadically. The earliest change seen is thrombosis; the anterior horn is softened, congested, and stands up above the cut surface. Microscopically there is hyperaemia; the vessels are surrounded by exuded serum and by round cells; there is proliferation of the nuclei of the neuroglia; the ganglionic cells are swollen, finely granular, with indistinct nuclei. Large epithelioid cells and, in the later stages, spider cells appear. This stage is followed by atrophy of the ganglionic cells and nerve fibres. The whole horn shrinks and is replaced by sclerotic tissue.

The condition is associated clinically with imperfect development of the limb concerned, frequently with club-foot.

Landry's paralysis in adults is possibly of similar nature. The posterior horns and neighbouring white matter may be affected.

The majority of investigators look upon the process as primarily an interstitial and vascular change, whereas others consider that the toxine acts upon the nerve cells as well as upon the connective tissue.

Chronic Anterior Poliomyelitis.—Primary chronic inflammation of the anterior horn terminates in atrophy with complete destruction of the nerve elements. The white matter is practically normal or shows atrophy of isolated fibres.

Acute Myelitis, or **softening of the spinal cord**, may affect the grey matter only, or both grey and white matter. It may be localized, or it may destroy the whole width of the cord—transverse myelitis. It may be disseminated. The affected part is swollen, soft; the pia-arachnoid over it is congested and shows recent adhesions to the dura mater. The softening may be red

or white. When the fresh cord is cut across its substance wells up and may be actually diffuent. Microscopically, the ganglionic cells are granular, oedematous and vacuolated; the nerve fibres show changes as in other degenerations; at a late stage, corpora amylacea may develop from swelling of the axis cylinders.

The disease follows exposure to wet or cold, great over-exertion, excesses of various kinds, concussion, various acute diseases, and injuries causing compression. The immediate cause is usually thrombosis.

Chronic Myelitis or disseminated sclerosis is a condition very similar to that occurring in the brain, and irregularly distributed, greyish, gelatinous-looking patches develop in the cord. In these there is increase of neuroglia and gradual disappearance of the nerve sheaths, followed at a much later stage by disappearance of the axis cylinders.

DEGENERATIONS.

The important spinal nerve tracts are :—

(1) **Ascending or Sensory Tracts.**—Postero-internal tract of Goll, containing fibres from the sacral and lumbar regions; Postero-external tract of Burdach, containing fibres from the dorsal and cervical regions and from the first and second lumbar roots; marginal zone of Lissauer (posterior root zone); direct cerebellar tract, containing fibres from the column of Clark on the same side; Gower's antero-lateral ascending tract containing fibres from the cells of the opposite posterior horn and column of Clark and passing principally to the cerebellum, but also in part to the thalamus, and corpora quadrigemina.

(2) **Descending or Motor Tracts.**—Direct pyramidal tract; crossed pyramidal tract; lateral limiting layer; comma tract of Schültze; septo-marginal tract of Bruce and Muir.

Locomotor Ataxia.—In locomotor ataxy there is degeneration of the white matter with secondary increase of neuroglia, specially localized to the posterior columns. It has been suggested that the disease results from the action of a toxine upon the lymphatics of the nerve sheaths and spinal membranes bringing about sclerotic changes in the tracts, with secondary degeneration of the nerve fibres, but there is much in favour of the opposite view. In the great majority of cases the individuals have suffered from syphilis, and a large proportion of them give the Wassermann reaction. The disease very rarely commences in childhood, but occurs principally in middle life, and much more often in men than in women. The condition commences in the posterior root zones, and gradually spreads upwards along the cord.

In the lumbar region Lissauer's tract is affected at an early stage, and in the lumbar and dorsal regions the whole of the posterior columns is affected, excepting the intrinsic fibres—the commissural tract of Marie, the oval field of Flechsig and the associated septo-marginal tract of Bruce and Muir. In the cervical region the postero-internal column alone may be affected, but in late stages the postero-external column may also show sclerosis. In exceptional instances (Cervical Tabes), the cervical and upper dorsal roots

and column of Burdach are alone affected in the upper part of the cord, whilst in the lower parts the whole of the posterior columns are unaffected. Clark's column is frequently involved, and often the direct cerebellar tract. The pia-arachnoid is often thickened, probably from pre-existing meningitis over the posterior region of the cord, which is flattened, and on section has a greyish aspect.

Certain of the posterior roots in the lumbo-sacral region, as a rule, are atrophied, and of smaller size than the anterior. The cells of the posterior root ganglia usually present a normal appearance.

The optic nerves are frequently atrophied. In a few cases other nuclei are affected. Degeneration of the peripheral nerves is sometimes found.

Associated Changes in Locomotor Ataxia.—The bones generally may become atrophied and may fracture easily. The heads of the bones, e.g. those of the hip, knee or ankle joints, may become absorbed so that deformity of the joints results, often with accumulation of fluid. The alteration is extensive and the thickening of the bone develops rapidly, as compared with the slow thickening, eburnation and lipping of the bone in rheumatoid arthritis. Two types of tabetic arthropathy may be distinguished, one characterized by atrophic, the other by hypertrophic changes.

Hereditary Ataxia.—**Friedreich's Ataxia** is a rare disease, often affecting several members of a family. It commences in childhood, and is associated with scoliosis, club-foot, hyper-extension of the toes, etc. Its pathological anatomy is ill-defined. The spinal cord is small, showing combined disease of the posterior and lateral columns. The postero-external and postero-internal tracts, the crossed pyramidal tract and to a lesser extent the antero-lateral ascending tract and direct cerebellar tract become sclerosed. Lissauer's tract is unaffected. Atrophy of the posterior roots is not constant. A peculiar feature is the development of dense neuroglia which is often arranged in whorls in the posterior columns.

Primary Affections of the Motor Neurons.—**Primary lateral Sclerosis** is a very rare disease, and is of very chronic course. It affects the upper motor neurons. The crossed pyramidal tracts on both sides are sclerotic and degenerated.

Progressive Muscular Atrophy (Spinal Form).—This condition arises usually in middle life, and the spinal lesions are met with in the lower motor neurons, but also, in many cases, the upper neurons—pyramidal tracts—are affected. The small muscles of the hand are most often first affected. They show a symmetrical atrophy with deepening of the interosseous spaces; then the shoulder muscles, especially the deltoid, also the muscles of the forearm and even those of the back, are affected. Later on, the respiratory muscles, especially the diaphragm, may become involved.

The affected muscles are pale red or yellowish, or show fatty streaks. Microscopically the fibres are narrowed, granular and fatty.

The ganglionic cells in the anterior horns of the spinal cord, particularly

in the cervical region, and their associated nerve bundles, undergo atrophic changes. The anterior nerve roots, and the nerves to the affected muscles are degenerated.

Amyotrophic Lateral Sclerosis is a disease of middle life, affecting the upper and lower neurons. The cause is unknown.

In the spinal cord the anterior horns and crossed pyramidal tracts are affected. The direct pyramidal tracts are not affected or only to a very limited extent. No change occurs in the sensory tracts. The posterior horn is usually unaffected. Microscopically, the nerve cells disappear. There is atrophy of the pyramidal tracts, the motor nucleus of the hypoglossal, the nuclei of the facial, the vagus and the spinal accessory, and the motor nucleus of the fifth nerve.

EXAMINATION OF THE SCALP AND SKULL

The body lies in the natural prone position upon its back. The examination of the surface of the scalp has already been carried out (pp. 20, 21).

The head being supported on a hollowed-out wooden block placed under the occiput, an incision is made across the vertex of the skull, connecting the bases of the mastoid processes on either side. In making this incision from without inwards, it is not always easy to avoid cutting away some of the hair; particularly in females, even if it be previously parted along the line to be followed by the knife, and if one desire to avoid this the scalp should be divided from within outwards. To do this, a small incision is made over one mastoid process down to the bone, then a ground-down old cartilage knife, or a *strong* curved probe-pointed bistoury is passed underneath the scalp with its back towards the bone, and carried across the vertex to the mastoid process of the opposite side. As it divides the scalp, it separates up the hair, and usually without cutting the latter. The remaining tissues are completely divided down to the pericranium, and then the anterior half of the scalp is dissected up and drawn forwards over the face until the line of reflexion reaches the upper margins of the orbits. The posterior half of the scalp is treated in a similar fashion, being drawn backwards until the external occipital protuberance is exposed. A periosteum elevator will be found of use in reflecting the scalp. Any abnormal degree of adhesion of scalp to pericranium should be noted.

The calvarium is now exposed, with the pericranium covering its greater extent, and with the expansions of the temporal muscles laterally with their fascial investments. These muscles need not be detached, as advised by some authorities, and indeed may be of use later in fixing on the skull-cap after the examination is completed.

Before proceeding further, the scalp should be examined carefully from its under aspect, for signs of mechanical injury, scars, cuts (incised or lacerated), bruises, haemorrhage, cephalhaematoma, inflammation, suppuration, new-growths—sebaceous cysts, dermoid cysts, plexiform angioma, or other tumours. Then the skull should be examined, as to size and symmetry; presence of defects, congenital or due to syphilis ("corona Veneris"); malformations; presence and character of fractures, and relation of these to scalp injuries; ivory exostoses, especially in the frontal region; scars and

depressions of bone; consistence of the bone—soft in craniotabes, or in tumour-growth, and porous, soft or hard, in osteitis deformans; patency or premature closure of the sutures; presence of Wormian bones (*ossa triquetra*); thickening along the margins of the bones bounding the anterior fontanelle, due to deposit of cancellous bone, in congenital syphilis (Parrot's nodes).

Removal of the Skull-cap.—In very young marasmic infants, it is always difficult to replace the thin flexible skull-cap, and sufficient access may be gained by opening up the sutures and fontanelles with strong scissors, if necessary partly sawing across the bones in the usual circumferential line so as to allow the walls to be bent outwards sufficiently to allow the brain to be extracted.

In all other subjects above six months to one year old, this procedure is rarely admissible, and the calvarium should be removed with the aid of the saw.

Before taking up the saw, the line it has to follow should be marked out on the skull, and the expansions of the temporal muscles, with the temporal fascia, divided down to the bone along that line.

Two lines are usually available, the one circumferential, in a plane, more or less perpendicular to the vertical axis of the body, beginning in front between the highest point of the orbital margins of the frontal bone and the frontal eminences, or in the adult $\frac{1}{2}$ in. (or 1 cm.) above the orbital margins; and behind, passing through the posterior occipital protuberance or Inion, or preferably a little above that point. This plane is at an angle of about 20° to 25° with the upper margin of the zygomatic arch.

I prefer to open the skull along another line which dips laterally, forming a wide obtuse angle in each temporal region.

Like the former, it commences in front between the orbital margins and the frontal eminences, but posteriorly, it is carried a little higher on the occipital bone, about half-way between the external protuberance and the lambda. The angle of meeting of the two planes should be upon the posterior end of the zygomatic ridge (supra-mastoid) of the temporal bone, in a vertical line over the tip of the mastoid process, i.e. in the line of the incision through the scalp. On the removal of the calvarium, this point will be found to be just over the junction of the free upper border of the petrous temporal with the squamous portion of that bone. The plane of the posterior part of the saw-cut, if continued forwards, would be parallel to the upper edge of the zygomatic arch. This method possesses all the advantages of that first described, which is the one more commonly adopted, and in addition, enables the calvarium to be replaced more accurately, and fixed more securely in position, a point of real importance when the body is to be viewed afterwards by relatives. A little more care is required, when tilting out the brain, to avoid injuring the occipital lobes and the cerebellum.

When sawing through the calvarium, the head is steadied with the left hand, which grasps the reflected scalp. It is a great help if an assistant steadies the head by placing his hand—protected with a towel—on the vertex. When cutting from the right side of the body, positions are reversed, the operator fixing the head with his left hand on the vertex, and the assistant grasping the reflected scalp.

Whenever *fractures* are evident or suspected, the bone should be sawn *completely through*, so that no hammering or forcible levering will be required to separate the calvarium. In other cases, the saw-cut need not pass right through the bone.

All button-holing of the scalp should be sedulously avoided.

The chisel is introduced into the frontal saw-cut, and an attempt is made to

separate the surfaces by a combined levering and twisting movement. If this be not successful, then, with the aid of the mallet, the chisel is driven into the saw-cut at different parts where required. A sharp "crack" indicates that the internal table has given way, and then the chisel is again applied to lever apart the cut surfaces. When this has been accomplished the hook at the end of the transverse limb of the chisel (Littlejohn's) may be used to wrench off the calvarium.

In children, in the aged, in alcoholics, in syphilitics and in individuals who have led a combative existence, the dura is usually unduly adherent, and may be detached from the calvarium with the aid of a curved periosteum separator. It is often advisable to remove the dura with the calvarium, dividing it along the line of the saw-cut, or, still better, the brain may be removed as it lies in the calvarium, separating it from the base of the skull in the usual manner.

Subsequently it is usually easy to ease the brain out of the dura mater, which is left adherent to the calvarium.

In young children this procedure should be adopted in most cases.

CALVARIUM

The thickness of the skull should be noted; the presence and proportion of diploë; the presence of necrotic or purulent areas. The inner table of the skull may be absorbed; pressure of the convolutions or of Pacchionian bodies causing smooth pits, whereas tumours, gummata, etc., usually cause irregular pits with rough inner surface. Patches of fine honeycombing of the internal table, in which vascular tufts from the dura have lain, are almost pathognomonic of tertiary syphilis, though they do not occur in all cases of that disease, and are occasionally seen in cases in which there is no syphilitic history. They are found either in the centre of the parietal bones or along either side of the sagittal suture (Figs. 176 and 177). A dirty green discoloration along the lines of the sutures is found in Chloroma. Sometimes the internal table is thickened so that the grooves for the meningeal vessels are deeper, and in parts these vessels may be enclosed within bony canals.

Fractures should be accurately located and described.

Bony projections — osteomata

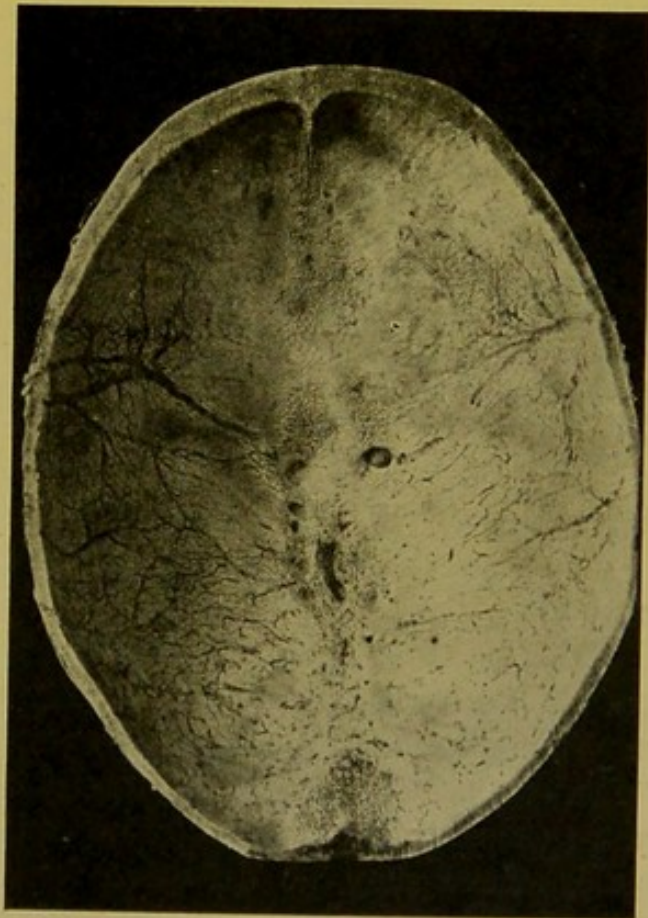


FIG. 176.—Calvarium, showing localized honeycombing, resulting from chronic syphilitic pachymeningitis. (\times circ. $\frac{1}{2}$.)

The areas are situated close to the middle line, along the course of the superior longitudinal sinus.

or of inflammatory origin (hyperostoses)—may be found on the inner table.

Congenital defects are usually due to arrest of ossification. Deficiencies are seen not only at the margins of the bones, but also within them, forming

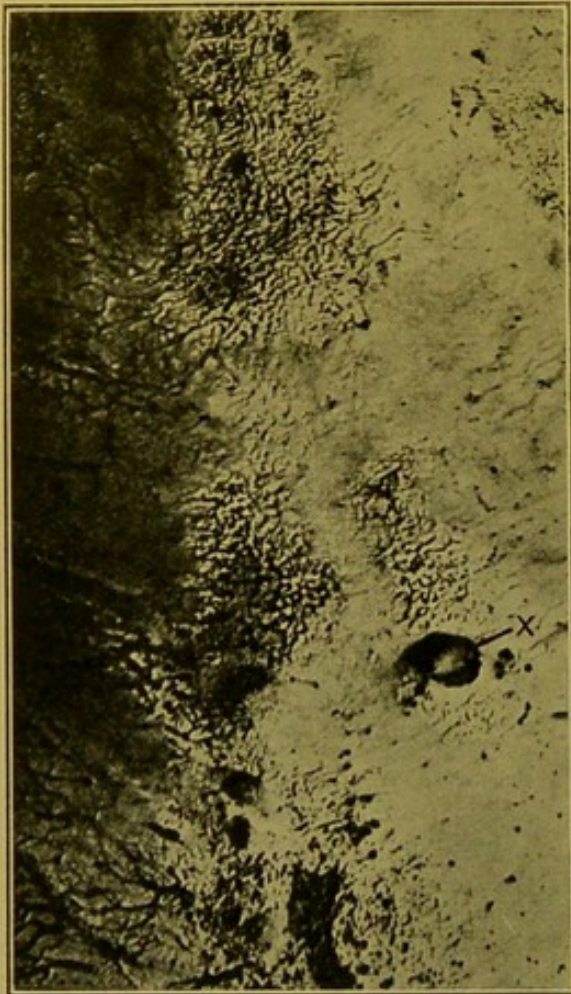


FIG. 177.—Portion of last figure ($\times 3$) to show better the honeycombing of the inner surface of the bone. (x.) a large Pacchionian depression.

shallow translucent depressions closed with membranes which can be cut with a knife (see *Craniotabes*, p. 369). Accompanying these defects there is often some malformation of the brain or ventricles, e.g. porencephaly, and they give some indication for care in subsequent manipulations, particularly in the young. Apart from internal changes, portions of the encephalon may project through the gaps in the sagittal plane, for example at the fronto-nasal junction or in the neighbourhood of the anterior fontanelle, but they are seen most commonly farther back in the upper part of the occipital bone. Less commonly projections are encountered at other parts of the vault and at the base of the skull. Protrusions may consist of meninges only, filled with cerebro-spinal fluid, **meningocele**; of brain and meninges, **encephalocele**; or of brain and meninges, the former hollow and communicating with the ventricles and containing cerebro-spinal fluid, the increased pressure in the ventricles, associated with

hydrocephalus, assisting in causing the projection, **hydrencephalocele**.

Dermoids are occasionally seen in the line of the sagittal suture. They may be attached to the dura.

The more gross defects and abnormalities, which are usually incompatible with life, need not be fully considered here. Such abnormalities may be so extreme that the individuals affected come under the category of "monsters." The more important examples of these have to do with a non-closure or incomplete closure of the medullary groove, or, if the groove closes, there may be defective formation of skin, subcutaneous tissues, muscle and bone covering the medullary tube, which is the rudimentary brain and spinal cord.

The factor preventing closure of the medullary groove may be adhesion of amnion to the dorsal aspect of the embryo.

When the medullary groove remains patent, fissure of the skull, **cranioschisis**, and back, **rachischisis**, results. If the groove have closed and the more superficial structures are defective, various degrees of herniation of the medullary tube result, forming the meningoceles, etc., of brain, or spinal cord (*see Spina bifida*, p. 361). Malformations are more rare in connexion with the fore-brain, particularly the optic vesicles and olfactory bulbs.

Following upon compound fracture, or on operations in septic cases, the brain substance may become herniated. Such fungous protrusions are easily distinguished from the congenital malformations mentioned above, for example, they are practically never in the middle line.

Defective development of the brain may result in **micrencephalus**. The convolutions are poorly developed and the condition is usually associated with premature closure of the sutures between the cranial bones, or with development of numerous Wormian bones in a *small* skull. Closure of the sutures (synostosis) is not invariably associated.

Sutures.—As a general rule, synostosis may be said to advance from behind forwards and from the middle line outwards. The less complex the suture the more readily does the synostosis occur, but it presents great irregularity both in time of onset and progress.

In **Rickets** the frontal and parietal bones are prominent. The cranium is more or less square (*Tête carrée*), the angles being formed by the centres of ossification of the bones mentioned. These retain something of their original curvature, which represents an arc of a small circle, and the parts between, in which ossification is delayed, remain flat. Osteophytic outgrowths may be present on the outer surface of the skull. The cranium is sometimes large in proportion to the size of the face, a degree of hydrocephalus often accompanying the rickety condition. In rickety infants the anterior fontanelle, in place of closing about the twentieth month of life, remains patent until the third or fourth year; the sagittal suture until the third year, instead of closing about the eleventh month; the coronal until the second year instead of closing about the fourth month, and the lambdoid suture until the eighteenth month instead of closing about the third month.

Craniotabes.—The appearances seen in this condition vary with the age of the individual, with the degree of ossification and with the amount of pressure exerted by the developing brain upon the skull. In very young infants the calvarium may be almost transparent except at the centres of ossification. Surrounding these, there are usually delicate osteoid deposits sometimes arranged in layers. These parts may be very vascular, and remain for a long time unossified. When the ossification does supervene, the newly formed bone may be very thick. The thickenings are especially seen near the margins of the cranial bones. Craniotabes is characterized by the presence in the cranial bones of patches of absorption. These result from pressure of the bone between the developing brain and the pillow or

other support. The occipital and parietal bones are necessarily the chief bones affected. The internal pressure conjoined to the weight of the brain—the infants being usually carried in the prone position—may be a sufficient determining cause, without any counter-pressure. The patches are rounded or oval, sharply circumscribed, filled in with a parchment-like membrane in which there may be delicate streaks of calcareous deposit, and may be so numerous as to give a sieve-like character to the bones.

The etiological relationship of craniotabes to rickets or to congenital syphilis, is still *sub judice*. The inclination at present is to place it with the manifestations of rickets. Some writers (e.g. Still) are of opinion that, when it does occur in congenital syphilitics, rickets accompanies that specific disease.

Osteitis Deformans (Paget) is a disease usually affecting individuals who have passed the fortieth year and is most frequently seen in advanced age. It is characterized by extensive absorption of bone, associated with

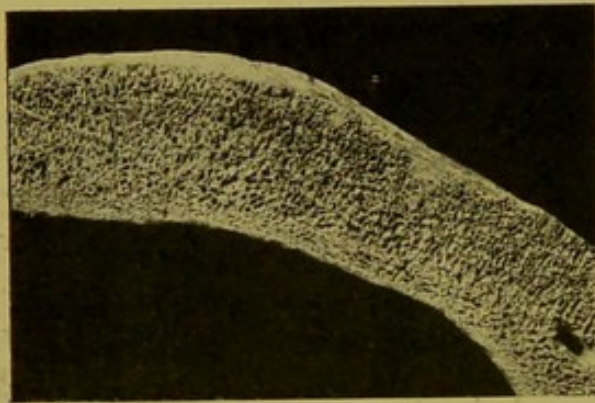


FIG. 178.—Osteitis deformans, skull.
(\times circ. $\frac{1}{2}$.) (Mus. R.C.S. Edin.)

great new formation of soft bone, containing less lime salts than normal.

—The base of the skull may be pushed upwards into the cranial cavity.—The thickness of the skull increases greatly, occasionally reaching 3 or 4 cm., and this without encroaching internally (Kaufmann) (Fig. 178). The resorptive changes are related to those which characterize osteomalacia. Osteitis deformans is sometimes followed by malignant disease in other parts of the body.

Cephalhaematoma.—In the course of difficult labours the sub-periosteal vessels may rupture, and haemorrhagic effusion take place between the pericranium and cranial bones of the infant, or internally between the bone and dura mater. The resulting swelling is sharply circumscribed by the attachment of pericranium to the sutures.

It occurs most commonly over the right parietal bone, though it is met with over both parietals and even on the frontal or occipital bones, the position depending on the presentation of the head. A shell of bone is rapidly formed from the detached pericranium in the course of a few days. On absorption of the blood, provided septic infection does not occur, irregular bony thickenings remain.

Alterations in the Cranium in Acquired Syphilis.—Extensive alterations may be found in the skull in tertiary syphilis. The most common conditions are *Caries sicca* and *Caries necrotica*. Both may be looked on as resulting from gummatous periostitis, the gummatous change extending along the vessels into the bone, causing resorption of the surrounding bone, and giving

it a worm-eaten appearance. Pus-formation may be absent or scanty (*Caries sicca*), and the skin over the affected part may long remain unaffected. The change may be more extensive, and large areas of bone—for example in the frontal or parietal regions—become surrounded by gummatous masses which cut off their nutritive supply. Large and extremely sclerosed worm-eaten sequestra form in the centre and separate with extreme slowness (*Corona Veneris*) (Fig. 179). Associated with these changes there is usually new-formation of bone—hyperostosis—in the surrounding parts of the skull.

If the syphilitic conditions heal, deep scars are left in the bones, which are usually sclerosed and may show central defects. The superficial tissues and skin are firmly bound down over the scar in the bone.

Tuberculous caries is not common in the skull, except in relation to middle ear disease.

Hyperostosis, Craniosclerosis.—While these terms may be used to indicate the thickening which accompanies old chronic inflammations, they are better confined to the diffuse alteration of the cranial bones with obliteration of the diploë and great sclerosis, which may occur without any distinct evidence of inflammation, and produce great thickening—up to 1 to 2 in.—(2.5 to 5 cm.). The newly formed bone tends to encroach upon the cranial cavity.

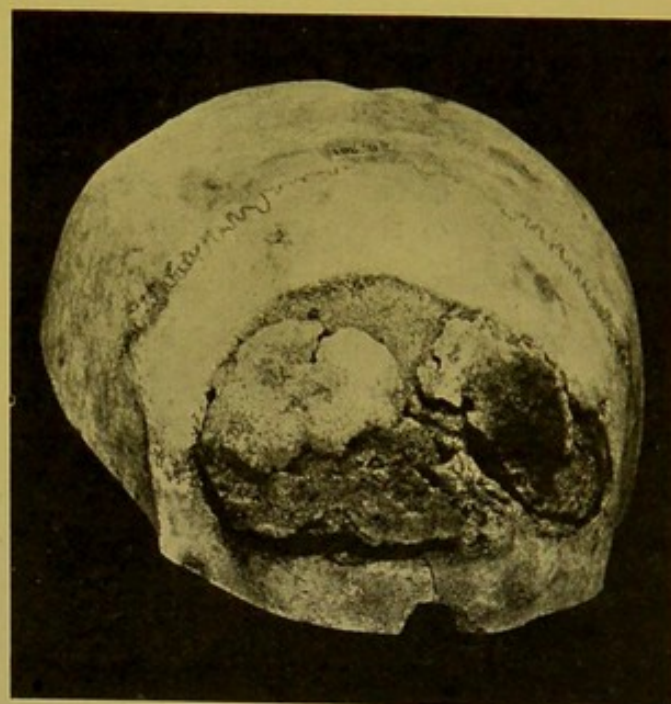


FIG. 179.—Syphilitic necrosis of frontal bone. "Corona Veneris." (\times circ. $\frac{3}{4}$.)
(Mus. R.C.S. Edin.)

Parrot's Nodes are rounded boss-like elevations on the bones adjoining the anterior fontanelle. They disappear after the first year. They are usually looked upon as manifestations of congenital syphilis, and when the thickening is due to deposit of new cancellous bone on the surface of the original bones, this is the view to be taken of their etiology (Still), but analogous swellings occur in rickets, as has already been noted.

In **Congenital Syphilis**, the changes in the cranium when well-marked are very similar to those found in acquired syphilis, gummatous formations appearing under the periosteum and following a course similar to that taken by the acquired form of the disease.

Ivory osteomata, with irregular nodulated surface, may penetrate the anterior walls of the frontal sinuses. They grow from the posterior walls. Warty or knob-like ivory exostoses may also develop at other

parts of the cranium, e.g. on the parietal and frontal bones, growing from the outer table.

THE BRAIN AND MEMBRANES

THE DURA MATER.

The superior longitudinal sinus is first slit up, and the condition of the contained blood noted—whether fluid, clotted, or thrombosed—and if thrombosed, whether the thrombus is purulent or non-purulent.

The dura mater is normally a tough, pearly, or greyish-white translucent membrane, through which the outlines of the cerebral convolutions and the larger pial vessels can be distinguished. If this be not possible, the dura is thickened, or meningitis is present.

Under normal conditions the brain sinks downwards (backwards) and renders tense the dura mater covering the posterior parts of the brain, whereas the frontal dura can be pinched up with forceps.

The tension of the dura is increased in hydrocephalus, in meningitis, in abscess and tumours of the brain. It is decreased in atrophy of the brain—whether general, from old age or chronic alcoholism, or local, from localized degenerative softening of the cortex,—so that it lies in folds. Normally, the outer surface shows some irregularities and may be a little rough.

It is unusual to find pus between the dura and skull, and in such cases the bone is involved, infection having passed from without inwards.

Extra-dural haemorrhage occurs most commonly in association with fractures of the bone, when the middle meningeal artery, or one of its branches, has been torn across. Occasionally the meningeal arteries are eroded in disease of the cranial bones.

The effused blood forms a large pad, which may be $\frac{1}{2}$ in. to $1\frac{1}{2}$ in. (1 cm. to 3.5 cm.) in thickness at its centre. It is usually over the position of the motor areas—pressing chiefly upon the lower part of the Rolandic area, the middle part of the first two temporo-sphenoidal convolutions and the supra-marginal convolution.

The *dura* should now be reflected. It is pinched up in the frontal region, divided along the line of the saw-cut in the bone, and drawn upwards on each side in succession. The character and amount of fluid which escapes should be noted. Normally the sub-dural space contains a little watery fluid.

The inner surface of the dura should be moist, smooth, glistening and pearly. If the internal pressure has been great this surface becomes dull and dry, and the arachnoid also is dry and sticky.

Opportunity may be taken to examine the *falx cerebri*, and the *tentorium cerebelli*, though these are more easily examined at a later stage. Either may be the seat of osseous deposit.

The attachment of the *falx cerebri* to the crista galli is severed and the dura drawn backwards to free the brain. The dura will be found to adhere to the deeper structures especially along the margins of the longitudinal fissure, where the Pacchionian bodies (*Arachnoidal villi*) penetrate it.

Removal of the Brain.—The brain being supported by the left hand, the handle of a bistoury is used to ease the frontal lobes gently out of the an-

terior fossae, and to free the olfactory bulbs from the cribriform plates of the ethmoid bone. The brain is now allowed to fall backwards by its own weight and the structures connecting it with the base of the skull are divided in succession from before backwards, and *close* to the skull. These structures are—optic nerves; internal carotid arteries and infundibulum with stalk of the pituitary body; third nerves (*oculo-motor*); fourth nerves (*trochlear*), close to the anterior border of the tentorium cerebelli, and cut through along with it as it is being detached from the upper border of the petrous bone; the sixth nerves (*abducens*), lying just underneath the tentorium, and liable to be divided along with that structure; the fifth nerves (*trigeminus*), a little posterior to and outside the sixth nerves as they penetrate the dura. Passing farther back, the seventh (*facialis*) and eighth (*acusticus*) roots are cut across close together; a little internal to the last come the ninth (*glossopharyngeus*); tenth (*vagus*), and eleventh (*accessorius*) roots in one clump, and, between these and the margin of the foramen magnum, the twelfth (*hypoglossus*) roots. The vertebral arteries are then divided, and, lastly, the cervical cord if it have not been divided previously. The cord should be cut through as nearly as possible in a transverse plane. To secure this result a myelotome—a long slender knife, resembling a cleft palate knife—may be employed. In the course of removal a number of fibrous connexions (some of them containing small veins) will be cut across between the arachnoid and dura mater.

The brain is now free, and slips out on to the palm of the left hand, the falx cerebelli and posterior attachments of the dura being divided if this membrane is to be removed along with the brain. It is better, however, to leave the dura attached to the base of the skull, except in cases in which one suspects pressure upon or thrombosis of the veins of Galen, which empty into the straight sinus at the anterior end of the junction of the falx cerebri with the tentorium cerebelli. The organ should now be weighed.

The weight of the brain—cerebrum, cerebellum and pons—taking the average of the figures given by Gray, Luschka, Krause, Cunningham and Nauwerck, is 1,428 gm. (50 oz.), in the male adult, and 1,262 gm. (44½ oz.) in the female. In a series of adult brains examined by me in the Edinburgh Royal Infirmary the average weights were as follows —

Males, 202 cases, average weight, 1,463.5 gm. (3 lb. 3½ oz.), or 51½ oz.

Females, 122 cases, average weight, 1,293.3 gm. (2 lb. 13½ oz.), or 45½ oz.

A maximum of 1,842 gm. (65 oz.) in the male, and of 1,687 gm. (56 oz.) in the female, and a minimum of 963 gm. (34 oz.) in the male and 878 gm. (31 oz.) in the female are recorded by Gray (14th Edition) from examination of a considerable number of brains. Weights below these minima are met with in idiots, but it must not be forgotten that the brains of the mentally unfit are not necessarily of light weight, for example, v. Walsen found that the brain of an idiot, twenty-one years of age, weighed 2,850 gm. Brains weighing more than 1,760 gm. (62 oz.) may be looked on as usually pathological.

In all important cases, if it be at all convenient, the brain may be injected gently by way of the basal arteries with strong formalin (25 to 50 per cent. "Formalin" in normal saline), and placed for at least twenty-four hours in 10 per cent. Formalin in saline (according to Jores', Pick's or Kaiserling's formulae, see Appendix), to fix and partly harden. The sections made will then be firmer, and the information gained as to relation of lesions to important structures more exact than if the organ be cut up forthwith.

This, however, is not always possible, particularly if the post-mortem examination is being conducted in a private house.

DISEASES OF THE CEREBRAL MEMBRANES

DURA MATER.

1. **Pachymeningitis—Externa.**—(a) **Acute pachymeningitis externa** is usually suppurative, and is characterized by a separation of the dura from the bone by a layer of pus which either may spread diffusely over the surface or is circumscribed.

In the latter case the centre of the area corresponds to the point of entrance of the infective agent. It may be secondary to infected wounds of the scalp, erysipelas, compound fractures of the skull, disease of the bones of the skull, especially caries of the petrous temporal following middle-ear disease. It may be accompanied by suppurative thrombophlebitis of the sinuses. There may be in addition a layer of pus upon the inner surface of the dura.

(b) **Chronic pachymeningitis externa.**—The sole evidence of the presence of this condition may be thickening of the dura mater with adhesion to the skull, but bony outgrowths may also develop. A very characteristic form is that found in syphilis, in which velvety areas made up of soft vascular fibrous outgrowths develop upon the outer surface of the dura mater. These fit into corresponding minute honeycomb-like depressions on the inner surface of the skull, which to a great extent depend on new-formation of bone in relation to the vascular tufts. These areas are seen especially along either side of the longitudinal sinus, and also over the most prominent parts of the parietal lobes. (See Figs. 176, 177, pp. 367, 368.)

Localized adhesions of the dura are constantly found at the sites of old fractures or of trephine openings.

2. **Pachymeningitis—Interna.**—(a) **Acute internal suppuration** is usually secondary to disease of the dura mater.

(b) In **Pachymeningitis Haemorrhagica Interna** a thin lympho reddish-brown layer forms over the inner surface of the dura, covering the vertex and lateral aspects of the brain. It occasionally extends downwards into the middle and posterior fossae. In certain cases, a flat laminated haemorrhagic layer—*haematoma* of the dura mater—develops, and may reach a thickness of $\frac{1}{3}$ in. to 1 in. in its centre. It is adherent to the dura mater and shows early organization from it. Thus it is usually denser near that membrane. Sometimes adhesions to the arachnoid develop.

The pathology of the condition is not well understood. It is most common in males, in later life. It occurs in senile dementia, general paralysis of the insane, chronic alcoholism, in chronic heart and kidney disease, and in the haemorrhagic diatheses. It is usually associated with atrophy of the brain substance underneath.

Two theories have been advanced to account for the condition:—

(1) There is primarily inflammation of the dura mater with exudation

and formation of a stratified membrane on its inner surface. The haemorrhage is due to rupture of the young vessels in the organizing exudate.

(2) The primary condition is an oozing of blood from diseased vessels, which are imperfectly supported as a result of the accompanying atrophy of the brain substance, and the young connective tissue, which is found penetrating it, is the result of organization of the clot.

The appearances found are, in my opinion, explained better by the second theory than by the first.

The haemorrhagic mass may be absorbed, leaving a cyst, in the wall of which calcification or even ossification may take place. The cyst contains clear, colourless or yellow, serous fluid.

Sub-dural haemorrhage is most often the result of mechanical injury causing rupture of the veins of the pia-mater, e.g., in *contre coup*. It may occur from sudden back pressure in the veins, for example in difficult labours, in whooping cough, occasionally in heart and lung disease, in sinus thrombosis, and in aneurysm of the cerebral arteries. Aneurysms develop more commonly upon the anterior cerebral arteries than upon the middle or posterior. (See also *Sub-arachnoid Haemorrhage*, p. 377.)

3. **Tuberculous pachymeningitis interna** is not of great importance. Miliary tubercles are found occasionally, especially over the basi-sphenoid and in the occipital region. Occasionally cheesy masses are found, occasionally multiple, but these in my experience are rare. In a few cases I have seen small granulomata projecting from the inner surface of the dura mater.

4. **Syphilis of the Dura Mater.**—In addition to the vascular fibrous outgrowths already mentioned, gummata may form in the dura mater either primarily in that membrane or extending to it from the bone. There is usually destruction of the bone and secondary thickening of the dura mater in the neighbourhood.

5. **Thrombosis of the Sinuses.**—Thrombosis may develop in obstructive conditions of the circulation and may be found in various stages of organization. I have found fully organized thrombi in the longitudinal sinus extending backwards as far as the torcular. In more recent cases the veins opening into the longitudinal sinus may be full of thrombus. Associated with this condition there are generally numerous small aggregated haemorrhages in the cortex and in rare cases larger haemorrhages may occur in the basal ganglia.

The lateral sinus and the cavernous sinus may be the seat of purulent or putrid thrombo-phlebitis. This results in the former case from caries of the petrous temporal, and in the latter from extension from suppuration within the orbit or from thrombosis of the ophthalmic veins. Septic thrombo-phlebitis is usually followed by acute suppurative leptomeningitis.

In thrombosis of the lateral sinus the condition may spread downwards to the jugular vein, or even lower, and, if the thrombus be suppurative, numer-

ous pyaemic abscesses are found, especially in the lungs. More local results are extradural abscess, or abscess of the brain or cerebellum. In caries of the petrous temporal the abscess usually occurs in the temporo-sphenoidal lobe. In suppuration of the mastoid cells the abscess is situated usually in the lateral lobe of the cerebellum.

Tumours of the Dura Mater.—Fibromata are rare; osteomata are somewhat more common, forming bony plates on the falx cerebri, in the tentorium, in the neighbourhood of the superior longitudinal sinus and rarely more diffusely.

Sarcomata are the most important tumours of the dura mater. They frequently begin in the sella turcica and cause compression of the brain and erosion of the bone. Fibro-sarcoma, spindle-celled sarcoma and, rarely, round-celled forms are encountered. Endotheliomata occasionally develop and also, in rare cases, psammomata. Secondary carcinomata rarely affect the dura mater.

THE LEPTOMENINGES—ARACHNOID MATER AND PIA MATER

Anatomical.—The arachnoid bridges across the sulci, not dipping into them as the pia mater does. It is usually thicker over the base than over the convexity of the brain. It stretches across between the lips of the Sylvian fissure, so that this appearance must not be mistaken for pathological adhesions in this situation. It also stretches across between the temporo-sphenoidal lobes, leaving a considerable space between it and the brain—the *anterior sub-arachnoid space*, or *cisterna pontis*. Another larger space is left upon the under surface of the cerebellum—the *posterior sub-arachnoid space* or *cisterna magna*. These two communicate across the crura cerebri. The anterior cistern communicates with the Sylvian sub-arachnoid space. The arachnoid is in close contact with the anterior surface of the pons and medulla. There is another sub-arachnoid space of considerable capacity along the upper surface of the corpus callosum.

The sub-arachnoid space communicates with the fourth ventricle by the foramen of Majendie at its lower end, and by the foramina of Key and Retzius at the terminations of the lateral recesses of the fourth ventricle.

The pia mater not only closely invests the cortex, but also forms the *velum inter-position*, and *choroid plexus*, and forms a delicate covering for the fourth ventricle before it passes off on to the under surface of the cerebellum.

The Pacchionian Bodies—Glandulae Pacchioni or arachnoidal villi—are small warty elevations of an opaque white colour, projecting from the arachnoid. Their interiors are in relation to the sub-arachnoid space, which they help to drain. They are most commonly situated along the margins of the great longitudinal fissure, and project into the superior longitudinal sinus or into the venous spaces of the dura mater. They may penetrate the dura and sink deep into the bony vault of the skull. (See Fig. 177, p. 368.) When of slight development they are frequently mistaken for tubercles of the pia mater.

Occasionally they are found at other parts of the convexity and rarely at the base of the brain. They are not found in infancy, but are usually distinct after the seventh year. They may be absent in the adult.

Arachnoid and Pia.—The arachnoid mater and pia mater practically form one membrane with numerous interspaces traversed by a delicate trabecular network.

Most of the vessels upon the surface are veins, the larger arteries lying deeper in the sulci, only appearing on the surface when sclerotic or atheromatous.

The sub-arachnoid fluid is increased in amount in atrophy of the convolutions with widening of the sulci, and in such cases the arachnoid is thickened. The fibrous thickening frequently involves the pia mater as well.

Fibrous thickening of the arachnoid is often patchy, along the vessels, less frequently diffuse, especially over the frontal region, in alcoholics; in some paralytics, and in old age, when it is accompanied by atrophy of the convolutions, and increase of the fluid in the sulci.

Sub-arachnoid Haemorrhage may follow rupture of pial veins. These have been referred to already in considering sub-dural haemorrhage.

Multiple sub-arachnoid haemorrhage, without great or even appreciable effusion between the arachnoid and the dura, occurs in acute infective conditions,—septicaemia and pyaemia. In cases of anthrax it is occasionally very marked, the layer of blood hiding the convolutions from view. It is also met with in chemical poisonings and in blood diseases such as scorbutus, purpura, leucocythaemia, and pernicious anaemia.

Multiple small haemorrhages into the cortical grey matter may accompany the meningeal haemorrhages.

Congestion is present when the redness is distinct even over the most prominent parts of the convolutions. It is usually general over the whole surface of the hemispheres. The larger veins having to a great extent emptied before this stage of the examination is reached, a diffuse, fine congestion may, even in absence of all exudate, be taken as denoting the arterial—active—hyperaemia of meningitis.

This frequent absence of all visible exudate in cases of fulminant meningitis should be borne in mind, and in such cases, whatever the age of the individual, films should be prepared and serum-agar inoculated from several different points of the surface.

The surface may be dry and “sticky.” This may accompany acute congestion, but it is found most characteristically when there is increased tension within the brain—dilatation of ventricles (e.g., in tuberculous meningitis), or growth of a tumour—pressing up and flattening the convolutions against the bones, and lessening the amount of sub-arachnoid fluid. The sulci are rendered so shallow as to be almost obliterated. The surface is dry and has lost its lustre. The best way of demonstrating this stickiness is to pass the back of the blade of a *light* bistoury *gently* over the surface. It sticks over parts affected, and moves smoothly and easily over the healthy arachnoid.

Exudations.—Exudation produces alterations in the membranes, varying from a diffuse turbidity—developing firstly along the veins in the sulci, and later, veiling all the convolutions—to a dense greenish-yellow purulent

infiltration completely hiding the convolutions, covering them as with a mantle. To differentiate from opacity of the arachnoid, due to thickening of that membrane, a small incision should be made in it, and the arachnoid fluid pressed out with the handle of the bistoury.

LEPTO-MENINGITIS.

(4) **Acute, Non-tuberculous meningitis** is usually of a purulent nature, but the condition may be of such rapid course that the membranes show simply congestion without any exudation. Commonly, however, an exudate is present and this may be **serous**, a stage through which probably all cases pass. Usually, however, the exudate is purulent or sero-purulent, filling up the subarachnoid space and in extreme cases veiling the convolutions and blood-vessels with the exception of the larger veins.

(1) Meningitis may be secondary to disease of the ears, particularly chronic suppuration with formation of *cholēsteatoma*. The infection may pass from the middle ear through the *tegmen tympani*, causing localized meningitis, or may pass along the lymph vessels into the temporo-sphenoidal lobe, causing an abscess. In *children*, infection may pass from the nasal mucous membrane or naso-pharynx along the Eustachian tube, which is wider and shorter than in the adult. From the middle ear it may pass to the cerebral membranes through the petroso-squamous suture, which may be still incompletely ossified. In other cases infection may pass along the sheaths of the facial and auditory nerves, and in others, an otitic suppuration may primarily cause a sinus thrombosis—in lateral sinus, petrosal sinuses or cavernous sinus—from which the membranes are attacked.

Anteriorly, the membranes may be infected by way of the lymphatics in the sheaths of the olfactory nerves and optic nerves, or the inflammation may spread directly through the cribriform plate from the accessory nasal sinuses.

(2) It may occur, independently of local suppurations, in the course of pyæmia, infective endocarditis, pneumonia, typhoid, influenza and other acute infections, including rarely *gonococcal* infections. The organisms present may be *pneumococci*, *pneumobacilli*, influenza bacilli, typhoid bacilli, *bacillus coli communis*, *bacillus lactis aërogenes*, *bacillus enteritidis* (Gaertner), *staphylococci*, *bacillus pyocyaneus*, *streptotricheae* and leptothrix forms.

Certain important varieties of acute meningitis are independent of evident inflammation elsewhere in the body. Amongst these are Posterior basic meningitis, Epidemic cerebro-spinal meningitis and certain forms of meningitis caused by *streptococci* and *pneumococci*.

In the first two the exudate is usually more pronounced at the base of the brain, filling up the cisterna magna and the cisterna pontis and also appearing at the tips of the temporo-sphenoidal lobes. It is localized to these parts in posterior basic meningitis which is the sporadic form of the

same infection which causes epidemic cerebro-spinal meningitis. In this the inflammation tends to spread upwards on to the vertex as in other varieties of suppurative meningitis.

Abundant greenish-yellow exudate over the convexity of the brain is usually of pneumococcal origin. A special characteristic of pneumococcal pus is its thick fibrinous nature. Similar exudate, however, is sometimes found over the convexity in cases of fulminant epidemic cerebro-spinal meningitis and in some cases of pyaemia. Pneumococcal meningitis, on the other hand, may be confined to the base, simulating closely that produced by Weichselbaum's diplococcus.

In **acute Leptothrix Meningitis**, the exudate is very similar to that in pneumococcal meningitis. It seems, however, to have a special tendency to spread from the base forwards and upwards over the frontal lobes (Fig. 180). Moreover, the exudate, as it spreads from the sulci on to the deeply-congested convolutions, possesses a more abrupt and more sharply-defined margin than does the pneumococcal exudate. The pus is crowded with organisms of leptothrix type and cultural characters.

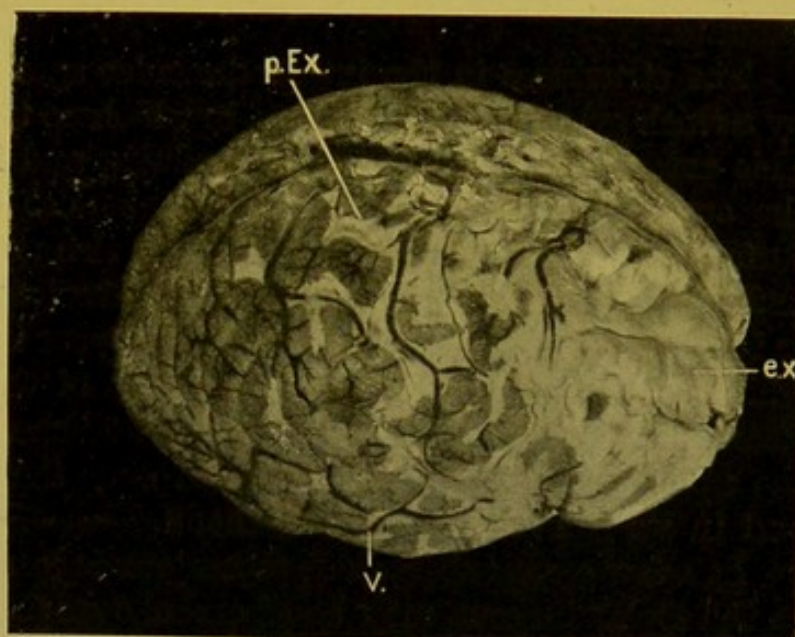


FIG. 180.—Acute Leptothrix Meningitis, in infant.

Resembles closely appearances in pneumococcal meningitis; but exudate especially marked over frontal lobes (*ex.*); and more recent parts show sharp margins (*p.Ex.*); (*v.*) vein. (\times circ. $\frac{1}{2}$.) (Brain lent by Dr. Carnegie Dickson.)

In all cases the inflammation tends to spread to the spinal membranes, and, especially in cases of posterior basic meningitis and epidemic cerebro-spinal meningitis, it spreads to the choroid plexus. It may extend farther by way of the Sylvian aqueduct to the ventricular system, causing its distension—"acute internal hydrocephalus"—a condition which is due partly to the swelling of the velum, causing obstruction of the iter, partly to increased exudation, the result of changes in the choroid plexus and ependyma.

In the spinal cord the exudate is usually most marked over its posterior surface and at its upper and lower ends. In epidemic cerebro-spinal meningitis and in posterior basic meningitis, the organism found almost invariably is the *micrococcus meningitidis cerebro-spinalis*, though some are still of opinion that the *pneumococcus* is occasionally the cause of this disease.

In twenty-eight consecutive cases of epidemic cerebro-spinal meningitis investigated by Dr. W. T. Ritchie and myself, Weichselbaum's *menin-*

gococcus was found. The cultures from nineteen of these cases were submitted to all the known carbohydrate tests, and gave agglutination with the sera of patients suffering from the disease.

Posterior basic meningitis is the chief cause of **chronic hydrocephalus**, seeing that it causes blocking of the foramen of Majendie and the foramina of Key and Retzius, thus interfering with the drainage of the ventricular system. (For further information on *Serous Meningitis*, see Bibliography.)

(B) **Tuberculous Meningitis.**—In **acute tuberculous meningitis** a large amount of turbid, watery fluid escapes during the removal of the brain.

There is usually very little exudate over the convexity, owing to the flattening of the convolutions from concurrent acute internal hydrocephalus. When the latter is not extreme, translucent greenish-grey fluid collects in the larger sulci. Occasionally one sees small patches of opaque yellow exudate.

The structures in the interpeduncular spot and the chiasma are hidden by a thick greyish-green exudate, in which no tubercles can be distinguished. This extends over the pons and medulla, and for a varying distance down the cord. Frequently only scanty tubercles can be seen on the general surface of the brain, and to demonstrate them one must open up the Sylvian and longitudinal fissures, separating adhesions which are usually present in the latter situation. The tubercles appear in the form of minute greyish-white spots interrupting the continuity of the minute arterioles. If not clearly visible elsewhere, I find that they can always be demonstrated on the upper surface of the cerebellum over the superior vermiform process and in its immediate neighbourhood.

In a few cases tuberculous meningitis is localized. Tubercles developing in the Rolandic area may be of embolic origin, but a localized tuberculous meningitis may occasionally be seen in the immediate neighbourhood of a caseous tuberculous nodule situated near the surface of the brain.

Acute hydrocephalus internus constantly accompanies the meningitis, and tubercles are occasionally found in the choroid, in the velum, or on the ependyma. There is usually also some extension of the tuberculous process along the pial vessels into the cortex.

Mode of Infection.—In 413 fatal cases of tuberculosis in children I found that tuberculous meningitis had caused death in 184 or 44·5 per cent. In 77 of these cases, dissemination had evidently taken place from mediastinal glands, and in 26, from caseating abdominal glands. In a small number of cases, active tuberculosis of the lungs, sometimes primary, sometimes apparently secondary to tuberculosis of the mediastinal glands proved to be the source whence dissemination had taken place.

The bacilli may travel either by the blood or by the lymph channels, and I have seen cases in which it seemed clear that extension had taken place from caseous thoracic or abdominal glands to the cervical or to the lumbar cord respectively, whence the disease had spread to the cerebral mem-

branes. In certain cases the meningitis results by direct extension from tuberculous disease of the ears.

Caseous tubercles—chronic tuberculous meningo-encephalitis—occur most often in the cerebellum or in the cerebrum near the surface. Occasionally they are multiple. In four out of twenty-eight cases examined, they occurred in the basal ganglia, and in one case in the choroid plexus.

(C) **Syphilitic Lepto-Meningitis** is really a meningo-encephalitis.

(a) **Acute syphilitic meningitis** is very rare, developing occasionally within nine to eighteen months after the primary sore. It is characterized by diffuse infiltration of the pia-arachnoid with round cells and is accompanied by superficial softening of the grey matter. The vessels are occasionally thrombosed and the infiltration passes into the brain along the perivascular lymph spaces. The vessels at the base of the brain may show proliferative endarteritis or gummatous arteritis.

(b) **Gummatous lepto-meningitis** begins usually in the sub-arachnoid space with the development of small miliary gummata. These increase in size, develop a yellowish centre and pinkish-grey periphery, extend in the pia-arachnoid forming a flattened caseating area. Later the change extends also into the brain substance, the neighbouring parts of which undergo yellow softening. The dura mater over the area becomes thickened and adherent to the arachnoid (Fig. 181).

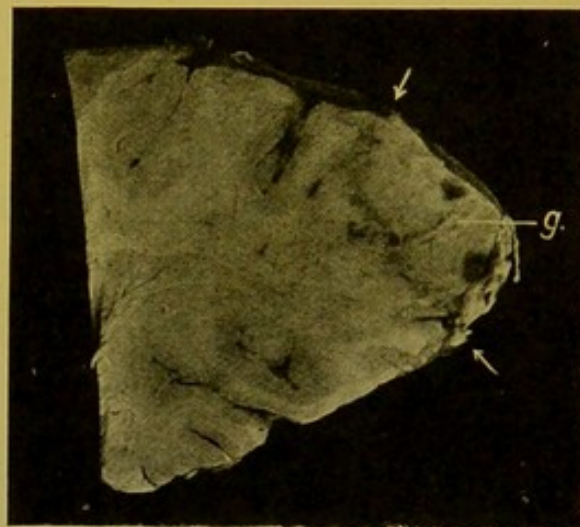


FIG. 181.—Syphilitic gumma (*g.*) at occipital pole of cerebrum,—sagittal section. (\times circ. $\frac{3}{4}$.)

The arrows indicate the limits of the gumma.

(c) **Chronic syphilitic inflammation**, with formation of connective tissue, is most common at the base of the brain. It occurs as a diffuse, fibrous, sometimes fibro-caseous, thickening which leads to compression of one or more of the cranial nerves.

(D) **Chronic Lepto-Meningitis**, apart from syphilitic conditions, may occur in alcoholics, though the condition is not necessarily diagnostic of alcoholism. The arachnoid is thickened along the lines of the veins, especially in the motor areas, or the membrane may show general thickening with opacity, or small thickened patches. Calcification may take place in these. Delicate adhesions usually form between the dura mater and the arachnoid mater and at the base there is usually also some diffuse thickening over the inter-peduncular space and over the pons and medulla. The convolutions are usually atrophied; the sulci widened and full of fluid.

EXAMINATION OF BRAIN

Surface of the Brain.—This can in most cases be examined without removing the leptomeninges.

Note any **widening and flattening**, or **narrowing** of the convolutions, with corresponding narrowing or widening of the sulci. The general flattening of the convolutions in conditions leading to increase of tension has already been referred to (p. 377). Localized more extensive widening and flattening of convolutions indicates presence of a subjacent tumour, abscess or cyst.

Compare the size of the hemispheres, and note if the longitudinal fissure be mesial; if one hemisphere bulge across the middle line the pathological change—tumour, haemorrhage, etc.—should be looked for in the larger hemisphere.

Note any asymmetry; any localized depressions with atrophy of convolutions (softening) or general atrophy or hypoplasia of one hemisphere. In these cases the longitudinal fissure remains vertical though possibly it may not be exactly mesial. Note any laceration of the surface of the hemispheres, its position, and relation to fracture or other injury.

Separate the lips of the great longitudinal fissure; note presence of adhesions, tubercles, thickenings of the arachnoid, and—in extremely rare cases—absence of the corpus callosum.

Base of the Brain.—Compare the cranial nerves on each side, as to atrophy or involvement in exudates. Examine the infundibulum; this forms a bulging translucent cyst in chronic hydrocephalus and stretches the optic chiasma over it.

Note any laceration over the tips or on the under surface of the temporo-sphenoidal lobe, occasionally about its middle just over the petrous bone, near the same spot to which direct infection may spread from the middle ear, causing a localized abscess in the inferior temporo-sphenoidal convolution (p. 389).

The cerebellum and pons may now be separated from the cerebrum by dividing the crura cerebri just above the pons, or better, by dividing the pons transversely just above the roots of the fifth pair of cranial nerves. The position of this section is important if one wish subsequently to investigate the nuclei of the third cranial nerves. These extend upwards in the crura and are cut through in the former line of section. In the second method the section passes through the nucleus of the fourth nerve only, and this is comparatively unimportant (*see Diagrams, Plate III.*).

The cerebrum may now be cut up. It is placed upon its base, and sections may be made either parallel to the base or in a vertical coronal plane. It is not necessary in doing this to follow rigidly the descriptions given by various authorities. The principal, and in fact the only, rule to follow is to cut up the brain into as few parts as possible consonant with the demonstration of the lesions and the suitable preservation of the parts for future examination if this be deemed necessary.

My own practice is to make one horizontal section crossing the Sylvian fissure at a point midway between the anterior and posterior poles of the brain. This section passes about $\frac{1}{2}$ to $\frac{3}{4}$ in. (1.3–2 cm.) above the anterior and posterior poles. If the section be made carefully so as to divide corresponding structures on both sides at the same level, most of the important pathological changes can be demonstrated, and the two parts of the brain can be put aside to fix in formalin either separately or with a double layer of blotting-paper between the cut surfaces: this helps to preserve the normal relationships, and supports the parts so that the surfaces are kept flat. Subsequently it is easy to make additional coronal or horizontal sections of the hardened brain so as to display every portion of its substance. This procedure is of especial importance in the presence of softening, haemorrhage or new-growth.

DISEASES OF THE BRAIN SUBSTANCE

Malformations and Congenital Defects.—The whole brain may show hypoplasia—*micrencephaly*. This may be associated with an abnormally small skull—*microcephaly*—which may result from premature closure of the sutures, or may be the result of a primary hypoplasia of the brain. Partial hypoplasia is less infrequent. It occurs most commonly in the cerebrum and cerebellum. The convolutions may be small—*microgyria*; they may be sclerotic. The whole of the grey matter may be affected; occasionally hypoplasia is unilateral, causing marked asymmetry of the brain.

Portions of the brain may be wanting, e.g. corpus callosum, fornix, or the small commissures. These defects may be due in some cases to absorption following softening, the result of foetal meningitis or encephalitis or obstructive circulatory changes. Defects on the surface may be associated with development of cysts underneath the membranes—*hydranencephaly*, or *porencephaly* (Fig. 182). This may be congenital, but is probably more often acquired, resulting from vascular or other alterations leading to atrophy and absorption.

General atrophy occurs most often in old age. It is also found in chronic lead-poisoning and in alcoholism. The membranes are thickened, and the brain substance usually shows increase of neuroglia with atrophy of the nerve cells and bundles. The weight of the organ as a whole is diminished. The hemispheres appear to be shrunken, the convolutions narrow, and the sulci widened, containing excess of fluid in the subarachnoid space, the presence of which is complementary to the atrophy of the convolutions—

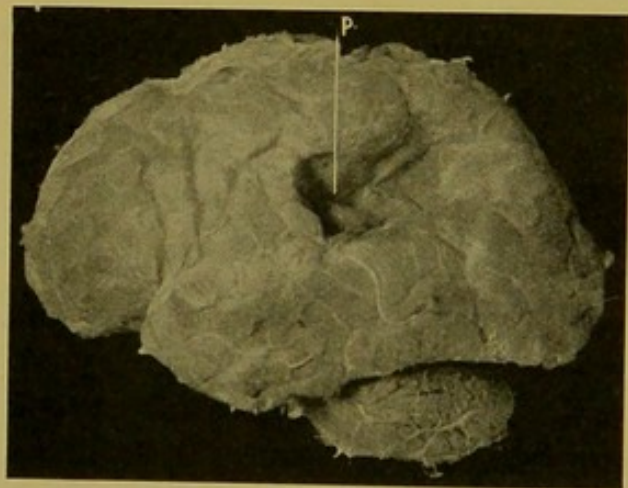


FIG. 182.—Localized defect in surface of brain. Porencephaly (p.) (\times circ. $\frac{1}{3}$.)

(From Dr. J. D. Comrie's collection.)

hydrocephalus externus, oedema ex vacuo. The ventricles also are enlarged, the ependyma granular and thickened. In the brain substance the perivascular spaces are often widened, so-called "sieve-like" degeneration—*état criblé*.

Partial atrophy results from the presence of tumours or from vascular change including haemorrhagic and ischaemic softening. This condition merges into that of porencephaly.

Oedema of the Brain.—This condition is met with post-mortem very commonly, and may be the only lesion present in cases in which the physical signs have pointed to haemorrhage, tumour or other pathological change, and it may even give rise to distinct localizing symptoms. It is very common in long-standing disease of the heart and kidneys, but is also very common in acute infective and toxic conditions, and in these cases may give rise during life to physical signs pointing to acute meningitis. Some degree of it is constantly present in acute meningitis. In some cases it is an agonal manifestation.

The brain is large and heavy; the convolutions may be flattened and pale or in some cases congested.

On section, the grey matter is distinctly marked off from the white matter. The grey matter may be slightly pink in colour from congestion, and the white matter is of a porcellanous white except in very young children, when it has the aspect of cold boiled starch. The white matter becomes very rapidly recessed below the level of the grey matter from the escape of fluid on to its surface, and is somewhat sticky, the knife often retaining a thin whitish covering upon it after making the section.

Microscopically there is dilatation of the lymphatic and neuroglia spaces. In severe forms the myelin sheaths become irregularly swollen and may break up into droplets; the axis cylinders may be wavy and in parts broken up; the nerve cells may be vacuolated and swollen.

Cerebral Haemorrhages.—Cerebral haemorrhage is usually characterized by escape of a large amount of blood—**apoplexy**—but in many conditions capillary haemorrhages are extremely common both internally and near the surface, e.g. in connexion with encephalitis; in relation to larger haemorrhages; following injuries, e.g. punctured wounds, *contre coup*; in acute infective conditions, or accompanying sinus thrombosis.

Here we shall specially consider the large cerebral haemorrhage. Haemorrhage of this kind results from great increase in arterial pressure in the presence, in most cases, of disease of the vessels. In internal haemorrhages, miliary aneurysms (*see p. 98*) can usually be demonstrated upon the minute arterioles of the basal ganglia, but these aneurysms are not invariably present, and the arteries may be the seat of other changes. For example, I have found extensive haemorrhage in the cerebrum, cerebellum and pons, in a case in which the vessels were in an advanced stage of hyaline degeneration.

Haemorrhage occurs especially in cases of cirrhosis or of arteriosclerotic

atrophy of the kidney. Usually, but not always, these conditions are associated with atheroma or sclerotic thickening of the medium-sized vessels and hypertrophy of the left ventricle of the heart (*see Atheroma and Arterial sclerosis* (p. 92). It occurs also in the haemorrhagic diatheses; in gout; often in syphilis and perhaps not infrequently in alcoholism and lead-poisoning. Other intoxications may also predispose to the condition.

While no age is exempt, haemorrhage is most common in the later periods of life. The middle cerebral is the artery most often concerned, and especially its branches passing between the external capsule and the lenticular nucleus and ending in the latter. As explaining the greater tendency to occurrence of haemorrhage in the interior of the brain, it should be noted that in the carotid system the branches to the interior of the brain pass off at right angles to their arteries of origin; they diminish in size abruptly; they have a short course and are strict end-arteries, hence the pressure in them must be almost as high as in the carotid arteries. The cortical branches on the other hand divide more gradually and dichotomously, hence the blood pressure diminishes more gradually. Moreover these branches are not end-arteries.

Local changes other than those already mentioned may be present, for example, *embolic aneurysms*; haemorrhage may take place in the interior of tumours—*sarcomata* and *gliomata*.

The haemorrhage at first is more or less local, tending to follow the lines of least resistance between the bundles of nerve fibres. As it increases in size it tends to spread towards the lateral ventricle, into which it may open. The brain substance on the outer side of the haemorrhage is lacerated and shows numerous small closely set haemorrhagic points (Fig. 183). In rare cases the haemorrhage opens on the cortical surface either laterally or anteriorly. I have never seen a haemorrhage opening upon the surface posteriorly, though I have seen it penetrating very close to the surface. On penetrating the lateral ventricle it spreads to the opposite side through the foramen of Monro, it may distend the third ventricle and appear at the base, the blood escaping through the infundibulum, when this is divided during removal of the brain. It passes down into the fourth ventricle

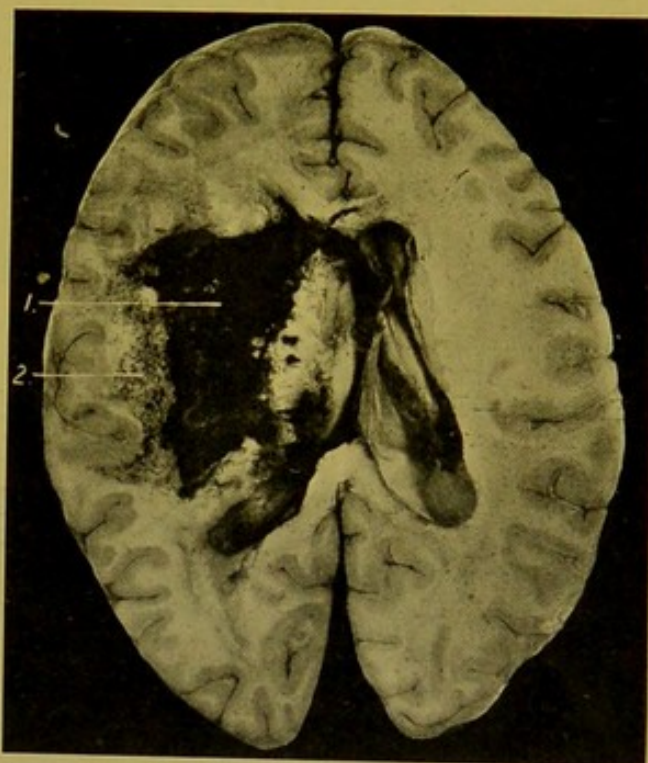


FIG. 183.—Cerebral Haemorrhage. Horizontal section of brain.

Showing haemorrhage (1) in common situation, penetrating into the lateral ventricle, anteriorly and posteriorly; and the laceration and softening (2) to its outer side. (\times circ. $\frac{1}{2}$.)

and reaches the surface through the foramen of Majendie or laterally between the pons and cerebellum, or it may escape through the great transverse fissure.

Haemorrhage may also occur from the penetrating branches of the anterior or posterior cerebral arteries, but this is a relatively rare occurrence.

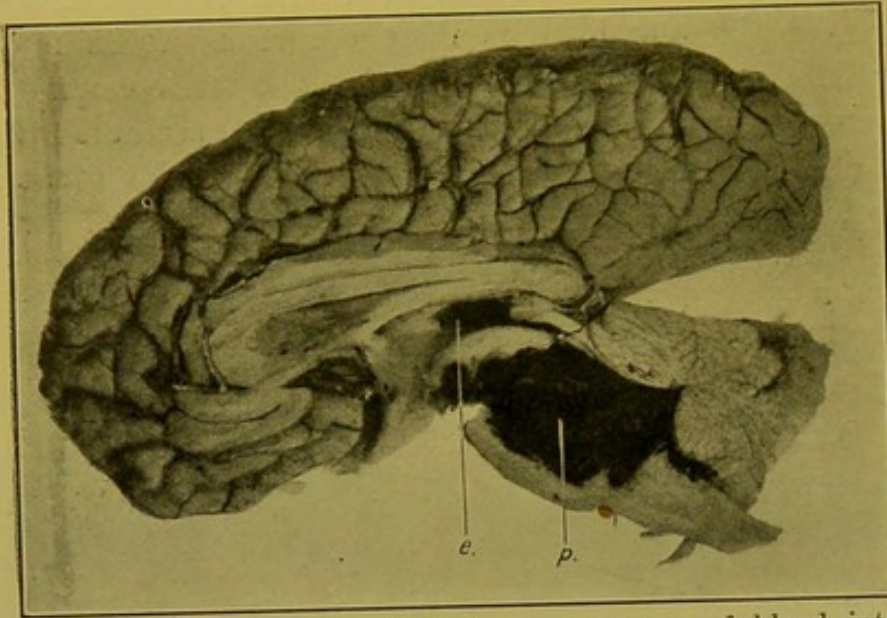


FIG. 184.—Pontine Haemorrhage (*p.*); escape of blood into fourth ventricle, and into third ventricle (*e.*). (\times circ. $\frac{1}{2}$.)

Pontine haemorrhage may be of small extent or may involve practically the whole substance of the pons. It tends to spread backwards into the fourth ventricle, from which it passes either upwards through the aqueduct of Sylvius, or downwards through the foramen of Majendie (Fig. 184).

In order of frequency Cerebral Haemorrhages occur in :—

(1) Lenticular nucleus. Here it must be remembered that the haemorrhage is sometimes so extensive that it is difficult to determine the actual site of origin.

(2) Pons.

(3) White matter of frontal lobe.

(4) Optic thalamus.

(5) White matter posteriorly.

(6) Cerebellum. In this situation it is rare and occurs usually from the branch of the superior cerebellar artery passing to the dentate nucleus.

(7) Into the subarachnoid space from the cerebral vessels.

In rare cases I have seen bilateral haemorrhages (Fig. 185).

Results.—If the haemorrhage be small, the clot may be absorbed. The lacerated brain substance undergoes fatty degeneration, is absorbed and an apoplectic cyst results, the walls of which are usually yellowish from presence of altered blood pigment. The cyst contains clear watery or yellowish fluid, in which phagocytes can be demonstrated containing haemosiderin granules and haematoidin crystals. If the haemorrhage be very small, absorption may be complete or a small patch of ochreous discoloration remains (*plaque jaune*).

Occasionally cases of medico-legal interest in which cerebral haemorrhage has occurred at an interval perhaps of months after an injury to the skull,

have to be investigated. Bollinger considered that these **delayed traumatic apoplexies** were secondary to alterations in the vessels and in the brain substance resulting from the traumatism. It is difficult to understand how alteration can occur in the vessels without other accompanying changes, such as thrombosis with softening of the area, and if softening occur, the vessel supplying the area must become obliterated within that area. I have frequently seen a haemorrhage at other parts of a brain in which softened areas were also present, but I have never seen a haemorrhage at the site of an old softening.

Cerebral Softening. — Encephalomalacia. — The middle cerebral artery gives off five branches to the cortex and in addition supplies penetrating arteries which supply the greater part of the caudate nucleus, the lenticular nucleus, the in-

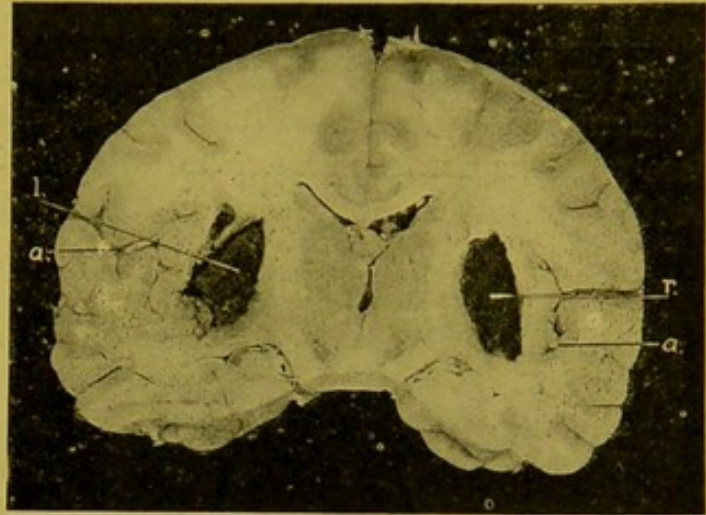


FIG. 185.—Bi-lateral Cerebral Haemorrhage. ($\times \frac{1}{2}$.)

Vertical, coronal section of brain. The haemorrhage on the right side (r.) was slightly more recent than that on the left side (l.). (a.) Atheromatous branches of middle cerebral arteries.

ternal capsule and part of the optic thalamus; the remaining parts of the caudate nucleus and optic thalamus being supplied by branches from the anterior and posterior cerebral respectively. When, for example, the Sylvian (middle cerebral) artery is blocked, softening follows in the central area of the *cortical* district supplied by the artery, provided the vessel be healthy, but if the artery and its branches be atheromatous, the softening may correspond practically to its entire area of distribution. When the penetrating (*central*) vessels are blocked, an area of softening develops corresponding to the distribution of the occluded vessels in all cases, in consequence of their being strict endarteries (Fig. 186). The area from which the blood has been cut off (white infarct) dies rapidly, signs of softening becoming evident during the second day, and it becomes gradually converted into a fluid or semi-fluid mass containing myelin, oil droplets, and compound granular corpuscles,—large phagocytic cells loaded with broken-down granules of myelin and oil droplets. In the early stages (up to 36 to 40 hours) the tissue becomes white or bluish, soft and easily broken down. Later it becomes fluid and has been compared to milk of lime.

Following complete necrosis the vessels also disappear. Finally granulation tissue forms round about and the final result is either a cyst containing clear colourless fluid—or if some blood have been present, brownish fluid—or the area becomes contracted and a brownish depressed cicatrix remains over which the pia-arachnoid is adherent. Both white (yellow) and red

softening occur, the colour of the latter being due to the presence of altered blood.

The cause of obstruction of the vessels may be either embolism or thrombosis. Embolism occurs more often on the left side and, it is said, more frequently in females than in males. It also occurs more often in the central arteries than in the cortical vessels in which thrombosis is more common. Emboli originate most often from the left side of the heart, e.g. from endocarditis of the aortic or mitral valves, or from thrombosis in the auricular appendix or within aneurysms of the heart. Occasionally emboli are portions detached from thrombi forming upon atheromatous patches or within aneurysms of the ascending aorta, and in rare cases they originate in the pulmonary veins, in presence of excavation or gangrene of the lung. In rare cases portions of thrombi in the cerebral arteries themselves may be detached and lead to embolism of their terminal branches.

The emboli are pale, reddish-grey or yellow, fairly firm and, if recent, lie loose in the vessel. This is usually closed up with secondary red thrombus.

Thrombosis of the cortical vessels depends upon disease of the walls. It may occur in old age, in chronic disease of the kidneys, or in alcoholism. In syphilis, thrombosis may follow proliferative endarteritis or gummatous arteritis. Thrombosis occasionally occurs in absence of disease of the vessel during the course of acute infective disease. Red softening may

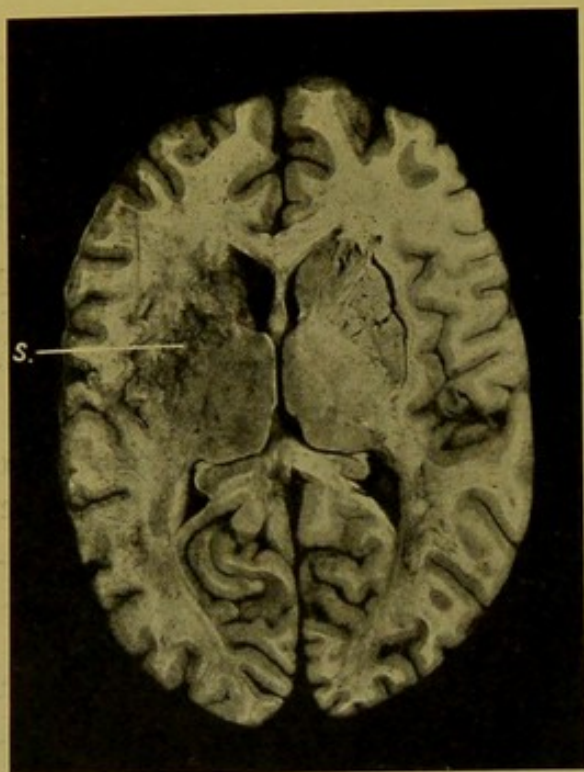


FIG. 186.—Cerebral central softening (s.).
(\times circ. $\frac{1}{3}$.)

also result from encephalitis or from thrombosis in the veins, following sinus thrombosis. The part affected becomes voluminous, is soft, diffusely reddened and beset with punctiform haemorrhages. Later on it softens down.

Encephalitis.—Acute encephalitis is a rare disease. It is primarily a vascular and interstitial inflammation which is followed by degeneration of the nerve elements. It may be associated with sinus thrombosis; it may occur without well-defined cause, or during the course of certain acute infective diseases, for example in influenza. It is said to be constant in hydrophobia, but as hydrophobia has been stamped out of this country I have had no opportunity of verifying this statement. Encephalitis is characterized by the presence of numerous closely set haemorrhagic points

(see Fig. 187, *b*.) often in symmetrical areas of the brain, usually in the centrum ovale minus, sometimes in the ganglia, less frequently in the cerebellum and pons.

Microscopically, the minute vessels are dilated, often with surrounding haemorrhage. There is infiltration of white blood corpuscles in the immediate neighbourhood and proliferation of the neuroglia cells.

Acute Suppurative Encephalitis. Abscess of the Brain. — Suppuration in the brain is rarely primary. It is usually secondary to disease of the cranial bones, for example septic wounds; or chronic purulent otitis media with caries of the petrous temporal or mastoid cells. Following the latter, suppuration occurs usually in the lateral lobe of the cerebellum, and following the former, it usually takes place in the temporo-sphenoidal lobe. Abscess of the cerebellum occurs more often on the right side. Encephalitis may also follow infected wounds of the scalp.

The suppuration may be metastatic, occurring usually under or in the cortex near the vertex (Fig. 187), or commonly in the temporo-sphenoidal lobe. It occurs in empyema, septic pneumonia, chronic lung disease (especially bronchiectasis), infective endocarditis, wounds of the surface, ulcerating tumours, and rarely in cases of thrush and actinomycosis. It may follow operations on haemorrhoids, or lithotomy. It may be followed by meningitis.

Suppuration is rare in the pons and medulla. In size the abscesses may be small or extensive, and they contain yellowish or greenish-yellow pus which may be foetid. In acute abscesses the cavity may contain yellow grumous material. The wall of the abscess may show acute encephalitis. Round about the abscess there is oedema and congestion, and yellow softening may be present. At a later stage it develops a definite wall, the thickness and density of which depend upon the age of the process. In about a month a wall of granulation tissue has formed. In about six weeks to two months the wall is more fibrous and tough, often with softer granulation tissue on its inner surface. Extension takes place more often towards the lateral ventricle than towards the surface. The organisms found may be *streptococci*, *staphylococci*, *pneumococci*, *bacillus pyocyaneus*, or various *anaërobæ*.

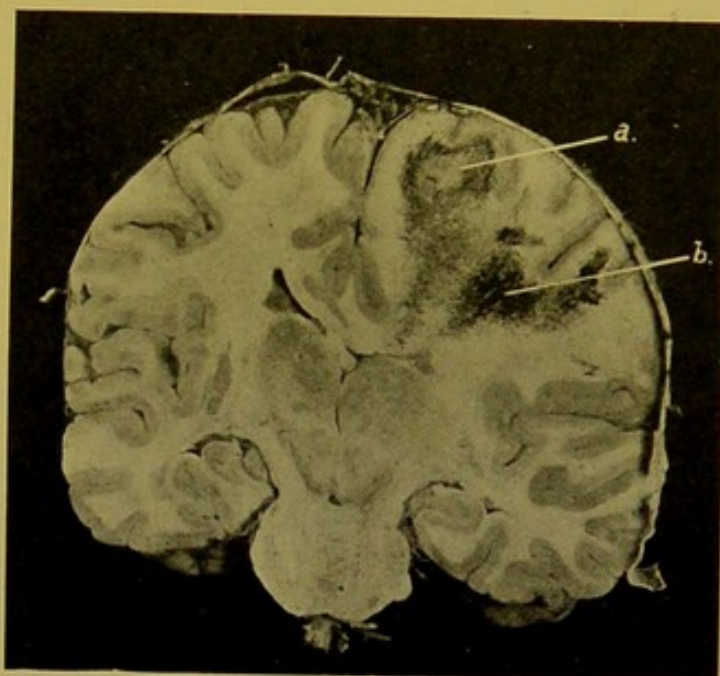


FIG. 187.—Abscess of Brain (*a.*), with surrounding encephalitis, best seen at *b.* (\times circ. $\frac{1}{2}$.)

Chronic Encephalitis.—**Insular or Disseminated, Multiple Sclerosis.**—This affects both brain and spinal cord, and even peripheral nerves. According to Bruce and Dawson the distribution of the patches in the brain follows that of the veins.

Sharply defined greyish or greyish-red, usually firm, sometimes soft, gelatinous patches are found along the horns of the lateral ventricles, and in various positions in the white matter. These are not followed by secondary degenerations.

Microscopically there is increase of the neuroglia in the area, with gradual disappearance of the nerve sheaths, the axis cylinders persisting for a considerable time.

Internal Hydrocephalus (For *Hydrocephalus externus*, refer to Diseases of the Pia-arachnoid, p. 384).—Acute internal hydrocephalus is almost

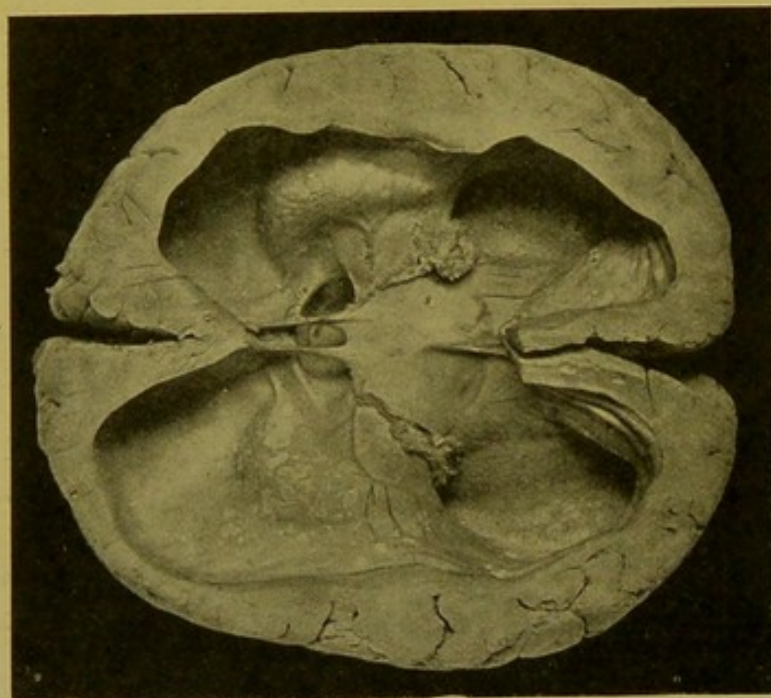


FIG. 188.—Chronic Internal Hydrocephalus. (\times circ. $\frac{1}{3}$.)

The foramen of Monro is well seen. Note the patchy thickenings of the ependyma. (From a specimen presented by the author to the Anatomy Department, Univ. of Edin.)

synonymous with tuberculous meningitis, but it also occurs in the course of acute meningitis caused by other organisms. In the latter, lines of pus may be seen along the veins on the floor of the ventricles. The ependyma is usually soft and granular, and the white matter near it is also softened and friable.

Chronic Internal Hydrocephalus may be either congenital or acquired.

(1) **Congenital Hydrocephalus.**—This condition may affect more than one of a family. It may develop *in utero*. Its pathology is still

obscure, but it appears to be generally of obstructive origin and is possibly due to intra-uterine meningitis causing adhesions of the membranes with occlusion of the foramen of Majendie, or formation of a septum across the aqueduct. In unilateral hydrocephalus the foramen of Monro may be obstructed. In some cases no obstruction is found, for example in those cases which are accompanied by spina bifida.

Watery fluid collects chiefly in the lateral and third ventricles. This is colourless and practically non-albuminous. As a result of pressure atrophy, the brain substance is reduced to a thin layer (Fig. 188). The basal ganglia and cerebellum are depressed, the fontanelles are enlarged, the

bones of the skull are separated and the spaces between them are filled either with membrane or with Wormian bones.

The bones themselves are usually thin and may show rounded or oval defects filled in with membrane (*see also Craniotabes*, p. 369). The orbital plates are oblique, rendering the eyes prominent. The face as a whole is small compared with the enlarged, rounded skull. One lateral ventricle only, or part of one, usually the posterior horn, may be dilated, or dilatation may be localized to the fourth ventricle or even to the fifth. The base of the skull is relatively short. Congenital hydrocephalus may be accompanied by other anomalies, for example, hare-lip, club-foot, encephalocele, or dwarfism.

(2) **Acquired Hydrocephalus.**—A slight degree of dilatation of the ventricles may be present without evident cause. In these cases there may be chronic nephritis, or the choroid plexus may show chronic changes, for example, cystic or calcareous alterations, but the relation of these changes to the dilatation is not always evident. In the cases to which the term is usually applied the ventricles show very considerable dilatation.

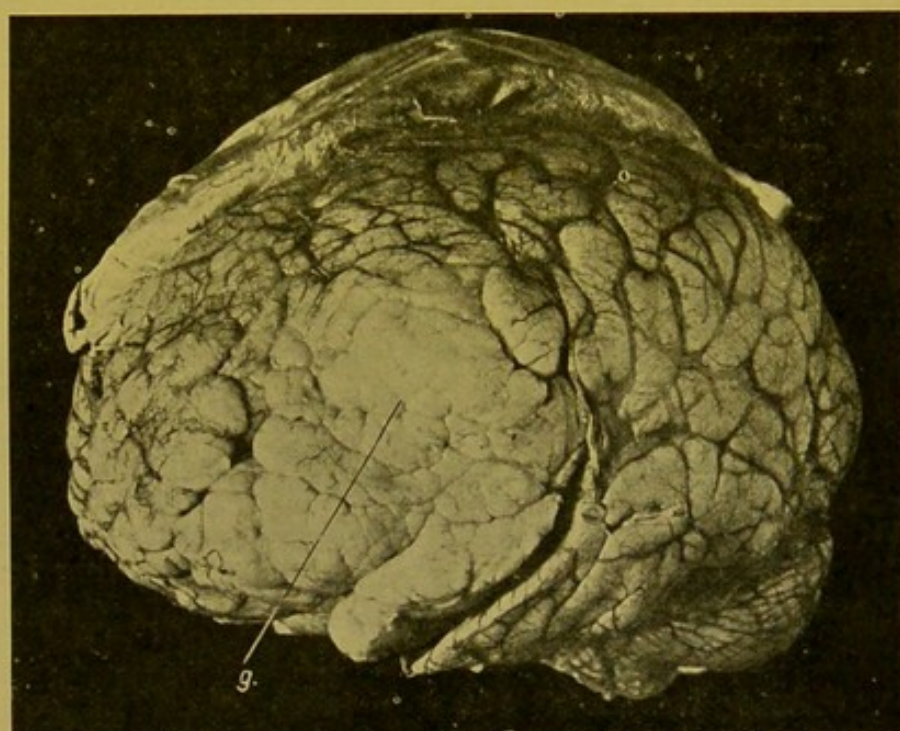


FIG. 189.—Glioma (*g.*) in left frontal lobe of cerebrum displacing the convolutions. (\times circ. $\frac{3}{4}$.)

The distension is caused by (*a*) closure of the foramen of Majendie and the lateral recesses of the fourth ventricle, following posterior basic meningitis, or by (*b*) the pressure of tumours,—for example, in the cerebellum or pons,—upon the veins of Galen, or by (*c*) closure of the aqueduct of Sylvius, by tumours within the fourth ventricle, cerebellum or pons. Dilatation of the third ventricle is frequently a prominent feature in these cases. This becomes evident at the base of the brain as a dome-like, translucent, prominence, corresponding to the position of the infundibulum, over which the optic chiasma is stretched. The appearances internally are, in general, similar to those encountered in congenital hydrocephalus. If the obstruction occur before closure of the sutures, the head may increase in size. In all

cases the inner table may show defects, and the hollows and fossae are deepened by the pressure of the lobes and convolutions.

Tumours of the Brain.—Many varieties of new-growth, chiefly secondary, may be found within the brain.

Glioma is the most important of the primary tumours. It may occur at any part of the brain, but most often in the cerebrum (Fig. 189, p. 391). Occasionally it develops within the pons, causing the so-called "hypertrophy" of the pons. It is rare in the cerebellum, and I have not yet met with glioma in this situation.

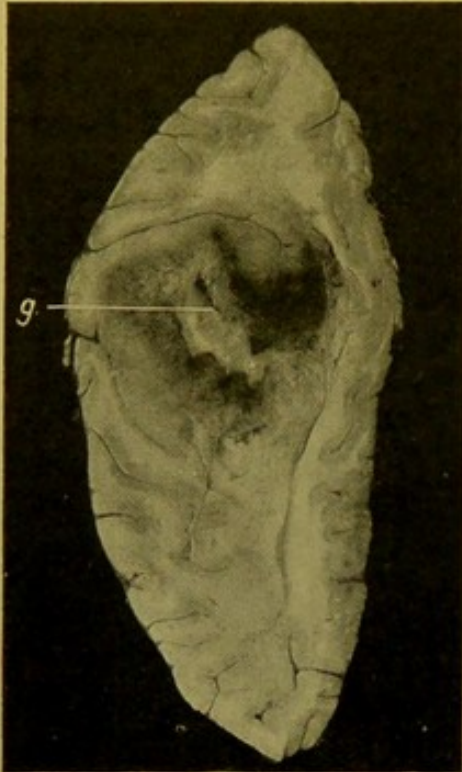


FIG. 190.—Glioma (*g.*) of the cerebrum. Horizontal section. (\times circ. $\frac{1}{2}$.)

The tumour is pale greyish in colour, resembling brain substance, and has an ill-defined infiltrating margin. It usually shows central haemorrhage and degeneration (Fig. 190). Microscopically it may show considerable variations, the commonest variety being that made up of branching glia cells, but other forms contain more fibrillar material; others again are oedematous, the appearance resembling myxomatous change within the tumour. Some contain large giant-cells, sometimes with more than one nucleus. Gliomata containing numerous cells and of rapid growth are termed "glio-sarcomata." Cystic glio-sarcomata may develop within the ventricles, apparently growing from the ependyma, and

they may show epithelial formation, so that they are frequently included under the epithelial tumours of the cerebrum.

Primary Sarcomata develop most often in connexion with the dura mater and bones, particularly at the base of the skull.

When occurring within the brain they are most often secondary, and although in many of their characters they resemble gliomata very closely they are distinguished from these tumours by possessing distinct sharp margins and by being usually of somewhat firmer consistence.

The varieties may be *spindle-celled sarcoma*, or *fibro-sarcoma*; very rarely *round-celled* and *mixed-celled sarcomata* occur. Spindle-celled sarcomata may develop in connexion with the seventh cranial root—ponto-cerebellar angle tumours (Fig. 191). These are usually rounded, and slightly flattened from before backwards.

Angio-sarcomata may occur in the young and cause death by haemorrhage.

Perithelioma may develop in connexion with the choroid plexus. It is a rare tumour and in one case I examined it distended the fourth ventricle

completely (Fig. 192, p. 394). Microscopically the cells are oval, elongated or rounded, epithelioid, and are closely related to the vessels, developing in their outer coat. The cells are supported by a delicate connective tissue framework.

Psammomata may develop in the substance of the brain or in connexion with the choroid plexus. These tumours, which are usually of small size, may reach a diameter of over 2 in. On the cut surface they are somewhat fasciculated and show little evidence of degeneration. Microscopically, the cells are for the most part spindle-shaped, forming closely set masses, often showing a concentric arrangement round about the vessels. Calcareous deposit may take place within these cell-balls.

Epithelial and Mixed Tumours.

—*Cystic squamous epithelioma* occasionally develops at the base of the brain near the infundibulum (Fig. 193, p. 395). It usually projects at the base and, in addition to its cystic character, there are usually irregular opaque areas of calcareous deposit.

Somewhat similar to the last is the rare *Teratoma* which, in one case I examined, was of the size of a hen's egg. It grew in the region of the basal ganglia and projected into the lateral ventricle (Fig. 194, p. 396). Microscopically, it contained many varieties of tissue, in this respect corresponding to the ordinary ovarian dermoid.

Cholesteatoma, or "pearly" tumour, occurs at the base of the brain in the neighbourhood of the pons, medulla, or cerebellum. It may also occur in the ventricles, growing from the choroid plexus, or in the membranes, growing from the pia mater. It is a white glistening growth somewhat resembling mother-of-pearl. It is probably of dermoid nature and in structure it corresponds to that class of new-growths. *Columnar-celled cancers* are occasionally primary, developing from the lining membrane of the ventricles. They are more frequently secondary, and I have seen

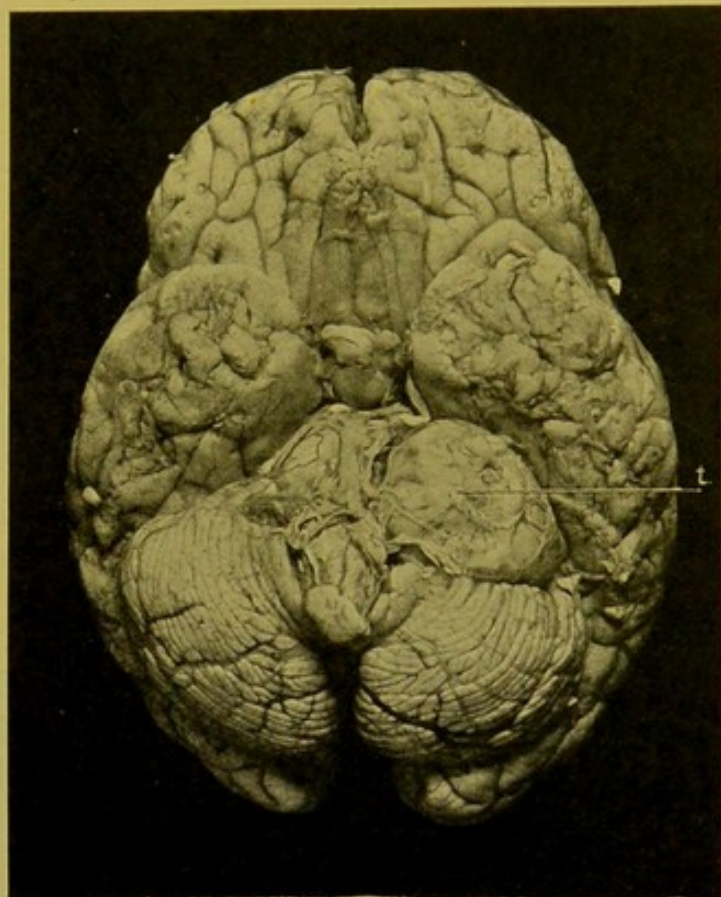


FIG. 191.—Spindle-celled Sarcoma, growing in the Ponto-cerebellar angle, from the seventh (and eighth) cranial nerve.

Duration at least 6 years. Woman became stone-blind and deaf. (\times circ. $\frac{1}{4}$.) (Dr. W. T. Ritchie's case.)

numerous metastases both of columnar-celled cancer and of scirrhous cancer. These may develop at any part of the brain.

Tuberculous "Tumours."—Caseous masses may occur in the cerebellum, cerebrum, pons, or medulla.

They occur most commonly in the more superficial parts either of the

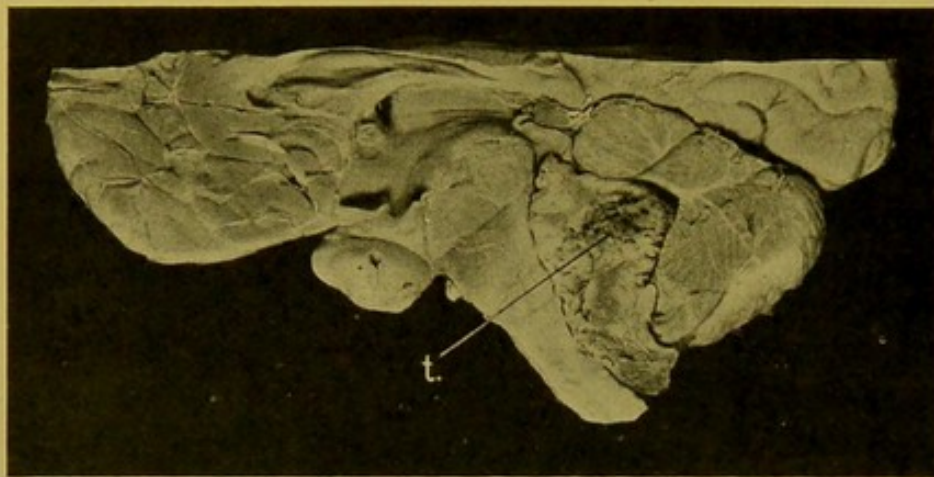


FIG. 192.—Perithelioma (*t.*) of choroid plexus, distending the Fourth Ventricle. (\times circ. $\frac{1}{2}$.)
(See text, p. 392.)

cerebellum or cerebrum, and in some cases they occur in both. In a small number of cases they develop in the basal ganglia and in rare cases in the choroid plexus. Occasionally the nodules are multiple and, as already stated (p. 380), local

dissemination (meningitis) may take place from them. In adults, old fibrous thickenings may be found, occasionally with evidence of a tuberculous origin, often wanting this, which from other evidence in the history or from other lesions in the body may be diagnosed as originally, with every probability, of tuberculous nature.

THE PITUITARY BODY. HYPOPHYSIS CEREBRI

The pituitary body can be dissected out of the sella turcica, after removal of the brain; the posterior clinoid processes being first detached with the chisel. It can be removed in continuity with the brain, by the exercise of a little care, the brain being supported while carrying out the dissection.

The anterior, larger lobe of the pituitary is composed of gland tubules, separated up by a narrow meshwork of vascular connective tissue. It is of ectodermic origin, being derived from a diverticulum from the nasopharynx. Remains of the pedicle of this diverticulum form the narrow cranio-pharyngeal canal, which passes down from the centre of the sella turcica, through the body of the sphenoid bone. Abnormalities of the canal are extremely rare. The posterior lobe is composed of vascular connective tissue in which are embedded numerous pigmented cells. Between the lobes there are spaces lined with ciliated epithelium. These may become cystic.

The glandular part may become cystic, and calcareous concretions may form.

Enlargement of the pituitary may be of adenomatous, or of sarcomatous nature. Enlargement is found in many cases of Acromegaly and Gigantism, and also in certain cases of Corpulence (*see Bibliography*). The sella turcica in consequence becomes greatly enlarged, and its walls may be absorbed. *Lipomata* and *teratomata* of the pituitary are rare tumours.

Cystic epitheliomata of the infundibulum have already been mentioned (p. 393 and Fig. 193). They are rare. They contain numerous calcareous areas.

Tuberculosis and *syphilis* attack the pituitary but seldom.

THE PERIPHERAL NERVES

In Neuritis there is exudation and cell-infiltration followed by degenerative changes; or these two types of change may proceed concurrently. Hence one cannot draw absolute distinctions between neuritis and degeneration of nerves.

Simple Degeneration of nerves results when they are cut, or it follows degeneration of the central ganglionic cells or of the end-organs. In two to four days the myelin breaks up into droplets and clumps, which are slowly absorbed; the axis cylinders a little later swell up irregularly and also break up; the neurilemma nuclei proliferate.

In **Neuritis**, the nerves are reddened and become swollen up, often forming spindle-shaped thickenings. In the perineurium and endoneurium, exudation and cell-infiltration take place; the nerves become congested, and haemorrhages may occur. The condition may proceed to suppuration. Degenerative changes follow in the myelin sheaths and axis cylinders. In the later stages—**Chronic neuritis**—there may be considerable formation of fibrous tissue. The nerves may remain thickened and firm; they are often grey in colour, or more distinctly pigmented.

Neuritis occurs in many acute infective diseases, but is most important when it occurs in the course of *diphtheria*. *Beri-beri* is an endemic form

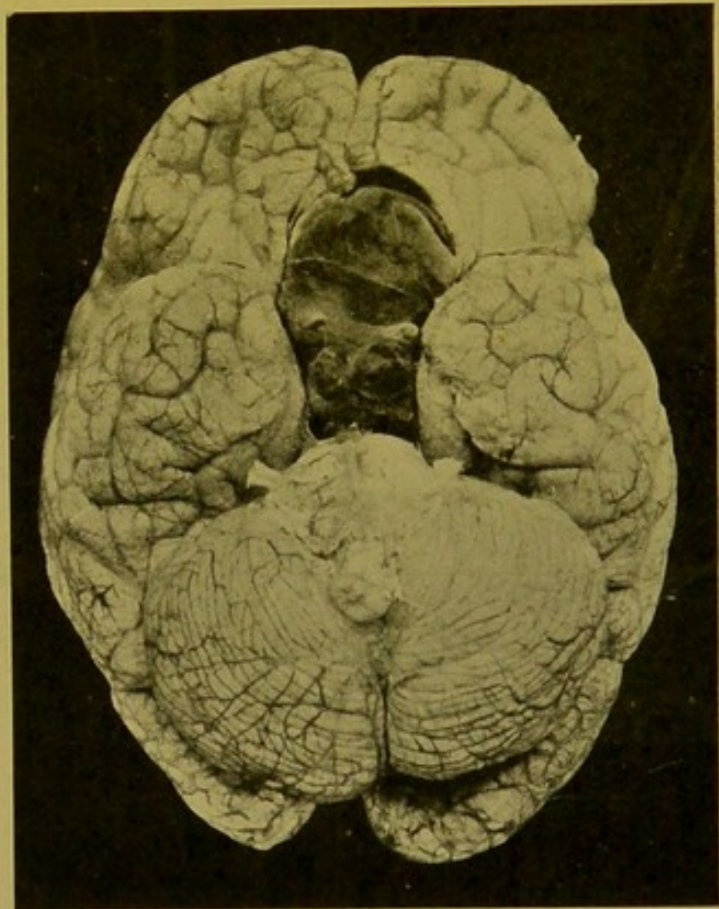


FIG. 193.—Cystic Epithelioma of the Infundibulum of the Pituitary. (\times circ. $\frac{1}{2}$.) (*See text, p. 393.*)
(Dr. Edwin Bramwell's case.)

of multiple neuritis, which is probably of toxic origin. In severe toxaemias, particularly in lead-poisoning and chronic alcoholism, neuritis is common. In *Lead-Poisoning* the nerves supplying the extensors of the hands and fingers are especially affected; *Alcoholic Neuritis* especially attacks the peroneal nerves. In the so-called *Puerperal Neuritis*, the median and ulnar nerves are especially affected.

Regeneration of Nerves.—(1) The axis cylinders grow out from the proximal **central** end of the divided nerve, or (2) the regeneration is **peripheral**, the neurilemma nuclei proliferating, and acting as neuroblasts, from which the young axis cylinders are formed. Adjacent axis cylinders join end-to-end, and this development goes on until they reach the central part of the nerve. Both these explanations have strong support.

Tuberculosis, Syphilis, and Leprosy attack the peripheral nerves, affecting chiefly the perineurium and endoneurium, and causing atrophy and degeneration of the myelin and axis cylinders.

Tumours.—The *Fibro-neuroma*, or *false neuroma*, is a diffuse fibroma of nerves. There is increase in the endoneurium and perineurium, forming spindle-shaped or

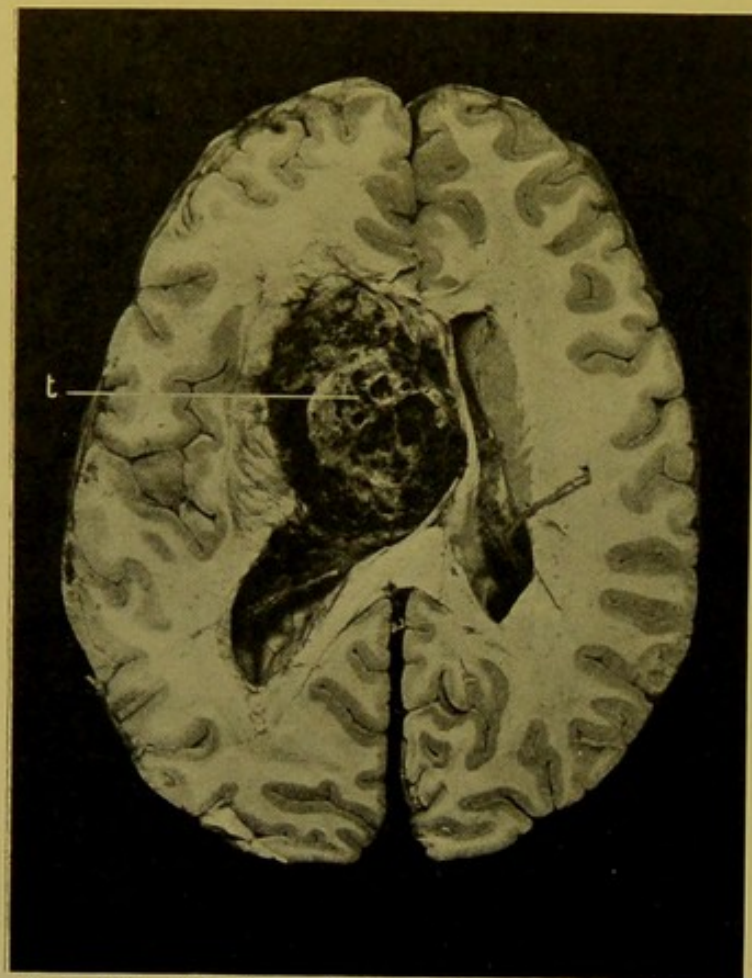


FIG. 194.—Teratoma (t.) growing near the base of the brain. (\times circ. $\frac{1}{2}$.)

From a male aet. 20. (Dr. Byrom Bramwell's case.)

(See text, p. 393.)

fusiform thickenings in the course of the nerve. For a long time the nerve conduction remains unimpaired. The swellings may grow to the size of a closed fist. A similar naked-eye appearance may be presented by *myxo-sarcoma*, or by *spindle-celled sarcoma* of nerves. In *Molluscum fibrosum*, or *multiple cutaneous fibroma*, the nodules are usually connected with cutaneous nerves, and the *Tubercula dolorosa*, or *painful subcutaneous tubercle* (Wood), is of similar nature.

CHAPTER XVIII

THE NASAL CAVITIES AND ACCESSORY SINUSES: THE MIDDLE AND INTERNAL EARS: THE ORBIT

THE NASAL CAVITIES AND ACCESSORY SINUSES

THESE cavities are most easily examined from the base of the skull, after the removal of the brain.

It is important, in the first place, to incise the dura mater surrounding the internal auditory meatus, so that the 7th and 8th nerves may not be dragged out of the meatus when the dura mater is removed. Then, with Thornton's T-shaped cyst-forceps, or other suitable instrument, the dura mater is stripped away from the base of the skull, exposing the bones, and incidentally rendering evident any fractures which may be present. By the removal of the dura, the Gasserian ganglia also are laid bare, and may be retained for histological examination, if this be desired.

(1) The most convenient method of exposing the nasal cavities and accessory sinuses is to divide the base of the skull into two lateral halves with the saw (Harke's method: *Berl. klin. Wochensch.* 1892, S. 744). The superficial soft parts are in the first place separated from the outer surfaces of the frontal and occipital bones as far down as possible. Then, with a narrow-bladed saw, the base of the skull is divided in an antero-posterior direction a little to the right of the mesial plane (Fig. 195, *H*). Anteriorly the saw-cut is carried deeply, so as to divide the hard palate and alveolar margin, this part of the operation necessitating the greatest care to prevent injury of the skin covering the root of the nose. The division of the frontal and occipital bones presents less difficulty. After completely dividing the base of the skull, it is advantageous to divide also the upper two cervical vertebrae with a broad chisel, as this allows the two halves of the skull to be more widely separated, and thus gives better access.

The nasal cavity on the right side, with the frontal and sphenoidal sinuses, are now exposed, and the ethmoid cells can be easily opened into with small bone-forceps, or with strong scissors. The left frontal sinus and the ethmoid cells on that side can then be opened in a similar manner, and by removal of the mes-ethmoid and the vomer, the nasal cavity on the left side is fully exposed. In the deeper parts of the original opening, the anterior nares, the floor of the nasal cavities, the soft palate with the uvula, the dorsum of the tongue, and the epiglottis are evident; and even the larynx can be examined, if a strong light be reflected into the cavity by means of a mirror. Posteriorly, the odontoid process of the axis vertebra, and the cut surfaces of the atlas vertebra are seen.

When the examination of the nasal cavities is completed, the halves of the

base of the skull are replaced in position, and the cut edges of the frontal and occipital bones secured with wire sutures.

(2) Another method, which is often employed to examine these cavities, is to remove with a chain saw the central portion of the base of the skull. This can be accomplished without previously

taking away the lower jaw-bone, as is usually advised. A hole is bored through the floor of the middle fossa, near the foramen ovale and the chain saw is passed down through it to the space left after removing the cervical structures and tongue (see pp. 37, 46 and 47). The head must be kept well extended. The saw-cut is carried backwards and inwards in a curve which crosses the middle line in front of the foramen magnum, and then forwards and outwards to a point in the middle fossa corresponding to that from which it started on the opposite side; it is then carried onwards through the great wing of the sphenoid, and curving inwards, crosses the middle line anteriorly, just behind the crista galli, and so on to the starting point (Fig. 195, O).

In making the anterior part of the cut, particular care must be taken to keep the saw *within* the alveolar margin of the upper jaw. The mass separated in this manner is easily removed, and can be accurately examined at leisure. The former method (Harke's), however, is so readily practised, and gives such good access, that I rarely employ the second method, which

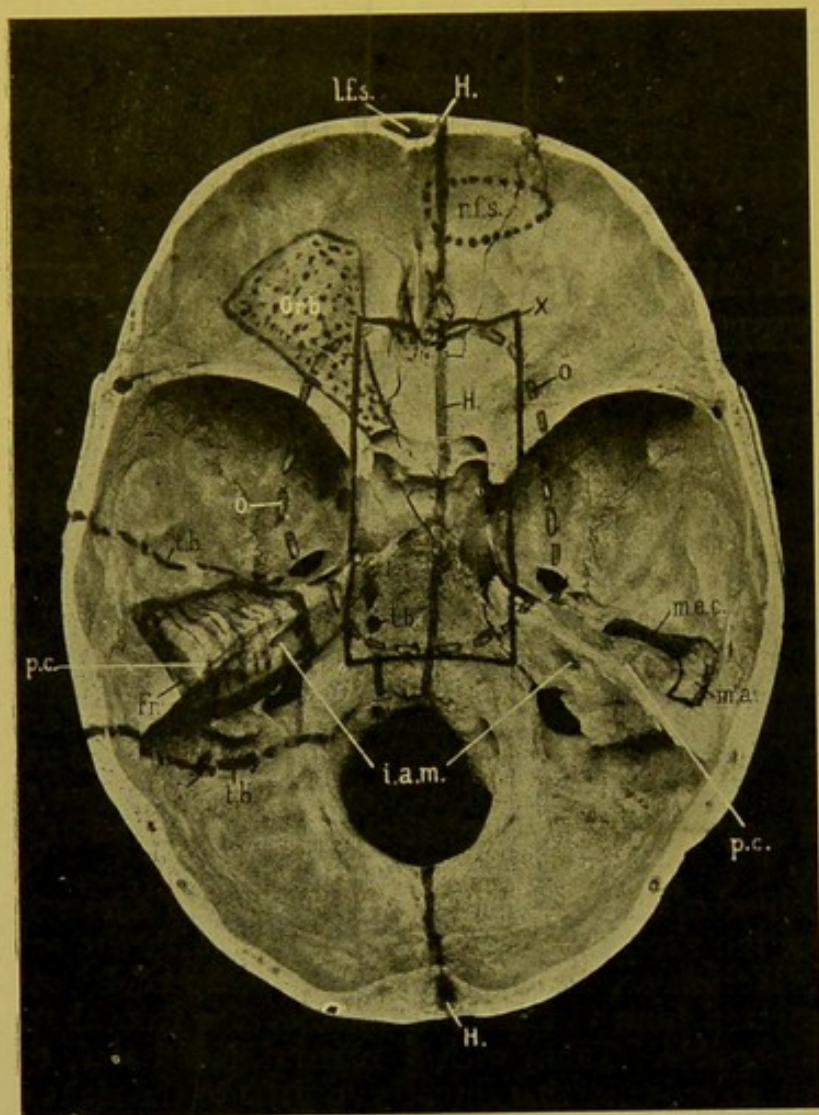


FIG. 195.—Base of Skull with markings to indicate the incisions necessary to expose the various cavities which can be examined from the interior of the skull, after removal of the brain.

(l.f.s.) Left frontal sinus; (r.f.s.) portion of bone to be removed to open frontal sinus from within skull; (H.) line of saw-cut in Harke's method; (Orb.) extent of orbital plate to be removed for examination of the orbit; (X.) incision used by Comrie and Fraser for removing portion of base (see text); (O.) line for incision with chain saw, for similar purpose; (m.e.c.) portion of bone covering middle ear cleft, and (m.a.) that covering mastoid antrum; (p.c.) eminence of the superior semicircular canal; the axis of the canal is slightly internal (anterior) to the most prominent part of the eminence; (t.b.) line of saw-cut to remove temporal bone; (Fr.) portion of petrous pyramid to be sawn out, and decalcified, for subsequent investigation of the middle and inner ears (Fraser); (i.a.m.) internal auditory meatus.

(See text for details.)

cannot be conveniently carried out without assistance in steadying and extending the head.

(3) Methods which should be employed when it is impossible or inexpedient to use either of these two methods.

The **Frontal Sinuses** can be easily exposed from the cranial cavity by gouging

away their posterior walls, commencing at the junction between the vertical and orbital plates of the frontal bone. (Fig. 195, *r.f.s.*)

Sufficient of the base of the skull to allow of a complete investigation of the condition of the **Ethmoidal cells** and **Sphenoidal sinus**, can be removed according to the method of operating adopted by Comrie and Fraser (*Edin. Med. Journ. Nov.*, 1910). "An antero-posterior saw-cut was made on each side of the sella turcica forwards to the level of the middle of the cribriform plate. These two cuts were joined anteriorly by a third made in a transverse direction and passing down into the nasal cavities. One blow with a broad chisel posteriorly went through the basi-occipital, and in this way a cuboidal block was removed containing the sphenoidal sinus and the most posterior ethmoidal cell on each side; the posterior ends of the middle and superior turbinals were removed and the sphenoidal sinus opened through its anterior wall." (Fig 195, X.)

(4) The **Maxillary Antrum**. With a little difficulty the maxillary antrum can be opened into from the nasal cavity, when this is exposed by Harke's method. It is, however, a much better procedure, and more satisfactory from every point of view, to open the antrum from below.

The upper lip and the nose are separated from the upper jaw by making an incision in the angle between the lip and the gums. On dragging upwards the superficial soft parts, the anterior wall of the antrum is exposed and can be removed easily with a gouge or chisel, so as to give sufficient access.

DISEASES OF THE NOSE AND ACCESSORY CAVITIES.

Haemorrhage from the Nose (*Epistaxis*) takes place usually from the veins of the septum, but it may also occur from the ethmoidal veins. The commonest cause is *rhinitis sicca*, in which a scab forms upon the septum. It may also be caused by traumatism; it may occur in hyperaemias; from vascular new-growths, such as the bleeding polypus—congenital angioma—of the septum, or from malignant growths; in infective diseases, especially typhoid, in which ulcers may form on the septum; in anaemias; in haemophilia; in scorbutus and in leucocythaemias. Sub-mucous haemorrhages occur in newly-born children who have died of suffocation.

Inflammations.—**Acute catarrhal rhinitis** may result from the action of thermal or chemical irritants, or may accompany acute infectious diseases, such as coryza or measles. The bacterial causes may be *staphylococci*, *streptococci*, but the commoner agents are *pneumococci*, *pneumobacilli*, *micrococcus catarrhalis*, and others. The mucous membrane is swollen, congested, and infiltrated with leucocytes.

Acute purulent rhinitis may be caused by the ordinary pyogenic cocci, by the *gonococcus*, or by the *bacillus mallei*. It may occur in the presence of foreign bodies, and may also be secondary to operative interference.

These inflammations may extend to the *Accessory Sinuses*, and thence may spread through the floor of the middle or anterior fossae to the meninges,

to the cavernous sinus or to the frontal lobe; the infection may pass by direct continuity or by way of the lymphatics or veins.

Membranous rhinitis may occur during the course of scarlet fever, and has been recorded as accompanying erysipelas, but, seeing that most cases are caused by the *Bacillus diphtheriae*, the presence of this organism should be excluded before admitting the possibility that the membranous inflammation is caused by other organisms, such as *streptococci* or *pneumococci*. This disease occurs in epidemics in children, and though due to the diphtheria bacillus, does not give rise to faucial or laryngeal diphtheria. It occasionally attacks adults.

Chronic rhinitis may be *hypertrophic* or *atrophic*. In *chronic hypertrophic rhinitis* the mucous membrane and submucosa are thickened, in the first instance, as the result of chronic inflammatory oedema. This inflammatory oedema is often localized, and tends to produce pendulous *polypoid swellings*, particularly from the middle turbinals; the inferior turbinals are also affected by chronic inflammatory oedema, but definite polypus-formation does not occur in them.

Chronic atrophic rhinitis is of two kinds. The *first* occurs in anaemic individuals, and is due to collapse of the erectile tissue spaces of the nasal submucosa. The *second*, as a rule, follows the purulent rhinitis and "snuffles" of children. The mucous membrane in this form is atrophied, thin, and may be covered with offensive crusts, producing **Ozaena** ("a bad smell"). The epithelium is altered from ciliated to squamous, the mucous glands and also the subjacent bone are atrophied. This condition may be accompanied by disease of the accessory sinuses. Ozaena may also result from tuberculous or from syphilitic ulceration. The so-called "*ozaena bacillus*" resembles very closely the *pneumobacillus*, if, indeed, it be not identical with that organism. It is probably responsible for the offensive smell, but it is doubtful whether it bears a causal relationship to the primary rhinitis.

Tuberculosis.—(a) *Miliary* tubercles or *caseating* tubercles may be found, the latter tending to coalesce, and break down to form ulcers. A favourite site for these ulcers is the cartilaginous septum, which may as a result become perforated. Another tuberculous manifestation is the formation of *polypoid masses* of tuberculous granulation tissue. Ulceration occurs in some cases of advanced pulmonary tuberculosis.

(b) *Lupus* usually begins about the anterior nares, and may invade the nasal cavities, in addition to spreading over the face. In the nose it attacks the mucous membrane of the septum and inferior turbinal, and leads to great infiltration, with hyperplasia of the epithelium, or to formation of warty excrescences. The anterior nares are often stenosed, and in advanced cases the tip of the nose may be lost.

Manifestations of primary **Syphilis** are seen occasionally; those of secondary stage very seldom. The tertiary manifestations are important.

Gummata may develop in the periosteum, or far back in the perichondrium of the septum. Great destruction may follow, and the subsequent cicatricial contraction causes falling-in of the bridge of the nose.

In **Glanders** there may be either diffuse infiltration, or nodules may develop. These tend to suppurate, forming pustules, or go on to the formation of crater-like ulcers. New nodules form at the periphery, and by breaking down of these the ulcers extend. Glanders ulcers may simulate those of tuberculosis, lupus, or syphilis. Bacteriological and histological investigations are required to make the diagnosis clear.

In **Leprosy**, granulomatous nodules develop in the mucous membrane and ulcerate. The septum may become perforated so that the nose becomes recessed. The discharge contains numerous leprosy bacilli, which, it should be remembered, when in a freshly made film, resist more strongly decolorization with mineral acids than when in sections of tissue which has been fixed a long time previously.

In **Rhinoscleroma**, which in this country is an extremely rare disease, flat or raised, firm, sharply circumscribed, granulomatous masses develop, at the junction of the upper lip and nose. They extend upwards into the nose, or downwards over the lip.

Nasal concretions may undergo calcification (*Rhinoliths*).

New-growths—Oedematous fibrous polypi have often erroneously been termed myxomata. (See *Chronic Hypertrophic Rhinitis*, p. 398.) The Bleeding Polypus of the septum has already been mentioned (p. 397). *Papillomata* may grow from the septum or from the inferior turbinals. *Fibromata* may develop in the neighbourhood of the posterior nares. *Chondromata* and *osteomata* are rare. Ivory osteoma of the ethmoid may invade the cranial cavity. *Sarcomata* occur more commonly than *carcinomata*. *Squamous epithelioma* occasionally develops from the mucous membrane of the nasal cavities or of the sinuses by a metaplasia of the epithelium.

For other diseases of the Accessory Sinuses, the reader should consult special Manuals.

THE MIDDLE AND INTERNAL EARS

The best method of opening up the **Middle Ear** is the following. After removing the dura mater, and cleansing away all blood or pus from the surface of the petrous bone, a narrow and sharp gouge is used to remove the portion of bone corresponding to the roof of the middle ear cleft to the extent indicated on Fig. 195, *m.e.c.* This portion of bone lies almost parallel to the *posterior* border of the petrous pyramid, and its anterior limit corresponds nearly to the angle between the middle fossa and the petrous bone. In this way the tympanum and Eustachian tube are exposed from above. By removing the portion of bone external to the prominence of the superior semicircular canal (Fig. 195, *p.c.*), the mastoid antrum is opened up.

The *Semicircular canals*, *Vestibule*, and *Cochlea* can be exposed to a limited extent by removing the dense bone over them; but the only really satisfactory method of examining the **Internal Ear** is to remove the temporal bone, saw out the internal ear, and after decalcifying it, to embed it in celloidin and make sections, either in a horizontal or in a vertical plane.

The superficial soft parts, including the outer ear, are reflected from the

outer surface of the temporal bone (the external, cartilaginous, meatus being cut through), and then with the saw an anterior cut is made through the bone in a line joining the root of the zygoma with the anterior border of the petrous bone at its apex, and then, posteriorly, another cut is made along a line joining the posterior border of the mastoid process and the foramen magnum. (Fig. 195, *t.b.*). After joining the inner ends of these saw-cuts with the aid of the chisel, the separated bone is levered outwards and the soft parts underneath severed with a knife.

The petrous bone is then divided transversely by one saw-cut posterior to the eminence of the superior semicircular canal, and by another in front of the internal auditory meatus (Fig. 195, *Fr.*). A third cut must be made through the external meatus, parallel to the posterior surface of the petrous pyramid. The cuboidal block separated in this manner contains the middle and internal ear. The superior canal should now be opened into with cutting bone-forceps.

[Preparation of the bone for cutting in celloidin. To decalcify, place in,
Nitric acid, 1 pt.

Formalin (10 per cent.), 9 pts.

Change every day during the first week; every other day during the second week; and twice a week during the third and fourth weeks. Wash in running water for three or four days, then place in 50 per cent. spirit for 1 day; 70 per cent. spirit, 1 day; 90 per cent. spirit, 3 days (changing every day); absolute alcohol, 1 day; absolute alcohol and ether, equal parts, 1 day; thin celloidin (Schering's), 1 month; thick celloidin, 1 month; allow specimen to dry, harden, and then mount on hard wood or vulcanite block.—Dr. J. S. Fraser.]

The cartilaginous portion of the Eustachian tube is left behind, but it can be removed subsequently, and examined by means of sections cut in paraffin.

DISEASES OF THE MIDDLE AND INTERNAL EARS.

Although often comparatively little can be made out with the unaided eye on opening up these structures, examination of them should not be neglected in cases in which there is a purulent meningitis apparently spreading from the neighbourhood, which appears to have followed inflammation of the middle or internal ear. Culture media should be inoculated in such cases from the cavities as soon as they are opened, and the growths obtained should be compared with those obtained from the meningeal pus. Sometimes in similar cases the petrous bone over the middle ear is discoloured, or it may be carious, and the dura mater may be adherent to the bone over the same situation.

The most important disease is **Otitis media**. On opening up the middle ear, the mucous membrane is vascular and swollen, so that it encroaches upon the cavity. The inflammation may be *serous*, *mucous*, *haemorrhagic*, *purulent*, or *membranous*. The purulent variety may attack the periosteum and lead to caries and necrosis of the bone. It usually spreads into the mastoid cells, and may involve the labyrinth; it may spread to the meninges, temporal lobe and cerebellum. The mastoid antrum and air-cells are almost invariably affected, and indeed they may be alone involved as the disease in the tympanum may pass off. The causal bacteria may be *staphylo-*

cocci, *streptococci*, *pneumococci*, *pneumobacilli*, *bacillus pyocyaneus*, *bacillus proteus*, or the *bacillus tuberculosis*, the last often accompanied by other organisms. In children otitis media may be associated with gastro-enteritis, or with septic pneumonia. In long-standing cases of suppurative otitis media, sclerosis of the bone may develop, particularly in the mastoid cells.

In chronic inflammations, the superficial epithelium assumes the squamous type and becomes desquamated, forming laminated masses which undergo decomposition, forming the so-called "*cholesteatoma*" of the middle ear and mastoid antrum.

In *Fracture of the base*, with implication of the middle and internal ear, *blood* is found within these cavities.

Tuberculosis may attack the middle ear from the naso-pharynx, the infection passing along the mucosa of the Eustachian tube, or the infective agent may be blood-borne. The former mode of infection is common in bottle-fed infants.

Nodules form in the mucous membrane; these become caseous, break down and ulcerate; a mixed infection soon occurs, and bone disease (caries and necrosis) rapidly supervenes. The internal ear is frequently affected.

For other diseases of the Internal Ear, the reader should consult special Manuals.

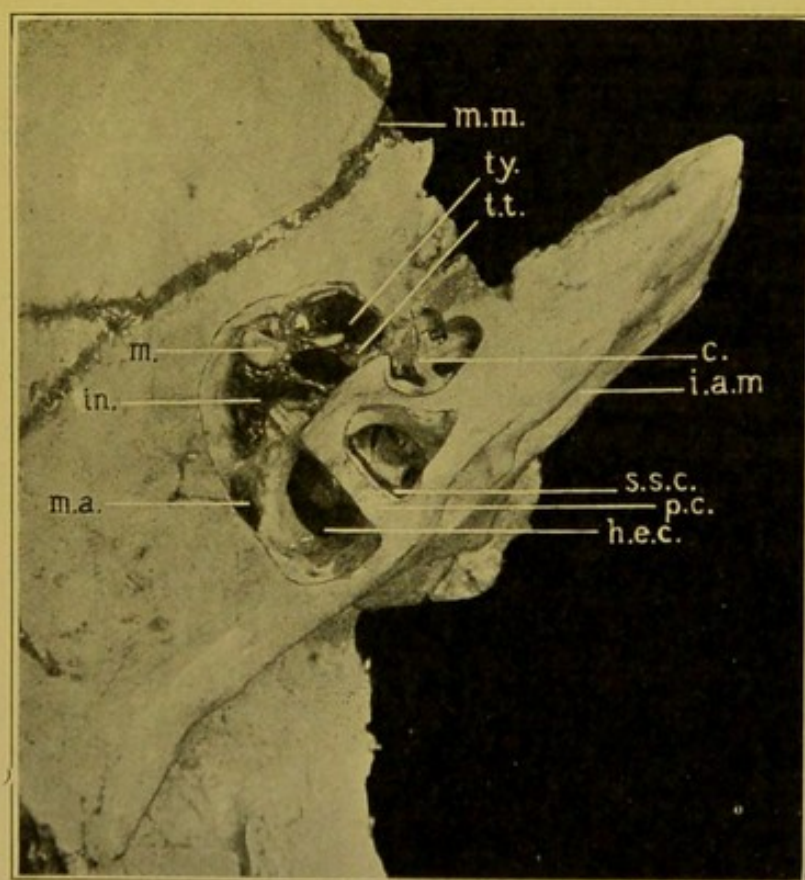


FIG. 196.—Upper surface of petrous pyramid of left temporal bone; the middle and internal ears exposed. ($\times 1\frac{1}{2}$.)

(*m.m.*) groove for middle meningeal artery; (*ty.*) tympanum; (*t.t.*) tensor tympani; (*c.*) cochlea; (*i.a.m.*) internal auditory meatus; (*s.s.c.*) superior semicircular canal, slightly internal (anterior) to most prominent part of the eminence (*p.c.*) of this canal; (*h.e.c.*) horizontal, external canal; (*m.a.*) opening into mastoid antrum; (*in.*) incus; (*m.*) malleus. (Preparation kindly lent by Dr. Logan Turner.)

THE ORBIT

To open up the orbital cavity, a triangular portion of the orbital plate of the frontal bone is removed with the chisel or with forceps, commencing behind at the optic foramen (*see* Fig. 195, *Orb.*). By removing the fat and muscles the operator exposes the optic nerve and the posterior part of the globe. With a very sharp knife he then removes the posterior half of the globe, taking with it the optic nerve. The best fixing fluids for the eye and optic nerve, are Müller's fluid, or Müller's fluid containing 5 to 10 per cent. of its bulk of formalin.

In restoring the parts, a piece of black cotton-wool, or a small piece of a dark organ such as the liver, should be placed within the portion of the eye left in the body, and the orbit packed with pledgets of moist cotton-wool, so as to restore to the eye its normal prominence and consistence.

DISEASES OF THE ORBIT.

In *Chloroma* masses of new-growth may occur within the orbit, developing from the periosteum (*see* p. 411). Other orbital tumours may be *dermoids*, *angiomata*, *neuro-fibromata*, *osteomata*, *sarcomata*, including the *melanotic sarcoma* which usually begins in the choroid of the eye; and *adenomata* or *carcinomata* of the lacrymal gland. The most important tumours of the eye are the *melanotic sarcoma* of the choroid, and the *glio-sarcoma* of the retina.

An important detail in connexion with mechanical injuries of the orbit is that when a blunt object (pencil, stick, ferrule of umbrella, to take actual cases which have occurred) has been pushed up into the orbit, the eye usually escapes serious injury, though the orbital plate of the frontal bone may be fractured and displaced upwards. Such cases may die from purulent meningitis, in which the actual causal agent is either a *streptococcus* or the *pneumococcus*, the latter of which may gain access from the accessory nasal cavities as a result of injury to the ethmoid bone.

Intra-orbital *suppuration* may follow external injury, or may be associated with suppuration in the accessory nasal sinuses, or with septic thrombosis of the venous sinuses of the dura mater.

For diseases of the Eye, the reader should consult special Manuals.

CHAPTER XIX

DISEASES OF BONES; JOINTS; MUSCLES

BONES

Repair of Fractures.—The periosteum is seldom completely torn asunder, and when the fragments of bones are replaced in position it forms a more or less complete sheath surrounding the site of fracture. Absorption of the blood, which escapes at the time of the injury, soon begins, and it is replaced by a soft, whitish, jelly-like material, partly cellular exudate, partly the result of oedema. This penetrates the medulla, separates the ends of the bone, and soaks into the surrounding soft parts. The periosteum soon becomes thickened, softer, more vascular, and as a result of the rapid proliferation of its deeper layer, plays an important part in the conversion of the jelly-like material into granulation tissue. Further changes follow, especially near the periosteum, and, in time, the soft, provisional *callus* is converted into spongy bone. Ossification begins about the end of the second week, in ordinary cases. The outer layers of the medulla also take part in these productive changes, but to a lesser extent. The ends of the bone undergo rarefying changes, so that their vascularity increases and they are then able to share in formation of the granulation tissue. Delay in union of a fracture may be accounted for by the slowness of these changes in the ends of the bone; for example, necrotic laminae may have to be absorbed before the vascular tufts can project from the dilated Haversian canals. After the bones have been bound together by this bony tissue, resorptive processes set in, which gradually remove the bony callus, with the exception of that between the ends of the bone.

INFLAMMATION OF BONE.

Acute Inflammation of Bone — Osteitis may be either of traumatic or of infective origin.

(a) *Traumatic.*—The injury results in sub-periosteal haemorrhage, followed by transitory inflammation and regenerative proliferation of the periosteum and medulla with complete recovery, provided the individual be in good health; in other individuals the condition may proceed to suppuration.

(b) *Infective* inflammation or **acute suppurative osteo-myelitis** may arise spontaneously or may follow infective diseases like typhoid, measles or scarlet fever. The exciting cause may be some slight mechanical injury. Micrococci are found, especially *staphylococci*—*aureus*, or *albus*, occasionally *citreus*—and *streptococcus pyogenes*. Typhoid bacilli may occasionally be found in periostitis, either alone or accompanied by other pyogenic organisms.

The disease affects primarily the medulla or periosteum, or both, or may primarily attack the epiphysis. It may attack one, or occasionally several, of the long bones. The femur and tibia are commonly affected, less commonly the bones of the upper extremity, and still less commonly the short and the flat bones.

On section of the bone, opaque grey or yellow patches are seen in the medulla, sometimes circumscribed, sometimes without definite margins (Fig. 197). These are surrounded by highly vascular marrow. The pus may penetrate the epiphyseal cartilage. Sub-periosteal pus may burrow into the neighbouring tissues, particularly in very acute periostitis. Very seldom the exudate underneath the periosteum is a tough albuminous or serous material.

Whether commencing in the marrow or under the periosteum, the process soon extends to the bone, so that osteitis is super-added. The results depend altogether upon the size or number of the suppurating foci, so that a limited or total, central or superficial, necrosis of the shaft follows, depending in the one case on obstruction of the nutrient arteries by pressure of the exudate, or by thrombosis, and in the other depending on separation of the periosteum by the pus which forms underneath it.

Localized suppurations are limited by a granulating inflammation which also separates dead bone if the patient does not die of pyaemia. The separated bone—*sequestrum*—lies in an abscess cavity. If small and superficial it may be completely removed in the course of a few weeks or months. In the meantime the separated periosteum becomes unduly active and forms a sheath of new bone encasing the old. Through this

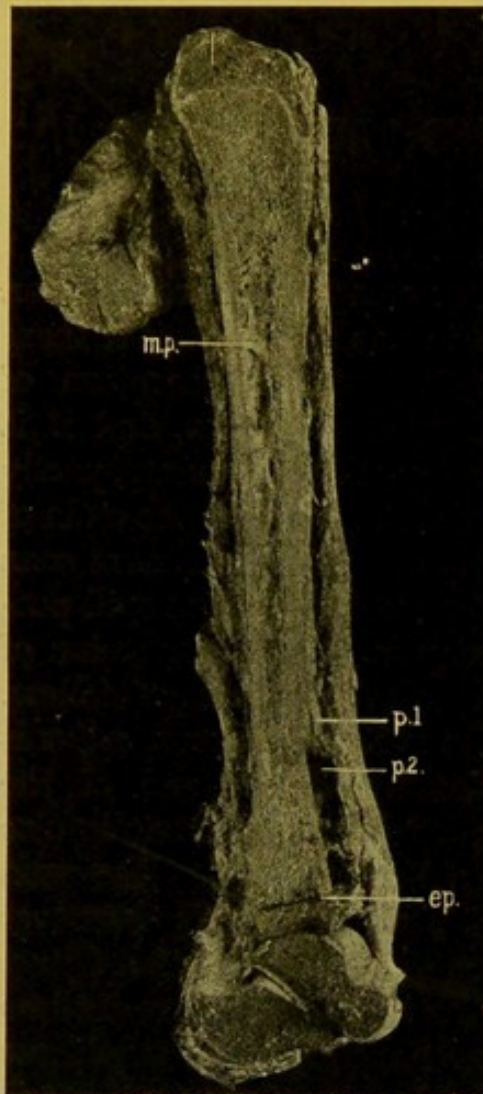


FIG. 197.—Acute Suppurative Osteo-myelitis: longitudinal section of Tibia, also Astragalus and Os Calcis. (\times circ. $\frac{1}{3}$.)

(m.p.) Pus in medullary cavity; (p. 1.) periosteum thickened; (p. 2.) periosteum, raised from bone by collection of pus; (ep.) epiphyseal cartilage destroyed. (Mus. R.C.S. Edin.)

casing the pus makes its way to the surface through openings in the new bone and fistulae in the soft parts. The absorptive process is usually inadequate to remove large sequestra. Generally these have to be removed by operation.

After the removal of all dead bone, the suppuration ceases, and the new shaft gradually returns towards its normal shape by a process of resorption. In cancellous bone, e.g. in the epiphyses, suppuration may become chronic, and a wall of dense bone, lined by granulation tissue, containing gritty particles, encloses the area—*Brodie's Abscess of bone* (Fig. 198). Somewhat similar chronic bone abscesses may occur as a sequel of tuberculous or syphilitic osteitis.

In chronic inflammation of bone, of whatever origin, young cellular vascular tissue forms on the surface of the bone. A network of osteoid tissue develops in this and later true bone-formation takes place, forming outgrowths or *osteophytes*. These tend to increase in density, and at a still later stage when the suppurative process is at an end, they are gradually absorbed.

The skin may be ulcerated over these osteophytic outgrowths.

Tuberculosis of Bone.—This is the most common disease of bone. It preferably attacks growing bone, hence is more frequently encountered in children than in adults.

Infection may take place by way of the nutrient arteries, producing gross lesions with formation of large sequestra or a diffuse tuberculous osteomyelitis; but infection of the head of the bone by way of the articular arteries is more common, the synovial membrane being frequently affected simultaneously. The process may also extend to the bone from the neighbouring tissues.

The cancellous bone is especially affected, for example, in the epiphyseal ends of the long bones; in the vertebral bodies; and in the bones of the ankle and wrist. In the young the whole length of the phalanges may be involved, but tuberculosis of the shafts of the *long* bones of the extremities is relatively infrequent. In the *spine*, the tuberculous process begins, as

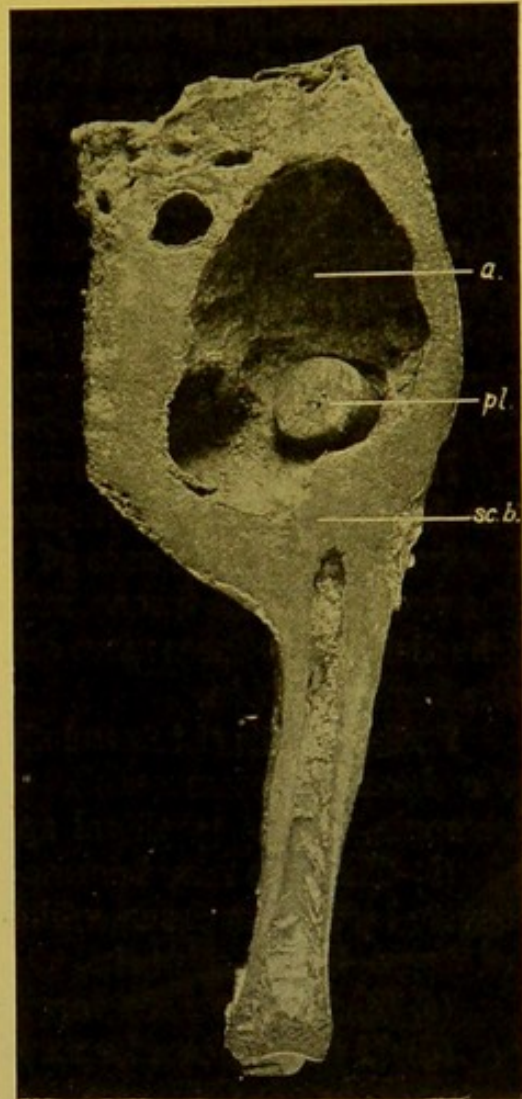


FIG. 198.—Chronic Abscess of Bone (Brodie's). (\times circ. $\frac{1}{2}$.)

Longitudinal section of Tibia of adult showing (a.) abscess cavity; (pl.) wooden plug made and used by the individual to close the sinus during life; (sc.b.) sclerosed bone, shutting off abscess from medullary cavity. (Mus. R.C.S. Edin.)

a rule, at the junction between the body and the epiphyseal plate, but it may begin at any part of the cancellous tissue. It occasionally begins in the joints, and then causes destruction of the articular processes, and the adjacent portions of the neural arches.

The appearances presented are similar to those which characterize tuberculosis elsewhere. The marrow becomes congested and small grey tubercles develop in connexion with the minute arterioles. As secondary tubercles develop, and the tuberculous granulation tissue extends, the trabeculae are absorbed and the medullary spaces widen—*tuberculous osteoporosis* or *caries*. The central part of the focus caseates and softens, a cavity being formed which contains caseous pus, and is lined with tuberculous granulation tissue—"Cold abscess of bone." If the spread be more rapid, the pus contains gritty particles of the incompletely absorbed trabeculae, and the walls are not so well-defined. Occasionally *sequestra* form, which may be of large size if the original lesion have been gross. *Fistulae* may or may not develop.

In the spine the caseous products collect in front of or at the sides of the bodies. The odontoid process may be removed by the caries. *Sequestra* rarely form. In the case of the lower vertebrae, the abscess may penetrate the sheath of the psoas muscle, and burrow downwards—psoas abscess. The disease produces more deformity in the upper regions of the spine than in the lumbar region.

Further results of tuberculosis of bone.—(a) If the process be sub-periosteal the bone becomes exfoliated, and an abscess forms on the surface, for example, in the popliteal space.

(b) The area may become encapsulated, and shut off from the medullary cavity by fibrous tissue, which, at a later period, becomes the seat of deposit of dense bone—*sclerosis*.

(c) The whole area may become sclerosed.

(d) If the process be near the epiphyseal or articular cartilages, it may extend through these, and then the neighbouring joint becomes affected. It may spread underneath the articular cartilage, separating it up and causing it to necrose. The exposed bone is covered with granulation tissue in which always, though sometimes with difficulty, evidence of its tuberculous nature is found. The synovial membrane may be attacked secondarily.

(e) Ankylosis of the neighbouring joint is a common result.

(f) The tuberculous process may remain latent for a long time, and again become active, the cause of this recrudescence not being always evident.

(g) Sub-periosteal osteophytes always develop in the neighbourhood.

Syphilis of Bone.—(a) **Congenital Syphilis.** The condition is best demonstrated by exposing the end of a long bone, e.g. humerus, and splitting it up with a strong knife. The epiphysis usually separates readily from the shaft, the end of which is covered with vascular soft tissue. The features

of the change are the great irregularity and widening of the zone of calcification, associated with great proliferation of the cartilage cells. On the diaphyseal side of the epiphysis, in marked cases, soft greyish-red cellular tissue fills up the widened medullary spaces. There is very little bony deposit, usually only deficient calcification of the narrow trabecular remains of the cartilaginous matrix.

(b) **Acquired syphilis** of bone usually shows tertiary manifestations, most frequently with formation of gummata underneath the periosteum or even in the medulla.

(1) Periosteal gummata are seen especially in bones uncovered by soft parts—e.g., tibia, ulna, sternum, or calvarium. Flat, sub-periosteal swellings of elastic consistence develop. In the early stages they are gelatinous, then they become of a more opaque aspect, more like pus, and at a later stage they are composed of fibrous tissue surrounding a dense white cheesy mass. Ultimately a dense fibrous thickening of the bone is left. The bone underneath is always absorbed and it may undergo necrosis. This condition frequently attacks the skull—"Corona Veneris." (See p. 371.)

(2) The medullary variety attacks the phalanges and diploë of the skull. It is rare in the long bones. Gelatinous pus forms, or a cheesy mass develops inside the bone which becomes carious and necrotic, whereas the neighbouring bone undergoes hyperostosis. Frequently superficial periosteal hyperostosis is present in syphilis without formation of gummatous nodules, for example on the surface of the long bones—*syphilitic nodes* (Fig. 199). The rest of the bone may be either sclerous or porotic. Hyperostosis may affect also the interior of the shafts.

Rickets.—Rickets is a disorder of nutrition, the supply of calcareous salts to the bone being deficient. The cause may be an absence of lime salts in the food or a lack of absorptive power in the intestines, or some failure to utilize these salts. It depends on faulty feeding. Children brought up on artificial foods, badly nourished, or suffering from digestive disorders, are especially liable to rickets, particularly if the hygienic conditions be defective. The following pathological changes are found.

(1) **Changes in the epiphyseal ends of the long bones.**—(a) Excessive multiplication of the cartilage cells causing a thick, irregular, bluish zone.

(b) Imperfect deposit of calcareous salts in the matrix.

(c) Excessive ingrowth of vessels from the medulla in an irregular fashion into this zone, the cells passing in with them not forming true bone upon

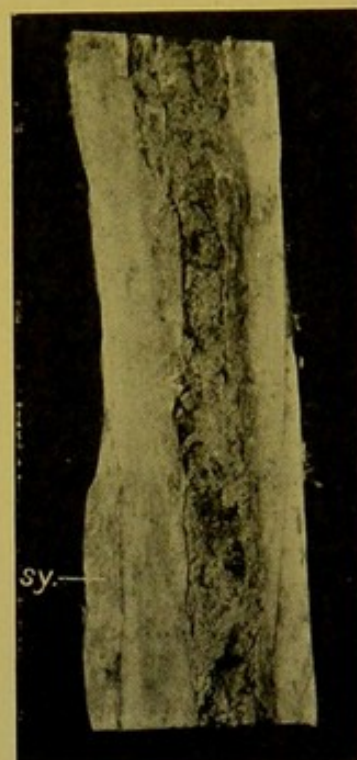

FIG. 199. — Syphilitic Hyperostosis—"node"—(sy.) on surface of femur,—longitudinal section of the bone. (\times circ. $\frac{2}{3}$.)

the remains of the cartilaginous matrix, but forming merely cellular, fibroid, tissue round about the vessels, which at a later stage becomes the seat of excessive deposit of calcareous salts and *sclerosis*.

(2) **Changes in the Periosteum.**—A soft vascular layer, sometimes reaching a thickness of about $\frac{1}{12}$ of an inch (2 mm.), forms underneath the periosteum. In this the vessels are surrounded by cellular fibrous tissue without lime salts. The sub-periosteal bone which has already developed undergoes partial absorption. Subsequently the soft vascular tissue becomes the seat of excessive deposit of lime salts and formation of bone which is denser than normal.

Hence the process in its active stages depends upon absorption of bone and formation of vascular tissue both in the medulla and under the periosteum; and formation of imperfect osteoid tissue, especially at the epiphyses but also under the periosteum. These changes result in softening of the bones so that they readily bend under pressure. Later on the excessive deposit of dense bone perpetuates the deformities thus produced.

The alterations are very characteristic. In infants all the epiphyses are markedly enlarged. This enlargement is especially evident at the wrist and ankle, and at the costo-chondral joints. In the last situation the enlargements form a row of nodules on either side, in a line extending downwards and outwards. To this row of nodules the name "*rickety rosary*" is commonly applied. The chest usually sinks in in the line of the costo-chondral articulations, and the sternum is excurved, projecting forwards as a whole—"pigeon-breast." At the same time, lateral curvature or kypho-scoliosis may be present. In well-marked rickets the pelvis becomes flattened, the sacrum more horizontal than normal, and the lumbar vertebrae curved forwards (lordosis). In the lower limbs, the long bones may be simply bent, with the concavity backwards, or the limbs may be extensively distorted and twisted, so that in the erect posture the body is not raised far from the ground. In the young the abdomen is usually very prominent, almost pendulous. The head may be larger than normal, the bones thin and the "bosses" prominent—*Craniotabes*. (See also p. 369.)

The liver is frequently diminished in size, the spleen enlarged; dentition is usually delayed.

The term "**Delayed Rickets**" is sometimes applied to a condition of softening affecting, for example, the bones of the shoulder-girdle and upper extremity, leading to bending of these bones. It occurs in young adults.

Osteomalacia,—**Malacosteon**, **Halisteresis**,—is a condition developing especially in connexion with pregnancy, and usually attacking women who have borne many children with only a short interval between each. The women have as a rule been healthy and well-formed.

It depends on a rapid decalcification of the bones, with increase of the marrow. The bones become extremely delicate and fragile; they sometimes

become wax-like, and bend easily, so that they are very liable to distortion. The marrow becomes hyperaemic; the fat disappears, and finally cysts filled with fluid take its place. The cortical layer of bone may become so thin that it may be cut easily with a knife.

Later on the decalcified bones may again take up lime salts.

The cause of the disease is unknown.

In the *puerperal form*, the disease attacks the bones of the pelvic girdle, to which it may be confined, or it may spread thence to the entire skeleton. The sacrum is pushed downwards by the weight of the trunk, and the acetabula are pushed upwards by the resistance of the femur, so that the pelvic brim assumes a trefoil shape, the oblique diameters being greatly reduced.

In the *non-puerperal form*, in which the disease usually commences in the vertebrae and thoracic bones, and occasionally in the bones of the skull, the vertebrae are distorted—*kyphosis*, *lordosis*, or *scoliosis*—the column being bent backwards, forwards, or laterally; the ribs may be bent inwards, and may show old fractures, often imperfectly healed; the sternum may be pushed forwards, becoming navicular or bent at an angle. The long bones may be affected only in their cancellous parts, but in extreme cases the shafts are distorted and may be fractured. In rare cases all the bones of the body may be affected.

In old age, a similar but slower process goes on in the bones. This is sometimes termed **Senile Osteomalacia**. The changes are best appreciated in macerated bones, in which the delicacy of the trabeculae and the thinning and porosity of the compact bone are very apparent.

Barlow's Disease, or Infantile Scurvy.—This disease is characterized by swelling of the bones, particularly those of the leg, but also the ribs. The bones tend to undergo fracture as a result of increased porosity and atrophy, especially near the ends of the long bones. The marrow is replaced by very cellular tissue, in which, at a later stage, bone may develop. The disease is accompanied by severe anaemia and by a great tendency to *haemorrhage*, e.g. in the marrow, under the peritoneum, under the skin, from the gums and other mucous membranes, and from the kidneys.

Osteitis deformans (Paget's disease of bone).—This condition sometimes accompanies *arthritis deformans*, but often the joints remain intact. It occurs in old age, and affects especially the tibia and the femur, but also the skull, vertebrae, clavicle, lower jaw, etc. The disease is seldom limited to single bones.

There are two varieties, one *painful* and the other *painless*, the former being the more common. It commences generally in the lower extremities. The painless variety commences most commonly in the upper extremities and is more common in females.

The long bones become greatly thickened, curved, and nodular on the surface. They are more porous and often poor in calcium salts, but the

bone is at times sclerotic. The medullary cavity is usually normal, although sometimes cysts form. Fractures are rare.

The cranial bones undergo great thickening. The bone is partially absorbed, and in addition new bone is deposited—hyperostosis—all distinction between outer and inner tables being lost (see Fig. 178, p. 370). The base of the skull may be pressed upwards.

Secondary hyperplastic osteitis, or **hypertrophic pulmonary osteoarthropathy**, affects especially the ends of the long bones, e.g. the terminal phalanges—leading to clubbing of the fingers. This is due to sub-periosteal thickening of the bone.

It occurs in heart and lung diseases, especially bronchiectasis, empyema and pulmonary phthisis; and chronic venous hyperaemia is a factor in bringing about the condition. The alterations are usually symmetrical. It has to be distinguished from *acromegaly* in which there is increase of the soft parts as well as of the bone.

Acromegaly.—This disease commences most frequently in individuals in the third decade of life, less frequently in middle life or in old age. Certain parts of the body increase in volume; the lower jaw becomes elongated, with widening of its angle; the nose, lips, and tongue become hypertrophied. The hands and feet are enlarged; the hands become spade-like, and the fingers greatly thickened. Sub-periosteal new-formation of bone occurs, frequently with production of osteophytes. Resorptive changes occur within the bones.

In many cases the anterior lobe of the pituitary is enlarged or is the seat of new-growth or of haemorrhage. (*See also* p. 395.)

Leontiasis Ossea begins as a rule in otherwise healthy young individuals of both sexes. Death takes place in from ten to thirty years after the commencement of the disease.

The etiology is unknown. The condition is characterized by the presence of diffuse hyperostosis, usually symmetrical, of the bones of the skull and face; sometimes extremely large, lobed exostoses occur upon the lower and upper jaw bones. The new-formation tends to narrow the fissures and foramina, so that taste and sight may be lost. The newly formed bone is at first porous, but tends later to become more and more dense.

Achondroplasia.—This condition depends on deficient proliferation of the epiphyseal cartilages and chiefly affects the long bones. These bones are short and thick; the cranial vault is high, the base often greatly shortened so that the root of the nose is deeply recessed.

Tumours of Bone.—Primary tumours of bone are all of connective tissue type, and originate either from the osteogenic layer of periosteum, or, if in the interior of bone, from endosteum or marrow.

Osteomata are mostly of periosteal origin:—

1. *Compact* or *ivory osteomata*. These are composed of extremely

dense, ivory-like, bone. They develop in connexion with the cranial bones, growing from either table of the skull, in the frontal sinuses, in the external auditory meatus, or in the mastoid.

2. *Spongy, cancellous osteomata*, occur most commonly on long bones. They include the prominent bony outgrowths resulting from ossification of tendons at their attachments. Bony outgrowths may develop in connexion with the upper or lower maxillae, or from the phalanges, e.g. the *sub-ungual exostosis*.

Fibromata are comparatively rare, and develop from the periosteum. At times they are distinguished with difficulty from sarcomata, on account of their vascular, cellular character. They may undergo ossification. (See Fig. 206, p. 422.)

Chondromata (Fig. 200) develop from periosteum or, in the interior of bone, from endosteum or from islets of epiphyseal cartilage separated off as a result of irregular ossification, e.g. in rickets. They occur most commonly in the bones of the hand, are often multiple—e.g. in the hands and feet—and develop usually in young individuals. They are liable to fatty, myxomatous, or cystic degeneration, and they may undergo calcification or ossification.

Myxoma, and Myxofibroma occur but rarely. The only myxoma of bone which I have examined, developed at the upper end of the tibia, apparently from endosteum; it penetrated the bone, and extended in the soft tissues forming a fluctuating mass filled with greyish gluey material.

Chloroma is a rare condition in which tumour-like masses develop in connexion with the periosteum, e.g. of the orbits, zygomatic fossae, etc. These masses may be of a grass-green colour. In other cases they closely resemble round-celled sarcomata, and secondary tumours may form in practically every organ and tissue. The condition of the blood and bone marrow is indistinguishable microscopically from that prevailing in acute lymphatic leucocythaemia (see *Bibliography*).

Sarcomata of Bone may be periosteal or central. They may be round-celled, spindle-celled, or giant-celled.

(a) *Periosteal sarcomata* may be round-celled but probably are more often spindle-celled. There is frequently a history of previous injury.

They develop usually towards one extremity of a bone, at one side, or they encircle the shaft, the bone either remaining to all appearance intact, or being penetrated and replaced by the growth. Periosteal sarcomata

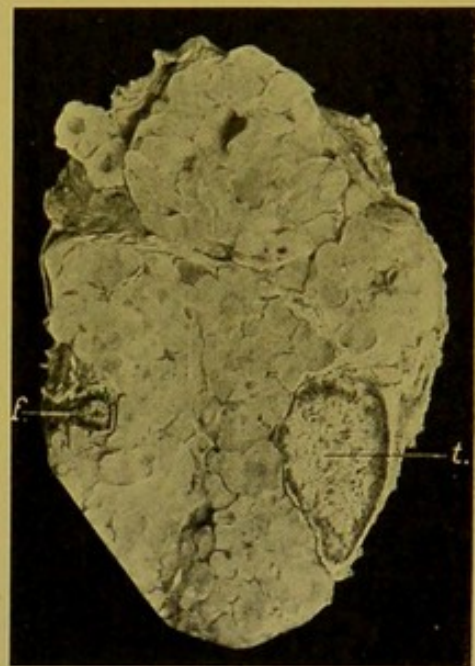


FIG. 200.—Chondroma of Leg. Transverse section.

(f.) Fibula; (t.) tibia. (\times circ. $\frac{1}{2}$.)

are frequently the seat of calcification—*osteoid sarcoma*—or of ossification—*osteo-sarcoma*—the bony spicules and plates developing in fibrous tissue or cartilaginous tissue which has formed within the tumour. The bony trabeculae are arranged usually perpendicular to the surface of the shaft.

In *chondro-sarcoma*, the cells are primarily oval or rounded, and cartilage develops instead of bone. Later the cartilage may undergo ossification—*osteo-chondro-sarcoma*.

(b) *Central Sarcomata.*

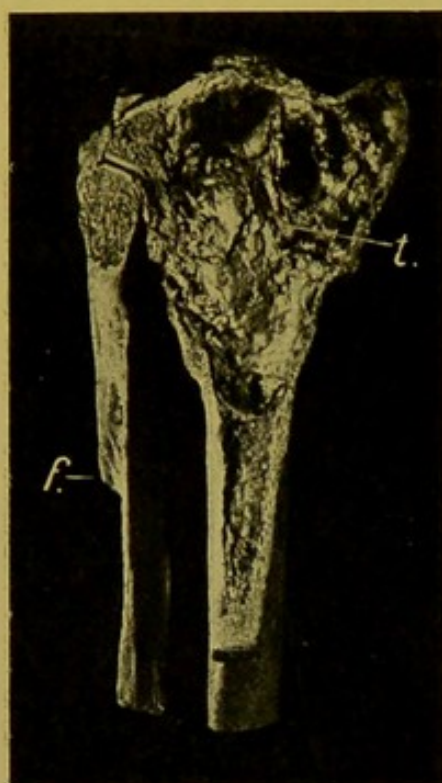


FIG. 201.—Central Sarcoma (myeloid) of head of Tibia (*t.*) (\times circ. $\frac{1}{2}$.)

Longitudinal section showing the thinning of the cortical layer of bone, and destruction of the epiphysis; (*f.*) fibula, showing old fracture. (Mus. R.C.S. Edin.)

These develop in the cancellous tissue at the ends of the long bones, or within the shafts. They affect the bones of the lower extremities more often than those of the upper extremities. Those in the shaft are usually round-celled, the cells being frequently of large size. The growth tends to penetrate the shaft, causing spontaneous fracture of the bone. The new-growth may extend to the neighbouring soft parts.

Those occurring at the ends of the long bones are usually composed chiefly of spindle-shaped cells, with a varying proportion of multinucleated giant-cells—myeloid or giant-celled sarcomata. They are regarded as of comparatively low malignancy. They may be of large size, and then cause pressure atrophy of the cortical layer of bone. This is reproduced by the periosteum, but in large or rapidly growing tumours, the bony capsule is either extremely thin or in parts defective (Fig. 201).

Myelomata.—These tumours are usually multiple. They develop in the old rather than in the young, and affect males more often than females. The disease runs its course in

about two years. They are primary formations in the marrow, especially of the sternum, ribs, vertebrae, and skull. The long bones are not exempt. The tumours develop simultaneously, often in widely separated bones. They form soft reddish masses with yellowish or greyish streaks. Their margins are homogeneous and not sharply defined. The outer layer of bone becomes thinned and bulges or is broken through, the tumour forming a nodular projection or even invading the surrounding tissues. The tumours are composed of cells, either round or oval or even polygonal. They are occasionally enlarged, and may contain more than one nucleus. The protoplasm is finely granular, slightly basophil; the nucleus is oval or rounded, relatively large, and often excentric. They resemble *plasma cells*.

The spine is frequently curved. The spleen and liver may be en-

larged. The blood has the characters of a secondary anaemia or pernicious anaemia.

Secondary Cancer invades the bone, usually by direct continuity, the bone being removed in front of the advancing tumour by osteoclasts.

Secondary Sarcomata, particularly of the round-celled variety, are frequently met with in the medulla.

In **lymphatic leucocythaemia** creamy tumour-like nodules may develop in the marrow of the bones.

Animal parasites of bone are rare, the varieties met with being the multiple hydatids of *Taenia echinococcus*, and the *Cysticercus cellulosae*.

DISEASES OF JOINTS

Acute Arthritis may be either non-suppurative or purulent, and the latter is frequently a sequel or further stage of the non-suppurative condition.

In **Acute, non-suppurative Arthritis** the synovial membrane is affected principally—**Acute Synovitis**.

In the early stages, the membrane is extremely congested, and multiple minute haemorrhages may be seen. The natural folds and fringes become soft, swollen and oedematous, and they overlap the articular cartilages. Under the microscope, in addition, there is infiltration with leucocytes. In severe cases fibrin is deposited upon the surface and within the sub-synovial tissue spaces.

The synovial fluid is increased, and tinged with blood. Transparent in the early stages, it becomes opalescent later, and turbid from the presence of cast-off endothelial cells, leucocytes, and particles of fibrin. Under certain conditions the fluid becomes purulent.

Chronic Synovitis.—In general appearances there may be little alteration, except swelling of the synovial membrane. Congestion is not a prominent feature. The synovial membrane may become indurated from formation of fibrous connective tissue; the synovial fluid is either practically normal, or it contains some albumen.

Changes such as are described above, as occurring in Acute Synovitis, are found in *acute rheumatism*, *gonococcal arthritis*, *acute gout*, and in joint affections following certain infective processes.

In **Acute Rheumatism** there is usually considerable sub-synovial and peri-articular infiltration; the cartilages may be swollen from proliferation of their cells, and fibrillation of the matrix; the fringes of synovial membrane are distinctly congested. Beattie recommends that, for the detection of the coccus of Poynton and Paine, portions of these fringes should be placed in suitable culture media (*see also* p. 84). The synovial fluid usually contains some fibrin. In **Subacute** and **Chronic Rheumatism** the exudate in the joint and in the surrounding tissues tends to become organized, causing thickening of the tissues. The synovial membrane is

especially affected in adults, and several joints may be attacked. The disease generally results in deformity.

In **Gonococcal Arthritis** the knee is most often affected, though any joint may be attacked.

In **Acute Gout** the initial changes are as described in acute synovitis. At a later stage, or on recurrence of the disease, one finds deposit of sodium urate, or of the urates of calcium, magnesium, or ammonium, in the articular cartilages—microscopically, firstly in the matrix—so that these appear as if covered with a thin layer of plaster of Paris. Associated with (probably caused by) the uratic deposit, there are always small areas of necrosis of the cartilage, with proliferation of the cells in the neighbourhood and fibrillation of the matrix. Less commonly, in **Chronic Gout**, the changes in the joint are more extreme; the cartilages become thickened and eroded; the capsule also is greatly thickened; and large deposits of urates take place in the capsule, in the ligaments and tendon-sheaths, in the periosteum, in the bursae, and in the subcutaneous and deep connective tissues.

Acute, Suppurative Arthritis.—All the component parts of the joint are involved in a suppurative inflammation.

Causes :—(a) Septic wounds of joints, or sloughing processes opening into them; (b) Pyaemia; (c) Spreading of suppurative processes from the vicinity—from bursae, from osteomyelitis of the head of the bone; from osteomyelitis or periostitis of the shaft—in osteomyelitis, the pus burrowing through the epiphyseal cartilage, and in periostitis, the pus tunnelling under the periosteum where this is bound down to the bone near the epiphyseal cartilage.

The opening into the joint may be of small size, or large and ragged, a sequestrum being contained within the abscess cavity. Brodie's circumscribed (chronic) abscess of bone (*see* Fig. 198, p. 407) rarely leads spontaneously to suppurative arthritis.

The changes in the synovial membrane correspond to those occurring in non-suppurative arthritis. The membrane becomes very vascular, swollen, dull and opaque, and covered with exudate. At a later stage it becomes converted into a layer of granulation tissue. The synovial fluid rapidly becomes milky, and then distinctly purulent—yellowish or greenish-yellow, often tinged with blood.

The articular cartilages become vascularized, and eroded in patches, the exposed bone undergoing rarefying osteitis. Occasionally, particularly in young children, great destruction of the head of the bone results, and even part of the shaft may be destroyed.

The capsule and ligaments are vascularized, infiltrated and softened, so that spontaneous dislocation may follow.

The suppuration may extend to the neighbouring tissues, and abscesses develop which usually communicate with the cavity of the joint, and burrow widely along the intermuscular planes.

Death results from pyaemia, or from toxæmia and exhaustion. If the individual recover, fibrous ankylosis takes place, with, later, ossification of the new tissue connecting the bones.

Acute suppurative arthritis may occur as a sequel of certain of the infective fevers—typhoid, scarlatina, measles, small-pox, mumps, influenza, dysentery, diphtheria, etc. It is not uncommon in pyaemia, puerperal fever, or erysipelas, and may occur in the course of pneumonia and glanders.

Bacteriology.—The organisms to be looked for are the common pyogenic bacteria, *pneumococcus*, *streptococci*, the typhoid bacillus, *gonococcus* and others, including Poynton and Paine's coccus.

If the condition be of any standing, osteophytic outgrowths develop in the vicinity.

Tuberculosis of Joints.—The disease begins either in the synovial membrane or, as is more common, in the articular ends of the bones. In all cases a primary source should be looked for elsewhere in the body—in tonsils, lymphatic glands, lungs, or intestine.

1. **Synovial Membrane.**—(a) *Miliary tuberculosis* of the membrane may occur as part of a generalized tuberculosis, especially following genito-urinary tuberculosis. It is rare, and is practically met with only in the knee-joint. Apart from the usual appearances of miliary tubercles, there may be little evidence of inflammation, to the naked eye. The synovial fluid may be turbid, either with or without flakes of fibrin.

(b) *Primary tuberculous synovitis.*—The membrane is the seat of chronic tuberculous inflammation, with formation of granulation tissue. Giant-cell systems (grey tubercles) may be numerous, and are usually accompanied by small foci of caseation (yellow tubercles). The synovial membrane becomes swollen, opalescent, oedematous, pale or greyish-pink, and granular on the surface; it is easily separated from the capsule—*gelatinous degeneration*. Along with the general swelling, yellow caseating areas, with ill-defined margins, may project upon the surface. In another form, the fringes of synovial membrane proliferate, forming vascular outgrowths which project over the articular surfaces.

Similar inflammatory changes extend to the ligaments, tendons, articular cartilages, and also frequently to the bone. The ligaments and tendons become vascularized, infiltrated and softened, so that spontaneous dislocation follows. The cartilages become dull, yellowish, and opaque, their margins overlapped by vascular fringes of synovial membrane and eroded, or these fringes become adherent to it and vascularize it, forming pits filled with granulation tissue (Fig. 202, 1). These pits tend to coalesce, and finally large areas of cartilage are destroyed, exposing the bone, which becomes the seat of tuberculous caries.

The joint cavity most commonly contains serous exudate, but sero-fibrinous, sero-purulent, fibrino-purulent or purulent exudate may be found. Frequently free bodies are present in the fluid—"rice bodies."

These are small, yellowish, elastic, laminated; they may correspond to separated portions of synovial fringes or of granulation tissue. They are not specially characteristic of tuberculous disease of joints.

2. Extension from Bone.—(a) The original focus may be small and communicate with the joint by a very small aperture. This produces a sub-acute or chronic tuberculous synovitis, with the characters just described,

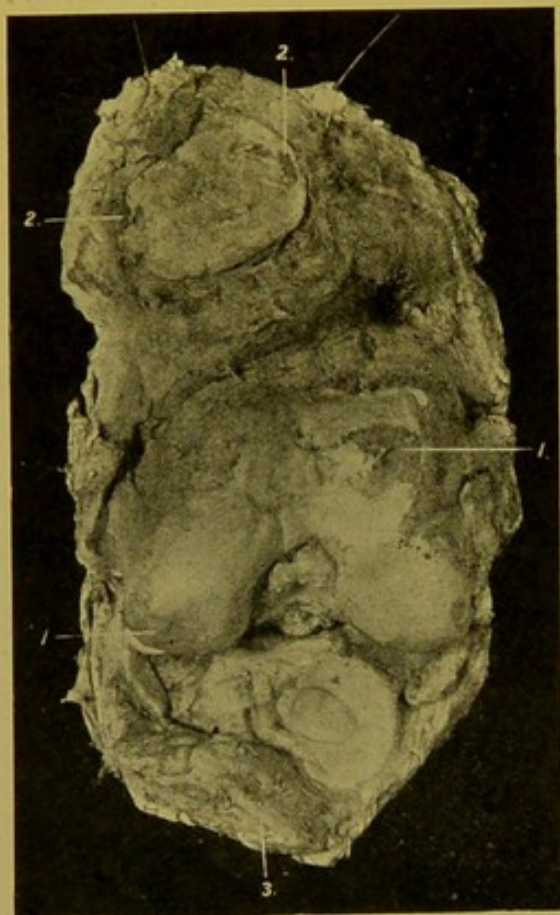


FIG. 202.—Tuberculous Arthritis of Knee-Joint. (\times circ. $\frac{3}{8}$.)

Joint laid open to show (1) Patches of erosion of cartilage on joint surface at lower end of femur; (2) similar areas on posterior surface of patella; (3) upper surface of head of tibia, with one semi-lunar cartilage. (Mus. R.C.S. Edin.)

or (b), the focus may be of larger size, and for long be limited by the articular cartilage. Suddenly a large escape takes place, causing an acute arthritis, leading to extensive destruction of the joint. In this form, which is more common than the other, a sequestrum may be found. (c) The tuberculous process may extend under the cartilage to the synovial membrane, there being, in the first place at least, no escape of caseous material. This variety is also common.

In the neighbouring periosteum osteoplastic changes are present, with development of osteophytes.

Syphilitic Disease of Joints.—Syphilis may give rise to synovitis with characters which may closely resemble those due to other causes.

In **Tertiary Syphilis**, the synovial membrane may become extremely thickened from infiltration, and gum-mata may project on the inner surface. The joint contains turbid inflammatory exudate. The cartilages may be eroded, the ligaments softened or destroyed.

In **Congenital Syphilis**, an arthritis may be found closely resembling chronic tuberculous arthritis.

Rheumatoid Arthritis.—Garrod and other authors draw a distinction between *rheumatoid arthritis* and *chronic articular rheumatism*, and bring forward data to prove that rheumatism has no causal relationship to rheumatoid arthritis.

Rheumatoid arthritis attacks females especially, particularly between the ages of 20 and 40. Several joints may be affected; the small joints of the hands and feet being the first to be attacked. In the early stages, the ligaments and capsule are thickened, and the synovial membrane is congested and swollen. The articular cartilages may be unaffected, though sometimes small erosions are seen at their margins. In late stages, the

cartilages may be completely destroyed; firm fibrous bands surround what were once the articular surfaces; and bony ankylosis may take place.

Arthritis Deformans (Osteo-arthritis).—This disease commonly attacks older individuals than are attacked by rheumatoid arthritis. It is commonest in females, from forty to sixty years of age. The disease is usually localized.

Degenerative processes commence in the cartilages and synovial membrane, and soon extend to the bone. These are associated with hyperplasia in the bones and soft parts. In the cartilages erosion takes place; localized splitting and softening; vascular tissue invades them; they become rough on the surface ("velvety") (Fig. 203). Hypertrophy of the cartilage occurs in other parts, particularly where not exposed to pressure, e.g. at the margins, and the hypertrophied cartilage, at a later stage, undergoes ossification, bringing about the characteristic *lippling* of the joint surfaces. Over the surface of the joint, the cartilage may disappear completely, and then the exposed bone becomes polished—*eburnation*. In the bones themselves osteoporosis takes place, or inflammatory atrophy. This atrophy is at times extreme, so that the whole head of the bone disappears (Fig. 204).

In arthritis deformans, therefore, both retrogressive and progressive changes occur in the joints and bones. The capsule and ligaments undergo thickening with subsequent shrinking. The synovial fluid is milky from the presence of debris of cells. The synovial fringes are hypertrophied (*see* Fig. 203), and frequently loose bodies are found within the joint cavity; these, in some cases, are broken-off portions of the hypertrophied and ossifying cartilage. Ankylosis never results. The ligaments may be destroyed and the joint become flail-like. The surrounding tissues are oedematous, and multilocular swellings are seen, caused by effusion into the tendon-sheaths.

The condition as a rule commences in the knee-joints or in the joints of the fingers, but also attacks the hip-, elbow-, and shoulder-joints, and those of the vertebral column. In the last situation bending of the column—kyphosis—results, whilst from the osteophytic new-formation of bone,

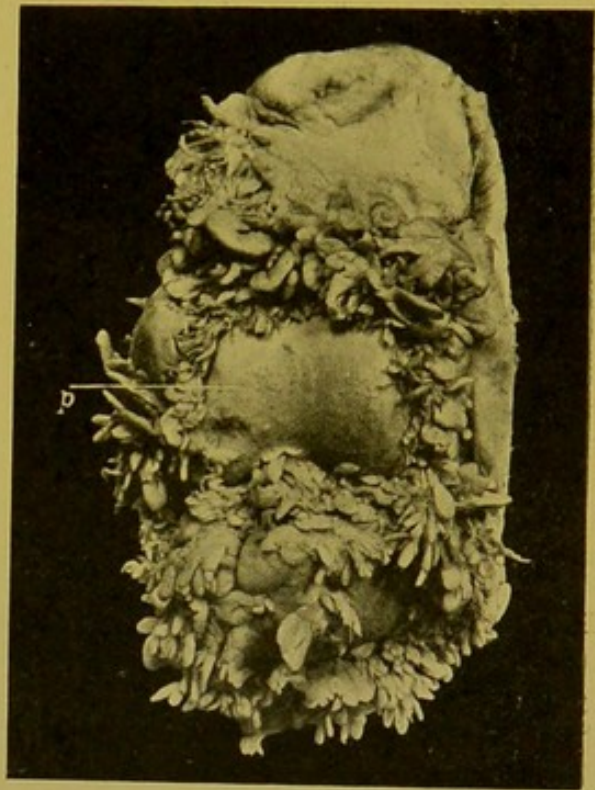

FIG. 203.—Arthritis deformans of Knee-joint; early stage. (\times circ. $\frac{1}{2}$.)

Anterior part of joint, showing (*p.*) patella, the articular surface of which is rough and "velvety"; showing also the hypertrophied fringes of synovial membrane. (Mus. R.C.S. Edin.)

adhesions develop between the individual bodies—spondylitis deformans. From this fixation, along with involvement of the costo-vertebral joints, the respiratory movements are interfered with, and death occurs usually from intercurrent pneumonia. The etiology of the disease is unknown.

Charcot's Disease of Joints.—This rare condition occurs in the course

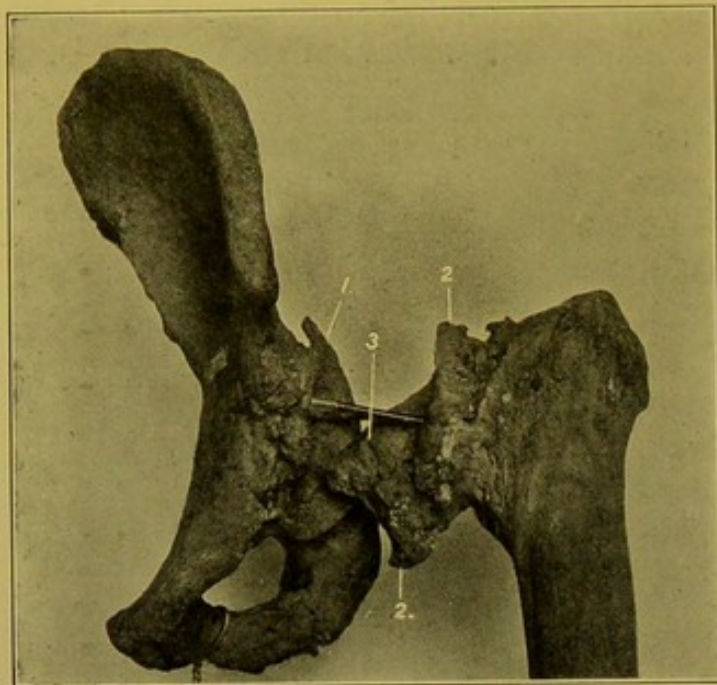


FIG. 204.—Arthritis deformans; macerated preparation of the bones forming the Hip-joint. (\times circ. $\frac{1}{3}$.)

(1) "Lipping" of acetabulum; (2) "Lipping" of articular surface of head of femur; (3) eroded head of femur. (Mus. R.C.S. Edin.)

of locomotor ataxia. It may begin with great effusion into the cavity. The synovial membrane is much thickened. A feature is the absorption of the ends of the bones, with formation of ridges and lips like those which form in arthritis deformans. The exposed bone becomes dense and sclerosed, or cancellous. Osteophytes also develop. The synovial membrane shows villous outgrowths. The cartilage becomes fibrous and may disappear almost completely. There is great destruction and loosening of the ligaments. The progress of the disease is rapid.

The changes in the joints in **Syringomyelia** are similar to those occurring in Charcot's joint disease; they may be *hypertrophic* or *atrophic*. The large joints of the upper extremity are usually affected.

(a) *Hypertrophic changes.*—The cartilages in great part disappear, and the exposed bone becomes worn down. The cartilage remaining at the margins of the articular surface undergoes hypertrophy; the capsule is distended, and thickened by deposit of bony or calcareous material; the inner surface of the synovial membrane is beset with polypoid outgrowths, which may become detached and lie free in the cavity. Osteophytes develop upon the shaft in the vicinity. The attachments of the tendons, ligaments, and fasciae become ossified.

(b) *Atrophic changes.*—The cancellous bone becomes rarefied, and extensive destruction of the articular ends of the bones occurs. There is little or no new-formation of osseous tissue. The bones may be actually reduced in length, and are light in weight. The tendons may become ossified.

DISEASES OF THE MUSCLES

In **Simple Atrophy**, the contractile substance may diminish in volume and become pigmented; or it may disappear completely. The sarcolemma nuclei

proliferate so that a line of cells may replace the fibre. Frequently fat develops in the perimysium internum—*lipomatosis*. This is the change which takes place as a result of disease of the peripheral or central nervous system, for example, after division or degeneration of the peripheral nerves, in multiple neuritis, in degeneration of the anterior cornual cells—*Spinal form of progressive muscular atrophy*—and in degeneration of the bulbar nuclei.

In the **Primary Myopathies**, in which the muscle lesions are primary, the appearances differ from those in simple atrophy. Many muscle bundles atrophy, but others hypertrophy, and in some cases this hypertrophy may predominate, at least in the earlier stages. Many fibres show fissuring and vacuolation. The perimysium becomes even more cellular than in simple atrophy, and the lipomatosis is often extreme, so that in the midst of the fat the persisting muscle fibres can be detected only with difficulty. These appearances are found in *Erb's Juvenile progressive muscular atrophy or dystrophy*; *syn.: Pseudo-hypertrophic muscular paralysis*. This disease attacks chiefly the muscles of the lower extremities, of the pelvis, and of the back.

Degenerations.—*Cloudy* and *fatty* changes occur under conditions similar to those in which they occur in the organs. *Vitreous* degeneration (Zenker's) affects especially the recti and other abdominal muscles, the adductors of the thighs, and the lingual muscles. Patches of the muscle become pale, grey, washed-out looking (see Fig. 5, p. 30). Microscopically, the fibres are swollen, fissured, and broken up into glassy fragments. In parts the striation is completely lost. The condition is to be classed with coagulative necrosis. Later, the sarcolemma nuclei proliferate, and in healing, fibrous tissue to a great extent takes the place of the muscle fibres.

Inflammations.—**Acute Polymyositis**, or **Dermatomyositis**.—The extremities become swollen from subcutaneous oedema, and from inflammatory changes in the muscles. These are swollen, soft and friable, yellowish-white with reddish-brown patches, and mottled with haemorrhages. Microscopically, the fibres are swollen and granular, often hyaline and vacuolated. There is great cellular infiltration, particularly in the vicinity of the blood-vessels. The name *dermatomyositis* was given to the disease on account of the associated urticarial cutaneous swellings.

In **Haemorrhagic Myositis**, hard swellings are found in the muscles. On dissection, recent and old haemorrhages are found. Microscopically, the blood clot is undergoing rapid organization. These have to be distinguished from *angiomata* of muscle. (See Bibliography.)

Acute Suppurative Myositis originates either by extension of a suppurative process from the bones or joints, or from the connective tissues, e.g. *carbuncle*; or results from infective embolism in ulcerative endocarditis, or in puerperal suppuration, in glanders, actinomycosis, or anthrax.

Scattered yellow foci of suppuration, surrounded by a zone of congestion and infiltration, may appear; or a more diffuse suppuration develops, in which the muscle is broken down into a dirty brown offensive creamy fluid. The pus should be investigated both for aërobic and for anaërobic bacteria. In a case of anthrax I examined, the broken-down muscle formed a thick pink fluid, like anchovy sauce.

Tuberculosis of muscle presents no special characteristics. It may spread from disease of the bones or of the joints, or be metastatic.

Syphilitic manifestations occur late in the disease, and take the form of gumata, for example in the lower extremities; or of diffuse fibrous change, for example in the quadriceps extensor, the calf muscles, the biceps, the masseters, and the pectorales.

In **Myositis Ossificans**, the muscle is replaced by bony tissue. The disease

may affect individual muscles, or exostoses may extend into a muscle; but the important variety of this rare disease is characterized by a progressive transformation affecting many muscles. The earlier stages apparently are those of acute myositis; the muscles are swollen, oedematous, soft and brownish. This stage is followed by one in which there is intramuscular increase of connective tissue, with contraction and atrophy and almost complete fibrous transformation of the muscles. Then the fibrous tissue becomes ossified. The disease commences in the muscles of the neck and back.

Parasites. Trichinosis.—The young trichinae penetrate the muscle fibres and coil themselves up in the interior. During this process, there is great swelling and cellular infiltration of the muscles. The fibres involved, and also others not entered by the parasites, become granular or hyaline; the sarcolemma nuclei proliferate. The muscle is specially affected near the attachment of its tendons.

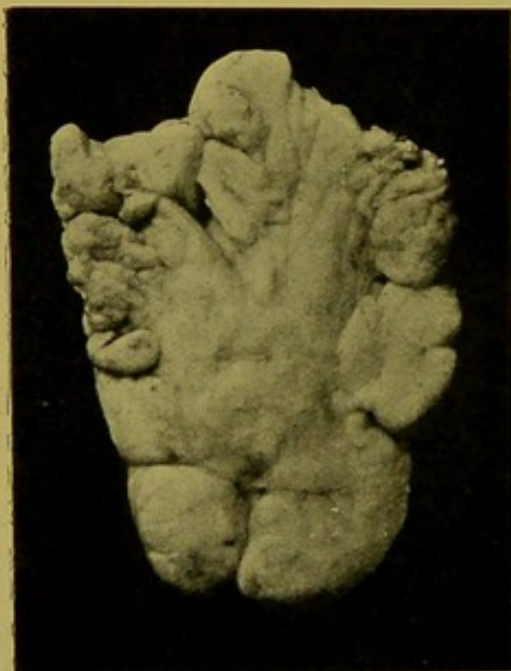

FIG. 205.—Lipoma, Fatty Tumour, showing lobulation. ($\times \frac{1}{2}$.)

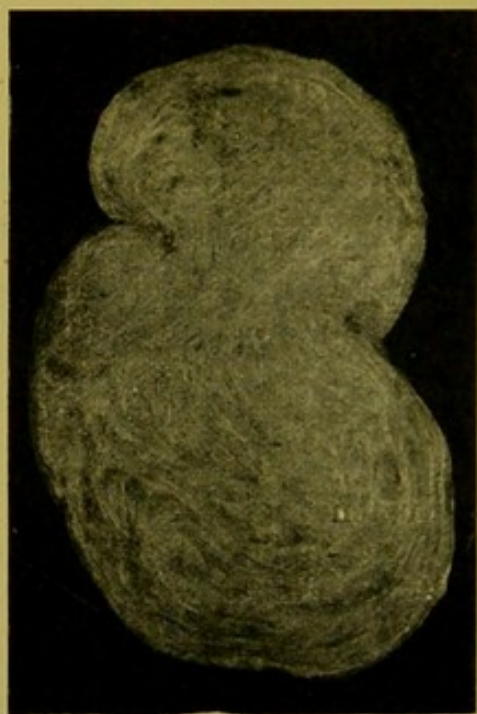

FIG. 206.—Fibroma. Cut surface, showing fasciculation and distinct encapsulation. ($\times \frac{1}{2}$.)

The encysted trichinae have the appearance of minute, oval, white specks, with their long axes parallel to that of the muscle.

The commonest **Tumours** of muscle are *Sarcomata*. These may be primary or secondary. Those termed primary develop actually in the intermuscular connective tissues. Frequently mixed forms occur, e.g., *Myxo-sarcoma*. These show apparent encapsulation; on section they are dark grey, gelatinous in parts; large areas of the tumour may be the seat of haemorrhage, the blood being either recently effused, or older and partially decolorized. Secondary sarcomata of all varieties are common.

Lipomata (Fig. 205) may develop in the intermuscular planes, and may reach a very large size. I have examined, one weighing 12 lb., which was removed from the thigh. *Fibromata* (Fig. 206) may develop in similar situations.

Carcinomata are never primary in muscle.

CHAPTER XX

POST-MORTEM CHANGES PRODUCED BY POISONS

In cases in which poisoning is suspected, the time which has elapsed between death and the post-mortem examination should be carefully ascertained; the presence or absence of rigor mortis and post-mortem lividity should be noted; and, if the latter be present, the tint, condition and extent of it are important. Signs of violence, bruises, or haemorrhages should be looked for, and the nature of stains or corrosions on the cutaneous surface or the lips, and the nature of fluids issuing from the nostrils or mouth should be investigated. The internal examination should begin with the abdominal cavity unless in the case of suspected poisoning by hydrocyanic acid, in which Casper recommended that the head should be opened first because the odour of the acid remains appreciable longer in the brain substance than elsewhere. In the abdomen one should note particularly the position and relationships of the stomach and the intestines; any indication of softening, increased friability, or perforation of their walls, and if perforation has occurred, the nature of the escaped contents; the presence or absence of peritonitis—local or general. Any escaped contents should be carefully collected in a clean glass vessel for subsequent investigation and analysis. Any unusual odour should receive attention. The condition of the blood-vessels, and the colour of their contents should be noted. Before proceeding further with the examination of the abdominal contents, the cervical structures should be exposed, and along with the floor of the mouth, tongue, and soft palate, the pharynx, larynx, trachea and oesophagus, separated from the vertebrae, as far down as the thoracic inlet (*see pp. 45, 46*). With a pair of sharp scissors, the pharynx and oesophagus, and then the larynx and trachea should be laid open from behind, and their contents, and the condition of their walls noted. The thoracic cavity should now be opened (*see pp. 32–36*), any abnormal odour noted, and the heart and lungs separated in the usual way, special care being exercised in the case of the heart. Its cavities should be opened before removal of the organ, and the condition of the blood as to coagulation, odour and colour, carefully investigated. Some of the blood which escapes into the pericardium should be collected in a separate glass vessel, in which, later, portions of the heart and the lungs may also be placed. Then a

ligature having been placed on the oesophagus at its lower end, and the jejunum having been divided between ligatures close to its commencement, the cervical structures, trachea, oesophagus, along with the thoracic aorta, stomach, liver, spleen, supra-renal glands and pancreas should be removed from the body, and placed upon a glass or porcelain surface, which has previously been carefully cleansed.

With a pair of probe-pointed scissors the posterior incision should be continued to the lower end of the oesophagus, and any pathological changes noted; then, in a similar manner, the trachea should be opened up along with the main bronchi. Subsequently the incision in the oesophagus is continued downwards through the cardiac opening of the stomach, and along its greater curvature, gradually passing on to the anterior (upper) surface of the pyloric portion, so as to pass through the pylorus in the middle of its anterior (upper) surface. It is then continued along the duodenum.

The nature of the contents of the stomach should be carefully noted, and these are to be collected in a separate glass vessel—for chemical analysis if this be deemed essential. The cervical structures, oesophagus and stomach may also be placed in the same vessel. The stomach itself should always be carefully examined at the time of the post-mortem examination in all cases of death from poisoning.

The examination of the liver, spleen and pancreas follows the usual course, and *large* portions of these organs should also be placed in a vessel for subsequent chemical examination.

The remainder of the intestinal tract should now be removed, any alteration in its serous surface being noted, and then it should be laid open upon the glass or porcelain surface, which has been carefully cleansed after the examination of the stomach and duodenum. The small intestine should be opened so that its contents fall directly into a clean receptacle; in which also the contents of the large intestine may be collected, provided that they do not include large masses of faeces. If these are present, the large intestine and its contents should be placed in a separate glass jar.

The kidneys should be removed in continuity with the ureters and bladder; and before proceeding further, the contents of the bladder should be collected in a separate vessel, or, before removing the urinary organs, the urine may be drawn off into a vessel by means of a catheter. Portions of the kidneys should also be preserved.

It is well in addition to put aside portions of the various organs in a fixative medium, such as alcohol or formalin, for microscopic examination.

The central nervous system should now be investigated in the usual manner, and portions of the brain placed in the jar containing the portions of lung and heart. In cases of narcotic poisoning the whole of the brain may be placed in a special vessel.

All these jars should be closed, carefully sealed, and fully labelled.

During the course of the examination the slab or platter should be

carefully cleansed after the examination of each set of organs, but in the actual examination of the organs *all washing with water should be avoided*. If there be any suspicion that a poison has been introduced after death, portions of the right lung and right kidney and of the left lung and left kidney should be placed in separate vessels (*see discussion of this question under Arsenic, p. 431*).

The following general consideration of the changes brought about by poisons is quoted from Orth's *Pathologisch-anatomische Diagnostik*, as it gives a good summary of the changes which may be met with.

"The poisons given by the mouth may be divided into two groups—the *Corrosive* and the *Non-corrosive*. To the first group belong the alkalies, a large number of mineral acids, e.g. sulphuric acid, hydrochloric acid, nitric acid, further, several vegetable acids such as oxalic acid, acetic acid, and also carbolic acid, etc.

"To the second group belong substances which produce either no, or only trifling, changes in the alimentary tract—death following upon their action upon the nervous system or upon their interference with tissue respiratory changes. Some of the substances which fall into the second group, e.g. arsenic and phosphorus, bring about degenerative changes in the alimentary tract and in other organs.

"The changes brought about by substances of the first group differ according to their nature, but still these differences, especially if large amounts are allowed to act, are *not* so marked as was formerly thought, and Lesser's investigations especially have demonstrated the greatest similarity in the action of the alkaline lyes and the mineral acids. They both produce more or less extensive sloughs which are distinguished only by their colour and consistence. The alkali sloughs are less friable than the acid sloughs, and they are also distinguished by their colour. In both cases, severe haemorrhagic inflammation develops in the tissues surrounding the sloughs; but in this inflamed tissue, necrotic changes may extend more quickly in the case of acids than in the case of alkalies, and perforation takes place more commonly as a result of the action of acids than in the case of alkalies. In the same stomach, a very varying picture may be presented from the fact that sloughing, ulcerated, inflamed and softened areas may be encountered near one another. The muscular coats of the oesophagus and stomach are constantly strongly contracted, so that their mucous membrane appears raised in coarse folds. The changes are necessarily greatest and most characteristic where the poisons have remained longest in contact with the surface. Hence the mouth and oesophagus may show a weaker action than the wall of the stomach, and similarly the mucous membrane between the high folds caused by the strong contraction of the muscular coats is less acted upon than the mucous membrane covering the summits of these folds. The action at the fundus of the stomach may be so strong that the wall is softened throughout and per-

forated. When small quantities of fluid are taken, it may happen that this travels right along the lesser curvature to the pylorus where it is detained and produces most evidence of its action."

In certain cases the action of the poison is not confined to the stomach and duodenum, but may also be detected in the neighbouring organs, and in other cases absorption readily takes place, and distant tissues are affected, the poison being conveyed to them through the medium of the blood. The most striking examples of this phenomenon are afforded by certain of the irritant poisons, amongst which weak solutions of the corrosive poisons must be grouped. In the lower part of the small intestine and also in the lower part of the large intestine, a very severe haemorrhagic enteritis may develop and, particularly in the case of poisoning by Corrosive Sublimate, the inflammation presents a membranous, or so-called "diphtheritic," or "croupous" character.

The changes brought about by the members of the second group are either those characteristic of irritant poisoning, the changes varying in degree from simple congestion to the most severe form of inflammation, or, particularly *in the case of many of the vegetable poisons, they may be slight, and without special characteristic*. In distant organs, particularly liver, kidney and heart, the irritant poisons characteristically bring about degenerative changes, and in the case of the kidney, these are specially marked in the secreting portions of the tubules, being in some cases, e.g. Corrosive Sublimate, especially marked in the ascending portion of Henle's loop. The changes which are found in typical cases will be detailed in connexion with the individual poisons.

POST-MORTEM APPEARANCES

(See also Bibliography for recent references.)

CORROSIVES.

Sulphuric Acid.—Strong sulphuric acid has been administered, instead of oils, syrups, or glycerine. It has been poured into the ears, given by enema, and even injected into the vagina. The smallest amount *per os* which has caused death is half a drachm (3ss). Death usually occurs within twenty-four hours.

Post-mortem changes.—If any drops have fallen upon the clothing, this is charred. The *lips* show brown, liver-coloured, corroded areas which may extend on to the surrounding skin. The mucous membrane of the *mouth* may be greyish-white or dark brown, dry, and may be extensively separated, the tissues beneath being greatly congested and swollen, and sometimes covered with blood. The superficial vessels are distended and the blood contained is black from formation of haematin. The appearances vary with the strength of the acid, from superficial corrosion to necrotic changes. The inner surface of the *pharynx* is dark grey in colour. The *oesophageal* mucous membrane is swollen and arranged in thick longitudinal folds, upon which the epithelium is greyish-white and opaque. It tends to separate in shreds. The tissues underneath are deeply congested. If some of the acid have penetrated the larynx, blackened sloughs may be formed there. Exceptionally the mouth and oesophagus escape.

The *stomach*, unless completely disorganized, is contracted and the walls may be corroded and hardened. The inner surface, in parts where the acid has acted longest, may be dark brown to black, the intervening mucous membrane being swollen, turbid, and projects above the necrotic areas. The mucous membrane in the affected areas is usually black, very soft, slimy; it tends to separate in shreds or patches, and is very friable. In some cases the whole of the mucous membrane of the stomach is charred and separated, lying free in the cavity. The walls of the stomach may give way. The aperture, if this has formed before death, is irregular, with irregular blackened edges which are soft and friable. Perforation takes place more frequently in poisoning with sulphuric acid than with any other corrosive poison. Following perforation the acid acts upon the neighbouring organs in a manner similar to that described in the stomach itself. Occasionally the pyloric end of the stomach is only slightly affected.

Contents of Stomach.—The stomach, if not perforated, contains viscid dark-coloured material made up of mucus and other fluids, mixed with haematin.

Duodenum.—The mucous membrane is usually swollen, hardened, greyish and opaque, or congested and thickened. Sometimes the corrosive action extends to the duodenum from the stomach.

The Peritoneum.—Death may be so rapid that peritonitis does not develop.

Other Organs.—The liver and kidneys may be affected. The blood in the larger vessels is dark and tarry. The tubules of the kidney, microscopically, frequently contain altered blood. The epithelium of the tubules may be necrosed.

If death be delayed for a few weeks or for some months the appearances are different. The parts affected by the corrosion are ulcerated and contracted. The mucous membrane is partly or wholly lost. The walls are thickened and show cicatricial contractions, which may produce tight strictures.

In cases of sulphuric acid poisoning, free acid cannot always be demonstrated, as it tends to combine with basic substances in the body. In children the acid may pass into the larynx and cause death from suffocation without the poison reaching the stomach or causing any manifestation there.

2. Hydrochloric Acid.—Smallest fatal dose reported, 3ii. Death occurs usually within twenty-four hours. The lips and skin surface may show no visible alteration, the acid usually producing no permanent stain or corrosion. The changes in the alimentary tract are very similar to those produced by sulphuric acid. The mucous membrane of the mouth, pharynx, and oesophagus is usually whitish or grey, or if the surface has been congested it becomes of a brownish colour. It is wrinkled and is easily detached. The stomach is contracted; the mucous membrane is dark brown in colour, with darker, almost black, lines along the course of the vessels, resulting from the action of the acid upon the blood contained in these. The mucous membrane may be irregularly eroded, or white, shrivelled, and necrotic. In less marked cases the surface is deeply congested. Perforation is exceptional. When it does occur, the neighbouring viscera are acted upon in a manner similar to that in the case of poisoning with sulphuric acid.

3. Nitric Acid.—Smallest fatal dose reported 3ii. Death occurs usually within twenty-four hours. The skin and lips may show yellow corroded patches. The mucous membrane of the tongue and mouth may be superficially ulcerated or covered with a thick loose brownish-yellow or fawn-coloured layer. The mucous membrane of the oesophagus is either swollen and of a yellowish or brownish colour; or hangs in shreds; or it may be separated completely, leaving a congested surface. The inner surface of the stomach also shows a yellow or orange-brown discoloration, and there may be greyish patches where the acid has acted upon bile-pigment. The surface may be corroded and the mucous membrane separated in some places, and hardened and thickened in others. There may

also be patches of a dark brown, almost black, colour where blood has been effused and has been acted upon by the acid. The larger superficial vessels, as in the case of sulphuric and hydrochloric acids, may contain cylinders of black altered blood. Perforation rarely occurs. The duodenum may be affected like the stomach, or it may be simply inflamed.

The yellow stains of nitric acid may be distinguished from those of iodine by touching the altered surfaces with ammonia. This intensifies the stains of nitric acid and causes those of iodine to disappear. If the patient survive for some time, the cavities show cicatricial contractions and stenoses. (*See also* p. 439.)

Oxalic Acid.—Smallest fatal dose reported 60 gr. Death occurs usually within half an hour to two hours. The skin and lips are not stained. The lips are pale. The further appearances vary with the amount of acid taken and its concentration; the stronger solutions or the solid acid causing marked corrosion, whereas, in the case of weaker solutions, the signs of irritation and inflammation are more marked. Usually the mucous membrane of the mouth, pharynx, and oesophagus is whitened, softened and eroded in patches. It may be contracted into folds or the surface is separated up by numerous grooves between which there are patches of raised mucous membrane. The mucous membrane of the oesophagus can sometimes be removed in flakes, in the upper parts whitish or grey in colour, in the lower parts slate-coloured, the difference in colour being due to the presence of altered blood. Weak solutions of the acid may cause simply congestion of the surface. The stomach contains a dark brown mucous fluid of an acid reaction. The mucous membrane is pale, flocculent, and shreddy or, at the pyloric end, it may be dark, almost black, in colour. Deep erosions may be present. The blood-vessels are marked out as black lines, the blood contained being dark brown or black. These blood changes are similar to those caused by other corrosives. Occasionally, haemorrhagic patches are found, upon which crystals of calcium oxalate are deposited. Perforation rarely occurs. If death have been rapid the degree of corrosion and erosion may not be great. The *kidneys* are usually congested and loaded with calcium oxalate which may form a white layer between the cortex and medulla. Microscopically, the deposit is found mostly in the convoluted and to a less extent in the collecting tubules. No deposit takes place in the glomeruli.

Potassium Oxalate.—The appearances are usually identical with those found in oxalic acid poisoning, the surfaces being inflamed and corroded. The changes extend in a few cases to the intestinal canal. Sometimes there is considerable bleeding. The haemorrhages may be punctiform, affecting principally the folds of the mucous membrane. In most cases there is no actual erosion, but the mucous membrane appears abnormally transparent. The kidney changes are similar to those found in oxalic acid poisoning.

Acetic Acid.—Smallest fatal dose reported 3ii. The concentrated acid acts as a corrosive. The diluted acid acts as an irritant poison. The fumes if inhaled may cause signs of asphyxia.

Post-mortem Changes resulting from the action of the Strong Acid.—The surfaces affected are softened, whitish or pale yellow in colour. There may be patches of erosion, particularly in the oesophagus and stomach. The upper air passages show either a corrosive action or signs of inflammatory reaction.

Hydrofluoric Acid.—The parts with which the poison has come into contact are corroded. The mucous membrane of the mouth and oesophagus is whitened and separated in patches. The mucous membrane of the stomach is blackened, and the stomach contains a dark brown fluid.

Ammonia.—Smallest fatal doses *per os*, recorded, 3i to 3ii. Death usually takes place on the second or third day, but an interval of minutes only may elapse

before death. In the case of a female, aged forty, in whom death occurred on the fifth day after swallowing strong ammonia, there were patches of corrosion in the mouth and throat, the mucous membrane being swollen. The mucous membrane of the posterior wall of the pharynx showed superficial erosion, and all the surfaces were covered with a membrane having a faint yellow tint. The epiglottis was congested and swollen, both surfaces being eroded. Similar changes affected the ary-epiglottic folds. The larynx was slightly affected,—but in other cases it has been found congested, infiltrated and covered with a false membrane resulting from the action of the gas or from actual contact with the liquid ammonia.—The oesophagus was covered throughout with a thin, easily detached, layer of a bright gamboge-yellow colour. The surface underneath was congested and granular. Here and there, there were superficial erosions. The area of most intense change was about 3 in. below the epiglottis. The stomach contained blood-stained fluid. The entire surface of the mucous membrane was dull and granular. Some of the rugae of the mucous membrane were covered with a yellowish layer of altered mucous membrane, similar to that found on the epiglottis, and along the rugae there was distinct superficial erosion. The walls generally were thickened. In the duodenum, the mucous membrane was to a large extent detached, leaving shreds and patches of an intense yellow colour. A few large ulcers had formed, with sharp, punched-out margins. Little change was found below a point about 4 ft. below the duodenum. The liver was hyperaemic and showed fatty changes. The spleen was enlarged and deeply congested. The kidneys were soft, flabby, and the seat of marked parenchymatous change. The heart muscle was pale, flabby and fatty.

In addition to the changes recorded in the above case the musculature of the oesophagus and stomach may be softened and degenerated. Perforation of the stomach sometimes occurs. The blood is dark-red and fluid, and sometimes there is partial coagulation. Broncho-pneumonia soon develops. If the patient has survived for some weeks the stomach is usually dilated and covered with scars, particularly at the pylorus, and the kidney and liver show marked fatty degeneration.

Caustic Potash, and Caustic Soda.—Smallest fatal dose of KOH, *per os*, gr. 40. Death follows in a few hours, or more frequently after several weeks from complications. As general characteristics, caustic poisons cause swelling of the tissues, with later darkening of their colour as a consequence of the solution of the blood corpuscles and diffusion of the blood pigment. The lips, mouth, and tongue are deeply congested and ulcerated or eroded. The mucous membrane of the mouth, pharynx and oesophagus is softened and of a brownish colour, in parts separated, and the deeper tissues are inflamed and oedematous. The stomach contents are coffee-coloured and turbid. They may show an acid reaction. The epithelium is loosened extensively; the mucous membrane soft, swollen and elevated into coarse folds. The colour is red or dark brown, or, if blood has been extravasated, it is black in colour, the haemoglobin having undergone alteration. If the patient has survived for some time the mucous membrane is extensively separated. Patches of ulceration and of cicatricial tissue are found at the lower end of the oesophagus and at the pylorus. Caustic soda is not quite so active as caustic potash. Cases of poisoning by these alkalies are comparatively rare and poisonous effects are more common from the use of concentrated solutions of the *carbonates*.

IRRITANT POISONS.

Potassium Chlorate.—Smallest fatal doses *per os*, recorded, in child, 45 gr.; in adult, 3ii. Death may take place in a few hours, or be delayed for several days.

The appearances found are those of severe gastro-enteritis. The mucous membranes are reddened, thickened, and easily detached. The blood is inspissated and of a dark chocolate colour, from the formation of met-haemoglobin. Microscopically, the red blood corpuscles are shrunken, crenated, and numerous free granules are observed. The presence of met-haemoglobin can be confirmed by use of the spectroscope. The heart is soft and flabby, the muscle being the seat of fatty degeneration. The liver may be inflamed, the cells cloudy and finely granular with occasional pigmentation. The spleen is generally inflamed and of a light-brown or chocolate colour. The kidneys are enlarged, and show a similar colour, this being most evident in the medulla. Cases of poisoning with chlorate of potassium may simulate poisoning with arseniuretted hydrogen, or such diseases as haemoglobinuric fever.

Potassium Nitrate—"Nitro."—Smallest fatal dose *per os*, 3ii; death follows usually in from five to sixty hours. The mucous membrane of the stomach is bright red or brownish-red; its appearance has been likened to that of scarlet cloth. The vessels of the mucous membrane are red and prominent, as if injected with vermilion. The blood is bright red as if it were hyper-oxygenated.

Barium Chloride or Nitrate.—Smallest recorded fatal dose, 3i; death may occur in one hour, or at any time up to seven days. (*Note.*—These salts have been taken by mistake for purgative salts.) The changes found may be insignificant. In severe cases there are signs of gastro-intestinal inflammation. The mucous membranes of the stomach and duodenum are swollen and diffusely congested or stippled with ecchymoses. Ulceration may take place and occasionally perforation follows. The rectum may be intensely inflamed. The kidneys are congested.

Arsenic.—Whether the poison be introduced directly into the stomach or applied to the surface of the body and absorbed, the stomach always shows the principal changes.

The body may have a shrunken appearance. The eye-balls are sunk in their sockets, and the general cutaneous surface cyanosed, but these changes are by no means constant. Decomposition is usually retarded, sometimes for many months, but, when death has followed rapidly upon small doses of the poison, putrefaction may not be appreciably delayed.

Acute Poisoning.—Smallest recorded fatal dose of arsenious acid, 2 gr.; death follows in from twelve to twenty-four hours. The effects are those of local irritation, the stomach and intestines being acutely inflamed. In addition there is acute nephritis, with fatty changes in the liver, the heart and the blood-vessels. In cases in which large doses of arsenious acid have been taken, the repeated vomiting which results may bring up the poison from the stomach more or less dissolved and active. Hence patches of corrosion may form in the mouth and on the lips. The oesophagus as a rule is not inflamed. The *stomach* shows intense inflammation. The surface is covered with mucus, pus, or lymph, in which are entangled white particles of the poison, or green particles, if Paris green has been taken. The mucous membrane may throughout have a reddened velvety appearance, or this appearance may be localized to patches on the greater curvature and posterior surface. The colour may be dark red or vermilion. Sometimes the arsenic penetrates as far as the serous coat, and there may be transformed into the yellow sulphide by the action of the gases produced during putrefaction. Minute haemorrhages may be found in the mucous membrane, or more diffuse extravasations form in the submucous coat. The mucous membrane may be readily detached, and in some cases the ridges are prominent. Occasionally localized gangrene occurs, rarely ulceration, and still less commonly perforation. Similar changes may be found in the duodenum, in the lower part of the descending

colon and upper part of the rectum, or these secondary changes may be localized to the first part of the duodenum. The solitary glands and Peyer's patches may be swollen. If death have been delayed for several days, the whole length of the intestine may be inflamed. The liver and the kidneys show cloudy swelling, or fatty degeneration.

Chronic Arsenical Poisoning.—There is general mal-nutrition, falling of the hair, pigmentation of the skin usually accompanied by eczematous eruptions. The exposed parts may be ulcerated, or the skin may be glossy and the epithelium thickened. The tongue may be dark and swollen. The mucous membrane of the stomach is inflamed in patches which correspond to deposits of the poison, round which the inflammation is concentrated. In the centre of these a gritty deposit of arsenious acid may be found. The surface is covered with tenacious mucus, streaked or tinged with blood. The mucous membrane is occasionally ulcerated or rarely gangrenous. The cardiac end of the stomach is usually more inflamed than the pyloric portion. The small intestine is inflamed, but the duodenum and upper part of the jejunum, ascending colon and rectum, show the most intense changes. The Peyer's patches are prominent and the general surface of the intestine is sometimes dotted over with minute ulcers. Fatty changes are found in the kidneys, stomach and heart. Most arsenic is found in the liver, less in the kidneys. The pigmentation of the skin may resemble that of Addison's disease. The pigment, the origin of which is still uncertain, is deposited in the lymphatics of the papillae. The pigmentation is usually concentrated in the flexures, on the nipples and areolae and on the lower part of the abdomen. The colour is yellowish-brown to dark brown, almost black.

In chronic arsenical poisoning, atrophy and degeneration of the cells in the anterior horn of the grey matter of the spinal cord are sometimes met with, and sometimes the degeneration extends to the white matter. The peripheral nerves are more often affected, a severe neuritis developing, with degeneration of the myelin. The axis cylinders may not be involved. In severe cases fatty and granular degeneration of the epithelium of the liver, kidneys and intestine, and of voluntary muscle, may be as marked as in cases of phosphorus poisoning.

In cases of poisoning with arsenic, in which the post-mortem examination has to be made long after death and burial, some of the *soil* in the near vicinity should be taken for examination to preclude the possibility of the arsenic having penetrated to the body from without. This procedure is essential even although it is hardly likely that an appreciable quantity of arsenic could be transferred even under favourable circumstances, particularly as arsenic in the soil is combined with iron in an insoluble form. A good deal of discussion has taken place as to the extent to which diffusion of a poison introduced into the body after death may take place. Experimentally it has been found that this is possible, but the extent of the diffusion depends altogether upon the anatomical relations of the parts. For example, when introduced into the stomach the organs on the left side—kidney, lung—may show it, while none is found in the corresponding organs upon the right side. Further, none of the inflammatory changes described above are found when introduction has taken place post-mortem, these changes depending upon a vital reaction.

Soamin (Sodium Para-aminophenylarsonate).—In one case of poisoning I examined the principal changes were found in the cerebrum. Punctate haemorrhages were seen throughout the white matter of the brain, each spot being surrounded by a yellow halo. Cerebral oedema was marked. Haemorrhages were also present in the middle peduncles of the cerebellum and in the dentate nucleus.

Antimony.—**Tartar Emetic** (smallest recorded fatal doses, 5–10 gr.; death occurring in seven hours up to several days) is the commonest form in which antimony

is used as a poison. Its effects are generally most marked in the gastro-intestinal mucous membrane. The mucous membrane of the pharynx and oesophagus may show ulceration and pustule-formation. The mucous membrane covering the epiglottis and the adjacent surfaces may also be affected, and ulceration may extend deeply in the oesophagus, exposing the muscular coat. The mucous membrane of the stomach is congested, inflamed, and oedematous, and its surface covered with tenacious mucus. Here and there submucous ecchymoses are found, and superficial erosions, or in more severe cases, deep ulcerations exposing the muscular coats may develop. These changes may be superficial, localized to the greater curvature and the cardiac end, or they may extend throughout the stomach. The contents of the stomach are scanty, dark-coloured, almost black. Similar changes are usually found in the duodenum. While these are the changes usually met with, it must be remembered that some of Pritchard's cases (Glasgow) showed no visible change *post mortem*. In some cases a yellowish discoloration of the surface is found.

In *chronic* poisoning with antimony there is usually considerable emaciation. Local changes are not so marked, but the mucous membrane of the tongue and mouth may be furred or covered with aphthous patches. Ulceration may occur in the stomach or in the intestine—particularly in the caecum and colon, or both stomach and intestine may be affected. When death has been brought about by isolated doses, inflammation of the kidneys and liver may be found, accompanied by fatty change.

Chloride of Antimony (butter of antimony) usually causes corrosion of the parts with which the poison has come in contact, with or without denudation of the mucous membrane, or corrosion may be absent and the mucous membrane engorged with blood, almost black in colour.

Mercury.—The salt of mercury most commonly used as a poison is **corrosive sublimate**. Smallest recorded fatal dose, 3 gr. ; death occurs in half an hour up to three or four days.

Acute Poisoning.—As in the case of other corrosive poisons, the mucous membrane of the pharynx, oesophagus and stomach is specially attacked, but the whole length of the alimentary tract from the mouth to the anus may be affected. The mucous membrane of the lips, mouth, and oesophagus are greyish-white and sodden-looking. The subjacent tissues are intensely inflamed. The mucous membrane of the oesophagus may be corrugated, as a result of contraction of the muscular coats. The changes found in the stomach vary to some extent. In extreme cases the mucous membrane is corrugated, greyish-white as if cooked, or if there have been congestion of the surface the mucous membrane may be of a pale violet or bluish-grey colour, this resulting from the combination of the dark grey of the coagulated blood in the vessels with the greyish-white of the coagulated superficial epithelium. There may be considerable extravasation of blood. The muscular coats are softened but perforation rarely takes place. In less severe cases a band of white corrosion may extend along the lesser curvature to the pylorus, or the surface may be intensely congested and display numerous minute haemorrhages. In other cases, particularly when a moderate amount of the poison has been absorbed through the skin surface, the congestion may be patchy in the neighbourhood of the lesser curvature and affect the mucous membrane of the pyloric antrum.

The duodenum may contain dark brownish fluid in which detached necrotic cells of the mucous membrane are suspended. In the intestine the changes may be somewhat similar to those described in the stomach, and widespread superficial necrosis may be found. The large intestine is often even more affected than the small intestine and may be the seat of ulceration and haemorrhage. The kidneys

are swollen and the mucous membrane of its pelvis shows haemorrhages; microscopically, there are acute parenchymatous and interstitial changes. A very characteristic appearance is a non-inflammatory necrosis of the epithelium of the ascending loop of Henle, with a deposit of lime salts in the necrotic cells. If death have been rapid this may not have time to develop. The liver is pale and anaemic.

In *Chronic Poisoning*, or when absorption has taken place from the cutaneous surface, a fibrinous exudate may form on the surface of the bowel, and the caecum, the lower part of the colon and the rectum may show violent inflammatory reaction. In very chronic cases the intestine may be almost black in colour from deposit of *melanin* in its wall, the surface being mottled with paler patches (see *Melanosis of Intestine*, in *Bibliography*). Some of the changes above noted, for example, the necrosis of the epithelium of the ascending loop of Henle in the kidney, and the fibrinous or membranous enteritis are looked upon as especially characteristic of mercurial poisoning, though these changes are also sometimes simulated in the case of other irritant poisons.

Lead.—The following compounds of lead or salts of lead have been used as poisons:—*Acetate*—smallest recorded fatal dose, Zi to Zii , but not well determined; fatal period not well known,—*oxide* (diachylon), the *carbonate* (white lead), the *tetroxide* (red lead), and *yellow chrome* or *chromate* of lead. *Acute poisoning* from absorption of lead salts is not common. The appearances in chronic lead poisoning are those of gastro-enteritis. There may be but slight inflammation of the mucous membrane of the stomach and intestines, or the inner surface of the stomach may be covered with a greyish-white deposit and the wall is thickened and softened, a change which may also extend to the duodenum. *Post mortem* changes are usually not characteristic. In fact, in most cases it is impossible to diagnose chronic lead poisoning solely from the appearances found at the post-mortem examination. Lead salts are excreted by the bowel and by the kidneys, hence one would expect important changes to occur in these organs.

The following changes may be found in marked cases of *chronic lead poisoning*. The gums are soft and usually ulcerated. They show a blue line at their edge in relation to the central and lateral incisors and canines, especially of the lower jaw. The stomach shows chronic gastric catarrh. The intestine is the seat of enteritis. The walls of the large intestine may be pigmented from deposit of *melanin* and the muscular coats may be contracted. Microscopically, the ganglionic cells in its walls and also those in the abdominal ganglia may be degenerated. Liver.—Oliver believes that inter-cellular hepatitis may develop. The kidneys are characteristically pale, contracted and granular, and the urine contains albumen. Chronic interstitial changes may be well-marked. In some cases fibrous changes are found in the endocardium—mural and valvular. Arteriosclerosis is common, though it is a question whether this is a direct result of the lead poisoning. In the nervous system the brain may show oedema, anaemia, softening of the convolutions, and thickening of the pia-arachnoid with small haemorrhages into this membrane. In the spinal cord there is occasionally degeneration of the large cells of the anterior horns. Bone Marrow.—Cadwallader found marked hyperplasia, numerous myelocytes, many nucleated red corpuscles, the latter of which were collected into characteristic erythroblastic areas.

In a small proportion of cases the lesions of gout are found.

Silver Poisoning results usually from swallowing of solutions of silver nitrate or lunar caustic; in some cases the solid salt has been swallowed. *Acute poisoning*.—The stains, at first white, but on exposure to light becoming dark brown or black, are found on white clothing, on the lips, in the mouth and wherever the caustic has come in contact with the mucous membrane of the digestive tract. The

parts specially affected are the oesophagus and the greater curvature of the stomach. Below the stomach the inflammation may have a patchy distribution. In *chronic poisoning*, in cases in which the silver salts have been administered for long-continued periods in place of salts of mercury, for example, in treatment of tertiary syphilis, the silver diffuses throughout the body in the form of a soluble albuminate, but becomes deposited as metallic silver in extremely fine granules in the superficial layers of the corium of the skin and mucous membranes of the passages opening on the surface, and also in the sweat glands. In the internal organs the deposit is most marked in the kidneys; in the choroid plexus; in the liver; in the walls of blood-vessels and in the tissues adjacent to these (see *Argyria*, pp. 17, 294).

Copper.—Salts of copper, particularly the *sulphate* and *subacetate*, are poisons. Metallic copper is not generally considered to be poisonous. *Acute poisoning*—fatal dose $\bar{3}$ i or less, but not well-known; death occurs in four hours, or may be delayed for several days. The mucous membrane of the stomach and intestine is swollen, softened, inflamed, and the surface may be excoriated or even ulcerated in large patches. The general colour of the wall is bluish or greenish, and the superficial epithelium is of a dark brown colour. The thickening and inflammation of the wall may affect especially the pyloric end of the stomach. Occasionally perforation of the intestine occurs. The large intestine is irregularly contracted.

To distinguish the staining of copper salts from that of bile, a solution of ammonia should be applied to the affected surface. This intensifies the blue of the copper staining or changes the green discoloration to blue.

The liver is fatty, soft, and friable. The kidneys are swollen, with yellowish fatty cortex, and, microscopically, blood casts are found in the tubules. In *chronic poisoning* ulceration of the rectum develops similar to that found in dysentery. Some authorities hold that chronic poisoning with salts of copper does not occur.

Zinc.— ZnSO_4 , fatal dose $\bar{3}$ iss; fatal period, thirteen hours and upwards; ZnCl_2 , fatal dose, 6 gr.; fatal period, four hours and upwards. Salts of zinc usually produce changes characteristic of irritant poisoning. The mucous membrane of the mouth, oesophagus and stomach is congested. The intestines may show areas of softening, ulceration, or even perforation. In poisoning with *sulphate of zinc* the changes are characteristic of very acute gastro-enteritis. The mucous membrane of the stomach may be softened and gelatinous, and covered with a yellowish, viscid, layer of mucus. In other cases patches of ecchymosis and erosion are found. The intestines show similar changes. In poisoning with *chloride of zinc* the changes are rather those of corrosive poisoning. The mucous membrane of the mouth, throat, and oesophagus is white, opaque, and readily detached. The wall of the stomach is usually hard and leathery, the surface dark grey and wrinkled. The mucous membrane may be softened or completely destroyed, and, when death has been delayed, the cavity contracts and comes to resemble that of a chronic abscess. In acute poisoning the stomach sometimes contains a fluid not unlike a mixture of curds and whey.

Chromic Acid (K_2CrO_4 , fatal dose, $\bar{3}$ ii; fatal period, forty minutes and upwards) and the chromates of potassium and sodium in concentrated solution, and in the solid form, act as corrosives. In dilute solution they act as irritant poisons affecting especially the central nervous system. In *acute poisoning*, yellow or orange-coloured stains are found on the lips or at the corners of the mouth. The stomach is the seat of acute inflammation; the mucous membrane is swollen and reddened in sharply defined patches. Portions of the epithelium may be detachable. The rest of the mucous membrane may be of a yellow-brown or orange-

green colour, and may be covered with greenish mucus. The intestines may contain a black fluid and the mucous membrane throughout may be swollen and show numerous extravasations. The kidneys are the seat of acute parenchymatous inflammation. The epithelium is granular and cloudy, and the tubules contain hyaline and fine granular casts. The blood is of a chocolate colour, and gives the spectrum of met-haemoglobin. In *chronic poisoning*, deep ulcers—"chrome holes"—develop on the hands, and the nasal septum may be destroyed.

Phosphorus.—Smallest recorded fatal dose, $1\frac{1}{2}$ gr. (Dixon Mann) $\frac{1}{8}$ gr. (Luff); usual fatal period, two to six days. *Yellow phosphorus* is poisonous. Safety matches which are ignited by striking upon a prepared surface of *red phosphorus* are non-poisonous. Phosphorus may be taken in the form of "vermin-killer" or "rat-paste," or occasionally match-heads are dissolved in water and the solution swallowed. The poison is more often used by women than by men, for example, for the purpose of inducing abortion. Phosphorus poisoning is to be distinguished from *icterus gravis*, and from *acute yellow atrophy*. Kobert suggests that some of these diseases may be actually cases of phosphorus poisoning resulting from the reduction, chiefly in the intestinal tract, of phosphorus compounds contained in such substances as lecithin and nucleïn. This has not been proved. In *acute phosphorus poisoning*, anything abnormal in the mouth and throat is seldom found. In some cases no lesions are found *post mortem*, or only reddening of the whole of the intestinal tract. The stomach may be healthy, but, characteristically, its mucous membrane is swollen from enlargement of the glands and occlusion of their orifices by large granular cells. The surface may be yellowish or greyish-white, and ecchymoses and superficial erosions may be present. This greyish-white swelling is due to infiltration and to fatty degeneration of the epithelial cells of the glands, and may be specially evident along the ridges of the mucous membrane. It is to be noted that similar changes may be found in diphtheria, in pyaemia and in septicaemia. Analogous changes may be found in the intestine, often associated with minute inflamed areas or with haemorrhagic foci. The stomach and duodenum may contain dark fluid, which smells of garlic, especially if heated. This fluid consists chiefly of altered blood and mucus. It may be luminous in the dark. If "rat-paste" has been taken the stomach contents may be of a bluish colour. Fatty changes are also found in the muscles, in the heart and kidney, and in the endothelium of vessels, but is always most extreme in the liver. The liver, in typical cases of phosphorus poisoning, may be enlarged and doughy; uniformly bright yellow or orange-yellow in colour from extreme fatty change combined with some degree of jaundice, or it may be marbled. The jaundice is due to occlusion of the terminal bile-ducts by swollen or degenerated epithelial cells, and by catarrhal mucus, which increases the viscosity of the bile. The lobules are large and distinct, separated by a fine mesh-work corresponding to the portal spaces. Under the microscope there is extensive deposit of fat in fairly large globules in the liver cells, some of which are nearly full of fat. The nuclei of some cells are stained, whereas others are degenerating or necrotic. The cells of the central zone of the lobule frequently contain bile. The fat is of the same nature as the fat of connective tissue, and it is derived from the "fat-depots." It is not formed, primarily, by degeneration of the protein of the liver cell. The connective tissue of the organ is usually unaffected. The pancreas shows an increased amount of fat. Frequently the fatty change in the heart and in the kidney is not evident to the naked eye, and it has been found by estimating the amount of fat present that this is not actually increased, though under the microscope it may be very evident. In the heart, in the serous membranes and in fatty tissues diffused scattered haemorrhages are extremely common. The blood has its power of coagulation

either reduced or lost altogether. The kidneys are enlarged and soft, the capsule strips easily, the cortex is thickened and pale grey or yellowish-grey in colour. The excretory tubules display marked catarrh. When death has been very rapid, the kidneys may be apparently healthy or are only a very little congested.

The heart is flabby, the myocardium pale or fatty and friable; the spleen enlarged, turgid in some cases; in others it is small and firm.

The principal points distinguishing phosphorus poisoning from yellow atrophy are the following:—In *phosphorus poisoning* the liver is large, doughy, uniformly yellow or may be marbled, some parts being less affected than others. The lobules are well-marked. The intestine shows marked catarrh and the faeces are fluid. The microscopical changes, as already described, are also very characteristic. In *acute yellow atrophy* the liver is diminished in size, tough, leathery, of a dark yellow or dark green colour and the lobules are not well-marked. Microscopically, the liver cells are replaced by finely granular debris and loosened, degenerated cells, the necrotic changes predominating over the fatty changes. In the portal spaces and their neighbourhood, particularly in *subacute* cases, there is new-formation of connective tissue and a varying degree of proliferation of the bile-ducts. The intestine contains greyish-white knotty faecal masses (*see also* p. 245).

Chronic phosphorus poisoning.—In man, the characteristic changes are necrosis of the maxillae and general fragility of the bones. The bones may also show numerous osteophytic out-growths. The liver may present an appearance very similar to that found in cirrhosis, the initial necrosis of the liver parenchyma being followed by extensive formation of connective tissue.

Chlorine Vapour.—The lungs are emphysematous and oedematous. The bronchi contain frothy fluid, and their mucous membrane is congested. Death is due to paralysis of the heart and *asphyxia*.

Bromine.—The lips and tongue are dry, hard, and dark brown in colour. The mucous membrane of the oesophagus is inflamed. On opening the abdomen the odour of bromine is noted. The stomach on its outer surface is congested and may show haemorrhages. The mucous membrane, particularly that covering the ridges, is tough, corrugated, hard and black, easily detached; that covering the areas between the ridges may be softened. Similar changes are present in the duodenum. The omentum and peritoneum may be stained of a reddish-yellow colour.

Iodine.—Fatal dose, ʒi of Tincture; fatal period varies up to twenty-four hours. The *post mortem* appearances are indefinite and inconstant. The mucous membrane of the mouth, oesophagus and stomach may be stained yellow and softened. Sometimes membranous changes are found in the larynx. Gastritis and duodenal catarrh may be present.

Hydrocyanic Acid (Prussic Acid).—Fatal dose, ʒss; fatal period, two minutes up to one and a half hours. The odour of hydrocyanic acid is one of the most characteristic indications at the *post mortem*; but it is never strong, and cannot be detected if decomposition has set in. It is said to persist longest in the interior of the skull and Casper recommended that, in these cases, the head should be opened first. The odour resembles that of nitro-benzene, but the odour of the latter persists for some time even on exposure of the organs to the air. The body is usually of a natural colour; the individual seems to be asleep. Lividity may be of a bright red hue which, however, is never so marked as in cases of carbon monoxide poisoning. The eyes may be open, fixed, and staring; the pupils dilated. The hands may be fixed in a convulsive attitude. The jaws are usually firmly closed. Internally the changes may be those of *asphyxia* unless an enor-

mous dose has been taken, when the blood may be of a bright red colour throughout. The mucous membrane of the pharynx, oesophagus, stomach and duodenum may show marked bright congestion, with ecchymoses. Petechial haemorrhages may also be found in the serous membranes. The air passages may contain frothy blood-stained mucus.

Potassium Cyanide.—Fatal dose, 5 gr. The appearances found resemble those of hydrocyanic acid poisoning, but added to these there may be a local caustic action resembling that of caustic potash. If the dose be just lethal, there may be very little change in the stomach. In large doses the mucous membrane of the stomach and oesophagus may be wrinkled and of a deep red or reddish-brown colour.

Ethylic Alcohol.—The fatal dose and fatal period vary greatly. The *post mortem* appearances are generally those of *asphyxia*.

Acute alcoholic poisoning.—Rigor mortis persists longer than usual, and putrefaction is retarded. If death be sudden, the pupils are usually dilated. In some cases the stomach and other organs appear to be quite normal, but, as a rule, some of the organs are of a deep red colour. Frequently punctiform haemorrhages are found in the gastric mucous membrane, and this may be easily separated. The contents of the stomach may have a well-marked odour of alcohol, and the surface be covered with thick ropy mucus. The walls of the oesophagus and intestines show bright red capillary injection. The blood is generally dark and fluid. The right heart is distended. The venous circulation is engorged. The brain and its membranes show marked congestion and oedema. If there has been previous intemperance, the signs of chronic alcoholism may also be present.

Chronic alcoholism.—The stomach is the seat of chronic catarrh. The walls are thickened, and the ridges and mammillations are prominent. The mucous membrane is atrophied and covered with a layer of thick, tough, tenacious mucus. The intestines may show similar changes. The liver is greatly enlarged and greenish-yellow throughout from fatty changes, or it may be diminished in size and the seat of coarse cirrhosis (*see p. 247*). The heart is usually dilated; the myocardium pale, of a brownish faded tint, showing diffuse fatty change (*see p. 69*). This diffuse character of the fatty degeneration is almost characteristic of chronic alcoholism, just as the "thrush breast" appearance may be regarded as almost typical of the fatty degeneration accompanying severe anaemias. The dura mater in characteristic cases is greatly thickened, opaque, and adherent to the skull. The pia-arachnoid is milky from fibrous thickening, and the convolutions, particularly over the vertex, are atrophied, the sulci widened, and the pia-arachnoid full of oedematous fluid. The arteries throughout the body are usually degenerated, the larger trunks being atheromatous and the medium-sized and smaller arteries being sclerosed or atheromatous. The kidneys are usually diminished in size, granular on the surface, and may display the changes characteristic of arteriosclerotic atrophy. The intestines are the seat of chronic catarrhal changes.

Chloroform.—Fatal dose, child, $\frac{3}{i}$; adult, $\frac{3}{vii}$ (Dixon Mann); fatal period varies from one to twenty-four hours. In cases in which *liquid* chloroform has been swallowed, the mucous membrane of the pharynx, epiglottis and oesophagus may be of a dirty-grey colour, softened and easily detached. The mucous membrane of the stomach is congested and occasionally ulcerated. In death from inhalation of chloroform *vapour* the lesions may not be characteristic. The organs, particularly the lungs and kidneys, may be simply congested. Many deaths described as due to delayed chloroform poisoning are in reality due to septic poisoning. In seemingly authentic cases the liver is pale, frequently enlarged, sometimes of a canary-yellow colour, intensely fatty, the fat appearing especially

in the cells of the central zone of the lobule; the nuclei of the cells usually, but not always, stain well with haematein; the portal spaces may be infiltrated with small cells. The heart may be cloudy and fatty. The epithelium of the kidneys shows granular and fatty change, the fat being placed mostly at the bases of the cells. Numerous petechial haemorrhages may be found in the mucous membrane of the stomach.

Chloral hydrate.—Smallest fatal dose, child, 3 gr.—0.2 gm.; adult, 20–30 gr.—0.7 to 2 gm.; fatal period varies from fifteen minutes to forty hours. No specially characteristic lesions may be found. The mucous membrane of the pharynx, oesophagus, and stomach may be reddened and inflamed. The contents of the stomach may have an odour of chloral. Occasionally the lungs are oedematous. The blood is usually dark and fluid. The brain is usually congested. In chronic cases, fatty degeneration of some of the organs—heart, liver, kidney—has been found.

Iodoform.—The heart, liver, and kidneys may be the seat of fatty degeneration and the kidneys may show acute inflammation. In some cases the meninges are oedematous.

Ether.—The *post mortem* appearances are not characteristic. Usually the mucous membranes are congested and if the *post mortem* is conducted soon after death the organs have an odour of ether.

POISONING WITH GASES.

Carbon Dioxide or Carbonic Acid Gas.—The *post mortem* appearances are those of death from *asphyxia*. The position of the body indicates that the individual has died without a struggle. The face may be livid, swollen, and the features distorted, but not infrequently the face is placid. Death may in error be ascribed to apoplexy, as there may be some superficial haemorrhages in the meninges and marked congestion of the brain and its membranes.

Carbon Monoxide (CO).—In *acute poisoning* the face is calm and may be of a rosy tint. The surface generally is of a rosy colour. In one case reported this was found to persist seventeen months after death. The pink colour is marked especially over the skin of the face, neck, shoulders, breast and thighs. It is less apparent on the back of the trunk. The lungs are congested and oedematous, and the bronchi full of blood-stained frothy fluid. The muscles are of a bright pink colour. The blood is fluid and of a light red colour in the organs. Sometimes if in large masses, as in the heart, it is of a dark colour. The rosy colour of the blood may be retained for some years and the presence of carbon monoxide has been detected many months after death by spectroscopic examination. A simple test for the presence of carbon monoxide is as follows:—First take a drop of normal blood from the finger and dilute it in a watch glass or in a test-tube until the solution appears of a yellow colour. Next take a drop of the suspected blood and dilute it to the same degree. If carbon monoxide be present, the colour remains of a pink tinge. Spectroscopic examination:—Diluted normal blood gives two bands between D and E of the spectrum. If now a drop of sulphide of ammonium be added, the normal blood spectrum of oxyhaemoglobin disappears and only one band remains, that characteristic of reduced haemoglobin. If carbon monoxide blood be treated in a similar way no alteration takes place on the addition of the ammonium sulphide (Glaister).

Water Gas.—Water gas may contain as much as 40 per cent. of carbon monoxide and the *post mortem* appearances in cases of poisoning resemble those produced by that gas.

Illuminating Gas.—Most authorities ascribe the poisonous properties of illuminating gas to the *carbon monoxide* it contains, and the *post mortem* appearances are similar to those described in connexion with that gas.

Carbon Bisulphide.—The *post mortem* changes produced are usually those of *asphyxia*. None of the changes found in cases of poisoning with this gas are characteristic. The odour of the gas may be noted in the cavities, particularly in the abdomen. The lungs and other organs are congested and full of dark coloured blood. The mucous membranes may show numerous punctiform haemorrhages.

Sulphuretted Hydrogen.—If death from poisoning with this gas has taken place rapidly and the *post mortem* is conducted at once, *nothing characteristic* may be found. If the examination has been delayed, putrefactive changes are found to have developed rapidly. Rigor mortis may be well-marked or absent. The blood is fluid and of a dark colour. The organs, particularly the spleen, are very dark, almost black, in colour. The lungs are oedematous. The muscles are of a dark purple colour. Sometimes they have a bluish tint. Otherwise the signs of *asphyxia* are predominant.

On spectroscopic examination, a narrow line—that of met-haemoglobin—is found between C and D of the spectrum, and this does not disappear on the addition of a reducing agent.

Sewer Gas.—Sewer gas is made up of a varying proportion of sulphuretted hydrogen, free hydrogen, carburetted hydrogen, ammonia, carbon dioxide, and atmospheric air deprived of some of its oxygen. The sulphides present are the most dangerous, and the post-mortem changes found may be those of poisoning by sulphuretted hydrogen, but in many cases death is due solely to the want of oxygen.

Gases produced by Explosives (Dixon Mann).—*Gunpowder* produces carbon dioxide, nitrogen and a considerable quantity of carbon monoxide and sulphuretted hydrogen. *Nitroglycerin* (dynamite), and *gun-cotton*, on exploding, also produce a large amount of carbon monoxide. *Tonite*—a combination of gun-cotton with barium nitrate—produces very little carbon monoxide. *Roburite* tested experimentally produces no carbon monoxide, but in actual practice some carbon monoxide is found, which may be produced either from the explosion of the detonator or from the passage of hot carbon dioxide over the surface of coal (Dixon).

Sulphur Dioxide.—The *post mortem* appearances are those of *asphyxia*, but the blood is usually darker than is the case in *asphyxia*, and it may have an acid reaction. The respiratory passages may show catarrhal changes and even sometimes an extensive croupous inflammation. On spectroscopic examination, two bands appear as in oxyhaemoglobin, with a third narrow band between C and D towards the red end of the spectrum. It is distinguished from that of met-haemoglobin, in that the third band does not disappear after the addition of a reducing agent to the sulph-haemoglobin.

Nitrous oxide gas produces *no characteristic* lesions. Fumes of **Nitric acid** cause congestion of the respiratory tract and excessive blood-stained secretion into the bronchi and alveoli, with speedy death from *asphyxia*.

Arseniuretted Hydrogen Gas.—The mucous membrane of the stomach and small intestines is deeply congested and shows petechial haemorrhages; the liver and kidneys are swollen, and the viscera generally are superficially tinged blue or blue-black; the lungs are oedematous. The gall-bladder and bile-ducts contain thick viscid bile, with a large amount of amorphous sediment. The bile pigments are increased, and there is usually jaundice. Microscopical examination reveals a tendency to fatty changes, and chemical analysis demonstrates the presence of arsenic in the tissues (Dixon Mann).

HYDROCARBONS.

Nitro-Benzene (fatal dose, 20 drops ; fatal period varies from one to twenty-four hours) is used in the manufacture of anilin and of perfumes, and as a substitute for oil of bitter almonds in flavouring extracts and as a flavouring agent in liqueurs and cheap confectionery.

On opening the body in cases of nitro-benzene poisoning, the organs have an odour of bitter almonds, resembling that of prussic acid, but much more persistent. Drops of the nitro-benzene may be found in the alimentary tract several days after death. The oesophagus, stomach and duodenum may be diffusely congested with numerous punctiform haemorrhages. The blood is dark brown or black, and coagulation may be wanting (*asphyxia*).

Anilin.—Fatal dose, ʒvi or less. The *post mortem* appearances are *not characteristic*. The mucous membranes of the bronchi and the stomach have been found red and swollen, and the veins are generally full of dark coloured blood.

Naphthol.—Parenchymatous nephritis and extensive changes in the skin are found *post mortem*.

Salicylic Acid.—Gastro-enteritis, acute nephritis, and general hyperaemia of the organs, are found at the *post mortem* examination. No lesions are produced specially *characteristic* of poisoning with this acid.

Pyridine.—The larynx, trachea and bronchi are lined with a friable yellow membrane. The lungs are congested and oedematous and the oesophagus and cardiac end of the stomach are greatly congested.

Benzine.—Fatal dose, ʒi ; fatal period, twelve hours and upwards. The *post mortem* appearances include hyperaemia of the meninges and brain ; sub-pleural haemorrhages ; haemorrhagic areas in the lungs, especially in the lower lobes ; acute inflammatory changes, frequently with haemorrhages, in the stomach and intestines. No changes occur in the blood, heart, muscle, or liver, but marked parenchymatous degeneration of the kidneys is present (*see Bibliography*).

Petroleum.—*Nothing* very *characteristic* is found on *post mortem* examination, but the odour of the oil may be detected in the stomach and small intestines. The mucous membranes are pale and show no excoriation.

VEGETABLE POISONS.

Opium and Morphine.—Fatal doses, *opium*, 4 gr., *tinct.* ʒii (child, ʒiv or less) ; *morphin. hydrochl.* i gr. ; *morph. acetatis* $\frac{1}{2}$ gr. All cause death from coma and asphyxia. The appearances are *not very characteristic*. In many cases nothing abnormal is found, and none of the appearances are sufficiently characteristic to enable one with confidence to state that opium or one of its preparations, has been the cause of death. The pupils sometimes remain contracted, but more often are of the ordinary size or even dilated. In some cases the stomach contains remains of the opium which had been swallowed. The liver and kidneys may show no characteristic change. The lungs are congested and oedematous and may show patches of early pneumonia. The spleen is acutely congested and the blood is fluid and dark coloured. The brain and membranes are congested and oedematous ; on section the grey matter is congested. There is frequently effusion into the meninges and ventricles.

Tobacco and Nicotine.—*Nicotine*, fatal dose, 1–3 drops ; fatal period, three or four minutes. No *characteristic* changes are found *post mortem*. The blood is dark and fluid and the organs are deeply congested.

Digitalis (Foxglove).—Fatal dose, *Pulv. fol.*, gr. 30–2 dr. ; *tinct.*, ʒix ; *digitalin*, $\frac{1}{4}$ to $\frac{1}{2}$ gr. ; fatal period, three-quarters of an hour to twenty hours or more.

No appreciable change may be found *post mortem*. In one case, Wynter Blyth found the blood dark and fluid; the right side of the heart full of blood, the left side empty; the mucous membrane of the stomach and intestines in parts was ecchymosed and patches of congestion were also found. The brain and its membranes were anaemic.

Ergot of Rye.—In *acute* poisoning, haemorrhages are found frequently in the submucous coat of the stomach and intestines, and also in the liver, kidneys, uterus, lungs and pericardium. The liver and kidneys may also show fatty changes. Frequently polyneuritis and arteritis are found in *chronic* poisoning with ergot.

Savin produces congestion of the pharynx and oesophagus, inflammation of the stomach and intestines with punctiform haemorrhages; acute nephritis may develop. Fragments of the leaves may be found in the stomach.

Castor Oil Seeds.—Smallest fatal dose, adult, 3 seeds; fatal period, about forty-eight hours. *Post mortem* changes are due to the action of the active principle "ricin." The severity of the action seems to be independent of the number of seeds eaten. The mucous membrane of the stomach and intestines is swollen and easily separated. Numerous small haemorrhages are found. Similar changes are found in poisoning with **Croton oil**.

The Jalap group of purgatives, including Jalap, Colocynth, Podophyllin, Gamboge, Elaterium.—In poisoning with these substances, the only *post mortem* appearance to be found is inflammation of the alimentary tract, sometimes accompanied by ulceration. Occasionally there is inflammation of the pericardium, liver, spleen, kidneys, and bladder.

Male Fern.—General venous congestion of the organs; bright red haemorrhages in the submucous coat of the stomach, and in the omentum and peritoneum.

Belladonna.—Fatal doses, *lin. bellad.* \mathfrak{z} i; *extract.* \mathfrak{z} i; fatal period, up to twelve hours. The *post mortem* appearances are those of *asphyxia*.

Aconite.—Fatal doses, *root*, \mathfrak{z} i; *extr. gr.* ii; *tinct.* \mathfrak{z} i; fatal period, three-quarters of an hour to four hours. The skin and muscles may be pale. The mucous membrane of the mouth is also pale. The internal organs are deeply congested. There is gastric catarrh. The blood is fluid, sometimes of a bright red colour. These changes are not different from those of ordinary *irritant poisoning*.

Strychnine.—Smallest fatal dose of *sulphate*, gr. $\frac{1}{2}$; fatal period from five minutes to two hours. Sometimes rigor mortis is prolonged, but this is not invariable, seeing that it depends on the time elapsing between the onset of the convulsions and death. If the excitability of the muscles has not been exhausted by the convulsions, the rigor will last longer. The changes found in the organs are those of *coma* and *asphyxia*. The lungs, brain and cord are engorged. The blood is dark and fluid and the right heart dilated.

Cocaine.—Smallest fatal dose, hypodermically gr. ii; fatal period, twenty minutes or less. The changes are not characteristic. Death is due to *asphyxia*. The blood is fluid, of a dark brown colour; cloudy swelling is present in the nerve cells and in the heart, liver, and kidneys.

Atropine.—Fatal dose, $\frac{1}{2}$ to 2 gr. The pupils are usually dilated. The mucous membrane of the stomach is congested. The blood is generally fluid and of a dark colour. There is great hyperaemia of the brain and of its membranes.

Colchicum.—Smallest fatal dose, *vinum*, \mathfrak{z} iiiss.; fatal period, seven to thirty hours. There is no inflammation of the throat or oesophagus. The mucous membrane of the stomach and intestines is congested and softened. The liver and spleen are congested.

Conine and Hemlock.—Smallest fatal dose of *conine*, 1 drop; fatal period,

one to three hours. The blood is dark and fluid. The lungs are engorged. The brain is congested, and its ventricles contain an excess of fluid.

Gelsemium.—Smallest fatal dose, *tinct.* ℥iv; *fl. extr.* ℥iii; fatal period, one to several hours. At the post-mortem examination there is little abnormal except for venous congestion of some of the organs.

Hellebore.—Fatal dose, *extr. aq.* ℥ss.; fatal period, three to twelve hours. The *post mortem* appearances are neither characteristic nor uniform. The same applies to poisoning with **Veratrum** and Calabar Bean—**Physostigmine** or **Eserine**.

Sulphonal.—There is congestion of the oesophagus, liver, spleen and kidney, and ecchymoses are found in stomach and duodenum.

Poisonous Fungi.—These are often taken by mistake for mushrooms. In cases of death due to their action, rigor mortis is usually absent. The pupils are dilated. The serous membranes show numerous punctiform haemorrhages, and the cavities may contain some dark blood. The heart blood is of a dark red colour and fluid. The lungs, liver, kidneys and spleen are engorged with dark blood. The mucous membrane of the stomach is usually congested; haemorrhagic spots, and even small erosions may be found in it. It may be softened and detached in some cases. The mucous membrane of the intestines is congested. Occasionally fatty degeneration has been found in the liver, heart and kidneys. In extreme cases the changes may bear some similarity to those found in cases of phosphorus poisoning.

Meat Poisoning. Botulism. Ptomaine Poisoning.—This form of poisoning especially follows the eating of tainted sausages, corned beef, brawn, potted meats, canned goods and pies. The mucous membrane of the mouth, throat and oesophagus may be white, dried, and parchment-like. The mucous membrane of the stomach may show congestion and petechial extravasations. The mucous membrane of the intestinal tract may show nothing abnormal, or it may be the seat of extensive haemorrhagic enteritis. The spleen is usually large and congested. The kidneys are congested, and the tubules may contain blood. The lungs are oedematous, and bronchitis or broncho-pneumonia may be present. The brain may be anaemic. Cultures should be made from the intestinal contents with the view of detecting members of the *Colon-Typhoid* group of bacilli, especially *Paratyphoid B.* and *Gärtner's bacillus* (on malachite green agar; on Drigalski and Conradi's medium; or on M'Conkey's bile salt broth).

APPENDIX

METHODS FOR PRESERVING THE NATURAL COLOURS OF ORGANS

Three methods are available, Pick's, Jores' and Kaiserling's. In all, the procedure is somewhat similar and they may be described together. For discussion of the chemical changes which take place, and for the indications and reasons, e.g., for modifying the composition of the mounting fluids for different tissues, the reader should consult the original papers.

Pick's Method (Berl. klin. Woch. 1900. No. 41, 42).

- | | | | |
|-----|---------------------------------|------------------------------|------------|
| (1) | Sod. Chloride | 120 | grs. |
| | Sod. Bicarb. | 240 | " |
| | Sod. Sulphate | 600 | " |
| | Water | 1 | gallon |
| | Formalin | 8 to 16 | oz. fluid |
| (2) | Meth. Spirit. | | |
| (3) | Glycerine (acid free) | 1 part | } 1 gallon |
| | Water | 2 parts | |
| | Pot. Acetate | $\frac{1}{10}$ part (16 oz.) | |

(No. 3 slightly modified.)

Jores' Method (Cent. f. allg. Path. u. path. Anat. 1896. vii. 134).

- | | | | |
|-----|--------------------------|------------------|---------------------------------------|
| (1) | Sod. Chloride | 1 part | |
| | Magn. Sulphate | 2 parts | } or { |
| | Sod. Sulphate | 2 " | |
| | Water | 100 " | |
| | Formalin | 5 to 10 " | |
| | | | |
| (2) | Meth. Spirit. | | |
| (3) | Glycerine | 2 parts | } or { |
| | Water | 3 " | |
| | Formalin | $\frac{1}{10}$ " | |
| | | | 64 oz. fl.
96 oz. fl.
2 oz. fl. |

(No. 3 modified.)

Kaiserling's Method (Virch. Archiv. 1897. cxlvii. 389).

- | | | | |
|-----|---------------------------|------------|----------------------------------|
| (1) | Pot. Nitrate | 15 gm. | |
| | Pot. Acetate | 30 " | } or { |
| | Water | 1000 c.cm. | |
| | Formalin | 200 " | |
| (2) | Meth. Spirit. | | |
| (3) | Potass. Acetate | 200 gm. | } or { |
| | Glycerine | 400 c.cm. | |
| | Water | 2000 " | |
| | | | 16 oz.
32 oz. fl.
1 gallon |

In each of these No. 1 is the fixing solution; No. 2—the alcohol—restores the colour; No. 3 is the mounting medium. In all cases I have also supplied

English measurements. In the original description of Pick's method the formalin is mixed with a 5% solution of artificial Carlsbad salts, but the formula given is the one which I have used for nearly ten years.

Method of Employment.—To insure good results it is essential that the organ or tissue should be as fresh as possible, and be placed in the fixing solution at once or at all events as soon as possible, and in any case without washing with water. This is of special importance in the case of hollow organs like the stomach or intestines. It is immaterial which method is used. I, myself, find Pick's method to be very satisfactory and I consider that the strength of the formalin (5 to 10 per cent.) in Pick's and Jores' methods is preferable to that in Kaiserling's method (20 per cent.), penetration being probably more perfect. The fixing solution should be changed if it becomes turbid, and it is well to transfer in any case into fresh solution after two days. Fixation has usually advanced as far as is possible in about a week, but I find in the majority of cases that longer exposure to the formalin solution is not disadvantageous. The surface becomes of a dull greyish-brown colour in the fixing solution. When fixation is complete the organ is transferred to used methylated spirit for about one hour and then to fresh methylated spirit (95 per cent. alcohol) for an average of six hours, the time varying with the individual organ or tissue under treatment. It is then transferred to the mounting solution without washing. It is important to emphasize that washing in water at any stage is not advisable. When the organ sinks in the mounting solution, it is transferred to fresh mounting solution for final preservation. (*See p. 452.*)

Mounting in Glass Jars.—The organ may be suspended in the usual manner within the jar, or it may be fixed to the surface of the jar with the following gelatine mixture.

Thymol Water (satd. in cold)	100 c.c.
Glycerin	20 „
Acetate of Potash	5 gm.
Coignet's (gold label) gelatin	10 „

Render acid to litmus with acetic acid ; clarify with white of egg and filter.

(Richard Muir.)

After the gelatine has hardened, the jar is filled up with one of the mounting solutions, or better, with the following :—

Thymol Water.	100 c.c.
Glycerin	20 „
Acetate of Potash	5 gm.

The cover is then fixed in position either with paraffin, the cover being heated beforehand, or the paraffin is run in between the cover and the edge of the jar with a hot soldering bolt. A better fixative for the cover is the following mixture :—

Litharge.

Archangel tar, q.s. to make a stiff paste.

After the cover is fixed in position, a narrow band of Berlin black is painted on to give a neat finish to the joint.

PRESERVATION AND FIXATION OF TISSUE FOR MICROSCOPIC EXAMINATION.

A great variety of fixing agents, some of which are also hardening agents, are available. The most convenient and generally applicable of these is *Formalin* in 5–10 per cent. solution of the commercial fluid. (Formalin is a 40 per cent.

solution of formaldehyde in distilled water. I have found its strength to vary from 28 per cent. to 42 per cent. so that it is essential to procure formalin made by a good maker, to use it fresh, and in any case to keep it well corked.)

For fixing purposes formalin solution may be made up with ordinary tap water, but it is preferable to use for this purpose 0.85 per cent. solution of common salt (physiological saline) or Jores', Kaiserling's or Pick's fixing solutions. The usual time allowed for fixation is 24 hours. Thereafter the tissues should be washed in running water for several hours.

Greater and sharper detail of minute structures, granules, etc., in cells is obtained by using a 5 per cent. solution of *Formalin* in *Müller's fluid*. After fixation for 24 hours, portions of the tissue should be changed into fresh Müller's fluid every day for a week. Even better results are obtained by fixing in Zenker's fluid. This is

Müller's fluid, 95 c.cm.

Corrosive sublimate, 5 gm.

Before using, add 5 per cent. of Glacial acetic acid (Woodhead). Fix for 24 hours, then wash for 24 hours.

Corrosive Sublimate is also an important fixing and hardening agent which is used in saturated solution in 0.85 solution of common salt. It occasionally gives better results than any other fixing media in the case of tissues which are taken at a considerable interval after death. After fixing for 24 hours, wash overnight in running water before embedding. Sections before being stained should be treated with Iodine solution (Iod., 1 gm.; Pot. Iod., 2 gm.; Aq. dest., 100 c.cm.) to remove remaining traces of the corrosive, then washed in ammoniated spirit (2 drops Liq. Ammon. to 1 oz. Spt.) to discharge the Iodine.

A very useful fixing and hardening agent is a 0.2 per cent. solution of *Iodide of Mercury* in *methyiated spirit*. This solution fixes and hardens perfectly and rapidly. It is useful for small pieces of tissue particularly.

Methyiated spirit may also be used alone, giving somewhat better results than absolute alcohol.

A mixture of *Formalin* (one part) and *Absolute Alcohol* (nine parts) is very useful for fixing bone marrow and small pieces of tissue, especially if one require rapid fixation of red blood corpuscles, and it is also useful for fixing granules in leucocytes.

METHODS OF PREPARING MICROSCOPIC SECTIONS.

EMBEDDING METHODS.

(1) EMBEDDING IN GUMS.

Ordinary Method.—After washing in water, the piece of tissue is placed in one of the following solutions, and allowed to soak for one to two hours at 37° C. or, preferably, at room temperature overnight:

(a) Dextrin	1 part
Dist. water	2 parts
Carbol. acid	1 per cent.
or (b) Gum acacia (satd. sol.)	3 parts
Syrup (B.P.)	1 part
Carbolic acid	1 per cent.

Very good results may be obtained by soaking in equal parts of gum acacia and water for an hour or two, but the above media give more consistent results. The tissue is then transferred to the stage of a microtome and frozen with an

ether spray, or preferably with carbonic acid. The sections as cut are transferred to a bowl containing water which has been boiled and then thoroughly cooled. Water coming on first turning on a hot water tap may be used for this purpose. The sections when separated from each other are dipped for half a minute into equal parts of methylated spirit and water, and then transferred to a second bowl of water in which they rapidly flatten out. They should be retained below the surface of the water until most of the spirit has diffused.

They are then floated on to slides, the excess of water drained off, and then they are gently pressed upon the slides with a double layer of fine filter paper which has previously been passed rapidly through the flame of a bunsen burner to burn off any loose hairs, or even a clean duster may be used for this purpose. Sections treated in this way will adhere to the slide during the subsequent manipulations. More perfect staining results are obtained by transferring the sections from one watch-glass to another containing the various solutions, and then mounting them on the slide when staining is completed.

Usual Stains.—Sudan and haemateïn; haemateïn and eosin; picrocarmine. Mount in Farrant's medium, or in dextrine and sugar. Sections stained with haemateïn and eosin should be dehydrated in absolute alcohol, cleared in xylol, and mounted in balsam dissolved in xylol.

(2) EMBEDDING IN PARAFFIN.

Ordinary Rapid Method.—After fixation, the tissues, which should not be over 2 mm. in thickness, may be placed in methylated spirit for two hours, being *supported near the surface* of the spirit by a small plug of cotton wool. They are then transferred to absolute alcohol for two hours, or preferably overnight. To insure dehydration being completed they may now be placed in *anhydrous* acetone for a half to two hours, then cleared in anhydrous benzol or xylol. This should not require more than a half to one hour, especially if the vessel be placed in the paraffin bath. They are then transferred to melted paraffin (melting point 52° C.) changed into fresh paraffin after half an hour, and embedded after other two hours.

Slow Method.—The tissue after washing is transferred to 30 per cent. alcohol for twenty-four hours and then placed for successive periods of twenty-four hours into 50, 70, and 90 per cent. alcohol. It is then transferred to absolute alcohol for twenty-four hours, into equal parts of chloroform and alcohol for twenty-four hours, pure chloroform twenty-four hours, equal parts of paraffin and chloroform in the water bath at 54° C. overnight, and then pure paraffin three to six hours, changing the paraffin once. As a rule, the slower the embedding method, the thinner the sections subsequently obtained. In all methods the essential point is to ensure *perfect dehydration* of the tissue.

The tissue is then placed in a paper boat or metal mould containing fresh melted paraffin, and as soon as the surface is caked over the whole is *rapidly* cooled by immersion in cold water.

(In paraffin embedding, benzol or xylol may replace the chloroform.)

After the tissue has been blocked in paraffin it may be cut with any of the mechanical microtomes. If the sections tend to curl up or fold, breathing upon the knife as the sections are being cut tends to produce a flatter section. The sections—glossy surface downwards—are now transferred to moderately warm water, of a temperature which the fingers can bear *very* comfortably (about 40° C.). If they refuse to flatten out at once on the surface of the water, a little of the water should be taken upon a clean slide and the sections transferred to this.

They can then be flattened out with the aid of needles, and are then transferred to the bowl of warm water. From the water they are taken up on to clean slides which may previously have been coated with a thin layer of egg albumen, and then they are placed above or within the paraffin oven to dry and fix. They may thereafter be stained upon the slide by any method desired. The most useful stains are hematein and eosin; haematoxylin and eosin, or picro-fuchsin; Pappenheim's stain, for which it is essential that fixation be carried out in corrosive sublimate or in alcohol; or, if it is desired to demonstrate organisms, Thionin blue, Leishman's method, Gram-Weigert's method, Ziehl-Neelsen's stain for the tubercle bacillus, or other staining methods for bacteria should be employed.

(3) EMBEDDING IN CELLOIDIN.

This material is used when one wishes to obtain sections of very large pieces of tissue, or of whole organs. It is also used in the study of medullated nerve fibres, and is better than paraffin for skin, for hard structures such as cartilage, and for decalcified bone.

After completely dehydrating in alcohol, the tissue is placed in equal parts of alcohol and ether for one to three days or longer, depending on the size of the tissue; in thin celloidin dissolved in alcohol and ether, and then in thick celloidin (consistence of thick cream), each for a similar length of time. To mount, the tissue is placed in a layer of thick celloidin upon the surface of a wooden or vulcanite block, and covered with the celloidin; allowed to harden slowly under a large glass cover such as is used to protect microscopes, the edge of the cover being only slightly raised to ensure that evaporation shall be slow; then placed in 80 per cent. methylated spirit to complete hardening, and to preserve. Sections are cut on a sliding microtome, under spirit, the knife being placed obliquely.

The sections are transferred from spirit to water, and then stained by any desired method; or they may be fixed upon the slides by removing the excess of spirit with filter paper, and pouring some vapour of ether over them, then again placed in the spirit to harden.

STAINING METHODS.

For staining sections (*rapidly*) any of the basic aniline dyes may be used, e.g., polychrome methylene blue (10 per cent.), or thionin blue (1 per cent. in 1.40 carbolic acid), or methylene blue in 1 per cent. solution.

In *ordinary* circumstances, methods should be employed which will differentiate the elements of the tissue more perfectly than is possible with the single anilin stains.

The **logwood dyes** are those most commonly used, either as haematoxylin or as haematein.

(a) The *haematoxylin* stains which I use are Ehrlich's glycerine-haematoxylin (stain for 10 mins.); and iron-haematoxylin. The latter is made up when required as follows:—

Liq. ferri perchloridi (1 per cent.).

Alcoh. sol. haematoxylin (10 per cent.),—equal parts.

Stain for five minutes. This stain keeps good up to three days.

Excess of the haematoxylin or haematein may be removed by immersion in a 1 per cent. solution of hydrochloric acid in methylated spirit, until the section is of a pink colour, and then the section is transferred to tap water—which is

slightly alkaline—until of a distinct blue colour. It may then be counter-stained in $\frac{1}{4}$ per cent. aqueous solution of eosin.

Sections stained with hematein and eosin may be mounted in Farrant's glycerine medium, which should be of neutral reaction if possible, or in a mixture of dextrine and candied sugar, or in Brun's glucose medium.

Dextrine and Candied Sugar :—

Dextrine,	} 1 part.	} Filter.	
Dist. water, eq. pts.			
White candied sugar,	} 4 parts.		
Dist. water, eq. pts.			

Brun's Medium :—

Glucose	40 c.cm.	
Glycerine	10 c.cm.	
Dist. water	140 c.cm.	
Camphorated spirit	10 c.cm.	Filter.

Permanent preparations should be "ringed" with balsam.

If one wish to mount in Canada balsam, the sections are dehydrated with absolute alcohol, cleared with xylol, and mounted in balsam dissolved in xylol.

Sections stained with haematoxylin may also be counter-stained in *van Gieson's picro-fuchsin*, which differentiates fibrous connective tissue from epithelial, muscular, or nerve tissue.

Aq. sol. acid fuchsin	10 c.cm.
Sat. aq. sol. picric acid	100 c.cm.
Precipitated chalk in excess, to neutralize.	

Stain until section is of reddish-brown colour. Dehydrate rapidly in alcohol (without washing in water); clear and mount in balsam.

(b) *Haematein*.—Mayer's haemalum (alum haematein) gives good results. Stain ten to twenty minutes.

At present I am using a modification of Mayer's stain made as follows, and find it gives results almost equal to those obtained with iron haematoxylin. I do not know who is the author of the modification.

To alcoholic solution of haematoxylin add excess of ammonia.

Allow to evaporate overnight.

Rub up the precipitate with 49 times its bulk of powdered potash alum; and make a 7 to 10 per cent. solution of the mixture in distilled water. Add a crystal of thymol, and allow to ripen for ten days.

For counter-staining, use 10 per cent. alcoholic eosin saturated with potash alum.

Mount as for (a).

Eosin and Methylene Blue Methods.—A very useful and generally applicable stain is *Leishman's solution*, diluted with two parts of distilled water. The sections remain in this stain until of a deep purple colour. They are then differentiated in a 1–1500 aqueous solution of acetic acid, washed in tap water, rapidly dehydrated, cleared in xylol and mounted in Canada balsam. Sections stained with other basic anilin dyes may also be treated in this way.

Blood films and films of bone marrow after fixing may be stained by *Louis Jenner's method*.—Flood the film with Jenner's stain—freshly prepared—allow to act for two minutes; wash with distilled water, remove excess of water, allow

to dry slowly, mount in cedar oil or in neutral Canada balsam. (Tabloid Jenner's and Leishman's stains are very satisfactory.)

Better results are obtained by staining in *Eosin* and *Methylene blue* separately.

Flood with equal parts of saturated alcoholic solution of eosin and distilled water. Set fire to the stain, and at once blow out the flame; repeat, until the alcohol is all discharged. Wash in distilled water; treat for five minutes with saturated aqueous solution of potash alum; wash; stain for one minute in freshly prepared saturated aqueous solution of methylene blue; wash; differentiate and dehydrate in absolute alcohol; clear in xylol; mount in cedar oil or balsam (Richard Muir). Ripened alkaline methylene blue (polychrome), or toluidine blue may be used instead of the freshly prepared methylene blue.

STAINS FOR FAT.

To demonstrate fat in frozen sections they should be dipped in 70 per cent. alcohol; then stained in a watch-glass containing a saturated solution of Sudan III or of Scharlach in 70 per cent. alcohol, for ten to twenty minutes, care being taken by using a sufficient quantity of the stain, and by covering the watch-glass, to avoid deposit of crystals of the colouring agent.

The sections are then washed thoroughly in water, stained in hematein as already described, and mounted in Farrant's medium, or in the dextrin and sugar medium, or in Brun's medium.

Lorrain Smith's Methods for Staining Fat.—1. Stain frozen sections in a 1 per cent. watery solution of one of the *basic* aniline dyes (methyl violet or fuchsin). Wash off the superfluous stain with water, and expose to the air in a thin layer of Farrant's glycerin medium. A trace of sulphurous acid added to the solution of the dye ensures more perfect staining of the fat.

2. Fat of frozen sections of tissue, fixed in formalin, stain readily in a 2 per cent. watery solution of Nile blue sulphate (for five mins.; mount in Farrant's medium). This gives a differential staining of fatty substances, some staining red, others blue, according to their composition. Hence this method is useful in studying necroses of the pancreas, and the degenerated medullated fibres in nerve tissues. *J. Path. and Bact.*, vol. xi. 1906, p. 413; vol. xii. 1907, p. 1; vol. xv. 1910, p. 53; also Thorpe, *Tr. Chem. Soc.* 1907, xci. p. 324.

RAPID METHODS OF PREPARING SECTIONS.

While feeling that it is essential to describe these rapid methods, I do not recommend those whose chief value is the saving of time. A pathologist may assume grave responsibility in circumstances in which there is no very pressing need for hurried diagnoses. In some cases, however, the welfare of the patient may demand haste, and it may be necessary to prepare a section and give a diagnosis while the patient is under the anaesthetic. Therefore, the pathologist is wise if beforehand he gain experience at leisure by practising such methods on different tissues—tumours and the like.

(A) Freezing Methods.

1. Sections of tissues, made without previous fixation.

Even the experienced histologist finds difficulty in manipulating sections of a tissue cut without previous fixation, and I do not recommend this procedure. The nuclear staining, in any case, is not so perfect as when the tissue is properly fixed, and fixation can be carried out so quickly, that no advantage, rather the opposite, is obtained by retaining such methods.

2. Sections made after rapid fixation.

(2) Place the tissues (1 to 2 mm. thick), in 10 per cent. formalin in water, or in Pick's, Jores', or Kaiserling's fixing fluids, or in 0.85 per cent. saline; bring to the boil, and keep boiling for one to two minutes. If the saline fluids be used, the tissue must be subsequently washed in running water for three to five minutes.

Place in a drop of gum or dextrin on the zinc plate of a freezing microtome, press flat while freezing, and cut as in the ordinary method for embedding in gums. Transfer to a bowl of cold boiled water.

Stain individual sections in a watch-glass containing *polychrome methylene blue* (diluted 1 in 10), or *thionin blue* (1 per cent. in 1.40 (2½ per cent.) carbolic acid); or if a little more time be available, in *haematein* and *eosin*.

Mount in Farrant's medium, or dextrin and sugar, or Brun's medium; or dehydrate in absolute alcohol, clear in xylol, and mount in Canada balsam. Time required, if the tissue be fixed in 10 per cent. formalin, about five minutes.

(B) Rapid Paraffin Method.

Fix the tissues as before;

Cut a thin section (1 mm.) from the tissue after fixing.

Place in absolute alcohol, supporting the tissue at the surface of the alcohol, one hour;

Anhydrous acetone, one hour;

Benzol or xylol, till clear;

Melted paraffin in water bath, one hour, changing once into fresh paraffin;

Embed in paraffin, and cut in the usual way;

Float sections on to albuminized slides; remove excess of water;

Place in sloping position in paraffin oven, to dry, one-quarter to half an hour;

Stain, as before.

In all dehydrating and clearing embedding methods, it is essential to ensure that the reagents—alcohol, acetone, benzol, and xylol—are absolutely anhydrous. To secure this end, I have, for many years, employed the following means, which others may also find of advantage. Separate exsiccators are used for each fluid (Fig. 207). The bottom part is occupied by a gauze bag (double thickness) containing desiccated sulphate of copper, the quantity being limited only by the size of the space. If the sulphate be placed direct in the bottom of the jar, as it cakes and expands on taking up water, there is a risk of the jar being broken. I experienced this troublesome accident several times before I realized what was the cause.

A round box (Fig. 207) with partitions, made wholly of wire gauze, rests on the narrowed part of the exsiccator at the bottom of the cylindrical, upper portion. This admits of numerous pieces of tissue being treated simultaneously. The fluid reaches to about three-fourths of the height of the gauze box.

I have put through from 120 to 150 pieces of tissue by this method without requiring to renew the fluids or the sulphate of copper, so that the initial cost of the apparatus is soon repaid by the saving in the expense of the reagents.

MEDIA FOR CULTIVATION OF BACTERIA.

The important media for immediate use are the following :—

Peptone broth to which has been added about one-fifth part of nutrient sterile ovarian fluid, sterile hydrocele fluid or sterile fluid from any of the serous cavities of the body.

Agar slopes or plates ; *Serum Agar*—Made by melting the nutrient agar, cooling to 15° Centigrade and adding about one-fifth part of any of the neutral fluids mentioned. This is used either as a sloped agar tube or poured into a Petri's dish. *Inspissated blood serum* is also of value in certain cases.




FIG. 207.—Exsiccator, with gauze box (see text, p. 450) as used by author to economize reagents, and to keep them anhydrous.

COMMON STAINING METHODS FOR BACTERIA.

Simple Stains.—

Jenner's and Leishman's Stains.—Flood *film* with stain, two minutes ; add twice volume of distilled water ; allow to act for five minutes ; wash in distilled water ; blot with filter paper ; dry in air, mount in balsam or in thickened cedar wood oil. If *section*, dehydrate, clear in xylol, mount in balsam or cedar oil.

Thionin Blue (p. 450).—Stain five minutes, wash, dry, mount ; or dehydrate, clear, and mount as in the case of the other simple stains.

Differential Stains.—

Gram's Stain.—Stain for five minutes in

Sat. alcoh. sol. gentian violet, 1 part.

1·20 (5 per cent.) carbolic acid, or anilin water (4 per cent.) 9 parts.

Wash off with iodine solution (iodine 1 gm. ; pot. iodide, 2 gm. ; aq. dest. 300 c.cm.) and allow to act for two minutes.

Decolorize in methylated spirit, till the colour is practically gone. Counter-stain for half a minute with weak carbol-fuchsin (1·10)—see below. Wash, dry, mount ; or if section, dehydrate, and clear as for simple stains.

Ziehl-Neelsen's Stain for the Tubercle Bacillus.—Stain five minutes in

Carbol-Fuchsin :—Satd. alcoh. sol. basic fuchsin, 1 part.

1·20 (5 per cent). carbolic acid, 10 parts.

heating *gently* until steam arises. Wash in water. Decolorize in 20 per cent. sulphuric acid for *at least* two minutes. *Decolorize in methylated spirit, for two minutes.* Wash in water. Counter-stain in 1 per cent. methylene blue or thionin blue. Wash, dry, mount; or if section, dehydrate and clear as for simple stains.

Burri's Indian Ink Method.

This method is useful for demonstrating *Spirochaetes* in scrapings and fluids from syphilitic tissues, and from the throat in Vincent's Angina.

Place some ordinary fluid Indian ink (e.g. Chin-chin brand) in a narrow test-tube and allow to sediment for at least two weeks. Pipette off the upper half into another tube for use.—Before sedimentation it is well to add a small quantity of formalin to the ink to render it aseptic. I find it unnecessary to dilute the ink further. Take a large drop of tap-water upon a clean slide. Mix up with this a small quantity of the material obtained by *gently* scraping the cut surface of an organ, e.g. syphilitic liver, or by *deeply* scraping near the margin of a syphilitic sore, excluding all blood if possible; or add to the drop of water a little of the fluid to be examined, or of the discharge from the throat. Allow the coarser particles to separate; then mix a loop-ful of the mixture with an equal quantity of the ink on a fresh slide and at once smear out over the surface in as thin a layer as possible. This dries quickly. Examine with the oil-immersion and choose for examination portions of the film which present an almost *homogeneous* light-grey appearance. Drennan finds that in films, already made in the ordinary manner, spirochaetes can be demonstrated by smearing the ink over the film in a thin layer.

Mounting Media. (See pp. 443, 444.)

Mr. R. Frost (*Proc. Path. Soc. Great Britain and Ireland, Jan. 1912*) proposes the following mounting medium in place of the glycerine media described on p. 443. He finds that it gives as good results.

Sod. Fluoride	80 gm.
Chloral hydrate	80 gm.
Potass acetate	160 gm.
Cane sugar, (Tate's cube)	3500 gm.
Satd. Thymol water	8000 c.cm.

Transfer [from the spirit to this solution. After a week, mount in fresh filtered solution, and seal down.

TABLES OF EQUIVALENT IMPERIAL AND METRICAL MEASUREMENTS

To aid in converting Imperial Measures into the Metrical Equivalents, or *vice versâ*, I have prepared the accompanying tables, which I find of great service for this purpose. To obtain any equivalent which is not given in the tables it is easy to calculate it from the data supplied, after the following examples :—

Measures of Weight

$$275 \text{ gm.} = 250 \text{ gm.} + 25 \text{ gm.}$$

$$250 \text{ gm.} = 9 \text{ oz. } 358 \text{ grn.}$$

$$25 \text{ „} = 0 \text{ „ } 386 \text{ „}$$

$$\underline{275 \text{ gm.}} = \underline{10 \text{ oz. } 306\frac{1}{2} \text{ grn.}} \text{ or roughly } 10\frac{3}{4} \text{ oz.}$$

$$126 \text{ lb. } 11 \text{ oz.} = 120 \text{ lb.} + 6 \text{ lb.} + 11 \text{ oz.}$$

$$120 \text{ lb.} = 54.432 \text{ kg.}$$

$$6 \text{ „} = 2.721 \text{ „}$$

$$11 \text{ oz.} = 0.312 \text{ „}$$

$$\underline{126 \text{ lb. } 11 \text{ oz.}} = \underline{57.465 \text{ kg.}} \text{ or roughly, } 57.5 \text{ kg.}$$

Measures of Length

$$82.8 \text{ cm.} = 80 \text{ cm.} + 2 \text{ cm.} + 0.8 \text{ cm.}$$

$$80 \text{ cm.} = 31.44 \text{ in.}$$

$$2 \text{ „} = 0.79 \text{ „}$$

$$0.8 \text{ cm.} = 0.32 \text{ „}$$

$$\underline{82.8 \text{ cm.}} = \underline{32.55 \text{ in.}} \text{ or roughly, } 32\frac{1}{2} \text{ in.}$$

$$5 \text{ ft. } 10\frac{3}{4} \text{ in.} = \begin{cases} 5 \text{ ft.} & = 147.4 \text{ cm.} \\ 10 \text{ in.} & = 25.4 \text{ cm.} \\ \frac{3}{4} \text{ „} & = 1.91 \text{ „} \end{cases}$$

$$\underline{5 \text{ ft. } 10\frac{3}{4} \text{ in.}} = \underline{174.71 \text{ cm.}}$$

Measures of Capacity

$$73.5 \text{ c.cm.} = 70 \text{ c.cm.} + 3 \text{ c.cm.} + 0.5 \text{ c.cm.}$$

$$70 \text{ c.cm.} = 2 \text{ oz. } 3 \text{ dr. } 42 \text{ min.}$$

$$3 \text{ „} = 50\frac{1}{2} \text{ „ approx.}$$

$$0.5 \text{ „} = 8\frac{1}{2} \text{ „ „}$$

$$\underline{73.5 \text{ c.cm.}} = \underline{2 \text{ oz. } 4 \text{ dr. } 41 \text{ min.}} \text{ or roughly } 2\frac{1}{2} \text{ oz.}$$

$$2 \text{ pt. } 10\frac{1}{2} \text{ oz.} = 2 \text{ pt.} + 10 \text{ oz.} + \frac{1}{2} \text{ oz.}$$

$$2 \text{ pt.} = 1136.64 \text{ c.cm.}$$

$$10 \text{ oz.} = 284.16 \text{ „}$$

$$\frac{1}{2} \text{ „} = 14.208 \text{ „}$$

$$\underline{2 \text{ pt. } 10\frac{1}{2} \text{ oz.}} = \underline{1435.008 \text{ c.cm.}} = 1.435 \text{ lit.}$$

3 gall. 2 pt. $10\frac{1}{2}$ oz. =

3 gall.	=	13.639	lit.
2 pt.	=	1.13664	,,
10 oz.	=	0.28416	,,
$\frac{1}{2}$,,	=	0.01420	,,

3 gall. 2 pt. $10\frac{1}{2}$ oz. = 15.07600 lit. or 15,076 c.cm. or 15 lit. 76 c.cm.

In the above examples, I have given the results worked out to the decimal fractions, but this is unnecessary in actual practice where in most cases it is sufficient to ascertain the approximate equivalents.

TO CONVERT METRICAL WEIGHTS INTO IMPERIAL AVOIRDUPOIS.

$437\frac{1}{2}$ grains = 1 ounce.

Gm.	lb.	oz.	grn.	Gm.	lb.	oz.	grn.
1 =	0	0	$15\frac{1}{2}$	170 =	0	5	$436 = 6$ oz.
2 =	0	0	31	180 =	0	6	$152\frac{3}{4}$
3 =	0	0	46	190 =	0	6	307
4 =	0	0	$61\frac{3}{4}$	200 =	0	7	24
5 =	0	0	77	250 =	0	9	358
6 =	0	0	$92\frac{1}{2}$	300 =	0	10	$254\frac{1}{2}$
7 =	0	0	108	400 =	0	14	$47\frac{1}{2}$
8 =	0	0	$123\frac{1}{2}$	500 =	1	1	278
9 =	0	0	$138\frac{3}{4}$	600 =	1	5	$71\frac{1}{2}$
10 =	0	0	154	700 =	1	8	302
11 =	0	0	$169\frac{3}{4}$	750 =	1	10	200
12 =	0	0	185	800 =	1	12	95
13 =	0	0	$200\frac{1}{2}$	900 =	1	15	326
14 =	0	0	216	1000 =	2	3	119
15 =	0	0	$231\frac{1}{2}$				
16 =	0	0	247				
17 =	0	0	262				
18 =	0	0	$277\frac{3}{4}$				
19 =	0	0	293				
20 =	0	0	$308\frac{1}{2}$				
25 =	0	0	386				
30 =	0	1	$25\frac{1}{2}$				
35 =	0	1	$102\frac{1}{2}$				
40 =	0	1	180				
45 =	0	1	257				
50 =	0	1	334				
55 =	0	1	411				
60 =	0	2	51				
65 =	0	2	128				
70 =	0	2	205				
75 =	0	2	282				
80 =	0	2	$359\frac{1}{2}$				
85 =	0	2	$436\frac{1}{2} = 3$ oz.				
90 =	0	3	$76\frac{1}{2}$				
95 =	0	3	$153\frac{1}{2}$				
100 =	0	3	$230\frac{1}{2}$				
110 =	0	3	385				
120 =	0	4	102				
130 =	0	4	256				
140 =	0	4	$410\frac{1}{2}$				
150 =	0	5	127				
160 =	0	5	$281\frac{1}{2}$				

Kilo.	lb.	oz.	grs.
1000 gm. = 1	2	3	119
2 =	4	6	238
3 =	6	9	357
4 =	8	13	39
5 =	11	0	158
6 =	13	3	277
7 =	15	6	396
8 =	17	10	78
9 =	19	13	197
10 =	22	0	31 [4 oz.
11 =	24	3	$435 = 24$ lb.
12 =	26	7	117
13 =	28	10	236
14 =	30	13	355
15 =	33	1	37
16 =	35	4	156
17 =	37	7	275
18 =	39	10	394
19 =	41	14	76
20 =	44	1	195
25 =	55	1	353
30 =	66	2	74
35 =	77	2	222
40 =	88	2	390
45 =	99	3	110
50 =	110	3	268

TO CONVERT METRICAL WEIGHTS INTO IMPERIAL AVOIRDUPOIS—*continued.*

Kilo.	lb.	oz.	grs.	Kilo.	lb.	oz.	grs.
55 =	121	3	426	110 =	242	4	414
60 =	132	4	148	120 =	264	8	296
65 =	143	4	296	130 =	286	9	154
70 =	154	3	6 $\frac{1}{2}$	140 =	308	6	13
75 =	165	3	164	150 =	330	6	328
80 =	176	5	343 $\frac{1}{2}$	160 =	352	11	249
85 =	187	6	63 $\frac{1}{2}$	170 =	374	12	127
90 =	198	6	220	180 =	396	13	2 $\frac{1}{2}$
95 =	209	6	368	190 =	418	13	298
100 =	220	4	98 $\frac{1}{2}$	200 =	440	8	117

To convert kilos to lbs. avoirdupois (approximately) $\times 2\frac{1}{2}$.

IMPERIAL WEIGHTS (AVOIRDUPOIS) CONVERTED INTO GRAMMES.

Drams.	oz.	gm.	lb.	Kilogram.
1 =	$\frac{1}{16}$ =	1.77	13 =	5.897
2 =	$\frac{1}{8}$ =	3.54	14 =	6.350
4 =	$\frac{1}{4}$ =	7.08	15 =	6.804
8 =	$\frac{1}{2}$ =	14.175	16 =	7.257
16 =	1 =	28.35	17 =	7.711
	2 =	56.70	18 =	8.164
	3 =	85.05	19 =	8.618
	4 =	113.4	20 =	9.072
	5 =	141.75	25 =	11.340
	6 =	170.1	30 =	13.608
	7 =	198.45	35 =	15.876
	8 =	226.8	40 =	18.144
	9 =	255.15	45 =	20.412
	10 =	283.5	50 =	22.680
	11 =	311.85	55 =	24.948
	12 =	340.2	60 =	27.216
	13 =	368.55	65 =	29.484
	14 =	396.9	70 =	31.752
	15 =	425.25	75 =	34.020
			80 =	36.288
			85 =	38.556
			90 =	40.824
			95 =	43.092
			100 =	45.360
			110 =	49.896
			120 =	54.432
			130 =	58.968
			140 =	63.504
			150 =	68.040
			160 =	72.576
			170 =	77.112
			180 =	81.648
			190 =	86.184
			200 =	90.720

N.B.—To convert ounces to grammes
 $\times 28.35$.

oz.	lb.	Kilogram.
16 =	1 =	0.453
	2 =	0.907
	3 =	1.360
	4 =	1.814
	5 =	2.268
	6 =	2.721
	7 =	3.175
	8 =	3.628
	9 =	4.082
	10 =	4.536
	11 =	4.989
	12 =	5.443

To convert lbs. avoirdupois to kilos.
(approximately) $\times \frac{1}{2\frac{1}{2}}$.

IMPERIAL-WEIGHTS (AVOIRDUPOIS) CONVERTED INTO GRAMMES—*continued*.

Stone.	Avoir. lb.	Kgm.	Stone.	Avoir. lb.	Kgm.
1 =	14 =	6.350	11 =	154 =	69.854
2 =	28 =	12.700	12 =	168 =	76.204
3 =	42 =	19.051	13 =	182 =	82.555
4 =	56 =	25.401	14 =	196 =	88.906
5 =	70 =	31.752	15 =	210 =	95.256
6 =	84 =	38.102	16 =	224 =	101.606
7 =	98 =	44.452	17 =	238 =	107.956
8 =	112 =	50.803	18 =	252 =	114.307
9 =	126 =	51.153	19 =	266 =	120.657
10 =	140 =	63.504	20 =	280 =	127.008

N.B.—To convert stones to kilos. (approximately) $\times 6.35$.

IMPERIAL AND METRICAL MEASUREMENTS OF LENGTH.

The measurements of length were not calculated; each was taken with calipers fitted with a vernier, and graduated for both imperial and metrical measurements.

Metrical. cm.	Imperial. in.	Metrical. cm.	Imperial in.
0.1 =	0.04 (0.0395)	65.0 =	25.54
0.2 =	0.08 (0.079)	70.0 =	27.51
0.3 =	0.12 (0.118)	75.0 =	29.47
0.4 =	0.16 (0.158)	80.0 =	31.44
0.5 =	0.20 (0.197)	85.0 =	33.40
0.6 =	0.24 (0.236)	90.0 =	35.37
0.7 =	0.28 (0.276)	95.0 =	37.33
0.8 =	0.32 (0.316)	100.0 =	39.30
0.9 =	0.36 (0.355)	105.0 =	41.26
1.0 =	0.40 (0.394)	110.0 =	43.23
2.0 =	0.79	115.0 =	45.19
2.5 =	0.98 = 1 in. approx.	120.0 =	47.16
3.0 =	1.18	125.0 =	49.12
4.0 =	1.57	130.0 =	51.09
5.0 =	1.97 (1.965)	135.0 =	53.05
6.0 =	2.36	140.0 =	55.02
7.0 =	2.75 = $2\frac{3}{4}$ in.	145.0 =	56.98
8.0 =	3.15 = 3 "	150.0 =	58.95
9.0 =	3.54 = $3\frac{1}{2}$ "	155.0 =	60.91
10.0 =	3.93 = 4 "	160.0 =	62.88
11.0 =	4.33 = 4 "	165.0 =	64.85
12.0 =	4.72 = $4\frac{3}{4}$ "	170.0 =	66.81
13.0 =	5.12 = 5 " approx.	175.0 =	68.77
14.0 =	5.51 = $5\frac{1}{2}$ "	180.0 =	70.74
15.0 =	5.90 = 6 " approx.	185.0 =	72.70
16.0 =	6.30 = $6\frac{1}{8}$ "	190.0 =	74.67
17.0 =	6.69	195.0 =	76.63
18.0 =	7.08 = 7 "	200.0 =	78.60
19.0 =	7.47 = $7\frac{1}{2}$ "		
20.0 =	7.86		
25.0 =	9.82	Imperial In.	Metrical. cm.
30.0 =	11.79	$\frac{1}{32}$ =	0.08
35.0 =	13.75	$\frac{1}{16}$ =	0.15
40.0 =	15.73	$\frac{1}{8}$ =	0.21
45.0 =	17.68	$\frac{1}{4}$ =	0.25
50.0 =	19.65	$\frac{3}{8}$ =	0.32
55.0 =	21.61	$\frac{1}{2}$ =	0.42
60.0 =	23.58	$\frac{3}{4}$ =	0.50

IMPERIAL AND METRICAL MEASUREMENTS OF LENGTH—*continued.*

Imperial in.	Metrical. cm.	Imperial In.	Metrical. cm.
$\frac{1}{4}$ =	0.64	$9\frac{1}{2}$ =	24.14
$\frac{1}{3}$ =	0.84	10 =	25.4
$\frac{1}{2}$ =	1.27	$10\frac{1}{2}$ =	26.6
$\frac{5}{8}$ =	1.60	11 =	27.94
$\frac{3}{4}$ =	1.91	$11\frac{1}{2}$ =	29.2
$\frac{7}{8}$ =	2.25	12 =	30.5
1 =	2.54	15 =	39.2
$1\frac{1}{2}$ =	3.82	18 =	45.7
2 =	5.08	21 =	53.2
$2\frac{1}{2}$ =	6.35	feet.	
3 =	7.63	2 =	61.0
$3\frac{1}{2}$ =	8.90	$2\frac{1}{2}$ =	73.7
4 =	10.18	3 =	91.4
$4\frac{1}{2}$ =	11.80	$3\frac{1}{2}$ =	104.0
5 =	12.70	4 =	122.0
$5\frac{1}{2}$ =	13.97	$4\frac{1}{2}$ =	134.7
6 =	15.25	5 =	147.4
$6\frac{1}{2}$ =	16.52	$5\frac{1}{2}$ =	160.0
7 =	17.80	6 =	182.8
$7\frac{1}{2}$ =	19.60	$6\frac{1}{2}$ =	195.5
8 =	20.33	7 =	208.0
$8\frac{1}{2}$ =	21.60	$7\frac{1}{2}$ =	220.7
9 =	22.87	8 =	244.0

IMPERIAL AND METRICAL MEASURES OF CAPACITY.

Metrical. c.cm.	Imperial.	Metrical. c.cm.	Imperial
0.5 =	8.445 min. (8.5, or $8\frac{1}{2}$ min.)	60 =	2 oz. 0 dr. 52 min. = $2\frac{1}{8}$ oz.
1 =	16.891 „ (16.9 min.)	65 =	2 „ 2 „ 17 „
2 =	33.782 „	70 =	2 „ 3 „ 42 „
3 =	50.674 „	75 =	2 „ 5 „
4 =	67.564 „	80 =	2 „ $6\frac{1}{2}$ „
5 =	84.456 „ = 1 dr. 24 min.	85 =	2 „ 7 „ 55 min. = 3 oz.
6 =	101.348 „ = 1 „ 41 „	90 =	3 „ $1\frac{1}{2}$ „
7 =	118.238 „ = 2 „ approx.	95 =	3 „ $2\frac{3}{4}$ „
8 =	2 dr. 15 min.	100 =	3 „ 4 „ = $3\frac{1}{2}$ oz.
9 =	2 „ 32 „	200 =	7 „ 0 „ 18 min. = 7 oz.
10 =	2 „ 49 „	250 =	8 „ 6 „ 23 „ = $8\frac{3}{4}$ „
11 =	3 „ 6 „	300 =	$10\frac{1}{2}$ „
12 =	3 „ 23 „	400 =	14 „
13 =	3 „ $39\frac{1}{2}$ „	500 =	$17\frac{1}{2}$ „
14 =	3 „ $56\frac{1}{2}$ „	600 =	21 „ = 1 pt. 1 oz.
15 =	4 „ 13 „	700 =	$24\frac{1}{2}$ „ = $1\frac{1}{4}$ „
16 =	4 „ $30\frac{1}{4}$ „	800 =	28 „
17 =	4 „ 47 „	900 =	$31\frac{1}{2}$ „
18 =	5 „ 4 „	1000 (1 litre)	
19 =	5 „ 21 „	lit.	
20 =	5 „ 38 „	1 =	$35\frac{1}{8}$ „ = $1\frac{3}{4}$ pt.
25 =	7 „ 2 „ [approx.]	2 =	70 „ 3 dr. = $3\frac{1}{2}$ „
30 =	8 „ 27 „ = $8\frac{1}{2}$ dr. = 1 oz.	3 =	105 „ $4\frac{1}{2}$ „ = $5\frac{1}{4}$ „
35 =	1 oz. 1 dr. 50 min.	4 =	140 „ 6 „ = $7\frac{3}{4}$ „
40 =	1 „ 3 „ 15 „	5 =	176 „ = 8 „ = approx. 1 gall.
45 =	1 „ 4 „ 40 „ = $1\frac{1}{2}$ oz.		
50 =	1 „ 6 „ 4 „ = $1\frac{3}{4}$ „	6 =	$10\frac{1}{2}$ pt. = $1\frac{3}{8}$ gall.
55 =	1 „ 7 „ 28 „	7 =	$12\frac{1}{2}$ „ = $1\frac{1}{2}$ „

IMPERIAL AND METRICAL MEASURES OF CAPACITY—*continued.*

Metrical. lit.		Imperial.		Imperial.		Metrical.
8 = 14 pt.		= 1 $\frac{3}{4}$ gall.		120 min. = $\frac{1}{4}$ oz. =		7.104 c.cm.
9 = 15 $\frac{4}{5}$ „		= 2 „		200 „ =		11.840 „
10 = 17 $\frac{3}{5}$ „		= 2 $\frac{1}{5}$ „		240 „ = $\frac{1}{2}$ oz. =		14.208 „
15 = 26 $\frac{2}{5}$ „		= 3 $\frac{1}{5}$ „		300 „ =		17.760 „
20 = 35 $\frac{1}{5}$ „		= 4 $\frac{3}{5}$ „		360 „ = $\frac{3}{4}$ oz. =		21.312 „
25 = 44 „		= 5 $\frac{1}{2}$ „		400 „ =		23.680 „
30 = 52 $\frac{1}{5}$ „		= 6 $\frac{3}{5}$ „		480 „ = 1 oz. =		28.416 „
35 = 61 $\frac{3}{5}$ „		= 7 $\frac{7}{10}$ „		2 oz. =		56.832 „
40 = 70 $\frac{2}{5}$ „		= 8 $\frac{4}{5}$ „		3 „ =		85.248 „
45 = 79 $\frac{1}{5}$ „		= 10 „		4 „ =		113.664 „
50 = 88 „		= 11 „		5 „ =		142.080 „
55 = 96 $\frac{4}{5}$ „		= 12 $\frac{1}{10}$ „		6 „ =		170.496 „
60 = 105 $\frac{3}{5}$ „		= 13 $\frac{1}{5}$ „		7 „ =		198.912 „
65 = 114 $\frac{2}{5}$ „		= 14 $\frac{3}{10}$ „		8 „ =		227.328 „
70 = 123 $\frac{1}{5}$ „		= 15 $\frac{2}{5}$ „		9 „ =		255.744 „
75 = 132 „		= 16 $\frac{1}{2}$ „		10 „ =		284.160 „
80 = 140 $\frac{4}{5}$ „		= 17 $\frac{3}{5}$ „		11 „ =		312.576 „
85 = 149 $\frac{3}{5}$ „		= 18 $\frac{7}{10}$ „		12 „ =		340.992 „
90 = 158 $\frac{2}{5}$ „		= 19 $\frac{7}{8}$ „		13 „ =		369.408 „
95 = 167 $\frac{1}{5}$ „		= 20 $\frac{9}{10}$ „		14 „ =		397.824 „
100 = 176 „		= 22 „		15 „ =		426.280 „
				16 „ =		454.656 „
				17 „ =		483.072 „
				18 „ =		511.488 „
				19 „ =		539.904 „
				20 „ = 1 pt. =		568.3 „
				2 pt. = 11 qt. =		1136.64 „ = 1.136 lit.
				2 qt. =		2273.28 „ = 2.273 „
				3 „ =		3409.92 „ = 3.409 „
				4 „ = gall. =		4.546 lit.
				2 gall. =		9.096 „
				3 „ =		13.639 „
				4 „ =		18.196 „
				5 „ =		22.732 „
				6 „ =		27.279 „
				7 „ =		31.835 „
				8 „ =		36.392 „
				9 „ =		40.929 „
				10 „ =		45.465 „

Imperial into Metrical Measure.

Imperial.		Metrical.
5 min.	=	0.296 c.cm.
10 „	=	0.592 „
15 „	=	0.888 „
20 „	=	1.184 „
25 „	=	1.476 „
30 „	=	1.776 „
40 „	=	2.368 „
50 „	=	2.960 „
60 „	=	3.552 „
70 „	=	4.144 „
80 „	=	4.736 „
90 „	=	5.328 „
100 „	=	5.920 „

BIBLIOGRAPHY

LIST OF ABBREVIATIONS EMPLOYED

A.J.M.Sc.	American Journal of the Medical Sciences. Philad. and New York.
A.M.E.	Archives de Médecine expérimentale, et d'Anatomie pathologique, Paris.
B.M.S.J.	Boston Medical and Surgical Journal, Boston, Mass.
B.M.J.	British Medical Journal, London.
E.M.J.	Edinburgh Medical Journal.
F.Z.	Frankfurter Zeitschrift für Pathologie, Wiesbaden.
J.A.M.A.	Journal of the American Medical Association, Chicago.
J.E.M.	Journal of Experimental Medicine, New York.
J.H.H.B.	Bulletin of the Johns Hopkins Hospitals, Baltimore, Ma.
J.H.H.R.	Johns Hopkins Hospitals Reports.
J.M.R.	Journal of Medical Research, Boston, Mass.
J.P. and B.	Journal of Pathology and Bacteriology, Cambridge.
L.	Lancet, London.
M.m.W.	Münchener medizinische Wochenschrift.
Q.J.M.	Quarterly Journal of Medicine, Oxford.
R.N.P.	Review of Neurology and Psychiatry, Edinburgh.
V.A.	Archiv für pathologische Anatomie und Physiologie (Virchow's), Berlin.
V.d.d.p.G.	Verhandlungen der deutschen pathologischen Gesellschaft.
Z.B.	Beiträge zur pathologischer Anatomie and zur allgemeiner Pathologie (Ziegler's), Jena.

References to all the more important original papers appearing in these journals from the beginning of 1908 down to the middle of 1911, have been inserted in the bibliography. In the case of several of them, e.g. *E.M.J.*, *B.M.J.*, *M.m.W.*, *J.H.H.R.*, the references have been carried farther back. All references have been personally verified.

For the literature of Pathology appearing prior to 1907-8, the reader should consult the full lists of references appended to the articles in Allbutt and Rolleston's *System of Medicine*; or to the Text-books of Pathology by Kaufmann and by Ziegler, in both of which the more important papers on a given subject are referred to.

Exhaustive digests of the literature are furnished in Lubarsch and Ostertag's *Ergebnisse der allgemeinen Pathologie*. This publication should always be consulted. For exhaustive references to any subject related to medicine, the *Index Medicus*, and the *Index Catalogue of the Surgeon-General's Library*, Washington, are reliable and indispensable guides.

The following publications are also important, and only time and want of space have prevented inclusion of references to their contents:—*Arbeiten auf dem Gebiete der pathologischen Anatomie* (Baumgarten's); *Arbeiten aus dem Kaiserliche Gesundheitsamt*, Berlin; *Centralblatt für allgemeine Pathologie, und pathologische Anatomie*, Jena; *Folia haematologica*, Leipzig; *Virchow's Jahresbericht*, Berlin; *Baumgarten's Jahresbericht* (for Bacteriology); *Centralblatt für Bakteriologie und Parasitenkunde*; *Journal of the Royal Army Medical Corps*, London; *Lyon Médical*; *Pathologica*, Genoa; *Il Policlinico*, Roma; *Proceedings of the Royal Society of Medicine*, London; *Revue médicale de la Suisse Romande*; *Schmidt's Jahrbücher d. gesammten Medizin*; *Lo Sperimentale*; *Zeitschrift für Hygiene*.

- Abdomen, Acute forms of Tuberculosis : *J.A.M.A.* 1909, i. 291.
- Acid Intoxication : *L.* 1908, i. 910 ; Acidosis : *A.M.E.* 1910, xvii. p. 600.
- Acne, see under Bacteriology.
- Acromegaly : *M.m.W.* 1907, i. 894 ; *E.M.J.* 1908, N.S. i. 218 ; *J. P. and B.* 1908, xii. 306 ; *L.* 1911, i. 993.—Acromegaly with Pituitary Tumour : *Z.B.* 1910, Bd. 47, s. 187 ; *F.Z.* 1910, Bd. 5, s. 351, 587 (Kritische Rundschau).—Acromegaly, Changes in Bones and Joints : *V.d.d.p.G.* 1909, s. 78.
- Addison's Disease : Lymphatic Apparatus and Thymus : *V.A.* 1910, Bd. 200, s. 399.
- Adenoids : Structure : *A.M.E.* 1911, xxiii. p. 387.
- Adiposis dolorosa : *A.J.M.Sc.* 1909, vol. 137, p. 705 refs. ; *J.A.M.A.* 1908, i. 1012.
- Age Incidence of Tuberculosis : *M.m.W.* 1908, i. 322.

Alimentary Tract

Mouth and Oesophagus.—Pyorrhoea alveolaris : *L.* 1909, ii. 1875.—Stomatitis fibrinosa (pneumococcal) : *M.m.W.* 1909, i. 72.—Tongue, Cancer of : *B.M.J.* 1909, i. 1.—Root of Tongue and Oesophagus, Cysts of : *Z.B.* 1909, Bd. 45, s. 325.—Tonsil, Sarcoma : *B.M.S.J.* 1909, vol. 160, p. 109.—Oesophageal Atresia, Congenital : *V.A.* 1908, Bd. 192, s. 112.—Oesophagus, Traction-diverticulum : *V.A.* 1908, Bd. 192, s. 126.—Oesophagus, Diffuse Dilatation : *M.m.W.* 1909, ii. 2113.

Stomach.—Angioma of Stomach, Multiple Cavernous : *M.m.W.* 1907, ii. 2189.—Contraction, "Hour-glass" : *B.M.J.* 1909, ii. 846., 1911, i. 669.—Erosions, Gastric : *M.m.W.* 1907, i. 1146 refs.—Erosions, Experimental Gastric : *F.Z.* 1909, Bd. 3, s. 566.—Gastritis, Phlegmonous : *B.M.J.* 1908, i. 558 refs. ; *A.J.M.Sc.* 1908, vol. 135, p. 662 refs. ; *L.* 1910, i. 292.—Hair-Ball : *J.A.M.A.* 1908, i. 512., 1909, ii. 617.—Hernia, diaphragmatic : *E.M.J.* 1908, N.S. i. 442 ; *L.* 1908, i. 931 ; *A.J.M.Sc.* 1909, vol. 137, p. 581 refs. ; *J.A.M.A.* 1909, i. 1574.—"Leather-bottle" Stomach : *L.* 1909, i. 464.—Leiomyoma, Stomach : *A.M.E.* 1910, xvii. 412.—Congenital Obstruction : *L.* 1910, i. 94.—Gastric Changes in Pernicious Anaemia : *V.A.* 1911, Bd. 204, s. 116.—Congenital Pyloric Stenosis : *A.J.M.Sc.* 1908, vol. 136, p. 1 ; *J.A.M.A.* 1909, ii. 1546, 1722 ; *B.M.J.* 1908, ii. 68, 71., 1910, ii. 1021 ; *L.* 1908, i. 779., 1910, ii. 458 ; *Z.B.* 1910, Bd. 49, s. 384.—Sarcoma of Stomach : *A.J.M.Sc.* 1909, vol. 138, p. 191 ; *J.A.M.A.* 1911,

i. 500 ; *Practitioner*, 1904, vol. 72, p. 810 for refs. ; *V.A.* 1909, Bd. 195, s. 341.—Syphilis : *A.J.M.Sc.* 1909, vol. 137, p. 685 refs. ; *J.A.M.A.* 1909, i. 1159 ; *V.A.* 1910, Bd. 199, s. 131.—Tuberculosis of Stomach : *J.H.H.B.* 1908, xix. 223.—Ulcers, gastrototoxic : *J. P. and B.* 1910, xiv. 418.—Gastro-duodenal Ulceration : *J.A.M.A.* 1909, ii. 1549 ; *J.M.R.* 1907-8, xvii. 365 ; *E.M.J.* 1910, N.S. v. 316 ; vi. 318, 391 ; *V.A.* 1910, Bd. 201, s. 243 ; *L.* 1910, ii. 993., 1911, i. 97 ; *B.M.J.* 1907, i. 922 ; *L.* 1908, i. 1330 ; *A.J.M.Sc.* 1911, vol. 141, p. 837 ; *V.A.* 1909, Bd. 195, s. 317.—Peptic Ulceration : *M.m.W.* 1911, ii. 1668.—Gastric Ulcer and Carcinoma : *A.J.M.Sc.* 1909, vol. 138, p. 846, illustr. ; *M.m.W.* 1910, i. 1269.—Appendicitis and Gastro-duodenal Ulceration : *L.* 1911, Jan. 14.

Duodenum.—Duodenal Hernia : *Z.B.* 1909, Bd. 46, s. 362.—Duodenum, Phlegmonous infl. : *L.* 1911, ii. 224 ; *V.A.* 1908, Bd. 193, s. 445.—Sarcoma of duodenum : *L.* 1909, i. 1823.

Intestine.—Cancer of Colon : *L.* 1908, ii. 1007.—Carcinomatous Polyposis of Colon : *J.A.M.A.* 1909, i. 1235.—Cancer of Jejunum : *B.M.J.* 1910, i. 435 ; *L.* 1908, ii. 304 ; *B.M.S.J.* 1909, vol. 161, p. 107 ref.—Cancer of Small Intestine : *F.Z.* 1909, Bd. 3, s. 593 ref.—Cancer in the Young : *J.A.M.A.* 1909, i. 1471.—Summer Diarrhoea : *L.* 1908, ii. 715., 1910, ii. 730 ; *J.A.M.A.* 1908, i. 607., 1910, i. 441 ; *J.H.H.R.* 1910, xv. 1 (Bacteriology).—Chronic Dilatation of Large Intestine in Old Age : *M.m.W.* 1909, i. 654.—Acquired Diverticula : *L.* 1908, i. 843.—Intestinal Diverticula : *F.Z.* 1910, Bd. 4, s. 167 ; *E.M.J.* 1908, xxiii. 304 ; *B.M.J.* 1910, i. 376 ; *A.J.M.Sc.* 1910, vol. 140, p. 174., 1911, vol. 142, p. 15 ; *J.A.M.A.* 1910, i. 208.—False Diverticula : *B.M.S.J.* 1911, vol. 164, p. 372.—Meckel's Diverticulum : *E.M.J.* 1907, xxi. 19 ; *B.M.J.* 1908, ii. 909 ; *L.* 1910, i. 567 ; *L.* 1908, i. 17 ; *J.A.M.A.* 1908, ii. 2060.—Meckel's Diverticulum, Inflammation of : *M.m.W.* 1908, i. 1236.—Ductus Omphalomesentericus, persistent : *M.m.W.* 1911, i. 85.—Dysentery : *M.m.W.* 1909, i. 384 ; *A.J.M.Sc.* 1909, vol. 138, p. 198 ; *J.A.M.A.* 1909, ii. 1526 ; *B.M.S.J.* 1909, vol. 161, p. 694 ; *B.M.J.* 1909, ii. 862.—Amaebic Dysentery : *B.M.J.* 1909, i. 771 ; *F.Z.* 1910, Bd. 4, s. 329.—Enteritis, Croupous : *M.m.W.* 1909, i. 1169.—Enteroptosis (Glénard's disease) : Glénard, Les Ptoses viscérales, Par. 1899 ; Keith, *L.*

1903, i. 631, 709; L. 1906, i. 947.—Fistulae: B.M.J. 1911, i. 1046.—Gas-Cysts (pneumatosis cystoides): J.P. and B. 1910, xiv. 259 refs.; F.Z. 1910-11, Bd. 6, s. 85; V.A. 1911, vol. 203, s. 170.—Hernia, Inguinal: A.J.M.Sc. 1909, vol. 138, p. 853.—Hernia in Lesser Sac: B.M.J. 1909, i. 641.—Hernia, Meso-jejunal: J.H.H.B. 1908, xix. 219.—Hernia, Perineal: B.M.J. 1911, i. 493.—Hernia, Retroperitoneal (parajejunal): F.Z. 1910-11, Bd. 6, s. 136 lit.—Hernia, Subdiaphragmatic Intercostal M.m.W. 1911, ii. 1777.—Hirschsprung's Dis.: E.M.J. 1906, xix. 357; M.m.W. 1907, ii. 1817; V.A. 1909, Bd. 198, s. 119; M.m.W. 1911, i. 1059.—Infarction: V.A. 1910, Bd. 200, s. 522.—Infarction of Transverse Colon: L. 1911, ii. 220.—Intestinal Absorption and Pulmonary Anthracosis: J.M.R. 1910, xxiii. 111.—Intestinal Infection in Pulmonary and other Tuberculosis: F.Z. 1910, Bd. 5, s. 395 refs., s. 447 refs.—Intussusception: L. 1908, i. 628.—Malformations of Palate: B.M.J. 1909, ii. 310; of Lips, ii. 363.—Malformations of Rectum and Anus: B.M.J. 1908, ii. 1737.—Melanoma of Vater's Ampulla: J.E.M. 1908, x. 465.—Melanosis of Mucous Membrane of Large Intestine: Berl. klin. Woch. 1911, i. 840, 884.—Myoma of Intestine, Malignant (Ghon): Z.B. 1909, Bd. 45, s. 89.—Rectum, Bilharzia: B.M.S.J. 1911, vol. 165, p. 51 refs.—Rectum, Double: F.Z. 1911, Bd. 8, s. 151.—Rectum, Fibrous Stricture: B.M.S.J. 1911, vol. 164, p. 445.—Rectum, Gonorrhoea: M.m.W. 1910, i. 963.—Rectum, Lymphoma: J.P. and B. 1909, xiii. 49.—Rectum, Sarcoma: J.P. and B. 1911, xv. 293.—Sigmoiditis: L. 1910, i. 1194.—Transposition of Viscera: B.M.J. 1910, i. 987; J.A.M.A. 1908, i. p. 1123.—Ileo-caecal Tuberculosis: B.M.J. 1907, i. 849; J.A.M.A. 1908, i. 655.—Primary Intestinal Tuberculosis in Adults: M.m.W. 1908, ii. 1966.—Tuberculous Ulceration: V.A. 1910, Bd. 201, s. 231.—Typhoid: J.A.M.A. 1909, ii. 1248-1264; see also under Bacteriology.—Typhoid Fever, Complications: A.J.M.Sc. 1908, vol. 135, pp. 224-244 refs.; 1911, vol. 141, p. 803; J.A.M.A. 1908, i. 1014.—Volvulus: B.M.J. 1909, i. 1277; L. 1910, ii. 302., 1909, i. 676, 678, 679., 1908, i. 1837.—Volvulus of Sigmoid: M.m.W. 1911, i. 1059.

Appendix Vermiformis.—Cancer, Primary: Q.J.M. 1907-8, No. 4, p. 454; A.J.M.Sc. 1908, vol. 135, p. 702 ref.,

p. 822 refs., p. 851; J.A.M.A. 1909, i. 1471; L. 1909, ii. 1210., 1910, ii. 1757; B.M.S.J. 1908, vol. 159, p. 339 (ref.), 748; M.m.W. 1907, ii. 1780.—Cysts: M.m.W. 1908, ii. 1746., 1909, ii. 1782.—Intussusception: B.M.J. 1911, i. 491.—Inversion: M.m.W. 1911, ii. 1564.—Oxyuris in Appendix: J.A.M.A. 1908, i. 1904.—Pathology of Appendix: E.M.J. 1906, xix. 240; M.m.W. 1909, ii. 2251.—Sarcoma: B.M.J. 1911, ii. 150.

Contents of Alimentary Tract.—Stomach Contents, Examination: J.A.M.A. 1909, ii. 1710, 1960.—Intestinal Bacteria: J.A.M.A. 1911, i. 1084.—Bacteriology of Faeces: A.M.E. 1909, xxi. p. 126.—Faeces, Examination of: L. 1910, ii. 95; J.A.M.A. 1910, i. 270.

Altmann's Granules: J.P. and B. 1909, xiii. 185.

Amyloid, Etiology: V.A. 1908, Bd. 192, s. 226; Unusual Sites of Amyloid Degeneration: Z.B. 1909, Bd. 46, s. 602, 635.

Animal Parasites

Amaebic Dysentery: F.Z. 1910, Bd. 4, s. 329; M.m.W. 1910, ii. 2300. See also under Alimentary System.—**Ankylostomiasis:** L. 1910, i. 356., 1911, i. 717, 783, 859; Haemolytic effects: M.m.W. 1908, i. 436.—**Anopheles:** J.A.M.A. 1908, ii. 2203.—**Arthropods as disease carriers:** M.m.W. 1910, ii. 2398.—**Bilharziosis:** B.M.J. 1910, ii. 965; L. 1910, ii. 375; L. 1909, ii. 1204; B.M.S.J. 1910, vol. 163, p. 937 refs.—**Bilharzia of Rectum:** B.M.S.J. 1911, vol. 165, p. 51.—**Elephantiasis:** B.M.S.J. 1910, vol. 163, p. 718 refs.—**Eosinophilia:** L. 1910, ii. 297.—**Filariasis:** L. 1908, i. 279.—**Hydatids of Liver:** B.M.J. 1910, ii. 957 refs.—**Hydatids, Serum diagnosis:** L. 1909, i. 1103., 1910, ii. 377.—**Kala-azar,** B.M.J. 1907, i. 427, 490, 557; L. 1908, ii. 443., 1909, i. 306, ii. 1495; M.m.W. 1909, i. 1072.—**Malaria:** L. 1909, ii. 1483; pernicious M.: L. 1908, ii. 16; J.E.M. 1911, xiii. 263.—**Myiasis:** J.A.M.A. 1910, i. 1687.—**Oriental sore:** B.M.J. 1909, ii. 647.—**Oxyuris in Appendix:** J.A.M.A. 1908, i. 1904.—**Paragonimiasis:** J.A.M.A. 1910, i. 697.—**Rhinosporidium Kinealyi:** L. 1910, ii. 726; J.P. and B. 1906, xi. 270.—**Sarcosporidia:** J.E.M. 1910, xii. 19.—**Schistosomum Japonicum:** V.A. 1908, Bd. 193, s. 323., 1909, Bd. 197, s. 425.—**Spirochaeta pallida in Congenital Syphilis:** J.P. and B. 1909, xiii. 239.—**Spirochaetes, Staining of living:** M.m.W. 1910, ii. 1452.—**Tick Fever:**

- L.* 1910, i. 11.—*Treponema Pallidum* Cultivation : *J.A.M.A.* 1911, ii. 102 ; *J.E.M.* 1911, xiv. 99.—*Trichinella spiralis*, anat. : *J.M.R.* 1908, xix. 301.—*Trichinosis* : *L.* 1909, i. 1381 ; *A.J.M.Sc.* 1910, vol. 140, pp. 157, 167.—*Trypanosomiasis* : *B.M.J.* 1910, ii. 864, 1911, i. 1049, 1309 ; *L.* 1910, i. 1631, 1909, ii. 1193 ; *J.M.R.* 1910, xxii. 379.—*Uncinariasis* : *A.J.M.Sc.* 1909, vol. 138, p. 40.—*Yaws* : *J.P. and B.* 1908, xii. 426, 1909, xiii. 248.
- Argyria* : *V.A.* 1908, Bd. 193, s. 148 refs. ; *F.Z.* 1909, Bd. 3, s. 398 refs. ; *Bramwell's Clinical Studies*, Ap. 1905.

Arteries

- Aneurysm.** — *Aneurysm, Dissecting* : *J.H.H.B.* 1909, xx. 9 ; *L.* 1908, i. 1693 ; *V.A.* 1908, Bd. 192, s. 52 ; *V.d.d.p.G. Leipz.* 1909, s. 207 ; *V.A.* 1910 Bd. 202, s. 283 ; *Z.B.* 1910, Bd. 48, s. 221.—*Aneurysms, Embolic* : *J.A.M.A.* 1909, ii. 1808.—*Aneurysms, Miliary* : *B.k.W.*¹ 1910, i. 7.—*Aneurysm, Syphilitic and* : *B.M.J.* 1909, ii. 1509.—*Aneurysm of Aorta* : *V.A.* 1910, Bd. 201, s. 390 ; *L.* 1909, ii. 8.—*Aneurysms of Cerebral vessels* : *L.* 1908, ii. 703, 1667.—*Aneurysm, Anter. Cerebral* : *R.N.P.* 1908, vi. 449.—*Aneurysm of Coronary Artery* : *F.Z.* 1910, Bd. 5, s. 98 ref.—*Aneurysm of Pulmonary Artery* : *F.Z.* 1910, Bd. 4, s. 286.
- Angina Pectoris* : *B.M.J.* 1909, ii. 1122, 1910, i. 126 ; *L.* 1910, i. 697, 839, 973 ; *L.* 1909, ii. 877.—*Aortic Degeneration* : *B.M.J.* 1908, ii. 1063.—*Aortitis, (Weber)* : *E.M.J.* 1908, xxiii. 318.—*Aortitis, Syphilitic* : *J.A.M.A.* 1909, ii. 118 ref.—*Congenital* : *J.P. and B.* 1908, xii. 11 ; *F.Z.* 1911, Bd. 7, s. 373 lit.—*Structure and Function, Arterial* : *E.M.J.* 1908, xxiii. 509, 1908, N.S. i. 47, 1911, N.S. vi. 197 ; *L.* 1910, ii. 1602 ; *L.* 1908, ii. 1126 ; *A.J.M.Sc.* 1908, vol. 136, p. 374 ref.—*Arteriosclerosis* : *R.N.P.* 1907, v. 830 ; *B.M.J.* 1910, ii. 1667, 1911, i. 853, 922.—(Adami) : *A.J.M.Sc.* 1909, vol. 138, p. 485 ; *J.A.M.A.* 1908, i. 169, 1910, i. 104 ref. ; *V.A.* 1909, Bd. 196, s. 232, 303, Bd. 198, s. 554 ; *V.A.* 1911, Bd. 203, s. 352 ; (Thoma) *V.A.* 1911, Bd. 204, s. 1.—*Arteriosclerosis and the Adrenals* : *Med. Rec. N.Y.* May 30, 1908.—*Arteriosclerosis, abdominal* : *M.m.W.* 1907, i. 1075, 1135.—*Arteriosclerosis in the Young* : *A.J.M.Sc.* 1908, vol. 135, p. 199 ref. ; *L.* 1908, i. 1025 ; *M.m.W.* 1911, i. 250.—*Sclerosis of Gastric*

- Arteries* : *Z.B.* 1908, Bd. 44, s. 327.—*Experimental Arterial Disease* : *A.J.M.Sc.* 1908, vol. 136, p. 241 ref. ; *V.A.* 1908, Bd. 192, s. 86 ; *J.P. and B.* 1908, xii. 15 ; *F.Z.* 1909, Bd. 3, s. 912.—*Arteries, Bone formation in* : *J.E.M.* 1908, x. 354 ; *J.M.R.* 1907-8, xvii. 25 ref.—*Coronary Arteries, relation to Heart muscle* : *V.A.* 1910, Bd. 199, s. 187.—*Ductus Arteriosus, Patent* : *A.J.M.Sc.* 1908, vol. 136, p. 381 ref.—*Ductus Arteriosus, Patent ; Ulcerative Endocarditis* : *F.Z.* 1910, Bd. 5, s. 103, 106.—*Embolism of Abdominal Aorta* : *L.* 1908, i. 1691, 1910, i. 1065.—*Endarteritis obliterans (see also Thromboangiitis)* : *M.m.W.* 1909, ii. 1994 ; *L.* 1908, i. 152 refs. ; *L.* 1909, ii. 1207 refs., 1908, i. 152 ; *J.A.M.A.* 1909, i. 1319.—*Intimal hyperplasia* : *J.E.M.* 1910, xii. 707.—*Mesarteritis, syphilitic* : *F.Z.* 1910, Bd. 5, s. 139.—*Normal and Pathological Arteries* : *B.M.J.* 1908, ii. 1477.—*Perforation of Aorta* : *L.* 1910, i. 1335.—*Periarteritis nodosa* : *J.P. and B.* xii. 1908, 31 ; *Z.B.* 1908, Bd. 43, s. 455 ; *V.d.d.p.G. Leipz.* 1909, s. 209 ; *Proc. Path. Soc. Philad.* 1909, Feb. ; *V.A.* 1908, Bd. 192, s. 305, 1909, Bd. 197, s. 71 ; *F.Z.* 1910, Bd. 5, s. 107 lit.—*Pulmonary Stenosis* : *L.* 1911, i. 150.—*Raynaud's Disease* : *A.J.M.Sc.* 1908, vol. 136, p. 560.—*Thromboangiitis obliterans* : *J.A.M.A.* 1909, i. 1319.

- Ascites, Chylous and Chyliform* : *E.M.J.* 1906, xix. 265 ; *Q.J.M.* 1909-10, No. 11, p. 301, 1911, No. 14, p. 153, full refs.

Bacteriology

- Investigations on Infective Diseases* : *V.A.* 1908, Beiheft zum Bd. 194.
- Bacteriology of Suppuration in Accessory Nasal Sinuses* : *E.M.J.* 1910, N.S. iv. 293.
- Acne* : *B.M.S.J.* 1909, vol. 161, p. 882 ; *B.M.J.* 1910, i. 1227 ; *L.* 1909, i. 1035.—*Anthrax* : *E.M.J.* 1910, N.S. iv. 61.—*Anthrax, Bronchial* : *J.P. and B.* 1910, xiv. 556.—*Anthrax, internal* : *M.m.W.* 1907, i. 526.
- Bac. Coli Infections* : *L.* 1909, ii. 1269 ; *A.J.M.Sc.* 1909, 138, p. 313 ; *B.M.S.J.* 1911, v. 164, p. 613.—*B. Dysenteriae, isolation* : *J.M.R.* 1910, xxiii. 481 ; *B.M.S.J.* 1909, vol. 161, p. 687, 689, 1910, vol. 163, p. 209.—*Bac. fecalis alkaligenes* : *M.m.W.* 1910, i. 239.—*B. perfringens* : *E.M.J.* 1906, xx. 562.—*Bacteria Carriers* : *B.M.J.* 1910, ii. 1499 ; *L.* 1908, ii. 1651.—*Bacteriuria, persistent* : *J.H.H.B.* 1909, xx. 12.—*Blastomycosis* : *E.M.J.* 1906, xix.

¹ *Berl. klin. Wochensch.*

(i., ii. = Vol. I, Vol. II ; s. = Seite, Seiten.)

- 372., 1906, *xx*. 72, 215; *J.A.M.A.* 1908, *i*. 184., 1911, *i*. 1095.—Blood Cultures: *J.M.R.* 1909, *xx*. 79; *M.m.W.* 1910, *ii*. 1432, *refs.*—Botryomycosis: *E.M.J.* 1910, *N.S.* *iv*. 115 *ref.*; *B.M.J.* 1910, *ii*. 971; *A.J.M.Sc.* 1911, *vol.* 142, 69.—Bronchopneumonia: *J.P. and B.* 1910, *xiv*. 160.
- Capsule staining: *J.A.M.A.* 1910, *i*. 1426., 1911, *i*. 1118, 1189.
- Diarrhoea, Summer: *L.* 1908, *ii*. 715., 1910, *ii*. 730; *J.H.H.R.*, 1910, *xv*. 1.—Diphtheria: *E.M.J.* 1906, *xx*. 510; *L.* 1908, *i*. 1143, 1302; *D.* Cutaneous: *B.M.S.J.* 1910, *vol.* 163, *p.* 730.—Diphtheria, latent: *B.M.J.* 1909, *ii*. 517; *L.* 1911, *i*. 795; *J.A.M.A.* 1909, *i*. 111, 439., 1910, *i*. 951.—Diphtheritic paralysis: *R.N.P.* 1906, *iv*. 608.—*B. diphtheriae*, staining: *A.J.M.Sc.* 1908, *vol.* 136, *p.* 880.—Dysentery Carrier: *M.m.W.* 1908, *ii*. 1833., 1910, *ii*. 2566 (*see* Bacteria Carriers).
- Erysipelas: *L.* 1909, *ii*. 1065.
- Glanders: *J.A.M.A.* 1908, *i*. 1593., 1909, *i*. 181., 1911, *i*. 1379; *B.M.J.* 1909, *i*. 319 (*refs.*); *L.* 1909, *ii*. 1201; *A.J.M.Sc.* 1909, *vol.* 138, *p.* 202, *cult. refs.*—Gonococcus from female, Cultivation: *J.M.R.* 1908, *xviii*. 291.—Gonococcus: *J.P. and B.* 1911, *xv*. 76; *L.* 1909, *ii*. 76.—General Infection: *M.m.W.* 1911, *i*. 466.
- Influenza, Infections: *L.* 1909, *ii*. 1661., 1910, *ii*. 1289., 1911, *i*. 1573; *Q.J.M.* 1910–11, *No.* 13, *p.* 7; *M.m.W.* 1908, *i*. 328.—Influenza Meningitis: *J.P. and B.* 1910, *xiv*. 615.—Intestinal Bacteria: *J.A.M.A.* 1911, *i*. 1084.
- Leprosy: *J.A.M.A.* 1909, *i*. 18; *J.E.M.* 1910, *xii*. 649; Cultivation: *J.E.M.* 1911, *xiii*. 365; *L.* 1908, *i*. 1333., 1909, *ii*. 575. 1910, *ii*. 728; in Rats: *J.A.M.A.* 1908, *ii*. 1153.—Leptothrix Meningitis: *R.N.P.* 1908, *vi*. 631.
- Measles: *J.A.M.A.* 1911, *i*. 476; *V.A.* 1910, *Bd.* 199, *s.* 378.—Meat-poisoning: *B.M.J.* 1909, *i*. 1171; *M.m.W.* 1908, *i*. 156., 1910, *i*. 1227.—Mediterranean (Malta) Fever: *L.* 1908, *i*. 1677.—Meningococcus, *B.M.J.* 1907, *i*. 1477. *See also* Meningitis, under Central Nervous System.—Meningococcus Septicaemia: *M.m.W.* 1908, *ii*. 1978 *ref.*—Morax-Axenfeld Diplococcus, Cultivation on Egg Medium: *J.A.M.A.* 1911, *i*. 1106.
- Oosporoses: *A.M.E.* 1909, *xxi*. 229.
- Paratyphoid: *M.m.W.* 1908, *ii*. 1725., 1911, *i*. 629.—Paratyphoid (A): *J.A.M.A.* 1909, *i*. 470.—Paratyphoid (B): *M.m.W.* 1908, *ii*. 1782.—Plague: *L.* 1908, *i*. 213., 1911, *i*. 1117.—Pneumococcus: *L.* 1908, *i*. 539.—Pneumococcus Septicaemia with Haemoglobinuria: *M.m.W.* 1910, *i*. 300.—Puerperal Uterus, Bacteriology of: *A.J.M.Sc.* 1908, *vol.* 136, *p.* 255.
- Rheumatism, Acute: *E.M.J.* 1908, *xxiii*. 391; *B.M.J.* 1907, *i*. 1233; *L.* 1910, *i*. 1524; *L.* 1909, *ii*. 1665; *J.P. and B.* 1910, *xiv*. 432.—Rhinoscleroma, Bacillus: *A.M.E.* 1910, *xxii*. *p.* 545.
- Scarlet Fever: *L.* 1908, *i*. 995.—Sporotrichosis: *B.M.J.* 1911, *ii*. 1; *L.* 1911, *i*. 659; *J.A.M.A.* 1911, *i*. 1312; *J.M.R.* 1910, *xxiii*. 146; *B.M.S.J.* 1911, *v*. 164, *p.* 179.—Streptococci: *J.P. and B.* 1911, *xv*. 323.—Streptococcus Infection in Diphtheria: *L.* 1909, *ii*. 1493.—Streptococcal Throats: *L.* 1908, *ii*. 1814; *J.A.M.A.* 1909, *i*. 1751.—Streptotrichoses and Tuberculosis: *L.* 1910, *i*. 551, 626, 769, 802.—Streptothrix, Brain Abscess: *M.m.W.* 1907, *ii*. 1523.
- Tetanus, Inguinal Glands: *B.M.S.J.* 1909, *vol.* 161, *p.* 927; Uterus: *B.M.S.J.* 1910, *vol.* 162, *p.* 461.—Tubercle Bacillus, Portals of Entry: *J.P. and B.* 1910, *xiv*. 615.—Tuberculosis in Children: *M.m.W.* 1909, *i*. 449; *L.* 1909, *i*. 315; *J.A.M.A.* 1909, *i*. 675.—Tuberculosis, Infection: *L.* 1910, *i*. 914., 1909, *i*. 1369; *L.* 1908, *ii*. 135, 362.—Tuberculosis, Avian and Human: *L.* 1909, *ii*. 1739.—Tuberculosis, Human and Bovine: (*T. Smith*) *B.M.S.J.* 1908, *vol.* 159, *p.* 707; *L.* 1908, *ii*. 362; *J.M.R.* 1910, *xxiii*. 205.—Tubercle Bacilli, Human and Bovine, experimental transformation: *M.m.W.* 1910, *i*. 115.—Tuberculosis, Acute Abdominal: *J.A.M.A.* 1909, *i*. 291.—Tubercle Bacilli within Thoracic Duct: *F.Z.* 1910, *Bd.* 5, *s.* 423.—Tubercle Bacilli in Urine, Detection of, (*Russ*): *L.* 1909, *ii*. 2.—Typhoid, *J.A.M.A.* 1909, *ii*. 1248–1264; *M.m.W.* 1908, *ii*. 1782.—Typhoid Bacilli, Demonstration of scanty, (*Conradi*): *M.m.W.* 1908, *ii*. 1523.—Typhobacillae: *L.* 1908, *ii*. 1440.—Typhoid Fever, Blood Cultures in: *A.J.M.Sc.* 1908, *vol.* 136, *p.* 190 *ref.*, 1909, *vol.* 137, *p.* 637; *J.A.M.A.* 1910, *i*. 756.—Typhoid Carriers: *B.M.J.* 1908, *i*. 15., *ii*. 1173., 1909, *ii*. 1056, 1813., 1910, *ii*. 1501; *L.* 1909, *i*. 311., 1910, *ii*. 723., 1911, *i*. 1002; *M.m.W.* 1909, *i*. 1011., 1910, *i*. 1213; *A.J.M.Sc.* 1910, *vol.* 140, *p.* 247; *J.A.M.A.* 1908, *ii*. 981., 1909, *i*. 48; *Q.J.M.* 1911, *No.* 14, *p.* 113; *B.M.S.J.* 1909, *vol.* 160, *p.* 38; *M.m.W.* 1909, *i*. 57.—Typhoid Fever, Complications: *A.J.M.Sc.* 1908, *vol.* 135, *pp.* 223–244 *refs.*, 1911, *vol.* 141, *p.* 803; *J.A.M.A.* 1908, *i*. 1014.—Typhoid

Infection of Foetus : *M.m.W.* 1909, i. 288.—Typhoid Meningitis : *M.m.W.* 1911, i. 357.—Typhoid Bacillus, Pyogenic : *M.m.W.* 1910, i. 232.—Typhoid Septicaemia : *M.m.W.* 1911, i. 1238.—Typhoid Vaccines : *L.* 1909, ii. 436.—Typhoid and Paratyphoid, Relation to the Bile-ducts : *M.m.W.* 1908, i. 1.

Vaccine Therapy : *L.* 1910, ii. 862.

Whooping Cough : *M.m.W.* 1909, i. 131.

Beri-beri, Pathological Anatomy : Dürck, monograph : *Suppl. viii. zur Ziegler's Beiträge, Jena, Fischer, 1908.*—Beri-beri : *E.M.J.* 1906, xix. 111 ; *B.M.J.* 1908, i. 201, 1908, ii. 1609 ; *L.* 1909, i. 451, 529, 561 ; *J.A.M.A.* 1908, i. 1785, 1911, i. 1237 ; *B.M.J.* 1909, ii. 935.

Bile and Bile-ducts. *See under Liver.*

Blood

Blood Cultivation, Method : *M.m.W.* 1910, ii. 1432 refs.—Blood Cultures with Amm. Oxalate : *J.M.R.* 1909, xx. 79.—Blood in Health and Disease : *J.P. and B.* 1906, xi. p. 64.

Achromasia : *L.* 1909, i. 226.—Amaeboid Movement, Substances Exciting : *L.* 1909, i. 152, 313, 389.—Anaemia, Aplastic : *A.M.E.* 1908, xx. p. 805 ; *A.J.M.Sc.* 1911, vol. 142, p. 57 ref.—Anaemia, Congenital : *J.P. and B.* 1909, xviii. 398.—Anaemia, Pernicious : *B.M.J.* 1907, ii. 1299 ; *A.J.M.Sc.* 1910, vol. 140, p. 563, refs. (*Sp. Cord.*)—Pernicious Anaemia, Gastric changes in : *V.A.* 1911, Bd. 204, s. 116.—Pernicious Anaemia, Changes in Haemopoietic Organs : *M.m.W.* 1908, i. 1164.—Auer's Bodies : *A.J.M.Sc.* 1909, vol. 138, p. 562.

Chlorosis, Changes in Thyroid : *M.m.W.* 1911, i. 1175.—Cholaemia, Congenital : *L.* 1910, i. 153, 227 refs. ; *Q.J.M.* 1908-9, No. 6, p. 165, No. 8, p. 432 ; *E.M.J.* 1911, N.S. vi. 101. *See also Chronic Familial Jaundice.*

Eosinophilia : *E.M.J.* 1908, xxviii. 275.—Erythraemia : *E.M.J.* 1911, N.S. vi. 129 ; *L.* 1908, i. 143 ; *A.J.M.Sc.* 1910, vol. 140, p. 827 ; *E.M.J.* 1906, xx. 360 ; *B.M.J.* 1907, i. 1165.

Leucocytes : *L.* 1910, i. 1736, ii. 8, 83, 153, 401.—Leucocytosis in Middle-ear Disease : *E.M.J.* 1908, xxviii. 125.—Leucocytosis, Quinine and : *L.* 1910, ii. 1342.—Leucocytosis in Whooping Cough : *E.M.J.* 1908, N.S. i. 222.

Leucocythaemia—Leukemia, Acute : *A.J.M.Sc.* 1909, vol. 138, p. 562 refs.—Leukaemia, Lymphatic and Myelogenous : *Z.B.* 1908, Bd. 43, s. 172, full refs.—Leukaemia, Acute Lymphatic : *Z.B.* 1910, Bd. 49, s. 338.—

Lymphatic Leukaemia and Chloroma : *J.P. and B.* 1906, xi. 333.—Lymphocythaemia, Acute : *J.P. and B.* 1906, xi. 462.—Leukaemia, Acute Myeloid : *F.Z.* 1910, Bd. 4, s. 87, 1910-11, Bd. 6, s. 167, lit.—Leukaemia, Myeloid : *M.m.W.* 1908, i. 1057.—Myelocythaemia : *J.P. and B.* 1908, xii. 214.—Leukaemia, Abscesses in Nasal Submucosa : *A.J.M.Sc.* 1911, vol. 141, p. 109.

Leukanaemia : *E.M.J.* 1906, xix. 339 refs. ; *A.J.M.Sc.* 1908, vol. 136, p. 400 ref. ; *Q.J.M.* 1907, No. 1, p. 89, 1909-10, No. 9, p. 1.—Lipaemia : *J.P. and B.* xi. 1906, p. 50, 371.—Lymphocytes, Flagellation : *B.M.J.* 1909, ii. 206.

Parasites in Blood, Demonstration : *M.m.W.* 1908, ii. 2601.—Phagocytosis, Bacterial Emulsions : *Q.J.M.* 1910-11, No. 15, p. 368.—Phagocytosis of Erythrocytes : *L.* 1910, ii. 1266.—Polycythaemia (*see also Erythraemia*) : *Q.J.M.* 1908-9, No. 5, p. 85.—Purpura haemorrhagica : *A.J.M.Sc.* 1911, vol. 142, p. 36.

Ricketts, Blood in : *L.* 1909, i. 1164.

Uraemia, Pathology : *Q.J.M.* 1908-9, No. 6, 231.

X-Bodies : *L.* 1911, i. 295 ; *J.R.A.M.C.*¹ 1908, x. 4.

Bone, Diseases of

Achondroplasia : *B.M.J.* 1907, i. 11 ; *J.A.M.A.* 1909, ii. 1614.—Spine, Ankylosing Diseases : *R.N.P.* 1908, vi. 12, 65.—Abscess, Brodie's, (Al. Thomson) : *E.M.J.* 1906, xix. 297.

Calcium Salts in Developing Bone and in Callus : *F.Z.* 1911, Bd. 7, s. 175 lit.—Cranio-cleido Dysostosis, Hereditary : *L.* 1910, ii. 1466.—Cysts : *L.* 1910, ii. 1202.

Defects in Skull, and Craniotabes, etc. : *V.A.* 1909, Bd. 197, s. 167.

Fibrous Atrophy : *V.A.* 1910, Bd. 201, s. 467.—Fractures of Skull : *J.A.M.A.* 1909, ii. 429.

Heterotopic Ossification (Bone-marrow) : *F.Z.* 1908-9, Bd. 2, s. 591. (*See skin.*)

Leontiasis Ossea : *B.M.S.J.* 1910, vol. 162, p. 216.

Malignant Disease of Spine : *B.M.J.* 1911, i. 988.—Myeloma. *See under Tumours.*

Osteitis deformans : Waterhouse, *L.* 1907, i. 1215, illustr. ; *B.M.J.* 1908, ii. 1675, 1910, i. 135 ; of Skull, *V.d.d.p.G. Leipz.* 1909, s. 107, illustr.—Osteogenesis imperfecta : *E.M.J.* 1906, xix. 55 ; *J.P. and B.* 1909, xiii. 467 ; *F.Z.* 1910-11, Bd. 6, s. 398.—Osteomalacia : *L.* 1908, ii. 154 ; *M.m.W.* 1908, ii. 758, 1911, i. 405 ; *F.Z.* 1911, Bd. 7, s. 231.

¹ *Journal Royal Army Medical Corps.*

- Periostitis (histology): *F.Z.* 1911, *Bd.* 8, s. 91.—Perithelioma, Multiple: *V.A.* 1910, *Bd.* 200, s. 101.
- Rickets: *B.M.J.* 1908, *ii.* 13; *Z.B.* 1908, *Bd.* 44, s. 197; *L.* 1909, *i.* 1164.—Rickets and Osteomalacia: *Verh. d. deutsch. patholog. Gesellsch., Leipzig*, 1909, s. 3-67.
- Sarcoma: *A.J.M.Sc.* 1910, *vol.* 140, 355.
- Teratoma of Vertebra: *F.Z.* 1911, *Bd.* 7, s. 127.
- Bone Marrow: *V.A.* 1910, *Bd.* 200, s. 258.—Myeloma: *see under* Tumours.
- Botulism: *see under* Meat-poisoning.
- Bronchial Lymphatic Glands: *Zeits. f. Hyg. u. Infekt.* 1907, *lviii.* 2, 194.
- Burning, Death from: *V.A.* 1905, *Bd.* 180, s. 367., 1910, *Bd.* 201, s. 208.
- Bursae: Ilio-psoas Tumour: *J.A.M.A.* 1910, *i.* 1181.—Bursitis, Tuberculous: *J.H.H.B.* 1911, *xxii.* 155.—Bursa, Calcification in: *M.m.W.* 1908, *ii.* 2699.
- Caisson Disease: *Q.J.M.* 1907-8, *No.* 3, p. 348; *B.M.J.* 1908, *i.* 914, 983, 1565., 1909, *i.* 257; *J.P. and B.* 1908, *xii.* 507; *Jl. of Hygiene*, 1908, *viii.* 342; *A.J.M.Sc.* 1910, *vol.* 139, p. 373.
- Cardiac Polyps: *see under* Endocardium (Heart).
- Cardiac Thrombosis: *see under* Endocardium (Heart).
- Carotid Gland: *see under* Ductless Glands.
- Chloroma: *F.Z.* 1909, *Bd.* 3, s. 541 *ref.*; *A.M.E.* 1909, *xxi.* p. 64.
- Cholesteatoma, Umbilicus: *M.m.W.* 1909, *ii.* 1583.
- Cholesterin: *M.m.W.* 1908, *i.* 211.
- Chromaffin Organs: *A.M.E.* 1909, *xxi.* p. 702., 1910, *xxii.* 491. *See also under* Ductless Glands.
- Concrements: *M.m.W.* 1908, *ii.* 77., 1909, *i.* 3.; *M.m.W.* 1911, *i.* 723.
- Correlation of Organs, and Hypertrophy: *M.m.W.* 1908, *i.* 377.
- Corpulence, Pituitary Tumours: *F.Z.* 1910, *Bd.* 5, s. 351, 587 (*Kritische Rundschau*).
- Cranio-pharyngeal Canal, Pathology: *F.Z.* 1910, *Bd.* 4, s. 96.
- Cultivation of Tissues in Vitro: *J.E.M.* 1911, *xiii.* 387, 416, 422, 495, 505, 571.
- Defences of the Body: *L.* 1908, *i.* 1816.
- Desmoid Tumours: *L.* 1910, *ii.* 1336.
- Diphtheritic Paralysis: *R.N.P.* 1906, *iv.* 608.
- Dropsy, Cardiac: *J.P. and B.* 1910, *xiv.* 49.
- Ductless Glands**
- Carotid Gland: *E.M.J.* 1906, *xx.* 459; *A.J.M.Sc.* 1908, *vol.* 136, p. 98 *ref.*—Chromaffin System: *V.A.* 1909, *Bd.* 198, s. 93.
- Hypophysis Pharyngea: *Z.B.* 1909, *Bd.* 46, s. 133., 1910, *Bd.* 49, s. 437.
- Parathyroids: *B.M.J.* 1906, *ii.* 1282 *fig.*, 1907, *i.* 1177, *ii.* 1508; *J.M.R.* 1908, *xix.* 135; *L.* 1908, *i.* 659; *A.M.E.* 1908, *xx.* p. 21; *J.M.R.* 1909, *xx.* 149; *A.M.E.* 1910, *xxii.* 462 (*in* Paralysis Agitans); *A.J.M.Sc.* 1911, *vol.* 141, p. 558; *Q.J.M.* 1907-8, *No.* 2, p. 150., *No.* 3, p. 287; *F.Z.* 1911, *Bd.* 7, s. 238, 249. (*See also* Tetany.)
- Parathyroids, Precocity in Relation to: *B.M.J.* 1907, *ii.* 747.
- Pituitary: *Z.B.* 1908, *Bd.* 44, s. 233; *B.M.J.* 1909, *ii.* 1609; *V.A.* 1910, *Bd.* 201, s. 289., 1911, *Bd.* 203, s. 1; *A.J.M.Sc.* 1910, *vol.* 139, p. 473; *J.H.H.B.* 1909, *xx.* 105., 1910, *xxi.* 127-169.—Pituitary in Pregnancy: *Z.B.* 1909, *Bd.* 46, s. 1.—Pituitary Tumours, in Acromegaly and Corpulence: *F.Z.* 1910, *Bd.* 5, s. 351, 587 (*Kritische Rundschau*); *M.m.W.* 1907, *i.* 894; *Z.B.* 1910, *Bd.* 47, s. 187. Pituitary Tumour: *F.Z.* 1910-11, *Bd.* 6, s. 398.—Pituitary Adenoma: *F.Z.* 1910, *Bd.* 4, s. 70.—Pituitary Sarcoma: *A.M.E.* 1909, *xxi.* p. 172.—Glycogen in Pituitary and Central Nervous System: *Z.B.* 1909, *Bd.* 45, s. 38.
- Suprarenal Capsules: *B.M.J.* 1908-1, 1277, 1346; *Q.J.M.* 1909-10, *No.* 9, p. 34; *V.A.* 1908, *Bd.* 192, s. 356, 494; *M.m.W.* 1910, *i.* 1380; Relation to Skin: *M.m.W.* 1911, *i.* 1005.—Die Pathologie der Nebennieren, Dr. Bittorf: *Jena, G. Fischer*, 1908, *refs.*—Suprarenals in Arteriosclerosis and Nephritis: *V.A.* 1908, *Bd.* 192, s. 338; *J.E.M.* 1908, *x.* 735; *Z.B.* 1910, *Bd.* 49, s. 228.—Suprarenal Haemorrhage in Infants: *J.A.M.A.* 1908, *ii.* 1964; *V.A.* 1908, *Bd.* 192, s. 137; *M.m.W.* 1910, *ii.* 1591.—Suprarenals, Morbid Histology: *J.P. and B.* 1910, *xiv.* 240.—Tumours of Suprarenals: *Q.J.M.* 1907, *No.* 1, p. 33; *A.J.M.Sc.* 1908, *vol.* 135, p. 871, *full refs.*; *Q.J.M.* 1910-11, *No.* 14, p. 123; *A.M.E.* 1911, *xxiii.* 466 *ref.*; *F.Z.* 1910, *Bd.* 5, s. 167 *ref.*—Suprarenal Carcinoma: *Q.J.M.* 1911, *No.* 14, p. 123; *J.P. and B.* 1909, *xiii.* 482.—Grawitz' Tumours: *Z.B.* 1910, *Bd.* 49, s. 476.—Suprarenal Fibroma and Neuroma: *A.M.E.* 1908, *xx.* p. 189.—Suprarenal Ganglioneuroma: *F.Z.* 1911, *Bd.* 7, s. 135 *refs.*—Hypernephroma: *Z.B.* 1908, *Bd.* 43, s. 393; *J.P. and B.* 1909, *xiii.* 382.—Hypernephroma, resembling Sarcoma: *Z.B.* 1908, *Bd.* 44, s. 17.—Ossification of Suprarenal: *A.M.E.* 1910, *xxii.* 762 *refs. to other papers on Heterotopic*

- Ossification.**—Syphilis of Suprarenal, Congenital: *A.M.E.* 1909, *xxi.* p. 154.—Primary Suprarenal Tuberculosis: *B.M.S.J.* 1910, *vol.* 163, p. 215.
- Thymus:** *A.M.E.* 1910, *xxii.* p. 98; *J.M.R.* 1910, *xxii.* 1 ref.—Thymus in Addison's Disease: *V.A.* 1910, *Bd.* 200, s. 399.—Thymus, Persistent, in Exophthalmic Goitre: *M.m.W.* 1907, *i.* 775., 1908, *i.* 668.
- Thyroid:** *A.J.M.Sc.* 1908, *vol.* 136, p. 851, *illustr.*; *J.P. and B.* 1908, *xii.* 101; *M.m.W.* 1908, *ii.* 1879; *J.P. and B.* 1910, *xiv.* 288; *B.M.S.J.* 1910, *vol.* 163, p. 196; *V.A.* 1911, *Bd.* 203, s. 246; *L.* 1911, *i.* 930, *ii.* 155; *M.m.W.* 1911, *i.* 1175 (in chlorosis); *J.A.M.A.* 1911, *i.* 658; *Z.B.* 1910, *Bd.* 49, s. 579. Bronchocele, Waxy: *J.P. and B.* 1906, *xi.* 426.—Carcinoma of Thyroid: *V.A.* 1909, *Bd.* 197, s. 240; *J.P. and B.* 1908, 557.—Thyroid in Children: *F.Z.* 1910, *Bd.* 5, s. 205 *lit.*, s. 322 (foetal), 1910–11, *Bd.* 6, s. 312 (15–25 yrs).—Thyroid, Changes in Chlorosis: *M.m.W.* 1911, *i.* 1175.—Endemic Cretinism: *L.* 1908, *ii.* 1275.—Sporadic Cretinism: *L.* 1910, *i.* 1684.—Goitre: *B.M.J.* 1909, *ii.* 855.—Endemic Goitre: *Q.J.M.* 1908–9, *No.* 7, p. 279.—Exophthalmic Goitre: *J.A.M.A.* 1908, *ii.* 1119; *M.m.W.* 1911, *i.* 833; *B.M.S.J.* 1910, *vol.* 162, p. 731 *refs.*—Myxoedema: *A.J.M.Sc.* 1909, *vol.* 138, p. 92.—Juvenile Myxoedema: *L.* 1909, *ii.* 926.—Sarcoma (Endothelioma) of Thyroid: *F.Z.* 1909, *Bd.* 3, s. 487.—Tuberculosis of Thyroid: *F.Z.* 1908.
- Electric Shock, Death from:** *M.m.W.* 1909, *i.* 1320.
- Embolism, Paradoxical:** *V.d.d.p.G. Leip.* 1909, s. 215.
- Embryological Problems:** *L.* 1910, *i.* 1247.
- Epignathus:** *M.m.W.* 1908, *ii.* 1950.
- Erb's Juvenile Muscular Atrophy:** *Z.B.* 1908, *Bd.* 44, s. 430.
- Fat-staining with Anilin Dyes:** *J.P. and B.* 1906, *xi.* 415., 1908, *xii.* 1. (See also in Appendix.)
- Fatty and Myelin Degeneration:** *F.Z.* 1909, *Bd.* 3, s. 793. (See also Lipoid Substances.)
- Free Bodies in Serous Cavities:** *A.M.E.*, 1910, *xxii.* p. 507 *refs.*
- Gall-bladder, and Gall-stones:** *see under* Liver.
- Gasserian Ganglion, Tumour:** *A.J.M.Sc.* 1908, *vol.* 136, p. 712 *ref.*
- Glioma of Sympathetic Nervous System:** *F.Z.* 1909, *Bd.* 3, s. 317.
- Goitre:** *see under* Ductless Glands.
- Grawitz' Tumours:** *Z.B.* 1910, *Bd.* 49, s. 476. (See also Suprarenal Tumours.)
- ### Heart and Pericardium.
- Cardiac Dropsy:** *J.P. and B.* 1910, *xiv.* 49.
- Congenital Heart Disease: *V.d.d.p. G. Leip.* 1909, s. 198; *L.* 1909, *ii.* 1198; *V.A.* 1909, *Bd.* 196, s. 127; *B.M.J.* 1909, *ii.* 1110; *V.A.* 1911, *Bd.* 203, s. 404; *L.* 1909, *ii.* 359, 433, 519; *J.P. and B.* 1910, *xiv.* 525.—Congenital Heart Disease with Polycythaemia: *Weber, E.M.J.* 1909, *N.S.* *ii.* 18.—Dextrocardia: *E.M.J.* 1910, *N.S.* v. 428.—Tricoelian (Trilocular) Heart: *B.M.J.* 1907, *i.* 614; *L.* 1911, *i.* 872; *V.A.* 1908, *Bd.* 192, s. 252.—
- Pericardium.**—Parietal Pericardium, Histology: *Z.B.* 1909, *Bd.* 45, s. 283.—Pericardium, Adherent: *B.M.J.* 1907, *i.* 63.—Haemopericardium (Syphilis): *L.* 1908, *ii.* 424.—Pericardium, Milk Spots: *F.Z.* 1909, *Bd.* 3, s. 220.—Pericarditis: *A.J.M.Sc.* 1909, *vol.* 138, p. 796.—Pericarditis, Tuberculous: *B.M.S.J.* 1909, *vol.* 160, p. 404 *refs.*
- Myocardium.**—Local Amyloid Degen. of Heart: *Z.B.* 1908, *Bd.* 44, 362.—Amyloid (Waxy) Degeneration: *V.A.* 1910, *Bd.* 202, s. 168.—Aneurysm of Sinus of Valsalva: *F.Z.* 1910, *Bd.* 5, s. 89 *refs.*
- Chronic Arrhythmia of Heart (Schönberg):** *F.Z.* 1908–9, *Bd.* 2, *H.* 1, s. 153, 462; (Hedinger) 1910, *Bd.* 5, s. 296.—Atrioventricular Bundle, Normal and Pathological Histology (Engel): *Z.B.* 1910, *Bd.* 48, s. 499., (Löw) *Bd.* 49, s. 1.—Heart Block: *Q.J.M.* 1907, *i.* 182; *E.M.J.* 1909, *N.S.* *ii.* 315, 507; *B.M.J.* 1908, *ii.* 1798; *L.* 1910, *i.* 856; *A.J.M.Sc.* 1910, *vol.* 139, p. 62.—Heart-block, Gumma of Septum: *M.m.W.* 1909, *i.* 916.—Calcification of Heart Muscle: *F.Z.* 1909, *Bd.* 3, s. 706.
- Hypertrophy, Experimental:** *J.E.M.* 1911, *xiii.* 187.—Heart, Hypertrophy and Insufficiency, Histology: *M.m.W.* 1909, *ii.* 1830 *refs.*
- Heart, Lipoma:** *M.m.W.* 1907, *i.* 472.
- Myocarditis, Rheumatic:** *Q.J.M.* 1908, *No.* 5, p. 26; *M.m.W.* 1908, *i.* 1101., 1909, *ii.* 2469.
- Primitive Muscle:** *B.M.J.* 1909, *i.* 149; *L.* 1910, *i.* 101.—Purkinje's Fibres: *Z.B.* 1908, *Bd.* 44, s. 296.
- Rhabdomyoma of Heart, Multiple:** *Z.B.* 1909, *Bd.* 45, s. 376 *refs.*; *Q.J.M.* 1910–11, *No.* 13, p. 50.—Rupture of Heart: *L.* 1908, *i.* 1481.

- Sarcoma of Heart : *A.J.M.Sc.* 1910, vol. 140, p. 216.—Congenital Syphilis of Heart : *A.J.M.Sc.* 1911, vol. 141, p. 398, *illustr.*
- Tachycardia, Paroxysmal : *J.A.M.A.* 1910, i. 1861.
- Wounds of Heart : *J.A.M.A.* 1909, i. 429 *full refs.*
- Endocardium.**—Endocardial Pockets : *V.A.* 1908, Bd. 192, s. 50.—Endocarditis, Amyloid : *Z.B.* 1910, Bd. 47, s. 525.—Cardiac Polyps, so-called Endocardial Tumours : *E.M.J.* (*Hughes Bennett*), 1853, xvi. 274 ; *V.A.* 1910, Bd. 199, s. 162 *refs. and illustr.* ; *F.Z.* 1910, Bd. 4, s. 214 (*also s. 30*).—Cardiac Thrombosis : *J.A.M.A.* 1909, ii. 1347.
- Heart-valves, Diseases of.**—Atheroma of Mitral Cusp : *F.Z.* 1910, Bd. 5, s. 515 *lit.*
- Endocarditis :** *E.M.J.* 1906, xix. 507 ; *B.M.J.* 1908, ii. 1053 ; *E.* Amyloid : *Z.B.* 1910, Bd. 47, s. 525 ; *E.* Infective : *Q.J.M.* 1908-9, No. 6, p. 219 ; No. 7, p. 325 ; *A.J.M.Sc.* 1910, vol. 140, p. 516 ; *L.* 1911, i. 1637 ; *E.* Influenzal : *V.A.* 1911, Bd. 204, s. 169.—*E.* Rheumatic : *L.* 1909, i. 1159, 1377.—*E.* Streptococcal : (*Schottmuller*) *M.m.W.* 1910, i. 617.—*E.* Chronic : *V.A.* 1910, Bd. 199, s. 273 ; Bd. 202, s. 341.—Amyloid in Endocarditis : *Z.B.* 1910, Bd. 47, s. 525.
- Haemorrhage into Cusps (Angioma) :** *V.A.* 1908, Bd. 192, s. 521 ; Bd. 193, s. 238 ; *J.E.M.* 1908, x. 368 ; *F.Z.* 1908-9, Bd. 2, s. 411 *ref.*, 1910-11, Bd. 6, s. 65.
- Primary Tumours of Heart-valves :** *F.Z.* 1908-9, Bd. 2, s. 295.
- White Spots on Inner Mitral Cusp, in the Young :** *F.Z.* 1910, Bd. 5, s. 515.
- Hemiatrophy, Facial :** *R.N.P.* 1906, iv. 1.
- Hypernephroma, see under Suprarenals (Ductless Glands).**
- Hypertrophy and Correlation of Organs :** *M.m.W.* 1908, i. 377.
- Inflammation and Cancer :** *F.Z.* 1911, Bd. 7, s. 465.
- Inflammation, Origin of Lymphocytes in the early stages of :** *Z.B.* 1909, Bd. 45, s. 400.
- Joints**
- Ankylosing Diseases of Spine :** *R.N.P.* 1908, vi. 12-65.—Arthritis Acute : *E.M.J.* 1907, xxii. 226 ; *L.* 1910, i. 1124.—Arthritis, Chronic : *E.M.J.* 1908, xxiii. 37.—Arthritis, Classification : *E.M.J.* 1911, N.S. vii. 48.—Arthritis Deformans : *A.M.E.* 1908, xx. p. 438 ; *J.M.R.* 1909, xxi. 149, 221, *many illustr.* ; *M.m.W.* 1909, ii. 1588 ; *L.* 1910, i. 997, 1908, ii. 1865.—Arthritis, Gonococcal : *J.A.M.A.*, 1908, i. 702, 1607.—Arthritis, pneumococcal : *J.H.H.B.* 1910, xv. 229.
- Coxa Valga :** *B.M.J.* 1908, ii. 185 ; *L.* 1910, ii. 727.—Coxa Vara : *M.m.W.* 1910, i. 1219.
- Joint-disease in Children, Non-tuberculous :** *B.M.J.* 1910, ii. 1117.
- Pulmonary Osteoarthropathy :** *E.M.J.* 1907, xxii. 505 ; *L.* 1909, i. 385.
- Rheumatism, Chronic :** *L.* 1910, i. 712.
- Rheumatoid Arthritis :** *B.M.J.* 1907, ii. 1143, 1911, i. 544 ; *L.* 1910, ii. 927 ; *L.* 1911, i. 639, 1908, ii. 1865 ; *J.A.M.A.* 1908, i. 1977, ii. 124.—Rheumatisme Tuberculeux of Poncet : *E.M.J.* 1910, N.S. v. 503.
- Synovial Fringes :** *J.A.M.A.* 1908, i. 1675.—Syphilitic Arthropathies : *B.M.J.* 1908, ii. 1072.
- Lacrimal Gland, Tumours :** *J.A.M.A.* 1910, i. 515.
- Lead Poisoning :** *R.N.P.* 1907, v. 441.
- Leucocyte Extracts in Infections :** *J.M.R.* 1908, xix. pp. 323-469, 1909, xxi. 223 ; *J.H.H.B.* 1908, xix. 145.
- Lipoid Substances, Morphology :** *Z.B.* 1910, Bd. 47, s. 1 ; Bd. 49, s. 491.
- Liver**
- Liver, Diseases of :** *Rolléston, London*, 1905.—Pathological Anatomy : *V.A.* 1908, Bd. 194, s. 212.
- Abscesses, Pneumococcal :** *P.M.*¹ 1910, Ap. 23.—Abscess, Tropical : *B.M.J.* 1908, ii. 1235.—Abscess in Typhoid Fever : *A.J.M.Sc.* 1911, vol. 141, p. 803.—Cavernous Angioma of Liver : *Z.B.* 1910, Bd. 49, s. 313 ;—Atrophy, Acute Yellow : *J.H.H.B.* 1902, x. 379, 1908, xix. 5 ; *B.M.S.J.* 1908, vol. 158, p. 729 *refs.* ; *M.m.W.* 1908, i. 959 ; *J.P. and B.* 1909, xviii. 53.—Atrophy, Sub-acute : *V.A.* 1908, Bd. 192, s. 254 ; *J.P. and B.* 1909, xviii. 161.
- Calcification of Liver in Chronic Nephritis :** *F.Z.* 1909, Bd. 3, s. 773.—Cancer of Liver, Primary : *F.Z.* 1909, Bd. 3, s. 242 ; *V.A.* 1910, Bd. 202, s. 57, 1911, Bd. 203, s. 75 ; *L.* 1910, i. 1066 ; *J.A.M.A.* 1909, i. 1741 ; *V.A.* 1908, Bd. 193, s. 407 ; *A.M.E.* 1910, xxii. 311 ; *J.P. and B.* 1909, xviii. 348.—Carcinoma, Adrenal : *J.P. and B.* xvii. 107.—Cavernous Degeneration of Liver : *Z.B.* 1909, Bd. 45, s. 306.—Chloroform Poisoning : *J.H.H.B.* 1909, xx. 278, *illustr. ref.*
- Cirrhosis, Causes and Stages.**—(*Mallory*) *J.H.H.B.* 1911, xxii. 69, *illustr.*—Cirrhosis of Liver : *A.M.E.* 1908, xx. p. 313 ; *B.M.J.* 1898, ii. 1215 ; *A.M.E.*

¹ *Presse Médicale, Paris.*

- 1906, xviii. 769.—Cirrhosis, Hypertrophic Biliary, of Liver: J.P. and B. 1901, vii. 203; *Trans. Path. Soc. Lond.* 1903, vol. 54, p. 103 refs.—Cirrhosis, Biliary: V.A. 1908, Bd. 193, s. 213.—Cirrhosis, Malarial: L. 1908, i. 1474, ii. 308.—Cirrhosis, Tuberculous: F.Z. 1908-9, Bd. 2, s. 125.—Cirrhosis in Children: V.A. 1908, Bd. 192, s. 266.
- Composite Tumour of Liver: A.M.E. 1909, xxi. 136; V.A. 1910, Bd. 201, s. 326.
- Eclampsia, Changes in: V.A. 1910, Bd. 201, s. 361.
- Fat in Liver: J.E.M. 1910, xii. 746; J.P. and B. 1908, xii. 371.—Foaming Liver: Welch, J.H.H.B. 1900, xi. 185.
- Glycogen in Liver: Z.B. 1910, Bd. 49, s. 284.—Hypoplasia: V.A. 1908, Bd. 194, s. 63.
- Icterus, *see* Jaundice.—Icterus Gravis of the newly born: M.m.W. 1908, ii. 2169.
- Inclusions in Nuclei of Liver-cells: Z.B. 1909, Bd. 45, s. 457.
- Jaundice, Pathogenesis: J.E.M. 1911, xiii. 115.—Jaundice, Acquired Achromic: A.J.M.Sc. 1909, vol. 138, p. 24.—Obstructive Jaundice, Experimental: J.E.M. 1911, xiv. 159.—Jaundice, Chronic Family: M.m.W. 1910, i. 1282; A.J.M.Sc. 1910, vol. 139, p. 847 refs.; J.H.H.B. 1911, xxii. 85, full literature; *see also* Cholaemia.
- Kupffer's Cells: V.A. 1909, Bd. 196, s. 1; A.M.E. 1908, xx. 145; F.Z. 1909, Bd. 3, s. 931.
- Melanoma: A.M.E. 1910, xxii. 276.—Metastases, Retrograde: A.M.E. 1910, xxii. 363.
- Necrosis: J.P. and B. 1908, xii. 279.
- Regeneration: B.M.J. 1908, ii. 1168; V.A. 1911, Bd. 204, s. 339, 1909, Bd. 195, s. 462; J.P. and B. 1908, xii. 287, 1909, xiii. 127.
- Sarcoma: J.P. and B. 1906, xi. 434, 1911, xv. 247.—Syphilis: M.m.W. 1907, ii. 2135.
- Teleangiectasia Hepatis Disseminata: Z.B. 1909, Bd. 45, s. 306.—Tuberculous Liver, Cystic: A.M.E. 1909, xxi. p. 353.
- Weill's Disease: *Deut. Archiv. f. klin. Med.* 1886, Bd. 39, s. 209.
- Bile, and Bile-ducts.—Bile, Bacteriology: Q.J.M. 1910-11, No. 14, p. 113.—Bile-ducts, Congenital Obliteration: L. 1901, ii. 520; B.M.J. 1907, ii. 385, 947; J.M.R. 1908, xviii. 61.—Bile-ducts, Congenital Syphilis: *Trans. Path. Soc. Lond.* 1903, p. 131, *lit. to* 1902.—Common Bile-duct, Cysts: A.J.M.Sc. 1909, vol. 137, p. 563 refs.
- Gall-Bladder.—Carcinoma: J.P. and B. 1909, xviii. 41.—Cholecystitis (Paratyphoid): M.m.W. 1908, i. 15.—(Influenzal): *Deut. med. Wochens.* 1907, i. 908.—Sarcoma, Primary: Z.B. 1909, Bd. 46, s. 429.
- Gall-Stones: Z.B. 1908, Bd. 44, s. 528 *Illustr.*; J.A.M.A. 1909, i. 1828; L. 1909, i. 1301, 1910, i. 413; Calculi, intra-hepatic: B.M.J. 1906, i. 434.
- Lupus, *see under* Skin Diseases.
- Lymphadenoma: J.H.H.B. 1902, x. pp. 157-196; L. 1911, i. 1132; J.H.H.B. 1911, xxii. 114; B.M.S.J. 1908, vol. 158, p. 677 full refs.; J.P. and B. 1909, xviii. 92.—Lymphadenoma, Spirochaetes in: M.m.W. 1907, ii. 1868.
- Lymphadenoma and Tuberculosis: V.A. 1910, Bd. 202, s. 222.
- Lymphatic Apparatus in Addison's Disease: V.A. 1910, Bd. 200, s. 399.
- Lymphatic Glands, Pathology: Q.J.M. 1909, -10, No. 12, p. 395.—Pap. Cystadenoma of Lymph Glands: F.Z. 1910, Bd. 4, s. 47.—Lymphatic Glands, Syncytial Endothelioma: V.A. 1909, Bd. 198, s. 422.—Relation of Fat to Lymph Glands: Z.B. 1910, Bd. 48, s. 170, Bd. 49, s. 595.—Sarcomatosis of Lymphatic Glands: L. 1908, ii. 82.—Tuberculosis of Glands: L. 1909, i. 315; A.J.M.Sc. 1908, vol. 136, p. 183; J.E.M. 1910, xii. 82; F.Z. 1910, Bd. 4, s. 203.—Lymphatic System: B.M.J. 1910, i. 853, 922; L. 1910, i. 977, 1052; ii. 365.—Origin of Lymphocytes in early Inflammation: Z.B. 1909, Bd. 45, s. 400.

Mamma

- Adeno-fibroma in Male: A.J.M.Sc. 1909, vol. 138, p. 244.—Cancer: B.M.J. 1908, ii. 970; J.A.M.A. 1909, i. 1645, 1648.—"Cancer en cuirasse": M.m.W. 1908, i. 510 *illustr.*; L. 1911, ii. 356.—Cancer, Cystic: J.A.M.A. 1909, ii. 1475; Cancer in Male: J.M.R. 1910, xxii. 145.—Cystic Disease: L. 1910, ii. 1604.—Diseases of Mamma: A.J.M.Sc. 1908, vol. 135, p. 157.—Fibroma (Inter-canalicular), becoming Sarcomatous: J.A.M.A. 1909, ii. 1485.—Hypertrophy: J.A.M.A. 1911, i. 1339.—Mastitis, Chronic: L. 1910, i. 285.—Mastitis, Tuberculous: A.J.M.Sc. 1909, vol. 138, p. 70; V.A. 1910, Bd. 202, s. 217.—"Peau d'orange": L. 1909, ii. 86; J.A.M.A. 1911, i. 793.—Polythelia and Polymastia: M.m.W. 1910, ii. 2295.—Sarcoma: E.M.J. 1909, N.S. ii. 23.—Tumours (*illustr.*): J.A.M.A. 1911, i. 793.—Tumours, doubtful: L. 1909, ii. 857.
- Measles: V.A. 1910, Bd. 199, s. 378; J.A.M.A. 1911, i. 476.

Meningitis, etc.: See Nervous System, Central.

Mesentery.—Cavernous Angioma: *M.m.W.* 1907, i. 282.—Cysts: *J.A.M.A.* 1909, i. 637.—Tumours: *J.A.M.A.* 1911, i. 534 *illustr. refs.*

Metaplasia in Cancer: *J.P. and B.* 1909, xiii. 99.

Mongolism, Pathology of: *Q.J.M.* 1908-9, No. 5, p. 49.

Mumps: *L.* 1909, i. 162.

Muscle, Voluntary

Amyotonia Congenita: *A.J.M.Sc.* 1910, vol. 139, p. 383 *refs.*, 1911, vol. 142, p. 165 *refs.*—Dystrophies: *M.m.W.* 1908, ii. 2188., 1911, i. 621 *ref.*—Progressive Muscular Dystrophy (sectio.): *F.Z.* 1908-9, Bd. 2, s. 577.—*Wien. Klin. Woch.* 16, 1, 1908; *Il Policlinico*, 1908, xv. C. p. 289.—Haemangioma: *J.H.H.B.* 1908, xix. 74.—Hernia of Muscle: *M.m.W.* 1910, i. 505.—Myasthenia Gravis: *J.E.M.* 1908, x. 308; *F.Z.* 1908-9, Bd. 2, s. 57; *R.N.P.* 1910, viii. 537; *B.M.J.* 1911, i. 133.—Myatonia Congenita, see Amyotonia Congenita.—Myopathies: *R.N.P.* 1906, iv. 192, 1908, vi. 137; *Q.J.M.* 1909-10, No. 11, p. 313, *Reviews.*—Myositis, Gonococcal: *A.M.E.* 1909, xxi. p. 24.—Myositis, Ischaemic: *B.M.J.* 1908, ii. 919.—Myositis ossificans: *E.M.J.* 1908, xviii. 344; *V.A.* 1911, Bd. 204, s. 209; *L.* 1911, i. 791-792.—Myositis, Chronic Rheumatic (Muskelschwien): *L.* 1909, ii. 292., 1911, i. 154.—Necrosis and Regeneration: *V.A.* 1909, Bd. 198, s. 374.—Polymyositis, Subacute: *J.A.M.A.* 1908, i. 177.—Regeneration of Voluntary Muscle: *Z.B.* 1909, Bd. 45, s. 424; Spinal Atrophy, Progressive: *L.* 1911, i. 1481.—“606,” The local effects of: *M.m.W.* 1910, ii. 2678.—Sprue: *Q.J.M.* 1907, No. 1, p. 1.—Trichinosis: *L.* 1909, i. 1381; *A.J.M.Sc.* 1910, 140, p. 157.—Vitreous Degeneration: *V.A.* 1909, Bd. 195, s. 93., 1910, Bd. 200, s. 22.

Myelin: *F.Z.* 1909, Bd. 3, s. 793. See also under Urinary Organs, Kidney.

Myeloid Metaplasia: *Z.B.* 1909, Bd. 46, s. 586; *V.A.* 1911, Bd. 204, s. 272.

Myeloma: see under Tumours.

Nerves

Nerve Regeneration: *Z.B.* 1908, Bd. 44, s. 574.—Neuritis, Familial Hypertrophic: *M.m.W.* 1911, i. 1238.—Neuritis, Optic: *B.M.J.* 1910, i. 553.—Neurofibromatosis: *J.A.M.A.* 1909, i. 945.—Neuroma, Multiple: *M.m.W.* 1910, ii. 2353.

Nervous System, Central

Abscess: *R.N.P.* 1910, viii. 77, 155; *L.* 1909, ii. 842; *J.A.M.A.* 1908, i. 1903, 1419.—Abscess, Streptothrix: *M.m.W.* 1907, ii. 1523.—Age Alterations in Ganglion Cells: *V.A.* 1908, Bd. 191, s. 168.—Alcoholism, Chronic: *Mott. B.M.J.* 1910, ii. 1403.—Amyotrophic Lateral Sclerosis: *R.N.P.* 1909, vii. 693., 1907, v. 441; *E.M.J.* 1907, xxi. 304.—Amyotrophy, Tabetic: *R.N.P.* 1911, ix. 401.—Aneurysm *R.N.P.* 1908, vi. 449; *L.* 1908, ii. 703, 1667.—Aphasia: *R.N.P.* 1906, iv. 324., 1909, vii. 151, 757, 763; *E.M.J.* 1907, xxii. 537.—Apoplexy, Traumatic Delayed: *M.m.W.* 1907, i. 214; *L.* 1909, ii. 1339 *refs.*; *R.N.P.* 1910, viii. 277.—Ataxia, Hereditary: *E.M.J.*, 1906, xix. 99.

Capacity, Cranial: *R.N.P.* 1911, ix. 54 *refs.*—Cerebellum: *B.M.J.* 1910, i. 497, 626.—Cerebellum, Cysts of: *F.Z.* 1910, Bd. 4, s. 372.—Cerebro-spinal Fluid: *E.M.J.* 1906, xix. 429; *R.N.P.* 1907, v. 539; *B.M.J.* 1909, i. 1352; *L.* 1910, i. 1056., 1910, ii. 1, 79; *Q.J.M.* 1907, No. 2, 109., 1909-10, No. 10, p. 152.—Chorea: *J.P. and B.* 1910, xiv. 446.—Chorea, Tetanoid: *R.N.P.* 1906, iv. 249.—Cysticercus Cellulosae: *R.N.P.* 1906, iv. 272.—Cortex, Histopathology of: *M.m.W.* 1908, ii. 2319.—Concussion, Spinal: *R.N.P.* 1910, viii. 271.—Cranial Capacity: *R.N.P.* 1911, ix. 54 *refs.*

Degenerations of the Spinal Cord, Subacute combined: *J.A.M.A.* 1908, i. 1109.—Delayed Apoplexy, Traumatic: *M.m.W.* 1907, i. 214; *L.* 1909, ii. 1339 *refs.*; *R.N.P.* 1910, viii. 277.—Diabetes Mellitus: *R.N.P.* 1907, v. 550.

Embryoma: *R.N.P.* 1906, iv. 338.—Encephalitis: *F.Z.* 1910, Bd. 5, s. 533 *refs.*; *R.N.P.* 1907, v. 89; *L.* 1909, i. 523.—Ependymitis: *A.M.E.* 1909, xxi. 458.—Epilepsy: *B.M.J.* 1910, i. 733, 803, 866; *L.* 1909, ii. 131; *M.m.W.* 1907, i. 894., 1908, ii. 2316.

General Paralysis: *R.N.P.* 1906, iv. 73, 169, 258, 537, 616, 813., 1907, v. 455., 1909, vii. 1, 379; *L.* 1909, i. 1047., ii. 209; in Childhood: *J.A.M.A.* 1908, ii. 1946; *E.M.J.* 1906, xix. 218.—Gumma, Pituitary: *R.N.P.* 1910, viii. 344.—Glycogen in Pituitary and Central Nervous System: *Z.B.* 1909, Bd. 45, s. 38;

Haemorrhage: *E.M.J.* 1909, N.S. ii. 129; Ditto from Obliterative Arteritis: *R.N.P.* 1906, iv. 407.—Hemiplegia, Double: *R.N.P.* 1906, iv. 182.—Heredity: *L.* 1910, ii. 1057.

Lymphatics of Spinal Cord: *R.N.P.* 1911, ix. 350; *J.P. and B.* 1911, xv. 169.—

- Lymphogenous Infection: *R.N.P.* 1907, v. 345., 1910, viii. 721.—Leptothrix Infections: *R.N.P.* 1908, vi. 631.—Localization: *L.* 1910, i. 905, 980, 1047.
- Macrocephaly: *R.N.P.* 1909, vii. 437.—Meningism: *M.m.W.* 1910, ii. 1984 (Schottmuller).
- Meningitis, Actinomycotic:** *J.P. and B.* 1910, xiv. 164.—Meningitis, B. anthracis: *R.N.P.* 1910, viii. 521 refs.; *J.P. and B.* 1909, xiii. 251.—Meningitis, *Bacillus coli immobilis*: *M.m.W.* 1907, i. 617.—Ditto, B. enteritidis: *J.P. and B.* 1909, xiii. 251.—Ditto, Epidemic Cerebro-Spinal: *B.M.J.* 1907, i. 387., 1908, ii. 1334; *L.* 1909, i. 829; *E.M.J.* 1908, N.S. i. 306; *R.N.P.* 1907, v. 249, 593, 686; *L.* 1908, i. 769., ii. 525; *M.m.W.* 1908, i. 791 (histology); 1908, ii. 914; *J.P. and B.* 1908, xii. 442, 456; *J.E.M.* 1911, xiv. 141.—Changes in Central Nervous System in Epidemic Cerebro-Spinal Meningitis: *Z.B.* 1910, Bd. 47, s. 282.—Ditto, Gonococcal: *R.N.P.* 1909, vii. 75.—Ditto, Influenzal: *L.* 1910, i. 1677; *A.J.M.Sc.* 1909, vol. 137, p. 74 ref.; *J.P. and B.* 1910, xiv. 615.—Ditto, Leptothrix: *R.N.P.* 1908, vi. 631.—Ditto, Pneumococcal: *B.M.S.J.* 1911, v. 165, p. 174; *M.m.W.* 1910, i. 1332.—Ditto, Serous: *A.J.M.Sc.* 1910, vol. 139, p. 542 refs.; *J.H.H.R.* 1904, xii. 382.—Ditto, Serous, Circumscribed Spinal: *A.J.M.Sc.* 1909, vol. 137, p. 95., 1910, vol. 140, p. 719 refs.—Ditto, Syphilitic: *V.A.* 1911, Bd. 204, s. 453.—Ditto, Tuberculous: *F.Z.* 1910, Bd. 5, s. 264., 1910-11, Bd. 6, s. 262.—Ditto, Typhoid: *J.H.H.R.* 1904, xii. 379 (histology), 411; *A.J.M.Sc.* 1908, vol. 135, p. 240; *J.A.M.A.* 1911, i. 882; *J.M.R.* 1908, xix. 513; *M.m.W.* 1908, i. 1009; *J.P. and B.* 1909, xiii. 251.—Pachymeningitis acuta and Meningism: *M.m.W.* 1910, ii. 1984.—Meningitis and Trauma: *M.m.W.* 1911, ii. 1545.
- Meningocele with Teratoma:** *M.m.W.* 1907, i. 569.—Meningocele: *F.Z.* 1909, Bd. 3, s. 358.—Microcephaly: *R.N.P.* 1909, vii. 437.—Motor Area, The: *B.M.J.* 1909, ii. 125.—Motor Cells, Changes following Injuries of Nerves: *Z.B.* 1908, Bd. 44, s. 495.—Multiple Sclerosis: *M.m.W.* 1907, ii. 2238.—Muscular Atrophy, Progressive Spinal: *L.* 1911, i. 1481.—Myelitis: *R.N.P.* 1906, iv. 401, 488; *L.* 1910, ii. 1531.—Myelitis, Compression: *B.M.S.J.* 1911, v. 165, p. 211.—Myelitis, Purulent: *V.A.* 1910, Bd. 200, s. 461.—Myoclonus Epilepticus: *R.N.P.* 1906, iv. 19., 1907, v. 532.
- Nerve Degeneration and Regeneration: *B.M.J.* 1907, i. 1041, 1111.—Neurone Doctrine: *B.M.J.* 1909, ii. 1389.—Neuronophagy: *R.N.P.* 1909, vii. 587.—Paralysis Agitans: *R.N.P.* 1906, iv. 689.—Paralysis, Landry's Acute Ascending: *R.N.P.* 1906, iv. 106., 1908, vi. 275.—Sclerosis, Multiple: *M.m.W.* 1907, ii. 2238.—Paraplegia, Spastic: *A.J.M.Sc.* 1909, vol. 138, p. 885 refs.; *J.A.M.A.* 1909, i. 1427.—Pernicious Anaemia, Spinal Cord in: *A.J.M.Sc.* 1910, vol. 140, p. 563, refs.—Pituitary (see also under Ductless Glands): *M.m.W.* 1910, ii. 1485; *J.A.M.A.* 1909, ii. 97, 249, 1001, 1704.—Infundibular Cysts: *V.A.* 1910, Bd. 199, s. 542; Glycogen: *Z.B.* 1909, Bd. 45, s. 38; Gumma: *R.N.P.* 1910, viii. 344.—Pituitary Tumours in Acromegaly and Corpulence: (Kritische Rundschau): *F.Z.* 1910, Bd. 5, s. 351, 587 (see also Tumours of Central Nervous System).—Plasma Cells in Tuberculous Meningitis: *F.Z.* 1910, Bd. 5, s. 264.—Poliomyelitis, Acute: *A.J.M.Sc.* 1908, vol. 135, p. 647 ref.; *J.A.M.A.* 1909, ii. 1639, 1913., 1910, i. 535, 1780, 1925; *R.N.P.* 1910, viii. 70., 1911, ix. 10; *B.M.J.* 1910, i. 221., 1911, i. 612; *L.* 1908, i. 484; *J.E.M.* 1911, xiv. 116; *M.m.W.* 1909, ii. 2353; (Beneke) *M.m.W.* 1910, i. 176.—Poliomyelitis, Experimental: *M.m.W.* 1910, i. 229.
- Sleeping Sickness: *R.N.P.* 1906, iv. 112; *L.* 1909, ii. 1193.—Softenings in Cord, in Pancreatic Tumour: *R.N.P.* 1911, ix. 297.—Spina Bifida: *J.P. and B.* 1909, xiii. 51.—Spina Bifida, in Dorsal Region: *J.P. and B.* 1910, xiv. 399.—Syphilis, Cerebro-Spinal: *M.m.W.* 1907, i. 1164; *B.M.J.* 1909, i. 454, 524.—Spinal Disease, Ac. Syphilitic: *A.J.M.Sc.* 1909, vol. 137, p. 216 refs.—Syringomyelia: *E.M.J.* 1906, xx. 467; *V.A.* 1909, Bd. 196, s. 385; *J.M.R.* 1908, xviii. 127, 149; *M.m.W.* 1908, ii. 2188; *J.P. and B.* 1906, xi. 364.
- Tabes Dorsalis:** *R.N.P.* 1907, v. 169, 455., 1908, vi. 5., 1909, vii. 522; *B.M.J.* 1908, i. 669; *L.* 1909, i. 749., 1908, i. 1401; *A.J.M.Sc.* 1908, vol. 136, p. 206 ref.; *J.A.M.A.* 1908, i. 1966; *Q.J.M.* 1909-10, No. 9, p. 27.—Tabetic Amyotrophy: *R.N.P.* 1911, ix. 401.—Thomsen's Dis.: *Montr. Med. J.* 1908, Nov.
- Tumours:** *R.N.P.* 1908, vi. 577, 677., 1910, viii. 325; *L.* 1910, i. 90; ii. 65., 1911, i. 222; *J.A.M.A.* 1909, ii. 1150, 2078., 1910, i. 579; *B.M.S.J.* 1909, vol. 161, p. 71.—Angioma of Brain: *F.Z.* 1910, Bd. 4, s. 482; *M.m.W.* 1911, i. 411.—Angioma of Pons: *M.m.W.* 1908, ii.

- 1646.—Cauda Equina, Tumours of : *A.J.M.Sc.* 1908, vol. 135, p. 365 ref.—Cerebellar Tumour : *J.A.M.A.* 1911, i. 1180.—Cerebello-pontine Tumour : *J.A.M.A.* 1910, i. 1600 ; *Über Geschwülste der hinteren Schädelgrube u.s.w.* (Folke Henschen.) Jena, 1910.—Cholesteatoma : *F.Z.* 1910-11, Bd. 6, s. 207 ; *Z.B.* 1910, Bd. 47, s. 392.—Chordoma : *A.M.E.* 1910, xxii. p. 703.—Embryoma : *R.N.P.* 1906, iv. 338.—Embryonal Ependymal Cyst : *Z.B.* 1910, Bd. 47, s. 248.—Endothelioma of Dura Mater : *J.A.M.A.* 1911, i. 1180 ; *V.A.* 1910, Bd. 200, s. 141 ; of Dura Mater Spinalis : *Z.B.* 1910, Bd. 49, s. 86.—Ganglia in Cancer, Posterior Root : *B.M.J.* 1907, ii. 140.—Glioma : *F.Z.* 1910, Bd. 5, s. 469 ref.—Glioma of Corpus Callosum : *M.m.W.* 1910, i. 462.—Glioma (Degenerations) : *F.Z.* 1911, Bd. 7, s. 351 ref.—Glioma, Reactive : *M.m.W.* 1909, ii. 2051.—Lipoma of Pia Mater : *V.A.* 1911, Bd. 203, s. 165.—Lipoma, Tuber Cinereum : *V.A.* 1911, Bd. 203, s. 157, 161.—Neuroglioma, Congenital : *F.Z.* 1910, Bd. 5, s. 255.—Pineal Tumour : *V.A.* 1910, Bd. 200, s. 122.—Pituitary Tumours : *R.N.P.* 1909, vii. 225 (of Duct), 445 ; *L.* 1910, ii. 1129 ; see also Pituitary, under Ductless Glands.—Sarcoma of Dura Mater : *V.A.* 1910, Bd. 201, s. 297.—Sarcoma of Spinal Meninges, Primary Melanotic : *M.m.W.* 1907, i. 725.—Tumour Spinal Cord : *R.N.P.* 1906, iv. 488.—Tumour of Spinal Cord, Tuberculous : *J.A.M.A.* 1909, ii. 1911.—Tuberosc Sclerosis : *V.A.* 1910, Bd. 202, s. 358 ; *Q.J.M.* 1910-11, No. 13, p. 43.—Ventricles, Tumours of : *V.A.* 1911, Bd. 204, s. 230 ; *A.J.M.Sc.*, 1910, vol. 140, p. 270 ; *A.M.E.* 1910, xxii. 379 ; *M.m.W.* 1909, ii. 2168.
- Neuritis, familial Hypertrophic : Neuritis, Optic : Neuro-fibromatosis : Neuroma, Multiple : see under Nerves.
- Noma : *A.J.M.Sc.* 1910, vol. 139, p. 705 refs. ; *J.A.M.A.* 1911, i. 1449 refs.
- Ochronosis : *Q.J.M.* 1907-8, No. 2, p. 199, refs., 1909-10, No. 12, p. 329 ; *V.A.* 1908, Bd. 198, s. 275 ; *Z.B.* 1910, Bd. 48, s. 346.
- Occupation Diseases : *J.A.M.A.* 1909, ii. 1873.
- Omentum, Endothelioma : *J.A.M.A.* 1911, i. 1871.
- Ossification, Heterotopic : *A.M.E.* 1910, xxii. 762.
- Pancreas**
- Abscess : *L.* 1909, ii. 17.—Aberrant Pancreas : *F.Z.* 1910, Bd. 4, s. 167.—Accessory Pancreas : *V.A.* 1909, Bd. 198, s. 392.—Adenoma of Is. of Langerhans : *J.A.M.A.* 1908, ii. 1075.—Atrophy : *J.P. and B.* 1906, xi. 458.—Cysts, Traumatic : *M.m.W.* 1910, ii. 2529.—Diabetes Mellitus : *V.A.* 1911, Bd. 204, s. 175 ; *L.* 1908, ii. 1499 ; *J.H.H.B.* 1909, xx. 265 ; *J.P. and B.* 1906, xi. 50, 371.—Diseases of Pancreas : *B.M.J.* 1908, i. 1153.—Pancreatitis : *A.M.E.* 1910, xxii. p. 860.—Acute Pancreatitis : *E.M.J.* 1910, N.S. v. 217 ; *A.J.M.Sc.* 1908, vol. 138, p. 180 ; *J.A.M.A.* 1908, i. 1162 ; *J.M.R.* 1907-8, xvii. 35.—Chronic Pancreatitis : *L.* 1911, ii. 221 ; *A.J.M.Sc.* 1910, vol. 140, 330 refs. ; *J.M.R.* 1909, xxi. 451.—Pancreas, Pathology (Ssobolew) : *Z.B.* 1910, Bd. 47, s. 399.—Sarcoma : *V.A.* 1908, Bd. 193, s. 395.—Internal Secretion : *J.A.M.A.* 1911, i. 655.—Structure and Function : *B.M.J.* 1909, ii. 681 ; *M.m.W.* 1907, ii. 2222, 2652.
- Parathyroids : see under Ductless Glands.
- Parotid Tumours : *V.A.* 1909, Bd. 193, s. 472 refs., Bd. 197, s. 472.
- Pellagra : See under Poisons.
- Perithelioma and Endothelioma : *B.M.J.* 1907, ii. 1400 ; *J.A.M.A.* 1908, ii. 1227 ; *L.* 1911, i. 17.
- Peritoneum, Endothelioma : *J.P. and B.* 1908, xii. 267.—Peritonitis, Gonococcal : *M.m.W.* 1910, ii. 1886.—Pneumococcal : *B.M.J.* 1909, ii. 756 ; *A.J.M.Sc.* 1911, vol. 141, p. 864 refs. ; *Q.J.M.* 1911, No. 14, p. 205 ; *J.H.H.B.* 1911, xxii. 219.—Retro-peritoneal Tumour : *L.* 1908, ii. 520.
- Photography, Stereo- : *J.M.R.* 1907-8, xvii. 487.
- Pituitary : see under Ductless Glands, and Acromegaly.
- Plasma Cells : *A.M.E.* 1909, xxi. 190 ; *R.N.P.* 1910, viii. 151, 721 ; *F.Z.* 1910, Bd. 5, s. 264. (See also Myeloma, under Tumours.)
- Poisons, Effects of**
- Arsenious Acid : *E.M.J.* 1906, xix. 26 ; *Z.B.* 1908, Bd. 44, s. 487.—Atoxyl : *M.m.W.* 1909, i. 972 refs.
- Benzene : *M.m.W.* 1909, i. 11.—Benzol Poisoning : *M.m.W.* 1907, ii. 2377 ; *J.H.H.B.* 1910, xxi. 33.—Bi-nitrobenzene : *L.* 1908, ii. 717.—Bismuth Subnitrate : *J.A.M.A.* 1909, i. p. 14 full refs.
- Carbolic Acid : *Z.B.* 1908, Bd. 44, s. 471.—Carbolic Acid Poisoning, Renal changes : *Z.B.* 1910, Bd. 47, s. 126.—Chloroform Poisoning, Delayed : *S.M.S.J.*¹ Aug., 1904 ; *B.M.J.* 1906, i.

¹ Scot. Med. and Surg. Journal.

- 1142 (refs.); *L.* 1908, *i.* 911; *L.* 1908, *i.* 623, 625, 626, 993; *A.M.E.* 1909, *xxi.* p. 443; *J.H.H.B.* 1909, *xx.* 278.—Corrosive Poisons, Action of: *Z.B.* 1908, *Bd.* 44, *s.* 458.—Corrosive Sublimite: *Z.B.* 1908, *Bd.* 44, *s.* 461.
- Hydrazine: *J.E.M.* 1908, *x.* 457.
- Illuminating Gas: *A.J.M.Sc.* 1909, *vol.* 137, *p.* 89.
- Lysol: *Z.B.* 1908, *Bd.* 44, *s.* 471.
- Meat Poisoning: *B.M.J.* 1909, *i.* 1171; *M.m.W.* 1908, *i.* 156., 1910, *i.* 1227.—Acute Mercurial P.: *L.* 1911, *ii.* 297.
- Melanosis of Mucous Membrane of Large Intestine in Chronic Metallic poisoning: *Berl. klin. Woch.* 1911, *i.* 840, 884.
- Nitric Acid: *B.M.J.* 1908, *ii.* 1679.—Nitrite Poisoning: *Z.B.* 1910, *Bd.* 49, *s.* 457.
- Pellagra: *J.A.M.A.* 1908, *ii.* 397, 1076., 1909, *ii.* 274, 1087, 1556., 1910, *i.* 859., 1911, *i.* 246, 734; *B.M.J.* 1910, *i.* 327; *A.J.M.Sc.* 1910, 139, 1., 1911, *vol.* 141, *p.* 94 (sectio.), *illustr. ref.*—Pellagra, Histology: *J.E.M.* 1911, *xiii.* 98; *J.H.H.B.* 1909, *xx.* 193.—Phosphorus: *L.* 1910, *i.* 163; *M.m.W.* 1908, *ii.* 436.—Potass. Bichromate: *E.M.J.* 1907, *xxii.* 235; *L.* 1910, *i.* 297.
- Quick-silver Poisoning: *M.m.W.* 1907, *ii.* 2138 *ref.*
- Savin: *E.M.J.* 1906, *xix.* 530.—Caustic Soda: *Z.B.* 1908, *Bd.* 44, *s.* 482.
- Polyps, Cardiac: *see under* Heart, Endocardium.
- Polyserositis: *M.m.W.* 1907, *i.* 572.
- Purpura Haemorrhagica: *J.H.H.B.* 1910, *xxi.* 33; *A.J.M.Sc.* 1911, *vol.* 142, *p.* 36.
- Purpura, Henoch's: *L.* 1909, *i.* 534, *ii.* 527.
- Raynaud's Disease: *A.J.M.Sc.* 1908, *vol.* 136, *p.* 560; *M.m.W.* 1908, *ii.* 2384; *F.Z.* 1910, *Bd.* 5, *s.* 571 *refs.*
- Regeneration of Nerves: *Z.B.* 1908, *Bd.* 44, *s.* 574.
- Reproductive Organs**
- Hermaphroditism: *F.Z.* 1909, *Bd.* 3, *s.* 339, 661, 829.—Pseudohermaphroditismus masculinus: *M.m.W.* 1908, *ii.* 918, 1527.—Sterility: *L.* 1910, *ii.* 705.
- Male Organs, External Organs.**—Prepuce: *B.M.J.* 1907, *i.* 1408., 1910, *i.* 137.—Gangrenous Balanitis: *J.A.M.A.* 1909, *i.* 1474.—Penis: *B.M.J.* 1907, *ii.* 725., 1908, *ii.* 1804; *L.* 1911, *ii.* 217.—Cancer of Scrotum: *B.M.S.J.* 1910, *vol.* 163, *p.* 755, 792.—Tumours of Penis, Scrotum, Testicle and Cord: *B.M.S.J.* 1909, *vol.* 161, *p.* 538.—Varicocele: *B.M.S.J.* 1910, *vol.* 162, *p.* 350.
- Prostate.—Hypertrophy: *V.A.* 1911, *Bd.* 204, *s.* 220; *L.* 1910, *ii.* 294.—Calculi: *L.* 1909, *i.* 1453; *J.A.M.A.* 1908, *i.* 679.—Cancer: *J.A.M.A.* 1909, *ii.* 272; *J.H.H.B.* 1909, *xx.* p. 200 (Bone Metastases).—Prostate, Myxosarcoma of: *B.M.J.* 1909, *ii.* 754.
- Funiculitis: *L.* 1909, *i.* 227.—Spermatocystitis—pyaemia: *M.m.W.* 1911, *i.* 1014.
- Epididymis and Testis.—Testicle: *B.M.J.* 1907, *ii.* 716; *L.* 1910, *ii.* 460, 874, 1407.—Testis, Carcinoma Myxomatodes, in Infant: *J.P. and B.* 1910, *xiv.* 522.—Epididymitis and Orchitis in Typhoid: *J.A.M.A.* 1908, *i.* 1014.—Epididymitis and Bac. Coli Communis: *M.m.W.* 1909, *ii.* 2583.—Fibrosis Testis: *V.A.* 1910, *Bd.* 201, *s.* 108.—Teratoma of Testis: *Z.B.* 1908, *Bd.* 43, *s.* 89; *F.Z.* 1908–9, *Bd.* 2, *s.* 232; *A.M.E.* 1909, *xxi.* p. 41.—Semen, Reactions for: *E.M.J.* 1908, *xxiii.* 410.
- Female Organs.**—Bartholin's Gland, Cancer of: *E.M.J.* 1908, *xxiii.* 149.—Elephantiasis: *L.* 1909, *i.* 538.—Granuloma Pudendae: *L.* 1910, *ii.* 1128.—Kraurosis Vulvae: *B.M.J.* 1909, *ii.* 1739.—Dermoid Cyst of Canal of Nuck: *B.M.S.J.* 1908, *vol.* 159, *p.* 242 *ref.*
- Vaginal, Adenoma: *E.M.J.* 1911, *N.S.* *vi.* 577, 600.—Sarcoma: *A.J.M.Sc.* 1911, *vol.* 141, *p.* 570 *ref.*
- Eclampsia, Pathology: *J.A.M.A.* 1909, *ii.* 1358., 1911, *i.* 5, 11.—Puerperal Sepsis: *M.m.W.* 1910, *ii.* 1817., 1911, *i.* 557.—Puerperal Uterus, Bacteriology of: *A.J.M.Sc.* 1908, *vol.* 136, *p.* 255; *M.m.W.* 1908, *ii.* 507.
- Uterus. — Malformations: *E.M.J.* 1908, *N.S.* *i.* 535.—Endometrium: *J.A.M.A.* 1909, *ii.* 1155., 1911, *i.* 169 *illustr.*—Endometritis: *F.Z.* 1911, *Bd.* 7, *s.* 150 *lit.*—Hernia of Uterus: *B.M.J.* 1909, *ii.* 1265.—Hydatid, Uterine: *L.* 1911, *i.* 1700.—Inversion of Uterus: *L.* 1908, *i.* 98, 119.
- Tumours of Uterus.—Adenomyoma Uteri: *B.M.J.* 1909, *i.* 198, 201; *J.A.M.A.* 1908, *i.* 107.—Squamous Epithelium in Uterine Cavity: *F.Z.* 1911, *Bd.* 8, *s.* 1.—Uterine Fibroids: *E.M.J.* 1908, *N.S.* *i.* 398., 1910, *N.S.* *v.* 133.—Cervical Fibroids: *E.M.J.* 1907, *xxi.* 297.—Fibroids with Perithelioma: *B.M.J.* 1908, *ii.* 1543.—Red Degeneration of Fibroids: *B.M.J.* 1909, *i.* 1471; *A.J.M.Sc.* 1911, *vol.* 141, *p.* 781.—Perithelioma of Uterus: *J.A.M.A.* 1908, *ii.* p. 1227.—Rhabdomyosarcoma of Uterus: *J.M.R.* 1909, *xx.* 297.

Placental Syphilis : *J.H.H.B.* 1908, *xix.* 326.

Tubes.—Salpingitis, Gonococcal : *J.M.R.* 1910, *xxiii.* 151; Gonococcal Salpingitis, Histology : *Z.B.* 1909, *Bd.* 45, *s.* 341.

Ovary.—Actinomycosis of Ovary : *L.* 1909, *i.* 758.—Ovarian Pregnancy : *B.M.J.* 1910, *i.* 1276; *J.A.M.A.* 1910, *i.* 461; *B.M.S.J.* 1911, *vol.* 164, *p.* 264.—Papillary Ovarian Cysts : *B.M.J.* 1910, *ii.* 1235.—Ovarian Dermoids : *Z.B.* 1908, *Bd.* 43, *s.* 356., 1909, *Bd.* 45, *s.* 1.—Perithelioma (Cylindroma) : *F.Z.* 1911, *Bd.* 8, *s.* 104.—Melanotic Sarcoma, Ovary : *J.H.H.B.* 1909, *xx.* 314.—Malignant Tumour of Corpus luteum : *B.M.J.* 1909, *ii.* 1032.

Respiratory System

Amyloid Degeneration of Respiratory Tract : *Z.B.* 1908, *Bd.* 43, *s.* 239.

Upper Air Passages.—Malformations of Nose, and Nasal Cavities : *B.M.J.* 1909, *ii.* 366.

Anginas, Pseudo-membranous : *J.A.M.A.* 1909, *ii.* 373.—Common Colds and Sore Throats : *B.M.J.* 1909, *ii.* 195, 534, 1338; *L.* 1908, *ii.* 1589, 1814; *B.M.S.J.* 1910, *vol.* 163, *p.* 58.—Septic Throats : *L.* 1908, *i.* 924., 1908, *ii.* 1814; *J.A.M.A.* 1909, *i.* 1751.—Pneumococcus Invasion of Throat : *B.M.J.* 1909, *i.* 1525.

Larynx, Keratosis : *E.M.J.* 1906, *xix.* 344.—Larynx, Tuberculosis and Syphilis of : *B.M.J.* 1907, *ii.* 952; *A.J.M.Sc.* 1908, *vol.* 136, *p.* 172.—Larynx in Typhoid Fever : *A.J.M.Sc.* 1908, *vol.* 135, *p.* 232 *refs.*; Larynx, Ulceration.—Fusiform Bacilli : *M.m.W.* 1907, *i.* 832.

Tracheal Scleroma : *A.J.M.Sc.* 1909, *vol.* 137, *p.* 264.—Ossification in Mucous Membrane of Trachea : *V.A.* 1910, *Bd.* 200, *s.* 433.

Lungs and Bronchi.—Accessory Lungs : *F.Z.* 1910–11, *Bd.* 6, *s.* 27.—Actinomycosis : *B.M.J.* 1908, *i.* 554.—Anthrax, Bronchial : *J.P. and B.* 1910, *xiv.* 556.—Asthma, Bronchial, Path. Anat. : *V.d.d.p.G.* 1909, *s.* 107.

Bronchial Glands, Relation between Tuberculosis of, and Pulmonary Tuberculosis : *F.Z.* 1910, *Bd.* 4, *s.* 203.—Bronchial Obstruction : *L.* 1910, *ii.* 1674.—Bronchiectasis : *J.H.H.B.* 1908, *xix.* 230.—Bronchiectasis, Bone Formation in : *F.Z.* 1910–11, *Bd.* 6, *s.* 461.—Bronchiectasis in Children : *Q.J.M.* 1908–9, *No.* 7, *p.* 251.—Bronchitis, Plastic : *L.* 1908, *i.* 489.—Broncho-pneumonia : *E.M.J.* 1906,

xx. 497.—Broncho-pneumonia, Bacteriology : *J.P. and B.* 1910, *xiv.* 160.

Carcinoma of Lung, Primary : *A.M.E.* 1909, *xxi.* *p.* 87; *A.J.M.Sc.* 1909, *vol.* 137, *p.* 857 *refs.*; *V.A.* 1910, *Bd.* 202, *s.* 38.—Cavities in Young, Tuberculous : *A.J.M.Sc.* 1909, *vol.* 138, *p.* 79.—Cerebral Abscess following Pulmonary Disease : *L.* 1909, *ii.* 843.—Chronic Disease in Children : *L.* 1909, *i.* 28.—Contusion of Lung : *B.M.J.* 1909, *i.* 139.—Corpora Amylacea : *V.A.* 1909, *Bd.* 196, *s.* 221., 1910, *Bd.* 202, *s.* 134.

Emphysema, Acute : *J.P. and B.* 1910, *xiv.* 550.

Gangrene of Lung : *Z.B.* 1910, *Bd.* 48, *s.* 70.—Glanders, Chronic : *L.* 1909, *ii.* 1201 *refs.*

Honeycomb Lung : *J.P. and B.* 1910, *xiv.* 550.

Interstitial Pneumonia, Chronic : *E.M.J.* 1910, *N.S.* *v.* 199.

Metastases, Lungs, Retrograde : *A.M.E.* 1910, *xxii.* 363.

Plague, Pneumonic : *B.M.J.* 1910, *ii.* 1489.—Pneumococcus Infections in Children : *B.M.J.* 1908, *ii.* 367., 1910, *i.* 1036.—Pneumonia caused by Friedländer's Bacillus : *M.m.W.* 1908, *i.* 833.—Pneumonia in Children, Giant Cells : *Z.B.* 1910, *Bd.* 48, *s.* 263.

Syphilis of Lung : *J.P. and B.* 1910, *xv.* 45.

Tuberculosis, Pulmonary : *B.M.J.* 1908, *i.* 545., *ii.* 61., 1909, *i.* 387.—Relation to Tuberculosis of Bronchial Glands : *F.Z.* 1910, *Bd.* 4, *s.* 203.—Pulmonary Tuberculosis, Intestinal Infection in : *F.Z.* 1910, *Bd.* 5, *s.* 395 *refs.*, *s.* 447 *ref.*—Tuberculosis, Traumatic : *B.M.J.* 1910, *i.* 1153.—Tumours of Lungs and Pleurae : *M.m.W.* 1910, *i.* 452 *full ref.*

Pleura.—Carcinoma of Pleura, Primary : *J.H.H.B.* 1911, *xxii.* 289.—Chylothorax : *M.m.W.* 1907, *ii.* 1876.—Empyema : *E.M.J.* 1908, *xxiii.* 199; *J.A.M.A.* 1909, *i.* 266; Empyema in Lobar Pneumonia : *J.H.H.B.* 1910, *xv.* *p.* 167.—Interlobular Exudates : *B.M.S.J.* 1911, *vol.* 165, *p.* 124 *refs.*—Pleural Lymphatics, Diseases of : *F.Z.* 1910–11, *Bd.* 6, *s.* 1.—Pleura. — New - Growths and Tuberculosis : *A.M.E.* 1910, *xxii.* *p.* 237.—Primary Sarcoma of Pleura : *V.A.* 1908, *Bd.* 193, *s.* 92 *refs.*, 1909, *Bd.* 196, *s.* 341; *B.M.S.J.* 1908, *vol.* 158, *p.* 691.—Sarcoma of Pleura : *A.M.E.* 1909, *xxi.* *p.* 221.—Pleura.—Tuberculosis and New - Growths : *A.M.E.* 1910, *xxii.* *p.* 237.—Tumours : *M.m.W.* 1910, *i.* 452 *full refs.*

- Pneumothorax: *J.H.H.R.* 1903, *xi*, pp. 1-150 (Etiology and Pathology, p. 204).
- Rodent Ulcer: *J.P. and B.* 1908, *xii*, 5; *A.J.M.Sc.* 1908, vol. 135, p. 719 refs.; (multiple) *L.* 1908, *ii*, 1133.
- Russell's Fuchsin Bodies: *V.A.* 1910, *Bd.* 199, s. 482 full refs.; *J.E.M.* 1910, *xii*, 533.
- Sacral Tumours: See under Tumours.
- Salivary Glands, Tumours of: *F.Z.* 1910, *Bd.* 4, s. 187.
- Sciatica: *R.N.P.* 1909, *vii*, 305.
- Scurvy: *L.* 1908, *i*, 1838; *V.A.* 1908, *Bd.* 194, s. 151.
- Serous Cavities, Free Bodies in: *A.M.E.* 1910, *xxii*, 507 refs.
- Shock, Cytology: *J.M.R.* 1910, *xxii*, 331.
- Skin.**—Bone - Formation, Heterotopic: *V.A.* 1910, *Bd.* 200, s. 395., 1911, *Bd.* 203, s. 131.—Carcinoma, X-ray: *J.M.R.* 1909, *xxi*, 357.—Congenital Syphilitics, Rhagades and Papulo-erosive Erythema: *A.M.E.* 1910, *xxii*, 256.—Cutaneous Syphilides: *J.A.M.A.* 1910, *i*, 18.—Darier's Disease: *E.M.J.* 1907, *xxi*, 32.—Dermatitis, Brown-tail Moth: *J.A.M.A.* 1909, *ii*, 1463.—Dermatitis, X-ray (Histology): *J.M.R.* 1909, *xxi*, 415.—Epithelioma, Squamous, following Injury: *M.m.W.* 1910, *i*, 137.—Fibroma, Multiple: *J.A.M.A.* 1909, *i*, 945; *V.A.* 1911, *Bd.* 203, s. 66.—Gonococcal Ulcer: *M.m.W.* 1910, *ii*, 1552.—Ichthyosis, Foetal: *A.M.E.* 1910, *xxii*, 138 refs.—Keloid: *J.A.M.A.* 1909, *ii*, 1276.—Lupus Erythematosus: *L.* 1908, *ii*, 1271.—Lupus Vulgaris: *M.m.W.* 1910, *i*, 1165.—Melanoma: *J.A.M.A.* 1910, *i*, 91.—Moles and Warts, Malignant Degeneration: *J.A.M.A.* 1908, *i*, 1236.—Molluscum Contagiosum: *J.A.M.A.* 1909, *ii*, 671.—Mycosis Fungoides: *B.M.J.* 1908, *ii*, 1255.—Pemphigus Neonatorum: *J.A.M.A.* 1909, *ii*, 358.—Rhagades: *A.M.E.* 1910, *xxii*, 256.—Scarlet Fever, Histology of Eruption: *Z.B.* 1910, *Bd.* 47, s. 455.—Tuberculides in Infants: *M.m.W.* 1908, *i*, 107.—X-ray Dermatitis, and Carcinoma: see above.—Xeroderma Pigmentosum: *J.M.R.* 1909, *xxi*, 331.—Yaws: *J.P. and B.* 1908, *xii*, 426., 1909, *xiii*, 248.
- Spleen.**—Banti's Disease: *Gazz. degli Osped.*, Jan. 19, 1908; *M.m.W.* 1909, *ii*, 2318. See also Splenic Anaemia and Splenomegaly.—Cysts, Multiple: *V.A.* 1908, *Bd.* 194, s. 306.—Endothelioma: *Z.B.* 1909, *Bd.* 46, s. 241.—Sarcoma, Primary: *J.A.M.A.* 1910, *i*, 453.—Splenic Anaemia: *A.J.M.Sc.* 1908, vol. 136, p. 157 ref.; *L.* 1909, *i*, 230., 1910, *i*, 1429.—Splenic Enlargements: *B.M.J.* 1908, *ii*, 1151.—Splenomegaly: *Q.J.M.* 1907, *i*, 11; *L.* 1909, *i*, 1243; *A.J.M.Sc.* 1909, vol. 137, p. 849.—Splenomegaly (Gaucher type): *Z.B.* 1909, *Bd.* 46, s. 241., 1910, *Bd.* 48, s. 598.—Torsion, Acute: *L.* 1909, *ii*, 917.
- Status Lymphaticus: *L.* 1908, *ii*, 1870., 1910, *i*, 1347; *B.M.J.* 1910, *i*, 103; *B.M.S.J.* 1911, vol. 164, pp. 115, 503.
- Stereo-photography: *J.M.R.* 1907-8, *xvii*, 487.
- Sub-phrenic Abscess: *B.M.J.* 1908, *i*, 371., 429.
- Suprarenal Bodies: see under Ductless Glands.
- Sympathetic, Ganglioneuroma of: *Z.B.* 1909, *Bd.* 46, s. 403.—Glioma: *F.Z.* 1909, *Bd.* 3, s. 317.
- Syphilis.—Congenital: *M.m.W.* 1910, *i*, 570. See also different Systems and Organs.—Placental: *J.H.H.B.* 1908, *xix*, 326.
- Tetany (and Parathyroids): *J.H.H.B.* 1908, *xix*, 91., 1909, *xx*, 269; *J.M.R.* 1909, *xxi*, 135; *V.A.* 1911, *Bd.* 203, s. 282, 321; *A.J.M.Sc.* 1911, vol. 141, p. 558 full refs.; *J.A.M.A.* 1911, *i*, 452 (in adults); *M.m.W.* 1911, *ii*, 1709.
- Thoracic Duct, Tubercle Bacilli in: *F.Z.* 1910, *Bd.* 5, s. 423 refs.
- Thrombosis of Veins.**—Veins of Lower Extremities: *J.A.M.A.* 1909, *i*, 1319.—Ovarian Veins: *L.* 1909, *i*, 147.—Portal Vein: *V.A.* 1908, *Bd.* 192, s. 278.—Vena Cava, Inferior: *A.J.M.Sc.* 1909, vol. 137, p. 333 refs.; *L.* 1910, *ii*, 311; *J.H.H.R.* 1911, *xvi*, pp. 363-548, full refs. and abstract of 296 other cases in literature.—Vena Cava, Superior: *L.* 1911, *i*, 1345.
- Thymus and Thyroid: see under Ductless Glands.
- Trachoma: *M.m.W.* 1909, *ii*, 1580, 1950.
- Transposition of Organs: *F.Z.* 1909, *Bd.* 3, s. 393.
- Tuberculosis, Age Incidence: *M.m.W.* 1908, *i*, 322.—Acute Abdominal: *J.A.M.A.* 1909, *i*, 291.
- Tumours.**—Independent New-Growths.—Altman's Granules: *B.M.J.* 1909, *ii*, 859., 1910, *ii*, 1422.—Cancer: *B.M.J.* 1910, *ii*, 1836; *L.* 1908, *ii*, 1508; Connective Tissues: 1908, *i*, 1389 etc., 1909, *ii*, 691., 1911, *ii*, 349.—Cancer, Modern Ideas: *J.A.M.A.* 1910, *i*, 1510.—Natural Cure of Cancer: *B.M.J.* 1909, *i*, 582.—Resistance to Cancer: *J.A.M.A.* 1909, *i*, 1731.—Resistance to New-Growths: *L.* 1910, *i*, 782.—Mitoses in Non-Malignant Tumours: *V.A.* 1911, *Bd.* 204, s. 105.—Rapid Microscopic Diagnosis:

- L.* 1910, ii. 939.—Urine in Malignant Growths: *L.* 1910, ii. 450.
- Cancer, Multiple Primary: *V.A.* 1911, *Bd.* 204, s. 85.—Carcinoma Sarcomatodes, Oesophagus: *Z.B.* 1908, *Bd.* 44, s. 150.—Carcinoma, X-ray: *L.* 1909, i. 821.—Chloroma: *B.M.J.* 1907, i. 929; *J.P. and B.* 1908, xii. 111; *Q.J.M.* 1907-8, No. 3, p. 239., 1909-10, No. 9, p. 78.—Chordoma: *A.M.E.* 1910, xxi. p. 703.—Tumours of Base of Skull (Chordoma Malignum): *Z.B.* 1909, *Bd.* 46, s. 573.—Chordoma (Sacrum): *Z.B.* 1910, *Bd.* 48, s. 630.—Chorionepithelioma: *J.P. and B.* 1908, xii. 487., 1910, xiv. 282.—Chorionepithelioma in Male: *J.M.R.* 1907-8, xviii. 219; *Med. Klin. Berl.* 1908, Aug. 2; *V.A.* 1909, *Bd.* 196, s. 43.
- Desmoid Tumours, Rectus: *L.* 1910, ii. 1336.
- Embryoma of Brain: *R.N.P.* 1906, iv. 338; of Testis: *see under* Reproductive Organs.—Endothelioma: *L.* 1909, ii. 136.—Endothelioma of Peritoneum: *J.P. and B.* 1908, xii. 267.—Endothelioma, Haemangio-: *F.Z.* 1911, *Bd.* 7, s. 427 *ref.*—Endothelioma Papilliferum, Lymphagio-: *M.m.W.* 1907, ii. 1985.—Endothelioma of Lymph Glands, Syncytial: *V.A.* 1909, *Bd.* 198, s. 422.—Epithelioma, Stomach, Squamous: *B.M.J.* 1907, i. 1293.—Epithelioma, Squamous, Giant-Cells in: *J.M.R.* 1910, xxiii. 107.—Epithelioma, Benign Cystic (Tricho-epithelioma): *J.M.R.* 1908, xviii. 159.
- Fibroma of Orbit: *J.A.M.A.* 1909, ii. 27.
- Ganglioneuroma: *Z.B.* 1910, *Bd.* 47, s. 354.—Ganglioneuroma, Retroperitoneal: *M.m.W.* 1908, ii. 2488.—Glioma (degenerations): *F.Z.* 1911, *Bd.* 7, s. 351 *refs.*—Glioma, Reactive: *M.m.W.* 1909, ii. 2051.
- Hygroma: *B.M.J.* 1907, ii. 904.
- Intra-abdominal Dissemination of Cancer: *B.M.J.* 1907, i. 306.—Intra-ocular Tumours: *J.A.M.A.* 1911, ii. 192.—Intra-thoracic New Growths: *L.* 1908, ii. 359.
- Jaw Tumours: *B.M.J.* 1907, i. 1525.
- Keloid: *J.A.M.A.* 1909, ii. 1276.
- Lymphangioma: *E.M.J.* 1908, N.S. i. 207.—Lymphangioma Hypertrophicum: *F.Z.* 1910-11, *Bd.* 6, s. 360.
- Melanomas and Skin Sarcoma: *J.A.M.A.* 1909, ii. 91; *V.A.* 1908, *Bd.* 192, s. 514., 1909, *Bd.* 198, s. 62., 1910, *Bd.* 199, s. 561, 567.—Mixed Tumours of Skin, Salivary and Mucous Glands: *Z.B.* 1908, *Bd.* 44, s. 51, 88.—Multiple Tumours (Endothelioma, etc.): *J.H.H.B.* 1910, xxi. 203.—Myeloma: *J.P. and B.* 1906, xi. 59; *B.M.S.J.* 1908, vol. 158, p. 617; *V.A.* 1909, *Bd.* 197, s. 112; *F.Z.* 1909, *Bd.* 3, s. 756., 1910-11, *Bd.* 6, s. 112, 180; *L.* 1910, ii. 1403; *J.A.M.A.* 1911, i. 1092; *F.Z.* 1911, *Bd.* 7, s. 343.—Myoma, Malignant: *Z.B.* 1909, *Bd.* 45, s. 89.—Myxoma: *F.Z.* 1910, *Bd.* 4, s. 30.—Myxo-lipoma: *A.M.E.* 1909, xxi. p. 580.
- Naevi, Pigmented: *Z.B.* 1908, *Bd.* 43, s. 43.—Neurofibroma: *J.A.M.A.* 1909, i. 945; *Z.B.* 1910, *Bd.* 48, s. 1.—New-Growths in Childhood: *J.A.M.Sc.* 1909, vol. 138, p. 49.
- Odontomes: *Z.B.* 1908, *Bd.* 44, s. 311.
- Parotid Tumours: *V.A.* 1909, *Bd.* 197, s. 472.
- Perithelioma and Endothelioma: *B.M.J.* 1907, ii. 1400; *L.* 1911, i. 17; *J.A.M.A.* 1908, ii. 1227.
- Rodent Ulcer (Multiple): *L.* 1908, ii. 1133.
- Sacral Tumour: *M.m.W.* 1909, ii. 2707.
- Sacro-coccygeal Cyst: *J.A.M.A.* 1910, i. 1288 *refs.*
- Sarcoma of Mamma (Beatson): *E.M.J.* 1909, n.s. ii. 23.
- Sarcoma, Multiple Haemorrhagic: *J.A.M.A.* 1908, ii. 1205.
- Sarcoma and Trauma (Orth.): *M.m.W.* 1907, ii. 2190.
- Syncytial Endothelioma of Lymph-Glands: *V.A.* 1909, *Bd.* 198, s. 422.
- Teratoma, Mediastinal: *V.A.* 1910, *Bd.* 202, s. 272.
- Tumours, Double (varieties in same individual): *J.P. and B.* 1910, xiv. 205.

Urinary Organs

- Malformations of Urinary Apparatus: *B.M.J.* 1908, ii. 1857; *F.Z.* 1910, *Bd.* 5, s. 149; *V.A.* 1911, *Bd.* 204, s. 372.—Unilateral Absence of Urogenital System: *A.M.J.Sc.* 1908, vol. 136, p. 111 *ref.*—Vessels of Abnormal Kidneys: *Z.B.* 1908, *Bd.* 44, s. 1.—Experimental Tuberculosis: *J.H.H.B.* 1911, xvi. p. 1.
- Urine.—Albumosuria: *L.* 1909, i. 682.—Bacteriuria, Persistent: *J.H.H.B.* 1909, xx. 12 *refs.*—Chyluria: *M.m.W.* 1908, i. 1367.—Haematoporphyrinuria: *L.* 1909, i. 1105.—Haematuria: *L.* 1909, ii. 444.—Haemoglobinuria: *J.P. and B.* 1906, xi. 167, 203; *E.M.J.* 1906, xix. 43., 1907, xxi. 440; *Q.J.M.* 1908-9, No. 8, p. 368; *J.H.H.B.* 1911, xxii. 238.—Indicanuria: *L.* 1908, i. 1621; *J.A.M.A.* 1909, ii. 1446.—Malignant Growths, Urine in: *L.* 1910, ii. 450.—Pentosuria: *E.M.J.* 1906, xx. 138.—Tubercle Bacilli in Urine: *L.* 1909, ii. 2.—Typhoid Bacilluria: *E.M.J.* 1906, xix. 116.—

- Urinary Casts, Origin of, Exper.: *B.M.S.J.* 1908, vol. 158, p. 696.
- Calculi: *J.A.M.A.* 1908, ii. 885., 1910, i. 665; *M.m.W.* 1909, i. 3.
- Urethra.**—Urethritis, Non-specific: *J.A.M.A.* 1910, i. 1675.—Chronic Urethritis (Histology): *F.Z.* 1908-9, Bd. 2, s. 548.
- Bladder.**—Urinary Bladder, Emphysema of: *F.Z.* 1908-9, Bd. 2, H. 2-3, s. 343.—Malakoplakia of Urinary Bladder: *Z.B.* 1910, Bd. 48, s. 205.—Intraligamentary Bladder: *Monatschr. f. Geburtsh. Berlin*, Bd. xxii. H. 5.—Urachus: *L.* 1910, i. 566; *L.* 1909, i. 1304.
- Kidneys.**—Abnormal Kidneys, Vessels of: *Z.B.* 1908, Bd. 44, s. 1.
- Carbolic Acid Poisoning, Renal changes in: *Z.B.* 1910, Bd. 47, s. 126.—Congenital Single Kidney: *A.J.M.Sc.* 1910, vol. 139, p. 313 refs.; *Q.J.M.* 1909-10, No. 9, p. 31.
- Fat in Kidney, Normal and Pathological: *Z.B.* 1910, Bd. 49, s. 34.
- Granular Kidney: *L.* 1908, ii. 517.
- Hyaline Degeneration (so-called) of Glomeruli: *Z.B.* 1909, Bd. 45, s. 253.—Hyaline Glomeruli of Infants: *F.Z.* 1908-9, Bd. 2, H. 1, s. 138.—Hydronephrosis: *V.A.* 1910, Bd. 202, s. 266; *Z.B.* 1910, Bd. 49, s. 127.—Hyperplasia, Diffuse: *Z.B.* 1910, Bd. 49, s. 529.
- Infarction of Renal Cortex, Massive: *J.P. and B.* 1906, xi. 237., 1911, Jan.; *L.* 1911, i. 99. See also Necrosis of Cortex.—Infection, *Bacillus Coli*: *L.* 1908, i. 615; *E.M.J.* 1910, N.S. v. 533.—Infections in Childhood: *A.J.M.Sc.* 1909, vol. 138, p. 313; *B.M.J.* 1908, i. 77., 1910, ii. 1128; *J.A.M.A.* 1911, i. 631; *Q.J.M.* 1909-10, No. 10, p. 251.
- Movable Kidney: *L.* 1909, i. 1155.—“Myelin” in Kidney (Adami and Aschoff): *J.M.R.* 1909, xx. 27 ref.
- Necrosis of Cortex: *J.P. and B.* 1906, xi. 237.—Necrosis of Renal Cortex, Symmetrical: *J.P. and B.* 1911, xv. 137; *L.* 1909, i. 601 refs., 1911, i. 99. See also Infarction.
- Nephritis.**—*B.M.J.* 1907, i. 725., ii. 730; 1908, ii. 917; *J.A.M.A.* 1911, ii. 179.—Experimental Nephritis: *J.A.M.A.* 1909, ii. 1792., 1911, ii. 179; *J.E.M.* 1910, xii. 196; *J.M.R.* 1908, xix. 269; *B.M.S.J.* 1908, vol. 159, p. 8.—Experimental Chronic Nephritis: *J.M.R.* 1908, xviii. 497.—Nephritis, Urine and Blood: *J. P. and P.* 1909, xiii. 296.—Nephritis, Thyreogenous (in Exophthalmic Goitre): *M.m.W.* 1910, ii. 1695.—Chronic Interstitial Nephritis, Renal Haemorrhage in: *L.* 1908, i. 1066.—Nephritis, Chronic, and Arteriosclerosis: *V.A.* 1909, Bd. 195, s. 228.—Chronic Nephritis, Calcification of Liver in: *F.Z.* 1909, Bd. 3, s. 773.—Nephritis, Chromaffin Organs in: *V.A.* 1910, Bd. 202, s. 189.
- Pathology of Kidney, Comparative: *F.Z.* 1911, Bd. 8, s. 34.—In Pernicious Anaemia: *V.A.* 1908, Bd. 192, s. 324.—Polycystic Kidney: *Q.J.M.* 1909-10, No. 9, p. 30; *V.A.* 1910, Bd. 200, s. 151.—Pyelitis: see Infections in Children.—Pyonephrosis: *J.A.M.A.* 1911, ii. 179.
- Regeneration of Renal Epithelium after Corrosive Sublimate Poisoning: *Z.B.* 1909, Bd. 45, s. 197.
- Syphilitic Nephritis: *B.M.J.* 1911, i. 1102.
- Tuberculosis: *L.* 1908, i. 833; *J.A.M.A.* 1909, i. 1560; *J.H.H.R.* 1904, xii. 455.—Tuberculosis, Experimental: *J.H.H.R.* 1911, xvi. p. 1.
- Tumours, Renal:** *B.M.S.J.* 1908, vol. 159, p. 457; *V.A.* 1910, Bd. 201, s. 150, 161, 282, 311, 321., 1911, Bd. 203, s. 463.—Kidney and Ureter, Tumours of: *B.M.S.J.* 1909, vol. 161, p. 547 ref.—Tumours of Kidney, Mixed: *A.M.E.* 1909, xxi. p. 546.—Tumours, Malignant Epithelial: *A.M.E.* 1911, xxiii. 446 ref.—Cystadenoma, etc.: *J.A.M.A.* 1911, i. 1336.—Hypernephroma: *L.* 1909, i. 1581; *J.A.M.A.* 1908, i. 1787. See also Suprarenal, under Ductless Glands.—Kidney, Lipoma: Virchow, *Die krankh. Geschwülst.* 1863, i. 385; *J.P. and B.* 1897, iv. 404.—Papilliferous Cysts: *J.M.R.* 1908, xix. 115.—Sarcoma of Kidneys: *E.M.J.* 1907, xxii. 57.
- Varix of Papilla: *A.J.M.Sc.* 1909, vol. 137, p. 98; *B.M.S.J.* 1908, vol. 158, p. 797
- Waxy (Amyloid) Etiology: *V.A.* 1908, Bd. 192, s. 226.

(i., ii. — Vol. I, Vol. II; s. — Seite, Seiten.)

PLATE I

Fig. 1. - *Amphiprion* *permanens*, showing the dorsal fin and the head. The dorsal fin is small and the head is large. The body is elongated and the tail is small.

Fig. 2. - *Amphiprion* *permanens*, showing the head and the dorsal fin. The head is large and the dorsal fin is small. The body is elongated and the tail is small.

Fig. 3. - *Amphiprion* *permanens*, showing the head and the dorsal fin. The head is large and the dorsal fin is small. The body is elongated and the tail is small.

Fig. 4. - *Amphiprion* *permanens*, showing the head and the dorsal fin. The head is large and the dorsal fin is small. The body is elongated and the tail is small.

Fig. 5. - *Amphiprion* *permanens*, showing the head and the dorsal fin. The head is large and the dorsal fin is small. The body is elongated and the tail is small.

Fig. 6. - *Amphiprion* *permanens*, showing the head and the dorsal fin. The head is large and the dorsal fin is small. The body is elongated and the tail is small.

Fig. 7. - *Amphiprion* *permanens*, showing the head and the dorsal fin. The head is large and the dorsal fin is small. The body is elongated and the tail is small.

PLATE I

FIG. 1.—Acute Lobar Pneumonia; stage of Red Hepatization (\times circ. $\frac{1}{2}$). Section of portion of upper part of right lower lobe; visceral pleura thickened; recent exudate on inter-lobar pleura. (*See text p. 131.*)

FIG. 2.—Acute Glomerular Nephritis; about the seventh day (\times circ. 2). Portion of cut surface of right kidney. (*See text p. 303.*)

FIG. 3.—Chronic Interstitial Nephritis. Segment removed from the kidney. Slightly enlarged.

Capsule thickened, and part stripped off to show the granularity of the outer surface, and the kidney substance removed on under-surface of stripped capsule.

Cortex narrow, with irregular vascular markings, general alteration in colour, and mottling. Loss of demarcation from Medulla.

Arteries moderately thickened. Small haemorrhages into the mucous membrane of the pelvis. (*See text p. 309.*)

FIG. 4.—Subacute Atrophy of the Liver, showing Regenerative changes. Transverse coronal section of liver including parts of both lobes (\times circ. $\frac{1}{3}$). Greenish-yellow part represents regenerated liver tissue; pink parts represent portions in which the liver cells have disappeared. (*See text p. 246.*)



Fig. 1.



Fig. 2.

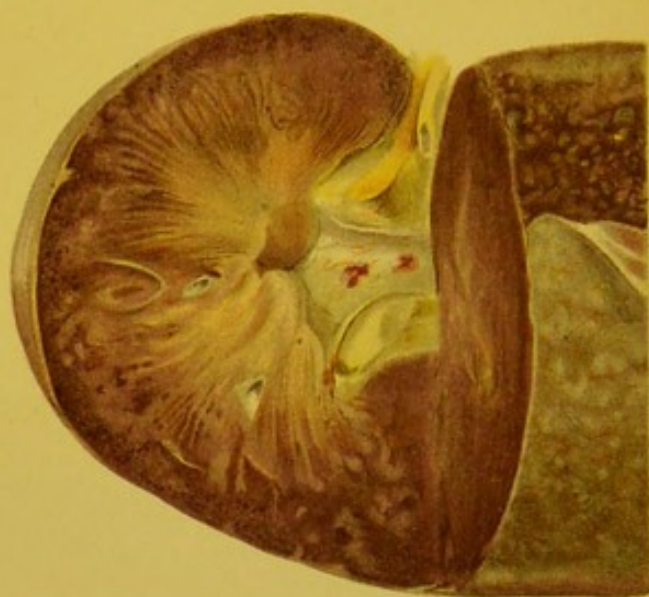

Fig. 3.

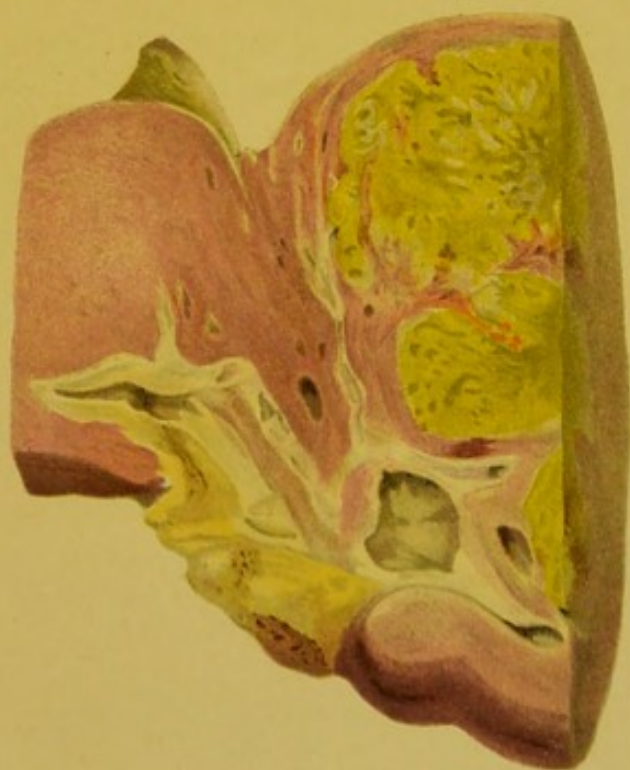

Fig. 4.



TABLE II

Summary of the results of the experiments on the effect of the concentration of the solution on the rate of reaction.

The following table shows the results of the experiments on the effect of the concentration of the solution on the rate of reaction.

The following table shows the results of the experiments on the effect of the concentration of the solution on the rate of reaction.

The following table shows the results of the experiments on the effect of the concentration of the solution on the rate of reaction.

The following table shows the results of the experiments on the effect of the concentration of the solution on the rate of reaction.

The following table shows the results of the experiments on the effect of the concentration of the solution on the rate of reaction.

The following table shows the results of the experiments on the effect of the concentration of the solution on the rate of reaction.

PLATE II

SECTIONS OF PORTIONS OF FEMORA, CUT LONGITUDINALLY,
TO SHOW DIFFERENT CHANGES IN THE BONE MARROW. ALL
SLIGHTLY LARGER THAN NORMAL. (*See Text pp. 352, 353.*)

FIG. 1.—Advancing Leucoblastic Reaction. The upper end
of the bone is to the right.

FIG. 2.—Marked Erythroblastic Reaction. A portion of the
marrow has been scooped out to show the absorp-
tion of the trabeculae.

FIG. 3.—Bone marrow in Chloroma. Child, æt. 7.

FIG. 4.—Gelatinous Degeneration of the Bone Marrow.

FIG. 5.—Marrow from a case of Spleno-medullary Leuco-
cythaemia, showing complete transformation,
marked pigmentation, and formation of pale
nodules, like secondary growths in the marrow.
Considerable absorption of trabeculae.

FIG. 6.—Marrow from a case of Lymphatic Leucoeythaemia,
showing patchy yellow pigmentation.



Fig. 1.



Fig. 4.



Fig. 2.



Fig. 5.



Fig. 3.

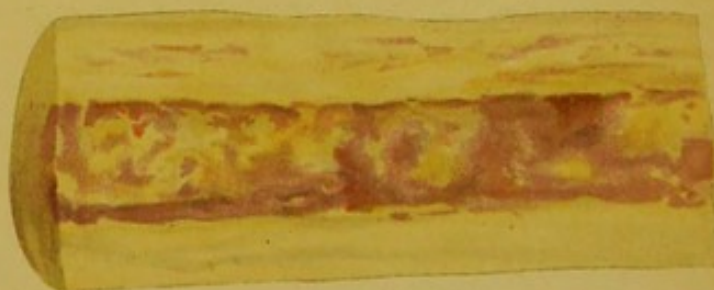

Fig. 6.



PLATE III

Fig. 1. - *Leptothorax* sp. (small, abundant, common).
This form is the most common of the group, and is
found in all the localities. It is a small, robust
fish, with a deep body, and a large head. The
faintly mottled coloration is very characteristic
of the species.

Fig. 2. - *Leptothorax* sp. (small, abundant, common).
This form is the most common of the group, and is
found in all the localities. It is a small, robust
fish, with a deep body, and a large head. The
faintly mottled coloration is very characteristic
of the species.

Fig. 3. - *Leptothorax* sp. (small, abundant, common).
This form is the most common of the group, and is
found in all the localities. It is a small, robust
fish, with a deep body, and a large head. The
faintly mottled coloration is very characteristic
of the species.

Fig. 4. - *Leptothorax* sp. (small, abundant, common).
This form is the most common of the group, and is
found in all the localities. It is a small, robust
fish, with a deep body, and a large head. The
faintly mottled coloration is very characteristic
of the species.

PLATE III

FIG. 1.—Longitudinal sagittal section (diagrammatic) through Crus, Pons, and Medulla, showing the *approximate* positions of the Nuclei of the Cranial Nerves. A.S., Aqueduct of Sylvius, with Crus in front, and Corpora Quadrigemina behind. The Olivary Body represented as an oval area, with sinuous outline, in the medulla.

FIG. 2.

- A. Transverse Section at level *A* in Fig. 1, showing position of Third nucleus, and the Red nucleus.
- B. Similar Section at level *B*, showing position of the Sensory (*s.*) and Motor (*m.*) nuclei of the Fifth nerve, and their relation to the fourth ventricle (immediately below the letter *B*).
- C. Similar Section at level *C*. The letter *C* is in the position of the fourth ventricle. The figure shows the position of the Fillet (*F.*), the Pyramid (*Pyr.*), the spinal root of the Fifth nerve; the Sixth and Seventh nuclei; the Vestibular (*v.*) and Cochlear (*c.*) nuclei of the Eighth nerve.
- D. Similar Section at level *D.*, that is, through the Olivary Body. Pyramid (*Pyr.*); Spinal root of Fifth; the Eighth, vestibular (*v.*) and cochlear (*c.*); the Ninth, Tenth, and Twelfth nuclei.

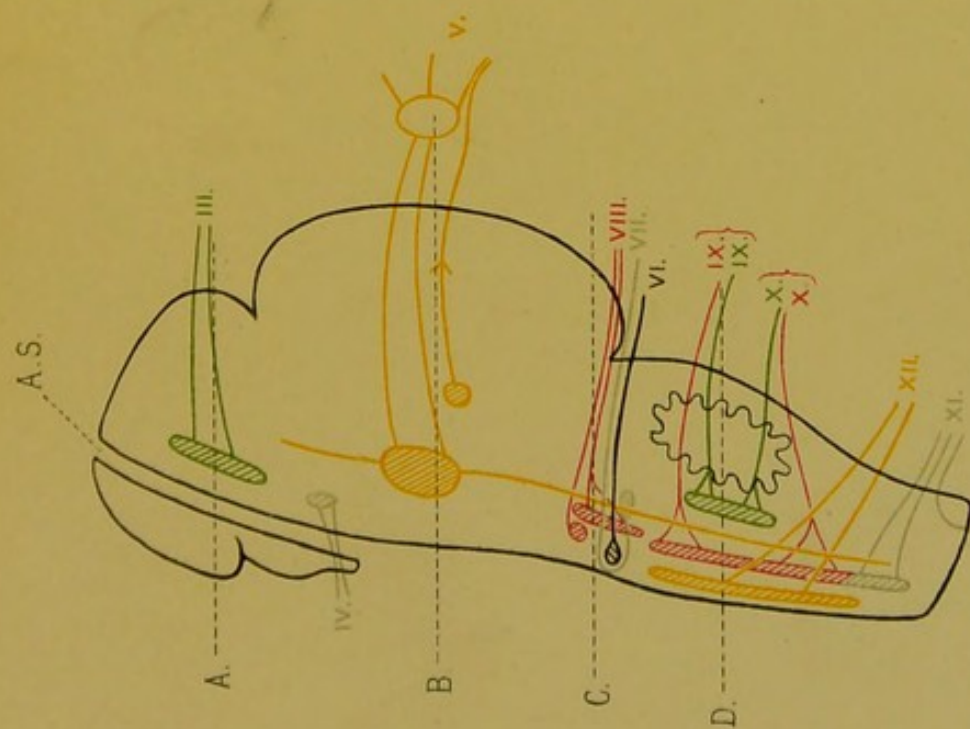


Fig. 1.

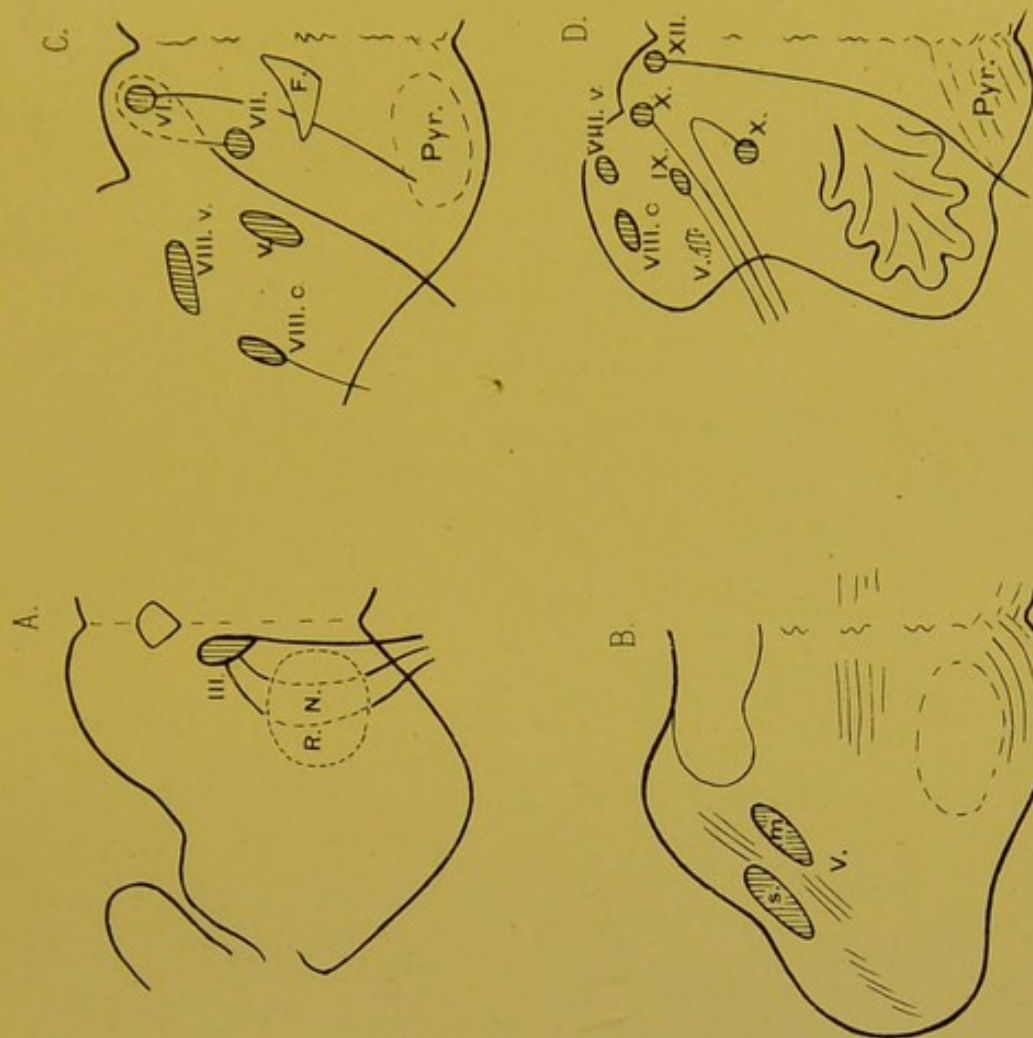


Fig. 2.



INDEX

- Abdomen, 168
 —, examination of organs, 32, 35, 173
 —, method of opening, 29
 —, removal of organs, 35
 —, alteration in size, 24
 —, surface of, 24
 Abscess, retro-pharyngeal, 162
 Accessories, *post-mortem* room, 3
 Achondroplasia, 412
 Acromegaly, 28, 395, 412
 Actinomyces of appendix, 224
 — of face, 22
 — of liver, 242
 — of lung, 149
 — of mamma, 342
 — of mouth, 160
 — of tonsils, 165
 Addison's disease, 17, 27, 321
 Adenoids, 164
 Adenoma, malignant, of appendix, 208
 —, —, of brain, 393
 —, —, of gall-bladder, 259
 —, —, of intestine, 208
 —, —, of larynx, 116
 —, —, of liver, 254, 255
 —, —, of mamma, 346
 —, —, of oesophagus, 167
 —, —, of pancreas, 224
 —, —, of prostate, 337
 —, —, of stomach, 189, 193
 —, —, of thyroid, 157
 —, —, of urinary bladder, 320
 —, —, of uterus, 330
 Adenomatous polypus, rectum, 208
 Adiposis dolorosa, 15
 Agonal intussusception, 200
 —, thrombosis, 87
 Alcoholism, chronic, 437
 Alopecia areata, 20
 Ampulla of Vater, Stenosis, 178, 199
 Amyloid Degeneration, *see* Waxy degeneration
 Amyotrophic lateral sclerosis, 365
 Anaphylaxis, in Status lymphaticus, 39
 Anaemia, changes in kidneys, 293
 —, changes in liver, 237
 —, pernicious, 17, 237
 Anasarca, 15, 30
 Aneurysm, arterio-venous, 99
 —, effect on heart, 96
 —, cirroid, 98
 —, dissecting, 99
 —, embolic, 98, 385
 —, false, 90, 96
 —, hernial, 98
 —, miliary, 98
 —, racemose, 98
 —, true, 96
 —, varicose, 99
 Aneurysm of aorta, 23, 39
 — of cusps of heart-valves, 84
 — of heart, 71, 73
 — of pars membranacea septi, 74
 — of popliteal artery, 97
 — of veins, 100
 Aneurysmal varix, 99
 Angina, Ludwig's, 161
 Angioma, 90
 —, cavernous, of liver, 252
 —, of mouth, 160
 Angular curvature of spine, 155
 Animal parasites of bladder, urinary, 313
 — of bone, 415
 — of intestine, 206
 — of kidney, 313
 — of liver, 258
 — of lungs, 128, 149
 — of lymphatic glands, 350
 — of muscle, 422
 — of peritoneum, 174
 — of stomach, 180, 188
 — of vertebrae, 356
 Ante-mortem thrombosis, 85
 Anthracosis, lungs, 139
 Anthrax, 19
 — of bronchi, 128
 — of lungs, 138
 — of mediastinum, 128
 — of meninges, 377
 — of stomach, 187
 Antiseptic lotions, 11
 "Antiseptic skin," 6
 Antrum, mastoid, 401, 402
 —, maxillary, 22, 399

- Anus, imperforate, 201
 Anus, prolapse, 200
 Aorta, abnormalities of, 62
 —, aneurysms of, 41
 —, atheroma of, 93-95
 —, syphilitic scars in, 100
 Aortitis, gummatous, 101
 Aphthae, 158
 Apoplexy, cerebral, 384
 —, delayed traumatic, 387
 —, pulmonary, *see* Infarction of lungs
 Appendicitis, 224
 —, peritonitis following, 69, 224
 Appendix vermiformis, 196, 224
 — —, absence of, 203
 — —, tumours of, 208
 Arachnoid mater, 376
 —, —, calcareous plates in, 358
 Argyria, 17, 434
 —, changes in kidney, 294
 Arterial sclerosis, 92, 95
 Arteries, atrophy of, 90
 —, calcification of, senile, 91
 —, diseases of, 90
 —, hypertrophy of, 90
 —, ossification of, 95
 —, rupture of, 90
 Arteriosclerotic atrophy of kidneys, 285
 Arteritis, acute, 92
 —, chronic, 92
 —, deformans, 93
 —, proliferative, 100
 —, suppurative, 92
 —, syphilitic, 100
 —, tuberculous, 101
 Arthritis, 415, *see also* Synovitis.
 —, deformans, 419
 —, gonococcal, 416
 —, rheumatic, 415
 —, rheumatoid, 418
 —, suppurative, 416
 —, syphilitic, 418
 —, tuberculous, 417
 Ascites, 172
 —, chylous and chyloform, 169
 Aspiration pneumonia, 135
 Asthma, thymic, 40
 Ataxia, Friedreich's hereditary, 155, 364
 —, locomotor, 363
 Atelectasis, lungs, 124
 Atheroma, 93
 Atrophy, brown, of heart, 65
 —, yellow, of liver, 245, 435, 436
 — of kidney, 285
 — of spleen, 266
 —, progressive muscular, 364, 421
 Auricle, left, 55, 67
 —, right, 54, 65
 Auricles, supernumerary, 23
 Auriculo-ventricular bundle, 76
 Axillae, 33
 Bacteria, cultivation of, 9, 451
 —, staining methods, 451
 Bacteriology, *see* individual diseases
 Balanitis, 336
 Ball thrombus, 85
 Barlow's disease, 411
 "Barrel-chest," 23, 125
 Bartholin's gland, 324
 Base of Skull, fracture, 403
 — —, cranial nerves, 373
 Bed-sores, 16, 27
 Beri-beri, 395
 Bifid ventricle, 59
 Bile, Gmelin's reaction, 261
 Bile-ducts, 225, 226
 Bile-duct cancer, 253
 Bilharziosis of rectum, 206
 — of stomach, 188
 Biliary cirrhosis, 250
 Billroth's myeloid alveolar carcinoma, 346
 Bladder, urinary, 26, 317
 —, —, calculi, 320
 —, —, tumours, 319
 Blisters, 17
 Blood, appearance of, *post mortem*, 45
 Blood-platelet thrombi, 86, 104, 105
 Blood-vessels, disease of, 90
 Bone, diseases of, 405
 —, fracture of, 405
 —, inflammation of, 405
 —, parasites of, 415
 —, syphilis of, 408
 —, tuberculosis of, 407
 —, tumours of, 412
 Bone-marrow, changes in, 350
 Botulism, 442
 Brain, diseases of, 383
 Brain, abscess of, 389
 —, atrophy of, 383
 —, base of, 382
 —, defects in, 383
 —, examination of, 382
 —, fixation and preservation of, 373
 —, haemorrhage into, 384
 —, malformations of, 383
 —, oedema of, 384
 —, removal of, 373
 —, sieve-like degeneration of, 384
 —, softening of, 387
 —, surface of, 382
 —, tumours of, 392
 —, weight of, 373
 "Bread-and-butter" appearance, pericarditis, 50
 Bright's disease of kidneys, 302
 Brodie's abscess of bone, 407

- Bronchi, diseases of, 117
 —, foreign bodies in, 120
 —, narrowing (stenosis) of, 120
 —, structure of, 117
 —, syphilis of, 120
 Bronchiectasis, 119
 —, causation, 119
 —, condition of other organs, 119
 Bronchitis, acute, 117
 —, chronic, 118
 —, croupous or plastic, 118
 —, putrid or gangrenous, 120
 —, suffocative, 134
 —, tuberculous, 120
 Broncho-pneumonia, acute, 133
 —, tuberculous, 144
 Bronzed diabetes, 17, 223, 238
 Brown atrophy of heart, 65
 Bruises, 16
 Brünner, glands of, 195
 Brun's glucose mounting medium, 448
 Bubo, hard or indolent, 349
 Burns of the surface, results, 71, 134, 181
 Burri's Indian Ink method, 452
 "Button-hole" mitral, 80

 Cadaveric sugillations, 16
 Caecum, 196
 Calcification of Arteries, senile, 91
 — of costal cartilages, 35
 — of plugs in pneumonia, 133
 Calculi, biliary, 258
 —, pancreatic, 223
 —, prostatic, 337
 —, urinary, 320
 Calculous pyelitis, 316
 Calipers, author's modified, 4
 Callus, 405
 Calvarium, 365, 367
 —, osteo-sarcoma, 20
 Cancer, *see* Colloid, Encephaloid, Scirrhus
 Cancers, and Malignant Adenoma
 — of appendix, 208
 — of bronchi, 39, 149
 — *en cuirasse*, 18, 24, 345
 Cancrum oris, 22, 159
 Capillary bronchitis, 134
 Carbol-fuchsin, 452
 Carbon monoxide poisoning, 13, 438
 Cardiac ganglia, 57
 — veins and sinuses, 44
 Caries of bone, 408
 Caries necrotica, 370
 — sicca, 370
 —, tuberculous, 371, 408
 Carnification of lungs, 133
 Cartilages, costal, 32
 —, —, calcification and ossification of, 35
 Casein in stools, 206
 Caseo-fibroid tuberculosis, lungs, 147
 — —, supra-renals, 321
 Cavernous angioma, liver, 252
 Cavities, methods of opening the, 29
 Celloidin embedding, 447
 Cephalhaematoma, 370
 Cerebral haemorrhage, 384
 — membranes, 374
 — softening, 387
 Cerebro-spinal meningitis, epidemic, 362,
 378, 379
 Chalicosis, 140
 Charcot's disease of joints, 420
 Chimney sweeps' cancer, 336
 Chloroma, bone marrow, 353
 —, kidney, 311
 —, larynx, 115
 —, lymphatic glands, 350
 —, lymphoid tissue, 115
 —, orbit, 403
 —, periosteum, 413
 —, pharynx, 115
 —, skull, 367
 Chloroform poisoning, 107, 437
 Chlorosis, 17
 Cholangitis, 240
 Cholecystitis, 258
 Cholesteatoma, brain, 393
 —, middle ear, 378, 403
 Cholesterine, reactions, 261
 Chorionepithelioma, 331
 —, liver, 256
 —, testis, 340
 "Chrome holes," 435
 Chylous and Chyliform effusions, 150, 169,
 172
 Circulation, posthumous, 18
 Cirrhosis of liver, 247
 Cirrhosis, biliary, 250
 —, Hanot's, 250
 —, monolobular, 250
 —, multilobular, 247
 —, pigmentary, 250
 —, syphilitic, 244
 Cisterna magna, 376
 — pontis, 376
 Clayey stools, 205
 Clinical information, at the *post-mortem*
 examination, value of, 13
 Cloudy swelling of heart, 68
 — — of liver, 231
 — — of kidney, 288
 Coal-miners' lung, 139
 Cochlea, 401
 Coffee-grounds, 180, 211
 Cold abscess of bone, 408
 Collapse of lungs, 124
 Colloid cancer of bronchi, 39, 149
 — — of gall-bladder, 259

- Colloid cancer of intestine, 208
 — — of lung, 149
 — — of mamma, 346
 — — of rectum, 208
 — — of omentum, 193
 — — of peritoneum, 174
 — — of stomach, 192, 194
 Colon, 196
 Colour of skin, 16
 Columnar-celled Carcinoma, *see* Malignant Adenoma
 Concentric hypertrophy of heart, 68
 Concretions, intestinal, 206
 —, preputial, 336
 —, prostatic, 337
 Condyloma acuminatum, 324, 336
 — latum, 324, 336
 Cones for measuring circumferences and depths of orifices, 2
 Congenital cystic kidney, 284
 — — pancreas, 223
 — heart-disease, 59–63
 "Contre coup," 384
 Cor bovinum, 44, 68
 — quadratum, 44
 — villosum, 50
 Corona veneris, 22, 371, 409
 Coronary arteries (heart), distribution, 57, 70
 — —, —, diseases, 88
 Corpora amylacea, prostate, 337
 Corpora lutea, 333
 Corpulence, 15, 395
 Costal cartilages, 32, 34
 — —, calcification, 35
 Cranial nerve roots, 373
 Cranio-pharyngeal canal, 394
 Cranioschisis, 369
 Craniosclerosis, 371
 Craniotabes, 369, 410
 Cream, emollient, 11
 Cretinism, 157
 Croupous bronchitis, 118
 — enteritis, 215
 — pneumonia, 130
 Cryptogenic pyaemia, 164
 Cryptorchism, 338
 Cuirass cancer, 18, 24, 345
 Culture media, 451
 Curvatures, spinal, 154
 Cusps, aneurysms of, 84
 —, tongue-shaped, 82
 Cutis anserina, 17
 Cystadenoma, of mamma, 345
 —, of ovary, 333
 Cystic epithelioma of infundibulum of pituitary, 393
 Cystic kidney, congenital, 284
 Cystitis, 318
 Cystocele, 326
 Cysts of mouth, 160
 — of ovary, 333, 334
 — of pancreas, 223
 — of pericardium, endothelial, 49
 Decalcifying fluid, 402
 Decidua, 327, 329
 Decomposition, 18
 Decubital necrosis, 166
 Delayed traumatic apoplexy, 387
 Delayed rickets, 410
 Deodorisers, 10, 11
 Dermatomyositis, 421
 Dermoid cyst of dura mater, 368
 — — of mamma, 344
 — — of ovary, 334
 — — of scalp, 368
 — — of testis, 368
 Dextrine mounting medium, 448
 Dextrocardia, 59
 Diabetes, bronzed, 17, 223, 238
 Diabetes mellitus, lipaemia, 107
 — —, changes in pancreas, 223
 Diffuse waxy spleen, 265
 Digestion of wall of stomach, *post mortem*, 180
 Digitalis poisoning, 440
 — —, condition of heart, 19
 Diphtheria, 163
 Disseminated sclerosis, brain, 390
 — —, spinal cord, 359, 363
 Dissemination of mammary cancer, 346
 Diverticula, intestine, 26, 201
 —, pharynx, 165
 Dropsical degeneration of fat, 64
 Duct cancer, 346
 Duct papilloma, mamma, 344
 Duodenum, 195
 —, congenital stenosis, 178, 201
 —, diverticulum, 201
 —, ulceration, 181
 Dura mater, cerebral, 372
 — —, spinal, 356
 Dura mater, diseases, 374
 — —, haematoma, 374
 — —, sarcoma of spinal (Fig 172), 358
 — —, syphilis, 375
 — —, tuberculosis, 375
 — —, tumours, 376
 Dysentery, 214
 Dystrophies, muscular, 421
 Ear, external, 23
 —, internal and middle, 401
 —, — —, removal, decalcification, and embedding in celloidin, 402
 Eclampsia, puerperal, changes in liver, 230
 Ectopia cordis, 59

- Electric shock, death from, 19
 Elephantiasis, lower extremity, 28
 —, scrotum, 336
 —, vulva, 324, 336
 Emaciation, 15, 25
 Embedding methods, Celloidin, 447
 —, Gums, 445
 —, Paraffin, 446
 Embolic aneurysms, 385
 Embolism, 104
 — of pulmonary artery, 45
 Embryoma of mediastinum, 39
 Emollient cream, 11
 Emphysema, lungs, 125
 —, stomach, 180
 —, subcutaneous, 15, 18
 Emphysematous gangrene, 24
 Empyema of pleura, 41, 153
 — of gall-bladder, 258
 Encephalitis, acute, 388
 —, chronic, 390
 —, suppurative, 389
 Encephalocele, 368
 Encephaloid cancer of heart, 49
 — of intestine, 208
 — of liver, 254
 — of mamma, 345
 — of oesophagus, 167
 — of pericardium, 49
 — of stomach, 190, 193
 — of testis, 340
 — of uterus, 330
 Encephalomalacia, 387
 Endarteritis, 92
 —, deformans, 93
 —, proliferative, 73, 100
 Endocarditis, bacteriology of, 84
 —, results of, 80
 Endocarditis, valvular, acute, 78, 81
 —, chronic, 79, 81
 —, redundant, 82
 —, ulcerative, 83
 Endocardium, 77
 Endometritis, 327
 Endothelioma of lung, 149
 Endothelium of blood-vessels, fatty degeneration of, 91
 —, Cysts of pericardial, 49
 Entamaeba histolytica, 241
 Enteritis, 212
 —, catarrhal, 212
 —, follicular, 213
 —, suppurative, 213
 —, ulcerative, 214 to 219
 Enterocyst, 202
 Enteroliths, 206
 Eosin and methylene blue staining methods, 449
 Epicardial fat, serous degeneration, 64
 Epidemic cerebro-spinal meningitis, 378, 379
 Epididymis, 338
 Epispadias, 26, 318
 Epistaxis, 399
 Epithelial-hyaline degeneration of Islets of Langerhans, 223
 Epithelioma, squamous, of anus, 208
 —, of gall-bladder, 259
 —, of intestine, 208
 —, of larynx, 116
 —, of lips, 160
 —, of mamma, 345
 —, of mouth, 160
 —, of nasal cavities, 401
 —, of oesophagus, 167
 —, of penis, 336
 —, of pituitary, 393
 —, of prostate, 338
 —, of scrotum, 336
 —, of stomach, 193, 194
 —, of thyroid, 157
 —, of tongue, 160
 —, of uterus, 330
 Epithelioma, cystic, 393
 Epithelium, metaplasia, 113, 116, 259
 Epityphlitis, 224
 Erb's Dystrophy, 421
 Erosions of cervix uteri, 326
 — of stomach, 184
 Eruptions, cutaneous, 18
 Erythroblastic reaction, bone marrow, 353
 "État criblé," 384
 Ethmoidal cells, 399
 Excentric hypertrophy of heart, 68
 Exterior of the body, Examination, 14, 20
 Extremities, Examination of the, 27
 Face, 21
 —, hemiatrophy, 21
 —, prominences on, 22
 —, syphilis of, 22
 —, tumours of, 22
 Fallopian tubes, 329
 "False tendons," (Tawara,) 73, 77
 Fat necrosis, 221
 Fat, normal, 30
 —, in blood, 149
 Fat, staining reactions for, 233, 449
 Fatty change, kidney, 289
 Fatty degeneration of endothelium, 91
 — of heart muscle, 67, 69
 — of liver, 231
 — of media of arteries, 91
 — of spleen, 266
 Fatty infiltration of heart, 63
 — of liver, 232
 Fatty loading of heart, 63
 Favus, 20

- Fibro-adenoma, mamma, 344
 Fibroid tuberculosis of lungs, 148
 Fibroma, 422
 —, lamellar, 172
 Fibro-myoma uteri (Fibroid), 328
 Fistula bimucosa, 218
 Focal necrosis, liver, 234
 — —, spleen, 270
 Foetal lobulation, kidney, 284
 Follicular enteritis, 213
 — tonsillitis, 163
 Fontanelles, 21
 Foramen ovale, patency, 60, 106
 Fracture of base of skull, 403
 Fractures of bone, repair, 405
 Fracture dislocations, 356
 Friedreich's ataxia, 155, 364
 Frontal sinuses, 398
 "Funnel-breast," 23
- Galactocoele, epididymis, 338
 —, mamma, 344
 Galen, veins of, 373
 Gall-bladder, 225, 227, 258
 —, catarrh of, 258
 —, empyema of, 258
 —, typhoid in, 259, 262
 —, tumours of, 259
 Gall-stones, 259
 —, effects of, 262
 Gangrene, dry, 27, 95
 —, emphysematous, 24
 —, moist, 28
 — of extremities, 27
 — of lungs, 122, 124, 137
 Ganister workers, disease of, 140
 Gas-formation, *post mortem*, 18
 Gastrectasis, 176
 Gastric catarrh, 185, 186
 — ulceration, 181
 Gastritis, membranous, 187
 —, phlegmonous, 187
 Gastromalacia, 180
 Gastropnoia, 177
 Gelatinous bone marrow, 353
 — degeneration of joints, 417
 Genitals, external, 26, 318, 324, 335
 Gestation, tubal, 332
 Glanders, larynx, 115
 —, lungs, 149
 —, nasal cavities, 401
 Glioma, brain, 385, 392
 —, retina, 403
 —, supra-renal, 322, 323
 "Globular heart," 44, 65
 Globular thrombus, 85
 Gloves, use and care of, 7
 Gmelin's reaction for bile pigment, 261
 Goitre, 156
- Gonococcal meningitis, 378
 Gonorrhoea, female, 324
 —, male, 337
 —, of rectum, 220
 "Goose-skin," 17
 Gout, 416
 Gram's method of staining, 451
 Granular contracted kidney, 285
 Gumma of bone and periosteum, 409
 — of heart, 75
 — of liver, 243
 — of lungs, 148
 — of mamma, 343
 — of meninges, 381
 — of muscle, 421
 — of nasal cavities, 401
 — of spinal cord, 359
 — of testicle, 339
 Gynecomastia, 341
- Haematocoele, 340
 Haematoma auris, 23
 — vulvae, 324
 Haematometra, 326
 Haematomyelia, 360
 Haematuria, 317
 Haemochromatosis, 223, 238
 Haemofuscin, 238
 Haemoglobin staining, 16, 45
 Haemoglobinuria, 317
 Haemopericardium, 42
 Haemorrhage, arachnoid, 377
 —, bladder, 317
 —, bronchi, 128
 —, cerebellum, 386
 —, cerebrum, 384
 —, conjunctiva, 23
 —, ear, 23
 —, endocardium, 71
 —, extra-dural, 372
 —, extra-peritoneal, 168
 —, intestine, 210, 211
 —, kidney, 317
 —, larynx, 111
 —, lungs, 128
 —, mammary cyst, 344
 —, mouth, 22
 —, nose, 22, 399
 —, pancreas, 220
 —, pericardium, 42, 71
 —, pleura, 41, 150
 —, pons, 386
 —, prostate, 317
 —, spinal cord, 359
 —, stomach, 179, 184, 185, 187
 —, sub-dural, 375
 —, supra-renal, 322
 —, thymus, 39
 —, tunica vaginalis testis, 340

- Haemorrhage, valves of heart, 71
 Haemorrhagic erosions of stomach, 184
 — infiltration of mediastinum, 128, 138
 — meningitis, 377
 Haemosiderin, 238
 Halisteresis, 410
 Halsted's adeno-carcinoma of mamma, 346
 Hands, care of the, 5, 11
 Harke's method of exposing the nasal cavities, 397
 Head, examination of, 20, 365
 Heart-block, 75, 80
 Heart, Examination of, 43, 54
 —, measurements of, 43, 58
 —, removal of, 47
 Heart, abnormalities of, 59, 62
 —, abscesses in myocardium, 72
 —, adiposity of, 63
 —, aneurysm, acute, 71
 —, —, chronic, 74
 —, aortic endocarditis, 81
 —, aortic opening, examination, 56
 —, atrophy, brown, 65
 —, atrophy of left ventricle, in mitral stenosis, 80, 68
 —, cavities of, 84
 —, cloudy swelling of, 68
 —, congenital disease, 59-63
 —, coronary arteries, diseases, 88
 —, — —, distribution, 57, 70
 —, defects at orifices, 61
 —, — in septa, 60
 —, — dextrocardia, 59
 —, dilatation of, 64
 —, diminution in size, general, 65
 —, — — —, local, 68
 —, diseases of, 59
 —, ectopia cordis, 59
 —, endocarditis, 77
 —, —, results, 80, 84
 —, endocardium, 76
 —, enlargement of, general, 64
 —, — —, local, 65
 —, examination of, 43, 54
 —, fatty degeneration of, 69
 —, — infiltration of, 63
 —, — loading of, 63
 —, fibroid myocarditis, 72
 —, fragmentation of muscle, 69
 —, globular, 44, 65
 —, gummata of, 75
 —, haemorrhage from, 42
 —, — sub-endocardial, 71
 —, hypertrophy of, left auricle, 67
 —, — —, left ventricle, 67
 —, — —, right ventricle, 66
 —, incisions for opening, 54
 —, infarction of, 70
 Heart, interstitial myocarditis, 72
 —, left auricle, 55, 67
 —, — ventricle, 56, 67
 —, measurements of, 43, 58
 —, mitral endocarditis, 79
 —, — opening, 56
 —, — stenosis, 79
 —, myocarditis, 72
 —, myocardium, 68
 —, pedunculated polyps of, 88
 —, pigmentation of, 65, 70
 —, primitive muscle of, 75
 —, pulmonary valve, endocarditis, 81, 78
 —, — —, examination, 55
 —, removal of, 47
 —, right auricle, 54, 65
 —, — ventricle, 55, 66
 —, segmentation of, 69
 —, sino-auricular node, 76
 —, syphilis of, 74
 —, three-chambered, 60
 —, thrombosis in, 85
 —, tricoelian, 60
 —, tricuspid valve, 55, 78
 —, tuberculosis of, 74
 —, tumours of, 49
 —, veins of, 44
 —, weight of, 57
 Hemiatrophy, facial, 21
 Hepatoptosis, 227
 Hereditary ataxia, 364
 Hermaphrodites, pseudo-, 324
 Hernia, 196
 Hirschsprung's disease, 203
 Hodgkin's disease, *see* Lymphadenoma
 "Horse-shoe" kidney, 283
 Hottentot apron, 324
 "Hour-glass" stomach, 178
 Hyaline degeneration, arteries, 94
 — —, kidneys, 293
 — —, lymphatic glands, 348
 — —, spleen, 266
 Hydatid mole, 331
 Hydatid of Morgagni, 331
 Hydranencephaly, 383
 Hydrencephalocele, 368
 Hydrocele, testis, 340
 Hydrocephalus, external, 314, 384
 —, internal, acute, 380, 390
 —, —, chronic, 390
 Hydrometra, 326
 Hydronephrosis, 314
 Hydro-pericardium, 43
 Hydrosalpinx, 332
 Hydrothorax, 41, 150
 Hypernephroma, 256, 312, 322
 Hyperostosis, skull, 371
 —, —, syphilitic, 367, (Figs. 176, 177.)
 Hypophysis cerebri, 394

Hypospadias, 26, 318

Ileum, 195

Incompetence of heart valves, 80, 82, 84

Indian Ink method, Burri's, 452

Infantile scurvy, 411

Infantile spinal paralysis, 362

Infarction of brain, 387

— of heart, 70

— of intestine, 108, 210

— of kidneys, 297

— of liver, 229

— of lungs, 128

— of spleen, 270

Infarcts, varieties, 109

Infections, at post mortems, 5

—, —, treatment of, 7

Inhalation pneumonia, 135

Instruments, 1

—, hints with regard to, 1

Insular sclerosis, brain, 390

— —, spinal cord, 359

Intestines, anatomy and blood-supply of, 195

—, amyloid degeneration of, 212

—, atresia of, 201

—, atrophy of, 212

—, concretions in, 206

—, contents of, 205

—, degenerations of, 212

—, dilatation of, 201, 203

—, displacements of, 196

—, diverticula of, false, 201, 202

—, diverticulum of, Meckel's, 202

—, dysentery, 214

—, enteritis, 212

—, examination of exterior of, 173

—, examination of interior of, 204, 207

—, gonococcal infection of, 220

—, haemorrhages into, 210

—, hernia, 196

—, —, external, 197

—, —, internal, 198

—, Hirschsprung's disease of, 203

—, hyperaemia of, 209

—, infarction of, 210

—, inflammation of, 212

—, intussusception or invagination of, 199

—, large, 196

—, malformations of, 203

—, malpositions of, 196

—, methods of opening, 205

—, necrosis of, 201

—, oedema of, 209

—, opening the, 205

—, parasites of, animal, 205

—, perforation of, 174, 215, 218, 219

Intestines, pigmentation of, 212, 433

—, prolapse of anus, 200

—, prolapse of rectum, 200

—, removal of, 204

—, rupture of, 174

—, serous surface of, 193

—, small, 195

—, stenosis of, 201

—, syphilis of, 219

—, tuberculosis of, 216

—, tumours of, 207

—, typhoid ulceration of, 216

—, varices of, lymphatic, 211

—, volvulus of, 200

—, walls of, 207

—, waxy degeneration of, 212

Intussusception or invagination of intestine, 199

Investigations, histological and bacteriological, 9

Ivory osteoma, skull, 371

Jaundice, obstructive, 257

—, toxic, 17, 258

Jaw, lower, 22

Jejunum, 195

Jenner's staining method, 448, 451

Joints, diseases of, 415, *see also* Arthritis

—, Charcot's disease of, 420

—, syphilis of, 418

—, tuberculosis of, 417

Jores' preserving method, 443

Kaiserling's preserving method, 443

Kidneys, actinomycosis of, 302

—, amyloid degeneration of, 290

—, anaemia, changes in, 293

—, anatomy of, 275

—, aplasia of, 282

—, in argyria, 281, 294

—, atheroma of vessels of, 286

—, atrophy of, 181, 285-288

—, —, arteriosclerotic, 285

—, bile-pigmentation of, 294

—, Bowman's capsule, 280

—, Bright's disease, of, 302

—, calcareous deposit in, 294

—, capsule, fatty, 276

—, —, fibrous, 276, 278

—, chloroma, 311

—, cirrhosis of, 309

—, cloudy swelling of, 288

—, congenital cystic, 284

—, congestions of, 295

—, consistence of, 279

—, cortex of, 277, 278

—, decomposition in, 279

—, degenerations of, 281, 288

—, diseases of, 282

- Kidneys, displacements of, 282
 —, duplicated, 283
 —, embolism in, 296
 —, examination of, 276
 —, fat, peripelvic, 279
 —, fatty capsule, 276
 —, fatty change in, 289
 —, floating, 282
 —, foetal lobulation of, 284
 —, fused, 283
 —, glomerulus of, 280
 —, granular, 285
 —, haematoblastic marrow in hilum of, 280
 —, haemorrhage into, 279, 317
 —, haemosiderin in, 293
 —, "horse-shoe," 283
 —, hyaline degeneration in, 293
 —, hydronephrosis, 314
 —, hypertrophy of, 281, 288
 —, hypoplasia of, 282
 —, infarction of, 297
 —, inflammation of, *see* Nephritis
 —, interstitial tissue of, 281
 —, intertubular plexus, 280
 —, labyrinth, in cortex of, 277
 —, leucocythaemia, 310
 —, macroscopic changes in disease of, 278
 —, measurements of, 276
 —, medulla and medullary rays of, 277, 279
 —, met-haemoglobin in, 293
 —, microscopical changes in disease of, 280
 —, movable, 282
 —, multiple pelvis, 283
 —, myelin in, 290
 —, nephritis, 303
 —, parasites of, animal, 313
 —, pelvis of, 277, 314
 —, protagon in, 290
 —, pyaemic abscesses in, 298
 —, pyelitis, 316
 —, pyonephrosis, 315
 —, removal of, 275
 —, scrofulous, 301
 —, size of, increase in, 278
 —, suppuration in, 298
 —, surgical, 299
 —, syphilis of, 302
 —, thrombosis in, 296
 —, tuberculosis of, 296
 —, tubules of, 277, 280
 —, tumours of, 311
 —, ureter, double, 275, 283
 —, uric acid deposits in, 294
 —, waxy degeneration of, 290
 —, weight of, 276
 Knives, precautions as to, 8
 Kraurosis vulvae, 324
 Labyrinth in renal cortex, 277
 Landry's paralysis, 362
 Lanolin emollient cream, 11
 Lardaceous degeneration, *see* Waxy degeneration
 Laryngeal phthisis, 113
 Laryngitis, 112, 113
 Larynx, 111
 —, in chloroma, 115
 —, glanders of, 115
 —, hyperaemia of, 111
 —, inflammation of, 112
 —, leprosy of, 115
 —, lupus of, 114
 —, metaplasia of epithelium of, 113
 —, mucous membrane of, 111
 —, oedema of, 112
 —, petechial haemorrhages in, 111
 —, stenosis of, 111
 —, suppuration in, 113
 —, syphilis of, 114
 —, tuberculosis of, 113
 —, tumours of, 116
 —, typhoid, changes in, 115
 Lateral curvature of spine, 154
 Lead poisoning, 395, 433
 Leishman's staining method, 448, 451
 Leontiasis ossea, 412
 Leprosy of larynx, 115
 — of liver, 242
 — of lungs, 149
 — of mouth, 160
 — of nasal cavities, 401
 — of nerves, 396
 Lepto-meninges, cerebral, 376
 —, spinal, 361
 Lepto-meningitis, acute, 378
 —, cerebro-spinal, 378, 379
 —, chronic, 381
 —, leptothrix, 379
 —, serous, 378
 —, syphilitic, 381
 —, tuberculous, 380
 Leptothrix meningitis, acute, 379
 Leucoblastic reaction in bone marrow, 352
 Leucocythaemia, changes in bone marrow, 353
 —, — in kidneys, 310
 —, — in larynx, 115
 —, — in liver, 242
 —, — in lymphatic glands, 350
 —, — in mouth, 160
 —, — in spleen, 271
 —, — in stomach, 188
 Leucoderma, 17
 Leucopenia, bone marrow, 352
 Leukaemia, *see* Leucocythaemia
 Ligamentum latum pulmonis, 41

Ligature of blood-vessels, changes following, 95

Linea nigra, 24

Lingula, 126

Lipaemia, in diabetes, 107

Lipomatosis, of muscles, 421

—, of pancreas, 223

Lips, diseases of, 158

Liver, 225

—, actinomycosis of, 242

—, amyloid degeneration of, 233

—, in anaemia, 237

—, anatomy of, 225

—, angioma of, cavernous, 252

—, atrophy of, acute yellow, 245, 435, 436

—, —, cyanotic, 235

—, —, subacute yellow, 246. Plate I, fig. 4

—, cholangitis, 240, 252

—, in chorionepithelioma, 256

—, cirrhosis of, biliary, 250

—, —, Hanot's, 250

—, —, monolobular, 250

—, —, multilobular, 247

—, —, syphilitic, 244

—, cloudy swelling of, 231

—, colour of, 229

—, congenital cystic, 284

—, congestions of, 235

—, consistence of, 230

—, cyanotic atrophy of, 235

—, degenerations of, 231

—, diminution in size of, 229

—, displacement of, 227

—, in eclampsia, 230

—, enlargement of, 228

—, examination of, 226

—, fatty degeneration of, 231

—, fatty infiltration of, 232

—, focal necrosis of, 234

—, grooves on surface of, 228

—, gummata of, 243

—, in haemochromatosis, 238

—, hydatid cysts of, 241

—, hypernephroma of, 256

—, infarction of, 229, 230

—, in leprosy, 242

—, in leucocythaemia, 244

—, in lymphadenoma, 245

—, measurements of, 224

—, nutmeg, 235

—, parasites, animal, 258

—, pigmentations of, 229

—, in pyaemia, 239

—, regeneration of cells of, 237, 246

—, removal of, 226

—, shape of, alterations in, 228

—, size of, 228

—, suppurations in, 239

Liver, syphilis of, 242

—, tropical abscess of, 241

—, tuberculosis of, 242

—, tumours of, 252

—, waxy degeneration of, 233

—, weight of, 225

Lividity, *post mortem*, 13, 16

Lochiometra, 326

Locomotor ataxia, 363

— —, changes in joints, 430

Logwood staining methods, 447

Lordosis, 155

Lungs, 120

—, abscesses of, 136

—, actinomycosis of, 149

—, air content of, 122

—, anthracosis of, 123, 139

—, anthrax of, 138

—, atelectasis of, 124

—, carnification of, 133

—, collapse of, 124

—, colour of, 122

—, congestions of, acute, 130

—, —, chronic, 127

—, —, hypostatic, 127

—, consistence of, 122

—, cut surface of, 123

—, emphysema of, 125

—, examination of, 121, 122

—, excavation of, 119, 124, 144–146

—, fluids escaping from cut surface of, 123

—, friability of, 123

—, gangrene of, 124, 137

—, glanders of, 149

—, haemorrhage into, 128

—, incisions into, 121

—, infarction of, 128

—, inflammation of, 130, *see* Pneumonia

—, leprosy of, 149

—, normal, 38

—, oedema of, 127

—, parasites of, 128, 149

—, in plague, 138

—, pneumonia, 123, 130

—, pneumoliths, 141

—, removal of, 46, 47, 121

—, silicosis of, 140

—, "suppuration" of, 133

—, surface of, cut, 123

—, —, pleural, 121

—, syphilis of, 148

—, tuberculosis of, 141

—, —, chronic, 147

—, —, lymphatic, 143

—, —, miliary (embolic), 142

—, tumours of, 149

—, weight of, 120

Lung-stones, 141

- Lupus, 22
 — of larynx, 114
 — of mouth, 160
 — of nasal cavities, 400
 Lymphadenitis, 348
 Lymphadenoma of lymphatic glands, 349
 — of liver, 245
 — of spleen, 272
 — invading vena cava, 103
 Lymphatic glands, 348
 —, atrophy of, 348
 —, cervical, 162
 —, hyaline degeneration of, 348
 —, inflammation of, 348
 —, infection of, 349
 —, in lymphadenoma, 349
 —, in leucocythaemia, 350
 —, parasites of, 350
 —, tumours of, 350
 —, waxy degeneration of, 348
 Lymphatic varices, intestine, 211
 Lymphomatous nodules, stomach, 188
 Lymphosarcoma, 40, 49, 204, 209, 350

 Macrocheilia, 22, 160
 Macroglossia, 160
 Malacosteon, 410
 Malaria, spleen, 267, 272
 Malignant adenoma, *see* Adenoma, malignant
 Mamma, 24, 31, 341
 —, actinomycosis of, 342
 —, cancer, dissemination of, 346
 —, hypertrophy of, 341
 —, inflammation of, 341
 —, malformations of, 341
 —, syphilis of, 343
 —, tuberculosis of, 342
 —, tumours of, 343
 Marrow, Bone-, 350
 —, erythroblastic, 353
 —, gelatinous, 353
 —, haematoblastic, in fat in hilum of kidney, 281
 —, leucoblastic, 352
 Mastitis, 31, 342
 Mastoid antrum, 401, 402
 Maxillary antrum, 399
 Measurements, Tables of Imperial and Metrical, 453
 Meckel's diverticulum, 26, 202
 Meconium, 205
 Media, culture, 451
 —, embedding, 445
 —, fixing, 444-445
 —, staining, 447
 Mediastinum, 38
 —, new-growths of, 39
 Mediastino-pericarditis, chronic, 40, 52, 64
 Megacolon congenitum, 203
 Melaena, 205, 211
 Melanosis, 17
 —, of intestine, 433
 Meninges, congestion of, 377
 —, exudation into, 377
 Meningitis, *see* Leptomeningitis and Pachymeningitis
 Meningitis, cerebro-spinal, 362
 —, serous, 362, 378
 —, spinal, 361
 —, syphilitic, 362
 —, tuberculous, 361
 Meningocele, 361
 Meningo-encephalitis, 381
 Mesentery, 196, 204
 Metaplasia of cartilage, in chronic bronchitis, 118
 — of epithelium, 112, 116, 259
 Met-haemoglobin, 293, 439
 Methods for economizing reagents, 450
 —, embedding, 445
 —, fixing, 444
 — for preserving the natural colour of tissues, 443
 —, staining, 447, 451
 Methylene blue and eosin, 449
 —, polychrome, 450
 Micrencephaly, 369, 383
 Microcephaly, 20, 383
 Microgyria, 383
 Microscopical examination of tissues, 443
 — sections, rapid methods of preparing, 449
 Miliary aneurysms, 98
 Milk spots, 51
 Mole, fleshy 331
 —, haemorrhagic, 330
 —, hydatid, 331
 Molluscum fibrosum, 17, 396
 Motor neurons, affections of, 364
 Mounting media for microscopical sections, 448
 Mounting specimens in glass jars, 444
 Mouth, 158
 —, actinomycosis of, 160
 —, cysts of, 160
 —, leprosy of, 160
 —, lupus of, 160
 —, in lymphatic leucocythaemia, 160
 —, syphilis of, 159
 —, tuberculosis of, 159
 —, tumours of, 160
 Mucous colitis, 206, 213
 Multiple sclerosis, brain, 390
 —, spinal cord, 359
 Muscle of heart, primitive, 75
 Muscles, voluntary, changes in, 30
 —, —, degenerations of, 30, 421

- Muscles, voluntary, diseases of, 420
 —, —, atrophy of, 420
 —, —, inflammation of, 421
 —, —, lipomatosis of, 421
 —, —, parasites of, 422
 —, —, syphilis of, 421
 —, —, tuberculosis of, 421
 —, —, tumours of, 422
 —, —, vitreous degeneration of, 30, 421
 Muscular atrophy, progressive (spinal), 364
 — dystrophies, 421
 Mycosis fungoides, 18
 Myelinic degeneration, 290
 Myelitis, 358, 359, 362
 Myeloid alveolar carcinoma, 346
 Myeloid sarcoma, 414
 Myeloma, 414
 Myocarditis, interstitial, 72
 —, parenchymatous, 72
 —, rheumatic, 72
 —, suppurative, 72
 Myocardium, cloudy swelling of, 68
 —, diseases of, 68
 —, fatty degeneration of, 69
 —, fragmentation of, 69
 —, inflammation of, 72
 —, tuberculosis of, 74
 Myomalacia cordis, 70
 Myopathies, primary, 421
 Myositis, 421
 — ossificans, 27, 421
 Myxoedema, 157

 Naevi, 17
 Nasal cavities and accessory sinuses, 397
 — —, glanders of, 401
 — —, gummata of, 400
 — —, haemorrhage from, 399
 — —, inflammation of, 399
 — —, leprosy of, 401
 — —, lupus of, 400
 — —, methods of exposing, 397, 398
 — —, rhinoscleroma, 401
 — —, syphilis of, 400
 — —, tuberculosis of, 400
 — —, tumours of, 400
 Neck, dissection of, 46
 —, surface of, 23
 Necrosis, decubital, 166
 —, focal, liver, 234
 —, —, spleen, 270
 Needle-grinders' lung, 140
 Nephritis, 303
 —, ascending, 299
 —, consecutive, 299
 —, desquamative, 305
 —, diffuse, 308
 —, disseminated suppurative pyelo-, 299
 —, glomerular, 303
 Nephritis, interstitial, acute, 305
 —, —, chronic, 309
 —, —, sub-acute, 307
 —, parenchymatous, acute, 304
 —, —, chronic, 308
 —, —, sub-acute, 306
 Nephrolithiasis, 318
 Nerves, cranial, 373
 —, —, nuclei, Plate III
 Nerves, peripheral, 395
 —, —, degenerations, 395
 —, —, leprosy of, 396
 —, —, regeneration of, 396
 —, —, syphilis of, 396
 —, —, tuberculosis of, 396
 —, —, tumours of, 396
 Neuritis, 395
 — in alcoholism, 396
 — in lead poisoning, 396
 —, puerperal, 396
 Neurons, motor, 364
 Nipple, Paget's disease of, 31, 345
 —, inflammation of, 341
 Node, auriculo-ventricular, 76
 —, sino-auricular, 76
 Nodes, syphilitic, 409
 Noma, 22, 159
 Nose, *see* Nasal cavities
 Nutmeg liver, 235

 Oedema, 15
 — of adhesions (pleuritic), 150
 — of brain, 384
 — of face, 22
 — of intestines, 209
 — of kidneys, 291
 — of larynx, 111
 — of lungs, 127
 — of scrotum, 336
 — of subcutaneous tissues (anasarca), 30
 Oesophagus, action of corrosives, 425
 —, anatomy of, 166
 —, dilatation of, 166
 —, diseases of, 166
 —, diverticula of, 166
 —, measurements of, 166
 —, peptic ulceration of, 164
 —, stenosis of, 164
 —, tumours of, 167
 —, varicose veins of, 102, 166, 178, 250
 Oidium albicans, 158, 167
 Operating room, 3
 — table, 4
 Operation, hints, 8
 Operator, precautions to be observed
 while performing a *sectio*, 5
 Orbit, diseases of, 403
 —, examination of, 403
 —, suppuration in, 404

- Orbit, tumours of, 403
 Orchitis, 338
 Order of examination, 9
 Organization of exudates, 50, 152
 — of thrombus, 85, 88, 152
 — of infarct, 110
 Orifices of heart, measurements, 58
 — —, measurement with fingers, 59
 Ossa triquetra, 366
 "Ossified man," 27
 Osteitis, 405
 —, deformans, 370, 411
 —, rarefying, 408
 —, syphilitic, 408
 —, tuberculous, 407
 Osteoarthropathy, hypertrophic pulmonary, 412
 Osteo-arthritis deformans, 411
 Osteomalacia, 410
 —, senile, 411
 Osteomyelitis, 406
 Osteophytes, 407
 Osteoporosis, senile, 411
 —, tuberculous, 407
 Osteosarcoma, calvarium, 20
 Otitis media, 402
 Ovary, 332
 —, abscesses of, 333
 —, cysts of, 333, 334
 —, removal of, 275
 —, tumours of, 333
 Ovula Nabothii, 327
 Ozaena, 400
- Pacchionian bodies, 376
 Pachymeningitis, 374
 —, chronic syphilitic, 367, 374
 Paget's disease of bone, 411
 — — of the nipple, 31, 345
 Pancreas, aberrant, 202, 220
 —, calculi in ducts, 223
 —, cysts of, 223
 —, degenerations of, 223
 —, in diabetes, 223
 —, diseases of, 220
 —, fat necrosis of, 221
 —, haemorrhage into, 221
 —, inflammations of, 220
 —, lipomatosis of, 223
 —, syphilis of, 223
 —, tuberculosis of, 223
 —, tumours of, 224
 Pancreatitis, 220
 Panniculus adiposus, 30
 Papillary muscles, rupture of, 75
 Papilliferous cystadenoma, of mamma, 345
 — —, of ovary, 333
 Papilloma, venereal, 324, 338
- Papilloma, villous, 319, 332
 Paraffin embedding, 446
 Paralysis, infantile spinal, 362
 —, Landry's, 362
 —, progressive muscular, 364
 —, pseudo-hypertrophic muscular, 421
 Paraphimosis, 335
 Parasites, *see* Animal parasites
 Parathyroids, 158
 "Parchment patches," on skin surface, 17
 — —, on lips, 23
 Parotid, 161
 Parrot's nodes or bosses, 21, 366, 371
 Pars membranacea septi, aneurysm of, 61, 74
 — — —, patency of, 61
 Patent foramen ovale, 60
 Pearly tumour, 393
 Pedunculated polyps of the heart, 88
 Pellagra, discoloration of skin, 17
 Pelvic organs, removal of, 204, 275
 Penis, diseases of, 26, 318, 335
 —, removal of, 335
 Peptic ulceration of the stomach and duodenum, 181
 Periarthritis, 102
 Peribronchitis, 115
 Pericarditis, acute, 50
 —, bacteriology of, 53
 —, etiology of, 53
 —, haemorrhagic, 51
 —, organized, 51
 —, putrid, 51
 —, recurrent, 51
 —, suppurative, 52
 —, tuberculous, 52
 Pericardium, 40, 42, 49
 —, calcification of, 52
 —, diseases of, 49
 —, exterior of, 40
 —, method of opening, 42
 —, new-growths of, 49
 Perichondritis, larynx, 113
 Perigastritis, 176
 Perihepatitis, 172, 243
 Perineum, 26
 Periostitis, 406
 Peripheral nerves, 395
 Perisplenitis, 172, 264
 Perithelioma of fourth ventricle, 392
 Peritoneum, diseases of, 168
 —, drainage of, 168
 —, inflammation of, 170
 —, parasites of, 174
 —, structure of, 168
 —, tumours of, 174
 Peritonitis, acute, 170
 —, channels of infection in, 171
 —, chronic, 171

- Peritonitis, tuberculous, 173
 Perityphlitis, 224
 Perl's Prussian-blue, reaction for iron, 238
 Perlsucht, 154
 Pernicious anaemia, 17, 232, 289, 353
 Peyer's patches in intestine, 195
 Pharynx, 163
 —, diseases of, 161
 —, diverticula of, 165
 —, necrosis of, decubital, 166
 —, syphilis of, 165
 —, tumours of, 165
 Phimosis, 335
 Phlebitis, varieties, 103
 Phleboliths, 103
 —, in angioma, 90
 —, in prostatic plexus, 335
 —, in spleen, 271
 Phtheiriasis, 18
 Phthisis, laryngeal, 113
 —, pulmonalis, 144
 Physometra, 326
 Pia mater, 376
 Pick's preserving method, 443
 Picro-fuchsin (van Gieson) 448
 "Pigeon-breast," 23, 410
 Pigmentation, of heart, 65, 70
 —, of mouth, 160
 "Pipe-stem" arteries, 91
 Pituitary body, 394
 Pityriasis versicolor, 24
 Placenta, 330
 Plague, pneumonic, 138
 "Plaques jaunes," 286
 Plastic bronchitis, 118
 Pleura, diseases of, 149
 —, effusions into, 150
 —, examination of, 40
 —, tuberculosis of, 153
 Pleurisy, 151
 —, diaphragmatic, 42
 Plica polonica, 21
 Pneumoconioses, 139
 Pneumoliths, 141
 Pneumonia, alcoholic, 132
 —, bacteriology of, 133
 —, broncho-, 133
 —, croupous, or fibrinous, 130
 —, fibrino-catarrhal, 134
 —, glands in, 133
 —, hypostatic, 127, 135
 —, interstitial, 138-141
 — —, histology, 139
 —, lobar, 130
 — —, results of, 132
 —, lobular, 135
 —, lymphatics in, 133
 —, pseudo-lobar, 136
 —, septic, 136
 Pneumonia, streptothrix, 136
 Pneumonic plague, 138
 Pneumonomycosis, 138
 Pneumopericardium, 43
 Pneumothorax, 41, 150
 —, detection of, 32
 Poisons, changes produced by, 423
 Acetic acid, 428
 Aconite, 441
 Alcohol, ethylic, 437
 Ammonia, 428
 Anilin, 440
 Antimony, 431
 Arsenic, 430
 Arseniuretted hydrogen, 439
 Atropine, 441
 Barium, 430
 Belladonna, 441
 Benzine, 440
 Bromine, 436
 Calabar bean, 442
 Carbon bi-sulphide, 439
 Carbon di-oxide, 438
 Carbonic acid, 438
 Carbon monoxide, 13, 19, 30, 438
 Castor oil seeds, 441
 Caustic potash, 429
 Caustic soda, 429
 Chloral hydrate, 438
 Chlorine gas, 436
 Chloroform, 437
 Chromic acid and chromates, 434
 Cocaine, 441
 Colchicum, 441
 Colocynth, 441
 Conine, 441
 Copper salts, 434
 Corrosives, 425, 426
 Corrosive sublimate, 426, 432
 Croton oil, 441
 Digitalis, 19, 440
 Dynamite, 439
 Elaterium, 441
 Ergot, 441
 Eserine, 442
 Ether, 438
 Ethylic alcohol, 437
 Explosives, 439
 Foxglove, 440
 Fungi, 442
 Gamboge, 441
 Gases, 438
 Gelsemium, 442
 Gun-cotton, 439
 Gunpowder, 439
 Hellebore, 442
 Hemlock, 441
 Hydrochloric acid, 427
 Hydrocyanic acid, 13, 436

- Poisons (contd.)*, Hydrofluoric acid, 428
 Illuminating gas, 439
 Iodine, 436
 Iodoform, 438
 Jalap, 441
 Lead, 395, 433
 Male fern, 441
 Meat poisoning, 442
 Mercury, salts of, 432
 Morphine, 440
 Naphthol, 440
 Nicotine, 440
 Nitre, 430
 Nitric acid, 427
 — —, fumes, 439
 Nitrobenzene, 440
 Nitroglycerine, 439
 Nitrous oxide, 439
 Opium, 440
 Oxalic acid, 428
 Petroleum, 440
 Phosphorus, 435
 Physostigmine, 442
 Podophyllin, 441
 Potassium chlorate, 429
 — cyanide, 437
 — hydrate, 429
 — nitrate, 430
 — oxalate, 428
 Prussic acid, 436
 Ptomaine poisoning, 442
 Pyridine, 440
 Ricin, 441
 Roburite, 439
 Salicylic acid, 440
 Savin, 440
 Sewer gas, 439
 Silver, salts of, 433
 Soamin, 431
 Soda, carbonate, 429
 —, caustic, 429
 Strophanthus, 19
 Strychnine, 19, 441
 Sulphonal, 442
 Sulphur di-oxide, 439
 Sulphuretted hydrogen, 439
 Sulphuric acid, 426
 Tartar emetic, 431
 Tobacco, 440
 Tonite, 439
 Veratrum, 442
 Water gas, 438
 Zinc, salts of, 434
 Poliomyelitis, 362
 Polyarteritis nodosa, 102
 Polymastia, 341
 Polymyositis, 421
 Polypi, nasal, 400, 401
 —, uterine, 329
 Polyps of the heart, pedunculated, 88
 Polypus, adenomatous, of rectum, 208
 Polythelia, 340
 Pons, 382
 —, haemorrhage, 386
 —, "hypertrophy," 392
 Porencephaly, 20, 383
 Portal pyaemia, 239
 Posthitis, 336
 Posthumous circulation, 18
 Post mortem digestion of the stomach, 180
 Post mortem examination, General considerations, 1
 Post mortem clots, 85
 — — rigidity, 19
 — — room, 3
 — — sink, 4
 — — table, 4
 Precautions to be observed by the operator, 5
 Premature burial, 12
 Primitive muscle of heart, 75
 Private houses, *post mortem* examinations in, 4
 Progressive muscular atrophy (spinal form,) 364
 — — —, Erb's juvenile, 421
 Prolapse, anus, 200
 —, rectum, 200
 —, uterus, 326
 Prostate, 335, 337
 Prostatic plexus of veins, 335
 Protagon, 300
 Prussian-blue reaction, 238
 Psammoma, 393
 Pseudo-hermaphrodites, 324
 Pseudo-hypertrophic muscular paralysis, 421
 Psoas abscess, 408
 Pulmonary anthrax, 138
 Pulmonary artery, embolism, 44
 — —, opening and valve, *see* under Heart
 Punctured wounds, 24
 Pyaemia, cryptogenic, 164
 Pyelitis, 316
 Pyelonephritis, suppurative, 299
 Pylephlebitis, 239
 Pyoid marrow, 353
 Pyometra, 326
 Pyonephrosis, 315
 Pyosalpinx, 332
 Quincke's reaction for iron, 238
 Rachischisis, 361, 363
 Rapid methods of preparing microscopic sections, 449
 Raynaud's disease, 27

- Records of post mortem cases, 14
 Rectocele, 326
 Rectum, gonorrhoea, 336
 —, prolapse of, 200
 —, syphilis, 219
 —, atresia, congenital, 203
 —, imperforate anus, 203
 —, tumours, 208
 Reidel's lobe, 227
 Removal of the viscera, general description, 35
 — of abdominal contents, 29, 35, 204, 226, 275
 — of bone marrow, 350
 — of brain, 372
 — of calvarium, 366
 — of cervical sympathetic, 162
 — of cervical tissues, 45, 162
 — of heart, 47
 — of intestine, 204
 — of kidneys and supra-renals, 275
 — of liver, 226
 — of lungs, 46, 47
 — of pancreas, 226
 — of pelvic contents, 204, 275
 — of penis, 335
 — of skull cap, 366
 — of spinal cord and ganglia, 354, 357
 — of spleen, 226
 — of stomach, 226
 — of sympathetic ganglia, 162
 — of testicles, 335
 — of thoracic contents, 45
 Reproductive organs, female, 324
 — —, male, 335
 Respiratory tract, 111
 Restoration of the body, after a *post mortem*, 10
 Retro-pharyngeal abscess, 162
 Rhabdomyoma of heart, 49
 — of kidneys, 312
 — of muscles, 422
 — of thyroid, 157
 Rheumatism, 415
 Rheumatoid arthritis, 418
 Rhinitis, 399
 —, membranous, 400
 — sicca, 399
 Rhinoliths, 401
 Rhinoscleroma, 400
 Rib marrow, 350
 "Rice-bodies" in joints, 417
 "Rickety rosary," 33, 410
 Rickets, 409
 —, changes in skull, 369, 410
 Rickets, delayed, 410
 Riders' bone, 27
 Rigor mortis, 18
 — —, contraction of heart, 19, 68
 Rigor mortis, contraction of stomach, 19, 178
 — —, in hemiplegia, 20
 Ringworm, 20
 Room, *post mortem*, 3
 Round ulcer of stomach, 181
 "Sago waxy" spleen, 265
 Salpingitis, 332
 Sarcoma of bone and periosteum, 413
 — of brain and membranes, 392
 — of dura mater, 376, 358
 — of heart, 49
 — of intestine, 207
 — of kidneys, 312
 — of larynx, 116
 — of liver, 253
 — of lungs, 149
 — of lymphatic glands, 40, 350
 — of mamma, 341
 — of mediastinum, 40, 49
 — of mesentery, 204
 — of mouth, 160
 — of muscles, 420
 — of nasal cavities, 401
 — of nerves, 396
 — of orbit, 403
 — of ovary, 335
 — of pancreas, 224
 — of parotid, 161
 — of pericardium, 49
 — of prostate, 338
 — of spleen, 274
 — of stomach, 194
 — of supra-renals, 323
 — of testicles, 340
 — of thyroid, 157
 — of uterus, 330
 — of vertebrae, 355
 Scalp, 20, 365
 —, depressions, 21
 —, prominences, 21
 —, tumours, 21
 —, wounds, 21
 Scarlatinal nephritis, 307
 Scirrhus cancer of appendix vermiformis, 208
 — — of gall-bladder, 259
 — — of heart, 49
 — — of intestine, 208
 — — of liver, 254
 — — of mamma, 345
 — — of pancreas, 224
 — — of pericardium, 49
 — — of stomach, 191, 193
 Scleroderma, 18
 Sclerosis, amyotrophic lateral, 365
 —, disseminated, insular, multiple, of brain, 390

- Sclerosis, disseminated, insular, multiple,
 of spinal cord, 363
 Sclerosis of bone, 407, 408
 Scoliosis, 154
 Scrotum, diseases of, 336
 Scurvy (scorbutus), infantile, 411
 Sella turcica, enlargement of, 395
 Semicircular canals, 401
 Seminal vesicles, 341
 Senile calcification of arteries, 91
 — osteomalacia, 411
 Septum ventriculorum, defects in, 60
 Sequestrum, bone, 406
 Serous degeneration of epicardial fat, 64
 — meningitis, 378
 Siderosis of lungs, 141
 Sieve-like degeneration of brain, 384
 Signs of death, 12
 Silicosis of lungs, 140, 154
 Silver, deposit of, *see* Argyria
 Sino-auricular node, 76
 Sinuses, accessory nasal, 397
 —, ethmoidal, 399
 —, frontal, 398
 —, sphenoidal, 399
 —, thrombosis of meningeal venous, 375
 Skin, colour of, 16
 —, eruptions, 18
 —, syphilis of, 28
 Skin incisions, preliminary, 29
 Skull, 365
 Skull cap, removal of, 366
 Skull, diseases of, 365
 —, osteitis deformans of, 370
 —, sutures, 369
 —, syphilitic changes in, 370, 371
 —, tuberculous caries of, 371
 —, hyperostosis, 371
 Softening, cerebral, 387
 —, of spinal cord, *see* Myelitis, 362
 Specific warts, 324, 336
 Spermatic cord, 341
 Spermatocoele, 338
 Spermatocystitis, 341
 Sphenoidal sinus, 399
 Spina bifida, 361, 369, 390
 Spinal cord, 354
 —, anatomy of, 354
 —, degenerations of, 359, 363
 —, examination of, 358, 359
 —, gummata of, 359
 —, haematomyelia, 360
 —, haemorrhages into, 359
 —, in Landry's paralysis, 362
 —, measurements of, 354
 —, meningitis, 361
 —, myelitis, 362
 —, paralysis, infantile, 362
 —, preservation of, 358
 Spinal cord, removal of, 354, 357
 —, sclerosis of, 359
 —, softening, 362
 —, syringomyelia, 360
 —, tracts of, 363
 —, tuberculous masses in, 359
 —, — meningitis of, 361
 Spinal curvatures, 154
 Spirochaetes, 180, 452
 Spleen, 263
 —, amyloid degeneration of, 264
 —, anatomy of, 263
 —, anomalies of, 264
 —, atrophy of, 266
 —, carbon pigmentation of, 267
 —, congestions of, 267
 —, degenerations of, 264
 —, discoloration of, *port mortem*, 267
 —, displacements of, 264
 —, fatty degeneration of, 266
 —, focal necrosis, 270
 —, in haemoglobinaemia, 267
 —, hyaline degeneration of vessels of, 266
 —, infarction of, 270
 —, in jaundice, 267
 —, lamellar fibroma, 264
 —, lardaceous degeneration of, 265
 —, in leucocythaemia, 271
 —, in lymphadenoma, 272
 —, lymphatics of, 263
 —, in malaria, 267
 —, measurements of, 263
 —, parasites of, 274
 —, phleboliths in, 271
 —, pigmentation of, 267
 —, tuberculosis of, 273
 —, tumours of, 274
 —, waxy degeneration of, 264
 —, weight and measurements of, 263
 Splenicula, Splenunculi, 263
 Spondylitis deformans, 420
 Squamous epithelioma, *see* Epithelioma
 Status lymphaticus, 39
 Stenosis of bronchi, 120
 — of duodenum, at Vater's ampulla, 178,
 201
 — of heart valves, 80
 — of intestine, 201
 — of pylorus, 177
 — of rectum, 203
 — of trachea, 117
 Sternum, 31
 Stomach, 175
 —, anatomy of, 175
 —, anthrax of, 187
 —, atrophy of, 185
 —, bilharziosis of, 188
 —, blood-vessels of, 175
 —, carcinoma of, colloid, 192

- Stomach, carcinoma of, columnar-celled, 189
 —, —, encephaloid, 190
 —, —, scirrhus, 191
 —, —, squamous-celled, 192
 —, catarrh of, 185
 —, contents of, 179, 424
 —, degenerations of, 185
 —, dilatation of, 176
 —, diminution in size of, 178
 —, erosions of, haemorrhagic, 184
 —, haemorrhage from, 179, 184, 187
 —, "hour-glass" contraction of, 19, 178
 —, hyperaemia of, 184
 —, inflammation of, 185
 —, in leucocythaemia, 188
 —, lymphomatous nodules in, 188
 —, measurements of, 175
 —, method of opening, 178
 —, parasites of, 180, 188
 —, peptic ulceration of, 181
 —, position of, alterations in, 176, 177
 —, *post mortem* digestion of, 180
 —, in *rigor mortis*, 19, 178
 —, sarcoma of, 194
 —, serous surface of, 176
 —, stenosis of pylorus, 177
 —, suppuration in, 187
 —, syphilis of, 188
 —, tuberculosis of, 187
 —, tumours of, 188
 —, in typhoid, 188
 —, ulceration of, peptic, 181
 Stone-masons' lung, 140
 Striae albicantes, 24
 — gravidarum, 24
 Sugillations, cadaveric, 16
 Supra-renal bodies, 275, 276, 321
 — —, tumours of, 322
 — "rests," 312
 — "rest" tumours, 312
 Sutures of skull, 369
 Symmetry, 15
 Sympathetic ganglia in neck, 162
 Synostosis of sutures in skull, 369
 Syphilis of arteries, 100
 — of bone and periosteum, 408
 — of bronchi, 120
 — of calvarium, 370, 371
 — of cerebral membranes, 381
 — of face, 22
 — of heart, 74
 — of intestine, 219
 — of joints, 418
 — of kidneys, 302
 — of larynx, 114
 — of liver, 242
 — of lungs, 148
 — of mamma, 343
 Syphilis of meninges, cerebral, 381
 — —, spinal, 362
 — of mouth, 159
 — of muscles, 421
 — of nasal cavities, 400
 — of nerves, 396
 — of pancreas, 223
 — of penis, 336
 — of pharynx, 165
 — of skin, 28
 — of skull, 370, 371
 — of stomach, 188
 — of testicle, 359
 Synovitis, 415
 —, tuberculous, 417
 Syringomyelia, 357, 358, 359, 360
 —, changes in joints, 420
 Syringomyelocele, 361
 Tabes, cervical, 363
 —, dorsalis, 363
 —, mesenterica, 349
 Tables of Equivalent Imperial and Metrical Measurements, 453
 Teratoma, brain, 393
 Testicle, actinomycosis of, 340
 —, abnormalities of, 338
 —, diseases of, 338
 —, gumma of, 339
 —, inflammation of, 335
 —, leprosy of, 340
 —, removal of, 335
 —, syphilis of, 339
 —, tuberculosis of, 339
 —, tumours of, 340
 Testis, undescended 338
 Tetanus, 19
 "Tête carrée," 369
 Theatre, *post mortem*, 3
 Thorax, examination of contents of, *in situ*, 39
 —, exposure of walls, 30, 32
 —, organs, examination after removal, 47
 —, —, removal of, 45
 —, outer surface of, 23
 —, walls of, changes in, 31, 154
 Three-chambered heart, 60
 Thrombi, agony or agonal, 87
 —, *ante mortem*, 85
 —, ball-, 85
 —, blood-platelet, 86
 —, diagnosis from emboli, 106
 —, globular, 85
 Thrombosis, 40
 —, in cortical vessels, 388
 —, in meningeal sinuses, 375
 —, in renal veins, 294
 "Thrush," mouth, 158
 —, oesophagus, 167

- "Thrush-breast" mottling, of heart muscle, 69
 Thymic asthma, 39
 Thymus, 38
 —, measurements of, 38
 —, weight of, 38
 "Thymus-Tod," 39
 Thyroid, diseases of, 156
 Tonsillitis, 163
 Trachea, diseases of, 116
 Traumatic apoplexy, delayed, 387
 Treatment of wounds received while performing a *post mortem* examination, 7
 Trichinosis, 422
 Tricælian heart, 60
 Tricuspid opening, 55
 — —, obliteration of, 61
 Tropical abscess, liver, 241
 Tubal gestation, 332
 Tubercle, painful subcutaneous (Wood's), 396
 Tubercle bacillus, channels of infection, 143, 349, 380
 — —, staining method, 143, 452
 Tuberculosis of arteries, 101
 — of bladder, urinary, 319
 — of bone, 407
 — of brain, 361, 394
 — of ear, middle, 403
 — of epididymis, 338
 — of Fallopian tubes, 329
 — of gall-bladder, 259
 — of heart, 74
 — of intestine, 216
 — of joints, 417
 — of kidneys, 300
 — of larynx, 113
 — of liver, 242
 — of lungs, 141
 — —, bacteriology, 147
 — of mamma, 342
 — of mouth, 159
 — of muscles, 421
 — of myocardium, 74
 — of nasal cavities, 400
 — of nerves, 395
 — of pancreas, 223
 — of renal pelvis, 316
 — of pericardium, 52
 — of pleura, 153
 — of spleen, 273
 — of stomach, 187
 — of testicle, 339
 — of urinary bladder, 319
 — of veins, 103
 Tuberculosis in children, 144, 380
 Tuberculous "tumours" in brain, 394
 Tumours of bladder (urinary), 319
 — of bone and periosteum, 412
 Tumours of brain, 392
 — of dura mater, 376
 — of Fallopian tubes, 333
 — of gall-bladder, 259
 — of heart, 49
 — of intestines, 207
 — of kidneys, 311
 — of larynx, 116
 — of liver, 252
 — of lungs, 149
 — of lymphatic glands, 350
 — of mamma, 343
 — of meninges, cerebral, 376
 — —, spinal, 358
 — of mouth, 160
 — of muscles, 422
 — of myocardium, 49
 — of nasal cavities, 401
 — of nerves, 396
 — of ovary, 333
 — of pancreas, 224
 — of penis, 336
 — of peritoneum, 174
 — of pleura, 152
 — of prostate, 337
 — of scrotum, 336
 — of spleen, 274
 — of stomach, 188
 — of supra-renals, 322
 — of testicle, 340
 — of thyroid, 156
 — of urinary bladder, 319
 — of uterus, 328
 Tunica vaginalis testis, 340
 Tympanites, 25
 Typhilitis, 224
 Typhoid fever, bile-ducts in, 262
 — —, gall-bladder in, 259
 — —, intestine in, 218
 — —, larynx in, 115
 — —, liver in, 234
 — —, lymphatic glands in, 219
 — —, meningitis in, 378
 — —, spleen in, 268
 — —, stomach in, 188
 — —, ulceration of intestine, 218
 Umbilicus, 25
 Urachus, patent, 26
 Ureteritis, 316
 Urethra, 335
 Uric acid deposits in kidneys, 294
 Urinary bladder, 317
 — calculi, 320
 Uterus, dilatation of, 326
 —, displacements of, 326
 —, double, 325
 —, endometritis, 327
 —, erosions in cervix of, 326

- Uterus, hypertrophy of, 326
 —, malformations of, 325
 —, polypi of, 329
 —, procidentia, 326
 —, prolapse of, 326
 —, syphilis of, 328
 —, tuberculosis of, 328
 —, tumours of, 328
- van Gieson's stain, 448
 Varices in intestine, lymphatic, 211
 Varicocele, 341
 Varicose veins, 45, 102
 — — of oesophagus, 102, 166, 180, 250
 Vas deferens, 335, 341
 Vater's ampulla, stenosis at, 178
 — —, diverticulum of duodenum, near, 201
 Veins, aneurysms of, 100
 —, diseases of, 102
 —, lymphadenoma of, 103
 —, tuberculosis of, 103
 —, varicose, 45, 102
 Venereal warts, 324, 326
 Venous trunks, distension of, 39
 Ventricle of heart, bifid, 59
 Ventricle of heart, left, 57
 — —, —, dilatation and hypertrophy of, 67
 Ventricle of heart, right, 55
 — —, —, dilatation and hypertrophy of, 66
 Vertebral column, 356
 — —, abnormalities, 356
 — —, caries of, 356
 — —, curvatures of, 154, 410, 411
 — —, fracture-dislocations of, 356
 — —, haemorrhage into canal, 356
 — —, parasites, 356
 — —, periostitis of, 356
 — —, spondylitis deformans of, 420
 — —, tumours of, 356
 Vesicles on skin, 17
 Vesiculæ seminales, 335, 341
 Vestibule of internal ear, 401
- Villous papilloma of urinary bladder, 319
 — — of Fallopian tubes, 332
 Viscera, removal of, 36
 —, abdominal, removal of, 35, 204, 226, 274
 —, thoracic, removal of, 46
 Vitreous degeneration of muscles, 30, 69, 421
 Volvulus, 200
 Vulva, 324
 —, elephantiasis, 324
 —, kraurosis, 324
- Warts, specific, 324, 326
 Water-supply in *post mortem* room, 3
 — in private *post mortems*, 5
 Waxy (amyloid, lardaceous) degeneration of arteries, 91
 — — of heart, 69
 — — of intestines, 212
 — — of kidneys, 290
 — — of liver, 233
 — — of lymphatic glands, 348
 — — of pancreas, 224
 — — of spleen, 264
 — — of stomach, 185
 — — of supra-renals, 321
 Weighing body and organs, 4
 Weight of brain, 373
 — of heart, 57
 — of kidneys, 276
 — of liver, 225
 — of lungs, 121
 — of spleen, 263
 — of supra-renals, 321
 — of thymus, 38
 "Womb-stones," 329
 Wormian bones, 366
 Wounds, punctured, 14
 — received at *post mortem* examination, 7
- Zenker's vitreous degeneration of muscles, 30, 421
 — — — of myocardium, 69
 Ziehl-Neelsen's method of staining the tubercle bacillus, 452







