**A handbook of pathological anatomy and histology : with an introductory section on post-mortem examinations and the methods of preserving and examining diseased tissues / by Francis Delafield and T. Mitchell Prudden.**


**Contributors**

Delafield, Francis, 1841-1915.
Prudden, T. Mitchell 1849-1924.
University of Leeds. Library

**Publication/Creation**

London : Baillière, Tindall and Cox, 1897.

**Persistent URL**

https://wellcomecollection.org/works/nwbxuzv8

**Provider**

Leeds University Archive

**License and attribution**

This material has been provided by This material has been provided by The University of Leeds Library. The original may be consulted at The University of Leeds Library. where the originals may be consulted.
This work has been identified as being free of known restrictions under copyright law, including all related and neighbouring rights and is being made available under the Creative Commons, Public Domain Mark.

You can copy, modify, distribute and perform the work, even for commercial purposes, without asking permission.

wellcome collection

Wellcome Collection
183 Euston Road
London NW1 2BE UK
T +44 (0)20 7611 8722
E library@wellcomecollection.org
https://wellcomecollection.org

WD/D
25

*The University Library*
*Leeds*




*Medical and Dental*
*Library*


30106 004089149

Stack
QZ 4
DEL

MEDICAL DEPARTMENT,
YORKSHIRE COLLEGE
VICTORIA UNIVERSITY

MEDICAL DEPARTMENT,
YORKSHIRE COLLEGE,
VICTORIA UNIVERSITY

# A HANDBOOK OF

# PATHOLOGICAL ANATOMY

AND

# HISTOLOGY

With an Introductory Section on

POST-MORTEM EXAMINATIONS AND THE METHODS OF PRESERVING AND EXAMINING DISEASED TISSUES

BY

FRANCIS DELAFIELD, M.D., LL.D.

Professor of the Practice of Medicine, College of Physicians and Surgeons, Columbia College, New York

AND

T. MITCHELL PRUDDEN, M.D.

Professor of Pathology and Director of the Laboratories of Histology, Pathology, and Bacteriology, College of Physicians and Surgeons, Columbia College, New York

**Fifth Edition**

ILLUSTRATED BY THREE HUNDRED AND SIXTY-FIVE WOOD ENGRAVINGS PRINTED IN BLACK AND COLORS

LONDON

BAILLIÈRE, TINDALL AND COX

20 & 21, KING WILLIAM STREET, STRAND

1897

PRINTED IN NEW YORK BY
WILLIAM WOOD & COMPANY

UNIVERSITY OF LEEDS
MEDICAL LIBRARY.

604695

# PREFACE TO THE FIFTH EDITION.

THE aims followed in the preparation of this the fifth edition of this work are identical with those which were kept in view in former editions. It has been the intention of the authors to give to students and practitioners of medicine, first, the knowledge necessary for the making of autopsies, the preservation of tissues and their preparation for microscopic study, and to outline the methods of study of pathogenic micro-organisms; second, to describe concisely, with such illustrations as seem necessary, the lesions of the acute infectious diseases and, so far as they are known, the micro-organisms concerned in their causation, the various phases of degeneration and inflammation, the character of tumors, the special lesions of different parts of the body, of the general diseases, of poisoning, and of violent deaths. All of the sections of the book have been revised, and some of them largely rewritten in the light of recent contributions to science. Many new cuts have been added. The section on the blood has been rewritten for us by Dr. James Ewing.

FRANCIS DELAFIELD,
T. MITCHELL PRUDDEN.

MEDICAL DEPARTMENT,
YORKSHIRE COLLEGE
VICTORIA UNIVERSITY

# CONTENTS.

## PART FIRST.

### THE METHOD OF MAKING POST-MORTEM EXAMINATIONS AND OF PRESERVING AND EXAMINING PATHOLOGICAL TISSUES.

The object in making post-mortem examinations.—Causes of death, 3.—External Inspection, 4.—Cadaveric lividity, 5.—Putrefactive changes, 5.—Cooling of the body, 6.—Rigor mortis, 7.—Contusions, 7.—Wounds, 8.—Fractures, scars, and tattoo marks, 9.—Internal Examination, 9.—*The Head.* Removal of calvarium, 10.—The dura mater, the pia mater, the brain, 11.—Methods of opening the brain, 11–18.—Base of the cranium, 18.—*The Spinal Cord,* 19. Preservation of cord and membranes, 21.—*The Thorax and Abdomen,* 22. General inspection of abdominal cavity, 23.—The heart, 25.—The pleural cavities, the lungs, 28–29.—Pharynx, larynx, and œsophagus, 29.—*The Abdomen,* 30. Kidneys, 31.—Suprarenal capsules, 32.—The spleen, 33.—Intestines, 34.—Stomach and duodenum, 35.—Liver, 36.—Pancreas, 37.—*Genito-Urinary Organs.* Male organs, 38.—Female organs, 39.

Autopsies in Medico-Legal Cases and of Suspected Poisoning, 41.

Examination of the Bodies of New-Born Children. *General Inspection,* 42.—*Internal Examination,* 46.

General Methods of Preserving Tissues and Preparing Them for Study, 50.—Fresh tissues, 50.—Decalcifying, 51.—Hardening and preservation, 52.—Müller's fluid, 53.—Formalin, osmic acid, Fleming's osmic-acid mixture, 54.—Corrosive sublimate, Long's solution, 55.—Embedding and section cutting, 56.—Staining, 60.—Preservation of museum specimens, 63.

## PART SECOND.

### CHANGES IN THE CIRCULATION OF THE BLOOD.—CHANGES IN THE COMPOSITION AND STRUCTURE OF THE BLOOD.—HYPERTROPHY, HYPERPLASIA, REGENERATION, DEGENERATION, ETC.—INFLAMMATION.—ANIMAL AND VEGETABLE PARASITES.—INFECTIOUS DISEASES.—TUMORS.

Changes in the Circulation of the Blood. Hyperæmia and anæmia, 69.—Hæmorrhage and transudation, 69–71.—Thrombosis and embolism, 72–75.

Changes in the Composition and Structure of the Blood. Coagulability of the blood, 76.—Anhydræmia, hydræmia, hæmoglobinæmia, anæmia, 76–77. *Changes in the Red Blood Cells,* 77.—*Changes in the White Blood Cells,* 82–86.

Melanæmia, 86.—Method of examination of the blood, 86–89.—*Foreign Bodies in the Blood*, 89.

HYPERTROPHY, HYPERPLASIA, REGENERATION, METAPLASIA. *Hypertrophy and hyperplasia*, 91.—*Regeneration*, 91. Direct cell division.—Indirect cell division, 92.—*Metaplasia*, 95.

DEGENERATIVE CHANGES IN THE TISSUES. Necrosis, coagulation necrosis, 96.—Cheesy degeneration, 97.—Parenchymatous degeneration, 98.—Fatty degeneration and fatty infiltration, 98.—Amyloid degeneration, 100.—Glycogen degeneration, Mucous degeneration, 102.—Colloid degeneration, 103.—Hyalin degeneration, 104.—Calcareous degeneration, 105.—Pigmentation, 106.

INFLAMMATION, 107.—Degeneration and necrosis, 107.—Congestion, transudation, and emigration, 108.—Production of new cells and tissues, 109.—Phases of inflammation, 110.—Exudative inflammation, 110.—Productive inflammation, 117.—Necrotic inflammation, 119.—*Reparative Production of New Tissue.*—Healing of wounds, 120.—Healing of fractures, 125.

PARASITES. *Animal Parasites.* Protozoa, 127.—Worms, 130.—Arthropods, 141.—Methods of study and preparation of animal parasites, 142.

*Vegetable Parasites. Bacteria*, 143.—Morphology and physiology of bacteria, 144–153.—Classification of bacteria, 153.—Methods of studying bacteria, 154.—Cultivation of bacteria, 158.—Bacterial examinations of post-mortem specimens, 167.—*Yeasts and Moulds*, 168.—*The Relation of Bacteria to Disease*, 171.—*Infection and Immunity*, 177.

THE INFECTIOUS DISEASES, 183.—INFECTIOUS DISEASES INDUCED BY THE PYOGENIC BACTERIA, 188.—ERYSIPELAS, 194.—PYÆMIA AND SEPTICÆMIA, 196.—ACUTE CEREBRO-SPINAL MENINGITIS, 199.—ACUTE LOBAR PNEUMONIA AND THE INFECTIOUS DISEASES INDUCED BY THE DIPLOCOCCUS PNEUMONLÆ, 201.—INFECTIOUS PSEUDO-MEMBRANOUS INFLAMMATION OF MUCOUS MEMBRANES, 204.—GONORRHŒA, AND OTHER INFLAMMATORY LESIONS INDUCED BY THE MICROCOCCUS GONORRHŒÆ, 206.—ANTHRAX, 209.—TUBERCULOSIS, 213–216.—LUPUS, 227.—LEPROSY, 229.—SYPHILIS, 231.—GLANDERS, 235.—RHINOSCLEROMA, 238.—BUBONIC PLAGUE, 239.—TYPHOID FEVER, 240.—DIPHTHERIA, 250.—TETANUS, 255.—INFLUENZA, 257.—BACTERIA WHICH MAY BE OCCASIONAL INCITERS OF INFECTIOUS DISEASE IN MAN, 259.—ACTINOMYCOSIS, 262.—ASIATIC CHOLERA, 265.—RELAPSING FEVER, 269.—VARIOLA, 271.—SCARLET FEVER, 273.—MEASLES, 274.—TYPHUS FEVER, 275.—HYDROPHOBIA, 276.—YELLOW FEVER, 279.—THE MALARIAL FEVERS, 280.—PHARYNGO-MYCOSIS, 284.—INFECTIOUS DISEASES OF ANIMALS, 285.

TUMORS. SECTION I. GENERAL CHARACTERS, 286.—Cause of tumors, 290.—Classification of tumors, 293.—Cysts, 296.—Various lesions sometimes described as tumors, 297.—Nomenclature of complex tumors, 297.—Preservation of tumors, 298. SECTION II. Special forms of tumors, 299–343.

## PART THIRD.

### MORBID ANATOMY OF THE ORGANS.

THE NERVOUS SYSTEM. THE MEMBRANES OF THE BRAIN.—*The Dura Mater*, 347. Hæmorrhages, 347.—Thrombosis.—Inflammation, 348.—Tumors, 351.—*The Pia Mater*, 352. Œdema, hyperæmia, and hæmorrhage, 353.—Tuberculous

meningitis, 359.—Syphilitic meningitis, 362.—Tumors, 362.—*The Ventricles of the Brain*, 365.—Acute and chronic ependymitis, 365.—Congenital hydrocephalus, 367.—Secondary hydrocephalus and primary hydrocephalus in adults, 368.—Tumors, 368.—*Pineal Gland and Pituitary Body*, 369.

THE BRAIN. Thrombosis and embolism, 370.—Hyperæmia, anæmia, and œdema, 373.—Hæmorrhage, 374.—Changes in ganglion cells in toxæmia, 376.—Secondary degenerations, 377.—Hypertrophy and atrophy, 378.—Wounds, 379. Holes or cysts in the brain, 380.—Inflammation of the brain, abscesses, 380. —Chronic interstitial encephalitis (sclerosis), 382.—Encephalitis in newborn, 383.—Syphilitic and tuberculous encephalitis, 384.—Lesions of brain in chronic paresis of insane, 385.—Pigmentation, tumors, 386.—Malformations, 387.

SPINAL CORD. *Dura Mater Spinalis.* Hæmorrhages, inflammations, 389.—Parasites, 390.—*Pia Mater Spinalis.* Hæmorrhages, inflammations, 390.—Tumors and parasites, 391.—*The Cord.* Hæmorrhage, 391. Hæmatomyelia and hæmatomyelopore, 391.—Injuries, secondary degenerations, 393.—Progressive spinal muscle atrophy, bulbar paralysis, amyotrophic lateral sclerosis, 396–397.—Poliomyelitis anterior, 399.—Chronic myelitis, multiple sclerosis, 400.—Posterior spinal sclerosis, 402.—Solitary tubercles, gummata, cysts, and tumors, 403.—Syringomyelia, 404.—Malformations, 404.

THE PERIPHERAL NERVES. Changes after division, acute and chronic neuritis, 408.—Tumors, 409.—Acromegalia, scleroderma, 410.—Preparation of nerve tissue for microscopical study, 410.

THE RESPIRATORY SYSTEM. *Larynx and Trachea.* Malformations, inflammation, 413.—Œdema glottidis, tumors, 416.

*The Pleura.* Hydrothorax, hæmorrhage, inflammation, 417.—Pleurisy with production of fibrin, pleurisy with production of fibrin and serum, 418.—Pleurisy with production of fibrin, serum, and pus (empyæma), 421.—Chronic pleurisy, 423.—Tuberculous pleurisy, 424.—Tumors, 425.

*The Bronchi.* Inflammations, 426.—Bronchiectasia, 429.—Tumors, 431.

*The Lungs.* Malformations, injuries, congestion, and œdema, 432.—Hæmorrhage, 433.—Emphysema, 434.—Atelectasis, 436.—Gangrene, 437.—Inflammation, classification, acute lobar pneumonia, 438.—Broncho-pneumonia, 443.—Secondary and complicating pneumonia, 448.—Pneumonia of heart disease, 449.—Interstitial pneumonia, 451.—Tuberculous pneumonia, 452. —Acute miliary tuberculosis, 453.—Subacute miliary tuberculosis, 456.—Chronic miliary tuberculosis, 457.—Acute pulmonary phthisis, 459.—Experimental phthisis, 460.—Chronic phthisis, 469.—Syphilitic pneumonia, 475.—Tumors, 476.—Parasites, 477.

*The Mediastinum*, 477. Inflammation, 481.—Tumors, 478.

THE VASCULAR SYSTEM.—*Pericardium.* Injuries, dropsy, hæmorrhage, pneumonatosis, 480.—Inflammation, tumors, 483.

*The Heart.* Malformations, 483.—Abnormal size and positions of heart, 485.—Wounds and ruptures, 486.—Atrophy, hypertrophy, 487.—Dilatation, 489.—Degeneration, 490.—Fatty infiltration, atrophy of pericardial fat, 492.—Myomalacia, fragmentation of endocardium, 493.—Inflammation, simple acute endocarditis, mycotic endocarditis, 494.—Chronic endocarditis, 496.—Chronic ulcerative and tuberculous endocarditis, myocarditis, 498.—Changes in heart valves, aneurism of the heart, 500.—Thrombosis of the heart, 501. —Tumors and parasites, 502.

*The Blood Vessels.* Atrophy and hypertrophy, 502.—Degeneration, 503.—*The Arteries.* Inflammation, acute arteritis, 503.—Chronic arteries, 504.—Dilatation and aneurism, 509.—Aneurism of the different arteries, 512.—Stenosis, 513.—Ruptures and wounds, 514.—Tumors, 516.—*The Veins.* Dilatation, 517.—Wounds and ruptures, inflammation, 518.—Tumors and parasites, 520.—*The Capillaries*, 520.—*The Lymph Vessels*, 520. Inflammation, 521.—Lymphangiectasis, tumors, 522.—*The Lymph Nodes*, 522. Inflammation, 523.—Pigmentation, 526.—Inflammation with cheesy degeneration, 527.—Tuberculous inflammation, 528.—Syphilitic inflammation, 529.—Degenerations, 530.—Hyperplasia, 531.—Tumors and parasites, 532.

THE ALIMENTARY CANAL. *The Mouth.* Malformations, 533.—Hypertrophy of cheeks and lips, inflammation, stomatitis, stomatitis ulcerosa, 533.—Syphilitic and tuberculous stomatitis, gangrene, 534.—Tumors, 535.—*The Tongue.* Malformations, hypertrophy, 536.—Inflammation, tumors, 537.—*The Pharynx and Œsophagus.* Malformations, 538.—Inflammation, 540.—Ulceration, 541.—Dilatation of œsophagus, 541.—Stenosis, 542.—Tumors, 543.

*The Stomach.* Malformations, post-mortem changes, injuries, hæmorrhage, 546.—Inflammation, 547.—Ulcers, 550.—Dilatation, 553.—Tumors, 554.—Degenerations. *The Intestines.* Malformations, 557.—Incarceration, 558.—Intussusception, 559.—Transposition, wounds, and ruptures, 560.—*The Small Intestine.* Inflammation, lesions of solitary and agminated nodules, 561.—Emboli, 562.—*Large Intestine.* Inflammations, 563.—Tumors, 575.—Concretions, parasites, 577.

THE PERITONEUM. Malformations, 578.—Inflammation, 579.—Tumors, 587.—Parasites, 589.

THE LIVER. Malformations, acquired changes in size and position, 590.—Anæmia and hyperæmia, 591.—Wounds, rupture, and hæmorrhage, lesions of hepatic artery, lesions of portal vein, 593.—Lesions of hepatic veins, atrophy of liver, degenerations, 599.—Pigmentation, 599.—Acute yellow atrophy, 600.—Inflammation, acute hepatitis (abscess), 601.—Chronic interstitial hepatitis (cirrhosis), 604.—Syphilitic hepatitis, 605.—Tuberculous hepatitis, 609.—Perihepatitis, 611.—Hyperplasia of lymphatic tissue in the liver, 611.—Tumors, 612.—Parasites, 641.

*The Biliary Passages and Gall Bladder.* Catarrhal inflammation, suppurative and croupous inflammation, 617.—Constriction, occlusion, and dilatation, 618.—Biliary calculi, 619.—Tumors, 614.

THE SPLEEN. Wounds, rupture, and hæmorrhage, 621.—Disturbances of the circulation, 612.—Inflammation, 624.—Perisplenitis, 628.—Alterations of spleen in leukæmia and pseudo-leukæmia, 628.—Degenerations, 629.—Pigmentation, tumors, 528.—Parasites, 630.—Malformations and displacements, 631.

THE PANCREAS. Hæmorrhage and inflammation, 632.—Degenerations, 633.—Fat necrosis, 634.—Tumors, 635.—Malformations and displacements, 636.

THE SALIVARY GLANDS. Inflammation, 637.—Tumors and parasites, 638.

THE THYROID GLAND. Hyperæmia, inflammation, degenerations, and tumors, 639.—Parasites, malformations, myxœdema, 641.—Exophthalmic goitre, 643.

THE THYMUS GLAND, 643.

THE SUPRARENAL BODIES. Malformations, hæmorrhage, thrombosis, inflammation, 644.—Degeneration, tumors, 645.

THE URINARY APPARATUS. *The Kidneys.* Malformations and changes in position, 646.—Bright's disease, classification, acute congestion, 647.—Acute degeneration, 648.—Acute exudative nephritis, 650.—Acute productive nephritis, 655.—Chronic congestion, 658.—Chronic degeneration, 659.—Chronic productive nephritis, chronic Bright's disease, 660.—Suppurative nephritis, 671.—Ureteritis, 672.—Pyelo-nephritis, 672.—Tuberculous nephritis, embolism, and thrombosis, 673.—Hydronephrosis, 674.—The cystic kidneys, 675. Perinephritis, 676.—Renal calculi, tumors, 677.—Parasites, 680.

*The Urinary Bladder.* Malformations, 680.—Changes in size and position, 681. Rupture and perforation, 682. Disturbances of circulation, inflammation, 683.—Tumors, 685.—Parasites, calculi, 687.

*The Urethra.* Congenital malformations, and changes in size and position, 688. —Wounds, ruptures, and perforations, 689.—Inflammation, 690.—Tumors, 691.

THE ORGANS OF GENERATION. FEMALE.—*The Vulva.* Malformations, hæmorrhage, and hyperæmia, 692.—Inflammation, 693.—Tumors and cysts, 694.

*The Vagina.* Malformations, changes in size and position, 695.—Wounds, perforations, inflammations, 696.—Tumors, 697.—Parasites, 698.—*The Uterus.* Malformations, 698.—Changes in size, 699.—Changes in position, 700.—Rupture, perforation, hyperæmia, and hæmorrhage, 702.—Inflammation, 704.—Puerperal inflammation, 708.—Ulceration, degeneration, tumors, 709.—Parasites and cysts, 718.—*The Ovaries.* Malformations, changes in size and position, hyperæmia, hæmorrhage, 719.—Inflammation, 720.—Tumors, 722.

*The Fallopian Tubes.* Malformations, changes in position and size, 730.—Hæmorrhage, inflammation, 731.—Tumors, extra-uterine pregnancy, 732.

*The Placenta.* Hæmorrhage, 733.—Inflammation, degenerations, 734.

*The Mamma.* Malformations, hæmorrhage, inflammation, 735.—Tumors, 738.

ORGANS OF GENERATION. MALE. *The Penis.* Malformations, 741.—Inflammation, tumors, 743.—*The Scrotum*, 744.—*The Testicles.* Malformations, hydrocele, 745.—Hæmatocele, 746.—Spermatocele, inflammation, 747.—Tumors, 750.—*The Seminal Vesicles*, 751.—*The Prostate.* Hypertrophy, 751.—Inflammation, 752.—Parasites, concretions, 753.—*Cowper's Glands*, 753.—*The Male Mamma*, 753.

THE BONES. Disturbances of circulation, injuries, 754.—Inflammation, periostitis, 755.—Osteitis, 757.—Osteomyelitis, 763.—Necrosis, 765.—Caries, rachitis, 766.—Osteomalacia, 769.—Alterations of the bone marrow in leukæmia and anæmia, 770.—Atrophy, tumors, 771.

DISEASES OF THE JOINTS. Inflammation, 775.—Tumors, 778.

MUSCLE. Hæmorrhage, infarction, wounds and ruptures, inflammation, 780.—Degenerations, atrophy, pseudo-hypertrophy, 783.—Tumors, 787.—Parasites, 788.

## PART FOURTH.

### THE LESIONS FOUND IN THE GENERAL DISEASES, IN POISONING, AND IN VIOLENT DEATHS.

DISEASES CHARACTERIZED BY ALTERATIONS IN THE COMPOSITION OF THE BLOOD. CHLOROSIS, 791.—PERNICIOUS ANÆMIA, 792.—LEUKÆMIA, 794.—PSEUDO-LEUKÆMIA (*Hodgkin's Disease*), 796.

SCORBUTUS, PURPURA, 798.—HÆMATOPHILIA, 799.

Addison's Disease, 800.
Gout, 802.
Acute Rheumatism, 803.
Diabetes Mellitus, 804.
Sunstroke, 806.
Death from Burning, 807.
Death from Electricity, 808.
Death from Suffocation, Asphyxia, 809.—*Death from Strangulation, Hanging*, 810.—*Death from Drowning*, 811.
Death from Poisoning, 814.

# LIST OF ILLUSTRATIONS.


| Fig. | | Page |
|---|---|---|
| 1. | Side view of the human brain, showing its fissures and convolutions, | 12 |
| 2. | Method of opening the brain, first incisions, | 13 |
| 3. | Method of opening the brain, final incisions, | 14 |
| 4. | View of the base of the brain, with the temporal lobes turned backward and outward, | 16 |
| 5. | Drawing of the brain axis, separated from the brain mantle, | 16 |
| 6. | Brain mantle, seen from below, | 17 |
| 7. | Outlines of spinal cord sections, | 21 |
| | Plate.—Blood cells, | opposite 80 |
| 8. | Phases of mitosis, or indirect cell division, | 92 |
| 9. | Cheesy degeneration (coagulation necrosis) in miliary tubercle of lung, | 97 |
| 10. | Fatty degeneration of heart muscle, | 98 |
| 11. | Fatty infiltration of liver cells, | 99 |
| 12. | Amyloid (waxy) degeneration of capillaries of a glomerulus in the kidney, | 101 |
| 13. | Corpora amylacea, | 102 |
| 14. | Mucous degeneration of epithelial cells, | 102 |
| 15. | Mucous degeneration of fibrous tissue of mamma, | 103 |
| 16. | Colloid degeneration of epithelial cells, | 104 |
| 17. | Hyalin degeneration of capillary blood vessels, | 104 |
| 18. | Pigmentation of connective-tissue cells of the lungs, | 105 |
| 19. | Emigration of white blood cells in inflamed bladder of frog, | 111 |
| 20. | Exudative inflammation—pneumonia, | 113 |
| 21. | Exudative inflammation—appendix, | 113 |
| 22. | Pus cells from catarrhal inflammation of bronchial mucous membrane, | 116 |
| 23. | Omentum of dog, showing peritonitis on fourth day, | 116 |
| 24. | Developing blood vessels in new-formed tissue, | 121 |
| 25. | Granulation tissue from wound of skin, | 122 |
| 26. | Fibroblasts from granulation tissue, | 122 |
| 27. | Cicatricial tissue, | 123 |
| 28. | Exuberant granulations, | 124 |
| 29. | New-formed cartilage and osteoid tissue from callus after fracture of the femur, | 125 |
| 30. | Amœba coli, | 127 |
| 31. | Coccidium oviforme, | 128 |
| 32. | Balantidium coli, | 129 |
| 33. | Cercomonas intestinalis, | 129 |
| 34. | Trichomonas vaginalis, | 129 |
| 35. | Distoma hepaticum, | 130 |

FIG. PAGE
36. Head of Tænia solium, . . . . . 131
37. Head and proglottides of Tænia mediocanellata, . . . . . 131
38. Cuticula of echinococcus cyst, . . . . . 133
39. Scolices of Tænia echinococcus, . . . . . 133
40. Hooklets from scolex of Tænia echinococcus, . . . . . 134
41. Ascaris lumbricoides, . . . . . 135
42. Oxyuris vermicularis, . . . . . 136
43. Eggs of nematode worms, . . . . . 137
44. Trichocephalus dispar, . . . . . 137
45. Trichinæ encysted in muscle, . . . . . 139
46. Filaria sanguinis hominis, . . . . . 140
47. Sarcoptes hominis, . . . . . 141
48. Pediculis capitis, . . . . . 141
49. Drawing of three typical forms of bacteria, . . . . . 143
50. Bacilli showing flagella, . . . . . 144
51. Growth aggregates of bacteria, . . . . . 145
52. Leptothrix buccalis with micrococcus colonies, . . . . . 145
53. Sarcina, . . . . . 146
54. Bacteria with capsule, . . . . . 146
55. Bacilli showing spores, . . . . . 147
56. A tube of solid transparent nutrient gelatin, . . . . . 160
57. Pure culture of bacteria on nutrient agar, . . . . . 161
58. A culture of bacteria on potato, . . . . . 161
59. A Petri gelatin plate culture of bacteria, . . . . . 163
60. A Petri gelatin plate culture of bacteria, . . . . . 164
61. Petri's agar plate culture of bacteria (mouth), . . . . . 165
62. Sterilized cotton swab in sterilized tube, . . . . . 166
63. Yeast—saccharomyces, . . . . . 168
64. Aspergillus glaucus, . . . . . 169
65. Achorion Schönleinii—favus, . . . . . 169
66. Bacterial embolus in the blood vessels of the glomerulus of the kidney in malignant ulcerative endocarditis, . . . . . 172
67. Small focus of necrosis in the liver caused by toxic material of bacterial origin, . . . . . 173
68. Colonies of micrococci in a blood vessel of the kidney, causing a small abscess, . . . . . 174
69. Staphylococcus pyogenes aureus, . . . . . 188
70. Staphylococcus pyogenes aureus in and among the pus cells, from an abscess of the kidney, . . . . . 190
71. Streptococcus pyogenes, . . . . . 191
72. Erysipelas of the skin, . . . . . 194
73. Streptococci in masses in the blood and lymph vessels of the skin in erysipelas, . . . . . 195
74. Micrococci in masses in the fibrinous exudation of pyæmic pleurisy, . 197
75. Diplococcus lanceolatus (pneumococcus) with capsules, . . . . 201
76. Pseudo-membranous inflammation of trachea, . . . . . 204
77. Infectious croupous inflammation of the trachea, . . . . . 205
78. Micrococcus gonorrhœæ (gonococcus), . . . . . 206
79. A cover-glass preparation of gonorrhœal exudate, . . . . . 207
80. Pus cells containing gonococci, . . . . . 207

| Fig. | | Page |
|---|---|---|
| 81. | Anthrax—malignant pustule—of the skin, | 209 |
| 82. | Bacillus anthracis growing in the blood vessels of the liver of a mouse inoculated with pure culture of the bacillus, | 210 |
| 83. | Bacillus anthracis containing spores, | 211 |
| 84. | Tubercle bacilli, with pus cells, in sputum, | 213 |
| 85. | Culture of tubercle bacillus on glycerin agar (bird), | 214 |
| 86. | Culture of tubercle bacillus on glycerin agar (man), | 214 |
| 87. | A miliary tubercle from a lymph node, | 216 |
| 88. | A miliary tubercle from the pleura, | 217 |
| 89. | Tuberculous tissue, | 218 |
| 90. | A nodule of tuberculous inflammation (miliary tubercle) in the lung, | 219 |
| 91. | Miliary tubercle in lung of child, showing tubercle bacilli, | 221 |
| 92. | Inflammatory nodule in the liver of the rabbit, produced by dead tubercle bacilli, | 222 |
| 93. | Lupus of face, | 225 |
| 94. | The bacilli of leprosy, | 229 |
| 95. | Small nodule of syphilitic inflammation (miliary gumma) in the liver, | 231 |
| 96. | New-formed tissue in syphilitic inflammation, | 231 |
| 97. | Section from a primary syphilitic nodule of the mucous membrane of the mouth, | 232 |
| 98. | Section of a portion of a syphilitic condyloma of the mucous membrane, | 233 |
| 99. | Bacillus mallei, | 236 |
| 100. | Cluster of typhoid bacilli in the spleen, | 247 |
| 101. | Bacillus typhosus, | 248 |
| 102. | Diphtheritic inflammation of the tonsil, | 251 |
| 103. | Bacillus diphtheriæ, | 252 |
| 104. | Bacillus tetani, | 255 |
| 105. | Actinomyces bovis, | 262 |
| 106. | Actinomyces growing in human bronchus, | 263 |
| 107. | Spirillum choleræ Asiaticæ, | 266 |
| 108. | Spirochæte Obermeieri, | 269 |
| 109. | A small-pox vesicle of the skin, | 271 |
| 110. | Section of spinal cord from a case of hydrophobia, | 276 |
| 111. | Hydrophobia, transverse section of small blood vessels in the spinal cord, | 277 |
| 112. | The hæmatozoön of malaria, | 281 |
| 113. | Epithelial cell "inclusions" in tumors, | 292 |
| 114. | Dense fibroma of abdominal wall, | 299 |
| 115. | Small papilloma of the skin, | 301 |
| 116. | Fibroma molle from subcutaneous tissue, | 301 |
| 117. | Myxoma of the larynx, | 302 |
| 118. | Myxoma growing into abdominal cavity, | 303 |
| 119. | Mucous polyp of the nose, | 303 |
| 120. | Large spindle-celled sarcoma, | 306 |
| 121. | Small spindle-celled sarcoma of forearm, | 306 |
| 122. | Small round-celled sarcoma of liver, | 307 |
| 123. | Large round-celled sarcoma of leg, | 307 |
| 124. | Melano-sarcoma from submaxillary region, | 308 |
| 125. | Giant-celled sarcoma of bone, | 309 |
| 126. | Angio-sarcoma of liver, | 310 |

FIG. PAGE
127. Myxo-sarcoma of pharynx, . . . . . 311
128. Adeno-sarcoma of parotid, . . . . . 312
129. Endothelioma of upper jaw, . . . . . 313
130. Endothelioma (endothelial sarcoma) of dura mater, . . . . 313
131. Endothelioma of pleura, . . . . . 314
132. Endothelioma of upper jaw, . . . . . 315
133. Cylindroma (adenoma) of antrum, . . . . . 316
134. Chondroma of subcutaneous connective tissue, . . . . . 318
135. Myxo-chondroma of cervical region, . . . . . 318
136. Glioma of brain, . . . . . 320
137. Neuroglia or "spider" cells from glioma of brain, . . . . 320
138. Myoma of uterus, . . . . . 321
139. Neuroma ganglioniforme, . . . . . 323
140. Fibroma (false neuroma) of lumbar nerve, . . . . . 324
141. Multiple fibromata of pneumogastric nerve, . . . . . 324
142. Multiple neuromata of the peripheral nerves, . . . . . 325
143. Angioma telangiectoides, . . . . . 326
144. Angioma cavernosum of liver, . . . . . 327
145. Congenital lymphangioma from arm of child, . . . . . 327
146. Adenoma of mamma, . . . . . 330
147. Adenoma of stomach, . . . . . 331
148. Cancer cells infiltrating the tissue near a tumor, . . . . . 333
149. Metastatic carcinoma in lymph vessels of the pleura, . . . . 335
150. Inflammation in carcinoma, . . . . . 335
151. Epithelioma of the neck, . . . . . 337
152. Metastatic carcinoma (epithelioma) in a lymph node, . . . . 337
153. Epithelioma of back of hand, . . . . . 338
154. Epithelioma of axillary lymph node, . . . . . 338
155. Section of a portion of a small epithelioma of the side of the nose; low power, . . . . . 339
156. Epithelioma of nose, . . . . . 339
157. Carcinoma mammæ (schirrhus variety), . . . . . 340
158. Medullary carcinoma of the stomach (carcinoma molle), . . . 341
159. Colloid carcinoma of rectum, . . . . . 342
160. Carcinoma myxomatodes mammæ, . . . . . 342
161. Chronic pachymeningitis interna hæmorrhagica, . . . . . 350
162. Brain sand from pachymeningitis interna, . . . . . 350
163. Acute cellular meningitis, . . . . . 354
164. Acute meningitis, . . . . . 356
165. Acute exudative meningitis, . . . . . 356
166. Fatty degeneration of cells along the blood vessels of the pia mater after exudative meningitis, . . . . . 357
167. A miliary tubercle of the pia mater, . . . . . 358
168. Miliary tubercle of the pia mater of a child, . . . . . 360
169. A miliary tubercle of the pia mater, . . . . . 360
170. Miliary tubercles of the ependyma of the lateral ventricle, . . . 361
171. A miliary tubercle of the ependyma of the lateral ventricle, . . 361
172. Endothelioma of the cerebellum originating in the pia mater, . . 363
173. Endothelioma of the pia mater of the cerebellum, . . . . . 364
174. Acute ependymitis, . . . . . 366

FIG. PAGE
175. Congenital hydrocephalus in child, . . . . . 367
176. Degenerated cells, cholesterin crystals, and corpora amylacea from brain tissue in embolic softening, . . . . . 371
177. Blood vessels from an area of embolic softening of brain, . . . 372
178. Ganglion cells of the spinal cord, . . . . . 377
179. Atrophy of a circumscribed portion of brain convolutions in a child, . 379
180. Syphilitic obliterating endarteritis of a cerebral artery, . . . 383
181. Solitary tubercle of cerebellum, . . . . . 384
182. Hæmorrhage in spinal cord, . . . . . 392
183. Hæmatomyelopore, . . . . . 392
184. Descending degeneration, spinal cord, . . . . . 395
185. Ascending degeneration, spinal cord, . . . . . 395
186. Ascending degeneration, spinal cord, . . . . . 396
187. Amyotrophic lateral sclerosis, . . . . . 397
188. Degenerated tissue, spinal cord, . . . . . 398
189. Poliomyelitis anterior, . . . . . 399
190. Poliomyelitis anterior, . . . . . 399
191. Multiple sclerosis, spinal cord, . . . . . 401
192. Posterior spinal sclerosis, . . . . . 401
193. Posterior spinal sclerosis, . . . . . 402
194. Syringomyelia, . . . . . 404
195. Hydromyelia, . . . . . 406
196. False heterotopia, . . . . . 406
197. Multiple neuritis, . . . . . 408
198. Ulcer of larynx, . . . . . 414
199. Tuberculous laryngitis, . . . . . 415
200. Pleurisy in dog, . . . . . 420
201. Tuberculous pleurisy, . . . . . 425
202. Catarrhal bronchitis, . . . . . 427
203. Croupous bronchitis, . . . . . 428
204. Bronchiectasia, . . . . . 430
205. Adenoma of bronchi, . . . . . 431
206. Emphysema, . . . . . 435
207. Emphysema, . . . . . 436
208. Acute lobar pneumonia, . . . . . 439
209. Acute lobar pneumonia with organized tissue, . . . . . 440
210. Acute lobar pneumonia with organized tissue, . . . . . 441
211. Acute lobar pneumonia with organized tissue, . . . . . 442
212. Broncho-pneumonia, child, . . . . . 443
213. Broncho-pneumonia, child, . . . . . 445
214. Broncho-pneumonia, adult, . . . . . 446
215. Broncho-pneumonia, persistent, . . . . . 447
216. Broncho-pneumonia, persistent, . . . . . 448
217. Broncho-pneumonia, in diphtheria, . . . . . 449
218. Lung of heart disease, . . . . . 450
219. Interstitial pneumonia, . . . . . 451
220. Miliary tubercle, lung of child, . . . . . 454
221. Peribronchitic miliary tubercle, . . . . . 455
222. Aggregation of miliary tubercles, . . . . . 456
223. Miliary tubercle, . . . . . 457

| Fig. | | Page |
|---|---|---|
| 224. | Miliary tubercle, | 458 |
| 225. | Miliary tubercle, | 459 |
| 226. | Experimental pulmonary tuberculosis, rabbit, | 460 |
| 227. | Experimental pulmonary tuberculosis, rabbit, | 460 |
| 228. | Experimental pulmonary tuberculosis, rabbit, | 462 |
| 229. | Tuberculous broncho-pneumonia, | 463 |
| 230. | Coagulation necrosis and pneumonia, | 464 |
| 231. | Acute phthisis, | 465 |
| 232. | Acute phthisis, | 467 |
| 233. | Acute phthisis, | 468 |
| 234. | Chronic phthisis, | 469 |
| 235. | Tuberculous inflammation of lung, | 470 |
| 236. | Chronic phthisis, | 470 |
| 237. | Chronic phthisis, | 471 |
| 238. | Chronic phthisis, | 471 |
| 239. | Chronic phthisis, | 472 |
| 240. | Healed phthisis, | 473 |
| 241. | Tubercle tissue, | 474 |
| 242. | Syphilitic pneumonia, | 475 |
| 243. | Adenoma of lung, | 476 |
| 244. | Obliteration of pericardial sac, | 482 |
| 245. | Fatty degeneration of heart, | 490 |
| 246. | Fatty infiltration of heart, | 491 |
| 247. | Atrophic pericardial fat, | 492 |
| 248. | Vegetation on heart valve, | 495 |
| 249. | Mycotic endocarditis, | 496 |
| 250. | Chronic endocarditis, | 497 |
| 251. | Chronic endocarditis, | 498 |
| 252. | Chronic interstitial myocarditis, | 499 |
| 253. | Chronic arteritis, | 505 |
| 254. | Chronic arteritis, | 506 |
| 255. | Chronic arteritis, | 507 |
| 256. | Chronic arteritis, | 508 |
| 257. | Chronic arteritis, | 509 |
| 258. | Atheroma of aorta, | 510 |
| 259. | Atheroma of aorta, | 510 |
| 260. | Tuberculous arteritis, | 511 |
| 261. | Tuberculous phlebitis, | 519 |
| 262. | Inflammation of lymph node, | 524 |
| 263. | Inflammation of lymph node, | 525 |
| 264. | Pigmentation of lymph node, | 526 |
| 265. | Cyst of neck, | 539 |
| 266. | Cyst of neck, | 539 |
| 267. | Adenoid polyp of pharynx, | 544 |
| 268. | Sarcoma of pharynx, | 545 |
| 269. | Chronic gastritis, | 548 |
| 270. | Necrosis of mucous membrane of stomach, | 553 |
| 271. | Fibroma in wall of stomach, | 554 |
| 272. | Catarrhal colitis, | 563 |
| 273. | Suppurative colitis, | 564 |

FIG. PAGE
274. Catarrhal colitis, . . . . . 565
275. Catarrhal colitis, . . . . . 565
276. Croupous colitis, . . . . . 566
277. Follicular colitis, . . . . . 567
278. Amœbic colitis, . . . . . 568
279. Amœbic colitis, . . . . . 569
280. Amœbic colitis . . . . . 570
281. Amœbic colitis, . . . . . 571
282. Necrotic colitis, . . . . . 572
283. Suppurative appendicitis, . . . . . 574
284. Acute cellular peritonitis, . . . . . 580
285. Acute exudative peritonitis, . . . . . 582
286. Chronic cellular peritonitis, . . . . . 583
287. Chronic peritonitis, . . . . . 585
288. Cystic papilloma of omentum, . . . . . 588
289. Chronic congestion of liver, . . . . . 592
290. Fatty infiltration of liver cells, . . . . . 597
291. Fatty infiltration of liver, . . . . . 597
292. Amyloid degeneration of liver, . . . . . 598
293. Pigmentation of liver, . . . . . 599
294. Abscess of liver, . . . . . 603
295. Chronic interstitial hepatitis, . . . . . 604
296. Hypertrophic cirrhosis, . . . . . 605
297. Chronic interstitial hepatitis, . . . . . 606
298. Syphilitic hepatitis, . . . . . 609
299. Gumma of liver, . . . . . 610
300. Echinococcus multilocularis, . . . . . 616
301. Adenoma of gall duct, . . . . . 619
302. Congestion of spleen, . . . . . 622
303. Chronic indurative splenitis, . . . . . 626
304. Chronic interstitial splenitis, . . . . . 626
305. Malarial spleen, . . . . . 627
306. Amyloid spleen, . . . . . 630
307. Fat necrosis in pancreas, . . . . . 634
308. Colloid struma, . . . . . 640
309. Thyroid gland in myxœdema, . . . . . 642
310. Acute degeneration of kidney, . . . . . 648
311. Acute exudative nephritis, . . . . . 650
312. Acute exudative nephritis, . . . . . 651
313. Acute nephritis, . . . . . 652
314. Acute nephritis, . . . . . 653
315. Acute exudative nephritis, . . . . . 654
316. Acute nephritis, . . . . . 655
317. Acute productive nephritis, . . . . . 656
318. Subacute productive nephritis, . . . . . 657
319. Chronic nephritis with exudation, . . . . . 663
320. Chronic nephritis with exudation, . . . . . 664
321. Chronic nephritis with exudation, . . . . . 665
322. Chronic nephritis with exudation, . . . . . 666
323. Waxy degeneration in kidney, . . . . . 667

| Fig. | | Page |
|---|---|---|
| 324. | Chronic nephritis without exudation, | 668 |
| 325. | Chronic nephritis without exudation, | 669 |
| 326. | Chronic nephritis without exudation, | 670 |
| 327. | Cysts of kidney, | 675 |
| 328. | Adenoma of kidney, | 678 |
| 329. | Adenoma of kidney, | 679 |
| 330. | Papilloma of bladder, | 686 |
| 331. | Vaginal epithelium, | 697 |
| 332. | Chronic endometritis, | 704 |
| 333. | Hyperplasia of uterine mucosa, | 705 |
| 334. | Chronic endometritis, | 706 |
| 335. | Uterine phlebitis, | 708 |
| 336. | Adenoma of the uterus, | 713 |
| 337. | Adenoma of the uterus, | 714 |
| 338. | Carcinoma of uterus, | 715 |
| 339. | Epithelioma of uterus, | 716 |
| 340. | Fragment of decidua, | 718 |
| 341. | Chronic oöphoritis, | 721 |
| 342. | Chronic oöphoritis, | 722 |
| 343. | Sarcoma of ovary, | 723 |
| 344. | Papilloma of peritoneum, | 724 |
| 345. | Cystic adenoma of ovary, | 725 |
| 346. | Cells from ovarian cyst, | 726 |
| 347. | Cystic adenoma of ovary, | 726 |
| 348. | Papillary cysts of omentum, | 727 |
| 349. | Adeno-sarcoma of ovary, | 728 |
| 350. | Hydro-salpinx, | 730 |
| 351. | Suppurative mastitis, | 736 |
| 352. | Chronic mastitis, | 737 |
| 353. | Intra-canalicular fibroma, | 738 |
| 354. | Peri-canalicular fibroma, | 739 |
| 355. | Chronic orchitis, | 740 |
| 356. | Chronic orchitis, | 748 |
| 357. | Rarefying osteitis, | 758 |
| 358. | Condensing osteitis, | 760 |
| 359. | Tuberculous osteitis, | 761 |
| 360. | Rachitic bone, | 767 |
| 361. | Chronic interstitial myositis, | 782 |
| 362. | Progressive muscle atrophy, | 783 |
| 363. | Progressive muscle atrophy, | 784 |
| 364. | Pseudo-hypertrophy of muscle, | 785 |
| 365. | Hyalin degeneration of muscle, | 787 |

# PART I.

## THE METHOD OF MAKING

## POST-MORTEM EXAMINATIONS

AND OF

## PRESERVING

AND

## EXAMINING PATHOLOGICAL TISSUES.

MEDICAL DEPARTMENT
YORKSHIRE COLLEGE
VICTORIA UNIVERSITY

# THE METHOD

OF MAKING

# POST-MORTEM EXAMINATIONS.

---

THE object in making a post-mortem examination varies in different cases. It may be to determine whether a person has died from violence or poisoning; to account for a sudden death; or to study the lesions of disease. In any case the examination should embrace all the important parts of the body, not merely a suspected organ, and it should be recorded at the time it is made.

In endeavoring to ascertain the cause of death, when the clinical history is imperfect or unknown, great care is necessary. Mechanical causes of death, which destroy life by abolishing the function of one of the important viscera, are relatively infrequent. Most of the lesions which we find after death indicate rather the ravages of disease than the cause of death. We do not know how great a degree of meningitis, or of pneumonia, or of endocarditis, or of cirrhosis, or of nephritis necessarily causes death. On the contrary, we find that one patient recovers with an extent of lesion which is sufficient to destroy the life of another. So with accidents; there is often no evident reason why fractures of the skull or of the pelvis should destroy life, but yet they usually do. In some of the general diseases, such as typhoid fever, the visible lesions cannot always be called the cause of death; in others, such as typhus fever, there may be no evident lesions at all. Sudden deaths of persons who have apparently been in good health up to the time of death are often par-

ticularly obscure. In many of them we have to acknowledge that we can find no sufficient cause for the death. This is of course due to our imperfect knowledge, but it is much better in such cases to avow our ignorance than to attribute the death to some trifling lesion. The brain and the heart are the organs which are especially capable of giving symptoms during life without corresponding lesions after death. Very well-marked cardiac or cerebral symptoms may continue for days or months, and apparently destroy life, and yet after death we find no corresponding anatomical changes. But it should be remembered that recent advances in our knowledge of the cell, which an improved technique in hardening and preparation has greatly fostered, have already shown that under various abnormal conditions the cells, especially of the nervous system, may undergo morphological changes of great significance without perceptible alteration in the gross appearance of the affected part, changes which even the microscopical examinations of the past have failed to disclose. So that while there often appears to be a wide discrepancy between symptoms and lesions, with the increase of knowledge the scope of this discrepancy is steadily narrowing. It is the novice in post-mortem examinations who is particularly apt to mistake ordinary post-mortem appearances for lesions.

## EXTERNAL INSPECTION.

Before commencing the examination of the internal viscera it is always necessary to make some inspection of the external surface of the body. The minuteness of this inspection will depend upon the character of the case. In the case of an unknown person, or of one suspected to have died from unnatural causes, it is necessary to search for and record not only all contusions, wounds, etc., their size, situation, and condition, but also deformities from disease and any physical peculiarities of hair, eyes, teeth, moles, etc., by which the person may be identified. In such cases it is well, if possible, to photograph, weigh, and measure the body. In cases of doubtful identity it is sometimes wise to make a wax or plaster cast of the outside of the teeth and jaws. In ordinary examinations we note the general nutritive condition of the body, and look for evidences of external injury, for skin diseases, ulcers, œdema, gouty deposits, abscesses, enlarged lymphatic glands, etc. The glans penis and prepuce are to be carefully searched for syphilitic cicatrices.

It is usual to find certain changes in the external appearances of the body which are due to the cessation of life and the commencement of decomposition. We speak now of bodies which have not been buried, but which have been kept in the ordinary way, lying on

the back, and loosely covered with a shroud or dressed with the ordinary clothes.

*Weight.*—It is well to weigh the body in all cases. There is of course large variation in the weight of individuals within the limits of the normal. But these averages may be useful in estimating the relative weight of single organs.

*Cadaveric Lividity.*—After life becomes extinct, and before the blood coagulates, it settles in the veins of the more dependent parts of the body, producing, usually within a few hours after death, a mottling of the surface with irregular livid patches. These patches may coalesce, forming a uniform dusky-red color over the back of the trunk, head, and extremities, and sometimes over the ears, face, and neck. The same effect is observed on the anterior aspect of the body if it has lain on the face. At points of pressure, from folds in the clothes or from the weight of the body on the table, the red color is absent or less marked. These changes occur before putrefaction sets in. This cadaveric lividity or hypostasis should not be mistaken for ante-mortem ecchymosis, from which it may usually be readily distinguished by its position and extent, by the fact that the surface of the skin is not elevated, and by the fact that on incision no blood is found free in the interstices of the tissues. Not infrequently the subcutaneous tissue in the vicinity of these post-mortem hypostases becomes infiltrated with reddish serum. Very soon after death, particularly in warm weather, the tissues immediately around the subcutaneous veins of the neck and thorax and in other situations may become stained of a bluish-red color from the decomposition and escape from the vessels of the coloring matter of the blood. If the epidermis has been detached at any point, the skin beneath soon becomes dry and brown.

*Putrefactive Changes.*—Usually in from one to three days, depending upon circumstances, a greenish discoloration of the skin appears, at first upon the middle of the abdomen, over which it gradually spreads, assuming a deeper hue and often changing to a greenish purple or brown. Greenish patches may now appear on different parts of the body, earliest upon those overlying the internal cavities; this discoloration is probably produced by the action on the hæmoglobin of gases developed by decomposition. The eyeballs now become flaccid, and if the eyelids are not closed the conjunctiva and cornea become brown and dry. The pressure of gases developed by decomposition in the internal cavities not infrequently forces a greater or less quantity of frothy, reddish fluid or mucus from the mouth and nostrils, producing distention of the abdomen, and, if excessive, may produce changes of position of the blood in the vessels, and even a moderate amount of displacement of the internal organs.

After five or six days, under ordinary circumstances, the entire surface is discolored green or brown. After this the epidermis becomes loosened from the formation of gases and separation of fluids beneath, and the tissues become flaccid. The abdomen and thorax may be greatly distended, the features distorted and scarcely recognizable from swelling, and the hair and nails loosened. Beyond this stage of putrefaction the consecutive changes, leading to more or less disintegration of the soft tissues, can scarcely be followed with certainty. The rapidity with which these changes follow one another depends upon a variety of conditions, such as temperature, moisture, access of air, and the diseases which have preceded or caused death. Thus an elevated temperature and the presence of air and moisture hasten the advent and progress of putrefactive changes. The bodies of infants usually decompose more rapidly than those of adults, fat bodies more quickly than lean ones. The infectious diseases, intemperance, and the puerperal condition promote rapid decomposition, as does also death from suffocating gases. Poisoning by arsenic, alcohol, antimony, sulphuric acid, strychnin, and chloroform may retard the progress of decomposition. Burial in dry soil and submersion in water also retard the progress of decay.

*Cooling of the Body.*—The internal temperature of the healthy living body is about 37.2° C. (99° Fahr.). But it may be increased several degrees in consequence of disease. After death the chemical changes upon which the maintenance of this temperature depends rapidly diminish, and the body gradually cools to the temperature of the surrounding medium. This usually occurs in from about fifteen to twenty hours, but the time required depends upon a variety of conditions. Immediately after death there is, in nearly all cases, a slight elevation of internal temperature, owing to the fact that the metabolic changes in the tissues still continue for a time, while the blood ceases to be cooled by passing through the lungs and peripheral capillaries. After death from certain diseases—yellow fever, cholera, rheumatic fever, and tetanus—a considerable elevation of internal temperature has been repeatedly observed. The time occupied by the cooling of the body may be prolonged after sudden death from accidents, acute diseases, apoplexy, and asphyxia. A number of cases are recorded in which the body retained its heat for several days without known cause.

After death from wasting chronic disease, and in some cases after severe hæmorrhages, the cooling of the body is very rapid, the external temperature being reduced to that of the surrounding air within four or five hours. Fat bodies cool less quickly than lean ones, the bodies of well-nourished adults less quickly than those of children or old persons. The temperature of the surrounding medium, the de-

gree of protection of the body from currents of air, will, of course, modify the progress of cooling; and the internal organs naturally retain their heat longer than the surface of the body. The rate at which cooling occurs is most rapid, as a rule, during the hours immediately following death, notwithstanding the post-mortem rise which may ensue.

It will thus be seen that if required to pronounce upon the time which has elapsed since death in a given case, we can do so only approximately. It is necessary to take into account all of the above-mentioned conditions which modify the rate of cooling of the body, and then we may be able to state only the probabilities of the case. It is furthermore unsafe in any case to infer the cause of death from the rate of cooling of the body.

*Rigor Mortis.*—Death is usually succeeded immediately by a period of complete muscular relaxation. The jaw drops and the limbs become flaccid. The muscles may retain for two or three hours, however, the capacity of contracting on the application of appropriate stimuli. On the average within six hours the muscles become firm and rigid. This post-mortem rigidity is called *rigor mortis.* On the occurrence of the rigor mortis the muscles become fixed in whatever position they may have had at the time of its occurrence. It usually begins in the muscles of the eyelids, extends to those of the back of the neck and lower jaw, then to the face and neck, and thence passing downward affects the muscles of the thorax and lower extremities. It usually disappears in the same order. Although commencing on the average six hours after death, it may set in almost instantly, or it may be delayed for twenty-four hours or more. It may pass off very rapidly, in rare cases in from one to three hours; or it may persist for two or three weeks or longer. It may be said in general that the average time of its disappearance is within twenty-four or forty-eight hours after its occurrence, depending on temperature, its intensity, the mode of death, the period of its advent, etc. Caspar states that in fœtuses before term he has never observed rigidity, and that in young children it is feeble and of short duration. Its occurrence and phenomena may be in some cases of the highest medico-legal importance; but its careful observation does not, with our present knowledge of its significance, appear to essentially further the aims of the practical pathologist.[1]

*Contusions.*—It is often important to determine whether violence has been inflicted upon a body before death. In regard to this point, we must remember, first, that blows and falls of sufficient violence

[1] For further details concerning rigor mortis, putrefactive changes, particularly the later stages, and the phenomena of cooling of the body, see *Tidy*, "Legal Medicine," vol. i., pp. 52–120, or other works on medical jurisprudence.

to fracture bones and rupture the viscera may leave no marks on the skin, even though the person has survived for several days; and, second, that there are post-mortem appearances which simulate ante-mortem bruises. A severe contusion during life may present, at first, no mark or only a general redness. After a short time the injured part becomes swollen and of a red color; this color may be succeeded by a dark blue, and this in turn fade into a greenish yellow or yellow; these later appearances are due to an escape of blood from the vessels and to a subsequent decomposition of hæmoglobin. If therefore we cut into such an ecchymosis after death, we find extravasated blood or the coloring matter of the blood, in the form of pigment granules, free in the tissues. Post-mortem discolorations, on the other hand, although their external appearance may resemble that of ante-mortem ecchymosis, are not formed by an extravasation of blood, but by a circumscribed congestion of the vessels or by an escape of blood-stained serum. If we cut into such discolorations, therefore, we find no blood outside the vessels.

Blows on the skin of a body which has not been dead for more than about two hours may produce true ecchymoses with extravasation of blood, such as can be distinguished with great difficulty or not at all from those formed during life. If putrefactive changes be present the difficulty of distinguishing between ante-mortem and post-mortem bruises is greatly enhanced.

Hanging and strangulation are attended with the formation of marks on the neck which are fully described in works on forensic medicine. These marks must not be confounded with the natural creases of the skin of the neck. Many adults during life have creases of the skin of the neck, one or more in number, running downward from the ear under the chin or encircling the neck. After death these creases may be much more evident than during life, and may be rendered more decided by the position of the head and the freezing of the body. They usually persist until the skin putrefies.

*Wounds.*—We should notice the situation, extent, and direction of a wound, the condition of its edges and the surrounding tissues. If it be a deep, penetrating wound its course and extent should be ascertained by careful dissection rather than by use of a probe.

If the edges of a wound be inflamed and suppurating, or commencing to cicatrize, it must have been inflicted some time before death. In a wound inflicted a short time before death the edges are usually everted; there may be more or less extravasation of blood into the surrounding tissues, and the vessels contain coagula; but sometimes none of these changes are observed. The chief characteristics of a wound inflicted after death are, absence of a considerable amount of bleeding, non-retraction of the edges, and the absence of

extravasation of blood into the tissues. But a wound inflicted within two hours after death may resemble very closely one inflicted during life. In general, unless a wound is old enough for its edges to present inflammatory changes, we must be very careful in asserting its ante-mortem or post-mortem character.

*Fractures.*—It may be important to determine whether a bone was fractured before or after death. This point cannot always be decided. Fractures inflicted during life are, as a rule, attended with more extravasation of blood and evidences of reaction in the surrounding tissues; but fractures produced within a few hours after death may resemble these very closely. Usually a greater degree of force is necessary to fracture bones in the dead than in the living body.

*Scars and Tattoo Marks.*—The presence and character of cicatrices should be noticed. Scars produced by any considerable loss of substance may become very much smaller and less conspicuous, but never entirely disappear. Slight and superficial wounds, however, produce marks which may not be permanent. The discoloration produced by tattooing may, although rarely, disappear during life.

## INTERNAL EXAMINATION.[1]

After completing the external inspection of the body we commence the internal examination. In order that this examination may be made both thoroughly and rapidly, we should follow a regular method. The method should be such as will enable us to examine the relations of parts to one another, without seriously disturbing them, and to remove and inspect the organs in such an order and manner as will not interfere with the examination of parts which are to follow. In certain cases it may be necessary to depart from the regular method; but, as a rule, the following plan will be found most advantageous.

It is important to remember the difference between the distribution of the blood in the body during life and after death. During life the blood is in constant motion and is distributed in a regular way in the heart, capillaries, arteries, and veins. Inflammations and obstructions to the circulation may disturb this natural distribution and produce congestion of particular parts of the body. After death the blood ceases to circulate; it leaves the left cavities of the heart, the arteries and capillaries, and collects in the veins and the right cavities of the heart. According to the character of the disease which causes death, coagulation of the blood takes place more

[1] Absolute and relative sizes and weights of various parts and organs of the body, and much other valuable statistical data, may be found in *Vierordt's* "Anatomische, Physiologische und Physikalische Daten und Tabellen," Jena, 1888.

or less extensively and at an earlier or later period. The local congestions which existed during life often disappear after death. On the other hand, local congestions are found after death which did not exist during life. Thus, after death the scalp often contains a large amount of venous blood. The veins of the pia mater and the sinuses of the dura mater may be filled with blood. The mucous membrane of the larynx and trachea may appear to be deeply congested. The lungs are congested if the patient has been comatose for some hours before death. All the tissues of the back and the membranes of the spinal cord are often gorged with venous blood. The right auricle and ventricle of the heart may contain fluid or clotted blood in considerable quantity.

### THE HEAD.

The scalp is divided by an incision across the vertex from ear to ear. The flaps are dissected forward and backward, taking up the temporal muscles with the skin and leaving the pericranium attached to the bone. The internal surface of the scalp and the pericranium are to be searched for ecchymoses and inflammatory lesions.

A circular incision is now made through the cranium with a saw. The incision should, in front, pass through a point about three and one-half inches above the bridge of the nose, behind through the occipital protuberance. Care should be taken not to cut through the dura mater with the saw. When the roof of the cranium is thus entirely loosened a stout hook is introduced under the upper edge of the calvarium, and this is wrenched off with a jerk.

Sometimes the dura mater is so firmly adherent to the calvarium that the latter cannot be torn from it without injury to the brain. In this case, and also if the dura mater should have been accidentally cut through by the saw in making the circular incision, the dura mater may be cut through at the level of the cranial incision, and the brain removed with the calvarium and separated afterward. Or, which is better, in addition to the circular incision, a longitudinal incision is made, from front to back, about three-quarters of an inch to one side of the median line of the skull, and a segment of bone removed. The knife blade may now be inserted from the open side, and the dura cut away from the skull-cap along the line of the longitudinal sinus, where the adhesions are apt to be most firm.

We should notice whether or not the calvarium is symmetrical. The cranial bones increase in size by a growth of bone at the edges of the sutures. If any suture become completely ossified and closed prematurely, the bones will be unequally developed. The thickness and density of the cranial bones vary considerably within the limits of health. There are often deep depressions on the inner surface of

the skull along the sagittal suture, caused by the pressure of the Pacchionian bodies, and of no pathological significance. We should observe the blood content of the bone, determine the existence or absence of fractures, inflammatory lesions, exostoses, etc.

*The Dura Mater* is now exposed to view. It will be found more or less adherent to the calvarium ; a moderate amount of adherence, especially in old persons, does not denote disease. Very extensive and firm adhesions are usually produced by inflammation. Near the median line the Pacchionian bodies often project through the dura mater and may produce indentations in the internal surface of the calvarium. We must look for clots and for tumors and for inflammatory lesions on the external surface of the dura mater. The longitudinal sinus should be laid open and its contents examined. A circular incision is then made through the dura mater in a line corresponding to the cranial incision ; the falx is divided between the anterior lobes of the brain, and the entire membrane drawn back. We should observe the existence of abnormal adhesions of the dura mater to the pia mater, bearing in mind that a moderate amount of adhesion along the longitudinal fissure is normal. The internal surface of the dura mater is to be examined for the products of inflammation and for tumors.

*The Pia Mater* covering the convex surface of the brain is now exposed. The degree of congestion, and the existence of serum, pus, or blood, beneath, within, or upon it, are now to be ascertained before the brain is removed. The pia mater in old persons frequently loses its transparency and becomes thick and white ; this change is most marked along the longitudinal fissure and large vessels. Marked and general thickening of the pia mater is produced by chronic inflammation. Along the longitudinal fissure, and sometimes at a considerable distance from it, we usually find small, elevated, whitish nodules, which are the *Pacchionian bodies* and are normal in the adult.

The amount of serum beneath the pia mater varies. A considerable amount, especially in cachectic persons, may exist without brain disease. Clear serum raising the pia mater and separating the convolutions of the brain may be simply dropsical or due to chronic meningitis. Turbid and purulent serum, beneath and in the pia mater, is produced by acute or chronic meningitis. The degree of flatness of the surface of the convolutions should be observed before removing the brain ; for, when marked, it affords an important indication of pressure, from hæmorrhage, inflammatory products, internal fluid effusions, and tumors. The pia mater should be carefully examined for miliary tubercles.

*The Brain.*—After examining the convex surface of the brain

the anterior lobes of the cerebrum are to be pulled gently backward, the nerves, vessels, and tentorium severed, and the medulla cut across as low down as possible.[1] The brain is now removed from the cranium by passing the fingers of one hand down, beneath and behind the lobes of the cerebellum, and drawing the brain out, supporting the convexity with the other hand.

The adult brain in the male weighs on the average about 1,400 gm. (49½ oz.); that of the female, about 155 gm. (5 oz.) less. The average proportional weight of the brain to that of the body is about one-

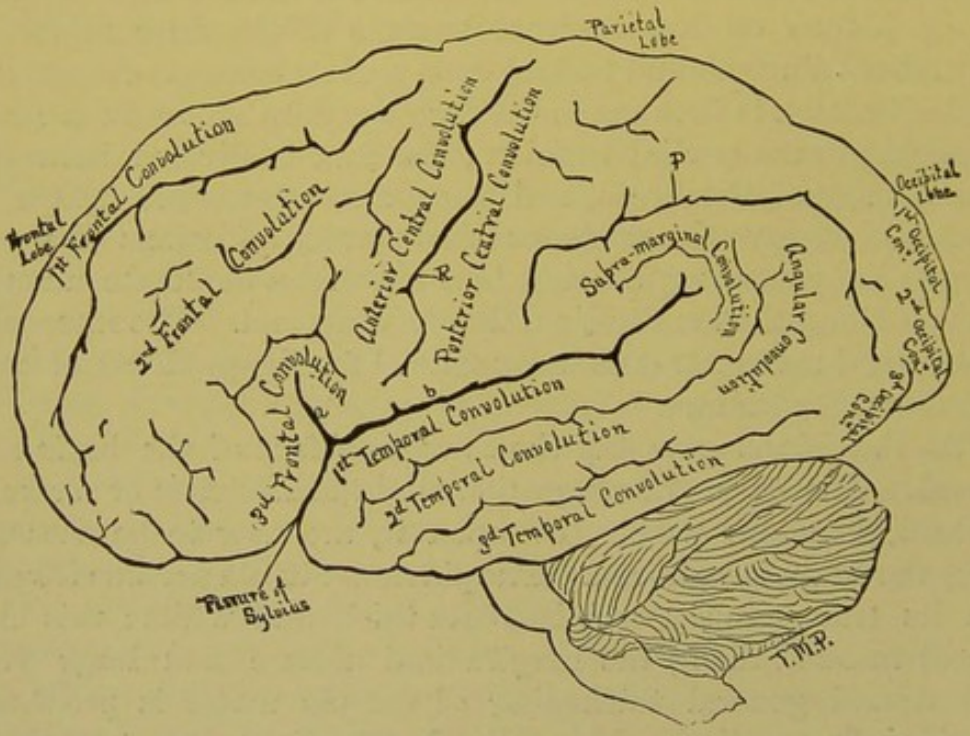


Fig. 1.—Side View of the Human Brain, showing its Fissures and Convolutions.

forty-fifth, although in this, as in the absolute weight, there is considerable variation.

The exact situation of any lesion which is apparent externally should be described by its relation to the lobes, fissures, convolutions, and sulci.

The brain is first laid upon its convex surface, and the anterior, middle, and posterior cerebral arteries, as well as the basilar and the carotids, are to be examined for emboli, thrombi, atheroma, and aneurisms. Evidence of extravasations of blood, tumors, and

[1] *Bailey* has devised a knife with a narrow bent blade which can be passed into the upper end of the spinal canal beside the cord and turned so as to cut directly across the latter, in this way avoiding the considerable loss of substance in an important region of the cord, which the usual oblique cut with a straight knife involves.

inflammatory lesions are now to be looked for. The brain is next turned over on to its base. An incision is made through the pia mater over the convex surface of the cerebrum. The membrane is stripped up, and its adherence to the brain and its thickness noted.

The more common method of opening the brain is as follows: The halves of the cerebrum are to be separated until the superior sur-

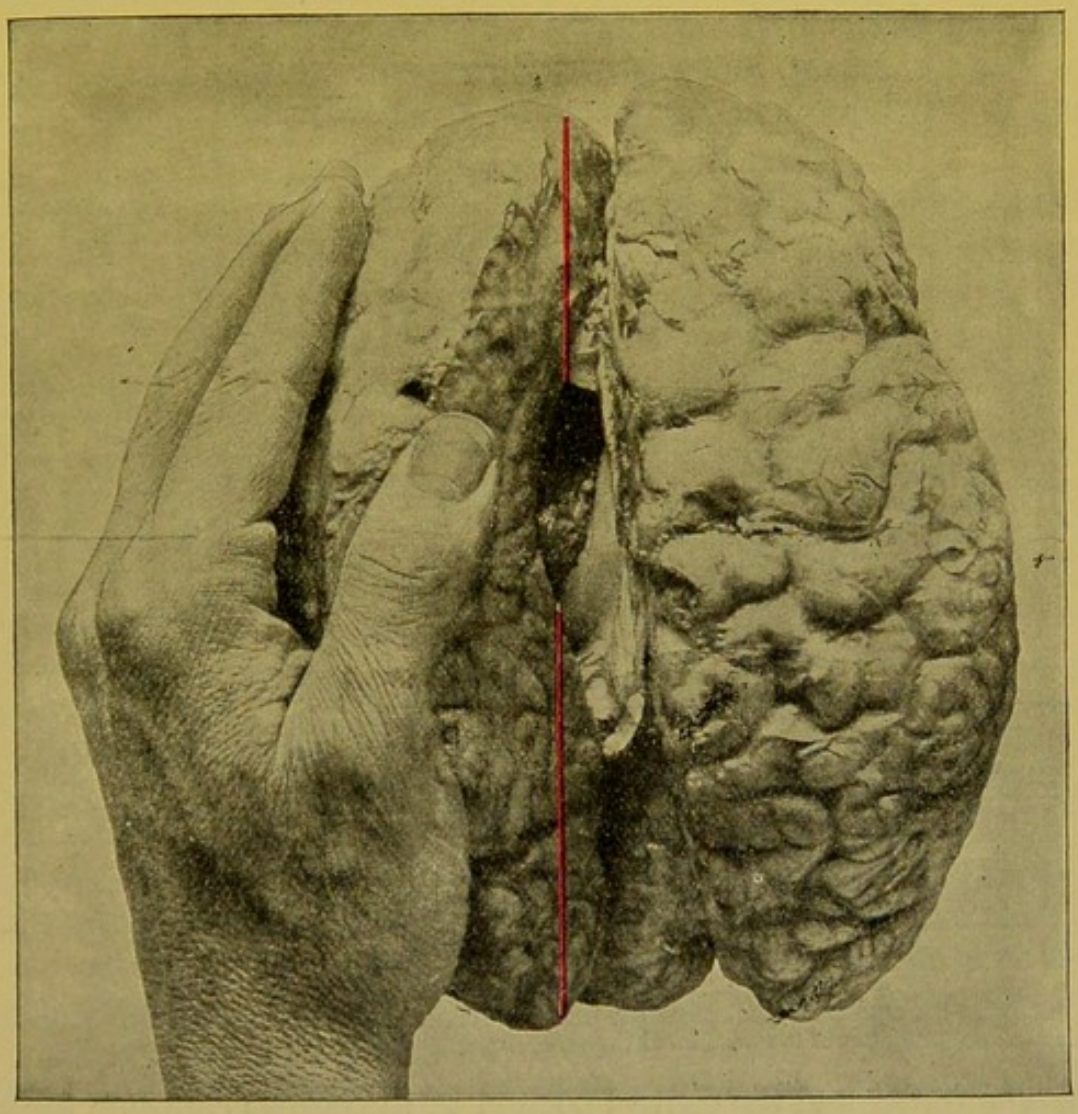

Fig. 2.—Method of Opening the Brain.
Showing the direction of first incision.

face of the corpus callosum is exposed (Fig. 2). A longitudinal incision is made through the junction of the corpus callosum and the cerebrum, and downward into the ventricle. The incision should be made carefully, so as not to cut through the ventricle into the ganglia below. The incision thus made through the roof of the ventricle is prolonged backward and forward in the direction of the cornua, so as to expose the entire ventricle. A longitudinal incision is then

made outward and backward into the hemisphere, from the outer edge of the lateral ventricle, nearly to the pia mater. A second incision is then made through this cut surface outward, and this is repeated until the hemisphere is divided into a number of long, prism-shaped pieces, held together by the pia mater and a small portion of the cortex. The brain is now turned around so as to bring the other hemisphere under the hand, and the operation is repeated on the other side.

The size, shape, and contents of the ventricles should be noticed, and the thickness and appearance of the ependyma.

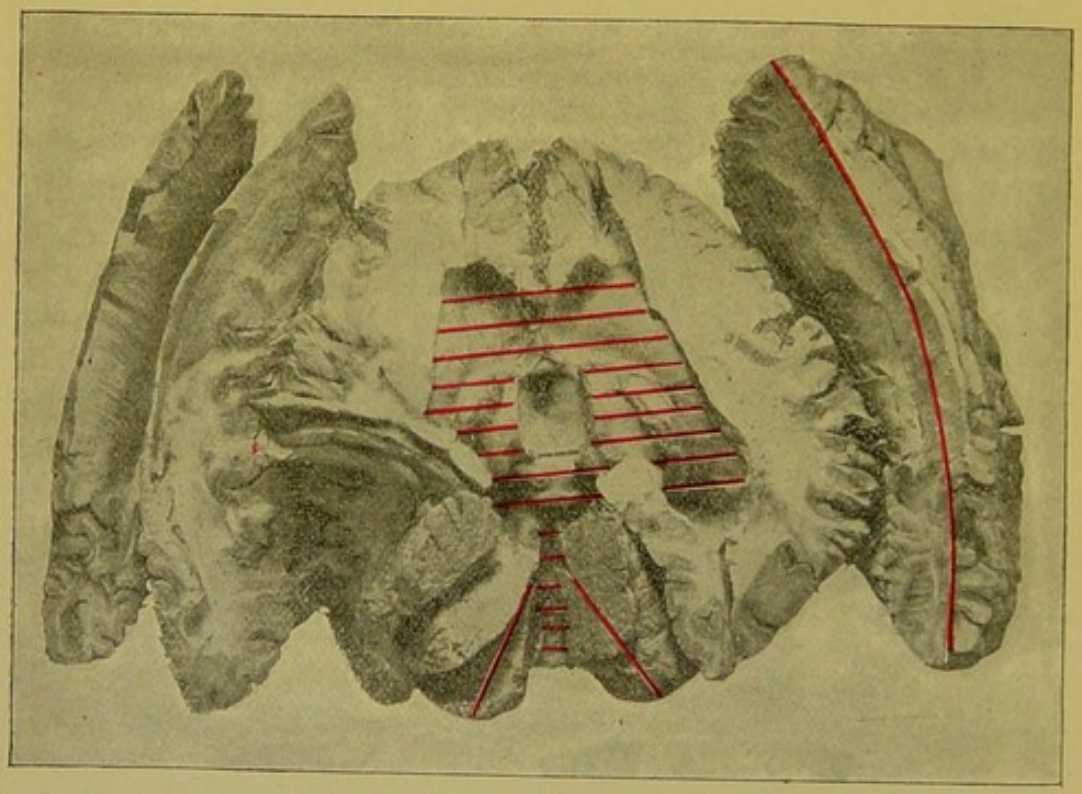

FIG. 3.—METHOD OF OPENING THE BRAIN.

Showing the unfolded segments of the cerebrum and lines of transverse incision of the basal ganglia and directions of the incision of the cerebellum.

The fornix and the central portion of the corpus callosum are cut across by passing the point of the knife through the foramen of Munro and cutting upward. They are then drawn backward, one of the posterior cornua of the fornix being severed and laid to one side. The velum interpositum and the choroid plexus are now dissected up, the blood contents and the general appearance noted, and the third ventricle examined. Not infrequently small cysts of the choroid are found, which seem to have little or no pathological significance.

The fourth ventricle is now opened by a longitudinal incision through the vermiform process. Each hemisphere of the cerebellum

is divided first into two parts by an incision through the upper and inner convex border, and then each segment is further divided by incisions in the same direction.

Thin transverse sections are now made through the cerebral ganglia, commencing in front (Fig. 3). The ganglia are supported, and the sections caused to fall apart as they are cut, by carrying the fingers of one hand under the brain, and gently lifting the ganglia at points just beneath where the sections are made. It is important to observe the exact position of any lesion which may be discovered in the cerebral ganglia, their relations to the external and internal capsule and to the caudate and lenticular nucleus.

Finally the segments of the cerebrum and cerebellum are folded up together into their original positions, the whole is turned over on to the vertex, and thin sections are made through the medulla. Small clots in the medulla should not be overlooked.

In case of the discovery of apoplectic clots, areas of softening, etc., either in the hemispheres or in the basal ganglia, after their location and extent are determined they should be carefully searched for lesions of the blood vessels, minute aneurisms, areas of degeneration, and ruptures. For this purpose it may be necessary to allow a stream of water to run over the affected portion, so as to wash out the brain substance and expose the vessels. In some cases the blood vessels are best exposed by macerating the brain tissue at the seat of the lesion for some hours in water, and then washing out the brain substance under the faucet.

While the above mode of dissecting the brain gives a very complete view of the seat and extent of lesions in general, where a more exact localization of lesions with a microscopical examination is to be made the following is a better method of opening the brain :

After completing the external examination, as detailed above, the brain is laid on its vertex, the cerebellar end toward the operator. The cerebellum is raised by the fingers of the left hand, and the pia cut through along the sides of the corpora quadrigemina, around the crura and along the inner margins of the temporal lobes to the middle cerebral artery on both sides (Fig. 4). Then, raising the temporal lobes, in turn, by their apices, the pia is cut through along the course of the middle cerebral artery into the Sylvian fissure, and along the course of its posterior branch to its end. Now drawing the temporal lobes one after the other upward and outward, their junction with the base is cut, the knife being held horizontally so as not to injure the basal ganglia, until the descending horn is opened. The point of the knife being in the descending horn, the incision through the brain substance then passes outward and backward well into the posterior horn, thus partially severing, at the lateral surface of the

brain, the junction of the occipital and temporal lobes. The temporal lobes are then turned outward and backward (Fig. 4).

The operculum is now pulled well outward, completely exposing

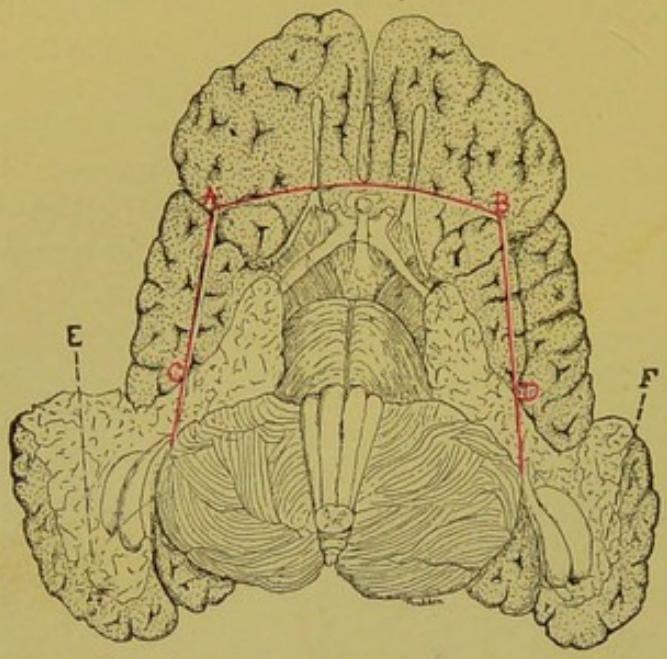


FIG. 4.—SCHEMATIC PICTURE OF BRAIN.

Showing the method of dissection from the base (Meynert's method). E and F, Temporal lobes turned backward and outward; A B, A C, B D, line of incision to remove basal piece.

the island of Reil, and a slightly curved transverse incision is made, deep enough to pass into the anterior horns of the ventricles, connecting the anterior sulci of the island of Reil (Fig. 4, A, B).

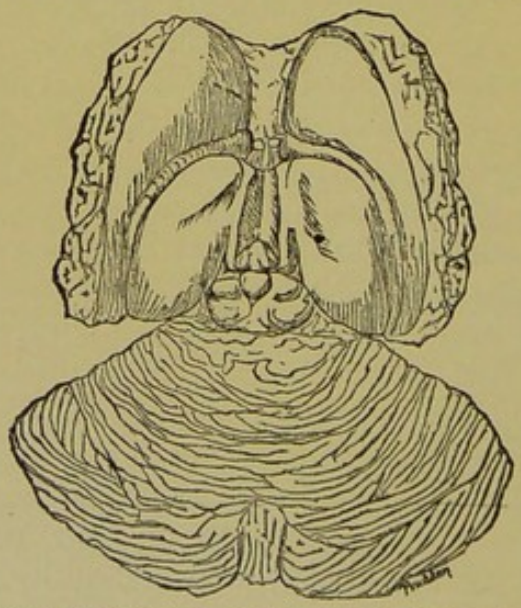

FIG. 5.—THE BRAIN AXIS SEPARATED FROM THE BRAIN MANTLE, AS SEEN FROM ABOVE.

Now raising the cerebellum and inserting the point of the knife into the ventricle, with short incisions from within outward cut

through the internal capsule on either side from back to front (Fig. 4, C A and D B) care being taken not to injure the basal ganglia. Then cut across the crura of the fornix and the septum lucidum, leaving the fornix lying on the corpus callosum.

The square basal piece thus freed—*the brain axis*—includes the island of Reil, the basal ganglia, the crura, pons, medulla, and cerebellum (Fig. 5).

The remaining portion—*the brain mantle*—includes the convolutions, corpus callosum, and fornix (Fig. 6).

The basal piece may be further examined by a series of transverse

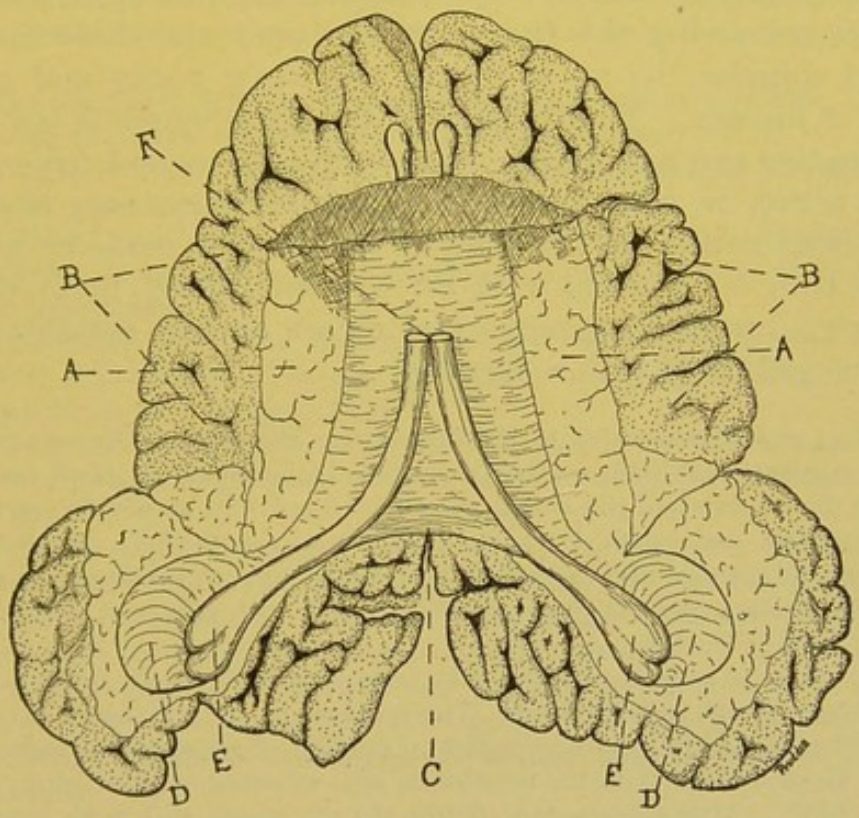


FIG. 6.—THE BRAIN MANTLE AS SEEN FROM BELOW.

A, Internal capsule B, operculum ; C, posterior border of corpus callosum ; D, descending horn ; E, cornu Ammonis.

incisions from one-half to three-quarters of an inch apart, and it may be hardened either with or without the cerebellum. The convolutions may be cut into small pieces by longitudinal and transverse incisions, made from within and not reaching quite to the pia mater, which will then serve to hold the pieces together in their proper relations to one another.[1]

[1] For further details of this method of opening the brain and a consideration of its advantages, see *Van Gieson*, Laboratory Notes, etc., New York Medical Journal, July 20th, 1889.

For the methods of hardening and preserving the brain tissues, see below.

*The Base of the Cranium.*—We now return to the skull. The remaining sinuses of the dura mater should be opened, and this membrane then entirely stripped from the bone. The bones at the base of the skull are to be examined for fractures, inflammatory lesions, and tumors. In cases of acute purulent meningitis the temporal and frontal bones should be carefully examined, as the inflammatory process is sometimes transmitted from the internal ear, or mastoid cells, or frontal sinuses.

The eyes may be removed by breaking the roof of the orbit with a hammer, removing the fragments of bone, and dissecting away bone and muscles, so as to expose the optic nerve and posterior segment of the eye. That portion of the globe which is not covered by conjunctiva can now be cut away with scissors and removed with the optic nerve, or, when permissible, the whole eye may be cut out.

The examination of the internal ear may be made by removing its entire bony encasement with the saw and chisel, or by the exposure of special parts by hammer and chisel, and by suitable opening of the removed parts with a fine saw.

*Hardening and Preservation of the Tissues for Microscopical Examination.*—For the study of tumors and inflammatory lesions of the bones of the skull and ossifications of the dura mater and pia mater, the affected portions should be cut into small pieces, decalcified, and subsequently hardened in strong alcohol. In the ordinary lesions of the dura mater, the tissues are best hardened and preserved by stretching the diseased portions on a flat piece of wood or cork with pins, and hardening them in Müller's fluid or alcohol. [1]

The pia mater is so delicate that if it be separated from the brain when quite fresh its tissues are apt to be injured. The portions of the pia mater which are to be preserved should therefore be removed by cutting off slices of the brain substance about half an inch thick, with the membrane still attached, and placing the whole in Müller's fluid. After twenty-four hours the pia mater will have become sufficiently hard to permit of its being stripped off without injury, and it is then spread loosely on a flat cork with pins, the free surface outward, and the cork floated, specimen side down, in a dish of alcohol (eighty per cent). The next day strong alcohol may be used, and the hardening is complete in three or four days. The pia mater should not remain longer than twenty-four hours in Müller's fluid before being stripped off, for after this time it usually becomes so firmly attached to the brain substance as to render its removal very difficult.

When sections are required showing the pia in its relationship to the underlying brain tissue, small blocks of the brain and pia together should be cut out and hardened in Müller's fluid or in alcohol, or in formalin (2 : 100) solution (see page 53).

When the ependyma is to be studied apart from the associated nerve tissue it may be sliced off with a sufficient quantity of underlying brain substance to prevent its

[1] For details of the methods of hardening, decalcifying, staining, etc., see the end of Part I.

folding, and hardened in Müller's fluid. Special care should be exercised not to touch the surface of the ependyma, since the epithelium is easily rubbed off.

The brain substance, after having been cut into sufficiently small pieces for the general examination, should be hardened in Müller's fluid. Large quantities of the fluid should be used, four or five times the bulk of the tissue, and the pieces of tissue should either be suspended in gauze or kept apart by a little absorbent cotton. The fluid should be kept cool, and changed on the second, fifth, and eighth days, and again in the third week.

In general, two or three months are required to secure a good hardening with Müller's fluid. When the hardening is complete the brain tissue is rinsed off with water and put in eighty-per-cent alcohol, in which it may be kept, preferably in the dark.

Great care is required in hardening and preserving nerve tissues, and most of the ordinarily practised methods give only caricatures and gross distortions of the brain structure.

Too long a soaking in Müller's fluid renders brain tissue very brittle. To get the best hardening the single pieces ought not to be larger than 1 c.c.

Hardening in sublimate solution for many purposes, especially for studies on the ganglion cells, gives excellent results.

Certain lesions, particularly the softenings of the brain, are best studied by teasing, when fresh, in one-half-per-cent solution of sodium chloride, or in frozen sections of the fresh tissue.

The blood-vessels should be stretched on cork with pins and hardened with Müller's fluid and alcohol. The eye and portion of the optic nerve, if removed, should be hardened with Müller's fluid.

Müller's fluid is especially useful for the preservation and hardening of the nerve fibres and neuroglia. The ganglion cells are better preserved in sublimate, formalin, or even in alcohol.

Van Gieson[1] has called attention to the value of *formalin* for the hardening of the brain and spinal cord. It should be used in from four- to ten-per-cent solution for ten days and the hardening completed with "graded" alcohols—that is, alcohol used in successive portions of gradually increasing strength.

In this way the ganglion cells, nerve fibres, and neuroglia are all well preserved, and the tissue may be stained by either Weigert's hæmatoxylin method or Nissl's method, although for the latter purpose the hardening is not quite so good as by absolute alcohol.

## THE SPINAL CORD.

The examination of the spinal cord is usually most conveniently made after the removal of the brain.

The body should be placed face downward, with a block under the thorax and the head hanging over the edge of the table. An incision is made through the skin and muscles along the entire length of the spine, and the soft parts dissected away on each side so as to expose the laminæ of the vertebral column. The laminæ are then divided close within the articular processes with the saw.

The saw should be so directed in severing the laminæ that the in-

[1] *Van Gieson*, Anatomische Anzeiger, Bd. x., No. 15, 1895.

cision shall touch the outer border of the spinal canal, as otherwise the laminæ and spinous processes are not easily separated.

Great care should be taken on the one hand not to injure the cord with saw, and on the other to completely loosen the portions of bone to be removed. These, which are the spinous processes and laminæ, are now torn away together with a stout hook, exposing the cord.

By means of a long, curved chisel, made for this purpose, the bodies of the vertebræ may be removed from the front after the thoracic and abdominal viscera are taken out, and the cord thus exposed and removed.

But in this anterior method of removing the cord, as well as by the use of chisel and mallet, bone shears, etc., in the ordinary method, there is great liability of injuring the delicate tissues of the cord and producing, as Van Gieson has shown,[1] mechanical alterations which are liable to be mistaken for malformations or the effects of disease.

When the body has lain on the back, the membranes of the cord may be found considerably congested without indicating the pre-existence of any disease. If the body has lain for some time, especially in warm weather, serous fluid may have accumulated within the membranes as a result of post-mortem change.

The roots of the nerves are now to be cut across, as far away as possible from the cord, and the cord removed in its membranes, care being taken not to press it in any way. It is the safest plan not to grasp the cord itself, but with a forceps to seize the dura mater and thus lift it up at once as it is freed from its attachments. It is now laid on the table, and the dura mater laid open with scissors on the anterior and posterior surfaces over its entire length, and searched for tumors, inflammatory lesions, etc. The finger should be passed gently along the cord as it lies on the table, so as to detect any marked softening or sclerosis. The weight of the spinal cord is from 33 to 38 gm. It should now be held lightly over the fingers, and smooth transverse incisions made, with a very sharp knife or razor, about half an inch apart through its entire substance between the segments, leaving these attached to the pia mater.

The segments of the spinal cord are those parts from which the spinal nerves arise, and it is convenient for the location and description of lesions to number the segments in correspondence with the nerves which arise from them and to indicate on outline diagrams of the cord the exact seat of small lesions.

The cut surfaces should be carefully examined for abnormal blood contents, hæmorrhages, inflammatory lesions, softening, scleroses,

[1] *Van Gieson*, "A Study of the Artefacts of the Nervous System," New York Medical Journal, 1892.

and pigmentations. Important lesion of the cord may be invisible to the naked eye, and hence, if disease be suspected, the organ should be preserved for microscopical examination. After removal of the

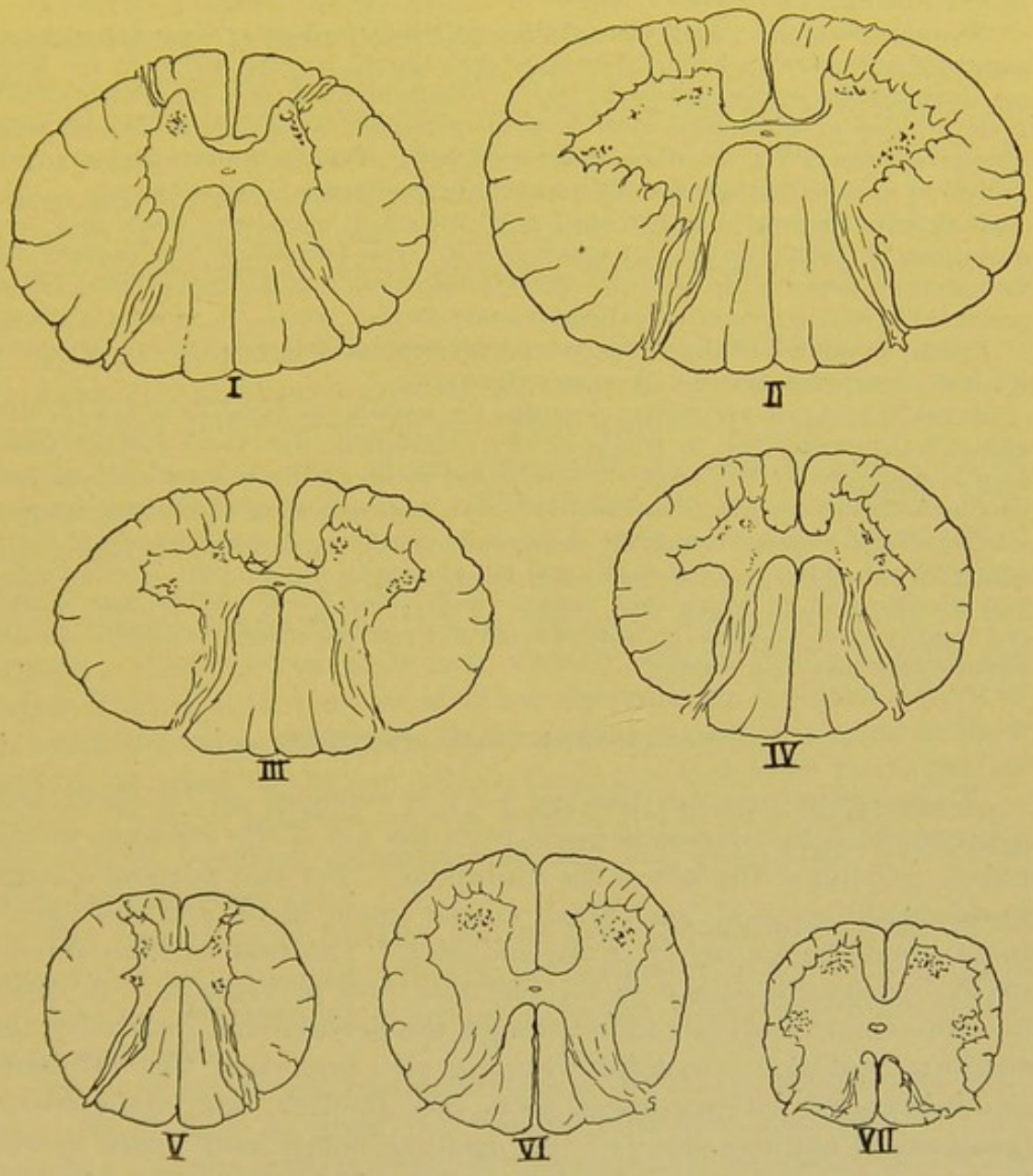


FIG. 7.—OUTLINES OF SECTIONS OF THE SPINAL CORD AT DIFFERENT LEVELS.

Copies of these outlines may be used for memoranda of the situations of lesion of the spinal cord. I, Second cervical; II, fifth cervical; III, eighth cervical; IV, first dorsal; V, eighth dorsal; VI, third lumbar; VII, fourth sacral.

cord fractures and displacements of the vertebræ are easily recognized.

*Preservation of the Spinal Cord and its Membranes, and of Peripheral Nerves.*—After the removal of the spinal dura, the entire cord with its nerve roots—the segments into which it has been cut for gross examination being left in place—should be laid on a wad of absorbent cotton in a large jar of Müller's fluid, the segments

being slightly separated from each other by a little absorbent cotton. Van Gieson recommends the careful rolling of the segmented cord into a loose spiral and laying this coil on a wad of absorbent cotton in the Müller's fluid. In this way the cut ends of the segments are held apart and accessible to the preservation fluid, and harden with little distortion.

The hardening and preservation of the cord should be done by the same method as suggested above for the brain. The same care should be exercised as in the brain not to permit the cord to become brittle by remaining too long in the Müller's fluid. If the dura mater of the cord alone is to be preserved, it should be treated in the manner suggested for the dura mater cerebralis. The pia mater spinalis is best studied in sections through the entire cord, the membranes being left *in situ*.

Peripheral nerves may be hardened in Müller's fluid, care being taken that they do not become brittle by too long soaking in it. The hardening is completed and the specimen preserved in alcohol, Kitchel has shown that the axis cylinder is well preserved in strong formalin solutions (twenty-five per cent).

For the hardening of the peripheral nerves osmic acid is very useful, especially when changes in the myeline are to be sought after.

As osmic acid does not readily penetrate the lamellar sheath so as to come in contact with the nerve fibres, in trunks of any considerable size, the following procedure as suggested by Van Gieson will be found useful: A piece about one-half inch long is cut from the nerve to be examined, and, seizing one end of this segment with a forceps, with another forceps the individual nerve fibres, or small clusters of these, are pulled out of the lamellar sheath and put at once in one-per-cent aqueous solution of osmic acid, in which they remain twenty-four hours, and are then washed and transferred to glycerin, to which twenty-five per cent alcohol is added. In this mixture they may be preserved.

## THE THORAX AND ABDOMEN.

To examine these cavities the body is replaced on its back, and a single straight incision is made from the top of the sternum to the pubes, passing to the left of the umbilicus. For this purpose a large knife should be used, held firmly in the whole hand, and the movement should be mainly from the shoulder. The first incision should divide everything down to the sternum and peritoneum. A short incision should then be made through the peritoneum, just below the ensiform cartilage. Into this opening two fingers of the left hand are introduced and separated from one another, and, the parietes being raised and the sides of the opening being held apart by the fingers, the peritoneum is divided to the pubes, care being taken to hold the knife horizontally so as not to cut the intestines. The skin and muscles are then dissected off from the thorax on both sides as far back as the false ribs.

This dissection should be made by long sweeps of the knife, which should be made to cut with the full blade and not with the point only; and if the skin and muscles be pulled strongly away from the chest with the left hand, it may be done very rapidly and with a few strokes of the knife. We notice here the amount of subcutaneous fat and the condition of the muscles. In order better to expose the

abdominal cavity, the rectus abdominis muscles should be divided transversely beneath the skin just above the pubes, and the abdominal flaps may then be turned freely outward.

*General Inspection of the Abdominal Cavity.*—We first notice the position and general condition of the viscera. It is best at this stage of the examination to note the condition of the vermiform appendix, and to look over the peritoneal cavity for serum, inflammatory lesions, evidences of perforation, and for the existence of invagination, incarceration, and herniæ of the intestines. A small quantity of reddish serum is frequently found in the abdominal cavity, particularly in warm weather, as the result of commencing decomposition.

It should be remarked here that a variety of striking changes in the character and appearance of the internal organs are produced by putrefaction—changes which are often mistakenly regarded as evidences of disease, and much experience is required in judging correctly of their significance. These changes are, in general, softening and discoloration, both of which may occur as the result of disease. It may be said in general that the post-mortem reddening or hypostases are most marked in the more dependent parts of the organs. Post-mortem softening usually affects entire organs, not being limited to a part as is often the case in disease. Gray or greenish-brown post-mortem discolorations are apt to appear in those organs or parts of organs which lie in contact with the intestinal canal. Parts of internal organs, such as the liver, which have been the seat of localized congestion during life, may after death take on a dark-greenish color.

The *omentum* is usually spread over the surface of the small intestines, but it may be rolled up and displaced in a variety of ways, or may be adherent at some point to the small intestines or the abdominal wall.

The surface of the *small intestines* should be smooth and shining. They may be greatly distended with gas, and thus so completely cover the other abdominal viscera that it becomes necessary to let out some of the gas by a small puncture. The transverse colon passes across the abdomen through the upper part of the umbilical region. It may be lower than the umbilicus or higher up against the liver and diaphragm; it may be distended with gas or contracted.

The *liver* is situated in the right hypochondriac and epigastric regions, filling the concavity of the diaphragm. Its upper border reaches, in the linea mammillaris, to the fifth intercostal space; in the linea axillaris, to the seventh intercostal space; close to the vertebral column, to the tenth intercostal space. At the median line the

upper border of the liver corresponds to the lower border of the heart. The left lobe extends about three inches to the left of the median line. The lower border of the right lobe usually reaches to the free border of the ribs, while the left lobe is visible for about an inch below the ensiform cartilage. In women the liver is usually lower than in men.

The position of the liver is affected by changes in the thoracic cavity, forcing it downward ; by changes in the abdominal cavity, forcing it upward ; by constriction of the waist in tight lacing, forcing it either upward or downward ; by changes in the size of the organ itself. The liver may not only be displaced downward but dislocated, so that its convex surface faces the abdominal wall and its posterior edge is turned upward against the diaphragm.

The *stomach* is situated in the left hypochondriac and epigastric regions, extending also into the right hypochondrium ; it lies in part against the anterior wall of the abdomen, in part beneath the liver and diaphragm, and above the transverse colon. Its anterior surface, which is directed upward and forward, is in contact above with the diaphragm and the under surface of the liver, and lower down with the abdominal wall opposite to the epigastric region. Its posterior surface is turned downward and backward, and rests on the transverse mesocolon, the pancreas, and the great vessels. To its lesser curvature or upper border are attached the gastro-phrenic ligament and the gastro-hepatic omentum. To the greater curvature or lower border is attached the gastro-colic omentum. Its cardiac orifice communicates with the œsophagus, its pyloric end with the duodenum.

When the stomach is distended the greater curvature is elevated and carried forward, the anterior surface is turned upward and the posterior surface downward. When distended with food or gas the organ is prominent ; when empty it may hardly be visible below the ribs ; when the intestines are dilated it may be entirely covered by them.

Before opening the thorax the hand should be passed up against the under surface of the diaphragm on either side to determine its height. According to Quain, the vault of the diaphragm rises, in the dead body, on the right side to the level of the junction of the fifth rib and sternum, on the left side as high as the sixth rib. Both the relative and the absolute height of the diaphragm vary under a variety of pathological conditions.

If the existence of air or gas in the pleural cavities be suspected, the abdominal cavity should be filled with water and the diaphragm punctured below the level of the fluid. If air be present it will escape in bubbles through the water.

## THE THORAX.

We now leave the abdominal viscera and proceed to the examination of the thorax. With a costatome or a strong knife the costal cartilages are divided close to the ribs, the clavicles are disarticulated from the sternum, and the latter removed, taking care not to wound the large veins. We first examine the position of the heart and lungs.

*The Heart.*—The upper border of the heart is on a level with the third costal cartilage; the lower border extends from 1.3 cm. (½ in.) below the lower end of the sternum to the fifth left intercostal space. The left boundary of the heart is situated to the left of the junction of the fifth rib with its costal cartilage, and behind or to the left of a vertical line drawn downward from the left nipple. The right boundary extends about 2.5 cm. (1 in.) to the right of the right edge of the sternum. The portion of the heart uncovered by the lungs is of an irregular quadrangular shape. Its lateral diameter is from 3.8 cm. to 11.1 cm. (1½–4½ inches); its upper boundary varies from the level of the second costal cartilage to that of the fifth, but it is usually behind the third or fourth cartilage or fourth space.

The area of the heart which is found uncovered will, however, vary much according to the degree to which the lungs collapse after opening the chest. Any disease which diminishes the size of the lungs, or pleuritic adhesions which retract or bind them down, may increase the area of exposed heart. On the other hand, emphysema, pneumonia, or any disease which increases the size of, or retains the air in, the lungs, may diminish the area of exposed heart. The exposed area varies also with the size of the heart itself.

*The Pericardium* is now opened by a slightly oblique incision on its anterior surface. The existence of serous, fibrinous, or purulent exudation, and of adhesions, is to be noticed. A small quantity of clear serum exists normally in the pericardial sac, and this serum may be blood-stained from beginning decomposition. White thickenings of the pericardium on the surfaces of the heart are often seen; they do not indicate important disease.

Now that the pericardial sac is open, the position of the heart can be clearly seen. It lies obliquely in the chest, its long axis at an angle of about 60 degrees with that of the thorax. The portion of the heart which is first seen is the anterior surface of the right ventricle; upward and to the right of this is the right auricle, which lies about two-thirds on the right of the sternum and about one-third behind it. Its upper border usually corresponds to the plane of the middle of the anterior end of the second intercostal space on the right side. Its size varies with the amount of blood which it con-

tains. The left auricle lies behind the root of the pulmonary artery, so that only its appendix is visible. The middle of the auricle corresponds to the third costal cartilage. Of the left ventricle only a narrow rim is seen, on the left side of the right ventricle. The pulmonary valve is usually entirely or in part on the left side of the sternum, behind the second space or third costal cartilage.

The aortic valve is usually at the level of the third cartilage or the third space, and behind the left two-thirds or half of the sternum. The mitral valve is oblique, the upper end to the left. It is on the level of the third to the fourth cartilage, near the middle of the sternum. The tricuspid is oblique, its upper end to the left; the upper end is at the level of the third cartilage, the third space, or the fourth cartilage. The valve is opposite the middle of the sternum.

The hand should now be passed over the arch of the aorta, to ascertain whether or not an aneurism is present. The heart is then grasped at the apex, raised out of the pericardium, tilted upward, and removed unopened by cutting through the vessels at its base.

To determine the sufficiency of the aortic and pulmonary valves, the heart is held horizontally by both auricles, so as not to pull the valves open, and water is poured into the aortic and pulmonary arteries, and we observe how well the valves support the column of liquid. To ascertain the sufficiency of the mitral and tricuspid valves, the auricles are first laid open so as to expose the upper surfaces of the valves. A large pipe is passed through the aorta or pulmonary artery beyond their valves, and a small stream of water allowed to flow into the ventricles. The auriculo-ventricular valves will be swollen upward, and we can observe their degree of sufficiency. The tricuspid valve is normally somewhat insufficient. These water tests, however carefully applied, are not very reliable, since under the most favorable conditions the natural bearings of the valves are not perfectly preserved.

To ascertain the size of the different valvular openings, we introduce the fingers, held flat with their sides in contact, into each of the orifices, and then measure the width of the fingers at the point where they fill the orifice. In this way we find that, under normal conditions in the adult, the aortic orifice measures about 2.5 cm. (1 in.), the mitral valve about 4.5 cm. (1.8 in.), the pulmonary about 3.1 cm. (1.2 in.), the tricuspid about 5 cm. (2 in.).

In order to examine the interior of the heart, we first make an incision through the anterior wall of the left ventricle, close to the septum, and reaching to the apex of the ventricle; through this opening the blade of the enterotome is passed up into the aorta, the pulmonary artery being drawn aside with the fingers, and the ventricle and aorta are laid open. With a little care the incision may

be made to pass through one of the points of junction of the aortic valves.

*Clots.*—The auricles and ventricles may be empty, or may contain fluid blood or the so-called heart clots. These heart clots are of two kinds—those which are formed some time before death, and those which are formed during the last hours of life and after death. The clots which are formed some time before death are usually associated with organic disease of the heart, especially with dilatation of the ventricles. They are firm, dry, and of whitish color; they may soften or be infiltrated with the salts of lime. They are free in the cavities of the heart, or entangled in the trabeculæ, or firmly adherent to the endocardium. They are usually composed of coagulated fibrin.[1] The clots which are formed during the last hours of life and after death are red, yellow, or white. They may be soft or succulent, or quite firm. They may be free in the heart cavities, or be adherent to the trabeculæ, or extend into the large vessels. They are usually most constant and of largest size in the right auricle and ventricle. Such clots may be formed within two hours after death. Clots of this character are a regular post-mortem condition and of no pathological significance. It is evident, however, if the blood did coagulate in the heart within twenty-four hours before death, that this coagulum could not be distinguished from the ordinary post-mortem clots. If it is supposed, therefore, that a person dies from heart clot developed a few hours before death, the proof of this must be derived largely from the clinical symptoms and not from the autopsy.

The condition of the aortic valves and of the endocardium, and the thickness and appearance of the walls of the left ventricle, papillary muscles, cordæ tendineæ, etc., are now noticed. The right ventricle is now opened by an incision through its anterior wall, close to the septum, and examined in the same way. We sometimes see the endocardium of the upper part of the left ventricle thick and white without the existence of valvular lesions or any clinical history of disease. The endocardium and valves are often stained red, particularly in warm weather, by imbibition of coloring matter of the blood set free by decomposition. To complete the examination of the cavities the enterotome is passed into each auricle, carried down into the corresponding ventricle, and an incision made along the outer border of both auricle and ventricle to the apex of the latter. In this way the auriculo-ventricular valves are completely exposed.

After removing the blood the heart should be finally weighed. In adults the normal average weight of the heart is about 292 gm. (about 10 oz.). The relative weight of the heart to that of the body

[1] For a description of special forms of heart thrombi see p. 501.

is in males about 1:158–178; in females, about 1:149–176. According to Buhl, the average thickness of the wall of the left ventricle at about the middle of the cavity is from 1.6 cm. to 1.7 cm. (from about $\frac{5}{8}$ to $\frac{2}{3}$ in.); of the right ventricle, from 0.4 to 0.6 cm. (from about $\frac{1}{6}$ to $\frac{1}{4}$ in.).

Generally speaking, the size of the heart corresponds to the size and the development of the individual. In judging of an increase or decrease in its size we must consider the weight of the organ and the thickness of its walls. If the person die while the heart is contracted, the walls of the ventricles will appear thicker, their cavities smaller than usual. If he die of some exhausting disease, like typhoid fever, or if decomposition have commenced, the heart walls will usually be flabby and the cavities will appear larger than usual.

*Preservation of Specimens.*—Parenchymatous and fatty degeneration of the heart may be studied microscopically by teasing the fresh muscle in one-half-per-cent salt solution, or by examining in the same solution fresh sections made with the freezing microtome, or by hardening small pieces of the muscle in one-per-cent osmic acid and teasing in equal parts of glycerin and water.

The heart valves may be stretched on a flat cork with pins and hardened in Müller's fluid or alcohol. For the methods of detecting bacteria in ulcerative endocarditis, see section on Staining Bacteria. When the presence of bacteria is suspected cultures should be made and the tissues should be preserved in strong alcohol.

*The Pleural Cavities* are next examined. The hand is passed into each, and the existence of serous or fibrinous exudations or of old adhesions ascertained. The method of detecting the presence of air has been given above. After the commencement of putrefaction reddish serum may accumulate in the pleural cavities. This should not be mistaken for the result of disease.

*The Lungs.*—Each lung is lifted up in turn, the vessels, etc., at its base divided, and the organ removed. If the pleura is very adherent it is better to strip off the costal pleura with the lung. After inspecting the external surface of the lung, observing its size, shape, color, and consistence, we open the bronchi. For this purpose we use scissors with long, narrow, blunt-pointed blades, one blade a little longer than the other. The lung is held in the left hand with its base upward. We first open the large bronchi which run on the inner side of the lower lobe, afterward those of the upper lobe. Each bronchus should be followed to its smaller ramifications.

We should observe the contents of the bronchi and the appearance of their walls. In the larger and medium-size bronchi the cartilages in their walls do not form complete rings, but appear shining through the mucous membrane like irregular white patches. This appearance should not be mistaken for a pathological change. In bodies which have been dead for some time, especially in cold

weather, the bronchial mucous membrane may be red and swollen as a post-mortem change. The contents of the stomach are sometimes forced, after death, into the pharynx, and thence find their way into the trachea and bronchi, giving them a peculiar reddish and even gangrenous appearance. Bronchitis does not always leave lesions which can be seen after death.

After the examination of the bronchi the lung is turned over, the vessels, etc., at its root grasped with the left hand, and a long, deep incision made from apex to base. We observe the appearance and texture of the lungs, whether the air vesicles are dilated (emphysematous) or filled with serum, blood, or inflammatory exudation. Fluid can be pressed out of the air vesicles without breaking down the lung tissue. Solid inflammatory exudation, on the other hand, renders the lung more resistant and easily broken down. Attention should be paid to the oozing of purulent or other fluid from the smaller bronchi when the lung is squeezed near the cut surface. It is the rule to find the lower lobes more congested than the upper.

*Preservation of the Lungs and Bronchi.*—If the lungs have been cut, small pieces from the affected portions of lung tissue or bronchi should be hardened in Müller's fluid, care being taken not to squeeze or handle them unnecessarily. It is better, when the microscopical examination is more important than the macroscopical, not to open the lungs at once, but to fill the air spaces with preservative fluid by means of a funnel attached to a short rubber tube and canula, which is tied into the main bronchus. In this way not only are the minute structures better preserved, but the air vesicles are filled out and hardened in an approximately natural condition. Care should be taken not to have too great a pressure from the inflowing fluid, since then exudations might be displaced or the lung distorted or ruptured. While the lung is being filled it should be immersed in a vessel of the same preservative fluid, in which it lies for twenty-four hours. It is then cut into small pieces and the hardening completed. A variety of hardening agents may be used: Strong alcohol, Müller's fluid, or formalin solution (2 : 100) are on the whole the best. If, however, the lung is commencing to decay, strong alcohol will stop the process most quickly and give as good results as are possible under the circumstances. Alcohol should be used when the lungs are to be examined for bacteria.

It is often desirable, and particularly in cases in which the topography of lesions is to be studied, as in acute miliary tuberculosis, acute and chronic phthisis, infarctions, etc., to inject the blood vessels with colored gelatin. The lung should, after the injection, be hardened in alcohol.

*The Pharynx, Larynx, Œsophagus, and Thyroid Gland.*—For the removal of these parts the incision through the skin should be carried upward as far as practicable—when allowable, to a point one inch below the chin, the head being allowed to hang backward over the edge of the table.

The soft parts are dissected from the larynx, taking care not to cut the thyroid body, and an incision is made through the floor of the mouth, following the internal surface of the inferior maxilla. Through this incision the fingers are introduced into the mouth, the

tongue drawn down, the posterior wall of the pharynx divided above the tonsils, and the pharynx and larynx drawn out together. These organs are then pulled downward, and with the aid of the knife the trachea and œsophagus are removed entire, the œsophagus being cut just above the stomach. If the contents of the stomach are to be preserved, as in cases of suspected poisoning, a ligature is put around the œsophagus just below the point at which it is to be cut off.

With the enterotome the pharynx and œsophagus are now slit open upon their posterior surfaces. The mucous membrane thus exposed is examined for evidences of caustic poisons, of inflammation, tumors, strictures, etc. The enterotome is next introduced into the larynx, and this organ and the trachea laid open along the posterior wall. Here we look for œdema of the aryteno-epiglottidean folds (œdema of the glottis), for evidences of catarrhal, croupous, ulcerative, and syphilitic inflammation, and for tumors and lesions of the laryngeal cartilages. Œdema and redness of the larynx may be produced by post-mortem changes, especially in bodies which have been kept for several days in cold weather. A well-marked œdema glottidis during life may leave no trace after death. Putrefactive changes usually commence early in the larynx and trachea.

The thyroid gland is dissected off and examined. Its weight varies a good deal, being, according to Krause, somewhat over 30 gm. (about 1⅛ oz.).

*Preservation of the Pharynx, Larynx, and Trachea.*—These structures are freed from superfluous tissue and suspended entire by a thread in a large quantity of Müller's fluid or alcohol or formalin solution (2 : 100), in which the hardening is completed in the usual way. The œsophagus should be stretched loosely on sheet cork with pins and hardened in either of the above fluids. The thyroid may be cut into small pieces and hardened in Müller's fluid, formalin, or alcohol. The colloid material in the acini of the thyroid and in goitres is apt to be preserved without shrinkage in formalin.

## THE ABDOMEN.

Returning now to the abdominal cavity, we first dissect off the omentum. If tubercles of the peritoneum exist, they are best seen and studied in the omentum. The colon is then raised and dissected free, to the cæcum on one side and to the rectum on the other. The colon and small intestines are then drawn first to the right and then to the left side, so as to expose in turn the right and left kidneys. As each kidney is brought into view an incision is made through the peritoneum over the track of the ureter. The ureter is followed through its entire length and its condition ascertained.

*The Kidneys* are then removed, separating the peritoneum and fat from them with the hand, and dividing the vessels with the knife. The suprarenal capsules, which are attached to the upper end of each kidney, are removed at the same time. The kidneys may be softened by putrefaction, or the surface may have a greenish-gray color caused by the post-mortem action of putrefactive gases on the hæmoglobin.

An incision is made through the capsule, along the convex border of the kidney, and the membrane stripped off. We notice the degree of adherence of the capsule to the kidney, and also the surface of the latter, whether smooth or roughened, pale, congested, or mottled; an incision is made along the convex surface down to the pelvis, so that the organ is divided into halves. We observe the relative thickness of the cortical and pyramidal portions, as well as the size of the entire organ. To ascertain the latter point, it is well to weigh each kidney; the normal weight is from 130 to 150 gm. (about 4½ to 5 oz.).

It is necessary to remember, however, that in a kidney which is much atrophied there may be an increase of fat in the pelvis, which gives the organ nearly its normal size and weight, while the kidney tissue proper may have in great measure disappeared.

The weight of the kidneys of adults is given by Vierordt in general as about 0.48 per cent of that of the entire body.

We now inspect the kidney tissue more closely, especially the cortical portion. The pyramids consist largely of tubes running in nearly straight lines from the apex to the base of each pyramid. These straight tubes pass from the pyramids into the cortex in bundles, called medullary rays, many of them retaining their straight course until they nearly reach the surface of the kidney. These straight tubules send off branches on all sides of the rays, which become convoluted, from Henle's loops, and finally terminate in the glomeruli or Malpighian bodies. In this way the cortex of the kidney, as seen in section, is divided into alternate bands of straight tubes, convoluted tubes, and glomeruli; both sets of bands being perpendicular to the surface of the kidney, and called respectively medullary rays and labyrinths. About the convoluted tubules and glomeruli is a rich venous plexus; and since after death the blood usually remains in this plexus and in the glomeruli, the bands containing the convoluted tubules, *i.e.*, the labyrinths, usually appear red, while the medullary rays are grayish-white. In a normal kidney, therefore, the cortex should be regularly striped in narrow alternating red and whitish bands.

The average thickness of the cortex of the kidney is about one-third of an inch.

If there be extensive congestion the entire cortex is red. If the epithelium of the tubules degenerates and fills them up, or if there are considerable changes in the interstitial tissue, the regular bands are lost and the cortex is irregularly mottled. If the tubular epithelium becomes filled with fat globules, this is indicated by an opaque yellow color of the affected parts; in many cases, therefore, the existence of kidney disease can be recognized with the naked eye.

If waxy degeneration be present to a marked extent, it may be manifest by a peculiar translucent appearance of the affected parts, but in most cases it is necessary to apply reagents to demonstrate it satisfactorily. The cut surface of the kidney is washed with water to free it from blood, and repeatedly brushed with an aqueous solution of iodine (iodine 1 part, potassium iodide 3 parts, water 100 parts). The glomeruli and the blood vessels are most frequently affected, and, if so, they may appear as mahogany-colored dots and lines on a yellow ground.

But this reaction is not constant, and for accurate detection of amyloid substance recourse shall be had to other reagents applied to sections of the hardened tissues (see page 101).

The pelvis of the kidney should be examined for inflammatory lesions and calculi. Sometimes a whitish fluid is seen in the pelvis and can be squeezed from the papillæ; this is produced by a post-mortem desquamation of the epithelium, but is liable to be mistaken for pus.

*Preservation of the Kidney.*—If the kidney be not opened the blood vessels may be injected through the renal artery, slowly and under a low pressure with formalin solution (2 : 100), or with Müller's fluid, or with eighty-per-cent alcohol. Afterfilling the vessels with either of the above fluids they are tied, and the entire organ is placed in a large quantity of the injecting fluid for twenty-four hours. The kidney is then cut into small pieces and the hardening is completed in the usual way.

In most cases, however, the kidneys will have been opened for inspection at the autopsy. Then small pieces are removed from the various regions and hardened in alcohol or formalin or Müller's fluid.

For special cell studies osmic acid, sublimate, and other hardening agents may be used.

Kidneys which are to be examined for the presence of bacteria should be cut into small pieces and placed at once in strong alcohol, which should be changed once or twice, and in which they are permanently preserved.

*The Suprarenal Capsules* are in the fœtus of an ovoidal, in the adult of a triangular shape. They are situated at the upper and inner border of the kidney, to which they are loosely attached by connective tissue. On the anterior surface is an irregular fissure, called the hilus, from which the veins emerge. The size varies considerably, but in the adult the average vertical diameter is from 3.2 cm. (1¼ in.) to 4.5 cm. (1¾ in.), the transverse diameter about 3.2 c.m.

(1¼ in.), and they are from 4.2 mm. (⅙ in.) to 6.4 mm. (¼ in.) in thickness. They weigh in the adult from about 4 gm. (1 ʒ) to 8 gm. (2 ʒ). They are composed of a cortical and medullary portion, the cortex forming a yellowish shell around the dark-red or brown medulla. They are enclosed in a connective-tissue capsule, from which fibrous processes extend inward, dividing the gland in a series of irregular chambers. Those in the cortex are mostly elongated, giving this portion a striated appearance, while those in the medulla are polyhedral. It is in these spaces that the parenchyma cells lie. The suprarenal capsules readily decompose; the inner layer of the cortex may soften and break down, so that the outer zone forms a sort of cyst filled with reddish-brown broken-down substance. Hypertrophy, tuberculosis and cheesy degeneration, fatty degeneration, and tumors are to be looked for.

*Preservation.*—The suprarenal capsules should be hardened in Müller's fluid, in formalin solution (2 : 100), or in strong alcohol.

*The Spleen.*—This organ has, when removed from the body, the general shape of a flattened ellipsoid, most curved on its external and posterior surface. It is situated in an oblique position on the left side of the stomach, and between its cardiac end and the diaphragm. The vessels are given off from its inner surface, which is crossed by a more or less well-marked vertical ridge. The point of emergence of the vessels is called the hilus. Its long diameter extends from the seventh intercostal space to the eleventh rib. Its upper portion is separated from the ribs by the lungs; its lower portion by the diaphragm.

Its usual length in the adult is, according to Vierordt, from 12 to 13 cm. (about 4¾ to 5 in.); its breadth from 7 to 8 cm. (about 2¾ to 3 in.); its thickness 3 cm. (about 1¼ in.). Its average weight is about 171 gm. (about 7 oz.). The dimensions of the spleen as given by Krause are somewhat greater than the above. But its measurement and weight vary considerably within the limits of health. It is in these respects the most variable organ in the body. In old age the average weight gradually diminishes.

The spleen is enclosed in a fibrous capsule covered with peritoneum. The parenchyma is formed of blood vessels and fibrillar connective tissue, and of a soft, dark-red pulp in which are embedded whitish spheroidal or elongated bodies, the glomeruli or Malpighian bodies. In the normal human spleen the glomeruli are hardly perceptible to the naked eye, but sometimes they are very plain. Sometimes the fibrous stroma is very apparent, sometimes not.

The size, consistence, and color of the organ vary a good deal without any known cause. Decomposition softens it. Thickenings

of the capsule and abnormal adhesions are very common, and often occur without any clinical history indicating disease. We should look for changes in size, pigmentations, hyperplasia of the connective tissue, amyloid degeneration, tubercles, and infarctions.

Not infrequently one or more spheroidal or flattened so-called accessory spleens are found in the vicinity of the spleen; they vary in size from that of a pea to that of a walnut.

*Preservation.*—In certain diseases of the pulp, leukæmia, leucocythæmia, etc., the tissue should be teased, when fresh, in one-half-per-cent salt solution, or examined by the staining methods described under the lesions of the blood. For general purposes small pieces of the organ are hardened in Müller's fluid or alcohol.

*The Intestines.*—The rectum is divided, the intestine seized with the left hand, and, being kept stretched, is separated from its attachments by repeated incisions through the mesentery close to the gut, until the duodenum is reached, where it is again cut off. The operation is more cleanly if, before dividing the gut, ligatures are placed around it at either end. The entire length of the gut is now laid open with the enterotome along the mesenteric attachment, the mucous membrane is cleaned with a stream of water and then examined.

In cases of suspected poisoning a ligature should be placed around the rectal end of the gut and two around the duodenal end, and it is then cut off below the former and between the latter ligatures. The gut is now opened and the contents emptied into a clean glass jar for delivery to the chemist, care being taken that they be not allowed to touch anything but the inner surface of the jar. After washing the intestine in pure fresh water and examining it, it should be placed entire in another clean jar and sealed.

Cadaveric lividities are very common in the intestines, and are usually most marked in the dependent portions. They are apt to occur in patches, but may be diffuse and very extensive. If the wall of the gut be stretched they are often seen to be discontinuous, owing to the pressure of the blood from the parts which are squeezed by folds. Small patches of arborescent or diffuse red staining are often seen, formed by the imbibition from the vessels of decomposing hæmoglobin. In the more advanced stages of decomposition the mucosa may be softened and loosened. A dark purple or brownish discoloration of the entire intestinal wall is frequently seen, either diffuse or in patches. Much experience and careful observation are requisite in forming a correct judgment regarding the significance of changes of color in the intestines. Caution is necessary in distinguishing normal digestive hyperæmia from abnormal congestion. A very considerable congestion may exist without disease. In chol-

era seasons especially, observers are prone to call the most moderate degree of congestion abnormal.

The lesions ordinarily to be looked for are catarrhal, croupous, and ulcerative inflammations, perforations, hæmorrhages, strictures, tumors, amyloid degeneration, swelling and ulceration of the solitary follicles and Peyer's patches, and pigmentation. For the detection of amyloid degeneration of the mucosa this structure should be carefully washed and brushed with a solution of iodine (see p. 32).

*Preservation.*—For the general purposes of microscopic study portions of the gut should be gently stretched on cork (the mucosa side free) and placed for a few minutes in strong alcohol, and then transferred to eighty-per-cent alcohol, in which the hardening is completed. The transfer to weaker alcohol is to prevent the specimen from becoming brittle. Formalin solution (2 : 100) may also be used for hardening the mucous membrane, the process being completed by alcohol.

For obvious reasons the mucous membrane should be handled as little as possible, for, in the majority of cases, decomposition and softening have already set in at the time of the autopsy, and, under the most favorable conditions, the epithelium is very easily rubbed off.

In cases in which the most perfect preservation of the topographical features, as well as the minute structure of the intestinal mucosa, is desirable, even at the expense of an inspection of the fresh tissue, another mode of procedure is to be recommended.

Selected segments of the gut are, after removal from the body, allowed to remain unopened on the table while ligatures are tied around the ends. The isolated segments, or the whole gut, are now to be moderately filled—not distended—with strong alcohol by means of a syringe with a needle canula; or one end of the segment may be tied and the alcohol introduced through a funnel at the other, which is then ligated. The segments to be preserved should now be placed unopened in strong alcohol. After twenty-four hours they may be opened with scissors or a sharp knife, cut into suitable pieces, and kept permanently in eighty-per-cent alcohol. Intestinal contents may be washed out with alcohol before filling the gut. Formalin (2 : 100) may be used instead of alcohol for the preliminary hardening.

Powers has found that an excellent preservation of a portion of the intestinal mucous membrane may be obtained even when the autopsy is postponed for a considerable time after death, by the injection of two-per-cent formalin directly into the intestine per anum, shortly after death.

At the autopsy the tissues are removed and the hardenings completed in the usual way.

*The Stomach and Duodenum.*—We now introduce the enterotome into the duodenum at its transverse portion, and open it on the convex border. When the pylorus is reached the incision is carried obliquely over to the greater curvature of the stomach, along which it is extended as far as the œsophageal opening, and the organ examined *in situ;* or, if a more careful examination of the stomach is called for, after ascertaining whether or not the bile duct is pervious (see below), the duodenum and stomach may be removed together, and the stomach opened and examined on the table. If poisoning be suspected a ligature should have been placed, earlier in

the examination (see above), around the lower end of the œsophagus and the duodenum. The stomach and duodenum are now removed together unopened. They are to be opened in a carefully cleansed glass jar, and after an inspection of the mucous membrane and the contents with the naked eye and a hand lens, stomach, duodenum, and contents are to be sealed in the jar for the chemist.

We now look for the orifice of the bile duct, which will be found about the middle of the descending portion of the duodenum on its concave border. Pressure on the gall bladder or on the common duct will usually cause the bile to flow into the intestine if the ducts are pervious. But a sufficient degree of stoppage may exist in the ducts to give rise to marked symptoms of disease without preventing the flow of bile under these conditions, even with a moderate pressure. A long director is now passed into the gall duct, which is laid completely open; ulcerations, cicatrices, gall stones, inflammatory lesions, and tumors are looked for. In stricture of the gall duct the mucous membrane above will often be found bile-stained, while below it is colorless. At this point, should there be any special reason for doing so, the portal vein, which lies close behind the ductus choledochus, should be opened and examined for periphlebitis, phlebitis, and thrombosis. The mucous membrane of the duodenum and stomach are now rinsed off and examined. Acute inflammations from caustic poisons, chronic catarrhal inflammations, hæmorrhages, ulcers, erosions, swelling of the solitary follicles (lymph nodules), and tumors are lesions most frequently seen. We sometimes find a diffuse congestion of the stomach similar to that produced by irritant poisons, as a result of doses of croton oil given just before death.

*Preservation.*—The same methods should be used as for the intestines (see above). Tumors should be cut into small pieces and hardened in Müller's fluid.

*The Liver.*—To remove the liver, the diaphragm is first divided on one side of the suspensory ligament as far back as the spine; the suspensory ligament is then divided; then the right and left lobes being in turn raised, the lateral ligaments are severed. Then, seizing the left lobe, the organ is dragged obliquely downward into the abdominal cavity, the remaining attachments being dissected away. The liver is first laid on its superior surface and the gall bladder and its contents examined. The character of the gall is to be determined, and gall stones, inflammatory lesions, and tumors sought for. To determine the actual size of the organ, it should be both measured and weighed. Its size varies greatly in different healthy individuals, but in general it may be said that it measures from 25 to 30 cm. (10 to 12 in.) transversely, from 15.3 to 18 cm. (7½ to 9 in.) antero-posteriorly, and about 12 cm. (6 in.) at its thickest part; the ordinary

bulk is about 229 to 252 c.c. (90 to 100 cu. in.); its ordinary weight between 1,550 to 1,860 gm. (50 to 60 oz.). In children its weight relative to that of the body is greater than in adults. The liver is increased in size and weight during digestion and by congestion from any cause.

The surface of the liver is now examined, and it is then laid on its lower surface and several deep incisions made from the convex surface downward. The color and consistence of the liver tissue should be noticed, also the distinctness with which the lobular outlines can be seen; whether or not the centres of the lobules are congested or their peripheries lighter in color than usual; the presence of tumors, tubercles, abscess, ecchinococcus, new connective tissue, and pigmentation. Suspected amyloid degeneration should be tested for by the iodine solution (p. 32).

We often find the surface of the liver of a greenish or very dark-brown color; less frequently the same color extends into the substance of the organ. This discoloration, which is entirely post-mortem, is, like the similar discoloration of other internal organs, produced by the action of the gases of putrefaction on the coloring matter of the blood.

*Preservation.*—For the study of parenchymatous degeneration, sections of the fresh frozen tissue or small teased fragments should be examined in half-per-cent salt solution. For general purposes small pieces should be hardened in Müller's fluid or in formalin solution (2 : 100) or in alcohol. Tumors should be treated in the same way. In many cases of marked cirrhosis the topography of the lesion is best demonstrated by injecting the organ with blue gelatin through the portal vein and then hardening in strong alcohol.

*The Pancreas.*—This organ, of a light yellowish-red color, is elongated, irregularly prismatic in shape, and flattened antero-posteriorly; the right end, called the head, is broader than the rest and lies in the concavity of the duodenum. The remainder of the organ, the body and tail, are usually tapering and lie transversely in the abdominal cavity, the tail reaching to the spleen. Its size and weight vary considerably; its usual length is from 15.3 to 20.3 cm. (6 to 8 in.); its breadth about 3.8 cm. (1½ in.); its thickness about 1.3 to 2.5 cm. (½ to 1 in.); its weight is usually from 70 to 108 gm. (2¼ to 3½ oz.). The organ may be rounded instead of flattened; the head and tail may be disproportionately large; the tail may be unusually long or may be divided or curved. The superior mesenteric artery and vein, which pass behind the gland, are usually partly embedded in it, but are sometimes completely enclosed.

A longitudinal incision should be made through the whole gland, which may remain *in situ*, and its substance and duct should be searched for calculi, tumors, malformations, and evidences of acute and chronic inflammation, fat necrosis, and amyloid degeneration of

the blood vessels. The pancreas is frequently of a dark-red color from post-mortem staining.

*Preservation.*—Portions of this organ should be hardened in strong alcohol, or in formalin or sublimate solution.

## THE GENITO-URINARY ORGANS.

*The Male Organs.*—If the urine is to be examined it may be drawn off with a catheter; or a vertical incision may be made into the bladder just above the symphysis pubis, and some of the urine dipped out. The cut end of the rectum should now be grasped with the left hand and raised up, and this and the bladder, prostate gland, etc., dissected away from the pelvis, the knife being carried close to the bone. The bladder is now drawn backward and the loose tissue close under the symphysis pubis cut. The body of the penis is then shoved backward within the skin and dissected away from behind beneath the symphysis, and finally cut off just behind the glans penis. The penis and bladder are now drawn backward and upward, and the pelvic organs removed together. Or, the penis may be removed by sawing away the bones above the pubic arch, and then dissecting away the penis, whose root is thus exposed.

The pelvic organs are then laid on the table, the bladder uppermost; a long director is passed into the urethra, which is opened on its upper surface through its entire length, and the bladder widely opened. In the *urethra* the presence of strictures, diverticulæ, ulcers, inflammatory lesions is to be noticed; in the *bladder* inflammatory lesions, hypertrophies, congestion and ecchymosis of the mucous membrane, hyperplasia and ulcers of the lymph nodules, and tumors. The organs are now turned over; the *rectum* opened and examined for varicose veins, hæmorrhages, ulcers, strictures, and tumors. The *prostate gland* is then cut into and the presence of calculi, inflammatory lesions, hypertrophies, and tumors sought for. Lastly, the *vesiculæ seminales* are examined, in which, though rarely, we may find evidences of tubercular inflammation and dilatation.

*The Testicles* may be removed, when necessary, without cutting the scrotum, by enlarging the inguinal canals from within and crowding the glands through them and cutting them off. The average weight of the adult testicle with its epididymis is, according to Krause, from 15 to 24.5 gm. (about ¾ oz.). Inflammatory lesions, tuberculosis, abscesses, and tumors are the most frequent lesions.

*Preservation.*—The urethral canal and bladder may be pinned open and hardened in strong alcohol, or in formalin solution, or in Müller's fluid. The prostate, vesiculæ seminales, testicles, and tumors may be hardened in the same fluids.

*The Female Organs.*—The position and general condition of the pelvic organs should first be determined by inspection. Abnormal adhesions of the ovaries, broad ligaments, Fallopian tubes, and uterus; malpositions of the uterus; subserous tumors of the uterus, and ovarian tumors, are frequently observed. Hæmorrhage into the posterior cul-de-sac is sometimes found. The urine should be collected, if necessary, as above directed; the organs should be dissected away laterally, as in the male, care being taken not to injure the ovaries and Fallopian tubes. The bladder is then drawn strongly backward and upward, and dissected away from the symphysis and the pubic arch, and, the point of the knife being carried forward and downward, the vagina is cut off in its lower third, the rectum severed just above the anus, the remaining attachments cut, and the pelvic organs taken out together. If it be necessary to remove the external generative organs, after freeing the lateral surfaces of the internal organs and the bladder, the legs are widely separated and the vulva and anus circumscribed by a deep incision. The tissues close beneath the pubic arch are now dissected away from below and the vulva thrust back beneath the symphysis; it is now seized above the bone, and together with the anus dissected away and removed with the other organs.

*The Bladder* is first opened and examined. The *vulva* may now be examined for hypertrophies, inflammatory lesions, ulcers, cicatrices, cysts, and tumors. The *vagina* is opened along the anterior surface; its more common lesions are inflammations, fistulæ, ulcers, tumors, and rarely cysts.

*The Uterus.*—Before opening this organ its size and shape should be determined. The adult virgin uterus is a pear-shaped body, flattened antero-posteriorly; the upper portion, or body, is directed upward and forward, whilst the lower portion, the cervix, is directed downward and backward. It is covered anteriorly by peritoneum to a point a little below the level of the os internum; posteriorly, to a point a little below the level of its junction with the vagina. The peritoneal investment separates from the organ at the sides to form the broad ligaments. The uterus is held in position by the broad and round ligaments and by its attachments to the bladder and rectum and vagina. The upper end, the fundus, does not extend above the level of the brim of the pelvis. Its average length is about 7.6 cm. (3 in.); its breadth about 5.1 cm. (2 in.); its thickness about 2.5 cm. (1 in.); its average weight is about 31 to 46 gm. (1 to 1½ oz.). During menstruation the uterus is slightly enlarged and the mucous membrane of the body becomes thicker, softer, and its vessels engorged with blood; while its inner surface is more or less thickly covered with blood and cell detritus. A descrip-

tion of the complicated changes in the uterus which pregnancy entails may be found in the works on obstetrics. After pregnancy the uterus does not return to its original size, but remains somewhat larger ; the os is wider and frequently fissured.

We not infrequently find in the mucous membrane of the lower part of the cervix small transparent, spheroidal structures, called ovula Nabothi ; these are small retention cysts caused by the closure of the orifices of the mucous glands of the part. The more common lesions observed in the uterus are malpositions, malformations, lacerations, ulcerations of the cervix, acute and chronic inflammation of the mucous membrane or muscularis, or both, thrombosis and inflammation of the veins, and tumors.

In the infant the uterus is small, the body flattened, the cervix disproportionately large. During childhood the organ increases in size, but the body remains small in proportion to the cervix. At puberty the shape changes and the body becomes larger.

*The Ovaries* are flattened, ovoidal bodies, situated one on each side and lying nearly horizontally at the back of the broad ligament of the uterus. Their size is variable and they are usually largest in the virgin state. Their average weight is from 3.9 to 6.5 gm. (3 to 5 ℈). They measure about 3.8 cm. (1½ in.) in length, 1.9 cm. (¾ in.) in breadth, and nearly 1.3 cm. (½ in.) in thickness. The sides of the ovary and its posterior border are free ; it is attached along the anterior border ; to its end is attached the ovarian ligament ; to its outer extremity one of the fimbriæ of the Fallopian tube. The ovary is covered on its free surface by cylindrical epithelium, and its surface is less glistening than the general peritoneum. The surface of the ovary is smooth in the young, but becomes rougher and depressed in spots as the process of ovulation goes on. In adult females we usually find corpora lutea in their various stages. We should seek for evidences of acute and chronic inflammations, for tumors and cysts.

*The Fallopian Tubes,* lying in the upper margin of the broad ligaments, are from 7.6 to 10 cm. (3 to 4 in.) in length. The length often differs considerably on the two sides. They commence at the upper angles of the uterus as small perforated cords, which become larger further outward and bend backward and downward toward the ovary. They terminate in an expanded fimbriated extremity about 2.5 cm. (1 in.) beyond the ovary. They are covered by peritoneum, and the mucous membrane lining them, continuous with that of the uterus, is thrown into longitudinal folds. Malpositions by adhesions, closure, inflammations, and cysts are the more common lesions. The possibility of tubal pregnancy should be borne in mind.

*Preservation.*—All of these organs and their tumors may be hardened in Müller's fluid, or in formalin solution, or in strong alcohol. The vagina should be stretched flat on cork and the cavity of the uterus laid wide open. Great care should be taken not to touch either the internal surface of the uterus or the external surfaces of the ovaries, since in both the epithelium is very easily rubbed off.

It is better, after opening them by a transverse incision, to suspend the ovaries by a thread in a jar of the preservative fluid than to let them lie on the bottom, since the epithelium is thus less liable to be rubbed off. Larger cysts of the ovary for exhibition purposes should be distended with preservative fluid (see p. 64).

## AUTOPSIES IN MEDICO-LEGAL CASES.

While every autopsy should be made as carefully and completely as circumstances will permit, it should be always borne in mind that in examinations which may have medico-legal bearings it is of the highest importance to examine thoroughly both macroscopically and microscopically every part of the body from which light may be derived as to the cause of death, for in medico-legal cases it is not infrequently as important to be able by a complete examination to declare the absence of lesions which could cause death as to determine the presence of those upon which the opinion as to the actual cause of death in a particular case rests. Bearing this in mind, the technique of autopsy making is essentially the same whatever the ends which the facts elicited may be destined to serve.

## AUTOPSIES IN CASES OF SUSPECTED POISONING.

It is always best, in cases of suspected poisoning, to preserve for the chemist not only the stomach and intestine, but the entire liver and brain; or, if portions of these only can be saved, these portions should be carefully weighed, as well as the entire organs, and the relative amount of tissue reserved carefully noted at the time. It is even well, particularly in cases in which the administration of the readily diffusible poisons, such as arsenic, strychnia, etc., is suspected, to preserve the whole of all the internal organs, together with a large piece of muscle and bone; since with large quantities of tissue the results of the chemical analysis depend less upon calculations, and are hence more comprehensible to the average jury. In all such cases jars should, if possible, be procured which have never been used before, and these should be carefully washed and rinsed with distilled water. They should have glass stoppers and be sealed at once and carefully labelled before leaving the hands of the operator. If they can be delivered to the chemist without much delay, no preservative fluid should be added. If they are to be kept for a considerable time, pending the action of a coroner's jury or for some other reason, a small quantity of pure strong alcohol may be

poured over them. In this case the operator should be particular to preserve a quantity, at least half a pint, of the specimen of alcohol used, in a clean, sealed, and labelled bottle, so that this may be tested by the chemist and be proven to be free from the poison. It is better in all cases, however, to avoid, if possible, the use of alcohol. In all autopsies which may have medico-legal importance full notes should be taken by an assistant as the operation proceeds, carefully read over immediately afterward, and dated and kept by the operator for future reference. The labelling and disposition of the jars should be recorded in the notes. The specimens should not for a moment be out of the sight of the operator until they are placed under lock and key and seal, or are delivered to some authorized person, so that there may be no question of their identity should the case come into court.

## EXAMINATION OF THE BODIES OF NEW-BORN CHILDREN.

In examining the bodies of new-born children we may have to determine, besides the ordinary lesions of disease, the age of the child, whether it was born alive, how long it has been dead, what was the cause of death.

### GENERAL INSPECTION.

*The Size and Age.*—Caspar[1] gives the following description of the fœtus during the different months of intra-uterine life:

At the *fourth week* the embryo is 8 to 13 mm. ($\frac{3}{10}$ to $\frac{5}{10}$ in.) long. The cleft of the mouth and two points indicating the eyes can be recognized in the head. The extremities are represented by little wart-like projections. The heart can be distinguished; the liver is disproportionately large. The umbilical vessels are not yet formed. The entire ovum has about the size of a walnut.

At the *eighth week* the embryo is 2.3 to 4 cm. ($\frac{9}{10}$ to $1\frac{5}{10}$ in.) long. The head forms more than a third of the entire body; the mouth is very large; the nose and lips can be distinguished, but not the external ear. The hand is longer than the forearm; the fingers are formed, but joined together; the toes look like little buds; the soles of the feet are turned inward. The position of the anus is indicated by a point. The abdomen is closed. All the viscera can be recognized. Centres of ossification are formed in the apophysis of the first cervical vertebra, the humerus, radius, scapula, ribs, and cranial bones. There are rudimentary external genitals, but the sex can

[1] *Caspar*, "Handbook of Forensic Medicine." Revised German Edition by Liman, or Sydenham Society Translation.

hardly be distinguished. The ovum has about the size of a hen's egg.

At the *twelfth week* the placenta is formed. The embryo is 5 to 6.5 cm. (2 to 2½ in.) long and weighs about 31 gm. The head is separated from the thorax by a distinct neck. The eyes and mouth are closed. The nails can be perceived on the fingers. The sex can be recognized. The umbilical cord is inserted near the pubes; the muscles begin to be recognizable. The thymus and suprarenal capsules are formed. The cerebrum, cerebellum, medulla, and the cavities of the heart can be recognized. The humerus is 1.7 mm. long; the radius 5.5 mm.; the ulna 6.6 mm.; the femur and tibia 4.4 to 6.6 mm.; the fibula 5.5 mm. The ovum is as large as a goose's egg.

At the *sixteenth week* the embryo is 13 to 15 cm. (5 to 6 in.) long and weighs 77 to 93 gm. (2½ to 3 oz). The skin is of a rose-red color and has considerable consistence. The formation of fat in the subcutaneous tissue has begun. The scrotum and labia are formed. The face begins to assume its characteristic appearance. There is whitish meconium in the duodenum. The liver is not so disproportionately large, and the gall bladder is formed; the anus is open. The length of the humerus, radius, and ulna is 1.7 cm.; the femur and tibia 8.8 to 11 cm. The calcaneus begins to ossify at the middle of the fourth month.

At the *twentieth week* the embryo is 26 to 28 cm. (10 to 11 in.) long; it weighs from 225 to 320 gm. (7$\frac{3}{10}$ to 10 oz.). The nails are quite perceptible. There is a thin down on the head. The head is still disproportionately large, occupying about one-fourth of the body. There is as yet none of the vernix caseosa. The secretion of bile has commenced and stains the meconium. The insertion of the umbilical cord is still further off from the pubes. The liver, heart, and kidneys are large in proportion to the other organs. The convolutions of the brain cannot be recognized. The humerus is 2.8 to 3 cm. long; the radius 2.6 cm.; the ulna 2.8 cm.; the femur, tibia, and fibula, each 2.6 cm. The astragalus and the upper part of the sternum begin to ossify.

From this time on the length of the fœtus forms an approximately accurate basis for the estimation of its age. *From this period till its maturity the length of the fœtus, determined in centimetres, corresponds to about one-fifth of the number of months of its age.* From this time on the weight exhibits marked individual differences, and is therefore a less reliable criterion of its age than is the length.

At the *twenty-fourth week* the embryo is 31 to 34 cm. (12 to 13 in.) long and weighs 750 to 875 gm. (24 to 28 oz.). The lanugo and vernix caseosa are formed. The skin is of a dusky cinnabar-red

color. The meconium is darker. The scrotum is empty, small, and red ; the labia majora are prominent and held apart by the projecting clitoris. The pupillary membrane is present and readily recognized. The length of the humerus and radius is 3.5 cm. ; of the ulna, femur, tibia, and fibula, each 3.7 cm.

At the *twenty-eighth week* the embryo is 36.4 to 39 cm. (14¼ to 15¼ in.) long and weighs 1,500 to 1,750 gm. (48 to 57 oz.). The hair is more abundant and longer. The great fontanelle measures about 4 cm. (1⅝ in.) in diameter, and all of the fontanelles are readily perceived. The skin is of a dirty-reddish color and abundantly beset with the lanugo and vernix caseosa. The large intestine contains much meconium. The humerus is 4.5 to 5 cm. long; the radius 3.7 cm.; the ulna 4 cm.; the femur, tibia, and fibula, each 4.2 to 4.6 cm.

At the *thirty-second week* the embryo is 39 to 41.5 cm. (15¼ to 16¼ in.) long and weighs 1,500 to 2,500 gm. (48 to 81 oz.). The skin is lighter in color ; the pupillary membrane has disappeared. The testicles are in the scrotum or the inguinal canal ; the labia are still widely apart and the clitoris prominent. The nails reach nearly to the ends of the fingers. The humerus is 5 to 5.2 cm. long; the radius 4 to 4.2 cm.; the ulna 4.8 to 5 cm.; the femur 5.2 cm.; the tibia and fibula, each 4.8 to 5 cm. The last sacral vertebra begins to ossify.

At the *thirty-sixth week* the embryo is 44.2 to 46 cm. (17.4 to 18 in.) long and weighs about 3,000 gm. (97 oz.). The scrotum begins to become wrinkled and the labia to close. The hair becomes more abundant, while the lanugo begins to diminish in amount.

At the *fortieth week* the fœtus is fully developed and the term of its intra-uterine life accomplished.

The fresh corpse of a new-born child at term no longer resembles that of the immature fœtus. The skin is firm and pale, like that of an adult. The lanugo has disappeared except on the shoulders. In the majority of cases the hair on the head is 1.5 to 2 cm. (⅝ to ¾ in.) long. The great fontanelle is, in the average, 2 to 3 cm. ($\frac{8}{10}$ to $1\frac{1}{10}$ in.) long. As determined by an analysis of 661 cases, the average length is 50 cm. (20 in.), the weight 3,256 gm. (105 oz.). The nails are hard and reach to the tips of the fingers, but not to those of the toes. The cartilages of the ears and nose are hard. The labia are more nearly closed. An ossification centre in the lower epiphysis of the femur should be sought for, as its presence is one of the most reliable signs of the maturity of the fœtus. If it is absent the fœtus is, as a rule, not more than thirty-seven weeks old ; but in rare cases it may be absent at term. A centre of ossification 1 mm. (.039 in.) in diameter indicates an age of 37 to 38 weeks, if the child was born

dead or died soon after birth. Rarely it is no larger than this at term. A diameter, at birth, of 1.5 to 9 mm. (.058 to .351 in.) indicates an age of 40 weeks. A diameter of less than 9 mm. (.351 in.) indicates, as a rule, that the child has lived some time after its birth; a less diameter than 7 mm. (.273 in.), however, does not prove the contrary.

*Twenty-four hours after the birth of the child* the skin is firmer and paler. The umbilical cord is somewhat shrivelled, although still soft and bluish in color. From the *second to the third day* the skin has a yellowish tinge and the cuticle sometimes appears cracked. The umbilical cord is brown and dry. From the *third to the fourth day* the skin is yellower, and the cuticle is apt to separate from the skin. The umbilical cord is of a brownish-red color, flattened, semi-transparent, and twisted. The skin around its insertion is red and congested.

The head should be examined for the marks of injuries. Very commonly some portion of the scalp will be found swollen and infiltrated with blood and serum. This may be the *caput succedaneum* formed during delivery. The mouth and nose should be examined for the presence of any foreign bodies which might have caused suffocation.

The neck should be examined for marks of strangulation. The umbilical cord may be twisted around the child's neck and strangle it. The mark left by the cord is usually continuous, broad, not excoriated, sometimes accompanied by ecchymoses in the skin.

The entire body should be examined for the presence of vernix caseosa, blood, marks of injury, and the existence of putrefaction. It should be remembered that putrefaction is apt to commence earlier in the bodies of young children than in those of adults.

*The umbilical cord* may be cut or torn. It usually separates by the fifth day, sometimes not until the tenth. If the umbilicus is cicatrized and healed the child has probably lived for three weeks. A zone of redness around the insertion of the cord may exist previous to birth. Redness and swelling (which may disappear after death) with suppuration can only be found in a child which has lived for several days. The drying and mummification of the cord may take place as well in dead as in living children. It is possible for a child to die by hæmorrhage from a cut or torn cord, either before or after it has breathed.

The extremities may exhibit fracture of the bones. These may occur during intra-uterine life, from injuries to the woman or from unknown causes; or may be produced by violence in delivery, or by injuries after birth.

INTERNAL EXAMINATION.

*The Head.*—The fontanelles and sutures should first be examined as to their size and for penetrating wounds. An incision should then be made through the scalp across the vertex, and the flaps turned backward and forward as in the adult. With a small knife the edges of the bones should be separated from the membranous sutures and the dura mater, beginning low down in the frontal and going back into the lambdoidal suture on either side. The bones are then drawn outward and cut through around the skull with strong scissors. The brain is removed and examined as in the adult.[1]

Effusions of blood—cephalhæmatoma—may be formed, soon after birth, between the pericranium and bone, or, more rarely, between the dura mater and bone. Clots are also found between the dura mater and skull; between the dura and pia mater; more rarely in the substance of the brain, as the result of protracted or instrumental deliveries, or of injuries after birth.

The cranial bones may be malformed, or exhibit the lesions of rickets or caries, or be indented, fissured, or fractured. These latter lesions may be produced during intra-uterine life by injuries to the mother, by unknown causes, by difficult deliveries, or by direct violence after birth.

In cases of chronic internal hydrocephalus in young children, in which the ventricles are much dilated and the brain substance thinned over the vertex, the brain is very apt to be torn in removal, and the amount of dilatation thus becomes difficult of determination. It is, therefore, better in such cases to place a pail of water beneath the head, or even immerse the latter in it, and remove the brain in the water. In this way it floats after removal, supported on all sides. It may now be opened in the water and the extent of the lesion determined at once, and parts saved for microscopical examination.

If it be desired to preserve the brain for demonstration of the lesion or for a museum specimen, it should be transferred unopened to a large jar containing a mixture of equal parts of alcohol and water. A portion of the ventricular fluid should now be removed with a syringe provided with a small canula, and replaced by strong alcohol. This may be done by puncturing the ventricles from below. The fluid in the jar, as well as in the ventricles, should be changed in forty-eight hours and then gradually increased in strength until the organ becomes hard. The brain may then be cut transversely across, when the degree of dilatation of the ventricles, etc., will be revealed. The brain, of course, shrinks considerably by this process, but the relative proportions are approximately preserved.

The brain is normally much softer and pinker than in the adult,

[1] Or an incision through the bones with a fine saw may be made as in the adult.

the pia more delicate; both may be much congested or anæmic without known cause. The ventricles contain very little serum. Malformations, apoplexies, hydrocephalus, simple and tubercular inflammatory lesions, are to be looked for.

*Spinal Cord.*—Extravasations of blood between the membranes of the cord may occur from the same causes as those in the brain. Spina bifida is the most frequent malformation.

*The Thorax and Abdomen.*—These are opened as in the adult. The *peritoneal cavity* contains a very little clear serum. A red fluid may be produced by decomposition. The peritoneum is often the seat of intra-uterine inflammation.

*The Diaphragm.*—In still-born infants its convexity reaches to the fourth or fifth rib. After respiration it reaches a point between the fourth and seventh ribs. Its position is, however, so variable that it is of little diagnostic importance.

*The Thorax.*—The *thymus gland*, at this period very large, occupies the upper portion of the anterior mediastinum, covering the trachea and large vessels. Its average weight is about 15.5 gm. (½ oz.). It is usually about 5 cm. (2 in.) long, 3.8 cm. (1½ in.) wide at its lower part, and about .63 to .85 cm. (¼ to ⅓ in.) in thickness. It may be hypertrophied and compress the large vessels, or be inflamed and suppurating.

The *heart* lies more nearly in the median line than in the adult. It weighs from 46 to 108 gm. (1½ to 3½ oz.). The ventricular walls are of nearly equal thickness. The pericardium contains very little serum. A considerable quantity of red fluid may accumulate here as a result of decomposition. There may be small extravasations of blood beneath the pericardium in still-born children and in those born alive. Pericarditis with effusion of serum and fibrin, and endocarditis with consequent changes in the valves, may exist before birth. Malformations and malpositions of the heart cavities and large vessels are not infrequent. The time of closure of the foramen ovale and the ductus arteriosus varies very widely in different cases.

The *pleural cavities* contain very little serum, but decomposition may lead to the accumulation of a considerable quantity of red fluid. Small extravasations of blood in the subpleural tissue may be found in children which have died before birth and after protracted labors. Inflammation, with exudation of serum, fibrin, and pus, may exist before birth.

The *lungs* in a still-born child are small, do not cover the heart, are situated in the upper and posterior portion of the thorax, are of a dark-red color and of firm, liver-like consistence, and do not crepitate. In a child born alive, and which has respired freely, the lungs fill the thoracic cavity, but do not cover the heart as much as in the adult;

they are of a light-red or pink color, and crepitate on pressure. It respiration has been incompletely performed we find various intermediate conditions between the fœtal and inflated states.

If any doubt exists as to respiration having taken place, it is customary to employ the *hydrostatic test.* This is done by placing the lungs, first together, then separately, and afterward cut into small pieces, in water. It is commonly said that if they sink the child has not breathed; if they float it has. This test is not, however, a certain one. Taylor says regarding it:

1. That the hydrostatic test can only show whether a child has or has not breathed, not whether it was born alive or dead.

2. That the lungs of children who have lived after birth may sink in water, owing to their not having received air or to their being in a diseased condition.

3. That a child may live for some time with the lungs only partly inflated.

4. That a child may live for twenty-four hours when no part of its lungs has been penetrated by air.

5. The sinking of the lungs is no proof that a child has been born dead.

6. That the lungs of children which have not breathed and have been born dead, may float in water from putrefaction or artificial inflation.

The lesions of inflammation, and vesicular and subpleural emphysema, may be found in the lungs of new-born children.

The *pharynx* should be opened and examined for foreign bodies.

The *larynx* and *trachea* should be examined for the lesions of inflammation and for injuries to the cartilages.

The *thyroid gland* weighs about 12 gm. (3 3). It may be so enlarged as to interfere with respiration.

*The Abdomen.*—The *kidneys* are lobulated and proportionately larger than in the adult. There may be ecchymoses on their surface; inflammation; deposits of uric acid and urates in the tubules of the pyramids; cystic dilatation of the tubules, sometimes reaching an enormous size. There may be absence or retarded development of one kidney. Malformations and malpositions of the kidneys are of frequent occurrence.

The *suprarenal capsules* are large. They may be dilated into large cysts filled with blood.

The *spleen* is large and firm. It may be abnormally enlarged, and its surface is sometimes covered with fresh inflammatory exudations.

The *intestines.* In the small intestines inflammation and swelling and pigmentation of the solitary and agminated follicles (lymph

nodules) are sometimes found. The large intestine usually contains meconium, but this may be evacuated before or during birth. The sigmoid flexure is not as marked as in the adult.

The formation of gas in the stomach and intestines does not usually take place until respiration is established. If decomposition has commenced, however, gas may be formed as a part of the process.

The *liver* is of a dark-red color, is large, and contains much blood. Its size diminishes after respiration is established. The size is so variable, before and after respiration, that it gives little information as to the age of the child. Large extravasations of blood are sometimes found beneath the capsule of the liver without known cause. A variety of pathological conditions, fatty and waxy degeneration, gummy tumors, etc., may be found.

The *bladder* may be full or empty, both in still-born children and in those which have breathed. Dilatation and hypertrophy may exist during intra-uterine life.

*Generative Organs.*—The external generative organs in both males and females are more prominent than in adults. The ovaries are high up in the pelvis and large ; the cervix uteri is long ; the body small and lax, resting forward against the bladder. Phimosis in the male is the normal condition. Malpositions and retarded development of the testicles should be noticed. It should be observed whether the anus is perforate.

*The Bones*, in suspected cases, should be examined for the lesions of inflammation, rickets, and syphilis.

*Preservation.*—The various fœtal tissues may be preserved by the same methods as are employed for those of the adult ; but as they are very delicate they should be handled with great care and the preservative fluids changed with sufficient frequency.

# GENERAL METHODS OF PRESERVING PATHOLOGICAL SPECIMENS AND PREPARING THEM FOR STUDY.

It is not our purpose in this section to give a complete account of the technical procedures required in the study of pathological specimens, since the methods are for the most part identical with those employed in the study of normal tissues, with which the student or practitioner is presumably familiar before prosecuting pathological studies. We wish simply to give a few brief hints as to the general methods which we have found most useful. Additional details will be found in parts of the book dealing with special tissues and organs.

*The Study of Fresh Tissues.*—Although for the most part the conditions for the minute study of tissues are more favorable after they have been fixed and hardened by a suitable chemical agent, it is yet in many cases very important to examine them in the fresh state. For this purpose they may be teased apart in a one-half-per-cent solution of sodium chlorid and mounted and studied in the same.

If the material to be studied be fluid or semi-fluid, such as exudates from mucous membranes, pus, etc., and requires dilution for the separation of its structural elements, a one-half of one-per-cent aqueous solution of sodium chlorid may be used, and in this the specimens may be covered and studied. Solid tissues may be teased apart and studied in the same solution.

When structural elements are mingled with a large quantity of fluid they may be gathered for study by sedimentation, or, better, as a rule, by the use of one of the numerous forms of centrifugal machines constructed for this purpose.

Much structural detail may be revealed in fresh tissue elements by allowing a drop of Carnoy's fluid to run under the cover glass and mingle with the salt solution, the flow being directed by a bit of filter paper put close to the edge of the cover glass on the side opposite to that on which the coloring fluid is added. Carnoy's fluid is made by adding to a saturated aqueous solution of methyl green one

per cent of acetic acid and one-tenth of one per cent of osmic acid. Specimens prepared in salt solution cannot usually be preserved, but those mounted in Carnoy's fluid may be kept for a time by replacing the latter with equal parts of glycerin and one-half-per-cent. salt solution.

When an immediate result of an examination of a solid tissue is required, satisfactory results may be obtained by a combination of the freezing method for fresh tissues with the use of formalin as a fixative as suggested by Cullen.[1] Any form of freezing microtome and either ether or liquid carbonic acid may be used.

Cullen's procedure is as follows: The frozen sections are put in a five-per-cent. watery solution of formalin (see p. 54) for from three to five minutes; in fifty-per-cent alcohol for three minutes; in absolute alcohol for one minute. They are now washed in water, stained with hæmatoxylin, decolorized in acid alcohol (one-per-cent hydrochloric acid), rinsed in water, contrast stained and dehydrated with eosin alcohol, cleared with creosote or oil of cloves, and mounted in balsam.

For very delicate tissues, and especially when the preservation of the blood is desirable, Cullen recommends the placing of small pieces of the fresh tissues in ten-per-cent formalin for two or three hours; then making frozen sections, staining, and mounting as before.

The disintegration of the sections after they thaw, and especially the considerable shrinkage which they undergo on treatment with alcohol, may both be largely obviated by spreading the sections as they thaw on an albumin fixative film upon a cover glass or slide as described for paraffin sections, page 59, and conducting the hardening and staining manipulations with the specimen in position upon the glass.

In case the freezing apparatus is not at hand, satisfactory sections for early diagnosis may be obtained within twenty-four hours by the following procedure, suggested by Hodenpyl.

Portions of tissue not more than 1 c.c. square and 0.3 c.c. thick are placed for two hours in eighty-per-cent alcohol; then for from one to two hours in ninety-five-per-cent alcohol; one-half hour in alcohol and ether equal parts; and then for from four to eight hours in moderately thin celloidin. The bit of tissue is now mounted upon a block in the usual way in celloidin, allowing the latter to become quite firm by drying it in the air, before it is placed in eighty-per-cent alcohol. After about one-half hour in alcohol, the sections may be cut with the microtome and are stained and mounted in the usual way.

*Decalcifying.*—Bones which are the seat of lesions and calcified

[1] *Cullen*, Johns Hopkins Hospital Bulletin, April, 1895.

tissues in which hard and soft parts are associated must be freed from lime salts before thin sections can be made from them.

Tissues which are to be decalcified should be in small pieces and first well hardened in alcohol or Müller's fluid.

A variety of agents may be used for the removal of the lime. But the following methods will suffice for almost all purposes:

It may be accomplished by the use of a saturated aqueous solution of *picric acid*. The bone or other tissues should be cut into small pieces, not larger than a cubic centimetre, and suspended by a thread in a large quantity of the fluid, which should have an excess of picric acid crystals at the bottom, and should be frequently shaken. Considerable time is required for decalcification by this method.

A method of rapid decalcification which gives excellent, and perhaps the best, results is by the combination with nitric acid of *phloroglucin*, the latter agent preventing the swelling of the tissue elements. One gramme of phloroglucin is dissolved with gentle heat in 5 c.c. of nitric acid. This solution, when effervescence has ceased, is of a ruby-red color. To this are added 70 c.c. of strong alcohol and 30 c.c. of water. Small pieces of bone or other tissue are suspended by thread in relatively large quantities of this fluid. In from one to twenty-four hours, depending upon the size of the piece of bone, the decalcification is usually complete, as may be ascertained by passing a needle through it. Now wash the specimens thoroughly in running water until no acid reaction is given by litmus paper; put for twenty-four hours in eighty-per-cent alcohol, and then in strong alcohol. Bone decalcified in this way is apt to stain much better with hæmatoxylin and eosin than after the use of other decalcifying agents. In all cases the decalcifying fluid should be abundant, exceeding the tissues in bulk at least twenty times.

*Hardening and Preservation.—Alcohol* is the most commonly employed tissue-hardening agent for routine purposes. It is used in the strength of from eighty to ninety-five per cent at first, the pieces of tissue to be hardened not being larger than 2 or 3 c.c. There should be in bulk at least ten times as much alcohol as of tissue to be hardened. A little absorbent cotton may be placed in the bottle to keep the blocks of tissue from sticking to the bottom. After twenty-four hours the alcohol should be renewed. On the third day the tissue is transferred to ninety-seven to one hundred per cent. alcohol for completion of the hardening, which will usually be within five or six days.

To obtain absolute alcohol for the purposes of hardening, the ordinary strong commercial alcohol (ninety-four to ninety-seven per cent) may be largely dehydrated by standing in a closed bottle with at least one-third its bulk of pulverized cupric sulphate which has been freed from its water of crystallization by heating. Alcohol thus rendered

approximately absolute should be filtered or carefully decanted before using. Commercial alcohol may be also dehydrated by shaking with pure quicklime and allowed to stand for some hours in closed bottles, then settled and decanted or filtered.

While for many purposes other and more delicate methods of hardening tissues are to be recommended, for most solid tissues in which bacteria are to be sought for and studied, for such specimens as are not quite fresh and in which the process of decay is to be immediately checked, and in general for tissues in which the determination of topographical features for diagnostic or other purposes is the chief end in view, alcohol is the most useful agent.

It is very often desirable to harden a part of a specimen for topographical purposes in alcohol, while other portions are treated with agents which secure a more perfect preservation of minute cell structure. When large specimens are to be preserved in alcohol for gross demonstration or for museum purposes, the alcohol may be used in the strength of from fifty to sixty per cent (see page 63). It should be always borne in mind that under the most favorable conditions the hardening of delicate tissues by alcohol involves considerable change in the minute structure of cells, owing to coagulation and shrinkage of their albuminous constituents.

*Müller's Fluid.*—In many cases pathological specimens are best hardened first in *Müller's fluid* and the process completed by alcohol.

*Müller's Fluid* is made by the following formula:

| | |
|---|---|
| Potassium Bichromate | 2 parts. |
| " Sulphate | 1 part. |
| Water | 100 parts. |

Most tissues are hardened in Müller's fluid with much less shrinkage of their delicate constituents than is the case with alcohol. For the use of certain staining methods, especially of nerve tissue, a preliminary hardening in Müller's fluid is indispensable. It should, however, be remembered that while Müller's fluid is a good hardening agent for nerve fibres, for ganglion cells it is very unsatisfactory.

The specimens for Müller's fluid hardening should be cut into small pieces, not more than 1 or 2 cm. square, and placed in a large quantity of the fluid, at least ten times the bulk of the specimen, where they remain for two or three weeks. The fluid should be changed three or four times within the first ten days, and after this as often as it becomes turbid or a sediment forms. After the specimens have acquired considerable consistence, or have been in the fluid for the proper time, they are removed from the fluid and soaked for from twenty-four to forty-eight hours in water, which should be

frequently changed. They are then placed in equal parts of alcohol and water for forty-eight hours, and then in strong alcohol, by means of which the hardening is completed. They may be preserved in eighty-per-cent alcohol.

For the special directions for hardening nerve tissues see page 19.

*Formalin*, or formol, is the trade name for a forty-per-cent aqueous solution of formaldehyd. In dilute solutions it is a valuable fixative and hardening agent for delicate tissues. It is most commonly used in a solution of 2 parts (of the commercial formalin) to 100 of water. The fresh tissues, in small pieces, are put in this solution for forty-eight hours, the fluid being renewed at the end of twenty-four hours. They are then transferred to sixty-per-cent alcohol for twenty-four hours, and the hardening is completed with strong alcohol.

Formalin in two-per-cent solution is also useful in the preservation of larger masses of tissue for demonstration or museum purposes.

*Osmic Acid* is of great value for the hardening of small portions of delicate tissues, since it serves to fix the elements in a nearly normal condition and stains them of a brown or black color. It is generally used in one-per-cent aqueous solution, the tissues, in very small pieces and when quite fresh, being placed in it and allowed to remain for twenty-four hours. They are now washed in water and may be preserved in eighty-per-cent alcohol.

Instead of using the one-per-cent osmic acid pure, very good results are obtained by diluting it with an equal volume each of water and strong alcohol. This is in many cases preferable, since the tissues are not stained so dark by the acid, and are more readily preserved subsequently in alcohol. But under these conditions a black precipitate forms which colors the alcohol and may be found in the specimens.

*Flemming's Osmic Acid Mixture.*—For the purpose of fixing delicate tissue elements to show minute structural detail, such as mitotic figures, this mixture is of great value. It is made of—

One-per-cent solution of Chromic Acid.....15 parts.
Two-per-cent solution of Osmic Acid..... 4 "
Glacial Acetic Acid..... 1 part.

This mixture does not keep well and hence should be made up in small quantities. Small portions of tissue should soak in the mixture for twenty-four hours and then, after thorough washing in water, are put for twenty-four hours in seventy-per-cent alcohol, then transferred to strong alcohol, in which they are kept.

Osmic acid stains fat black and on this account is a valuable agent for the detection of this substance in the tissues. When used

with this intent it is necessary to wash the superfluous solution thoroughly out of the tissues with water and by repeated changes of the alcohol with which the hardening is completed, since otherwise a black precipitate may form in the tissue and lead to error. Flemming's osmic acid mixture is excellent for the demonstration of fat.

Extremely delicate tissues or films may be fixed by direct exposure to the vapor of osmic acid in a closed vessel. But under these conditions the operator must be on his guard against artefacts which may be developed should the structural elements dry and shrivel before becoming fixed by the vapor.

*Corrosive Sublimate* is a most excellent fixative for delicate structures. It does not penetrate dense tissues readily, and hence all pieces of tissue should, when it is used, be very small.

A simple solution is made by saturating a one-half-per-cent. solution of sodium chlorid with corrosive sublimate and allowing to cool (between seven and eight per cent of the sublimate will be taken up). The excess of sublimate will deposit on cooling, and the solution is decanted.

*Lang's Solution.*—Mixtures of corrosive sublimate with acetic acid are valuable as fixatives in delicate tissues. A very useful form of this mixture is Lang's solution. Its formula is:

| | |
|---|---|
| Mercuric Chlorid | 5 gm. |
| Sodium " | 6 " |
| Hydric Acetate | 5 c.c. |
| Water | 100 " |

The tissues should remain in sublimate solution as a rule not longer than from one to three hours.

Specimens fixed in sublimate do not stain well, and become brittle unless the excess of sublimate is removed. This can be largely done by prolonged washing in running water. But it is much more easily and certainly accomplished by the chemical action of dilute iodine solution. The specimen is removed from the sublimate mixture and put at once into seventy-per-cent. alcohol. To this is added from time to time a sufficient quantity of saturated alcoholic solution of iodine (or tincture of iodine) to give the alcohol a moderately deep iodine color. At first this color gradually disappears, and the iodine solution should be repeatedly added until the color persists. The specimens are now transferred to seventy-per-cent alcohol, and after twenty-four hours to strong alcohol.

A very excellent preservation of fragments of tissue to show minute cell structure, mitotic figures, etc., may be obtained by scraping the cut surface of an organ, tumors, etc., and dropping the scraped-off mass into the sublimate solution. This, after from one

to five minutes, is decanted, the tissue fragments thoroughly and repeatedly washed in water and finally preserved in alcohol. These tiny cell clusters may now be embedded in a mass of celloidin or paraffin (see below), and from this sections of extreme thinness may be obtained.

Although the above is the routine method of hardening tissues, departures from it are occasionally desirable in the preparation of different organs or for the accomplishment of special ends. Thus, in some cases—as in the kidneys, for example—the preservative fluids are brought into more direct and immediate contact with the tissue elements if they are injected under low pressure directly into the blood vessels. Or by means of a hypodermic syringe the fluids may be thrown directly into the interstices of the tissue by thrusting the needle into them and slowly injecting the preservative agent. This is called *interstitial injection.*

Pathological specimens which occur, or are isolated in the form of membranes, should be stretched with pins on a piece of wood or flat cork before being immersed in the preservative fluids.

Minute structures, such as occur in exudations from the mucous membranes and in cyst fluids, renal casts, etc., may be hardened by the osmic acid mixture, by Müller's fluid, or by formalin (two per cent) followed by alcohol. Under these conditions renewals or changes of the fluids may be effected in tubes by the use of the centrifugal machine. The specimens may finally be preserved in eighty-per-cent alcohol or in glycerin to which one-per-cent formic acid has been added to prevent the growth of moulds.

*Embedding and Section Cutting.*—Some dense tissues, after being well hardened, are sufficiently solid to permit of thin sections being made from them without further preparation, but in most cases very thin sections cannot be prepared without filling the interstices of the tissue with some embedding material, which gives it greater consistence and holds the tissue elements firmly in their natural relations to one another while the section is being made. Celloidin and paraffin are the most generally useful materials for this purpose.

*Celloidin*, a non-explosive, purified form of gun-cotton used in photography, is best obtained in the form of thin shavings, since it is most easily dissolved in this form. A strong solution is made in equal parts of sulphuric ether and alcohol. The solution should have the consistence of thick molasses. The specimen, having been soaked for twenty-four hours in a mixture of equal parts of alcohol and ether, is placed in the celloidin solution, where it remains until permeated by it. This will ordinarily occur, if the specimen be of moderate size, in from twelve to twenty-four hours. For this prelim-

inary soaking the celloidin solution may be a little thinner than above mentioned. If the specimen be small and require but little support, it may now be laid directly on the end of a small bit of wood and a few drops of celloidin poured around it. In most cases, however, it is better to make a small paper box, in which the specimen is placed in a proper position and the celloidin poured in around it so as to completely enclose it. In either case a considerable quantity of celloidin should be poured around the specimen, since the celloidin shrinks considerably in hardening. If sections are to be cut with the microtome the paper box should be made by winding a strip of thin paper around the end of a short cylinder of wood,[1] allowing it to project for a sufficient distance beyond the end. The paper is held in place by a rubber band. We have thus a cylindrical box with a wooden bottom projecting below it by which the whole can be held in the clamp of the microtome.

After the specimen, either free on the end of the cork or in its box, is surrounded by celloidin, it should be allowed to stand for a short time exposed to the air, so that it may harden on the outside by the evaporation of the ether. If the temperature be high the too rapid evaporation of the ether will cause bubbles to appear in the mass. This should be avoided by covering the specimen with a bell-jar. After the celloidin mass has acquired sufficient hardness on the outside to keep its shape, the whole should be floated, specimen side down, in seventy- or eighty-per-cent alcohol, in which the celloidin will harden and acquire a sufficient consistence for cutting in a few hours. When this is accomplished the paper may be stripped off, and the specimen is ready for section cutting. A little practice will teach the operator of what consistence to make the celloidin solution, how long to expose to the air, etc.

After the sections have been cut they may be stained in the usual way (see below) and mounted in glycerin or balsam. If mounted in balsam, the oil of cloves, which is ordinarily used for clearing up the sections, will dissolve the celloidin. For some tissues this does no harm, since they are firm enough to hold together even in thin sections ; but in handling friable and delicate tissues it is well to keep the celloidin in place, mounting it with the specimen, with the study of which it does not interfere. This may be accomplished by using the oil of origanum instead of oil of cloves for clearing.

The uncut portion of tissue may be preserved, embedded in celloidin, by keeping it in eighty-per-cent alcohol. It is better, in per-

[1] The short wooden cylinders of various sizes, known as "deck plugs," are very convenient for this purpose. They are cheap and may be bought of dealers in ship-builders' supplies.

manent preservation of uncut celloidin-embedded specimens in bulk, to cut them off from the wooden blocks, since alcohol extracts from these a dark resinous material which colors the specimen and interferes with the staining of sections made later. The severed specimen can be readily refastened to fresh bits of wood by a drop of celloidin when more sections are to be made.[1]

*Paraffin.*—For some purposes, especially when extremely thin though not large sections are required, paraffin embedding is almost indispensable. The sections of tissues thus embedded may be cut exceedingly thin (2–3 mic.) and when these are fixed to the slide and appropriately stained the conditions for the study of cytological details are more favorable than by any other method. For the paraffin technique the specimen should be small, say ½ c.c. as a maximum limit. The specimen is freed from the preservative fluid by washing in water and then is transferred to a series of graded alcohols as follows: thirty per cent, fifty per cent, and seventy per cent, and finally ninety-five per cent. The specimen remains in each of these alcohols for two or several hours and is then placed in absolute alcohol. Complete dehydration of the specimen in absolute alcohol is indispensable for the success of this method, for if the slightest trace of water be left in the specimen shrinkage or other artificial changes in the tissues are produced, when the specimen is transferred to the clearing media preparatory to immersion in the melted paraffin.

When the specimen is thoroughly dehydrated by absolute alcohol it may be transferred to xylol, remaining in this until it sinks and becomes clear, which takes place in an hour or two. It is then immersed in a small dish or glass box of melted paraffin, kept in a constant temperature bath held at 52° C., where it remains until completely permeated by the paraffin. It is best to use paraffin which has a melting point of 50° C. After the specimen has remained for a while in the first dish of melted paraffin it is transferred to a second dish of the same in order to remove any traces of xylol remaining in the specimen, for traces of xylol are liable to make the paraffin soft or cohesive after the specimen is embedded. The length of time of the paraffin immersion depends upon the size and density of the specimen; as a genneral rule one-half hour is sufficient for small, soft, or porous fragments. An hour or one-and-a-half hours at the utmost is sufficient for the melted paraffin permeation. A longer period of

[1] Small squares of thick glass or small cubes of hard rubber, though somewhat more expensive than the "deck plugs," are cleaner and more convenient, since the embedded tissue can be preserved in alcohol, fastened to the block and ready for cutting at any time.

immersion may interfere with the finer structural details of the tissues.

A small paper box considerably larger than the specimen itself is filled with melted paraffin, and with a warm needle or forceps the specimen is transferred to the paper box and set in its proper position in the bottom so that the surface to be cut lies against the bottom of the box. In order to avoid the slow cooling of the paraffin around the specimen in successive layers, which prevent the formation of a homogeneous mass, the paper box with its contents is quickly cooled by being put into cold water, even iced water. When the paraffin block is hard it is fastened with paraffin on to one of the various disks belonging to the paraffin microtome, trimmed so as to have exactly a rectangular cutting surface, and sections are cut with a dry knife. In order to stain these sections the paraffin must be removed from the interstices; this may be done with xylol. But when the supporting paraffin is removed from the sections they are liable to fall to pieces during the further staining and other manipulations. The only practical plan therefore with the great majority of paraffin sections is to affix them to a slide and carry them in this way through the various staining and mounting procedures.

The best way of affixing delicate paraffin sections to a slide is by means of a thin film of "albumen fixative." This is a mixture of albumen and glycerin. Equal parts of white of egg and glycerin are thoroughly stirred together, filtered through paper, and a small amount of carbolic acid added to prevent the growth of micro-organisms. A very small drop of this albumen mixture is placed on one end of the slide, and with the ball of the finger or a fold of cloth it is spread over the rest of the slide in as thin a film as possible. While this scarcely perceptible film of albumen fixative is still moist, the paraffin sections or the ribbons of serial sections divided into proper lengths, are laid upon the film and gently tapped down flat with a small camel's-hair brush or the finger-tip.[1]

[1] Not infrequently very thin paraffin sections will curl or become corrugated as they leave the knife, so that it is difficult to place them flat upon the fixative film. Should this occur, a few drops of water may be spread out in a thin layer over the fixative film while it is still moist on the slide, and the whole slide, with the layer of water upon its surface, is very gently heated over the flame—just sufficiently to soften but not to melt the paraffin. If the sections are then floated out on the warm layer of water they will uncurl and flatten out. The layer of water is then drained off, when the flattened sections will lie flat upon the fixative film and remain fastened there. All traces of the water are now allowed to evaporate in the air; or, the evaporation of the water may be hastened by exposure to a temperature four or five degrees below the melting point of the paraffin. A convenient plan is to place such slides on top of the paraffin bath where the temperature is not sufficient to melt the paraffin and yet expedites the evaporation of the water. The slides must be absolutely dry before going on with subsequent procedures.

The slide with the attached paraffin sections is now heated over a flame, warmed just sufficiently to begin to melt the paraffin; this is a very delicate point in the operation. Just enough heat must be used to melt the paraffin and no more. If the slide be heated beyond this point the sections may be shrunken or completely ruined. While the slide is still warm it is plunged into a jar of xylol, oscillated to and fro for a few seconds, then placed in a jar of absolute alcohol, then passed through a series of jars containing different strengths of alcohol—say ninety-five per cent, seventy per cent, fifty per cent, and thirty per cent, remaining a few minutes in each, and finally into water. Now the sections upon the slide may be stained in whatever way desired, carried up through the graded alcohols to absolute alcohol, then cleared in xylol or other clearing media, and mounted in balsam.

Tightly covered cylindrical jars or wide-mouthed bottles are used for the better manipulation of paraffin sections, the whole slide being dropped into a bottle for staining as well as for the dehydration and clearing.

*Section Cutting* may be done in an emergency by the free hand with a razor ground flat on the lower side, but better sections can be obtained by means of a microtome, and practically all section cutting for microscopical purposes is done by some form of this instrument. One of the most useful of these is Thoma's, which is made in three sizes, the intermediate or the larger one being the more useful. The Schanze microtome is also well adapted for general work, as are some of the American instruments made on the same plan. For cutting sections of tissues embedded in paraffin, and especially for serial sections, the Minot microtome of the improved form is excellent.

*Methods of Staining.*—Sections of hardened tissues may be stained for microscopical study in a variety of ways, but for routine work the double staining with hæmatoxylin and eosin is most generally useful and is applicable to nearly all cases.

*Hæmatoxylin* solution (Delafield's) is prepared as follows: To 100 c.c. of saturated solution of ammonia alum add 1 gm. of hæmatoxylin crystals dissolved in 6 c.c. of ninety-five-per-cent alcohol. This solution is exposed to the light for three or four days, the color meanwhile changing from a dirty red to a deep bluish-purple color. Then 25 c.c. each of glycerin and wood naphtha are added. This mixture is allowed to stand for a day or two and is then filtered, and the filtration is repeated at intervals until a sediment no longer forms.

The solution is now ready for staining, and should be considerably diluted with water as it is used, the best results being obtained by diluting the fluid with from ten to twenty times its bulk of water. The sections are immersed in the fluid, and allowed to remain until

they have acquired a distinct purple color which persists after rinsing in water. They are now placed for a moment in a dilute alcoholic solution of *eosin*, and then mounted in glycerin which has been colored lightly with a alcoholic solution of eosin. In this way the nuclei of the cells will be stained of a purple color, while the cell bodies, and to a certain extent the intercellular substance, will be colored a light rose-red.

If specimens are to be mounted in Canada balsam, they are stained with hæmatoxylin as before, and the eosin staining is done by tinging with a saturated alcoholic solution of eosin the alcohol with which the final dehydration of the specimen is accomplished. A similar result may be obtained by tinging the oil of cloves or origanum with which the clearing of the sections is effected.

Gage's hæmatoxylin is more dilute than the above, and chloral hydrate is added as a preservative in place of the wood naphtha. Its formula is as follows:

| | |
|---|---|
| Sterilized Distilled Water | 200 c.c. |
| Potash or Ammonia Alum | 7.5 gm. |
| Chloral Hydrate | 4.0 " |
| Hæmatoxylin crystals | 0.1 " |

Add to the mixture of water and chloral hydrate the hæmatoxylin crystals dissolved in 10 c.c. of ninety-five-per-cent alcohol. The proper color is developed after a few days' standing ("ripening"). This stain keeps rather better than Delafield's, which occasionally reddens and precipitates. It may be diluted for use.

*Iron Hæmatoxylin* (*Heidenhain's*).—Sections are soaked for an hour in a two-per-cent solution of ammonia sulphate of iron, then rinsed with water and put for an hour in a one-half-per-cent aqueous solution of hæmatoxylin (prepared by heating); again rinsed and put again in the iron solution, in which the color gradually fades. The section must be watched during the process of the differentiation which takes place in the iron solution, and when this is accomplished to a proper extent the section is thoroughly washed in running water and mounted in the usual way. This method is especially valuable for the study of nuclear structures, the color of these ranging from blue to black, depending upon the length of time of immersion in the stain and the grade of differentiation.

By the use of this method micro-organisms may be stained black, and in this condition are, as Leaming has shown, well fitted for the purposes of photomicrography.

*Picro-Acid Fuchsin* (*Van Gieson's*).—This double stain, first suggested by Van Gieson,[1] especially for the nerve tissue, has wide

[1] Van Gieson, Laboratory Notes, etc., New York Med. Jour., July 20th, 1889.

applications in both normal and pathological histology, and is most useful when following a deep hæmatoxylin stain.

It colors the fibrillated connective-tissue fibres and the neuroglia in general a bright or garnet red, and also the axis cylinders and ganglion cells. Myelin, muscle fibres, and certain other cells are stained yellow, while the nuclei after the hæmatoxylin stain are brownish-red in color. Van Gieson's stain is also of value, although its limitations in this particular are not yet fully determined, as a coloring agent for hyalin amyloid colloid and mucin in the tissues. As a differential stain for fibrillated connective-tissue fibres it is of value in the study of various tumors and especially of the sarcomata.

It is commonly prepared in two strengths, the stronger for use especially in nerve tissue staining, the weaker for general purposes. The formulæ and method of using as suggested by Freeborn[1] are as follows:

*Picro-acid Fuchsin. Stronger solution—*

| | |
|---|---|
| One-per-cent aqueous solution Acid Fuchsin.. | 15 c.c. |
| Saturated aqueous solution Picric Acid and Water .....each | 50 " |

*Weaker solution—*

| | |
|---|---|
| One-per-cent aqueous solution Acid Fuchsin... | 5 " |
| Saturated aqueous solution Picric Acid .....| 100 " |

The tissues may be hardened either in alcohol, Müller's fluid, or formalin, but Müller's fluid is preferable.

Sections are first stained deeply with hæmatoxylin, washed in water, and put into the staining fluid, in which they remain for varying periods, depending upon the tissue and the strength of the stain, but in general from one to five minutes. The sections are now rapidly dehydrated by alcohol cleared with oil of origanum and mounted in balsam.

*Golgi's Silver Stain.*—While this well-known method has commended itself most highly to morphologists for special and largely for topographical purposes, it has not as yet taken so definite a position in the armamentarium of the pathologist as to bring it within the scope of this handbook.

There are many methods of staining and numerous slight modifications of old and approved methods. While some of the special staining methods are useful in the attainment of certain ends, the few simple methods which have been here described will suffice for most of the routine morphological work of the pathologist.

[1] Freeborn, Transactions New York Path. Soc., 1893, p. 73.

*Methods of Preserving Specimens for Gross Demonstration and for Museums.*—When specimens of diseased tissues or organs are to be preserved entire for exhibition in jars in a museum, it is in most cases desirable first to get rid of the blood. This may be accomplished, as a rule, by putting them for twenty-four hours in running water, after they have been sufficiently opened so that the water can get to them. They are now brought into proper condition by the removal of superfluous parts and the requisite dissections. Then they are carefully brought into the position and form which it is wished to preserve by stuffing with horsehair or absorbent cotton and by the use of thread. When thus carefully adjusted they are either suspended or laid on a wad of absorbent cotton in sixty- to eighty-per-cent alcohol. In this they usually become hard, and are finally, after the removal of the temporary stuffing and braces, transferred for permanent exhibition to fresh, clear eighty-per-cent alcohol. This description applies especially to such specimens as have cavities to distend or display.

The more simple specimens, such as the solid viscera, tumors, etc., may be freed from blood in the same way and hardened in sixty-per-cent alcohol.

In many cases an excellent hardening is obtained by injecting the preservative fluid through the blood vessels. The lungs are well hardened by pouring the fluid through the trachea into the air spaces.

Methods have been from time to time suggested for the preservation of gross specimens so as to show in part at least their natural colors. None of these methods have proved very satisfactory. On the whole a recent method devised by Jores [1] is the most promising, for in many specimens the color of the blood is in a measure preserved. This method is summarized as follows. The fresh specimens arranged in proper position for display are put for twenty-four hours in the following solution

| | |
|---|---|
| Formalin | 5 parts. |
| Sodium Chlorid | 1 part. |
| Magnesium Sulphate | 2 parts. |
| Sodium Sulphate | 2 " |
| Water | 100 " |

The quantity of the solution should be liberal, and if the specimens be large they may remain for two days in the solution, the latter being renewed at the end of the first day.

The specimens, rinsed off with alcohol, are now put into strong

[1] See *Jores*, Centbl. f. allg. Path. u. Path. Anat., February 29th, 1896.

alcohol (ninety-five per cent), where they remain until they are permeated by the fluid (usually twenty-four to forty-eight hours).

The color of the specimens, lost in the formalin, is partially restored by the alcohol. They are now placed for permanent preservation in equal parts of glycerin and water.

Formalin (two-per-cent solution) and alcohol alone are useful for preserving gross specimens either for demonstration or museum purposes. The fresh specimen should be placed directly, without removal of blood, into an abundant quantity of the solution which is renewed at the end of forty-eight hours. After three or four days the hardening is completed with sixty-per-cent and eighty-per-cent alcohol. Certain color features of gross specimens are often fairly well preserved in such formalin specimens.

Firm-walled cysts of various kinds are well preserved in a natural condition of distention by drawing off the natural contents through a fine canula and refilling with and immersing in the following solution, known as *Flemming's Chromic and Acetic Acid Mixture:*

| | |
|---|---|
| One-per-cent Chromic Acid solution | 20 parts. |
| " " Acetic Acid solution | 10 " |
| Water | 70 " |

After soaking for forty-eight hours in this mixture the tissue, as far as it has penetrated, becomes firm and stiff and of a greenish-gray color. The specimen is now washed thoroughly in running water and preserved in eighty-per-cent alcohol.

*Cysts*, such as echinococcus cysts, small embryos in their membranes, cystic kidneys, etc., may be preserved in a nearly natural condition by placing them in a five-per-cent aqueous solution of chloral hydrate, and after a week replacing this by a ten-per-cent solution of the same, in which they may be permanently preserved. Such specimens may be preserved in a saturated aqueous solution of chloroform, or in formalin (two per cent).

We would most urgently commend to the reader the importance of putting pathological specimens which are to be hardened and subsequently examined microscopically, at the earliest possible moment into the preservative fluids, which should always be abundant. And, furthermore, when specimens are large it is very desirable to cut them open, so that the fluids may come into direct contact with the tissues. It should be borne in mind that immediately after death or the removal of parts from the body, especially in warm weather, changes commence in the tissues and progress very rapidly, so that in some cases a few hours' or even a few moments' delay will not only render subsequent microscopical examinations difficult and un-

satisfactory, but may lead to serious errors. As above stated, Müller's fluid, alcohol, and formalin are the most generally useful agents. *Carbolic acid and glycerin should not be used, even for the temporary preservation of fresh tissue.* They not only do not harden and preserve the tissue elements, but they—especially glycerin—render them almost wholly useless for microscopical examination.

The not uncommon practice of wrapping a specimen in a cloth soaked in alcohol or carbolic acid, and permitting it to remain in this for hours or days, is of no use whatever in preserving specimens of which microscopical examinations are to be made. Almost equally useless is the too common practice of placing a specimen in a bottle which it nearly fills, and pouring a little preservative fluid around it. Not only should the proper fluid be used, but it should be abundant, and the specimen so prepared and arranged that it may come into direct contact with it.

# PART II.

## CHANGES IN THE CIRCULATION OF THE BLOOD.

## CHANGES IN THE COMPOSITION AND STRUCTURE OF THE BLOOD.

## HYPERTROPHY, HYPERPLASIA, REGENERATION, DEGENERATION, ETC.

## INFLAMMATION.

## ANIMAL AND VEGETABLE PARASITES.

## INFECTIOUS DISEASES.

## TUMORS.

# CHANGES IN THE CIRCULATION OF THE BLOOD.

## HYPERÆMIA AND ANÆMIA.

There is an important series of changes in the character of the circulation during life which may, when death ensues, either alter considerably in appearance or disappear altogether. Among the more important of these changes are *hyperæmia*—excess of blood in a part; and *anæmia*—deficiency of blood in a part. These conditions and the causes which lead to them will not be described in detail in this book, which has chiefly to do with alterations of the tissue which persist and may be studied after death. Tissues which have been the seat of a temporary, and sometimes of a prolonged, hyperæmia, may show to the naked eye nothing abnormal after death, or they may look redder than normal; they may be œdematous, and more blood than usual may flow from them when incised. On microscopical examination the blood vessels may be normal in appearance, or more or less distended with blood. Long-continued hyperæmia may lead to hæmorrhage and transudation, to pigmentation, to hyperplasia of tissue, or to an atrophy of tissue through pressure, or even to death of tissue.

The paleness which is characteristic of *anæmic* tissues may not be evident after death. Anæmia may lead to no recognizable microscopical changes. On the other hand, if long continued it may induce atrophy and fatty degeneration, and, if excessive, may lead to death of tissue.

## HÆMORRHAGE AND TRANSUDATION.

*Hæmorrhage* is an escape of blood from the heart or vessels. It may occur from a rupture of the walls of the vessels, and is then called hæmorrhage by *rhexis*. The rupture may be occasioned by injury, by some disease of the walls of the vessels which renders them too weak to resist the blood pressure from within, or it may occur from the blood pressure in the thin and incompletely developed walls of new-formed vessels in granulation tissue, tumors, etc.

Under other conditions, without recognizable changes in the walls of the vessels, all the elements of the blood may become extravasated by passing, without rupture, through the walls of the vessels. This is called hæmorrhage by *diapedesis*. These hæmorrhages are usually small, but may be very extensive. They usually occur in the smaller veins and capillaries, the cells and fluids of the blood passing out through the cement substance between the endothelial cells. Although no marked morphological changes have as yet been detected which explain this extravasation, it is probable that some change in the nutrition of the walls does occur which renders them more permeable. Hæmorrhage by diapedesis is apt to occur as a result of venous congestion, or when the flow of blood in the smaller vessels has been suspended for some time; or it may result from the action of some poison, or from an injury not leading to rupture; or it may occur in incompletely developed blood vessels, in tumors and other new-formed tissues.

In the extravasation of blood by diapedesis the white blood cells may pass through the walls of the vessels, partly at least in virtue of their amœboid movements; the red cells, on the other hand, having no power of spontaneous movement, are, according to Arnold, carried passively through the walls by minute currents of fluid which, under the changed condition, stream in increased force and volume through the endothelial cement substance into the lymph spaces outside.

The altered condition of the blood vessels leading to hæmorrhage may be local or general, and in the latter case it may either be congenital, as in some cases of the hæmorrhagic diathesis, or it may be the result of some general disease, as scurvy, purpura, etc. The presence of bacteria in the vessels, as in malignant endocarditis and in hæmophilia neonatorum, is believed in some cases to produce changes in the walls of the vessels, leading to extravasation.

Very small hæmorrhages are called *petechiæ;* larger, diffuse accumulations of blood in the interstices of the tissues are commonly called *ecchymoses* or *suggillations*. A complete infiltration of a circumscribed portion of tissue with blood is called a *hæmorrhagic infarction*. A collection of blood in a tumor-like mass is called a *hæmatoma*. Sometimes the elements of the tissue into which the blood escapes are simply crowded apart; sometimes, as in the brain, they are broken down.

The extravasated blood in the tissues usually soon coagulates, although exceptionally it remains fluid for a long time. A certain number of the white blood cells may wander into adjacent lymph vessels, or they may remain entangled with the red cells in the meshes of the fibrin. The fluid is usually soon absorbed; the fibrin and a

portion of the white blood cells disintegrate and are absorbed. The red blood cells soon give up their hæmoglobin, which decomposes and may be carried away or be deposited either in cells or in the intercellular substance at or near the seat of the hæmorrhage, either in the form of yellow or brown granules or as crystals of hæmatoidin. Sometimes all trace of extravasations of blood in the tissues disappears, but frequently their seat is indicated for a long time by a greater or less amount of pigment or by new-formed connective tissue. Occasionally the blood mass, in a more or less degenerated condition, becomes encapsulated by connective tissue, forming a cyst.

The action of phagocytes in the disposal of dead material is here, as it is under a great variety of conditions, an important factor in the restoration of the body after lesion to its normal conditions.

*Transudation* is the passage, through the walls of the blood vessels into the lymph spaces outside, of fluid from the blood, with little or no admixture of its cellular elements. This occurs constantly, to a certain extent, under normal conditions, and forms the commencement of the lymph circulation. But when the amount of fluid passing through the walls of the blood vessels is increased, or its outflow into the larger lymph trunks is hindered so that it accumulates in undue quantity in the interstices and lymph channels of the tissues, the condition is pathological and is called transudation. An accumulation of transuded fluid in the interstices of the tissues is called œdema; in the serous cavities, dropsy.

Its occurrence may depend upon some hindrance to the venous circulation, upon some mechanical alteration in the walls of the blood vessels induced by changes in the nutrient efficiency of the blood, or in other ways. There is furthermore strong and increasing evidence that the endothelial cells of the capillaries possess active secretory or other functional capacities which should be taken account of in the attempt to comprehend this as well as many other pathological phenomena and lesions.[1]

A simple interference with the outflow of lymph does not usually alone suffice to induce transudation, although it may favor its occurrence. The transuded fluid, called *transudation* or *transudate*, is usually transparent and colorless or yellowish; it contains the same salts as the blood plasma, but less albumen. It may contain fat, mucin, urea, biliary acids, coloring matter of the bile; fibrinogen is usually present in variable quantity, and rarely fibrin. It may contain endothelial cells from the lymph spaces, and a variable number of red and white blood cells. The amount of fluid which

[1] Consult *Hamburger*, Ziegler's Beiträge zur path. Anat., Bd. 14, p. 443.

may accumulate in the tissues varies greatly, depending upon whether they are loose or dense in texture. The fibres and cells of loose tissues may be crowded widely apart; the cells are apt to be more granular than normal and may be atrophied. Transudations occurring in inflammation usually contain a considerable number of white blood cells and more or less fibrin, and differ in this from the non-inflammatory transudations; but there is no sharp distinction in some cases between them. The inflammatory transudations are often called *exudations* or *exudates.*

### THROMBOSIS AND EMBOLISM.

*Thrombosis.*—Thrombosis is a coagulation of blood in the heart or vessels during life. The coagulum is called a *thrombus.* Thrombi may lie against the wall of a vessel, only partially filling the lumen, and are then called *parietal thrombi ;* or they may entirely fill the vessel, and are then called *obliterating thrombi.*

Thrombi may occur as the result of an injury to the wall of a vessel, or may follow its compression or dilatation ; they may result from some alteration of the wall of the vessel by disease or by the retardation of the circulation. So long as the endothelial linings of the vessels are intact, simple retardation of the circulation does not usually alone suffice to induce coagulation ; but changes in the endothelium from a great variety of causes, such as inflammation, degeneration, atheroma, calcification, and the presence of tumors and foreign bodies, favor its occurrence.

Thrombi may be composed of fibrin and of red and white blood cells, intermingled in about the same proportion as in an ordinary extravascular blood clot. These are called *red thrombi,* and usually occur from some sudden stoppage of the circulation. Other thrombi, usually such as form while the blood is in motion, may consist almost entirely of white blood cells with a little fibrin, or of these intermingled with blood plates, or they may consist almost entirely of blood plates ; all of these forms are called *white thrombi.* Red thrombi, when decolorized by changes in the blood pigment, may somewhat resemble genuine white thrombi. *Mixed thrombi* are usually lamellated and contain varying proportions of fibrin and red and white blood cells.[1]

The changes which occur in the thrombus after its formation may be either in the direction of degeneration or organization. In some cases it seems to undergo a simple shrinkage and decolorization.

[1] The character and significance of the so-called "hyalin thrombi," which are seen in the smaller blood vessels under a variety of conditions, are not yet entirely clear.

The leucocytes, the fibrin, and the blood plates may degenerate, forming a granular material which may become infiltrated with salts of lime, forming the so-called *phleboliths*, or *vein stones;* in other cases the thrombi may soften and disintegrate. Certain thrombi contain bacteria or other infectious material, and on softening of the thrombus these may be carried into the circulation, producing very disastrous results. Finally, the thrombus may be replaced by a new formation of vascular connective tissue, itself disappearing as the new tissue is formed. This is called organization of the thrombus, but in reality the new connective tissue is produced, in large measure at least, not from the cells of the thrombus itself, but from the cells of the walls of the affected vessel, from whose vasa vasorum the new blood vessels of the thrombus also arise (compare page 124). In this way the vessel may be completely and permanently occluded, or, more rarely, a channel may be re-established through the new connective-tissue mass.

Thrombi in veins may lead to hyperæmia and œdema; in arteries, to an anæmia whose significance will vary greatly, depending upon the situation of the occluded vessel.[1]

*Embolism.*—This is the stoppage of a blood vessel by the arrest in its lumen of some material carried along in the circulating blood. The mass causing the stoppage is called an *embolus*. This may be composed of a great variety of substances. The most common emboli are detached portions of thrombi, and these may have all the variety of structure which thrombi present. Masses of bacteria or other parasites, fragments of the heart valves and of tumors, droplets of fat from the medulla of fractured bones, parenchyma cells,[2] masses of pigment, bubbles of air, etc., may form emboli. Embolism is, in a majority of cases, confined to the arteries and to the branches of the portal vein.

The primary effect of the stoppage of an arterial trunk is, of course, to largely deprive the region of the body to which its branches are distributed of its normal supply of blood. If the branches of the occluded artery form anastomoses with other arteries beyond the point of stoppage, a collateral circulation may be established and the

---

[1] Consult *Beneke*, "Die Ursachen der Thrombusorganization," Ziegler's Beitr. zur path. Anat., etc., Bd. vii., p. 158, 1889.

[2] The presence of liver-cell emboli in the lung capillaries and in heart clots after traumatic rupture of the liver and in infectious diseases involving local necroses of the liver has been described by various observers. Emboli believed to be composed largely of placental cells or of cells from the bone marrow are also described under various conditions. The facts relating to this subject of parenchyma-cell emboli and its alleged significance may be found summarized by *Lubarsch*, Fortschritte der Medizin, Bd. xi., Nos. 20 and 21, 1893; and by *Aschoff*, Virchow's Archiv, Bd. 134, p. 11.

embolus do no harm. If, however, the occluded vessel be a so-called *terminal artery*—that is, one whose branches do not form anastomoses with other arteries—the result of the embolism is quite different. When a terminal artery is occluded by an embolus the tissue of the affected region usually dies, and there may be an extravasation of blood by diapedesis, leading to the formation of a dark-red, solidified area, called a *hæmorrhagic infarction.*[1] The area of infarction corresponds to the region supplied with blood by the occluded vessel, and is usually more or less wedge-shaped.

After a time the infarction becomes decolorized, inflammatory changes may occur in its periphery, the blood and involved tissues may undergo degeneration and be absorbed, and finally the seat of the infarction may be indicated only by a mass of cicatricial tissue, which frequently contains more or less pigment.

In another class of cases, instead of an extravasation of blood in the affected region, the tissue is simply deprived of nourishment and undergoes necrosis. The affected area is then usually light in color and is called a *white infarction.* Inflammatory changes may occur in its periphery and a new connective-tissue capsule form around it, and the dead mass may thus persist for some time, or be gradually absorbed and replaced by cicatricial tissue. The scope of this book does not permit us to consider the somewhat complicated and often obscure reasons why in one case we have hæmorrhagic, in another white infarction, as a result of embolus.

If the embolic material consists of or contains infectious substances, such as some forms of bacteria, in addition to the mechanical effects of simple emboli we may have gangrene, suppuration, and formation of abscesses, etc., as the result of the local action of the infectious material, even though this may be present in very small amount.

The organs in which embolic infarctions most frequently occur are the spleen, kidney, brain, lungs; less frequently the retina, liver, and small intestines. Hæmorrhagic infarctions are not liable to oc-

---

[1] When an embolus lodges in a terminal artery, and the circulation in the territory supplied by its branches ceases, the pressure from the side of the artery is reduced to zero; but, on the other hand, according to Cohnheim, the venous pressure now makes itself felt in a backward direction, and the capillaries and small veins in the affected region become crowded with blood. This blood is stagnant, however, and the walls of the small vessels, being deprived of their usual nourishment, undergo, it is believed, degenerative changes which favor the occurrence of extensive diapedesis. Thus, in the hæmorrhagic infarction, not only the blood vessels but the extravascular tissues also are crowded with stagnant blood. The researches of Litten make it seem probable that, in most cases, the back pressure in the region of infarction comes, not from the veins, or not from them alone, but from adjacent arterial twigs which communicate with the capillaries of the affected region.

cur in the liver from emboli in the branches of the portal vein, on account of the blood supply which may come to the affected region through the branches of the hepatic artery. On the other hand, embolic abscesses from infectious emboli are of not infrequent occurrence here. Hæmorrhagic infarctions may occur exceptionally in regions not furnished with terminal arteries, as in the small intestines.

# CHANGES IN THE COMPOSITION AND STRUCTURE OF THE BLOOD.

The *coagulability of the blood* and the characters of the resulting clot vary widely, depending partly upon the composition of the blood and partly upon the conditions under which the coagulation occurs. There may be very little coagulation of the blood in death from the exclusion of air from the lungs, or from diseases and accidents which in any way interfere with the aëration of the blood and permit the accumulation of carbonic acid within it. Thus, in death from strangulation or drowning, many chronic diseases, scurvy, and under many conditions which we do not understand, the blood may remain fluid, or nearly so, after death. On the other hand, in a variety of acute inflammatory diseases, such as rheumatism, pneumonia, etc., very voluminous clots may be formed, although this is by no means constantly the case. The fact that large clots form after death is not conclusive evidence that an undue amount of fibrin-forming elements were present in the blood, nor does the absence of marked coagulation prove a diminution in the blood of fibrin-forming elements.

The composition of the clot varies with the rapidity of its formation and with the specific gravity of the plasma. Clots very rapidly formed in plasma of high specific gravity, or in still slowly circulating blood, are apt to be dark red, from admixture of red cells and fibrin. After complete failure of circulation, especially in plasma of low specific gravity, the red cells tend to settle to dependent vessels. Yellowish-white succulent clots then form in the clear supernatant plasma, while soft black clots result from the excess of red cells collected in the dependent vessels.

The *alkalinity of the blood* varies greatly in disease, being reduced in severe forms of anæmia, in diabetes, and in infectious fevers. Diminution in the alkalinity of the blood continues during the course of infectious fevers, is progressive and extreme in fatal cases, and increases gradually with successful resistance to the infectious process.

*Anhydræmia*—the condition in which the blood contains an exces-

sive proportion of albumen, cells, and other solid elements—occurs in diseases associated with excessive serous discharges from the intestines. It is extreme in some cases of cholera, and has been noted in a lesser degree in other infectious diseases, as pneumonia and diphtheria.

*Hydræmia* is that condition in which the blood contains a large amount of water in proportion to the solid ingredients. It occurs in a variety of diseases of the heart, lungs, liver, and kidneys, and characterizes all forms of anæmia.

Owing to the destruction of red blood cells in some forms of poisoning, burning, etc., the blood plasma may contain free hæmoglobin, by which it is discolored (*hæmoglobinæmia*), or it may be stained from the absorption of bile pigment.

The blood may be actually increased in volume (plethora), either by an increase in fluids, or in cells, or by simultaneous and proportionate increase of both fluid and cellular elements.

*Anæmia.*—In general anæmia means a diminished quantity of blood or of red blood cells in the vessels of the whole or any part of the body. With one exception,—mild chlorosis,—it is invariably characterized by a reduction in number and change in form of the red cells (oligocythæmia), and by diminished alkalinity and coagulability. It is always associated with a reduction in specific gravity, hæmoglobin, and in solid elements. Hydræmia and an increased tendency toward osmosis are equally constant features of this condition. The albumens remaining in the serum after coagulation are very slightly diminished in anæmia.

Generally speaking, anæmia is produced by excessive hæmatolysis, or by defective hæmatogenesis, or by actual loss of blood, in bulk, (hæmorrhage), or in its fluid ingredients (transudation).

Clinically, anæmia may be secondary to hæmorrhage, to exudative processes, to prolonged innutrition, to chronic organic diseases of many kinds, to the action of poisons, to congenital hypoplasia of heart and arteries, to functional disturbances of an unknown nature in the blood-forming organs, and to wholly unknown causes. Simple atrophic changes in many tissues, hypertrophy of the red marrow, lymph nodes, spleen, liver, and thymus, fatty degeneration of the liver, kidneys, heart and blood vessels, with capillary hæmorrhages and transudations, are frequent accompaniments of severe anæmia.[1]

### CHANGES IN THE RED BLOOD CELLS.

These may be diminished in number and may undergo various changes in shape and size and structure.

[1] *Ehrlich* and *Birch-Hirschfeld:* "Ueber schwere anæmische Zustände," Verhand. xi., Cong. Inn. Med., Wiesbaden, 1892.

*Oligocythæmia* is that condition of the blood in which the number of the red cells is reduced. This reduction in number may be temporary, as after hæmorrhage, or it may be persistent, as in some forms of anæmia. The number of red blood cells may in extreme cases of anæmia be reduced to one-tenth of the normal, or even less; that is, from the normal number, which is between four and five million, there may be a reduction to half a million or less.

A persistent diminution in the number of red cells may be effected either by increased destruction (*hæmatolysis*) or by defective formation (*hæmatogenesis*) of these elements, but the relation of the two factors in the production of the chronic anæmias is as yet imperfectly determined.

*Excessive hæmatolysis* is observed after burns, is produced by many mineral poisons, as arsenic, phosphorus, and potassium chlorate, and may occur in infectious diseases through the action of bacterial toxines. All stages of a peculiar destruction of red blood cells may readily be followed in the blood in malaria. In chronic infectious diseases, prolonged suppuration, and in the cachexia attending malignant new growths, destruction of red cells is probably effected, in part, by toxic agents circulating in the blood. In pernicious anæmia the condition of the blood may, with considerable certainty, be referred largely to a destruction of red cells by some unidentified toxic material in the blood.

In the process of destruction of the red cells, especially if rapid, hæmoglobin may be separated from the cells, dissolved in the plasma (hæmoglobinæmia), and may then be excreted unchanged in the urine (hæmoglobinuria).

The gradual and more common form of destruction of red cells is attended with an alteration of the hæmoglobin, effected chiefly in the liver, and with its deposit in the endothelial and glandular cells of various organs, especially in the liver, spleen, kidneys, bone marrow, and secondarily in any of the tissues.

A part of the altered hæmoglobin is to be found in the form of pigment granules, or as a diffuse deposit, in the cells of the above-named organs, where its content of iron may or may not be demonstrable by microchemical tests (*hæmosiderin*). Another product of the hæmoglobin, not containing iron, may be found in the same situations, in the forms of granules or crystals (*hæmatoidin*). Finally, the derivatives of hæmaglobin are excreted largely in the form of normal or pathological urinary pigment. The remaining fragments and stroma of the red cells are soon removed from the circulation largely by leucocytes, and partly by endothelial cells and giant cells, in the liver, spleen, and marrow.

*Defective hæmatogenesis* must be regarded as a cause of such

anæmias as are associated with pathological changes in the bone marrow (pernicious anæmia), and in the lymph nodes, spleen, and liver (leukæmia). This too is probably the chief cause of the anæmia following prolonged innutrition (secondary anæmia). The pathological changes in the blood-producing organs may sometimes arise as primary diseases of these organs, or similar changes may be secondary to excessive demands for the regeneration of the blood. In mild grades of anæmia the regeneration of the blood is attended with an hyperplasia of the red marrow [containing nucleated red cells of normal size (*normoblasts*)], which replaces the yellow marrow of the long bones. The chief defect in the production of red cells may then be a deficiency in hæmoglobin (chlorosis). In severe and prolonged anæmia, under the influence of toxic agents in the blood, the reproduction of cells may be insufficient, and these new cells may be more susceptible to the action of the toxic agent, which is itself the cause of their structural defects. A "circulus vitiosus" is thus established, the normal development of red cells fails and is in part replaced by an abnormal type of blood formation closely resembling the embryonal type. In such cases the normoblasts of the marrow are replaced by very large nucleated red cells (*megaloblasts*); from these are developed very large red cells which are comparatively incapable of the functions of the normal cell. In this way may be established a secondary anæmia which steadily progresses and becomes a self-perpetuating disease entirely disproportionate to the original cause (secondary pernicious anæmia).

As a combined result of defective hæmatogenesis and increased hæmatolysis, there may be found in the blood a variety of pathological and degenerative forms of red cells.

In *mild forms of anæmia*, the red cells are deficient in hæmoglobin, the blood may be pale or watery in appearance, and the cells appear in the fresh condition as very pale disks or as slightly refractive rings enclosing a nearly colorless central mass. In dry preparations stained with eosin, such cells may show only a narrow red ring surrounding a central portion which is entirely devoid of hæmoglobin. In this grade of anæmia there may be noted moderate differences in size and irregularities in shape of the red cells. In severe anæmia, under a variety of conditions, as after certain forms of poisoning, extensive burns, etc., varying numbers of very small red cells are seen, called *microcytes*. They are spheroidal or irregular in shape, may be excessively minute, and their hæmoglobin is either increased, normal, or diminished. They are produced by direct separation of a portion of the protoplasm of other red cells. Under similar conditions, a variety of bizarre forms of red cells are found, called *poikilocytes*. In very severe anæmia very large red cells

## EXPLANATION OF PLATE.

FIG. 1. NORMAL BLOOD.—Ehrlich's triacid stain. The red cells are of nearly uniform size and shape. There is an abundance of hæmoglobin which is evenly distributed, but less densely at the centre of the cells, except in those cells which have been very rapidly dried, when the central lighter area does not appear. On the left is a *lymphocyte* without visible protoplasm. Above and below are two *mononuclear cells* showing varieties in the staining quality of the nucleus. In the centre is a *large mononuclear* or *transitional* leucocyte. The fine *neutrophile granules* and the large *eosinophile granules* are nearly identical in color and are to be distinguished, with this stain, only by difference in size.

FIG. 2. CHLOROSIS.—M. M., female, 28 years. Red cells, 3,400,000. Hb., thirty-five per cent. Eosin and methylen blue. The red cells are moderately reduced in number and there are moderate variations in their size and shape. They show a uniform and nearly invariable diminution in hæmoglobin. In the upper left quadrant is a cell showing a gathering of hæmoglobin into a dense central mass. In a cell on the left is represented the appearance in the central portion of a mass devoid of hæmoglobin and staining lightly with methylen blue. Such degenerative changes are common in anæmic blood and are not to be confounded with nucleated red cells, *normoblasts*, one of which is shown in the upper right quadrant. The polynuclear and large mononuclear leucocytes are intended to represent the mixed leucocytosis of this condition. Above are a few blood plates.

FIG. 3. PRIMARY PROGRESSIVE PERNICIOUS ANÆMIA.—O. H., 44 years. Red cells, 675,000. Hb., fifteen per cent. Eosin and methylen blue. The red cells are very much reduced in number, and do not form rouleaux. There are extreme variations in size, shape, and quantity of hæmoglobin. The large nucleated red cells, *megaloblasts* and *gigantoblasts*, were rather numerous. The upper one shows a small nucleus in the resting stage, the lower one a nucleus in early mitosis. The *megalocyte* in the centre shows an excess of hæmoglobin, the one at the base of the field is deficient in hæmoglobin and its outline is imperfect. In this case the eosinophile cells and the mononuclear leucocytes were increased in number.

FIG. 4. SECONDARY PERNICIOUS ANÆMIA.—C. N., 29 years. Chronic malaria. Red cells, 1,900,000. Hb., twenty-five per cent. Triacid stain. The red cells show extreme differences in size, shape, and content of hæmoglobin. Most of the cells are deficient in hæmoglobin. Nucleated red cells were not seen. The leucocytes, especially the polynuclear forms, were increased in number, and a few *myelocytes* were present, one of which is shown on the right.

FIG. 5. LIENO-LYMPHATIC LEUKÆMIA.—Eosin and methylen blue. The red cells are much reduced in number but do not show great differences in size, shape, or content of hæmoglobin. No nucleated red cells were found. The increased number of leucocytes consisted principally of small and large mononuclear cells. On the left is seen a basket-shaped nucleus without demonstrable cell body.

FIG. 6. MYELOGENOUS LEUKÆMIA (NEARLY TYPICAL).—Triacid stain. The red cells are much reduced in number, show moderate differences in size and shape, but usually contain an abundance of hæmoglobin. A few normoblasts were seen. The increased number of leucocytes consists largely of *myelocytes* and *polynuclear leucocytes*. In the centre is a large myelocyte with very pale eccentric nucleus (*Cornil's myelocyte*). Above are myelocytes of ordinary size and with more deeply staining nuclei (*Ehrlich's myelocyte*). On the left is a large *eosinophile myelocyte*. On the right is a smaller cell with some very large granules, staining very dark red, and showing many of the characters of the "*mast cell*."

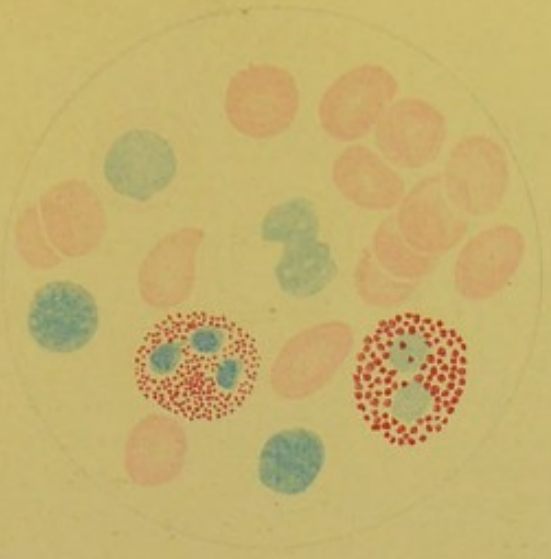

FIG. I. NORMAL BLOOD.
(Ehrlich's Triacid Stain.)

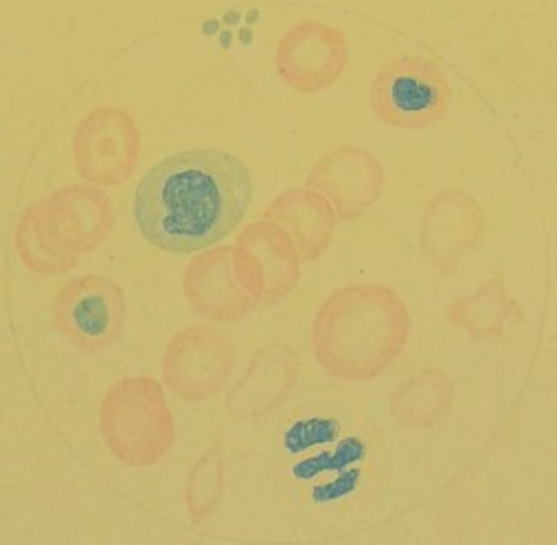

FIG. II. CHLOROSIS.
(Eosin and Methylene Blue.)

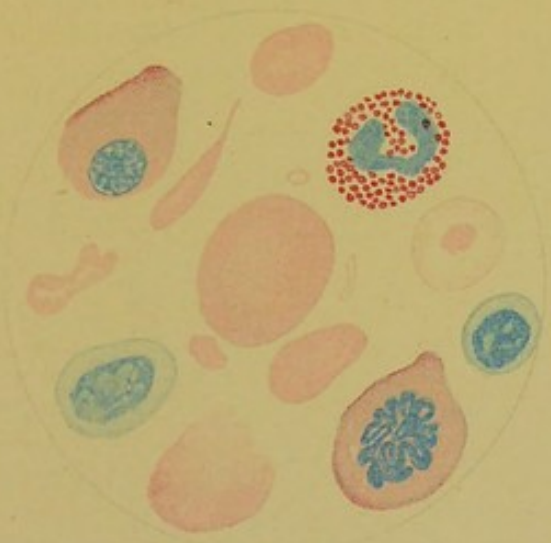

FIG. III. PRIMARY PERNICIOUS ANÆMIA.
(Eosin and Methylene Blue.)

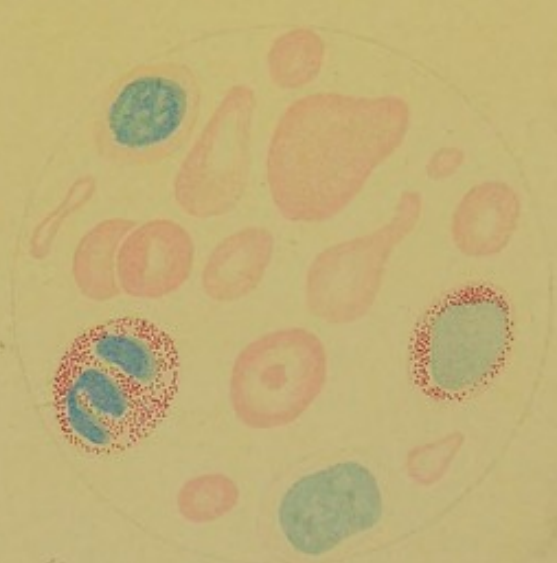

FIG. IV. SECONDARY PERNICIOUS ANÆMIA.
(Ehrlich's Triacid Stain.)

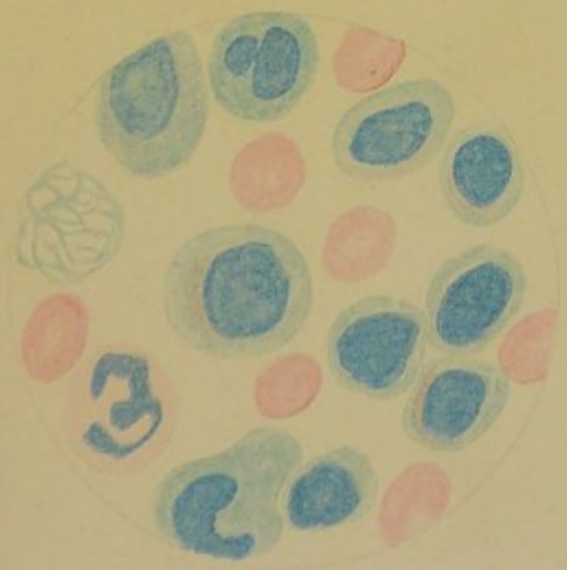

FIG. V. LIENO-LYMPHATIC LEUKÆMIA.
(Eosin and Methylene Blue.)

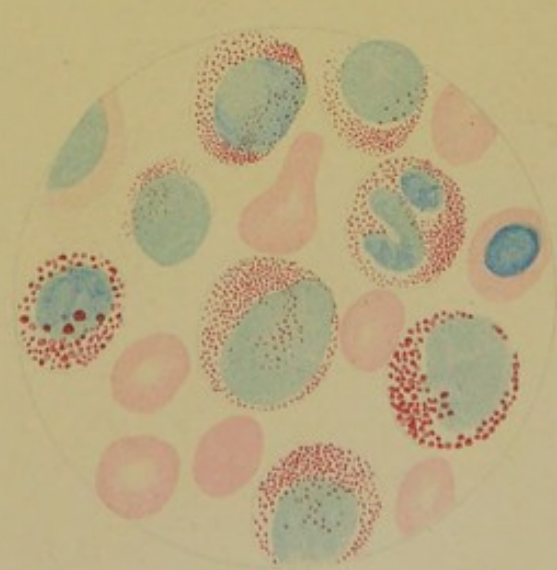

FIG. VI. MYELOGENOUS LEUKÆMIA—NEARLY PURE TYPE.
(Ehrlich's Triacid Stain.)

# CHANGES IN THE STRUCTURE OF THE BLOOD.

DRAWN BY JAMES EWING.

occur in considerable numbers. These cells, called *megalocytes*, are derived from the large nucleated red cells of the marrow, and their appearance in the blood indicates the early onset or actual establishment of some form of progressive anæmia (see PLATE, Fig. 3).

Amœboid movement of megalocytes has been observed in specimens examined on a warm stage from the blood of pernicious anæmia and malaria. The tendency of the red cells to form rouleaux is much diminished or absent in very grave anæmia.

In addition to the loss of hæmoglobin, as observed in most cells in chlorosis, the megalocytes may show an altered reaction to eosin, staining brownish-red with this dye instead of the usual light-red. This abnormality has been referred to a change of hæmoglobin to methæmoglobin (Ehrlich). In malarial blood, red cells frequently show an altered reaction to eosin and other dyes, indicating an altered form of hæmoglobin.

Not infrequently a loss of hæmoglobin is associated with a change in the stroma of the cell, so that the central mass stains slightly with methyl blue. To this change the name of anæmic degeneration has been given (Ehrlich). Instead of a uniform loss of hæmoglobin this constituent of the cell may be condensed in the form of small granules occupying the centre of the cell body and staining more deeply with eosin than do normal cells (PLATE, Fig. 2).

It should be remembered that during the manipulations required in making dried specimens the red cells may suffer a variety of artificial changes, many of which are very confusing.

*Nucleated Red Blood Cells* are found in the blood in all forms of anæmia, and their appearance indicates regenerative activity on the part of the blood-producing organs. Their presence in the blood, though at all periods of extra-uterine life abnormal, may usually be regarded as of favorable import in disease. Within a few hours after severe hæmorrhage nucleated red cells may be noted in considerable numbers. During the regeneration of the blood in chlorosis, the occurrence of nucleated red cells is nearly constant, but subject to rather sudden periodical variations sometimes called "blood crises." In favorable cases of anæmia nucleated red cells of normal size only (*normoblasts*) (PLATE, Fig. 2) are to be seen, whose compact, darkly staining nucleus may be found either in the centre of the cell or slightly protruding from the periphery, or apparently quite extruded from the cell and free in the plasma.

In severe anæmia attended with an abnormal type of blood formation, very large nucleated red cells (*megaloblasts*) (PLATE, Fig. 3) appear in varying numbers. The protoplasm of these cells often shows an excess of hæmoglobin, but frequently the reddish-brown stain produced by eosin indicates an altered form of hæmoglobin, or rarely

very fine basophile granules may be demonstrated by treatment with methyl blue. The nuclei of the megaloblasts may be single and compact, or a single large nucleus may show stages of direct division, or in extremely large cells (*gigantoblasts*) (PLATE, Fig. 3), the nuclei may present phases of normal or pathological mitosis.

### CHANGES IN THE WHITE BLOOD CELLS.

The leucocytes of normal blood may be classified according to their place of origin, or by the character of their nuclei, or by the reaction of the granules in their protoplasm to certain dyes. The most serviceable classification is that based both upon the character of the nucleus and upon the reaction of the protoplasm to dyes, according to which we may distinguish in normal blood the following forms (see PLATE, Fig. 1):

1. *Lymphocytes*, small leucocytes of about the size of red cells or larger, with a single compact, deeply staining nucleus, surrounded by a thin rim of homogeneous protoplasm. Large and small lymphocytes may be distinguished.

2. *Large Mononuclear Leucocytes*, with a single, compact or vesicular, rather faintly staining nucleus and a relatively large amount of protoplasm, in which fine basophile granules may sometimes be demonstrated by treatment with basic dyes such as methyl blue.

3. *Transitional Leucocytes*, of the same size as many of the large mononuclear leucocytes, with a compact or vesicular, irregular or incurved nucleus, and a considerable mass of protoplasm, in which fine basophile granules can usually be demonstrated by methyl blue. See page 88.

4. *Polynuclear Neutrophile Leucocytes*, of the same size as the transitional leucocytes, with a partially or completely divided nucleus, of which the separate portions are either compact or vesicular, deeply or faintly staining, and with considerable protoplasm in which distinct granules may be demonstrated by the neutral dyes.

5. *Eosinophile Cells*, of the same characters as the ordinary polynuclear leucocytes, but containing in their bodies large refractive granules which stain deeply with so-called acid dyes such as eosin.

These various forms of leucocytes occur in normal blood, with slight variation, in the following proportions:

| | | |
|---|---|---|
| Polynuclear neutrophile leucocytes | 64 | per cent. |
| Large mononuclear " | 28 | " |
| Lymphocytes | 6 | " |
| Transitional leucocytes | 1 | " |
| Eosinophile " | 1 | " |

The numbers and proportions of the polynuclear leucocytes are in disease subject to very wide variations, and some abnormal forms of colorless cells make their appearance in the blood.

*Leucocytosis* is that condition of the blood in which the leucocytes are temporarily or persistently increased in number. When several forms of leucocytes are increased in number and the usual proportions are but partially disturbed, we speak of *mixed leucocytosis.* Such a condition is seen in some forms of anæmia. When the polynuclear neutrophile leucocytes alone are increased the condition is termed *polynuclear leucocytosis*, or simply *leucocytosis.* If the mononuclear cells are chiefly affected, the condition may be denoted as *lymphocytosis.* The eosinophile cells alone may be increased.

*Polynuclear Leucocytosis* may be either physiological or pathological.

*Physiological Polynuclear Leucocytosis* is seen during normal digestion, in the latter months of pregnancy, and in the first days of infancy, and is usually of moderate grade.

*Pathological Polynuclear Leucocytosis* is produced by many inflammatory and infectious diseases, and accompanies the various cachexias. Of the infectious diseases attended with leucocytosis may be mentioned pneumonia, diphtheria, scarlet fever, erysipelas, rheumatism, suppurative cerebro-spinal meningitis, and any disease associated with a pronounced exudative or suppurative lesion. On the other hand, leucocytosis is absent in uncomplicated typhoid fever, typhus, malaria, measles, and tuberculosis.

The origin and significance of the leucocytosis of infectious diseases is imperfectly understood, but may be partially explained by the principles of chemotaxis and phagocytosis. From experimental evidence and clinical observation it is known that during the onset of some infectious diseases the entrance of bacteria or their products into the blood is followed by a disappearance from the circulation of many polynuclear leucocytes, which are removed from the larger vessels and lodged in the capillaries, principally in the lungs and liver. This condition of the blood, called *hypoleucocytosis*, may be attended with a transient reduction in temperature and weakening of the heart's action, and is usually succeeded shortly by the reappearance of polynuclear leucocytes in large numbers, and by a rise of temperature. These leucocytes are apt to gather in regions in which micro-organisms are abundant, and are believed to take up and destroy micro-organisms (phagocytosis), and to prevent their further entrance, and possibly the entrance of their products also into the circulation. Of the place and method of origin of these new leucocytes very little is definitely known.

In many very severe cases of infectious disease, such as pneu-

monia, diphtheria, and peritonitis, the initial hypoleucocytosis persists, in which event the disease usually runs an asthenic and fatal course, with a tendency to low temperature and feeble pulse, and without the customary increase of leucocytes.

When leucocytosis is established the grade varies frequently with the extent of the local lesion and the height of the fever produced by the infectious process, and disappears with, or soon after, the decline of the disease. In general, according to our present knowledge, the leucocytosis of infectious diseases may be regarded as the effort of the blood-producing organs to protect the blood and tissues by means of leucocytes against the invasion of micro-organisms and against the action of toxins present in the circulation.

The blood in typhoid fever presents a peculiar variation from that in most infectious diseases. In the first weeks of the disease there is usually a reduction in the number of leucocytes, especially of the polynuclear forms. In the latter weeks the lymphocytes may form eighty per cent of the leucocytes present in the blood. Each relapse is attended with an increase of the lymphocytosis, while an increase of polynuclear leucocytes usually occurs with complications only.

In the various forms of tuberculosis there is no leucocytosis unless the lesion is markedly exudative in character, or is complicated by suppuration, or chronic anæmia. It is especially in pulmonary tuberculosis that secondary infection with the pyogenic cocci produces exudative or suppurative lesions such as are apt to accompany leucocytosis.

*Cachectic Leucocytosis* is a feature of altered conditions of the blood, such as are associated with the growth of malignant tumors, and with many diseases producing secondary anæmia. This increase of polynuclear leucocytes may serve to distinguish many forms of secondary from primary anæmia. The inflammation and toxæmia accompanying many new growths is a sufficient reason for the appearance of cachectic leucocytosis, but under many other circumstances its direct cause is less apparent.[1]

*Hypoleucocytosis* occurs not only in infectious diseases, when the polynuclear cells alone are reduced in numbers, but also from shock, reduction of body temperature, and exhaustion, when all forms of leucocytes may be diminished. It is a fairly constant feature of primary pernicious anæmia.[2]

In *mixed leucocytosis* several forms of white cells are simulta-

[1] For further data concerning Leucocytosis, consult *Rieder*, Beiträge zur Kenntniss d. Leucocytose, Leipsic, 1892.

[2] For Hypoleucocytosis, consult *Lowit*, "Studien über Physiol. de Pathol. d. Blutes u. d. Lymphe," Jena, 1892. *Ewing*, "Toxic Hypoleucocytosis," New York Medical Journal, March, 1895.

neously increased in number, including the mononuclear, polynuclear, and eosinophile cells, and a new form of colorless cell, not found in normal blood, the *myelocyte*, makes its appearance in the circulation.

*Myelocytes* are mononuclear cells of the same size as the polynuclear leucocytes, presenting a single, round nucleus, usually staining faintly with nuclear dyes, and containing neutrophile granules in the protoplasm (PLATE, Fig. 6). These cells are normally present in the bone marrow, and their presence in the circulation indicates increased activity of the blood-producing organs, especially of the bone marrow. Very large myelocytes with a faint eccentric nucleus are occasionally seen in grave anæmias (Cornil's myelocyte), and eosinophile cells, with a single, large, faintly staining nucleus, are usually considered as derivatives of similar cells in the bone marrow (eosinophile myelocytes). Mixed leucocytosis, with the presence of one or all of these forms of myelocytes, may accompany any of the severe primary anæmias, while in secondary anæmia the myelocytes may be found in addition to the increased number of polynuclear leucocytes. In leukæmia, the mononuclear cells and the myelocytes may be found in enormous numbers. Myelocytes usually fail to exhibit amœboid movement, and their nuclei may present many phases of normal or pathological mitosis.

In leukæmia a special variety of colorless cell, the "*mast*" *cell*, is found, often in considerable numbers, and the great rarity of its occurrence under other conditions lends special diagnostic importance to its appearance in the blood. The mast cell is usually of about the same size as the large mononuclear leucocyte, with a single, rarely double, faintly staining nucleus occupying the larger part of the cell mass, and with a moderate area of protoplasm thickly studded with large granules which stain deeply with some basic dyes, such as dahlia. Mast cells are found in many tissues, usually when these tissues have been inflamed or subjected to prolonged disturbance of nutrition. Their appearance in the blood has been demonstrated almost exclusively in leukæmia. (PLATE, Fig. 6, shows a cell resembling the "mast cell," but this cell can be positively identified only by a special stain. See page 88.)

*Lymphocytosis*, frequently seen in the anæmia of childhood or in any severe circulatory disturbance in early life, has also been noted in some forms of secondary anæmia (syphilis), and in an extreme degree is the chief characteristic of the blood of splenic and lymphatic leukæmia.

A moderate increase of eosinophile cells has been noted under a great variety of circumstances, as after the crisis of pneumonia, in conditions of prolonged innutrition, and in splenic and myelogenous leukæmia, but its significance is largely undetermined. The Char-

cot-Leyden crystals are occasionally found in the blood, usually at the same time with an increased number of eosinophile cells.

Degenerative changes of the blood are usually indicated in the leucocytes by variations in the percentage of normal and abnormal varieties, rather than by alterations in the individual cells, for degenerating leucocytes are usually quickly removed from the circulation. Staining reactions of the various granules, by which degenerative changes may be recognized, have not yet been devised. In leukæmia, pernicious anæmia, and diphtheria, a diminished reaction to nuclear dyes has been observed. In leukæmia, and in the severe infectious diseases, the leucocytes may be extremely cohesive, and it is believed that a large quantity of bacteria or toxins in the circulation may even affect a complete solution and destruction of leucocytes (leucocytolysis). Fatty degeneration of leucocytes has been demonstrated.

*Melanæmia.*—In this condition the blood contains larger and smaller irregular-shaped particles or masses of brown or black pigment. This condition is most frequently the result of intermittent and remittent fever, particularly the severer forms. It may be accompanied by anæmia and leucocytosis. It does not occur in all cases of the above-named affections. It may be transient in character. The pigment may be free, or more usually is enclosed in leucocytes. Under the same conditions pigment may be deposited in the liver, spleen, lymph nodes, bone marrow, and blood vessels. Owing to the deposit of pigment in the organs they may assume a gray or slate color. The pigment developed in malaria originates in the decomposition of the hæmoglobin under the influence of the plasmodium. Pigment which has been taken into the lungs from the air, such as coal dust, etc., may find its way into the blood either before or after deposition in the bronchial or other lymph nodes, and may be afterwards deposited in the spleen and liver.

## METHOD OF EXAMINATION OF THE BLOOD.

The blood may be examined fresh on the warm stage without the addition of any fixative, simply surrounding the cover with oil or vaselin to prevent evaporation. For most purposes, however, the cells should be treated the instant the blood leaves the vessels in such a way as to retain their normal form. This fixation may be accomplished by the use of chemical agents (wet method) or by quick drying on the cover glass or slide (dry method).

*Wet Method.*—Among the chemical fixative agents are osmic acid and a solution of corrosive sublimate. *Osmic Acid:* A drop or two of blood drawn from the cleansed finger-tip by a needle prick is allowed to fall into a cubic centimetre of from one- to two-per-cent

osmic acid. After an hour the blood cells may be transferred by a pipette to a solution of acetate of potash, in which they may be preserved.

*Sublimate* may be used in the form of Hayem's solution:

*Hayem's Solution.*

| | | |
|---|---|---|
| Chloride of Sodium | 1 | gm. |
| Sulphate " | 5 | " |
| Corrosive sublimate | 0.5 | " |
| Water, distilled | 200 | " |

The blood is received directly into this solution, in which it is studied.

*Dry Method.*—It has been found that if the freshly drawn blood from a finger prick be immediately dried on a glass in a very thin layer, the cell forms are quite well preserved and may be exposed to the action of staining agents, by which many features are developed not easily seen by the wet method.[1]

For this purpose square cover glasses of medium size should be cleaned in strong nitric acid, rinsed in alcohol and ether, carefully dried, and kept free from dust. A drop of blood may be expressed by very light pressure only from the finger tip, previously cleansed with alcohol and ether, and for the best results the drop must be spheroidal and about one-sixteenth of an inch in diameter. One cover glass should be held in the forceps, or between the fingers if thoroughly dry, and its central point touched to the drop of blood. After contact with the blood this cover glass should be instantly laid upon a second glass so as to cover all but an eighth of an inch along one side, and as soon as the blood has spread to the edges the cover glasses should be quickly separated without pressure and dried in the air. If, instead of drying in the air, the specimens are rapidly dried over an alcohol flame, the fixation will be more successful, and many artificial changes in the red cells will be avoided. By this method the red and white cells, in the same proportions in which they existed in the drop, will be uniformly distributed over the cover glasses, and there is an opportunity for the formation of rouleaux.

Another method, more successful in many hands, consists in touching the drop with the smooth edge of a glass slide, applying this edge with its adherent blood obliquely to a cover glass, and when the blood has spread along the edge of the slide, drawing it rapidly across the cover glass.

---

[1] For further details concerning methods of blood examination, etc., consult *Ehrlich*, "Gesam. Mittheilungen," Berlin, 1891. *V. Limbeck*, "Grundriss einer klin. Path. d. Blutes, v. Jena, 1896.

For the permanent fixation of the cells and to prevent their solution by strong dyes, one of three methods may be recommended, with preference in the order named:

1. *Ehrlich's Method.*—The specimens are heated in a hot-air bath or on a copper plate, for from two to five minutes (or better twenty minutes) at a temperature of 105° to 110° C.

2. *Nikiforoff's Method.*—The specimens are placed for five to ten minutes in equal parts of alcohol and ether.

3. *Hayem's Method.*—The specimens are exposed for five seconds to the vapor of a two-per-cent solution of osmic acid in water, to accomplish which they may be laid over a wide-mouthed bottle containing this solution.

Various staining agents are to be employed according to the object in view. Probably most information is gained from specimens stained by the triacid mixture of Ehrlich, which is thus prepared:[1]

Saturated aqueous solutions of

| | |
|---|---|
| Orange G | 120–135 c.c. |
| Acid Fuchsin | 80–165 " |
| Methyl Green | 125 " |

To the mixture of these add

| | |
|---|---|
| Water | 300 c.c. |
| Absolute Alcohol | 200 " |
| Glycerin | 100 " |

The specimens should be stained in this fluid for three to five minutes, washed in water, dried, and mounted in balsam.

The red cells are then found stained orange-yellow, the nuclei dark-green or blue, the neutrophile and eosinophile granules dark-red.

Rather more uniform results, especially as regards the red cells may be obtained by the following method, which also demonstrates the malarial plasmodium and basophile granules, but not the neutrophile granules. Place the specimens for two minutes in a saturated alcoholic solution of eosin, wash in water, and counterstain for five minutes in a saturated watery solution of methyl blue. The red cells and eosinophile granules then appear bright-red. The nuclei, basophile granules, and malarial plasmodium are stained blue.

For the demonstration of mast-cell granules, the following Ehrlich's dahlia solution may be used:

---

[1] Great care must be used in selecting these dyes. Those made by Grübler, of Leipsic, are reliable. A solution known as "Ehrlich's triacid mixture" is on the market and is to be recommended.

| | |
|---|---|
| Alcohol, absolute | 50 c.c. |
| Distilled Water | 100 " |
| Glacial Acetic Acid | 12.5 " |

To this mixture add dahlia till a saturated solution is formed.

Stain several hours, wash in water, decolorize in alcohol, or more rapidly in twenty-per-cent acetic acid, wash in water, dry, and mount in balsam.[1]

For the demonstration of mitotic figures Delafield's hæmatoxylin (diluted), or Heidenhain's iron alum hæmatoxylin, may be used.

For the demonstration of fat in blood from a finger prick, cover-glass preparations dried in the air should be stained for twenty-four hours in one-per-cent aqueous solution of osmic acid. To avoid numerous sources of error, a control preparation should be previously placed in chloroform for twenty-four hours to dissolve the fat, and the two specimens carried together through the osmic acid. In the one, black fat droplets will be seen, which should be entirely absent in the other.[2]

## FOREIGN BODIES IN THE BLOOD.

Various bodies which do not belong there, aside from those above mentioned, may find access to the vessels and mingle with the blood. Pus cells may get into the blood from the opening of an abscess into a vessel or from some inflammatory change in its walls. Desquamated endothelial cells from the vessel walls, either in a condition of fatty degeneration or in various stages of proliferation, may be mingled with the normal blood elements; also tumor cells of various kinds, fragments of disintegrated thrombi, portions of heart valves, etc. Crystals of bilirubin have been found in the blood in icterus.

*Fat*, in a moderate amount, is a normal ingredient of the blood during digestion and in lactation. Under pathological conditions it may occur in larger and smaller droplets. This *lipæmia* occurs as a result of deficient oxidation, in diabetes, in drunkards, and in some cases of dyspnœa from various causes. The droplets are small and liable to escape observation.

In many cases of injury, particularly in crushing fractures of the bone, the fat of the marrow finds its way into the blood, and it may collect in large drops in the vessels of the lungs, forming the so-called *fat emboli;* or it may pass the lungs and form emboli in other

[1] In the application of any of these methods of staining the closest attention to detail is required for satisfactory results.

[2] For various other methods of staining blood cells, and for detailed consideration of morphological changes in disease, we refer to *Von Limbeck*, "Klin. Pathologie des Blutes," 1896.

parts, as the brain, kidneys, etc. Fat embolism in eclampsia is of occasional occurrence.

The fat may be absorbed from the vessels, having produced little or no disturbance ; or in some cases it may produce serious results by the stoppage of a large series of vessels in the lungs, brain, or other parts of the body.[1]

The fat may be best seen by cutting sections of the fresh tissues with the freezing microtome and staining them at once for twenty-four hours with one-per-cent aqueous solution of osmic acid. They may then be mounted in glycerin.

*Air in the blood*, as the result of an opening in the veins, is of occasional occurrence. If the amount of air be small it appears to be readily absorbed and does little or no harm. If, on the other hand, a large quantity is admitted to the veins at once, it collects in the right side of the heart, from which the contractions of the organ are unable to force it in any considerable quantity, and, the supply of blood being thus cut off from the lungs, death very quickly ensues. It is especially from wounds of the veins of the neck and thorax that the accident is most apt to occur. But it may be due to the introduction of air into the uterine veins in intra-uterine injection or in the removal of tumors.[2]

The occurrence of animal and vegetable parasites is considered more in detail in parts of this book devoted to these organisms. It will suffice to mention here that the more important of the animal parasites of the blood are : the *Filaria sanguinis hominis*, the *Distoma hæmatobium*, and the embryos of *trichina* and *echinococcus*, which are of occasional and usual temporary occurrence.

The various species of bacteria which may be found in the blood will be considered in parts of this book in which these organisms are treated in detail.[3] Parenchyma-cell emboli are considered on page 73.

---

[1] Consult for résumé of this subject, with good bibliography, article by *Park* on "Fat Embolism," New York Medical Journal, August 16th, 1884.

[2] Consult *Couty*, "Études exp. sur l'entrée de l'air dans les veines," Paris, 1875, for experiments and older literature ; also later article by *Couty*, Arch. de Physiol. nor. et path., 2d ser., t. iv., p. 429, 1877; more recent consideration of the subject in Archiv für klin. Medicin, Bd. xxxi., p. 441, 1882, by *Jürgensen*.

[3] For methods of bacterial study of blood with bibliography consult *Sittmann*, Deutsches Archiv f. klin. Med., Bd. liii., p. 323, 1894.

MEDICAL DEPARTMENT,
YORKSHIRE COLLEGE,
VICTORIA UNIVERSITY.

# HYPERTROPHY, HYPERPLASIA, REGENERATION, METAPLASIA.

## HYPERTROPHY AND HYPERPLASIA.

Under a variety of conditions parts of the body or organs become larger than normal—hypertrophied. When we look for the structural changes to which hypertrophy is due, we find that it may be owing to a simple increase in size of the elementary structures of the part, cells, and other tissue elements. This is called *simple hypertrophy.*

On the other hand, it is found in many cases that the increase in size of a part or organ is due not only, or not at all, to the increase in size of its elementary structures, but to an increase in their number. This increase in number of the structural elements of a tissue or organ is called numerical hypertrophy, or *hyperplasia.*

Simple hypertrophy and hyperplasia are frequently associated.

## REGENERATION.

The wear and tear of the body in the performance of its varied functions and labors, and the greater or smaller injuries to which it is frequently exposed, make indispensable for the maintenance of its integrity a more or less constant and widespread regeneration of tissue.

This regeneration of injured or worn-out tissues, all new growths, as well as the hyperplasias above mentioned, are invariably brought about by proliferation or other changes in living cells.

A new formation of cells in the body, so especially characteristic of this period of development, thus persists through life with varying degrees of activity. It is in the adult, however, under pathological conditions—in the course of inflammation in the growth of tumors—that those cell proliferations occur which especially concern us here.

Just as the cells of the adult organism are the offspring of one original cell, the ovum, so are all the new cells which appear in the body under abnormal conditions derived from some pre-existing cells by a division of their bodies.

The careful and minute study of cells during the act of division, which has been recently made, has revealed many most curious phenomena and has opened a new world of observation nearer to the elementary expression of life than has seemed possible in earlier times. It will suffice for our purposes to briefly indicate some of the more striking features of the new cell lore.

The earliest morphological changes in cell division are seen in the nucleus.

*Direct (Amitotic) Cell Division.*—In this, which although relatively rare appears to be the most simple mode of cell division, the

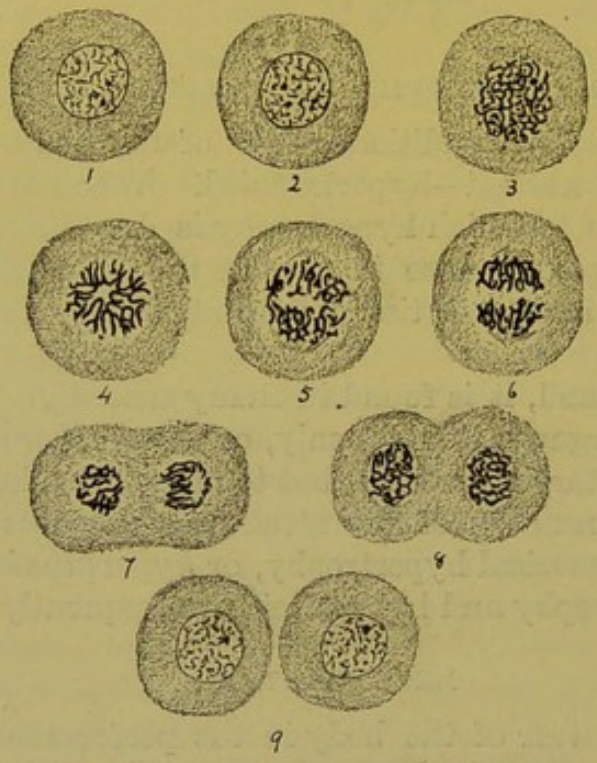


Fig. 8.—Phases of Mitosis, or Indirect Cell Division.

nucleus with its membrane becomes constricted and finally divides into two or more parts which become new nuclei. Hand-in-hand with or following this simple nuclear division the cell body divides, and thus two or more cells may form in the place of one. Sometimes the nuclear division is not followed by a division of the cell body, and thus multinuclear cells, or "giant cells," may be formed. Whether in this mode of cell division there may not be as yet unrecognized minute changes in the cell nucleus, ushering in the process, seems not to be altogether clear.

*Indirect (Mitotic) Cell Division.*—In this mode of cell multiplication certain minute changes in the nucleus usher in the coarser process of division. The earlier changes which are to be seen in a cell about to divide are a thickening and rearrangement of the

chromatin forming the intranuclear network (Fig. 8; *1* and *2*). As the chromatin fibres or filaments—called *chromosomes*—thicken, they group themselves into an irregular snarl or contorted mass, the nucleolus disappears, and the nuclear membrane becomes indistinct (Fig. 8; *3*).

Now the chromosomes separate by longitudinal division into equal parts, and these arranging themselves in various, often stellar forms, slowly draw asunder in two or more groups (Fig. 8; *4*, *5*, and *6*). Then the cell body shows a beginning constriction corresponding to the division of the chromosomes into masses (Fig. 8; *7*). Finally a nuclear membrane develops around each of the new nuclei, their fibres become more slender and assume the resting arrangement, and the cell body completes its division by a deepening of its constriction (see Fig. 8; *8* and *9*). There are countless variations and details in the minute processes of cell division which the scope of this work does not permit us to consider. But the facts already at hand are of extreme significance to the biologist and point toward large fields of research in pathology when the normal processes shall have been more clearly and exhaustively determined.

In the mean time far-reaching conclusions based upon preliminary observations on asymmetrical karyokinesis in abnormal tissues should be accepted with reserve, since the details of the condition are not yet fully studied and simple degenerative processes not sufficiently taken into the account.[1]

The term *mitosis* or *karyomitosis* is applied to this indirect mode of cell division on account of the involvement of the nuclear threads. It is also sometimes designated as *karyokinesis*, from the form changes which these threads undergo. Aside from its intrinsic biological interest, a knowledge of mitosis in proliferating cells is of importance in pathology, because the recognition of mitotic figures often enables us to decide with certainty what particular cells or cell groups are involved in the formation of new tissue.

The most significant feature, however, of the whole process of mitosis, with all its intricate variations, appears to be that the chromosomes, during their separation into two or more clusters to form the basis of new cells, undergo an exact longitudinal division, so that under normal conditions all of the new nuclei share alike in the chromatin substance of the parent cell. This fact appears to be of extreme importance in the recognition of a physical basis of inheritance.[2]

---

[1] *Hansemann*, Virchow's Archiv, Bd. cxxix. *Lustig* and *Galeotti*, Ziegler's Beiträge zur path. Anat., Bd. xiv., pp. 225 and 249.

[2] Consult *Wilson*, "The Cell in Development and in Heredity," 1896.

It is not necessary for us to follow in detail here the processes of regeneration and repair in the different tissues and organs. It should be borne in mind that individual cells may, even after having undergone marked structural changes—as, for example, in acute granular degeneration—be restored to a perfectly normal condition.

After injury or loss a full and complete regeneration of cells and tissues can occur only as the result of a proliferation of cells of the same type as those to be restored. Thus a regeneration of epithelium occurs by proliferation and growth of epithelial cells alone ; regeneration of muscle by muscle cells ; of nerve by nerve cells, etc. In fact, however, in the higher types of tissue, after considerable injuries with loss of substance or after destructive pathological processes, complete regeneration is not common. This is because the highly specialized cells of the body are limited in their capacity for reproduction closely to the domain of physiological regeneration.

What we ordinarily call healing, in extensive wounds of the more highly specialized tissues, is usually a provisional makeshift repair by means of new-formed connective tissue. Such regeneration as takes place in peripheral nerves after partial destruction is brought about by the action of constituents of the nerve fibres themselves. But it is a fibrous or neuroglia-tissue healing only which is possible when the loss is central or extensive, and it is this alone which, after large injuries to the brain, achieves a patchwork repair.

In injuries of muscle, too, the remains of muscle protoplasm may undergo proliferation in moderate degree and lead to a partial restitution of muscle tissue. This, however, is usually atypical in structure and of little functional importance. Losses of substances in muscle are largely repaired, with varying functional success, by connective tissue.

Specialized gland tissue, while readily enough maintaining by cell proliferation its integrity under the ordinary functional wear and tear, is incapable as a rule, by proliferation of its specially endowed cells, of making good extensive losses of substance, either from injury or destructive pathological processes. It should not be understood by this that healing and a general restoration of the part may not occur after extensive injuries to such organs as the liver, kidneys, thyroid gland, etc. ; such a general healing may occur, but it is largely through growth of a new connective tissue. The specialized gland cells, be it in the liver, kidney, salivary, or other glands, or in the mucous membranes, under favorable conditions are apt to respond to an injury with destruction of tissue by proliferation, or, it may be, by the actual production of considerable new gland tissue. But the new gland tissue thus produced is usually inconsiderable in amount, atypical in form, and often of questionable value. The

liver and the thyroid gland seem, however, to possess in an exceptional degree the power of regeneration.

We thus see that though specialized cells in the body express, in the face of tissue injuries, distinct recuperative tendencies, they are not in general able to make good extensive losses of substance. This is usually done by the cells of a group of tissues more lowly in organization, but retaining largely the proliferative power of undifferentiated protoplasm, namely, the connective tissues.[1]

The formation of leucocytes appears to occur chiefly in those masses of lymphoid tissue which are so widely scattered in the body in the lymph nodes, in the spleen, and in the bone marrow.

Both mitotic and amitotic cell division are to be observed in the new formation of leucocytes, but the exact relationship between the new cells produced in these two ways, and their respective destinies, is not yet very clear (see Blood).

Regeneration of red blood cells seems to occur in the bone marrow through mitotic division of nucleated forms. The latter may, under pathological conditions, appear in the vessels in varying numbers.

## METAPLASIA.

The members of the connective-tissue group—fibrous tissue, mucous and fat tissue, cartilage, bone, etc.—are so closely related in nature and structure that not infrequently and under a variety of conditions one form of tissue will assume the characters of another. This change of one form of tissue into another is called *metaplasia*.

Thus, by a gradual change in the cells and stroma of fibrous tissue this may be converted into bone, as mucous tissue may become fat tissue, and hyalin cartilage become fibrous. Metaplasia is a process involving active changes on the part of the living cells of the tissue, and should be clearly distinguished from certain degenerative processes, in the course of which one form of connective tissue may assume superficial resemblances to others of the group, as in calcareous and mucoid degeneration. While metaplasia is most common among the members of the connective-tissue group, it sometimes occurs in other tissues. Thus, for example, under certain conditions one type of epithelium may assume the morphological characters of another.

---

[1] A summary of recent studies on the regenerative capacities of the nervous tissues may be found in the "Ergebnisse der allg. path. Morphologie und Physiologie," Abth. 2, 1895.

# DEGENERATIVE CHANGES IN THE TISSUES.

*Necrosis.*—Necrosis is the death of a circumscribed portion of tissue. It may be the result of insufficient nutrition from the cutting-off of the blood supply; or it may depend upon the action of destructive chemical agents, extreme degrees of temperature, certain materials produced by the life processes of some forms of bacteria; or it may be due to mechanical injury. The appearances which dead tissues present under the microscope vary greatly. In some cases we have a simple and gradual disintegration and softening of the tissue, resulting in a mass of degenerated cells and cell detritus, with more or less fluid and various chemical substances arising from decomposition. The softening of the brain in embolism is an example of simple necrotic softening. In some cases the dead tissues simply gradually dry and shrivel and become hard and dark colored.

In another class of cases the dead tissues are permeated by fluids which may be dark red in color from the solution of coloring matter from the blood, and contain bacteria which induce putrefaction with the production of gases and various new chemical substances. The tissues become swollen and granular, and disintegrate; and finally the whole may form a mass of irregular granules with fat droplets, tyrosin, leucin, and various forms of crystals, shreds of the more resistant kinds of tissue, and bacteria.

*Coagulation Necrosis.*—If dead areas of tissue (whether this condition be due to mechanical injury, to disturbances of nutrition, or to the local action of bacterial or other poisons) contain the elements necessary for the coagulation of their albuminous constituents, or if they be bathed with body fluids from adjacent parts in which the circulation is maintained, a characteristic coagulation of the necrotic elements is apt to occur. The composition of the cells of the tissue is altered, so that the cell bodies are shining and translucent, diminished in size, sometimes altered in shape, and the nuclei of the cells disappear. The white infarctions of the spleen and kidneys, the areas of coagulation necrosis in tuberculosis, and the pseudo-membrane in croupous inflammation of the mucous membranes are the most common examples of this lesion.

If, for example, in the spleen, one of the small arteries is plugged by an embolus, a corresponding portion of the spleen becomes anæmic and appears as a white, wedge-shaped mass, sharply defined from the surrounding splenic tissue. If such a white infarction has existed but a short time there is hardly any difference between the appearance of its anatomical elements and those of the surrounding spleen, except that they are differently affected by staining fluids. If the infarction is older the cells are small and shiny and their nuclei cannot be seen.

In croupous inflammations of mucous membranes the epithelial cells become shiny, the nuclei disappear, and the shape of the cells is changed by the coagulation necrosis, so that a number of them together often look like a network of coagulated fibrin.

*Cheesy Degeneration.*—As commonly used this term embraces

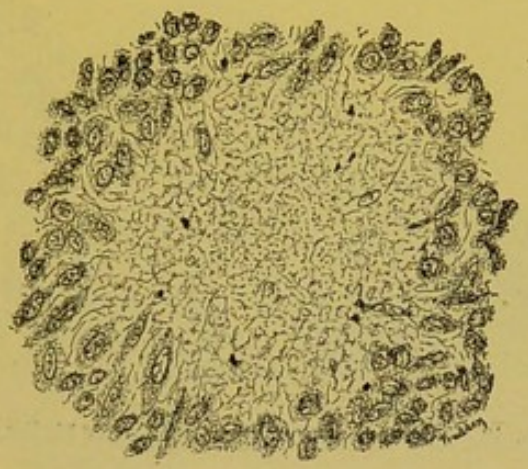

FIG. 9.—AN AREA OF CHEESY DEGENERATION (COAGULATION NECROSIS) IN MILIARY TUBERCLE OF LUNG.

the changes in the tissues which we have just considered under the more appropriate name of coagulation necrosis. But it is also applied to that form of degeneration in which, under a variety of conditions, the dead tissue elements lose their normal structural features and become converted into an irregularly granular albuminous and fatty material which sometimes tends to disintegrate and soften, sometimes dries and becomes dense and firm, or may become infiltrated with salts of calcium. Thus cheesy degeneration may, and very often does, occur in tissues which are in the condition of coagulation necrosis; but it also occurs in tissues which are not the seat of coagulation necrosis, but which, for a variety of reasons and in a variety of ways, have lost their vitality.

The terms coagulation necrosis and cheesy degeneration, as commonly used, in part actually cover the same degenerative conditions in the tissues. Both are indefinite, and will no doubt remain so until

we obtain a more precise knowledge of the lesions which they represent.

*Parenchymatous Degeneration* (Acute Degeneration; Granular Degeneration; Cloudy Swelling).—In this condition the cells of tissues and organs are swollen and filled with small albuminous granules, which may be so abundant as to entirely conceal the original cell structure. The granules disappear on treatment with acetic acid, and are insoluble in ether. This degeneration may be present in the parenchyma cells of any inflamed organ, but is most marked and frequent in the liver, kidney, heart muscle, and mucous membrane of the gastro-intestinal canal. It may occur in infectious or severe febrile diseases, after severe burns, and in poisoning with arsenic, phosphorus, or mineral acids. It is often associated with various phases of exudative inflammation. The cells in a condition of paren-

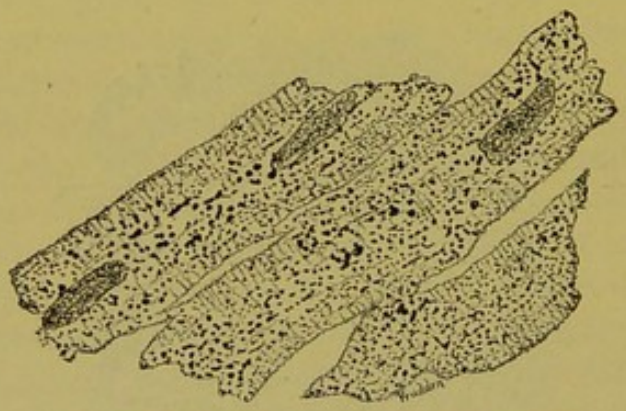

FIG. 10.—FATTY DEGENERATION OF HEART MUSCLE.

chymatous degeneration may regain their normal condition, or become fatty, or disintegrate. In such organs as the liver, kidney, and heart the gross appearances are often very characteristic; the tissue is swollen and has a less translucent and more dull and grayish look than under normal conditions.

The microscopical study of this lesion is best done in sections of the fresh tissue made with the freezing microtome, by the rapid formalin method, page 51, or in teased fresh tissue in one-half-per-cent salt solution.

*Fatty Degeneration.*—This is the conversion of the protoplasm of cells into fat, which accumulates in the cell body. The fat is usually present in the cell in very small particles or droplets, but these may coalesce to form large drops. The protoplasm may even be almost entirely replaced by the fat.

*Fatty Infiltration* of cells is a common occurrence under normal as well as pathological conditions. The fat is believed to originate outside of the cells and simply accumulate in them, causing a passive atrophy of the protoplasm. In this way fatty infiltration is believed

to differ essentially from fatty degeneration, but in many cases a definite distinction between the two is impossible with our present knowledge of the chemistry of cell life. In general the fat droplets are larger in fatty infiltration than in fatty degeneration, yet to this there are many exceptions. Fat granules and droplets are recognized in cells by their strong refraction, by their solubility in alcohol and ether and their insolubility in acetic acid, and by the black color which they assume when the fresh tissue is treated with osmic acid. Not infrequently feathery clusters of delicate fat crystals occur within the cells. Fatty-degenerated cells may break down and form an oily detritus, in which, especially when much moisture is present, cholesterin crystals may be formed by decomposition of the fat.

To the naked eye, organs in a condition of marked fatty degenera-

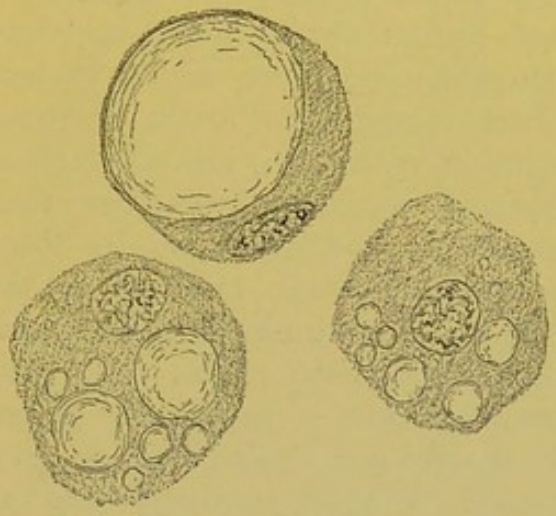

FIG. 11.—FATTY INFILTRATION OF LIVER CELLS.

tion are usually larger and softer than normal, have a grayish-yellow color or are mottled with yellowish streaks or parches, and the normal markings of cut surfaces are more or less obscured.

Fatty degeneration may be due to local or general disturbances of nutrition, from a great variety of causes—disturbances which either directly affect the life processes of the cells themselves, or which produce alterations in their nutritive supply. In addition to its local occurrence, as a result of local disturbances of circulation, in the vicinity of inflammations or in tumors, etc., it is apt to occur in the liver, heart muscle, and kidney in chronic exhausting diseases and in conditions and diseases to which profound anæmia is incident, or as the result of the action of certain poisons, such as phosphorus and arsenic. Fatty degeneration is, as a rule, a more serious lesion than fatty infiltration.

Tissues in a condition of fatty degeneration or infiltration may be teased fresh in salt solution; or they may be hardened in Flemming's osmic acid solution, see page

54, in preparation for sectioning. Hardening in Müller's fluid and afterward in alcohol gives moderately good results if the lesion be extensive. But it should be remembered that in tissues which have been soaked in alcohol the fat is no longer present, its former seat being indicated by clear spaces which are filled with the mounting medium. The fat crystals, however, often persist after prolonged soaking in alcohol.

*Amyloid Degeneration* (Waxy or Lardaceous Degeneration).—This is a process by which the basement substance of various forms of connective tissue, and especially the walls of the blood vessels, become swollen and thickened by their conversion into a translucent, firm, glassy, colorless material, albuminous in character. This albuminous material may be present in the tissues in such small amount as to be recognizable only under the microscope, or it may be so abundant as to give a very characteristic appearance to the tissue. Parts in which the lesion is marked are usually larger and contain less blood and feel harder than normal, and have a peculiar dull shining and translucent appearance which varies in character, depending upon the extent and distribution of the degenerated areas and upon its association with other lesions, such as fatty degeneration. It most frequently occurs in the smaller arteries and capillaries, whose lumen becomes encroached upon by the thickening of the walls which the process involves. It is usually the media and intermediary layers of the intima which are earliest and most extensively affected. The change also often occurs in the interstitial connective tissue and membranæ propriæ of organs and in reticular connective tissue. It is both asserted and denied that it may affect the parenchyma cells of organs. We have not been able to find unmistakable evidence of its occurrence in parenchyma cells. These, however, frequently undergo atrophy as the result of pressure from the swollen, degenerated tissue.

It is not yet known whether amyloid degeneration is due to a direct transformation of the tissue, or is an infiltration of the tissue by some abnormal material formed elsewhere and brought to it, or is derived from the blood.

Amyloid degeneration occurs most frequently and abundantly in the liver, spleen, kidneys, intestinal canal, and lymph nodes; but it may occur, usually in a less marked degree, in other parts of the body : in the larger blood vessels, in the interstitial tissue of the heart and mucous membranes of the air passages, and in the generative organs. It may occur locally or appear in various parts of the body at once. It may exist without any known cause, but it most frequently occurs in connection with severe wasting diseases, particularly in those involving chronic suppuration and ulceration, especially of the bones. It frequently occurs in tuberculosis, syphilis,

in the cachetic condition induced by malignant tumors, and is occasionally seen in severe malarial infection, dysentery, and leukæmia.

For microscopical examination, the tissue, either fresh or after preservation, should be cut into thin sections, and these deeply stained with one-per-cent aqueous solution of methyl violet; the sections are washed in water and mounted in glycerin. The differentiation between the amyloid and other parts is more distinct if, after staining, the specimen be dipped for an instant in HCl and alcohol 1 : 100, and then carefully rinsed, before mounting in glycerin. The degenerated areas are thus stained rose-red (Fig. 12), while the normal tissue elements have a bluish-violet color. In some cases, for reasons which we do not know, the amyloid substance does not show a well-marked reaction with methyl violet. A sharp differentiation of the amyloid material may be obtained by picro-acid fuchsin (Van Gieson's stain), page 61. Other anilin dyes also differentiate amyloid substance from normal tissues. On treating sections of amyloid tissue with solution of iodine the degenerated

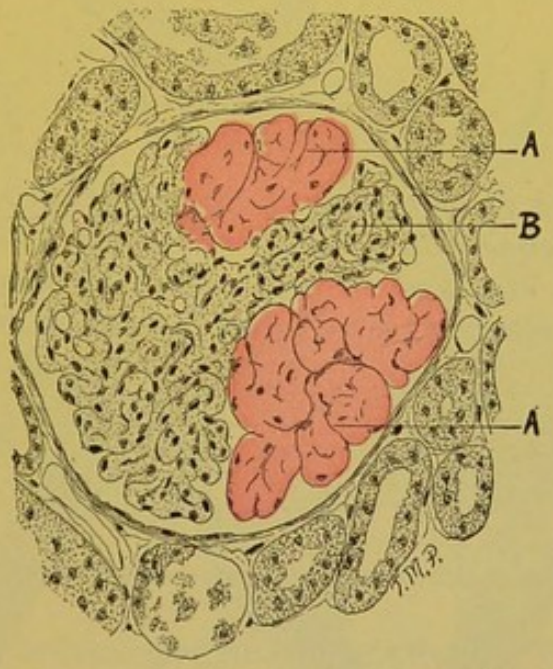


FIG. 12.—AMYLOID (WAXY) DEGENERATION OF CAPILLARIES OF A GLOMERULUS IN THE KIDNEY.
A, waxy capillaries stained with methyl violet; B, normal capillaries.

parts acquire a mahogany color. If they are then treated with sulphuric acid the degenerated portions acquire a greenish or blue color; but the latter reaction is not very reliable.

*Corpora Amylacea* are small, spheroidal, homogeneous or lamellated bodies (Fig. 13), which assume a bluish color on treatment with solution of iodine or iodine and sulphuric acid. They are frequently found in the acini of the prostate gland, sometimes in large numbers; in the ependyma of the ventricles of the brain, and in areas of sclerosis of the brain and cord; also in extravasations of blood and in various other situations. They may occur under normal as well as pathological conditions, and are apparently of little importance. They seem to have nothing to do with amyloid degeneration, although

they somewhat resemble its products. Some of the tube casts of the kidney resemble in many respects the corpora amylacea.

*Glycogen Degeneration.*—Glycogen appears under abnormal conditions in the body as hyalin, mostly globular masses of varying size. It is soluble in water, is stained brownish-red by iodine, and does not assume a greenish color by the further addition of sulphuric



FIG. 13.—CORPORA AMYLACEA.
From prostate gland.

acid. In diabetes it may occur in large quantities in the liver cells and in the epithelial cells of the uriniferous tubules, especially in those of Henle's loop and in leucocytes. It may be found in fresh pus cells, in the cells of various forms of tumors, and in leucocytes in

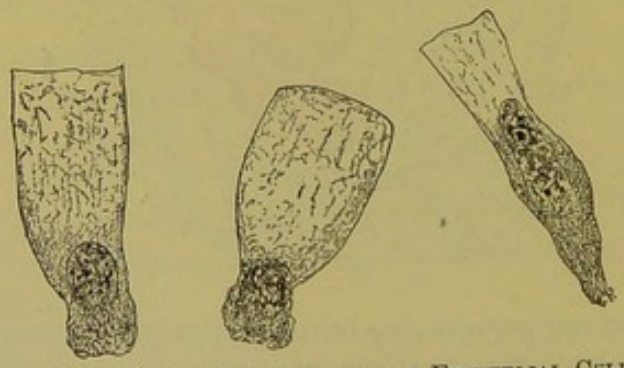

FIG. 14.—MUCOUS DEGENERATION OF EPITHELIAL CELLS.
From cyst adenoma of ovary.

the blood in leukæmia, in chronic diseases of the gastro-intestinal tract in children, and in various chronic diseases.

If the tissue to be examined for glycogen be fresh the iodine should be used in solution in glycerin (equal parts of Lugol's solution and glycerin), in order to avoid its solution. If specimens are to be hardened this should be done in absolute alcohol to avoid the solution of the glycogen. Sections may be stained with picro-acid fuchsin (Van Gieson's stain) or with a dilute solution of iodine in alcohol (tincture iodine 1 part, absolute alcohol 4 parts), cleared up and studied in oil of origanum.

*Mucous Degeneration* may occur in cells or in intercellular substance. When occurring in cells it consists, under pathological as under normal conditions, of the transformation of the protoplasm

into a translucent, semi-fluid material, occupying more space than the unaltered protoplasm, and hence causing a swelling of the cells (Fig. 14). This new-formed material contains mucin in solution, which is precipitated by acetic acid. It occurs under a variety of conditions, sometimes as a morbid increase of a normal function of cells, as in many catarrhs, sometimes as an entirely abnormal transformation. The cells may be entirely destroyed by the accumulation of the mucoid material within them.

In certain cases, as in many tumors, in cartilage, bone, and other tissues, the intercellular substance undergoes conversion into mucin-containing material, losing almost entirely its original structure (Fig. 15). The cells in such cases may be affected only secondarily by the pressure which the new-formed material exerts upon them.

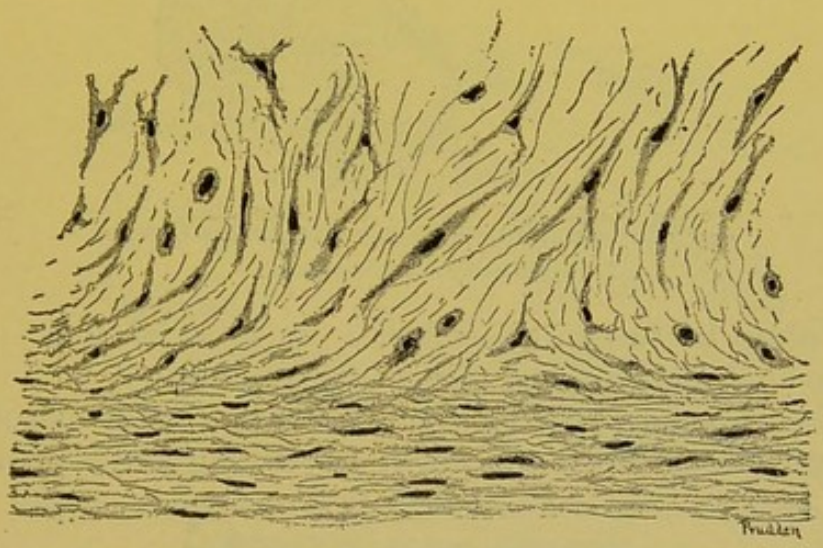

FIG. 15.—MUCOUS DEGENERATION OF FIBROUS TISSUE OF MAMMA.

Tissues should be hardened in Müller's fluid or formalin, followed by alcohol, and sections stained with picro-acid fuchsin or with hæmatoxylin, which colors the mucin-containing portions.

*Colloid Degeneration* is very closely allied, both in chemical and morphological characters, to mucous degeneration, and in many cases there is no definite microscopical distinction between them. But colloid material is firmer and more consistent than mucous, does not yield a precipitate on addition of acetic acid or alcohol, and its formation is usually confined to cells; not involving intercellular substance, except by an atrophy which its accumulation sometimes induces. The cells may contain larger and smaller droplets of colloid material (Fig. 16), or it may nearly or entirely replace the protoplasm and accumulate to such an extent as to cause rupture and destruction of the cell. In this way, and by the atrophy of intercellular substance which its accumulation causes, cysts may be formed contain-

ing colloid material and cell detritus. Colloid degeneration is of frequent occurrence in certain tumors and in the thyroid gland, and occurs occasionally in other places.

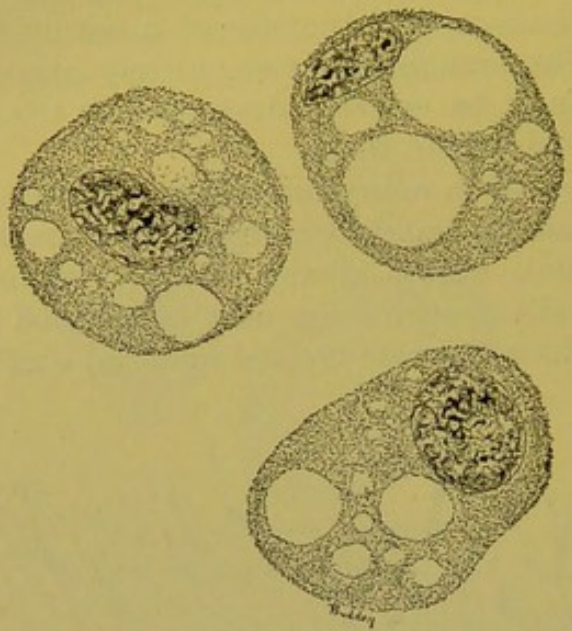

FIG. 16.—COLLOID DEGENERATION OF EPITHELIAL CELLS.
From carcinoma of rectum.

Hardening in formalin, Müller's fluid, or alcohol. Staining with picro-acid fuchsin.

*Hyalin Degeneration* is the transformation of tissues into a transparent, glassy substance, much resembling amyloid in its mor-

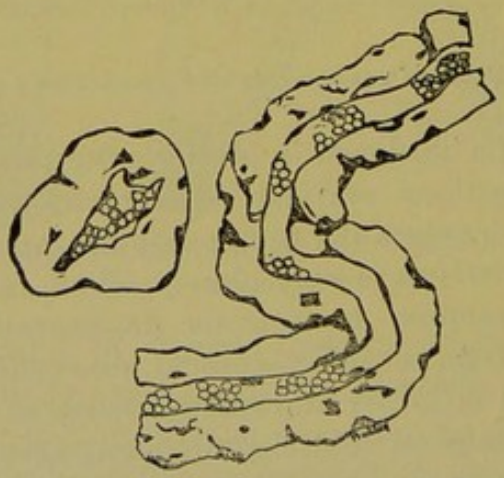

FIG. 17.—HYALIN DEGENERATION OF CAPILLARY BLOOD VESSELS.
From a sarcoma of the optic nerve.

phological characters (Fig. 17); but it does not give the microchemical reactions of amyloid, and appears under different conditions. Hyalin substance is quite resistant to the action of acids and stains readily with acid fuchsin and eosin. It occurs especially in

the walls of the smaller blood vessels in various parts of the body, in voluntary muscle fibres, and is said to sometimes involve interstitial tissue. It has been described as occurring in the brain, lymph nodes and ovaries; in the tubules of the kidney, in the walls of aneurisms, in muscle fibres, in the lesions of diphtheritis, tuberculosis, and syphilis, in the hyaloid membrane and vessels of the eye, and elsewhere. It is sometimes called vitreous or fibrinous, and also waxy, degeneration. It is believed by some observers that fibrin, blood plates, and leucocytes may undergo hyalin degeneration, and in the forms of the so-called hyalin thrombi this substance may block the capillaries in many infectious diseases—typhoid fever, pneumonia, diphtheria, pyæmia, etc., and under a variety of other conditions. Hyalin degeneration seems to be, in some ways, allied to coagulation

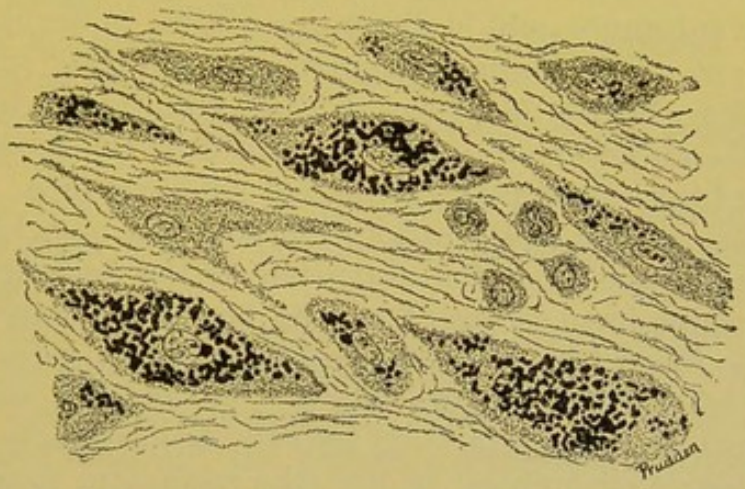

FIG. 18.—PIGMENTATION OF CONNECTIVE-TISSUE CELLS OF THE LUNGS.
From inhaled coal dust—anthracosis.

necrosis, but its exact significance and relations to other forms of degeneration, and the conditions of its occurrence, are not yet known.[1]

Hardening in alcohol, Müller's fluid, or formalin. Staining by picro-acid fuchsin, or by hæmatoxylin and eosin.

In *Calcareous Degeneration* there is a deposition, either in cells or in the intercellular substance, of larger and smaller granules composed chiefly of phosphate and carbonate of calcium. These particles, when abundant, give hardness, brittleness, and a whitish appearance to the affected tissue. Under the microscope they appear dark by transmitted, white and glistening by reflected, light. Tissues may be nearly completely permeated with the salts, or the latter may be scattered in patches through them. Sometimes large lamellated concretions are formed in tissues, usually at the seat of some old inflammatory process. Calcification usually occurs in parts of tissues which

[1] Consult "Ergebnisse der allg. path. Morphologie und Physiologie," etc., Abth. 2, 1895.

are dead or are in a condition of reduced vitality as a result of some antecedent morbid process, usually of an inflammatory nature. Among the most common and important examples of calcareous degenerations may be mentioned those which occur in the valves of the heart and walls of the blood vessels.

The carbonate of lime deposited in the tissues is dissolved by dilute acids with evolution of carbonic acid gas.

This process may be observed under the microscope by running five per cent hydrochloric acid under the cover glass upon unstained sections; the gas bubbles are caught as they evolve beneath the cover. Those parts of tissues which are in an early stage of calcification, as well as those from which the lime has been removed by acids, are usually stained an intense blue by hæmatoxylin.

*Pigmentation.*—The pigment which is present in the body under abnormal conditions may be formed in the body or may be introduced into it from without. It may be deposited in the cells or in the intercellular substance, and is sometimes visible to the naked eye and sometimes not. The pigment occurring in the body may be in the form of yellow, brown, black, or reddish granules or in crystalline form. In the majority of cases it is formed by the decomposition of hæmoglobin from extravasated masses of red blood cells. Parts which have been the seat of long-continued hyperæmia may have a diffuse grayish appearance from the alteration of the hæmoglobin in red blood cells which have escaped from the vessels by diapedesis. Pigment may be formed in the blood vessels in severe cases of malarial infection, and circulate in the blood. In another class of cases various forms of cells seem to be actively concerned in elaborating pigment; this is exemplified in the true melanotic tumors, and the process has its physiological prototype in the formation of pigment in the choroid, skin, and some connective tissues. Pigmentation of tissue from the bile occurs under a variety of conditions, and may be the result of the deposition of granules or crystals. A diffuse staining also frequently occurs from the bile without the formation of solid particles.

In many cases the mode of formation of pigment is not at all understood. In tissues which are normally somewhat colored the color may greatly deepen by a simple atrophy of the tissue without the new formation of pigment, as in simple atrophy of the heart muscle and in atrophied fat.

As examples of pigment introduced into the body from without, we may mention the deposition of minute particles of silver from the internal use of silver nitrate; the coloring of the skin and lymph glands from tattooing; and especially the pigmentation of the lungs and bronchial glands (Fig. 18) from the inhalation of coal and other dust, which is universally present under the conditions which modern civilization imposes.

# INFLAMMATION.

The phenomena which are embraced under the name of inflammation are:

Degeneration and death of tissue.

Changes in the circulation of the blood.

Escape of the elements of the blood from the vessels.

Formation of new cells and new tissue.

These morbid changes either occur separately or are combined in various ways.

The growth of the body of pathogenic micro-organisms and the formation by them of toxic substances is a frequent inciting cause of inflammation.

We have therefore to consider first, separately: Degeneration and Necrosis; Congestion, Transudation, and Emigration; the Production of New Cells and Tissues; the Presence and Action of Micro-organisms; and secondly, the different combinations of the various phases of inflammation.

## DEGENERATION AND NECROSIS.

*Degeneration.*—This change, which is limited to the parenchyma cells of the viscera and to the nerve and muscle fibres, is always caused by the presence of some toxic substance. The poison may be an inorganic one, such as arsenic, phosphorus, or mercury; or it may be an organic one, such as is often produced in the growth of pathogenic micro-organisms.

The microbic poisons of the different infectious diseases vary as to the parts of the body which they especially affect. In all the infectious diseases the renal epithelium is especially vulnerable and seldom escapes degeneration.

The changes in the cells vary with the virulence and the quantity of the poison introduced into the body. A mild poisoning only produces an increase in the size of the cells and a change in their composition, so that they are more opaque and more coarsely granular.

This change in the cells is not necessarily attended with any evident disturbance of their functions. If the poison be withdrawn, the cells return to their normal condition.

A more severe poisoning not only causes the cells to become swollen, but they are also infiltrated with granules of albuminoid matter and of fat, and some of them disintegrate and break down.

In the more intense forms of poisoning there is a rapid death of the cells. They either disintegrate and break down, or pass into the condition of coagulation necrosis.

When the degeneration of the cells is marked and rapid there are often added congestion of the blood vessels, exudation of serum, and emigration of white blood cells.

The severe forms of degeneration cause disturbance or abolition of the functions of the cells of the viscera. Degeneration of the nerve fibres may produce motor paralysis and pain. Degeneration of the voluntary muscles may be followed by their rupture. The interference with the functions of the viscera and the paralysis may cause death. If the patients recover, the degenerated cells are replaced by new cells of the same kind.

*Necrosis.*—The ordinary causes of death of tissue are: a cutting off of the blood-supply, the direct action of caustic substances; extreme heat or cold; severe concussions, and the poisons developed in the growths of pathogenic micro-organisms.

The dead tissue is either changed into a mass of amorphous granules, or the cells pass into the condition of coagulation necrosis. The area of dead tissue may afterward shrink, be absorbed, and finally disappear; it may remain indefinitely in the condition of coagulation necrosis; it may soften, break down, and form a cavity; or it may undergo putrefaction.

Such a necrosis of tissue may occur as an isolated process without changes in the surrounding tissues. Much more frequently there are associated with it congestion and infiltration of the surrounding tissues with the serum, fibrin, and pus.

These changes around the portion of dead tissue seem to be due partly to the irritation caused by dead tissue, partly to the presence of micro-organisms. In the necrotic forms of inflammation there is often a mixed infection.

## CONGESTION, TRANSUDATION, AND EMIGRATION.

*Congestion.*—The blood vessels, especially the capillaries and veins, in any part of the body may for a shorter or longer time contain an increased quantity of blood. This part of the body is then said to be in the state of active or chronic congestion.

Either active or chronic congestion interferes with the functions of the viscera.

Active congestion is often followed by exudative inflammation.

Chronic congestion is often followed by productive inflammation.

*Transudation.*—During life in the human body there is a constant escape of the fluid constituents of the blood from the capillaries into the lymph spaces and an absorption of the fluid from the lymph spaces by the lymphatic vessels. If the equilibrium between transudation and absorption is disturbed the fluid accumulates in the lymph spaces and serous cavities. When such an accumulation of fluid occurs with inflammation it is called an exudate, when it occurs under other conditions it is called an œdema or dropsy.

*Emigration.*—The escape of the white blood cells from the capillaries and veins is usually associated with the transudation of blood serum, but may occur without it.

One cause for emigration is the presence in the tissues near the blood vessels of substances produced by bacteria which are positively chemotactic—that is, of substances which attract white blood cells toward them.

It is also found that a variety of irritating substances in the tissues are capable of causing an emigration of white cells. Apparently whenever the emigration of white blood cells is very large it is due to the presence of pathogenic bacteria, especially the streptococci and staphylococci and the pneumococci.

The white blood cells which have emigrated into the tissues may remain for a time as pus cells and afterward degenerate and be absorbed. Furthermore, these cells are capable of taking into themselves bacteria as well as other foreign bodies, and in this way they may be of use in limiting infection.

It is also to be noticed that when an extensive local emigration of white blood cells is caused by bacteria there may be at the same time an increase in the number of white cells in the blood throughout the body—leucocytosis.

## PRODUCTION OF NEW CELLS AND TISSUES.

With or without other inflammatory changes, there may be a production of new cells and a growth of new tissue. When new tissue is formed it usually follows the type of connective tissue, consisting of cells of various forms and sizes and of a more or less fibrillar basement substance.

This new tissue may be called granulation tissue, round-celled tissue, indifferent tissue, connective tissue, fibrous tissue, tubercle tissue, etc.

As a rule the more acute the process the greater the number of cells; the more chronic the process the greater the quantity of basement substance.

In an acute inflammation the production of new tissue may occur by itself, but is more frequently associated with exudation. In chronic inflammation the growth of new tissue is often not attended with congestion or exudation.

Whenever in any inflammation there is at the first a production of new tissue, that inflammation regularly goes on to assume the subacute or chronic form.

*The Relation of Micro-organisms to Inflammation* is considered in the section devoted to the Infectious Diseases.

## FORMS OR PHASES OF INFLAMMATION.

In classifying and naming the different forms of inflammation it is convenient to name them according to the most prominent of the different changes which go to make up the whole process. We distinguish:

1. *Exudative Inflammation.*
2. *Productive Inflammation.*
   (*a*) *Simple Acute Productive Inflammation.*
   (*b*) *Productive Inflammation with Exudation.*
   (*c*) *Chronic Productive Inflammation.*
3. *Necrotic Inflammation.*

1. *Exudative Inflammation.*—An exudative inflammation is one characterized by the presence of an exudate—serum, fibrin, and pus. The production of such an exudation may or may not be attended with marked changes in the inflamed tissues. The process may run an acute, a subacute, or a chronic course. The structure of the inflamed tissue, whether connective tissue, a mucous membrane, or a viscus, modifies the character of the inflammation.

The most characteristic and common of the exudations are *serum*, *fibrin*, and *pus*. In order to understand the way in which these are produced and the varied post-mortem appearances to which their presence gives rise, it is well at the outset to study some variety of exudative inflammation in actual occurrence in a living animal. The frog is the most convenient animal for this purpose.[1]

If we expose the mesentery or bladder of the frog so that we can study it under the microscope, marked inflammatory changes soon occur without other inciting agency than is furnished by the changed position and exposure to the air. At first the arteries, veins, and

[1] That essentially the same phenomena occur in the warm-blooded animals as in the frog has been shown by the studies of Thoma and others.

capillaries dilate, and the blood, encountering less resistance from the walls, flows more rapidly through them. This increased rapidity of the blood current does not, however, last long, although the vessels still remain dilated. After a variable period, owing, it is believed, to changes of the inner surface of the vessels, the blood meets with so much resistance that it now flows more slowly than under normal conditions. Temporary or even permanent stasis may occur in some of the vessels, but this is not a constant nor characteristic occurrence. White blood cells—leucocytes—now begin to accumulate along the inner walls of the veins and to become fixed there, so that after a time the whole inner surface of the veins may be more

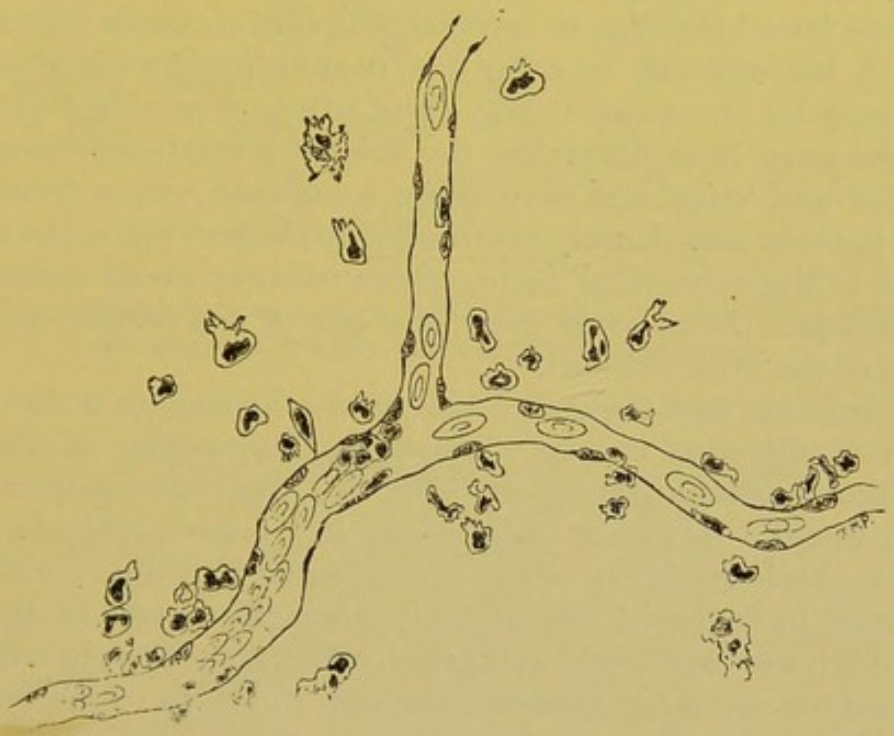

Fig. 19.—Emigration of White Blood Cells in Inflamed Bladder of Frog.

or less thickly sprinkled, and even closely crowded, with adherent leucocytes. These may either lie firmly against the endothelium or be dragged slowly along by the current of blood sweeping past them. Some are dragged by the blood current into pyriform shapes, showing that they are adherent only at a small point, and thus they may be detached from the wall and rejoin the circulating blood. In the capillaries, also, leucocytes may be seen clinging firmly to the wall.

After a time, which varies considerably—in the bladder sometimes within an hour after its exposure; in the mesentery usually much later—some of the leucocytes commence to make their way slowly through the walls of the veins and capillaries. At first a little

shining knob appears on the outside of the wall opposite to the cell which is sticking within, and this outer portion grows larger and larger as the part still within grows smaller, until at length the entire cell is outside of the vessel. The cell now may immediately detach itself and wander off in the lymph spaces, or it may remain for some time attached to the outside of the wall. This passage of the leucocytes through the walls of the capillaries and veins—it does not occur in the arteries—is called *emigration*. The emigrating cells are, largely at least, the polynuclear leucocytes (see page 82).

The cells pass between the endothelium through the cement substance, which becomes in some way changed in the inflammatory process. They may pass through very rapidly, but usually their progress is slow and often interrupted, so that cells may be seen motionless for a long time in various stages of progress through the walls. A half-minute, or even less, may suffice for their passage, or they may be hours about it. Thus, after a variable time, if the conditions have been favorable, the tissues immediately around the capillaries and veins, and even those somewhat remote from them, may be more or less densely crowded with leucocytes, some motionless and in the spheroidal form, others moving about through the lymph spaces. Leucocytes may pass out of the tissues on to free surfaces of the inflamed part.

It is probable that the emigration of the leucocytes is due in part to a sort of filtration process with which the pressure of the blood within the vessels is concerned. But the inherent contractility of the cells themselves forms, doubtless, a very important factor.

While this is going on the red blood cells, although for the most part carried in the usual way along in the axial current of the veins and through the capillaries, still usually find their way, in small, but sometimes in very large numbers, through the walls of the veins and capillaries into the surrounding tissues. They are, it is believed, carried passively through the cement substance between the endothelium by currents of fluid which under these conditions are flowing in abnormal quantities through the walls. This extravasation of the red blood cells is called *diapedesis*.

By this time it will usually be found that the tissue around the vessels is somewhat swollen and more succulent than normal, and fluid may be poured out on the free surface.

The fluid which is thus formed is called *serum*, and it is somewhat similar to simple non-inflammatory transudation, except that it contains more albumin and is mixed with cells. This serum has evidently passed out of the blood vessels along with the blood cells, and, as its composition differs somewhat from that of blood plasma, it is evident that it has undergone some sort of change as it passed

through the cement substance of the endothelium. The way in which this alteration in the composition of the blood plasma occurs

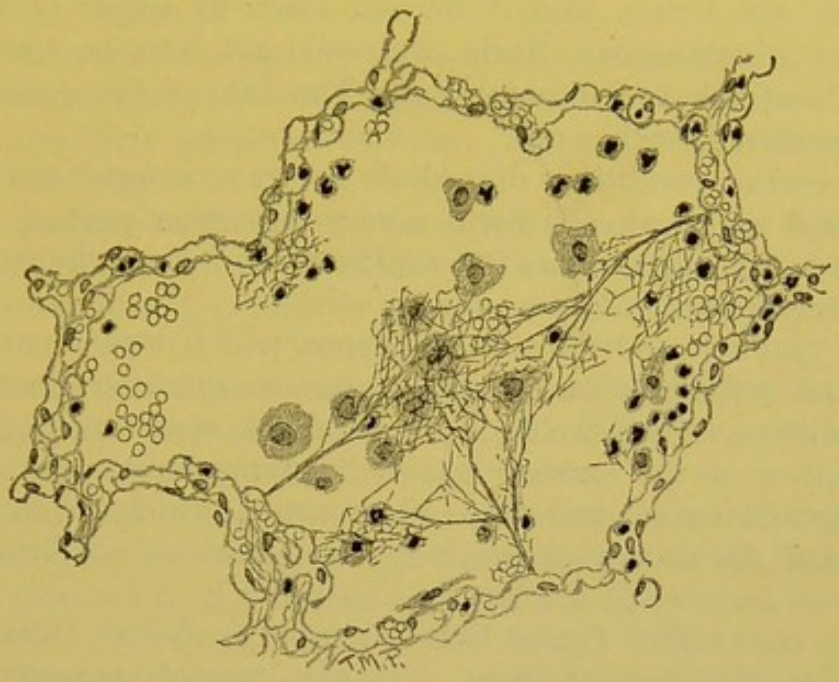

FIG. 20.—EXUDATIVE INFLAMMATION—EXUDATE IN AIR VESICLE OF THE LUNG IN LOBAR PNEUMONIA
Showing fibrin, pus ceils, red blood cells, and epithelium.



FIG. 21.—EXUDATIVE INFLAMMATION IN THE WALL OF THE APPENDIX VERMIFORMIS.
Showing extravasated leucocytes in the vicinity of the blood vessels with œdema of the surrounding connective tissue. (Specimen loaned by Dr. Ely).

as it passes through the walls of the vessels and becomes the serum of exudation, we do not understand.

The fluid exudate contains fibrinogenous substance, and from this, when the conditions are favorable, fibrin may be formed by a change similar to that which occurs in the coagulation of the blood.

Thus in the living animal we can learn by direct observation the way in which serum, fibrin, and cells get into the tissues and upon free surfaces in inflammation. The fate of these exudations will be considered further on.

Under certain conditions diapedesis occurs so extensively that the extravasated red blood cells form a very important part of the exudation, and when this occurs it constitutes the *hæmorrhagic* variety of exudative inflammation.

Under varying conditions, furthermore, which depend partly upon the seat of inflammation, partly upon its intensity, but oftener upon conditions which we do not understand, sometimes one, sometimes another of the exuded materials preponderate, and we may thus have varieties of exudative inflammation which we call *serous*, *purulent*, or *fibrinous;* or we may have various combinations of these.

It is in *connective tissue* that a simple exudative inflammation is seen in its most typical form. The structure of connective tissue is simple—a basement substance, cells, blood vessels, lymphatics, and nerves. The inflammation is attended with an increased quantity of blood in the vessels, more or less swelling of the basement substance and cells, and exudation in the natural cavities of the tissue.

The structure of the *mucous membranes* is more complex. They are all composed of a layer of epithelium, of a connective-tissue stroma containing the blood vessels, nerves, and lymphatics, and of glands which produce mucus. The inflammation not only causes congestion and exudation into the stroma, but there are also changes in the epithelium and in the glands. In the epithelium there is a more active desquamation of old cells and growth of new cells; mucus may be formed within the epithelial cells, sometimes superficial ulcers are formed. The function of the mucous glands is interfered with. At first the production of mucus is stopped, later it is increased and altered. The increased production of mucus is regularly attended with a diminution of the congestion and swelling of the mucous membrane. Such an inflammation in a mucous membrane is often called "acute catarrhal inflammation."[1]

---

[1] The term catarrhal inflammation is, however, often used differently. Thus Ziegler says that escape of fluid on the surface of a mucous or serous membrane gives the picture of a serous catarrh; if the fluid exuded on the surface of a mucous membrane is associated with marked mucoid change of the superficial epithelium and of the mucous glands it is a mucous catarrh; if the secretion is mixed with much epithelium, it is a desquamative catarrh.

The *viscera* are composed of a connective-tissue stroma containing the blood vessels, lymphatics, and nerves, and of cells. The cells are peculiar to each viscus, and are concerned in performing the functions of the viscus.

The principal changes effected by the inflammation are the congestion and consequent swelling and the inability of the visceral cells to perform their proper functions. The quantity of exudation may be small or large.

The changes in the blood vessels and tissues which belong to exudative inflammation are produced by a variety of causes, and these causes seem to act primarily either on the tissues or on the blood vessels.

Heat and cold seem to act directly on the blood vessels, producing first congestion and then exudation. Chemical irritants act first on the tissues and through these on the vessels.

The different inorganic poisons and the toxins of bacteria may circulate in the blood and irritate the vessels from the inside, or they may be situated in the tissues and irritate the vessels from the outside.

The character of the exudation, whether serum, fibrin, or pus, corresponds to the character of the irritant which causes the inflammation. Thus we find that the toxin of cholera causes large exudations of serum, that of pneumonia a large production of fibrin, that of cerebro-spinal meningitis a considerable emigration of white blood cells.

We have now to consider what becomes of these exudations and of the degenerated and proliferated cells. *Mucus* usually passes off on the surface with other exuded materials, but may collect in considerable quantities in the cells in which it is formed or in the acini and ducts of the mucous glands. The extravasated *red blood cells* lose their hæmoglobin, which decomposes and may be absorbed or deposited as granules or crystals in the tissues, while the cells themselves disintegrate and are absorbed. The *serum* may pass off on free exposed surfaces, or in a short time be taken again into the circulation by means of the lymph channels; or it may accumulate in serous cavities, where it may remain for a long time, mingled with other exudations. The *fibrin* may form in such dense masses in the interstices of the tissues as to interfere with their nutrition, and thus circumscribed portions of tissue may die and be absorbed or thrown off as sloughs with their contained fibrin. Fibrin may disintegrate and be finally entirely absorbed, it may be thrown off on exposed surfaces, or it may be gradually replaced by a new-formed vascular organized membrane or mass of tissue, the absorption of the fibrin going on hand-in-hand with the formation of the new tissue.

The fate of the *leucocytes* varies greatly and is in many respects still obscure. A certain number of them, after leaving the blood vessels, wander through the tissues, and, entering the larger lymph vessels, again join the circulating blood. Others, there is reason to believe, undergo proliferation and thus add to the number of the

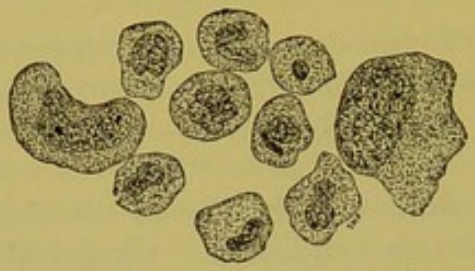

FIG. 22.—PUS CELLS FROM CATARRHAL INFLAMMATION OF BRONCHIAL MUCOUS MEMBRANE.

infiltrating cells. Still other leucocytes die, either in the interstices of the tissues or after passing off on free surfaces; they may then disintegrate and be absorbed, or they may collect in masses with

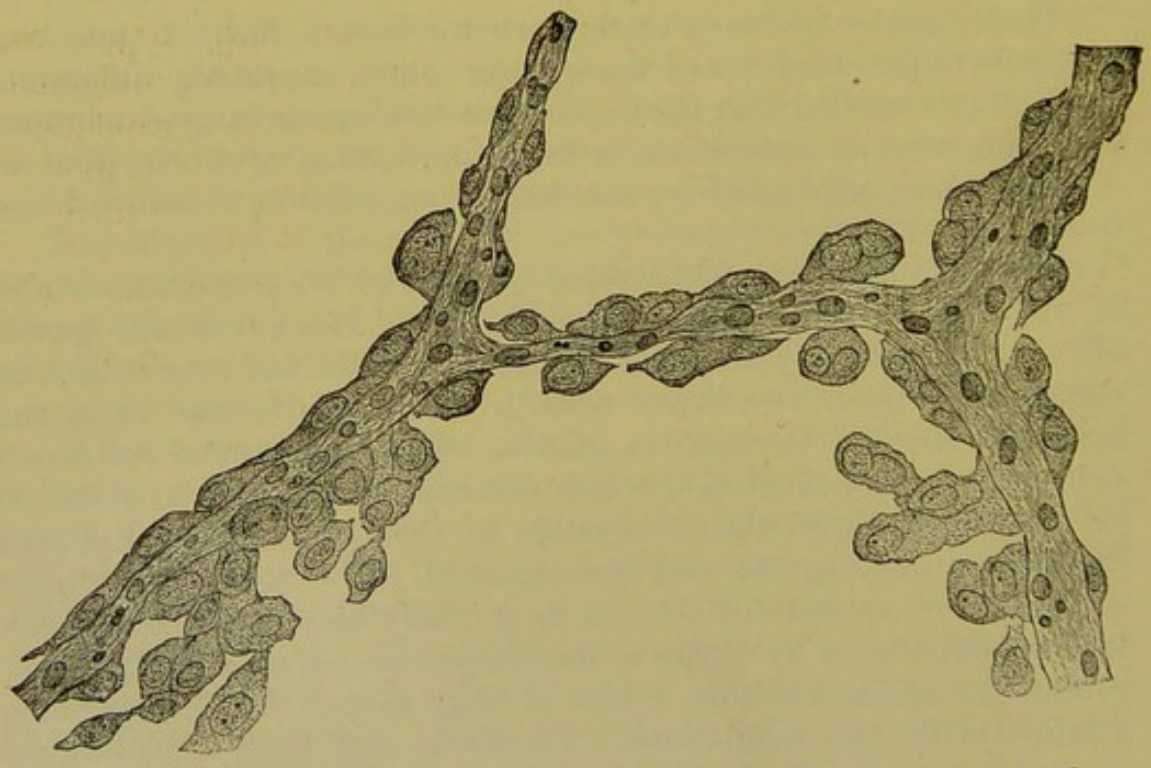

FIG. 23.—OMENTUM OF DOG, SHOWING PERITONITIS ON FOURTH DAY, × 500 and reduced.

other exudations in internal cavities, or they may collect in circumscribed masses in the interstices of the tissues, and, in connection with other cells and more or less fluid and broken-down tissue, form abscesses.

The term *pus* is rather loosely and indiscriminately applied to the

new cells which we find in the tissues in exudative inflammation, when these are not actually concerned in the formation of new tissue. It would be better to speak of these new cells, whose morphological characters give us no clue to their destinies, as *indifferent cells*, and limit the term pus cells to those cells, mostly polynuclear leucocytes, which, produced in inflammation, have evidently died in or about the tissue, and which we call, in the surgical sense, pus.

Since the great majority of new cells seen in acute exudative inflammation are in fact extravasated leucocytes or their progeny, the appearances of the ordinary pus cells are essentially the same as those of the leucocytes, except that they may exhibit degenerative changes. Thus they may present various degrees of fatty degeneration and disintegration, and the nucleus is frequently broken into fragments, thus simulating the commencement of proliferative changes.

In exudative inflammation of the serous and mucous membranes we often find, in addition to the ordinary pus cells, larger and variously shaped cells, which are detached epithelial or endothelial cells (Figs. 22 and 23) or the result of their proliferation. These, although usually present in relatively small numbers, must still be considered pus cells in accordance with the views above laid down. Moreover, we must remember that the fixed connective-tissue cells, as well as endothelium and epithelium, may give rise by proliferation to cells which resemble mononuclear leucocytes.

2. *Productive Inflammation.*—(*a*) Simple acute productive inflammation. In this form there is no exudation, no serum, fibrin, or pus. Congestion is sometimes, but by no means always, visible after death. The inflammatory product consists of new cells formed from the old connective-tissue cells. The pia matter and the peritoneum offer the best examples of this form of inflammation.

(*b*) Productive inflammation with exudation. In this form of inflammation the changes in the blood vessels, the exudation and emigration, the formation of serum, fibrin, and pus are well marked, but in addition there is from the first a growth of new tissue. This new tissue at first consists principally of cells, later a basement substance and blood vessels are added. This form of inflammation has a marked disposition to continue for a long time in a subacute or chronic form.

In connective tissue the serum, fibrin, and pus are found in varying quantities. The new tissue forms thickenings and adhesions.

In the mucous membranes the inflammation involves the stroma, and it is in the stroma that the exudation is infiltrated and the new tissue formed. The glandular coat may remain unchanged, or be the seat of catarrhal inflammation.

In the viscera the quantity of the inflammatory product varies.

The new tissue is formed in the stroma. The visceral cells undergo more or less atrophy or degeneration.

The recognition of this form of inflammation with its combination of exudation from the vessels and growth of new tissue is a matter of great clinical importance. It is a matter of ordinary observation that while some inflammations of the lungs, of the kidneys, and of the colon run an acute course and terminate in recovery or death at the end of a few days, on the other hand, apparently similar inflammation of these organs may be protracted for weeks or months. A study of these inflammations in all their different stages shows that the key to the problem is the presence or absence of the growth of new tissue. The simple exudative inflammations are transitory in their character, and after they have subsided—if loss of substance have not occurred—the tissues may go back to their normal condition. But in a productive inflammation with both exudation and a new growth of tissue, while the exudation may stop and the exudate be absorbed, the new tissue is permanent and by its presence keeps up the disposition to long-continued inflammatory changes.

(*c*) In chronic productive inflammation the inflammatory product is round-celled tissue, granulation tissue, or connective tissue. In some cases this is the only change; in others there is added an exudation from the blood vessels, or degeneration of cells. The new tissue that is formed may degenerate or become calcified.

*In connective tissue* this form of inflammation produces thickenings and adhesions, and serum in the serous cavities.

*In mucous membranes* the growth of new tissue is in the stroma. This is thickened, either diffusely or in the form of polypoid growths. The layer of epithelium may be thickened or thinned. The mucous glands are atrophied or hypertrophied, or become cystic. The production of mucus is diminished, or increased, or altered. This condition in the mucous membranes is commonly called a "chronic catarrhal" inflammation.

*In the viscera* there is a growth of indifferent tissue, or of connective tissue, in the stroma. The visceral cells are compressed, or degenerated, or fatty, or disappear. The functions of the viscus are seriously interfered with. In the viscera this is often called an "interstitial" inflammation.

The most marked features of this form of inflammation are its slow course and its tendency to continue. The lesions of chronic productive inflammation, especially in old persons, are by some believed to be due to chronic degeneration.

These chronic productive inflammations constitute a large proportion of the diseases which the physician is called upon to treat.

Some of them follow an acute or subacute productive inflammation, many are chronic from the outset.

Such inflammations may be caused by repeated irritations, such as we see in the lungs from the inhalations of coal and dust. They may be caused by the presence and growth of bacteria, as in some forms of tubercular inflammations. They may follow the long-continued action of the poisons of syphilis, gout, rheumatism, and alcohol. They are often influenced by the mode of life and environment.

3. *Necrotic Inflammation.*—In this form of inflammation, in addition to the congestion, exudation, and growth of new tissue there is added death of parts of the tissues in which the inflammation exists. This character of the inflammation is given to it by the presence and growth of pathogenic bacteria. Among the bacteria frequently present may be mentioned the Staphylococcus pyogenes aureus and albus, the Streptococcus pyogenes, the bacilli of diphtheria, of typhoid fever, and of tuberculosis. The amœba coli is also a cause of necrosis.

There is a good deal of variety as to the way in which the necrosis and the other phenomena of inflammation are associated. There may be necrosis and very little else, as in gangrene of the lung and in some of the abscesses of the liver. There may be necrosis with a large production of pus, as in ordinary abscesses. There may be necrosis with a large production of fibrin, as in the croupous inflammations of the mucous membranes. There may be necrosis with a growth of new tissue, as in tuberculous inflammation of the lungs and in some of the forms of colitis. There seems in many of these cases to be a double infection: one form of micro-organisms producing the necrosis, and another the exudation, or growth of new tissue.

When necrotic inflammation occurs in connective tissue, it is apt to produce abscesses. A circumscribed portion of tissue is congested, infiltrated with serum, fibrin, and pus, and parts of the tissue die. The dead tissue softens, breaks down, and cavities are formed which contain serum, pus-cells, and portions of dead tissue.

In mucous membranes there are congestion, exudation of serum rich in fibrino-plastic substances, emigration of white blood cells, and necrosis of tissue.

The fibrin infiltrates the stroma, and coagulates on the surfaces of the mucous membranes so as to form false membranes. The pus cells are entangled in the fibrin. The necrosis involves only the epithelium, which passes into the condition of coagulation necrosis, and forms part of the false membranes; or it involves also the stroma. The death of the epithelium forms superficial erosions, that of the stroma ulcers of varying size and depth.

Such an inflammation of the mucous membranes is called "croup-

ous" or "diphtheritic." We also find with catarrhal and productive inflammations circumscribed necrosis of the epithelium.

In the viscera we find congestion, exudation of albuminous serum, and emigration of white blood cells. In addition there may be degeneration or death of the visceral cells; or death of portions of the stroma with groups of cells, and the formation of abscesses.

The micro-organisms which produce necrosis also form poisons which permeate the entire body. So we find that persons suffering from this form of inflammation have a rise of temperature and other evidences of general poisoning.

### REPARATIVE PRODUCTION OF NEW TISSUE.

In many cases of exudative inflammation, after the subsidence of the active changes in the blood vessels, the exudations are entirely absorbed and the tissue returns to its normal condition; this we call *resolution.* Under certain conditions, on the other hand—for example, in the case of a wound with loss of substance, or in an acute exudative inflammation of a serous membrane where the surface is deprived of its normal endothelial covering, or in the healing of an abscess—new tissues may be formed through the agency of the new cells produced in the inflammatory process.

Such inflammation with the formation of new tissue is sometimes called *reparative inflammation,* and the new tissue may be conservative and of value to the organism, as when it fills up a wound; or it may be very detrimental when tissues are formed where they do not belong.

*Healing of Wounds.*—The way in which new inflammatory tissues are formed may be best understood by following the process of healing in a wound with loss of substance—say, for example, a wound through the skin into the tissues beneath. At first there may be hæmorrhage. After this has ceased, the injury to the tissue, the unusual exposure of deep-seated parts, the presence of foreign substances, etc., may induce the same series of events which we have seen occurring in exudative inflammation with production of serum, fibrin, and pus. The blood vessels dilate, the circulation becomes slower, serum transudes, and emigration sets in. Certain of the cells and fragments of intercellular substance near the seat of injury may die and in time are cast off or absorbed, the tissue becomes soaked and swollen by the transuded serum, and the connective-tissue cells in the vicinity may undergo proliferative or degenerative changes.

After a variable time, usually on the second or third day if all goes well, the surfaces of the wound may be more or less covered with tiny red nodules called granulations. These granulations con-

tain numerous thin-walled blood vessels which have sprouted out from the old vessels near the seat of injury, and around these a new loose, succulent tissue is formed, largely, if not wholly, it is believed, from proliferation of connective-tissue cells. On the surfaces of the granulations are usually a greater or less number of pus cells.

In the formation of new blood vessels in granulation tissue there are at first delicate sprouts of solid protoplasm, from the cells of the wall of the original vessels of the part or from those which have been newly formed, reaching out among the exudation cells. These sprouts may extend for long distances and may form anastomoses with similar sprouts from the same or other vessels (Fig. 24). They consist at first of solid protoplasm, and become gradually channelled out by the pressure of the blood in the vessels from which they spring; the blood finally entering them and forcing its way along

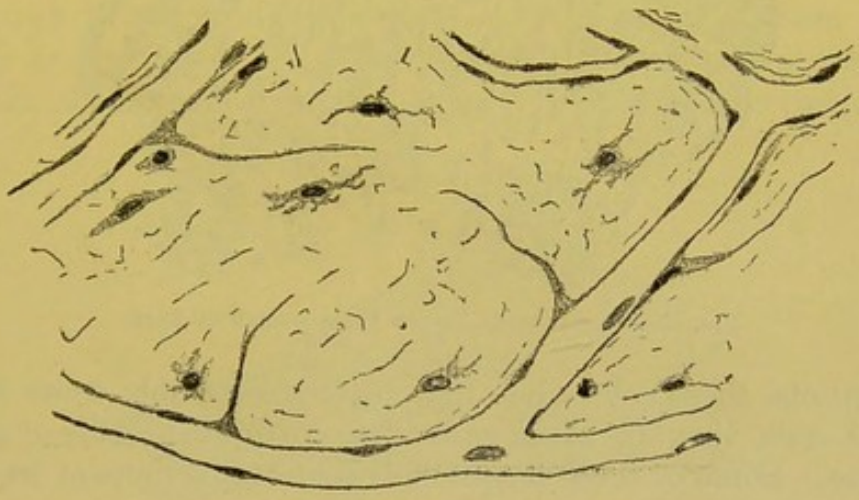

Fig. 24.—Developing Blood Vessels in New-formed Tissue.

them, producing a lumen as it goes. Before this channelling of the lumen, and hand-in-hand with its progress, new nuclei are formed in the protoplasm and the new-formed walls gradually assume a distinctly cellular character. At length they have well-defined endothelial walls, cells from without range themselves along outside of them, and they take their place in the vascular system of the new tissue. Thus, in a very short time, multitudes of new blood vessels may form, furnishing nutritive centres around which the organization of tissue proceeds.

The cells of the granulation tissue are at first mostly small and spheroidal, and are usually packed pretty closely together with only a small amount of fluid intercellular substance. Presently some of the cells become larger, elongated, fusiform, or branched, and after a while a delicate, fibrillar intercellular substance makes its appearance about them and grows more and more abundant (Fig. 25).

These larger, variously shaped cells, which appear to be formed out of the small spheroidal or indifferent cells of the granulation tissue, are usually granular, and the nucleus is usually large and distinct, frequently exhibiting a well-marked intranuclear network. Since, in

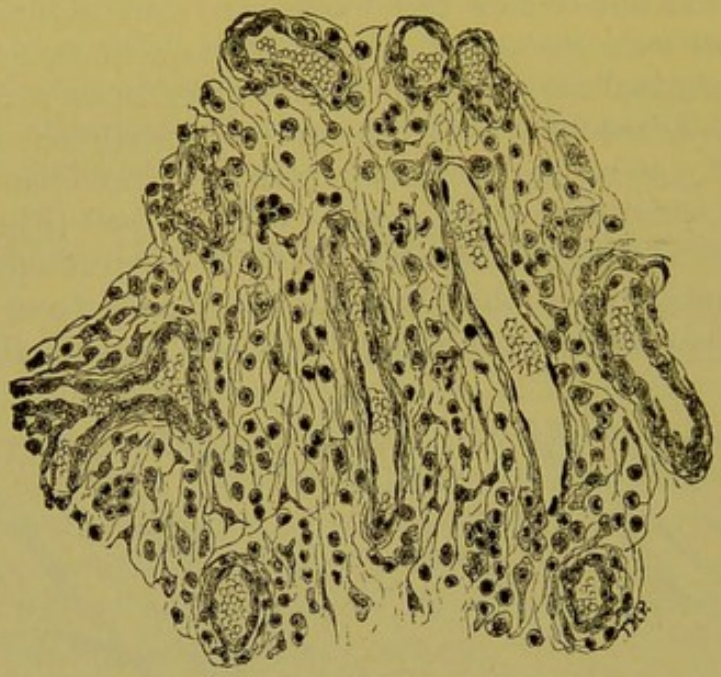

FIG. 25.—GRANULATION TISSUE FROM WOUND OF SKIN.

some respects, these cells when first formed resemble some kinds of epithelial cells, they are often called the *epithelioid* cells of granulation tissue. Some of these larger cells seem to be more or less direct-



FIG. 26.—FIBROBLASTS FROM GRANULATION TISSUE.

ly concerned in the formation of intercellular fibres. These appear to develop either as filamentous branches of the cells or to be formed along their sides. Such fibre-forming cells are called *fibroblasts* (Fig. 26).

All this time new small spheroidal indifferent cells are gathering, by proliferation or by continued emigration. Some of these seem to participate in the formation of the granulation tissue, while others, not finding conditions suitable for their further development, or even for their continued existence, die and pass off on the surface, together with some transuded fluid, as pus. The new tissue gradually becomes more and more dense, the intercellular substance more abundant, while the cells decrease in number and become flatter and less conspicuous. The epithelium may now grow over from the sides and cover the new tissue. The new tissue, having at last undergone more or less shrinkage, consists of a dense, firm mass composed largely of fibrillar basement substance with a few flattened cells (Fig. 27); and with this, which is the *cicatrix*, the healing is complete.

Although in the production of new tissue in connection with or following exudative inflammation essentially the same processes are involved in all cases, there are yet very marked differences in the

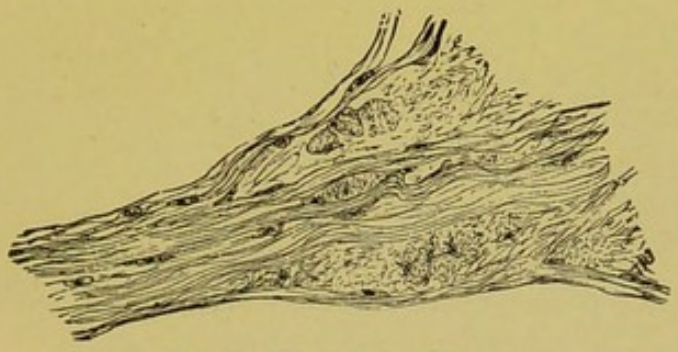

Fig. 27.—Cicatricial Tissue.

degree in which the different factors share. Thus the vascular and exudative phenomena may predominate and very large quantities of serum, fibrin, or pus be formed, while the amount of new-formed tissue may be very insignificant. In other cases the formation of new tissue is the dominant feature in the process, and the production of exudations seems to be almost entirely subordinated to this end.

The distinction between healing by the first and second intention, which is of practical importance in surgery, is, from the pathological standpoint, only a quantitative one. For the restitution of the parts to the healthy condition is in both cases brought about by exudation, and proliferation of cells under the influence of vascular changes ; but in one case the latter changes are very slight, in the other more or less extensive.

A good deal of variation is frequently seen in the formation of granulation tissue in the healing of wounds, as well as under other conditions. Thus sometimes the body cells respond but imperfectly

to the inflammatory stimuli, and neither cell proliferation nor blood-vessel growth is active. On the other hand, the development of blood vessels may be excessive, other tissue formation lagging behind. Under these conditions loops and tangles of thin-walled, contorted new vessels may project from the granulating surface, while useful tissue formation remains in abeyance (Fig. 28). The result of this disproportionate growth of ill-formed blood vessels is the exuberant granulations which the surgeon frequently removes from unhealthy healing surfaces.

Cavities formed by abscesses or by necrosis in any part of the body may be filled up and their sides drawn together in a cicatrix by the formation of a provisional mass of granulation tissue similar in character to that which grows in external wounds. So, similarly, cysts may be obliterated and ulcers partially filled and drawn into

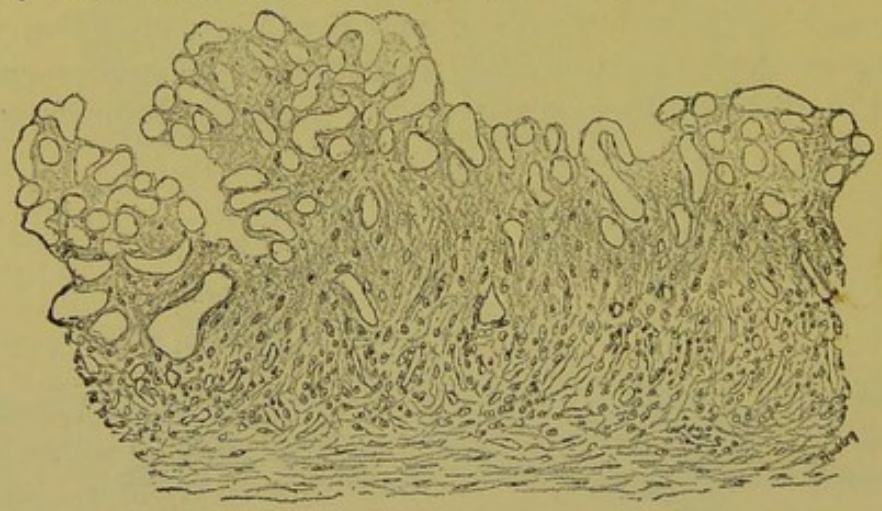

FIG. 28.—EXUBERANT GRANULATIONS.
From the inner surface of a granulating ovarian cyst containing pus.

cicatricial healing. Large free surfaces, like the pleura and the peritoneum, may, through the intervention of granulation tissue, pass from the denuded condition of an active exudative inflammation, either with or without adhesions, into a condition which, though by no means a return to the normal, we yet designate as cure.

The so-called organization of a thrombus in a blood vessel is brought about by processes practically identical with those which have just been described in the formation of new tissue in reparative inflammation. The endothelial cells of the vessels and the connective-tissue cells in their walls proliferate, new blood vessels develop by sprouts from the already existing smaller vessels in their walls or close about them. The new cells and new blood vessels thus derived gradually penetrate the clot (see Fig. 73), forming new connective tissue, which replaces step by step the fibrin and blood which are gradually absorbed or removed by phagocytes.

The part which the thrombus plays in its so-called organization is thus a wholly passive one. It acts only as a temporary supporting texture for the development of the new tissue derived from other sources which step by step replaces it.

Some phases of the formation of fibrous tissue—such for example as are seen in the spinal cord after secondary degenerations in nerve tracts, and such as are presented by interstitial connective-tissue growth with atrophy of the parenchyma, in the kidney, liver, heart muscle, etc.—are commonly believed to be of inflammatory origin; but they are, on the other hand, regarded by many as fibrous hyper-

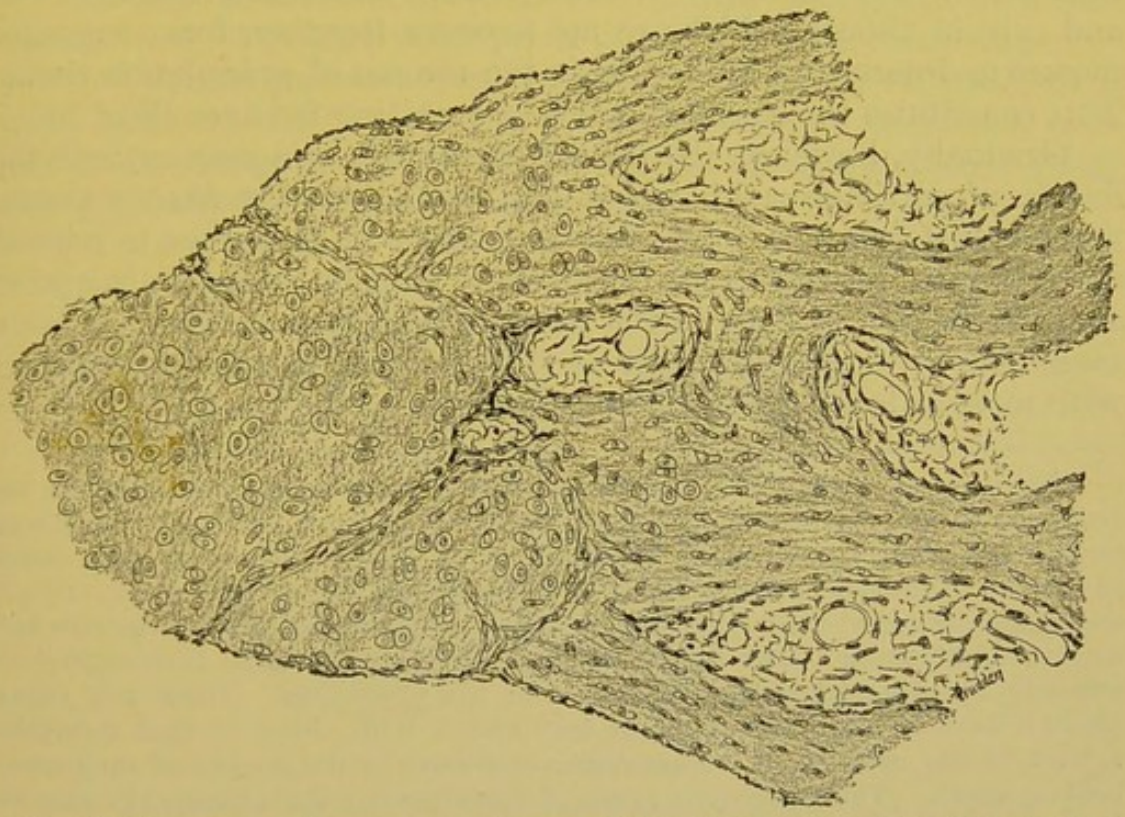

Fig. 29.—New-formed Cartilage and Osteoid Tissue from Callus after Fracture of the Femur.

plasiæ secondary to parenchymatous atrophy and from this point of view may be called *replacement fibrous hyperplasiæ*. The relationship between a chronic productive inflammation and simple fibrous hyperplasia, or as it is often called simple fibrosis, is still obscure, and while the result—a formation of new connective tissue associated with atrophy of the parenchyma in important viscera—is of great frequency and serious import, the determining factors in the change are not evident.

*Healing of Bone Fractures.*—The process of healing in bone after fracture is, when uncomplicated, at first similar to that in ordinary healing by second intention in fibrous tissue. The blood

and other exudates and the tissue detritus are gradually absorbed or disposed of by phagocytes.[1] By a proliferation of connective-tissue cells of the region a larger or smaller mass of granulation tissue is formed. This granulation tissue does not at first differ in appearance from similar tissue formed elsewhere in the body in the reparative phase of exudative inflammation.

But soon, under the influence of the specially endowed cells of cartilage or bone or periosteum, but especially of the latter, the granulation tissue becomes partially replaced either by cartilage, or by a substance resembling bone in general appearance, but containing no lime salts. This is called *osteoid* tissue. These new cartilaginous and osteoid tissues, which are apt to occur together, form irregular masses or interlacing trabeculæ in the stroma of granulation tissue. This constitutes the so-called callus of a uniting fracture (Fig. 29).

Gradually, however, the osteoid tissue becomes osseous, and the masses of cartilage and bands of periosteal and other fibrous tissue, under transformations practically identical with those seen in normal development, are converted into bone. Thus by gradual absorption and reformation of bone in the usually redundant provisional bony mass, and by the readjustment of its vascular channels, the healing, with more or less permanent deformity, is accomplished.[2]

---

[1] The disposal of small foreign particles which in one way or another get into the body, and the removal of dead and useless fragments of tissue which may be present as the result of injury or disease, are cared for by larger and smaller cells, called *phagocytes*. The cells having this matter in charge are largely leucocytes, and all are apparently mesodermal lowly organized cells. Some of them are large cells and may be multinuclear. The disposal of dead or foreign material is accomplished primarily by being taken into the bodies of the phagocytes. These may either retain it more or less permanently, or may absorb it in virtue of their metabolic powers, or may carry it off to some region of deposit by the exercise of their amœboid capacities. This phagocytic action of mesodermal cells is believed to have an important bearing upon immunity from, and cure of, bacterial disease (see page 178).

[2] For a more detailed consideration of the themes treated in this and the three preceding chapters, comprising an important section in general pathology, the reader may consult *Thoma's* "Text-book of General Pathology," English translation by *Bruce*.

# PARASITES.

The scope of this work permits us to do little more than enumerate and give a very brief description of some of the more important forms of animal parasites found in man. Among the vegetable parasites, however, the bacteria have assumed such an important place in our knowledge of the etiology of certain diseases that they justly claim a somewhat extended consideration.

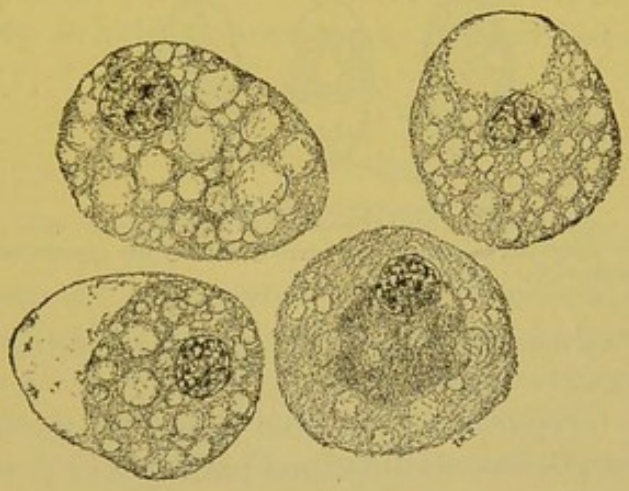

FIG. 30.—AMŒBA COLI.

From the intestinal wall near an ulcer. Drawn from a specimen prepared by Prof. W. T. Councilman.

## ANIMAL PARASITES.

### PROTOZOA.[1]

*Rhizopoda.*—In this group the Amœba coli (Amœba dysenterica, Councilman and Lafleur) is, so far as our knowledge goes, of the greatest pathological significance.

It has been repeatedly found in acute and chronic dysentery, in the intestinal contents, at the bottom of the intestinal ulcers, and in

[1] For a résumé of our present knowledge of the parasitic protozoa consult *Mannaberg*, "Ergebnisse der allg. Ætiologie der Menschlichen und Thierkrankheiten," 1896, p. 916.

the secondary abscesses, especially of liver, which may accompany ulcerative colitis. The amœba is believed to be the cause of both the primary ulcerative colitis and its complicating abscesses (see page 569).

The Amœba coli (Fig. 30) is a single spheroidal cell, from five to eight times the diameter of a red blood cell, with granular protoplasm and a vesicular nucleus. It often contains larger and smaller vacuoles. Frequently, especially when the amœba is active, a portion of the protoplasm appears almost homogeneous—ectosarc—while the rest—endosarc—is granular. When in action, in virtue of the amœboid movement, it may assume various forms, thrusting out and withdrawing nearly homogeneous pseudopodia. It may also change its shape without progressive movement. It occurs in connection with acute and chronic dysentery, frequently in Egypt, occasionally in Russia, and is often seen in the United States.[1]

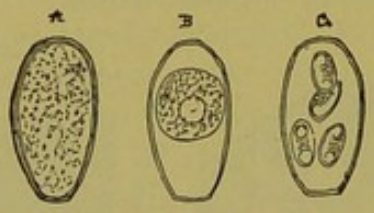

FIG. 31.—COCCIDIUM OVIFORME.

From liver of rabbit. Showing phases in the development of the psorospermiæ, which are seen separate within the capsule in C. After Braun.

Other species of amœba have been found parasitic in the human intestines.

*Sporozoa, or Gregarinæ.*—In this group of the Protozoa some forms of *coccidia* possess well-defined pathogenic powers. The so-called *psorospermiæ*—minute oval structures about 0.035 mm. long, with a thick capsule and coarsely granular contents—which are of very frequent occurrence in the liver of the rabbit, forming a part of the contents of yellowish, irregular-shaped cysts, have been found in the liver, in a pleuritic exudate, and in the kidney, ureter, and heart muscle in man. The organism is more properly called *Coccidium oviforme* (Fig. 31), while the spores which it forms are termed psorospermiæ.

Another, smaller form, occurring in the intestinal epithelium of dogs, cats, and rabbits, has been found in two cases in a similar situation in man.

Organisms apparently belonging in the group of Sporozoa have

[1] We refer for further details concerning the Amœba coli to the work of *Councilman and Lafleur* on "Amœbic Dysentery," Johns Hopkins Hospital Reports, vol. ii., Nos. 7, 8, 9, 1891.

been found in certain contagious epithelial growths—Molluscum contagiosum.

It is believed by many that Paget's disease and other somewhat similar skin affections are due to the presence of coccidia.[1] The

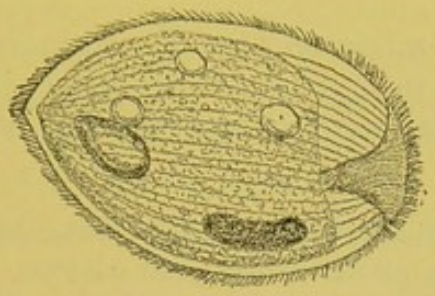

FIG. 32.—BALANTIDIUM COLI. After Braun.

claim that some of the carcinomata may be caused by Sporozoa has not as yet been sustained (see page 292).

The *Plasmodium malariæ*, which is believed to be the primary etiological factor in intermittent fever, is described elsewhere.

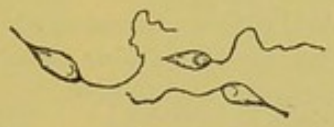

FIG. 33.—CERCOMONAS INTESTINALIS. After Braun.

The *Infusoria* are represented in man by several genera.

*Balantidium coli* is an ovoidal organism, from 0.06 to 0.1 mm. long, with cilia along the sides, which occurs occasionally in diarrhœal discharges in northern Europe (Fig. 32).

*Cercomonas intestinalis* is a pear-shaped, flagellate structure

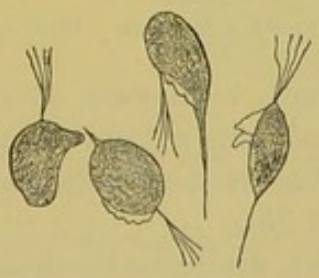

FIG. 34.—TRICHOMONAS VAGINALIS. After Dock.

(Fig. 33), about 0.012 mm. long, making, when alive, rapid movements. It has been found in the evacuations of persons suffering from cholera, typhoid fever, and diarrhœa.

*Trichomonas vaginalis* has a oval or pear-shaped body from 0.015 to 0.025 mm. long, with a cluster of flagella at one end and

[1] Consult *Stroebe*, Central. f. allg. Path. und Path. Anat., Bd. v., pp. 63, 67, 1894.

an undulating membrane, frequently mistaken for cilia, upon the side (Fig. 34). It is of occasional occurrence in vaginal exudates.

Trichomonas has been found in the urine of men, in the intestines, and in the sputum. Its pathogenic power is not yet definitely determined.[1]

The possibility of mistaking the T. vaginalis for human spermatozoa should be borne in mind in medico-legal examinations, although to an observer familiar with either structure such a mistake could hardly occur.

The protozoa may be studied in the living condition either in the fluids in which they are found or in three-quarter-per-cent salt solution. They may be killed and preserved by allowing a drop of one-per-cent osmic acid to run under the cover glass, and replacing this after an hour by glycerin lightly tinged with eosin. Or they may be killed and preserved in sublimate solution.

Many of the smaller forms show well when dried on the cover glass and stained by the anilin dyes by the methods used for bacteria (see page 154).

The movements of the Amœba coli may be studied on the warm stage in the fæces or in the contents of abscesses which frequently contain them in enormous numbers, in three-quarter-per-cent salt solution. Its morphology may be studied in tissue containing them, such as intestinal ulcers, abscesses, etc., which have been hardened in alcohol and stained either with methylen blue or hæmatoxylin, the former being especially commended by Councilman and Lafleur.

## WORMS.

TREMATODA (Flukes).—These worms are small, flat, tongue-shaped or leaf-like creatures, with an intestine, and discoidal struc-



FIG. 35.—DISTOMA HEPATICUM. About natural size.

tures on the under surface, by means of which they attach themselves. There are several genera and species found in man. The most common genus is *Distoma*. Of these *D. hepaticum* is of most frequent occurrence (Fig. 35).

It is about 30 mm. long, and usually occurs in the gall ducts and gall bladder. The embryos are attached generally to water plants, from eating which the infection is believed to occur. *D. lanceolatum* is more slender, pointed at the ends, 8 to 10 mm. long, and has been found a few times in the gall bladder. *D. sinense* is a slender worm about 15 mm. long, and has been found in the bile in considerable numbers, particularly in the Chinese. *D. hæmatobium* is a

[1] For important original observations on Trichomonas with an historical summary and literature see *Dock*, "Trichomonas as a Parasite of Man." The American Journal of the Medical Sciences, vol. cxi., p. 1, 1896.

more nearly cylindrical worm; the sexes are distinct; the male from 12 to 14 mm. long, the female 16 to 18 mm. long, and occurs, especially in Egyptians, in the portal and other abdominal veins.

CESTODA (Tape Worms).—These important worms consist, in the mature state, of more or less rectangular or elongated segments, each one of which represents a single individual, arranged in a linear series to form a colony, at one end of which, called the head, is a variously formed structure for the attachment of the colony to its host. The neck and head are called the *scolex*, while the segments are called *proglottides*. These worms have neither mouth nor alimentary canal. They are hermaphrodites, the sexes being united

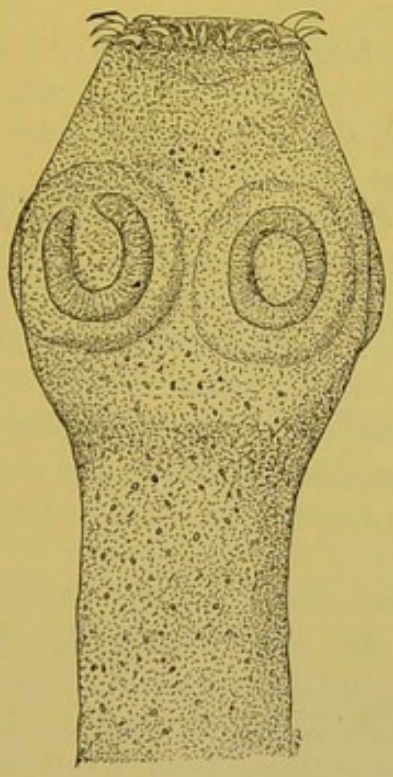

FIG. 36.

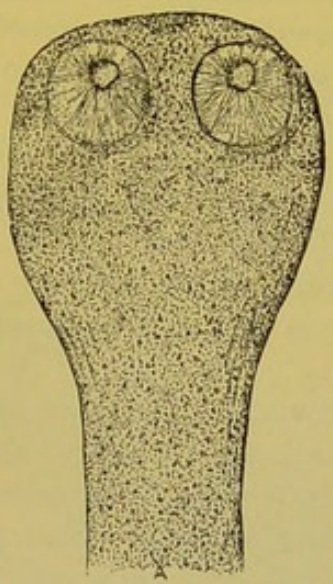

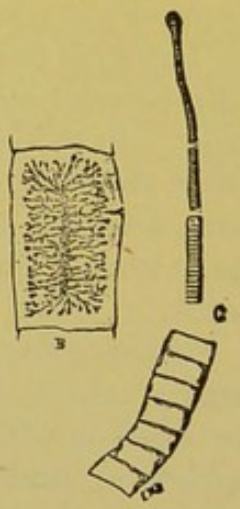

FIG. 37.

FIG. 36.—HEAD OF TÆNIA SOLIUM, × about 40.

FIG. 37.—HEAD AND PROGLOTTIDES OF TÆNIA MEDIOCANELLATA.

A, head, × about 15.

B, mature proglottid, showing generative apparatus.

C, head and fragments of immature proglottides, showing gradual tapering of the neck. Natural size.

in the proglottides. The head and neck (scolex) may exist as an immature form in various tissues and organs where they are encysted, and are often called cysticercus.

*Tænia solium* is of frequent occurrence in man. It may be several metres in length, and may be coiled up or stretched out in the small intestines. Several worms may be in the gut at one time. The head, about the size of a pin's head (Fig. 36), has a projecting

proboscis or rostellum, around which are arranged a double row of horny hooklets. Below these are four sucking discs at the sides of the head. The hooklets of the anterior row are larger than those in the posterior row, and are from 0.16 to 0.18 mm. long. The proglottides, when fully developed, are from 10 to 12 mm. long and from 5 to 6 mm. wide, but those nearest the head are much shorter and immature. The eggs of T. solium are ovoidal structures, about 0.03 mm. in diameter. The embryo of this worm is most commonly seen in the muscles of the pig as an encysted scolex, commonly called a "measle." It occasionally occurs in man in the muscles, brain, eye, etc., and is called *cysticercus cellulosæ*. It is usually about the size of a pea, but may be as large as a pigeon's egg and surrounded by a connective-tissue capsule.

Infection with the worm occurs in the human subject from the ingestion of insufficiently cooked "measly" pork, or, in the case of cysticercus cellulosæ, from the ingestion of the eggs, which may, in a variety of ways in uncleanly persons, get into the food.

*Tænia mediocanellata* (*T. saginata* LEUCKART).—The head of this species is somewhat cuboidal, without either rostellum or hooklets, but with four sucking discs (Fig. 37). The segments are generally broader and shorter than in T. solium, and the worm is usually larger. In the embryonal form the scolex occurs as the *Cysticercus tæniæ mediocanellatæ* in the form of small cysts in the muscles of cattle, from the eating of which in the uncooked condition the infection occurs. This is the most common tapeworm in the United States.

*Tænia echinococcus.*—This worm in the mature condition forms a short, small colony inhabiting the intestine of the dog. The head is about 0.3 mm. in diameter and has a double row of hooklets around the rostellum. The proglottides are three or four in number, the last being the larger. The entire colony is not more than 4 to 5 mm. in length. The significance of this parasite in human pathology depends upon the cysts, called hydatids, which it forms, in the immature or cysticercus stage, in various parts of the body. Intimate association with dogs favors the acquirement of this parasite. When the eggs of the mature worm get into the intestinal canal of man they undergo partial development and find their way into the tissues and organs, most frequently into the liver. Here cysts are formed which become encapsulated by a connective-tissue membrane produced by the inflammatory reaction of the organ.

The cyst wall of the parasite is formed of two layers—an outer, finely lamellated layer called the *cuticula* (Fig. 38), and an inner, granular layer, containing muscle fibres and blood vessels, called the *parenchymatous layer*. Inside of the primary cyst secondary cysts

sometimes form, called *daughter cysts*, and within the latter tertiary cysts, called *granddaughter cysts*, may develop. On the inner surface of the cysts, either primary, secondary, or tertiary, the scolices or heads of the immature worm are formed. These develop in the walls of the pediculated vesicles called *brood capsules*. The walls of these vesicles have a lamellated cuticula and a parenchymatous layer similar to those of the primary cysts. The scolices, of which

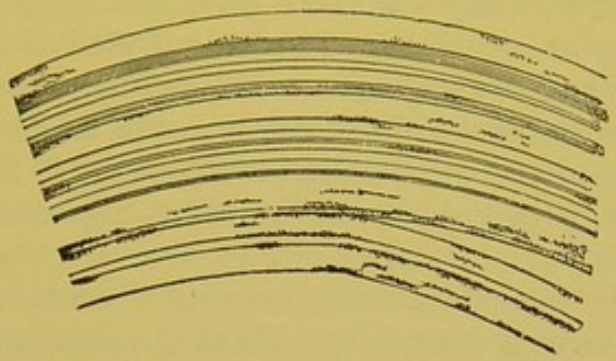

FIG. 38.—CUTICULA OF ECHINOCOCCUS CYST.
Showing lamellated structure.

there may be several in each brood capsule, are similar to the heads of the mature tapeworm. They are about 0.3 mm. in diameter, having a rostellum surrounded by a double row of hooklets and four sucking discs. At the posterior end of the scolex is a pedicle by which

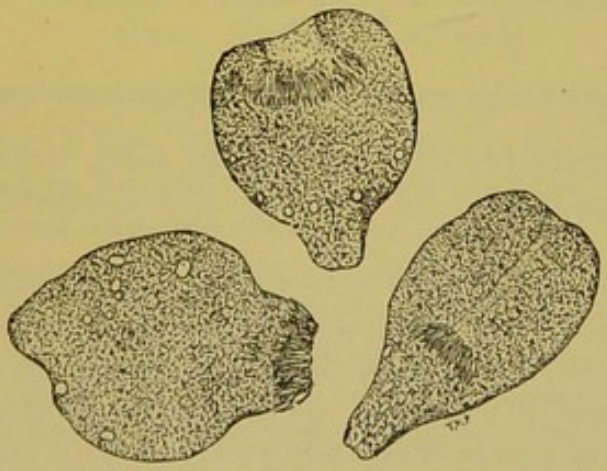

FIG. 39.—SCOLICES OF TÆNIA ECHINOCOCCUS, × 60.
In one the rostellum is projected, in the others it is withdrawn.

it is originally attached to the wall of the brood capsule (Fig. 39). Little, lamellated concretions of lime salts are often present in the scolex. The anterior portion of the scolex, the rostellum, hooklets, and suckers, are often invaginated in the posterior portion. The scolices may be free inside of the brood capsules, or, owing to the rupture of the latter, they may be free in the cavity of the primary cysts. They may die and degenerate, forming a granular mass in which the hook-

lets may be embedded, or the hooklets may be free in the brood capsules or in the primary cysts. Sterile cysts are often found, that is, those in which neither brood capsules nor scolices are developed.

The cysts contain, in addition to the scolices, a clear, gelatinous fluid. This fluid may become turbid by admixture with disintegrated scolices or fragments of the parenchymatous layer, or it may contain fatty detritus, cholesterin crystals, and particles of lime salts. The fluid may be partially absorbed, leaving a thick, grumous material within the cysts, which may become calcified or converted into a stony mass. When the scolices are not found entire the diagnosis may be made by the discovery of the separate hooklets (Fig. 40) or fragments of the characteristically lamellated cyst walls. The connective-tissue walls of the primary cysts may become fatty or cheesy or calcified.

Sometimes the secondary vesicles project outward instead of inward, forming a series of cysts outside of the primary one. This va-

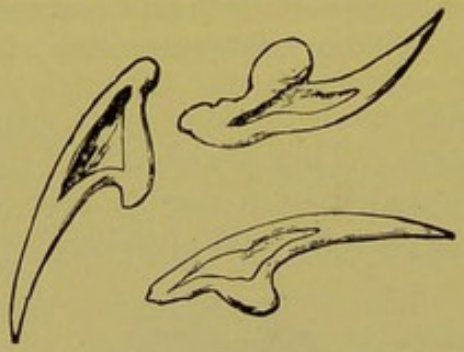

Fig. 40.—Hooklets from Scolex of Tænia echinococcus.

riety of development is sometimes seen in man, but is more common in the domestic animals. It is called *Echinoccocus scoleciparíens* or *exogena*.

Another variety of echinococcus, called *E. multilocularis*, is almost always found in the liver, and appears to be the result of incomplete and disturbed development of the embryos or cysts. It consists of a congeries of irregular, usually small cysts, surrounded by broad and narrow bands of connective tissue, and sometimes containing gelatinous fluid and scolices or hooklets; but the latter structures are commonly absent or difficult of detection. The whole is often surrounded by a dense connective-tissue capsule which may be calcified. The entire mass often presents an alveolar structure and was formerly regarded as a tumor—alveolar cancer. The diagnosis may be established by the discovery of the hooklets or scolices, or fragments of the lamellated cuticula (see page 109).

There are four or five other species of tænia, occurring rarely in man.

*Tænia nana.*—This species occurs in the form of small colonies. about 15 mm. in length. The rostellum is surrounded by a single row of hooklets. It has been seen once in large numbers by Bilharz in the duodenum of a child which died of meningitis in Cairo.

*Tænia flavopunctata*, a species about which little is known, is reported twice in America as occurring in the intestine of young children.

*Tænia madagascariensis*, also little known and rare, has been seen in two children in Madagascar.

*Tænia cucumerina.*—This species occurs in colonies about 20 cm. long. The head is very small and spheroidal, and has four rows of hooklets. It is frequent in the small intestines of dogs or cats. It occurs occasionally in man. Its scolex inhabits the dog louse, and infection may occur in man by the transference of the lice or the embryos of the parasite to the mouth, as the result of the filthy habit of kissing dogs and cats or permitting the face to be licked by them.

*Bothriocephalus latus.*—This, the largest of the human tape-

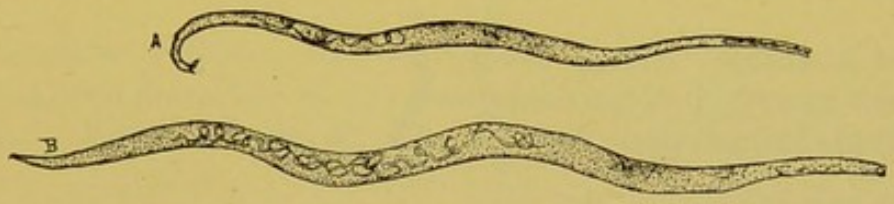


FIG. 41.—ASCARIS LUMBRICOIDES. About half natural size.
A, Male. B, Female. After Perls.

worms, has very broad, quadrangular proglottides. The head is ovoidal and about 2 mm. long and 1 mm. broad. It has no proper sucking discs and no hooklets, but by long grooves on either side of the head the animal attaches itself to its host. The neck is long and filiform. It occurs most frequently in Europe, particularly in the northern provinces. The eggs undergo partial development in water, and are taken up by the pike and eel-pout, and perhaps by other fresh-water fish, from the ingestion of whose flesh in an imperfectly cooked condition the human infection occurs. Two other species of Bothriocephalus have been described as of rare occurrence in man: *B. cordatus* in Greenland and Iceland, and *B. cristatus.*

NEMATODA (Round Worms).—These worms are in general cylindrical, elongated, usually pointed at the ends, and sometimes filiform. The surface is sometimes smooth, sometimes irregularly beset with hairs and papillæ, or possesses longitudinal elevated striæ or transverse rings; but the body is not segmented. There is a mouth at the anterior portion, and a ventral anus near the posterior end. The intestine is straight. The sexes are in most forms distinct, the male being in general smaller than the female.

*Ascaris lumbricoides.*—This is one of the most common of the human intestinal parasites, and is of particularly frequent occurrence in children. It is of a light-brownish or reddish color. The female is from 30 to 40 cm. long and from 5 to 6 mm. thick. The male is somewhat more than half as large (Fig. 41). Both sexes are pointed at the ends, the posterior end of the male being curved into a spined hook. The eggs, from 0.05 to 0.06 mm. in diameter, are surrounded by an albuminous envelope (Fig. 43) and are quite resistant to destructive agencies. The mode of development and life history of these parasites are not very well understood. Their usual seat in man is the small intestine, but they may wander into the stomach, and exceptionally get into the mouth, nose, bronchi, gall passages, peritoneal cavity, etc. They may be single in the gut or present in great numbers.

Two other species of ascaris have been found in man. *A. maritima* was found in the vomit of a child in Greenland, in an immature condition. *A. mystax*, a tolerably common form in cats and dogs, has been found a few times in man. It is smaller than A. lumbricoides.




FIG. 42.—OXYURIS VERMICULARIS.
A, Female. B, Male.

*Oxyuris vermicularis* (Threadworm or Pinworm).—This species is very small; the female has a pointed tail and is about 1 cm. long. The posterior end of the male, which is about 4 mm. long, is blunt, and after death somewhat curled (Fig. 42). The eggs (Fig. 43) are produced in great numbers, are oval, and about 0.052 mm. long. This parasite is very common in children, and may be present in large numbers in the colon. They may, in the female, enter the vagina and uterus. This worm is only known to infest the human subject, and infection doubtless occurs by the ingestion of the eggs, which are widely distributed in a variety of ways on many objects, fruits, etc.

*Strongylus gigas.*—This is a slender red worm, the female being sometimes 1 metre long and over 1 cm. in diameter. It has been

found several times in the pelvis of the kidney in man. It is more common in the wolf, fox, horse, seal, and some other animals. *Strongylus longevaginatus.*—The female is about 2.5 cm. long, the male, as usual, shorter. It is of a yellowish-white color, and has been found once in the lung of a boy in Germany.

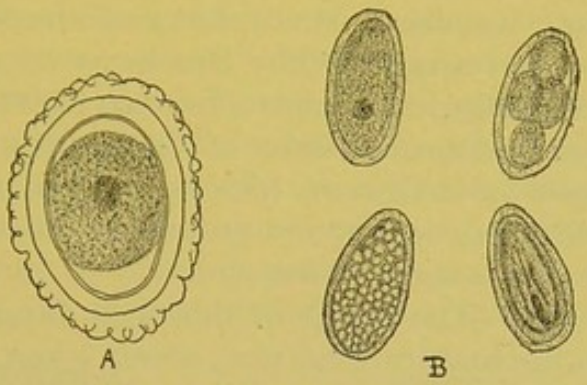


FIG. 43.—EGGS OF NEMATODE WORMS.
A, eggs of Ascaris lumbricoides, × about 300. B, eggs of Oxyuris vermicularis, × about 250.

*Strongylus subtilis.*—A very small species (female 5.6–7 mm. long) has been described by Loos as occurring in Egypt in the human intestine. But it is believed to be without pathological significance.

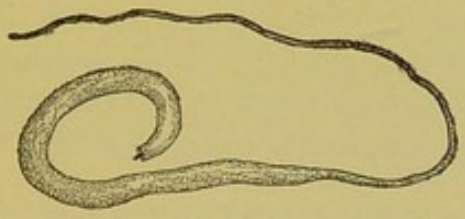

FIG. 44.—TRICHOCEPHALUS DISPAR.
From the skin of the mons veneris.

*Dochmius duodenalis.*—The female is from 1 to 2 cm. long, the male about 1 cm. long. The body of the male is dilated anteriorly and curved backward. Its mouth is furnished with a chitinous capsule and chitinous claws and teeth. It is found in the small intestine of man in Italy, Switzerland, Egypt, and Brazil. The head is burrowed into the mucous membrane of the host, and the animal is nourished by the blood which it sucks out, and which is usually seen in its intestine. An ecchymosis is produced at the point of attachment, or even severe hæmorrhage, and marked anæmia may be the result of the presence of large numbers of the parasites.

*Trichocephalus dispar* (Whipworm).—The males and females are of nearly equal size, 4 to 5 cm. long. A little less than one-half of the body (the posterior portion) is about 1 mm. thick, and in the

male is rolled into a flattened spiral, but in the female is but slightly bent. The anterior part of the body is very slender (Fig. 44) and is embedded in the mucous membrane of the host. The eggs are elongated, oval-shaped, about 0.05 mm. long and about one-half as wide, with a thick brown capsule. This parasite is very common in some countries, especially in France and southern Italy. It is commonly found in the cæcum, usually in small, but sometimes in very large, numbers. A specimen was found by Brockway in a case reported to the New York Pathological Society, January, 1892, with the head embedded in the subcutaneous tissue of the mons veneris in a dissecting-room subject of unknown history. It is usually of little pathological significance, commonly producing no symptoms. Its developmental history is not well known.

*Trichina spiralis.*—The female of this most dangerous and common parasite is, in the mature condition, about 3 mm. long, the male from 1 to 1.5 mm. long; they are filiform in shape and white in color. The young are born in the form of tiny worms about 0.01 mm. in length and somewhat similar to the adult in shape. Infection occurs in man from the ingestion of insufficiently cooked pork. The muscle of the diseased pig contains the embryos of the parasite in an encysted condition. In the stomach the capsule of the worm is dissolved and the embryos are set free. They very rapidly mature, increasing in size, and the females give birth in the small intestine to very large numbers of young. It is estimated that a single female may give birth to from 1,300 to 1,500 young. These find their way, through the mucous membrane and wall of the gut, into various parts of the body.

The exact course which they take in getting out of the gut is not fully established; probably they traverse the tissues in different ways. At any rate, they find their way to the voluntary striated muscle tissue, which they penetrate, and enter the muscle fibres. Here they cause a disintegration of the contractile substance, and coil themselves inside of the sarcolemma. In this situation they become encapsulated by material in part furnished by themselves, in part by means of the inflammatory reaction which their presence induces in the connective tissue of the muscle. The worms are surrounded inside the capsule by granular material (Fig. 45). The capsule after a time becomes partially calcified, and in this condition may be readily seen by the naked eye as a tiny white speck. In this encysted state they may remain inactive but living for an indefinite, often for a very long time. Most frequently the cysts contain but one embryo, but they may contain from two to four. The embryo may die and its remains become calcified.

The same course of events transpires when the muscle trichinæ are eaten by the pig or a variety of other animals.

The embryos in the muscle are killed by a temperature of 55° C. and by some of the methods of curing pork.

The embryos may mature and a new generation be born within from five to eight days after the ingestion of the diseased meat.

As the result of the presence of these parasites in the body, if the invasion be severe, acute catarrhal enteritis, with diarrhœa and vomiting, high fever, and severe pains, is apt to occur. Œdema of the face and of other parts of the body, broncho-pneumonia, and fatty degeneration of the liver may be found at the post-mortem examination of cases which have succumbed to the disease. The encapsulated embryos may be found in enormous numbers in various voluntary muscles of the body, but they are most apt to be found, when

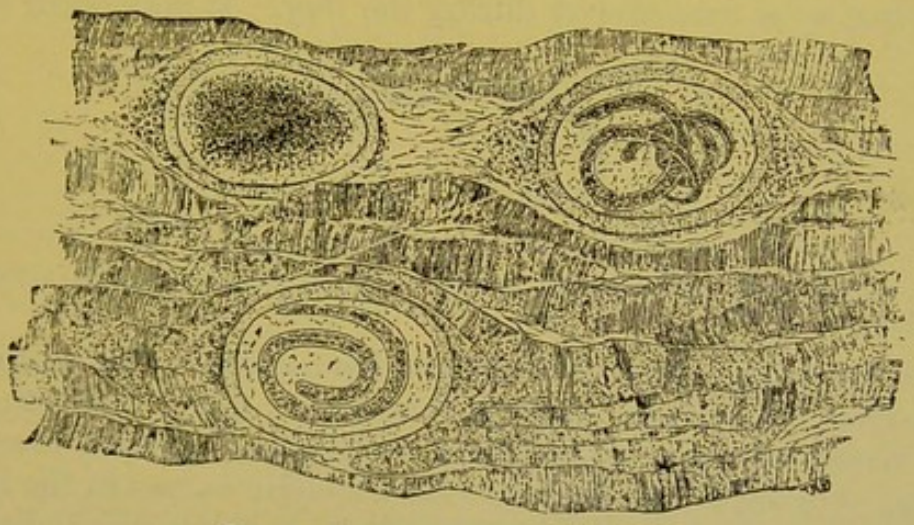

FIG. 45.—TRICHINÆ ENCYSTED IN MUSCLE.
In one capsule the parasite is dead and its remains calcified.

not very abundant, in the muscles of the neck and larynx, in the intercostals and the diaphragm. They tend to collect toward the tendinous extremities of the muscles. Trichinæ also occur in the rat, cat, mouse, and other animals.[1]

[1] For the examination of muscles for the detection of the presence of the parasite, small pieces are snipped out with the scissors, and squeezed into a thin sheet between two slides, and examined with a low power. A considerable number of bits of muscle should be examined, particularly from the above mentioned favorite situations, before excluding them in a suspected case, because they are sometimes present in small numbers. A thorough search is of especial importance in the examination of pork, since, owing to the enormous fertility of the parasites, even a moderate number may give rise to a severe infection.

For the minute examination of the parasite, bits of muscle should be hardened in Müller's fluid and alcohol, and decalcified if necessary, and, after embedding in celloidin, thin sections cut and stained double with hæmatoxylin and eosin, and mounted

*Filaria medinenis* (Guinea worm).—This is a thread-like worm; the female, which is alone known, being sometimes as much as 80 cm. long and from 0.5 to 1.7 mm. thick. It is common in the East, and inhabits the subcutaneous connective tissue, in which it often gives rise to abscesses and ulcers. The embryos live for a time free in fresh water, and are then taken up by a species of fresh-water crustacean, in whose body they undergo further development, and by the ingestion of which the infection of the human subject occurs.

*Filaria sanguinis hominis.*—The embryo of this parasite, which inhabits the blood and lymph of man, especially in Brazil, Egypt, and some parts of the Orient, and occasionally occurs in this country, is about 0.35 mm. long, rounded anteriorly, and pointed at the tail (Fig. 46). It has about the diameter of a red blood cell. It occurs, sometimes in great numbers, in the blood during the night time, being as a rule absent during the day. It may occur in the



FIG. 46.—FILARIA SANGUINIS HOMINIS.

From a case in the New York Hospital. The specimen was prepared and loaned to the writer by Dr. F. Ferguson.

urine in connection with chyluria and hæmaturia. The mature female is from 8 to 10 cm. long, and has been found inhabiting the lymph vessels of man, particularly in the scrotum and lower extremities. Owing to the obstructions which it causes in the lymph circulation, and to the local irritation which its presence induces, it sometimes gives rise to lymphangiectasis, œdema, abscesses, and perhaps elephantiasis. One of the embryonic stages of development is believed to transpire in the body of a species of nocturnal mosquito. Through the bodies of the dead mosquitoes, which are liable to fall into the drinking water, it is believed that the spread of the parasite may occur.

There are several other species of filaria occasionally found in man which it is not necessary to enumerate here.

*Rhabdonema strongyloides.*—A small, filiform worm from 1 to

in balsam. Bits of muscle may be also teased, the embryos picked out with a needle, and the cysts either broken open under a lens with the needle, or squeezed under the cover glass. The embryo worm thus set free may be mounted in a mixture of equal parts of glycerin and picric acid. The adult forms, which may be obtained by feeding rabbits with uncooked trichinous muscle, and examining after the proper interval, may be hardened in Müller's fluid, and mounted in a mixture of equal parts of picric acid and glycerin, or in the same mixture which has been lightly tinged with eosin.

2 mm. in length is found, often in enormous numbers, in the intestines, biliary and pancreatic ducts of man in Cochin China and in Italy, giving rise to endemic chronic diarrhœa. It has been thought that there are at least two species, which have been described under the generic name *Aguillula*, but recent researches by Leuckart have led him to believe them to be different developmental stages of the same form, for which he suggests the above name.

## ARTHROPODS.

The scope of this work does not permit us to enter in detail into the subject of external parasites, which will be found described in treatises on diseases of the skin or in the general works on parasites

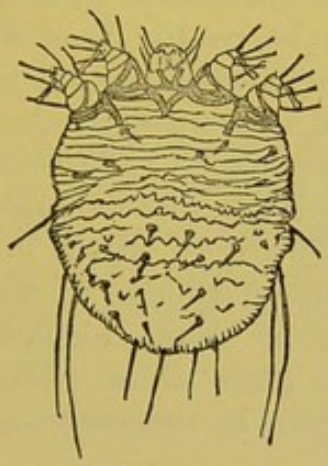

FIG. 47.

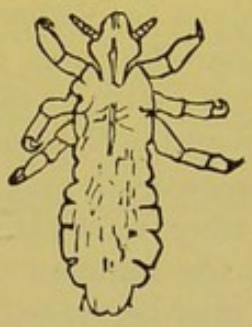

FIG. 48.

FIG. 47.—SARCOPTES HOMINIS—the "itch insect." Female; back view. After Fürstenberg.
FIG. 48.—PEDICULUS CAPITIS—the "head louse." Male. After Braun.

referred to below. But, owing to their frequent occurrence and practical importance, we may briefly describe two of the more common forms of arthropods, the "itch insect" and the "louse."

The common "itch insect"—*Sarcoptes hominis* (*Acarus scabiei*)—is shaped somewhat like a turtle, with a chitinous covering, and presents the general appearance seen in Fig. 47. The female is about 0.45 mm. long, the male a little smaller.

The parasite bores little tunnels in the skin, in which the eggs are laid and the young hatched. After a few days these bore fresh channels in the skin. For their detection a bit of the superficial layer of the skin is snipped out with curved scissors, dehydrated and cleared up with oil of cloves, and examined under a low power, when the tunnels and the parasites, if present, will be readily visible.

The head louse, *Pediculus capitis*, is from 1 to 2 mm. long, the

female being slightly the larger. The general appearance of the insect is seen in Fig. 48.

## MODES OF STUDY AND PREPARATION OF THE ANIMAL PARASITES.

The methods of studying the protozoa have been given above.

The smaller and embryonic forms of the various kinds of parasitic worms may be hardened, best under the cover glass, with Müller's fluid or osmic acid, and these may be, when the hardening is completed, replaced by dilute, and this by strong alcohol, and the latter finally replaced by eosin-glycerin, in which the specimens are permanently preserved; or they may be stained lightly by tinging the alcohol with eosin, and then cleared up by oil of cloves, and finally mounted in balsam.

It is necessary, however, for detailed study of the larger parasites, to make thin longitudinal and transverse sections from different parts of the body. This can be readily done, even in very small forms, by embedding the animal—after careful hardening in osmic acid or in Müller's fluid, and afterward in alcohol—in celloidin or paraffin, and using the microtome. The sections may be stained double with hæmatoxylin and eosin, and mounted in balsam.

The general arrangement of the generative organs in the proglottides of tapeworms may be well seen by staining in eosin or eosin-glycerin after moderate hardening in dilute alcohol, and then squeezing the segment between two glass slides. The itch insect and louse may be soaked for a few hours in turpentine and mounted in balsam.[1]

---

[1] *Bibliography.*—Especially to be recommended for detailed description of human animal parasites, together with practical suggestions for their study, is the small work of *Braun*, "Die thierischen Parasiten des Menschen," 1883, which contains also the more important older bibliography.

The more extended classical works of *Cobbold*, "Entozoa of Men and Animals," 1879, and *Küchenmeister and Zürn*, "Die Parasiten des Menschen," 2d ed., and the work of *Leuckart*, "Die menschlichen Parasiten," should be consulted, and contain valuable bibliography. Various forms of external parasites of men and animals are fully described and illustrated in the work of *Mégnin*, "Les parasites et les maladies parasitaires chez l'homme," etc., 1880. The plates of *Stein*, illustrating the *Cestoda*, 1882, are carefully executed. In the "Report on Trichinæ and Trichinosis," in 1880, by *Glazier*, Surgeon in the Marine Hospital Service, will be found an illustrated account of the natural history of this parasite, history of the disease, etc., and a section on its occurrence in the United States.

## VEGETABLE PARASITES.

The vegetable parasites of man belong among the lowly plants, three distinct forms of which are of frequent occurrence in or upon the body. These are:

1. *Bacteria*, or fission fungi (Schizomycetes).
2. *Yeasts*, or yeast fungi, or sprouting fungi (Saccharomycetes).
3. *Moulds*, or mould fungi (Hyphomycetes).

The first group, the bacteria, is of the greatest significance, because it contains organisms which are very frequently the cause of serious disease.[1]

### I. BACTERIA.

Bacteria are minute unicellular plants devoid of chlorophyll, multiplying by transverse fission and in some cases by means of spores.

The colorless, sometimes granular, protoplasm is enclosed by a membrane, and some forms are surrounded by a transparent capsule. Not infrequently parts of the protoplasm appear less dense than the

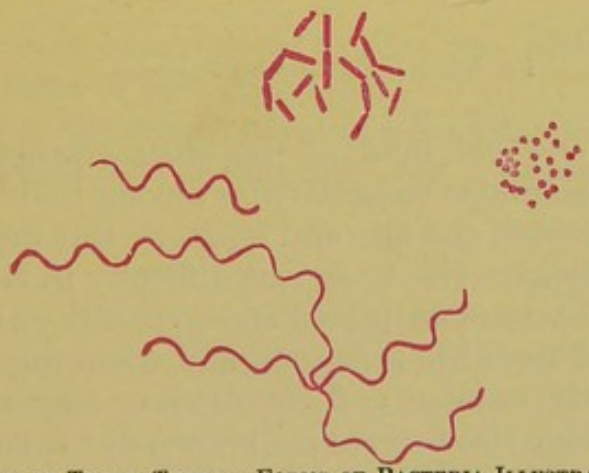

FIG. 49.—DRAWING OF THREE TYPICAL FORMS OF BACTERIA ILLUSTRATING THE THREE CLASSES. Stained with fuchsin.

rest, as if from vacuolation, and a few observers have claimed to demonstrate in certain forms a nuclear structure. But owing to their minuteness, studies of the structure of the protoplasm of bacteria have thus far led to but meagre results.

The various forms of bacteria may be grouped into three classes.

---

[1] The term *micro-organism* includes all of these forms of minute and lowly plants. They are also sometimes spoken of collectively as *germs*.

1. Spheroidal bacteria-cocci or micrococci (singular, coccus,[1] micrococcus).

2. Rod-like bacteria-bacilli (singular, bacillus).

3. Spiral bacteria-spirilla (singular, spirillum).

All straight bacteria which have one axis longer than the other are called bacilli, even though the form is oval rather than rod-like. The ends of bacilli may be square or rounded.

While the cocci elongate a little in preparation for fission and in this condition present a slight irregularity in the length of their axes, and thus resemble bacilli, the complete observation of their life cycle rarely permits error in the determination of the primary group to which a given micro-organism belongs.

Some bacteria present slight modifications of the fundamental form in certain phases of their growth. Thus some of the cocci after division are slightly flattened on their contiguous sides; certain bacilli may bulge slightly in the middle—*clostridium* forms; others

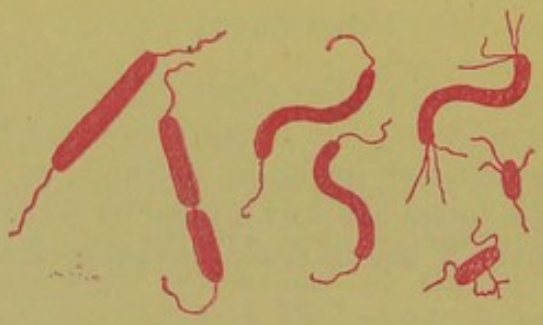

FIG. 50.—BACILLI SHOWING FLAGELLA.

may be larger at one end than at the other—racket-shaped; some bacilli present considerable irregularities among individuals from the same growth in breadth and size and length. But these slight variations in form rarely give rise to serious difficulty in classification.

Finally, when bacteria are placed under conditions unfavorable for the maintenance of their life processes, and when they are dead, they are often irregularly swollen and contorted or may undergo partial disintegration, giving rise to what are known as "*involution* forms."

While all bacteria are minute there is among them considerable diversity in size, some being many times larger than others.[2]

Many of the bacteria, especially the bacilli and spirilla, less frequently the cocci, are furnished with hair-like processes called flagella.

---

[1] Pronounced *kok'-us*, plural *kok'-si*.

[2] For convenience of expression microscopists have agreed to let the letter $\mu$ stand for the word micromillimetre, which is one-thousandth part of a millimetre. This unit of measure, equal to about one-twenty-five thousandth of an inch, is often called a *micron*.

(Fig. 50), which are single or in tufts, and are apparently organs of locomotion.

When the bacteria are about to multiply by fission they elongate, a partition line develops, they become constricted at a right angle to the axis of elongation, and finally two independent organisms are formed.

The multiplication of bacteria by fission may, when the conditions

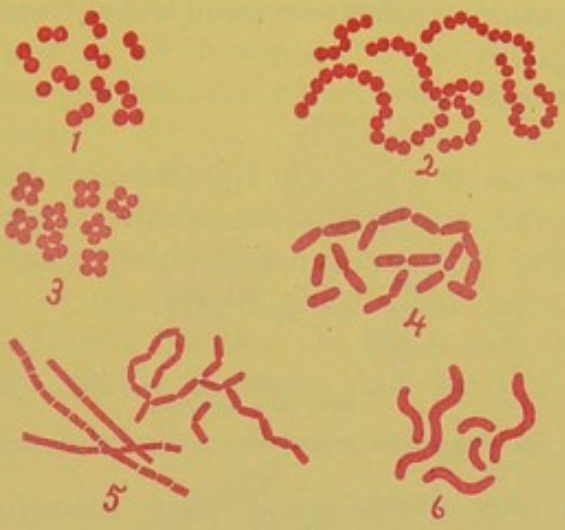


FIG. 51.—GROWTH AGGREGATES OF BACTERIA.

1, Diplococcus; 2, streptococcus; 3, merismopedia; 4, diplobacillus; 5, streptobacilli; 6, curved bacilli forming spiral chains.

are favorable, occurs so rapidly as to give rise within a few hours to an enormous number of new individuals.

In many cases, the new individuals thus developed fall apart in a form identical with that of the parent cell. In some species, on the



FIG. 52.—LEPTOTHRIX BUCCALIS WITH MICROCOCCUS COLONIES.

From the mouth of a healthy person.

other hand, the new-formed individuals are prone to cling together with greater or less tenacity, thus giving rise to growth aggregates which are more or less characteristic (Fig. 51). Thus among the cocci there are those in which a large part of the new individuals cling together in pairs. These forms are called *diplococci*. In others the pairs cling together in longer aggregates or chains. Such are called *streptococci*.

A similar occurrence in the bacilli gives rise to *diplobacilli* and *streptobacilli*. Some of the spiral forms are due to the close junction end to end of oppositely curved segments. Certain long thread-like micro-organisms closely allied to the bacteria are called *leptothrix*.

Certain cocci divide in two directions at right angles to each other, giving rise to four cocci clinging together and lying in the same plane. These are called *merismopedia* forms.

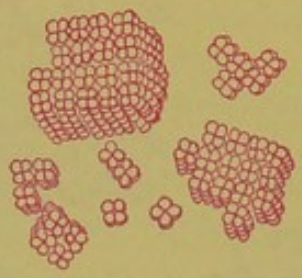

FIG. 53.—SARCINA.
Showing growth aggregates in cuboidal masses.

Finally cocci may divide along three planes at right angles to each other, giving rise to cuboidal packets of eight germs or some multiple of this—such growth groups are called *Sarcina*[1] (Fig. 53).

There are a few branching or filamentous forms of micro-organisms closely allied to, if not wholly characteristic of, the bacteria



FIG. 54.—BACTERIA WITH CAPSULE.

called cladothrix, crenothrix, and beggiotoa, which may be merely mentioned here.

*Actinomyces*, also closely related to the bacteria, will be considered in another section of this book. Many bacteria are surrounded by a broad homogeneous envelope called the *capsule* (Fig. 54).

Their apparently simple structure and the lowly position which bacteria occupy in the scale of living things have given rise to the conjecture that marked changes in form within the limits of the primary groups, or even changes from one primary group to another,

[1] Bacteria in masses embedded in and held together by a more or less abundant homogeneous material which they elaborate are called zoöglœa.

might be brought about by alterations in environment, food, etc. In the early days of the exact study of bacteria this belief in pleomorphism in bacteria found ready currency.

But the more exact study of separate forms which the new technique has made possible has led to the general acceptance of the view that variations do not occur except within comparatively narrow limits, and that what we are accustomed to call species of bacteria maintain their morphological characteristics with tenacity under the most varied changes in environment, even though these persist through the countless generations which may pass within the limits of a single experiment.

The physiological characters of bacteria are, as we shall presently see, subject to wide and significant alterations, but so far as we can now see monomorphism widely if not exclusively prevails.

Under a variety of conditions, the limitations of which are not very well understood, new bacteria are produced, and the species is perpetuated, not by simple division, but by the development of



FIG. 55.—BACILLI SHOWING SPORES.
The bodies of the bacilli are stained with methylen blue, the spores with fuchsin.

*spores*. The most common mode of spore formation is called *endogenous*. A small, shining mass makes its appearance within the protoplasm from which it is formed, grows more and more distinct, and finally appears as a sharply defined spheroidal or oval, strongly refractile colorless body (Fig. 55), which can be separately stained and may remain within the old cell membrane or may free itself by rupture of the latter. Only one spore develops in a single germ. Endogenous spore formation is common in bacilli, rare in spirilla, unknown in cocci. The spores appear to be surrounded by a dense envelope, and are, as a rule, much more resistant to deleterious agencies, such as heat, drying, etc., than are the negative forms of the bacteria themselves.

Vacuoles in bacteria are often mistaken for spores. Spores, when placed under favorable conditions in the presence of moisture and nutriment, swell, become less refractile, and develop into the usual vegetative form. Another mode of sporulation—*arthrogenous*—has been described, but its nature is not well understood, and even its occurrence is doubted by many.

The bacteria require for their nutrition carbon, hydrogen, oxygen, and nitrogen, and certain mineral salts. All of these they can obtain from albuminoids and carbohydrates. Free oxygen is necessary for the growth and activities of some forms of bacteria and for others not.

Those bacteria which require free oxygen are called *aërobic*. Those which do not grow in its presence are called *anaërobic*. But between these extremes there are forms which make shift to grow without oxygen under favorable conditions, though they make use of it when present; others grow in its presence, though flourishing best in its absence: these are called *facultative* aërobes or *facultative* anaërobes, in distinction from those first mentioned, which we call *obligate* aërobes or anaërobes.

Nitrogen may be obtained by some bacteria from inorganic salts of ammonia, from nitrites and nitrates.

Bacteria are active only in the presence of moisture; but when this and other conditions favoring their activity fail they do not necessarily die, but some forms may remain, either as spores or as fully developed organisms, for long periods wholly dry and inert, but capable of resuming their activity whenever they are again restored to favorable conditions.

They grow best, as a rule, when in an organic food medium which is neutral or slightly alkaline.

Some bacteria are and some are not very sensitive to changes of temperature. At a temperature below +5°C. they are incapable of marked activity or proliferation.

At +7° C. a slow growth has been observed in various species. Many forms may remain alive for long periods frozen in ice,[1] while some are not killed by a temperature of −111° C. As the temperature is raised their activities increase up to a certain point. It may be said in general that they are most active at about the temperature of the body, although species differ considerably in this respect. In fluids many bacteria are killed by a prolonged exposure to a temperature of from 60° to 70° C. or even less. On the other hand, certain species grow at a temperature of from 60° to 75° C. Such are called *thermophyllic* bacteria.[2]

All known bacteria, save for a few very invulnerable spore-forming species, are killed by prolonged exposure in the presence of moisture to a temperature of 100° C.

When dry they resist much higher temperature than when moist.

---

[1] *Prudden*, "On Bacteria in Ice, etc." Medical Record, March 26th and April 2d, 1887.

[2] Consult *Rabinowitsch*, Zeitschrift f. Hygiene u. Infectionskr., Bd. xx.

The spores are, as a rule, more resistant to high temperatures than the bacteria themselves, some having been exposed, dry, to a temperature of 140° C. without destruction of life. Fluids containing the spores of bacteria which resist very high temperatures may be sterilized by boiling for a short time, then being allowed to stand at ordinary temperatures for several hours, and then again boiling; this process being repeated several times. In this way, although the spores themselves are not killed by the heat, the bacteria into which, if the conditions be favorable, they develop during the intervals are killed, so that finally the medium is entirely freed from both living spores and adult bacteria.

Strong light is in general inimical to the life and growth of bacteria, and by direct sunlight many forms are readily killed.

Certain disinfecting agents, when brought into contact with bacteria, are capable of greatly reducing their activities or destroying them altogether; but different forms differ greatly in their power of resisting the action of these agents. The spores of certain bacteria are exceedingly resistant, much more so than the bacteria themselves, to the action of disinfecting agents. Among these disinfectants may be mentioned formalin, carbolic acid, and especially solutions of corrosive sublimate, which is very inimical to the life of most bacteria and their spores, even in extremely dilute solutions.

Some bacteria are capable of performing rapid movements, others are not; and the same form may be at one time mobile and at another immobile, depending upon external conditions. Movement is largely confined to the rod-like and spiral forms, but has been observed in the spheroidal.

It has been shown that certain of the motile bacteria, when suspended in fluids, are attracted toward, or repelled from, dissolved chemical substances. This is called *chemotaxis*, and it is termed positive or negative according as the organisms are attracted or repelled.

The bacteria play a very important rôle in nature in virtue of their power of feeding upon and pulling to pieces dead organic materials. A part of the new chemical compounds which are thus formed may be used by the bacteria for the purposes of their own nutrition and growth, while the rest are set free to serve, sooner or later, as food for other forms of plants or animals.

In the decompositions which are brought about in nature by the bacteria those compounds of nitrogen and carbon dioxide are set free which are essential for the nutrition of the higher plants.

Without the activities of bacteria, life could not be long maintained upon the earth, since the necessary carbon, hydrogen, oxygen, and nitrogen would soon be permanently locked up in unavailable form in organized material.

Through the action of the various nitrifying bacteria in the soil, ammonia is decomposed with the formation of water and nitrous acid; nitrous is converted into nitric acid.

The so-called denitrifying bacteria reduce nitrates to ammonia and to nitrites. In these ways, among others, water percolating through the soil may be purged of objectionable organic compounds.

A large number of complex chemical substances are elaborated during the growth of bacteria, their nature varying with the species of bacteria and the composition of their nutrient material.

Some of the chemical compounds set free by the growing bacteria are bad-smelling or aromatic; some are inert and harmless substances; some are powerful poisons, and may, when they have accumulated in the fluids where they grow, inhibit the activity and growth or even destroy the bacteria which have produced them.

Fermentations and putrefactions are due to the activities of micro-organisms, some to bacteria, some to yeasts.

Putrefaction is a form of fermentation in which nitrogenous compounds are decomposed by micro-organisms setting free bad-smelling substances.

Bacteria which induce fermentation are called *zymogenic*—and each species induces fermentation of a special character. Some of these are important in the arts; some are concerned in the changes which food products undergo under natural or artificial conditions, such as the development of koumyss from milk and the common butyric, lactic, alcoholic, and other fermentations.

The chemical changes which are induced by micro-organisms in the process of fermentation are extremely complex and little understood.

Bacteria may develop in their metabolic activities soluble ferments or *enzymes* of various kinds resembling diastase, pepsin, trypsin, rennet, etc.

Many bacteria produce pigments as they grow (*chromogenic* bacteria). This pigment may be developed in or upon the germs themselves or may be diffused through the surrounding media. Gas-producing bacteria are called *aërogenic*. Certain species when growing in masses emit a phosphorescent light—*photogenic* bacteria.

Certain of the basic chemical compounds resembling the vegetable alkaloids, which are formed by the action of bacteria in organic matter, are called *ptomaïns*.[1] The ptomaïns of certain special forms of bacteria are believed to be of importance in inducing deleterious effects in many of the infectious diseases; these are called *toxins*.

---

[1] *Leucomains* are basic products produced in the tissues of living animals by cell metabolism.

Complex proteid bodies may be produced during the growth of bacteria; these may be in part set free, in part assimilated in the bacterial cell protoplasm. These proteid bodies belong in part to the albumins, in part to the albumoses, while some of them resemble the peptons. Many of them seem to be most potent factors in the induction of the phenomena and lesions of the infectious diseases. The poisonous albuminous substances produced in the body by the growth of certain disease-producing bacteria are called *toxalbumins*.

Bacteria are widely distributed in the air, in water, and in the superficial layers of the soil, where they may be present in enormous numbers. They are especially abundant among the habitations of man, or wherever under favorable conditions of moisture and temperature animal or vegetable substances are undergoing decay.

They cling tenaciously to moist surfaces, but when dried, and especially when dried upon comminuted material, they may float in the air as dust. In quiet air they gradually settle with other forms of dust on to the horizontal surfaces, and thus in closed, still rooms the bacteria-laden air may over night almost wholly free itself of its living contaminations by a process analogous to sedimentation in water.

This widespread transportation of bacteria as dust by moving air, and the spontaneous cleansing of the latter by the settlement of the germs, are important factors in the sanitary problems which the complex conditions of modern life present. Large numbers of mould spores are frequently mingled with the bacteria in dust and soil.

While bacteria may live for long periods in the dried state in dust they do not in this condition multiply. But the upper three or four feet of the soil forms the great abiding, and when moist the breeding, place of the myriads of germs which are concerned in the salutary work of food preparation for higher plants.

Surface waters almost always contain bacteria, which may have entered by aërial dust or from the wash of adjacent soil or from direct human or animal contamination. Many bacteria find in water favorable conditions of life and flourish on what to other forms would be but scanty nutriment. Many pathogenic bacteria may remain alive for considerable periods in water, but they do not usually thrive there.

The water which in many places lies in hollows of the rocks, bathing the deeper layers of the soil or gathered in caverns and recesses beneath, is called *ground water*. This under favorable conditions is almost wholly free from micro-organisms, these, through the complex process of filtration, germ metabolism, etc., which go on in the upper soil layers, having, together with inorganic contaminations, been largely retained or transformed as the surface water has slowly sought the lower levels. It should always be borne in mind

that, so far as we know, with few exceptions the bacteria whose natural habitat is the soil or air or water are not under usual conditions harmful to man. On the other hand, it is germs from the bodies of men or animals who are the victims of infectious disease, which in one way or another gain access to these great reservoirs and sources of distribution, which render the bacterial flora of soil and air and water occasionally of especial direct personal significance to man.

It will be seen from what has been said about bacteria and their various modes of life that some live in or upon and at the expense of other living beings—the hosts—these are *parasites.*

Others which live and grow apart from a living host are called *saprophytes.* In either class there are forms which, through the capacity of adapting themselves to their environment, can maintain at one time a parasitic, at another a saprophytic life. Such germs are called respectively *facultative* parasites or *facultative* saprophytes. Those, on the other hand, whose life is strictly limited to the parasitic or saprophytic condition are called *obligate* parasites or saprophytes.

Not all the bacteria which live in or upon the bodies of men and animals are in the stricter sense parasites. The terms *messmates* and *commensals* have been applied to such organisms as simply live with, but do not necessarily derive nutriment from, the host.

In some cases parasitic life on the part of the micro-organism may contribute to the welfare of the host. This is the case in some bacteria which live upon the roots of certain leguminous plants, and to whose nutrition they contribute by rendering atmospheric nitrogen directly available for the host. This condition of life is called *symbiosis.*

As has already been indicated, the morphological characters of bacteria are so little subject to permanent variation under the widest diversity in the conditions to which they are subject that we are justified in the belief in fixed species.

But so susceptible to external conditions are the functional activities of many species that not only is the occurrence of what may be called varieties within specific limits frequent under natural conditions, but more or less permanent variations may be experimentally produced.

Almost all of the functional activities of bacteria upon which we rely as descriptive characters may be experimentally altered; thus the color-producing capacity may be diminished, the peptonizing and fermentative activities lowered, the pathogenic powers reduced or exalted, and even the capacity for spore formation may be abolished.

These more or less permanent modifications of function in bacteria are usually induced by artificial cultivation under adverse conditions of temperature and nutrition, by the presence of deleterious chemical

agents, antiseptics, etc., or by association with the body cells and juice in susceptible or insusceptible animals (see page 179).

## CLASSIFICATION OF BACTERIA.

The beginning of the systematic study of bacteria by exact and reliable methods is of such recent date, they are so minute, and our present optical apparatus reveals so few differential morphological characters beyond the limits of the three primary classes already mentioned, and so few withal of the many existing forms have as yet been studied, that a satisfactory classification or nomenclature of the bacteria is not yet possible.

Outside of the limits of the primary classes we are obliged to use for the purposes of identification and description the results of physiological activities which the special forms of bacteria display when placed under diverse and usually entirely artificial conditions of food, temperature, and general environment. It is evident from this condition of affairs that what in our attempts at classifications we are wont to call genera and species, are not such in the strict sense in which these terms are used in other domains of biology. That which corresponds to the generic name in the more exact vocabularies is in ours usually the growth form which indicates the primary class to which the germ belongs, as coccus, bacillus, or spirillum, or some growth modification of this, as diplococcus, streptococcus, streptobacillus, and the like. To this is usually appended a more or less distinctive specific name, which usually indicates some noteworthy physiological capacity of the germ, such as its peptonizing power, the pigment which it elaborates, some prominent chemical reaction which it initiates, some marked effect upon an artificial culture medium, its disease-producing power in men or animals, or some fact about its habitat, or the situation in which it was found. All of these and other heterogeneous characteristics, largely functional, which may be developed under natural or artificial conditions, constitute data in the life history of germs upon which the classification and nomenclature of bacteria are at present based.

As examples of names of bacteria thus derived may be cited *Micrococcus luteus*, *Diplococcus lanceolatus*, *Sarcina ventriculi*, *Bacillus acidi lactici*, *Spirillum choleræ Asiaticæ*.

Notwithstanding the value of this principle of grouping and nomenclature, its inadequacy even for temporary use is becoming painfully evident as research proceeds, partly because of the large variations to which physiological activities are liable, and partly because we cannot sharply distinguish between races, varieties, and species.

It is not yet possible to say whether it will ever be practicable in this limited field of lowly life to draw such exact distinctions between genera and species as the wider domains of biology permit.

## METHODS OF STUDYING BACTERIA.

The simplest mode of studying bacteria is to examine them either in the fluids in which they lie or in one-half-per-cent salt solution. For the study of many of the phenomena of life this method is important.

This may be accomplished by the examination of a thin layer of the fluid under a cover slip, in the usual way, or a small drop may be placed on the cover slip and this inverted on a hollow slide so that the observation is made in the hanging drop. A streak of vaselin painted around the edge of the cover will prevent evaporation of the fluid.

By far the most important aid in the morphological study of the bacteria is derived from the use of staining agents. Most of the bacteria are stained more or less readily by one or more of the basic anilin dyes. The ease with which they are colored varies considerably in different species and with the different dyes. The tissue elements, and a variety of other materials with which the bacteria may be associated, also stain more or less readily at the same time; but most of these part with their color more readily than do the bacteria on being treated with alcohol or dilute acids. We are thus enabled to obtain a differentiation in color between bacteria and other structures. The bacteria, moreover, differ among themselves in respect to the tenacity with which they hold their stain in the presence of decolorizing agents, and upon this fact is based one of the important methods of distinguishing between different species.

Among the anilin dyes more commonly employed for bacteria staining may be mentioned fuchsin, gentian violet, and methylen blue. A saturated alcoholic solution of these dyes should be kept in a tightly stoppered bottle, and from this the more dilute solutions required for staining may be prepared. For ordinary purposes one part of alcoholic solution of fuchsin or gentian violet, added to twenty parts of water, will give a staining solution of suitable strength. This should be prepared in small quantities as required, since it does not keep well and a granular precipitate is apt to form in a few days.

Special stains and modes of staining, such as are necessary for some forms of bacteria—the tubercle bacillus, for example—will be described under the appropriate headings. We are speaking here only of the general methods.

*To Stain Bacteria in Fluids.*—A small drop of the fluid is

placed on a cover glass which is perfectly clean and free from grease; spread a little with a needle, and allowed to dry by evaporation in the air or by gentle heating, held by the edges in the fingers, high over a flame. The cover glass is now held with the forceps, and, specimen side up, passed moderately rapidly three times through the flame of an alcohol lamp or a Bunsen burner. The material on the cover should not be burned. This heating not only fixes the contents of the fluid firmly on to the glass so that it will not easily soak off, but it renders insoluble any albuminous materials which may be mixed with the bacteria, and which might otherwise interfere with subsequent examinations by forming granular precipitates.

A drop of the aqueous staining fluid is now put on to the dried specimen on the cover glass, and if this be held in the forceps and tilted slightly up and down a few times so as to bring fresh portions of the staining fluid into contact with the bacteria, the staining will usually be completed in two or three minutes. The stain is now washed off with a jet of water from the wash bottle, and the specimen is either mounted in a drop of water for temporary study, or the washing water is drained off and, after drying in the air, it is mounted directly in balsam.

It is well to use balsam which has been softened, when this is necessary, with oil of cedar or xylol rather than with chloroform, since this is apt to decolorize the bacteria.

If the bacteria which are to be stained are in solid masses, as is usually the case in pure cultures on solid media (see below), a small drop of distilled water should be first put on the middle of the cover glass, and a very minute quantity of the bacterial mass rubbed into it with a platinum needle and then dried and stained as before.

Gram's method (see page 156) is often useful and in some cases almost indispensable for the differential staining of bacteria.

*Spore Staining.*—For staining spores the method of Moeller is generally useful.

The cover-glass preparation of the bacteria is made in the usual way and fixed by heat or by immersion for two minutes in absolute alcohol. It is then placed for one minute in a five-per-cent solution of chromic acid, then thoroughly rinsed in water and stained for one minute in a small dish of Ziehl's solution (page 224) heated to boiling. From this it is transferred without rinsing to five-per-cent solution of sulphuric acid, in which it is decolorized. The spores are now red, the bodies of the germs uncolored. A contrast stain of the body may be made with an aqueous solution of methylen blue.

The *rationale* of this method is that the maceration of the spore membrane by chromic acid permits the penetration of the stain to the

spore substance. If the chromic acid act too long the subsequent differentiation may be impossible, owing to the too ready decolorization of the spore by the acid. The exact periods during which the various agents should be permitted to act may not be hit upon without repeated efforts with slight variations.

Immersion of the cover slip in chloroform for two minutes is necessary after the fixation of the specimen, should fat cholesterin crystals or allied materials be mingled with the germs, since in the presence of these the differentiation of the spores is apt not to be clear.

*To Stain Bacteria in Tissues.*—The tissues should be well hardened in alcohol. Thin sections are placed in the above-described aqueous coloring solutions, where they may remain from five to fifteen minutes. In some cases a much longer staining is necessary. Gentle warming (40° to 50° C.) will hasten the staining. The entire tissue as well as the bacteria is in this way deeply colored. The sections are rinsed with distilled water and then placed in alcohol. This, with varying degrees of rapidity with different stains and tissues, gradually extracts the color from the tissue, most slowly from the nuclei. The time required and the exact degree of decolorization to be sought for must be learned by experience in different cases. Sometimes five, sometimes thirty minutes are required, sometimes only a few seconds. It is often necessary, and the decolorizing of the tissue is thereby hastened, to add a few drops of acetic acid to the alcohol. When acetic acid is used it should be finally thoroughly washed out by alcohol. The specimens are now cleared up by oil of cloves and mounted in balsam. Oil of cloves removes the color from some forms of bacteria, and in this case xylol or oil of bergamot should be substituted for it. In specimens prepared in the above way, the nuclei of cells usually retain to some extent a color similar to that of the bacteria, but their size and shape serve for the differentiation.

*Gram's Method.*—This is a much more generally useful method of staining bacteria in the tissues than that just given, although not in all cases applicable. The tissues from which the sections are made should have been hardened and preserved in alcohol. The sections are stained for from two to four minutes in *anilin-gentian-violet solution.* This is prepared as follows: 1 c.c. anilin oil is added to 20 c.c. distilled water; this mixture is well shaken, and the excess of anilin oil is filtered off through a moistened paper filter. To the clear filtrate saturated alcoholic solution of gentian violet is added until the fluid becomes opalescent (about 1 part of the dye to 10 of the water will usually be enough). A small quantity only of this fluid should be prepared at once, as it does not keep very well.

From the staining solution the sections are transferred directly to a solution of iodin in potassium iodid and water (I 1.0—KI 2.0—$H_2O$ 300.0). In this they remain from one to three minutes, a precipitate forming in the solution and the sections becoming of a dark-reddish or slate color. The sections are now transferred to absolute alcohol, which should be changed two or three times so as to dehydrate the specimen, which at the same time will lose much of its color. Finally the decolorization is completed and the section cleared up by oil of cloves, and it may then be mounted in balsam. Very little of the violet color should be visible to the naked eye in the specimen when it is ready to mount. If the specimen have been embedded in celloidin for the purpose of section cutting, this will be dissolved from the sections by the oil of cloves. Then it is well to use a second portion of oil of cloves, so as to get rid of the superfluous half-dissolved celloidin. It is also well to tint the oil of cloves lightly with a few drops of alcoholic solution of eosin, and then the violet-colored bacteria will stand out in sharp contrast with the reddish tissue elements. The iodin solution should never be used a second time, and a platinum needle should be used in manipulating the sections, since steel instruments are injured by the iodin. Oil of origanum tinged with eosin may be used in place of oil of cloves. It does not dissolve celloidin and is thus best adapted to delicate or friable sections.

Some bacteria are decolorized by Gram's method of differentiation.

In this as in other methods of staining bacteria in tissue the sections are liable to shrivel and curl. This may in many cases be avoided by fixing the sections on to the cover slip with albumen fixative (see page 59) before the staining begins, carrying cover glass as well as section through the subsequent processes.

*Weigert's Modification of Gram's Method.*—The sections are laid for half an hour in the anilin-gentian-violet solution prepared as above, then rinsed off in three-quarter-per-cent salt solution and spread on a slide. They are now dried with blotting-paper and covered for two minutes with the iodin solution. The iodin solution is now removed with blotting-paper and the sections decolorized with anilin oil or a mixture of 2 parts of anilin oil and 1 part of xylol, several times renewed. Finally the sections are cleared in xylol and mounted in balsam.

In many cases it is well to accomplish a double staining by a preliminary contrast stain. Thus, before the use of Weigert's modification of Gram's stain the sections may be put for half an hour in a solution of picro-carmin, then rinsed in water and stained as above. By this modification of Gram's method fibrin is deeply stained.

*Löffler's alkalin-methyl-blue solution* is a very valuable and powerful stain for bacteria, either in fluids or in tissues.

It consists of—

Saturated alcoholic solution of Methyl Blue.... 30 parts.
Aqueous solution of Caustic Potash 1:10,000..100 "

For staining bateria in tissues the stain is allowed to act for a few minutes. The section is then put for a few seconds in one-half-per-cent acetic acid, then rinsed in water, and the superfluous color removed from the tissue by repeated rinsing in alcohol, which at the same time dehydrates it. Then it is cleared with oil of cedar and mounted in balsam. Care should be taken not to remove too much color with the alcohol. For staining bacteria in fluids in which there is little solid material other than the germs, Löffler's blue is used as are the ordinary simple anilin dyes, described above.

It should always be borne in mind in staining the bacteria that great exactness is not usually necessary either in the strength of the coloring solutions or in the time of exposure of the bacteria to them. We are seeking for certain effects—namely, the staining of the germs—and this depends not only upon the quality and strength of the dye, the time of exposure, etc, but also upon the nature of the bacterial species and its conditions at the time the staining is attempted. Thus it not infrequently happens that bacteria which will stain readily and deeply with a given solution when they are in a condition of active growth, may scarcely be at all colored if they have been dead or inactive for a long time, although their outward shape appears to be unchanged. So it should be remembered that, while there is little difficulty in most cases in staining the bacteria, the operation is not one of mere routine, but requires intelligent attention to the particular conditions of the species in hand.

*The Microscope.*—For the recognition and study of bacteria, especially of the minuter forms, the best optical apparatus is requisite. With good high-power dry lenses a certain amount of instructive observation on the bacteria may be made. But for finer study and research homogeneous immersion lenses (at least one-twelfth) with the Abbé condenser must be used.

## ARTIFICIAL CULTIVATION OF BACTERIA.

For the complete investigation of the different forms of bacteria, particularly in their relations to disease, we must isolate them so as to be able to study their life history and the effects of their inoculation into healthy animals. It has long been known that bacteria could be cultivated in a variety of artificially compounded, so-called

nutrient media or soils. Fluids were formerly used for this purpose, but it is very difficult to separate single species in fluid media, and to detect contaminations when they occur. Moreover, the inevitable mechanical disturbances of the fluid prevent, for the most part, the formation of gross characteristic appearances in the masses of growing bacteria. Robert Koch introduced, a few years ago, a technical improvement of inestimable value in suggesting and formulating the details of using solid media for the cultivation of bacteria. Among these may be mentioned sterilized boiled potatoes and gelatinized infusions of various natural or artificially compounded substances sterilized by heat. Different species of bacteria often require different nutrient media, and some require different temperatures for their most flourishing growth. They usually grow within or upon the surface of the solid nutrient media in sharply circumscribed masses, called *colonies*, and different species may grow side by side in the same receptacle for considerable periods without in the slightest degree interfering with one another or tending to mix. The mode of growth and general appearances of the proliferating bacterial masses on the solid medium often present very characteristic differences between different forms, and thus not only furnish valuable means of identifying species, but render possible an early detection of contamination from chance admixture of species. A given species of bacteria may be cultivated through a series of generations by transferring, with proper precautions, a minute portion from a growing colony to a fresh surface of sterilized soil. After cultivation through several generations the species may be presumed, and by microscopical examinations proved, to be entirely pure, and the effects, if any, produced by its inoculation into healthy animals, to be due to it alone.

*The Preparation and Use of Culture Substances.*—There are many culture media, some of which are best suited for one, some for another species of bacteria. Those most commonly used are meat broth (bouillon), broth rendered solid by gelatin or agar-agar (called "nutrient gelatin" or "nutrient agar"), boiled potatoes, coagulated blood serum, and milk.

*Nutrient Gelatin.*—One pound of lean beef is chopped fine, stirred into one litre of water, covered, and set away in the refrigerator for twelve hours. The red fluid is now completely separated from the meat by squeezing through a cloth into an enamelled saucepan, which fits into a larger vessel serving as a water bath. To the beef juice are added ten per cent of clear French gelatin, one per cent of beef pepton, and one-half per cent of common salt. The mixture is now heated in the water bath until the gelatin is dissolved, when it is carefully neutralized by the addition of a sufficient quantity of a

dilute solution of caustic soda. It should be made exactly neutral or *very slightly* alkaline. The reaction may be determined by litmus or, which is better for exact researches, by the use of a solution of phenolphthalein.

The white of two eggs well beaten is now added—to clear the media—and the whole boiled vigorously for half an hour. It is then filtered through a thick layer of sterilized cotton into a flask, and should form a perfectly clear, slightly yellowish mass which is quite firm and solid on cooling. It is now filled into test tubes which have been plugged with cotton and sterilized by heating for an hour in a

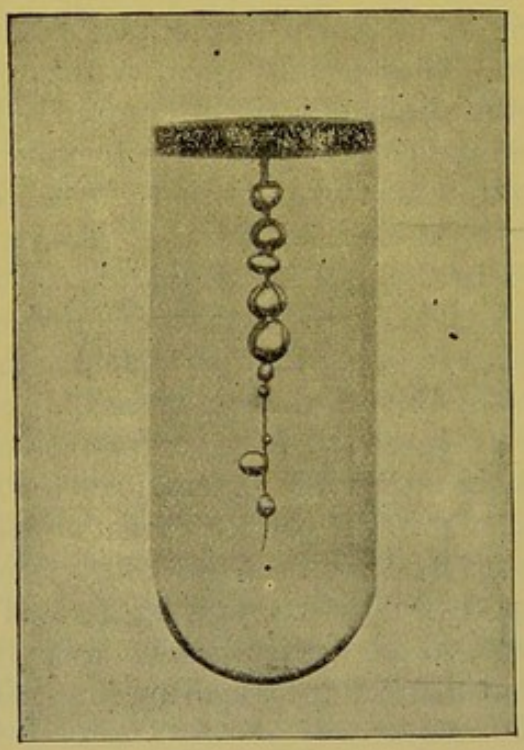

FIG. 56.—A TUBE OF SOLID TRANSPARENT NUTRIENT GELATIN.

Showing growth of bacteria with formation of gas along the line of inoculation by a needle plunged into the solid gelatin and withdrawn. The bacterial masses are held fast where they grow, and the gas bubbles cannot escape through the solid media.

dry oven at 160° C.—about two inches in depth of the material being put into each tube—and these are steamed for twenty minutes to half an hour, and again for an equal period on the following day, when they are ready for use (see Fig. 56).

*Nutrient Agar.*—This is made and filled into tubes in the same way as the nutrient gelatin, save that one per cent of the agar is added in place of the gelatin. As the agar is less readily soluble than the gelatin, it will have to be boiled longer on the water bath before neutralizing. After the last sterilization the agar tubes are placed in a slanting position to cool, so that the agar may present a long, oblique surface (see Fig. 57).

The *Nutrient Broth* is made in the same way, save that no solidifying material is added and it may be filtered through paper.

*Milk.*—This should stand in the ice chest for a few hours, so that the cream may be removed. The milk is then filled into sterile

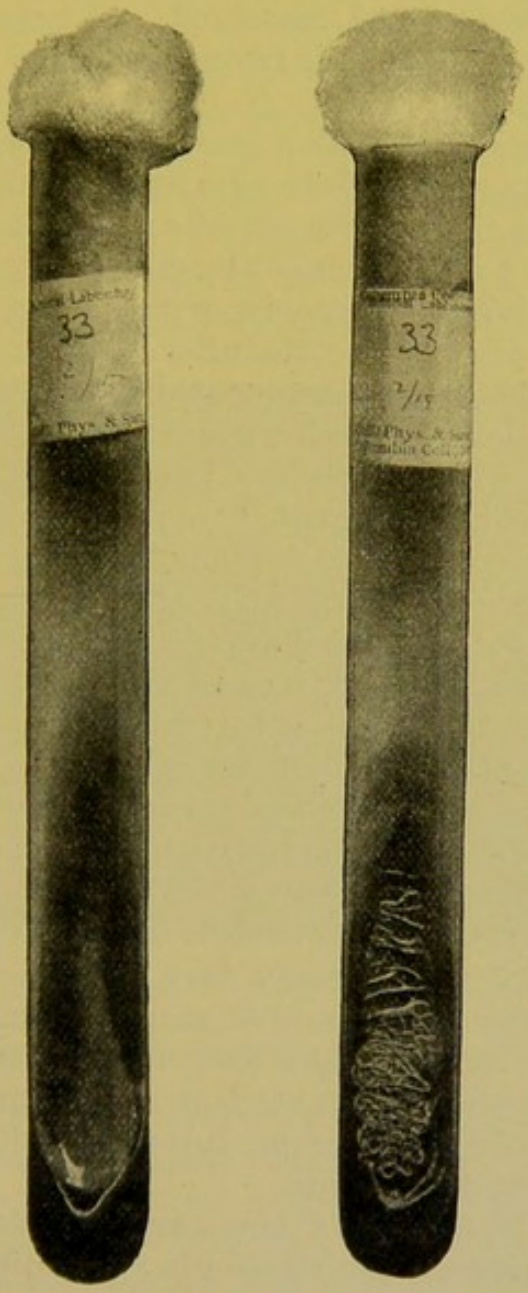


Fig. 57.

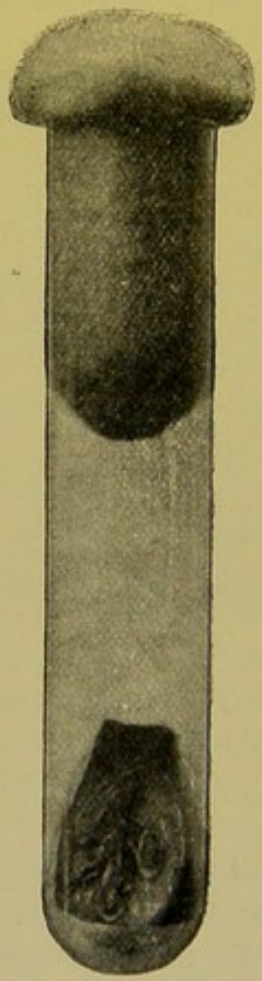

Fig. 58.

Fig. 57.—Pure Culture of Bacteria on Nutrient Agar in Sterilized Tubes. Showing at the left a smooth, at the right a wrinkled growth upon the surface.

Fig. 58.—A Culture of Bacteria on Potato. In a tube plugged with cotton and then sterilized.

cotton-plugged test tubes, and steamed for half an hour on three successive days.

To these culture media various substances may be added which

serve to exhibit one or other functional capacity of the germ under observation. Thus to the nutrient agar or gelatin litmus is sometimes added to reveal the presence of acids, should these be developed in the complex metabolism of the growing germs. Sugar may be added to the nutrient bouillon and the culture so arranged that should gases be developed they may be collected, measured, and tested in a closed arm of the culture tube. Glycerin is frequently added to culture media.

*Potatoes.*—The potato is scrubbed with a brush under the water faucet and the ends cut off with a knife, leaving a segment about an inch and a half long. With a tin cylinder about an inch in diameter, made like an apple corer, a cylinder is cut lengthwise out of the potato segment, and this is divided lengthwise with the knife into two oblique sections. These pieces of potato, after lying for a few minutes in running water to prevent subsequent discoloration, are placed, the narrow end up, in large test tubes about five inches long and a little more than an inch wide, which have been plugged at the mouth with cotton and sterilized. These tubes are now steamed for an hour and again for an hour on the following day.[1]

*Blood Serum.*—The blood should be drawn from the vein at the slaughter house, with as little contamination as possible, directly into sterile jars. When the blood has clotted, a clean glass rod may be passed around the clot to free it from the sides of the jar, and the whole set aside for twenty-four to forty-eight hours in an ice chest. During this time the clot contracts and the serum is expressed.

The clear colorless serum is then distributed with a sterile pipette into sterile test tubes, 4 or 5 c.c. in each tube. The serum may now be coagulated by heating the tubes, set aslant in a dry oven, at from 80° to 90° C. Then on three successive days it is steamed at 100° C. for twenty minutes. Or, the tubes containing the fluid serum may be set aslant and kept for two hours at a temperature just below 100° C. so that the serum will solidify but not boil. It is important for certain purposes to use human blood serum; this may be obtained in small quantities from the human placenta.

The use as culture media of pleuritic ("chest serum") and other transudates into the serous cavities, either alone or in association with agar, is important in certain lines of work.[2]

The addition to the blood serum before coagulation of one-third of its volume of nutrient bouillon to which ten per cent of glucose has been added affords a medium (Löffler's blood-serum mixture)

[1] Since the reaction of potatoes varies considerably, it is well to control this and secure a neutral or slightly alkaline reaction in the whole batch by soaking in dilute alkali before tubing and sterilization.

[2] Consult *Heiman*, New York Medical Record, June 22d, 1895.

very favorable to the growth of the diphtheria bacillus, which is much used in the culture method of diagnosis in that disease.

Having thus seen how some of the nutrient media are prepared, let us see briefly how they are used in studying the bacteria.

In the first place, it is necessary to get from the various mixtures of several species, as they are apt to occur in nature or in diseased parts, single species growing by themselves, so that their life history and characters may be studied in detail. To show by an example how this is done, we will suppose that we have a sample of milk containing bacteria, and wish to learn how many there are and of what species, and to get them into separate receptacles for study. We melt the gelatin in one of the test tubes, prepared as above described, which we know to contain no living bacteria—because we



FIG. 59.—A PETRI GELATIN PLATE CULTURE OF BACTERIA.

In one plate there are few colonies showing difference in size and character. In the other the colonies are much more abundant. (From a milk culture prepared by Dr. Freeman.)

have sterilized both the tube and its contents by heat—and add to it a measured volume, usually 1 c.c., of the milk, and mix them by gentle shaking; we now take a shallow covered glass dish called a Petri plate (see Fig. 59), which has been sterilized by heat, lay it upon a cold surface, and pour out the mixture of water and nutrient gelatin in a thin layer upon it. When the gelatin solidifies, the invisible germs which the milk contained are caught and held in position by it, and if the whole be now set away in a sufficiently warm place the living bacteria will presently commence to grow.

After a few hours or days, from each one of the single living bacteria scattered through the gelatin so many new germs may have developed that they form a mass, called a colony, large enough to be visible to the naked eye. As different species grow in different ways,

some forming colored colonies, some fluidifying the gelatin, some growing much more rapidly than others (see Fig. 60), we can usually recognize the difference in species either with the naked eye or under the microscope, and with a fine, sterilized platinum needle can pick out portions of the different colonies and transfer them to the tubes of nutrient media of one kind or another which we have prepared, and study their growth there in the form of pure cultures.

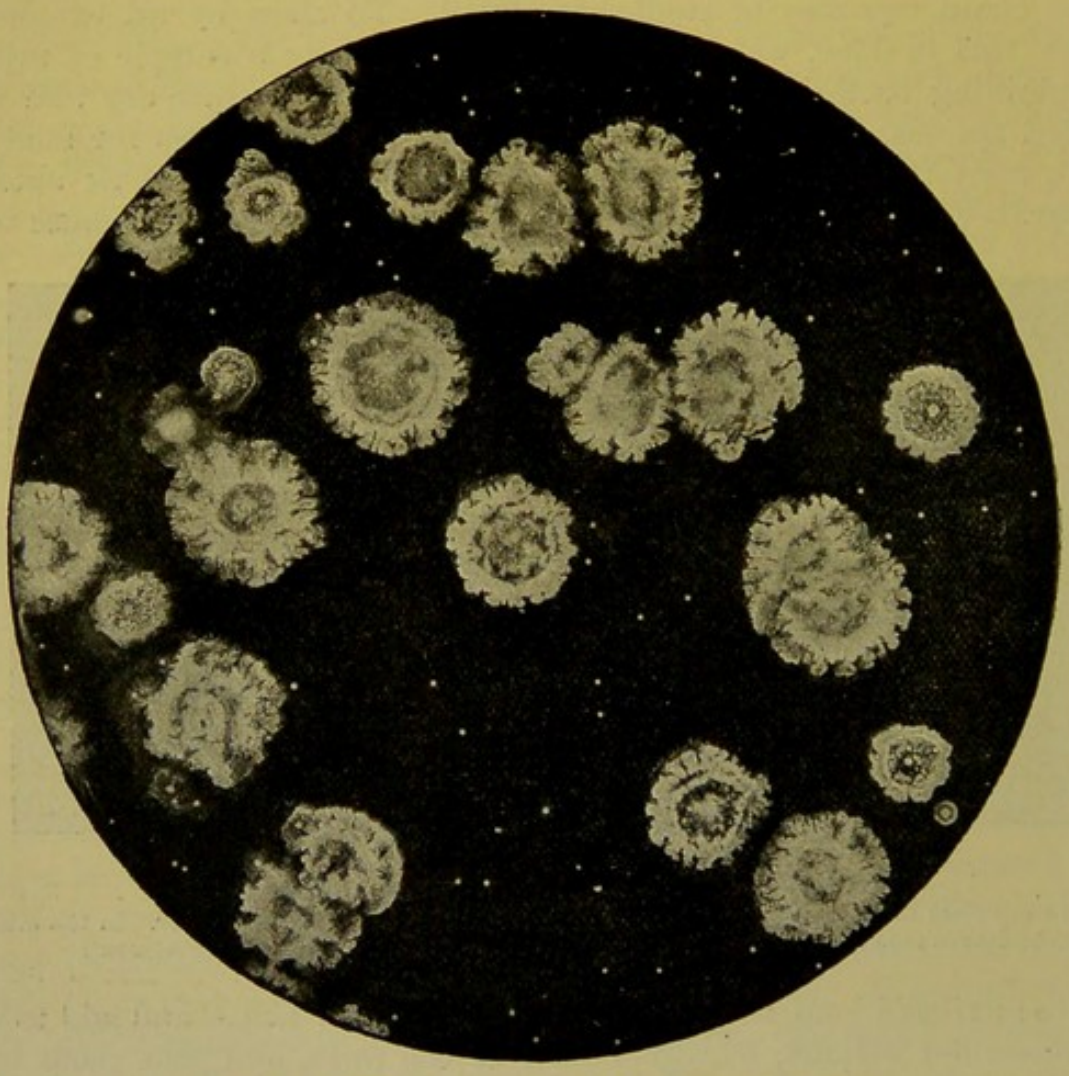

FIG. 60.—A PETRI GELATIN PLATE CULTURE OF BACTERIA.

Showing colonies of various shapes and sizes; the larger colonies are formed of bacteria of different species from those which form the small ones, and which were mixed together in the fluid (milk) originally planted in the gelatin plate. The plate is more highly magnified than in Fig. 59.

The transfer of the germs to the tubes is made by plunging the needle which has touched the plate colonies down into the gelatin (Fig. 56) or agar, or drawing it over the surface of the potato. This is called inoculating the culture media.

Not infrequently it is necessary to use the agar culture medium for plate cultures, because many disease-producing forms of germs do

not grow at a temperature below that of the body, at which gelatin fluidifies.

In many cases, especially when we make agar plate cultures, we do not mix the material to be studied with the fluidified culture medium and then let it cool, but spread the material in very thin streaks, with a sterilized platinum needle, over the surface of the already cooled nutrient film. Then setting the culture, carefully



FIG. 61.—PETRI'S AGAR PLATE CULTURE OF BACTERIA FROM THE MOUTH.

Made by streaking the surface of sterilized nutrient agar—previously poured into the shallow dish and cooled—with scrapings from the mouth, and allowing to stand in a warm place for forty-eight hours. The lighter spots are the "colonies" or masses of germs of various forms which have grown from the invisible germs of the mouth.

covered, in the incubator, we await the development of colonies along the surface streaks (see Fig. 61).

Instead of pouring the melted nutrient gelatin or agar in which germs have been sown into the bottom of a flat dish, a small quantity of the mixture may be put into a sterilized test tube, the cotton plug replaced, and the whole cooled by twirling the tube horizontally in cold water or upon a block of ice.

Thus the nutrient medium forms a thin, transparent lining to the tube in which subsequent colonies are readily seen. Such cultures are known as Esmarch roll cultures or roll tubes.

By the use of this principle of the plate culture, sometimes with one form of nutrient medium, sometimes with another, and with various modifications of the technique, the species of bacteria can be separated and each studied by itself.

Anaërobic germs may be cultivated in an atmosphere of hydrogen, the air in the closed culture receptacles being replaced by this gas. Or the oxygen may be removed from this confined portion of air in contact with the cultures by chemical means. A description of the various simple and complex devices for anaërobic cultivations falls beyond the scope of this work.

The most scrupulous care is required in sterilizing the nutrient media and the utensils and instruments used, and the greatest caution should be exercised, in transferring the bacteria from one receptacle to another, to prevent contamination. A large experience in this



FIG. 62.—STERILIZED COTTON SWAB IN A STERILIZED TUBE FOR COLLECTING FLUIDS CONTAINING BACTERIA.

sort of manipulation is necessary before reliable results can be obtained in original investigation, since the slightest error or carelessness in manipulation, or failure to observe the occurrence of contamination, are liable to entirely vitiate the results of long series of experiments. It is only by an extended preliminary training in the cultivation of some of the more characteristic and easily recognizable forms, under a variety of conditions, in a perfectly pure state, through a series of generations, that one can be assured of his capacity to carry on researches in this most difficult and intricate field.

The methods of inoculation of animals with pure cultures, and the precautions to be observed, as well as a description of the various forms of apparatus made use of in practical bacteriology, must be sought in more extended treatises on this subject.

It is wiser for one purposing to carry on bacterial researches to gain a practical acquaintance with methods and apparatus in a well-appointed laboratory, than to make the attempt to work out the methods from books.

Material obtained from the human body which is to be subjected

to bacterial examination should be collected with every precaution against accidental contamination.

A convenient mode of collection and transportation of small quantities of fluid or semi-fluid material, such as exudates, discharges, etc., for purposes of bacterial examination is to twist a small wad of absorbent cotton on to the end of an iron or steel wire about five inches long, put this, swab end foremost, into the tube (Fig. 62), plug the mouth with cotton, and sterilize the whole in a dry oven for an hour at 160° C.

Several of these cotton swabs may be prepared at once and kept on hand. The swab, carefully removed and saturated with the material to be examined, is at once returned to the tube; this is plugged, and may be so safely transported.

### BACTERIAL EXAMINATION OF POST-MORTEM SPECIMENS.

It is often important to make a thorough post-mortem examination by cultures as well as morphologically of the blood and of all the viscera. This is not only important in those cases which during life gave clinical evidence of general infection, but also in many forms of disease whose nature is still wholly obscure.

In the interpretation of the results of all such examinations, however, it should be borne in mind that after death a new distribution of germs may occur, and that from the gastro-intestinal canal and from other surfaces or cavities of the body micro-organisms may, as decomposition progresses, penetrate the tissues and the viscera.[1]

A careful consideration of the general conditions under which the body has been kept and its state of decomposition is of especial importance in the interpretation of the significance of the Bacillus coli communis, which is always present in such enormous numbers in the intestinal canal and which is not only apt to effect wide distribution in the body after death, but as a result of careless manipulation is liable to be accidentally brought in contact with other viscera after the opening of the gut. The preparation of cover slips for staining and the making of cultures is as a rule best done at the autopsy table.

It is well as each organ is exposed—commencing with the heart—to sear the surface of the organ to be examined with a broad-bladed knife heated over a flame, and then, making an incision through the seared surface with a sterilized scalpel, to press one of the above-mentioned sterilized cotton swabs into the opening and absorb the juices which exude, or to pick out a small fragment of the solid tissue from the depths of the opening; and then with the material thus procured make the required cultures and afterward the cover-slip smears for staining.

[1] Consult *Achard* and *Phulpin*, Arch. de med. Experimentale, January, 1895.

If it be necessary to transport the material to the laboratory before making cultures, it is well to reserve the unopened organs, or large portions of these in the case of the solid viscera, and to wrap each separately in a cloth saturated with sublimate solution, or to put each in a separate sterile receptacle for transportation.

Welch, Wright and Stokes, and Flexner have published the results of series of systematic post-mortem examinations of the viscera for bacteria.[1]

## II. YEASTS.

These micro-organisms—mostly saprophytes—consist of oval or spheroidal cells with granular protoplasm and a thin membrane. They multiply by sprouts or buds from the parent cell. The new individuals may separate from the old, or may cling to them so that chain-like combinations may occur (Fig. 63). Some species of yeast set up fermentation in fluids containing sugar. Some grow to



FIG. 63.—YEAST—Saccharomyces.

a certain extent in the stomach and in the bladder in diabetes, but they appear to be usually of little importance in human pathology.[2]

## III. MOULDS.

The moulds are considerably more complex in structure than either the bacteria or the yeasts. Some of the forms are very common and universally known. In general, it may be said that the moulds consist of a series of delicate, translucent, jointed threads—*mycelium*—from which, either directly or through the intervention of a special structure, the *sporangium*, the spores are developed (Fig. 64). The moulds which are apt to occur in the human body may be of the former, more simple, or of the latter, more complex type.

Among the simpler forms of moulds which occur in the body may be mentioned the Achorion Schönleinii, Microsporon furfur, Trichophyton tonsurans. There is a close morphological resemblance between these forms.

---

[1] *Welch*, "A System of Surgery by American Authors," *Dennis*, p. 311. *Wright and Stokes*, Boston Medical and Surgical Journal, March 21st and 28th, and April 4th, 1895. *Flexner*, Trans. Assoc. American Physicians, 1896.

[2] *Rabinowitsch*, "Pathogene Hefearten," Zeitschrift f. Hygiene, etc., Bd. xxi., 1895.

*Achorion Schönleinii*, the favus fungus, is formed of a much-branching mycelium from which the spores are directly developed (Fig. 65). It grows readily on artificial culture media, such as nutrient agar and gelatin, at the temperature of the body. This



Fig. 64.—Aspergillus Glaucus.
Showing mycelium, from which arise the spore-bearing structures.

fungus is most apt to grow upon the hairy part of the head, where it forms small surface crusts and grows into the shafts and root sheaths of the hair, exciting inflammation in the adjacent tissue.

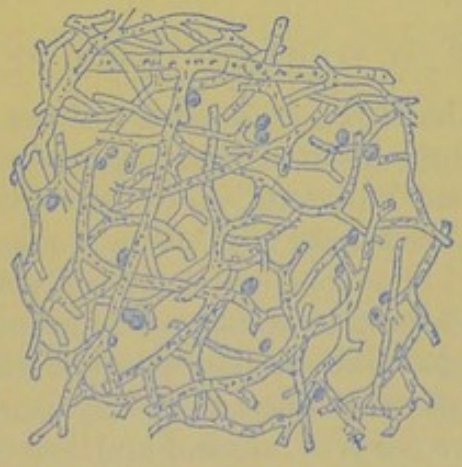

Fig. 65.—Achorion Schönleinii—Favus.
From a culture.

*Trichophyton tonsurans* develops in the form of a moderately branching mycelium, forming comparatively few spores. It grows in the skin, either about or apart from the hairs, or in the nails, pro-

ducing the lesions of various phases of herpes, which differ considerably, depending upon the particular structures involved. At body temperature it grows readily on artificial culture media, differing markedly in appearance from Achorion, to which it is morphologically quite similar.

*Microsporon furfur*, the mould fungus causing pityriasis versicolor, is more prone than the Achorion to the development of many spores, but otherwise considerably resembles it morphologically. It has not yet been cultivated on artificial media. By its infiltration of the epidermis, especially of the body and upper extremities, it causes larger and smaller yellowish or brownish patches.

The more complex types of moulds are only occasional dwellers in the human body and appear to be but rarely the cause of disease, passing, rather, a saprophytic existence on dead material in parts of the body which are in communication with the air. Thus they may be found growing on accumulations in the external auditory canal, in dead tissue in the lungs, on walls of cavities, dilated bronchi, etc.

A lowly form of micro-organism frequently found growing in the mouth and fauces and œsophagus of children, in the form of a whitish pellicle—aphthæ—is the so-called *Oidium albicans*, which consists of branching, jointed threads and spores which penetrate between the epithelial cells. This fungus may assume considerable importance, when in very feeble children it blocks the œsophagus, or when, as is rarely the case, from the surface of ulcers it penetrates the blood vessels and gives rise to visceral metastasis. The exact relationship of this fungus to the moulds is not yet very clear.

### METHODS OF STUDYING YEASTS AND MOULDS.

The yeast organisms are in general stained and cultivated by the same methods as those used in studying the bacteria. The moulds may be simply teased and studied in glycerin or in glycerin and water. They may be stained with dilute aqueous fuchsin solution or with alkalin-methyl-blue solution (Löffler's solution, see page 158). When spores have formed in considerable numbers on the more complex forms of moulds, these are not easily wetted by the usual staining fluids, because the air clings so closely among the spore masses. In a mixture of four parts of alcohol and one of aqueous solution of ammonia they are instantly wetted, and may then, with or without staining, be teased and mounted in glycerin. In studying the fungus masses in the above-described skin diseases it is well, when crust-like masses are to be teased apart, to allow them first to soak for a few moments in a five-per-cent solution of caustic potash. In this solution they may be studied, or they may be teased and mounted

in glycerin for preservation. Most of the more common moulds are readily grown on the ordinary culture media.[1]

## THE RELATIONS OF BACTERIA TO DISEASE.

Bacteria are invariably present in greater or less numbers in the mouth, nose, upper air passages, gastro-intestinal and genito-urinary tracts of men and animals.[2]

Into these places they are more or less constantly brought by the respired air, by food and drink, and in other ways. But common and often abundant as are these germs upon the external and internal surfaces of the body, they do not pass through the healthy mucous or cutaneous surfaces, so that under normal conditions the tissues, the viscera, and the circulating fluids are germ-free.

Except for certain pathogenic forms which may under unsanitary conditions have been set free and transported from men or animals suffering from infectious disease, the bacteria upon the cutaneous or mucous surfaces of the body are for the most part harmless; while certain intestinal forms may even be useful in promoting digestion.

Certain bacteria which do not often and some which never induce disease, find in or upon the human body such favorable conditions for their existence that they are commonly present there. The Bacillus lactis aërogenes and the Bacillus coli commune in the intestines, the Leptothrix in the mouth, the pyogenic and other bacteria of the skin, vagina, etc., exemplify the germs which find in the human body a favorite habitat.

The body is guarded in various ways from the incursions of pathogenic and other bacteria, which may be commonly present or only occasionally lodged upon its surfaces. Among the protective agencies of the body may be mentioned the firm, dense skin which while intact protects the interior from the entrance of almost all known micro-organisms; the epithelial investment of the mucous membranes in several places swept by cilia; the protected situation of most of the mucous surfaces.

Furthermore, the lymph nodes are important features in the protective mechanism of the body, frequently filtering out of the lymph micro-organisms which have entered the body juices and holding them back from the general circulation.

---

[1] For résumé and bibliography of relationship of yeasts and moulds to human diseases consult *Ricker*, "Ergebnisse der allg. Aetiologie des Menschen- u. Thierkrankheiten," Abth. i., 1896, p. 892.

[2] For a summary of facts concerning the bacterial flora of the body surfaces, consult *Welch*, "Surgical Bacteriology," "System of Surgery by American Authors," *Dennis*, p. 250 *et seq.*

Finally, the power of certain of the body fluids and of living cells under favorable conditions to kill and dispose of germs, should these gain entrance through injuries or other structural lesions or functional disturbance in the barriers, is of great importance and will be referred to again.

On the other hand, the cells and tissues in the vicinity of bacteria which have gained access to the body may show very marked alterations, which are presumably due to their influence. The cells may be swollen, their nuclei may break down or disappear, and the protoplasm may be converted into a mass of shining or coarsely granular particles, or may completely disintegrate. The intercellular substance near the bacteria may also soften and disintegrate. In a

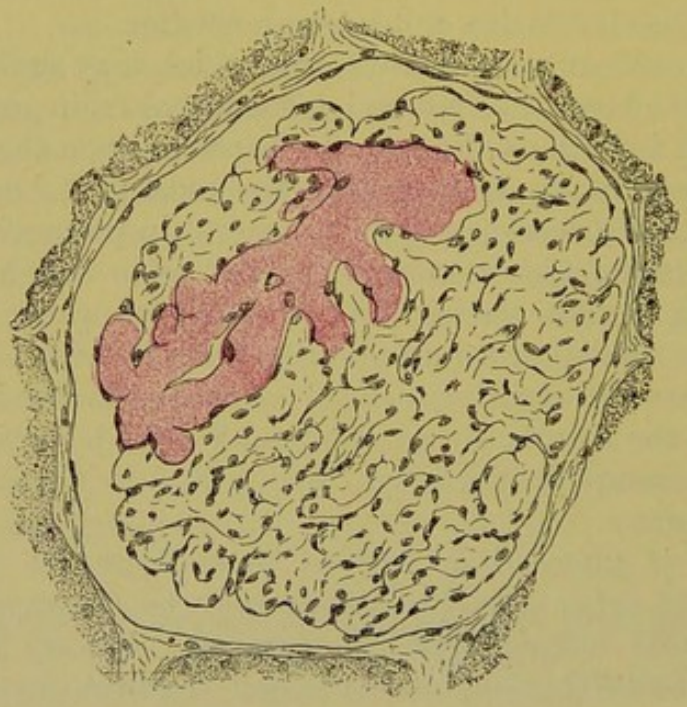

FIG. 66.—BACTERIAL EMBOLUS IN THE BLOOD VESSELS OF THE GLOMERULUS OF THE KIDNEY IN MALIGNANT ULCERATIVE ENDOCARDITIS.

word, the tissue in their immediate vicinity is often found in a condition of necrosis of one kind or another. The walls of blood vessels near which they lie may die, and the blood which these carry may form thrombi. The bacteria may themselves enter the vessels and proliferate in the blood; they may be swept away as emboli to remote parts of the body (Fig. 66), and establish new foci of bacterial proliferation and tissue necrosis.

But the presence of the micro-organisms themselves is not necessary for the causation of small foci of necrosis in the tissues. These may be caused by the toxic agents alone circulating in the body fluids (Fig. 67). This form of lesion is very frequent in the infectious

diseases of the toxæmic type. Similar local effects may be induced by other poisons than those of microbic origin.[1]

Some bacteria, instead of inducing a simple necrosis, incite at the same time more or less intense inflammation (Figs. 68 and 294). This inflammation may be of a simple productive form, similar in its effects to that produced by the presence of any irritating foreign body; or it may be active, progressive, and exudative in character; or the bacteria may determine, in some way as yet unknown to us, very peculiar and characteristic inflammatory changes, which result in the formation of new tissues of various kinds (see Tuberculosis). Some forms of bacteria find in the blood, others in the lymph spaces and vessels, the conditions most favorable for their proliferation.

When we inquire more closely into the exact way in which these

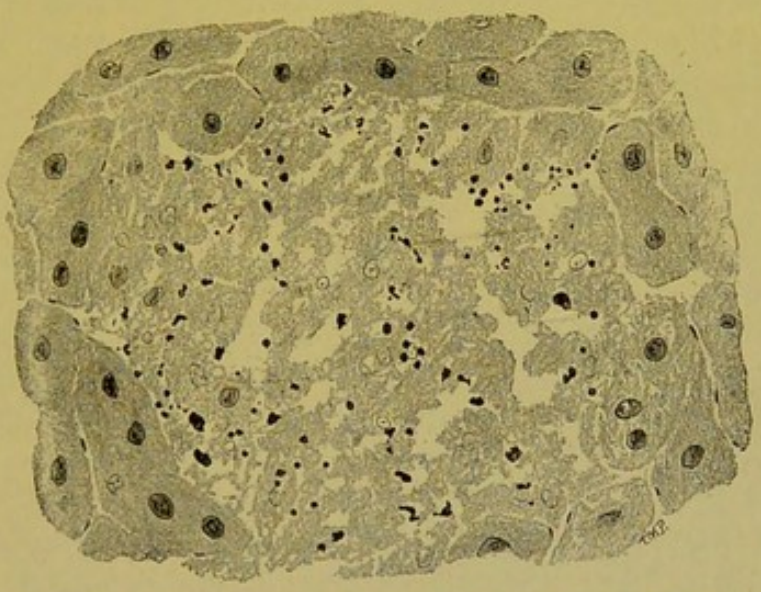

Fig. 67.—Small Focus of Necrosis in the Liver caused by Toxic Material of Bacterial Origin.

various deleterious effects are produced in the body by pathogenic bacteria, we find that they are in but small measure simply mechanical. They appear to be largely due to the various chemical products eliminated or stored up in their protoplasm by the metabolism of the germs. These deleterious bacterial products may, as we have already seen, be those alkaloidal substances called poisonous ptomaïns or *toxins*, or they may be albuminoid substances—*toxalbumins* or *toxalbumoses*. Stored up in the protoplasm of the germs themselves, this poisonous material has been called *bacterio-protein*.

The chemical constitution of these varied products is so complex and little understood, and the conditions under which they are

[1] Consult *Flexner*, "The Pathologic Changes caused by Certain So-Called Toxalbumins," Medical News, August 4th, 1894.

developed, and the parts of the body to which they are spread and on which they may act, are so varied, that it is not possible to make very positive statements to-day as to their individual characters or the nature of their action.[1] Some of the poisons act locally at or near the seat of their manufacture by the growing germs. Others gain access to the body at large and are widely distributed, inducing what may be called the phenomena of septic *intoxication—toxæmia*.

The phenomena of septic intoxication may be induced by the pro-

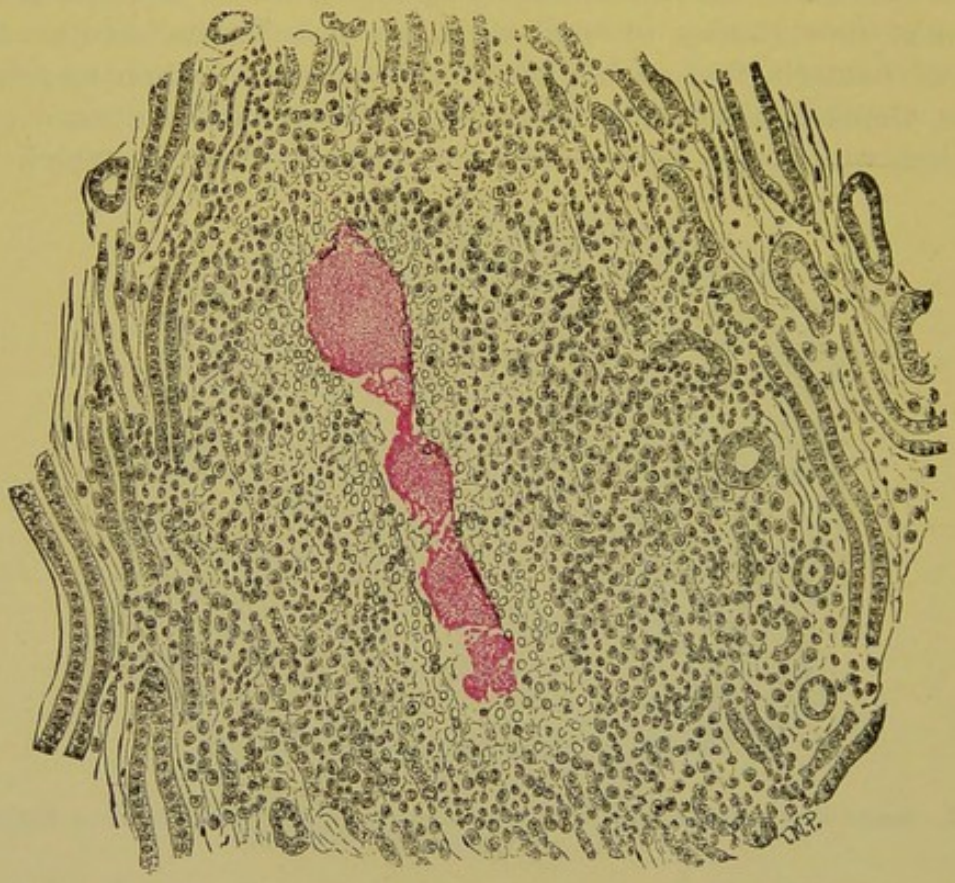

FIG. 68.—COLONIES OF MICROCOCCI IN A BLOOD VESSEL OF THE KIDNEY, CAUSING A SMALL ABSCESS. From a case of pyæmia.

Around the dilated and partially necrotic blood vessel in which the bacteria lie is an area of necrotic tissue and a small-celled infiltration or zone of pus.

ducts of bacterial growth outside of the body when these in considerable quantity are in any way taken into it. This is true not only of poisons elaborated outside the body by pathogenic bacteria, but also of many forms of bacteria usually harmless. Thus are caused many forms of food poisoning which simulate but are not actually infectious diseases, because there is no development within the body of

[1] Much of the literature on this subject has been brought together by *Vaughan and Novy*, "Ptomaines and Leucomaines," 3d ed., 1896. The general chemical relationship of bacterial products to other organic compounds is set forth in *Halliburton's* "Text-Book of Chemical Physiology and Pathology."

the disease-producing germs. It should be remembered also that toxic effects closely resembling those due to bacterial poisons may be caused by toxic agents developed within the body as a result of defective elimination or faulty cell metabolism.

It has been found that the proteid constituents of the protoplasm of various species of bacteria, both parasites and saprophytes, are capable, when set free by the disintegration of the germs in the body, of attracting leucocytes in large numbers to their vicinity. This drawing of living cells by chemical agents is called *chemotaxis*,[1] and it seems probable that the gathering of cells in suppurative foci may be due to the chemotactic power of the bacterial protein of the disintegrating germs which have gathered there.[2] This chemotactic power is not confined, however, to the bacterial protein, but is exhibited by proteids from a great variety of sources. It has furthermore been shown that bacterial proteids are capable of stimulating cell proliferation. This has been shown in the case of leucocytes and many other forms of cells (see action of the bacterial protein of the tubercle bacillus, page 223).

It will be seen, from what has now been said of the bacteria, that in different parts of the system in health, and in a large number of abnormal conditions, various forms of bacteria occur; but it is quite evident that the significance which we must attach to their mere presence varies greatly. In a large number of cases, especially when on parts exposed to the air or in the gastro-intestinal canal, they are evidently of no more importance than so much inorganic dust. When, however, special forms of bacteria are found to occur uniformly in connection with well-defined diseases, or in their lesions, the conjecture is certainly justified that they may have something to do with their production. Yet in all such cases we have to consider the possibility that it is the abnormal state of the body or the character of the lesion, produced perhaps by other causes, which affords conditions suitable for bacterial growth, and that they may consequently occur in considerable numbers, while in the absence of these conditions they would be unable to develop. Even the constant occurrence in the body, in certain diseases, of bacteria which evidently produce well-marked local effects, either inflammatory or degenerative, does not absolutely prove their causative relation to the disease, although it renders it in a high degree probable.

It is desirable in every case in which the evidence of the causative relationship of a specific micro-organism to a disease is to be set

---

[1] *Negative chemotaxis* is the repelling of living cells by chemical substances.

[2] For a résumé of observations on chemotaxis see New York Medical Journal, June 6th, 1891.

forth, that we should be able to demonstrate the constant presence in the body of the special form of micro-organism, obtain this by culture in a pure condition unmixed with any other living thing or with any chemical substance not belonging to it, and finally, by the introduction of the purified organisms into a healthy animal, be able to produce the disease in some definite form. When all this is done, and not before, can we assert that the evidence establishing the causative relationship between a given form of bacteria and any special infectious disease, is entirely at our command.

But the fulfilment of these strict logical requirements is very difficult in many cases, and in some, apparently, almost if not quite impossible; for we must remember, in the first place, that the lower animals, upon which alone, for the most part, inoculation experiments are practicable, are apparently not subject to certain important diseases of man; and, second, that they present among themselves the most marked differences in the degree and manner in which they are affected by inoculation with pathogenic bacteria. Desirable as is the complete fulfilment of the above requirements in every case, it must be admitted that a reasonable certainty regarding the bacterial origin of a given disease may be arrived at without positive results from the inoculation of the bacteria associated with its lesions.

The discussion of the probabilities of the bacterial origin of certain classes of disease, and the long series of phenomena exhibited by them, which the bacterial theory very satisfactorily explains, does not fall within the scope of this book.

The complete demonstration which is desirable has as yet been furnished in but a moderate number of cases. In many others, however, enough has been done in the way of study and experimentation to render it altogether certain that the diseases are infectious and to establish beyond reasonable doubt the identity of the micro-organism or micro-organisms involved.

*Conditions Influencing the Occurrence of Infectious Diseases.*—It has been learned, as the result of a great deal of observation and experiment, that although certain diseases are invariably caused by the presence and growth in the body of particular species of micro-organisms, and never occur without them, there are still various other accessory factors which have an important bearing upon the inception and course of the diseases. Thus, while the presence in the body of a particular species of micro-organism is the most significant and fundamental of the determining agencies in the infectious diseases, the numbers in which they are present—*i.e.*, the size of the dose—and the varying virulence which the same species under different conditions possesses, as well as the varying capacity of resistance to the incursions of the germs which the body cells at

different times and under differing conditions exhibit, are all factors of the greatest moment.

It should be always borne in mind that the human body is a great aggregate of groups of co-ordinated cells which, under normal conditions, all act in harmony for the maintenance of the life and functions of the individual. The cells and cell communities in health not only do this, but they have the power of resisting and to a certain extent overcoming the various deleterious agencies to which the body is more or less constantly liable.

What we call hereditary or acquired predisposition to an infectious disease, such as tuberculosis, for example, is simply a lack of the usual capacity of the cells of the body—whether through a structural or physiological fault we do not yet know—to cope with the destructive tendencies of the living micro-organisms when once these gain a foothold in the body.

We thus see that, in studying the conditions under which infectious diseases occur, the work is by no means complete when we have demonstrated the bacterial species which causes the disease, but that then the more obscure determining and influencing agencies must be worked out in each particular case.

## INFECTION AND IMMUNITY.

*An infectious disease is one caused by the entrance into the body and proliferation there of pathogenic micro-organisms.*

The fact that all animals are not equally susceptible to the ravages of pathogenic micro-organisms, and that in man an individual and often a changing predisposition or invulnerability to the incursions of these organisms exists; the further observation that one attack of an infectious disease often protects the victim for a longer or shorter time against a recurrence; finally, the fact that recovery is ever possible when once self-multiplying disease-producing germs have obtained a foothold in the body—all these facts and observations are of such singular import and interest that, especially of late years, much study has been expended on the nature of the forces which the body brings into play in establishing immunity in the face of microbic invasion, and in coping with the various deleterious agencies at work when once a foothold is obtained. The scope of this book does not permit us to enter in detail into this most fascinating and important field. But some conception of recently acquired facts is indispensable for the comprehension of acute infectious diseases and of the lines along which we may confidently anticipate success by new methods of treatment.

*Immunity is insusceptibility, or capacity for resistance on the part of the body, to infection or its effects.*

Immunity from an infectious disease may be *hereditary*.

Thus our domestic animals enjoy a natural or hereditary immunity from many of the infectious diseases of man; while among themselves some animal species are susceptible, others not, to the same disease.

On the other hand, immunity may be *acquired*. Acquired immunity may be effected by an attack of the disease from which the individual has recovered—*natural immunization*—or by the introduction into the body of some material which gradually diminishes susceptibility without inducing distinct disease—*artificial immunization*. Acquired immunity may be transmitted from parent to offspring.

Most of the infectious diseases appear to confer a certain degree of insusceptibility to subsequent attacks of the same disease, though this may be partial and temporary. But the exanthemata afford the most striking examples of acquired immunity after an attack of infectious disease.

It is well known that bacteria artificially introduced into the blood of animals may after a short time wholly disappear from the circulating fluid and be found in large numbers in leucocytes and other cells.

It is believed that certain cells of the body are capable not only of taking up micro-organisms which get into the tissues, into their protoplasm, but of there killing and perhaps digesting them, and that thus the destruction of germs in the body may be brought about.[1] The cells which take up into their bodies the micro-organisms, as well as other foreign bodies, are called *phagocytes*. This mode of destruction of micro-organisms, largely by leucocytes but also by other mesodermal cells, forms a most suggestive and fascinating study, but its full significance and importance are not yet determined.

On the other hand, certain albuminous ingredients of the body juices, "*alexins*" or "defensive proteids," have been shown to possess marked germicidal powers, which may be of extreme importance in protecting the organism. But how important this is we cannot yet say.

While thus two fairly distinct influences are believed to be of

---

[1] The elimination of micro-organisms from the body through its secretions, such as urine, bile, milk, sweat, saliva, etc., is a matter of great significance, but which the scope of this book does not permit us to enter upon. Consult *Sherrington*, "Experiments on the Escape of Bacteria with the Secretions," Journal of Pathology and Bacteriology, February, 1893; *Biedl and Kraus*, Arch. f. exp. Path., Bd. 37, p. 1, 1895, Bibliography; and *Hintze and Lubarsch*, "Ergebnisse der allg. Aetiologie der Menschen- und Thierkrankheiten," 1896, p. 287.

importance in enabling the body to resist the incursions of pathogenic germs—cellular or "phagocytic" and what may be called the "humoral" or chemical—it is obvious that ultimately whatever protecting power the body possesses must be due, directly or indirectly, to cell activities.[1]

But however incomplete our comprehension may be of the exact nature of the protective agencies of the body against pathogenic micro-organisms, the clinical and experimental data have led to and steadily encouraged the hope that artificial immunization might become an important factor, both in the prevention and in the treatment of certain forms at least of infectious disease.

If we briefly summarize the results of a vast amount of the most painstaking research in this direction, we find that in fact artificial immunization can be accomplished in several ways. These processes of artificial immunization depend upon gradually rendering the body tolerant in one way or another to the presence of the infective agencies without actually inciting the characteristic specific disease.

I. *In one class of procedures artificial immunity is conferred directly or indirectly through the action in the body of bacteria or bacterial poison whose virulence has been in one way or another reduced but not rendered altogether inert; or by the action in the bodies of relatively insusceptible animals of germs or germ poisons of unimpaired virulence.*

1. Insusceptibility to particular forms of infectious disease may be conferred by inoculation with cultures whose *virulence* has been *artificially reduced.* This reduction of virulence of the micro-organisms may be accomplished in various ways—by cultivation at temperatures above their optimum; by successive inoculations into insusceptible animals; by prolonged artificial cultivation in the presence of oxygen; by exposure to certain inorganic chemical substances, as the diphtheria bacillus to trichlorid of iodin, anthrax to bichromate of potash, etc.; by exposure of cultures to organic extracts or products of animal or vegetable cell metabolism; by drying or by exposure to sunlight; and in other ways.

With the virulence of the micro-organisms reduced in varying degrees in one or other of the ways just mentioned, the gradual habituation of the bodies of animals to the presence of pathogenic germs may be pursued until cultures of full virulence are tolerated.

---

[1] For a summary of the prevalent views on the cellular theory of immunity, with bibliography, consult *Metschnikoff.* "Ergebnisse der allg. Aetiologie der Menschen- und Thierkrankheiten," 1896, p. 298. For a summary of the chemical aspects see *Frank*, ibid., p. 344.

2. Immunity may be conferred by the injection, in gradually increasing doses, of the *metabolic products of bacterial growth*, either with or without the dead bodies of the germs themselves. The primary virulence of these usually toxic products of microbic growth may be in various ways diminished, by heating, by mixing with organic extracts such as that of the thymus gland, or with an inorganic chemical substance such as trichlorid of iodin.

3. Immunity may be secured in some cases by the inoculation of animals which are but moderately susceptible to the species employed, with small but increasing quantities of germs having *unimpaired virulence*. Under these conditions the animal becomes more and more unresponsive to the germ, until finally he may display no reaction after a quantity of the virulent culture which at first would have been inevitably fatal. Thus gray mice have been gradually made refractory to the typhoid bacillus, many animals to the diphtheria bacillus, etc.

II. *In a second class of procedures artificial immunity is conferred by the direct mingling of the body fluids of an already immune individual with those of the individual to be protected.*

1. Extracts of various organs and tissues of animals suffering from infectious disease, rendered germ-free and injected into healthy animals, have been found in some cases to confer a certain degree of immunity.

2. The blood serum of animals naturally immune to a particular infectious disease has been found on injection into those which are susceptible to the same disease to impart in some cases a certain degree of insusceptibility.

3. The blood serum finally of animals which have been rendered in one way or another artificially immune to certain diseases, if introduced under proper conditions into another susceptible animal, has been found not only to confer a temporary immunity, but if administered to an already stricken individual to aid him in the most marked and efficient way to overcome the deleterious agencies at work.

The knowledge of this immunizing and curative action of specially endowed blood serum has been most fully developed in diphtheria and tetanus. The application of a wide range of facts experimentally revealed in the lower animals has led to the opening of a new method for the prevention and control of infectious disease, which under the name of serum-therapy is not only full of promise but has already proved to be of inestimable practical value.

The fact that many of the pathogenic micro-organisms act harmfully upon the body largely through their self-engendered toxins, and

that the effect of the introduction of the blood serum of artificially immunized animals appears to be to neutralize this deleterious effect, has led to the use of the word *antitoxin* for the substance or substances, still unknown, which the serum of the immunized animal is presumed to contain.

The facts which have just been set forth seem to indicate that in the artificial immunization we are bringing into play and reinforcing the conservative agencies which under natural conditions the body commands. In the direct immunization of animals by the toxic product of germ metabolism considerable time is consumed in rendering available the protective agencies which the body finally secures.

On the other hand, in the employment of the blood serum of artificially immunized animals for protective and curative purposes we make use of the accomplished results of the protective mechanism of one animal for the more direct, speedy, and certain protection of another, and this effect is produced without those evidences of profound disturbance which the use of toxic agents frequently discloses. Moreover, the efficiency of the immunizing or curative blood serum is directly proportionate, as a rule, to the degree of immunity which the animal from which it is derived enjoys, and upon the amount of serum, or, which is the same thing, the amount of antitoxin introduced. Whether this substance, antitoxin, acts by directly neutralizing the poison which is determining the manifestations of the infectious disease, or whether, as seems on some accounts more probable, it stimulates the body cells which constitute the natural protective mechanism of the stricken individual to greater activity or to more purposeful accomplishment—these are questions of great theoretic interest which the knowledge of to-day does not enable us definitely to answer.

In the case of diphtheria the perfection of the process of artificial immunization and the establishment of a definite and successful curative method are the direct results of a long, patient, logical series of animal experiments with a definite end in view and by the use of the absolutely identified and well-known germ which causes the disease. On the other hand, it is not a little curious that in small-pox and in hydrophobia effective methods of immunization should have been perfected absolutely without knowledge of the micro-organisms which cause the diseases, and yet by procedures which, though somewhat empirically hit upon, are nevertheless in close accord with those which the most recent studies on immunity in general have shown to be effective. Thus in both small-pox and hydrophobia the material used for protective inoculation is that which has been artificially reduced in virulence; in the one case—small-pox—by its passage

through the body of a relatively insusceptible animal; in the other—hydrophobia—by drying in the air (see pages 272 and 277).[1]

[1] For a fuller treatment of the themes considered in this section the reader may consult the admirable article by *Welch*, "General Considerations Concerning the Biology of Bacteria, Infection and Immunity," "Text-Book of the Theory and Practice of Medicine," *Pepper*. *Hueppe's* "Naturwissenschaftliche Einführung in die Bakteriologie" is an excellent rational summary. For fuller exposition and bibliography see *Sternberg's* "Immunity, Protective Inoculations, etc."

The most comprehensive treatise on bacteriology is *Sternberg's* "Manual of Bacteriology." The works of *Heim*, *Hueppe*, *Frankel*, *Günther*, *Baumgarten*, *Klemperer and Levy*, and of *McFarland*, contain valuable technical and historical data.

The best laboratory manual for beginners is *Abbot's* "Principles of Bacteriology," 3d ed., 1895.

A comprehensive annual review of bacteriology, especially in its relations to the infectious diseases of men and animals, and indispensable for reference, is *Baumgarten's* "Jahresbericht über die Fortschritte in der Lehre von den pathogenen Mikroorganismen."

*Lubarsch and Ostertag's* "Ergebnisse der allg. Aetiologie der Menschen- u Thierkrankheiten" contains valuable résumés and bibliography.

A large part of the record of recent detailed study is widely scattered in monographs and journals.

# THE INFECTIOUS DISEASES.

*Infectious diseases* are those which are caused by the entrance into the body and proliferation there of pathogenic micro-organisms. *Infection* is the act or process by which such diseases are caused. In the more exact usage of the words infectious and infection which our new knowledge demands, it is customary and convenient to limit the term micro-organism to the fungi—bacteria, yeasts, and moulds—and (representing the animal kingdom to the protozoa), excluding altogether the entozoa and other animal parasites.[1]

The modern conception of infection implies the presence in the body of the *living* micro-organisms themselves, that is of something capable of multiplication, and not alone of the poisons which they may and usually do produce. It is customary to look upon the effects of the absorbed poisons which micro-organisms produce as *intoxications*,[2] whether these poisons be formed inside the body in infectious diseases or outside of it and subsequently introduced. That condition in which there is evidence of wide distribution of pathogenic micro-organisms and their products in the blood is called *septicæmia*. On the other hand, *toxæmia* may be appropriately used to indicate the condition in which, with a situation and development of micro-organisms largely local (or outside of the body altogether), such constitutional disturbance exists as indicates the distribution of toxic products in solution.

From this point of view diphtheria and tetanus are infectious diseases of the toxæmic type, while general anthrax infection and some of the severer phases of infection with pyogenic streptococci represent the septicæmic type. But it should not be forgotten that the greatest diversity exists in the local and general manifestations of infectious diseases, not only among the different diseases but also in the same disease; in different individuals, and even in the same individual at different times.

---

[1] With this somewhat arbitrary limitation, neither trichinosis nor scabies, for example, would be considered an infectious disease.

[2] Intoxication phenomena, in this sense, are not limited to those caused by the metabolic products of the fungi, whether parasites or saprophytes, but may be induced by various animal products also—snake venom for example.

With this diversity in view, one may for convenience assort the cases of infectious disease into: 1st, Those in which the manifestation of the disease is limited to a local lesion: 2d. Those in which there is, with or without demonstrable evidence of the seat of this local lesion, either (*a*) such constitutional disturbance as indicates distribution of toxic products, without dissemination of the micro-organisms themselves; or (*b*) a general dissemination of the micro-organisms as well as their toxic products. But if this grouping be adopted it should be with the clear understanding that such distinctions are applicable only in the comparatively few wholly typical manifestations of infection. For in most cases transitional phases, varying susceptibility, and doubt as to the place and nature of the primary lesion render difficult or hopeless the maintenance of close distinctions.

To-day we know definitely the particular organisms which cause some of the infectious diseases, and this knowledge, absolute and precise as it is in particular cases, enables us to assume with greater confidence than has hitherto been possible that the causative factor which in certain others of similar general characters still eludes us, will, when discovered, prove to be micro-organisms capable of indefinite multiplication and closely allied to those with which we are to-day familiar.

*Mixed or Concurrent Infection.*—It should always be borne in mind that the body which is already the seat of an infectious disease is usually especially susceptible to the action of other pathogenic germs, should these once gain entrance; and also that the lesions which are associated with many of the infectious maladies afford portals of entry through the skin or mucous membranes to other micro-organisms, against the entrance of which the healthy body opposes most efficient barriers. In fact, we now know that the action of two or more pathogenic micro-organisms in the body at the same time is of very frequent occurrence, many of the so-called complications of the infectious diseases being due to secondary infection with a new germ species.

Numerous examples of this "mixed" or, better, "concurrent," infection are noticed in other parts of this book.

A great many important facts have been revealed by the study of bacterial association in cultures as well as in infectious diseases of men and animals which cannot here be considered.[1] It may be said in general that in animals as in man the concurrent infection with a second micro-organism increases the gravity of the original situation.

On the other hand, certain series of experiments seem to indicate

[1] Consult *Th. Smith*, Trans. Association American Physicians, vol. 9, p. 85, 1895.

that the concurrent action of other germs—streptococci, for example, with the anthrax bacillus—may render the latter comparatively innocuous. But the conditions of the experiments are in either case so complex that the full significance of many curious phenomena is not yet apparent.

*Congenital Infections.*—Infection of the fœtus through such lesions of the placenta as permit of the passage of pathogenic micro-organism from the blood of the mother to that of the child is of occasional, but not frequent, occurrence.

While the barriers against such transmissions are, under normal conditions, effective, disturbance in the placental circulation, lesions of the vessel walls or of the tissues and covering of the chorionic villi favor it. But infection may occur without demonstrable evidence of such lesions.

Thus fœtal infection is known to have occurred in various phases of suppurative inflammation, in tuberculosis, typhoid fever, anthrax, syphilis, the exanthematous fevers, etc. There is considerable evidence that rarely the tubercle bacillus may be transmitted from mother to offspring, and remaining for a time inactive may later induce the characteristic lesions.[1]

*Terminal Infections.*—The victims of chronic disease of the heart, blood vessels, kidneys, liver, etc., are particularly susceptible to the incursions of pathogenic micro-organisms and to infectious diseases of one kind or another. Such persons, with or without definite lesions, are in fact liable finally to succumb to the complicating disease.

The phrase "*terminal infection*" has been applied by Osler and others to this concurrence of diseases of such different nature, in which the chance infection of a vulnerable organism is so apt to prove fatal.[2]

*Communicability of Infectious Diseases.*—It is important in practical dealings with the infectious diseases to consider them in the light of the relative liability of transmission of the actually known or assumed micro-organisms from diseased to healthy individuals.

In the first place, it should be borne in mind that the lower animals are insusceptible to the ravages of some of the micro-organisms which readily incite infectious disease in man. Thus the lower animals are, so far as we know, naturally immune to syphilis. To certain diseases of the lower animals, on the other hand, man is not subject. But to certain other infectious diseases, tubercu-

[1] For bibliography and summary of fœtal infection see *Lubarsch*, "Ergebnisse der allg. Aetiologie der Menschen- und Thierkrankheiten," 1896, p. 427.

[2] For a study of this class of cases see *Flexner*, Transactions Association American Physicians, vol. xi., 1896.

losis, for example, both men and the lower animals are liable and both are, in fact, under the prevailing conditions of modern life, frequent victims.

So far as the liability to the transmission of the infectious agents from man to man is concerned, there is a very marked and significant difference between the infectious diseases. It is common usage to speak of the transmission or communication of disease, as if disease were a self-existent thing. This usage fosters much loose thinking. What we call disease is a departure from, failure in, or perversion of normal physiological action, either in the material constitution or in the functional integrity of the living organism. When, therefore, we speak of the transmission or communication of disease, what we really mean is not that the disease, but the agent capable under suitable conditions of inciting the disease, is transmitted or communicated. If we hold this obvious implication in mind, however, it is convenient to group the infectious diseases of man into two great primary classes: 1st, Those which under the usual conditions of life are not communicable. 2d, Those which under the usual conditions of life are communicable.

There are then two classes of infectious disease: the *non-communicable* and the *communicable*. In the first class are malaria and yellow fever. In the second class are all the rest. Among the communicable infectious diseases there exists, however, the widest difference in the liability to transmission under ordinary circumstances. Thus the infectious agents in small-pox and scarlatina are given off from the body under such conditions as to render possible and frequent their direct transmission through the air to another individual. In syphilis, tetanus, and rabies, on the other hand, transmission of the infectious material is rare or impossible without a direct inoculation.

Between these extremes the widest diversity exists in the liability to transmission of the infectious agents of the diseases of this class. In fact the liability to infection on the part of a healthy individual in the presence of a victim of infectious disease is largely dependent upon the intelligent care which is exercised in the disposition of the material containing the pathogenic micro-organism which in one way or another the infected body sets free.

So that while it may be useful to arrange the communicable infectious diseases in groups or in such serial order as may indicate the degree of communicability of each under the ordinary conditions of life, it should always be borne in mind that this classification is not fundamental as is that by which the infectious diseases as a whole are set apart from other morbid states, but is closely dependent upon the sanitary conditions under which each case may be placed. Thus

tuberculosis or diphtheria or pneumonia may be high on the list as readily communicable, if housed in a crowded tenement with ignorant or careless attendance, while if subjected to the intelligent ministry of sanitary science these diseases may be accounted as relatively slightly communicable.[1]

[1] Before the knowledge of pathogenic micro-organisms had become precise, readily communicable diseases were called contagious in a rather loose and ill-defined way, and the unknown causative agent was called the contagium. The word contagious is still used, in various senses, to the detriment of science. We can get along well enough without it by the use of the word communicable in the way above indicated. But if it must still be cherished it might be most safely limited to the exanthemata, whose inciting agents are more readily and commonly transmitted through the air from the body of the patient than are those of any of the other infectious maladies.

## INFECTIOUS DISEASES INDUCED BY THE "PYOGENIC BACTERIA."

There are many very important inflammatory lesions, closely allied in their character, and commonly, though not always, associated with suppuration, which are due to the presence and growth in the body of the spheroidal bacteria or cocci known as Staphylococcus pyogenes and Streptococcus pyogenes. While other micro-organisms may and frequently do induce suppuration, these are commonly considered as *par excellence* the pyogenic bacteria.[1]

### SUPPURATIVE INFLAMMATION.

We will first consider the morphological and biological characters of these germs and their relation to suppurative inflammation, and then, in order, the other special forms of disease with which they are associated.

The *Staphylococcus pyogenes aureus* (Fig. 69) is in general a



FIG. 69.—STAPHYLOCOCCUS PYOGENES AUREUS.
From a beef-tea culture. Stained with gentian violet.

small coccus, the individuals varying, however, considerably in size (0.7–1.2 $\mu$ in diameter). In its growth it does not show a characteristic grouping, but grows in irregular masses and heaps (the somewhat crude resemblance, when studied under a cover glass, to a bunch of grapes gave rise to the generic name); sometimes, however, pairs and groups of four or short rows of the cocci are seen. The germ is readily stained by the anilin dyes, and does not lose its color in

[1] It should be borne in mind that while a limited suppurative inflammation can be incited by chemical agents, such as ammonia, turpentine, etc., in the great majority of cases it is incited and sustained by micro-organisms or their metabolic products.

Gram's method of staining. It does not show spontaneous movement, and, like other spheroidal forms, does not appear to develop spores. It is quite tenacious of vitality, surviving long drying and degrees of heat and cold and an exposure to chemical bactericides to which many pathogenic germs readily succumb. It grows well at ordinary room temperature in such artificial culture media as nutrient gelatin, agar, beef tea, and milk, and on potatoes, forming somewhat voluminous masses of culture. It rapidly fluidifies gelatin, coagulates milk, and in the various media develops a yellowish-white or a deep golden-yellow color, whence its specific name, *aureus*, and its common name, "golden coccus." Its color-producing capacity is subject to wide variation. The virulence of cultures obtained from different sources varies a good deal, but in general suppuration is not readily induced in the lower animals by its subcutaneous injection. Liability to suppuration is greatly increased by mechanical or chemical injury to the tissues with which the germ is brought in contact.

Injection of a virulent culture into the ear vein of the rabbit is usually followed by multiple abscesses in the kidney and muscles, and by suppuration of joints, etc.

In man this coccus grows readily and rapidly, and may cause necrosis and exudative inflammation, especially its suppurative phases (Fig. 70). The lesions which it induces are apt to be circumscribed. It may cause pustules, boils, and abscesses, and various suppurative inflammations of the viscera and serous membranes, joints, bones, endocardium, etc. These effects may be induced by the staphylococcus alone or by it in association with other species of germs. Its relationship to pyæmia will be considered under that heading.

The Staphylococcus pyogenes aureus apparently produces its effects in the body in virtue of certain toxins or toxalbumins which are produced as the result of its metabolism, and which are either at once set free or stored up in the body of the germs until their release by disintegration after the death of the germs. The special power of the staphylococcus to cause the gathering of leucocytes is doubtless due to the marked chemotactic powers of some of the proteid substances in its protoplasm. But here, as with other pathogenic germs, we shall do well not to be too precise in assigning closely the minute phases of lesions to definite chemical products of germ metabolism; because these are very complex indeed, and our field of observation on them is but newly opened. Nor is our knowledge of the particular element in the germ or its products which is prone to induce necrosis at all precise.

The Staphylococcus pyogenes may obtain entrance to the body

through wounds, small or large, of the skin or mucous membranes. The possibility of its entrance through uninjured surfaces has been demonstrated. In many cases we are quite unable to trace its mode of access. While in the natural course of events this germ tends to die in the body, it may yet remain for a long time alive.

It is widespread in inhabited regions, especially in towns, being frequently found on the surface of the body, and in the saliva, especially of those with acute or chronic catarrh of the upper air passages. As the result of the filthy habit of indiscriminate public spitting, it is common in the dust of hospitals, houses, towns, and places of public assembly.

*Staphylococcus pyogenes albus.*—This appears to be a variety of

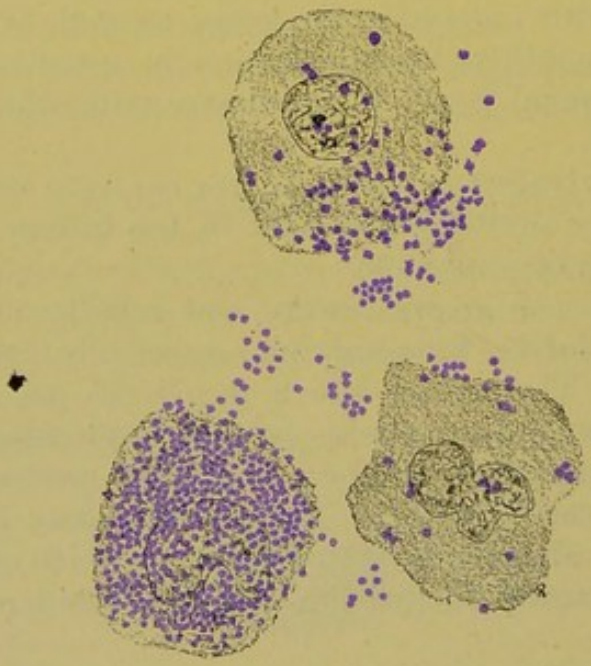

FIG. 70.—STAPHYLOCOCCUS PYOGENES AUREUS, IN AND AMONG THE PUS CELLS, FROM AN ABSCESS OF THE KIDNEY.

the Staphylococcus pyogenes aureus which does not develop the yellow color in cultures. It is of frequent occurrence both in connection with the aureus and alone. Its action on the body is similar, but it has seemed to many observers to be in general less virulent.

*Staphylococcus epidermidis albus.*—This coccus has been described by Welch[1] as of frequent occurrence in the epidermis, and although of rather feeble pyogenic power, yet seems frequently to cause small stitch abscess and moderate suppuration along drainage tubes. Welch regards it as possibly a variety of Staphylococcus pyogenes albus.

[1] *Welch*, "Wound Infection," American Journal of the Medical Sciences, vol. cii., p. 457, 1891.

The *Streptococcus pyogenes* is distinguished morphologically from the cocci just described by the marked tendency which the individuals exhibit, when growing, to hang together in longer or shorter chains (Fig. 71). It is like the Staphylococcus pyogenes, immobile, and stains easily in the same way.

It grows readily, but more slowly than Staphylococcus pyogenes, on the ordinary culture media. It does not fluidify gelatin, on which it grows as small, inconspicuous, grayish-white colonies. On the surface of agar plates kept in the thermostat at 37° C. for twenty-four hours, the small grayish colonies usually show, under the microscope, loops and fringes of the chain-like cocci extending off from the borders. The growth on potatoes is inconspicuous. In nutrient broth it usually forms delicate, flocculent masses, which cling to the sides of the tubes, leaving the fluid clear. Occasionally the masses of streptococci are dense and compact. Not infrequently the growth is diffused through the nutrient broth, rendering it turbid.

When in vigorous growth it coagulates milk.



FIG. 71.—STREPTOCOCCUS PYOGENES. From a broth culture.

There is considerable difference in the tenacity with which, in broth cultures of streptococci from different sources, the individual cocci cling together, so that in one set of cultures the chains may be very long, in another short. It has been thought by some observers that this difference was so constant as to justify special names for these growth variants of the streptococcus, and they have been called respectively *Streptococcus longus* and *Streptococcus brevis.* The growth in dense masses has given rise to the name *Streptococcus conglomeratus.* It is questionable, however, whether these names should be considered as implying more than rather inconstant growth varieties.

Streptococci which give evidence of little virulence in animal inoculation are very common in the mouths of healthy persons. The significance of these germs in healthy mouths is not yet clear.

The results of animal inoculation with the Streptococcus pyogenes are in general similar to those with the Staphylococcus pyogenes aureus, but its effects are rather less marked and its action more

uncertain. The streptococcus is very frequently associated with Staphylococcus pyogenes aureus both in its distribution outside the body, in healthy persons, and in disease. In general it may be said that the streptococcus incites those forms of suppuration and fibro-purulent inflammation which tend to spread both locally and through metastasis.

We may summarize the prominent local effects of the pyogenic cocci in the body by saying that they tend to induce the gathering of leucocytes by chemotaxis, they stimulate cell proliferation, and they are prone to induce tissue necrosis.

Staphylococcus pyogenes and Streptococcus pyogenes have been found, either separate or in association, in a large number of suppurative processes in various parts of the body, the condition in some cases receiving special names, in others not. Thus in boils and carbuncles, in abscesses and phlegmons, in herpes, impetigo and panaritium, in phlebitis and lymphangitis, in suppurative inflammation of various mucous and serous membranes, and in some forms of pneumonia, one or other or both of these germs are frequently concerned.[1]

One of the most important features of the relationship of Streptococcus pyogenes to man is the frequency with which it enters as a concurrent pathogenic agent in already established infectious diseases due to other forms of micro-organisms. Thus some of the most serious complications to which the victims of scarlatina, diphtheria, typhoid fever, and pulmonary tuberculosis are liable are due to the action of the streptococcus in the body rendered unusually vulnerable by the existence of another form of infection.

Streptococci which upon their isolation from the body in suppurative or other infectious processes are very virulent, usually, and sometimes very quickly, partially or wholly lose this virulence under artificial cultivation.

On the other hand, cultures of streptococci which have largely lost virulence under artificial cultivation, or whose initial virulence was slight, may experience a great exaltation of virulence by a long succession of inoculations from animal to animal.

The metabolic products formed by virulent streptococci growing in nutrient broth, when freed from the germs by filtration, have been found to cause in animals the symptoms of toxæmia. The results of

---

[1] For an exhaustive review of suppurative inflammation from the modern standpoint with bibliography consult *Janowski*, Ziegler's Beiträge zur path. Anatomie, etc., Bd. xv., p. 128, 1894.

For a table showing relative frequency of different forms of pyogenic bacteria in one hundred and thirty-five surgical cases in New York, consult *Dowd*, New York Medical Record, September 8th, 1894.

preliminary experiments on immunization with these toxic products of Streptococcus pyogenes and the use of the blood serum of the immune animal for therapeutic purposes appear to be promising. But the details of preparation and the practical value of the so-called *streptococcus antitoxin* are at this date not fully determined.

Other forms of bacteria than the "pyogenic cocci" may incite suppurative inflammation. Thus the pneumococcus, the typhoid bacillus, and the tubercle bacillus not infrequently, in addition to their more common and characteristic action in the body, set up complicating suppurations. Several other forms of germs have been found in suppurative inflammation, among which we need only mention here: Staphylococcus gilvus; Staphylococcus pyogenes citreus; Staphylococcus salivarius pyogenes; Staphylococcus cereus albus and flavus; Micrococcus tetragenus; Bacillus coli communis; Bacillus pyogenes fœtidus; Bacillus pyocyaneus; Diplobacillus pneumoniæ (Friedländer); Bacillus proteus; Bacillus aerogenes capsulatus; Bacillus pyogenes soli (Bolton);[1] Bacillus pyogenes filiformis (Flexner).[2]

The bacteria which are found in the various phases of suppurative inflammation may lie free in the interstices of the tissue with the exudate, or they may be in part within the cells which have gathered (see Fig. 69).

---

[1] *Bolton*, American Journal of the Medical Sciences, June, 1892.

[2] *Flexner*, The Journal of Experimental Medicine, vol. i., p. 211, 1896.

## ERYSIPELAS.

Erysipelas is a diffuse inflammation of the skin and subcutaneous tissue which tends to spread, and which especially involves the lymph spaces and the lymph vessels. It is characterized locally by swelling of the tissue and a bright-red color of the integument. It is regularly accompanied by constitutional disturbances, the most marked of which is fever. The morphological changes at the seat of lesion, as we see them after death, vary considerably in different cases and in different stages of the disease. The redness of the disease usually disappears after death. But the tissues may be swollen by the accumulation of serous fluid. This fluid may be

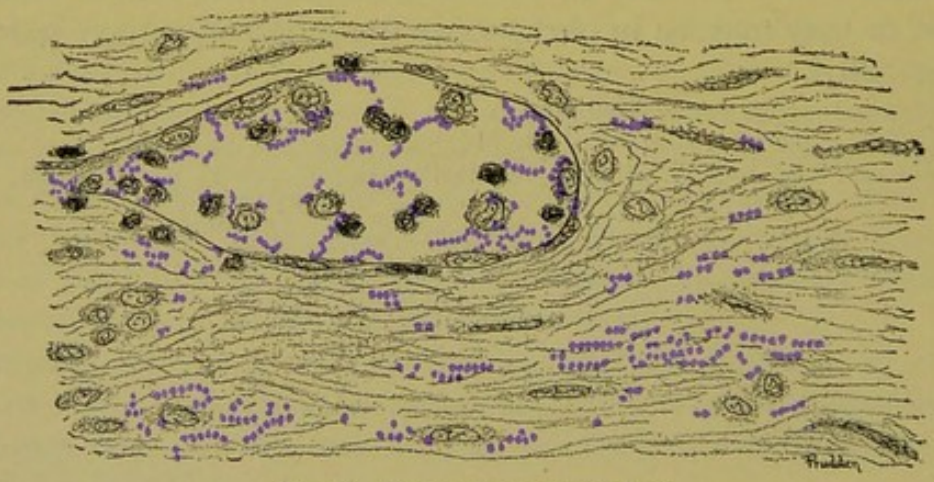

FIG. 72.—ERYSIPELAS OF THE SKIN.
Showing streptococci in the lymph spaces.

nearly transparent, or turbid from admixture with pus cells. Pus cells may infiltrate the tissues either sparsely or in dense masses. Sometimes vesicles are found on the surface, or scabs; sometimes more or less of the affected region becomes filled with abscesses or gangrenous. In some cases we find, aside from the local lesions, petechiæ in the serous membranes, swelling of the spleen, and parenchymatous degeneration of the kidneys and liver.

The researches of Fehleisen and others have shown that erysipelas is caused by the presence and action in the tissues of a chain coccus (Fig. 72) called *Streptococcus erysipelatis*. These bacteria are usually most abundant in the lymph vessels and lymph spaces along

the advancing borders of the inflammatory area, but they may be contained in the blood vessels (see Fig. 73).

In its morphological and biological characters the so-called Streptococcus erysipelatis appears to be identical with the Streptococcus pyogenes.

Subcutaneous inoculation of rabbits with the pure culture may induce a fairly typical erysipelatous inflammation, but, as these animals are not especially susceptible to its action, the results of inoculations are not constant.

There appears to be good reason for the belief that many forms of simple phlegmonous and other exudative inflammation, and many if not all forms of erysipelas, are different phases of the inflammatory

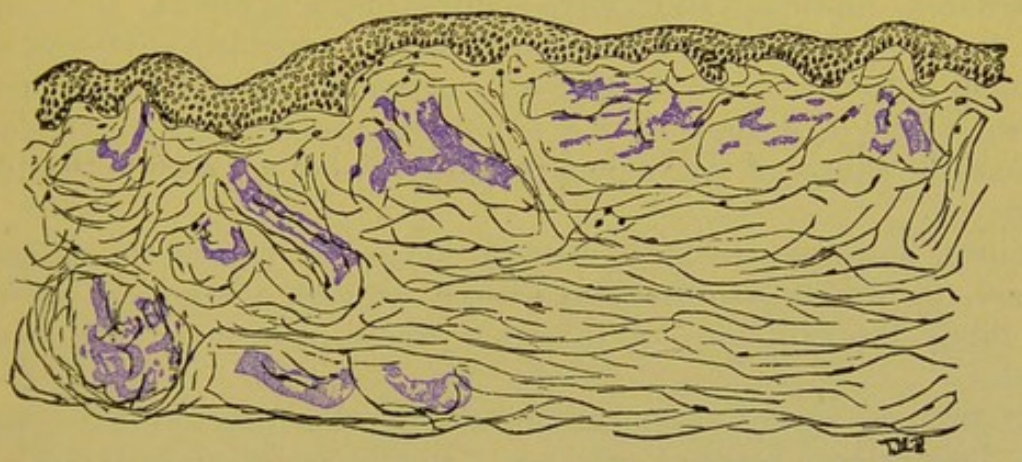

FIG. 73.—STREPTOCOCCI IN MASSES IN THE BLOOD AND LYMPH VESSELS OF THE SKIN IN ERYSIPELAS.

process due to the same organism; the difference in the reaction of the tissues which in the main constitute the clinical differences characteristic of the different diseases being due, perhaps to differences in the tissues involved, perhaps to variations in the characters and virulence of the germ, and perhaps to causes which at present we know nothing about.

Further researches are required to explain fully the exact relationship of these at least closely allied forms of inflammation to one another and to the bacteria which cause them.

In the mean time it should be borne in mind that in the use of such names as Streptococcus erysipelatis one intends to express simply the source of the germ rather than to convey an implication of specific character, or of essential variation from the common Streptococcus pyogenes.

## SEPTICÆMIA AND PYÆMIA.

It has long been known that a certain number of persons who have received injuries or wounds, by accident, in childbirth, or far less frequently than formerly by the hands of the surgeon, may suffer from constitutional symptoms and develop local or disseminated lesions. To designate the condition of these patients the terms pyæmia, septicæmia, septico-pyæmia, pyo-septicæmia, ichoræmia, inflammatory fever, surgical fever, traumatic fever, suppurative fever, and purulent infection have been used. Attempts to distinguish these several forms of disease have not hitherto proved very satisfactory, because the causes of the various conditions were not definitely understood.

Since, however, we have come to know the nature of infectious disease, we are able to make at least a general distinction between two fairly typical phases of infection which have long been recognized.

If from a focus of suppurative inflammation due to micro-organisms, or if from a point of entrance of micro-organisms without local reaction, the germs and their products become distributed through the body, inducing disease, the general condition is called *septicæmia*.

If in the invasion of the body by the micro-organisms and their products new suppurative foci be established, it is now customary to designate the condition as *pyæmia*.

The term *pyæmia* then indicates a clinical and anatomical phase of septicæmia, and the relationship of the two conditions is frequently expressed by the term septico-pyæmia or pyo-septicæmia.[1]

The new foci of suppuration in pyæmia are called metastatic abscesses, and in distribution these may bear an obvious relationship to the seat of the primary lesion. Thus in suppurative processes in the intestinal tract metastatic abscesses are liable to occur in the liver. From suppurations in the skin, bones, muscles, etc., infectious emboli may be transmitted to the lungs, causing infarctions and abscess; or, passing these organs, the germs may induce multiple abscesses in the kidneys and in other viscera.

---

[1] The word pyæmia was originally framed to express the conception that the invasion of the blood by pus cells was the significant thing in this condition. This conception we now know to be incorrect.

It should also be remembered that the point of introduction into the body of the offending germs may be wholly concealed and not associated with any form of demonstrable external lesion. This is often called *cryptogenetic* pyæmia or septico-pyæmia.

While septicæmia and pyæmia are most commonly due to the presence and growth and distribution in the body of the pyogenic staphylococci and streptococci, these phases of infection are not infrequently associated with the pneumococcus, gonococcus, the typhoid bacillus, the anthrax bacillus, the colon bacillus, certain gas-forming bacilli, and various other germs.[1]

Finally, the possibility should not be lost sight of here that under certain little understood conditions toxic materials may be elaborated



Fig. 74.—Micrococci in Masses in the Fibrinous Exudation of Pyæmic Pleurisy.

by the body cells themselves, which may give rise to some of the phenomena of septic poisoning.

The varying phases of so-called *puerperal fever* are to be classed under the heading of septicæmia or pyæmia, and it is unusually caused by the Streptococcus pyogenes.[2]

After death from septicæmia and pyæmia there is a considerable variety in the post-mortem appearances.

1. There are cases in which there are no recognizable lesions.
2. There are cases characterized by early post-mortem decomposi-

[1] *Canon*, "Bakteriol. Blutunters. bei Sepsis," Deutsche med. Wochenschrift, October 26th, 1893, p. 1038. Consult also *Petruschky*, Zeitschrift f. Hygiene, Bd. xvii., pp. 59 and 109, for methods of detection of bacteria in the blood of septicæmia.

[2] Consult *Goldscheider*, "Klin. u. Bak. Mitth. u. Sepsis Puerperalis," Charité-Annalen, Jahrgang 18, p. 237.

tion; post-mortem staining of the tissues; congestion of the lungs, stomach, intestines, and kidneys; extravasations of blood in the serous membranes; swelling of the solitary and agminated lymph nodules in the small intestine; swelling of the spleen and parenchymatous degeneration of the liver and kidneys.

3. In some cases there are localized inflammations. The joints, the connective tissue around the joints, the pleura (Fig. 74), the pericardium, the peritoneum, the pia mater, and the connective tissue in different parts of the body may be inflamed. These local inflammations are of a purulent character, except in the serous membranes, where the principal inflammatory product may be fibrin.

4. There are cases in which the veins in the neighborhood of the wound contain softened, puriform thrombi; without infarctions in the viscera, there may be inflammation of the joints and serous membranes.

5. In other cases the veins contain thrombi; there are infarctions and abscesses in the viscera; local inflammations of the joints and serous membranes may be present or absent. The thrombi are formed regularly in the veins near the wound, but they may be situated in veins at a distance, and sometimes, although infarctions and abscesses are present, no thrombus can be discovered. The veins may be distended by the thrombi or only contain small coagula. The different kinds of thrombi, and the varieties of emboli and infarctions which they produce, are described in the article on Thrombosis, page 72.

Various lines of research on minute changes in cells which bacterial and other poisons may induce justify the expectation that more and more we shall be able to associate characteristic groups of symptoms in septicæmia, for which there is now no morphological basis, with well-defined cell alterations.

## ACUTE CEREBRO-SPINAL MENINGITIS.

This is usually defined as an acute infectious disease of which the characteristic lesion is an exudative inflammation of the pia mater of the brain and cord. It may, however, be regarded as an infectious inflammation of the pia mater accompanied by constitutional symptoms. At all events, there are inflammations of these membranes, which occur both as isolated cases and also in epidemics, with similar symptoms and similar lesions, and which are not apparently caused by traumatism nor by infection from other foci of inflammation.

As a rule the inflammation of the pia mater results in a large production of serum, fibrin, and pus, which infiltrate the pia mater and accumulate in the ventricles, so that the gross appearance of the brain is characteristic. The exudation is especially abundant at the base of the brain and over the posterior surfaces of the cord. In children the distention of the lateral ventricles with purulent serum may be a marked feature, while in adults the quantity of serum is apt to be small.

It is important to remember that a meningitis which induces marked cerebral symptoms, continues for a number of days, and causes death, may produce so little change in the pia mater that after death this membrane upon gross examination looks normal. This is especially common when the disease is not epidemic, but occurs in the sporadic form.

When, however, we look at the pia mater in these cases with the microscope we find a slight infiltration with pus and fibrin, or a growth of new cells resembling the cells of the pia mater.

While the above are the characteristic lesions of this disease, there are a number of secondary or associated changes in different parts of the body which are not constant, but which occur with sufficient frequency to render their mention necessary. There may be subserous punctate hæmorrhages in the endocardium; petechiæ in the skin; hyalin and granular degeneration in the voluntary striated muscle; occasional multiple abscesses in various parts of the body; suppurative inflammation of the joints; parenchymatous degeneration of the heart, liver, and kidneys; and swelling of the gastro-intestinal lymphatic apparatus and of the spleen.

Cerebro-spinal meningitis may occur by itself or in connection with some other acute infectious disease, such as acute lobar pneumonia, mycotic ulcerative endocarditis, pyæmia, multiple suppurative arthritis, otitis media, puerperal fever, typhoid fever, etc.

The lesions are essentially the same in epidemic and in sporadic cases of acute cerebro-spinal meningitis, and in both modes of occurrence the disease is probably caused by bacteria.

Numerous careful studies have been made on the bacteria occurring at the seat of lesion in *sporadic* cases occurring both with and without complicating lesions in other parts of the body.

The *Streptococcus pyogenes* has been demonstrated in a few cases, occurring in connection with suppurative inflammations elsewhere.

The *Diplococcus lanceolatus* (pneumococcus) (see page 201) has been found in several cases, and in some of these without any lung lesion. Weichselbaum has described the occurrence in several cases of a diplococcus not known to occur elsewhere, which was found largely confined to the pus cells, and which he called *Diplococcus intracellularis meningitidis*. Animal experiments with this as well as the pneumococcus would indicate that they may stand in a causative relation to the disease. Some other scattering forms of bacteria have been described, but not with sufficient frequency and definiteness to enable us to judge of their significance.

It seems probable, therefore, from what we know at present, that several forms of bacteria are capable of causing acute cerebro-spinal meningitis. Which is the most frequent and important, it remains for further researches to show.

Bacterial studies of the cases in *epidemics* of cerebro-spinal meningitis have not been numerous since the development of the new technique. But there is reason to believe that the Diplococcus lanceolatus plays here also an important rôle.[1]

The close topographical relationships which the nasal cavities and the middle ear bear to the meninges is significant in this connection on account of the possibility of the transmission to the brain membranes of bacteria not uncommonly present and usually harmless in the former situations.

---

[1] For literature and a study of cases consult article on "Epidemic Cerebro-Spinal Meningitis," by *Flexner and Barker*, American Journal of the Medical Sciences, 1894. Also *Jäger*, Zeitschrift f. Hygiene, etc., Bd. xix., p. 351.

## ACUTE LOBAR PNEUMONIA AND OTHER INFECTIOUS DISEASES INDUCED BY THE DIPLOCOCCUS LANCEOLATUS.

(*Pneumococcus: Diplococcus pneumoniæ.*)

This germ is frequently spoken of as the *pneumococcus of Fränkel*, because its significance and life history in connection with acute lobar pneumonia were first demonstrated by him.[1] During their development these germs are distinctly spheroidal. But in their mature condition they are apt to become slightly elongated and often a little broader at one end than at the other, assuming a lanceolate form. They are very apt to occur in pairs, and frequently are seen in short chains, rarely in long chains. Very frequently, when



FIG. 75.—DIPLOCOCCUS LANCEOLATUS (PNEUMOCOCCUS) WITH CAPSULES.
Stained by Welch's method.

growing in the living animals, the pneumococcus is surrounded by a distinct, homogeneous capsule of varying thickness (see Fig. 75). This capsule does not, as a rule, develop in artificial cultures. The coccus itself is readily stained; the capsule is not easily demonstrated except by special staining methods.

The pneumococcus has no spontaneous movement and grows but feebly at ordinary room temperature. It grows much better at the temperature of the body, forming on the surface of very slightly alkaline agar[2] plates faint grayish, dewdrop-like, inconspicuous

[1] It was discovered by Sternberg in saliva, and its pathogenic power demonstrated, some years before its full significance was understood in connection with pneumonia.

[2] The growth of the pneumococcus is less certain and abundant on the ordinary agar than on Guarnieri's gelatin agar mixture or on Welch's modification of this. The formula for this modification is: 950 gm. meat infusion, 5–10 gm. pepton, 6–8 gm. agar, 30–40 gm. gelatin. The gelatin and agar are boiled separately in 50

colonies, somewhat similar to those of Streptococcus pyogenes, but usually more delicate. In beef tea it forms at body temperature a faint whitish sediment with slight turbidity of the fluid. As a rule, the cultures are prone to soon lose their virulence and to die off early, but the virulence may be maintained by successive inoculations in the rabbit.

The pneumococcus injected, while virulent, subcutaneously into mice and rabbits induces a rapidly fatal septicæmia, often with little marked anatomical change, save enlargement of the spleen. Sometimes there are necrotic foci in the liver, fibrin in the glomeruli of the kidneys, fatty degeneration of the heart. Suppurative inflammation at the seat of inoculation and elsewhere may follow. The blood and viscera may show under these conditions numerous cocci, mostly with capsules, or they may be confined to the seat of inoculation. Cultures which have been reduced in virulence, so as not to cause early death by septicæmia, may, when introduced into the trachea of rabbits, induce a fairly typical lobar pneumonia.

Different species of animals show marked differences in vulnerability to the ravages of the pneumococcus. This germ is the exclusive inciter of typical acute lobar pneumonia in man. It appears to act, in part at least, by the development of an albuminous poison which has been tentatively called *pneumotoxin*. It would seem to be the pneumotoxin which induces the symptoms in acute lobar pneumonia indicative of systemic poisoning, since the bacteria themselves are usually confined to the lungs.[1]

For a more detailed description of these lesions of pneumonia, and an account of other bacteria which may be present, see page 438.

In addition to its more common effect in inducing lobar pneumonia, this diplococcus has been very frequently found in, and stands apparently in a causative relation to, some forms of exudative inflammation of the serous membranes, either in connection with or without a primary lobar pneumonia. Thus it has been repeatedly found in pleuritis, otitis, meningitis, empyæma, pericarditis, endo-

---

c.c. of water before mixing. The reaction should be made distinctly but feebly alkalin. The mixture solidifies at room temperature. It should be used in Petri plates, and though it softens the colonies remain separate at 35° C. (see Johns Hopkins Hospital Bulletin, December, 1892). It is especially important in preparing culture media for the pneumococcus to use the most exact tests available for fixing the reaction, since the vigor of the growth is, as *T. C. Janeway* has shown, closely dependent upon this.

[1] The observations of the Klemperers suggest the possibility that at a certain period of the disease the blood or body juices are capable of developing a substance antidotal to this pneumotoxin, the advent of the former being signalized by the so-called "crisis." Satisfactory applications of this alleged "pneumonia antitoxin" in therapeutics have not yet been made.

carditis, and in peritonitis. It has also been found in abscesses of the viscera and in exudative inflammation of the joint.

The Diplococcus lanceolatus is a frequent inhabitant of the mouth, even in health. It has been found in the mouths of about twenty per cent of healthy persons examined. It is thrown off in the sputum in lobar pneumonia, and no doubt from these sources in the dried condition, as dust, furnishes the infectious agent which in favoring conditions of the body lights up the inflammatory process in the lungs.

For staining the pneumococcus with its capsule the method suggested by Welch[1] gives the most satisfactory result.

The exudate containing the germ is dried and fixed upon the cover glass in the manner described on page 154. It is now treated with glacial acetic acid, which is at once drained off and replaced by anilin-gentian-violet solution (page 156) this being drained off and renewed several times until the acetic acid is displaced. The specimen is now washed with a two-per-cent solution of sodium chlorid, in which it may be covered and studied.

Such specimens are not usually suited for permanent preservation, although occasionally after drying and mounting in balsam the capsules retain their color. Annoying color precipitates frequently interfere with full success by this method.

The pneumococcus may be stained in sections by Weigert's modifications of Gram's method with preliminary contrast stain (see page 157). By this method the fibrin in the pneumonic exudate is also stained.

---

[1] *Welch*, Johns Hopkins Hospital Bulletin, December, 1892, p. 128.

## INFECTIOUS PSEUDO-MEMBRANOUS INFLAMMATION OF MUCOUS MEMBRANES.

*(Pseudo-Diphtheria: Diphtheroid-Angina; Membranous Angina.)*

Under a variety of conditions, as during scarlatina and measles, whooping-cough, typhoid fever, etc., or entirely apart from any complicating disorder, an acute exudative inflammation of the mucous membranes, especially of the upper air passages, occurs, which

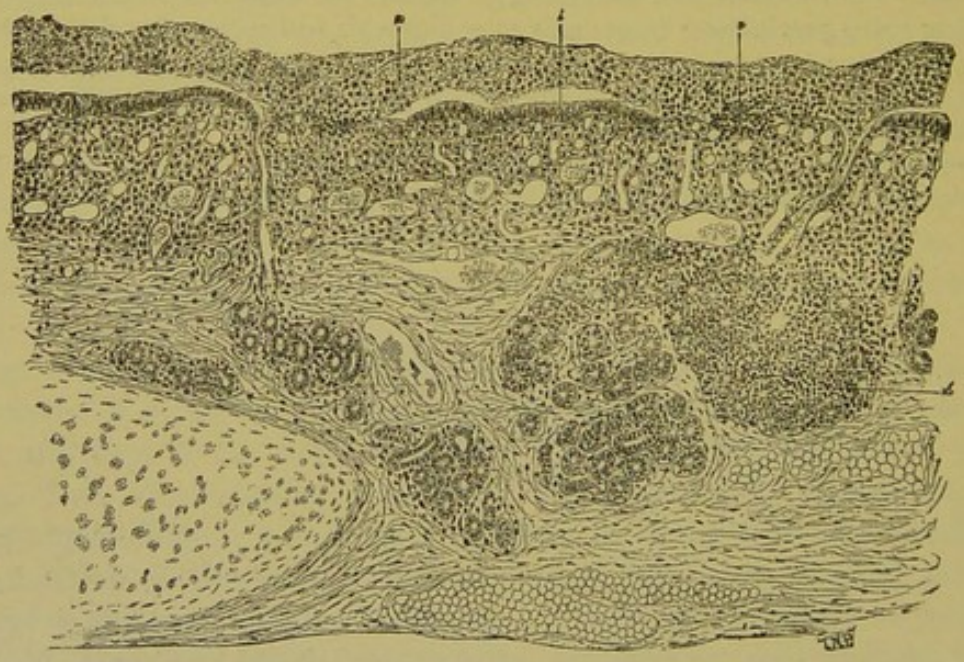

FIG. 76.—PSEUDO-MEMBRANOUS INFLAMMATION OF TRACHEA.

In this case there is purulent infiltration of the mucosa and submucosa, and of portions of the mucous glands. *a*, false membrane; *b*, portion of intact epithelium; *c*, infiltration of the mucosa with fibrin; *d*, portion of mucous gland infiltrated with pus.

is associated with, and is apparently caused by, the growth of a streptococcus (Fig. 77) which in morphological and biological characters seems to be identical with the Streptococcus pyogenes. There may be much or little fibrinous exudate; there may in early stages, or even throughout, be none at all. The pellicle when formed may be loose or adherent, sharply circumscribed or tending to spread. The submucous tissue may show little change, or may be congested

and œdematous, or may be the seat of suppurative inflammation (see Fig. 76), necrosis, or gangrene. The process may be confined to the tonsils. While under these varying conditions the inflammatory process is usually a local one and runs its course with or without the symptoms of septicæmia, occasionally the streptococcus finds access to the blood and may induce the lesions of pyæmia. On the other hand, it may by aspiration gain access to the lungs and induce varying phases of complicating broncho-pneumonia. The Staphylococcus pyogenes is not infrequently associated with the streptococcus in these lesions, but is not apparently of primary significance. Simulating very closely, as it does in many cases, both the local and general phenomena of diphtheria, this disorder has formerly been confounded with it, and has been only recently recognized as a distinct phase of disease. It is now most frequently called pseudo-diphtheria. It seems in part to cover the condition formerly known as croup, in part those cases formerly thought to be mild diphtheria.[1] In many phases of acute angina, in many cases of follicular tonsillitis, streptococci have been found in large numbers.



FIG. 77.—INFECTIOUS CROUPOUS INFLAMMATION OF THE TRACHEA.

Section through the pseudo-membrane and underlying tissue, showing large numbers of streptococci.

[1] For a general consideration of the relationship between this form of pseudo-membranous inflammation and diphtheria, with original studies and bibliography, consult *Park*, "Diphtheria and Allied Pseudo-Membranous Inflammations," Medical Record, July 30th and August 6th, 1892.

## GONORRHŒA AND OTHER INFLAMMATORY LESIONS INDUCED BY THE MICROCOCCUS GONORRHŒÆ (GONOCOCCUS).

The Micrococcus gonorrhœæ is most commonly found in the exudate of gonorrhœal inflammation of the mucous membranes, especially of the urethra. It may be found free or enclosed in leucocytes or other cells within or between the superficial epithelial cells. It is also often present in the exudate in arthritis, and in tubal, ovarian, perimetritic, and other inflammations, arising as complications of gonorrhœa.

Under these complicating conditions the gonococcus may occur alone or in association with the pyogenic cocci. It is generally most abundant during the acute stage of the inflammation.

The gonococcus is apt to occur in pairs, the apposed sides being more or less distinctly flattened (Fig. 78). It stains readily with the



Fig. 78.—Micrococcus Gonorrhœæ (Gonococcus).

anilin dyes, and differs from most known cocci which might be mistaken for it in that it is decolorized by the iodin solution in the Gram's method of staining.

If after the use of the iodin solution in Gram's method the cover glass be rinsed with alcohol to complete the decolorization and then with water, and the specimen be stained for a few minutes in a dilute aqueous solution of Bismark brown, rinsed and mounted in balsam, the gonococci will appear of light-brown color, while most other germs will retain the violet color (see Fig. 79). In exudates a considerable part of the gonococci are usually contained in the bodies of pus cells.

The gonococcus thrives best at about the temperature of the body (37° C.), and has been artificially grown on a variety of culture media which contain considerable albuminous material in solution. Human

blood serum—squeezed from the placenta—and mixed with peptonized agar in accordance with the method of Wertheim, has been in the past most commonly employed for cultures.

Heiman[1] has found the clear exudate or transudate from the pleural cavities in man ("chest serum") to form a convenient and ex-



FIG. 79.—A COVER GLASS PREPARATION OF GONORRHŒAL EXUDATE.

Stained by Gram's method with gentian violet; contrast stain with Bismark brown. The gonococci have been decolorized by the iodine solution and restained by the brown; while other bacteria cocci and bacilli which were mingled with them still retain the original violet color.

cellent substitute for blood serum. This is sterilized by the discontinuous or fractional method[2] (or it may be filtered through an unglazed porcelain filter), and then mixed with two-per-cent agar—containing

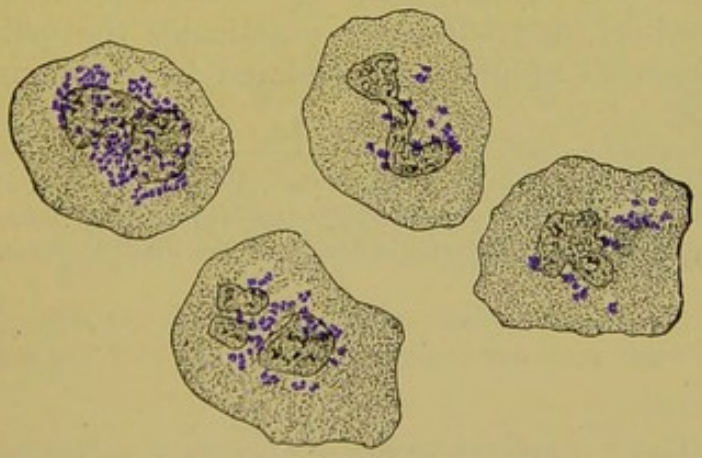

FIG. 80.—PUS CELLS CONTAINING GONOCOCCI. From a case of gonorrhœal urethritis.

one-per-cent pepton and one-half-per-cent salt—in the proportion of one part of the serum with two parts agar, melted at about 40° C.

[1] *Heiman*, "A Clinical and Bacteriological Study of the Gonococcus," etc. New York Medical Record, June 22d, 1895, contains bibliography.

[2] In fractional or discontinuous sterilization, the serum, filled into tubes, is exposed for an hour on five successive days to a temperature of from 65° to 68° C., standing in the interval at the ordinary temperature of the room. In this way the serum may be rendered sterile without coagulation, which seriously interferes with its value as a culture medium for the gonococcus.

In this chest-serum agar the surface growth of the gonococcus is in the form of small circular, sharp-edged, slightly raised, grayish-white colonies, coarsely mottled in the central portion, finely granular toward the borders. The lower animals are not, as a rule, susceptible to inoculations of the mucous membranes with the gonococcus, but suppurative inflammation has been induced in mice and guinea-pigs by intraperitoneal injections. Inoculations of pure cultures of the gonococcus upon the urethral mucous membranes of man is followed by a characteristic catarrhal inflammation.

The evidence is now complete that the gonococcus stands in a causative relationship to the characteristic inflammation with which it is so constantly associated.

But in what measure this germ, in what measure the streptococcus and staphylococcus may be responsible for the complicating inflammations when both germs occur together, is yet to be determined. Inasmuch as one or more forms of cocci and diplococci occurring in the normal and in the inflamed urethra are morphologically similar to the gonococcus, great caution should be exercised in doubtful cases in pronouncing upon the nature of suspicious germs. But the pronounced tendency of the gonococcus to gather within cells; the sometimes conspicuous but often ill-defined flattening of the apposed sides of the gonococci; the decolorization by Gram's method, which leaves most other germs apt to be associated with the gonococcus still stained, and whenever practicable the artificial culture characters—these all should be considered in the summary of evidence.[1]

[1] *Von Hibler*, Centralbl. f. Bakteriologie, etc., Bd. xix., p. 120, 1896. For summary of current work on the gonococcus with bibliography consult *Neisser and Schäffer*, "Ergebnisse der allg. Aetiologie der Menschen- u. Thierkrankheiten," 1896, p. 477.

## ANTHRAX.

(*Splenic Fever; Malignant Pustule; Charbon; Carbuncle.*)

This disease, which is much more common in the lower animals, especially the herbivora, than in man, is widely prevalent in Europe. It is rare in the United States, but seems in certain regions to be more common than formerly.

It is induced in man by accidental inoculation with the Bacillus anthracis, which causes the disease in the lower animals. Inoculation may occur through the skin by the agency of flies and other insects which have been feeding on animals infected with this disease; by handling their carcasses or hides, or in other ways. Following



FIG. 81.—ANTHRAX—MALIGNANT PUSTULE—OF THE SKIN.

From a man in New York who had been handling foreign hides. Bacilli stained with gentian violet.

this skin inoculation a pustule is apt to develop—"malignant pustule"—and varying phases of an acute exudative inflammation, which may be hæmorrhagic, sero-fibrinous, purulent, or necrotic, accompany the local proliferation of the germs (Fig. 81). From this local source a general infection may ensue. In some cases general infection may occur without evident external lesion.

Infection with anthrax may occur through the lungs, most often among those who handle infected wool or hides, the dust from which is inhaled ("wool-sorter's disease"). Under these conditions there may be œdema, lobular pneumonia with involvement of the pleura,

mediastinum, and other adjacent structures. Infection through the gastro-intestinal canal occurs through the ingestion of food containing anthrax spores, and is apt to be accompanied with inflammatory and necrotic changes, which are described in detail among lesions of the intestine.

When general infection occurs the post-mortem appearances vary.

Decomposition, as is usual in acute infections, generally sets in early. The blood is frequently not much coagulated and dark in color. Hæmorrhages and ecchymoses are frequently found in the serous and mucous membranes and in various other parts of the body.

The lungs may show small hæmorrhages and œdema, and the

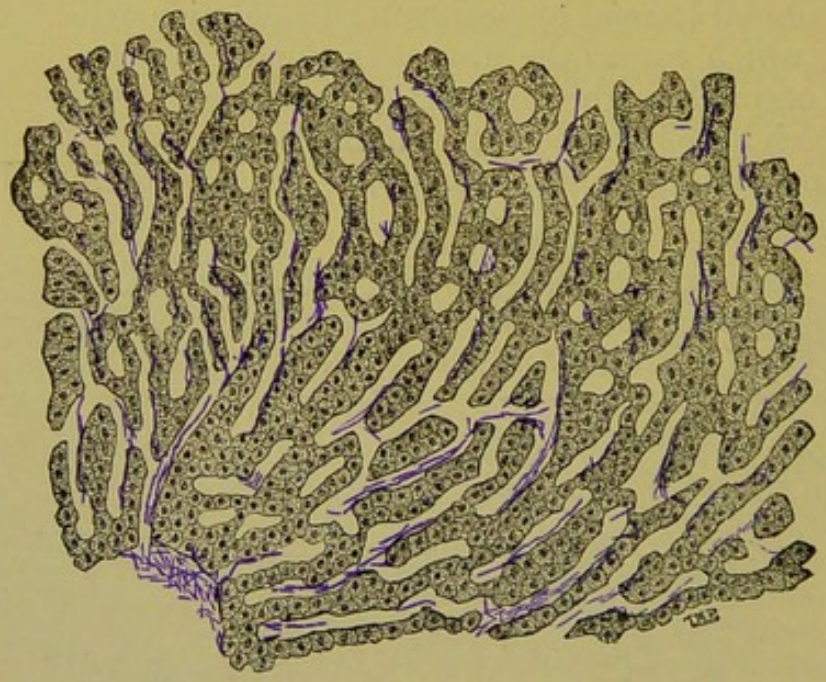

FIG. 82.—BACILLUS ANTHRACIS GROWING IN THE BLOOD VESSELS OF THE LIVER OF A MOUSE INOCULATED WITH A PURE CULTURE OF THE BACILLUS.

bronchi may be deeply congested. The pleural cavities may contain serum. The intestines may exhibit the lesions of the so-called *intestinal mycosis*. The bronchial and other lymph nodes may be swollen. The spleen may be swollen, very dark in color, and soft, sometimes almost diffluent.

The bacillus which causes the disease may be found, usually in large numbers, in the spleen and in the capillary blood vessels, especially in the liver (see Fig. 82), lungs, kidneys, and intestine.

The Bacillus anthracis is from 5 to 20 $\mu$ long and about 1 $\mu$ broad, and is often uneven along the sides. The ends of the bacilli are not rounded, but square or slightly concave, and the bacilli often hang together end to end, forming thread-like structures (see Fig. 83).

While the bacilli in the vegetative condition are easily killed, they develop spores, outside of the body only, and these are very invulnerable to the action of the ordinary germicidal agents and to heat, resisting often for many days the action of from two to five-per-cent carbolic acid and defying for some minutes the action of live steam. Anthrax bacilli are immobile and are easily stained by the anilin dyes. A capsule may be demonstrated upon them. They grow readily on artificial culture media at ordinary room temperatures, fluidifying gelatin and usually growing out, before they do so, in a network of delicate filaments into the solid medium. These linear or thread-like outgrowths from a central colony give in puncture inoculations in gelatin tubes a brush-like appearance which is quite characteristic. Surface colonies on agar and gelatin plates show a delicate, felt-like outgrowth from the central mass. The growth on potatoes is voluminous. Subcutaneous inoculations of the anthrax bacillus into various species of animals—white mice, guinea-pigs, rabbits, sheep and cattle—induce anthrax. White mice are especially susceptible,

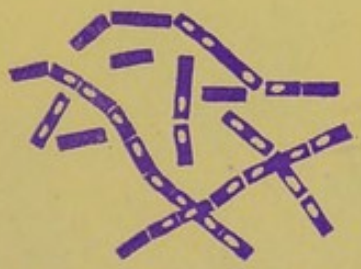

FIG. 83.—BACILLUS ANTHRACIS CONTAINING SPORES.

usually succumbing to the anthrax septicæmia in from two to four days. In the blood of the diseased animals multitudes of the bacilli are found, showing their proliferation in the blood vessels and elsewhere. The anthrax bacillus is of especial interest and importance, because it was this bacterium which was first absolutely demonstrated to be the cause, and the only cause, of a well-defined disease in man, and because we know more of its life history than of almost any other of the bacteria.

If cultures of the anthrax bacillus be made at a temperature of about 42° C. growth occurs, but it is meagre. Spores are not formed as they are at body temperature, and the virulence of the germ diminishes day by day, so that at last the most susceptible animals are not affected by large inoculations of the living organisms (page 179). If fresh cultures of these organisms be made in various stages of their diminishing virulence and maintained at their optimum temperature, spores will again form, the growth will become vigorous, and in morphology quite characteristic; but the physiological qualities which determine virulence will remain more or less in abeyance.

By inoculation of animals with anthrax cultures, beginning with those which, having been maintained at 42° C. for from fifteen to twenty days, and thus possessing but feeble virulence, and passing to those cultivated at 42° C. for a shorter time and which were therefore more virulent, Pasteur was able to secure immunity from anthrax in a series of the lower animals. Based upon these experiments a method of protective vaccination has been practised on a large scale among sheep and other animals in some parts of Europe and has been of great economic value. According to some authorities the death rate from anthrax has under these preventive inoculations been reduced in sheep from ten per cent to about nine-tenths of one per cent, and in cattle from five per cent to less than four-tenths of one per cent.

## TUBERCULOSIS.

Tuberculosis is an infectious disease characterized by inflammatory and necrotic processes in the body due to the presence and growth of the Bacillus tuberculosis (tubercle bacillus). The most distinctive morphological feature of tuberculosis is the development under the influence of the tubercle bacillus of larger and smaller gray or white or yellow, firm or friable masses of tissue called *tubercles*.

The Bacillus tuberculosis is a long, slender bacterium varying in length from 3 to 4 $\mu$ (from one-quarter to one-half the diameter of a red blood cell) and in breadth from 0.2 to 0.5 $\mu$. It is frequently

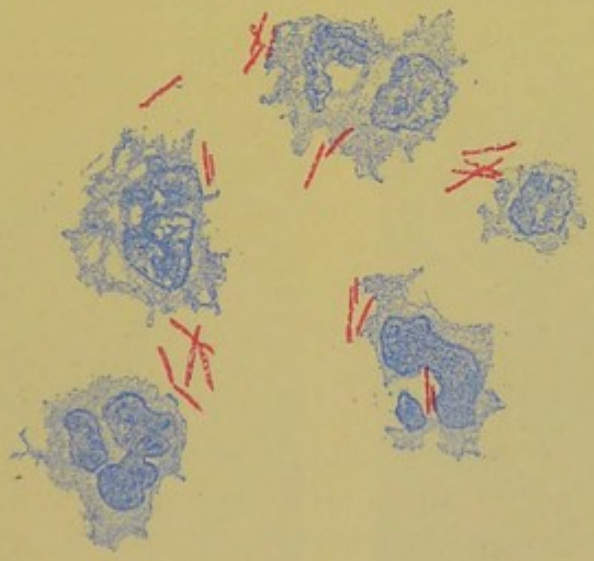

FIG. 84.—TUBERCLE BACILLI IN SPUTUM FROM A CASE OF PULMONARY TUBERCULOSIS.
Showing the bacilli in pus cells.

more or less curved, and the individual bacilli may cling together end to end, forming threads or chains. The bacillus (Fig. 84) is stained with difficulty by the anilin dyes (see below), and when stained often presents an irregular beaded or knobbed appearance, due to an unevenness in the coloring of the protoplasm, or to involution changes. It is immobile and spores have not been demonstrated in it.

At the temperature of the body it can be grown on many of the artificial culture media, such as coagulated blood serum, five-per-cent glycerin-agar, five-per-cent glycerin-nutrient broth, on potato, and in a variety of organic and inorganic mixtures.

The growth of the tubercle bacillus in cultures is very slow in comparison with that of most of the pathogenic micro-organisms. After several weeks' growth it forms dry, scaly masses or thin, wrinkled pellicles on the surface of the media (Figs. 85 and 86).

It requires a certain amount of oxygen for its growth, and thrives best in the dark. It is killed by an exposure of a few hours to direct

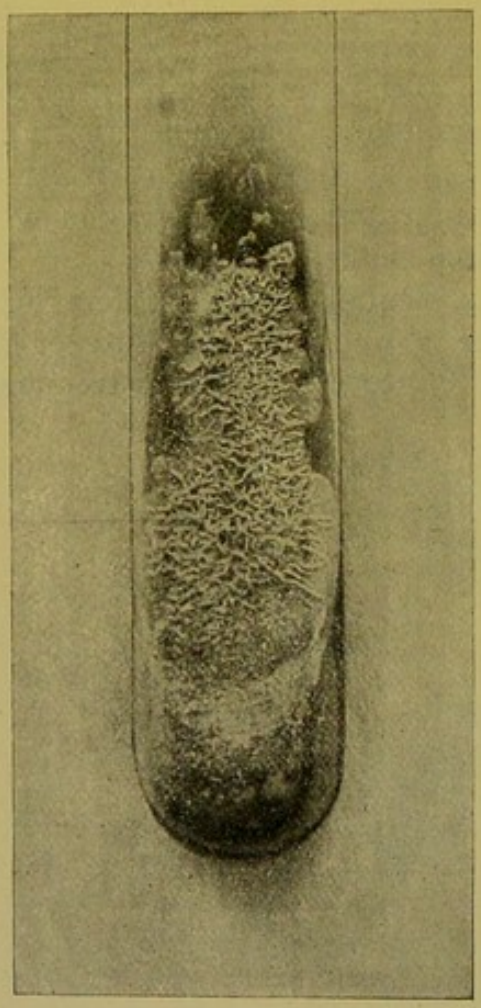

FIG. 85.

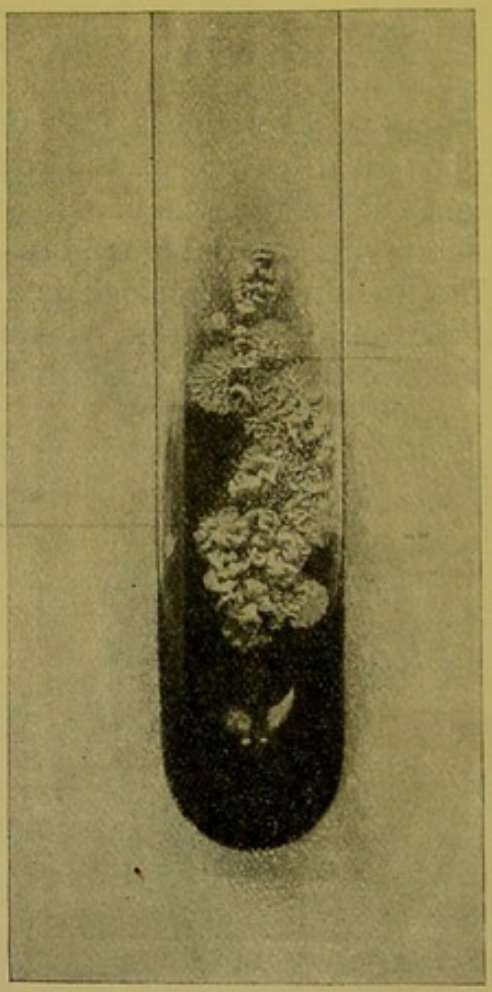

FIG. 86.

FIG. 85.—CULTURE OF TUBERCLE BACILLUS ON GLYCERIN AGAR.—From tuberculosis in the bird.
FIG. 86.—CULTURE OF TUBERCLE BACILLUS ON GLYCERIN AGAR.—From tuberculosis in man.

sunlight, or if moist is killed by an exposure of from ten to fifteen minutes to 70° C. On the other hand, it may long retain its vitality in the dried condition.

Cultures can be continued indefinitely from generation to generation with a slowly diminishing virulence which finally is largely lost. Under certain conditions the virulence may be restored or enhanced by successive inoculations into susceptible animals. Certain modified forms or varieties or races of the tubercle bacillus are

known, notably that which is concerned in inducing the lesions of fowl tuberculosis.

The tubercle bacillus does not, so far as we know, grow in nature outside of the bodies of men and certain warm-blooded animals. It is thus strictly parasitic.

Tuberculosis is a very common disease not only of man but also of many of the lower animals, especially of cattle, and inasmuch as the victims of this disease, both men and animals, are apt to throw off enormous numbers of the bacilli in the sputum and other excreta, the germ is very widely dispersed in inhabited regions, especially in buildings frequented by uncleanly tuberculous persons or by infected cattle. It may be conveyed by the milk and milk products of tuberculous cows.

Among the lower animals, guinea-pigs, rabbits, monkeys in confinement, and cattle are particularly susceptible to the action of the tubercle bacillus. Although tuberculosis is widespread in man, he is not, as compared with some of the lower animals, particularly susceptible. While the tuberculous process presents some special differences in different animal species in rate of development, amount of necrosis, tendency to softening, calcification, etc., the fundamental effects are similar in man and in the lower animals.

The effect on the body cells of the presence and growth of the tubercle bacillus varies considerably, depending upon the number and virulence of the germs present, the character of the tissue in which they lodge, and the vulnerability of the individual. In general, it may be said that tubercle bacilli may stimulate the connective-tissue cells in their vicinity to proliferation; or they may excite emigration of leucocytes from blood vessels and lead to the production of other exudates; or they may cause death of tissue. Thus the phases of inflammation which are excited by the tubercle bacillus are productive, exudative, and necrotic. The tubercle bacillus may produce these effects separately or simultaneously, in the sequence just indicated or in some other; and now one, now another of them may preponderate.

Tuberculosis manifests itself most often in the form of an inflammation affecting some one part of the body, as the lungs (the part most frequently involved in adults), the gastro-intestinal tract or the skin—"*localized tuberculosis.*" While the lungs are most frequently involved in tuberculosis in adults, in children it is the lymph nodes which are most commonly affected,[1] and very often the bones and joints. Such a localized tuberculosis may retain throughout the characters of a local inflammation, or it may be accompanied by the clinical evidences of systemic infection. It may give rise

[1] See *Northrup*, New York Medical Journal, February 21st, 1891.

through metastasis to the successive development of tuberculous inflammation in other parts of the body, or to a sudden development of tuberculous inflammations in many parts of the body at the same time—*general miliary tuberculosis.*

A general infection may be caused by the diffusion through the body of bacilli derived from a local tuberculosis, such as tubercular phlebitis or arteritis, or from the breaking into a vessel of a tuberculous lymph node, or by the inspiration into the lungs of large numbers of bacilli.

In a considerable proportion of cases the local lesions produced by

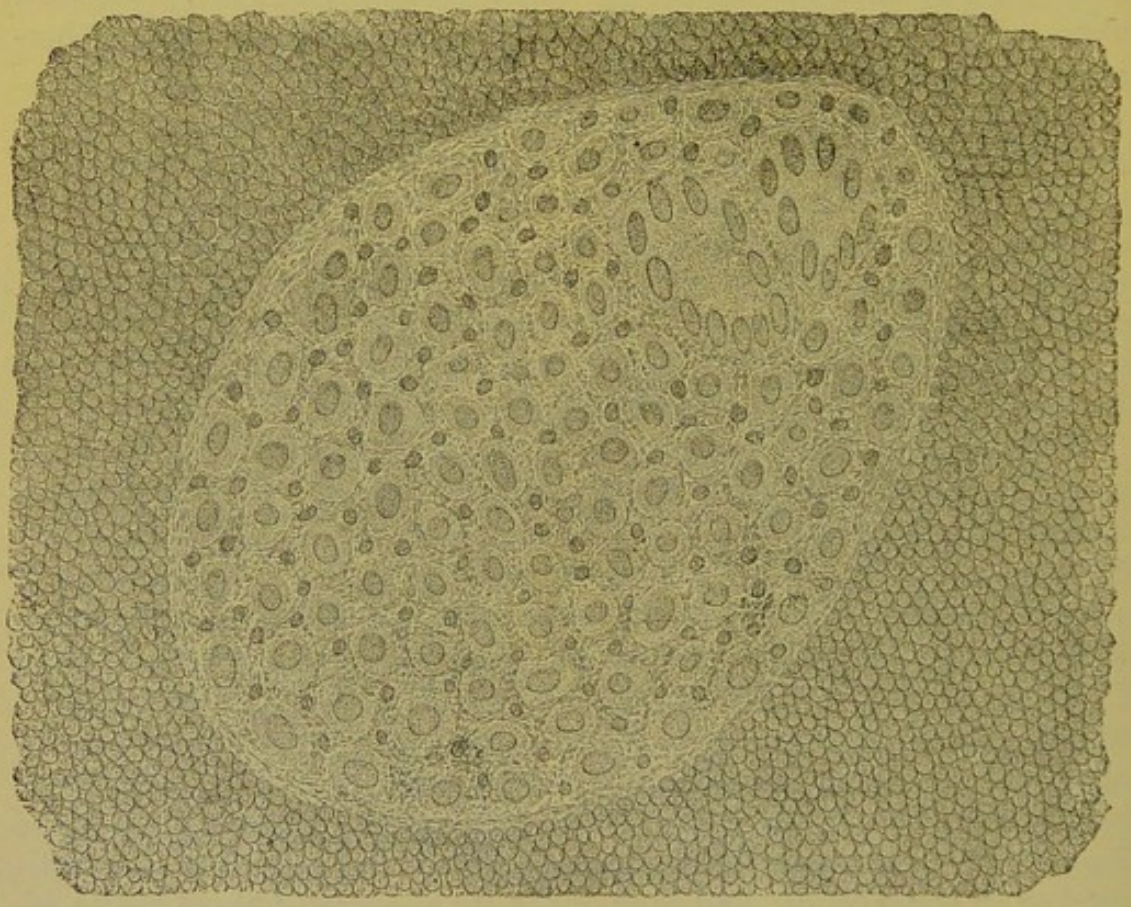

FIG. 87.—A MILIARY TUBERCLE FROM A LYMPH NODE, × 850 and reduced.
The giant cells are enclosed by the basement substance.

the tubercle bacillus are in the form of circumscribed nodules or masses of new-formed cells or tissues which are called *tubercles*, or if small *miliary tubercles.*

In many cases, however, the lesion is not circumscribed but diffuse, and more or less widely infiltrates or replaces the tissues involved. This is called *diffuse tuberculous inflammation* (diffuse tubercle).

*Miliary Tubercles.*—Miliary tubercles are small nodules of irregularly spheroidal shape (Figs. 87, 88, 90, 223 and 224), the smallest

hardly visible to the naked eye, the largest as large as a pea.[1] The smaller tubercles are gray and translucent; the larger are usually, especially in the central parts, opaque and white or yellow on account of the necrosis which is apt to commence here.

In studying the effects caused by the tubercle bacillus on living tissues it should be always borne in mind that while as a whole the lesions produced are quite characteristic, there is still no one structural feature or combination of features of tubercles or tuberculous inflammation which is absolutely distinctive of the action of this germ. In

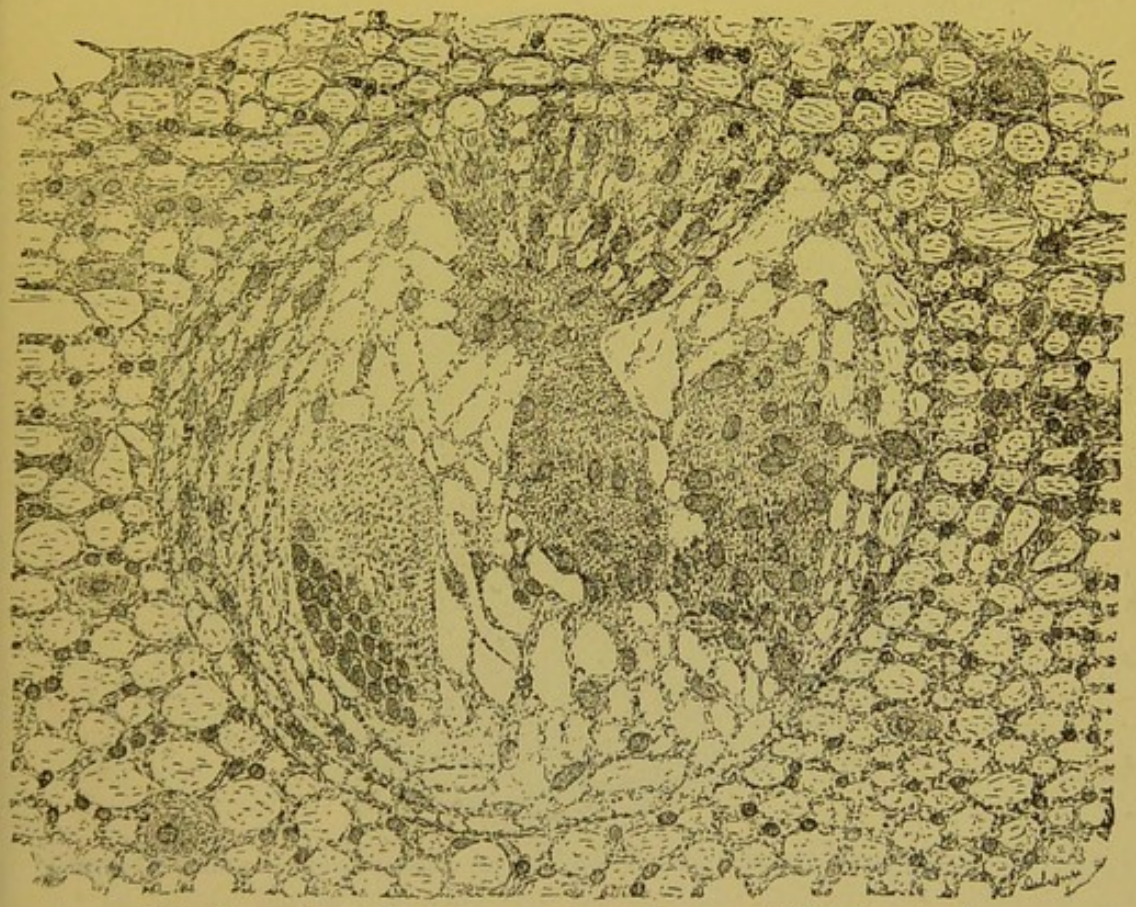

FIG. 88.—A MILIARY TUBERCLE FROM THE PLEURA. × 850 and reduced.
The branches of the giant cells form part of the basement substance.

doubtful cases the demonstration of the presence of the germ itself may be necessary for the establishment of the character of the lesion.[2]

[1] The term *miliary tubercle*, which arose from the crude coincidence in size between small foci of tuberculous inflammation and some forms of millet seed, is now very liberally applied to tubercles which are very much larger as well as to those which are very much smaller than millet seeds. It is convenient to designate a spheroidal mass of new tissue formed under the influence of the tubercle bacillus, whatever its minute structure, as a *tubercle granulum* (see Fig. 188). Very frequently two or more tubercle granula are joined together by a more diffuse formation of tubercle tissue to form larger or smaller miliary tubercles—*conglomerate tubercles* (see Fig. 189).

[2] The term *tubercle tissue*, which is in common use, indicates a tissue formed

The experimental studies in animals, as well as the morphological data gathered from the examination of tuberculosis in man, show that when tubercle bacilli in moderate numbers lodge and develop in the living body one of the early local effects is a proliferation of the connective tissue and endothelial cells. These become larger and polyhedral, with conspicuous nuclei. These new cells are often called *epithelioid* on account of their approach in form to the epithelial cell type (Fig. 87).

A new reticulum or stroma may form hand-in-hand with the

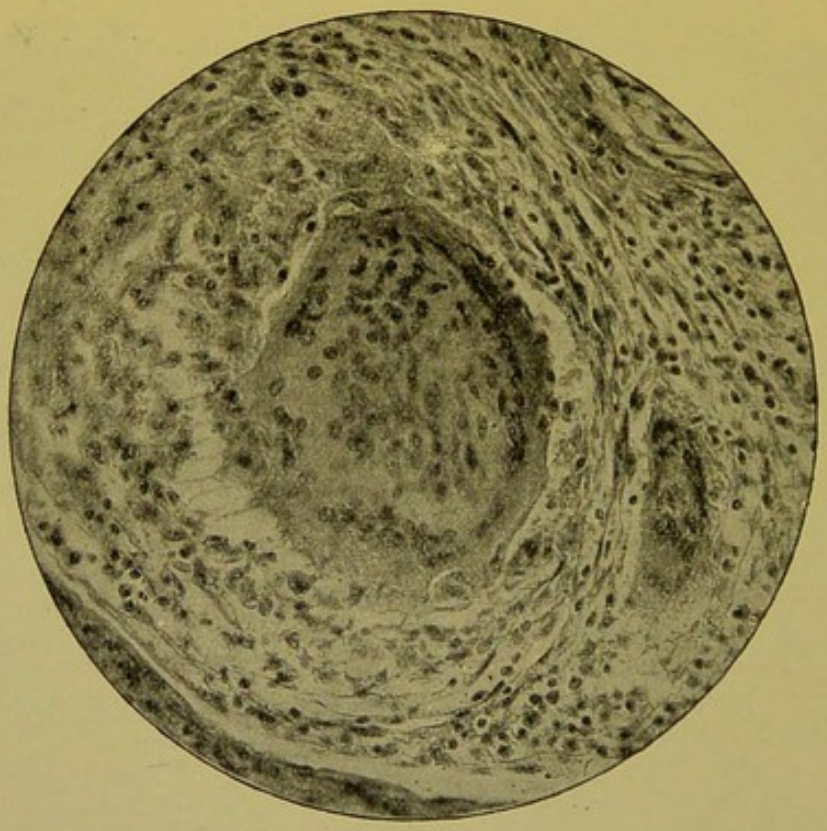

Fig. 89.—Tuberculous Tissue. Showing giant cells. Photograph from a miliary tubercle.

growth of these new cells (Fig. 88), or the old stroma may persist, adapting itself in form and arrangement to the new conditions.

Either after the connective-tissue cell proliferation or hand-in-hand with it, or preceding it, or altogether independently of it, emigration of leucocytes and extravasation of serum may take place from blood vessels in the vicinity of the germs. During the more or less active cell proliferation which occurs under the stimulus of the tubercle bacillus multinuclear cells[1]—giant cells—may be formed

under the influence of the tubercle bacillus rather than a tissue which is morphologically characteristic of tuberculosis in distinction from other forms of new tissue.

[1] For an account of giant cells, which are found under various conditions and are by no means confined to tuberculous inflammation, consult *Marchand*, Virchow's Archiv, Bd. xciii., p. 518.

(Fig. 89), either by persistent nuclear division in growing protoplasmic masses which do not divide into separate cells, or by the coalescence of the bodies of cells already formed.

More or less new tissue with numerous small spheroidal mononuclear cells and little stroma may form in and about the tuberculous foci. Blood vessels are not apt to develop under the influence of the tubercle bacillus. Old blood vessels are, on the other hand, usually obliterated as the new tissue forms.

Sooner or later the tubercle bacillus is apt to associate with its

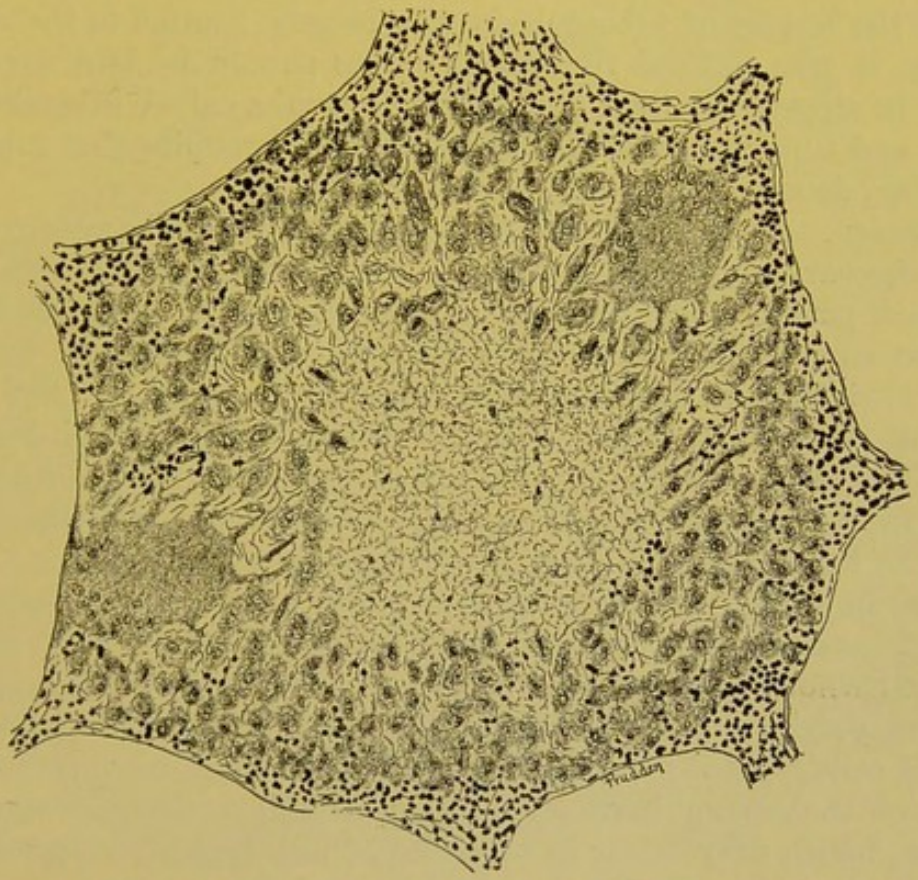

Fig. 90.—A Nodule of Tuberculous Inflammation (Miliary Tubercle) in the Lung. Showing polyhedral cells, small cells, giant cells, and coagulation necrosis at the centre.

stimulative a destructive action, which leads to coagulation necrosis in the new-formed tissue as well as in the old tissue of the infected region. This necrosis is more apt first to manifest itself in the central portions of the tuberculous foci (Fig. 90) and may progress outward; the nuclei become fragmented or disappear, or fail to stain in the usual way, the protoplasm becomes more homogeneous, and cells and stroma form at last a structureless mass of tissue detritus which tends to disintegrate (coagulation necrosis or cheesy degeneration), forming cavities or, if on free surfaces, ulcers.

As coagulation necrosis progresses, the tubercle masses lose the

gray translucent appearance which in their early stages they are apt to present to the naked eye and become more opaque and of yellowish-white appearance at the centres.

Finally dense fibrous tissue may form in and about foci of tuberculous inflammation, encapsulating or sometimes entirely replacing the more characteristic new-formed structures.

It is in this way—by the formation of connective tissue—that such repair as is possible after local tuberculous inflammation, is brought about.

Before the discovery of the tubercle bacillus and while our knowledge of the lesions of tuberculosis was largely limited to their morphology, it was natural that much stress should be laid upon the variety in structure which the nodular growths called tubercles presented, and that elaborate classifications and groupings of tubercles were often deemed important.

With an exact knowledge of the inciting cause of the new growths and of the varying phases of their development in the body, the morphological peculiarities of tubercles are not now to be regarded as of such extreme significance, since they for the most part indicate simply variations in the local effect of a definite poison. These variations are due to differences in the amount and intensity of the poison, to the degree of susceptibility of the individual, to the structure of the particular tissue or organ involved, and to the extent and variety of local complications caused by other agencies.

It is, however, usually convenient and sometimes important to recognize structural types in miliary tubercles. Thus they may be composed wholly of small spheroidal cells—"lymphoid tubercles," or of larger polyhedral cells—"epithelioid-celled tubercles" or of both forms of cells together and with or without a new-formed stroma; or of any of these combinations with giant cells. Then coagulation necrosis, which may occur in tubercles of any type; development of new dense connective tissue; association with various phases of simple exudative inflammation—all of these contribute to the variety in the structural types of miliary tubercles.

*Diffuse Tuberculous Inflammation* (Diffuse Tubercle).—1. If the infection with tubercle bacilli be extensive, or if step by step the bacilli are distributed in the tissues about the primary seat of infection, considerable amounts of tubercle tissue of one or other form may develop and pass into the condition of coagulation necrosis, so that at length large necrotic masses, with a comparatively small amount of well-defined tubercle tissue, either diffuse or in the form of granula, may alone remain to indicate the character of old and slowly progressive local infection. This form of lesion is found in the large tuberculous masses in the brain, in the mucous membrane

of the bronchi, in large flat masses of the serous membranes, and in the diffuse, cheesy infiltration of the lymph nodes, kidneys, ureters, bladder, prostate, testicle, and uterus.

These large areas of tuberculous inflammation are apt to be white or yellow in the central and necrotic portions, which are sometimes dense, compact, and hard, sometimes soft and friable.

These areas are not infrequently surrounded by an irregular gray zone of tubercle tissue or by a dense fibrous tissue capsule.

2. In marked contrast with the phase of diffuse tuberculous in-



FIG. 91.—MILIARY TUBERCLE IN LUNG OF CHILD.

Showing the Bacillus tuberculosis—stained with fuchsin—in the contents of the air vesicles and in their thickened walls. (The size of the bacilli relative to other elements is slightly exaggerated.)

flammation just described, though often associated with it, is that in which the formation of inflammatory exudates is a prominent feature. This exudative form of tuberculous inflammation is best exemplified in the lungs by some of the forms of acute phthisis (see page 466). The tubercle bacillus is under certain conditions markedly pyogenic and when it rapidly develops in the air spaces of the lungs or suddenly gains access to them in large quantities pus, serum, fibrin, and exfoliated or proliferated epithelial cells may collect in and largely fill the air spaces, and then the whole new exudate and the old lung tis-

sue may, over larger or smaller areas, rapidly undergo coagulation necrosis.

Thus in one phase of tuberculous inflammation the intensity and rapidity of the local poisoning by the bacillus do not permit of the formation of organized new tissue at all, but only of exudative products (Fig. 91). Less intense degrees of exudative inflammation are liable to develop in the vicinity of miliary tubercles anywhere in the body, but especially in the lungs.

It has been found that tubercle bacilli which have been killed by boiling or otherwise, when introduced into the body of the rabbit



FIG. 92.—INFLAMMATORY NODULE (PSEUDO-TUBERCLE) IN THE LIVER OF THE RABBIT PRODUCED BY THE INTRAVENOUS INJECTION OF DEAD TUBERCLE BACILLI.

Most of the dead bacilli have disintegrated, setting free the bacterial proteid peculiar to this germ, which has stimulated the new cell growth. A few fragments of the bacilli, however, still remain.

either beneath the skin, into the serous cavities, or into the blood vessels and the air spaces of the lungs, are capable, as they slowly disintegrate, of stimulating the cells of the tissues where they lodge to proliferation, and to the production of new tissue morphologically identical with tubercle tissue in its various phases (Fig. 92). Coagulation necrosis, however, does not occur. Dead tubercle bacilli are also markedly chemotactic and capable of causing local suppuration and abscess.[1]

[1] For further details concerning the effects of dead tubercle bacilli in the body see *Prudden and Hodenpyl*, New York Medical Journal, June 6th and 20th, 1891, and *Prudden*, ibid., December 5th, 1891.

It would seem probable then that while the power of the tubercle bacillus to induce necrosis and the fever which in many cases indicates a systemic intoxication, may be due to metabolic products of the living germ, the local lesions characteristic of exudative and productive inflammation may be due to a peculiar bacterio-protein which is set free by the disintegration of the bacilli in the tissues.

The number of bacilli which are present in the lesions of tuberculosis is subject to great variations. They are usually abundant in the walls and contents of phthisical cavities, and in tubercle tissue which is undergoing cheesy degeneration and disintegration. In these situations they may be found in myriads, forming sometimes a large part of the disintegrated mass. They are found in cells and scattered among them. Sometimes they are present in considerable numbers in the giant cells of miliary tubercles. In the acute general tuberculosis of children they are often present in large numbers, particularly in the lungs (Fig. 91). They may be found in tuberculous inflammation in any part of the body, and have been seen in the blood. The bacilli are almost constantly discharged in the sputa of patients suffering from pulmonary tuberculosis, often in enormous numbers—from one to four billion in twenty-four hours, according to Nutall's estimate—and their presence sometimes affords valuable diagnostic aid in early stages of obscure forms of the disease.

Under a variety of conditions, especially in the older tuberculous lesions, the bacilli may not be demonstrable. This apparent occasional absence of the bacilli is probably due either to their disappearance as the process grows older, or to some unknown changes which interfere with the ordinary staining procedures.

In human beings cases of direct local inoculation of tuberculosis in the skin and accessible mucous membranes have been reported, but they are not very common.

There is no doubt that the bacilli may be introduced into the alimentary canal by infected milk and meat of tuberculous cattle.

They may be transmitted from the sick to the well by means of the sputum, which is allowed to dry and becomes pulverized and which is inhaled as dust, and this, under the ordinary conditions of modern life, is the chief means of infection.

Whether the tubercle bacillus can enter the tissues of the body through intact mucous membranes, or whether a lesion, however minute, is a necessary condition is not yet fully determined. The observations of Loomis and others on the occurrence of tuberculous bronchial lymph nodes in persons exhibiting no appreciable tuberculous lesions elsewhere would indicate the probability of access of the bacilli to the lymph channels without primary lesion at the portal of entry.

*Tuberculin.*—When the tubercle is grown on glycerinated nutri-

ent broth certain metabolic products are formed and pass into solution in the fluids. If after some weeks of vigorous growth the germs are separated by filtration and the broth concentrated by evaporation, a dark-brown fluid results which is called *tuberculin*. This substance —at one time believed by many, and still by a few observers, to possess distinct curative properties in certain forms of tuberculosis—has assumed great economic importance on account of its value as a diagnostic agent in bovine tuberculosis. For it is found that if administered subcutaneously in small quantity to cattle, a definite and marked temperature reaction follows in tuberculous animals, while those which are sound are unaffected. The existence of even very slight lesions may be detected in this way. In man also tuberculin has proved of value in cases in which the efforts to establish a diagnosis by the usual method have proved futile.

*Concurrent Infection in Tuberculosis.*—A concurrent infection with the tubercle bacillus and other pyogenic micro-organisms is of extreme significance in that phase of tuberculous inflammation of the lungs commonly called phthisis (see page 459).[1] While the so-called cold abscesses may be caused by the tubercle bacillus alone, this germ is not infrequently found under these conditions to be associated with other pyogenic micro-organisms, especially the streptococcus and staphylococcus.

### METHODS OF STAINING THE TUBERCLE BACILLUS.

*In Fluids.*—For the examination of fluids, such as sputum,[2] etc., the material should be spread in a thin layer on a cover glass, dried in the air, and then passed thrice through the flame (see page 155).

While, as has been said above, the tubercle bacillus is stained much less easily with the anilin dyes than are most bacteria, it can be deeply colored by the use of accessory agents which intensify the stains or render the protoplasm of the bacilli more accessible to them. But when once stained the tubercle bacillus clings with great tenacity to its color in the presence of the usual decolorizing agents.

A variety of methods are in vogue for staining the tubercle bacillus, most of them being more or less unessential modifications of the original process formulated by Koch and Ehrlich. The staining fluid which we have found most generally useful is known as Ziehl's solution. This is made by adding to a five-per-cent aqueous

[1] Consult *Spengler*, Zeitschrift f. Hygiene, etc., Bd. xviii., p. 342, 1894 (Bibliography.

[2] It is well in obtaining sputum for examination in cases of suspected pulmonary tuberculosis to secure that which has been raised during several hours, including the early morning discharge.

solution of carbolic acid about one-tenth its volume of saturated alcoholic solution of fuchsin. This carbolic fuchsin will keep unchanged for a long time.

The prepared cover glass is floated in a watch glass or porcelain capsule—specimen side down—on this coloring fluid, and gently heated almost to boiling for from three to five minutes.

The entire specimen is thus completely stained, tubercle bacilli, tissue elements, and other bacteria which may be present, all in the same way. The next step is to remove the color with acid from all the structures which may be intermingled with the tubercle bacilli; the later, owing to the tenacity with which they retain the color, being but slightly affected. This is done by dipping the cover glass into an aqueous or alcoholic solution of five-per-cent sulphuric acid, and shaking it about for a few seconds. The acid may be even a little more dilute than this. Under the influence of the acid the specimen on the cover glass loses its red color and becomes gray or colorless. It is then thoroughly rinsed in three or four successive portions of alcohol, and finally in water. By this manipulation the red color may be to a slight extent restored.

Care should be taken not to expose the specimen too long to the action of the acid, because then the bacilli may be also partially or completely decolorized. A little experience will enable the experimenter to judge of the proper time for the action of the acid.

The specimens may be studied in water with the use of an oil immersion and the Abbé condenser, or they may be dried in the air and mounted in balsam.

Inasmuch as not infrequently some other bacteria besides the tubercle bacilli retain a slight red color, it is well, after the specimen is rinsed in water, to float the cover glass for a few minutes in a dilute aqueous solution of methylen blue, which will replace the red color in all of the bacteria except the tubercle bacilli and which might be mistaken for it, forming a marked color contrast between them. The contrast stain should not be intense.

Various other anilin dyes may be used instead of the fuchsin, and there are various minor modifications of the process which are often employed; but, on the whole, for routine sputum examinations we recommend the method here given.

*In Sections.*—Thin sections of tuberculous tissue which has been hardened in alcohol are stained in the same way, except that instead of drying and fixation by heat the sections should be fixed to the cover glass by means of the albumen fixative (see page 59), and then cover glass and section are manipulated together.

When differentiation is complete the section is cleared in oil of cloves or cedar or origanum and mounted in balsam.

For purposes of simple recognition of the bacilli in sections it seems to the writer usually better to have no color in the preparation other than that which the tubercle bacilli possess. But it is often convenient to demonstrate the nuclei of the cells at the same time, and this may be accomplished by staining lightly afterward with a dilute solution of some color which will contrast with that of the bacilli, such as Bismark brown or methylen blue.

In the examination of *urine* for the presence of the tubercle bacillus it is well to collect the sediment by means of a centrifugal machine. In the examination of milk, or other fat containing fluids for tubercle bacilli, it is well, after the film has been formed upon the cover glass and before staining, to rinse with chloroform followed by alcohol, and this by water.

Occasionally one finds in urine acicular crystalline bodies considerably resembling the tubercle bacillus in size and shape, and retaining a red color after the decolorization of the specimen. A careful study of the form, however, will suffice to prevent mistakes.

The only other bacilli which are liable to be mistaken for the tubercle bacilli are the bacillus of leprosy and the so-called smegma bacillus which sometimes occurs beneath the prepuce. The lepra bacilus may be distinguished from the tubercle bacillus by the following differential staining process: If the lepra bacillus be stained for ten minutes in a dilute alcoholic solution of fuchsin (five drops of saturated alcoholic solution of fuchsin to 3 c.c. of water), and then rinsed for a few seconds in a solution of nitric acid (1 part) in alcohol (10 parts), it will retain a red color, while under the same treatment the tubercle bacillus remains uncolored.

The smegma bacillus is readily decolorized by alcohol after staining by Ziehl's solution, and is thus to be distinguished from the tubercle bacillus.

The bacillus described by Lustgarten as occurring in syphilitic lesions resembles the tubercle bacillus in form, but after staining with Ziehl's solution is said to be decolorized by sulphuric acid. So little certainty exists, however, as to the existence or significance of the so-called syphilis bacillus that differential staining methods are not now to be considered as trustworthy (see page 234).[1]

[1] The announcement of the discovery of the Bacillus tuberculosis by *Koch* was made in the Berliner klin. Wochenschrift, 1882, No. 15. A most elaborate and valuable article on the same subject by *Koch* is contained in the "Mittheilungen aus dem Kaiserlichen Gesundheitsamte," vol. ii.

The very voluminous literature on the subject of the tubercle bacillus which has accumulated since 1882 is for the most part scattered through the German, English, and French journals. It may be best obtained by consulting files of the Index Medicus of dates since April, 1882, or *Baumgarten's* "Jahresbericht über die Fortschritte in der Lehre von den pathogenen Mikroorganismen."

## LUPUS AND OTHER FORMS OF TUBERCULOSIS OF THE SKIN.

Local tuberculous inflammation of the skin may occur in the form of small nodules or wart-like thickenings, as the result of accidental inoculation. Local skin infection may occur about the orifices of the

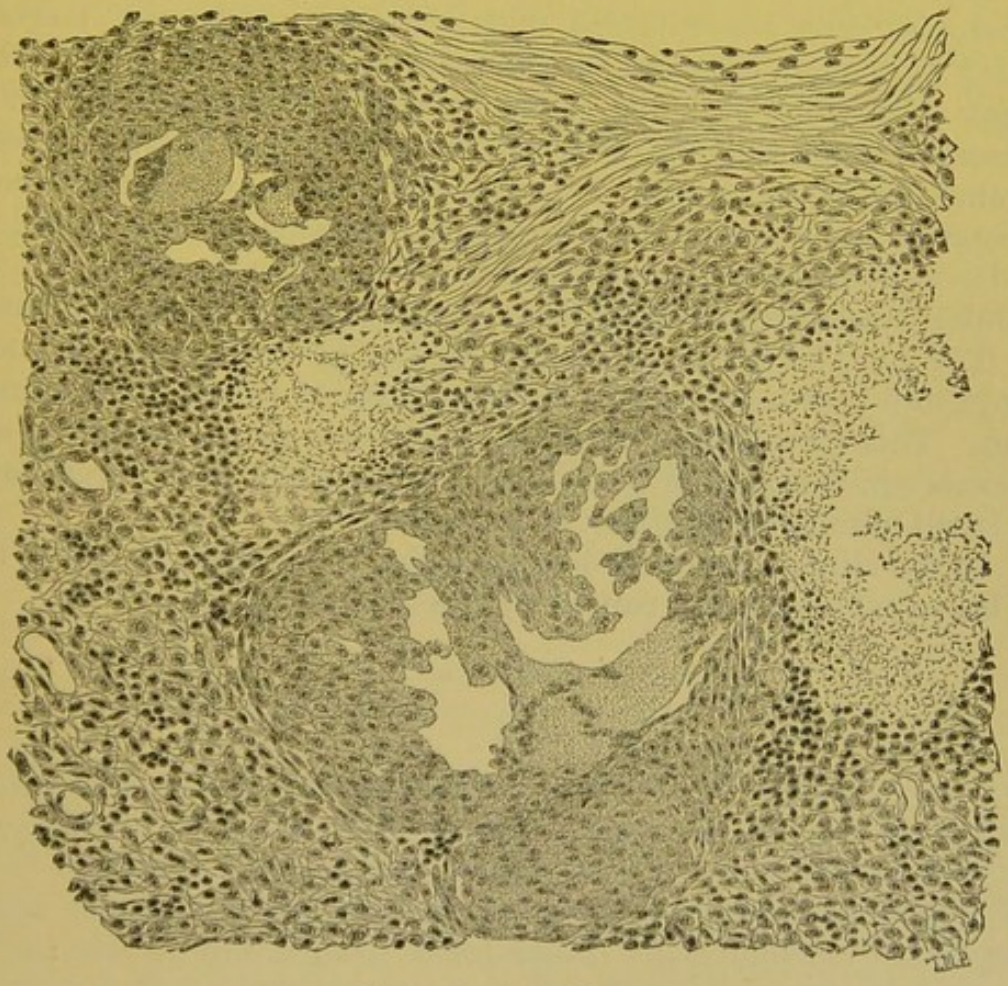

FIG. 93.—LUPUS OF FACE.

body in tuberculous persons from contact with secretions or excretions containing the tubercle bacilli, or about sinuses leading to tuberculous abscesses, joints etc., or in the vicinity of tuberculous lymph nodes. Finally, a chronic form of tuberculous inflammation which presents

special clinical features has long been known under the name of *lupus*.

*Lupus*.—This form of inflammation most frequently occurs in the skin of the face, but also in the mucous membrane of the mouth, pharynx, conjunctiva, vulva, and vagina. The lesion consists of small, multiple nodules of new-formed tissue, somewhat resembling granulation tissue, in the cutis or mucosa and submucosa. By the formation of new nodules and a more diffuse cellular infiltration of the tissue between them, the lesion tends to spread, and by the confluence of the infiltrated portions a dense and more or less extensive area of nodular infiltration may be formed. There may be an excessive production and exfoliation of epidermis over the infiltrated area, or an ulceration of the new tissue.

Microscopical examination shows the lesion to consist of small spheroidal cells intermingled with variable numbers of larger, so-called epitheloid cells and cell masses, and in many cases contains giant cells (Fig. 93). In some cases a well-marked reticulum is present between the new cells, and these are often grouped in masses around the blood vessels. In some cases there is, without previous ulceration, a formation of new connective tissue in the diseased area, and a well-marked cicatrization; in other cases the cells and intercellular substance undergo a disintegration which leads to ulceration.

The morphological characters of the lesion long ago led to the conjecture that lupus was in reality a form of tuberculous inflammation. This view has now become established by the numerous observations which show the very constant presence of the tubercle bacillus in small numbers at the seat of inflammation.

In the clinical group of diseases called lupus there are other forms of lesion which are not caused by the tubercle bacillus.

## LEPRA (LEPROSY).

This disease is very common in India and in other hot countries. It is not common in America, but in the Gulf States, in Mexico, among the Norwegians in the Northwest, and in the eastern British provinces a considerable number of cases are grouped. Isolated cases are, however, encountered now and then in various parts of the United States.

Leprosy is characterized by the development of nodular and sometimes diffuse masses of tissue, consisting of larger and smaller cells of various shapes—spheroidal, fusiform, and branched, with a fibrous stroma—the whole somewhat resembling granulation tissue. The

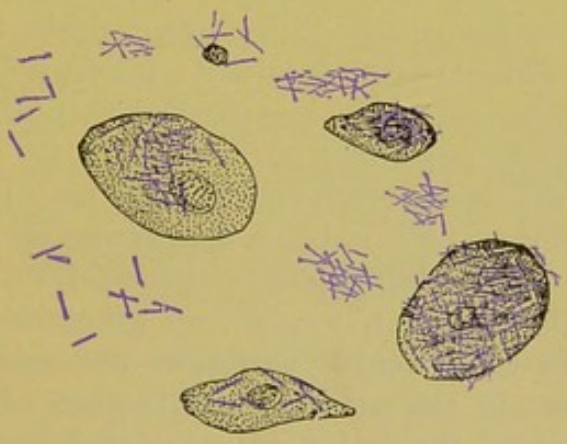

FIG. 94.—THE BACILLI OF LEPROSY.
Stained with gentian violet. From a nodule in the skin.

new tissue is most frequently formed in the most exposed parts of the skin, as the face, hands, and feet, but it may occur in the skin of any part of the body. It is formed more rarely in the subcutaneous connective tissue, in intrafascicular connective tissue of nerves, in the viscera, and in the mucous membranes. The mucous membranes most frequently affected are those of the eye, nose, mouth, and larynx. The nodules may be very small or as large as a walnut, and may be single or joined together in groups or masses. The tissue of the part in which the new formation occurs may be atrophied and replaced by, or may remain intermingled with, the leprous tissue, or it may be hypertrophied. The nodules may persist for a long time without

undergoing any apparent change, or they may soften and break down, forming ulcers; but ulceration, except in the mucous membranes, is said usually to occur as the result of injury or unusual exposure. The leprous tissue may change without ulceration into cicatricial tissue, or cicatrization may follow ulceration.

Various secondary lesions and disturbances of nerve function are associated with the formation of leprous tissue in the nerve and central nervous system, but these we cannot consider here.

In all the primary lesions of leprosy, bacilli are said to be present, mostly in the cells, and particularly in the larger transparent spheroidal forms, but sometimes free in the intercellular substance. The bacilli have been found in the skin, mucous membrane of the mouth and larynx, in peripheral nerves, in the cornea, in cartilage, in the testicles, and in lymph nodes. Sometimes the cells contain but few bacilli, but they are frequently crowded with them. The bacilli are from 4 to 6 $\mu$ long and very slender, being usually less than 1 $\mu$ in thickness. They are sometimes pointed at the ends and sometimes present spheroidal swellings (Fig. 94). In their comportment toward staining agents, as well as in general morphological characters, they considerably resemble the Bacillus tuberculosis, but they are more readily stained. They may be stained with fuchsin or gentian violet by the ordinary method, or by the method employed for staining the tubercle bacillus (see page 224).

According to Neisser, the lepra bacillus may be artificially cultivated at body temperature on blood serum and on boiled eggs.

Bordoni-Uffreduzzi claims to have grown it on glycerinated blood serum. It is said by Byron to grow on glycerin-agar with two per cent of sugar, in tubes sealed to retain the moisture.[1] But these reports of success in the artificial cultivation of the lepra bacillus have not yet received the seal of experimental confirmation.

Lepra is communicable from man to man by direct inoculation. Under modern and proper sanitary conditions the disease is not readily communicable. In a few cases animal inoculations have been made with what appears to be positive results.

The structure of the new tissue growth, the absence of coagulation necrosis, and the peculiar grouping of the bacilli in the large transparent cells are characters which usually clearly distinguish the lesions caused by the leprosy bacillus from those of tuberculosis.

---

[1] *Byron*, New York Pathological Society, January 27th, 1892.

## SYPHILIS.

The lesions of this form of infectious disease are in many respects morphologically similar to those of tuberculosis, and are unquestionably due to the presence in the body of some form of micro-organism.

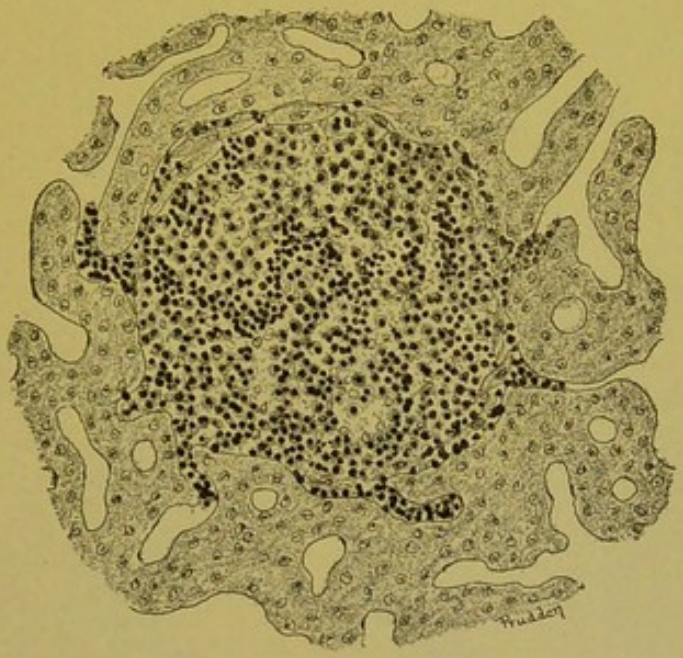

FIG. 95.—SMALL NODULE OF SYPHILITIC INFLAMMATION (MILIARY GUMMA) IN THE LIVER.

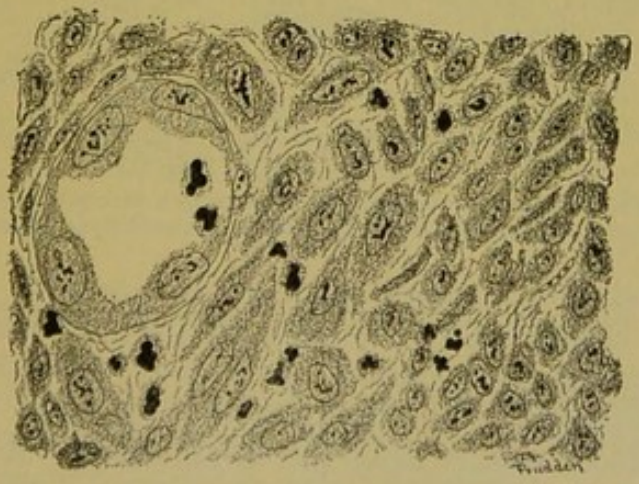

FIG. 96.—NEW-FORMED TISSUE IN SYPHILITIC INFLAMMATION.
From a "hard chancre," showing swollen endothelium in a small blood vessel.

That this is so, however, we do not know by direct observation and experiment, but by inference.

The characteristic lesions of syphilis consist in a more or less circumscribed formation of new tissue. This new tissue may be made up largely of small spheroidal cells (Fig. 95), or of these with polyhedral cells and of occasional giant cells. All of these new cell masses, which may be very small or occupy large areas, tend to



Fig. 97.—Section from a Primary Syphilitic Nodule of the Mucous Membrane of the Mouth. Showing collections of cells about the blood vessels in the submucous tissue.

undergo coagulation necrosis and to disintegrate at the centres. They may be converted into cicatricial tissue. The new tissues in syphilitic inflammation contain, as a rule, few blood vessels. It may form diffusely or in circumscribed masses. The endothelial cells of the blood vessels near the inflammatory foci in syphilitic inflammation are not infrequently swollen and may proliferate (Figs. 96 and 98, B). The vessels may otherwise undergo extensive changes.

In the primary lesion, which is called *chancre*, there may be obliterating endarteritis, a small spheroidal cell infiltration of the connective tissue (Fig. 97), proliferation of connective-tissue cells, swelling of the vascular endothelium, and an occasional development of giant cells. This new tissue may become fibrous or necrotic and may ulcerate.

Following the primary lesion there may be inflammation of the

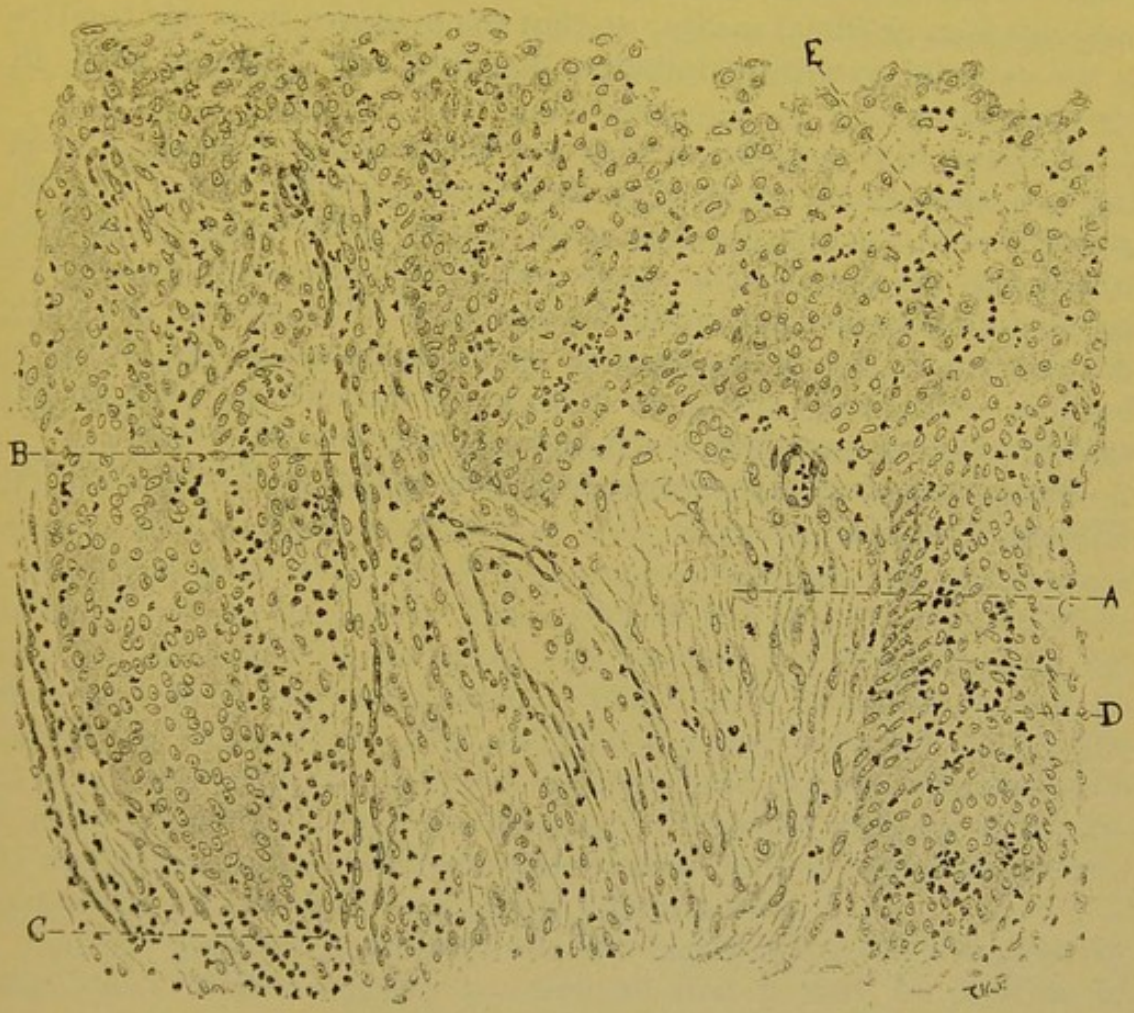


FIG. 98.—SECTION OF A PORTION OF A SYPHILITIC CONDYLOMA OF THE MUCOUS MEMBRANE.

A, Œdematous papilla; B, swollen endothelial cells in small blood vessels of a papilla; C, pus cells in the submucous connective tissue; D, pus cells in the epithelium; E, disintegration of the epithelium in the superficial portion of the mucous membrane.

lymph nodes, of the skin and mucous membranes, of the bones and viscera.

One of the most characteristic phases of the secondary inflammations of syphilis results in the formation in the periosteum or the viscera of masses of new tissue called *gummata*.

The smaller gummata consist of a mass of small spheroidal and epithelioid cells (see Fig. 95). As these cell masses grow larger they

are apt to become necrotic at the centre, and we may then have, as seen by the naked eye, a grayish-white, usually firm mass, with a more or less dense and irregular cheesy centre and a translucent, often radially striated border of dense fibrous tissue (see Fig. 247).

A bacillus closely resembling the tubercle bacillus in form and size has been described by Lustgarten and others as occurring in the lesions of syphilis. It is found in very small numbers. A distinctly characteristic mode of staining is not known, and it has never been cultivated on artificial media; so that the evidence that this bacillus is the cause of syphilitic inflammation does not appear to us at all convincing.

It is not always easy to distinguish on morphological grounds between the lesions of syphilis and those of tuberculosis, but the greater variety in the developmental stages of the tuberculous foci which may be found in a single individual; the grouping of the lesions in a manner indicative of progressive local infections, and in the last resort the demonstration of the presence of the tubercle bacillus, will usually suffice to distinguish the tuberculous from the syphilitic lesion, even without recourse to the clinical history.

For further details regarding syphilitic lesions see Changes in the Viscera, Part III.

## GLANDERS.

Glanders is an infectious disease caused by the presence and growth in the body of a bacillus called the *Bacillus mallei*.

It is most common in the horse, affecting the mucous membrane of the nose (when involving the skin the disease has been called *farcy*), and can be communicated to man and to certain other of the domestic animals by direct or accidental inoculations.

The disease is most frequent in those who come much into direct contact with horses. The seat of primary local infection in man is most often the skin, more rarely the mucous membranes about the nose and mouth.

The local lesions are similar in man and the lower animals. In the presence of the Bacillus mallei there is usually a circumscribed or more rarely a diffuse infiltration of the tissue with small spheroidal cells—leucocytes—with which new connective-tissue cells (epithelioid in form) may be mingled. These whitish foci of cells accumulation may be small and to the naked eye resemble miliary tubercles; or, they may be larger and nodular. The tissues about them may be infiltrated with blood. But the accumulated cells are apt in the presence of the bacilli to become necrotic and disintegrate and thus lead to smaller and larger abscesses, or, if near the surfaces, to ulcers. If occurring on mucous membranes these lesions are often accompanied by intense diffuse catarrhal inflammation.

As the glanders nodules soften, the bacilli are apt to diminish in number or in the capacity to stain, so that it may be possible to detect their presence only by inoculation or culture methods.

The disease may begin at a single point, so that it may be mistaken for a carbuncle or gangrenous erysipelas. But the infection is apt not to remain local; the bacilli, finding their way along the lymph channels into various parts of the body, set up fresh foci of inflammation and necrosis. Then the skin may be covered with a pustular eruption; furuncles, carbuncles, and abscesses may form beneath the skin and in the muscles. Nodules are found in the nasal mucous membrane, the lungs, kidneys, testes, spleen, and liver. The joints may be inflamed, and there may be osteomyelitis.

The glanders infection may, however, pursue a more chronic course, with hard, persistent nodules and sluggish ulcers. Under

these conditions the detection of the bacillus in the tissue by a simple morphological examination may be difficult.

While some forms of glanders nodules somewhat resemble in gross and microscopic appearance certain forms of miliary tubercles, the absence in the former of coagulation necrosis and of giant cells, and the tendency to rapid disintegration and softening in the latter will usually suffice for the distinction between the two sets of lesions. But the demonstration of the bacilli characteristic of each is in all cases decisive.

The Bacillus mallei is a slender bacillus proportionately thicker than the tubercle bacillus, with rounded ends, occurring singly or in pairs (Fig. 99). It stains easily with the anilin dyes, but readily gives up the color in presence of even feeble decolorizing agents such as dilute alcohol or acids. It is left decolorized by Gram's method. When stained, uncolored areas are apt to remain in the body of



FIG. 99.—BACILLUS MALLEI.

the germ. Whether these are spores or not is not yet definitely determined.

In the tissues the bacilli may be stained with Löffler's alkaline methylen blue, or with Ziehl's solution, great care being taken not to stain too deeply lest in the decolorization which is to follow the bacilli as well as the tissue elements may lose their color. It is well to decolorize in very dilute acetic acid (1:300), then wash carefully in water, dry the section on the slide with blotting paper and very gentle heat, clear with xylol, and mount in balsam.

The glanders bacillus grows readily on almost all of the ordinary artificial culture media, and best at blood heat. The growths on solid media are apt to be viscid. On potatoes it forms in two or three days an abundant yellowish pellicle which in a few days darkens and finally becomes brown in color. It gradually loses its virulence in successive generations of artificial cultures. The germ is easily killed by moist heat, but may remain alive in a dried state for months. Field mice and guinea-pigs are very susceptible to infection with the Bacillus mallei, and after inoculation develop highly characteristic local and general lesions.

In cases in which an early diagnosis is imperative it is well, in

addition to the morphological examination and cultures of the suspected exudate, to inject a small amount into the peritoneal cavity of a male guinea-pig. If the virulent glanders bacilli be present, within two or three days the testicles will swell and develop an intense suppurative inflammation.

As the glanders bacillus grows in nutrient broth a proteid substance—or substances—develops, which when concentrated by evaporation of the broth is called *mallein*. This substance prepared and administered to horses suffering from glanders, as tuberculin is prepared and administered to tuberculous cattle (see page 224), gives a similar temperature reaction, and is thus an important diagnostic agent.

## RHINOSCLEROMA.

This disease, which occurs especially in eastern Europe and occasionally in other parts of the world, is a chronic inflammation of the nasal, pharyngeal, and laryngeal mucous membrane. In this inflammation a diffuse or nodular formation of new tissue, somewhat resembling granulation tissue, occurs, which tends to assume a dense cicatricial character.

Constantly associated, it is said, with this lesion is a bacillus called *Bacillus rhinoscleromatis*. This bacillus in most of its morphological and biological characters closely resembles the pneumobacillus of Friedländer, growing readily on the common culture media and developing a capsule, and it may be identical with it.

The relationship of this bacillus to the lesions of rhinoscleroma do not appear to be as yet definitely established, since inoculations in men and animals have not given positive results.

## BUBONIC PLAGUE.

(Oriental Plague; Black Death.)

This readily communicable and extremely fatal infectious disease is especially characterized morphologically by an acute inflammatory swelling of the lymph nodes, most often those of the inguinal region, which are apt to suppurate or to become gangrenous. Hæmorrhages are common. Carbuncles may occur.

This disease, formerly not uncommon, has gradually become extinct in Europe. In the early summer of 1894 a severe epidemic occurred at Hong-Kong, and both Kitasato and Yersin discovered that the disease is caused by a short, thick, motile bacillus with rounded ends, staining more deeply at the ends than in the middle. It grows readily on the ordinary culture media at blood heat, and on inoculation into mice, rats, guinea-pigs, and rabbits effects are produced similar to those of the disease in man. The bacilli are present in the blood, in the lymph nodes, and in the viscera. The germs appear to gain entrance to the body through the abraded skin, the lungs, and the gastro-intestinal tract.[1]

---

[1] Consult *Yersin, Calmette and Borrel*, Annales de l'Institut Pasteur, July, 1895, p. 589.

## TYPHOID FEVER.

Typhoid fever is an infectious disease constantly associated with a bacillus called the *Bacillus typhi abdominalis.*

The lesions of typhoid fever are usually well marked and constant. They may conveniently be divided into two classes:

I. Those lesions which are characteristic of the disease. To this class belong the hyperplasia and ulceration of the lymph nodules (lymph follicles) of the intestine; the hyperplasia of the mesenteric lymph nodes (lymph glands), and of the spleen.

II. Those lesions which frequently occur with this fever and yet are not peculiar to it. To this class belong the parenchymatous degenerations in the viscera, especially in the liver and kidney; hyalin degeneration of voluntary muscles; suppurative inflammation in various parts of the body; endarteritis and thrombosis, infarctions, complicating pneumonitis, etc.

I. *The Intestines.*—The lesions of the intestines consist of an inflammatory enlargement (hyperplasia) of the solitary lymph nodules and of the agminated lymph nodules (Peyer's patches). Necrosis of the nodules with ulceration frequently follows the hyperplasia.

The process appears to begin with a catarrhal inflammation of the mucous membrane, accompanied or immediately followed by changes in the lymph nodules. The lesions in the lymph nodules begin early; they have been observed in persons who have died forty-seven hours after the commencement of the disease.

The increase in size of the agminated and solitary nodules may be rapid or gradual. The nodules may be only slightly enlarged, or may project so as to fill up the cavity of the intestine. The enlargement is usually more marked in the agminated than in the solitary nodules. Usually the whole of a Peyer's patch will be enlarged, but sometimes only a part of it. If the enlargement is gradual the different nodules which make up a Peyer's patch are enlarged, while the septa between them remain but little changed and give the patch an uneven appearance.

The patches which are only moderately enlarged are of reddish or reddish-gray color, are soft and spongy, and their edges blend gradually with the adjoining mucous membrane. The patches which are

more intensely affected are of gray or brownish color, of firm consistence, and rise abruptly from the surrounding mucous membrane, or even overhang it like a mushroom. The largest patches are sometimes more than three-eighths of an inch thick.

The enlargement and infiltration may spread from the patches to the surrounding mucous membrane, so that the patches appear very large; a number of them may become fused together, and there may be even an annular infiltration entirely around the lower end of the ileum.

The infiltration of the Peyer's patches may also extend outward into the muscular coat, and even appear beneath and in the peritoneal coat as small, gray, rounded nodules. This condition is usually found only with a few patches in the lower end of the ileum; sometimes in the cæcum and appendix vermiformis. These little gray nodules usually correspond to diseased patches beneath them; sometimes they appear to excite an inflammation of the peritoneum, accompanied by the production of numbers of similar nodules all over that membrane. Hoffmann describes a case in which the inflammation extended to the pleura, with the production of similar nodules there.

The solitary nodules are affected in the same way as Peyer's patches. They may be hardly enlarged at all, or be quite prominent, or may be affected over a larger portion of the intestine than are the patches. Very rarely the solitary nodules are enlarged, while the patches are not at all or but slightly affected.

The inflammation and enlargement of the agminated and solitary nodules may be followed by a healing process. The character of this process varies according to the intensity of the previous inflammation.

1. If the disease was mild and the enlargement of the nodules moderate, the enlargement gradually disappears and they resume their normal appearance (resolution).

2. In moderate enlargements resolution proceeds first in the nodules, leaving the septa between them for a time still swollen and prominent. This gives to the surface of a patch a reticulated appearance. After a time, however, the entire patch becomes flattened and uniform.

3. The solitary nodules or the separate nodules of a patch soften, break down, and their contents are discharged with some attendant hæmorrhage. This leaves a bluish-gray pigmentation, due to altered hæmoglobin, in the situation of each nodule, and this may remain for years.

4. In more severe types of the disease the enlargement of the nodules ends in ulceration. This takes place in two ways:

(*a*) The enlarged nodules soften, break down, and discharge into the intestine. In this way are formed small ulcers. These ulcers increase in size by the same softening process, which gradually attacks their edges, and in this way ulcers of large size may be formed. The ulcers may extend outward only to the peritoneal coat, or they may involve the peritoneal coat also and perforate.

(*b*) In the severest forms of the disease considerable portions of the enlarged patches may slough and become detached, leaving large ulcers with thick, overhanging edges. The slough may involve only the nodules, or it may involve also the muscular and peritoneal coats. These ulcers also may afterward increase in size, and several of them may be joined together.

If the patient recover the ulcers cicatrize, their edges become flattened, their floors are converted into connective tissue covered with cylindrical epithelium.

Both forms of ulceration sometimes end in perforation. This is effected by the extension of the ulcerative process through the peritoneal coat or by the rupture of the floor of the ulcer. Peritonitis and death are the usual result. In rare cases, however, the patient recovers and the perforation is closed by adhesions.

The minute changes which take place in the development of the intestinal lesion are as follows:

At first the blood vessels around the nodules are dilated and congested, while the nodules are swollen and the epithelium falls off. Then the nodules increase in size, largely from a growth of new cells. The new cells are, in part, similar to the lymphoid cells which normally compose the nodules; in part are large, rounded cells, some of which contain several nuclei. The production of new cells is not confined to the nodules, but extends also to the adjacent mucous membrane. In many cases also little foci of the same cells are found in the muscular, subserous, and serous coats. This increased number of cells compresses the blood vessels and the parts become anæmic. Soon the cells degenerate, either by granular degeneration of individual cells or by gangrene of part of a nodule. In either case the degenerated portion is eliminated into the intestine and leaves an ulcer of which the floor and edges are infiltrated with cells. After this the cell growth goes on and the ulcer enlarges, or the cells are gradually replaced by connective tissue and cicatrization follows.

The lesions which we have described are found most frequently and are most pronounced in the lower part of the ileum. They are not always, however, confined to this situation. Enlarged and ulcerated nodules may be found over the entire length of the ileum and even in the jejunum. They may also extend downward and be found

in the colon, even as far down as the rectum. The same changes may also take place in the appendix vermiformis.[1]

Besides the regular typhoid lesions of the intestines which have been described, we occasionally meet with others of a secondary and more accidental character.

*Gangrene* of the intestinal wall sometimes occurs. It most frequently involves a portion of the wall corresponding to an ulcer, but may also affect other portions where no ulcer exists. The process may terminate in perforation or in healing.

*Croupous Inflammation* may attack the mucous membrane of either the large or small intestine. The mucous membrane between the typhoid ulcers is then more or less covered and infiltrated with an exudation of fibrin and pus.

*Peritonitis* of a mild type is a frequent accompaniment of the intestinal lesions. It appears to have but little influence on the course of the disease.

Severe peritonitis is usually due to perforation, less frequently to ulcers which reach the serous coat but do not perforate. When there is infiltration of the serous coat with the typhoid new growth, the peritonitis may be accompanied by a production of little gray nodules of the same character throughout the peritoneum.

*Infarctions* of the spleen, inflammation of the ovaries, and perforation of the gall bladder are sometimes the cause of peritonitis.

*Hæmorrhage* from the intestines may be slight and due to the inflammatory swelling and congestion of the mucous membrane; or it may be due to the ulceration of the follicles and opening of the blood vessels, and is then often profuse.

*Mesenteric Lymph Nodes.*—The mesenteric nodes undergo changes similar to those in the nodules of the intestines, and are usually affected in a degree corresponding to the intensity of the intestinal lesion.

The nodes are at first congested and succulent; then there is a production of lymphoid cells and large cells (Fig. 262), as in the intestinal nodules, and the node becomes enlarged. When the enlargement has reached its full size the congestion diminishes and the cells begin to degenerate. The degeneration may take place slowly, and then the node gradually returns to its normal condition; or more rapidly, and then little foci of softened, purulent matter are formed. If the patient recovers the small foci are absorbed, leaving a fibrous

[1] Owing to the frequent involvement of Peyer's patches the larger intestinal ulcers in typhoid fever are apt to have their longest diameter lengthwise of the gut in contrast to spreading tubercular ulcers, which, owing to the extension of the local inflammation along the encircling lymph channels, are apt to have the longest diameter crossing the gut. But exceptions to this general rule are common.

cicatrix; the larger foci may become dry, necrotic, and enclosed in a fibrous capsule. The inflammation of the nodes may produce a local or general peritonitis. Intense exudative inflammation may occur in the nodes, which may be densely infiltrated with serum, fibrin, and pus.

*The Spleen.*—In nearly every case of typhoid fever the spleen is enlarged. This enlargement begins, as a rule, soon after the commencement of the disease, increases rapidly until the third week, remains stationary for a few days, and then diminishes. The organ is congested, of dark-red color, and of firm consistence while it is increasing in size. After it has reached its maximum size its consistence becomes soft and there is a considerable deposit of brown pigment. The enlargement appears to be due to congestion and hyperplasia (compare page 624).

In rare cases the softened spleen ruptures, with an extravasation of blood into the peritoneal cavity.

There may be infarctions of the spleen, which sometimes soften and cause peritonitis.

II. The second class of lesions comprises those which are frequently found with typhoid fever, but are not peculiar to it.

*The Mouth.*—A number of changes are found about this region. The follicles at the root of the tongue and the tonsils may be enlarged; the muscles of the tongue may undergo waxy and granular degeneration; gangrenous ulcers may attack the floor and sides of the mouth and destroy large areas of tissue.

*The Pharynx* may be the seat of catarrhal or croupous inflammation, producing superficial and deep ulcers.

*The Parotid* is, in a moderate number of cases, the seat of an inflammation which tends to suppuration. In this process both the glandular acini and the connective tissue between them are involved. Which of the two has the larger share in the process is still in dispute.

A slight enlargement and induration of the parotid and submaxillary glands is said by Hoffmann to be a frequent lesion, and to depend on increase of the gland cells and dilatation of the acini with their secretion.

*The Pancreas* undergoes changes similar to those in the salivary glands. It becomes at first swollen and red, then hard and grayish, then yellow. The vessels are at first congested, afterward there is increase of the gland cells, and lastly degeneration.

*The Liver* may preserve its normal character or may present changes.

In many cases the organ will be found swollen, pale, soft and flabby. Minute examination then shows that the liver cells have

undergone parenchymatous degeneration. They are filled with fine granules and small fat globules, and the degeneration may go on so far that the outlines of the hepatic cells are lost and nothing but a mass of granules can be seen.

Less frequently we find in the liver very small, soft, grayish nodules. They are situated along the course of the small veins, and there is at the same time a diffuse infiltration of lymphoid cells along the small veins. The nodules consist of lymphoid cells; they are often too small to be distinguished with the naked eye.[1] Small necrotic foci are sometimes present.

*The Heart.*—In a considerable number of cases the muscular tissue of the heart is altered by granular, fatty, or hyalin degeneration or by pigmentation. Myocarditis, endocarditis, and pericarditis are of occasional occurrence.

Thrombi in the cavities of the heart and vegetations on the valves are sometimes found. Detached fragments of these may be lodged as emboli in the different arteries.

*The Arteries.*—There may be an acute inflammation of the arteries, especially at the commencement of convalescence. There are two varieties: an obliterating and a parietal arteritis. In the obliterating arteritis there is infiltration of all the coats of the artery, with roughening of the intima and the formation of a thrombus within the vessel, and this may be followed by dry gangrene of the part supplied by the artery. In the parietal variety the wall of the artery is infiltrated with cells, but the intima is not roughened and no thrombus is formed.

*The Veins.*—Thrombosis of the larger veins, especially of the femoral vein in the third and fourth weeks of the disease, is not uncommon.

*The Larynx* is very frequently the seat of catarrhal inflammation, with or without superficial erosions. Less frequently there is croupous inflammation, followed in some cases by destructive ulceration.

*The Lungs.*—Catarrhal inflammation of the large bronchi is very common. Broncho-pneumonia occurs in two forms. There may be a severe inflammation of most of the bronchi of both lungs, with cellular infiltration of the walls of the bronchi and zones of peribronchitic pneumonia; or there is an intense general bronchitis, with lobules of the lung corresponding to obstructed bronchi, either collapsed or inflamed, or both.

From the long-continued recumbent position of the patients the posterior portions of the lungs become congested, dense, and un-

[1] *Reed*, "An Investigation into the so-called Lymphoid Nodules in the Liver in Typhoid Fever," American Journal of Medical Sciences, November, 1895. Johns Hopkins Hospital Report, vol. v., p. 379.

aërated. Sometimes, in addition to this, irregular portions of the lungs become hepatized. Less frequently there is a regular acute lobar pneumonia. There may be infarctions.

Gangrene of the lungs occasionally occurs, either associated with lobular pneumonia or with infarctions, or as an independent condition.

Fibrinous pleurisy and empyema occasionally occur.

*The Kidneys* very frequently present the lesions of acute degeneration, and occasionally those of acute inflammation. Small collections of lymphoid cells and small abscesses may be found in the kidney.

Catarrhal and croupous inflammation of the *bladder* may occur.

*The Ovaries.*—Hæmorrhage and gangrenous inflammation have been observed in rare cases.

*The Testicles.*—Orchitis has been described.[1] It is usually developed during convalescence; is unilateral; and usually affects the testicle alone, less frequently the epididymis; it may terminate in suppuration.

*The Brain.*—Acute meningitis is rare. Thrombosis of the venous sinuses, and obliterating endarteritis of the cerebral arteries, are occasionally observed.

*The Voluntary Muscles*, especially the abdominal muscles, the adductors of the thigh, the pectoral muscles, the muscles of the diaphragm and of the tongue, frequently undergo the hyalin degenerative changes described under muscle lesions.

*The Skin.*—Gangrenous inflammation of the skin frequently occurs in the form of bed sores, affecting especially the skin over the sacrum and trochanters, where it is subjected to the constant pressure of the bed.

There may be suppurative inflammation in almost any part of the body. Perhaps the most important of these local suppurations is that which results in retropharyngeal abscess.

The post-typhoid bone lesions are important.[2] In the secondary bone lesions after typhoid as well as elsewhere the bacillus may remain alive for long periods, even several months.

## THE BACILLUS OF TYPHOID FEVER.

The presence of a bacillus in various parts of the body in typhoid fever, in a considerable proportion of the cases examined, has been well established by a large number of observers. This bacillus does not occur in the body, so far as is known, except in connection with this disease.

---

[1] *Ollivier*, Rev. de Méd., November and December, 1883.

[2] *Parsons*, Johns Hopkins Hospital Reports, vol. v., p. 417.

In the early stages of the disease the bacillus may be found in the lymphatic structures of the intestines and in the mesenteric lymph nodes and the spleen. It may be present in the bone marrow, kidney, liver, bile, lungs, and in the blood, and it may be found, though not in such abundance as was formerly assumed, in the intestinal contents after the disease had become well established. In the viscera it is apt to occur in larger and smaller masses or clusters (see Fig. 100). It has been repeatedly found in the urine. The typhoid bacilli may be present alone or in association with other germs in the foci of suppuration which so frequently complicate typhoid fever, also in the exudates in inflammations of the serous membranes and in the endocardial vegetations.[1]

The typhoid bacillus is usually about three times as long as broad, being about one-third as long as the diameter of a red blood cell.

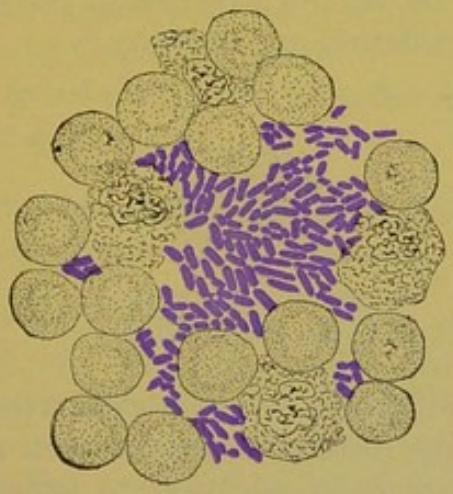

FIG. 100.—CLUSTER OF TYPHOID BACILLI IN THE SPLEEN.

But it varies considerably in size when growing on different media. It is rounded at the ends, and frequently contains rounded structures which have been regarded as spores, but which further researches have led us to believe are not spores but vacuoles. The bacillus is beset with flagella.

The typhoid bacillus can be readily cultivated on the ordinary culture media at room temperature. It forms delicate, bluish-white, sinuous-edged, spreading colonies on the surface of nutrient gelatin, which it does not fluidify. Several other bacteria grow in a similar way on gelatin. The growth of the typhoid bacillus on boiled potatoes,

[1] See *Flexner*, Journal of Pathology and Bacteriology, April, 1895, and Johns Hopkins Hospital Reports, vol. v., p. 343. Also for full consideration of the pyogenic powers of the typhoid bacillus consult *Dmochowski and Janowski*, Ziegler's Beitr. z. path. Anat., etc., Bd. xvii., p. 221.

in a nearly invisible pellicle, is a marked culture characteristic. If, however, the potato be slightly alkaline the surface growth becomes evident. In cultures the typhoid bacilli often cling together end to end, forming long, thread-like structures (Fig. 101). The bacilli in fluids are actively motile.[1]

Inoculations of the typhoid bacillus into animals, while not producing a disease in all respects like that in the human subject, may cause death with symptoms and lesions as closely resembling those in man as we are often able to produce in animal experimentation. Although similar effects may be induced in animals by the inoculation with other germs, the evidence that typhoid fever in man is produced by the typhoid bacillus, and by this alone, is altogether so strong as practically to amount to a demonstration.

It is probable that the usual symptoms and lesions of typhoid fever are largely due to the absorption of toxic substances which are produced as the result of the life processes of the bacteria at the point of their greatest accumulation and activity.



FIG. 101.—BACILLUS TYPHOSUS.
From a gelatin culture.

During artificial cultures in nutrient broth a poisonous albuminoid product or products are formed and have been named *typhotoxin*. Injection into rabbit may in addition to general toxic symptoms induce hyperplasia of the intestinal lymph nodes.

Some of the inflammatory complications which occur in typhoid fever are due to the growth of the bacillus in unusual places in the body, but many of them are due to a secondary infection with other germs, notably with the pyogenic cocci.

Infection with the typhoid bacillus seems to occur largely through the gastro-intestinal canal.

In a large proportion of cases the disease is communicated by means of food, and especially of milk and drinking-water which have been polluted with the excretions of persons suffering from the disease. Many serious epidemics of typhoid fever have been traced

[1] Several bacilli are known which considerably resemble the typhoid bacillus in form and general biological characters under cultivation. Most noteworthy among these is the Bacillus coli communis, which is a constant resident of the gastro-intestinal canal. This germ, which in the past has no doubt been frequently mistaken for the Bacillus typhosus, may now be differentiated from it.

to pollutions of milk and drinking-water from such sources.[1] Oysters which have been taken from grossly polluted waters, as near sewer openings, have been the means of conveying the germs.[2]

In milk the typhoid bacillus not only remains alive for long periods but undergoes active multiplication. It may remain long alive in water and even for a time multiply. In the soil and when dried it may remain alive for months. Frozen in ice it has been found alive after more than three months. It is readily killed by exposure to strong sunlight.

### METHODS OF STAINING THE TYPHOID BACILLUS.

The bacilli, when taken from cultures, stain readily with the ordinary anilin dyes, such as fuchsin and gentian violet (see page 130.)

In sections of the organs they do not take the stain so readily. They are decolorized by Gram's method.

One of the most satisfactory solutions for this purpose is that of Ziehl, which is made as follows:

Filtered saturated aqueous solution of Carbolic Acid, 90
Saturated alcoholic solution of Fuchsin.....10

The sections are soaked for half an hour in this solution and then decolorized by alcohol, cleared in oil of cedar, and mounted in balsam. The decolorization should be done carefully, the section being examined from time to time as it proceeds, so as to avoid the removal of too much color. The nuclei should remain faintly colored, but not so much so as to conceal the clusters of more deeply stained bacilli.[3]

---

[1] *Freeman*, New York Medical Record, March 28th, 1896.

[2] *Foote*, Medical News, March 23d, 1895.

[3] For recent summary of studies on the typhoid bacillus and typhoid fever, with bibliography, consult *Dunbar*, "Ergebnisse der allg. Aetiologie der Menschen- u. Thierkrankheiten," 1896, p. 605.

## DIPHTHERIA.

Diphtheria is an acute infectious disease caused by the *Bacillus diphtheriæ* (Löffler), and usually characterized by a pseudo-membranous inflammation on some of the mucous membranes or occasionally on the surface of wounds, and by immediate or remote effects of absorbed toxic substances.

The mucous membranes which are the most frequently affected in diphtheria are those of the tonsils, pharynx, soft palate, nares, larynx, and trachea; less frequently those of the mouth, gums, conjunctiva, œsophagus, and stomach.

The local inflammation in mucous membranes may present various phases, which represent clinical types of the disease. Thus there may be a simple redness of the affected surfaces which leaves no trace after death, or a catarrhal inflammation. On the other hand, in the more marked forms of the lesion there may be a fibrinous exudate which infiltrates the mucous membrane, or, intermingled with pus cells, epithelial cells, red blood cells, bacteria, and granular material, forms a thick or thin pellicle on the affected surfaces. This pellicle may undergo coagulation necrosis, and hand-in-hand with this there may be superficial or deep coagulation necrosis of the mucous membrane.

The false membrane in diphtheria is thus formed by a combination of inflammation and necrosis, the extent of the necrosis and the amount of inflammatory products varying in the different cases.

The pseudo-membrane may disintegrate or exfoliate, with or without loss of tissue in the underlying mucous membrane. Phlegmon, abscess, and œdema are liable to occur as local complications. Adjacent and distant lymph nodes are apt to be swollen, and often show, on microscopical examination, small foci of cell necrosis and disintegration. Similar necrotic foci and areas of small spheroidal-cell accumulation with fatty degeneration may be found in the kidney, spleen, and liver. Acute nephritis and degeneration of the heart muscle are not infrequent.[1] The exact nature of the nerve lesions which may be associated with the late paralyses of diphtheria is not yet clear.

---

[1] For a study of heart lesions in diphtheria consult *Schamschin*, Ziegler's Beitr. z. path. Anat., Bd. xviii., p. 64, 1895.

Catarrhal bronchitis and broncho-pneumonia or lobular pneumonia frequently complicate diphtheritic lesions of the upper air passages and fauces.

Bacteria of various forms are commonly present in the false membrane, and some of the forms may penetrate deeply into the underlying tissue. The germ, however, which stands in a causative relationship to this disease is the Bacillus diphtheriæ of Löffler.

In man the diphtheria bacilli are largely confined to the seat of local lesion, and sometimes occur in enormous numbers (see Fig. 102), especially in the older layers of the pseudo-membrane. But they may become widely distributed through the blood. The systemic effects in diphtheria appear to be due to the absorption into the body of toxic material elaborated by the germs.

The very frequent association of the pyogenic cocci with the diph-



FIG. 102.—DIPHTHERITIC INFLAMMATION OF THE TONSIL.
Showing Löffler's bacilli in the pseudo-membrane.

theria bacillus give rise to a complicating series of results which make the clinical picture and the lesions of diphtheria sometimes very complex. Thus the complicating bronchitis and broncho-pneumonia, as well as pyæmic symptoms and lesions, may be due to the presence in the pseudo-membrane, and the entrance into the deeper air passages and the blood, of the Streptococcus pyogenes and the Staphylococcus pyogenes, the Diplococcus lanceolatus, Bacillus coli communis, and others.

The Bacillus diphtheriæ, first described and definitely associated with this disease by Löffler, is from 2.5 to 3 $\mu$ in length and 0.5 to 0.8 $\mu$ in thickness, and is characterized morphologically by marked irregularities in its form (Fig. 103). While the typical form is that of a

moderately stout, round-ended, straight, or slightly curved bacillus, it is very apt—perhaps as a result of degeneration—to appear club-shaped or pointed at the ends, irregularly segmented, and to develop at the ends or elsewhere a strongly refractile material which stains more deeply than the rest of the protoplasm.

The diphtheria bacillus is immotile, grows slowly and scantily at room temperature, but at body temperature develops rapidly in bouillon and on agar, glycerin-agar, and blood serum. On glucose-broth serum (Löffler's blood-serum mixture) the growth is particularly vigorous (see page 162). On glycerin-agar plates it grows in the form of moderately small, grayish-white, slightly spreading, rough-edged colonies. According to Welch and Abbott, it grows abundantly in an invisible pellicle on potatoes. It does not form spores. Welch and Abbott have found that in fluids it may be killed by an exposure of ten minutes to a temperature of 58° C. But it may remain alive for weeks, or even months, in fragments of dried membrane.[1]



FIG. 103.—BACILLUS DIPHTHERIÆ.

From exudate in the throat of a case of diphtheria; showing irregularities of the bacilli in shape and size and coloration.

It may be stained with Löffler's alkalin methylen-blue solution or by Gram's method.

The diphtheria bacillus is subject to extreme variations in virulence, forms being met with in which all the usual cultural characteristics are not in the slightest degree virulent. These are sometimes inadvisably called *pseudo-diphtheria* bacilli.

The name pseudo-diphtheria bacillus is more wisely limited to such germs as, though resembling the diphtheria bacillus, still present distinct cultural peculiarities.[1]

Inoculations of virulent cultures subcutaneously in guinea-pigs are regularly followed by a localized hæmorrhagic œdema with a variable amount of whitish exudate. Death usually follows the inoculation in from two to five days. In addition to the local lesions there may be—but this is not constant—swelling of the adjacent and

[1] Consult *Park and Beebe*, "Report on Bacteriological Investigations; Diagnosis of Diphtheria," Bulletin No. 1, Health Dept., New York City, 1895; Studies and Bibliography.

of the abdominal lymph nodes, serous effusions into the pericardial, pleural, and peritoneal sacs, swollen spleen, and acute parenchymatous and fatty degeneration in the liver, kidney, and heart muscles; congestion and sometimes hæmorrhage of the suprarenals. Microscopical examination shows, in a considerable proportion of cases, fragmentation of nuclei and other evidences of cell death at the seat of inoculation and in the viscera.[1] Animals which survive the inoculations may later develop paralysis, and a similar result may follow the injection into rabbits of culture fluids. The bacilli do not gain access to the body at large, but may be found at the seat of inoculations. Inoculation into the mucous membranes of rabbits, pigeons, and certain other animals may result in the development of a pseudo-membrane somewhat resembling that of the disease in man.[2]

During the growth of the diphtheria bacillus in nutrient broth an albuminous toxic substance is developed which mingles with the broth. This is called diphtheria toxin, and subcutaneous injections of this toxin in animals—guinea-pigs, for example—proves fatal, in appropriate dosage, with symptoms and lesions similar to those caused by inoculation with the living germ.

It has been found that by repeated injections of the diphtheria toxins in susceptible animals, at first with small, then with gradually increasing doses, the animal may at length become so insusceptible to the action of the poison that many times the usually fatal dose is borne without sensible reaction.

Similar immunity can be conferred in certain animals by the use of the living cultures of the diphtheria bacillus either fully virulent or with reduced virulence (see page 179), administered at first in small doses which are gradually increased.

In whichever way immunity be conferred it has been found that the blood of the artificially immunized animal contains a substance, or substances, called *diphtheria antitoxin*, which on being introduced with the blood serum into other susceptible organisms, may not only confer a quickly established immunity, but, without destroying the diphtheria germ, may protect against its toxic effects when the disease is already under way. Thus through the artificial immunization of horses the so-called "serum therapy" has assumed a

---

[1] For a detailed description of minute cell changes in animals following inoculation with diphtheria bacilli, see *Welch and Flexner*, Bulletin of the Johns Hopkins Hospital, August, 1891; also *Abbott and Ghriskey*, ibid., April, 1893.

[2] It is important from the prophylactic standpoint to remember that the Bacillus diphtheriæ may remain alive in the mouth of the human subject for many weeks after recovery from the local lesions of the disease, and also that healthy persons when the disease is prevalent may harbor the bacilli in their mouths.

very important and beneficent rôle in the prevention and management of diphtheria.

Although there is no differential stain for the diphtheria bacillus, its morphological peculiarities are, as above indicated, so marked that when occurring in considerable numbers in the membranes or when examined from serum cultures definite conclusions as to its identity can usually be arrived at without recourse to complete biological analysis. But this as well as animal inoculations will often be necessary when the morphological characters are doubtful, and when the degree of virulence is to be determined.

For the practical ends of early diagnosis it has been found that if a smear of material from the local lesion be made over the surface of a "slant tube" of Löffler's blood-serum mixture, and placed in an incubator at blood heat for twelve hours, the diphtheria bacilli, if present, will usually have outstripped in growth most of the other germs which were present in the exudate. If now cover-glass preparations be made of a considerable quantity of the new growth which is dotted in scarcely visible colonies over the surface of the serum, the presence or absence of the diphtheria bacillus can, in a large proportion of cases, be determined from its peculiar morphological features (Fig. 103). This method, elaborated by Park[1] and put into practice on a large scale by the Health Department of New York, has now become an almost indispensable factor in the control of diphtheria by health officials in many parts of the world, and is of especial importance in connection with the use of diphtheria antitoxin serum, whose highest promise lies in early administration.

[1] Consult *Biggs, Park and Beebe,* "Report on Bacteriological Investigation and Diagnosis of Diphtheria," Bulletin No. 1, Health Dept., City of New York, 1895.

## TETANUS.

(*Lockjaw.*)

This disease is caused by a bacillus—*Bacillis tetani*—which is rather widespread and in some places very abundant, occurring with other germs in the soil, especially in manured soil, and gaining entrance to the body through wounds, which are often very slight. The Bacillus tetani is a rather long, slender, motile germ, often growing in pairs or threads and prone to develop a spore in one end (Fig. 104), under which condition the bacillus swells at the end and becomes club or racket-shaped. It is readily stained. At the room temperature it grows on artificial culture media, and is strictly anaërobic, flourishing in an atmosphere of hydrogen. It fluidifies gelatin after sending out into it irregular-shaped, ray-like outgrowths.



FIG. 104.—BACILLUS TETANI.
From a culture.

The spores of the tetanus bacillus are very resistant to drying, to heat, and to various chemical disinfectants.

Characteristic tetanic symptoms followed by death may be induced in mice, guinea-pigs, and rabbits by subcutaneous inoculation of cultures.

Man and the horse are markedly susceptible to tetanus; birds are as a rule insusceptible.

The local lesion in tetanus is usually slight and not characteristic, often consisting in a slight suppuration.

The morphology of the lesions of the nervous system to the existence of which the symptoms of tetanus so directly point is yet obscure. Overfilling of the blood vessels, cellular exudate into the perivascular spaces, and rather indefinite changes in the ganglion cells have been recorded. The bacillus remains at the seat of local

lesion and produces its effect by the elaboration of a most intense poison or toxin, called *tetano-toxin.* The action of this toxic substance appears sometimes to continue in the body after the death of the organisms which have elaborated it. This infectious disease affords a most typical example of toxæmia.

If the tetanus bacillus be grown in nutrient broth at blood heat out of contact with oxygen the toxin is developed and mingles with the fluid. This toxin when freed from living germs is capable of producing all the symptoms of the disease.

Broth cultures may after some weeks have acquired such an extreme intensity that the dried poisonous material, separated from the inert fluids and partially purified, may be fatal to a mouse weighing 15 gm. in a dose of 0.00000005 gm.

Estimating according to the relative weights of the subjects, the minimal fatal human dose would be about 0.23 mgm.

This toxin is rendered inert by a temperature above 65° C. and by light.

By procedures similar to those described in diphtheria immunization (page 253), the tetanus toxin has been used to secure artificial immunity in dogs, goats, and horses, and here also the blood serum of the immunized animals has been prepared in a dried state and employed in man for therapeutic purposes with some degree of success.

The theoretical promise of the tetanus antitoxin for therapeutic purposes in man is, however, in practice rendered in large measure futile, because the existence of the disease is not recognizable until the toxæmia is sufficiently marked to produce the nervous symptoms, at which time an enormous and not easily determined dosage is required to neutralize or counteract the effects of the already elaborated poison.

Statistics are as yet too meagre to justify a definite opinion as to the practical value of serum therapy in tetanus.

For purposes of diagnosis it may be necessary to inoculate a white mouse at the base of the tail with suspicious material at the same time that morphological examination and anaërobic cultures arel made. Should tetanus develop in the mouse within a few days control cultures may be made from the exudate at the seat of inoculation.

## INFLUENZA.

(*Epidemic Catarrhal Fever; La Grippe.*)

This is an infectious disease characterized by fever, physical and mental prostration, and inflammations of different parts of the body. It differs from the other infectious diseases in that, instead of a single characteristic lesion, there is a disposition to acute exudative inflammation of either the pia mater, the sheaths of the peripheral nerves, the conjunctiva, the ears, the nose and throat, the larynx, the bronchi, the lungs, the pleura, the stomach, or the colon. Either one or several of these inflammations may be developed at the same time, or successively in one individual. It is, however, not uncommon to see cases of influenza in which no one of these inflammations is present.

The numerous bacterial studies which up to 1892 had been made on epidemic influenza had failed to reveal any micro-organism which could fairly be regarded as of etiological significance, although some of the complicating inflammations of the lungs had been shown to be very frequently associated with the pyogenic cocci—Staphylococcus pyogenes and Streptococcus pyogenes and the Diplococcus pneumoniæ.[1]

Early in 1892 Pfeiffer, Kitasato, and Canon[2] described the occurrence in the bronchial exudate and in the blood of influenza patients of a very small bacillus, hitherto unknown or possibly noted earlier by Babes. This bacillus was sometimes present in the bronchial exudate in enormous numbers, and often with little contamination with other germs. In the blood it was sometimes abundant, sometimes scanty. It stains with some difficulty with the simple anilin dyes; but by Ziehl's solution (page 224); or by warmed Löffler's methyl blue (page 158); or by Czenzysnki's fluid (page 283), heated with the specimen at body temperature for from three to six hours, it is readily colored. The bacilli are very slender and short (one to one and a half times as long as broad), sometimes lie singly, sometimes in pairs or short chains or heaps, and are not motile.

This so-called influenza bacillus grows best at body temperature. On glycerin-agar it forms very small, scarcely visible dewdrop-like

[1] Consult *Finkler*, "Die acuten Lungenentzündungen," 1891, p. 452.

[2] Deutsche medicinische Wochenschrift, January 14th and May 26th, 1892.

colonies; these, although growing close together, do not tend to coalesce, as many germs do.

According to Pfeiffer the growth is more voluminous if the surface of the agar be smeared with blood—best of man or the pigeon—since the hæmoglobin appears to favor the growth. It does not grow at a temperature at which nutrient gelatin remains solid. In beef tea it forms a scanty, cloudy growth. It has been cultivated through several generations, but is prone to die. Animal inoculations have given diverse and not very marked results.

The earlier observations have been in general confirmed by later studies of others.[1]

On the whole, we can only say at present that while the occurrence of the above-described bacillus in influenza, and exclusively here, is interesting and apparently significant, we cannot yet definitely regard it as of established importance in the etiology of the disease. The observations of the writer upon this germ have been too limited to permit of an independent opinion.

---

[1] For bibliography and later data consult *Beck*, "Ergebnisse der allg. Aetiologie der Menschen- u. Thierkrankheiten," 1896, p. 742.

## BACTERIA WHICH MAY BE OCCASIONAL INCITERS OF INFECTIOUS DISEASE IN MAN.

*Bacillus œdematis maligni.*—This bacillus, which is frequently present in dust, in putrefying substances, and in garden earth, considerably resembles the anthrax bacillus in form, but is more slender and has rounded ends. When it develops spores the bacillus is swollen or bellied at the middle. It is strictly anaërobic, growing readily in gelatin-agar and blood serum. It fluidifies gelatin. Gas is developed in its growth on blood serum.

Several times this bacillus has been found in persons who have received dirty wounds, and it has been associated with hæmorrhagic œdema, gas formation in the tissue, and gangrene. Similar lesions are produced by inoculation of the pure cultures in animals.

This bacillus is readily stained by any of the common anilin dyes.[1]

*Bacillus pneumoniæ (Friedländer).*—In a small proportion of cases of lobar and lobular pneumonia, and in a few cases of exudative inflammation of the pleura, pericardium, meninges, and middle ear, this bacillus has been found. It is sometimes found alone, but in pneumonia is frequently associated either with the Diplococcus pneumoniæ or with the pyogenic cocci. It has been found in the nasal secretion and mouths of healthy persons. While belonging definitely among the bacilli, it so frequently occurs in the form of very short rods or ovals or short chains that it was formerly thought to belong among the cocci. The bacilli, whether longer or shorter, single or in short chains, in cultures as well as in exudates, are surrounded by a narrow hyalin capsule.

It grows readily, at ordinary room temperature, in gelatin, which it does not fluidify, forming a white mass, which, heaping itself upon the surface and less markedly along the puncture line, forms a rather characteristic "nail-like" growth. It grows abundantly on other culture media. It is moderately pathogenic for mice. It seems highly probable rather than proven that it may be at least partially responsible for the lesions with which it is infrequently associated in man. This germ was formerly believed to be of great importance

[1] Consult *Novy*, Zeitschrift f. Hygiene, etc., Bd. xvii., p. 209 (bibliography).

in connection with acute lobar pneumonia, and for a time was generally spoken of as the pneumocccus of Friedländer. It is now known not to be a coccus, and is certainly of subordinate if at all of serious importance in the induction of inflammation of the lungs.

Its identity with the so-called Bacillus rhinoscleromatis (page 238) is claimed by some observers. If it be not identical with them it is closely related to capsulated bacilli found by Nicolaier[1] in pus, by Abel[2] in ozœna and found under various conditions and described under various names by Bordoni-Uffreduzzi, Pfeiffer, Mori, and others.

*Bacillus coli communis* ("colon bacillus").—This germ, which is of constant occurrence in the intestinal canal of man, is commonly reckoned among the saprophytes.

It is both morphologically and biologically very similar to the typhoid bacillus, to which it appears to be closely related. It is distinguishable from the typhoid germ by several well-marked cultural features, as well as by its pathogenic power. The points involved in the differential diagnosis of the colon from the typhoid bacillus are too intricate and numerous to be considered here.

Recent studies, especially those of Welch, have shown that not infrequently when the Bacillus coli communis finds access to the peritoneal cavity or other parts of the body where it does not belong, it is capable of inciting serious and even fatal disease. It may induce local suppurative inflammation, necrosis, and toxæmia.

In the kidney, in the gall passages, in hæmorrhagic pancreatitis, in appendicitis, and repeatedly in peritonitis, as well as in other lesions, it has been found either alone or in association with other germs.

It would appear from the observations of Welch,[3] who found it in one or more of the organs of the body in thirty-three out of about two hundred autopsies, that lesions of the mucous membrane of the intestine, hæmorrhage, ulceration, perforation, catarrhal and diphtheritic inflammation, strangulation, injury, etc., may open the way for its access to various parts of the body. In some cases its presence was associated with lesions, in some not. On the whole, it would seem that we are justified in regarding the colon bacillus as of occasional pathogenic importance in man. The limitations of its significance must be determined by further studies.[4]

---

[1] *Nicolaier*, Centralb. f. Bak., October 13th, 1894, p. 601.

[2] *Abel*, ibid., Bd. xiii., Nos. 5 and 6, 1893.

[3] *Welch*, "The Bacillus Coli Communis: The Conditions of its Invasion of the Human Body, and its Pathogenic Properties," Medical News, December 12th, 1891.

[4] For résumé of properties of the Bacillus coli communis, with bibliography, consult *Darling*, Boston Med. and Surg. Jour., November 15th and 22d, 1894.

*Micrococcus tetragenus.*—This coccus growing in tetrads has been repeatedly found in cavities in the lungs in pulmonary tuberculosis and in abscesses elsewhere.

While its usual significance is not yet clear, it has been shown to be pyogenic.

*Bacillus pyocyaneus.*—A pyogenic organism producing a greenish fluorescence in culture media, is of occasional occurrence in suppurative inflammation. It has been found in peritonitis and pericarditis, in broncho-pneumonia, in phlegmon, and under a variety of conditions in the gastro-intestinal canal.[1]

*Bacillus proteus.*—This germ is common in putrefying substances, is frequently present in the intestinal contents; it grows in bizarre and irregular forms on gelatin and agar, and may apparently under certain conditions be pathogenic.

*Bacillus aërogenes capsulatus.*—Several observers have described an anaërobic, gas-forming bacillus occurring in emphysematous phlegmons, in gangrene, in peritonitis, and also after death in cases with early and abundant post-mortem gas formation in the tissues, especially in the blood vessels and in the liver (see page 614).

It is probable that the gas-forming anaërobic bacillus above named, which was first described by Welch and Nuttall in 1892, is identical with some of those which under different names has been since described by various observers.[2]

---

[1] *Kossel*, Zeitschrift f. Hygiene und Inf. Kr., Bd. xvi., p. 368; also *Jakowski*, ibid., p. 474.

[2] For a full consideration of this important micro-organism see *Welch and Flexner*, Journal of Experimental Medicine, vol. i., p. 5, 1896.

## ACTINOMYCOSIS.

This disease is due to the growth in the body of a micro-organism whose botanical position is not quite clear, but which seems to belong among the bacteria. This micro-organism, the actinomyces, appears to belong to one of the more complex groups of bacteria called the Cladothricaceæ, which develop in the form of branching filaments. These filaments in actinomyces frequently separate into longer and shorter rod-like or almost spheroidal segments.

It may be grown on artificial culture media, flourishing best at body temperature. It at first develops in the form of delicate,

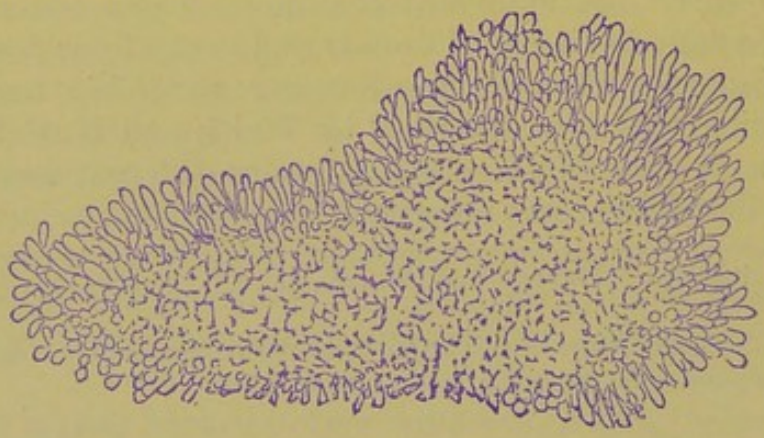

FIG. 105.—ACTINOMYCES BOVIS.

Showing one of the yellowish masses of the parasite separated from the surrounding tissue.

branching threads, the older cultures showing segments which resemble bacilli and cocci, and various bulbous, flask-like or club-shaped forms which appear to be the result of degeneration ("involution" forms) (Fig. 105). Successful inoculations of cultures have been made in animals. This micro-organism grows in radiate masses, especially in the jaws of cattle, but is of occasional occurrence in man. The fungous mass may form a large tumor in the jaw, by its own growth and by the formation of granulation tissue, which is apt to slough and spread, so that not only may the tissues of the tongue, pharynx, larynx, etc., be involved, but nodules of similar character may form in the gastro-intestinal canal, lungs, skin, etc. In man suppuration with necrosis and the formation of abscesses,

ulcers, and fistulæ may be the marked accompaniments of its growth in parts near the surface of the body.

In the *lungs* the lesions may be essentially those of an acute general bronchitis or in the form of broncho-pneumonia (Fig. 106), with the formation of new tissue. Abscesses and cavities may form which extend into adjacent parts. The characteristic masses of the micro-organism may be found in the sputum in these cases of actinomycosis of the lungs.[1]

In intestinal actinomycosis nodular masses of new tissue with



FIG. 106.—ACTINOMYCES GROWING IN HUMAN BRONCHUS.
The bronchus is filled with a purulent exudate and its wall is becoming involved.

ulceration may develop in the mucosa and submucosa. Metastases have been described.

The fungus forms little yellow masses as large as a millet seed or smaller, which are scattered through the new-formed granulation tissue or mingled with the pus, giving the growths a very characteristic appearance. It is the peculiar radiate grouping of the filaments of the growth (Fig. 106) which gave rise to the name "ray fungus."

[1] For a detailed description of the lung lesions in actinomycosis, with general bibliography, see *Hodenpyl*, "Actinomycosis of the Lung," New York Medical Record, December 13th, 1890.

The disease is propagated from one animal to another by inoculation or by contact of the growth with a wound or an abrasion of the mucous membrane. The fungous masses may become calcareous.

In the examination of sputum, fæces, pus, etc., for the presence of actinomyces, the naked-eye appearances may be of value, since the yellowish-white granules are often quite visible, especially on a black background. Suspicious masses may be teased and studied unstained, or stained by Gram's method. Sections of tissue containing actinomyces may be hardened in alcohol, and sections stained by Gram's method with contrast eosin stain.

In some cases of cholera there are no marked changes to be found after death. In no case are the lesions distinctive of this disease.

If death occur during the invasion of the disease or in the stage of collapse, the appearances may be as follows in the more marked cases:

The bodies remain warm for some time, and the temperature may rise for a short time after death. The rigor mortis begins early and lasts for an unusually long time. The muscles sometimes exhibit a peculiar spasmodic twitching before the rigor mortis sets in, especially the muscles of the hand and arm.

*The Skin* is of a dusky gray color, the lips, eyelids, fingers, and toes of a livid purple. The ends of the fingers are shrivelled, the cheeks and eyes fallen in.

*The Brain.*—The sinuses of the dura mater are filled with dark, thick blood. The pia mater may be normal, or œdematous, or ecchymosed, or infiltrated with fibrin. The brain is usually normal, but may be dry and firmer than usual.

*The Lungs* are retracted and anæmic, the pleura may be dry or coated with fibrin.

*The Heart* is normal.

*The Peritoneum* may be dry or coated with a layer of fibrin.

*The Stomach* is usually unchanged, but may be the seat of catarrhal inflammation.

*The Small Intestine.*—There may be ecchymoses in the mucous membrane; the mucous membrane may be soft and œdematous; there may be general congestion, or the congestion may be confined to the peripheries of the solitary and agminated nodules, and these nodules may be swollen; or there may be croupous inflammation and superficial necrosis. All these changes are regularly most marked at the lower end of the small intestine. There is apt to be post-mortem desquamation of the epithelium. The characteristic rice-water fluid may be found in the intestines after death, or instead of this dark-colored, bloody fluid.

*The Large Intestine* is usually normal, but in some epidemics croupous inflammation occurs in a considerable number of cases.

*The Spleen* may be soft. *The Liver* may show small areas of granular or fatty or hyalin degeneration.

*The Kidneys* are often increased in size, with white and thickened cortex and congested pyramids. The epithelium of the cortex tubes may contain coarse granules and fat globules, or be necrotic. The tubes may contain cast matter and broken-down epithelium. These changes may be looked upon as being simply of a degenerative character or as the results of an acute degeneration from absorbed toxins.

*The Uterus* and *Ovaries* may be congested and contain extravasated blood.

If the patient do not die until the stage of reaction, the body does not preserve the same collapsed appearance, and there are often inflammatory changes in different parts of the body, especially in the larynx, the lungs, the stomach, and the intestines.

According to the researches of Koch, which have been abundantly confirmed by others, there are constantly present in the small intes-

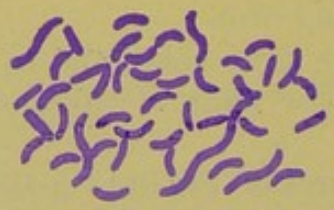

FIG. 107.—SPIRILLUM CHOLERÆ ASIATICÆ.
From a culture.

tines of cholera patients, during the early and active stages of the disease, characteristic curved rods which are not known to occur in the body under any other conditions, and which have been proved to cause the disease. These rods are from 0.8 to 2.0 $\mu$ long, and are sometimes slightly, sometimes considerably curved (see Fig. 107). When growing under suitable conditions, the individual rods are apt to cling together by their ends, forming S-shaped figures or spirils of considerable length. From the curved shape of the individuals they are also often called "comma bacilli;" but the organism appears to belong among the spirilla and is therefore called *Spirillum choleræ Asiaticæ* (or "Cholera vibrio"). The spirilla may be present in moderate numbers in and beneath the mucous membranes of the intestine, and in very large numbers in the intestinal contents and in the dejections in the acute forms and early stages of the disease.

In the process of their growth and multiplication in the intestinal canal they apparently produce a poisonous substance, the local action and absorption of which into the body fluids produce the symptoms and lesions of the disease. The systemic effects appear to be in

the nature of a septic intoxication. The cholera bacillus may retain its vitality for a considerable period in water, and on moist substances, such as damp linen, earth, and vegetables, it may increase in numbers with great rapidity.

A temperature of from 30° to 40° C. is most favorable for its growth. At about 16° C. proliferative activities cease, but the germs are not killed by —10° C. They are readily killed by drying, and the presence of acids is very inimical to their growth.

There is not sufficient evidence that they form spores, and their period of life is short.

The cholera bacillus is readily cultivated on artificial culture media, such as gelatin, agar, milk, beef tea, potatoes, etc. In fluids it is capable of performing active movements and is furnished with flagella.

While it may be readily stained by the ordinary methods when present in the dejecta, its morphological characters are not absolutely distinctive, since several forms of curved bacilli belonging to the same group and closely resembling the cholera vibrio have, under varying conditions, been found in the dejecta and in the mouth.

It is often of the highest importance to determine, at the earliest possible moment, whether or not a suspected case be one of Asiatic cholera or some other form of acute intestinal disorder, so that in the former case the proper measures may be instituted to prevent the spread of the disease. The characters which are developed in cultures of the cholera bacillus enable an expert biologist to distinguish this organism from all other known forms.

But the scope of this work does not permit a detailed description of the cultural peculiarities of the germ. Nor should the responsibility of such determinations be assumed without adequate preliminary laboratory experience.

By taking together the morphological and biological characters, it is possible, usually on the second or third day, to determine whether the intestinal contents of a suspected case do or do not contain the bacillus of Asiatic cholera.

The cholera vibrio, both in the dejecta and in pure cultures, is readily stained by the ordinary anilin dyes. The results of animal experiments with the cholera germ are not in themselves decisive in determining its relationship to this disease, since animals do not react in its presence as man does.

However, the constant occurrence of this organism in Asiatic cholera, its absence under other conditions from the body, and the accidental laboratory infections which have several times occurred in men handling pure cultures of the germ, leave no doubt as to its instrumentality in the causation of the disease.

The disease is communicated from one person to another by the pollution of food or drink with the discharges which contain the virulent germs.

The results of a large amount of work which has been done, looking toward a practical artificial immunization of man against Asiatic cholera in the East have not yet been sufficiently definitely formulated to permit a final judgment as to its value.[1]

---

[1] For the details of his researches on Asiatic cholera, see *Koch's* report, "Arbeiten a. d. kaiserlichen Gesundheitsamte," Bd. iii., 1887. Consult also *Shakespere's* "Report on Cholera in Europe and India," 1890.

For bibliography of recent studies see *Dunbar*, "Ergebnisse der allg. Aetiologie der Menschen- u. Thierkrankheiten," 1896, p. 804.

## RELAPSING FEVER.

(*Typhus recurrens; Famine Fever; Spirillum Fever; Seven Day Fever.*)

The lesions which may be present in this disease are not distinctive of it.

Its distinguishing feature, apart from symptoms, is the presence in the blood at certain periods of the specific micro-organism.

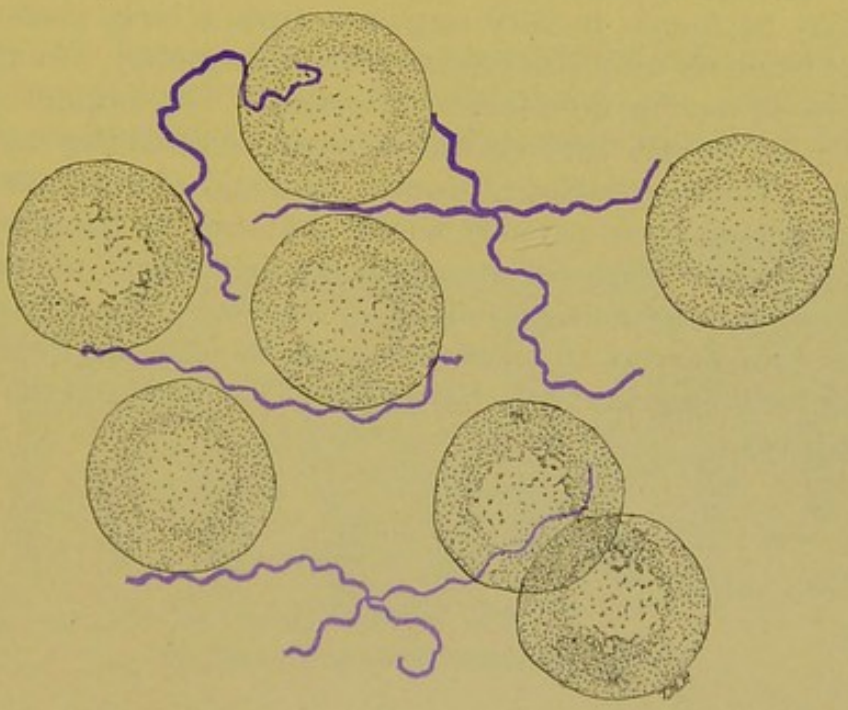

Fig. 108.—Spirochæte Obermeieri in the Blood in a case of Relapsing Fever.

*The Skin* may be jaundiced; it may be mottled by extravasations of blood.

*The Brain* and *Spinal Cord* are unchanged.

*The Pharynx* and *Larynx* may be the seat of catarrhal or croupous inflammation.

*The Lungs.*—There may be bronchitis, broncho-pneumonia, lobar pneumonia, hypostatic congestion, and pleurisy.

*The Heart* is often soft and flabby, with degeneration of its muscular fibres. There may be ecchymoses in the pericardium.

*The Stomach* and *Small Intestine* may be congested; there may be ecchymoses in the mucous membrane; there may be catarrhal inflammation.

*The Colon* may be the seat of catarrhal or croupous inflammation.

*The Mesenteric Nodes* may be swollen.

*The Liver* is often enlarged and the hepatic cells are swollen and granular.

*The Spleen* is large and soft. The change in its consistence is so marked that the spleen may rupture spontaneously during life. The spleen may also contain infarctions of different sizes; some are red, some yellow, some necrotic. Those which are necrotic may give rise to a local or general peritonitis.

*The Kidneys* show the lesions of parenchymatous degeneration.

Degenerative and hyperplastic changes in the medulla of the bones have been described.

*Bacteria.*—In the blood of all parts of the body during the febrile attacks may be found, in very large numbers, a long, slender spirillum called from its discoverer Spirochæte Obermeieri. It disappears from the blood during the afebrile intervals. The organism is from 14 to 40 $\mu$ in length, and performs rapid, undulating movements (Fig. 108). The inoculation of healthy men and of monkeys with the blood of relapsing-fever patients which contains the bacteria induces a similar disease. Pure cultures have not as yet been made of these bacteria, but for the reasons indicated, and since the organism has never been found except in connection with the disease, there is every reason for believing that the Spirochæte Obermeieri is the cause of relapsing fever.

## VARIOLA.

*(Small-pox.)*

Small-pox is an acute, readily communicable, infectious disease, especially characterized anatomically by an inflammation of the skin which passes through a series of more or less distinctive phases of papule, vesicle, pustule, with a final drying of the exudate and necrotic tissue constituting the crust.

Various phases of the exanthem are used to designate forms of the disease.

Secondary lesions are diffuse suppurative inflammation of the skin, inflammations of the mucous membrane, hæmorrhages in various parts of the body, and acute degeneration of the kidney, liver, and spleen.

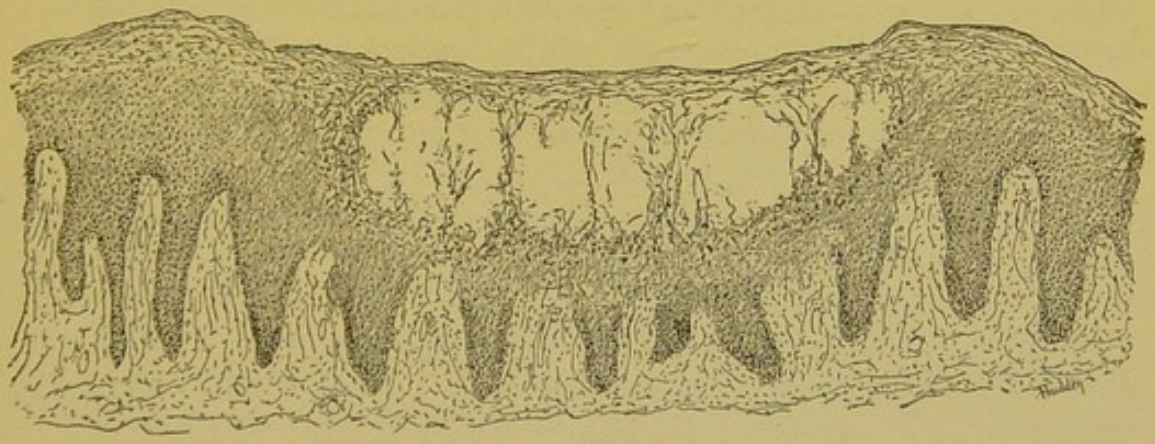

FIG. 109.—A SMALL-POX VESICLE OF THE SKIN.

The skin lesion shows in general at first circumscribed areas of inflammation above the ends of the papillæ, with the development of a fluid-filled reticulum, so that vesicles are formed (Fig. 109). These at first contain a clear fluid, but by the gathering of pus cells the fluid becomes turbid and accumulates to form a pustule. Hand-in-hand with these changes the papillæ and adjacent layers of the corium may become infiltrated with cells. The contents of the pustules and the necrotic tissue above dry and form the crusts. When the changes are largely confined to the epidermis the lesion may leave no deformity. But if the changes in the cutis are considerable, cicatricial

tissue may form, leaving scars. The association of local hæmorrhage with the above changes gives rise to the hæmorrhagic form of exanthem.

Various micro-organisms, both bacteria and protozoa, have been described as occurring in the local skin lesions of small-pox, but the cause of the disease is still unknown.

The protection conferred by a successfully weathered attack of small-pox is one of the most striking examples of this form of acquired immunity (see page 179). The more recent views of the immunity conferred by vaccination against small-pox is based upon the demonstration that the disease variola in man and the disease vaccina in the bovine species are the same, and not different, as was formerly believed; that the disease in the cow is only a modified form of the human disease. The effect of the passage of the unknown but certainly existing micro-organisms through the insusceptible bovine—thus runs the rationale in the new light—is to so diminish the virulence of the germ that by its subsequent inoculation in man immunity is produced without the profound disturbance which infection with a germ of unmitigated virulence would involve.

## SCARLET FEVER.

*(Scarlatina.)*

This is an infectious, readily communicable disease characterized by a diffuse skin eruption, and frequently accompanied by inflammation, either catarrhal, croupous, or gangrenous, of the tonsils, pharynx, and larynx.

There may be acute hyperplasia or suppuration of the cervical lymph nodes. There is very frequently an acute exudative or an acute diffuse nephritis. The spleen may be enlarged. Bronchopneumonia, endocarditis, and pericarditis may occur.

The exanthem or skin eruption in scarlatina is a simple dermatitis, as the result of which the papillæ and subpapillary stratum become infiltrated with fluid or leucocytes, or both, the leucocytes being gathered especially about the blood vessels. There may be small hæmorrhages, and the acute phase of the inflammation is followed by an increased production of epithelium and an exfoliation of the superficial layers. These lesions of the skin are, excepting the hæmorrhages, very slightly marked after death.

That the disease is due to some form of micro-organism there can be no doubt. The exact nature of this organism is not yet known. The acute nephritis so often present appears to be due to some poison produced in the body during the disease. One of the most marked features of the disease is the predisposition which it entails to the incursions of pathogenic germs other than those which we believe to cause the disease itself. Thus an infectious croupous inflammation in the mouth, tonsils, pharynx, larynx, and trachea, due to a streptococcus (see page 205), is a frequent complication. True diphtheria due to the Löffler bacillus is also prone to establish itself upon the vulnerable inflamed mucous membranes.

So also the frequently associated pneumonia, the inflammatory hyperplasia and suppuration of the lymph nodes, suppurations in various parts of the body, the endocarditis and pericarditis which are not uncommon, may all be due to a secondary infection with the pyogenic cocci.

## MEASLES.

A readily communicable infectious disease, the most prominent features of which are an intense hyperæmia with inflammation of the skin, associated with catarrhal inflammation of the mucous membrane of the air passages. The inflammation of the skin is anatomically of the same general type as that in scarlatina. Acute degeneration of the kidney or acute exudative nephritis may follow. The more common secondary lesions are broncho-pneumonia, pseudo-membranous inflammation of the pharynx and larynx, suppurative inflammation in various parts of the body, and diphtheria. These complications, as in scarlatina, are doubtless, in part at least, due to secondary infection with other germs than those causing the disease itself.

The micro-organism causing measles is not known.[1]

---

[1] *Canon and Pielicke* in 1892 (Berliner klin. Wochenschrift, April 18th, No. 16) recorded the discovery in the blood in fourteen cases of measles of a very small bacillus, about as long as the radius of a red blood cell, but varying considerably in size. It is best stained with Czenzynski's solution (p. 68), or with a solution containing one-half the amount of eosin. Sometimes the staining is uniform, sometimes the middle portion is paler. These bacilli were sometimes abundant, sometimes scanty in the blood, lying singly or in heaps. Meagre cultures were obtained in three cases in beef tea. They did not seem to grow on the ordinary solid media. Bacilli similar in form were found in the exudate from inflamed mucous membranes in measles. The observations of these writers are interesting and suggestive, but until they shall have been confirmed by others and been greatly extended nothing can be regarded as established regarding the etiological significance of the germs.

## TYPHUS FEVER.

(*Hospital Fever; Spotted Fever; Jail Fever; Ship Fever; etc.*)

This disease has not, so far as we know, any characteristic lesion save the petechial skin eruption; but yet after death we may find a number of morbid conditions, such as are common to many of the infectious diseases.

The entire body has a tendency to rapid putrefaction.

The blood is often darker and more fluid than in other diseases.

The voluntary muscles may undergo waxy and granular degeneration.

The brain and its membranes may be congested.

The mucous membrane of the pharynx and larynx may be the seat of catarrhal or croupous inflammation.

In the lungs there may be bronchitis, broncho-pneumonia, or hypostatic congestion.

The walls of the heart may be soft and flabby.

The agminated nodules of the ileum, and the mesenteric nodes may be a little swollen.

The spleen is often large and soft.

The kidneys and liver are frequently the seat of parenchymatous degeneration.

The nature of the infective agent in typhus is unknown. Several observers have recorded the finding of micro-organisms of one kind or another in the disease, but proof that any of these have causative relationship to the disease has not yet been furnished.[1]

---

[1] *Brannan and Cheesman*, "A Study of Typhus Fever," Medical Record, June 25th, 1892.

## HYDROPHOBIA.

### (*Rabies.*)

The lesions which have been found in this disease are not constant nor are they characteristic. Though well marked in some cases, they are but very slightly developed in others.

The lesions, when present, are apt to be most marked in the medulla oblongata and pons, but they may be present in the cord (Fig. 110). They consist of small hæmorrhages, accumulation of



FIG. 110.—SECTION OF SPINAL CORD FROM A CASE OF HYDROPHOBIA.

Showing large accumulation of leucocytes about the blood vessels, both in the gray and in the white matter. (From a specimen prepared by Van Gieson.)

leucocytes about the blood vessels in the perivascular lymph spaces and around the ganglion cells, and of thrombi in the smaller blood vessels, and of degeneration of the ganglion cells especially in the spinal cord.[1] None of these lesions are, however, pathognomonic of this disease.

---

[1] *Babes*, Annales de l'Institut Pasteur, April, 1892, and August, 1895.

For an account of lesions in experimental rabies consult *Golgi*, Berliner klin. Wochenschrift, April 2d, 1895.

While there is every reason for believing that hydrophobia is due to the introduction into the body of some special form of micro-organism, and while the recent researches of Pasteur and others have brought to light many interesting and important facts regarding the general nature and distribution in the body of the infectious agent, nothing is yet definitely known about the particular organism which induces the disease.

It is known that the infectious agent is in the saliva and salivary glands of rabid animals, and that it may be present in the saliva of the dog two or three days before the symptoms of the disease are manifest. It is not present in the blood, but seems to be especially

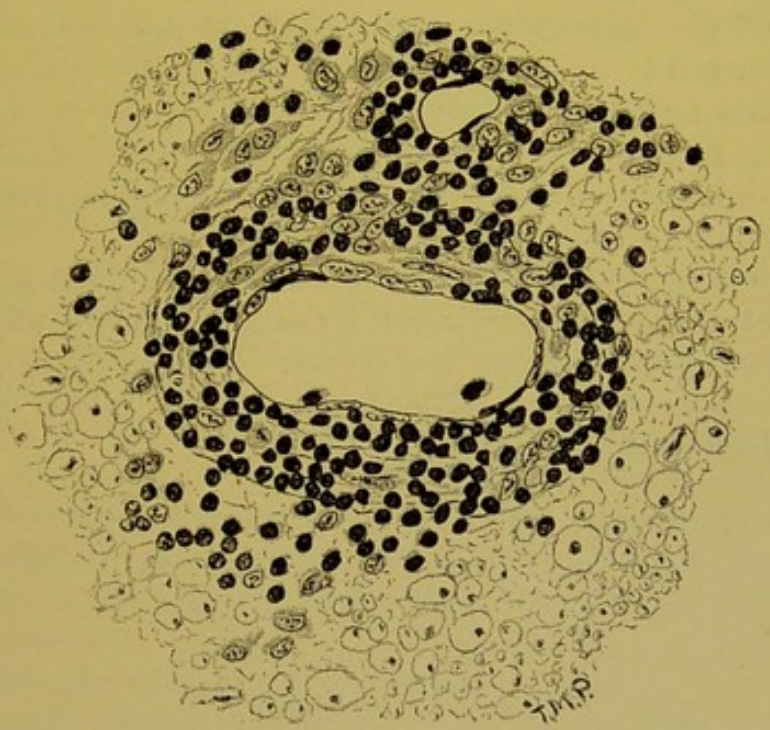

FIG. 111.—HYDROPHOBIA, TRANSVERSE SECTION OF SMALL BLOOD VESSELS IN THE SPINAL CORD.

From the same case as Fig. 110, more highly magnified. Showing accumulation of leucocytes and proliferation of connective-tissue cells in the adventitia of the vessels.

concentrated in the central nervous system and particularly in the medulla oblongata.

Notwithstanding the total ignorance of the micro-organism concerned in inciting hydrophobia, his genius in wise experiment enabled Pasteur to discover and to establish a method for artificial immunization against the disease which has proved most beneficent.

After obtaining a virus of definite intensity, which was accomplished by a series of inoculations beneath the dura mater in rabbits of portions of the spinal cords of rabid animals, it was found that by drying spinal cords of definite and high virulence in the air, with due protection against aërial contamination, the virulence diminished

day by day. With virus thus obtained of virulence ranging from that which is practically inert to that of the utmost potency, it has been found possible to safely accustom both animals and men to the presence of amounts of hydrophobia virus contained in the spinal cord emulsion, which under ordinary conditions would prove speedily fatal. In other words, it has been found possible to confer artificial immunity against the disease.

This process occupies several days, and immunization must be completed before the disease has begun to manifest itself; but as the incubation period in hydrophobia is a long one, it has been possible, in a large and increasing number of cases, to save the lives of persons bitten by rabid animals.

In view of the importance of diagnosis, in dogs which have died or have been killed under suspicion of rabies, the spinal cord and medulla should be saved. Portions of the fresh medulla in emulsion water should, if possible, be inoculated beneath the dura mater of two healthy rabbits and the development of rabic paralysis and other symptoms observantly awaited.

Other portions of the medulla and cord should be hardened in Müller's fluid and alcohol, and carefully examined especially for small perivascular accumulations of leucocytes. The existence of these in the medulla and cord of an animal suspected of rabies will go far toward confirming the suspicion.

## YELLOW FEVER.

This infectious disease is without characteristic lesions save for the hæmorrhages and pigmentation in the skin. The following conditions are, however, frequently present after death:

Rigor mortis is marked and occurs early.

*The Brain* and its meninges are usually congested.

*The Skin* is of a yellow color from the presence of bile pigment, and may be mottled by ecchymoses.

*The Heart* is of a pale or brownish-yellow color. Its muscular fibres may be the seat of fatty degeneration.

*The Lungs* may be congested.

*The Stomach* often contains the characteristic black fluid due to altered blood pigment which is vomited during life. Its mucous membrane may be congested, softened, and is sometimes eroded.

*The Intestines* are dark-colored, often distended with gas, and sometimes contain blood.

*The Liver* in the earlier stages of the disease may be intensely congested. More frequently it contains but little blood, is of a light-yellow color, and the hepatic cells show the changes of an intense acute degeneration, much more marked than are found in any other disease except acute yellow atrophy of the liver. The gall bladder is apt to be contracted.

*The Spleen* shows no marked changes.

*The Kidneys* present the lesions of an intense form of parenchymatous degeneration. Tubules usually contain masses of hyalin material.

While its mode of occurrence and the characters of its symptoms and lesions afford a strong presumption that yellow fever is an acute infectious disease, none of the various studies which have been made upon its etiology have as yet revealed the presence of any micro-organism to the action of which it can be fairly attributed.[1]

[1] The studies of *Sternberg* on the "Etiology and Prevention of Yellow Fever," published in the form of a Government report in 1890, contain the result of a great deal of research by modern methods, and should be consulted for a full exposition of this disease and its lesions.

## THE MALARIAL FEVERS.

The characteristic lesions of malarial poisoning are certain changes in the blood, the spleen, and the liver.

In the more intense and acute form of malarial poisoning the blood contains numerous particles of black or brown pigment, which are either free or embedded in cells resembling the white blood cells or in the endothelium of the blood vessels. After death this pigment is found in the blood vessels throughout the body, but is most abundant in the blood vessels of the liver (see Fig. 293) and spleen. These organs are then usually of large size and of a peculiar brown or black color.

In some of these severe cases there are also extravasations of blood from the mucous membranes and in their substance. There may also be general jaundice. Focal necroses in the viscera similar to those occurring in other infectious diseases have been described.

In the milder and more protracted cases of malarial poisoning the composition of the blood is altered and the patient may become profoundly anæmic. The spleen may become the seat of chronic interstitial inflammation with pigmentation (see Fig. 305). The liver may exhibit the changes of chronic interstitial hepatitis.

The attempts to establish a causative relationship between the various forms of bacteria which from time to time have been found in the bodies of persons who are the victims of malarial poisoning, and the symptoms and lesions of the disease, have all been unsuccessful.

On the other hand, a large number of careful studies by various observers have led to the general belief that the disease is due, not to vegetable, but to intercellular animal organisms which are very constantly found in the blood of affected persons.

These organisms, which belong among the protozoa, may be appropriately called the *hæmatozoa of malaria*. They are, however, often called the Plasmodia malariæ.

In brief, the facts upon which this belief rests are as follows: The blood of those suffering from malarial poisoning may contain, which the blood under other conditions does not, one or more of the structures which are shown in Fig. 112.

1. Inside of the red blood cells may be found colorless bodies, sometimes occupying a small part, sometimes nearly filling the cell. These bodies may or may not contain pigment granules. They may exhibit amœboid movements (*a* and *b*). They are called the *amœboid bodies.*

2. Colorless discoidal bodies, usually a little larger than the red blood cells, which contain pigment particles, sometimes scattered irregularly, sometimes grouped toward the centre. These are believed by some observers to be the later developmental stages of the

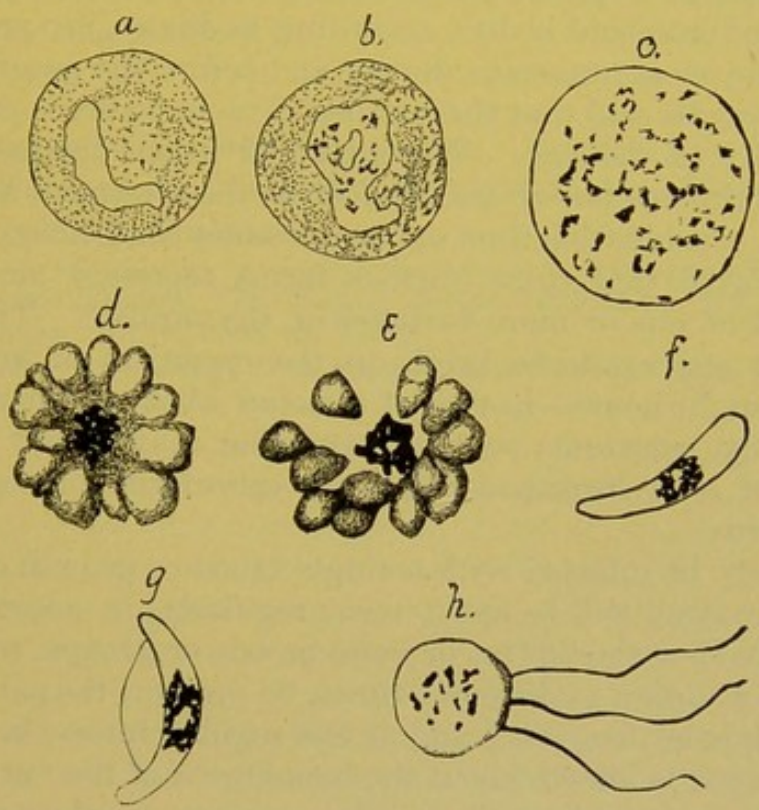


FIG. 112.—THE HÆMATOZOÖN OF MALARIA (PLASMODIUM MALARIÆ) IN THE BLOOD.

*a*, unpigmented amœboid body in a red blood cell; *b*, pigmented amœboid body; *c*, colorless discoidal body with pigment; *d*, segmenting body; *e*, fragments of segmenting body; *f* and *g*, crescentic bodies; *h*, flagellate body. *a*, *b*, *d*, *e*, *f*, *g* are drawn from specimens of malarial blood prepared by Dr. Walter James; *c* and *h* are drawn after sketches by Dr. James.

amœboid bodies, which have increased in size at the expense of the red blood cells. A grouping of pigment granules indicating segmentation is sometimes seen in these bodies. These are called the *encysted bodies* (*c*).

3. Bodies, about the size of a red blood cell, which are composed of a congeries of irregularly rounded structures grouped about a central mass of pigment. These are called *segmenting bodies* or *rosettes* (*d*).

4. Smaller isolated or clustered structures which are apparently

the result of the breaking apart of the segmenting bodies, as seen at *e*. Often called *spores*.

5. *Crescentic* bodies containing a central mass of pigment (*f* and *g*).

6. Bodies, smaller than a red blood cell, which are actively mobile and are furnished with one or more flagella at one side—*h*, *flagellate form*. These are the main forms which have been described.

The amœboid forms are apt to occur in the acute stages of the disease, the crescentic forms in the chronic stages. The segmenting bodies are apt to be present immediately before or during the chill; the pigmented amœboid bodies, according to James, are present at all times, but are most numerous during and before the paroxysms. In general, it may be said that the number of these bodies is proportional to the gravity of the case. The amœboid forms disappear shortly after the administration of quinine, while the crescentic bodies often persist for a considerable time under the same conditions.

It is believed that these various forms represent phases in the development of one or more varieties of the parasite. The cycle of development appears to be brief—in the organism of tertian fever about forty-eight hours—in that of quartan about seventy-two hours—and quickly recurrent; so that paroxysm may follow paroxysm, the height of each corresponding to the sporulation or segmentation of the parasite.

If the body be infected with a single brood or growth of the parasites the paroxysm will be apt to recur regularly, in accordance with a simple type; but should two or more broods or groups, reaching the period of sporulation at different times, be present, the paroxysm will recur with greater frequence and at less regular intervals.

While much is known about the hæmatozoa of the various phases of malarial fever, much study is still necessary for the completion of their life histories, and much more light is needed on the way in which the parasites produce their effects in the body, aside from the destruction of the blood cells, to which pigmentation is due. All attempts to cultivate the organisms under artificial conditions have thus far failed. While by the direct transference of malarial blood from animal to animal and from man to man the disease may be induced, under the ordinary conditions of life it is not communicable; nor do we know the habitat of the organism in nature or its portals of entry to the body.

Whatever its full etiological significance or its life history, its discovery in the blood, even with our present knowledge, since it is unknown except in malarial disease, is of great diagnostic value in doubtful cases.[1]

[1] For bibliography and a résumé of the work already done on this subject con-

*Method of Examination.*—The fresh blood taken from a finger prick may be examined in thin layers on the warm stage with one-twelfth oil immersion.

For stained preparations the method described on page 88 may be followed, or, after spreading and fixing the blood film as above, the cover may be floated, specimen side down, for from ten to fifteen minutes in Czenzynski's fluid:

| | |
|---|---|
| Aqueous Methylen Blue, saturated solution..... | 20 c.c. |
| One-half-per-cent solution of Eosin in seventy-per-cent Alcohol..... | 10 " |
| Water..... | 20 " |

Rinse in water and mount in balsam. In this way the plasmodia and the nuclei of the leucocytes are stained blue, the red blood cells and eosinophile granules red.

---

sult *Thayer and Hewetson*, "The Malarial Fevers of Baltimore," etc., Johns Hopkins Hospital Reports, vol. v., 1895, pp. 5–215.

Also *Barker*, "A Study of Some Fatal Cases of Malaria," ibid., pp. 221–270.

## PHARYNGO-MYCOSIS LEPTOTHRICA.

Certain filamentous micro-organisms called *Leptothrix*, and believed by some observers to be more closely allied to the algæ than to the fungi, are of common occurrence in the mouths of healthy persons. Occasionally, however, a persistent recurrent attack of "sore throat" with local tenderness and sometimes cough and fever, are associated with the growth of masses of leptothrix in the crypts of the tonsils, at the base of the tongue, on the walls of the pharynx, or in the nose or superior portion of the œsophagus.

The leptothrix masses or colonies form thick whitish pellicles or patches which may be superficial, or in the tonsils may extend deep into the crypts. These masses are usually firmly adherent, often leave bleeding surfaces when removed, and the growth is apt to persistently recur.

Microscopical examination of removed portions of the growth show tufts and bundles of the thread-like micro-organisms, growing among or directly out from flat epithelial cell masses and mingled with various other forms of micro-organisms, mostly cocci and short bacilli.

There may be overgrowth of epithelium and collections of leucocytes in and about the leptothrix masses.

In sections of the tissue or in teased fragments treated with iodin (Lugol's solution) the leptothrix threads are readily differentiated from the tissue elements and from other micro-organisms, by their dark color.[1]

---

[1] For further details and bibliography, consult *Campbell*, Medical News, April 4th, 1896.

## INFECTIOUS DISEASES OF ANIMALS.

The study of comparative pathology is of great and increasing importance, and already much light has been thrown on the nature of human diseases by the study of the diseases of the lower animals.

While this is true of pathology in general, it is of especial significance in the study of the infectious diseases of the lower animals, not only as they occur spontaneously, but also in fields of experimental research.

The scope of the book does not permit of a more than occasional reference to animal diseases, but the reader may consult: *Nocard* and *Leclainche*, "Les Maladies Microbiennes des Animaux," Paris, 1896, aud the translation by *Dinwiddie* of the "Manual of Veterinary Microbiology," by *Mosselman* and *Liénaux*, 1894.

# TUMORS.

## SECTION I. GENERAL CHARACTERS.

Tumors are composed of the same types of tissue as those normally existing in the body, and from the latter they are derived by a proliferation of pre-existing cells. The tissues of tumors may be similar to those of the part in which they grow, when they are called *homologous ;* or they may be dissimilar, and are then called *heterologous.* Tumors are not only analogous to the normal tissues of the body in structure, but their life history transpires under the same general laws of nutrition, growth, reproduction, etc. With this important difference, however : that while the normal tissues, serving as they do a definite purpose in the organism, are closely limited in their growth and minute characters by physical and other conditions which determine the uniform development and correlation of various parts, the tissues of tumors exhibit a certain lawlessness in growth, structure, and life history which gives them a distinctive character while not removing them from the physiological types. Thus in the Chondromata[1] the tissue, while distinctly cartilaginous in type, presents itself not only in places where it does not belong, but may show a tendency to the development of fibres in one part of its basement substance, while another may be distinctly hyalin, or another soft and almost gelatinous. The cells also are apt to exhibit great lack of uniformity in size, shape, and grouping. The lawlessness in tumor tissues is shown in their tendency, under certain conditions, to change from one form into another, as from fibrous tissue into bone.

Tumors are supplied with blood vessels which grow into them from adjacent healthy parts, just as they do into granulation tissue, so that they may finally possess a more or less independent vascular system of arteries, capillaries, and veins. They are furnished with lymph vessels and some of them with nerves. The cell division by

[1] Tumors are designated by the termination *oma* (plural *omata*).

which tumors grow exhibits the same minute phenomena as does cell division in normal tissues (see page 72). Tumor tissues are subject to the same degenerative changes as other tissues; they may become fatty or calcified, ulcerated, gangrenous, pigmented, etc. By necrotic changes a tumor may be largely destroyed, but complete obliteration rarely occurs in this way. They are liable to undergo the ordinary inflammatory changes, granulation tissue may form in them, and abscesses and cicatrices.

The rapidity of growth of tumors varies greatly; some grow very slowly indeed and may change but imperceptibly in size and appearance for years, while others, on the other hand, grow so fast that they do not acquire solidity, and their elements remain in an incompletely developed condition and are thus more liable to destructive changes than normal tissues are. In healthy tissues the blood vessels are supported by surrounding elements, which aid them in sustaining the blood pressure from within. In rapidly growing tumors this external support is often lacking, and, as the walls of the blood vessels are themselves badly formed, the result is that the walls are apt to become pouched or aneurismal, and they often burst, giving rise to larger or smaller interstitial hæmorrhages.

Tumors have various shapes: nodular, tuberous, fungoid, polypoid, papillary, dendritic, etc.

Tumors may occur singly or in greater or less numbers in the same or in different parts of the body. If they are multiple they may have occurred simultaneously or at different times as independent structures. Or multiple tumors may occur as the result of the dissemination in the body, from a primary tumor, of cells which form a starting point for new tumors. Many tumors are sharply circumscribed, may be even encapsulated, and influence surrounding parts only by the pressure which they exert upon them. In this way they may cause displacement, atrophy, or necrosis; they may, by pressure on neighboring vessels, cause œdema, thrombosis, etc.; they may in the same way cause dislocation and caries of bones.

Tumors may grow largely by increase of elements within them, thus simply expanding; this is called *central growth*. They may grow in part or largely at the surface—*peripheral growth*. In this case the growth may be a direct, continuous enlargement of the mass at or near the periphery, or it may be by the formation of secondary nodules near the primary growth, which, gradually enlarging, finally coalesce with the latter, forming a part of the nodular tumor. This mode of enlargement is called *discontinuous peripheral growth*, and is due to the dissemination of cells from the mother tumor into the adjacent tissue through the blood or lymph channels, and their proliferation at the points of lodgment. This dissemination may

occur by the agency of blood or lymph currents or by the amœboid movements of the cells.

It is not yet certain whether the new cells which are produced in tumors are altogether the result of the proliferation of the primary tumor cells, or whether the ordinary tissue cells of the part, connective-tissue cells, white blood cells, etc., may undergo transformation and proliferation under the influence of the characteristic cells of the tumor. It is not unlikely that both modes of increase occur, although the former is probably the more common and important. Some tumors increase by an infiltration of surrounding tissues, whose elements they gradually replace. In certain tumors the old tissue of the part in which they grow may remain with its vessels and form a sort of matrix whose interstices are infiltrated with the new tumor tissue. The irritation of the tumor may induce inflammatory new formation of tissue of the old matrix about or within the tumor.

But all tumors are not limited to that part or region of the body in which they first occur. Sooner or later secondary nodules resembling the first may be found in the most distant parts of the body, sometimes singly, sometimes in great numbers. These may grow like the parent tumor, and themselves form foci for new disseminations.

This dissemination of tumors is one of the most important elements of malignancy, and is called *metastasis*, the secondary tumors being called *metastatic tumors*. This occurs by the transportation of tumor cells through the blood or lymph channels. Since the tumor itself may be filled with new and badly formed blood and lymph vessels, and its structures be in close contact with the vessels of the tissue in which it grows, the cells of the primary tumor may, by ulceration through, or by atrophy of, the walls, readily find their way into the lumen of the vessels and be swept away by currents as emboli, and, finding lodgment, proliferate and grow, forming secondary tumors; or the proliferation may occur in the vascular endothelium itself, when the formation of emboli is easy to understand. When carried through the lymph vessels the tumor cells may for some time be kept from the larger channels and from general dissemination by lodgment in the lymph nodes, where they may establish independent tumors. The parts of the body in which metastatic tumors are most apt to form depend, of course, upon the situation of the primary tumor and the distribution of the vascular channels through which dissemination occurs.

The tumors in which metastasis is most apt to occur are, as a rule, those which grow rapidly, are vascular and succulent, and contain many cells.

Not less variable than the size, mode of growth, and structure of

tumors is their significance in the organism. Surgeons have in the past, and to a certain extent still do classify tumors, for practical purposes, as *malignant* and *benign*, and for a long time malignant tumor and carcinoma were synonymous terms. Now we know that other tumors as well as carcinomata are malignant, and, furthermore, contrary to the former belief, that malignancy does not depend upon any specific extra-cellular agent in the tumor. If we mean by a malignant tumor one which may cause death, any tumor may be malignant if growing in the right place. Thus a simple fat tumor, by pressing on the trachea, may cause suffocation, and any tumor may secondarily cause death by hæmorrhage or septicæmia. The real signs of malignancy in a tumor are: 1. Invasion of adjacent tissues by eccentric or peripheral growth. 2. The tendency to local recurrence after removal. 3. The formation of metastases. 4. A tendency to interfere with the nutrition and general well-being of the body, which may give rise to a condition known as cachexia. The modes of invasion of surrounding tissues and the formation of metastases have been considered above. The tendency to local recurrence after removal is probably, in most if not all cases, due to the incomplete removal of the peripheral infiltrating cells. These may be very few in number and lacking in characteristic structural features, but are none the less endowed with the capacity of proliferation and development into a new and similar tumor at or near the seat of the extirpated one. The infiltrating peripheral cells may remain dormant for a long time after an operation, or may immediately commence to grow. The mere fact that a second tumor develops in the place of one removed does not imply malignancy, since it may result from the same mechanical cause which produced the first, as in the case of certain carcinomata of the lip induced by the mechanical irritation of a pipe.

The drain upon the system by the rapid growth of a tumor, together with the absorption from it into the body of deleterious putrefactive materials, from sloughing, ulceration, and degeneration, may give rise to fever and other constitutional disturbances. Or they may induce feebleness, anæmia, and that general impairment of the nutritive functions of the body known as cachexia. This condition is frequently rendered worse by the mental status of the patient in the presence of such a traditional object of alarm.

It should be remembered, however, that so long as they are localized and have not undergone degenerative changes, even the most malignant tumors do not usually give rise to a cachexia, since the drain upon the nutritive powers of the system by their simple growth is not, under ordinary conditions, very considerable. When the system is deteriorated by the absorption of septic materials from

tissue degeneration, however, this may become a very important factor.

This condition of cachexia, so evidently secondary to the growth and degeneration of the tumor, was formerly termed a dyscrasia or diathesis, and was supposed to precede and induce the growth of malignant tumors, particularly cancers.

It is further to be noted that the fragments of tumors which have found access to the veins may act as simple emboli and produce immediate death or simple metastatic abscesses.

It was formerly supposed, when the doctrine of the specific nature of tumors prevailed, that the cells of malignant tumors, particularly of carcinomata, had a characteristic structure and appearance, and that by the examination of single or of a few separated cells the nature of the tumor could be determined. From the above considerations it will be evident, as all tumor cells have their prototypes in the normal body, that therefore there is nothing pathognomonic in the appearances of single cells. It is by a study of the general structure and of the topography of tumors, as well as of the characters of the individual cells, that we are enabled to determine their nature. And even then we must often bring to our aid the clinical history and gross appearances of the growth before we can arrive at a definite conclusion. We may, indeed, sometimes, aided by the clinical history or gross appearances, be able, by the microscopical examination of scrapings from a tumor or of fluids from an internal cavity in which it is growing, to form a reasonable conjecture regarding its nature.

As a rule, the peripheral portions of the more rapidly growing tumors are best adapted for microscopical examination, because here secondary degenerative changes are less likely to have occurred than in the central parts.

## THE CAUSE OF TUMORS.

In regard to the causation of tumors our actual knowledge is still very meagre. In a certain number of cases mechanical influences are undoubtedly sufficient inciting causes. In other instances heredity is an important factor. But to both of these influences too much importance has been attributed in former times. The most recent, and to a certain extent plausible, hypothesis, and one which most satisfactorily accounts for the occurrence and character of many tumors, is that of Cohnheim, called the *hypothesis of the embryonal origin of tumors.* This is to the effect that all true tumors are due to faulty embryonal development; that certain embryonal cells of various kinds, in the course of the development of the body, are

superfluous, or become displaced, or do not undergo the normal changes, and remain ready, when the conditions shall become favorable in later life, from whatever reason, to commence growing with all the potencies of embryonic and lowly organized cells in the midst of the mature tissues. Not being restrained, however, by the regulating influences which determine the nature and relative extent of growth in normal development, they go on to the production of tumors, which represent, though in atypical form, the various tissues which the strayed or unused cells were destined normally to produce.

The evident hereditary character of many tumors, the congenital nature and early development of others, their atypical structure in general, and the tendency of many forms to occur in situations in which, during the development of the embryo, considerable complexity exists, as well as their heterologous occurrence and their frequent primary multiplicity—all of these characters of tumors seem to favor Cohnheim's hypothesis. On the other hand, the theory leaves unexplained the sudden growth of the alleged embryonal cells which have long remained dormant, and lacks as yet the absolute demonstration of a morphological basis, since no one has seen the strayed or delayed embryonic cells. These may, of course, be very small and difficult of demonstration, and this, according to Cohnheim, fully explains the lack of a definite histological basis to his hypothesis. It should be remembered, furthermore, that, under ordinary conditions in the body, certain cells which are destined to replace others which have fulfilled their destinies, as in the skin, possess to a greater or less degree the characters of embryonal cells, and that while in the struggle for existence the growth of these cells may be held in check, as by conditions of pressure, nutritive supply, etc., if these conditions be altered these cells may undergo proliferative changes as significant as those of the alleged belated germs of Cohnheim. Such a changed condition of affairs has been shown by Thiersch to occur frequently in the skin in old age, and to explain in large measure the occurrence of certain epithelial tumors.[1] It should be remembered that this hypothesis was offered by Cohnheim only as a suggestion to facilitate research, and that he expressly warned his confrères against attaching a premature importance to the possibility to which he called attention. Thus, while the hypothesis of the embryonal origin of tumors is most fascinating, and for certain forms quite satisfactory, we may well demand a more definite basis of fact before accepting it as of universal application.

[1] Consult *Ribbert* on the "Histogenesis of Carcinoma," Virchow's Archiv, Bd. cxxxv., p. 433, 1894.

Bacteria have in recent times been claimed by some observers to stand in a causative relation to certain tumors, and bacteria have been occasionally demonstrated in, and cultivated from, the tissues of tumors. But no complete and reliable experiments or observations have as yet been made which prove that they have anything to do in causing the tumors, or are of any significance save as chance contaminations of the tissues or as inducing secondary complications.

A great deal has recently been written—in view of the more or less plausible notion that tumors might be of parasitic origin—about certain structures which are not infrequently found mostly in, but sometimes between, tumor cells, especially in the carcinomata, and which have been rather hastily assumed to be animal or vegetable parasites. These cell "inclusions" are for the most part larger or smaller rounded bodies (Fig. 113); with or without nuclei; sometimes with double contours, sometimes not; usually sharply outlined against

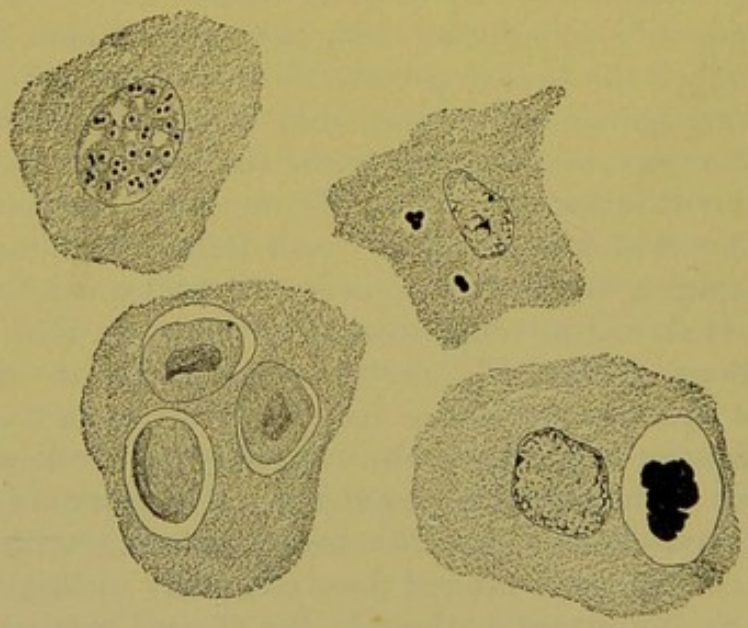

FIG. 113.—EPITHELIAL CELL "INCLUSIONS" IN TUMORS.
Showing various forms. From carcinoma.

the cell protoplasm in which they lie; often crowding the cell nucleus to one side, often situated within the nucleus, often apparently replacing it. These structures seem to be invaginated epithelial or other cells, or cell nuclei which have undergone various degenerative metamorphoses, fragmentation, etc. In some vacuoles are developed; some lie in vacuoles in the tumor cells. They may be single or there may be several in a single tumor cell. Some of the questionable structures appear to be the metamorphosed nuclei of the tumor cells themselves.

They are found in other than tumor tissues.

These protean structures are no doubt of varied origin, and have

been most frequently thought of late to belong among the coccidia. They are readily stained with varying degrees of intensity by hæmatoxylin, by eosin, by safranin, or by fuchsin.[1] Some of the cell inclusions in carcinoma may be coccidia or allied organisms.

We do not, of course, assert that tumors *cannot* be caused by parasites, but at present it seems to us that no adequate ground exists for believing that they *are*.

The nearly uniform failure of success in the transplantation of tumors from one species of animal to another, and the absolute failure to cultivate, either directly or by inoculation, any constant organisms from them, speak with much force against the notion of the parasitic origin of malignant tumors.

It seems to the writer that to seek for a single external cause or group of causes for the aberrant tissue growths which we call tumors, is to ignore the many still obscure inherent influences which are at work in all tissue growth, especially those influences which foster simple cell proliferation and tend, under the influence of heredity, to specialization in form or function. On the other hand, not to be ignored are those influences, whether of nutrition or pressure or exposure, which mould the cell growth under normal conditions into purposeful and fixed forms.

It is rather a matter of surprise that ever-changing, self-regenerating living tissue does not oftener go astray in its activities than that it only now and then should do so. This latter somewhat inverted point of view may be useful in calling away the attention, in discussing the etiology of tumors, from a too close regard to extraneous factors, and directing it to the many still unexplored fields in cell physiology which we must perhaps become familiar with before we can, with fair hope of success, attack the problems, both in cause and cure, which crowd thickly about these significant tissue aberrancies—the tumors.[2]

## CLASSIFICATION OF TUMORS.

The fact that tumors are composed of structures which resemble the various types of tissue found in the normal body suggests the guiding principle in their classification. But in order to thoroughly understand either the classification of normal tissues or the grouping of the tumors, we must keep in mind the way in which the tissues are developed in the embryo.

According to the more recent views of embryologists, particularly of His and Waldeyer, the primitive tissues of the body belong to two groups: those of *archiblastic* and those of *parablastic* origin. In the early stages of fœtal development the new cells which are

[1] Consult *Stroebe*, Centralb. f. allg. Path., etc., Bd. v., p. 110, 1894.

[2] See reference to asymmetrical karyokinesis in footnote, p. 93.

formed at first arrange themselves in three layers, to which collectively the name *archiblast* is applied.

Of these three archiblastic layers, the outer, called the *epiblast*, furnishes the material for the epithelium of the skin and its adnexa, for the epithelium of the terminal portions of the alimentary canal, and for the nervous system, including the neuroglia.

The middle layer—the *mesoblast*—furnishes the material for the epithelium of the genito-urinary organs, and for both the smooth and striated muscle tissue.

The inner layer—the *hypoblast*—affords the material for the development of the epithelium of the respiratory and the digestive systems, with that of the various glands and passages which develop out of and in connection with them.

The exact origin of the parablast, which develops later than the archiblast, is still uncertain; but it furnishes the material out of which are formed the connective tissues, including cartilage, bone, teeth, and fat; the blood cells and blood vessels; the lymphatic tissues and lymph vessels; and the true endothelial cells.

Now, if we wish to arrange in groups the different kinds of tumors found in the body, we have only to recall the varieties of tissue which normally exist there, and their grouping, and upon the classification of the physiological types to construct the classification of tumors. It should be remembered that the usual separation of the normal tissues into groups is useful, rather because it facilitates their study than because it expresses absolute and fundamental distinctions; and the same may be said of all the classifications of tumors. In both, an increase of our knowledge concerning their structure and genesis will doubtless lead to a more accurate grouping; but, for the present, such an arrangement as that indicated below will be found of practical value for the purpose of studying tumors.

*I. Tumors composed of Tissues of the Type of those forming the Connective-Tissue Group.—*

Histioid or Connective-Tissue Tumors.

| *Physiological Type.* | *Tumors.* |
|---|---|
| 1. Fibrillar connective tissue. | 1. Fibroma. |
| 2. Mucous tissue. | 2. Myxoma. |
| 3. Embryonal connective tissue. | 3. Sarcoma. |
| 4. Endothelial cells. | 4. Endothelioma. |
| 5. Fat tissue. | 5. Lipoma. |
| 6. Cartilage. | 6. Chondroma. |
| 7. Bone. | 7. Osteoma. |
| 8. Neuroglia.[1] | 8. Glioma. |

[1] It will be seen, from the account given above of the origin of the various tissues in the different embryonic layers, that the neuroglia has a different origin from the

*II. Tumors composed of Tissues of the Type of Muscle Tissue.* —Myomata.

| *Physiological Type.* | *Tumors.* |
|---|---|
| 1. Smooth muscle tissue. | 1. Leiomyoma. |
| 2. Striated muscle tissue. | 2. Rhabdomyoma. |

*III. Tumors composed of Nerve Tissue.*—Neuromata.

| *Physiological Type.* | *Tumors.* |
|---|---|
| 1. Nerve tissue. | 1. Neuroma. |

*IV. Tumors composed of Vascular Tissue.*—Angiomata.

| *Physiological Type.* | *Tumors.* |
|---|---|
| 1. Blood vessels. | 1. Angioma. |
| 2. Lymph vessels. | 2. Lymphangioma. |

*V. Tumors in which the Predominant or Characteristic Elements are Epithelial Cells.*

| *Physiological Type.* | *Tumors.* |
|---|---|
| 1. Glands. | 1. Adenoma. |
| 2. Various forms of epithelial cells and associated tissues. | 2. Carcinoma. |

*VI. Tumors formed by Various Combinations of the above Types.*—Mixed Tumors.

Aside from the above well-marked classes, we may mention here for the sake of completeness :

(*a*) *Complex Congenital Tumors—Teratomata.*—These are congenital tumors which frequently contain a great number of different forms of tissue, such as various forms of fibrillar connective tissue, cartilage, bone, teeth, hair, skin, muscle, and glands. They are most frequently found at the lower end of the spine, about the head and neck, or in the generative organs. Some of them probably arise by an inclusion of portions of another fœtus. These are called *teratoid tumors*, or *teratomata*. Among them are sometimes classed other and simpler congenital formations, such as dermoid cysts, congenital angiomata, and the so-called pigmented moles.

(*b*) *Cysts.*—These structures, for the sake of convenience, are usually classed among the true tumors, although in general characters, structure, and genesis they are of entirely different nature. They are usually divided into two classes :

I. *Cysts which develop in pre-existing cavities.*

II. *Cysts which originate independently as the result of pathological changes.*

---

other connective tissues. The neuroglia, as well as the tumors derived from it, presents marked peculiarities in structure, but its structural and functional alliance with the other connective tissues justifies its grouping among them.

I. Cysts which develop in pre-existing cavities :

1. *Retention Cysts.*—These are chiefly formed by the accumulation in glands or their excretory ducts of the more or less altered secretion of the gland. They usually occur as the result of some hindrance to the normal discharge, as from inflammatory contractions, pressure, etc. The contents of such cysts are usually mucous, sebaceous, serous, or of a mixed character. Their walls are the more or less altered walls of the original structure. To this class belong comedones, milium, atheroma, chalazion, ranula, the ovula Nabothi, milk cysts, and certain serous cysts of the ovaries, Fallopian tubes, gall ducts, and uriniferous tubules.

2. *Exudation Cysts.*—These arise usually, though not always, as the result of a chronic inflammatory process in lymph spaces or serous sacs, and among them are to be classed the so-called ganglia, hydrocele, etc. Certain of the so-called hæmatoceles, in which blood is extravasated into closed cavities, form a variety of the cysts of this group.

II. Cysts which originate independently as the result of pathological changes :

1. *Cysts formed by the softening and disintegration of tissue.*—Such cysts may at first be small and have very meagre contents and no well-defined wall. A wall may finally be present either as an entirely new-formed structure, or the more or less modified capsule of the organ in which they occur may partly or entirely form the wall. The contents of such cysts are usually the more or less altered detritus of the tissue by whose disintegration they are formed. Such cysts are very apt to occur within true tumors, particularly those which are succulent and of rapid growth, since these, as above stated, are very liable to degeneration. Old abscesses may change into well-defined cysts of this kind.

2. *Cysts formed around foreign bodies.*—The inflammatory reaction induced by the presence of foreign bodies of various kinds, parasites, masses of extravasated blood, etc., frequently results in the formation of well-defined encapsulated cysts.

3. *Cysts formed by a new growth of tissue in whose spaces various kinds of fluid accumulate.*—These spaces may or may not be lined with epithelium and have something of the glandular character. Such forms are exemplified in some of the compound ovarian cysts—the so-called ovarian cystomata.

4. *Congenital Cysts.*—These are of various forms, and their mode of origin is in most cases but imperfectly understood. The so-called dermoid cysts of the subcutaneous tissue and ovary are marked examples of this class. Certain congenital cysts of the kidney and other internal organs are conveniently grouped in this

class, although it is quite probable that some of them at least originate during fœtal life in one or other of the above-described ways, and hence are not essentially different in nature from some of the cysts of other classes. For the mode of formation of certain cysts of the neck see page 538.[1]

*Various Lesions sometimes described as Tumors.*—There are certain enlargements of the lymph nodes which are in reality hyperplasias, sometimes inflammatory in character and sometimes not, and which are often grouped among the tumors as *lymphomata.* They are not, strictly speaking, true tumors, and will be considered under the lesions of the lymph nodes.

In the same group are often classed the enlargements of the lymph nodes in leukæmia and in other general diseases, which will be treated in another part of this book. Another group of tumors sometimes called lymphomata are in reality sarcomata, and these will be described under the latter heading.

There is also a group of nodular new formations, the so-called *Infective Granulomata,* which are sometimes classed among the tumors. These are found in tuberculosis, leprosy, syphilis, lupus, glanders, and actinomycosis. They seem, however, to be more closely allied to inflammatory new formations than to true tumors, and, as our knowledge regarding them increases, have one by one been proven to be dependent upon the irritation caused by the presence of vegetable parasites (see section devoted to Infectious Diseases). In the case of syphilis the absolute proof is still lacking.

*Nomenclature of Complex Tumors.*—The simple occurrence of more than one kind of tissue in a tumor does not make it a complex or mixed tumor. It is only when a special kind of tissue occurs in sufficient quantity to be of definite significance, or is of such a nature as to render its presence, in any amount, of importance, that we recognize its presence in the name. The name of mixed tumors is usually formed by joining the names of the tissues to be recognized. Thus a combination of fibroma and sarcoma is called fibrosarcoma ; the general rule of construction being that the name of the more important tissue shall serve as the substantive which that of the less important one qualifies. It should be remembered, however, that the more important tissue is not always the one which is present in greatest amount. Thus, owing to the great clinical significance of carcinomatous tissue, a very large fibroma with a small quantity of cancer tissue intermingled would be a *fibro-carcinoma* and not a carcino-fibroma.

[1] Consult for consideration of ciliated and other cysts, *Hess*, Ziegler's Beitr. zur path. Anat., Bd. viii., p. 98, 1890; also *Zahn*, Virchow's Archiv, Bd. cxliii., p. 170, 1896.

*Preservation.*—In general, tumors, like all tissues for microscopical study, should be cut into small pieces before immersing them in the preservative fluids, and the sooner they can be placed in these after removal the better will be the preservation. In some cases much may be learned from large sections of tumors together with their surrounding tissues. In this case the proper part of the tumor must be preserved whole, and is best hardened in strong alcohol.

It is often important in the study of tumors to examine not only the fully developed or mature tumor structures, but also those portions in which the new growth is forming and in which it is encroaching on adjacent parts.

So that in selecting portions of tumors for preservation and study, it is not wise to snip off a small piece at random, but a careful selection should be made, liberal portions being saved, from the centre, from the periphery, and from such surrounding tissues as are available. For the ordinary routine hardening of tumors, Müller's fluid followed by alcohol; strong alcohol: formalin, or sublimate may be recommended.

For the methods of rapid preparation of sections for immediate diagnosis see p. 51. For studies on mitosis in tumor cells, sections may be made very thin by the method given on page 55, and stained with Heidenhain's hæmatoxylin.

## SECTION II. SPECIAL FORMS OF TUMORS.

### FIBROMA.

The fibromata are composed of fibrillar connective tissue, which, as in the physiological type, is sometimes dense and firm, *Fibroma durum*, and sometimes loose in texture and soft, *Fibroma molle*. They are usually sharply circumscribed and are frequently encapsulated, but they may be diffuse and merge imperceptibly into the surrounding tissue. Some fibromata consist almost entirely of intercellular substance, containing but few flattened or spindle-shaped cells (Fig. 114) ; others contain very many variously shaped cells. The cells are often more abundant in one part of the tumor than in

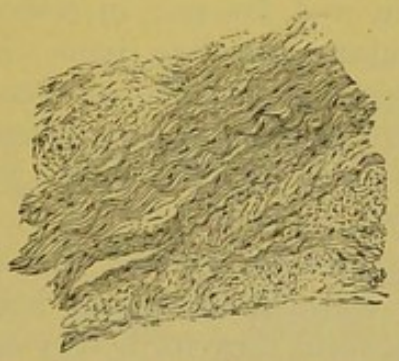

FIG. 114.—DENSE FIBROMA OF ABDOMINAL WALL—FIBROMA DURUM.
Some of the bands of connective-tissue fibres are cut across, others are cut lengthwise.

another. The denser varieties usually contain but few blood vessels, although they are occasionally quite vascular. Many of the softer varieties are very vascular. Nerves also are occasionally seen. The course and arrangement of the fibres in these tumors are usually quite irregular, often crossing and interlacing in a most complex manner. The fibromata are usually of slow growth, but exceptionally they grow very rapidly. They are benign tumors, but by pressure on important organs, by ulceration, or by changing into other varieties of tissue, they may become of serious import. Pure fibromata do not form metastases, but they are often multiple, and when so are frequently congenital.

It seems probable that in the multiple fibromata of the skin (*Fibroma molluscum*) the new growths occur in some special form of

connective tissue, as that of the nerves, blood vessels, or glands. Some of these multiple fibromata are classed among the neuromata.

While the fibromata are more commonly nodular in form, when they develop on the skin or mucous membranes they frequently form papillary outgrowths covered more or less thickly with epithelium, and are then called *papillomata* (Fig. 115). Common warts of the skin are papillomata with excessive production of surface epithelium. To the papillomata also belong some of the so-called condylomata.

Fibromata may, like most tumors, exhibit local recurrence when not fully removed. They are frequently very small and insignificant, but, on the other hand, may grow to an enormous size.

They are quite frequently combined with other kinds of tissue to form complex tumors. The looser, softer varieties not infrequently become œdematous, when they may closely resemble myxomata. They are liable to calcification and to fatty and mucous degeneration. By metaplasia they may partially change to form fibro-chondroma, fibro-lipoma, fibro-sarcoma, or fibro-osteoma. The latter transformation frequently occurs when they form in the periosteum. Developing, as they do, in the connective tissue, they occur in the most various parts of the body : in the skin and subcutaneous tissue ; in intermuscular tissue and fasciæ ; in periosteum ; in the nerve sheaths and intrafascicular connective tissue ; in the dura mater, the interstitial tissue of organs, and in the mucous membranes. Many of the so-called polypi of the mucous membranes (see Fig. 119) and some psammomata are forms of fibroma, the former often approaching the myxomata in type.

Occasionally, in the ducts of glands, fibrous polypi grow to an enormous extent, their epithelial covering keeping pace in growth with their development, until they form very large, irregular, loose-textured tumors, which often finally ulcerate. Such forms are seen in the mammary gland, where they are frequently mistaken for carcinomata. They are called *Intracanalicular Fibromata* (see Tumors of the Mamma). It is often difficult to distinguish between genuine fibromata and inflammatory or other connective-tissue hyperplasias, such as elephantiasis ; and perhaps the fuller knowledge of the future will show that the distinctions are not as definite as we are now disposed to believe.

### MYXOMA.

Mucous tissue is essentially an embryonic tissue, for in the normal adult it is present only in a very imperfect and atypical form in the vitreous of the eye, and perhaps exceptionally in small amount about the heart, kidneys, and medulla of bone.

The myxomata are thus essentially embryonic-tissue tumors.

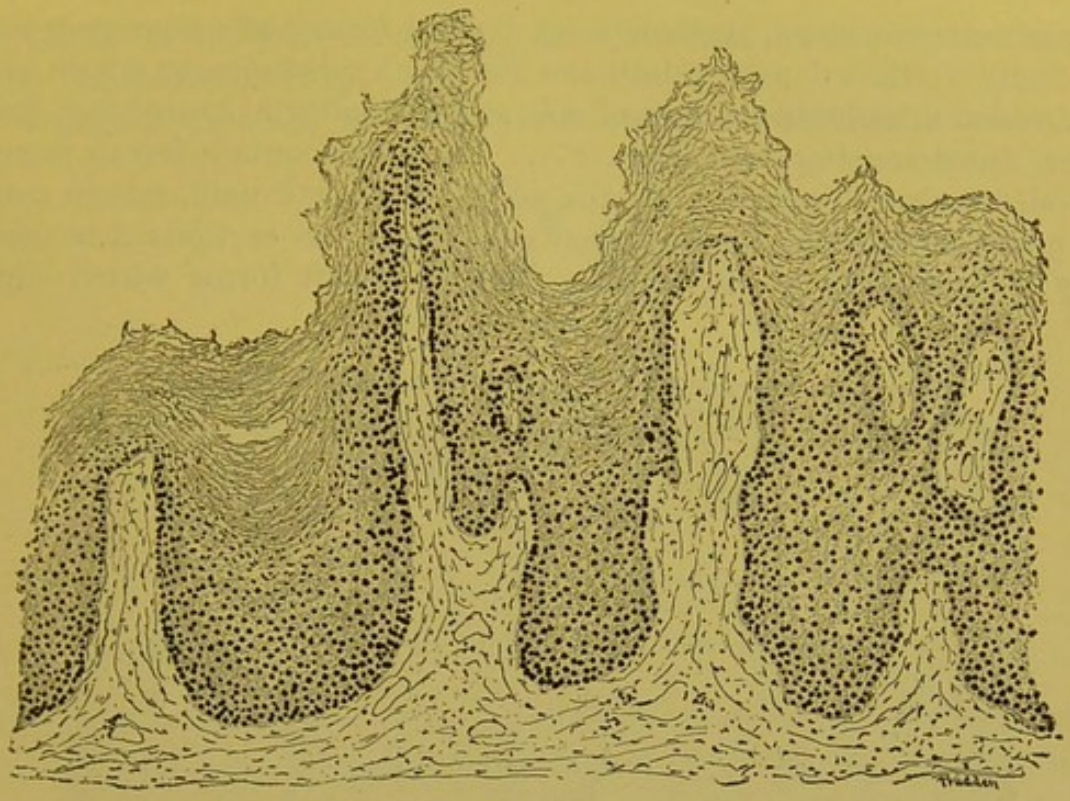

FIG. 115.—SMALL PAPILLOMA OF THE SKIN.

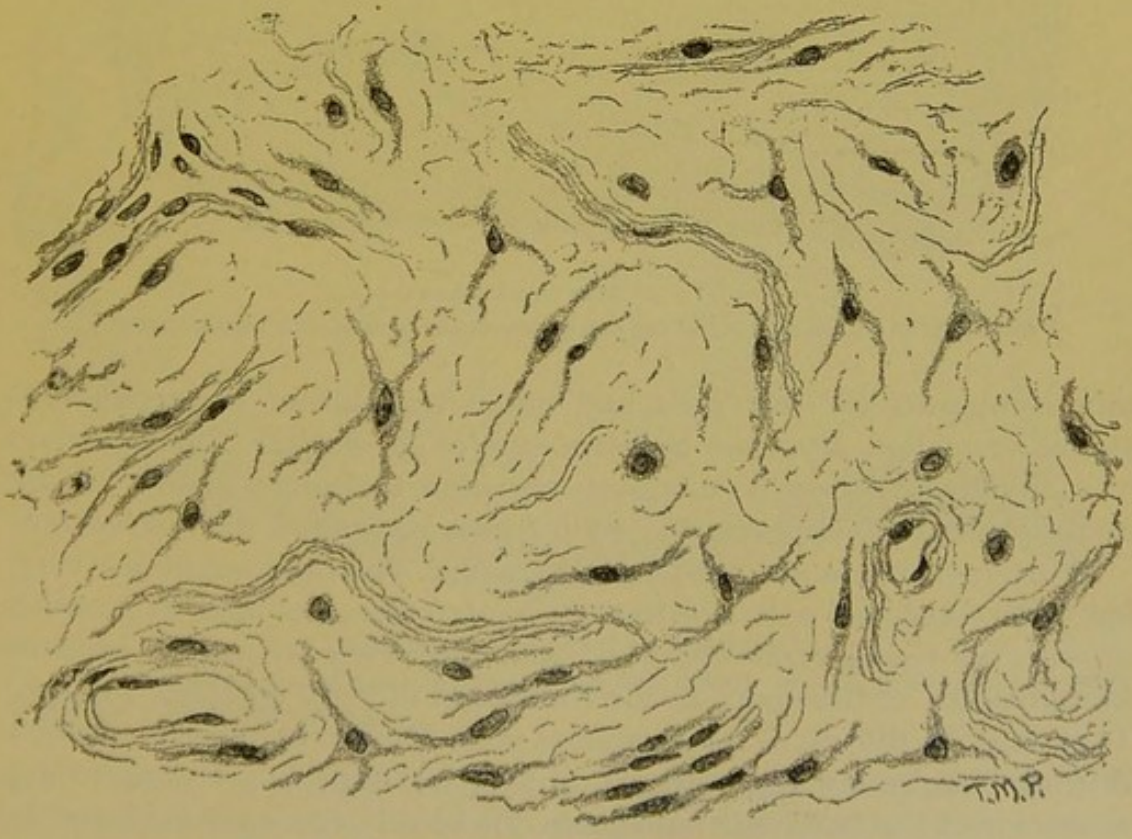


FIG. 116.—FIBROMA MOLLE FROM SUBCUTANEOUS TISSUE.
The stroma is œdematous, and in gross appearance the tumor resembled a myxoma.

These tumors consist, in their most typical forms, of a homogeneous or finely fibrillated, soft, gelatinous basement substance, in which are embedded a variable number of spheroidal, fusiform, branching, and often anastomosing cells (Fig. 117). They may contain few or many blood-vessels and nerves. By the addition of acetic acid, mucin may be precipitated from the basement substance. In sections it is usually stained with hæmatoxylin. The very soft forms which con-

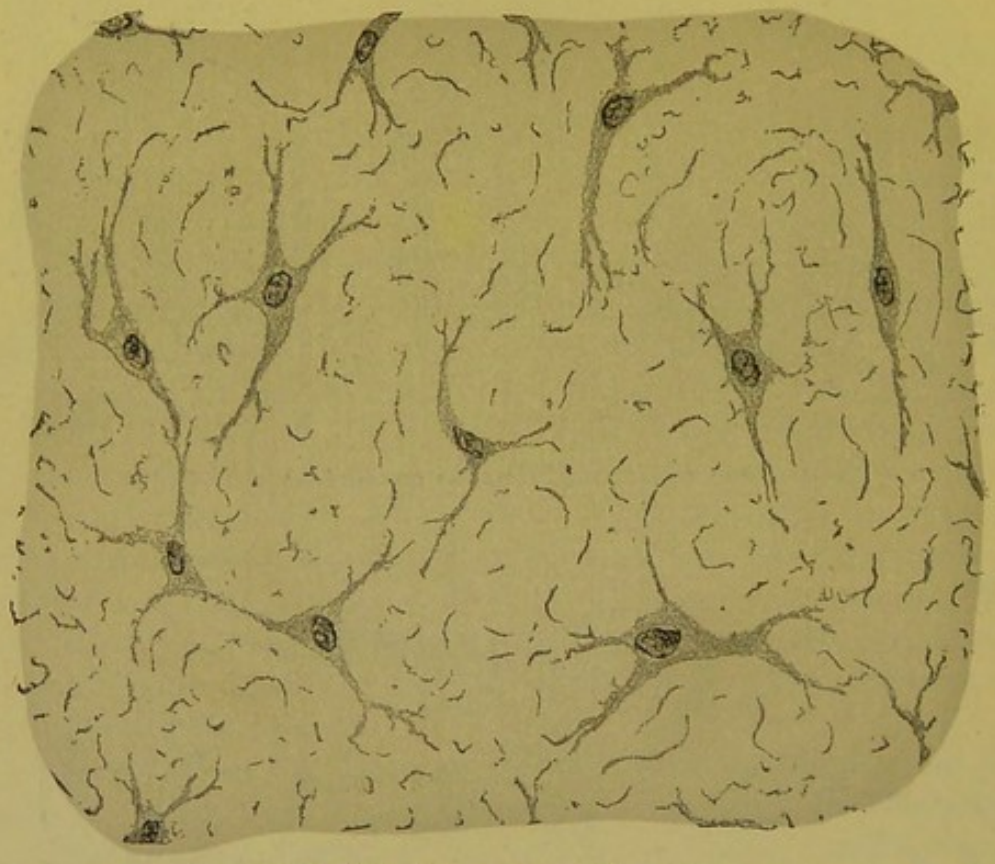

FIG. 117.—MYXOMA OF THE LARYNX.
Showing the diffuse staining of the mucin-containing stroma with hæmatoxylin.

tain comparatively few cells and much translucent basement substance are called *Myxoma gelatinosum* or *M. molle*. The presence of many cells renders them more consistent and gives them a whiter and more opaque appearance; such forms are called *M. medullare*.

Pure myxomata are not very common. The myxomata are very apt to be combined with fibrillar connective tissue as *fibro-myxoma;* or with fat tissue, *lipo-myxoma;* and they very frequently become sarcomatous, or take part in the formation of very complex tumors. They may be diffuse or encapsulated with fibrillar connective tissue; they are frequently very large, and may be multiple. Owing to the character of the basement substance, the blood vessels not infrequently rupture, giving rise to larger or smaller hæmorrhages within the

tumor, or to the formation of cysts. The cells are liable to undergo fatty degeneration (Fig. 118).

Composed, as they are, of a type of tissue from which fat tissue is

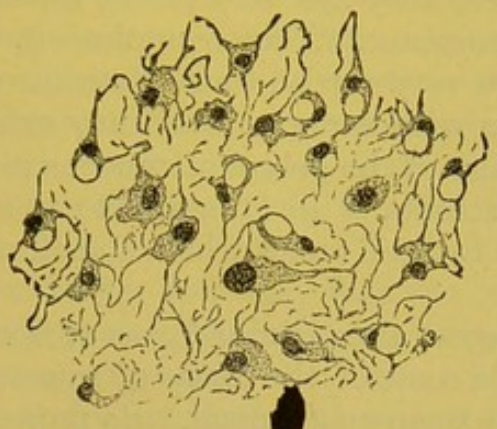

FIG. 118.—MYXOMA GROWING INTO ABDOMINAL CAVITY.
Showing the accumulation of fat droplets in some of the cell bodies.

developed in the embryo, the relations of these tumors to fat tissue are very intimate. They are most frequently developed in, and prob-

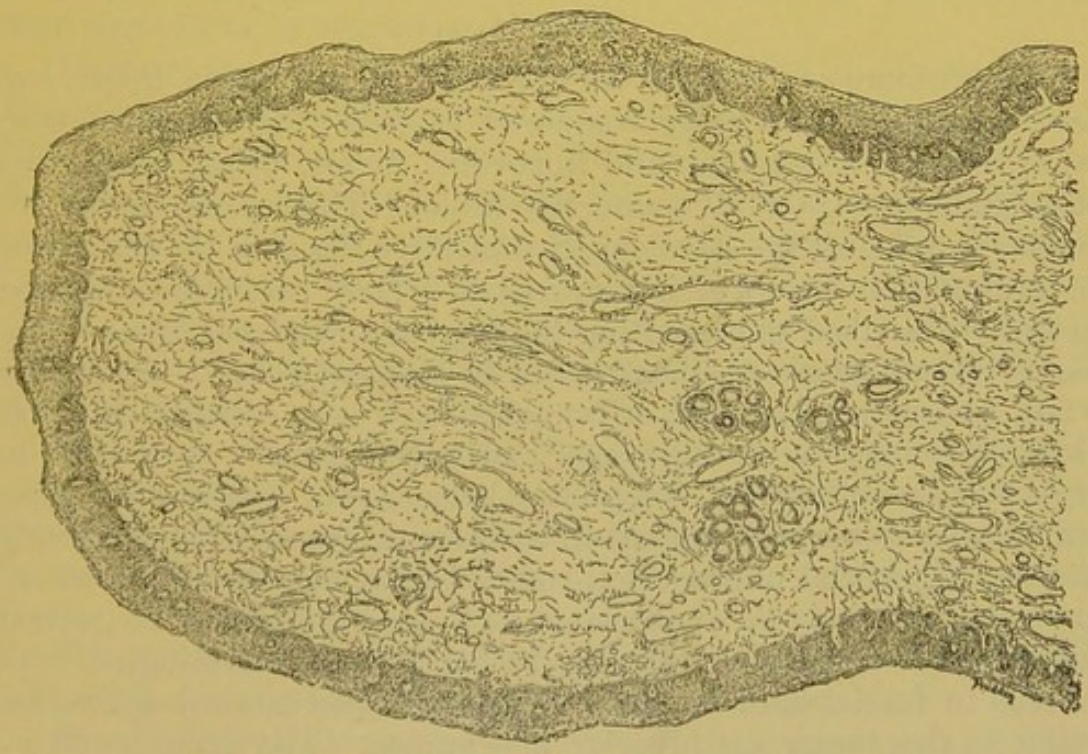

FIG. 119.—MUCOUS POLYP OF THE NOSE.
The section shows the epithelial covering of the new growth, as well as its numerous blood vessels and a few mucous glands.

ably directly from, fat tissue, and are very often combined with it as lipo-myxoma. They are also found in the subcutaneous, submucous, and subserous tissue, in the marrow and periosteum; in the

brain and cord ; in the sheaths and intrafascicular tissue of peripheral nerves ; in intermuscular septa ; and in the interstitial tissue of glands, such as the mamma and parotid. The myxomata are in general benign ; yet they are very prone, especially the lipomatous forms, to local recurrence. They sometimes grow very rapidly, and sometimes, though very rarely, form metastases. In the not infrequent combination with sarcoma they may exhibit the most marked malignancy. Many of the polypi of mucous membranes are myxomata or fibro-myxomata (Fig. 119), and to this class of growths belong the so-called hydatid moles which sometimes develop in the villi of the chorion.

Œdematous, loose, and cellular forms of fibrillar connective tissue so closely resemble some of the forms of mucous tissue that certain observers consider them as identical. So prone are many tumors to undergo mucous degeneration, and so frequent are the combinations of the myxomata with other forms of tumors, that it is often difficult, sometimes impossible, to say whether the mucous tissue in a given composite tumor is primary or secondary.

## SARCOMA.

These tumors are formed on the type of connective tissue, but they are, as a rule, largely composed of cells ; the basement substance, though a constant and important factor, being much less conspicuous than in adult connective tissue. They more closely resemble, in general, the developing connective tissue of the embryo or the granulation tissue of inflammation. They are, therefore, conveniently described as presenting the type of embryonal tissue. The cells of the sarcomata are most varied in size and shape. They may be flat, fusiform, spheroidal, or branched, and even cuboidal or cylindrical; they may be multinuclear and very large, or they may be very small and spheroidal, resembling leucocytes. The fibrillar basement substance may be present in such small quantity as to entirely escape a superficial observation, covered as it may be by the abundant cells; or it may be so abundant as to give the tumor the general appearance of a fibroma. It may be intimately intermingled with the cells in fascicles, or it may be in large open-meshed networks, giving to the tumor an alveolar appearance. The cells, however, always stand in an intimate relationship to the basement substance, which they sometimes reveal by fibrillar processes continuous with it. Blood vessels also form a constant and important structural element in these tumors, being in some of them so predominating a factor that they give structural outline and general character to the growth. They, too, as in the normal connective tissue, are intimately associated with the basement substance and with the tumor cells.

A single form of cells is often so predominant as to furnish a suitable qualifying name for the tumor, but in many cases the cell form varies greatly in the same growth. It may be said, in general, that there is a tendency to reproduce in these tumors some of the special characteristics of the tissues in which they originate. Thus, sarcomata of the bones are apt to be osteo-sarcomata ; those of pigmented tissue, like the choroid, are apt to be pigmented sarcomata. It will be more convenient for our present purpose to briefly describe the more common forms one after another than to attempt any systematic classification of them.

It should be remembered, however, that the various forms are not sharply specific in character, but are apt to merge into one another and to intermingle in various ways.

Sarcomata are most frequently found in the skin, subcutaneous tissue, fasciæ, subserous connective tissue, the marrow or periosteum, and in the choroid. They may also occur, though more rarely, in the dura mater ; brain and cord ; lymph nodes ; in the adventitia of blood vessels, and in nerve sheaths ; in submucous tissue ; in the uterus and ovary, and in the kidney. In the liver and lungs and heart they may occur by metastasis.

They are more apt to occur at an early period in life than later. The cellular character, the rapid growth, the vascularity and succulence of many forms, the marked tendency to local recurrence, and the formation of metastases, stamp the sarcomata as malignant tumors. But in this they vary greatly ; while some of the forms belong in every sense to the most malignant of tumors, others grow slowly, are very dense, and may remain localized and harmless for years. Their tendencies in this respect will be mentioned under the special forms.

Intimately related as they are to the blood vessels, metastasis is more apt to occur through the blood than through the lymph channels, and consequently adjacent lymph nodes are much less apt to be involved than in some other forms of tumor, notably the carcinomata.

The richly cellular and vascular forms of sarcoma are especially prone to hæmorrhages, degeneration, and ulceration.

*Spindle-celled Sarcoma.*—The cells in these tumors may be large —*large spindle-celled S.* (Fig. 120) ; or they may be small—*small spindle-celled S.* (Fig. 121). They may consist largely of cells, or may contain so much intercellular fibrous tissue as to be appropriately called *fibro-sarcoma.* The cells are frequently arranged in fascicles, which surround the blood vessels, and these fascicles may cross and interlace. These tumors, especially the small-celled forms, are, as a rule, denser and firmer and less malignant than other forms of sar-

coma, but to this there are many exceptions. They may be encapsulated or infiltrating. To this class belong the growths formerly



FIG. 120.—LARGE SPINDLE-CELLED SARCOMA.

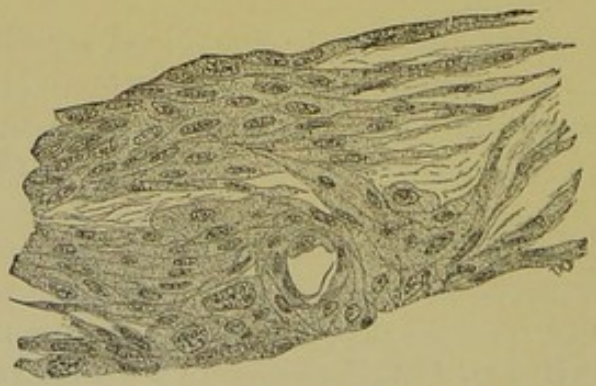

FIG. 121.—SMALL SPINDLE-CELLED SARCOMA OF FOREARM.

described as fibro-plastic tumors and recurrent fibroids. They frequently occur in the periosteum, subcutaneous tissue and muscle; in the uterus, and in various glands, notably in the mamma, tes-

ticle, thyroid, etc. These forms are among the most frequent of the sarcomata.

*Round-celled Sarcoma.*—Of these there are two classes—1, *small round-celled sarcomata* and, 2, *large round-celled sarcomata.*

1. The small round-celled sarcomata consist of cells of about the

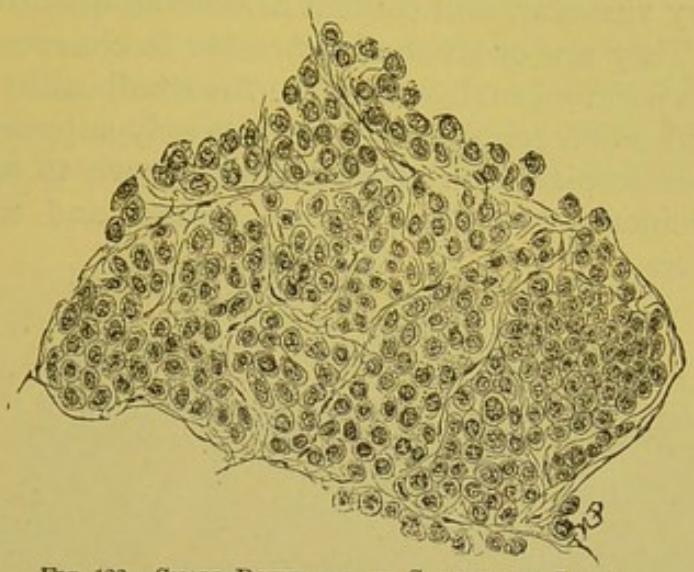

FIG. 122.—SMALL ROUND-CELLED SARCOMA OF LIVER.

size and appearance of mononuclear leucocytes (Fig. 122), and may have much or little intercellular substance, which may be irregularly disposed or arranged in large meshes resembling alveoli. In many

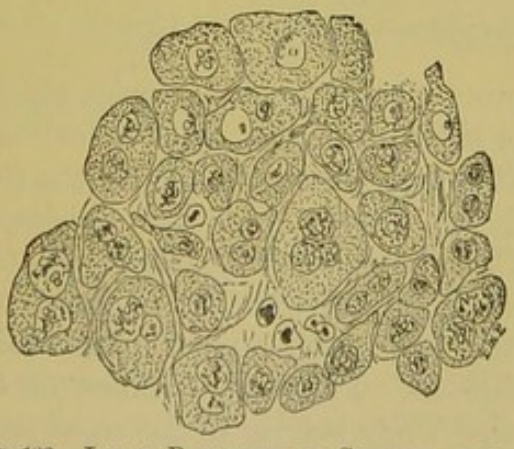

FIG. 123.—LARGE ROUND-CELLED SARCOMA OF LEG.

cases, so small is the quantity of intercellular substances that it is difficult of detection without special modes of preparation. These tumors are apt to contain many blood vessels, and be very soft and succulent. Their growth is sometimes rapid and they are often very malignant.

They most frequently occur in the connective tissue of the mus-

cles and fasciæ, in bone, and in lymph nodes (*lympho-sarcoma*). They also occur in the internal organs, not infrequently in the brain, associated with glioma as *glio-sarcoma* (see page 386).

2. In the large round-celled sarcomata (Fig. 123) the cells vary in size, but are usually very much larger than in the last variety. Their nuclei are usually large and contain prominent nucleoli. They, too, are often very vascular, and contain a variable quantity of basement substance. They are occasionally alveolar in character. They are, as a rule, less soft and malignant than the small-celled varieties.

The round-celled sarcomata were formerly supposed, on account of their macroscopical and clinical resemblance to some of the soft forms of carcinoma, to belong to these tumors, and were called medullary cancers.



FIG. 124.—MELANO-SARCOMA FROM SUBMAXILLARY REGION.

*Melano-Sarcoma.*—These tumors consist most frequently of spindle cells of various sizes, although cells of other shapes frequently occur in them. They are characterized by the presence in the cells, and less frequently in the intercellular substance, of larger and smaller particles of brown or black pigment (Fig. 124). The pigment is usually quite irregularly distributed in patches or streaks, and is located chiefly in the cell body. They arise most frequently in the skin and in the choroid. Pigmented moles of the skin often form their starting points. They belong to the most malignant of tumors. They very readily form metastatic tumors in various parts of the body, which are, like the parent tumor, pigmented.

Various forms of tumors may contain brownish pigment deposited in them by the degeneration of the hæmoglobin from extravasated blood; these should not be mistaken for melanotic sarcomata.[1]

*Myeloid or Giant-celled Sarcoma.*—Tumors of this class are usually formed chiefly of spheroidal or fusiform cells of variable size,

[1] On the occurrence of melanuria in cases of melano-sarcoma consult *Thacher*, Transactions New York Pathological Society, 1893, p. 105.

but their characteristic feature is the presence of larger and smaller multinuclear cells, called giant cells (see foot note on page 218). These are closely intermingled with the other cells, and may be very abundant or very few in number (Fig. 125). Giant cells may occasionally occur in other tumors, but are most abundant and characteristic in these. These tumors are chiefly formed in connection with bone, and may commence in the marrow or in the periosteum. They are sometimes very soft and vascular, and subject to interstitial hæmorrhages. Some of these vascular sarcomata were formerly classed together with other kinds of vascular tumors as fungus hæmatodes. Some of the forms of *epulis* are giant-celled sarcomata.



FIG. 125.—GIANT-CELLED SARCOMA OF BONE.

When these tumors originate in the marrow of the long bones, which is a favorite place for them, they are apt to cause resorption of the bone ; and although the tumor may be for a long time enclosed by a shell of new-formed bone, which enlarges with the enlarging tumor, it usually, sooner or later, breaks through this and infiltrates adjacent tissues. They are liable to form metastases and frequently grow to a very great size. The periosteal forms are apt to be firmer in texture, and are prone to the development of irregular masses of new bone within them, thus forming one of the varieties of osteosarcoma.

*Osteo-Sarcoma.*—These are spindle or round-celled tumors, usually, but not always, connected with bone, in which irregular masses of bone tissue are present. The bone is usually of irregular atypical

structure, the regular lamellation and typical Haversian canals being usually absent. They may form metastases which present similar characters.

Calcification, which should be distinguished from ossification, may occur in various forms of sarcoma.

*Angio-Sarcoma.*—In many of the sarcomata in various parts of the body the blood vessels form so prominent and important a feature as to give special character to the growth, not alone by their size and general prominence, but sometimes by the peculiar arrangement which their presence gives to the cells. While in most of the sarcomata the blood vessels have a very important influence in determining the topography of the tumor, in most of the denser and in

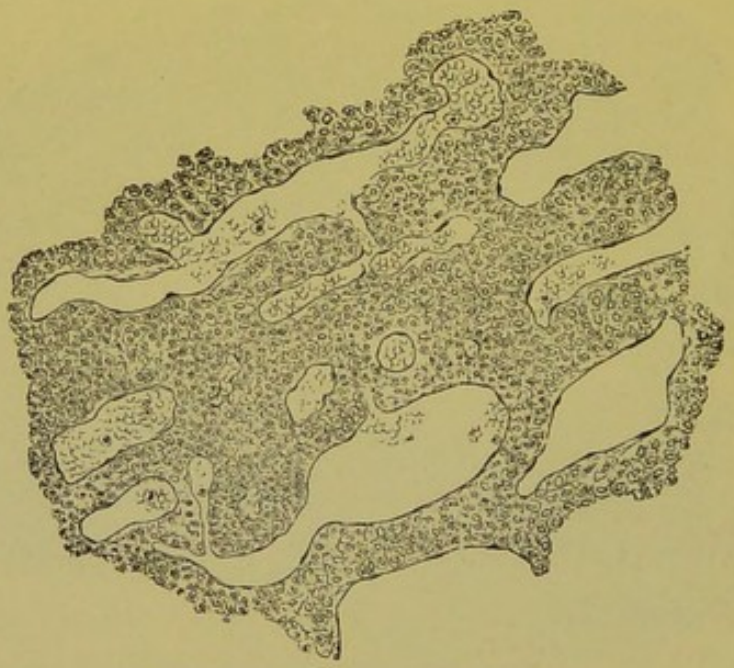

FIG. 126.—ANGIO-SARCOMA OF LIVER.
The thin-walled blood vessels, around which the tumor cells are formed, are irregularly dilated.

many of the softer varieties this influence is not easily traced. In many forms, however, particularly those which are soft and very cellular, the cells are closely grouped around the vessels, as if they were developed in their adventitiæ and had formed close sheaths around them. The masses of cells thus formed, with a blood vessel for a centre, may be closely packed together in long strings with more or less frequent anastomoses (Fig. 126), or they may be arranged in rounded groups, giving to the tumor an alveolar appearance. Such tumors are called angio-sarcomata. Simple vascularity, although this be extreme, does not make of a tumor an angio-sarcoma.

*Alveolar Sarcoma.*—Sometimes, as above stated, the basement substance of the sarcomata, particularly in some of the round-celled varieties, is quite abundant and arranged in a wide-meshed net, in the meshes of which the cells lie. These spaces are called alveoli, and this variety of structure has acquired importance from the general resemblance which these tumors have to the well-defined and characteristic alveolar structure which many of the carcinomata exhibit. It is true that occasionally the resemblance is very close indeed, but usually the sarcomata present a more or less intimate



FIG. 127.—MYXO-SARCOMA OF PHARYNX.

relation between the cells and basement substance. The cells usually do not simply lie in the cavities, but are often attached to the intercellular substance, which not seldom sends finer trabeculæ into the alveoli between the cells. Sometimes a careful shaking of sections in water is necessary to reveal the characters of the reticulum. The cells, moreover, are usually, though not always, distinctive in character. This form of tumor is, in some cases at least, determined, as above stated, by the new formation and peculiar arrangement of the blood vessels. Tumors of this kind are not common, but may occur in the skin, lymph nodes, bones, and pia mater. They are usually very malignant.

*Mixed Forms of Sarcoma.*—In addition to the above more or less well-defined forms of sarcoma, there exist various modifications which have received special names. The sarcomata in which cysts form, either by the softening of tissue by degeneration, or by the dilatation of gland ducts by pressure, or by the new formation of

tissue in gland ducts or alveoli which dilate with the growth of the tumor, have received the name of *cysto-sarcomata.*

Mucous degeneration is frequent in the various forms of sarcoma. A combination of myxoma and sarcoma—myxo-sarcoma—is common (see Fig. 127).

Combinations of sarcoma with fat tissue, *lipo-sarcoma;* with glandular structures, *adeno-sarcoma* (Fig. 128); with cartilage, *chondro-sarcoma;* with muscle tissue, *myo-sarcoma;* and with various other tissues, are of frequent occurrence. Some forms of *psammoma,* or "brain sand," found chiefly in the dura mater, are *fibro-*



FIG. 128.—ADENO-SARCOMA OF PAROTID.

*sarcomata* which have undergone calcification, the lime being deposited in lamellated masses of various shapes within them.

Some of the soft papillomata and warts, and occasionally the polypi of the mucous membranes, belong to the type of sarcoma or myxo-sarcoma.

The so-called *chloromata,* which have been found in a variety of places in the body, but are rare, are apparently forms of sarcoma. Chloroma is characterized by a greenish color, the nature of which is not known.[1]

## ENDOTHELIOMA (ENDOTHELIAL SARCOMA).

Under the name *endothelial sarcomata* or *endotheliomata* are grouped a number of tumors which on the one hand are closely related

[1] For a review of literature of chloroma see *Lang,* Arch. gén. de Méd., 1893, vol. ii., p. 555: 1894, vol. i., pp. 63, 186, 313. For the relationship of chloroma to leukæmia see *Dock,* American Journal of the Medical Sciences, August, 1893.

to the sarcomata in genesis, and in some cases in appearance, while on the other hand some of them so closely resemble some forms of

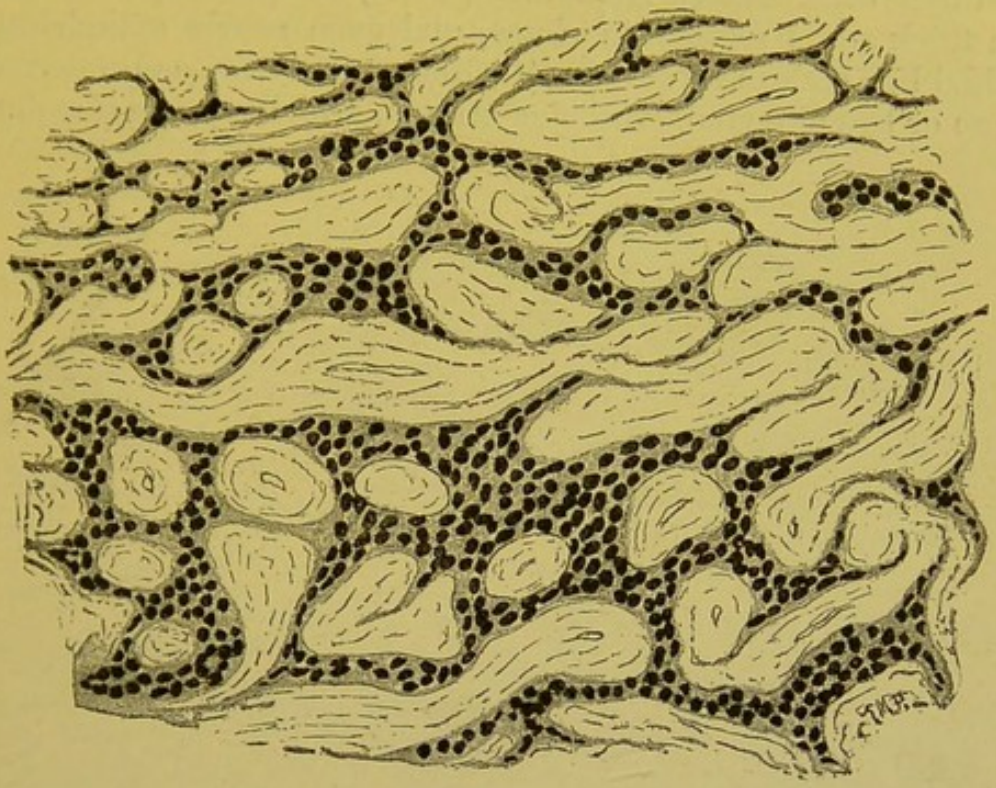

FIG. 129.—ENDOTHELIOMA OF UPPER JAW.

Showing dense connective tissue surrounding the blood vessels between the reticular endothelial cell masses.

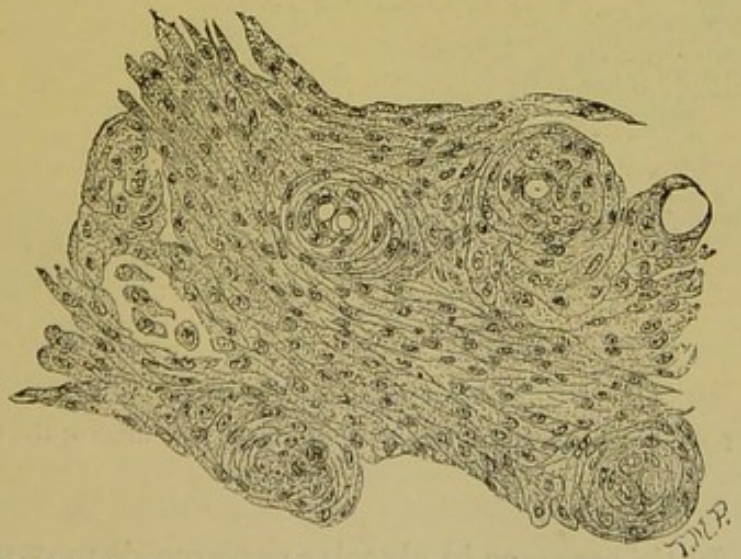

FIG. 130.—ENDOTHELIOMA (ENDOTHELIAL SARCOMA) OF DURA MATER.

carcinoma as to be difficult of distinction from them. The endotheliomata originate in that form of connective-tissue cells called endothelium, lining lymph vessels or lymph spaces, and develop by a

proliferation of these cells. Sometimes the cells of the endotheliomata resemble closely the normal endothelium; sometimes, however, they differ considerably from them, being occasionally very large, often thick and irregular in shape, and even nearly cylindrical or cuboidal like certain forms of epithelium. They are associated with a more or less abundant vascular stroma, which may be alveolar in

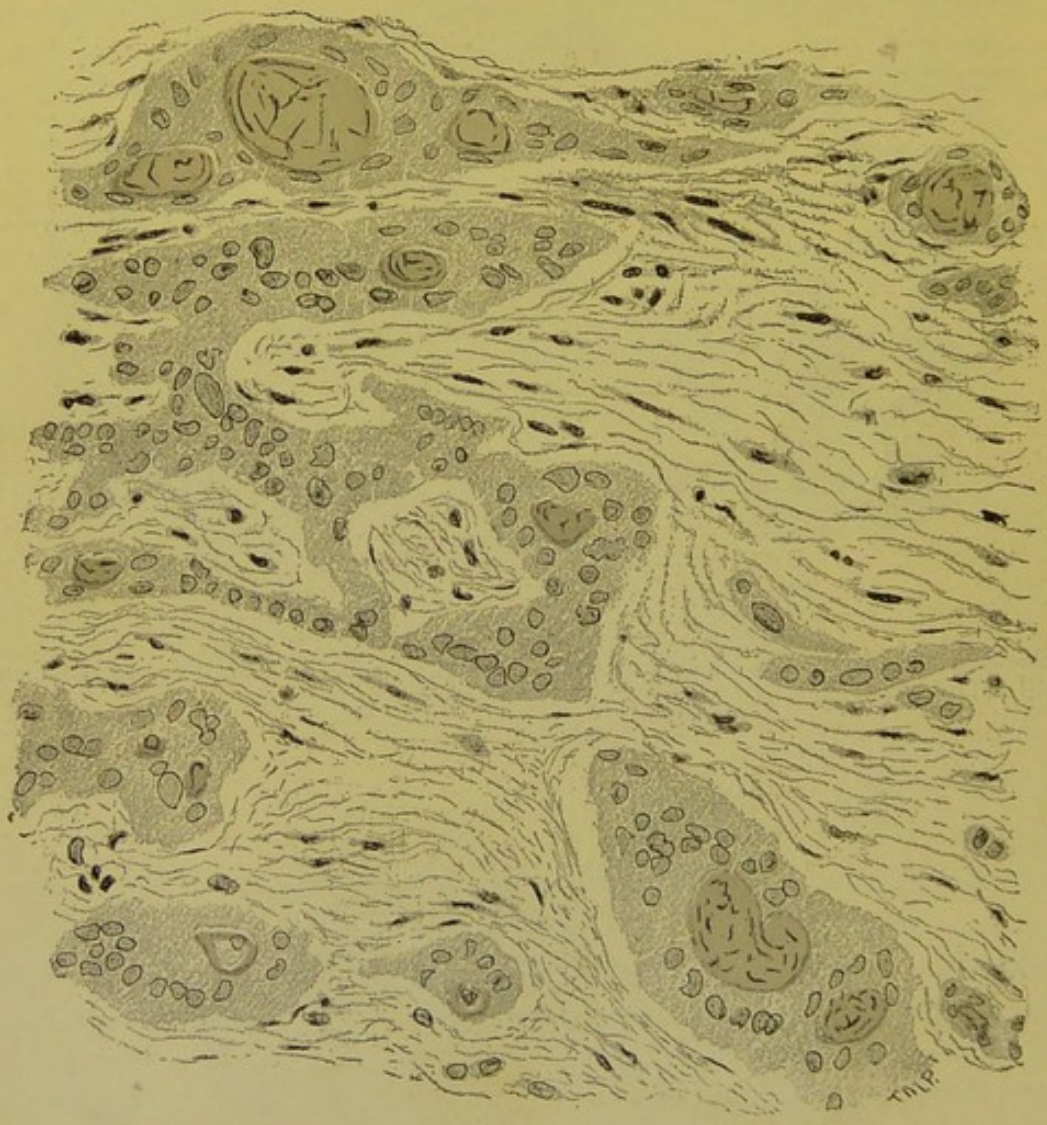

FIG. 131.—ENDOTHELIOMA OF PLEURA.

Showing the formation of mucus within the endothelial cell masses; the mucus is stained with hæmatoxin.

formation. In this case, as in alveolar sarcoma, it may often be seen that the cells have an intimate relationship to the trabeculæ of the stroma.

Developing from the endothelium of the lymph vessels, these tumors sometimes exhibit a structure closely simulating that of

tubular glands lined with more or less cuboidal epithelium. It is in many cases difficult to decide from the structure in the fully developed parts of tumor whether it is an endothelioma or a carcinoma. In such cases a careful study of the peripheral portions of the tumor and parts into which it is extending may reveal early phases of proliferation in the endothelium of lymph vessels or spaces (Fig. 129). In this case its genetic relationship will determine the nature of the tumor, however similar it may be in morphology to carcinoma.

Sometimes the cells of the endotheliomata are packed together in dense concentric masses (Fig. 130), which may have a glistening ap-

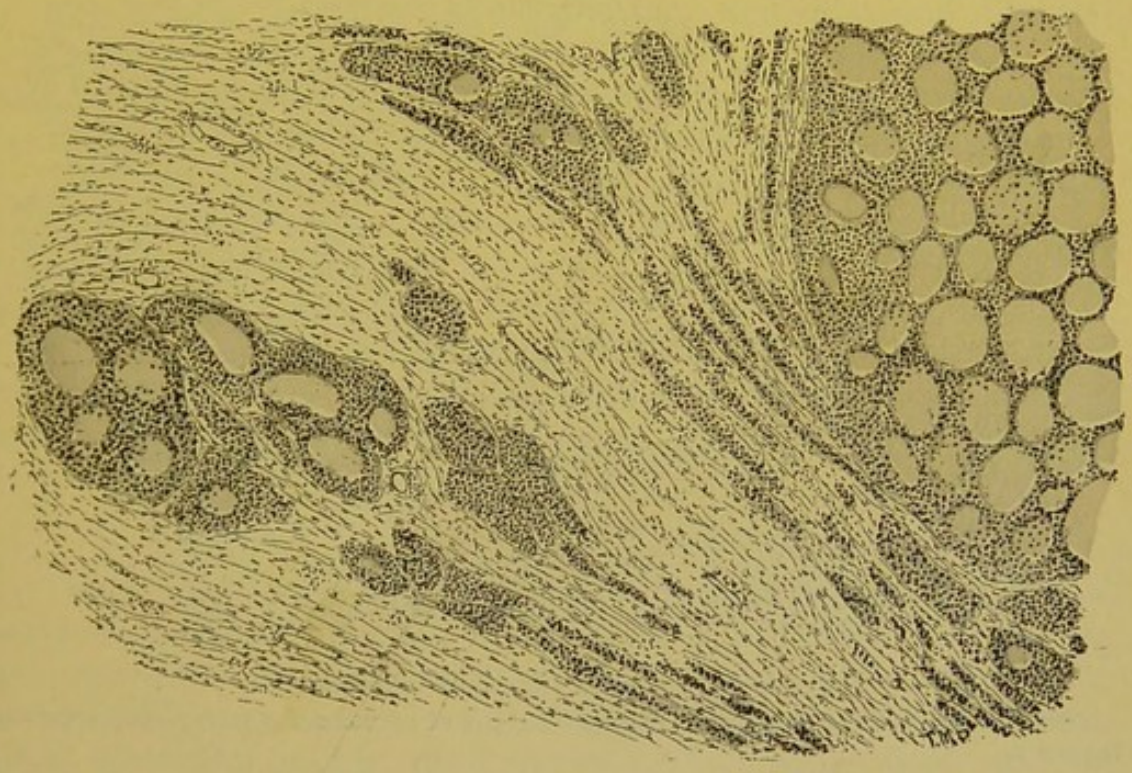

FIG. 132.—ENDOTHELIOMA OF UPPER JAW.

Showing formation of mucus in the gland-like endothelial cell masses. This form of tumor is often called "cylindroma."

pearance, and such tumors are sometimes called *cholesteatomata*. Although, for the most part, the peculiar glistening appearance of these tumors is due to the closely packed thin cells which compose them, they not infrequently contain crystals of cholestearin, which may share in producing this characteristic appearance. But the cholestearin may be absent, or present in small amount.

The stroma of the endotheliomata may undergo various forms of alteration, developing hyalin, myxomatous, or cartilaginous or very dense fibrous characters (Fig. 129); or it may atrophy, leaving the proliferated endothelium and the blood vessels as the chief structural

elements. On the other hand, hyalin and mucous degeneration of the endothelial cells may occur (Fig. 131), and considerable collections of these materials, free from the cells but surrounded by the cell masses, may give a cystic character or lend a glandular appearance to the growth (Figs. 132, 133).

Such tumors—in which homogeneous or striated cylinders of hyalin or mucoid material, often closely surrounded by layers of cuboidal or flattened cells, form a striking feature—have sometimes been called *cylindromata*. The stroma of the endothelioma may be-



FIG. 133.—CYLINDROMA (ADENOMA) OF ANTRUM.

This complex form of cylindroma, resembling types of adenoma, not infrequently occurs in the ovary.

come sarcomatous and thus a mixed tumor—a sarcomatous endothelioma—may be formed.

The endotheliomata may be single, nodular, and of considerable size; or they may be multiple, numerous small tumors being scattered over the surface of the part in which they grow. They may even form a thick or thin pellicle over surfaces, or cause adhesions between adjacent organs. They may form metastases. They occur in the dura mater and pia mater, in the pleura and peritoneum, and have been described in the skin, bone, gums, lymph nodes, ovary, liver, brain, testicle, glandula carotica, and salivary glands.[1]

[1] For an admirable study of the endotheliomata with bibliography consult *Volkmann*, Deutsche Zeitschr. f. Chirurgie, Bd. xli., p. 1.

## LIPOMA.

Lipomata are tumors formed of fat tissue. The fat tissue occurs in lobules and is similar to normal fat, except that the cells and lobules are usually larger and less regularly arranged. There may be little connective tissue in the tumors, when they are very soft, almost fluctuating—*lipoma molle*—or there may be so much as to give the tumor considerable firmness—*fibro-lipoma*. They may be in part transformed into mucous tissue—*myxo-lipoma*. Cartilage not infrequently develops in them, or they may undergo partial calcification.

Occasionally the blood vessels are very abundant and dilated—*angio-lipoma*. They are usually sharply circumscribed, but may infiltrate surrounding tissues. They are not infrequently pedunculated. They sometimes grow to enormous size and may ulcerate.

They are usually isolated, but may be multiple. They are the most common of tumors, occurring usually in the subcutaneous or other fat tissue. They may occur in the mucous membrane of the gastro-intestinal canal, in the peritoneum, more rarely in the dura mater, kidney, liver, and lungs. They are benign tumors, not forming metastases; but they may be deleterious by ulceration or gangrene, and when not fully removed may exhibit local recurrence.

## CHONDROMA.

These tumors, composed of either of the physiological forms of cartilage, are usually hard, but sometimes quite soft. The cells do not present the same uniformity in size, shape, number, and relative position that they do in normal cartilage. Sometimes they are very large, spheroidal, and grouped in masses, and again small and far apart. They are frequently fusiform or branching. Fibrillar connective tissue in varying quantity is usually present in the chondromata, either as a capsule, or running in bands between the nodules of cartilage, or passing in fascicles into them (Fig. 134). The cartilage may change to mucous tissue, forming *myxo-chondroma*[1] (Fig. 135); the cells may undergo fatty degeneration or they may calcify or ossify. Chondromata frequently form a part of mixed and complex tumors.

They may form in connection with bone or cartilage, and are often traceable to irregularities in fœtal development. Or they may

---

[1] This change of one form of tissue into another is called *metaplasia* (see page 95), and is not uncommon among tumors formed on the connective-tissue type.

occur in soft parts where cartilage is not normally present, as in the parotid, testicle, mamma, and ovaries, where they are apt to be

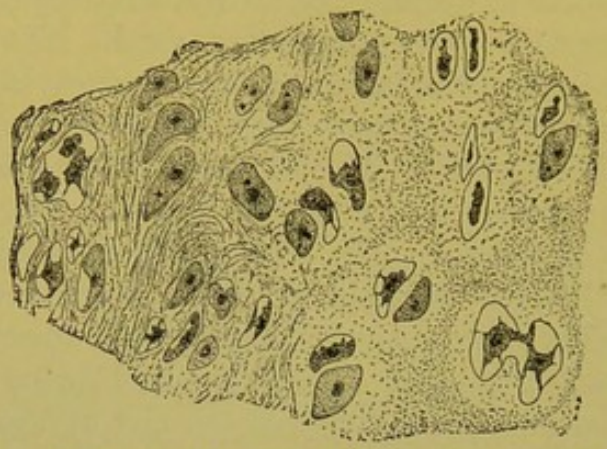

FIG. 134.—CHONDROMA OF SUBCUTANEOUS CONNECTIVE TISSUE.

mixed with other tissue; or in subcutaneous connective tissue and fasciæ.

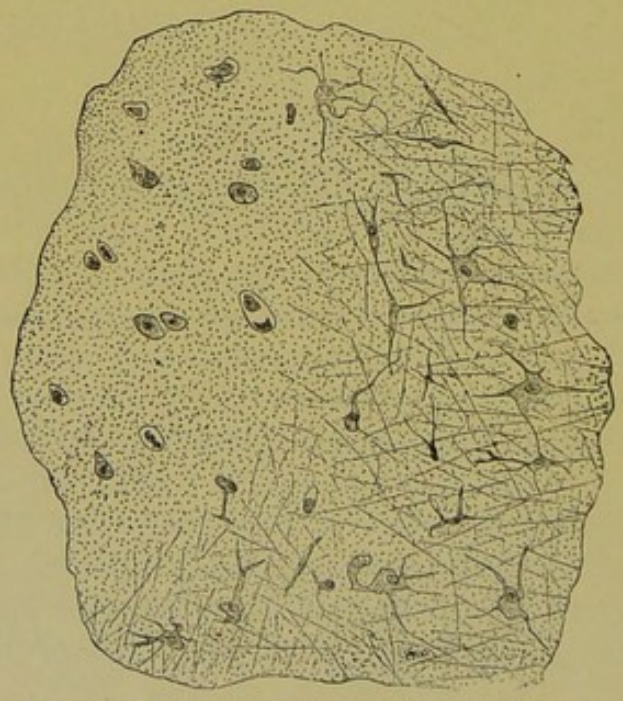

FIG. 135.—MYXO-CHONDROMA OF CERVICAL REGION.

They are in general benign tumors, but metastases sometimes occur, most frequently in the lungs, sometimes in the heart.

Small hyperplastic growths on the surfaces of cartilage are called *ecchondroses.*

## OSTEOMA.

The formation of bone in the body in abnormal places occurs quite frequently and under a great variety of conditions. It is on this account not easy to define the term osteoma, and it is frequently difficult to determine whether or not a given mass of new-formed bone is an osteoma or not. Bone tissue often occurs in tumors of the connective-tissue group as a secondary or complicating structure—*osteo-fibroma, osteo-chondroma, osteo-sarcoma*, etc. It may occur in muscles as a result of certain exercises, or as a result of a peculiar inflammatory process (see Lesions of the Muscles), or it may occur in connection with chronic inflammation in a variety of tissues. A circumscribed mass of abnormal bone, not of inflammatory origin, may be called an osteoma. Small masses of new-formed bone of various shape, projecting from a bony surface and frequently of inflammatory origin, are usually called *osteophytes*. Bony tumors projecting from the surface of bones are frequently called *exostoses*.

An osteoma may be loose in texture, consisting of bone tissue similar to cancellous tissue ; or it may be denser, resembling compact bone tissue ; or it may be very hard and dense like ivory, so-called *ivory exostoses*. The difference between these forms lies chiefly in the varying number and size of the vascular and medullary spaces which they contain.

Osteomata may develop in connection with the bone or periosteum, which is most frequently the case, or, independently of bone, in soft parts.

New-formed bone has been found in the soft parts of the body, in the brain substance, dura mater, and pia mater ; in the pleura, diaphragm, and pericardium ; in the skin, choroid, air passages, lungs, and penis, and in other places. To what extent some of these bone formations may have been due to inflammatory action it is not possible to say, and it is quite probable that the fuller knowledge of the future may show relationships between the development of certain tumors and some forms of chronic inflammation which we do not now recognize.

The growth of the osteomata is, as a rule, slow. They are benign tumors, and are not infrequently multiple.

## ODONTOMA.

Tumors are sometimes formed from the pulp during the development of the teeth. When these contain dentin they are called odontomata.

## GLIOMA.

The gliomata are developed in connection with the characteristic connective-tissue framework of nerve tissue, the neuroglia, which in structure many, though usually not all, of its cells closely resemble. Small cells with inconspicuous bodies and numerous delicate branching processes are most characteristic; but in connection with these

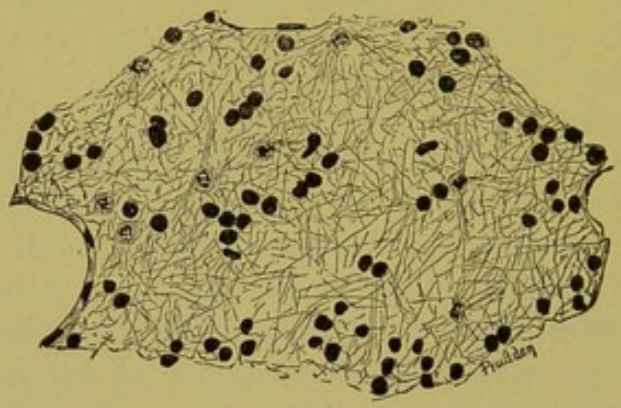

FIG. 136.—GLIOMA OF BRAIN.

there is usually a greater or less number of small spheroidal cells with proportionally large nuclei (Fig. 136). It is usually necessary to shake sections in water or carefully tease fragments of the tumor

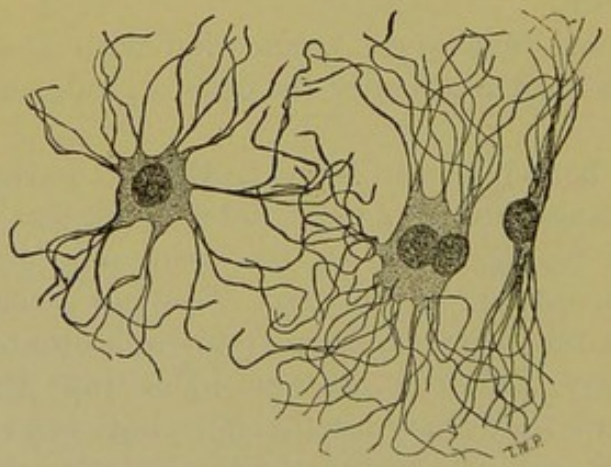

FIG. 137.—NEUROGLIA OR "SPIDER" CELLS FROM GLIOMA OF BRAIN.
Teased specimen.

in order to see the characteristic neuroglia or so-called "spider" cells (Fig. 137). These tumors may contain very numerous and frequently dilated thin-walled blood vessels. They may be very soft or moderately hard; and, especially when occurring in the substance of the brain, are frequently not sharply outlined against the adjacent normal tissue. They usually occur singly, and are comparatively slow in growth.

They are very apt to be complicated with other tumor tissue, forming *glio-myxoma*, *glio-sarcoma*, etc. Owing to the abundance of thin-walled blood vessels and the softness of the growth, they are liable to interstitial hæmorrhages, and may then, when occurring in the brain, readily be mistaken for ordinary apoplectic clots. They are liable to fatty degeneration. They usually occur in the brain, spinal cord, and in the optic and other cerebral nerves. The so-called gliomata of the retina are usually small spheroidal-celled sarcomata.

Pure gliomata are benign tumors, though in their most common combination with sarcoma they may be very malignant. Their usual situation, however, is such as to make them almost always significant, although technically they are benign tumors.[1]

## MYOMA.

Tumors composed of muscular tissue are of two kinds, following the two physiological types of muscle tissue, the non-striated and the striated.

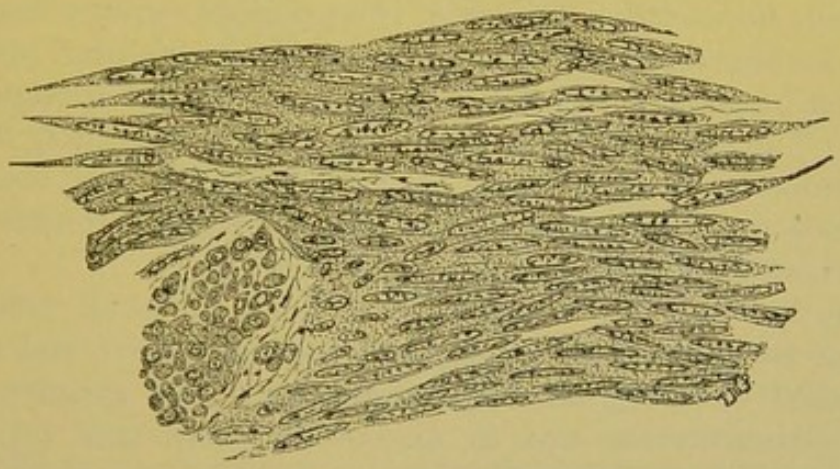

FIG. 138.—MYOMA OF UTERUS—LEIOMYOMA.

I. *Leiomyoma, Myoma levicellulare.* — The characteristic elements of these tumors are fusiform, smooth muscle fibres, with elongated or rod-shaped nuclei. These are packed closely together, frequently interlacing and running in various directions, and are intermingled with a variable quantity of more or less vascular fibrillar connective tissue (Fig. 138). When, as is not infrequently the case, the connective-tissue elements are present in large amount, the tumor is called *fibro-myoma*. It is not always easy in sections to distinguish between these tumors and certain cellular fibromata, but the characteristic shape of the isolated cells and their nuclei, together with

[1] Our knowledge of the normal neuroglia is still too meagre to permit us to understand very thoroughly this class of tumors, and to separate it as precisely as could be wished from certain of its allies among the abnormal connective-tissue growths.

their uniformity in size, will usually suffice. These tumors are frequently infiltrated with lime salts, and, owing to their density and lack of blood vessels, they not infrequently degenerate, forming cysts or becoming gangrenous. They may occur singly or be multiple, are usually of slow growth, may be large or small, and are benign. They may occur wherever smooth muscle tissue exists. They are most frequently found in the uterus, where they are often multiple. They may occur in the wall of the gastro-intestinal canal, and have been seen in the bladder and in the skin. The so-called hypertrophies of the prostate, so frequent in advanced life, are sometimes considered leiomyomata of the interstitial muscle tissue of that gland.

II. *Myoma striocellulare*, or *Rhabdomyoma.*—In these rare tumors striated muscle fibres are the characteristic elements. They very rarely compose a great part of the tumor, but are intermingled with other elements, fibrillar connective tissue, spindle-shaped and spheroidal cells of various forms, which often appear to be incompletely developed muscle cells. They are not infrequently associated with sarcomatous tissue. Blood vessels and sometimes nerves are also present. The muscle fibres differ, as a rule, from normal striated muscle fibres in their arrangement, which is usually quite irregular, and also in size, being in general smaller than normal fibres, although varying greatly. The sarcolemma is either absent or incompletely developed. These tumors are usually small or of moderate size, and are supposed to originate from inclusions of cells destined to form muscle tissue in places where they do not belong.

In the heart and certain other muscular parts small circumscribed masses of striated muscle tissue have been described, and are sometimes called *homologous rhabdomyomata.* But genuine heterologous rhabdomyomata are, in almost all cases thus far recorded, confined to the genito-urinary organs, kidney, ovary, and testicles. The writer has described an exceptional case of rhabdomyoma occurring in the parotid gland.[1]

These tumors, when not associated with other and malignant tumors, are benign and are of much greater theoretical than practical interest.

### NEUROMA.

A true neuroma is a tumor containing new-formed nerve tissue. Such tumors are comparatively rare. Tumors developed in the connective tissue of nerves and composed usually of fibrous or mucous tissue are common, and are frequently called neuromata, but they should be called fibromata or myomata, etc., of the nerves, or *false*

[1] American Journal of the Medical Sciences, April, 1883. For literature and bibliography consult *Ribbert*, Virchow's Archiv, Bd. cxxx., p. 249.

*neuromata.* The true neuromata are of two kinds, *ganglionic* or *cellular neuromata* and *fibrillar neuromata*, depending upon the character of nerve tissue which they contain. The ganglionic neuromata—neuroma ganglioniforme—in which new-formed nerve cells are present (Fig. 139), are found associated with other structures in certain of the teratomata in the ovaries, testicles, and in the sacral region; they also occur in the gray matter of the brain. They have been found in the suprarenal glands.

The fibrillar neuromata are, according to Virchow, of two kinds, *myelinic* and *amyelinic*, depending upon whether the nerve fibres which they contain are medullated or not. The *neuroma myelinicum* is the more common and the best understood. The medullated nerve fibres in these tumors are associated with fibrillar connective tissue, and are usually curled and intertwined in a most intricate manner. They occur either singly or multiple on the peripheral



FIG. 139.—NEUROMA GANGLIONIFORME.
From the suprarenal gland.

nerves. They may occur in considerable numbers as nodular tumors on the branches of a single nerve trunk, or they may form an irregular, diffuse, nodulated enlargement of the nerve branches—*plexiform neuroma.* These neuromata may or may not be painful. They not infrequently form at the cut ends of the nerves in amputation stumps. They are benign tumors, never forming metastases.

The false neuromata (Fig. 140) are myxomata, or fibromata, or sometimes myxo-sarcomata of the nerve sheaths or intrafascicular connective tissue, and may occur singly or multiple. In the latter case they may affect the branches of a single nerve trunk, or they may be found on nearly all the cerebro-spinal peripheral nerves. The writer has described a case (Figs. 141 and 142, pages 324 and 325), in which over eleven hundred and eighty-two distinct tumors were found distributed over nearly all the peripheral nerves of the body.[1]

[1] American Journal of the Medical Sciences, July, 1880.

The nerve fibres in these tumors may be crowded apart by the new growth and considerably atrophied; or, in cases in which the

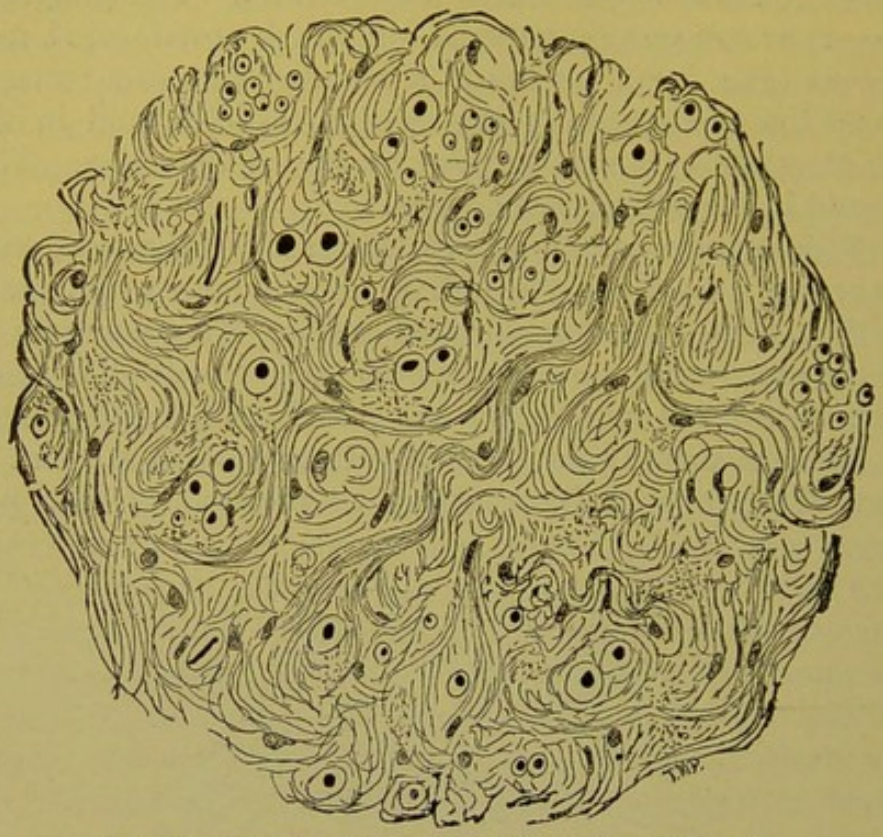

FIG. 140.—FIBROMA (FALSE NEUROMA) OF LUMBAR NERVE.

The fibrous tissue is loose in texture and in places œdematous, so that it considerably resembles mucous tissue.

tumor is composed of soft tissue, as in myxoma or the soft fibroma, they may pass through or around the tumor entirely unchanged. The multiple false neuromata are in many cases congenital.

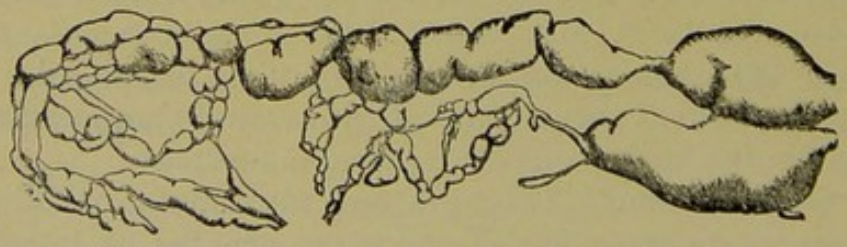

FIG. 141.—MULTIPLE FIBROMATA (FALSE NEUROMATA) OF PNEUMOGASTRIC NERVE. One-quarter natural size.

## ANGIOMA.

Angiomata are tumors consisting in large part or entirely of new-formed blood or lymph vessels or cavities. In many tumors of various kinds the new-formed or the old blood and lymph vessels may be

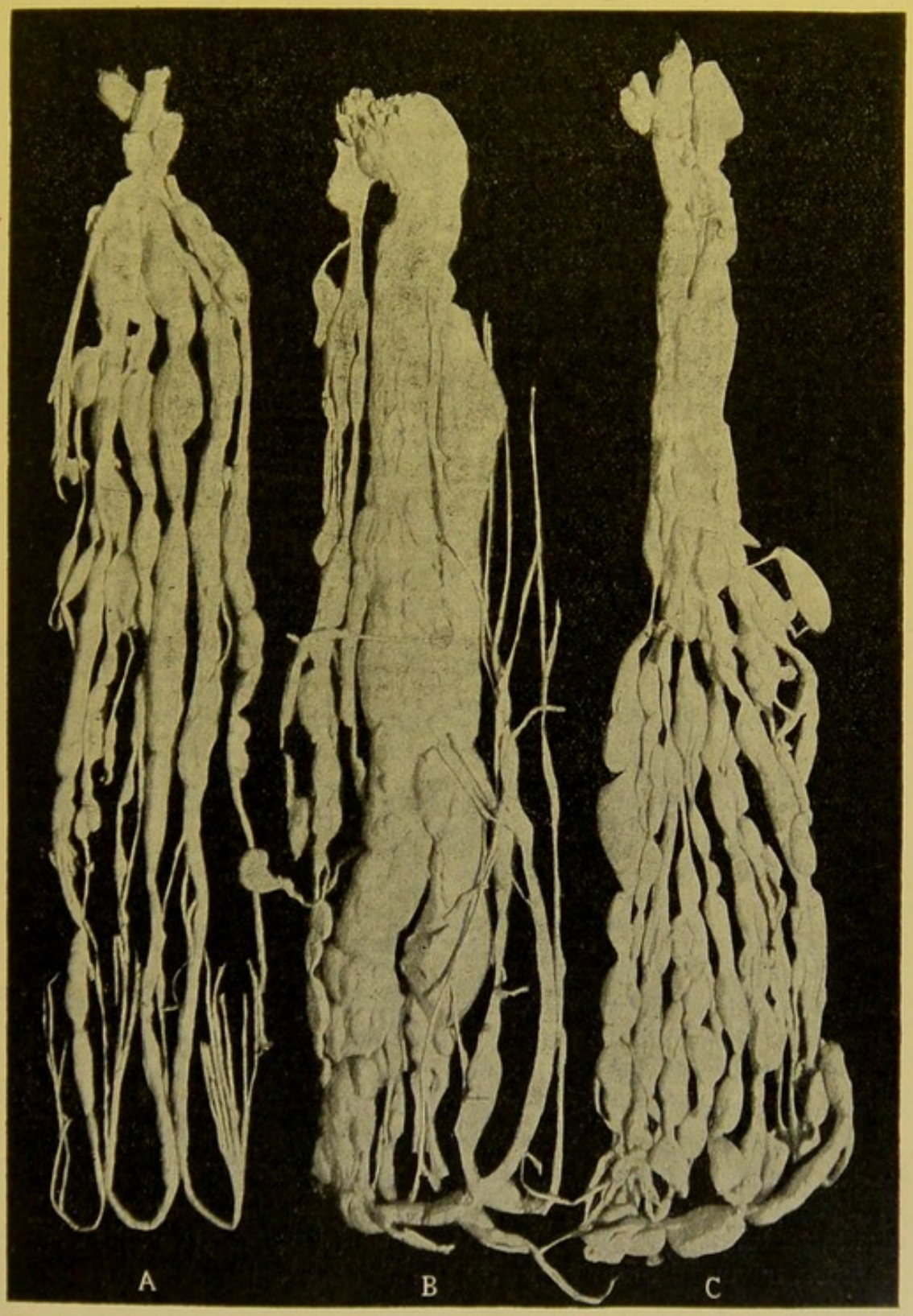


FIG. 142.—MULTIPLE NEUROMATA OF THE PERIPHERAL NERVES.

A, Nerves of the right arm; B, the left sciatic with its branches; C, the left anterior crural with its branches.

very abundant or prominent by reason of their dilatations; the vessels of otherwise normal tissues may also be largely dilated, thus simulating vascular tumors. These are, however, not true angiomata, although sometimes reckoned among them, and in many cases closely allied to them. Such are the so-called arterial varix, or cirsoid aneurisms, and hæmorrhoids, and various lymphectasiæ. *True angiomata* are of two kinds—I., *Hæmangioma*, and II., *Lymphangioma*.

I. *Hæmangiomata.*—These tumors are of two types: 1. Those formed largely of capillary blood vessels with either thin or thickened walls, embedded in a more or less abundant connective-tissue stroma. These are called *simple angiomata* or *angioma telangiectoides*. The walls of the vessels in these tumors are frequently dilated or pouched,

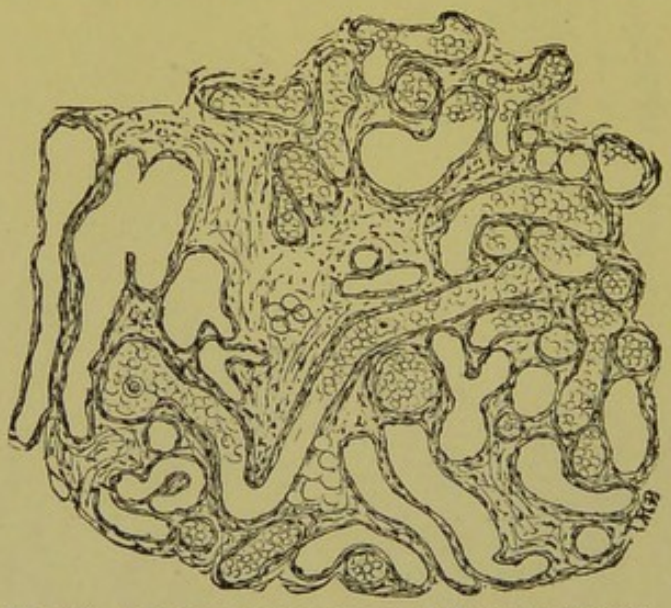

FIG. 143.—ANGIOMA TELANGIECTOIDES (Vascular Nævus).
From skin over scapula of child.

and usually form a tangle of curled and intertwined vessels (Fig. 143). They occur most frequently in the skin or subcutaneous tissues, usually about the face, and may project above the general surface or be on a level with it. Such are the so-called *vascular nævi*, or *strawberry marks*, which are usually congenital. They are sometimes sharply circumscribed, and sometimes merge imperceptibly into the surrounding skin. They sometimes occur in the mucous membranes, in the mamma, bones, and brain. They are benign tumors, never forming metastases, but may be associated with sarcomata.

2. The second form of hæmangioma, called *angioma cavernosum*, consists largely of a series of intercommunicating, irregular-shaped larger and smaller blood spaces lined with endothelium, and surrounded by a variable quantity of fibrillar connective tissue, which

may contain smooth muscle cells (Fig. 144). They resemble the erectile tissue of the corpora cavernosa of the penis and clitoris. They are apparently formed by a dilatation of old and new-formed capillaries and veins. They are sometimes erectile and sometimes pulsating, and are not infrequently multiple. They may be seated in the

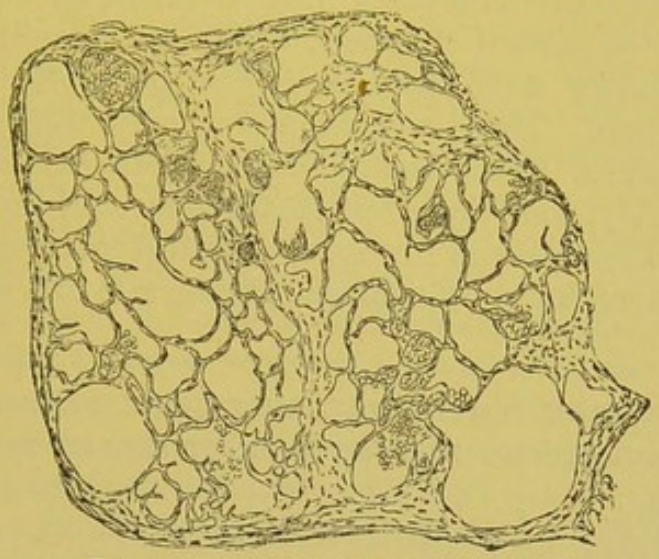

FIG. 144.—ANGIOMA CAVERNOSUM OF LIVER.

skin and subcutaneous tissue, forming the so-called projecting nævi, or in internal organs. They are often found in the liver and less frequently in bone, the brain, spleen, uterus, kidney, intestines, bladder, and muscles. They are usually of little significance, though they may give rise to hæmorrhages.

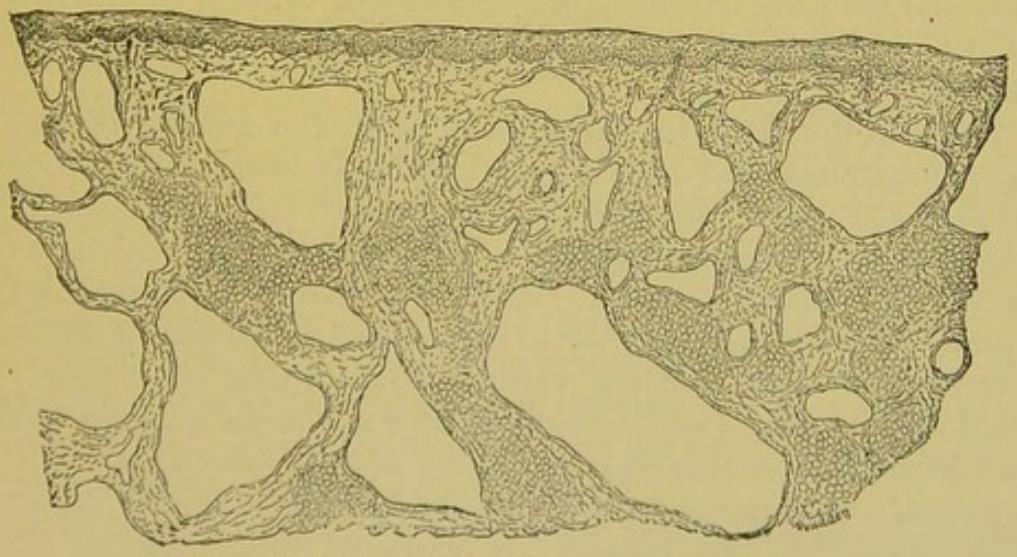

FIG. 145.—CONGENITAL LYMPHANGIOMA FROM ARM OF CHILD.

II. *Lymphangioma.*—These tumors consist of dilated lymph channels, which either preserve approximately the general shape of the original lymph vessels, or are distinctly cavernous in character, or even cystic (Fig. 145). They probably originate in part in new-

formed, in part in old lymph channels. A strict distinction between tumors formed by a dilatation of preformed and new-formed lymph channels is not possible, owing to the very primitive character of some of the ultimate lymph spaces and our lack of knowledge of their exact relations to adjacent parts.

In the lymphangiomata there may be much or little connective tissue between the dilated channels, which are usually filled with a translucent or milky fluid resembling, and probably identical with, the normal lymph. These tumors are usually congenital, but are sometimes acquired. They usually occur in the skin as soft, sometimes considerably, sometimes but slightly elevated tumors, and may occur in the tongue—some forms of so-called macroglossia. They are benign tumors, but may rupture, giving rise to a serious lymphorrhœa.

### TUMORS IN WHICH EPITHELIAL CELLS ARE PREDOMINANT OR CHARACTERISTIC ELEMENTS—EPITHELIAL TUMORS.

I. Adenoma.

II. Carcinoma.

*General Considerations.*—The tumors thus far described in detail, with the exception of the gliomata, are formed on the type of tissues which develop from the parablast. The epithelial tumors, on the other hand, originate in one or other of the layers of the archiblast, and we have accordingly two series of criteria by which to describe and identify them : first, morphological, and second, histogenetic criteria.

While in the main, in the normal body, the general distinctions between epithelial and other tissues are fairly well marked, there are still particular cases, especially those in which epithelial tissues are in process of physiological growth or rejuvenation, in which the distinctions are quite ill-defined. When we remember the rapid growth of many tumors, the tendency to incomplete formation of their cells, their diverse seats, and the various complicating conditions under which they originate and develop, it does not seem strange that the exact limitations of this class of tumors are not easy to fix, nor that they seem sometimes to merge into one another and into tumor tissues belonging to other classes. If epithelial cells, under all circumstances, had a definite and characteristic structure, or if, on the other hand, we could always know whether a given cell group originated in epithelium or not, the matter of distinguishing between tumors of this and other classes would be simple and easy enough. As it is, in some cases both morphological and histogenetic criteria fail us, and the clinical history and gross appearance are not characteristic. Such cases—which are indeed rare, but which do sometimes occur—suggest

to us the possibility that the desirability of accurate classification has led us into seeking distinctions which Nature herself has not sharply drawn. While these difficulties in special cases must be acknowledged, the distinctions are in the main definite enough, and very useful both for clinical and scientific purposes.

Epithelial tumors always contain, in addition to the more or less characteristic cellular elements, a connective-tissue stroma which gives them support and carries the vessels. This stroma may be sparse or abundant, may contain few or many cells, is sometimes arranged in irregular fascicles or bands, and very frequently forms the walls of well-defined, variously-shaped spaces or cavities called *alveoli*, in which the epithelial cells lie. The epithelial cells, in most cases, lie along the walls of the alveoli without an intimate connection with them, as is the case in the alveolar sarcomata. They are, moreover, packed together without more intercellular substance than the usual cementing material common to epithelial cell masses. In this lack of fibrillar intercellular substance within the alveoli, and in the loose relationship between the cells and the alveolar walls, lie in many cases the chief morphological distinctions between certain carcinomata and alveolar sarcomata.

In certain of the epithelial tumors there is a reproduction of typical gland tissue of various kinds, depending upon the seat and conditions of growth of the tumor. Such tumors are called *adenomata*. A simple hypertrophy of a gland, or an increase in its size by excessive growth of its interstitial tissue, does not constitute an adenoma. There must be an actual new formation of more or less typical gland tissue. This is not always or frequently of exactly the same character as the gland tissue in which it originates, and always exhibits a certain lack of conformity to the type in structure and mode of growth. The alveoli and ducts usually have a lumen and sometimes a membrana propria, but the cells may differ in shape from one another and from those of the gland from which they spring.

Epithelial tumors in which there is no close conformity to a glandular type, but a lawless growth of various kinds of more or less typical epithelial cells in the meshes of an old or new-formed connective-tissue stroma, are called *carcinomata*.

It will readily be seen that there must be a border region between the adenomata and carcinomata, where conformity to the glandular type merges into the lawlessness of growth characteristic of carcinomata. In this border region a certain degree of individual bias must be permitted in assigning a name to the new growth. In some cases a sharp distinction cannot be made, or the tumor may share in the characteristics of both, and then we very properly make use of the term *adeno-carcinoma* or *carcino-adenoma*.

### I. ADENOMA.

The structure of the cellular elements of these tumors, and their arrangement into acini and ducts, vary even more than do those of the normal glands whose types they follow. The acini usually possess a more or less well-defined lumen and membrana propria (see Fig. 146). The adenomata sometimes merge into the surrounding tissue, or are continuous with the gland tissue in which they originate; sometimes they are distinct in outline and encapsulated. The interstitial tissue is sometimes abundant, sometimes sparse, and may contain few or many cells. The irregularities of their growth

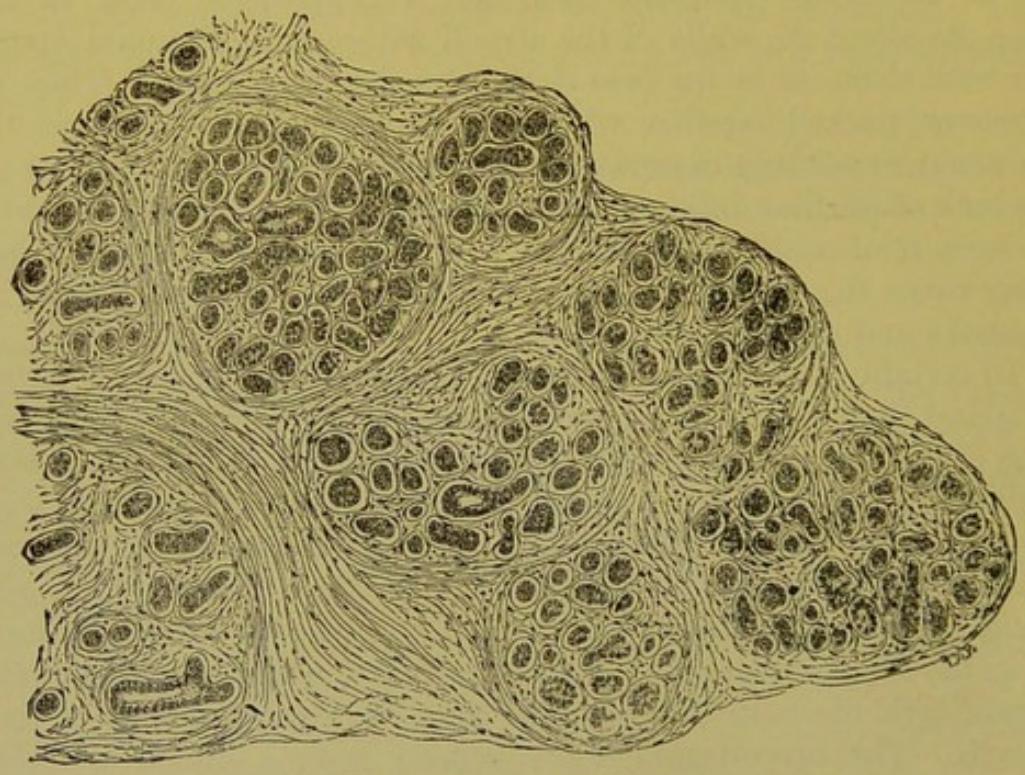

FIG. 146.—ADENOMA OF MAMMA.

often lead to the stoppage of the lumina of their ducts and the formation of cysts. They may undergo mucous metamorphosis and may become sarcomatous.

Adenomata occur in the mamma, ovary, liver, kidney, thyroid, salivary, and lachrymal glands, and in the caruncle; in the mucous membrane of the nose, pharynx, stomach, intestine, and uterus; and occasionally in the sebaceous and sweat glands of the skin. The so-called multilocular cystomata of the ovary are among the most important of the adenomata. There are numerous papillary and polypoid growths, in gland ducts and on mucous membranes, in which there is an actual new formation of gland epithelium; but this is usually secondary to a primary growth, beneath the epithelial layer, of

some other tissue, such as fibrous or mucous tissue, and the new growth of gland epithelium simply keeps pace with the growth of the latter, to which it serves as an investment. Such growths are sometimes classed among the adenomata, but do not, strictly speaking, belong there.

The adenomata are in general benign tumors, being slow of growth and localized, but there are very important exceptions. Some of the adenomata of the stomach and intestines belong to the most malignant of tumors in rapidity of local extension, in the formation of metastases, and the development of cachexia. Certain of the adenomata of the mamma and thyroid are also very malignant. It should be remarked, however, that, as a rule, the malignant adenomata are those which, in structure, lie close upon the border line

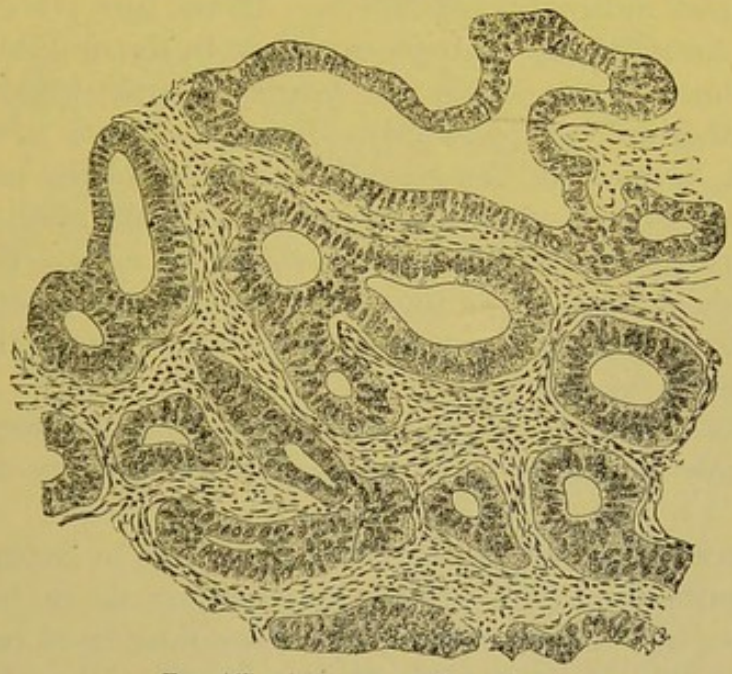

FIG. 147.—ADENOMA OF STOMACH.
A form which is on the border line of carcinoma.

between tumors of this class and carcinomata (see Fig. 147), and by such observers as incline to lay more stress upon clinical than morphological distinctions they are usually classed among the latter.

Adenomata are not infrequently of such bizarre types that their nature is not evident without very thorough study. Some of the atypical forms lie very close to the border zone of the carcinomata.

### II. CARCINOMA.

The tumors of this highly important class are composed, as above stated, of a connective-tissue stroma, forming more or less well-defined communicating spaces or alveoli, in which lie variously shaped epithelial cells arranged in an atypical manner. The stroma,

containing few or many cells, may be, especially in the advancing portions of the tumor, composed largely of the old connective tissue of the part. It may, however, be entirely new formed. The cells which lie in the spaces or alveoli bear sometimes a very close, sometimes but a very general resemblance to epithelium.

It was formerly believed that new epithelium might be formed, both from old epithelial cells and from the connective-tissue cells, and possibly from white blood cells, and among many observers this belief still exists and has never been disproved. Still, within the last twenty years the opinion that new epithelial cells in tumors arise exclusively from old epithelium has found general acceptance, and for very good reasons. No one has actually seen an epithelial cell originate under the microscope, and until this can be done our beliefs must rest upon indirect observations. In the first place, all the epithelial structures in the embryo originate in the archiblastic layers, that is, in those layers which are largely characterized by the presence of epithelium (see page 294). In regeneration after an injury in the adult, a study of the successive phases of the process shows that new epithelium is always formed in continuity with the old, and apparently by a proliferation of old epithelial cells. Epithelial tumors are almost exclusively found in parts normally containing epithelium, and frequently the new growth can be distinctly seen to be continuous with the old cells.

Finally, the observations on mitosis have greatly strengthened the view that new epithelial cells in tumors are always derived from the old.

The occurrence of primary epithelial tumors in parts of the body in which epithelium does not normally occur, as in bone and the lymph nodes, has been recorded; but these may have been metastatic tumors, in which the primary tumor was small and overlooked, or they may have been displaced embryonic germs, which, according to Cohnheim's hypothesis (see page 290), would explain their heterologous occurrence. These possibilities of error should be taken into the account in the apparently exceptional cases, and it is to be remarked that these are becoming less and less as our knowledge increases and our technical facilities for research improve.

A considerable number of the tumors formerly described as heterologous primary carcinomata are now known to be formed by proliferation of endothelium, and hence to belong to another class—endothelioma—although sometimes considerably resembling the carcinomata in structure.

The occurrence of primary carcinoma of the peritoneum, pleura, and pericardium, which is not infrequent, was for a long time inexplicable, and seemed wholly inconsistent with the belief that all car-

cinomata originate in epithelial cells. Because it was, and to a large extent still is, believed that the flat cells lining these great body cavities are true endothelium, and closely related in origin, as they are in structure, to the genuine endothelium of the blood and lymph vessels, etc.

But recent embryological researches have shown that this belief is not well founded. It was formerly thought that the great serous cavities were large lymph vessels formed by the splitting apart of the connective-tissue layers of the mesoblast. But we now know that the great primitive body cavity, which after a time becomes divided into the pleural, pericardial, and peritoneal sacs, is originally

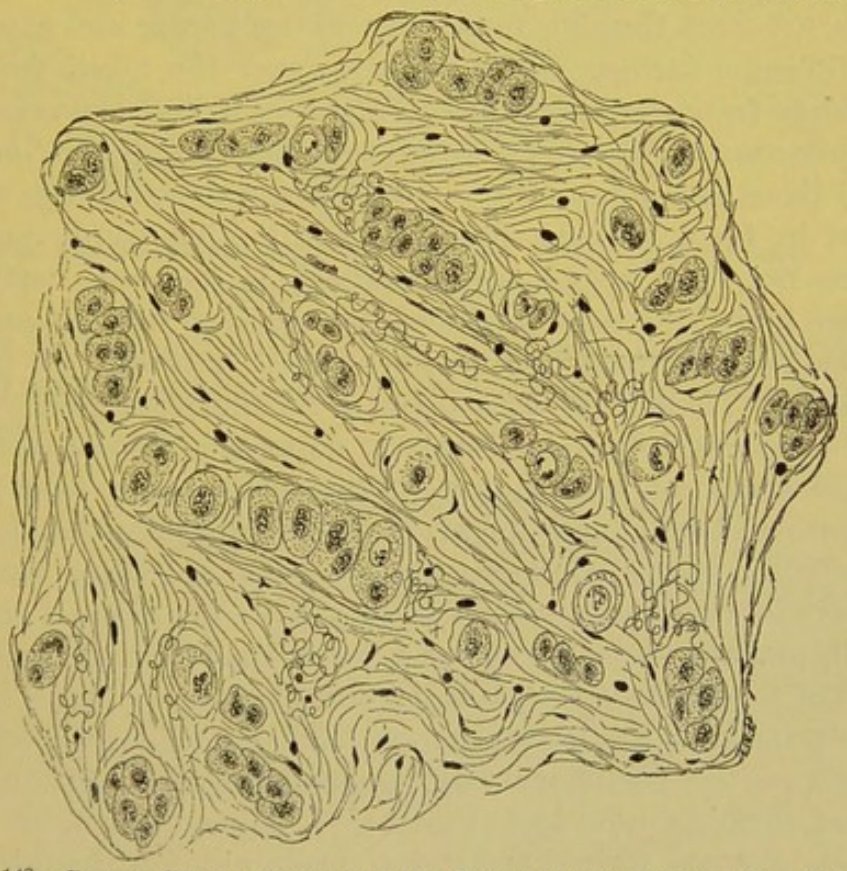

FIG. 148.—CANCER CELLS INFILTRATING THE TISSUE IN THE VICINITY OF A TUMOR.
From carcinoma mammæ.

an outgrowth from the alimentary canal. The epithelium of the alimentary canal, however, is of archiblastic origin, while the connective tissue, blood and lymph vessels are developed later from the parablast. Genetically, therefore, the so-called endothelial cells lining the pleural, pericardial, and peritoneal cavities are of archiblastic origin and belong among the epithelium. Thus a fuller knowledge of the histogenesis of the cells lining the great body cavities has shown us that the occurrence of primary carcinoma in these cavities is not only not in contradiction with the principle of the epithelial origin of carcinoma, but strongly confirmatory of it.

A great practical difficulty in the description, and, to beginners, in the recognition, of the carcinomata and their varieties, lies in the great diversity in shape which their cells present. It should be always borne in mind that the shape of cells depends in part upon their inherited tendencies in growth, which we cannot see under the microscope; but to a greater degree upon the varying conditions of nutriment and pressure to which they are exposed during life. In the normal body these conditions conform to a certain standard, so that cells of a given kind at a given stage of development are approximately similar.

In tumors, however, the lawlessness and lack of fixed conditions in growth are such that we may have many young and atypical so-called indifferent forms of cells; while even the adult forms may depart widely from normal shapes. Thus, in cylindrical-celled carcinomata there are many fully developed cells which are never cylindrical; there are many others not fully developed which are quite indifferent in form, looking just like many other young cells—cells which are not, but which are destined to become, epithelium. Finally, we have the cells produced by ordinary inflammatory processes about and within the tumor, which acts like an irritating foreign body. Thus it is that there is no morphologically characteristic "cancer cell," as was formerly supposed. Some of them are typical and some not, and the more typical ones may look just like normal epithelial cells, and the atypical ones just like simple inflammatory cells, or young connective-tissue cells, or white blood cells. It is always in the topography, together with the general characters of the cells and the situation of the growth, that we must seek for the evidences of the nature of a given tumor.

The carcinomata are very prone to local extension, the advancing tumor cells in the periphery making their way through the lymph spaces and forming new foci (Fig. 148). Metastasis is of frequent occurrence in some forms, and takes place chiefly, though not exclusively, through the lymph vessels, frequently involving adjacent or remote lymph nodes. The growth of the tumor cells in the lymph vessels, either in the immediate vicinity of the original tumor or following metastasis in a distant part of the body, may cause these to become distended, and, on free surfaces like the pleura and peritoneum, to form a whitish, elevated network. Transverse sections of such distended lymph vessels are shown in Fig. 149. The secondary tumors are in the main similar in general structure to the primary foci, but may differ from them in vascularity and the abundance of the stroma, or in the shape of the cells. The carcinomata are, as a rule, malignant tumors, but the different forms vary much in this respect. They are liable to fatty, colloid, mucous, and amyloid de-

generation, and are especially prone to ulceration, to hæmorrhage,

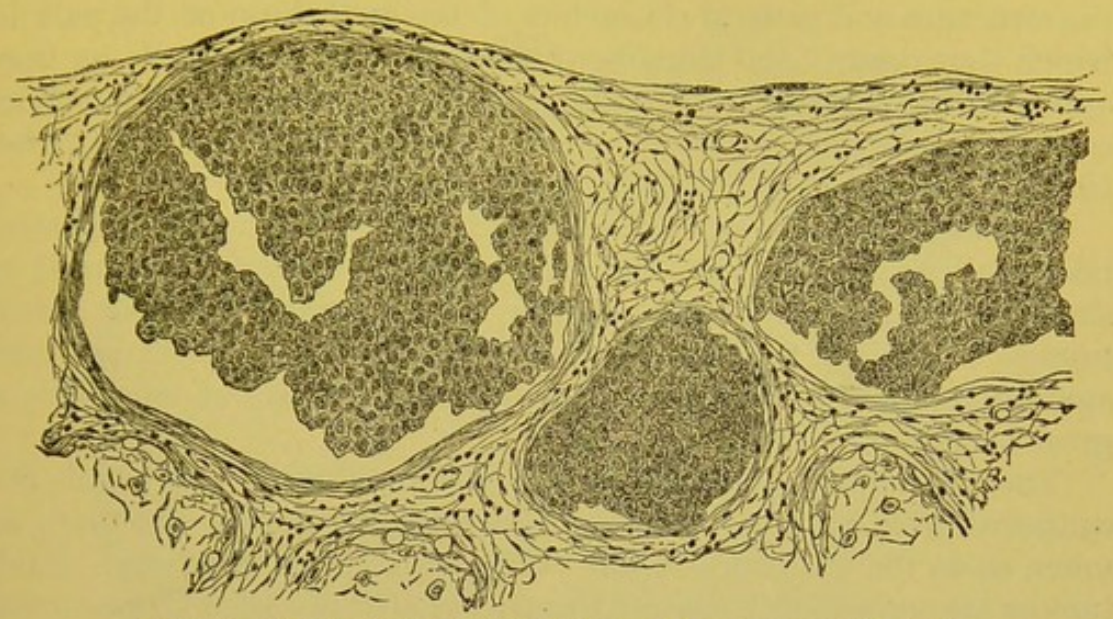

FIG. 149.—METASTATIC CARCINOMA IN LYMPH VESSELS OF THE PLEURA.
(The primary tumor was in the liver.)

and simple inflammation (Fig. 150). They may become partially calcified, and are not infrequently combined with other forms of tissue in the mixed tumors.



FIG. 150.—INFLAMMATION IN CARCINOMA.
Showing pus cells in the stroma and in the epithelium.

They are more frequent in middle and old age than in the young, but they may occur at any age.

*Forms of Carcinoma.*—In certain cases of carcinoma which occur in the skin and in some mucous membranes, the cells present the structure and general characters of the epithelium of the part in which they occur; and since here the tendency of the cells as they approach the surface is to become flattened or squamous, these tumors are called *Squamous* or *Flat-celled Carcinomata*, or simply *Epitheliomata.*

In another class of tumors, such as frequently occur in the gastro-intestinal canal and uterus, the cells are more or less cylindrical in shape, forming a palisade-like lining to the irregular alveoli; such tumors are called *Cylindrical-celled Carcinomata*, although here again many of the cells are not cylindrical at all, but may have a great variety of forms.

There is a third and very common form of tumor, in which the epithelial cells have no constant characteristic shape, but vary as much as do the cell forms in the various glands of the body. Such tumors are conveniently classed together as *Gland-celled Carcinoma*, or *Carcinoma simplex.*

In addition to these forms there are several others which depend for their characteristics upon various metamorphoses or degenerations, or upon the preponderance of one or other of the anatomical constituents of the growth. It will be most convenient to give a brief description of these various kinds, one after another, with the understanding that they are not absolute specific forms, but are simply varieties which it is convenient to recognize for clinical as well as anatomical purposes.

*Flat-celled Carcinoma, or Epithelioma.*—These tumors occur in the skin and in the mucous membranes which are covered with squamous epithelium. The cells present all of the various forms which normally exist in these parts—the cuboidal and polyhedral cells of the rete Malpighii, as well as the more superficial flattened forms (Fig. 151). Frequently the spined cells, or so-called "prickle cells," are largely reproduced. Having to a certain extent the same life history as the cells in which they originate, many of the tumor cells become dry, thin, and horny, like the epidermis cells, as they grow older; and since their growth and changes often occur within the old lymph spaces of the affected tissue or in the new-formed alveoli, the cells are sometimes packed together in spheroidal, concentric masses called "epithelial pearls" (Figs. 151 and 154), which may sometimes be seen with the naked eye upon or near the surface of the growth. The new cell masses may be large or small, may be separated by much or little stroma; often form reticular masses, and may infiltrate the tissues deeply or remain near the surface; or may project above the surface, forming wart-like or papillary growths. These tumors

frequently ulcerate on the surface, and the skin about them is apt to become thickened (Fig. 153).



FIG. 151.—EPITHELIOMA OF THE NECK.
Shows epithelial pearls, spined cells, and reticular masses of variously shaped epithelial cells.

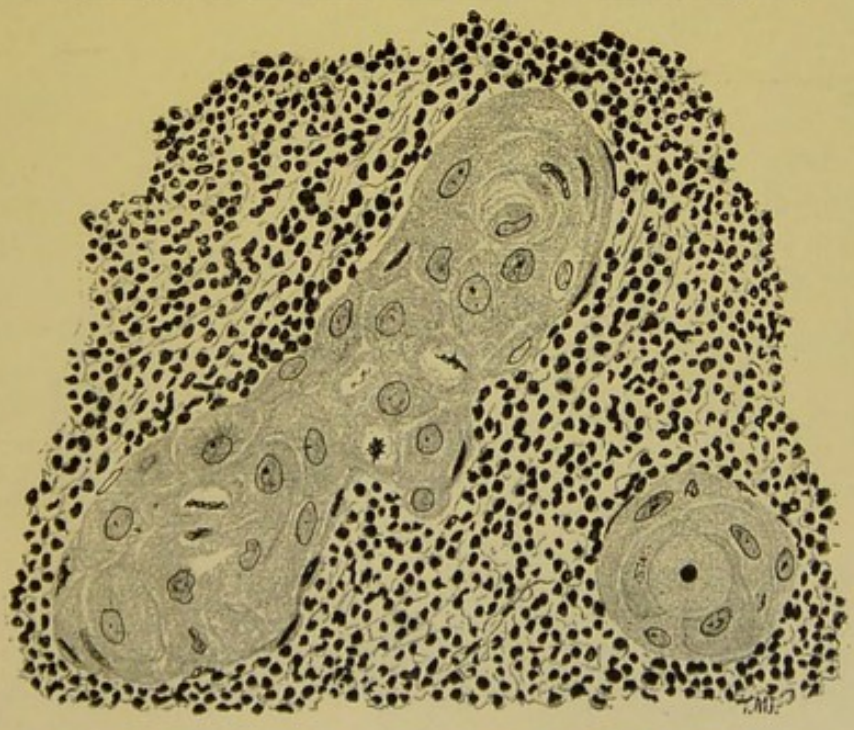

FIG. 152.—METASTATIC CARCINOMA (EPITHELIOMA) IN A LYMPH NODE.
The primary tumor was in the vagina; showing at the right a small "epithelial pearl."

They are most apt to occur in the skin, especially in those parts in which it becomes continuous with mucous membranes—lips, exter-

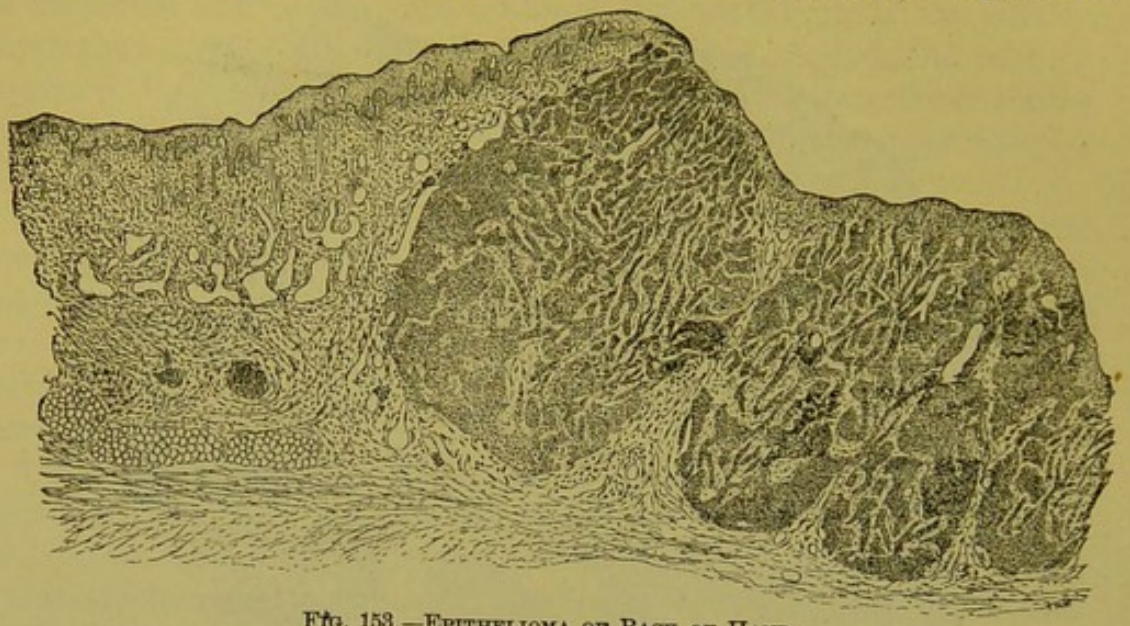

FIG. 153.—EPITHELIOMA OF BACK OF HAND.

The flat tumor occupied nearly the entire back of the hand, and was ulcerating at the centre. The figure shows the edge of the tumor and a portion of the ulcer. The papillæ of the skin over the edge of the growth are hypertrophied, and the tissue about infiltrated with small spheroidal cells. Fig. 154 shows a section from a metastatic tumor of the axillary lymph node in this case.

nal nasal openings, eyelids, labia, and glans penis—and are frequent in the mouth, œsophagus, vagina, and about the cervix uteri.

There are also carcinomata of the skin, composed of cuboidal cells

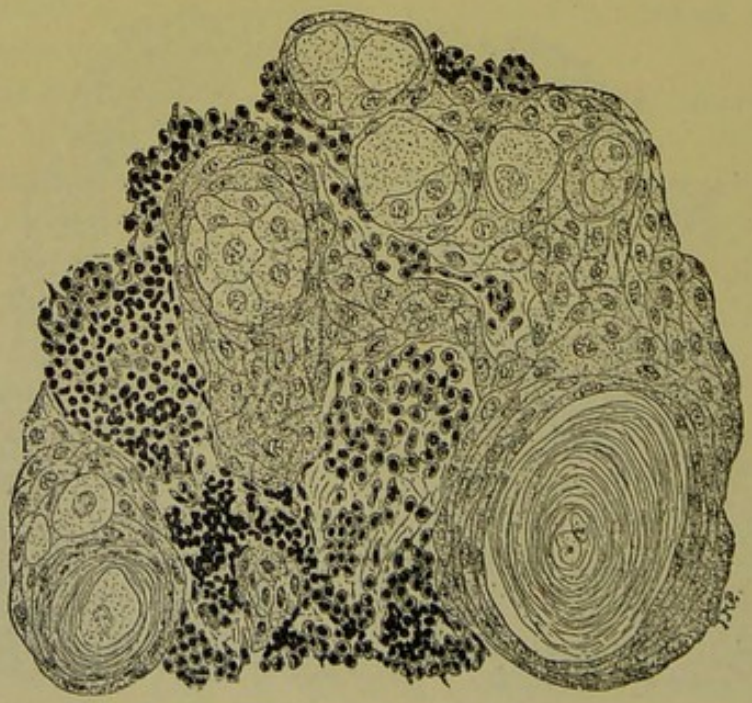

FIG. 154.—EPITHELIOMA OF AXILLARY LYMPH NODE.

This metastatic tumor was secondary to a large epithelioma of the back of the hand, Fig. 153. The small cells with darker nuclei are the cells of the lymph node. It shows the epithelial pearls.

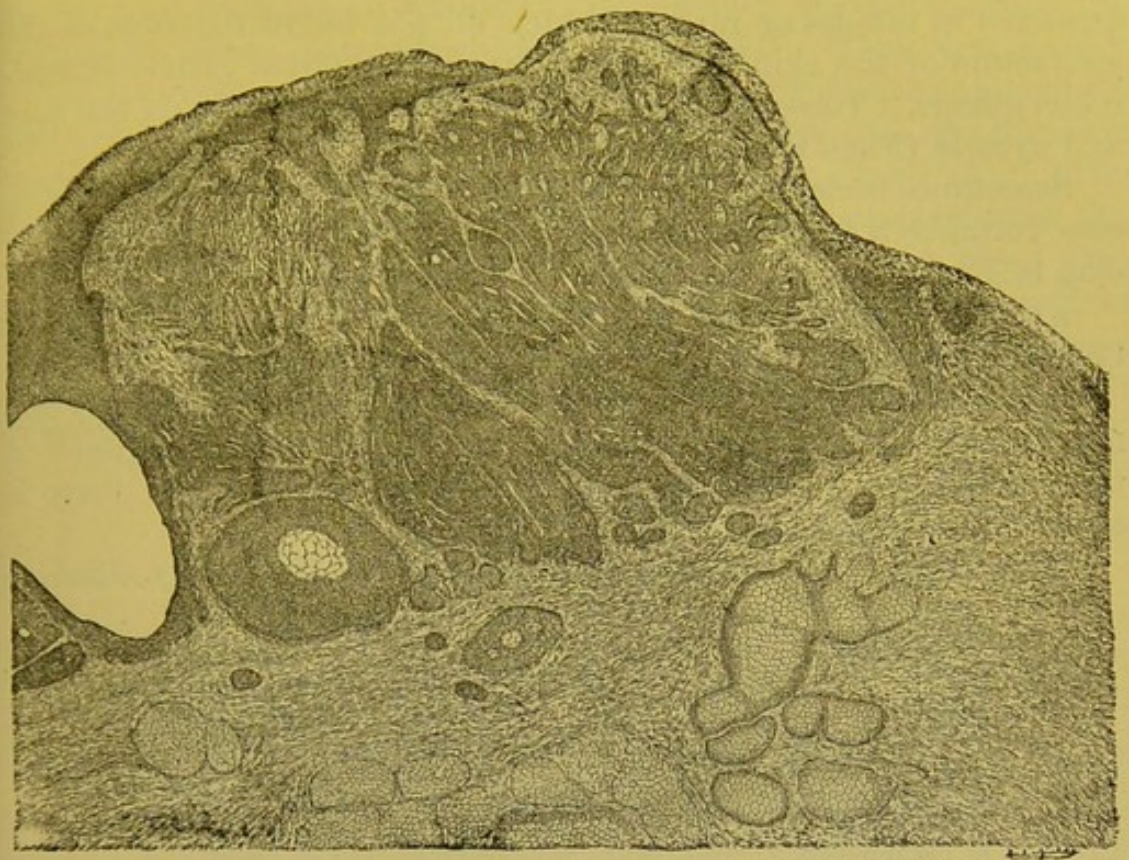

FIG. 155.—SECTION OF A PORTION OF A SMALL EPITHELIOMA OF THE SIDE OF THE NOSE. LOW power.

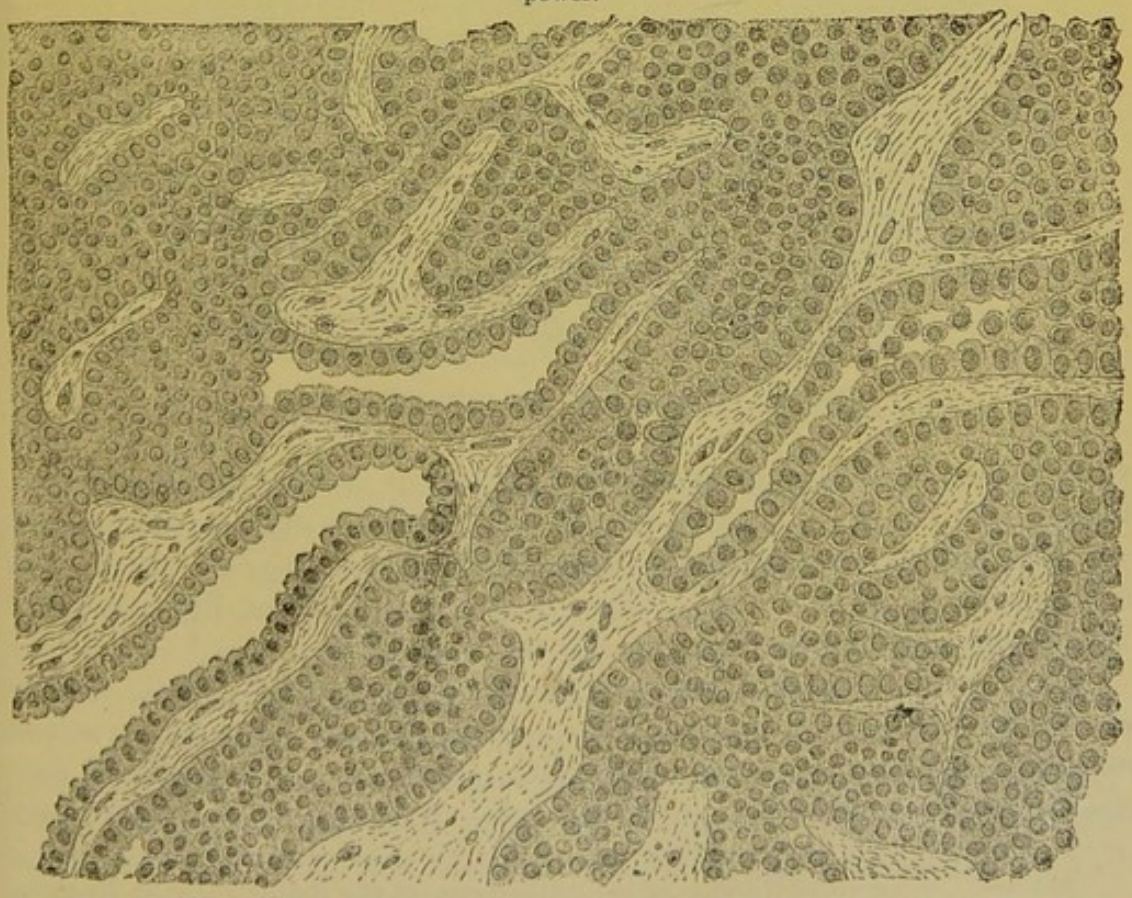

FIG. 156.—EPITHELIOMA OF NOSE.
A portion of the tumor shown in Fig. 155 more highly magnified.

arranged in tubules or masses, which do not follow the type of the epithelium of the skin, but rather that of the sweat glands or sebaceous glands. These tumors are found most frequently on the nose and eyelids (Figs. 155 and 156).

Sometimes certain of the cells in an epithelioma appear to coalesce, forming a large multinuclear mass. This variety of epithelioma is sometimes called *giant-celled epithelioma.*

Flexner[1] has described a rare tumor arising from the epithelial layers of the retina, which he calls a *neuro-epithelioma.*

Epitheliomata are apt to recur if not thoroughly removed, and may form metastases, but in general they are the least malignant of the carcinomata. The prognosis is in most cases good if there is early and complete removal.

*Cylindrical-celled Carcinoma.*—These tumors, closely allied to



FIG. 157.—CARCINOMA MAMMÆ (Scirrhus variety).

some forms of adenoma (see Fig. 147), occur in the stomach, intestines, and uterus. The cells may be only in part cylindrical, the remainder having various shapes, and all being loosely or closely packed in larger or smaller alveoli. They may have much or little stroma. They merge imperceptibly into the next class :

*Gland-celled Carcinoma, or Carcinoma simplex.*—These, which are by far the most frequent of the carcinomata of internal parts, are characterized by the alveolar structure and by the absence of any special characteristic shape in the cells, which may be spheroidal,

[1] *Flexner*, "A Peculiar Glioma (neuro-epithelioma) of the Retina," Johns Hopkins Hospital Bulletin, August, 1891.

polyhedral, fusiform, or cuboidal. They may or may not resemble the epithelium of the gland in which they originate. They are usually nodular tumors, and may be hard or soft. If the stroma is abundant and dense, and preponderates over the cellular elements, the tumor is usually hard and is called *scirrhus* or *fibro-carcinoma* (Fig. 157). If, on the other hand, the cellular elements largely preponderate, the tumor is usually soft, and, if it do not contain too many blood vessels, may have a general resemblance to brain tissue, and is then called *encephaloid* or *medullary cancer;* or, better, *Carcinoma molle* (Fig. 158). These are among the most malignant of the carcinomata.

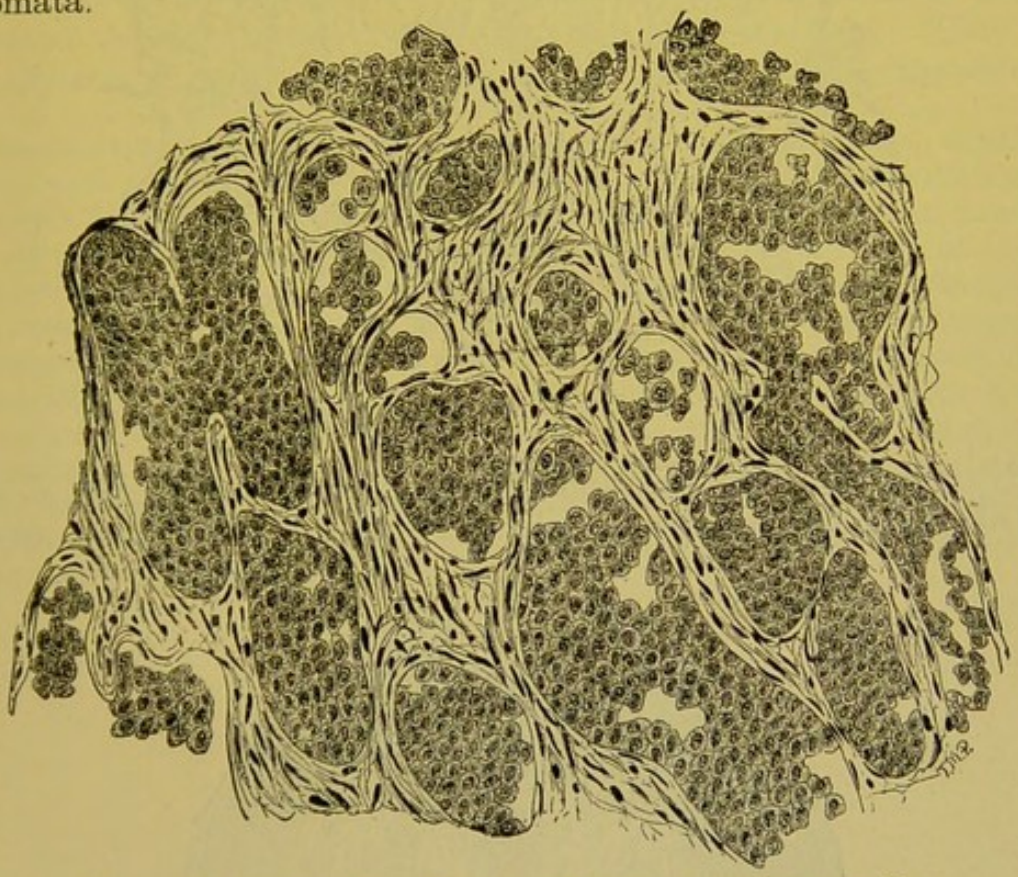

FIG. 158.—MEDULLARY CARCINOMA OF THE STOMACH (Carcinoma molle).

The intercellular tissue in these carcinomata may become so abundant as to nearly obliterate the cellular elements, but it is doubtful if they ever undergo spontaneous cure in this way. These tumors may be hard in one portion and soft in another. They may contain very many blood vessels, *C. telangiectoides.* They occur as primary tumors in the mamma, liver, thyroid, salivary, and prostate glands, in the pancreas, kidney, testicle, and ovary.

*Colloid Carcinoma.*—The cells of certain carcinomata, especially of the gastro-intestinal canal, may suffer a more or less complete infiltration with a translucent material somewhat resembling gelatin and called colloid, whose nature is not well understood. Sometimes this

infiltration is only partial, when the protoplasm of the cells may be more or less encroached upon by the translucent droplets of the colloid material; but in other cases, over large areas the cells are par-



FIG. 159.—COLLOID CARCINOMA OF RECTUM.

tially or entirely destroyed, and replaced by the new material, so that the alveoli of the tumor are distended by it, and their walls appear

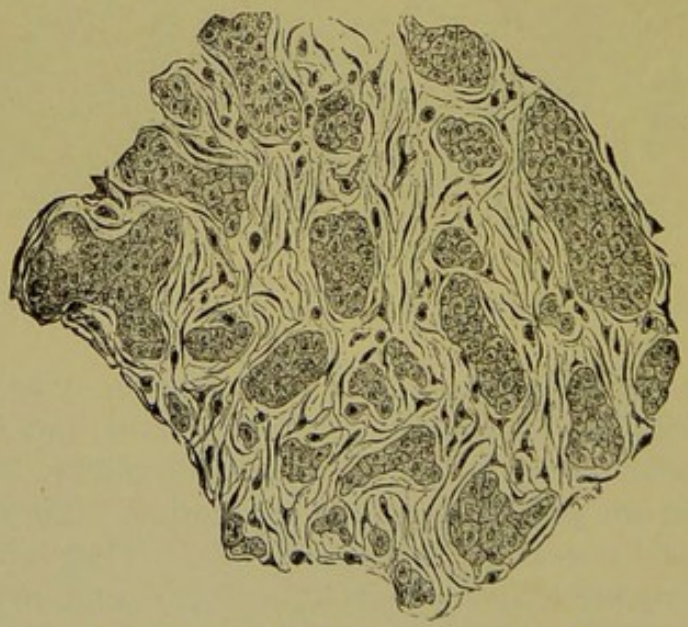

FIG. 160.—CARCINOMA MYXOMATODES MAMMÆ.

very distinct in the midst of the colloid substance (Fig. 159). In such cases the alveolar structure of the tumor is sometimes very evident to the naked eye, and these tumors are therefore often called *alveolar*

*carcinoma.* Sometimes only a part of the tumor is affected in this way.

*Carcinoma myxomatodes.*—The cellular elements of carcinomata may suffer mucous softening, and thus larger and smaller cysts containing a mucous fluid are sometimes formed. To this form of metamorphosed tumor the above name is sometimes applied, but it more properly belongs to carcinomata in which the stroma is composed of mucous tissue (Fig. 160). Such tumors are most frequently found in the gastro-intestinal canal and mamma.

*Melano-Carcinoma.*—Tumors of this class are rare, and are characterized by the presence of a variable quantity of black or brown pigment particles either in the stroma or in the cells. They are usually soft and malignant, and most frequently occur in the skin.[1]

---

[1] *Bibliography.*—The most extensive and important work on tumors, containing a vast store of information, is that of *Rudolph Virchow*, "Die krankhafte Geschwülste." It is not completed and is somewhat old, but is still invaluable as a work of reference. The section on tumors in Von Pitha and Billroth's work on surgery ("Handbuch der allgemeinen u. speciellen Chirurgie"), which comprises the first section of the second volume, by *Dr. Lücke*, is very complete. A valuable bibliography and digest of recent observations on tumors will be found in the last edition of *Birch-Hirschfeld's* work on pathological anatomy ("Lehrbuch der pathologischen Anatomie"), vol. i.; also in *Ziegler's* "Lehrbuch der path. Anat.," Band i., 7th ed., 1892. An important résumé on the Malignant Tumors in Childhood, by *Stern*, may be found in the Deutsche med. Wochenschrift, June 2d, 1892, p. 494. "An Introduction to General Pathology," by *Sutton*, contains many suggestive facts about tumors drawn from comparative pathology.

# PART III.

## PATHOLOGICAL ANATOMY AND HISTOLOGY OF THE ORGANS.

# THE NERVOUS SYSTEM.

## THE MEMBRANES OF THE BRAIN.

### THE DURA MATER.

The dura mater is a dense connective-tissue membrane which serves the double purpose of a periosteum for the inner surface of the cranial bones, and of an investing membrane for the brain. It is itself but poorly supplied with blood vessels, but it contains the large venous sinuses which carry the blood from the brain. Lesions of the dura mater, therefore, are apt to be associated with lesions of the cranial bones, of the pia mater, or of the venous sinuses.

In young children the dura mater adheres closely to the inner surface of the cranial bones, in adults it is more readily detached, and in old persons it is again more adherent. Chronic inflammation of the external layers of the dura mater also renders it more adherent to the bones.

#### HÆMORRHAGES.

We find extravasations of blood between the dura mater and the cranial bones, in the substance of the membrane, and between the dura mater and the pia mater.

The hæmorrhages in the substance of the dura mater are usually small and of little consequence.

The hæmorrhages between the dura mater and the pia mater occur with chronic pachymeningitis, or are derived from the vessels of the pia mater.

The hæmorrhages between the dura mater and the cranial bones are produced by blows and injuries of the head. They are often of considerable size, separate the membrane from the bones, and may compress the brain. They are often associated with laceration of the brain, and hæmorrhages between the dura mater and pia mater.

The pressure on the head of the infant in labor may produce, in addition to the extravasations of blood between the bones and the pericranium, additional extravasation between the bones and the dura mater.

### THROMBOSIS.

*Thrombosis of the venous sinuses* is not uncommon. Any inflammation of the dura mater is liable to produce it; injuries and inflammations of the brain and pia mater, of the cranial bones, of the middle ear, and of the scalp may also produce thrombosis. The changes in the blood produced by the exhausting and infectious diseases may induce thrombosis of the venous sinuses, as they do of the veins in other parts of the body. There are also rare cases in which such a thrombosis is developed without discoverable cause in persons previously healthy, and produces marked symptoms and death.

Some of these thrombi are firm, of white or red color, and apparently produce no secondary lesions.

Others are of firm consistence, but they produce softening with small hæmorrhages of portions of the brain. In these cases the thrombus extends from the venous sinus into one of its veins, and the portion of brain belonging to this vein is softened and hæmorrhagic. Such a softening of the brain is often attended with inflammation of the pia mater.

In other cases the thrombi are soft and puriform; fragments of them become detached and lodge as infectious emboli in the arteries in different parts of the body.

### INFLAMMATION.

*Inflammation* of the dura mater is called *pachymeningitis*, and this may involve the external layers of the membrane, *pachymeningitis externa*, or the internal layers, *pachymeningitis interna*. It may furthermore be either acute or chronic. The tissues of the substance of the dura mater participate to a greater or less degree in these changes, but the chief lesions are upon the surfaces.

Acute *pachymeningitis externa* is usually secondary to injuries or diseases of the cranial bones; thus fractures of the skull, either depressed or not, ostitis, caries, suppurative inflammation of the internal and middle ear and mastoid cells, may produce it. The dura mater is usually congested, thickened, and softened, and may present small ecchymoses. The inflammation is usually suppurative, and pus may accumulate between the membrane and the bone, or in the substance of the membrane. The areas of inflammation are not usually extensive. It sometimes induces thrombosis of the venous sinuses, and sometimes gangrene of the dura mater occurs. The inflammation may extend to the inner surface of the dura mater, to the pia mater and brain, or it may remain localized and undergo resolution.

Acute *pachymeningitis interna* may be secondary to inflamma-

tion of the external surface, or it may occur as a complication in pyæmia, puerperal fever, chronic diffuse nephritis, in the exanthemata and erysipelas, or idiopathically. There is a general or circumscribed production of fibrin and pus, so that the internal surface of the membrane is lined with a layer of soft, yellow exudation.

Simple *chronic pachymeningitis* consists in the formation of new connective tissue in the dura mater, by which it becomes thicker and in many cases abnormally adherent to the bones of the skull. This thickening may be general or circumscribed, and may involve the entire thickness of the membrane. Not infrequently, when the external layers are especially involved, firm adhesions to the skull occur, with ossification of the outer layers, so that shreds of the membrane containing little masses of bone (osteophytes) remain sticking to the skull when the membrane is stripped off.

There is an important form of chronic inflammation of the internal layer of the dura mater, called *pachymeningitis interna hæmorrhagica*, characterized by the formation of layers of new delicate connective tissue with numerous very thin-walled blood vessels from which the blood is prone to escape. The membrane may at first appear as a delicate fibrinous pellicle, with small red spots scattered through it, or it may look like a simple reddish or brown staining of the inner surface of the dura mater. Microscopical examination shows this membrane to consist of numerous blood vessels, mostly capillaries with very thin walls, which may be distended or pouched, and which have grown out from the vessels of the dura mater (Fig. 161). Between the vessels is a homogeneous or slightly differentiated basement substance, containing a variable number of spheroidal, fusiform, or branching cells. Red blood cells in variable quantity, and blood pigment in various forms, frequently enclosed in the new cells, and small calcareous concretions (brain sand) (Fig. 162), also lie in the intervascular spaces. In more advanced stages the new membrane may become greatly thickened, its outermost layers being changed into dense fibrous tissue with obliteration of the vessels; while the more recently formed layers are similar in structure to those at first developed. Considerable blood usually escapes from the vessels of the new membrane by diapedesis, in all stages of its formation, and the vessels are also very liable to rupture, giving rise to extensive hæmorrhages either into the substance of the membrane or between it and the pia mater. Sometimes masses of new tissue and blood, from half an inch to an inch or more in thickness, are in this way formed, greatly compressing the brain. These new membranes are most frequently formed over the convexity of the brain, but may extend over nearly the entire surface of the dura mater. Sometimes, when old, the entire membrane, densely pigmented and

firm, lies loosely beneath the dura mater without compressing the brain or giving any clinical indication of its presence. The membrane may induce chronic changes in the pia mater, with or without accompanying changes in the cortical portion of the brain.



FIG. 161.—CHRONIC PACHYMENINGITIS INTERNA HÆMORRHAGICA.

Rarely, serum accumulates between the layers of the new membrane, and in this way cysts of large size may be formed. In rare cases diffuse suppuration of the entire new membrane occurs.



FIG. 162.—BRAIN SAND FROM PACHYMENINGITIS INTERNA.

The slighter degrees of this form of inflammation may occasion no symptoms during life. They are not infrequently found in persons suffering from various chronic brain lesions and from chronic alcoholism, but they may occur unassociated with complicating lesions.

The more advanced forms of the lesion are frequently found in idiots, epileptics, etc.

*Tuberculous pachymeningitis* may occur secondarily to that form of inflammation in the pia mater or the bones, or as a part of general miliary tuberculosis. The tubercles may be situated on either surface of the membrane or in its substance, and may be single or aggregated, forming large masses.

*Syphilitic pachymeningitis* manifests itself by the formation of so-called gummy tumors upon either the external or internal surface of the dura mater. These tumors may be single or multiple, and vary greatly in size. They may be accompanied by simple inflammatory changes in the dura mater in their vicinity. They may undergo suppuration with the formation of abscess; the inflammation may extend to the pia mater, inducing simple or syphilitic meningitis and adhesions between the dura mater and pia mater. The gummata may, on the other hand, when occurring on the outer surface of the membrane, cause absorption and perforation of the bones of the skull.

### TUMORS.

The most common tumors of the dura mater are *sarcomata*, and of these the spindle-celled forms are of more, the round- and polyhedral-celled of less frequent occurrence. They may grow from either surface of the membrane. Some of the round- and polyhedral-celled forms are soft and very vascular, and are apt to involve the neighboring pia mater and brain tissue, or the bones of the skull, which they may perforate. They sometimes project through the opening in the skull in fungous, bleeding masses.

*Psammomata* are small globular tumors, often multiple and pediculated, growing from the inner surface of the dura mater. They are usually composed of tissue sarcomatous in character, and contain variously shaped calcareous concretions similar in appearance to the so-called brain sand.[1]

*Endotheliomata.*[2]—These tumors may grow inward or outward, causing pressure on the brain or absorption and perforation of the bones; they often attain considerable size. Some of these tumors somewhat resemble certain forms of epitheliomata (see Fig. 116), and have often been described as primary carcinomata.

*Fibromata* and *Lipomata* occur rarely in the dura mater and are of small size.

---

[1] For a study of psammoma consult *Ernst*, "Ueber Psammoma," in Ziegler's Beiträge zur path. Anatomie, Bd. xi., page 234, 1892.

[2] For a consideration of tumors of the dura mater allied to the endotheliomata consult *Dogonet*, Arch. de Méd. Exp., May 1st, 1892.

Small *Chondromata* are sometimes found connected with the dura mater at the base of the brain.

*Osteomata.*—In addition to the formation of osteophytes in chronic external pachymeningitis, plates and, more rarely, globular masses of bone may be formed in the dura mater, unconnected with the bones of the skull. They are most frequently found in the falx cerebri, but may occur elsewhere. The new bone may be dense or loose in texture, and usually produces no symptoms.

## THE PIA MATER.

The external surface of the brain is invested by a connective-tissue membrane which covers the convolutions, dips down into the sulci, and extends into the ventricles. This membrane is abundantly supplied with blood vessels, and from it numerous vessels extend into the brain, so that any disturbance in the circulation of the blood in the pia mater involves a disturbance in the circulation of the blood in the brain also.

The connective tissue which makes up the pia mater is arranged in a series of membranes and fibres reinforced by elastic tissue, so arranged as to form a spongy membrane containing numerous cavities more or less filled with fluid. These cavities are continuous with the perivascular spaces which surround the vessels that pass from the pia mater into the brain.

The outer layers of the pia mater are the most compact, and are covered on their outer surface by a continuous layer of endothelial cells. This external layer of the pia mater is often described as a separate membrane called the "arachnoid," but it is really only part of the pia.

The deeper layers of the pia contain the blood vessels. The membranes and fibres which compose the pia mater are partly coated with cells which have irregular and delicate cell bodies and large, distinct nuclei.

In all inflammations of the pia mater the inflammatory products regularly collect in the spaces within it.

Along the borders of the longitudinal fissure, and, more rarely, on the under surface of the brain, are a number of small, white, firm, irregular bodies—the Pacchionian bodies. They vary in their size, their number, and in the extent of the surface of the hemispheres which they cover. They may perforate the dura mater, or, more rarely, the wall of the longitudinal sinus, and may produce erosions of the skull bones. They are composed of fibrous tissue and may undergo fatty or calcareous degeneration. As they are so commonly found and are not known to be of any pathological significance, they

may almost be regarded as normal structures; at any rate, we do not know what causes them or their variations in size and number.

The pia mater is frequently thickened, opaque, and white, either in diffuse patches or, more commonly, along the course of the vessels. In other cases single or multiple small white spots, of the size of a pin's head or smaller, may be seen in the membrane, not appreciably elevated above the surface, but due to localized thickening. These slight opacities of the pia mater are commonly believed to be dependent upon repeated congestions of the membrane or upon chronic meningitis, but there is no evidence that this is always the case. They are most frequently found in old persons, but may exist at any age, and do not necessarily indicate the pre-existence of disease, although similar appearances are common in the chronic insane and in drunkards.

The amount of blood contained in the vessels of the pia mater after death varies greatly, and is by no means a reliable indication of the amount present during life. In general anæmia the vessels of the pia mater may contain little blood, but, on the other hand, they sometimes seem to contain a relatively larger amount than other parts of the body. In œdema of the brain and pia mater the vessels of the latter may contain but a small amount of blood.

### ŒDEMA.

The quantity of serum beneath the pia mater and infiltrating its tissue is very variable in amount. It may accumulate as a result of atrophy of the brain substance or of venous hyperæmia, and sometimes is, and sometimes is not, accompanied by œdema of the brain substance. It may be diffuse or localized. It is not infrequent to find in hospital patients suffering from chronic nephritis, cardiac or pulmonary disease, or chronic alcoholism, a very considerable amount of serum in this situation, and yet the patient has been free from cerebral symptoms. In other cases, again, a serous effusion may accompany grave cerebral symptoms. It is necessary to be very careful in judging of the importance of this accumulation of fluid, especially in determining the cause of death in the absence of other marked lesions (see page 373).

It should always be borne in mind that an accumulation of fluid beneath and in the meshes of the pia mater may occur as a result of post-mortem changes.

### HYPERÆMIA AND HÆMORRHAGE.

The pia mater may be *hyperæmic* in early stages of meningitis, after death from delirium tremens or following epileptic convul-

sions, from various infectious diseases, certain poisons, the presence of tumors or exudations pressing on the veins, as well as from general and local diseases of the circulatory apparatus. But whether they are overfilled or comparatively empty after death seems to depend upon the position in which the body has lain, upon the time which has elapsed between death and the examination, upon the rapidity with which the blood coagulates, and upon conditions entirely unknown to us.

*Hæmorrhage.*—This may occur either into the space between the dura mater and the pia mater—*intermeningeal hæmorrhage*—or in the meshes of the pia or between the latter and the brain. It may be due to injury, to rupture of aneurisms or otherwise diseased blood vessels, to thromboses of the venous sinuses, or to causes which we are unable to ascertain. Hæmorrhages, without known cause, not infrequently occur in the substance of the pia mater in young children, but in adults they are apt to be the result of injury. Multiple ecchymoses, however, in the substance of the pia mater sometimes occur in infectious diseases and also in acute inflammation of the pia mater. Hæmorrhages in the brain substance may lead to the accumulation of blood beneath or in the meshes of the pia mater. Intermeningeal hæmorrhage in infants as a result of injury during birth is not uncommon. Small, and sometimes considerable, extravasations of blood may occur from diapedesis, and sometimes, as a result of chronic congestion, degenerated blood pigment collects along the walls of the vessels. The extravasated blood in meningeal hæmorrhage, if small in quantity, may be largely absorbed, leaving a greater or smaller accumulation of pigment at the seat of the hæmorrhage, and such pigmentations may last for a long time.

## INFLAMMATION.

Inflammation of the pia mater is called *lepto-meningitis*, or simply meningitis. We distinguish acute, chronic, tubercular, and syphilitic meningitis.

*Acute Meningitis* occurs most frequently as the characteristic lesion of epidemic cerebro-spinal meningitis; it is a not very infrequent complication of pneumonia, Bright's disease, typhus and typhoid fever, and the exanthemata; it is secondary to injuries and inflammation of the cranial bones, of the dura mater, and of the middle ear, and it is sometimes an idiopathic lesion (see page 200).

In acute meningitis the inflammation is apt to extend downward and involve the pia mater of the cord. It may also involve the ependyma of the ventricles, and cause the distention of these cavities with serum. This latter condition belongs especially to young children.

There are two anatomical varieties of acute meningitis, which give, however, the same clinical symptoms.

(1) *Acute Cellular Meningitis.*—The pia mater is congested, its surface is dry and lustreless, and it is somewhat opaque. These changes in the gross appearance of the membrane are not marked and are easily overlooked, but the minute changes are more decided. There is an abundant production of cells somewhat resembling the cells which coat the surfaces of the membranes and fibres which make up the pia mater (Fig. 163). This cell growth is

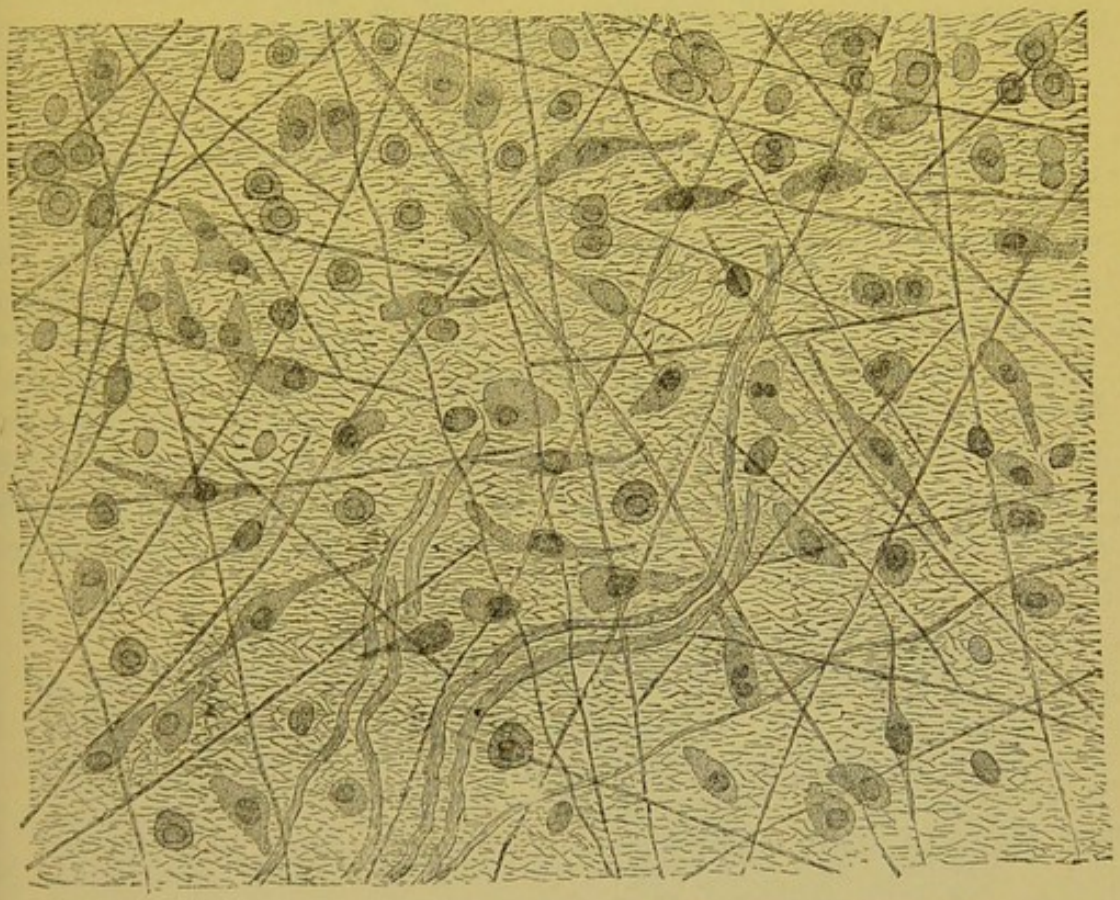

Fig. 163.—Acute Cellular Meningitis, × 850 and reduced. (Surface view.)

general, involving the pia mater over most of the surface of the brain. The inflammation, then, is one which results in the production, not of fibrin, serum, or pus, but of new connective-tissue cells. This form of meningitis is of frequent occurrence and is attended with the ordinary clinical symptoms of acute meningitis.

(2) *Acute exudative meningitis* is characterized by the accumulation, chiefly in the meshes of the pia mater and along the walls of the blood vessels, of variable quantities of serum, fibrin, and pus. Sometimes one, sometimes another of these exudations preponderates, giving rise to serous, fibrinous, or purulent forms of the inflammation. The absolute quantities, too, of the exudations vary

greatly. In some cases death may be caused with so slight a formation of exudation that to the naked eye the pia mater may look quite normal or perhaps only moderately hyperæmic or œdematous; the microscope, however, in these cases will reveal pus cells in small numbers (Fig. 164) and sometimes flakes of fibrin in the meshes and



FIG. 164.—ACUTE MENINGITIS.

Proliferation of connective tissue cells and extravasation of leucocytes in the adventitia of a small blood vessel of the pia mater.

along the walls of the vessels. In other cases turbid serum in the meshes of the membrane is all that can be seen, and the microscope shows the turbidity to be due to pus cells or a small amount of fibrin. Again, either with or without marked œdema of the pia mater, yellowish stripes are seen along the sides of the veins, sometimes appearing like faint turbid streaks, and at others dense, opaque, thick, and wide, and almost concealing the vessels. These are due to the accumulation of pus cells and fibrin in large quantities along the ves-

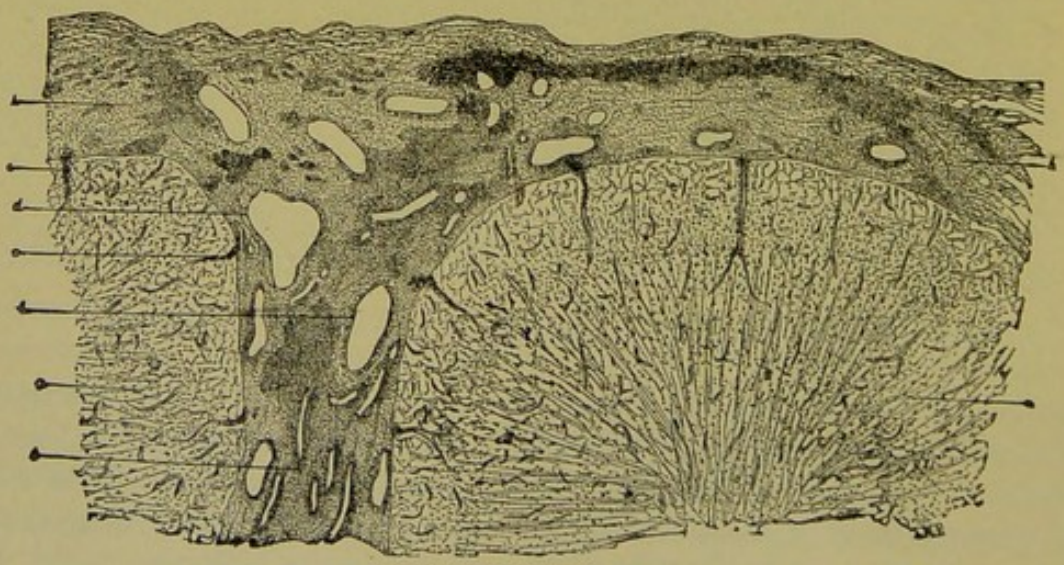

FIG. 165.—ACUTE EXUDATIVE MENINGITIS.

*a*, convolutions of cerebrum; *b*, pia mater thickly infiltrated with pus; *c*, blood vessels entering brain from pia and surrounded by a zone of pus cells; *d*, congested blood vessels of pia mater; *e*, smaller blood vessels of pia, around which pus cells are collected in dense masses.

sel, and they are best seen and most abundant around the larger veins which run along over the sulci. In still other cases the infiltration

with pus and fibrin is so dense and thick and general that the brain tissue, convolutions, and most of the vessels of the pia mater themselves are concealed by it. This is usually of a greenish-yellow color, and is sometimes so thick as to form a sort of cast of the brain surface at the seat of the lesion (Fig. 165). Sometimes extravasated red blood cells are mingled with the other exudations, as the result of diapedesis. Microscopical examination shows numerous white blood cells sticking in the walls of the veins and capillaries, or the vessels may be blocked with them. It is evident that a large part of the pus cells accumulate as the result of emigration. The connective-tissue cells of the pia mater may be detached from their places or

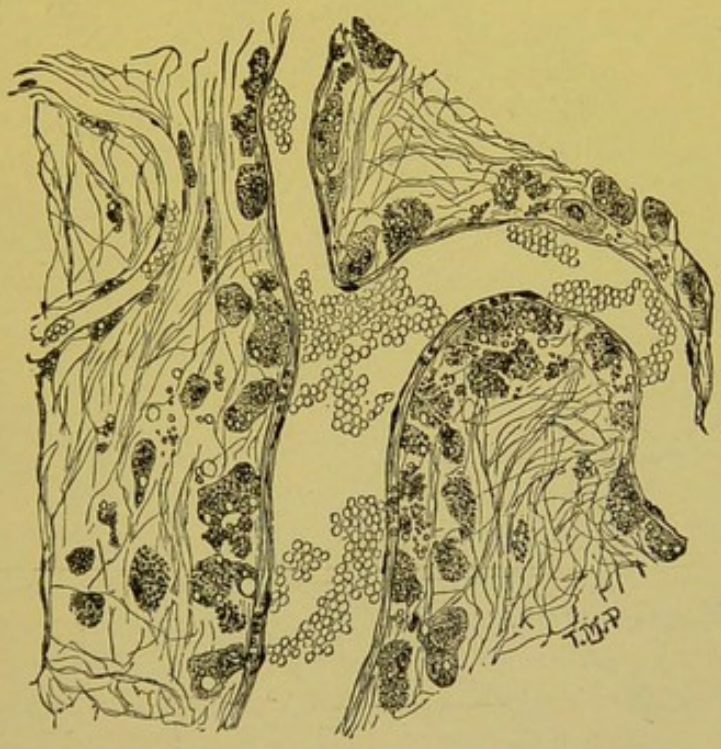

FIG. 166.—FATTY DEGENERATION OF CELLS ALONG THE BLOOD VESSELS OF THE PIA MATER AFTER EXUDATIVE MENINGITIS.

From the pia mater of a child five years old.

degenerated. In some cases there are considerable accumulations of pus between the pia mater and the brain substance and along the vessels which enter the latter. More rarely pus is found upon the free surface of the membrane. The brain substance may be compressed by the accumulated exudation, so that the convolutions are flattened. The cortical portion of the brain may be simply infiltrated with serum—œdematous—or it may undergo degenerative changes, or it may be the seat of punctate hæmorrhages. Not infrequently the inflammation extends to the ventricles, which may contain purulent serum, and to the pia mater of the cord. This form of inflammation is most frequent on the convexity of the brain, but may ex-

tend, or even be confined to the base. It may be localized, but frequently extends widely over the surfaces of the hemispheres. Bacteria are often present in the exudation. For their relationship to the lesions see Cerebro-spinal Meningitis.

When recovery from acute exudative meningitis occurs there may be fatty degeneration of the cells which have accumulated in the pia mater, particularly along the vessels (Fig. 166), and this may produce white patches in the membrane and threads along the blood vessels, which resemble the appearance of an accumulation of exuda-

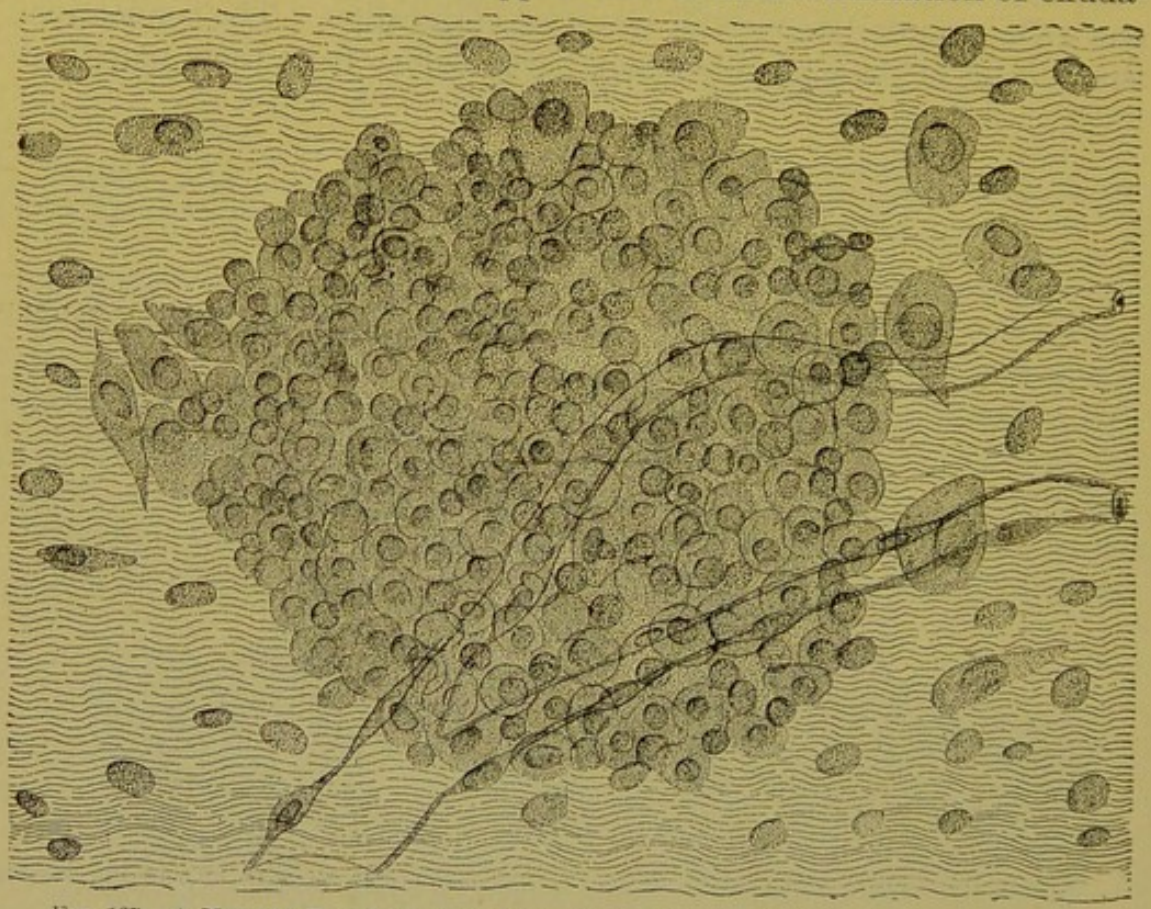

FIG. 167.—A MILIARY TUBERCLE OF THE PIA MATER, × 850 and reduced. (Surface view.) Composed of a simple aggregation of cells.

tion in the acute stage. Fatty degeneration of the blood vessels and cells of the pia mater may also occur without acute inflammatory changes.

Sometimes, in children and young adults, inflammatory changes in the ventricles persist for days and weeks after the subsidence of the inflammation of the pia mater.

*Chronic Meningitis.*—Either the pia mater at the base of the brain alone may be inflamed (basilar meningitis), or the pia mater over the convexity alone, or the entire pia mater, or circumscribed patches of the membrane. The pia mater is thickened and opaque, the thickening being sometimes very considerable. There is a formation of new connective tissue and a production of pus, fibrin, and

serum; the relative quantity of these inflammatory products varies in different cases. Firm and sometimes extensive adhesions may be formed between the dura mater and the pia mater. Not infrequently the cortical portions of the brain participate in the morbid process, and we find an infiltration of small spheroidal cells around the blood vessels, thickening of the walls of the vessels, and degenerative changes and atrophy of the nerve tissue. New connective tissue may also form in the brain substance, which may become closely adherent to the pia mater. The ventricles of the brain also may contain an increased amount of serum and may be dilated, and the ependyma may be thickened and roughened. This form of inflammation may be the result of injury or disease of the cranial bones, or secondary to chronic pachymeningitis or to inflammation of the brain substance. It may occur in the vicinity of tumors of the brain or meninges. It may be a complication of chronic diffuse nephritis or the result of chronic alcoholic poisoning. It may occur in marked form in the general paralysis of the insane.

*Tuberculous Meningitis.*—This is especially characterized by the formation in the pia mater of miliary tubercles, associated with more or less well-marked exudative inflammation. It may occur in adults and in children, but is more common in the latter. The dura mater may be unchanged, or its inner surface may be sprinkled with miliary tubercles. The pia mater may or may not be congested; it may look dry on the surface or it may be œdematous. Usually the brain seems to fill the cerebral cavity to an unusual degree, and the convolutions are flattened. If the pia mater be œdematous the serum may be clear, or turbid with pus and fibrin. The membrane may present any of the general appearances of exudative meningitis. But always in addition to these, and sometimes without them, miliary tubercles, either widely scattered or in great numbers, may be seen, usually more abundant over the sulci than elsewhere. They are usually more abundant at the base of the brain than on the convexity, and are frequently confined to the base. Some of the tubercles are so small as to be scarcely visible or entirely invisible to the naked eye; others are as large as a pin's head or larger. They are usually most abundant along the blood vessels, but may occur elsewhere. They may be formed in the membranous prolongations of the pia mater which dip into the sulci, around the vessels which enter the brain substance, in the choroid plexus and ependyma of the ventricles, and may exist in the spinal cord.

The miliary tubercles do not all have the same structure. Some of them are simply small aggregations of round cells within the perivascular sheaths of the smaller arteries. Others are composed of small masses of polyhedral and round cells (Fig. 167) without any

basement substance between them, and without any special relation to the blood vessels. Many others have the ordinary structure of tubercle tissue, basement substance, polyhedral cells, and giant cells (Fig. 168). These tubercles are usually situated around or near a blood vessel, and this blood vessel is apt to be at the same time the

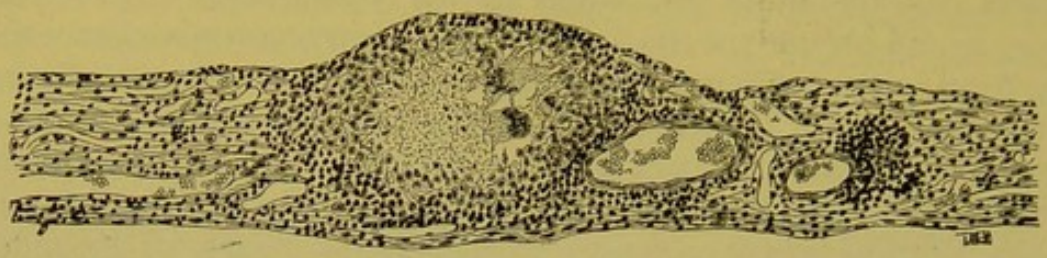

FIG. 168.—MILIARY TUBERCLE OF THE PIA MATER OF A CHILD, UNDERGOING CHEESY DEGENERATION AT ITS CENTRE.

seat of an obliterating endarteritis (Fig. 169). This form of tubercle is also prone to cheesy degeneration (Fig. 168).

In children the ventricles are usually more or less distended by an accumulation of transparent or turbid serum, and the walls of the ventricles may be studded with miliary tubercles (see Figs. 170 and 171). In adults the ventricles are less frequently involved. The brain tissue around the ventricles is often softened. The central

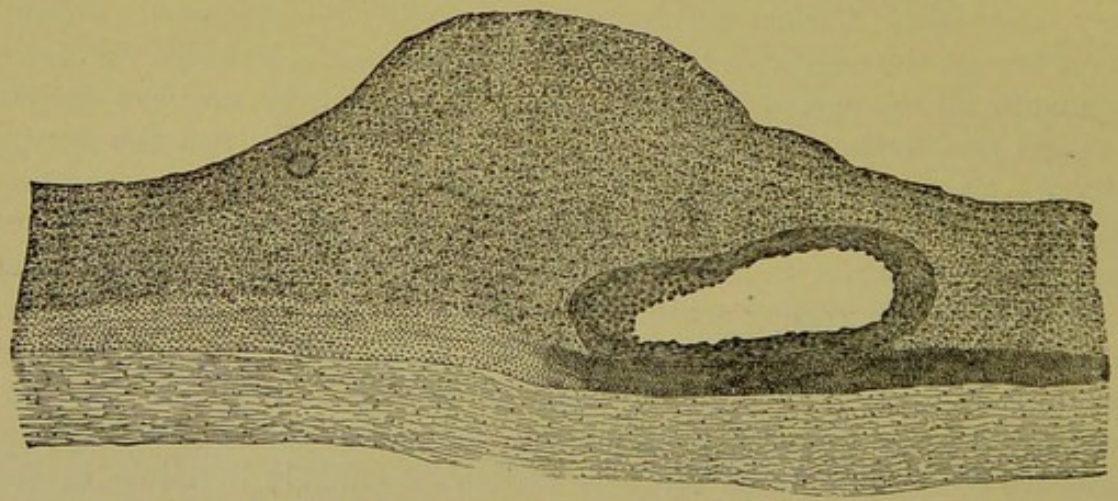

FIG. 169.—A MILIARY TUBERCLE OF THE PIA MATER.
Situated on the wall of a small artery which is the seat of endarteritis.

canal of the spinal cord may also be dilated. It is that dilatation of the ventricles which causes the flattening of the convolutions, and the flattening is usually in direct proportion to the amount of accumulated fluid. Miliary tubercles in the choroid of the eye are present in a considerable proportion of cases.

The cortex of the brain may be hyperæmic, and punctate hæmorrhages may be present in the cortex and in the pia mater.

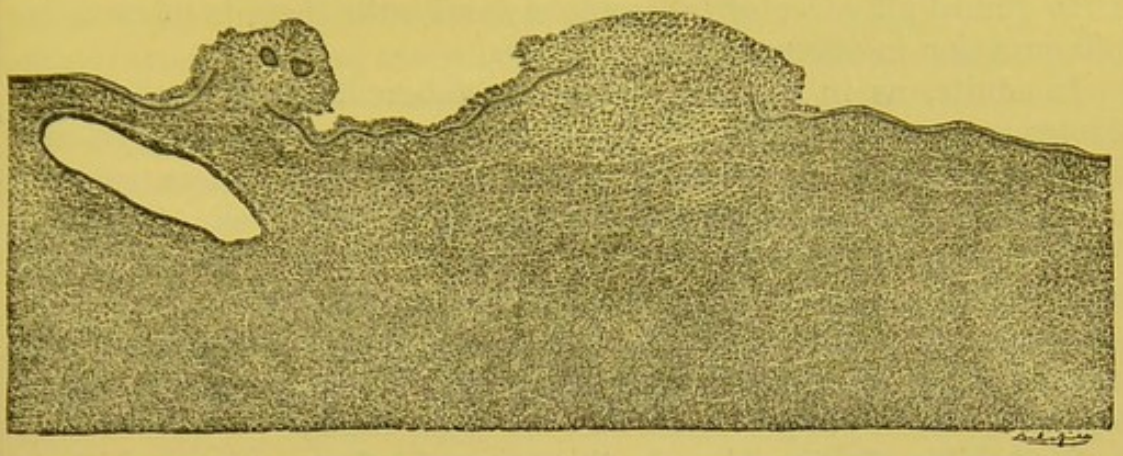

FIG. 170.—MILIARY TUBERCLES OF THE EPENDYMA OF THE LATERAL VENTRICLE, × 70 and reduced.

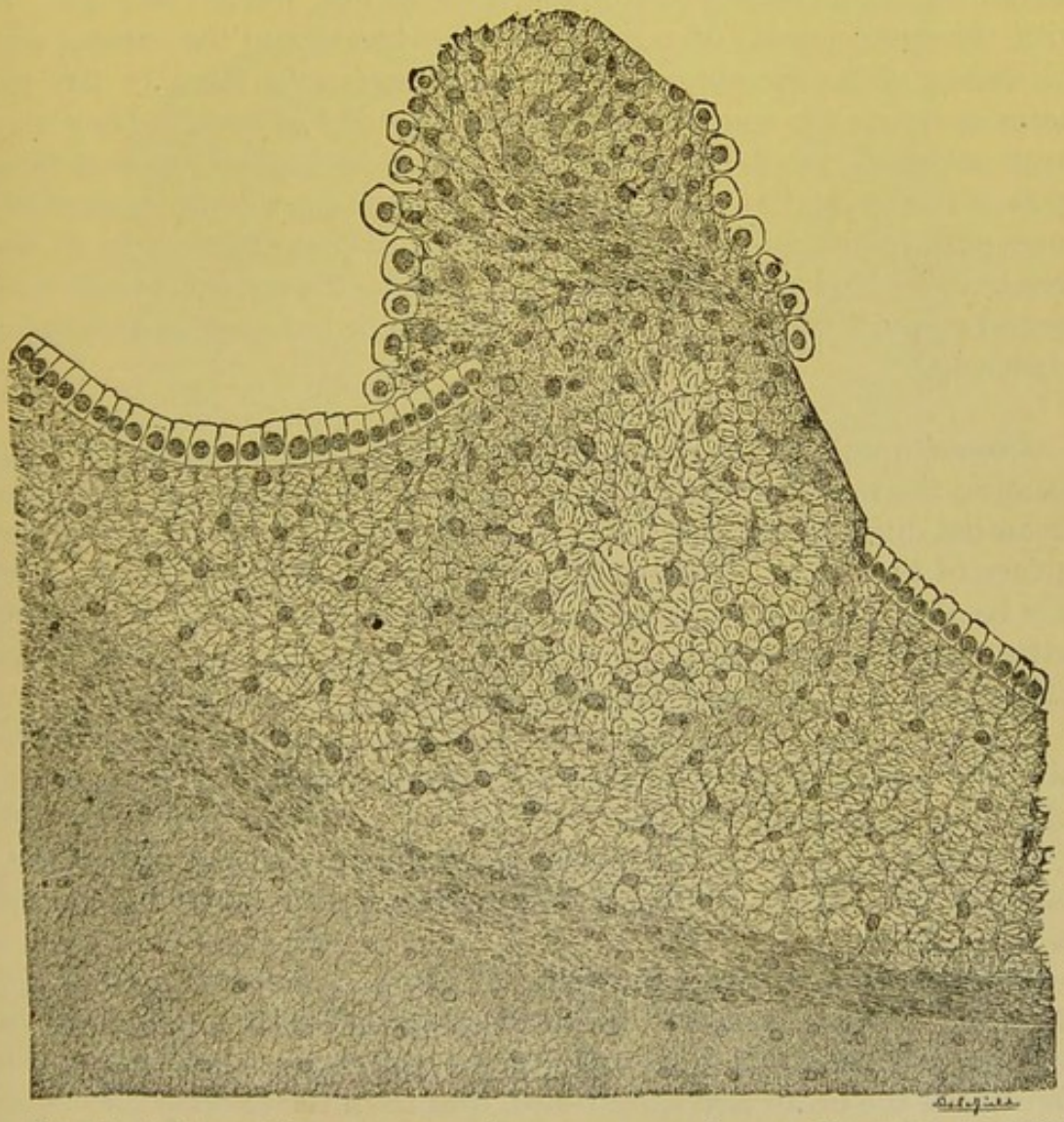

FIG. 171.—A MILIARY TUBERCLE OF THE EPENDYMA OF THE LATERAL VENTRICLE, magnified, × 500 and reduced.

In almost all cases of tuberculous meningitis there is tuberculous inflammation in other parts of the body.

In adults, as in children, while the tuberculous inflammation is always present, the accompanying simple inflammation may be very slight or extensive, and the degree to which it develops does not seem to depend upon the abundance of the miliary tubercles. Owing to the frequency of the dilatation of the ventricles with serum in children, the disease is often called *acute hydrocephalus.*

In both children and adults the tuberculous inflammation may produce large masses of tuberculous tissue, which undergo cheesy degeneration, in the pia mater and the brain tissue.

*Syphilitic Meningitis.*—In this form of inflammation, which is usually circumscribed, there is a development of gummy tumors of variable size, frequently associated with simple inflammation of the membrane, either with the formation of serum, fibrin, and pus, or with the development of new connective tissue and the consequent thickening of the membrane. The gummata may form in the pia mater covering the convexity, or at the base of the brain. They may grow outward, involving the dura mater; or inward, encroaching upon or involving the brain tissue. Although usually circumscribed, the syphilitic inflammation may occur as a diffuse thickening of the membrane. The syphilitic nodules, including the gummata and new-formed connective tissue, are often very small, but may be as large as a hen's egg.

### TUMORS.

*Hæmatoma.*—In the cases of chronic pachymeningitis of long standing the new connective tissue may form large, flat cysts between the dura mater and the pia mater, which may compress the surface of the brain. The blood originally contained in these cysts may be absorbed and replaced by serum, the attachments to the dura mater may disappear, and the whole appearance becomes that of an independent cyst between the dura mater and pia mater.

It is believed by some observers that these cysts are not formed in this way, but that they represent a blood clot which has become enveloped in connective tissue.

*Endotheliomata.*—These tumors are of not infrequent occurrence, and may grow from the pia of the cerebrum or cerebellum or from the choroid plexus.

They may be single or multiple. They may be small or so large as to seriously compress the brain. One of us (Delafield) has seen a case in which there were several tumors growing in the dura, in the pia of both the brain and spinal cord, and from the choroid plexus.

Some of them are composed of a connective-tissue stroma which encloses regular spaces filled with large, flat, nucleated cells. The

whole appearance resembles that of an ordinary carcinoma, but the cells are apparently of endothelial and not of epithelial origin.

Some of them are composed of a connective-tissue stroma which forms cavities lined with cylindrical epithelium. In such tumors the stroma may grow so as to form papillæ covered with cylindrical epithelium; or in addition there may be mucous degeneration of the stroma.

In some of them there is a connective-tissue stroma which contains large numbers of blood vessels. Around these blood vessels are arranged regular masses of polyhedral cells (Figs. 172 and 173).

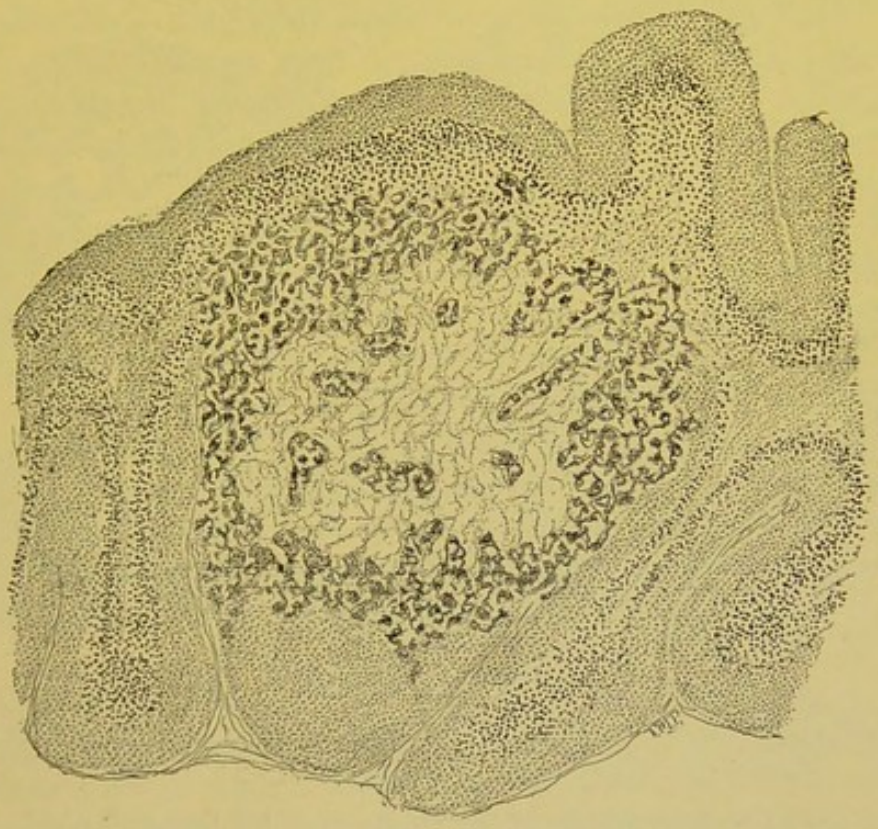

FIG. 172.—ENDOTHELIOMA OF THE CEREBELLUM ORIGINATING IN THE PIA MATER.
From a specimen loaned by Dr. Wood.

In some of them the stroma is scanty. The cells are numerous, large, flat, and arranged in little globular masses or nests.

If in these little nests there is a deposition of the salts of lime, forming concretions like the so-called "brain sand," the tumor is called a "psammoma."

Some of the tumors seem to be formed of very thin, nucleated membranes arranged in concentric layers like the layers of an onion.

Some of the tumors are composed of balls or nests of large, flat cells, with which are found crystals of cholesterin—"cholesteatoma."

*Sarcoma.*—Tumors belonging to the ordinary types of round- and

fusiform-celled sarcoma, of myxo-sarcoma, and of myxoma are occasionally found in the pia mater.

Fibromata, lipomata, chondromata, and osteomata are of rare occurrence.

*Cysts.*—Small cysts are often found in the choroid plexus. Rarely such cysts reach a larger size, even as large as a pigeon's egg.




FIG. 173.—ENDOTHELIOMA OF THE PIA MATER OF THE CEREBELLUM.

From specimen shown in Fig. 172 more highly magnified. A, Section of pia mater dipping into a sulcus; B, tumor cells growing at each side of the pia; C, surface of cerebellar convolutions.

Cysts of the pia mater containing serum, with walls and septa of connective tissue, and compressing the brain, have been described.

Variously shaped *pigment cells* not infrequently occur in the pia mater, either scattered or sometimes in considerable masses; they seem to have little pathological significance. Not infrequently thin plates of new-formed *bone* are found in the pia mater, associated with a thickening of the membrane.

### PARASITES.

*Cysticercus* has been observed in the pia mater.

## THE VENTRICLES OF THE BRAIN.

### THE EPENDYMA AND CHOROID PLEXUS.

As the lymph spaces of the pia mater and the ventricles of the brain are in communication, it might be supposed that they would share alike in the accumulation of fluids. This, however, is not the case. The membranes of the brain may be highly œdematous while the ventricles contain about the normal quantity of fluid ; or, on the other hand, the ventricles may be widely dilated and the pia mater unusually dry. Many of these varying conditions may be understood by remembering that the skull and spinal canal form a closed cavity, and that accumulations of fluid in one part must be at the expense of some material occupying other parts, either blood, serum, or brain tissue. It is not always easy to see, however, exactly how the compensation occurs.

There may be an unusual amount of fluid in the ventricles of the brain as a result of post-mortem change ; in connection with senile or other atrophy of the brain, or in the general vascular changes which lead to œdema of the brain ; in connection with inflammation of the meninges or of the ependyma ; or under conditions which we do not understand, as in some cases of congenital and acquired hydrocephalus. Accumulations of fluid in the ventricles are often called *internal hydrocephalus* to distinguish them from accumulations in the meninges—*external hydrocephalus.*

### INFLAMMATION.

*Acute Inflammation of the Ependyma* (*Acute Ependymitis*).—In this condition, which may occur by itself, but is usually associated with inflammation of other parts of the brain, the ependyma is congested, the vessels are more prominent than usual and are often tortuous. The ependyma and the adjacent brain tissue may be thickened and infiltrated with pus cells, and the surface of the ependyma covered with fibrin and pus in variable quantity (Fig. 174). The cavities of the ventricles may contain purulent serum. Small hæmorrhages may also be present in the tissue of the ependyma. This, as well as other forms of inflammation, is more common in the lateral ventricles than in the others, but not infrequently involves the fourth ventricle. The choroid plexus may participate in the inflammatory changes of the ependyma. Tuberculous inflammation of the ependyma is, as above mentioned, a not infrequent accompaniment of tuberculous meningitis.

*Chronic Inflammation of the Ependyma* (*Chronic Ependy-*

*mitis*).—This lesion, which is much more common than simple acute inflammation of the ependyma, occurs under a variety of conditions, and its nature and causation are in general very obscure. The ependyma is thicker, whiter, and more opaque than normal, so that the vessels may be nearly or quite invisible. The thickening may occur in patches or diffusely, and the surface of the ependyma may be smooth, or roughened and granular. On microscopical examination the surface of the ependyma may be covered with the usual epithelium, but the new connective tissue which forms beneath it often raises it up in places, causing the roughness of the surface.



FIG. 174.—ACUTE EPENDYMITIS.

Showing replacement of the epithelium of the ventricle by inflammatory exudate; collections of pus cells near the epithelium and about the adjacent small blood vessels. (From specimen prepared by Dr. Hodenpyl.)

The new tissue is usually rather loose in texture and may contain many small spheroidal cells; but it may be dense in texture and contain few cells. The brain tissue beneath the thickened ependyma may be softened or infiltrated with cells. The sides of the ventricles may be grown together in places by the adhesion of the thickened and roughened ependyma. The ventricles usually contain more serum than normal, and sometimes this accumulation is so great as to cause an enormous dilatation of them. While these are in general the prominent lesions in chronic inflammation of the ependyma, the cases vary greatly in the degree to which these changes are developed.

The accumulation of fluid and the dilatation of the ventricles being the most marked feature in all this class of lesions, they are often called *chronic hydrocephalus*, and indeed in many cases we have no evidence that the change in the ependyma is an important or even an actual primary factor.

We may, for convenience of study, consider three classes of cases of chronic hydrocephalus : first, congenital hydrocephalus in young children ; second, secondary hydrocephalus in children and adults ; third, primary hydrocephalus in adults.

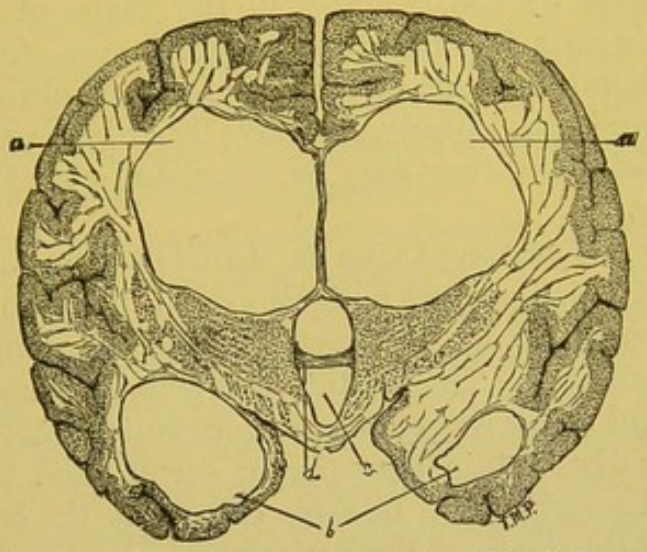

FIG. 175.—CONGENITAL HYDROCEPHALUS IN CHILD. About half natural size.

*a*, *a*, dilated lateral ventricles; *b*, cornua, unequally dilated ; *c*, third ventricle; *d*, middle commissure.

1. *Congenital Hydrocephalus.*—The lesion may be in an advanced stage at the time of birth, or it may be scarcely evident or but moderately developed. It may progress rapidly and cause the early death of the child, or it may develop gradually or come to a standstill. In the more marked forms of the disease the ventricles are widely dilated and filled with serum, which is usually transparent. Not only the lateral ventricles, but also the third and fifth, may be involved ; the fourth is less apt to participate in the lesion, although it is sometimes dilated, as well as the central canal of the cord.

The distention, especially of the lateral ventricles, may be so great that the brain tissue over the vertex is crowded up into a thin layer beneath the dura mater, or it may be entirely destroyed. When the dilatation of the ventricles is considerable, the convolutions are flattened (see Fig. 175) and may be almost entirely obliterated. The skull bones may be thin and bulging over the forehead and vertex ; the fontanelles and sutures widely open. The ependyma in these cases is usually thick and rough, but it may be softened, and the

blood vessels may be dilated. The basal portions of the brain may be flattened, but are usually much less affected than the upper portions. The brain tissue is usually soft and anæmic.

2. *Secondary Hydrocephalus.*—This may occur in children and adults, and may be a result of epidemic cerebro-spinal meningitis, or of acute meningitis, or of chronic meningitis. It sometimes occurs in chronic alcoholic poisoning and in general paralysis of the insane. The amount of dilatation of the ventricles varies greatly in these cases, but it is never so great as in congenital hydrocephalus, and is not accompanied by the changes in the shape of the skull which form so prominent a feature in the latter disease, since the bones are firmer and the sutures united. In this form of chronic hydrocephalus the changes in the ependyma above described are usually more or less well marked, and they may be associated with the production of fibrin and pus.

3. *Primary Hydrocephalus in Adults.*—The conditions leading to this form of lesion are not understood. It is apt to occur in persons over thirty years of age. Sometimes one, sometimes both lateral ventricles are dilated. The dilatation is usually moderate, sometimes very slight, and never as great as in congenital hydrocephalus. The ventricles usually contain transparent serum, and the ependyma is thickened and roughened. In some cases it is the only lesion found to account for the death of the patient.

## TUMORS.

The new formation of connective tissue in the ependyma, although usually diffuse, may be circumscribed and form small, projecting connective-tissue nodules, which may be reckoned among the *fibromata.* Small fibromata are sometimes detached from the walls of the ventricles and lie free in the cavity. Small *lipomata, angiomata,* and also *sarcomata* and *gliomata* occur rarely. *Chondromata* and *angiomata* may occur in the choroid plexus, and the latter are sometimes as large as a hen's egg. The choroid plexus is not infrequently the seat of transparent *cysts,* usually of small size; they may contain a clear fluid, or colloid material, or droplets of fat, or calcareous particles. A small *dermoid cyst* containing hairs has been described. These cysts have no special pathological significance.

Primary *carcinomata* are sometimes found in the ventricles.

The calcareous bodies called *brain sand*[1] occur frequently in the choroid plexus (see Fig. 162), and *corpora amylacea* may occur here and beneath the ependyma.

---

[1] The little, hard masses called *brain sand* consist of aggregations of small parti-

Cysticercus and echinococcus cysts are sometimes found free in the fluid of the ventricles.

## PINEAL GLAND.

This little body, about the size of a cherry stone, is composed of connective tissue enclosing cavities, which are filled with reticulated tissue and round cells. The cavities often contain brain sand. It is said [1] that the pineal gland is an aborted or rudimentary organ and may be related to a median eye of invertebrate type.

A small number of tumors belonging to the class of teratoma have been described as originating in the pineal gland.

Weigert [2] describes a tumor, about 3½ cm. in diameter, composed of epidermis, hair follicles, hair, sebaceous glands, cartilage, fat, smooth muscle, and cylindrical epithelium.

Falkson [3] describes a chondro-cysto-sarcoma, 5.8 cm. in diameter, which apparently originated in the pineal gland.

Turner [4] describes a tumor of the pineal gland, projecting into the third ventricle and the left lateral ventricle, of the size of a kidney. The tumor was composed of fusiform cells, of nerve ganglion cells, of tubules and acini lined with cylindrical epithelium, and of more irregular spaces filled with large polygonal cells.

Coats [5] describes a tumor, three inches in diameter, growing into the third ventricle, the aqueduct of Sylvius, and the fourth ventricle. It was composed of fusiform cells, of tubules lined with cylindrical epithelium, of irregular masses of epithelium, of cartilage, and of smooth muscle.

## THE PITUITARY BODY.

This structure, called the Hypophysis cerebri, consists of two lobes. The anterior lobe is composed of a connective-tissue stroma enclosing cavities which are packed full of nucleated cells of various sizes and shapes, some of them resembling nerve cells. The posterior lobe is composed of vascular connective tissue.

Weigert [6] describes a tumor, as large as a hen's egg, which resembled in its structure the normal anterior lobe of the pituitary body, and which he regards as a hypertrophy of that body.

---

cles of carbonate and phosphate of lime, with a very small amount of phosphate of ammonia and magnesia. With these there is more or less organic matter.

[1] Quarterly Jour. of Micr. Science, 1886.

[2] Virch. Arch., lxv., p. 212.

[3] Ibid., lxxv., p. 550.

[4] Trans. Lond. Path. Soc., xxxvi.

[5] Ibid., xxxviii.

[6] Virch. Arch., lxv., p. 219.

Weigert also describes a gummy tumor of the pituitary body as large as a hazelnut.

Weichselbaum describes an adenoma of the pituitary body, as large as a pigeon's egg, closely resembling the structure of the normal anterior lobe of this body ; a small lipoma ; and a pituitary body with colloid cysts, lined with ciliated epithelium. [1]

## THE BRAIN.

### THROMBOSIS AND EMBOLISM.

In studying the occurrence and effects of thrombosis and embolism in the brain, certain peculiarities of the circulation should be borne in mind. The arteries of the brain are in part terminal arteries (see page 74), in part such as have anastomoses among their branches. Thus the arteries which are distributed to the cortical region form abundant anastomoses in the pia mater and are very small when they enter the brain, while those which are distributed to the basal region, and which supply the basal ganglia, are larger and do not, beyond the circle of Willis, form anastomoses with one another. Thus it is that occlusions of the arteries supplying the basal ganglia are of much more serious import, aside from the importance of the parts involved, than those passing to the cortex.

*Thrombi* may form in the arteries as a result of any degenerative or inflammatory process in the wall of the vessel leading to a roughening or death of its intima, or from pressure upon the vessel from without, or they may occur in vessels in whose walls we can detect no primary lesion. The most common causes are atheroma and simple endarteritis. Thrombi may also form around an embolus which does not entirely occlude the vessel.

Emboli of the cerebral arteries most commonly arise from acute or chronic endocarditis or cardiac thrombi ; they may arise from aneurisms or atheroma of the aorta, from the carotid or vertebral arteries, or from the pulmonary veins. The materials constituting emboli vary greatly, depending on their mode of origin (see page 73). The effects on the brain tissue of emboli and thrombi of the arteries are essentially the same in their main features. In some cases, however, in which large emboli, usually from endocarditis, suddenly block up a large vessel, the individual may die almost instantly without other apparent lesion than the stoppage of the vessel.

In general, the first effect of the occlusion of an artery is to

[1] Consult *v. Hippel*, Virchow's Arch., Bd. cxxvi., p. 124, 1891.

deprive the region to which it is distributed of blood. In arteries whose branches anastomose, as in the cortex of the brain, the affected area is soon supplied with blood by the establishment of a collateral circulation. In terminal arteries, on the other hand, the blocking of the vessel is followed, as a rule, by degenerative changes and softening in the brain tissue. The appearances which these degenerated areas present vary greatly, depending upon the stage of the degeneration and the amount of blood which may be extravasated. Dense infiltrations of the brain tissue with blood, as in hæmorrhagic infarctions from emboli in other parts of the body, do not usually occur, although considerable blood may be extravasated.

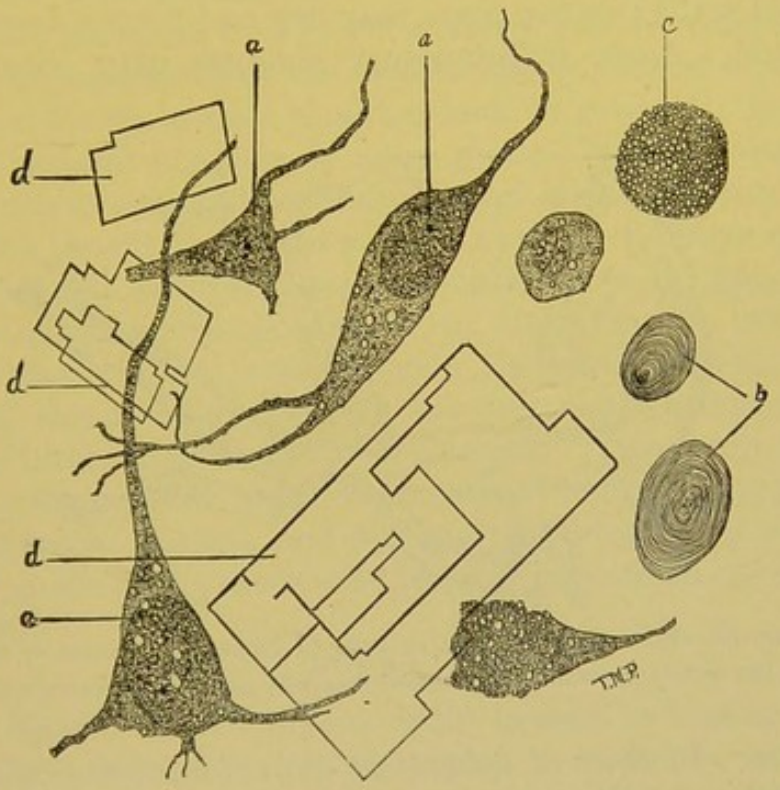


FIG. 176.—DEGENERATED CELLS, CHOLESTERIN CRYSTALS, AND CORPORA AMYLACEA FROM BRAIN TISSUE IN EMBOLIC SOFTENING.

*a*, fatty ganglion cells; *b*, corpora amylacea; *c*, cell containing very large number of fat droplets (compound granular or Gluge's corpuscles); *d*, cholesterin crystals.

Areas of softening in which there is little extravasation of blood are usually white or yellow in color (*white or yellow softening*). When much blood is present the process is frequently called *red softening*. The tissue in the affected area gradually softens and may become diffluent. Microscopically, the softened tissue is seen to consist of more or less fluid with broken-down brain tissue, fragments of nerve fibres, droplets of myelin, nerve cells, shreds of neuroglia tissue and blood vessels, and red and white blood cells. Then evidences of degeneration are seen in the presence of fat

granules and droplets, larger and smaller cells densely crowded with droplets of fat (so-called *Gluge's corpuscles* or *compound granular corpuscles*) (see Fig. 176). Various kinds of cells and cell fragments, more or less granular and fatty, and also corpora amylacea, blood pigment, fat crystals, and cholesterin crystals, may be found. The walls of the blood vessels may also be in a condition of fatty degeneration (Fig. 177). The color of the softened mass will of course depend upon the relative amounts of these elements.

The tissue may remain for a long time in the soft condition, or it may be absorbed and replaced by a connective-tissue cicatrix which may be more or less pigmented ; or a wall of connective tissue may form about it, converting it into a well-defined cyst, with or without pigmented walls ; or the mass may dry and form a dense, structureless nodule. Acute inflammatory changes may occur about the

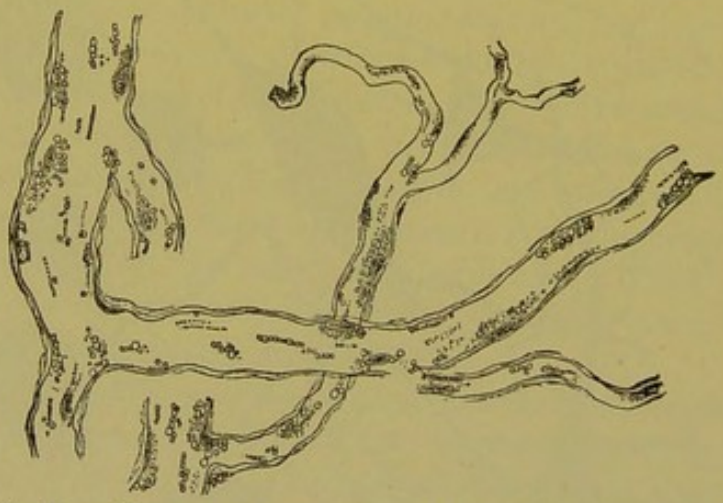

FIG. 177.—BLOOD VESSELS FROM AN AREA OF EMBOLIC SOFTENING OF BRAIN.
The walls of the vessels, particularly the endothelial cells, contain fat granules and fat droplets.

dead tissue. In cases of infectious emboli numerous abscesses may be formed in addition to their mechanical action.

Thrombi are most frequent in the internal carotids, less so in the middle cerebral, basilar, and vertebrals. They may occur, but still less frequently, in other cerebral arteries. Emboli are most common in the middle cerebral artery, next in the internal carotid, and then in the basilar. The relative frequency with which embolism occurs in the middle cerebral artery is attributable to the directness with which the blood passes into this artery from the heart. The great significance attaching to embolism of the middle cerebral artery is evident when we remember that its branches are terminal arteries, and are distributed to such important structures as the lenticular and caudate nucleus, the internal capsule, and the optic thalamus.

### HYPERÆMIA AND ANÆMIA.

The appearance of the brain tissue after death does not always furnish reliable indications of its blood contents during life, though they are perhaps more to be depended on than the appearance of the meninges.

Some of the more common conditions determining *hyperæmia* which are mentioned above as influencing the meninges apply also to the substance of the brain. In sections of hyperæmic brains the small blood points from the cut ends of small vessels are more numerous and conspicuous than under normal conditions, and the brain tissue, particularly the gray matter, may have a diffuse red color. If excessive the convolutions may be somewhat flattened, and the brain tissue and pia mater may be œdematous, and the ventricles contain fluid. The congestion of the vessels may be general or localized.

*Anæmia* of the brain may be either local or general. It may depend upon a general anæmia or upon general disturbances of the circulation, such as mitral stenosis or regurgitation ; or upon local interference with the arterial blood supply, such as complete or partial obstruction of the arteries from thrombi, emboli, inflammatory changes, spasmodic contractions, etc., or from tumors, exudations, and blood extravasations pressing upon the vessels from without. In œdema of the meninges, and in the presence of internal hydrocephalus, the brain tissue is apt to be anæmic. The brain tissue in anæmia looks whiter than usual, the contrast between the gray and white matter is less marked, and the small blood points usually seen on section from divided vessels may be very inconspicuous or almost entirely absent.

### ŒDEMA

of the brain tissue may accompany either general or localized hyperæmia or it may accompany anæmia, and it seems in most cases, though not always, to be dependent upon conditions which induce these alterations in the blood contents of the brain. In some cases of marked impoverishment of the blood a so-called *hydræmic œdema* of the brain is found. Very marked œdema of the brain may exist without any accompanying brain symptoms. On the other hand, persons may die comatose with no other gross lesion than œdema, either with or without œdema of the pia mater. This is seen with especial frequency in acute and chronic alcohol poisoning, but may occur under other conditions. A careful microscopical examination of the brain under these conditions will frequently reveal structural lesions of far more serious import than the œdema.

Under the designation of "serous apoplexy," œdema of the brain was formerly considered of importance, in the absence of other le-

sions, as a cause of death. But the accumulation of knowledge on this subject has led to the general belief that simple cerebral œdema as an independent condition has not the significance formerly ascribed to it, and it should be accepted, if ever, with great reserve as a cause of death.

### HÆMORRHAGE.

Hæmorrhages in the substance of the brain may be very small and punctate, and are then usually called *capillary hæmorrhages;* or they may result in the collection in the brain tissue of masses of blood of considerable size, which are called *apoplectic foci* or clots. These forms of hæmorrhage may be associated, or a number of capillary hæmorrhages may join to form an extensive clot.

*Capillary hæmorrhages* may look, on section of the brain, like the severed ends of hyperæmic blood vessels, or the tissue about them may be more or less tinged with blood. Microscopically, the perivascular spaces will be found distended with blood, which may have escaped into them and more or less broken down the brain tissue. They may occur singly, but are frequently multiple, so that the brain tissue is besprinkled with blood points. Degeneration of the extravasated blood may give rise in later stages to reddish or brown or yellowish circumscribed discoloration of the brain tissue, due to granules and crystals of blood pigment intermingled with broken-down brain tissue, with more or less fatty degeneration of its elements. Capillary hæmorrhages may be due to fatty degeneration of the vessels leading to rupture ; or the extravasation may be due to diapedesis, or it may depend upon conditions which we do not understand. They frequently occur in the vicinity of apoplectic clots and tumors , they may be due to thrombosis of the veins or of the sinuses of the dura mater ; they not infrequently occur in acute encephalitis, in congestive hyperæmia, in acute mania, and in delirium tremens ; and they may be associated with general diseases, such as scurvy, purpura hæmorrhagica, typhus fever, pyæmia, ulcerative endocarditis, etc.; they may be associated with embolic softening.

*Apoplectic foci* may result from the coalescence of numerous capillary hæmorrhages ; from injury, or from rupture of diseased arteries, either with or without changes in the blood pressure. Hæmorrhages from injury to the skull may occur as well without as with fracture, and may be situated over the vertex as well as at the base of the brain, and vary in extent and seat, depending upon the character and point of the injury and the size of the vessels involved. The so-called spontaneous hæmorrhages, other than those of capillary origin, which give rise to masses of blood and broken-down brain tissue, may vary in size from that of a pea to those occupying

a large part of a hemisphere. They are due, in a very considerable proportion of cases, to the rupture of small arterial aneurisms, but may arise from weakening of the walls of the arteries, from arteritis, atheroma, or fatty degeneration. These latter forms of disease doubtless give rise in most cases to the formation of the aneurisms whose rupture is in so many cases the immediate cause of the hæmorrhage. Aneurisms of the cerebral arteries may be as large as a pea or hazelnut, but those most frequently met with and causing apoplexy are usually small—called miliary aneurisms—and may be microscopic in size, varying from this up to that of a large pin's head or larger. They may be sacculate or fusiform, and frequently exist in considerable numbers. They may occur in any of the small arteries of the brain, but are said to be most frequent on the branches of the middle cerebral artery. It is asserted that the bursting of miliary aneurisms is the nearly if not quite exclusive cause of the formation of spontaneous apoplectic clots, but this we do not believe to be true. As to the immediate cause of rupture, either of aneurisms or otherwise diseased blood vessels in the brain, we are in many cases entirely ignorant. In some cases it seems to be due to an increased arterial tension in such diseases of the heart as induce this change, as in the cardiac hypertrophy which may accompany some forms of chronic diffuse nephritis ; or it may result from unusual exertion or mental excitement ; but, as above stated, in many cases the immediate inciting cause is not evident.

The most frequent seat of hæmorrhage is in the corpora striata and optic thalami, and the brain tissue in their vicinity, and here they occur most often in the parts supplied by the branches of the middle cerebral artery. The possibility of hæmorrhage in the floor of the fourth ventricle as a cause of sudden death should be borne in mind in investigating cases of sudden death from obscure causes.

Hæmorrhages frequently seriously affect other portions of the brain than those immediately supplied by the ruptured vessels. Thus hæmorrhages in the cortical substance or beneath the pia mater may force their way deep into the brain substance ; or, in hæmorrhage in the brain substance, the blood may burst into the ventricles or work its way into the intermeningeal space, and, either at the seat of its occurrence or in the situations into which it is forced, it may give rise to serious compression of the brain. Portions of the brain containing large extravasations may be enlarged, the tissue anæmic from pressure, the convolutions flattened, and the surface dry. As the blood is poured out the brain tissue is usually torn and lacerated, so that the apoplectic clot usually consists of detritus of brain tissue intermingled with blood. If, however, the blood is poured out from

a single vessel, the lacerated brain tissue may be pressed aside, and the greater portion of the red mass may consist of pure blood clot.

The appearances presented by hæmorrhages in the brain vary greatly, depending upon the time which has elapsed since their occurrence. If life continue, the œdema which usually soon occurs in the vicinity of the hæmorrhage disappears and the clot becomes drier and firmer; gradually the blood undergoes the usual series of changes seen in extravasation: the hæmoglobin decomposes, forming granules and crystals of blood pigment: the blood cells and fibrin undergo degeneration and absorption; the detritus of brain tissue undergoes fatty degeneration. As these alterations occur the color changes to reddish-brown, orange, or yellow, and the adjacent brain tissue may be discolored by imbibition.

Inflammatory reaction may occur in the vicinity, leading either to the formation of a more or less pigmented cicatrix, or to a cyst with yellowish fluid contents and a fibrous, more or less pigmented wall. The process of degeneration and absorption of the blood and broken-down brain tissue, and their replacement by a cyst or by a cicatrix, is a slow one, and the cysts and cicatrices may resemble those formed at the seat of embolic softening. Not infrequently we find in the brain of a person dead from recent apoplexy the remains of old clots presenting some one of the above-described stages of absorption. The apoplectic cysts and cicatrices persist for a long time after their formation.

### CHANGES IN THE GANGLION CELLS IN TOXÆMIA.

There is much reason for believing that in many of the acute infectious diseases, particularly in those which are characterized by the wide distribution of toxic agents in the blood from some special seat of microbic growth, there may be important and often profound changes in the ganglion cells of the central nervous system, some of which are associated with marked structural alterations in the cytoplasm. Such changes have been already demonstrated in hydrophobia and in tetanus as well as in local inflammatory and destructive lesions in the spinal cord. These changes may be looked upon, at least for the present, as the analogues of the degenerative changes which are more familiar in the parenchyma cells of such viscera as the liver, kidney, etc., and like them may vary greatly in degree and significance. The whole subject of ganglion-cell changes in toxæmia offers a most promising field for research.

The chromophylic masses in the ganglion cells may, under the influence of various poisons and other deleterious agencies, disintegrate or largely disappear, being finally represented only by fine granules scattered through the cytoplasm or gathered in masses or

about the periphery. The nucleus may undergo various degrees of disintegration or may entirely disappear (see Fig. 178).

Various degrees of pigmentation may be associated with these changes in the cell.

These finer alterations in the ganglion may be demonstrated by the use of Nissl's stain (see page 412).

It is important to recognize the possibility of serious structural changes in the nervous system as the result of the action of toxic agents of microbic origin, but also as the result of so-called "auto-intoxication," from the presence in the body of excrementitious substances which have failed of proper elimination.

But great care is necessary not only in the technical procedures to which these delicate structures must be subjected, but also in the




FIG. 178.—GANGLION CELLS OF THE SPINAL CORD.

Stained by Nissl's method with methylene blue. Showing, A, normal ganglion cells; B, ganglion cells in acute myelitis with marked changes in the chromophylic masses of the cell bodies.

interpretation of appearances in a field in which the morphological norm has been as yet so inadequately investigated and in which nutritional and functional changes are still so obscure.[1]

## SECONDARY DEGENERATIONS.

Lesions of the brain which involve the destruction of motor gan-

[1] An interesting consideration of the relation of infectious processes to diseases of the nervous system, by *Putnam*, may be found in the American Journal of the Medical Sciences, March, 1895.

For a résumé of the recent observations on the degenerative and regenerative processes in the nervous system, with bibliography, consult *Stroebe*, Centralbl. f. allg. Path. und Path. Anat., December 15th, 1895. Consult also *Berkley*, Medical Record, March 7th, 1896.

glion cells or nerve fibres are regularly followed after a time by degenerative changes in these nerve fibres below the seat of lesion. It is particularly lesions in the central convolutions, the internal capsule, portions of the corona radiata, and the pes pedunculi, which destroy the motor fibres passing through these parts, and are followed by degenerative changes in the fibres below. The most important and frequent lesions followed by this effect are those involving the anterior two-thirds or three-fourths of the internal capsule. It will suffice merely to mention these changes here, as they are considered more in detail in the section devoted to lesions of the spinal cord (page 393).

### HYPERTROPHY AND ATROPHY OF THE BRAIN.

*True Hypertrophy* of the brain is rare, and probably always congenital. An increase in the size of the brain from the proliferation of the neuroglia sometimes occurs in children either before or after birth, less frequently in youth, and very seldom in adults. The white substance of the hemispheres is increased in amount. If it take place before the ossification of the cranium, the bones are separated at the sutures and fontanelles; if after this, the inner table of the skull may be eroded and thinned. When the cranium is opened the dura mater appears tense and anæmic, the convolutions of the brain are flattened, the brain substance is firm and anæmic, the ventricles are small, the ganglia and cerebellum are either of normal size or compressed.

The disease is usually very chronic, and destroys life with symptoms of compression of the brain. There may, however, be acute exacerbations.

*Atrophy.*—This may occur as a senile change, or, in adults, in chronic alcohol, opium, or lead poisoning, in chronic insanity, and in chronic meningitis or from local interference with the circulation. In children who are much reduced by chronic diseases atrophy of the brain may accompany atrophy of the rest of the body.

The atrophy affects principally the cerebral hemispheres, and may be uniform or more marked in some parts than in others, involving the whole of a hemisphere or of a lobe or only single convolutions or groups of these (Fig. 179). The convolutions are small, the sulci broad, the ventricles usually dilated, the brain tissue firm, the gray matter discolored, the white substance grayish in color; the blood vessels may be dilated. The basal ganglia may be small. Serum accumulates in the pia mater and the ventricles; the pia mater, and often the skull, become thickened; the brain tissue may be œdematous or contain small hæmorrhages. The nerve elements of the brain

tissue are those most involved in the atrophy, the diminished areas being usually harder and firmer than normal.

### WOUNDS OF THE BRAIN.

The brain may be directly wounded by a foreign body, or indirectly by fragments of bone driven into it, or it may be lacerated by severe contusion without fracture or solution of continuity of the skull. It is very difficult to estimate the degree of injury which must cause death, since persons frequently die from slight, and may

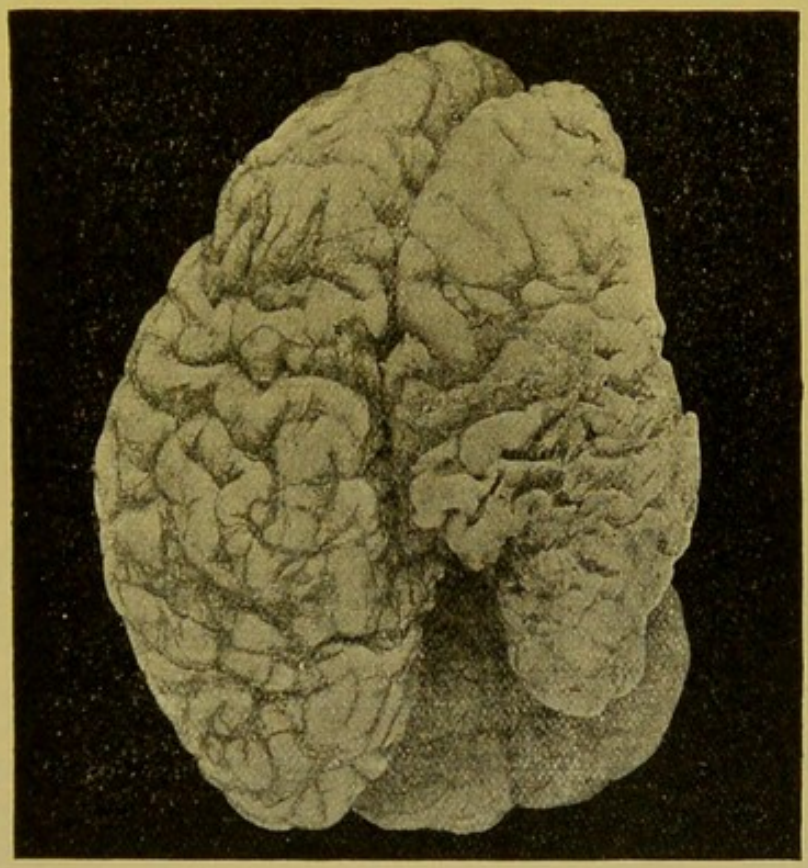

FIG. 179.—ATROPHY OF A CIRCUMSCRIBED PORTION OF BRAIN CONVOLUTIONS IN A CHILD. From a lesion of the corresponding blood vessels. (From a specimen loaned by Dr. Freeman.)

recover from very severe, wounds of the brain. In incised wounds of the brain more or less hæmorrhage occurs at the seat of lesion, and the brain tissue in the vicinity soon undergoes degenerative changes. These may be comparatively slight or extensive. Inflammatory reaction may occur in the vicinity, and the adjacent brain tissue, as well as the hæmorrhagic and degenerated area, become infiltrated with pus cells. After a time the injured and degenerated area may become surrounded by new-formed connective tissue, and the decomposed extravasated blood and detritus of brain tissue, more or less fatty, may be absorbed, and thus after a time the part heals by

a more or less pigmented cicatrix. The healing is in most cases very slow and may occupy months or even years. The pia mater may participate to a marked degree in the inflammatory healing process. Abscesses may form near the seat of injury.

After wounds which involve the removal of portions of the cranial bones, it is not uncommon after a few days to see a bleeding fungous mass project through the opening. This mass, sometimes wrongly called hernia cerebri, consists of degenerated brain tissue, blood, and granulation tissue, with more or less pus. The brain tissue below it is degenerated, broken down, soft, and purulent, and there is often abscess in the adjacent brain tissue. Such wounds may finally heal by the absorption of the broken-down brain tissue and blood, and its substitution by granulation tissue.

Lacerations of the brain tissue without fracture may appear shortly after the injury as simple more or less circumscribed areas of capillary hæmorrhage ; the brain tissue about these may degenerate, pus may form, and abscesses be developed ; or the degenerated and lacerated tissue may be gradually replaced by granulation tissue which finally forms a cicatrix. The process of degeneration and softening and of healing in such lacerations of brain tissue may occur very slowly indeed, even occupying years, and not infrequently the degenerative changes are very extensive and progressive. In many cases, of course, the injury is so extensive, or involves such important parts of the organ, that very little or no inflammatory or degenerative change takes place before death.

### HOLES OR CYSTS IN THE BRAIN (PORENCEPHALUS).

Larger and smaller holes may be found in the brain tissue from dilatation of the perivascular lymph spaces, or well-formed cysts may exist from hæmorrhage, inflammatory softening, hydatids, etc. There are, however, cases in which one or several holes of varying size are found in the brain which cannot be determined to have either of the above modes of origin. They may lie deep in the brain substance or close under the pia mater, or may communicate with the ventricles. This condition is sometimes called *porencephalie*, and may co-exist with various mental aberrations, hydrocephalus, etc.[1]

### INFLAMMATION OF THE BRAIN (ENCEPHALITIS).

It has been already mentioned that the brain tissue about hæmorrhages and areas of embolic and thrombotic softening may undergo

[1] Consult *v. Kahlden*, "Ueber Porencephalie," Ziegler's Beitr. zur Path. Anat., etc., Bd. xviii., p. 231.

inflammatory changes leading to the formation of new connective tissue. There is a class of cases in which localized areas of the brain undergo softening, with more or less extravasation of red and white blood cells and hyperæmia of the blood vessels, so that the softened material consists, as seen under the microscope, of detritus of brain tissue in a condition of fatty degeneration, with more or less pus cells or pigment. When such areas are red in color from intermingled blood cells or pigment the condition is called *red inflammatory softening.* When fatty degeneration prevails, and the red blood cells or their derivatives are not abundant, the softened area looks yellow or yellowish-white, and this is often called *yellow inflammatory softening.* The origin of these processes is very obscure and their inflammatory nature not well defined.

*Abscess of the Brain.*—The small multiple abscesses of the brain which occur with pyæmia form part of that disease and require no separate description.

The large single abscesses occurring under different conditions are those to which the name of "abscess of the brain" is usually applied.

These abscesses occur in two forms :

The non-capsulated abscess, an irregular cavity containing thin pus and softened brain tissue. The walls of the cavity are ragged and infiltrated with pus, and outside of the walls is a zone of œdematous and softened brain tissue. If the abscess is near the pia mater it may set up a meningitis ; if it is near the lateral ventricles it may rupture into them ; if it is near the sinuses of the dura mater it may cause thrombosis.

The encapsulated abscess has a capsule of connective tissue, and contains thin or cheesy pus.

Abscesses of the brain are usually single ; they may attain a considerable size. They are most frequent in the cerebral and cerebellar hemispheres, rare in the central ganglia, the pons, and the medulla oblongata.

The most common cause of this disease seems to be chronic suppurative otitis (42.5 per cent, Gowers), while acute otitis is a comparatively rare cause. With the otitis there may also be caries of the temporal bone, suppuration of the mastoid cells, and inflammation of the dura mater. The abscess is usually situated deep in the brain ; only rarely is it continuous with the inflamed dura mater and bone. When the abscess is deeply situated, and the bone and dura mater are not diseased, it is difficult to tell how the infection travels from the ear to the brain. Abscesses due to this cause are situated in the temporo-sphenoidal, the frontal, the occipital, and the parietal lobes, or in the cerebellum.

Another frequent cause of abscess of the brain is traumatism—blows or falls on the head (24 per cent, Gowers). Such injuries may not hurt the skull, or may produce fractures or necrosis. There is often a considerable interval between the time when the injury is inflicted and that when the symptoms of the abscess are developed.

When the cranial bones are uninjured the abscess is situated deep in the brain; when there is necrosis of the bones the abscess may be superficial; when the bones are fractured the abscess may be either superficial or deep. The abscess is regularly situated beneath the point of injury, rarely in the opposite side of the brain.

Chronic disease of the nose, either the mucous membrane or the bones, has been the cause of a few abscesses in the frontal lobes. Disease of the orbit has also given rise to abscesses in the same position. In a few cases the abscesses have been due to caries of various portions of the cranial bones.

In a considerable number of cases (one-sixth, Gowers) no cause for the abscess has been discovered.

Very frequently in acute meningitis there is an infiltration of pus cells along the walls of the vessels which enter the brain from the pia mater; and under a variety of conditions which we do not understand, as in some cases of typhoid fever, delirium tremens, erysipelas, and under many other conditions, there are numerous and sometimes very large numbers of leucocytes scattered through the substance of the brain, sometimes around the ganglion cells, sometimes along the vessels in the perivascular sheaths.

*Chronic Interstitial Encephalitis—Sclerosis.*—This lesion of the brain tissue may occur diffusely, occupying an entire lobe or more or less of the whole brain, or in circumscribed small areas. It consists essentially in an increase of the connective-tissue elements, the neuroglia, and an atrophy of the nerve elements, particularly the ganglion cells and the medullary sheaths of the nerves. With these changes are usually associated the formation of Gluge's corpuscles, corpora amylacea, granular and fatty degeneration of the nerve elements, and thickening and proliferation of cells of the walls of the blood vessels. The areas of sclerosis may be very dense and hard, or gelatinous in consistence.

The diffuse form of sclerosis is most frequently seen in general paresis of the insane, and not infrequently in the brains of drunkards.

The circumscribed form of sclerosis, *multiple sclerosis* (*sclérose en plaque*), is much more common than the diffuse form, and may occur in the brain alone, or may be associated with a similar lesion in the spinal cord. It is almost entirely confined to the medullary substance, and the areas of sclerosis vary in size from that of a pea

to that of an almond. They may be few or numerous, they may be white, grayish, or grayish-red in color, and are usually, but not always, sharply outlined against the unaltered brain tissue. Although in many cases the increase in the connective-tissue elements seems to be the primary lesion, and the degeneration of the nerve elements secondary to this, it is quite possible that in some cases the increase in connective tissue may be secondary to a degeneration of the nerve elements from loss of nutrition or from other causes.

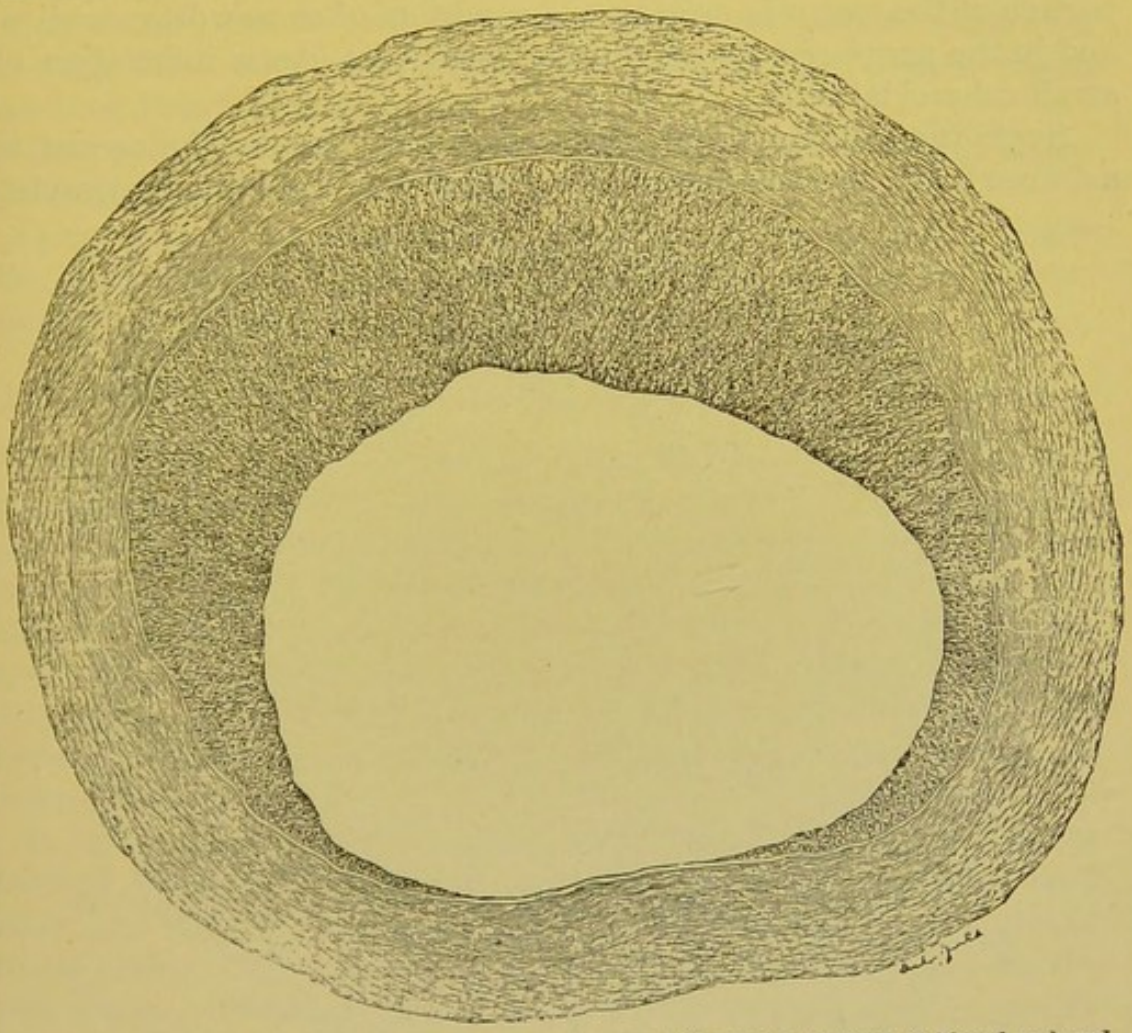

FIG. 180.—SYPHILITIC OBLITERATING ENDARTERITIS OF A CEREBRAL ARTERY, × 50 and reduced.

There is reason for the belief that multiple sclerosis may be the result of disseminated local necrotic lesions of acute infectious diseases —scarlatina, for example—occurring at an early period of life.[1]

*Encephalitis in the New-born.*—This condition, first described by Virchow, is said to consist in the formation of circumscribed collections of cells of various sizes containing many fat granules (granular corpuscles) and forming yellowish masses, from 1 mm. to 6 mm.

[1] See *Oppenheim*, Berl. klin. Wochenschrift, March 2d, 1896.

in diameter, in the brain tissue. A more diffuse occurrence of granular corpuscles is also described, but this is said by some observers to be physiological. The nature of this lesion is but little understood and is still the subject of controversy.

*Syphilitic Inflammation of the Brain* sometimes results in the formation of so-called gummy tumors. These are most frequently found near the periphery of the brain, not infrequently connected with the meninges, and may be sharply circumscribed. The central portion of the tumor is usually in a condition of cheesy degeneration, and in the periphery we see fibrous tissue or a dense infiltration of small spheroidal cells.

Syphilitic inflammation of the brain very frequently occurs in a diffuse form, characterized by the formation of a gelatinous, grayish

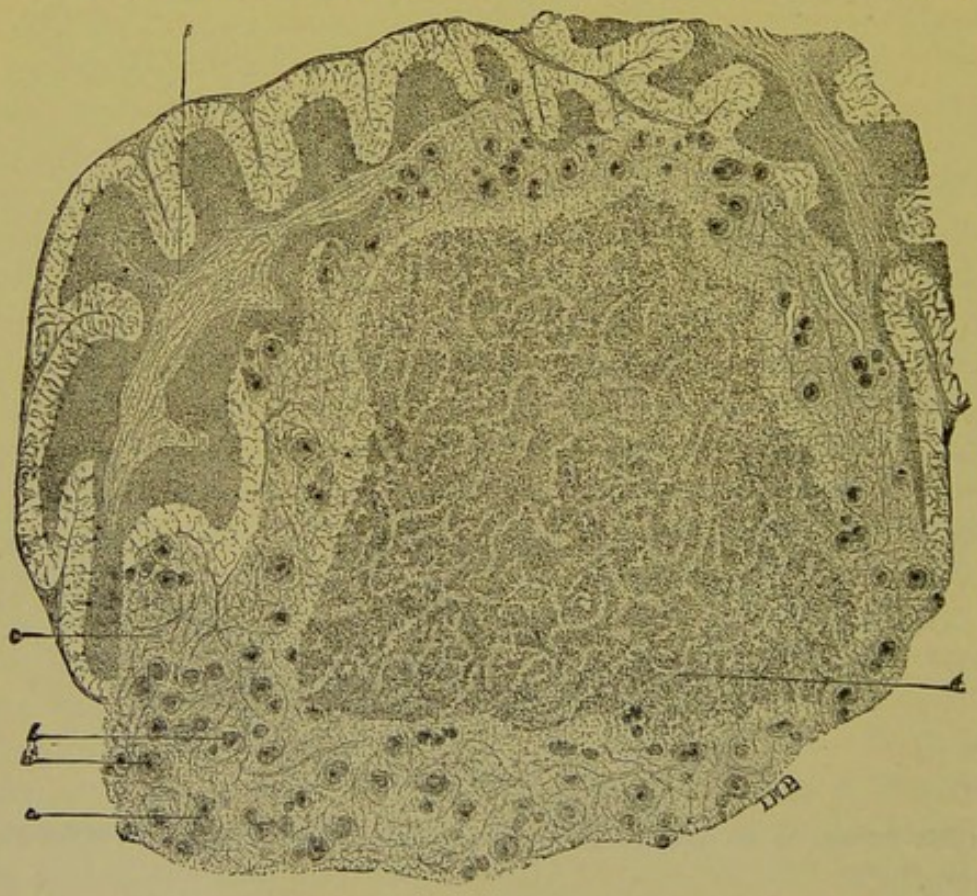

FIG. 181.—SOLITARY TUBERCLE OF CEREBELLUM.

*a*, *a*, miliary tubercles with giant cells; *b*, *b*, miliary tubercles without giant cells; *c*, diffuse tubercle tissue; *d*, central cheesy mass; *e*, nerve tissue of the cerebellum.

tissue consisting of a more or less homogeneous or granular basement substance, with numerous small spheroidal cells. The nerve elements are atrophied. Obliterating endarteritis may occur as a result of syphilitic poisoning (Fig. 180).

*Tuberculous Inflammation* of the brain substance usually manifests itself in the formation of circumscribed masses of new tissue

from 0.5 cm. to 1 cm. in diameter, or larger. These may be single or multiple, are most common in young persons, and very frequently occur in the cerebellum. They are apt to occur in connection with tuberculous inflammation of other organs. They are frequently called *solitary tubercles*, and usually consist of a dense central cheesy mass, around which is a grayish zone containing tubercle granula, numerous small spheroidal cells, with occasionally larger polyhedral cells and giant cells (Fig. 181). They do not, as a rule, seem to be formed by an aggregation of miliary tubercles, although these may be present in the periphery. Tubercle bacilli have been found in these solitary tubercles.

They sometimes suppurate and break down, and then may simulate simple abscesses.

Conglomerate and scattered miliary tubercles of the ordinary form sometimes occur in the brain, usually in connection with tubercular inflammation of the meninges or ependyma.

### LESIONS OF THE BRAIN IN GENERAL PARESIS OF THE INSANE.

The changes in this disease are in the main those of chronic diffuse encephalitis, but the appearances vary greatly and depend to some extent upon whether the brain is examined in early or late stages of the disease. According to Meyer, in the early stages of the disease the convolutions, particularly of the anterior cerebral lobes, are swollen, the gray matter congested and softened in places. The brain tissue is more or less infiltrated with leucocytes. Fatty degeneration of the walls of the capillaries, and punctate hæmorrhages, are also common.

In later stages of the disease a great variety of changes may be observed: hæmorrhagic pachymeningitis, thickening of the dura mater, and close adhesions to the skull; thickening and opacities of the pia mater, adhesions of the latter to the dura mater and to the brain tissue. The brain tissue is apt to be atrophied, and the ventricles dilated and filled with fluid. The pia mater may be œdematous, the ependyma thickened and roughened. On microscopical examination the neuroglia is found to be increased in amount, the ganglion cells shrunken and sometimes pigmented; the nerve fibres may also be atrophied, and the blood vessels in a condition of fatty or hyalin degeneration. There may be an accumulation of fatty and granular cells along the walls of the blood vessels. Secondary degenerations in the spinal cord are not infrequently observed.

It is very difficult to make positive and definite statements regarding many such lesions of the brain as those just indicated, or in general of brain lesions whose nature must be revealed by microscopical study, because our technical procedures in the study of the

brain, even in normal conditions. are still quite unsatisfactory and incomplete. The brain tissue is so delicate and liable to post-mortem changes, and the effects of different preservative agents are so liable to variations, that great caution is necessary in arriving at conclusions regarding the minuter lesions affecting the nerve tissue of the brain.

### PIGMENTATION.

This may occur in any portion of the brain or its meninges from the decomposition of extravasated blood. In persons affected by malaria the gray matter of the brain has sometimes an unusually dark or even blackish appearance. This color is due to the presence of black pigment granules within the capillary blood vessels. The obstruction to the vessels by masses of these pigment granules may cause capillary apoplexies. The pigment may also be found in the walls and in the lumina of the vessels of the pia mater.

Pigmented patches of congenital origin are not infrequently seen in the pia mater. They may be due to the presence of branching pigmented cells.

### TUMORS OF THE BRAIN.

*Neuroglioma ganglionare.*—This is a form of tumor probably due to disturbances in the development of the brain. It occurs in the form of circumscribed tumors or of diffuse enlargements of portions of the brain. The pia mater over these tumors is unchanged and the convolutions retain their shape. The tumors are formed of neuroglia, in which are contained little groups of ganglion cells (Ziegler).

*Glioma.*—This is the most common tumor of the brain. It occurs with especial frequency in children and young adults. Such tumors occur in all parts of the brain, but they are found most frequently in the cerebrum. There may be a single tumor, or there may be several such tumors in different parts of the brain ; some of them attain a large size. These tumors may be sharply circumscribed, or merge imperceptibly into the brain substance ; sometimes the tumor is arranged so as to form the wall of a cyst which contains clear serum. They may be white and hard ; gray, soft, and gelatinous ; infiltrated with small hæmorrhages ; or partly degenerated and softened. The brain tissue around these tumors may be inflamed or necrotic. The tumors are composed of neuroglia, the relative quantity of neuroglia cells (Fig. 137) and of fibrils (Fig. 136) varying in the different tumors.

If the cells are very numerous, with but little basement substance, the tumor is called a glio-sarcoma.

*Sarcomata* occur in any part of the brain. They are single or multiple. They are composed of round or fusiform cells with more or less basement substance.

*Endotheliomata* are found in the substance of the brain. They are of the same types as have been described as occurring in the pia mater.

*Myxoma, fibroma, lipoma,* and *osteoma* are rare forms of brain tumor.

*Angioma.*—Small collections of dilated vessels are found in the substance of the brain. They seem to be congenital, like the nævi of the skin.

*The cysts of the cerebellum* are very curious bodies. They are found in young persons and in adults. They occur in any one of the lobes of the cerebellum. They may be as large as a hen's egg. They contain clear serum or colloid matter, and their walls are formed of thickened neuroglia. We are ignorant of their mode of origin. They give marked clinical symptoms and are regularly fatal.

### PARASITES.

Cysticercus and, more rarely, echinococci are found in the brain.

### MALFORMATIONS.

*Cyclopia.*—This malformation consists in an arrest of development affecting the cerebrum, which, instead of separating into two hemispheres, remains single, with one ventricle, and the rudiments of the eyes usually become joined and form one eye. This single eye is in the middle of the face, near the place of the root of the nose, in a single orbit. Over this is an irregular body representing the nose. The rest of the face is well formed. Or the eyeball may be wanting entirely, or there are two eyes joined together, or, more seldom, two separate eyes. The orbit is surrounded by rudiments of four eyelids. The frontal bone is single, the nasal bones undeveloped ; the ethmoid, vomer, and turbinated bones are absent. The optic nerve is double, single, or absent. There may be hydrocephalus. Such children are incapable of prolonged existence.

*Anencephalia.*—This malformation may be of various degrees. The brain may be entirely absent, and the base of the cranium is covered with a thick membrane, into which the nerves pass. Or the membranes may form a sort of cyst containing blood and serum, or portions of brain. Of the cranial bones, only those which form the base of the skull are present (*Acrania*). The scalp is usually partly or entirely absent over the opening in the skull ; the eyes stand prominently out, and the forehead slopes sharply backward. This malformation may occur in otherwise well-developed children.

*Hydrocephalus.*—This lesion has been already considered on page 367. It is probable that in some cases *hydrocephalus internus* is due to a primary *partial anencephalia*, and that the accumulation of fluid is of secondary occurrence. In rare cases, only part of one lateral ventricle is hydrocephalic, giving to the head a protuberance on one side. The viability of the fœtus depends upon the degree of the hydrocephalus. *Hydrocephalus externus* is an accumulation of serum beneath the pia mater, or, according to some authors, between the pia and dura mater. It causes dilatation of the cranium and compression of the brain. It is of very rare occurrence, and may also be secondary to partial anencephalia.

*Cephalocele, or Brain Hernia.*—When abnormal openings exist in the skull from malformation, the contents of the cerebral cavity are apt to protrude in the form of larger or smaller sacs. This may occur in cases of well-marked anencephalia or in cases in which the brain is well developed. The protruding sac formed of the meninges may or may not be covered with skin. If the contents of the sac are simply fluid, the lesion is called *hydromeningocele ;* if composed of brain substance, *encephalocele ;* if the sac contain both fluid and brain substance, it is called *hydrencephalocele.* The sacs may be very small or as large as a child's head. They may protrude from the top of the skull in acrania. They most frequently protrude through openings in the occipital bone, often hanging down in large sacs upon the neck ; also at the root of the nose, along the line of the sutures, at the base of the skull, and elsewhere.

*Microcephalia.*—This is an abnormally small size of the brain, with a correspondingly small cranium. The diminution in size affects principally the cerebral hemispheres, though the other parts of the brain are also small. The convolutions are few and simple, the cavities often dilated with serum ; on the membranes there may be traces of inflammation. The cranium is small, the face large, the rest of the body small. The malformation is in some cases caused by inflammation or dropsy of the brain during fœtal life. It is endemic in some countries, but single cases may occur anywhere. The fœtus is viable. Absence or incomplete development of portions of the brain may occur, not only in idiots, but in persons whose minds are perfect.[1]

[1] For a general consideration of malformations of the central nervous system consult *Thoma*, "Text-Book of Pathological Anatomy," vol. i., p. 206 et seq.

# THE SPINAL CORD.

## THE MEMBRANES OF THE SPINAL CORD.

### A.—THE DURA MATER SPINALIS.

The dura mater spinalis, unlike that of the brain, does not serve as periosteum to the bones forming the cavity, so that the lesions of the two membranes differ somewhat.

#### HÆMORRHAGE.

Hæmorrhage may occur, as the result of injury, between the dura mater and periosteum, or it may occur in tetanus, as a result of circulatory changes induced by muscular spasm, or in the asphyxia of new-born children. Small hæmorrhages on the surfaces of the membrane may occur as the result of inflammation.

Serous fluid may accumulate outside of the dura mater as a result of post-mortem changes, or in connection with circulatory or inflammatory changes in the membranes.

#### INFLAMMATION.

*Acute external pachymeningitis* is usually secondary to disease or injury of the spinal column, and may result in collections of pus between the dura mater and periosteum, usually most abundant posteriorly. *Hæmorrhagic pachymeningitis* occurs in the dura mater spinalis, with the formation of products similar to those observed in the brain, in the chronic insane and in drunkards. *Simple chronic pachymeningitis interna*, with the formation of new connective tissue containing brain sand, is not infrequent. The new tissue may form minute projections or roughness of the surface, or, when more abundant, the *psammomata*. *Tuberculr inflammation* of the dura mater spinalis may occur in connection with tubercular meningitis, or be secondary to tubercular inflammation of the vertebræ.

### TUMORS.

*Fibromata, lipomata, chondromata, myxomata, endotheliomata,* and *adeno-sarcomata*[1] occur in the dura mater spinalis as primary tumors. *Carcinomata* and *sarcomata* may occur as secondary tumors. Small plates of new-formed *bone* are rarely found in the dura mater spinalis.

### PARASITES.

Echinococcus developing outside of the spinal canal may perforate the dura mater; or the cysts may lie between the dura mater and the pia mater.

It is obvious that even small tumors in the spinal canal may give rise to serious results from compression.

## B.—THE PIA MATER SPINALIS.

It is almost impossible in most cases in the pia mater, as well as in the dura mater spinalis and in the spinal cord, to judge with certainty, from the appearances after death of the blood contents of the vessels, of these parts during life. The same is true of abnormal quantities of serum found after death. The veins of the pia mater, especially in the posterior region, may be greatly distended with blood after death, without pre-existing disease; and the intermeningeal space may contain much fluid under the same condition.

### HÆMORRHAGE.

Hæmorrhages may occur from injury in connection with severe convulsions, or general diseases such as the hæmorrhagic diathesis, scurvy, small-pox, etc. The hæmorrhages under these conditions, except from injury, are not usually extensive. But in some cases of injury or cerebral apoplexy; from the bursting of aneurisms of the basilar or vertebral arteries; or in cases in which we cannot find a cause, a very large quantity of blood may collect between the dura and pia mater, and in the meshes of or beneath the latter.

### INFLAMMATION.

*Acute exudative spinal meningitis* occurs under essentially the same conditions and with essentially the same post-mortem appearances as acute cerebral meningitis, though it is less frequent. The exudations are apt to be most abundant in the posterior portions. It may be associated with a similar inflammation of the pia

[1] *Hodenpyl,* American Journal of the Medical Sciences, March, 1888.

mater cerebralis, and the inner surface of the dura mater may be involved. The disease may be circumscribed, but usually affects the entire length of the membrane.

*Tuberculous inflammation* is usually most marked, when associated with a similar condition of the pia mater cerebralis, in the upper portions of the cord ; but it may extend over the entire membrane. The conditions under which it occurs and the character of the lesions are similar in both. *Chronic spinal meningitis* is not infrequent, manifesting itself in the formation of larger or smaller patches of new connective tissue or thickenings of the pia mater. The pia and dura mater may thus be firmly united in places by adhesions, or the pia mater may become closely adherent to the substance of the cord.

Not very infrequently large numbers of pigment cells are found in the pia mater spinalis, sometimes giving it a distinct gray or blackish color.

### TUMORS.

Small plates of *cartilage* and *bone* are sometimes found in the pia mater.

*Fibromata, myxomata, sarcomata,* and *endotheliomata* have been found.

### PARASITES.

Cysticercus sometimes occurs in the meshes of the pia mater.

## THE SPINAL CORD.

### HÆMORRHAGE.

This is much less frequent than in the brain, but may occur either as *capillary apoplexy* or as larger *apoplectic clots.* Capillary hæmorrhages, similar in appearance to those of the brain, may occur as the result of injury, or near areas of softening or tumors, or may accompany severe convulsions, as in tetanus. Apoplectic clots, which are comparatively rare in the spinal cord, are usually small, commonly not more than one cm. in diameter, and are similar in their appearances, and in the changes subsequent to their formation, to those of the brain. They are usually the result of injury ; but they may occur spontaneously, probably in most cases as a result of inflammation, and are then most apt to occur in the gray matter. Sometimes, however, hæmorrhagic foci are found in the spinal cord without traumatism or evidence of inflammatory change.

### HÆMATOMYELIA AND HÆMATOMYELOPORE.

Several cases have been described in which long tubular canals

were found in the spinal cord. These have been considered the result of central necrosis, myelitis, etc., varieties of syringomyelia, and variously named. These long cavities have no well-defined

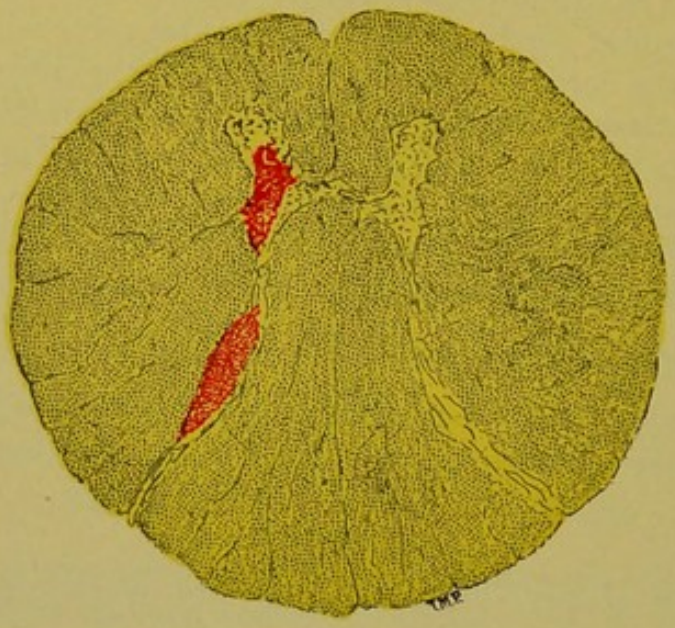

FIG. 182.—SECTION OF THE SPINAL CORD SHOWING HÆMORRHAGE INTO THE GRAY MATTER AND EXTENDING LENGTHWISE OF THE CORD.
Showing an early phase of hæmatomyelopore. (Van Gieson.)

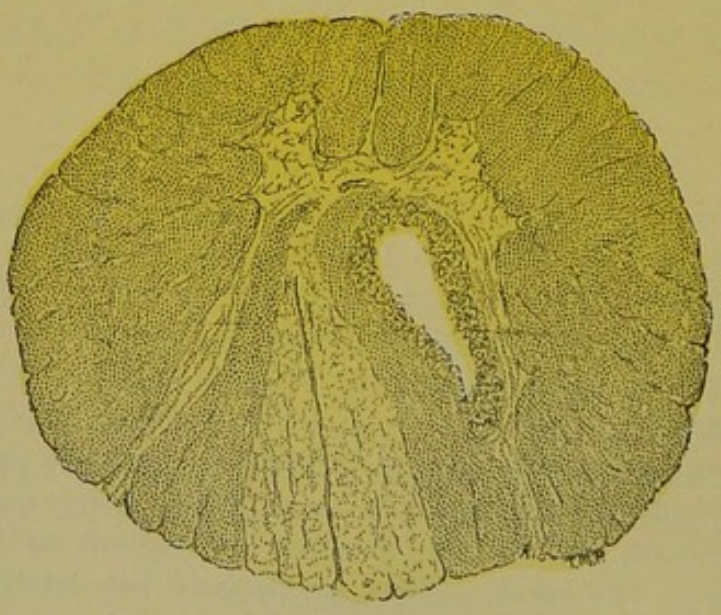

FIG. 183.—HÆMATOMYELOPORE. (Van Gieson.)
The section shows at one point a cyst-like cavity in the spinal cord, originating in a hæmorrhage in the posterior root and extending nearly the entire length of the cord. The sides of the cavity are now covered with tissue detritus.

wall and no distinct lining membrane. They are filled with blood and tissue detritus.

Van Gieson has shown that they correspond to columnar hæmor-

rhages within the cord, usually following traumatisms in which the blood forced its way lengthwise of the cord, forming columnar masses. On the absorption of this blood the long cavities or canals are left. This condition Van Gieson has called *hæmatomyelopore*.

### INJURIES.

The spinal cord may be compressed or lacerated by penetrating wounds, by fracture or dislocation of the vertebræ, or by concussion without injury to the vertebræ. The spinal cord is found simply disintegrated, or there may be much hæmorrhage and the disintegrated nerve tissue be mixed with blood. If life continue, the nerve elements may degenerate; Gluge's corpuscles and free fat droplets may form; blood pigments may be formed; and when inflammation supervenes more or less pus may be intermingled with the degenerated detritus. There may be marked changes in the minute structure of the cord, without any change being evident to the naked eye.

### SECONDARY DEGENERATIONS IN THE SPINAL CORD.

The modern conception of the structural elements of the nervous system is that they are complex cell units called *neurons*, which may extend over long distances, and although without direct anastomoses stand in intimate topographical and functional relationships with one another.

The neuron consists of a *cell body*, an axis-cylinder process, the *neuron*, and protoplasmic processes of the cell called *dendrites*.

A destruction of the cell body or a separation of the processes from the cell body is accompanied by a degeneration of the processes.

The cell bodies are grouped together in the gray matter of the brain and cord and in the ganglia situated along the peripheral nerves.

Through the dendrons impulses are conducted *to* the cell bodies; through the axis-cylinder processes they are conducted *from* the cell body.

When the cell bodies of the neurons of certain parts of the brain and of the spinal cord are destroyed, or when the motor nerves leading from them are severed or seriously injured, that portion which is deprived of or separated from its cell body degenerates.

After a time—frequently two to four weeks—the medullary sheath and axis cylinder disintegrate, becoming granular and fatty. These products of degeneration may be in part absorbed at once, or may collect in cells, forming the so-called compound granular corpuscles. After a still longer time—sometimes several months—the degenerated

areas become gray in color from the absorption of the degenerated myelin, harder, and somewhat shrunken. These changes are partly due to the formation of new connective tissue which takes the place of the degenerated nerve fibres.

Since the affected portion of nerve tissues becomes gray or translucent after the myelin is broken down and absorbed, and the new connective tissue is formed, this is often called *Gray Degeneration;* or, as the degenerated areas are harder than normal, it is sometimes called *Sclerosis.*

Now, it is found that this secondary degeneration takes place in the direction in which the fibres conduct—in centripetal or sensory fibres, upward ; in centrifugal or motor fibres, downward. Thus we have *Descending Secondary Degeneration* (*Descending Sclerosis*), and *Ascending Secondary Degeneration* (*Ascending Sclerosis*).

*Descending Secondary Degeneration.*—This change affects chiefly the motor nerve fibres, and may reach but a short distance from the seat of lesion, or may extend for a long distance, depending upon whether the severed fibres run a short or long course before reaching their termination. Lesions of the brain, such as embolic softenings and apoplectic clots, which destroy or interrupt any of the motor nerve fibres originating in the central convolutions, may be followed by degeneration of the portion of the fibres situated peripherally to the lesion. These fibres pass through the corona radiata, anterior portion of the internal capsule, pes pedunculi, pons, and thence to the anterior pyramids, where most of them decussate and pass to the posterior part of the lateral columns of the opposite side. Those which do not decussate form a narrow band at the inner part of the anterior columns of the same side, constituting the *columns of Türck.* These fibres which convey motor impulses from the brain to the cord form a system called the *pyramidal tract.*

Now, a lesion in the brain separating the motor nerve fibres of one side from their cells of origin in the motor cortex will be followed by areas of degeneration in the posterior part of the lateral column of the opposite side, and in a narrow band near the anterior longitudinal fissure of the same side (see Fig. 184). A lesion below the medulla, involving the fibres of the pyramidal tract on one side, will be followed by degeneration of the fibres on the same side below the point of lesion. If a part only of the fibres in any of these regions is interrupted the amount of degeneration is of course proportionately small.

*Ascending Secondary Degeneration.*—Any lesion interrupting the course of the centripetal (mostly sensory) nerve fibres in the cord is followed by degeneration of the central ends of the involved fibres,

because these are separated from their cells of origin either in the spinal ganglia or in the gray matter of the cord itself.

Part of these sensory fibres—some of which are short, others long—

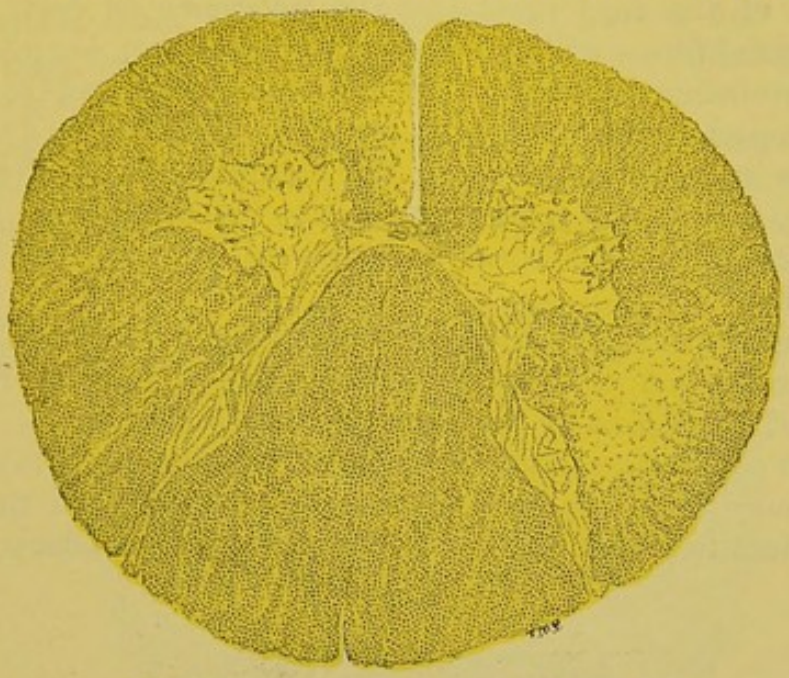

FIG. 184.—DESCENDING SECONDARY DEGENERATION.

Section of cord in cervical region. Degeneration of the column of Türck and of the crossed pyramidal tract.

are situated in the posterior columns and form communications between different parts of the gray matter.

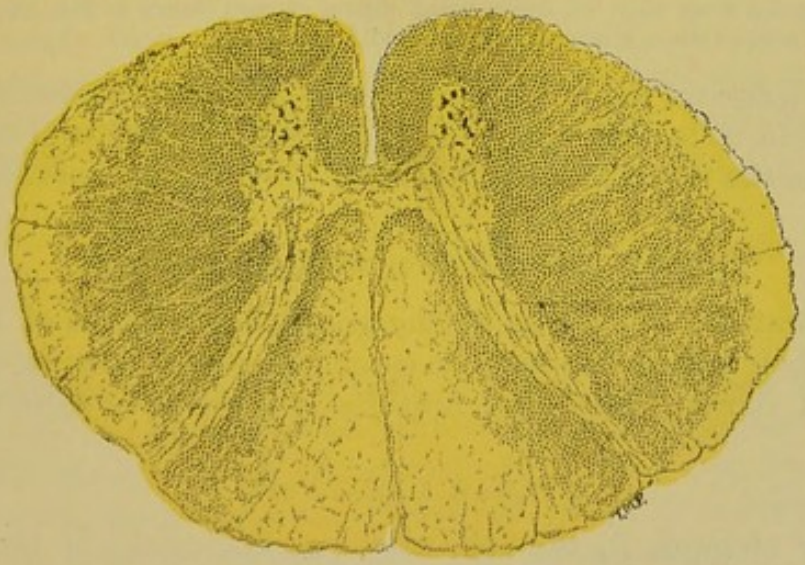

FIG. 185.—ASCENDING SECONDARY DEGENERATION IN THE SPINAL CORD (UPPER CERVICAL REGION).

After fracture of the spine destroying the eighth cervical segment; the lesion involves the columns of Goll, the direct cerebellar tract, and the columns of Gowers.

Others of the sensory fibres are grouped in a narrow band near the posterior longitudinal fissure, forming the *columns of Goll*,

while other sets, forming the so-called *direct cerebellar tract* and *the columns of Gowers*, are situated in the periphery of the lateral columns.

A lesion of the cord involving the severance or destruction of these centripetal fibres will be followed by ascending degeneration of the direct cerebellar tract and of the columns of Goll and Gowers and of the entire posterior column, just above the lesion (Fig. 185). The degeneration may be traced along the columns of Goll to the restiform bodies, and in the cerebellar tract to the cerebellum. Lesions involving the entire thickness of the cord will produce bilateral degenerations.

Following the secondary degeneration of the nerve fibres, whether ascending or descending, new connective tissue may form, filling the space formerly occupied by the nerve elements (Fig. 186).

This new connective-tissue development was formerly looked upon as the primary factor in various forms of sclerosis in the central nervous system to which the nerve changes were secondary; but the

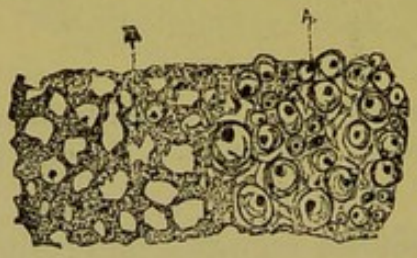

FIG. 186.—ASCENDING GRAY DEGENERATION.

A small portion from edge of degenerated region of cord shown in Fig. 185, more highly magnified. A, normal nerve fibres; B, degenerated area.

new knowledge on the subject makes it evident that the connective tissue should be looked upon not as a chronic interstitial inflammation, but as the result of a *replacement fibrous hyperplasia.*

### PROGRESSIVE SPINAL MUSCLE ATROPHY.

Degeneration or atrophy of the anterior nerve cells of the spinal cord and their neuraxons may be associated with varying degrees of atrophy of the corresponding muscles—*progressive spinal muscle atrophy.*

### BULBAR PARALYSIS.

Similar changes in the cells of the motor nuclei of the medulla may be associated with paralysis of the tongue, lips, and larynx, and constitute the so-called *bulbar paralysis.*

### AMYOTROPHIC LATERAL SCLEROSIS.

Under obscure conditions there may be degenerative changes of

both the central motor neurons from the brain to the cord and of the peripheral motor neurons from the motor cells of the cord to the muscles. These conditions determine a replacement fibrous hyperplasia (sclerosis) in the lateral column and also in the anterior cornua of the spinal cord. If small groups of neurons are involved the sclerosis may be slight. This condition has been called *amyotrophic lateral sclerosis* (Fig. 187).

It should be borne in mind, in looking for these secondary lesions, that they are not developed until considerable time has elapsed since the development of the primary lesion, and that when small areas



FIG. 187.—SECTION OF SPINAL CORD IN AMYOTROPHIC LATERAL SCLEROSIS.
Shows degeneration of the crossed pyramidal tracts on both sides.

are involved they are usually inconspicuous. In any event, the lesions are apt to be more evident to the naked eye in specimens hardened in chromic fluids than when fresh, and microscopical examination is often necessary for their recognition.

## INFLAMMATION.

### *Acute Myelitis.*

This lesion of the spinal cord, which is sometimes distinctly inflammatory in character and sometimes of a degenerative nature, is usually confined to a comparatively limited longitudinal extent of the cord, and hence is sometimes called *transverse myelitis.* When the cord is removed and laid upon the table, if the lesion is marked, a flattening of the cord at its seat may be observed; or on passing the finger gently along the organ the affected segment will be found softer than the rest of the cord. On making a section through the diseased portion the nerve tissue may be white or red

or yellowish or grayish; it may be quite firm, but is usually more or less softened and sometimes almost diffluent.[1]

Microscopical examination shows different appearances, depending upon the stage of the inflammatory or degenerative process. There may be much blood, or, if the lesion has existed for some time, blood pigments; also fragments of more or less degenerated nerve fibres and ganglion cells (Fig. 188), myelin droplets, free fat granules, and larger and smaller cells filled with fat granules (Gluge's corpuscles), pus cells, granular matter, neuroglia cells, and sometimes corpora amylacea. The various combinations of these elements give rise to the different gross appearances which the diseased part presents. In earlier stages of the lesion the blood vessels may be dilated, the nerve fibres and cells swollen; or the walls of the blood vessels may be thickened or fatty, or surrounded by a sheath of leu-



Fig. 188.—Degenerated Tissue from Acute Myelitis.

cocytes and cells derived from the connective-tissue cells of the adventitia.

The lesion is apt to commence in the gray matter or at its edge, and then extend first laterally and afterward upward and downward.

In a certain number of cases the degenerated material may be absorbed and a cicatrix or cyst formed. In the least extensive forms of the lesion there is apparently a regeneration of the nerve fibre, and a restoration of the functions of the cord.

Secondary gray degeneration, both ascending and descending, may occur in the form of myelitis, varying in extent according to the size of the primary lesion.

*Acute disseminated myelitis* runs a rapid course, and proves fatal in a short time. The inflammation may involve nearly the whole length of the cord, but is more intense in some places than in others. The cord is swollen and congested, it is infiltrated with pus

[1] It should be remembered that a mechanical injury to the cord in removal, such as crushing or bruising, may reduce the injured portion to a pulpy consistence and thus produce appearances somewhat similar to those of some forms of inflammatory softening (see p. 381).

cells, the connective-tissue framework is swollen, and the nerve elements are degenerated (see Poliomyelitis).

*Poliomyelitis Anterior* (*Myelitis of the anterior horns*).—This

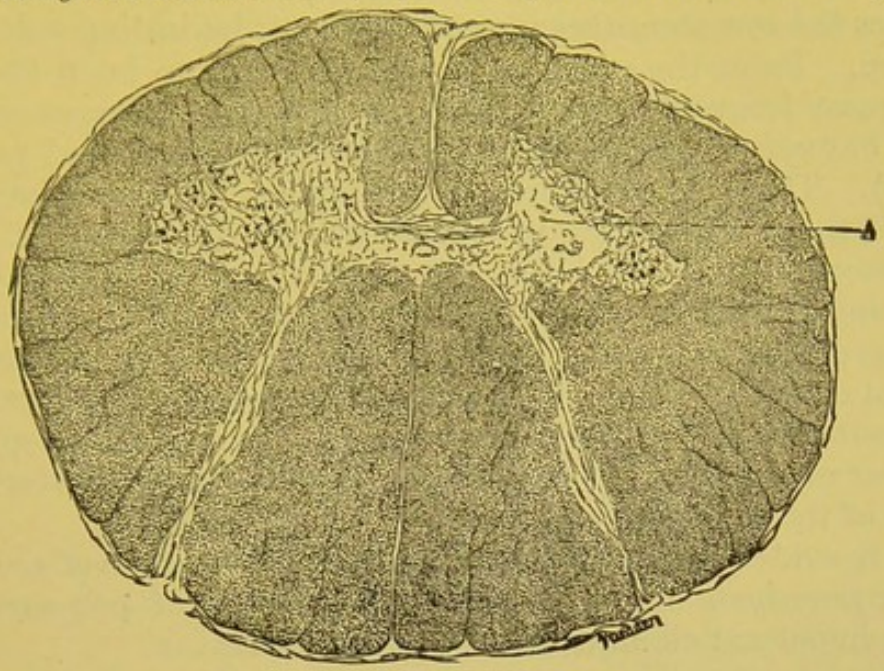

FIG. 189.—POLIOMYELITIS ANTERIOR.

Showing degenerated area in anterior cornua, with atrophy of gray matter. A, Atrophic region. Specimen prepared by Dr. Ira Van Gieson.

name is applied to a group of cases which are characterized by clinical symptoms indicating changes in the anterior gray cornua. The disease occurs both in children and in adults, and varies in the

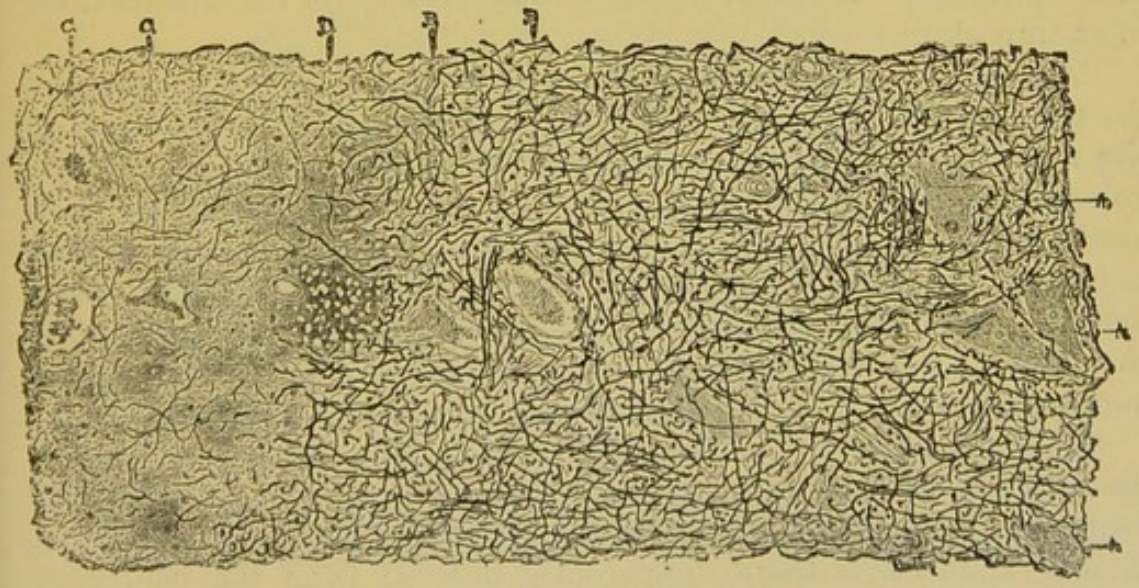

FIG. 190.—POLIOMYELITIS ANTERIOR.

Showing portion of Fig. 189 at edge of affected area, more highly magnified. A, normal ganglion cells surrounded by nerve fibres; B degenerated ganglion cells; C, granular masses at place of ganglion cells; D, small cavity containing fluid

severity, acuteness, and duration of its symptoms. In many cases there is complete recovery, and then we must suppose that the changes in the nervous tissue were not destructive in their character. In other cases the symptoms are more permanent, indicating a destructive lesion. From the autopsies so far recorded we learn that the lesion is most frequent at the lumbar and cervical enlargements of the cord, but may occur anywhere, and is often in scattered patches (Fig. 189). There is degeneration, shrinkage, pigmentation, and atrophy of the ganglion cells in the anterior gray cornua (Fig. 190). The chromophyllic masses in the ganglion cell bodies may be disintegrated and in various ways altered (see page 376). There may be an increase of connective tissue in the gray cornua and in the anterior and lateral columns. There may be degeneration and destruction of a considerable part of the anterior cornua; there may be atrophy of the anterior nerve roots. The cord may be considerably distorted as the result of the lesion.

There is evidence that the lesion in many of the cases of so-called *Landry's paralysis* are those of acute myelitis or of poliomyelitis, involving important changes in the ganglion cells.[1]

## CHRONIC MYELITIS.

*Chronic Interstitial Myelitis.*—Under this heading are embraced a variety of lesions which probably differ from one another somewhat in the nature of the changes involved, but more in the seat of the disease. We shall consider without special classification the most important forms.

*Chronic Transverse Myelitis.*—In certain cases of pressure on the spinal cord from a tumor or from displacement of the bones of the vertebral column, etc., instead of becoming softened or undergoing acute inflammatory changes, the cord becomes the seat of a localized formation of new connective tissue, with consecutive atrophy of more or less of the nerve elements in the gray and white matter. The cord becomes in this way harder, and sometimes shrunken at the seat of lesion, and grayish in color. This change may be followed by ascending and descending gray degeneration.

*Multiple Sclerosis.*—This lesion, similar in its nature to multiple sclerosis of the brain, often occurs with it. It consists in the formation, in more or less numerous scattered, circumscribed areas, of new connective tissue, apparently derived from the neuroglia. The formation of new connective tissue is preceded or accompanied by degeneration and atrophy of the nerve fibres and ganglion cells. The new connective tissue consists of the characteristic branching

[1] Consult *Bailey and Ewing*, New York Medical Journal, July, 1896.

neuroglia cells, surrounded by a more or less dense network of fine fibrillæ, many if not most of which seem to be branches of the neuroglia cells. Corpora amylacea and sometimes fat droplets, either free or contained in cells, may be present in the sclerosed areas.



FIG. 191.—MULTIPLE SCLEROSIS IN SPINAL CORD.

Showing larger and smaller areas of atrophy of nerve elements with formation of connective tissue.

The areas of sclerosis may involve both gray and white matter, and may be very small or large (Fig. 191). If very small or in early stages of formation, they may not be recognizable by the naked eye,



FIG. 192.—POSTERIOR SPINAL SCLEROSIS (TABES DORSALIS).

Section of the spinal cord in the cervical region.

but when visible they are grayish, translucent, and firmer than the surrounding tissue, and may or may not present a depressed surface; they sometimes project above the general level. The cause of

this, as of other forms of so-called idiopathic interstitial myelitis, is very obscure.

*Posterior Spinal Sclerosis* (*Locomotor Ataxia; Tabes Dorsalis*).—The lesions of this condition consist essentially of degeneration in the peripheral sensory neurons, especially in the spinal ganglia and posterior roots. This change involves degeneration and atrophy in greater or less degree of the nerve fibres in the posterior columns of the spinal cord and an associated replacement fibrous hyperplasia or sclerosis (Fig. 192).

Not infrequently the posterior portion of the lateral columns are also involved. Exceptionally a large part of the lateral columns is involved, and also the anterior cornua. The change usually com-

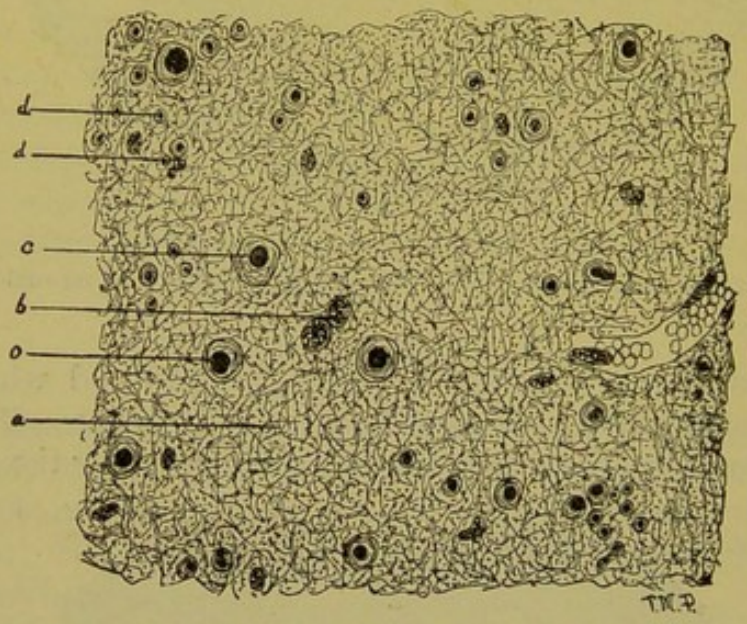


FIG. 192.—POSTERIOR SPINAL SCLEROSIS.

A portion of sclerosed area in the posterior columns of the spinal cord. *a*, New formed connective tissue; *b*, blood vessels; *c*, nerve fibres; *d*, atrophied nerve fibres.

mences in that portion of the posterior columns bordering on the posterior cornua, but may involve, as above stated, the adjacent parts. It is usually most marked in the lower dorsal and lumbar regions. The sclerosis may extend upward to the restiform bodies, but in the cervical region it is apt to be confined lagely to the columns of Goll, although there are exceptions to this.

When the lesion is well developed the pia mater over the affected area is usually thickened and adherent to the cord. In its early stages there may be no change evident to the naked eye; but when advanced the posterior columns may appear somewhat depressed, and grayish and firmer than the rest of the cord. The microscopical appearances vary, depending upon the stage and extent of the lesion.

The walls of the blood vessels may be thickened; there is more or less new connective tissue consisting of neuroglia cells and very numerous interlacing, delicate fibrils. There may be numerous corpora amylacea and fat granules, either free or collected in cells. The nerve fibres may be numerous, but separated more or less widely by the new connective tissue, or they may be very few in number and irregularly scattered through the new tissue (Fig. 193). The atrophy may involve the fibres of the posterior nerve roots and cornua, and even the ganglion cells of the latter. The peripheral nerves and the cells of the spinal ganglia may be degenerated.

According to the researches of Lisauer,[1] the columns of Clarke in the dorsal region show in this disease a very constant and marked diminution in the number of delicate fibrils which under normal conditions surround the ganglion cells.

In the rare cases in which the sclerosis extends to the lateral columns and to the anterior cornua, the minute characters of the lesions are the same. There is much reason for the belief that the formation of connective tissue in tabes is not the primary factor in the disease but is secondary to degeneration of the nerve fibres in the involved portion of the cord, and is thus in the nature of a replacement connective-tissue hyperplasia or fibrosis.

*Solitary tubercles* and *gummata* may occur in the spinal cord, but are not common.

### TUMORS.

*Cysts* may occur as a result of softening or from unknown causes. Sometimes very long, narrow canals are found in the spinal cord, even reaching nearly its whole length. Some of these are evidently the dilated central canal, as they are lined with epithelium. Others, however, doubtless originate in hæmorrhages (see Hæmatomyelopore, p. 391).

In the pia mater of the cord are sometimes found small fibromata, osteomata, and lipomata.

*Endotheliomata*, of the same types as have been described as existing in the pia mater of the brain, are much more rarely found in the pia mater of the cord.

A fatty sarcoma[2] of the pia mater, which infiltrated the cord, formed a tumor as large as a filbert, and had for twelve years caused gradually increasing paraplegia, has been described.

Two curious cases[3] of diffuse sarcoma and one of endothelioma of the pia mater of the whole length of the cord are recorded. They

[1] Fortschritte der Medicin, Bd. ii., No. 4, 1884.

[2] Trans. Lond. Path. Soc., xxxix.

[3] Trans. London Path. Soc., xxxviii.; Arch. für Psych., 1885.

occurred in girls of 4½, 16, and 22 years of age. In each case the pia mater of the whole length of the cord was diffusely thickened and studded with nodules. In two of the cases the growth was composed of round cells, in the third case of large endothelial cells arranged in alveoli. In two of the cases the clinical symptoms lasted only for about three weeks, in the third case for five months. The acuteness of the symptoms was such as to indicate the existence of spinal meningitis.

In the spinal cord itself gliomata, fibromata, sarcomata, glio-sarcomata, and angio-sarcomata occur, but are rare.

When gliomata or glio-sarcomata do occur in the spinal cord, the new growth is apt to extend for some distance lengthwise in the cord and to be attended with the formation of a cavity; this condition is usually described under the name of *syringomyelia.*

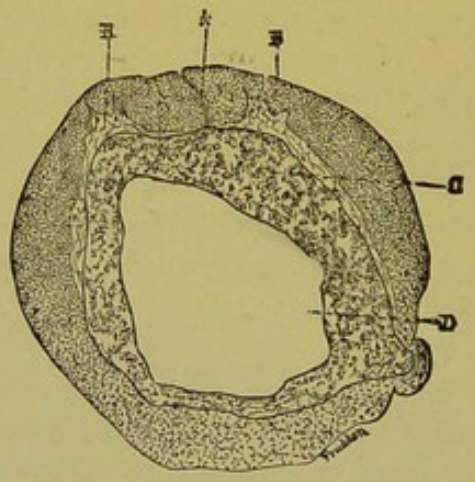


FIG. 194.—SYRINGOMYELIA.

Transverse section of cord. A, white substance of cord, distended by tumor; B, B, distorted and atrophied gray substance of anterior cornua; C, tumor mass (glio-sarcoma); D, cavity in cord. Drawn from specimen prepared by Dr. Van Gieson.

## SYRINGOMYELIA.

This lesion of the spinal cord consists in the formation of gliomatous or glio-sarcomatous tissue in the vicinity of the central canal, and its subsequent partial disintegration with the formation of one or more cavities within the substance of the cord (Fig. 194). These cavities, which are filled with fluid, vary greatly in size, shape, and extent, and, while usually situated in the central region of the cord, they may involve the anterior and posterior cornua and invade the posterior columns. There may be two communicating cavities, and these may, but usually do not, open into the central canal. The longitudinal extent of these cavities varies greatly. The lower cervical and upper dorsal regions are most frequently involved. The cavity is usually lined with tissue somewhat denser than that which makes

up the bulk of the tumor. The gliomatous or glio-sarcomatous tissue which forms the basis of the lesion in syringomyelia probably originates from the layer of neuroglia which surrounds or extends away from the central canal.

Syringomyelia is frequently mistaken for hydromyelia (see below), which is a congenital malformation, and in which the longitudinal cavity in the cord is at some period lined with epithelial cells. Syringomyelia has also been confused with hæmatomyelopore (see page 392).

There seems, furthermore, to be a class of lesions of the cord, usually classed as syringomyelia, in which cavities of various forms co-exist with a tumor in the vicinity of the central canal. But these cavities do not appear to be formed by a breaking down of the tumor tissue, but in some other way as yet little understood.

## MALFORMATIONS.

The malformations of the spinal cord may be conveniently classed as follows (Van Gieson):[1]

I. Congenital Deformities Associated with Monstrosities, and Incompatible with Extra-Uterine Life.

These may be divided into:

1. *Amyelia*, or absence of the spinal cord. This is almost invariably associated with absence of the brain.

2. *Atelomyelia*, or partial development of the spinal cord. This is often seen in the anencephalous or acephalic monsters, where, corresponding to the incompletely developed brain, there may be various degrees of defective development in the length of the cord.

3. *Diastematomyelia*, a condition in which a portion of the whole of the cord is split into two lateral halves. Each half of the cord, being enveloped in its own membranes and giving rise to its own nerve roots, may fuse together to form a single cord at some region.

4. *Diplomyelia*, or a formation of two spinal cords—a duplication of the spinal cord. This happens in the various kinds of double monsters.

II. Minor Congenital Malformations not Inconsistent with the Maintenance of Life.

1. *Hydrorrhachis interna* is a defective closure or arrangement of the divisions of the primary fœtal central canal often resulting in the dilatation of the central canal by fluid (*Hydromyelia*) Fig. 195). This dilatation may be moderate, or so extreme that but little of the substance of the cord is left as a thin shell around the central cavity.

[1] *Van Gieson*, "Artefacts of the Nervous System," New York Medical Journal, 1892.

When they have not been destroyed by atrophy, epithelial cells may be found lining the cavity.

This condition may be accidentally found after death. Its presence may also be indicated by its association with spina bifida.[1]

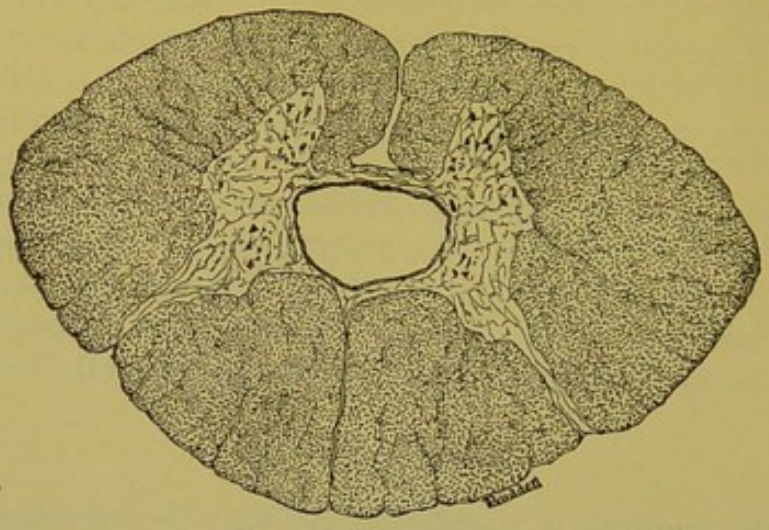

FIG. 195.—HYDROMYELIA.

In the section from which this drawing was made, the epithelial cells surrounding the dilated central canal were well preserved.

2. *Heterotopia*, or misplacement of the substances of the cord.

(*a*) There may be misplaced portions of the gray matter.

(*b*) Portions of the white matter may be arranged in an unusual manner.

3. *Anomalies of the Spinal Nerve Roots.*

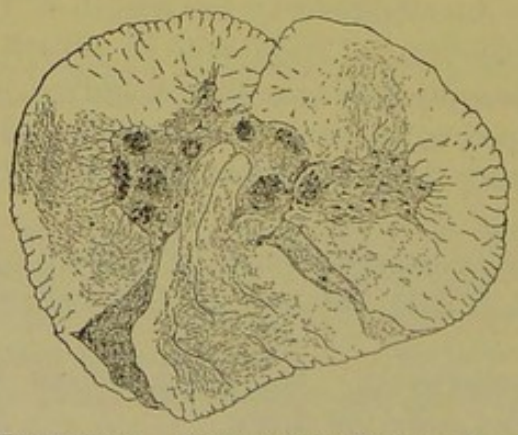

FIG. 196.—FALSE HETEROTOPIA. SECTION FROM CERVICAL REGION OF SPINAL CORD.

Showing artificial displacement of the structures by an experimental bruise ("false heterotopia") after the removal of the cord from the body. (Van Gieson.)

[1] Under this subdivision the condition known as *hydrorrhachis externa* may be conveniently alluded to, which consists in an abnormal congenital accumulation of fluids between the meninges of the cord, causing more or less diminution in the volume of the latter.

4. *Asymmetries of the Spinal Cord.*

III. Malformations of the Spinal Cord Acquired during Extra-Uterine Life or Secondary to Defective Development in other Parts of the Body.

1. Distortions following other cord lesions.

2. Asymmetry of the cord due to arrested development after birth or to secondary atrophy of portions of the cord in association with defective development or absence of some other part of the body.

3. Asymmetry of the cord with congenital defects of the extremities or muscles, such as intra-uterine or other amputations, clubfoot, etc.

4. Variations in the volume of the cord as a whole.

*False Heterotopia.*—Congenital displacement of the gray or white matter of the spinal cord—*heterotopia*—has been frequently described. Van Gieson[1] has shown, however, that in a large proportion of cases the so-called heterotopia is an artefact (Fig. 196) and has been caused by bruises or careless handling of the cord during its removal from the body or in the process of examination or hardening.

*Spina bifida.*—In the majority of cases hydrorrhachis is accompanied by a more or less complete lack of closure of the spinal canal posteriorly, so that the collections of fluid within may pouch outward through the opening in the form of a sac. The sac may be covered by skin, or this may be absent, either from the beginning or as a result of thinning and rupture. The walls of the sac may consist of the dura mater and the pia mater, or, in cases of hydrorrhachis externa, of the dura mater alone; when both are present they are usually more or less fused together. Inside of the membranes of the sac there may be a shell of distended nerve tissue of the cord; or the spinal cord may be split posteriorly and the sides crowded sideways; or there may be a rudimentary fragment of the cord suspended in the sac or attached to the walls; or the cord may be but little changed and remain inside the spinal canal. The openings in the spinal canal may be due to the complete or partial absence of the vertebral arches, or more rarely the sac may protrude through openings between the completely formed arches. Spina bifida most frequently occurs in the lumbar and sacral regions, but it may occur in the dorsal or cervical regions, or the canal may be open over its entire length. Very rarely it is open on the anterior surface. The protruding sac may be very small or as large as a child's head. The fluid in the sac is usually clear, but may be turbid from flocculi of degenerated nerve tissue.

[1] *Van Gieson*, loc. cit.

## THE PERIPHERAL NERVES.

### CHANGES IN NERVES AFTER DIVISION.

When nerves are divided or a portion destroyed by injury, the nutrition of certain parts of the fibres is interfered with, apparently because of the separation of these from their neurons, and they suffer degeneration; but after a time, if the conditions be favorable, they may undergo regeneration and restitution of function. The degeneration not only affects the entire severed portion, but it occurs at nearly the same time in all parts. The degeneration consists in the breaking-up of the medullary sheaths into variously shaped droplets, and the decomposition of these, with the formation of fat, which may remain for some time either free or enclosed in cells, and finally be absorbed (see Fig. 197). The axis cylinder, too, is, in many cases at least, more or less completely destroyed. The neurilemma and its nuclei do not seem usually to undergo degeneration, but may persist and take part in the regeneration of the nerve when restitution occurs.

After a variable time, if the conditions are favorable, the divided



FIG. 197.—DEGENERATION OF NERVE FIBRES IN MULTIPLE NEURITIS.

From a case of alcohol poisoning. Specimen stained with osmic acid. The broken-down medullary sheath and fat droplets are stained deep black.

ends of the nerve may be united, and a regeneration or new formation of nerves in or about the severed portions may occur, so that the function may be resumed. Considerable time is required, frequently months, for the completion of the regenerative process. Degeneration of the nerves not only follows mechanical injuries, such as incision, crushing or tearing, and compression, as from a tumor or dislocation of the bones, but it may result from disease of the special nerve centres with which the nerves communicate, or from inflammation of the nerves themselves.

### INFLAMMATION.

*Acute Exudative Neuritis.*—Primary acute inflammation of the nerves may occur as the result of injury, or it may be secondary to an inflammatory process in its vicinity, although, owing to the dense lamellar sheaths and the special blood supply, the nerve trunks may escape participation in even very severe inflammatory processes

in surrounding tissues. The inflamed nerve may be red and swollen and infiltrated with serum and pus cells. The process may undergo resolution or terminate in gangrene and destruction of the nerve, or it may become chronic and result in the formation of new connective tissue.

Degeneration and regeneration of the nerve fibres, similar to those above described as following division of nerve trunks, may occur in acute neuritis.

*Chronic Interstitial Neuritis.*—This is essentially a chronic interstitial inflammation resulting in an increase of connective tissue in the nerve sheath and intrafascicular bands. As a result of this the nerve fibres undergo atrophy from pressure; the medullary sheath, and finally the axis cylinder, being, in more or less of the fibres, partially or completely destroyed.

*Multiple Neuritis.*—Under a variety of conditions, such as exposure to cold and wet, overexertion, poisoning by alcohol, arsenic, lead, etc., and in connection with the acute infectious diseases, a degeneration of the nerve fibres in various parts of the body may occur (Fig. 197), which may be accompanied with or followed by proliferative changes in the neurilemma cells. Regeneration of the affected nerve fibres may occur under these conditions, as after experimental division of the nerves, leading to their restitution.[1] In some forms of multiple neuritis the inflammation is exudative in character, and new cells of various forms are found within and between the nerve fibres. The exact part which the neurilemma and other intrafascicular cells play in the inflammatory and regenerative changes of nerves is not yet very fully made out.

*Syphilitic* and *Tuberculous Inflammation* of the nerves is not common except at their central ends, in connection with similar inflammations of the meninges, or when they are secondarily involved in connection with these inflammations in neighboring tissues.

*Leprous Inflammation.*—This consists in the formation within the nerve of masses of new-formed tissue somewhat resembling granulation tissue, in whose cells multitudes of characteristic bacilli are uniformly found (see Leprosy). It constitutes the variety of leprosy known as *lepra anæsthetica*.

## TUMORS.

The tumors of the nerves are such as consist largely of or contain new-formed nerve tissue—*true neuromata;* and the so-called

[1] Consult *Starr*, "Multiple Neuritis." The Middleton Goldsmith Lecture for 1887. Trans. New York Pathological Society, 1887, p. 1.

*false neuromata* (Figs. 141 and 142), which are for the most part *fibromata* or *myxomata* of the connective tissue of the nerve. *Myxo-sarcomata* are less common, and *primary sarcomata* rare. The nerves may be secondarily involved in *sarcomata* or *carcinomata*, though not infrequently nerves pass through these tumors without being in the least involved in their peculiar structure. Paltauf has described as endotheliomata rare tumors of the glandula carotica.[1]

### ACROMEGALIA.

This rare disease is especially characterized by an overgrowth of the terminal portions of the extremities and of the bones of the face. But there may be a general involvement of the skeleton. This excessive growth is in the diameter and not in the length of the bones, accompanied by local exostoses, and is associated with an overgrowth of the soft parts composing the involved extremities. A marked enlargement of the pituitary body has been found in some of the cases, and this has been claimed to be the causative factor in the nutritional abnormality leading to the hypertrophic lesions of the bone.[2]

### SCLERODERMA.

Under little understood conditions a sharply circumscribed or widely extended hardening of the skin may occur as the result of a swelling of the old and formation of new connective tissue in the skin. This is associated with thickening of the walls of the blood vessels. The new-formed tissue may contract, it may continue to form so that the lesion is progressive; or, cessation of the process and recovery may occur.[3]

## METHODS OF PREPARATION OF NERVE TISSUE FOR MICROSCOPICAL STUDY.

The general methods of hardening have already been given on pages 18 and 21. For minute study there is no one method of staining and mounting upon which we can rely exclusively for the study of all lesions. A preliminary examination of areas of *inflammatory softening*, or of the disintegrated tissue in *apoplectic clots*, or of the new-formed tissue in *chronic hæmorrhagic pachymeningitis inter-*

[1] *Paltauf*, Ziegler's Beiträge zur path. Anatomie, etc., Bd. xi., p. 260, 1882.

[2] For a careful description of a case and a discussion of its relationships to similar abnormalities consult *Arnold*, "Acromegalie, Pachyacrie oder, Ostitis," Ziegler's Beitr. z. path. Anat., Bd. x., 1891.

[3] *Lewin and Heller*, "Die Sclerodermie," Berlin, 1895, bibliography.

*na*, may be made by teasing portions of the affected tissues in one-half-per-cent salt solution. Or the tissues in these lesions, or in any others in which fatty degeneration is suspected, may be placed for twenty-four hours in one-per-cent aqueous solution of osmic acid, and then washed and teased in glycerin. In this way the myelin and the fat will be stained brown or black. Secondary and other degenerations of medullated nerves may be studied by soaking the nerves for twenty-four hours in one-per-cent solution of osmic acid, and then staining with picro-carmin and teasing and mounting in glycerin. Suppurative inflammation of the central nervous system and its membranes, or the connective-tissue changes in general, may be studied in sections from the tissues hardened in Müller's fluid and alcohol, stained double with hæmatoxylin and eosin (see page 60), and mounted in Canada balsam.

A very useful method of staining sections of nerve tissue, especially of the brain and cord, is that known as Weigert's hæmatoxylin method. The tissue is first well hardened in Müller's fluid.

Blocks of the hardened tissue are embedded in celloidin and sections made in the usual way. The sections are first soaked for twenty-four hours in a saturated aqueous solution of neutral cupric acetate diluted with an equal bulk of water. They are now thoroughly washed twice in water, then in alcohol, and then are transferred to the hæmatoxylin solution, made as follows :

| | |
|---|---|
| Hæmatoxylin crystals | 1 gm. |
| Alcohol, 97 per cent | 10 c.c. |
| Water | 90 " |
| Saturated aqueous solution Lithium Carbonate | 1 " |

In this solution the sections remain for two hours. (If the finer fibres of the cerebral cortex are to be brought out the sections must remain for twenty-four hours in the hæmatoxylin solution.) The sections are now thoroughly washed in two or three waters and transferred to the bleaching solution, composed as follows :

| | |
|---|---|
| Potassium Ferricyanid | 2.5 gm. |
| Sodium Biborate | 2. " |
| Water | 200 c.c. |

In this fluid the sections discharge a brownish color, and they remain in it until the gray matter has a distinct yellow color and the white matter is bluish-black. The time required to produce this effect varies considerably, and is usually from half an hour to an hour. The sections are now washed, dehydrated with alcohol,

cleared up in oil of cloves or oil of origanum, and mounted in balsam. The sections may be stained in alum carmine before dehydration, to bring out the nuclei. In sections stained by this method the gray matter, connective-tissue elements, and ganglion cells have a yellow or yellowish-brown color, the axis cylinders are uncolored or have a slight yellowish tint, while the medullary sheaths are bluish-black or black.

To demonstrate the presence of miliary aneurisms in or about apoplectic clots, it is usually necessary to macerate the brain tissue in water until the nerve elements disintegrate, and they may then be washed away under a stream of water, leaving the blood vessels with their aneurisms exposed.

*Nissl's Staining Method.*—There are several variations of this method, but the following gives good results in most cases:

The essential feature of the so-called Nissl's method is the application of the anilin dyes to the staining of certain structural elements in the nucleus and cytoplasm, which are distinguished from the other structures of the cell by a differentiating decolorization with alcohol.

Methylen blue is the most generally useful of the anilin dyes for this purpose.

The specimens should have been carefully hardened in sublimate solution or in alcohol or in formalin.

Very thin sections are stained in one-per-cent solution of methylen blue. The staining may be effected on a slide on which the sections are floating in the blue solution by gently heating over a lamp until the fluid steams.

The sections are now transferred to a mixture of absolute alcohol 90 parts, with anilin oil 10 parts, in which the differentiation is effected by the use of successive fresh portions of fluid until slight but distinct differentiation in color is seen between the gray and white matter of the nerve tissue. The exact degree of decolorization which gives the best pictures will be learned by practice of the method. The sections are now freed from the bulk of the alcohol upon the slide, cleared in xylol, and mounted in dammar varnish, in which the color is apt to be preserved better than in balsam. By this procedure the chromosomes and the chromphylic bodies in the cytoplasm of ganglion cells are sharply differentiated, and thus abnormal conditions may be detected in them (see Fig. 178).

The applications of this method of staining to other cells than those of the nervous system are wide and of great promise.

# THE RESPIRATORY SYSTEM.

## THE LARYNX AND TRACHEA.

### MALFORMATIONS.

The larynx and trachea may be entirely absent in acephalic monsters. The larynx may be abnormally large or small. The epiglottis also may be too large or too small, or may be cleft. There may be communications between the trachea and the œsophagus, and then the pharynx generally ends in a cul-de-sac, and the œsophagus opens into the trachea. There may be imperfect closure of the original branchial arches, so that there are fissures in the skin leading into fistulæ which open into the pharynx or trachea. The fissure in the skin is small and is situated about an inch above the sterno-clavicular articulation, usually on one or both sides, more rarely in the middle line. Individual cartilages, as the epiglottis, or one or more rings of the trachea, may be absent, or there may be supernumerary rings. The trachea may divide into three main bronchi instead of two, and in that case two bronchi are given off to the right lung and one to the left. The trachea may be on the left side of the œsophagus or behind it.

### INFLAMMATION.

*Acute Catarrhal Laryngitis.*—This occurs as an idiopathic inflammation, as a complication of the exanthemata and the infectious diseases, and is produced by the inhalation of irritating vapors and of hot steam and smoke. The inflammation varies in its intensity in different cases. The mucous membrane is at first congested, swollen, and dry ; then the mucous glands become more active and an increased quantity of mucus is produced. There is an increase in the desquamation of the superficial epithelial cells and in the production of the deep cells. A few pus cells are found in the mucus and in the stroma of the mucous membrane. For some reason inflammation of the larynx is frequently attended with spasm of its

muscles, thus producing attacks of suffocation. In severe cases œdema of the glottis may be developed.

After death the congestion of the mucous membrane frequently disappears altogether.

*Chronic Catarrhal Laryngitis.*—The surface of the mucous membrane is dry or coated with muco-pus. The epithelium is thickened in some places, thinned in others, or in places entirely destroyed. The stroma is somewhat infiltrated with cells, diffusely thickened, or forming little papillary hypertrophies, or thinned, or necrotic and ulcerated (Fig. 198).

The mucous glands are swollen and prominent. The inflamma-

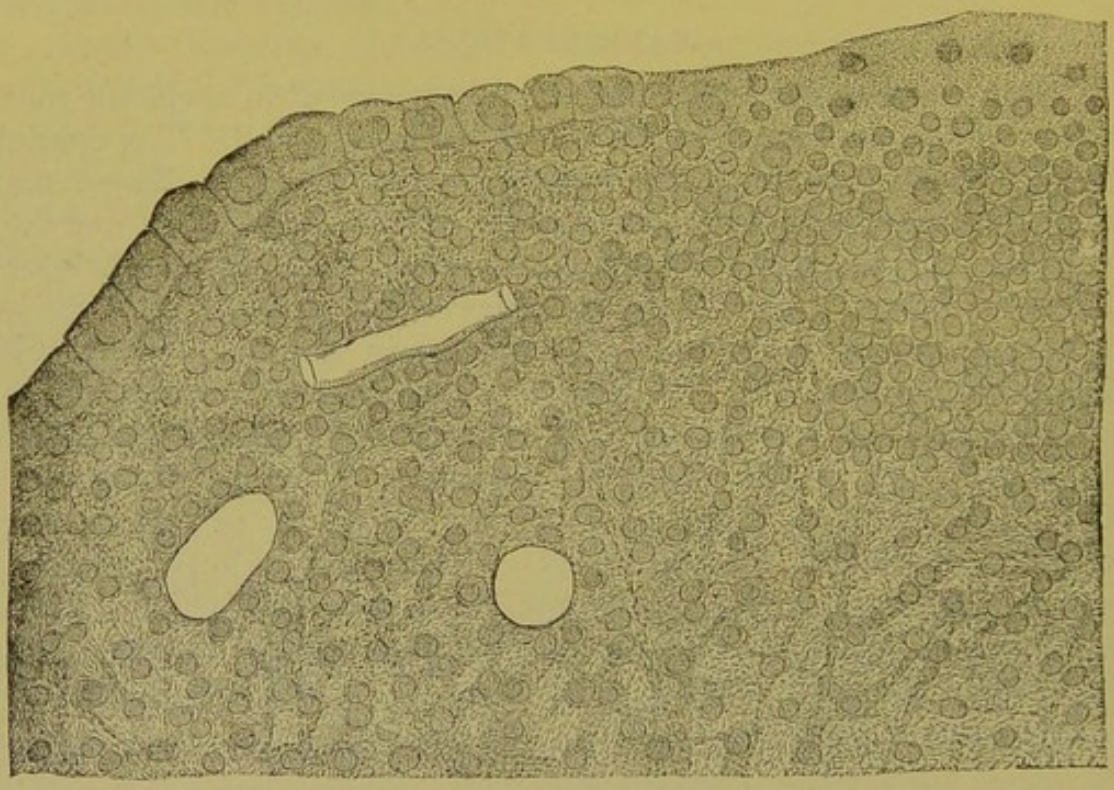

Fig. 198.—An Ulcer of the Larynx in Chronic Catarrhal Laryngitis, × 850 and reduced.

tion may extend to the perichondrium of the cartilages and thus cause their necrosis. The most severe forms of chronic laryngitis are those associated with pulmonary phthisis. Some forms of chronic laryngitis with thickening of epithelial and submucous tissue are called *Pachydermia laryngis.*

*Acute Suppurative Inflammation* may attack the posterior surface of the epiglottis and the aryepiglottidean ligaments. The stroma of the mucous membrane is swollen and infiltrated with serum and pus. Abscesses may be formed in the stroma, which rupture internally, or extend outward into the neck, or into the wall of the pharynx or of the œsophagus. Suppurative inflammation may accompany catarrhal, croupous, tubercular, and syphilitic laryn-

gitis, inflammations and injuries of the pharynx and tonsils; it may complicate typhoid fever and the other infectious diseases.

*Croupous Laryngitis* occurs most frequently as one of the lesions of diphtheria; it complicates the exanthemata and the infectious diseases. It is produced by the Bacillus diphtheriæ, by streptococci, by the inhalation of irritating gases, hot steam or smoke, and by the introduction of foreign bodies.

The mucous membrane is swollen and congested. Its surface is coated with fibrin and pus, and its stroma is infiltrated with fibrin and pus. The epithelial cells undergo coagulation necrosis. It is not often that there is necrosis of the deeper tissues.

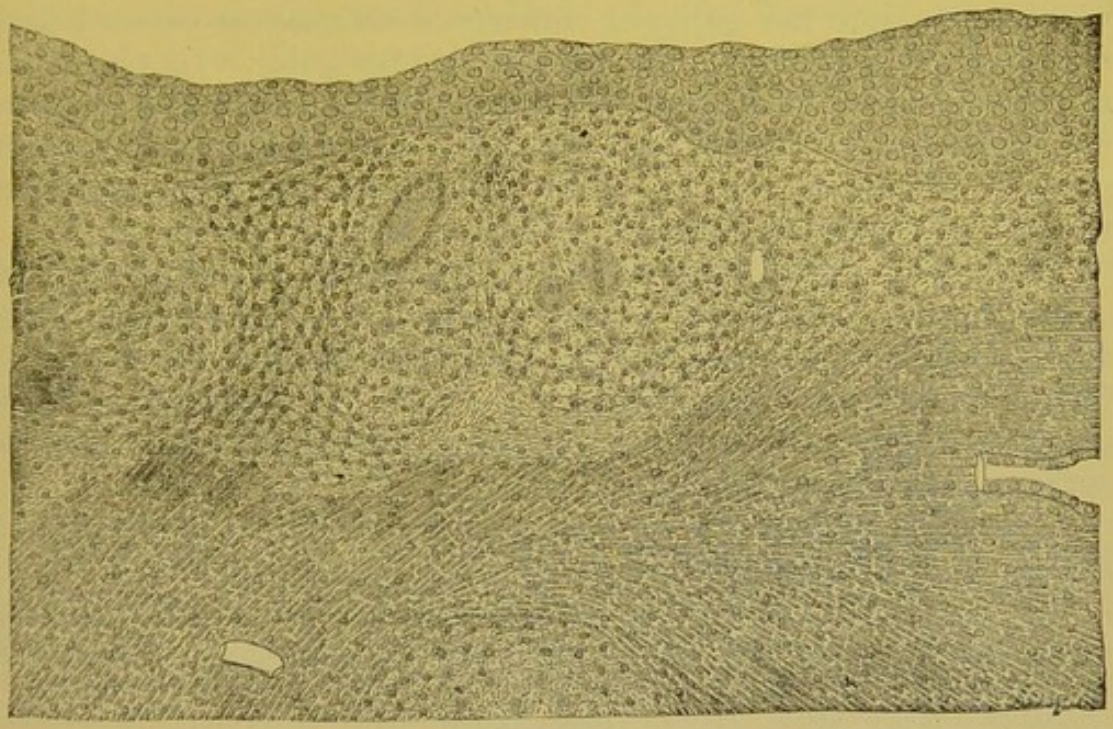

FIG. 199.—TUBERCULOUS LARYNGITIS.

*Syphilitic Laryngitis.*—Syphilis often causes laryngitis. The inflammation may have the ordinary characters of an acute or chronic catarrhal inflammation, or it is a productive inflammation with the formation of new tissue in the stroma of the mucous membrane. This new tissue is principally composed of small cells, which often degenerate and die. In this way the mucous membrane of the larynx and the tissues beneath are thickened in some places and destroyed in others, these changes being especially marked in the upper portion of the larynx. If the perichondrium is involved by these changes there may be necrosis of the laryngeal cartilages.

*Tuberculous Laryngitis* in its simplest form consists of a catarrhal inflammation, a growth of new cells in the stroma, and the forma-

tion of tubercle granula in the stroma without necrosis. The mucous membrane is thickened; it is coated with a layer of mucus, pus, and desquamated epithelium. From the epithelial layer outward the stroma is infiltrated with cells and with tubercle granula (Fig. 199).

When there are added to the production of tubercle tissue an excessive formation of cells and a tendency to necrosis, the conditions become much more serious and complicated. The catarrhal inflammation is intense, with the production of large quantities of pus and mucus. The necrosis results in the formation of ulcers of different sizes and shapes; the inflammation and necrosis extend from the mucous membrane to the wall of the larynx. The epiglottis, the vocal cords, and the adjacent mucous membrane are coated with muco-pus; their surfaces are ragged and irregular. In places the mucous membrane is destroyed, so that ulcers are formed; in places it is thickened and infiltrated with cells and tubercular tissue; in places it is necrotic. In the most severe cases the entire thickness of the wall of the larynx, with its cartilages, is involved.

*Œdema of the Glottis* is the name given to serous infiltrations of the mucous membrane of the upper part of the larynx. The swelling is most marked on the posterior wall of the epiglottis, in the aryepiglottidean ligaments and the false vocal cords. In these places the œdema of the stroma of the mucous membrane may be sufficient to close the larynx.

Acute œdema is due to an inflammatory exudation of serum, and accompanies inflammations of the pharynx, larynx, and neck.

Chronic œdema is of dropsical character and is caused by disease of the heart, pulmonary emphysema, and compression of the veins of the neck.

### TUMORS.

*Retention cysts* of the mucous glands of the larynx may reach such a size as to form sacs projecting into its cavity.

*Papilloma* is the most frequent form of tumor of the larynx. The tumors grow most frequently from the vocal cords. They consist of a connective-tissue stroma arranged so as to form papillæ covered with epithelium. They are sometimes congenital.

*Fibromata, lipomata, myxomata,* and *angiomata* are occasionally met with.

*Chondromata* grow from the normal cartilages and are usually multiple and sessile. They may project into the cavity of the larynx.

*Sarcomata* of the larynx have been seen in a considerable number of cases. They occur both in children and in adults. They are composed of fusiform or round cells, with a stroma which varies in quantity in the different cases.

*Carcinomata* may invade the larynx from the tongue or the pharynx, or may originate in it. They are composed of flat epithelial cells packed together in the usual way.

In the trachea tumors are of rare occurrence, but occasional examples of growths similar to those in the larynx have been met with.

Cheesy and otherwise altered bronchial lymph nodes may by ulcerative processes enter and obstruct the trachea.

## THE PLEURA.

### HYDROTHORAX.

Non-inflammatory accumulations of clear serum in the pleural cavities are of frequent occurrence. They are produced by the same causes which effect dropsy in other parts of the body—lesions of the heart, liver, and kidneys, and changes in the circulation and in the composition of the blood.

If the amount of serum is small it is of little consequence ; if it is large it may compress the lower lobes of the lungs and interfere with respiration.

There may be changes in the endothelium of the parietal pleura. Instead of the regular endothelium, large and small flat cells of irregular shape are found.

### HÆMORRHAGE.

Extravasations of blood in the substance of the pleura are found in persons who have died after suffering from the infectious diseases ; and as the result of injuries to the wall of the thorax.

Blood in large quantity in the pleural cavities is found after rupture of an aneurism of the heart with rupture of the pericardium.

Bloody serum in the pleural cavities is not often found with ordinary pleurisy. But with tubercular pleurisy and traumatic pleurisy it is not infrequently present.

### INFLAMMATION.

The inflammations of the pleura are all spoken of by the common name of pleurisy, or pleuritis.

All the different inflammations of the lung are capable of being accompanied by pleurisies, which begin in the pulmonary pleura and extend to the costal.

Besides these, however, there are many pleurisies which belong primarily to the costal pleura and extend from there to the pulmonary pleura.

Such pleurisies occur as idiopathic inflammations, as complica-

tions of various diseases, as the result of injuries, or are produced by the inflammation of adjacent parts.

We can distinguish :

I. Pleurisy with the production of fibrin.
II. Pleurisy with the production of fibrin and serum.
III. Pleurisy with the production of fibrin, serum, and pus.
IV. Chronic pleurisy with the formation of adhesions.
V. Tuberculous pleurisy.

All the varieties of pleurisy can best be studied in the lesions which are developed in and on the costal pleura. The lesions can be observed in the human subject, and can be produced artificially in the lower animals. It is in these artificial pleurisies especially that we are able to see the early changes produced by the inflammation and to watch the process step by step.

The free surface of the costal pleura is covered with a single layer of flat cells—the endothelium. The pleura itself is formed of planes of connective tissue reinforced by elastic fibres. Connective-tissue cells with large bodies and branching processes are present in considerable numbers, being most abundant in the layers beneath the endothelium. In the connective tissue are embedded blood vessels, lymphatics, and nerves.

### *I. Pleurisy with the Production of Fibrin—Dry Pleurisy—Acute Pleurisy.*

This form of pleurisy is apt to involve circumscribed areas of the costal, mediastinal, diaphragmatic, or pulmonary pleura, less frequently the entire pleura of one side of the chest. While the inflammation is going on the affected portion of pleura is coated with fibrin, the surface of the opposite portion of pleura is coated in the same way, and bands of fibrin join the two together. After the inflammation has run its course we find the affected portion of pleura thickened by the formation of new connective tissue, while bands of connective tissue extend between the opposed pleural surfaces.

As an exceptional condition there is inflammation of the entire pleura of one side, with the production of such an enormous amount of fibrin as to compress the lung and cause death.

### *II. Pleurisy with the Production of Fibrin and Serum—Pleurisy with Effusion—Subacute Pleurisy.*

This is the most common form of pleurisy. As a rule, it involves the greater part of the pleura of one side of the chest. Sometimes, however, the pleura of both sides of the chest is involved, and then the pericardium also is often inflamed.

While the inflammation is in progress the surface of the affected pleura is coated with fibrin, and bands of fibrin stretch between the parietal and pulmonary pleura. In the pleural cavity is serum in variable quantity. This serum is clear, or turbid from the presence of pus cells and flocculi of fibrin. The lung is compressed in different degrees and positions, according to the quantity of the serum and the character of the adhesions.

If the patient recover the serum is absorbed, the fibrin disappears, and there are left behind connective-tissue thickenings of the pleura and adhesions.

These two forms of pleurisy, although different in their clinical histories, are yet anatomically essentially the same. In both of them we find a regular sequence of changes. First, the production of fibrin and a few pus cells, either with or without serum. Second, a gradual absorption of the serum and fibrin. Lastly, the formation of permanent new connective tissue in the form of adhesions or of thickenings of the pleura. Throughout the whole process the tissue of the pleura is but little changed; the products of inflammation, although they originate in the tissue of the pleura, do not infiltrate it, but make their way to its surface, there accumulate, and there undergo their different changes. Variations from the regular course of the inflammation are effected by the excessive formation either of the fibrin, the pus, or the serum, and by the manner in which these inflammatory products are absorbed.

If we endeavor to follow out the successive changes by which the fibrin, pus, and serum make their appearance and then disappear, and the way in which permanent new connective tissue takes their place, we encounter several difficulties. It is difficult to obtain autopsies which will give the lesions belonging to each successive day of the disease; the pleura does not really show well if the patient has been dead more than two or three hours before the autopsy; and in most cases the inflammation is too intense, its products are too abundant, to be easily studied.

To obviate these difficulties we must resort to experiments on the lower animals. By injecting a solution of chlorid of zinc into the pleural cavities of dogs we can excite pleurisies closely resembling those which we see in the human subject. By varying the amount of fluid injected we can obtain pleurisies of different degrees of intensity. By using a number of animals we can observe the course of the inflammation from hour to hour and from day to day.

In such an artificial pleurisy the first change is congestion. The pleura is of a uniform bright-red color, its surface moist and shining. There is as yet no serum and no fibrin. Already, however, the endothelial cells have fallen off in patches, the superficial connective-

tissue cells are swollen and increased in number, and a few pus cells are present. These are all the changes for from half an hour to six hours after the irritant has been applied to the pleura.

The next step in the inflammatory process is the production of serum and fibrin. The serum collects in the bottom of the pleural cavity, the fibrin coats the pleura. As the fibrin is produced the pleura loses its natural moist and shining appearance. The fibrin appears first in the form of little granules, knobs, and threads between the edges of the endothelial cells and overlying them. A few pus cells are entangled in the fibrin and infiltrated in the superficial layers of the pleura. The swelling and new growth of the connec-



FIG. 200.—AN ARTIFICIAL PLEURISY IN THE DOG, OF TWENTY-FOUR HOURS' DURATION, × 750 and reduced.

Swelling and growth of connective-tissue cells in the pleura.

tive-tissue cells are now well marked. The bodies of the branching cells are swollen, and small polygonal, nucleated cells, arranged in rows between the fibres of the basement substance, make their appearance. By the end of twenty-four hours these changes are fully developed (Fig. 200).

After this the production of fibrin, serum, and new connective-tissue cells continues, and by the third or fourth day the new connective-tissue cells are present, not only in the superficial layers of the pleura, but also in the layer of fibrin coating its surface and forming adhesions.

By the fourth or fifth day the cells in the fibrin are still more

numerous; blood vessels make their appearance, which can be injected from the arteries of the pleura.

After this the serum is gradually absorbed. The layer of fibrin and cells on the surface of the pleura exhibits a constant decrease of fibrin and increase of cells, and becomes more intimately connected with the surface of the pleura.

By the fourteenth day the fibrin has disappeared and a basement substance has been formed between the cells. Of the new cells the superficial ones are changed into endothelium, the deeper ones into branching cells. The changes in the adhesions between the pulmonary and costal pleura are the same as those in the layer of fibrin coating the costal pleura.

The lesions of human pleurisy seem to be essentially the same as those of the artificial pleurisy just described. But the inflammatory products are formed in larger quantities, a much longer time is required for their absorption, and the formation of new connective tissue follows more slowly.

In these forms of pleurisy, therefore, two distinct processes take place:

1. The blood vessels are congested, and through their walls transude the plasma of the blood and a few white blood globules.

2. The superficial connective-tissue cells are increased in size and number.

The products of the first of these processes, the fibrin and serum, are regularly reabsorbed.

The product of the second of these processes, the new connective-tissue cells, regularly increases until a layer of new connective tissue is formed.

The natural termination of such a pleurisy is the recovery of the patient, with thickenings of the pleura and adhesions.

The irregular terminations are: The death of the patient, the protracted existence of the fibrin and serum, and the change of the character of the inflammation so that pus is produced.

In a considerable proportion of cases the examination of the exudate in a simple uncomplicated case of sero-fibrous pleurisy fails to reveal the presence of micro-organisms.

### *III. Pleurisy with the Production of Fibrin, Serum, and Pus—Empyema.*

This form of pleurisy may occur under several different conditions.

1. The inflammation is at the very outset of severe character, with the formation of pus.

2. A pleurisy with the production of fibrin and serum, either gradually or suddenly, changes its character and pus is formed.

3. Phthisical areas of softening, or abscesses of the lung, abscesses in the wall of the thorax, or in the liver, or in the abdomen, rupture into a pleural cavity and set up an empyema.

4. The inflammation may be not only purulent but also gangrenous in character. The fluid in the pleural cavity, the fibrin and pus coating the pleura, and the pleura itself, may putrefy, with the proliferation of bacteria and the evolution of gases. This may take place either in a closed pleura or in one which has been opened.

5. If there is an opening into a pleural cavity, either through the lung or through the wall of the thorax, there is air in the pleural cavity, in addition to the inflammatory products. Such a condition is called *pyo-pneumothorax.*

In all these different cases the pleural cavity is partly or completely filled with purulent fluid, and the lung is either compressed against the vertebral column or partly adherent to the chest wall. Sometimes, however, the purulent fluid is shut in by adhesions, either between parts of the lung and the thoracic wall, or between the lung and the diaphragm, or between the lung and the pericardium, or between the lobes of the lung.

The fluid in the pleural cavity is usually a thin, purulent serum, composed of serum, pus globules, endothelial cells, and pieces of fibrin. But sometimes this fluid is very thick and viscid.

In empyema in its earlier stages the lesions are the same as those in pleurisy with effusion, with the addition of pus in the serum, the fibrin, and the superficial layers of the pleura.

In children the inflammation may remain in this condition for a long time, but in adults other changes in the pleura are soon developed.

These changes consist in the growth of a large number of small polygonal and round cells, the basement substance is split up, and the pleura is changed into a tissue resembling granulation tissue.

The pleura is thus considerably thickened. Its surface is coated with fibrin and pus, or is bare like the surface of an ulcer.

In this condition the pleura may remain for months or years, its inner layers formed of granulation tissue, its outer layers of dense connective tissue.

Sometimes the cell growth is more active, necrotic changes are added, and so there is a conversion of portions of the pleura into pus. Such a suppuration may extend from the pleura to the fasciæ, the muscles, the skin, the diaphragm, or the lungs. Thus the pus may find an exit, through the wall of the thorax, into the peritoneal cavity or into the lungs.

If the empyema becomes gangrenous the pleural cavity contains foul gases, the purulent serum is dirty and stinking and swarms with bacteria. The fibrin coating the pleura is of green or brown color. Portions of the pleura itself may also become gangrenous.

In old cases the thickening of the pleura may reach an enormous degree and it may become calcified.[1] The perichondrium of the cartilages and the periosteum of the ribs may become inflamed, with necrosis of the cartilages and ribs or a production of new bone.

Empyema is, therefore, a very much more serious lesion than the two forms of pleurisy just described. The lesions involve not merely the surface of the pleura, but its entire thickness. When the pleura has thus been converted into granulation tissue it is hardly possible for it to return to a normal condition.

It is important to remember that in children the changes in the pleura itself are less profound, and that in adults they become more and more marked, according to the duration of the disease.

Bacteria[2] are present in the exudate in a large proportion of cases of empyema. The Streptococcus pyogenes, Staphylococcus pyogenes, Diplococcus lanceolatus, and the Bacillus tuberculosis are the most common inciters of suppurative inflammation of the pleura.

*Interlobular Lymphangitis.*—Inflammations of the pleura with the production of pus and fibrin may extend to the lymphatics in the interlobular septa, around the bronchi, and around the blood vessels. This occurs with pleurisies due to septic poisoning and with those which occur without discoverable cause. It is seen more frequently in children than in adults. The lymphatics in the interlobular septa, and those around the bronchi and blood vessels are distended with pus cells, the septa are much thickened, and the lobules separated from each other.

### *IV. Chronic Pleurisy with the Formation of Adhesions.*

This form of pleurisy may follow one of the varieties of pleurisy just described, it may be associated with emphysema and chronic phthisis, or it may occur by itself.

After death the pulmonary and costal pleura are found thickened and joined together by numerous adhesions. These changes may involve only a part or the whole of the pleura on one or both sides of the chest.

---

[1] For a résumé of our knowledge of various calcifications in the lungs, and allied conditions often called "lung stones," consult *Polaillon*, "Les Pierres du Poumon," etc., Paris, 1891; or *Legry*, Arch. gen. de Méd., March and April, 1892.

[2] Consult "Ætiology of Exudative Pleuritis," *Prudden*, New York Medical Journal, June 24th, 1893. On the relationship between empyæma and subphrenic abscess, consult *Meltzer*, New York Medical Journal, June 24th, 1893.

The thickened pleura is covered with endothelial cells, which are increased in size and number; the connective-tissue cells in the pleura are also increased in number, and the blood vessels are more numerous.

The adhesions are formed of connective tissue resembling that of the costal pleura, containing blood vessels and covered with endothelium.

### *V. Tuberculous Pleurisy.*

In acute general tuberculosis miliary tubercles are often present in the pleura. In acute and chronic phthisis, besides the fibrin, pus, serum, and new connective tissue so often produced, there may also be miliary tubercles or larger, flat, cheesy nodules.

There are, however, cases of tuberculous pleurisy which have the characters of a local tubercular inflammation. Tubercles are either absent altogether from the rest of the body or of secondary importance to the pleurisy.

This form of pleurisy involves the pleura of one side of the thorax only. It may be rapidly developed, the patient dying at the end of two weeks; or it may continue for months. It seems to be very fatal.

The inflammation may be confined to the costal pleura or may involve also the diaphragmatic and pulmonary pleura. The gross appearance of the lesion varies.

1. The pleura is thickened, its surface is bare of fibrin; it is of a bright-red color from the congestion of the blood vessels, and this red surface is mottled with white dots—the miliary tubercles. In the pleural cavity is bloody serum.

2. The pleura is thickened; it is thickly coated with fibrin; no tubercles are visible to the naked eye; the pleural cavity contains clear serum.

3. The pleura is thickened and the pleural cavity contains purulent serum.

In all the cases the changes in the pleura itself are essentially the same. The thickened pleura is infiltrated with new connective-tissue cells. Scattered through its entire thickness are tubercle granula, either single or joined together by diffuse tubercle tissue (Fig. 201). The smaller blood vessels show a growth of their endothelial cells.

In the exudate of tuberculous pleuritis the tubercle bacillus may frequently be detected by simple staining, especially if the solid elements be brought together from a considerable quantity of the fluid by a centrifugal machine.

But in suspicious cases of exudative pleurisy which give negative results on morphological examination of the fluid, the inocula-

tion of guinea-pig with a considerable amount of the exudate or with the material concentrated by the centrifuge is more decisive and may reveal the nature of the lesion when the simple morphological tests have failed.

## TUMORS.

*Fibroma.*—Little white or pigmented fibromata, of the size of a pin's head and scarcely raised above the surface, are often present in the pulmonary pleura.

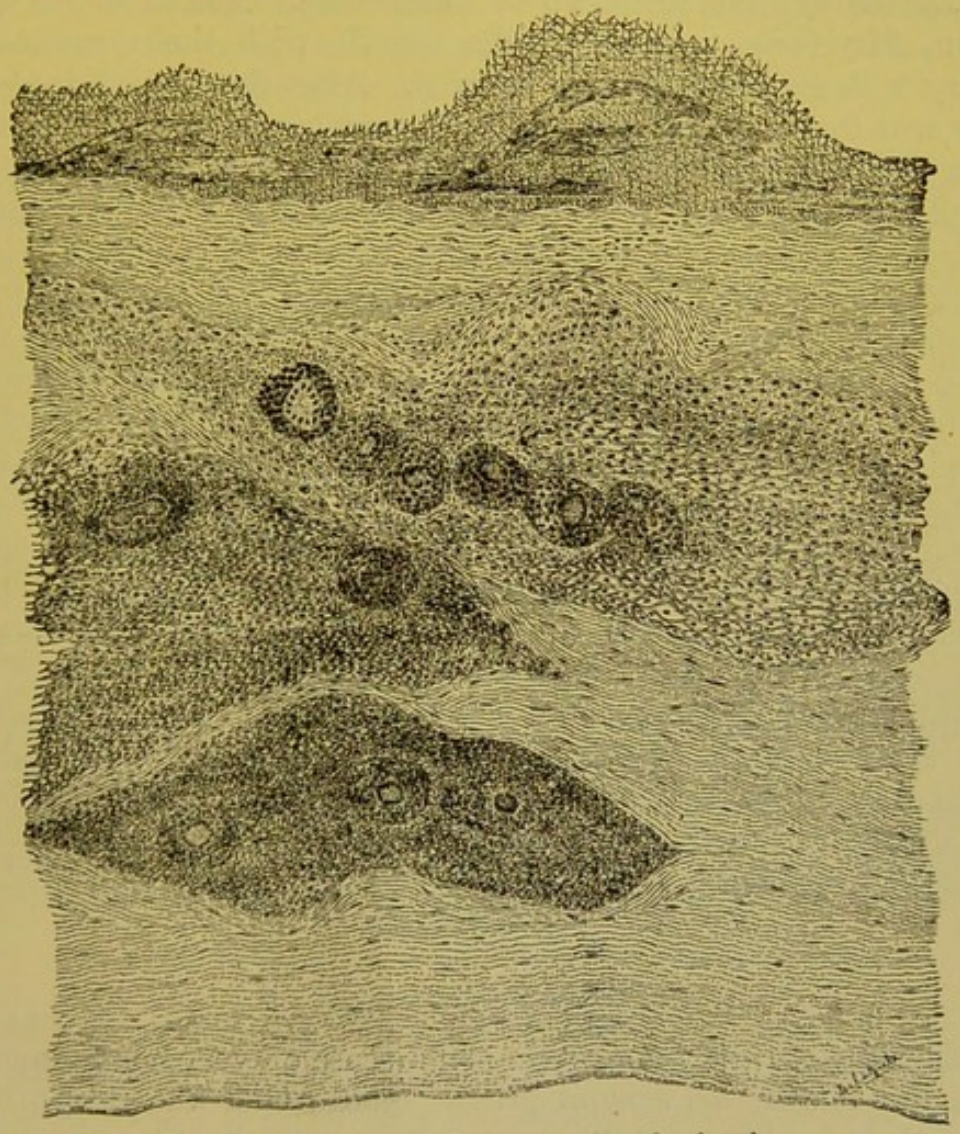

FIG. 201.—TUBERCULOUS PLEURISY, × 90 and reduced.
Drawn from a vertical section of the costal pleura.

Larger fibrous tumors are formed in the deeper layers of the costal pleura, and project into the pleural cavity. They may become detached and are then found loose in the pleural cavity (Lebert).

*Lipoma.*—Fatty tumors are formed beneath the costal pleura and project into the pleural cavity (Lebert).

*Carcinomata*, *sarcomata*, and *lymphomata* are usually secondary to similar tumors in other parts of the body.[1]

A peculiar form of primary new growth in the pleura has been described by several observers.[2] It is associated with a pleurisy with the production of fibrin and serum. There is a diffuse thickening of the costal pleura, or circumscribed nodules of different sizes.

The new growth seems to begin in the lymphatics of the pleura, which are distended with flat, nucleated cells.

I (Delafield) have seen two of these cases. The first case was a woman, fifty-three years old, who was ill, with the symptoms of pleurisy with effusion, for four months. After death the left pleural cavity was found to be full of bloody, purulent serum. The costal pleura was moderately thickened and coated with a layer of fibrin and pus. Beneath the fibrin and pus was a thin layer of granulation tissue. In this tissue and in the pleura were anastomosing tubules filled with flat, nucleated cells. The tubules looked like lymphatics.

The second case was a man, sixty-three years old, who had symptoms of pleurisy with effusion, for four months. After death the right pleural cavity was found half-full of bloody serum. The costal, diaphragmatic, and pulmonary pleura were coated with fibrin and contained numerous white nodules, some of them as large as a pigeon's egg. These nodules were formed of a connective-tissue stroma enclosing irregular spaces and tubules filled with flat, nucleated cells.

While these tumors are often puzzling, and the observer may be in doubt whether they should be called endothelioma or carcinoma or sarcoma, recent studies seem to indicate that they are, for the most part at least, endotheliomata (see page 312).

## THE BRONCHI.

### INFLAMMATION.

*Acute Catarrhal Bronchitis* is a disease of very common occurrence, but one which seldom proves fatal. Our knowledge of its lesions is derived from severe cases, from experiments on animals, from cases which are complicated by other diseases, and from the symptoms which we observe during life.

The inflammation involves regularly the trachea and the larger and medium-sized bronchi, less frequently the smaller bronchi also. As a rule, the bronchi in both lungs are equally affected.

---

[1] For description of ciliated cysts of the pleura, consult *Zahn*, referred on p. 543.

[2] *Birsch-Hirschfeld*, "Path. Anat.," p. 768. *E. Wagner*, Arch. d. Heilkunde, xi. *R. Schulz*, Arch. d. Heilkunde, xv. *Thierfelder*, "Atl. d. path. Hist.," 4 Lief. *Fränkel*, Berliner klin. Wochenschrift, May 23d, 1892.

The first change seems to consist in a congestion and swelling of the mucous membrane, with an arrest of the functions of the mucous glands. This is attended with pain over the chest, a feeling of oppression, sometimes spasmodic dyspnœa, and a dry cough. After this the mucous glands resume their functions with increased activity, the congestion diminishes, there is an increased desquamation of epithelium, an increased formation of the deeper epithelial cells, and a moderate emigration of white blood cells. Sometimes the red blood cells also escape from the vessels. The patient now has less pain and oppression; the cough is accompanied with an expectoration of mucus mixed with epithelium, pus, and sometimes blood.

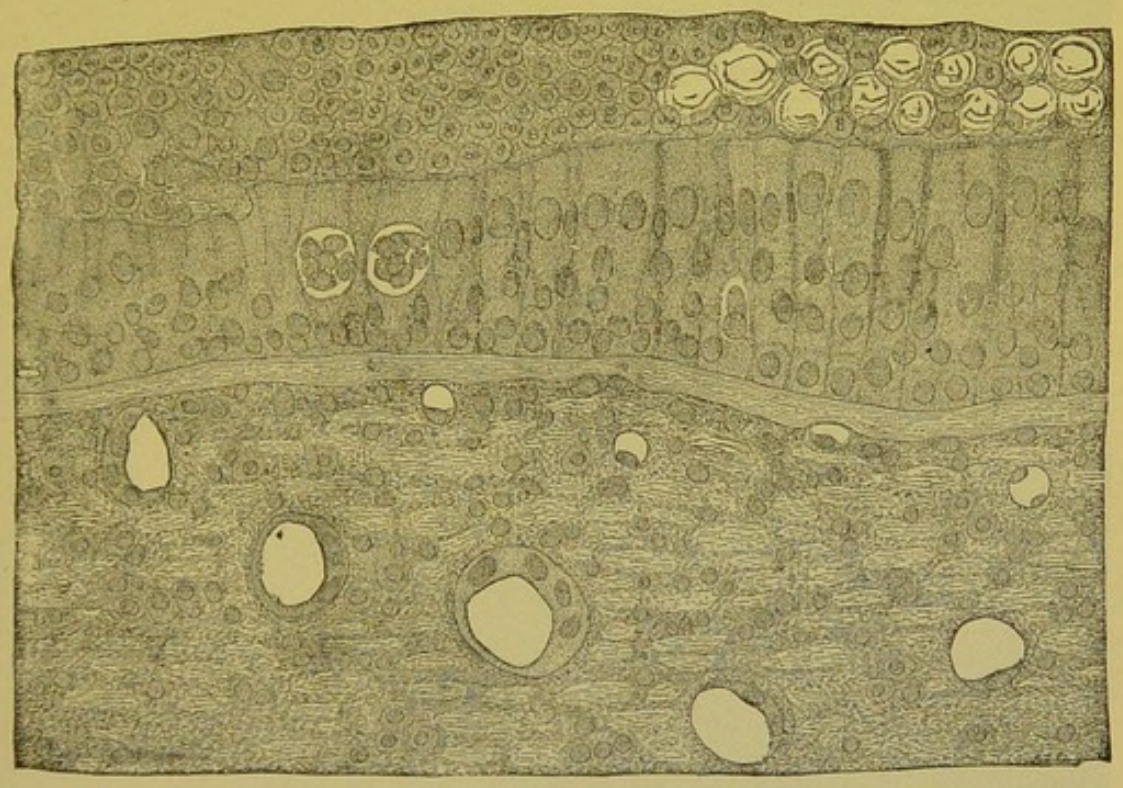

Fig. 202.—Acute Catarrhal Bronchitis, × 850 and reduced.

After death the only lesions visible are the increased amount of mucus, the growth of new epithelium, mucous degeneration of the epithelial cells, a few pus cells infiltrating the stroma, and the general congestion of the mucous membrane. The whole process is a superficial one, not producing any changes in the walls of the bronchi beneath the mucous membrane (Fig. 202).

When the inflammation involves the smaller bronchi also they may be full of pus, but their walls are unchanged.

The filling of the small bronchi may result in the collapse of the groups of air vesicles to which they lead, and thus are produced areas of atelectasis, which may be further changed by inflammatory processes.

*Chronic Catarrhal Bronchitis.*—This form of bronchitis may be the sequel of one or more attacks of acute bronchitis. More frequently it is associated with emphysema, heart disease, interstitial pneumonia, phthisis, pleuritic adhesions, or the inhalation of irritating substances.

There is in most cases a constant production of mucus, pus, and serum in considerable quantities, and these inflammatory products may have a very foul odor. Less frequently these products are very scanty—dry catarrh.



FIG. 203.—CROUPOUS (FIBRINOUS) BRONCHITIS.

Fibrinous casts of the bronchi, similar to those shown in the photographs, were coughed up at irregular intervals for several years.

In examining the bronchi in these cases after death we are often struck by the want of proportion between the symptoms and the lesions. The same bronchi which during life were constantly producing large quantities of inflammatory products and injuring the patient's health, after death may be but little changed from the normal. In other cases, however, the lesions are more marked.

The bronchi contain mucus and pus; they may be congested; their walls are often trabeculated. The epithelium is deformed and desquamating, with a production of new cells in the deeper layers.

the mucous glands are large or atrophied. The connective-tissue stroma is thickened and infiltrated with cells. The coats of the arteries in the walls of the bronchi may be thickened. There may be cylindrical dilatation of one or more bronchi. The muscular coat may be thickened or thinned. Very frequently the epithelial cells of the air vesicles and air passages are increased in size and number.

*Acute Croupous Bronchitis* occurs as a lesion of diphtheria, as associated with croupous laryngitis, as the result of the inhalation of hot steam, with lobar pneumonia, and sometimes as an idiopathic disease.

The bronchi are lined or filled with a mass of fibrin, pus, and desquamated epithelium. Fibrin and pus may also be found beneath the epithelium and infiltrated in the stroma.

*Chronic Croupous Bronchitis* is attended with the formation in one or more bronchi of masses of fibrin which are expectorated by the patient in the form of branching casts of the bronchi (Fig. 203). The disease is a very chronic one, and is often associated with phthisis. After death the bronchi are said to be found but little altered from the normal.

Curschmann [1] has described under the name of "bronchiolitis exudativa" a form of bronchitis in which small threads and bands of gray or yellow, partly transparent, coagulated matter are formed in the small bronchi. Vierordt [2] has found similar formations in lobar pneumonia. Leyden and Levi have found them in broncno-pneumonia.

In different forms of bronchitis, especially in those associated with asthma, the exudation may contain small, octahedral bodies, probably composed of mucin. They are accidental formations, probably formed from cells, and may be found in the sputa.

## BRONCHIECTASIA.

Dilatation of the bronchi presents itself under three forms: the cylindrical, the fusiform, and the sacculated.

The cylindrical dilatation is a uniform enlargement of one or more bronchi for a considerable part of their length. It is found in bronchi of every size, but most frequently in the medium-sized.

The fusiform dilatation is a mere variety of the cylindrical. The bronchus is uniformly dilated for a short distance, and then resumes its natural size. Several such dilatations may be found in the same bronchus.

The sacculated dilatations form the largest cavities. These cavi-

[1] Deutsch. Arch. f. klin. Med., xxxii.

[2] Berl. klin. Wochensch., 1883. *B. Levi*, Zeitsch. f. klin. Med., ix. *Leyden*, Virch. Arch., Bd. lxxiv.

ties communicate with one side of the bronchus; the peripneral portion of the bronchus may be obliterated. The bronchus leading to the cavity may be of normal size, or dilated, or stenosed, or even completely obliterated. Such sacculated dilatations may reach a very large size and may communicate with each other.

Any inflammatory process which involves the thickness of the wall of a bronchus seems to be capable of producing dilatation of that bronchus.

In acute general bronchitis and broncho-pneumonia in children, cylindrical dilatation of a number of the medium-sized bronchi is often produced.

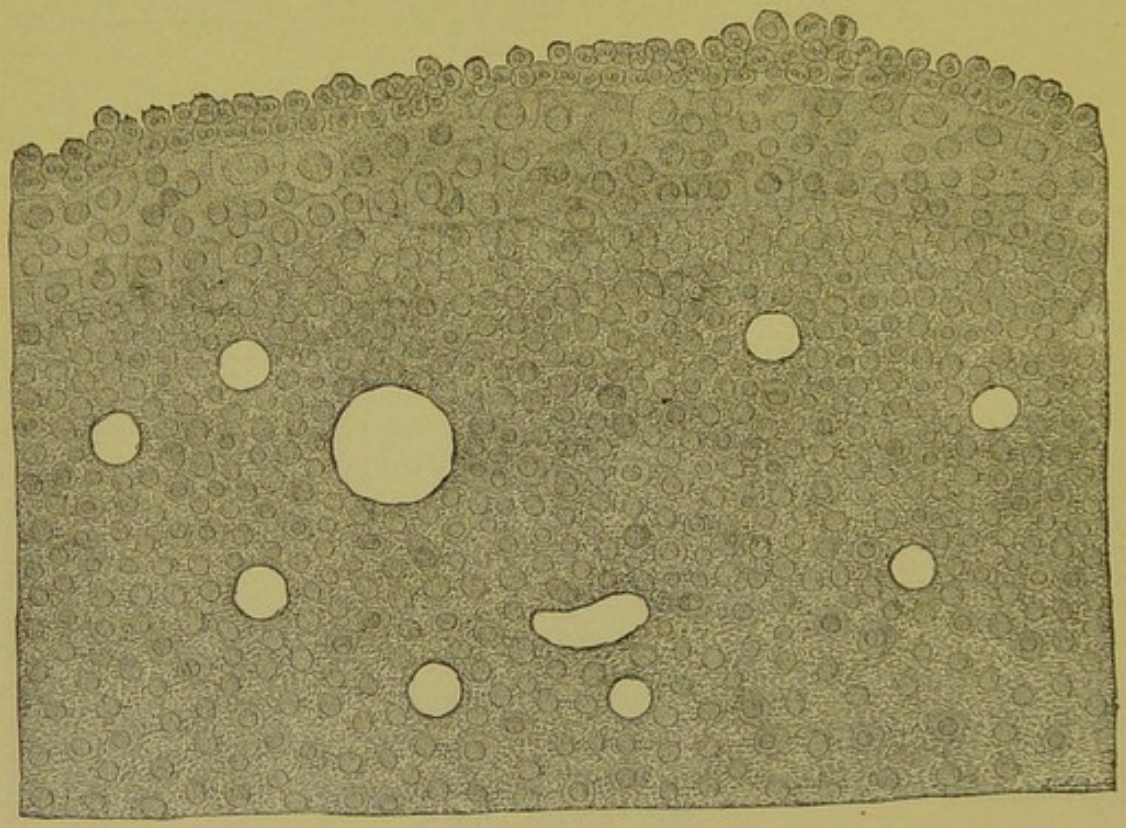

Fig. 204.—Section of the Wall of a Bronchiectasia, × 850 and reduced.

In the persistent broncho-pneumonia of children such dilatations reach a still greater development.

In acute and chronic phthisis tubercular inflammation gives rise to sacculated dilatations, which expand with time and are made still larger by the destruction of the adjacent lung tissue.

Chronic bronchitis may lead to cylindrical or sacculated dilatations, sometimes of great size.

Occlusion of some of the bronchi, consolidation of portions of the lung, and extensive pleuritic adhesions, may also produce bronchiectasia.

The walls of these dilatations may preserve the characters of the wall of the bronchus, more or less altered by inflammation (Fig. 204), or these characters may be altogether lost. The dilatations may contain mucus and pus, or they may be empty.

## TUMORS.

*Ossification* of the walls of the bronchi is sometimes found.

*Lipoma* in the submucous connective tissue has been described by Rokitansky. Fibroma and chondroma have been described.

*Sarcomata* of the walls of the bronchi occur as secondary growths, and as extensions of similar growths in the mediastinum. Primary

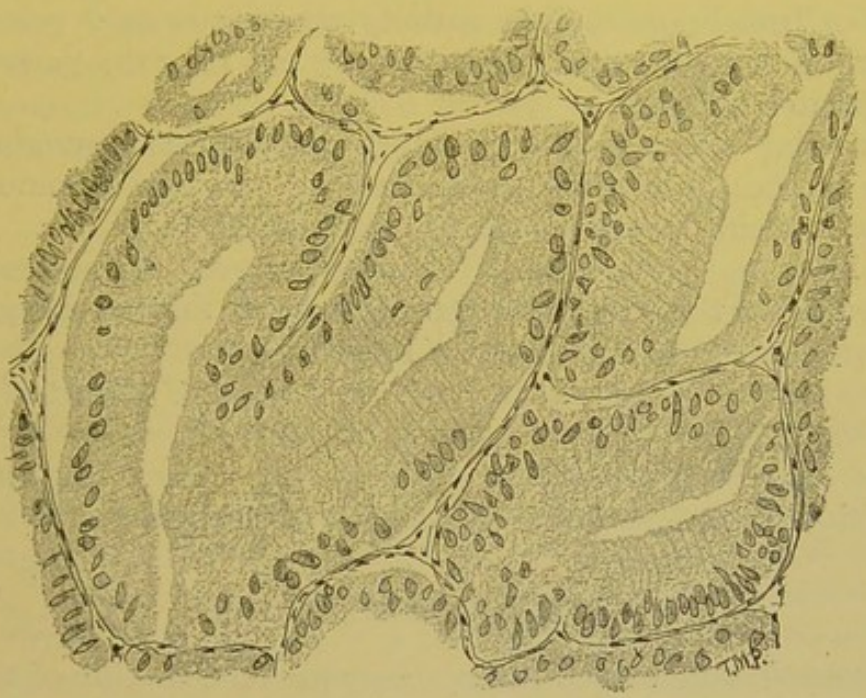

FIG. 205.—ADENOMA OF THE BRONCHI.
From a specimen loaned by Dr. Stewart.

sarcoma of the bronchi[1] seems to be rare. Hesse describes a form of lympho-sarcoma forming nodules around the bronchi as of common occurrence among the miners in some cobalt and nickel mines.

Adenoma of the bronchi is of rare occurrence (Fig. 205).

*Primary carcinoma* of the bronchi is described by several authors, but it is not common.

Langhans describes a primary carcinoma of the lower end of the trachea and the large bronchi in a man forty years old. The lower end of the trachea and the large bronchi showed a general thickening of their walls, with flat tumors projecting inward. The new growth

[1] *Hesse*, Archiv d. Heilkunde, xix., p. 160.

was composed of a stroma enclosing cavities filled with cells. The cells were small, nucleated, polygonal or cylindrical in shape, and packed closely together. Apparently the new growth originated in the mucous glands.

*Carcinoma* of the walls of the bronchi may occur as a secondary lesion. It may be formed in the large or small bronchi, follow the course of the bronchial tree, or extend to the lung tissue or to the trachea.

## THE LUNGS.

### MALFORMATIONS.

One or both lungs may be entirely wanting or only partially developed. In some of the cases with only one lung the patients have grown up to adult life.

A peculiar degeneration, by which the lung is converted into a number of sacs containing air and serum, the sacs communicating with the bronchi, has been seen in a few instances.

The lobes may be subdivided by deep fissures. An accessory lobe, separated from the lung, between the base of the left lung and the diaphragm, has been described by Rokitansky.

There may be hernia of the lung, with absence of part of the wall of the thorax.

There may be transposition of the lungs, with similar changes in the position of the heart and the abdominal viscera.

### INJURIES—PERFORATIONS.

Severe contusions of the thorax may produce rupture of the lungs, with extravasations of blood into the pleural cavities.

The lungs may be wounded by a fractured rib and by penetrating weapons and projectiles. Such injuries often produce bleeding into the lung tissue and inflammatory changes. The lungs, however, exhibit a considerable degree of tolerance for such injuries, and the patients often recover.

Collections of pus in the pleural cavities, the mediastinum, the liver, the spleen, the kidneys, and the peritonal cavity may perforate the lungs. Abscess of the lung may be secondary to liver abscess from amœba coli.

### CONGESTION AND ŒDEMA.

These two conditions are regularly associated with each other in the lungs, although one or the other of them may preponderate in different cases.

A moderate degree of congestion and œdema of the posterior portions of the lungs is often found as a result of post-mortem changes.

In persons who have been comatose from any cause for some hours before death, congestion and œdema of the lungs are regularly developed.

With disease of the heart, kidneys, and lungs the congestion, and especially the œdema, may be excessive. The lungs may be so completely infiltrated with serum as to be unaërated. Such a solid œdema of the lungs is sufficient of itself to cause death. It has been asserted by Welch[1] that the cause of such an excessive œdema is a paralysis of the left side of the heart, while the force of the right heart is unimpaired. Such an explanation seems to be plausible.[2]

Patients confined to bed for a considerable length of time may develop congestion of the dependent portions of the lungs—*hypostatic congestion*. The affected portion of lung is shrunken, congested, and imperfectly aërated.

## HÆMORRHAGE.

Extravasations of blood within the air cavities are found with the general diseases which produce a disposition to bleeding in different parts of the body.

Blood from the bronchi or from cavities may be inspired into the air vesicles.

Valvular lesions of the heart, especially of the mitral valve, are often accompanied by the production of hæmorrhagic infarctions in the lungs. These infarctions are circumscribed, of rounded or wedge-shaped forms, from the size of a walnut to that of an orange. They are of dark-red color, unaërated, the air passages distended with blood, and are often surrounded by a zone of pneumonia. They may be situated in any part of the lungs, but are most common in the lower lobes. When they are near the surface of the lungs a circumscribed pleurisy is often produced.

Such infarctions may produce death; they may become gangrenous, or the blood may become absorbed, or they may be gradually changed into a smaller mass of pigmented fibrous tissue.

These infarctions are usually produced by emboli or by thrombosis of branches of the pulmonary artery.

Infarctions of smaller size, and with more disposition to be surrounded by inflammatory changes, are produced by emboli from the right side of the heart and from thrombi in the veins of pyæmic

[1] Virchow's Archiv, Bd. 72.

[2] For bibliography, etc., of pulmonary œdema consult *Löwit*, Ziegler's Beiträge zur path. Anat., etc., Bd. xiv., p. 401, 1893.

patients. These infarctions are usually situated near the surface of the lung.[1]

Hæmorrhages with rupture of the lung tissue are produced by severe contusions, by penetrating wounds, and by the rupture of aneurisms.

### EMPHYSEMA.

Emphysema is of two kinds—interlobular and vesicular.

*Interlobular Emphysema* is produced by the rupture of air spaces and the escape of air into the interstitial tissue of the lung. Or the pulmonary pleura may also be ruptured and the air escape into the pleural cavity, or into the mediastinum and from thence into the neck. Such a rupture of the air spaces is most frequently caused by broncho-pneumonia with consolidation of portions of the lungs.

*Vesicular Emphysema* is a dilatation of the air passages and vesicles of the lungs. A temporary emphysema can be produced in a variety of ways. The bronchi may be obstructed in such a way that the air can enter the air spaces, but cannot escape from them. A portion of the lungs may be consolidated or compressed, and then the air spaces of the rest of the lungs will be dilated. Death may take place, with a dilatation of the lungs which remains after death.

Permanent emphysema may change an entire lung if the other lung becomes permanently unaërated ; it may change portions of a lung if other portions are consolidated.

"Substantive emphysema" is a term which is now used in a clinical rather than in an anatomical sense. It is used to designate a group of cases in which there are regularly developed changes in the shape of the thorax, certain characteristic physical signs, a liability to bronchitis, to constant and spasmodic dyspnœa, to venous congestion of the viscera and of the skin. In patients who present such symptoms during life, we find after death diffuse changes of both lungs, of which dilatation of the air spaces may form a part (Fig. 206). If the dilatation of the air spaces does exist, the term "substantive emphysema" is appropriate; if it does not exist we employ a term which contradicts itself.

The real lesion of substantive emphysema is a chronic productive inflammation of the lung with the formation of new connective tissue—a process analogous to similar chronic inflammations of the endocardium, arteries, and kidneys, and one which, like them, may constitute a formidable disease or an unimportant senile change.

Both lungs are moderately or considerably increased in size. Very often they are partly covered by connective-tissue pleuritic adhesions.

[1] Recent studies on lung infarctions have been made by *Grawitz*, "Festschrift" for Virchow's 71st birthday, 1891.

The mucous membrane of the bronchi may be coated with mucus or with muco-pus. The muscular coat of the bronchi may be thickened; their entire wall may be thickened or thinned and infiltrated with cells; they may be narrowed or dilated; they may be surrounded by zones of pneumonia. The cells which line the walls of

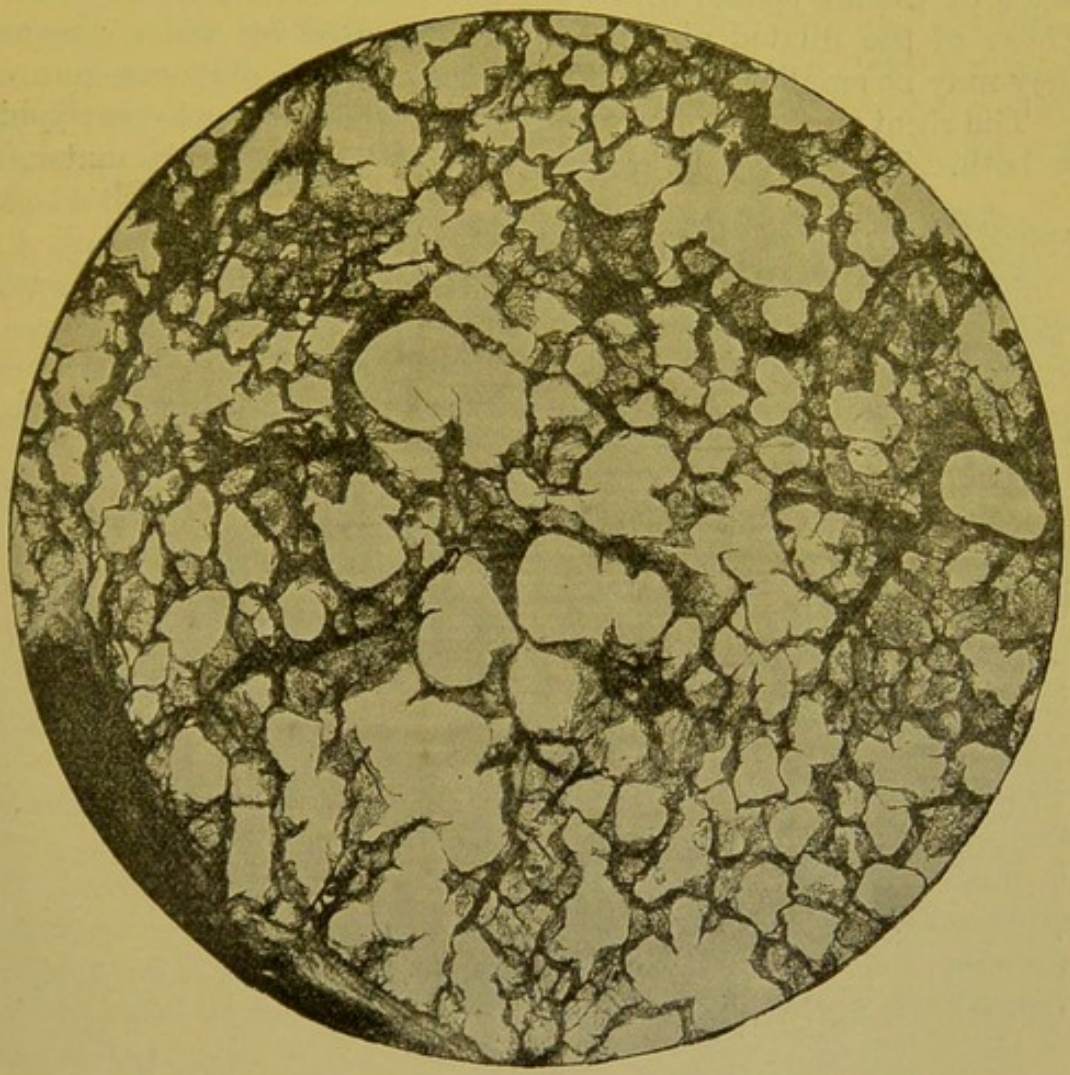

FIG. 206.—PULMONARY SUBSTANTIVE EMPHYSEMA.

Blood vessels injected, showing dilatation of the air spaces and new growth of interstitial connective tissue.

the air spaces are increased in size and number. The walls of the air spaces are more or less thickened, except in the case of some of the air spaces which are dilated. In the walls of some of the air spaces, those which are thickened as well as those which are thinned, are formed small holes (Fig. 207) which may later reach a large size, so that adjacent air spaces become fused together.

In some cases of substantive emphysema no dilatation of the air spaces exists. In many of the fatal cases the dilatation is but moderate; in some cases it is very marked. The dilatation may

involve the air passages alone, or both the air passages and the vesicles. It is not uniform, but involves some parts of the lungs more than others.

The arteries throughout the lungs and in the walls of the larger bronchi may have their coats thickened. The capillaries in the walls of the air spaces which are but little dilated are unchanged. Those of the dilated air spaces are separated by wider intervals; they may be smaller; it is said that they may be obliterated.

The right ventricle of the heart may be dilated or hypertrophied, or both. There may be venous congestion of the pia mater, the

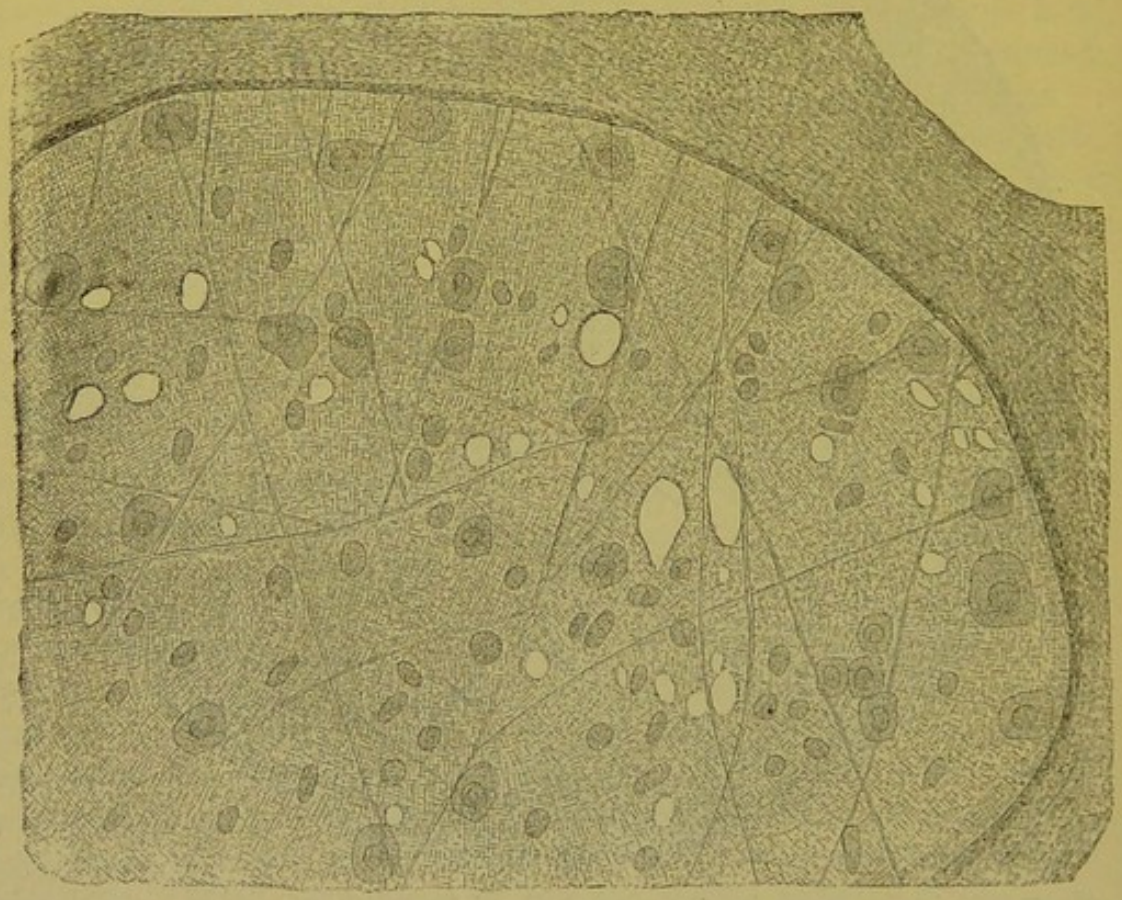

FIG. 207.—EMPHYSEMA, SHOWING HOLES IN THE WALLS OF THE AIR VESICLES, × 850 and reduced. From a case of chronic miliary tuberculosis.

stomach, the small intestine, the liver, the spleen, the kidneys, and the skin. There may be dropsy.

## ATELECTASIS.

A collapsed and unaërated condition of portions of lung tissue is either congenital or acquired.

1. In congenital atelectasis portions of the lung are firm, non-crepitant, of a dark-blue or purple color, depressed and smooth on section. These portions can usually be artificially inflated, and then

cannot be distinguished from the surrounding pulmonary tissue. This condition is produced by the inability of the child after birth to fully inflate its lungs, either from want of sufficient vitality or from obstruction of the bronchi. If the child lives for some time, and the collapsed lobules are not inflated, they become hard and dense.

2. In young children the smaller bronchi may become obstructed by the inflammatory products of bronchitis and the corresponding air vesicles will then collapse. We then find scattered through the lungs collapsed lobules like those in the new-born child. Inflammatory changes may be subsequently developed in the collapsed lobules.

3. In adults, large or small portions of lung tissue may become collapsed as the result of bronchitis, of stenosis of a large bronchus, of compression of a bronchus, of paralysis of the pneumogastric, of compression of the lungs by fluid or by new growths, and of long-continued feebleness of the act of respiration.

## GANGRENE OF THE LUNGS.

It is customary to distinguish two forms of gangrene of the lung, the circumscribed and the diffuse ; yet both can occur together.

Circumscribed gangrene occurs in the form of one or more rounded or irregular masses of variable size. The gangrenous portion of lung is at first brown and dry. The surrounding lung tissue is congested or œdematous, or infiltrated with blood, or inflamed. If the gangrenous focus is near the pleura the latter will be coated with fibrin. Gradually the gangrenous portion of lung assumes a dirty-green color and a putrid odor. It becomes soft, broken down, and separated from the surrounding lung. The blood vessels may be obliterated by thrombi, or eroded, so that there are profuse hæmorrhages.

Such a gangrenous process may extend to the adjacent lung tissue, or a zone of gray or red hepatization or of connective tissue may be formed.

The fluid from the gangrenous lung may pass into the bronchi and be expectorated; or it may run from one bronchus into another and set up new gangrenous foci or diffuse gangrene.

The pulmonary pleura may be perforated and a gangrenous pleurisy produced. Gangrene may follow lobar or broncho-pneumonia, especially such phases of the latter as result from the inspiration of foreign material containing micro-organisms from the mouth ; it may arise from infectious emboli in the lungs, or by an extension of a gangrenous process from an adjacent part.

Diffuse gangrene may follow the circumscribed form; it may

complicate lobar pneumonia or occur as an idiopathic condition. A large part of a lobe or of an entire lung becomes greenish, putrid, and soft, and the pulmonary pleura is inflamed. There may be hæmorrhages from eroded vessels. There may be general septicæmia.

Various forms of bacteria may be present in gangrenous areas of the lungs. Among those frequently present is the Staphylococcus pyogenes, Streptococcus pyogenes, pneumococcus, and various saprophytic micro-organisms.

## PNEUMONIA.

The inflammations of the lungs, as distinguished from those of the bronchi and pleura, are called "pneumonia."

In the present state of our knowledge the classification of the different forms of pneumonia must be an arbitrary one. We describe separately:

*I. Acute lobar pneumonia.*
*II. Broncho-pneumonia.*
*III. Secondary and complicating pneumonia.*
*IV. The pneumonia of heart disease.*
*V. Interstitial pneumonia.*
*VI. Tuberculous pneumonia.*
*VII. Syphilitic pneumonia.*

### *I. Acute Lobar Pneumonia.*

This is an acute exudative inflammation, which involves regularly the whole of one lobe, or the larger part of one lung, or portions of both lungs. It is an infectious inflammation, caused by the growth in the lung of the Diplococcus lanceolatus (Diplococcus pneumoniæ of Fränkel) (see page 201).[1]

The inflammation is of pure exudative type, characterized by congestion, emigration of white blood cells, diapedesis of red blood cells, and exudation of blood plasma, while the tissue of the lung itself is but little changed.

During the first hours of the inflammation, only irregular portions of the lobe which is to be inflamed are involved; later the entire lobe. The lung is congested, œdematous, tough, but not consolidated. The air spaces contain granular matter, fibrin, pus cells, red

[1] There are occasional irregular forms of pneumonia attended with the growth of other species of bacteria, and which involve whole lobes.

blood cells, and epithelial cells (see Fig. 208). The epithelium remaining on the walls of the air spaces is swollen; there are large numbers of white blood cells in the capillaries. The larger bronchi are congested, dry, or coated with mucus; the small bronchi contain the same inflammatory products as do the air spaces. The pulmonary pleura, as a rule, is not coated with fibrin. This is called the stage of "congestion." The stage of congestion regularly only lasts a few hours, but it may be protracted for several days.

When the exudation of the inflammatory products has reached

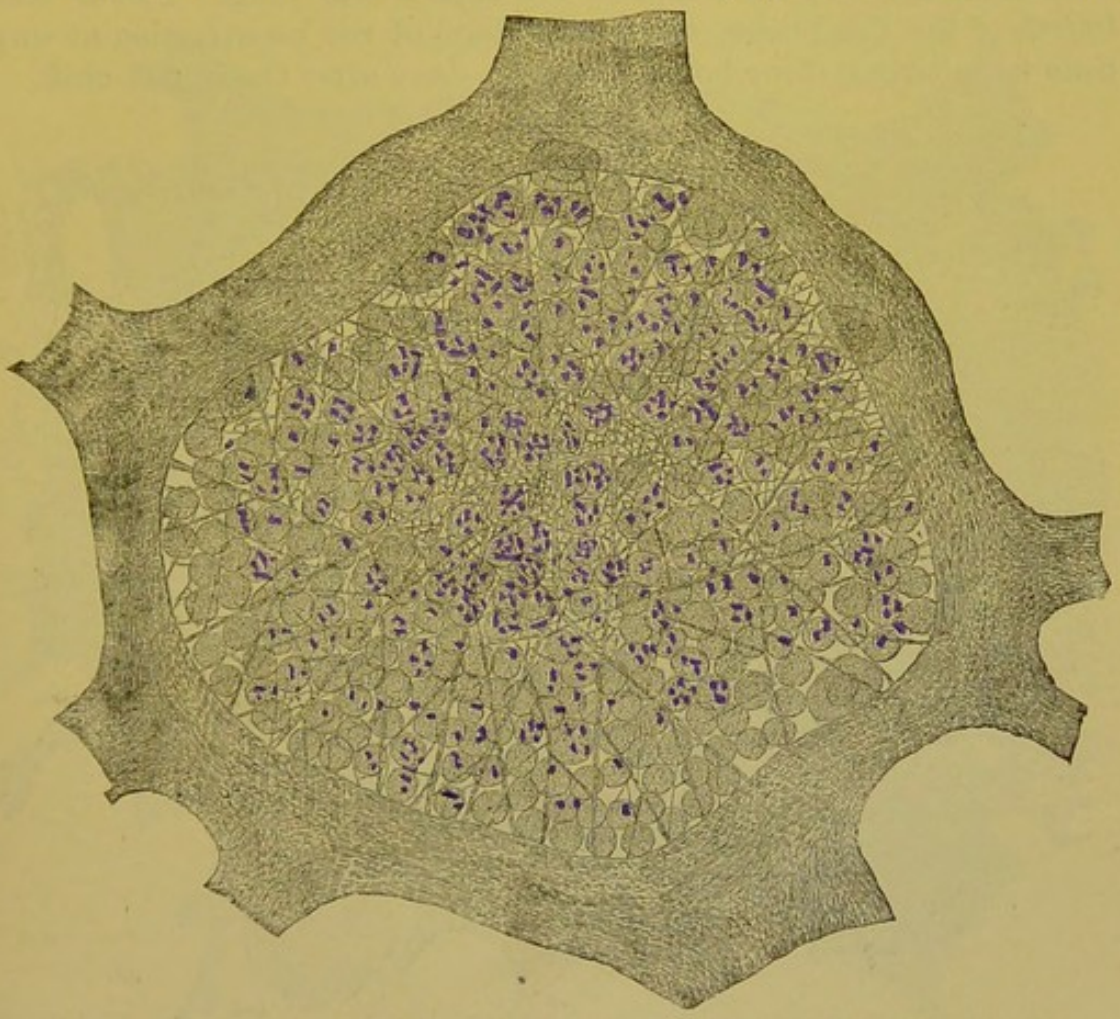

FIG. 208.—ACUTE LOBAR PNEUMONIA—RED AND GRAY HEPATIZATION, × 850 and reduced. Showing the pneumococci of Fränkel in the exudation, stained violet.

its full development the presence of these products within the air spaces and bronchi causes the lung to be solid, and at this time the lung is said to be in the condition of "red hepatization." The lung is now consolidated, red, its cut section looks granular, the granules corresponding to the plugs of inflammatory matter within the air spaces. For some time after death the inflammatory products remain solid and the cut section of the lung dry; but later, with the commencement of post-mortem changes, these products soften and

the cut section is covered with a grumous fluid. The air vesicles, the air passages, the small bronchi, and sometimes the large bronchi, are filled and distended with fibrin, pus cells, red blood cells, and epithelium, and may contain large numbers of bacteria (Fig. 208). In spite of the pressure on the walls of the air spaces the blood vessels in their walls remain pervious. The pulmonary pleura is coated with fibrin and the interstitial connective tissue of the lung is infiltrated with fibrin. The hepatized lobe is increased in size, sometimes so much so as to compress the rest of the lung. About one-fourth of the fatal cases die in the stage of red hepatization at any time from twenty-four hours to eleven days after the initial chill.

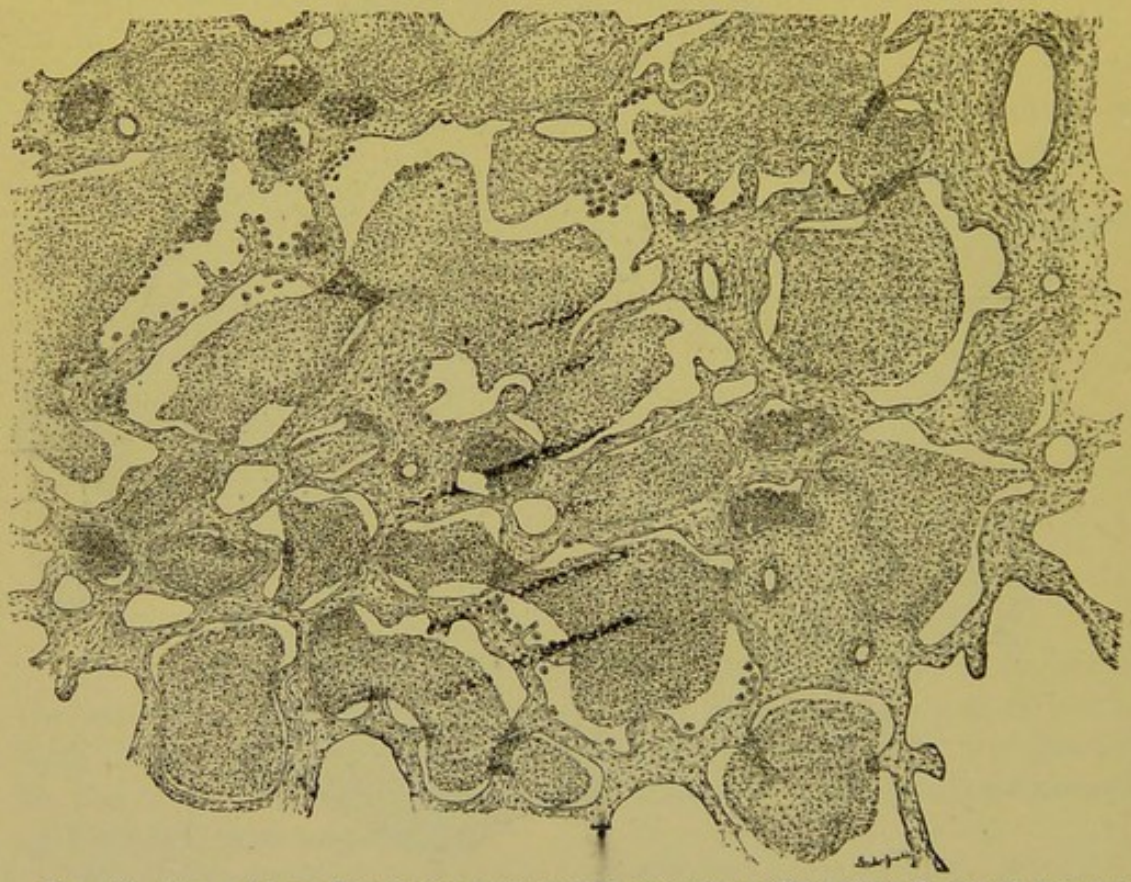

FIG. 209.—ACUTE LOBAR PNEUMONIA WITH THE PRODUCTION OF ORGANIZED TISSUE IN THE AIR SPACES, × 130 and reduced.

The section shows a number of air vesicles containing organized tissue.

After the air spaces have become completely filled with the exudation, if the patient continues to live, there follows a period during which the exudate becomes first decolorized and then degenerated. This is the period of "gray hepatization." The lung remains solid, its color changes, first to a mottled red and gray, then to a uniform gray. The coloring matter is discharged from the red blood cells and the exudate begins to degenerate and soften. The lung is found passing from red to gray hepatization at any time between the

second and the eighteenth day of the disease. It is found completely gray at any time from the fourth to the twenty-fifth day. About one-half of the cases die in the condition of mottled red and gray hepatization ; about one-fourth in the condition of gray hepatization.

If the patient recovers the exudate undergoes still further degeneration and softening and is removed by the lymphatics. This is the stage of "resolution." It should commence immediately after

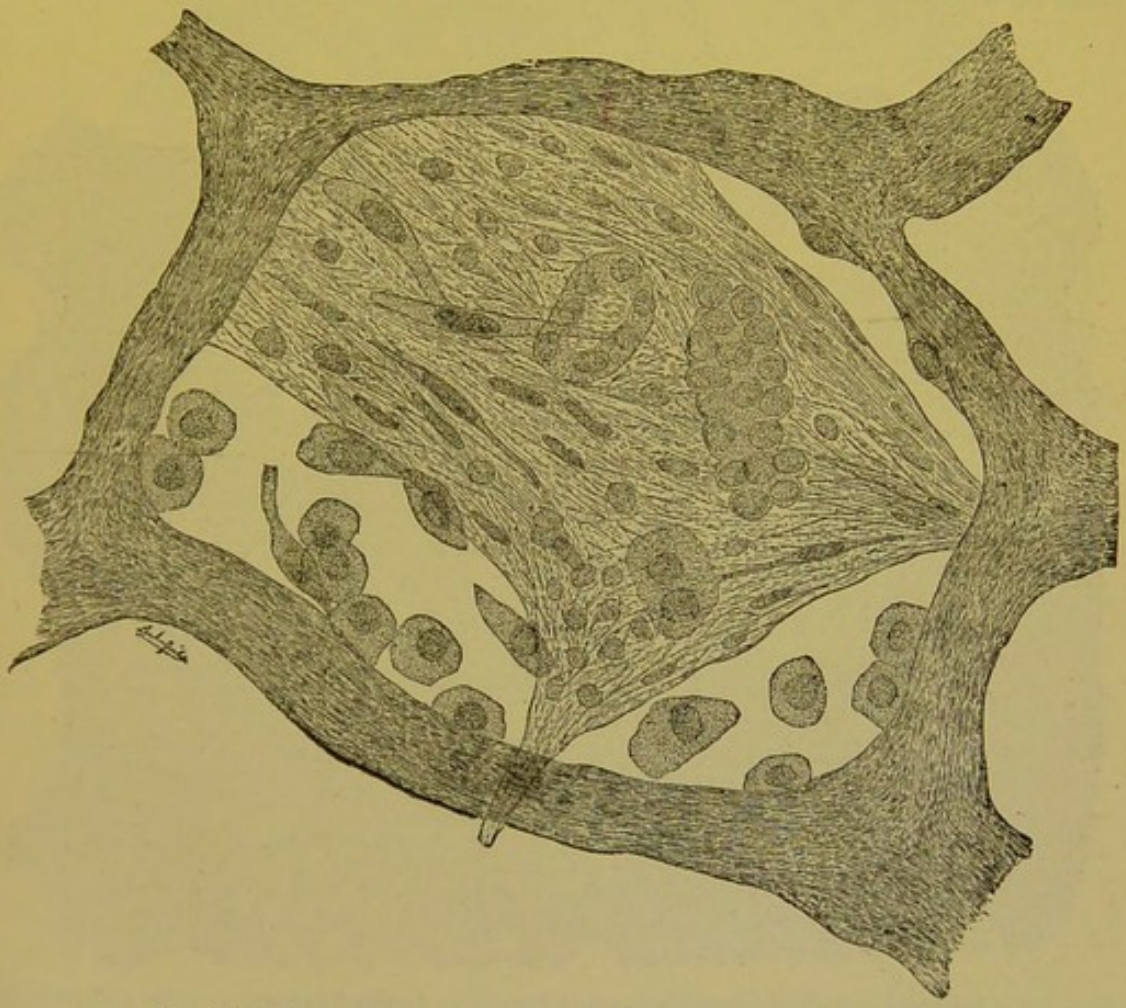

FIG. 210.—ORGANIZED TISSUE IN AN AIR VESICLE, × 850 and reduced.

defervescence and be completed within a few days. But it may not begin until a number of days after defervescence, or it may be unusually protracted.

The pneumococcus of Fränkel (often also called the Diplococcus pneumoniæ of Fränkel) is the bacterium most often present in the lungs in acute lobar pneumonia, and the form which there is much reason to believe, in the large proportion of cases, to be the cause of the disease. The germ is described on page 201.

There is a form of lobar pneumonia in which the inflammation is not simply an exudative one, but there is also a growth of new con-

nective tissue in the walls of the air spaces and in their cavities (Fig. 209).

This condition has been usually described as a chronic inflammation following an ordinary lobar pneumonia. It seems really to be from the outset a special form of pneumonia. For we find, in patients who have not been sick for more than a few days, that the pneumonia already has its characteristic form. Still further, even in its earlier stages the clinical history is somewhat different from that of an ordinary lobar pneumonia.

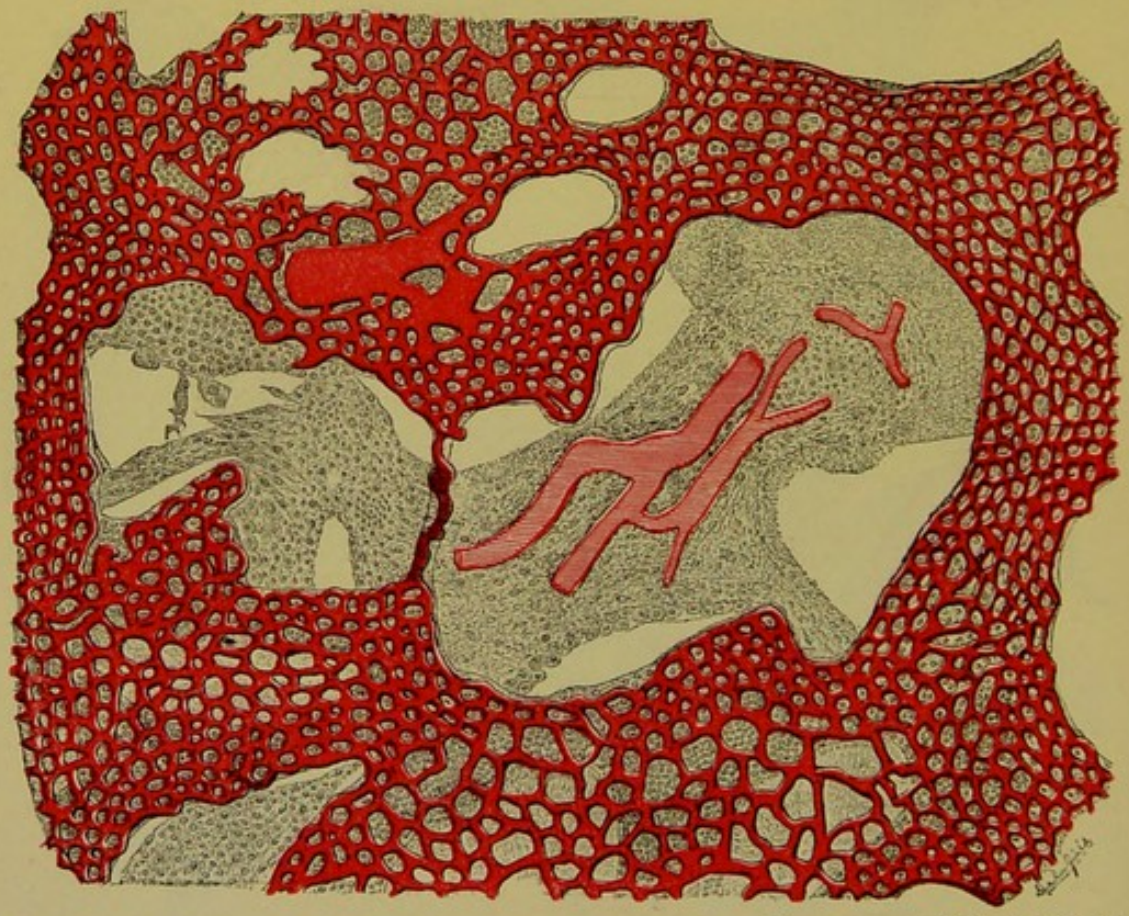

Fig. 211.—Air Vesicles containing Organized Tissue in Lobar Pneumonia, × 350 and reduced. The blood vessels are injected.

If the patient dies within three weeks of the commencement of the pneumonia we find one or more lobes consolidated but not much enlarged. The hepatization is smooth and dense. The walls of the air spaces are thickened and coated with an increased number of epithelial cells. Some of the air spaces contain only fibrin and pus, but in others there is new connective tissue, basement substance and cells (Fig. 210). In this new tissue there may be new blood vessels, which can be artificially injected from the vessels of the lung (Fig. 211).

If the patient lives for several months we find the lung very dense and smooth. The growth of new connective tissue is more extensive, the air spaces are completely filled, their walls are much thickened, and in some places the lung tissue is completely changed into smooth connective tissue.

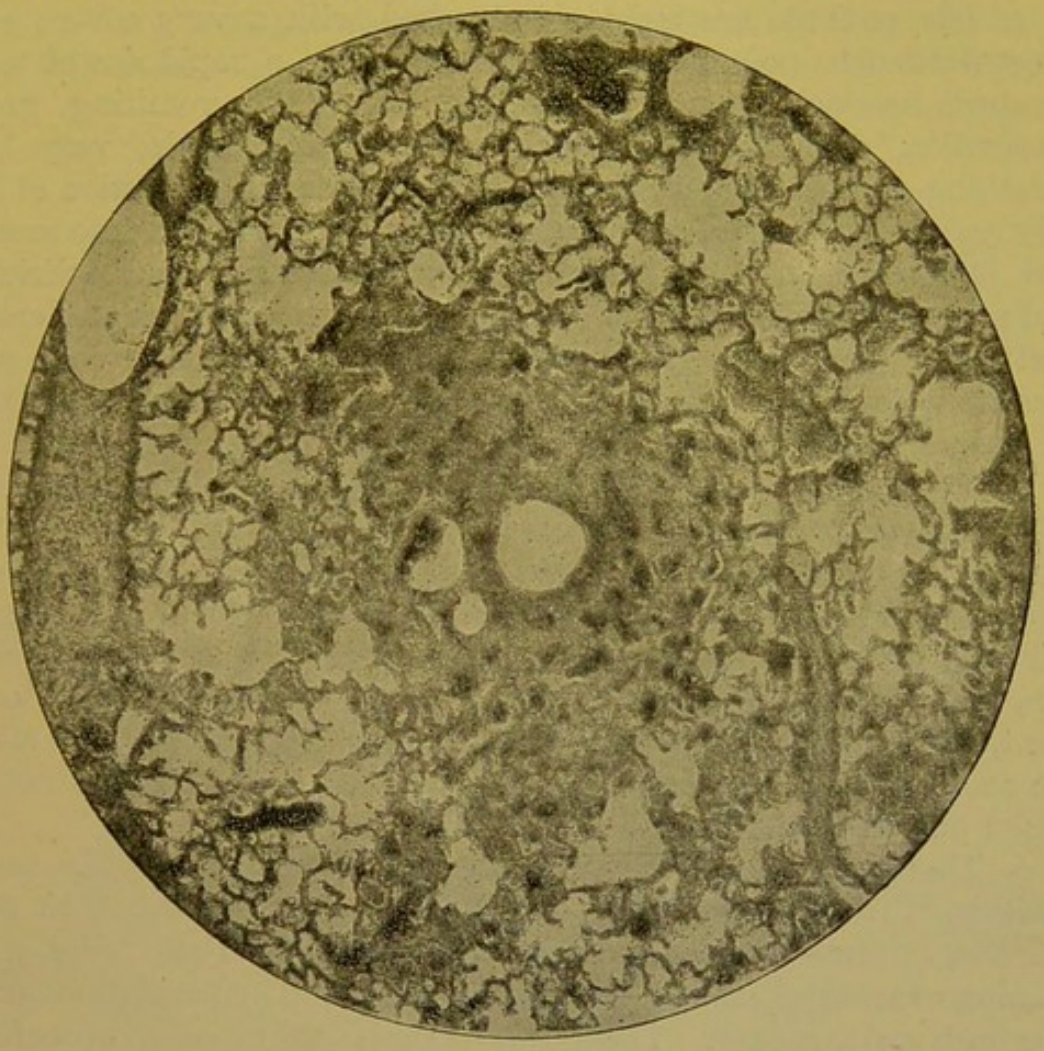

FIG. 212.—BRONCHO-PNEUMONIA FROM A CHILD.
The walls of the bronchi thickened with zones of peribronchitic pneumonia.

### *II. Broncho-pneumonia (Capillary Bronchitis, Lobular Pneumonia, Catarrhal Pneumonia).*

This is the ordinary pneumonia of young children; it is frequent also in young persons, but not as common in adults.

In children it seems to be usually due to causes similar to those which produce lobar pneumonia in adults—that is, to micro-organisms, especially the pyogenic cocci, and sometimes to the inhalation or inspiration of inorganic irritating substances.

In adults the disease may present itself to us in a variety of ways.

1. The patients have an ordinary attack of catarrhal bronchitis lasting for several days. Instead of getting well promptly, how-

ever, the patients continue to cough and to feel sick, and on examining the chest we found a circumscribed area where there is dulness on percussion and loud, high-pitched voice. This consolidation of the lung does not, however, last very long, and the patients make a good recovery.

2. The patients are suddenly attacked with a very severe and general broncho-pneumonia. There are chills, a rapid rise of temperature, headache, pains in the back and chest, vomiting, great prostration, a rapid pulse which soon becomes feeble, very bad breathing—rapid, labored, and insufficient—venous congestion of the skin and of the viscera, cough, at first dry, then with profuse mucus and blood-stained sputa, sleeplessness, restlessness, and delirium, and albumin in the urine. There are coarse subcrepitant and crepitant râles over both lungs, sibilant and sonorous breathing; the percussion note is normal, or exaggerated, or dull. The disease lasts for from seven to fourteen days, and is very apt to prove fatal.

3. There is a form of broncho-pneumonia in adults which resembles lobar pneumonia. There is a general catarrhal bronchitis, with broncho-pneumonia and consolidation of one or more lobes. The symptoms and physical signs are like those of lobar pneumonia, but with some difference. The invasion of the disease is not as sudden, the pulse is more rapid, the cerebral symptoms are more constant, the expectoration is like that of bronchitis, the physical signs are more slowly developed, the duration of the disease is rather longer and resolution is slower.

4. There is a form of broncho-pneumonia which resembles acute phthisis. The patients have a cough with expectoration, at first mucous, afterward muco-purulent. There is a moderate fever, with evening exacerbations and sweating at night. The patients steadily lose flesh and strength. The physical signs are those of bronchitis and of consolidation of parts of the lung. The disease is protracted, continuing as long as ten weeks, and is apt to prove fatal.

With substantive emphysema there may be developed a subacute or chronic broncho-pneumonia.

The essential or constant lesion of broncho-pneumonia is an inflammation of the walls (not the mucous membrane) of the bronchi and of the air spaces immediately surrounding the inflamed bronchi. The walls of the bronchi are thickened and infiltrated by a growth of new cells. The walls of the air spaces are thickened, their cavities are filled with fibrin, pus, and epithelium or with new connective tissue. The inflammation involves the medium-sized and smaller bronchi of both lungs, but is not everywhere equally severe; in some parts of the lungs the lesions are much more marked than in others. In some of the cases there are no other changes except some general congestion of the lungs. In other cases there may be

added a catarrhal inflammation of the mucous membrane of the bronchi, diffuse consolidation of parts of the lung, pleurisy, dilatation of the inflamed bronchi, areas of atelectasis, simple or tubercular inflammation of the bronchial glands.

The trachea and the larger bronchi are congested and coated with mucus. The smaller bronchi contain pus, their walls are thickened and infiltrated with cells, and they may be dilated. Around many

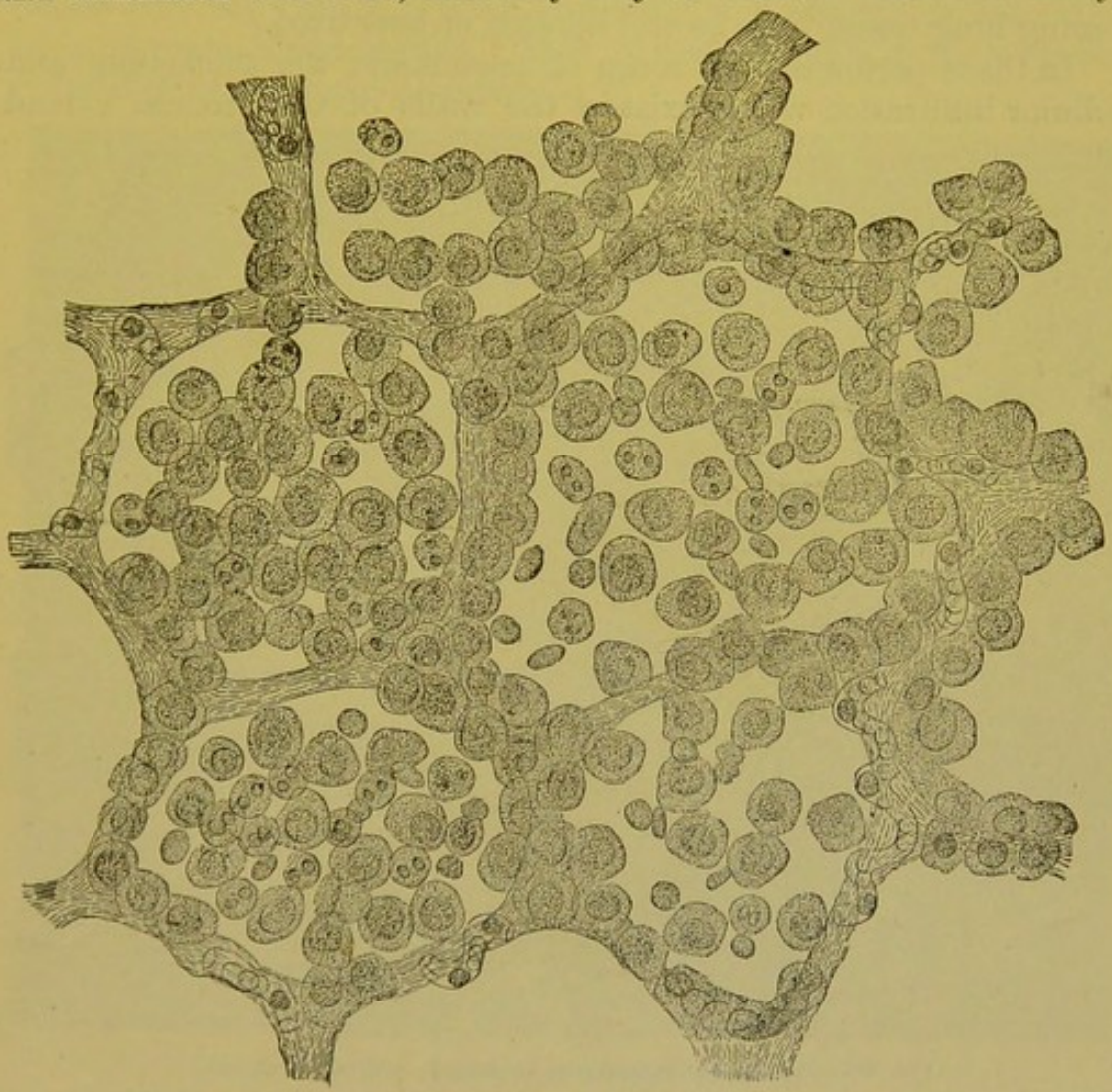

FIG. 213.—BRONCHO-PNEUMONIA IN A CHILD, × 750 and reduced.
Air vesicles in diffuse hepatization.

of the small bronchi are narrow zones of congestion or hepatization The rest of the lungs is congested and œdematous.

Or the zones of peribronchitic pneumonia are larger, so that a section of the lung is mottled with little whitish nodules, each nodule corresponding to a cut bronchus surrounded by its zone of pneumonia.

Or between these zones of peribronchitic pneumonia are areas of diffuse hepatization which render portions of the lung completely solid (Fig. 213).

Or there may be areas of atelectasis corresponding to occluded bronchi.

There is often a thin layer of fibrin on the pulmonary pleura. The bronchial glands are the seat of simple or tubercular inflammation.

The dilatation of the bronchi is not constant. When present it is of the cylindrical character and involves the medium-sized bronchi for a considerable part of their length. Such dilated bronchi are each of them surrounded by a narrow zone of pneumonia; the intervening lung tissue may be still aërated or hepatized.

In these peribronchitic zones of pneumonia the thickening and cellular infiltration which exist in the walls of the bronchi extend

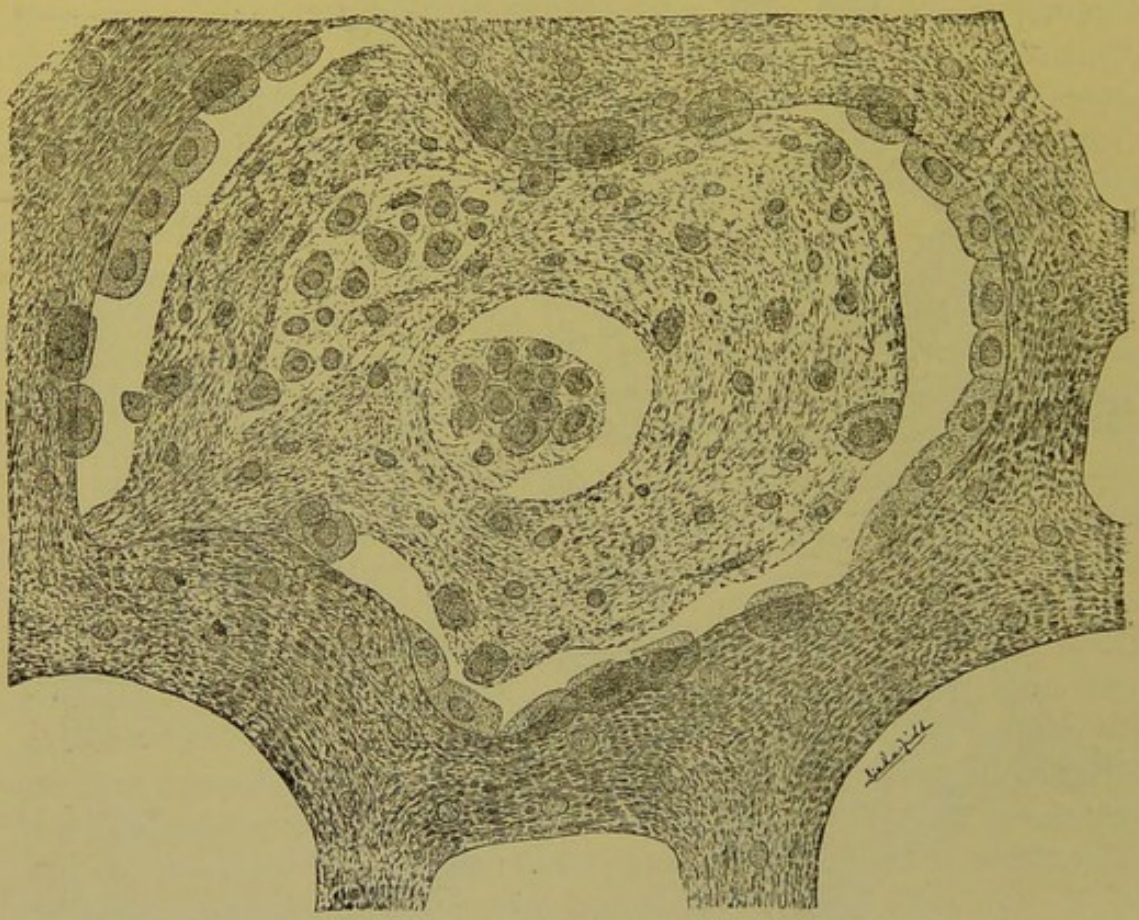

FIG. 214.—BRONCHO-PNEUMONIA IN AN ADULT. × 850 and reduced.
An air vesicle containing organized tissue in a zone of peribronchitic pneumonia.

also to the walls of the air spaces. These walls are thickened and infiltrated with cells, while the cavities of the vesicles are filled with pus and epithelium or with tissue resembling granulation tissue (Fig. 214). In the diffuse hepatization the air vesicles are filled with epithelium, pus, and fibrin in varying proportion and quantity; the walls of the air spaces remain unchanged.

The portions of lung which are not hepatized are congested and œdematous. The cavities of the vesicles are diminished by the enlarged capillaries, the epithelium is swollen, and in many vesicles a few pus or epithelial cells are to be found.

Such a broncho-pneumonia differs from the ordinary lobar pneumonia very decidedly. The inflammatory process is not a superficial one, resulting only in filling the bronchi and air spaces with inflammatory products, but it affects also the tissue of the lung, infiltrating the walls of the bronchi and of the air spaces.

This interstitial character of the inflammation seems to be the reason why the disease is often protracted and sometimes succeeded by a chronic inflammation. This chronic condition we will call "*Persistent Broncho-pneumonia.*"



FIG. 215.—PERSISTENT BRONCHO-PNEUMONIA.

The original acute broncho-pneumonia is succeeded by a chronic inflammation involving especially the interstitial tissue.

This inflammation may involve only some of the smaller bronchi and small zones of vesicles around them, and then a section of the lung will seem to be studded with fibrous nodules (Fig. 215). Or all the bronchi of some part of the lung will be inflamed, the peribronchitic zones of pneumonia will become continuous, and so part of a lobe or an entire lobe become converted into a dense mass of connective tissue. The air vesicles are obliterated by the new connective tissue, the interlobular septa and the pulmonary pleura are thickened (Fig. 216), and the inflamed bronchi may be dilated. The blood vessels, however, are, for the most part, not obliterated, so

that the lung does not become necrotic or degenerated, although occasionally areas of cheesy degeneration exist.

### *III. Secondary and Complicating Pneumonia.*

Inflammation of the lungs occurs frequently as a complicating condition with lesions of the brain and spinal cord, with pyæmia, with the continued fevers, after injuries and surgical operations, and in patients who are confined to bed for a long time from any cause.

The pneumonia developed in these cases may follow one of two different types.

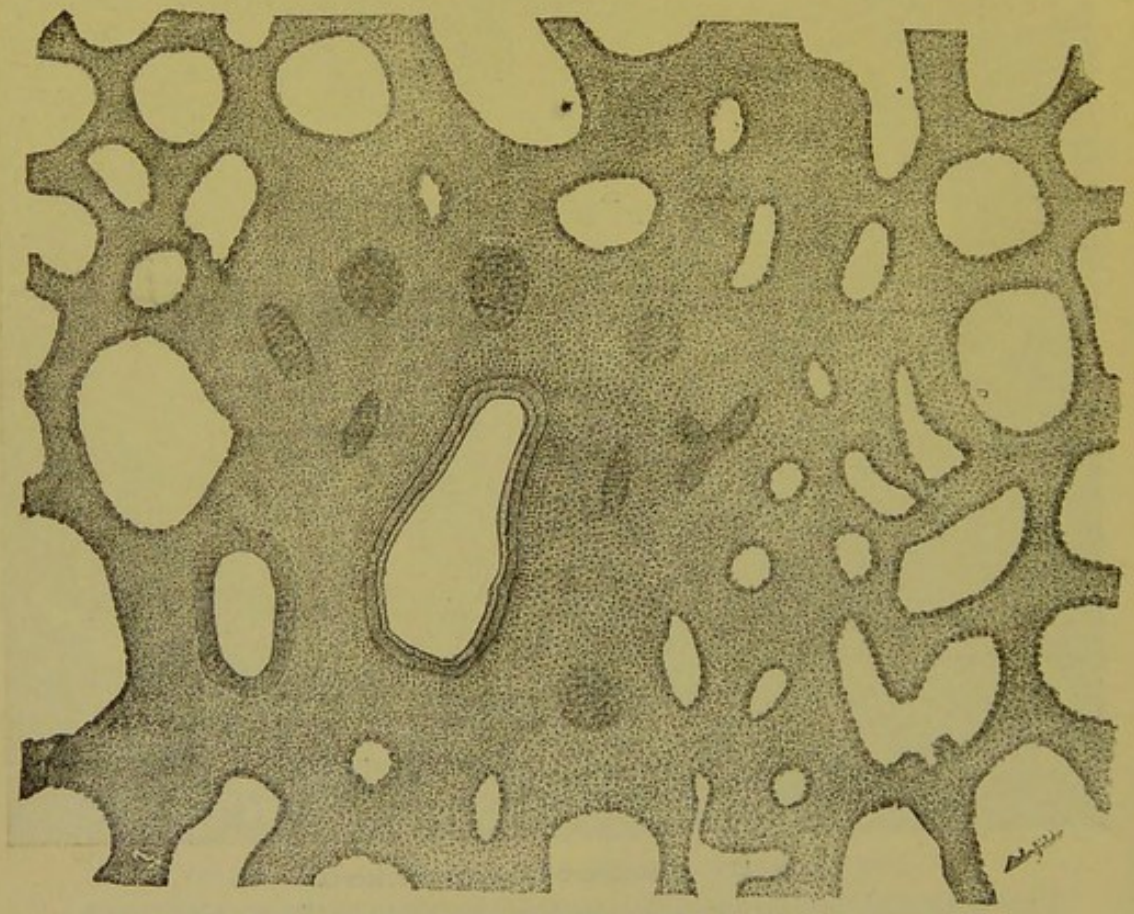

FIG. 216.—PERSISTENT BRONCHO-PNEUMONIA.

1. Part of the lung, usually the posterior portion, is congested, leathery, only partly aërated, and mottled by irregular patches of red or gray hepatization which have no relation to the bronchi. In the hepatized portions of the lung the air spaces are filled with pus and fibrin.

2. The inflammation has the characters of a broncho-pneumonia. The small bronchi are filled with pus, their epithelium is altered, their walls are infiltrated with pus, and around each bronchus is a zone of air vesicles filled with pus and fibrin. The lung is mottled with little whitish nodules, corresponding to the bronchi and the

peribronchitic zones, and between these there may be a diffuse hepatization.

In children suffering from diphtheria, with pseudo-membranes containing pathogenic bacteria in the fauces and upper air passages, a secondary pneumonia may apparently occur as the result of the entrance into the lung spaces of the germs from above (Fig. 217).[1] Although the pyogenic bacteria are the most frequent inciters of secondary and complicating pneumonia, other forms of germs are capable of inducing it.



FIG. 217.—BRONCHO-PNEUMONIA IN A CHILD, COMPLICATING DIPHTHERIA.

Air vesicle showing inflammatory products and large numbers of bacteria (streptococci) stained with methyl violet.

### *IV. The Pneumonia of Heart Disease.*

Lesions of the aortic and mitral valves, and dilatation of the left ventricle, often produce a diffuse, chronic inflammation of both lungs of a peculiar character. This condition is often called pigment induration, or brown induration, but it is really a chronic pneumonia.

The lungs are diminished in size and of a peculiar yellow-pink color, mottled with spots of black or brown pigment. They are not congested, but are of a dry, leathery consistence ; or portions of them

[1] Consult *Prudden and Northrup*, "Studies on the Etiology of Pneumonia complicating Diphtheria in Children," American Journal of Medical Sciences, June, 1889.

may be in the condition of a smooth red hepatization. The appearance of these lungs may be modified by the presence of hæmorrhagic infarctions, by the pre-existence of emphysema, or by œdema.

Minute examination of these lungs shows four separate pathological conditions.

1. A change in the capillaries in the walls of the air spaces. These capillaries are dilated and tortuous, so that they project into the cavities of the vesicles (Fig. 218). The degree of the dilatation varies in the different lungs; in some it is very marked, in others but light.

2. A thickening of the walls of the air spaces, due partly to the



FIG. 218.—LUNG OF HEART DISEASE.

Showing dilated capillaries of the walls of the air vesicles and the presence of hæmatogenous pigment in the exfoliated epithelial cells of the air vesicles.

dilatation of the capillaries, partly to a growth of smooth muscle, and partly to a growth of connective tissue. The degree of the thickening varies very much in different cases.

3. A formation of black or brown pigment in the shape of granules and small masses. This is deposited in the walls of the vesicles, in the interstitial connective tissue, and in the new cells within the vesicles (Fig. 218).

4. A formation of cells within the air spaces. The walls of the vesicles are coated with a layer of flat, nucleated cells. Similar cells, or swollen and granular cells, are present in the cavities of the

vesicles (Fig. 218). If these cells are numerous the cavities of the vesicles are filled, and there results a smooth red hepatization.

### *V. Interstitial Pneumonia.*

This name is given to a chronic productive inflammation, which involves the connective-tissue framework of the lung and the walls of the air spaces, and results in the formation of new connective tissue and the obliteration of the air spaces (Fig. 219).

Such an interstitial pneumonia may follow acute lobar pneumonia

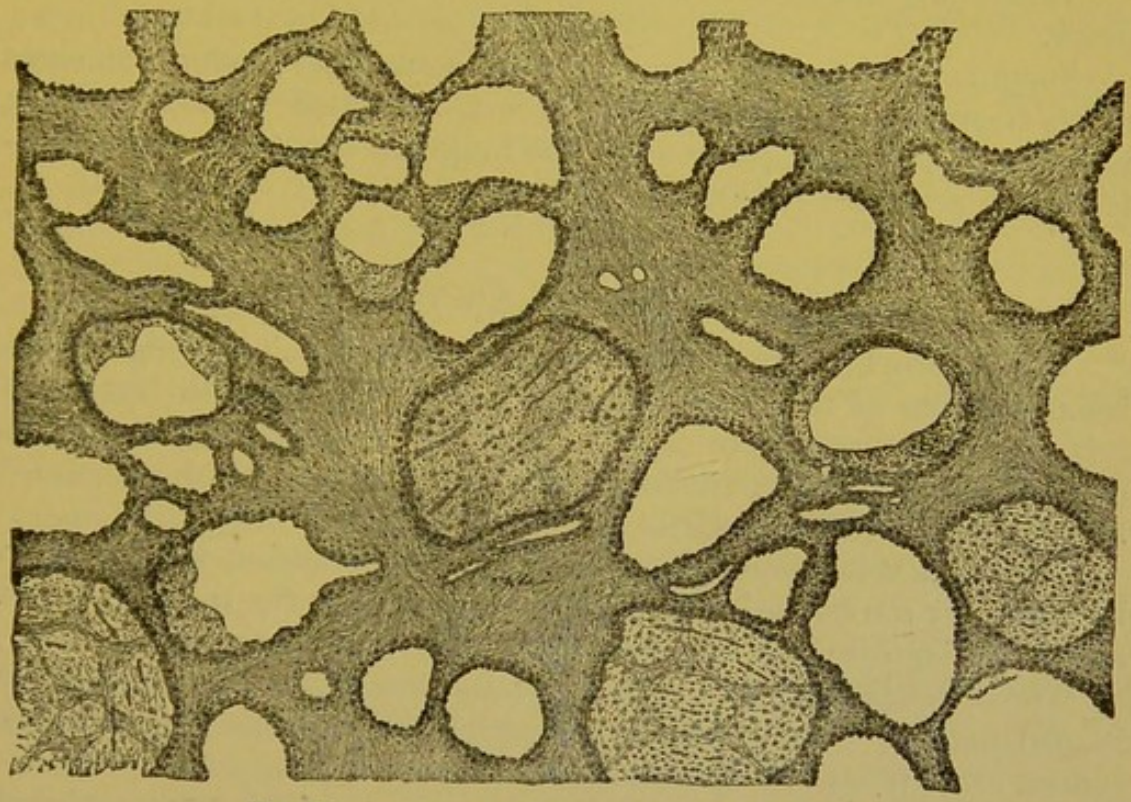

FIG. 219.—INTERSTITIAL PNEUMONIA, × 90 and reduced.
From a case of chronic phthisis.

with the production of new connective tissue; broncho-pneumonia; chronic pleurisy; chronic bronchitis; or be caused by the inhalation of the dust of coal or of stone.

The condition of the lung varies with the cause of the interstitial pneumonia.

If it follows acute lobar pneumonia with the production of new connective tissue, one lobe, or the whole of one lung, is covered with pleuritic adhesions. The lobe or the lung is small, smooth on section and dense. The air spaces and small bronchi are obliterated by the new connective tissue.

If it follows broncho-pneumonia, one or more lobes are studded

with fibrous nodules, which correspond to the inflamed bronchi; or the whole of a lobe is converted into dense fibrous tissue. The pleura is thickened, the bronchi are inflamed and often dilated.

If it follows thickening of the pleura, bands of connective tissue extend from the pleura into the lung, the bronchi are inflamed and often dilated.

If it follows chronic bronchitis, there are fibrous nodules around the bronchi, with more or less diffuse connective tissue.

If it is due to the inhalation of coal or dust, we find in both lungs fibrous peribronchitic nodules and diffuse connective tissue.

When only one lung is involved the other is apt to be emphysematous.

Suppurative interstitial pneumonia is sometimes produced in cases of septicæmia. The pulmonary pleura is coated with fibrin, the bronchi contain pus, portions of the lung are hepatized, and the interlobular septa are infiltrated with pus.

### *VI. Tuberculous Pneumonia.*

We employ the name of "tuberculous pneumonia" to designate the inflammations of the lungs which are caused by the introduction of tubercle bacilli into these organs. Such tuberculous inflammations of the lungs may be confined to them, or they may be accompanied by tuberculous inflammations of other parts of the body.

For the development of a tuberculous inflammation there seem to be necessary the irritation of the tissues caused by the tubercle bacilli and a predisposition on the part of the individual.

The development of such an inflammation in any part of the body is also favored by the conditions which favor or the causes which induce other phases of inflammation.

The tubercle bacilli are capable of setting up different anatomical forms of inflammation, either separately or together. They may give rise to exudation from the blood vessels, to the production of new tissue, or to necrosis (see page 218).

The introduction of tubercle bacilli into the lungs, therefore, may produce: an exudative inflammation with fibrin and pus cells in the air spaces; a productive inflammation with the growth of epithelial cells, or of round-celled tissue, or of a tissue composed of basement substance, large and small cells, and giant cells, called tubercle tissue (see page 217); or there may be added necrosis of the new tissue and of portions of the lung.

The character of the inflammation in each case seems to be governed by the number of bacilli which are introduced into the lungs and the way in which they are introduced, as well as by the suscepti-

bility of the individual. If a large number of tubercle bacilli are inhaled through the bronchi, both productive and exudative inflammations may be set up in a considerable portion of the lungs. If, on the other hand, but a small number of bacilli are inhaled, or if these find their way into the lungs through the blood vessels or lymphatics, then there are small foci of productive inflammation with but little exudation.

There are two ordinary ways in which the lungs are infected: (*a*) The bacilli which float in the air are inhaled and irritate the small bronchi and the air spaces; (*b*) the bacilli contained in a focus of tuberculous inflammation in some other part of the body are carried by the blood vessels to the lungs, become lodged there and set up small areas of inflammation.

The changes in the lungs may also be modified by an infection with other pathogenic micro-organisms.

As the gross appearance of the lungs varies with the character, extent, and development of the different phases of inflammation excited by the tubercle bacilli, a number of arbitrary names have been given, which may still be conveniently used. We describe, therefore, *Acute Miliary Tuberculosis; Subacute Miliary Tuberculosis; Chronic Miliary Tuberculosis; Acute Phthisis and Chronic Phthisis.*

*Acute Miliary Tuberculosis.*—The acute development of miliary tubercles in the lungs is usually only part of general tuberculosis, although the lesion may be most extensive in the lungs.

Both lungs are apt to be involved, but the distribution, number, size, and character of the miliary tubercles differ in different cases.

The larger bronchi are the seat of catarrhal inflammation; the lung tissue is congested; the air spaces contain epithelium, pus, and fibrin in small quantity.

The tubercles are found in the parenchyma of the lung, in the connective tissue forming the septa, along and in the walls of the bronchi and blood vessels, and in the pulmonary pleura.

They are scattered singly through the lungs, or aggregated in groups. They may be separated by considerable interspaces, or so close together that the lung is rendered nearly solid. Some are so small and transparent that they can hardly be seen with the naked eye; others are larger and more opaque. In children's lungs large masses are found of the same structure as miliary tubercles.

In many cases it seems evident that the lungs are infected through the blood vessels, or perhaps through the lymphatics, for the general tuberculous infection is secondary to a localized tuberculosis of some other part of the body. But in other cases no such localized primary focus can be found, so that infection by inhalation is possible. The

whole picture of acute tuberculosis is such, however, as to give the impression that the infection usually takes place through the blood vessels and lymphatics.

The anatomical forms of miliary tubercles are as follows:

1. Miliary tubercles composed of a group of air vesicles containing amorphous granular matter, with a few shrunken cells and an external zone of pus cells. The walls of the air spaces may be still visible, and may be infiltrated with exudate, or they may be necrotic



FIG. 220.—MILIARY TUBERCLE IN LUNG OF CHILD.

Showing the Bacillus tuberculosis—stained with fuchsin—in the contents of the air vesicles and in their thickened walls. (The size of the bacilli relative to other elements is slightly exaggerated.)

and lost in the mass of granules. The only changes are exudation and necrosis (Fig. 220).

In adults such tubercles are usually small, but in children they may reach a large size.

2. Miliary tubercles formed by the infiltration of the wall of a bronchiole or air passage with tubercle tissue or granulation tissue. This infiltration is apt to involve only one side of the bronchiole or air passage (Fig. 221). It may be confined to this or it may extend to the walls of the adjacent vesicles. These vesicles may remain

empty, they may be dilated, or they may be filled with tubercle tissue or with epithelium, fibrin, and pus.

In these tubercles we see productive inflammation by itself in some cases, combined with exudation in others. The inflammation seems to begin in the walls of the small bronchioles and to extend from them to the adjacent air spaces.

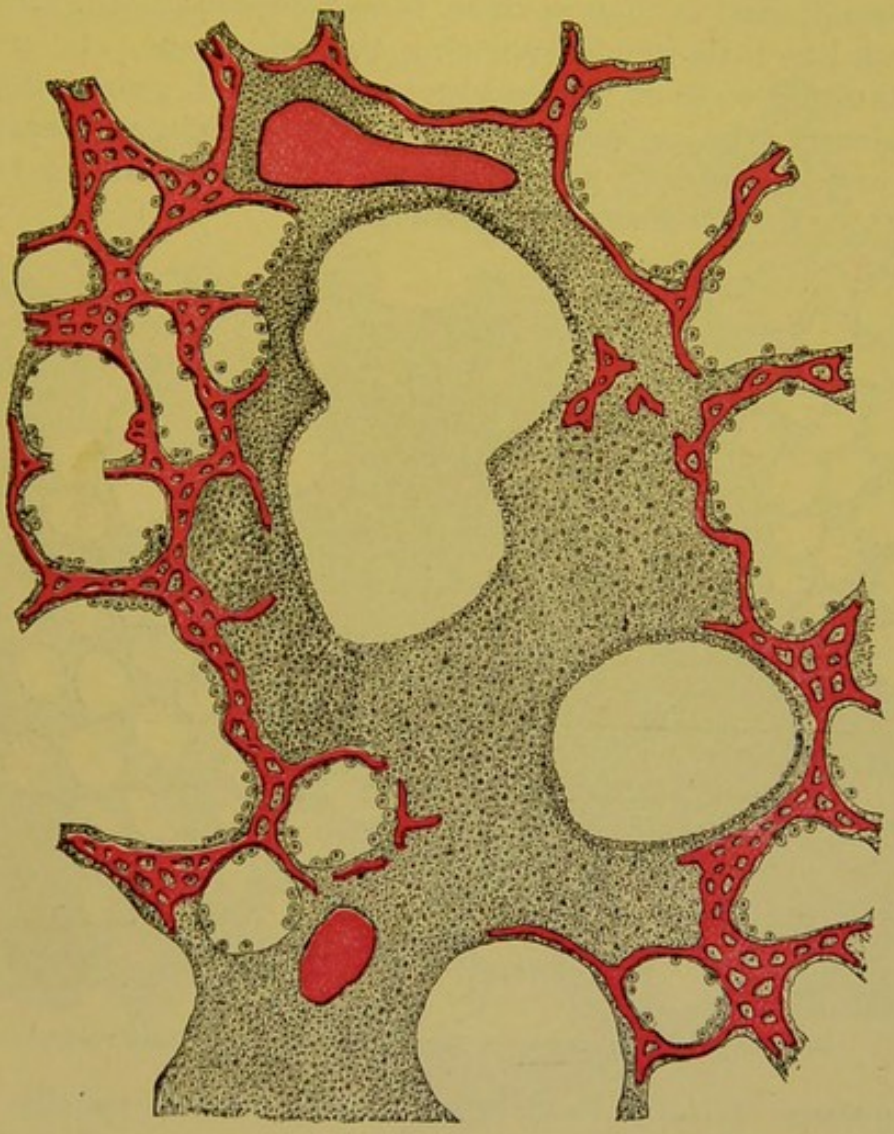

FIG. 221.—A PERIBRONCHITIC MILIARY TUBERCLE.

In all miliary tubercles there is often cheesy degeneration of the central portions. Although all miliary tubercles are caused by the presence of tubercle bacilli, it may be quite difficult to demonstrate the bacilli in each. These tubercles are formed by a combination of productive and exudative inflammation which involves groups of air spaces.

3. Miliary tubercles composed of a group of air spaces of which the walls are infiltrated and the cavities filled (Fig. 222) with granu-

lation tissue or tubercle tissue; as the infiltration progresses the blood vessels are obliterated (Fig. 223). Such an infiltration may involve symmetrically the whole of the wall of an air space, or only a portion of the wall. The cavities of the air spaces are filled with tubercle tissue, or with epithelium, fibrin, and pus.

In some of these tubercles the tubercle tissue, both in the walls of the air spaces and in their cavities, is well developed (Fig. 224); then they look like little tumors replacing the lung tissue. In others the outlines of the walls of the vesicles are preserved, granulation tissue predominates, the cavities of the vesicles contain pus, epithelium, fibrin, and less tubercle tissue (Fig. 225); then the tubercle look, like little areas of a composite hepatization.

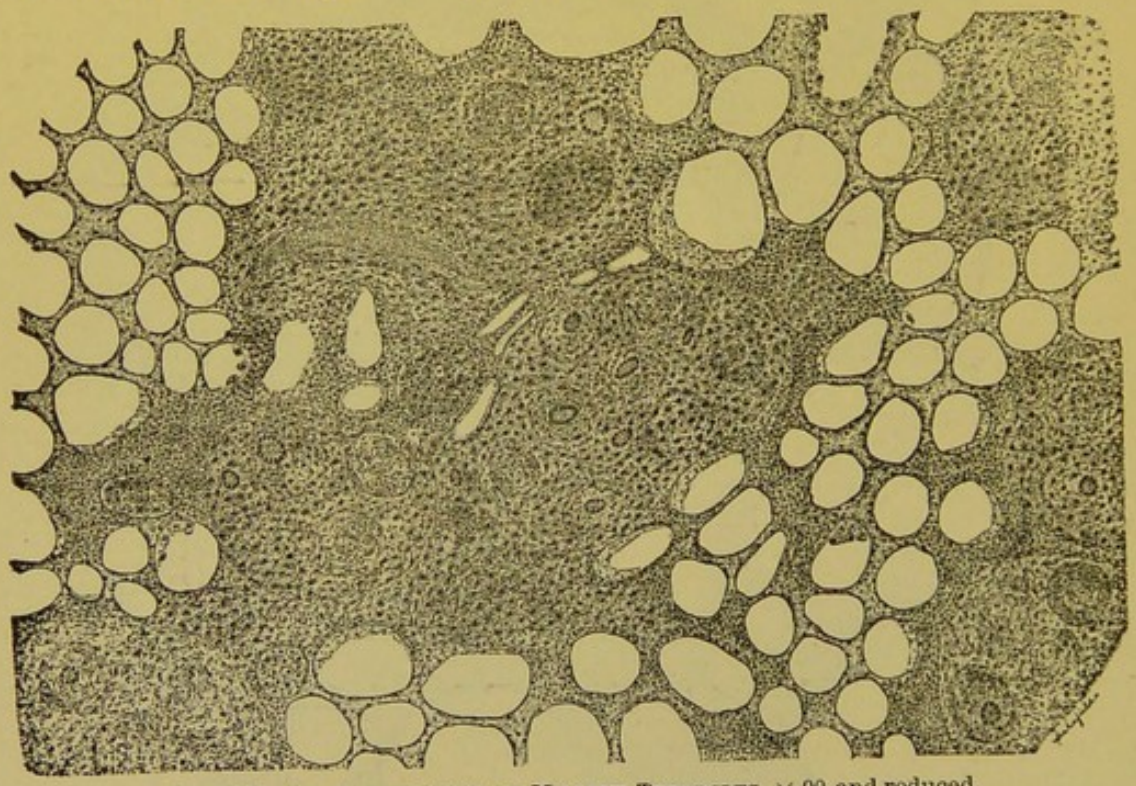

FIG. 222.—AN AGGREGATION OF MILIARY TUBERCLES, × 90 and reduced.

*Subacute Miliary Tuberculosis.*—The disease usually involves only the apex of one lung, or one lobe, or portions of both lungs. The inflammation may continue for weeks or months, then stop and the patient recover. Or the patient may have a number of attacks, from each one of which he recovers. Or the disease may continue, extend, and cause death within a few months. Or it may be succeeded by chronic miliary tuberculosis.

The miliary tubercles are small. Most of them are formed within the air spaces or around the bronchioles. They are composed principally of tubercle tissue or of round-celled tissue. In the portion of lung where the tuberculous inflammation is going on there may also be localized catarrhal bronchitis and pleurisy.

It seems evident that the infection is produced by a small number of bacilli, and that the principal effect of their presence is a productive inflammation of the walls of the air spaces and of the small bronchi. It is much to be regretted that we are still uncertain as to the method of infection in these cases. There is no demonstration as to whether the bacilli are usually introduced through the bronchi or the blood vessels.

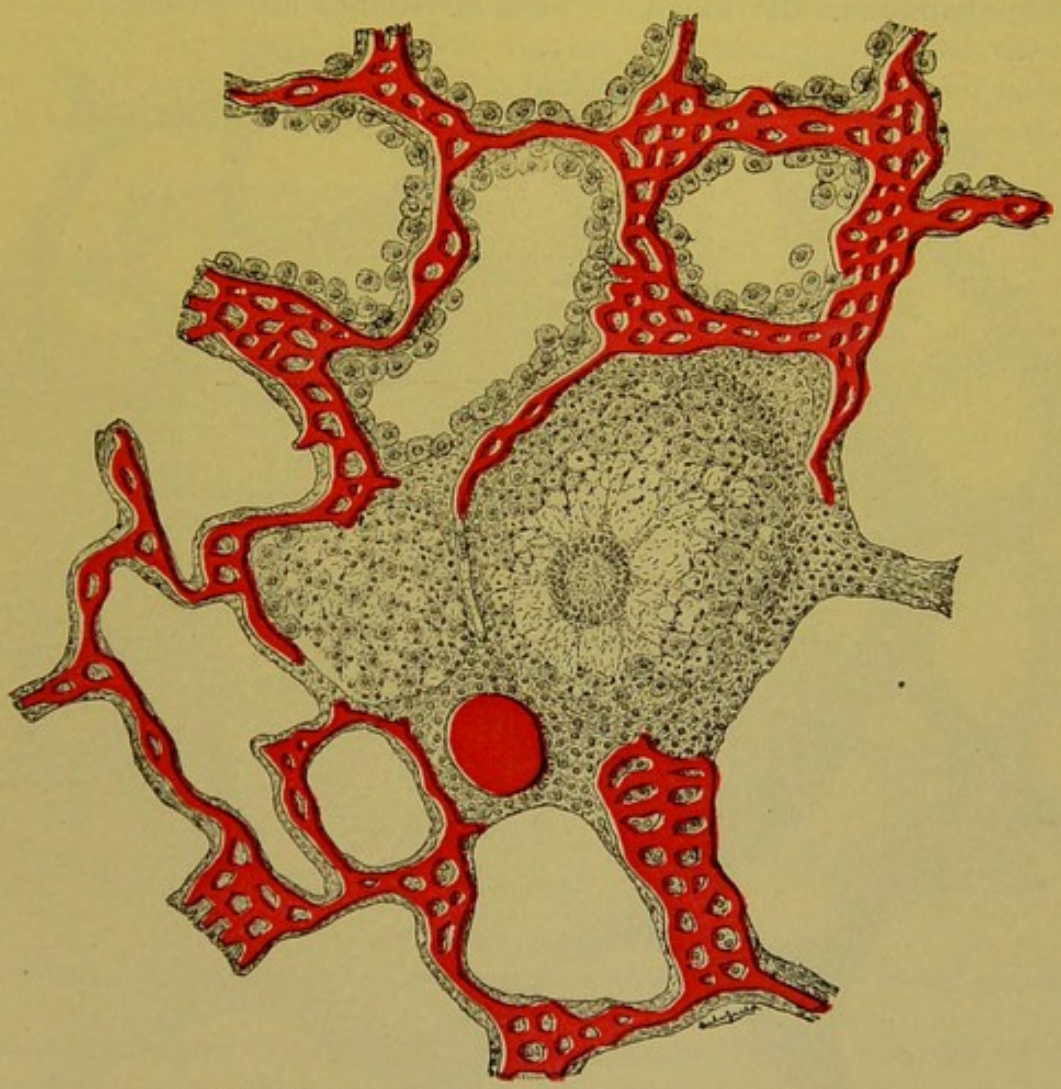

FIG. 223.—A MILIARY TUBERCLE, × 300 and reduced

Involving only two air vesicles, of which the walls are infiltrated and the cavities filled with tubercle tissue. The blood vessels of the air vesicles are injected.

*Chronic Miliary Tuberculosis.*—The morbid process is apt to begin at the apex of one lung and then slowly extend, either progressively or in attacks, until a large part of the lungs is involved.

The whole course of the disease is such as to give the impression of an infection through the blood vessels and lymphatics and not by inhalation. The inflammation excited is of the productive form running a slow course.

In the simplest form of the disease the only change in the lungs is the formation of miliary tubercles. These tubercles are harder and denser than those found with general tuberculosis or with subacute pulmonary tuberculosis. They are composed of tubercle tissue, or round-celled tissue, or connective tissue, or are in the condition of cheesy degeneration.

Usually, however, in addition to the miliary tubercles there are other changes in the lungs. These additional lesions begin in the

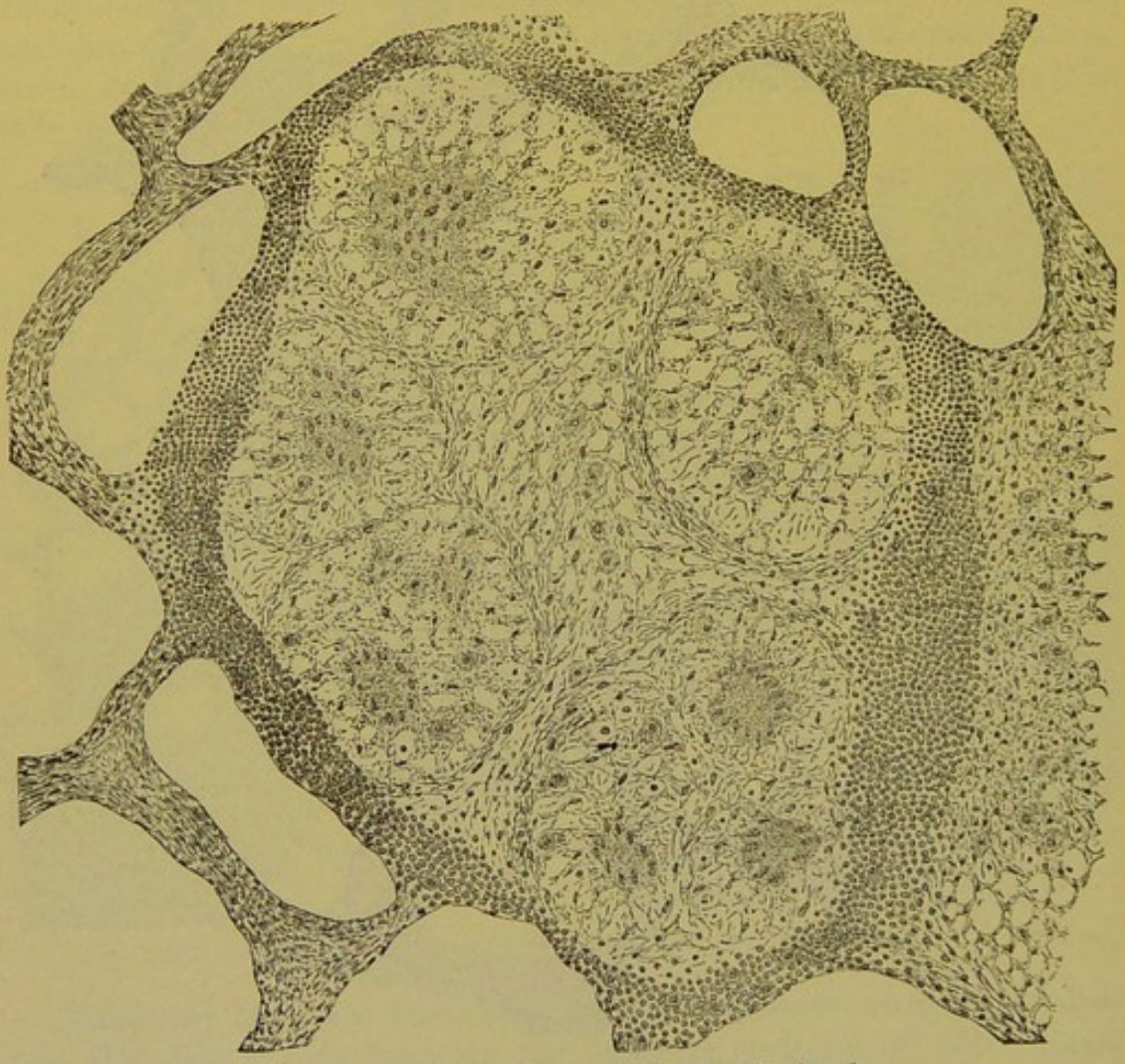

FIG. 224.—A MILIARY TUBERCLE, × 330 and reduced.

Formed of several air vesicles filled with tubercle tissue and surrounded by a zone of tissue resembling granulation tissue.

same part of the lung where the tubercles are formed, and accompany the development of the tubercles in fresh parts of the lungs.

There may be a localized catarrhal bronchitis.

There may be an inflammation of the walls of the bronchi, with partial destruction of these walls and the formation of cylindrical or sacculated bronchiectasiæ. The walls of the cavities thus formed may be converted into connective tissue, or they may remain suppurating and necrotic.

There may be an interstitial pneumonia with the production of new connective tissue, the obliteration of the air spaces, and the consolidation of portions of the lungs.

There may be dilatation of the air spaces of the portions of the lungs which are not consolidated.

There may be thickening of the pulmonary and costal pleura, with connective-tissue adhesions.

While the morbid process begins as a localized tuberculous inflammation of the lungs, and often retains throughout this local character, yet it may also happen that from this local lesion other parts of the body may be infected. Tuberculous laryngitis, and tuberculous

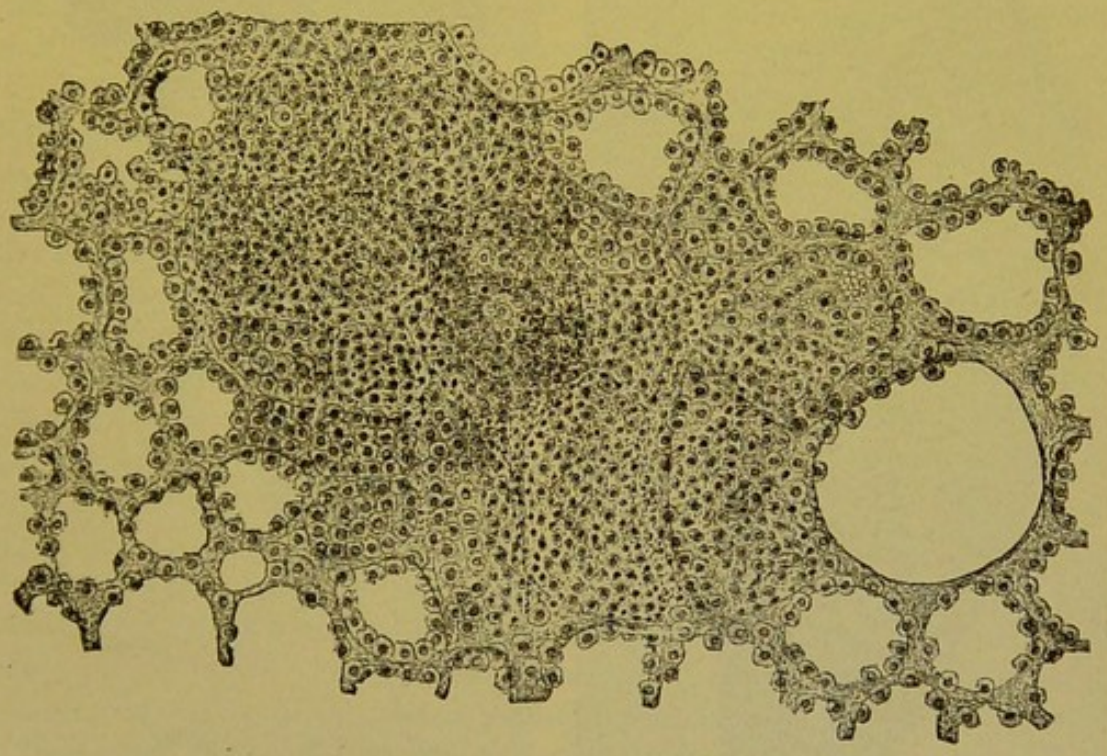

FIG. 225.—A MILIARY TUBERCLE, × 300 and reduced.
Formed of a number of air vesicles, some containing tubercle tissue, others pus and epithelium.

inflammation of the solitary and agminated lymph nodules of the small intestine, often complicate the pulmonary lesion, and sometimes even acute general tuberculosis is produced.

*Acute Pulmonary Phthisis.*—This name is used to designate the tuberculous inflammation of the lungs in which exudative inflammation preponderates, but is associated with productive inflammation. It seems evident that this feature of the inflammation is due to the large number of bacilli introduced by inhalation through the bronchi, or which rapidly grow in the lung, and to the frequent association of an infection with other bacteria, especially streptococci.

The changes produced in the lungs by the introduction into the bronchi of tubercle bacilli can be well studied in animals. One of us

(Prudden)[1] by the injection of tubercle bacilli alone and associated with streptococci into the tracheæ of rabbits has been able to reproduce very closely the lesions of acute phthisis.

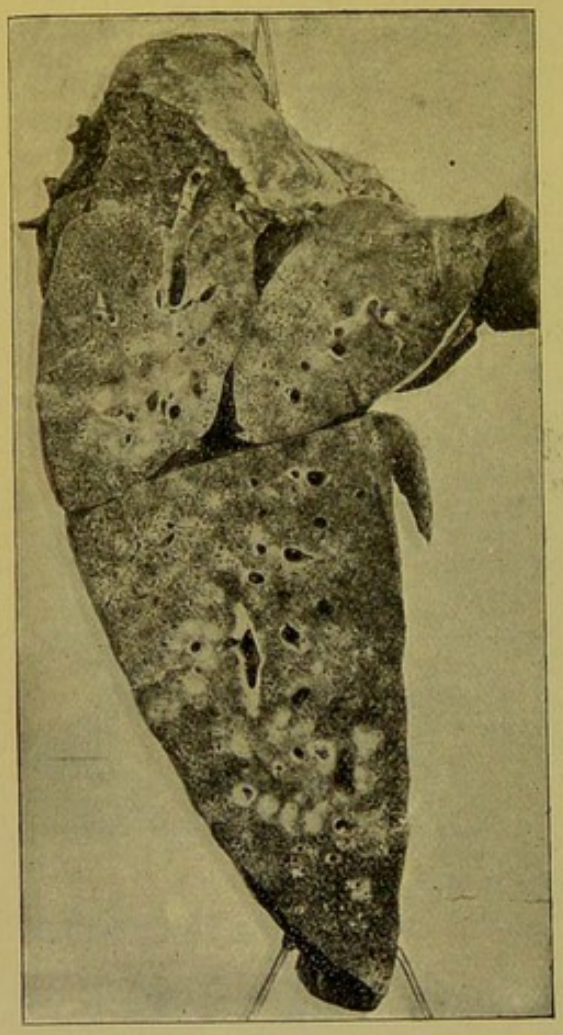

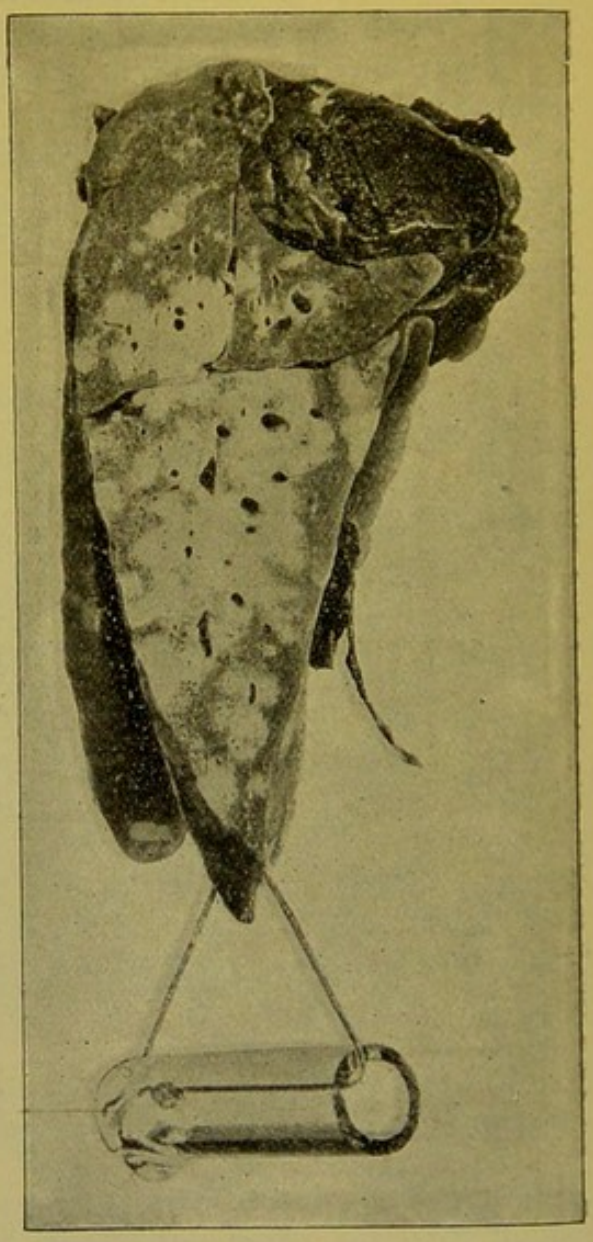

Fig. 226. Fig. 227.

Fig. 226.—Experimental Tuberculous Inflammation (Miliary) in the Lung of a Rabbit.
The rabbit's lung shows miliary foci of tuberculous inflammation, twenty-two days after the injection through the trachea of a small quantity of broth culture of the tubercle bacillus.

Fig. 227.—Experimental Tuberculous Inflammation in the Lung of a Rabbit.
Large areas of solidification in the lung twenty-eight days after the injection through the trachea of a considerable quantity of a pure culture of the tubercle bacillus. The lesions resemble those of acute phthisis in man.

If a small quantity of a pure culture of the tubercle bacillus in very minute flocculi is mixed with a considerable quantity of salt

[1] New York Medical Journal, July 7th, 1894.

solution and introduced into the lungs through the trachea a number of small areas of consolidation are produced which have the gross appearance of miliary tubercles (Fig. 226). These small areas of consolidation are composed of epithelial cells and leucocytes. After the development of these cell masses, which may occur within a few hours, they may remain with little apparent change, or become more or less infiltrated with leucocytes, or become cheesy, or be surrounded by a dense zone of small spheroidal cells.

When larger quantities of the tubercle bacillus are introduced into the lungs through the trachea large areas of consolidation are formed (Fig. 227), which may involve whole lobes or whole lungs. The first effect upon the lungs is the collection about the bacilli, in the air spaces where they have lodged, of dense masses of leucocytes. These cell collections immediately about the germs form the centres of the inflammatory foci which develop later. They correspond in shape to the shapes of the small bronchi and the connecting air spaces in which the bacilli have lodged. The walls of these cell-filled spaces may soon become necrotic, even within twenty-four hours. The blood vessels about these intra-alveolar masses of small cells and tubercle bacilli are intensely congested, and within forty-eight hours a considerable proliferation of alveolar epithelium has occurred in the zone of air spaces surrounding the primary foci. Giant cells may form in the air spaces, apparently by the fusion of the new-formed epithelial cells. The changes of a productive inflammation may begin in the walls of the air spaces about the primary small-celled foci as early as the third day. The smaller bronchi belonging to the involved air spaces may also be densely packed with small spheroidal cells. Within the first three days, if the quantity of injected tubercle bacilli be large, the air spaces about the involved areas may be the seat of an exudative inflammation, so that they are closely filled with fibrin and leucocytes as well as with epithelium. Almost as soon as they have collected a large part of the leucocytes about the tubercle bacilli may die, so that within three days after the introduction of the bacilli these cell masses are converted into a granular mass—coagulation necrosis—in which only the nuclei can be distinguished. The tubercle bacilli are confined to these central cell masses, so that both the epithelial cell proliferation and the exudative inflammation appear to result from some soluble product of the tubercle bacillus which may be diffused.

As time passes the naked-eye distinction is maintained between a larger or smaller irregular-shaped central white area of consolidation, the seat of lodgment of the bacilli, and a surrounding translucent zone of consolidated lung which contains few bacilli. The central mass of necrotic cells and lung tissue gradually undergoes

coagulation necrosis and increases in size by encroachment on the surrounding zone of consolidation. The translucent border zone of consolidation grows wider, the air spaces in it are filled with epithelium, fibrin, and leucocytes. There is a growth of new tissue in the walls of the air spaces. Giant cells are often abundant in this zone.

The changes thus far indicated are such as may occur within the first two weeks after the injection of the bacilli. From this time on

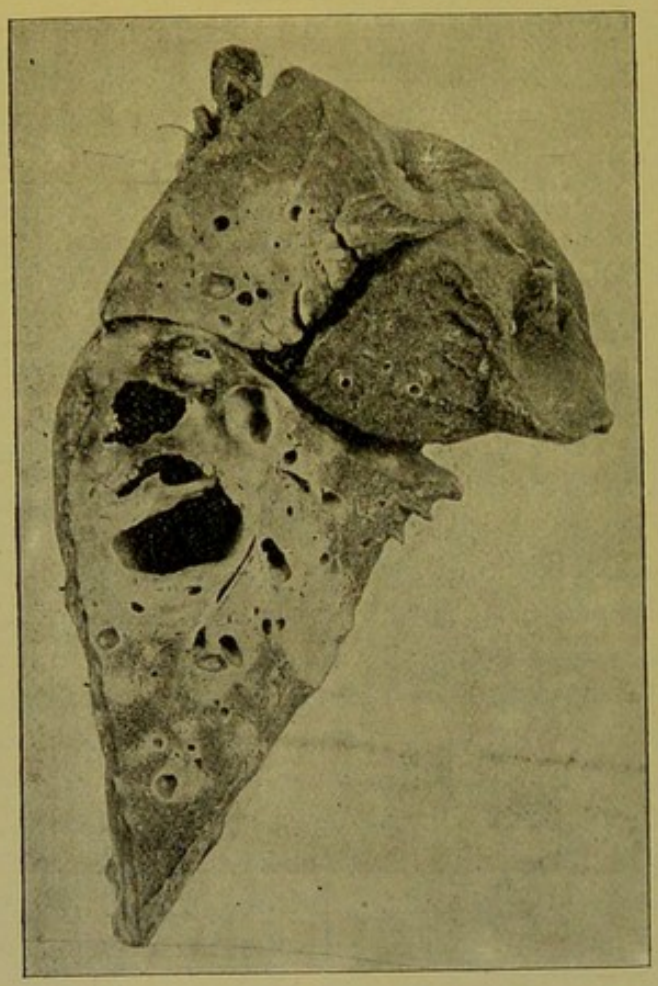

FIG. 228.—EXPERIMENTAL TUBERCULOUS INFLAMMATION IN THE LUNG OF A RABBIT, WITH THE FORMATION OF CAVITIES.

The lung was injected with a considerable quantity of tubercle-bacillus culture through the trachea, followed after twenty-eight days by the injection of the broth culture of the streptococcus pyogenes. Animal killed seven days after the streptococcus injection. The specimen shows large areas of consolidation with cavities. The lesions resemble those of acute phthisis with cavities in man.

up to the seventh week the changes are quantitative rather than qualitative. The central necrotic mass may become fully cheesy, and may grow slowly larger by encroachment upon the surrounding zone of epithelial cell proliferation and productive and exudative inflammation. The areas of consolidation may coalesce so as to render whole lobes or lungs solid, so that to the naked eye the cut surface

presents an irregular mottling with large or small white masses and more translucent intervening areas. The intima of the large blood vessels near the involved areas may be thickened and smaller trunks may be obliterated.

In the presence of the tubercle bacillus alone the cheesy areas but rarely soften and break down so as to form cavities. If, however, after the tuberculous inflammation of the lung has been produced and allowed to continue for a number of days, a culture of Streptococcus

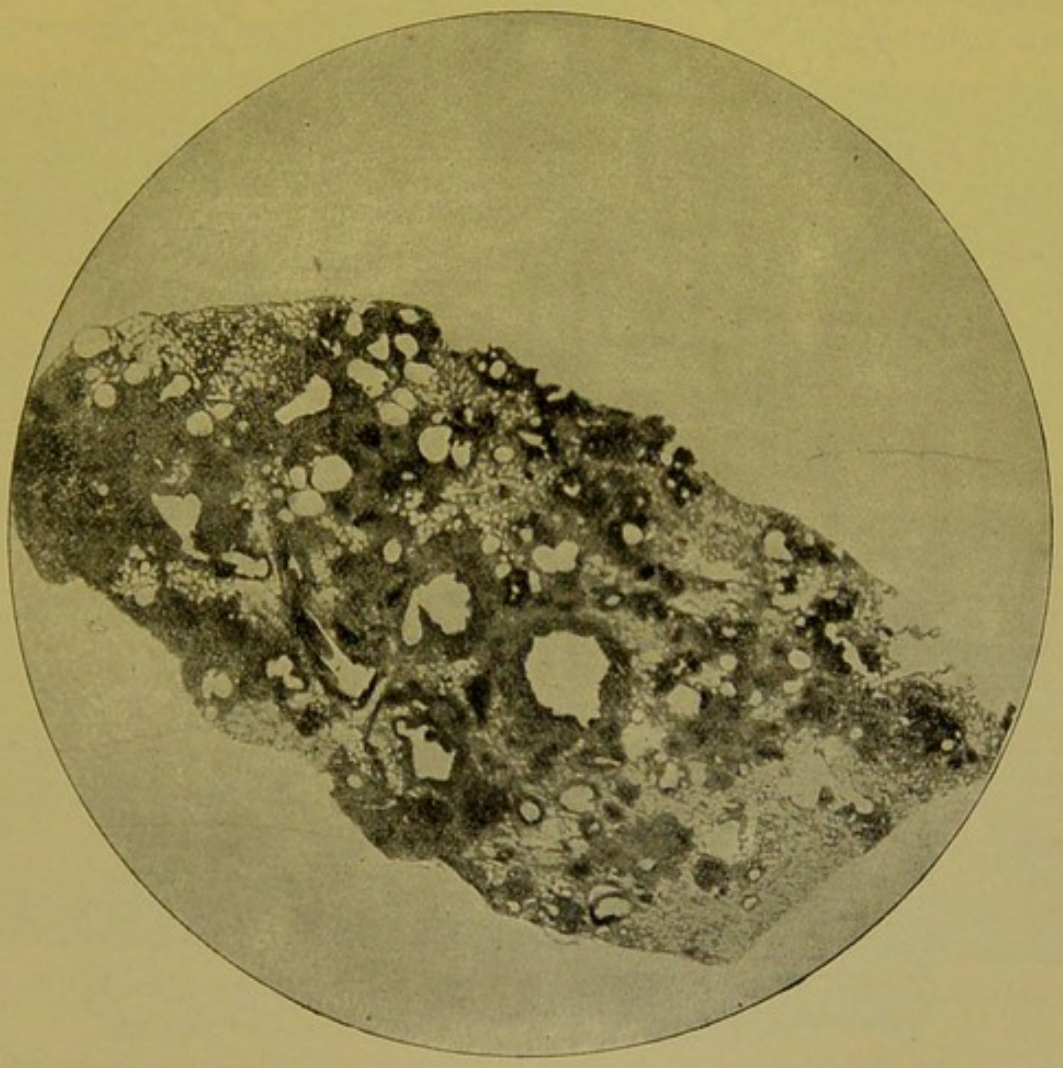

FIG. 229.—TUBERCULOUS BRONCHO-PNEUMONIA.
The walls of the bronchi are thickened and surrounded by zones of pneumonia.

pyogenes be introduced into the trachea in a rabbit, within twenty-four hours the cheesy areas begin to soften. The softening may begin at the centre of a cheesy area, or may surround a central portion of the necrotic mass. The softening is soon followed by absorption, and so cavities are formed of varying sizes and shapes (Fig. 228).

It will thus be seen that in the rabbit a concurrent infection with the tubercle bacillus and the streptococcus has an important bearing

upon the breaking down of lung tissue which leads to the formation of cavities. While it would not be wise to assume from these experiments on the rabbit that a similar condition exists in man, it will be seen presently (page 467) that in fact a similar concurrent infection in man in acute phthisis actually does often exist.

The tuberculous inflammation of the lungs in human beings pro-

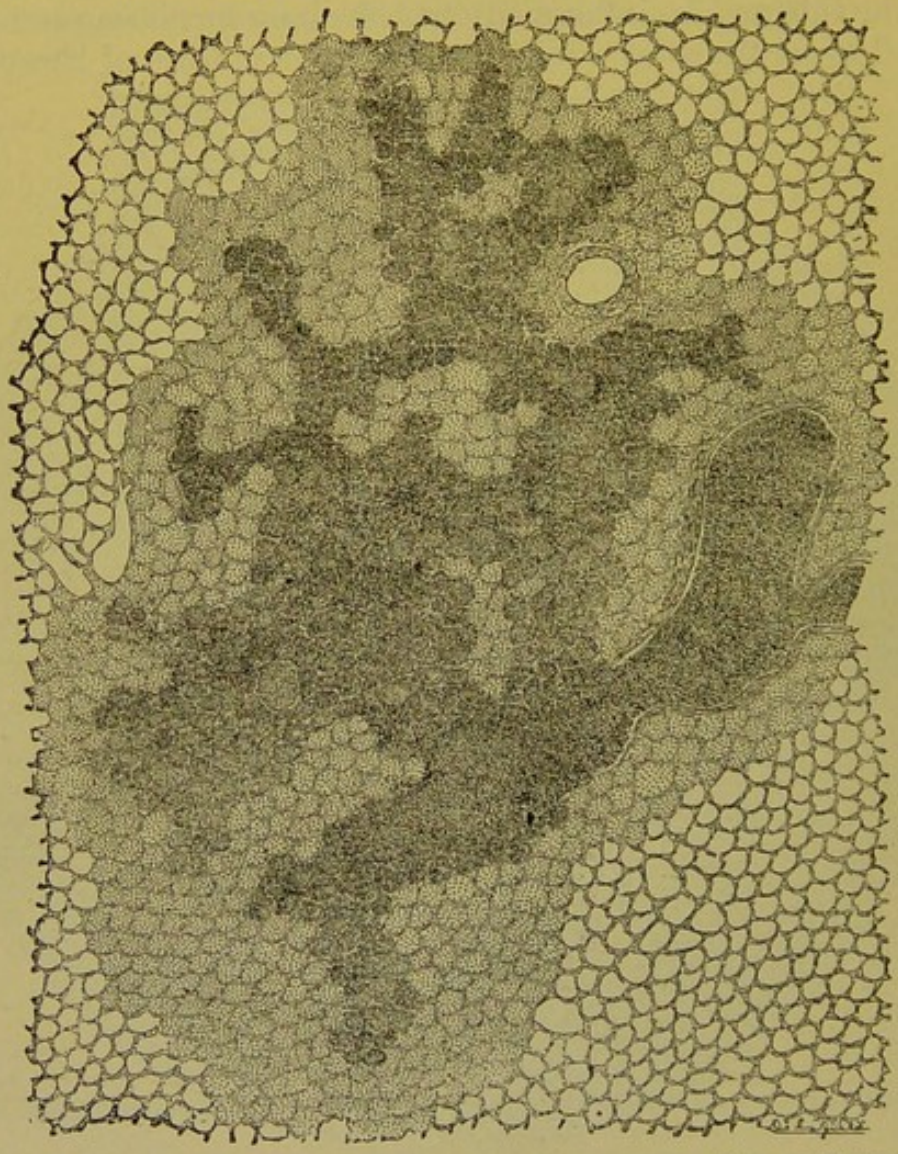

FIG. 230.—AN AREA OF COAGULATION NECROSIS SURROUNDED BY A ZONE OF PNEUMONIA, × 40 and reduced.

duced by the inhalation of a large number of tubercle bacilli presents five varieties which have well-marked anatomical and clinical characteristics.

I. In one or more lobes there are miliary tubercles in considerable numbers, and a diffuse hepatization. The miliary tubercles have the structure already described under the head of acute tuberculosis. The diffuse hepatization is like that of lobar pneumonia—the air spaces are filled with fibrin, pus, and epithelium.

This form of acute phthisis is not of common occurrence. If an entire lung is consolidated the patients usually die within a short time. If only one lobe is involved, it is possible for them to recover, for the fibrin, pus, and epithelium to be absorbed, and only the miliary tubercles left as a permanent change.

II. There is a general catarrhal bronchitis and a tuberculous inflammation of the walls of some of the bronchi and of small zones of air spaces immediately surrounding them, but there is no diffuse consolidation. The inflammation of the walls of the bronchi is productive with the formation of tubercle tissue and round-celled tissue.

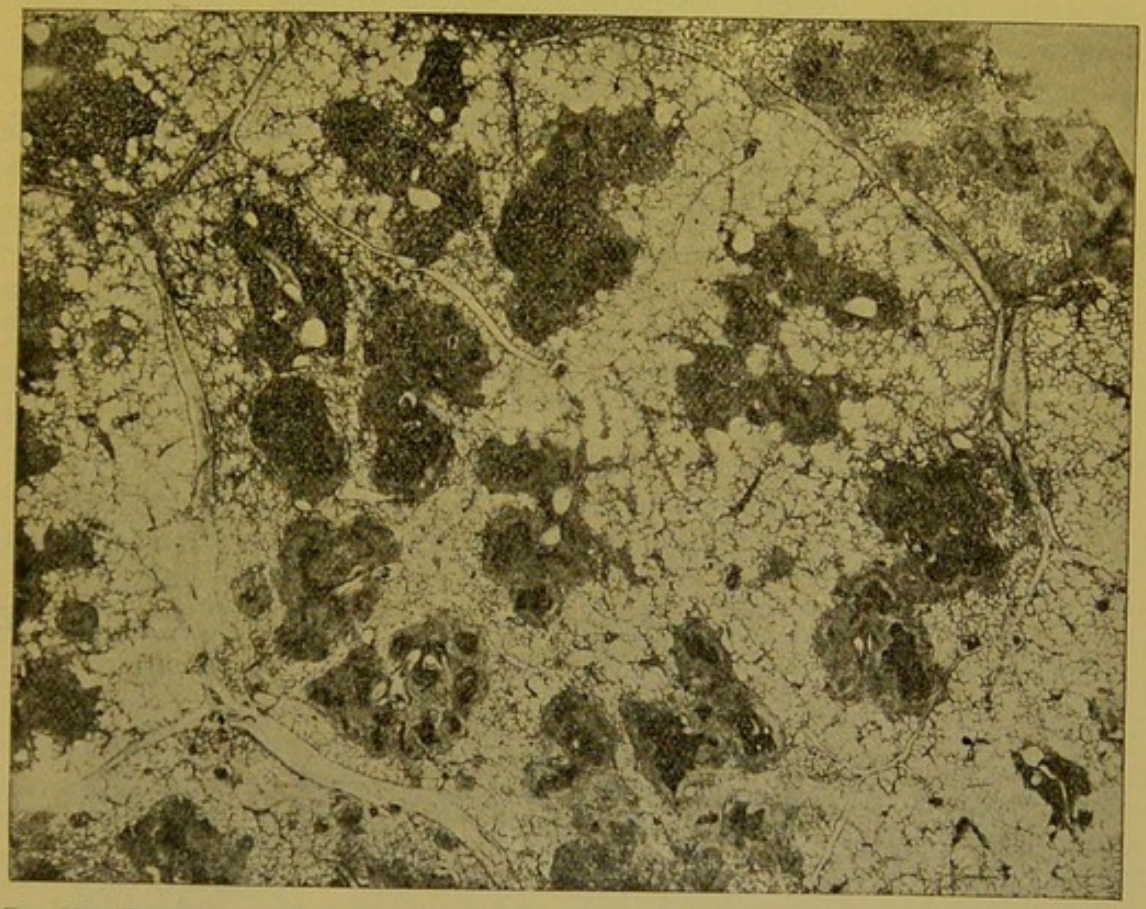

FIG. 231.—TUBERCULOUS INFLAMMATION OF THE LUNG WITH CHEESY DEGENERATION ABOUT THE BRONCHI IN A SINGLE LOBULE OF THE LUNG—ACUTE PHTHISIS.

That of the surrounding zone of air spaces is partly productive, partly exudative. Some of the air spaces are filled with epithelium or with fibrin and pus, some with tubercle tissue.

In these patients the only physical signs are those of the general bronchitis. If the lesion is not too extensive recovery is possible.

III. There is a catarrhal bronchitis, a tubercular inflammation of the walls of the bronchi and of the air spaces surrounding them, and a diffuse consolidation of rather complex character.

One or more lobes are competely consolidated, while in other parts of the lung there are little whitish nodules, but no general con-

solidation. The consolidated portion of lung is not of uniform appearance. It is evidently made up of white or yellow areas of different sizes and shapes, surrounded by zones of red or grayish hepatization. The blood vessels of the white and yellow areas are occluded and cannot be injected, the vessels of the surrounding zones of hepatization are pervious. The white and yellow nodules are formed in three different ways.

1. One or more air passages with the air vesicles belonging to them have their cavities filled with fibrin, pus, epithelium, and tubercle tissue, while their walls are more or less infiltrated with tubercle tissue. The tubercle bacilli find their way into these air passages and excite an inflammation which is principally productive.

2. There is an inflammation of the walls of the small bronchi and of the air spaces around them so that on section these bronchi and associated air spaces look like nodules. These little bronchi are inflamed in three ways: (*a*) The bronchus contains pus and epithelium, its wall is infiltrated with round cells, the surrounding air spaces are filled with epithelium, pus, and fibrin. (*b*) The wall of the bronchus is infiltrated with tubercle tissue and the surrounding air spaces contain tubercle tissue. (*c*) There is no change in the wall of the bronchus, but the surrounding air spaces contain tubercle tissue. The tubercle bacilli lodge in the small bronchi and set up exudative or productive inflammation in their walls and in the air spaces which surround them.

3. There are small or larger areas of the lung in the condition of coagulation necrosis or of cheesy degeneration. These areas are surrounded by zones of exudative or of productive inflammation. They correspond exactly to the changes produced in the lungs of rabbits by the injection of tubercle bacilli into the trachea. It is from the rabbit's lungs that we can learn the early stages in the formation of these areas of coagulation necrosis. The tubercle bacilli lodge in groups of air spaces and set up in them an exudative inflammation. These air spaces are quickly filled with pus and epithelium, and the blood vessels in their walls become obliterated. Then follow degeneration, coagulation necrosis, and cheesy degeneration. At the same time these necrotic areas seem to act as irritants and around them are set up zones of exudative or productive inflammation. In the diffuse hepatization between the nodules the blood vessels remain pervious and can be readily injected. The air spaces are more or less completely filled with inflammatory products. The inflammatory products are: pus cells, fibrin, large epithelial cells, minute shining granules, and a peculiar transparent substance. Some air spaces are entirely filled with granules, others with fibrin, others with epithelial

cells, and still others with pus cells, while in still other air spaces these products are combined in different proportions.

IV. In a certain number of the cases of acute phthisis, with the



FIG. 232.—ACUTE PHTHISIS—CAVITIES FORMED BY SOFTENING OF AREAS OF COAGULATED NECROSIS.

changes in the lungs just described, within a short time the areas of coagulation necrosis soften and form cavities. Then the lung is honeycombed with irregular, ragged holes of different sizes (Fig. 232).

The conditions are the same as those seen in the rabbit's lung when infection with tubercle bacilli is followed by infection with streptococci. It seems probable that in the human lung the softening of the areas of coagulation necrosis is due to a secondary infection with streptococci.

Numerous observers have in fact found that the Streptococcus pyogenes is present often in enormous numbers both in the consolidated areas and in the walls of the cavities in acute phthisis in man.

It is probable, furthermore, that in this concurrent infection with



Fig. 233.—Acute Phthisis—Tuberculous Inflammation of the Lung and Dilatation of Bronchi.

the tubercle bacillus and the streptococcus the latter may play a most important part not only in the local lesion, but in the systemic poisoning of which the hectic fever is so frequent a symptom.[1]

V. There are cases of acute phthisis in which the changes in the walls of the bronchi are especially marked. (*a*) The walls of the small and larger bronchi are infiltrated with tubercle tissue which undergoes cheesy degeneration. The cavity of the bronchus is dilated and contains inflammatory products also in a condition of

[1] Citation of the earlier studies on concurrent or mixed infection in pulmonary tuberculosis will be found in the study by *Prudden*, New York Medical Journal, July 7th, 1896. Consult also *Petruschky*.

cheesy degeneration (Fig. 233). The adjacent air spaces may be unchanged, or may contain tubercle tissue, pus, fibrin, or epithelium. The necrosis may extend to the surrounding lung. In this way, partly by dilatation, partly by necrosis, cavities of considerable size are formed.

(*b*) There is a general dilatation of the bronchi in a considerable portion of the lung without any marked change in their walls, and

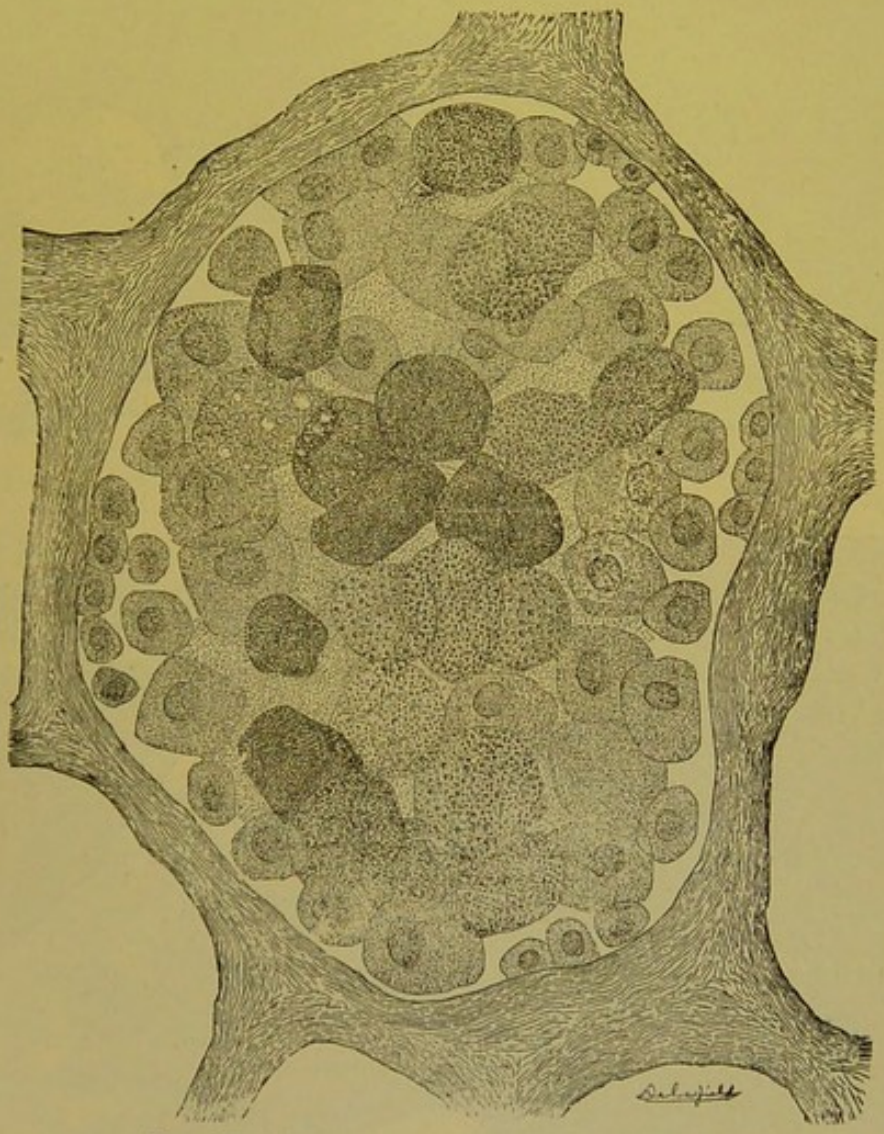

FIG. 234.—CHRONIC PHTHISIS, × 850 and reduced.
An air vesicle filled with fatty epithelium.

with only a moderate quantity of inflammatory products in their cavities. This change is especially apt to affect the medium-sized and small bronchi. The lung tissue between the bronchi is usually consolidated. When such a lung is cut it looks as if it were honeycombed with small cavities, but these cavities are only sections of the dilated bronchi.

*Chronic Pulmonary Phthisis.*—The lesions are of the same

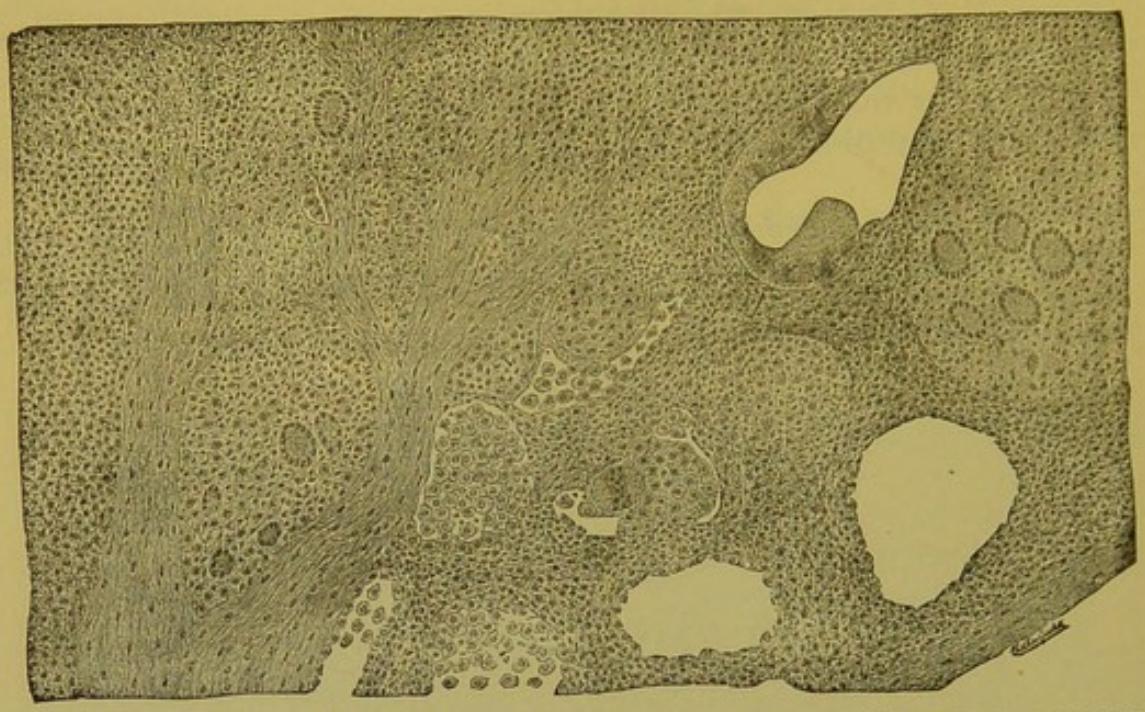

FIG. 235.—DIFFUSE TUBERCULOUS INFLAMMATION PRODUCING DIFFUSE CONSOLIDATION OF THE LUNG, × 300 and reduced.



FIG. 236.—CHRONIC PHTHISIS—INTRA-ALVEOLAR PNEUMONIA.

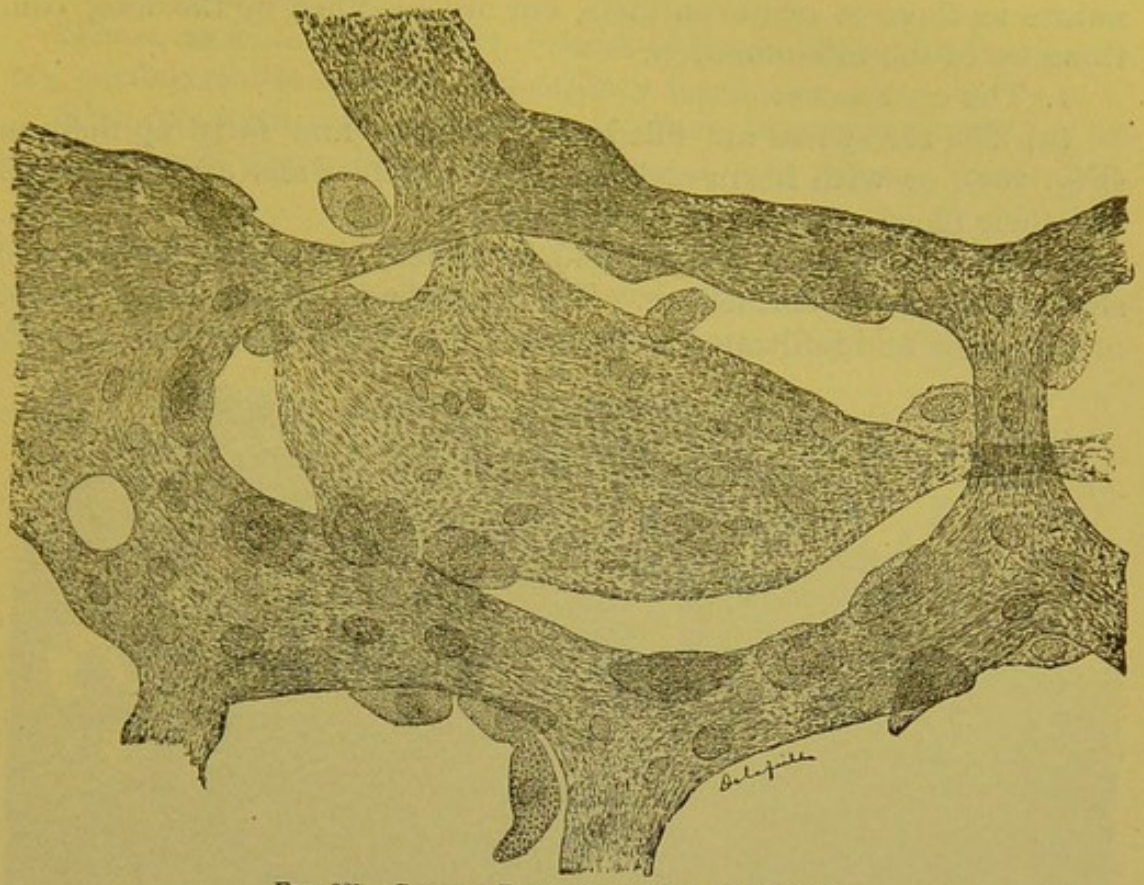

FIG. 237.—CHRONIC PHTHISIS, × 850 and reduced.
Showing growth of connective tissue within an air vesicle.

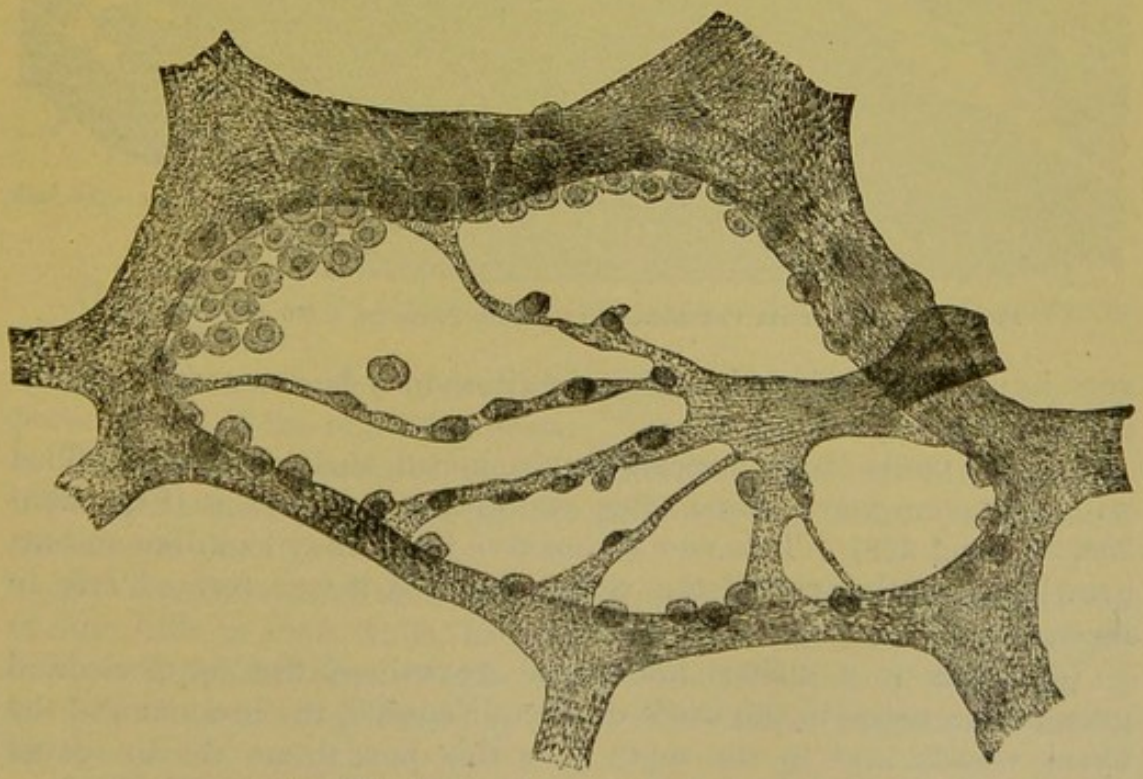

FIG. 238.—CHRONIC PHTHISIS, × 850 and reduced.
Showing growth of connective tissue within an air vesicle.

nature as those of acute phthisis, but are modified by the long continuance of the inflammation.

1. The air spaces:

(*a*) The air spaces are filled with swollen and fatty epithelium (Fig. 234), or with fibrin and pus, while their walls are unchanged and their blood vessels remain pervious.

(*b*) The air spaces are filled and distended with compact fibrin and shrivelled pus and epithelium. Their walls are compressed and thin, or thickened and infiltrated with cells. The blood vessels can be only

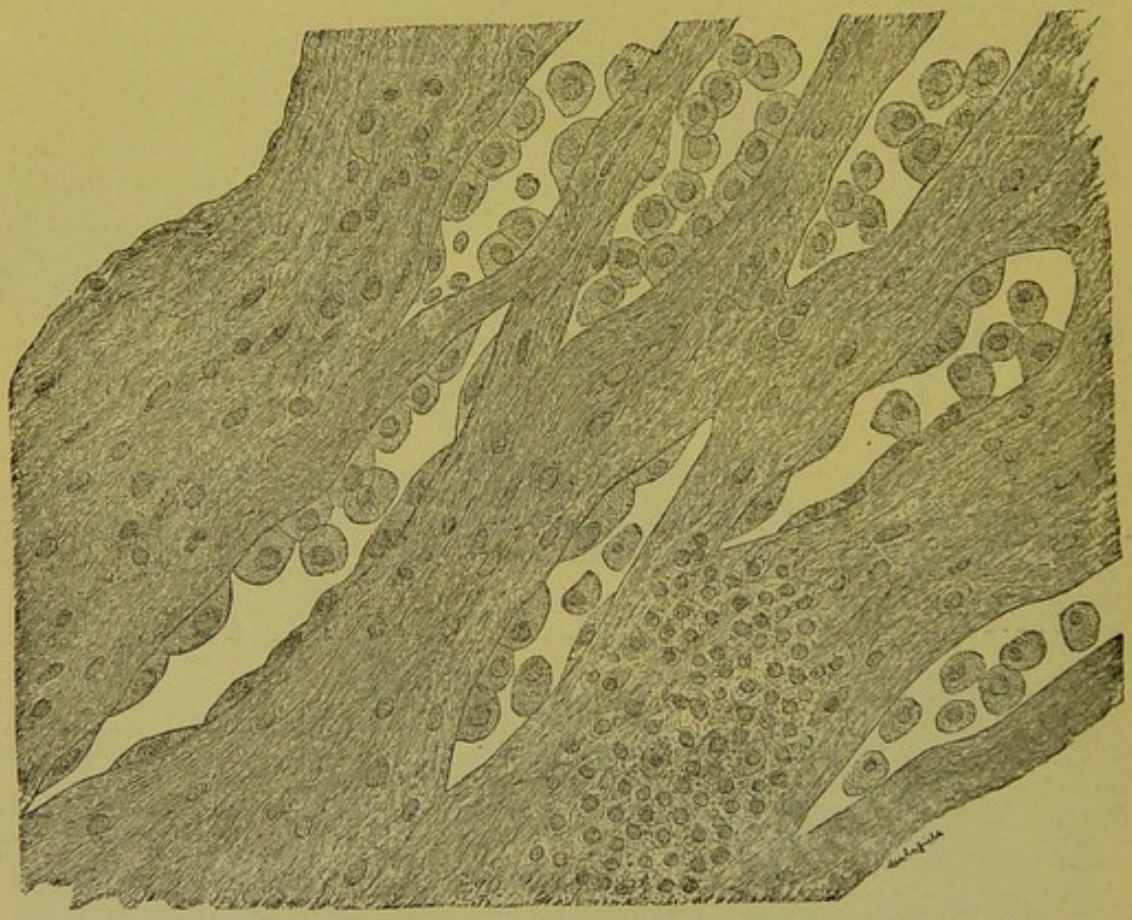

FIG. 239.—INTERSTITIAL PNEUMONIA OF CHRONIC PHTHISIS, × 850 and reduced.

very imperfectly injected. This condition may be succeeded by complete cheesy degeneration.

(*c*) The walls of the vesicles are thickened, their cavities are filled with new connective tissue often containing new vessels (Figs. 235, 236, 237, and 238). This new connective tissue may look like an outgrowth from the wall of the vesicle, or as if it was formed free in its cavity.

(*d*) There is a diffuse interstitial growth of fibrous tissue and granulation tissue in the walls of the air spaces, the bronchi and the blood vessels, and in the septa. By this new tissue the air spaces are compressed and deformed or completely obliterated (Fig. 239).

2. The nodules:

These, as in acute phthisis, consist of areas of coagulation necrosis, peribronchitic nodules, and miliary tubercles.

The tubercles may preserve their characteristic structure, or undergo cheesy degeneration, or be changed into fibrous tissue (Fig. 240).

The areas of coagulation necrosis undergo cheesy degeneration, or soften and form cavities. They are surrounded by tubercle tissue, or granulation tissue, or connective tissue (Fig. 241).

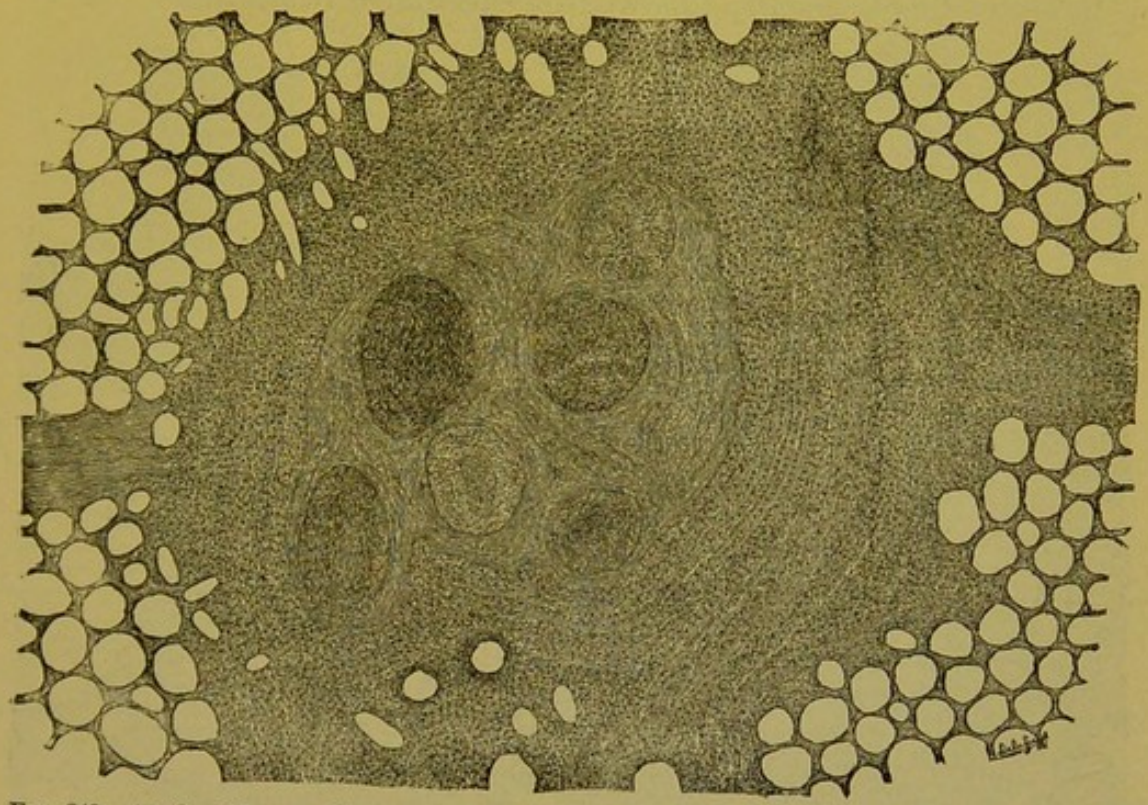

FIG. 240.—AN OLD MILIARY TUBERCLE CONVERTED INTO FIBROUS TISSUE ("HEALED TUBERCLE"), × 90 and reduced.

The peribronchitic nodules are much the same as in acute phthisis.

3. The bronchi:

The changes in the bronchi in chronic phthisis form a very important part of the morbid process.

(*a*) The larger bronchi may be the seat of a chronic catarrhal inflammation, accompanied by the production of large quantities of mucus and pus.

(*b*) The bronchi of all sizes may be inflamed, with the production of new cells in their walls, in addition to the inflammatory changes of their inner surfaces. Such a cellular infiltration of the walls of the bronchi is often followed by dilatation—either fusiform or sacculated.

(*c*) Tubercle granula and granulation tissue are found in the

walls of the bronchi. These tissues may degenerate, soften, and thus form ulcers.

(*d*) The entire thickness of the wall of a bronchus may become the seat of inflammation of a peculiar character. The surface of the mucous membrane is coated with pus, the epithelial layer can no longer be seen, the wall of the bronchus is infiltrated with cells. The inflammatory products undergo cheesy degeneration, so that we find the inner surface of the bronchus coated with cheesy matter, while its wall is also changed into cheesy matter. Such a condition of the bronchus is usually followed by sacculated dilatation.



FIG. 241.—TUBERCLE TISSUE AROUND AN AREA OF COAGULATION NECROSIS, × 850 and reduced.

The cavities of chronic phthisis, therefore, are formed by the dilatation of inflamed bronchi, by the softening of areas of coagulation necrosis, or by the combination of both these processes.

When cavities are once formed they are apt to continue and to become larger as the disease goes on. Their walls may be converted into granulation tissue, which ulcerates in some places and proliferates in others; or portions of the wall become necrotic; or all active processes cease and the wall of the cavity is formed of new connective tissue. The lung tissue between the cavities becomes compressed and altered in various ways. As the cavities increase in

size they touch and open into each other. In this way large portions of the lung may be converted into a dense mass honeycombed with cavities.

### *VII. Syphilitic Pneumonia.*

Persons suffering from inherited or acquired syphilis sometimes develop inflammations of the lungs which seem to be due to the syphilitic infection. The lungs may then be affected in several different ways.



FIG. 242.—INTERSTITIAL SYPHILITIC PNEUMONIA. × 170 and reduced.

1. There is an interstitial pneumonia, beginning around the larger bronchi and blood vessels at the root of the lung, and extending to the walls of the air spaces and interstitial connective tissue, so that the central portions of one or both lungs are converted into a dense mass of connective tissue (Fig. 242).

2. There is an interstitial pneumonia, with the formation of gummy tumors.

3. There is an inflammation of the wall of the trachea and of the larger bronchi. There are ulcers in the mucous membrane, their walls are very much thickened, and their cavities are narrowed or dilated.

4. There are circumscribed areas of interstitial inflammation

around the smaller bronchi, forming small, hard peribronchitic nodules.

5. There is a diffuse hepatization, involving lobules or an entire lobe. The affected portion of the lung is red or white or grayish. The walls of the air vesicles are infiltrated with cells, and their cavities are filled with epithelial cells.

6. There may be a broncho-pneumonia, like the ordinary broncho-pneumonia of children ; or a lobar pneumonia, like that of adults.

7. There may be an obliterating endarteritis of branches of the

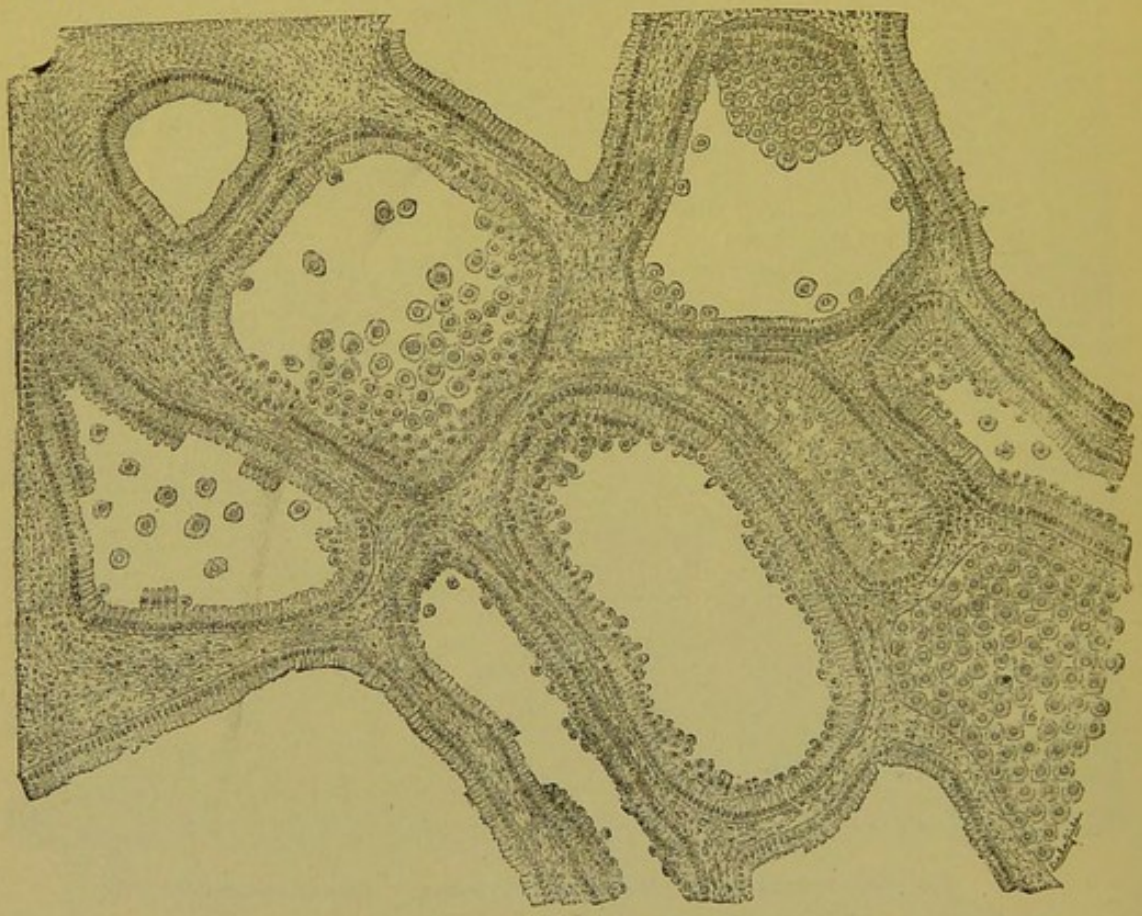

FIG. 243.—PRIMARY ADENOMA OF THE LUNG, × 300 and reduced.

pulmonary artery, with the formation of white infarctions surrounded by zones of connective tissue.[1]

## TUMORS.

*Dermoid cysts* have been found in the lungs in a few instances.

*Fibromata* have been described by Rokitansky.

*Enchondromata* may occur both as primary and secondary tumors. The primary tumors are small and are believed to originate in the cartilages of the bronchi. The secondary tumors often attain a very large size.

[1] *Hiller*, Charité Annalen, 1884, p. 184.

*Osteoma* is very rare. A case is described by Luschka.[1]

*Sarcomata* as secondary tumors are of not infrequent occurrence. A primary adeno-sarcoma is described by Weichselbaum.[2]

*Lymphomata* are found in cases of leukæmia and pseudo-leukæmia.

*Adenoma* of the lungs is of rare occurrence as a primary tumor (Fig. 243).

*Carcinoma* as a secondary growth may have the form of nodules or of diffuse infiltration. Primary carcinoma of the lung has been described by a number of authors. The new growth is in the form of small nodules surrounded by pneumonia. As the result of the new growth and the pneumonia a considerable part of both lungs may be rendered solid. The bronchial glands may be infiltrated, and there may be secondary nodules in the pleura.

The new growth may originate in the walls of the air spaces or in the walls of the bronchi.[3]

### PARASITES.

*Echinococci* occur in the lungs in their ordinary cystic form. The sacs may suppurate and discharge through the pleura, the bronchi, the wall of the chest, or the diaphragm.

In bronchiectasiæ and in gangrenous cavities in the lungs vegetable parasites of various kinds have been described—both moulds and bacteria.

The Bacillus tuberculosis is regularly found in the walls and contents of cavities in acute and chronic phthisis, sometimes in enormous numbers. It is also often present in great numbers in the nodules of tubercular inflammation, particularly when these are softening and beginning to break down to form cavities (see Tuberculosis).

## THE MEDIASTINUM.

The anterior mediastinum is situated in front of the pericardium, between it and the sternum. At its superior part the two layers of pleuræ separate somewhat to enclose the vestiges of the thymus gland; behind the second piece of the sternum they are in contact, but below this the left pleura recedes from its fellow toward the left side, leaving an angular space of some breadth. The triangularis sterni muscle bounds this space in front.

---

[1] Virch. Archiv, Bd. x., p. 500.

[2] Ibid., Bd. lxxxv., p. 559.

[3] On the diagnosis of malignant tumors of the lungs, consult *Betschart*, Virch. Archiv, Bd. cxlii., p. 86, 1895; also *Adler*, New York Medical Journal, February 8th and 15th, 1896.

The posterior mediastinum, stretching from the pericardium to the bodies of the vertebræ, encloses between its layers the lower part of the windpipe and gullet, the thoracic duct, the descending aorta, the azygous vein, the pneumogastric nerve, and some lymphatic glands.

### INFLAMMATION.

Suppurative inflammation may occur either in the anterior or posterior mediastinum. It may be caused by fractures, caries, or necrosis of the sternum and vertebræ, by perforation of the œsophagus, by suppuration of the lymphatic glands, by pleurisy, or may occur without discoverable cause.

The pus may infiltrate the connective tissue, or may form abscesses which may attain a large size. The inflammation may extend to the pleura or the pericardium, the abscesses may displace the heart, the lungs, or the sternum; or they may perforate through the skin into a pleural cavity, the œsophagus, the trachea, or a bronchus.

### TUMORS.

The most common form of new growth in the mediastinum is that known by the names of lymphoma, lympho-sarcoma, and lymph-adenoma.

These tumors are confined to the mediastinum, or they are associated with similar growths in other parts of the body in the disease called "pseudo-leukæmia."

Persons between the ages of twenty and thirty years seem to be the most liable to the growth, but it is also not uncommon in children.

The growth begins in the lymphatic glands in the mediastinum, and at the root of the lung. It increases at first slowly, then more rapidly, and gradually infiltrates the adjoining tissues. In this way the walls of the trachea, bronchi, and aorta, the pericardium, the pleura, and the lung, become infiltrated with the growth. The tumor also compresses the surrounding organs.

The growth is composed of a connective-tissue stroma infiltrated with small round cells, the relative quantity of cells and stroma varying in the different cases.

Besides this form of tumor there may also occur in the mediastinum tumors similar to those which grow in the pleura and behind the peritoneum—tumors which resemble both the sarcomata and carcinomata, and which it is difficult to classify. Aberrant thyroid-gland tissue may be found in the mediastinum.

Complex tumors belonging among the fœtal inclusions or terato-

mata are of occasional occurrence in the anterior mediastinum. They may contain bone, cartilage, connective tissue, muscle, hairs, skin, etc. Cysts sometimes lined with ciliated epithelium may form in such tumors.[1]

[1] Consult *Hare*, "Tumors of the Mediastinum," Philadelphia, 1889; also *Zahn*, Virchow's Archiv, Bd. cxliii., pp. 170 and 416, 1896.

# THE VASCULAR SYSTEM.

## THE PERICARDIUM.

### INJURIES.

The pericardium may be wounded by penetrating weapons, by gunshot wounds, and by fragments of bone. It may be ruptured by severe contusions of the thorax, and by rapid extravasation of blood into the pericardial sac.

Perforations may be produced by empyema, by mediastinal abscesses, by abscesses of the chest wall and of the liver, by aneurisms of the aorta, and by suppurative inflammation of the pericardium.

### DROPSY.

In most post-mortems we find a little serum, from one-half ounce to one ounce, in the pericardial sac. This serum is usually clear and of a light-yellow color; if decomposition has commenced it may be of a reddish color, or it may be slightly turbid from the falling-off of the pericardial epithelium.

Large accumulations of serum are found as part of general dropsy from heart disease, kidney disease, etc. The serum is clear and of a light-yellow color. Hydro-pericardium is usually moderate in comparison with the accumulations of serum in the other serous cavities; sometimes, however, there is a very large amount of serum, which hinders the movements and interferes with the nourishment of the heart.

### HÆMORRHAGE.

Extravasations of blood in the cavity of the pericardium are produced by wounds and rupture of the heart, rupture of the aorta and of aneurisms, and occur with pericarditis. Small extravasations in the substance of the pericardium are found with scurvy, purpura, fevers, etc.

### PNEUMONATOSIS.

Air or gas in the pericardium is sometimes found as a post-mor-

tem appearance, accompanied with drying of portions of the pericardium.

Wounds or paracentesis of the pericardium ; the perforation of ulcers of the stomach, cavities of the lungs, and ulcers of the œsophagus, may admit air into the pericardial cavity. In purulent pericarditis with foul, decomposing exudation, gases may be evolved.

## INFLAMMATION.

Pericarditis is very rarely a primary lesion. It is most frequently associated with rheumatism and Bright's disease, but is also found with pneumonia, pleurisy, phthisis, endocarditis, pyæmia, and may be produced by injuries.

The inflammations of the pericardium resemble those of the pleura. They usually begin acutely or subacutely, but may become chronic. There is a greater disposition to the escape of blood from the vessels than in pleurisy, so that the inflammatory products are often mixed with blood. The inflammatory process usually begins at the base of the heart and from there extends over the rest of the pericardium.

### *Exudative Pericarditis.*

We may distinguish :

1. *Pericarditis with the Production of Fibrin.*—In the milder examples of this form of pericarditis the pericardium is congested, or also studded with minute hæmorrhages ; its surface is roughened by the deposition of a thin layer of fibrin. In the more severe cases the entire surface of the pericardium is covered with a thick layer of fibrin, and there are fibrinous adhesions between the visceral and parietal pericardium. If the inflammation continues for any length of time the pericardium itself becomes thickened and infiltrated with cells, and the wall of the heart may also undergo inflammatory changes.

If the patient recovers the fibrin may be absorbed and the pericardium return to its normal condition. Or, instead of this, as the fibrin disappears there is a growth of new connective tissue which forms permanent thickenings and adhesions of the pericardium, which may afterward become calcified.

2. *Pericarditis with the Production of Fibrin and a good deal of Serum.*—In these cases the pericardium is coated with fibrin, but, in addition, there is a large effusion of serum into the pericardial sac. This serum accumulates at first between the floor of the pericardium and the lower surface of the heart, and, as it increases, distends the pericardial sac in all directions, pushing the heart upward and forward. The pericardial sac may be so much distended as to compress

the trachea, the left bronchus, the œsophagus, or the aorta. If the patients recover the serum is absorbed, and permanent adhesions and thickenings are left.

3. *Pericarditis with the Production of Fibrin, Serum, and a good deal of Pus.*—This variety may have the purulent character from the outset, or it may begin as one of the forms just described and afterward assume the purulent character. These latter cases are apt to run a chronic course.

In the chronic cases the pericardial sac contains a large amount of purulent serum. The pericardium is coated with fibrin and is itself thickened and infiltrated with cells. The walls of the heart

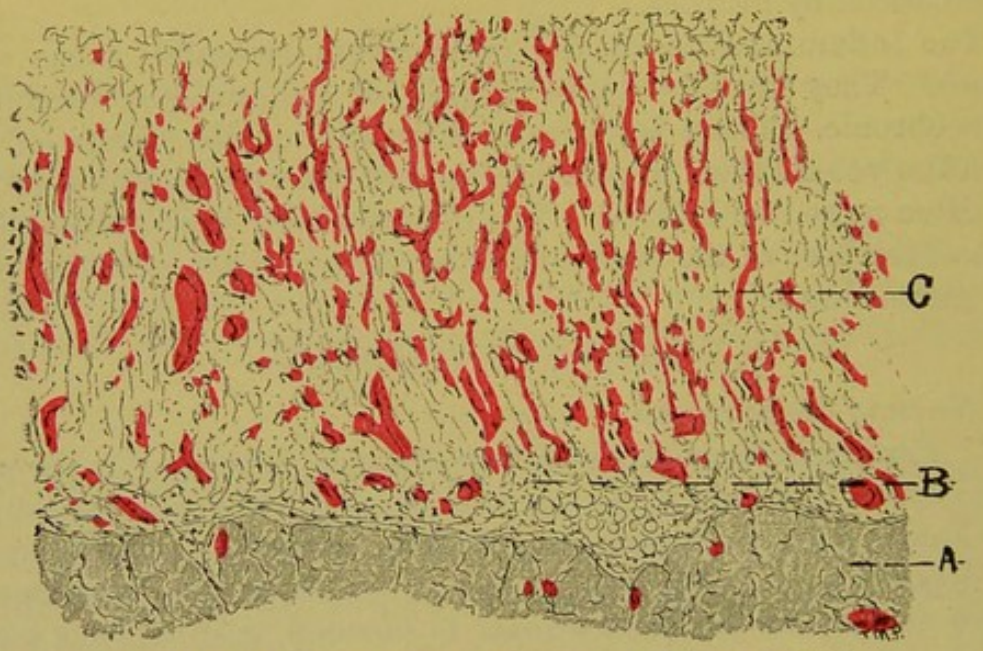


FIG. 244.—OBLITERATURE OF THE PERICARDIAL SAC IN A CHILD.

Showing blood vessels growing from the visceral pericardium into the blood clot filling the sac. Transverse section. A, Heart; B, pericardium; C, new-formed vascular tissue extending above to the unorganized clot. A similar layer of new vascular tissue was present over the parietal pericardium, and in places the two layers had coalesced, obliterating the sac. (Specimen loaned by Dr. Freeman.)

may be the seat of interstitial myocarditis. In some cases the products of inflammation undergo putrefactive changes ; in some cases the serum is absorbed and the fibrin and pus undergo cheesy degeneration ; in some cases extensive connective-tissue adhesions and calcific plates are formed.

The pathogenic bacteria most frequently found in the above varieties of pericarditis are the Streptococcus and Staphylococcus pyogenes and the Diplococcus pneumoniæ.

*Obliteration of the Pericardial Sac.*—As the result of the formation of vascular new connective tissue between the pericardial walls, the sac may be partially or wholly obliterated.

This may be the conclusion of an acute inflammatory process or it may result from the organization of a blood clot (see page 73) following hæmorrhage into the sac. It may occur as the result of the latter process early in life.

### *Tuberculous Pericarditis.*

This lesion may occur by itself, but is apt to be associated with other tuberculous inflammation in the vicinity of the heart. There may be miliary tubercles scattered diffusely, or limited to certain regions in the pericardium, which is otherwise little changed. Not infrequently, however, there is a considerable thickening of the pericardium, either visceral or parietal, or both.

In such cases the new-formed tissue consists of fibrous tissue and of tubercle tissue which has undergone extensive cheesy degeneration. The thickened visceral and parietal pericardium are often more or less grown together, so that the pericardial sac may be partially or almost completely obliterated. An inflammatory exudate often accompanies the tuberculous process.

### TUMORS.

*Fibromata* sometimes are developed in the pericardium. They are often of polypoid form, and from atrophy of the pedicle may become free in the pericardial sac.

*Sarcomata* and *carcinomata* occur as secondary growths either from continuous infiltration or as metastatic tumors.

*Cysts* of the visceral pericardium have been described.

We have seen a pedunculated cyst, containing about 6 c.c. of clear fluid, hanging into the pericardial sac from its attachment near the pulmonary artery. The origin of these cysts is obscure.

*Endothelioma.*—There may be a growth of flat cells arranged in anastomosing tubules which look like lymphatics, in the pericardium, resembling similar growths in the pleura.

## THE HEART.

### MALFORMATIONS.

The malformations of the heart are usually closely connected with malformations of the aorta and pulmonary artery. They depend on arrest of, or abnormal, development; on endocarditis, myocarditis, thrombosis, or mechanical causes.

I. The common arterial trunk is only partially, or not at all, separated into aorta and pulmonary artery. The divisions between the heart cavities are at the same time defective :

1. There is one ventricle and no auricle.

2. There is one ventricle and one auricle.

3. There is one ventricle and two auricles; the aorta is alone or incompletely separated from the pulmonary artery.

II. The trunk of the pulmonary artery or of the aorta is stenosed or obliterated, and from the obstruction to the current of blood the development of the septa between the heart cavities is prevented.

1. The aorta, at its origin, or in the ascending portion of the arch, is stenosed or closed. The pulmonary artery gives off the descending aorta, and supplies the carotids and subclavians. The foramen ovale remains open, or there is no septum between the auricles. The ventricular septum is also usually defective. The right ventricle is hypertrophied.

2. The pulmonary artery is stenosed or closed. Its branches are supplied by the aorta, through the ductus arteriosus. The ventricular septum is defective, the foramen ovale is open, or the auricular septum defective.

III. The malformation affects the aorta and pulmonary artery after they are more fully developed.

1. There is stenosis of the aorta between the left subclavian and ductus arteriosus, or just at the opening of the ductus arteriosus. The descending aorta is then a continuation of the pulmonary artery.

2. The aorta gives off all its branches from the arch, but the descending aorta is a continuation of the pulmonary artery; or the carotids may spring from the aorta, the subclavians from the pulmonary artery.

3. The vessels are transposed; the pulmonary artery arises from the left, the aorta from the right ventricle; the pulmonary veins empty into the left, the venæ cavæ into the right auricle; or the veins also may be transposed. The septa are defective.

IV. The aorta and pulmonary artery are normal, but the cardiac septa are defective.

1. The foramen ovale remains partly open. This condition may continue through life without giving any trouble.

2. The ductus arteriosus may remain open for many years; this also may cause no disturbance.

3. There is a small or large opening in the ventricular septum. This may give rise to no symptoms, unless disease of the heart or lungs be superadded.

V. Either of the auriculo-ventricular orifices may be entirely closed. The foramen ovale remains open, and the ventricular septum is defective.

VI. The valves of the different orifices of the heart may be absent or defective. The arteries or the ventricles are usually defective at the same time.

The aortic and pulmonary valves may consist of two large or four small leaves, instead of the usual three. The edges of the semilunar valves may be fenestrated. These alterations are usually of no significance.

Generally speaking, the existence of openings between the two auricles or the two ventricles, admitting some admixture of venous and arterial blood, produces no marked change in the circulation. If, however, the passage of the current of venous blood into the right heart is in any way interfered with, the consequences are very serious. Cyanosis is produced, the skin is of a bluish color, the small veins and capillaries are dilated, exudation of serum and hypertrophy of connective tissue take place, especially in the fingers and toes.

Besides the malformations already mentioned we may find :

Entire absence of the heart.

Abnormal septa and chordæ tendineæ in the heart cavities.

Abnormal shapes of the heart.

Abnormal positions of the heart.

(*a*) There is a smaller or larger defect in the walls of the thorax, so that the heart projects on the outside of the chest ; the pericardium is usually absent.

(*b*) The diaphragm is absent, and the heart is in the abdominal cavity.

(*c*) The heart is in some part of the neck or head ; this occurs only in fœtuses very much malformed.

(*d*) The heart is transposed, being on the right side.

### ABNORMAL SIZE OF THE HEART.

(*a*) The heart may be abnormally large in connection with obstructive anomalies of the great vessels.

(*b*) The heart may be abnormally small (hypoplasia). This most frequently occurs, according to Virchow, in chlorotic individuals and those who are the victims of the hæmorrhagic diathesis. In these cases the aorta and other large arteries are apt to be unusually small and thin-walled.

Very rarely two more or less perfect hearts are found in the same thorax.

### CHANGES IN POSITION.

Changes in the position of the heart are congenital or acquired. The congenital malpositions have already been mentioned.

The acquired malpositions are caused by:

1. Hypertrophy of the heart; its long axis approaches the horizontal direction.

2. Changes in the thoracic viscera. Emphysema of both lungs pushes the heart downward. Emphysema, pleurisy with effusion, or pneumothorax of one side pushes the heart to the other side. Pleurisy or chronic pneumonia, producing retraction of one side of the thorax, draws the heart to that side. New growths, aneurisms, and curvatures of the spine displace the heart in various directions.

3. Changes in the abdomen. Accumulations of fluid and new growths in the abdomen, and tympanites, may push the heart upward.

### WOUNDS AND RUPTURES.

*Wounds* of the heart are produced by penetrating instruments, by bullets, and by fragments of bone. The right ventricle is the more frequently wounded; next the left; rarely the auricles.

The wound may penetrate into the cavities of the heart or only pass partly through its wall, or a bullet or the broken end of a weapon may be embedded in the wall. If the wound penetrate a cavity and be gaping, death may follow instantly and the pericardium be found filled with blood. If the wound be small and oblique, the blood may escape gradually and death may not ensue for several days. In rare cases adhesions are formed with the pericardium and the wound cicatrizes. Wounds which do not penetrate may cause death by the inflammation which they excite, or may cicatrize.

Bullets and foreign bodies may become encapsulated in the heart wall and remain so for years.

*Ruptures* of the heart wall occur in various ways:

1. Severe contusions of the thorax may produce rupture, usually of one of the auricles.

2. Spontaneous rupture occurs usually in advanced life. Rupture is most frequent in the left ventricle, and, in a considerable proportion of cases, near the apex. There is usually one rupture, but sometimes more. The rupture is usually oblique and larger internally than externally. The heart wall, near the seat of rupture, may be infiltrated with blood, or blood may infiltrate the subpericardial fat. The heart wall may be of normal thickness, or thin; it is usually soft and in a condition of fatty infiltration or degeneration. The rupture very frequently takes place when the patient is quiet. Death may be almost instantaneous or may not ensue for several hours.

Fatty degeneration leading to rupture of the heart may be general, or it is frequently circumscribed and due to obliterating endarteritis, atheroma, thrombosis, or embolus of one of the coronary arteries, whereby a portion of the heart wall is deprived of nourish-

ment and degenerates. Or rupture of a branch of one of the coronary arteries may induce rupture of the heart wall. Acute and chronic myocarditis, with or without the formation of abscess or cardiac aneurism, or the presence of tumors in the heart wall, or hydatids, may lead to the rupture.[1]

3. In very rare cases rupture is produced by stenosis of the aorta and dilatation of the heart cavities.

4. Rupture of the papillary muscles and tendons may be produced by fatty degeneration or inflammatory or ulcerative processes.

### ATROPHY.

Atrophy of the walls of the heart may be accompanied with no change in the size of its cavities ; or with dilatation (the same as passive dilatation); or, more frequently, with diminution in the size of the cavities.

The atrophy involves most frequently all the cavities of the heart, but may be confined to one or more of them.

The muscular tissue appears normal, or brown from the presence of little granules of pigment in the muscular fibres, which are sometimes present in large numbers—*brown atrophy ;* or the muscular fibres may undergo fatty degeneration ; or there may be an abnormal accumulation of fat beneath the pericardium ; or there may be a peculiar gelatinous material beneath the pericardium—this consists of fat which has undergone mucous degeneration. The heart may be so much atrophied as to weigh four ounces.

The causes of atrophy of the heart are :

1. It is a congenital malformation ; the heart of an adult then looks like that of an infant.

2. Any chronic and exhausting disease, repeated hæmorrhages, old age, typhus fever, dysentery, etc., may produce atrophy.

3. Chronic pericarditis, with large serous effusion, or with thickening of the pericardium, producing constriction of the coronary arteries.

4. Stenosis, atheroma, calcification, or thrombosis of the coronary arteries may produce partial or total atrophy.

5. Myocarditis, with fatty or fibrous degeneration.

6. Mitral stenosis may cause atrophy of the left ventricle.

### HYPERTROPHY.

All the cavities of the heart may have their walls hypertrophied, or the thickening may involve one or more. While the wall of a

[1] Consult *Councilman*, "On Sudden Deaths due to the Heart," Boston Medical and Surgical Journal, November 9th, 1893.

ventricle is thickened, its cavity may retain its normal size—*simple hypertrophy;* or be dilated—*eccentric hypertrophy;* or it may be contracted—*concentric hypertrophy.*

Care should always be exercised in judging of this condition, for a firmly contracted heart seems to have a small cavity and thick walls. The existence of such a condition as concentric hypertrophy is denied by some authors. Eccentric hypertrophy is the most common form. Simple hypertrophy is not common, but may occur in connection with the atrophied kidneys of chronic diffuse nephritis. The muscle tissue in hypertrophied hearts is firmer and denser than normal, and is apt to have a darker color. Fatty degeneration may, however, be associated with it, giving the walls a lighter appearance. It is probable that the increase of tissue in the hypertrophied heart wall is the result of increase both in size and number of the muscle fibres.

Hypertrophy of both ventricles increases both the length and breadth of the heart. Hypertrophy of the left ventricle (alone) increases its length. The apex is then lower and further to the left than usual. Hypertrophy of the right ventricle (alone) increases the breadth of the heart toward the right side; but sometimes the right edge of the heart retains its normal situation and the apex is displaced to the left. With large hypertrophy of both ventricles, the base of the heart may sink, so that its long axis approaches a horizontal direction.

Hypertrophied hearts may weigh from forty to fifty ounces, or even more.

Hypertrophy of the heart may depend upon a variety of causes:

1. Changes in the valves; either insufficiency or stenosis in the valves leading from a cavity, and insufficiency in valves leading to a cavity, may induce hypertrophy of its walls.

2. Obstruction to the passage of blood through the arterial system, as in atheroma and other diseases of the intima; congenital or acquired stenosis of vessels, pressure of tumors, etc., on vessels; certain forms of chronic diffuse nephritis, especially atrophied kidneys, lead to hypertrophy of the left ventricle, and sometimes secondarily to hypertrophy of the right ventricle.

3. Obstruction to the passage of blood through the pulmonary artery by stenosis or by certain diseases of the lungs, particularly emphysema and chronic phthisis, may lead to hypertrophy of the right ventricle, and, secondarily, of the right auricle and left ventricle.

4. Any cause, whether muscular or nervous, which increases the rapidity and force of the heart's contractions, may produce hypertrophy.

5. Dilatation of the ventricles, from any cause, is frequently followed by hypertrophy.

6. Pericarditis may produce hypertrophy by inducing softening and dilatation of the ventricles, or by leaving adhesions which obstruct the heart's action. Chronic myocarditis also may lead to hypertrophy.

Finally, for some cases of hypertrophy no satisfactory cause can be found. Howard's table of 105 cases of cardiac hypertrophy shows its association with arterio-sclerosis in 59 per cent; with nephritis in 13.4 per cent; with valvular lesion in 12.4 per cent.[1]

It should be borne in mind that an increase in the amount of fat in and about the heart may make the organ appear larger, when there may be actually a considerable decrease in the amount of muscle tissue.

## DILATATION.

Dilatation may be combined with hypertrophy—*active dilatation;* or there may be no increase of muscle tissue, but a thinning of the walls proportionate to the dilatation of the cavity—*passive dilatation.*

Either one or all of the heart cavities may be dilated, the auricles most frequently; next the right ventricle; least often the left ventricle.

Active dilatation has been considered under hypertrophy.

Passive dilatation may be produced by:

1. Changes in the valves. Mitral or aortic stenosis or insufficiency may produce dilatation of the auricles and right ventricle. Pulmonary stenosis or insufficiency may produce dilatation of the right auricle and right ventricle. Aortic insufficiency, with or without stenosis or mitral insufficiency, may produce dilatation of the left ventricle. Dilatations from these causes are often succeeded and compensated for by hypertrophy of the heart walls.

2. Changes in the muscular tissue of the heart walls. Serous infiltration from pericarditis, myocarditis, fatty degeneration and infiltration, atrophy of the muscle fibres, may all lead to dilatation.

3. A heart which is already hypertrophied may, from degeneration of the muscle, become dilated.

4. Acute exudative inflammations of the lungs and acute pleuritic exudations, by rendering a large number of vessels suddenly impermeable to the blood current, may produce sudden stasis in the pulmonary artery and dilatation of the right heart.

5. There are curious cases of acute and chronic dilatation of the

[1] *Howard*, Johns Hopkins Hospital Reports, vol. iii., p. 265.

ventricles for which no mechanical cause can be found and which are very fatal.

### DEGENERATIONS.

*Acute Degeneration; Parenchymatous Degeneration of the Heart Muscle.*—This lesion frequently occurs in typhoid and typhus fever, pyæmia, erysipelas, and other infectious diseases, as well as in the exanthemata, as a result of burns, and under a variety of other conditions. It is characterized by the presence in the muscle fibres of the heart of greater or less numbers of albuminous granules of various sizes, most of them very small. They are not as refractile as fat droplets, and are insoluble in ether, while swelling up and becoming almost invisible under the influence of acetic acid. Sometimes they are so abundant as to conceal the striations of the fibres. The degeneration is usually quite uniformly diffused through

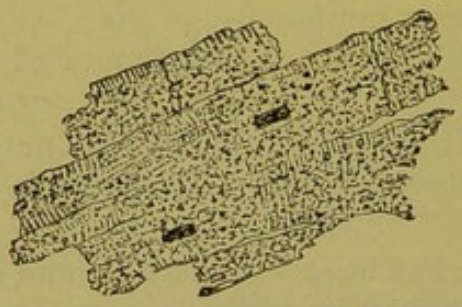

Fig. 245.—Fatty Degeneration of the Heart Muscle. Teased.

the heart, whose walls are softer than normal and of a grayish color. This lesion may be associated with or followed by fatty degeneration.

*Fatty Degeneration of the Heart Muscle.*—This consists in the transformation of portions of the muscle fibres of the heart into fat, which collects in the fibres in larger and smaller droplets, sometimes few in number, sometimes so abundant as to entirely destroy or conceal the normal striations (Fig. 245). These droplets are soluble in ether, and remain unchanged on treatment with acetic acid. This degeneration is sometimes quite universal, but is more apt to occur in patches, giving the heart muscle a mottled appearance. This mottling may usually be best seen on the papillary muscles. The degenerated areas have a pale-yellowish color, and the muscle tissue is soft and flabby; but when moderate or slight in degree the gross appearance may be little changed, and the microscopical examination be necessary for its determination. This degeneration may lead to thinning of the walls, or to rupture of the heart, or to

inability to fulfil its functions. It is not infrequently the cause of sudden death.

It may be secondary to hypertrophy of the heart, to inflammation of the heart muscle, or to pericarditis; to disturbances of the circulation in the coronary arteries by inflammation, atheroma, etc. It may be due to deteriorated conditions of the blood in wasting diseases, excessive hæmorrhages, exhausting fevers, leukæmia, etc., to poisoning with phosphorus and arsenic and to the toxins of microbic origin developed in infectious diseases, such as diphtheria, scarlatina, typhoid fever, etc.[1] It may occur in otherwise apparently healthy persons.

*Fatty Degeneration of the Endocardium.*—It is not uncommon to find, especially in elderly persons, fatty degenerations occurring

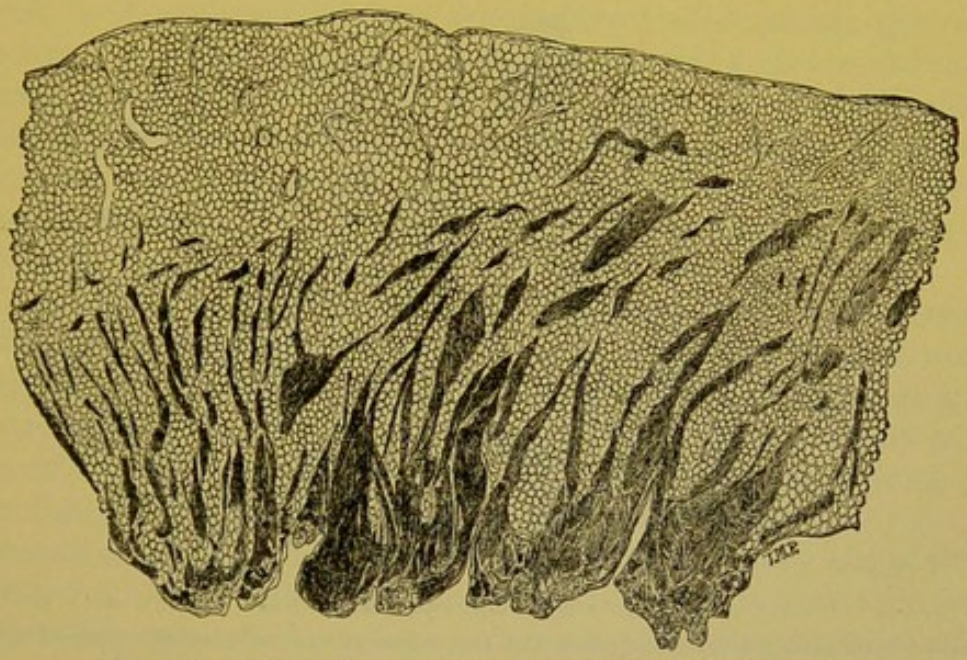

Fig. 246.—Fatty Infiltration or Lipomatosis of the Heart.

The lesion is excessive, the heart muscle being to a large extent atrophied. (The fat cells are represented in the drawing, for the sake of clearness, of relatively too large size.)

in patches, especially on the valves, but also on the general endocardium. They may also occur in ill-nourished and anæmic individuals. Small, or even considerable, areas of fatty degeneration appear, as a rule, to be of little or no clinical significance. They are at least not inconsistent with perfect health. In these areas of fatty degeneration the connective-tissue cells are more or less completely filled with larger and smaller fat droplets.

*Amyloid Degeneration* of the endocardium or the walls of the

[1] Consult *Flexner*, Johns Hopkins Hospital Bulletin, March, 1894; also *Schamschin*, Ziegler's Beiträge zur path. Anat., etc., Bd. xviii., p. 64, 1895.

blood vessels and intermuscular connective-tissue septa is a not very infrequent, but usually not very important lesion.

*Hyalin Degeneration* sometimes occurs.

*Calcification* of the products of inflammation in pericarditis, or of connective-tissue membranes in chronic pericarditis, sometimes occurs, and in the latter case the heart may be more or less enclosed by a calcareous shell. The muscle fibres of the heart wall may, though rarely, become densely infiltrated with salts of lime.

*Fatty Infiltration or Lipomatosis of the Heart.*—This lesion, which should be clearly distinguished from fatty degeneration, consists of an unusual accumulation of fat about the heart and between its muscle fibres (Fig. 246).

The subpericardial fat, which may be present in considerable quan-

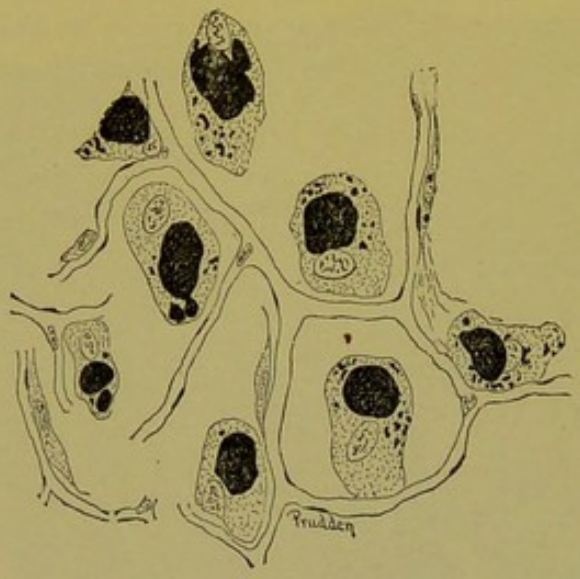


FIG. 247.—ATROPHIC PERICARDIAL FAT.

From young person dead of carcinoma of the stomach and peritoneum. Stained with osmic acid and teased.

tity under normal conditions, may be so greatly increased in amount as to form a thick envelope enclosing nearly the entire organ. Sometimes the accumulation of fat extends into the walls of the heart, between the muscles, causing atrophy of the latter, frequently to a very great extent, so that the function of the heart is seriously interfered with. This occurs sometimes in general obesity, or as a result of chronic pericarditis, or in drunkards, or in debilitated or old persons.

*Atrophy of the pericardial fat tissue* not infrequently occurs in persons emaciated by chronic disease, and then the usual situations of the fat are occupied by a tissue resembling mucous tissue in its gross characters. Microscopical examination shows that in this atrophic fat the fat cells have largely lost their contents, and the

whole tissue has undergone a partial reversion to its original embryonic form (see Fig. 247).

*Myomalacia.*—When, through obliterating endarteritis, atheroma, thrombosis, or embolus of a branch of the coronary arteries, the blood supply is cut off from a circumscribed portion of the heart wall, the tissue in the affected area may undergo fatty degeneration, leading to rupture. Or, instead of extensive fatty degeneration, the muscle fibres may break down into a granular detritus and the connective tissue about them suffer retrograde metamorphosis, so that the whole affected area may be soft and yellowish-white or grayish in color. If, as not infrequently occurs, there is considerable extravasation of blood, the degenerated area may be of a dark-red color. Under these conditions the wall may rupture; or acute inflammatory processes may occur; or the degenerated tissue may be gradually absorbed, and replaced by new connective tissue which gradually grows dense, shrinks, and assumes the characters of cicatricial tissue. This may occur in any part of the heart wall or in the papillary muscles, but is most common in the region supplied by the anterior coronary arteries. When the heart wall is involved the new-formed connective tissue may yield to the blood pressure from within and aneurism of the heart be formed.

Impaired nutrition of a portion of the heart wall as the result of narrowing or obliteration of the coronary arteries or their branches is of great significance, whether it lead to such extreme lesions as those just described, or to fatty degeneration, or to atrophy of the muscle cells with a production of new connective tissue, because it is the dominant factor in many cases of sudden death.

According to Sternberg[1] the right coronary artery supplies the following regions of the heart: most of the right auricle; the posterior part and most of the anterior part of the right ventricle; most of the interauricular and interventricular septa; the posterior part of the left ventricle and the posterior papillary muscles. The remainder of the heart is supplied by the left coronary artery.

*Fragmentation of the Myocardium.*—Attention has been called by a number of observers to a condition of the heart muscle sometimes observed, it is said, in acute infectious diseases, in acute and chronic diseases of the central nervous system, and in sudden death from a variety of causes. The muscle tissue is soft, friable, opaque, and often yellowish. Examination shows a loosening of the muscle cells from one another, as if by some change in the cement substance.[2] It is still questionable whether this may not be a post-mortem change.

[1] Inaug. Diss., Marburg, 1887.

[2] *Oestreich*, Virchow's Archiv, Bd. cxxxv., p. 79, bibliography; also *Dunin*, Ziegler's Beiträge zur path. Anat., etc., Bd. xvi., p. 134, 1894.

## INFLAMMATION.

### *Endocarditis.*

The endocardium is a connective-tissue membrane which lines the cavities of the heart and forms its valves. Its inner surface is covered with a layer of endothelial cells. It is but poorly supplied with vessels, and the inflammations which attack it are of the cellular variety. The ordinary products of inflammation, pus, fibrin, and serum, are scanty or absent altogether. The connective-tissue cells and basement substance are principally concerned in the inflammatory processes. The new tissue thus produced is prone to degeneration and calcification. The roughening of the endocardium due to the inflammation often causes a coagulation of fibrin on the inflamed surface.

In fœtal life it is the endocardium of the right heart, in extra-uterine life that of the left heart, which is usually inflamed.

The endocardium which forms the valves is that which is most frequently inflamed, but the other portions of it are by no means exempt.

1. *Simple Acute Endocarditis.*—This is most apt to occur in connection with rheumatism, but may occur under other conditions. It may attack a heart which was previously healthy, or one in which the lesions of chronic endocarditis already exist.

In some cases the only lesion is a simple swelling of the valves. They are thick and succulent, but their surfaces remain smooth. The basement substance is swollen, and there is a moderate production of new connective-tissue cells.

In other cases the growth of connective-tissue cells is very much more marked, the basement substance is split up, and little cellular fungous masses, called vegetations, project from the free surface of the endocardium. On these roughened surfaces the fibrin of the blood is deposited, and so vegetations of considerable size may be formed (see Fig. 248).

In still other cases the cell growth, while in some places it forms vegetations, in other places degenerates, and thus portions of the valves are destroyed. This is *simple acute ulcerative endocarditis.*

In some cases of this disease the patients recover and the valves seem to return to a normal condition ; in other cases the valves are left permanently damaged ; and in still others chronic endocarditis follows the acute form.

2. *Mycotic or Malignant Endocarditis* (malignant ulcerative endocarditis).

The direct inciting cause of simple acute endocarditis of the forms

described above is unknown. But in a considerable number of cases of acute endocarditis bacteria have been found in and about the vegetations (see Fig. 249), and proved, by careful experiments, to stand in a causative relation to the lesion.

Those cases of acute endocarditis in which the lesions are induced by the direct action of bacteria are called *mycotic* or *malignant endocarditis;* or, since the new-formed as well as the old tissue about the bacteria is apt to become necrotic and thus lead to larger or smaller losses of substance, the lesion is often called *ulcerative endocarditis.* Cases of multiple aneurism in connection with mycotic endocarditis have been reported.

Cultivations of the bacteria occurring in the heart lesions in

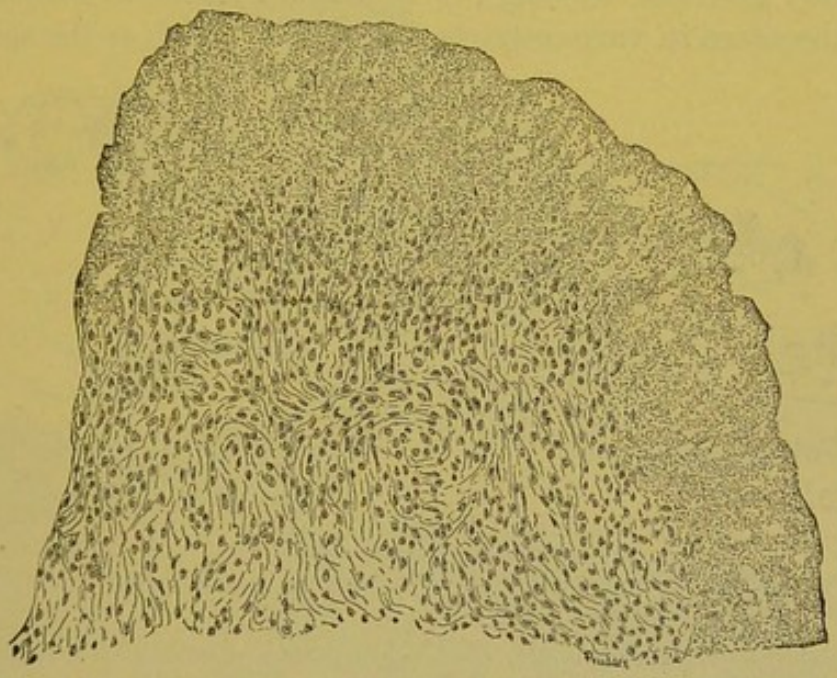

FIG. 248.—VEGETATION ON AORTIC VALVE IN ENDOCARDITIS.
Showing granular thrombus over the surface.

malignant endocarditis have shown that, while various species of bacteria may occasionally act as an inciting cause, it is most commonly induced by the Staphylococcus pyogenes aureus and the Streptococcus pyogenes. The Diplococcus lanceolatus, B. typhosus, B. tuberculosis, B. anthracis, Micrococcus gonorrhœæ and others have been occasionally found.

It has been, furthermore, found that a lesion or injury of the endocardium, either on the heart valves or elsewhere, predisposes to the lodgment and growth upon them of the disease-producing bacteria when once they have gained access to the circulating blood.[1]

[1] For a detailed consideration of the relationship of bacteria to malignant endocarditis, with experiments and literature, see *Prudden*, Am. Jour. Med. Sciences, January, 1887; *Weichselbaum*, Ziegler's Beiträge zur path. Anat., Bd. iv., 1888, p. 127; *Thayer and Blume*, Bull. Johns Hopkins Hospital, April, 1896.

Mycotic endocarditis is frequently a secondary complicating lesion, but may occur as a primary disease. It is most apt to be associated with the acute infectious diseases, and in many cases may be regarded as one of the local manifestations of pyæmia.

In some cases there is a formation of new tissue in the form of organized vegetations on the valves or general endocardium; in other cases necrosis either of the new-formed or the old tissue is the most marked feature. Blood clots are apt to form on the affected surfaces and often largely make up the so-called vegetations. The mitral and aortic valves are frequently the seat of the lesion, but it may occur elsewhere.

Detachment of bacteria containing fragments of the vegetations or clots may give rise to single or multiple infectious emboli (see p. 73) and abscesses in various parts of the body, such as the spleen, kid-



FIG. 249.—MYCOTIC ENDOCARDITIS.
Schematic drawing of a section of vegetation, showing colonies of micrococci stained with methyl violet.

neys, brain, skin, heart wall, etc. Bacteria similar to those in the heart lesion may be found in these secondary abscesses (see Fig. 66).

It is probable that these abscesses in ulcerative endocarditis do not always arise from cardiac emboli, but may precede the heart lesion.

3. *Chronic Endocarditis* may succeed acute endocarditis, or the inflammation may be chronic from the outset. It affects most frequently the aortic and mitral valves, and the endocardium of the left auricle and ventricle; similar changes in the right side of the heart being much less frequent.

There are two main anatomical varieties of chronic endocarditis, which may occur separately or together.

(1) The endocardium is thick and dense, its surfaces are smooth or covered with small, hard vegetations or ridges; it is often infiltrated with the salts of lime. (Fig. 251).

(2) There is a growth of connective-tissue cells in the endocardium, with a splitting-up of the basement substance. Some of the new cells continue to live, others degenerate. By the combination of such a cell growth and destruction the endocardium is in some places destroyed, in others changed into projecting vegetations. Fibrin is deposited on the roughened surfaces (Fig. 250). After a time the condition may be further complicated by the shrinkage and deposition of the salts of lime in the new tissue and

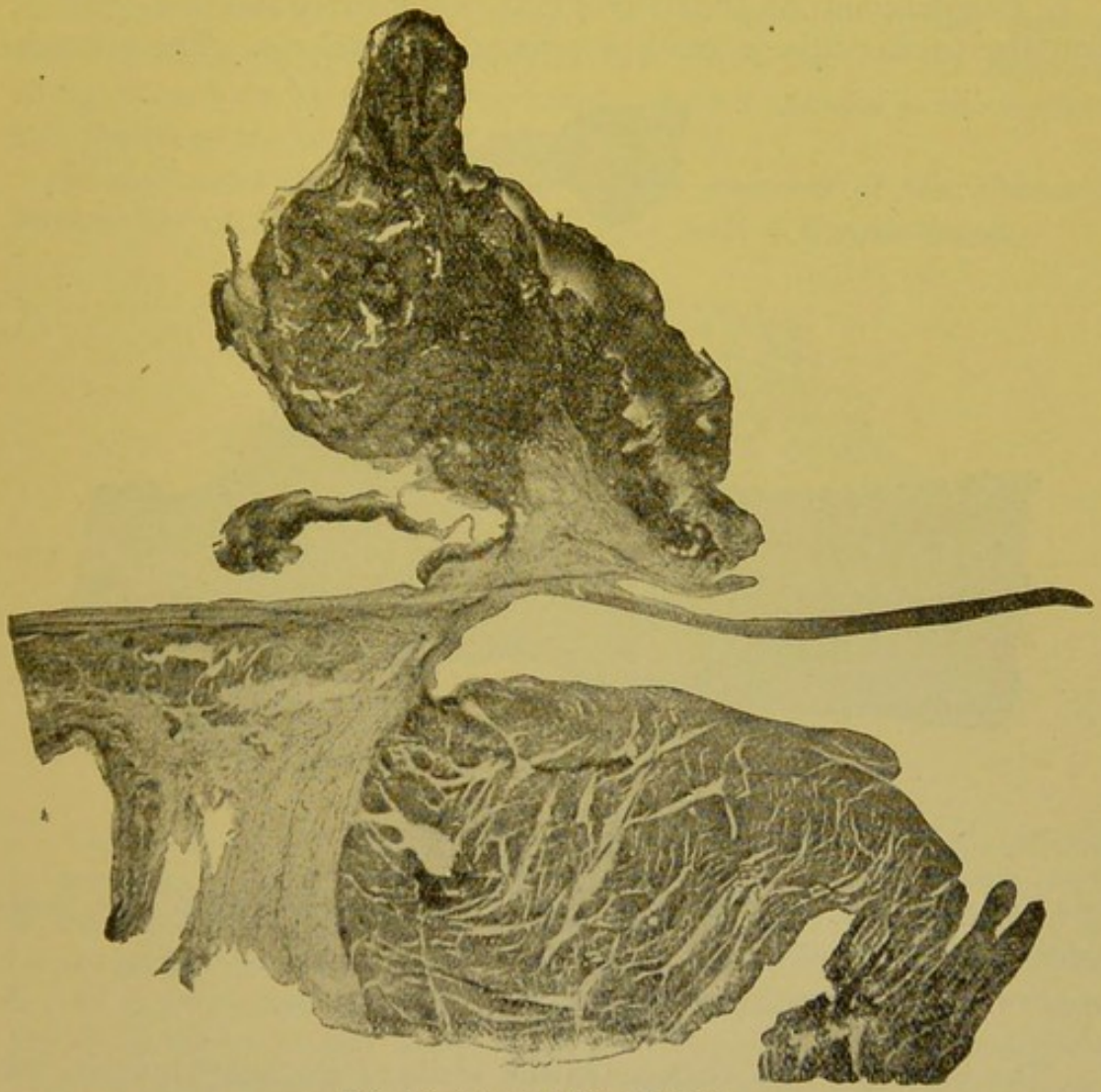

FIG. 250.—CHRONIC ENDOCARDITIS.
Showing "vegetation" on heart valve with large blood clot—mitral valve.

in the endocardium. All these changes may extend to the wall of the heart beneath the endocardium.

The most important result of chronic endocarditis is its effect on the heart valves, producing insufficiency and stenosis. The changes in the valves are followed by changes in the walls and cavities of the heart, and disturbances of the circulation throughout the body.

**4.** *Chronic Ulcerative Endocarditis.*—Large ulcers or perforations of the valves may be formed in chronic endocarditis, upon which clots may form, so that in gross appearance a great similarity exists between this and malignant ulcerative endocarditis, particularly if the latter have been engrafted upon an already chronically diseased endocardium. The microscopical and biological examinations must usually be resorted to in order to determine the exact significance of the lesion.

5. *Tuberculous Endocarditis* may occur in connection with tubercular pericarditis or general miliary tuberculosis. The tubercles

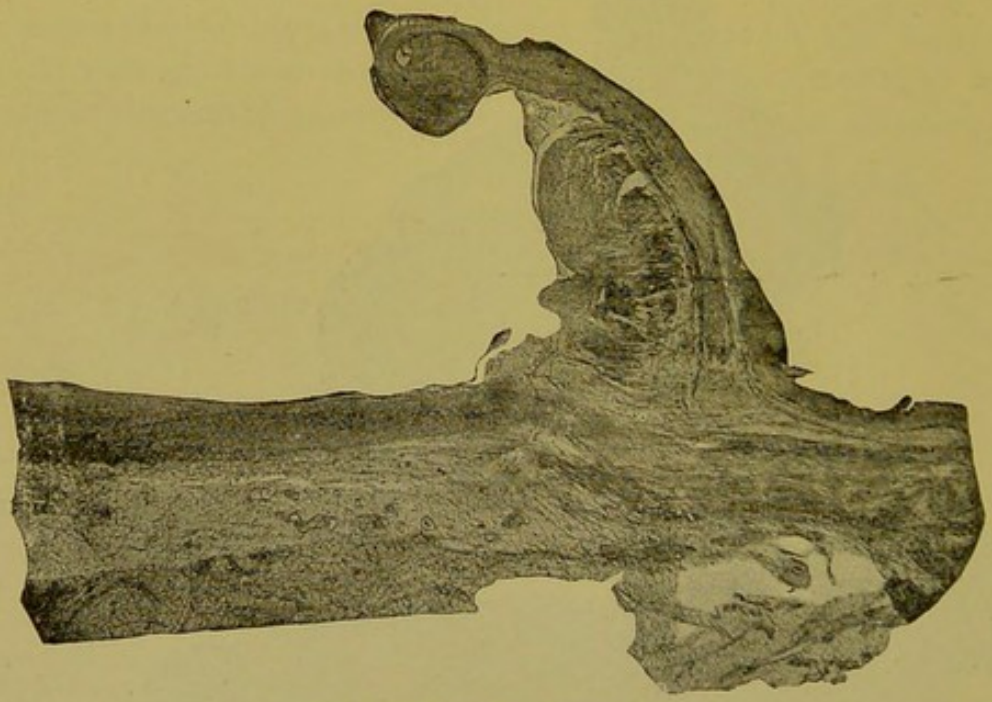

FIG. 251.—CHRONIC ENDOCARDITIS.
Thickening of the aortic valve.

may be small and single, or grouped in masses, and show the usual degenerative changes.

## *Myocarditis.*

The inflammatory changes in the walls of the heart involve primarily the interstitial tissue and blood vessels, the muscle fibres being secondarily affected by atrophic and degenerative changes.

*Interstitial Myocarditis* may be acute and purulent, or chronic with the formation of new connective tissue.

*Acute Purulent Myocarditis* may be diffuse, infiltrating the wall of the heart with pus. This may occur as a complication of scarlatina and from unknown causes.

More frequently the purulent inflammation is circumscribed, producing abscesses. These occur with pyæmia, mycotic ulcerative en-

docarditis, and other infectious diseases. They are of different sizes and either single or multiple. They are produced by the lodgment of infectious emboli in small vessels. The contents of the abscesses consist of pus, broken-down muscle tissue, and bacteria. These abscesses may open into the pericardial sac and set up a purulent pericarditis; or into a heart cavity, giving rise to thrombi in the heart and emboli in different parts of the body; or the wall of the heart is weakened by the abscess so that it ruptures, or an aneurismal sac is formed; or an abscess in the interventricular septum may establish an opening between the ventricles; or the suppurative process may extend upward and form an abscess in the connective tissue at the base of the heart.

In rare cases the patients recover, the contents of the abscesses become dry and hard, and enclosed by a wall of fibrous tissue.

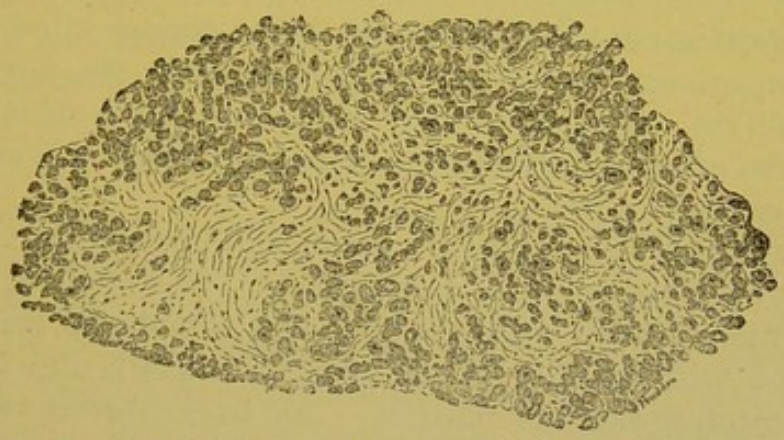

FIG. 252.—CHRONIC INTERSTITIAL MYOCARDITIS.
Showing transverse section of a portion of a papillary muscle.

*Chronic Interstitial Myocarditis* may be associated with chronic pericarditis or endocarditis or myomalacia, but in a large proportion of cases it occurs in connection with lesions of the coronary arteries. Occasionally, however, there is a formation of new connective tissue in the myocardium as well as in the endocardium without evident lesion of the coronary arteries or the above-mentioned conditions. There is a growth of new connective tissue or of granulation tissue between the muscular fibres, with atrophy and degeneration of the muscle. This growth may be in the form of circumscribed patches (Fig. 252), or diffused over a considerable part of the wall of the heart. Such an interstitial inflammation is often followed by dilatation of the cavities of the heart, by the formation of aneurisms of the wall of the heart, and of thrombi in the cavities of the heart.

It is believed by many observers that the new connective tissue which develops in the heart in connection with atrophy of the muscle fibres, as a result of impaired nutrition due to a narrowing of the

lumen of the coronary arteries, is not in the stricter sense inflammatory in its nature, but is rather a *fibrous hyperplasia*, the new-formed connective tissue forming secondarily, to replace the muscle fibres which have atrophied. It is interesting in this connection to note that under these conditions the muscle fibres immediately beneath the endocardium and close around the blood vessels where the nutritive supply is most abundant are often not atrophied, nor is the growth of connective tissue marked.

*Syphilitic Myocarditis* is accompanied by the growth of connective tissue or granulation tissue in the wall of the heart between the muscular fibres. The pericardium and endocardium may also be thickened, and pericardial adhesions may be formed. Gummata of the heart are of rare occurrence.[1]

### CHANGES IN THE VALVES.

*Fenestration* of the valves is usually a change productive of no bad consequences. It occurs very frequently in the aortic and pulmonary valves. The valves may be thinner than usual, and close to their free edges are small slits extending from the centre to the attached edges of a leaf.

*Aneurisms* of the valves are produced in two ways :

1. They are the result of endocarditis. One of the lamellæ of the leaf of a valve is destroyed, and the other lamella is converted into a sac filled with blood. These aneurisms are found in the aortic valve, projecting into the ventricle ; and in the mitral valve, projecting into the auricle. Not infrequently the wall of the aneurism gives way, so that there is a rupture entirely through the valve.

2. The entire thickness of a leaf of a valve is converted into a sac filled with blood. This occurs in the aortic, mitral, and tricuspid valves ; its cause is unknown.

*Hæmorrhage* in the substance of the valves is sometimes found in very young children. It does not appear to have much clinical importance.

### ANEURISM OF THE HEART.

Sacs filled with blood, situated in the walls of the heart and communicating with its cavities, are formed in several different ways.

1. In consequence of inflammatory processes in the endocardium and muscular tissue, a small or large portion of the wall is converted into fibrous tissue. The portion thus changed no longer resists the pressure of the blood from within, and is driven outward. Such a pouch may be a circumscribed sac communicating with the heart

[1] For consideration of gonorrhœal myocarditis consult *Councilman*, Am. Jour. Med. Science, September, 1893.

cavity by a small opening, or may look like a dilatation of part of the ventricle. The wall of such an aneurism becomes thinner as the sac increases in size. It is composed of the endocardium, new fibrous tissue, visceral pericardium, and sometimes the adherent parietal pericardium. The walls may calcify, or rarely they become so thin as to rupture externally or into the right ventricle. The sacs may contain fluid blood or be filled up with fibrin.

Such aneurisms are usually situated in the wall of the left ventricle ; rarely in that of the left auricle. If they are in the septum they may project into the right ventricle. They are usually single, but sometimes two or three are found in the same heart.

2. Fatty degeneration of the heart wall may reach such a point that the wall yields and is pouched out into an aneurismal sac.

3. Endocarditis and myocarditis, or fatty degeneration, may so soften a portion of the heart wall that the endocardium and part of the muscular tissue are ruptured and a ragged cavity is formed. This form of aneurism usually does not attain a large size, but soon ruptures externally and causes the death of the patient.

### THROMBOSIS OF THE HEART.

It is very common to find after death, in the heart cavities, yellow, succulent, semi-translucent masses. They are most common and of firmest texture in persons who die of acute inflammatory diseases. They may adhere quite firmly to the walls of the heart, and may extend in long, branching cords into the vessels. They are formed in the last hours of life and just after death. They have no clinical or pathological importance.

Coagulations of the fibrin of the blood in the heart do, however, occur during life, and may exist for years. If the fibrin adheres to the valves in small masses these are called vegetations ; if it coagulates in the heart cavities in larger bodies they are called thrombi or heart polypi.

Such thrombi are found in all the heart cavities. They form flattened masses firmly adherent to the endocardium; or rounded bodies in the spaces between the trabeculæ; or have a polypoid shape and are attached by a narrow pedicle, or very rarely are globular and free in the cavity of the auricle.

They are usually found in connection with some valvular lesion which prevents the free circulation of blood through the heart.

They are firm, dry, and of a whitish color; they may soften and break down at their centres, so as to look like cysts filled with pus, or they may calcify. They are usually entirely unorganized, consisting simply of fibrin, but may become organized.

One of us (Delafield) has seen an organized thrombus in the heart

of a man, whose history was unknown, who was found dead in the street.

Wilson presented before the New York Pathological Society, 1892, a large thrombus of the auricle which was partly organized. Cases are reported of organized thrombi in the auricles, which were the seat of tuberculous inflammation, which sometimes does not involve the heart wall.[1]

Sometimes sarcomatous and carcinomatous tumors in different parts of the body are accompanied by the formation of thrombi in the heart cavities, which are composed partly of coagulated blood, partly of tissue like that of the primary tumor.

### TUMORS.[2]

Primary tumors in the heart are rare, but *sarcomata*, *myxomata*, *fibromata*, and *lipomata* may occur. *Rhabdomyomata*, probably congenital, may occur in the heart wall as circumscribed nodular masses.[3] A *cavernous* tumor of this kind has been described. Secondary tumors, as a result of metastasis or of continuous growth from adjacent parts, are not very infrequent. These are usually *carcinomata* or *sarcomata*. Secondary *chondromata* have been observed. Syphilitic gummata may occur in the heart wall.[4]

### PARASITES.

Echinococcus sometimes occurs in the heart wall and may perforate into the cavities. Cysticercus cellulosæ has been observed.

## THE BLOOD VESSELS.

### ATROPHY AND HYPERTROPHY.

*Atrophy* of the blood vessels may involve the entire trunk or some of its elements. It may occur as a part of general malnutrition of the body, or in connection with atrophy of particular organs, or as an accompaniment of various diseases of the vessels themselves.

*Hypertrophy*, which is especially seen in the arteries, may occur in the establishment of a collateral circulation upon the closure of arterial trunks; or it may occur as the result of increased blood pressure, as in some forms of hypertrophy of the heart.

---

[1] *Kotlar*, Rev. Centralblatt f. Bakteriologie, April 7th, 1894, p. 498.

[2] For bibliography of heart tumors consult *Berthenson*, Arch. de Med. exp., vol. v., p. 386.

[3] *Justi*, Centralblatt f. path. Anat., etc., January 18th, 1896.

[4] *Loomis*, Am. Jour. of the Med. Sciences, October, 1895, bibliography.

### DEGENERATION.

*Fatty Degeneration.*—This may occur in the walls of otherwise unaltered vessels, or in those which have undergone a variety of inflammatory or degenerative changes. It may occur either in the intima or media, or both, and may be so extensive as to form a very prominent gross lesion, or so little developed as to require the microscope for its recognition. When marked, especially if occurring in the intima of large vessels, smaller and larger spots or stripes or patches may be seen, of a yellowish-white color, usually sharply circumscribed, and sometimes smooth, sometimes roughened on the surface. It is most apt to occur in the aorta, but may be found in any of the vessels. In moderate degrees of the lesion we find on section that the cells of the intima contain fat droplets in greater or less number. When further advanced, not only are the cells crowded with fat droplets, but the intercellular tissue also may be more or less densely infiltrated with them. Sometimes the infiltration is so dense that the tissue breaks down, and there may be an erosion of the surface, forming a so-called fatty ulcer. When the media is involved the muscle cells contain fat droplets. It may lead to the formation of aneurism or to rupture of the vessels.

*Calcification* usually occurs in vessels otherwise diseased, and may involve either the intima or media. It consists in the deposition of salts of lime either in the cells or intercellular substance. The lime may be in the form of larger or smaller granules or in dense translucent plates.

*Amyloid Degeneration*, which may affect all the coats of the arteries, but especially the intima and media, will be considered under the lesions of the organs in which it most commonly occurs.

*Hyalin Degeneration* may cause thickening of the intima of the blood vessels by its conversion into or infiltration with a homogeneous material somewhat similar to amyloid (see page 84). Or it may involve the entire wall of smaller vessels, converting them into irregular lumpy cords. The lumen of vessels thus changed may be obliterated or occluded by thrombi.

## THE ARTERIES.

### INFLAMMATION.

#### *Acute Arteritis.*

Acute inflammation of the walls of the arteries is, in the majority of cases, the result of injury, or of an inflammation in the vicinity of the vessel, or of the lodgment within it of some foreign body of an irritating or infectious nature. The inflammatory process may

be largely confined to the inner layer of the vessels—*endarteritis;* or it may commence in the outer layers—*periarteritis ;* or it may involve the entire wall.

The blood vessels in the outer layers may be congested, the tissue œdematous and infiltrated with pus cells, and the entire wall may become necrotic. The intima, if this layer is involved, loses its natural gloss, looks dull and swollen. It may become infiltrated with pus from the outer layers, and it may become necrotic. Under these conditions thrombi usually form, and in these may occur the various changes which have been already described on page 60

### *Chronic Arteritis.*

Since the publication of the studies of Gull and Sutton on arterio-capillary fibrosis, attention has been every year more and more directed to morbid changes in the arteries as one of the most frequent of diseased conditions.

It is evident that these morbid changes are caused by alcohol, lead, gout, and syphilis; that the disposition to them is hereditary in some families ; that they constitute one of the regular senile changes ; that they are often associated with chronic diseases of the viscera ; that the patients can be unconscious of their existence, and that, on the other hand, they can cause most distressing symptoms, and even death.

At the present time it is customary to speak of these morbid conditions under the names of arterio-sclerosis and atheroma, and to accept the conclusions drawn by Thoma from an extended series of studies. Thoma teaches that :

1. Every long-continued slowing of the blood current causes contraction of the middle coat of the aorta, and, if this is not sufficient to accelerate the blood current, to a growth of connective tissue in the intima.

2. Primary diffuse and nodular arterio-sclerosis depends upon a weakening of the wall of the blood vessel due to constitutional conditions. This is followed by dilatation of the vessel, slowing of the blood stream, and then the growth of connective tissue in the intima.

3. Secondary arterio-sclerosis is caused by slowing of the blood current produced by changes of the circulation in the capillary vessels.

It appears to me (Delafield) that the most practical view of these morbid changes in the arteries is to consider them the results of a combination of chronic productive inflammation and of degeneration occurring in connective tissue. We shall then think of the arteries as we do of the heart or the liver or the kidneys, as a definite part of the body, liable to become the seat of chronic inflammation from

the same causes as those which produce similar changes on other parts of the body.

In all the arteries the wall is composed of an outer connective-tissue coat supplied with blood vessels, of a middle coat formed of smooth muscle, and of an inner connective-tissue coat not supplied with blood vessels. In the small arteries inflammation simply causes the formation of new tissue; in the large arteries and in the aorta, besides the formation of new tissue, there is also the death and degeneration of tissue.

There is sufficient difference between the changes in the small arteries, the large arteries, and the aorta to make it convenient to described them separately.

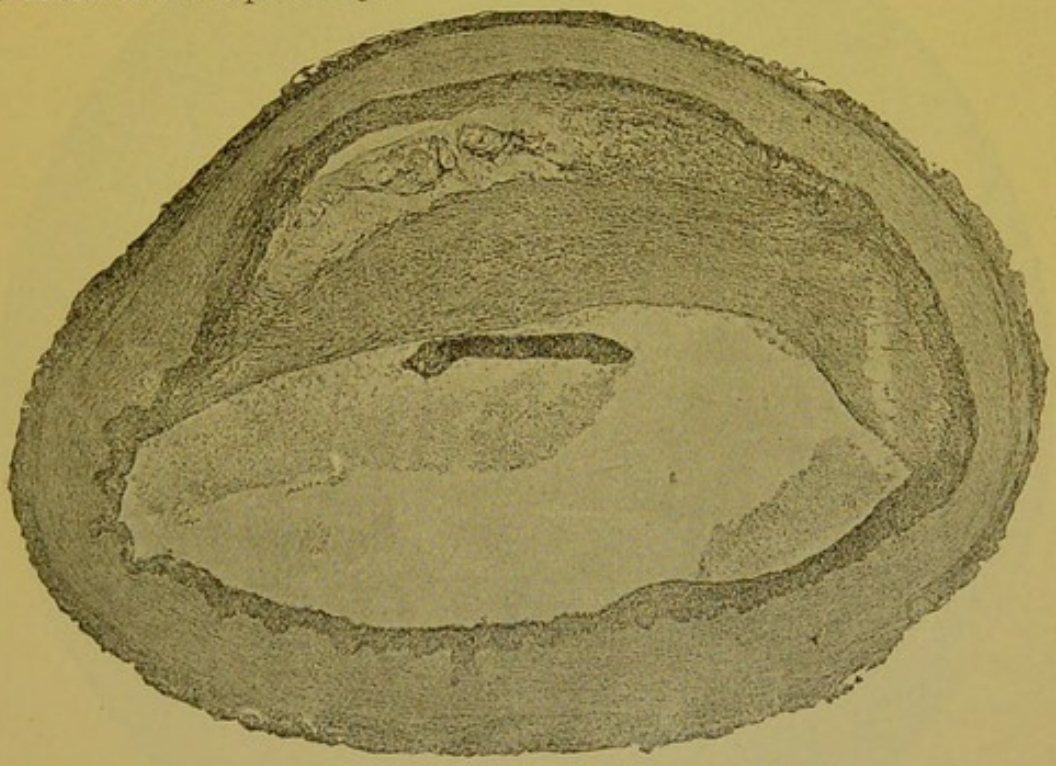

FIG. 253.—CHRONIC ARTERITIS—CEREBRAL ARTERY.

Inner coat thickened; degeneration and softening (atheroma) of a part of the thickened area.

1. *The Small Arteries.*—(*a*) The simplest change in the small arteries is an increase in the size and number of the endothelial cells. This is best seen in the arteries in miliary tubercles and in small gummata.

(*b*) There is a growth of new connective tissue from the endothelium which encroaches upon the lumen of the artery and finally occludes it. The growth is composed of large branching cells, small round cells, and basement substance; later the cells become smaller and less numerous, the basement substance denser. The growth forms a ring on the inside of the intima which is not symmetrical, but is thicker in some one place. This change always narrows the calibre

of the artery, and, when far advanced, occludes it. It is seen very frequently in the small arteries in every part of the body. It is often called "obliterating endarteritis" (Figs. 253 and 254).

(*c*) There is a thickening of the inner coat beneath the endothelium. The change begins by a growth of cells and a splitting-up of the basement substance in the intima immediately beneath the endothelium. Then there is a growth of basement substance, with but a moderate number of cells, which renders the inner coat thicker and

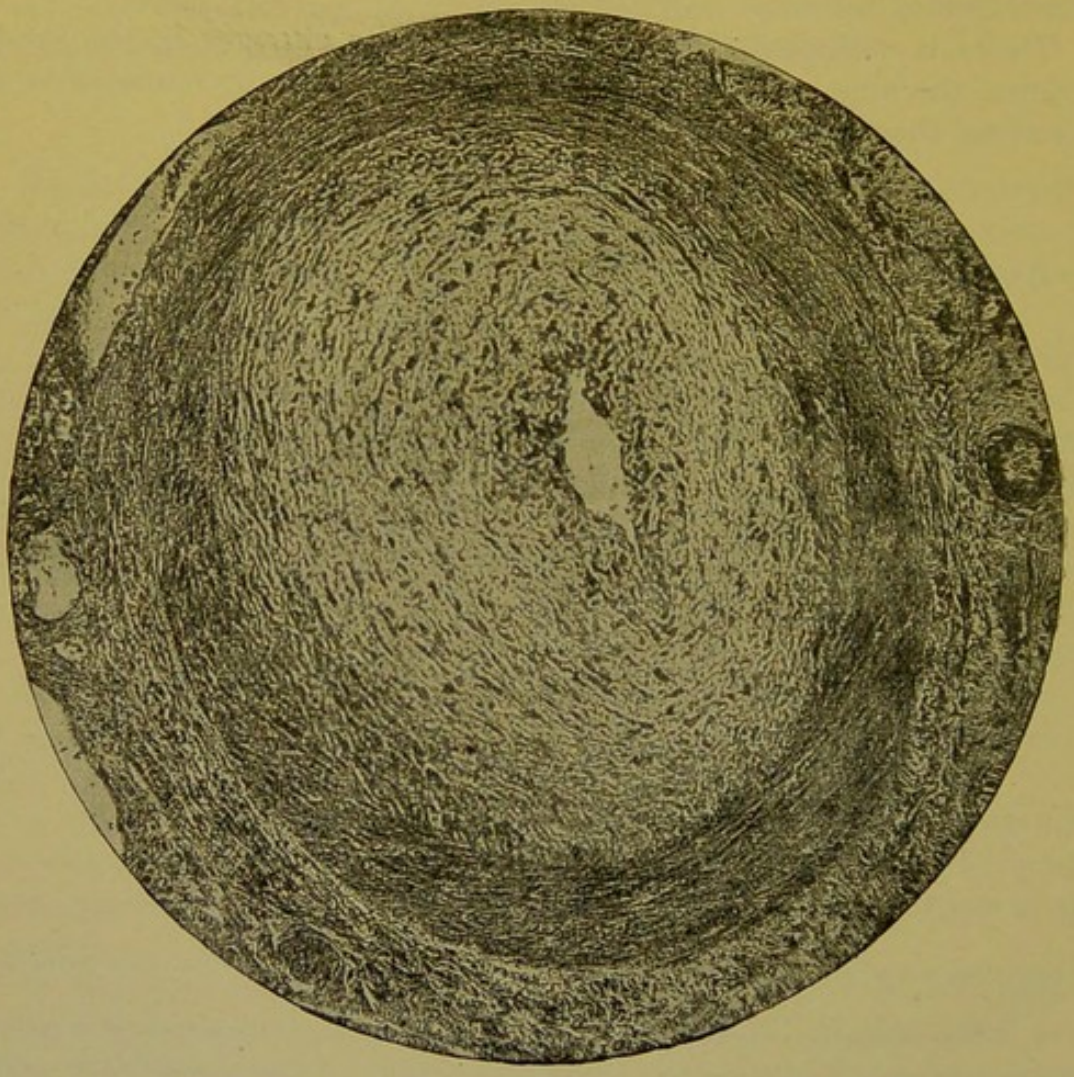

FIG. 254.—CHRONIC OBLITERATING ENDARTERITIS—KIDNEY.

thicker until the lumen of the artery is considerably narrowed, but yet the artery is not occluded. The endothelial cells may remain in place and unchanged over the thickened intima. This change is of very frequent occurrence, so that it is easy to see all the stages of the growth, from the first splitting-up of the intima until it is changed into a dense thickening.

(*d*) The thickening of the inner coat just described, instead of occurring by itself, may have joined with it either a thickening of

the muscular coat alone or a thickening of both the muscular and outer coats (Figs. 255 and 256).

(*e*) There is a thickening of the intima, a replacement of the muscular coat by connective tissue, and a thickening of the outer coat. This can properly be called a "sclerosis" of the artery.

*Periarteritis Nodosa.*—A few cases have been described in which many of the small arteries in the muscles and in the viscera were beset with small white knobs projecting from inside or surrounding the vessels. These circumscribed thickenings of the vessel wall are apt to involve all the layers of the vessel and may encroach

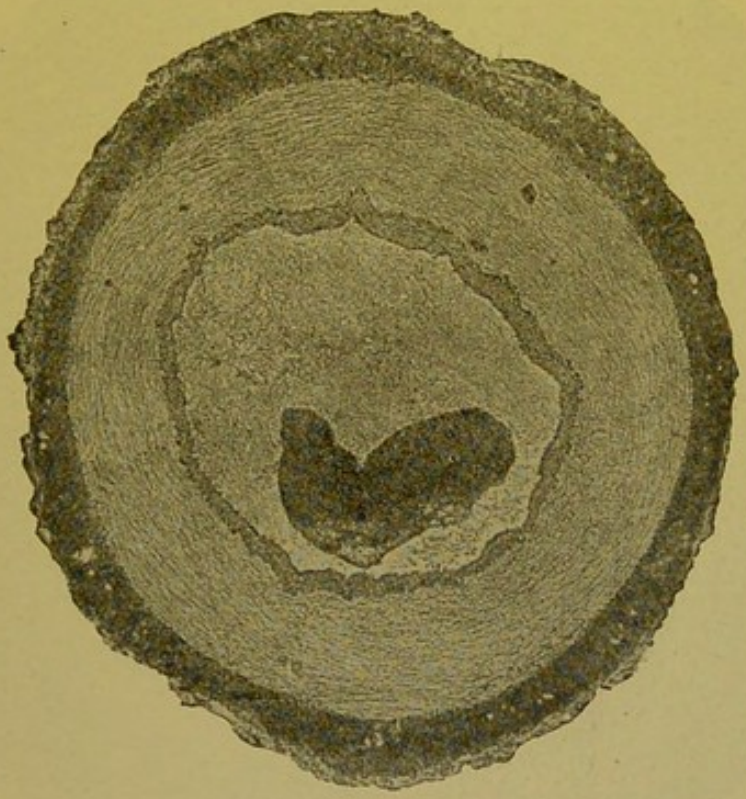

FIG. 255.—CHRONIC ARTERITIS.
Inner and middle coat thickened—radial artery.

upon the lumen. The thickened portions are infiltrated with small spheroidal cells. Multiple aneurisms may develop at the seat of the local thickenings.[1]

2. *The Large Arteries.*—In the large arteries altogether the most frequent change is the thickening of the intima. This is often present in arteries which look normal to the naked eye. But besides the thickening of the intima there is often in addition a thickening of

[1] Consult *v. Kahlden*, Ziegler's Beiträge z. path. Anat., etc., Bd. xv., 1894; also *Graf*, ibid., Bd. xix., p. 181, 1896.

the middle and outer coats, or a replacement of the muscular coat by connective tissue. When all the coats are thickened in this way the arteries often become elongated and tortuous. Occasionally there are areas of degeneration in the thickened wall of the artery, or even infiltration with the salts of lime.

*The Aorta.*—The changes in the aorta differ from those in the arteries by reason of the combination of degeneration and necrosis with the growth of new tissue due to the chronic inflammation, by

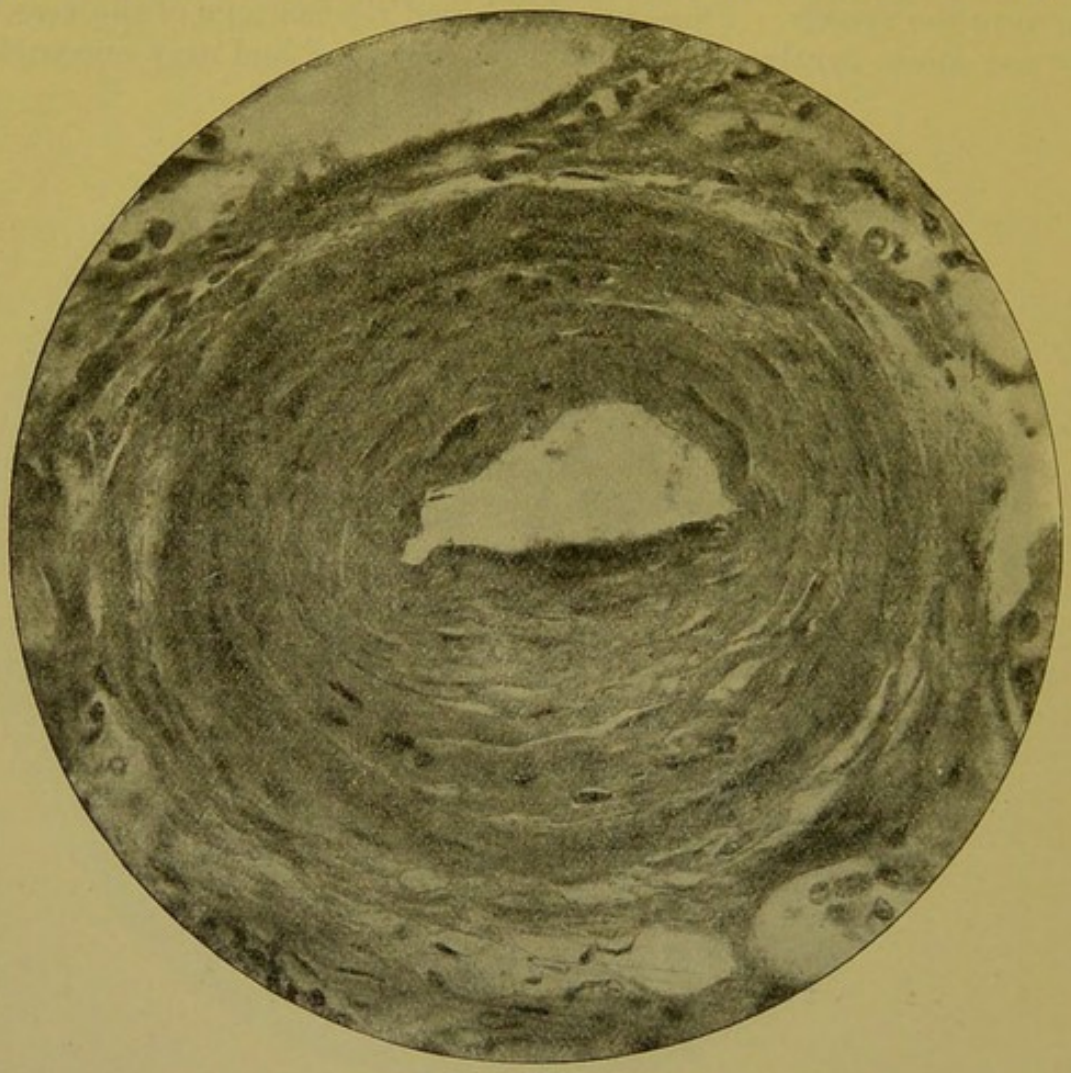

FIG. 256.—CHRONIC ARTERITIS.
With sclerosis of all the coats of the vessel—kidney.

the frequency of calcification, and by the liability of the outer coat to purulent infiltration. We find, therefore, in the aorta:

(*a*) Simple thickening of the inner coat by new connective tissue.
(*b*) Degeneration and softening of the inner and middle coats.
(*c*) Calcification of the inner and middle coats.
(*d*) Infiltration of the outer and middle coats with pus cells.
(*e*) Thinning and atrophy of the inner and middle coats.
(*f*) The formation of thrombi on the roughened surface of the inner coat.

Inflammatory changes in the aorta associated with degeneration, calcification, etc., are often called "atheroma" (See Figs. 258 and 259).

### *Tuberculous Inflammation of the Arteries.*

In tuberculous inflammation the walls of the arteries, particularly the smaller ones, may be thickened and their lumina obliterated (Fig. 260).

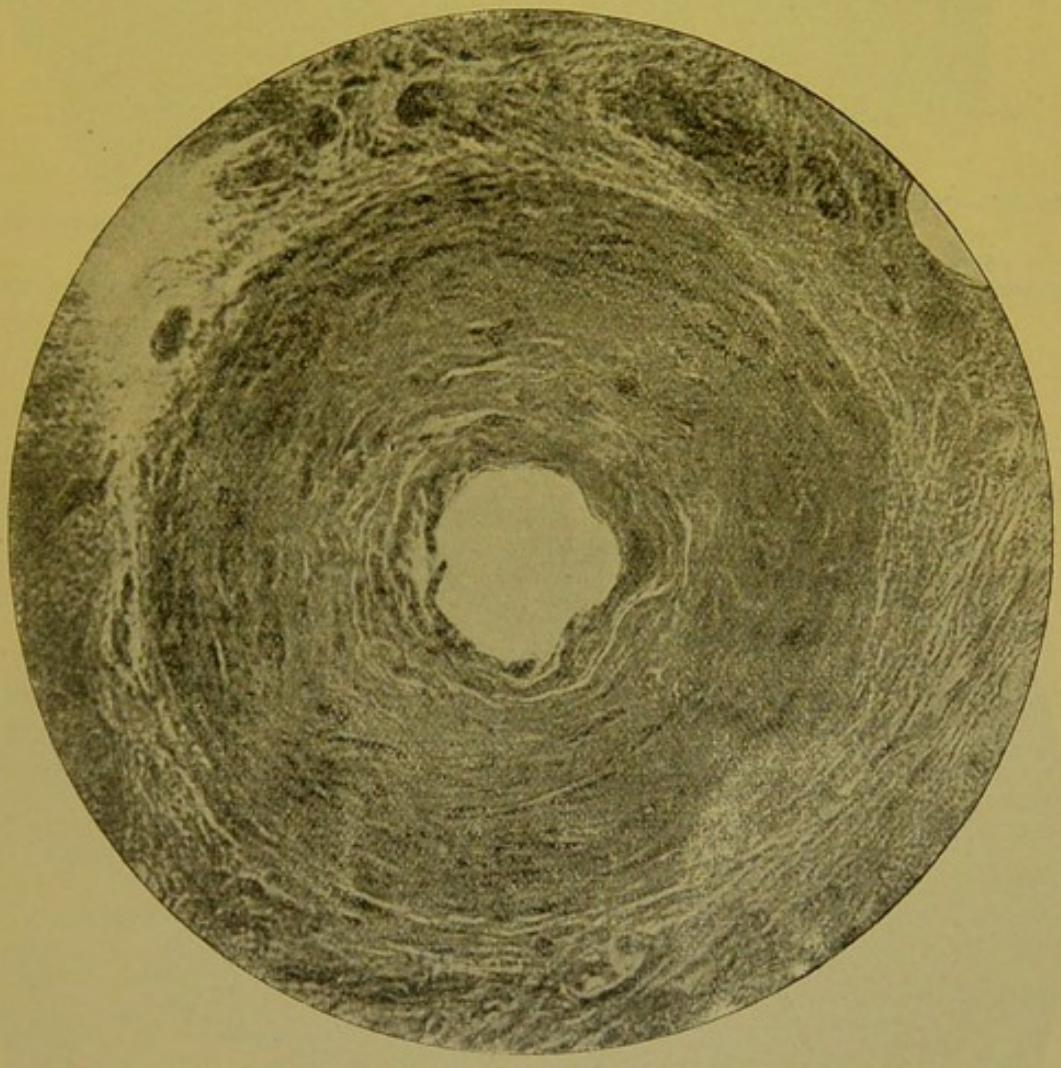

FIG. 257.—CHRONIC ARTERITIS.
With thickening of all the coats of the vessel—kidney.

### DILATATION AND ANEURISM.

1. *Cirsoid aneurism* consists in the dilatation and lengthening of large or small arteries. The walls of the artery are thinned, the vessel is tortuous and in places sacculated. These changes are most frequent in small arteries, especially the temporal and occipital.

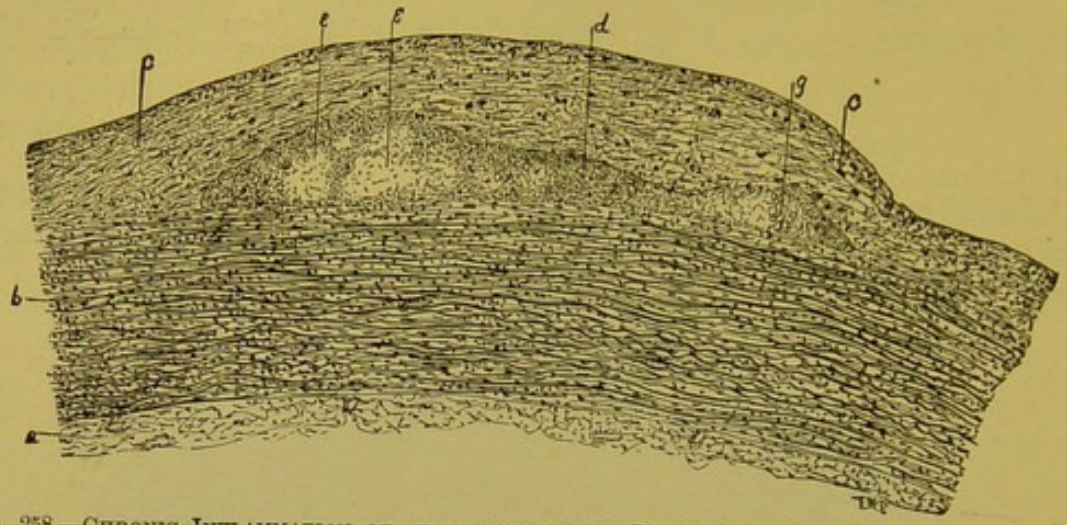


FIG. 258.—CHRONIC INFLAMMATION OF THE AORTA, WITH DEGENERATION OF NEW-FORMED TISSUE (ATHEROMA).

*a*, adventitia; *b*, media; *c*, new tissue developed in the intima; *d*, degenerated area; *e*, area of softening; *g*, fat droplets in softened area.

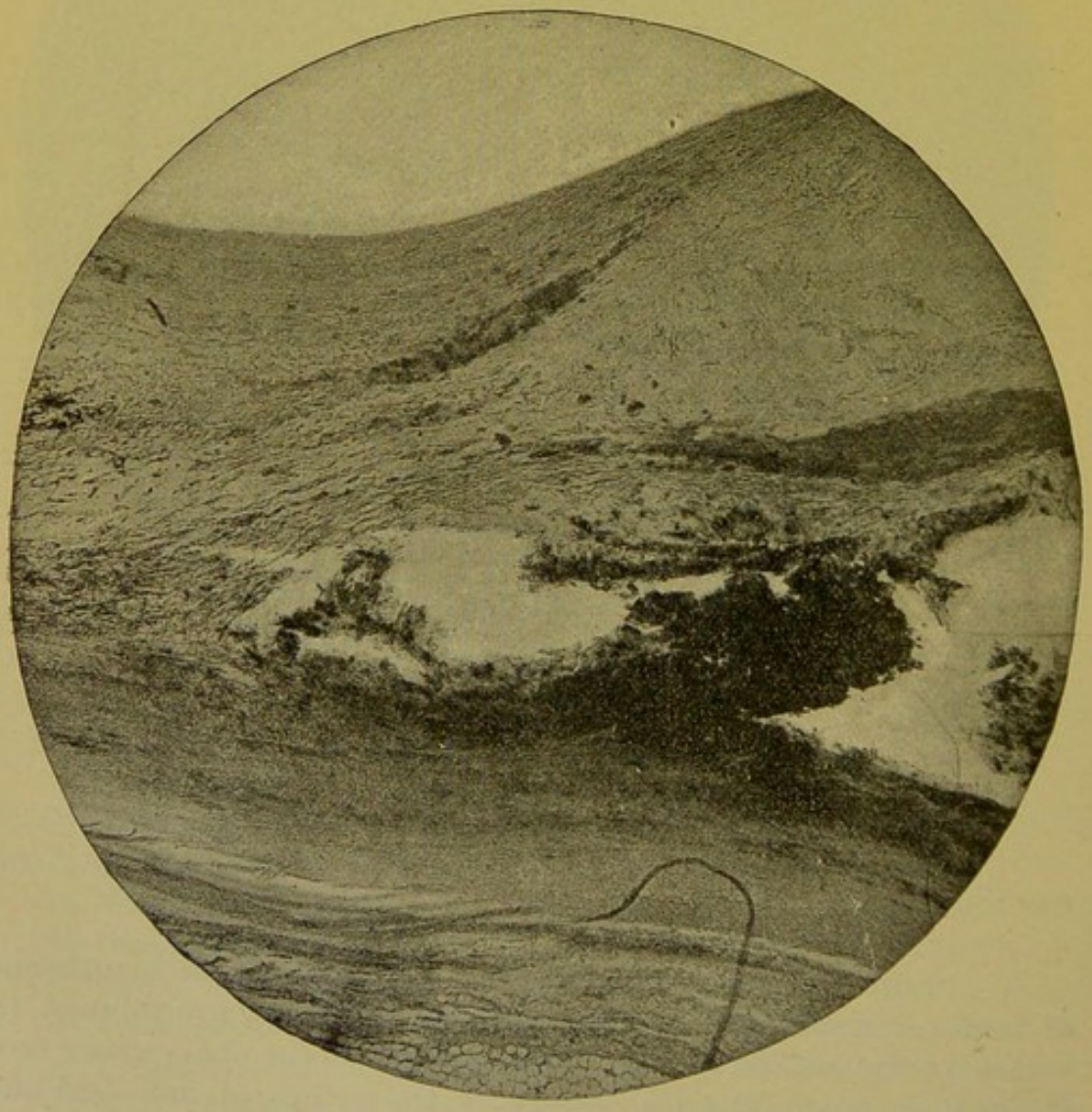

FIG. 259.—CHRONIC INFLAMMATION OF THE AORTA.

Inner coat thickened and necrotic; middle coat calcified, necrotic, and breaking down (atheroma).

They involve the trunk of the vessel and its branches, or may extend to the capillaries and small veins. They form larger or smaller tumors beneath the skin.

Rarely they are found in the larger arteries, and even in the aorta.

2. *The ordinary aneurism* is a dilatation of the coats of the artery over a larger or smaller part of its course. Such dilatations are usually due to chronic endarteritis and atheroma. The blocking



FIG. 260.—TUBERCULOUS ARTERITIS IN THE LUNG.

Showing the encroachment of an area of tuberculous inflammation upon the wall of the artery and the formation of a mass partly occluding the lumen of the vessel. This section shows how the generalization of the tubercular inflammation through the body may occur by the sweeping away of the tubercle bacilli by the blood and the establishment of new foci in various parts of the body. From specimen prepared by Dr. J. S. Ely.

of a vessel by an embolus may lead to the development of an aneurism. According to their shape we may distinguish two varieties of aneurism: the diffuse and the circumscribed.

(*a*) The diffuse, cylindrical, or fusiform aneurism consists in a uniform dilatation of all the coats of an artery, so that it assumes the shape of a fusiform or cylindrical swelling. In the walls of the dilated portion of the vessel there are often smaller, circumscribed dilatations. The wall of the aneurism is atheromatous or calcified; the middle coat may be atrophied. The arch of the aorta is the most common seat of this form of aneurism, but the entire length of the aorta, or parts of any other arteries, may be dilated in the same way.

(*b*) The circumscribed or sacculated aneurism consists either in a dilatation of the entire circumference of an artery over a short portion of its length, or in a dilatation of only a small portion of one side of the wall, so that the aneurism looks like a swelling attached to one side of the artery. The aneurism commences as a dilatation of all the coats of the vessel; but as soon as it attains any considerable size the middle coat atrophies, so that the wall is composed of the inner and outer coats; or the inner coat is destroyed by endarteritis, so that the outer coat alone forms the wall of the aneurism. As the aneurism increases in size it presses upon and causes the destruction of the neighboring tissues and viscera, and portions of these tissues and viscera become incorporated with, or take the place of, the wall of the aneurism. The cavity of the aneurism is filled with fluid or clotted blood, or with layers of fibrin which adhere closely to its wall. The communication between the aneurism and the artery may be small or large. If arterial branches are given off from the aneurism they may remain open or become plugged with fibrin; or their walls are thickened and their cavities narrowed by endarteritis. Death is produced by the pressure and interference of the aneurism with the adjoining viscera, or by rupture. The rupture may allow enough blood to escape to destroy life, or the blood may be held in by the soft parts and a second false aneurism formed about the original one.

*Dissecting aneurisms* are those in which, owing to a solution of continuity of the inner layers of the artery, the blood gets between the media and adventitia, and forces its way for a greater or less distance between them. Or it may separate the media into two layers.

### ANEURISMS OF THE DIFFERENT ARTERIES.

*The aorta* may be dilated over its entire length, or there may be diffuse or circumscribed dilatations at any portion of its course; or there may be several aneurisms, situated at different points. The ascending portion of the arch of the aorta may be uniformly dilated in a fusiform shape, or there may be circumscribed dilatations on its anterior wall, or, more rarely, on its posterior wall. The sacculated aneurisms may be of all sizes and may rupture within the pericardium; or they may form a cavity in the upper part of the ventricular septum and communicate by openings into the pulmonary artery and left ventricle; or they may dilate downward between the visceral and parietal pericardium, in front of the heart, pushing that organ backward. They may perforate into the right or left auricle or right ventricle, the superior vena cava, or the pulmonary artery; or they may reach a large size, press on and erode the right side of the

sternum and adjoining ribs, project under the skin, and even rupture externally.

The transverse portion of the arch may be dilated in a fusiform shape, or there may be sacculated aneurisms at any point in its wall. The sacculated aneurisms usually reach a considerable size. They press on the sternum and ribs in front, or on the œsophagus, trachea, and bronchi behind. The large arteries given off from the arch may be occluded. They cause death by pressure on the air passages, the œsophagus, and the vena cava ; or may rupture externally or into the œsophagus, trachea, bronchi, pulmonary artery, or pleural cavities.[1]

On the abdominal aorta we usually find aneurisms sacculated. If they are situated high up they may project into the pleural cavities; if lower down, into the abdomen. They may compress and displace the viscera, vessels, and nerves, and erode the vertebræ. They may rupture behind the peritoneum, into the peritoneal cavity, the pleural cavities, the inferior vena cava, the bronchi, the lungs, the duodenum, the colon, the pelves of the kidney, or the posterior mediastinum.

*The coronary arteries* may be dilated throughout, or may be the seat of small sacculated aneurisms. These may rupture into the pericardium, or may cause rupture of the heart wall.

*The pulmonary arteries* are rarely the seat of aneurisms. Diffuse and circumscribed dilatations, however, sometimes occur on the main trunk and on the two principal branches of the artery. They do not usually reach a large size, but may cause death by rupture. General dilatation of all the branches of the pulmonary artery is more common. It is found in connection with stenosis of the mitral valves and with compression or induration of the lung tissue.

Of the other arteries of the body there is hardly any one which may not become the seat of an aneurism, but those of the popliteal artery are most common.

A very few cases of multiple small aneurisms have been described, involving many of the smaller arterial trunks (see Periarteritis nodosa,[2] page 507).

### STENOSIS.

Stenosis and obliteration of the aorta, at the point of entrance of the ductus arteriosus, have been described in a considerable number of cases.

The situation of the stenosis is either exactly at the entrance of the ductus arteriosus or close on either side of this point. The de-

[1] For an analysis of thirty-four cases of aortic aneurism consult *Biggs*, Am. Jour. of the Med. Sciences, March, 1889.

[2] *Graf*, Ziegler's Beiträge zur path. Anat., etc., Bd. xix., p. 181, 1896.

gree of stenosis varies. The aorta may be entirely closed and converted into a solid cord for a length of half an inch; or there may be a circular constriction through which there is a larger or smaller opening—the constriction is uniformly circular; or there is a septum springing from the concave side of the vessel at the opening of the ductus arteriosus; or there is a cicatricial-like contraction of the aorta. The walls of the aorta at this point may be thickened and sclerosed. The ductus arteriosus may be closed or open. Above the constriction the aorta is usually dilated; below it, it is normal, dilated, or stenosed.

Stenosis of the aorta produces hypertrophy of the left ventricle, and, later, of the right ventricle, with venous congestion throughout the body; or there may be a collateral circulation developed between the arteries given off above and below the constriction; or there may be rupture of the aorta, the right ventricle or auricle.

This condition is found at all ages, but is produced during fœtal life or in the first year of extra-uterine life. It is probable that it may be caused after birth by an abnormal closure of the ductus arteriosus. This vessel normally becomes closed without the formation of a thrombus. If a thrombus is formed it may extend into the aorta and obstruct it; or the ductus arteriosus is filled with a thrombus, but increases for a time in size; afterward, as the thrombus is absorbed, the vessel contracts and draws the walls of the aorta together.

Stenosis of the aorta and of some of the other arteries has been observed, in a few rare cases, without any known cause.

Endarteritis, with the production of atheromatous and calcareous patches, may obstruct or entirely obliterate the smaller arteries. This is especially seen in the arteries of the leg, foot, and brain, and in the coronary arteries. The writer has seen a case in which the subclavian was completely occluded in this way.

Narrowing of the aorta and of all its branches, with thinning of the arterial coats, is found as a congenital condition. It usually occurs in females, in connection with imperfect development of the whole body.

Stenosis from thrombosis or embolism is treated of elsewhere.

### RUPTURES AND WOUNDS.

Rupture of arteries may occur under the following conditions:

1. Fatty degeneration or endarteritis, with atheromatous changes, may so soften and destroy the inner and middle coats of an artery as to admit of its rupture. Rupture of the aorta in connection with tuberculous inflammation of the vessels has been described. The aorta, just above the valves, is the most frequent seat of this lesion. The rupture may run in any direction; its edges are irregular and

jagged. The blood may burst through all the coats of the aorta at the same point; or more frequently the external coat remains and the blood is infiltrated in the middle coat and between it and the external coat. In this way a *dissecting aneurism* is formed, which may extend along the aorta for a considerable distance. After a short time the external coat usually gives way at some point, and the blood escapes. In rare cases life is prolonged for some time, the rupture being closed by a new membrane.

We also find ruptures from fatty degeneration and atheroma in the arteries of the brain and lungs; in the coronary arteries, the cœliac axis, the mesenteric arteries. and in the arteries of the extremities

2. In rare cases stenosis of a portion of the aorta may cause rupture at some point between the seat of stenosis and the heart.

3 Contusions, wrenchings, and severe falls may rupture the walls of an artery, either partially or completely, producing traumatic or dissecting aneurisms, or completely severing the vessel.

4. Penetrating wounds may injure or entirely sever an artery. If the vessel be large and the injury severe, death from hæmorrhage is the usual result. A small artery may become closed or be the seat of a false aneurism.

In the healing of a wounded artery two conditions co-operate. The vessel retracts and contracts, and a thrombus is formed within it. The contraction may be alone sufficient to close the vessel; its coats thicken, and the inner surfaces finally are fused together; or the blood coagulates and forms a thrombus in the vessel near the wound. This thrombus later becomes organized and the vessel is converted into a fibrous cord.

*Spurious or false aneurisms* are found most frequently connected with vessels of the extremities. When an artery is wounded the blood escapes into the surrounding soft parts, and a cavity is formed filled with blood and broken-down tissue. This condition may terminate in several ways.

(*a*) The wound in the artery may heal and the effused blood be absorbed.

(*b*) The effused blood and broken tissues may become gangrenous and the surrounding soft parts be inflamed.

(*c*) A sort of sac wall may be formed by the soft parts, while the wound of the artery remains open, so that we have an aneurismal sac through which the blood is constantly pouring.

5 If an artery be wounded, and at the same time the vein which accompanies it, we have as the result the conditions called aneurismal varix and varicose aneurism. In aneurismal varix the artery and vein become adherent at the seat of injury, so that the arterial

blood passes directly into the vein. There is a smooth, rounded opening between the two vessels, the vein is dilated into a sac, and the veins emptying into it are dilated and tortuous.

In varicose aneurism the artery and vein do not communicate directly, but a false aneurismal sac is formed between the vessels, into which the blood is poured before passing into the vein.

Varicose aneurism may also be produced by the spontaneous rupture of an aneurism into a vein. The aneurism presses against the vein, becomes adherent, and finally ruptures into it. This condition has been observed between the aorta and pulmonary artery; the aorta and inferior and superior vena cava; the popliteal artery and vein; the femoral artery and vein; the splenic artery and vena azygos; the internal carotid and sinus cavernosus. Even in cases of perforation by aortic aneurisms life is usually prolonged for some time.

6. Destructive inflammation or tumors of the surrounding tissues may invade and destroy a portion of the wall of an artery. Thus ulceration of the trachea, bronchi, bronchial glands, and œsophagus, or tumors of these parts, may perforate the aorta; gangrene of the lungs, the pulmonary arteries; ulcer of the stomach, the gastric arteries, etc.

### TUMORS.

Secondary tumors, chiefly carcinomata and sarcomata, may occur in the walls of the arteries by continuous growth from without, involving first the external layers. To these layers they are usually confined, for the density of the inner layers affords such marked resistance to the infiltration of the tumor cells that they are apt to pass intact through the tumor, which grows around them. More frequently the arteries become secondarily involved in the growth of malignant tumors by the occurrence within them of emboli formed by larger and smaller masses of tumor cells.

These emboli are usually of small size, and are apt to get into the circulation by growing through the walls of the veins into their lumina. Large emboli from tumors are most apt to occur in the branches of the pulmonary artery. The emboli, formed as they are for the most part by cells capable of growth and proliferation, are apt to soon form connection with the walls of the vessels, and, by the growth into them of blood vessels from the *vasa vasorum* to find the conditions necessary for their development, and they may thus soon involve the entire wall of the vessel and grow out into adjacent parts.

## THE VEINS.

### DILATATION.

Dilatation of the veins, or phlebectasia, presents itself under a variety of forms.

1. *Simple Dilatation.*—The vein is uniformly dilated in a cylindrical or fusiform shape; its length is not increased; its walls are of normal thickness or thinned; the valves increase in size, or are insufficient, or atrophic, or are torn.

2. *Cirsoid Dilatation.*—The vein is uniformly cylindrically dilated, but is also increased in length, so that it assumes a very tortuous course. The walls are normal, thickened, or thinned.

3. *Varicose Dilatation.*—A circumscribed portion of the wall of the vein is dilated so as to form a globular sac. The sac communicates with the vein through a large or small opening. The wall of the sac is formed of the coats of the vein, which preserve their normal thickness, are thickened or thinned; the middle coat may disappear entirely. There may be only one such dilatation, or there may be a number on the same vein, or a number of veins may be affected at the same time. The vein may be otherwise normal, or, more frequently, is dilated in the cirsoid form.

4. *Anastomosing Dilatation.*—A number of contiguous and anastomosing veins are dilated, both in the cirsoid and varicose forms. The vein then looks like a series of cavities separated by thin partitions. The dilatations of the same vein become adherent to each other and to those of the adjoining veins; portions of the wall of the dilated parts may disappear, and we find a number of cavities containing venous blood and separated from each other by thin partitions. The course of the vein can no longer be followed out.

Spontaneous cure of dilatations of the veins is not common, and usually occurs only in the lesser degrees of the lesion. Most phlebectasiæ increase steadily in size and extent. Very frequently thrombi form in the dilated veins, and either partially or completely fill them; and these in rare cases may become organized, or the clots may dry and become calcified, forming *phleboliths* (see page 60), and, by the formation of new connective tissue in the walls, they may become enclosed in a fibrous capsule, with the obliteration of the vessel. The wall of the dilated sac may become so thin that it finally ruptures, and the blood is discharged externally. Sometimes inflammation is set up in the tissues surrounding the vein, and we find both the surrounding tissues and the wall of the

vein the seat of purulent infiltration or fibrous thickening. The parts of the body from which the dilated veins draw their blood may exhibit the results of chronic venous congestion, œdema, hyperæmia, and hypertrophy or ulceration.

When occurring in mucous membrane, dilated veins are usually associated with persistent catarrh. There is hardly one of all the veins of the body which may not be dilated. The hæmorrhoidal veins; the veins of the leg and thigh; those of the pelvis and pelvic viscera; those of the spermatic cord, scrotum, and labia; those of the abdominal wall; those of the neck and arms—are the ones most frequently found in this condition.

The causes of dilatation are principally some mechanical obstruction to the passage of the blood through the veins toward the heart; but changes in the walls of the vessels from inflammation or injury, etc., are not without influence.

### WOUNDS—RUPTURE.

*Wounds* of the veins usually heal by a simple contraction and an adhesive inflammation of their walls; sometimes by the formation of a thrombus. *Rupture* of the veins may be produced by severe contusions and crushings of the body and by violent falls. *Perforation* of a vein may be produced by suppuration of the soft parts and the invasion of the walls of the vessel; by the pressure of an aneurism or of a new growth; by the thinning of the wall of the vein in phlebectasia.

### INFLAMMATION.

Inflammation of the veins, *phlebitis*, may involve chiefly the external layers—*periphlebitis;* or the internal—*endophlebitis;* or, as is very frequently the case, the entire wall may be affected. Phlebitis may be caused by the presence of a thrombus, by injuries, or by an infectious inflammation of the surrounding tissues. Thrombosis of the vein, either primary or secondary, is a very constant accompaniment of phlebitis.

*Acute Phlebitis* may commence as a suppurative periphlebitis or as a result of inflammatory processes about the vessel. The outer layers of the venous wall are congested, swollen, infiltrated with serum and pus. The inner coats may become infiltrated with pus; they may become necrotic and disintegrate. A thrombus is constantly formed under these conditions, which may for a time stop the circulation and keep the products of inflammation and degeneration from mixing with the blood; but the thrombus itself is prone to

disintegration, and thus the exudations and decomposing fragments of tissue may enter the circulation.

On the other hand, owing to the presence of irritating or infectious material within the vein and the formation of a thrombus, the inflammatory process may be at the commencement an endophlebitis, but usually, if the inflammation be at all severe, the entire wall of the vessel will eventually be involved. The pus cells in both cases doubtless come from emigration from the vasa vasorum. Acute phlebitis may terminate in the absorption of the thrombus and the return of the vein to its normal condition; in the obliteration of the vein; or portions of the thrombus may become detached and find their way as emboli into various parts of the body. The most im-

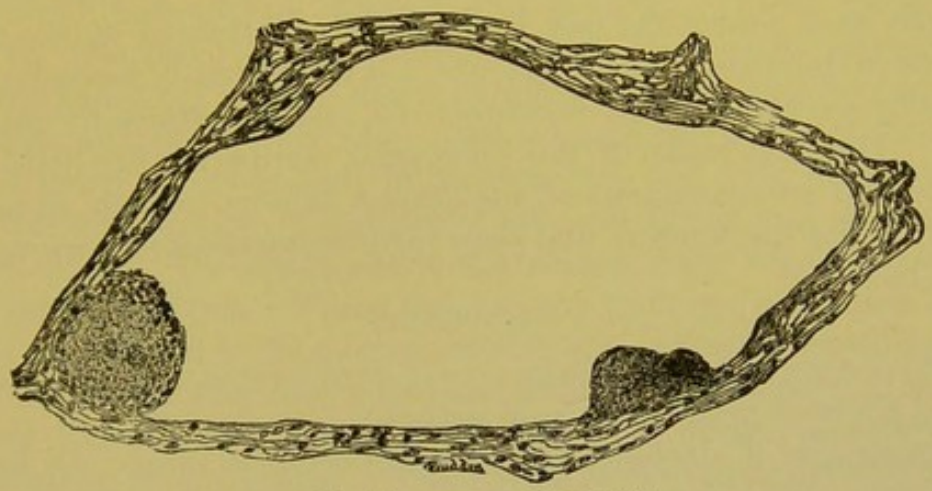

FIG. 261.—TUBERCULOUS PHLEBITIS.

The section is from one of the pulmonary veins in a child dead of acute general miliary tuberculosis. Specimen loaned by Dr. W. P. Northrup.

portant results of phlebitis are usually those which depend upon the introduction into the blood of these emboli or of septic material (see Thrombosis and Embolism, page 72, and Pyæmia).[1]

Chronic periphlebitis produces thickening, principally of the outer coats of the veins, but the inner coats may also be involved. The surrounding tissue may be also thickened and coalesce with the walls of the vein. There may or may not be thrombosis.

Chronic endophlebitis is a not very common lesion, of the same general character as chronic endarteritis. More or less circumscribed patches of new connective tissue are formed in the inner coats, which may undergo fatty or calcareous degeneration.

*Tuberculous Inflammation* of the walls of the veins may occur as an extension of the process from without or from a lodgment of the tubercle bacilli in the blood current on the intima (Fig. 261).

[1] Consult *Freudweiler*, "Experimental Phlebitis," Virch. Arch., Bd. cxli., p. 526, 1895.

This is not infrequent in the pulmonary veins, and Weigert has called attention to the fact that in acute miliary tuberculosis the growth of tubercle tissue into the lumina of these veins from tubercular lymph nodes is of frequent occurrence and readily explains the topography and mode of occurrence of the general disease. The tubercle bacilli which are present in the tubercular tissue growing into the lumen of the veins find thus an easy distribution.

*Syphilitic Inflammation* may involve the walls of the veins either as gummy tumors or as more diffuse thickenings.

### TUMORS.

Primary tumors of the veins are rare. Small *leiomyomata* have been described in the saphenous and ulnar veins. A *myo-sarcoma* as large as a man's fist has been described, situated in the dilated vena cava inferior. The veins are not infrequently secondarily involved by *sarcomata* and *carcinomata*, and sometimes by *chondromata*. The thin walls of the veins offer comparatively little resistance to the encroachment of malignant tumors, which thus gain access to the circulation and may form metastases in various parts of the body.

### PARASITES.

*Echinococcus* is sometimes found in the veins, having either developed there or perforated from without.

Two species of *distoma* (*liver fluke*) occur in man. *D. hepaticum* occurs rarely in man, and, while usually found in the bile ducts, may occur in the vena cava. *D. hæmatobium* is very common in man in Egypt and in other parts of Africa, and usually occurs in the portal vein or its branches, and frequently in other veins.

## THE CAPILLARIES.

The walls of the capillaries are so thin and so intimately connected with the surrounding tissues that their lesions are studied most appropriately among the diseases of the several organs. Dilatation of the new-formed capillaries in tumors, granulation tissue, etc., and fatty and hyalin degeneration of their walls, may be mentioned here as readily observed lesions occurring under a variety of conditions. The changes which we assume to occur in the walls of the smaller veins and capillaries in exudative inflammation, by reason of which fluids and blood cells pass through them, are not yet sufficiently understood to be described with definiteness.

## THE LYMPH VESSELS.

The smaller lymph vessels can hardly be treated as independent

structures, since their walls are so closely joined with the tissues through which they pass ; the lymph radicles, indeed, being nothing more than the spaces in the connective tissue in which the variously shaped connective-tissue cells lie. In the larger lymph vessels we find a moderate number of more or less independent lesions.

## INFLAMMATION.

### *Lymphangitis.*

Inflammation of the larger lymph vessels is usually secondary and connected with some wound or injury. Owing, it is believed, to the entrance into the lymph trunk of some septic material or bacteria, the vessels, sometimes for a considerable distance away from the wound, become red, tender, and painful. Under these conditions the microscopical appearances which the vessels present vary. In some cases the redness disappears after death and we find no appreciable alteration. In other cases we find the walls of the lymph vessels more or less densely infiltrated with pus cells, and the lumen may contain variable quantities of pus and fibrin and desquamated endothelium. The tissue about the vessels may also be infiltrated with serum and pus. These lesions may undergo resolution and the vessel be restored to its normal condition ; or the vessel wall and surrounding tissue may die or become involved in abscess ; or new connective tissue may form in and about the vessel, sometimes with obliteration of its lumen. The lymph nodes may participate in the inflammatory process.

Inflammation of the lymph vessels may occur as the result of dissection and other wounds, and the bites of venomous reptiles. It may occur in the uterine lymphatics in the phlegmonous form of puerperal fever, and under other conditions.

*Tuberculous Lymphangitis.*—Tuberculous inflammation occurs both in large and small lymph vessels. Miliary tubercles and diffuse tubercle tissue may form in the walls and project into the lumen of the larger trunks ; or in the smaller vessels the new growth may entirely fill the lumen, and grow in this, with more or less involvement of the walls. This may occur independently, but it is most frequently seen in connection with tubercular inflammation of adjacent tissues. Thus from tubercular lymph nodes in the vicinity of the thoracic duct there may be a direct extension of the tubercular inflammation, an involvement of the walls of the duct, and a growth of tubercle tissue into its lumen. Such growths in the thoracic duct have been shown by Weigert to be frequent in acute general miliary tuberculosis, and very satisfactorily explain the dissemination of the tubercle bacilli. In the vicinity of tubercular ulcers in the intestines,

furthermore, we often see the subserous lymph vessels, which pass from the vicinity of the ulcers, distended with the products of tubercular inflammation and looking like dense white knobbed cords.

*Syphilitic Inflammation* of the lymph vessels not infrequently occurs in the vicinity of syphilitic ulcers in the primary stage. In later stages there may be thickening of the walls of the vessels and the development of gummy tumors in and about them.

### LYMPHANGIECTASIS.

Dilatation of the lymph vessels occurs under a variety of conditions. It may be congenital, or it may be due to some hindrance to the flow of lymph onward—as by pressure from any cause, or from the occlusion of the vessels by inflammation—or it may be produced by unknown causes. If the dilated vessels form a circumscribed mass, this is often called a *lymphangioma* (Fig. 127). In certain forms of *elephantiasis* and in *macroglossia* the dilatation of the lymph vessels is an important factor. Its occurrence is not infrequent in the labia, prepuce, and scrotum.

### TUMORS.

The relation of the endothelium of the lymph vessels and spaces to endotheliomata has been already mentioned in the section on Tumors.

The dissemination of malignant tumors through the lymph channels is of frequent occurrence, and is particularly marked in the case of carcinoma. In the vicinity of carcinomata the lymph vessels are not infrequently crowded with the tumor cells, forming white, irregular cords; or small masses of the tumor cells may be found in the lymph vessels, either near to or remote from the tumor. White, irregular networks are often formed in this way beneath the pleura in carcinoma of the lung (Fig. 131), or beneath the capsule of the liver. Transverse sections of lymph vessels thus distended show sometimes swelling and detachment of the endothelium and a crowding of the lumen with tumor cells. Whether or not the endothelium participates in the new formation of the characteristic carcinomatous cells is not known.

## THE LYMPH NODES (*Lymph Glands*).[1]

It is well, in studying the lesions of the lymph nodes, to remember that they are structures so placed in the course of the lymph vessels

[1] What we call *lymphatic tissue* embraces not only the so-called lymph glands and the less complex but still well-defined structures found in the stomach, intestines, tonsils, and elsewhere, and called lymph follicles, but also the less well-defined,

that the lymph, in flowing toward the larger central trunks, passes through them, undergoing a sort of filtration as it percolates through the trabeculæ of the lymph sinuses. If this simple fact be borne in mind the diseases of the lymph nodes, which are in the majority of cases secondary, are much more readily understood. Particles of pigment which in any way get into the lymph vessels are carried along until a lymph node is reached, and here they are, in part at least, deposited among the trabeculæ of the sinuses, while the lymph passes on and out of the efferent vessels (Fig. 264). The same thing occurs when cells from malignant tumors, bacteria of various kinds, etc., gain access to the lymph vessels; and also, as there is good reason for believing, in the case of many poisonous materials which our present knowledge does not enable us to associate with bacteria. These various materials, filtered out of the lymph by the glands, may act in a variety of ways to produce lesions in them.

### INFLAMMATION.

*Acute Inflammation* of the lymph nodes usually occurs in connection with some inflammatory process in the region from which its lymph is gathered. The nodes are in the majority of cases swollen, reddened, and softer than normal, and often the seat of smaller and larger hæmorrhages. Sometimes one, sometimes several nodes of a cluster are affected.

The microscopical examination shows the most prominent change to be a great increase in the number of cells in the follicles and cords, as well as in the lymph sinuses. These cells are, in part, small and spheroidal, and similar to those normally filling the meshes of the follicles; in part large polyhedral or variously shaped cells with prominent nuclei; the latter cells are most abundant in the lymph sinuses. In addition to this there is swelling of the endothelial cells of the reticulum of the sinuses (Fig. 262). The blood vessels may be distended with blood, or there may be blood, in greater or less quantity, free in the sinuses and follicles. The origin of the large

---

irregular masses of tissue resembling that of lymph follicles, which, as *Arnold* has shown (Virchow's Archiv, Bd. lxxx., p. 315; Bd. lxxxii., p. 394; Bd. lxxxiii., p. 289; Bd. lxxxvii., p. 114), is widely disseminated in variable amounts in different parts of the body; in the lungs, beneath the pleura, and elsewhere; in the liver, kidneys, etc. Although the exact nature of these more diffuse masses of lymphatic tissue is too little understood, as indeed is that of the lymph follicles and glands themselves, there is reason to believe that they are analogous structures and prone to be affected by similar deleterious agencies. It seems better, in view of the fact that the so-called lymph glands are not glands at all, in the ordinary sense of the word, to call them *lymph nodes*, and the smaller masses of lymphatic tissue scattered through various parts of the body *lymph nodules* instead of "lymph follicles."

number of new cells which may form in a very short time is not yet definitely known. They may be emigrated leucocytes or their derivatives; they may be derivatives of the endothelium of the reticulum; or they may be in some cases, at least in part, cells which have been brought into the node, through the afferent trunks, from some external inflammatory focus. The capsule of the nodes, and not infrequently the connective tissue about them, may also be infiltrated with round cells.

Acute inflammation may terminate in resolution, the new cells disappearing either by fatty or other degeneration, or by being carried off in the lymph, and the node return to its normal condition.

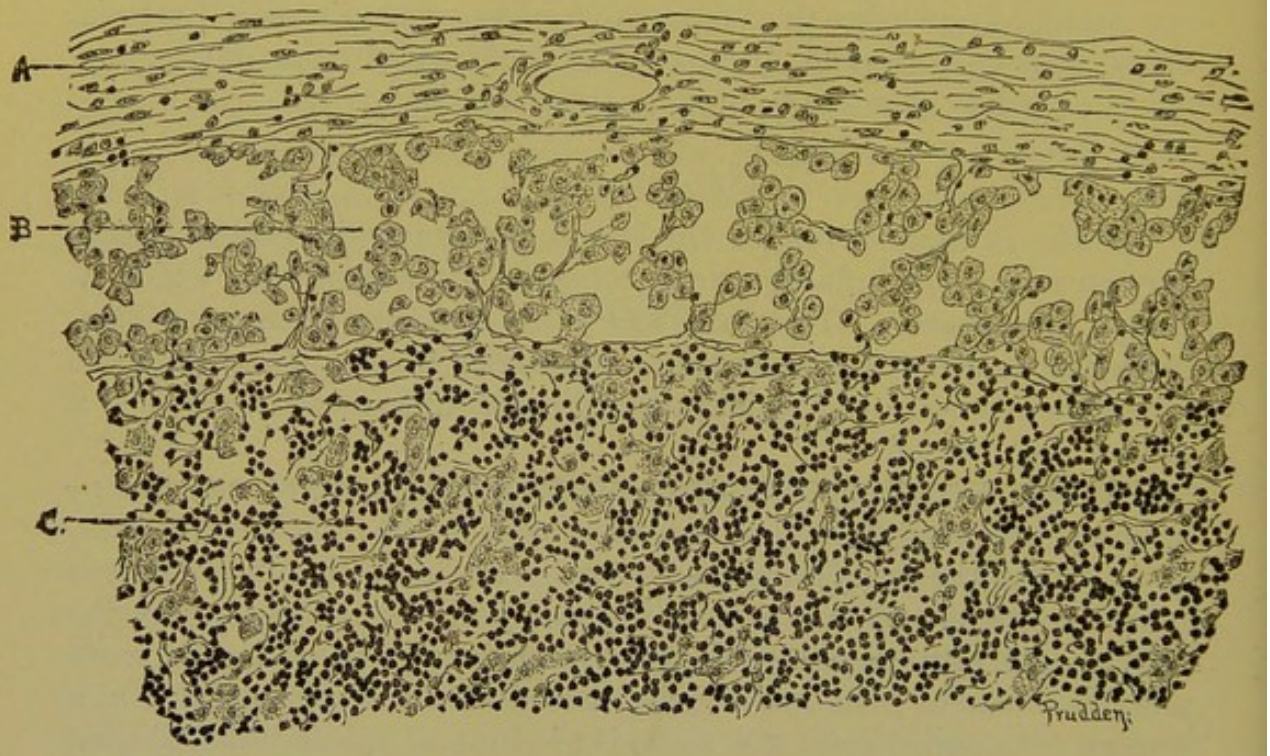


262.—Acute Inflammation of Lymph Node in Typhoid Fever.

Showing a portion of one of the mesenteric nodes. A, capsule; B, perifollicular space or lymph sinus, containing in its meshes many large cells; C, portion of one of the follicles, with large and small cells in the meshes of its reticulum.

This is the rule in the less intense forms of inflammation. On the other hand, the inflammatory process may become purulent and so intense as to lead to the formation of abscess, usually with a greater or less involvement of the tissue about the nodes. Fibrin and fluid exudate may be present in considerable quantity. There may be at first numerous small abscesses, which coalesce to form larger ones. These abscesses—*buboes*—may open externally or internally, or they may become dried and converted into cheesy masses which may calcify and, by a chronic inflammation in their periphery, become

enclosed by dense connective tissue. Sometimes, instead of abscess being formed, the tissue of the inflamed nodes becomes necrotic and breaks down, inducing more or less severe inflammatory or necrotic changes in the tissues in their vicinity. Small necrotic foci alone may form.

In still other cases acute inflammation of the lymph nodes passes into the chronic form.

Moderate degrees of inflammation in the lymph nodes are very common in connection with various forms of inflammation in neighboring parts. Thus simple pharyngitis, gastro-enteritis, erysipelas, simple purulent inflammation, etc., are often associated with this lesion of the nodes. The lymph nodes of children are, as a rule, more easily affected by moderate inflammations in neighboring parts than

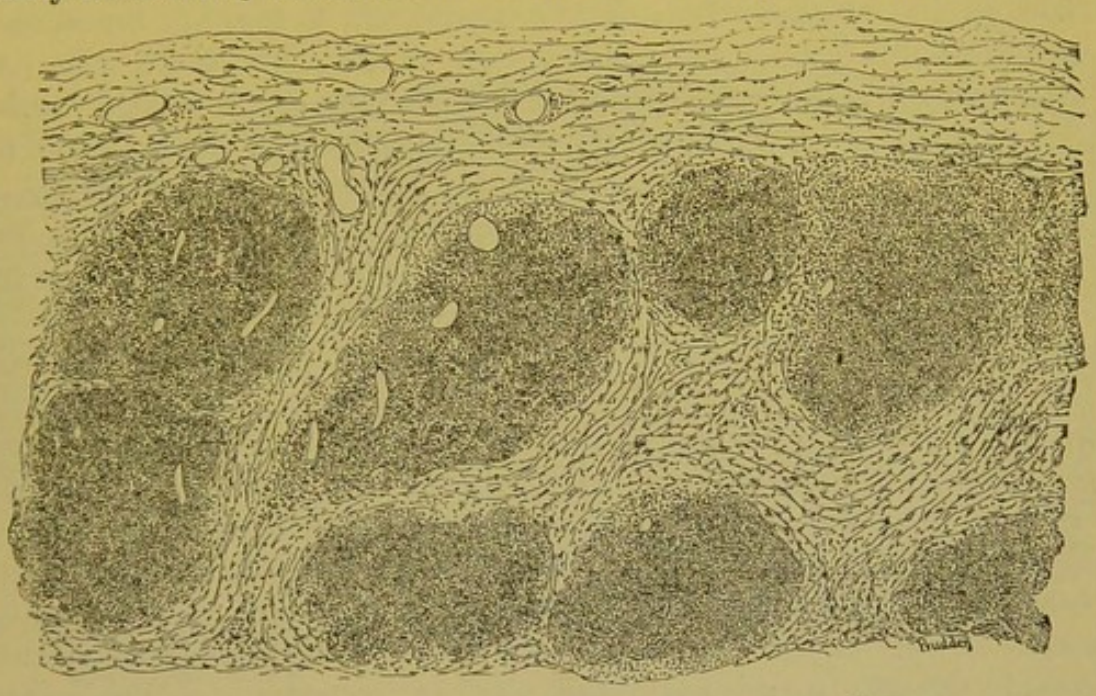

FIG. 263.—CHRONIC INFLAMMATION OF BRONCHIAL LYMPH NODE.

Showing obliteration of the lymph sinuses and atrophy of the lymph follicles by the new-formed connective tissue.

are those of adults. Purulent inflammation of the lymph nodes is most frequently associated with severer forms of inflammation of adjacent or related parts, especially those of an infectious character, syphilitic inflammation, poisoned wounds, pyæmia, etc. In a certain number of cases we find bacteria in the inflamed lymph nodes, either singly or in zoöglœa colonies, which have presumably something to do with the lesion.

In many cases the lesion of the lymph nodes appears to be induced, not by bacteria in the nodes themselves, but by poisons produced elsewhere by the action of bacteria and brought to the nodes by the lymph. The swelling of the lymph nodes in typhoid fever

and diphtheria is probably induced in this way. Necrotic urea in the lymph nodes may result from the presence of bacterial poison.

*Chronic Inflammation.*—This is characterzed by the increase of the connective-tissue elements of the node, with a gradual and commensurate disappearance of the lymphoid cells. The reticulum of the follicles and sinuses becomes thickened and fibrous, and in the trabeculæ and capsule new connective tissue is formed, until, in advanced cases, the entire node may be more or less completely converted into a mass of connective tissue. This condition is very frequently seen in the lower tracheal and in the bronchial nodes, apparently as a result of the lodgment in them of respired pigment particles; but it may occur in any nodes, either as a result of repeated moderate degrees of inflammation or from causes which we

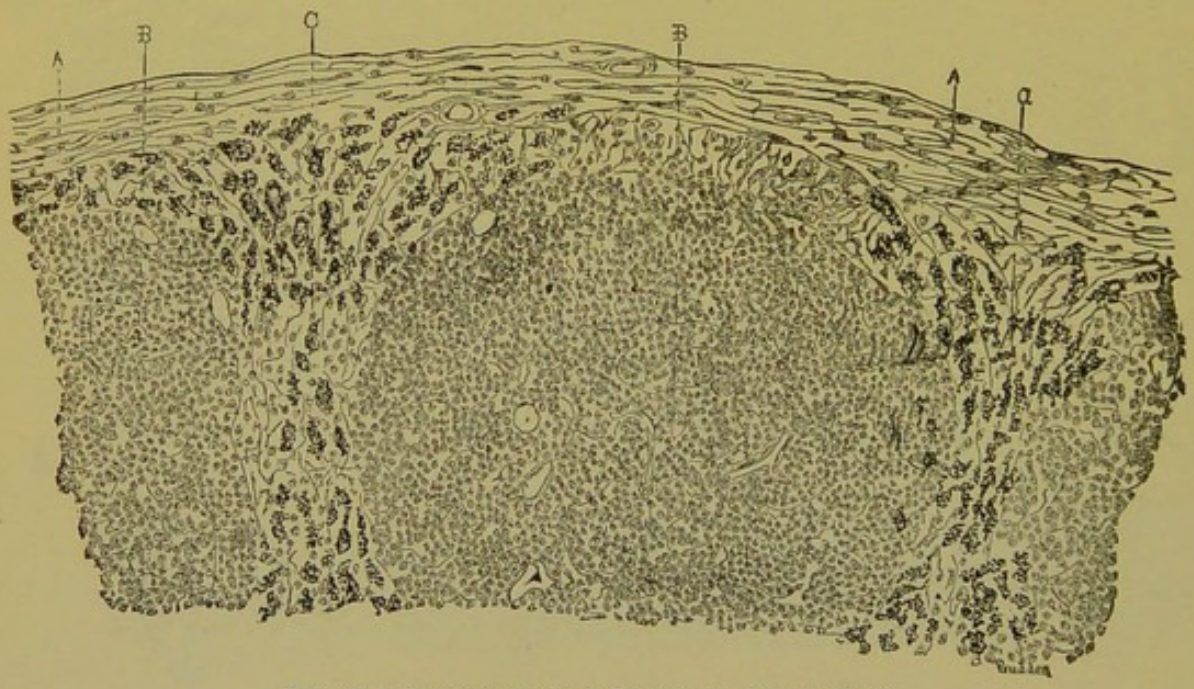


FIG. 264.—PIGMENTATION OF BRONCHIAL LYMPH NODE.

The pigment is largely in the lymph sinuses and enclosed in cells. A, capsule of node; B, lymph follicle; C, perifollicular lymph sinuses.

do not know. In some cases the nodes are greatly enlarged and the new tissue contains many large cells, while in other cases the connective tissue is dense and contains but few cells (Fig. 263).[1]

*Pigmentation.*—The pigment which is very frequently found in lymph nodes may be derived from the hæmoglobin of the blood, either in the nodes themselves or in remote parts, or it may be formed of various materials introduced into the body from without, such as the pigments used in tattooing, respired dust particles of va-

[1] Consult *Ribbert*, "Ueber Regeneration und Entzündung der Lymphdrüsen," Ziegler's Beiträge zur path. Anat., Bd. vi., 1889, p. 187.

rious kinds—coal, stone, iron, etc. (Fig. 264). The pigment particles, which usually first lodge in the lymph sinuses, may collect here in large quantities, either in the reticulum or the cells lying in its meshes, they may penetrate the follicles and cords and find permanent lodgment there. They usually induce a greater or less degree of chronic inflammation, so that in extreme cases, such as are frequently seen in the bronchial lymph nodes, nothing is finally left of the node but a more or less deeply pigmented mass of dense connective tissue. The function of the node is, of course, in this way partially or entirely destroyed. The pigment in these cases appears to reach the node, in part by being carried along free in the lymph current, in part by becoming enclosed in leucocytes and being transported by them. Pigmentation of the nodes is most marked in those about the root of the lungs, which are frequently of a mottled gray or a black color, but it may occur in the mesenteric and other nodes. Under similar conditions the diffuse lymphatic structure in the lungs and liver may be similarly pigmented.

*Inflammation of the Lymph Nodes with Cheesy Degeneration.*—This lesion of the lymph nodes, which is distinct from the above-mentioned comparatively infrequent cheesy degeneration of the contents of old abscesses, commences with changes similar to those above described in simple inflammation. The node in this condition is swollen and feels harder than normal; on section it has a uniform reddish-gray color. Microscopical examination reveals a great increase in the number of parenchyma cells, some small and spheroidal, others large and polyhedral. Sometimes the larger cells are multinuclear, and not infrequently the reticular framework and the capsule are thickened. As the process advances the characteristic necrotic changes make their appearance. We may find at first a greater or less number of the cells converted into a strongly refractile material, and the nuclei no longer capable of being stained. Then larger and smaller masses of cells undergo cheesy degeneration, with complete destruction of the blood vessels, reticulum, and the spheroidal and other cells, and their conversion into a granular material. A section through the node in this condition shows the cut surface mottled with irregular-shaped, larger and smaller opaque white patches, which indicate the areas of cheesy degeneration. These patches may increase in size and coalesce, so that a large part of, or even the entire gland may be converted into a more or less dense, cheesy mass which may be surrounded by the thickened capsule.

In this condition they may remain for a long time, and not infrequently, owing to the involvement of a series of associated nodes, either simultaneously or one after another, and the increase of con-

nective tissue about them, we find large, irregular nodular masses made up of a congeries of similarly affected nodes.

On the other hand, the cheesy material may soften and break down, and, by the establishment of purulent and necrotic inflammation about them, abscesses may form which may open externally. These abscesses may heal; but usually the healing is difficult and slow, and long-continued suppurations, frequently with the development of fistulæ, are very common. Under these conditions the inflammation may assume a tubercular character. Instead of softening, the cheesy material in the glands may become dry and hard and undergo calcification.

Cheesy inflammation of the lymph nodes is most common in the cervical, bronchial, and mesenteric groups, but may occur anywhere. It is most apt to occur in badly nourished young persons, who, in addition to the lesion of the lymph nodes, are very liable to suffer from chronic inflammations of the mucous membranes, skin, periosteum, joints, and the subcutaneous and other connective tissues. This general condition is known as *scrofula*, and the lesion of the nodes is sometimes called *scrofulous inflammation*. It is not infrequently associated with tuberculous inflammation of the nodes, either as an independent lesion or as a part of a general tuberculosis, and by some writers tuberculous and scrofulous inflammation of the lymph nodes are considered to be identical. In a considerable proportion of cases, however, of so-called scrofulous inflammation of the lymph nodes, there is no formation of tubercle tissue and we find no tubercle bacilli, so that we must consider this class of cases as simply inflammatory, with a tendency to cheesy degeneration.

*Tuberculous Inflammation* may occur in connection with simple inflammatory changes in the lymph nodes, or with the form of inflammation which tends to cheesy degeneration. It may be local, confined to the nodes, or it may occur in connection with general acute miliary tuberculosis or with tuberculous inflammation of single organs. It may occur in single nodes, or in several nodes of the same group, or in groups situated in different parts of the body. In its simple and acute form there may be no evident change to the naked eye in the appearance of the nodes, or they may be besprinkled with small, grayish-white, translucent spots. Under these conditions the nodes may be reddened and soft, or swollen and denser than normal. In more advanced forms of the lesion the tubercles coalesce and undergo a greater or less degree of cheesy degeneration. Under these conditions the cheesy areas are evident to the naked eye as more or less sharply circumscribed, opaque, whitish areas, frequently surrounded by an irregular, more translucent, grayish zone of tubercle tissue which merges insensibly into the adjacent tissue. The entire

node may become involved, and more or less completely converted into a cheesy mass, in the periphery of which a zone of tubercle tissue may or may not be evident.

Microscopically the small nodules or miliary tubercles are seen to consist of more or less circumscribed collections of small spheroidal, or more frequently larger polyhedral cells, with or without well-defined giant cells. They usually commence to form in the follicles and lymph cords of the nodes, and from these may spread and involve the entire surrounding tissue. The cheesy degeneration, which here as elsewhere is apt first to involve the central portions of the tubercles, presents the usual appearances. Tubercle bacilli may be found in the edges of the cheesy areas or in the tubercle tissue about them.

Simple inflammatory changes regularly occur in the periphery of the tubercles. There is an increase of cells in the lymph sinuses and follicles, and a more or less marked swelling, and apparently a proliferation of the cells of the reticular tissue of the node. In cases in which the process is chronic there is often marked increase of the connective tissue of the nodes, the reticular tissue becomes dense and fibrous, and the trabeculæ and capsule are thickened. The tubercles themselves, instead of undergoing cheesy degeneration, may become fibrous or be converted into a hyalin material.

The cheesy material may dry and shrink, and become enclosed by a capsule of dense connective tissue and become calcified; or it may soften, and thus cavities be formed in the glands, filled with grumous material; or inflammatory changes may be induced in the vicinity of the nodes, leading to abscesses. On the other hand, hyperplastic inflammation in the periphery of the affected nodes may result in their becoming bound together into a dense nodular mass.

When cheesy degeneration has occurred, to the naked eye tuberculous lymph nodes may not be distinguishable from those in scrofulous inflammation, but in some cases the nodular character of the new tissue around the cheesy centres is evident. The process is usually a slow and chronic one, except when occurring in connection with acute miliary tuberculosis in other parts of the body. It may occur in any of the nodes, but is most frequent in those of the bronchial, mesenteric, and cervical regions.[1]

*Syphilitic Inflammation.* — The lesions of the lymph nodes which occur in connection with syphilitic poisoning vary greatly, depending upon the stage of the disease. In the primary stage the lymph nodes in the region of the seat of infection are apt to present the lesions of an ordinary acute inflammation, with a tendency to the assumption of the purulent form.

[1] For a consideration of the significance of tuberculous bronchial lymph nodes in children, consult *Northrup*, New York Medical Journal, February 21st, 1891.

In the secondary stage of the disease the nodes of other regions, neck, elbow, axilla, etc., are frequently swollen and hard. On microscopical examination there may be an increase of connective tissue in the capsule and trabeculæ, but the chief change is in the accumulation in the follicles and lymph sinuses of larger and smaller spheroidal and polyhedral cells. The reticular tissue may be thickened and the walls of the blood vessels infiltrated with cells. In this condition the nodes may remain for a long time, not tending to form abscess; or they may undergo resolution through degeneration and absorption of the cells.

In the tertiary stage of the disease the nodes may be the seat of chronic inflammation characterized by the formation of gummy tumors. Under these conditions they may form large, firm nodular masses by the growing together by new connective tissue of several altered nodes. The gross and microscopical characters of gummata of the lymph nodes are, in the main, similar to those in other parts of the body.

There are important changes in the lymph nodes which occur as local manifestations of general diseases, such as *typhoid fever*, *leprosy*, etc., which will be considered under the headings of these diseases.

*Degenerative changes* in the lymph nodes, with the exception of those above described, are not of great frequency or significance.

*Atrophy* is a very regular occurrence in old age. In this condition the nodes are small, hard, and, unless pigmented, white. Microscopical examination shows a marked diminution in the number of parenchyma cells, while the reticulum and the capsule and trabeculæ may be thickened. There may be an accumulation of fat around the node in connection with senile atrophy.

It should be remembered, in this connection, that the lymph nodes, as well as the lymphatic tissue in general, in children are more voluminous and contain a greater number of parenchyma cells than in adults.

*Amyloid degeneration* of the blood vessels and reticulum of the lymph nodes occurs under the conditions which favor this change in general. It may occur in connection with amyloid degeneration of other parts of the body, or by itself. It may occur in nodes otherwise normal, or in those which are the seat of other lesions—thus in simple chronic or tubercular inflammation. It is frequently found in the mesenteric lymph nodes, in connection with waxy degeneration of the intestinal mucous membrane.

*Hyalin degeneration* of the external layers of the smaller arteries and the capillaries of the lymph nodes, and also of the parenchyma cells, occurs occasionally in old age or in connection

with wasting diseases. The vessels and cells are swollen and converted into a translucent, strongly refractile substance resembling amyloid optically, but not responding to its micro-chemical tests. By the accumulation of this material the uninvolved parenchyma of the nodes may be compressed and atrophied.

### HYPERPLASIA OF THE LYMPH NODES (*Lymphoma*).

In addition to the considerable enlargements of the lymph nodes in inflammation which have been described above, they become enlarged under a variety of conditions which we do not understand. This lack of knowledge of the etiology, together with our ignorance of the function of the lymph nodes, and the morphological similarity, or even identity, which these enlarged nodes present, render it very difficult to decide upon the exact nature of the change, and in many cases to distinguish one form from another.

In the first place, there is a class of cases in which, sometimes slowly, sometimes with great rapidity, the lymph nodes of certain regions, especially the abdominal, axillary, cervical, and inguinal, enlarge not infrequently to an enormous extent. They may be either hard or soft, even almost fluctuating; the individual nodes may be distinct or merged into one another. Sometimes the nodes in nearly all parts of the body are affected. Microscopically we find that the enlargement is due, in the soft varieties, to an enormous increase of small spheroidal and polyhedral cells and a growth of the reticular tissue. It is a new formation of lymphatic tissue, but the normal relations of follicles, cords, and lymph sinuses are not preserved. In the harder varieties there is a thickening of the reticular tissue in addition to an increase of cells. In very rare cases portions of the nodes may become cheesy. Sometimes larger and smaller hæmorrhages occur in the nodes, especially in the softer forms. In addition to these changes in the lymph nodes there is, in a considerable proportion of cases, a new formation of lymphatic tissue in greater or less quantity in other parts of the body, in the spleen, in the gastro-intestinal canal, in the marrow of bones, in the liver, kidneys, etc., and the number of leucocytes in the blood and in other parts of the body is increased. This general condition is known as *leukæmia* and will be considered under the general diseases. The enlarged lymph nodes in this disease may be called, for convenience, *leukæmic lymphomata*.

In the second place, there is a form of disease in many respects, particularly in the lesion of the lymph nodes, resembling leukæmia. There is, however, usually a less prominent involvement of the spleen and other lymphatic structures, and, what is more striking, no increase in the number of leucocytes in the blood. This is called *Hodg-*

*kin's disease*, or *pseudo-leukæmia*, and the enlarged lymph nodes may in this case be called *pseudo-leukæmic lymphomata*. The lesions of the lymph nodes are similar in both diseases, and it is convenient to assign different names to them simply because, for reasons which we do not at all understand, they seem to arise under different conditions and to be associated with a constant difference in the character of the blood (see page 794).

### TUMORS.

*Sarcomata* occur in the lymph nodes as primary and secondary tumors, and these may be of various forms: spindle-celled, large and small round-celled, and angio-sarcomata. It is not easy in many cases to distinguish morphologically between the small round-celled sarcomata and the above-described lymphomata. *Fibromata*, *myxomata*, and *chondromata* occur in the lymph nodes, but are rare. Endotheliomata are described, but are not common. *Secondary carcinomata* are of frequent occurrence, the form of the cells and the nature of their growth depending upon the seat and character of the primary tumors.

### PARASITES.

Aside from various forms of *bacteria* which are not infrequently found in the lymph nodes—thus in diphtheria, splenic fever, typhoid fever, tuberculosis, etc.—*filaria*, *trichinæ*, and *pentastomum* have been described.

# THE ALIMENTARY CANAL.

## THE MOUTH.

### MALFORMATIONS.

Malformations of the lip and cheeks are usually associated with defective formation of the bones of the mouth. The entire process is generally due to an arrest of development.

1. The lower jaw is absent; the upper jaw and hard palate small and imperfectly formed; the temporal bones nearly touch in the median line. The lower part of the face is, therefore, wanting; the mouth is absent, or small and closed posteriorly; the tongue is absent. Such a malformation is rare; the fœtus is not viable.

2. The face remains in its early fœtal condition of a large cleft; the mouth and nose form one cavity; the orbits may be united in the same cavity. The fœtus is not viable.

3. There is a cleft in the upper lip, upper jaw, and hard palate. The cleft corresponds to the point of junction of the processes of the superior maxilla with the intermaxillary bone. There may be one cleft or two, one on either side of the intermaxillary bone. The cleft involves the lip alone, or the lip and superior maxilla, or the lip, maxilla, and palate. There may be a single or a double cleft in the palate, and the cleft may involve either the hard or soft palate, or both. If there are two clefts of the lip and maxilla the portion of lip and bone between them may be small, or entirely absent so as to leave a large open space. The soft palate may be entirely absent. This is a common malformation and does not endanger life.

4. Rarely we find a cleft involving the middle of the lower lip, and sometimes extending into the inferior maxilla.

5. Either the inferior, the superior, or both maxillary bones may be abnormally small.

6. The edges of the lips may be partly or completely joined together. The opening of the mouth may be only a round hole.

7. The lips may be absent or imperfectly developed.

8. The corners of the mouth may be prolonged by clefts in the cheeks nearly to the ears.

### HYPERTROPHY.

The skin of the cheeks and lips may be hypertrophied in connection with elephantiasis of the face.

There may be a thickening of the lips alone, so that they appear double. This thickening may be due to an increase of all the anatomical elements of the lips; or there may be an increase and dilatation of the lymphatic vessels, giving to the growth a soft, œdematous character.

### INFLAMMATION.

*Catarrhal Stomatitis* is found most frequently in children. It is produced by a great variety of local and constitutional causes. Of the conditions which are seen during life, the congestion, increased production of mucus, and swelling of the mucous membrane, but little remains after death.

During life the congestion and swelling of the mucous membrane are well marked. There are often white patches, produced by the death of the superficial epithelial cells. There may be an increased production of mucus, which runs constantly from the mouth, or, instead of this, the entire mucous membrane is unnaturally dry.

The only structural changes which can be demonstrated are the degenerative changes of the epithelial cells and the production of pus cells, which infiltrate to a moderate degree the stroma of the mucous membrane and appear upon its surface. Small clear vesicles may form beneath the epithelium from the collection of serous exudate.

*Croupous Stomatitis* is produced by local irritants, by extension of the same form of inflammation from the pharynx, and it occurs with the exanthematous fevers and with diphtheria.

Portions of the mucous membrane are swollen and congested, and covered with a false membrane. This false membrane is composed of a thickened layer of epithelium in the condition of coagulation necrosis, and of fibrin and pus in variable relative quantity. The stroma of the mucous membrane may be infiltrated with pus and fibrin, and portions of it may become necrotic.

### STOMATITIS ULCEROSA[1] (*Stomacace; Stomatite Ulcero-membraneuse*).

This form of stomatitis occurs in children between the ages of four and eight years, and in adults between the ages of eighteen and twenty-five years. It is apt to occur in localized epidemics, in hospitals and asylums, and among soldiers and sailors. Some of the forms of mercurial stomatitis seem to be identical with this form of inflammation.

[1] *Bergeron*, "Stomatite ulcerosa," Union Médicale, 1859. *Bohn*, "Mundkrankheiten der Kinder," 1880.

The inflammation begins at the margin of the gums of the lower jaw. The gums are swollen and coated with a grayish, soft matter composed of bacteria and detritus. Then follows destruction of tissue; the gums are destroyed around the teeth, and these fall out; the inflammation extends to the lips, cheeks, and tongue. The ulcers are coated with a thick, soft, gray membrane. The surrounding soft parts are swollen, and there may be necrosis of the jaws.[1]

*Syphilitic Stomatitis.*—As a result of syphilis there may be produced either the so-called mucous patches or gummy tumors. In the mucous patches we find at first the epithelial layer thickened and the papillæ of the stroma swollen and infiltrated with cells. This may be followed by desquamation of the epithelium and ulceration of the stroma.

The deeper gummy tumors may also soften and form ragged ulcers of some size.

*Tubercular Stomatitis* commences with the formation of miliary tubercles or of larger tubercular masses in the stroma of the mucous membrane. These masses soon degenerate, soften, and form ragged ulcers resembling very closely syphilitic ulcers.

### GANGRENE.

Gangrene of the lips and cheeks, or noma, is most frequent in cachectic children as a consequence of the abuse of mercury. Much more rarely it occurs in adults after typhus and other exhausting diseases. The disease begins in the mucous membrane of the cheeks near one of the corners of the mouth. The mucous membrane becomes black and gangrenous; the gangrene extends rapidly through the entire thickness of the cheek and produces perforation; it extends laterally in all directions.

### TUMORS.

*Adenomata* are formed in the mucous membrane covering the mouth, lips, and soft palate. The tumors are rounded, usually small, sometimes as large as a hen's egg. They may be situated in the thickness of the mucous membrane, or project in a polypoid form. They are formed by an hypertrophy of the normal mucous glands. The glandular acini are increased in number and size, the epithelial cells are increased in number and may undergo colloid degeneration.

*Papillomata* occur most frequently at the edges of the lips, but are also found on the gums, the floor of the mouth, and the cheeks.

---

[1] *R. Volkmann*, Virch. Arch., Bd. 1., p. 142, describes five cases of inflammation of the mucous glands of the lower lip. The lip was swollen and hard, the mucous glands and their ducts were dilated.

They are formed of hypertrophied papillæ, covered with thickened epidermis. They very often ulcerate.

*Carcinomata* are of frequent occurrence. They may be found at any part of the mucous membrane of the mouth, but as a rule begin in the edge of the lower lip.

They may orginate in an ulcerating papilloma, or as a flat, superficial growth from the deeper layers of the epithelium, or as deep nodules starting in the mucous glands. They are composed of large masses of epithelial cells, closely packed together, often forming nests, and arranged in anastomosing tubular masses. The stroma surrounding these masses is infiltrated with cells. In a few cases the infiltration of the stroma with small round cells may be very marked, so marked that the epithelial growth may be obscured. The new growth increases in size, ulcerates, infiltrates the adjacent tissues, and may give rise to metastatic tumors.

*Angiomata* are found in the lips. They may be congenital or developed after birth.

*Fibromata*, *lipomata*, and *enchondromata* have been seen in a few cases in the lips. When they appear in the mouth they usually grow from the bones.

## THE TONGUE.

### MALFORMATIONS.

Absence of the tongue is found in connection with the extreme defects of development of the face already mentioned.

The anterior portion of the tongue may be absent while its base remains. The lower jaw is then small.

The tongue may be partly or completely adherent to the floor of the mouth. The frenulum may be abnormally short, or may extend to the tip of the tongue. In rare cases the sides of the tongue are adherent, or its upper surface may be adherent to the roof of the mouth.

### HYPERTROPHY.

Macroglossia, or hypertrophy of the tongue, is almost always a congenital lesion, and is especially common in cretins. The tongue is so large that the cavity of the mouth cannot contain it; it is protruded through the lips and displaces the jaws. The lips may also be hypertrophied in the same way.

There is an hypertrophy of all the anatomical elements which make up the tongue, and in addition to this there may be a dilatation of the lymphatic vessels.

## INFLAMMATION.

Inflammations of the tongue may be associated with similar changes in the mouth, or may occur by themselves.

*Superficial Glossitis.*—Inflammation involving only the mucous membrane of the tongue may occur as an acute or chronic process.

The acute forms present no marked lesions.

The chronic forms result in an increased production of epithelium and an hypertrophy of the papillæ of the tongue.

A moderate development of such an inflammation is not infrequently associated with derangements of the stomach. The tongue is large, its surface is irregular from the hypertrophy of the papillæ. There may be no change in the epithelium, and then the surface of the tongue is clean and red; or the epithelium is increased and the tongue is covered with a white fur.

More severe forms of the disease also occur, especially with syphilis. The hypertrophied papillæ and increased epithelium then alter very decidedly the appearance of the tongue.

*Parenchymatous Glossitis* may be produced by mercurial poisoning, by injury, or by unknown causes. The tongue is swollen, the muscular and connective portions are congested and infiltrated with serum and pus. The inflammation may stop at this point or it may go on to the formation of an abscess.

*Syphilitic Glossitis.*—In persons suffering from constitutional syphilis there may be mucous patches on the surface of the tongue; or gummy tumors in its stroma, which often soften and form deep ulcers; or a diffuse, chronic inflammation of the surface of the tongue, with hypertrophy of the papillæ.

*Tubercular Glossitis.*—There may be a tubercular inflammation of the connective tissue of the tongue just beneath the epithelial layer, resulting in the formation of tubercle granula and granulation tissue. In this way tumors of some little size are formed, which may remain unchanged for some time, or may degenerate, soften, and form ulcers.

## TUMORS.

*Cysts.*—The most common forms of cysts are the sacs beneath or partly in the substance of the tongue (ranula). They are formed by dilatation of the ducts of the submaxillary and sublingual glands, or make their appearance in the connective tissue beneath and in the tongue.

*Angioma.*—Cavernous vascular tumors are found in the substance of the tongue and projecting from its surface.

*Lipoma* and *fibroma* are rare. They form nodules in the substance of the tongue or project in a polypoid form. Composite

tumors, composed largely of fat, are found on the tongue as a congenital condition.

*Lupus* occurs in the form of nodules and ulcers at the base of the tongue.

*Sarcomata* are not common in this situation, but they may occur both in children and in adults.

*Carcinoma.*—This form of new growth may begin in the tongue or may extend to it from the adjacent tissues. The growth is composed of large, flat epithelial cells packed closely together in anastomosing tubular spaces and surrounded by a connective-tissue stroma.

Amyloid tumors of the tongue have been several times reported. Micro-organisms of various forms; bacteria, moulds, and yeasts, are always present in the mouth, often in enormous numbers. They are for the most part not of significance save for the putrefactive processes which they initiate and maintain in mouths not properly cleansed. On the other hand, Staphylococcus and Streptococcus pyogenes and the pneumococcus are of frequent occurrence in the mouths especially of those who live in towns and crowded dwellings.

The tubercle bacillus may be present in the mouth as well as in the nose of those who care for uncleanly consumptives. The fungus of aphthæ (soor), and leptothrix, which under usual conditions are not harmful, may incite serious local disease.

The so-called Mycosis pharyngis is apparently due to the growth in susceptible persons of a form of leptothrix not yet thoroughly studied, on account of the technical difficulties in the way of its artificial cultivation[1] (see page 284).

## THE PHARYNX AND THE ŒSOPHAGUS.

### MALFORMATIONS.

When, as not infrequently occurs, the embryonal gill clefts do not properly close, fistulæ may remain. These may in rare cases be complete, so that an opening exists from the pharynx, larynx, or trachea to the side of the neck. More frequently, however, these fistulæ are incomplete and shallow, and open either inward into one of the above-named organs or outward on to the neck. Small portions of the gill clefts may persist without external openings, and from these subcutaneous cysts of the neck are often developed. Or a por-

[1] For the results of systematic studies on the bacteria of the mouth consult the works of *Miller* and of *David*. For bibliography and studies on micro-organism associated with acute angina see *Stoos*, Mitth. a. d. klin. med. Inst. der Schweiz, 3. Reihe, Heft 1, 1896, and for membranous rhinitis, *Abbott*, Medical News, May 13th, 1893; for ozœna, *Abel*, Zeits. f. Hygiene und Infectkr., Bd. xxi., p 89.

tion of the cleft may be cut off, forming a cyst, while the fistula persists with its external opening.

The walls of these fistulæ and cysts may be covered with mucous membrane having cylindrical or flattened or ciliated surface cells.

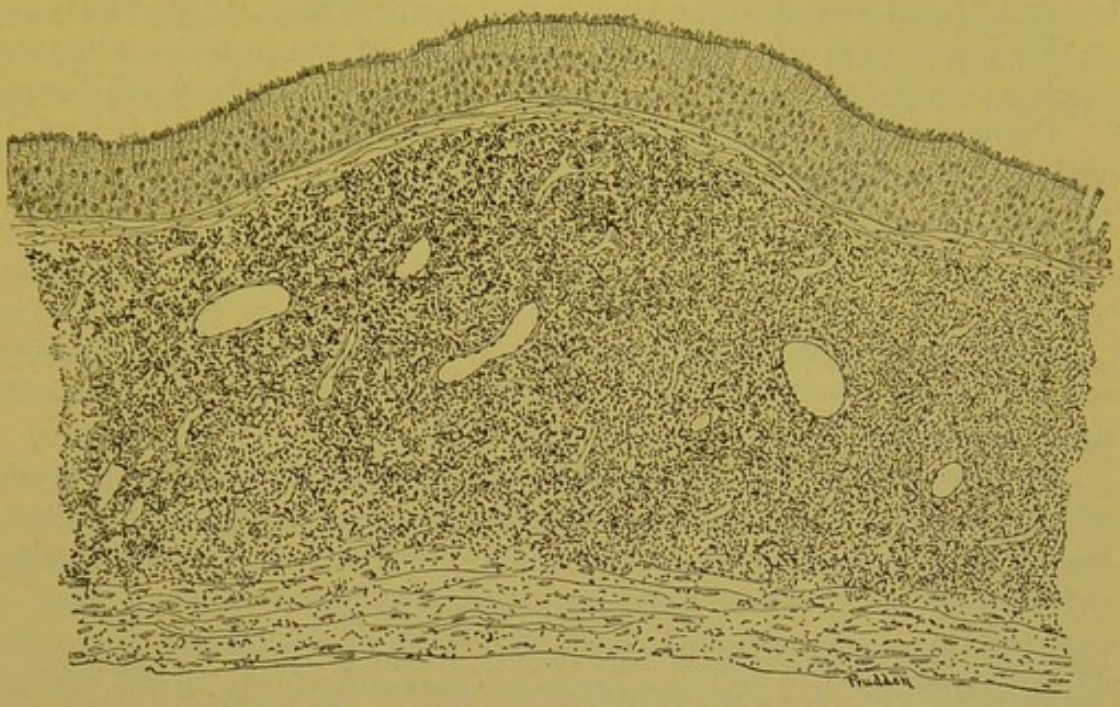

FIG. 265.—SECTION OF THE WALL OF A CYST OF THE NECK.
Formed from imperfect closure of embryonal gill cleft—diffuse lymphatic tissue.

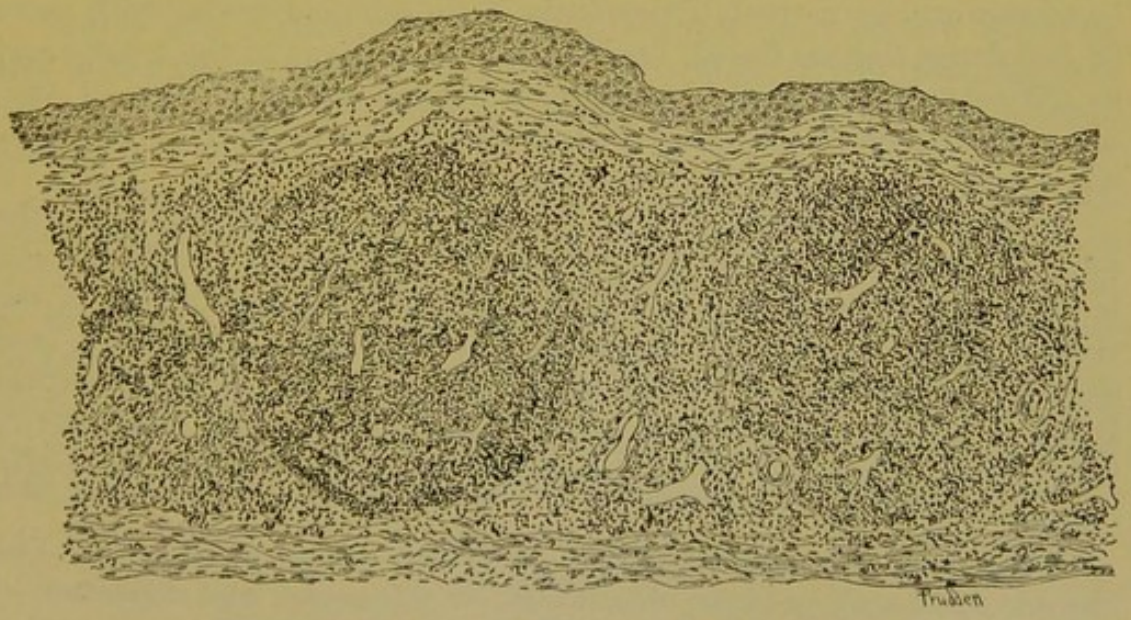

FIG. 266.—SECTION OF THE WALL OF A CYST OF THE NECK.
Formed from imperfect closure of embryonal gill cleft—nodules of lymphatic tissue.

Or, when formed from the outer gill clefts, they may be lined with skin.[1]

[1] *Schmidt*, Virch. Arch., Bd. cxliii., p. 369. Literature of amyloid tumors in general.

Not infrequently the walls of these cysts and fistulæ are embedded in lymphatic tissue, which may be diffuse or gathered in nodular form (see Figs. 265 and 266).

The œsophagus may be entirely absent, or its lower portion may be present and joined to the pharynx by a solid cord; or the pharynx, or the lower part of the œsophagus, may be continuous with the trachea; or the entire œsophagus may be represented by a solid cord.

Diverticula of the pharynx, dilatations of the œsophagus, and division of the middle portion of the œsophagus into two branches have all been observed.

### INFLAMMATION.

*Catarrhal and Croupous Pharyngitis* are usually associated with the same forms of inflammation in the mouth and have the same characters.

In catarrhal inflammation involving the tonsils and those portions of the pharynx richly supplied with the so-called submucous adenoid tissue,[1] leucocytes may penetrate in considerable numbers the peculiar thin epithelium.[2] These may, on exposed surfaces, form a part of the exudate and be removed; or in the crypts of the tonsils they may, with epithelium and various forms of bacteria, form those whitish plugs characteristic of follicular tonsillitis.

In chronic inflammation of the tonsils and pharynx there may be a large and permanent hyperplasia of the adenoid tissue, with more or less dense fibrous tissue, leading to enlargement of the tonsils and to diffuse or circumscribed nodular or pedunculated masses of vascular new tissue in the vault or elsewhere in the pharynx. The tonsils, on the other hand, may atrophy.

*Submucous Pharyngitis* may occur with inflammations of the mucous membrane, with caries of the cervical vertebræ, with inflammation of the cervical and parotid glands, with periostitis of the cranial bones, or may be idiopathic. It may result in swelling and œdema, in induration, or in suppuration. It is most important when it affects the posterior wall of the pharynx and forms retro-pharyngeal abscesses. Such abscesses may cause death by suffocation.

*Catarrhal Œsophagitis* may be either acute or chronic. The chronic form may produce ulceration, or relaxation and dilatation of the walls, or hypertrophy of the muscular coat.

---

[1] Consult *Dobrowolski*, "Lymph Nodules of the Larynx, Œsophagus, etc.," Ziegler's Beiträge z. path. Anat., Bd. xvi., p. 43.

[2] See *Hodenpyl*, "Anatomy and Physiology of the Faucial Tonsils," Am. Jour. Med. Sciences, March, 1891.

*Croupous Œsophagitis* is found with croup of the pharynx, and after the exanthemata and other severe diseases.

Irritating and caustic acids and alkalies destroy larger or smaller portions of the mucous membrane. The necrosed portions are of a black or whitish color, surrounded by a zone of intense congestion. If the patient recover the patches of membrane which have been destroyed slough, fall off, and leave a granulating surface. In this way dangerous stenosis of the œsophagus may be produced.

Foreign bodies which are swallowed and become fixed in the œsophagus cause inflammation of the mucous membrane and of the adjoining soft parts. The inflammation may go on to produce abscesses around the œsophagus, or to destroy the wall of the canal, and the foreign body finds its way into the trachea, aorta, or pericardium.

Inflammation of the submucous tissue of the œsophagus, apart from the cases just mentioned, is not common. It may cause the formation of abscesses, or of fibrous tissue, which may produce stenosis.

### ULCERATION.

Ulceration of the pharynx occurs in rare cases as the result of catarrhal inflammation. More frequently it is produced by syphilis, either in the form of superficial ulcers or of deep and extensive destructions of tissue from the softening of gummy tumors.

Lupus also sometimes attacks the upper part of the pharynx and produces extensive ulceration. Ulceration of the œsophagus is not common, but a few cases of simple perforating ulcers have been described.[1]

Foreign bodies in the œsophagus may perforate its wall, as already mentioned. Perforation of the œsophagus from without may be produced by inflamed bronchial glands, by cavities and gangrene of the lungs, by abscesses in the mediastinum, by abscesses accompanying caries of the vertebræ, and by aneurisms of the aorta. Cases have been described of rupture of the wall of the œsophagus by violent coughing and vomiting, but it seems probable that there was really some previous disease to account for the rupture.

### DILATATION.[2]

Simple cylindrical dilatation of the œsophagus is usually the result of long-continued stenosis of the œsophagus or of the cardiac end of the stomach, although not nearly all the stenoses are followed by dilatation. These dilatations are formed at first immedi-

[1] *Graefe u. Walther*, Jour. für Chir. und Augenheilk., Bd. xix. Med. Chir. Trans., vol. xxxvi. *Rokitansky*, "Path. Anat."

[2] *Ziemssen*, "Cyclopædia of Medicine," viii., p. 47.

ately above the stenosis and then extend upward. Only in rare cases does the dilatation involve the whole length of the tube. The entire wall of the dilated portion of the œsophagus is thickened, and there may be polypoid growths from the mucous membrane.

In rare cases there is cylindrical dilatation of part or of the whole of the œsophagus without a stenosis or any discoverable cause. In these cases the dilatation is usually greatest near the middle of the œsophagus and diminishes upward and downward, so that the œsophagus has a fusiform shape. The dilatation may reach a very considerable degree, the walls of the œsophagus are thickened, its mucous membrane may be covered with papillary outgrowths or ulcerated.

*The Sacculated Dilatations* of the œsophagus are of two kinds : those due to pressure, and those due to traction.

The dilatations due to pressure are situated in the posterior wall of the pharynx, just at its junction with the œsophagus. The smaller sacs are from the size of a pea to that of a hazelnut; the larger sacs may reach an enormous size and hang down between the œsophagus and the vertebral column, the opening into the œsophagus remaining comparatively small. It is supposed that a limited area of the wall of the œsophagus loses its power of resistance against the pressure exercised upon it in each act of swallowing ; it then is forced outward by the pressure, and so there is formed first a protrusion and then a sac. When a sac is formed the food enters it, accumulates there, and so the sac becomes larger and larger.

The dilatations due to traction are situated on the anterior wall of the œsophagus, at a point nearly corresponding to the bifurcation of the trachea. They are of funnel shape, with the small end outward. Their length varies from two to twelve millimetres ; the width of the opening into the œsophagus is from six to eight millimetres.

These dilatations are due to inflammation of the parts adjoining the œsophagus, especially of the bronchial glands, followed by adhesions to some part of the anterior wall of the œsophagus. These adhesions then contract and draw the wall of the œsophagus outward, and in this way the dilatations are formed.

At a later time these sacs may perforate into the bronchi, the lungs, the pleural cavity, the pericardium, the aorta or pulmonary artery.

### STENOSIS.

*Congenital Stenosis.*—Besides the defects of development of the œsophagus which are incompatible with life, there may be a congenital stenosis of some part of it which causes difficulty in swallowing, but yet does not destroy life.

*Stenosis by Compression* is not uncommon. Tumors of the

neck and mediastinum, and aneurisms of the aorta are the usual causes.

*Stenosis by Obstruction.*—Foreign bodies may be lodged in the œsophagus. Tumors may hang down from the pharynx into the œsophagus, or may be situated in the wall of the œsophagus. Inflammation of the œsophagus, due to the ingestion of irritating poisons, produces cicatricial stenoses. A few cases of stenosis due to syphilitic inflammation have been reported.

### TUMORS.

*The veins* of the œsophagus may be enormously dilated. They may rupture and so give rise to hæmorrhage.[1]

*Cysts.*—Small retention cysts of the follicles of the mucous membrane are sometimes found. Larger cysts of the œsophagus lined with ciliated epithelium have been described.[2]

*Papillomata* of small size may be found in considerable numbers throughout the entire length of the œsophagus, or may occur singly. Large papillary tumors are more rare.

*Fibromata* grow from the periosteum of the bones at the base of the skull, and project into the cavity of the pharynx and posterior nares in the form of large polypoid tumors. Small fibrous tumors are formed in the submucous connective tissue of the œsophagus. Tumors, which attain a very large size, originate in the submucous connective tissue on the anterior wall of the lower part of the pharynx, and as they grow hang down into the œsophagus. Soft polypoid tumors consisting largely of loose succulent connective tissue and lymphatic tissue are often called "adenoid polyps" (see Fig. 267). Hairy polyps of the pharynx have been described by Arnold[3] and others. The occurrence of cartilage and bone in the tonsil has been described by Stoeltzner.[4]

*Lipomata* of small size are sometimes found in the walls of the œsophagus.

*Myomata* composed of smooth muscle may grow in the muscular coat of the œsophagus and attain a considerable size.[5]

*Adenoma.*—A polypoid adenoma composed of tubules lined with cylindrical epithelium, and growing from the anterior wall of the œsophagus, has been described by Weigert.[6]

---

[1] *Bristowe*, Trans. London Path. Soc., 1856.

[2] *Zahn*, Virch. Arch., Bd. cxliii., p. 171.

[3] *Arnold*, Virch. Arch., Bd. cxi., p. 176. Bibliography.

[4] *Stoeltzner*, Virch. Arch., Bd. cxli., p. 446.

[5] Virch. Arch., Bd. xliii., p. 137. Med. Times and Gazette, November 28th, 1874. Glasgow Med. Journal, February, 1873.

[6] Virch Arch., Bd. lxvii., p. 516.

I (Delafield) have seen one tumor, the size of a chestnut, growing in the soft palate, which was composed of a stroma of connective and mucous tissue in which were irregular, anastomosing tubules filled with small, polygonal, nucleated cells. It should be called an adenoma or a carcinoma.

Another composite tumor grew from the mucous membrane of the pharynx behind the left tonsil. It filled the pharynx below the level

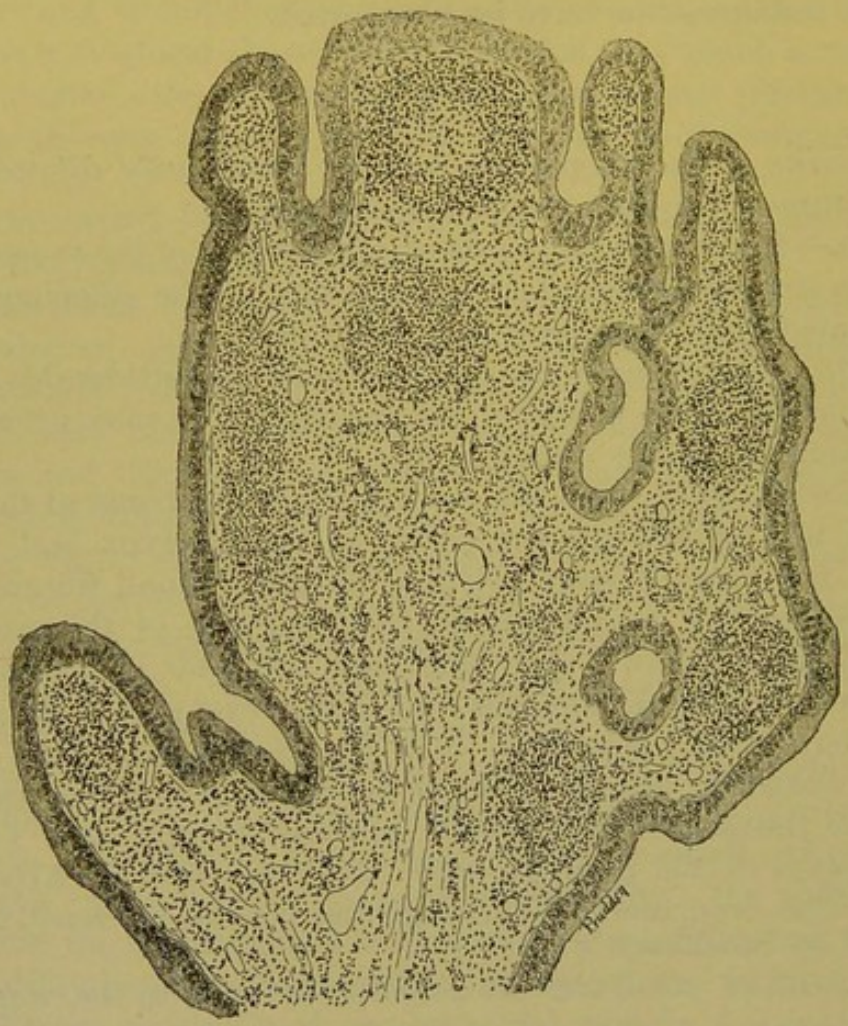

FIG. 267.—ADENOID POLYP OF PHARYNX.

of the palate. It had the gross appearance of a myxo-sarcoma, the central portions being very soft. It was composed of connective tissue, mucous tissue, fat, sarcomatous tissue, and irregular tubules lined with small, polygonal, epithelial cells. Some of the tubules were distended with masses of hyalin matter. The whole structure resembled that of the tumors so often found in the parotid region—tumors which can be called "adenoid myxo-sarcomata."

*Carcinomata* may originate at any part of the wall of the pharynx and œsophagus. They are composed of flat epithelial cells closely packed together in masses in the usual way. In the œso-

phagus the new growth begins in the deeper layers of the mucous membrane, and grows so as to encircle the tube for a length of one or more inches. The tumor remains as a flat infiltration, or it ulcerates, or it projects inward in large, fungous masses. The growth may extend up and down the œsophagus, and even involve the pharynx or stomach.

The ulcerative process may extend outward so as to produce perforation into the air passages, the lungs, pleuræ, pericardium, and large blood vessels.

The new growth may extend outward and infiltrate the surround-

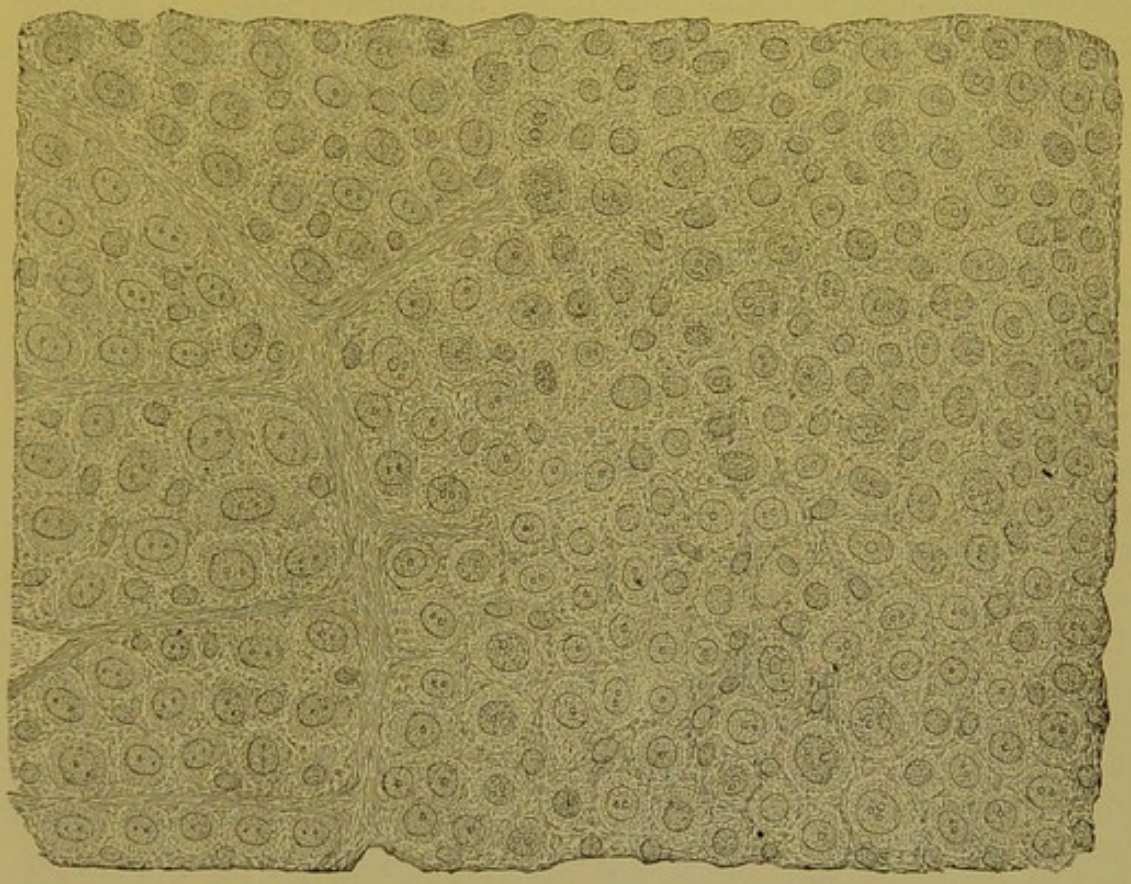

Fig. 268.—Diffuse Sarcoma of the Pharynx, × 850 and reduced.

ing soft parts, so that the œsophagus is surrounded by large, solid, cancerous masses. Metastatic tumors are also sometimes formed.

*Sarcoma.*—I have seen one case in which there was a diffuse growth involving both the tonsils, the posterior and lateral walls of the pharynx, the base of the tongue, and the epiglottis. The new growth replaced the mucous membrane, infiltrated the soft parts for a short distance, and projected inward in polypoid masses. It was composed of small, polygonal, nucleated cells contained in a very delicate nucleated stroma[1] (Fig. 268).

[1] For literature of malignant disease of the tonsils, consult *Newman*, American Journal of the Medical Sciences, May, 1892. *Housell*, Beitr. zur klin. Chirurgie, Bd. xiv.

## THE STOMACH.

### MALFORMATIONS.

Malformations of the stomach are not common. The organ may be entirely wanting in acephalous fœtuses. It may be of various degrees of smallness, sometimes no larger than the duodenum. It may be divided into two halves by a deep constriction in the middle. The pyloric orifice may be stenosed or entirely closed. The stomach may be outside of the abdominal cavity from a hernial protrusion through the diaphragm or at some point in the abdominal wall. It is found on the right side, instead of the left, when the other viscera are transposed, and the position of the cardiac and pyloric orifices is correspondingly inverted.

### POST-MORTEM CHANGES.

In adults the stomach after death is of a grayish or pinkish color, sometimes mottled with red ecchymoses. The mucous membrane is soft and the epithelium easily brushed off. At the fundus the food is usually found collected, and here the mucous membrane is the softest. It is very common to find the epithelium removed from the entire fundus of the stomach, so that all that portion of its wall is grayer and thinner, there being a sharp dividing line between the two portions. Sometimes this post-mortem softening process goes on to destroy all the coats of the stomach, and even the adjoining portion of the diaphragm. In this way the contents of the stomach may be emptied into the pleural cavity by a large, ragged opening in the stomach and diaphragm. When the softening affects all the coats of the stomach the softened portion is not sharply limited. The entire thickness of the affected portion of the wall is converted into a gray or yellow semi-transparent jelly, or into a blackish, broken-down pulp.

This softening is most frequent in children, but also occurs in adults, usually in connection with severe and exhausting diseases.

### INJURIES.

Perforating wounds of the stomach usually give rise to a fatal peritonitis. It is possible, however, for the wound to heal, or a gastric fistula may be formed.

Rupture of the stomach may be produced by severe blows or falls.

### HÆMORRHAGE.

Small extravasations of blood in the wall of the stomach are frequently found in persons who have died from one of the infectious diseases.

Hæmorrhage into the cavity of the stomach may be produced in a variety of ways.

In ulcers of the stomach there may be bleeding from the small vessels of the ulcer or from the perforation of a larger artery.

In cancer of the stomach there may be bleeding from the tumor.

Some cases of chronic gastritis are characterized by general bleeding from the mucous membranes of the stomach.

Cirrhosis of the liver is not infrequently attended with large hæmorrhages from the mucous membrane of the stomach.

Small aneurisms of the arteries in the wall of the stomach may rupture internally.

In yellow fever and some of the other infectious diseases there is hæmorrhage into the cavity of the stomach.

Patients may vomit blood during life, and after death no lesion to account for the bleeding be found.

## INFLAMMATION.

*Acute Catarrhal Gastritis*, as we see it after death, is usually due to the ingestion of irritating substances, or forms part of the lesions of cholera morbus. If we can judge from clinical symptoms, it occurs during life as a temporary condition from a variety of causes.

After death the mucous membrane is found congested and swollen, or the congestion may have disappeared. The mucous membrane is coated with an increased amount of mucus, especially at the pyloric end of the stomach. Sometimes there are a number of minute white dots in the substance of the mucous membrane.

The structural changes in the mucous membrane consist simply in a swelling of the cells of the gastric tubules, a slight infiltration of the stroma with pus cells, and a swelling of the patches of lymphatic cells. The little white dots, when they are present, are composed of small foci of pus between the gastric tubules, with degeneration and destruction of some of the tubules.

*Chronic Catarrhal Gastritis* is a very common disease. There is, however, no very close relation between the severity of the symptoms during life and the extent of the lesions found after death.

In some cases chronic alcoholism, or the abuse of drugs, or the mode of life of the patient seems to be the cause of the lesion. Chronic phthisis, chronic Bright's disease, cirrhosis of the liver, and fatty liver are often accompanied by chronic gastritis. Organic disease of the heart, or pressure on the ascending vena cava, produces a form of chronic gastritis characterized by intense general congestion.

After death the stomach is found either empty or still containing food. It is of normal size, or dilated, or small, sometimes hardly larger than the duodenum. Its inner surface is coated with a thick

layer of tenacious mucus, most abundant at its pyloric end. The mucous membrane is congested, or white, or slate-colored, or mottled with small white spots. It is of normal thickness, or thinned, or thickened, or there are little polypoid projections from its surface, or there is cystic dilatation of the gastric tubules (Fig. 269). The connective tissue and muscular coats remain unchanged, or they are

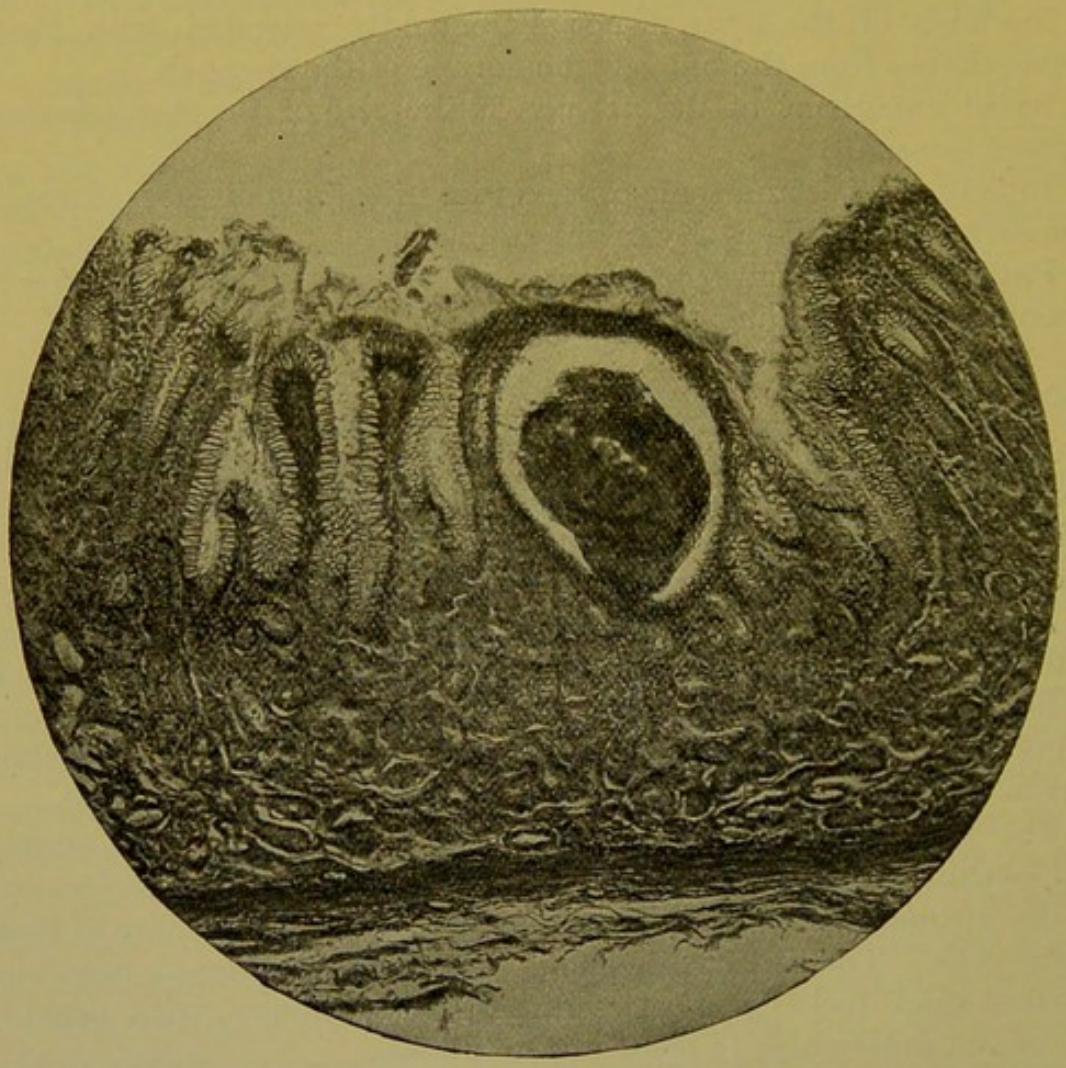

FIG. 269.—CHRONIC GASTRITIS.
Showing changes in the glandular coat. A small cyst formed by dilatation of a tubule.

thinned and relaxed, or they are hypertrophied. The hypertrophy may be diffuse, or it is confined to the pyloric end of the stomach and may then produce stenosis of the pylorus.

The minute lesions consist principally in changes in the mucous membrane. The cells of the gastric tubules are swollen, degenerated, and broken down. The tubules are atrophied and deformed, or dilated into cysts. The patches of lymphatic tissue about the blind

ends of the tubules are increased in size. The connective tissue between the tubules is infiltrated with cells and increased in quantity.

*Croupous Gastritis* is of rare occurrence. It is found in children with croupous inflammation of the pharynx and œsophagus, and is then usually in small patches. In adults it is almost always secondary to typhus, pyæmia, puerperal fever, cholera, dysentery, the exanthemata, and irritating poisons. The false membrane is in small patches, or may line a large part of the stomach. The disease is usually not diagnosticated during life, the symptoms of the primary disease diverting attention from the gastritis.

I (Delafield) have seen one case of idiopathic croupous gastritis in an adult. A man, forty-six years old, was in good health until eight days before his death. At that time he caught cold, had pains over his bowels, tenderness over the liver, constipation, cough with mucous expectoration, temperature 102½°, pulse 120. On the day of his death, the eighth day of the disease, the temperature was 100°, pulse 112, tongue dry, abdomen tympanitic and tender, and he died in a prolonged attack of syncope. At the autopsy all the viscera were examined. Excepting evidences of bronchitis in the lungs, there were no lesions save in the stomach. About two-thirds of the internal surface of the stomach, including the lesser curvature and anterior and posterior walls, appeared to be covered with a thick false membrane, which did not quite reach to the cardiac or pyloric orifices. Minute examination showed that there was a layer of exudation on the internal surface of the mucous membrane. This exudation consisted of fibrillated fibrin and lymphoid cells dipping into the mouths of the follicles. Beneath the exudation the mucous membrane was thickened and altered. A large number of lymphoid cells separated the follicles, and even replaced them entirely. The submucous layer was very much thickened by the presence of lymphoid cells, fibrillated fibrin, and fibrous tissue. The muscular coat was separated into layers by groups of lymphoid cells.

Wilks and Moxon mention a similar case in a man with chronic Bright's disease, and a case of both croupous gastritis and colitis with abscess of liver.

*Suppurative or Phlegmonous Gastritis.*—A formation of circumscribed collections of pus may occur in the connective-tissue coat of the stomach, as it does in other parts of the body, in puerperal fever and the infectious diseases.

Idiopathic suppurative gastritis is a disease of rare occurrence. Leube [1] has collected thirty-one cases, of which twenty-six were males and five females. In some of the cases the inflammation was

[1] *Leube*, "Ziemssen's Cyclopædia," vii., p. 157.

ascribed to the excessive use of alcohol, in others to a wound in the region of the stomach, in others to some error in diet.

Fagge[1] describes a case in a male of fifty-one years of age, without discoverable cause.

Silcock[2] describes a case in which the gastritis followed the operation of gastrostomy.

I have seen one case occurring in an adult male, without any known cause.

The suppurative inflammation seems to begin in the connective-tissue coat of the stomach. From thence it may extend to the glandular coat and produce perforations, or outward to the muscular and peritoneal coats. In some cases there is added a local or general peritonitis.

The inflammation may involve one or more circumscribed areas and so produce abscesses, or it may be a diffuse process involving the whole extent of the wall of the stomach.

*Toxic Gastritis.*—The mineral acids, the caustic alkalies, arsenic, corrosive sublimate, and the metallic salts, phosphorus, camphor, and all other irritating materials, cause different lesions of the stomach, according to their quantity, their strength, and the length of time that has elapsed before death.

In large quantities they destroy and convert into a soft, blackened mass both the mucous membrane and the other coats, so that perforation may take place. In smaller quantities they produce black or white sloughs of the mucous membrane, surrounded by a zone of intense congestion. If death does not soon ensue the ulcerative and cicatricial processes which follow such sloughs may contract and deform the stomach in various ways.

If the poisons are of less strength they produce a diffused congestion of the mucous membrane, with catarrhal or croupous exudation on its surface and serous infiltration of the submucous coat (see chapter on Poisons).

## ULCERS OF THE STOMACH.

*The Chronic Perforating Ulcer.*—This form of ulcer is often seen; according to Brinton, in five per cent of persons dying from all causes. It occurs in females nearly twice as frequently as in males. As regards the age, Brinton concludes that the liability of an individual to become the subject of gastric ulcer gradually rises,

[1] Trans. Lond. Path. Soc., 1875, p. 81.

[2] Ibid., 1883, p. 90.

from what is nearly a zero at the age of ten, to a high rate, which it maintains through the period of middle life; at the end of which period it again ascends, to reach its maximum at the extreme age of ninety. Lebert gives one hundred and ninety-eight cases in which the ulcers were found at the autopsy, as follows:

| AGE. | NUMBER OF CASES. | AGE. | NUMBER OF CASES. |
|---|---|---|---|
| 15 to 20 years | 20 | 50 to 60 years | 29 |
| 20 to 30 years | 48 | 60 to 70 years | 19 |
| 30 to 40 years | 28 | 70 to 80 years | 5 |
| 40 to 50 years | 43 | | |

Hauser[1] gives thirty autopsies from Erlangen of ulcers which were still open, as follows:

| AGE. | NUMBER OF CASES. | AGE. | NUMBER OF CASES. |
|---|---|---|---|
| 20 to 30 years | 3 | 50 to 60 years | 7 |
| 30 to 40 years | 3 | 60 to 70 years | 8 |
| 40 to 50 years | 3 | 70 to 80 years | 6 |

Moore[2] gives the following table of the fatal cases of ulcer of the stomach occurring at St. Bartholomew's Hospital from 1867 to 1879:

| SEX. | AGE. | POSITION. | CAUSE OF DEATH. |
|---|---|---|---|
| M. | 36 | Near pylorus | Perforation. |
| M. | 19 | Greater curve near pylorus | Hæmorrhage. |
| M. | 47 | Near pylorus | Exhaustion. |
| M. | 47 | Pylorus | Phthisis. |
| M. | 41 | " | " |
| M. | 52 | " | Exhaustion. |
| M. | 46 | Lesser curve near pylorus | Perforation. |
| F. | 47 | | Sinus in liver to lung. |
| M. | 57 | Cardiac end | Hæmorrhage. |
| M. | 19 | Near pylorus | Perforation. |
| M. | 40 | " | " |
| F. | 46 | Posterior wall | " |

Goodhardt[3] describes an ulcer of the stomach, which proved fatal, from hæmorrhage in an infant at birth.

The situation of these ulcers, according to Brinton, is as follows: In 43 per cent, the posterior surface; in 27, the lesser curvature; in 16, the pyloric extremity; in 6, both the anterior and posterior surfaces; in 5, the anterior surface only; in 2, the greater curvature; in 2, the cardiac pouch. Thus about 86 ulcers in every 100 occupy the posterior surface, the lesser curvature, and the pyloric sac.

The analysis of 793 hospital cases by Welch shows that the ulcers

[1] "Das chron. Magengesch.," 1883. [2] Trans. Lond. Path. Soc., 1880, p. 110. Ibid., 1881, p. 79.

were on the lesser curvature in 288, in the posterior wall in 235, at the pylorus in 95, on the anterior wall in 69, at the cardia in 50, at the fundus in 29, on greater curvature in 27.

As regards the number of ulcers, two or more are present in about twenty-one per cent; there may be two, three, four, or even five ulcers. In cases of multiple ulcers the ulcers are often developed successively.

In size the ulcers vary from one-quarter of an inch to five or six inches.

They are usually of circular shape, sometimes oval; sometimes two or more are fused together.

The perforation is largest in the mucous membrane. It may remain confined to this, or extend outward and involve the connective tissue, muscular and peritoneal coats, its diameter becoming smaller as it advances. The ulcer looks like a clean hole punched out of the wall of the stomach. Its floor shows no active inflammatory changes. Its edges may be in the same condition, or they may be thickened by the growth of connective tissue and cells. The rest of the mucous membrane of the stomach is apt to be in a condition of chronic catarrhal inflammation.

The ulcer may perforate directly through the wall of the stomach, and the contents of the latter are discharged into the peritoneal cavity; or adhesions are formed between the wall of the stomach and the neighboring viscera, so that the bottom of the ulcer is closed; or if the liver, the intestines, or the abdominal wall become adherent, they may be invaded by the ulcerative process, and cavities or fistulæ are formed communicating with the stomach; or, if the adhesions are incomplete, a local peritonitis and collections of pus may be developed.

During the progress of the ulcer there may be repeated small hæmorrhages from the erosion of small blood vessels, or large hæmorrhages from the erosion of large arteries.

In many cases these ulcers cicatrize, and such a cicatrization may produce various deformities of the stomach.

It is very difficult to understand how these ulcers are produced. It seems probable that the nutrition of a circumscribed part of the wall of the stomach is interfered with, and that this portion is then destroyed by the action of the gastric juice. But we are still ignorant of the way in which the obliteration of the arteries is effected. It has, indeed, been demonstrated in animals that an artificial embolism of the branches of the gastric arteries will produce ulcers of the stomach; and in the human stomach we occasionally meet with cases of embolism of the branches of the gastric artery and ulcers. But the clinical history of most cases of ulcer of the stomach will

not correspond with such a method of causation. A chronic obliterating endarteritis would seem to be a more probable cause.

*Hæmorrhagic Erosions* occur as rounded spots or narrow streaks, formed by a loss of substance of the mucous membrane. The mucous membrane at these points is congested, soft, and covered by small blood clots. The destruction of the mucous membrane is usually superficial, but may involve its entire thickness. The number of these erosions may be so great that the entire internal surface of the stomach is studded with them. They give rise to repeated hæmorrhages, and are accompanied by catarrhal inflammation of the rest of the mucous membrane.

They occur at all periods of life, even in infants. Their usual seat is the pyloric portion of the stomach.

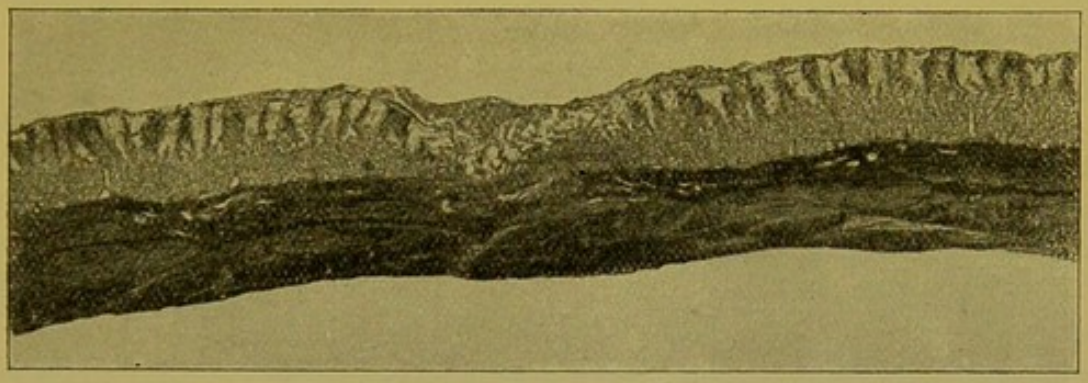

FIG. 270.—SUPERFICIAL NECROSIS OF THE MUCOUS MEMBRANE OF THE STOMACH—CHILD.

They may be idiopathic. Usually, however, they occur in connection with some serious general disease.

*Follicular Ulcers* somewhat resembling the ulcers of the small intestine are occasionally met with. They are produced by changes in the aggregations of lymphatic tissue which are situated about the blind ends of the gastric tubules.

I have seen in the stomach of a child numerous small ulcers formed by a superficial necrosis of the glandular coat. There were similar ulcers in the colon. There was no clinical history (Fig. 270).

## DILATATION.

Very considerable degrees of dilatation of the stomach are found at autopsies, without stenosis of the pylorus or any other mechanical cause to account for them. It is usually difficult to determine how long these dilatations have existed and how much effect they have in causing death. Nine such cases are recorded by Goodhardt.[1]

*Acute Dilatation* of the stomach, with vomiting of very large

[1] Trans. Lond. Path. Soc., 1883, p. 88.

quantities of thin fluid, has been observed in a few cases.[1] It is a very curious condition, the dilatation of the stomach being developed suddenly and without discoverable cause.

Of the mechanical causes which produce dilatation of the stomach, a stenosis of the pylorus is the most common. Such a stenosis may be effected by a tumor, by chronic inflammation and thickening, and by the cicatrization of ulcers. Less frequently obstructions of the small and large intestines act in the same way.

Some forms of chronic gastritis are attended with dilatation of the stomach without stenosis.

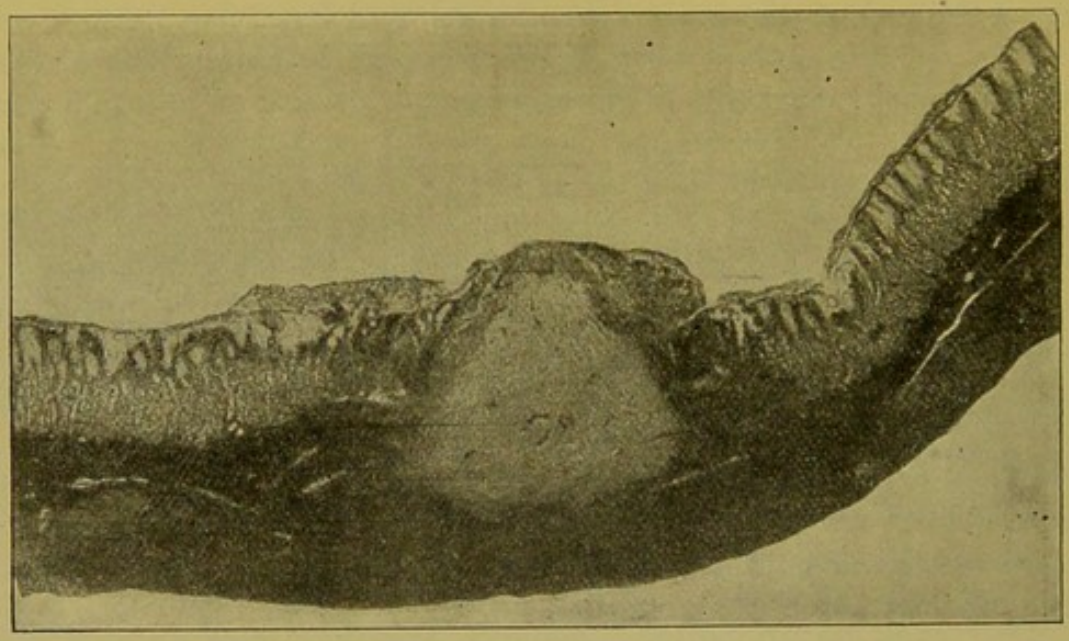

FIG. 271.—FIBROMA IN THE WALL OF THE STOMACH OF A CHILD,
There were several of these small tumors in the wall of the stomach.

In rare cases circumscribed, sacculated dilatations are produced by the presence of foreign bodies—portion of wood, metal, etc.

## TUMORS.

*Papilloma.*—It has already been mentioned that in some cases of chronic gastritis there are small, polypoid hypertrophies of the mucous membrane. Besides these we find polypoid tumors which may reach a considerable size. They are composed of a connective-tissue stroma arranged so as to form tufts covered with cylindrical epithelium. In some cases there are also tubules lined with cylindrical epithelium, so that the tumor has partly the structure of an adenoma. *Fibromata* of small size are sometimes found in the con-

[1] Ibid., vol. iv. and vol. xxxiv., p. 82. *Hughes Bennett*, "Practice of Medicine." *Fagge*, Guy's Hospital Reports, vol. xviii., p. 1. *Andral*, Clinique Médicale.

nective-tissue coat. Lipomata are formed in the submucous connective tissue in the shape of rounded or polypoid tumors. They usually project inward, but sometimes outward beneath the peritoneum. They may also appear in the form of numerous yellow nodules beneath the mucous membrane.

*Myomata* occur in the form of rounded tumors which originate in the muscular coat, but may gradually separate themselves from it and project inward or outward. The submucous myomata are at first small tumors lying loosely attached in the submucous tissue. As they grow larger they push the mucous membrane inward and take the shape of polypoid tumors. *Lymphomata* in the wall of the stomach are seen in some cases of leukæmia.

*Sarcomata* are said to occur in the wall of the stomach in rare instances. It must be admitted that in some of the tumors of the wall of the stomach, which are ordinarily called cancerous, the structure is not well defined, and it is possible that some of them are sarcomata.

A myo-sarcoma growing outward from the greater curvature of the stomach is described by Brodowski.[1] The tumor weighed twelve pounds. It was composed largely of smooth muscle cells. There was a secondary tumor in the liver.

*Adenoma.*—It has been already mentioned that in some of the papillary tumors of the mucous membrane there is a considerable growth of tubules lined with cylindrical epithelium.

Besides these we find in the submucous coat circumscribed tumors composed of tubules like those of the gastric mucous membrane.

Small tumors resembling the pancreas have also been seen in the submucous and subserous coats.

*Carcinoma* of the stomach is almost always primary. But very few secondary cases have been recorded.[2]

Primary carcinoma of the stomach is of the colloid variety, or common cancer, or cancer with cylindrical epithelial cells, or it is pigmented.

Colloid cancer is composed of a connective-tissue stroma, arranged so as to form cavities of different sizes, which contain colloid matter and polygonal cells. It infiltrates first the submucous connective tissue and then extends inward and outward. In this way there is formed a diffuse thickening of the pyloric end of the stomach rather than a circumscribed tumor. Sometimes the whole of the wall of the stomach is changed in this way. Secondary tumors are usually situated in the peritoneum.

---

[1] Virch. Arch., Bd. lxvii., p. 227.

[2] Ibid., Bd. xxxviii. and lxxxvi., p. 159. Trans. Path. Soc., London, 1876, p. 264.

Carcinoma with cylindrical epithelial cells. These tumors are formed of a connective-tissue stroma, which may contain numerous round cells, and of tubules lined with cylindrical epithelium like that of the mucous membrane of the stomach. In these tumors the new growth seems to begin in the gastric tubules. As the arrangement of the tubules is more or less regular, these tumors may be called adenomata or carcinomata (see Fig. 147).

Common cancer is formed of a connective-tissue stroma enclosing rounded and tubular spaces filled with small, polygonal, nucleated cells. In some cases this structure is well marked. In others the stroma is abundant and filled with round cells, the spaces are very small, and the epithelial cells few; it may then be difficult to distinguish between inflammatory thickening, sarcoma, and carcinoma.

Both these forms of carcinoma, common cancer and cancer with cylindrical cells, run the same course as regards their gross appearance, their situation, and their development of metastatic tumors.

About sixty per cent of these tumors are situated at the pyloric end of the stomach, on the lesser curvature or on the posterior wall. The cardiac end of the stomach, the greater curvature, or nearly the entire wall of the stomach may also be the seats of the new growth, but not as frequently.

The new growth usually follows one or other of three types.

1. There is a circumscribed, flat tumor formed in the deeper layers of the mucous membrane and pushing this membrane inward. After a time the mucous membrane over the centre of the tumor dies, the destructive process involves the tumor also, and so an ulcer with thickened edges is formed. In some cases the new growth extends laterally and outward, while the central destruction still continues; then the ulcers reach a large size, their walls and floor are thick, and peritoneal adhesions are formed over them. In other cases the ulcer perforates completely through the wall of the stomach, unless the opening is closed by adhesions to the neighboring viscera.

2. Large rounded tumors are formed, often several inches in diameter, which project into the cavity of the stomach.

3. There is a diffuse, flat infiltration of the deep layers of the mucous coat, of the connective-tissue coat, and sometimes of the muscular coat, which does not ulcerate and hardly forms a tumor. This infiltration may be confined to the pyloric end of the stomach, or may involve nearly the whole of its wall.

There is in most of the cases a good deal of chronic catarrhal inflammation of the mucous membrane.

If the pylorus is obstructed the stomach is often dilated.

The new growth may extend from the stomach to the œsophagus, but it very seldom involves the duodenum.

Metastatic tumors are very common. The liver, the lymphatic glands, and the peritoneum are the parts most frequently affected, but such metastases have been seen in nearly every part of the body.

### DEGENERATIONS.

*Calcification* of the mucous membrane of the stomach sometimes occurs as a metastatic process in connection with extensive diseases of the bones.

*Waxy Degeneration* sometimes involves the blood vessels of the mucous membrane.

### FOREIGN BODIES.

Among the various foreign bodies which by accident or design may be present in the stomach may be mentioned hairs, thread, string, etc., which having been swallowed from time to time, usually by hysterical women. These may be closely packed together into a large mass nearly filling the cavity of the stomach, to which in shape it may correspond. Such a specimen of gastric hair ball, mentioned by Osler, is in the museum of McGill University, and another, reported by Findler, is in the museum of the College of Physicians and Surgeons, New York.

## THE INTESTINES.

### MALFORMATIONS.

*Diverticula* of the intestines occur in several different ways :

1. The abdominal walls are cleft asunder at the navel. The ileum opens through this cleft by a narrow aperture in its wall. The lower portions of the ileum and the colon are small or entirely closed.

2. There is an opening in the abdominal wall as before, but there is not a direct opening into the ileum. There is a long diverticulum of the ileum, with an open end projecting into the opening in the abdominal wall.

3. The abdominal wall is closed. There is a diverticulum of the ileum, connected with the navel by a solid cord.

4. There is an unattached diverticulum of the intestine. This is much the most common form. The diverticula occur only in the lower part of the ileum. They usually spring from the convex surface of the intestine, more rarely from its attached border. In the latter case they are joined to the mesentery by a fold of peritoneum. The diverticulum forms a pouch, one to six inches long, of about the same diameter as the intestine, smallest at its free extremity.

Such diverticula do not interfere with the functions of the intestines. They sometimes form part of a hernia. Sometimes the remains

of these intestinal diverticula—called Meckel's diverticula—form soft, projecting tumors at the umbilicus in children. Microscopical examination of such tumors often shows the structure of the intestinal mucosa and muscularis. If they remain attached by a fibrous cord to the navel, this cord may be the cause of incarceration of a portion of the intestines.[1]

Cloacæ consist in the union of the rectum, bladder, and organs of generation in a common outlet.

1. *Simple Cloacæ* are : (*a*) Complete, and consist in the common opening of the urethra or ureters, the vagina, and the rectum into the closed bladder, or into a sinus opening outward which represents either the vagina or the rectum. (*b*) Incomplete. The rectum opens into the vagina, the bladder, or the urethra, while the lower part of the rectum is closed or absent.

2. *Cloacæ combined with Cleft Bladder.*—(*a*) The simple cleavage of the intestines is combined with cleft bladder. The anterior abdominal wall from the umbilicus to the symphysis, the symphysis, and the anterior wall of the bladder are absent ; the gap is filled with a membrane which represents the posterior wall of the bladder. On to this membrane open the ileum, ureters, and vagina. (*b*) The intestine is perfectly formed, but the rectum opens into a common sinus with the ureters and vagina ; or the ureters open into the cleft bladder, and the rectum and external genitals are united ; or the ureters open into the rectum, and the latter terminates normally.

3. *Cloacæ combined with Abdominal Hernia.*—There is a hernial sac containing all the abdominal viscera. At the lower end of the sac is an opening leading into a sinus in which open the lower end of the ileum, the bladder or urethra, and the ureters. The rectum is absent.

*Atresia Ani* consists in a deficient development of the colon or rectum. The entire colon may be absent ; the rectum may be absent, or represented by a solid cord ; or the upper or lower part of the colon may be absent, or separated by a solid cord.

More rarely blind terminations of the small intestines are found, and sometimes a narrowing so complete as to close the canal.

The intestines are also found abnormally shortened in various degrees. A colon of unusually large size has been described as of occasional occurrence.[2]

### INCARCERATION.

1. The most common form is that in which a portion of intestine is strangulated by a fibrous band. Such fibrous bands are produced

[1] For false intestinal diverticula, see p. 577.

[2] *Formad*, University Medical Magazine, June, 1892.

by peritonitis or the remains of fœtal growth. They pass from the intestines to the abdominal wall, or from one part of the intestines to another. The intestine becomes in some way caught under one of these bands and is compressed by it. The stricture thus produced may cause a gradual accumulation of fæces in the intestine above it, and may last for a long time before death ensues. In other cases the stricture interferes at once with the circulation of the blood ; the intestine is intensely congested, becomes gangrenous, and death takes place with the symptoms of general peritonitis.

2. A portion of intestine becomes caught in some abnormal opening in the mesentery or omentum, or in the foramen of Winslow, or between the two layers of the mesentery. We have seen a case in which twelve feet of intestine had passed through a small opening in the mesentery.

3. A coil of intestine makes half a turn at its base, so that the two sides of the loops cross at its base. In this way the lumen of the intestine is completely closed and the vessels are compressed, so that congestion, peritonitis, and gangrene result. This form of incarceration is most frequent in the ascending colon. In the small intestine it only occurs when the gut is fixed by old adhesions.

4. A portion of the intestine, with its mesentery, makes one or more complete turns on itself, closing the canal and compressing the vessels.

5. A portion of the intestine makes a half or entire turn about its longer axis. This is very rare, and only occurs in the colon.

6. The mesentery of a part of the intestine is long and loose, in consequence of a dragging down of the intestine by a hernia or by habitual constipation. The portion of intestine thus permitted to hang down is habitually filled with fæces, and by its pressure on some other part of the intestine produces an incomplete stricture.

### INTUSSUSCEPTION.

This change of position consists in the invagination of one portion of intestine in another portion. Usually this takes place in the direction of the peristaltic movements, from above downward ; more rarely in the opposite direction.

The parts are found in the following condition : There are three portions of intestine, one within the other. The inner portion is continuous with the intestines above the intussusception ; its peritoneal coat faces outward. The outer portion is continuous with the intestine below ; its peritoneal coat also faces outward. The inner portion is turned inside out, its mucous membrane is in contact with the mucous membrane of the outer portion. In rare cases the intussusception is complicated by the invagination of a second portion of

intestine in the inner tube, and even by a third intussusception into the second one. These changes occur both in the large and small intestine; most frequently the lower part of the ileum is invaginated in the colon. The invaginated portion may be from a few inches to several feet in length. The lesion is most frequently found in early childhood.

The intussusception, by the dragging and folding of the mesentery which it produces, causes an intense congestion of the parts, and even large hæmorrhages between the coats of the intestine. The congestion may induce fatal peritonitis, or gangrene of the intestine, or chronic inflammation and adhesions, and the patient lives for a considerable time with symptoms of stricture. In other cases the invaginated portion of intestine sloughs, the outer and inner portions become adherent, and the patient recovers, with or without some degree of stricture.

Besides this grave form of intussusception we often find, especially in children, one or more small invaginations not attended with congestion or inflammation. These are formed during the death agony or immediately after death.

### TRANSPOSITION.

The position of the intestines may be the opposite to that which is usually found. The transposition may affect all the abdominal viscera, or only a single viscus is transposed.

### WOUNDS—RUPTURES.

Penetrating wounds of the intestine usually prove rapidly fatal, either from shock or from peritonitis. Sometimes, however, the wound becomes closed by the formation of adhesions with the neighboring parts. Sometimes the wound in the intestines becomes adherent at the position of the wound in the abdominal wall, and an intestinal fistula is formed.

Rupture of the small intestine is not infrequently produced by severe blows on the anterior abdominal wall. It is noticeable that such blows may not produce any marks or ecchymoses of the skin. Such ruptures usually prove fatal very soon, but sometimes the patient lives several days and the edges of the rupture undergo inflammatory changes.

Strictures of the intestine are sometimes followed by rupture of the dilated intestine at some point above the stricture.

## THE SMALL INTESTINE.

### INFLAMMATION.

*Acute Catarrhal Inflammation* of the greater part of the small intestine is developed as part of the lesion of cholera morbus, and after the ingestion of irritant poisons.

Acute inflammation of the duodenum accompanies gastritis, and occurs as an idiopathic condition.

Acute inflammation of the ileum occurs as an idiopathic condition, and accompanies inflammation of the colon and of the solitary and agminated lymph nodules.

In many of these cases we infer the existence of the inflammation from the clinical symptoms.

After death the most marked lesions are the increased production of mucus and the congestion. In very severe cases the inflammation may extend to the peritoneal coat.

*Chronic Catarrhal Inflammation* of the small intestine accompanies heart disease, phthisis, emphysema, cirrhosis of the liver, and Bright's disease. The intestine is coated with an increased amount of mucus ; it is often congested ; there may be a general thickening of all its coats.

*Croupous Inflammation* is produced by irritant poisons; it is associated with croupous colitis, and it occurs as an idiopathic disease. The mucous membrane is coated with fibrin, its stroma is infiltrated with fibrin and pus, and this infiltration extends to the connective tissue, muscular and peritoneal coats.

*Suppurative Inflammation* of the submucous connective-tissue coat is said to occur in rare cases. It is usually metastatic. It takes the form of purulent foci of variable extent, which perforate either inward or outward.

### THE SOLITARY AND AGMINATED GLANDS (LYMPH NODULES).

It is not uncommon to find in healthy adults who have died from accidental causes a considerable swelling of the solitary and agminated glands (lymph nodules) of the ileum, without any reason which we can discover to account for this swelling.

Extensive burns of the skin may be followed by a very marked swelling of the solitary and agminated nodules.

In persons who have died from the infectious diseases it is not uncommon to find these nodules swollen.

In children, swelling of these nodules, often followed by softening and the formation of ulcers, accompanies many of the catarrhal inflammations of the large and small intestines.

In pulmonary phthisis we very frequently find changes in the solitary and agminated nodules of the small intestine, less frequently in the solitary nodules of the colon. The changes seem to be of the same character as those which take place in tubercular inflammation of lymphatic nodules in other parts of the body.

The nodules become swollen, their elements are multiplied, tubercle granula are formed, the central portions of the nodules become cheesy. The cheesy degeneration extends; it is followed by softening and by death of the mucous membrane over the nodules; the softened tissue is discharged into the intestine, and ulcers are formed with overhanging edges. After this the ulcer shows no tendency to heal, but, on the contrary, becomes larger, usually extending laterally so as sometimes to nearly encircle the gut. After death we find, in different patients, these ulcers in all their stages of development. They vary much as to the proportion between the tubercular and the ordinary inflammatory changes. In some the tubercle granula are numerous, in others they are few or even absent altogether. The tubercle bacilli are very constantly found in them. There is also usually a tubercular inflammation of the peritoneum over the ulcers, and sometimes of the lymphatics and nodes of the mesentery. Although these ulcers often reach a large size, it is but very seldom that they perforate into the peritoneal cavity.

*Ulcers of the Duodenum.*—A few cases have been recorded in which extensive burns of the skin have been followed within a few days by the formation of deep ulcers of the duodenum. It is still uncertain how these ulcers are produced.

Chronic perforating ulcers, resembling the chronic ulcers of the stomach, are found in the duodenum. They are associated with similar ulcers in the stomach or occur by themselves.

Some curious ulcers of the upper part of the small intestines are described by Israel.[1] There were five ulcers, from two and one-half to ten centimetres long, encircling the intestine, with irregular, granulating surfaces.

*Syphilitic ulcers* produced by changes in the solitary and agminated glands of the small intestine are sometimes found in infants.

## EMBOLI.

Emboli have been found in the superior mesenteric artery in a number of cases; in the inferior mesenteric artery they are less frequent. They produce an intense venous congestion of the entire wall of the intestine, with hæmorrhage into its cavity and its wall.

[1] Charité-Annalen, 1884, p. 707.

## THE LARGE INTESTINE.

### INFLAMMATION.

The mucous membrane of the large intestine is very frequently the seat of acute and chronic inflammatory processes. The larger number of these belong to the condition which is described clinically under the name of dysentery. The inflammation affects most fre-

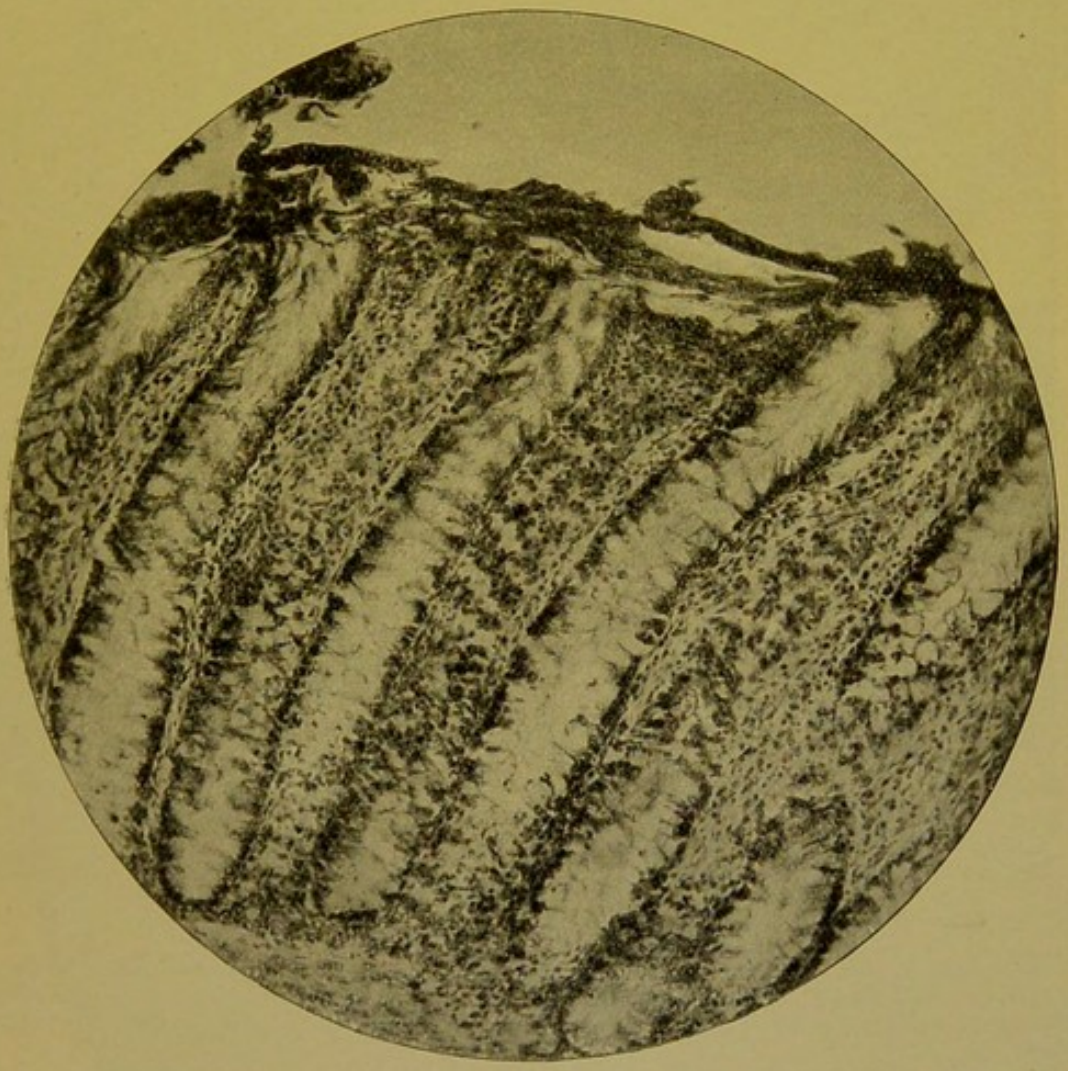

FIG. 272.—ACUTE CATARRHAL COLITIS.

With mucus on the surface of the mucous membrane, distending the tubules and filling some of the cells (beaker cells).

quently the rectum, sometimes the entire length of the colon, sometimes only the upper part of the colon.

*Acute Catarrhal Colitis.*—The lower end of the colon is the portion most frequently involved in this form of inflammation, but it may be its upper end or the entire length of the gut. The name ca-

tarrhal colitis is the only term used at the present time to designate three morbid conditions of the colon, which differ from each other both in their anatomical and clinical features.

1. The inflammation is of simple exudative type. It is usually confined to the lower end of the colon, runs its course within a week, and is not fatal. The glandular and connective-tissue coats of the colon are swollen and congested, with more or less infiltration with

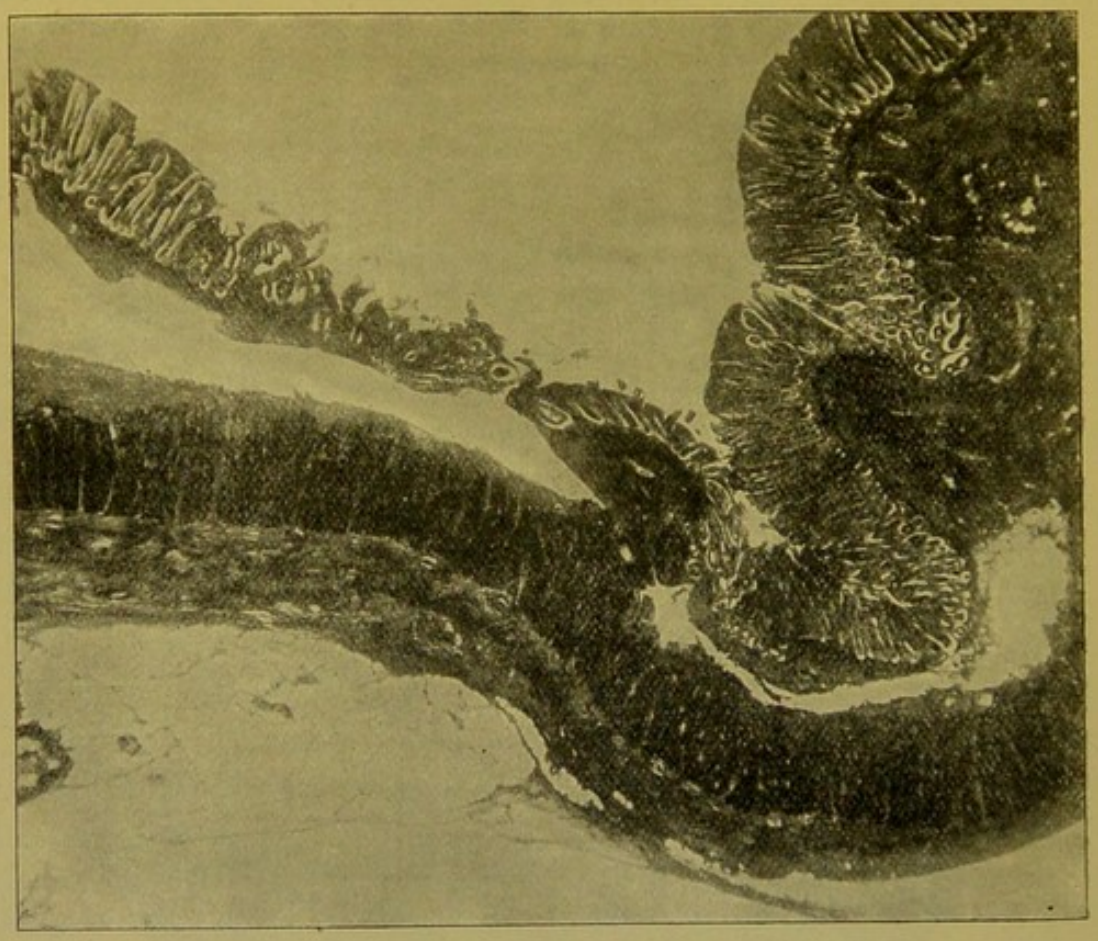

FIG. 273.—SUPPURATIVE COLITIS.

The inflammation is confined to the connective-tissue coat, causing destruction of large portions of this coat, thus undermining the glandular coat. The photograph is from a vertical section through the whole wall of the colon, and shows a separation of the glandular from the vascular coat.

serum and pus cells. There is an increased production of mucus (Fig. 272) which coats the surface of the colon and comes away with the stools in the form of membranes or cord-like shreds.[1] There may be bleeding from the surface of the inflamed mucous membrane.

[1] Numerous observations have been made and a large bibliography has been gathered on what is called *membranous enteritis* or *colitis*, for which the reader may consult *Butler*, New York Medical Journal, December 28th, 1895, or *Akerlund*, Arch. f. Verdauungs Krankheiten, Bd. i., p. 396, 1896.

2. The inflammation is of exudative type, but with an excessive production of pus cells. It may involve any part of, or the entire

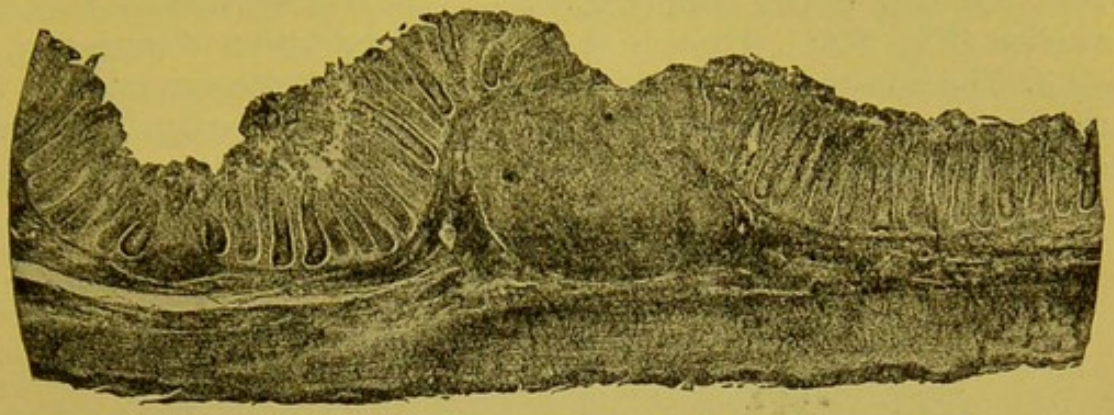

FIG. 274.—CATARRHAL COLITIS.
Showing swollen lymph nodule.

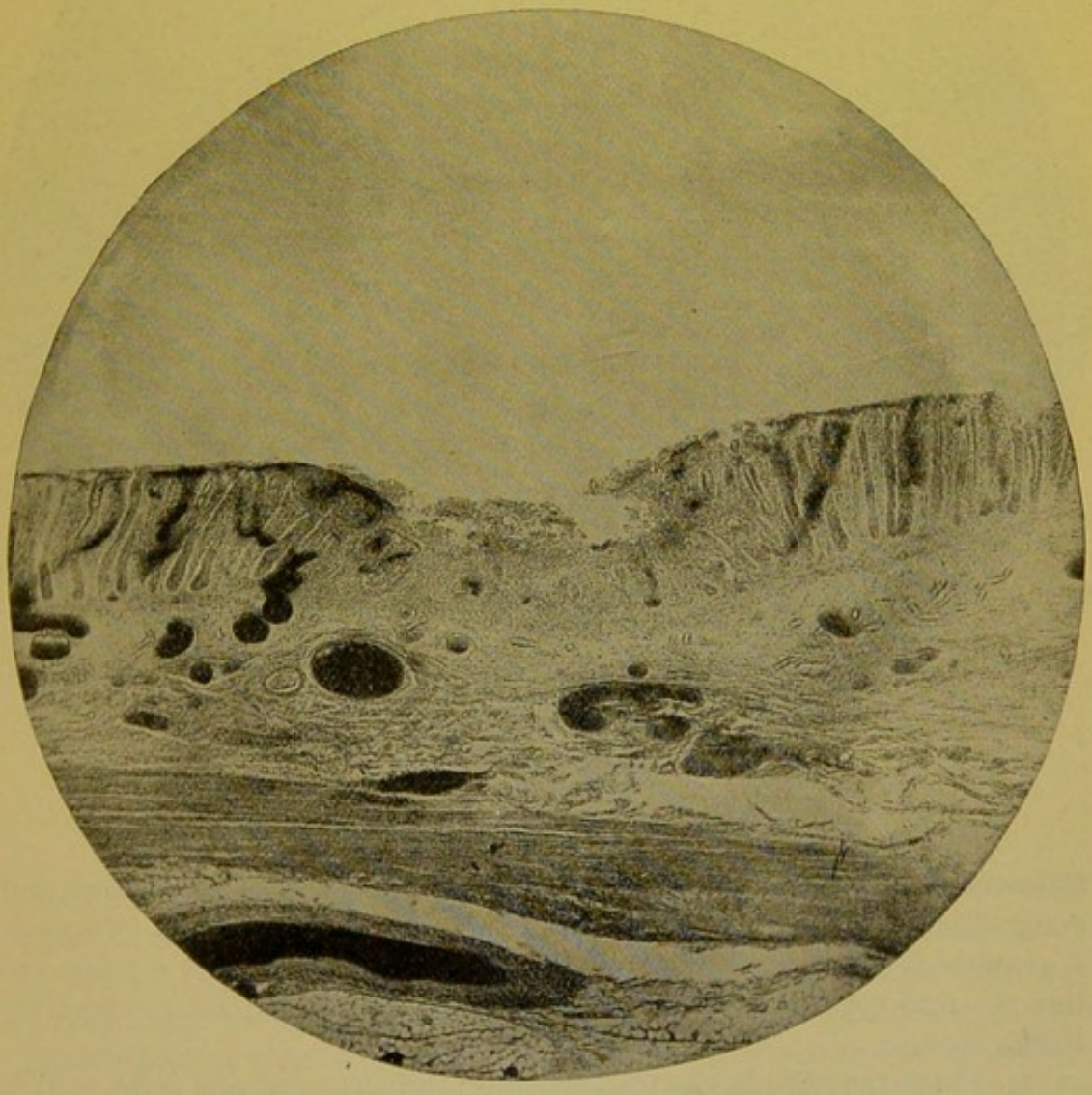

FIG. 275.—CATARRHAL COLITIS, PRODUCTIVE AND NECROTIC.

length of, the colon. It may cause death within a few days or continue for several weeks. The wall of the colon is swollen and con-

gested. The stroma between the tubules, the connective-tissue coat, and sometimes the muscular and peritoneal coat are infiltrated with large numbers of pus cells (Fig. 273). The solitary nodules may be swollen (Fig. 274). There is an increased production of mucus.

3. The inflammation is of the productive type with exudation. It may involve any part, or the entire length, of the colon. It may cause death within a few days, or continue for several weeks, or be

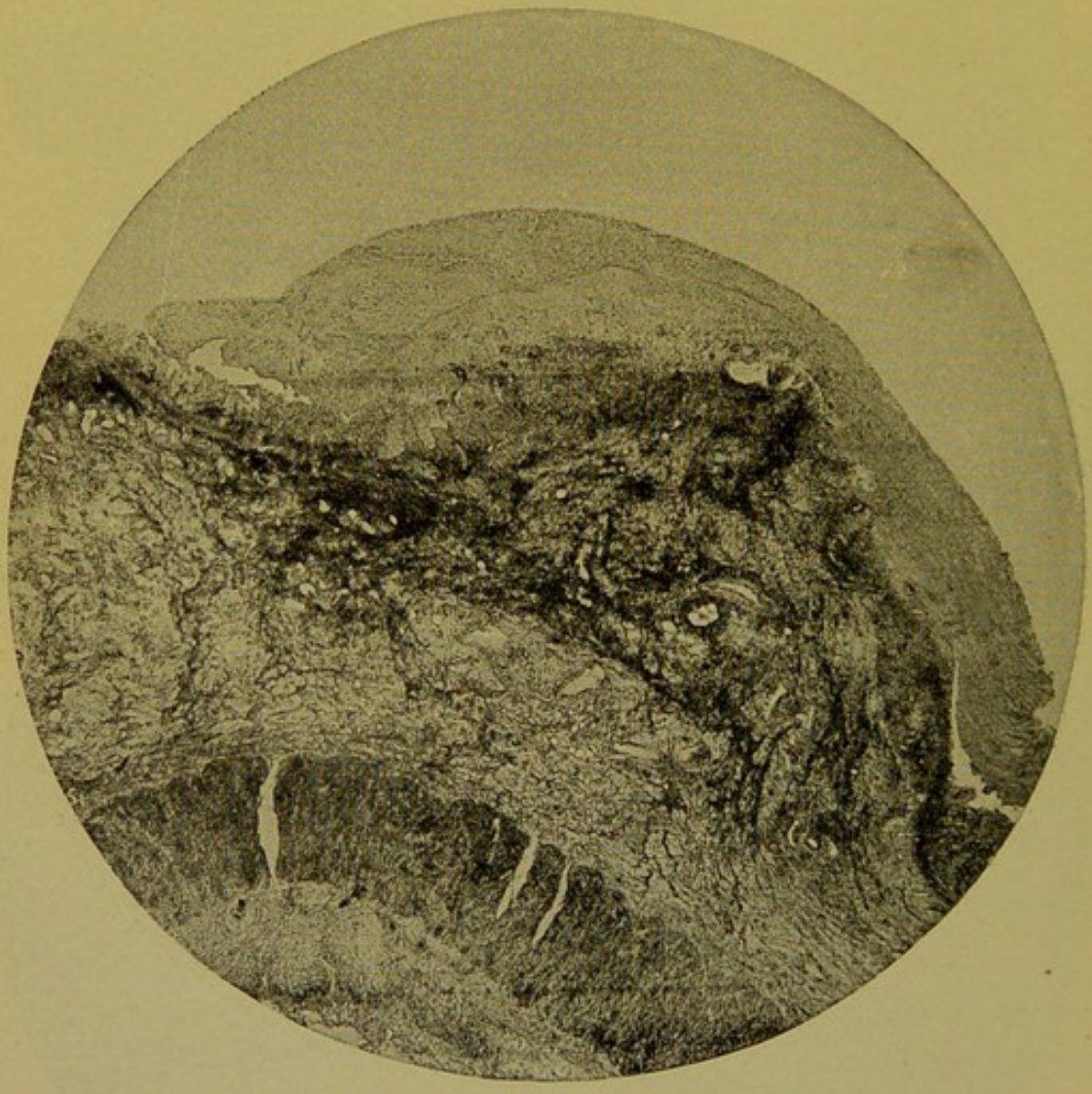

FIG. 276.—CROUPOUS COLITIS. False membrane in patches.

followed by chronic colitis. The wall of the colon is swollen and congested. There is an increased production of mucus. There is a growth of new connective tissue with an excess of cells, confined to the stroma between the tubules or also involving the connective-tissue coat.

4. There may be also a considerable production of pus cells, which are found adherent to the surface of the mucous membrane and infiltrating the glandular and connective-tissue coats. In addition we

find numerous small ulcers in the glandular coat. The ulcers are often so small that they cannot be seen with the naked eye. They seem to be formed by necrosis of small areas of the glandular coat (Fig. 275).

*Croupous Colitis.*—This form of inflammation may involve the rectum alone, or the entire length of the colon, or only its upper portion. The mucous membrane is congested and swollen, and coated

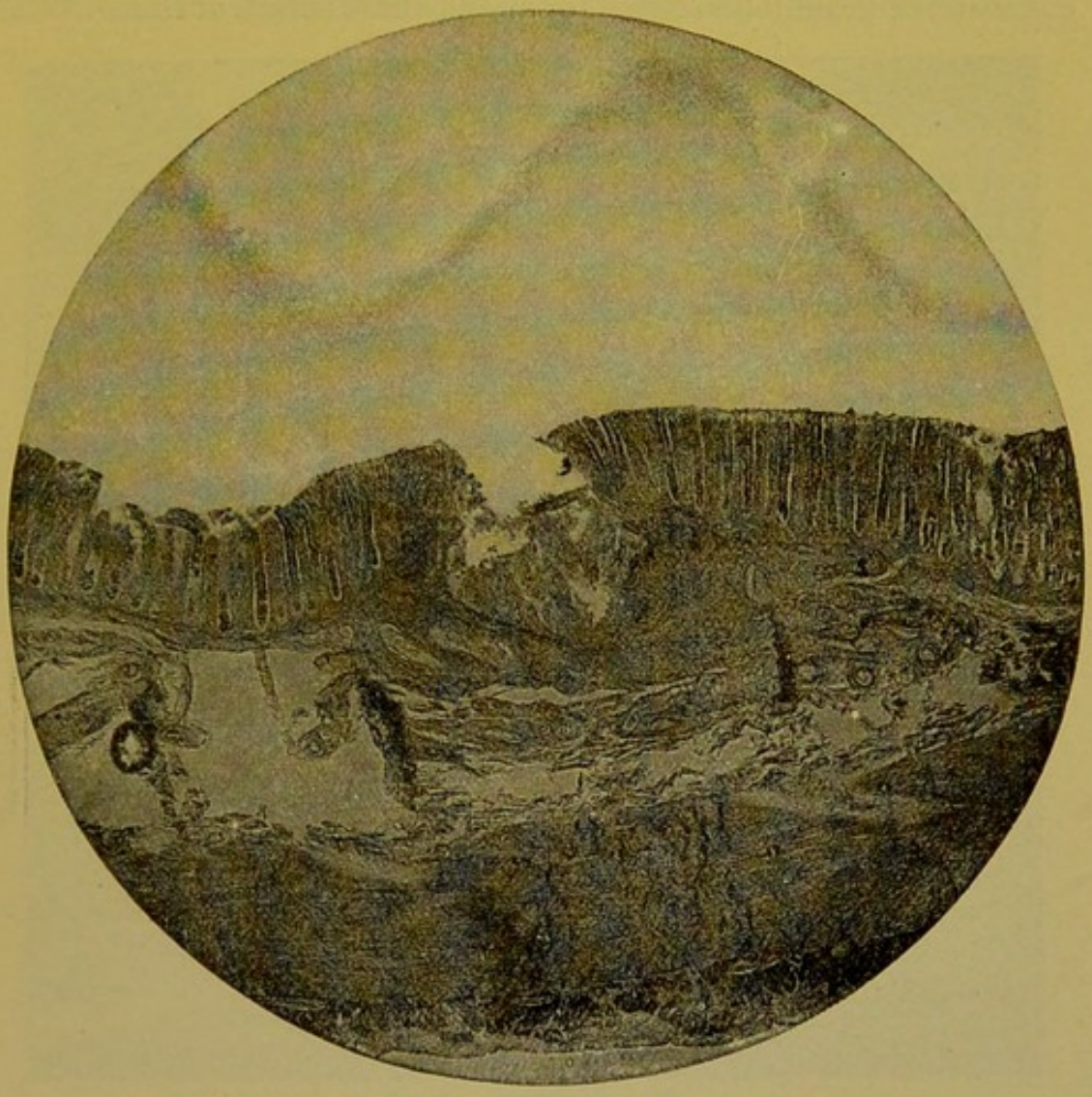

FIG. 277.—FOLLICULAR (NODULAR) COLITIS.

with a layer of false membrane; the connective tissue between and beneath the glandular tubules is infiltrated with fibrin and pus, and in severe cases the inflammation involves the muscular and peritoneal coats also. The inflammation is usually more intense at some places than at others, so that the surface of the mucous membrane shows the false membrane in isolated patches (Fig. 276). Less frequently there is a uniform coating with the false membrane. In mild cases, as the inflammation subsides, the products of inflammation are

absorbed and the wall of the intestine returns to its normal condition In more severe cases the quantity of the inflammatory products is so great that portions of the wall of the intestine become necrotic. This necrosis may involve only the glandular coat, or it may extend deeper into the wall of the intestine. The necrosed tissue after a time sloughs away, leaving behind ulcers of different sizes and depths. After this the ulcers may cicatrize, or their floors and walls may remain in the condition of granulation tissue for an indefinite length of time. When



FIG. 278.—AMŒBIC COLITIS.

Connective-tissue coat of the intestine infiltrated with new cells and with amœbæ. The larger spherical structures in the section are sections of blood vessels; the smaller darker nuclei belonging to the new-formed tissue cells; the spheroidal nucleated structures of intermediate size are the amœbæ.

the latter is the case there is added a chronic inflammation of the wall of the intestine between the ulcers, with changes in the mucous membrane and thickening of the connective-tissue and muscular coats.

*Follicular Colitis* (Nodular Colitis).—In many cases of catarrhal and croupous inflammation of the colon the solitary follicles (lymph

nodules) become more or less swollen and necrotic. Besides these cases, however, there are others in which the changes in the nodules form the principal part of the lesion, while the catarrhal or croupous inflammation is but slightly developed. The nodules are first swollen, then necrotic, then slough away and leave little circular ulcers with overhanging edges (Fig. 277). These ulcers are usually numerous and extend over a large part of the colon. The patients have diarrhœal rather than dysenteric passages. The ulcers are apt

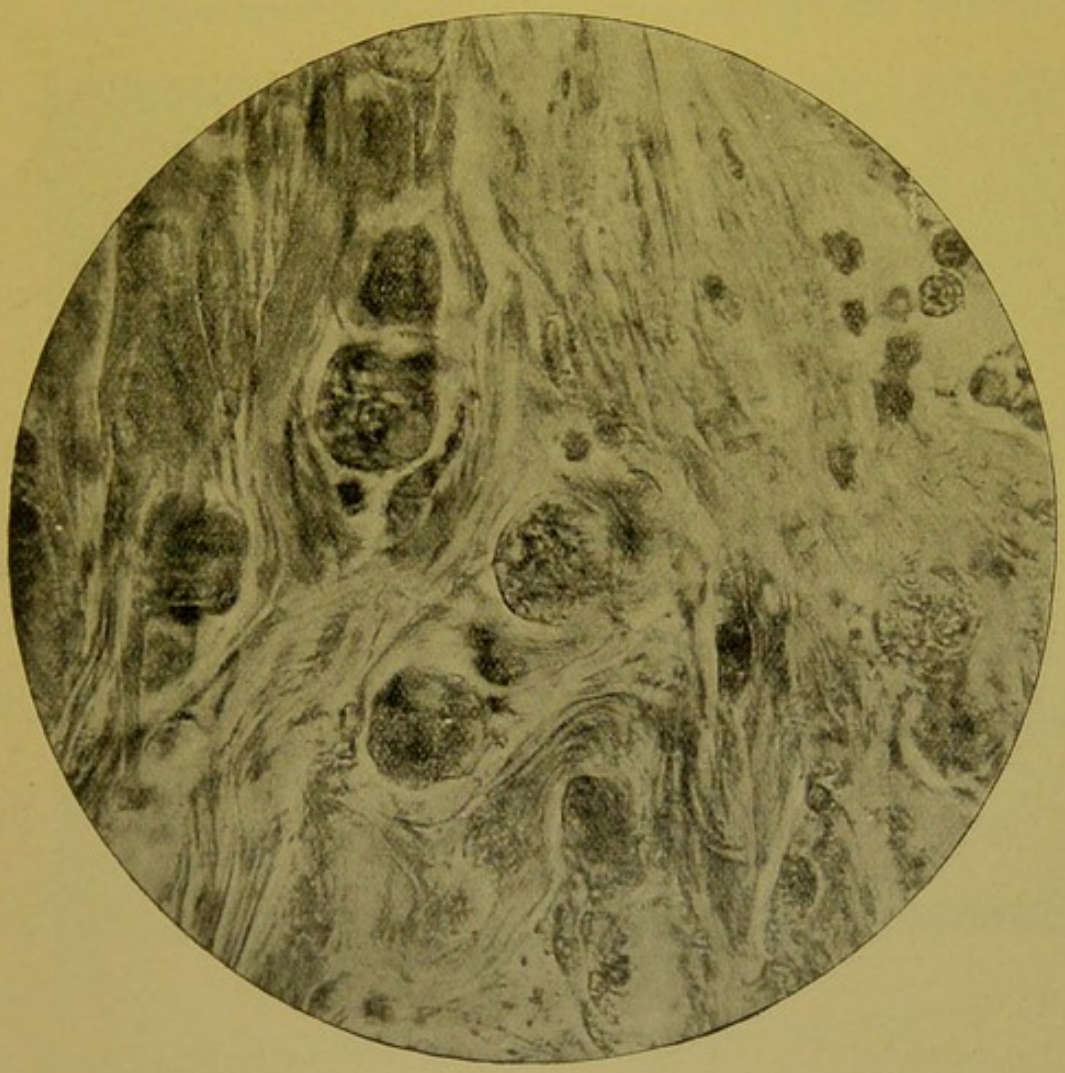

FIG. 279.—AMŒBIC COLITIS.
Showing amœbæ in connective tissue. Magnified 1,000 diameters and reduced.

to show but little disposition to heal, and the acute colitis often becomes chronic. It seems probable that some of the cases which look like follicular colitis are really examples of amœbic colitis.

*Amœbic Colitis.*—This form of colitis is caused by the presence in the wall of the intestine of amœbæ. These organisms were first recognized by Lambl in 1859. Since then they have been described by a number of observers, most fully by Kartulis and by Councilman (see page 128).

The amœbæ are found in the little, gelatinous masses which are found in the stools. They are of rounded shape, and, when alive, change their position and shoot out and retract little projections (pseudopodia). Their outer portion is composed of a pale hyalin or homogeneous substance; the inner contains vacuoles and is more refractive (see Fig. 30).

In the colon the amœbæ are found in the connective-tissue coat and in the floors of the ulcers (Figs. 278 and 279). The principal



Fig. 280.—Amœbic Colitis—twelve days' duration.
A deep ulcer with overhanging edges formed by circumscribed necrosis.

effect of the presence of the amœbæ seems to be to cause the death of tissue. The addition of inflammatory changes seems to depend upon an additional infection with streptococci, or other micro-organisms. As an amœbic colitis may last for many months and as the same patient may have a number of attacks, by the time of death the changes in the colon are very considerable. The cases which have come under our observation have followed one of these anatomical types.

(*a*) There is a diffuse inflammation of exudative and productive

type which involves a considerable part of the colon. The changes are confined to the glandular and connective-tissue coats. In the glandular coat there is a growth of new connective tissue and an infiltration of pus cells between the tubules. In the connective-tissue coat we find new connective-tissue cells, pus cells, and amœbæ. The ulcers are superficial and involve only the glandular coat. We find also in many places portions of the glandular coat which are necrotic, but have not sloughed away.

(*b*) There are foci of circumscribed exudation and necrosis scat-

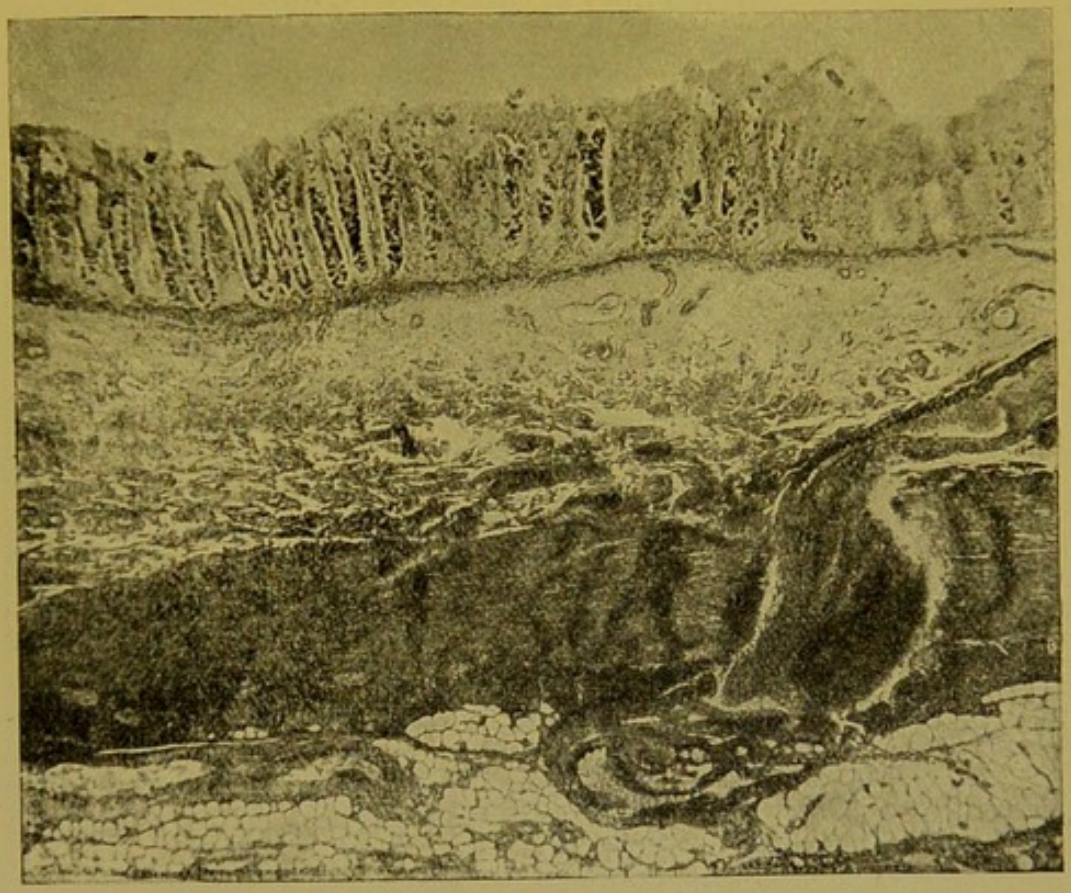

Fig. 281.—Amœbic Colitis.
Showing diffuse necrosis of glandular coat.

tered through the colon. These foci begin in the connective-tissue coat, but may be so large as to involve all the other coats of the colon. The exudation forms a sort of nodule which soon becomes necrotic and sloughs away, leaving a deep ulcer with overhanging edges (Fig. 280). The amœbæ are found in the walls and floors of the ulcers. The glandular coat between the ulcers shows various changes due to catarrhal and productive inflammation.

(*c*) Considerable areas of the glandular, connective-tissue, and muscular coats are necrotic. The dead tissue is found still in place, or has sloughed away, leaving very large and deep ulcers (Fig. 281).

In some cases of amœbic colitis necrotic and inflammatory changes of the same character are found in the liver and in the right lung.

*Necrotic Colitis.*—There is a form of inflammation of the colon in which considerable areas of the connective-tissue coat become necrotic, leaving the glandular coat undermined and separated from the muscular coat. In this way large ulcers with overhanging edges are formed. This form of colitis is very fatal.

There is another very fatal and obscure form of necrotic colitis in which the symptoms are rather of septic poisoning than of inflam-

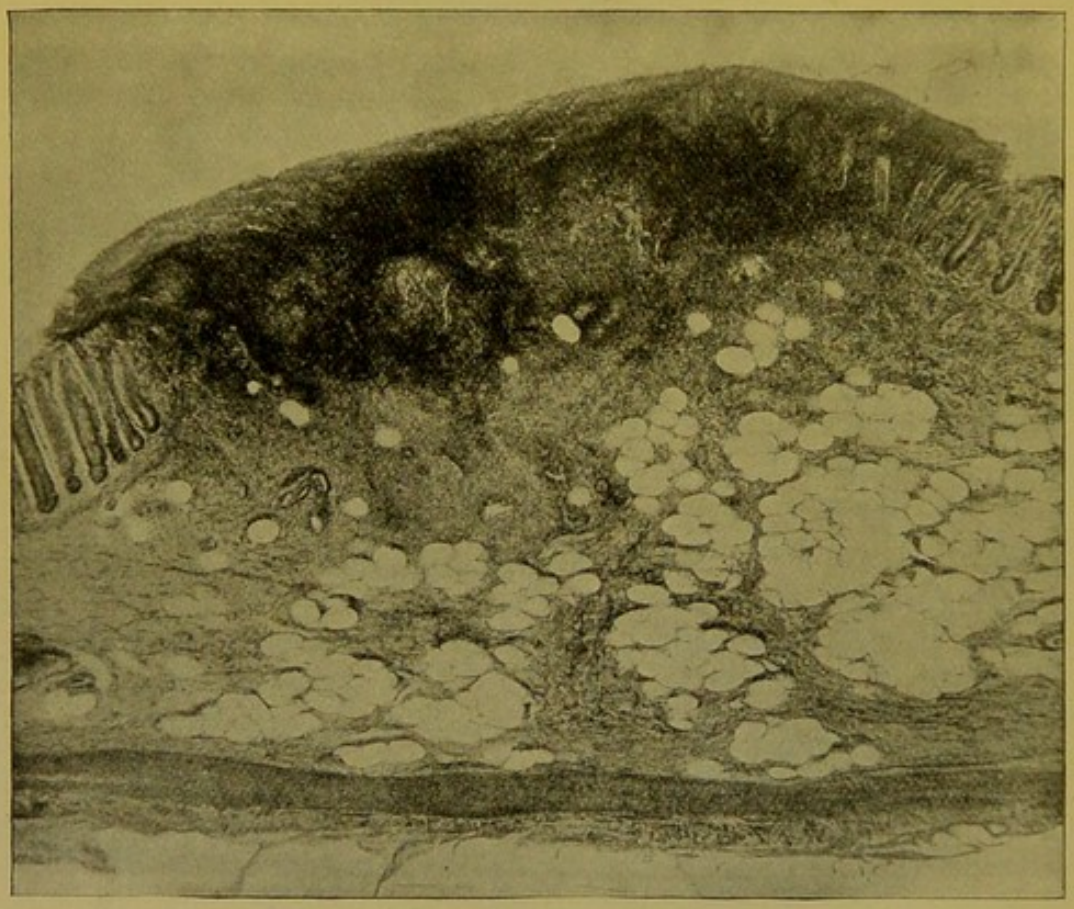

Fig. 282.—Necrotic Colitis.
Circumscribed congestion and necrosis of the glandular and connective-tissue coats.

mation of the colon. After death the inner surface of the colon is found studded with little blackish swellings. In these swellings the blood vessels are gorged with blood. The glandular and connective-tissue coats are infiltrated with pus cells and there is a superficial necrosis (Fig. 282).

Various forms of micro-organisms have been found in connection with suppurative and necrotic lesions of the colon: Streptococcus pyogenes, Staphylococcus pyogenes, Bacillus coli communis, Bacillus proteus, Bacillus pyogenes, and others.

The exact significance of these germs is yet obscure.[1]

*Chronic Colitis.*—If a chronic inflammation of the colon has continued for any length of time, the wall of the gut is found to be very much changed. The glandular coat may be uniformly thickened, or thrown into the form of polypoid tumors, or atrophied, or destroyed by ulcers of various sizes and shapes. The connective-tissue and muscular coats may be thickened or thinned. Apparently chronic colitis may follow any of the forms of acute colitis.

*The Cæcum.*—Catarrhal inflammation of the cæcum is not uncommon. It is usually produced by an habitual accumulation of fæces in this part of the intestine. The course of the inflammation is chronic, but marked by acute exacerbations. At first the mucous membrane undergoes the ordinary changes of chronic catarrhal inflammation; then there is a slow suppurative inflammation which extends through the wall of the intestine and produces ulcers and perforations. Through these perforations the fæces may pass into the peritoneal cavity, or the perforations are partly closed by adhesions, and abscesses are formed, or sinuses into the surrounding soft parts.

*The Rectum.*—Besides the inflammatory changes already described as existing in the colon, we sometimes find a suppurative inflammation of the connective tissue which surrounds the rectum, either associated with lesions of the mucous membrane or occurring by itself.

In adults the lower end of the rectum is the part of the intestine which is the most frequent seat of syphilitic ulceration. Most of these ulcers seem to be the result of unnatural coitus, or of infection from specific sores of the vulva; but some of them seem to be due to the softening of gummy tumors.

*The Vermiform Appendix.*—The appendix is given off from the inner and posterior aspect of the lower end of the caput coli. It is from two to six inches in length. It may be turned upward behind the cæcum, or it may hang downward free in the peritoneal cavity. It is composed of peritoneal, muscular, connective-tissue, and glandular coats.

1. The mucous membrane may be the seat of acute catarrhal inflammation. This is of mild type and short duration, with congestion, swelling, and an increased production of mucus; or it is of severer type, of longer duration, and the cavity of the appendix is distended by large quantities of mucus and pus.

2. The entire thickness of the wall of the appendix may be the seat of an acute exudative inflammation. The appendix is very

[1] See *Kruse and Pasquale*, Zeits. f. Hygiene und Infkr., Bd. xvi., p. 1, 1894; also *Cérenville, Tavel*, and others, Ann. Suisses des Sc. Méd., sér. ii., p. 531, 1895.

much increased in size, sometimes to the size of a man's finger. This increase in size is due, not to a dilatation of the cavity of the appendix, but to a thickening of its walls. The walls are congested, swollen, infiltrated with fibrin and pus, the peritoneal coat covered with fibrin. There is no necrosis and no perforations. If the appendix is behind the cæcum, or if adhesions are formed early, there is only a localized peritonitis. If the appendix projects freely into the peritoneal cavity and no adhesions are formed, a general peritonitis is soon established.

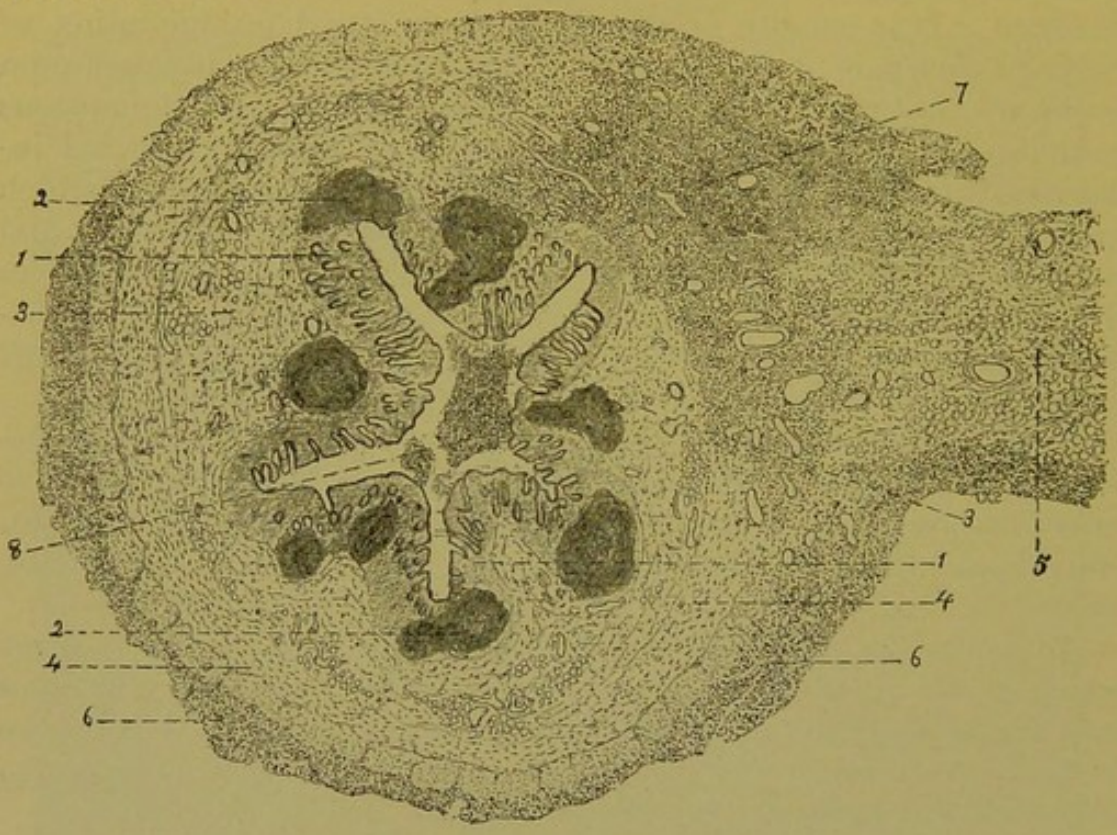


FIG. 283.—ACUTE SUPPURATIVE APPENDICITIS.

Appendix removed by operation twelve hours after first symptoms. Streptococcus was found in the exudate. (Specimen prepared by Dr. Van Gieson.) 1, Mucous membrane of the appendix; 2, lymphatic nodules in the mucous membrane; 3, submucosa; 4, muscularis; 5, mesentery of the appendix; 6, pus and fibrin covering the appendix; 7, dense infiltration of the wall of the appendix with pus.

3. At one or more points in the wall of the appendix there is an exudative inflammation with necrosis. In this way small or large portions of the wall of the appendix are destroyed, large or small perforations are formed, and the contents of the appendix escape into the abdominal cavity. In these cases the appendix usually contains a fæcal concretion. Such perforations are regularly followed by the formation of an abscess around the appendix (Fig. 283). The pus may extend from this abscess in any direction and for long distances, so that we find abscesses deep in the pelvic cavity, or under the diaphragm, or at other remote points.

4. The entire appendix becomes gangrenous within one or two days, with the formation of an abscess, or general peritonitis. This is the most fatal form of appendicitis; its etiology is obscure.

5. In catarrhal or croupous colitis the inflammation may extend to the appendix.

6. In typhoid fever there may be changes in the wall of the appendix of a character similar to those in the wall of the small intestine.

7. There may be a tuberculous inflammation of the appendix, with the formation of ulcers.

As the result of chronic inflammation in the appendix strictures or obliteration of the lumen of the appendix may occur.

The lumen of the appendix frequently contains concretions of fæcal material which have often been mistaken for foreign bodies. Foreign bodies, such as grape and apple seeds, and various small objects which have been swallowed, sometimes, though rarely, find their way into the appendix. Both the fæcal concretions and the foreign bodies may act as important predisposing agents of inflammation and perforation of the appendix, through pressure, erosion, etc., of the mucous membrane, affording portals of entry to various forms of pathogenic micro-organisms.

The Streptococcus pyogenes, Staphylococcus pyogenes, the Bacillus coli communis, and Bacillus proteus are the bacteria most commonly found associated with the lesions of acute appendicitis and its accompanying peritonitis.[1]

## TUMORS.

*Myomata.*—Tumors composed of smooth muscle and connective tissue grow in the muscular coat and project inward. They may be large enough to obstruct the intestine, and may then give rise to intussusception. In the duodenum such tumors may obstruct the common bile duct. Less frequently these tumors project outward into the peritoneal cavity.

*Lipomata* may be developed from the submucous coat and grow inward, or from the subserous coat and project outward into the peritoneal cavity.

*Polypoid Tumors*, projecting into the cavity of the intestine and composed of connective tissue and covered with epithelium, are frequently found. They are associated with catarrhal inflammation or

[1] *Hodenpyl*, "Etiology of Appendicitis," New York Medical Journal, December 30th, 1893. Consult also, *Kelynack*, "The Pathology of the Vermiform Appendix," 1893. *Berry*, Jour. of Path. and Bact., vol. iii., p. 160, 1895 (bibliography). *Ribbert*, Virch. Arch., Bd. cxxxii., p. 66.

occur by themselves. They are found throughout the intestinal tract and may be single or multiple. They grow from the submucous coat and project inward. Some of them are small, solid, connective-tissue tumors, covered by the mucous membrane which they have pushed inward. Others are of the same character, but of large size. In others the connective tissue is arranged in branching tufts, covered with cylindrical epithelium; and in these last tumors there may also be tubules lined with cylindrical epithelium, giving to the growth the characters of an adenoma.

*Adenomata* are found in the duodenum and colon. They form flat infiltrations of the wall of the intestine, or project inward as polypoid tumors. They are composed of tubular follicles, like those of the intestinal mucous membrane, and of a connective-tissue stroma. In some of these tumors the tubules have a tolerably regular shape and arrangement; there is no infiltration of surrounding tissue; the tumor is of benign nature. In other tumors the tubules are irregular in shape and arrangement, and the growth infiltrates the surrounding parts. There is no sharp dividing line between these tumors and the carcinomata.

*Carcinomata* are found in the colon and the duodenum, and are of three varieties.

1. The new growth is composed of tubules lined with cylindrical epithelium. It begins as a flat infiltration of the submucous coat, which soon surrounds the intestine, infiltrates the whole thickness of the wall of the gut, and may extend to the surrounding soft parts. Fungous masses project into the cavity of the intestine, while at the same time ulcerative and destructive processes are going on. According to the exact arrangement of the growth, there is more or less stenosis of the intestine.

2. The growth has the characters of colloid cancer and forms a diffuse infiltration of the intestinal wall, completely surrounding it and often extending over a length of several inches.

3. In the rectum there is sometimes a carcinomatous growth, with flat epithelial cells (epithelioma), like similar growths in the skin.[1]

*Lymphoma.*—Tumors composed of tissue resembling that of the lymphatic glands originate in the solitary and agminated nodules, and in the intestinal wall in cases of leukæmia and pseudo-leukæmia.

Similar tumors are found as an idiopathic lesion both in the large and small intestines. These tumors are irregular, diffuse growths infiltrating the wall of the intestine, the mesentery, and the neighboring lymph nodules, and reaching a considerable size. They often

[1] Consult *Bohm*, Virch. Arch., Bd. cxl., p. 524 (bibliography).

ulcerate internally and produce dilatation or stenosis of the intestine. It is hard to tell whether some of these tumors should be called lymphomata or sarcomata.[1]

### CONCRETIONS (ENTEROLITHS).

There are sometimes found in the intestines round, oval, or irregular masses of firm consistence. They are usually small, but may reach the size of a man's fist. They are composed of fæcal matter, mucus, bile, the carbonate and phosphate of lime, and triple phosphate. They may produce inflammation, ulceration, and perforation.

### FALSE DIVERTICULA OF THE INTESTINE.

Not infrequently one finds at autopsies either in the small or large intestine diverticula or herniæ, consisting of the mucous membrane which has been crowded through the muscularis and is covered by the serosa, which project from the exterior of the gut usually near its mesenteric attachment. These so-called "false diverticula" may be large, but are usually not larger than a pea; they may be single or numerous. They usually cause no functional disturbance, but may, through the accumulation of fæcal material within them, be the seat of perforation.[2]

### ANTHRAX INTESTINALIS (MYCOSIS INTESTINALIS).

The anthrax bacillus may find lodgment in the intestinal mucous membrane either by the ingestion of food containing the germ or by metastasis through the blood from some other seat of infection, especially the skin.

The intestinal lesions are most apt to occur in the small intestines and in the upper part of the colon.

The mucous membrane is studded with larger and smaller brown or black frequently elevated patches, or areas of local congestion, or hæmorrhage, or necrosis. The mucous membrane near the inflammatory and necrotic foci may be œdematous. Hyperplasia of the spleen and lymph nodes is apt to accompany the intestinal anthrax. The anthrax bacillus may be found about the seat of local lesion in the intestine, in the associated lymph nodes, and when secondary to local infection elsewhere it may be found in the primary lesion and in the blood. It is believed that other forms of bacteria may cause

[1] For study of congenital tumors of the intestines consult *Huetes*, Ziegler's Beitr. z. path. Anat., Bd. xix., p. 391, 1896.

[2] Consult *Edel*, Virch. Arch., Bd. cxxxviii., p. 347; also *Hanseman*, ibid., Bd. cxliv., p. 400.

intestinal lesions somewhat similar to those of anthrax, but the researches in this direction are not yet sufficiently numerous to permit of very definite statements.

*Ascaris lumbricoides* is found in the small intestine, either singly or in considerable numbers. In rare cases a number of worms may form a mass which produces inflammation, ulceration, and perforation.

*Oxyuris vermicularis* is found in large numbers in the rectum.

*Tricocephalus dispar* is found in the cæcum.

*Ankylostomum duodenale* is found in the duodenum and may give rise to considerable hæmorrhages.

*Trichina spiralis* is found in its adult condition in the small intestine.

*Pentastomum denticulatum* occurs in the submucous tissue of the small intestine in an encapsulated condition.

*Cysticercus cellulosæ* has been seen, in a few cases, on the mucous membrane.

*Tænia solium*, *Tænia mediocanellata*, and *Bothriocephalus latus* are all found in the small intestine.

Very large numbers of various forms of bacteria are regularly found in the intestinal cavity, intermingled with its contents and clinging to its walls. Among the most common of these is the Bacillus coli communis (see page 260).

## THE PERITONEUM.

The free surface of the parietal peritoneum is covered with a single layer of flat, polygonal, nucleated cells. Beneath these cells are successive planes of connective tissue extending down to the muscles and fasciæ. These planes are formed of a fibrillated basement substance reinforced by elastic fibres, and of branching cells. Embedded in the connective tissue are the nerves, blood vessels, and lymphatics. The lymphatic system is very extensive.

The omentum consists of fibrillated connective tissue arranged so as to form a meshwork. The trabeculæ of the meshwork are completely covered by large, flat cells. In the basement substance, beneath the endothelium, are branching cells. In the larger trabeculæ are blood vessels, lymphatics, and fat. Sometimes we find on the larger trabeculæ little nodules formed of polygonal or branched cells.

### MALFORMATIONS.

Arrest of development of the peritoneum occurs in the shape of fissures in the mesial line or external to it; in the case of the diaphragm being absent, of a fusion with the pleura; and as defective

development of the mesentery, the omentum, and the other folds of the peritoneum.

Excess of development occurs in the shape of unusual length of the mesentery, the omentum, and the other folds of the peritoneum; or of supernumerary folds and pouches. These are chiefly found in the hypogastric, iliac, and inguinal regions and near the fundus of the bladder. There is access to these sacs by a well-defined fissure or ring, which is frequently surrounded by a tendinous band lying in the duplicature. They may give rise to internal incarceration of the intestines.

## INFLAMMATION.

The very great extent of the peritoneum, and the readiness with which its lymphatic system absorbs foreign matters from the peritoneal cavity, render peritonitis a most severe and dangerous form of inflammation.

If the greater part of the peritoneum is inflamed we call the lesion a *general peritonitis*. If only a circumscribed area is involved it is a *local peritonitis*. The course of the inflammation may be rapid or slow, so that we speak of *acute* and *chronic* inflammation. The inflammation may be attended with the production of tubercle tissue, and then it is a *tubercular peritonitis*.

### *I. Acute Peritonitis.*

The acute inflammations of the peritoneum may occur as idiopathic lesions without discoverable cause; but much more frequently they are directly due to some appreciable cause.

Wounds and contusions of the wall of the abdomen; wounds, ulcers, new growths, incarcerations, intussusceptions, ruptures, perforations, and inflammations of the stomach and intestines; inflammation of the vermiform appendix; injuries, ruptures, and inflammations of the uterus, ovaries, and Fallopian tubes; rupture and inflammation of the bladder; inflammation of and about the kidneys; abscesses and hydatid cysts of the liver; inflammation of the gall bladder and large bile ducts; thrombosis of the portal vein; inflammations of the spleen, pancreas, lymphatic glands, retroperitoneal connective tissue, vertebræ, ribs, and pelvic bones; septicæmia and the infectious diseases, and chronic Bright's disease—are all ordinary causes of acute peritonitis.

According to the exact cause of the inflammation, the peritonitis is at first either local or general. A local peritonitis may remain circumscribed, or it may spread and become general.

We can distinguish two anatomical forms of acute peritonitis.

1. *Cellular Peritonitis.*—This form of peritonitis may be produced by any irritant which does not act too energetically. It can be

excited in dogs by injections of very small quantities of a solution of chloride of zinc. In the human subject we find it with perityphlitis, with circumscribed abscesses in the peritoneal cavity, and in cases of puerperal fever which die within forty-eight hours after the development of symptoms.

After death we find the entire peritoneum of a bright-red color from the congestion of the blood vessels; but there are no fibrin, no serum, no pus, no other lesions visible to the naked eye. Minute examination, however, shows a very marked change in the endo-

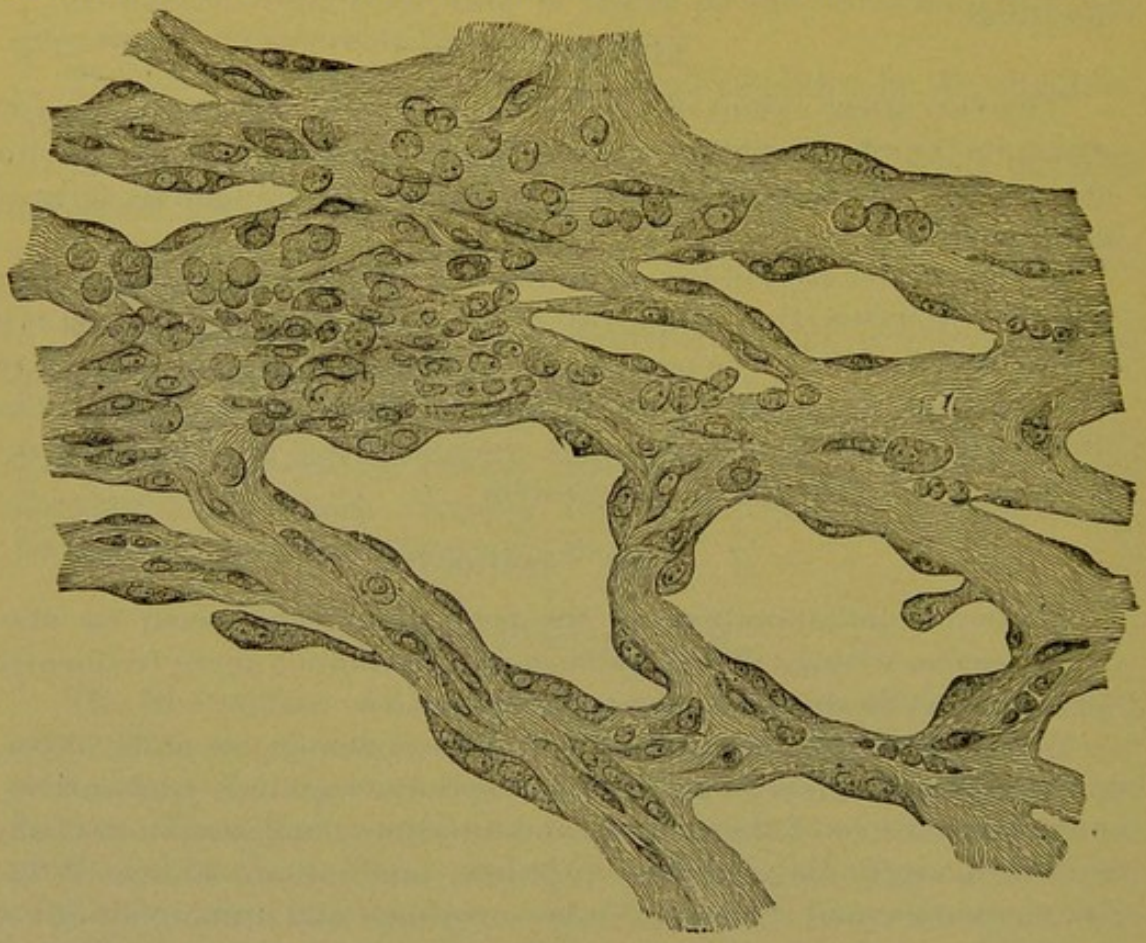

Fig. 284.—Acute Cellular Peritonitis.
Human omentum, × 750 and reduced.

thelial cells. They are increased in size and number, and the new cells coat the surface of the peritoneum and project outward in little masses (Fig. 284).

2. *Exudative Peritonitis.*—The ordinary form of acute peritonitis is attended with the production of serum, fibrin, and pus, and with changes in the endothelium and connective-tissue cells.

If we inject a solution of chloride of zinc or of some other irritant into the peritoneal cavity of a dog, we find that by the end of one or two hours inflammatory changes are evident. There is a little serum in the peritoneal cavity, a general congestion of the peri-

toneum, and little knobs and threads of fibrin on its surface. There are no marked changes in the endothelium or connective-tissue cells, but pus cells are present in moderate numbers in the stroma just beneath the endothelium, and white blood cells in the vessels.

After the lapse of twenty-four hours the lesions are more marked. The congestion of the peritoneum is much more decided, there is more serum in its cavity and a thicker layer of fibrin and pus on its surface. Minute examination shows that two distinct sets of changes are going on at the same time : (1) a production of fibrin, serum, and pus ; (2) a swelling and multiplication of the endothelial cells. If the inflammation is very intense the pus and fibrin are most abundant ; if the inflammation is milder the changes in the endothelium are more marked. The fibrin coagulates on the free surface of the peritoneum. The white blood cells collect in large numbers in the blood vessels, and as pus cells infiltrate the stroma and collect on its surface. There is no special change in the connective-tissue cells. The endothelial cells may remain in place, although their edges and corners are separated by pus cells and knobs of fibrin ; or the endothelium falls off in large patches ; or the surface of the peritoneum is covered with numerous cells which look like endothelial cells more or less deformed. But few dogs survive the third day of an acute artificial peritonitis.

In the human subject, if death takes place before the third day, both the gross and minute changes are the same as those seen in the dog. There are present the same general congestion, the pus, fibrin, and serum, the desquamation and multiplication of the endothelial cells (Fig. 285).

In many cases of peritonitis, however, death occurs between the sixth and fourteenth days of the disease. The appearance of the peritoneum at this period of the inflammation is not always the same. The congestion of the blood vessels may persist, it may be very intense and accompanied with extravasations of blood, or it may be entirely absent. There may be a thin coating of fibrin and pus gluing together neighboring surfaces of peritoneum, or this layer may be very thick. The accumulation of pus may be superficial, or it may infiltrate the whole thickness of the peritoneum and the subperitoneal connective tissue. The quantity of purulent serum in the peritoneal cavity may be small or large, and this serum may contain few or many pus cells, or the serum may be of a dirty-brown color and filled with bacteria. When the purulent serum is shut in by adhesion it is often thick and yellow, like the pus of an abscess.

The minute appearances differ from those seen at an earlier stage, chiefly in the larger amount of inflammatory products and in the changes in the fixed connective-tissue cells. During the first three

days of an acute peritonitis the connective-tissue cells are but little changed, but by the seventh day there is a marked increase in their size and number.

Acute peritonitis may prove fatal by the fourteenth day; or it may be succeeded by chronic peritonitis; or the patients recover and permanent connective-tissue adhesions and thickenings of the peritoneum are left behind. Recovery is most common when the peritonitis has been a local one.

Many species of bacteria have been found in the exudate in acute exudative peritonitis, but the significance of many of them is very

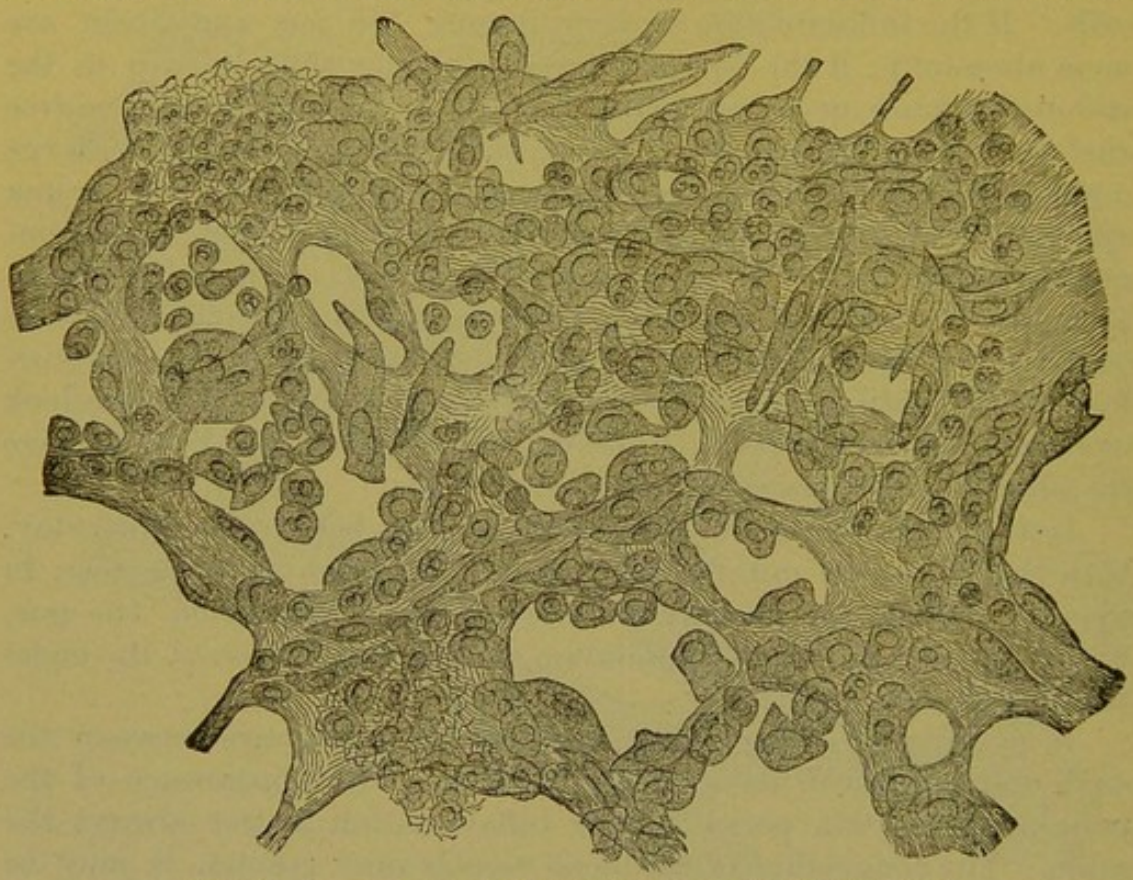

FIG. 285.—ACUTE EXUDATIVE PERITONITIS, EIGHT DAYS' DURATION.
Human omentum, × 850 and reduced.

uncertain on account of the liability to contamination of the exudate, either before or after death, by the germs in the intestinal contents.

Streptococcus pyogenes, Bacillus coli communis, Staphylococcus pyogenes, Micrococcus lanceolatus, Bacillus pyocyaneus, Bacillus aërogenes capsulatus, and many others have been reported. The Streptococcus and the Bacillus coli communis appear to be most frequently present. Very often two or more micro-organisms are associated in the exudate.

---

[1] Consult *Tavel and Lanz*, "Peritonitis," Mitth. a. Kl. u. Med. Inst. d. Schweiz, 1 Reihe, Heft i., p. 1, 1893; also *Silberschmidt*, ibid., Heft 5, p. 432.

The probability of the passage of bacteria without visible perforation through the intestinal wall should be borne in mind.[1]

## *II. Chronic Peritonitis.*

We find the following varieties of chronic peritonitis:

1. *Cellular Peritonitis.*—This form of peritonitis is found as a complication of chronic endocarditis, of cirrhosis of the liver, of chronic pulmonary phthisis, and of acute general tuberculosis.

Neither fibrin nor pus is present, but there may be clear serum in the peritoneal cavity. The peritoneum may look normal to the naked eye, or it may be studded with very minute, translucent nodules.



FIG. 286.—CHRONIC CELLULAR PERITONITIS OCCURRING WITH PULMONARY PHTHISIS.
Human omentum, × 750 and reduced.

Minute examination shows changes in the endothelial cells and the connective-tissue cells. These cells are everywhere increased in number and altered in shape; or, to speak more guardedly, the surface of the peritoneum is covered with cells which look as if they were derived from the endothelium and the connective-tissue cells (Fig. 286). Some are large, flat cells; some smaller, polygonal cells; some irregularly fusiform; some large, granular masses con-

[1] *Arnd*, ibid., Heft 4, p. 395.

taining a number of nuclei. Although these new cells are found over most of the surface of the peritoneum, yet they are more numerous in little patches which are scattered here and there.

2. *Peritonitis with Adhesions.*—There may be a formation of permanent adhesions without the production of fibrin or pus. It is often, indeed, difficult to tell whether old peritoneal adhesions are due to the form of chronic peritonitis of which we are now speaking, or whether they are the result of an acute peritonitis. But there are some cases in which the mode of development of the adhesions seems evident.

If, from perityphlitis or some other cause, a collection of pus is shut in in some part of the peritoneal cavity, we may find the rest of the peritoneum smooth and shining; no serum, fibrin, or pus, no thickening; but the neighboring surfaces of the peritoneum are attached to each other by adhesions. These adhesions are in the shape of threads and membranes, often of the most extreme tenuity. They are formed of a fibrillated basement substance, the fibrils crossing each other in all directions. In the basement substance are cells, some fusiform and stellate, but most of them look like large branching cells, of which the cell bodies have become fused with the basement substance while the nuclei remain.

Close to these adhesions the peritoneum may appear normal to the naked eye, but if it is put in water very fine threads and membranes will float upward from its free surface. Minute examination shows that the connective-tissue cells are increased in size and number, that the endothelial cells are replaced by cells of a great variety of shapes, and that the thin little threads and membranes on the surface are formed of large branching cells (Fig. 287).

Such a peritonitis with adhesions appears to be a more advanced stage of the cellular peritonitis just described, but the inflammation, instead of stopping at the production of cells alone, goes on to the formation of membranes.

We sometimes find in the same patient chronic pleurisy with adhesions and chronic peritonitis with adhesions.

3. *Chronic Peritonitis with Thickening of the Peritoneum.*—This form of peritonitis occurs quite frequently as an idiopathic lesion. It may involve the greater part of the peritoneum or be confined to the capsules of the liver and spleen.

The most marked feature of the lesion is the thickening of the peritoneum—a thickening which may reach as much as an inch. The outer portions of the thickened peritoneum are composed of dense connective tissue, the inner layers of granulation tissue. The surface of the peritoneum is smooth or covered with fibrin. There may also

be connective-tissue adhesions between different parts of the peritoneum. The peritoneal cavity contains clear and purulent serum.

In some cases the parietal peritoneum is principally involved; in others the peritoneum of the stomach, intestines, liver, and spleen. The thickening of the capsule of the liver is attended with a diminution in the size of that viscus.

4. *Chronic Peritonitis with the Production of Fibrin, Serum, and Pus.*—This form of peritonitis may follow acute peritonitis, may be due to lesions of the abdominal viscera, or may occur without known cause.

The abdominal cavity contains purulent serum, either free or shut

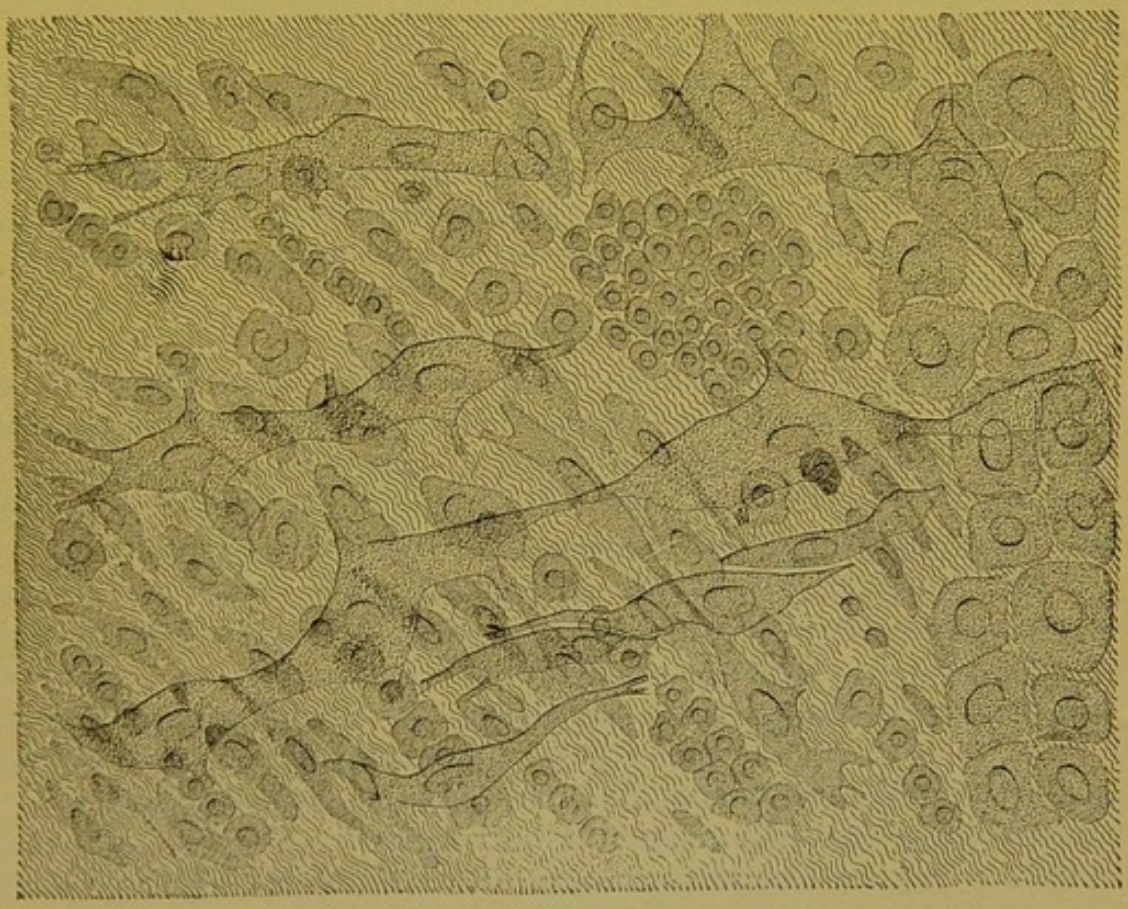

FIG. 287.—CHRONIC PERITONITIS WITH ADHESIONS, × 750 and reduced.
Parietal peritoneum.

in by adhesions. The surface of the peritoneum is coated with fibrin and connective-tissue adhesions. The coils of intestine, and all the neighboring surfaces of the peritoneum, are matted together partly by fibrin, partly by permanent adhesions.

5. *Hæmorrhagic Peritonitis.*—This occurs most frequently as a local inflammation. It involves the peritoneum behind and around the uterus in the female, and that covering the recto-vesical excavation in the male. The affected portion of the peritoneum is covered

with layers of new membrane infiltrated with blood. The membranes are formed of connective tissue containing numerous blood vessels and infiltrated with blood. The extravasations of blood may form tumors of considerable size.

General hæmorrhagic peritonitis is described by Friedreich. In two cases of ascites, which had been frequently tapped, he found the visceral and parietal peritoneum covered with a continuous membrane of a diffuse yellowish-brown color, mottled with extravasations of blood. The membrane was thickest over the anterior abdominal wall. It could be separated into a number of layers. These layers were composed of blood vessels, masses of pigment, branching cells, and fibrillated basement substance. In many places the extravasated blood was coagulated in the shape of round, hard, black nodules. The entire new membrane could be readily stripped off from the peritoneum.

6. *Tuberculous Peritonitis.*—This occurs as one of the lesions of acute general tuberculosis, with chronic pulmonary phthisis, with tuberculous inflammation of the genito-urinary tract, and as a local inflammation.

The gross appearance of the lesion varies.

When tuberculous peritonitis occurs as one of the lesions of general tuberculosis, there are numerous small miliary tubercles, increase in the size and number of the endothelial and connective-tissue cells, and sometimes a little fibrin. Some of the miliary tubercles are composed of tubercle tissue, others of round and polygonal cells.

As a complication of tuberculosis of the genito-urinary tract we find the peritoneum studded with miliary tubercles, coated with fibrin, and serum is also present in the peritoneal cavity.

As a complication of chronic phthisis there are miliary tubercles in the peritoneum of the small intestine immediately over the tubercular ulcers of the mucous membrane. There may also be thickening of the peritoneum and permanent adhesions.

The anatomical forms of primary tuberculous peritonitis are:

1. The peritoneum is everywhere studded with miliary tubercles, its surface is coated with a thin layer of fibrin.

2. The peritoneum is studded with miliary tubercles, or with larger cheesy nodules; in its cavity are large quantities of serum.

3. The peritoneum is studded with miliary tubercles or with cheesy nodules. Its cavity contains large quantities of fibrin, which not only coat the peritoneum but fill up the spaces between the viscera.

4. In addition to the presence of miliary tubercles in the perito-

neum its apposed surfaces are fastened together by connective-tissue adhesions. The coils of small intestine especially are fastened together in this way.

5. The tuberculous inflammation is confined to the omentum. By the formation of tubercle tissue and of connective tissue the omentum is converted into a hard tumor, which occupies the upper part of the abdominal cavity.

6. There are miliary tubercles in the peritoneum, connective-tissue adhesions, and collections of serum and pus. In this way the abdominal cavity becomes divided up into cavities of different sizes, each cavity containing more or less serum and pus.

## TUMORS.

*Fibromata* are developed from the subperitoneal connective tissue and project inward into the peritoneal cavity. They are found beneath the parietal peritoneum and that covering the intestines. Such tumors may reach a very considerable size. Papillary fibromata of the peritoneum may be secondary to papillary fibroma of the ovary.

*Lipomata.*—Circumscribed tumors composed of fat tissue are formed beneath the intestinal and parietal peritoneum and in the mesentery. These tumors may become changed into fibrous tissue or calcified. Their pedicles may become atrophied so that they are left free in the peritoneal cavity.

When they grow beneath the parietal peritoneum they may form fat herniæ. At the umbilicus, in the inguinal canal, along the vas deferens, in the crural ring, and in the foramen obturatorium, fatty tumors may grow, project outward under the skin like herniæ, and, by drawing the peritoneum after them into a pouch, may open the way for a future intestinal hernia.

*Plexiform Angio-Sarcoma.*—Very large tumors, resembling in their gross appearance colloid cancer, have been described by Waldeyer.[1] They are formed by a new growth of blood vessels, with a production of gelatinous tissue from their adventitia.

*Carcinoma* of the peritoneum is either secondary or primary. The primary tumors assume the character of colloid cancer or of common cancer.

The colloid form frequently involves the greater part of the peritoneum and forms a large mass which distends the abdomen. The omentum is changed into a large, gelatinous mass; the subjacent muscles, the lymphatic glands, and the liver are infiltrated with the new growth, and soft, gelatinous masses project into the peritoneal

[1] Virch. Arch., Bd. lv., p. 134.

cavity. The umbilicus is sometimes invaded, so as to project outward in the form of a semi-translucent tumor. The appearance of the new growth is that of a soft, jelly-like mass embedded in a fibrous stroma. The minute structure is that of a connective-tissue

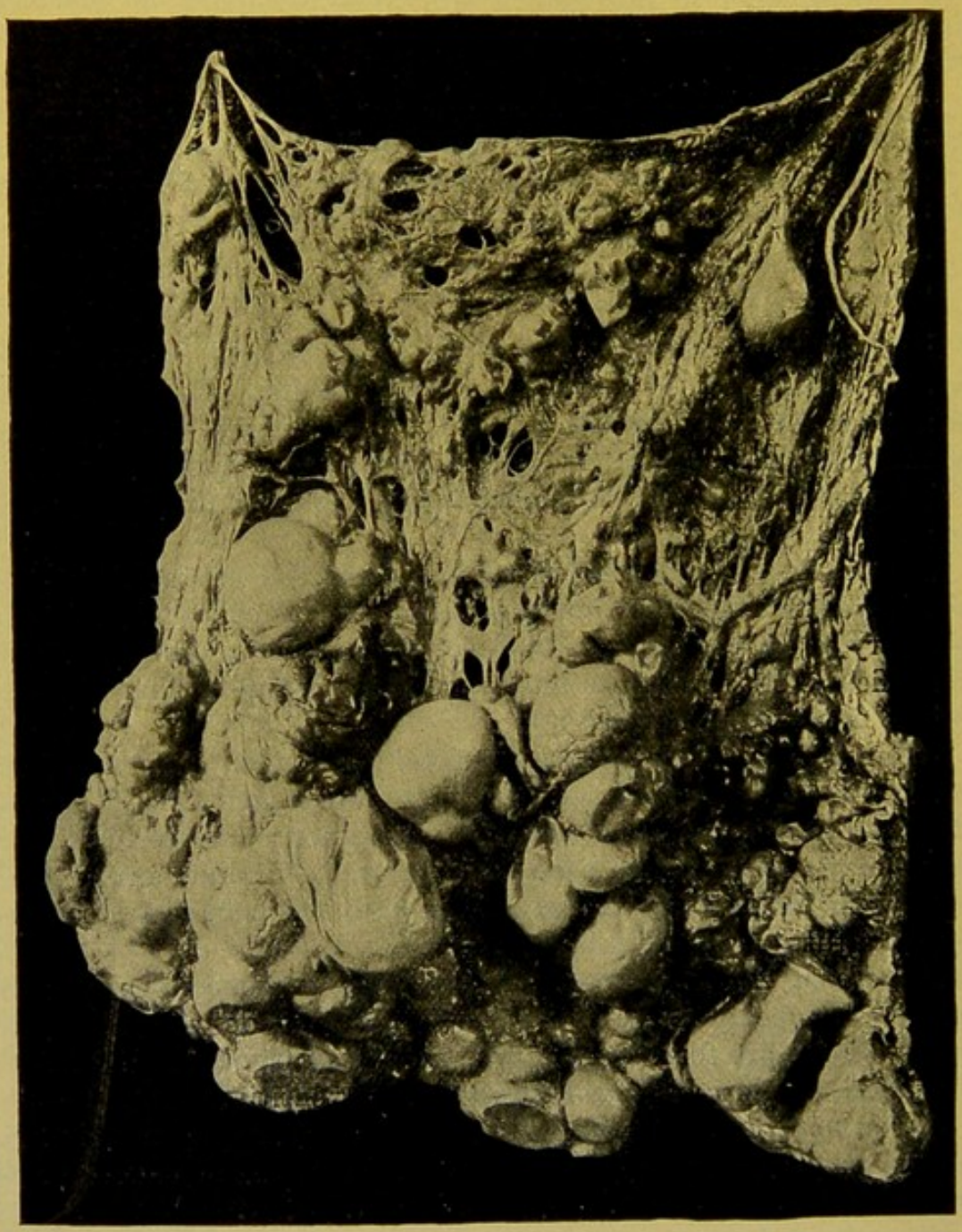

FIG. 288.—CYSTIC PAPILLOMA OF THE OMENTUM.
Secondary to papilloma of the ovaries (Freeborn).

stroma, arranged so as to form cavities of different sizes. These cavities are filled with a homogeneous, gelatinous basement substance and with polygonal cells.

Common carcinoma appears in the form of numerous small

nodules scattered everywhere in the inner layers of the peritoneum. These nodules are small, firm, and white, and are composed of a fibrous stroma enclosing cavities filled with polygonal cells. With the formation of these nodules there are often associated a general thickening of the peritoneum, an accumulation of serum in the peritoneal cavity, and adhesions.

*Sarcomata* appear in the form of solitary, slowly growing tumors behind the peritoneum or between the folds of the mesentery.

These retroperitoneal sarcomata are found both in children and adults. They usually originate behind the peritoneum covering the posterior part of the abdominal wall.

The retroperitoneal sarcomata may be of the small spheroidal-celled type (lympho-sarcoma) or of the fusiform-celled type. They are often very vascular. At first they grow slowly inward, pushing forward the peritoneum and abdominal viscera. After a time they assume a more noxious character, infiltrating the soft parts with which they come in contact, and forming metastatic tumors in the omentum, mesentery, intestinal wall, liver, lungs, and in other viscera.

*Endotheliomata* similar in structure to those originating in the pleura are of occasional occurrence in the peritoneum. They may form single well-defined tumors or flattened masses in the thickened peritoneum.

Cuboidal or polyhedral cell masses often grouped along the side of anastomosing channels in the new-formed or old connective-tissue stroma sometimes lend a glandular character to the type of growth.[1]

Cysts of the mesentery are of occasional occurrence. They may be filled with chyle, with blood, or with serous fluid,[2] or may be due to the echinococcus. Lipomata of the mesentery are recorded.

Multiple cysts of the omentum may form by transplantation of papillary cyst-adenomata from the ovary (see Fig. 288).

### PARASITES.

*Echinococci* can be formed in their regular way at any part of the visceral and parietal peritoneum, or be free in the peritoneal cavity. These cysts may be small, or so large as nearly to fill the abdominal cavity.

*Cysticercus cellulosæ* may also be developed in the subperitoneal connective tissue.

---

[1] See Endothelioma, p. 312.

[2] Regarding cysts of the mesentery consult *Weichselbaum*, Virchow's Archiv, Bd. lxiv., p. 145; *Bramann*, Archiv für klin. Chirurgie, Bd. xxxv., p. 201; *Hahn*, Berliner klin. Wochenschrift, June 6th, 1887, p. 408; *Robinson*, British Medical Journal, January 31st, 1891.

# THE LIVER.

## MALFORMATIONS.

*Congenital malformations* of the liver are not common and are of little practical importance. The organ may be entirely wanting; the lobes may be diminished or increased in number; its form may be altered, so that it is rounded, flattened, triangular, or quadrangular. The gall bladder or gall ducts may be wanting; the ductus choledochus may be double, both ducts emptying into the duodenum, or one emptying into the duodenum, the other into the stomach. The single ductus choledochus may also empty into the stomach. Owing to abnormal openings in the diaphragm or the abdominal parietes, the liver may suffer displacement upward or forward. In congenital transposition of the viscera the liver is found on the left side, the stomach and spleen on the right side.

Small, isolated bodies, having the same structure as the liver, have been a few times found in the suspensory ligament and in the lesser omentum.

## ACQUIRED CHANGES IN SIZE AND POSITION.

As a result of tight lacing very marked changes are sometimes produced in the shape of the liver. By the narrowing of the base of the thorax the organ is compressed from side to side, and its convex surface is pressed against the ribs. In consequence of this there are found ridges and furrows on its convex surface. In consequence also of the circular constriction, a part of the right, and usually of the left lobe also, becomes separated by a depression. Over this depressed and thinned portion of the liver the capsule is thick and opaque. In extreme cases the depressing and thinning reach such an extent that there is only a loose, ligamentous connection between the separated portion and the liver.

A series of depressions are sometimes found on the upper surface of the right lobe of the liver, running from front to back, apparently caused by folds of the organ.

Structural changes in the liver may induce changes in its size and shape. It may be increased in size by tumors, hydatid cysts, abscesses,

fatty and amyloid degeneration, by congestion, and sometimes by cirrhosis, etc.

It may be diminished in size by atrophy, by cirrhosis, by acute parenchymatous degeneration, etc.

Changes in the position of the liver are produced by alterations in its size, by pressure downward from the thoracic cavity and upward from the abdomen, by the constriction of tight lacing, by tumors or circumscribed serous exudation between the liver and diaphragm, by curvature of the spine.

The liver is readily turned, by pressure from above or below, on its transverse axis. The transverse colon may be fixed above the liver so as to push it backward, downward, and to the right. There are a few cases recorded of dislocated and movable livers. These occurred in women who had borne children and whose abdominal walls were lax. With ascites it is not uncommon to find the liver quite movable.[1]

### ANÆMIA AND HYPERÆMIA.

*Anæmia* of the liver may be general or partial. It may be due to general anæmia or to local disturbances of the circulation, such as swelling of the cells in parenchymatous or other degeneration, pressure of tumors, etc. The organ appears pale, often of slightly yellowish or brownish color. It may be harder than usual, and smaller.

*Hyperæmia* of the liver is either an active or a passive process. In health the amount of blood in the liver varies at different times, being regularly increased during the process of digestion. When the digestive process is unduly influenced by the ingestion of spirits, spices, etc., the hyperæmia assumes abnormal proportions, and when this is often repeated it may lead to structural changes in the organ. Severe contusions over the region of the liver sometimes cause a hyperæmia, which may result in suppurative or in indurative inflammation. In hot climates and in malarious districts active and chronic hyperæmia of the liver are frequent and often cause structural lesions. In scurvy, also, the liver is sometimes congested. Cessation and suppression of the menses and of hæmorrhoidal bleeding may cause hyperæmia of the liver. In all these varieties of active congestion the liver is enlarged, of a deep-red color, and blood flows freely from its cut surface.

The passive congestions of the liver are produced by some obstruction to the current of blood in the hepatic veins. Valvular diseases of the heart, emphysema and fibrous induration of the lungs, large pleuritic effusions, intrathoracic tumors, angular curvature of the spine, aortic aneurisms pressing on the vena cava, and constrictions

[1] Consult *Graham*, "Displacements of the Liver," Trans. Assn. Am. Phys., vol. x., p. 258, 1895 (bibliography).

of the vena cava and of the hepatic veins, may all produce a chronic hyperæmia of the liver. In all these cases, as the congestion affects principally the hepatic veins, we find the centre of each acinus congested and red while its periphery is lighter in color. This gives to the liver a mottled or nutmeg appearance (*nutmeg liver*). The liver cells in the centre of each acinus are frequently colored by little granules of red or black pigment, and the cells at the periphery become fatty, so that the nutmeg appearance is still more pronounced. A liver in this condition is usually of medium size, but may be smaller or larger than normal.

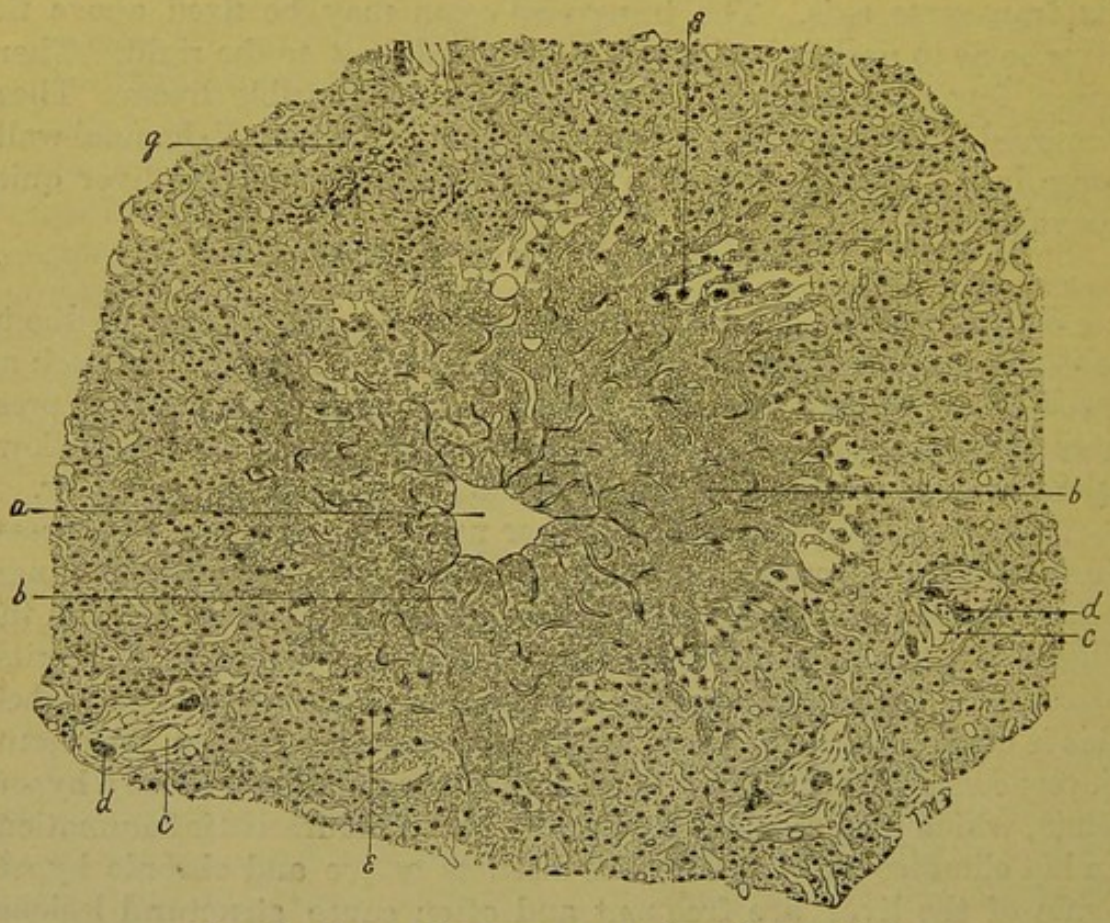


FIG. 289.—CHRONIC CONGESTION OF THE LIVER (nutmeg liver).

This section shows complete atrophy of the liver cells at the centre of the lobule. *a*, dilated vena centralis; *b*, dilated capillaries filled with blood; *c*, portal vein surrounded by connective tissue; *d*, gall duct; *e*, atrophied liver cells; *g*, nearly normal liver tissue.

When the congestion is long-continued the veins at the centre of each acinus may become permanently dilated, the hepatic cells in their meshes become atrophied (Fig. 289), so that the centre of each acinus consists only of dilated capillaries or of these and new connective tissue; or the dilatation and atrophy of the liver cells may, in circumscribed portions of the organ, involve the entire acinus. In long-continued congestion the liver is usually smaller than normal, and may be slightly roughened or uneven on the surface; but it is

sometimes enlarged. The peculiar nutmeg appearance may be very well marked, or it may not be evident, the organ being of a dark-red color.

### WOUNDS, RUPTURE, AND HÆMORRHAGE.

*Wounds* of the liver may induce hæmorrhage, which, if life continue, is followed by inflammation. Serious wounds of the liver are usually fatal, but recovery may occur even after the destruction of a considerable portion of the organ.

*Rupture* of the liver may be produced by severe direct contusions or by falls. It may be produced in children by artificial delivery. The rupture usually involves both the capsule and a more or less considerable portion of the liver tissue. It is commonly accompanied by large hæmorrhage, and is usually fatal.

*Hæmorrhage.*—Extravasations of blood in the substance of the liver, or more frequently beneath the capsule, are found in new-born children after tedious or forcible labors. In adults hæmorrhage, except as the result of injury, is uncommon. Extravasations of blood are sometimes seen in malignant malarial fevers, especially in tropical climates; in scurvy, purpura, and phosphorus poisoning; and bleeding may occur in and about soft tumors, abscesses, and echinococcus cysts. It may also occur as a result of thrombosis of the hepatic vein.

### LESIONS OF THE HEPATIC ARTERY.

The hepatic artery is in rare cases the seat of aneurisms which may attain a large size. Such aneurisms may displace the liver tissue, compress the bile ducts so as to cause jaundice, and may rupture into the stomach or abdomen.

Owing to its abundant anastomoses, emboli of the branches of the hepatic artery usually induce no marked lesions, but they sometimes result in hæmorrhagic infarctions.

### LESIONS OF THE PORTAL VEIN.

*Thrombosis, Embolism, and Inflammation.—Thrombosis* of the branches of the portal vein may be produced by weakening of the circulation from general debility—*marasmatic thrombi;* by pressure on the vessel from without, as in cirrhosis, tumors, gall stones, dilatation of the bile ducts, etc.; by injury; by the presence of foreign materials within the vessel; and as a result of inflammation of its wall, or of embolus. The thrombus may form in the vessels in the liver or be propagated into them from without. It may partially or

entirely occlude them. The clot may become organized as a result of endophlebitis, and a permanent occlusion of the vessel ensue. If the clot be a simple, non-irritating one, leading to occlusion, the consequences are usually more marked in the abdominal viscera than in the liver itself. The branches of the hepatic artery form sufficient anastomoses to nourish the liver tissue and prevent its necrosis, even in complete occlusion of the portal vein; and if occlusion occur slowly the organ may continue to perform its functions. But this obliterative form of thrombosis is usually attended by ascites, enlargement of the spleen, dilatation of the abdominal veins, and sometimes by hæmorrhage from the stomach and intestines.

In another class of cases, in addition to the local and mechanical effects of a thrombus, there may be necrotic changes and suppurative inflammation in the walls of the vessels or in the liver tissue about them. The thrombi are apt to soften and break down, and the fragments may be disseminated through the smaller trunks of the portal vein. In this way, by the distribution through the smaller vessels of a disintegrated thrombus from a large trunk, or by the introduction into the branches of the portal vein of purulent or septic material from some of the abdominal viscera or from wounds, multiple foci of purulent inflammation in the portal vein, and multiple abscesses involving the liver tissue, may be produced. In many cases the presence of bacteria may be detected in the inflammatory foci.

These soft thrombi of the portal vein and the accompanying pylephlebitis and abscess may be caused in a variety of ways. Ulceration of the intestines and stomach, abscesses of the spleen, suppurative inflammation of the mesentery and mesenteric glands, inflammation and ulceration of the bile ducts from gall stones, inflammation of the umbilical vein in infants, may all induce thrombi in their respective veins, which may be propagated to the portal vein or may give rise to purulent or septic emboli. Two cases are recorded in which a fish bone in the portal vein induced suppurative inflammation in that vessel. One of these cases, occurring in Bellevue Hospital in 1867, was reported by Dr. E. G. Janeway. Male, 47; dying, after a four weeks' illness, in a typhoid condition, with lesions of sero-fibrinous peritonitis and chronic diffuse nephritis. There were numerous small abscesses in the right lobe of the liver, two in the left lobe. The left division of the portal vein contained a firm red and white clot over an inch long; the right division was lined with a firm thrombus. The walls of the vein were thickened and contained purulent fluid. A fish bone, two inches long, its centre covered by a thrombus, lay half in the mesenteric and half in the portal vein.

In infants inflammation of the umbilical vein may not only induce inflammation of the portal vein and abscesses in the liver, but multiple

abscesses in various parts of the body, and acute peritonitis may be induced.

*Rupture of the Portal Vein*, with fatty degeneration of its walls, has occurred in a few instances.

*Chronic Endophlebitis*, with atheroma and calcification, may occur in the walls of the portal vein, giving rise to thrombosis.

*Dilatation of the Portal Vein*, either uniform or varicose, may occur in various parts of the vessel or its branches. It may be caused by destruction of the liver capillaries in cirrhosis, or by occlusion of the vein by thrombi, tumors, etc.

### THE HEPATIC VEINS.

The hepatic veins present lesions similar to those of the portal vein and its branches, but they are much less frequent. They may be dilated by obstruction to the passage of venous blood into the heart. They may be the seat of acute and chronic inflammation, and soft thrombi and suppurative inflammation may be produced by abscesses in the liver.

### ATROPHY OF THE LIVER.

Atrophy of the liver may affect the entire organ or be confined to some part of it. General atrophy may occur in old age as a senile change, or may be induced by starvation or chronic exhausting diseases. The organ is diminished in size, is usually firm, and the acini appear smaller than usual. Microscopically the change is seen to be due to a diminution in size of the liver cells, and hand-in-hand with this there occurs frequently an accumulation of pigment granules within the atrophied cells. The cells may entirely disappear over circumscribed areas, leaving only shrivelled blood vessels and connective tissue; or, in some cases, there may be an increase of connective tissue in connection with the atrophy of the cells. When much pigment is formed in the cells the lesion is often called *pigment atrophy*.

Essentially the same changes may occur in circumscribed portions of the liver, as the result of pressure from new connective tissue in cirrhosis, from tumors, hydatids, amyloid degeneration, gall stones, etc. In atrophy from pressure the liver cells are apt to become very much flattened and squeezed together as they diminish in size.

### DEGENERATIVE CHANGES.

*Acute Degeneration; Parenchymatous Degeneration* (Cloudy Swelling).—In a variety of acute and infectious diseases—pneumonia, typhoid and typhus fevers, scarlatina, variola, diphtheria, erysipelas, yellow fever, septicæmia, and in certain cases of acute anæ-

mia and phosphorus poisoning—the liver is somewhat swollen and, on section, of a dull yellowish-gray color, looking somewhat as if it had been boiled. It contains less blood than usual, and the outlines of the lobules are indistinct. Microscopical examination shows the lesion to consist of a swelling of the liver cells and an accumulation in them of moderately refractile, finer and coarser albuminous granules. Those granules may disappear and the cells return to their normal condition, or, as is frequently the case, they may pass into a condition of fatty degeneration. Very frequently fatty and parenchymatous degenerations are associated together.

Small areas of necrosis of liver cells may be found in certain acute infectious diseases (see Fig. 67).

*Fatty Infiltration.*—In the normal human liver there is usually a certain amount of fat in the liver cells, and this amount varies considerably under different conditions.

The gross appearance of pathological fatty livers varies a good deal, depending upon the amount and distribution of fat and its association with other changes. If the lesion is uncomplicated and considerable the organ is increased in size, the edges rounded, the consistence firm, the color yellowish, and the cut surface greasy. The lobules are enlarged and their outlines usually indistinct, and the blood content diminished. The liver is increased in weight. If the amount of infiltration be moderate the outlines of the lobules may be more distinct than usual and the centres appear unusually red. This is due to the fact that the accumulation of fat usually commences in the periphery of the lobules and progresses toward the centre, so that the centre appears darker by contrast with the fatty periphery. The lesion may be uniform throughout the organ or it may occur in patches. In the latter case the liver has a mottled appearance, irregular yellowish patches alternating with the brownish-red, unaffected portions.

Fatty infiltration is often associated with chronic congestion (*nutmeg liver*), with cirrhosis and amyloid degeneration; the picture may then present considerable complexity. Fatty livers may be stained brown or greenish with bile pigment.

Microscopically the liver cells are seen to contain larger and smaller droplets of fat (Fig. 290), and frequently large drops of fat occupy nearly the entire volume of the cell, so that the protoplasm may be visible only as a narrow, nucleated crescent at one side, or it may disappear altogether (Fig. 291). The microscopical appearances of course vary, depending upon the degree of infiltration and the association with other lesions.

Fatty infiltration of the liver may occur as a result of excessive ingestion of oleaginous food; in chronic alcohol, phosphorus, and

arsenic poisoning ; in certain exhausting diseases accompanied by malnutrition, as in pulmonary phthisis, chronic dysentery, etc.; and under a variety of conditions which we do not understand.

*Fatty Degeneration.*—In this condition, which in many cases cannot be morphologically distinguished from fatty infiltration, the fat is believed to be formed by a transformation of the protoplasm

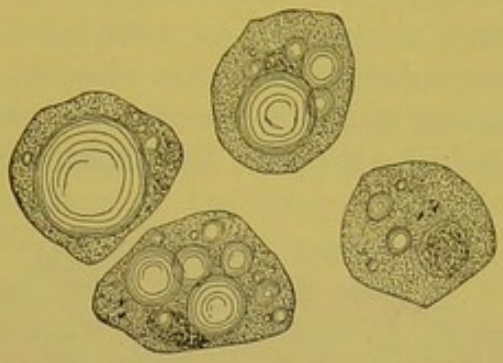

FIG. 290.—FATTY INFILTRATION OF LIVER CELLS.

of the liver cells. The fat droplets are, for the most part, very small and abundant, though this is not constant. Fatty degenera-

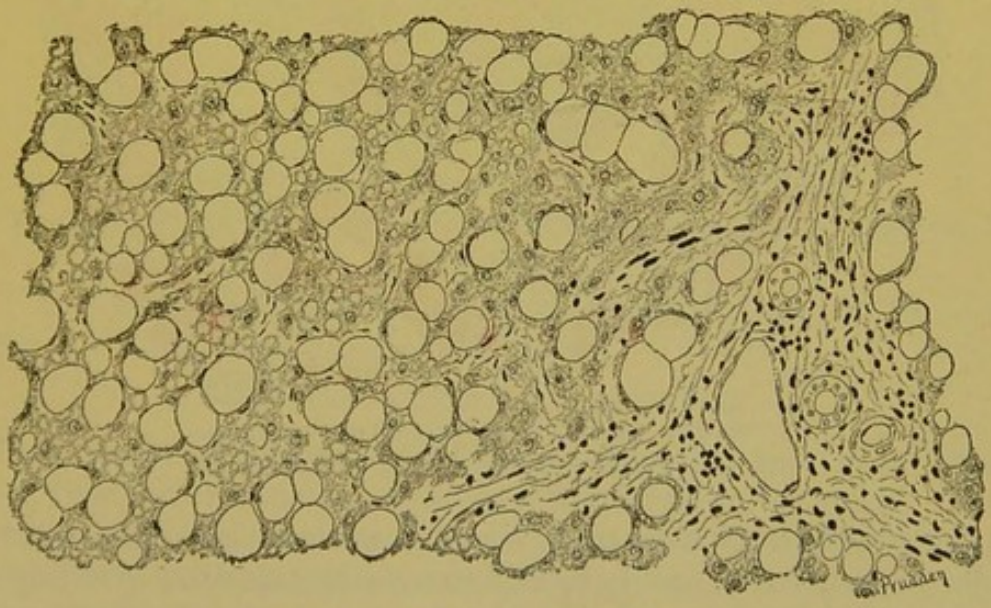

FIG. 291.—FATTY INFILTRATION OF LIVER.
Portion of the periphery of a lobule.

tion of the liver cells frequently follows, and is associated with, cloudy swelling under the varying conditions in which this occurs, or it may appear in profound anæmia and in acute phosphorus and arsenic poisoning.

*Amyloid Degeneration* (Waxy Liver).—In the liver amyloid degeneration may be general or local ; so extensive as to give the

organ very characteristic appearances, or so slight as to be unrecognizable without the aid of the microscope. It may be associated with other lesions. When the change is extensive and general the liver is enlarged sometimes to more than twice its normal size; the edges are thickened and rounded; the surface smooth; the tissue tough, firm, inelastic, more or less translucent, and of a brownish-yellow color. The lobular structure may be more or less indistinct, or it may become very evident by an associated fatty degeneration of the peripheral or central cells of the lobules. The translucency and peculiar appearance of the tissue may be best seen by slicing off a thin section and holding it up to the light. When the lesion is

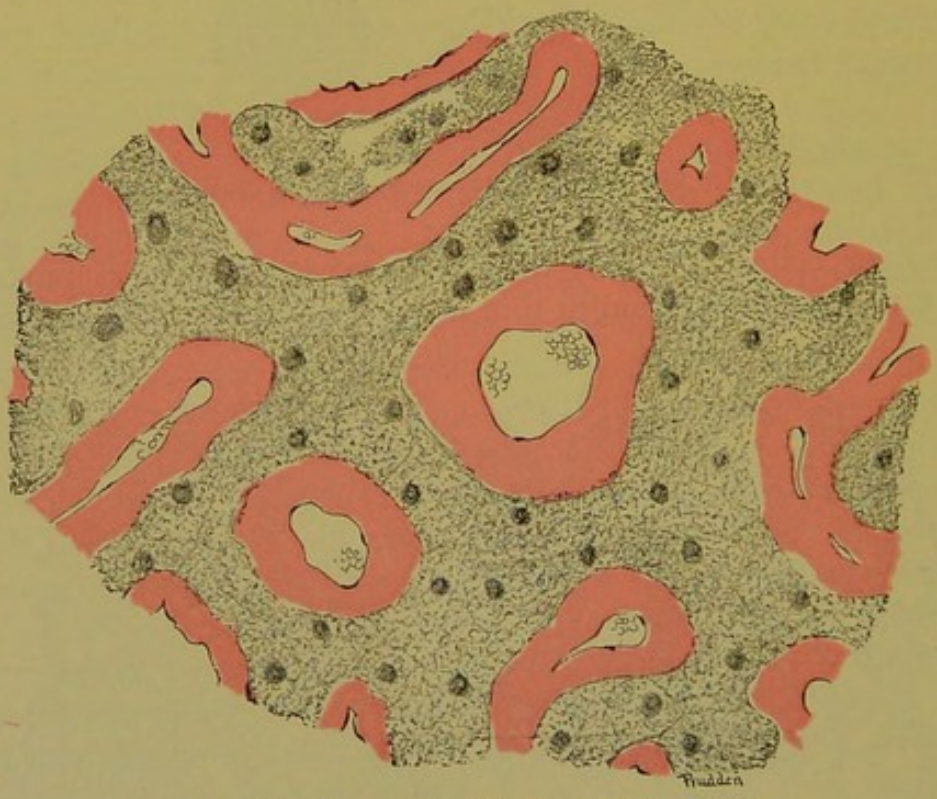

FIG. 292.—AMYLOID DEGENERATION OF THE LIVER.
The degenerated walls of the vessels are stained red.

less considerable the liver may be of the usual size, and may feel harder than normal, and here and there a translucent mottling may be evident, or the degeneration may be apparent only on the addition of staining agents. When, as is frequently the case, it is associated with cirrhosis, the liver may be small and nodular, and the appearance of the cut surface will vary greatly, depending upon the character of the cirrhotic change and the presence or absence of fat.

This degeneration usually commences in the walls of the intralobular blood vessels, causing them to become thickened and translucent. The liver cells are squeezed by the thickening of the vessels and may become partially or completely atrophied (Fig. 292).

It is stated by some observers that the liver cells may also become waxy, but we have been unable to find them unmistakably thus changed. The liver cells not infrequently undergo fatty metamorphosis. Amyloid degeneration may also involve the interlobular vessels, and in advanced stages larger and smaller areas of liver tissue may be nearly or completely converted into the dense, refractile substance which in its arrangement but obscurely represents the grouping and structure of the affected lobules. Not infrequently atrophic or fatty liver cells are seen scattered singly or in clusters through the amyloid masses. In the affected regions the blood content of the liver is considerably diminished, or it may be nearly entirely absent.

Amyloid degeneration of the liver is usually associated with a similar lesion of other organs, such as spleen, kidneys, intestines, etc., although it may occur in this organ alone. It usually occurs in cachectic conditions, as in chronic phthisis ; in chronic suppurations, especially of the bones ; in syphilis, and sometimes in malarial poisoning. It occasionally occurs unassociated with any of these conditions.

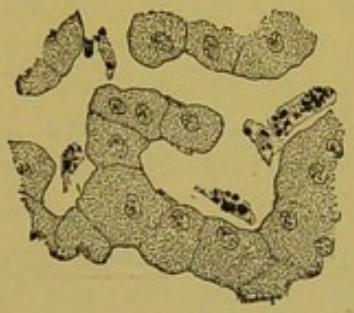

FIG. 293.—PIGMENTATION OF THE LIVER IN MALARIAL FEVER.
The pigment in this specimen was contained in cells lying within the liver capillaries.

## PIGMENTATION OF THE LIVER.

As a result of severe malarial poisoning a variable amount of brown, black, or reddish pigment is often found in the blood. This is usually mostly taken up by the leucocytes and deposited in various parts of the body, chiefly in the liver, spleen, and marrow of the bones. In the liver it is usually found enclosed in variously shaped cells which lie especially in the blood vessels, but sometimes in the tissue between them (see Fig. 293). The liver cells frequently contain bile pigment, but usually are free from the melanotic pigment characteristic of this malarial condition. As the result of this accumulation of pigment the liver may have a dark reddish-brown, an olive-brown, or black color (sometimes called *bronze* liver). This condition may be associated with various other lesions of the liver, depending upon the nature and extent of which the organ will present

a great variety of appearances. Thus there may be fatty or waxy degeneration, cirrhosis, chronic congestion, etc.

Pigment may be found in the connective tissue along the portal vessels similar in character to that which occurs in the lungs from the inhalation of coal dust. This inhaled pigment, according to the researches of Weigert, doubtless finds access to the blood and is deposited in the liver as it is in the spleen and hepatic lymph nodes.

Pigmentation of the liver cells, which is to a certain extent normal, may be greatly increased as a result of atrophy, localized hæmorrhage, and of obstructive jaundice.[1]

### ACUTE YELLOW ATROPHY OF THE LIVER.

This disease is characterized anatomically by a rapid diminution in the size of the liver as the result of a granular and fatty degeneration and disintegration of the liver cells. The liver, sometimes within a few days, may be reduced to one-half its normal size. On opening the abdominal cavity the organ may be found lying, concealed by the diaphragm, close against the vertebral column. The amount of diminution and the general appearance of the affected organ depend to a considerable extent upon its previous condition—*i.e.*, whether or not it was the seat of other lesions—as well as upon the degree of degenerative change. In general, if the lesion is well marked, the liver is small, flabby—sometimes almost fluctuating—and the capsule wrinkled. On section the cut surface may show but little trace of lobular structure, but presents an irregular mottling with gray, ochre-yellow, or red; sometimes one, sometimes another color preponderating.

Microscopical examination shows varying degrees of degeneration and destruction of the liver cells. Most evidently in those parts which have a grayish appearance, the outlines of the cells are preserved and the protoplasm is filled with larger and smaller granules. In the yellow portions the outlines of the liver cells may be preserved, and they may contain varying quantities of larger and smaller fat droplets and granules of yellow pigment. Or the cells may be completely disintegrated, and in their place irregular collections of fat droplets, pigment granules, red and yellow crystals, and detritus; only the connective tissue and blood vessels of the original liver tissue remaining. The red areas may show nearly complete absence of liver cells and cell detritus, and sometimes irregular rows of cells which are variously interpreted as being new-formed gall ducts or proliferated liver cells. In these areas it appears to be, in part at

[1] The distribution and amount of the pigment may be well seen by staining thin sections with eosin and mounting in eosin-glycerin or balsam.

least, the blood contained in the vessels which imparts the red color. Sometimes the interstitial tissue is infiltrated with small spheroidal cells resembling leucocytes. Crystals of leucin and tyrosin are sometimes found intermingled with the cell detritus. In some cases the liver is not diminished in size.

These lesions of the liver are frequently associated with enlargement of the spleen and parenchymatous degeneration of the kidney and of the heart muscle. Multiple hæmorrhages may occur in the gastro-intestinal canal, kidneys, bladder, and lungs. There is usually marked jaundice. Rod-shaped bacteria and micrococci have been found in the liver, but their significance is doubtful; we have not been able to find them in the cases which we have examined. The cause of the disease is unknown, and it is doubtful whether it is a disease primarily of the liver or an acute infectious disease with local lesions. It is not unlikely that more than one form of lesion is grouped under this heading.[1]

### INFLAMMATION OF THE LIVER.

*Acute Hepatitis* (Purulent Hepatitis; Abscess of the Liver).—Purulent or suppurative inflammation of the liver may be the result of injury; it may be secondary to inflammation of the gall ducts or the branches of the portal vein. It may occur as the result of the presence of tumors, parasites, or from propagation of an inflammatory process from without, as in ulcer of the stomach with adnesions to the liver and secondary involvement of the latter. It is often directly due to the introduction into the organ, through the blood vessels or gall ducts or otherwise, of bacteria. Purulent inflammation in the liver almost always results in abscess.

Large abscesses of the liver may be traumatic, but are often due to unknown causes. They are not infrequently associated with dysentery, and may then be due to the conveyance of micro-organisms through the veins, or lymph channels, or peritoneum, or gall ducts from the intestinal ulcers. They may be due to the presence of the amœba coli. They occur most frequently in tropical climates, but are not very uncommon in the temperate zone. They are usually single, but there may be several of them. They are sometimes so large as to occupy a large part of the lobe. They are most frequent in the right lobe, but may occur in any part of the organ. They tend to enlarge, and as they do so they approach the surface of the liver. Here the contents of the abscess may be discharged into the perito-

[1] For an account of a bacterial study of a case of Infectious Febrile Icterus (Weil's disease) consult *Jaeger*, Zeits. f. Hygiene u. Infectkr., Bd. xli., p. 525, 1892.

neal cavity. More frequently, however, as they approach the surface, a localized adhesive peritonitis ensues, so that the liver becomes bound to adjacent parts, and thus the abscess may open into the pleural cavity, or, owing to a secondary pleurisy with adhesions, into the lung tissue. They may open into the pericardium. They may open externally through the abdominal wall; into the stomach, duodenum, colon, or pelvis of the right kidney; into the hepatic veins, portal vein, vena cava, or gall bladder or gall ducts.

The early stages in the formation of large abscesses of the liver are but little known. It is probable, however, that in many cases they are the result of the confluence of smaller abscesses. Their contents, usually bad smelling, may be thick and yellow like ordinary pus, but more commonly they are thin, reddish-brown, or greenish in color from admixture with the pus of blood, gall pigment, and broken-down liver tissue. Microscopical examination shows the contents to consist of fluid with pus cells, more or less degenerated blood, degenerated liver cells, fragments of blood vessels, and pigment granules and crystals. The walls of the abscess are usually ragged, shreds of necrotic liver tissue hanging from the sides. Microscopical examination of the liver tissue near the abscess shows infiltration with pus, flattening of the liver cells from pressure, cloudy swelling, and necrosis of those lying along the cavity. Bacteria or the amœba coli or both may be present. Liver abscesses due to the presence of the amœba coli have certain peculiarities, concerning which reference is made to the studies of *Councilman and Lafleur*, "Amœbic Dysentery," Johns Hopkins Hospital Reports, vol. ii., p. 490, 1892.

The amœbic abscesses are usually free from bacteria. Other abscesses may contain the Bacillus coli communis, or the Streptococcus pyogenes or Staphylococcus pyogenes.

Not infrequently, however, especially in old abscesses, examination both morphological and cultural fails to reveal the presence of microorganisms.

After the discharge of the contents of the abscess or without this if it be not very large, granulation tissue may form in the wall of the cavity and a fibrous capsule be produced, enclosing the contents, which become thickened and often calcareous, and in this condition may remain for a long time. Or the connective-tissue walls may approach one another and join, forming a fibrous cicatrix at the seat of the abscess.

Several large abscesses may, one after another, heal in this way after evacuation of their contents, with little diminution in the size of the liver.[1]

[1] *Edebohls*, "Dysentery and Hepatic Abscess with Amœba Coli," Proceedings of the New York Pathological Society, 1892.

Abscesses of the liver accompanying inflammation of the portal vein and gall duct are considered elsewhere in this section.

Small *multiple metastatic abscesses* are not infrequent in pyæmia, and are called *pyæmic abscesses*. In these abscesses we can readily study the various stages of formation. Suppurative processes in any part of the body—in the head, upper and lower extremities, etc.—may act as distributing centres for micro-organisms.[1] These, entering the circulation, may pass the heart and pulmonary capillaries, with or without inducing lesions in the lungs, and, lodging in the vessels of the liver, induce circumscribed necrosis of the liver

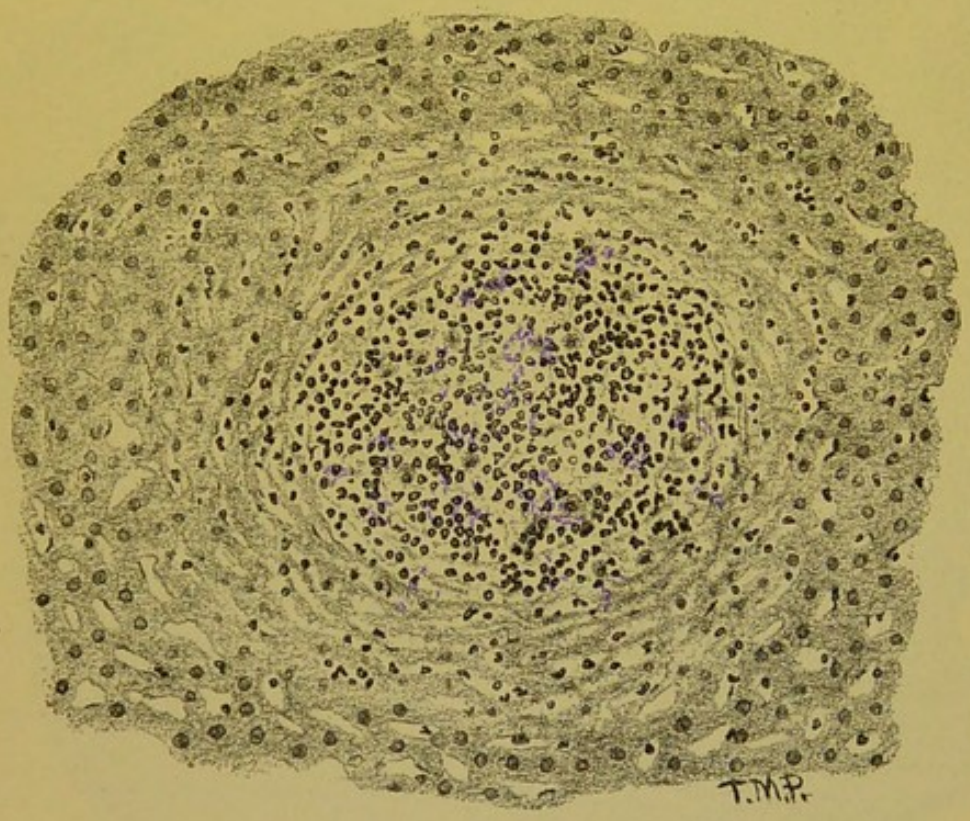


FIG. 294.—SMALL ABSCESSES IN THE LIVER CONTAINING BACILLI.
Associated with a suppurative inflammation of the gall bladder and gall ducts.

tissue (see Fig. 294) and suppurative inflammation. Under these conditions we may find on a section of the liver larger and smaller yellowish or grayish spots, the larger of which may be soft and present the usual characters of abscesses. The smaller, which may not be larger than a pin's head, may present the usual consistence of liver tissue with the lobular structure still evident; others may be softer, more yellow, and surrounded by a zone of hyperæmic liver tissue. Microscopical examination of the earlier stages often shows the blood vessels filled with micrococci, scattered and in masses. Around

[1] *Kruse and Pasquale*, Zeits. f. Hygiene u. Infkr., Bd. xvi.

these the liver cells are found in various stages of necrosis; in many the nuclei do not stain and the bodies are very granular, or the entire cell is broken down into a mass of detritus. About these necrotic islets of liver cells pus cells collect and often form a zone of dense infiltration. Thus, by the increase of pus cells and the necrosis of liver tissue, small abscesses are formed whose contents are intermingled with greater or less numbers of bacteria, which seem to increase in number as the process goes on. By the confluence of small

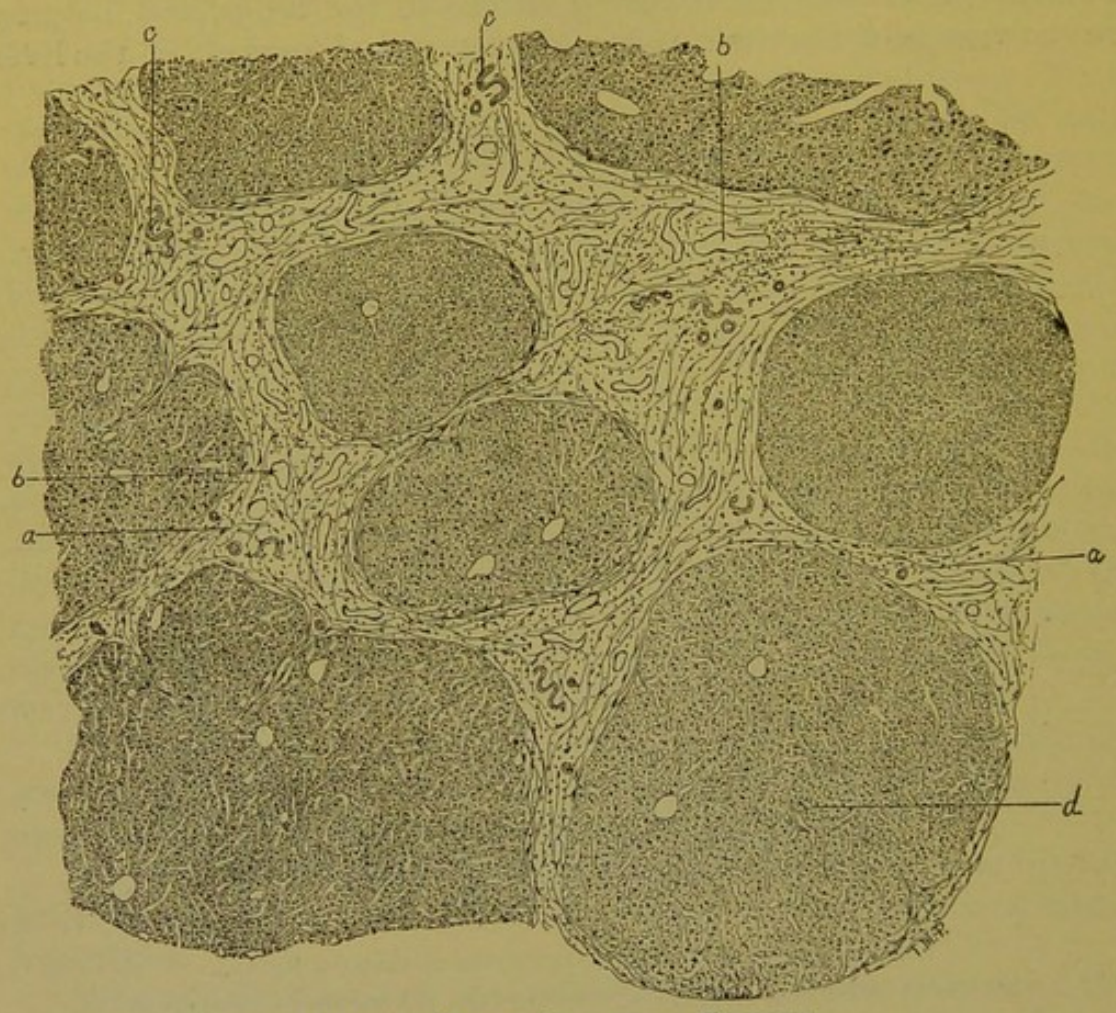


FIG. 295.—CHRONIC INTERSTITIAL HEPATITIS.

*a*, new-formed connective tissue; *b*, dilated blood vessels of the new tissue; *c*, gall duct; *d*, parenchyma of liver.

abscesses larger ones may be formed. Death usually ensues, however, before the abscesses attain a very large size.

*Chronic Interstitial Hepatitis* (Cirrhosis).—The most marked result of chronic interstitial hepatitis is the formation of new connective tissue in the liver. The character, amount, and distribution of the new tissue vary greatly in different cases. Secondarily there are usually marked changes in the liver cells and in the blood vessels and gall ducts. The new tissue is most commonly formed and most

abundant in the periphery of the lobules along the so-called capsule of Glisson, but it may extend into the lobules between the liver cells. It may surround single lobules, or more frequently larger and smaller groups of lobules (Fig. 295). It may occur in broad or narrow, irregular streaks or bands. It is frequently more abundant in one part of the liver than in another. The new-formed tissue tends to contract, and thus compromise by pressure the enclosed islets of liver tissue, causing them to project, in larger and smaller nodules, from the surface of the organ. The liver cells may be flattened or atrophied from pressure; or, from interference with the portal circulation, they may atrophy or become fatty; or they may become colored with bile pigment. The varied appearances with cirrhotic livers present to the naked eye depend largely upon the amount and distri-



FIG. 296.—HYPERTROPHIC CIRRHOSIS OF THE LIVER.
Showing formation of connective tissue between the liver cells.

bution of the new connective tissue and upon the secondary changes in the liver cells.

In some cases the liver is enlarged, sometimes so much so as to weigh nine or ten pounds, the surface smooth or slightly roughened —*hypertrophic cirrhosis:* in other cases it may be finely or coarsely nodular on the surface. It may be smaller than normal, sometimes very small indeed, so as to weigh only one or two pounds—*atrophic cirrhosis.* The surface may then be very rough and uneven from the projection of larger and smaller nodules of liver tissue, or it may be quite smooth; or the organ may be greatly distorted by the contraction of large bands or masses of new connective tissue. In section through cirrhotic livers the new tissue may not be visible to the naked eye, or it may appear as grayish, irregular streaks, or bands, or patches, often sharply outlined against the dark-red, or brown, or

yellow, or greenish-yellow parenchyma. When, as is often the case, fatty infiltration is associated with atrophic cirrhosis the liver, may not only not be diminished in size but may be larger than normal.

On microscopical examination the new connective tissue is found in some cases loose in texture and containing many variously shaped cells; or it may be dense and contain comparatively few cells; it is usually quite vascular. In some forms of hypertrophic cirrhosis there may be a very general and extensive growth of new fibrous tissue in and along the capillaries between the liver cells (Fig. 296). In other cases of hypertrophic cirrhosis the new growth of connective




FIG. 297.—CHRONIC INTERSTITIAL HEPATITIS.

Showing a portion of the section shown in Fig. 244, but more highly magnified. *a*, portions of liver lobules; *b*, new-formed connective tissue; *c*, gall ducts, apparently new formed; *d*, blood vessels in the new tissue.

tissue is abundant between the liver lobules and along the smaller gall ducts, without encroaching materially upon the parenchyma. Not infrequently, when occurring largely between the lobules, it will be found to have encroached more or less upon their peripheral portions. Very frequently there are found in the new connective tissue cylindrical ducts lined with cuboidal cells, and resembling gall ducts (Fig. 297, *c*); or irregular rows of more or less cuboidal or polyhedral cells, which look somewhat like the lining cells of the medium-sized gall ducts, or like altered liver cells. The branches of the hepatic

and portal veins, particularly the latter, often become obliterated by pressure from the new connective tissue or from chronic thickening of their walls, so as to seriously interfere with the functions and nutrition of the liver cells. The bile ducts also may become obliterated, or there may be catarrhal inflammation, especially of the larger trunks. The branches of the hepatic artery are much less liable to alterations than the other vessels. The capsule of the liver is usually thickened, either uniformly or in irregular patches; or its surface may be roughened by larger and smaller papillary projections. The liver is frequently bound to the diaphragm or other adjacent organs by connective-tissue adhesions. Amyloid and fatty degeneration may be associated with cirrhosis. Cirrhotic livers frequently show an unusual number of leucocytes in the blood vessels.

The obstruction to the portal circulation induced by cirrhosis usually gives rise to a number of secondary lesions, since collateral circulation is rarely established in sufficient degree to afford much relief. The hæmorrhoidal and vesical veins may be greatly enlarged, and also veins of communication between Glisson's capsule and the diaphragmatic veins.

In rare cases a very peculiar dilatation of the cutaneous veins about the umbilicus is observed. The enlarged veins form a circular network around the umbilicus, or a pyramidal tumor alongside of it, or all the veins of the abdominal wall, from the epigastrium to the inguinal region, are dilated. This condition is said to be produced by the congenital non-closure and subsequent dilatation of the umbilical vein and its anastomoses with the internal mammary, epigastric, and cutaneous veins. According to Sappey, it is not the umbilical vein which is dilated, but a vein which accompanies the ligamentum teres.

There is very frequently also a dilatation of the veins of the abdominal wall, which has a different cause. It is produced by the pressure of the fluid of ascites on the vena cava, and is found with ascites from any cause and with abdominal tumors.

Ascites is the most common secondary lesion of cirrhosis. It usually begins at an early stage of the disease, and is apt to increase constantly. It usually precedes œdema of the feet, but both may appear at the same time. This fluid is of a clear yellow or brown, green or red; it is sometimes mixed with shreds of fibrin, and more rarely with blood. The peritoneum remains normal, or becomes opaque and thick, or there may be adhesions between the viscera.

The spleen is very frequently enlarged, and the enlargement may be very considerable. When it is not increased in size this seems usually due to previous atrophy of the organ, or to fibrous thickening

of its capsule, or to hæmorrhages from the stomach and bowels occurring just before death.

The stomach and intestines are often secondarily affected by the obstruction to the portal circulation. Profuse hæmorrhage from the stomach and intestines may occur and sometimes cause sudden death. The mucous membrane is then found pale, or congested, or with hæmorrhagic erosions. Sometimes the blood is infiltrated in the coats of the stomach and intestines. The mucous membrane of the stomach, and of the entire length of the intestines, is frequently the seat of chronic catarrhal inflammation, and is sometimes uniformly and intensely congested and coated with mucus. In other cases both the mucous and muscular coats are pale, but very markedly thickened.

Cirrhosis of the liver is not infrequently accompanied by chronic diffuse nephritis.

The causes of cirrhosis are imperfecly understood. It is a disease of adult life, but exceptionally occurs in children. In adults it seems in many cases to be directly dependent upon the continued ingestion of large quantities of strong alcoholic liquors. It very rarely occurs as a result of beer drinking. There are many cases of cirrhosis for which no cause can be discovered. It is probable that in certain cases a degeneration of circumscribed areas of liver parenchyma precedes and probably determines the new formation of connective tissue. Welch[1] has described the occurrence of small circumscribed areas of fibrous tissue in the liver, replacing liver cells and containing coal pigment. This rare lesion he has called *cirrhosis hepatis anthracotica.*

*Syphilitic Hepatitis.*—Chronic interstitial inflammation of the liver very frequently results from syphilitic infection, either congenitally or in the later stages of the acquired form. It may occur in a diffuse manner, new connective tissue being formed either between the lobules, or within them between the rows of liver cells. The new tissue may be rich in cells, or dense and firm. This form is frequently seen in children, and cannot be distinguished, either macroscopically or microscopically, from similar forms of interstitial hepatitis from other causes.

In other cases, particularly in children, there may be numerous small gummata (so-called *miliary gummata*) scattered through the liver, together with more or less new connective tissue (Fig. 298). In adults gummata are usually larger, varying in size from that of a pea to a hen's egg, and may be surrounded by larger and smaller irregular zones of ordinary connective tissue (Fig. 299). In still

[1] *Welch*, "Cirrhosis hepatis anthracotica," Johns Hopkins Hospital Bulletin, February and March, 1891.

other cases in adults we find larger and smaller dense, irregular bands or masses of connective tissue running through the liver, drawing in the capsule and often causing great deformity of the organ. These bands and masses of new tissue may or may not enclose gummata, either large or small. These deforming cicatrices, either with or without gummata, are very characteristic of syphilitic inflammation of the liver.

This, like the simple interstitial inflammation of the liver, may be



FIG. 298.—SYPHILITIC HEPATITIS.

A so-called miliary gumma from the liver of a child with congenital syphilis.

associated with fatty and waxy degeneration, and with atrophy of the parenchyma from pressure.

*Tuberculous Hepatitis.*—This lesion, which is usually secondary to tubercular inflammation in some other part of the body, or a part of acute general miliary tuberculosis, is most frequently characterized by the formation of larger and smaller miliary tubercles, which may be either within or between the liver lobules or in the walls of the bile ducts. Many of the tubercles are too small to be seen with the naked eye; others may be just visible as grayish points; still others may be from one to three mm. in diameter, with distinct yellowish-white centres. Microscopical examination shows considerable varia-

tion in the structure of the tubercles in different cases, as well as in the same liver. Some of them, usually the smaller ones, consist simply of more or less circumscribed collections of small spheroidal cells, which are not morphologically distinguishable, so far as the form and arrangement of the cells are concerned, from simple inflammatory foci, or from the diffuse masses of lymphatic tissue which occur normally in the liver.

In other forms we find a well-marked reticulum with larger and smaller spheroidal and polyhedral cells, with or without giant cells. In still other forms there is more or less extensive cheesy degeneration. The larger forms are conglomerate, being composed of several tubercle granula joined together to form a single nodular mass. The

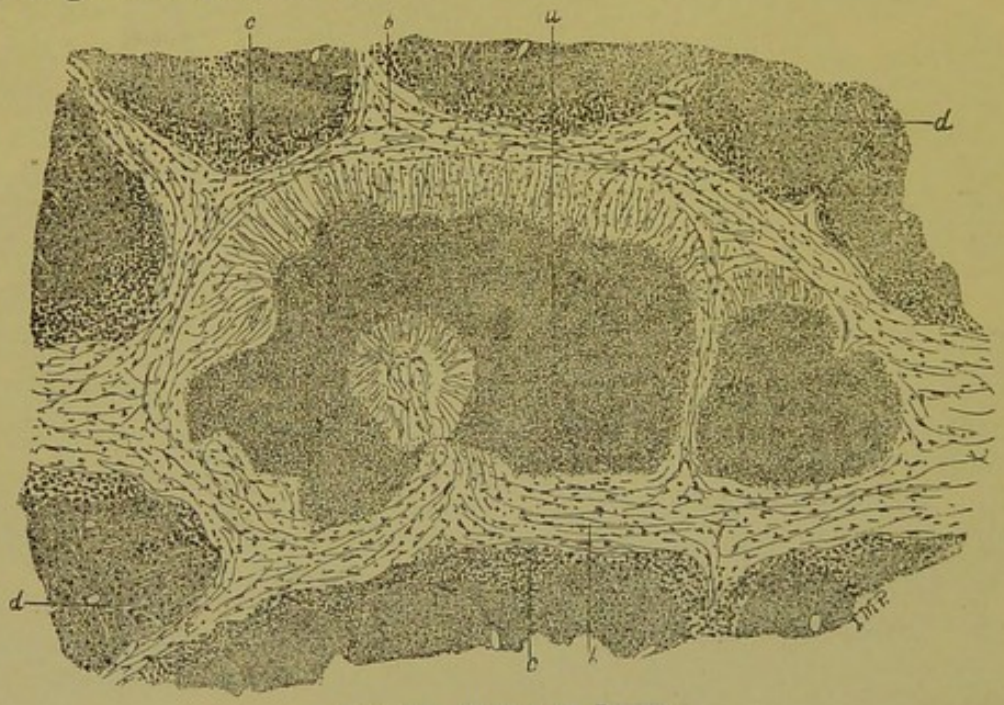


FIG. 299.—GUMMA OF LIVER.

*a*, cheesy centre; *b* fibrous periphery; *c*, small-celled peripheral infiltration; *d*, portions of live lobules.

liver cells at the seat of the tubercle are destroyed, and the interstitial tissue and blood vessels either destroyed or merged into the tubercle tissue. In the periphery of the tubercles the liver cells may be in a condition of coagulation necrosis, and the tissue round about may be infiltrated with small spheroidal cells. There is in some cases a new formation of gall ducts or of structures which resemble these, and which in transverse sections look considerably like giant cells. Tubercle bacilli, frequently in small numbers, but often in great abundance, may be found within the tubercles.

Tuberculosis of the liver may be associated with cirrhosis, waxy and fatty degeneration.

Much more rarely than the above form there are found in the liver

more or less numerous scattered tubercular masses from the size of a pea to that of a walnut or larger, with cheesy centres and usually a new growth of connective tissue in the periphery. These so-called *solitary tubercles* of the liver may be softened at the centres. Tubercular inflammation of the gall ducts may give rise to numerous scattered, cheesy nodules, as large as a pea or larger, which may be softened at the centre and stained yellow with bile. This lesion is rare and seems to be more frequent in children than in adults.

*Perihepatitis.—Acute inflammation* of the serous covering of the liver, with the formation of fibrin, may occur as a part of acute general or localized peritonitis, and over the surface of abscesses, tumors, hydatids, etc., of the organ, when these lie near or approach the surface; or it may be secondary to acute pleurisy.

*Chronic perihepatitis*, resulting in the thickening of and formation of new connective tissue in and beneath the capsule of the liver, may be secondary to an acute inflammation of the capsule, or it may be chronic from the beginning and associated with chronic pleurisy, chronic peritonitis, and cirrhosis. In this way more or less extensive adhesions of the liver to adjacent structures may be formed; or, by contraction of the new-formed connective tissue, considerable deformity of the liver may be produced. The capsule is sometimes uniformly thickened, sometimes the new tissue occurs in more or less sharply circumscribed patches. The surface is sometimes roughened from little, irregular projecting masses of connective tissue. Microscopically the new-formed tissue is usually dense and firm, but it may be loose in texture and contain many cells. Not infrequently bands or masses of connective tissue run inward from the thickened capsule between the superficial lobules, causing localized atrophy of the parenchyma.

*Hyperplasia of Lymphatic Tissue in the Liver.*—In some forms of leukæmia and pseudo-leukæmia the liver is not infrequently enlarged and soft and besprinkled with small white spots, or streaked with narrow whitish, irregular bands, or of a diffuse grayish color. Microscopical examination shows this change to be due to an accumulation of cells resembling leucocytes, either along the portal vein, or diffusely through the liver tissue, or in small circumscribed masses. The amount of accumulation of these small cells varies much, but is sometimes so great as to seriously compromise the liver cells. The origin of these new cells is not yet definitely known. They may be, and doubtless in part are, brought to the organ through the portal vein; but they may, in part at least, be formed in the liver itself, possibly from the capillary endothelium.

In typhoid fever, small-pox, scarlatina, diphtheria, and measles small circumscribed masses of cells resembling leucocytes are some-

times found in the liver, lying in the meshes of a delicate reticular tissue. These are sometimes called *miliary lymphomata;* but it should be remembered that small masses of lymphatic tissue normally occur in the liver, and that as, under the above conditions, an hyperplasia of the lymph nodes and spleen is wont to occur, these so-called lymphomata are very probably normal structures, which have become more prominent under the conditions of disease owing to an acute inflammatory condition induced by absorbed ptomaines.

## TUMORS OF THE LIVER.

Tumors of the liver may be primary or secondary; the latter are most common.

*Cavernous Angiomata.*—These tumors, usually small, from five to fifteen mm. in diameter, are most common in elderly persons and are of no practical significance. They may be situated at the surface or embedded in the organ, and are of a dark-red color; sometimes sharply circumscribed by a connective-tissue capsule, sometimes merging imperceptibly into the adjacent liver tissue. Microscopically they consist of a congeries of irregular cavities (Fig. 144, page 327) filled with blood and frequently communicating freely with one another. The walls of the cavities consist of connective tissue, often containing small blood vessels, and are sometimes thick, sometimes thin. They are believed to be formed by dilatation of the liver capillaries, with subsequent thickening of their walls and atrophy of the adjacent liver cells.

Small *fibromata* and *lipomata* have been described, as also *fibro-neuromata* of the sympathetic.

*Adenomata* of the liver are of not infrequent occurrence. They are sometimes small and circumscribed, sometimes very large and multiple. They present two tolerably distinct types of structure. In one form the tissue presents essentially the same structure as normal liver tissue, except that the arrangement of the cells is less uniform and the cells are apt to be larger. They look like little islets of liver tissue, sometimes encapsulated and sometimes not, lying in the liver parenchyma. In the other form the cells are less like liver cells, are frequently cylindrical, and are arranged in the form of irregular masses of tubular structures with more or less well-defined lumina. These tumors are sometimes large and multiple, and in one case described by Greenfield there were metastatic tumors in the lungs. These tubular adenomata are in some cases so closely similar to some of the carcinomata as to be scarcely distinguishable from them, and seem, indeed, to merge into them. Cysts may develop in adenomata.[1]

[1] See *Dmochowski and Janowski*, Ziegler's Beitr. z. path. Anat., Bd. xvi., p. 102.

*Carcinomata* are the most common and important of the liver tumors, and may be primary and secondary. Primary carcinomata of the liver are probably developed from the epithelium of the gall ducts, and in some cases are arranged along the larger trunks. Their cells are usually polyhedral, sometimes cylindrical, and may be arranged irregularly in alveoli or form more or less well-defined tubular structures.

Secondary carcinomata of the liver, which are by far the most common, are most frequently due to the dissemination in the organ of tumor cells from carcinomata of the stomach, intestines, pancreas, or gall bladder. But they may be the result of metastases from the mamma, œsophagus, uterus, and various other parts of the body. In secondary carcinomata the cells resemble more or less closely the type of those forming the primary tumor.

The form in which the carcinomatous nodules in the liver present themselves is subject to considerable variation. Sometimes they are single, but more often multiple ; they may be very large, or so small as to be scarcely visible to the naked eye ; very frequently numerous small nodules are grouped in the periphery of a larger cancerous mass. They are sometimes deeply embedded in the liver, sometimes they project from the surface. The liver is frequently enlarged, sometimes enormously so. The nodules are usually whitish or yellowish or pink in color, but they are often the seat of hæmorrhages, and may become softened at the centre, forming cysts filled with degenerated tumor tissue which is often mixed with blood. The nodules are sometimes hard, sometimes soft and almost diffluent. Fatty degeneration is frequent, and may be evident to the naked eye in the form of yellowish streaks or patches on the cut surfaces. Owing to the degeneration and partial absorption of the central portions of the tumors, the nodules on the surface frequently present a shallow depression at the centre. The tumors may be sharply outlined against the adjacent liver tissue, or may merge imperceptibly into it. They may be so large or numerous as to occupy the greater part of the enlarged organ. The liver tissue in their vicinity shows flattening and atrophy of the liver cells from pressure, and there may be infiltration with small spheroidal cells. The tumors may press upon the portal vein or its branches, or upon the gall ducts, and thus seriously interfere with the functions of the organ. Sometimes, however, the tumors are very large and abundant without causing any apparent detriment to the liver functions. They are not infrequently stained with bile. *Melanotic carcinomata* sometimes occur in the liver, most frequently as secondary tumors.

In some cases, instead of forming separate, distinct nodules, the cancerous growth develops in the form of a diffuse infiltration of the

organ, so that the often greatly enlarged liver is irregularly mottled with white and reddish-brown masses, and may then somewhat resemble some forms of chronic interstitial hepatitis.

*Sarcomata.*—Spindle-celled, melanotic, and telangiectatic sarcomata may occur in the liver as secondary tumors. Secondary *myxomata* and *chondromata* have also been described, but they are very rare. Angiosarcoma may occur as a primary tumor.[1]

*Cavernous lymphangiomata* have been described in a few cases. *Cysts*, usually of small size, may occur by dilatation of the bile ducts. They may be multiple and contain serum, mucus, and degenerated epithelium. Single cysts, apparently unconnected with the gall ducts, are occasionally found in the connective tissue of the liver. They may be lined with ciliated epithelium.

The liver is sometimes the seat of larger and smaller *multiple cysts*, varying from microscopical size up to that of a pea, and sometimes larger. They do not appear to communicate with the gall ducts. They are sometimes associated with multiple cysts of the kidney. Their origin and nature are not understood.[2]

Occasionally the liver is found at the autopsy, even if this be made but a few hours after death, more or less completely riddled with small, irregular-shaped cavities, from the size of a pin's head to that of a pea. These holes are due to the accumulation of gases in the liver, and are frequently associated with the presence of the Bacillus aërogenes capsulatus (see p. 261).

## PARASITES.

*Echinococcus.*—This parasite is the most common and important of those which occur in the human liver. It forms the so-called *hydatids* of the liver. These represent one of the developmental stages of the small tapeworm of the dog, *Tænia echinococcus* (see page 108). The cysts in the liver may be very small and multiple, but they may be as large as a man's head or larger. The liver may be greatly increased in size, and the tissue about the cysts atrophied. The liver itself furnishes a connective-tissue capsule, within which is the translucent, lamellated membrane furnished by the parasite. On the inside of this we may find a layer of cells, granular matter, and a vascular and muscular system belonging to the parasite. Projecting from this inner capsule are the brood capsules and heads or scolices of the immature tapeworm. The sco-

[1] *Arnold*, Ziegler's Beitr. z. path. Anat., Bd. viii., p. 123.

[2] Consult *Pye-Smith*, "Cystic Disease of Liver and both Kidneys," Trans. London Path. Soc., vol. xxxii., p. 112, 1881.

lices may become detached from the wall and lie free in the cavity, which is filled with a transparent or turbid fluid. Not infrequently the cysts are sterile, and are then simply filled with clear or turbid fluid; or the embryos may have died and disintegrated, and their detritus, including the hooklets, may be intermingled with the fluid contents of the cysts. The contents of the cysts may be mixed with fat, cholesterin crystals, pus, bile, or blood; or form a grumous mass, in which we may or may not be able to find the hooklets of the scolices or fragments of the lamellated wall. The connective tissue of the walls of the cysts may be greatly thickened, or they may be calcified.

In other countries the lesion is much more common and frequently more formidable than in the United States. The cysts reach an enormous size, the veins of the liver may be compressed and filled with thrombi, the bile ducts compressed and ulcerated. So much of the liver tissue may be replaced by the hydatids that the patient may die from this cause alone. Very frequently there is local peritonitis, and adhesions are formed between the liver and the surrounding parts. In some cases the cysts rupture, and their contents are emptied into the peritoneal cavity, the stomach, the intestines, the pleural cavity, or the lung tissue. Sometimes the cysts perforate the bile ducts, the vena cava, or some of the branches of the portal or hepatic veins. Sometimes the abdominal wall is perforated and a fistula formed between the cavity in the liver and the surface.

In cases in which we do not find the scolices entire, a careful examination of the inner cyst wall or of its contents will frequently establish the diagnosis by revealing single hooklets (see Fig. 40, page 134) or fragments of the characteristically lamellated wall (see Fig. 38, page 133).

*Echinococcus multilocularis*, which is apparently an abortive form of the above species (see page 132), is very rare indeed in the United States. The writer (T. M. P.) has examined a specimen sent to him by Dr. Edward J. Ill, of Newark, N. J., and which is now in the museum of the College of Physicians and Surgeons, New York. The patient was a male, age thirty-one, German, single, farmer. He had been in the United States five years. For a year previous to his death he had been out of health, and jaundiced and somewhat emaciated. A large, indistinctly fluctuating tumor was evident in the right lumbar and umbilical regions, and apparently connected with the liver. Aspiration of the tumor gave a milky fluid believed to be pus. An opening was made into the tumor by one of the surgeons attending the case, and death occurred, after ten hours, from hæmorrhage.

The liver was found adherent to the abdominal walls, and about one-fourth of the right lobe of the liver was occupied by an irregular cavity with very rough, ragged walls. These walls were in some places from one to two inches in thickness, and appeared to the naked eye to consist of dense connective tissue in irregular bands and fascicles, which enclosed very irregular, mostly small cavities. Microscopical examination showed that the cavities were lined with the delicate, lamellated cuticula characteristic of the echinococcus cysts. No hooklets were found. Fig. 300 is a drawing from this specimen.

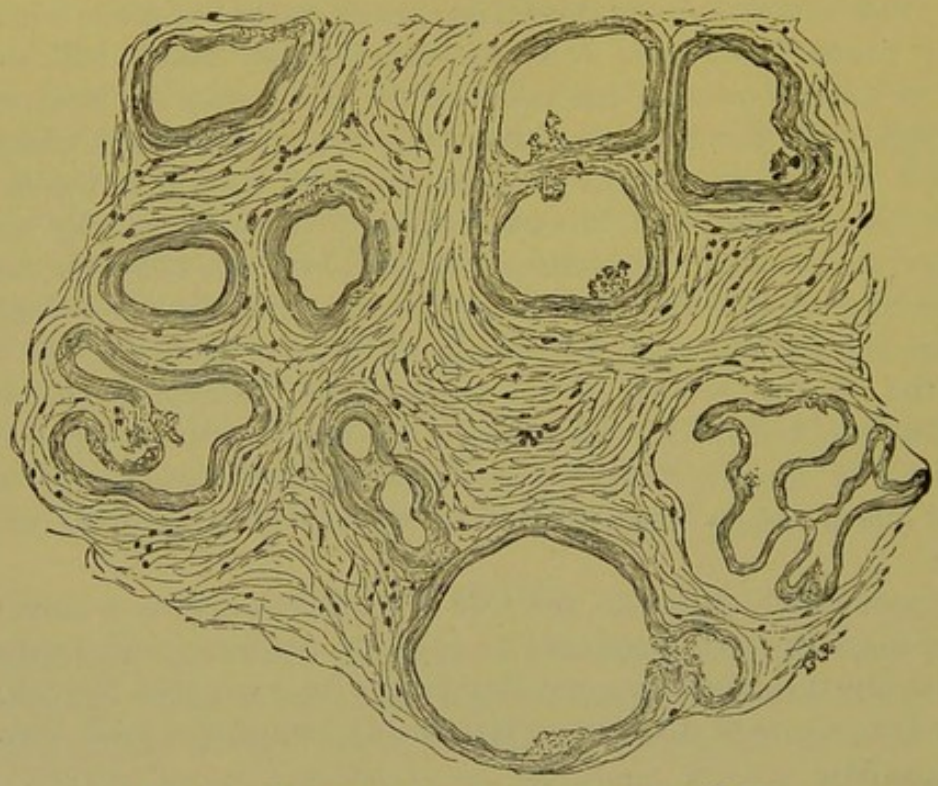

FIG. 300.—ECHINOCOCCUS MULTILOCULARIS OF THE LIVER.

*Distoma hepaticum*, *D. sinense*, *D. lanceolatum*, may occur in the gall ducts and gall bladder. *D. sinense* occurs especially in the East, and has been found in great numbers in the bodies of Chinamen. *D. hæmatobium* is very common in Egypt and Abyssinia, occurring in the blood vessels of the liver.

*Pentastoma denticulatum* is the undeveloped form of Pentastoma tænioides, a parasite which inhabits the nasal cavity of dogs and some other animals. In the liver of man it usually occurs in the form of small, rounded, calcified cysts. The cysts may contain fat, calcareous matter, and the remains of the dead parasite, among which the hooklets may be found.

*Ascaris lumbricoides* sometimes finds its way from the intestines

into the bile ducts. It may cause no disturbance here, but in some cases the worms have been present in large numbers and caused occlusion, dilatation, and ulceration of the biliary passages, and have led to the formation of abscess of the liver.

*Psorospermia*, the very common parasite in the rabbit's liver, has been found a few times in the liver of man.

## THE BILIARY PASSAGES.

*Catarrhal Inflammation* most frequently attacks the lower portion of the common duct and the gall bladder. In the acute form it usually leaves but few changes appreciable after death. An abnormal coating of mucus, and sometimes congestion of the blood vessels, are almost the only post-mortem lesions. Owing to the swelling of the mucous membrane and the accumulation of mucus in the lumen, the ducts may be temporarily occluded, but this occlusion may not be evident after death. If, however, the inflammation becomes chronic, the walls of the bile ducts may become thickened and their lumina more or less permanently obstructed. In consequence of this, dilatation or ulceration of the bile ducts may ensue. Temporary obstruction of the bile ducts may produce marked pigmentation of the liver, owing to the accumulation of pigment granules in the liver cells, particularly in the vicinity of the capsule of Glisson, and jaundice of the entire body.

The gall bladder may be inflamed by itself—cholecystitis—or in connection with inflammation of the biliary passages. If the disease is chronic the wall of the bladder may be thickened; polypoid growths may occur in the mucosa; the duct may be occluded; dilatation, ulceration, the formation of gall stones, calcification, and atrophy may ensue.

Inflammation of the stomach and duodenum, hyperæmia and inflammation of the liver, concretions, and parasites are the usual causes of catarrhal inflammation of the biliary passages, but it may occur without these.

### SUPPURATIVE AND CROUPOUS INFLAMMATION OF THE BILE DUCTS (ANGIOCHOLITIS).

The walls of the ducts may be covered or infiltrated with a fibrinous or a purulent exudate; they may ulcerate.

These lesions occur most frequently in connection with obstruction of the bile ducts by gall stones or otherwise, and in typhoid and typhus fever, pyæmia, cholera, or they may be due to the extension of inflammatory processes from without. They also occur under unknown conditions.

In many cases of inflammation of the gall ducts, the Bacillus coli communis, in fewer, the pyogenic streptococcus and staphylococcus are apparently concerned.

Suppurative inflammation may produce perforations of the ducts or bladder, with escape of bile and peritonitis; or fistulous openings between the gall bladder and the duodenum, colon, and stomach, or through the abdominal wall. Or the inflammation may extend to the liver tissue and produce abscesses. Under the latter conditions we may find a series of small abscesses ranged along the walls of the suppurating gall ducts. In more advanced stages the abscesses may become large and communicate with one another, so that a considerable portion of the liver may be occupied by a series of communicating cavities with ragged walls, containing pus and detritus of liver tissue more or less tinged with bile.

Such abscesses may become more or less completely enclosed by conective-tissue walls. The portal vein may also become inflamed, and perforations may be formed between it and the bile ducts.

*Constriction and Occlusion* may be produced by inflammation of the ducts themselves, by new growths in their walls, by calculi or parasites in their lumina, by changes in the hepatic tissue in chronic and acute hepatitis, by aneurisms, or by pressure on the duct from without, as by tumors in the head of the pancreas, etc.

The obliteration of the smaller bile ducts produces no marked lesions. When the ductus communis or the hepatic duct is obstructed, the ducts throughout the liver are frequently dilated and the liver tissue bile-stained. The liver may undergo atrophy and the whole body be intensely jaundiced. When the cystic duct is obstructed the gall bladder is dilated.

*Dilatation* of the bile ducts is usually produced by strictures in the ways just mentioned, or by calculi. When calculi have produced the dilatation this condition may sometimes continue after they have found their way into the intestines. Sometimes, however, we meet with very marked dilatation of the bile ducts without being able to make out any present or past obstruction. The dilatation may affect only the common and hepatic ducts, or it may extend to the smaller ducts in the liver, which are then dilated uniformly or sacculated. They may contain bile, mucus, or calculi. The liver is at first enlarged, but may afterward atrophy. The gall bladder may be dilated in consequence of obstruction of the common or the cystic duct. In the latter case it may reach an immense size and form a large tumor in the abdominal cavity. The dilatation is generally uniform, the bladder retaining its normal shape; sometimes, however, there are diverticula, which are usually produced by calculi. If the obstruction to the hepatic duct is incomplete or movable the

gall bladder may contain bile, and often calculi. If the obstruction is complete the contained fluid may gradually lose its biliary character and become a serous or mucous fluid of a light-yellow color—*hydrops cystidis fellæ*. The walls of the bladder may be of normal thickness, or thinned, or thickened, or calcified. If the obstruction is due to a calculus, this may pass into the intestine and the gall bladder be suddenly emptied. Usually the bladder fills again, owing to its loss of contractile power.

*Biliary Calculi.*—These bodies are of common occurrence. They are found usually in the gall bladder, sometimes in the hepatic, cystic, and common ducts; less frequently in the small ducts of the liver. In the gall bladder from 1 to 7,800 calculi have been counted.



FIG. 301.—ADENOMA OF THE GALL DUCT.

This section is from a small tumor growing within one of the larger gall ducts within the liver. Prepared by Dr. Larkin.

They vary in size from that of a pin's head to that of a hen's egg, or they may be larger. Single gall stones are usually spheroidal or ovoidal; when multiple they are usually flattened at the sides or faceted.

They may be composed:

1. Principally of *cholesterin*, and may be of pure white color, or tinged with various shades of yellow or brown by bile pigment. The fractured surface shows a radiating crystalline structure.

2. Of *cholesterin, bile pigment,* and salts of *calcium* and *magnesium.* These are usually dark-colored, brown, reddish-black, or green, and may be spheroidal or faceted, smooth or rough on the surface; the fractured surface is usually radiating crystalline. This is the most common form.

3. Principally of *bile pigment.* Such calculi are rare, usually small, very dark-colored, and not numerous.

4. Of *calcium carbonate.* These are rare, have a nodular surface, and a clear crystalline, not radiating fracture.

Most calculi are formed around a central mass, sometimes called the nucleus, which may consist of cholesterin, bile pigment, mucus, or epithelium, or more rarely of some foreign body. Thus a dead parasite, a needle, and fruit seeds may serve as nuclei. The body of the calculus may be homogeneous, or lamellated, or crystalline.

Biliary calculi in the gall bladder may produce no symptoms and only be discovered after death. In the hepatic and common ducts they may obstruct the flow of bile and produce fatal jaundice; or they may pass from time to time into the intestine, producing biliary colic. If they are impacted in the cystic duct they may produce dilatation of the gall bladder. They may get into the duodenum by ulceration through the walls of the ducts or gall bladder, or in the same way into the peritoneal cavity. Gall stones which get into the intestinal cavity usually pass off without doing any further injury, but very large calculi may cause occlusion of the gut with fatal results.

### TUMORS OF THE GALL BLADDER AND LARGER GALL DUCTS.

Small *fibromata* have been described in the gall bladder and in the common duct, but they are very rare. The most common tumors are *carcinomata.* These may be primary or secondary, and present the usual structural variations. The cells may be cylindrical, polyhedral, or they may present the characteristics of colloid cancer. Primary carcinomata of the gall bladder and larger gall ducts are not uncommon. Not infrequently the pancreatic and common ducts are both involved, and it is difficult to say whether the tumor is primary in the head of the pancreas or in the gall duct. The bladder and ducts may also be secondarily involved in carcinomata of the stomach, liver, and duonenum. Adenoma of the gall ducts is of occasional occurrence (Fig. 301).

# THE SPLEEN.

In studying the alterations produced in the spleen in disease it is important to bear in mind the peculiar relations in which this organ stands to the blood vessels and to the circulation. After passing through the various branches of the splenic artery and the limited systems of capillaries which are associated with it, the blood is not received at once into venous trunks, as in other parts of the body, but is poured directly into the pulp tissue. In this it circulates, under conditions which render it liable to stagnation and undue accumulation, before it is taken again into well-defined vessels through the open walls of the cavernous veins. Moreover, these conditions, naturally unfavorable to undisturbed and vigorous circulation, are reinforced by the association of the splenic with the sluggish and often interrupted portal circulation. Bearing these considerations in mind, it will be in a measure plain why, as is in fact the case, the spleen should be more liable to alterations in size than any other organ in the body, and why, serving as it does as a sort of blood filter, it should be especially susceptible to the influence of deleterious materials of various kinds which in one way or another gain access to the blood. In this respect the relations of the spleen to the blood, and of the lymph nodes to the lymph, present suggestive analogies.

## WOUNDS, RUPTURE, AND HÆMORRHAGE.

*Wounds* of the spleen are usually accompanied by extensive hæmorrhage and are commonly fatal. Death usually occurs as the result of this hæmorrhage, but it may be due to secondary inflammatory changes. Healing and recovery may, however, occur.

*Rupture* of the spleen may be traumatic or spontaneous. In the former case it may be due to direct violence in the region of the organ or to injury to the thorax, falls, etc. In certain diseased conditions the spleen is more liable to rupture than when it is normal. The rupture usually involves not only the capsule, but a more or less considerable portion of the parenchyma, and of course leads to

hæmorrhage. Spontaneous rupture is rare, but may occur as the result of excessive enlargement of the organ, as in typhoid fever, malaria, etc.—see below—or as the result of abscess.

*Hæmorrhage.*—Aside from the extensive hæmorrhages from injury and rupture, the spleen may be the seat of small circumscribed hæmorrhages in various infectious diseases, although, owing to the peculiar distribution of the blood, it is often very difficult to distinguish between a moderate interstitial hæmorrhage and hyperæmia.

## DISTURBANCES OF THE CIRCULATION.

*Anœmia.*—This may be associated with general anæmia, but it is not always present in this condition When marked and unasso-

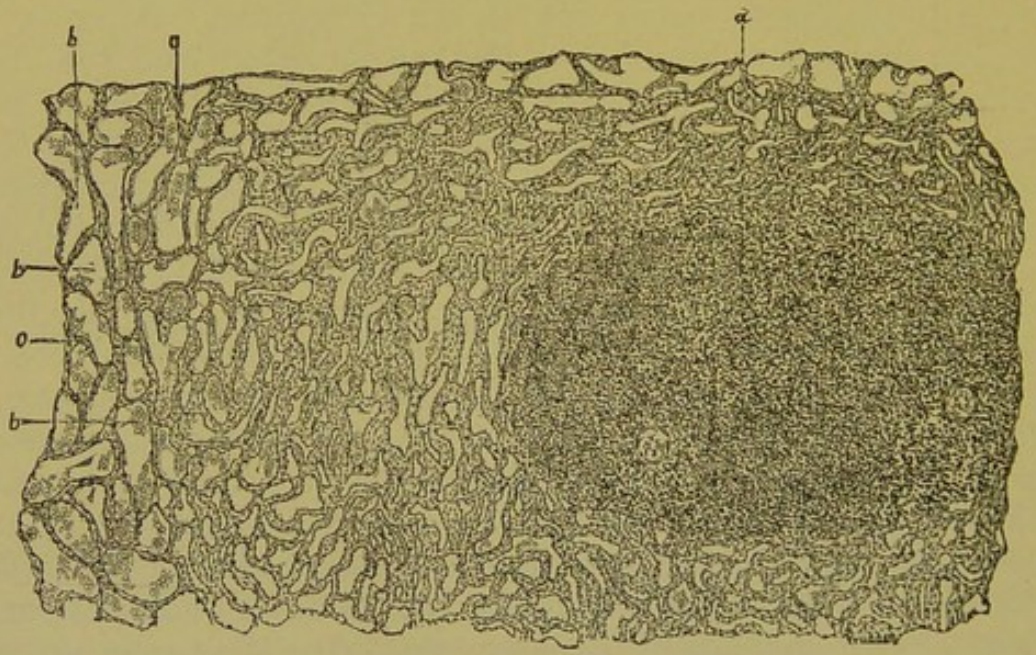


FIG. 302.—CONGESTION OF THE SPLEEN.

*b*, dilated cavernous veins; *c*, trabeculæ of pulp tissue compressed between dilated cavernous veins; *d*, glomerulus.

ciated with other lesions the spleen is apt to be diminished in size, the capsule more or less wrinkled, the cut surface dry and lighter in color than normal, the trabeculæ unduly prominent.

In this, as in other alterations simply of the blood content of the spleen, neither the gross nor microscopical appearances are constant, because of the redistribution of blood which is apt to occur in the viscera after death.

*Hyperæmia.*—This may be passive, occurring when some obstruction to the portal circulation exists, most frequently in cirrhosis of the liver, but also with certain valvular lesions of the heart, emphysema, etc. The spleen is enlarged, but usually only to a moderate degree. The capsule is apt to be tense, and on section the

pulp is dark-red and may be soft or firm. The cavernous veins are dilated (see Fig. 302). Usually, when the lesion has existed for some time, there is a thickening of the trabeculæ and reticular framework of the spleen, so that they are prominent on section. In other words, there is a chronic interstitial splenitis following the chronic congestion.

*Active Congestion* of the spleen, which in most cases is scarcely to be differentiated from some forms of acute inflammation, and probably in many cases is associated with it, very frequently occurs in a great variety of acute and infectious diseases, such as typhoid fever, pneumonia, diphtheria, pyæmia, the exanthemata, etc. The spleen is enlarged, the capsule tense; on section the pulp is soft, dark-red in color, often swelling out from the cut surface and concealing the glomeruli and trabeculæ. Under these conditions we may find the cavernous veins distended with blood and the interstices of the pulp infiltrated with a variable, sometimes large quantity of red and white blood cells. Or we may find, in addition to this, an increase in cells, which characterizes acute inflammation or hyperplasia of the spleen (see below).

*Infarctions of the Spleen.*—Embolic infarctions of the spleen are of frequent occurrence. They may be single or multiple, small or very large, sometimes occupying half of the organ. They are in general approximately wedge-shaped, corresponding to the area of tissue supplied by the occluded artery. They may be hæmorrhagic, *i.e.*, red, or they may be white (see page 62). Infarctions, originally red, may become white after a time from changes in the blood pigment. They may usually be seen as dark-red, reddish-white, or white, hard, sometimes slightly projecting areas on the surface of the organ. Not infrequently the centre of the infarction is light in color, while the peripheral zone is dark-red. A layer of fresh fibrin is sometimes seen over the surface of the infarction. The general as well as the microscopical appearances which they present depend largely upon the age of the infarction. In the earlier stages the hæmorrhagic infarctions present little more under the microscope than a compact mass of red blood cells, among which may be seen the compressed necrotic parenchyma. The white infarction may show at first in a general way the usual splenic structure, but the entire tissue is in a condition of coagulation necrosis. The tissue may disintegrate and soften, and be more or less completely absorbed, with or without fatty degeneration. A zone of inflammatory tissue may appear around the infarction and upon the capsule, and this tissue, becoming denser, assumes the characters of cicatricial tissue and contracts around the unabsorbed remnant of the infarction, so that finally nothing may be left but a dense mass of

fibrous tissue, which frequently draws in the surface, causing more or less distortion of the organ. This cicatrix may be pigmented or white.

If the embolus be of an infectious, irritating nature, in addition to its mechanical effects there may be suppuration, gangrene, and the formation of abscess. There may be perforation of the capsule and fatal peritonitis.

### INFLAMMATION.

*Acute Hyperplastic Splenitis* (Acute Splenic Tumor).—The conditions under which acute inflammation of the spleen occurs have already been mentioned under active hyperæmia, with which it is usually associated. It is a frequent though not a constant accompaniment of the acute infectious diseases, and seems in all cases to be a secondary lesion. The spleen is enlarged, sometimes to two or three times its normal size. On section the pulp is soft, often almost diffluent, and projects upon the cut surface. The color is sometimes dark-red, sometimes grayish-red, or mottled red and gray. The trabeculæ and glomeruli are usually concealed by the swollen and softened pulp, but the glomeruli are sometimes unusually prominent.

Microscopical examination shows the marked increase in size to be due in part to the hyperæmia; in part to a swelling and increase in the number of cells, sometimes of the pulp, sometimes of the glomeruli, or of both. We find large, multinucleated cells; cells resembling the ovoidal and polyhedral cells of the pulp, but larger and with evident division of the nuclei. Cells resembling leucocytes may be present in large numbers, and larger and smaller cells in a condition of fatty degeneration, or containing pigment, are often seen. The elongated cells lining the cavernous veins may be swollen or increased in number. Not infrequently larger and smaller cells are found which contain structures looking like red blood cells or their fragments. In some cases, particularly in scarlatina, hyperplasia of the glomeruli is a prominent feature. In some cases, particularly in typhus and recurrent fevers, the cells of the glomeruli undergo marked degenerative changes, so that they may form small softened areas looking like little abscesses. Small necrotic areas, often associated with localized suppuration, are sometimes found in typhus and typhoid fever, scarlatina, etc., and may be due to infectious emboli. As the primary disease runs its course the swelling of the spleen subsides, the capsule appears wrinkled, the color becomes lighter, and sometimes the organ remains for a long time, or permanently, small and soft.

The cause of these marked changes in the spleen in infectious diseases is not understood. It seems probable that they are due to

the lodgment in the organ of some deleterious materials which have found access to the blood. Whether these materials are bacteria, or products of the life processes of bacteria, or something entirely apart from these, we do not in many cases know. Bacteria have, indeed, in many cases been found in the organ under these conditions, but by no means with the frequency and abundance which the commonness and prominence of the lesion would lead us to expect if it were in all cases due to their presence.

*Suppurative Splenitis* (Splenic Abscess).—Small abscesses may be found in the spleen as the result of minute infectious emboli, and these may coalesce to form larger abscesses; but larger and smaller abscesses may form in the spleen without evidence of their embolic origin. Sometimes the entire parenchyma is converted into a soft, necrotic, purulent mass surrounded by the capusle. It is rare for simple infarctions to result in abscess, but it does occasionally occur. Abscess of the spleen may occur from the propagation of a suppurative inflammation to the organ from adjacent parts; from perinephritic abscesses, ulcer and carcinoma of the stomach, etc. Abscesses of the spleen may open into the peritoneal cavity, inducing fatal peritonitis, or, owing to an adhesive inflammation, the opening may occur into the post-peritoneal tissue, into the pleural cavity, lung, stomach, intestines, or it may open on the surface. On the other hand, the contents of the abscess may dry, shrink, and become encapsulated and calcified. Abscesses may occur in ulcerative endocarditis, pyæmia, typhoid fever, and more rarely in intermittent fever, and under a variety of other conditions whose nature is unknown to us.

*Chronic Indurative Splenitis* (Chronic Splenic Tumor).—There may be, as we have already seen, a new formation of connective tissue in the spleen as a result of chronic congestion or infarctions, or about abscesses. But there is a more diffuse formation of connective tissue, usually in the nature of an hyperplasia, which occurs under a variety of conditions, and is now marked and extensive, and again comparatively ill-defined. It is always associated with more or less extensive changes in the parenchyma. In its most marked form it is found in chronic malarial poisoning, and under these conditions it may be found not only in persons who have suffered from repeated attacks of intermittent fever, but also in those who have not thus suffered but have resided in malarial regions. The enlarged spleen is often called "ague cake." Similar conditions, though usually less marked, may occur in congenital and acquired syphilis, from prolonged typhoid fever, and as a result of acute hyperplastic splenitis from various causes, and also in leukæmia and pseudo-leukæmia.

The gross appearance of the spleen in chronic indurative splenitis varies greatly, both in the size of the organ and in the appearance of the section. The spleen may be enormously enlarged or it may be of about normal size. It is usually, however, enlarged. The cap-

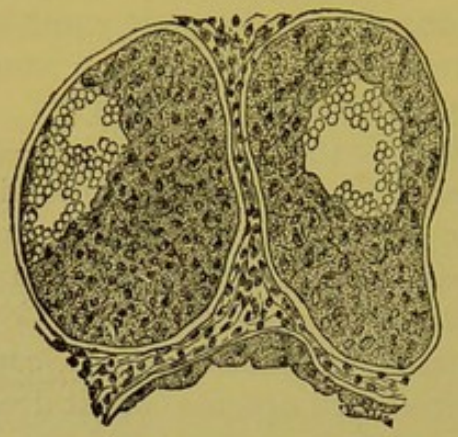

FIG. 303.—CHRONIC INDURATIVE SPLENITIS.
Showing swelling or proliferation of the lining cells of the cavernous veins.

sule is usually more or less thickened, frequently unevenly so. The consistence is usually considerably increased, but this is not always the case. The color and appearance of the cut surface present

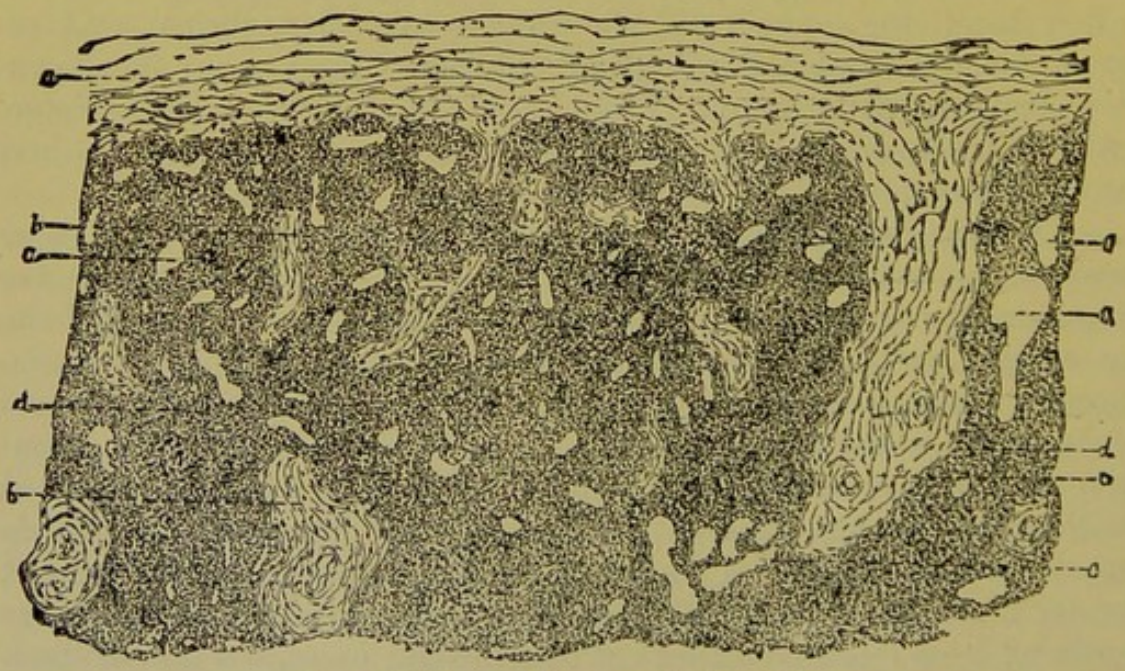


FIG. 304.—CHRONIC INTERSTITIAL SPLENITIS.
*a*, thickened capsule; *b*, thickened trabeculæ; *c*, dilated cavernous veins; *d*, dense pulp tissue with obliterated cavernous veins.

much variation. It may be nearly normal or it may be grayish, or dark-brown, or nearly black. The color may be uniform or the surface may be mottled. The glomeruli may be scarcely visible or

very prominent; the trabeculæ are in some cases nearly concealed by the pulp; in others they are large, prominent, and abundant, so that the surface is crossed in all directions by an interlacing network of broader and narrower irregular bands, between which the red or brown or blackish pulp lies.

Not less varied are the microscopical appearances of the spleen under these conditions. In one class of cases there is more or less uniform hyperplasia of both pulp and interstitial tissue. The parenchyma cells are increased in size and number; there may be swelling and proliferation of the lining cells of the cavernous veins (see Fig. 303). The reticulum of the pulp, as well as that of the glomeruli, and also the trabeculæ, are thickened. In another class of cases the thickening of the reticular and trabecular tissue, either uniformly or in patches, is the prominent feature (Fig. 304), while the changes in the pulp are rather secondary and atrophic. In both forms irregular pigmentation is frequent, the pigment particles being

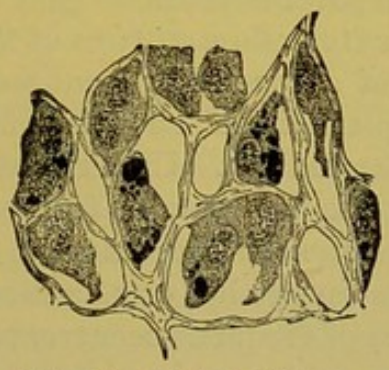

FIG. 305.—MALARIAL SPLEEN.
Showing thickening of the trabecular network of the pulp, with pigmentation of the pulp cells.

deposited either in the cells of the pulp or glomeruli, or in the new-formed interstitial tissue (Fig. 305). Finally, there are all intermediate forms of induration between those described, and the changes are by no means uniform in the same organ. When these spleens are large they are liable to displacement.

*Syphilitic Splenitis.*—This lesion may present itself as an indurative process due to the formation of new connective tissue, and present no distinct morphological characteristics. In rare cases, however, gummata may be present in connection with the new fibrous tissue; then the nature of the lesion becomes evident.

*Tuberculous Splenitis.*—This lesion is secondary, either to tubercular inflammation in some other part of the body, or is the result of the general infection in acute general miliary tuberculosis. The tubercles may be very numerous and still invisible to the naked eye, or they may be just visible, or as large as a pin's head or thereabouts, and very thickly strewn through the organ or sparsely scattered. In other

cases the tubercles are larger, sometimes as large as a pea, and they are then usually not very numerous. Microscopically they present the usual variety of structure, sometimes as simple tubercle granula, sometimes as conglomerate tubercles; they may consist simply of a collection of small spheroidal cells, or there may be larger polyhedral cells and giant cells with a well-defined reticulum. Cheesy degeneration occurs under the usual conditions. Tubercle bacilli are usually present, particularly in the more acute forms, sometimes in small, sometimes in enormous numbers. They seem to be especially abundant in acute general miliary tuberculosis of children. These tubercles may be formed in the glomeruli, in the walls of the smaller arteries, in the pulp tissue, and in the trabeculæ and capsule. Owing to the peculiar character of the spleen tissue the earlier stages are not readily recognized, since simple collections of small spheroidal cells are not distinctly outlined against the normal tissue. There is frequently a moderate swelling of the spleen, owing to hyperæmia and hyperplasia of the parenchyma.

*Perisplenitis.—Acute inflammation* of the capsule of the spleen may occur as a part of a general or localized peritonitis, or as a result of lesions of the spleen itself, such as infarctions, abscesses, and acute hyperplastic inflammation. Under these conditions a fibrinous pellicle, with more or less pus, may be formed on the surface of the organ. *Chronic perisplenitis*, resulting in the production of new connective tissue, either in patches or as a more or less general thickening of the capsule, is of frequent occurrence. It may follow acute inflammation of the capsule, or be a part of general or localized chronic peritonitis. It is common in connection with chronic indurative splenitis, and it may occur from unknown causes. Sometimes the capsule is three or four mm. in thickness over a considerable area; sometimes very small nodular thickenings or papillary projections occur. As a result of this process adhesions, sometimes very extensive, may form between the spleen and adjacent parts. The thickened capsule is sometimes more or less extensively calcified.

*Alterations of the Spleen in Leukæmia and Pseudo-Leukæmia.*—The lesions of the spleen are essentially the same under both of these conditions. They consist, in general, of an hyperplasia, sometimes most marked in one, sometimes in another of the structural elements of the organ, but usually they all participate in the alterations. The changes which occur in the earlier stages are but little known. The gross appearances of the spleen, as we find them in persons dying of either of the above diseases, present considerable variation. They are usually enlarged and sometimes are ten or fifteen times the normal size. They are usually hard, but are sometimes of the ordinary consistence, or softer. The capsule is usually

thickened and rough. The section of the spleen may be of a uniform dark-red color, but it is more frequently mottled red and gray. Sometimes the glomeruli are inconspicuous, but they are very often enlarged and prominent. They may be two to four mm. in diameter, and, owing to an infiltration of the arterial sheaths with lymph cells, may appear to the naked eye as grayish, round or elongated bodies, arranged along branching, interrupted, grayish streaks. The trabecula may be greatly thickened, as also the reticulum of the pulp, so as to be evident to the naked eye. Brown or black pigment may be collected around the glomeruli or in the pulp. Hæmorrhagic infarctions or circumscribed extravasations of blood may further complicate the picture.

Microscopically the appearances are essentially the same as those above described in acute hyperplasia and in chronic interstitial splenitis, depending upon the stage and variety of the disease. Owing to the great size which some of these spleens attain they are liable to displacement, and they may interfere by pressure with the functions of neighboring organs.

### DEGENERATIVE CHANGES IN THE SPLEEN.

*Atrophy.*—The spleen may become atrophied in old age; as a result of prolonged cachexiæ, and in connection with profound and persistent anæmia; or, more rarely, from unknown causes. The capsule may be wrinkled and thickened, the color pale, the trabecula prominent, the consistence increased. The change is largely in the pulp, whose parenchyma cells are decreased in number.

*Amyloid Degeneration.*—This degeneration may affect the glomeruli or the pulp tissue, or both together. When confined to the glomeruli the spleen may or may not be enlarged, and the cut surface is more or less abundantly sprinkled with round or elongated, translucent bodies resembling considerably in general appearance the grains of boiled sago. These are the waxy glomeruli. Such spleens are often called "sago spleens" (Fig. 306). Microscopical examination shows that the degeneration is confined to the walls of the arteries, capillaries, and reticulum of the glomeruli, with atrophy and disappearance of the lymphoid cells.

In other cases, either with or without involvement of the glomeruli, there is waxy degeneration of the blood vessels and reticulum of the pulp, which may occur in patches or be general and more or less excessive. If the alteration is general and considerable the spleen is enlarged, its edges rounded, its consistence increased. On section it appears translucent, and the distribution of the degenerated areas may be readily seen by holding a thin slice up to the light. The spleen may be alone affected, or there may be

similar degenerations in other organs. The general conditions under which this lesion occurs, and the methods of staining and studying, are given on page 100.

*Pigmentation* of the spleen may occur as the result of the decomposition of hæmoglobin in the organ under a great variety of conditions: thus after hæmorrhagic infarctions, small multiple hæmorrhages, acute hyperplastic splenitis, etc. Or the pigment may be anthracotic and be brought to the organs from the lungs or bronchial glands (see page 106). Bile pigment may also be deposited in the spleen in jaundice. The pigment may lie in the walls of the smaller arteries, in the cells and reticulum of the pulp, or free in the latter tissue, or in the follicles. It is usually quite unevenly dis-

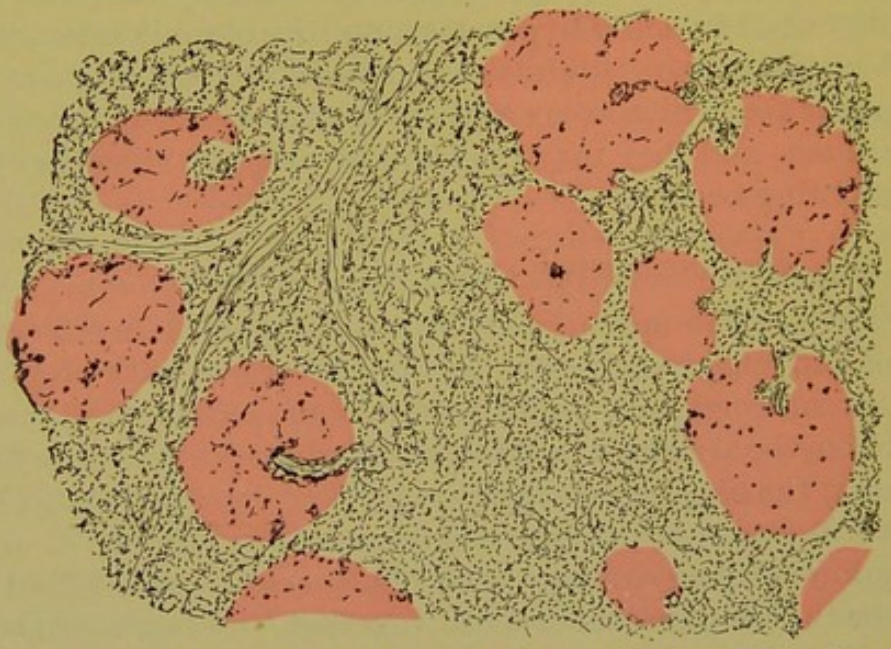

FIG. 306.—AMYLOID DEGENERATION OF GLOMERULI OF THE SPLEEN—"SAGO SPLEEN." The "waxy" portions are stained pink.

tributed. The pigment may be red, brown, or black. According to Weigert anthracotic pigment may be sometimes seen with the naked eye in the periphery of the glomeruli as dark crescents.

Primary tumors of the spleen are rare. Small *fibromata*, *sarcomata*, and *cavernous angiomata* sometimes occur. *Sarcomata* and *carcinomata* may occur in the spleen secondarily either as metastatic tumors or by extension from some adjacent part, as the stomach. Dermoid cysts are described, but are rare. Other larger and smaller cysts, whose mode of origin is in most cases obscure, not infrequently occur.

### PARASITES.

*Pentastomum denticulatum* is not infrequently found in the spleen, usually encapsulated and calcified. *Cysticercus* is rare.

*Echinococcus* is occasionally found, and, if the cysts are large or numerous, may cause more or less extensive atrophy of the organ.

Various forms of bacteria have been found in the spleen. *Micrococci* have been found in pyæmia, small-pox, ulcerative endocarditis, diphtheria, and under other conditions. The *Bacillus anthracis* occurs here in anthrax; the *Bacillus tuberculosis* in tubercular inflammation; and bacilli have been described in typhoid fever. *Spirochæte Obermeieri* may be found in relapsing fever.

### MALFORMATIONS AND DISPLACEMENTS.

The spleen may be absent in acephalous monsters, and with defective development of other abdominal viscera. Very rarely it is absent in persons who are otherwise perfectly developed. Small accessory spleens, from the size of a hazelnut to that of a walnut, are not infrequent. They usually lie close to the spleen, but may be considerably removed from it; thus they have been found embedded in the head of the pancreas. Two spleens of about equal size have been observed. The form of the spleen is subject to considerable variation. It may be made up of several distinct lobes. It may be displaced congenitally or as the result of disease. It may be on the right side in transposition of the viscera. As the result of congenital defects in the diaphragm the spleen may be found in the thorax; or in deficient closure of the abdominal wall it may, together with other abdominal viscera, be found outside of the body.

The spleen may be pressed downward by any increase in the contents of the thorax. It may be fastened by adhesions to the concave surface of the diaphragm, so that its long axis is nearly horizontal instead of vertical. It may be displaced by changes in the contents of the abdominal cavity. If the organ is increased in size it frequently becomes tilted, so that its lower border reaches the right iliac region. If the ligaments are too long congenitally, or if they are lengthened by traction, and if the organ is at the same time increased in weight, it may become very movable. It may sink downward, with its hilus turned upward; or it may be rotated on its axis, and, owing to torsion of the vessels thus produced, the organ may atrophy; or the pressure of the ligaments and vessels across the duodenum may cause occlusion of the gut.

# THE PANCREAS.

The diseases of the pancreas appear, so far as we know, with a few exceptions, to be of little practical importance; that is, they do not often give rise to symptoms of disease or cause death, but the lesions are found in the bodies of persons dead from other diseases. It is probable, however, that in many cases their apparent insignificance is due to our lack of knowledge of the interference with functions which lesions of the gland induce, and to the incomplete examination of the pancreas which is so common at autopsies.

*Hæmorrhage* into the substance of the pancreas may occur as the result of injury[1]; in the hæmorrhagic diathesis; in connection with valvular diseases of the heart or interference with the portal circulation; or in connection with extensive fatty degeneration and fat necrosis of the organ. Such hæmorrhages may be minute or extensive. Several cases of sudden death are recorded in which the only discoverable lesion was an extensive hæmorrhage into the substance of the gland and the tissue about it. In these cases it has been assumed that death was caused by interference with the heart's action, through pressure on the solar plexus and semilunar ganglion, but it may be due to other causes (see below, Fat Necrosis). The hæmorrhage may be moderate and limited to the pancreas, or it may extend into the subperitoneal tissue for a considerable distance.

Hæmorrhage of the pancreas may be associated with acute inflammatory changes and with more or less extensive *gangrene* of the organ. The gangrenous pancreas may be more or less encapsulated; it may lie, bathed in pus, in the abdominal cavity; it may, by ulceration of the intestinal wall, get into the gut and be discharged with other intestinal contents.

### INFLAMMATION.

In some cases of typhoid fever, pyæmia, yellow fever, and other acute infectious diseases, the pancreas is red, swollen, and œdematous. Microscopically the most prominent lesion is a swelling and

[1] Consult *Lieth*, "Rupture of Pancreas," Lancet, September 28th, 1895.

undue granulation of the glandular epithelium, and hyperæmia. This condition is known as *Parenchymatous Pancreatitis.*

*Suppurative Pancreatitis* is not very common, and may be primary or due to the extension of a suppurative inflammation from adjacent or distant parts of the body. There may be a diffuse infiltration of the organ, with pus cells or larger and smaller abscesses. The abscesses may open into the gastro-intestinal canal or into the peritoneal cavity. The causes of primary suppurative pancreatitis are often most obscure. It may be associated with fat necrosis and with hæmorrhage and gangrene of the pancreas.

*Chronic Interstitial Pancreatitis* (Cirrhosis of the Pancreas).—This lesion consists in an increase of interstitial connective tissue, which may be general or confined to some particular portion of the gland. The organ is sometimes enlarged, sometimes smaller than normal. It is usually dense and hard ; secondary atrophy of the parenchyma regularly occurs. It may be due to chronic inflammatory processes in the vicinity of the organ.

*Syphilitic Inflammation.*—Chronic interstitial pancreatitis is frequently found in congenital syphilis of the new-born, and the gross and microscopical lesions are similar to those above described. It is not definitely established whether or not a similar lesion may be caused by acquired syphilis. Gummata are very rare in the pancreas, but have been described in congenital syphilis in very young children.

*Tuberculous Inflammation.*—Larger and smaller tubercles and tubercular, cheesy nodules are occasionally found in the pancreas in connection with acute general miliary tuberculosis or with tubercular inflammation in some other organ, particularly with that of adjacent lymph nodes, the lungs, and the intestine.

### DEGENERATIVE CHANGES IN THE PANCREAS.

*Atrophy* of the pancreas may occur in old age and as a result of pressure from tumors or other adjacent structures. Marked atrophy of the pancreas is found in a certain proportion of cases of diabetes mellitus, but it is not constant.

*Fatty Degeneration* of the parenchyma cells may occur, and in some cases is so extensive as to lead to nearly complete destruction of their protoplasm.

*Fatty Infiltration,* which should be distinguished from fatty degeneration, consists in the accumulation of fat in the interstitial tissue of the gland. This may be so excessive as to cause nearly entire destruction of the gland structures. Under these conditions the outline of the organ may be preserved, the fat being enclosed by the capsule.

*Amyloid Degeneration.*—This usually occurs in connection with similar degeneration in other organs, and is confined to the walls of the blood vessels and the interstitial tissue.

*Fat Necrosis.*—A very peculiar lesion of the fat tissue, most frequently seen in the fat tissue about the pancreas or between its lobules, but sometimes in fat tissue in other parts of the body, has been a few times described and called *fat necrosis.* White or yellowish nodules, varying from the size of a pin's head to that of a pea or larger, are seen embedded in the fat, the central portion being often soft and grumous and readily squeezed out. They are sometimes calcified and sometimes surrounded by a connective-tissue

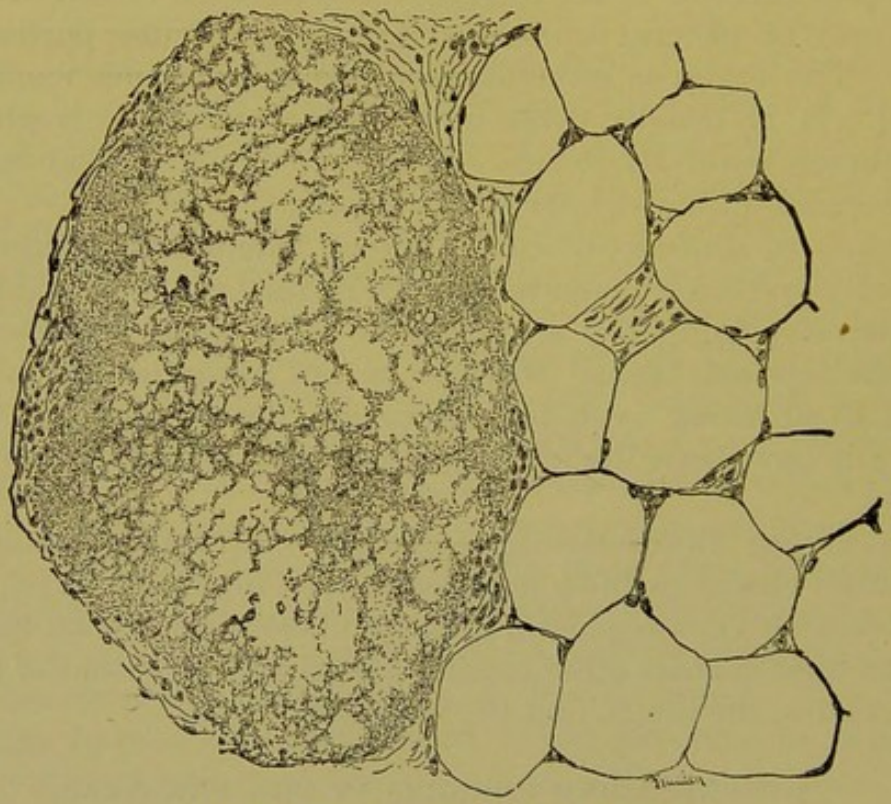

FIG. 307.—FAT NECROSIS IN THE PANCREAS.

Drawn from a specimen prepared by Dr. Ira Van Gieson and reported to the New York Pathological Society, 1888.

capsule. Microscopical examination shows degeneration and disintegration of the fat tissue (Fig. 307). They are most frequently found in marasmatic persons. When the lesion is extensive, according to Balser, it may cause death, either directly or by inducing hæmorrhage. Some of the extensive hæmorrhages about the pancreas, above mentioned, may be caused in this way.[1]

[1] For a detailed consideration of acute inflammation, hæmorrhage, gangrene, and fat necrosis of the pancreas, with bibliography, consult *Fitz*, Middleton Goldsmith lecture for 1889 on "Acute Pancreatitis," Transactions New York Pathological Society, 1889. For special studies on fat necrosis consult *Langerhans*, Virchow's Archiv, Bd. cxxii., p. 252, and in the "Festschrift" for Virchow's seventy-first birthday.

## TUMORS.

*Carcinomata* are the most common and important of the tumors of the pancreas. They may be primary or secondary. Primary carcinomata are most frequently found in the head of the organ, but may occur in other parts. The hard or scirrhous form is most common, but occasionally soft and succulent and colloid forms are found. They are liable to involve adjacent parts by continuous growth, and may form metastases in the liver, adjacent lymph nodes, etc. Secondary carcinoma in the pancreas may occur in carcinoma of the stomach, duodenum, and the gall ducts and gall bladder. As a result of carcinoma of the pancreas, aside from the extension of the growth, there may be pressure on the ductus choledochus, with jaundice ; or on the pancreatic duct, with cystic dilatation ; or pressure on the duodenum, with stenosis of the gut ; or pressure on the vena cava, or portal vein, or superior mesenteric vein, etc., with disturbances of the circulation.

*Concretions* of carbonate and phosphate of lime are frequently found in the pancreatic ducts. They are usually multiple, small, whitish, smooth, or of rough and irregular shape. Sometimes, however, they reach a diameter of more than an inch. They consist chiefly of calcium phosphate and carbonate. Besides these free concretions the walls of the ducts are sometimes encrusted with salts of lime. Such concretions may produce dilatation of the pancreatic ducts and large cysts, or more rarely abscesses.

*Foreign Bodies.*—Gall stones sometimes find their way into the pancreatic duct. Ascarides have been found in the ducts in a considerable number of cases.

*Cysts.*—These are mostly due to *dilatation* of the pancreatic ducts.

1. The entire duct may undergo a uniform cylindrical dilatation. With this cylindrical dilatation we sometimes find associated small sacculi.

2. There may be sacculated dilatations at some points in the ducts. These dilatations form cysts of large size, as large even as a child's head. Their walls frequently undergo degeneration and calcification. These cysts often become filled with blood, and may then be mistaken for aneurisms.

3. The small branches of the pancreatic duct may be dilated so as to form a number of small cysts. These cysts are filled with serum, mucus, pus, or a thick, cheesy material.

Cysts of the pancreas may result from old areas of necrosis or hæmorrhage, and in other ways.[1]

---

[1] Consult *Tilger*, "Cysts of Pancreas," Virch. Arch., Bd. cxxxvii., 348 (bibliography).

## MALFORMATIONS AND DISPLACEMENTS.

The pancreas may be entirely absent in anencephalous and double monsters, and in congenital umbilical herniæ. The pancreatic duct may be double; it may open into the duodenum at some distance from the biliary duct, or into the stomach. The head of the pancreas may be unduly developed, and sometimes even completely separated from the rest of the organ, opening into the duodenum with a duct of its own. Occasionally there is a small accessory pancreas situated beneath the serosa of the duodenum or stomach.

The pancreas is so firmly bound down that its position is not often changed. Sometimes, however, it is found pressed downward by tight lacing, displaced by aneurisms, or contained in umbilical and diaphragmatic herniæ.

# THE SALIVARY GLANDS.

## THE PAROTID, SUBMAXILLARY, AND SUBLINGUAL.

### INFLAMMATION.

This condition is most frequent and important in the parotid. The lesions of the epidemic disease known as *mumps* are most frequently confined to the parotid gland of one side, but the submaxillary and sublingual may be at the same time involved. The gland is swollen and there is often œdema of the mucous membrane of the mouth and pharynx. Very little is known of the actual minute changes which the gland undergoes in this disease.

Acute parotiditis occasionally occurs as a secondary lesion in a variety of diseases, as in typhoid and scarlet fever, pyæmia, pneumonia, etc., and by propagation of inflammation from the mouth. Under these conditions the inflammation is usually suppurative and frequently results in abscess or sloughing. The interstitial tissue of the gland is more or less densely infiltrated with pus cells, and the parenchyma cells may undergo fatty degeneration and disintegration. The inflammation may be confined to the gland or it may spread to adjacent parts, sometimes causing much destruction of tissue, and may give rise to inflammation of the brain or of the inner ear, or even to metastatic pyæmic abscesses in different parts of the body. Healing may occur, with the formation of salivary fistulæ.

The submaxillary gland may be involved with the parotid in the suppurative inflammation.

Acute suppurative inflammation of the connective tissue about the *submaxillary gland* is sometimes of serious import. Sloughing and gangrene may occur and are apt to spread to adjacent parts. Septicæmia, œdema of the glottis, or pneumonia may complicate the process and cause death.

The sublingual gland is not often the seat of inflammation.

*Chronic inflammation*, leading to the formation of dense inter-

stitial tissue, sometimes occurs in the salivary glands. This may occur by itself or follow an acute inflammation.

The *Excretory Ducts* of the salivary glands may become inflamed from the presence of foreign bodies or of concretions formed in them. They may become occluded from the presence of calculi or as the result of inflammation, and may thus become widely dilated both in the main branches and in the finer ramifications. The dilatation of Wharton's duct to form larger and smaller cysts containing salivary fluid, sometimes gives rise to very large and troublesome tumors which constitute one of the forms of *ranula*.

## TUMORS.

*Fibromata* are of occasional occurrence in the parotid. *Chondromata*, *endotheliomata*, *sarcomata* and *fibro-sarcomata*, and *myxomata*, or more frequently mixed tumors formed of varied combinations of these, are of frequent occurrence in the parotid and of occasional occurrence in the submaxillary gland. These complex or mixed tumors are of more frequent occurrence in these glands than in any other part of the body, except possibly the ovary. They are sometimes rendered still more complicated in structure by the formation of cysts, and what has been regarded usually as an atypical glandular growth, lending them an adenomatous character. The more recent studies upon the mixed tumors of the salivary glands, however, have led to the belief that a large part of these complex growths are *endotheliomata*, which are especially prone in these regions to undergo secondary degenerative or metaplastic changes.[1] Carcinomata of the salivary glands are rare.

*Fibro-sarcoma* and *melano-sarcoma* have been described. *Primary carcinoma* of these glands is very rare.

A case of *rhabdomyoma* of the parotid gland, with evidences of atypical development of portions of the gland, has been described by one of us.[2]

## PARASITES.

*Echinococcus* has been observed in the parotid gland.

---

[1] *Volkmann*, Deutsche Zeits. f. Chir., Bd. xli., p. 61.

[2] *Prudden*, "Rhabdomyoma of the Parotid Gland," American Journal of the Medical Sciences, April, 1883.

# THE THYROID GLAND.[1]

*Hyperæmia* of the thyroid gland, often accompanied by considerable enlargement of the organ, may be the result of valvular disease of the heart; it occurs in Basedow's disease; it may be temporary or permanent, and in the latter case may give rise to the formation of new connective tissue. Hæmorrhages may occur, causing pigmentation of the organ.

*Inflammation* of the thyroid gland is not very common and may occur from a variety of causes. It may result in the formation of larger and smaller abscesses or in the production of new connective tissue. *Tuberculous inflammation*, with the formation of miliary tubercles, is of infrequent occurrence. *Syphilitic inflammation*, with the formation of gummata, has been described, but is rare.

*Degeneration.—Colloid degeneration* of the epithelial cells of the gland, and the filling of the alveoli with colloid material, is of common occurrence, and when occurring in moderate degree may be regarded as a normal event, since a certain amount of this change is found in many otherwise apparently normal glands. It may occur, however, to such an extent as to constitute a lesion (see below).

*Amyloid degeneration*, particularly of the blood vessels, is of infrequent occurrence.

*Hyaline degeneration* of the stroma of the thyroid may occur.

*Inflammation* (Thyroiditis).—Suppurative inflammation of the thyroid is of occasional occurrence. Chronic interstitial inflammation, and tuberculous and syphilitic inflammation are rare.

## TUMORS.

Among the most important of the lesions of the thyroid is the enlargement of the organ commonly known as the *goitre* or *struma*. The enlargement of the gland may occur in several different ways, and in only a part of the cases is to be considered as a tumor. Thus, a simple hyperæmia may, as above stated, cause considerable enlargement of the organ, and this is sometimes called *struma hyper-*

[1] For a study of the normal and pathologic histology of the thyroid, with bibliography, consult *Müller*, Ziegler's Beitr. z. path. Anat., etc., Bd. xix., p. 127, 1896.

*æmica.* The true goitre, however, consists in the enlargement of the old and the formation of new gland alveoli, while with these changes there is very frequently associated a greater or less amount of colloid degeneration. When there is new formation of gland tissue the growth has the character of an *adenoma.* The hyperplasia may occur diffusely, so that the whole gland is more or less enlarged; or it may occur in the form of circumscribed nodules. When the colloid degeneration is prominent, so that the tumor has a gelatinous look, it is called *colloid struma* (Fig. 308).[1] Accumulations of fluid, blood, colloid, etc., in the old or new-formed alveoli, may cause dilatation and atrophy of the walls of the alveoli, so that cysts, some-

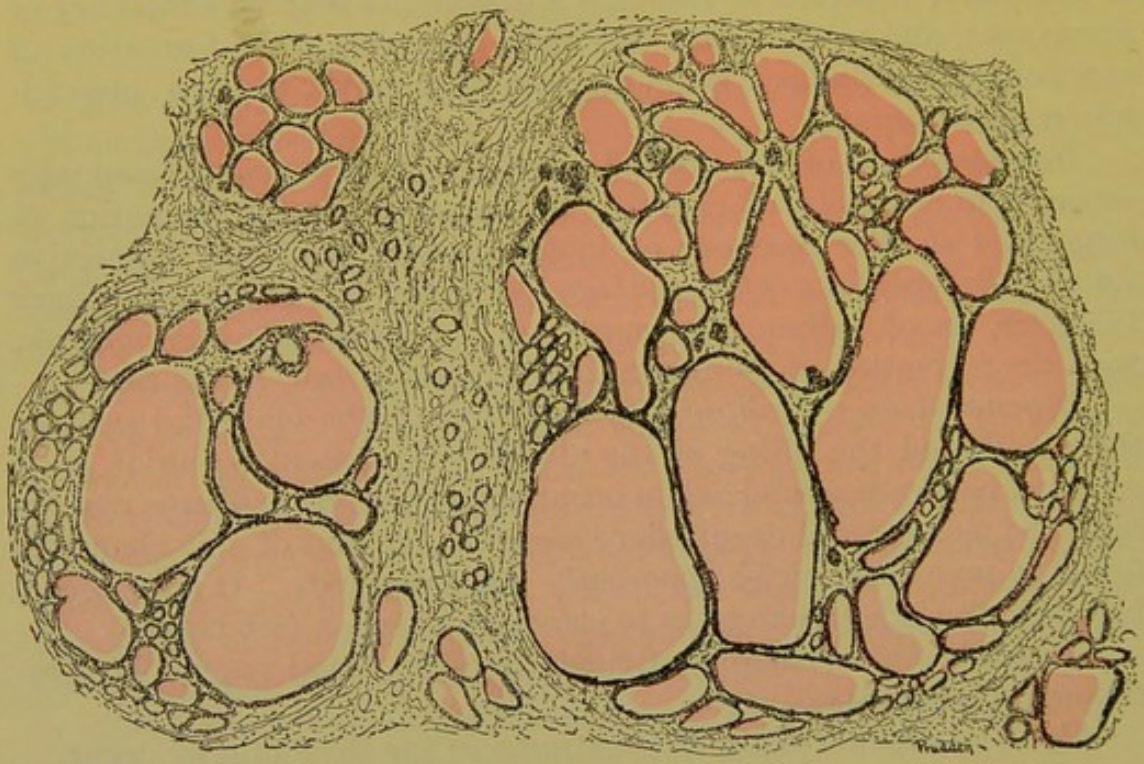

FIG. 308.—COLLOID STRUMA—GOITRE.
The colloid material filling the alveoli is stained red.

times of large size, are formed. Thus occurs the *cystic struma.* Again, the blood vessels may undergo marked dilatation, so that we may have a *telangiectatic struma;* or *cavernous angiomata* may form within them. Very frequently all these varieties of lesions are present in the same goitre. The appearances may be rendered still more complex by the occurrence of hæmorrhages and pigmentation, calcification, purulent or indurative inflammation (strumitis), and by the not very infrequent association with carcinoma and sarcoma. The cause of goitre is not well understood. The growth is, as a rule,

[1] For a consideration of the nature of colloid and its formation in struma see *Reinbach,* Ziegler's Beitr. z. path. Anat., etc., Bd. xvi., p. 596 (bibliography).

slow, but occasionally a very rapid enlargement occurs as the result of a sudden increase of the colloid degeneration. In many cases even very large goitres give rise to but moderate inconvenience, but they may assume great significance by encroaching upon neighboring parts. Thus death may be caused by pressure on the trachea, œsophagus, or on the large vessels.

*Sarcoma*, either spheroidal or spindle-celled, may occur as primary tumors in the thyroid, either in otherwise normal glands or in connection with struma. *Melano-sarcoma* has been observed. Secondary sarcomata are rare.

Primary *carcinoma*, both glandular and scirrhous, occurs in the thyroid, and, particularly in the softer forms, may spread to adjacent parts and occasionally form distant metastases.

### PARASITES.

*Echinococcus* cysts have been found in the thyroid.

### MALFORMATIONS.

The thyroid gland is sometimes very small, either as the result of atrophy or as a congenital deficiency. This is most marked in the condition called *myxœdema* (see below).

It may be irregularly lobulated. There may be small accessory glands situated at some distance from the normal position, as in the mediastinum or pleura.

### MYXŒDEMA.

This disease occurs most frequently in middle-aged women, and its cause is unknown. The skin of the face is apt to be swollen and waxy, causing a peculiar and rather characteristic appearance of the features. The skin of the body is apt to be dry and rough, and the hair may fall out. Perspiration is, as a rule, diminished. The mental condition is dull, and loss of memory and insanity may occur. Bodily movement and speech are apt to be impaired.

The fat tissues may be atrophic, and the subcutaneous tissue has been shown in some, though not all, of the cases to contain an unusual amount of mucin. In some cases the fibres of the upper layers of the corium are crowded apart by fluid.

The most marked and constant lesion in this disease is an atrophic condition of the thyroid gland. The parenchyma of the gland is more or less completely replaced by fibrillar connective tissue and by new-formed reticular tissue resembling the lymphatic tissue of the lymph nodes.

The general appearance of the atrophied thyroid gland is shown in Fig. 309.

In a case reported by Hun, which one of us has examined, the

lobes of the thyroid measured less than one-half of an inch in diameter, and the entire gland weighed only about 7.2 gm. (112 grains).

In addition to the lesion of the thyroid there are apt to be chronic endarteritis and chronic diffuse nephritis. In some cases there is an accumulation of small spheroidal cells about the smaller blood vessels in various parts of the body, and also petechial hæmorrhages.

While the atrophy of the thyroid is the most marked and frequent lesion in this disease, our lack of knowledge about the function of this gland prevents a definite conception as to the relationship of this change to the symptoms.

By the destruction of the thyroid from disease, or as the result of its removal in men and animals, a condition considerably resembling myxœdema is apt to be induced.

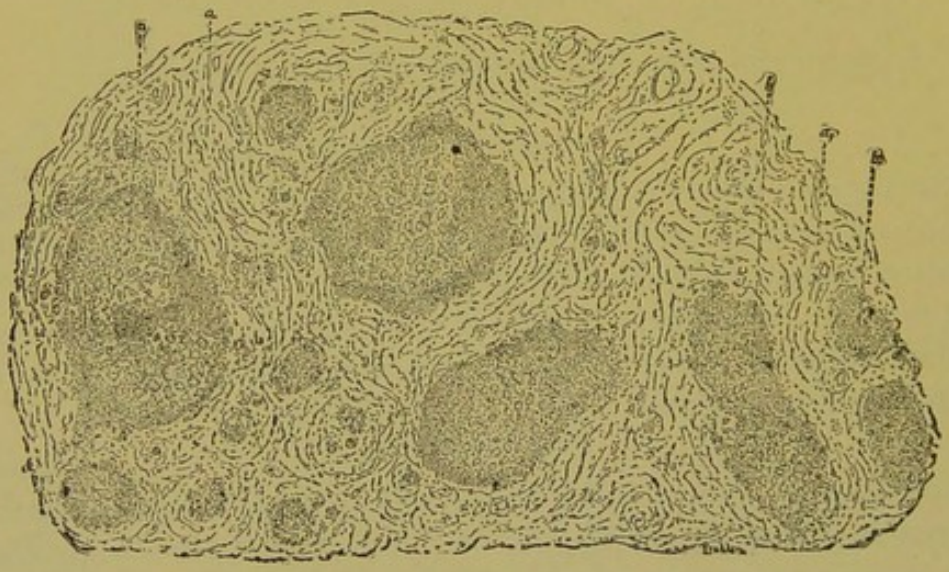

FIG. 309.—SECTION OF THE ATROPHIED THYROID GLAND IN MYXŒDEMA.

*a*, interstitial tissue; *b*, atrophied lobules with small spheroidal-celled or lymphatic tissue in their peripheries.

Myxœdema appears to be identical with that condition which has been described as *cachexia strumipriva*.[1]

The relationship of an atrophied thyroid to sporadic cretinism is worthy of investigation.[2]

---

[1] For detailed descriptions of myxœdema, and the literature, see *Hun* and *Prudden*, "Myxœdema," Am. Jour. Med. Sciences, July and August, 1888, and "Report on Myxœdema" in Supplements to the Clinical Society Transactions, vol. xxi., London, 1888.

[2] Consult *Osler*, "Sporadic Cretinism in America," Trans. Assn. Am. Phys., vol. v., p. 380, 1893, and *Noyes*, N. Y. Med. Jour., March 14th, 1896.

## EXOPHTHALMIC GOITRE.

*(Basedow's Disease, Graves' Disease.)*

The characteristic lesions of this disease are unilateral or bilateral enlargement—largely hyperæmic—of the thyroid and protrusion of the eyeballs. These lesions are apt to be associated with functional disturbance of the heart.[1]

## THE THYMUS.

Small accessory thymus glands are occasionally found near the thyroid.

The thymus occasionally but not usually persists until youth or middle age instead of undergoing the usual developmental atrophy.

Small *hæmorrhages* are described in the thymus of young children as the result of venous congestion in asphyxia, etc. They may also occur in the hæmorrhagic diathesis.

*Suppurative inflammation* of the thymus is of occasional occurrence, and is usually secondary to a similar inflammatory process in some other part of the body.

Tubercular and syphilitic inflammation of the thymus are described. The sarcomata are the most common tumors of the thymus.[2]

---

[1] On the relationship between the thyroid and Basedow's disease consult *Eulenberg*, Deutsche med. Wochensch., October 4th, 1894; also *Edmunds*, Jour. of Pathology and Bacteriology, vol. iii., p. 488, 1896; *Farner*, Virchow's Archiv, Bd. cxliii., p. 509, 1896 (bibliography); *Kinnicutt*, Med. Record, April 18th.

[2] On the relationship of hyperplasia in a persistent thymus to Hodgkin's disease consult *Brigidi and Piccoli*, Ziegler's Beitr. z. path. Anat., etc., Bd. xvi., p. 388.

# THE SUPRARENAL BODIES—ADRENALS.[1]

## MALFORMATIONS.

In acephalic and other monsters the suprarenal capsules may be atrophied or entirely absent. Sometimes in well-formed adults these organs cannot be discovered.

There may be little rounded nodules loosely attached to the surface of the capsules and having the same structure.

Accessory and misplaced adrenals are not uncommon.

If one of the kidneys is absent or in an abnormal position its suprarenal capsule usually retains its proper position.

## HÆMORRHAGE.

In children, soon after birth, it is not very infrequent to find large hæmorrhages in one of the capsules, converting it into a cyst filled with blood. The same lesion has been observed in a few cases in adults.

## THROMBOSIS.

Klebs describes a case of capillary thrombosis of the cortex in both capsules in a woman after excision of the knee joint.

## INFLAMMATION.

*Suppurative inflammation*, with the formation of abscesses, has been seen in a few cases.

The most frequent lesion of the suprarenal capsules is *tuberculous inflammation*. They are usually increased in size, their surfaces are smooth or nodular. The normal structure of the gland is lost, and is replaced by tubercle tissue, connective tissue, and cheesy matter (see Addison's Disease).

*Syphilitic inflammation*, with and without the development of gummata, is of occasional occurrence.

---

[1] For consideration of relationship of adrenals to nervous system see *Alexander*, Ziegler's Beitr. z. path. Anat., Bd. xi., p. 145 (bibliography).

## DEGENERATION.

*Fatty degeneration* of the cortical portion of the capsules is the rule in the adult. It sometimes occurs in nodular areas. In children under five years of age it is a pathological condition.

*Amyloid degeneration* may involve both the cortical and medullary portions. In the cortex it usually involves only the walls of the blood vessels; in the medulla both the blood vessels and the cells of the parenchyma may undergo this degeneration. The capsules are usually firm and of a grayish, semi-translucent color.

Pigmentation of the inner cortical zone is frequent in old persons.

## TUMORS.

*Carcinoma* of the adrenals is not common. It may be primary, but is much more frequently secondary. Either one or both of the capsules may be the seat of the new growth.

*Sarcoma* occurs as a primary and secondary growth. Probably many of the older cases described as cancers were really sarcomata.

*Cylindroma.*—Klebs describes a growth of this character in one of the adrenals, secondary to a tumor of the same kind in the supra-orbital region. He gives to such tumors the name of lymphangioma cavernosum. The exact character of these growths is still obscure. They consist of irregular follicles and cavities, lined with epithelium, and containing peculiar hyalin, structureless bodies.

*Cysts* are found, both single and multiple. They are usually situated in the cortex.

*Neuroma.*—Ganglionic neuromata have been described by Weichselbaum and Freeman.

*Glioma* has been described as occurring in the medullary region.

An hyperplasia of the gland tissue (*adenoma* or *struma lipomatosa suprarenalis*) with fatty degeneration in the form of circumscribed nodules, is described by Virchow and others.

Some of the so-called adenomata of the kidney are probably adenomata of displaced accessory adrenals.[1]

---

[1] Consult *Ulrich*, Ziegler's Beitr. z. path. Anat., Bd. xviii., p. 589, 1895.

# THE URINARY APPARATUS.

## THE KIDNEYS.

### MALFORMATIONS.

Entire absence of both kidneys is sometimes associated with great malformation of the entire body. Such fœtuses are not viable.

Absence of one kidney is not uncommon, the left kidney being more frequently absent than the right. The absence of the kidney may be complete, the ureter being also absent; there may be an irregular mass of much-atrophied kidney tissue with connective tissue and fat, or there may be only a little mass of connective tissue and fat representing the kidney, and a ureter running down to the bladder. The single kidney which is present is usually much enlarged. It may be in its natural position or displaced downward.

Since the extirpation of the kidney has been practised by surgeons it has been found that absence of one kidney is more common than was formerly believed.

When both kidneys are present one of them may be much larger than the other.

Sometimes one kidney will have two pelves or two ureters.

A rather frequent malformation is the so-called *horseshoe kidney*. The lower ends of the kidneys are joined together by a commissure. The commissure is usually composed of kidney tissue, but sometimes of connective tissue. The two kidneys may be normal, except for the commissure; or their shape, the arrangement of the vessels and ureters, and the position, may be unnatural.

The two kidneys may be united throughout so as to look like a single misshapen kidney with two or more pelves and irregular blood vessels. The united kidneys may be both situated on one side of the vertebral column or in the pelvis.

### CHANGES IN POSITION.

The kidneys may be placed in an abnormal situation, in which they are either fixed or movable.

The change in position is either lateral or downward. When displaced downward the kidney may be over the sacrum or below this in the cavity of the pelvis. The vessels also have an irregular origin and distribution. The kidney is firmly attached in its abnormal position.

Movable or wandering kidneys are found in adult life as a result of tight lacing, of pregnancy, of overexertion, and of unknown causes. They are more frequent in females than in males. The right kidney is the one more frequently affected. The blood vessels become lengthened and the attachments of the kidney longer and looser.

## BRIGHT'S DISEASE.

This name is used as a convenient term to group together a certain number of diseases of the kidney. This group may be subdivided as follows :

*I. Acute Bright's Disease.*
1. *Acute Congestion of the Kidney.*
2. *Acute Degeneration of the Kidney.*
3. *Acute Exudative Nephritis.*
4. *Acute Diffuse Nephritis.*

*II. Chronic Bright's Disease.*
1. *Chronic Congestion of the Kidney.*
2. *Chronic Degeneration of the Kidney.*
3. *Chronic Diffuse Nephritis with Exudation.*
4. *Chronic Diffuse Nephritis without Exudation.*

## ACUTE CONGESTION OF THE KIDNEYS.

Acute congestion is caused by the ingestion of certain poisons, by extirpation of one of the kidneys, by severe injuries inflicted on any part of the body, by surgical operations, especially those on the bladder and urethra, and by over-exertion. We are rarely able to obtain human kidneys in the state of acute congestion, for the condition is not usually a fatal one. In animals, however, the condition can be produced experimentally by cantharidin. It is found that the kidneys are enlarged, that the veins, capillaries, and Malpighian tufts contain an increased quantity of blood, and that the epithelial cells of the cortex tubes are flattened. There may be an exudation of serum and an escape of red blood cells from the vessels.

## ACUTE DEGENERATION OF THE KIDNEYS.

*(Acute Bright's Disease; Parenchymatous Nephritis; Parenchymatous Degeneration.)*

The introduction of certain poisons into the body is regularly followed by changes in the cells of the viscera. The poisons which exert this effect may be mineral poisons, such as arsenic, mercury, and phosphorus; or the poisons of infectious diseases, such as diphtheria, typhoid fever, etc. According to the quantity and virulence of the poison received into the body, there are more or less marked changes produced in the cells of the viscera.

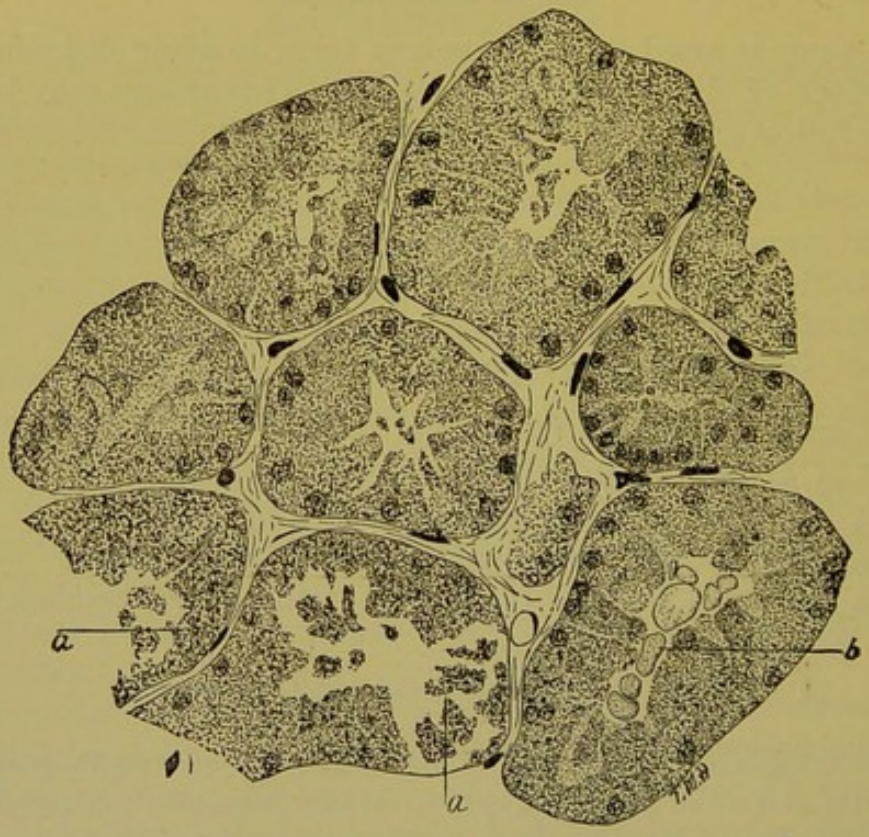


FIG. 310.—ACUTE DEGENERATION OF THE KIDNEY (Acute Parenchymatous Degeneration). From a case of yellow fever. *a*, the swollen and granular epithelium peeling off and disintegrating; *b*, hyalin material in the lumen of the tubule.

Small doses of such poisons, acting only for a moderate length of time, produce simple swelling of the cells. The cells are swollen, more opaque, more coarsely granular (Fig. 310). They are not dead, nor broken down, nor do they contain any new substances; the change in their appearance is due to the swelling of the network which forms a part of every cell. Under these circumstances there are either no changes at all in the blood-vessels of the viscera, or a slight congestion, with, perhaps, a little exudation of serum.

Larger doses of such poisons, or more virulent poisons, or a longer

duration of the action of a poison, are attended by the deposition in the cell bodies of granules of albuminous matter and gloubles of fat. At the same time there is a change in the nutrition of the cells, and they are often broken and disintegrated. Under these conditions there may be considerable congestion of the vessels and an exudation of serum.

Very large doses of such poisons cause the death of the cells of the viscera, a death which may take the form of coagulation necrosis or of disintegration and breaking down of the cell. With these changes there will often be an excessive congestion of the vessels and a large exudation of serum and the formation of casts.

As the kidneys are excreting organs it is rather natural to think that the substances which cause degeneration of the renal epithelium do so because they are excreted by the kidneys. But, as the same poisons produce similar degeneration in many other parts of the body, it seems more probable that the effect of the poison is produced in the same way that it is in the nerves, the muscles, the liver, and the spleen.

The well-known fact that temporary cutting off of the arterial blood from the kidneys in animals is followed by degeneration or death of the renal epithelium, has led to the idea that degeneration of the kidneys, especially in cholera, is due to ischæmia. This seems possible, but it is a theory not at all applicable to most cases of acute degeneration.

It is a question of much importance whether the same toxin produces degeneration or nephritis according to its dose, or whether two or more different toxins are necessary. In scarlatina and diphtheria, for example, the rule is that acute degeneration comes in the early days of the disease, acute exudative nephritis in the late days of the disease, and acute productive nephritis just after the close of the disease. Does this mean three different toxins, or that the same toxin varies at different stages of the disease, or that the only differences is in the dose?

For clinical purposes the recognition of the fact that acute degeneration is the ordinary lesion of the infectious diseases is of much practical importance.

The gross appearance of the kidney varies with the extent of the degeneration. In the ordinary mild cases, such as accompany pneumonia, the kidney is a little larger, the cortical portion a little thicker and paler. In the severe cases, such as accompany acute yellow atrophy of the liver, the kidney is considerably enlarged and more or less congested.

## ACUTE EXUDATIVE NEPHRITIS.

(*Acute Bright's Disease; Parenchymatous Nephritis; Tubal Nephritis; Desquamative Nephritis; Catarrhal Nephritis; Croupous Nephritis; Glomerulo-Nephritis.*)

Acute exudative nephritis is frequently a primary inflammation, occurring either after exposure to cold or without discoverable cause. It may complicate any one of the infectious inflammations

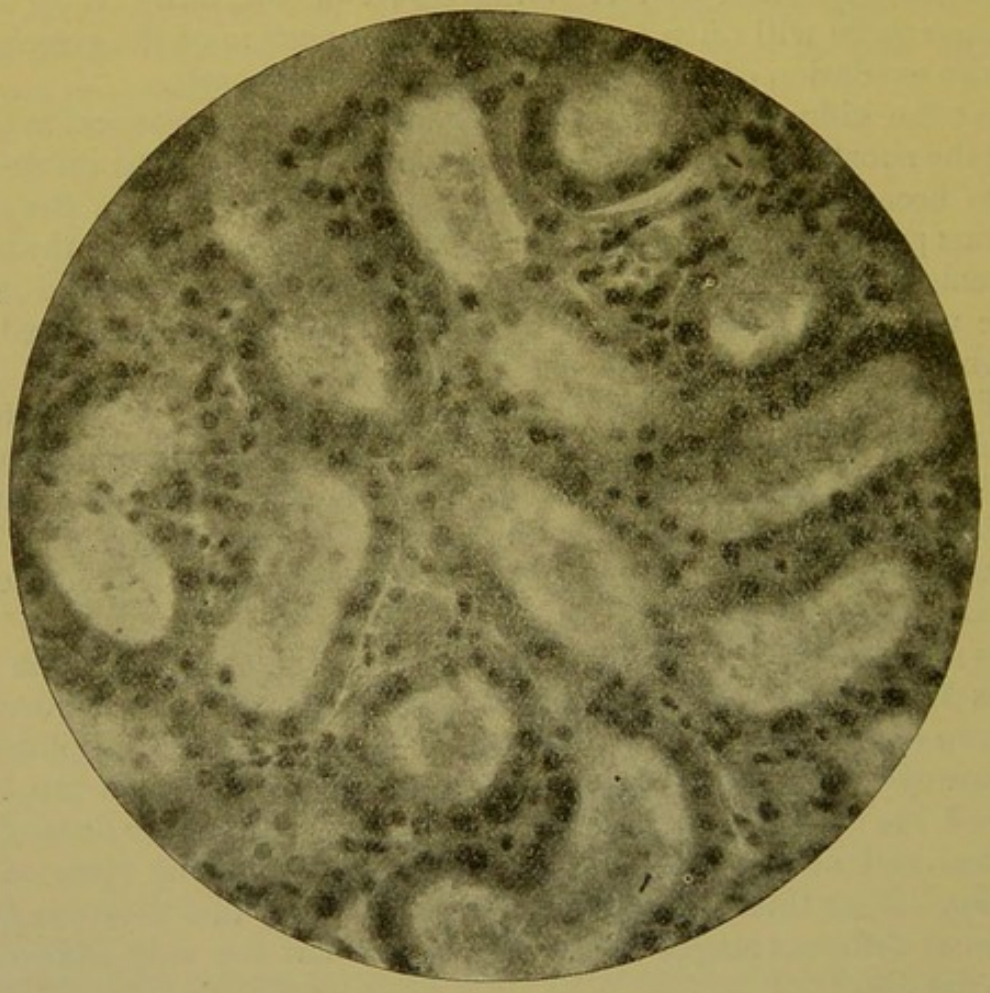

FIG. 311.—ACUTE EXUDATIVE NEPHRITIS.
Showing cortex tubes containing coagulated matter and with flattened epithelium.

or diseases, but is especially common with scarlet fever. It is one of the forms of nephritis which are apt to accompany pregnancy.

The infectious diseases are often complicated with inflammations of different parts of the body. The probable causes of these are the chemical poisons produced by the growth of the pathogenic bacteria belonging to each disease. It seems also that the poison of each disease has a preference for particular portions of the body. In rheumatism the joints and heart are regularly inflamed; in measles the bronchi; in scarlet fever and diphtheria the throat and the kidneys.

As regards the presence of bacteria in the kidneys themselves as exciting causes of inflammation our knowledge, save for certain phases of suppurative lesion, is incomplete.

Whether nephritis in puerperal women and after exposure to cold is due to disturbances of circulation or to some poison in the blood, is not certain.

The nephritis has the ordinary characters of an exudative inflam-

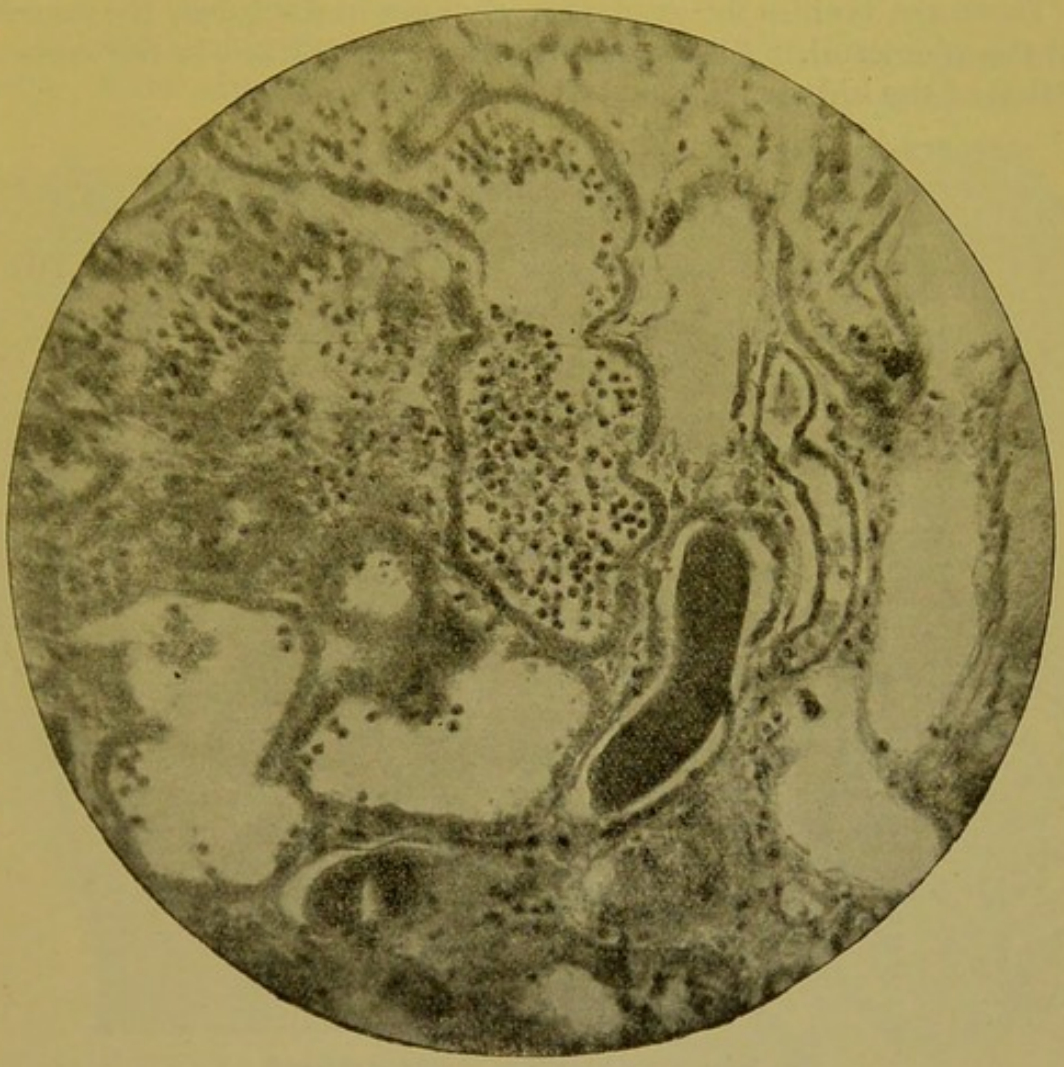

Fig. 312.—Acute Exudative Nephritis.
Showing tubes with flattened epithelium and containing red and white blood cells and casts.

mation: congestion, an exudation of blood plasma, an emigration of white blood cells, and a diapedesis of red blood cells; to which may be added swelling or necrosis of the renal epithelium and changes in the glomeruli.

In the milder cases we find the inflammatory products—serum, casts, white and red blood cells—in the urine. But in the kidneys after death we find no lesions, unless it may be a few casts in the straight tubes. The morbid process is confined to the blood vessels

of the kidney, and its only result is the exudation into the renal tubules.

In the more severe cases we find the kidneys large and smooth, the cortex thick and white, or white mottled with red, or the entire kidney intensely congested. If the stroma is infiltrated with serum the kidney is succulent and wet; if the number of pus cells is very great there will be little, whitish foci in the cortex.

There are, besides the exudation, changes in the tubes, the stroma, and the glomeruli. All the changes are most marked in the cortical portion of the kidney.

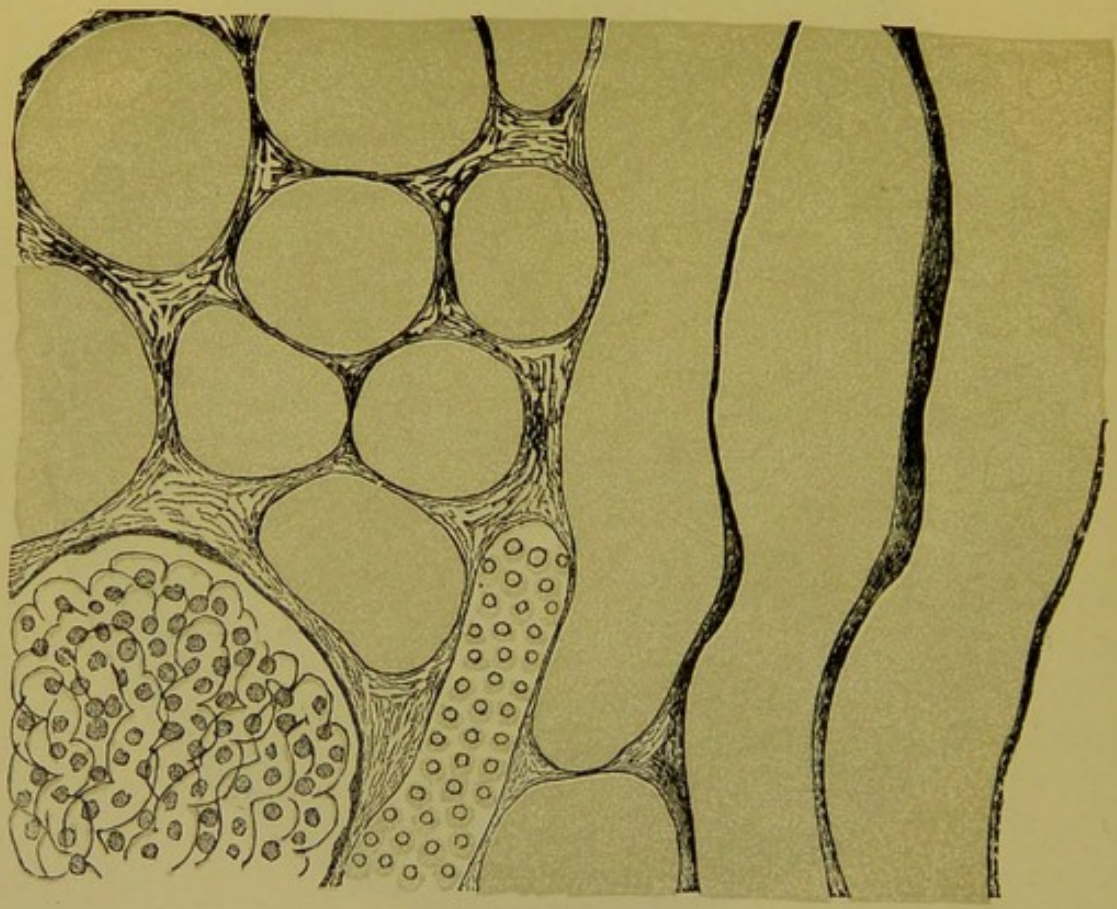

FIG. 313.—ACUTE NEPHRITIS, × 850 and reduced.
Paris green twenty hours before death.

In the tubes the epithelium may be flattened, or swollen, opaque, and detached from the walls of the tubes. There may be a uniform, symmetrical dilatation of all the cortex tubes. The tubes may be empty or they may contain coagulated matters in the form of irregular masses and of hyalin cylinders. The irregular masses are found principally in the convoluted tubes; they seem to be formed by a coagulation of substances contained in the exuded blood plasma, and are not to be confounded with the hyalin globules so often found in normal convoluted tubes.

The hyalin cylinders are more numerous in the straight tubes, but are also found in the convoluted tubes. They are also formed of matter coagulated from the blood plasma, and are identical with the casts found in the urine. The tubes may also contain red and white blood cells.

The hyalin casts, the coagulated matter, and the red and white blood cells may be all found in the urine while the nephritis is going on.

In some cases there is an excessive emigration of white blood cells. This excessive emigration is not necessarily attended with

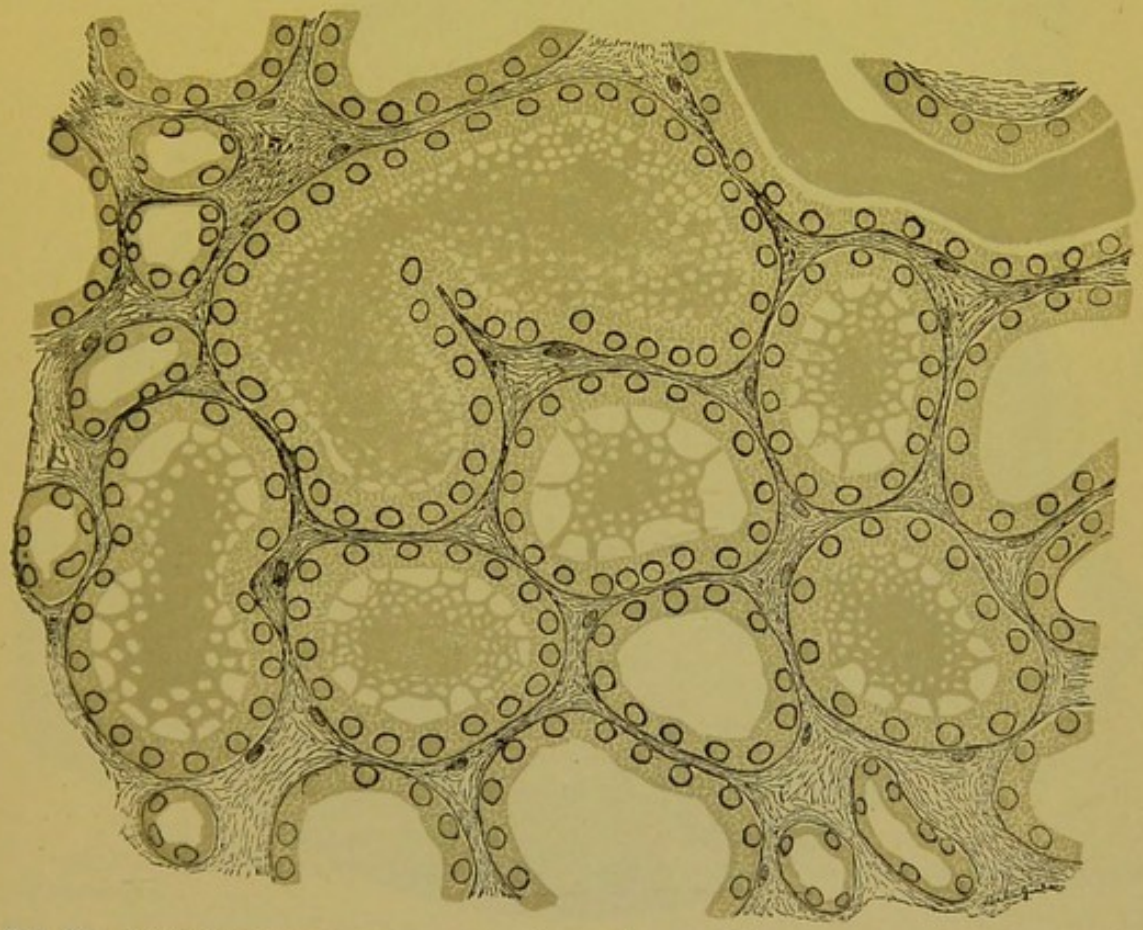

FIG. 314.—ACUTE NEPHRITIS OCCURRING WITH ACUTE GENERAL TUBERCULOSIS, × 850 and reduced.

exudation of the blood serum, and so the urine of these patients may contain no albumin.

The white blood cells are not found equally diffused throughout the kidney, but are collected in foci in the cortex. These foci may be very minute or attain a considerable size. They do not resemble the suppurating foci seen with embolism or with pyelo-nephritis.

In the glomeruli we find considerable changes. The cavities of the capsules may contain coagulated matter and white and red blood cells, just as do the tubules. The capsular epithelium may be

swollen, sometimes so much so as to resemble the tubular epithelium, and this change is most marked in the capsular epithelium near the entrance of the tubes.

The most noticeable change, however, is in the capillary tufts of the glomeruli. These capillaries are normally covered on their outer surfaces by flat, nucleated cells, so that the tuft is not made up of naked capillaries, but each separate capillary throughout its entire length is covered over with these cells. There are also flat cells which

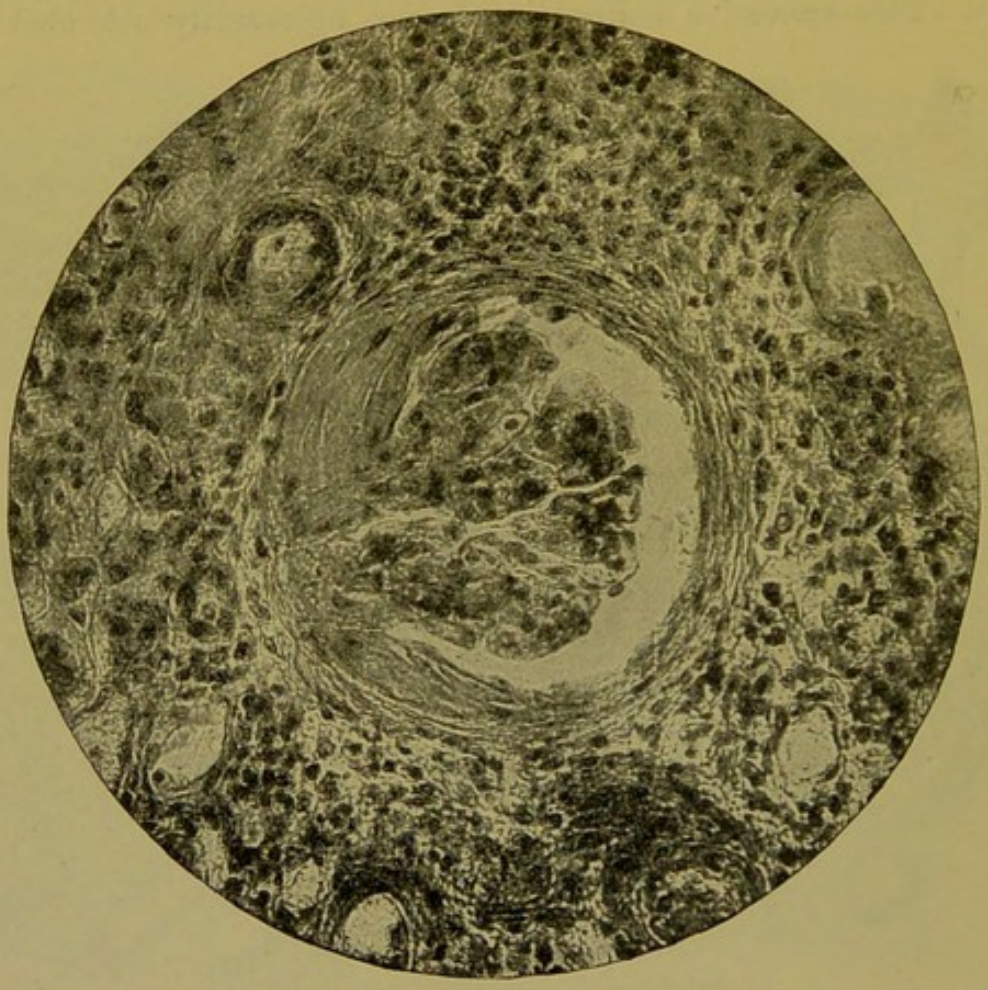

FIG. 315.—ACUTE EXUDATIVE NEPHRITIS.
Showing a glomerulus with growth of tuft cells and thickening of the capsular epithelium.

line the inner surfaces of the capillaries, but not continuously as in the case with capillaries in other parts of the body.

In exudative nephritis the swelling and growth of cells on and in the capillaries change the appearance of the glomeruli. They are larger, more opaque; the outlines of the main divisions of the tufts are visible, but those of the individual capillaries are lost. This change in the appearance of the glomeruli is due to the swelling and growth of the cells on and in the capillaries (Fig. 316).

In very severe cases the growth of the cells on the tufts is so considerable that they form large masses of cells between the glomerulus and its capsule.

The walls of the arteries in the kidneys may be thickened by a swelling of their muscular coats.

Acute exudative nephritis is regularly a transitory lesion. It may, indeed, be so severe as to destroy life in a short time. But, as

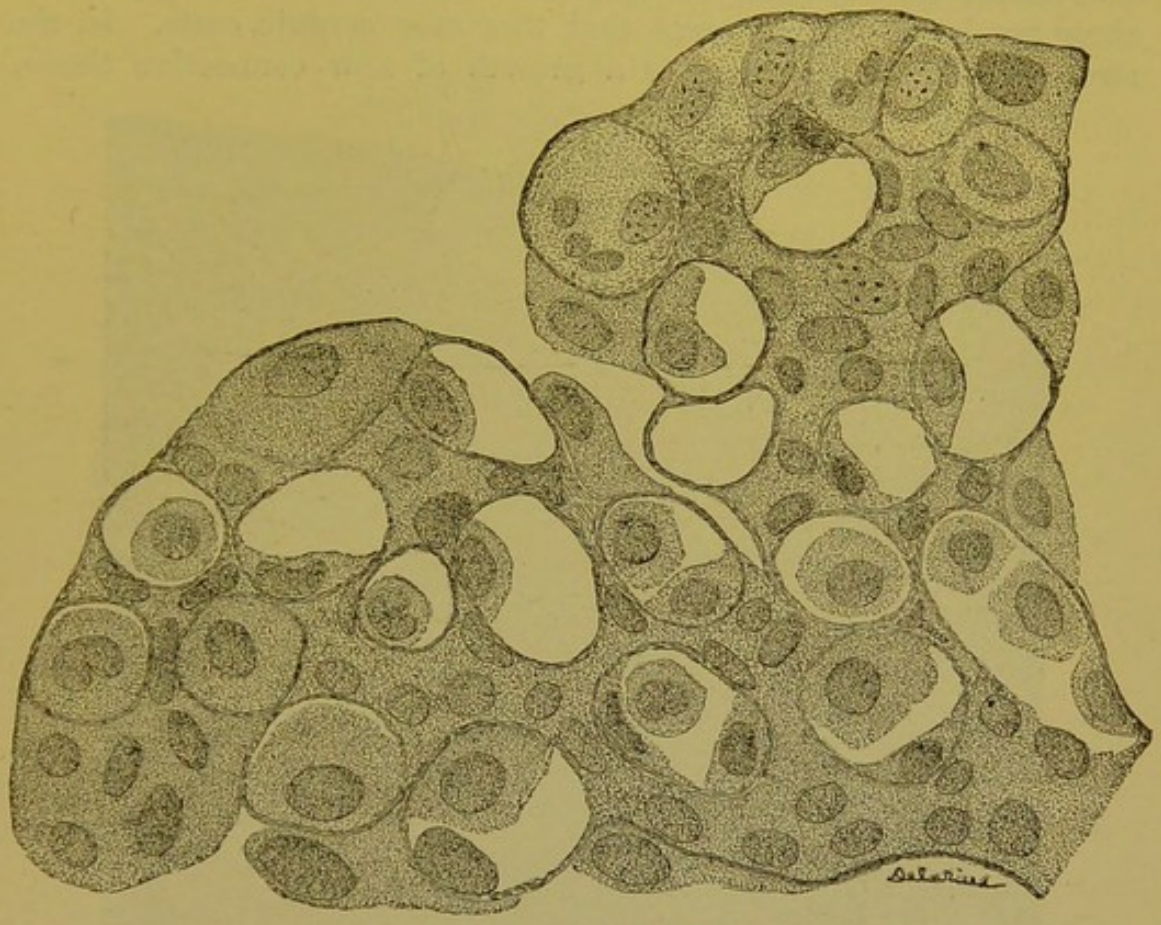

FIG. 316.—ACUTE NEPHRITIS.

Showing the swelling and growth of cells in and on the capillaries of a glomerulus in a case of scarlatina.

a rule, if the patients do recover from it they recover completely and the kidneys return to their natural condition.

## ACUTE PRODUCTIVE (OR DIFFUSE) NEPHRITIS.

(*Acute Bright's Disease; Parenchymatous Nephritis; Croupous Nephritis; Glomerulo-Nephritis.*)

This is an acute inflammation of the kidneys, characterized by exudation from the blood vessels, a growth of new connective tissue in the stroma, and changes in the epithelium and the glomeruli.

The kidneys are increased in size, the capsules are not adherent, the surfaces are smooth. The cortical portion is red, or white, or mottled. The mucous membrane of the pelvis is sometimes congested. Of the tubules in the cortex, in some the epithelium is flattened, in some there is coagulated matter or casts, in some the epithelium is swollen, degenerated, or contains globules of fat. In those parts of the cortex in which there is a growth of new connective tissue, the tubes may be atrophied. The tubules of the pyramids show but little change except that they may contain casts. In the stroma of the cortex there is a growth of new connective tissue,

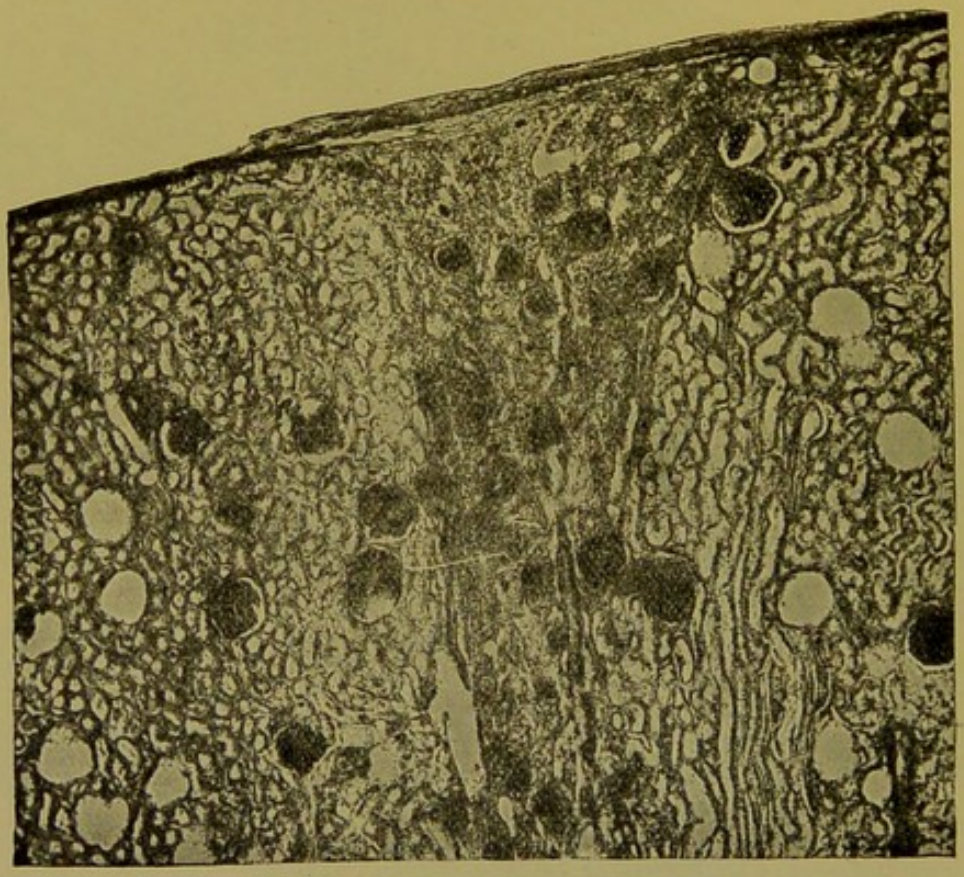

FIG. 317.—ACUTE PRODUCTIVE NEPHRITIS.
A vertical section of the cortex, showing the wedge-shaped growth of connective tissue.

varying in different kidneys as to the relative proportion of cells and basement substance. This new tissue in many of the kidneys follows the line of the arteries which run up into the cortex in the form of elongated wedges (Fig. 317). But in other kidneys the new tissue is diffuse, or in irregular patches.

Many of the glomeruli show only an increase in the size and number of the cells which cover the capillaries, with some swelling of the capsule cells. But in others there is an extensive new growth of capsule cells which compresses the tuft of vessels. This growth of new cells from the capsule cells must not be confounded with ac-

cumulations of white blood cells within the capsules, nor with the growth of new cells on the walls of the capillaries. The glomeruli which are changed in this way are in groups, each group corresponding to some one artery.

The whole picture of the nephritis is that of a combination of exudative and productive inflammation.

When such a nephritis becomes chronic it is often possible to follow its course for many years, and to see at the end of that time that

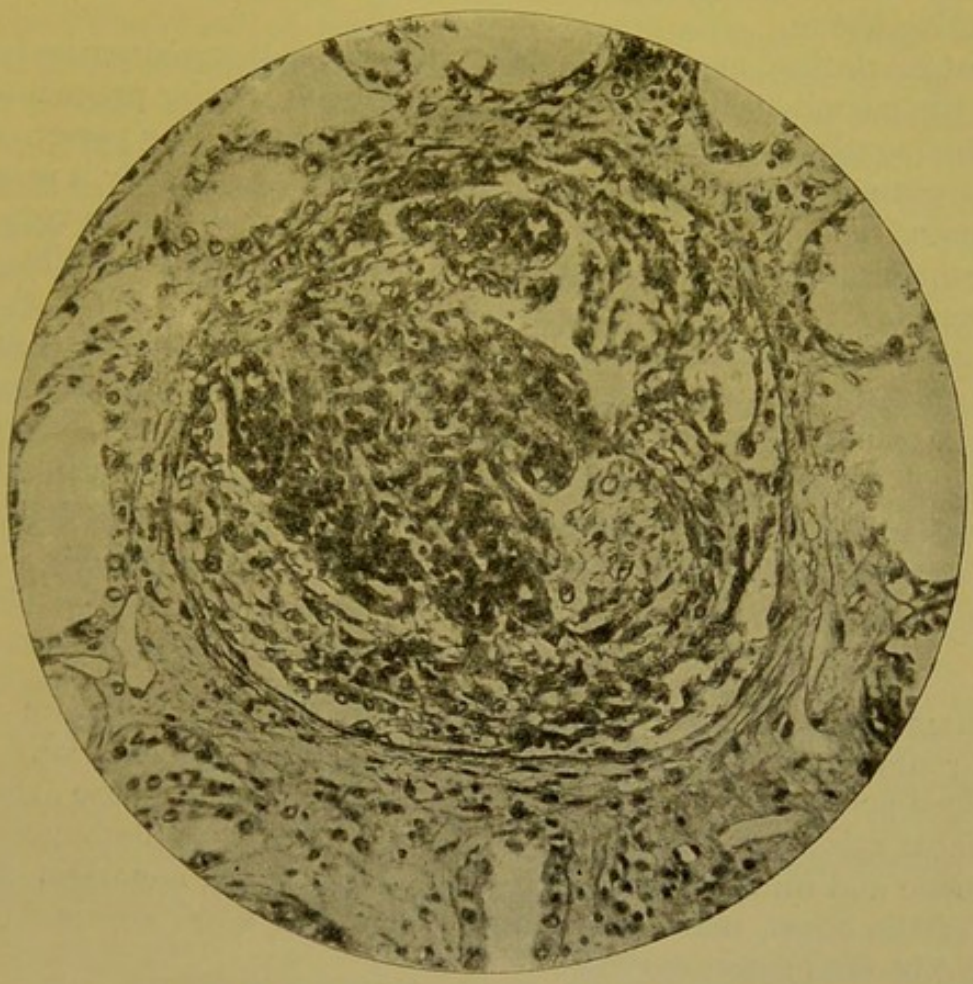

FIG. 318.—SUB-ACUTE PRODUCTIVE NEPHRITIS.
Glomerulus showing the growth of capsule cells.

the anatomical changes in the kidneys are of the same kind, but much more extensive.

This is the most serious and important of the forms of acute nephritis, for the reason that its lesions are from the first of a permanent character. It does not follow exudative nephritis, nor is it merely a modification of it; from the very outset it is a different form of inflammation. In the kidneys of persons who have been sick only a few days, the characteristic lesions are already evident. Pro-

ductive nephritis is governed by the same law as that which belongs to productive inflammation in other parts of the body—the disposition of the inflammation to continue as a subacute and chronic condition. It is of importance to recognize that in exudative nephritis the lesions are temporary, and after their subsidence the kidneys return to their normal condition, just as the lungs do after a lobar pneumonia. In productive nephritis, on the other hand, some of the lesions are permanent, the kidneys can never return to their normal condition, just as in an interstitial pneumonia the lung never gets rid of the new connective tissue.

Post-scarlatinal nephritis is nearly always of the productive form. Nephritis complicating diphtheria or developed during pregnancy is very frequently of this type. A primary nephritis in a person over twelve years old, if of subacute form, is almost invariably a productive nephritis. On the other hand, this form of nephritis very seldom complicates any of the infectious diseases except scarlatina and diphtheria.

These facts assist very much in making the diagnosis between the two forms of acute nephritis. It is easy to remember that post-scarlatinal nephritis and primary nephritis of subacute type are nearly always of the productive form; and that nephritis with diphtheria and pregnancy is often of the productive form; while acute nephritis under all other conditions is regularly of the exudative form.

### CHRONIC CONGESTION OF THE KIDNEYS.

There are a number of morbid conditions which interfere with the circulation of the blood in the aortic system in such a way that the blood accumulates in the veins and is diminished in the arteries. The most common of these conditions are: chronic inflammation of the aortic and mitral valves, dilatation of the heart, aneurism of the arch of the aorta, pulmonary emphysema, and large accumulations of fluid in the pleural cavities.

In pulmonary emphysema the disturbances of circulation are confined to the cases in which there is obstruction to the passage of blood through the lungs, dilatation and hypertrophy of the right ventricle, and then venous congestion of the aortic system. More or less dropsy is regularly developed at about the same time as the congestion of the kidneys.

Large accumulations of fluid in the pleural cavities, if they remain for any length of time, may produce well-marked chronic congestion.

By far the most common cause of chronic congestion of the kidneys is disease of the heart. So long as a heart with chronic endo-

carditis, or myocarditis, or dilatation, is able, in spite of its damaged state, to carry on the circulation fairly well, no secondary changes in the kidneys are produced. But as soon as the blood accumulates in the veins to any considerable extent the kidneys may suffer. One of three things regularly happens to them: either chronic congestion, or chronic degeneration, or chronic nephritis is developed. It is also necessary to remember that chronic endocarditis and chronic nephritis often exist in the same person, although neither one of them is secondary to the other.

The kidneys are of medium size, or rather large. Their weight is increased, somewhat out of proportion to the increase in size. The color is dark-red, the consistence is very hard, the surfaces are smooth, the capsules are not adherent. The congestion is most marked in the veins of the pyramids; these contain an increased quantity of blood, and are often dilated. The capillaries of the cortex are also congested, but it is rather exceptional to find them dilated. The epithelium of the convoluted tubes is swollen, and the separate cells of which it is composed are more evident. Or, instead of this, the epithelium is much flattened so that the lumen of the tube is larger.

The most constant and characteristic change is in the glomeruli. The capillaries which make up the glomerulus are dilated, with more or less thickening of their walls. This change in the glomeruli is usually, if not always, present and persists, even if the congestion is succeeded by a true nephritis.

While the congestion often persists up to the time of the patient's death, it may, instead of this, be followed by a chronic nephritis. If that is the case the specific gravity of the urine falls and the excretion of urea is diminished. The nephritis follows the anatomical type of a chronic nephritis without exudation, but the dilatation of the capillaries of the gomeruli persists.

### CHRONIC DEGENERATION OF THE KIDNEY.

*(Chronic Bright's Disease; Chronic Parenchymatous Nephritis; Fatty Kidney.)*

The same mechanical obstructions to the circulation—heart disease, pleuritic effusions, etc.—which produce chronic congestion, can, instead of this, produce chronic degeneration of the kidney.

It is said that anæmia of the kidneys produces degeneration of the renal epithelium. Experiments upon animals show that this view is possible. It may be that the degeneration of the kidneys seen in old and feeble persons is due to a diminished blood supply, but we can hardly speak with certainty on this point. Chronic

diseases, such as phthisis and cancer, are followed by chronic degeneration of the kidneys. There is a group of cases in which, although the health of the patients is not good, it is not easy to fix on a definite cause for the chronic degeneration. Apparently, many of the authors who describe a "chronic parenchymatous nephritis" include under this head both chronic degeneration and chronic nephritis. The matter is further complicated by the fact that kidneys may be in the condition of chronic degeneration for some time, and then become further altered by a chronic nephritis with exudation, and by waxy degeneration of the glomeruli.

If the degeneration follows heart disease the kidneys are large, and together may weigh from sixteen to twenty ounces. Their surfaces are smooth; the cortical portion is thickened, of pink or white color, the pyramids are red. The gross appearance is that of the so-called large white kidney. The epithelium of the cortex tubes is swollen and coarsely granular. The capillaries of the glomeruli are dilated, with more or less thickening of their walls. The veins in the pyramids are congested. There are no changes in the stroma, or in the arteries.

If the degeneration follow phthisis, cancer, or any wasting disease, the kidneys are usually large, with a white or yellowish cortex. There are no changes except in the cortex tubes. In these the epithelial cells are either coarsely granular, or infiltrated with fat.

If the degeneration occur in old people, or without discoverable cause, the kidneys may be either large and white, or of the size and appearance of a normal kidney, or small and red. There are the same degenerative changes in the epithelium of the cortex tubes, with no lesions in the stroma or the glomeruli.

### CHRONIC PRODUCTIVE (OR DIFFUSE) NEPHRITIS WITH EXUDATION.

(*Chronic Bright's Disease; Chronic Parenchymatous Nephritis; Chronic Glomerulo-Nephritis; Waxy Kidney; Large White Kidney; Chronic Diffuse Nephritis; Chronic Desquamative Nephritis.*)

This is a chronic inflammation of the kidney attended with a growth of new connective tissue in the stroma, permanent changes in the glomeruli, degeneration of the renal epithelium, exudation from the blood vessels, and sometimes changes in the walls of the arteries.

It has been customary to hold that in these kidneys the primary and most important changes are in the renal epithelium, while in another set of kidneys the primary and important changes are in the

stroma. In other words, that the cases of chronic nephritis can be divided into two classes—parenchymatous nephritis and interstitial nephritis.

I (Delafield) do not think that this classification is supported by facts.

In all the forms of chronic nephritis changes are to be found in the renal epithelium, the glomeruli, and the stroma. Whether the changes in the stroma, the glomeruli, or the epithelium are the more marked makes no difference in the clinical symptoms. But the presence or absence of exudation from the renal blood vessels does correspond to a marked difference in the symptoms. The existence of the exudation from the renal vessels is easily shown by the presence of serum albumin in the urine. In this way we readily distinguish two forms of chronic nephritis, one with exudation and one without.

The way of looking at the matter, then, is this:

We find after death from chronic nephritis a great many varieties in the gross appearance of the kidneys. Some are large, some are small, some are red, some are white, etc. There is no regular correspondence between these different gross appearances of the kidneys and the clinical symptoms.

We find in these same kidneys changes in the renal epithelium, in the stroma, in the glomeruli, and in the arteries. Sometimes one, sometimes the other of these elements of the kidneys is the most changed. There is no regular correspondence between the predominance of the changes in one of the kidney elements over the other and the clinical symptoms.

The easiest working scheme is to admit that in chronic nephritis all the elements of the kidney are more or less changed, but that the cases vary as to whether there is or is not an exudation of serum from the blood vessels. The presence or absence of such an exudation does correspond to a well-marked difference in the clinical symptoms.

In the present state of our knowledge and for clinical purposes, we divide all the cases of nephritis into two classes, chronic nephritis with exudation and chronic nephritis without exudation.

It is admitted that it is easy to divide up these kidneys according to their anatomical changes, into a number of fairly well-marked classes. But as this division does not correspond to clinical divisions it is valueless for clinical purposes.

Although it is convenient to describe two forms of chronic nephritis—one with much albuminuria and dropsy, and one with little or no albuminuria, or dropsy—yet it must be remembered that these are not separate lesions of the kidneys, but varieties of the same lesion. For in all these kidneys two changes are constant—produc-

tive inflammation of the glomeruli and stroma, and degeneration of the renal epithelium. The only real difference between the kidneys is whether, besides the growth of new tissue and degeneration of renal epithelium, there is or is not an exudation of serum from the blood-vessels of the kidneys.

In speaking of the exudation of serum from the vessels and its presence in the urine, we speak of it as it occurs during the whole course of the disease, and not as it occurs for short periods. We mean that in an exudative chronic nephritis there is usually a large quantity of albumin in the urine, but that there may be periods during which the albumin diminishes or entirely disappears. In the same way, in a non-exudative nephritis there may be periods during which albumin is present in considerable quantities. Generally speaking, the character of the clinical symptoms will vary with the presence or absence of the albumin.

A considerable number of cases of chronic nephritis follow an attack of acute or subacute productive nephritis. The conditions of chronic congestion and chronic degeneration of the kidney are not infrequently followed by a true nephritis.

Syphilis, chronic tubercular inflammation of any part of the body, chronic endocarditis, and chronic suppurative inflammations are often complicated with chronic nephritis.

It is very difficult to find a satisfactory cause for the primary cases. There are many of these, especially in young and middle-aged adults. The nephritis is developed in a slow, insidious way in persons whose previous health had been good, and in whom no exciting cause is discoverable.

*Gross Appearance of the Kidney.*—There is considerable variety in the gross appearance of the kidneys. The types which I (Delafield) have seen most frequently are as follows:

1. Large white kidneys, weighing together sixteen ounces or more, the capsule adherent or not, the surface smooth or nodular, the cortex thick and white, the pyramids large and red.

2. Large mottled kidneys. These resemble the large white kidneys in every respect except that the cortex, instead of being white, is mottled in a variety of ways with white, yellow, red, and gray.

3. Kidneys which resemble types one and two, but are not enlarged, the kidneys together not weighing over nine ounces.

4. Small kidneys, weighing together not more than five ounces, the capsules adherent or not, the surfaces nodular, the cortex thin, atrophied, white, the pyramids rather large and red. These kidneys belong to persons who have had symptoms of kidney disease for many years, with periods of apparent recovery.

5. Kidneys which have the ordinary appearance and consistence

of the chronic congestion due to heart disease, but in addition the capsules are adherent and the surfaces finely nodular.

6. Kidneys of different sizes—large, medium-sized, and small, with adherent capsules and nodular surfaces. The cortex is gray, or gray mottled with red. The kidneys do not look at all like the large white kidneys. This is a type of frequent occurrence.

7. Kidneys which in their size, color, and general appearance are



FIG. 319.—CHRONIC NEPHRITIS WITH EXUDATION.
Cortex with flattened epithelium and containing coagulated matter.

hardly to be distinguished from normal kidneys, except that their capsules are adherent.

8. Kidneys of small size, weighing together not more than four ounces, with adherent capsules. The cortex is atrophied, red, and irregular. These kidneys are found in persons who have given symptoms of kidney disease for a number of years.

It might naturally be supposed that such marked differences in the gross appearance of the kidneys would correspond to equally marked differences in the clinical histories and minute lesions.

This, however, is not the case. The clinical histories are practically interchangeable, and the minute lesions are essentially the same.

*Microscopical Appearances.*—If we make vertical sections of the cortex of all these kidneys, no matter what their size or color, we get with a low magnifying power the same general picture. Instead of the uniform and orderly arrangement of tubes and glomeruli which we see in the normal kidney, the tubes seem to be obliterated in some places and dilated in others. There is a growth of fibro-cellular

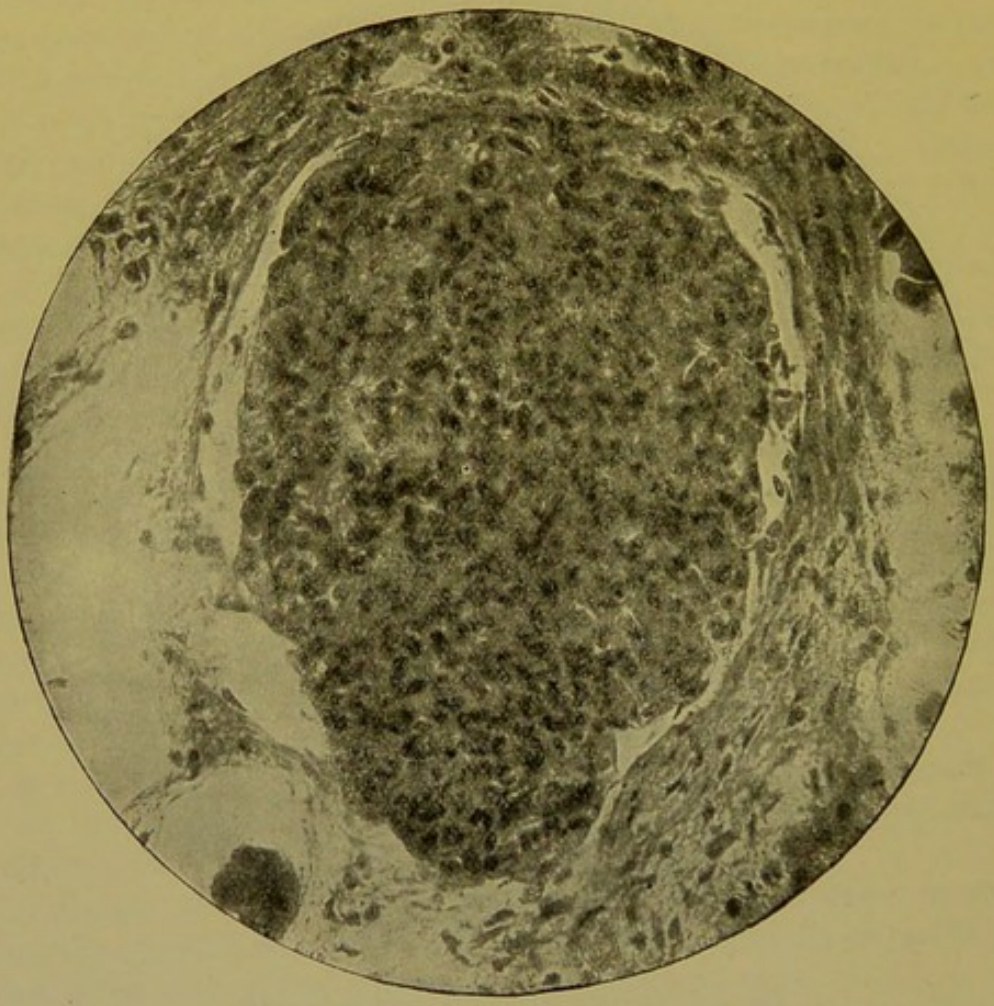

FIG. 320.—CHRONIC NEPHRITIS WITH EXUDATION.
A glomerulus, showing growth of the tuft cells.

tissue in regular wedges, in irregular patches, or diffuse between the tubules.

If we examine the different constituents of the kidney in detail we find:

*The tubes* are in some places of normal size, in some places atrophied, in some places dilated. The atrophied tubes are in the patches of new connective tissue. The dilated tubes are not very large, nor do they form cysts.

The epithelium of the tubes is in some places merely flattened. These tubes are empty, or contain coagulated matter, casts, and red and white blood cells. In other tubes the epithelium is more or less swollen, sometimes so much so as to completely fill the tubes. In still other tubes the epithelial cells are swollen, their reticulum is very coarse with large meshes, and they are infiltrated with fat. The kidneys vary as to which of these changes in the epithelium predominates, but all of them may be found in the same kidney.



FIG. 321.—CHRONIC NEPHRITIS WITH EXUDATION.
Glomerulus showing a growth of the tuft cells.

The new connective tissue is in the form of wedge-shaped masses in the cortex which follow the line of the straight arteries and veins, or it is in irregular masses, or it is arranged diffusely so as to separate the tubes from each other. The longer the nephritis lasts, the greater is the quantity of new connective tissue. The relative proportion of basement substance and cells and the density of the basement substance vary in the different kidneys. The new tissue is well supplied with blood vessels.

*The glomeruli* are changed in several different ways:

1. They resemble the glomeruli in acute exudative nephritis. They are large, the convolutions of the capillaries are seen with difficulty, there is a very great increase in the number of the cells which cover the capillaries, but these new cells are not of large size. We also see glomeruli, which apparently have been of this type, small and atrophied.

2. There is an increase not only in the number, but also in the



FIG. 322.—CHRONIC NEPHRITIS, WITH EXUDATION.
Glomerulus showing a growth of capsule cells.

size, of the cells which cover the capillaries. These cells are so large that they project outward from the surface of the glomerulus. There is also an increase in the size and number of the cells within the capillaries. These glomeruli are found in all stages of atrophy.

3. The capillaries are changed in the same way by a growth of large cells on their outer surfaces and within them. In addition there is a very extensive cell-growth beginning in the cells which line the capsule. The mass of new cells produced in this way may be so

great as to compress the capillaries (Fig. 322). The glomeruli also become atrophied, the capillaries are shrunken, and the capsule cells changed into connective tissue.

4. If chronic congestion of the kidneys is followed by chronic nephritis, the dilatation of the capillaries due to the congestion continues, and there is added an increase in the size and number of the cells which cover the capillaries.

5. The walls of the capillaries are the seat of waxy degeneration, while the cells which cover them are increased in size and number (Fig. 323).

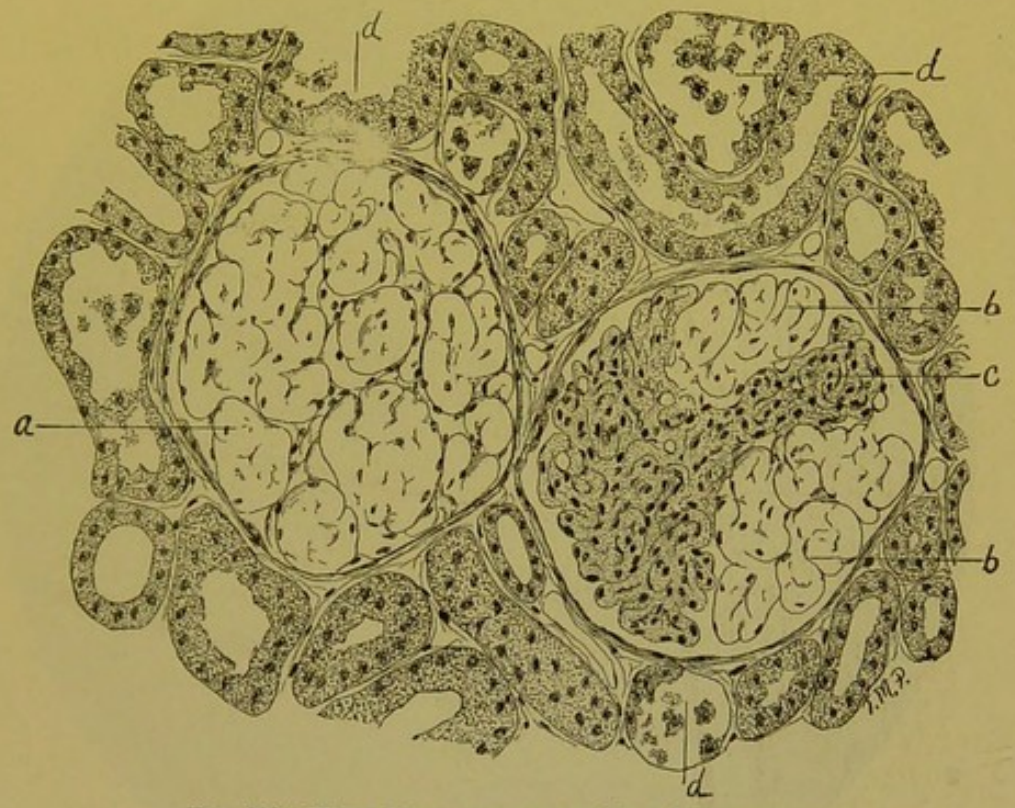


FIG. 323.—WAXY DEGENERATION OF TUFT CAPILLARIES.

*a*, the tuft is completely transformed into a waxy mass; *b*, portions of tuft waxy; *c*, tuft capillaries normal; *d*, convoluted tubule with disintegrating epithelium.

6. Besides the atrophied glomeruli already described, there are others which are small and shrunken, with comparatively little new growth of cells.

*The arteries* are not infrequently much altered by inflammatory changes. There is a growth of cells and basement substances from the inner surface of the artery which obstructs its lumen; or there is a thickening of each of the three coats of the artery; or all the coats of the artery are thickened and converted into a uniform mass of dense connective tissue; or the wall of the artery undergoes waxy degeneration.

## CHRONIC PRODUCTIVE NEPHRITIS WITHOUT EXUDATION.

(*Chronic Bright's Disease; Cirrhosis of the Kidney; Granular Degeneration; Interstitial Nephritis; Chronic Indurative Nephritis; The Arterio-Sclerotic Kidney.*)

While this form of nephritis is especially common in persons over forty-five years old, it is by no means rare in young adults, and is occasionally seen in children.

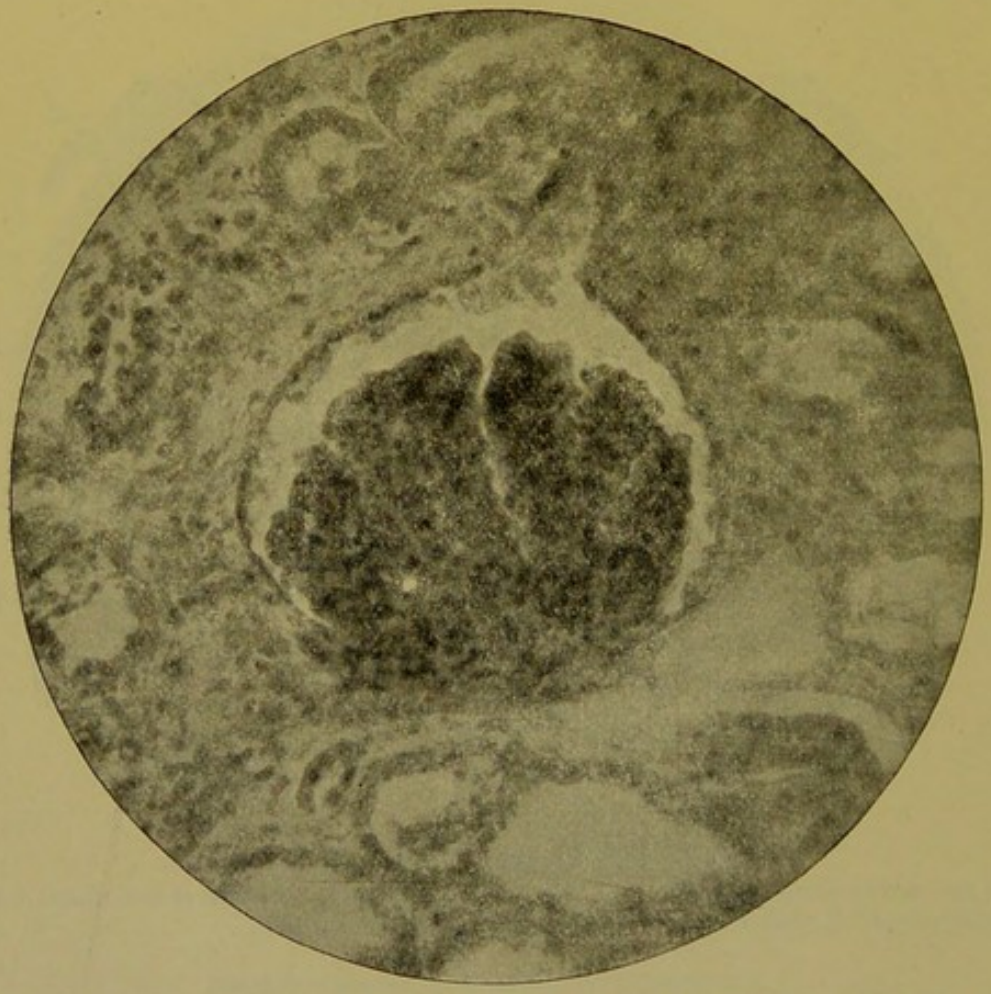

FIG. 324.—CHRONIC NEPHRITIS WITHOUT EXUDATION.
Atrophied glomerulus.

It seems to be caused by chronic alcoholism, lead poisoning, gout, and by the same conditions as those which cause emphysema, endocarditis, and cirrhosis of the liver. It follows chronic congestion of the kidney, hydro-nephrosis, and chronic pyelitis.

The larger number of the affected organs are found after death to be diminished in size; the two kidneys together may not weigh more than two ounces. The capsules are adherent; the surfaces of the

kidneys are roughened or nodular, the cortex is thin and of a red or gray color.

A considerable number of these kidneys, however, do not differ in their size or appearance from normal kidneys, except that their capsules are adherent and their surfaces roughened.

Occasionally the kidneys are large, weighing together from 16 to 32 ounces, with smooth or nodular surfaces, and a cortex of red, gray, or white color.

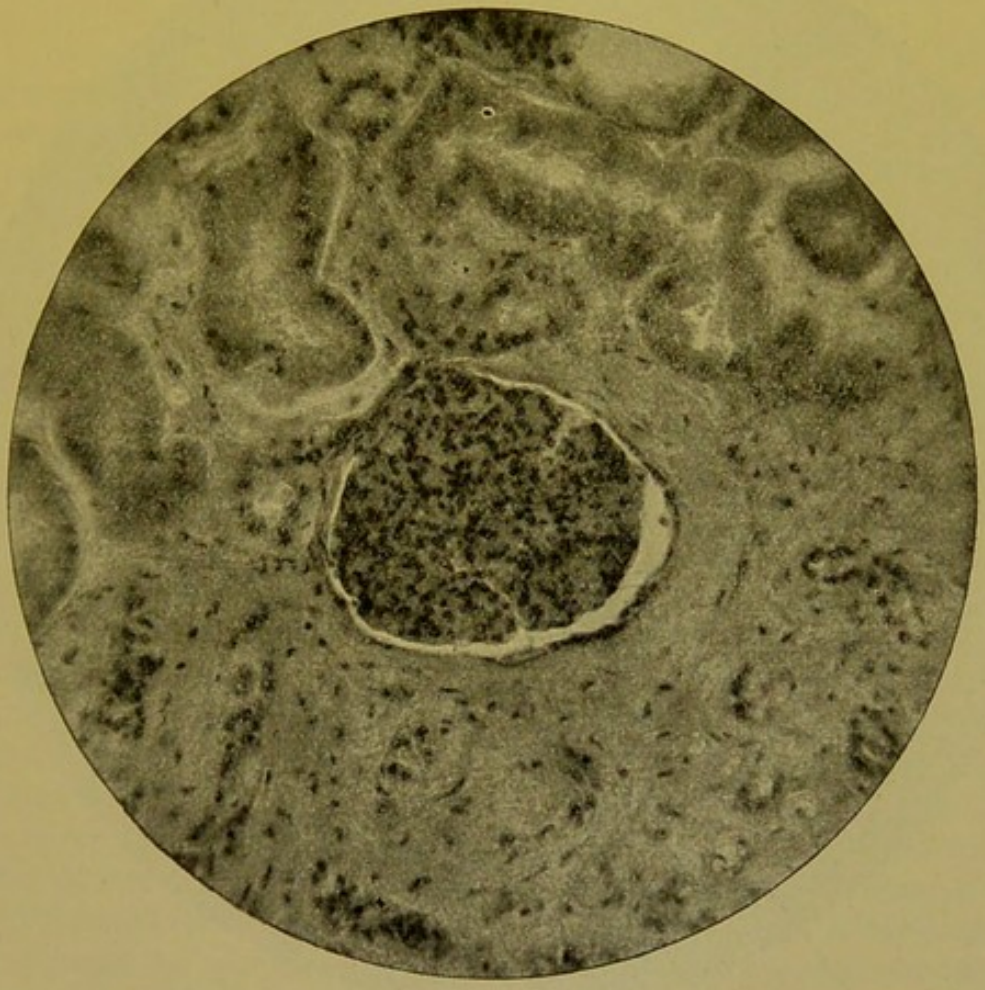

FIG. 325.—CHRONIC NEPHRITIS WITHOUT EXUDATION.
Showing an atrophied glomerulus.

If the nephritis follows chronic congestion, the kidneys remain hard, but the cortex becomes thinned, the capsules adherent, and the surface roughened.

There is a growth of new connective tissue in the cortex and also in the pyramids, which becomes more and more extensive as the disease goes on. In the cortex the new tissue follows the distribution of the normal subcapsular areas of connective tissue, is in the form

of irregular masses, or is distributed diffusely between the tubes. In the pyramids the growth of new connective tissue is diffuse.

*The tubes*, both in the cortex and pyramids, undergo marked changes. Those included in the masses of connective tissue are diminished in size, their epithelium is flattened, some contain cast matter, many are obliterated. The tubes between the masses of new



FIG. 326.—CHRONIC NEPHRITIS WITHOUT EXUDATION.
An atrophied glomerulus.

connective tissue are more or less dilated; their epithelium is flattened, cuboidal, swollen, degenerated, or fatty. The dilatation of the tubes may reach such a point as to form cysts of some size, which contain fluid, or coagulated matter. These cysts follow the lines of systems of tubes, or are situated near the capsules.

Of the *glomeruli* a certain number remain of normal size, but with the tuft cells swollen or multiplied. Many others are found in all stages of atrophy and of change into connective tissue (Figs. 324 and 325). The atrophy seems to depend partly on the growth of

tuft cells and intra-capillary cells, partly on the thickening of the capsules, partly on the occlusion of the arteries. If the chronic nephritis follow chronic congestion of the kidneys the glomeruli remain large, with an increased growth of tuft cells, or they become atrophied, but with the dilatation of the capillaries still evident. The capillaries of the glomeruli may be the seat of waxy degeneration (Fig. 326). The arteries exhibit the same changes as have already been described in speaking of chronic exudative nephritis.

### SUPPURATIVE NEPHRITIS.

Suppurative inflammation in the kidney may follow injuries to the organ, the lodgment in its vessels of infectious emboli, and may accompany pyelitis and cystitis.

1. *Suppurative Nephritis from Injury.*—Gunshot wounds, incised or punctured wounds, falls, blows, and kicks are the ordinary traumatic causes. If the injury be a very severe one it usually causes the death of the patient in a short time; if it is less severe, suppurative inflammation is developed. The inflammatory process may be diffuse, so that nearly the whole of one or of both kidneys is converted into a soft mass composed of pus, blood, and broken-down tissue; or it is circumscribed and one or more abscesses are formed in the kidney.

2. *Abscesses.*—In pyæmia and in malignant endocarditis small infectious emboli find their way into the arteries of the kidneys and produce necrosis of small areas of tissue, with surrounding zones of suppurative inflammation. The entire kidney is enlarged and congested, and is dotted with little white foci surrounded by red zones. The foci are formed by an infiltration of pus cells between the tubes, with more or less degeneration of kidney tissue. Sometimes abscesses of one or both kidneys are met with which have existed for a long time and for which no cause can be discovered. After death the kidney may be changed into a sac of pus surrounded by fibrous tissue. The pelvis and calyces may be dilated and their walls thickened. The connective tissue around the kidney, and its capsule, may be also thickened. Suppurating sinuses may extend from the kidney into the surrounding soft parts.

Whatever the form in which it may manifest itself, suppurative inflammation of the kidney may be induced by some one or combination of the pyogenic micro-organisms which may lodge within it under favorable conditions.

Thus Streptococcus pyogenes, Staphlococcus pyogenes, Bacillus coli communis; the pneumococcus, the typhoid bacillus, and others may be found in the suppurative foci. Sometimes, however, espe-

cially in the more chronic processes, the technical procedures at our command fail to reveal the presence of micro-organisms.

When the suppurative inflammation is consecutive to similar processes in the bladder or ureters the processes are usually due to the same infective agent (see page 684).

*Suppurative Pyelitis* is often associated with suppuration of the kidney substance on the one hand, and on the other hand, and more frequently, with a similar process in the bladder or ureters, or both on the other. But it may occur by itself. It is incited by the same micro-organisms as are concerned in the induction of the associated lesions in the kidney and bladder. In the latter case, it is most often the Bacillus coli communis, the Streptococcus pyogenes, and Staphylococcus pyogenes which are concerned.

The mucous membrane of the pelvis may be congested, thicker and more opaque than normal, and coated with pus or with patches of fibrin. The presence of pelvic calculi is to be regarded as a predisposing rather than as a direct inciting agent in suppurative pyelitis.

### SUPPURATIVE URETERITIS.

The conditions under which suppurative inflammation of the ureter occurs are similar, as is the general appearance of its mucous membrane, to these just indicated in the pelvis.

### SUPPURATIVE PYELO-NEPHRITIS WITH CYSTITIS.

("*Surgical Kidney.*")

In this grouping of lesions, which is usually initiated by the inflammation of the bladder, the affection of the kidneys is usually bilateral. The suppurative areas in the kidney may be in the form of small abscesses scattered through the kidneys, or in the form of elongated whitish streaks or wedges between the tubules. The purulent foci are often surrounded by a red zone of congestion.

The kidney tissue in the vicinity of the abscesses may be necrotic, the outlines of the cells being preserved but their nuclei absent or not revealed by the usual staining agents (see Fig. 68).

The infective agent may traverse the ureters in the passing from the inflamed bladder to the kidneys without leaving the mucous membrane of the ureter intact.

### CHRONIC PYELO-NEPHRITIS.

Chronic cystitis or calculi in the pelvis of the kidneys may set up

a chronic inflammation which involves both the pelvis and calyces and the kidney tissue. The mucous membrane of the pelvis and calyces is thickened, the epithelial layer is changed, there is a growth of granulation tissue beneath the epithelium, and there may be little polypoid outgrowths. The surface of the mucous membrane is coated with pus or fibrin, or the cavity of the pelvis is dilated and distended with purulent serum.

The kidney itself is the seat of a chronic interstitial inflammation with the production of new connective tissue, and sometimes of pus, with obliteration of the renal tubules.

### TUBERCULOUS NEPHRITIS.

This lesion is usually, though not always, associated with tubercular inflammation in other parts of the genito-urinary tract.

It is usually unilateral, occurring most frequently on the left side. The process may commence in the kidney or in some other part of the genito-urinary tract. If only one kidney is involved the other is apt to become the seat of chronic diffuse nephritis with waxy degeneration of the walls of the arteries. The tubercular inflammation may occur in a kidney already the seat of chronic inflammatory changes.

The lesion is apt to begin in the mucous membrane of the pelvis and calyces, and extends from thence first to the pyramidal and afterward to the cortical portion of the kidneys. In the mucous membrane of the pelvis and calyces there is a growth of granulation tissue studded with tubercle granula in the stroma, while the epithelial cells proliferate, become deformed, and desquamate. This process is often rapidly succeeded by cheesy degeneration of all the inflammatory products.

In the kidney there is the same production of granulation tissue and tubercle granula, which soon undergo cheesy degeneration, the degeneration involving the adjacent kidney tissue. In addition to this there is in the rest of the kidney chronic interstitial or suppurative inflammation. So the entire kidney is enlarged, portions are in the condition of cheesy degeneration or have sloughed away, while the rest of the kidney is dense and hard. Or, if suppuration takes place, the kidney is hollowed out into cavities filled with cheesy matter and pus.

Sometimes the process comes to a standstill, and then the cheesy portions are infiltrated with salts of lime.

### EMBOLISM AND THROMBOSIS.

Acute and chronic endocarditis affecting the left side of the heart, and chronic endarteritis of the aorta, frequently result in the forma-

tion of vegetations, portions of which become detached and lodged as emboli in the branches of the renal artery.

The occlusion of an artery in this way produces in the kidneys wedge-shaped infarctions, varying in their size with the size of the obstructed artery. The infarction loses the natural red color of the kidney and becomes first yellow and then white. The renal epithelium degenerates and disappears, the tubes become collapsed and shrunken; around the infarction is a zone of congestion and of infiltration with pus cells. After this the infarction becomes shrunken, dense, and changed into connective tissue. The kidney is then left deformed by the cicatricial depressions and contractions. It is possible, however, for the infarction to become gangrenous, or to be surrounded by a zone of purulent infiltration, and break down so as to form an abscess. Rarely the infarctions are of the hæmorrhagic variety.

Embolism of the trunk of the renal artery produces complete necrosis of the kidney.

Infectious emboli are small and produce little purulent foci (see above).

Thrombosis of the renal vein and its branches may occur in patients suffering from chronic Bright's disease.[1] It can also be produced by tumors pressing on the veins, by thrombi of the vena cava, and occurs as a primary lesion dependent on the general condition of the patient.

## HYDRONEPHROSIS.

Dilatation of the pelvis and calyces of the kidneys is found as a congenital condition. In some cases other malformations, such as club-foot, hare-lip, and imperforate anus, are also present. The pelves and calyces of both kidneys, and the ureters, are distended with urine; the bladder is also distended and its wall may be hypertrophied. The urethra may be closed, or no obstruction can be demonstrated. In these latter cases it is supposed that there does exist some membranous obstruction, which is broken by the probe or catheter used to explore the urethra.

In adult life hydronephrosis is produced by mechanical obstruction of the urethra or ureters, due to inflammation, tumors, or calculi. According to the position of the obstruction, either one or both kidneys are involved.

The pelvis and calyces are dilated, sometimes enormously, and filled with urine alone or urine mixed with pus. The kidney tissue is flattened and thinned over the distended cavities. Its texture may

[1] *Moxon*, Trans. Lond. Path. Society, 1870, p. 248.

remain unchanged, or there may be developed suppurative pyelonephritis or chronic diffuse nephritis.

### THE CYSTIC KIDNEY.

Cysts are formed in the kidneys, both during intra-uterine and extra-uterine life.

The congenital cystic kidney is a very remarkable pathological condition. Either one or both kidneys are enormously enlarged and converted into a mass of cysts. The cysts are of all sizes and are separated from each other by fibrous septa or compressed kidney tis-

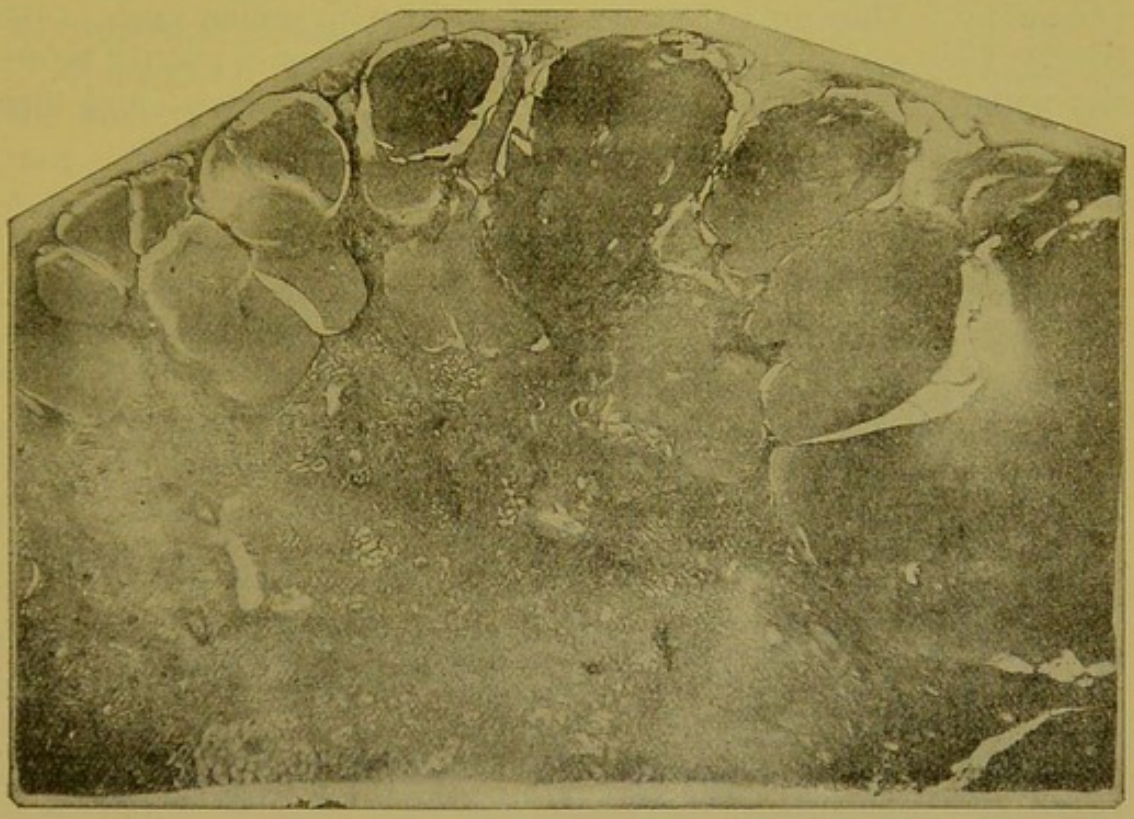

FIG. 327.—CYSTS OF KIDNEY—CHRONIC NEPHRITIS.

sue. They contain a clear yellow, acid fluid holding in solution the urinary salts. Or the fluid is turbid and brown, and contains blood, uric acid crystals, and cholesterin. The cysts are lined with a single layer of flat, polygonal cells. They seem to be formed by a dilatation of the tubules and of the capsules of the Malpighian bodies. As causes for such dilatations are found obliteration of the tubes in the papillæ, and stenosis of the pelvis, ureters, bladder, or urethra. Other congenital malformations are often associated with this one.[1]

In adult life we find three varieties of cystic kidney :

1. In kidneys which are otherwise normal there are one or more

[1] Virch., Ges. Abhandl.

cysts filled with clear or brown serum or colloid matter. These cysts do not appear to interfere at all with the function of the kidneys.

2. In chronic diffuse nephritis, especially in the atrophic form, groups of tubes are dilated. Apparently one or more of the larger tubes in the pyramids is obstructed, and this causes dilatation of a corresponding group of tubes. Such a dilatation may be moderate in size, or it may form cysts visible to the naked eye.

3. Both kidneys are very much enlarged and converted into a mass of cysts containing clear or colored serum or colloid matter. The nature of these cysts is uncertain. It is possible that they are congenital. They are sometimes associated with similar cysts in the liver. They seem to produce no renal symptoms until shortly before the patient's death, unless chronic nephritis also exists, and then there are the ordinary symptoms of chronic Bright's disease.

## PERINEPHRITIS.

The loose connective tissue which is situated around and beneath the kidney may become the seat of suppurative inflammation, and in this way abscesses of considerable size are formed.

Such a perinephritis may be either secondary or primary. The secondary cases are due to extension of the inflammation from abscesses in the vicinity, such as are formed with caries of the spine, pelvic cellulitis, puerperal parametritis, perityphlitis, and suppurative nephritis.

The primary cases occur after exposure to cold, after contusions over the lumbar region, and after great muscular exertion; or no cause can be discovered.

Complicating cases occur in the course of typhus and typhoid fevers and of small-pox.

Most of the reported cases have been in persons between the ages of twenty and forty years. Less frequently children and older persons are affected.

In the idiopathic cases the connective tissue behind the kidney seems to be the point of origin of the inflammatory process, and it is here that the pus first collects. After the abscess has formed the suppuration extends and the pus burrows in different directions: backward through the muscles; downward into the iliac fossa, the perineum, the bladder, the scrotum, or the vagina; forward into the peritoneal cavity or the colon; upward through the diaphragm.

The kidney itself is simply compressed by the abscess, or its tissue becomes involved in the suppurative inflammation.

## RENAL CALCULI.

In the kidneys of new-born children, from the first to the fourteenth day after birth, the large tubes of the pyramids often contain small, brownish, rounded bodies composed of the urates of ammonium and sodium. Similar masses may also be present in the calyces and pelves. In still-born children these masses are usually absent. The carbonate and phosphate of lime may be deposited in the tubes of the pyramids, in the form of white linear masses, in the kidneys of old persons and of those who have suffered from destructive diseases of the bones.

Urate of soda in the form of acicular crystals is deposited both in the tubes and stroma of the kidneys of gouty persons.

Concretions of the urinary salts are often formed in the pelves of the kidneys. They may remain there as rounded masses, or they may attain a large size and be moulded into the shape of the pelvis and calyces. Smaller calculi may pass into the ureter and either become impacted there or pass through it into the bladder. The most common form of calculus is that composed of uric acid. But they may also be formed of uric acid with a shell of oxalate of lime, or of oxalate of lime alone, or of the phosphates, or of cystin.

The most serious result of the presence of these calculi is the occlusion of the ureters or the production of pyelo-nephritis.

## TUMORS.

*Fibroma.*—Small, hard, white fibrous nodules are frequently found in the pyramids. They are of no special importance. They may be mistaken for miliary tubercles. Large fibromata are very rare.[1]

*Lipoma.*—Small fatty tumors are found in the cortex of the kidney just beneath the capsule. They are composed of fully developed fat tissue. The fat is developed in the stroma so as to replace the kidney tissue.[2]

*Papilloma.*—Villous tumors, formed of tufts of connective tissue covered with epithelium, may grow from the mucous membrane of the pelvis.[3] A peculiar form of papillary and cystic growth of the ureter is described.[4]

*Myxo-Sarcoma.*—Large tumors may grow from the pelvis of the kidney. They are not simple myxomata, but are composed of mucous tissue, fat, and sarcomatous tissue.

---

[1] *Wilks*, Trans. Lond. Path. Soc., xx.

[2] For bibliography of fat tumors of the kidney consult *Ulrich*, Ziegler's Beitr. z. path. Anat., Bd. xviii., p. 603.

[3] Trans. Lond. Path. Soc., 1870, p. 239.

[4] Virch. Arch., Bd. lxvi., p. 139.

*Myoma.*—Small tumors composed of smooth muscular fibres and of round cells are found in the cortex close to the capsule.

A tumor composed of striated muscle and round cells is described by Cohnheim.[1]

A tumor composed partly of smooth muscle, partly of striped muscle, and partly of sarcomatous tissue is described by Eberth.[2]

*Angioma cavernosum* occurs in the form of small nodules situated in the cortex.

*Lymphoma.*—Small white tumors composed of tissue like that of the lymphatic glands are found in cases of leukæmia and pseudo-



FIG. 328.—ADENOMA OF THE KIDNEY.
Papillary form.

leukæmia. Less frequently they are found with typhoid fever, scarlet fever, and diphtheria.

*Adenoma.*—This form of tumor is situated in the cortex of the kidney and may invade the pyramidal portion also. Usually there is only a single tumor, but sometimes two or more, or they may even occur in both kidneys. They vary in size; some are not larger than a pea, others are as large as a hen's egg. They are of rounded form, of whitish color, and separated by a capsule from the kidney tissue. The tumors are most frequent in persons over forty years of age.

---

[1] Virch. Arch., Bd. lxv., p. 64.

[2] Ibid., Bd. lv., p. 518.

There are two principal varieties of these tumors, the papillary and the alveolar, which are, however, closely related.

1. *The Papillary Adenoma.*—There are cavities of different sizes, from the walls of which spring branching tufts covered with cylindrical or cuboidal epithelium (Fig. 328). These tufts nearly fill the cavities.

2. *The Alveolar Adenoma.*—There is a connective-tissue framework enclosing small round, oval, or tubular alveoli, lined or filled with cells (Fig. 329).

The cells are usually large and may be cylindrical, cuboidal, or polyhedral, and may be pigmented in a manner similar to the cells of the adrenals.



FIG. 329.—ADENOMA OF THE KIDNEY.
Glandular form.

Fatty degeneration of the epithelium may be excessive and glycogen may form in the cells. In these tumors the stroma may be present in considerable quantity, or the blood vessels may form conspicuous features, or a cystic distention of the alveoli may occur. Large areas in these tumors may become necrotic.

Many of these tumors appear to have developed from adrenal cells estray in the kidneys. They may form metastases.

The relationship between true adenoma of the kidney, adenomata which appear to develop from strayed adrenal elements, and similar tumors which are regarded by some observers as endotheliomata or

endothelial sarcomata, and certain forms of angio-sarcoma, is not yet altogether clear.[1]

*Carcinoma.*—Besides secondary carcinoma of the kidney there is also a primary form. Our knowledge of this has been much obscured by confounding with it adenomata and sarcomata.

There seems to be, however, a real epithelial growth, originating in the kidney tubules, which forms tumors of large size and malignant character.

*Sarcoma.*—Tumors formed of connective-tissue cells may originate either in the pelvis of the kidney or in the kidney itself. They form tumors of large size and malignant character. Those which grow from the pelvis are usually myxo-sarcomata. Those which originate in the kidney tissue reach a large size and are soft and hæmorrhagic. Their stroma forms irregular alveoli filled with small round cells.

### PARASITES.

*Echinococcus*, in its ordinary form of mother and daughter cysts, is sometimes found in the kidney. The cysts may open into the pelvis of the kidney, into the pleura, or through the wall of the abdomen.

*Cysticercus cellulosæ* is of very rare occurrence.

*Pentastomum denticulatum* has been seen once by E. Wagner.

*Filaria sanguinis hominis* is found in the arteries, veins, lymphatics, and stroma.

*Strongylus gigas* has been found several times in the pelvis of the kidney.

## THE URINARY BLADDER.

### MALFORMATIONS.

*Exstroversion* of the bladder is one of the most frequent malformations, and may occur in either sex. It presents several varieties :

1. The umbilicus is lower down than usual, the pubic bones are not united at the symphysis, the pelvis is wider and shallower than it should be. Between the umbilicus and pubes the abdominal wall is wanting. In its place is a projecting, ovoid mass of mucous membrane, in which may be seen the openings of the ureters. The penis is usually rudimentary ; the urethra is an open fissure (epispadias) ; the clitoris may be separated into two halves. The ureters usually

[1] Consult *Paoli*, Ziegler's Beitr. z. path. Anat., Bd. viii., p. 140 ; *Askanazy*, ibid., Bd. xiv., p. 33, 1893 ; *v. Kahlden*, ibid., Bd. xv., p. 626 ; *Sudeck*, Virch. Arch., and *Ulrich*, Ziegler's Beitr. z. path. Anat., Bd. xviii., p. 589, 1895 ; *Lubarsch*, Virch. Arch., Bd. cxxxv., p. 149.

open normally; sometimes their openings are displaced or are multiple. They may be dilated.

2. There may be a fissure in the abdominal wall, filled up by the perfectly formed bladder.

3. The umbilicus may be well formed, and there is a portion of abdominal wall between it and the exstrophied bladder.

4. The external genitals and urethra may be well formed, and the symphysis pubis united, while only the bladder is fissured.

5. The genitals, urethra, and symphysis may be well formed, the bladder closed except at the upper part of its anterior wall. The bladder is entirely or in part inverted and pushed through the opening in the abdominal wall.

The *Urachus* normally remains as a very small canal, five to seven cm. long, with a small opening into the bladder, or entirely closed at that point. If there is a congenital obstruction to the flow of urine through the urethra, the urachus may remain open and the urine pass through it. Or the bladder may present, even in the adult, a slender distention reaching close to the umbilicus as the result of a persistent urachus.[1]

*Absence of the Bladder* is of rare occurrence. The bladder may be very small, the urine passing almost directly into the urethra. The bladder may be separated into an upper and a lower portion by a circular constriction. It may be completely divided by a vertical septum into two lateral portions. Diverticula of the wall of the bladder are sometimes found in new-born children. Partial or complete closure of the neck of the bladder may occur. This may lead to hydronephrosis, or the urine may be discharged through the open urachus.

### CHANGES IN SIZE AND POSITION.

*Dilatation.*—This may be *general* or *partial*, leading to the formation of diverticula.

General dilatation of the bladder is produced by the accumulation of urine in consequence of some mechanical obstacle to its escape, or of paralysis of the muscular walls of the organ. The dilatation is usually uniform and may be very great, so that the bladder may reach to the umbilicus. If the walls of the bladder are paralyzed, or the obstruction occurs suddenly or is complete, the wall of the bladder is thinned. When an incomplete obstruction exists for some time the walls of the bladder are apt to hypertrophy, so that, although the bladder is larger than normal, the walls may not only be of the usual thickness, but even very much thicker. In the fœtus

[1] *Ely*, Trans. N. Y. Path. Soc., 1893, p. 64.

dilatation of the bladder may reach such a size as to interfere with delivery.

The retained urine in dilated bladders is liable to decomposition, leading to inflammation or gangrene of the mucous membrane.

*Diverticula* of the bladder may be produced by the pouching-out of circumscribed portions of the wall of the bladder, the wall of the pouch containing all the layers of the bladder wall. More frequently, however, they are produced by a protrusion of the mucous membrane between hypertrophied bundles of muscle fibre. They may be very small, or they may be as large as a child's head. They may communicate with the bladder by a large or a small opening. The decomposition of stagnant urine in diverticula is apt to induce inflammation. Calculi may be formed in them or may slip into them from the bladder.

*Hypertrophy* of the muscular coat of the bladder is usually produced by mechanical obstructions to the outflow of urine, such as stricture of the urethra, enlarged prostate, calculi, new growths, etc. The muscular coat is thickened uniformly or assumes a trabeculated appearance. The organ retains its normal capacity, or is dilated, or becomes smaller. The mucous membrane is frequently the seat of chronic or acute inflammation. Dilatation of the ureters and hydronephrosis frequently accompany this condition.

*Herniæ* of the bladder sometimes accompany intestinal herniæ through the inguinal and crural canals and the foramen ovale. The changes in position of the bladder, produced by displacements of the vagina and uterus, will be mentioned with the lesions of those organs.

In the female the base of the bladder may press downward, causing protrusion of the vaginal wall (*vaginal cystocele*); or there may be inversion and prolapse of bladder through the dilated urethra.

### RUPTURE—PERFORATION.

Penetrating wounds of the bladder may permit escape of urine into the abdominal cavity, or infiltration into the surrounding connective tissue, or permanent fistulæ. Such wounds are always serious and frequently fatal, owing chiefly to the severe and often gangrenous inflammation which decomposing urine sets up in the connective tissue, or to the peritonitis induced by the same cause.

Rupture of the bladder may be produced by severe blows and falls when the bladder contains urine. More rarely rupture takes place from overdistention. Death may occur from rupture of the bladder with escape of urine into the peritoneal cavity, without evidences of peritonitis.

Perforations of the bladder are produced by ulceration and gangrene, by abscesses from without, and by cancerous ulceration from the adjoining organs. Fractures of the pelvic bones may produce laceration of the bladder. Perforations of the bladder may lead to the establishment of fistulæ, communicating with the rectum, vagina, uterus, or opening externally.

### DISTURBANCES OF CIRCULATION.

*Hyperæmia.*—Aside from active hyperæmia of the mucous membrane in acute inflammation, the bladder is not infrequently the seat of chronic congestion from obstruction to the venous circulation. Under these conditions there may be chronic catarrhal inflammation, or a marked dilatation of the veins (vesical hæmorrhoids), which may give rise to hæmorrhage or to obstruction of the opening of the ureters.

*Hæmorrhage.*—Extensive hæmorrhages into the bladder are commonly due to injury or to the presence of calculi or tumors. Small hæmorrhages into the substance of the mucous membrane may accompany inflammation, the hæmorrhagic diathesis, scurvy, purpura, small-pox, etc. If the hæmorrhage is considerable and occurs rapidly in an empty bladder, a clot is apt to form; but when the blood mixes with urine as it is extravasated it more commonly remains liquid and is discharged as a reddish-brown fluid.

### INFLAMMATION.

*Acute Cystitis.*—This may be incited by the presence of urine which has decomposed under the influence of bacteria; by cantharides or other drugs; by the presence of foreign bodies and calculi; or it may be due to an extension of gonorrhœal urethritis or vaginitis; or it may occur without assignable cause. The mucous membrane is swollen and congested, although these alterations may not be very evident after death. The surfaces may be coated with mucus containing red blood cells and pus. The epithelium is apt to be loosened and in some places peeled off, so that superficial or deep ulceration may occur. We may find mixed with the urine in the organ shreds of mucus, pus cells, epithelial cells of various shapes, usually more or less swollen and granular, or fragments of such cells; red blood cells and bacteria. Resolution may occur from acute catarrhal cystitis, but it very frequently assumes a chronic character.

*Chronic Cystitis.*—In this form the mucous membrane may be swollen, succulent, grayish, or mottled with spots of congestion or extravasation, and covered with a layer of mucus and pus. Microscopically the membrane may be more or less infiltrated with pus

cells, and pus may be constantly produced and thrown off into the urine. Later the mucous membrane may become thickened either diffusely or in the form of tufts or polypi. In some cases it becomes atrophied. Owing to decomposition of the hæmoglobin in the extravasated blood the mucosa may become pigmented, brown, or slate-colored. The mucous membrane frequently becomes eroded, especially on the most elevated portions, or deep ulcerations may occur. The muscular coats may become paralyzed and the bladder dilated; or the submucosa or the muscularis, or both, may become hypertrophied. The mucous membrane may become encrusted with urinary salts.

In another class of cases the inflammation assumes a more intense and necrotic character. Larger and smaller shreds and patches of the mucosa die, become brown or gray in color, loosen or peel off, and become mixed with the urine and exudations. The gangrenous process may extend to all the coats of the bladder, so that perforation and fatal peritonitis may occur. The gangrenous form of cystitis is more apt to occur in paralytics. In still another class of cases the inflammation assumes a suppurative character. The submucosa, the intermuscular connective tissue, and the adjacent parts become infiltrated with pus, either diffusely or in the form of larger and smaller abscesses, which may open externally or internally, forming deep ulcers. In all these cases the inflammation may extend to the ureters and kidneys; it may skip the ureters and involve the kidneys.

The small nodules of lymphoid tissue in the mucous membrane of the bladder, especially near the neck, may become enlarged and prominent in cystitis, and may then be mistaken for miliary tubercles (nodular cystitis).[1]

*Croupous Inflammation.*—In connection with any of the above lesions the mucous membrane of the bladder may be covered, in patches or sometimes over a considerable portion of its surface, with a layer of fibrin, either granular or fibrillar, enclosing pus and epithelial cells and bacteria. The mucosa may be infiltrated with fibrin.

This form of inflammation may occur in connection with severe infectious diseases—measles, diphtheria, scarlatina, typhoid fever; in connection with similar inflammation of the external genitals, in puerperal fever, noma, and sometimes in the presence of foreign bodies. It is rarely an idiopathic disease.

Various forms of bacteria have been found in the urine in connection with the various phases of inflammation of the bladder.

Aside from the tubercle bacillus which is always concerned with

---

[1] *Alexander*, Journal Cutaneous and Nervous Diseases, July, 1893.

tuberculous lesions, the most common micro-organisms are the Bacillus coli communis, Streptococcus pyogenes, and Staphylococcus pyogenes and Bacillus proteus. Many other forms are of occasional occurrence.

While the exact significance of the germs named in connection with cystitis is not yet fully clear, there is much reason to attribute serious importance especially to the Bacillus coli communis.[1]

*Tuberculous Inflammation.*—This disease commences by the formation of miliary tubercles in the mucous membrane of the bladder. By the coalescence of the tubercles and the degeneration of tissue about them, ulcers are formed, and it is most frequently in the ulcerative stage that the lesion is seen. The ulcers, which may be large or small, are usually most abundant at the base of the organ. Their edges may be cheesy, and miliary tubercles in greater or smaller numbers are usually found in the mucosa about them. Not infrequently large shreds of tissue are loosened and cast off. The mucosa about the ulcers is apt to be infiltrated with small spheroidal cells. Tubercle bacilli are present in many of the tubercles and in the edges and base of the ulcers. They may also be found in the urine, and are then of diagnostic significance. Catarrhal inflammation is a very constant accompaniment of this lesion. Tubercular cystitis may occur in connection with tubercular inflammation of the lungs, intestines, or of the kidney, uterus, prostate, etc.

## TUMORS.

*Fibromata* have been described, occurring as small nodular tumors in the submucosa, but they are rare.

Aside from the polypoid thickenings of the mucosa occurring in chronic cystitis, soft vascular *papillomata* are of frequent occurrence. These tumors vary in size from that of a pea to that of a pigeon's egg or larger. They consist of a fibrous, often very vascular stroma, and are covered on the surface with numerous small, closely set, villous projections, over which are irregular layers of elongated or cylindrical cells. These tumors are very liable to bleed, are often accompanied by vesical catarrh, and may be covered by a precipitate of urinary salts. The epithelium is liable to peel off from the surface of the villi and appear in the urine. *Sarcoma* of the bladder has been described.

*Carcinoma.*—Carcinoma of the bladder is most frequently secondary, and is then rarely due to metastasis, but usually to an ex-

[1] Consult *Schmidt and Aschoff*, "Die Pyelonephritis," Jena, 1893; also *Barlow*, Arch. f. Dermatologie u. Syphilis, 1893, p. 355; also *Melchior*, "Cystitis and Urinary Infection," 1895 (bibliography).

tension of the growth from neighboring parts, as the uterus, vagina, or rectum.

Primary carcinoma of the bladder may occur :

1. As a diffuse *scirrhous infiltration* of the entire wall of the bladder, usually with ulcerations of its inner surface.

2. As *a circumscribed nodule* which grows inward and outward, ulcerating on its inner surface, and sometimes producing perforations.

3. As *villous* or *papillomatous growth.* The tumor grows from one or more points of the inner surface of the bladder. It is



Fig. 330.—Papilloma of the Bladder.

formed of tubular follicles lined with cylindrical epithelium, and, on its inner free surface, of tufts covered with cylindrical epithelium. The new growth may involve the entire thickness of the wall of the bladder.

4. A few cases of carcinoma have been described in which the stroma contained a varying quantity of smooth muscle tissue.[1]

*Cysts.—Dermoid cysts* of the wall of the bladder have been described, but are rare. Small cysts with serous contents sometimes occur in the mucous membrane ; a part of them, at least, are believed to be due to faulty embryonal development.

[1] The literature of tumors of the bladder may be found in *Stein's* "Study of the Tumors of the Bladder," 1881.

### PARASITES, ETC.

Among the animal parasites occasionally found in the bladder may be mentioned *Echinococcus*, *Distoma hæmatobium*, *Filaria sanguinis*, *Ascarides*, and *Oxyurides*.

A great variety of foreign bodies may be found in the bladder, particularly in the female. If their stay is long they are apt to become encrusted with urinary salts.

### CALCULI.

Vesical calculi may occur singly or in great numbers, and vary greatly in size, ranging from small, sand-like particles up to masses four or five inches in diameter, but the usual range is from the size of a pea to that of a hen's egg. They are usually oval, spheroidal, or elongated; or, when several are present, they are apt to be faceted. The surface may be smooth or rough. They are usually more or less distinctly lamellated, and are frequently formed around a central body called a nucleus, which may either be formed of urinary salts or some foreign body. Their most common constituents are *phosphates*, *uric acid* and *urates*, and *calcium oxalate*, or various combinations of these.

*Uric Acid Calculi.*—These are the most common of vesical calculi. In the form of small brownish-red, crystalline aggregations they may be passed as "gravel." The larger uric acid calculi are not commonly of very great size, are frequently finely nodulated on the surface, but may be smooth. The color varies from light yellow to dark reddish-brown; they are usually dense and lamellated.

*Calculi formed of Urates.*—Calculi composed of pure urates are rare, these salts being more commonly combined with uric acid and the phosphates to form the complex calculi. Sodium urate, in the form of small spined, more or less globular crystalline masses, forms one of the varieties of "gravel."

*Phosphatic Calculi.*—Pure *calcium phosphate* calculi are, rarely, found as whitish, usually smooth, and small lamellated concretions.

*Mixed or Triple Phosphate* calculi are common, and frequently attain large size. These calculi are sometimes pure, but the deposit is more frequently associated with other salts, either as encrusting or intercalated lamellæ. Triple phosphate calculi are usually rough on the surface, of grayish-white color, lamellated, and frequently very friable.

Small gray or white, hard, and usually smooth calculi of pure *calcium carbonate* occur rarely. Calcium carbonate is sometimes passed as gravel in the form of minute spheroidal bodies, either singly or in clusters.

*Calcium Oxalate* calculi (mulberry calculi) are comparatively

common, either pure or in combination with uric acid or the phosphates. Calcium oxalate may occur in the form of very small, hard, smooth concretions, or as larger, heavy, hard, finely or coarsely nodulated brown or blackish lamellated masses. The nucleus or some of the lamellæ, or both, are often composed of uric acid.

*Cystin Calculi* are usually ovoidal in shape, of waxy consistence, of clear or brownish or greenish-yellow color, with mammillated surface and crystalline fracture. Cystin may be associated in a variety of ways with other calculi.

*Xanthin Calculi*, which are very rare, are usually of moderate size, smooth, of a cinnamon or cinnabar-red color, lamellated, and oval or flattened in shape.

Solid masses of fibrin and blood sometimes occur in the bladder, and may exist as independent structures, or form nuclei for the deposit of urinary salts.

For a detailed account of calculi, the conditions under which they form, modes of analysis, etc., we refer to special works on this subject.

## THE URETHRA.

### CONGENITAL MALFORMATIONS.

Some of the malformations of the urethra are described with those of the penis.

The urethra may be impervious or may open at the root of the penis. More commonly there is partial obliteration or stricture of some part of the canal.

The entire urethra may be dilated into a sac full of urine.

There may be a canal on the dorsum of the penis, formed by the fusion of the spermatic cords, and opening in the glans above the urethra.

There may be two or more openings of the urethra.

The canal may be dislocated so as to open in the inguinal region.

A number of cases have been reported in which a valve in the urethra has produced hypertrophy of the bladder, dilatation of the ureters, and hydronephrosis.[1]

Owing to its narrowness, greater length, and peculiar connections with the internal generative organs, the male urethra is much more liable to disease than the female.

### CHANGES IN SIZE AND POSITION.

*Dilatation* of the urethra may be produced by strictures, or by

[1] Virch. Arch., Bd. xlix., p. 348.

calculi or other bodies fixed in its lumen. The dilatations are fusiform or sacculated in shape, and may reach the size of an orange or be even larger.

Strictures of the urethra are usually produced by inflammation of its walls.

The stricture may be *temporary*, produced by a diffuse inflammatory swelling of the mucous membrane, or by the raising of the relaxed membrane into a fold or pocket.

*Permanent strictures* are produced by structural changes in the walls of the urethra.

1. The mucous membrane and submucous tissue are left hard and unyielding by the preceding inflammation. Subsequently the new fibrous tissue contracts and narrows the canal.

2. Ulceration of the mucous membrane leaves cicatricial tissue, which contracts, and also produces adhesions and bands of fibrous tissue.

3. There is fibrous induration of the corpus spongiosum and consequent constriction of the urethra.

The most frequent position of strictures is at the junction of the membranous and spongy portions of the urethra, or close to this point. They also occur at the fossa navicularis and the meatus, but frequently in the prostatic portion. There may be one stricture or several. The consequences of stricture are dilatation of the urethra, the bladder, the ureters, and hydronephrosis; inflammation and ulceration of the urethra behind the stricture, with perforation, infiltration of urine, or the formation of fistulæ.[1]

The urethra may also be obstructed by folds of the mucous membrane; by muscular valves at the neck of the bladder; by wounds; by polypi and swollen glands; by new growths; by changes in the prostate and perineum; by calculi, mucus, blood, and echinococci coming from the bladder; by foreign bodies introduced from without.

*Prolapse* and inversion of the mucous membrane is seen in young girls and women in rare cases. There is a bluish-red swelling, from the size of a pea to that of a walnut, at the meatus. In the male invagination of the mucous membrane of the urethra has been seen after injuries of the perineum

### WOUNDS—RUPTURE—PERFORATION.

Wounds of the urethra are produced in many ways, but most commonly by catheters and bougies. The wounds may cicatrize, or

[1] For literature of stricture of urethra, and plates illustrating several forms, see article by *Dittel* in Pitha and Billroth's "Handbuch der allg. Chirurgie," Bd. iii., Abth. 3.

there may be infiltration of urine or the formation of fistulæ or false passages.

Ruptures of the urethra are produced by severe contusions and by fracture of the pelvic bones. Extravasations of blood and urine, and gangrenous inflammation of the surrounding soft parts, are the ordinary results.

Ulceration and perforation of the urethra may lead to the formation of fistulæ, which open in various directions through the skin.

### INFLAMMATION.

*Catarrhal Urethritis* may be simple and due to the action of chemical irritants, to the extension to the urethra of inflammation from other parts, and to unknown causes; but it is most frequently due to the action of the gonorrhœal poison. In its acute form it involves either a portion or the whole of the urethra. The mucous membrane is red, swollen, and covered with muco-pus. The inflammation may extend to the fibrous wall of the urethra, the corpora spongiosa and cavernosa. This may result in the formation of new connective tissue or of abscesses, especially near the fossa navicularis. The inflammation may also extend to the bladder, the glands of Cowper, the prostate, the spermatic cord, and the testicles. The inguinal glands also may be swollen and inflamed, and the lymphatic vessels on the dorsum of the penis may be involved in the same process.

Chronic inflammation of the urethra may exist for a long time with the production of a muco-purulent exudation, but without the occurrence of marked structural lesions. In other cases it leads to ulceration, to fibrous induration of the wall of the canal, to induration and swelling of the mucous follicles, to polypoid thickenings of the mucous membrane.

The exudation in gonorrhœal inflammation of the mucous membranes, not only of the urethra but also of the vagina and of the eye, constantly contains, in greater or less numbers, a form of micrococcus which is said by some observers—although this is denied by others—to present characteristic morphological characters.

The Micrococcus gonorrhœæ—called gonococcus—which is spheroidal or ovoidal in shape, usually occurs in pairs or in groups of four or more, and may be contained in the pus cells (Fig. 80) or lie on their surfaces or free in the fluid. The pus cells sometimes contain very large numbers of the micrococci.

The gonococcus may be stained by drying the exudation on a cover glass and using Gram's method.

For details as to the biology of the gonococcus see page 206.

*Croupous Inflammation* is sometimes seen in children. Fibrinous casts of a small or large portion of the canal may be formed.

*Syphilitic Ulcers* may be situated at the meatus or as far back as the fossa navicularis. They are apt to produce strictures.

*Tubercular Inflammation* rarely occurs in the mucous membrane of the urethra in connection with tubercular inflammation of the bladder, prostate, or testicles.

## TUMORS.

Aside from the polypoid outgrowths from the mucous membrane of the urethra as the result of chronic inflammation, fibrous polyps may occur congenitally, or polyps containing glandular structures or cysts rarely occur. *Carcinoma* may occur as a result of local extension from adjacent organs or metastasis from the bladder. *Cysts* may occur in the mucous membrane as a result of the dilatation of the mucous glands. Circumscribed masses of dilated veins occasionally occur in the urethra, forming the so-called *urethral hæmorrhoids.*

The sinus pocularis may be dilated in children by the retention of its secretion, so as to form a tumor which may obstruct the exit of urine, cause hypertrophy of the bladder and dilatation of the ureters.

# THE ORGANS OF GENERATION.

## FEMALE GENERATIVE ORGANS.

### THE VULVA.

#### MALFORMATIONS.

The external genitals may be entirely absent or imperfectly developed. The fissure between the labia may be unformed, or the labia may grow together, with or without obstruction of the urethra. The clitoris and nymphæ may be abnormally large, or the nymphæ may be increased in number. The clitoris may be abnormally long, resembling a penis; at the same time the vagina is narrow, the uterus small and undeveloped or malformed; the ovaries small, sometimes situated in the labia; the mammæ small, and the body of a masculine character. Such cases are sometimes called pseudo-hermaphrodites. The clitoris may be perforated by the urethra or may be cleft and apparently double.

The hymen frequently exhibits various anomalies. It may be entirely absent. The opening may be very large or in unusual places; there may be several openings; the free edge may be beset with papillary projections; there may be no opening at all.[1]

#### HÆMORRHAGE, HYPERÆMIA, ETC.

Hæmorrhage may take place from wounds or ulcers of the vulva, but the most important form of hæmorrhage is that which occurs in the connective tissue of the labia majora. This is produced during labor or from external injury. One of the labia may be swollen and distended by the extravasated blood until it is as large as a child's head. The blood may be gradually absorbed, or it may decompose with suppuration or gangrene of the surrounding tissue. The puru-

[1] For description and illustrations of anomalies of the hymen, which may be useful for medico-legal purposes, see *Courty's* "Diseases of Uterus, Ovaries, Fallopian Tubes," Trans. by McLaren, 1883, p. 90.

lent matter may escape through the skin and the patient recover, or the suppuration may extend into the pelvis and cause death.

A varicose condition of the veins of the labia is not infrequent. *Œdema* may occur in acute form in pregnant and puerperal women, and may terminate in suppuration or gangrene. Œdema of the labia majora frequently accompanies disturbances of the venous circulation, as in certain heart and lung diseases ; or it may occur in chronic diffuse nephritis or other wasting diseases, or as a result of thrombosis or other disturbances of circulation in the uterine or perivaginal venous plexuses. This may be excessive, leading to the transudation of fluid through the skin, to the formation of vesicles, to superficial erosion, or even to gangrene.

### INFLAMMATION.

The skin, mucous membrane, connective tissue, and glands of the vulva may be the seat of inflammation. Acute catarrh of the mucous membrane may be caused by a variety of irritating influences, but is most frequently due to gonorrhœal infection. The mucous membrane is swollen and red and covered with a muco-purulent exudation. The labia may be swollen, the glands of Bartholin are liable to be involved, and abscesses of the labia may be developed. Chronic catarrhal inflammation may lead to superficial or deep ulceration of the mucous membrane, or to papillary outgrowths, or to thickening of the labia. Suppurative inflammation of the tissue of the labia may occur in connection with a similar process in neighboring parts. Erysipelatous inflammation of the skin of the vulva is frequent in young children and may cause death. In adults it is less common. Inflammation of the vulvo-vaginal glands may be acute and produce abscesses, or chronic and produce induration of the gland.

Gangrene may follow erysipelatous inflammation, may occur after parturition, may accompany severe exhausting and infectious diseases, or may occur as an epidemic disease, especially among children. It may be the result of bruises or other injuries. In some forms, such as those known as *noma* and *hospital gangrene*, the destruction of tissue proceeds with extreme rapidity.

Herpes, eczema, lichen, prurigo, etc., may be found on the skin of the vulva.

Syphilitic inflammation and ulceration are of frequent occurrence on the vulva, particularly on the mucous surfaces, and frequently lead to considerable destruction of tissue and cicatricial contractions.

*Simple Croupous Inflammation* may occur, with or without diphtheria and a similar lesion of the fauces or elsewhere, and is frequently associated with gangrene.

*Lupus.*—This form of inflammation, usually with more or less destructive ulceration, occasionally occurs in the vulva.

### TUMORS.

*Fibroma.*—Circumscribed fibrous tumors are found in the connective tissue of the labia, mons veneris, perineum, clitoris, and entrance to the vagina. They may attain a large size, and, attached only by a pedicle, may hang far down between the legs. The skin is usually movable over the surface of these tumors.

*Fibroma diffusum* (elephantiasis).—This usually involves the clitoris or the labia, or both, and may extend to surrounding parts of the skin. It consists essentially of a diffuse hypertrophy of the skin and subcutaneous tissue, with or without involvement of the papillæ and epidermis. The surface may be smooth or rough. Sometimes when the new growth is circumscribed, rough or smooth polypoid growths, often of large size, are formed. When the papillæ and epidermis are much involved, larger and smaller cauliflower-like excrescences may cover the hypertrophied parts and the surface be very rough and scaly.

*Papillomata.*—These growths consist of hypertrophied papillæ covered with thick layers of epithelium. They vary in size from that of a pea to that of an apple, and have a cauliflower appearance.

*Syphilitic Condylomata.*—In one form, the so-called *mucous patch*, there is an infiltration of the papillary layers of the skin or mucous membrane with variously shaped cells and fluid, so that the tissue has a gelatinous appearance. In other cases there is an hypertrophy of the papillæ, so that larger and smaller wart-like excrescences are formed. This is called the *pointed condyloma*. *Lipomata*, *fibro-myomata*, and *fibro-sarcomata* are of occasional occurrence in the vulva. A few cases of *melano-sarcoma* are recorded. *Chondroma* of the clitoris has been described. *Carcinoma* of the vulva may be primary, usually in the form of epithelioma of the clitoris or labia, or it may be secondary to cancer of the uterus, vagina, etc.

*Cysts* are found in the connective tissue of the labia majora and minora. They are from the size of a pea to that of a child's head. They may contain serum, colloid material, purulent or bloody fluid, or they may have the characters of dermoid cysts or atheroma cysts. Their origin is in many cases obscure. In some cases they are doubtless due to dilatation of lymph vessels. Cysts may be formed by a stoppage and filling with fluid of the canal of Nuck, or by a dilatation of the ducts or acini of the vulvo-vaginal glands.

## THE VAGINA.

### MALFORMATIONS.

The vagina may be entirely absent, and the internal organs of generation also absent or imperfectly developed.

Either the upper or the lower portion of the canal may be absent while the remaining portion is present.

The vagina may be closed by an imperforate hymen or by fibrous septa at any part of its canal. The canal may be abnormally small without being occluded.

The vagina may be double, in connection with a double uterus; or, while the uterus is normal, the vagina may be incompletely divided by a longitudinal septum.

### CHANGES IN SIZE AND POSITION.

*Dilatation* of the vagina is produced by tumors, by the prolapsed uterus, and by the accumulation of blood and mucus behind constrictions or obliterations of the canal. *Lengthening* of the vagina is produced by any cause which draws the uterus upward. *Narrowing* of the vagina is found as a senile change; is produced by tumors and by ulceration of the wall of the canal. Extensive ulcers may even cause entire obliteration of the canal.

*Prolapse* of the vagina occurs by itself, usually as a result of thickening or laxity of its walls, or in connection with prolapse of the uterus. As an idiopathic process it usually takes place soon after parturition. A larger or smaller portion of the canal is inverted and projects through the vulva. The entire circumference of the canal may be inverted and prolapsed, or only the anterior or posterior wall. The prolapse is at first small, but may afterward gradually increase in size and may drag down the uterus with it. In other cases prolapse of the uterus is the primary lesion, and the vagina is inverted by the descent of that organ; or the body of the uterus may retain its normal position, while an hypertrophy and lengthening of the cervix alone drag down the vagina.

*Hernia vesico-vaginalis*—cystocele—may be either the cause or effect of a prolapse of the vagina and uterus. If the cystocele is the primary lesion, it begins as a small projection of the wall of the bladder into the anterior part of the vagina. As the urine accumulates in this sac it increases in size, projects through the vulva, draws down the vagina and the anterior lip of the cervix, and finally the entire uterus. If the cystocele is the secondary lesion, it is simply produced by the dragging-down of the posterior wall of the bladder by the inverted vagina.

*Hernia intestino-vaginalis.*—A portion of the intestines may become fixed in Douglas' cul-de-sac between the rectum and the uterus. This portion of intestine gradually becomes larger, pushes forward the posterior wall of the vagina, inverts and fills up that canal, and finally projects through the vulva. It may drag with it the posterior wall of the vagina and the uterus.

*Rectocele vaginalis.*—A sac is formed by the projection of the anterior wall of the rectum and the posterior wall of the vagina. This lesion is of rare occurrence and does not reach a large size.

When the vagina is prolapsed there is usually an inflammatory condition of the lining membrane or a thickening of the epidermis.

### WOUNDS—PERFORATIONS.

Wounds of the vagina are made by penetrating instruments, by forceps and other obstetrical weapons, and by the fœtus during delivery. Such wounds may heal, may give rise to large hæmorrhages, may suppurate, may produce abscesses in the surrounding tissues, may leave fistulous openings into the vagina or may cause constriction or obliteration of its canal.

*Vesico-vaginal Fistulæ* are usually produced by injuries from instruments or from the fœtus during delivery ; less frequently by ulceration of the vagina, bladder, or adjacent connective tissue, or by abscess in the surrounding parts. The fistulæ form an opening between either the bladder or the urethra and the vagina. They allow the urine to pass into the vagina. Spontaneous cure does not take place.

*Recto-vaginal Fistulæ* are formed in the same way as the last-mentioned. They allow the passage of gas or fæces into the vagina. They sometimes heal spontaneously.

### INFLAMMATION.

*Catarrhal Inflammation* of the vaginal mucous membrane may be acute or chronic. It is most frequently caused by gonorrhœal infection, but may be due to local irritation or depend upon general causes. It not infrequently occurs in the new-born. In the acute form the mucous membrane is swollen and frequently covered with a muco-purulent or a purulent exudation. In the chronic form the mucous membrane may be swollen, covered with a purulent exudation ; there may be an exfoliation of epithelium, shallow or deep erosions, or ulcers.

Sometimes large shreds or membranes are cast off from the vagina which consist wholly of exfoliated, flat epithelium (Fig. 331). In other cases the mucous membrane is thickened, dense, and some-

times pigmented, or it may be roughened, covered with papillæ, or it may be relaxed and prolapsed.

*Croupous Inflammation* may occur after parturition, in dysentery, in typhus and typhoid fever, diphtheria, scarlatina, measles, and other infectious diseases. The mucous membrane is swollen and covered with a grayish layer of fibrin and pus. The mucosa and submucosa may be infiltrated with fibrin and pus. The infiltrated portions of the mucosa and submucosa may die and become gangrenous, and thus deep and extensive ulcers be formed.

*Suppurative Inflammation* of the fibro-muscular coat of the vagina may occur after injuries or in pregnant and puerperal women. Abscesses may be formed which penetrate into the labia or into the pelvic connective tissue. In other cases the intense phlegmonous inflammation may lead to the death and casting-off of portions of the vaginal wall, or even of the entire wall.

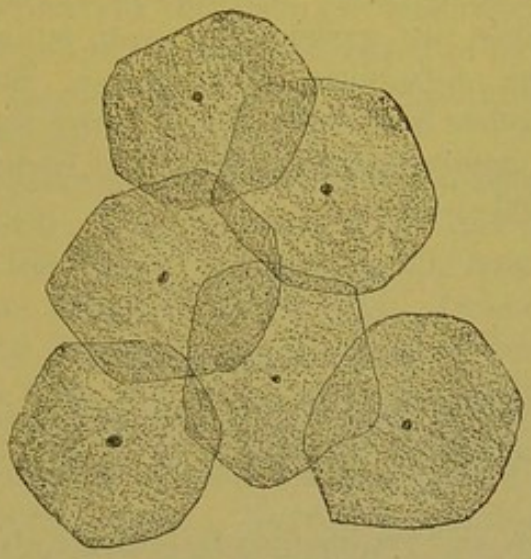

FIG. 331.—VAGINAL EPITHELIUM
A fragment from a large exfoliated mass.

*Gangrene* of the vagina may occur as a result of croupous or intense suppurative or syphilitic inflammation, or from unknown causes. In the form of *noma* it may be very extensive and rapidly destructive.

*Tuberculous* and *Syphilitic Inflammation*, usually leading to more or less extensive ulceration, may occur in any part of the vagina. Tuberculous inflammation is secondary to tuberculosis of other parts. Syphilitic ulcers may heal, sometimes leaving marked cicatrices, and sometimes not.

## TUMORS.

*Fibroma, fibro-myoma, sarcoma, myoma lævicellulare*, are of

occasional occurrence in the vagina. *Myoma striocellulare* is of rare occurrence.

*Papillomata* are of frequent occurrence as a result of chronic inflammation. *Carcinoma* of the vagina is usually secondary to cancer of the uterus. It may be primary as a circumscribed nodular tumor, or more frequently it occurs in a papillary and ulcerating form and often spreads to neighboring parts.

*Cysts.*—These are not very common and may be small or as large as a hen's egg. They may be lined with flattened epithelium, and contain serous or viscid, dark-colored or transparent fluid.

### PARASITES.

Among the animal parasites *Oxyuris* and *Trichomonas vaginalis* are of occasional occurrence. Among the vegetable forms *Oidium albicans*, *Leptothrix* are occasionally seen, while *micrococci* and various other forms of bacteria are common. Staphylococcus and Streptococcus pyogenes have been found many times in the normal vagina. The pathogenic significance of the bacteria in the vagina is not yet established.

## THE UTERUS.

### MALFORMATIONS.

The uterus, up to the third month of intra-uterine life, consists of two large cornua, which by the fusion of their lower ends form the uterus.

The uterus, tubes, and vagina may be entirely absent, with or without absence of the external genitals. Or the uterus alone, or the upper part of the vagina also, may be absent.

The uterus may be only rudimentary while the vagina is normal. It then appears as a flattened solid body with solid cornua. Or there are two cornua joined at their lower extremities so as to form a small double uterus. Or the uterus is represented by a small sac, which may or may not communicate with the vagina. Or there is a very small uterus, with thin muscular walls and two large cornua.

Only one of the cornua which should form the uterus may be developed while the other is arrested in its growth. The uterus is then a long, cylindrical body, terminating above in one tube. On the side where the other horn should have been developed there is no tube, or only a rudimentary one. Both ovaries are usually present.

The two cornua may be fully developed, but their lower ends remain separated and form a double uterus. An entire separation into two distinct uteri and vaginæ is very rare. More frequently the uterus consists of one body, divided by a septum into two cavities.

There are then two cervical portions of the uterus projecting into a single vagina, or each into a separate vagina. Or there is only a single cervix. The septum in the uterus may be complete or only partial.

We also find abnormal size of the uterus, abnormal flexions; the cervix may be solid or may be closed by the vaginal mucous membrane. Or the cervix may have an abnormal form with a small opening or canal.[1]

### CHANGES IN SIZE.

In the new-born infant the uterus is small, the body flattened, the cervix disproportionately large. During childhood the organ increases in size, but the body remains small in proportion to the cervix. At puberty the shape changes and the body becomes larger.

At every menstruation the uterus is somewhat swollen and congested. After pregnancy it does not return to its virgin size, but remains somewhat larger. In old age it gradually becomes smaller; its walls are harder and more fibrous.

*Abnormal Smallness* of the uterus is sometimes found as an arrest of development. The uterus in adult life retains the size and shape of that of the infant. It may result, however, from chronic endometritis, from repeated pregnancies, from old age, or from chronic exhausting diseases. Its cavity may be smaller than normal, or distended with mucus. Large myomata sometimes cause marked atrophy of the uterine wall. Atrophy of the vaginal portion of the uterus is sometimes observed after repeated pregnancies, sometimes without known cause. Narrowing and obliteration of the cavity of the uterus and of the cervix are usually produced by chronic inflammation.

*Enlargement of the Uterus* may be due to too early development. It is accompanied by abnormally early development of all the sexual organs and functions. The uterus may be enlarged in connection with heart disease, prolapse and abnormal flexions and versions, chronic inflammations, repeated pregnancies, myomata, and accumulations of blood or mucus in the uterine cavity. Enlargement of the vaginal portion may be produced by the above causes, and is also found without known cause. One or both lips of the cervix may be uniformly increased in size, or they may be lobulated.

Dilatation of the uterus is produced by accumulations of blood, mucus, or pus in consequence of narrowing or obliteration of the cervix or vagina. The uterine walls may retain their normal thickness, be thickened or thinned. The most frequent position of the stenosis

[1] Illustrations of various forms of malformation of the cervix may be found in the translation by McLaren of *Courty's* "Diseases of the Uterus, Ovaries, etc.," 1883.

is the os internum. The retained contents after a time change in character, forming a thin, serous fluid—*hydrometra*—or they may be mixed with blood. The dilated uterus is not usually larger than an apple, but it sometimes reaches enormous dimensions. If both os internum and os externum are closed the cervical cavity may be also dilated and the uterus have an hour-glass shape. If the obstruction is in the vagina, the uterus and vagina may form a large, flask-shaped body, and the line of demarcation between cervix and vagina be lost. In some cases the dilatation is confined to the cervix. If the obstruction is not complete the retained fluid may escape into the vagina and afterward accumulate again.

Accumulation of menstrual blood in the cavity of the uterus—*hæmatometra*—is usually produced by congenital stenosis of the cervix or vagina. The dilated uterus may reach an enormous size. If the fluid is not evacuated by surgical interference there may be either rupture or ulcerative perforation of the uterus. The blood may escape into the abdominal cavity, or be shut in by adhesions, or perforate into the bladder or intestines. Sometimes the blood passes into the Fallopian tubes, dilates them, and escapes through their abdominal ends.

### CHANGES IN POSITION.

The body of the uterus may become fixed in an abnormal position, while the situation of the cervix is unchanged. The body may be bent forward—*anteflexion;* backward—*retroflexion;* or sideways —*lateral flexion.* The flexion may be slight, or so great that the neck and body form an acute angle. Anteflexion is the most common variety, and that in which the flexion is greatest. Peritoneal adhesions, flaccidity of the uterine walls, particularly after delivery, atrophy of the walls, ovarian and other tumors, etc., are the usual causes of flexions.

*The Versions* of the uterus consist in an abnormal inclination of the long axis of the organ to that of the vagina. The uterus may be inclined backward, forward, or to one side.

*Retroversion* is very much the most common. The fundus uteri is directed backward and downward, the cervix forward and upward. This condition is found in various degrees; in the highest the fundus lies in Douglas' cul-de-sac with the cervix upward, so that the axis of the uterus is parallel to that of the vagina, but in a direction nearly opposite to the normal one. Abnormal looseness of the uterine ligaments, abnormally large capacity of the pelvis, hypertrophy or tumors of the uterus, and pregnancy during the first four months, are some of the more common conditions under which this lesion occurs.

*Anteversion.*—Inclination of the fundus forward and downward,

and of the cervix backward and upward, is not common and seldom reaches a high degree. It occurs under the same general external conditions as anteflexion.

*Lateroversion* is not very common as a simple lesion, but is not infrequently combined with other displacements. It may be produced by congenital shortening of one of the broad ligaments, by adhesions, or by the pressure of tumors.

The greater degrees of version may produce very grave lesions. The urethra and rectum may be compressed. Cystitis, perforation of the bladder, dilatation of the ureters and hydronephrosis, and fatal obstruction of the bowels may follow. If pregnancy exists abortion may take place, or the inverted uterus may be forced through the peritoneum and posterior wall of the vagina and project through the vulva. In the non-pregnant uterus pressure on the veins and consequent chronic inflammation of the organ may follow.

*Prolapsus Uteri* consists of a descent of the uterus into the vagina. The uterus may be only slightly lowered or it may project at the vulva. In complete prolapse we find a tumor projecting through the vulva, partly covered by the distended vagina, and presenting the opening of the os externum near its centre. The bladder and rectum may be drawn down with the vagina or may remain in place. The exposed cervix and vagina usually become inflamed and sometimes ulcerated, or the mucous membrane may become thickened. The lesion is frequently complicated by hypertrophy of the cervix.

Gradual prolapse, which is most frequent, may be due to an increased weight of the uterus, as in pregnancy, inflammatory enlargement, the presence of tumors, etc.; or to some abnormal condition of the uterine supports. It is frequently caused by a vaginal cystocele or rectocele. Sudden prolapse is most apt to occur in an enlarged uterus or one unduly heavy by reason of tumors connected with it. It is most common in subinvolution after parturition.

*Elevation* of the uterus is produced by mechanical causes crowding or dragging it upward, as adhesions, tumors, etc. The vagina is drawn up and lengthened, and the vaginal portion of the cervix may be obliterated.

*Inversion* of the uterus consists of an invagination of the fundus. The fundus may be invaginated in the body, the fundus and body in the cervix, or the entire organ in the vagina. It usually occurs when the uterine walls are relaxed, and is very frequently due to traction on the placenta during parturition. It may take place spontaneously after parturition. It may be produced by intra-uterine tumors. The mucous membrane of the inverted organ is frequently inflamed, particularly when the inversion is complete.

*Herniæ* of the uterus are rare. *Ventral herniæ* may occur during the latter months of pregnancy, the peritoneum, aponeuroses, and skin being forced outward to form a sac in which the uterus lies. *Crural herniæ* are produced by the drawing-down of the uterus and ovaries into the sac of an intestinal hernia. *Inguinal hernia* may be produced in the same way or be congenital. *Ischiatic hernia* has been seen. Pregnancy may occur in the uterus while situated in a crural or inguinal hernia.

### RUPTURE AND PERFORATION.

*Rupture* of the unimpregnated uterus is rare. It may, however, occur when the uterine cavity is distended with blood or serum, or in connection with large myomata of the uterine walls.

In the gravid uterus ruptures have been seen in nearly every month of pregnancy, but most frequently toward the end. The rupture may be produced by thinning of the uterine wall by tumors, or by violent contusions, or as the result of cicatricial contraction of the os.

The act of parturition is the most frequent cause. Malpositions of the fœtus, narrowing of the pelvis, protracted labor, thinning of the uterine wall from tumors, forcible use of the forceps and other instruments, are the ordinary causes. The rupture may be in the body of the uterus or the cervix, or both ; it may be large or small ; it may extend completely or only partly through the uterine wall. The consequences of partial rupture are hæmorrhage, gangrenous inflammation of the edges of the rupture, peritonitis, and usually death. In rare cases the rupture cicatrizes and the patient recovers. Complete rupture usually causes death in a short time. The fœtus escapes partly or completely into the abdominal cavity. If the patient survives the immediate shock, fatal peritonitis soon ensues. In rare cases the fœtus is shut in by adhesions and the patient survives.

*Perforations* of the uterus may be produced by carcinoma, by abscesses in its neighborhood, and by ovarian cysts.

### HYPERÆMIA—UTERINE AND PERI-UTERINE HÆMORRHAGE.

*Hyperœmia.*—Aside from the active menstrual hyperæmia, the uterus may be hyperæmic in acute and chronic inflammation, as a result of displacement of the organ, and in certain forms of heart disease. The organ is usually enlarged, the mucous membrane swollen, and the veins more or less evidently dilated.

*Hæmorrhage.*—Effusion of blood into the cavity of the uterus occurs normally at the menstrual periods. For the abnormalities to which this function is subject we refer to works on gynæcology.

Effusions of blood at other than the menstrual periods may be caused by mechanical hyperæmia, by hæmorrhoids, by acute hyperæmia, by intra-uterine polypi and other tumors, by acute and chronic inflammation, by typhus fever, scurvy, etc., by ulcerating carcinoma, by abortions and miscarriages.

A peculiar form of hæmorrhage is the polypoid hæmatoma, or fibrinous polypus of the uterus. It occurs after parturition and after abortions. The portion of the uterine wall where the placenta was attached, with or without a portion of retained placenta, forms the point of attachment of the pedicle of the polypus. We find a large, polypoid, bloody mass firmly attached by a pedicle to the uterine wall. The uterus enlarges with the growth of the polypus, the cervix is dilated, and the thrombus projects into and may even fill up the vagina. The formation of such a thrombus is accompanied by repeated hæmorrhages.

Hæmorrhage in the substance of the uterus occurs in old age. The mucous membrane and uterine wall are infiltrated with blood, and there is some blood in the uterine cavity. Several cases of hæmorrhagic infarction in the cervical portion of the uterus have been described.[1]

*Peri-uterine* or *Retro-uterine Hæmatocele* consists in an accumulation of blood around the uterus or in Douglas' cul-de-sac. It may consist of blood extravasated into the abdominal cavity, which settles into the pelvis; or, in consequence of local hyperæmia, there may be repeated extravasations of blood. In the latter case the local peritonitis may produce false membranes, between the layers of which hæmorrhages take place. A similar condition rarely occurs in the male. The hæmorrhagic mass may become encapsulated, or may soften or suppurate and perforate into the rectum or vagina, or may be absorbed. A form of extraperitoneal hæmatocele is described in which the blood lies between the folds of the broad ligament. The extravasation may proceed from hæmorrhage of any of the abdominal viscera or rupture of aneurisms; from vascular new-formed false membranes; from rupture of the varicose veins of the broad ligaments; from rupture of hæmorrhagic cysts of the ovaries; from the Fallopian tubes in tubal pregnancy or in hæmatometra; or from general causes, such as scurvy, purpura, etc. In some cases the extravasation begins at a menstrual period, and increases at the succeeding periods.

*Ante-uterine Hæmatocele* is of occasional occurrence, either in connection with the retro-uterine form or when the posterior cul-de-sac is obliterated.

---

[1] See *Chiari*, Prager med. Wochenschr., Bd. xxi., No. 12, 1896.

## INFLAMMATION.

### *I. Inflammation of the Unimpregnated Uterus.*

*Acute Catarrhal Endometritis.*—In this disease, which in its lighter grades may leave but little alteration after death, the mucous membrane is swollen, hyperæmic, and sometimes the seat of punctate hæmorrhages. The epithelium may desquamate, and the mu-

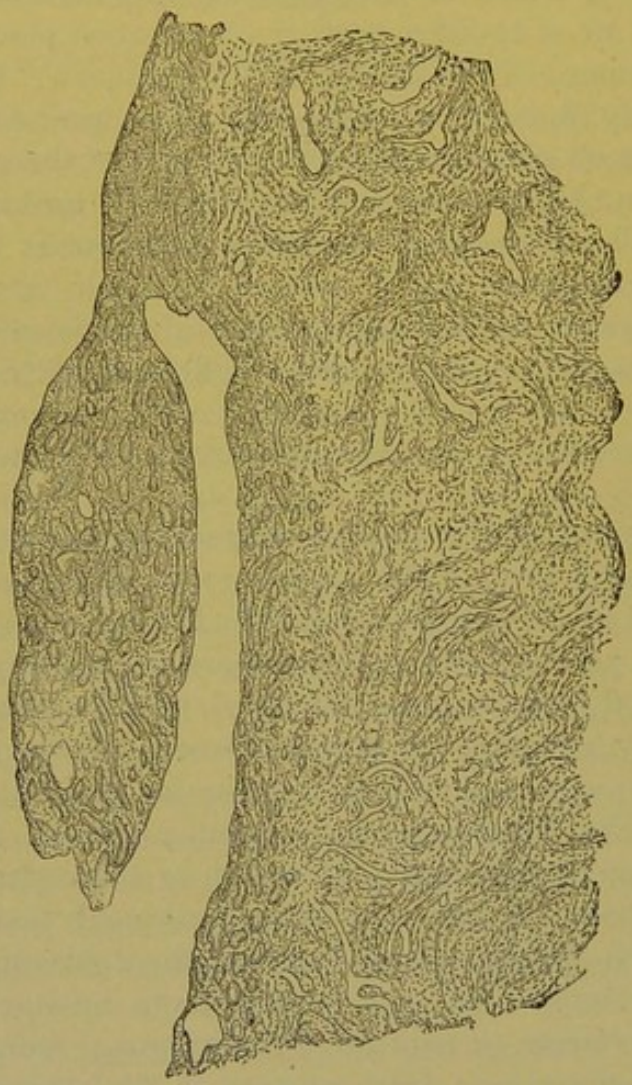

FIG. 332.—CHRONIC ENDOMETRITIS WITH THE FORMATION OF A POLYPOID OUTGROWTH FROM THE MUCOUS MEMBRANE.

cosa contain an undue quantity of small spheroidal cells. The surface is more or less thickly covered with muco-purulent exudation. In severe cases shreds of mucous membrane may be exfoliated. The lesion is usually most marked in the mucous membrane of the body, but may involve the cervix at the same time, or the cervix alone. The body of the uterus may be swollen and hyperæmic. In *dysmenorrhœa membranacea* there may be an expulsion, with more or less blood, of membranous masses consisting of fibrin mingled with blood and pus cells, or consisting of exfoliated superficial layers of

epithelium. This exfoliated epithelium is frequently much flattened so as to considerably resemble the vaginal epithelium. When the shreds are large the openings of the uterine glands may be seen as perforations. Acute catarrhal inflammation of the uterus may be due to injury, exposure during menstruation, the gonorrhœal infection, local infection with other bacteria, or it may accompany the general acute infectious diseases.

*Chronic Endometritis.*—This may be a continuation of an acute infiammation or begin as a chronic disease. In some of the lesser degrees of inflammation we find but slight changes after death. The mucous membrane, on the other hand, may be swollen, hyperæ-

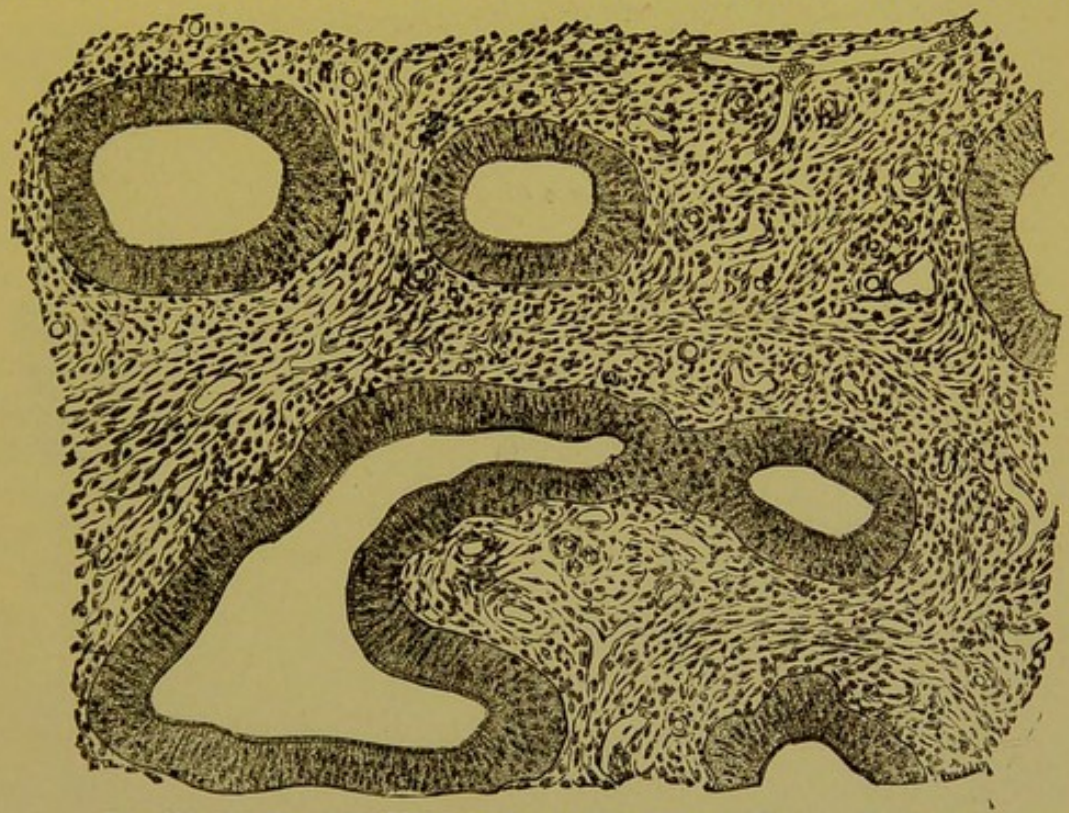

FIG. 333.—ADENOMATOUS HYPERPLASIA OF THE UTERINE MUCOUS MEMBRANE.
This section is from a large polypoid outgrowth which protruded from the cervix uteri.

mic, and covered with muco-purulent exudation. In other cases there is more or less well-marked thickening of the mucous membrane, which may present a smooth or a rough papillary surface or polypoid outgrowths (Fig. 332). Owing to the hypertrophy of the uterine glands in this condition, these papillary outgrowths, which are not infrequently scraped off by the surgeon, often present the appearance of adenomata. This condition is called "adenomatous hyperplasia of the uterine mucous membrane" (see Fig. 333). Sometimes a thick layer of new-formed, very vascular tissue develops over the surface of the mucous membrane, largely covering in the uterine glands (Fig. 334). From the decomposition of extravasated blood in the mucous membrane the latter may be mottled with brown or

black. The glandular elements of the mucosa may be partially or almost entirely destroyed. The papillæ of the cervix may be hypertrophied, the mucous follicles swollen and their outlets obstructed, leading to the formation of the so-called ovula Nabothi. The uterine wall becomes flaccid and atrophied, or it may be hypertrophied, especially in the cervical portion. Ulceration of the mucous membrane, especially of the cervix, may occur. Contraction or obliteration of the cervical canal may occur. The inflammation may extend to the Fallopian tubes or to the vagina.

Chronic endometritis may exist at any age, but is most common

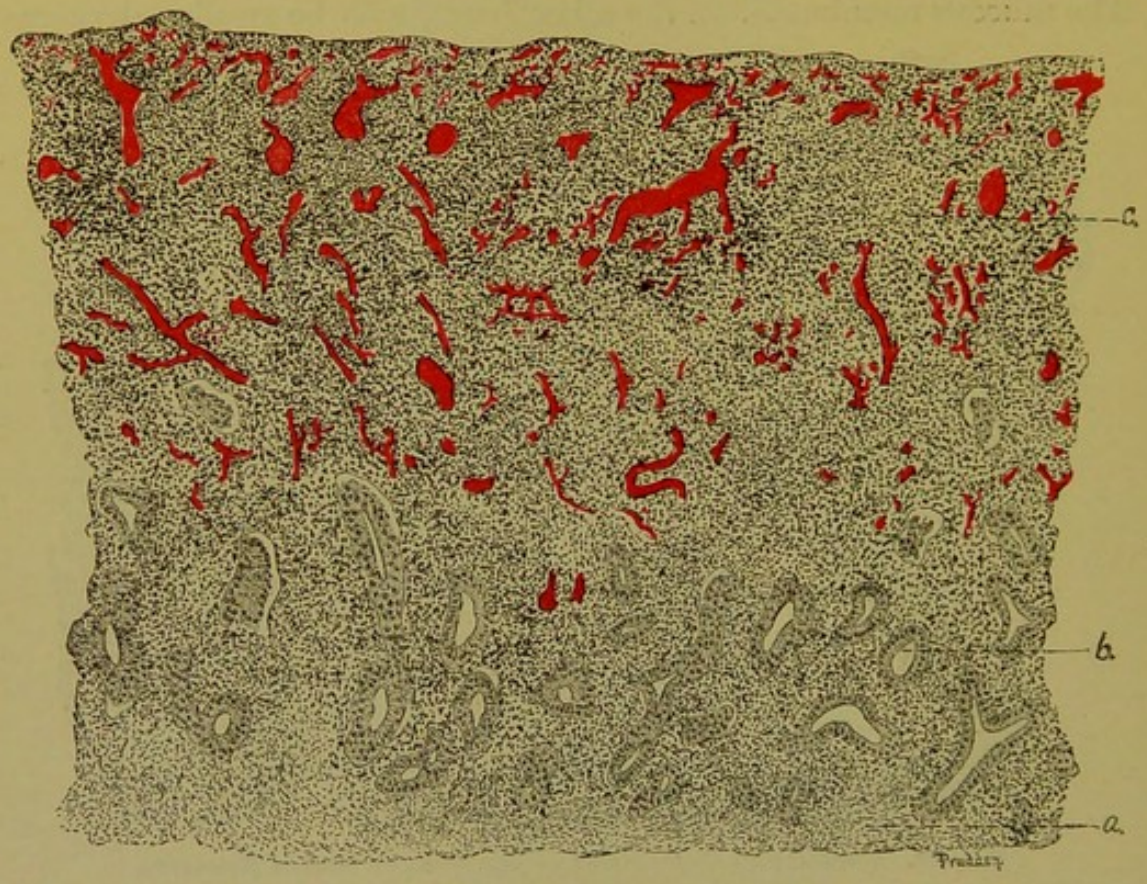


FIG. 334.—CHRONIC ENDOMETRITIS WITH THE FORMATION OF A THICK LAYER OF NEW-FORMED, VERY VASCULAR TISSUE OVER THE SURFACE OF THE MUCOUS MEMBRANE.

*a*, uterine muscle tissue; *b*, mucous membrane of uterus; *c*, new-formed vascular tissue.

after puberty, and is produced by a great variety of causes. It may occur in ill-nourished persons or in those suffering from exhausting diseases. It may be due to displacements and tumors of the uterus, subinvolution, injuries, etc.

*Croupous Endometritis.*—This form of inflammation is not very common. It occasionally occurs in the puerperal uterus, in acute infectious diseases, cholera, typhoid fever, the exanthemata, etc. The disease sometimes involves the vulva, vagina, and Fallopian tubes. It may co-exist with croupous inflammation of the colon.

*Tuberculous Endometritis.*—This usually occurs as part of tuber-

culous inflammation of the genito-urinary tract. We find a part or the whole of the cavity of the uterus lined with a rough, yellowish or gray, cheesy mass, which may deeply involve the muscular walls of the organ. At the edges of the ulcerating cheesy areas we may find well-defined miliary tubercles, or we may find tubercles scattered through the otherwise intact mucosa. The lesions resemble those of tuberculous nephritis.

*Syphilitic Endometritis.*—The results of this infection are usually confined to the cervical portion, and consist of shallow or deep ulcerations and condylomata of the mucous membrane; or there may be a diffuse thickening of the mucosa.

*Acute Metritis* is usually the result of acute catarrhal endometritis. The organ is swollen, succulent, congested; the mucous membrane covered with muco-pus; the peritoneal coat congested. There may be small extravasations of blood in the wall or cavity of the uterus. The inflammation, in rare cases, becomes suppurative, and abscesses are formed in the uterine wall; these may perforate into the peritoneal cavity or into the rectum.

*Chronic Metritis* is the result of an acute metritis or accompanies acute or chronic endometritis, and is dependent upon the same conditions: subinvolution, displacements, tumors, active irritants, etc. The uterus is enlarged, the wall congested, thickened, and soft, or, owing to the new formation of connective tissue, hard and dense. The lesion may be most marked in the body or in the cervical portion.

*Perimetritis.*—The peritoneal coat of the uterus may be inflamed, with the production of membranous adhesions or of pus. The adhesions may be small or very extensive, and, owing to their contractions, may cause various distortions and displacements of the pelvic organs. The inflammation is usually an accompaniment of chronic metritis and endometritis. In prostitutes such adhesions are of very common occurrence.

*Parametritis.*—The connective tissue about the uterus, between that organ and the reflexions of the peritoneum, may be the seat of suppurative inflammation. It most frequently causes the death of the patient, but may result in the formation of dense connective tissue about the uterus.

### *II. Inflammation of the Pregnant Uterus.*

The forms of inflammation which have just been described may attack the pregnant uterus. Catarrhal endometritis may produce effusion of serum, extravasations of blood, and abortions. Metritis may lead to softening of the uterine wall, so that rupture takes place during labor. Perimetritis and parametritis produce adhesions and abscesses about the uterus.

*Puerperal Inflammation.*

For a week or more after delivery we find the inner surface of the still dilated uterus rough, especially at the insertion of the placenta, and covered with blackened, gangrenous-looking shreds of blood, mucous membrane, and placenta. This condition is not to be mistaken for inflammation.

As a result of some injury to the uterus or vagina during or after delivery, and the action of some infectious material which may gain access to the tissues, the puerperal uterus is liable to become

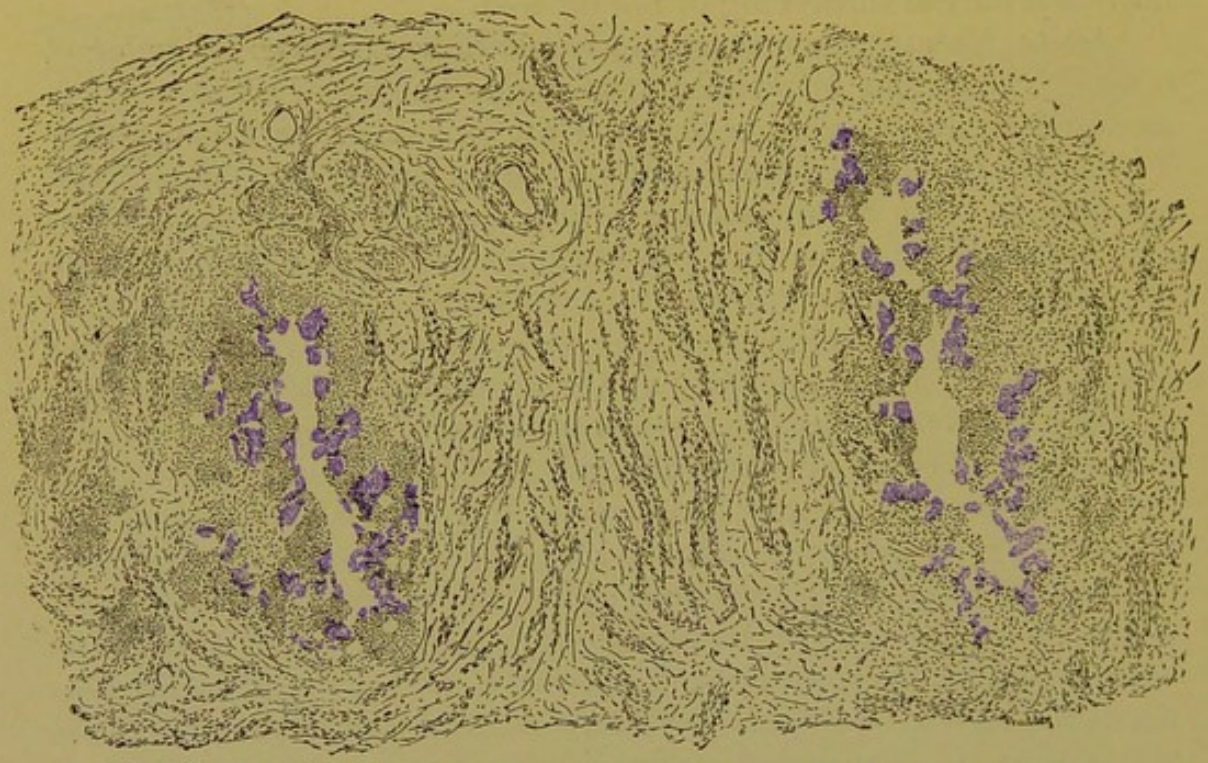

FIG. 335.—UTERINE PHLEBITIS FOLLOWING DELIVERY WITH RETAINED PLACENTA.
Death nine days after delivery. Micrococci in the walls of the inflamed veins stained violet.

the seat of a series of severe and often destructive inflammatory and necrotic changes. These may be confined to the uterus; they may induce serious alterations in surrounding parts; they may lead to an involvement of the peritoneum, or to pyæmia and its accompanying lesions in the most distant parts of the body. In one series of cases a more or less extensive gangrenous inflammation of the mucous membrane and the underlying parts may lead to the casting-off of larger and smaller shreds of necrotic tissue and the formation of deep and spreading ulcers, which may be accompanied by severe parametritis and fatal peritonitis. This condition may be due to injury or to the presence of decomposing portions of retained placenta. In other cases the inflammation has a croupous character, which may

affect the vagina and lead to necrosis and gangrene, ulceration, and peritonitis. In connection with either of the above forms of inflammation, or without them, there may be thrombosis of the uterine sinuses, purulent inflammation of the veins, suppuration and abscess in the uterine wall, suppurative inflammation of the ovaries and tubes, and, owing to the generalization of the infectious material, metastatic abscesses in the lungs, spleen, kidneys, etc. Or acute pleurisy, ulcerative endocarditis, purulent inflammation of the joints, hyperplastic swelling of the spleen and lymph nodes, may furnish characteristic features of the presence of an acute infectious disease. In some cases which rapidly pass to a fatal termination the local lesions may be but slightly marked, and general alterations characteristic of pyæmia, such as metastatic abscesses, etc., be entirely wanting. Life seems to be overcome by an acute septic intoxication.

Micrococci are very constantly present in the exudation, in the lymph vessels, veins, and inflamed tissue of the uterus (see Fig. 335) ; often in enormous quantities in the peritoneal exudation and in the metastatic inflammatory foci. There is good reason for believing that the destructive local processes are due, in the majority of cases, to the presence of the Streptococcus pyogenes, and that the general infection in this, as in other forms of septicæmia and pyæmia, is dependent upon the same cause (see Septicæmia).

### ULCERATION AND DEGENERATION.

*Catarrhal, tubercular,* and *syphilitic ulceration* have been mentioned above.

*Phagedenic or Corroding Ulcer.*—This rare form of ulceration usually occurs in old age, without assignable cause. It begins in the cervix and gradually extends until it may destroy the greater part of the uterus or even invade the bladder and rectum. The ulcer is of irregular form ; its base is rough and blackish, its walls indurated. It should not be confounded with carcinomatous ulcer, which it considerably resembles.

*Fatty Degeneration.*—This may occur in connection with inflammatory changes, in acute infectious diseases, and in phosphorus poisoning.

*Amyloid Degeneration* in the uterus is of rare occurrence. It may affect the muscle fibres or the walls of the blood vessels.

### TUMORS.

*Fibromata.*—Dense nodular fibromata of the uterus are exceedingly rare, the so-called fibromata being in most cases myomata or fibro-myomata. *Fibroma papillare,* on the other hand, is a com-

mon form of growth from the mucous membrane. It consists of a more or less vascular connective-tissue stroma covered with epithelium. The surface may be smooth or villous. It may contain very numerous gland follicles, and then approaches the type of adenoma, or even carcinoma. The stroma may be loose and succulent, and resemble mucous tissue, forming the so-called *mucous polypi;* and these again may contain glandular structures. In any of these forms the blood vessels may be abundant and dilated, forming telangiectatic or cavernous polypi. The adenomatous polypi may become cystic from the dilatation of the gland follicles.

Polypi of the uterus may be multiple or single, small or large. Numerous smaller and larger papillary outgrowths from the mucous membrane may occur in chronic endometritis. Single polypi may grow from the mucosa of the body of the uterus or from the cervix, and hang by a long pedicle down into the vagina.

The large number of glandular structures in many of these chronic inflammatory, papillary, and polypoid outgrowths (Figs. 332 and 333) often justifies the name of adenomatous hyperplasia of the mucous membrane or of adenomatous papillomata or polyps.

Syphilitic papillary growths in the form of pointed condylomata may form finely papillary, wart-like excrescences of variable size, particularly on the cervix.

*Myomata.*—These tumors, whose characteristic structural elements are smooth muscle cells (see Fig. 137), are the most common of uterine tumors and are frequently of no special practical importance, but are sometimes of very serious import. They are especially common in negroes. They are most frequently composed of both muscular and fibrous tissue—fibro-myomata—but the relative amount of the two kinds of tissue is subject to great variation. They are most apt to occur after puberty, and usually in advanced life. They may be single or multiple, small or of enormous size; are usually sharply circumscribed, whitish or pink, dense and hard, or sometimes soft, and present on section interlacing bands or irregular masses of glistening tissue. Their favorite situation is in connection with the body of the uterus, but they may occur in the cervix or in the folds of the broad ligaments. According to their position we may distinguish subserous, submucous, and intraparietal forms. The *subserous myomata* grow from the outer muscular layers of the uterus in the form of little nodules. As they increase in size they may become separated from the uterine wall and remain attached only by a narrow pedicle or by a little connective tissue. They may work their way between the folds of the broad ligament until they are at some distance from their point of origin. Some authors mention cases in which the tumors became entirely detached

from the uterus and were free in the abdominal cavity. In some cases the tumors excite inflammation of the adjacent peritoneum, leading to the formation of adhesions or of collections of pus. Cases are recorded in which, owing to the atrophy of the pedicle, subserous myomata have become completely detached from the uterus and were held in place and nourished by peritoneal adhesions. In other cases the tumor reaches a large size, but remains firmly attached to the uterus. This organ may then be drawn upward, the cervix and vagina being elongated and narrowed. The traction may be so great that the body of the uterus is entirely separated from the cervix. The bladder may also be drawn upward, producing incontinence of urine and cystitis. Subserous myomata are very often multiple and frequently attain great size.

*The submucous myomata* grow from the inner muscular layers of the uterine wall. They commence as rounded nodules which lift up the mucous membrane. The usual position is the fundus uteri. They rarely occur in the cervix. As the tumors increase in size they project into the uterine cavity. They then remain continuous with the uterine wall over a large area, or are attached by a large or small pedicle. They are usually well supplied with vessels. The uterus dilates with the growth of the tumor, and its walls may be also thickened. The tumor may reach such a size as to entirely fill the cavity of the dilated uterus and project through the cervix into the vagina.

The submucous myomata are usually single, although there may be at the same time subserous and intraparietal tumors. They are frequently soft. If they are of large size and polypoid in form, they may project through the cervix and drag down the fundus of the uterus, producing inversion. The mucous membrane covering them may be atrophied or hyperæmic, with dilated blood vessels, and may thus give rise to severe and repeated hæmorrhages. Hæmorrhage may occur in the substance of these tumors. Inflammation, suppuration, and gangrene may also occur. The surface may be ulcerated. In some cases the pedicle of the tumor is destroyed and it is spontaneously expelled.

The *intraparietal myomata* grow in the substance of the uterine wall, but, if they attain a large size, project beneath the serous or the mucous coat. They are found in every part of the uterus, but are most frequent in the posterior wall.

The shape of the uterus is altered in a great variety of ways by the presence of these tumors; its cavity is narrowed, dilated, or misshapen; it undergoes flexion and version in every direction. The tumors may sink downward and become attached to the posterior wall of the vagina, looking as if they grew from it. They may,

without the formation of a pedicle, project into the cavity of the uterus, fill it up, and project through the cervix. The uterus is dilated, its wall hypertrophied or atrophied.

The tumors themselves may undergo a variety of secondary alterations. The muscle fibres may undergo *fatty degeneration*, and the tumor diminish in size, or may even undergo, it is said, entire destruction and atrophy. *Calcification* may occur, converting a part or the whole of the tumor into a stony mass. The intraparietal and submucous myomata may give rise to profuse hæmorrhages ; thay may suppurate and become gangrenous.

Sometimes the tumors or circumscribed portions of them are very vascular, constituting the *telangiectatic* or *cavernous* variety. These tumors, which possess some of the characters of erectile tissue, may suddenly change in size from a variation in the amount of blood which they contain.

A very important change which is sometimes found in these tumors is the development of cysts in their interior (fibro-cystic tumors). This sometimes takes place in those tumors which grow outward beneath the peritoneal coat. We find one or more cavities communicating with each other, with rough, trabeculated walls. The appearance is more that of cavities than of cysts. There may be a number of smaller cavities, or they may fuse to form one large one. The fluid contained in the cavities is like synovia, or is mixed with blood. These cystic myomata may reach an immense size and fill the abdominal cavity. The diagnosis, during life, between them and ovarian cysts is often very difficult, and they have frequently been the subjects of fatal operations. The cystic may be lined with ciliated epithelium.[1]

In the cervix uteri myomata are rare. They may grow as polypi beneath the mucous coat, or produce enlargement of the anterior or posterior lips, or may grow outward into the abdominal cavity.

Combinations of myoma and sarcoma sometimes occur—*myosarcoma.*

*Sarcomata* may occur as primary tumors in the mucous membrane of the uterus, either in the form of a diffuse infiltration or as a circumscribed nodular or polypoid mass. They frequently involve the muscular wall, are liable to hæmorrhage and gangrene, and, particularly in the diffuse form, are liable to recur after removal. They may consist largely of spindle or spheroidal cells, or both. It is said that sarcoma of the uterus is more liable to occur at an advanced age than at an early period, as is the rule with sarcomata of other organs. Giant-celled sarcomata have been described.

[1] Consult monograph by *Brens*, "Ueber wahre Epithel. führende Cystenbildung d. Uterus-Myomen," Leipzig, 1894.

*Angioma.*—Cavernous angiomata of the wall of the uterus have been described.

*Adenoma.*—Between a simple adenomatous hyperplasia of the mucous membrane of the uterus, on the one hand (see Figs. 332 and 333), and carcinoma on the other, there is no absolutely sharp morphological distinction. But there is a considerable group of growths, to which the name *adenoma* is properly applied, which lie on the border zone between the distinctly benign and the definitely malignant new epithelial tissue growths.

Many epithelial cell growths of the uterus, while adenomatous in structure, are so distinctly malignant, and are so liable to develop that structural lawlessness characteristic of carcinoma, that it has seemed



FIG. 336.—ADENOMA OF THE UTERUS.
Showing papillary outgrowths and commencing infiltration of the submucous tissue.

wise to many observers to avoid the name adenoma altogether and class all the epithelial tumors of the uterus among the carcinomata. Others, recognizing the benign character of many of the epithelial tumors of the uterus, have adopted a sharp distinction between benign and malignant adenoma.

It seems to the writer wise to preserve here, as elsewhere in the body, the morphological distinction between adenoma and carcinoma. But in doing this it should always be borne in mind that the adenomata of the uterus, as those of the gastro-intestinal canal, may not only be extremely malignant as adenomata, but that the more benign forms are extremely prone to develop, both in structure and malignancy, into carcinomata. In fact, in many cases we can only express

the peculiarities of structure in these tumors by calling them *adeno-carcinoma.*

The adenomata of the uterus may begin in a simple hyperplasia of the mucous membrane, in which glandular development is preponderant. This new glandular growth is most common in the form of irregular, often dilated follicular structure with a well-marked lumen lined with cylindrical or cuboidal cells. The new growth may project from the inner surface of the uterus in the form of papillary masses, or it may infitrate the submucous tissues. Or growth in both directions may occur at once. (See Figs. 336 and 337.)

The topographical features and clinical stories of many adeno-



FIG. 337.—ADENOMA OF THE UTERUS.
Small portion of specimen shown in Fig. 272, more highly magnified.

mata of the uterus are identical with those of the infiltrating and ulcerating carcinomata.

*Carcinoma.*—The carcinomata of the uterus commence most frequently in the cervix and portio vaginalis, and the most common form is the epithelioma. The growth of epitheliomata of the cervix uteri proceeds under three tolerably distinct forms, which, however, frequently merge into one another.

1. *The Flat, Ulcerating Epithelioma.*—This form of cancer commences as a somewhat elevated, flat induration of the superficial

layers of the cervix, sometimes circumscribed, sometimes diffuse. This induration is due to the growth of plugs and irregular masses of epithelial cells into the underlying tissue. Ulceration usually commences early and may proceed slowly or rapidly. The edges of the ulcer are irregular, indurated, and somewhat elevated. The ulceration of the new-formed cancerous tissue at the edges is usually progressive, so that the vaginal portion of the cervix, the cervical canal, the vagina, and even the bladder and rectum may be involved. More or less extensive hæmorrhages and necrosis of the base of the ulcer are liable to occur. The entire cervix may be destroyed.

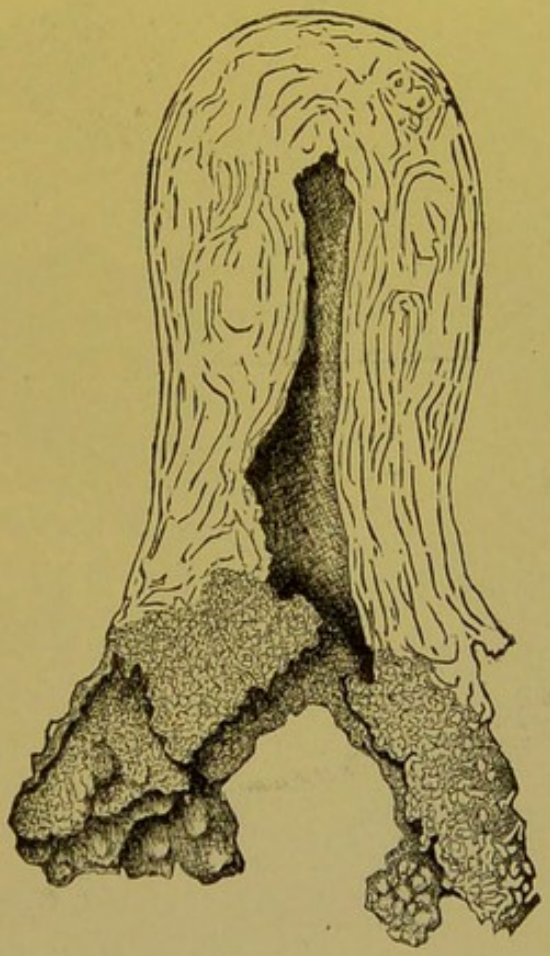

FIG. 338.—CARCINOMA OF THE CERVIX UTERI (Ulcerating).

2. In another class of cases the carcinomatous growth develops under the form of papillary or fungous excrescences, which may form larger or smaller masses composed of epitheliomatous tissue. Hand-in-hand with this projecting growth there may occur an epithelial infiltration of the underlying tissue of the cervix. These growths are often quite vascular and may give rise to severe hæmorrhages. They may ulcerate and thus produce great destruction of tissue.

3. In still another class of cases there is a more or less deep infiltration of the submucous tissue, either diffuse or in circumscribed nodules, with epithelial cell masses. We find at first, in the vaginal portion of the cervix, in the submucous connective tissue, either nodules or a general infiltration of a whitish new growth. The cervix then appears large and hard. Very soon the mucous membrane over the new growth degenerates and falls off; the superficial layers of the new growth undergo the same changes. After this the

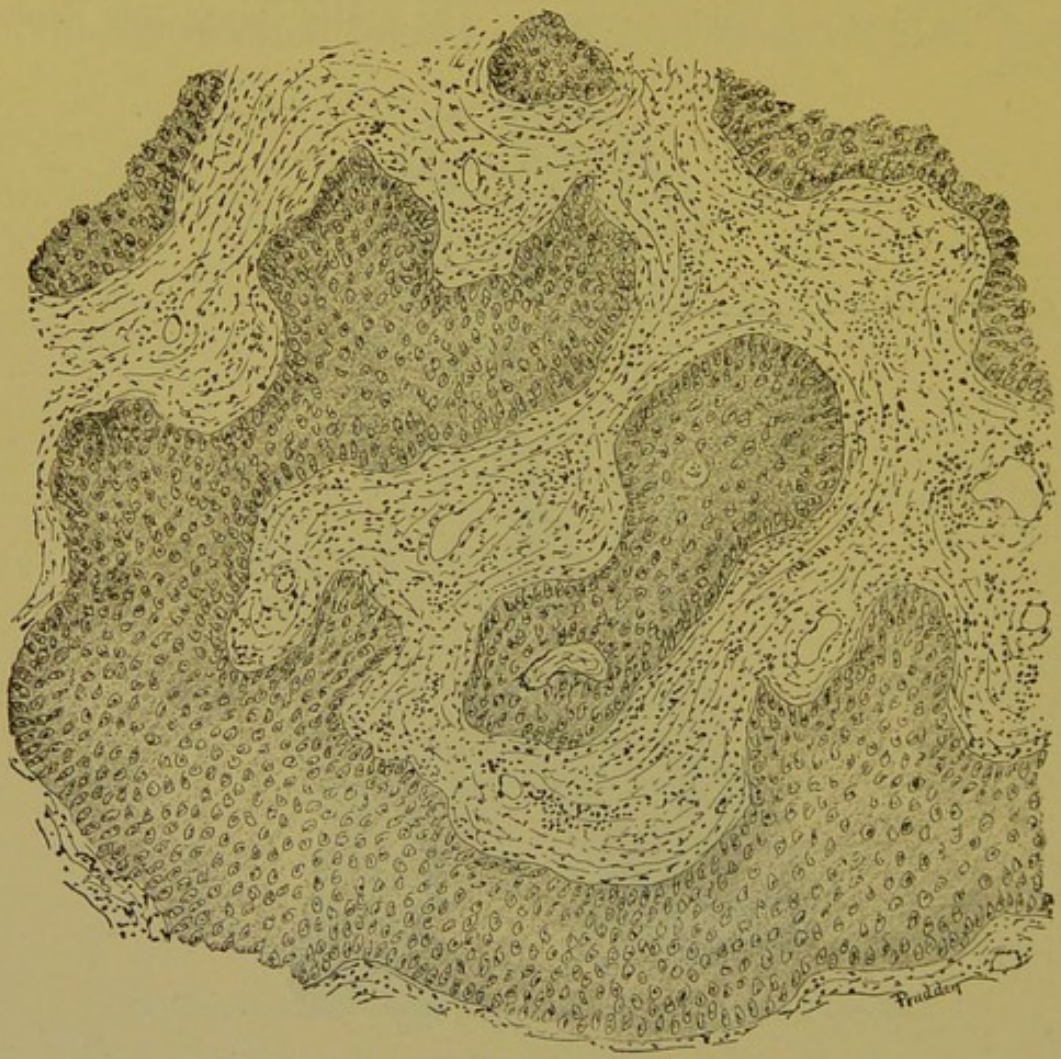

FIG. 339.—CARCINOMA (EPITHELIOMA) OF THE UTERUS.
Showing ramifying epithelial cell masses.

formation of the new growth and its ulceration go on simultaneously, producing first an infiltration and then destruction of the cervix, and often of a part of the body of the uterus. The growth frequently extends to the vagina, the bladder, and the rectum with the same destructive character, so that we often find the cervix and upper part of the vagina destroyed, and in their place a large cavity

with ragged, gangrenous, cancerous walls (Fig. 338). Less frequently the pelvic bones are invaded in the same way. Not infrequently the ureters are surrounded and compressed by the new growth, so that they become dilated. The dilatation may extend to the pelves and calyces of the kidneys. The new growth may begin in the cervix and extend uniformly over the internal surface of the cervix and of the body of the uterus. The entire uterus is converted into a large sac, of which the walls are infiltrated with the new growth, while the internal surface is ulcerating and gangrenous. In some cases there is a considerable formation of new, dense connective tissue, so that the growth has a scirrhous form.

In rare cases the growth begins in the upper part of the cervix or in the body of the uterus, while the lower part of the cervix is not involved. In all of these cases the epithelial cells of the new growth follow more or less closely the type of the epithelial cells of the part from which they spring (Fig. 339).

In still another class of cases, in which the new growth may be in the form of nodules, or diffuse infiltrations, or polypoid masses, or may present more or less extensive alterations, the cells are irregular, polyhedral in shape, the tumor belonging to the class of glandular or medullary carcinomata. These also usually commence in the cervix, and, according to the views of many writers, probably in the mucous glands.

In rare cases the entire wall of the uterus is infiltrated with the new growth and the organ is much enlarged. *Colloid carcinoma* sometimes occurs, but is rare.

While we may for convenience recognize the above types of carcinoma of the uterus, it should be borne in mind, as above stated, that they are not apt to be perfectly distinct, and some of them may merge into one another or exist simultaneously. Exudative inflammation is of frequent occurrence in these as in other tumors of the uterus.

As a result of the ulceration of these various forms of carcinoma recto-vaginal fistulæ may be formed ; the lumbar lymph nodes may be involved, and metastases in distant organs are occasionally though not frequently formed. Frequent and profuse hæmorrhages, gangrenous destruction of tissue, the absorption of deleterious materials, etc., are apt to lead to the development of a more or less profound anæmia and cachexia.

*Deciduoma Malignum.*—Under various names several curious tumors of the uterus have been described which resemble each other, but which differ in structures from any of those in the usual lists. They are, however, most closely allied to the sarcomata. They all occur in the uterus after pregnancy, and all appear to be derived from remains of the decidua or its associated structures (Fig. 340). They

frequently give rise to hæmorrhages and are apt to form metastases, especially in the vagina and lungs.

The structure of these tumors varies considerably. The most typical forms consist of irregular clusters of trabecula of large irregular-shaped cells with prominent nuclei or of masses of protoplasm. These cells and cell masses often enclose blood spaces. There is little or no stroma.

On the other hand, some of the tumors in which the connective tissue elements more largely share are appropriately called *Sarcoma deciduo-cellulare.*

Whether these tumors are derived from the fœtal or from the

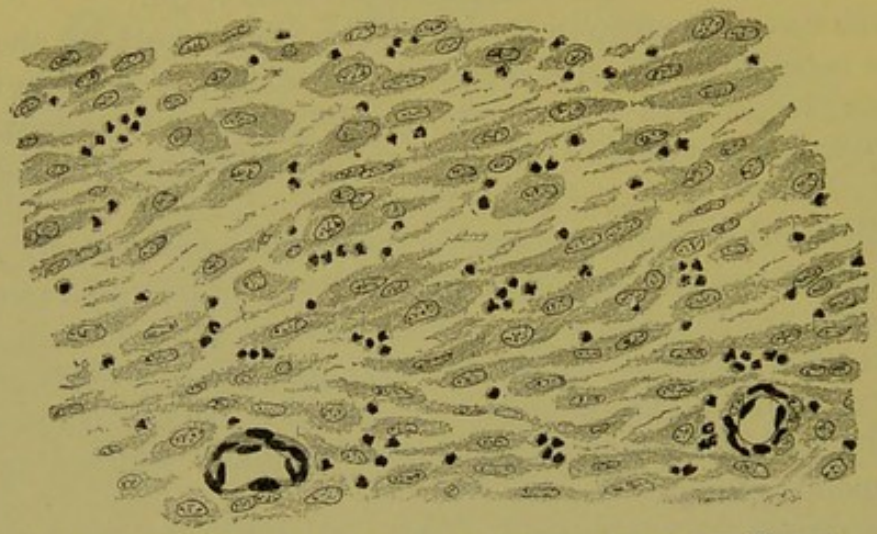

FIG. 340.—FRAGMENT OF DECIDUA IN CURETTINGS FROM THE UTERUS.

maternal tissues is not in all cases clear; perhaps only one or both may in the different cases be concerned in the growth.[1]

## PARASITES AND CYSTS.

Various forms of *bacteria* are of frequent occurrence in the cavity of the uterus when the organ is diseased. The presence of some is significant, and of others not. *Echinococcus* has been found in the body and neck of the uterus, and may rupture into the peritoneal cavity or into the vagina.

*Cysts.*—Aside from the cysts which develop in tumors of the uterus, in the cervix uteri the mucous follicles are frequently so dilated as to form cysts filled with a gelatinous material and more or less epithelium. These cysts may be large or small, and are frequently called *ovula Nabothi.* Sometimes there is an inflammatory growth of new connective tissue about these cysts. In other cases

[1] For a careful description and consideration of these tumors consult the article by *Williams* in the Johns Hopkins Hospital Reports, vol. iv., No. 9, 1895.

the cysts may project from the mucous membrane in the form of polypi. Similar changes are infrequently found in the body of the uterus from the dilatation of occluded uterine glands. Dermoid cysts are rarely found in the walls of the uterus.

## THE OVARIES.

### MALFORMATIONS.

One or both ovaries may be absent, the other organs of generation being also absent or undeveloped. Or the ovaries may be only partially developed. Absence or arrest of development of one ovary is sometimes met with in otherwise well-formed individuals. It is sometimes accompanied by a low position of the kidney on the same side. The ovaries may pass into the inguinal canal or into the labia majora, and remain fixed there through life. Less frequently they are found in the crural canal or the foramen ovale.

### CHANGES IN SIZE.

The ovaries may become larger than normal by chronic inflammation, by the formation of cysts and tumors. They may become atrophied in old age, the Graafian follicles disappearing and the organ shrivelling into a small, irregular, fibrous body. Atrophy may be produced by ascites, by chronic inflammation, or from unknown causes. As the result of the maturing and rupture of the Graafian follicles, with and without pregnancy, the surface of the ovary, which before puberty is smooth, may become roughened by irregular cicatricial depressions.

### CHANGES IN POSITION.

In adult life the ovaries may pass as herniæ into the inguinal or crural canal, the foramen ovale, or the umbilicus.

The position of the ovaries in the abdomen may be changed by the pressure of tumors, the traction of false membranes, etc. It may occur in enlarged ovaries or in those of normal size, and by the compression of the veins may lead to congestion and chronic inflammation of the organ.

### HYPERÆMIA AND HÆMORRHAGE.

Aside from the normal hyperæmia of the ovaries during menstruation, the vessels may be congested in inflammation, in displacements with interference with the venous circulation, in certain diseases of the heart, etc., and may then be followed by chronic inflammation.

The menstrual periods are accompanied by the effusion of blood

into a Graafian follicle. Normally the amount of blood is small, becomes solid, is decolorized and then gradually absorbed. Sometimes the effusion of blood is much greater; the follicle filled with blood is as large as a pigeon's egg. The blood may remain in the follicle and be absorbed, and replaced by a serous fluid, or it may rupture it and escape into the peritoneal cavity. Death may ensue from the hæmorrhage, or the blood may collect in Douglas' cul-de-sac and be enclosed in false membranes. Hæmorrhages also occur in follicles which have become cystic. Interstitial hæmorrhage in the ovary sometimes occurs without known cause.

### INFLAMMATION (OÖPHORITIS).

*Acute Inflammation* of the ovaries occurs most frequently in the puerperal condition, either as part of a general peritonitis or as a primary affection.

With puerperal peritonitis both ovaries are usually inflamed; they are swollen, congested, soft, infiltrated with serum or pus, or gangrenous. The inflammation may attack principally the capsule, the stroma, or the follicles. Inflammation of the capsule results in adhesions and collections of pus, shut in by false membranes; of the stroma, in abscesses and fibrous induration; of the follicles, in their dilatation with purulent serum. If the inflammation of the ovary is the primary lesion it is usually confined to one organ. The stroma of the ovary is infiltrated with serum and pus, and may contain abscesses of large size. In other cases the ovary itself is but little changed, but is surrounded by a mass of fibrinous and purulent exudation. Such idiopathic forms of inflammation may terminate in recovery; or the abscesses may perforate into the rectum and vagina; or the ovary is left indurated and bound down by adhesions; or the patient dies from the violence of the disease.

Acute inflammation of the ovaries unconnected with the puerperal condition is not common, but it may occur in connection with acute or chronic peritonitis or perimetritis. It is usually confined to one ovary. Either the follicles, stroma, or capsule, or all together, may be involved. The inflamed follicles are enlarged, their walls thickened; they may contain bloody or purulent fluid. The stroma becomes infiltrated with serum or pus, and later we may find abscesses or fibrous induration of the organ. The inflammation of the capsule may lead to the formation of membranous adhesions between the ovary, Fallopian tube, and surrounding parts.

*Chronic Interstitial Oöphoritis* is not infrequently preceded by an acute inflammation, or it may gradually develop as an independent condition, often determined by some mechanical interference with the blood current. The organ may be increased in size, owing

to the formation of loose cellular or of dense, firm, new connective tissue. Under these conditions the blood vessels, especially the veins, may be widely dilated, and cysts in varying number and size may be present (Fig. 341). Sometimes the new-formed dense connective tissue may be largely limited to the surface of the organ, so that the albuginea may become so dense and thick that the functions of the organ must, as it would seem, be permanently interfered with. Under these conditions the surface of the ovary may be smooth or rough.

On the other hand, the organ may be smaller than normal as the result of the formation of dense new interstitial connective tissue, and its surface greatly roughened and distorted. Sometimes the forma-

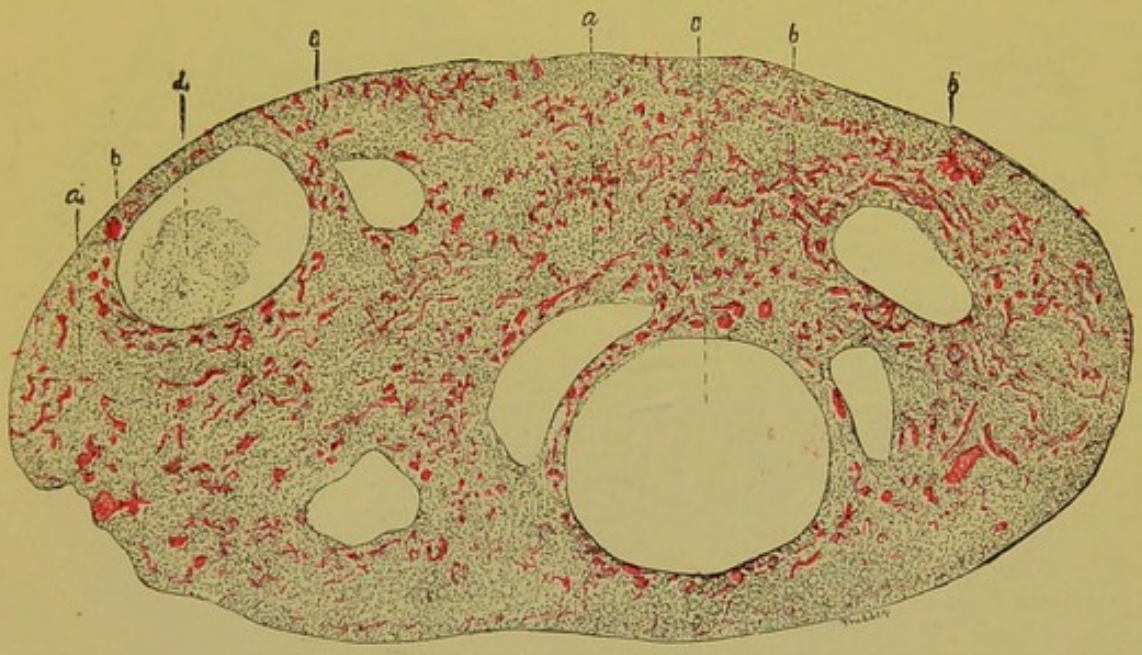


FIG. 341.—CHRONIC OÖPHORITIS WITH DILATED BLOOD VESSELS AND CYSTS.

*a*, dense connective-tissue stroma; *b*, dilated veins; *c*, cysts; *d*, cyst with granular contents; *e*, cortical zone of immature Graafian follicles.

tion of new dense tissue may be largely confined to the walls of the arteries, which become prominent and tortuous. Obliterating endarteritis is not infrequently present. The atrophied ovary may be largely made up of thick-walled arteries and fibrous masses which are the result of incomplete resolution of the corpora lutea (Fig. 342).

Sometimes a more or less extensive hyperplasia of cells in the corpus luteum leads to the development of larger or smaller new-formed, convoluted, nodular masses in the ovary, which are sometimes regarded as tumors. These structures may, according to Freeborn, soften at the centre and thus give rise to a special form of small

ovarian cyst. Certain sarcomata of the ovary appear to originate in such an hyperplasia (see Fig. 343).

*Tuberculous Inflammation* of the ovaries is rare, and may accompany tubercular inflammation of other organs, particularly the peritoneum and Fallopian tubes. It usually results in the production of cheesy nodules of considerable size.

*Syphilitic Inflammation* in the form of gummata is uncommon.

### TUMORS.

*Fibromata.*—These tumors are not very common nor usually of great importance. They may be very small or of great size. They are usually dense in texture, and in a considerable number of cases seem to originate in the tissue formed in the closure of the ruptured

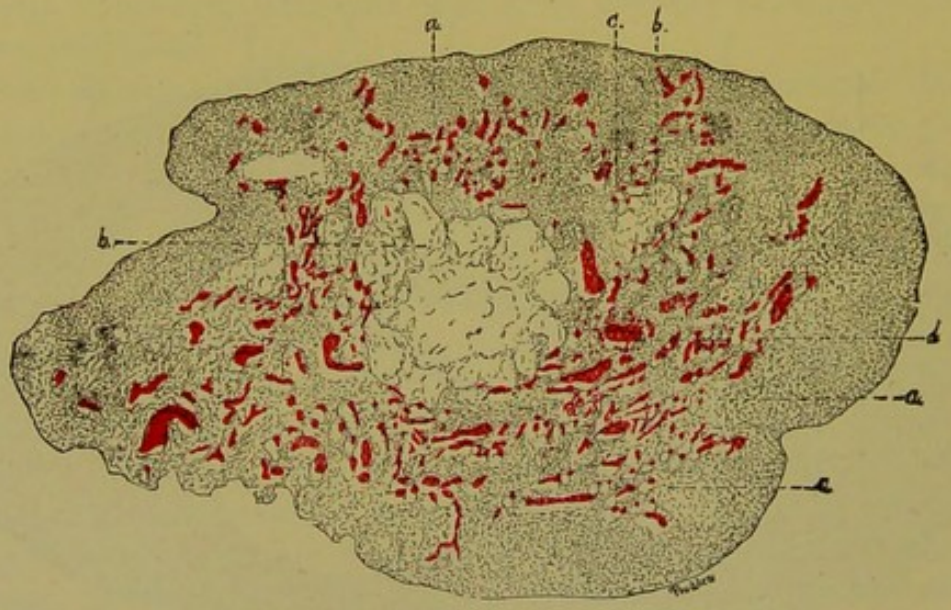


FIG. 342.—CHRONIC OÖPHORITIS WITH ATROPHY.

From a case of valvular disease of the heart with chronic metritis and endometritis. *a*, thickened and dense interstitial tissue; *b*, old corpora lutea; *c*, arteries with greatly thickened walls; *d*, dilated veins.

Graafian follicle. They may contain cysts or be accompanied by cysts of the surrounding stroma. Papillary fibromata of the surface of the ovary are sometimes seen, and the growth may be transplanted from this situation to the general peritoneal surfaces (Fig. 344).

*Leiomyomata* containing more or less fibrous tissue are of occasional occurrence.

*Sarcoma* of the ovaries is not common. It is usually primary, but may be metastatic. It is usually of the spindle-celled variety, but may contain areas of spheroidal-celled tissue or more or less fibrous tissue. The tumors may be hard or soft, and are apt to involve both ovaries. Endotheliomata may be found in the ovaries.

*Chondroma* of the ovaries is described, but is rare; cartilage not infrequently occurs, however, in dermoid cysts.

*Carcinoma*, usually of the glandular variety, may occur as a primary tumor of the ovary. It may be due to a continuous infection from neighboring organs, or more rarely it is of metastatic origin. Although the glandular medullary carcinomata are the most common, scirrhous, melanotic, and colloid cancer sometimes occur. Some forms of carcinoma stand in very close relation with certain of the cystic adenomata (see below).

*Adenomata* (Cystic Adenomata ; Compound Ovarian Cysts).—These growths, which may occur in one or both ovaries, form one of the most common and important classes of ovarian tumors. Some of their most noteworthy and important features depend upon their

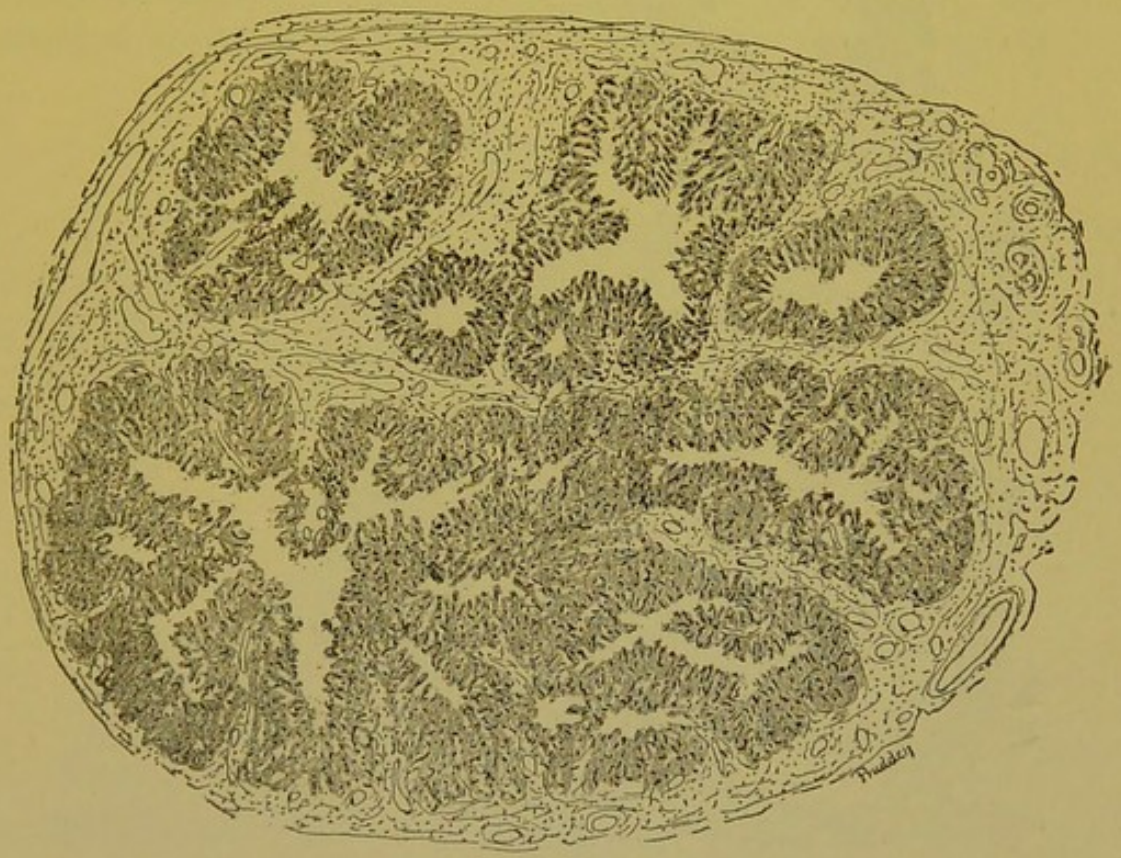

FIG. 343.—COMMENCEMENT OF SARCOMATOUS GROWTH IN THE OVARY.
From hyperplastic cells of corpus luteum. Specimen prepared by Dr. G. C. Freeborn.

tendency to the formation of cysts. It should be remembered, however, that the primary lesion is a true new formation of glandular tissue, and not, as in the case of most cysts, a transformation, by retention or otherwise, of pre-existing structures.

The growth primarily consists of a fibrous stroma, in which are tubular follicles lined with cylindrical epithelium. Or, in some cases, it consists of papillary outgrowths from a fibrous stroma, which are covered with cylindrical epithelium.

*Glandular Cyst-Adenoma.*—There is, as above stated, a marked tendency, particularly in the glandular form of adenoma, to a dilata-

tion of the follicles by a semi-fluid material, and the formation of cysts. There may be a number of follicles equally dilated, so as to form a number of cysts of moderate size ; or only a few follicles are enormously dilated to form a large *multilocular cyst* with but few compartments. The walls of the cysts may fuse together and be absorbed, so as to form one large cyst divided by incomplete septa—*unilocular cysts.* The stroma in which the follicles and cysts are embedded may be largely developed or very scanty.

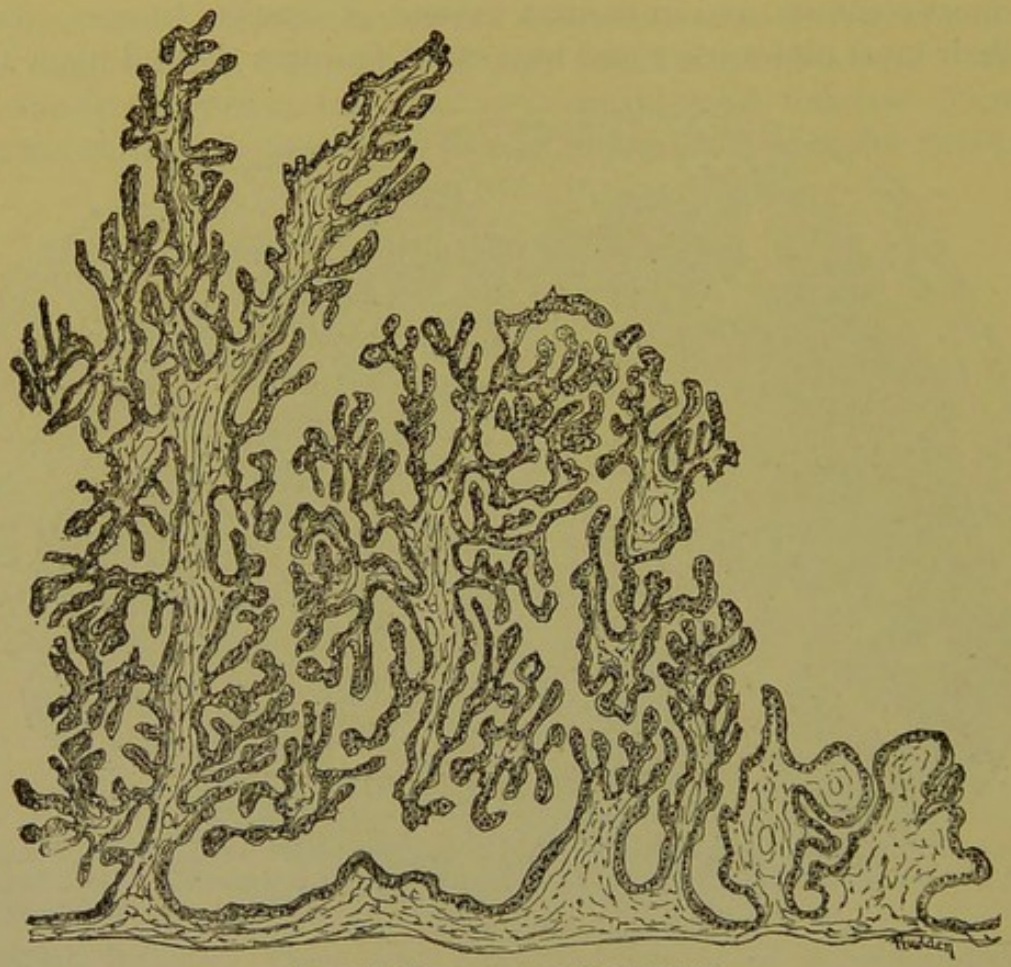

FIG. 344.—PAPILLOMA OF PERITONEUM.
Transplanted from a similar growth on the surface of the ovary.

The walls of the larger cysts are composed of fibrous tissue which is dense in the outer layers, more cellular in the inner, upon which the epithelium is placed. They may be thin and membranous, or we find developed on their internal surfaces an intracystic growth composed of a fibrous stroma and tubular follicles. These secondary follicles may also be filled with fluid and form larger and smaller cysts. The intracystic growths may be so large as to fill up the original cysts. Sometimes the intracystic growth presents very little dilatation of its follicles, so that the entire tumor has more the character of a solid growth than of a cyst.

The cylindrical epithelium lining the cysts usually forms a single layer (Fig. 345), but, owing to the accumulation of fluid, the cells may become flattened and atrophied, or they may be fatty or desquamated. The contents of the cysts differ considerably in different cases, and even in different cysts in the same case. They may be tough and ropy, or gelatinous or serous; transparent and colorless, or yellow or reddish, or reddish-brown; or they may be turbid and colorless, or variously colored—red, brown, or chocolate.

Chemically the cyst contents, when thick and ropy, contain mucin or paralbumin, and perhaps other less well-known compounds belonging to the same class. It is believed that the peculiar ropy character which the fluid often possesses is due to the paralbumin, but the chemical nature and relations of this substance are still matters of

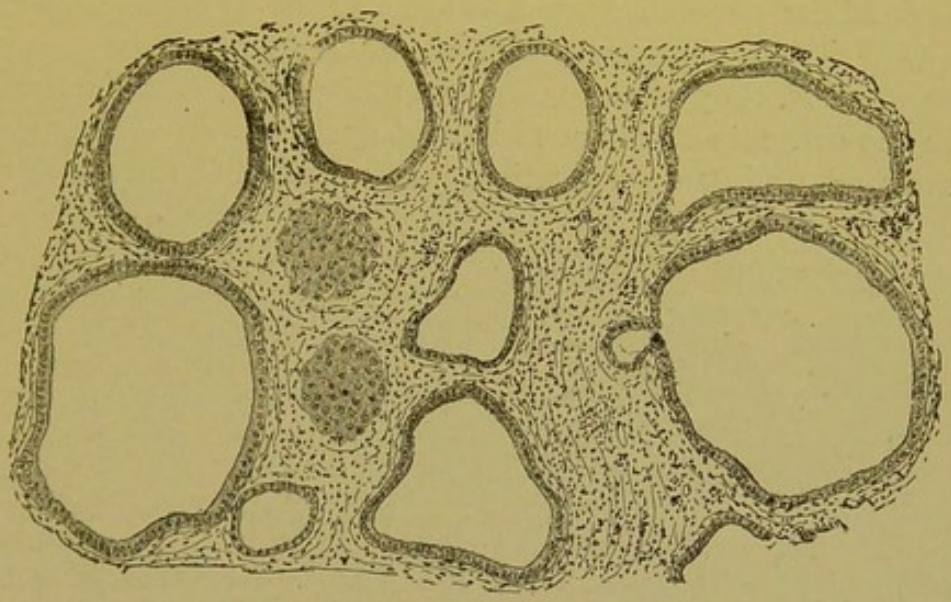

FIG. 345.—CYSTIC ADENOMA OF OVARY.
Glandular form.

dispute. It is probable that the contents of these cysts are, so far as the mucin and paralbumin are concerned, produced by a metamorphosis of the protoplasm of the lining cells, similar to that by which the mucin is produced in the mucous glands and in mucous membranes. We frequently find the cylindrical cells presenting the form of the so-called "beaker cells," and in some cases the mucous contents of the cysts are seen to be continuous with the similar contents of the beaker cells. It is probable that much of the fluid contents of the cysts comes from simple transudation.

Microscopically the contents of these cysts present also considerable variation. We may find almost no structural elements; or there may be red blood cells in variable quantity, and pus cells in various stages of granular or fatty degeneration or of disintegration, so that

variously shaped fragments of the cells appear. Then we may find cylindrical, or flattened, or polyhedral cells, either well preserved, swollen, or in a state of fatty degeneration (Fig. 346), or we may find fragments of these cells. It is these various forms of cells, often more or less swollen and in a condition of more or less well-marked

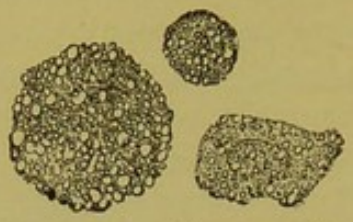

Fig. 346.—Cells from Contents of an Ovarian Cyst in a Condition of Fatty Degeneration.

granular and fatty degeneration, which have been considered characteristic of the ovarian cysts and are sometimes called *Drysdale's* corpuscles. While, however, they are of frequent occurrence under these conditions, they are by no means pathognomonic, since we find them in the contents of various kinds of cysts and cavities where the cells are undergoing degeneration. In addition to the above struc-



Fig. 347.—Cystic Adenoma of Ovary (Papillary form).

tural elements we may find free fat droplets, cholesterin crystals, pigment granules, and more or less granular detritus. The material filling these cysts is sometimes called colloid, and the cysts are frequently called colloid cysts; but we believe that the above view of their nature is the correct one.

Numerous secondary changes are liable to occur in these cysts.

The cells may become fatty and peel off, so that we may find in some parts only a connective-tissue wall. The walls may atrophy, may become infiltrated with salts of lime, or contain concentrically lamellated lime concretions. Inflammatory changes may occur in them. There may be a suppurative inflammation of the walls leading to the formation of abscesses, or pus may be mingled with the cyst contents; the epithelium may be exfoliated and granulation tissue may form in the walls. Chronic inflammation may lead to considerable thickening of the walls and to adhesions with neighboring parts. Hæmorrhages, sometimes very extensive, may occur in inflammation, or as the result of other disturbances of the circulation, so that some of the cysts may be filled with blood. Inflammatory softening, gangrene, etc., of the walls may lead to perforation, so that the contents

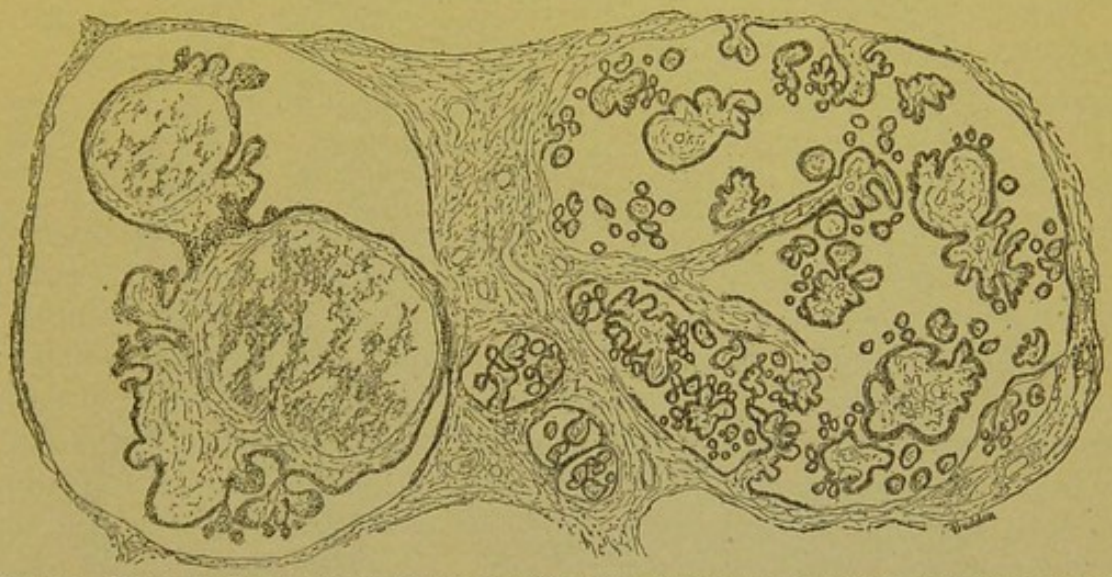

FIG. 348.—MULTIPLE PAPILLARY CYSTS OF THE OMENTUM, SECONDARY TO A SIMILAR GROWTH IN THE OVARY.

The papillary outgrowths are themselves becoming softened at their centres, forming accessory cysts. Drawn from specimen loaned by Dr. G. C Freeborn.

of the cysts may be discharged into the peritoneal cavity, or, in virtue of adhesions, into the bladder, vagina, or rectum. Carcinoma may be developed from the epithelium of the cysts. Since these cysts sometimes reach a very large size, they may produce the greatest variety of disturbances in the abdominal cavity, which need not be enumerated here.

They probably originate in the glandular epithelium of the ovary either before or after the formation of the Graafian follicles.[1]

[1] For more extended descriptions of the cyst-adenomata of the ovaries see *Waldeyer*, "Die epithelialen Eierstöcksgeschwülste," Archiv für Gynäkologie, Bd. i., Heft 2, pp. 252–316, 1870. Also *Klebs*, "Handbuch der pathologischen Anatomie," vierte Lieferung, p. 796, 1873. *Pozzi*, "Treatise on Gynæcology," edited by Brooks H. Wells, M.D., 1892.

*Papillary Cyst-Adenoma.*—This form of cyst-adenoma was formerly regarded as but a variety of the form above described—a variety characterized by papillary outgrowths in cauliflower-like tufts from the walls of the cysts, which often in large degree fill the cyst spaces (Fig. 347). There appears, however, to be sufficient evidence, both anatomical and clinical, to justify the separation of the papillary from the glandular form of cyst-adenoma.

The papillary cyst-adenomata are not, as a rule, as large as the glandular form. The cysts are fewer and they do not contain colloid material. The papillary outgrowths often break through the cyst

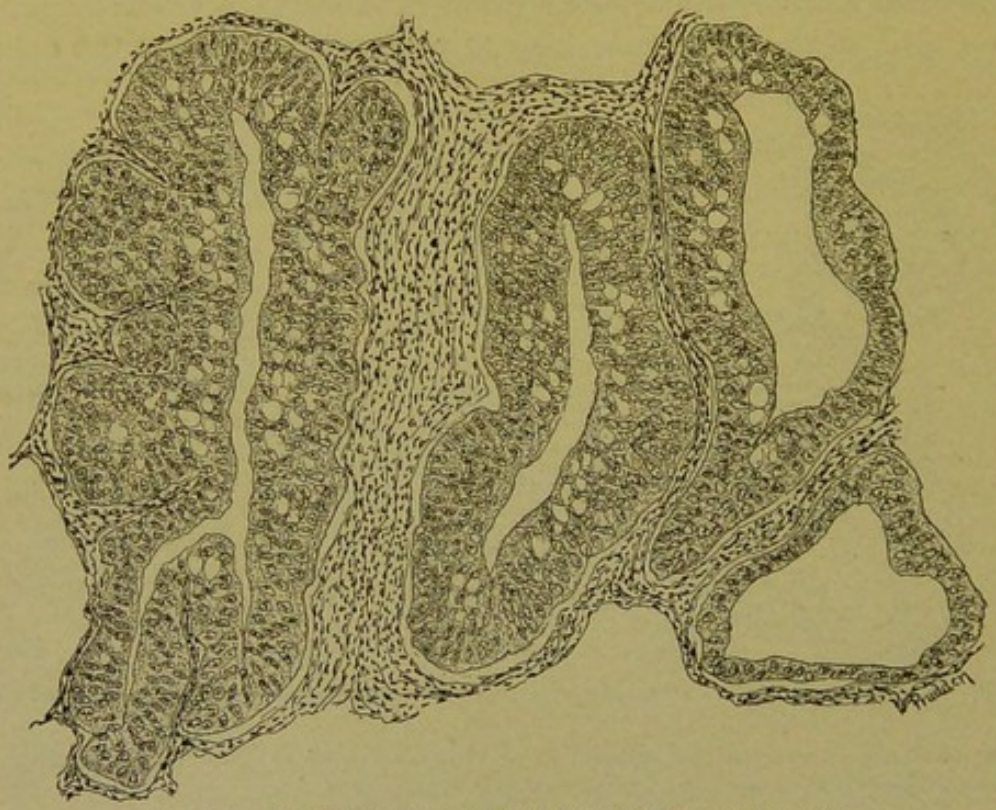

FIG. 349.—ADENO-SARCOMA OF THE OVARY (ENDOTHELIOMA?).
Specimen loaned by Dr. G. C. Freeborn.

walls, and may be transplanted to the peritoneal or other surfaces in the form of multiple cystic or papillary tumors (Fig. 348). The papillæ and cyst walls may be lined by cylindrical and often by ciliated epithelium. They may develop from the follicular or germinal epithelium, and probably, according to Williams, sometimes from the tubular epithelium. [1]

Cyst-adenomata of the ovary may, through an unusual prolifera-

[1] *Williams*, Johns Hopkins Hospital Reports, vol. iii., 1893; also *Freeborn*, Amer. Jour. of Obstetrics, June, 1895, p. 846.

tion of the epithelial cells, form such dense, closely packed cellular masses that the type of structure seems changed. Such a change is shown in Fig. 349, in which, in addition to the excessive production of epithelium, the stroma is sarcomatous.

*Follicular Cysts of the Ovary.*—The Graafian follicles may be dilated so as to form cysts. This may occur in one or both ovaries, and the cysts may be small or large, single or multiple. They are usually found after middle life, but may occur during youth, childhood, or even in the fœtus. The follicles dilate from the accumulation of fluid within them; the ovum is destroyed, the epithelium flattened. The contents are usually serous and colorless, but may be viscid, turbid, purulent, or variously colored, red, yellow, or brown. The ovary may be crowded with numerous cysts of moderate size, whose adjacent walls may coalesce and atrophy, forming communications between them.

A variety of this form of cyst is formed by the dilatation, either with or without the hyperplasia above described, of a corpus luteum. Such cysts may communicate with a Fallopian tube.

*Dermoid Cysts.*—These cysts may be uni- or multilocular, are usually of moderate size, but sometimes become as large as a man's head or larger. Their fibrous walls may be thick or thin, and portions of the internal surface may present more or less completely developed cuticular structures, such as corium, papillæ, epidermis, hairs and hair follicles, sebaceous glands, etc. The cavity may contain a thick, whitish, greasy material composed of flattened epithelium, fat, or cholesterin crystals. Or the cavity or walls may contain masses of irregularly formed hair, teeth, bone, cartilage, striated muscle, and nerve fibres and cells. Such growths, which are doubtless of embryonal origin, may exist for many years without causing inconvenience; but inflammatory changes may occur in them, leading to adhesions and perforations into adjacent organs. They may form the nidus for the development of carcinoma, or they may calcify.

In addition to the above-described adenoid, dermoid, and simple follicular cysts, there are a number of composite forms of not infrequent occurrence. Thus, in connection with dermoid cysts or separately, we find larger and smaller cysts lined with ciliated epithelium. Then there are several cases described of cysts which partake of the characters of both adenoid and dermoid cysts. Such cysts may be multilocular and be lined with flattened, cylindrical, or ciliated epithelium, and may contain epidermal cells, cholesterin or mucin, etc.

Small cysts, sometimes pediculated, sometimes not, of doubtful origin and usually of no special significance, are frequently found growing from the broad ligament near the ovary. The walls are

usually very thin, lined with flattened epithelial cells, and the contents serous. Solid teratomata are of occasional occurrence in the ovary.[1]

*Cysts of the Parovarium*, lying between the peritoneal layers of the broad ligament, are usually small, but may be as large as a man's head. They are usually lined with ciliated epithelium, but sometimes with flattened non-ciliated cells. The contents may be serous, or may be thick and contain mucin and paralbumin.

## THE FALLOPIAN TUBES.

### MALFORMATIONS.

Absence of both tubes occurs with absence of the uterus. One tube may be absent, with arrested development of the corresponding

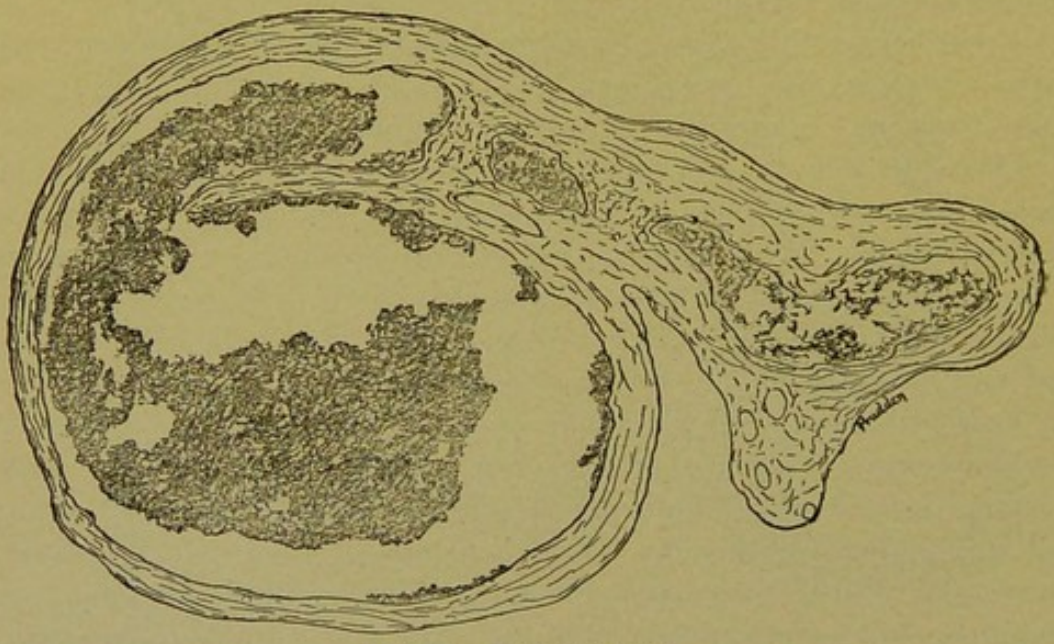

FIG. 350.—HYDRO-SALPINX.

side of the uterus. Both tubes may be imperfectly developed; either of their ends may be closed; they may be inserted into the uterus at an abnormal place; they may terminate in two or three abdominal ostia.

### CHANGES IN POSITION AND SIZE.

The Fallopian tubes may participate in the various malpositions of the uterus and ovaries; but they are most frequently displaced by the contraction of adhesions formed in perimetritic and periovarial inflammations.

The lumen of the tube may be partially or completely closed as the result of inflammation of the mucous membrane; of peritonitis about the fimbriated extremity; of tumors or inflammation of the

[1] Consult *Wilms*, Ziegler's Beitr. z. path. Anat., Bd. xix., p. 367, 1896.

uterus; or by pressure from without, or by adhesions, tumors, etc. It may become stopped by plugs of mucus or pus.

Dilatation of the tubes may be produced by an accumulation of catarrhal or other exudation, when there is partial or complete stenosis at some portion of the tube. The dilatation may be moderate, converting the tube into a tortuous, sacculated canal containing mucous or serous fluid; or, more rarely, large cysts may form containing several pounds of serous fluid—*hydro-salpinx* (Fig. 350). As the fluid collects the epithelium may become flattened or fatty or may desquamate. As a result of an inflammation in the walls of the dilated tube, the contents may be mixed with pus or blood. Rupture of a dilated tube sometimes occurs; or severe and even fatal hæmorrhage may take place into its cavity. Papillary growths are sometimes found springing from the inner wall of the cysts.

### HÆMORRHAGE.

Hæmorrhage into the tube may occur in puerperal women with retroversion of the uterus, with abortions; hæmatometra and tubal pregnancy; in acute infectious diseases. The blood may undergo degenerative changes and be largely absorbed, or it may escape into the peritoneal cavity and cause peritonitis.

### INFLAMMATION (SALPINGITIS).

*Catarrhal Inflammation* of the mucous membrane of the Fallopian tubes commonly occurs in connection with endometritis, frequently in the puerperal condition. In the acute stage the mucous membrane is hyperæmic and swollen, and covered with a mucopurulent exudation. The inflammation may subside, leaving no lesions, but it more frequently becomes chronic, and may then result in peritoneal adhesions, thickening of the walls, obliteration of the tubes, dilatation, etc.

*Suppurative Salpingitis.*—This inflammation of the mucous membrane may assume a suppurative character, particularly in connection with puerperal metritis and peritonitis, but sometimes as a result of gonorrhœal inflammation.

Under these conditions the wall of the tube may be involved and pus may exude from the abdominal ends. It is difficult, in many cases of suppurative salpingitis associated with peritonitis, to say which is the primary lesion.

In some cases there is a considerable collection of pus in the tubes, causing dilatation—*pyo-salpinx*. These collections may rupture into the peritoneal cavity, or the pus may escape into a cavity shut in by adhesions, or may perforate into the intestine or bladder. Or it may dry and finally become calcified.

Suppurative salpingitis is believed to be most commonly caused by the gonococcus or the pyogenic bacteria.

*Tuberculous Inflammation.*—This form of inflammation in the tubes is most frequently seen in its later stages, when the mucous membrane is partially or entirely converted into a thick, cheesy, often ulcerating layer. The lumen of the tubes may be dilated, the walls thickened from chronic inflammation. This lesion may occur by itself, or may be associated with tubercular inflammation of the lungs, or of the other genito-urinary organs, or of the peritoneum. The lesion usually commences at the abdominal ends of the tubes, and both tubes are apt to be involved.

*Syphilitic Inflammation*, in the form of a diffuse thickening of the wall by gummatous tissue, has been described.

### TUMORS.

Small *fibromata* and *fibro-myomata* sometimes occur in the wall of the tubes or in the fimbriæ. Small *lipomata* have been seen between the folds of the broad ligament in close connection with the tubes.

*Carcinoma* of the tubes is usually, if not always, secondary to carcinoma of the uterus or the ovaries.

*Cysts*, usually of small size, sometimes pediculated and with thin walls, are frequently seen in the peritoneal covering of the tubes or in the fimbriæ. They are believed to be of embryonal origin.

Dilatation of the tubes, as above described, may convert them into cyst-like structures.

### EXTRA-UTERINE PREGNANCY.

*Tubal Pregnancy.*—The impregnated ovum is in some way hindered from passing into the uterus, becomes fixed in the tube, and is there developed. The villi of the chorion grow into the mucous membrane of the tube, forming an incomplete placenta. Rare cases are recorded in which the placenta was situated in the uterus while the fœtus was developed in the tube. The embryo and its membranes are developed until they reach such a size that the tube surrounding them ruptures. This may occur in the first month or not until much later. In rare cases, when the wall of the tube was extensively involved in the formation of the placenta, the development has gone on until term. The ovum may remain in the tube after the rupture; or may escape into the peritoneal cavity, still enveloped in its membranes; or the membranes may be ruptured and left in the tube. The rupture is generally attended with fatal hæmorrhage. In some cases death is caused by the rupture of a dilated vein while the

tube is still intact. Hæmorrhage into the sac may occur before its rupture.

In rare cases death does not take place and the fœtus is shut in by adhesions and false membranes. The embryo soon dies. In favorable cases there is a slow absorption of the soft parts of the fœtus, the bones are separated and left embedded in a mass of fibrous tissue, fat, cholesterin, and pigment; or the fœtus retains its shape and becomes mummified, and may then be encrusted with the salts of lime (lithopedion).

In unfavorable cases degeneration and gangrene of the fœtus take place rapidly, with inflammation and suppuration of the surrounding tissues. There may be perforation and escape of the broken-down fœtus through the rectum, vagina, bladder, or abdominal wall. The patient may die from peritonitis or exhaustion, or may recover after the escape of the fœtus.

In some cases the fœtus may escape through a rupture of the tube into the space between the folds of the broad ligament.

*Tubo-abdominal Pregnancy* is produced by the development of the ovum in the fimbriated extremity of the Fallopian tube. Adhesions are formed, so that the fœtus is partly in the end of the tube and partly in the abdomen.

*Interstitial Pregnancy.*—The ovum in these cases is arrested and developed in the portion of the tube which passes through the wall of the uterus.

*Abdominal Pregnancy.*—The ovum, after escaping from the ovary, does not enter the Fallopian tube, but becomes fixed to the peritoneum, usually at some part near the ovary. It is surrounded by thickened peritoneum and develops in that position.

*Ovarian Pregnancy.*—The existence of this form of pregnancy is doubtful and difficult to prove, but there are some cases in which it seems probable that the ovum develops in its Graafian follicle. The placenta may be attached to the tube or to the abdominal wall.

In all forms of extra-uterine pregnancy the uterus becomes enlarged and a sort of decidua is formed on its internal surface.

## LESIONS OF THE PLACENTA.[1]

Aside from the variations from the normal in size, shape, and position, for a description of which we refer to the works on obstetrics, we may briefly mention here some of the more important structural changes which the placenta may undergo.

*Hæmorrhage.*—This may occur either on the maternal surface in the decidua; or between the fœtal surface and the membranes; or in the substance of the placenta. The latter form of hæmorrhage con-

[1] For structure of placenta consult *Eden*, Journal of Pathology and Bacteriology, vol. iii., p. 449 (bibliography).

stitutes the true *placental apoplexy*. This may occur as the result of rupture of a placental sinus. The placental tissue is crowded apart, and a blood clot, often infiltrating the parenchyma, is formed. This may lead to abortion, or the blood may undergo disintegration and absorption and its place be occupied by a cicatrix. The placental tissue in its vicinity may undergo fatty degeneration. Under other conditions, without evidence of rupture of the vessels, the placental tissue may become infiltrated with blood in the form of an infarction. In this, degenerative changes similar to the above may occur, leading to fibrous induration of the placenta.

The so-called "white infarctions" of the placenta appear to be altered thrombi in the maternal blood spaces. They consist of lamellated or homogeneous or fibrillar fibrin, and form important larger and smaller yellowish-white or reddish, irregular masses, and appear to be of pathological significance only when they occur early or are of great extent.

### INFLAMMATION (PLACENTITIS).

*Suppurative Inflammation* of the placenta, with the formation of abscesses, is of rare occurrence as the result of injury.

*Chronic Indurative Inflammation* of the placenta may result in the formation of circumscribed masses of cellular and loose, or dense and cicatricial, connective tissue, or in a diffuse formation of connective tissue, which may interfere with the nutrition of the fœtus and cause abortion. The new-formed connective tissue may undergo fatty degeneration or calcification.

In another class of cases the new connective tissue is formed mainly in the walls of the vessels, particularly the arteries. This may occur in circumscribed portions of the vessels, leading to nodular growths around the arteries, or it may occur extensively along the various ramifications of the vessels, converting them into thick fibrous cords. The change is primarily in the adventitia, but all the coats of the vessel may become involved, leading to more or less complete obliteration of the lumen.

Various proliferative and indurative changes in the placenta may occur as the result of syphilitic infection.

### DEGENERATIONS.

Fatty and amyloid degeneration and calcification of the placental tissue are of not infrequent occurrence.

Cysts of the placenta are of occasional occurrence; their origin is in most cases obscure.[1]

---

[1] See *Ahlfeldt*, Arch. für Gynäkologie, Bd. ii., p. 397. *Fenomenodes*, ibid., Bd. xv., p. 343. *Hofmeier*, "Die menschliche Placenta," 1890.

Fragments of placenta remaining in the uterus after delivery may serve as a nidus for a blood thrombus, or they may undergo proliferation, thus forming tumors, *deciduomata* (see page 718).

An hypertrophy of the villi of the chorion may give rise to the fibrous structures known as *fibrous moles*. When to the fibrous change mucous degeneration is added the so-called *hydatid moles* are formed.[1]

## THE MAMMA.

### MALFORMATIONS.

Absence of both mammæ is only found in connection with other marked malformations.

Absence of one mamma has been observed in a few cases, with and without defective development of the corresponding half of the thorax.

Absence of one or of both nipples is more common.

Arrest of development of the mammæ is found in connection with arrest of development of the organs of generation, and, to a less degree, alone.

Supernumerary mammæ and nipples have been observed in a number of cases. The glands may all secrete milk during lactation.

Too early development of the mammæ is sometimes found in young children in connection with abnormal development of the organs of generation.

### HÆMORRHAGE.

In young women who suffer from amenorrhœa or dysmenorrhœa, small hæmorrhages sometimes occur in the mammæ at the time of menstruation. The blood may find its way into the milk ducts and exude in small quantities at the nipple.

Contusions of the breast may produce extravasations of blood in the mammary gland or the surrounding connective tissue. This may become absorbed, or may remain and be surrounded by fibrous tissue or be converted into cysts.

### INFLAMMATION.

During lactation the nipple is liable to become inflamed in three ways, which may occur separately or be combined together.

1. The epidermis is rubbed off by nursing, the cutis becomes inflamed and converted into granulation tissue ; in this way small or large ulcers may be formed.

2. Fissures are formed at the base of the nipple, which extend completely through the skin, and are lined at the bottom with granulation tissue.

---

[1] Consult *Marchand*, Zeits. f. Geburtsh. u. Gynäk., Bd. xxxii., p. 405; also *Fraenkel*, Arch. f. Gynäk., Bd. xlix..

3. There is a diffuse inflammation of the whole nipple, which does not, however, go on to suppuration. The nipple is conical, red, swollen, and very painful.

There is a form of eczema-like inflammation of the nipple and areola which tends to ulcerate and develop into carcinoma. This is known as Paget's disease, and is believed by some observers to be associated with coccidia (see page 129).

*Acute Inflammation of the Mamma* (Mastitis) occurs most frequently during lactation; it also occurs during pregnancy, and occasionally in women who are neither pregnant nor nursing.

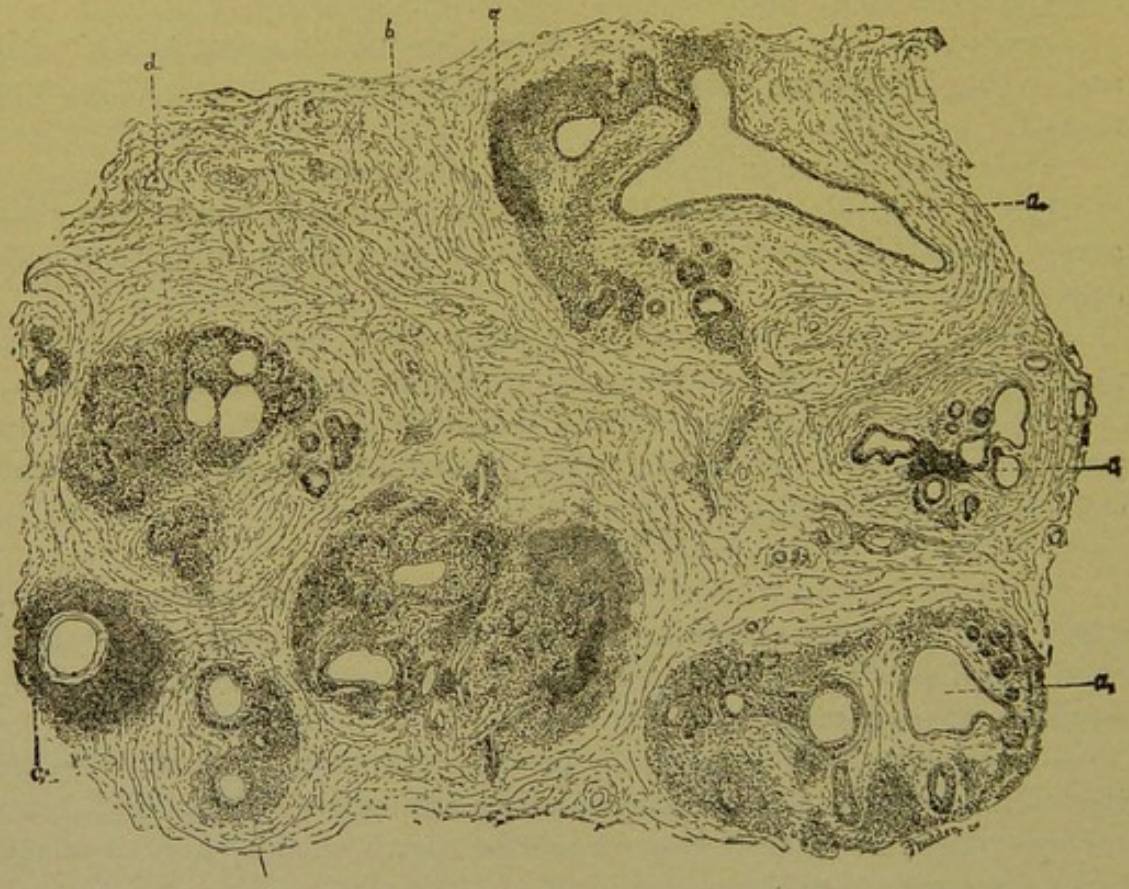


FIG. 351.—SUPPURATIVE MASTITIS OCCURRING IN THE NON-FUNCTIONATING GLAND.

*a*, milk duct; *b*, interstitial tissue; *c*, dense collections of pus; *d*, diffuse infiltration of lobule with pus.

The inflammation may involve the subcutaneous connective tissue, the gland itself, or the connective tissue between the gland and the wall of the thorax. The inflamed tissues are at first congested, swollen, hard, and painful. The inflammation may stop at this point and resolution take place, but more frequently it is succeeded by suppuration. If the inflammation involves the subcutaneous connective tissue the abscess may be superficial and soon open through the skin. If the gland is involved one lobule after another may

become inflamed (Fig. 351), so that successive abscesses are formed in different parts of the gland. If the connective tissue beneath the gland is inflamed a deep abscess of large size may be formed, which usually perforates through the skin, but sometimes into the pleural cavity. In both these latter forms of abscess there is apt to be necrosis of large portions of tissue. These abscesses may cicatrize, or they may pass into a chronic condition and remain as suppurating, fistulous tracts for a long time. Suppurative mastitis is usually due to the presence of Streptococcus and Staphylococcus pyogenes.

In new-born children there is often a painful swelling of the breasts, which usually subsides in a few days, but may go on to suppuration.

Epidemic parotitis is sometimes complicated by mastitis.

*Chronic Inflammation* of the interstitial connective tissue of the

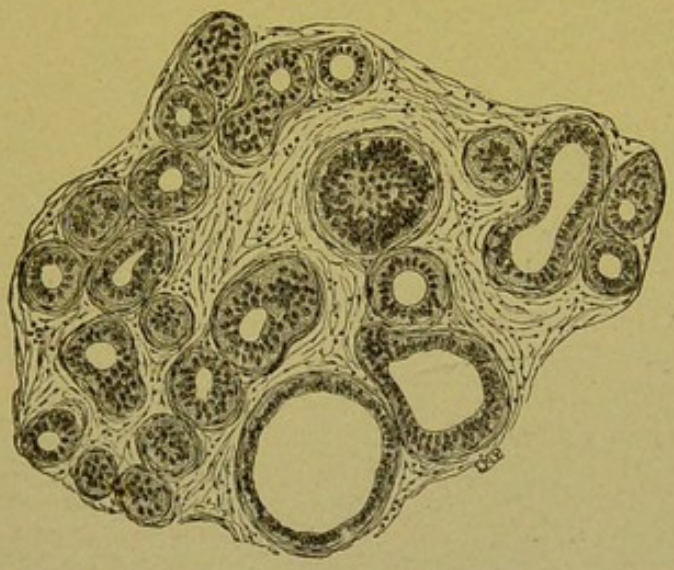

Fig. 352.—Chronic Inflammation of Mammary Gland.

mammary gland may result in the formation of dense connective tissue (Fig. 352), with or without cystic dilatation of the milk ducts and atrophy of the glandular elements. Acute exudative inflammation may occur in a gland which is the seat of chronic inflammation, and abscesses may be formed.

Eczema sometimes affects the skin of the nipple. Attention has lately been drawn to the relationship between this inflammation and carcinoma of the nipple, for the two are frequently associated. It is possible that the eczema may lead to the subsequent development of the carcinoma.

*Tuberculous Inflammation* of the mammary gland and its excretory ducts is of occasional occurrence. It may manifest itself in the form of miliary tubercles, larger and smaller cheesy masses of new-formed tissue, or cold abscesses.

*Syphilitic* ulcers may occur in the nipple either as primary chancres or as mucous patches. Gummy tumors have been observed in the mamma.

### TUMORS.

There may be a general hypertrophy of one or both breasts. This is usually found in young, unmarried women, but sometimes in

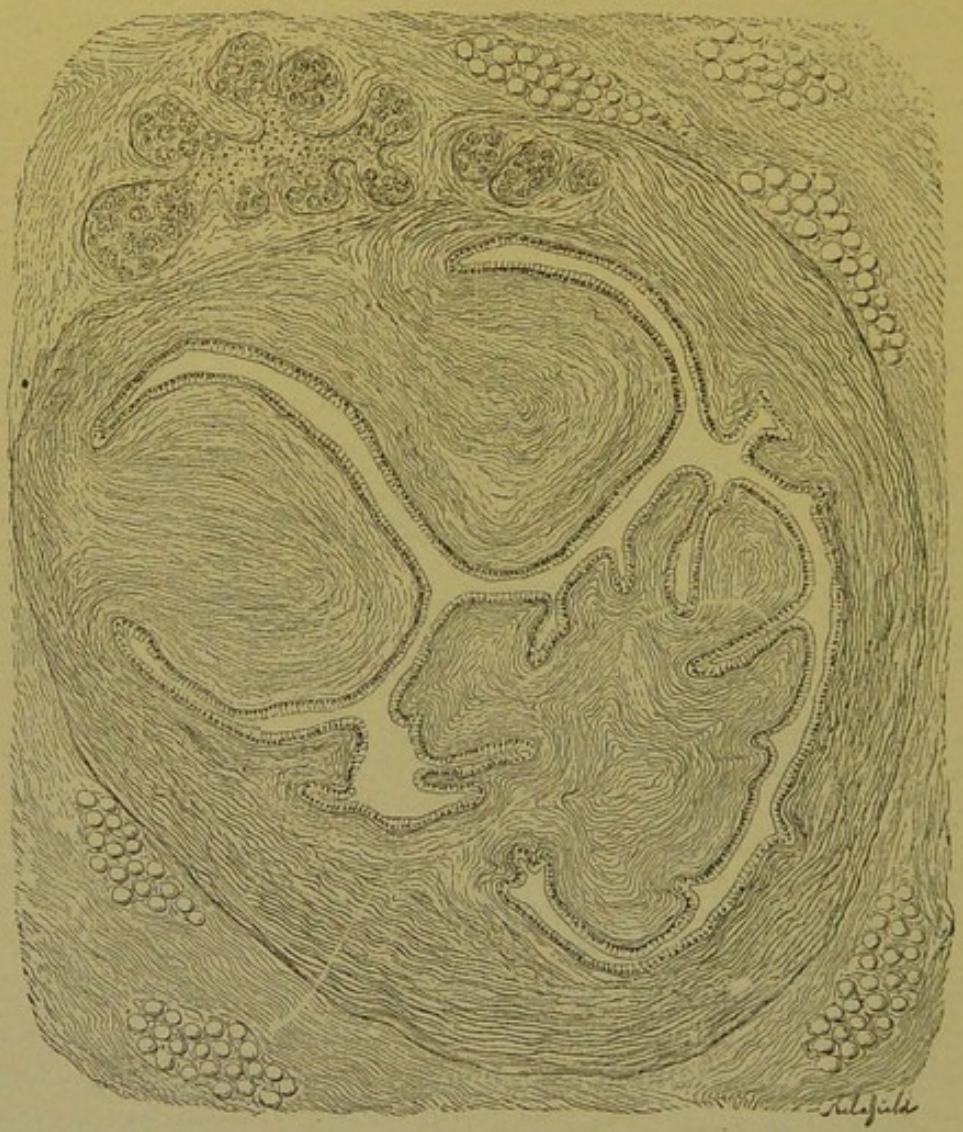

FIG. 353.—INTRACANALICULAR FIBROMA OF THE MAMMA, × 170 and reduced. Cross-section of a milk duct with polypoid ingrowths.

advanced life. There is an increase in all the elements of the gland, both the glandular and the connective-tissue.

*Cysts* of the mamma seem to be for the most part retention cysts, formed by the dilatation of the glandular ducts or acini. During lactation such retention cysts are sometimes formed, and then contain milk. They may reach an enormous size. At other times retention cysts are formed containing serous or viscid, brownish fluid,

which often exudes through the nipple. These cysts may be large or small, single or multiple. There is usually at the same time some growth and induration of the connective tissue of the gland. In some cases there are polypoid outgrowths of connective tissue from the wall of the cyst. These cysts are not to be confounded with the cysts which are developed with the intracanalicular tumors, of which we shall speak below.

*Fibroma.*—Circumscribed tumors composed of connective tissue are sometimes found in the breast. They are dense and hard, and may enclose in them some of the gland ducts and acini.

*Intracanalicular Fibroma.*—These tumors are formed by a dif-



FIG. 354.—PERICANALICULAR FIBROMA OF THE MAMMA.

fuse growth of connective tissue, a dilatation of the milk ducts, and a growth of polypoid fibrous tumors from the walls of the ducts into their cavities. The glandular acini may be atrophied, or enlarged, or cystic. A section of such a tumor looks like a solid mass of fibrous tissue, divided by clefts and fissures lined with cylindrical or cuboidal epithelium (Fig. 353), or containing cysts into which project polypoid fibrous outgrowths. These tumors grow slowly, but if left to themselves may reach an enormous size. The skin over them may ulcerate and the tumor project through the opening in fungous masses.

*Pericanalicular Fibroma.*—Sometimes the new connective tissue forms a more or less thick cylindrical investment of the duct with-

out growing into its lumen. This formation, which is shown in Fig. 354, is sometimes called *pericanalicular fibroma.*

*Myxoma.*—This form of tumor may occur as a circumscribed growth replacing part of the mamma, or it may be developed in the same way as the intracanalicular fibromata. It is not uncommon in these intracanalicular tumors to find a combination of fibrous, mucous, and sarcomatous tissue in the same tumor.

*Chondroma* is a very rare form of tumor in the mamma. A few cases have been described in which it was combined with carcinoma.

*Adenoma.*—Tumors composed of glandular acini, and ducts surrounded by connective tissue, are of frequent occurrence in the mamma (Fig. 145). They are either single or multiple, or several may be developed successively in the same breast. They grow at first slowly, afterward more rapidly. Their structure may be further complicated by the dilatation of one or more of the ducts which compose the tumor into cysts, and the ingrowth of connective tissue from the walls of these cysts.

*Sarcoma.*—This form of growth may be developed as a circumscribed tumor of small or large size. Its basement substance is that of connective or of mucous tissue, and may be scanty or abundant. The cells are spheroidal, fusiform, branched, or polygonal. These tumors may simply replace the gland ; or glandular acini and ducts may be enclosed within them ; or these ducts and acini may be dilated so as to form cysts ; or there may be a new growth of the gland tissue so as to form an adeno-sarcoma.

In other cases the sarcoma takes the intracanalicular form. There is a diffuse growth of sarcomatous tissue, a dilatation of milk ducts, and an outgrowth of sarcomatous tissue from the walls of the dilated ducts into their cavities. These tumors often reach an enormous size, and there is apt to be ulceration of the skin over them.

*Carcinoma* of the mamma is most common in women between the ages of thirty-five and fifty-five, but it sometimes occurs in women not over twenty years old, and sometimes in old persons. It occurs in either breast, in the right rather more frequently than in the left, but sometimes in both. The growth begins more frequently at the periphery of the gland than at its centre, and more frequently in the upper edge of the gland than in any other place.

The growth most frequently begins as a small, circumscribed nodule, which enlarges and involves more and more of the breast ; sometimes, however, it is diffuse from the first, and sometimes it begins in the nipple.

It may infiltrate the adjacent tissues and the axillary and cervical glands, and form metastatic tumors in different parts of the body.

There are several different anatomical forms of the growth :

1. Those in which the epithelial elements preponderate, the soft or so-called *medullary carcinomata.*

2. Those in which both the connective-tissue stroma and the epithelial cells are prominently developed, the cells lying in well-defined larger and smaller irregular-shaped spaces, so that the simulation of gland tissue is tolerably close. These are called *carcinoma simplex.*

3. The tumors in which the connective-tissue stroma preponderates, giving the tumor its hard, dense character. This is the *carcinoma fibrosum*, or *scirrhous.*

Colloid carcinoma of the mamma is rare. Various secondary changes may occur in these tumors, such as have been described in the section on Tumors.

In any of these forms of cancer there may be cystic dilatations of the ducts and acini.

Besides the primary carcinomata of the mamma, secondary carcinomata are met with in rare cases.

## MALE GENERATIVE ORGANS.

### THE PENIS.

#### MALFORMATIONS.

Entire absence of the penis is met with in connection with great defects of development of the rest of the body.

Absence of the penis, with proper development of the other organs of generation, is rare. The urethra then usually opens into the rectum.

An abnormally small penis is found, with absence or arrested development of the testicles.

Absence or a rudimentary form of the prepuce has been observed in a number of cases. Congenital phimosis is also not infrequent.

*Hypospadia* consists in an arrest of development of the penis and scrotum. In its highest degree the penis is one-half to one inch long, the glans penis small and resembling a clitoris. On the lower side of the penis is a deep cleft lined with mucous membrane. Into this cleft the urethra opens at the root of the penis. The scrotum remains separated into two halves, resembling labia majora. The testes descend into their proper position on each side or remain in the abdomen. If the testicles continue to develop normally the individual has the appearance and capacities of a man ; if their development is arrested the individual is small and has a womanish appearance.

In lesser grades of the same malformation the two halves of the scrotum are joined and the penis is larger, but a part of the urethra remains open as a cleft at any point of the penis.

*Epispadias* is an opening of the urethra on the upper side of the penis. It presents various grades and forms.

*Hermaphroditism.*—This is a union of two sexes in the same person, the test of which is the presence of the secreting organs, the ovaries and testicles. True hermaphroditism is rare, but it does occur, while most of the conditions called hermaphroditism are in reality due to varying malformations of the external generative organs.

*Pseudo-hermaphroditism.*—This malformation consists in an abnormal change in the transition from the fœtal condition of the parts to their fully developed form. In the male, normally, the greater part of Müller's canal disappears and its lower end forms the vesicula prostatica. In this malformation Müller's canal is changed, as it is in the female, into Fallopian tubes, uterus, and vagina, while at the same time the testes, epididymes, vesiculæ seminales, and spermatic cord are formed as usual. In the lesser degrees of this malformation we find, in the place of the vesicula prostatica, a pear-shaped sac as large as a pigeon's egg, with muscular walls and an epithelial lining. This sac may be incompletely divided into a uterus and vagina, and it opens into the urethra. In the higher grades we find a well-formed vagina and uterus. The uterus may or may not have Fallopian tubes. The testicles are usually retained in the abdomen or inguinal canals, and are small. The spermatic ducts run on the sides of the uterus and open into the urethra or are closed. The penis and scrotum appear as in hypospadia, or are well formed. The appearance of the individual varies with the development of the testicles.

*True Hermaphroditism* may be lateral. In this condition there is hypospadia ; a vagina and uterus and a Fallopian tube and ovary on one side, and a testicle and spermatic cord on the other.

In certain cases, which may be called *bilateral hermaphroditism*, there is a testicle on one side and an ovary on the other.[1]

*Enlargement* of the penis is sometimes caused by venous congestion from heart disease ; by long-continued masturbation, as a result of which the corpus cavernosum may lose its contractility ; and in rare cases by hypertrophy of the stroma of the corpus cavernosum.

---

[1] For a detailed consideration of the malformations of the male and female generative organs consult *Klebs*, "Handbuch der pathologischen Anatomie," and more recent cases of hermaphroditism by *Heppner*, Arch. f. Anat. u. Physiol., 1870, and by *Hofmann*, Wien. med. Jahrb., 1877.

*Injury and Hæmorrhage.*—Injuries to the penis are liable to give rise to severe hæmorrhage on account of its peculiar vascular character ; suppurative inflammation, gangrene, infiltration with urine and its consequences, are also liable to occur. The contractions of the cicatricial tissue by which wounds are healed frequently give rise to various distortions of the organ and not infrequently prevent subsequent erections.

### INFLAMMATION.

*Balanitis*, inflammation of the prepuce, is usually produced by gonorrhœa or by accumulations of smegma. The skin is red and swollen and may ulcerate. Condylomata may be formed, and adhesions between the prepuce and glans. The glans may ulcerate and the prepuce may be much thickened. If the prepuce is long there is an inflammatory phimosis, and the products of inflammation accumulate within the swollen prepuce. In some cases the prepuce becomes gangrenous.

*Paraphimosis* is produced by the retraction of a narrow prepuce behind the glans, with consequent stricture, inflammation, and sometimes gangrene.

*Inflammation of the Corpora Cavernosa* may be the result of injury, may follow fistulæ, may occur in connection with inflammation of the connective tissue of the pelvis, and may accompany the acute infectious diseases, such as pyæmia, small-pox, measles, typhus, etc. It may result in fibrous induration of portions of the corpora cavernosa ; in rare cases in abscesses or diffuse purulent infiltration ; sometimes in gangrene. Tubercular inflammation of the penis has repeatedly followed circumcision performed by uncleanly tubercular persons.

*Syphilitic Ulcers* frequently occur on the glans penis and prepuce. The indurated chancre is formed either from an excoriation in which a pustule is formed or from a little nodule. The pustule breaks and its walls are infiltrated with small round cells. The nodule softens, breaks down, and forms an ulcer, of which the walls are infiltrated with cells in the same way.

Syphilitic condylomata are of frequent occurrence on the glans.

Phagedenic ulcers occur and may destroy a considerable part of the penis. Herpes of the prepuce occurs in the form of small vesicles, which may later become ulcers. Erysipelatous and furuncular inflammation sometimes involves the skin of the penis.

### TUMORS.

*Papilloma* is found on the prepuce and glans penis. It occurs in the form of little warty growths, or of composite, cauliflower masses,

even as large as a fist. In either case the structure is the same—hypertrophied papillæ covered with epithelium. Sometimes the epithelial layers become thick and horny, forming large, dense projections.

*Fibroma diffusum*, or elephantiasis of the prepuce, may occur, leading to immense thickening of the structure. It consists in a diffuse growth of the deep fibrous tissue of the cutis. *Lipomata, angiomata, circumscribed fibromata*, and sebaceous cysts may occur in the penis. *Carcinoma* of the penis usually occurs in the form of epitheliomata. These are most frequent in the prepuce and glans penis. They may have the form of flat ulcers, or of infiltrating, ulcerating nodules, or very frequently assume the form of papillary outgrowths, which may attain great size, ulcerate, or undergo a variety of inflammatory changes. These growths may involve the entire skin of the penis ; they may invade deeper parts. The inguinal glands may be invaded. Distant metastases may occur, but are not frequent.

Glandular carcinoma of the penis is not common. It may be secondary to carcinoma in some other part of the body.

*Calcification* and *Ossification* of the connective tissue of the corpora cavernosa sometimes occur. Large and small preputial calculi are occasionally found between the prepuce and the glans. These may be formed *in situ*, may come from the bladder or from without, and may later increase in size.

## THE SCROTUM.

The skin of the scrotum is subject to the various forms of lesions which may occur in any part of the integument.

*Elephantiasis* of the scrotum consists in the main of a development of new connective tissue from the cutis, which is sometimes accompanied by dilatation of the lymph vessels. The thickened scrotum sometimes forms very large tumors, often rough upon the surface, which may entirely cover in the penis. *Lipomata, fibromata, atheromatous* or *sebaceous cysts*, and *dermoid cysts* containing hair, bone, cartilage, etc., are sometimes found. Occasionally the skin of the scrotum is beset with numerous larger and smaller sebaceous cysts, which raise the surface into little globular or wart-like projections. *Epitheliomata*, in the form of flat or papillary ulcerating tumors, are of frequent occurrence among chimney sweepers, and may lead to extensive ulcerations of the adjacent parts and involvement of neighboring lymph nodes.

*Dermoids and Teratomata* of the scrotum are not uncommon. In very rare cases tumors containing a considerable portion of a fœtal skeleton have been found in the scrotum.

## THE TESTICLES.

### MALFORMATIONS.

Absence of both testicles, either with or without absence of the epididymes, spermatic cords, and vesiculæ seminales, occurs in rare cases. The scrotum is only indicated or may contain the epididymes. The penis is small, and the individuals are small and poorly developed.

Instead of being entirely wanting, the testes may be imperfectly developed. The individuals are weakly and effeminate. Absence of one testicle, with healthy development of the other, is more frequent. The corresponding epididymis and cord may be absent or present.

The spermatic cords and vesiculæ seminales may be absent or imperfectly developed on one or both sides, while the testes are normal.

Either one or both testicles may remain permanently in their fœtal position, or may not descend into the scrotum for several years after birth (*cryptorchismus*). Their descent may even be delayed until the thirtieth year of life. This condition may depend on an arrest of development in the testes or the gubernaculum testis; on adhesions produced by intra-uterine peritonitis; on narrowing of the inguinal canal; on narrowing or shortening of the vaginal process of the peritoneum; or on abnormal size or position of the testicle. Usually the malformation is confined to one testicle, and then is more frequent on the left side. The testicle is usually found in the abdomen close to the mouth of the inguinal canal, or in the inguinal canal just below the external ring; but it may be beneath the skin in the perineum, or in the crural canal with the femoral vessels, or elsewhere. The retained testis is usually not fully developed, or undergoes fatty or fibrous degeneration. The retention of one or even of both testicles does not preclude the possibility of procreation. Retained testicles are prone to inflammatory changes and liable to become the seat of malignant tumors.

Sometimes, while the testis is retained, the epididymis and spermatic cord descend into the scrotum. In rare cases the position of the testis may be changed so that the epididymis and cord are in front. The existence of a supernumerary testis has been asserted in some cases, but is rather doubtful.

*Atrophy* of the testicle may occur in old age or in persons who are in a condition of premature senility; or as the result of pressure from herniæ, hydrocele, or inflammatory products.

### HYDROCELE.

Hydrocele of the tunica vaginalis consists in an accumulation of

serum in the cavity of this membrane. It is usually confined to one side. It is caused by acute or chronic inflammation of the tunica vaginalis, by varicocele, or by general dropsy. The serum is found in small or in large quantities ; it is usually transparent, may contain cholesterin, or be purulent and contain the pyogenic bacteria, or be mixed with blood. The tunica vaginalis remains unchanged, or is thickened, or contains plates of bone, or is covered with polypoid fibrous bodies which fall off and are found free in the cavity of the sac. There may be adhesions between the layers of the tunica vaginalis, and in this way the fluid becomes sacculated. The testis is pushed downward and backward ; it remains unchanged or is atrophied.

Hydrocele of the processus vaginalis consists in an accumulation of serum in the cavity of the vaginal process of the peritoneum, which remains open after the descent of the testicle. There are several different varieties.

(*a*) The vaginal process is entirely open and there is a free communication with the peritoneal cavity. The serum may originate in the cavity of the peritoneum or of the vaginal process, and passes freely from one to the other.

(*b*) The processus vaginalis is closed in the inguinal canal, while its lower portion is filled with serum.

(*c*) The processus vaginalis is closed about the testis and the visceral layer of the tunica vaginalis is formed. The serum accumulates in the upper part of the vaginal process which communicates with the peritoneal cavity.

(*d*) The vaginal process is closed in the inguinal canal and over the testis ; the serum accumulates so as to form one or more sacs between these two points. Inguinal hernia may complicate this form of hydrocele.

Hydrocele of the spermatic cord consists in a general œdema of the connective tissue of the cord, or in the development of circumscribed cysts in this connective tissue.

A peculiar form of hydrocele is produced by the accumulation of serum in the sac of an inguinal hernia, from which the intestine has become retracted.

### HÆMATOCELE.

Hæmatocele of the tunica vaginalis consists in an effusion of blood into the cavity of this sac. It may be produced by injury ; in scurvy, or the hæmorrhagic diathesis ; or it may complicate a pre-existing hydrocele. The effused blood usually soon degenerates, and we find the sac filled with a brownish fluid or a thick, grumous mass. The tunica vaginalis may be thickened. The testis remains normal or is atrophied.

Effusion of blood into the loose connective tissue of the scrotum is often called *extravaginal hæmatocele.*

Hæmatocele of the spermatic cord occurs in rare cases as a diffused infiltration of blood in the connective tissue of the cord. Or blood may be effused into a hydrocele of the cord.

### SPERMATOCELE.

Cysts containing spermatic fluid not infrequently arise from the epididymis or from the rete testis. These sometimes acquire a large size and crowd the tunica vaginalis before them, so that they simulate a collection of fluid in the cavity of the latter. The wall of the cyst may be lined with ciliated or with flattened epithelium. The contents are sometimes simply serous, but more frequently opalescent and contain great numbers of spermatozoa.

### INFLAMMATION.

Inflammation of the testicles may be caused by injuries, exposure to cold, inflammation of the urethra, syphilis ; or it may occur in parotitis and in connection with various infectious diseases. The testes, epididymis, or tunica albuginea may be principally involved. Usually only one testicle is inflamed, sometimes both. The inflammation may extend to the vas deferens. The inflammation may be acute or chronic.

*Acute Orchitis* is most frequent in the epididymis and tunica albuginea. When the testis is involved the organ is congested and infiltrated with serum or pus. From this condition it may return to the normal state ; or small abscesses may form which may be absorbed, or they may increase in size so as to involve nearly the entire organ. They may perforate externally, and then healing may occur by means of granulation tissue ; or extensive gangrenous destruction of the scrotum may occur. They may become enclosed in a fibrous capsule, and the contents dry and become cheesy or calcified, and so persist for a long time. The acute inflammation may pass over into the chronic form. *Acute epididymitis* is frequently the result of gonorrhœal infection, and may or may not be associated with inflammation of the testis.

The products of inflammation may collect in varying quantity in the lumina of the seminiferous tubules and in the ducts of the epididymis, and the epithelium of these structures may degenerate.

*Chronic Orchitis* occurs as a sequel of acute inflammation or as an original condition. It may affect the testis, the epididymis, or the spermatic cord. The seminiferous tubules may be filled with desquamated and degenerated epithelium ; they may be atrophied, or their walls may be greatly thickened so that they are converted into

dense fibrous cords, with almost or quite complete obliteration of their lumina. There is usually a marked increase in the interstitial tissue, which causes atrophy of the tubules (Fig. 355). The albuginea may be greatly thickened. In some cases the testis is converted into a mass of dense connective tissue, in which but little trace of the original structure can be made out. The new-formed connective tissue may become calcified. A periorchitis may lead to thickening and union of the layers of the tunica vaginalis testis. Abscesses are not infrequent in connection with chronic orchitis.

*Tubercular Orchitis* may occur in connection with tuberculosis

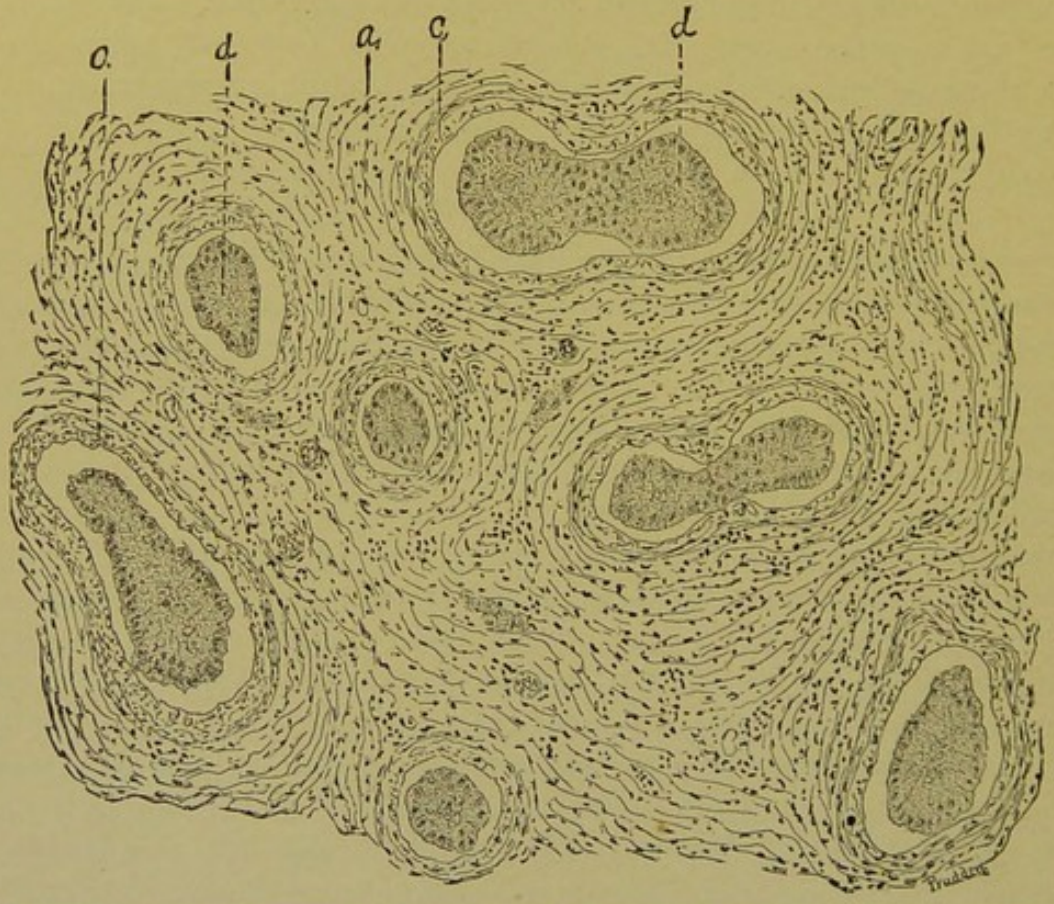


FIG. 355.—CHRONIC INTERSTITIAL ORCHITIS WITH ATROPHY OF THE SEMINIFEROUS TUBULES.

*a*, thickened interstitial tissue; *c*, thickened membrana propria of the tubules; *d*, separated epithelial cell mass in the lumen of the tubules.

of the other genito-urinary organs or the lungs, in acute general miliary tuberculosis, or by itself. It usually begins in the epididymis and may extend from there to the testis, or it may commence in the testis itself. The appearances which the testicles present, when the seat of this form of inflammation, are exceedingly varied and difficult of interpretation. This is partly due to the complex structure of the organ, partly to the varied complicating simple inflammatory changes which the different parts of the organ undergo in connection with the special tubercular inflammation, and the impos-

sibility of making any definite morphological distinction between them. Further researches are urgently needed in this direction, and it seems probable that in the presence or absence of the tubercle bacillus we shall find the needed differentiating factor between various inflammatory processes which are at present grouped under the general heading of tuberculosis testis.

We may find in the testicle small circumscribed masses of cells, visible to the naked eye as whitish spots, which are sometimes composed of small spheroidal cells or of larger polyhedral or fusiform or round cells. These occur in the walls of seminiferous tubules and blood vessels, and in the interstitial tissue. Sometimes associated with these smaller nodules, and sometimes not, we find larger, irregular yellowish or gray cheesy masses, which are believed by many to be formed by the confluence and degeneration of the smaller

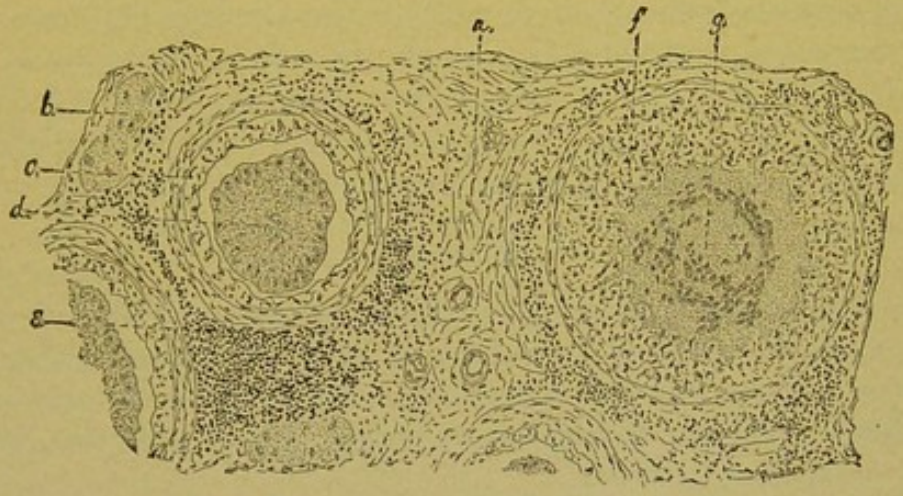


FIG. 356.—CHRONIC ORCHITIS WITH THE FORMATION OF STRUCTURES RESEMBLING MILIARY TUBERCLES.

*a*, thickened interstitial tissue; *b*, mass of granular cells in the interstitial tissue; *c*, thickened membrana propria of seminiferous tubule; *d*, mass of separated epithelium in tubule; *e*, accumulation of small spheroidal cells around tubules; *f*, thickened membrana propria enclosing *g*, a multinuclear mass resembling a giant cell.

nodules. The cheesy masses may break down and open externally, giving rise to fistulæ, gangrenous inflammation, etc. Hand-in-hand with this nodular formation of tissue, which is disposed to degenerative changes, there are various more or less diffuse alterations of the parenchyma and interstitial tissue of the organ which must not be overlooked, and which often constitute a most prominent and important factor in the lesion. The interstitial tissue may be more or less densely and diffusely infiltrated with small spheroidal cells. The arteries are often the seat of obliterating endarteritis. The walls of the seminiferous tubules may be very much thickened, so that the lumen may be entirely obliterated. The epithelium lining the tubules may be fatty, disintegrated, and peeled off, or it may have largely

disappeared. The lumen of the tubules may be filled with a granular, nucleated mass which in transverse sections looks like a giant cell. The thickened walls of the tubules may be infiltrated with small spheroidal cells, so that the underlying stroma is scarcely visible. When this occurs in connection with a similar infiltration of the interstitial tissue and the formation of giant cells in the lumina, we have structures which present the greatest resemblance to some forms of tubercle granula (Fig. 356).

Tubercular inflammation may extend from the testis to the vas deferens, vesiculæ seminales, and prostate.

*Syphilitic Orchitis.*—This may occur in the form of a diffuse new formation of connective tissue, which may occur in some particular part of the organ or be widely distributed through it, and by reason of which the organ becomes dense and firm. Morphologically there is no difference between this form of orchitis and chronic indurative orchitis from other causes. It may occur in children affected with congenital syphilis. Gummata may form in connection with the interstitial induration. These may disappear, leaving irregular cicatrices.

Inflammatory foci in the testicle are common in leprosy.

### TUMORS.

*Fibroma* occurs in the form of small dendritic or polypoid growths of the visceral layer of the tunica vaginalis. These sometimes become free and are found in the sac, usually in connection with hydrocele. Small nodular fibromata occasionally occur in the albuginea and in the spermatic cord.

*Lipomata*, either pure or in combination with myxoma and sarcoma, may arise from the connective tissue of the spermatic cord or from the tunica albuginea.

*Chondroma*, sometimes in a pure form, but more frequently combined with myxoma and sarcoma, occurs in the testicles and may attain a large size. *Osteoma* has been described.

*Sarcomata* occur in the testes and epididymis, most frequently in the former. They present the greatest variety in structure. They may be composed of spheroidal or spindle-shaped cells; they may be soft or contain much fibrous tissue; they are very frequently combined with myxoma, chondroma, lipoma, etc. Owing to the occlusion of the seminiferous tubules, cysts may be formed in these sarcomata. In these cysts polypoid growths of sarcomatous tissue may occur in the form of intracanalicular growths. Thus the so-called *cysto-sarcomata* of the testicle are formed. The walls of these cysts may coalesce, so that large, irregular cavities may be formed. When the cysts are not filled by polypoid outgrowths from their walls they

may contain a mucous, serous, or bloody fluid, or masses of flattened cells, fat, and cholesterin. The cysts may be lined with cylindrical, ciliated, or flattened cells.

*Rhabdomyomata* have been several times observed, frequently in combination with cysts.

*Adenoma* is occasionally found, usually in combination with sarcoma or carcinoma, or with cyst formation.

*Carcinoma* of the testicle is commonly of the soft medullary form, of rapid growth, and usually primary. It may commence in the testis or epididymis. Usually only one testicle is involved. Frequently the entire glandular portion of the organs is replaced by the new growth. The albuginea expands with the growth of the tumor, and may continue to enclose it even when of large size. The tissues are often very vascular, and hæmorrhages, areas of softening, fatty and mucous degeneration are frequent. The inguinal and lumbar lymph nodes are apt to become involved, and distant metastasis may occur. Rarely the growth assumes a scirrhous form.

*Cysts.*—Aside from the above-mentioned cysts which occur in connection with tumors and spermatocele, cysts may be formed from persistent remnants of Müller's canal in the epididymis, or from obstruction of the seminiferous tubules or ducts by inflammatory products or tissue.

*Teratoid tumors* of various kinds, with or without cysts, are of infrequent occurrence, and are sometimes quite complex in character. They may be embedded in the substance of the gland.[1] Probably some of the above-mentioned cystic rhabdomyomata belong here.

### PARASITES.

*Echinococcus* may occur in the testis or epididymis.

## THE SEMINAL VESICLES.

The seminal vesicles may be the seat of acute or chronic inflammation, which is most frequently connected with inflammatory changes in adjacent parts, prostate, urethra, etc. As a result of chronic inflammation the vesicles may be atrophied, or they may be greatly dilated as a result of constriction of the ducts.

Tubercular inflammation is usually secondary. Carcinoma of the rectum or other genito-urinary organs may secondarily involve the seminal vesicles. Small concretions, sometimes containing masses of permatozoa, are occasionally found in the seminal vesicles.

## THE PROSTATE.

*Hypertrophy* of the prostate is a frequent senile change; it is general or partial.

---

[1] Consult *Wilms*, Ziegler's Beitr. z. path. Anat., Bd. xix., p. 233, 1896.

In general hypertrophy the entire organ is enlarged and may reach the size of a man's fist. The enlargement is symmetrical, or is most marked in one half or in the so-called middle lobe. The organ is hard and dense, or soft or alveolar, containing numerous small openings from which a turbid fluid exudes. These different appearances depend upon the character of the hypertrophy. The muscular and fibrous tissue alone may be increased, which is most common, or at the same time the glandular tissue, or the glandular tissue alone. In the latter case the lesion is more properly an *adenoma*. The increase of muscular tissue properly constitutes a *myoma*.

In partial hypertrophy we find circumscribed nodules of muscular tissue or of muscular and glandular tissue. They are usually situated at the periphery of the organ and project into the bladder. They may become detached from the prostate, and are found as small, movable tumors beneath the mucous membrane of the bladder.

Both forms of hypertrophy frequently produce, by pressure, retention of urine and changes in the bladder.

*Atrophy* of the prostate is sometimes seen in connection with atrophy of the testicles, with castration, and as a result of inflammation. Sometimes the ducts of the glandular portion are enlarged, or there may be fibrous degeneration of the organ.

### INFLAMMATION.

Inflammation of the prostate is caused by gonorrhœa, by injuries, or, more rarely, is idiopathic. It may run an acute or chronic course. The gland may after a time return to its normal condition, or is gradually converted into a mass of fibrous tissue filled with abscesses. The abscesses may perforate into the bladder, urethra, vesiculæ seminales, rectum, or peritoneum. Or the inflammation may extend to the connective tissue of the scrotum or beneath the pelvic peritoneum. The pus may become thickened and cheesy, or even calcified.

*Tubercular Inflammation* of the prostate usually accompanies a similar lesion of some of the other genito-urinary organs, and is rarely of primary occurrence. Large cheesy masses are often formed, which may break down and open into the bladder or rectum.

### TUMORS.

*Adenoma* of the prostate occurs in one of the forms of hypertrophy of the gland, either with or without an increase in the fibro-muscular interstitial tissue.

*Carcinoma* is of occasional occurrence, and may be primary or secondary.

*Cysts* of the prostate are sometimes found either as a result of occlusion of the ducts by hypertrophy of the interstitial tissue, tumors, etc., or as a result of faulty development.

### PARASITES.

*Echinococcus* of the prostate has been described, but is rare.

### CONCRETIONS.

Small ovoidal or spheroidal, often brown or black bodies, having the characters of corpora amylacea, are of very frequent occurrence in the alveoli of the prostate, particularly in old persons. We find a certain number of them in the prostate of nearly all old men, but they are sometimes present in great numbers. Larger, irregular concretions, apparently formed by the coalescence or growth of the smaller ones, are less frequently found, and may be encrusted with lime salts. These concretions may give rise to ulceration of the ducts of the gland or to interference with the passage of urine, but in a majority of cases they seem to be of little or no practical importance.

### COWPER'S GLANDS.

These glands may be enlarged and encroach upon the lumen of the urethra, either in acute or chronic inflammation. Cysts formed by the closure of the excretory ducts may also project into the urethral canal.

## THE MALE MAMMA.

There may be an abnormal number of mammæ. In boys, at about the time of puberty, the mammæ may be swollen and inflamed or they may secrete milk. Cases are recorded in which adult males possessed large mammæ which secreted milk. The breasts may be enlarged from an increase of fat or of connective tissue.

*Cysts* of the male breast are not very infrequent. *Fibromata, sarcomata, cysto-sarcomata, myxomata,* and various forms of *carcinomata* are recorded.[1]

[1] For literature of tumor of male mamma see *Gross,* "Tumors of the Mammary Gland," p. 237.

# THE BONES.

## DISTURBANCES OF CIRCULATION.

*Hyperæmia.*—The evidences of this condition are most marked to the naked eye in the periosteum and marrow, particularly the latter. It should be remembered that the color of the marrow varies considerably under normal conditions, depending upon age and situation. In the bones of the fœtus and new-born, and near the areas of ossification in the young, the marrow is normally red in color. In adults the marrow of the sternum, vertebræ, and to a certain degree that of the ribs, pelvic and cranial bones, and the cancellous tissue of the ends of the long bones, is red or reddish in color. But most of the marrow, particularly in long bones of the extremities, is of a yellowish color from the presence of fat cells. In old age the marrow of all the bones is apt to become pale, and to assume a more or less translucent or gelatinous appearance.

Hyperæmia usually occurs as an accompaniment of inflammatory processes in the bone, and, when marked, the periosteum is swollen and red; the compact bone tissue may appear of a pink color, while the marrow, either by an increase in the amount of blood or absorption of its fat, or both, may be of a uniform dark-red color or mottled with red and reddish-yellow.

*Hæmorrhage.*—This may be due to wounds and injuries, to inflammatory and necrotic processes; and small hæmorrhages often accompany scurvy, purpura, hæmorrhagic diathesis, and leukæmia. Hæmorrhages of considerable size between the periosteum and bone may lead to serious consequences, by cutting off the blood supply to the superficial layers of bone and thus inducing necrosis; but when not in contact with the air they are not usually of serious import, since they are readily absorbed. The smaller hæmorrhages of the medulla are not usually of much importance. The decomposition of the extravasated blood may lead to extensive pigmentation of the marrow.

## WOUNDS, FRACTURES, AND DISLOCATIONS.

For details of the varied alterations produced under these conditions, and the secondary changes involved in the healing process,

we refer to the section on repair, page 98, and to works on surgery. It may be stated here, however, that the healing of fractures occurs by the formation of granulation tissue in greater or less amount about the seat of fracture, and the direct formation of bone under the influence of osteoblasts, or by a preliminary formation of cartilage or fibrous tissue and the gradual conversion of this into bone by metaplasia.

## INFLAMMATION.

The periosteum, bone tissue, and marrow are so intimately connected that in most cases they all share to a greater or less degree in the pathological alterations of the bones. But as sometimes one, sometimes another is most markedly involved, it is convenient to consider separately here the inflammatory changes by which they are respectively affected.

### *Periostitis.*

We may distinguish several varieties:

1. *Simple Acute Periostitis.*—This form is apt to occur in children and ill-nourished persons from comparatively slight injuries or from unknown causes. The periosteum is thickened, succulent, congested, and more or less abundantly infiltrated with leucocytes, while the connective-tissue fibres are swollen. The periosteum becomes less firmly adherent to the bone, and the cells of the inner layers are increased in number. This variety of inflammation may terminate in the disappearance of the new elements and complete resolution, or it may represent a preliminary stage of one of the other varieties of inflammation.

2. *Suppurative Periostitis* may begin as a simple or as a purulent inflammation. The pus is formed in the inner layers of the periosteum, and between it and the bone. The outer layers of the periosteum may resist for a long time the suppurative process. The accumulation of pus may dissect up the membrane from the bone and leave the latter bare. The pus thus formed may remain in this position for a long time, may be absorbed, may become dry and cheesy, or may burst through the periosteum and form abscesses in the soft parts. The bone, if separated from its nutrient membrane, may remain unchanged, but more frequently necrosis or inflammation of the bone itself is set up. Such a periostitis may run an acute or a chronic course.

Sometimes suppurative peritostitis takes on a very *malignant* character. Pus is developed not only beneath but in the periosteum, forming abscesses filled with foul pus. The periosteum breaks down into a gangrenous, foul-smelling mass, and the same change may affect the neighboring soft parts. The medulla may take part in the

process and break down into a purulent, gangrenous mass. Hæmorrhages may complicate the process. The lymphatic nodes are enlarged and swollen; abscesses may form in different parts of the body, and the patient may die with the symptoms of pyæmia. The pyogenic cocci may be found, under these conditions, in the exudations of the periosteum as well as in the metastatic abscesses.

3. *Fibrous Periostitis.*—This is a slow, chronic form of inflammation, resulting in the formation of new connective tissue in the periosteum, which becomes thickened and dense and unusually adherent to the bone. It may be the result of necrosis, chronic arthritis, chronic ulcers of adjacent soft parts, etc. It may follow a simple acute periostitis.

4. *Ossifying Periostitis* results in the formation of new bone from the inner layers of the periosteum. The masses of new-formed bone, called *osteophytes*, are of variable shape. They may form a thin, velvet-like, villous layer; or they are little spiculæ; or they form larger, rounded masses, or a thick, uniform layer extending over a large part of a bone. They may be at first very loosely connected with the bone. The new bone has at first a loose, spongy character. It is formed of thin plates of bone enclosing large cavities filled with marrow. Layers of compact bone tissue are formed from the medulla on the sides of the original plates, and thus the medullary cavities are gradually filled up with bone. The new bone may thus become as compact or even denser than normal bone. The hyperostoses and exostoses thus formed may remain indefinitely, or they may gradually become smaller and finally disappear by absorption.

The formation of new bone in the form of osteophytes, or in dense masses beneath and in the periosteum, occurs as a result of the same process by which bone tissue is normally formed. Certain rather large cells, called *osteoblasts*, which are formed along the blood vessels, possess the power of depositing osseous basement substance about themselves and so forming bone. Pathological new formation of bone differs from the normal mainly in the conditions under which it occurs. The blood vessels around which the pathological bone develops, which grow out of the old vessels, as in the formation of granulation tissue, are irregularly arranged and subject to a variety of abnormal nutritive and mechanical conditions, so that the new bone is not usually formed in a series of definite systems of lamellæ, but, as above described, in a series of irregular spiculæ or masses. Moreover, as will be seen further on, the conditions under which it is formed being liable to change, and itself serving no definite purpose in the economy, as does normal bone, pathological new bone is often an evanescent structure. The details of its disappearance will be considered below.

5. *Syphilitic Periostitis.*—Syphilitic poisoning may give rise to simple, purulent, fibrous, and ossifying periostitis. Or, in addition to these, gummy tumors may be developed in the periosteum. The bone tissue is usually more or less involved. The gummata may be absorbed or undergo cheesy degeneration, or be converted into fibrous tissue, or they may suppurate.

6. *Tuberculous Periostitis.*—In badly nourished persons, particularly in children suffering from so-called scrofula (see page 528), a chronic purulent periostitis is frequently associated with the formation of miliary tubercles. Abscesses are apt to form in and about the periosteum, and when these are evacuated granulation tissue may develop, in which miliary tubercles are formed. In these tubercles the Bacillus tuberculosis may be found. The bone is apt to be involved to a greater or less extent in the form of inflammatory changes or caries.

## *Osteitis.*

Inflammation in bone tissue is dependent upon the same general conditions and presents essentially the same series of phenomena as inflammation in other kinds of connective tissue. But it is variously modified in detail by the peculiar dense and unyielding character of the basement substance, and by certain peculiarities of the blood supply and the nutritive conditions under which the cells are placed. In simple exudative inflammation the same series of phenomena occur in connection with the blood vessels, resulting in the production of serum, fibrin, and pus, as in other tissues; but the extent to which these changes can occur is limited and constantly associated with striking alterations in the basement substance. It is these secondary alterations in the basement substance which lend to inflammations of the bone their most peculiar characters, and in the prominence which these assume the fundamental alterations are often overlooked. The most common of these secondary alterations are the absorption of the hard basement substance of the bone and its replacement by, or conversion into, young cellular forms of fibrillar connective tissue or marrow tissue, and the new formation, in more or less atypical manner, of new bone. As a result of these changes the bones in simple inflammation undergo alterations either in the direction of greater vascularity and increase of the spaces filled with granulation or marrow tissue, and so become more porous and less compact at the expense of the dense basement substance; or they undergo alterations in the direction of an increase in density at the expense of new-formed or pre-existing marrow spaces. Or, as is frequently the case, both series of changes occur either simultaneously in different regions, or follow one another, or are variously associated together. Very frequently one or the other of the opposing forms of alteration pre-

dominates, or one may occur to the exclusion of the other, and we thus have two prominent forms of inflammation, which are called *rarefying osteitis* or *osteo-porosis*, and *condensing osteitis* or *osteo-sclerosis*. The exact nature of the conditions under which in one case the bones become more, in another less dense, we do not understand.

In addition to these phases of inflammation in bone, and in frequent and varied association with them, there are alterations leading to death and destruction of bone tissue in greater or less amount, which we call *caries* and *necrosis;* and also inflammatory changes, more or less characteristic, due to the influence of peculiar specific agencies, such as the syphilitic and tuberculous infection, and we

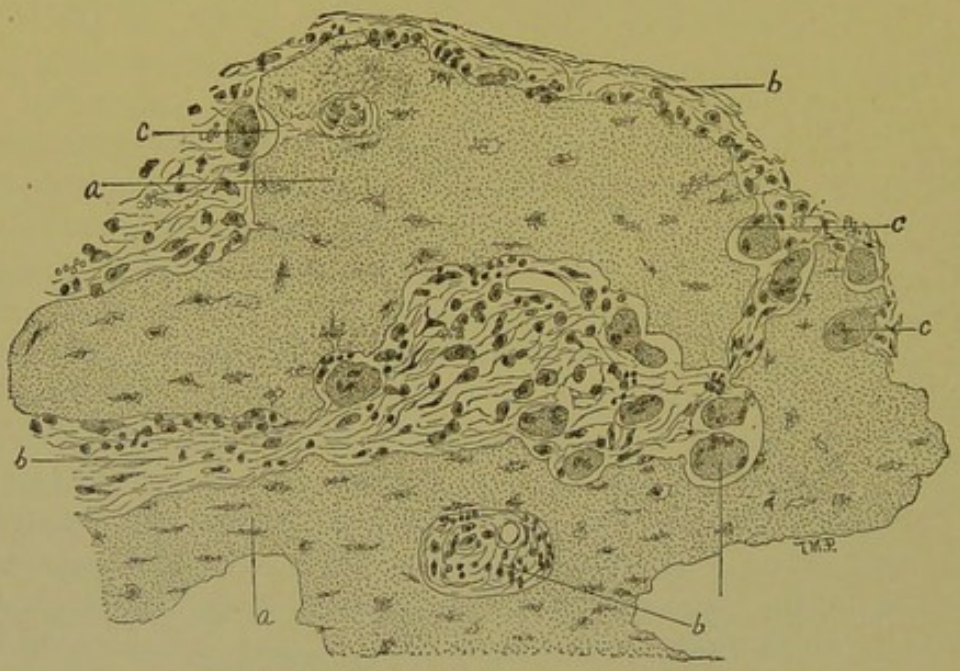


FIG. 357.—RAREFYING OSTEITIS IN ULNA OF CHILD.

*a*, isolated bone fragment with rough edges; *b*, marrow tissue; *c*, Howship's lacunæ with osteoclasts.

thus recognize *tubercular* and *syphilitic osteitis*. Again, the production of pus is so prominent a feature in some cases as to represent a *purulent* phase of the inflammatory process. Finally, any of these forms, and commonly several of them at once, are variously associated with more or less marked inflammatory or degenerative alterations of the periosteum on the one hand, or the marrow tissue on the other, or of both combined.

*Rarefying Osteitis* consists essentially in the formation in the marrow spaces, Haversian canals, or beneath the periosteum, of new, very cellular and vascular tissue, resembling granulation or young marrow tissue, in connection with which, or under whose influence, the basement substance of the bone is absorbed. The

absorption of the bone occurs chiefly in the same way in which the bone is absorbed in normal growth, namely, under the influence of certain large cells, called *osteoclasts,* which are grouped around the blood vessels. If we examine a thin section of bone which is undergoing absorption (Fig. 357), we find the edges of the bone which border on the vascular surfaces irregularly indented by deep or shallow depressions, sometimes simple, sometimes quite complex. These are called *Howship's lacunæ* and are usually filled or lined by larger and smaller granular, frequently multinuclear cells—the so-called *osteoclasts.* In the larger lacunæ there may be granulation tissue with loops of blood vessels, with or without cells which have the morphological characters of osteoclasts. Under the influence of these peculiar cells, or of the new vascular tissue, the bone is gradually absorbed. In other cases we find irregular branching channels through the bone across the lamellæ, which appear to be due to the enlargement and coalescence of the lacunæ and canaliculi, without the direct influence of blood vessels or other cells than the fixed cells of the bone. The tissue which replaces the absorbed bone may be very rich in small spheroidal cells, or it may be more or less fibrillar. As a result of this process irregular islets of bone tissue may be entirely separated from adjacent bone and surrounded by a more or less fibrillar vascular tissue ; this is most apt to occur in the cancellous tissue. Or the originally compact bone may become traversed by a series of larger and smaller irregular branching, communicating channels with ragged walls. These progressive alterations may cease and be succeeded by a new formation of bone along the edges of the channels or cavities ; it may result in necrotic changes ; the vascular changes may become prominent and suppuration ensue.

Rarefying osteitis may occur as an idiopathic disease from unknown causes ; it is often associated with the scrofulous diathesis, with diseases of the joints, with fractures or other injuries to the bone ; it often forms a predominant feature in tubercular inflammation of the bones, etc. It is chiefly by a rarefying osteitis that bone tissue is eroded and destroyed in the vicinity of tumors, aneurisms, etc., which exert pressure on the bones. By the same process the sharp ends of fractured bones may be rounded off as healing proceeds.

When this form of inflammation occurs in cancellous bone tissue the marrow is red or gelatinous, and the bony septa may disappear altogether, so that in extreme cases we may have, instead of cancellous bone, a mass of granulation tissue. When the disease occurs in the articular extremity of a bone the granulating medulla may send little offshoots through the articular cartilage. These may

become fused together and inflammation of the joint follow. The walls of the shafts of the long bones may be converted into spongy tissue. If, as is sometimes the case, an ossifying periostitis occurs at the same time, the bone is thickened but spongy; or sometimes there are concentric layers of compact bone tissue, separated by rarefied bone.

*Condensing Osteitis* (Osteo-sclerosis).—This lesion is characterized by the new formation of bone in the walls of the marrow cavities or Haversian canals. The bone is formed under the influence of the blood vessels and osteoblasts, as in normal bone formation, but with less regularity. It may result in the conversion of cancellous tissue into compact bone, in the filling-up of the medullary cavity of

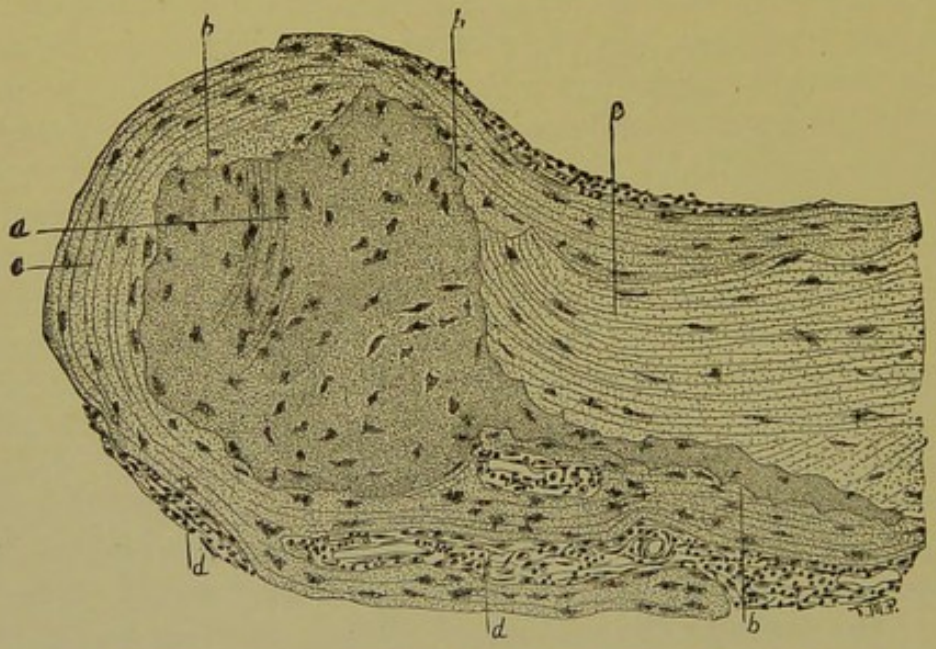


Fig. 358.—Condensing Osteitis, or Osteo-sclerosis, of Ulna of Child.

*a*, fragment of old bone with roughened, sinuous edges; *b*, old Howship's lacunæ covered with more recently formed bone lamellæ.

long bones with more or less dense bone tissue. The compact bone, owing to the filling of its Haversian canals, may become very dense and ivory-like. When the medullary cavities of long bones are involved the yellow marrow is converted into red marrow by the absorption of fat and increased vascularity. It is frequently associated with ossifying periostitis.

It very frequently follows rarefying osteitis, and under the microscope we can then often see the Howship's lacunæ resulting from the original absorption process filled and covered in with new bone lamellæ (Fig. 358). It is apt to occur in connection with necrosis or some chronic inflammation of adjacent soft parts, but it is sometimes idiopathic or occurs under unknown conditions.

*Suppurative Osteitis* (Abscess of Bone).—This process occurs usually in the ends of the long bones. It begins with a rarefying osteitis. The medulla undergoes actual suppuration, the bone tissue is destroyed, and a circumscribed cavity is formed in the bone, filled with pus and lined with granulation tissue.

Less frequently abscesses are formed in the shaft of a long bone by a circumscribed suppuration of the medulla. These abscesses usually occur in old people. They last for many years, have little tendency to perforation, may gradually enlarge and be accompanied by an ossifying periostitis, so that the bone is expanded. Very rarely acute suppurative osteitis, with rapid formation of an abscess, and perforation, has been observed.

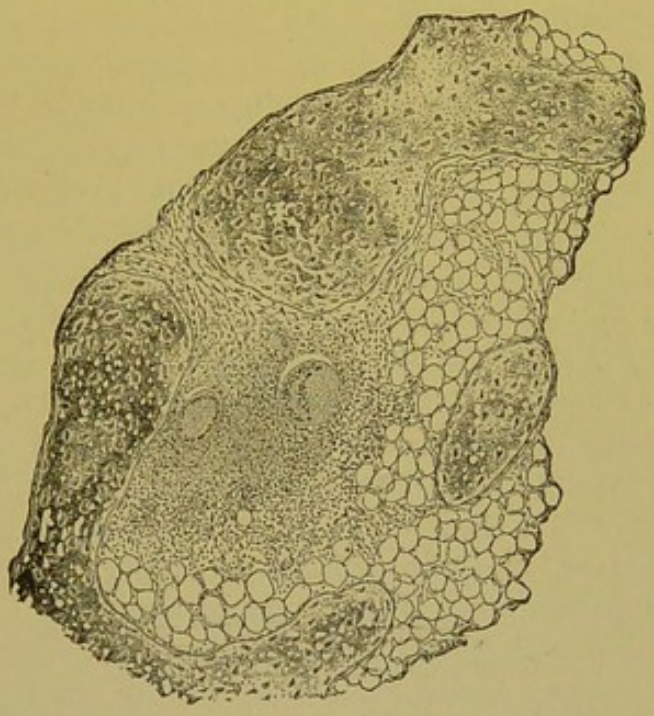

FIG. 359.—TUBERCULOUS OSTEITIS.

A miliary tubercle formed in the cancellous tissue near the joint in tubercular arthritis.

In some cases, instead of abscess, there may be a diffuse infiltration with pus of the Haversian canals or the spaces formed by rarefying osteitis (see Osteomyelitis, page 763).

*Tuberculous Osteitis* is essentially a rarefying osteitis associated with the formation of tubercle tissue and cheesy degeneration. The tubercles are sometimes small, scattered, and miliary in form (see Fig. 359); sometimes they unite to form larger and smaller masses. There may be extensive involvement of the medulla. There may be much simple granulation tissue or the formation of abscess associated with the process. Condensing osteitis and necrosis are not infrequently present. Tuberculous osteitis is often associated with tubercular inflammation of the joints. It is most apt to occur in cancellous

bone tissue, and is most common in the bodies of the vertebræ and in the carpal and tarsal bone. Tubercle bacilli may be found in the tuberculous masses, sometimes in considerable numbers.

*Syphilitic Osteitis.*—The syphilitic poison may induce one of the above-mentioned varieties of osteitis, or it may produce gummy tumors. The gummatous osteitis usually commences in the periosteum, which becomes thickened and infiltrated with cells, so that there may be a circumscribed thickening of the periosteum, with or without distinct gummata. The vessels which extend from the periosteum into the bone become surrounded by new cellular tissue, which causes an enlargement of the canals. At this stage, if we strip off the periosteum, we drag with it the vessels surrounded by the new cell growth, leaving the bones beneath with numerous small perforations extending inward. As the disease progresses the gummatous tissue around the vessels continues to increase, and the channels in the bone enlarge by a rarefying osteitis and coalesce, forming large, irregular defects filled with gummatous tissue. In these masses of new tissue cheesy degeneration and the formation of fibrous tissue occur, giving them the characteristic appearance. In the vicinity of these gumma-filled spaces a condensing osteitis may occur, both in the substance of the bone and on the surface, in the form of osteophytes, so that the opening in the bone may be surrounded by an elevated, irregular ring of bone tissue. All this may occur beneath the uninvolved skin, or the skin may participate by a suppurative inflammation, resulting in ulceration. These processes may be circumscribed or involve a large part of a bone. It is not infrequently associated with necrosis of larger and smaller portions of bone. The gummatous tissue may be absorbed and its place be more or less filled with fibrous tissue. Syphilitic osteitis is most frequent in the cranial bones, but may occur elsewhere, as in the sternum, clavicle, tibia and fibula, the ribs, etc.

*Congenital Syphilis.*—The bones of young children in this condition may occasionally show increased density or evidences of periostitis, or irregular thickenings, particularly of the skull. The researches of Wegner,[1] which have been frequently confirmed by other observers, have shown that exceedingly characteristic changes very uniformly occur in the long bones in still-born or young children who are the victims of hereditary syphilis. These changes are found for the most part along the border zone between the epiphysis and diaphysis. It will be remembered that, in normal ossification of the long bones, the border line between the calcification and ossification zones is narrow, sharply defined, and straight, or gently and

[1] Virchow's Arch., Bd. l., 1870, p. 305.

evenly curved. In the syphilitic bones, on the contrary, this line is broader, uneven, and presents various modifications, depending upon the stage of the disease. Wegner distinguishes three prominent stages, which, however, merge into one another, so that all intermediate forms may be seen. In the first stage there may be seen, between the cartilage and the new-formed spongy bone, a white or reddish-white zone, about two mm. in breadth, with very irregular borders, consisting of calcified cartilage, in which the linear groups of cartilage cells are more abundant than normal. In the second stage the calcified zone, still containing an unusual number of cartilage cells, is broader and still more irregular and less sharply outlined against the ossification zone. The cartilage just beyond it is softer and almost gelatinous, and may contain numerous blood vessels, islets of connective tissue or of calcification, or irregular ossification. In the third stage the bone may be pouched out at the sides around the ossification and calcification zones, and the perichondrium and periosteum thickened. The whitish, irregular calcified zone is hard and friable. Between this and the new-formed bone there is an irregular, soft, gray or grayish-yellow zone, from two to four mm. in thickness, which forms a loose, readily separated connection between the cartilage and the diaphysis. The white, friable zone consists mainly of irregular rows of degenerated and distorted cartilage cells lying in a calcified basement substance, of irregular masses of atypical bone tissue, and of blood vessels surrounded by variously shaped cells. The soft zone consists of more or less vascular tissue with homogeneous basement substance, and round and spindle-shaped cells. This soft zone is not sharply outlined against the adjoining new-formed spongy bone, which, instead of consisting of the normal marrow spaces with bony lamellæ between them, is largely composed of granulation tissue.

Different stages of this faulty development may be seen in different bones in the same individual. According to Wegner the lesion is usually most advanced in the lower end of the femur, then in the lower ends of the leg bones and of the forearm, then in the upper ends of the tibia, femur, and fibula.

Not infrequently there is fatty degeneration of the marrow cells and blood vessels, giving the marrow a reddish-yellow color. These alterations of the bones may occur, not only in children who have gummata in other parts of the body, but also in those in which other evidences of syphilitic poisoning are absent. So uniform is their occurrence that their presence alone suffices for the establishment of a diagnosis.

### OSTEOMYELITIS.

In most of the inflammatory processes which affect the bones the

medulla has an important share, so that many conditions described as osteitis are really osteomyelitis. It is customary, however, to reserve the latter name for these cases in which the medulla is primarily or chiefly involved.

### *Acute Infectious Osteomyelitis.*

This may occur as the result of a local injury which permits the access or favors the development of pyogenic micro-organisms; it may be metastatic, resulting from the transportation of infectious material from other part of the body in septicæmia and pyæmia, in typhoid fever, in the exanthematous fevers, and under other conditions; or it may occur without evidence of local predisposition or of infectious processes in other parts of the body.

The lesions of acute infectious osteomyelitis are, in the large majority of cases at least, due to the presence and action of the pyogenic cocci, the Staphylococcus pyogenes and the Streptococcus pyogenes, and in many of its forms it may be regarded as one of the phases of septicæmia or septico-pyæmia.

While the lesions vary widely, the following general description is applicable to a considerable proportion of the cases:

At the commencement of the disease, which usually begins in the shaft of one of the long bones, there is hyperæmia and œdema of the medulla, so that if the bone be opened the marrow is soft and of a dark-red color. A diffuse suppuration now rapidly ensues, and the marrow becomes streaked or mottled with gray. Occasionally, though not often, larger and smaller abscesses may form in the marrow. The inflammatory areas may be circumscribed; or, in the more malignant cases, the entire marrow may become rapidly involved. The cancellous tissue of one or both of the epiphyses usually becomes involved. The disease, however, is not commonly confined to the medullary spaces. The periosteum becomes œdematous and infiltrated with pus, and the surrounding soft parts may become the seat of intense inflammatory changes. Abscesses of the periosteum or surorunding tissues are apt to form. As a result of these changes necrosis of greater or less portions of the bone may ensue. The medullary cavity may become enlarged as pus accumulates, and the wall of the bone may be broken through, permitting the discharge of pus outward. Sometimes several bones are involved at once. Secondary involvement of the joints is very frequent. There may be only a serous or purulent exudation; or the acute and destructive inflammatory process may extend to the joint and produce extensive alterations. In young persons the epiphyses very frequently become separated from the shaft by the destruction of the cartilage which binds them together.

In the severer cases, which are often denominated, *par excellence*, malignant osteomyelitis, the changes may be very rapid and destructive. The medulla becomes broken down and gangrenous; the joints are soon involved; large portions of the bone, sometimes the whole shaft, necrose; the periosteum and surrounding parts become gangrenous; the veins contain thrombi, and pyæmic infarctions and abscesses may form in various parts of the body.[1]

*Chronic Osteomyelitis.*—In the more chronic forms of osteomyelitis there is apt to be more or less ossifying periostitis and osteosclerosis, and fistulæ may form in the bone, through which the exudations are discharged.[2]

## NECROSIS.

By necrosis we understand the death of a larger or smaller portion of bone. This condition is induced by causes which deprive the bone of its proper vascular supply from the periosteum and medulla. Suppurative periostitis, osteomyelitis, and osteitis, traumatic separation of the periosteum, ulcers of neighboring soft parts, emboli, the action of phosphorus vapor, and diseases, like typhus, which diminish the vitality, may cause necrosis. Necrosis is a pure form of gangrene, differing from gangrene of soft parts in that the dead bone has at first, and may retain for a long time, the general outward characters of the normal bone; while in dead soft parts the phenomena of decomposition, under the influence of bacteria, rapidly ensue, inducing marked complicating appearances in the dead tissue.

When a portion of bone has died an inflammation is set up at the dividing line between the dead and living bone. This inflammation has the characters of a rarefying osteitis (see above), and finally separates the dead from the living bone. The dead bone, or *sequestrum*, may remain smooth and unaltered, or it may be eroded by the influence of surrounding pus or granulation tissue or osteoclasts. In this way it is possible for the sequestrum, if it be small, to be entirely absorbed. More frequently there is a production of new bone around the sequestrum, either beneath the periosteum or in the substance of the bone, and this becomes lined with granulation tissue, from which pus may continue to be formed, bathing the sequestrum.

Necrosis may involve the superficial layers, or the entire thick-

[1] Consult for an elaborate treatment of acute osteomyelitis in its relationship to other forms of inflammation, with bibliography, *Jordan*, Beitr. z. klin. Chir., Bd. x., p. 587. For a study of this condition in childhood see *Koplik and Van Arsdale*, Am. Jour. Med. Sciences, April and May, 1892.

[2] For a résumé of the deformities resulting from osteomyelitis consult *Park*, Medical Record, November 2d, 1895.

ness of the wall of a long bone, or only the spongy tissue and inner layers of the wall, or an entire bone, or a number of different portions of the same bone, but it is most apt to occur in compact bone.

The death and separation of the bone are very soon followed by the growth of new bone to repair the loss. The periosteum, the medulla, and the surrounding soft tissues may all take part in this new growth. The new bone is usually irregular, rough, perforated with openings through which pus formed around the sequestrum may be discharged. If the sequestrum be removed healing may occur by the formation of new bone ; but the bone is usually more or less distorted by the irregular new ossification.

*Phosphorus Necrosis.*—Under the influence of phosphorus vapor, periostitis and osteitis, particularly of the jaw, are apt to occur, which usually lead to more or less extensive necrosis, usually associated with prolonged and often extensive suppuration.

## CARIES.

Caries of bone is essentially an ulcerative osteitis resulting in progressive molecular destruction of the bone tissue. It differs from necrosis in that, in the latter, larger and smaller masses of bone die, while in caries the destruction is molecular and gradual. It may occur in connection with any form of osteitis, with periostitis and osteomyelitis, or it may be secondary to inflammatory or destructive processes in the joints or adjacent soft parts. The depressed surfaces of bones in which caries is progressing are rough and more or less finely jagged, and may be covered with granulations. The minute changes by which ulceration and destruction of the bone are produced in caries are somewhat analogous with those in rarefying osteitis, but there are marked degenerative changes in the bone cells, which may become fatty or converted into a granular material. Moreover, the basement substance of the bone, instead of being absorbed, may disintegrate, with the formation of larger and smaller masses of detritus. Sometimes the lime salts are removed from the basement substance, which is converted into atypical fibrillar tissue and fatty and granular detritus. Very extensive suppurations and necrosis may be associated with caries.

Long-continued caries, especially in badly nourished individuals, is apt to become complicated with tubercular inflammation.

There is very little tendency to spontaneous healing in caries, but it may occur, and the defects produced may be more or less supplied by means of new-formed bone.

## RACHITIS (RICKETS).

Rickets is a disease affecting the development of bone, prevent-

ing its proper ossification. The disease usually occurs during the first two years of life, but may be congenital,[1] or may occur as late as the twelfth year.

The physiological growth of bones depends upon three conditions. They grow in length by the production of bone in the cartilage between the epiphysis and diaphysis ; in thickness, by the growth of bone from the inner layers of the periosteum. At the same time the medullary canal is enlarged, in proportion to the growth of the bone, by the disappearance of the inner layers of bone.

In rickets these three conditions are abnormally affected. The cartilaginous and subperiosteal cell growth, which precedes ossification, goes on with increased rapidity and exuberance and in an

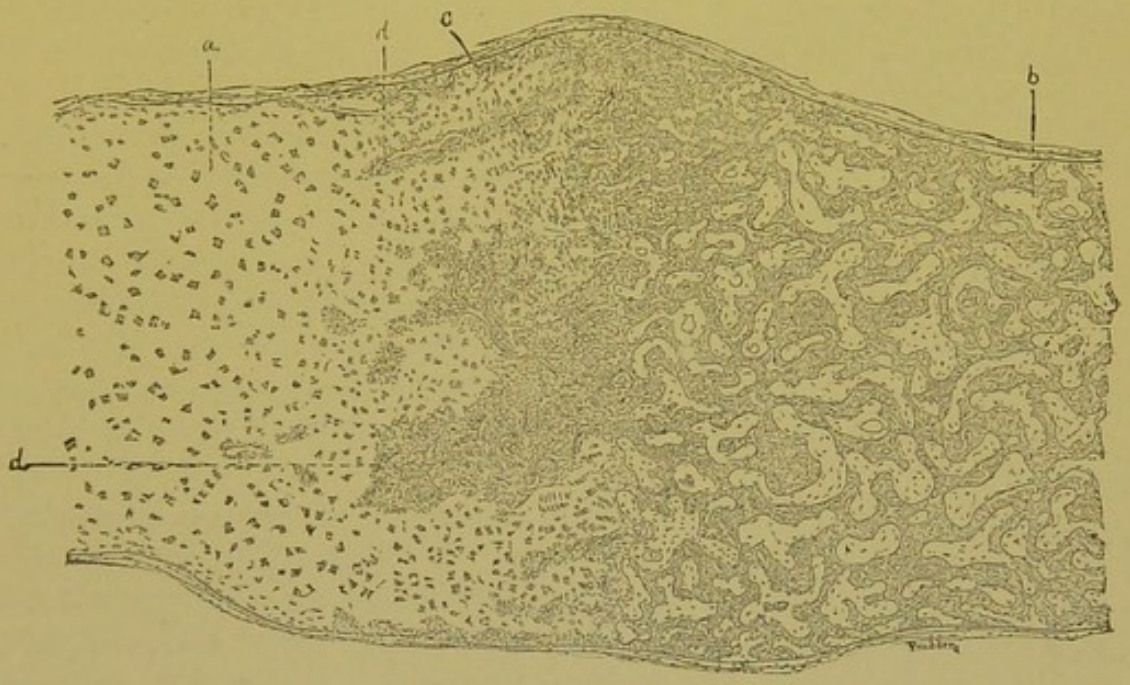


FIG. 360.—RACHITIC BONE.
Showing ossification zone in a longitudinal section of a rib.

irregular manner, both between the epiphyses and diaphyses and beneath the periosteum, while the actual ossification is imperfect, irregular, or wanting. At the same time the dilatation of the medullary cavity goes on irregularly and often to an excessive degree.

If we examine microscopically the region between the epiphysis and diaphysis (Fig. 360), we find that the cartilage cells are not regularly arranged in rows along a definite zone in advance of the line of ossification, as in normal development, but that there is an irregular heaping-up of cartilage cells, sometimes in rows, sometimes not, over an ill-defined and irregular area. The zone of calcification also, instead of being narrow, regular, and sharply defined, is quite lacking in uniformity. Areas of calcification may be isolated in the re-

[1] Consult *Salvetti*, Ziegler's Bietr. z. path. Anat., Bd. xvi., p. 29 (bibliography).

gion of proliferating cartilage cells, or calcification may be altogether absent over considerable areas.

Corresponding to these irregularities the ossification zone is also irregular. New-formed bone and marrow cavities containing blood vessels may lie in the midst of the cartilage, or masses of cartilage may lie deep in the region which should be completely ossified. In other places it seems as if the cartilage tissue were directly converted into an ill-formed bone tissue by metaplasia or direct transformation. It will readily be seen from this that the medullary spaces of the new-formed bone are irregular, and this abnormality is enhanced by the premature intramedullary absorption of the bone.

The same sort of irregularity in the bone formation may be seen beneath the periosteum. An excessive proliferation of cells in the inner layers of the periosteum, the irregular calcification which occurs about them, and the absence of uniformity in the elaboration of ill-structured bone, conspire to produce an irregular, spongy bone tissue instead of the compact, lamellated tissue which is so necessary here for the solidity of the structure. The increased cell growth between the epiphyses and diaphyses produces the peculiar knobby swellings which are characteristic of rickets. At the same time the medullary cavity increases rapidly in size and the inner layers of the bone become spongy. The medulla may be congested, and fat, if it has formed, may be absorbed, and a modified form of osteitis may ensue.

The result of these processes is that the bones do not possess solidity and cannot resist the traction of the muscles or outside pressure. The epiphyses may be displaced or bent, especially in the ribs, less frequently in the long bones. The long bones and the pelvic bones may be bent into a variety of forms. Incomplete fractures are not infrequent. Complete fractures do not usually occur until the later stages of the disease, when the bones have become more solid. In the head, the cranium may be unnaturally large for the size of the face ; the fontanelles and sutures may remain open ; the bones may be soft, porous, and hyperæmic, while at their edges there may be rough, bony projections beneath the pericranium. Sometimes, especially in the occipital bone, there are rounded defects in the bone, filled only with a fibrous membrane ; this constitutes one of the forms of so-called *craniotabes*.

It does not fall within the scope of this work to describe the various deformities which may occur as a result of this disease. The familiar pigeon breast ; the rows of knobs along the sides of the chest from bending and dilatation of the ribs at the point of junction of cartilage and bone ; the knock-knee, bow-legs, spinal curvatures, etc., may all be the result of rachitic weakening of the bones.

After a time the rachitic process may stop and the bones take on a more normal character. The porous bone tissue becomes compact and even unnaturally dense ; the swellings at the epiphyses disappear ; many of the deformed bones may become of a normal shape. In severe cases, however, the deformities continue through life ; especially is there a cessation of the growth of the bones in their long axis, so that the persons affected are dwarfed.

The disease may have an acute or a chronic character. The acute form begins usually during the first six months of life. The children are apt to suffer from vomiting, diarrhœa, profuse sweating, chronic bronchitis and pneumonia, general anæmia, and wasting. They either die or the rachitic process is gradually developed. The chronic form is seen in older children, and often in those apparently healthy. The changes in the bones may take place without any constitutional symptoms, though there is often catarrhal bronchitis, pneumonia, and anæmia.

### OSTEOMALACIA.

This lesion consists in the softening of fully formed hard bone tissue by the removal of its inorganic salts. It is to be clearly distinguished from rickets, whose lesions are due to a faulty development of bone, although in certain external characters the two diseases sometimes present considerable similarity. Osteomalacia usually occurs in adults, most frequently in females during pregnancy and after parturition ; more rarely it occurs in males, and in females unassociated with the above conditions. Its cause is not known.

Microscopical examination shows that the decalcification occurs first in the periphery of the Haversian canals and in the inner layers of the walls of the marrow spaces. As the salts of lime are removed the basement substance at first remains as a finely fibrillated material, still preserving the original lamellation. The bone cells may be changed in shape or degenerated. After a time the decalcified tissue may disintegrate and be absorbed, and its place occupied by new-formed marrow or granulation tissue. As the disease goes on the marrow tissue is congested and red, the fat absorbed, and there is a great accumulation of small spheroidal cells ; or the marrow may assume a gelatinous appearance. The decalcification and absorption of the bone from within may proceed so far that the bony substance in the cancellous tissue almost entirely disappears, and the compact bone is reduced to a thin, soft, decalcified tissue. The disease is not always continuously progressive, but may be subject to temporary cessation.

As a result of this softened condition of the bones, the weight of the body and the actions of the muscles may induce a series of

deformities which are sometimes excessive: curvatures of the spine, complete and incomplete fractures of the bone, distortions of the pelvis, sternum, etc. There is a tendency in this disease to a general involvement of the bones, but the changes are sometimes confined to single bones or groups of bones. The cranium is rarely much affected.

### ALTERATIONS OF THE BONE MARROW IN LEUKÆMIA AND ANÆMIA.

In certain forms of leukæmia the marrow of the bones is very markedly altered. The change consists mainly in an accumulation in the marrow tissue of spheroidal cells, often in a condition of fatty degeneration, which lie in the meshes of reticular connective tissue and in and along the walls of the blood vessels. There may also be absorption of the fat, and sometimes enlargement of the marrow cavity from absorption of the bone. These alterations seem to be primarily due to an hyperplasia of the marrow cells. The new cells which accumulate in the marrow under these conditions are of various forms. Most characteristic are colorless, spheroidal cells which considerably resemble the large lymphocytes of normal blood (see page 82). But they are usually larger, though varying much in size, have one large, often vesicular nucleus staining less strongly than the lymphocyte nuclei, while the protoplasm usually contains neutrophile granules (page 85). These cells are called *myelocytes*. In addition to these the marrow may contain, mingled with its usual elements, nucleated red blood cells, spheroidal cells containing red blood cells, and not infrequently considerable numbers of small octahedral crystals (called Charcot's crystals).

The degree to which this accumulation of cells varies much in different cases, and the gross appearances of the marrow are consequently very variable. In some cases the marrow is soft and has a uniform red appearance, or it is variously mottled with gray and red. Occasionally circumscribed hæmorrhages are seen. In another class of cases, in which the cell accumulation is more excessive, the marrow may be gray, grayish-yellow, or puriform in appearance.

These changes may occur in the central marrow cavity, as well as in the marrow spaces of the spongy bone. They may be present in several or many of the bones. They are usually accompanied by analogous changes in the spleen and lymph nodes.

In certain cases of acute and chronic *anæmia*, particularly in the pernicious and progressive varieties, the marrow, especially of the larger long bones, may lose its yellow color from absorption of the fat, and become red. Microscopical examination of the marrow under these conditions may show myelocytes and sometimes an abundance of developing nucleated red blood cells and Charcot's crystals.

In many of the acute infectious diseases, typhus and typhoid fever, ulcerative endocarditis, recurrent fever, etc., the bone marrow has been found hyperæmic and may, it is asserted by Ehrlich, contain myelocytes in increased numbers.

All of these lesions of the marrow, although our knowledge of them is still very incomplete, together with what is known of the physiological functions of the marrow, point to a close relationship between the marrow and the spleen and lymph nodes as blood-producing organs.[1]

## ATROPHY.

In old age or in senile conditions the bones may become atrophied by the absorption of the hard tissue; the medullary spaces are enlarged, the marrow tissue contains less fat and is often gelatinous in appearance. As the result of the lack of use, or from any cause which interferes with the nutrition of the bone, such as paralysis of the muscles or diseases of the joints, the bones may atrophy. In connection with atrophy there may be an ossifying periostitis, which results in making the bone look even larger than normal. Many of the conditions commonly called atrophy, such as the erosions of bones from tumors, etc., pressing upon them, are really due to a rarefying osteitis.

The bones, sometimes as the result of atrophy and sometimes from causes which we do not understand, are unusually brittle and liable to fracture. This disposition is sometimes hereditary.

## TUMORS.

Tumors of the bone may involve either the periosteum, the compact bone, or the medulla, or, as is more frequently the case, two or more of these structures are involved at once. Tumors of the bone are usually accompanied by various secondary and sometimes very marked alterations of the bone tissue, osteoporosis, osteosclerosis, ossifying periostitis, etc. The new growths are very apt to undergo calcification and ossification.

*Fibromata* may grow either from the periosteum or medulla. Their most common seat is in the periosteum of the bones of the head and face. They are apt to form polypoid tumors projecting into the posterior nares, pharynx, mouth, and antrum of Highmore. Central fibromata, *i.e.*, those growing from the medulla, are rare. They usually occur in the lower jaw, but have been found in the ends of the long bones, the phalanges of the fingers, and the vertebræ. The

[1] The literature of the researches on the diseases of the spleen, which are important in this connection, may be found in part in *Orth's* "Lehrbuch der speciellen pathologischen Anatomie," Berlin, 1883, erste Lieferung, p. 119 et seq.

fibromata may calcify or ossify, contain cysts, and not infrequently occur in combination with sarcoma.

*Myxomata* are of occasional occurrence in bone.

*Osteomata.*—New formations of bone as a result of inflammatory processes are, as we have already seen, of frequent occurrence in bone, and although not, strictly speaking, tumors, some of their forms are very closely allied to them, and they may therefore be conveniently mentioned here. New growths of bone which arise from the surfaces are called *exostoses* or *enostoses*, according to their origin from the external surface or interior of the bone. They may contain all the constituents of normal bone: bone, medulla, vessels, periosteum, and cartilage. The new bone may be compact and like ivory, or spongy, or contain large cavities filled with marrow.

The shape of exostoses varies greatly; they may be in the form of sharp, narrow spiculæ and processes, and, occurring in connection with periostitis, are called *osteophytes*. They may be polypoid in shape or form rounded tumors with a broad base. They may form a general enlargement of the bone, with much roughening of the surface; this condition is often called *hyperostosis*.

The bone beneath these new growths may be normal, or sclerosed, or rarefied, or the medullary cavity of the bone may communicate with that of the exostosis. Exostoses are usually developed from the periosteum, sometimes in the insertion of tendons and ligaments. They are very frequently multiple and may occur at all ages, even during uterine life.

Enostoses are developed in the interior of bones from the medulla. They may increase in size, with absorption of the surrounding bone, until they project from the surface like exostoses. Their most frequent situation is in the bones of the cranium and face.

*Chondromata.*—These tumors may be single or multiple, and most frequently grow from the interior of the bone, but sometimes from the periosteum. They are prone to form various combinations with other forms of tumors, as fibroma, myxoma, sarcoma, etc. They are frequently congenital, and are most common in young people. They occur most frequently in the bones of the hand and foot.

There is a form of chondroma, called *osteoid chondroma*, which develops beneath the periosteum, most frequently in the femur and tibia near the knee joint, forming a club-shaped enlargement of the bone. The characteristics of the tissue composing these tumors are that it resembles somewhat the immature bone tissue which is seen beneath the periosteum in developing bone. It differs from cartilage in the irregular shape of its cells, in the fibrillation and density of the basement substance, and in its general vascularity. On the other hand, it has not the inorganic contents or appearance of true

bone. It resembles considerably the callous tissue forming about fractures of the bones. It may, however, and most frequently does, become converted, in some parts of the tumor, into true bone. On the other hand, combinations with sarcomatous tissue are of frequent occurrence (see below).

*Sarcoma.*—This form of tumor is especially common in the bones. It grows from the inner layers of the periosteum or from the medulla, so that we may distinguish a *periosteal* and a *myelogenic* sarcoma. Sometimes the tumor attacks the bone itself so early that it is impossible to say whether the tumor began in the periosteum or in the medulla. There is also a variety which grows close to the outside of the periosteum and becomes connected with it —*parosteal* sarcoma.

The *periosteal sarcomata* usually belong to the varieties fibro-, myxo-, chondro-, and osteo-sarcoma, more rarely to the medullary variety. They commence from the inner layers of the periosteum, pushing this membrane outward. After a time the periosteum is attacked and the tumor invades the surrounding soft parts. The bone beneath may remain normal, or may be eroded and gradually disappear until the tumor is continuous with the medulla. Portions of the tumor may be calcified, or a growth of new bone may accompany its growth. The new bone usually takes the form of plates, or spiculæ, radiating outward. The minute anatomy of these tumors is very variable. The simplest—the fibro-sarcomata—are composed of fusiform, round, stellate, and sometimes giant cells (myeloplaxes), in varying proportions, packed closely in a fibrous stroma. In the medullary form the stroma is diminished to a minimum and the round cells are most numerous. In the chondro- and myxo-sarcoma the basement substance may be hyalin or mucous, and the cells follow the type of cartilage and mucous tissue more or less closely. There is a mixed form of tumor, called *osteoid sarcoma*, which is very apt to spread and to form metastases. The growth consists in part of tissue corresponding to fibro-sarcoma and round-celled sarcoma. In addition to this there occurs, in greater or less quantity, immature bone tissue, called osteoid tissue, which may in part become calcified, the calcification usually occurring in the central portions, leaving a softer peripheral zone. This form of tumor is most apt to occur at the ends of the long bones, and may form tumors of large size. It is often called, on account of its tendency to spread and to form metastases, *malignant osteoma* or *osteoid cancer*.

*Myelogenic sarcomata* commence in the medulla and may grow rapidly. The bone surrounding them is destroyed and they project as rounded tumors. Most frequently new bone is formed beneath the periosteum, so that the tumor is enclosed in a thin, bony shell;

sometimes there are also plates of bone in the tumor ; sometimes the periosteum is unaltered ; sometimes it is perforated and the tumor invades the surrounding soft parts. The tumors are frequently very soft, vascular, and hæmorrhagic in parts, or may enclose cysts filled with tumor detritus and blood. They are usually of the spindle or round-celled variety, and not infrequently contain giant cells.

The *parosteal sarcomata* resemble the periosteal, but they appear to grow from the outer layers of the periosteum. They may be as firmly connected with the bone as the periosteal form. The periosteum may remain intact between the tumor and the bone, or it may disappear and leave them in apposition.

*Angiomata and Aneurism of Bone.*—A very large number of the tumors which have been described under these names are really sarcomata, or other tumors which happened to be very vascular. Some authors, indeed, are disposed to deny altogether the existence of real vascular tumors in bones. There are, however, reliable cases of cavernous angiomata growing between the periosteum and bone and intimately connected with the latter. Whether myelogenic angiomata occur is doubtful. There are several cases described of cavities filled with blood in the interior of bones, which it is difficult to interpret. They have mostly been found in the head of the tibia. They are said to have consisted of single sacs composed of thickened periosteum, lined with plates of bone, and filled with fluid and clotted blood. No large vessels communicated with the sacs, but their walls were covered with a rich vascular plexus, branches of which opened into the cavity of the sac.

*Carcinomata.*—Primary carcinomata are of very doubtful occurrence in the bones. Most of the structures thus named have doubtless been sarcomata. Secondary carcinomata, on the other hand, as a result of metastases or local extension, are of not infrequent occurrence and present various structural forms. Metastatic carcinomata may occur in the bones of various parts of the body at the same time, and are most apt to be secondary to carcinoma of the mamma.

*Cysts.*—These most frequently occur in the maxillary bones, doubtless in connection with the teeth. They may be unilocular or multilocular, and contain clear serum or a mucous or brown fluid, and sometimes cholesterin. They may be lined with epithelium. They begin in the interior of the bone, and, as they increase in size, expand it until they may be covered with only a thin shell of bone. They may reach a large size, even as large as a child's head.

*Dermoid Cysts* are occasionally found in connection with the bones, particularly of the skull.

# DISEASES OF THE JOINTS.

For a description of the dislocations, misplacements, and injuries of the joints we refer to works on surgery.

## INFLAMMATION.

*Acute Arthritis.*—The earlier stages of acute inflammation of the synovial membranes are better known from experiments on animals than from post-mortem examinations. The first changes are swelling and congestion of the membrane, with increased growth and desquamation of epithelium, and infiltration of the membrane with lymphoid cells. These conditions are soon followed by an exudation. The exudation may be a clear serum, in which epithelial cells, lymphoid cells, and sometimes blood will be found. Or flocculi of fibrin may float in the serum, or the fibrin may be in excess and the serum nearly absent. Or there is an excessive production of lymphoid cells, and the synovial sac is filled with pus.

In *Serous Arthritis* the accumulation of serum within the synovial sac is the most prominent lesion. The disease may terminate in recovery, or become chronic, or pass into the suppurative form. It may be caused by contusions, penetrating wounds, gonorrhœa, rheumatism, or it may occur without evident cause.

*Sero-fibrinous Arthritis* may occur under the same conditions as those which lead to simple serous inflammation. The fibrin may be present largely as flocculi in the serum, or it may form false membranes over the surfaces of the joint.

*Purulent Arthritis* may follow or be associated with the above forms of inflammation. The synovial membrane is thickened and cloudy, and there may be but a moderate amount of pus in the joint, and a slight degree of infiltration of the synovial membrane with pus cells. Under these conditions resolution may readily occur.

In other cases the accumulation of pus in the cavity may be great, the synovial membrane and its surrounding tissue densely infiltrated with pus cells. Under these conditions granulation tissue is apt to be found and the cartilages of the joints are apt to become

involved. There are swelling and proliferation or degeneration of the cartilage cells ; the basement substance becomes disintegrated, ulcerates, and exposes the bone, in which osteitis, caries, rarefaction, etc., may occur. The new-formed granulation tissue may penetrate the cartilage, absorbing the basement substance, and by metaplasia the cartilage tissue may be converted into embryonal or granulation tissue. The pus may break through the capsule of the joint and form large abscesses in the adjacent soft parts. Sometimes the inflammation is not only suppurative but gangrenous and runs a rapidly fatal course. The synovial membrane, articular cartilages, and ends of the bone all undergo a rapid suppuration and gangrene. Pyæmia and septicæmia, small-pox, measles, scarlet fever, pneumonia, gonorrhœa,[1] diphtheria, mumps, typhus fever, glanders, the puerperal condition, exposure to cold, penetrating wounds, and injuries, may all give rise to or favor the development of purulent synovitis.

*Chronic Arthritis* may begin as such or it may be the result of previous acute inflammation. There is an increase of fluid in the joint. This fluid is thin and serous, or is thickened with flocculi of fibrin and epithelial and lymphoid cells, or is thick, syrupy, or even gelatinous. The synovial membrane is at first congested, its tufts prominent. Later it becomes thickened, sclerosed, and anæmic ; the epithelium is destroyed and the tufts become large and projecting. From the distention of the capsule there may be subluxations or luxations of the joint, or the capsule may be ruptured.

*Chronic Rheumatic Arthritis* is most common in elderly persons, usually affecting several joints and advancing slowly and steadily. There is a chronic thickening of the synovial membrane and the fibrous tissue adjacent to it. Fluid accumulations are not common. The articular cartilages are apt to degenerate or ossify, or become softened and fibrillated, and they may disappear. The contracting synovial membranes and fibrous tissue render the joints stiff and may cause considerable deformity. Not infrequently fibrous and bony anchyloses are formed between the ends of the bones.

*Arthritis deformans.*—This name has been applied to a variety of chronic inflammation of the joints which, combined with degeneration of parts of the joint and the new formation of bone, may result in marked deformities of the part.

It usually occurs in elderly persons and is apt to involve several joints, most frequently the hip, knee, fingers, and feet. It may be idiopathic, or due to rheumatism or to injuries, or follow an acute arthritis. The capsules of the affected joints are thickened and scle-

[1] For discussion of gonorrhœal arthritis consult *Northrup*, Trans. Assn. Am. Phys., vol. x., p. 141, 1895

rosed. The synovial fluid is at first increased in quantity; later, diminished and thickened. The tufts of the synovial membrane become much enlarged and vascular; they may be converted into cartilage. Sometimes the capsule becomes ossified. The new bone grows from the edge of the cartilage within the capsule and its articular surface is covered with cartilage. The articular cartilages are much changed. The basement substance splits into tufts, while the cartilage cells are increased in number. Or the basement substance becomes fibrous; or it is split into lamellæ and the cartilage cells are multiplied; or there is fatty degeneration and atrophy.

As a result of these changes larger or smaller portions of the cartilage are destroyed and the bone beneath is laid bare. The exposed bone may become compact and of an ivory smoothness. The ends of the bones are much deformed. They are flattened and made broader by irregular new growths of bone, while at the same time they atrophy. The new growth of bone starts from the articular cartilages. The cartilage cells increase in number and the basement substance in quantity. This growth is most excessive at the edge of the cartilage, so that a projecting rim is formed there. This projecting rim may ossify next the bone, and at the same time new cartilage may form on its surface, so that we may find large masses of bone covered with cartilage. All these changes occur in various combinations and sequences, so that joints in this condition present the greatest variety of appearances.

*Arthritis uritica* (Gouty Arthritis).—This disease is characterized by the deposit of salts of uric acid in the cartilages, bones, and ligaments, and also in the cavities of joints. The deposits may be in the form of stellate masses of acicular crystals in and about the cartilage cells or in the basement substance; or they may be deposited in the fibrillar connective-tissue structures of the joint in single crystals, or in the subcutaneous tissue about the joint as white concretions. The deposits may occur in repeated attacks of the disease, and are accompanied by acute inflammatory changes. They may lead to various forms of chronic inflammation of the joints.

*Tuberculous Arthritis* (Chronic Fungous Arthritis; Strumous Arthritis).—This disease may commence in the joint itself, or be transmitted to it from a tubercular inflammation of the bone. It is characterized by the formation of granulation tissue containing tubercles, sometimes in great quantity, and usually associated with secondary inflammatory and degenerative changes of surrounding parts. According to the prominence of one or other of these secondary alterations, several forms of tubercular arthritis may be distinguished. If there is an excessive growth of granulation tissue without much suppuration, this constitutes a *fungous form*. Some-

times there is extensive *suppuration*, so that the cavity of the joint may be filled with pus, which may be discharged through openings in the skin ; or there may be more or less extensive formation of abscesses, or infiltration of the soft parts about the joint with pus. In other cases there is a predominant tendency to breaking-down of the new-formed tubercular tissue and of the tissues of the joint—*ulcerative form.* The cartilage basement substance may become split into fragments and the cells degenerate, and thus deep and destructive ulcers of the cartilage be formed. Or the granulation tissue may work its way through the cartilage into the bone beneath, by absorption of the basement substance of the cartilage, with or without proliferation of its cells. Caries and necrosis of the underlying bone may lead to extensive destruction. Hand-in-hand with these alterations subperiosteal new formation of bone may occur, or sclerosis of the adjacent bone tissue. There may also be a great increase of fibrous tissue about the joint. Tubercle bacilli may be found in the tubercular tissue and in the exudations.

This disease is most common in children and young persons. The so-called scrofulous diathesis is said to predispose to it, but local injuries are frequently the predisposing factors. It is most common in the large joints. It may occur in connection with tubercular inflammation in other parts of the body, but it is frequently quite local, and may remain so for a very long time or permanently, since general infection from tubercular arthritis is comparatively infrequent.

The disease always runs a very chronic course and may destroy the patient's life. If recovery takes place before the cartilages and bones are involved the joint is preserved ; but it may be stiffened, or even immovable, from the contraction of the new fibrous tissue around it. If the cartilages and bones are diseased the joint is destroyed, and either bony or fibrous anchylosis results. Sometimes from the change in the articulating surfaces, and the contraction of the muscles and the new fibrous tissue, partial or complete dislocations are produced.

Occasionally miliary tubercles occur in the synovial membranes in cases of general miliary tuberculosis, with but little accompanying simple inflammatory change.

### TUMORS.

Secondary tumors of the joints as a result of local extension from the adjacent parts are not uncommon, and the tumors may be of various kinds. Primary tumors of the joints, on the contrary, are not very common.

*Lipoma.*—A new growth of fatty tissue may begin in the other

portions of the synovial membrane, push this inward, and project into the joint in a mass of tufts—lipoma arborescens.

*Fibroma* occurs as an hypertrophy of the little tufts and fringes of the synovial membrane. In this way large polypoid and dendritic bodies are formed. The pedicles of these growths may atrophy and even disappear, so that the growths are left free in the cavities of the joints.

*Corpora aliena Articulorum* (Loose Cartilages in the Joints).—This name is given to bodies, of various structure and origin, which are found free or attached by slender pedicles in the cavities of the joints. They are most frequently found in the knee; next in order of frequency in the elbow, hips, ankle, shoulder, and maxillary joints. They may be single or in hundreds. Their size varies from that of a pin's head to that of the patella. They are polypoid, rounded, egg-shaped, or almond-shaped; their surface is smooth or faceted, or rough and mulberry-like. They are composed of fibrous tissue, cartilage, and bone in various proportions.

These bodies are formed in different ways.

1. By hypertrophy of the synovial tufts and production of cartilage and bone in them.

2. More frequently by a change into cartilage of portions of the synovial membrane. Small, flat plates of cartilage form on the inner surface of the synovial membrane, and these increase in size and their outer layers ossify. They may remain fixed in the synovial membrane; or they project and become detached from it, and they then appear as flattened, concave bodies composed of bone covered with cartilage on one side.

3. The growth of cartilage and bone begins in the outer layers of the synovial membrane or in the periosteum near the joint. The new growth pushes the synovial membrane inward, and projects into the joint as a polypoid body covered with the inner layers of the synovial membrane. Later the membrane atrophies and the growth becomes free in the joint.

4. There may be cartilaginous outgrowths from the edges of the articular cartilage.

5. Rarely portions of the articular cartilages may be detached by violence or disease; or fibrinous and other concretions may result from arthritis, or under conditions which we do not understand.

# MUSCLE.

## LESIONS OF VOLUNTARY STRIATED MUSCLE.

*Hæmorrhage.*—This may occur as a result of mechanical injury; from rupture of the fibres by convulsive contraction, as in tetanus; or it may occur when the muscle fibres are degenerated, as in typhoid fever; or in connection with certain general diseases, as scurvy, purpura, hæmorrhagic diathesis, septicæmia, etc. The blood is usually readily absorbed.

*Embolic Infarction of Muscles* in connection with heart disease has been described in a few cases, but it is rare.

*Wounds and Rupture.*—When the muscle fibres are severed by wounds or rupture there is more or less degeneration of the divided fibres, and the wound may heal by the production of granulation tissue, which gradually becomes converted into cicatricial tissue, thus binding the severed parts together. In some cases there is a new formation of muscle fibres, which penetrate the cicatrix and establish muscular connection between the parts. When the wound does not gape, so that the severed ends are not much separated, there may be, it would seem, a direct re-establishment of muscular continuity by new development of muscle, without the formation of much new connective tissue.

The exact way in which muscle fibres are regenerated is yet somewhat uncertain. In many cases there seems to be a proliferation of the so-called muscle corpuscles, leading to the formation of elongated cells or strings of cells, which are gradually converted into striated muscle. In some cases the appearances would seem to indicate that connective-tissue cells may participate in the formation of new muscle fibres, but this is not certain.[1]

## INFLAMMATION.

*Suppurative Myositis.*—In the early stages of this lesion we

[1] For literature on muscle regeneration consult *Zaborowski*, Arch. für exp. Pathologie u. Pharm., Bd. xxv., Heft. 5 und 6, p. 415, 1889.

find the muscle hyperæmic and œdematous, and the interstitial tissue more or less infiltrated with small spheroidal cells, doubtless the result of emigration. If the inflammation becomes intense there may be an excessive accumulation of pus cells, either diffusely in the interstitial tissue or in larger and smaller masses. Hand-in-hand with this cell accumulation occur degenerative changes in the muscle fibres. By pressure their nutrition is interfered with and they undergo granular, fatty, or hyalin degeneration. They may completely disintegrate and gangrene may occur, so that larger and smaller masses of the infiltrated muscle tissue become soft, foul-smelling, and converted into a mass of detritus in which but little muscle structure can be detected, and which is intermingled with bacteria. In other cases there may be larger and smaller abscesses formed in the muscle, the muscle tissue itself either degenerating and disintegrating and mixing with the contents of the abscess, or being pressed aside and undergoing atrophy and degeneration. In some cases, when the formation of pus is moderate in amount, there may be restoration by formation of granulation tissue between the muscle fibres. This becomes gradually dense and firm, and leads to more or less atrophy of the muscle fibres by pressure.

Acute suppurative myositis may accompany wounds; it is very common in acute phlegmonous inflammations of the skin and subcutaneous tissue, and often accompanies acute infectious diseases, such as pyæmia, erysipelas, etc. In most cases the pyogenic bacteria are present in the inflammatory foci. It is not infrequently seen in the muscles adjacent to the inflamed mucous membranes in diphtheria.

*Chronic Interstitial Myositis.*—In this lesion there is a new formation of connective tissue between the muscle fibres or bundles of fibres. This new tissue is sometimes very cellular, resembling granulation tissue, and this probably represents an early stage of the disease. In other cases (Fig. 361) we find dense cicatricial tissue crowding the muscle fibres apart, inducing atrophy in them, and sometimes causing their complete destruction. This lesion, which is the analogue of chronic interstitial inflammation of the internal organs, may occur in muscles which are adjacent to other parts which are the seat of chronic inflammatory processes. It may occur in muscles which are not used. The new formation of connective tissue would in some cases seem to be secondary to atrophy of the muscle fibres. In this case it would more appropriately be called *replacement fibrous hyperplasia.*

*Myositis ossificans.*—Under conditions and for reasons which we do not understand, there occasionally occurs, usually in young persons, a new formation of bone tissue in the interstitial tissue of muscles, in the tendons, ligaments, fasciæ, and aponeuroses. This

sometimes apparently starts as outgrowths from the periosteum, sometimes not. The bone formations are apt to commence about the neck and back, and may become very widespread over the body. So far as the muscles are concerned, there is usually an increase of connective tissue between the fibres and bundles, in which new bone is formed, usually in elongated and sometimes in spicula-like masses. The muscle fibres undergo secondarily a greater or less degree of atrophy or degeneration. There may be fatty infiltration between the

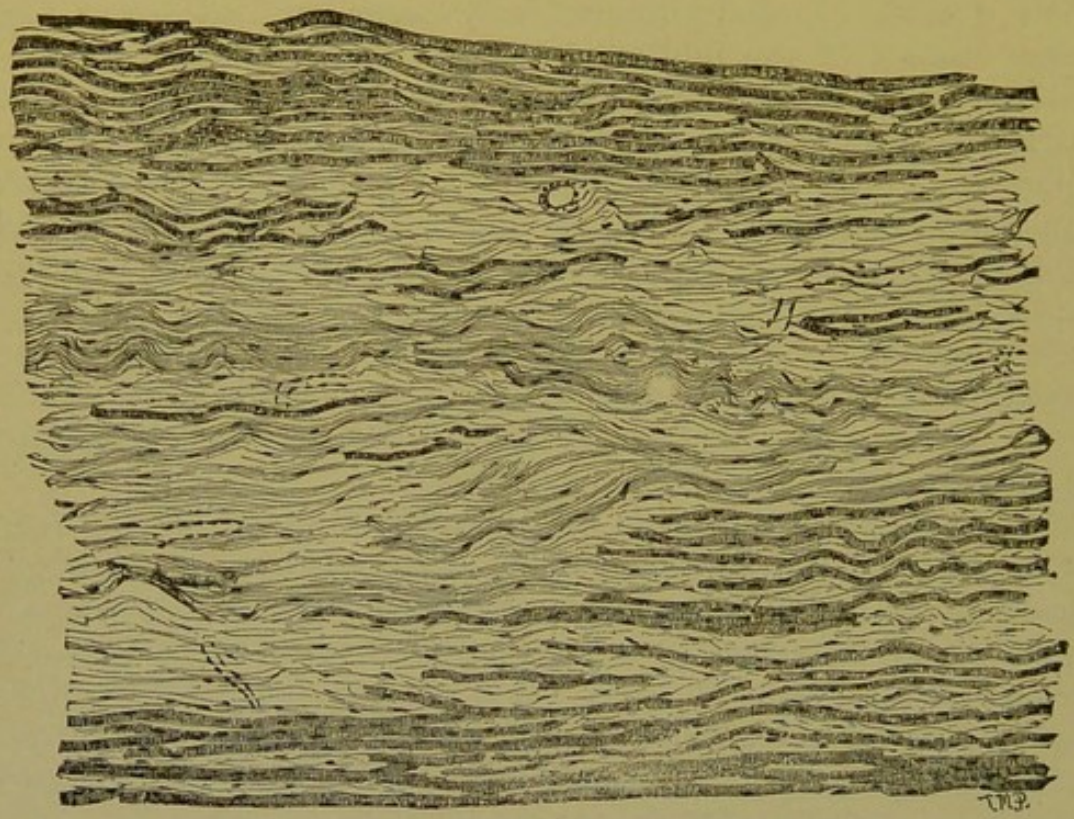

Fig. 361.—Chronic Interstitial Myositis.

The connective tissue is dense in texture, and the muscle fibres are atrophied and partially destroyed.

fibres, and various deformities are produced by the shortening and progressive immobility of the affected parts.[1]

While the above disease is a progressive and frequently a general one, there may be new formation of bone in muscle as a result of prolonged or repeated mechanical irritation. Thus in the adductors of the thigh in persons who are constantly in the saddle, or in the deltoid muscle of soldiers who strike this part with their weapons in drill, there may be a formation of bone.

*Gummata* and occasionally *tubercles* occur in the connective tissue of muscle.

[1] The literature of Myositis ossificans may be found, together with a description of some interesting cases, in an article by *Mays* in Virch. Archiv, Bd. lxxiv., p. 145.

## DEGENERATIVE CHANGES IN THE MUSCLES.

*Simple Atrophy.*—This may occur in old age, in prolonged exhausting diseases, or as a result of pressure from a foreign body, tumors, etc. The muscle fibres grow narrower, the degree of narrowing frequently varying considerably in different parts. They usually retain the striations, but these may be obscured by degenerative changes. The sarcolemma may become thickened, and there may be a considerable increase in connective tissue between the muscle fibres and bundles.

*Progressive Muscular Atrophy.*—This lesion consists essentially in a combination of simple or degenerative atrophy of the muscle fibres with chronic interstitial inflammation, and is sometimes associated with proliferative changes in the muscle nuclei. In the earlier

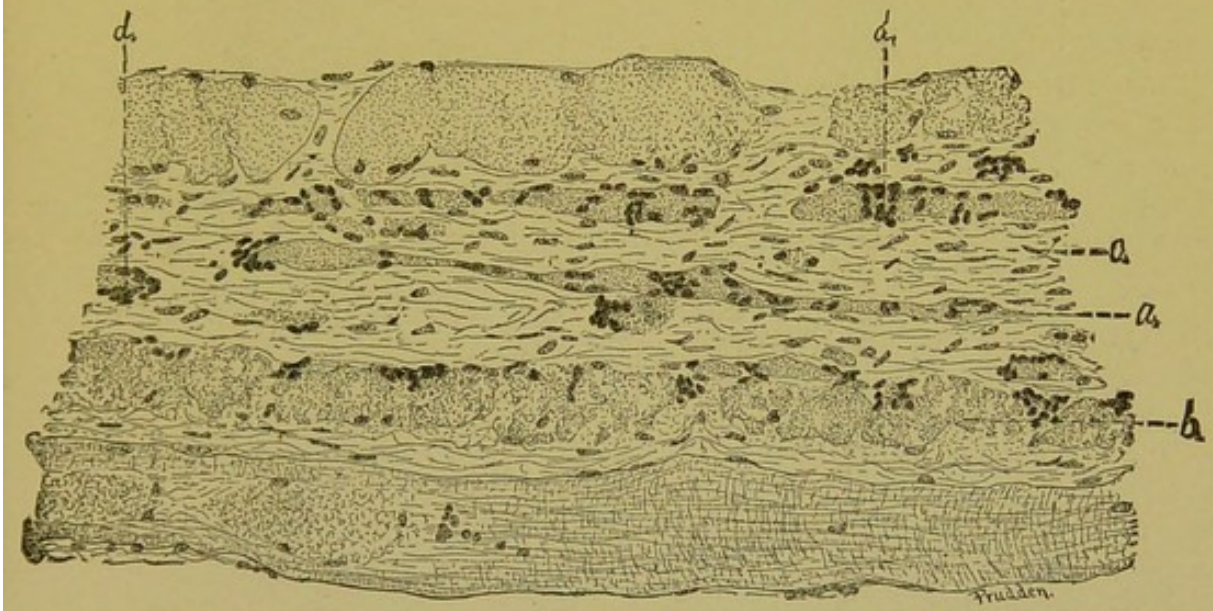


FIG. 362.—PROGRESSIVE MUSCULAR ATROPHY (Soleus muscle, longitudinal section).

*a*, atrophied muscle fibre; *b*, degenerated muscle fibre; *c*, interstitial tissue; *d*, clusters of proliferated muscle nuclei.

stages of the disease the muscles may be pale and soft, but exhibit otherwise to the naked eye but little alteration. Gradually, however, the muscle substance becomes replaced by connective tissue, so that in marked and advanced cases the muscles are converted into fibrous bands or cords, whose cicatricial contraction may induce great deformities.

Microscopical examination shows in the early stages of the disease a proliferation of cells in the interstitial tissue, so that this may have the appearance of granulation or embryonal tissue; also in some cases marked proliferative changes in the muscle nuclei (Fig. 362),

leading to the formation of new cells which may more or less replace the contractile substance within the sarcolemma. The new interstitial tissue increases in quantity and grows denser, and may crowd the muscle fibres apart (Fig. 363). The walls of the blood vessels may also become thickened. Hand-in-hand with these interstitial alterations the atrophy of the muscle fibres proceeds. These may simply grow narrower, retaining their striations; or they may split up into longitudinal fibrillæ, or transversely into discoid masses, and in this condition disappear. In other cases a certain amount of fatty or hyalin degeneration may be present. These degenerative and

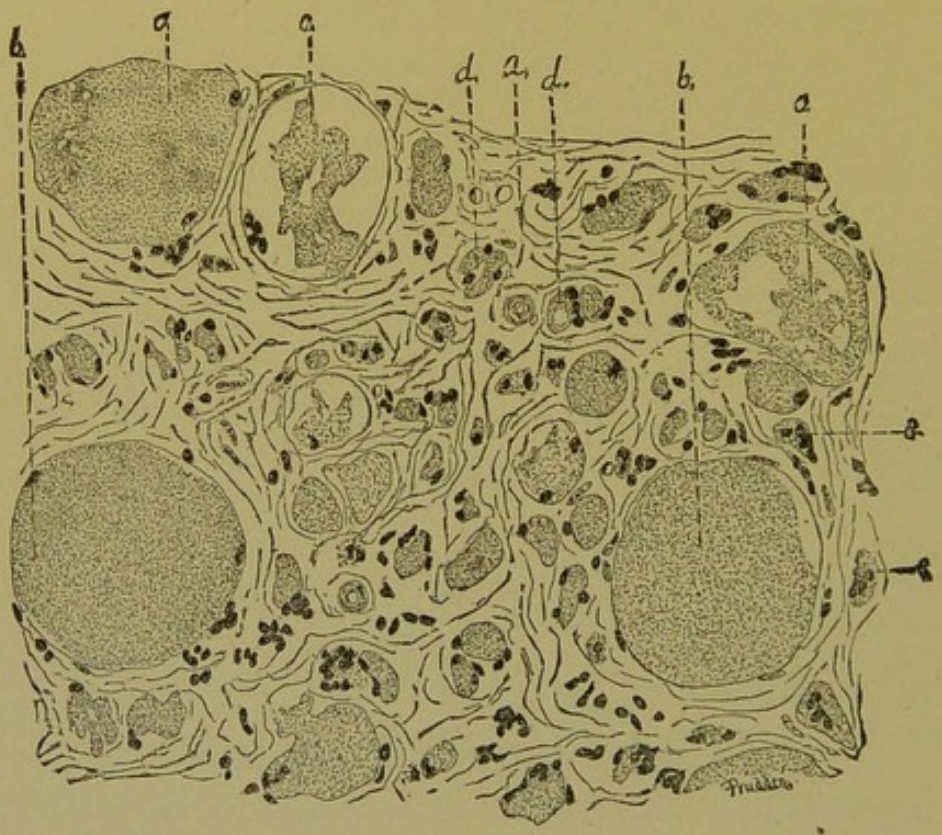

FIG. 363.—PROGRESSIVE MUSCULAR ATROPHY (Soleus muscle, transverse section).

*a*, increased interstitial tissue; *b*, nearly normal muscle fibres; *c*, degenerated muscle fibres; *d*, atrophied muscle fibres; *e*, clusters of proliferated muscle nuclei.

proliferative changes do not, as a rule, occur uniformly in the affected muscles, but some parts are affected earlier and more markedly than others. The atrophied muscle may be replaced by fat.

Progressive muscular atrophy is apt to commence in the small muscles of the extremities, in many cases in the muscles of the ball of the thumb. It may commence in the muscles of the shoulder, the arms, or the back. It may have a continuous extension, or it may jump single muscles or groups of muscles. Death may be induced by the affection of the muscles of respiration or deglutition.

The causes of this lesion are in many cases unknown, and there

is considerable lack of unanimity of opinion as to whether it is primarily a disease of the muscles or of the nervous system. In a considerable proportion of cases the muscle lesion is associated with atrophy of the ganglion cells in the anterior cornua of the spinal cord and the development of connective tissue about them. In other cases these changes in the cord may apparently be absent.

It is sometimes accompanied by atrophy of the nerves which are distributed to the muscles, and atrophy of the anterior roots has been described.

It is probable that there are several varieties of progressive muscular atrophy, which our present knowledge does not enable us to

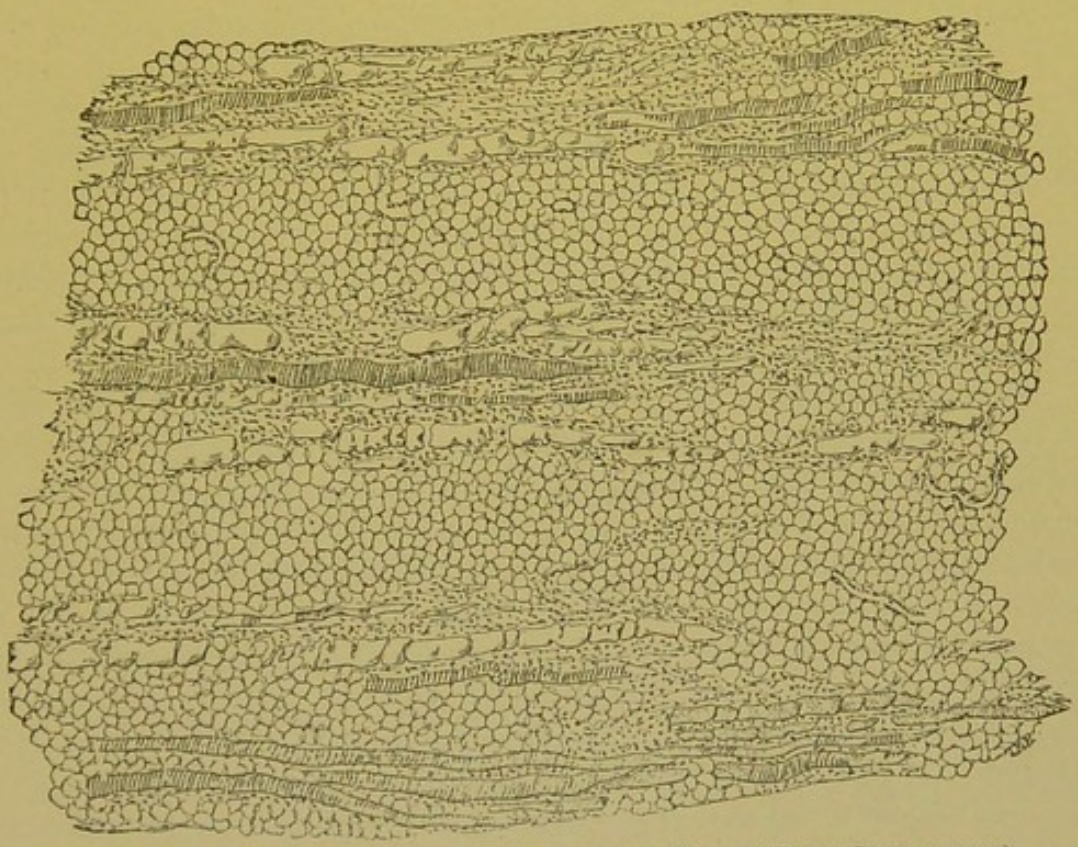

FIG. 364.—PSEUDO-HYPERTROPHY OF GASTROCNEMIUS MUSCLE (FATTY INFILTRATION). The specimen is from the case mentioned below, accompanying multiple neuroma.

clearly distinguish. Muscular atrophy in some cases follows overstraining of groups of muscles, or injuries, and may occur as one of the sequelæ of typhoid fever and diphtheria.

*Atrophia Musculorum lipomatosa* (Pseudo-hypertrophy of the Muscles).—In some cases, hand-in-hand with the production of new connective tissue in the muscles and the atrophy of the muscle fibres, or after these changes have made considerable progress, there occurs a development of fat tissue between the fibres (Fig. 364) which may prevent any apparent diminution in the size of the muscles, or in some cases may even give them a great increase in size. This condi-

tion is of most frequent occurrence in children, and is most apt to appear in the gastrocnemii muscles. In the upper extremities the deltoid and triceps are most frequently involved. The lesion may be symmetrical, affecting similar muscles on both sides of the body, or it may be unilateral. Parts of muscle bellies may be affected.

The cause of this form of atrophy is not definitely known. Various lesions of the spinal cord have been described as occurring with it; but, in many cases at least, alterations of the nervous system cannot be detected. The writer has described a case [1] in which this lesion was marked in the gastrocnemii in connection with multiple false neuromata.[2]

*Fatty Degeneration*, with greater or less destruction of the muscles, may commence with a simple swelling and fine granulation of the fibres. As the process goes on, smaller and larger fat droplets appear in the contractile substance, which loses its striations and becomes friable, and may be entirely destroyed, leaving within the sarcolemma a mass of fatty detritus which may finally be absorbed and disappear. This alteration may occur in acute parenchymatous myositis in connection with various forms of atrophy, in prolonged exhausting diseases, and in phosphorus poisoning.

*Hyalin Degeneration.*—Under a variety of conditions the muscle fibres undergo a peculiar series of changes, leading to their conversion into a translucent, highly refractile material, somewhat resembling amyloid but not giving its micro-chemical reactions, and apparently more nearly allied to the material produced in the so-called hyalin degeneration. The lesion in the muscle which we are considering is commonly called *waxy degeneration*, from the peculiar appearance which the muscles present. When the lesion is far advanced and extensive the muscles are brittle and have a grayish-yellow, translucent appearance. Microscopical examination of various stages of hyalin degeneration of muscle shows that the contractile substance of the fibres becomes at first swollen and granular, and gradually converted into hyalin material which may present the outlines of the swollen fibres, but is more frequently broken into larger and smaller shapeless clumps (Fig. 365), which may disintegrate and finally be absorbed. Hand-in-hand with these changes there usually occurs an increase in the interfibrillar connective tissue, and in certain cases there may be a proliferation of the muscle nuclei and a new formation of variously shaped cells within the sarco-

[1] *Prudden*, American Journal of Medical Sciences, July, 1880, p. 134.

[2] For bibliography of muscular atrophy consult *Friedreich*, "Ueber progressive Muskelatrophie," etc., Berlin, 1873; also "Dictionnaire encyclopédique des Sciences médicales," 2 ser., i., x.; or Eulenberg's "Real-Encyclopädie der gesammten Heilkunde," article by *Pick* on Muskelatrophie.

lemma which leads to the regeneration of the fibres. As a result of the brittleness of the degenerated muscles they are apt to rupture, and in this way hæmorrhage may occur.

This form of degeneration may occur in progressive muscular atrophy, in variola, cerebro-spinal meningitis, trichinosis, in connection with inflammation, injuries, freezing, etc. It is, however, most marked and frequent in typhoid fever. In this disease the rectus abdominis and the adductors of the thigh are most frequently affected.

Experimental investigations have shown that, under certain conditions, very similar appearances may be produced in the muscles by post-mortem changes. It is not unlikely that a variety of changes are at present included under the name waxy or hyalin degeneration of the muscles.[1]

*Hypertrophy of Muscle.*—True hypertrophy of muscle as a pathological condition is rare, but it has been described in a few

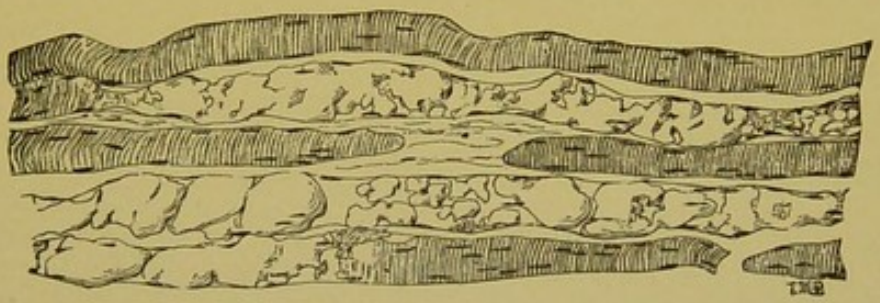

FIG. 365.—HYALIN DEGENERATION (SO-CALLED WAXY DEGENERATION) OF ABDOMINAL MUSCLE IN TYPHOID FEVER.

cases. It is usually confined to circumscribed groups of muscles. On microscopical examination the diameter of the fibres is increased, sometimes considerably, though not uniformly. The transverse striation is unaltered and the muscle nuclei are in some cases enlarged. The cause of the change is unknown.

## TUMORS.

The tumors of the muscles usually develop in the connective tissue. *Fibroma, chondroma, lipoma, myxoma, sarcoma* may occur as primary tumors. *Carcinomata* and *sarcomata* may occur secondarily in the muscles as a result of local extension from adjacent parts. The muscle fibres are, as a rule, only secondarily affected by pressure, etc., in tumors of the muscles, but there exist observations

[1] Consult *Zenker*, "Ueber die Veränderung der willkürlichen Muskeln in Typhus abdominalis," Leipzig, 1864; also *Weihl*, "Exp. Unters. ü. d. wachsartige Degeneration der quergestr. Muskeln," Virch. Arch., Bd. lxi., p. 253, 1874.

which point to the possibility of a proliferation of the muscle nuclei and the new formation from them of cells which may take part in the growth of the tumor.

### PARASITES.

The *Trichina spiralis* is the most common parasite in the muscles.

*Cysticercus cellulosæ* and *Echinococcus* occasionally occur.

# PART IV.

## THE LESIONS FOUND

IN

## THE GENERAL DISEASES,

IN

## POISONING,

AND IN

## VIOLENT DEATHS.

# DISEASES CHARACTERIZED BY ALTERATIONS IN THE COMPOSITION OF THE BLOOD.

There is a group of diseases in which the essential lesion seems to be an alteration in the composition of the blood, although in some members of the group other lesions are also present. This group embraces Chlorosis, Pernicious Anæmia, Addison's Disease, Leukæmia, and Pseudo-leukæmia.

## CHLOROSIS.

Chlorosis is a disease of the blood attended with a diminution in the hæmoglobin, and usually in the number of the red blood cells.

Of the essential element in the causation of this disease and of the exact method of its origin we are ignorant. The condition has been attributed to congenital hypoplasia of the heart and blood vessels, to prolonged innutrition, to intestinal intoxication, and to functional disturbance of an unknown nature in the blood-producing organs.

In the mildest grade of chlorosis the only change to be observed is a uniform diminution of hæmoglobin. In severer forms may be added a diminution in number and moderate variations in size and shape of the red cells. In very severe and relapsing cases the hæmoglobin may be excessively decreased; the red cells may number less than two million per centimetre; considerable alterations in size and shape of the red cells may occur; megalocytes, microcytes, and poikilocytes may appear, and the morphology of the blood as well as the clinical aspect of the disease may closely resemble or even become identical with progressive pernicious anæmia (see PLATE, Fig. 2, page 80).

The albuminous constituents of the plasma and the specific gravity of the blood are uniformly diminished, but the alkalinity and power of coagulation are slightly or not at all affected. Even in cases of considerable severity the degenerative changes in the viscera characterizing other forms of anæmia have been found wanting, although degenerative changes in the red cells may occur in accordance

with the severity of the disease. Hæmoglobin is not set free in the plasma, the liver does not contain an excess of iron, and the urine is free from pathological urinary pigments.

The regeneration of the blood in chlorosis under rest and treatment with iron may usually be rather promptly effected by increased activity probably accompanied by hyperplasia of the red marrow. This regenerative process may be indicated in the blood by the periodical appearance of considerable numbers of normoblasts. The appearance of these nucleated red cells may be accompanied by a moderate increase of leucocytes, both mononuclear and polynuclear, constituting the mixed leucocytosis characteristic of primary chlorosis. Myelocytes also may rarely be seen.

## PERNICIOUS ANÆMIA.

Pernicious anæmia is a disease of the blood and blood-forming organs, characterized by excessive destruction associated with defective production of red cells.

The exact relation of the factors concerned in the causation of the disease has not been determined. It may be said, however, that while very rapid cases of pernicious anæmia have been observed unaccompanied by the usual lesions in the bone marrow causing defective hæmatogenesis, the disease seems not to exist without excessive hæmatolysis.

Pernicious anæmia may probably originate as a primary disease of the blood or bone marrow, but many cases apparently idiopathic have been shown at autopsy to be secondary to such conditions as cancer, nephritis, tuberculosis, atrophy of the gastric mucosa, or the presence of parasites in the blood or intestine. The studies of Hunter indicate that the destruction of the blood may in some cases result principally in the portal circulation and particularly in the spleen from the action of toxic principles absorbed from the intestines. Whatever its origin, the distinguishing feature of pernicious anæmia is the fact that the anæmia is entirely disproportionate to any apparent cause, and when once established tends to progress to a fatal issue.

The essential lesion is an extreme and progressive diminution in number and very great variation in size and form of the red blood cells (see PLATE, Figs. 3 and 4, page 80). Nearly constant is a general lesion of the bone marrow in which the normal nucleated red cells are replaced by an excessive number of larger nucleated corpuscles with hyperæmia and atrophy of fat cells. There is thus established an abnormal type of development of red cells which closely resembles the embryonal type. The destruction of hæmoglobin is followed by a considerable deposit of iron in the liver, spleen, marrow, and other

organs, by the appearance of abnormal pigments in the urine, and by a yellowish discolorization of the skin. The prolonged anæmia may cause fatty degeneration of the viscera, especially of the liver, kidneys, and heart muscle. As a combined result of fatty changes in the arterial walls and of the diminution in albuminous principles and coagulability of the blood, hæmorrhages in various parts of the body are of frequent occurrence. Disseminated areas of sclerosis in the spinal cord have been described and regarded as the result of minute hæmorrhages in this region.

In the blood the red cells are usually reduced to less than two million and often to half a million per cubic millimetre. Of the remaining cells a considerable percentage or nearly all may be abnormally large (megalocytes). On the other hand, in a certain type of the disease many of the red cells are very small (microcytes). Cells of very irregular shape are often present in abundance (poikilocytes). The quantity of hæmoglobin in the majority of the cells is either increased as in one distinct type of the disease, or diminished as in other cases in which the individual cells may resemble those of chlorosis. The "hæmoglobin index"—that is, the relation of the total percentage of hæmoglobin to the total number of cells—may be normal when a deficiency of hæmoglobin in one cell is counterbalanced by a proportionate excess in another.

A variety of degenerative changes in the red cells are commonly present, including especially the change from hæmoglobin to methæmoglobin, as indicated in those cells which stain reddish-brown with eosin.

Nucleated red cells of normal size (normoblasts) are of rather infrequent occurrence in the blood of well-established pernicious anæmia. Abnormally large nucleated red cells (megaloblasts) are a nearly constant element and of great diagnostic importance, as they indicate the presence of a grave lesion in the bone marrow.

Megalocytes and megaloblasts usually show an excess of hæmoglobin, may exhibit amœboid movement, and have no tendency toward the formation of rouleaux. Extremely large nucleated red cells (gigantoblasts) are frequently found in advanced cases, and in these cells as well as in the megaloblasts the nuclei may be seen in various stages of normal or pathological mitosis, while in their protoplasm may occasionally be demonstrated small basophile granules. In very rapid cases of pernicious anæmia both normoblasts and megaloblasts may be absent from the blood, in which event the yellow marrow of the long bones is not replaced by normal or pathological red marrow. During the rapid destruction of red cells hæmoglobin may be dissolved in the plasma, which in dry preparations stained with eosin takes on a reddish tinge.

In the absence of complications producing leucocytosis, in pernicious anæmia the leucocytes are usually diminished in number. Of the remaining white cells the mononuclear cells may be most abundant and a few myelocytes may be found.

## LEUKÆMIA (LEUCOCYTHÆMIA).

Leukæmia is characterized by a progressive increase of the white cells and decrease of the red cells of the blood, and by alterations of varying extent in the spleen, lymph nodes, and bone marrow. Leukæmia is probably to be regarded as a primary disease of the blood-forming organs. Many authorities, however, consider a change in the blood plasma to be the primary cause, and others, influenced by the discovery of bacteria in the blood of a few cases, believe in the infectious nature of the malady. The increase of uric acid in the blood and urine of leukæmia is thought by many to be of etiological importance. A close relation between leukæmia and some other diseases of the blood is indicated by the occasional undoubted development of leukæmia during the course of pernicious anæmia or pseudo-leukæmia.

According to the predominance of the changes in one or other of the organs, various types of the affection may be distinguished. *Myelogenous leukæmia* indicates a special involvement of the bone marrow, but a pure form of this variety is extremely rare. *Splenomyelogenous leukæmia* with changes in the spleen and marrow is more commonly seen. *Lymphatic leukæmia*, with alterations prominent in the lymph nodes, absent or inconsiderable in the spleen or marrow, is a common variety. Usually all three organs are simultaneously involved. As a rule, other internal organs, liver, kidneys, lungs, etc., show an infiltration of their capillaries with leucocytes, or the presence of numerous small collections of spheroidal cells.

The lymphatic tissue in the gastro-intestinal tract and of other regions may be in a condition of hyperplasia. The changes referable to diminution of red cells and prolonged anæmia are similar to, but less pronounced than, those of pernicious anæmia.

Ecchymoses in the serous and mucous membranes, or severe hæmorrhages on slight provocation, and fatty degeneration of the heart and kidneys, are frequent complications. Aside from various other foreign chemical substances which may exist in the blood in leukæmia, there are very frequently found in the blood, marrow, spleen, liver, etc., after death elongated octahedral crystals, called Charcot's crystals, which are believed to be formed by a combination of phosphoric acid with some organic base.

For a detailed description of the lesions of the different parts of the body in leukæmia, see chapters on Blood, Spleen, Lymph Nodes, Bones, etc.

The specific gravity, alkalinity, and coagulability of the blood are uniformly diminished in leukæmia, as in other forms of progressive anæmia, but the morphology of the blood varies with the type of the disease and the predominance of the lesion in different organs. Aside from the rare conditions when, under proper treatment, the number of colorless cells may approach the normal, or when the toxæmia of an infectious disease replaces the mixed leucocytosis by the ordinary polynuclear leucocytosis, leukæmic blood always contains an excessive number of leucocytes (see PLATE, Figs. 5 and 6, page 80). The colorless cells may even outnumber the red, but often more characteristic than the increase in numbers is the abnormal proportion of mononuclear cells and the abundance of myelocytes. In splenic and lymphatic leukæmia the increase is in the small and large mononuclear leucocytes. The presence of myelocytes in considerable numbers is a very constant feature of leukæmic blood and is believed to indicate the hyperæmia or further involvement of the bone marrow. Although found in moderate numbers in many other conditions, a considerable percentage of myelocytes is important diagnostic evidence of leukæmia. In nearly pure lymphatic leukæmia, large mononuclear and polynuclear leucocytes, myelocytes, and nucleated red cells may be comparatively infrequent, while the lymphocytes are greatly increased.

The chronic process in the blood-producing organs, and the general disturbance of nutrition, may be indicated by an increase of eosinophile cells which is frequently observed, least often in the lymphatic type of the disease.

Mast cells are very constantly found in leukæmic blood, and the great rarity of their occurrence in other conditions renders their identification in the blood a valuable diagnostic sign.

The leucocytes of leukæmia commonly show a diminution or absence of amœboid motion. In the nuclei of myelocytes mitotic figures may be seen; more frequently the nuclei show a deficiency of chromatin. In dry preparations from the blood of advanced cases, large, basket-shaped, faintly staining nuclei, apparently devoid of protoplasm, are frequently encountered (PLATE, Fig. 5, page 80). Fatty degeneration of the protoplasm of leucocytes has been demonstrated, both in the circulation and in the bone marrow, and an increase cohesiveness may frequently be noted.

The red blood cells in leukæmia exhibit, in a lesser degree, many of the changes characteristic of pernicious anæmia. In the lymphatic type, normoblasts and megaloblasts may be very infrequent,

but with the involvement of the marrow, especially in children, they may appear in considerable numbers.[1]

### PSEUEO-LEUKÆMIA ("HODGKIN'S DISEASE," "ADÉNIE").

Under this term it has been customary to describe a rather heterogeneous group of cases characterized by progressive anæmia, by hyperplasia of the lymph nodes and nodules, with an occasional but by no means constant involvement of the spleen, liver, and bone marrow, and by new growths of lymphatic tissues in many parts of the body. While anæmia of moderate or severe grade is very constantly present in this disease, the increase of leucocytes characteristic of leukæmia is wanting.

Of the exact nature of the disease (if it be a single disease) very little is definitely known. The enlargement of the lymph nodes is in typical cases due to simple hyperplasia. The blood changes may present the type of pernicious anæmia, and in well-authenticated cases the condition has developed into true leukæmia. Recent evidence favors the belief that some cases classed under this heading may be of an infectious character.[2] Cases of primary sarcoma of the lymph nodes have been described as cases of pseudo-leukæmia.

The condition found at autopsy varies greatly according to the distribution and character of the new growths of lymphatic tissue. The lymphatic nodules involved may be principally limited to the subcutaneous connective tissue (dermal type). Or the lymph nodes of the pharynx and neck may be chiefly involved (tonsillar type). Or the axillary or inguinal or mediastinal or retroperitoneal groups may be involved. A somewhat characteristic condition is produced by hyperplasia, often followed by ulceration, of the lymph nodules of the gastro-intestinal tract (intestinal type). The hyperplastic lymph nodes may be isolated or they may be joined to form large lobulated masses. The enlarged lymph nodules may in the intestine project far into the lumen in spheroidal or polypoid form, and are sometimes dark in color as the result of the decomposition of hæmoglobin of extravasated blood in the congested mucous membrane covering the nodules. Hyperplasia of the thymus has been described in association with the lesions of the lymph nodes.[3] A distinct sub-variety is that which terminates in leukæmia. In general any of the lymph-nodes or collections of lymphoid tissue may be involved, and nearly

[1] For further data with bibliography consult *Müller*, Central. f. allg. Pathol., v., 1894.

[2] *Flexner*, "Multiple Lympho-sarcomata," Johns Hopkins Hospital Reports, vol. iii., p. 153.

[3] *Brigidio and Piccoli*, Ziegler's Beitr. z. path. Anat., Bd. xvi., p. 388.

every region has been a site of origin for the new growths of lymphoid tissue, so that a great variety of combinations may be seen.

The leucocytes in the blood may be slightly increased or diminished, and in either case the mononuclear forms are usually in excess. Myelocytes have been observed in moderate percentage, but never in such proportions as in leukæmia.[1]

*Anæmia infantum pseudo-leukæmica* (von Jaksch) is a somewhat peculiar form of anæmia occurring in children, and characterized by progressive anæmia, by a considerable increase of leucocytes, by enlargement of the spleen and liver, and often by hyperplasia of the lymph nodes.

By some authorities it is regarded as an early stage of leukæmia, by others as a form of secondary anæmia following rachitis, tuberculosis, or syphilis.

The histological changes in the blood-forming organs are, so far as is known, very similar to, but less pronounced than those of leukæmia. The enlargement of the spleen is usually greater than that of the liver, thus differing from infantile leukæmia, in which the liver and spleen are equally affected—while the involvement of the lymph nodes is less frequent than in leukæmia.

The red cells present most of the changes of pernicious anæmia, but nucleated red cells are often found in great abundance. The leucocytes may number one hundred thousand per cubic millimetre, the increase affecting the mononuclear cells chiefly, the eosinophile cells slightly, and of both a considerable percentage may be myelocytes.

---

[1] Consult *Monte and Berggrun*, "Die chronische Anæmie d. Kindesalter," Leipsic, 1892.

# SCORBUTUS—PURPURA—HÆMATOPHILIA.

## SCORBUTUS (SCURVY).

This disease appears to result from imperfect nutrition under conditions which cannot be considered here, and whose immediate cause we do not understand. The lesions are variable, the most prominent being anæmia; extravasation of blood in the skin, subcutaneous tissue, and muscles; swelling and ulceration of the gums. Small and sometimes extensive hæmorrhages are apt to occur in the mucous membranes and on serous surfaces. Small ulcers may form in the mucous membranes. Fatty degeneration of the heart, liver, and kidneys is not uncommon. The spleen may be large and soft. No constant characteristic changes have been discovered, either in the blood vessels or the blood, which would satisfactorily account for the extravasations and other lesions.

The body is apt to decompose early. The skin may be mottled with small and large purple, blue, brown, or blackish spots produced by degenerative changes in the extravasated blood in the cutis. Sometimes ulcers are produced by the perforation of effused blood on to the surface.

The joints may be inflamed, may contain serum or blood. Rarely the hæmorrhages are followed by destruction of the cartilages and ends of the bones.

Very rarely there is hæmorrhage between the periosteum and bone, and in the bone itself, producing softening and destruction of the bone, and separation of the epiphyses. The sternal ends of the ribs are the most frequent seat of this change.

That some forms or phases of scorbutus are of infectious nature is not improbable, but definite data in this direction are wanting.[1]

## PURPURA HÆMORRHAGICA (MORBUS MACULOSUS).

This disease is characterized by the occurrence of ecchymoses in the skin, mucous and serous membranes. Hæmorrhages, particu-

[1] For a study of scorbutus in infants consult *Northrup and Crandall*, New York Med. Jour., May 26th, 1894.

larly from the mucous membranes, may be very severe and even fatal. The cause of the disease is unknown. A few cases have been described under this name in which the characteristic ecchymoses were associated with the pyogenic bacteria, representing, it would seem, a phase of pyæmia. Whether any considerable number of cases of this disease are associated with bacteria we do not yet know.[1]

## HÆMATOPHILIA (HÆMORRHAGIC DIATHESIS).

This abnormal condition consists in a liability to persistent hæmorrhage on the slightest provocation, and is dependent upon some constitutional peculiarity which is unknown to us. It is frequently hereditary. An unusual thinness of the intima of the arteries has been noticed in some cases, and other changes have been described; but there are no constant lesions associated with hæmorrhages, as yet discovered, which would satisfactorily explain their occurrence. The hæmorrhages may be traumatic in origin, or they may occur spontaneously from the mucous membranes.

---

[1] For a more detailed consideration in the light of recent studies of cases often grouped under the name "Hæmorrhagic Infections," consult *Honl*, Ergebnisse der allg. Aetiologie, 1896, p. 793 (bibliography).

# ADDISON'S DISEASE.

This name is applied to a disease especially characterized by a peculiar pigmentation of the skin and by certain changes in the adrenals. The patients become very anæmic, but are not emaciated. They suffer from cerebral symptoms, great prostration, syncope, and derangements of the functions of the stomach and intestines.

The pigmentation of the skin is the symptom which has especially attacted attention. The change in color usually begins and becomes most marked in those parts of the skin which are not covered by the clothing or are naturally darker colored. The rest of the skin afterward changes color, but not uniformly, white patches being left. The color is at first a light yellow or brown; this becomes darker until it is of a dark greenish, grayish, or blackish brown. The mucous membrane of the tongue, lips, and gums may be pigmented in the same way.

Under the name of Addison's disease different observers have described cases in which the symptoms and bronzed skin existed without disease of the adrenals; cases in which the bronzed skin was the only lesion; and cases in which the adrenals were diseased without symptoms or bronzed skin.

We hardly know as yet what are really the characteristic lesions of the disease.

*The Skin.*—The discoloration of the skin is due to deposit of yellowish-brown pigment in the deeper layers of the epidermis, especially in the layer covering the papillæ, and less constantly in the connective tissue of the cutis.

*The Brain.*—Pigmentation of the gray matter, acute meningitis, chronic meningitis, and distention of the ventricles with serum have been observed.

*The Heart.*—The muscular fibres may be the seat of fatty degeneration.

*The Sympathetic Nerves* may show a variety of changes apparently due to chronic inflammation, especially the nerves which are in contact with the adrenals. Various changes in the semilunar ganglia have been described.

*The Adrenals.*—The most common lesion of these bodies is a tuberculous inflammation, and this or some other lesion of the adrenals has been found in nearly one-half of the cases. On the other hand, it should be remembered that similar lesions of the adrenals often occur without other indications of Addison's disease.

Tuberculous adrenals may be large, hard, and nodular; less frequently of normal size or smaller than normal. On section they may contain cheesy masses surrounded by zones of gray, semi-translucent tissue. Later the cheesy masses may become calcified or they may soften and break down. The grayish zones are composed of tubercle tissue, or denser connective tissue.

Other cases have been described in which the adrenals were the seat of carcinoma or of fatty or waxy degeneration. The adrenals in some cases appear normal or they may be atrophied.

On the whole the clinical, morphological, and experimental data now available seem to point to both the sympathetic system and to the adrenals as of greatest significance in determining this disease. But exact knowledge in the matter depends upon a much more definite understanding than is now possible of the functions and relationship of the adrenals and the nervous system.[1]

---

[1] For a summary of the available observations on Addison's disease up to 1893 consult *Thompson*, Trans. Assn. Am. Phys., vol. viii., p. 34. Consult also *v. Kahlden*, Ziegler's Beitr. z. path. Anat., Bd. x., p. 494. On the relationship of the suprarenal bodies to the nervous system, consult *Alexander*, ibid., Bd. xi., p. 145. For observations on the effects of removal of suprarenal body see *Tizzoni*, ibid., Bd. vi. For recent and general bibliography consult *Lubarsch*, Ergebnisse d. spec. path. Morphologie u. Physiologie, 1896, p. 488.

# GOUT.

The characteristic lesion of gout is the presence of an abnormal amount of uric acid in the blood and the deposit of urate of soda in the articular cartilages, the ligaments of the joints, the ears, and the eyelids.

The most frequent situation is the metatarso-phalangeal joint of the great toe. The cartilage may be infiltrated or encrusted with the deposit.

A very important feature of gout is that patients with the gouty diathesis are especially liable to derangements of digestion and to certain chronic inflammations, such as chronic inflammation of the arteries, chronic bronchitis, and chronic nephritis.

# ACUTE RHEUMATISM.

There are no characteristic lesions in this disease, which in many respects resembles the infectious maladies. It is apt to be associated with inflammation, with little exudate in various joints, and with inflammation of the heart or pericardium. In cases in which suppurative inflammation has occurred, pyogenic bacteria have been occasionally found. But the cause of the disease itself is unknown.

# DIABETES MELLITUS.

There are no constant or characteristic morphological lesions of this disease, which involves such defects in nutrition as lead to an abnormal accumulation of sugar in the blood and its discharge by the urine.

A great variety of lesions have been found in the body after death from diabetes, but none of them and no combination of them appear to be of well-defined significance in this special relationship.

*The Brain* may appear to be entirely normal; it may be congested; there may be an increase of serum; the convolutions may be shrunken; there may be meningitis; there may be dilatation of the blood vessels, small extravasations of blood around the vessels, enlargement of the perivascular spaces, and alterations in the perivascular sheaths and nerve tissue bounding the cavities; there may be tumors at the base of the brain.

*The Spinal Cord* may present dilatation of the blood vessels; dilatation of the central canal; changes in the gray matter of the anterior cornua.

*The Lungs.*—There may be pleurisy, bronchitis, broncho-pneumonia, lobar pneumonia, gangrene of the lung, chronic pulmonary phthisis.

*The Heart* is often small; there may be chronic endocarditis.

*The Stomach and Intestines.*—The stomach may be dilated, its walls may be thickened, there may be hæmorrhagic erosions of the mucous membrane. In the intestines there may be tuberculous ulcers or enteritis.

*The Liver* may be cirrhotic or fatty.

*The Kidneys* may be enlarged; they may be the seat of parenchymatous degeneration or diffuse nephritis; there may be glycogenic degeneration of the epithelium of Henle's loops.

*The Blood.*—In a few cases fat has been found in the blood, and fat emboli in the vessels of the lungs.

Attention has, however, been called to the pancreas, which in a considerable proportion of cases may show atrophy of the parenchyma

with increase of the interstitial tissue or other lesions. Similar lesions of the pancreas may, however, occur without the existence of diabetes. The results of partial or total extirpation of the pancreas lend weight to the importance of this organ in the etiology of diabetes.[1]

[1] Reference to the more important work on this subject may be found in an article by *Kasahara*, Virch. Arch., Bd. cxliii., p. 111, 1896.

# SUNSTROKE (INSOLATION).

During the hot summer months cases of sunstroke are of frequent occurrence in New York. The persons affected are, for the most part, adult male laborers, usually of intemperate habits.

It is necessary to separate from the cases of sunstroke proper, when the patient is attacked while exposed to the heat of the sun, the cases of exhaustion from heat and fatigue, which may occur as well in the house.

The patients who are seriously affected by sunstroke exhibit, during life, an intense heat of the skin, convulsions, and coma. Death in many cases soon ensues. In other cases the symptoms are more protracted.

After death, decomposition sets in very early, owing to the state of the weather. In autopsies which we have made within two hours after death the increased heat of the skin was still maintained.

*The Brain* and its membranes were in some cases congested, in others not. Sometimes there was an increased amount of serum beneath the pia mater ; sometimes there were small and thin extravasations of blood beneath the pia mater and between the pia and dura mater.

In the other viscera there were no lesions except those due to the condition of coma existing before death. The lungs and kidneys were frequently congested.

In the cases in which cerebral symptoms are protracted for a number of days the lesions of meningitis have been found after death.

Attention has been called by Dr. H. C. Wood, Jr., to the rigid condition of the wall of the heart after death, but this rigidity is certainly not present in all cases.

According to Cramer,[1] persons surviving for some time the first severe effects of the heat may suffer important alterations in certain nerve fibres of the brain.

---

[1] *Cramer*, Centralblatt fur allg. Path., etc., March 15th, 1890.

# DEATH FROM BURNING.

Death may be caused by the inspiration of smoke and flame; by drinking of hot fluids; by the direct contact of flame or hot substances with the external surface of body. It may be due to the direct effect of the agents, to secondary affections of the viscera, or to the exhaustion produced by long-continued inflammation and suppuration.

Sudden death may occur after extensive burnings of the skin.[1]

The entire body may be burned to a coal or completely roasted, or only a larger or smaller area of the skin be burned.

We find the burned skin divested of epidermis and presenting a peculiar red, hard, parchment-like appearance. If the patient has lived some time, this is replaced by a suppurating surface. Or there are small, bladder-like elevations of the epidermis. The base of these blisters is red and they are surrounded by a red zone, or suppuration may have commenced.

These appearances cannot be produced by heat applied to the skin after death.

*The Brain* may be congested, œdematous, or softened. More frequently it is normal.

*The Larynx and Trachea* may be congested and the seat of croupous inflammation. There may be œdema of the glottis.

*The Lungs* may be congested and œdematous, or hepatized, or the seat of pyæmic infarctions. There may be pleurisy.

Inflammation of the *peritoneum* is not very infrequent. There may be swelling of the *solitary* and *agminated nodules* of the small intestine.

The duodenum may be the seat of perforating ulcers, and the mucous membrane of the entire gastro-intestinal canal may be congested. The *Liver*, *Spleen*, and *Kidneys* may be the seat of parenchymatous degeneration or of pyæmic infarctions.

[1] For literature on sudden death following severe burns consult *Silbermann*, Virch. Arch., Bd. cxix., p. 488, 1890.

# DEATH FROM ELECTRICITY.

*Lightning.*—Persons who are struck by lightning may die instantly; or may continue for several hours comatose or delirious, and then either die or recover; or they may die after some time from the effects of the burns and injuries received.

The post-mortem appearances are very variable. Sometimes there are no marks of external violence or internal lesions. Sometimes the clothes are burnt and torn, while the skin beneath them is unchanged. Usually there are marks of contusion and laceration, or ecchymoses, or lacerated, punctured wounds, or fractures of the bones, or superficial or deep burns. The track of the electric fluid may sometimes be marked by dark-red arborescent streaks on the skin. Fractures are rare.

The internal viscera may be lacerated and disorganized from lightning.

*Artificial Electrical Currents.*—In death from powerful artificial electrical currents, either by accident, as in linemen and others, or in electrical executions, there may be local burnings of varying degree where the wires or electrodes come in contact with the skin. The clothes may be pierced with holes at the point of exit of the current.

Internally there appear to be no marked or characteristic lesions, either gross or microscopical, in this form of death.

Van Gieson[1] and others have observed the occasional, but not constant, occurrence of small hæmorrhages in the floor of the fourth ventricle, the significance of which is doubtful. Other petechial spots have been observed beneath the serous surfaces of the endocardium, pericardium, and pleura, and on the spleen.

[1] *Van Gieson*, "A Report of the Gross and Microscopical Examination of Six Cases of Death by Strong Electrical Currents." Reprint from the New York Medical Journal, May 7th and 14th, 1892.

# DEATH FROM SUFFOCATION—ASPHYXIA.

By suffocation we understand that condition in which air is prevented from penetrating into the lungs without direct pressure on the larynx or trachea. The interruption of the function of respiration which is thus brought about induces the condition known as *asphyxia*. Many deaths from drowning and strangulation take place in this way.

The methods in which the supply of air may be cut off from the lungs are very various. The mouth and nose may be closed by the hand, by plasters and cloths, by wrapping up the head in cloths, by covering the face with earth, hay, grain, etc. Foreign bodies may be introduced into the mouth, pharynx, and larynx. Blood may pass into the trachea from an aneurism or from a wound. The glottis may be closed by inflammatory swelling. Matters which are vomited may lodge in the larynx.

On the other hand, injury or disease of the medulla oblongata, or paralysis or spasm of the muscles of respiration from drugs, tumors pressing upon the air passages, or diseases of the lungs themselves, may induce asphyxia.

### EXTERNAL INSPECTION.

The body should be examined for marks of violence, the cavities of the mouth and nose for foreign substances.

The face may be livid and swollen or present a natural appearance. The conjunctiva may be congested and ecchymotic. There may be small ecchymoses on the face, neck, and chest. The mouth often contains frothy blood and mucus. The tongue may be protruded.

### INTERNAL EXAMINATION.

*The Brain* and its membranes may be congested, or anæmic and œdematous, or unchanged.

*The Blood* throughout the body is unusually dark-colored and fluid.

*The Larynx* may contain foreign bodies which have produced the suffocation. The mucous membrane of the larynx, trachea, and bronchi is congested and sometimes ecchymotic. These passages contain frothy blood and mucus.

*The Lungs* are usually congested and œdematous, but sometimes do not differ from their ordinary appearance. There may be small patches of emphysema near the surface of the lungs. Sometimes, especially in infants, small ecchymoses are found in the costal and pulmonary pleura.

*The Heart* usually presents its right cavities full of blood, its left cavities empty; but to this there are frequent exceptions.

*The Abdominal Viscera* are usually congested.

## DEATH FROM STRANGULATION—HANGING.

Strangulation is effected by the weight of the body in hanging, by pressure on the neck with the hands or by some other object, or by constriction of the neck with a cord or ligature of some kind. Death is usually produced by asphyxia, or by asphyxia combined with the effect of the cutting-off of the blood supply to the brain by pressure on the large vessels of the neck. In some cases of hanging, death ensues as a result of fracture or dislocation of the cervical vertebræ.

### EXTERNAL INSPECTION.

The face may be livid and swollen, the eyes prominent, the lips swollen, and the tongue protruded. These appearances are, however, often absent. Erection of the penis, ejaculation of semen, and evacuation of fæces and urine are frequently observed.

In most cases marks are left upon the neck by the objects which have directly produced the strangulation.

In cases of hanging, the mark about the neck varies considerably in position, direction, and general characters, depending upon the kind of ligature employed, the time of suspension, period after death at which the observation is made, etc. The most common mark left by a cord about the neck is a dry, dense, brownish furrow, whose breadth corresponds but in a very general way with the diameter of the cord. In some cases, according to Tidy and others, there may be no mark at all if the hanging is quickly accomplished with a soft ligature and the body cut down immediately after death. There may be abrasions and ecchymoses of the skin at the seat of ligature.

In cases of strangulation by the fingers the marks on the neck may correspond in a general way to the shape of the fingers.

The application of the same forces immediately after death may produce the same marks as when death is induced by them.

### INTERNAL EXAMINATION.

*The Brain* and its membranes may be congested, or there may be extravasation of blood, or there may be no abnormal appearances.

*The Neck.*—In some cases there is effusion of blood beneath the ligature, rupture of the cervical muscles, fracture of the os hyoides and cartilages of the larynx, fracture and dislocation of the cervical vertebræ, rupture of the internal vertebral ligaments and of the inner and middle coats of the carotid arteries. Similar changes may be produced in the dead body by the use of great violence. In death from asphyxia the lesions are similar to those described above. In some cases—for example, where death has occurred from fright or shock—the results of post-mortem examination are entirely negative.

## DEATH FROM DROWNING.

In examining the bodies of persons who have been drowned it is necessary to bear in mind a number of questions which may arise: Whether the person came into the water alive or dead? How long a time has elapsed since death? Whether the person committed suicide, or was drowned by accident, or was murdered? These questions are to be solved sometimes certainly, sometimes with probability, sometimes not at all, by the post-mortem examination. Persons dying in the water, to which condition the term drowning is commonly applied, may die from asphyxia, from exhaustion, from fright or syncope, from diseases of the heart, apoplexy, injuries, etc. While in the majority of cases asphyxia is a predominant or important factor in death by drowning, the conditions under which death occurs are so apt to be complex that in the minority of cases only are the lesions of pure asphyxia found after death, while in most cases the bodies present the more or less well-marked lesions of asphyxia together with those indicative of complicating conditions. There are no post-mortem conditions which alone are absolutely characteristic of drowning, and it is only by considering all the facts elicited by the autopsy together that any just conclusion can be arrived at. It should always be borne in mind, moreover, that even the most characteristic of the evidences of drowning are apt to be modified or to disappear as decomposition goes on.

### EXTERNAL INSPECTION.

Post-mortem rigidity usually sets in early, sometimes immediately after death. Decomposition goes on, especially in summer, with

unusual rapidity in bodies which have been removed from the water. Frequently, but by no means constantly, the peculiar roughening of the skin, known as goose skin (cutis anserina), is found, but this may occur after death from other causes. A light, lathery froth, either white or blood-stained, is frequently seen about the mouth and nostrils within twelve to twenty-four hours after removal of the body from the water, but it may be absent, and may be seen after death from other causes. After the body has lain for several hours in the water (twelve to twenty-four) the thick skin of the palms of the hands and soles of the feet may become macerated and thrown into coarse wrinkles, just as it may after prolonged soaking during life, or in a dead body thrown into the water. The penis and nipples may be retracted and the scrotum shrunken, but this is not constant nor characteristic.

If the person has struggled in the water and clutched at objects within his reach, there may be evidences of this in excoriations of the fingers or in the presence of sand, weeds, etc., under the nails or grasped in the hands.

External marks of injury, bruises, etc., should be sought for, since persons in diving, or on being thrown into the water with homicidal intent, may have died from the violence, and not, strictly speaking, from drowning. It should also be borne in mind in such complex cases that injuries, not in themselves fatal, may, when the body is in the water, prove so on account of the inability of the person to rescue himself or gain time for recovery from the injury, and that then the struggle for breath may be but slight, and the more prominent signs of drowning but little marked.

### INTERNAL EXAMINATION.

*The Brain.*—Congestion of the brain and its membranes is found only in a small proportion of cases.

*The Blood*, when death occurs from asphyxia, is usually fluid throughout the body and of a dark color, as in asphyxia from other causes.

*The Air Passages.*—In persons who die from asphyxia the mucous membrane of the larynx, trachea, and bronchi is usually congested, and the air passages contain a variable quantity of bloody or mucous froth. In persons dying in the water from other causes than asphyxia these appearances are absent. Foreign substances from the water, such as sand, weeds, etc., or matters regurgitated from the stomach, may find their way into the air passages during the act of drowning or as a post-mortem occurrence. Thus, in bodies washed about on the bottom, sand or mud may get into the air passages for a certain distance, from the mechanical action of the water.

*The Lungs* in typical cases are distended so that they fill the thorax and cover the heart. The increased size is due partly to congestion, partly to the presence of the fluid in which the person was drowned, which is often inspired during the act of drowning, and partly to the distention of the air vesicles with air. While, in cases of drowning in which there is a struggle and water is breathed in, the lungs contain more or less fluid, this may, as a result of decomposition, find its way in greater or less quantity into the pleural cavities by transudation, leaving the lungs comparatively empty. It should be remembered, however, that a considerable quantity of reddish fluid may collect in the pleural cavities under other conditions than drowning, as a post-mortem change, by transudation from the blood vessels and other adjacent tissue.

*The Heart.*—In those who die from asphyxia the right cavities are usually filled with fluid blood, while the left cavities are empty. But where death is due to complex causes this may not be the case.

*The Stomach.*—The fluid in which the person was drowned, sometimes mixed with sand, weeds, etc., may be swallowed during the act of drowning. Sand may wash for a short distance into the œsophagus after death, in bodies washing about the bottom.

*The Abdominal Viscera* may be congested in persons who die from asphyxia.

In persons dying from syncope, shock, etc., we may find no lesions. When the death is partly due to asphyxia and partly to other causes, the conditions will vary in various ways, which need not be described in detail here.

In important cases of doubtful drowning it is desirable to carefully collect and save some of the fluid from the lungs and stomach for micro-chemical examination, since the identification of these fluids with those in which the person was presumably drowned will often give certainty to an otherwise doubtful case.

For the detailed consideration of the anatomical diagnosis of drowning, the changes which bodies dead from drowning undergo from decomposition, and the factors bearing on the question of suicide, homicide, etc., we refer to works on medical jurisprudence.[1]

---

[1] *Tidy*, "Legal Medicine," vol. ii , pp. 342–373. *Guy and Ferrier*, "Forensic Medicine," pp. 274–285.

# DEATH FROM POISONING.

In cases of suspected poisoning which may possibly have a medico-legal bearing the examination should be made with extreme care and thoroughness. The inspection of the body and the examination of *all* the viscera should be thorough and detailed. Every appearance should be noted at the time and nothing left to the memory. It is well to have an assistant record the observations as they are made. The disposition of the parts and organs in jars should also be noted at the same time.

It is important to remember that many poisons destroy life without producing appreciable lesions, and also that many cases of sudden death occur, not due to poisons, and without any discoverable cause.

In bodies which are exhumed for examination the tissues may be so changed by decomposition that it is impossible to say whether lesions have or have not existed. In such cases the careful and separate preservation of the viscera and other parts for chemical examination is often all that can be done. For directions for preserving tissues and organs for the chemist in medico-legal cases, see Part I. (page 41).

## SULPHURIC ACID.

The effects of this poison vary with the amount taken and with its strength. Death usually takes place in from two to twenty-four hours after the taking of the concentrated acid. A case of death within an hour is recorded. When the poison is less concentrated or its effects less intense, the patient may survive for months.

The skin of the face about the mouth may be blackened and charred by the acid. The mouth and pharynx are of a grayish or blackish color, or are covered with a whitish layer, while the deeper tissues are reddened. Sometimes these regions escape the action of the poison.

The *larynx, trachea,* and *lungs* are sometimes acted on, softened and blackened by the accidental passage of the acid into them.

This may even take place when the acid does not pass into the œsophagus.

The *œsophagus* seldom escapes. It is grayish or blackish colored, softened, and the mucous membrane comes off in shreds. If life is prolonged, cicatrices and strictures are formed. The *stomach* may contain a blackish, pulpy fluid, due to the action of the acid on mucus, blood, etc. It is coated on its internal surface with a black, sticky layer, beneath which the mucous membrane is reddened. The mucous membrane may be blackened in patches or stripes. The organ may be contracted and the mucous membrane corrugated. Sometimes perforation takes place and the acid blackens and softens the adjoining viscera. In protracted cases cicatrices are formed and the organ is contracted. If the poison is dilute there may be only the lesions of chronic gastritis.

The *blood* is sometimes thickened, syrupy, acid, and may form thrombi in the vessels.

The body may be partially preserved from decomposition, owing to the action of the acid upon the tissues.

Fatty degeneration of the renal epithelium is mentioned by some authors.

The solution of indigo in sulphuric acid, commonly known as sulphate of indigo, produces the same lesions as sulphuric acid, and also stains the tissues with which it comes in contact of a dark-blue color. It is stated that an indigo-blue tint is often found in the mucous membranes after poisoning by pure sulphuric acid.[1]

## NITRIC ACID.

Death may occur very soon after the taking of the poison, but does not usually occur for several hours, and may not take place for several days or weeks.

The surface of the mucous membrane of the *mouth*, *pharynx*, and *œsophagus* is covered with yellow eschars wherever the acid has touched it. Beneath and around the eschars the tissues are congested and red. The poison may be introduced into the œsophagus without acting on the mouth. The *stomach* contains a viscous, sanguinolent, yellow or greenish fluid. The mucous membrane is congested, red, swollen and softened, ecchymotic. It is rarely perforated. The *duodenum* may be inflamed, and the inflammation extend to its peritoneal coat. The rest of the intestines usually escapes the action of the acid.

The *larynx* is very frequently acted on by the acid. There are

[1] *Woodman and Tidy*, "Forensic Medicine and Toxicology," ed. 1877, p. 237.

yellow eschars, congestion and swelling of the mucous membrane, sometimes œdema of the glottis. The *trachea* may be inflamed and the *lungs* congested.

If the patient survives the first effects of the poison the lesions of chronic inflammation, cicatrization, and contraction may be found at a later period.

The acid nitrate of mercury, if taken in a concentrated form into the stomach, may produce the same lesions as nitric acid.

## HYDROCHLORIC ACID.

In fatal cases death occurs on the average in about twenty-four hours. The lesions are in general similar to those produced by sulphuric and nitric acids, except that the eschars are usually of a whitish color at first, becoming, after a time, discolored and disintegrated. It is also more common to find false membranes on the inflamed surfaces.

## OXALIC ACID.

In fatal cases death may occur within ten minutes (in one case in three minutes) or may be delayed for two or three weeks. The period of death does not depend, as do in general the symptoms, upon the amount and concentration of the poison.

The mucous membrane of the *mouth*, *pharynx*, and *œsophagus* is usually white and shrivelled, and easily peeled off, and may be covered with brownish vomit from the stomach. The œsophagus may be much contracted. The *stomach* is usually contracted and contains a dark-brown, acid, mucous fluid. The mucous membrane of the stomach may be pale, soft, and easily detached, sometimes looking as if it had been boiled in water. Sometimes it is red and congested ; sometimes blackened and gangrenous ; sometimes peeled off in patches. Perforation is of rare occurrence. If life be prolonged the whitened condition of the mucous membrane is succeeded by congestion and inflammation. The *small intestines* may be inflamed. Inflammation of the *pleura* and *peritoneum*, and congestion of the *lungs*, are of occasional occurrence. In some cases of death from oxalic acid there are no well-marked lesions.

Potassium oxalate produces the same lesions as oxalic acid.

## TARTARIC ACID.

This acid is seldom used as a poison, but in large doses may prove fatal. The lesions in the cases observed were redness and inflammation of the mucous membrane of the gastro-intestinal canal.

## POTASH, SODA, AND THEIR CARBONATES.

These substances are not commonly used as poisons with suicidal or homicidal intent, but may be taken by mistake. They may cause death in a few hours, or life may be prolonged for several weeks.

The mucous membrane of the *mouth*, *pharynx*, *œsophagus*, and *stomach* is softened, swollen, congested, and inflamed, or may be peeled off. It may be blackened from local changes in the blood. The mucous membrane of the *larynx* and *trachea* may also be swollen and inflamed.

If life is prolonged for some time, cicatrices and strictures of the *œsophagus* and *stomach* are apt to be produced as a result of the reparative inflammation.

## AMMONIA.

The vapor of strong ammonia may cause death from inflammation of the larynx and air passages. The strong solution of ammonia produces lesions similar to those of potash and soda. The *larynx*, *trachea*, and *bronchi* are frequently inflamed, and may be covered with false membranes. Fatal inflammation of the rectum and colon has been produced by an enema of strong solution of ammonia.

## POTASSIUM NITRATE.

Accidental poisoning sometimes occurs from large doses of this salt. In the observed cases there were intense congestion and inflammation of the *stomach* and *intestines*, and in one case a small perforation of the stomach.

For the effects of several infrequently employed salts of the alkalies and alkaline earths, which for the most part produce simple inflammation of the gastro-intestinal canal, we refer to special works on toxicology.

## PHOSPHORUS.

Poisoning by phosphorus is much more common in France and Germany than in this country. Some of the forms of rat poison, of which this is a frequent ingredient, and the ends of matches, are common media for its administration. It is more often used with suicidal than homicidal intent.

The post-mortem appearances vary according to the length of time which elapses before death, which may be from a few hours to several months.

If death takes place in a few hours the only lesions may be those produced by the direct local action of the poison. The mouth, pha-

rynx, and œsophagus usually escape. The stomach may be only slightly reddened, or there may be patches of inflammation and erosion. The contents of the stomach are often mixed with blood and may have the peculiar smell of phosphorus. There may be little bits of wood present when the poison has been taken from the heads of lucifer matches. It is said that the mucous membrane of the stomach may emit a phosphorescent light in the dark.

If death does not ensue until after several days the lesions are more marked. The body is usually jaundiced. There may be ecchymosis beneath the pericardium, pleura, and peritoneum, in the lungs, the kidneys, the bladder, the uterus, the muscles, and the subcutaneous connective tissue, and bloody fluid in the visceral cavities.

The *heart and voluntary muscles*, the walls of the *blood vessels*, and the endothelium of the air vesicles of the lungs may be in the condition of fatty degeneration. The blood is usually dark and fluid.

The *stomach* sometimes presents no very striking changes. There may be small circumscribed spots of inflammation, erosion, or gangrene, and occasionally perforation. The most constant change is a granular degeneration of the cells which fill the gastric follicles. In consequence of this the mucous membrane appears thickened, opaque, of white, gray, or yellow color.

The *small intestine* appears normal or is congested.

The *liver* is found in different degrees of parenchymatous and fatty degeneration, and is often stained yellow from the jaundice. It is usually increased in size and of a grayish, grayish-yellow, or light-yellow color, unless stained by the bile. Less frequently the centres of the acini are congested, or the entire liver is congested, or there are small hæmorrhages in the liver tissue. The liver may be soft, flabby, and smaller than normal. In the interstitial tissue of the liver and along the branches of the portal vein there may be marked infiltration with small spheroidal cells.

The *kidneys* often present parenchymatous and fatty degeneration of the epithelium. The *mesenteric lymph nodes* may be soft and swollen.

## ARSENIC.

This poison is very frequently employed with suicidal intent. Death may occur in a longer or shorter time from the direct irritative effects of the poison upon the gastro-intestinal canal, with the symptoms which usually accompany the ingestion of irritant poisons; or it may occur with symptoms of collapse, or coma, or shock; or the symptoms may resemble those of cholera. The average time of death in acute fatal cases is about twenty hours, but death has occurred in twenty minutes and has been prolonged for two or three weeks.

The *mouth, pharynx,* and *œsophagus* may be inflamed, but are more frequently unaltered. The *stomach* may be empty or contain mucus mixed with blood. The arsenic, in substance, may be found adherent to the mucous membrane or mixed with the contents of the organ. It has, in rare cases, been found encysted in the stomach in considerable quantity. When invisible to the naked eye a microscopical examination of the stomach contents will not infrequently reveal characteristic crystals of arsenious acid or some of its compounds. The stomach may be contracted and its mucous membrane corrugated. The entire inner surface may be red and inflamed, or there may be patches or streaks of inflammation or deep congestion. The inflamed and congested patches may be thickened and covered with false membrane mixed with larger and smaller particles or masses of the poison. Ulceration, perforation, and gangrene are rare. Blood may be extravasated into the mucosa and submucosa, and with the congestion give the mucous membrane a very dark-red or brown appearance. Frequently the mucous membrane is studded with small petechiæ. Sometimes the arsenic is converted in the stomach into the yellow sulphide. There may be acute gastritis, even when the poison is absorbed by the skin or otherwise and not introduced into the stomach. Taylor mentions a case in which the coats of the stomach were thickened and gelatinous, but not congested. The epithelium of the gastric glands may undergo granular and fatty degeneration.

The entire length of the *intestine* may be congested and inflamed, but the action of the poison does not usually extend beyond the duodenum. In some cases the *solitary lymph nodules, Peyer's patches,* and the *mesenteric nodes* are swollen. Inflammation of the *bladder* and *peritoneum,* and congestion and œdema of the *brain,* have been observed, but are neither frequent nor in any way characteristic.

Fatty degeneration of the *muscles, liver, kidneys, blood vessels,* and *vesicular epithelium* of the *lungs* may be produced in arsenical poisoning.

Alterations in the spinal cord indicative of acute myelitis have been described by Popon[1] as occurring in dogs poisoned with arsenious acid.

The walls of the stomach and intestines and other parts of the body may be preserved from decomposition for a long time after death by arsenical poisoning.

It should always be borne in mind, in examining cases of sus-

[1] *Popon,* "Ueber die Veränderungen im Rückenmarke nach Vergiftung mit Arsen," etc., Virch. Arch., Bd. xciii., p. 351.

pected arsenical poisoning, that death may be produced by arsenic and its compounds without any appreciable lesions. While in general it may be said that in the cases in which no lesions are discovered death has been rapid, the death may be delayed in such cases until long after a period at which, in other cases, marked inflammatory changes have occurred.

Compounds of arsenic, such as the chloride and sulphide, and the arsenite (Scheele's green, Paris green), are sometimes used for suicidal purposes, and produce lesions similar to those of arsenious acid. Paris green is a favorite article in New York, particularly among Germans, for suicidal purposes. It is usually taken in considerable quantities, and is often found in the stomach after death. [1]

## CORROSIVE SUBLIMATE.

The mucous membrane of the *mouth* and *throat* may be swollen, inflamed, or have a grayish-white appearance. The *œsophagus* may be swollen and white, or congested, or unaltered. The mucous membrane of the *stomach* is usually congested or inflamed, or there may be patches of softening, ulceration, or gangrene. Perforation is of rare occurrence. Small ecchymoses in the mucosa are not uncommon. Sometimes there is little or no change in the stomach. Sometimes the mucous membrane of the stomach is slate-colored from the deposition of metallic mercury from the decomposed salt. The *intestines* may appear normal, or there may be patches of congestion and ecchymosis.

The *larynx* and *trachea* may be congested. The *kidneys* may show parenchymatous and fatty degeneration of the epithelium.

## LEAD.

The different preparations of lead may prove fatal either from the immediate effect of large doses or from the gradual effects of re-

[1] It is advisable, in cases of suspected arsenic poisoning, particularly if the body have lain for some time, as in exhumations, to preserve not only all of the internal organs entire for the chemist, but also portions of the muscles (back, thigh, arm, and abdomen), and also one of the long bones, preferably the femur, since arsenious acid and its compounds are quite diffusible, and may be present in proportionately larger quantity in other parts than in the gastro-intestinal canal. It is desirable to save the whole of the internal organs, and to weigh the muscle and bones as well as the whole body at the autopsy, in order that the calculations of the chemist, in case arsenic be found, may rest upon a definite basis, and be as little as possible dependent upon estimates, whose value may be questioned by lawyers should the case come into the courts.

An interesting article on arsenic as a poison, with various collateral data by *Pellew*, will be found in Hamilton's "System of Legal Medicine," vol. i., p 349.

peated small doses. Although there may be marked symptoms during life, the post-mortem lesions are few and variable.

Large doses may produce acute gastritis, and sometimes a whitening of the mucous membrane. The intestines are generally contracted, and there may be fatty degeneration of the renal epithelium; very frequently there are no appreciable lesions.

In chronic lead poisoning the intestines may be contracted, the voluntary muscles flabby and light-colored, or partially replaced by connective tissue, and there may be chronic meningitis.

## COPPER.

Acute poisoning by salts of copper is not very common, but it is of occasional accidental occurrence, and the salts are infrequently used with suicidal intent. The sulphate and acetate are the most important salts in this respect. Soluble salts of copper may be formed in the use of copper cooking utensils, and accidents most frequently occur in this way.

The post-mortem appearances are somewhat variable. The *pharynx* and *œsophagus* may be somewhat inflamed or unchanged. The mucous membrane of the *stomach* and *intestines* may be inflamed, ulcerated, or gangrenous, and perforation and peritonitis may occur. The mucous membrane may have a diffuse greenish color, or particles of the salt may be found adhering to it.

## TARTAR EMETIC.

This preparation of antimony may prove fatal when administered in a single large dose or in repeated small doses. The post-mortem lesions are not constant. In cases of chronic poisoning there are usually no appreciable lesions.

In cases of acute poisoning there may be evidence of acute inflammation of the *œsophagus*, *stomach*, *intestines*, and *peritoneum*. Sometimes the stomach exhibits no lesions, while the intestine is involved. The *larynx* and *lungs* may be deeply congested.

## VEGETABLE IRRITANTS.

*Aloes, colocynth, gamboge, jalap, scammony, savin, croton oil, colchicum, veratria, hellebore, elaterium,* and *turpentine.*

All these drugs may produce poisonous effects. The post-mortem lesions are congestion, inflammation, and sometimes ulceration of the gastro-intestinal mucous membrane; but these lesions are sometimes present and sometimes absent.

## CANTHARIDES.

This substance may be given in powder or tincture. The entire length or only a portion of the *alimentary canal* may be congested or inflamed. There may be patches of gangrene of the mucous membrane of the *stomach*. When the poison was taken in substance a microscopical examination of the contents of the alimentary canal or of the mucous membrane may reveal the glistening green and gold particles of the fly.

The *kidneys*, *ureters*, and *bladder* may be congested and inflamed. There is sometimes congestion of the *brain* and its membranes.

## OPIUM.

The post-mortem appearances in persons who have died from opium poisoning are inconstant and not characteristic. Congestion of the *brain* and its membranes, with serous effusion in the membranes and ventricles, and congestion of the lungs, are changes occasionally seen, but they are frequently entirely absent, and when present are not characteristic of death from this poison.

## POISONOUS FUNGI.

The action of these substances varies greatly, and the post-mortem appearances are inconstant and not characteristic. In general, when any lesions are present, they are those of gastro-intestinal irritation or of venous congestion, or both.

Microscopical examination may reveal characteristic fragments of fungi in the contents of the alimentary canal.

## HYDROCYANIC ACID.

This poison in fatal doses may destroy life in a very short time. The post-mortem appearances are inconstant and not characteristic. The skin may be livid and the muscles contracted. The *stomach* may be congested or normal. The most frequent internal appearances are those of general venous congestion. Under favorable conditions the odor of prussic acid may be detected in the stomach or blood or brain, or other parts of the body. It may be absent in the stomach and present in other parts of the body. If the patient have lived for some time the odor may be absent altogether.

*Cyanide of potassium* may produce the same lesions as prussic acid, and there is the same inconstancy in their occurrence.

*Nitrobenzole.*—This substance produces general venous conges-

tion, and the odor of the oil of bitter almonds may be more or less well marked in the body after death.

## CARBOLIC ACID.

When this poison is taken into the stomach the mucous membrane of the *mouth*, *œsophagus*, and *stomach* may be white, corrugated, and partially detached in patches, and the edges of the affected parts may be hyperæmic or there may be patches of extravasation. Brownish, shrunken patches may be present about the mouth. The *brain* and *meninges* may be congested. There may be congestion and œdema of the *lungs*, and congestion of the *liver* and *spleen*. The blood is usually dark and fluid. The *urine* is usually of a dark or greenish color. The odor of the poison may be evident in the body and in the urine.

## ALCOHOL.

The different preparations of alcohol, when taken in concentrated form or in large quantities, sometimes produce sudden coma and death in from half an hour to several hours. In acute poisoning, if death have followed soon after the ingestion of the poison, the body may resist decomposition for an unusual length of time. The stomach and tissues may even have a more or less well-marked alcoholic odor. The *stomach*, and even the *œsophagus* and *duodenum*, may be of a deep-red color. There may be punctiform ecchymoses in the gastric mucous membrane. In many cases the stomach is apparently quite normal. There is apt to be venous congestion in some of the internal organs, but this is not constant. There is frequently congestion and sometimes extravasation of blood in the *brain* and its *membranes*, and œdema of the membranes or of the brain substance, or both. There may be a serous effusion in the ventricles of the brain. The bladder is frequently distended with urine, as in other cases in which death is preceded by a period of unconsciousness.

Chronic alcohol poisoning is of a different nature. The subjects of it may die from some other disease, or they die after a debauch without anything else to account for their death. In the latter case there may be *delirium tremens*, or the patient dies exhausted and comatose. Chronic alcoholism is not infrequently mistaken clinically for meningitis. The post-mortem lesions are sometimes marked, sometimes absent. There may be chronic pachymeningitis, resulting in thickening of the *dura mater* and its close adherence to the skull. The *pia mater* may be thickened and œdematous. The *brain* may be normal or œdematous or atrophied. The *lungs* are frequently

congested. The heart may be thickly covered with fat, and its walls may be flabby and fatty. The *stomach* frequently presents the lesions of chronic gastritis. The *liver* may be cirrhotic, with or without fatty infiltration. The *kidneys* may present the lesions of parenchymatous or fatty degeneration or of chronic diffuse nephritis.

It should always be remembered, however, that all or a part of the above lesions may be absent in the bodies of drunkards, and, furthermore, that the same lesions may be due to other causes.

## CHLOROFORM.

Chloroform may cause death when it is taken in fluid form into the stomach or when inhaled. Death from swallowing liquid chloroform is rare, and its immediate cause is usually uncertain. The post-mortem changes are variable ; sometimes there are no lesions. In some cases there is simple reddening of the gastric mucous membrane ; occasionally there is acute gastritis or ulceration of the mucous membrane. The odor of chloroform may or may not be evident. Discoloration and softening of the mucous membrane of the pharynx, œsophagus, and duodenum have been observed. There may be general venous congestion ; the heart may be flabby. Bubbles of gas have been frequently seen in the blood, but this is not characteristic. Death from inhalation of chloroform is a not infrequent accident in surgical practice. After death from inhalation the results of the examination are usually quite negative.

## ETHER.

The inhalation of ether occasionally causes death. The post-mortem examination is negative. The ingestion of fluid ether may induce inflammation of the stomach. The odor of ether may be perceptible if the autopsy is made soon after death.

## CHLORAL HYDRATE.

There are no characteristic post-mortem appearances after death by chloral. Hyperæmia of the brain, and the odor of the drug, have been noticed.

## STRYCHNIA—NUX VOMICA.

The post-mortem appearances after poisoning by these drugs are not characteristic and are inconstant. The body is usually relaxed at the time of death, but the rigor mortis usually comes on early and remains long. There may be congestion of the *brain* and *spinal cord*, and sometimes of the *lungs* and *stomach*.

### CONIUM, ACONITE, LOBELIA INFLATA, DIGITALIS, STRAMONIUM.

These vegetable poisons are administered in their natural form of leaves, berries, and roots, or in tinctures, infusions, and extracts, or in the form of their active alkaloid principles.

If the leaves, berries, or seeds are given they may be detected in the contents of the stomach by microscopical examination. Otherwise the results of autopsies are not characteristic.

The *brain* and its membranes, and the lungs, may be congested. The *stomach* may present patches of congestion, inflammation, and extravasation, or its entire mucous coat may be inflamed, or it may appear normal.

Microscopical examination of the contents of the alimentary canal may reveal characteristic seeds or fragments of leaves.[1]

### PTOMAÏNES AND OTHER PUTREFACTIVE PRODUCTS.

The effects upon the tissues of various forms of bacterial poisons have been considered in the section on Infectious Diseases and elsewhere. Too little is as yet known of the chemistry of these toxic products to render their systematic consideration at all satisfactory. But it seems likely that these products may have medico-legal bearings which will in the future make their consideration of importance in certain cases of death from obscure causes.[2]

### CARBONIC OXIDE.

This is one of the gases formed in the burning of charcoal, and forms one of the ingredients of illuminating gas. The most characteristic post-mortem appearance is the cherry-red color of the *blood*, and of the tissues and viscera which contain blood. The presence of carbonic acid in the gas may obscure the bright red of the carbonic oxide by the dark color which it induces in the blood.

### CARBONIC ACID.

The lesions are essentially those of asphyxia, but the brain is said

---

[1] Consult *Guy and Ferrier*, "Principles of Forensic Medicine," 7th ed., 1895.

[2] For certain chemical aspects of this newly opened field in toxicology consult *Vaughan* in Hamilton's "System of Legal Medicine," vol. i., p. 475, and *Vaughan and Novy*, "Ptomaïnes and Leucomaïnes," 3d ed., 1896.

to be more frequently congested than in asphyxia by simple obstruction of respiration.

For a more detailed consideration of poisons, their effects, modes of detection, etc., consult *Taylor* on Poisons; *Maschka's* "Handbuch der gerichtlichen Medicin," Bd. ii.; *Woodman and Tidy*, "Forensic Medicine." *Wormley's* "Micro-chemistry of Poisons" contains a series of good plates of the microscopical appearance of various forms of crystals of poisonous substances.

*Lesser's* "Atlas der gerichtlichen Medicin" contains a series of fine colored plates showing the appearance of the stomach after the action of various poisons. The work of *Guy and Ferrier* on "Forensic Medicine," 7th ed. revised by *Smith*, contains in very compact and reliable form much information on the general subjects treated in the foregoing section.

MEDICAL DEPARTMENT
YORKSHIRE COLLEGE
VICTORIA UNIVERSITY

# INDEX.

*Abbot*, bacteriology, ref., 182
*and Ghiriskey*, diphtheria in animals, ref., 253
rhinitis, membranous, ref., 538
*Abel*, capsulated bacillus, ref., 260
ozæna, ref., 538
Abdomen, examination of portion of, 22, 30
*Achard and Phulpin*, bacteria in body after death, 167
Achorion Schönleinii, 169
Acid, carbolic, poisoning, lesions of, 823
carbonic, poisoning, lesions of, 825
hydrochloric, poisoning, lesions of, 816
hydrocyanic, poisoning, lesions of, 822
nitric, poisoning, lesions of, 815
osmic, use of, in preserving tissues, 54
oxalic, poisoning, lesions of, 816
picric, use of, in decalcifying, 52
sulphuric, poisoning, lesions of, 814
tartaric, poisoning, lesions of, 816
Aconite poisoning, lesions of, 825
Acrania, 387
Acromegalia, 410
Abscess, 124
of the brain, 381
Actinomyces, 262
Actinomycosis, 262
Addison's disease, 800
Adénie, 796
Adenoid polyp of pharynx, 544
Adenoma, 328, 330
Adrenals, examination and preservation, 32
lesions of, 644, 801
Aërobic bacteria, 148
Agar, nutrient, 160
Aguillula, 141
*Ahlfeldt*, placental cysts, ref., 734
*Akerlund*, membranous enteritis, ref., 564
Albumen fixative, 59
Alcohol, as preservative and hardening agent, 19, 52
poisoning, 823
*Alexander*, lymph nodules in bladder, ref., 684
*Alexander*, adrenals and nervous system, ref., 644
Alexins, 178
Alimentary canal, 533
Aloes poisoning, 821
Ammonia poisoning, 817
Amœba coli, 127, 569
colitis, 569
dysenterica, 127
Amyelia, 405
Amyloid degeneration, 100
degeneration, tests for, 32, 35, 101
Amyotrophic lateral sclerosis, 396
Anæmia, 69, 77
changes of blood in, 79
infantum pseudo-leukæmica, 797
of children, 797
pernicious, 792
pernicious, changes of blood in, 79, 793
Anaërobic bacteria, 148
Anencephalia, 387
Aneurism, aortic, 512
cirsoid, 509
dissecting, 515, 516
false, 515
heart, 500
miliary, of brain, 375
minute, of brain, 15
multiple, 507
Angina, membranous, 204
Angiocholitis, 617
Angioma, 324, 326
Anhydræmia, 76
Anilin-gentian-violet solution, 156
Animals, infectious diseases of, 285
Anthrax, 209
bacillus of, 210
immunity, artificial, in cattle, 212
intestinalis, 577
Antitoxin, 181
diphtheria, 253
pneumonia, 202
streptococcus, 193
tetanus, 256
Aorta, aneurism of, 512

Aorta, inflammation of, 508
Aphthæ, 170
Apoplexy, brain, 374
serous, 373
Appendicitis, 573
bacteria in, 575
Appendix vermiformis, tumors of, 575
Archiblast and parablast, relation of tumors to, 294
*Arndt*, peritonitis, ref., 583
*Arnold*, acromegalie, ref., 410
hairy polyps of pharynx, ref., 543
lymphatic tissues in liver, ref., 614
Arsenic poisoning, lesions of, 818
Arteries, atheroma of, 509
dilatation of, 509
inflammation of, 503, 509
rupture of, 514
sclerosis of, 507
stenosis of, 513
terminal character of, 74
tumors of, 516
wounds of, 514
Arteritis, 503
aneurisms of, 509
chronic, 504
obliterating, 505
tuberculous, 509
Arthritis, acute, 775
chronic, 776
deformans, 776
gouty, 777
tuberculous, 777
Arthropods, 141
Arthrogenous spores in heart, 147
Ascaris, 136, 141
*Aschoff*, parenchyma-cell emboli, ref., 73
Asiatic cholera, 265
*Askanazy*, endothelioma of kidney, ref., 680
Asphyxia, 809, 813
Atelectasis of lungs, 436
Atelomyelia, 405
Atheroma of arteries, 509
Autopsies, medico-legal, 41
method of making, 3

*Babes*, hydrophobia, ref., 276
Bacillus, 144
aërogenes capsulatus, 193, 261
anthracis, 210
coli communis, 193, 260
diphtheriæ, 250
lepræ, 230
mallei, 235
œdematis maligni, 259
of bubonic plague, 239
Bacillus of influenza, 257
of measles, 274
pneumoniæ (Friedländer), 259
proteus, 193, 261
pyocyaneus, 193, 261
pyogenes, 193
pyogenes fœtidus, 193
pyogenes soli, 193
rhinoscleromatis, 238
tetani, 255
tuberculosis, 213, 215
typhi abdominalis, 240, 246
Bacteria, 143
action of cold on, 148
action of heat on, 148
action of, in the body, 172, 173, 174
aërobic, 148
anaërobic, 148
blood serum as culture medium for, 162
capsules of, 146
changes in the body induced by, 172
chromogenic, 150
classification of, 153
collection of, by sterilized swab, 166, 167
colonies of, 159
cultivation of, 158
culture medium for, 159
disinfectants, action on, 149
distribution in nature, 151
Esmarch's soil culture of, 166
examination for, at post mortems, 167
fermentations by, 150
forms of, 144
growth, forms of, 145
importance, relative, of, in disease, 175
in fluids, to stain, 154
in tissues, to stain, 156
in water, 151
light, action of, on, 11, 19
method of staining, Gram's, 156
method of study of, 154
morphological examination of, 154
nitrifying, 150
nutrition and functions of, 148
parasites, 152
Petri plate culture of, 163
photogenic, 150
plate culture of, 163
proof of relation of, to disease, 175
protective mechanism of the body against, 171
putrefaction by, 150
relations of, to diseases, 171
rôle of, in nature, 149

Bacteria, safeguards of the body against, 171
saprophytic, 152
solid media for cultivation of, 159
spore staining in, 155
spores of, 147
staining of, 154
thermophyllic, 148
various forms of, 152
varieties in, 147
zymogenic, 150
Bacterial emboli, 172
inoculations of animals, 166
Bacterio-protein, 173
*Bailey and Ewing*, Landry's paralysis, 400
Bailey's knife for division of spinal cord, 12
Balanitis, 743
Balantidium coli, 129
*Barker*, malaria, ref., 283
*Flexner and*, meningitis, ref., 200
*Baumgarten*, "Jahresbericht," ref., 182, 226
Basedow's disease, 643
*Beck*, influenza bacillus, ref., 258
*Beebe, Park and*, diphtheria, ref., 252
*Benecke*, 73
*Bergeron*, stomatite ulcerosa, ref., 534
*Berkley*, nerve lesions, ref., 377
*Berry*, appendicitis, ref., 575
*Berthenson*, heart tumors, ref., 502
*Biedl and Kraus*, bacteria eliminated from the body, 178
*Biggs, Park, and Beebe*, diphtheria, bacteriological diagnosis in, ref., 254
Biliary calculi, 619
passages, inflammations of, 617
*Birch-Hirschfeld*, epithelioma of pleura, ref., 426
Bladder, urinary, bacteria in, 685
calculi, 687
dilatation of, 681
displacements of, 681
diverticula of, 682
hæmorrhage of, 683
herniæ of, 682
hyperæmia of, 683
inflammation of, 683, 685
lesions of, 680
malformations, 680
parasites of, 687
perforation of, 682
rupture of, 687
Blood, air in, 90
alkaline changes in, 76
anæmia, pernicious, 792
chlorosis, 791
Blood composition, alterations of, 791
changes in, after extravasation, 71
changes in circulation of, 69
changes in structure of, 77
circulation of, changes of, in inflammation, 111
clots in heart, 27
coagulability, changes in, 76
coagulation of, in body after death, 10
composition of, changes in, 76
distribution of, in body after death, 10
examination, morphological, 86, 87
extravasation of, 69, 70
fat in, method of staining, 89
foreign bodies in, 89
leukæmia, 794
plethora, 77
Blood cells, diapedesis of, in inflammation, 112
red, changes in, 77
red, nucleated, 81
red, regeneration of, 95
white, changes in, 82
white, forms of, 82
white, regeneration of, 95
Blood serum, as culture medium, 162
immunization, 181
Blood, staining methods, 88
Blood vessels, atrophy of, 502
brain, preservation of, 19
calcification of, 503
degeneration of, 503
formation of new, 121
hypertrophy, 502
inflammation of, 503
volume of, increase of, 77
Bone, abscess, 761
atrophy, 771
caries, 766
dislocations, 754
fractures, 754
hæmorrhage, 754
healing of fractures of, 125
hyperæmia, 754
inflammation, 755
necrosis, 765
parasites, 774
tumors, 771
wounds, 754
Bone marrow, alterations of, in anæmia, 770
alterations of in leukæmia, 770
*Bolton*, Bacillus pyogenes soli, ref., 193
*Bordoni-Uffreduzzi*, cultivation of lepra bacillus, 230
Bothriocephalus, 135
Brain, abscess, 381

Brain, anæmia of, 373
atrophy of, 378
axis, method of separation of, 17
changes in toxæmia, 376
cysts in, 380, 387
degeneration of, 371
dura mater, 347
embolism, 370
hæmorrhage in, 379
hernia of, 388
holes in, 380
hyperæmia of, 373
hypertrophy of, 378
inflammation of, 380, 382
inflammation in new-born, 383
inflammation, syphilitic, 384
inflammation, tuberculous, 384
malformations of, 387
Meynert's method of dissection, 15
œdema of, 373
parasites in, 387
paresis, lesions of, in, 385
pia mater, 352
pigmentation, 86
post-mortem examination and preservation of, 11, 13, 15, 17, 18
sand, 368
sclerosis of, 382
secondary degeneration of, 377
softening, 381
thrombosis, 370
tumors of, 386
ventricles, 365
weight of, 12
wounds of, 379
*Bramann*, cysts of mesentery, ref., 589
*Brannan and Cheesman*, typhus fever, ref., 275
*Brens*, cysts of myomata, ref., 712
Bright's disease, acute, 650, 655
chronic, 659, 660, 668
*Brigidi and Piccoli*, persistent thymus, ref., 643, 796
*Brockway*, specimen of trichocephalis dispar, 138
Bronchi, examination and preservation of, 28, 29
inflammation of, 426
tumors of, 431
Bronchiectasia, 429
Bronchiolitis exudativa, 429
Bronchitis, croupous, 429
acute catarrhal, 426
chronic catarrhal, 428
Broncho-pneumonia, 443
Broth, nutrient, 161
Brown induration, 449
Bruises, post-mortem, appearance of, 8
Buboes, 524
Bubonic plague, 239
Bulbar paralysis, 396
Burning, death from, 807
*Butler*, membranous enteritis, ref., 564
*Byron*, cultivation of lepra bacillus, 230

Cadaveric lividity, 5
Cæcum, 573
Calcareous degeneration, 105
Calcification, 105
Calculi, biliary, 619
renal, 677
urinary, 687
Calvarium, method of opening of, 10
*Campbell*, pharyngo-mycosis, ref., 284
Cancer of brain, 351
*Canon*, bacteria in sepsis, ref., 197
*Pfeifer, Kitasato and*, influenza bacillus, ref., 257
*and Pielicke*, bacillus of measles, ref., 274
Cantharides poisoning, 822
Capillaries, blood, 520
Capillary bronchitis, 443
Capsules, suprarenal, 32
Carbonic oxide poisoning , 825
Carbuncle, 209
Carcinoma, 331
alveolar, 342
cells, 334
colloid, 341
epithelial pearls in, 340
forms of, 336
genesis of, 328, 333
metastasis in, 334
myomatous, 343
relation of sporozoa to, 129
Caries, 766
Carnoy's fluid, 50
*Caspar*, description of fœtus, 42
Catarrhal fever, 257
inflammation, 114
Cell division, 92
nucleus, changes in, during division, 92
Cells, epithelioid, in granulation tissue, 122
new, in inflammation, 109
pus, 117
Celloidin as embedding agent, 56
Cephalocele, 388
Cercomonas intestinalis, 129
Cerebro-spinal meningitis, bacteria in, 200
Cestoda, 131
Chancre, 233

Charbon, 209
Charcot's crystals, 85
Chemotaxis, 149, 175
*Cheesman and Brannan*, typhus fever, ref. 275
Cheesy degeneration, 97
Chest serum as cultivating medium for bacteria, 162
*Chiari*, infarction of uterus, ref., 703
Chloral hydrate poisoning, 824
Chloroform poisoning, 824
Chloroma, 312
Chlorosis, 791
Cholecystitis, 617
Cholera, Asiatic, 265
Cholesteatoma, 315
Chondroma, 317
Choroid plexus, lesions of, 14, 365
Chromic and acetic acid mixture of Flemming, 64
Chromosomes, 93
Cicatrices, post-mortem appearance of, 9
Cicatrix, formation of, 123
Circulation, changes in, 69
Cirrhosis, hypertrophic, of liver, 605
of kidney, 668
of liver, 604
Clostridium forms of bacteria, 144
Clots of heart, pre-examination of, 27
Cloudy swelling, 98
Coagulation necrosis, 96
of blood in heart, 27
*Cobbold*, entozoa of man, 142
Cocci, 144
Coccidium oviforme, 128
Colchicum poisoning, 821
Colitis, amœbic, 569
bacteria in, 572
catarrhal, acute, 563
chronic, 573
croupous, 567
follicular, 568
membranous, 564
necrotic, 572
Colloid degeneration, 103
carcinoma, 341
Colocynth poisoning, 821
Colon bacillus, 260
Comma bacillus, 266
Commensals, bacterial, 152
Concurrent infection in tuberculosis, 224
Condyloma, syphilitic, 233
Congestion in inflammation, 108
*Cohnheim*, theory of origin of tumors, 290, 332
on infarction, 74
Conium poisoning, 825
Contagious diseases, 187
Contusions, post-mortem appearance of, 7
Cooling, post-mortem rate of, 6
Copper, poisoning by, 821
*Cornil*, myelocytes, 85
Corpora aliena articulorum, 779
amylacea, 101
Corrosive sublimate fixative agent, 55
sublimate poisoning, 821
*Councilman*, sudden death from heart, ref., 487
*and Lafleur*, on amœbic dysentery, 182
*Courty*, hymen, lesions of, 692
Cowper's glands, 753
*Cramer*, sunstroke, ref., 806
Craniotabes, 768
Croton oil poisoning, 821
Cryptogenetic pyæmia, 197
Cryptorchismus, 745
Cultivation of bacteria, 158
*Cullen*, rapid method of hardening, 51
Cyclopia, 387
Cylindroma, 316
Cystitis, 683
Cysts, 295
ciliated, 297
method of preserving, 64

*Darling*, Bacillus coli communis, ref., 260
*David*, bacteria of mouth, ref., 538
Death, causes of, 3.
Decalcification of bone, 51
Decidua, remains of, in uterus, 718
Deciduoma malignum, 717
Deck plugs, for mounting specimens in celloidin, 57
Decomposition, post-mortem, 495
Defensive proteids, 178
Degeneration, acute, 98
amyloid, 100
calcareous, 105
cheesy, 97, 219
coagulation necrosis, 96
colloid, 103
fatty, 98
forms of, 96
glycogen, 102
granular, 98
gray, of nervous system, 396
hyalin, 104
inflammatory, 107
mucous, 102
parenchymatous, 98
secondary, of spinal cord, 393
Degeneration, waxy, 100

Delafield's hæmatoxylin, 60
Demonstration specimens, and preservation of, 63
Dentrites, 393
Diabetes mellitus, 804
Diapedesis, 70, 112
Diastematomyelia, 405
Digitalis poisoning, 825
*Dinwiddie*, veterinary microbiology, ref., 285
Diphtheria, 250
antitoxin of, 181, 250, 253
heart lesions in, ref., 250
pseudo, 204
toxin, 253
Diphtheroid-angina, 204
Diplobacillus, 146
pneumoniæ, 193
Diplococcus, 145
intracellularis meningitidis, 200
lanceolatus, 200, 201, 438
pneumoniæ, 438
Diplomyelia, 405
Discoloration, post-mortem, 5
Distoma, 130
*Dittel*, urethral strictures, ref., 689
*Dmochowski and Janowski*, adenoma of liver, ref., 612
pyogenic powers of typhoid bacillus, ref., 247
*Dobrowolski*, lymph nodules, ref., 540
Dochmius duodenalis, 137
*Dock*, chloroma, ref., 312
trichomonas, 130
*Dowd*, pyogenic bacteria in New York, ref., 192
Dropsy, 71
Drowning, 811
*Dunbar*, Asiatic cholera, ref., 268
typhoid fever, ref., 249
*Dunin*, fragmentation of heart muscle, ref., 493
Duodenum, removal, examination, and preservation of, 35
ulcers of, 562
Dura mater, 347
examination and preservation of, 11, 18
hæmorrhage, 347
inflammation, 348
thrombosis, 348
tumors, 351
Dust, anthrax bacilli in, 309
bacilli in, inducing tuberculosis, 223
pyogenic bacteria in, 190

Ear, internal, pre-examination of, 18
Echinococcus, 132, 134
multilocularis of liver, 615
of liver, 614
Ecchondroses, 318
Ecchymoses, 8, 70
*Edebohls*, hepatic abscess, ref., 602
*Edel*, diverticula, false, intestines, ref., 577
*Eden*, placental structure, ref., 733
*Edmunds*, Basedow's disease, ref., 643
*Ehrlich*, change in red blood cells, ref., 81
*and Birch-Hirschfeld*, anæmia, ref., 77
Ehrlich's method of fixing blood, 88
Elaterium poisoning, 824
Electricity, death from, 808
*Ely*, diverticula of bladder, ref., 681
Embedding in celloidin, 56
in paraffin, 58
Emboli, 73
fat, 89
parenchyma cell, 73
Embolism, 73
Embryo, human, size of, at various periods, 42
Emigration in inflammation, 109, 111
Empyema, 421
Encephalitis, 380
chronic, 382
in new-born, 383
Encephalocele, 388
Encephaloid cancer, 341
Endogenous spores in bacteria, 147
Endocarditis, acute, 494
chronic, 496
malignant, 494
mycotic, 494
tuberculous, 498
ulcerative, 494, 498
Endocardium, fatty degeneration of, 491
post-mortem appearance of, 27
staining process of, 27
Endometritis, acute, 704
chronic, 705
croupous, 706
syphilitic, 707
tuberculous, 706
Endothelioma, 312
Enteroliths, 577
Enzymes, bacterial, 150
Eosin, use of, in tissue staining, 61
Eosinophile cells, 82
Ependyma, 365
inflammation of, 365
preservation of, 18
tumors of, 368
Ependymitis, 365
Epispadias, 742

Epithelioma, 336
Epulis, 309
Erysipelas, 194
Esmarch roll culture, 166
Ether poisoning, 824
*Eulenberg*, Basedow's disease, ref., 643
*Ewing, Bailey and*, Landry's paralysis, ref., 400
Exophthalmic goitre, 643
Exostoses, 319
Exudates, 72
in inflammation, 110
inflammatory disposal of, 115
Eyes, post-mortem examination of, 18

Fallopian tubes, displacement and distention of, 730
tubes, hæmorrhage of, 731
tubes, inflammation of, 731
tubes, length of, 40
tubes, malformation of, 730
tubes, tumors of, 732
Famine fever, 269
Farcy, 235
*Farner*, Basedow's disease, ref., 643
Fatty degeneration, 98
infiltration, 98
*Fenomenodes*, placental cysts, ref., 734
*Ferguson*, specimen of filaria, 140
Fibrin, formation of, in inflammation, 114
Fibroblasts, 122
Fibroma, 299
Fibrosis, 125
Filaria, 140
*Finkler*, pneumonia, ref., 257
Fission fungi, 143
Fistula, vesico-vaginal, 696
Fistulæ, recto-vaginal, 696
*Fitz*, pancreas lesions, ref., 634
Fixative, albumen, 59
Flemming's chromic and acetic acid mixture, 64
osmic acid mixture, 54
*Flexner*, action of toxalbumins, ref., 173
Bacillus pyogenes filiformis, ref., 193
bacteriological examination at autopsies, ref., 168
lympho-sarcoma, ref., 796
neuro-epithelioma, ref., 340
terminal infections, ref., 185
typhoid bacilli, ref., 247
*and Barker*, meningitis, ref., 200
*Welch and*, Bacillus aërogenes capsulatus, ref., 261
*Welch and*, effects of diphtheria bacilli in animals, ref., 253
53

Fœtal tissues, preservation of, 49
Fœtus, size of human, at various periods, 42
*Foote*, oysters and typhoid, ref., 249
*Formad*, colon, large, ref., 558
Formalin as preservative and hardening agent, 19, 54
Fractures, healing of, 125
post-mortem marks of, 9
*Fraenkel*, endothelioma of pleura, ref., 426
hydatid moles, ref., 735
pneumococcus of, 201
*Freeborn*, formula for picric acid fuchsin, 62
ovarian papillomata, ref., 728
*Freeman*, milk and typhoid fever, ref., 249
*Freudweiler*, phlebitis, ref., 519
Friedländer's pneumococcus, 259
*Friedreich*, muscle atrophy, ref., 786
Frog, exudative inflammation in, 110
Frozen sections, 51
Fuchsin, picro-acid, 61
Fungi, poisonous, 822

Gage's hæmatoxylin, 61
Gall bladder, lesions of, 617
tumors of, 620
Gall ducts, inflammation of, 617
tumors of, 620
Gamboge poisoning, 821
Ganglion cells, changes of, in toxæmia, 376
Gangrene, hospital, of vulva, 693
Gastritis, catarrhal, acute, 547
catarrhal, chronic, 547
croupous, 549
phlegmonous, 549
suppurative, 549
toxic, 550
Gelatin, nutrient, 159
Generative organs, female, 39, 692
organs, male, 38, 741
Genito-urinary organs, post-mortem examination of, 38
Germs, 143
*Ghriskey, Abbott and*, diphtheria in animals, ref., 253
Giant cells, 92, 218
Gigantoblasts, 82
Gill clefts, persistent, 538
Glanders, 235
Glands, agminated, of intestine, 561
*Glazier*, trichina, ref., 142
Glioma, 320
Gliomyxoma, 321
Glio-sarcoma, 321

Glomerulo-nephritis, 650, 655, 660
Glossitis, 537
Gluge's corpuscles, 372
Glycogen degeneration, 102
Goitre, 639
exophthalmic, 643
Golden coccus, 189
*Goldscheider*, puerperal fever, bacteria in, ref., 197
Golgi, silver stain, 62
hydrophobia, ref., 276
Gonococcus, 206, 207
bacterial associates of, 208
Gonorrhœa, 206
Gout, 802
*Graham*, displacements of liver, ref., 591
Gram's method of staining bacteria, 156
method of staining bacteria, Weigert's modification of, 157
Granulation tissue, 121, 124
Granulomata, 397
Graves' disease, 643
*Grawitz*, lung infarctions, ref., 434
Gregarinæ, 128
*Gross*, tumors of male mamma, ref., 753
*Guarnieri*, agar for pneumococcus, 201
Guinea-worm, 140
Gumma, 233

Hæmangioma, 326
Hæmatocele, 746
uterine, 703
Hæmatogenesis, defective, 78
Hæmatoidin, 78
Hæmatolysis, excessive, 78
Hæmatoma, 70
Hæmatomyelia, 391
Hæmatomyelopore, 391
Hæmatophilia, 799
Hæmatoxylin, Delafield's, 60
Gage's, 61
Heidenhain's iron of, 61
Hæmatozoon of malaria, 280
Hæmoglobinæmia, 77
Hæmorrhage by diapedesis, 70
by rhexis, 69
Hæmorrhagic diathesis, 799
infarction, 70
infections, 799
Hæmosiderin, 78
*Hahn*, cysts of mesentery, ref., 589
*Halliburton*, chemical physiology, ref., 174
Hanging, 8, 810
*Hansemann*, diverticula, false, of intestine, ref., 577
Hardening of tissues, 52
Hayem's method of fixing blood, 88
solution in blood examination, 87
Head, method of post-mortem examination of, 10
Healing, first and second intention, 123
of wounds, 120
regeneration of tissue in, 94
Heart, abnormal size of, 485
aneurism of, 500
atrophy of, 487
changes in position of, 485
clots in, 27
degeneration of, 490
dilatation of, 489
examination of, 25, 26, 28
fat tissue of, atrophy of, 492
fatty, 490, 492
fragmentation of muscle of, 493
hyperplasia of, fibrous, 500
hypertrophy of, 487
inflammation of, 494
lipomatosis of, 492
malformations of, 483
malpositions of, 485
parasites in, 502
rupture of, 486
softening of, 493
thrombosis of, 501
tumors of, 502
valves, lesions of, 500
valves, test for sufficiency of, 26
vegetations, 494, 497
weight of, 27
wounds of, 486
Heidenhain's iron hæmatoxylin, 61
*Heiman*, chest serum, 162
study of gonococcus, ref., 207
Hellebore poisoning, 821
Hepatic artery, lesions of, 593
veins, 598
Hepatitis, acute, 601
chronic, 604
syphilitic, 608
tuberculous, 609
*Heppner*, hermaphroditism, ref., 742
Hermaphroditism, 742
Hernia intestino-vaginalis, 696
uterine, 702
vesico-vaginalis, 695
*Hess*, cysts, ciliated, ref., 297
Heterotopia, 406
false, 407
*Hewetson, Thayer and*, malaria, ref., 283
*Hintze and Lubarsch*, elimination of bacteria from body, 178
*Hodenpyl*, actinomycosis of lung, ref., 263

*Hodenpyl*, on appendicitis, ref., 575
rapid method of hardening, 51
tonsils, faucial, ref., 540
*Prudden and*, action of dead tubercle bacilli, 222
Hodgkin's disease, 796
*Hoffman*, hermaphroditism, ref., 742
*Hofmeier*, placenta, ref., 734
Horseshoe kidney, 646
Hospital fever, 275
*Houl*, hæmorrhagic infections, 799
*Hueppe* on bacteriology, ref., 182
*Huetes*, intestinal tumors, ref., 577
*Hun and Prudden*, myxœdema, ref., 642
Hyalin degeneration, 104
thrombi, 72
Hydatid moles, 304, 735
Hydræmia, 77
Hydrencephalocele, 388
Hydrocele, 745
Hydrocephalus, 362, 367, 388
Hydromeningocele, 388
Hydromyelia, 405
Hydronephrosis, 674
Hydrophobia, 276
Hydrothorax, 417
Hydrorrhachis interna, 405, 406
Hymen, 692
Hyperæmia, 69
Hyperplasia, 91
replacement, fibrous, 125
Hypertrophy, 91
Hyphomycetes, 143
Hypoleucocytosis, 83, 84
Hypophysis cerebri, 369
Hypospadia, 741
Hypostasis, post-mortem, 5

Identification, post-mortem features to be noticed in, 4
*Ill*, echinococcus of liver, ref., 615
Immunity, 177
artificial, 178, 179, 180
forms of, 178
Infarction, hæmorrhagic, 70, 74
Infarctions of lungs, 433
Infection, 183
and immunity, 177
concurrent, 184
congenital, 185
mixed, 184
terminal, 185
Infectious disease, 183
disease, communicability of, 185
disease, conditions influencing occurrence of, 176
Infectious disease, definition of, 177
disease, nature of, 183
disease, non-communicable, 186
disease, predisposition to, 176
disease, hypoleucocytosis in, 83
disease of animals, 285
disease produced by the pyogenic bacteria, 188
inflammation, pseudo-membranous, 204
Infiltration, fatty, 98
Inflammation, 107
catarrhal, 114
congestion in, 108
croupous, 119
degeneration in, 107
diphtheritic, 120
emigration in, 109, 111
exudative, 110
exudative fibrinous, 114
exudative, hæmorrhagic, 114
exudative, mucous, 114
exudative, purulent, 114
exudative, serous, 114
forms of, 110
interstitial, 118
necrotic, 107, 119
productive, 117
productive, reparative, 120
pseudo-membranous, of mucous membranes, 204
reparative, 120
suppurative, 188
syphilitic, 232
transudation in, 109
tuberculous, 215, 216, 220
Influenza, 257
Infusoria, 129
Inoculation, protective, 181
Insolation, 806
Intestinal mycosis, 210
Intestine, large, inflammation, 563
small, emboli, 562
small, inflammation, 561
small, lesions of lymph nodules, 561
Intestines, appearance of, at autopsies, 34
atresia of, 558
concretions in, 577
diverticula of, 557, 577
examination and preservation of, 36
examination, post-mortem, of, 23, 30, 34
incarcerations of, 558
intussusception, 559
malformations of, 557
parasites in, 578
post-mortem changes in, 34

Intestines, preservation of, 35
rupture of, 560
transposition, 560
tumors of, 575
waxy degeneration of, test for, 35
wounds of, 560
Intoxication by bacterial products, 174
Involution forms of bacteria, 144
Iodin as test for amyloid in fresh tissue, 32
solution in Gram's stain, 157
use of, in removal of sublimate from tissues, 55
Itch insect, 141

*Jäger*, acute yellow atrophy of liver, ref., 601.
meningitis, ref., 200
Jail fever, 275
*Jakowski*, pyocyaneus, ref., 261
Jalap poisoning, 821
*Janeway, E. G.*, foreign body in portal vein, 594
*Janeway, T. C.*, reaction of culture media for pneumococcus, 202
*Janowski*, inflammatory suppuration, bacteria in, ref., 192
Joints, inflammatory, 775
loose bodies in, 779
tumors of, 778
*Jordan*, osteomyelitis, ref., 765
*Jores*, formula for gross specimen preservation, 63
*Jürgenson*, air in the blood, ref., 90
*Justi*, tumors of heart, ref., 502

Karyokinesis, 93
asymmetrical, ref., 93
Karyomitosis, 93
*Kelynack*, appendicitis, ref., 575
Kidney, abscess, 671
arterio-sclerotic, 668
bacteria in, 671, 672
Bright's disease of, 647
calculi of, 677
cirrhosis of, 668
congestion, acute, 647
congestion, chronic, 658
cysts of, 675
degeneration, acute, 648
degeneration, chronic, 659
degeneration, granular, 668
degeneration, parenchymatous, 648
degeneration, waxy, tests for, 32
displacements of, 646
embolism of, 673
Kidney, examination of, 31, 32
fatty, 659
hydronephrosis, 674
inflammation of, 650
malformations, 646
parasites of, 680
perinephritis, 676
surgical, 672
thrombosis, 673
tumors of, 677
waxy, 660
*Kinnicutt*, Graves' disease, ref., 643
*Kitasato, Pfeiffer, Canon and*, influenza bacillus, ref., 257
*Klebs*, cysts of ovaries, ref., 727
malformations of genital organs, ref., 742
*Klemperer*, pneumonia antitoxin, ref., 202
Koch's culture media, solid, 159
discovery of tubercle bacillus, ref., 226
report on Asiatic cholera, ref., 268
*Koplik and Van Arsdale*, osteomyelitis, ref., 765
*Kossel*, Bacillus pyocyaneus, ref., 261
*Kotlar*, heart thrombus, ref., 502
*Kraus, Biedl and*, bacteria, elimination of, from body, 178
*Kruse and Pasquale*, intestinal microbes, ref., 573
liver, micro-organisms in abscess of, ref., 603
*Küchenmeister and Zürn*, parasites, 142

La grippe, 257
Landry's paralysis, *Bailey and Ewing*, ref., 400
*Lang*, chloroma, ref., 312
Lang's solution, 55
*Langerhans*, fat necrosis, ref., 634
Laryngitis, 413
Larynx, examination and preservation of, 29
inflammation, 413
malformations, 413
tumors of, 416
Lead poisoning, 820
*Legry*, lung stones, ref., 423
Leiomyoma, 321
Lepra, 229
bacillus, 230
Leprosy, 229
Leptothrix, 145, 146, 284
Leptomeningitis, 354
*Leuckart*, parasites, 142
Leucocytes, changes in, 82
degeneration of, in blood, 86

Leucocytes, emigration of, in inflammation, 112
fate of, in inflammatory exudates, 116
formation, of, 95
forms of, 82
Leucocythæmia, 794
Leucocytosis, form of, 83
in infectious disease, 83
Leukæmia, 794
changes in blood cells in, 85
pseudo-, 796
*Lewin and Heller*, scleroderma, ref., 410
Lipæmia, 89
Lipoma, 317
Lividities, post-mortem, 5
Liver, abscess of, 601
abscess, micro-organism in, 602
amyloid, 597
amyloid, tests for, 37
anæmia, 591
atrophy of, 595
atrophy, acute yellow, 600
bronze, 599
cirrhosis of, 604
congestion of, 591
cysts of, 612–614
degenerations of, 598
discoloration, post-mortem of, 37
examination and preservation of, 36
examination, post-mortem, 23
fatty, 596
hæmorrhage of, 593
holes in, 614
hyperæmia, 591
inflammation of, 601
lymphatic tissue, hyperplasia of, 611
malformations of, 590
nutmeg, 605
parasites of, 614
pigmentation of, 599
portal vein, lesions of, 593
position of, 36
position of, changes in, 24, 590
preservation of, 37
regenerative powers of, 95
rupture of, 593
size and weight of, 36
tumors of, 612
veins, lesions of, 595
waxy, 597
wounds of, 593
Lobelia poisoning, 825
Lockjaw, 255
Locomotor ataxia, 402
Löffler's alkalin-methyl-blue stain, 158
Löffler's blood serum mixture as culture medium, 162
*Loomis*, gumma of heart, ref., 502
*Löwit*, œdema of lungs, ref., 433
*Lubarsch*, Addison's disease, ref., 801
endothelioma of kidney, 680
*and Hintze*, elimination of bacteria from body, ref., 178
*and Ostertag's* "Ergebnisse," etc., ref., 182
Lungs, atelectasis of, 436
congestion of, 432
emphysema of, 434
examination and preservation of, 28, 29
gangrene of, 437
hæmorrhage of, 433
hepatization of, 439
hypostatic congestion of, 433
infarctions of, 433
inflammation of, 438
inflammation, syphilitic, of, 475
inflammation, tuberculous, of, 452
injuries of, 432
malformations of, 432
œdema of, 432
organized tissues in air vesicles of, 441
parasites in, 477
perforations of, 432
phthisis, acute, 459
phthisis, chronic, 469
tuberculous, 452
tuberculous, miliary acute, 453
tuberculous, miliary chronic, 457
tuberculous, miliary subacute, 456
tumors of, 476
Lung stones, 423
Lupus, 227
Lustgarten's bacillus, 234
Lymphangiectasis, 522
Lymphangioma, 327, 522
Lymphangitis, 521
Lymph glands, see Lymph nodes, 522
nodes, 522
nodes, degeneration in, 527, 536
nodes, hyperplasia of, 531
nodes, inflammation of, 523
nodes, inflammation of syphilitic, 529
nodes, parasites of, 532
nodes, pigmentation of, 526
nodes, scrofulous inflammation of, 528
nodes, tuberculous inflammation of, 528
nodes, tumors of, 532
nodules, intestinal, 561
nodules of larynx, œsophagus, etc., ref., 540

Lymph vessels, 520
vessels, inflammation of, 521
vessels, tumors of, 522
Lymphocytes, forms of, 82
Lymphocytosis, 85
Lymphoma, 531

Malarial fevers, 280
Malignant pustule, 309
Mamma, inflammation of, 735
hæmorrhage of, 735
male, lesions of, 753
malformations of, 735
tumors of, 738
*Manneberg*, résumé of parasitic protozoa, ref., 127
*Marchand*, giant cells, ref., 218
hydatid moles, ref., 735
Mast cells, 85
Mastitis, 736
*Mays*, myositis ossificans, ref., 782
Measles, 274
Mediastinum, 477
inflammation of, 478
tumors of, 478
Megaloblasts, 79, 81
Megalocytes, 81
Melanæmia, 86
*Mégnin*, parasites, ref., 142
*Melchior*, cystitis, ref., 685
*Meltzer*, empyema and subphrenic abscess, ref., 423
Meningitis, 354
acute cellular, 355
acute exudative, 355
cerebro-spinal, 199
chronic, 358
spinal, 390
syphilitic, 362
tuberculous, 359
Merismopedia, 146
Mesentery, cysts of, 588
tumors of, 589
Messmates, bacteria as, 152
Metaplasia, 95
Methyl-blue, Löffler's alkalin formula for, 158
Metritis, 707
Meynert's method of opening brain, 15
Microbes, safeguards of the body against, 171
Microcephalia, 388
Micrococci, 144
Micrococcus gonorrhœæ, 206
tetragenus, 193, 261
Microcytes, 79
Micron, 144
Micro-organisms, 143
safeguards of the body against, 171
Microscope, form of, for bacterial study, 158
Microsporon furfur, 170
Microtome, forms of, 60
Miliary tubercles, 216
Milk as culture medium, 161
*Miller*, bacteria of mouth, ref., 538
Mitosis, 93
Moeller's method of spore staining, 155
Moles, 735
hydatid, 304
*Monte and Berggrun*, anæmia of childhood, ref., 797
Morbus maculosus, 798
*Mosselman and Liénaux*, veterinary microbiology, ref., 285
Moulds, 143, 168, 170
Mouth, bacteria in (footnote), 538
gangrene, 535
hypertrophy, 534
inflammation, 534
malformations, 533
tumors, 535
Mucous degeneration, 102
membranes, pseudo-membranous inflammation of, 204
polyp, 303
*Müller*, leukæmia, ref., 796
thyroid gland, structure of, ref., 639
Müller's fluid as hardening and preservative agent, 19, 53
Muscle atrophy, 396, 783
degeneration of, 783
emboli, 780
hæmorrhage, 780
hypertrophy, 787
hypertrophy, pseudo-, 785
inflammation, 780
parasitic, 788
regeneration, 780
rupture, 780
tumors, 787
wounds, 780
Museum specimens, preservation of, 63
Mycelium in moulds, 168
Mycosis, intestinal, 210, 577
of pharynx, 284
Myelitis, 397, 400
Myelocytes, 85
Myocarditis, 498
Myocardium, fragmentation of, 493
inflammation of, 498
Myoma, 321
Myomalacia, 493

Myositis, chronic, 781
ossificans, 781
suppurative, 780
Myxœdema, 641
Myxoma, 300

Nævi, vascular, 326
Neck, cysts of, 538
Necrosis, 96, 107
coagulation, 96, 219
fat, of pancreas, 634
foci of, caused by bacteria, 172
foci of, caused by toxins, 173
*Neisser and Schäffer*, gonococcus, ref., 208
Nematoda, 135
eggs of, 137
Nephritis, acute diffuse, 655
catarrhal, 650
croupous, 650, 655
desquamative, 650, 660
diffuse, 655, 660
exudative, acute, 650
glomerulo-, 650, 655
indurative, chronic, 668
interstitial, 668
parenchymatous, 648, 650, 655, 659, 660
productive, 655, 660
productive chronic, without exudation, 668
suppurative, 671
tubal, 650
tuberculous, 673
Nerves, peripheral, inflammation of, 408
peripheral, degeneration and regeneration, 408
peripheral, tumors of, 409
Nerve fibres, method of preservation of, 22
tissue, hardening and study of, 410
Nervous system, 347
Neuritis, 408
Neuro-epithelioma, 340
Neuroglia, character of, 294, 320
Neuroma, 322
false, 323
multiple, 325
Neuron, 393
*Nicolaier*, capsulated bacillus, ref., 260
Nikiforoff's method of fixing blood, 88
Nissl's staining method, 412
*Nocard and Leclainche*, animal infections, ref., 285
Noma, 693, 697
Normoblasts, 79, 81
*Northrup*, tuberculosis in children, ref., 215
*Northrup, Crandall and*, scorbutus in children, ref., 798
*Prudden and*, etiology of pneumonia, ref., 449
*Novy*, bacillus of malignant œdema, ref., 259
*Vaughan and*, ptomaïnes, ref., 174
*Noyes*, sporadic cretinism, ref., 642
Nucleus, changes in, during cell division, 92
*Nuttall, Welch and*, capsule bacillus, ref., 261
Nux vomica poisoning, 824

Obermeier, spirochæte of, 270
Odontoma, 319
Œdema, 71
malignant bacillus of, 259
of glottis, 416
of lungs, 432
Œsophagitis, 540
Œsophagus, cysts of, 542
dilatation, 541
examination of, 29
inflammation of, 540
malformations, 538
perforation, 541
rupture of, 541
stenosis of, 543
tumors, 543
*Oestreich*, fragmentation of heart muscle, ref., 493
Oidium albicans, 170
Oligocythæmia, 77, 78
*Ollivier*, lesions of typhoid, ref., 246
Omentum, displacement of, 23
lesions of, 578
Oöphoritis, 720
Opium poisoning, 822
*Oppenheim*, brain sclerosis, ref., 383
Orchitis, 747
*Orth*, spleen in leukæmia, ref., 771
*Osler*, sporadic cretinism, ref., 642
Osmic acid as hardening agent, 54, 56
Osteitis, 757
syphilitic, 762
tuberculous, 761
Osteoid tissue, 126
Osteoma, 319
Osteomalacia, 769
Osteomyelitis, 763
Osteophytes, 319
Osteosclerosis, 760
Ovaries, cysts of, 723
displacements of, 719
examination of, 40

Ovaries, hæmorrhage, 719
hyperæmia, 719
inflammation of, 720
malformations of, 719
size of, 719
tumors of, 722
Oxyuris, 136
Ozœna, bacteria in, ref., 538

Pacchionian bodies, 11, 352
Pachydermia laryngis, 414
Pachymeningitis, 348
Paget's disease, coccidia in, 129
*Paltauf*, endothelioma of nerves, ref., 410
Pancreas, concretions of, 635
cysts of, 635
degenerations of, 633
displacements of, 636
fat necrosis of, 634
foreign bodies in, 635
hæmorrhage of, 632
inflammation of, 632
malformations of, 636
situation, removal, examination, and preservation of, 37
size and weight of, 37
tumors of, 635
Pancreatitis, 632
*Paoli*, endothelioma of kidney, ref., 680
Papilloma, 300
Paraffin embedding, 58
Parametritis, 707
Paraphimosis, 743
Parasites, 127
animal, 127
animal, methods of study, 142
animal, bibliography, 142
bacterial, 152
vegetable, 143
Parenchymatous degeneration, 98
Paresis, general, of tissue, brain lesions, 385
*Park*, diphtheria, etc., ref., 205
chronic osteomyelitis, ref., 765
fat embolism, 90
*and Beebe*, diphtheria, ref., 252
*Biggs and Beebe*, diphtheria, bacteriological diagnosis in, ref., 254
Parotid gland lesions of, 637
Parovarium, cysts of, 730
*Parsons*, bone lesions of typhoid, ref., 246
Pearls, epithelial, in carcinoma, 336
Pediculus capitis, 141
Penis, calcification, 744
hæmorrhage, 743
inflammation, 743
injury, 743
Penis, malformation, 741
tumors, 743
Periarteritis nodosa, 507
Pericarditis, 481
tuberculous, 483
Pericardium, air in, 480
dropsy, 480
hæmorrhage, 480
inflammation of, 481
injuries, 480
obliteration of, 482
post-mortem examination of, 25
tumors of, 483
Perihepatitis, 611
Perimetritis, 707
Perinephritis, 676
Periostitis, 755
Perisplenitis, 628
Peritoneum, 578
inflammation, 579
malformations of, 578
parasites of, 589
tumors, 587
Peritonitis, acute, 579
bacteria in, 582
chronic, 583
hæmorrhagic, 585
tuberculous, 586
Petechiæ, 70
Petri's plates for bacteria cultures, 163
*Petruschky*, bacteria in septicæmia, ref., 197
*Pfeiffer, Kitasato, and Canon*, influenza bacillus, ref., 257
Phagocytes, 178
in disposal of extravasated blood, 71
nature and action of, 126
Pharyngitis, 540
Pharyngo-mycosis, 284
Pharynx, diverticula, 540
inflammation of, 540
malformations, 538
removal from body, examination and preservation of, 29
ulceration of, 541
Phlebitis, 518
tuberculous, 519
Phleboliths, 73
Phloroglucin for decalcification, 52
Phosphorus poisoning, 817
Phthisis, pulmonary, 459
pulmonary, acute, 459
pulmonary, chronic, 469
pulmonary, experimental, 460
Pia mater, 352
hæmorrhage, 354
hyperæmia, 353

Pia mater, inflammation, 354
method of preservation of, 18
œdema, 353
parasites in, 364
post-mortem examination of, 11
spinalis, hæmorrhage, 390
spinalis, inflammation, 390
spinalis, tumors and parasites, 391
tumors, 362
Picric acid for decalcification, 52
Picro-acid fuchsin as staining agent, 61
*Pielicke, Canon and*, bacillus of measles, ref., 274
Pigmentation, 106
Pineal gland, 369
Pin worm, 136
Pituitary body, 369
degeneration, 734
inflammation, 734
Placenta, lesions of, 733
Placentitis, 734
Plague, bubonic, 239
Plasmodium malariæ, 129, 280
Plate cultures of bacteria, 163
Pleura, cysts of, 426
hæmorrhage of, 417
hydrothorax, 417
inflammation of, 417
lymphangitis of, 423
tumors of, 425
Pleural cavities, method of post-mortem determination of presence of air in, 24
cavities, post-mortem examination of, 28
Pleurisy, 417
chronic, 423
Pleuritis, 417
acute, 418
chronic, 423
tuberculous, 424
Pneumococcus, 201, 438
capsule, to stain, 203
Pneumonatosis, 480
Pneumonia, 438
acute lobar, 201, 438
broncho-, 442
catarrhal, 443
complicating, 448
interstitial, 451
interstitial, in phthisis, 472
lobular, 443
of heart disease, 449
"organizing," 441
secondary, 448
syphilitic, 475
Pneumonia, tuberculous, 452
Pneumonitis, 438
Pneumotoxin, 202
Poikilocytes, 79
Poisoning, autopsies in cases of, 41
suspected, care of stomach and duodenum in, 35
Poisons, action of, in body, 814
*Polaillon*, lung stones, ref., 423
Poliomyelitis anterior, 399
Polyp, mucous, 303
*Popon*, arsenic poisoning, 819
Porencephalus, 380
Portal vein, lesions of, 593
Post-mortem bacterial examination, 167
changes, 4
changes in abdominal organs, 23
cooling of the body, 6
decomposition, 4
discolorations, 4, 5, 23, 34
examination in suspected poisoning, 35, 41
examination, internal, 9
examination, medico-legal, 41
examination, objects in, 3
examination, observations on identity in, 4
examination of abdomen, 30
examination of brain, 11
examination of new-born children, general inspection, 42
examination of new-born children, internal inspection, 46
examination of spinal cord, 19
examination of thorax, 22
examination of wounds, 8
examinations, external inspection, 4
examinations, methods of making, 3
examinations, weight of the body in, 5
fractures, 9
hypostasis, 5
injuries, 8
putrefaction, 5
rigidity, or rigor mortis, 7
Potash poisoning, 817
Potassium nitrate poisoning, 817
Potatoes, as culture media for bacteria, 162
*Pozzi*, ovarian tumors, ref., 727
Predisposition to infectious diseases, 176
Pregnancy, extra-uterine, 732
Preservation of tissues, importance of careful, 64
of tissues, methods of, 52
Productive inflammation, 117
Progressive spinal muscle atrophy, 396
Prostate, atrophy of, 752

Prostate, concretion of, 753
hypertrophy of, 751
inflammation of, 752
tumors of, 753
Proteids, defensive, 178
Protozoa, 127
*Prudden*, cold on bacteria, 148
endocarditis, malignant, ref., 495
rhabdomyoma, ref., 638
Psammoma, 312, 351, 363
Pseudo-diphtheria, 204
Pseudo-leukæmia, 796
Pseudo-tubercles, 222
Psorospermiæ, 128
Ptomaïne poisoning, 825
Ptomaïnes, 150
Puerperal fever, 197
Pulmonary phthisis, 459
Purpura hæmorrhagica, 798
Pus cells, 117
nature of, 116
*Putnam*, nervous system in infectious diseases, ref., 377
Putrefaction, post-mortem, 5
Putrefactive changes in abdominal viscera, 23
Pyæmia, 196
Pyelitis, suppurative, 672
Pyelo-nephritis, chronic, 672
suppurative, 672
*Pye-Smith*, cysts of liver, ref., 614
Pyogenic bacteria, 188
Pyo-pneumothorax, 422
Pyo-salpinx, 731

Rabies, 276
*Rabinowitsch*, pathogenic yeasts, ref., 168
thermophyllic bacteria, ref., 148
Rachitis, 766
Ray fungus, 263
Rectocele vaginalis, 696
Rectum, 573
*Reed*, lymph nodules in typhoid, ref., 245
Regeneration of tissues, 91, 94
*Reinbach*, colloid, ref., 640
Relapsing fever, 269
Respiratory system, 413
Rhabdomyoma, 322
Rhabdonema, 140
Rheumatism, 803
Rhexis, hæmorrhage by, 69
Rhinitis, membranous, ref., 538
Rhinoscleroma, 238
Rhizopods, 127
*Ribbert*, appendicitis, ref., 575
carcinoma, histogenesis, ref., 291
*Ribbert*, lymph glands, ref., 526
myoma, ref., 322
*Ricker*, yeasts and moulds, ref., 171
Rickets, 766
Rigor mortis, 7
*Robinson*, cysts of mesentery, ref., 589

Saccharomyces, 168
Saccharomycetes, 143
Salivary glands, 637
Salpingitis, 731
*Salvetti*, rachitis, ref., 767
Saphrophytes, 152
Sarcina, 146
Sarcoma, 304
adeno-, 312
alveolar, 311
angio-, 310
chondro-, 312
cysto-, 312
endothelial, 312
fibro-, 305
giant-celled, 308
glio-, 308
lipo-, 312
lympho-, 308
melano-, 308
mixed forms of, 311
myeloid, 308
myo-, 312
myxo-, 311
osteo-, 309
round-celled, 307
spindle-celled, 305
Sarcoptes, 141
Savin poisoning, 821
Scammony poisoning, 821
Scarlatina, 273
Scarlet fever, 273
Scars, post-mortem, appearance of, 9
*Schamschin*, heart lesions in diphtheria, ref., 250
*Schmidt and Aschoff*, pyelonephritis, ref., 685
*Schulz*, endothelioma of pleura, 426
Scirrhus, 341
Scleroderma, 410
Sclerosis, amyotrophic lateral, 396
of spinal cord, 394, 400, 402
Scolices of tapeworms, 131
Scorbutus, 798
Scrofula, 528
Scrotum, lesions of, 744
Section cutting, 56, 60
Seminal vesicles, 751
Septicæmia, 183, 196

Septic intoxication, 174
Serum, inflammatory, 112
therapy in diphtheria, 253
Seven-day fever, 269
*Shakespere*, report on cholera, ref., 268
*Sherrington*, bacteria in secretions, ref., 178
Ship fever, 275
*Silbermann*, death from burning, ref., 807
*Silberschmidt*, peritonitis, ref., 582
Silver stain, Golgi's, 62
*Sittmann*, bacterial study of blood, ref., 90
Skull-cap, method of removal of, 10
Small-pox, 271
Soda poisoning, 817
Spermatocele, 747
Spider cells, 320
Spina bifida, 407
Spinal cord, bruising of, in removal, 20
cysts of, 403
degenerations of, 393
dura mater of, lesions of, 387
examination and preservation of, 19–21
hæmatomyelia, 391
hæmatomyelopore, 391
hæmorrhage, 391
inflammation, 397
injuries, 393
malformations of, 405
membranes of, 387
parasites, 390
pia mater, lesions of, 390
progressive muscle atrophy of, 396
sclerosis of, 326
syringomyelia, 404
tubercles of, 403
tumors of, 397
Spirillum, 144
choleræ Asiaticæ, 266
fever, 269
Spirochæte Obermeieri, 270
Spleen, accessory, 34
anæmia of, 622
atrophy of, 629
bile duct, post-mortem examination of, 736
congestion of, 623
degenerations of, 629
displacements of, 631
examination and preservation of, 33
hæmorrhage of, 622
hyperæmia of, 622
infarctions of, 623
inflammations of, 624
malformations of, 631
parasites of, 630
Spleen, pigmentation of, 630
rupture of, 621
sago, 629
tumors of, 630
wounds of, 621
Splenic fever, 309
Splenitis, 624
Sporangium in moulds, 168
Sporozoa, 128
Spotted fever, 275
Sprouting fungi, 143
Sputum, tuberculous, number of bacilli in, 223
Staining, methods of, 60
Staphylococcus epidermidis albus, 190
cereus albus, 193
cereus flavus, 193
gilvus, 193
pyogenes albus, 190
pyogenes aureus, 188
pyogenes citreus, 193
salivarius pyogenes, 193
*Starr*, multiple neuritis, ref., 409
*Stein*, bladder tumors, ref., 686
plates of cestoda, 142
*Stern*, tumors in childhood, ref., 343
*Sternberg*, discovery of pneumococcus by, 201
"Manual of Bacteria," ref., 182
yellow fever studies, ref., 279
*Stoeltzner*, cartilage in tonsils, ref., 543
*Stokes, Wright and*, bacteriological examination at autopsies, 168
Stomach, appearance, post-mortem, of, 24
care of, in cases of suspected poisoning, 35
degenerations of, 557
dilatation of, 553
erosions of, 553
examination and preservation of, 35
foreign bodies in, 557
hæmorrhage, 546
inflammation, 547
injuries, 546
malformations, 546
post-mortem changes, 546
tumors of, 554
ulcers of, 550–553
wounds of, 546
Stomacace, 534
Stomatite ulcero-membraneuse, 534
Stomatitis, 534
*Stoos*, bacteria in angina, ref., 538
Stramonium poisoning, 825
Strangulation, 8, 810
"Strawberry marks," 326

Streptobacillus, 146
Streptococcus, 195
antitoxin, 193
brevis, 191
conglomeratus, 191
erysipelatis, 194
in meningitis, 200
longus, 191
pyogenes, 191, 204
*Stroebe*, parasites in tumors, ref., 293
regeneration in nerve tissue, ref., 377
Strongylus, 136, 137
Struma, 639
lipomatosa suprarenalis, 645
Strumitis, 640
Strychnia poisoning, 824
Sublimate, corrosive, as fixative agent, 55
Sublingual gland, lesions of, 637
Submaxillary gland, lesions of, 637
*Sudeck*, endothelioma of kidney, ref., 680
Suffocation, 809
Suggillations, 70
Sunstroke, 806
Suprarenal bodies, 32, 644
*Sutton*, tumors, ref., 343
Swab, sterilized, for bacteria collection, 166, 167
Symbiosis, 152
Syphilis, 231
Syringomyelia, 404

Tabes, 402
Tænia, 131–135
echinococcus of liver, 614
Tape-worms, 131
Tartar emetic, poisoning by, 821
Tattoo marks, post-mortem appearance of, 9
*Tavel*, intestinal bacteria, ref., 573
*and Lanz*, peritonitis, ref., 582
Temperature, post-mortem, 6, 7
Teratomata, 295
Testicle, atrophy of, 745
cysts of, 751
inflammation of, 747
malformations of, 745
parasites of, 751
tumors of, 750
weight of, 38
Tetano-toxin, 256
Tetanus, 255
*Thacher*, melanuria, ref., 308
*Thayer and Blume*, bacteria in malignant endocarditis, ref., 495
*and Hewetson*, malaria, ref., 283
*Thierfelder*, endothelioma of pleura, ref., 426
*Thiersch*, carcinoma, ref., 291
*Thoma*, nervous system malformations, ref., 388
*Thoma's* text-book, ref., 126
microtome, 60
*Thompson*, Addison's disease, ref., 801
Thorax, examination of, 22, 25
Thread worm, 136
Thrombi, forms and occurrence of, 72
Thrombosis, 72
Thrombus, organization of, 124
Thymus, 643
Thyroid gland, examination of, 29
exophthalmic goitre, 643
lesions of, 639
malformations of, 641
myxœdema of, 641
parasites of, 641
regenerative power of, 95
*Tilger*, cysts of pancreas, ref., 635
Tissues, fresh, methods of study of, 50
methods of preservation, 52
Tongue, cysts of, 537
hypertrophy of, 536
inflammation of, 537
malformations of, 536
tumors of, 537
Tonsillitis, 540
Tonsils, faucial, 540
Toxæmia, 174, 183
ganglion cell changes in, 376
Toxalbumins, bacterial, 151, 173
Toxins, bacterial, 150, 173
Trachea, malformations of, 413
tumors of, 416
Transudation, 71, 109, 112
Trematoda, 130
Triacid mixture of Ehrlich for blood staining, 88
Trichina spiralis, 138, 139
Trichocephalus, 137
Trichomonas vaginalis, 129
Trichophyton tonsurans, 169
Tubercle, 216
bacilli, 213
bacilli, action of, in lungs, 452
bacilli, cultivation of, 214
bacilli, dead, lesions caused by, 222
bacilli, numbers of, in tuberculous sputum, 223
bacilli, staining of, 224
granulum, 217
tissue, 217
Tubercles, coagulation necrosis in, 219

Tubercles, conglomerate, 217
epithelioid-celled, 220
forms of, 220
lymphoid, 220
Tuberculin, 224
Tuberculosis, concurrent infection in, 224
in the lower animals, 215
localized, 215
Tuberculous inflammation, 213. 216
Tumors, archiblastic, 294
cause of, 290
classification of, 294
congenital,295
cystic, 295
epithelial, 358
histioid, 294
hypoblastic, 294
inclusions of, 292
malignancy, nature of, 289
mesoblastic, 294
metaplasia in, 317
mixed, 295
nature and growth of, 286, 287
nomenclature of, 294, 297
parablastic, 294
parasitic origin of, 292
preservation of, 298
special forms of, 299
spread of, 288
Turpentine poisoning, 821
Typhoid fever, 240
Typhus fever, 275
recurrens, 269

*Ulrich*, adrenals and adenoma of kidney, ref., 645
Ureter, examination of, 30
Ureteritis, 672
Urethra, bacteria in, 690
displacement of, 688
inflammation of, 690
malformations of, 688
perforation, 689
prolapse, 689
rupture of, 689
strictures of, 689
tumors of, 691
wounds of, 689
Urethral hæmorrhoids, 691
Urethritis, 690
Urinary apparatus, 676
bladder, lesions of, 680
Uterine hæmatocele, 703
Uterus, cysts of, 718
degeneration of, 709
displacements of, 700
Uterus, examination of, 39
hyperæmia of, 707
hyperplasia of mucous membrane of, 705
inflammation, 704, 707, 708
malformations of, 698
parasites of, 718
perforation of, 702
rupture of, 702
size, changes in, 699
tumors of, 709
ulceration of, 709

Vagina, displacements of, 695
gangrene of, 697
hernia of, 695
inflammation of, 697
malformations of, 695
parasites of, 698
perforations of, 697
prolapse of, 695
tumors of, 697
wounds of, 696
Variola, 271
Vascular system, 480
*Vaughan and Novy*, ptomaïnes, ref., 174
Veins, dilatation of, 517
inflammation of, 518
parasites of, 520
rupture of, 518
tumors of, 520
wounds of, 518
Vein stones, 73
Ventricles of brain, 365
Veratria poisoning, 821
Vermiform appendix, 573
Vibrio of cholera, 266
*Virchow*, tumors, ref., 343
*Van Gieson*, false heterotopia, ref., 407
hæmatomyelopore, 392
malformation of spinal cord, ref., 405
picro-acid fuchsin, 61
stain for amyloid hyalin, etc., 101
*Volkmann*, endothelioma, ref., 316
*Von Hibler*, gonococcus, ref., 208
*Von Kahlden*, Addison's disease, 801
endothelioma of kidney, ref., 680
porencephalic, ref., 380
*Von Limbeck*, blood examination, 89
Vulva, hæmorrhage, 692
hyperæmia, 692
inflammation, 693
malformations, 692
tumors, 694

*Wagner*, endothelioma of pleura, ref., 426

*Waldeyer*, cysts of ovaries, ref., 727
Water, bacteria in, 151
contamination of, with bacteria, 152
Waxy degeneration, 100
*Weichselbaum*, cysts of mesentery, ref., 589
malignant endocarditis, ref., 495
*Weigert*, adenoma of œsophagus, ref., 543
modification of Gram's stain, 157
stain for nerve tissue, 411
*Weihl*, waxy degeneration of muscle, experimental, ref., 787
Weil's disease, 601
*Welch*, Bacillus coli communis, ref., 260
bacterial flora of body, ref., 171
bacteriological examination at autopsies, ref., 168
infection and immunity, ref., 182
modification of Guarnieri's agar for pneumococcus, 201
œdema of lungs, ref., 433
staining method for capsules of bacteria, 203
wound infection, ref., 190
*Welch and Flexner*, Bacillus aërogenes capsulatus, ref., 261
effects of diphtheria bacilli in animals, ref, 253
Whip worm, 137
*Wilks*, kidney fibroma, ref., 677
*Williams*, deciduoma, ref., 718
ovarian papillomata, ref., 728
*Wilms*, tumors of testicle, ref., 751
"Wool-sorters'" disease, 309
Wounds, 130
healing of, 120
post-mortem, 8
*Wright and Stokes*, bacteriological examination at autopsies, ref., 168

Xylol, use of, in paraffin embedding, 58

Yeasts, 143, 168, 170
Yellow fever, 279
*Yersin, Calmette, and Borrel*, bubonic plague, ref., 239

*Zaborowski*, muscle regeneration, ref., 780
*Zahn*, ciliated cysts, ref., 297, 543
ciliated cysts of pleura, ref., 426
*Zenker*, muscle degeneration, ref., 787
*Ziegler*, views on catarrhal inflammation, 114
Zoöglœa, 146