A text-book of anatomy / edited by Frederic Henry Gerrish.

Contributors

Gerrish, Frederic Henry, 1845-1920.
University of Leeds. Library

Publication/Creation

London : Henry Kimpton, 1899.

Persistent URL

https://wellcomecollection.org/works/b3t55k5x

Provider

Leeds University Archive

License and attribution

This material has been provided by This material has been provided by The University of Leeds Library. The original may be consulted at The University of Leeds Library. where the originals may be consulted.
This work has been identified as being free of known restrictions under copyright law, including all related and neighbouring rights and is being made available under the Creative Commons, Public Domain Mark.

You can copy, modify, distribute and perform the work, even for commercial purposes, without asking permission.

wellcome collection

Wellcome Collection
183 Euston Road
London NW1 2BE UK
T +44 (0)20 7611 8722
E library@wellcomecollection.org
https://wellcomecollection.org

Unable to display this page

The University Library
Leeds

Medical and Dental
Library

30106 004065784

Stamp indicates date for RETURN. Fines for late returns will be charged in accordance with the regulations.

Books required by another reader will be recalled. This also applies during vacations.

TO RENEW THIS ITEM
TELEPHONE 0113 2335668

Digitized by the Internet Archive
in 2015

https://archive.org/details/b21506620

AUTHORS.

BEVAN, ARTHUR DEAN.

GERRISH, FREDERIC HENRY.

KEILLER, WILLIAM.

McMURRICH, JAMES PLAYFAIR.

STEWART, GEORGE DAVID.

WOOLSEY, GEORGE.

TEXT-BOOK OF ANATOMY.

GERRISH.

HENRY KIMPTON'S

STANDARD MEDICAL WORKS

For Specialists, General Practitioners, and Students.

PRACTICAL DIAGNOSIS.—The Use of Symptoms in the Diagnosis of Disease. By HOBART AMORY HARE, M.D., Professor of Therapeutics and Materia Medica in the Jefferson Medical College of Philadelphia, etc. New (4th) edition. 623 pages, with 205 engravings, and 14 full-page coloured plates. Cloth, 21s., *net*. *Just ready.*

"We can thoroughly recommend this book to practitioners and students."—*Lancet.*

A TEXT-BOOK OF PRACTICAL THERAPEUTICS; with Especial Reference to the Applications of Remedial Measures to Disease and their Employment upon a Rational Basis. By HOBART AMORY HARE, M.D., Professor of Therapeutics and Materia Medica in the Jefferson Medical College of Philadelphia. With special chapters by DRS. G. E. DE SCHWEINITZ, EDWARD MARTIN, and BARTON C. HIRST. New (7th) edition. In one octavo volume of 775 pages. Cloth, 21s., *net*. (Revised in accordance with the new edition (1898) British Pharmacopœia.)

"We may repeat the words of our last notice. We can thoroughly recommend this book to practitioners and students."—*Lancet.*

A MANUAL OF CLINICAL DIAGNOSIS BY MICROSCOPICAL AND CHEMICAL METHODS. For Students, Hospital Physicians, and Practitioners. By CHARLES R. SIMON, M.D., Late Assistant Resident Physician, Johns Hopkins Hospital, Baltimore. New (2nd) edition. In one very handsome octavo volume of 565 pages, with 133 engravings and 14 full-page coloured plates. Cloth, 16s., *net*.

"One of the best and most compendious manuals for the clinical laboratory that has yet appeared."—*Lancet.*

TILLMANNS' SURGERY.—3 Vols. **A Text-Book of General Surgery.** By Dr. HERMANN TILLMANNS, Professor in the University of Leipzig. Edited by Lewis A. Stimson, M.D., Professor of Surgery in the New York University. Octavo, cloth, £1 1s., *net*, per vol.

Vol. I.—The Principles of Surgery and Surgical Pathology. General Rules governing Operations and the Application of Dressings. Translated from the Third German Edition by John Rogers, M.D., and Benjamin T. Tilton, M.D. With 447 Illustrations.

Vol. II.—Regional Surgery. Translated from the Fourth German Edition by Benjamin T. Tilton, M.D., New York. With 417 Illustrations.

Vol. III.—Regional Surgery. With 517 Illustrations.
Complete work now ready, price £3 3s., *net*.

"One of the best works on modern surgery available in the English language."—*Practitioner.*

"There is no English text-book on the subject which can in any way be compared with it. . . . Indeed, there has been nothing issued at all comparable to this work."—*Scottish Medical and Surgical Journal.*

MANUAL OF THE DISEASES OF CHILDREN. By JOHN MADISON TAYLOR, A.M., M.D., Professor of Diseases of Children, Philadelphia Polyclinic, etc.; and WILLIAM H. WELLS, M.D., Adjunct Professor of Obstetrics and Diseases of Infancy in the Philadelphia Polyclinic, etc., etc. Complete in one illustrated volume of 743 pages, gilt top, price 16s., *net*.

"One of the best books for the use of the student and the practitioner."—*Lancet.*

A MANUAL OF MODERN SURGERY, GENERAL AND OPERATIVE. By JOHN CHALMERS DA COSTA, M.D., Demonstrator of Surgery, Jefferson Medical College, Philadelphia; Chief Assistant Surgeon, Jefferson Medical College Hospital; Surgical Registrar, Philadelphia Hospital, etc. 2nd edition, revised and enlarged with 386 illustrations, nearly 1,000 pages. Royal octavo, cloth, price 21s., *net*.

"We regard Dr. Da Costa's Manual as the most concise, reliable, and up-to-date of the many works on surgery."—*Glasgow Medical Journal.*

OPERATIVE GYNECOLOGY. By HOWARD A. KELLY, A.B., M.D., Fellow of the American Gynecological Society; Professor of Gynecology and Obstetrics in the Johns Hopkins University, and Gynecologist and Obstetrician to the Johns Hopkins Hospital, Baltimore, etc. In two royal octavo volumes, with 24 plates and 590 illustrations. Handsomely bound in half-morocco, gilt tops. Vol. I., 580 pages; Vol. II., 573 pages. Price £3 3s., *net*.

"The volumes are of the highest merit, will long remain the standard work upon the subject of which they treat, and should be in the hands of all gynecologists and surgeons performing pelvic operations."—*Lancet.*

A TREATISE ON THE PRINCIPLES AND PRACTICE OF GYNECOLOGY. For Students and Practitioners. By E. C. DUDLEY, M.D., Professor of Gynecology in the Chicago Medical College. In one very handsome octavo volume of 652 pages with 422 engravings, of which 47 are coloured, and two full-page plates in colours and monochrome. Cloth, 21s., *net*.

"The illustrations are all remarkably good, and reflect great credit on the publishers."—*British Medical Journal.*

LONDON: HENRY KIMPTON, 82, HIGH HOLBORN, W.C.

A

TEXT-BOOK OF ANATOMY.

EDITED BY

FREDERIC HENRY GERRISH, M.D.,

PROFESSOR OF ANATOMY IN THE MEDICAL SCHOOL OF MAINE, BOWDOIN COLLEGE.

ILLUSTRATED WITH 950 ENGRAVINGS IN BLACK AND COLORS.

LONDON:

HENRY KIMPTON,

82, HIGH HOLBORN, W.C.

1899.

All rights reserved.

605214

PREFACE.

In their work as teachers of anatomy the authors of this volume have long felt the need of a text-book, which, while presenting the essential facts of human structure, judiciously avoids the unimportant and exceptional. They believe that the students in medical schools should neither be encouraged to depend upon pocket manuals nor be compelled to resort to encyclopædias. Between the extremes of flavorless condensation and universal inclusiveness is a middle ground whereon should be marshalled in systematic array those portions of anatomical knowledge which, with our present information, are seen to be necessary preliminaries to the intelligent study of physiology, surgery, and internal medicine; and from this field should be excluded the much greater collection of facts, which, however important to a work which designs to be exhaustive, have no known practical bearing, or only such possible application as will make them available for a useful purpose once or twice in a generation.

The authors have endeavored to make a text-book which, as far as possible, shall stand in the place of a living teacher to the student—selecting from the vast accumulation of material those portions which are likely to be of actual service to the pupil in his subsequent study and to the practitioner in his clinical work, emphasizing the most important, striving to clarify obscurities, giving the greatest amount of help in the parts which are most difficult to learn, and illustrating everything by all available methods. They may have slighted facts which others would have introduced; they certainly, as a matter of policy, have admitted many things which, in their judgment, are not essential to the student, except for the aid they afford him in meeting certain conventional demands, especially on the part of examiners, who may not have emancipated themselves from the trammels of tradition.

The material facts have been gathered from the rich stores of information, which are recognized as the common property of science. No attempt is made to give credit to the discoverers, to whose efforts the present advanced state of anatomy is due; and this omission is justified by two reasons: first, the impossibility of determining the original source in a majority of cases, and, second, the undesirability of loading a primary text-book with historical data which are not helpful in practical work.

The various topics have been arranged on familiar lines, the ordinary divisions of systematic anatomy having been followed in the main; but each author has set forth his subjects according to the methods which his experience has shown him to be profitable, and some of these will be seen to be different from (and, it is hoped, better than) those in ordinary vogue. Greater relative stress has been laid upon visceral structure, without neglect of the other branches; surface anatomy has received attention more in proportion to its usefulness than is usual;

and the pictorial and diagrammatic illustrations (thanks to the remarkable liberality of the publishers) are phenomenally abundant and of striking artistic excellence. The method of direct labelling of the pictures, which has been proved to be so helpful to the student, has been applied wherever practicable.

It is thought that the plan of giving the directions for dissection in a separate chapter will be appreciated as a marked convenience to the student in the laboratory.

The nomenclature employed is that in general use among English-speaking anatomists. A few words, sanctioned by the approval of the Association of American Anatomists, or the Anatomische Gesellschaft, or both, have been used in preference to the customary, though less desirable, terms; but, in every such case, the synonym is given, so that no confusion can arise.

When a term, which has not been employed previously in the text, is introduced, its etymologic meaning is given parenthetically, unless its signification is manifest without such assistance. By this means a new and helpful aspect of the topic is often presented to the mind.

The articles on the bones, the joints, and the veins have been written by Dr. Woolsey, those on the peripheral nervous system, the eye, the nose, and the skin by Dr. Keiller, that on embryology by Dr. McMurrich, that on the arteries by Dr. Bevan, that on the reproductive organs by Dr. Stewart, and the remainder by Dr. Gerrish.

PORTLAND, MAINE, 21 March, 1899.

PUBLISHERS' NOTE.

PERHAPS the obvious magnitude of such an undertaking as the present may be connected with the fact, often observed, that although America has enriched medical literature with systematic treatises on all other branches, its anatomical instruction has been derived from foreign works. The creation of another volume would, however, be justified neither by this fact alone, nor by the growing and natural wish of American readers for works by home authors. The very multiplicity of books on Anatomy proves that the science is advancing in discoveries of fact, relationship, and methods of presentation, and moreover that no volume fully satisfies all requirements.

No effort has been spared by those responsible for this work to render it one in which Americans might take a justifiable pride, and which the fraternity of medicine abroad might equally welcome as a contribution to the advancement of a vital science. Text, illustration, and typography represent the best endeavors in their respective kinds. For many of the engravings individual acknowledgment has been made to Testut's admirable *Traité de l'Anatomie*, published by M. Doin, of Paris, a work deserving wide recognition by English-speaking students. The series of illustrations in the present work is original to an unusual degree, and far more extensive than hitherto attempted. Colors have been abundantly employed, and particular care has been bestowed in engraving the labels of parts directly upon them wherever possible, whereby the student gains at a glance a knowledge of their names, position, and relations.

LIST OF AUTHORS.

ARTHUR DEAN BEVAN, M. D.,

Professor of Anatomy in Rush Medical College in affiliation with the University of Chicago; Surgeon to the Presbyterian and St. Luke's Hospitals, Chicago, etc.

FREDERIC HENRY GERRISH, A. M., M. D.,

Professor of Anatomy in the Medical School of Maine, Bowdoin College; Consulting Surgeon to the Maine General Hospital, Portland; Fellow of the American Surgical Association; sometime President of the American Academy of Medicine, etc.

WILLIAM KEILLER, F. R. C. S. (EDIN.),

Professor of Anatomy in the Medical Department of the University of Texas, Galveston; sometime Lecturer on Anatomy in the Edinburgh Medical School, etc.

JAMES PLAYFAIR McMURRICH, A. M., PH. D.,

Professor of Anatomy in the University of Michigan, Ann Arbor; sometime Professor of Biology in the University of Cincinnati and Associate Professor of Animal Morphology in Clark University, etc.

GEORGE DAVID STEWART, M. D.,

Professor of Anatomy in the University and Bellevue Hospital Medical College, New York City; Visiting Surgeon to Bellevue Hospital, etc.

GEORGE WOOLSEY, A. B., M. D.,

Professor of Anatomy and Clinical Surgery in the Cornell University Medical College, New York City; Visiting Surgeon to Bellevue Hospital, etc.

CONTENTS.

INTRODUCTORY.

By F. H. Gerrish.

	PAGE
Definition	17
Names and Delimitations of Surface Parts	21
The Systems of Organs and their Functions	29
Organs removing Waste Matters	30
The Vascular System	30
Organs Supplying Nourishment	31
Organs of Internal Secretion	32
Organs of Motion	32
Framework Organs	32
Organs of Relation	32
Organs of Reproduction	33
The Order of Topics	33
Methods of Study	33

ELEMENTARY TISSUES.

By F. H. Gerrish.

	PAGE
Cells.	
Cell-reproduction	39
Classes of Tissues.	
The Epithelial Tissues	41
The Sustentacular Tissues	45
White Fibrous Tissue	46
Yellow Fibrous Tissue	47
Areolar Tissue	47
Adipose Tissue	49
Gelatinous Tissue	50
Adenoid Reticular Tissue	50
Neuroglia	50
Cartilaginous Tissues	51
Osseous Tissue	52
Dentinal Tissue	56
The Liquid Tissues	57
The Lymph	57
The Blood	57
The Muscular Tissues	58
Plain Muscular Tissue	58
Cross-striped Muscular Tissue	59
Cardiac Muscular Tissue	61
The Nervous Tissues	62
Membranes	64
Serous Membranes	66
Serous Membranes Proper	68
The Lining Membrane of the Vascular System	68
The Lining Membrane of Certain Cavities in Sustentacular Tissues	69
The Lining Membrane of the Cavity of the Cerebro-spinal Axis	69
Synovial Membranes	69
Articular Synovial Membranes	70
Vaginal Synovial Membranes	70
Bursal Synovial Membranes	71
Mucous Membranes	71
Cutaneous Membrane	74
Glands	75

EMBRYOLOGY.

By J. P. McMurrich.

	PAGE
Spermatogenesis	77
Ögenesis	78
The Early Stages of Development	79
The Umbilical Cord and the Placenta	83
Organs Derived from the Endoderm	86
The Teeth and Salivary Glands	86
The Branchial Clefts and the Structures Derived from them	87
The Trachea and Lungs	88
The Intestine and Mesenteries	88
The Liver and Pancreas	90
Organs Derived from the Mesoderm	91
The Skeleton	91
The Heart and Blood-vessels	93
The Diaphragm	97
The Lymphatic Vessels, the Spleen, and the Suprarenal Capsules	98
The Muscular System	98
The Excretory and Reproductive Organs	98
Organs Derived from the Ectoderm	103
The Nervous System	103

THE BONES.

By G. Woolsey.

PAGE

General Considerations 113

The Spine 115
The Cervical Group 116
The Thoracic Group 117
The Lumbar Group 119
The Sacral Vertebræ 120
The Coccyx 122
The Spine as a Whole 123
Ossification of the Vertebræ 124

The Thorax.

The Sternum 126
The Ribs 127
The Costal Cartilages 129
The Thorax as a Whole 130

The Bones of the Upper Limb.

The Clavicle 131
The Scapula 133
The Humerus 135
The Ulna 137
The Radius 139
The Carpal Bones 140
The Scaphoid 141
The Semilunar 141
The Cuneiform 141
The Pisiform 143
The Trapezium 143
The Trapezoid 143
The Os Magnum 143
The Unciform 143
The Metacarpal Bones 144
The Phalanges 144

The Bones of the Lower Limb.

The Hip-bone 146
The Ilium 146
The Ischium 148
The Os Pubis 149
The Pelvis 150
The Femur 151
The Patella 154

PAGE

The Tibia 155
The Fibula 157
The Tarsal Bones 158
The Astragalus 158
The Calcaneum 159
The Cuboid 159
The Navicular 160
The Cuneiform 160
The Internal Cuneiform 160
The Middle Cuneiform 161
The External Cuneiform 161
The Metatarsal Bones 161
The Phalanges 162
The Foot as a Whole 163
Homologies of the Bones of the Two Extremities 164

The Skull.

The Bones of the Cranium.

The Occipital Bone 165
The Parietal Bone 168
The Frontal Bone 169
The Temporal Bone 171
The Sphenoid Bone 176
The Ethmoid Bone 179

The Bones of the Face.

The Maxilla, or Superior Maxillary Bone . 181
The Palate-bone 183
The Vomer 184
The Inferior Turbinate Bone 185
The Nasal Bone 185
The Lachrymal Bone 186
The Malar Bone 186
The Mandible, or Inferior Maxillary Bone . 187
The Hyoid Bone 189
The Skull as a Whole 190
The Sutures 190
The Exterior of the Skull 190
The Interior of the Cranium 196
General Morphology of the Skull . . . 199
Various Forms of the Skull 200

THE ARTICULATIONS.

By G. Woolsey.

General Considerations 203
Kinds of Joints 204
Kinds of Movement 205
The Articulations of the Trunk and Head . 205
The Articulations of the Vertebral Column 205
The Articulations and Ligaments between the Atlas, Axis, and Occipital Bone 208
The Articulations of the Thorax . . . 211
The Temporo-mandibular Articulation . 214
The Articulations of the Upper Extremity . 216
The Sterno-clavicular Articulation . . 216
The Scapulo-clavicular Articulation . . 217
The Shoulder-joint 218
The Elbow-joint 221

The Radio-ulnar Articulations and Ligaments 223
The Wrist-joint or Radio-carpal Articulations 224
The Carpal Articulations 225
The Carpo-metacarpal and Intermetacarpal Articulations 226
Metacarpo-phalangeal and Interphalangeal Articulations 227
The Articulations of the Pelvis 227
The Articulations of the Pelvis with the Last Lumbar Vertebra 227
The Sacro-coccygeal and Intercoccygeal Articulations 228
The Sacro-iliac Joint 228
The Symphysis Pubis 229

PAGE
The Articulations of the Lower Limb . . . 230
The Hip-joint 230
The Knee-joint 233
The Tibio-fibular Union 237
The Ankle-joint 239
The Tarsal Joints 240
The Tarso-metatarsal and Intermetatarsal Articulations 243
Metatarso-phalangeal and Interphalangeal Articulations 244

THE MUSCLES.

By F. H. Gerrish.

General Considerations 245
The Nomenclature of Muscles 248

The Muscles of the Upper Limb.

Movements of the Upper Limb 251
Muscles Moving the Shoulder 253
Muscles Moving the Arm 258
Muscles Moving the Whole Forearm . . 263
Muscles Moving the Outer Part of the Forearm 266
Muscles Moving the Whole Hand 269
Muscles Moving the Fingers 272
Muscles Moving the Thumb 280

The Muscles of the Lower Limb.

Muscles Moving the Thigh 289
Muscles Moving the Leg 301
Muscles Moving the Whole Foot 308
Muscles Moving the Digits of the Foot . . 316

The Muscles of the Trunk.

The Muscles of the Back 325
Muscles in the Third Layer of the Back 325
Muscles in the Fourth Layer of the Back 327
Muscles in the Fifth Group of the Back 329
The Muscles of the Abdomen 331
The Muscles of the Thorax 334

The Muscles of the Neck.

Muscles of the Front and Side of the Neck . 337

The Muscles of the Head.

Superficial Muscles of the Head 342
Muscles of Mastication 342
Muscles of Expression 343

THE FASCIÆ.

By F. H. Gerrish.

The Superficial Fascia 349

The Deep Fasciæ.

The Fasciæ of the Head 350
The Temporal Fascia 350
The Masseteric Fascia 350
The Buccinator Fascia 350
The Cervical Fascia 351
The Outer Cervical Fascia 351
The Middle Cervical Fascia 352
The Inner Cervical Fascia 352
The Thoracic Fascia 353
The Pectoral Fascia 353
The Clavi-coraco-axillary Fascia . . . 354
The Intercostal Fasciæ 354
The Fasciæ of the Shoulder 354
The Subscapular Fascia 355
The Supraspinous Fascia 355
The Infraspinous Fascia 355
The Deltoid Fascia 355
The Fascia of the Arm 355
The Fascia of the Forearm 355
The Posterior Annular Ligament . . . 356
The Fasciæ of the Hand 356
The Anterior Annular Ligament . . . 356
The Palmar Fascia 356
The Dorsal Fascia of the Hand 357
Fascial Sheaths of Tendons in the Hand 357
The Fasciæ of the Back 358
The Vertebral Fascia 358
The Lumbar Fascia 358
The Fasciæ of the Abdominal Cavity . . . 359
The Transversalis Fascia 359
The Iliac Fascia 360
The Pelvic Fascia 360
The Obturator Fascia 360
The Recto-vesical Fascia 361
The Fasciæ of the Perineum 361
The Fasciæ of the Hip and Thigh 362
The Fasciæ of the Leg 362
The Fasciæ of the Foot 364

THE BLOOD-VASCULAR SYSTEM.

THE HEART.

By F. H. Gerrish.

Descriptive Anatomy of the Heart 365
The Pericardium 373
The Physiological Anatomy of the Blood-vessels 374
The Arteries 375
The Capillaries 377
The Veins 377

THE ARTERIES.

By A. D. Bevan.

PAGE

The Pulmonary Arterial System . . 379
A Syllabus of the Systemic Arterial System 381
The Aorta 383
The Arch of the Aorta 383
The Brachio-cephalic Artery 386
The Left Carotid Artery in the Thorax . . 389
The Common Carotids in the Neck 389
The External Carotid Artery 392
The Internal Carotid Artery 401
The Subclavian Artery 404
The Internal Mammary Artery 409
The Thyroid Axis 410
The Superior Intercostal Artery 411
The Triangles of the Neck 411

PAGE

The Axillary Artery 412
The Axillary Space 415
The Brachial Artery 415
The Ulnar Artery 417
The Radial Artery 421
The Descending Aorta 423
The Abdominal Aorta 426
The Common Iliac Arteries 432
The Internal Iliac Artery 433
The External Iliac Artery 438
The Femoral Artery 439
The Superficial Femoral Artery 440
The Posterior Tibial Artery 446
The Anterior Tibial Artery 450

THE VEINS.

By G. Woolsey.

The Pulmonary Veins . . . 454
The Systemic Veins 455
The Veins of the Heart 455
The Superior Vena Cava and its Tributaries 456
The Brachio-cephalic Veins 457
Veins of the Head and Neck 457
Veins of the Neck 460
The Venous Sinuses of the Cranium . . 463
The Ophthalmic Veins 467
The Emissary Veins 467
The Veins of the Brain 467
The Veins of the Upper Extremity 468
The Superficial Veins of the Upper Extremity 468
The Deep Veins of the Upper Extremity 470
The Veins of the Thoracic Wall . . . 470
The Azygos Veins 471
Veins of the Spine 472
The Inferior Vena Cava and its Tributaries . 474
The Common Iliac Veins 476
The External Iliac Veins 477
The Portal System of Veins 477
The Veins of the Pelvis 479
Veins of the Lower Extremity 481
Superficial Veins of the Lower Extremity 481
Deep Veins of the Lower Extremity . . 482

THE LYMPHATIC SYSTEM.

By F. H. Gerrish.

The Lymph-vessels 484
Lymph-nodes and other Lymphadenoid Structures 487
Lymph-nodes 487
The Nodes of the Head and Neck 489
The Nodes of the Upper Limb 492
The Nodes of the Lower Limb 493
The Nodes of the Thorax 495
The Nodes of the Abdomen 497

THE CEREBRO-SPINAL AXIS.

By F. H. Gerrish.

General Considerations 499
The Cavity of the Cerebro-spinal Axis . . . 501
The Walls of the Cerebro-spinal Axis . . . 505
A Diagrammatic Description of the Brain . 506
The Cerebrum 509
The Surface of the Cerebrum 509
Relation of the Principal Lobes to the Parts of the Lateral Ventricle . . . 517
Situation of the Lobes in the Cranium . 517
The Callosum 517
The Fornix 520
The Anterior Commissure 522
The Septum Lucidum 522
The Caudate Nucleus 524
The Lenticular Nucleus 525
The Claustrum 525
The Amygdaloid Nucleus 526
The Velum Interpositum 526
The Region of the Third Ventricle—The Thalamencephalon 531
The Thalami 532
The Internal Capsule 537
The Mesencephalon 538
The Region of the Aqueduct 538
The Epencephalon 540
The Pons 540
The Cerebellum 541
The Oblongata 545
Internal Structure of the Oblongata . . 547
The Lemniscus 550
The Fourth Ventricle 550
The Spinal Cord 552
The Membranes of the Cerebro-spinal Axis . 557
The Membranes of the Brain 558
The Membranes of the Spinal Cord . . 561

THE NERVES.

By W. Keiller.

PAGE

The Cerebro-spinal Nerves . . 563
The Cranial Nerves 565
The First or Olfactory Nerve 567
The Second or Optic Nerve 568
The Third or Oculo-motor Nerve . . . 571
The Fourth or Trochlear Nerve . . . 574
The Fifth or Trifacial Nerve 574
The Sixth or Abducent Nerve 585
The Seventh or Facial Nerve 585
The Eighth or Auditory Nerve 589
The Ninth or Glossopharyngeal Nerve . 591
The Tenth, Pneumogastric, or Vagus Nerve 592
The Eleventh or Spinal Accessory Nerve 596
The Twelfth or Hypoglossal Nerve . . 596
The Spinal Nerves 598
The Anterior Primary Divisions . . . 603
Cervical Nerves 603
Branches given off Above the Clavicle . 606
Branches given off Below the Clavicle . 607
The Musculo-cutaneous Nerve 608
The Median Nerve 608
The Small Internal Cutaneous Nerve . . 612
The Internal Cutaneous Nerve 612
The Ulnar Nerve 612
The Circumflex Nerve 613
The Musculo-spiral Nerve 614

PAGE

The Thoracic Nerves 619
The Lumbar Nerves 622
The Lumbar Plexus 622
The Iliohypogastric Nerve 623
The Ilioïnguinal Nerve 624
The Genitocrural Nerve 624
The External Cutaneous Nerve 624
The Anterior Crural Nerve 624
The Obturator Nerve 626
The Accessory Obturator Nerve . . . 626
The Sacral and Coccygeal Nerves 627
The Sacral Plexus 628
The Pudic Nerve 631
The Great Sciatic Nerve 631
The Internal Popliteal Nerve 632
Posterior Tibial Nerve 633
External Popliteal or Peroneal Nerve . 636
Fourth and Fifth Sacral and the Coccygeal Nerves 638

The Sympathetic Nerves. . . 639
The Sympathetic in the Neck 642
The Thoracic Portion of the Gangliated Cord 644
The Lumbar Portion of the Gangliated Cord 646
The Sacral Portion of the Gangliated Cord . 648

THE ORGANS OF THE SPECIAL SENSES.

THE SKIN 651

By W. Keiller.

Nails and Hairs 655
The Sebaceous Glands 658
The Sweat-Glands 659

THE TONGUE 660

By F. H. Gerrish.

Other Organs of Taste 662

THE NOSE 663

By W. Keiller.

The Nasal Cartilages 664
The Nasal Fossæ 664
Cavities Opening into the Nasal Fossæ . 666

THE EAR 668

By F. H. Gerrish.

The Internal Ear or Labyrinth 668
The Membranous Labyrinth 668
The Osseous Labyrinth 672
The Middle Ear or Tympanum 674
The External Ear 677

THE EYE 680

By W. Keiller.

The External or Fibrous Tunic 682
The Sclerotic 682
The Cornea 682
The Middle or Vascular Tunic 683
The Choroid 684
The Ciliary Zone 684
The Iris 685
The Inner or Nervous Tunic 686
The Vitreous 689
The Lens 689
The Aqueous 689
The Muscles of the Eyeball 690
The Superficial Appendages of the Eye . 691
The Eyelids 691
The Conjunctiva 693
The Lachrymal Gland 694

THE ORGANS OF DIGESTION.

By F. H. Gerrish.

General Considerations 695

The Mouth 698

The Lips 699
The Cheeks 699
The Hard Palate 699
The Soft Palate 700
The Teeth 702
Sets of Teeth 703
The Gums 707
The Tongue 707
The Extrinsic Muscles of the Tongue . 709

PAGE

THE PHARYNX 710
The Tonsils 711
THE GULLET 712
The Abdominal Cavity 713
Regions of the Abdomen 714
THE STOMACH 715
THE SMALL INTESTINE . . . 717
The Duodenum 721
The Jejuno-ileum 723
THE LARGE INTESTINE 724
The Cæcum 727
The Appendix 728
The Colon 728
The Ascending Colon 729
The Transverse Colon 729
The Descending Colon 729
The Sigmoid Colon 730
The Rectum 732
The Anal Canal 734
GLANDS ACCESSORY TO THE ALIMENTARY TUBE.
The Salivary Glands 734
The Parotid Gland 735
The Submaxillary Gland 735
The Sublingual Gland 736
The Pancreas 736
The Liver 738
Physiological Anatomy of the Liver . . 738
A Typical Lobe 738
Arrangement of the Vessels 739
The Form of the Liver 740
The Surfaces of the Liver 741
Borders of the Liver 744
The Extremities of the Liver 744
Tunics of the Liver 744
Supports of the Liver 745
Vessels of the Liver 745
The Bile-ducts 746
The Gall-bladder 746
THE PERITONEUM 748
Mesenteries 748
Omenta 749
Ligaments 750
General View of the Peritoneum 750
Retroperitoneal Fossæ 753

THE ORGANS OF RESPIRATION.

BY F. H. GERRISH.

Physiological Anatomy 755
The Trachea 757
The Bronchi 758
The Bronchia 758
Minute Anatomy of the Lungs 759
Gross Anatomy of the Lungs 762
The Pleuræ 765
The Larynx 767
The Cartilages of the Larynx 768
The Ligaments of the Larynx 769
The Muscles of the Larynx 771
The Lining of the Larynx 773

THE URINARY SYSTEM.

BY F. H. GERRISH.

THE KIDNEYS 777
The Excretory Apparatus of the Kidneys . . 784
The Ureters 784
The Bladder 785
The Urethra 787
The Female Urethra 788
The Male Urethra 789

THE DUCTLESS GLANDS.

BY F. H. GERRISH.

The Spleen 793
The Thyroid Body 796
The Thymus 797
The Suprarenal Capsules 798
The Parathyroids 799
The Carotid Glands 800
The Coccygeal Gland 800

THE ORGANS OF GENERATION.

By G. D. Stewart.

The Male Organs of Generation.	PAGE
The Testicles	801
The Vas Deferens	807
The Seminal Vesicles	808
The Ejaculatory Ducts	809
The Scrotum	809
The Spermatic Cord	812
The Penis	812
The Prostate Gland	818
The Bulbo-urethral Glands	820
The Muscles of the Male Perineum	820
The Anal Group	821
The Genito-urinary Group	821

The Female Organs of Generation.	PAGE
The Ovaries	822
The Fallopian Tubes	827
The Uterus	829
The Vagina	835
The Vulva	837
The Mons Veneris	838
The Labia Majora	838
The Labia Minora	839
The Interlabial Space	839
Erectile Organs	840
Glands	841
The Muscles of the Female Perineum	842
The Mammary Glands	843

RELATIONAL ANATOMY.

By F. H. Gerrish.

Plane Sections	847
Surface Anatomy	857
Normal Skiagraphs	871

PRACTICAL ANATOMY.

By F. H. Gerrish.

Directions for Dissecting	883
Division of the Cadaver	885
The Thorax and Upper Limb	886
Thoracic Cavity	886
Front of the Arm	886
Front of the Forearm	886
The Palm	886
Back of Thorax and Upper Limb	887
Back of the Arm	887
Back of the Forearm	887
Back of the Hand	887
The Abdomen and Lower Limb	887
The Abdomen	887
Abdominal Cavity	888
Abdomen Proper	888
The Pelvic Cavity of the Male	888
The Pelvic Cavity of the Female	888
The Male Perineum	888
The Female Perineum	889
Front of the Thigh	889
Inner Side of the Thigh	889
Front of the Leg and Dorsum of the Foot	889
Outer Side of the Leg	889
Back of the Hip	890
Back of the Thigh	890
Back of the Leg	890
The Sole	890
The Head and Neck	890
Cranial Region	890
Inside of the Cranium	891
Back of the Neck	891
Side of the Neck	891
The Face	892
Temporal and Zygomatic Fossæ	892
Mandibular Region	892
Deep Parts of the Neck	892
Prevertebral Region	892
The Orbit	892
The Back	893

A

TEXT-BOOK OF ANATOMY.

INTRODUCTORY.

By F. H. GERRISH.

Definition of Anatomy, and Divisions of the subject.—Names and Delimitations of Surface Parts.—The Systems of Organs, and their Functions.—The Order of Topics.—Methods of Study.

ANATOMY is the science of organization. It treats of the structure of organized beings. Not all of the beings in the world can properly be said to have a structure. We may speak of the structure of a flower, however simple, but we never associate the idea of structure with a crystal. The flower has petals, and calyx, and stamen, and other parts, each differing in look, texture, strength, and use from all the rest. The crystal is of the same material and appearance throughout: it is a mass which is equally dense, equally strong, equally colored in one part as in another—it is homogeneous; that is to say, its physical qualities are evenly distributed. The flower is easily seen to have organs, each of which has its own peculiar office; the crystal has no organs whatever. The one is organized—it has a structure; the other is not organized—it has no structure. Therefore we may study the anatomy of a flower, but there is no anatomy of a crystal for us to study.

Let us here draw a distinction between the words *organized* and *organic*. The first relates to anything which has organs—parts which are differentiated from each other; the second is applied to things which result from the vital activity of organized beings. Thus, caseine, which exists in milk and is the characteristic material in cheese, is organic, for it is a result of the activity of a living creature; but it is not organized, having no structure, one portion being exactly like every other. Many things—for example, water—are neither organized nor organic; they are inorganic.

All organized beings belong to one or the other of two great groups—plants and animals. The distinction may not be essential; indeed, there are creatures upon the dividing-line between these groups whose nature is not yet determined—perhaps they are plants, perhaps they are animals. But, although it may be impossible to give a definition which shall include all of either group without taking in some belonging to the other, these terms are not in the least likely to mislead us. The study of the structure of plants is called *vegetable anatomy*, and is thus distinguished from *animal anatomy*, which has to do with the organization of the members of the other group of creatures.

Physiology is often used, carelessly, synonymously with anatomy, but they are absolutely distinct. Anatomy is the science of structure; physiology is the science of function. Anatomy teaches us what organs a plant or animal has; physiology teaches us to what use these organs are put. Anatomy shows what

an organ is; physiology shows what an organ does. Anatomy may be, and usually is, studied upon the dead creature; physiology can be studied only upon the living—it requires organization in action.

Of all animals, the human was the first whose anatomy was studied with great care. Naturally, men were more interested to know what they could about their own bodies than about those of other creatures; and when they did investigate the structure of the members of lower orders, it was to be expected that they would institute comparisons between the organs of the latter and those in themselves which seemed to correspond. Thus it came about that they called the science of the structure of all other animals *comparative anatomy*, to distinguish it from the science of their own organizations, which is *human anatomy*. If they had begun their study of animal structure at the other end of the scale, taking first animals of the simplest organization and working up gradually through a series, each member of which was more elaborately constituted than its immediate predecessor, until they reached man, the term comparative anatomy would not be used in the sense in which it is usually employed. But, although we recognize the defects of their method, we must confess that in the same circumstances we would doubtless have done precisely as they did. Now-a-days, however, the student is counselled to begin with simple and easily understood structures, in order to prepare himself for the readier comprehension of the more complex, and finally of the most intricate. The study of the anatomy of the lower animals is an admirable—indeed, the best—preparation for that of human anatomy. One who is familiar with the structure of one animal in the great group in which man belongs, as the cat, for example, will find human anatomy immensely simplified. But comparative anatomy, as a separate branch, has no right to a place in the course of study in a medical school, and only occasionally and incidentally will it be referred to in this book.

Human anatomy is subdivided, according to the means employed in its study, into two great parts: *gross* or *macroscopic anatomy*, in which no aids to vision are employed, and *minute* or *microscopic anatomy*, in which the assistance of optical instruments is used.

According to the method pursued in its study gross anatomy is subdivided into *systematic* and *relational*. Systematic anatomy, called also *descriptive anatomy*, regards the body as made up of systems or sets of organs. For example, considering the human being from this point of view, we find that it has a nervous system (brain, spinal cord, nerves, etc.), a circulatory system (heart, blood-vessels, etc.), a digestive system (stomach, intestines, etc.), an osseous system (bones, etc.), a muscular system (muscles, etc.), a respiratory system (lungs, windpipe, etc.), an excretory system (kidneys, bladder, etc.), a reproductive system (ovaries, testicles, etc.). Knowledge of the various organs comprised in each of these systems is essential to the practitioner of medicine and surgery. But if he knows each of these systems only in a separate and unassociated way, he is far from being equipped anatomically as he ought to be. He still needs to learn how each part of every system is related to each part of every other system, and particularly what are the relations of each object to all of the other objects in its neighborhood or region. In other words, he must know his anatomy not only from the systematic point of view, but from the *relational*. Other names given to this method of study are *regional anatomy*, because by it the body is divided into regions for investigation; *topographical* (from the Greek word meaning "place"), a term used by civil engineers to designate a survey in which the position of every part of the territory involved is determined relatively to every other part; *surgical*, because operations cannot safely be performed without knowledge thus acquired; *medical*, because it is necessary to accurate diagnosis of disease of internal organs.

Systematic anatomy is made possible by *dissection*, by which is meant the careful and delicate cutting apart of the various structures, so that they can be observed and studied. It is practised upon the dead body. Much of relational

anatomy also can be acquired in this way; but a very modern method has revealed a multitude of facts in this connection which were previously unknown, and are incapable of demonstration by dissection alone. This new method is that of *plane sections*. The sections are made in the following manner: a body is frozen so hard that a saw, in cutting through it, encounters no more resistance in bone than in muscle. Cuts with a saw are made in any direction which one chooses, but the most common are the horizontal, the vertical sidewise (also called "coronal" or "frontal"), and the vertical fore-and-aft (known also as "sagittal"). The cut having been made, the saw-dust is very carefully cleared away from the surfaces, and the relations of the parts which have been brought to view are studied. As an elevation of temperature above the freezing-point will impair the fixity of the specimens, and as it is manifestly out of the question to maintain such a degree of cold permanently or to study the specimens comfortably during its continuance, it is usual to photograph them, or immerse them in a preservative fluid in flat vessels covered with plain glass, or to adopt both of these devices for continuing the study. Students are not expected to do this work, which involves great labor, skill, and, for interpretation of the appearances of the sections, a high degree of anatomical knowledge; but they can avail themselves of the results of this method by studying the actual sections or casts of them in their medical schools, or, what is sometimes better because more intelligible, pictures of sections made from photographs and labelled in detail.

Minute or *microscopic anatomy* deals with those features of structure which are too small to be recognized by the unaided eye. It can be studied only with the assistance of a microscope. A branch of microscopic anatomy is *histology* (the name coming from the Greek word for "texture"), which is the science of the tissues. But the name histology has been much used synonymously for microscopic anatomy, the whole getting its designation from a part, as in many other cases in our language. Histology is sometimes called *general anatomy*, because the tissues are distributed to all parts—are general to the various organs.

A homely illustration will serve to make the difference between these various subdivisions of anatomy clear. We may use the word "anatomy" with reference to artificial structures, as, for instance, the anatomy of a steam-engine or of a watch or of a house. Let us, then, regard a house from the points of view successively of the systematic anatomist, the topographic anatomist, and the histologist. The first of the trio considers the house as made up of sets of organs, a series of apartments devoted to alimentary purposes, as the kitchen and dining-room; another set used for sleeping—the bed-chambers; one for study—the library, and so on; a system of tubes conveying water to various parts of the establishment; another lot bearing illuminating gas to every room; a third supplying steam or hot air for raising the temperature; and still another carrying off liquid waste materials; large, vertical pipes by which injurious products of combustion are conducted away; a quantity of wires adapted to the conveyance of electricity for various purposes within the house, and a set of rods designed to keep electricity out of it. Thus he finds whatever organs go to compose a house, and describes each set by itself, so that a person who desires to know about any system of apparatus—as, for example, that used for heating or that for sewerage—can learn about it by consulting the record of the investigator's observations.

The topographic anatomist approaches the question of the structure of the house in an entirely different way. He examines the building by such means that, without actually cutting it into slices, he is able to make drawings which show just what these plane sections would display if they were made. He does not concern himself with any separate system of rooms or rods or pipes or wires, but he studies the relations which obtain between all of the objects which he sees in each of his imaginary sections. For example, he observes that the parlor is related to the cellar below, to a bed-chamber above, to a library behind,

to a corridor at one side, and a roofed piazza on two sides. He notes the electric wires, the gas- and steam- and water- and waste-pipes within the walls of the room, the chimney which projects into it, and the relations which these sustain to the room itself and to each other. He proceeds thus until every region of the house is investigated and mapped out, and when he has done all this one can get from his records a complete idea of the relations of every piece of the structure to every other.

Finally comes the histologist, who, disregarding systems of organs and heedless of the relations between various parts, looks only at the structural materials entering into the composition of the house; in other words, its tissues. He finds that the house is made up of stones, bricks, boards, beams, nails, slates, and many other things, which present to the eye definite forms by which they are recognizable. It may be that some one kind of these structural elements varies in shape and in other respects in different parts, as, for instance, the bricks, which are of one form, size, and smoothness in the outside wall, different in all of these respects in the inner wall, and unlike either of the other kinds in the fire-places; but they are all readily seen to belong in the same category.

Each of these three methods of considering the house has its uses; each alone is seen to be inadequate to convey a comprehensive idea of the building. An architect employs all of them: he is, as regards houses, a systematic anatomist, a relational anatomist, and a histologist; he knows what the organs of a building are, how they stand in space with reference to each other, and of what textures they are constructed. For exactly the same reason every practitioner of medicine must be a human anatomist in all three of these ways. He finds one disease affecting a given system—as, for example, the alimentary—and therefore has to know the organs of this system as a continuous series; he meets with another disease involving, not a set of physiologically associated organs, but a number of parts which are related to each other in a geographical way, occupying a limited region, and consequently he needs to be acquainted with the organs or parts of organs belonging to half a dozen different systems. In either case he may be unable to appreciate the condition of affairs if he is ignorant of the tissues entering into the composition of the structures which are invaded.

The body may be considered anatomically from still other points of view. If it is in a state of health, the study of its structure is *normal anatomy;* if it is in a condition of disease, *pathological* or *morbid anatomy.* When the organization is studied with especial reference to function, we pursue the method of *physiological anatomy.* The consideration of the plan or model upon which organs are formed constitutes *morphological anatomy;* and as the discussion of such matters is attended necessarily with more or less of speculation, the synonyms *philosophic* and *transcendental anatomy* are often employed. The object which the investigator has in view determines the division of the subject. Thus, if he studies the body with the purpose of representing it in a pictorial or plastic way, it is *artistic anatomy;* if his only intent is to acquire knowledge which will be especially serviceable in the practice of the healing art, it is *applied* or *clinical anatomy. Practical anatomy* is a name employed to indicate the study of the body by dissection.

It will be understood, however, that we confine ourselves to human anatomy solely; that we regard it only in its normal aspects; that, unless otherwise specified, the adult condition is assumed; and that we consider anatomy chiefly with a view to the interest which it must have for the student who desires to fit himself for the work of the medical profession. This will involve the study of systematic, relational, and microscopic anatomy, and in the treatment of many topics all three of these methods will go along hand in hand. Frequently the physiological anatomy will be presented at the opening of a section, because it is so much easier to understand a machine if we enter upon its study with a distinct idea of the work which it is capable of performing, than if we have no notion of its function.

The following tabulation will aid in recalling the principal points which have been made:

- Anatomy
  - Vegetable
  - Animal
    - Comparative (all lower animals)
    - Human (man)
      - Gross, or Macroscopic
        - Systematic, or Descriptive.
        - Relational, Topographic, or Regional.
      - Minute, or Microscopic (Histology)

NAMES AND DELIMITATIONS OF SURFACE PARTS.

At the outset of anatomical study it is important to have the clearest possible conception of the limits set by nature or by convention to the various parts which will be referred to constantly in the following pages, and also to have for each of these parts a name which shall be used for that and for nothing else. All parts, even the minutest, have technical names, which are Latin in form, and almost all parts which are visible without dissection, and those which are brought into view by accident, have, besides the scientific, vernacular appellations—names given by non-medical people who never had a thought of knowing anatomy. The scientific name of a part is understood in every land where medicine is cultivated; the vernacular designation in one language is generally different from that in every other, and frequently essentially so. Thus, what we call "head" in English is "tête" in French, "kopf" in German, "testa" in Italian; and the anatomist who is acquainted with no modern language but his own can understand only that one of these words which belongs to his native tongue. "Caput," however, means the same thing to English, French, German, and Italian, for all scientific men are supposed to know something of Latin, the language of scientific nomenclature. Only a small proportion of the names applicable to anatomical parts is included in the vocabulary of the common people, but anatomists generally use these in their writings; for the suggestion of pedantry which inevitably would come from the invariable employment of the technical terms instead of the existing vernacular words would be almost intolerably offensive. Unfortunately, however, quite a number of these vernacular titles are used by anatomists with different significations from those which they have to the unscientific; and hence it seems necessary to explain what meaning we shall attach to these words, which have been familiar to us from the cradle.

It may seem to some readers needless to undertake this enumeration and definition. But a large observation of medical students through many years has demonstrated that it is highly desirable to do exactly this thing. People of much more than ordinary intelligence and education rarely have any idea of the difference between the meaning which many a word has to medical men and that which is attached to it generally. When a surgeon hears through a non-medical source that a person has broken a leg or an arm, he simply gathers the impression that a fracture is supposed to have occurred in a lower limb in the one case and in an upper limb in the other case; but if leg or arm is mentioned by a medical man, he knows that the third segment of the lower extremity is meant in the first instance, and the second segment of the upper extremity in the second. "Wrist" to the laity means anywhere from the upper level of the palm to nearly halfway up the forearm; "hip" is used instead of "thigh," mention of the latter, for some inexplicable reason, being at present considered even more indelicate than that of "leg," for which polite usage has substituted "limb." These few selections from a considerable number will serve, it is hoped, to justify the attempt which is here made in the interest of precision of language and of thought.

In order to understand the application of the terms intended to designate the relation in space which different parts of the body sustain to each other, it is necessary to know what is regarded as the *anatomical position*. This is the erect attitude, with the palms of the hands turned to the front, and the soles of the feet horizontal—that is, facing downward.

To the anatomist "head" (*caput*) means all of the mass which is balanced

on the neck, the front and lower portions being "face" (*facies*), the upper and back "cranium," the dividing-line between the two parts starting at the so-called root of the nose in the mid-line, and extending on each side beneath the overhanging brows and downward and backward to the ear. But "head," in common parlance, means at some times all that we have included, as in decapitation; at others only the cranium, as in the use of the word headache. "Face" with the people embraces the anatomical face and also the anterior portion of the cranium: a beautiful face would be considered desecrated if its picture showed nothing above the eyeballs. And yet "face" is often used in a more restricted sense than the anatomical, as when one speaks of faceache, meaning pain in the cheek region only.

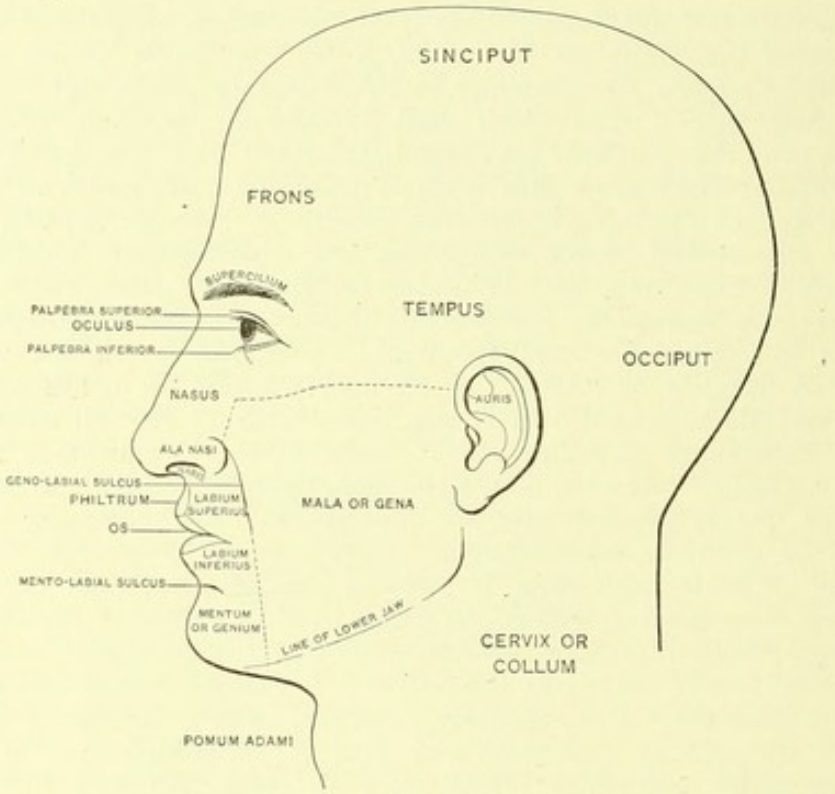

FIG. 1.—Side view of cranium and face. (F. H. G.)

The cranium is subdivided (Fig. 1) into an anterior part, the "forehead" (*frons*); an upper, the "crown" (*vertex* or *sinciput*); a back, the *occiput;* and, on each side, the temple (*tempus*). There are no surface-markings by which these are absolutely delimited. At the lower portion of the temporal region is the flaring part of the ear, known by anatomists to be the least important division of the organ of hearing (*auris*), but thought by people commonly to be about all of it, and consequently named "ear." The forehead terminates below at the "nose" (*nasus*) in the middle line, and on each side of this, in an arched border, usually covered with short, crisp hairs, and called the "brow" (*supercilium*). In the face immediately beneath each brow is an "eye" (*oculus*), that is, an eyeball or globe, shielded above by an "upper lid" (*palpebra superior*) and below by a "lower lid" (*palpebra inferior*), their edges fringed with short hairs, the "lashes" (*cilia*). Between the eyes and in the middle of the face, below their level, is the projecting part of the nose, which is all that is generally recognized as nose. This has on each side below an opening, presenting downward, the "nostril" (*naris*), guarded on the outer side by a flaring projection, the "wing of the nose" (*ala nasi*). What is commonly called the "bridge of the nose," a prominence caused by the nasal bones, has no technical designation. At a short distance beneath the nose is a transverse slit, to which, as well as to the cavity of which it is the opening, is given the name "mouth" (*os*). Above this aperture is the "upper

lip" (*labium superius*), and underneath it the "lower lip" (*labium inferius*). Popularly, the word mouth is often applied to the lips, as when a woman is said to have a pretty mouth—a comment which manifestly is not intended for the slit-like opening, and still less for the cavity behind it. (It may not be amiss to call attention to the fact that the Latin *os*, meaning a mouth, has *oris* for its genitive, and gives origin to our English oral; whereas *os*, meaning a bone, is *ossis* in the genitive, and thus stands behind our English osseous.) The upper lip extends vertically from the nose above to the free border below, and laterally to the crease which courses down and out from the hind border of the wing of the nose, and is called the *geno-labial sulcus;* the lower lip extends from its free edge above to a transverse crease, the *mento-labial sulcus*, which presents a downward concavity, and separates the lip from the chin. The middle portion of the upper lip projects farther downward than do the parts which bound it laterally, and its skin surface is marked by a somewhat triangular depression, the *philtrum*. The border of the skin of this lip describes a line which is a mark of beauty, and is called by artists the bow of Cupid. The "chin" (*mentum*, *genium*) is the central prominence which finishes the face below, in and near the mid-line. It is not distinctly separated from the cheeks. The main part of each lateral aspect of the face is the "cheek" (*mala*, *gena*), which presents a broad, quadrilateral expanse, bounded below by the inferior border of the lower jaw, behind by the vertical portion of the bone of this jaw, above by the lower margin of the orbit (the cavity lodging the eye) and by the ridge of bone running back from it, and in front above by the side of the nose, below this by the geno-labial sulcus, which separates the cheek from the upper lip. The outlines of the lower part of the face are determined largely by its framework, the inferior jaw-bone (*mandibula*), which, with its various attachments and coverings, constitutes the under jaw (*maxilla inferior*). The upper jaw-bone is the staging upon which the greater part of the central zone of the face reposes. On separation of the lips the "teeth" (*dentes*) are seen projecting beyond the "gums" (*gingivæ*) in two arches with the convexities forward; and on depressing the lower jaw a view of the cavity of the mouth is obtained. In its floor we see the muscular "tongue" (*lingua*) with its rough upper surface; its roof is formed by the "hard palate" (*palatum durum*), and behind is the "soft palate" (*palatum molle*) hanging like a short curtain over the base of the tongue. Between the two upright ridges to which the soft palate extends on each side is the "tonsil" (*tonsilla*, *amygdala*), and beneath the pendulous veil of the palate we can see a part of the rear wall of a cavity for which the laity have no name, but which we know as the *pharynx*.

The "neck" (*cervix*, *collum*) connects the head and the trunk (Fig. 2). In front it extends from the level of the lower jaw to the "breast-bone" (*sternum*) in the middle line and the "collar-bone" (*clavicula*) on each side. These bones can readily be felt through the overlying structures. Behind, in the middle line, the neck extends from the base of the cranium to the seventh segment of the back-bone or spine, the tip of which can be both felt and seen projecting beyond the plane of any of its fellows above. Between this segment (*vertebra prominens*) and the collar-bones—that is, at the sides—there is no clear demarcation of the neck from the trunk when the upper limbs hang passively: there is usually an unbroken slope from the head to the peak of the shoulder. But if the shoulders are raised straight upward, a crease is produced which sharply indicates the boundaries of the neck for two-thirds or more of the distance, and suggests the line for the remainder. In this attitude of hunched shoulders the neck rises like a column from a depressed base. Although not exact in every respect, this technical delimitation of the neck is vastly more definite, as well as more restricted, than that which is in popular vogue concerning women arrayed in what is known as "full dress," whose necks, varying at different times according to the dictates of fashion, may find their lower limits anywhere between the collar-bones and the nipples in front, and between the vertebra prominens and

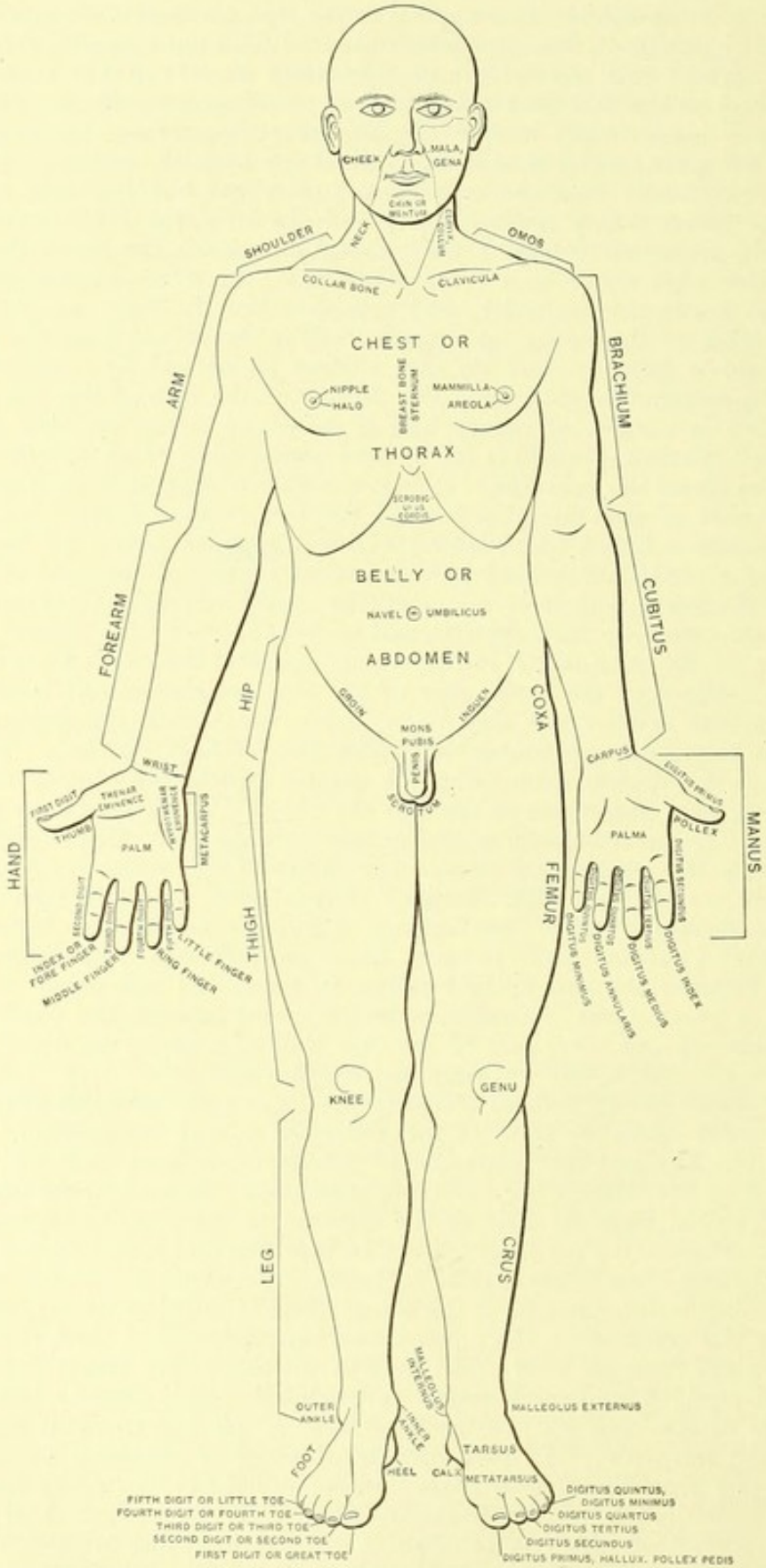

FIG. 2.—Front view of a man in the anatomical position. On one lateral half the parts are labelled in English, on the other in Latin. (F. H. G.)

the small of the back behind. The word "throat" has no anatomical equivalent. It is variously used to designate the front part of the neck, or the tonsils and adjacent parts of the soft palate, or the pharynx, or the organ of voice (*larynx*). High up on the neck in front is a hard protrusion, more prominent in men than in women, caused by the thyroid cartilage of the larynx, and called "Adam's apple" (*pomum Adami*) in playful celebration of the most noted and unfortunate gastronomic performance on record. The median portion of the neck behind is the "nape" (*nucha*). Just above the top of the breast-bone is often seen a little pit, esteemed a mark of beauty by artists, who have named it "Diana's pool."

The body proper, as distinguished from the entire organism, is known as the "trunk" (*truncus*), and presents two grand divisions, the upper of which is the "chest" (*thorax*), the lower the "belly" (*abdomen*). The superficial line of separation between them is pronounced, and is made by the bones and cartilages which form the lower border of the thoracic cage, as the skeleton of the upper cavity is called. Sloping downward and outward from the lower part of the breast-bone, the boundary-line is continued backward at the sides, and then obliquely upward behind. But this surface marking is by no means an indication of the relative size of the two cavities: it only shows the line along which is attached the base of a muscular dome, the *diaphragm* or midriff, whose central portion rises to the level of a point about halfway up the sternum, and shuts off the cavity of the thorax from that of the abdomen. Thus, the summit of the belly-cavity is rounded, presenting a marked convexity upward, and the base of the chest-cavity, into which the former rises, is correspondingly concaved.

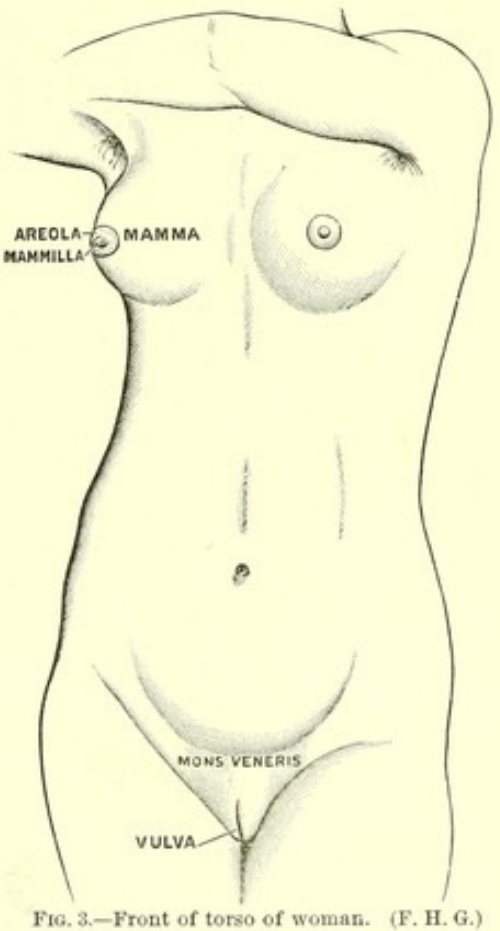

FIG. 3.—Front of torso of woman. (F. H. G.)

From the front of the chest of the adult female there projects a nearly hemispherical mass on each side (Fig. 3). This is the "breast" (*mamma*), the organ in which milk is formed. The valley between these hillocks is properly the "bosom," but this word is often used as synonymous with breast. At about the central point of each mamma stands out the nipple or teat (*mammilla*, literally "the little breast"), its base surrounded by a circular space which is distinguished by the darkness of its skin, and is called the *areola* (literally "the little area") or the "halo." The male has no milk-forming organ, but he has in the same relative situation upon the chest-wall slightly developed mammillæ. These are good illustrations of a rule that the generative organs which are fully developed in one sex are aborted in the other, being represented in the latter by some little bulge or dimple, whose only use seems to be to suggest the narrow escape of its possessor from being of the opposite sex.

The belly at its upper central part presents a shallow depression, popularly called the "pit of the stomach," but technically *scrobiculus cordis*, which literally means "the little pit of the heart." This confusion of names arises from the physical (not the figurative) nearness of the heart and stomach, the one resting upon, the other lying underneath, the diaphragm, and both being in the region of this slight hollow. Farther down in the mid-line, and usually nearly on

a horizontal drawn between the highest points of the haunch-bones, is an irregular, puckered dimple, the "navel," called in Latin *umbilicus*, from *umbo*, the button in the centre of an ancient shield; so that we see that the childish name for the part—belly-button—has the sanction of a noble classical derivation. Following down in the middle line, we find at its lowest part an area which extends considerably sidewise, and is covered in the adult with crisp, curly hairs. This is the *pubes*. Behind the skin of the pubes the male has a little pad of fat, and the slight elevation which is thus produced is sometimes called *mons pubis*—that is, the mountain of the pubes. In the grown female there is so marked an accumulation of fat here as to make a very noticeable hillock, which is named *mons Veneris* (the mount of Venus), in honor of the Roman goddess of love.

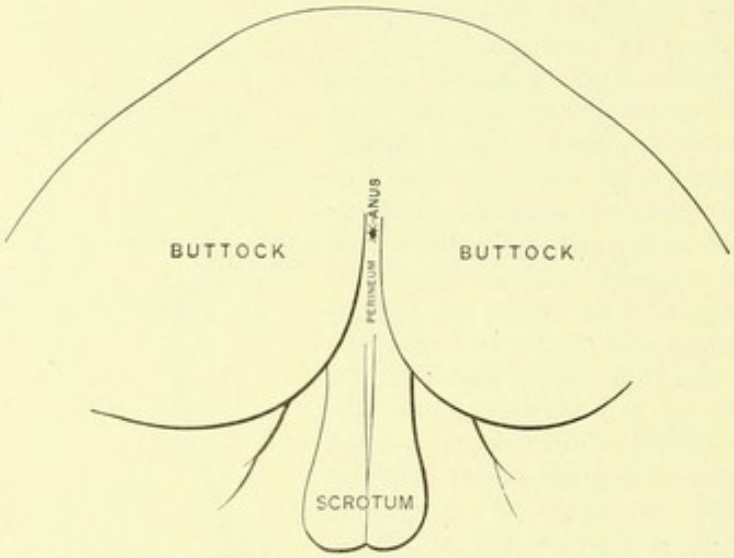

FIG. 4.—The male perineum and surrounding parts. (After His.)

Running obliquely upward and outward from the pubic region on each side is a crease which separates the trunk from the lower limb in front, and is called the "groin" (*inguen*). The name is usually applied to a narrow but indeterminate area of the abdomen immediately above this shallow furrow, and the adjacent area of the thigh just below it.

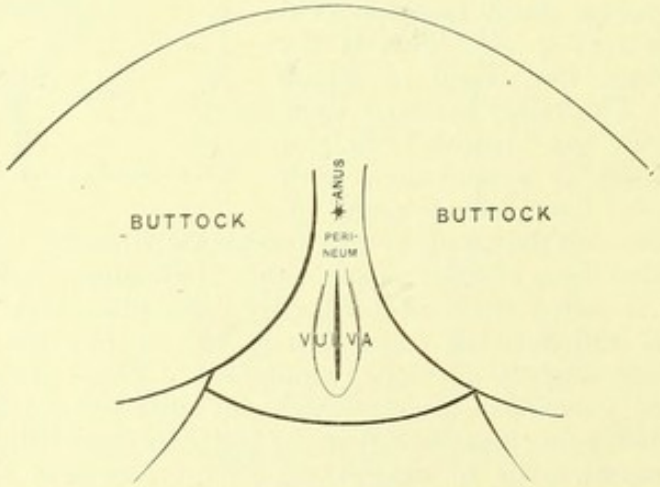

FIG. 5.—The female perineum and surrounding parts. (After His.)

Below the pubes are some of the generative organs—those which are superficially located, the external genitals (*genitalia externa*). In the male is the organ of copulation, whose technical title, *penis*, has practically displaced the entire

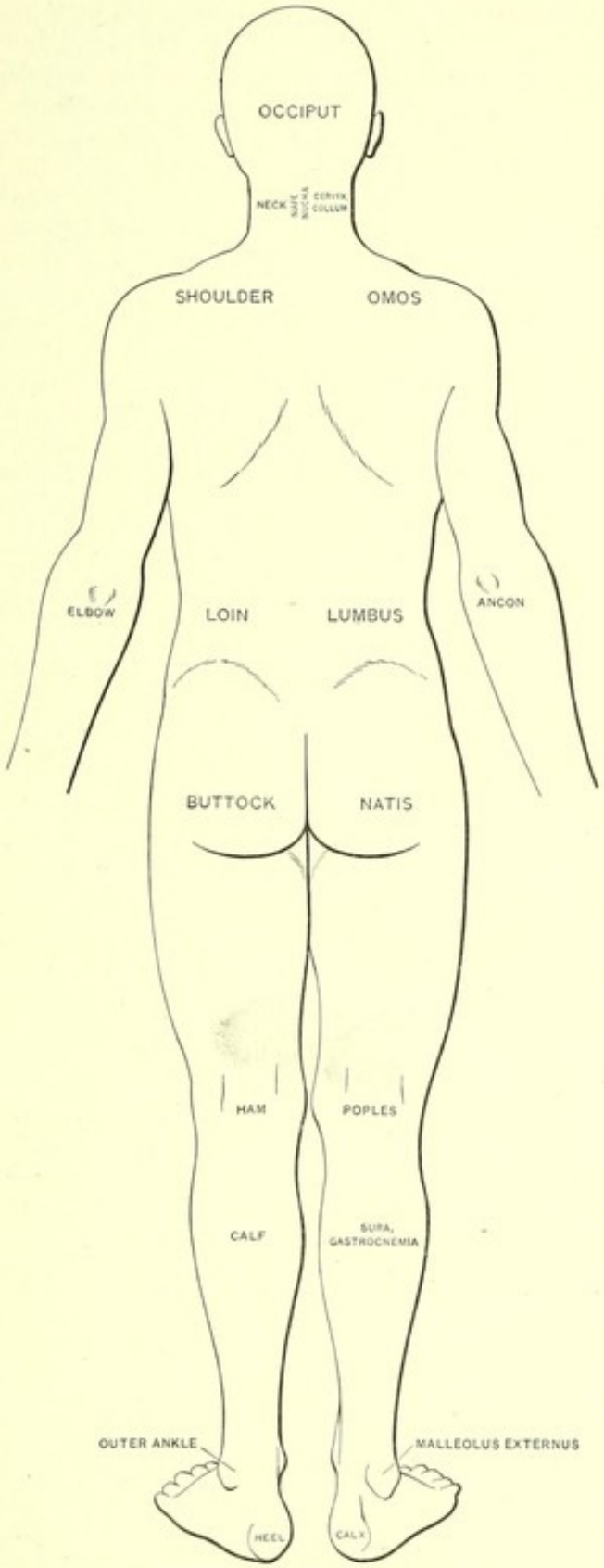

FIG. 6.—Back view of a man. On one lateral half the names of the parts are given in English, on the other in Latin. (F. H. G.)

group of Anglo-Saxon names by which it was formerly known. The free end of the penis, the "head," or *glans penis* (literally "the gland of the penis," from its resemblance to some internally located secreting glands), is covered by a long, movable fold of integument, the "foreskin," or "prepuce" (*preputium*). At the tip of the glans is a little slit, *meatus urinarius*, the termination of the common passage-way of the urine and semen. Behind the penis hangs the "bag" (*scrotum*) in which are suspended the essential male organs of generation, the two "balls" or "stones," which are more usually called by their Latin name *testes* (witnesses) or by the Anglicized diminutive of this word, "testicles." In the female the group of external genitals is designated by the name *vulva*, for which modern English dictionaries, with a fastidiousness not always imitated in popular speech, afford no single-word synonym. These structures are sometimes called *pudenda*, which means "things to be ashamed of"—as if such a criticism could justly be applied to the organs which are necessary for the perpetuation of the human race. The vulva presents a fore-and-aft cleft, which starts just below the pubes and runs backward between the thighs. This fissure is bounded laterally by thick folds of skin, *labia majora* (the greater lips), upon separation of which are seen the *clitoris* (which is the suppressed representative of the penis), two thin folds of membrane, *labia minora* (the smaller lips), the *meatus urinarius*, and the opening of the *vagina*, the tube which leads to the "womb" (*uterus*). Behind the external genitals of both sexes, between the thighs, and in front of the lower opening of the bowels is a narrow antero-posterior area called *perineum*, a word with no vernacular equivalent (Figs. 4 and 5). The rear limit of the perineum is marked by the outer opening of the *anus*, the terminal portion of the alimentary canal.

The posterior surface of the trunk (Fig. 6), generally called the "back" (*dorsum*), shows in the middle line from end to end a furrow in which appears a continuous series of bony prominences, each of which belongs to a separate segment of the pile of bones called the spinal column, or, naming the whole from a part, merely the spine or back-bone. Between the lower margin of the thoracic cage and the crest of the hip on each side, in the region known as the small of the back, is a "loin" (*lumbus*).

Projecting from the trunk are the "limbs" or "extremities" (*membra* or *extremitates*,) arranged in two pairs, an upper and a lower. Each pair has a bilateral symmetry, and therefore the statements which apply to one limb need not be repeated for its mate of the opposite side.

The "upper limb" or "upper extremity" (*membrum superius* or *extremitas superior*) is divided naturally into four distinct segments. These, in regular order from above downward, are shoulder, arm, forearm, and hand. The "shoulder" (*omos*) connects the trunk and arm. The "arm" (*brachium*) extends between the shoulder- and elbow-joints. Beneath the shoulder-joint, and between the side of the chest and the arm, is a pyramidal space, with its base presenting downward, called the "arm-pit" (*axilla*). The "forearm" is known as *antebrachium*, which is the exact Latin equivalent of the English name, and also as *cubitus*, from which comes the name of a measure of length anciently employed. It includes all between the elbow- and wrist-joints. Its upper end is marked behind by a prominence, the "elbow" (*ancon*). The fourth and final segment of the upper limb is the "hand" (*manus*). This is subdivided into a proximal portion, the "wrist" (*carpus*), a central part, which constitutes the body of the hand, the *metacarpus* (meaning "beyond the carpus"), and a distal part, the digits" (*digiti*). The front surface of the metacarpus is the "palm" (*palma*), and the hind surface is the "back" (*dorsum manus*). There are five digits to each hand, numerically named, beginning with that farthest from the median line of the body and counting inward. They have also other designations, which are used with equal or greater frequency. The first digit (*digitus primus*) is the "thumb" (*pollex*); the second (*digitus secundus*) is the "fore finger" (*digitus index*); the third (*digitus tertius*) is the "middle finger" (*digitus medius*); the fourth (*digitus quartus*) is

the "ring finger" (*digitus annularis*, from *annus*, "a ring"); and the fifth (*digitus quintus*) is the "little finger" (*digitus minimus*, literally "the least finger"). Each digit has three segments, except the thumb, which has but two.

The lower limb is the homologue of the upper—that is, it is built on substantially the same structural plan.[1] It has four segments: hip, thigh, leg, and foot, which correspond respectively to shoulder, arm, forearm, and hand. Between hip and thigh is the hip-joint; between thigh and leg, the knee-joint; and between leg and foot, the ankle-joint. The "hip," or haunch (*coxa*), is so firmly united to the back-bone that it serves as a portion of the wall of the abdomen, the greater cavity of the trunk. Behind the hip and immediately below the loin is a large mass of muscle and fat, the "buttock" (*natis*). The "thigh" extends from the hip to the leg, and is technically called *femur*, which name is also applied to the single bone that forms its framework. The prominence in front at its lower end is the "knee" (*genu*), and the space opposite the knee on the posterior aspect is the "ham" (*poples*). The mistake of calling the buttocks the hams is often made, but has no justification. From knee-joint to ankle-joint is the "leg" (*crus*). Its rear bulge is the "calf" (*sura* or *gastrocnemia*, literally "the belly of the leg"), and the sharp vertical ridge in front is the "shin." At the lower end of the leg are two bony prominences, the "inner ankle" (*malleolus internus*) and the "outer ankle" (*malleolus externus*). *Malleolus* means "a little hammer." The "foot" (*pes*), like its homologue the hand, is divided into three parts—a hindmost, the *tarsus*, a middle, the *metatarsus*, and a foremost or distal, the "digits" (*digiti*). The "instep" of popular nomenclature has no equivalent in anatomical terminology, as it includes parts of both tarsus and metatarsus; and, on the other hand, there are no vernacular words corresponding to tarsus and metatarsus. The part of the tarsus which projects to the rear is the heel (*calx*); the top of the foot is its "back" (*dorsum pedis*); and the entire under surface is the "sole" (*planta*). The five digits are designated numerically, like their homologues in the hand, the count beginning, however, not at the outer end of the series, but at the inner—that nearer the median line of the body. Thus, the "toes" or digits of the foot (*digiti pedis*) are first, second, third, fourth, and fifth (*primus*, *secundus*, *tertius*, *quartus*, and *quintus*), respectively. But the first and last have other names also, the one being commonly called the "great toe" (*pollex pedis*, "the thumb of the foot," or *hallux*); and the other the "little toe" (*digitus minimus pedis*, literally "the smallest digit of the foot"). In giving the Latin names for the toes it is rarely necessary to employ *pedis* ("of the foot") to distinguish those of the lower extremity, as the context indicates which limb is concerned; and it is never essential to say *manus* ("of the hand"), as this is understood unless the contrary is obvious.

THE SYSTEMS OF ORGANS AND THEIR FUNCTIONS.

In studying anatomy the thoughtful learner is almost certain to conclude that he needs to know a great deal about every other part in order to comprehend fully the one which he has in hand. No organ, however simple, is independent: every one is so related to others, perhaps to many others, that they are absolutely essential to its life. In the same way it is true that some knowledge of many is necessary to the complete, or even sufficient, understanding of a single one. This fact constitutes a chief obstacle in the path of the anatomical student; but it may be diminished very considerably, and its residue rendered less discouraging, by his having presented to his mind at the beginning of his course a con-

[1] The difference between homology and analogy must be borne in mind. *Homology* relates to similarity of structure, *analogy* to likeness of function. The two do not always go together. For example, the upper limb of a man and that of a bird are homologous, because they are constructed on the same plan; but they are not analogous, because the one is used for prehension (grasping), and the other for locomotion (flying). The organization in the two cases is strikingly similar; the function is radically different. But compare the wing of a bird with that of a butterfly; both are devoted to the same use—namely, flying; but they are essentially different in structural plan, as can be seen on the most cursory inspection. Therefore they are analogous, but not homologous.

cise recital of the principal organs of the body and a statement of the chief function of each. In this way he will learn a number of most useful anatomical facts, and they will be grasped all the more readily because they are strung on a physiological thread. In the few succeeding pages an effort is made to afford the student just this assistance.

Organs Removing Waste Matters.

The human body is a machine, and, like every other machine, wears out in using. We all know that even in circumstances favorable for the preservation of a corpse, such as coolness and dryness of the atmosphere, it undergoes destructive changes so rapidly that before many days have passed what was once an object of beauty and the occasion of delighted admiration becomes altogether grewsome and revolting. And yet, swift as is this putrefaction, the wearing out of the tissues in life is more speedy. The greater the physical activity of a man, the more rapidly are his textures broken down. Every movement, however trifling, every glance of the eye, every thrill of sensation, every thought or emotion, is attended with destruction of substance. The products of this waste are poisonous, and if retained in the system in any considerable amount cause sickness and even death. But there are channels by which these effete and toxic materials are continually escaping—namely, the *lungs*, the *skin*, the *kidneys*, and the *bowels*. Water, the common vehicle in the body-changes, carries them out in solution. The solvent and vehicular services of water are very manifest in the case of the urine, which is loaded with the waste escaping through the kidneys; and they are often as plain in the case of the perspiration, which contains the effete matters discharged through the skin. The excrement which comes from the bowels is not in solution when it appears, but this is due to its loss of water subsequently to its formation and during its detention in the intestine. Other products of decomposition are borne out with every expired breath, this being saturated with water, as appears by its visible condensation whenever the surrounding air is sufficiently cooled.

The Vascular System.

At this point there naturally arises the question of the means by which the various effete materials that are constantly being formed in every part of the body get to the four outlets named. This carriage is accomplished by the vascular system, which consists, first, of a complicated series of tubes, the *blood-vessels*, connected with which is a powerful organ, the *heart*, which drives the blood in a continuous current through them; and, second, of another set of tubes, the *lymph-vessels*, whose stream of lymph flows into that of the blood. Almost everywhere in the body there are minute crevices between the elementary particles and threads of the tissues, and into these chinks the textures discharge their wasted molecules, always in solution in water. These tissue-crannies communicate with little cylindrical tubes, into which the liquefied waste is poured. The tubes are lymph-vessels, and they conduct their contents to certain blood-vessels, where it mingles with the current of blood. Some effete matters pass from the tissues directly into the blood. The blood is contained in and completely fills the heart and the blood-vessels associated with it, these being, first, the arteries, which are tubes through which the blood flows from the heart *to* the tissues; second, capillaries, microscopic tubes of wonderful thinness and delicacy, through which the blood flows *in the midst of* the tissues; and, third, veins, through which the blood flows *away from* the tissues. The heart, which is a kind of force-pump, drives the blood through this great system of tubes in a ceaseless stream, and thus brings it in practical contact with the tissue-elements that make up the various organs. When the blood, laden with impure matters from every part of the body, comes to one of the organs (kidneys, lungs, bowels,

or skin) which is capable of withdrawing decomposition-products from it, the particular poison which this organ can abstract is removed, and the blood is by just so much rendered less impure. Coming to another one of them, it gets rid of the foul material which can be unloaded at this door of exit; and so on at the others. The lungs are sewers for certain excrementitious substances, the kidneys for others, the skin for a third group, and the intestines for the remainder. In this way are eliminated all of the materials which result from the constant wearing out of the body.

Organs Supplying Nourishment.

If there were no compensation for the destructive changes which are going on incessantly, in a very short time every life would cease. But just in proportion to the extent of the waste, and practically simultaneously with it, repair takes place. As an old particle lapses from a tissue a new one supplies its place without delay, even as the ranks of an army, though constantly suffering from the ravages of disease, death, and desertion, are kept full by the enrolment of fresh recruits. The portals of the body by which the new materials are introduced are the respiratory and the alimentary organs.

First of all in importance is the *respiratory system*, which embraces the nasal passages, the pharynx, the larynx, the windpipe, the bronchi, the bronchial tubes, and the lungs, the last being the essential parts. But some critic observes immediately that the lungs have been mentioned already as channels of elimination. Very true, but they are also channels of appropriation. Not only do they expel vile and injurious waste matters with every outgoing breath, but they admit to the blood pure and sustaining nutrient material with every incoming breath. Here is one of the economies of nature—the wagon is never empty: it carries out the offal and it returns with a load of food. Second, we have the *alimentary tube*, with its attendant organs, the *salivary glands*, the *pancreas*, and the *liver*. This tube is very long, including the mouth, part of the pharynx, the gullet, the stomach, the small and the large intestines, the last mentioned having, like the lungs, the double and contrary functions of appropriation and excretion. It is furnished with apparatus by which solid food can be chopped, crushed, moistened, and reduced to a pulp, and other contrivances which dissolve and change the food in various ways until it is in such condition that it can pass through the walls of the tube and enter the capillary blood-vessels and lymph-vessels, which form fine networks in the substance of its walls. Passing into these two sets of vessels by the process of absorption, some of it reaches the blood immediately, and the remainder somewhat indirectly by way of the lymphatics. The blood, therefore, is seen to be enriched by gaseous material in the lungs and by liquids and liquefied solids in the alimentary tube. All of these additions are brought by the veins to the heart, and thence are pumped into the arteries. The latter pour their contents into the capillaries, which are embedded in the tissues. These minute vessels are so thin that the nutrient substances in the blood can pass through their delicate wall, come into direct contact with the tissues, and flood them with food. To each tissue is offered a repast substantially identical with that furnished to every other, but no two of them choose the same articles from this sumptuous table, each having a selective capacity for those things which are best adapted to the preservation of its own peculiar characteristics. So, each tissue having appropriated whatever it needs, the residue of the nutrient material is carried away by the lymphatics along with the waste products already mentioned. It will be observed that it is the vascular system which takes supplies to the tissues, and the same system which carries from them the products of waste.

In connection with the alimentary tube were mentioned, as accessory parts, the salivary glands, the pancreas, and the liver. These are true glands—that is, organs which abstract certain materials from the blood, manufacture them into

new substances, and discharge these last into cavities or upon surfaces. The salivary glands empty their products into the mouth; the pancreas and the liver pour theirs into the small intestine; and these fluids—saliva, pancreatic juice, and bile—effect certain digestive changes in the food.

Organs of Internal Secretion.

There are other organs which resemble true glands in their general gross appearance, but are unlike them in an important respect: they have no tubes through which their products can be discharged upon a surface or into a cavity, and hence they are called ductless glands. They are the *thyroid*, *thymus*, and *suprarenal bodies*. It is supposed that they furnish substances which produce a profound impression upon nutrition, and that these matters, as soon as formed, are thrown into the blood, whence the material for their formation was originally derived.

Organs of Motion.

Certain organs are devoted to the work of movement. Through their instrumentality man is enabled to seize and retain his food, to defend himself from and to assail his enemies, to move about from place to place, and to do numberless other acts in which motion is the principal factor. The organs giving man such power are *muscles*. They form the most of the bulk of the limbs and a great part of the walls of the cavities of the trunk. The lean meat of animals, which is a part of our food, is muscular tissue.

Framework Organs.

All of the organs of the body are held in suitably close relation to each other, and are yet kept from crowding together with injurious force, by certain structures which are called skeletal. The most striking and familiar of these are the bones, which form a stable framework for the various parts, a strong protective wall for cavities containing organs of great delicacy, and powerful levers upon which the muscles act. Cartilages are usually closely associated with bones, but there are cases in which cartilages by themselves perform just such services as bones more commonly do. However conspicuous these hard structures may be in their peculiar line of work, it is doubtful if they are of more use in the animal economy, even in their peculiar province, than are certain soft, flexible tissues. The fibrous tissues do almost all of the minute detail of support, the bones and cartilages being devoted only to the coarser kinds. All through the organs is a fine network of these tissues, furnishing a veritable skeleton for the microscopic elements of which the organs essentially consist. There are also substances which serve as stuffing and cushion-material for various parts.

Organs of Relation.

Of all the organs, those constituting the nervous system are the most exquisite in structure and the highest in function. They are the *brain*, the *spinal cord*, numerous small collections of nervous tissue called *ganglia*, and a great number of cords, the *nerves*, each of which has a connection at one end with some one of the nervous masses above mentioned. The nervous system gets its proper share of attention from the other organs which have been spoken of as engaged in carrying off waste, furnishing material for repair, moving parts or the whole of the body, and doing the passive service of framework. But it acts as if it recognized the great obligation resting on nobility, and it returns the devotion of its humbler neighbors by services of the most exalted order. It regulates and harmonizes the operations of all of the other parts, keeping them up to their work, restraining them if a tendency to overdoing appears, sustaining the equilibrium of all the functions. But, in

addition to all this, it brings the individual into conscious relation with the world around him through the medium of the organs of special sense. Without this last service our lives would be purely vegetative.

Organs of Reproduction.

The functions of the organs thus far mentioned concern only the individual, providing, first, for his preservation, and, second, for his relation to the things around him. There are other organs—not, however, in a condition of functional activity during the whole of life—which are necessary to the preservation of the race. These are the organs of generation. One series of them is present in the female, and its chief members are the *ovaries*, which furnish eggs; the *Fallopian tubes*, by which the eggs are conducted to the womb (uterus); the *womb* itself, in which the eggs, if fertilized, may remain during the period of pregnancy; the *vagina*, which receives the penis of the male in copulation and gives passage to the young when the time for its birth has arrived; and the *mammæ*, from which the progeny obtain sustenance for a considerable period. The other set of organs belongs to the male, and its principal parts are the *testicles*, which furnish the essential part of the semen for the impregnation of the eggs; certain *tubes* by which the semen flows to the *urethra*, the conduit common to the urine and the generative fluid; and, finally, the *penis*, the member by which sexual connection is effected and the male product deposited in the female generative passages.

THE ORDER OF TOPICS.

The chapters in this book are arranged substantially in the conventional order. First comes a brief presentation of the elementary tissues, followed immediately by a chapter on embryology. Then succeeds the descriptive anatomy, in which the organs are treated in systems, and after this the topographical, which deals with the relations of the different organs to each other.

That the account of the histologic materials composing the various organs should precede the description of these structures, and that the mutual relations of the latter should not be presented until the organs themselves have been described, are so logically necessary as to require no explanation. But the succession of topics in the systematic anatomy should be made to vary according to circumstances.

If the learner is studying anatomy only, the arrangement set forth in the table of contents is useful. But if he is studying physiology at the same time, he would do well so to modify the order that he may obtain a knowledge of the structure of each organ just before its function is considered. As physiology is concerned largely with the contents of the cavities of the body, this plan will involve the study of the viscera, including the brain and cord, early in the course. Any hours which are fairly due to anatomy and are not consumed in this preparation for the profitable study of functions should be devoted to osteology, and after this has been mastered the topics would best be taken up in the order as stated—joints, muscles, fasciæ, vessels, and nerves.

METHODS OF STUDY.

Any work which is done according to a prearranged system is more economical of time and effort and more productive of desirable results than that which is done in an unmethodical way. It is particularly important for the student of anatomy to follow lines wisely laid down for his guidance, because of the limited time at his disposal in which to acquire a mastery of the multitude of facts needful for his subsequent progress. Some words of counsel, therefore, are here offered as to the methods of study which experience has shown to be advantageous.

Merely reading the text-book is productive of but little good. Many a man who has done this faithfully is utterly unable to answer a question which would be likely to be included in the list prepared by any competent board of examiners. The facts are so numerous, and often so seemingly unrelated to each other, the names of objects are so unlike anything previously known, and the allusions are so frequent to matters which must remain unexplained until a later part of the course, that it is wellnigh impossible to bring away from a single reading, however careful, much more than a chaotic impression of the subjects considered. Some students in their desperation resort to the plan of verbal memorizing—learning word for word the descriptions in the book. It is hard to conceive of a method more wasteful of energy and less fruitful of results. One who has done this may be able to pass a brilliant oral or written examination, but he has not begun to be an anatomist; he is helpless in the presence of the dissected subject, and incapable of using what he has studied in any practical way. A student should not allow himself to adopt this method. He must learn the facts in such a way that a permanent image of every object is produced in his mind, and thus his knowledge will be available at the bedside. Of course it is necessary to acquire a nomenclature—to learn the names of the objects dealt with—for without these labels of things it is impracticable to receive information, to retain it easily, or to impart it after it has been gained. But this is a vastly different thing from committing to memory the precise phraseology in which any author, however learned and eloquent, has framed his presentation of the facts. The clearer and more forcible a statement in the book, the better is it for the student; but, the idea having been grasped, its clothing of words should be ignored. The student should be satisfied with nothing less than such a comprehension of the fact that he can lucidly convey it in his own language to one who never heard of it before.

It is generally very advantageous for the student to have before him the object while he is reading the description of it, for thus he is able to verify or correct the account which is given, and to get more concrete and enduring ideas of the various qualities of the thing itself. When osteology is under consideration, it is not difficult to pursue this ideal course; for even if the student cannot afford to buy a complete articulated skeleton, he can obtain by a small expenditure a sufficient number of separate bones to supply almost all of his needs. The little outlay required for this purpose will be more than justified by the returns, however impecunious he may be.

Many of the organs cannot be preserved in such condition that they can be studied to advantage in any such way as can the bones; but as substitutes for them we have casts and models—the former representing exactly the external form, size, and color of the originals, the latter in many cases doing this and also showing some details of internal structure. Both casts and models may be more instructive to the beginner than the objects for which they stand, even supposing the latter to be entirely normal, inasmuch as the real specimens are generally so soft and flabby that they do not retain their shape as do their artificial representatives, which are made of rigid materials and possess the additional merit of comparative indestructibility and can be used year after year without appreciable diminution of value. When minute parts are in question models are far preferable to the real objects, as they are of collosal size. The pigmy organ tells its story in a tiny voice which we cannot understand unaided; the giant model shouts its message in tones which a whole roomful of people can hear.

But even casts and models are usually not available except in medical schools, and we are consequently driven to employ pictures, which, fortunately, are to be had in such abundance and of so admirable quality that we often hardly miss the the really ideal means of illustration. Every one learns more quickly from a good pictorial representation than from the best description, for the mind stores up the impressions of form and color which enter it by the channel of sight far more eagerly and tenaciously than it does those which reach it by way of spoken

words. Where the subject is very complex, a diagram is commonly more useful than the best pictorial representation, because it eliminates everything but the essence of the matter, and thus does not confuse the mind by too vast an array of facts. The student, however, should scrupulously avoid allowing himself to be content with a merely diagrammatic knowledge of any part of anatomy: he should use the schematic picture only as a prelude to the actual thing, as the map which informs him where and how to find and learn about the unknown land and its contents.

Although descriptions, diagrams, pictures, models, and casts have their distinct value, each in its peculiar field, it must never be forgotten that after learning all which they can teach it is of the greatest importance to have contact with the natural object. Dissection of the dead body supplements and rounds out the knowledge which has been previously gained, and its service is indispensable. It is not well to attempt dissection until one has learned by other means the principal facts about the part to be dissected, because without such antecedent knowledge material, which in most places is scarce and costly, will be wasted by unintelligent cutting. But after the student has qualified himself to appreciate the views which can be obtained only in the anatomical laboratory, he should embrace every opportunity to dissect, for thus only can he become a practical anatomist. When a human body cannot be procured for this work, the manual dexterity which is so important an accomplishment for a surgeon may be cultivated by the dissection of cats, dogs, and other animals, which are abundant and cheap; and this practice is a most desirable preparation for the study of human anatomy for other reasons than the mere skill in the use of some instruments which it bestows.

Among the aids to the acquisition of anatomical knowledge, two which are but little appreciated deserve especial mention.

The first of these is the recitation. In this exercise the student is obliged to describe the things which he has been studying. This is a severe but most wholesome test of his knowledge. By it his attention is attracted as in no other way to the defects of his attainments. Some matters which he had flattered himself were perfectly understood are found to have been only partially learned, and in others he discovers that he has acquired mistaken notions. The ability to describe a thing clearly and fully to others is a convincing evidence of attainment, and the exercise of it is a capital method of fastening the truth in the mind. If possible, the student should associate with himself another of the same class, and no day should be allowed to pass without a serious, exacting quiz, the two alternating in the office of questioner.

Valuable as are the quiz and recitation in correcting and increasing one's knowledge, they are almost equalled in these respects by drawing. Sight and touch give an excellent idea of the form of a bone, but the information gained by these means is greatly intensified by making a free-hand picture of it; and in the process one is almost sure to see features which were not previously appreciated, and to rectify some faulty opinions. The same is true of all other objects, and the student is earnestly advised to make a drawing of every one of his dissections. If the natural objects are not available, he should draw the casts and models which he has the privilege of studying, and, in default of better representations, even the pictures in his text-book.

But the objection is at once raised that only a few peculiarly gifted persons are capable of drawing. It is not uncommon to hear men declare that they cannot learn to draw. This statement, however, is absurdly incorrect, for every such objector can already write, and writing is nothing but the drawing of certain arbitrary characters. One who makes a capital A can surely outline a tent; if he can make an S, he can draw a wriggling snake; in forming an X he has pictured a St. Andrew's cross; and thus every one who signs his name demonstrates his ability to draw. The talent is undoubtedly more marked in some persons than in others, but is possessed in some degree by all; and, however,

slight it may be originally, it can be cultivated to such an extent as to be wonderfully serviceable to the medical student.

Although the few succeeding paragraphs are not specifically anatomical in their bearings, they have a pertinency in this place because every medical student at the beginning of his career should be given the advice which they carry and which he is unlikely to find elsewhere.

Among the articles of equipment which a medical student needs none is more important than a good medical dictionary. It is an indispensable. If he ignores its aid, he is doomed to stumble and blunder in every direction; if he accepts the assistance which it will give for the asking, he can progress readily and vigorously in all the paths of medical study.

A medical dictionary, in order to be thoroughly serviceable, ought to possess the following characteristics: The inclusion of substantially all of the words employed by the English-writing medical authors of the time; the arrangement of these words in alphabetical order; the various accredited spellings of the words; the pronunciation of those words on whose orthoëpy one might go astray; the etymon or original form of each, and the simplest translation of it; and a concise definition of the word in each signification in which it is employed. Several lexicons constructed on these lines are available, any one of which will do good service; but one which is less ample will not satisfy the reasonable requirements of the student.

Although the so-called Roman pronunciation of Latin is generally taught in the schools and colleges of this country, the dictionaries, for sufficient reasons, use the English pronunciation of the Latin and Latinized words which form the principal part of the vocabulary of medicine; and this method is recommended to the student for his adoption.

The student is earnestly advised to establish the habit of consulting his dictionary whenever he encounters a word whose meaning he does not know. He should fix the spelling in mind, learn the definition, observe and remember the derivation, and repeat the proper pronunciation until the tongue has fully mastered it. Finally, he will do well to ascertain the kinship of the word, if any exists, to other words already known, and to group these all together in his memory as relatives. By this method he will rapidly acquire a large vocabulary, the ability to employ words with strict regard to their meaning, to spell correctly, to pronounce elegantly, and, as an accompaniment and result of this training, he will be content with nothing less than precision of thought.

ELEMENTARY TISSUES,

AND THE STRUCTURE OF MEMBRANES AND GLANDS.

By F. H. GERRISH.

A FULL presentation of microscopic anatomy would require a large volume. It is the main purpose of this chapter merely to give a brief description of the elementary tissues which enter into the formation of the body. Without a knowledge of these primary textures much that must be said of the gross anatomy of different parts will be unintelligible; indeed, it is impossible to understand any organ, either from the anatomical or physiological point of view, unless the materials of which it is composed and the various physical properties of these substances are known with perfect familiarity; for the tissues are to the organs as the letters of the alphabet are to written words.

The minute structure of the viscera will be described in connection with the macroscopic features of each organ in turn.

CELLS.

The word "tissue" means, in ordinary parlance, a web-like structure or a woven fabric. Anatomically, it is applied to any organized substance in the body. Notice that in this definition the word "organized" is used, not "organic." The latter would, indeed, exclude the substances which are inorganic—that is, all of the ultimate elements, of which there are many in the body—leaving them to the consideration of the chemist; but it would include quite a number of substances found in the body which, although organic, have no title to be called structures, and belong in the domain of the physiologist, who deals with the proximate principles. Thus, albumin and fibrin are organic substances, but not organized; and, consequently, they are not tissues, for tissues are always organized.

Every tissue originally consists of microscopic particles, named "cells," which have been aptly called the simplest expression of tissue. Etymologically, the word "cell" is an unfortunate designation, based upon a mistaken belief as to the structure of the corpuscle. At first it was thought that cells were cysts, sacs, vesicles, with fluid contents. But it was long ago learned that they are usually solid bodies, and hence a word which implies the existence of a cavity, as does "cell" (Latin, *cella*, "a small, hollow cavity"), is a misnomer in the majority of cases. However, the substitutes proposed have not met with general favor, and "cell" has become so firmly fixed in our nomenclature that we shall not attempt to displace it; indeed, there is no call to do so, since no confusion need arise from its use in this arbitrary sense.

Not only is it true that all of the tissues primarily are composed of cells, but, going back much farther than this, we recognize the origin of the entire body from a single cell, the ovum (egg). This enforces the saying, which has become almost an axiom, that every cell comes from a pre-existing cell.

Of the numerous definitions of cells, that which seems most exact is the *ultimate morphological elements of the tissues.* It is not sufficient to say that they are the "ultimate elements" of the tissues, because that term refers to their chemical constituents: it is necessary that the definition should include a word which explains that the elements referred to have a definite, distinguishable, and characteristic shape, and this requirement is fulfilled by the word "morphological," the adjective from "morphology," the science of form. Thus is conveyed the idea that in histological analysis—which is to the microscopic structures what dissection is to the macroscopic—we do not go beyond the cell; that this is the last thing reached by the process; and that in all of the textures it has such definiteness of form as to enable us to differentiate one tissue from another.

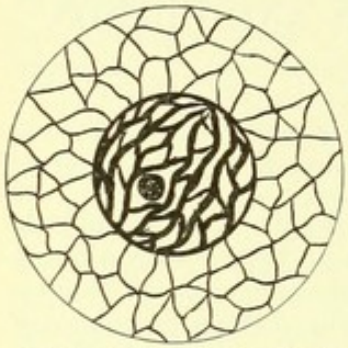

FIG. 7.—Diagram of a cell. (F. H. G.)

The typical cell (Fig. 7), capable of development and reproduction, is a round or ovoid mass of protoplasm in which is a nucleus.

Protoplasm (from Greek words meaning "the first" and "the thing formed") is a substance whose properties underlie the vital functions, and therefore it has been called the physical basis of life. It is homogeneous, soft, and jelly-like, and possesses contractility—the power of shortening a diameter, of drawing one of its parts nearer to another. It usually looks granular, but this appearance will be explained a little later.

The *nucleus* is a roundish mass, generally central in location, and named from the Latin word which means "the kernel," because its situation is so suggestive of the meat of a nut. Sometimes the nucleus contains a small body (perhaps more than one) bearing to it a relation similar to that which the nucleus itself sustains to the cell; and this is called the *nucleolus* ("the little kernel").

The typical cell has no investing membrane. The granular appearance of its protoplasm is due to a network (*spongioplasm*) which becomes visible with lenses of high power. In the meshes of this plexus is a nearly fluid, homogeneous material (*hyaloplasm*). The nucleus has a similar construction, but has additionally a limiting membrane. The nucleoli are connected with the reticulum (network) of the nucleus. One point on the nucleus is called its pole, and the exactly opposite point is its antipole.

The protoplasm may become condensed at the surface, and this hardened peripheral part is called the cell-wall. A deposit of chemical substances in the wall frequently occurs, and contributes to its solidity. Cells may produce material superficially in large amounts without essential change of their own shape; and thus are formed substances called intercellular ("between the cells"). Tissues consist of cells and intercellular substance. In shape cells differ widely: the various forms will be described in connection with the discussion of the respective textures. Some cells are less than $\frac{1}{2500}$ inch in diameter, others more than $\frac{1}{200}$, and between these extremes are all possible gradations.

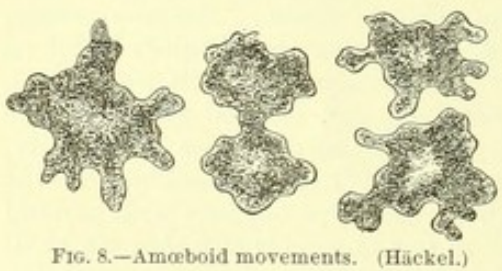

FIG. 8.—Amœboid movements. (Häckel.)

As has been said, the protoplasm of the cell possesses contractility, and this property enables it to display movements which are known as amœboid, because they are observed in a typical form in a unicellular, aquatic creature called *amœba.* In its amœboid movements (Fig. 8) the cell alters its form rapidly, assuming indescribably fantastic outlines, due to the irregular contraction, first, of one portion of the mass, and then of another part. By virtue of this quality the cell can move from place to place, one point becoming fastened, and the rest of the cell moving up to it and pushing out a process to a farther point in the same

direction. Thus is accounted for the migration of cells from blood-vessels, and their wandering from one point to another outside of the vessels.

CELL REPRODUCTION.

The formation of new cells is accomplished by division of old cells. The direct method, by which every element of a cell was equally divided by a transverse constriction, was formerly supposed to obtain generally, but is now known to be very rare. The indirect plan of division is almost, if not quite, universal. By this method the nucleus undergoes a series of complicated modifications, which, taken as a whole, are called *karyokinesis*, a name derived from the Greek words for "nut" and "change," the signification of the compound being "the changes in the kernel" or nucleus. In studying the details it is well to bear in mind that in this process, which is the principal movement toward the creation of two cells out of one, there occurs such a division of the cell-protoplasm and of the nucleus that each of the new-born cells inherits a half of every portion of the parent-cell's estate.

When division is about to take place the nucleus noticeably enlarges (Fig. 9). The nuclear membrane and the nucleoli disappear, and the secondary filaments of the reticulum are drawn into the primary threads, making them thicker and more conspicuous (Fig. 10). It is not positively determined whether these threads

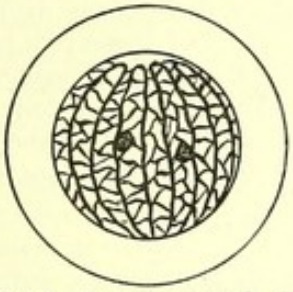

FIG. 9.—Nucleus enlarged. The body of the cell is represented merely in outline in this series of diagrams. (F. H. G.)

FIG. 10.—Nucleoli and secondary filaments have disappeared. (F. H. G.)

FIG. 11.—The spindle and V loops, side view. (F. H. G.)

all unite and make one, or are separate; whichever is true, they form a peculiar and complicated tangle which is called the *skein*. The diagram does not attempt to display all of the tortuosities of the skein, as they are rather confusing. There now appears a skeleton *spindle* (Fig. 11), formed of delicate filaments of the interstitial substance, placed with one extremity at the pole and the other at the antipole. At each end of the spindle fibrils of the protoplasmic network converge and produce the appearance of rays. At the next step (Fig. 12) a number of

FIG. 12.—V loops, end view. (F. H. G.)

FIG. 13.—Daughter loops, end view. (F. H. G.)

V-shaped loops are observed in place of the skein, these resulting either from the breaking of the single thread, on the one theory, or, on the other, from the plainer manifestation of the always separate threads. These V-shaped pieces are short and thick, and marshal themselves around the equator of the spindle, with apices to the centre and limbs outward, producing a star-like appearance, which is

sometimes called the *wreath*. Simultaneously with this movement the loops are split lengthwise (Fig. 13), so that each original (or mother) loop is made into a pair of secondary (or daughter) loops—a most important part of the series of changes. Next, the twin sisters in each V-shaped loop turn away from each other, one moving her head toward the pole, the other toward the antipole, their limbs being interlocked (Fig. 14). Presently they separate entirely, and migrate to pole and antipole respectively, travelling along the lines of the spindle, which seem to serve as guides to their movements. Arrived at their destination, each

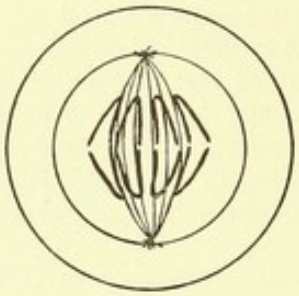

FIG. 14.—Migration of daughter loops toward pole and antipole, side view. (F. H. G.)

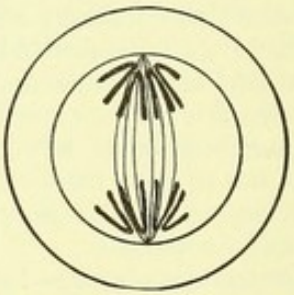

FIG. 15.—Arrival of daughter loops at pole and antipole. (F. H. G.)

forms a *star* (Fig. 15). Now, as far as can be seen, there has been accomplished an equal partition of the original reticulum of the nucleus, and the mass divides into two masses which are henceforth distinct nuclei. In each of these two bodies there takes place a reversal of the steps with which the karyokinesis was inaugurated: the V-shaped loops of the stars elongate, their limbs stretch out to the opposite side of the nucleus (Fig. 16), and the skein-like appearance is observed. Then branches are put forth from the main or primary filaments, and

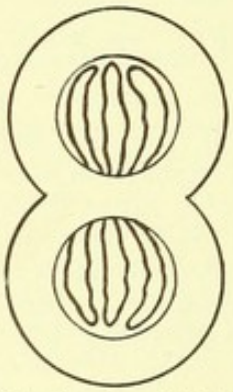

FIG. 16.—Division of nucleus into two nuclei, and elongation of V loops. (F. H. G.)

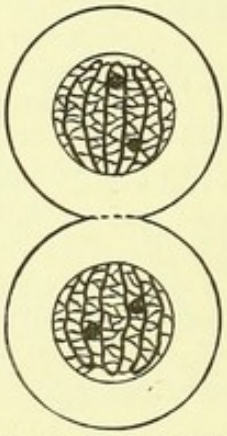

FIG. 17.—Reappearance of secondary filaments and nucleoli. Division of entire cell into two. (F. H. G.)

form the secondary filaments necessary to complete a network. Nucleoli come in sight, and a wall is formed around the nucleus (Fig. 17). Before these last stages are accomplished the protoplasm of the cell shows a constriction which rapidly deepens, and continues to increase until the cell is bitten in two, each part being furnished with a perfect nucleus in which is no sign of a spindle. It is held by some authors that the wall of the nucleus is not complete, and that thus is permitted a mingling of the interstitial substance of the nucleus with the cell-protoplasm. However this may be, nobody questions the intercommunication after the disappearance of the nuclear wall.

Various modifications of karyokinesis are frequently observed, but the foregoing description comprises the main features in a typical and complete case.

CLASSES OF TISSUES.

I. Tissues furnishing the free surfaces of the body : **Epithelial Tissues.**
II. Tissues passively supporting other parts : **Sustentacular Tissues.**
III. Tissues performing a nutritive function : **Liquid Tissues.**
IV. Tissues devoted to movement : **Muscular Tissues.**
V. Tissues essential to sensation : **Nervous Tissues.**

THE EPITHELIAL TISSUES.

Tissues furnishing the Free Surfaces of the Body.

There is a peculiar propriety in speaking of this class first, as it is composed entirely of cells, and also because the male and female cells, by whose union every human being is created, are, to all intents and purposes, epithelial cells.

On every surface which is free, as distinguished from attached, are found multitudes of cells, and with hardly an exception the surfaces are covered with them or, more properly speaking, completely composed of them. Thus, the top layer of the skin is made wholly of cells ; so also is the exposed surface of every cavity, tube, or passage which connects directly or indirectly with the skin ; as, for example, the alimentary canal from mouth to anus, all of the air-passages, the urinary organs, the generative ways ; the surface of cavities which are entirely closed, which cannot be reached without dissection, such as the pleura, the heart, the blood-vessels ; and others which need not now be enumerated.

These cells, thus spread out in close contact with each other, are *epithelial cells*, and the sheet of tissue which they form is *an epithelium*. Etymology does not suggest the character of the tissue, the extent of its distribution, its uses, or any other valuable fact about it, the word being derived from the Greek words signifying "upon the nipple." It is best, therefore, to employ it in a perfectly arbitrary way. Many groups of these cells—indeed, all of those which limit the surfaces of shut sacs, shut tubes, and other cavities which are not directly or indirectly continuous with the skin—are called *endothelial*, and the sheet of tissue which is formed by them is named an *endothelium*, the derivation giving it the meaning of "within the nipple"—a term which has not even the minute justification to be accorded to "epithelium ;" for there is epithelium upon the nipple, but there is no endothelium within it, except as there is in every part which contains blood- and lymph-vessels. As Macalister most pertinently says, "The distinction between endothelium and epithelium is not always either histologically certain or functionally possible, nor can its development be relied on as a criterion." It would be well if the attempt to keep up the distinction were abandoned ; but, as some writers still employ the term endothelium, it is well to understand that they refer to a cellular tissue which develops from what will presently be described as connective tissue. In this book all such will be included under the head of epithelium.

Originally all epithelial cells are nucleated : in most of them the nucleus can be demonstrated at any stage of their existence ; but in some it becomes obliterated, usually as the result of pressure or exposure to the drying effects of the air.

The cells almost literally constitute the entire tissue, the intercellular substance being reduced to its lowest terms, and consisting of a minute quantity of a semi-fluid, adhesive material called the *interstitial cement-substance*, which glues the cells together.

Usually an epithelium rests upon a transparent, structureless sheet of extreme thinness, rather difficult of demonstration, the *membrana propria* or *basement membrane*. Though called structureless, it is shown to be made up of flattened plates of typical connective tissue, which will be treated of a little later.

An epithelium contains no blood-vessels and a very diminutive supply of

nerves. When destroyed or in any way lost the cells are regenerated, as a rule, with rapidity.

Epithelium performs many important services, among which may be mentioned the protection which it furnishes to underlying tissues, the prevention of the escape of lymph from the parts which it covers, the absorption of nourishing materials into the blood, the maintenance of motion in the fluid which comes in contact with it, the smoothness which it imparts to surfaces, the formation of secretions, and assistance in the appreciation of certain sensory impressions.

The materials composing epithelial cells and the substance uniting them are sufficiently yielding to permit considerable alterations in their form without injury. Thus, when the structures upon which an epithelium rests enlarge or contract, it readily adapts itself to the changed conditions, without cracking in the one case or wrinkling in the other.

No classification of epithelial cells is very satisfactory, but the study of them is made somewhat easier by the knowledge that (excepting a few—the spheroidal—whose form presents but a slight departure from that of the typical cell) they may be placed in two classes, in one of which they are long and slender, and are arranged with their chief axis perpendicular to the surface, and in the other of which they are broad and thin, with the long axis parallel with the surface upon which they rest.

In the first class—the cells standing on end—are columnar (cylindrical), prismoidal, conoidal (pyramidal), pyriform (pear-shaped), club-shaped, fusiform (spindle-shaped) cells. In the second class—the cells lying on side—are flattened (scaly or squamous) cells (Fig. 18).

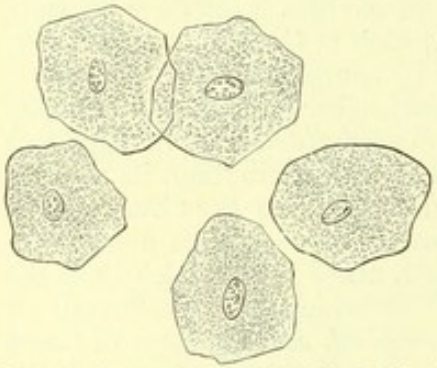

FIG. 18.—Flattened epithelial cells. (Dalton.)

It will be observed that this classification is based upon form only, and that the difference between one and another is accounted for by the direction in which pressure is applied. For example, suppose that a large number of soft, globular cells are placed upon an even plane, side by side, each just touching every immediate neighbor, and imagine that an equal number of exactly similar cells are introduced additionally upon the same area. Of course something must give way, or the proposed problem has no solution; and what actually yields is the shape of each of the plastic cells. The cell cannot go downward, for the surface upon which it rests prevents this; sidewise pressure of every adjacent cell deprives it of a considerable part of its former standing-room; and, as its bulk remains unaltered, it is obliged to move a part of its mass upward, and its free surface, reduced by the lateral squeezing, is thrust two or three times as far from its attached surface as it was originally. The cell has become elongated, changed from a sphere to a cylinder or column, by pressure applied in a number of lateral and parallel directions. If the surface upon which the cells originally rested was convex in every direction, instead of flat, the cells would be changed from spheres to cones or pyramids by pressure made laterally on each at many points, and progressively increasing in force from the part nearest the surface downward. The difference in results depends upon the variation of the supporting surface. If the cells are pressed between two parallel planes, one of which is the surface upon which they rest, the result is a flattened cell. It is easy to imagine how the other and less common shapes have been evolved.

Flattened epithelium is often called tessellated, or pavement, because, when one looks directly down upon it, it presents the appearance of a flagging of stones. The names, however, are objectionable, not only because they are superfluous, but more because they are equally applicable to the columnar variety when it is viewed in the same way; for the flat, free ends of the latter look just

as much like a pavement—indeed, are even more suggestive of one than are the others (Figs. 19, 20).

While these classes include nearly all epithelial cells, many cells have peculiarities which are distinguishing, and it is convenient to designate them by descriptive names, such as *ciliated* and *prickle*, from their appendages; *sensory* or *neuro-*, from their relation to the periphery of a special-sense organ; *pigmented*, from their coloration; *goblet* or *chalice*, from their modification of shape; *transitional*, from their being of a rapidly varying form; *glandular*, from their work in secretion. A brief mention of the chief points of each variety is desirable.

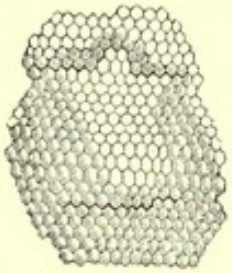

FIG. 19.—End view of a number of epithelial cells, presenting the appearance of a pavement. (Retzius.)

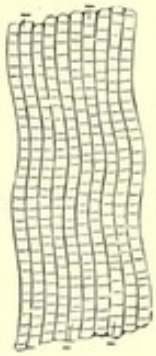

FIG. 20.—Side view of some of the cells of Fig. 19, showing that they are long and slender. (Retzius.)

Ciliated cells (Fig. 21) in man are always of the columnar form, and are characterized by the projection from their free extremity of a number of delicate processes strongly suggestive of eyelashes, and hence called *cilia*. The cilia have a constant vibrating motion, with a strong stroke in one direction and a weak one in the other. They are situated in various parts, but never where they are likely to be subjected to hard usage. Thus, they are nowhere in the alimentary tract, where the masses of food and excrement would injure them; but they exist almost everywhere in the breathing passages, which transmit nothing hurtful to them. Their more powerful stroke is always made in the same direction; thus, in the respiratory tract it is invariably such that the mucus which smears the surface is moved toward the open end of the system—that is, from the deep parts of the lung to the surface of the body. Cilia are found in the adult mainly in the organs of breathing and those of generation.

FIG. 21.—Two conoidal epithelial cells, their free ends furnished with cilia. (F. H. G.)

Prickle-cells (Fig. 22) exist in the middle layers of the stratified epithelium of the epidermis, the outer layer of the skin. They are polyhedral, and the little spaces between them are bridged over with delicate threads, which break when the cells are separated and present the appearance of short, rigid spines.

FIG. 22.—Prickle-cells. (F. H. G.)

Sensory epithelium, or **neuro-epithelium cells** (Figs. 23, 24), are found in close relation with the filamentous terminals of the nerves devoted to taste, smell, hearing, and sight; from which fact the names *sensory* and *neuro-* ("nerve") are derived. Such a cell is intimately associated at its attached end with the periphery of a sensitive nerve, and at its free extremity is quite generally prolonged into a stiff, hair-like process, which may project beyond the plane of the surrounding surface. These distal bristles receive a shock from a wave of the fluid into which they protrude, and this causes a thrill to pass through the cell and to agitate the nerve-filament, which carries the impression to the nerve-centre.

Pigmented cells are found in various situations. They are of different shapes, generally very irregular, and have been invaded by (perhaps filled with) black particles. In the colored races the lower layers of the epithelium of the skin are highly charged with them.

Goblet or chalice cells (Fig. 25) are a modification of the cylindrical or conoidal, and their names are explanatory of their form. The nucleus retreats to the attached end of the cell, and the rest of the cell becomes filled with a granular material. The granules swell, causing the part in which they are contained to bulge out at the sides and crowd over into the territory of the adjacent cells; and, finally, the internal pressure becomes so great that the cell bursts at its free end, its contents escaping upon the surface as a glairy substance called *mucus*. A goblet-cell, therefore, is a one-celled gland, doing real secreting work. In the true mucous glands the secreting cells are of this variety. A goblet-cell may soon return

FIG. 23.—Neuro-epithelial cells. Three cells project beyond the general surface, and are supported by intermediate cells. (Frey.)

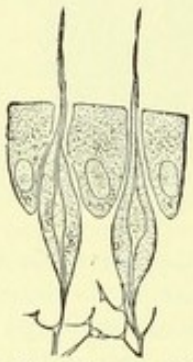

FIG. 24.—Neuro-epithelial cells. Two send long processes beyond the general surface. (Schultze.)

FIG. 25.—Goblet-cell, surrounded by cylindrical cells. (F. H. G.)

to the condition of an ordinary cylindrical or conoidal cell or remain a chalice for a long time.

Transitional epithelium (Fig. 26) partakes of the features of a number of other groups. Its typical illustration occurs in the bladder, where the superficial layer is composed of thick, flattened cells, with dimples on their under surface into which the large ends of pear-shaped cells of the next layer are received, the spaces between the last being filled with the inverted cones of the lowest set.

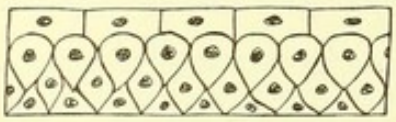

FIG. 26.—Transitional epithelium. (F. H. G.)

No two layers are alike, and a lower is in a state of transition to a higher plane.

Glandular epithelium (Fig. 27) is composed of cells of differing shapes—cuboidal, cylindrical, conoidal, polyhedral, and spheroidal, the last being rarely found except in the remotest recesses of tubular and racemose glands. The various forms of these cells are accounted for by the different shapes of the cavities to which each series is compelled to adapt itself. The function of glandular cells is secretion.

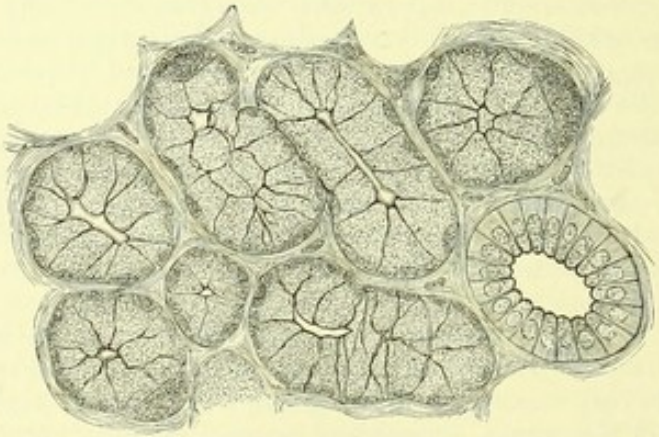

FIG. 27.—Glandular epithelium as seen in a salivary gland. At the lower right-hand corner is a duct lined with conoidal epithelial cells. (Kölliker.)

When an epithelium consists of only one stratum of cells it is called *simple* or *single-layered;* when it has two or more layers it is known as *stratified*. If a ciliated epithelium is stratified, only the cells of the upper layer are furnished with cilia.

THE SUSTENTACULAR TISSUES.

TISSUES PASSIVELY SUPPORTING OTHER PARTS.

1. *Mostly fibrous.*
   - (*a*) White Fibrous Tissue (Connective Tissue Proper).
   - (*b*) Yellow Fibrous Tissue (Elastic Tissue).
   - (*c*) Areolar Tissue.
   - (*d*) Adipose Tissue.
   - (*e*) Gelatinous Tissue.
   - (*f*) Adenoid Reticular Tissue.
   - (*g*) Neuroglia.
2. *Cartilaginous.*
   - (*a*) True Cartilage.
   - (*b*) White Fibro-cartilage.
   - (*c*) Yellow Fibro-cartilage.
3. *Osseous.*
4. *Dentinal.*

The members of this large group present many violent contrasts in their physical qualities: we find the soft and the hard, the transparent and the opaque, the flexible and the rigid, the nearly liquid and the almost stonily solid, the fibrous and the granular, the moist and the dry, the colorless, the white, the yellow, the pearly, and the pink. And yet, in spite of these antipodal traits, the individuals making up this class have certain common characteristics which distinguish it from all others. One which strikes the attention most forcibly is the absolute passivity of every member of it: not one of them does anything actively; they stand still like stocks and stones, and are acted upon by the other tissues; they originate no action. But the service which they perform, though humble, is of essential importance, and is measurably presented to the mind by any one of the various names borne by the group. "Sustentacular" suits our purpose excellently, suggesting mechanical support, the upholding that requires strength and endurance. "Connective substance" is good, as referring to a very prominent function—the uniting of neighboring parts. "Connective tissue," of course, inherently carries an equal significance, but the term has been so much used to designate a leading member of the group, that it is not always certain to convey one's intent to include all of them. "Skeletal" is highly descriptive to one who has divested his mind of the popular notion that nothing but bony structures are entitled to be considered a skeleton. Probably the best term of all in our language is "framework," because everybody knows that a framework may be made of any materials which have suitable physical qualities, and understands that it does the work of supporting mechanically, of connecting near and distant parts of the whole, and of keeping these same parts away from each other—the last being an office quite as important as the more prominently mentioned connective work. As, however, the term is so little used in a titular way by anatomists, another has been selected to distinguish the group.

The word "framework," like "skeletal," to an anatomist suggests far more than the massive, bony staging, which is the gross basis of the human form. To him it means the delicate, and even microscopic, rafters, beams, and shelves, which serve to give definite shape to minute organs and to small parts of large structures, and to keep their active portions from pressing upon and being pressed upon by each other. So, too, in his mind, "connective" has both macroscopic and microscopic applications. It is a name given to the tissue of which are made the bands which tie the bones together, and the strong, flexible sinews which unite contractile organs to the parts which they move; and it is equally deserved by minute parts which, on a small scale, do work of a comparable kind.

These tissues are very widely distributed in the body—so extensively, indeed, that their diffusion may almost be declared to be universal. If every particle of material except the sustentacular tissues were to be withdrawn from the body of a person with whom we were well acquainted, there would be no difficulty in recognizing him, even in minute details of form.

It is interesting to observe not only that the sustentacular tissues are similar in a functional way, but that they are structurally allied. They originate in the same elements of the embryo, to a certain extent they are interchangeable, and they often shade into each other.

They consist of cells and intercellular substance, though in most of them, when mature, the cellular elements are inconspicuous, and the material between the cells is so largely developed as to constitute almost the entire bulk of the tissue.

White Fibrous Tissue.

The name of this tissue is highly descriptive, for it is distinctly white when seen in a mass, and its fibrous character is manifest. It is often called "connective tissue proper," or even merely "connective tissue," because of its great abundance, both absolute and comparative, and its very wide distribution; but, while its conspicuousness among the sustentacular tissues entitles it to the name which implies the fact, the designation is confusing, and would better be dropped in favor of the descriptive appellation which is here chosen. Teased out with needles and viewed with the microscope, it is seen to consist almost wholly of extremely fine, colorless fibrils, arranged side by side in bundles which have an undulating outline (Fig. 28). The fibrils may be very long—some inches—and do not branch. Closely applied to the bundles of fibrils are cells; but these are not a prominent feature in the adult tissue, and are liable to escape attention unless staining agents are used. The cells proper to the tissue are flattened, irregular, nucleated, granular, and have long processes (Fig. 29).

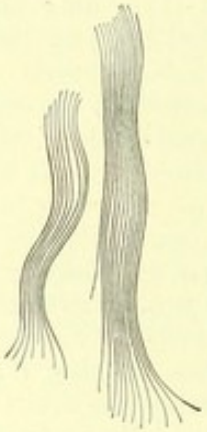

FIG. 28.—White fibrous tissue. (F. H. G.)

FIG. 29.—Cells of white fibrous tissue, often called connective-tissue cells. (F. H. G.)

White fibrous tissue is distinguished chiefly for its great strength and flexibility, and is found where these qualities by themselves are needed. For example, it is almost the only tissue in most of the bands (ligaments) which fasten the bones together, and in the cords (tendons) by which the force of muscular tissue is transmitted to and applied at distant points. In these situations great strength is required, for without it the bones would readily become dislocated and the muscular contractions would be fruitless of result; flexibility is demanded, since rigid ligaments and tendons would either prevent movement or break, and thus prove useless. If, in addition to strength and flexibility, elasticity were added, the bones would get out of place during many movements, and muscular contraction, instead of moving the object to which the distal end of the tendon was attached, would be devoted in large part to the stretching of the tendon itself.

These illustrations will show that this tissue is well fitted by its physical qualities to make up the ropes, cords, protective sheets, and outer shells of organs.

Yellow Fibrous Tissue.

This texture is composed mainly of fibres, and in large masses presents a delicate yellow hue, from which facts it is named. Under the microscope its fibres are seen to differ materially from those of white fibrous tissue: they are ribbon-like, thick, branched, and curled at the ends into hooks, which result from their fracture in the preparatory teasing (Fig. 30). The chief physical properties of this tissue are strength, flexibility, and elasticity, the last being that which distinguishes it from all others, and gives it the name by which it is often known, "elastic tissue." Elasticity, the quality which restores bodies possessing it to their normal shape after distortion, is not to be confounded with contractility, the attribute which enables a body to shorten a diameter (for example, to draw its two ends nearer to each other) under the influence of a stimulus. Elasticity is a merely passive property: it cannot display itself until some outside force has stretched or otherwise deformed the substance in which it resides; but contractility is active, and is manifested under influences which have no such effect upon elastic bodies. The elasticity of yellow fibrous tissue, while disqualifying it for the work of tendons, eminently fits it for other duties, and it is found performing valuable service in many places. Wherever it is located, it does precisely such work as india-rubber would do, if similarly arranged. It is commonly associated with white fibrous tissue, though in relatively small quantities. The amount of it in the system is not large as compared with that of white fibrous tissue. The clearest masses of it are the ligamenta subflava between the laminæ of the vertebræ. Its strength is not equal to that of the white fibrous.

FIG. 30.—Yellow fibrous tissue. (Queckett.)

Areolar Tissue.

Areola is the Latin word for "a little space," and areolar tissue gets its name from its appearance of being full of minute spaces. It is sometimes called "cellular tissue"—a term which has no justification to the histologist, to whom the word "cell" has come to have an arbitrary meaning, entirely independent of its etymology. The designation "cellular tissue" is applicable properly only to a texture made up substantially of the histological elements called cells—such a tissue, for instance, as epithelium.

In areolar tissue we discover no material different from those which we have already studied—only a new arrangement of some of them. It is composed of a mixture of white and yellow fibrous tissues, so disposed in irregularly criss-crossed bundles as to make a network, the meshes of which bound innumerable areolæ (Fig. 31). The bulk of each bundle is white fibrous tissue, and around it are loosely twined threads of yellow fibrous tissue. The little spaces between the meshes are not definitely walled, but are indescribably irregular cavities, which communicate in the freest way with each other (Fig. 32). The fasciculi are moistened by a lymph-like fluid, which contributes to their flexibility and diminishes the friction between them.

Areolar tissue is found almost everywhere subjacent to the skin and mucous and serous membranes, between muscles, blood-vessels, nerves, and other parts. It forms a layer which is attached on one side to the deeper structure, on the other side to the more superficial. When one of these structures moves, the areolar tissue permits it to slide upon the other for a little distance, the wavy bundles of white fibrous tissue being straightened out, and the narrow ribbons of yellow fibrous being put on the stretch. The motion ceasing and the disturbing

agency being removed, the strained yellow fibres assert their elasticity, pull the white fasciculi back into their undulations, and assist a little in the restoration of the parts between which it lies to their former attitude of repose. The tissue is connective in a typical sense.

Disease and accident afford striking illustrations of the freedom of intercommunication of the areolæ,

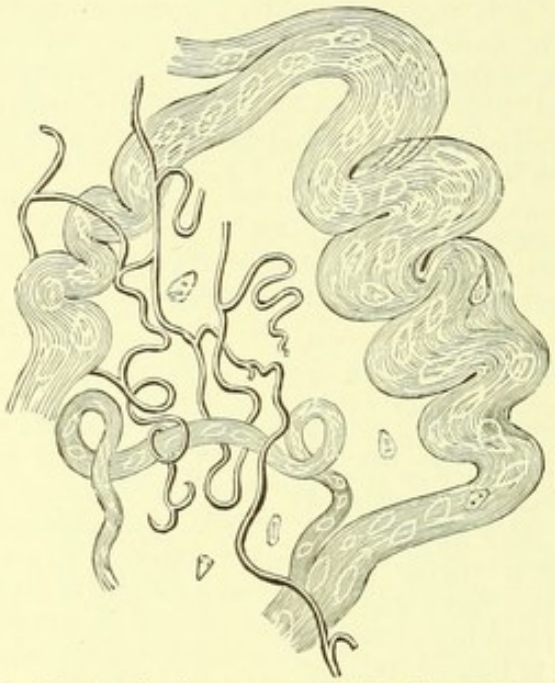

FIG. 31.—Areolar tissue, composed of bundles of white fibrous tissue and branched strands of yellow fibrous tissue loosely intertwined.

FIG. 32.—A portion of areolar tissue inflated and dried, showing areolæ.

and also of the vast extent of this structure just beneath the skin—here called the subcutaneous areolar tissue. The lymph-like fluid mentioned above is sometimes formed more rapidly than is normal, or, what amounts to the same thing in effect, its absorption is less rapid than its formation, and the excess accumulates in the areolæ. But, as each of these spaces opens into all of its neighbors, the fluid gravitates from one to another into those which are most dependent, and these it distends proportionately to its amount. In such a case, when the feet have been upon the floor all day, by evening they are swollen; but, after the patient has passed a night in bed in the horizontal position, the enlargement disappears almost entirely, because the fluid has gravitated back again and has become widely diffused. Sometimes, as in fracture of a rib, a sharp fragment of bone perforates the chest-wall and slightly punctures the lung, leaving an open tract between some of the air-vesicles of the latter organ and the areolar tissue near the surface of the body. Every time that air is drawn into the lung, some of it escapes through the accidental opening into the subcutaneous areolar tissue, the spaces of which become inflated, at first only in the region of the injury, but at each breath more and more extensively, until finally all of the areolæ under the skin are so ballooned that the victim presents such an appearance as is shown in Fig. 33.

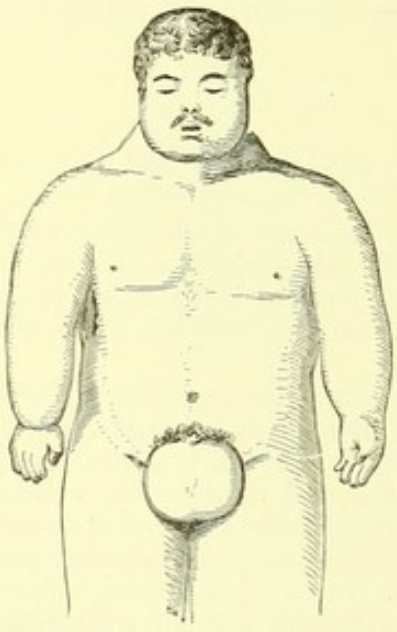

FIG. 33.—Inflation of subcutaneous areolar tissue, due to introduction of air through a wound in the chest-wall and lung. (Gross.)

The areolar tissue around certain organs, as vessels, becomes somewhat condensed and forms a distinct sheath. The nourishing vessels of a part are situated in its areolar tissue. In the narrow spaces between the lobules of a solid organ, as the liver; forming a layer outside of the mucous coat of hollow organs, as the

stomach; everywhere among bundles of fibres, as in muscle,—in all such situations is areolar tissue, furnishing a springy bed for the blood-vessels. Indeed, it may be laid down as a rule that vessels are developed in this sort of tissue, and always continue to occupy it.

Adipose Tissue.

Areolar tissue has been described as composed of white and yellow fibrous tissues, disposed in such a way as to leave irregular spaces between their bundles. Some of the cells of the white fibrous tissue of this combination in certain circumstances undergo peculiar changes. The outer layer hardens, forming a delicate cell-wall; the most of the substance of the cell is converted into liquid oil; and the nucleus, previously central, is crowded off to one side, thus becoming peripheral, and is fastened to the cell-wall. Thus is formed a *fat-cell* (Fig. 34)—a veritable sac of liquid oil, deserving the name "cell" in the etymological as well as in the histological sense. Such cells are lodged in the

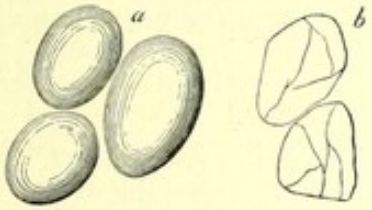

FIG. 34.—Fat-cells: *a*, filled with oil; *b*, exhausted of oil, the cell-wall shrivelled. (Kölliker.)

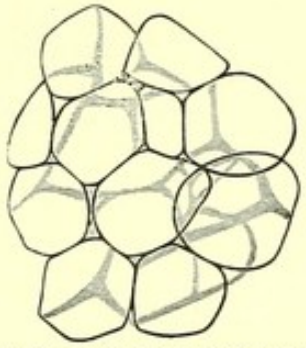

FIG. 35.—Fat-cells packed closely together, and thus becoming polyhedral.

spaces of areolar tissue very generally; but in a few localities they are never seen—the penis, the eyelids, the cavity of the cranium, and the lungs (excepting a little near the roots). When the number of fat-cells is sufficient to fill the areolæ even moderately, the *tissue* is called *adipose* or *fatty*. The cells are round or ovoid, except when they are closely packed, and then the mutual pressure produces angular facets all over them (Fig. 35). Fatty tissue is yellow, soft, and resilient when living, but hard when dead. Its quantity is very variable, and there is no absolute criterion of the normal quantity. But when its shifting line of healthful development is overstepped, obesity or corpulence is reached—a pathological condition which may interfere with the proper performance of vital functions. Sometimes the fat in the abdominal wall attains a thickness of six inches.

The uses of adipose tissue are various. It is a cushion for organs—the kidneys always lie in a bed of fat, and other organs are similarly provided, though less lavishly. Being a slow transmitter of heat, it is a protection against cold—it is always found in the great serous apron which hangs down in front of the bowels, and doubtless serves to keep them warm. Adipose tissue is a reservoir of nutrient material which is drawn upon in starvation. If an animal is deprived of suitable food, his system relies largely upon its store of fat in the emergency. If a wolf and a sheep are starving, each feeds upon its own fat, the herbivorous animal becoming for the time practically a carnivorous one, since it lives on fat mutton. A man wasting with fever lives on his own tissues—cannibalistically consumes human flesh. The adipose, being a cheap tissue, is used most freely; nervous tissue, the most costly, suffers the least loss of weight. During the process of starvation the oil is abstracted from the cells, and the walls become wrinkled and collapsed. The nucleus, however, keeps alive; and, when nourishment is again appropriated by the system, the nucleus becomes active, takes from the blood the materials suitable for the manufacture of oil, combines them properly, and deposits the product in the cell-cavity, which soon becomes plump again. Finally, it is not unworthy to mention the æsthetic effect of a reasonable amount of adipose, which softens the asperities of sharp angles, and contributes to the production of the graceful contours, which are so essential to perfect beauty of form.

Gelatinous Tissue.

This tissue is jelly-like, as its name implies. It is also called *mucous tissue* and *mucoid tissue*. No typical example of it occurs in the adult body; but the gelatin of Wharton in the umbilical cord illustrates it perfectly. Here is seen a protoplasmic network, formed by the union of the processes of cells, which are identical with those of white fibrous tissue. In the meshes of this reticulum is a semifluid ground substance. This tissue is the most immature form of fibrous tissue.

The vitreous body (or humor) of the eye is composed of gelatinous tissue; but the fibrous element is so slightly developed that its existence is by some observers denied, and almost all of the cells have disappeared, the few which remain being shrunken and indistinct. The vitreous is in large part (about 99 per cent.) water, and its appearance is that of a mass of beautifully transparent, colorless, and delicate jelly.

The service performed by the vitreous is strictly sustentacular. It is the stuffing which keeps the ball of the eye in its globular shape, preventing the wrinkling of the retina, which would be utterly destructive of definiteness of sight. When lost, the vitreous is not restored, having a low vitality and practically no recuperative power.

Adenoid Reticular Tissue.

The word *reticulum* is the diminutive of the Latin *rete*, "a net," and consequently means "a little net." "Adenoid" comes from the Greek word for "gland," and signifies "gland-like." *Adenoid reticular tissue*, therefore, means the tissue forming the network in gland-like structures, particular reference being had to the framework of the so-called lymphatic glands, which are far better named "nodes," since they are not real glands.

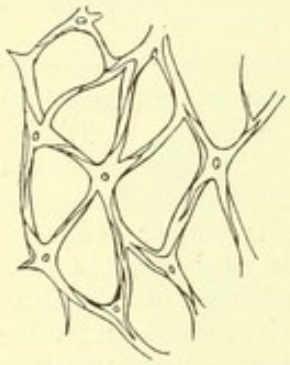

Fig. 36.—Adenoid reticular tissue. (F. H. G.)

This network has points of resemblance to areolar tissue—may, indeed, be regarded as a modification of it. The reticulum consists of strands of white fibrous tissue, with few, if any, yellow fibres intermingled, and these delicate trabeculæ ("little beams"), which support the proper substance of the node, are nearly or quite covered by fibrous-tissue cells in the shape of broad, thin plates closely applied and wrapped around them (Fig. 36).

Though the most characteristic display of this tissue is in the lymphatic nodes, it is widely distributed in the body, and is particularly abundant in mucous membranes.

Neuroglia.

Literally, the word *neuroglia* means "nerve-glue," and is misleading, for it is used as the name of a network supporting the nerve-substance of the brain

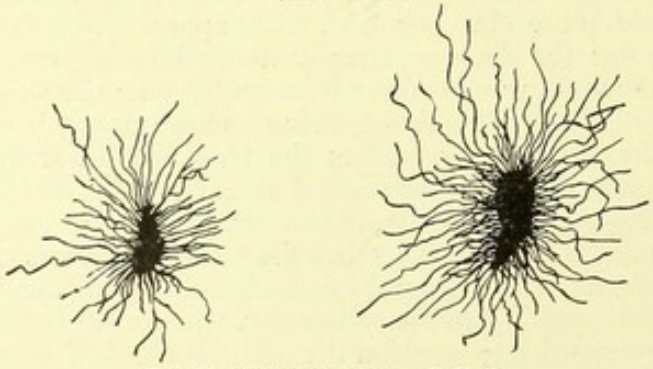

Fig. 37.—Neuroglia cells. (F. H. G.)

and spinal cord. This reticulum is not made of white fibrous tissue, as is that

of adenoid tissue, but is composed of peculiar bodies, called glia-cells, and their processes. The cells (Fig. 37) are irregular and stellate, and their branches are frayed out at the end in tufts of minute fibrils, which ramify everywhere between the nerve-cells and fibres.

Besides the neuroglia, there are two other means of mechanical support for the tissues of the great nervous centres. From the attached portion of the epithelial cells which line the cavities of the brain and spinal cord delicate fibrils run peripherally and end in the pia, the fibrous and vascular covering of these masses. Finally, the pia itself sends prolongations inward, which are of manifest sustentacular value.

Cartilaginous Tissues.

Cartilage, popularly called "gristle," is a dense tissue, but much less hard than bone, elastic, and serving important skeletal uses.

It occurs in three varieties:

True or Hyaline Cartilage.
White Fibro-cartilage.
Yellow Fibro-cartilage.

Hyaline cartilage is so named from the Greek word for "glass," because of the transparency of a thin slice of it. It is also called *true cartilage*, because it is the only variety which presents pure and unmixed the features which characterize this tissue. It encrusts the parts of bones which enter into the composition of movable joints, in such situations, being called articular cartilage; it forms the extensions of the ribs to or toward the breast-bone; it constitutes the bulk of the larynx; it stiffens the windpipe and bronchial tubes with strips and plates; it is the framework of the front of the nose, and does similar service in one or two other places. Hyaline cartilage is opaque, bluish-white, firm, elastic, and readily and smoothly cut with a knife. Covering it closely is a coat, called *perichondrium* ("around the cartilage"), which has an outer fibrous and an inner cellular layer, and is the agent by which the protection and growth of the cartilage are effected. Under the microscope cartilage is seen to consist of small clusters of roundish, nucleated cells (Fig. 38), each group crowded into a little cavity (*lacuna*, "a little lake"), between which and its neighbors is an expanse of apparently homogeneous intercellular substance (*matrix*). The cells are modified fibrous-tissue cells (the so-called connective-tissue cells), and the matrix is really composed of extremely delicate fibrillæ, the mass of which is pervaded by minute lymph-channels. Cartilage is non-vascular, and the nourishing material for the parts farthest from the surface permeates the tissue through these lymph-paths.

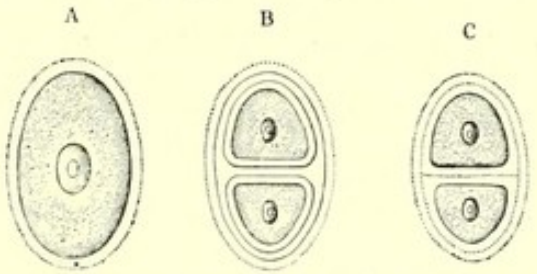

FIG. 38.—Cartilage-cells: *A*, mother cell; *B*, *C*, daughter cells. (Testut.)

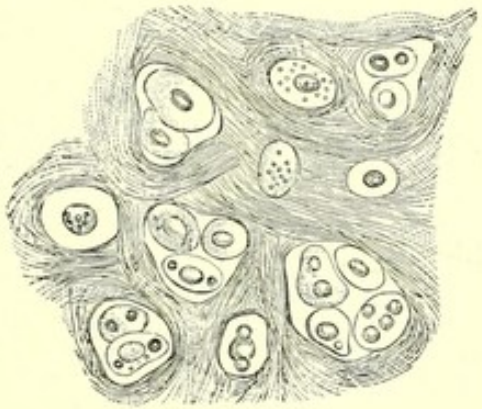

FIG. 39.—White fibro-cartilage.

White fibro-cartilage is otherwise known as *fibrous cartilage* and *fibro-cartilage*. It makes the great disks between the bodies of the vertebræ, the plates at the movable symphyses, the masses between the bones in the freely-movable joints, and the nodules which strengthen tendons in exposed situations. It has no proper perichondrium, and, indeed, is more like tendon than it is like true cartilage. Microscopically (Fig. 39), it is seen to consist of a dense

felting of white fibrous tissue, imbedded in which are nests of cartilage-cells, as if the seeds of cartilage and those of connective tissue proper were sown together in the same field and developed in an intimate mixture. The physical properties of the tissue are such as would be expected from such an association of ingredients—elasticity from one element, flexibility and toughness from the other.

Yellow fibro-cartilage is called also *elastic cartilage* and *reticular* ("network") *cartilage*, for structural reasons which will presently be manifest. Its principal examples are the framework of the auricle and that of the epiglottis in the larynx. It is opaque and yellowish, and more elastic, flexible, and tough than hyaline cartilage. Viewed with the microscope, it is seen to consist of a close network of yellow fibrous tissue, containing scattered groups of true cartilage-cells (Fig. 40)—a composition which readily explains its physical qualities.

As both the second and third varieties of cartilage have a fibrous tissue mingled with the true cartilage,

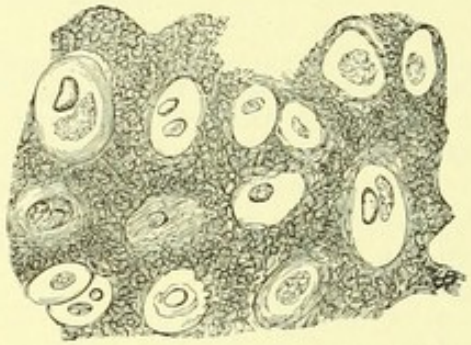

FIG. 40.—Yellow fibro-cartilage. (Kölliker.)

the names "fibro-cartilage" and "fibrous cartilage" do not differentiate one from the other. As all cartilage is elastic, the name "elastic cartilage" is not clearly helpful in the designation of that containing yellow fibrous tissue; and "reticular" is no better as a title for the third variety than is "fibrous" for the second, since in each its fibrous tissue is arranged as a network. The names which are given above are preferred because they actually convey a correct idea of the structure of each form respectively.

Osseous Tissue.

The word "osseous" is derived from the Latin *os*, meaning "a bone." Osseous tissue, therefore, is bony tissue, and it is the characteristic material in the bones. A bone is one of the numerous hard organs, which, taken together, make up the skeleton. One of the long bones of the limbs will show typically all of the features which we need for the study of osseous histology.

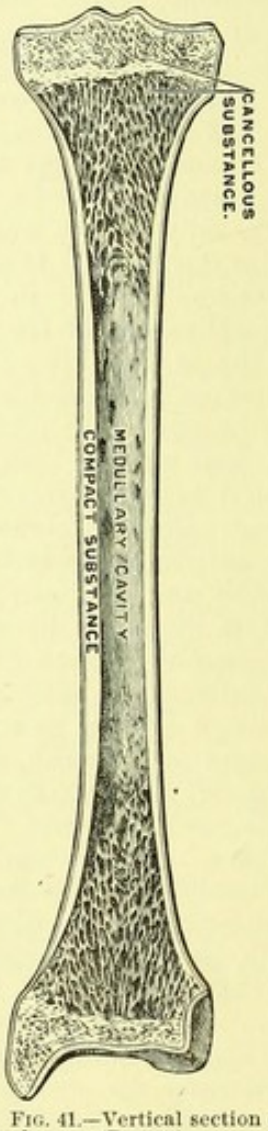

FIG. 41.—Vertical section of a long bone. (Testut.)

A long bone has a central cylindrical portion, the shaft, and an expanded portion at each end. The parts of the extremities of the bone which present surfaces in movable joints are crusted over with a layer of cartilage, and the rest of the bone is covered with a fibrous and vascular membrane, called the *periosteum*, meaning the structure "around the bone." The fibrous part of the periosteum makes it protective; the vascular serves for the nourishment of the bone. If the bone is divided into halves by a vertical cut, its shaft is found to be hollow (Fig. 41). The open space is called the *marrow-cavity*, and is lined by a fine,

fibrous layer, the *endosteum*, meaning the structure "within the bone." The material in the outer parts of the bone is very dense, and is, consequently, known as *compact osseous tissue*. It is very thick in the shaft, but shades off toward the expanded extremities, and in them is merely a thin shell. The residue of the bone has the appearance of a network, with the finest meshes nearest the outer surface, the coarsest next to the marrow-cavity. It is called *spongy osseous tissue*, on account of its porous character, and *cancellous*, from its being a latticework. But compact and spongy are terms which have reference only to gross appearances, which are caused by the arrangement of the material: the structure is essentially the same everywhere. The *marrow-cavity* is occupied by the *marrow* or *medulla*, a very vascular material, containing many peculiar bodies (*marrow-cells*), which are largely changed into oil as adult life is approached, the color of the marrow being, therefore, altered from red to yellow.

Osseous tissue is one of the hardest materials in the body, being surpassed in density by two tissues only—dentine and enamel—both of which exist in the teeth. It is very tough and elastic, as well as hard, and will resist great strain without breaking. It is composed of two kinds of substance, earthy and animal, so intimately commingled that, if either is removed, the other maintains the form of bone even in its minute details. The earthy matter, which is mostly salts of lime and makes up two-thirds of the weight of the bone, can be removed by the action of a dilute acid. The bone is thus decalcified, and consists of a brownish, tough, flexible, and elastic material, so free from stiffness that the bone, if a very long one, may be tied into a knot (Fig. 42). The animal matter can be driven off by heat. When this has been done, the bone is white, rigid, and brittle to the last degree: it can be crushed into fragments between the thumb and finger. In the fresh condition the color of bone is delicate pink in the compact portion, deep red in the cancellated.

FIG. 42.—Human bone which has been deprived of its earthy matter and tied in a knot. (Dalton.)

If the shaft of a long bone is sawed in two transversely, and a very thin slice is removed from the cut surface and examined with the microscope, it will be seen that there are numerous nearly circular or oval perforations, around each of which is a series of concentric rings, which represent long, hollow cylinders fitted accurately one over another, so as to form a solid rod perforated from end to end (Fig. 43). This constitutes a *Haversian system*, named from the celebrated anatomist, Havers. The concentric rings are *lamellæ* or *laminæ* ("layers"), and the hole in their midst is a Haversian canal. In the solid substance of the rod are numerous small excavations called *lacunæ* ("little lakes"), from which radiate in every direction fine channels, called *canaliculi* ("little canals"), which, by uniting with those from neighboring lacunæ, establish a free communication between the Haversian canal and the lacunæ farthest away from it. The lacunæ and canaliculi are lymph-paths, and are important agents in the nutrition of the bone. The Haversian canal is occupied by blood-vessels, nerves, and lymphatic vessels, all imbedded in a mass of areolar tissue. The canals have a general longitudinal direction, but some run more obliquely and connect the more vertical. Immediately subjacent to the periosteum and parallel to it is a series of lamellæ which form a continuous sheath for the more central parts, and are called *circumferential lamellæ*. A similar arrangement obtains at the inner free surface, several concentric lamellæ encircling the medullary cavity, and standing in the relation to it that the Haversian lamellæ do to their central canal. Indeed, this inner circumferential series with its contained marrow has been called a mammoth Haversian system. In the spaces between the Haversian systems are series of layers arranged at irregular angles to each other. They are called *intermediate lamellæ*, and, like the inner and outer

circumferential, are of periosteal formation, the remnants of an earlier stage of growth than is shown in any Haversian system.

The lacunæ are occupied by nucleated corpuscles, called *bone-cells*, fine processes of which extend into the canaliculi. Lacunæ and canaliculi are characteristic of osseous tissue, and are found in all true bone. But Haversian canals are not present in plates of bone which are so thin that sufficient nourishment is afforded by blood-vessels upon their opposite surfaces, as in many lamellæ of the cancellous tissue, and frequently in a part of the lachrymal bone.

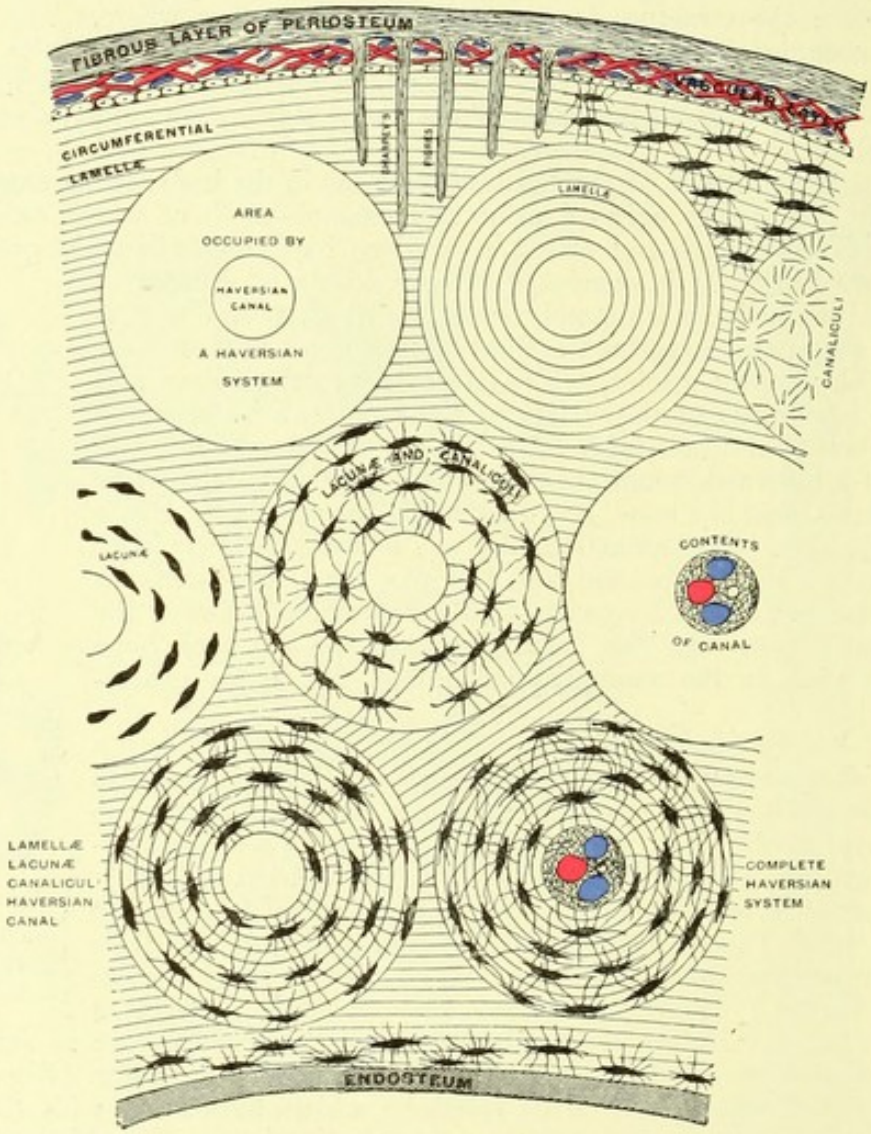

FIG. 43.—Diagram of the structure of osseous tissue. A small part of a transverse section of the shaft of a long bone is shown. At the uppermost part is the periosteum covering the outside of the bone; at the lowermost part is the endosteum lining the marrow-cavity. Between these is the compact tissue, consisting largely of a series of Haversian systems, each being circular in outline and perforated by a central canal. In the first one is shown only the area occupied by a system; in the second is seen the concentric arrangement of the lamellæ; and in the others, respectively, canaliculi; lacunæ; lacunæ and canaliculi; the contents of the canal, artery, vein, lymphatic, and areolar tissue; lamellæ, lacunæ, and canaliculi; and, finally, all of the structures composing a complete system. Between the systems are circumferential and intermediate lamellæ, only a few of which are represented as lodging lacunæ, though it is to be understood that lacunæ are in all parts. The periosteum is seen to be made up of a fibrous layer and a vascular layer, and to have upon its attached surface a stratum of cells. From the fibrous layer project inward the rivet-like fibres of Sharpey. (F. H. G.)

If a thin layer is peeled off of the surface of a decalcified bone, minute projections from its under surface may be seen. These are inward prolongations of the periosteum, and are known as the perforating *fibres of Sharpey*. They are not found in Haversian systems, but only in the circumferential and intermediate lamellæ, which, as has been already said, are developed from the periosteum. They seem to contribute to the strength of the portions of bone in which they

exist by riveting them together; and they certainly make the attachment of the periosteum firmer by giving it a more than superficial hold. Tendons, when attached to bone, are prolonged into it as perforating fibres.

A delicate, longitudinal sliver of bone is seen to have minute openings, which

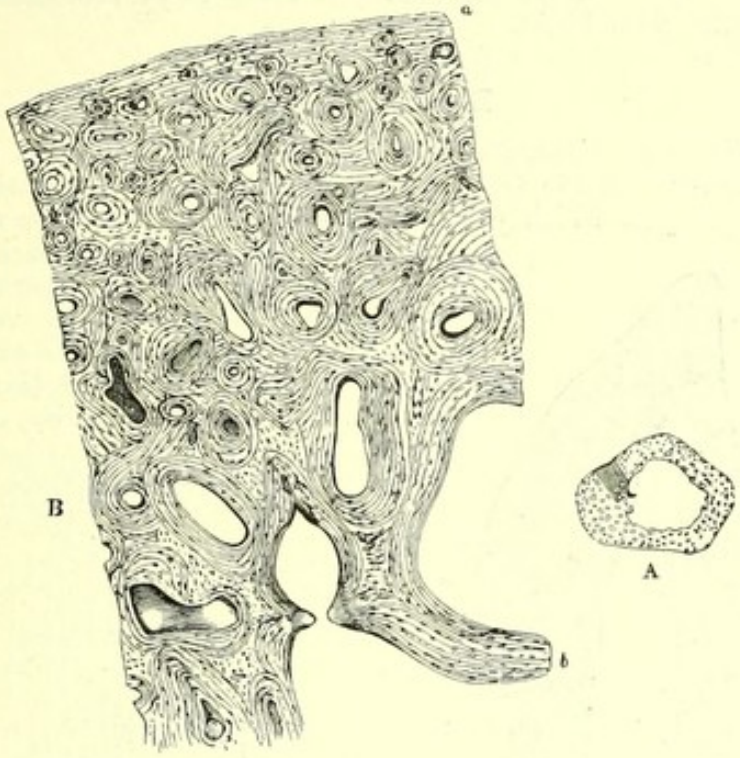

FIG. 44.—*A*, transverse section of a long bone, natural size; *B*, the dark part of *A*, magnified 20 diameters. Haversian systems of different sizes are seen, with canals, lamellæ, and lacunæ. The enlargement is not sufficient to show canaliculi. At *b* is a portion of the cancellated tissue. (Peaslee.)

represent the tracks of canaliculi; and, if the flake is superficial in origin, larger holes also appear wherein have lain the perforating fibres. Between the apertures is a very fine reticulum of fibrillæ, showing the essentially fibrous character of the tissue and its consequent homology with ordinary connective tissue.

Marrow fills the cavity of the shaft of the bone and extends into the interspaces of the cancellous portion. Its elements are supported on an areolar network, and it is extremely vascular, especially in the spongy bone, where, on account of the great number and size of the vessels, its color is red. In the shaft of an adult bone the marrow has been mostly changed into adipose tissue, and is yellow. In the marrow are multitudes of cells, like those of fibrous tissue, and they are called *marrow-cells*. There are also great, irregular masses, with many nuclei—*giant-cells*. The marrow and the contents of the Haversian canals are practically identical; indeed, they are continuous one with the other, and the comparison of the marrow and its encircling lamellæ with the Haversian canal and its surrounding lamellæ is not fanciful.

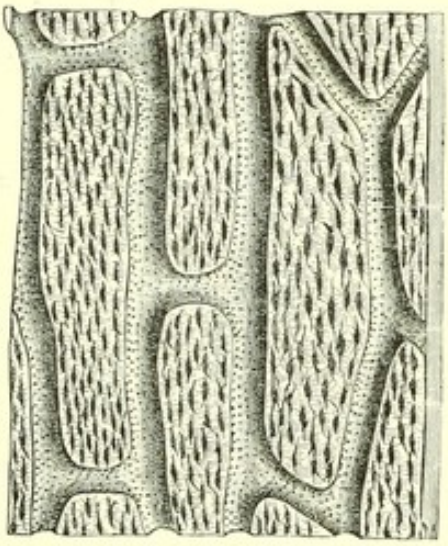

FIG. 45.—Longitudinal section of compact osseous tissue, greatly magnified. The Haversian canals are cut lengthwise. The dots in the canals are the openings of canaliculi. (Testut.)

From what has been said, it will be understood that osseous tissue consists of cells, fibres, and an interstitial substance, which is saturated with lime salts; and, consequently, that the feature in which

it principally differs from white fibrous tissue is its impregnation with this earthy matter.

It is important to remember that the integrity of the periosteum is essential to the proper nourishment of bone, and, if it becomes peeled off by accident or by disease, it should be replaced speedily in order to prevent death of the part which it supplies with blood.

Dentinal Tissue.

Dentinal tissue gets its name from the fact that it makes up the bulk and determines the form of the teeth, the Latin for "tooth" being *dens*. A tooth has a crown, the part which projects from the gum; a fang or root, the part buried in the jaw; and a neck, the narrow and sometimes constricted part embraced by the edge of the gum. If a vertical section is made through the middle of a tooth (Fig. 46) which has a single root, there is brought to view a long central cavity, containing the

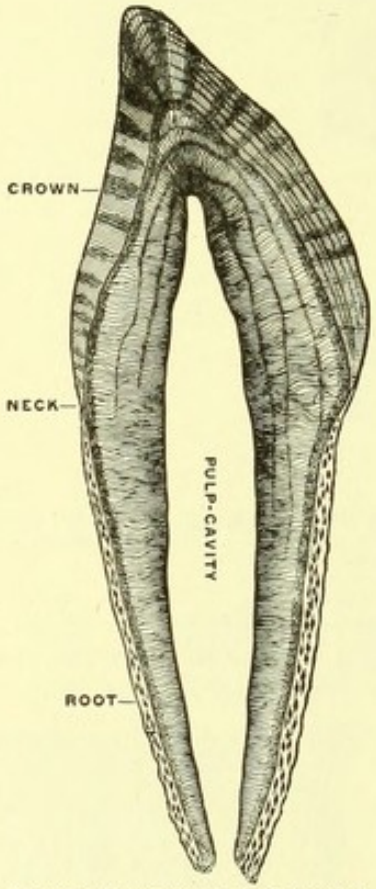

FIG. 46.—Tooth in vertical section.

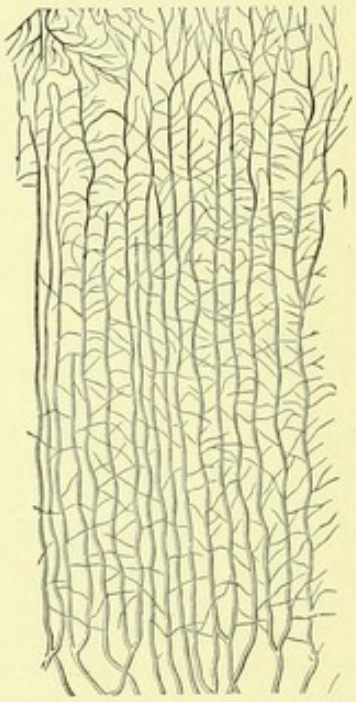

FIG. 47.—Dentinal tubules, in longitudinal section. The lower part of the cut shows the portion of dentine near the pulp-cavity. (Kölliker.)

pulp, the latter being composed of vessels and nerves, supported on a staging of areolar tissue, and also a great number of cells of the connective-tissue class arranged at the periphery of the cavity. Around this pulp-cavity is the hard portion of the tooth, in which are three different tissues: a crust of epithelial tissue all over the crown, the enamel; a crust of osseous tissue all over the fang, the cementum; and the main mass of the structure, the dentine or ivory.

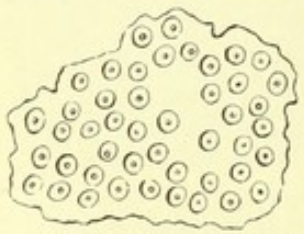

FIG. 48.—Dentinal tubules in cross-section, showing their cavities, walls, and the intertubular substance.

The *dentine* is white, very dense, closely allied to bone, than which it is a little harder. It is developed from closely-packed white fibrous tissue, which becomes infiltrated with lime-salts. This compact mass is riddled with minute channels, *dentinal tubules* (Fig. 47), which radiate in wavy lines from the pulp-cavity in every direction, except at the tip of the fang, where there is an opening through which pass

the vessels and nerves. The tubules branch as they pass toward the surface of the tooth, and the matrix is particularly dense just around them, thus forming a thick wall for each (Fig. 48). The peripheral pulp-cells, called *odontoblasts* ("tooth-germs"), send delicate processes into the tubules. The undulations of the microscopic tubules produce an appearance of striation which is visible to the naked eye.

THE LIQUID TISSUES.

Tissues Performing a Nutritive Function.

An elaborate presentation of the liquid tissues is not needed in an elementary work on anatomy, for a knowledge of them, except in a superficial way, is not required for the comprehension of the description of macroscopic structures. Consequently, they are treated here in a cursory manner, and the student is referred to his text-book on physiology for more detailed accounts of them.

The liquid tissues are—

The Lymph.

The Blood.

They originate in connective tissue, but are so different from it in appearance, physical properties, and function as to merit consideration in a group by themselves.

The Lymph.

Fine and closely stowed as are the elements of the tissues, there are between them spaces, mere chinks and crannies, extremely diminutive and indescribably irregular, into which ooze from the blood of neighboring vessels nutrient materials, and from the tissues themselves the substances which result from their waste. Thus, the tissues are constantly bathed in a mixture of their food and excrement. The spaces containing this fluid communicate freely with each other, and open into the beginnings of minute and delicate tubes, which last, uniting with others of similar size, form larger tubes; these pursue a like course, and so on until tubes of considerable capacity are reached. The little crevices and the tubes are respectively *lymph-spaces* and *lymph-vessels*, and their contents are called *lymph*. The word "lymph" etymologically means "water," but histologically and physiologically it is much more than this. It varies in composition in different parts, being poorest at the periphery and richest near the centre. Examined microscopically, it is seen to consist of a clear, fluid portion, *liquor lymphæ* ("the liquid of the lymph"), and a cellular portion, the latter floating in the former, so that this is a tissue whose intercellular substance is liquid. The cells are *lymph-corpuscles*, and are spheroidal, granular, jelly-like, colorless bodies, averaging $\frac{1}{2500}$ inch in diameter each, with a vaguely defined nucleus, and capable of amœboid movements. They are sometimes called *leucocytes* ("white cells"), because of the whitish appearance of a mass of them.

The lymph-vessels which absorb lymph from the small intestines contain, during the intestinal digestion of food, not only ordinary lymph, but also products of the digestive process. This mixture is called *chyle*, and is milky-looking from the fact that, like milk, it contains a large proportion of oily material finely subdivided—pulverized, we would say, if it were a solid.

The Blood.

Like the lymph, the blood is a tissue composed of cells and a liquid intercellular substance. The fluid portion is called *liquor sanguinis* ("the liquid of the blood") or *plasma*. In it float microscopic particles of various kinds (Fig. 49), of which the most conspicuous and easily demonstrated are the colorless and the colored corpuscles, the former, though without a tint, often being called white, and the latter, though yellowish, red, because, when seen in heaps, they present respectively the hues which these names suggest.

The *colorless corpuscles* are globular, granular, about $\frac{1}{2500}$ inch in diameter, and possess nuclei which are indistinct during the life of the cell. At rest they display amœboid movements. This description will be seen to coincide with that of the lymph-corpuscles; and this will not be surprising to one who has learned that the lymph-stream pours incessantly into the current of blood, so that what is at one moment a lymph-corpuscle, at the next, having entered the blood-vascular system, is a blood-corpuscle. The colorless corpuscles are divisible into a number of varieties, which are chiefly differentiated by means of staining tests.

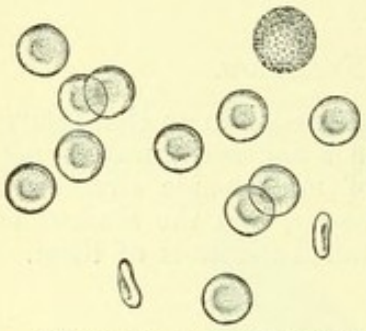

FIG. 49.—Blood-corpuscles. One colorless corpuscle is seen at the top; the others are colored. (Dalton.)

The *colored corpuscles* are very abundant, numbering perhaps five hundred to one of the colorless, and making about one-half of the volume of the blood. They are circular, non-nucleated discs, with rounded edges and centrally depressed surfaces, smooth, amber, transparent, flexible, elastic, and about $\frac{1}{3333}$ inch broad. Besides these bodies are others, inconspicuous and somewhat difficult of demonstration, which need not be mentioned here.

The blood is contained in the chambers and tubes of the blood-vascular system, from which it does not normally escape, excepting in the spleen, where it courses in wall-less channels, and in the case of women during menstruation, when it is discharged through ruptures in the vessels.

THE MUSCULAR TISSUES.

Tissues Devoted to Movement.

Contractility is in some degree an attribute of various tissues. The typical and original cell manifests its amœboid movements by virtue of its contractility, which it brings to bear now in one direction, presently in another. The cilia on the free surface of an epithelium are made to perform their rhythmical lashings because of contractility in their cells. But the muscular tissues alone depend upon this property for the sole functional quality which distinguishes them. Their contractility is displayed on a macroscopic scale, and results in the active movements by which locomotion of the body and changes in the relation of its different parts are effected.

We distinguish three kinds of muscle, which differ anatomically, and, for the most part, physiologically also. They are—

1. Plain muscular tissue.
2. Cross-striped muscular tissue.
3. Cardiac muscular tissue.

Plain Muscular Tissue.

This tissue is known by a variety of names besides that just given. It is called *smooth*, for the same reason that it is called *plain*, because of the usual appearance of its cells; *non-striated* or *unstriped*, to distinguish it from the second kind of muscle, which is characterized by a regular criss-cross of lines on its cells; *involuntary*, from the fact that it is not under the control of the will; *vegetative* and the *muscular tissue of organic life*, because it aids directly in the performance of those offices which are classed as vegetative—in the organic action which is beneath consciousness.

It is found, for the most part, in the walls of the hollow organs, as, for example, the alimentary tube, the urinary bladder and the tubes leading to and from it, and the arteries and veins.

It is made up of cells (Fig. 50) which typically are fusiform; but their ends

are sometimes forked instead of being single-pointed, and sometimes the spindle shape is lost by the rounding of the extremities. Often there is observed a faint appearance of lines running lengthwise, as if the cell were trying to develop into a striped fibre. A transverse cut shows that the cell has flattened sides, evidently the result of pressure from forcible contact with its fellows. The cell is always nucleated, and generally beyond each end of the nucleus is a little collection of granules. The cell has a delicate structureless sheath. The length of the cells varies between $\frac{1}{500}$ and $\frac{1}{10}$ inch, the greater part being very small. In some situations, as in the arterioles, the cells are separate; but usually they are associated in such a way as to make bundles (*fasciculi*) or layers (*strata*), being united by a small amount of adhesive material. The cells are aggregated with much regularity, the bulge of one being adjusted to the tapering tips of its nearest neighbors (Fig. 51). When distinct bundles are

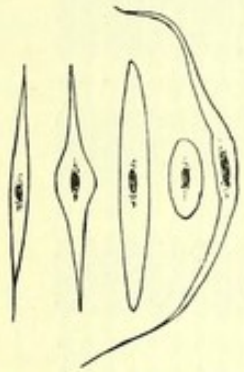

FIG. 50. — Cells of plain muscular tissue. (F. H. G.)

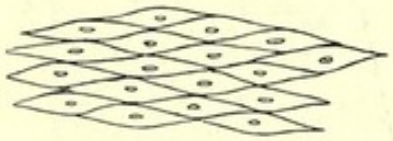

FIG. 51.—Cells of plain muscular tissue arranged in a sheet. (F. H. G.)

formed, they are usually attached at their extremities to some other structure through the agency of a fibrous prolongation.

Cross-striped Muscular Tissue.

This variety, also, like the plain, has a number of other names: *striped* or *striated*, from its microscopic appearance; *voluntary*, because the most of it is under the control of the will; the *muscular tissue of animal life*, because, while it has little direct effect upon the organs of the vegetative functions, it is largely concerned in those manifestations which are peculiar to animals. This tissue makes up a very considerable part of the bulk of the body, is principally connected with the bony skeleton, and is that material which, in other mammals, is called "flesh" or "lean meat." It is commonly found in coherent masses, of varying but definite shape, each of which, taken in connection with a fibrous prolongation at each end, is known as a muscle.

The histological unit of cross-striped muscular tissue is a *muscle-fibre*, which is the homologue of the cell of the plain muscular tissue. This fibre is like a long cylinder, with somewhat flattened sides, and rounded or conical ends. It is completely enveloped in a very delicate sheath, the *sarcolemma* ("the flesh-husk"). When examined under an objective of moderate power, it seems to be marked with delicate, longitudinal, parallel, and equidistant lines, and with broad, transverse, regularly placed bands or stripes, from which the ordinary names of striated or striped (better, cross-striped) originate (Fig. 52). Between these cross-stripes are lighter areas, which, with a stronger objective, seem to be divided by a fine line. The cause of these peculiar appearances is not manifest until the tissue is studied with a microscope of great power, but then it is found that they are deceptive. There are no continuous bands or lines running transversely, and the apparent breaks in the longitudinal continuity of the cross-lines are an illusion, caused by the extreme fineness of the contractile material at regularly alternating intervals. The accompanying diagram (Fig. 53) will illustrate this. The fibre is represented as composed of a series of threads placed side by side in longitudinal rows. Each of these threads is a fibril (*fibrilla*), and is marked by alternating bulges and constrictions, regularly placed, and arranged in the following order: a long, wide, fusiform bulge, a constriction, a small, globular bulge, a constriction, and so on

from one end of the fibril to the other. Or, to put it in a different way, a fibril looks like a fine thread, upon which are strung large, spindle-shaped beads and small, round beads, regularly alternating, and leaving a little of the thread exposed between each bead and its two neighbors. These fibrils do not touch each other, but between them, and also separating them from the sarcolemma, is a thin (probably fluid) substance, called *sarcoplasm*. The fibrils are the contractile por-

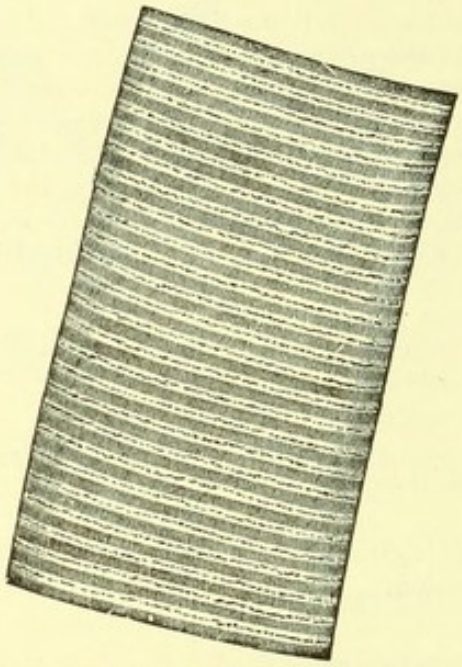

FIG. 52.—Part of a fibre of cross-striped muscular tissue, showing the alternating bands.



FIG. 53.—Diagram showing the minute structure of cross-striped muscular tissue. (F. H. G.)

tion of the fibre, and, when they contract, their spindles and beads shorten in the line of the long axis of the fibre, and swell out in the lateral direction. This causes a displacement of the sarcoplasm, which, consequently, pushes out the sarcolemma, and thus produces regularly placed protrusions along the surface of the fibre.

If the diagram is viewed at a distance (as across the room), which will obscure some of its details, the effect is very like that produced by the examination of a fibre of muscle with a microscope of mod-

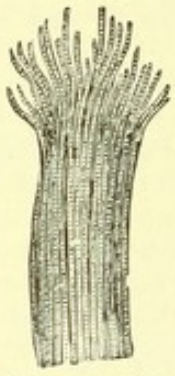

FIG. 54.—Fragment of a fibre of cross-striped muscular tissue, showing fibrils separated at one end by teasing.

FIG. 55.—Fragment of a fibre of cross-striped muscular tissue, hardened, showing transverse cleavage. (Kölliker.)

FIG. 56.—Transverse section of muscle-fibre, showing nuclei. (Testut.)

erate power—faint, longitudinal lines and broad, transverse stripes, the latter separated by light intervals, which are crossed from side to side by a thin, dark streak.

The spindle portion of the fibril is called a *sarcous element;* the round beads in a single transverse plane constitute what is known as *Krause's membrane.*

In the teasing of a bit of muscular tissue with needles, it happens that many fibres are torn, and the broken ends of the fragments sometimes are frayed out

like a coarse brush, the fibrils standing for the bristles (Fig. 54). When the fibre has been hardened by certain reagents, it will occasionally show a cross-cleavage, by which it is divided into discs (Fig. 55).

Upon the inner surface of the sarcolemma are scattered a number of oval nuclei, the *muscle-corpuscles* (Fig. 56), so unobtrusive that they generally escape observation unless reagents are used in the examination. They are regarded as nucleated accumulations of the sarcoplasm.

In a fibre are many groups of fibrils, each collection being called a *muscle-column*. The fibres are aggregated in bundles (*fasciculi*), and the bundles are assembled in the contractile portion of the muscle. The fibres may be 2 inches long and $\frac{1}{250}$ inch thick, or only a tenth part of these measurements. In muscles or fasciculi whose length is greater than that of their component fibres the latter are joined to each other end to end. Fibres commonly do not branch; but in some of the lingual and facial muscles terminal divisions may be observed.

The fasciculi, as a rule, run from one end to the other of the contractile part of a muscle; but exceptions occur in double-bellied muscles and in others which have a tendinous interruption of the muscular continuity. The fasciculi, from the closeness with which they are packed, have flattened sides, and are thus more or less prismoid.

As has been said above, each fibre has, as its true and perfect investment, the *sarcolemma*. Between the fibres is a delicate areolar tissue continuous with a thicker layer of the same, which sheathes the fasciculi; and this is merely an inward prolongation of a still more pronounced lamina which coats the entire muscle. The outer tunic (Fig. 57) of the muscle is called *epimysium* ("upon muscle"); the sheaths of the bundles constitute the *perimysium* ("around muscle"); and the tissue between the fibres is the *endomysium* ("within muscle"). All of these are continuous, each with the others, and all are composed of areolar tissue.

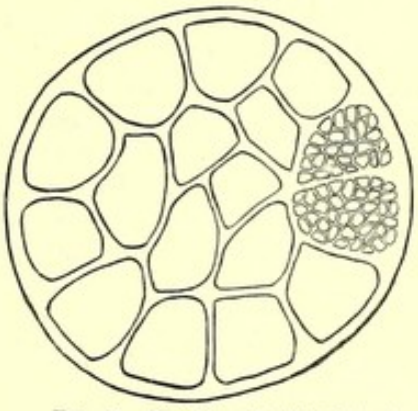

FIG. 57.—Sheaths of muscular tissue in cross-section. The muscular tissue does not appear, but is represented by the spaces between the partitions. Outside of the entire muscle is *epimysium*; between the bundles is *perimysium*; between the fibres is *endomysium*—the last shown in two areas at the right. Diagrammatic. (F. H. G.)

Fibres which end in tendon come to it either in line with its axis or obliquely to it. The sarcolemma of the end of the fibre is very closely attached to the tendon, and there is a continuity of the areolar tissue between the fasciculi of the muscle and that between the bundles of the tendon. In these ways the two parts of the muscle are so firmly united that their separation by violence is extremely rare.

The blood-vessels course between the fibres in the areolar tissue, making a network of long meshes. Lymphatics, also, are numerous in the areolar tissue, and the nerves of the muscle are abundant.

Cardiac Muscular Tissue.

The muscular tissue of the heart has peculiarities, which ally it to the plain muscular tissue on the one hand and to the cross-striped on the other. It is like the former in being composed of nucleated cells, and in being beyond the control of the will; it resembles the latter in being cross-striped, and in presenting in a mass a color similar to that of voluntary muscle. The cells (Fig. 58) are short, branched at one end, cross-striped (though with less regularity and plainness than in the case of ordinary striated muscle), and are not furnished with sarcolemma. The cells are connected with their

FIG. 58.—Cell of cardiac muscular tissue. (Testut.)

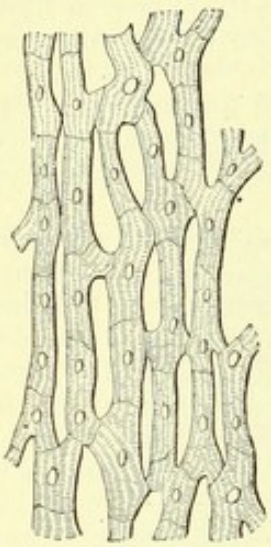

FIG. 59.—Cardiac muscular tissue, the cells united in a network. (Testut.)

neighbors by an abrupt union, and form fasciculi and networks (Fig. 59). The cardiac muscular tissue has a remarkably abundant supply of blood- and lymph-vessels.

THE NERVOUS TISSUES.

TISSUES ESSENTIAL TO SENSATION.

The nervous apparatus is conveniently considered under two heads—the central portion and the peripheral portion. The former comprises the brain and spinal cord, and is otherwise known as the cerebro-spinal axis; the latter includes the cords which radiate from this axis, and also the ganglia ("knots") upon these cords. In both the central and the peripheral regions two kinds of tissue are recognized, which are distinguished by their color as gray and white. The white is much the more abundant in both regions, but there is a great deal more of the gray in the central than there is in the peripheral. Functionally regarded, the gray matter is that which receives impressions, retains, converts, and marshals them in various ways, and originates impulses: it is the part which feels, thinks, remembers, wills; the white matter merely conveys impressions and impulses, connecting the gray matter with distant parts and associating one portion of it with another. The gray is cellular; the white is made up of fibres. Nerves consist of fibres of this kind, grouped together in bundles of small or large size.

The *gray nervous tissue* is composed of cells, called *nerve-cells* or ganglion-cells (Fig. 60). These vary greatly in shape and size in different parts, but they all have certain common features which are characteristic. They are granular, nucleated, usually pigmented, and have projections or processes which are called poles. At least one pole of a cell is prolonged as a nerve-fibre (Fig. 61), and thus it is seen that there is a structural connection between the two kinds of nerve-tissue. The other processes of the cell—of which there may be many—radiate from its general mass, divide again and

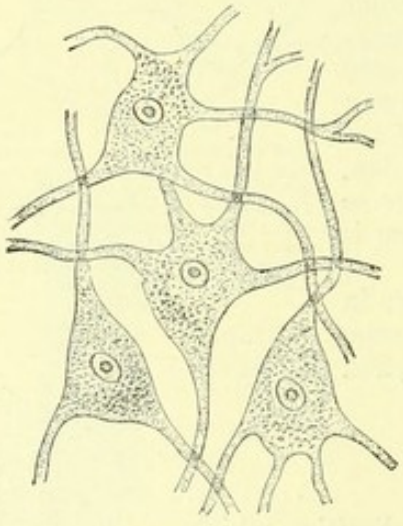

FIG. 60.—Nerve-cells. (Dalton.)

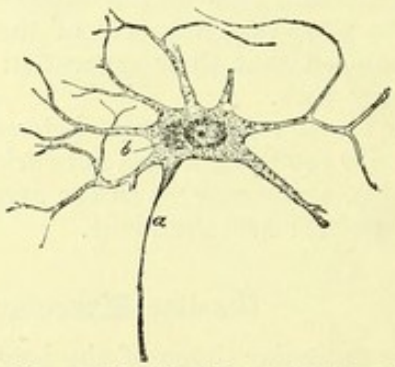

FIG. 61.—Nerve cell. All of the processes are protoplasmic except that marked *a*, which is the axis-cylinder process; *b* indicates a clump of pigment-granules. (Gerlach.)

again, and terminate in minute twigs, which mingle with, but do not become continuous with, corresponding ramifications from neighboring cells. These processes are called protoplasmic processes or dendrites ("tree-like"). A nerve-cell, with its dendrites, and the nerve-fibre which is continuous with the cell, constitute a *neuron*.

The *white nervous tissue* (called white on account of the appearance of a mass of it) is made up of fibres which vary in diameter and length, but have their

main difference in the presence or absence of a certain coat. The simplest, because least clothed, of the fibres are small, pale, fibrillated, nucleated threads of tissue, whose component fibrillæ are the minutest independently recognizable portions of the tissue. Such a thread is called a *pale fibre*, and also bears the name "non-medullated," on account of the lack of the tunic which distinguishes the other kind. It sends off minute filaments at a right angle with its course soon after emerging from the cell, and then continues without further branching until near its end, where it divides into bundles of fibrillæ, each of which splits up into smaller bundles, and so on, until the fibre has frayed out into its ultimate filaments.

Besides the pale fibres is a more numerous class, called *white* or *medullated fibres*. A typical representative of this variety has three parts, of which the first and essential is centrally located, and from this fact is named the *axis-cylinder* (axis-band or axial fibre). The axis-cylinder is like a pale fibre, being fibrillated, giving off fine, lateral twigs near its origin, and dividing into its ultimate fibrillæ at its periphery in the same manner.

Outside of the axis-cylinder is a thick, insulating tunic, composed of a soft, oily material (myelin), and known as the *medullary sheath* or white substance of Schwann. Surrounding this first coat is a second, very delicate and thin, but sufficiently strong to keep the medullary sheath in shape. It is called the *primitive sheath*, *neurilemma* ("nerve-husk"), or nucleated sheath. The medullary sheath is evenly spread upon the axis-cylinder, excepting at regular intervals, where it is lacking for a minute space, thus leaving the primitive sheath as the sole covering of the fibre. At these places the fibre presents the appearance of being encircled with a cord so tightly as to squeeze the medullary substance away from the part. These constrictions are known as the *nodes of Ranvier*, and the lengths of fibre between them are called the *internodes* (Fig. 62).

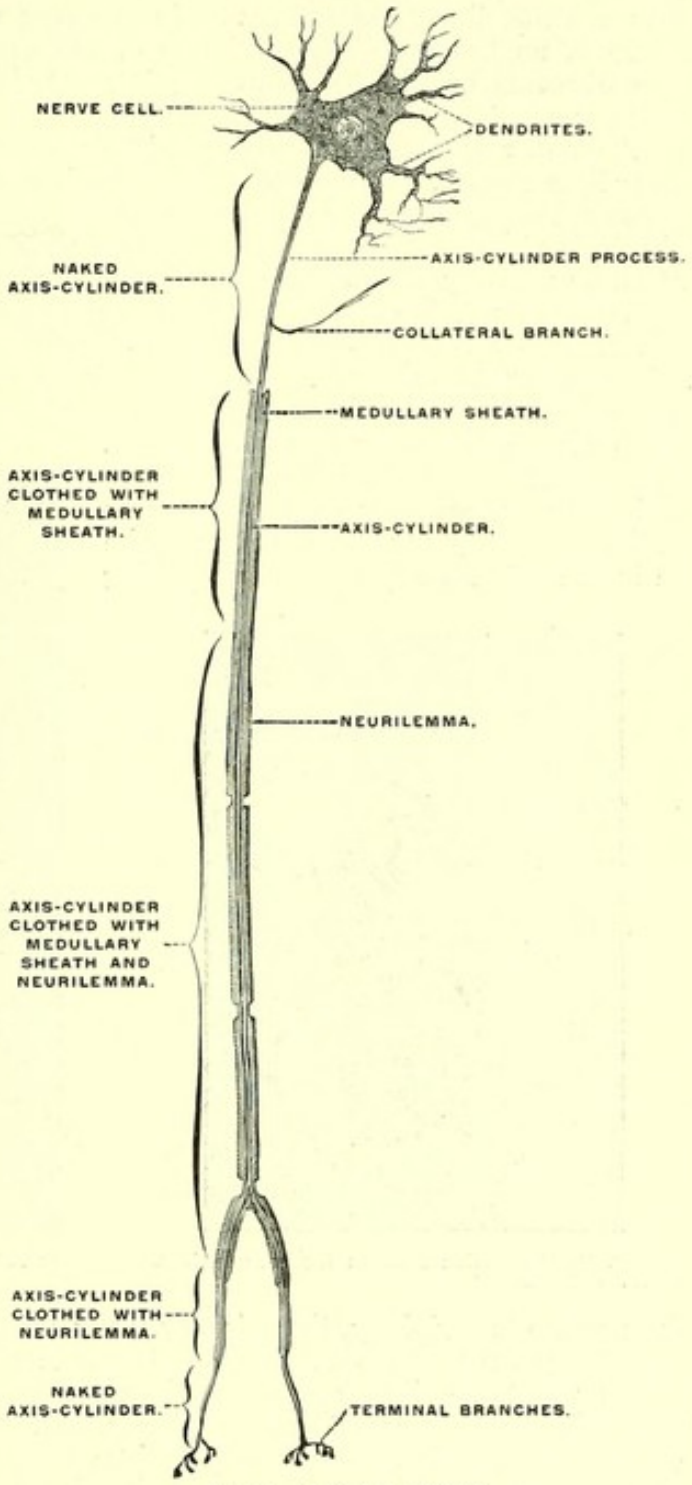

FIG. 62.—A neuron. (Stöhr.)

The primitive sheath has on its inner surface a nucleus for each internode, midway between the ends of the latter. Either or both of the sheaths may be lacking; and in the latter case the axis-cylinder alone is left, and we have a pale fibre instead of a white one. In brief, the axis is always present as the one essential thing in a nerve-fibre; if it is coated with the medullary sheath, it is a white fibre; and it may be in one part naked and in another clothed. There is no break in the continuity of the axis from one end to the other. The filaments or fibrillæ composing it are held together by a cement called *neuroplasm*.

A number of nerve-fibres gathered into a coherent bundle constitutes a *funiculus* ("little rope"). It is enclosed in a sheath of laminated fibrous tissue, called *perineurium* ("around nerve"), from the innermost layer of which shelf-like trabeculæ project between irregular groups of nerve-fibres, and compose the *endoneurium* ("within nerve"). A single funiculus with its wrappings may constitute a nerve; but usually a number of funiculi are grouped together in a nerve, and, when this obtains, they are kept in close relation to each other by a common sheath, the *epineurium* ("upon nerve"). The bundles in a nerve have a network arrangement, each funiculus splitting up more or less at short intervals, and its component fibres passing into neighboring funiculi (Fig. 63). The fibres, however, always retain their individuality: while they cross and recross in the nerve, and any one of them may be an ingredient of many funiculi in passing from centre to periphery, there is never any coalescence between them. In the branching of nerves the same rule is observed: a funiculus lets some of its fibres switch off at the side or separates them into substantially equal parts, but the fibres themselves remain undivided (Fig. 64). The larger vessels of a nerve course in its sheath, and the capillaries are arranged in long meshes between the fibres. The epineurium is also supplied with nerves, called *nervi nervorum* ("the nerves of the nerves").

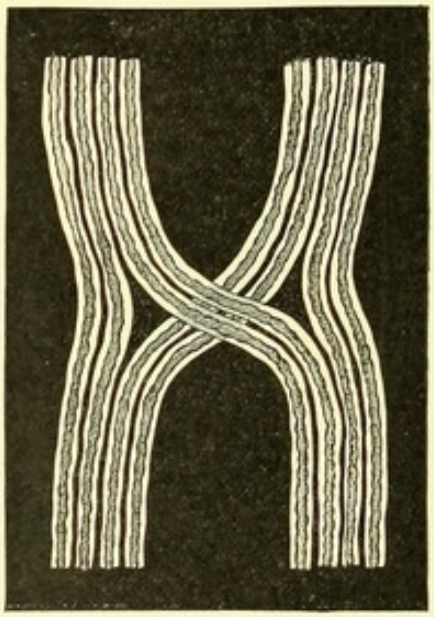

FIG. 63.—Connection between the bundles in a nerve. (Dalton.)

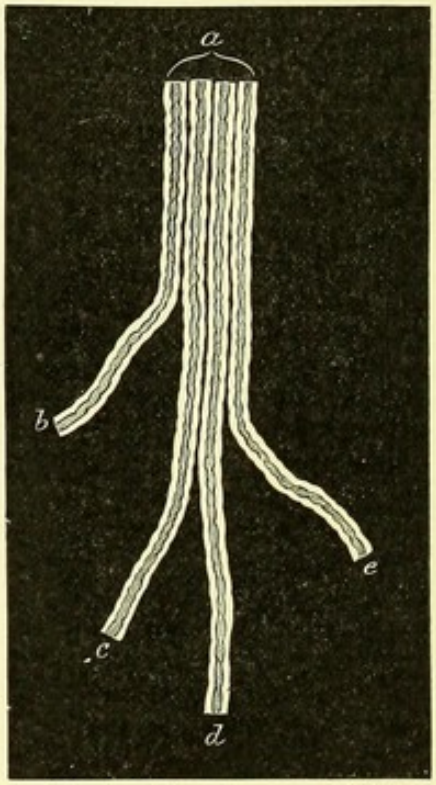

FIG. 64.—Branching of a nerve. (Dalton.)

The origin of nerves varies with their function. Those which convey impulses from the centre to the periphery, called *efferent nerves* (meaning "carrying from"), grow outward from nerve-cells in the centre; while those which convey impressions from the periphery to the centre, called *afferent* (meaning "carrying to") or sensory nerves, grow inward from nerve-cells in organs of special sense or in

ganglia. These fibres branch within the nerve-centre, and send their ultimate twigs among the cells, but do not unite with them.

Ganglia ("knots") are bunches of various sizes occurring in the course of nerves. They are made up of nerve-cells and their coverings, massed upon and between the fibres of nerves (Fig. 65). Each cell of a ganglion has one or more axis-cylinder processes, which are prolonged into nerve-fibres. The ganglion is clothed with areolar tissue, which sends trabeculæ through it in every direction.

FIG. 65.—Arrangement of nerve-cells and nerve-fibres in a ganglion. (Dalton.)

Before coming to their peripheral division many medullated nerves lose their white substance; but others retain it during several stages of branching, and in these last the division takes place at nodes. After the disappearance of the medullary sheath the primitive sheath continues for a variable distance.

Afferent (sensory) *nerves* have various peripheral terminations. Some of them end in cells, others in special organs, as tactile corpuscles, end-bulbs, and Pacinian bodies. These will be described in the chapter devoted to the organs of the senses. Certain afferent nerves end peripherally by the final separation of the axis-cylinder into its component fibrils, which run between the tissue-elements, and generally either end there or else penetrate the cells. The sensory nerve-endings in tendons are often suggestive of the ending of motor nerves of voluntary muscle, to be described presently. Close to the muscle proper a medullated fibre passes into the tendon, divides repeatedly, and the filaments of the axis-cylinder penetrate widely into the tendon.

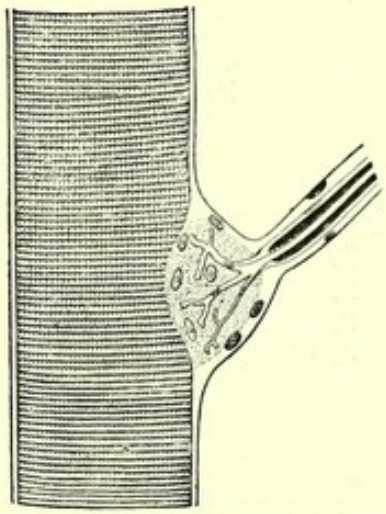

FIG. 66.—Motorial end-plate, the termination of a nerve in a fibre of cross-striped muscle. (Testut.)

Efferent nerves have different endings according to the variety of muscle to which they are distributed. In the case of the plain muscular tissue the fibrillæ of the nerve are brought close to the muscle-cells, after the nerve has formed a plexus in which ganglion-cells often occur. In cardiac muscle the nervous filaments come from a long-meshed plexus, and are applied to the contractile fibres. Finally, in striated muscle, after the formation of a close plexus, the nerve loses its white sheath, the axis-cylinder enters the muscle-fibre, and just beneath the sarcolemma splits up into its fibrillæ, which spread out in a thin mass of granular material in which nuclei are embedded. This is the *motorial end-plate* (Fig. 66).

MEMBRANES.

In its widest meaning the word "membrane" is used to designate any thin expansion of tissue, either simple or compound. Thus, we speak of the periosteum, the covering of bone, as a fibrous membrane; we call the layer of cells beneath the epithelium of free surfaces the basement membrane; and a structure composed largely of blood-vessels may be known as a vascular membrane. But in a restricted, although the commonest, sense the word is applied to a broad, sheet-like organ, with a free (unattached) surface, furnishing the covering of a

part or the lining of a cavity. With the latter signification the term is employed in this section.

The type upon which all of the members of the group are constructed consists of a foundation of white and yellow fibrous tissue, which is limited toward the free surface by a single layer of very thin, plate-like cells, and upon this last an epithelium (Fig. 67). The fibrous tissues are felted into a layer of variable thick-

FIG. 67.—A typical membrane in vertical section. (F. H. G.)

ness, strength, flexibility, and elasticity, according to the proportion and arrangement of its ingredients, and is called the *corium* ("leather"). The lamella of flattened cells surmounting this is really a part of the corium, for it consists merely of cells of the white fibrous tissue, greatly attenuated and adhering to each other at their edges. It is termed the *basement membrane*. Finally comes the *epithelium*, which presents upon the free surface, and may be either simple or stratified in numberless layers.

In most cases the attached surface of the membrane is connected with the underlying structures by areolar tissue, abundant or scanty, which permits some gliding of the membrane on the subjacent parts. This areolar tissue is called subserous, submucous, subcutaneous, and so on, according to the kind of membrane under which it lies. The line between it and the corium of the membrane is not exactly determinable, as a rule, the two structures being made of precisely the same materials, differing only in their mode of arrangement, and gradually shading from one into the other. When the membrane is peeled off from the areolar tissue its under surface is flocculent, on account of the attachment of bundles of the fibrous tissues of the latter. In the areolar tissue course the larger vessels and nerves of the region, sending their branches to, or receiving their radicles from, the corium.

There are four classes of membranes:

1. Serous Membranes.
2. Synovial Membranes.
3. Mucous Membranes.
4. Cutaneous Membrane.

SEROUS MEMBRANES.

Of all the membranes, the serous are the simplest—the nearest the type which has been described. They are always moist with a fluid very like blood-serum, and from this fact they derive their name. They are thin and transparent, permitting a view of the immediately subjacent parts, fairly strong, considering their delicacy, and somewhat elastic. With a single exception, which obtains in all females, but never in males, the serous membranes are shut sacs; that is to say, they have no opening by which they communicate with the surface of the body (Fig. 68). In the simplest of them this condition is so plain as to be easily understood; in the most complicated it is not especially difficult to demonstrate, even though the form of the membrane

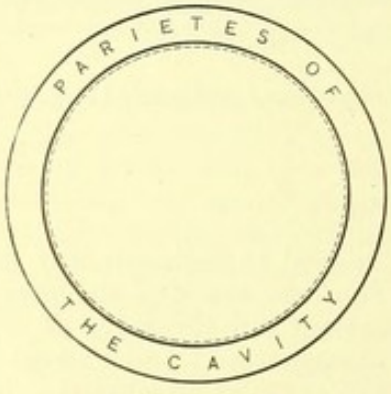

FIG. 68.—Diagram showing arrangement of a serous membrane. The broken line represents the membrane lining the closed cavity. (F. H. G.)

suggests but remotely that of a sac. In those which are manifestly bag-like, and which furnish a complete or partial coating to internal organs, two parts are recognized—that which is attached to the viscus, and that which is fastened to the walls of the cavity in which the organ is contained. The former is called the *visceral layer*, the latter the *parietal* ("on the wall") or *reflected portion*. The relations of parts will be easily comprehended by reference to Fig. 69.

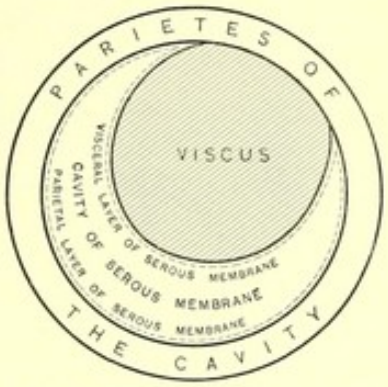

FIG. 69.—Diagram showing that when a viscus encroaches upon the space of a cavity, it still remains outside of the serous membrane, which gives it an external tunic while continuing to line the cavity. (F. H. G.)

The diagram represents a viscus pushing one wall of the serous sac inward, thus making this portion serve as a tunic for the organ; consequently, this is the visceral part. The other portion of the sac lines the wall of the cavity in which the viscus now is enclosed, and is, therefore, the parietal part. It is not asserted that this is the precise way in which the viscera procure their serous coat; but the condition which exists is such as would obtain if this procedure were actual. For the sake of clearness in the diagram, a cavity is represented between the epithelial surface of the visceral layer and that of the parietal layer; but, as a matter of fact, the two layers are in actual contact, and the serous cavity, of which mention is often made, is not real, but virtual.

Serous membranes present many folds, which connect viscera with each other or with the walls of a cavity, or simply project into a cavity and return on themselves, forming a tassel or an apron. A serous membrane may line a fibrous bag, and be reflected over the surface of a contained viscus, and in such case is denominated a *fibro-serous membrane*.

The *corium* is thin, but contains blood-vessels, lymph-vessels, and lymphoid and adipose tissues. The lymphatics are especially abundant. The nervous supply is small and is sympathetic in origin.

The *epithelium* (Fig. 70) is always single and flattened, the cells having irregular, notched edges and fitting accurately together, except that, at intervals, little apertures are found, some of which are the beginnings of lymph-vessels, and from this fact are named *stomata*, from the Greek word for "mouth;" and others are filled with processes from cells in the corium, and hence are called *pseudo-stomata* ("false mouths"). The true stomata are distinguished by a little boundary of cells, much smaller than those furnishing the general surface. The demonstration of their immediate connection with lymph-vessels led to the belief that serous membranes are only expansions of lymphatics, and, consequently, are to be regarded as belonging to the lymphatic system. Their physiological performance and their behavior in disease support this theory.

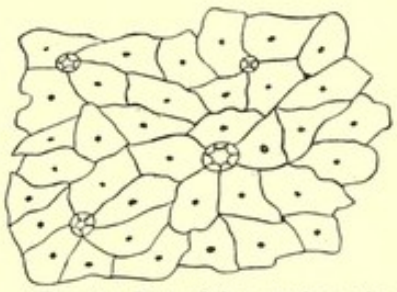

FIG. 70.—Part of free surface of a serous membrane, showing the flattened epithelial cells and the stomata. (F. H. G.)

The *epithelial surface* is particularly smooth and glistening, and thus the gliding of opposing portions is accomplished with very slight friction, which is still further reduced by the presence of the thin fluid constantly secreted by the cells. This fluid, which lubricates the membrane, is normally present in so small an amount that it merely moistens the surface. Just as fast as it is formed it is withdrawn by the lymphatics through the stomata. But, in disease, when the equilibrium between secretion and absorption is so disturbed that the lymphatics do not carry the fluid away as rapidly as the cells manufacture it, an accumulation occurs, the parietal layer is pushed away from the visceral by the intervening liquid, and in this way the virtual cavity is converted into a real one.

Serous membranes may be divided into tolerably distinct classes, as follows:

1. Serous membranes proper.
2. The lining membrane of the vascular system.
3. The lining membrane of certain cavities in sustentacular tissues.
4. The lining membrane of the cavity of the cerebro-spinal axis.

1. Serous Membranes Proper.

Under this head are included the various membranes which result from the division of the original serous membrane lining the thoracico-abdominal cavity (Fig. 71). These are derived from the single sac by constriction, the thoracic first

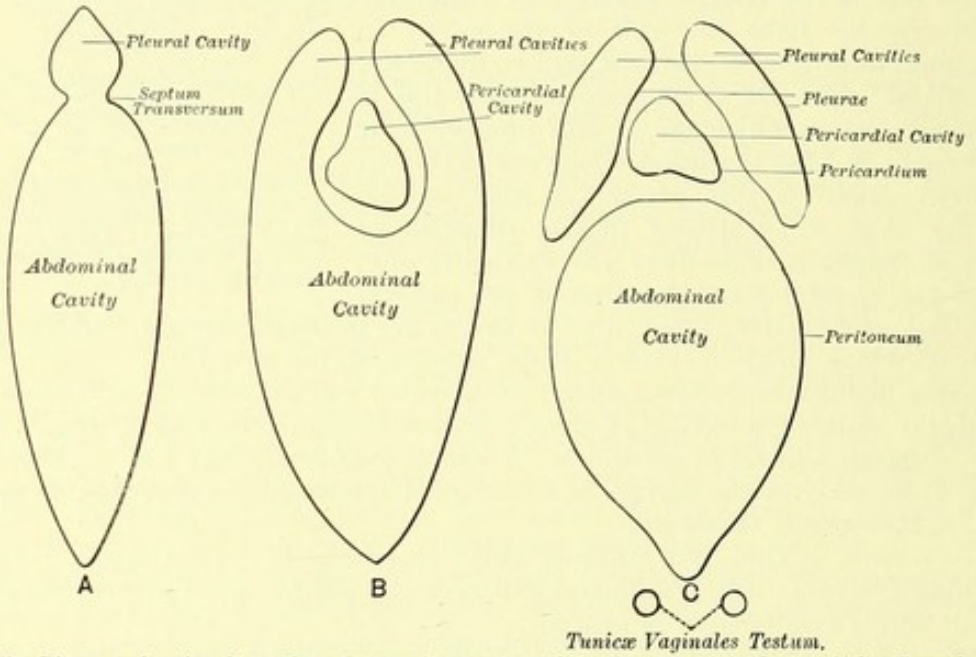

FIG. 71.—Diagram showing formation of several serous sacs from the one original sac. (After Gegenbauer.)

being separated from the abdominal, and then subdivisions of each of these making three distinct sacs of the upper grand division—the two pleuræ and the pericardium—and three of the lower grand division—the peritoneum and the two vaginal tunics. They are called serous membranes *proper*, because they present, to an extent which the others do not, the features which have been mentioned as characterizing this class of structures. The pleuræ are the serous covering of the lungs; the pericardium encloses the heart; the peritoneum lines the abdominal cavity and clothes its contained viscera; and the vaginal tunics perform a similar service for the two chambers of the scrotum and the testicles, to which they give lodgement. These serous membranes will be treated of in detail in connection with the organs to which they are respectively related.

2. The Lining Membrane of the Vascular System.

This is the internal coat of the heart and vessels, known also as the *tunica intima*. It bears a close resemblance to the proper serous membranes in structure and appearance. Its power of forming a fluid like that of the great serous sacs is not to be doubted, but is not demonstrable, as the fluid must mingle with the current of blood or lymph as soon as it is formed. One at all acquainted with the circumstances favoring the coagulation of the blood, and the necessity of having it flow freely through the microscopic tubes which we call capillaries, would feel warranted in the declaration that no other membrane than a serous would be practicable as a lining to the blood-vessels and lymphatics. If a mucous membrane were employed for the purpose, the small vessels would

speedily become clogged with its thick and slimy secretion; and the thinnest and most delicate cutaneous membrane would obviously be too thick and coarse to permit the transudation necessary for the nutrition of the tissues. Only a serous membrane with its almost frictionless surface and its watery secretion could possibly meet the requirements of the case.

The details of structure of the tunica intima will be presented in connection with the description of the heart, blood-vessels, and lymphatics, respectively.

3. The Lining Membrane of Certain Cavities in Sustentacular Tissues.

The most conspicuous illustration of this form of serous membrane is found in the internal ear. Around the greater part of the membranous labyrinth, which is the essential portion of the organ of hearing, and between it and the bone in which it is lodged, is a considerable space, lined with serous membrane and filled with a watery fluid, which is called perilymph. Another example is found between the back of the eyeball and the bed of fat upon which it reposes. It is called the capsule of Tenon, and is a shut sac, with a visceral layer upon the globe of the eye and a parietal layer attached to the postjacent adipose tissue. It permits free movements of the eye in the orbit with the least possible friction. In character and function it closely resembles the proper serous membranes.

4. The Lining Membrane of the Cavity of the Cerebro-spinal Axis.

The brain and spinal cord are hollow organs. Their cavities are lined with a delicate membrane, serous in character, its epithelium being in embryonic life ciliated, and its secretion thin and watery. The membrane is known as the *endyma* ("garment") or *ependyma*. It will be described in the chapter on the Cerebro-spinal Axis.

SYNOVIAL MEMBRANES.

By certain authorities the synovial membranes are classed with the serous, and there are some good arguments in favor of this association. But, while these membranes have no communication with the surface, and have the same order of function as the serous membranes, there are such differences as to justify a separation of the one from the other. The group of synovial membranes with which surgeons have most to do are not shut sacs, although each forms a part of the wall of a closed cavity; they have a different lining from serous membranes; their secretion is not serous; and they are not associated with the viscera. Therefore, they are here treated by themselves.

The synovial membranes form a part or the whole of the enclosure of certain cavities, which are associated with the osseous framework or the muscular system, or both; and the service which they render is the lubrication of parts which glide upon each other.

A synovial membrane is composed of fibrous tissue, having on its free surface an imperfect covering of cells (Fig. 72), and thus affording the great exception to the rule that free surfaces are completely clothed with cells. These cells are of no regular shape, are branched, and are gathered into little patches, which are scattered over the surface, leaving considerable areas upon which no cellular structure appears. The cells are often called *epithelioid*, which means "like epithelium." Their secretion is a glairy fluid, which smears the entire free surface of the membrane, and is called *synovia*, from its resemblance to the white of egg.

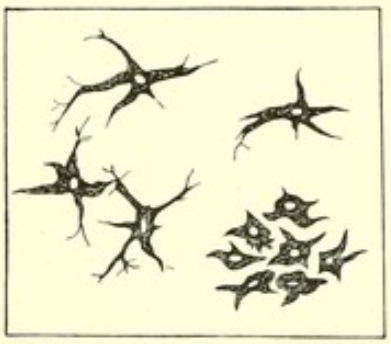

FIG. 72.—Synovial membrane—free surface, showing imperfect covering of cells. (F. H. G.)

Synovial membranes are divided into the following groups:

1. Articular.
2. Vaginal.
3. Bursal.

1. Articular Synovial Membranes.

These occur in those articulations of the bony skeleton wherein two surfaces move upon each other. The bones concerned in such a joint are covered on the surfaces, which enter into the composition of the articulation, with a crust of cartilage, whose free surface is very smooth and hard. The bones are held together by strong bands of white fibrous tissue—the ligaments—which encapsulate the expanded ends of the bones, forming hollow cylinders, which bound the joint. The inner surface of a capsular ligament is covered with a synovial membrane, which is reflected from it a little way upon the margin of each of the cartilages. Thus, the synovial membrane is a short tube with its edges turned inward. The arrangement of the parts will be seen in Fig. 73.

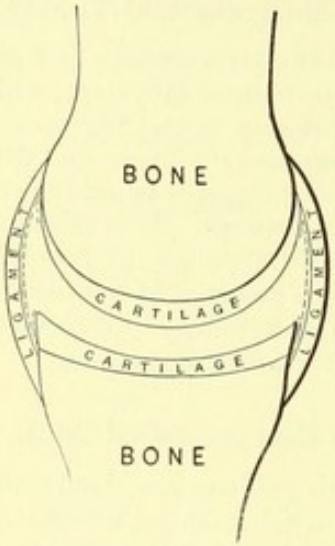

FIG. 73.—Diagram of articular synovial membrane. The cartilages are represented as drawn apart for the sake of clearness. The synovial membrane is shown by a broken line. (F. H. G.)

If, as sometimes occurs, a ligament or a tendon passes across or through the joint-cavity, the synovial membrane ensheaths it. Occasionally the membrane exhibits folds, which cross the cavity or hang into it like fringes, and perhaps contain some adipose tissue. In all cases the synovia secreted by the membrane lubricates the cartilages and other structures, which present a free surface in the joint.

2. Vaginal Synovial Membranes.

These are so named from *vagina*, "a sheath," and are also known as *synovial sheaths*. They are found in situations where the tendons of muscles run over bones, to which they are bound down by strong, fibrous bands. The bone in these cases is grooved, and the fibrous tissue bridges over the gutter, thus making a very strong, fibro-osseous canal, through which a tendon passes to its destination. The synovial membrane is arranged in the form of a tubular sheath, one portion lining the canal, the other investing the enclosed tendon, as will be seen in Figs. 74 and 75.

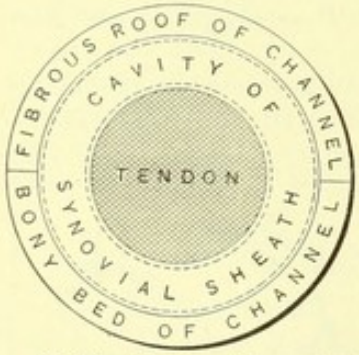

FIG. 74.—Diagram of a vaginal synovial membrane in cross-section. The membrane is shown by the broken lines. A space is left between the tendon and channel-wall for the sake of clearness. (F. H. G.)

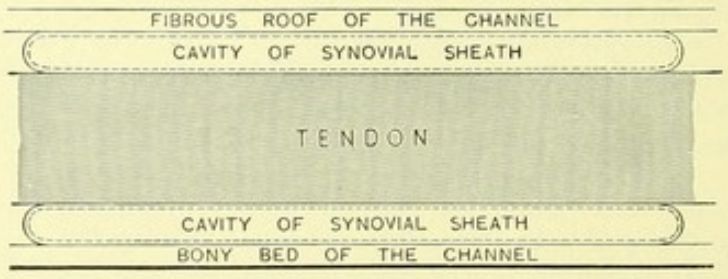

FIG. 75.—Diagram of a vaginal synovial membrane in longitudinal section. Compare with Fig. 74. (F. H. G.)

In the movements of the tendon friction is reduced to its lowest terms by the lubricating agency of the synovia.

3. Bursal Synovial Membranes.

Other names for these structures are *synovial bursæ* ("synovial purses"), *bursæ mucosæ* ("mucous purses"), and *vesicular synovial membranes*. A synovial bursa is a little bag of fibrous tissue, lined with synovial membrane, and placed between parts which move upon each other, as two muscles, two tendons, a muscle or tendon and a bone, the skin and a bone. The sac is connected with surrounding parts by areolar tissue, and the opposite sides of its internal surface are in contact, and kept moist with synovia. Some of these membranes are developed from spaces of areolar tissue by closure of connection with surrounding spaces, and condensation of the contiguous fasciculi of the tissue.

MUCOUS MEMBRANES.

The serous and synovial membranes line closed sacs; the mucous membranes (*membranæ mucosæ*) line passages and cavities which have a direct communication with the outer surface of the body. Indeed, from the physiological point of view, the parts which are covered by them are external, for they are regarded as inversions of the integument—portions of the outer investment tucked in and modified, but never lacking continuity with it.

There are two separate sets of mucous membranes—the gastro-pulmonary and the genito-urinary. Each of these consists of a continuous membrane, which lines two series of organs, and varies in many respects according to the organ of which it forms a part. The *gastro-pulmonary mucous membrane* (Fig. 76) furnishes a free surface for the alimentary and respiratory systems, and gets its name from a principal organ of each—the stomach and the lungs. The *alimentary part* of it begins at the lips and passes through the mouth, the middle and lowest parts of the pharynx, the gullet, stomach, small and large intestines, and anal canal, and then comes to the skin-surface. In its course it sends offsets to the ducts of the salivary

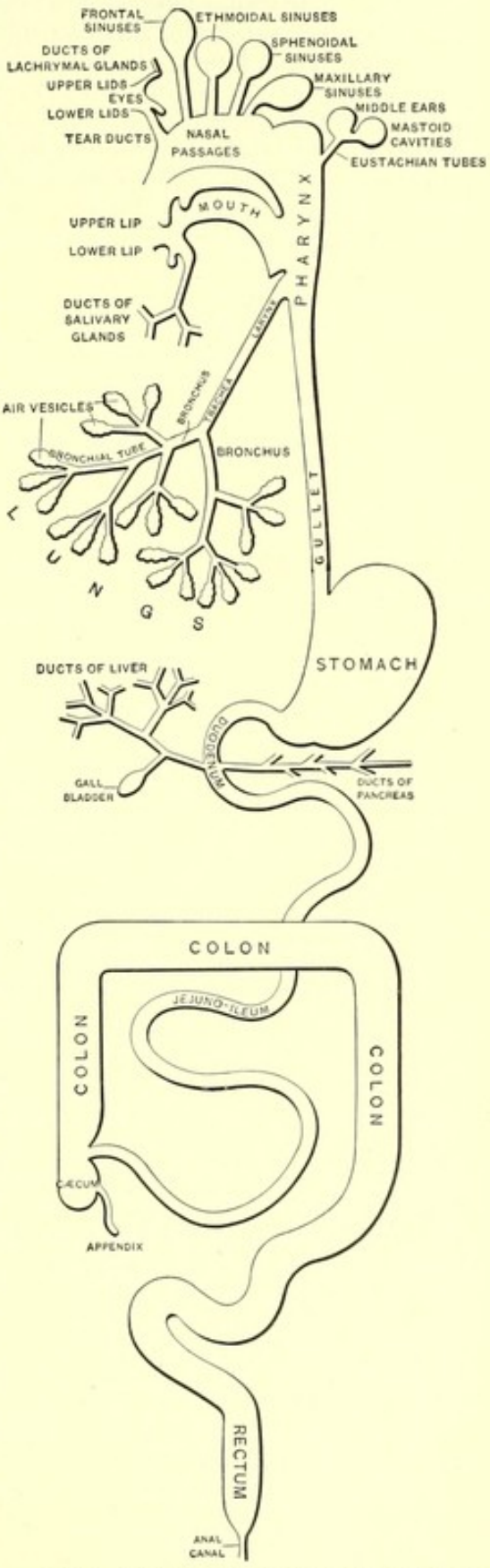

FIG. 76.—Diagram of the gastro-pulmonary mucous membrane, showing the continuity of all its parts. (F. H. G.)

glands, of the pancreas, and of the liver, to the gall-bladder, and to the vermiform appendix. The *respiratory portion* begins in the nostrils, and passes through the entire pharynx, the larynx, trachea, bronchi, and bronchial tubes, ending in the air-vesicles of the lungs. From the nasal cavities it gives prolongations to the inner surfaces of the eyelids and the front of the eyeballs, and to the chambers in the frontal, ethmoid, sphenoid, and upper-jaw bones; and from the pharynx it runs through tubes to the drums of the ears and the cavities of the mastoid portion of the temporal bones. The *genito-urinary mucous membrane* lines the genital and urinary tracts, as its name implies. The portion which forms a part of the male reproductive organs (Fig. 77) leaves its junction with the skin at the distal open-

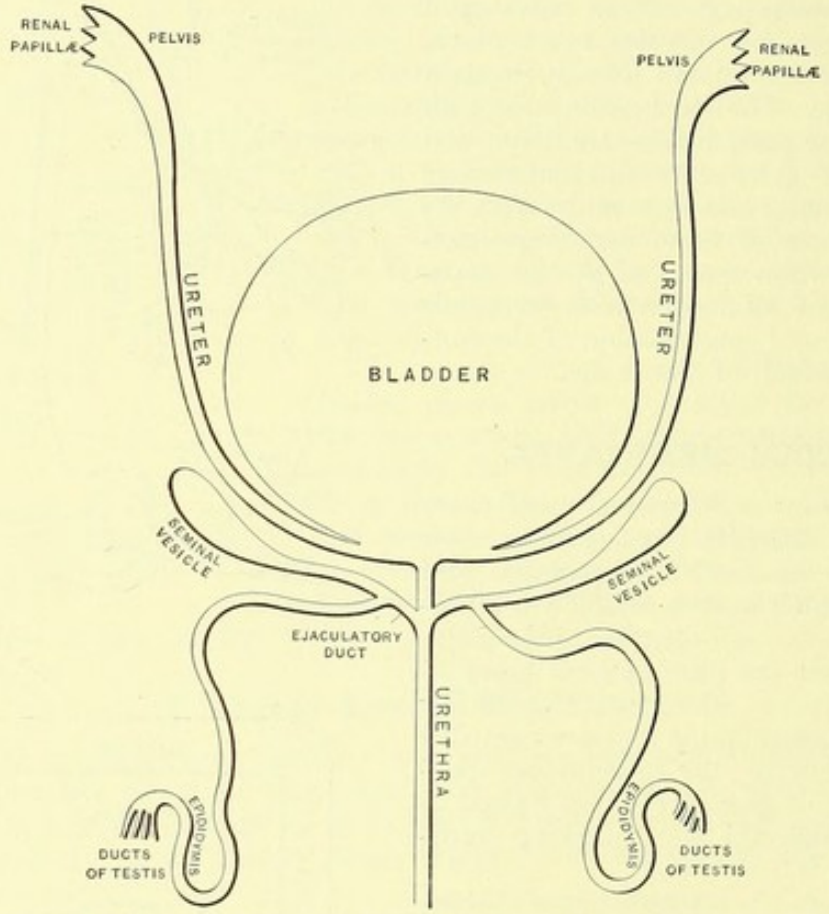

FIG. 77.—Diagram of male genito-urinary mucous membrane, showing continuity of all its parts. (F. H. G.)

ing of the penis, and is traced through the urethra to within an inch of its proximal end, where it enters the male womb and switches off on each side into the ejaculatory duct, from which it sends one prolongation to the seminal vesicle and a second to the vas deferens, and through this last runs to the epididymis and the ducts of the testicle. In the female the genital tract (Fig. 78) begins at the vulva, goes through the vagina, the uterus, and the two Fallopian tubes, at the free extremities of which it is continuous with the serous membrane lining the abdominal cavity. In both sexes the *urinary mucous membrane* lines the urethra, bladder, and ureters, ending at the papillæ of the kidney.

The variations in the character of the mucous membrane in different parts are very great, and changes are extremely abrupt at several points, while in other cases the modifications are effected very gradually. The *corium* (Fig. 79) is generally much thicker than in serous and synovial membranes. It contains a comparatively small proportion of yellow fibrous tissue. When it is largely occupied by follicular glands, the ordinary fibrous tissue is to a considerable extent replaced by adenoid-reticular, in whose meshes are entangled lymphoid cells, thus consti-

tuting a diffuse lymphatic tissue. Usually the corium is bounded toward the free surface by a basement membrane, and deeply by a thin layer of plain muscular tissue, which is named *muscularis mucosæ* ("the muscular [coat] of the mucous

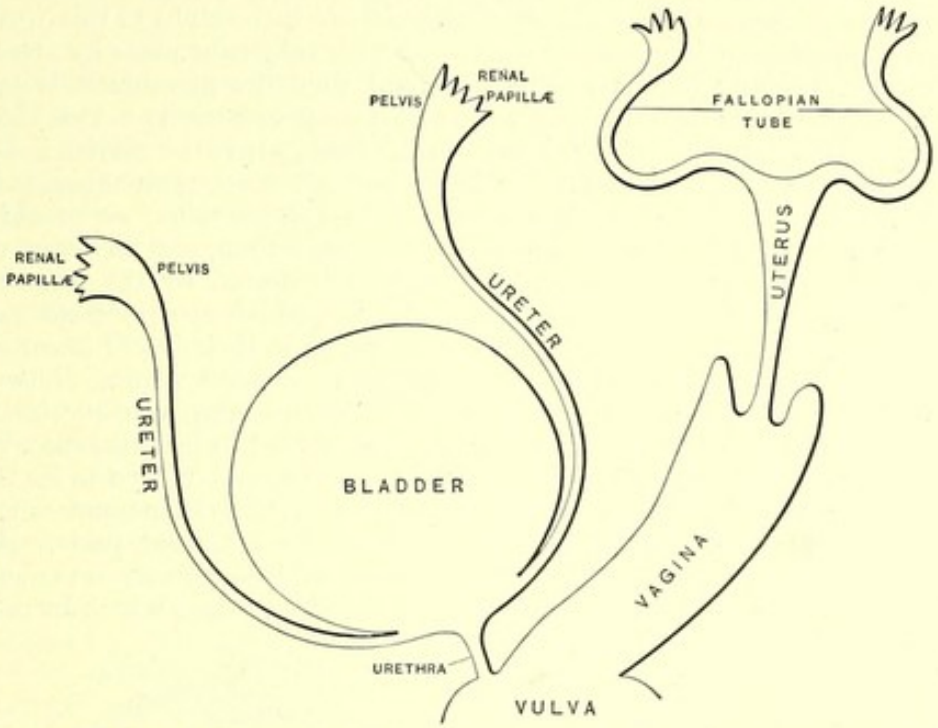

FIG. 78.—Diagram of female genito-urinary mucous membrane, showing continuity of all its parts. (F. H. G.)

[membrane]"). The *epithelium* is the one element in the membrane which is never wanting; but there are only a few cases and very limited areas in which it is the sole representative, the covering of the cornea being the most conspicuous.

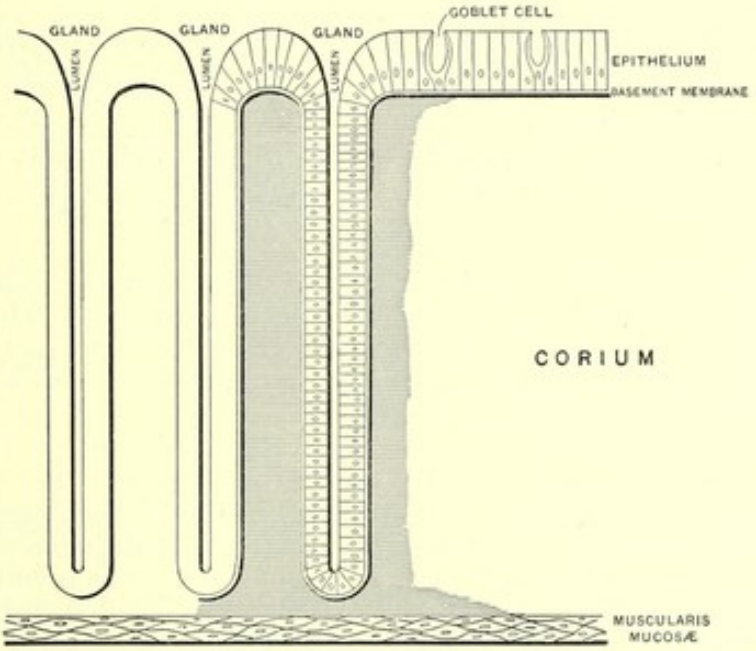

FIG. 79.—Diagram of mucous membrane in vertical section. (F. H. G.)

The epithelium may be single or stratified, of any possible shape, and with or without cilia. The membrane derives its name from the glairy fluid, *mucus*, which always covers it. This secretion is protective, and is abundant in propor-

tion to the amount of irritation to which the membrane is subjected. Where the epithelial coat is columnar and single, the mucus is furnished very largely by the goblet-cells of the epithelium ; but, as these chalices are a modification of columnar cells, they are not found where the epithelium is flat ; and in such cases all of the mucus comes from distinct glands, which devote themselves to this work.

Mucous membrane is generally connected with subjacent parts by areolar tissue ; but exceptionally this is not present, and then the membrane is attached directly. This occurs only in cases where the passage or cavity which the membrane lines is not subject to distention, as in the nose, where the corium is fastened to the bone. In general, the areolar layer beneath mucous membrane is very abundant, and the usefulness of this arrangement appears when we consider that the corium has but little elastic tissue in its composition, and in many cases is pervaded by glandular structures, which would be injured by the stretching of the membrane. As a rule, the cavities and tubes which are lined with mucous membrane are liable to great changes of size, owing to their intermittent occupation by solids and fluids to such an extent as to distend them. Between the periods of distention are times of collapse. If the membrane were elastic, like serous membrane, and had no delicate glands embedded in its substance, it could be stretched within a large range without harm, and would return to its state of relaxation on removal of the distorting force ; and in such circumstances it would need but a moderate areolar layer between it and the subjacent parts. As it is, the membrane when relaxed becomes more or less folded—thrown into shallow or deep wrinkles—and presents a series of ridges, called *rugæ*, which in tubes are arranged in line with the longitudinal axis of the organ (Fig. 80). When a

Fig. 80.—Diagram showing the folding of the mucous membrane in a collapsed tube. (F. H. G.)

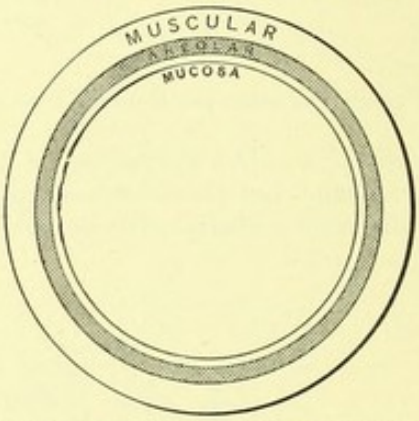

Fig. 81.—Diagram showing the effacement of the folds of mucous membrane and the compression of the areolar layer when the tube is distended. Compare with Fig. 80. (F. H. G.)

distending force is applied, as in the passage of a bolus of food through the gullet, or after a large dinner has been deposited in the stomach, these folds are effaced, the membrane becomes smoothed out, and presents an even surface (Fig. 81). This extensive change is rendered possible by the abundance of the submucous areolar coat, which is strong and elastic.

Mucous membrane is very vascular, the vessels for its supply running in the submucous areolar tissue, and sending minute branches into the corium above. Its nerve-supply varies greatly in different parts—some being extremely sensitive, others dull of feeling. As would be inferred from the amount of lymphoid tissue in the corium, its lymphatics are very abundant. The peculiarities of the mucous membrane of each part where it exists will be detailed in the description of the organs respectively concerned.

CUTANEOUS MEMBRANE.

By this term is indicated the membrane which furnishes the outer covering of the body, and is ordinarily called *skin*. It is a complex structure, and has

a variety of functions, among which is the distinguishing of impressions of touch. It will, therefore, be more appropriately considered with the organs of the senses.

GLANDS.

A gland is an organ, which abstracts from the blood certain materials and makes of them a new substance, which is then discharged into a cavity or upon a surface. In other words, a gland is a secreting organ, its process and its product both bearing the name of secretion. Simply constructed membranes, such as the serous, doubtless perform some secretory work; but it is always of a low order, and the resulting product is only slightly different from the materials of which it is composed. It would not be expected that the cells upon a plane surface, whose principal function is protective, and which are constantly subjected to hard usage on account of their exposed situation, would be able to do secretory work of any but the most primitive kind. It would be as reasonable to demand a high grade of work from an artisan stationed in the middle of a thoroughfare, where he would be jostled by every passer. Such a one needs freedom from interference, and withdraws from the bustle of the throng into a secluded retreat, where he has every facility for doing the most delicate and elaborate tasks. Nature acts in precisely this way in constructing an organ which is to make a secretion: a depression appears in a membrane—an inversion of the surface-structure takes place—and the cells, which are thus removed from the worries and dangers of the open and exposed locality, experience various changes. They become plumper and softer, their nuclei enlarge, and they develop a capacity for secretion, which their less favorably environed neighbors never emulate. The materials which they abstract from the blood are so wrought over that their original character is not suggested by the nature of the secretion of which they are the ingredients. The organ which accomplishes this thing is a true gland; and, as a rule, the more completely it is guarded from annoyances and interruptions, the more elaborate and valuable is its work.

The essential thing in a gland, as has already been intimated, is the *epithelial cell*. The forms of secreting cells are as varied as possible, but the tendency is to keep near the spherical type. Indeed, spheroidal epithelium is hardly to be looked for outside of glands.

The simplest form of a gland is the follicular, a mere dimple in the surface (Fig. 82, *A*). Enlargement of the embedded tube, without dilatation of its open-

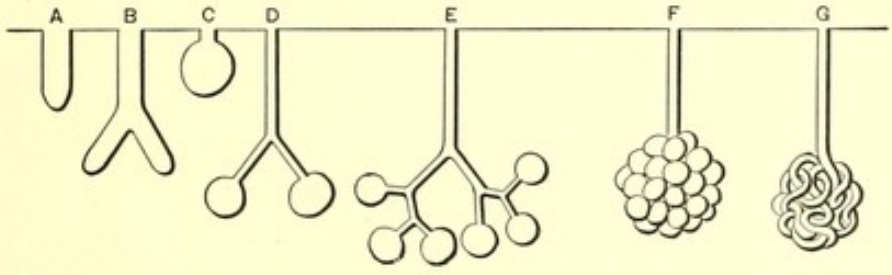

FIG. 82.—Diagram showing development of glands: *A*, a mere dimple in the surface; *B*, enlargement by division; *C*, enlargement by dilatation; *D*, a combination of *B* and *C*; *E*, a racemose gland; *F*, development of method of *E*; *G*, a single tube intricately coiled. (F. H. G.)

ing, makes a saccular or flask-shaped gland (Fig. 82, *C*). Branching of the lower parts changes a simple gland into a compound (Fig. 82, *B*), and what was previously the upper part of the secreting organ now becomes the duct of discharge, its epithelium losing its true glandular character, and becoming more like that upon the general surface. By repetition of these processes the gland becomes not only larger, but more complicated — fibrous or reticular tissue occupies the interstices, and affords mechanical support; muscular

tissue forms around the ducts; and in many ways elaboration goes on, until in some glands not a suggestion of the original type remains to casual observation. And yet, the parentage of the most intricately constructed gland can be traced back to the little inversion of the surface, which has been shown to be a simple follicular gland, and the structural principle is identical in the two.

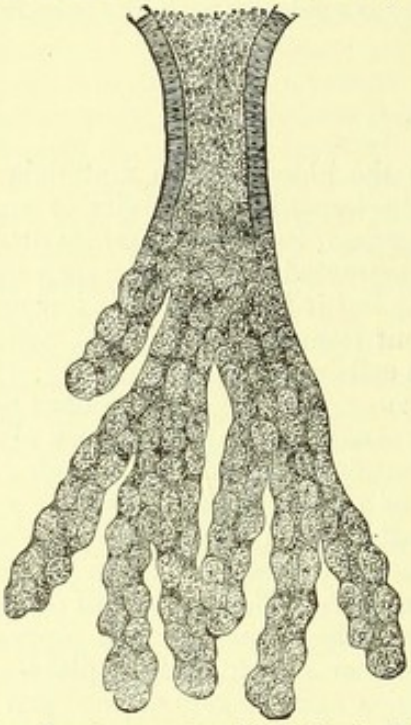

FIG. 83.—Compound tubular gland. The upper part is the duct; the lower is the secreting portion. (Kölliker.)

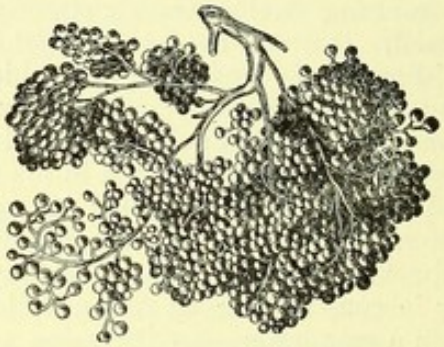

FIG. 84.—Compound racemose gland. The resemblance to a bunch of fruit is very marked. (Milne-Edwards.)

EMBRYOLOGY.

By J. P. McMURRICH.

AT one period of its existence every vertebrate animal is represented by a single cell, from which the adult individual develops by its repeated division and by the functional and histological differentiation of the aggregate of cells so formed. The cell, however, which has the power of undergoing this development is one which results from the complete fusion of two distinct elements, likewise cells, one of which is termed the *ovum*, and represents the female element of reproduction, the other being the *spermatozoön*, the male element.

Spermatogenesis.

The male cell is formed in the testis, and, if a section of a seminiferous tubule be examined, an arrangement will be seen which is represented diagramatically in Fig. 85. The cells lining each tubule are arranged in several layers, the outermost

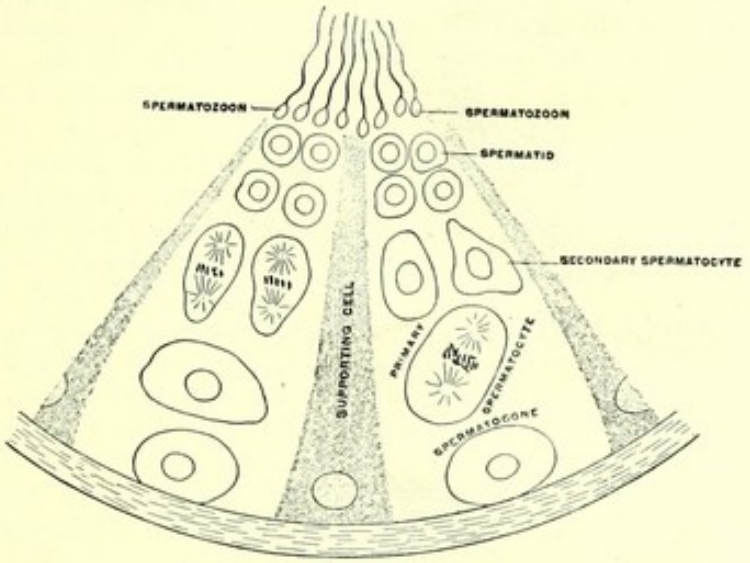

FIG. 85.—Development of spermatozoa.

layer being formed principally by a number of cells known as *spermatogones*. Each of these from time to time divides, one of the cells so produced persisting as a spermatogone, while the other becomes what is termed a *primary spermatocyte*. This cell later divides into two cells, each of which is a *secondary spermatocyte*, and these, undergoing a further division, give rise to cells termed *spermatids*. Thus, from each primary spermatocyte, by two divisions, four spermatids are developed, and each of these last becomes a *spermatozoön*. In addition to these various cells, others are to be found resting upon the basement membrane of the tubule, and extending through the various layers of the developing cells, the spermatozoa being grouped upon their inner ends. These are the *Sertoli cells*, or *supporting cells*, and they do not take any part in the formation of the spermato-

zoa, but, as their name indicates, serve for the support of the germ-cells, and probably assist in their nutrition.

The spermatozoa are the result of modification of the spermatids. Each of these latter is at first a round cell with a rather large nucleus, near which lies the *centrosome*. Gradually this cell elongates, the nucleus takes up a position near one extremity, an axial filament develops in the cell-body, the centrosome comes to lie behind the nucleus, and, as the final result, there is produced the mature spermatozoön, a body measuring in length about $\frac{1}{500}$ inch, and consisting of (*a*) a pyriform head composed of the nucleus of the original spermatid, surrounded by an exceedingly thin layer of protoplasm; (*b*) of a "middle piece," immediately behind the head, and representing probably the centrosome of the spermatid; (*c*) of the tail, derived from the cell-body of the spermatid, and composed of an axial filament surrounded by a sheath of protoplasm, somewhat variable in form, though usually simply cylindrical; and (*d*) of a terminal filament, which is the end portion of the axial filament.

Oögenesis.

The ovum, as it exists in the ovary, corresponds to the primary spermatocyte of the male, and must undergo certain changes ere it is ready for union with the spermatozoön.[1] When ready to burst from the Graafian follicle, the human *ovum* (Fig. 86) is a spherical cell about $\frac{1}{150}$ inch in diameter, enclosed within a membrane, the *zona radiata*, and containing a large *nucleus*, situated somewhat excentrically, while centrally there are a number of granules of *food-yolk*, a substance much more abundant in the ova of other mammals, such as the cat, and which forms the greater mass of the ovum of birds and reptiles. The maturation phenomena (Fig. 87) by a series of divisions convert the ovum into a structure homologous with a spermatid. At the first division (*A*, *B*, *C*) the *oöcyte*, as the ovum at this stage may be termed, divides into two cells, one of which is, however, very small and is termed a *polar globule*, while the other is practically as large as the original oöcyte. By a second division (*D*, *E*) a second polar globule is formed, and the nucleus then passes into the resting stage and moves toward the centre of the ovum (*F*). There are thus two maturation divisions, just as there are two divisions of the spermatocytes in spermatogenesis; and the polar globules are to be regarded as abortive ova, which take no further part in development, but degenerate.

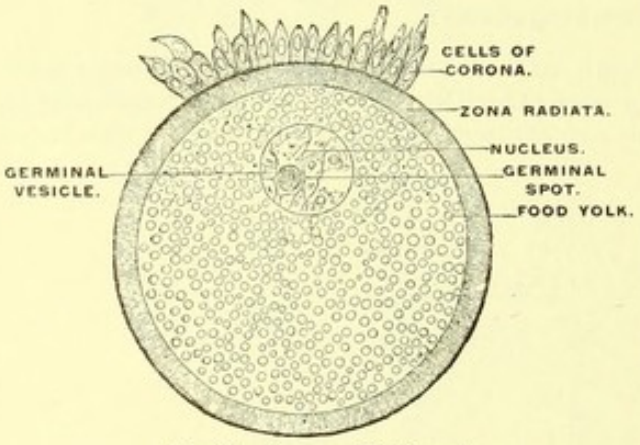

FIG. 86.—Ovum. (Waldeyer.)

After the extrusion of the polar globules the ovum is ready for union with the spermatozoön—a process which occurs probably, as a rule, in the upper part of the Fallopian tube. A spermatozoön penetrating the zona radiata is received into the substance of the ovum, and gradually passes centrally toward the ovum-nucleus. The tail of the spermatozoön is sooner or later absorbed; but the head—which, it will be remembered, represents the nucleus of the spermatid—and the middle piece pass on to come into close apposition, and finally to fuse, with the ovum-nucleus, the compound nucleus so produced soon becoming converted into a division spindle which inaugurates the segmentation of the ovum.

[1] Neither these changes nor the phenomena of fertilization have yet been observed in the human ovum. They have been observed, however, repeatedly in the ova of many of the lower animals, both vertebrate and invertebrate, and their general similarity in all cases makes the probability that they occur also in the human ovum almost a certainty.

It would seem from these phenomena that the essential feature of fertilization is the union of the nuclei of two cells, the small amount of protoplasm present in the head of the spermatozoön seeming to play little part in the process. Since both paternal and maternal characteristics may be inherited, it has been supposed

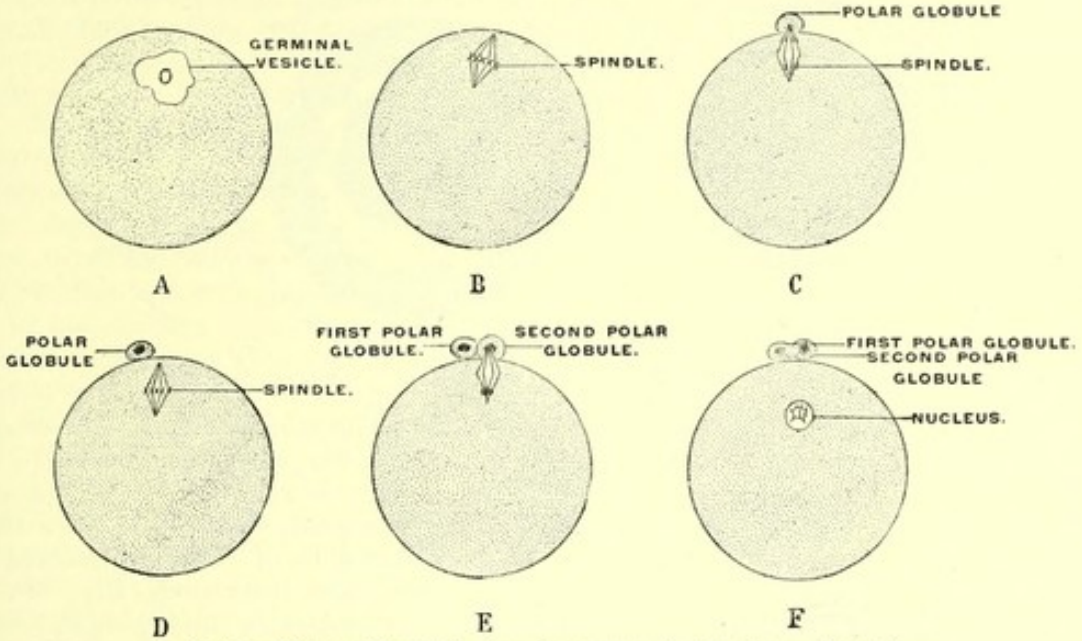

FIG. 87.—Diagram illustrating the phenomena of maturation. (Testut.)

that the nuclei must be the material bearers of heredity; and, since the characteristic substance of a nucleus is the chromatin, this has been regarded by many authors as the actual substance concerned in transmitting inherited peculiarities from the parent to the offspring.

The Early Stages of Development.

By segmentation is meant the conversion of the unicellular ovum into a mass of cells, a process which results from a series of divisions. The ovum first divides (Fig. 88) into two cells (*a*), each of these again dividing, so that four cells are

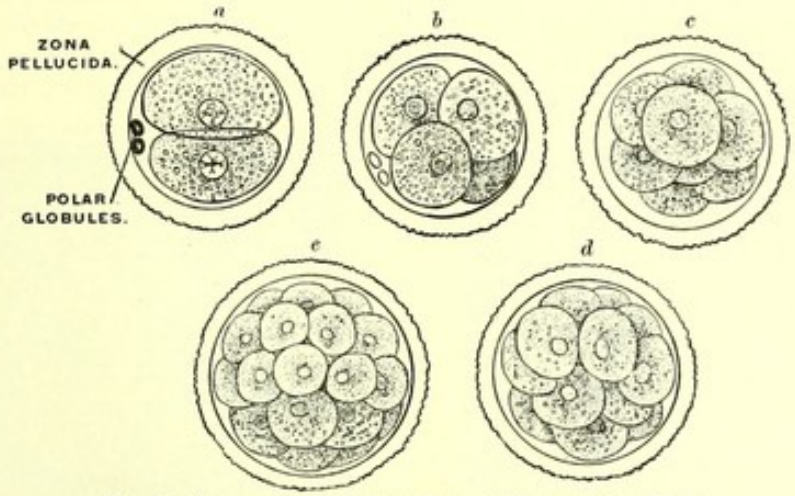

FIG. 88.—Segmentation of the ovum. (After van Beneden.)

formed (*b*), and, the divisions continuing (*c*, *d*), a solid mass of cells, termed a *morula*, is produced (*e*). A section through such a mass (Fig. 89, *A*) will show that it is composed of an outer layer of somewhat flattened cells enclosing a

number of distinctly granular cells. At first no cavity exists in the centre of the morula, but soon the outer cells become in large part forced away from the inner ones by the imbibition of a fluid supplied by the walls of the uterus, and what is

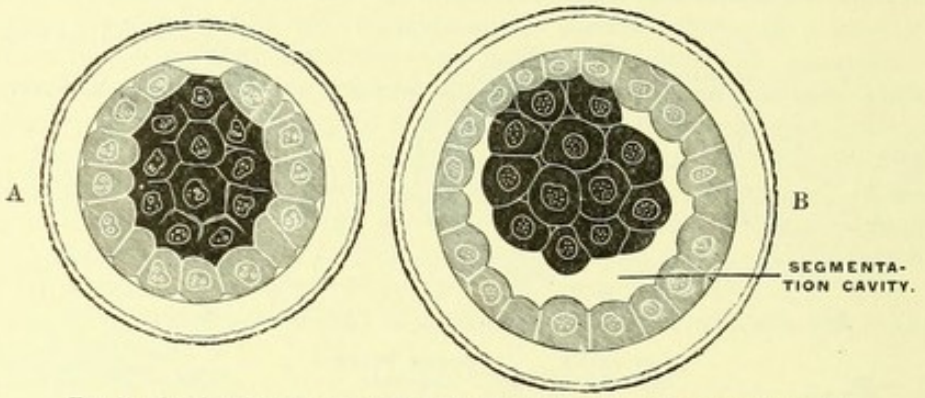

FIG. 89.—Sectional views of ovum, after segmentation. (After van Beneden.)

termed a *segmentation cavity* is formed (Fig. 89, *B*). The morula is thus converted into a hollow vesicle, termed the *blastodermic vesicle*, whose wall is formed by a single layer of cells, except at one region, where what were the inner cells of the morula form a lenticular thickening (Fig. 90).

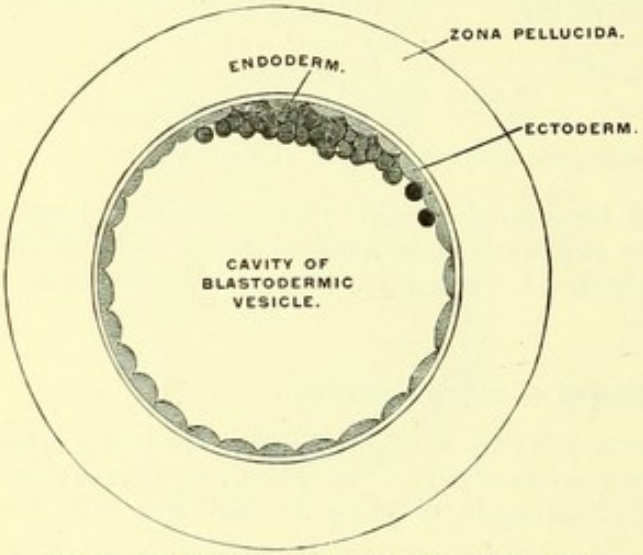

FIG. 90.—Blastodermic vesicle. (After van Beneden.)

Later, this thickening flattens out, its cells becoming arranged in two layers, the innermost of which is composed of thin flattened cells, and forms what is termed the *endoderm* layer, while the outer one, consisting of cylindrical cells, is known as the *ectoderm*. External to these two layers, again, is a third one of flattened cells, termed the *covering cells*, which is continuous with the wall of the vesicle, but which eventually disappears so as to expose the ectoderm cells upon the surface. Still later, the endoderm layer, increasing in size, extends outward in all directions, and the vesicle presents a differentiation into three regions. One

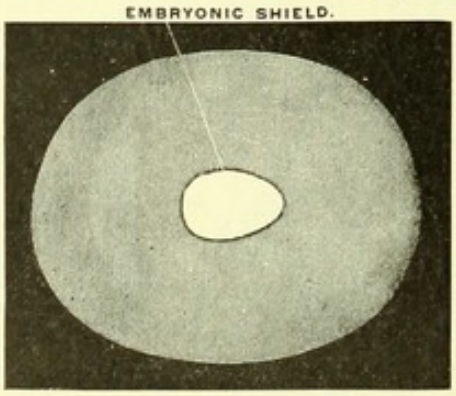

FIG. 91.—Blastodermic vesicle, viewed from above. (Kölliker.)

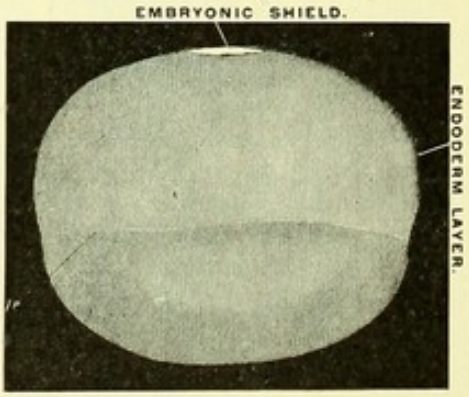

FIG. 92.—Blastodermic vesicle, viewed from the side. (Kölliker.)

portion of its surface is occupied by a clear area composed of ectoderm and endoderm, and termed the *embryonic shield* (Fig. 91); extending from this to about the

equator of the vesicle is the region over which the endoderm layer has extended; and, lastly, the lower half of the vesicle is formed only of a single layer of cells, as in earlier stages. As development proceeds the embryonic shield increases in size and assumes an oval shape, and near one end of it there appears a dark longitudinal band which is termed the *primitive streak* (Fig. 92, *B*), and which is formed by the fusion of the ectoderm and endoderm. From this line of fusion cells grow out on either side into the space between the ectoderm and endoderm, and constitute a middle layer, the *mesoderm*.

The three layers of cells thus produced constitute what are termed the *germ-layers*, and it is by the differentiation of the cells composing them that the various tissues and organs of the embryo are developed, each layer giving rise to certain definite structures. There has not yet appeared, however, any distinct indication of the embryo proper. This makes its appearance soon after the formation of the primitive streak in the form of a groove (Fig. 93), extending from what may be considered the front end of the streak almost to the front edge of the embryonic shield; the groove is bounded by two ridges, which unite in front, but diverge somewhat behind, so as to embrace the front end of the primitive streak. The groove is termed the *medullary groove*, and the ridges are the *medullary ridges*, the whole forming the anlage or rudiment of the central nervous system. Immediately beneath the medullary groove another groove likewise appears in the endoderm, the convexity of this groove being directed toward the floor of the medullary groove; its two lips later unite, the cavity of the canal so formed disappears, and a solid rod of peculiar texture, known as the *notochord*, is produced, lying immediately beneath the central nervous system (Fig. 94).

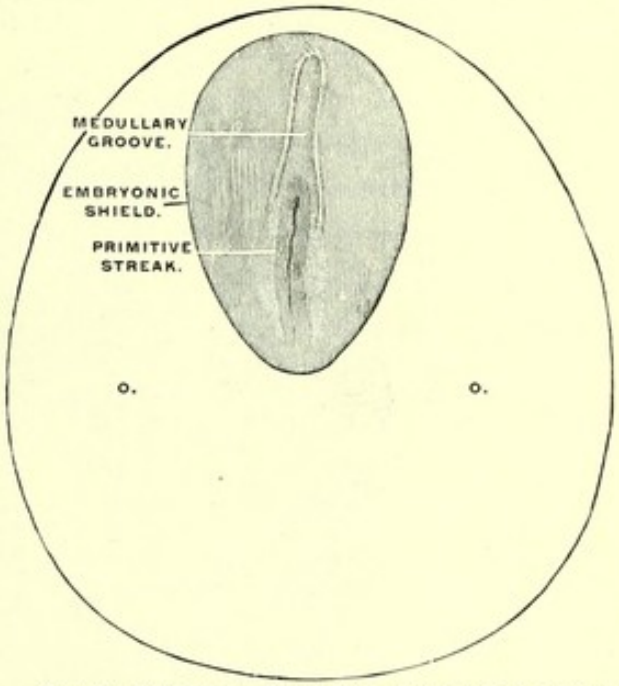

FIG. 93.—Formation of primitive streak and medullary groove. (Kölliker.)

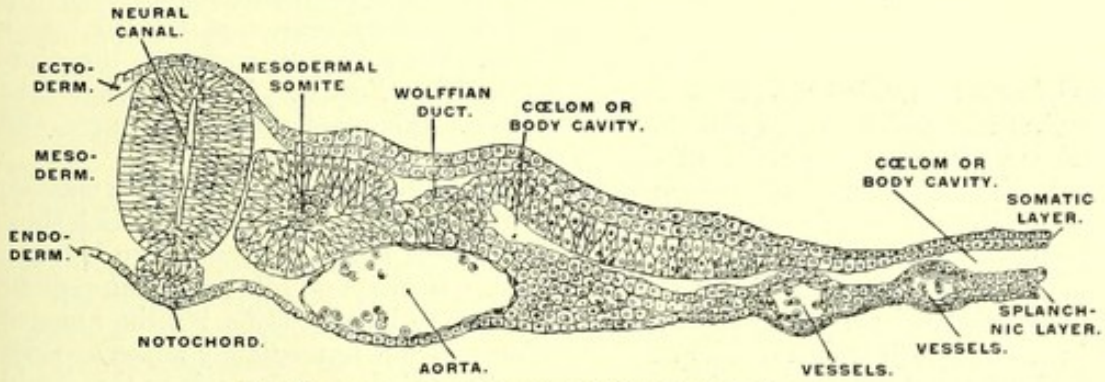

FIG. 94.—Transverse section through dorsal region of embryo.

It has already been stated that the mesoderm forms in the region of the primitive streak; it also arises from those portions of the endoderm which are immediately adjacent to the notochordal groove on either side, and there is thus produced on each side of the middle line of the embryonic shield a sheet of mesoderm, which, however, early undergoes differentiation. In the first place,

the sheet does not long remain single, but a split occurs in it, so that it becomes separated into two layers (Fig. 94), an outer one adjacent to the ectoderm and termed the *parietal* or *somatic layer*, and an inner one adjacent to the endoderm and known as the *visceral* or *splanchnic layer*. The cavity which separates these two layers is known as the *cœlom*, or *body-cavity*, and at first is continuous throughout the entire extent of the mesoderm. A second differentiation, however, early supervenes, consisting of the separation, on each side, of a small portion of the cœlom from the rest, the somatic and splanchnic layers of mesoderm coming into contact and fusing a short distance external to the median line, while, at about the same time, a series of transverse constrictions divides this inner, narrower portion of the mesoderm into a series of oblong boxes which are termed *protovertebræ*, or, better, *mesodermal somites* (Fig. 95). The formation of these somites begins in

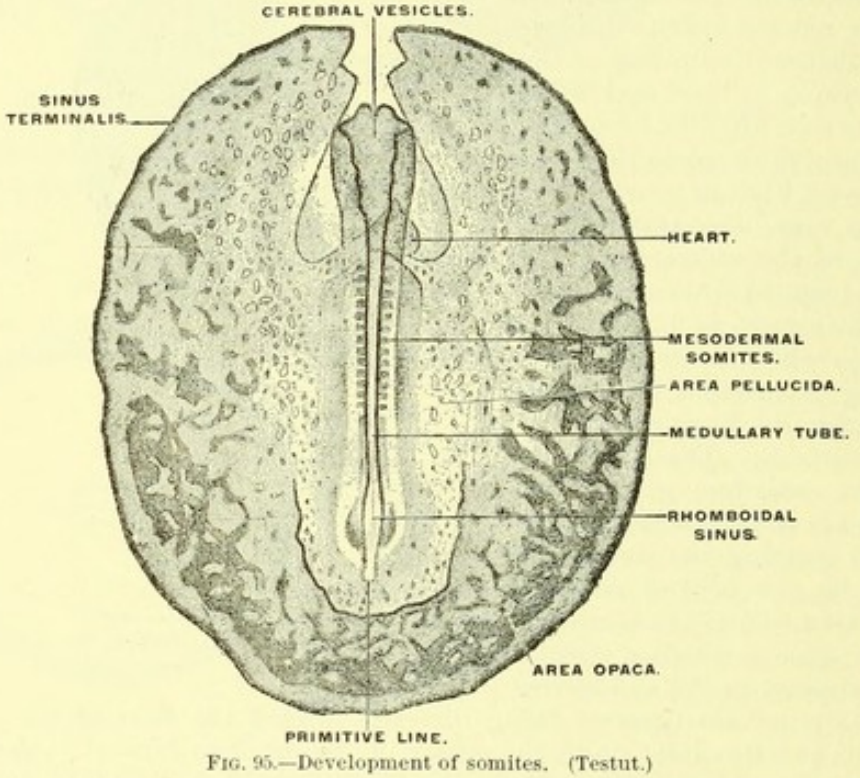

FIG. 95.—Development of somites. (Testut.)

what will be the neck region of the embryo, and thence extends forward and backward until the entire median portion of the mesoderm, not only in what will be the trunk of the future embryo, but also in the head region, is divided into a series of somites. Each of these in the trunk region is connected with the more peripheral undivided mesoderm by an *intermediate cell-mass*, which represents the longitudinal fusion of the somatic (parietal) and splanchnic (visceral) layers, and each contains a small portion of the originally continuous cœlom.

While these changes have been going on, the endoderm continues its extension, and finally its edges fuse at the lower pole of the blastodermic vesicle, which thus, throughout its entire extent outside the embryonic shield, becomes two-layered. The shield itself has also increased considerably in size, and allows certain regions to be distinguished. Along its median line are to be seen (Fig. 95) the anlagen of the embryo just described, and this region and the immediately adjacent parts may be termed the *embryonic area*; external to this is a region where the shield presents a somewhat transparent appearance, and this is termed the *area pellucida*; while the more peripheral portions are opaque and receive the name of the *area opaca*. In this last region extensive changes have been taking place in the mesoderm: some of its cells arrange themselves so as to form a network of cords, into the substance of which fluid penetrates from the surrounding tissues, the cords being thus transformed into canals in which lie numerous cells. These

canals are blood-vessels; the fluid which they contain becomes the plasma of the blood; the outermost cells of the original cords flatten and produce a thin wall for the vessels, while the more central cells group themselves into masses, which project here and there into the interior of the vessels from their walls, and are termed the *blood-islands*. An abundant network of blood-vessels traversing the area opaca is thus formed, the intervals of the network being occupied by masses of unspecialized cells, which are termed *substance-islands*, and later give rise to embryonic connective tissue. Toward the periphery of the area opaca a circular blood-vessel, known as the *sinus terminalis*, is formed, marking the extreme periphery of the vascular region; and, though the area opaca may extend beyond this, the blood-vessels do not, and it is thus possible to divide the area opaca into a more central *area vasculosa* and a more peripheral area opaca proper. The formation of blood-vessels begins a little later in the area pellucida, and thence they grow in toward the body of the embryo.

The Umbilical Cord and the Placenta.

The embryo at this stage is represented by a thickening occupying the median portion of the embryonic shield. The anterior end of the thickening now begins to sink down into the interior of the vesicle, a process which is continued until finally only the posterior extremity of the embryo remains at the surface (Fig. 96, *A*). The embryo thus comes to occupy the floor of a depression, which, relatively deep in front, becomes shallower posteriorly, and is surrounded by a well-marked lip or fold, consisting of ectoderm and somatic mesoderm, and known as the *amniotic fold*. By this time the mesodermal layers, as well as the endoderm, in their extension over the inner surface of the blastodermic vesicle, have reached its lower pole, where they fuse together, and, the cœlomic cavities extending *pari passu* with the mesoderm, the extra-embryonic portion of the vesicle becomes throughout its entire extent double-walled, the outer wall being composed of the original wall of the vesicle (which may be regarded as ectoderm) *plus* the somatic layer of the mesoderm; while the inner wall is composed of splanchnic mesoderm *plus* endoderm. These two walls are separated by the cœlomic cavity, which becomes relatively voluminous, the inner wall, enclosing a cavity known as the *umbilical vesicle* (Fig. 96) or *yolk-sac*, being separated by a considerable interspace from the outer wall, which is now termed the *chorion*.

While these changes have been taking place the embryo has begun to constrict itself from the embryonic shield by a tucking in, as it were, of the wall of the embryonic vesicle in front and at the sides under the body of the embryo. The anterior portion of the embryo thus becomes cylindrical and completely shut off from the yolk-sac, which, as the result of the constriction, becomes converted into a pyriform vesicle connected with the intestine of the embryo by a narrow stalk. The constriction, continuing to develop from before backward, finally reaches the posterior end of the body, where it wraps itself around the connection of the embryo with the surface of the embryonic vesicle, converting this connection into a stalk known as the *belly-stalk* or *Bauchstiel*. In its passage backward the constriction carries with it the yolk-sac, which thus becomes enclosed within the belly-stalk, as does also a small evagination of the ventral wall of the intestine of the embryo, situated behind the attachment of the stalk of the yolk-sac, and known as the *allantois*, a rudiment of a structure of considerable size in some of the lower mammalia and in the birds and reptiles, where it functions as an embryonic respiratory organ. In the subsequent development the belly-stalk elongates greatly, its cavity, which is continuous with the cœlom of the embryo, becoming filled by a peculiar mesodermal, jelly-like connective tissue, the *Whartonian jelly*, in which are imbedded the rudimentary allantois, the umbilical vesicle, and certain blood-vessels, the whole forming what is termed the *umbilical cord*, the outer end of which comes into intimate relation with the walls of the uterus, forming the *placenta* (Fig. 96, *B*).

It has been seen that the depression of the embryo into the embryonic vesicle gives rise to the formation of an amniotic fold. As the constriction of the embryo from the embryonic shield progresses, this fold increases in size, and eventually its lips unite at the outer end of the belly-stalk, the depression in which the embryo lies being thus converted into a closed cavity, the *amniotic*

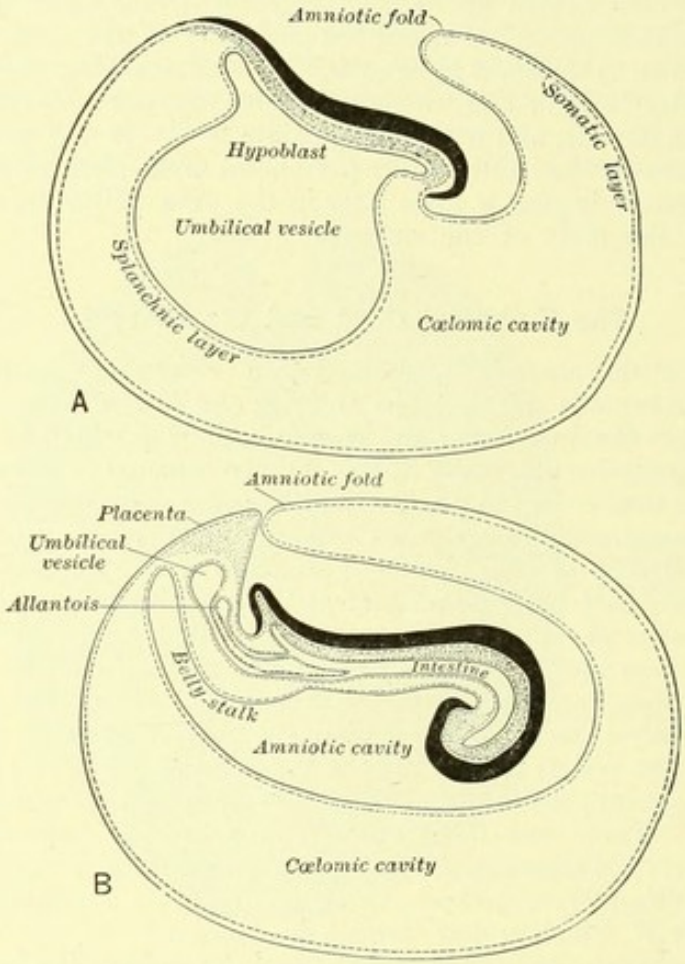

FIG. 96.—Diagram showing the formation of the belly-stalk. The heavy dotted line represents the embryonic portion of the epiblast, the dotted portions and broken lines the mesoblast, and the inner continuous line the hypoblast.

cavity. The formation of this cavity takes place very early in the development, the earliest known embryo having it already completely closed; and the same remark applies to the formation of branched outgrowths, which develop from the surface of the chorion and are known as the *chorionic villi*. These appear at first over a broad equatorial zone of the embryonic vesicle, but later are developed also at either pole, that portion of the vesicle to which the belly-stalk is attached also developing them. In this last region the villi continue to develop probably throughout gestation, taking part in the formation of the placenta, while over the rest of the vesicle they atrophy during the second month of development; and it is thus customary to speak of the placental chorion as the *chorion frondosum*, while the remainder is termed the *chorion lævе*. Concomitantly with the formation of these embryonic structures important changes take place in the walls of the uterus (Fig. 97). In the first place, the mucous membrane lining it becomes thickened, forming what is termed the *decidua vera*, that portion of it which is in contact with the chorion frondosum of the embryo becoming especially thick and highly vascular, and forming the *decidua serotina;* and, secondly, from the margin of the serotina a fold arises, which grows up around the embryo, and finally encloses it, forming what is termed the *decidua reflexa*. Into the villi of

the chorion frondosum blood-vessels pass from the embryo along the umbilical cord, and the vessels of the decidua serotina, developing into large sinuses, have projecting into them the villi, the blood of the embryo being thus brought into such intimate relation with that of the parent that an interchange by osmosis through the thin walls separating the two fluids readily takes place, and the nutrition, as well as the respiration and excretion, of the embryo is thus provided for. The entire region in which the interchange takes place is termed the *placenta*, which, as has been seen, is composed of a fœtal and a maternal portion intimately related. At birth the placenta and the other deciduæ separate from the uterus and are cast off, forming what is known as the *after-birth*.

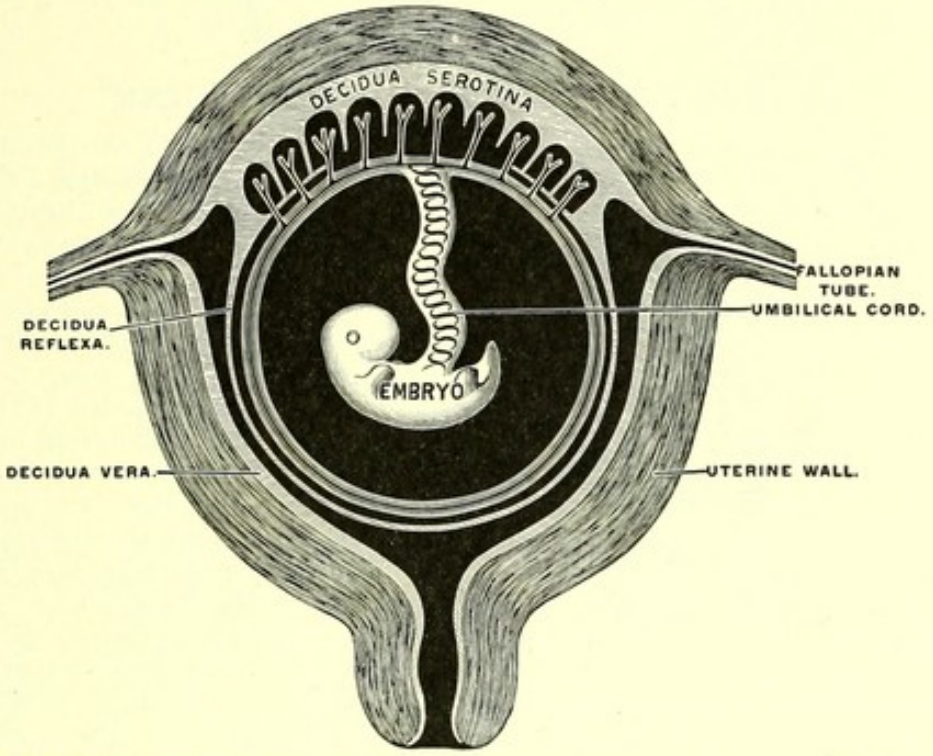

FIG. 97.—Diagram of gravid uterus, showing formation of deciduæ and placenta. (Testut.)

To return now to the embryo proper. At its first separation from the embryonic shield it is practically straight, but a bend soon makes itself apparent in what will later be the region of the mid-brain, the fore-brain being bent ventrally until it is almost at a right angle to the rest of the body; and, at about the same time, a linear depression directed dorso-ventrally appears on each side of the neck region, and gradually deepens until it almost unites with the cavity of the digestive tract. This depression is known as a *branchial cleft*, and is succeeded by three others which develop successively from before backward (Fig. 98). When the second cleft is developed a second flexure of the embryo appears, the posterior portion of the body being bent dorsally. This flexure, however, is of short duration, and leaves no permanent trace of its existence; but, when the third branchial cleft forms, a third and more prominent flexure appears, this time a ventral flexure situated in the neck region, and, as the dorsal portion of the body also becomes curved in the same direction, the embryo seems to be coiled upon itself. Soon after the development of this neck-flexure the limbs make their appearance as simple paired, bud-like outgrowths from the sides of the body, and, as development proceeds, they increase in size, and rudiments of the fingers and toes appear. Gradually in later stages

FIG. 98. — Development of the embryo—first month. (His.)

the branchial clefts disappear or are modified into special structures not seen from the exterior, the features are gradually developed, the neck-flexure straightens out, and by about the third month of development the embryo has acquired a distinctly human appearance.

It will now, after this sketch of the formation of the embryo, be convenient to consider the development of the more important organs of the body, and these may be grouped according to the germ-layers from which they are principally formed. For convenience the development of the organs derived from the endoderm will first be considered.

ORGANS DERIVED FROM THE ENDODERM.

At the stage with which the description of the formation of the germ-layers ended the endoderm formed a tube closed at either end, and having connected with it two outgrowths, the umbilical stalk and the allantois. An examination of the surface of the embryo at this stage will show a pentagonal depression opposite the anterior end of the endodermal tube (Fig. 99). This depression is the *oral sinus*, or *stomodæum*, and it is bounded in front by the edge of a median fold of tissue known as the *fronto-nasal process*, while on either side is a >-shaped ridge, the anterior limb of each ridge being termed the *maxillary*, and the posterior the *mandibular process*. The thin partition which forms the floor of the oral sinus soon ruptures, and the endodermal tube is thus placed in communication with the exterior, its endoderm becoming continuous with the ectoderm of the sinus. Soon after the mouth is thus formed the two maxillary ridges, growing toward each other, meet beneath the fronto-nasal process, and, in the connective tissue which they contain, the maxillary bones develop. From each of these bones a horizontal lamella grows inward, and meets with its fellow of the opposite side and with corresponding lamellæ from the palatine bones behind, and the hard palate is thus formed, separating the original mouth-cavity into an upper or nasal and a lower or oral portion, these two cavities communicating behind with the upper or pharyngeal part of the intestinal tube.

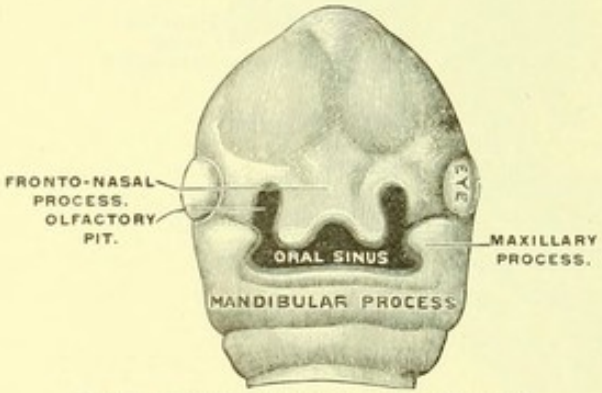

FIG. 99.—Development of the face. (Testut.)

The Teeth and Salivary Glands.

As early as the sixth week of development there appears, dipping into the lower and upper surfaces respectively of the maxillary and mandibular processes, a thickening of the ectoderm, whose cells subsequently arrange themselves into an anterior and posterior layer, the space which appears between these layers becoming the groove between the lip and the gum (Fig. 100). From the posterior layer a horizontal ridge grows inward into the substance of each gum, forming the *dental shelf*, and upon the under or upper surface of each shelf ten thickenings arise, each of which forms a more or less globular mass of cells, the *enamel organ*, connected with the dental shelf only by a narrow neck which ultimately disappears. In the mesoderm beneath each organ a rapid proliferation of cells forms a papilla, over which the enamel organ is folded like a cup, those cells of the papilla which are in contact with the enamel organ becoming, like the outermost cells of the latter, cylindrical, and forming the *odontoblasts*, whose office it is to deposit the dentine between themselves and the enamel organ. This they begin to do at about the end of the fourth month of development, and at about the same

time the *enamel* begins to be formed by the lower ends of the deeper layer of cells of the enamel organ becoming transformed into calcareous prisms. Finally, around the outside of that portion of the papilla which is not covered by the enamel organ

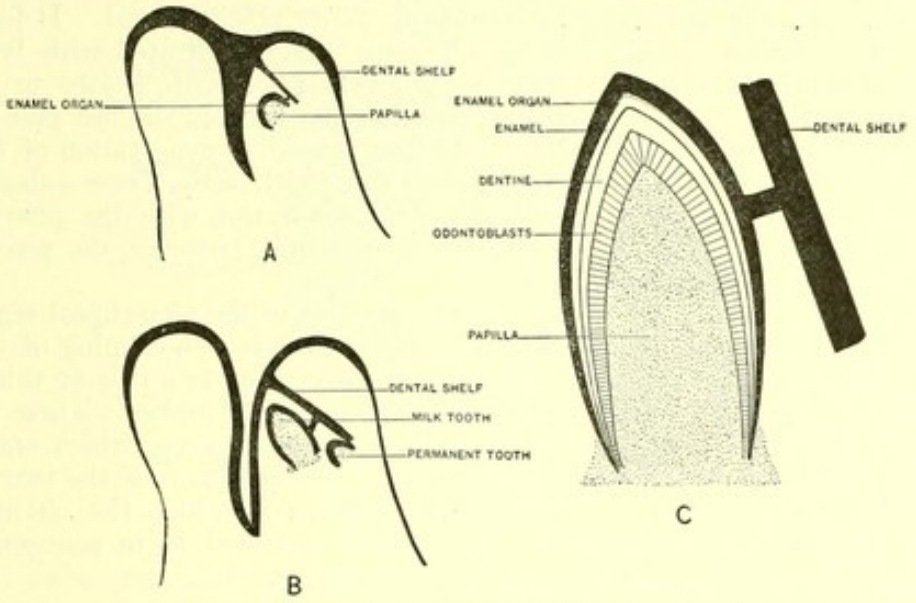

FIG. 100.—Diagram of the development of a tooth.

there appears, about the fifth month, a deposition of bony matter derived from mesodermal cells and constituting the *cement*.

After the separation of the anlagen of the milk teeth from the dental shelf the latter continues to sink deeper into the substance of the jaw, and opposite each milk tooth a *second enamel organ* arises from it, and, mesodermal papillæ also forming as before, the anlagen of the permanent incisors, canines, and premolars are formed. The permanent molars arise in a similar manner from a lateral extension of the dental shelf, and as soon as all the anlagen are formed the tissue of the shelf in the intervals between the various teeth begins to disappear, occasionally, however, persisting in irregular masses until adult life, and producing various abnormalities.

In addition to the teeth certain glandular structures develop from the epithelium of the oral cavity, the most important of which are the *salivary glands*, which arise as simple tubular evaginations, and gradually, by branching, become more and more complicated.

The Branchial Clefts and the Structures derived from Them.

At each side of the pharynx there are, as already stated, four furrows (Fig. 99), represented internally by corresponding depressions, so that along each furrow the pharyngeal epithelium is in contact with the ectoderm of the surface of the body. In the lower vertebrates actual perforation of the thin membrane so formed occurs, forming the gill-slits, but in birds and mammals the perforations do not develop. The first furrow lies immediately behind the mandibular process, and between the members of each successive pair of furrows is a thickened ridge, constituting a branchial arch, each arch being homologous with the maxillo-mandibular processes, which really represent the first arches, the mouth being the first branchial cleft. As development progresses the second arch of each side grows more rapidly than the others, which are in consequence pushed inward toward the median line, and a deep depression is formed at the side of the neck, the *sinus præcervicalis*. From the posterior edge of the second arch a fold grows backward over the mouth of this sinus, and eventually completely covers it in by uniting posteriorly with the side of the body.

From or in connection with the branchial arches or clefts a number of structures develop, some of which may be considered here. From the epithelium of the fourth pair of clefts two thickenings develop, and subsequently fuse together, the single mass so formed growing backward toward the pericardium, separating from the clefts, and enlarging by branching at its posterior end. It forms the *thymus gland*, whose epithelial anlage becomes early infiltrated with lymphatic tissue, and which, subsequent to the second year after birth, begins to undergo degenerative changes. The *thyroid gland* arises partly from the last pair of clefts as paired hollow evaginations, and partly from a median evagination of the floor of the pharynx in the vicinity of the second branchial arch. These anlagen early fuse together, and the gland usually loses all connection with the pharynx, the foramen cæcum at the base of the tongue representing, however, the place of the origin of the median anlage.

The tongue is, embryologically, partly a product of the pharyngeal region, and arises from two anlagen. Its anterior portion arises as a thickening of the floor of the oral cavity, its back portion, however, developing as a pair of thickenings situated in the vicinity of the second and third branchial arches. These thickenings extend forward and outward, forming a V-shaped mass, which encloses in front the posterior end of the anterior anlage. The junction of the two anlagen is indicated in the adult by the V-shaped groove in which the circumvallate papillæ are situated, the foramen cæcum, already referred to in connection with the thyroid gland, lying at the apex of the groove.

The Trachea and Lungs.

Below, the pharynx communicates with the tubular œsophagus, and on the inner surface of the upper part of this there early appears a longitudinal groove, from the lower end of which two pouch-like outgrowths develop. As soon as these begin to form the groove begins to be constricted from below upward from the œsophagus, and becomes the trachea and larynx, the constriction not continuing to complete separation, so that the larynx communicates above with the pharynx. In the connective tissue of the walls of the trachea cartilaginous rings develop, the uppermost of which form the cricoid and arytenoid cartilages of the larynx, the thyroid cartilage being produced by the fusion of the ventral ends of two pairs of cartilaginous bars which are primarily developed in the mesoderm of the fourth and fifth branchial arches. The pouch-like outgrowths are the anlagen of the lungs, and at an early stage become lobed, three lobes appearing in the right lung and two in the left. Secondary and tertiary sacculations later appear, and the complicated structure of the adult lung is acquired. It is to be noted that the epithelium of the lungs, trachea, and larynx is of endodermal origin.

The Intestine and Mesenteries.

From that portion of the primitive intestine which succeeds the œsophagus, the stomach and intestines, together with the liver and pancreas, develop. Of the two structures which in early embryonic life are connected with it, the allantois early separates, its intra-embryonic portion persisting as the urinary bladder and the urachus, while the stalk of the umbilical vesicle retains its connection until after birth, the intra-embryonic portion of it occasionally persisting even into adult life as a more or less pronounced diverticulum of the lower part of the small intestine, known as Meckel's diverticulum.

At first the intestine is a simple straight tube attached to the dorsal wall of the abdominal cavity by a dorsal mesentery, formed by the reflection over it of the peritoneal lining of the abdominal cœlom. Its upper portion is also attached to the anterior wall of the abdomen by a ventral mesentery, whose lower border is falciform in shape, and is attached to the abdominal wall at the umbilicus. This simple arrangement, however, soon disappears, as the intestine,

growing in length more rapidly than the cavity in which it lies, is pushed out into a loop, as is represented in Fig. 101. The elongation continuing, the loop

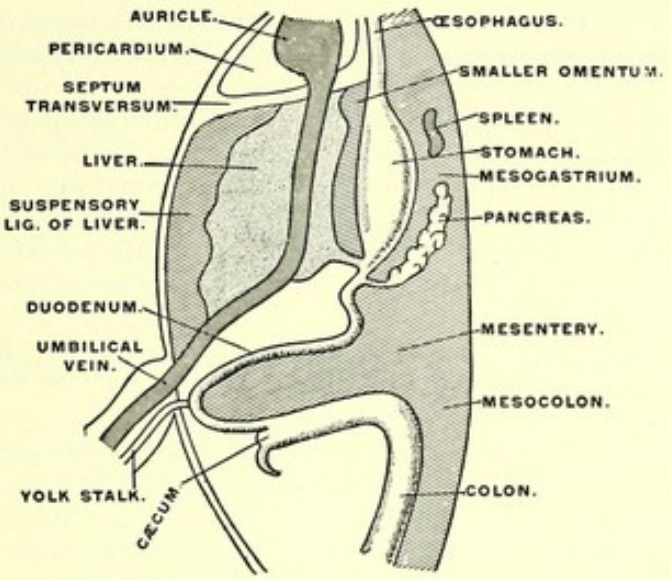

FIG. 101.—Diagram of the human mesentery in its primitive relations. (C. S. Minot.)

bends upon itself, that portion of the intestine which will become the *transverse colon* passing over the portion which is to become the *duodenum*. During the elongation of the intestine the edge of the dorsal mesentery which is attached to it undergoes a corresponding increase in length, while at the line of attachment to the body-wall it increases but slightly, the mesentery of the loop in consequence assuming a fan-like form, and, when the twisting of the loop supervenes, becoming funnel-like.

By this time a differentiation of the intestinal tube has occurred, the portion of it above the loop becoming enlarged to form the *stomach*, while the portion of the loop which passes transversely across the abdominal cavity and the portion of the intestine below this becomes the *large intestine*. The *cæcum* develops as an outgrowth from the large intestine at the point where it is joined by the small intestine, and the *vermiform appendix* is an outgrowth from the cæcum. The

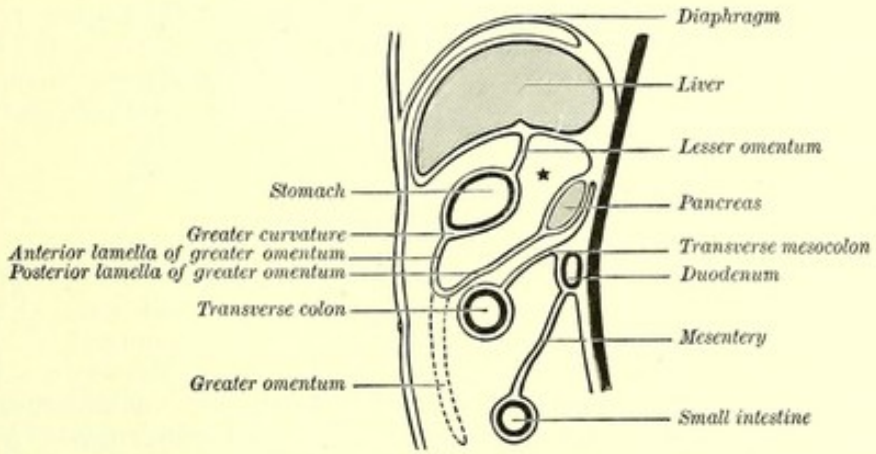

FIG. 102.—Diagram to illustrate the history of the human mesentery—earlier stage. (Hertwig.)

further changes in the intestine consist principally of a continued elongation, especially of the *small intestine*, and of the occurrence of fusion and degeneration of certain portions of the mesentery. Thus, the *mesentery* attached to the transverse colon, primarily radiating from the apex of the mesenterial funnel, later

extends its insertion laterally upon the body-wall, forming a transverse sheet, the mesocolon. This passing over the duodenum binds it fast to the posterior wall of the abdomen, and as a result the duodenal mesentery degenerates. The ascending and descending colon likewise come to lie in contact with the abdominal wall, and their mesentery degenerates to a certain extent, their lower portions being only covered, and not enclosed, by peritoneum.

The *stomach*, in the mean time, has also been undergoing certain changes in position. At first it is straight, what later becomes the small curvature being directed anteriorly; but soon its pyloric end shifts over toward the right side of the body, and, at the same time, the entire structure twists in such a manner that its original left surface becomes anterior, and the small curvature is directed to the right.[1] As the result of this the portion of the dorsal mesentery which is attached to the stomach becomes thrown into a pouch lying behind the stomach, the cavity of the pouch forming the omental cavity, and its floor later being drawn downward to form the great omentum, the posterior layer of which, as it passes back to the body-wall, fuses with the mesocolon.

During the progress of these changes a pair of outgrowths have been developing from the duodenum and passing forward between the two layers of the ventral mesentery. They unite to form the *liver*, which quickly reaches a large size—so large, in fact, that the two layers of the mesentery cannot quite meet around it,

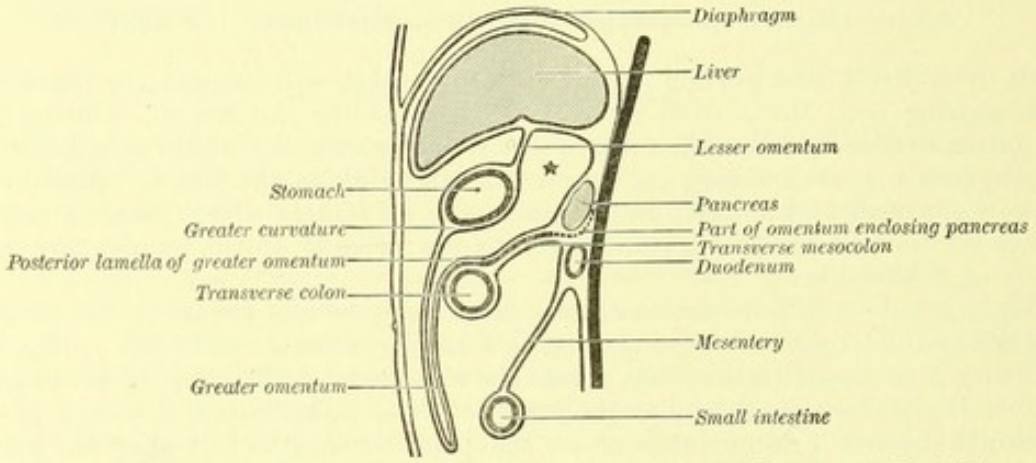

FIG. 103.—Diagram to illustrate the history of the human mesentery—later stage. (Hertwig.)

but are reflected from its sides as the coronary ligaments. The upper portion of the mesentery, above the liver, remains unchanged, however, forming the falciform ligament, while the portion below is affected by the torsion of the stomach, so that its faces come to lie dorsally and ventrally, instead of right and left, and it forms the small omentum (Figs. 102, 103).

The Liver and Pancreas.

The *liver* arises as a pair of hollow outgrowths from the ventral surface of the upper part of the duodenum. Each outgrowth, which represents one of the lobes of the adult liver, becomes greatly complicated by the development of numerous lateral solid branches, these developing others, and so on, the various branches uniting with one another to form a network in the meshes of which are found capillary blood-vessels. The solid branches, termed *hepatic cylinders*, become converted partly into *bile-ducts* and *capillaries* by hollowing out, and partly into the liver *parenchyma*, the original network becoming more or less inconspicuous. The various bile-capillaries unite to form the right and left hepatic ducts, which

[1] It may be pointed out that this twisting is the cause of the position of the pneumogastric nerves in their course over the stomach in the adult, the left nerve passing in front of and the right nerve behind the viscus.

at first open separately into the duodenum; but later the duodenum becomes pouched where they enter, and this pouch is drawn out to form the *common bile-duct*, from which the *gall-bladder* and *cystic duct* arise as a hollow evagination.

The *pancreas* arises as a hollow evagination of the dorsal wall of the duodenum opposite the point where the liver anlagen appear, and grows dorsally between the two layers of the dorsal mesentery, gradually becoming very much branched. It is affected by the torsion of the stomach, so that it assumes a transverse position in the abdominal cavity, and on the development of the mesocolon is pushed with the duodenum against the dorsal wall of the abdomen, its mesentery in consequence undergoing degeneration. Its duct, which at first is attached to the dorsal surface of the duodenum, gradually moves around toward the ventral surface, and finally, as a rule, unites with the common bile-duct.

ORGANS DERIVED FROM THE MESODERM.

The primitive layers of the mesoderm have their cells arranged at first in an epithelial manner, and this arrangement is preserved by certain portions of the layers for a considerable time, even, it may be, throughout life; to these portions the term *mesothelium* may be applied. At certain regions, however, cells are budded off from the primitive layers to form irregular masses, or become scattered throughout the body without any definite arrangement; and these cells are termed *mesenchyme*. It is possible, in accordance with this division of the mesoderm, to recognize mesothelial and mesenchymatous organs.

The Skeleton.

From the mesenchyme are derived the connective and supportive tissues of the body, whose histological differentiation need not be considered here. A few statements may be made, however, concerning the development of the skeleton. The first trace of a supportive structure in the embryo is the *notochord* (Fig. 104),

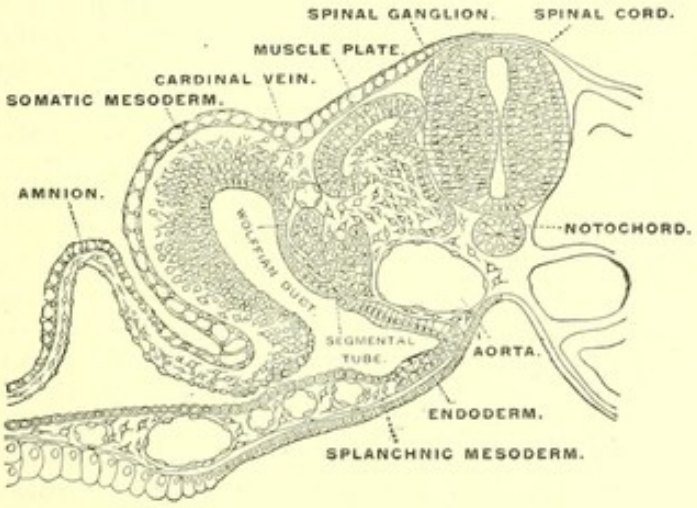

FIG. 104.—Cross-section of embryo.

whose formation has already been described, and which is practically a transitory structure, being replaced later by the spinal column and skull. From a portion of each of the mesodermal somites a mass of cells is budded off, and these masses arrange themselves on either side of the notochord, which they eventually enclose, growing dorsally at the same time around the spinal cord. In the intervals between the members of each pair of mesodermal somites each mesenchymatous mass begins to be transformed into cartilage, which later ossifies to form the *vertebral centrum;* and, as the ossification proceeds, the portions of the notochord enclosed by the

centra are gradually encroached upon and finally disappear, the intervening portions persisting as the gelatinous substance of the intervertebral disks. The *neural arches* develop a little later than the centra, and ossify separately, uniting with the centra only after birth.

The *ribs* arise by the chondrification and subsequent ossification of the mesenchymatous tissue situated between the members of each pair of mesodermal somites, the ribs of the thoracic region being, however, the only ones which undergo complete development, extending in the wall of the body to the ventral surface, where a number of them unite to form the sternum. In the other portions of the trunk and in the neck they remain small, and become united with the vertebræ, being represented in the cervical region by the ventral portions of the transverse processes, in the lumbar region by the costal processes, and in the sacrum by the lateral masses.

The *skull* shows from the beginning no trace of being composed of distinct vertebræ, except in the occipital region. The first trace of the skull is found in two cartilaginous bars, placed one on each side of the anterior end of the notochord. These are the *parachordal cartilages* (Fig. 105), and in front of them two other cartilages known as the *trabeculæ cranii* are formed. These four cartilages eventually unite together, and the trabeculæ uniting at their anterior extremities to form a plate, known as the *ethmo-vomerine plate*, a cartilaginous basis cranii is formed, which later extends dorsally behind and at the sides, leaving, however, the greater portion of the brain covered only by membrane. About the third month of development centres of ossification begin to appear in this chondro-cranium, resulting in the formation of a number of separate bones, which later fuse with one another to a certain extent to form the occipital, sphenoid, and ethmoid bones, all of which are really composite bones.

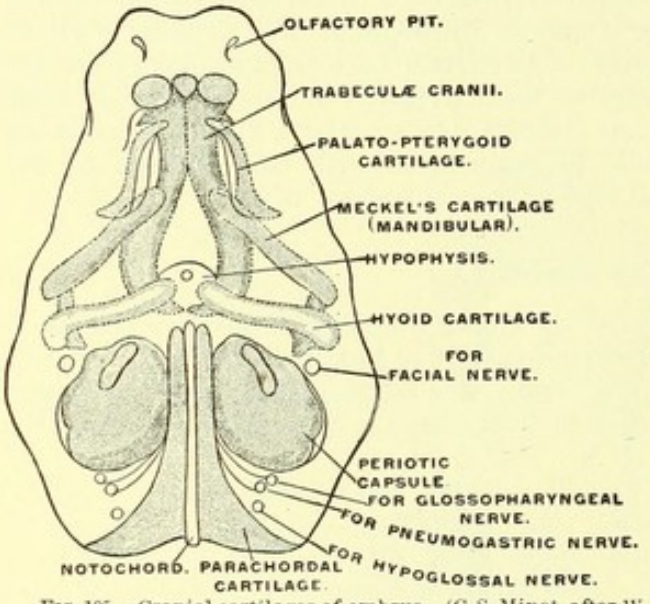

FIG. 105.—Cranial cartilages of embryo. (C. S. Minot, after W. K. Parker.)

In addition to the bones which are thus developed, other elements occur in the skull and may be arranged in three groups: (I.) A number of bones are developed without being preformed in cartilage, their osseous matter being deposited directly in fibrous connective tissue. In this way—as *membrane bones*, as they are termed—are formed the parietals and frontals and the bones of the face, such as, for example, the nasals, malars, lachrymals, palatines, and maxillæ. (II.) Around each auditory organ a cartilaginous case, the *periotic capsule*, develops, quite independently of the primary chondro-cranium, filling up a gap in its walls on each side between the occipital and sphenoid bones, and from it are formed the petrous and mastoid portions of the temporal, the squamous and tympanic portions being membrane bones, which secondarily unite with the capsule. (III.) In each branchial arch a cartilaginous bar develops, these bars forming what is termed the *visceral skeleton*, and certain of them become intimately related to the skull. The dorsal end of the maxillo-mandibular cartilage becomes entirely replaced by membrane bones, the maxillæ, palatines, and internal pterygoid plates of the sphenoid; while its lower end, known as *Meckel's cartilage*, ossifies and unites with a number of membrane bones, which enclose it, to form the lower jaw or mandible, and also takes part in the formation

of the ossicles of the middle ear. The cartilages of the second and third arches unite to form the hyoid bone, the small horn, the stylo-hyoid ligaments, and the styloid processes of the temporals representing the complete second arch, while the great horn represents the incomplete third arch. The fourth and fifth arches become greatly reduced, and fuse together, as already indicated, to form the thyroid cartilage of the larynx.

The *bones of the extremities* are all preformed in cartilage, and for the long bones at least two or three centres of ossification are usually present, one being for the shaft and one for each epiphysis, these latter, however, being merely provisions for the growth in length of the bone, and not representing originally distinct bones. In the scapula, however, two primary centres are formed, one for the greater portion of the bone, and one for the coracoid process, which in the lower vertebrates is a distinct bone; and similarly three primary centres are found in each hip-bone, one for the os pubis, one for the ischium, and one for the ilium, each of these being primarily a distinct bone. In the carpus and tarsus certain fusions also occur. Typically, each consists of nine bones arranged in a proximal row of three bones, a distal row of five bones, and a single bone between the two. The following scheme will show the fusions which have taken place, each composite bone ossifying from two centres, the rest from one:

Carpus.		*Tarsus.*	
Scaphoid,	Radiale.	Tibiale, Intermediate,	Astragalus.
Semilunar,	Intermediate.		
Cuneiform,	Ulnare.	Fibulare,	Calcaneum.
(Fused with Scaphoid)	Centrale.	Centrale,	Navicular.
Trapezium,	Carpal I.	Tarsal I.,	Internal Cuneiform.
Trapezoid,	" II.	" II.,	Middle Cuneiform.
Os Magnum,	" III.	" III.,	External Cuneiform.
Unciform,	" IV.	" IV.,	Cuboid.
	" V.	" V.,	

The pisiform does not belong to the same category as the other carpal bones, being an ossification in the tendon of the flexor carpi ulnaris, just as the patella is an ossification in the tendon of the quadriceps extensor femoris. Such bones are known as sesamoid bones.

The Heart and Blood-vessels.

It has already been seen that the formation of the blood-vascular system begins in the area opaca of the blastodermic vesicle, and thence extends toward the embryo, two vessels, the *vitelline veins*, carrying the blood from the yolk-sac to the embryo. While the embryo is still spread out flat upon the surface of the blastodermic vesicle the splanchnic layer of the mesoderm on each side of the body buds off a small collection of cells (Fig. 106, *endocardium*) into the space between it and the endoderm; these early arrange themselves in a tubular form, and become enclosed within a fold of the splanchnic mesoderm. This folds (Fig. 106, *myocardium*), and tubes so formed are the anlagen of the heart, the two halves of which are at first widely separated; but as the embryo becomes constricted off from the yolk-sac they are brought nearer together, and finally unite to form a single double-walled tube, the folds becoming the muscular walls of the heart, while the mesenchymatous tubes form its endocardium.

The *heart*, thus formed, is situated in the neck region of the embryo, and has communicating with it behind the vitelline veins, while anteriorly it is continued into the aortic trunk. This simple tubular heart now undergoes a considerable increase in length, and, as a result, bends upon itself in an S-shaped manner (Fig. 107), the aortic end being ventral to the venous. The venous end now begins to enlarge, and pouches out into a sac on each side, forming the *right* and *left auricles;* and

from its dorsal wall between the two auricles a vertical partition begins to form, which, growing backward toward the horizontal portion of the heart, would separate the auricles completely were it not that a foramen forms in its upper part

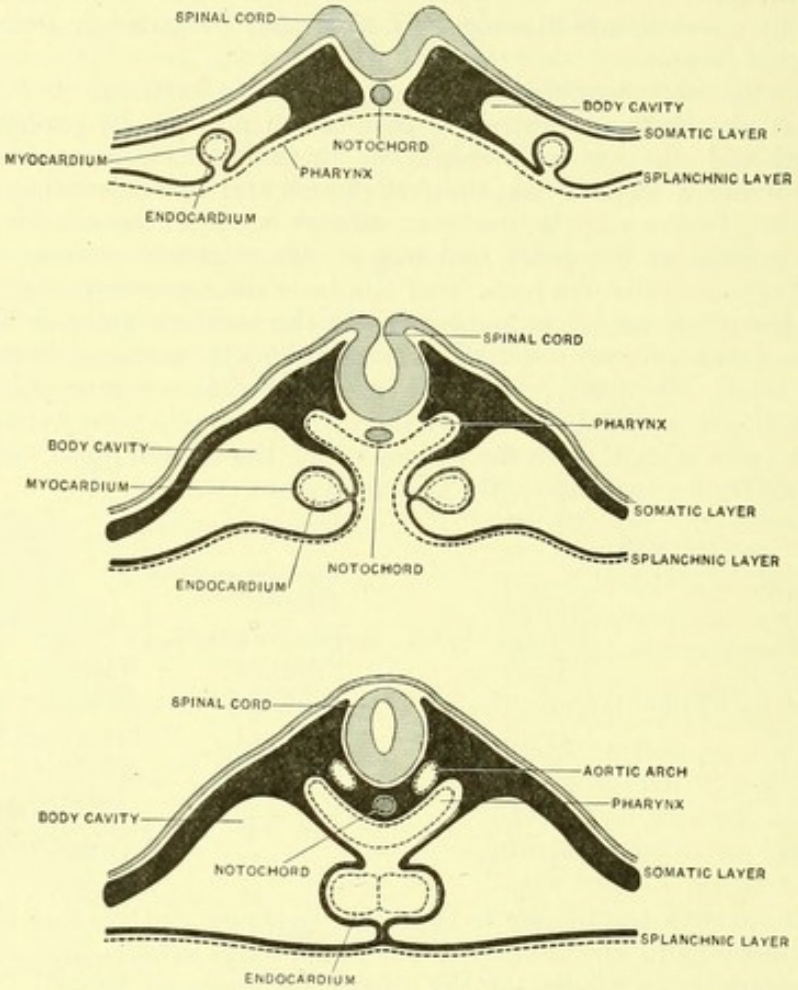

FIG. 106.—Development of the heart: cross-sections of the cervical region of an embryo; diagrammatic. (Testut.)

(the *foramen ovale*), which persists until birth, closing normally shortly thereafter. The partition passes to the left of the opening by which the blood from the vitelline

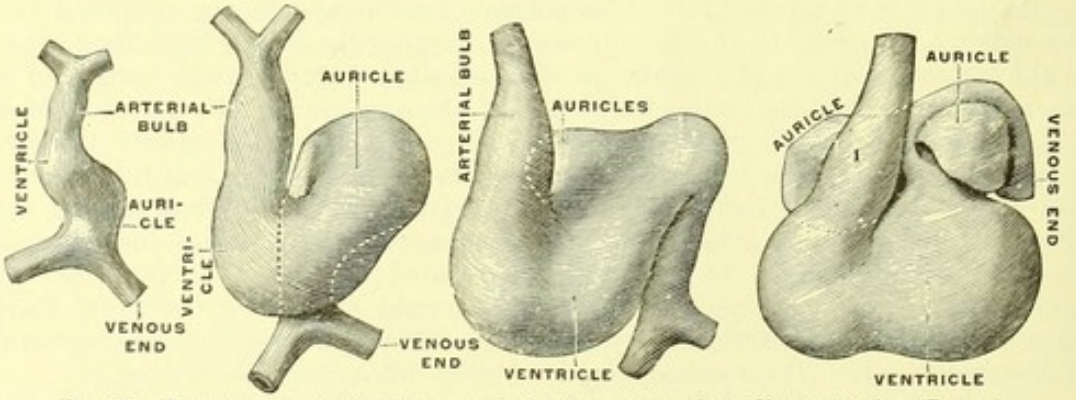

FIG. 107.—Four stages in the development of the heart: front view; diagrammatic. (Testut.)

veins flows into the heart, and, consequently, this opening now communicates with the right auricle, the left receiving four small veins which come to it from the lungs.

The point of union of the auricular and ventricular regions has in the mean time become considerably constricted, and the auricular septum extends far enough

downward to divide the opening between them into two parts. In the ventricle a crescentic partition develops from the posterior and dorsal walls, and grows upward toward the auricular septum, with the lower border of which it unites, ending, however, in a free edge beneath the opening by which the aortic trunk communicates with the ventricle. The *aortic trunk* has meanwhile flattened dorso-ventrally, and on the inner surfaces of the flat sides two ridges develop, and finally unite, dividing the lumen of the aortic trunk longitudinally into two portions (Fig. 108). The partition extends down into the ventricle, and unites

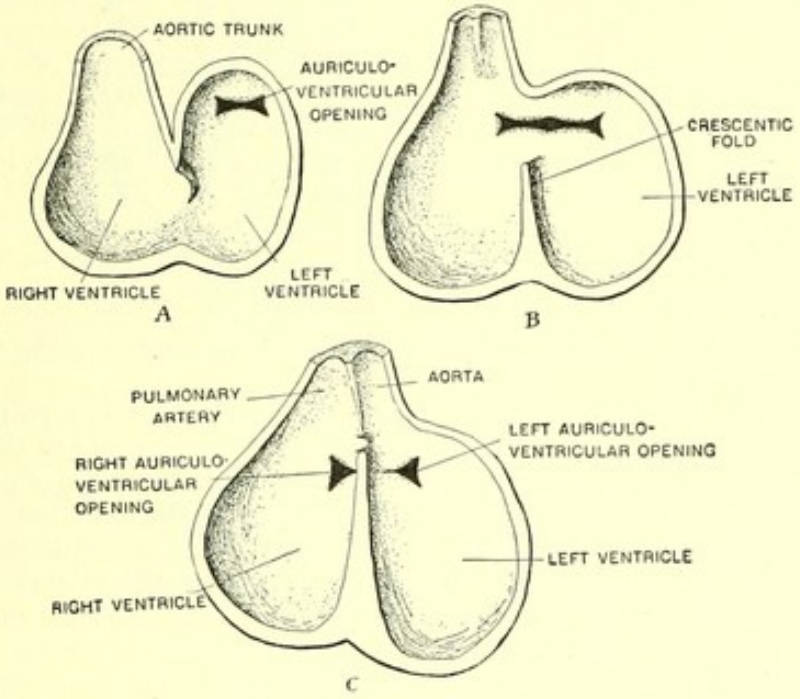

FIG. 108.—Development of the aorta and pulmonary artery. (After Born.)

with the free edge of the ventricular septum, so that the *division of the ventricle* becomes complete, and the aortic trunk then separates completely into two tubes, one of which, the *aorta*, communicates with the left ventricle, while the other, the *pulmonary artery*, opens into the right ventricle. The original tubular heart has thus become converted into a four-chambered organ which differs from the adult heart only in the existence of the foramen ovale in the auricular septum.

The aortic trunk, prior to its division, in passing forward from the heart gives off from time to time pairs of lateral branches, which pass dorsally in the branchial arches. These are the *aortic arches*, which, on each side, unite above the branchial clefts to form a longitudinal vessel, and this, passing backward, unites with its fellow of the opposite side to form the *dorsal aorta* (Figs. 109, 110). This primitive condition is, however, merely transitory, the first arches early disappearing, and then the second, the continuations of the aortic trunk from which these arches arise persisting, however, to form the *external carotid arteries*, while the branches of the dorsal aorta into which they opened likewise persist to form the *internal carotids*. The third arches persist, becoming portions of the internal carotids, and forming the connections between those arteries and the external carotids; but the portions of the branches of the dorsal aorta which intervene between the third and fourth arches disappear, thus cutting off the direct connections of the internal carotids with the dorsal aorta. The fourth arch of the left side persists in its entirety, forming the arch of the aorta of the adult, and is the only connection between the heart and the dorsal aorta, since the right branch of the dorsal aorta disappears completely behind the third arch, the right fourth arch forming part of the right *subclavian artery*. The fifth arches give rise to an artery on each side, the pulmonary arteries, and the portion of the arch distal to the branch on the right

side disappears, but persists on the left side to form the *ductus arteriosus*, uniting the pulmonary artery with the dorsal aorta—a connection functional for the passage of blood up to birth, but aborting later.

FIG. 109.—Aortic arches, early arrangement. (After Rathke.)

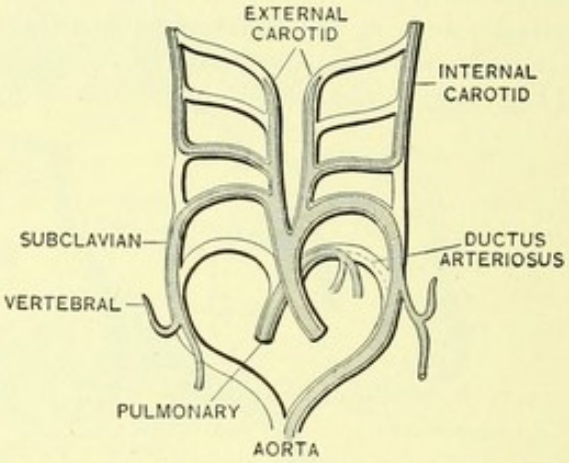

FIG. 110.—Aortic arches, final condition. (After Rathke.)

Of the *venous system* it has already been seen that there is a pair of vitelline veins coming from the yolk-sac and opening into the venous end of the embryonic heart. In addition to these, other veins are developed at an early period, which unite together and with the vitelline veins before entering the heart, forming a *sinus venosus*, which later is taken up into the right auricle. Of these veins there are, first, the umbilical veins, which bring back the blood from the placenta, entering the body of the embryo at the umbilicus (Fig. 111). The left umbilical vein

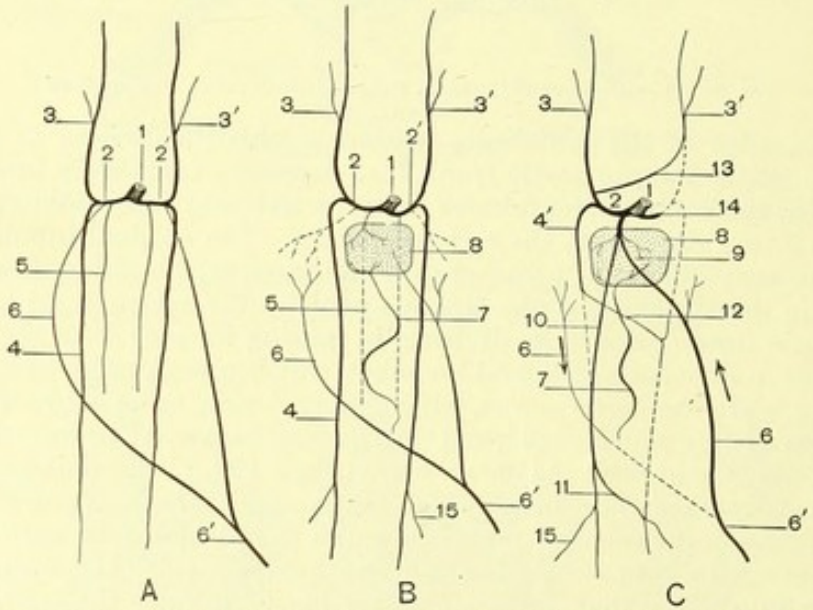

FIG. 111.—Development of the veins: *A*, primitive condition, bilateral symmetry; *B*, formation of portal system; *C*, final condition; diagrammatic. 1, sinus venosus; 2, right ductus Cuvieri; 2′, left ductus Cuvieri; 3, right jugular vein; 3′, left jugular vein; 4, cardinal vein; 4′, vena azygos major; 5, vitelline vein; 6, umbilical vein; 6′, umbilical vein in cord; 7, portal vein; 8, liver; 9, ductus venosus; 10, vena cava inferior; 11, common iliac vein; 12, vena hemiazygos; 13, left brachio-cephalic vein; 14, coronary sinus; 15, veins of lower limbs. Atrophied parts in broken lines. (Testut.)

degenerates later almost entirely, but the right passes forward in the ventral mid-line of the abdomen to the under surface of the liver, to which it distributes blood, continuing onward, however, to open into the sinus venosus. During embryonic life this vein increases in size, the vitelline veins, on the other hand, becoming smaller and, forming connections with one another, eventually giving rise to the portal vein. After birth, however, as soon as the placental circulation ceases, the

umbilical vein becomes converted into a solid cord of tissue, which, from the transverse fissure of the liver to the umbilicus, is known as the *round ligament*, while the portion above this becomes the *ductus venosus*, the uppermost part persisting as the upper part of the *vena cava inferior* and receiving the hepatic veins.

Secondly, there are two other pairs of veins which are entirely confined to the embryo—the *jugulars*, which bring back to the heart the blood from the head and upper extremity, and the *cardinals*, which return the blood from the trunk and lower limb, the jugulars and cardinals of each side of the body uniting together before opening into the sinus venosus to form a transverse branch, the *ductus Cuvieri*. As the embryo develops the jugulars increase in size more rapidly than the cardinals, so that the Cuvierian ducts seem to be the continuations of the jugulars; and when the sinus venosus is taken up into the right auricle the two Cuvierian ducts and the umbilical vein, which open into the sinus from the right and left sides and from below, respectively, come to have separate openings into the auricle, forming the three principal openings found in the adult.

The cardinal veins do not, however, persist until adult life in their original condition, but are to a certain extent replaced by an unpaired venous trunk, the *vena cava inferior*, which makes its appearance in the tissue between the two primitive kidneys, and early unites with the cardinals by means of transverse branches, through which it receives the blood from the kidneys and rapidly increases in size. In the mean time, a connecting trunk has formed between the left and right cardinals, and the main mass of the blood from the left lower limb flows over into the right cardinal, which thus becomes enlarged and forms apparently the continuation of the inferior vena cava. Above, the vena cava opens into the umbilical vein, and, on the degeneration of the umbilical after birth, this uppermost part of it persists as the upper end of the vena cava. This vessel is, therefore, composed of three originally distinct parts: (1) the independent trunk between the primitive kidneys; (2) the lower end of the right cardinal vein; and (3) the uppermost part of the umbilical. When completely formed it receives the blood from the greater part of the territory originally drained by the cardinals, the upper portions of these latter still continuing, however, to receive the blood from the intercostal spaces of the thorax. The lower part of the left cardinal completely disappears, and it also loses its connection with the left ductus Cuvieri, forming instead a transverse connection with the right cardinal, and becoming the *vena hemiazygos* (azygos minor) of adult anatomy, the upper part of the right cardinal becoming the *vena azygos major*.

In the mean time, a slight change has taken place in the jugulars, a branch passing across from the left to the right, and forming the *left brachio-cephalic vein* of the adult, which receives and passes over to the right jugular all the blood returning by the left jugular. As the result of this the portion of the left jugular between the origin of the left brachio-cephalic vein and the left ductus Cuvieri becomes greatly reduced, being represented in the adult only by the small oblique vein on the back of the left auricle; but the left ductus Cuvieri, thus separated from both the jugular and the cardinal vein which originally opened into it, does not degenerate, since it still receives a large proportion of the blood returning from the tissue of the heart itself through the coronary veins, but persists as the coronary sinus.

The Diaphragm.

Closely associated with the development of the venous trunks is the formation of the diaphragm. At first the body-cavity or cœlom is a continuous cavity extending the entire length of the trunk, and even into the head region; but during development the portions in the head and neck disappear, the thoracic and abdominal portions persisting, and being at first continuous. After the heart has formed, however, a thick transverse partition, the *septum transversum*, begins to grow from the ventral and lateral walls of the body toward the sinus venosus,

enclosing the venous trunks which open into the sinus. By its formation the thoracic and abdominal portions of the cœlom are almost completely separated, the only communication between them being by a pair of small canal-like openings, one on each side of the dorsal mesentery; and, as the lungs develop, they push the walls of the canals in front of them, these walls thus forming the pleuræ. At a comparatively early stage of development the pericardial portion of the thoracic cavity becomes separated from the pleural portions; and considerably later the latter become cut off from the abdominal cavity, then known as the peritoneal cavity, by the growth forward from the dorsal wall of the body of a partition which unites with the free edge of the septum transversum.

The Lymphatic Vessels, the Spleen, and the Suprarenal Capsules.

Of the development of the *lymphatic vessels* comparatively little is known with certainty, though they seem to be formed similarly to the blood-vessels by a hollowing out of strands of mesenchymatous cells. The mode of development of the *spleen* is also but imperfectly known: it arises as a collection of mesenchymatous cells situated between the layers of the dorsal mesentery of the stomach, and early receives a rich supply of blood-vessels.

The *suprarenal bodies* arise as two distinct portions, one of which is derived from a collection of mesenchymatous cells in the vicinity of the inferior vena cava, and gives rise to the cortical portion of the organ; while the other originates from the anlagen of the abdominal sympathetic ganglia and forms the medullary portion. The significance of these organs is, however, not yet understood.

The Muscular System.

From the mesothelial portions of the mesoderm the voluntary muscles and the urino-genital system develop. The voluntary muscles are derived from the mesodermal somites, the greater portions of which become transformed into muscle-tissue, and, consequently, the voluntary musculature has primarily a segmental arrangement, consisting of a series of muscle-plates placed one behind the other on each side of the body, and extending forward even into the head-region of the embryo. Each plate is supplied by a cranial or a spinal nerve, and has the fibres of which it is composed directed longitudinally, and arising from and inserted into the connective-tissue membranes which separate each pair of plates. This primitive arrangement, however, is not long retained, the various muscle-plates fusing together to a greater or less extent, and dividing longitudinally and into various layers, and so producing the complicated muscular system of the adult.

The involuntary muscle-tissue which occurs distributed through the walls of the various viscera seems to arise by the differentiation of mesenchymatous cells, and to have nothing to do with the mesodermal somites.

The Excretory and Reproductive Organs.

The excretory and reproductive systems arise from certain of the mesodermal somites just where they join the splanchnic and somatic layers, and the first portion of the excretory system to appear arises from certain somites in the vicinity of the heart, a solid cord of cells growing out from each somite toward the ectoderm. Each cord later becomes converted into a canal, which opens at one end into the cœlom, and is connected at the other end with the ectoderm. This collection of tubules is termed the *pronephros* (Fig. 112), and as it develops there is formed from the ectoderm, along the line where the tubules are in contact with it, a longitudinal canal, which later separates from the ectoderm and comes to lie close to the mesoderm (Fig. 104). This is the *pronephric* or *Wolffian duct*, with which the tubules of the pronephros unite, and which opens posteriorly into the urogenital sinus, to be described later.

The pronephros, however, is but a transitory organ, and it soon degenerates; a second excretory organ, the *mesonephros* or *Wolffian body*, makes its appearance, its development being similar to that of the pronephros. Its tubules, which open at one end into the cœlom and at the other into the Wolffian duct, reach a consider-

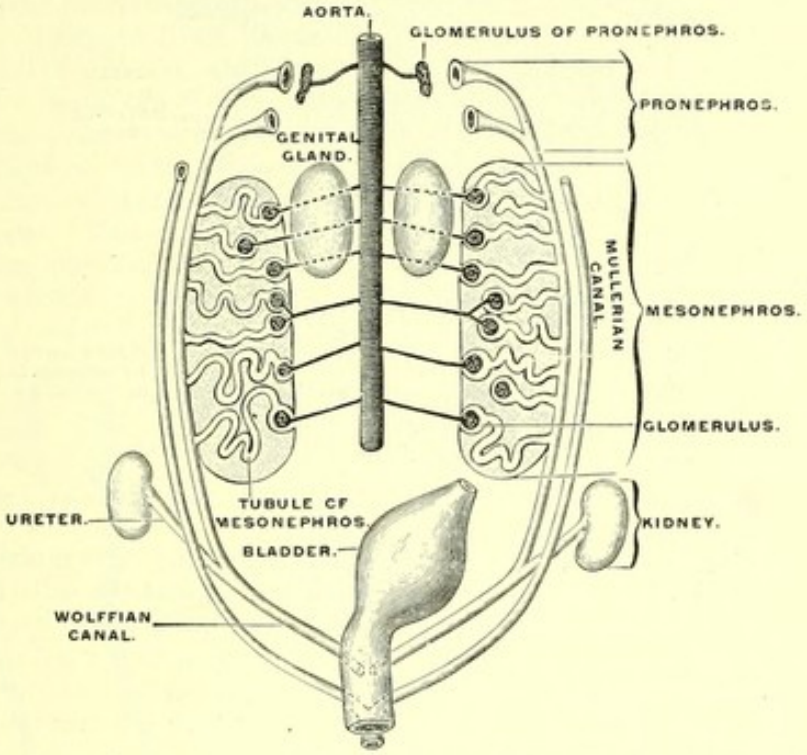

FIG. 112.—Diagram of the various excretory organs successively developed in the formation of the urinary system. (Testut.)

able length, and become much contorted, and a knot of capillary blood-vessels, developing in contact with each tubule, pushes its wall in front of it to form a *glomerulus* projecting into the tubule. The tubules early lose their connection with the cœlom, and, though at first they present a strictly segmental arrangement, this is not adhered to, as secondary and tertiary tubules arise from each mesodermal somite, develop glomeruli, and unite with the primary tubules to open into the Wolffian duct. The Wolffian body thus becomes an exceedingly complicated organ, which, on account of its size, forms a strong projection into the cœlom from the dorsal wall of the body.

But even this second kidney does not persist into adult life as a functional excretory organ, but portions of it degenerate, while other parts are adapted to new functions, its excretory functions being assumed by a new kidney, the *metanephros*. This appears as a tubular outgrowth from the dorsal surface of the lower part of each Wolffian duct, and from the anterior end of this a number of tubules grow out and push their way into a mass of mesodermal tissue which has concentrated around them. The original outgrowths become the *ureters*, and the tubules, which become very numerous, develop into the *urinary tubules*, in connection with which *glomeruli* (Malpighian corpuscles), derived from the mesodermal mass, develop. The compact organ thus formed becomes the functional kidney of the adult.

When the Wolffian bodies are fully developed a cord of cells appears on the lateral surface of each of them, and becomes converted into a canal opening behind into the cloaca and in front into the cœlom. This is the *Müllerian duct*, and by the time it is established a thickening of the peritoneal cells covering the mesial surfaces of each Wolffian body appears, forming the *germinal ridges*, from which the ovaries or testes develop. In the case of the *ovaries* the mesenchyma-

tous tissue immediately beneath the thickenings develop into the stroma, into which cords of cells (Fig. 113) grow from the thickening. Certain of the cells

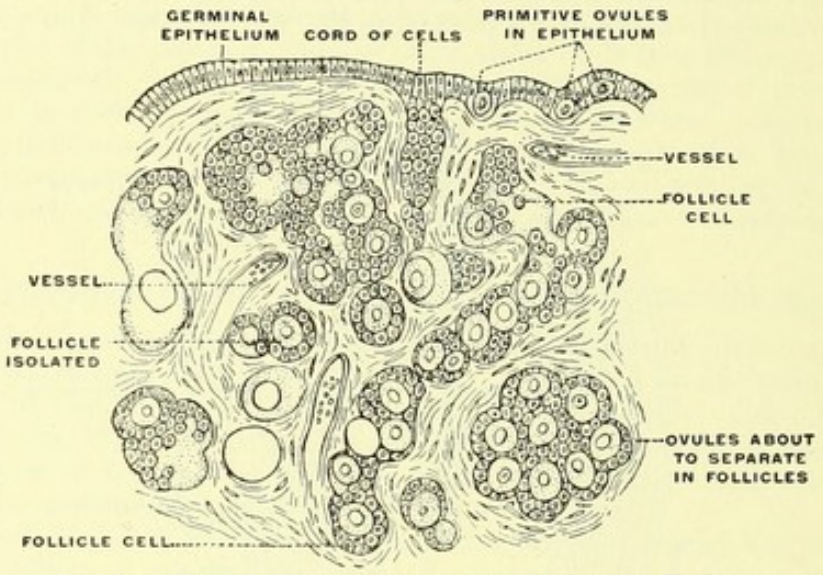

FIG. 113.—Section of the ovary of a new-born child. (After Waldeyer.)

of the cords enlarge greatly and become ova, the remaining cells multiplying rapidly by division and becoming the follicle-cells. Division of the cells which are to form ova appears to cease at about the second year after birth, by which time, therefore, all the ova are differentiated. The *testes* are at first very similar to the ovaries, and have a similar development, the spermatic cells being derived from the cells of the germinal ridge, and the stroma of the ovary being represented by the tunica albuginea and the trabeculæ of the testis.

When mature the ova are extruded from the ovary practically into the peritoneal cavity, though, as a matter of fact, they are usually received at once into funnel-like openings by which the Müllerian ducts communicate with the peritoneal cavity, these ducts becoming the *Fallopian tubes* of the adult, and their lower portions fusing to form the *uterus* and *vagina*. In the embryo, however, the Müllerian ducts extend much farther forward than the position of the ovary, the ostium of the Fallopian tubes being a new formation and not the original terminal opening, the more anterior portion of each duct being probably represented in the adult by the *hydatid of Morgagni* (Fig. 114), a small vesicular structure attached to one of the fimbriæ of the secondary opening. While the ovary and the metanephros have been developing the mesonephros has been degenerating, and all those portions of the Wolffian ducts which lie anterior to the points of outgrowth of the metanephric ducts disappear, except small portions at each end. The upper end, through mesonephric tubules which communicate with it, comes into intimate relation with the ovary, forming with its tubules the *parovarium*, which in the adult lies close to the ovary in the substance of the broad ligament. The lower ends of the Wolffian ducts persist as the *canals of Gärtner*, situated on each side of the upper end of the vagina, while the mesonephros almost completely disappears, its uppermost tubules just mentioned and a small portion of its lower end alone persisting, the latter forming a cyst-like structure lying between the layers of the broad ligament, and termed the *paroöphoron*.

It has been seen that the ovaries appear at the level of the mesonephros—that is to say, well forward in the abdominal wall. This position, however, is not retained, but they descend as development proceeds, and finally lie in the pelvic cavity. This descent is partly produced by the contraction of a band of connective tissue which descends from the lower end of the mesonephros to be attached to the skin in the region where the labia majora will later appear, and which is represented by the *round ligament* of the adult.

The testes and the parts in their neighborhood undergo changes comparable to those just described for the ovaries, the principal difference being that the Müllerian ducts degenerate except at their two extremities, the anterior ends persisting as a small vesicle attached to each epididymis, and known as the *hydatid of the epididymis*, while the lower ends unite together to form a small sac, which opens into the prostatic portion of the urethra, and is termed the *sinus pocularis*. This latter structure from its mode of formation is evidently homologous with the uterus of the female, and has consequently been termed the *uterus masculinus*. On the other hand, the Wolffian ducts persist, forming the *vasa deferentia*, and, as in the female, the tubules of the upper portions of each Wolffian body grow inward toward the testes, with which they unite, their testicular ends forming the *tubuli recti* and *rete testis*, while the ends connected with the Wolffian ducts form the *epididymis*. The remainder of the Wolffian bodies undergoes almost complete degeneration, portions, however, as in the female, persisting, and forming the structures known as the *vasa aberrantia* of the epididymis and the *paradidymis* or *organ of Giraldès*.

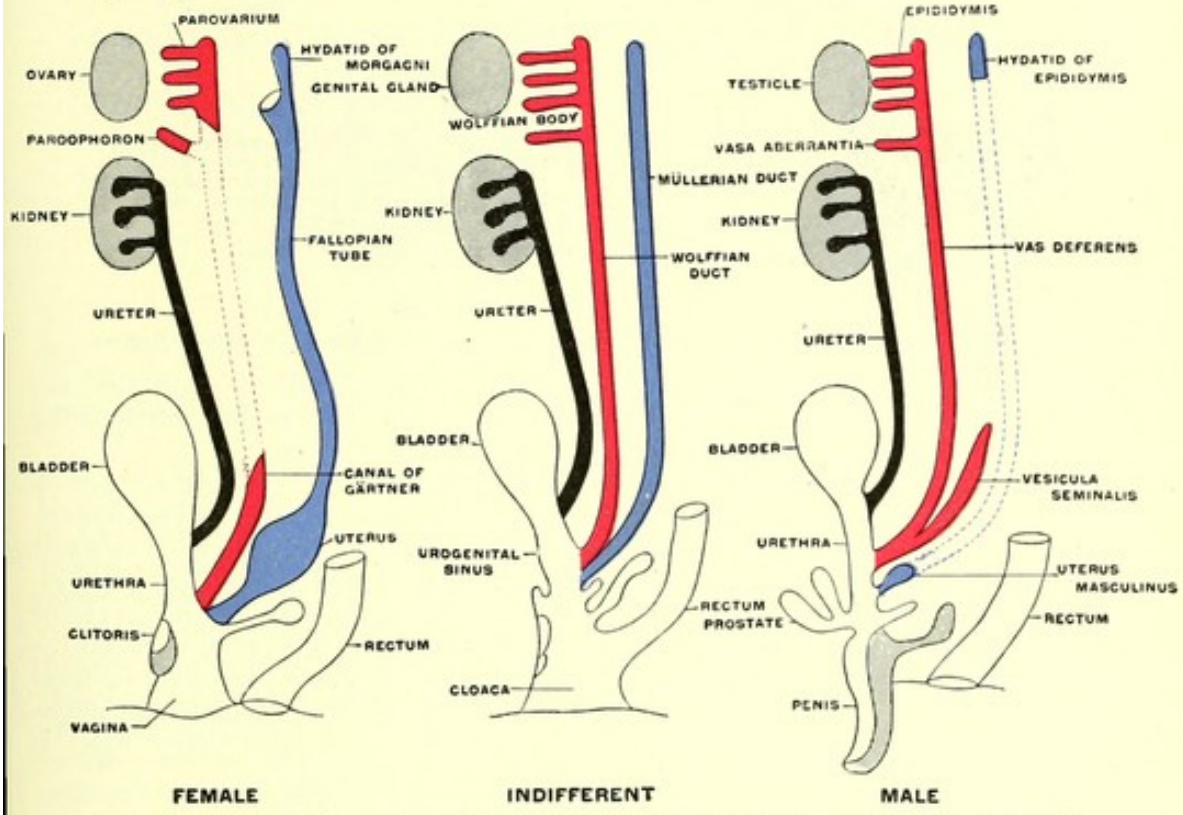

FIG. 114.—Diagram of the development of the genito-urinary apparatus. (Modified from Huxley.)

The round ligament, whose contraction occasions the descent of the ovary into the pelvic cavity, since it is primarily in connection with the mesonephros, has naturally a representative in the male, passing from the lower end of the mesonephros to that region of the skin where the scrotum will develop. By its contraction the descent of the testis is brought about, this organ being drawn first into the cavity of the false pelvis, and then into the inguinal region. Here, in the mean time, on each side, a downgrowth of a finger-like process of peritoneum into the scrotum by the side of the round ligament has occurred, the downgrowth being preceded by prolongations of various muscular layers of the abdominal wall. The testes, continuing their descent, follow these peritoneal downgrowths, and thus come to lie within the scrotum, the peritoneal processes wrapping themselves around them and forming the *tunicæ vaginales*, the neck by which the process communicates with the general peritoneal cavity subsequently closing by the fusion of its walls, while the remaining coverings of the testes are produced by the

muscle- and fascia-layers of the abdominal walls which preceded the peritoneal process. The cord, which represents the round ligament, is to be found in the adult in a small cord which passes from the epididymis to the wall of the scrotum, and is termed the *gubernaculum*.

It has already been stated that the allantois does not entirely degenerate at birth, the middle part of its intra-embryonic portion persisting as the *urinary bladder*, and the part between this and the umbilicus becoming converted into a solid cord, known as the *urachus*. The part between the bladder and the intestine forms what is termed the *urogenital sinus*, and into it the Müllerian and Wolffian ducts open. In the development of the *ureters* the portions of the Wolffian ducts between their point of origin and the sinus are, in the male, gradually taken up into the sinus, so that the ureters and the vasa deferentia have separate openings, the former uniting with the base of the bladder, while the latter open into the sinus. Since the allantois is connected with the intestine, that portion of the digestive tract receives the urinary and genital products as well as the fæces, and thus receives the name of the *cloaca* (Fig. 115). At an early period this cloaca becomes divided by a partition into a dorsal and a ventral portion; this partition becoming gradually thicker, the dorsal portion, representing the lowermost part of the rectum, becomes separated from the ventral portion, the region intervening between the two being the *perineum* (Fig. 117).

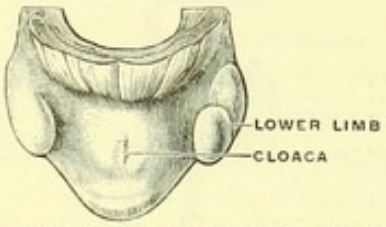

FIG. 115.—External view of the cloaca. (Hertwig.)

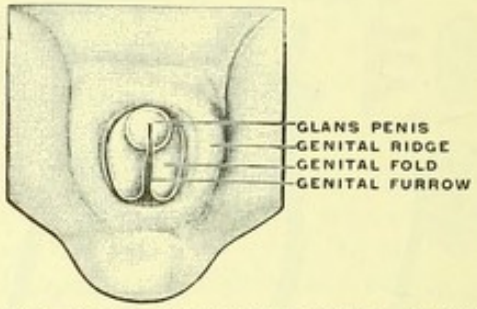

FIG. 116.—Anlage of the penis or clitoris. (Hertwig.)

In the mean time, however, on each side of the urogenital opening a ridge of skin, the anlage of the scrotum in the male and the labia majora of the female, has appeared, and between the anterior (ventral) ends of the ridges a tubercle develops, along whose posterior surface a groove is formed which opens proximally into the urogenital sinus. This tubercle is the anlage of the *penis* or *clitoris* (Fig. 116), and at this stage there is practically no difference between the male and female genitalia. In the male the lips of the penial groove now meet together and fuse, the groove being thereby converted into a canal continuous with the urogenital sinus, the canal and sinus together constituting what is termed the *urethra* of the adult. As a result of this closure of the groove the scrotal ridges of either side are brought into contact, and fuse together below the penis to form the adult *scrotum* (Fig. 118). In the female the lips

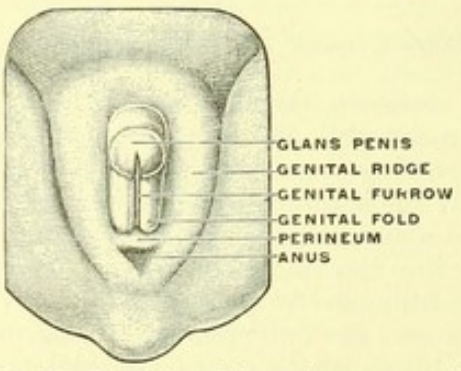

FIG. 117.—Formation of the perineum, separating the alimentary and the genito-urinary passages. (Hertwig.)

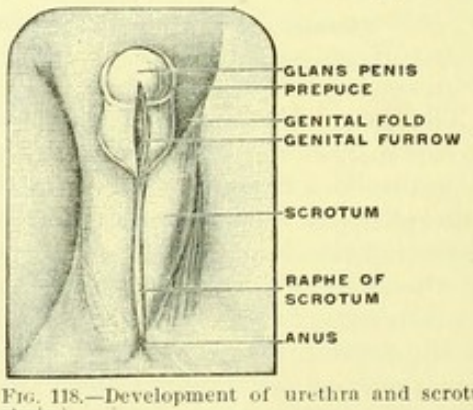

FIG. 118.—Development of urethra and scrotum. (Hertwig.)

of the groove on the clitoris do not fuse, but become greatly enlarged and form the *labia minora*, and the *labia majora* remain separated by a depression into which the urethra, developed in this case from the urogenital sinus alone, and the *vagina* open (Fig. 119). The final arrangement of the female external

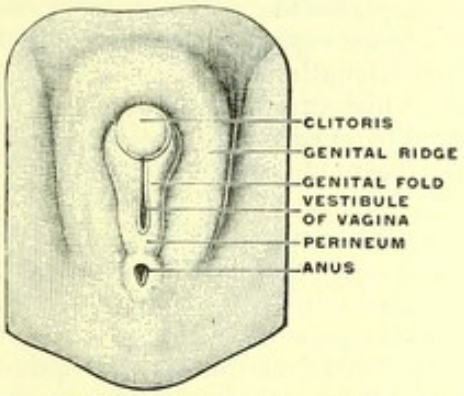

FIG. 119.—Development of vagina. (Hertwig.)

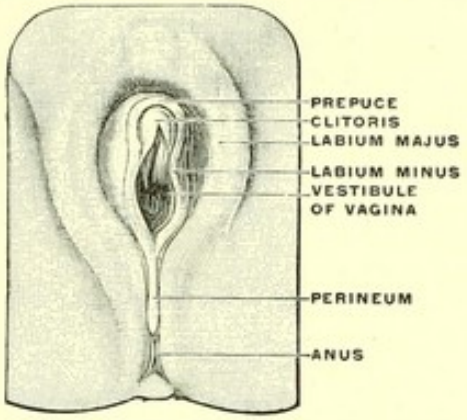

FIG. 120.—Development of the female external genitals. (Hertwig.)

genitalia may thus be readily compared with an early stage of development of the male organs, the latter undergoing a greater amount of differentiation than those of the female.

ORGANS DERIVED FROM THE ECTODERM.

Of the ectoderm the derivatives are the outer layers of the skin and its appendages—hairs, nails, sudoriparous, sebaceous, and mammary glands—and the nervous system and sense-organs. Of the former a detailed account is unnecessary here, but the nervous system requires due consideration.

The Nervous System.

As has been seen, the central nervous system makes its appearance as the medullary groove. As development proceeds the lips of the groove gradually come together, and eventually fuse, transforming the groove into the medullary canal, broader in front than behind, and running the entire length of the body. The cavity of the canal becomes the *central canal of the spinal cord* and the *ventricles of the brain*, while its walls become converted into the various parts of the central nervous system.

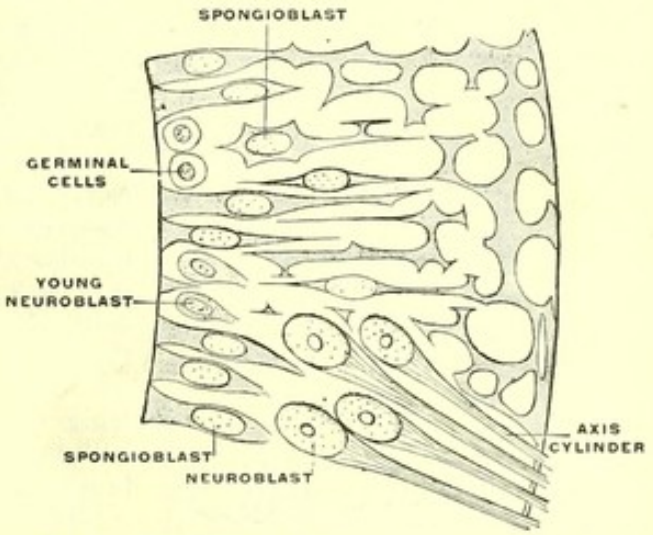

FIG. 121.—Development of nerve-cells and neuroglia-cells in wall of the medullary canal. (Testut and His.)

At first the cells composing the walls of the canal are practically similar, but later certain of them, the *neuroblasts*, lying nearer the central canal, begin to proliferate rapidly, forming *nerve-cells* (Fig. 121), while the remainder, the *spongioblasts*, scatter themselves among the nerve-cells and become the *neuroglia*, some of them eventually coming to line the central canal and forming the *ependyma* (*endyma*). The walls of the canal also become of unequal thickness, the portions in the dorsal and ventral mid-lines becoming thin and forming

respectively the *roof-plate* and the *floor-plate*, while each of the lateral thicker portions becomes divided by a longitudinal groove into a *dorsal* and a *ventral zone*.

The spinal cord develops from the narrower posterior portion of the medullary canal, and is formed mainly by the growth of the cells of the ventral zones, the dorsal zones being represented only by the dorsal horns of the gray matter, while the parts contributed by the roof- and floor-plates are comparatively insignificant. At an early period a series of constrictions, separated from one another by definite intervals, appear throughout its entire length, and give it the appearance of being composed of a series of segments, which are termed *neuromeres*, and to each of which a pair of nerves corresponds. The existence of the constrictions is, however, transitory, and it is probable that their appearance is related to the occurrence of the mesodermal somites.

Up to the end of the third month the cord is practically as long as the spinal canal, but later the canal grows in length more rapidly than the cord, so that the latter becomes relatively shorter, though actually it elongates. As a result of this unequal growth, the nerves which pass out between the lower vertebræ must lengthen, and so the bunch of nerves termed the *cauda equina* is formed. The *motor nerves* arise from cells situated in the ventral horn of the cord, and grow out toward the muscles for which they are destined; the *sensory nerves*, however, arise from a series of thickenings situated just external to the lips of the medullary groove, which, on the closure of the groove, separate from the ectoderm and sink down into the mesoderm. From each cell of these thickenings, which are the *dorsal root-ganglia*, two processes are sent off, one of which penetrates the substance of the cord, while the other extends peripherally. There is thus a fundamental distinction between the motor and the sensory nerve-fibres, the former always growing out from the central system, while the latter arise externally to the cord and brain, and grow inward toward them.

In the anterior portion of the medullary canal, from which the brain develops, neuromeres are present as in the cord; but, in addition, two more distinctly marked constrictions appear and divide the brain into three primary vesicles. The roof-plate of the most posterior vesicle forms a thin roof to the cavity of the vesicle (Fig. 122), which broadens out to form the *fourth ventricle*, a transverse thickening, however, developing in the more anterior part of the roof, and later enlarging to form the *cerebellum*. In the posterior part of the vesicle the dorsal and ventral zones become well developed, forming the *medulla oblongata*, while anteriorly fibres grow downward on each side from the cerebellum toward the ventral mid-line, forming the *pons*. In consequence, it is customary to regard the third vesicle as being secondarily divided into two vesicles, the posterior of which is termed the after-brain, or *metencephalon* (myelencephalon), while the anterior, which includes the cerebellum and pons, is known as the hind-brain, or *epencephalon*.

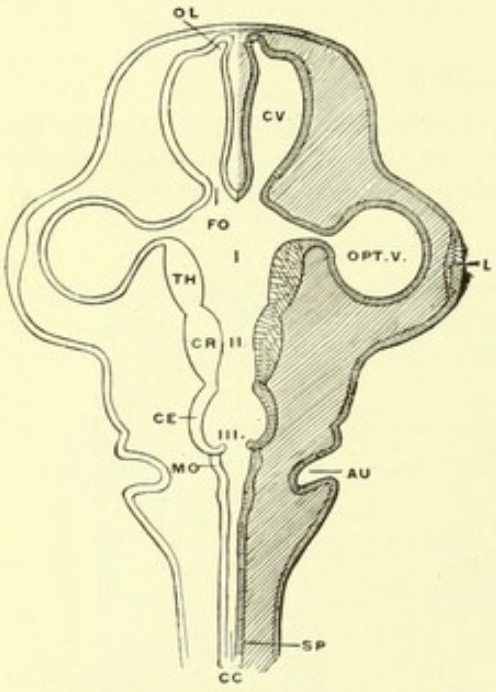

FIG. 122.—Diagram of the brain at an early stage of development: *I*, cavity of primary prosencephalon; *II*, cavity of mesencephalon; *III*, cavity of epencephalon; *AU*, auditory pit; *CC*, central canal of spinal cord; *CE*, cerebellum; *CR*, crura cerebri and quadrigemina; *CV*, cerebral vesicle; *FO*, foramen of Monro; *MO*, medulla oblongata; *OL*, olfactory lobe; *OPT. V.*, optic vesicle; *SP*, spinal cord; *TH*, thalamus opticus. (Martin.)

The cavity of the middle vesicle does not increase in size as rapidly as the others, but assumes the form of a canal, and is termed the *iter* or *aqueduct*. The roof-plate retains its primitive slight development, the dorsal zones, however, giving rise to four well-marked thickenings, the *corpora*

quadrigemina, while the ventral zones become modified to form the *crura cerebri*. To this differentiated middle vesicle is given the name of the mid-brain, or *mesencephalon* (Fig. 123).

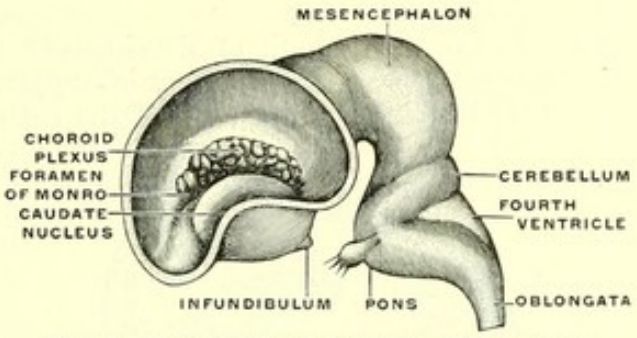

FIG. 123.—Brain of embryo, side view. (Mihalcovics.)

The anterior vesicle undergoes greater changes than either of the others. First, from the lower part of its lateral walls two pouches grow out, finally come into contact with the ectoderm of the sides of the head, and form the optic vesicle (Fig. 122), and later a constriction of the original wall of the vesicle appears, the vesicle thus becoming divided into two portions, the anterior of which, growing most rapidly on each side of the median line, eventually gives rise to the cerebral hemispheres, which are together termed the fore-brain, or *prosencephalon*, while the median portion, together with the entire posterior portion of the original vesicle, forms the 'tween-brain, or *thalamencephalon*, which contains the *third ventricle*.

The anterior wall of the third ventricle is evidently, since the hemispheres are lateral outgrowths, the front wall of the primitive brain, and it constitutes the *lamina terminalis* of the adult. The greater portion of the roof of the third ventricle becomes reduced to a thin layer of cells, which, together with the pia, which lies immediately above it, forms the *velum interpositum*, while more posteriorly an evagination of the roof produces a stalk surmounted by a solid oval body, the *epiphysis*, or pineal body, which comparative anatomy shows to be the rudiment of an unpaired, median eye. In the floor of the ventricle there is to be found, in addition to the optic stalks, a hollow, funnel-like downgrowth, the *infundibulum*, which ends in a solid body, the *hypophysis*, or pituitary body, formed partly by a dilatation of the extremity of the infundibulum, and partly by a mass of tissue which arises as an upgrowth from the roof of the mouth, from which it becomes separated; and lastly, in each of the lateral walls of the ventricle there is to be found an oval thickening, the *optic thalamus* (Fig. 122), developed from the dorsal zone, the subthalamic tissues being the product of the ventral zones.

Since the cerebral hemispheres develop as lateral enlargements of the anterior of the two secondary portions of the vesicle, and since this portion contains a cavity (a part of the third ventricle), it is clear that each hemisphere will contain a lateral prolongation of this cavity, a *lateral ventricle*, and that each lateral ventricle will communicate with the sides of the anterior end of the third ventricle, this communication being the *foramen of Monro*. The hemispheres are, strictly speaking, excessive developments of the dorsal zones of the anterior vesicle, and there occurs in the wall of each of them a thickening, termed the *corpus striatum*, which is continuous behind with the optic thalamus. As the hemispheres continue to develop they project in front of the lamina terminalis and overlap behind the roof and sides of the 'tween- and mid-brains; and the lateral ventricles, increasing in size *pari passu* with the growth of the hemispheres, become prolonged into anterior, posterior, and lateral horns. Into the outer layers of the hemispheres an immigration of cells occurs, the cerebral cortex being thus formed, and during the earlier months of development division of these cells occurs with considerable rapidity, gradually becoming rarer, however, until some time before birth, when it completely ceases, there being, in all probability, no normal increase in the number of cells forming the cerebral cortex after birth.

At about the fourth week of development a finger-like dilatation forms on the anterior part of the under surface of each cerebral hemisphere, a prolongation from the lateral ventricle of the same side passing into it. Anteriorly, the dila-

tations fuse with the olfactory ganglia, to which the olfactory nerves pass from the mucous membrane of the nasal cavity, and they form the *olfactory lobes*, or *rhinencephalon*, the cavities which they contain becoming obliterated before adult life is attained.

Up to the fifth month of development the surface of the hemispheres is smooth, but at this time a depression appears at the side of each hemisphere (Fig. 124) involving that portion of the cortex which lies immediately external to the corpus striatum; this is the *Sylvian depression*. Later the lips of the depression grow toward each other, the upper one growing more rapidly and forming a distinct fold, the *operculum*, which covers in the floor of the depression. This covered portion of the cortex is the *insula* of descriptive anatomy, the fissure between the edge of the operculum and the lower lip of the depression being the *Sylvian fissure*. In the subsequent months of development additional fissures appear, some of which are of sufficient depth to form elevations projecting into the cavities of the lateral ventricles, the *hippocampus* of the middle horn and the *calcar* of the posterior horn being formed in this manner.

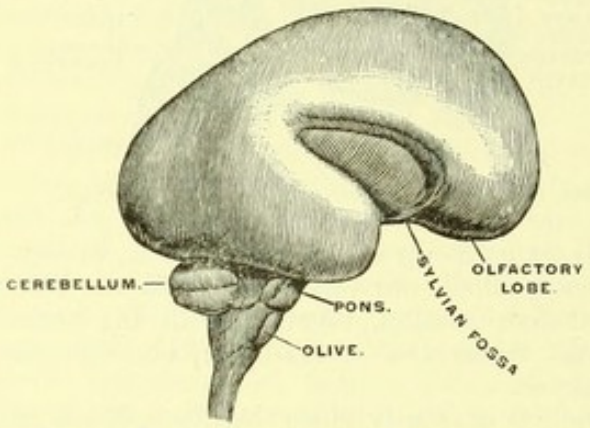

FIG. 124.—Brain of six-months' human embryo, natural size. (Kölliker.)

The lamina terminalis, as has been seen, forms the front wall of the third ventricle, and accordingly connects the two cerebral hemispheres in front. Its lower part remains relatively thin, but above it becomes much thickened from before backward, the thickening having a triangular shape. In the thickening a slit-like cavity appears, and through that portion of the thickening which forms the roof of the cavity nerve-fibres pass across from the cortex of each cerebral hemisphere to that of the other, forming the *corpus callosum*, while in the floor of the cavity longitudinal fibres develop, forming the pillars of the *fornix*. The cavity itself is the so-called *fifth ventricle*, its lateral walls being the *septum lucidum*, and it is evident from its mode of development that it cannot be considered homologous with the other ventricles of the brain.

One other set of structures require notice here, though they are not actual constituents of the central nervous system. These are the *choroid plexuses*, which consist of collections of blood-vessels developed in the pia over certain portions of the brain where the walls are exceedingly thin—as, for instance, over the roof of the third and fourth ventricles and along the floor of the lateral ventricles. The vessels push these thin membranes in front of them into the interior of the brain, and thus come to lie apparently in the interior of the ventricles, though in reality they are separated from them by the prolongation of the roof or floor which they carry in front of them.

The Sympathetic System.—The sympathetic ganglia have usually been regarded as formed by a proliferation of cells from the anlagen of the dorsal root-ganglia, and as being, therefore, of ectodermal origin. More recent observations tend to assign them to the mesenchyme, their first indication being found in a cord of cells in the mesenchyme just external to the dorsal aorta. The history of the system needs further study, however, before definite statements can be made concerning it.

The Olfactory, Gustatory, and Tactile Organs.—Of the organs of special sense the tactile and gustatory are not as yet thoroughly understood embryologically. The olfactory organ appears as two circular thickenings of the ectoderm, one on each side of the fronto-nasal process, just in front of the mouth, and these, sinking beneath the surface, come to form the floor of a pair of depressions (Fig. 99)

whose lips, gradually approaching, finally fuse, except below, to form a pair of cavities, the openings into which are the *anterior nares*. These at first communicate with the mouth, but become separated from it by the union of the two maxillary processes, a separation further perfected by the formation of the hard palate.

The Eye.—The first indications of the eye are a pair of hollow outgrowths from the anterior vesicle of the brain (Fig. 122), and these take the form of vesicles in contact with the ectoderm externally and united to the 'tween-brain by narrow optic stalks. That portion of the wall of each vesicle which is in contact with the ectoderm becomes invaginated, and the vesicle thus becomes converted into a double-walled cup, from whose walls the *retina* is formed. The invagination proceeds more rapidly on the under side of the vesicle, and is continued backward some distance on the optic stalk, which thus becomes grooved on its under surface, the optic cup being imperfect along a narrow line on its under surface, this opening being the *choroidal fissure* (Fig. 125). When the retina is established nerve-fibres grow from its cells toward the brain, choosing the optic stalk as the path of least resistance, and thus converting it into the solid *optic nerve*.

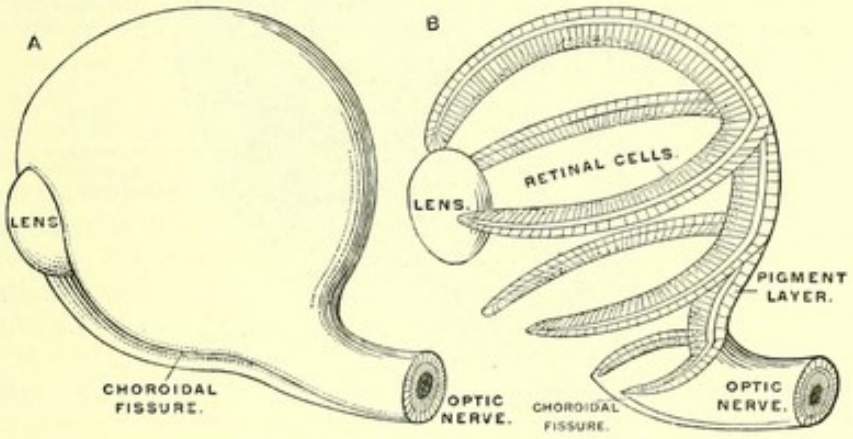

FIG. 125.—Diagrams of the formation of the optic cup and choroidal fissure.

That portion of the surface ectoderm with which the optic vesicle came in contact early begins to thicken, and later becomes invaginated, pressing upon the wall of the vesicle. This ectoderm gradually separates from the surface and forms a spherical, hollow structure, lying in the mouth of the optic cup; it is the anlage of the *lens* (Fig. 126). Later, the cells of its anterior wall flatten down to form the epithelium of the lens (Fig. 127), while those of the posterior wall become much elongated, and are converted into fibres running in various directions and completely filling the original cavity. At first the lens is in close contact with the surface ectoderm; but later mesenchymal tissue pushes in between it and the ectoderm, forming a layer which becomes converted into the *cornea* (Fig. 127), the ectoderm external to it forming the *conjunctiva*. At the same time a concentration of mesenchyme takes place all around the optic cup to form the *sclerotic* and *choroid coats* of the eyeball, and between the outer surface of the lens and the cornea fluid collects, forming the *aqueous humor*. The *vitreous body* is formed by the migration of mesenchyme into the interior of the optic cup through the choroid fissure, and is at first richly supplied with blood, the artery bringing it running along the groove on the under surface of the optic stalk, and so entering the choroid fissure. In the later

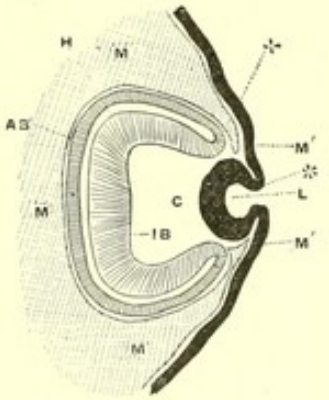

FIG. 126.—Semi-diagram of the secondary optic vesicle and the developing lens: *AB*, layer which becomes pigmentary retinal layer; *C*, posterior chamber, to be occupied by vitreous; *H*, remnant of cavity of primary optic vesicle; *IB*, layer which becomes greater part of retina; *L*, lens, as a cup open on exterior; *M*, *M*, *M*, mesoderm; *M'*, *M'*, points from which mesoderm grows in to form iris and body of cornea; +, place at which the primary optic vesicle has been doubled back on itself; *, point of invagination of ectoderm to form lens. (Wiedersheim.)

development the choroid fissure closes completely, and the lips of the groove on the stalk also meet and close, the artery thus becoming enclosed by the stalk, and forming the *arteria centralis retinæ* of the adult. Later on, the mesenchyme in

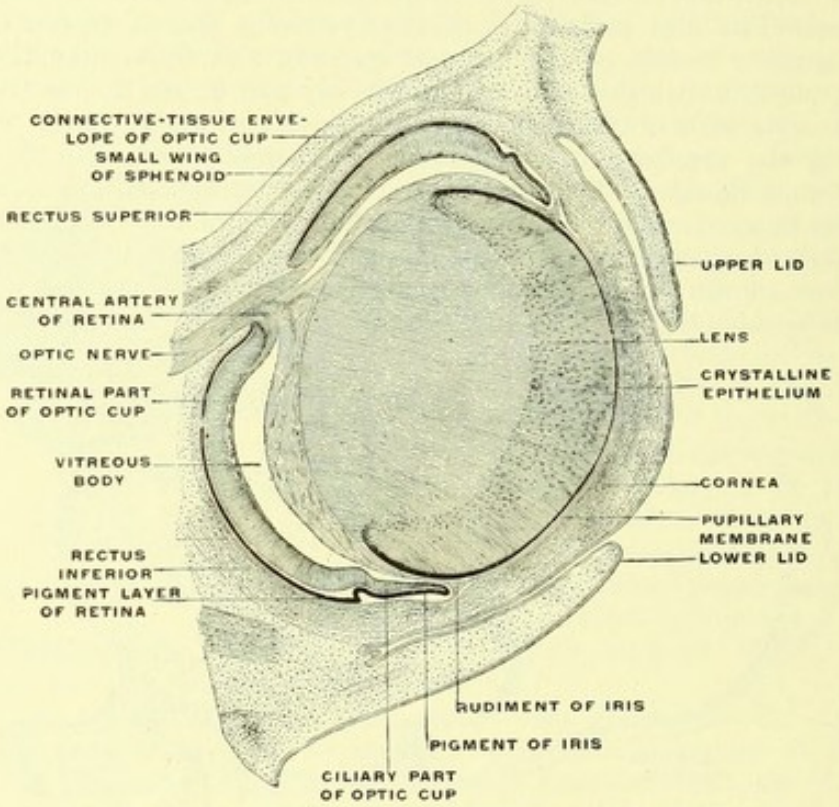

FIG. 127.—Horizontal section of the developing eye. (After Kölliker.)

the interior of the optic cup becomes converted into the peculiar gelatinous tissue of which the vitreous is composed, and its blood-supply becomes cut off, the only trace of the existence of the artery in front of the retina being the space originally occupied by the artery, persisting as a canal traversing the centre of the vitreous, and known as the *hyaloid canal*. When the blood-supply of the vitreous is at its highest development it extends as far forward as the lens, which it surrounds with a vascular capsule, which later normally disappears completely.

Of the structures accessory to the eye, the *eyelids* develop as folds of skin, which grow together over the eye, and remain fused together until shortly before birth. The *lachrymal glands* are formed as solid ingrowths (later becoming hollow) from the conjunctiva, just at the point where the upper-eyelid folds arise, while the *lachrymal duct* is developed as a thickening of the ectoderm, which forms the floor of the groove found at an early stage between the fronto-nasal and the maxillary processes. This thickening later becomes hollowed out, and the lips of the groove meet over the canal so formed, completely enclosing it, and, as the nasal cavity differentiates, the lower end of the duct comes to communicate with it.

The Auditory Organ.—The *membranous labyrinth* or inner ear is the first portion of the auditory organ to develop, appearing as a circular depression of the ectoderm over the first visceral cleft (Fig. 122). This auditory pit deepens, sinking down into the subjacent mesenchyme, its floor at the same time thickening, and it eventually becomes constricted off from the ectoderm as a completely closed sac, a small process from one side of this representing the remains of its connection with the surface, and forming the *ductus endolymphaticus*. From the ventral wall of the sac a tubular outgrowth forms, which is the anlage of the *cochlea*, and in the angle between this and the sac proper is to be found the *auditory ganglion*, which had previously formed as a thickening of the ectoderm

near the auditory pit, and had migrated into the subjacent mesenchyme. A constriction now begins to form in the inner wall of the sac (Fig. 129), dividing it into an upper and a lower portion; and from the upper portion two flat hollow disc-like outgrowths develop, one of which lies in a horizontal plane, while the other is directed vertically, but is bent so that the anterior half of it lies almost at right angles with the posterior. These are the anlagen of the *semicircular canals* (Fig. 130), which are finally formed from the edges of the discs, the central portion of the horizontal disc and of each half of the vertical one disappearing, so that three canals are formed, each opening at both extremities into the upper portion of the auditory sac. At one end of each canal a widening occurs, and, from the mode of development just outlined, it will be seen that the two vertical canals will be united together at one end to form a common canal before opening into the sac (Fig. 131). The constriction of the wall of the sac deepens gradually, until finally the upper portion, or *utriculus*, communicates with the lower portion, or *sacculus*, only by a slender canal, which represents that portion of the original sac with which the ductus endolymphaticus communicates. While these processes have been going on, a second constriction has formed between the cochlear anlage and the sacculus, whereby the connection of these two parts is also reduced to a slender canal, the *canalis reuniens*. In correspondence with this division of the original sac a division of the auditory ganglion also occurs, one portion of it, the *vestibular*

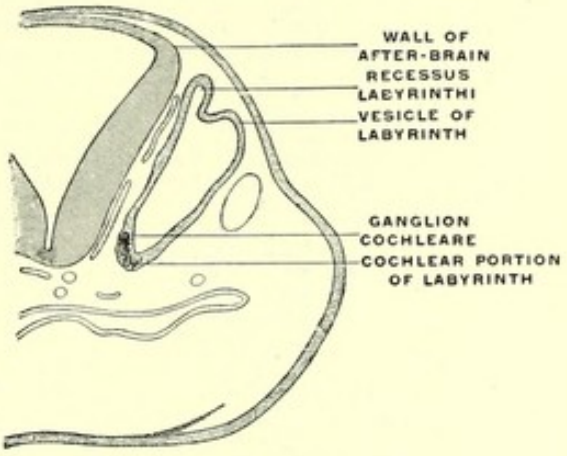

FIG. 128.—Section through the auditory vesicle of a sheep embryo. (Hertwig, after Boettcher.)

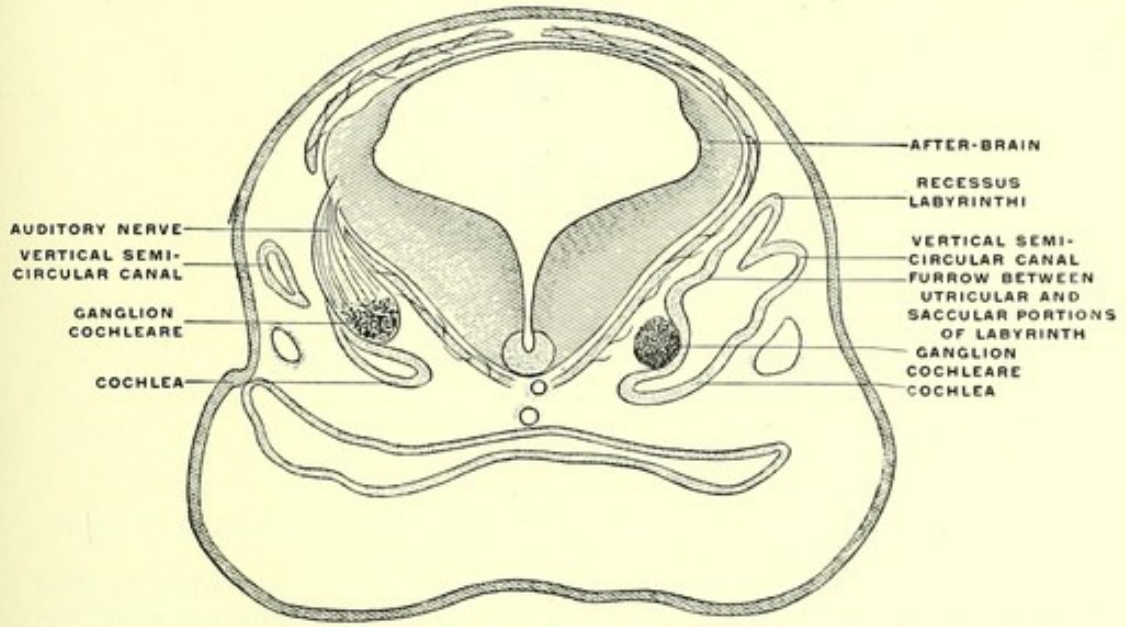

FIG. 129.—Section through the auditory vesicle of sheep embryo, somewhat older than that in Fig. 128. (Hertwig, after Boettcher.)

ganglion, being in relation to the sensory epithelium of the utriculus, sacculus, and semicircular canals, while the other is drawn out into an elongated band, the *spiral* or *cochlear ganglion*, which follows the coils into which the cochlea becomes thrown, and stands in relation to the *organ of Corti*, which develops from the cochlear epithelium.

In the mean time, a condensation of the mesenchyme surrounding each audi-

tory sac has been taking place, and the portions of the tissue immediately in contact with the walls of the sac become converted into fibrous connective tissue, and so strengthen the walls of the membranous ear, while the outermost portions become converted into cartilage, and later into bone, forming the periotic capsule, in whose walls, however, three membranous areas are left, one of these being where a canal, the *ductus perilymphaticus*, leads from the perilymphatic space to the surface of the bone. Between the inner wall of the capsule (which is composed of dense bone, and forms what is termed the *osseous labyrinth*) and the connective tissue a layer of the mesenchyme is left in the form of a loose connective tissue, which subsequently degenerates, leaving a space, which becomes filled with fluid, around the membranous ear. This is the *perilymphatic space*, which, in the cochlea, is separated into two parts by the membranous cochlea, being attached on either side to its wall, so that a section of any coil of the cochlea will show the membranous cochlea, known in anatomy as the *scala media*, with a perilymphatic space above it, the *scala vestibuli*, and another below it, the *scala tympani*, these two spaces communicating, however, at the apex of the cochlea.

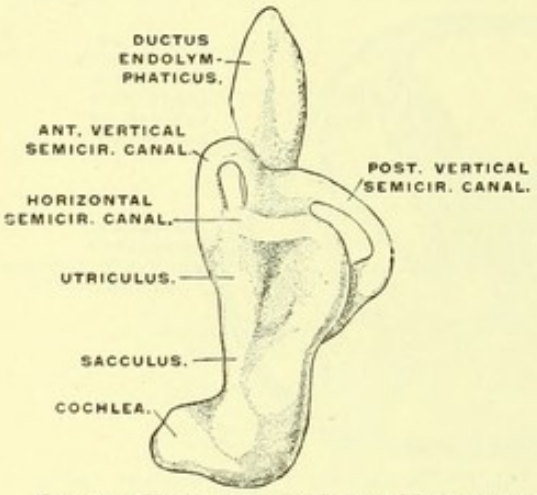

FIG. 130.—Model of internal ear of human embryo of about five weeks. (C. S. Minot, after W. His, Jr.)

The middle ear is the remains of the first visceral cleft, the groove on the wall of the pharynx which represents the cleft becoming converted into a canal

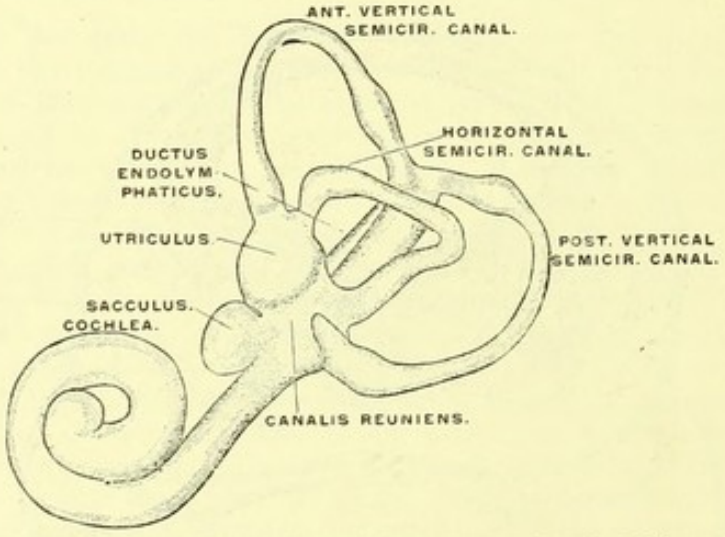

FIG. 131.—Model of internal ear of human embryo of about two months. (C. S. Minot, after W. His, Jr.)

by the fusion of its lips, the upper end of this canal being enlarged to form a cavity, the *tympanic cavity*, while the rest of it forms the *Eustachian canal*, which opens below into the pharynx. The tympanic cavity is, however, up to birth exceedingly narrow, practically merely a slit, its walls, beneath the mucous membrane lining it, being largely composed of a loose gelatinous tissue, in which lie imbedded three small bones, the *malleus*, *stapes*, and *incus*. The upper end of Meckel's cartilage, which develops, as has been seen, in the first branchial arch, separates from the lower portion, and forms two small bones, which are imbedded in the front wall of the tympanum, and are the malleus and incus; while the stapes seems to be produced by the fusion of two distinct parts. Its flat portion,

which rests in one of the three unossified spots of the osseous capsule of the internal ear, the *foramen ovale*, seems to be really the portion of the wall of the capsule which should fill this foramen, the mesenchyme immediately around it having remained membranous, while its arch is the ossified upper end of the cartilage of the second branchial arch. These bones are at first imbedded in the gelatinous tissue of the wall of the tympanic cavity. After birth, air is taken into this cavity through the Eustachian tube, and the cavity enlarges, pressing aside the gelatinous tissue and surrounding bones, which thus form a chain extending from the tympanic membrane to the foramen ovale, and apparently passing through the middle of the tympanic cavity, though in reality they are enclosed by the mucous membrane which lines the cavity.

Two of the three unossified spaces in the wall of the osseous capsule of the inner ear have been accounted for in the ductus perilymphaticus and the foramen ovale; the third opening is the *foramen rotundum*, which is closed by a membrane on which the scala tympani abuts. The outer wall of the tympanic cavity is formed by the *tympanic membrane*, and is at first thick with the gelatinous tissue which encloses the auditory ossicles, it being only after birth that it is reduced to the thin membrane found in the adult. It is formed partly by the partition between the external and internal grooves of the first branchial cleft, and partly by the upper ends of the first and second branchial arches.

Just as the inner groove of the first branchial cleft forms the Eustachian tube and tympanum, so the upper end of the outer groove of the same cleft forms the outer ear, the *pinna* developing from elevations appearing on the first and second visceral arches in the vicinity of the persistent part of the groove.

THE BONES.

By GEORGE WOOLSEY.

THE adult human skeleton consists of a number[1] of *bones*, with a small amount of *cartilage* in some parts, where they are joined or articulated with one another. The bones, as they are generally studied after maceration and drying, are composed of mineral or earthy salts, principally phosphate and carbonate of lime.[2] The soft organic parts, of which a prepared bone is deprived, consist partly of the fibrous and vascular *periosteum*, which covers the surface and is continuous with the connecting ligaments, and the *medulla* or marrow, which fills the internal cavities.

The main *functions* of bones are to afford a solid framework, to support softer parts, to protect delicate organs, and to serve for the attachment and leverage of muscles which produce the different movements. To serve these different purposes bones must differ in their *outward form*, according to which we distinguish—(1) *Long bones*, consisting of a shaft or diaphysis and two expanded extremities or epiphyses, as in the limbs. They afford support and leverage for motion, and are usually somewhat curved in one or two directions, thus securing greater strength and elasticity; (2) *Flat bones*, as in the pelvis, scapula, and the roof of the skull, affording protection and support to the contained parts, and also muscular attachment; (3) *Short bones*, as in the wrist and ankle, where strength combined with free motion is required; (4) *Irregular or mixed bones*, like the vertebræ and many of the bones of the skull.

FIG. 132.—The longitudinal section of a long bone.

Internal Arrangement.—On longitudinal section of a long bone (Fig. 132) notice that there is an outer layer of hard, *compact substance*, varying in thickness and enclosing a central or *medullary cavity*, in the shaft of the bone, and porous, spongy or *cancellous* bony tissue at the extremities. In the recent state the medullary cavity is filled with yellow or *fatty marrow*, and the cavities of the cancellous tissue with *red marrow*. Short, flat, and irregular bones have an outer layer of compact substance, enclosing cancellous tissue containing red marrow. The cancellous tissue at the ends of long bones and in other bones bearing pressure is so arranged that its bony lamellæ are principally directed in the lines of pressure or of muscular tension. The porosity or hollowness of bones serves to combine requisite size and strength with lightness.

Development of Bones.—In the early embryo the bones are preformed either

[1] Exclusive of the ossicles of the ears, the teeth, and the Wormian bones, there are 200 bones, of which 64 are in the upper extremity, 62 in the lower, and 74 in the trunk, distributed as follows: the vertebral column 26, the skull 22, the ribs and sternum 25, and the hyoid bone 1.

[2] Respectively 51 per cent. and 11 per cent. of the solids of fresh bone.

in membrane or, in the majority of cases, in cartilage covered by membrane, so that all are possessed of membranes, and ossification beneath membrane is found in all, and exclusively in some.[1] One or more original or *primary centres* appear for each bone, from which ossification proceeds, forming the *diaphysis* ("between-growth") or body. After a varying time one or several *secondary* or *tertiary centres* may appear, which form the *epiphyses* ("upon-growth"), united to the diaphysis for some time by cartilage. Some of these form the extremities of long bones, others projecting processes like the acromion of the scapula or the trochanters of the femur.[2]

Bone formed in cartilage is not adapted to be permanent, for the cartilage is non-vascular, and, further, it is not true bone, but a mere calcification. It is therefore resorbed and replaced by vascular bone from an ossific centre beneath the membrane.

In the long bones the first or primary centre in the shaft appears before birth.[3] Later, one or more secondary centres appear at either end, all but three[4] after birth. The bone-centres in the shaft and extremities of long bones are separated from one another by a layer of cartilage (*epiphyseal cartilage*), which continues to grow at the same time that the bone-centres on either side grow into it. By this means the bone is enabled to grow in length until first one, and, when growth is completed, finally both, cartilages cease to grow, and the shaft and extremities unite by ossification of the intervening layer of cartilage. Such bones grow in diameter by the deposit of bone beneath the periosteum. Bones in which ossification is begun and completed in membrane, as in the vault of the skull, are enabled to increase in size by the growth of the membrane in the sutures separating them, until they have attained their full size, when this growth stops.

Until the epiphyseal cartilage has ossified separation without bony fracture may occur here. The date of this ossification is therefore of importance in some cases. The bony union of shaft and extremities takes place according to the following rules:

1. The extremity whose ossific centre is the first to appear is the last to unite with the shaft. Exception: the lower end of the fibula, but the upper end is vestigial.

2. The extremity toward which runs the nutrient artery is the first to unite.

3. The nutrient arteries run toward the elbow and away from the knee—*i. e.*, down hill—if elbow and knee both be flexed.

4. Union of the epiphyses and diaphyses of long bones occurs from the sixteenth to the twenty-second year (occasionally twenty-fifth year, tibia), and earlier in the upper than in the lower extremity.

5. When two or more centres of ossification occur in an epiphysis, these unite together before the epiphysis unites with the diaphysis or shaft.

Many bones of the skull are *composite*, or made up of two or more elements, separate in their embryonic development, in young bones, and in the skulls of other vertebrates.

The study of these details and the comparison of the human anatomy with that of other vertebrates, on the basis of their development, constitute the study of *morphology*, in which the most recent and interesting advances in anatomy have been made.

Descriptions of Bones.—The student of osteology should always have the actual bones in his hand as he follows their descriptions, remembering that the latter represent the average of bones, and that it is very rare to meet with a bone in which every detail corresponds to the description.

[1] Ossification commencing in membrane may invade and replace cartilage, as in the clavicle.
[2] Prominent projections not developed from independent centres are called apophyses.
[3] Many primary centres of ossification appear after birth, as in the carpal bones.
[4] The adjoining ends of the femur and tibia, and sometimes the head of the humerus.

The surface of young bones is comparatively smooth. The rough lines and ridges on adult bones are due to ossification at the attachment of muscles. Any marked bony prominence may be called a *process* or *apophysis* ("out-growth"); if blunt, a *tuberosity* when large, a *tubercle* when small; if sharp, a *spine* or *spinous process;* if long, a *line* or *ridge*, when narrow, a *crest*, when broader; if articular, a *condyle* ("knuckle"), or a *head* when supported on a constricted part or *neck*. A depression or hollow space in or upon a bone or between several bones is sometimes called a *fossa* ("ditch"). A *glenoid* ("cavity-like") *fossa* refers to a shallow articular depression, a *cotyloid* ("cup-like") *fossa* to a deeper one. *Sinus* and *antrum* are terms applied to cavities within certain bones. A *fissure* is a narrow slit; a *foramen* a short opening; a *canal* or *meatus*, a longer, tube-like passage-way. Other terms used require no explanation.

In describing the different aspects of a bone or other anatomical part the body is supposed to be in the erect position. A surface, extremity, or other part directed toward the head is called *superior;* toward the feet, *inferior;* toward the front, *ventral* or *anterior;* toward the back, *dorsal* or *posterior*. That aspect directed toward the median, vertical, antero-posterior plane of the body is called *internal* or *mesial;* that away from the same plane, *external* or *lateral*.

THE SPINE.

The *spine*, or *vertebral column*, is composed of 26 superimposed bones called *vertebræ* ("capable of turning"). The name *spine* is derived from the series of spines or spinous processes which are the most obvious portions of the column of bones in the undissected body. Of these the upper 24 are *true* or *movable vertebræ*, and are divided from above downward into 7 *cervical*, 12 *thoracic*, and 5 *lumbar*. Of the two lower composite bones comprising the *false vertebræ*, the upper one, or *sacrum*, is formed by the fusion of 5 vertebræ, and the lower one, or *coccyx*, of 4 ankylosed, vestigial, terminal vertebræ, all separate in early life.

A **typical vertebra** consists of a *body* or *centrum* in front, with a *neural arch* behind, which completes the *vertebral foramen*, in the series of which the spinal cord and its membranes are lodged and protected.

The disc-like *body* supports and bears the weight of the head and trunk. Its superior and inferior surfaces are flattened or slightly concave, and rough for the connecting intervertebral discs. The circumference is concave vertically, convex horizontally, but behind it is concave in both directions, where it bounds the foramen and presents large foramina for veins.

The *neural arch* is formed of two symmetrical halves, and consists of two pedicles and two laminæ, supporting seven processes—four articular, two transverse, and one spinous.

The *pedicles* ("little feet"), or ventral parts of the arch, consist of two narrow, thick piers of bone, projecting horizontally back from the upper part of the dorsal and external aspect of the body. Above and below the pedicles are the *vertebral notches*, which, with notches of adjacent vertebræ, form the *intervertebral foramina* for the passage of the spinal nerves and vessels.

The *laminæ*, broad and flat, complete the arch by fusing together in the median line behind. Their upper borders and lower anterior parts are rough for the attachment of the ligamenta subflava.

The *spinous process* projects backward in the median line from the junction of the laminæ, and serves for the attachment of muscles and ligaments.

The *transverse processes* project outward from the junction of the pedicles and laminæ on each side.

The *articular processes* present an upper and a lower pair, extending upward and downward from the roots of the transverse processes, for articulation with the pairs above and below. The articular surfaces of the upper and lower pairs look in the opposite direction.

THE CERVICAL GROUP.

The *typical cervical vertebræ* (from the third to the sixth, inclusive) (Fig. 133) are especially characterized by the foramina in the transverse processes. The *centrum*, or *body*, is small, oval, and transversely elongated. Its upper surface is concave transversely, due to the elevation of its lateral margins into lips which articulate with the rounded lateral margins of the lower surface of the vertebra above. The lower ventral margin projects downward, so as to overlap the rounded ventral margin of the upper surface of the vertebra below. The depth of the body is equal in front and behind. The *pedicles* are directed obliquely outward and backward from about midway between the upper and lower borders of the body. The *laminæ* are long, narrow, and more or less flattened from above downward. The *spinous process* is short, bifid at the extremity, and nearly horizontal. The *transverse processes*, directed outward and forward, are seen to be rather short, and their bifid extremities present ventral and dorsal tubercles. Its base is perforated by the *costo-transverse foramen*, which transmits the vertebral artery and vein in the upper six vertebræ, and which divides the base into two roots. The dorsal root springs from the junction of the pedicles and laminæ, like the thoracic transverse processes; the ventral root springs from the side of the body, corresponding in position to the vertebral end of a rib. It is a vestigial rib (*costa*), and is called the *costal process*. The superior *articular processes* look upward and somewhat backward, the inferior downward and somewhat forward. The *foramen* is triangular, and larger than in the other regions.

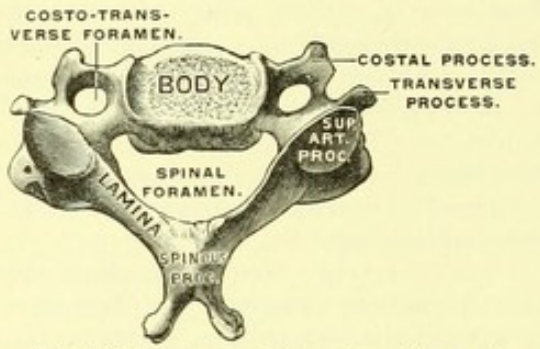

FIG. 133.—Cervical vertebra, viewed from above. (Testut.)

Peculiar Cervical Vertebræ.—These are the first, second, and seventh. The peculiarities of the first and second are such as to allow the freest movement of the head on the spinal column which is consistent with the safety of the spinal cord.

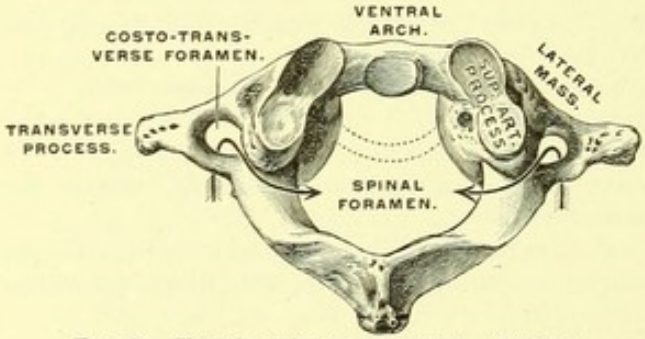

FIG. 134.—The atlas, viewed from above. (Testut.)

The **atlas** or **first cervical vertebra** (Fig. 134) lacks a body and spinous process, and forms a ring consisting of two *arches*, ventral and dorsal, connecting two *lateral masses*. The *body* has become separated from the atlas and ankylosed to the axis as the odontoid process. The *ventral arch*, one-fifth of the ring, presents in the median line in front a small tubercle for muscular and ligamentous attachment, and behind a round facet for articulation with the odontoid process. The *dorsal arch*, two-fifths of the ring, has a median tubercle behind, the rudiment of a spinous process, which, if present, would interfere with the rotation between the atlas and axis. On its upper surface, at the junction with the lateral mass, is a deep groove, sometimes a foramen, for the passage of the vertebral artery and the first spinal nerve. The groove or notch on the under surface, for the second spinal nerve, is also behind the articular process, while the lower nerves pass out in front of the articular processes. The *lateral masses* present above two oval, elongated, articular surfaces looking upward and inward, and diverging behind. These articulate with the condyles of the occipital bone and permit the nodding movements of the head. Transverse grooves may divide these surfaces

in two or give them a kidney-shaped outline. The inferior articular processes, or the facets on the under surface of the lateral masses, are nearly flat and circular, looking downward and slightly inward. Their articulation with the axis permits the rotatory movements of the head. On the inner surface of each lateral mass, between the two articular processes, is a tubercle for the transverse ligament, which divides the interior of the ring into a smaller ventral segment for the odontoid process and a larger dorsal segment, the spinal foramen, for the spinal cord. The transverse processes are long, serve for the leverage of the rotator muscles of the head, and are to be felt below the mastoid process of the temporal bone. The foramen in them is large, their costal processes are slender, and their extremities broad and not bifid.

The **axis** or **second vertebra** (*vertebra dentata*, "toothed vertebra") (Figs. 135, 136) has a large, strong body, surmounted by the *odontoid* ("tooth-like") *process*,

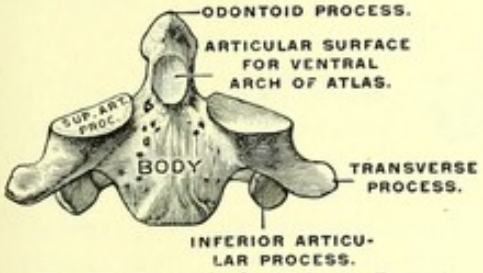

FIG. 135.—The axis, front view. (Testut.)

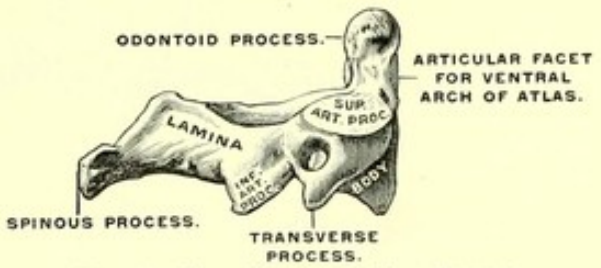

FIG. 136.—The axis, its right side. (Testut.)

on which as a pivot the atlas rotates, carrying with it the head. This process has in front a smooth surface for articulation with the atlas, and behind, at a slightly lower level, a smooth groove, which forms a constriction, the neck, and receives the transverse ligament. The lower surface of the body is like that of the typical cervical vertebra, except that the overlapping lip is more prominent. In front the body presents a vertical median ridge and two lateral depressions. The pedicles are stout, and partly on them, partly on the body, rest the oval superior articular surfaces, close to the base of the odontoid process, and directed upward and slightly outward. The weight of the head is transmitted to these surfaces through the lateral masses of the atlas, and from them it passes largely to the body and less to the inferior articular processes of the axis through a strong arch, the piers of which are the body and inferior articular processes. From this point down the weight is borne mostly by the bodies. The inferior articular processes resemble those below in form, position, and direction. The spinous process is strong, deeply bifid, and grooved below. It attaches muscles which rotate the head. The transverse processes are short. The costal processes are thick at their bases, and the anterior tubercles are very rudimentary. The foramina for the vertebral arteries are directed obliquely upward and outward toward those in the atlas.

The **seventh cervical vertebra** is called the *vertebra prominens*, from the length of its spinous process, which is a landmark readily felt beneath the skin. This is not bifid, and it attaches the ligamentum nuchæ. The costal processes and their anterior tubercles are small, but sometimes are larger and segmented off as cervical ribs. The costo-transverse foramen is small. The transverse processes are large.

The spinous process of the *sixth cervical vertebra* is occasionally so long as to be mistaken for that of the seventh, and the anterior tubercle of its transverse process is called the *carotid tubercle*, as against it the carotid artery may be compressed.

THE THORACIC GROUP.

The *thoracic vertebræ* (Figs. 137–139) are typically characterized by the presence of articular facets on the bodies and transverse processes, for articulation with the ribs which they support. The disc-like *body*, or *centrum*, is oval or

heart-shaped, only slightly wider transversely than from before backward, and deeper behind than in front. Where the body joins the arch two demi-facets are found on either side, one at the upper and one at the lower border. Each facet with the contiguous one on the adjacent vertebra completes a cavity for the head of a rib. The lower *vertebral notches* are deeper than the upper. Each broad, flat pair of the *laminæ* is imbricated, or sloped, over the pair below, like the tiles

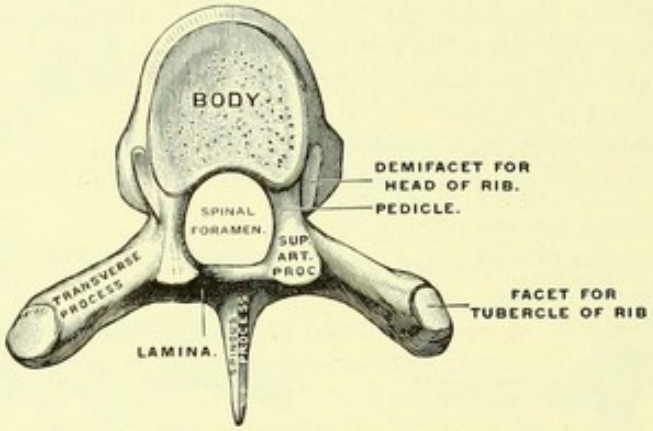

FIG. 137.—A thoracic vertebra, upper surface. (Testut.)

of a roof. The *spinous process* is long and three-sided, and projects considerably downward, especially in the middle of the series. The *transverse processes* project outward and slightly backward. The oval facets on the front of their tips are for articulation with the tubercles of the ribs. The rib in situ forms with this process a costo-transverse foramen. Of the two pairs of *articular processes*, the articular

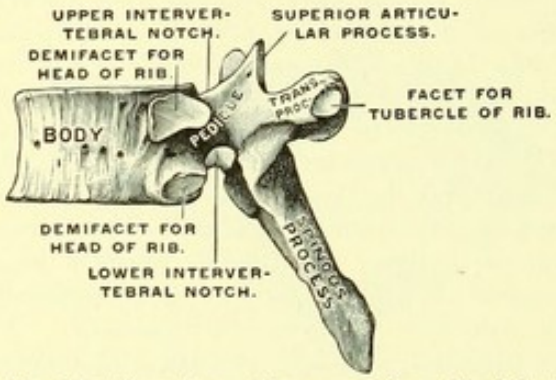

FIG. 138.—Thoracic vertebra, seen from the left side. (Testut.)

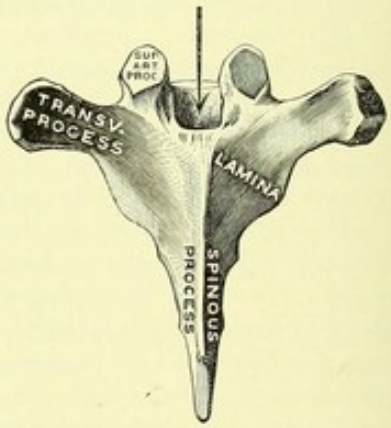

FIG. 139.—Thoracic vertebra, viewed from behind. (Testut.)

surfaces of the upper pair look backward and slightly outward and upward, those of the lower pair forward and slightly inward and downward. The *foramen* is round, and not as large as in the cervical or lumbar region.

Peculiar Thoracic Vertebræ.—These are the first, ninth, tenth, eleventh, and twelfth.

The **first** is a transitional vertebra, resembling the lower cervical vertebræ, especially on its upper surface. The body is elongated transversely, and lipped laterally above. There are entire facets above for the first pair of ribs, and demi-facets below for the second pair. The superior articular processes have largely an upward direction. The spinous process is long, nearly horizontal, and even more prominent than that of the vertebra prominens.

The **ninth** has demi-facets above, but frequently none below. If the lower ones are present, it is a typical vertebra.

The **tenth** articulates with but one pair of ribs. It has no demi-facets below, and the upper facets are usually complete, and mainly on the pedicle.

The **eleventh** has a complete facet on the base of each pedicle, and none on the short transverse processes. The large body is elongated transversely, and the spinous process is short, stout, and horizontal, thus approaching the lumbar type.

The **twelfth** resembles the lumbar still more in its body, spinous and transverse processes. The latter are short, and present external, superior, and inferior tubercles, corresponding to the transverse, mammillary, and accessory processes of the lumbar vertebræ. The inferior articular processes look outward, as in the lumbar. As to facets, it resembles the eleventh.

All the thoracic vertebræ are thus seen to have either entire or demi-facets above, and only the first eight or nine have demi-facets below.

Variety.—The tenth vertebra occasionally has no facets on the transverse processes.

THE LUMBAR GROUP.

The five *lumbar vertebræ* (Fig. 140) are characterized by their large size and the absence of costal articular facets. The *bodies* are elongated transversely, and are slightly deeper in front than behind from the third down. The *laminæ* are strong, short, and deep. The *spinous processes* are thick, horizontal, and broad from above downward. The slender so-called *transverse processes* project outward from the pedicles in serial line with the lower ribs. They are in reality costal processes, and sometimes are developed into lumbar ribs, especially in the first lumbar vertebra. At their bases, dorsally, a small process is seen to project downward—the *accessory tubercle* or rudimentary transverse process. The facets of the *superior articular processes* are slightly concave, and look inward and somewhat backward. From their outer edges a tubercle projects backward, the *mammillary process*, which corresponds to the superior tubercle of the lower thoracic vertebræ. The facets of the *inferior articular processes* look outward and slightly forward. They are nearer together, and are embraced by the superior processes, but not so closely as to prevent slight lateral and rotatory movements between the vertebræ. The *foramen* is triangular and larger than in the thoracic vertebræ.

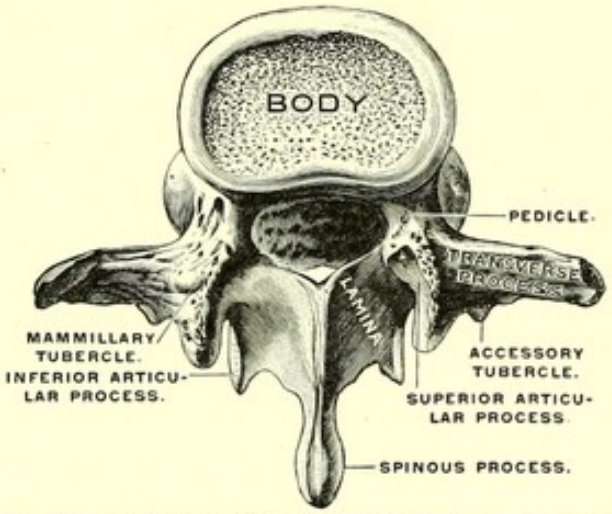

FIG. 140.—Lumbar vertebra, viewed from above. (Testut.)

The **fifth lumbar vertebra** is transitional, approximating the sacral. Its body is large, wedge-shaped, and much deeper in front than behind. To articulate with the first sacral vertebra its inferior articular processes are as wide apart as the superior. The transverse processes are large, broad, and conical, sometimes articulating with the sacral alæ. The spinous process is short.

Varieties.—In a small percentage (estimated at 5 per cent.) of cases the fifth lumbar vertebra is so separated into two parts through the arch that the dorsal segment consists of laminæ, spinous and inferior articular processes.

Varieties as to the Number of Movable Vertebræ.—The cervical vertebræ are remarkably free from variation in number, not only in man, but in all mammals, with two or three exceptions. Variation in the number of thoracic and lumbar vertebræ may be reciprocal when it depends upon an increase or decrease in the number of pairs of lower ribs, causing an increase in the thoracic and a decrease

in the lumbar, or the reverse. Whether the extra vertebra be thoracic or lumbar, the characters of this vertebra are more those of the lumbar type. Or, again, the number of movable vertebræ may be increased or decreased by one, causing an increase or decrease of one in the thoracic or lumbar group. This increase is usually in the lumbar series, the lower one of which may be partly united to the sacrum.

Table showing the Characters of the Typical Vertebræ of Each Group.

	Cervical.	Thoracic.	Lumbar.
Bodies:	Small, transversely elongated. Sloped downward and forward. Lipped laterally. No costal facets.	Heart-shaped. Deeper behind. Nearly equal transversely and anteroposteriorly. Costal facets.	Large, elongated transversely. No costal facets.
Pedicles:	Pass outward and backward. Notches above and below nearly equal.	Pass backward. Inferior notches deeper than superior.	Pass backward and slightly outward. Inferior notches deep.
Laminæ:	Long, slender, flattened.	Broad, short, imbricated.	Short, deep, and thick.
Spinous processes:	Short, strong, bifid, and nearly horizontal.	Long, projecting downward and overlapping.	Quadrate, horizontal; of medium length.
Transverse processes:	Short, slender, directed outward and forward.	Long, strong. Project outward and backward. Articulate with tubercles of ribs.	Rudimentary, as "accessory process."
Costal process:	Slender, flat, ossified to the vertebra and transverse process.	A separate bone (*i. e.* a rib).	Ossified to vertebra. Flat, thin, "transverse process."
Superior articular processes:	Flat. Directed upward and slightly backward.	Flat. Directed backward and slightly outward.	Slightly concave. Directed inward and slightly backward.
Inferior articular processes:	Flat. Directed downward and slightly forward.	Flat, Directed forward and slightly inward.	Slightly convex. Directed outward and slightly forward.
Spinal foramen:	Large, triangular, wide.	Smaller, circular.	Larger than in the thoracic. Triangular, wide.

The one distinguishing feature of a cervical vertebra is the costo-transverse foramen; of a thoracic vertebra, the articular facet or demi-facet on the body; and of a lumbar, the absence of both of these peculiarities.

THE SACRAL VERTEBRÆ.

These in early life present the elements of five distinct vertebræ, but in the adult they are united into a curved triangular bone, the *os sacrum*, so called from its use in sacrifice (Figs. 141–143). It articulates laterally with the two hip-bones of the pelvic girdle, and, with the coccyx, completes the pelvis behind and above. In the erect position the sacrum lies obliquely, its upper surface or base inclined well forward.

The sacral vertebræ decrease in size from above downward, thus giving a triangular shape, with a base, apex, ventral, dorsal, and lateral surfaces. Its separate elements present most, if not all, of the component parts of the movable vertebræ; and the different parts of the sacrum are best understood when studied with reference to these parts.

The *base* of the sacrum, or the upper surface of the first sacral vertebra, resembles that of a lumbar vertebra. The large, transversely oval upper surface of the body extends forward to meet the ventral surface at the *promontory* of the sacrum which forms the dorsal boundary of the pelvic brim. Its superior *articular processes*, widely separated, look backward and inward like the lumbar, and have well-marked mammillary processes. The *foramen* is triangular. On the sides of the body we see the smooth *alæ*, or wings, on the upper surface of the *lateral masses*, which are formed by the fusion of the transverse and costal processes on either side. The alæ are continuous with the iliac fossæ on each side.

The *apex* of the sacrum, directed downward and a little forward, is formed by the transversely oval inferior surface of the body of the fifth sacral vertebra. This articulates with the coccyx by means of an intervertebral disc which in advanced life often ossifies.

The *ventral surface* looks downward as well as forward. It is concave vertically, less so transversely. In the female it is broader, less curved vertically,

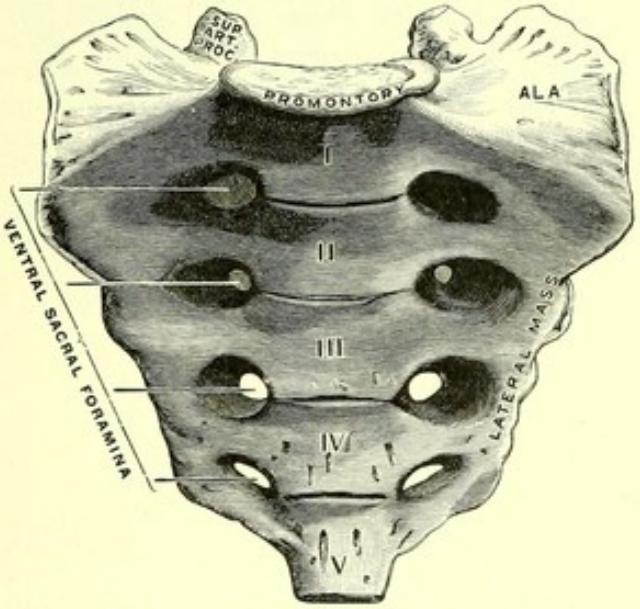

FIG. 141.—The sacrum, ventral view. (Testut.)

and the apex is directed more obliquely backward. The five bodies form the middle of this surface. The upper two are large, the lower three smaller. They are separated by four transverse ridges, the ossified intervertebral discs, which are bounded laterally by the four pairs of *ventral sacral foramina*, the ventral openings of the intervertebral foramina. The ventral foramina transmit the ventral divisions of the first four pairs of sacral nerves, and lead externally into grooves in the lateral masses, which in front consist of fused costal processes.

The *dorsal surface* is convex, rough, and narrower. It presents in the median line the spinous processes of the three or four upper vertebræ, united into one or two ridges by ossification of the connecting ligaments. The fifth spine always, the fourth usually, and all rarely, are wanting. On either side is the *sacral groove*, continuous with the vertebral groove above, and formed by the ankylosed laminæ. The laminæ of the fifth vertebra always, and those of the fourth often, are incomplete, leaving a triangular gap in the lower dorsal wall of the spinal canal. The lower margins of this gap are prolonged down as two tubercles, the *sacral cornua* ("horns"), which represent the inferior articular processes of the fifth sacral vertebra, and are connected by ligaments with the coccygeal cornua.

On each side of the sacral groove is a series of small prominences, the *articular* and *mammillary processes*, separated from a more external series of larger eminences, the *transverse processes*, by the four *dorsal sacral foramina*. The latter are opposite to, but smaller than the ventral sacral foramina. The four sacral intervertebral grooves on each side pass outward as canals as far as the lateral mass, where they bifurcate and pass forward and backward to the ventral and dorsal foramina.

That part of the bone external to the foramina represents the *lateral mass*, whose lateral surfaces are broad and thick above, narrow below. The upper broad part of each lateral surface presents in front an uneven articular surface, called the *auricular surface*, from its ear-like shape, which articulates with the ilium, and behind a rough surface for the attachment of the posterior sacro-iliac

ligaments. Below this the narrower rough margin attaches the sacro-sciatic liga-

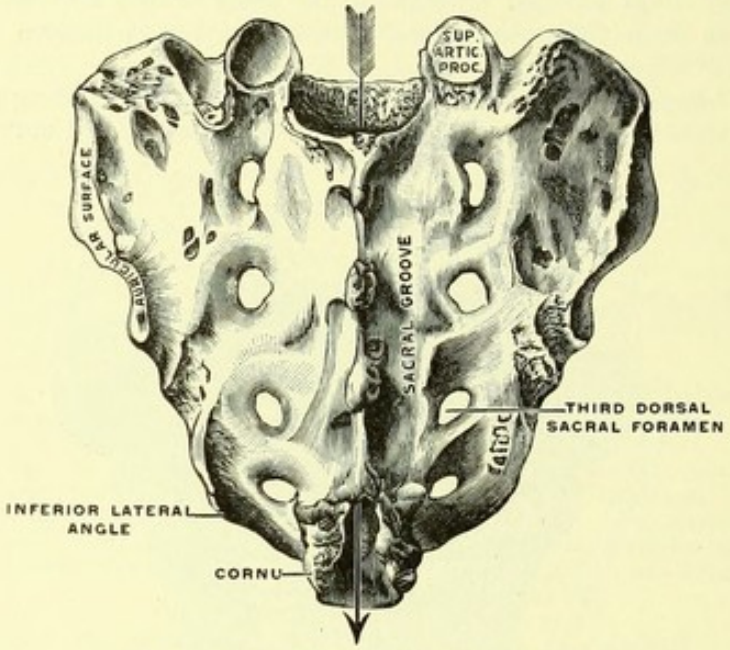

FIG. 142.—The sacrum, dorsal view. (Testut.)

ments, and ends in a projection, the *inferior lateral angle*, below which there is a notch, converted into a foramen by ligaments from the coccyx. Through this foramen passes the anterior division of the fifth sacral nerve.

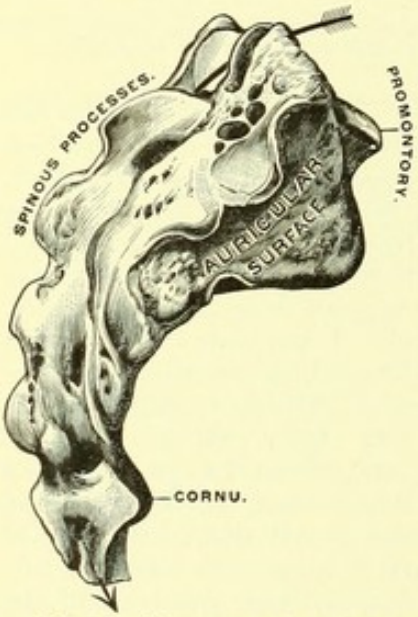

FIG. 143.—The sacrum, its right side. (Testut.)

The sacral *spinal canal* curves and narrows with the bone. It is triangular above on transverse section, flattened or semilunar below, and lodges the lower end of the cauda equina and filum terminale with the spinal dura.

Peculiarities and Varieties.—The second and third sacral vertebræ represent the sacrum of mammals—the fourth and fifth the first two caudal vertebræ, while the first represents the sixth lumbar of most quadrupeds. This explains the occasional partial or complete separation, and the transitional and partly lumbar character of the first sacral, not rarely present. The large number of sacral vertebræ in man is associated with his upright position. The sacrum sometimes consists of six segments, more rarely of only four. In the former instance the first coccygeal is usually included. The breadth of the sacrum as compared with its length is remarkably great in man as compared with mammals, and especially so in the European specimens.

THE COCCYX.

The *coccyx*[1] (Fig. 144) consists of four, but sometimes of five and rarely of three, rudimentary vertebræ. These consist of little else than bodies tapering in size from above downward, so as to give the bone a triangular outline. They are ankylosed together, and oftentimes with the sacrum, in advanced life; but in middle life, especially in the female, the first is movable on the succeeding three and on the fifth sacral, with which it is united by fibro-cartilage.

[1] Named from its resemblance to a cuckoo's beak.

The **first coccygeal vertebra** presents vestiges of a neural arch in two upward projecting *cornua* and two laterally projecting *transverse* or *costal processes*. The cornua, representing pedicles and superior articular processes, complete the last intervertebral foramina for the fifth sacral nerves by their connection with the sacral cornua. The transverse processes complete the notches below the lateral sacral angles, which are converted by ligamentous tissue into the fifth anterior sacral foramina.

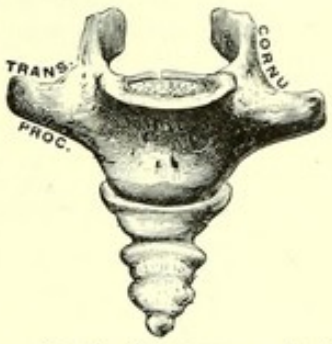

FIG. 144.—The coccyx, ventral surface. (Testut.)

The **second coccygeal vertebra** presents two knobs dorsally and two laterally, vestiges of the neural arch and costal processes respectively. Three grooves separate the four bodies. The ventral surface is concave, is closely related to the rectum, and attaches inferiorly the levator ani muscle. To the thin lateral borders are attached parts of the coccygeus muscle and great sacro-sciatic ligaments, to the tip the external sphincter ani, and to the posterior surface some fibres of the gluteus maximus.

THE SPINE AS A WHOLE.

The *vertebral* or *spinal column* (Fig. 145) is the central axis of the skeleton, and occupies the median line of the trunk dorsally. It supports the head superiorly, the ribs laterally, and through them the weight of the upper extremities. It transmits the weight of these parts to the lower limbs through the hip-bones, with which the sacrum articulates. It also encloses and protects the spinal cord in the bony spinal canal, which is provided with a series of thirty intervertebral foramina for the exit of the spinal nerves. The average length of the spine from the atlas to the tip of the coccyx, following the curves, is twenty-eight inches in the male and twenty-seven inches in the female. About one-quarter of its length is made up of the intervertebral discs.

The *profile view* presents four curves, convex forward in the cervical and lumbar regions, backward in the thoracic and sacral. The thoracic and sacral curves are primary, and occur in the early embryo, accommodating the thoracic and pelvic viscera. They are due to the shape of the bodies, while the secondary cervical and lumbar curves are due largely (if not entirely in the cervical) to the shape of the intervertebral discs. The latter two curves are compensatory to allow the erect position, and are developed after birth. Notice that the upper three curves pass imperceptibly into one another, while the junction of the lumbar and sacral curves makes an angle, the *lumbo-sacral* (or *sacro-vertebral*) *angle*, which forms the overhanging *promontory* of the pelvis. Weight is transmitted by the upper three curves and the first one or two pieces of the sacrum to the hip-bones and lower extremities. In the erect position the chords of these three curves are in the same vertical line, the line of gravity of the head, which passes through the odontoid process, the middle of the bodies of the second and twelfth thoracic, and the ventro-inferior edge of the last lumbar vertebra. The curves add greatly to the elasticity and strength of the column, and thus break shocks and increase its resistance to injury. In addition to these, a slight lateral curve, usually convex to the right, exists in the upper thoracic region, due probably to the greater muscular use of the right side of the body. Pathological exaggerations of all these curves may exist. Such a curvature is called *scoliosis* ("curved") if lateral, *kyphosis* ("humpback") if dorsal, and *lordosis* ("bend") if ventral, the latter being usually compensatory to an ankylosed hip.

The *front view* presents the bodies of the vertebræ becoming broader from the axis to the first thoracic, and from the fourth thoracic to the sacrum; and becoming narrower from the first to the fourth thoracic, and from the first sacral to the tip of the coccyx. Thus, four pyramids are formed; but the total surface area of the

bodies steadily increases from above downward to the sacrum. The bodies are widest in the cervical and lumbar regions, where motion is most free.

The *rear view* presents in the middle line the series of spines, nearly horizontal and about opposite the corresponding bodies in the cervical and lumbar regions, thus allowing free motion. The spines of the upper cervical vertebræ are not readily felt in the living body until we reach the seventh, or sometimes the sixth, spine. The upper thoracic spines are easily felt as subcutaneous, the lower thoracic and lumbar less so, for they lie in the deep *spinal furrow* bounded by the masses of muscles which occupy the vertebral grooves.

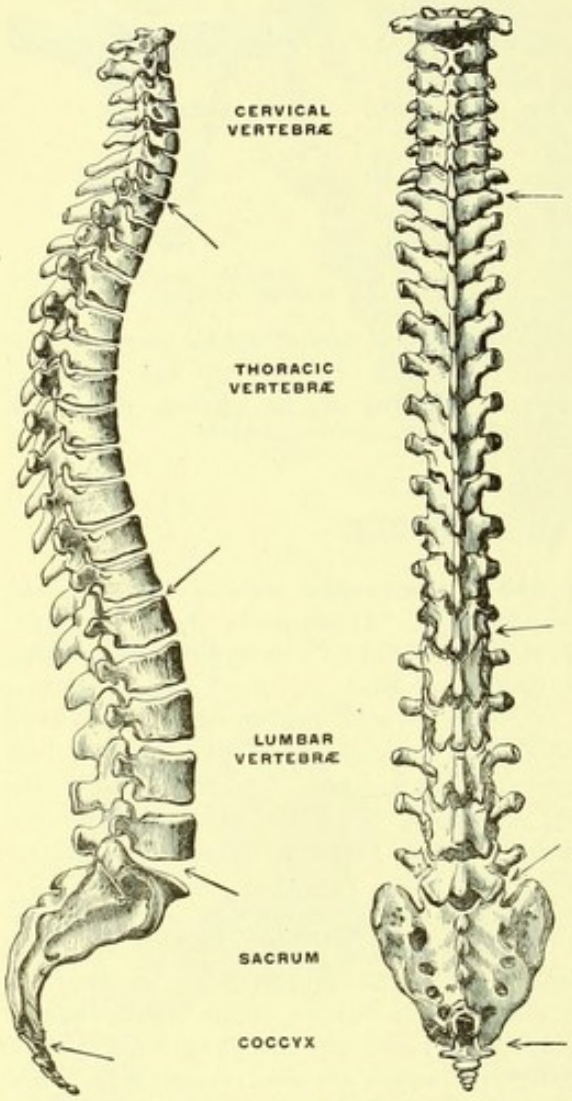

FIG. 145.—The spinal column, right lateral view and dorsal view. (Testut.)

At the sides of the spines are the *vertebral grooves*, bounded externally by a row of transverse processes. The floor of these grooves is formed by the laminæ, connected by the ligamenta subflava, and by the articular processes with the mammillary processes in the lower part of the spine. The *spinal canal* is large and triangular in the cervical and lumbar regions, smaller and round in the thoracic region, and still smaller and flattened in the sacral region.

The weakest point in the spine is found between the second and third cervical vertebræ, but the union of the thoracic and lumbar curves, or the twelfth thoracic vertebra and those on either side of it, is most liable to injury, for here a fixed part joins the most movable, there is a long leverage on both sides, and the transverse width is least. Notice that the plane between any two vertebræ is interrupted by the upward and downward projection of the articular processes and other parts connected with the neural arch. Simple dislocation between two vertebræ is, therefore, almost impossible, unless perhaps in the cervical region, where the surfaces of the articular processes are more nearly horizontal. This is borne out in practice, where we find fracture-dislocation the common injury, the processes or neural arch being commonly fractured, if not the body itself.

Ossification of the Vertebræ.

The vertebræ are preformed in cartilage (Fig. 146) around the notochord and enclosing the spinal cord. In most cases three primary centres of ossification occur—one on either side in the neural arch, and one in the body. The former unite together in the median line dorsally to form the arch. But sometimes this union fails for a distance, especially in the lumbar and sacral regions, leaving a gap through which a spina bifida may occur. The part formed by the ossific centres of the neural arch constitutes a varying amount of the lateral and dorsal aspects of the bodies (including the rib facets), separated for a time

from the rest of the body by the cartilaginous neuro-central suture. At birth a vertebra consists of three ossified parts—a body and the two lateral halves of the neural arch—connected by cartilage. Later five epiphyseal centres appear—three of which form tips for the spinous and transverse processes, and two form thin plates on the upper and lower surfaces of the bodies. The mammillary processes of the lumbar vertebræ have each a small centre. The costal processes of the sixth and seventh cervical usually, of the first lumbar sometimes, and occasionally of other cervical vertebræ, are formed from separate centres. These may remain separate and become cervical or lumbar ribs. The various centres are not wholly united until about the twenty-fifth year.

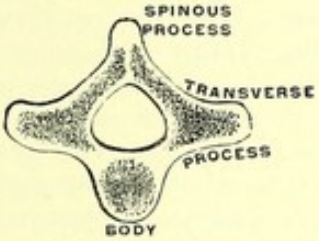

FIG. 146.—Beginning of ossification in the cartilaginous vertebra of a fœtus. (Testut.)

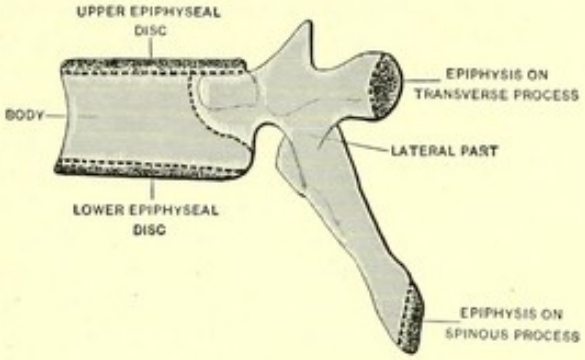

FIG. 147.—Ossification of a thoracic vertebra. (After Testut.)

The *atlas* has regularly three centres—one for either half of the neural arch, formed by the lateral masses and the dorsal arch, and the third for the ventral arch. The *axis* (Fig. 148) ossifies much like other vertebræ, but its odontoid process has two laterally placed centres, which unite together, and later with the body of the axis, though the centre of the intervening cartilage persists through life. An epiphyseal centre also occurs for the apex of the odontoid process. The *sacrum* (Fig. 149) also ossifies essentially like other vertebræ, except that there are separate centres for the costal processes of the upper three vertebræ, and the auricular articular surfaces have two secondary centres each. The intervertebral discs ossify on the surface, but not in the centre, from the eighteenth to the twenty-fifth year, from below upward. The *coccyx* is cartilaginous at birth, and each segment has commonly but one centre. The lower three ankylose before middle life, and these with the first still later, while bony union with the sacrum belongs to advanced life.

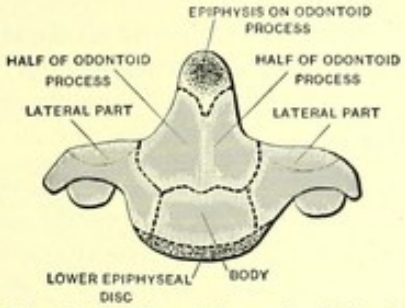

FIG. 148.—Ossification of the axis. (After Testut.)

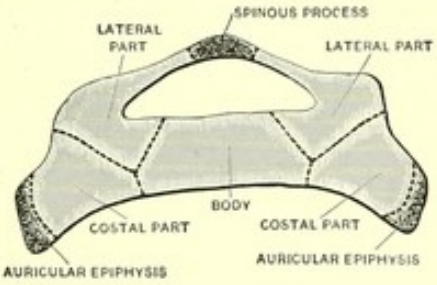

FIG. 149.—Ossification of the sacrum—horizontal section through first piece. (After Testut.)

Variations.—Two or a single lateral centre may exist in a vertebral body, forming a divided or a half vertebra. In the fifth lumbar vertebra the neural arch often has four centres. The pairs on either side may fail to unite with each other, causing a separation of the laminæ and inferior articular processes from the pedicles, etc.

Serial Morphology of the Vertebræ.—The similarity of construction of the vertebræ in each region of the column is evident from the study of their development and ossification. Centra or bodies are present for all the vertebræ in man,

but that of the atlas is dissociated from its neural arch and joined to the body of the axis as the odontoid process. The anterior arch of the atlas probably belongs to a series of hypophyses or subvertebral wedge-bones (found in lizards, etc.). Nothing need be said of the neural arches and spines, except that they are incomplete or wanting in the lower sacral and coccygeal regions. The articular processes are not morphologically important ; but the upper three are not homologous with other articular processes, but rather with the lateral parts of the bodies formed by the neural arches. The transverse processes, so called, present more difficulty as well as interest. We find two transversely directed processes—a ventral or *costal process* and a dorsal or transverse process proper. They present themselves in the simplest form in the thoracic region, where the ventral or costal process is a separate rib, which by articulation with the transverse process encloses an arterial foramen, the costo-transverse. This foramen is seen also in the cervical region, where, however, the costal processes are ankylosed with the transverse processes and bodies, except when, in the lower cervical vertebræ, they form separate cervical ribs. In the lumbar region the costo-transverse foramen is only indicated by a group of holes at the base of and between the transverse process and the accessory tubercle. The latter represents the tip of the suppressed dorsally situated transverse process, while the former represents a costal process, and in the first lumbar sometimes exists as a separate lumbar rib. In the upper three or true sacral vertebræ the large ventral costal processes and the dorsal transverse processes unite to form the lateral masses which articulate with the hip-bones by means of their costal parts. The mammillary processes (best seen in the lumbar and lower thoracic regions) are rudiments of the much-elongated articular processes in some animals, as the dog, etc.

THE THORAX.

Besides the thoracic vertebræ already described, the skeleton of the thorax ("breast-plate") consists of the sternum, ribs, and costal cartilages.

THE STERNUM.

The *sternum* or *breast-bone* (Fig. 150) is a long, thin, flat bone, situated subcutaneously in the middle of the ventral wall of the thorax. It is connected with the thoracic part of the vertebral axis by the cartilages of the first seven ribs on each side, and, through the attachment of the clavicle, it connects the shoulder-girdle and the upper extremity to the vertebral axis. It lies obliquely, so that its lower end is farther forward than the upper. The upper end corresponds to the lower border of the second, the lower end to the middle of the ninth, thoracic vertebra.

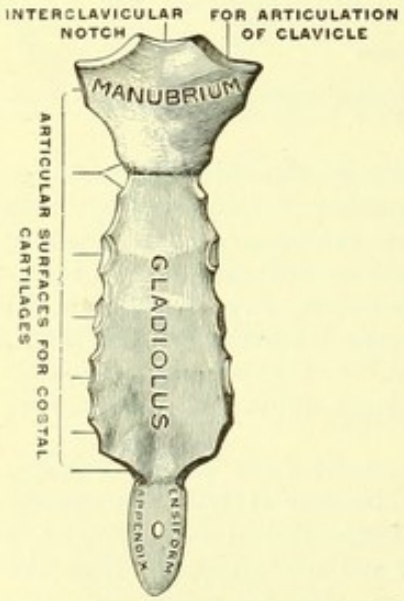

FIG. 150.—The sternum, ventral aspect. (Testut.)

It consists of three parts, derived from six original segments. The first segment, or upper part, remains separate through life as the *manubrium* ("handle") or pre-sternum, united by fibro-cartilage to the succeeding four segments which form the *gladiolus* ("little sword") or *body* (meso-sternum). The sixth or lower segment, forming the *xiphoid* or *ensiform* ("sword-like") *process* (meta-sternum), remains cartilaginous and distinct to advanced age, when it may ossify in whole or in part, and ankylose with the body. It is usually bent, and

often perforated, notched, or bifid. It lies in a plane behind that of the body of the sternum and the cartilages of the seventh ribs. The sternum is longitudinally convex in front, concave behind, and presents transverse ridges where the segments unite. It consists of loose cancellous tissue with a thin shell of compact bone.

The manubrium forms the upper border of the sternum, which is deeply notched in the middle (*interclavicular notch*), and presents at its lateral angles two depressed surfaces looking upward, outward, and backward, where the clavicles articulate. On each side of the manubrium, at the widest part of the sternum, is a rough, triangular surface for union with the cartilage of the first rib. Below this the sternum rapidly narrows to the junction of the manubrium and the body, indicated by a prominent transverse ridge, easily felt through the skin and important as a landmark. Here the second costal cartilage articulates with a surface formed of two demi-facets, one on the manubrium and one on the body. The third, fourth, and fifth costal cartilages articulate with the sides of the body at the ends of the transverse ridges between the segments.[1] The sixth and seventh costal cartilages articulate with the sloping and narrow sides of the lower segment of the body, the facet for the seventh cartilage being completed by a demi-facet on the ensiform process. The spaces between the articular facets correspond to the intercostal spaces, and narrow from above downward.

Muscles Attached.—In front: laterally, to the manubrium and body, the pectoralis major; below the notch for the clavicle, the sterno-cleido-mastoid; to the base of the ensiform process, the rectus abdominis; to the sides and tip of the ensiform process, the aponeurosis of the oblique and transverse abdominal muscles. Behind: near the superior angles, the sterno-hyoid and sterno-thyroid; laterally, in the lower four segments, the triangularis sterni; to the ensiform process, the diaphragm. On the sides: between the facets, the internal intercostals.

The sternum articulates with seven, and occasionally eight, costal cartilages and the clavicle on each side.

The sternum is subcutaneous at the bottom of the *sternal groove*, which is due to the lateral prominences of the pectoral muscles, and is limited above by the interclavicular notch and below by the infrasternal depression, due to the prominence of the seventh costal cartilages above the level of the ensiform process. The proportionate length of the body is greater in the male than in the female. Its average length is six inches in the adult male, somewhat less in the female.

Development.—The sternum is formed by the fusion of the ventral cartilaginous ends of the upper ribs into two lateral bars, which later fuse together mesially, except in rare cases where a cleft sternum exists.

Ossification is irregular, but usually the first two segments present a single primary centre, while two laterally placed centres commonly occur in the succeeding segments. By the failure of the latter to unite across the median line a median foramen or a vertical fissure may be left.

THE RIBS.

The *ribs* (costæ) extend in twelve pairs from the thoracic vertebræ in an outward and forward curve toward the median line in front. They form the lateral walls of the thoracic cage, and are prolonged in front by the costal cartilages. As the upper seven pairs of the latter pass to the sternum, the corresponding seven pairs of ribs are called *true* or *sternal ribs*, while the lower five pairs are called *false* or *asternal ribs*. Of the latter, the lower two pairs are called *floating ribs*, as their forward ends are free, while those of the three pairs above them are connected together. The length of the ribs increases from the first to the eighth, and thence it decreases to the twelfth. The greatest breadth is found at the sternal end. The ribs are highly elastic, owing to their slenderness and curvature.

[1] The second, third, fourth, fifth, and seventh costo-sternal articulations correspond to the articulations of the heads of their ribs with two vertebræ.

The general characters of typical ribs are best marked in ribs like the seventh, near the centre of the series. A *typical rib* (Fig. 151) consists of an enlarged

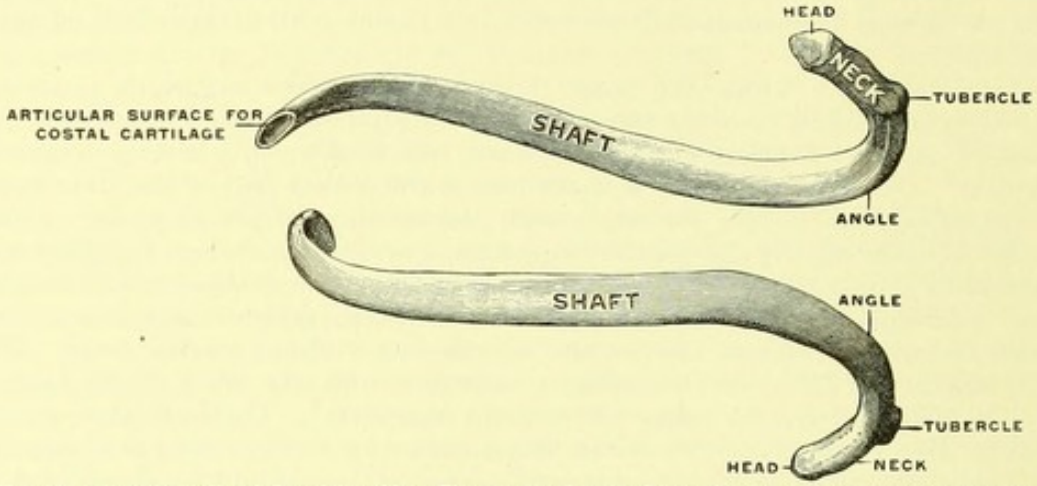

FIG. 151.—A typical rib of the right side. The upper picture shows the inner surface, the lower one the outer surface. (Testut.)

vertebral end, or head, joined by a constricted neck to a shaft, presenting a tubercle, an angle, and a sternal end. The *head* shows two articular facets, separated by a slight horizontal ridge, to which the interarticular ligament from the intervertebral disc is attached. The facets articulate with the two demi-facets on the sides of the bodies of two contiguous vertebræ. The lower facet is the primary and larger one, and articulates with the vertebra which corresponds to the rib in number, and it is the only facet where there is but one. The *neck* is that part between the head and the tubercle. It is rough behind and along the upper and lower borders for the costo-transverse ligaments, and forms the ventral boundary of the costo-transverse foramen. The *tubercle* is divided by an oblique groove into an inner and lower smooth portion for articulation with the front of the tip of the transverse process of the vertebra of the same number as the rib, and an outer and upper rough part for the posterior costo-transverse ligament. The *body*, or *shaft*, beginning with the tubercle, extends to the cupped *sternal end*, which receives the costal cartilage. It is laterally compressed, so as to present inner and outer surfaces and upper and lower borders. On the inner aspect of the inferior border is the *subcostal groove*, which lodges the intercostal vessels and nerves. It is best marked near the angle, and is limited above by a ridge which is continuous with the inferior border of the neck and attaches the internal intercostal muscle. The inferior border, which begins near the angle, attaches the external intercostal muscle; the superior border attaches both intercostal muscles; the convex external surface affords attachment for muscles.

The shaft is curved around a vertical axis, or rather two axes. The dorsal and sharper curve is in line with the neck, and extends outward to the *angle*, where the rib takes a sudden bend, in front of which the curve is more gradual. The curvature of the ribs decreases from the first, the most curved, to the twelfth, the least curved. The back of the angle is rough, for the attachment of the iliocostalis muscle and its upward continuation. At the angle the ribs from the third to the twelfth are also bent on a horizontal axis, so that if they be rested on their lower borders the head end of the ribs curves upward from the angles. This curve increases from the third to the seventh, and thence decreases to the twelfth. The head end of the first and twelfth bend slightly downward; that of the second is in line with the shaft. This curve is sometimes spoken of as a twisting of the rib on itself. It increases the obliquity of the ribs as far as the seventh or eighth.

Peculiar Ribs.—The *first rib* (Fig. 152) is the least oblique, and is so placed that its surfaces present upward and downward. If laid on its lower surface, the

head end does not bend up, but slightly down. The small head has but a single facet, the neck is long and narrow, and the tubercle and angle coincide. On the broad superior surface and close to the centre of the internal border is a rough mark, the *scalene tubercle*, the origin of the scalenus anterior muscle. It separates a groove in front for the subclavian vein from one behind for the subclavian artery. Behind the latter groove are attached the first digitation of the serratus magnus externally and the scalenus medius internally. The subcostal groove is wanting. The *second rib* (Fig. 152) has no upward curve of the head end, but it lies almost perfectly flat. The upper surface looks obliquely outward, and has a prominent roughness for the serratus magnus. The angle is but slightly marked. The *tenth rib* has usually a single facet on the head, sometimes two facets. The *eleventh rib* has but one facet, no neck or tubercle, a feeble angle, and a shallow subcostal groove. The *twelfth rib* resembles the eleventh, but has no angle and no subcostal groove. It is shorter, and may be rudimentary, measuring less than 1 inch in length—an important point in lumbar incisions. It either lies flat on its lower border, or its head end may bend slightly downward. Its outer surface may incline somewhat downward.

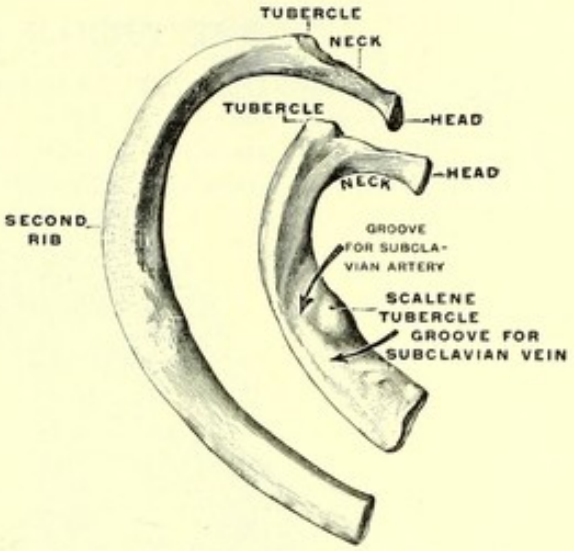

FIG. 152.—The first and second ribs of the right side, viewed from above. (Testut.)

Variations.—Thirteen ribs may occur on one or both sides, from the presence of a cervical or lumbar rib. The additional ribs are developed from the costal processes, and are usually short and imperfect, especially when lumbar. Very rarely a thirteenth thoracic rib occurs. The tenth rib may have no articular facet on the tubercle.

Ossification.—The ribs are preformed in cartilage, and have a single primary centre near the angle. Much later two epiphyseal centres appear—one for the head and one for the tubercle—which become united to the rest of the bone by the twenty-fifth year.

THE COSTAL CARTILAGES.

The *costal cartilages* are bars of hyaline cartilage prolonging the ribs toward the sternum. In direction the first passes slightly downward as well as inward, the second is horizontal, and the rest, down to the eleventh, are directed successively more and more upward in passing inward. Their breadth diminishes from the first to the twelfth, and is greater at the costal than at the sternal end of each cartilage. Their length increases to the seventh, and thence becomes gradually less. In shape they resemble the sternal ends of the ribs. The inner extremities of the upper seven are connected with the sternum, the first being fused with it, the others articulated. The cartilages of the upper three false ribs are attached at their upturned, narrow, inner ends to the lower border of the cartilages next above. The cartilages of the floating ribs are short, and have a pointed free end. The borders and surfaces afford attachment to muscles—internally to the triangularis sterni, from the second to the sixth, and to the diaphragm and transversalis in the lower six. The costal cartilages represent unossified epiphyses of the rib-shafts. The costal cartilages are covered by a thick perichondrium, beneath which superficial ossification may occur in advanced life. This change occurs quite regularly in the first cartilage, but in the others less

commonly, at a later period, more particularly in front, and more often in the male than in the female.

THE THORAX AS A WHOLE.

The bony thorax (Figs. 153, 154) forms an irregular, truncated cone, compressed from before backward. It is longer behind than in front, so that its upper small reniform aperture, or *inlet*, looks slightly forward as well as upward, and the plane of the lower opening, or *base*, also looks forward and downward.

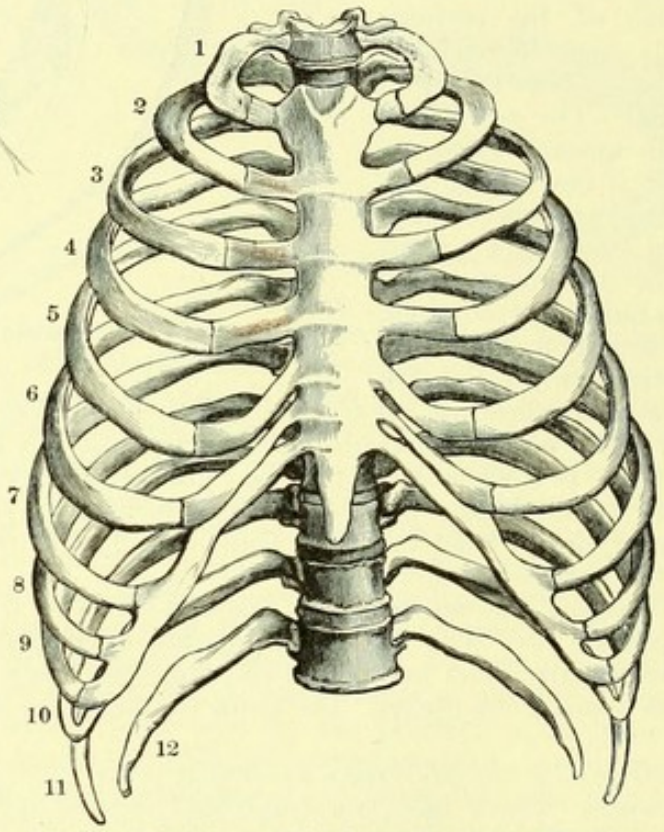

FIG. 153.—The skeleton of the thorax, front view. (Testut.)

The margin of the irregular base is formed by the two curved lines of the edges of the lower six pairs of ribs and cartilages, converging to the xiphi-sternal junction, and bounding the subcostal angle, in the centre of which projects the ensiform process. The *dorsal wall*, formed by the thoracic vertebræ and the ribs as far as the angles, is convex from above downward. The backward curve of the ribs forms a broad furrow, the *vertebral groove*, between the angles of the ribs and the vertebral spines, which lodges the erector-spinæ muscle group. This backward position of the angles of the ribs, about on a level with the thoracic spines, causes the flatness of the back which allows the supine position characteristic of man. The *ventral wall*, formed by the sternum and costal cartilages, is inclined downward and forward at an angle of 20° or 25° with the vertical plane, and is only slightly convex. The *sides*, formed by the ribs, from the angles to the cartilages are convex from above downward; much more so from before backward. From about the ninth rib down they slant inward. The *interior* corresponds in shape to the exterior, except for the median projection of the vertebral bodies, which makes the median diameter less than that on either side, and only little more than one-half of the external median diameter. The lateral grooves formed by the forward projection of the vertebral bodies and the backward curvature of the ribs lodge about as much of the lungs as lies in front of a transverse plane tangent to the bodies. This circumstance, together with the

wide transverse diameter characteristic of man, throws the weight farther back, and makes easier the balance around the spinal axis in the erect position.

The ribs are more and more oblique from above downward as far as the seventh or lower—a fact due in part to the increasing downward curvature from the head to the angle, and in part to the increasingly lower position of the transverse processes of the lower thoracic vertebræ. This increasing obliquity of the

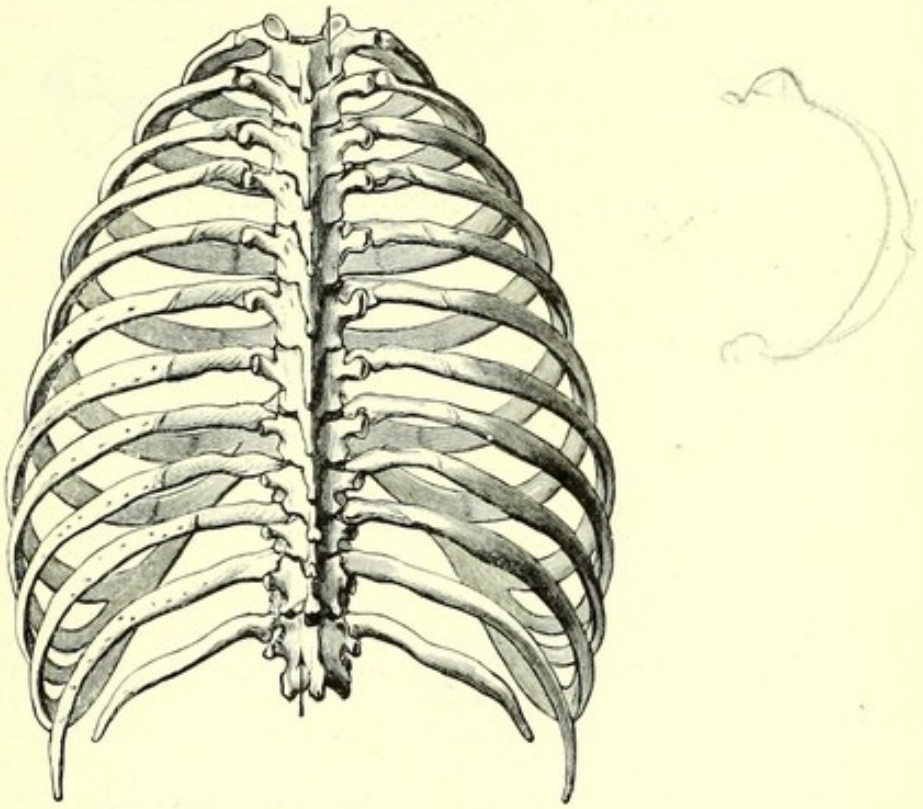

FIG. 154.—The skeleton of the thorax, dorsal view (Testut.)

ribs makes the eleven intercostal spaces wider at the sides than behind. These spaces contract again somewhat in front from the third to the eighth. They are widest in the upper three spaces, and wider in inspiration than in expiration. It should be remembered that the circumference of the right half of the thorax is usually about half an inch larger than that of the left. Note that the lower palpable end of the gladiolus is on a level with the lowest part of the fifth rib. At birth the thorax may measure even more from before backward than transversely, as is the case with quadrupeds. This is due to the absence of the angles and to the less curvature of the ribs at this period. In the female the thorax is relatively shorter, and deeper from before backward, though the latter diameter is actually less than in the male.

THE BONES OF THE UPPER LIMB.

The skeleton of the upper limb comprises the clavicle and scapula, forming the pectoral arch or shoulder-girdle, the humerus in the arm, the radius and ulna in the forearm, and the carpal, metacarpal, and phalangeal bones in the hand.

THE CLAVICLE.

The *clavicle* ("little key") or *collar-bone* (Figs. 155, 156) passes outward and backward from the top of the sternum to the acromion process of the scapula, and forms the connecting link between the trunk and the upper limb, affording a

fulcrum in the movements of the latter. It is curved like an italic *f*. Its inner two-thirds, prismatic or cylindrical, is convex forward like the thorax below it;

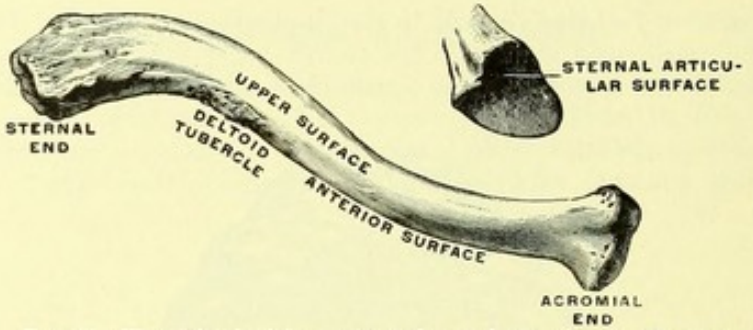

FIG. 155.—The right clavicle, upper surface and sternal end. (Testut.)

its outer third, flattened from above downward, is concave forward, corresponding to the hollow between the thorax and the shoulder.

The *superior surface* is flat and broad in its outer third, where it is overlapped by the attachment of the trapezius behind and the deltoid in front, with a subcutaneous area between. In the inner two-thirds it is rounded and subcutaneous externally, and marked by the attachment of the sterno-cleido-mastoid internally. The *ventral surface* in its outer third is merely a rough border for the origin of the deltoid, near the inner limit of which is the *deltoid tubercle*, when present. In its inner two-thirds it is broader, and rough for the origin of the pectoralis major muscle. The *inferior surface* presents the rough *trapezoid line*, running inward and backward from near the front of the outer end to the *conoid tubercle*, near the dorsal border at the junction of the outer fourth and the inner three-fourths. These attach respectively the trapezoid and conoid portions of the coraco-clavicular ligament. Internal to the conoid tubercle is a shallow groove for the insertion of the subclavius muscle. Near the sternal end is a rough impression for the rhomboid ligament which binds the clavicle to the first rib. Internal to this impression is a facet where the clavicle plays on the first costal cartilage. This

FIG. 156.—The right clavicle, under surface. (Testut.)

facet is continuous with the sternal facet, and close beside it the sterno-hyoid muscle is attached. The *dorsal surface*, like the ventral, is merely a rough border in its outer third, where the trapezius muscle is inserted. In its inner two-thirds it is broader and smooth, and arches over the subclavian vessels and the brachial plexus. The nutrient foramen is usually seen passing outward near the middle of this surface, but sometimes it is on the inferior surface. Part of the clavicular attachment of the sterno-cleido-mastoid is found at the sternal end of this surface. The border[1] separating the dorsal and inferior surfaces passes from the conoid tubercle to the rhomboid impression.

The *sternal end* is expanded into a triangular or oval articular surface, which plays upon the interarticular fibro-cartilage between it and the sternal facet. Its rough borders attach the sterno-clavicular and interclavicular ligaments. The *acromial end* presents an oval articular surface, elongated from before backward,

[1] No other border needs description. The clavicle is often described as having three surfaces and three borders in its inner two-thirds, and two in its outer third. In this less common or less accurately described condition the ventral border is expanded in its centre for the attachment of the pectoralis major muscle.

and bevelled inferiorly, which articulates with the acromion process of the scapula. Its upper surface is on a little higher level than that of the acromion.

The clavicle has no medullary cavity, but is composed of cancellous tissue with a shell of compact bone. It is more or less subcutaneous throughout, but especially so in the intermuscular interval near its centre. Fracture is very common, especially at the junction of its two curvatures (inner two-thirds and outer one-third). The clavicle is longer, stronger, rougher, and more curved in the male than in the female, and on the right side than on the left. In the male it also inclines slightly upward as it passes outward.

Ossification.—The clavicle is the first bone to ossify. It begins in membrane, but quickly extends into the underlying cartilage of the precoracoid bar. An epiphysis, appearing at the sternal end between the eighteenth and twentieth years, is united to the shaft about the twenty-fifth year.

THE SCAPULA.

The *scapula* (Figs. 157, 158) is a large, flat, triangular bone, forming the dorsal part of the shoulder-girdle. It rests upon the upper and back part of the thorax, and from it is suspended the humerus. Its surfaces are ventral and dorsal; its borders superior, internal, and external; and from its external angle or head, which bears an articular surface, projects the coracoid process. The spine, prolonged into the acromion process, projects from its dorsal surface.

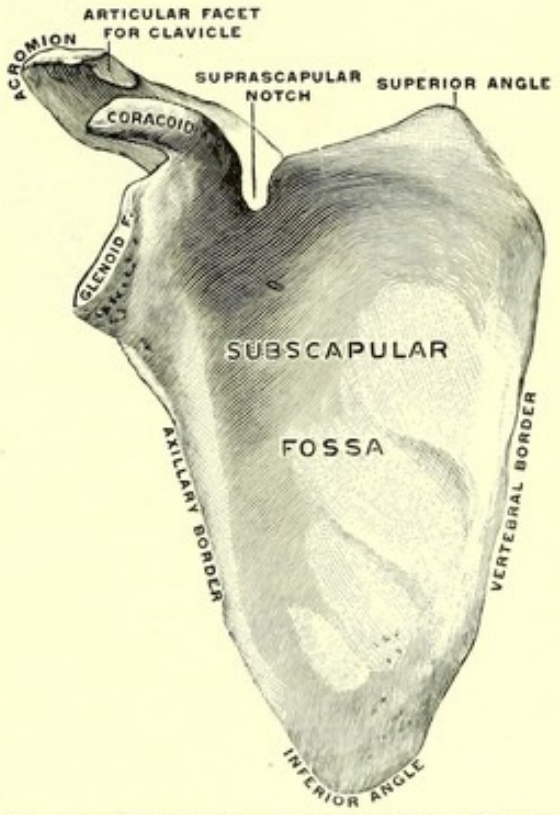

FIG. 157.—The right scapula, ventral view. (Testut.)

The *ventral surface*, or *venter*, presents the *subscapular fossa*, a deep concavity most marked above. From the inner two-thirds of this, which is marked by three or four oblique ridges, the subscapularis muscle arises. This fossa is separated from the internal border by a linear area, which, with its two triangular expansions opposite the upper and lower angles, attaches the serratus magnus muscle. Externally, the fossa is limited by a smooth, prominent ridge descending from the head of the bone. From the narrow groove between this ridge and the external border arise some *fibres* of the subscapularis. The convex *dorsal surface* or *dorsum* is unequally divided by a prominent ridge, the *spine*, into an upper smaller *supraspinous fossa*, and a lower larger *infraspinous fossa*, giving origin to the supraspinatus and infraspinatus muscles, respectively. The two fossæ communicate around the outer border of the spine by means of the *great scapular notch*, which corresponds to the neck of the bone, and transmits the suprascapular nerve and vessels from one fossa to the other. An oblique ridge running from below the glenoid fossa to the vertebral border just above the inferior angle separates the infraspinous fossa from the external border by a narrow space, which attaches the teres minor muscle above and the teres major on the broader portion below.

The massive triangular *spine* of the scapula commences about the upper fourth of the vertebral border as a smooth, expanded, triangular surface, covered by a bursa over which the lower part of the trapezius glides to be inserted into a

tubercle beyond. From this point, projecting backward and upward, and becoming more and more elevated, it extends outward and a little upward to the middle of the neck of the scapula. Thence it is continued forward and outward as the flat, quadrate *acromion* ("summit of the shoulder") *process*, overhanging the shoulder-joint. The upper and lower smooth, concave surfaces of the spine form part of the supra- and infraspinous fossæ respectively. Of the two

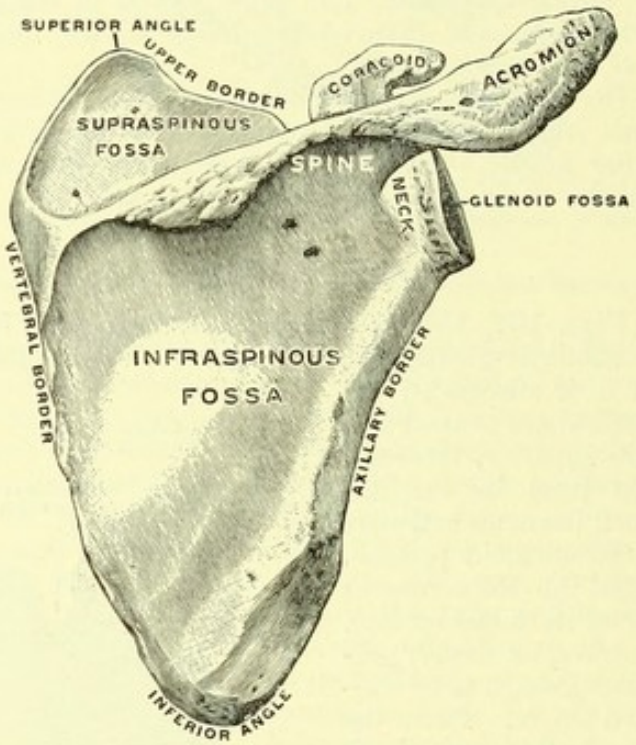

FIG. 158.—The right scapula, dorsal view. (Testut.)

unattached borders the short, smooth, and concave *external border* arises at the neck of the scapula, where it bounds the great scapular notch, and is continuous with the under surface of the acromion. The more prominent subcutaneous *dorsal border*, or *crest*, is rough, broad, and serpentine. Commencing at the above-mentioned triangular surface, it passes outward to become continuous with the rough, subcutaneous *upper* surface of the acromion. The upper lip of the crest is continuous with the *inner* border of the acromion, and to them is attached the trapezius muscle as far as the oval facet for the outer end of the clavicle, on the inner border of the acromion near its tip. The lower lip of the crest is continuous with the outer border of the acromion, with which it forms an angle, the *acromial angle*, and from them the deltoid takes origin. The apex of the acromion attaches the coraco-acromial ligament, and its under surface, continuous with the upper surface and outer border of the spine, is smooth and covered by a bursa.

The *internal* or *vertebral border* (or base) is long and irregularly convex. Opposite the commencement of the spine it bends more sharply, and here attaches the rhomboideus minor muscle, while below this area the rhomboideus major is attached by a fibrous arch, and above it the levator scapulæ is inserted. The *superior border*, short, sharp, and concave, extends from the superior angle to the base of the coracoid process, where it presents the *suprascapular notch*, converted into a foramen by the transverse ligament (sometimes by a spicula of bone). The foramen transmits the suprascapular nerve, and from the ligament and the adjacent border the omo-hyoid muscle arises. The *external* or *axillary border* is quite thin, and just below the glenoid fossa presents a rough impression, from which the long head of the triceps arises. A little below this is a groove for the dorsal artery of the scapula.

The long, rounded, thick *inferior angle* is often called *the* angle of the scapula.

To its dorsal aspect some fibres of the latissimus dorsi muscle are frequently attached. The *external angle* presents the *head*, supported on a slightly constricted *neck*, and bearing the articular *glenoid cavity* for the humerus. The glenoid cavity is shallow and pear-shaped, with the narrow end above, and indented on its ventral lip above its centre. It looks outward, upward, and forward. To its rim is attached the glenoid ligament, which deepens the shallow cavity, and outside of this the capsular ligament is attached. The long head of the biceps arises from its upper extremity. From the upper border of the neck the thick, strong *coracoid* ("like a crow's beak") *process* rises nearly vertically for a short distance, and then bends sharply forward and outward in front of, and more or less parallel with, the acromion. From the tip of the process arise the short head of the biceps, the coraco-brachialis, and the costo-coracoid ligament. To its inner border the pectoralis minor muscle is attached, and to its outer border the coraco-acromial ligament. Its superior surface is rough, and affords attachment, near the base, to the coraco-clavicular ligament (conoid and trapezoid portions).

When the arm hangs by the side the scapula rests upon the ribs, from the second to the seventh inclusive, and the inner end of its spine corresponds to the third thoracic spine[1] or the space below it. The distance between the spines of the vertebræ and the vertebral border averages two inches. The tip of the coracoid process is palpable below the clavicle and internal to the humeral head, except in fat subjects. The dorsal border of the spine, the upper surface of the acromion, and the lower part of the vertebral border are also subcutaneous.

Ossification occurs in cartilage from two primary and five secondary centres, from the former of which the body and coracoid process are formed. The coracoid joins the body about the fifteenth year, when two centres appear in the acromion, which soon unite together and join the spine about the twentieth year, though sometimes this union fails, and the acromion is movable on the spine. Two other centres appear in the cartilage along the vertebral border, and another between the glenoid cavity and the coracoid process.

Morphology.—The coracoid process represents the coracoid bone, or ventral bar of the shoulder-girdle of other animals. Its ventral end has degenerated into the costo-coracoid ligament. The glenoid fossa is the meeting-point of the coracoid and the dorsal segment or scapula. The precoracoid bar of the shoulder-girdle is replaced by the clavicle in man.

THE HUMERUS.

The *humerus* (Figs. 159, 160) constitutes the skeleton of the arm, and extends downward and slightly inward from the shoulder to the elbow. It presents, like all long bones of the limbs, an upper and a lower extremity and a shaft.

The large *upper extremity* includes the head, neck, and two tuberosities. The large cartilage-clad *head* represents about one-third of a sphere, whose vertical diameter is slightly longer than the transverse. It is directed inward, upward, and backward, at an angle of 130° with the axis of the shaft, to articulate with the glenoid cavity of the scapula. The *anatomical neck* is the slight constriction below and external to the head, to which the capsular ligament is attached. Superiorly, it is a mere groove between the head and the tuberosities. The latter are separated from one another by the commencement of the bicipital groove. The *great tuberosity*, the higher and more dorsally placed, is continued up from the outer surface of the shaft nearly to the level of the head. Of the three facets on its upper and dorsal aspect, the upper attaches the supraspinatus, the middle the infraspinatus, and the lower the teres minor muscle. The prominent *small tuberosity* looks forward and attaches the subscapularis muscle. The *surgical neck*, so called from the frequency of fracture here, is where the shaft joins the upper extremity.

The *shaft*, cylindrical above, transversely expanded and triangular below, is

[1] And also to the fissure between the upper and lower lobes of the lung.

twisted inward in descending. It presents external, internal, and dorsal surfaces separated by external, internal, and ventral borders. The *external* and *internal borders*, slightly marked above, become prominent below as the *external* and *internal supracondylar ridges*, which descend to the condyles. From each of

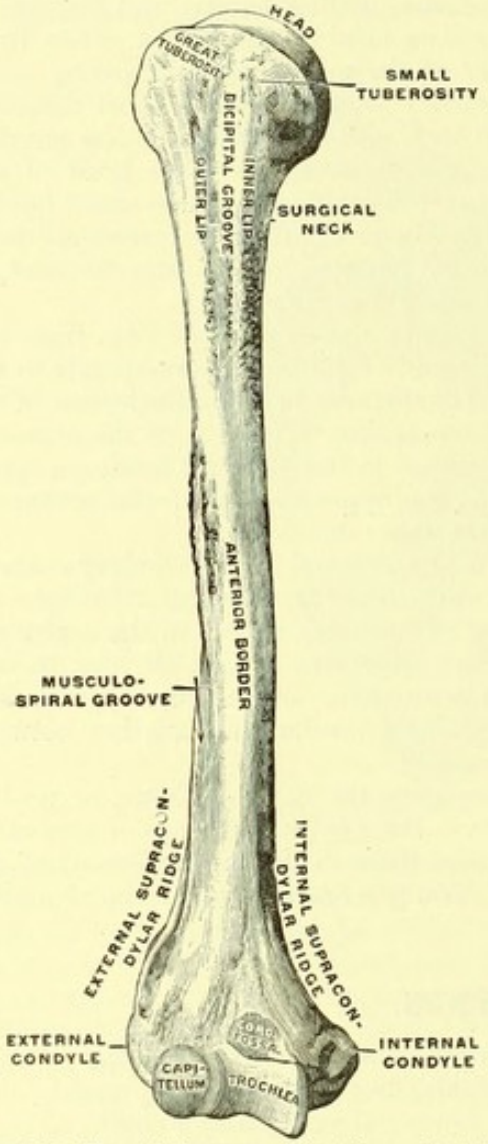

FIG. 159.—The right humerus, front view. (Testut.)

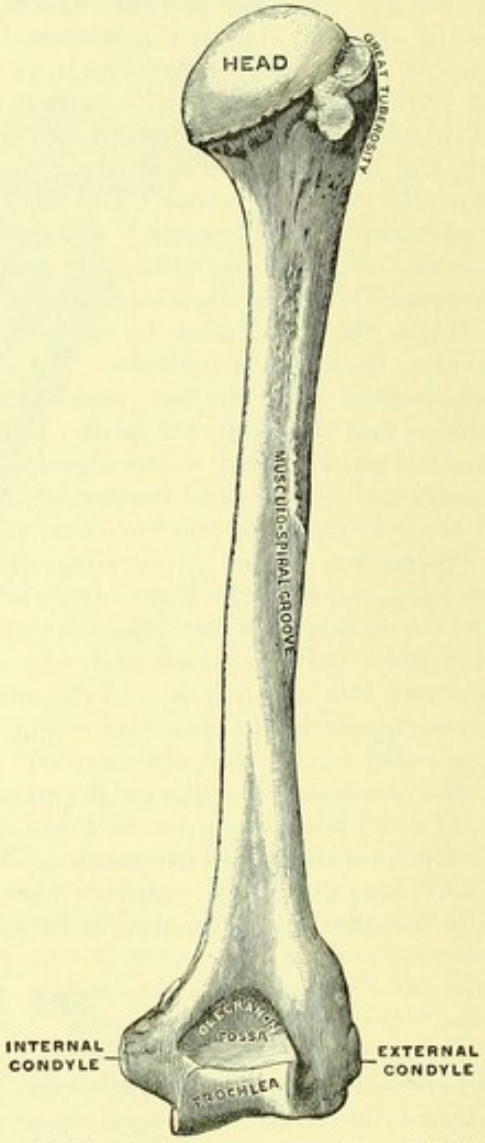

FIG. 160.—The right humerus, rear view. (Testut.)

these an intermuscular septum arises, and from the upper two-thirds of the external ridge arises the brachio-radialis muscle, and from its lower third the extensor carpi radialis longus. The *external border* extends down from the back of the great tuberosity, and is interrupted near the middle of the shaft by the musculo-spiral groove. The *internal border* commences above just below the head,[1] and near its centre presents a rough impression, extending on to the adjacent inner surface, for the coraco-brachialis muscle. The *ventral border* starts above from the front of the great tuberosity as the outer lip of the bicipital groove, and ends below in the ridge separating the trochlea and capitellum. The *internal surface* in its upper third presents the vertical *bicipital groove*, which lodges the long tendon of the biceps. Its two rough lips give insertion, the outer to the pectoralis major, the inner to the teres major below, and to the latissimus dorsi above, which is also attached to the floor of the groove. A little below the centre is seen the *nutrient foramen*, directed downward. The *external surface* pre-

[1] It is usually described as continuing the inner lip of the bicipital groove.

sents just above the centre a rough V-shaped impression for the deltoid insertion, immediately below which the *musculo-spiral groove* is seen winding downward and forward after grooving the outer border. The hind or lower portion of this groove is traversed by the musculo-spiral nerve and the superior profunda vessels, while its upper part, together with the lower half of the external and internal surfaces and of the ventral border, gives origin to the brachialis muscle. The *dorsal surface*, unequally divided by the musculo-spiral groove, attaches above the latter the external head of the triceps, and below it the internal head.

The *lower extremity* is transversely elongated, flattened from before backward, and curved forward. From within outward notice the following parts: The prominent *internal condyle* is flattened and inclined slightly backward, forming a shallow groove behind, traversed by the ulnar nerve. From the front of its extremity arise the pronator radii teres and the common tendon of the superficial flexor muscles in the forearm, below which the internal lateral ligament is attached. The *articular surface* is divided by a ridge (which corresponds to the interval between the radius and ulna) into a large internal and a smaller external part. The internal part, or *trochlea* ("pulley"), is a pulley-like surface, grooved in the middle, which articulates with the great sigmoid cavity of the ulna. It is obliquely placed, so that it ascends upward and outward behind, and its inner margin descends much lower than its outer. It is broader behind than in front, and its surface forms three-fourths or more of a circle. Above it notice the large *olecranon fossa* behind and the smaller *coronoid fossa* in front, receiving, respectively, the olecranon process in extension and the coronoid process in flexion of the forearm. The external part, the *capitellum* ("little head"), or *radial head*, is a small rounded surface, which, with the groove internal to it, articulates with the head of the radius. It looks forward, and is confined to the ventral and a part of the inferior surface. Above it in front is a slight depression for the edge of the head of the radius in complete flexion of the elbow. The *external condyle*, on the same horizontal plane with, but less prominent than, the internal, attaches inferiorly the common tendon of the forearm extensor muscles, the external lateral ligament, and, more dorsally and internally, the anconeus muscle.

In its natural position the humerus is rotated inward so much that the internal condyle, which is in line with the head above, looks more backward than inward. The principal or longest axes of the upper and lower extremities make an angle of torsion of 30° with one another, which represents the amount of twisting of the bone. The humerus averages 13 inches in length in the male and 12 inches in the female. The condyles alone are subcutaneous, and are important as landmarks.

Varieties.—The thin plate of bone between the olecranon and coronoid fossæ is sometimes perforated, forming the *supratrochlear foramen*. A small hook-like *supracondylar process*, connected by a fibrous band with the internal condyle about 2 inches below, is occasionally found. It represents a similar bony foramen in many animals, and, like it, transmits through the arch the median nerve and often the brachial artery or a large branch of it.

Ossification occurs from a primary centre in the shaft and six or seven secondary centres in the extremities. In the upper extremity centres appear in the head, great tuberosity, and sometimes in the small tuberosity, which, after fusing together, join the shaft about the twentieth year. In the lower extremity centres appear in the trochlea, capitellum, and outer and inner condyles, the three former of which, after coalescing, unite with the shaft in the seventeenth year, the inner condyle somewhat later.

THE ULNA.

The *ulna* ("elbow-bone") (Figs. 161, 162), the inner bone of the forearm, is parallel with, but longer than, the radius by nearly the length of the olecranon. It is inclined downward and outward from the humerus, so that the great tuber-

osity and capitellum of the humerus and the lower end of the ulna are in a straight line.

The irregular *upper extremity* is the thickest part, and presents for articulation with the trochlea of the humerus the *great sigmoid* ("sigma-like") *cavity*. This looks forward and upward, is concave from above downward, and presents a longitudinal ridge which fits into the groove of the trochlea. At the middle of the cavity is a constriction (sometimes a groove) which represents the limit between the upper and hind part formed by the olecranon, and the lower and fore part formed by the coronoid process.

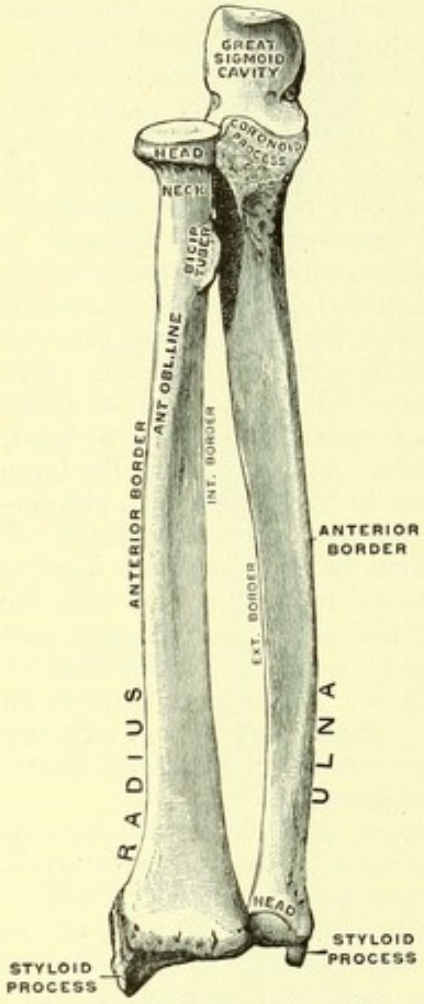

FIG. 161.—The bones of the right forearm, rear view. (Testut.)

The thick *olecranon* ("elbow-head") *process* forms the highest part of the ulna. On its broad upper surface the triceps is inserted dorsally, while the front of this surface projects in a beak which overhangs the great sigmoid cavity, and fits into the olecranon fossa of the humerus in extension of the elbow. The dorsal surface is triangular and subcutaneous, except for a bursa covering it. The margins of the ventral or articular surface attach the internal and posterior ligaments of the elbow. From a tubercle on its inner side part of the flexor carpi ulnaris arises. The *coronoid* ("crown-like") *process* projects forward from the upper end of the shaft. Its sharp ventral edge, or *apex*, is received into the coronoid fossa of the humerus in flexion. The ventral and internal edges of its upper or articular surface attach the anterior and internal ligaments of the elbow. The inferior or ventral surface is rough, and, together with the *tuberosity* at its lower end, gives insertion to the brachialis. The oblique ligament is attached to the outer part of the tuberosity. On the inner edge of the ventral surface is a tubercle from which part of the flexor sublimis digitorum arises, and from the ridge below this parts of the pronator radii teres and flexor longus pollicis arise. On the outer side of the upper end of the coronoid process, and continuous with the great sigmoid cavity, is the concave, oval, *small sigmoid cavity* for articulation with the side of the head of the radius.

The *shaft* tapers from above downward. It is curved inward above, outward below, as well as slightly backward. Triangular in the upper three-fourths, more rounded below, it presents the following parts: The *anterior* or *ventral border* runs from the inner margin of the coronoid process to the front of the styloid process, becoming continuous with the oblique pronator ridge in its lower fifth. The *posterior* or *dorsal border* begins at the apex of the subcutaneous triangle behind the olecranon, and runs sinuously to the back of the styloid process, becoming less distinct below. The *external* or *interosseous border*, faintly marked below, is sharply marked in the middle, and attaches the interosseous membrane. It bifurcates above into two lines which pass to the two ends of the small sigmoid cavity, and enclose a triangular space which, with its prominent dorsal border, called the *supinator ridge*, gives origin to the supinator muscle. The *ventral surface* gives origin in the concave upper three-fourths to the flexor profundus digitorum, and in the lower fourth, below the oblique *pronator ridge*, to the pronator quadratus. In the middle third is the *nutrient foramen*, directed upward. The *internal surface* gives origin to the flexor profundus digitorum in

its upper three-fourths, below which it is subcutaneous. The *dorsal surface* is inclined slightly outward. To a triangle on its upper fourth, marked off by an oblique line from the supinator ridge to the dorsal border, the anconeus is inserted behind and internal to the supinator triangle. Below this a vertical ridge separates an internal area, covered by the extensor carpi ulnaris, from an external area, for the origin of the extensors of the thumb and index finger.

The *lower extremity* is small, and presents (1) a rounded *head* with a flattened, semilunar articular facet inferiorly, which plays upon the triangular fibro-cartilage, and a convex facet externally received into the sigmoid cavity of the radius; (2) the cylindrical *styloid* ("pillar-like") *process*, which descends from the inner and back part of the head. To its extremity is attached the internal lateral ligament, and to the depression at its base, externally, the triangular fibro-cartilage. In the groove behind and between it and the head glides the tendon of the extensor carpi ulnaris.

The *subcutaneous parts* are the triangular surface back of the olecranon, the dorsal border, the lower fourth of the inner surface, the styloid, and, in pronation, the outer and fore part of the head. Notice that the ulna does not articulate directly with the carpus.

Ossification occurs in cartilage from one primary centre for the shaft. The upper end of the olecranon, ossified from a secondary centre, joins the shaft in the sixteenth or seventeenth year. The lower extremity, ossifying from an earlier formed centre, joins the shaft from about the eighteenth to the twentieth year.

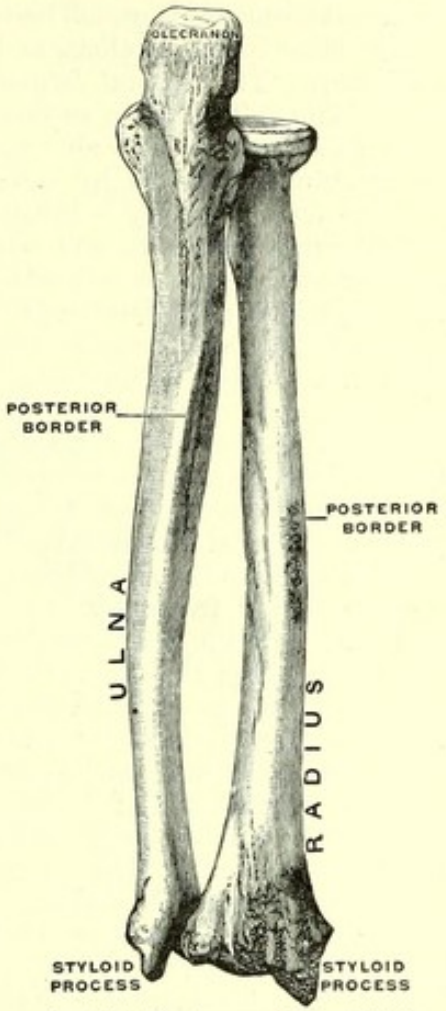

FIG. 162.—The bones of the right forearm, front view. (Testut.)

THE RADIUS.

The *radius* ("spoke"), the outer bone of the forearm, takes little part in the elbow-, but the principal part in the wrist-joint, articulating with the scaphoid, semilunar, and ulna below, the humerus and ulna above.

The disc-shaped *upper extremity*, or *head*, presents, superiorly, a shallow articular depression with an encircling rim, which articulate respectively with the capitellum of the humerus and the groove internal to it, especially in flexion of the elbow. Its smooth, short, vertical margin is deeper internally, where it articulates with the small sigmoid cavity of the ulna, than externally, where it is embraced by the orbicular ligament. Below the head is a constricted *neck*, which joins the shaft opposite the *bicipital tuberosity*. The latter, situated ventro-internally, has a rough dorsal portion for insertion of the biceps tendon and a smoother ventral part covered by a bursa.

The *shaft* is triangular, curved outward and slightly backward, and becomes larger below. The *internal* or *interosseous border*, commencing below the tuberosity, is prominent in the middle three-fifths, and in the lower fifth it divides into two lines, which pass to the two ends of the sigmoid cavity. The interosseous membrane is attached to it. The *ventral* and *dorsal borders*, commencing at the tuberosity, pass obliquely downward and outward as the *ventral and dorsal oblique lines* to the junction of the upper and middle thirds, and thence descend to the front and back of the styloid process, becoming less marked below. To the ventral

oblique line the flexor sublimis digitorum is attached. The area between the two oblique lines, externally, gives insertion to the supinator as far down as the rough impression for the pronator radii teres, situated about the middle and at the most prominent part of the *external surface*. Below this the external surface is covered by the extensor tendons. The *ventral surface* gives origin in its upper two-thirds to the flexor longus pollicis, and its lower fourth gives insertion to the pronator quadratus. The *nutrient foramen*, directed upward, is seen above the middle of this surface. The *dorsal surface* in the middle third gives origin to the extensor ossis metacarpi pollicis above and to the extensor brevis pollicis below. Its lower third is covered by extensor tendons.

The *lower extremity* is broad, thick, and quadrilateral. The large *inferior* or *carpal surface*, concave and triangular, is divided by a ridge into an outer triangular surface, which articulates with the scaphoid, and an inner quadrilateral surface, which articulates with the semilunar. At the lower end of the inner surface is the narrow *sigmoid cavity*, concave from before backward, which articulates with the head of the ulna. It is at right angles to the carpal surface, and to the smooth margin between them is attached the base of the triangular fibro-cartilage. A transverse ridge at the lower end of the *ventral surface* limits the attachment of the pronator quadratus, and to it and the narrow space below it the anterior ligament of the wrist is attached. The *outer* or *dorso-external surface* is prolonged downward as the stout, pyramidal, subcutaneous *styloid process*. It is lower than the styloid process of the ulna, and is an important landmark in diagnosticating fractures. To its tip is attached the external lateral ligament, and to its base the brachio-radialis. Two grooves, separated by a ridge, are seen on this surface; the ventral one gives passage to the tendons of the extensor ossis metacarpi pollicis and the extensor brevis pollicis; the dorsal and inner one, sometimes subdivided by a low ridge, gives passage to the tendons of the extensores carpi radiales longus and brevis. The *dorsal surface* extends lower than the ventral, and of its two grooves the external narrow one for the extensor longus pollicis is separated from the last-mentioned groove by a prominent subcutaneous tubercle. The inner groove transmits the extensor communis digitorum and the extensor indicis tendons. The posterior annular ligament converts these grooves into canals by its attachment to the dividing ridges, the styloid process, and the inner margin.

The radius is more deeply placed than the ulna. In supination the two bones are parallel; in pronation the radius crosses the ulna.

Ossification proceeds from one primary centre in the shaft, a secondary centre in the head, which joins the shaft in the seventeenth year, and a secondary centre in the lower extremity, which appears first, but does not ankylose with the shaft until the twentieth year.

THE BONES OF THE HAND.

The skeleton of the hand is composed of the bones of the carpus, of the metacarpus, and the phalanges, forming the skeleton of the wrist, the palm, and the digits respectively.

THE CARPAL BONES.

The eight carpal bones (Figs. 163–165) are arranged in two rows of four each. The carpus is transversely convex dorsally, and concave on the palmar surface, on which, at the inner and outer extremities of each row, there is a prominence, attaching the anterior annular ligament, which completes a canal for the flexor tendons and the median nerve. The upper surface of the upper row is convex, articulating with the concavity of the radius and the triangular fibro-cartilage. The convexity extends on to the dorsal more than on to the palmar surface. In

the line of articulation between the two rows the convexity of the os magnum and unciform is received into the concavity of the bones of the first row, and the convexity of the scaphoid is received into the slight concavity of the trapezium and trapezoid. The lower surface of the lower row is irregularly transverse and articulates with the metacarpus. In general the carpal bones are short

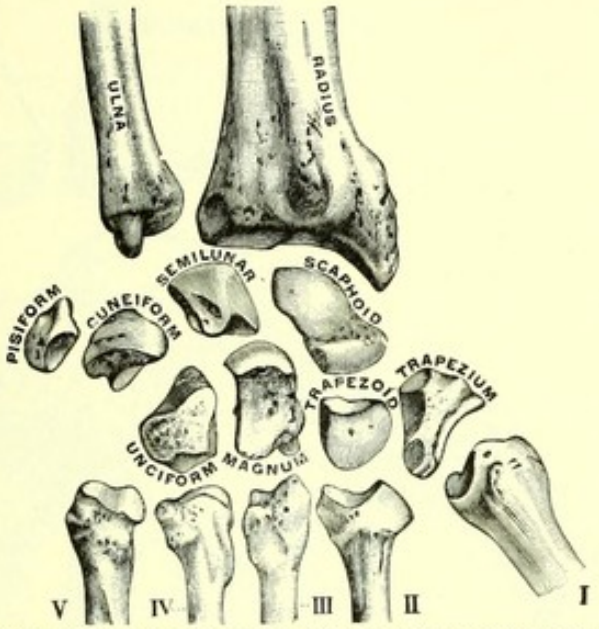

FIG. 163.—The bones of the right carpus, the distal ends of the forearm bones, and the proximal ends of the metacarpal bones, ventral aspect. (Testut.)

and irregularly cuboidal. The dorsal surfaces, usually the larger, and the palmar surfaces, more irregular, are rough for ligamentous attachments. As a rule, the upper and lower, outer and inner surfaces of these bones are articular to articulate with the bones above and below and on either side; but a lateral surface of the terminal bones of each row is non-articular. Enumerated from the radial to the ulnar side, the upper row consists of the scaphoid, semilunar, cuneiform, and pisiform, and the lower row of the trapezium, trapezoid, os magnum, and unciform. The principal individual points of the separate bones are as follows:

The Scaphoid.

The scaphoid ("boat-like"), the largest bone of the upper row, is elongated downward and outward. Of the three articular surfaces, the upper is convex and triangular, articulating with the radius; the lower is convex for the trapezium externally and the trapezoid internally; and the internal is concave below for the os magnum, flat and crescentic above for the semilunar. The outer end or surface is prolonged forward into a strong conical *tuberosity*, which attaches the annular ligament. The dorsal surface is a mere groove attaching the posterior ligaments of the wrist.

The Semilunar.

The *semilunar* ("half moon") presents four articular surfaces, of which the upper is convex for the radius; the lower is concave for the os magnum, and, near its inner margin, for the unciform; the external is crescentic and narrow for the scaphoid; and the internal is quadrilateral and larger for the cuneiform.

The Cuneiform.

The *cuneiform* ("wedge-shaped") or *pyramidal bone* is placed with its blunted apex directed downward and inward. This bone also presents four articular

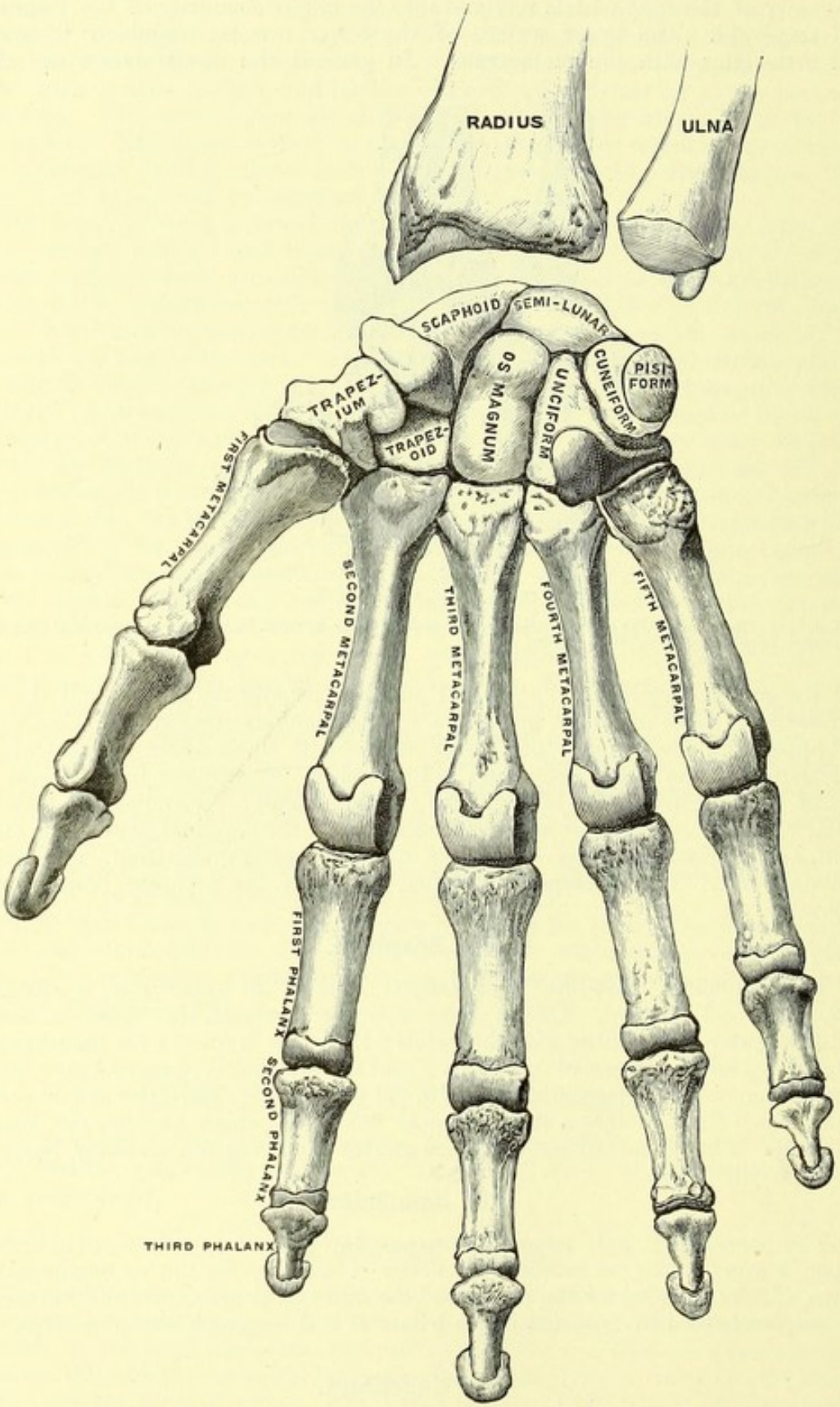

FIG. 164.—The bones of the right hand, palmar aspect. (Modified from Testut.)

facets. The base articulates with the semilunar. The upper surface is convex and smooth externally for the triangular fibro-cartilage, rough internally for ligaments. The lower surface is concavo-convex for the unciform. On the palmar surface near the apex is a circular facet for the pisiform bone. The internal lateral ligament of the wrist is attached to the apex.

The Pisiform.

The *pisiform* ("pea-shaped") bone is vertically spheroidal, and has a single oval articular facet behind for the cuneiform. The rest of the bone projects forward as one of the internal eminences for the anterior annular ligament, and gives insertion to the flexor carpi ulnaris. The outer side is slightly concave.

The Trapezium.

The *trapezium* ("table"), rhombic in form, is the most external bone of the lower row, and therefore has but three articular surfaces—a superior, slightly concave, for the scaphoid; an inferior, saddle-shaped, for the base of the first metacarpal bone; and an internal, divided by a ridge into an upper and larger for the trapezoid and a lower and smaller for the base of the second metacarpal bone. On the palmar surface there is a vertical groove for the passage of the flexor carpi radialis tendon, and external to this a ridge or *tuberosity* forming the second external prominence for the attachment of the anterior annular ligament.

The Trapezoid.

The *trapezoid* ("table-like"), the smallest bone of the lower row, has its longest diameter from before backward. Its dorsal surface is much larger than the palmar; its four articular surfaces are nearly continuous, and present superiorly a small, concave, triangular facet for the scaphoid; inferiorly, a long saddle-shaped facet for the second metacarpal bone; externally, a convex facet for the trapezium; and internally, a facet for the os magnum.

The Os Magnum.

The *os magnum* ("great bone"), the largest carpal bone, is elongated vertically, and occupies the centre of the wrist. It presents above a rounded *head* joined by a slightly constricted *neck* to a quadrilateral *body* below. It articulates above by its rounded head with the socket formed by the scaphoid and semilunar; below, by three facets, of which the middle is the largest, with the second, third, and fourth metacarpal bones; externally, with the trapezoid by a small facet below that for the scaphoid; and internally, by an elongated facet, sometimes two facets, with the unciform. Its broad dorsal surface is larger than the palmar, and is prolonged downward and inward.

The Unciform.

The *unciform* ("hook-shaped") is named from a large flattened hook-like process, concave externally, which projects forward from its palmar surface to attach at its apex the anterior annular ligament. Triangular in form, it articulates above by a narrow facet on its apex with the semilunar, below by two facets with the fourth and fifth metacarpal bones; externally with the os magnum, and internally by a concavo-convex facet inclined upward, with the cuneiform, having but a narrow non-articular surface on the inner side.

The carpal bones afford origin by their palmar surfaces to most of the short muscles of the thumb and little finger.

Ossification occurs for each bone from a single centre, which appears after birth. The cartilaginous *os centrale*, situated dorsally between the scaphoid,

os magnum, and trapezoid in the fœtus, is occasionally ossified, but usually suppressed.

THE METACARPAL BONES.

The metacarpus ("beyond the carpus") (Figs. 164, 165) contains five long bones, which support the fingers and form the skeleton of the palm. They diverge slightly from each other below, and, besides continuing the transverse arch of the carpus, they are slightly curved longitudinally, forming the hollow of the palm. They are numbered from without inward. The first is the broadest and shortest, the second the longest, and the rest decrease in length from the third to the fifth.

General Characteristics.—The *upper end* or *base* is irregularly cuboidal, and presents two non-articular, rough surfaces for ligamentous and muscular attachments, a broader dorsal and a narrower palmar surface; and three articular surfaces, an upper for the carpus, and an inner and outer for articulation and ligamentous union with each other. The *shaft* is triangular and slightly curved, with its concavity in front. On the dorsal surface a ridge starts at the carpal end, and divides into two lines, each of which ends in a *dorsal tubercle* on the side of the head, the two enclosing a triangular surface covered by the extensor tendons. The dorsal surface on the sides of the ridge attaches the dorsal interossei muscles. The two lateral surfaces separated by a palmar ridge afford attachment to the palmar interossei muscles. The carpal end of the shaft is the most slender part. The shaft of the first metacarpal is broad and flattened, its dorsal surface is smooth, and its palmar aspect looks inward. The *head* presents for articulation with the first phalanx a rounded articular surface, broader and extending farthest on the palmar aspect, where it projects into two lateral cornua, or *palmar tubercles*, separated by a groove for the flexor tendons. The sides of the head are flattened, and marked by a depression for the lateral ligaments. The articular surface of the head of the first metacarpal bone is flatter than that of the others, and its two palmar tubercles are prominent for the two sesamoid bones in the flexor brevis pollicis tendons.

Special Characteristics.—Besides those above given, these concern mainly the *bases* or carpal extremities. That of the *first metacarpal* has a saddle-shaped facet for the trapezium and no lateral facet, but a tubercle externally for the extensor ossis metacarpi pollicis. That of the *second metacarpal* has no external lateral facet, and three superior facets—a large, concave, central one for the trapezoid, and marginal ones for the os magnum and trapezium. Dorsally, near the external angle it has a tubercle for the extensor carpi radialis longus. That of the *third* has a prominent projection, the styloid process, at the outer and upper angle of the dorsum, below which the extensor carpi radialis brevis is inserted. That of the *fourth* has two facets externally, corresponding to two internally on the *third*, and, besides the main facet for the unciform above, there is a small facet for the os magnum on the outer angle dorsally. The base of the *fifth* has no facet internally, but a tuberosity for the extensor carpi ulnaris. Its upper end is saddle-shaped and directed slightly outward.

Ossification of the metacarpal bones and phalanges proceeds from one primary centre in the shaft, and a secondary centre in the base of the first metacarpal bone and of the phalanges and in the head of the other metacarpals. The secondary centre joins the shaft by the twentieth year. In the terminal phalanges the shaft centre begins in the distal end.

THE PHALANGES.

Of the fourteen phalanges ("ranks") (Figs. 164, 165), each finger contains three and the thumb two. Like all long bones, they have two extremities and a shaft. The *shafts*, semi-cylindrical, are convex dorsally, and the rough margins of the flat palmar surfaces give attachment to the sheaths of the flexor tendons.

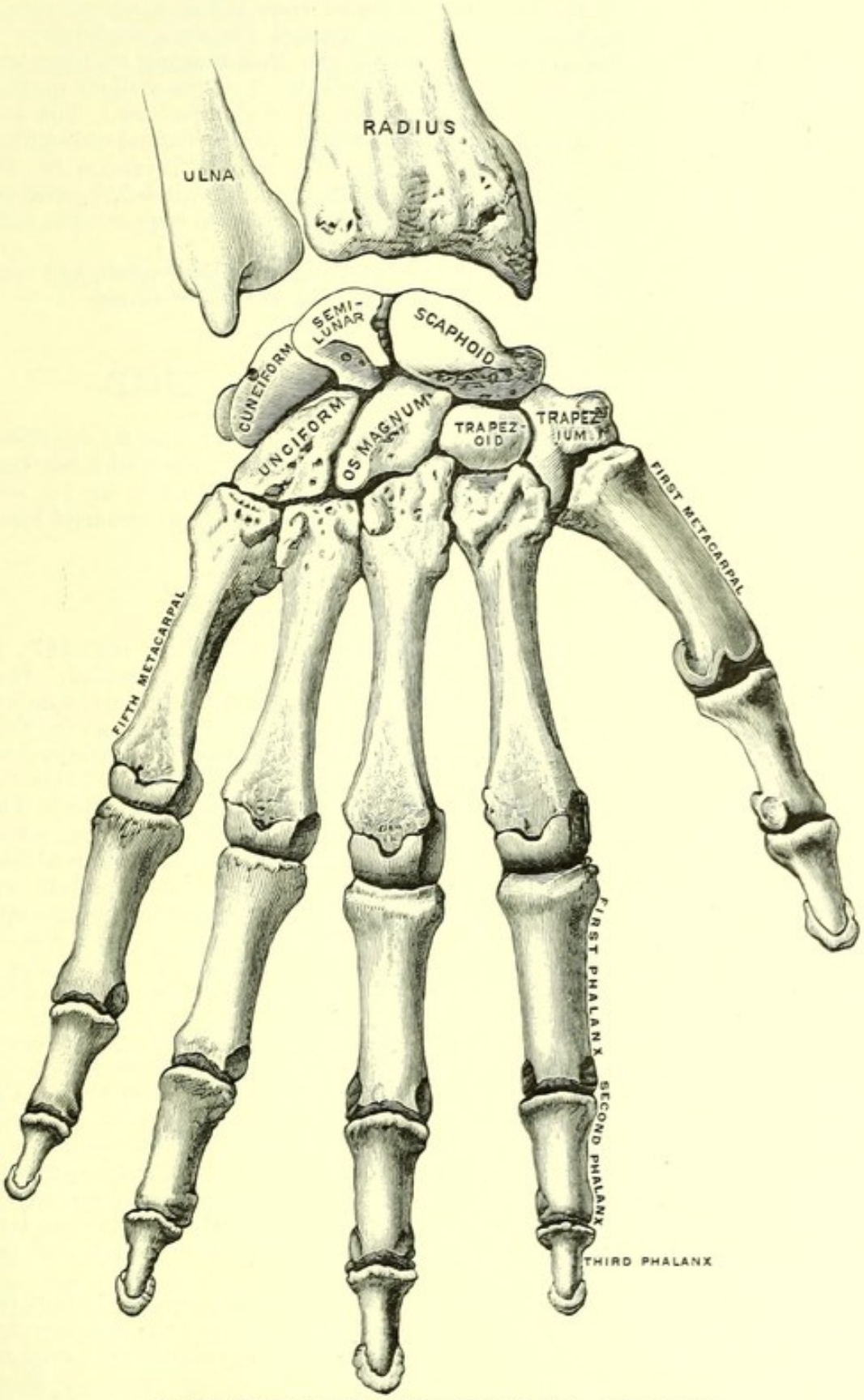

FIG. 165.—The bones of the right hand, dorsal aspect. (After Testut.)

The five of the *first row* are the longest, and are slightly curved longitudinally. The thicker upper end, or *base*, has a transversely elongated, concave articular facet (*glenoid cavity*), and the *distal end*, flattened from before backward, has a facet prolonged onto the palmar aspect, and divided into two condyles by a groove. The four of the *second row*, that of the thumb being wanting, are smaller, but similar, except that the proximal articular facet has a slight median ridge and two lateral depressions to fit the condyles of the first row. The five *terminal* or *ungual* (from *unguis*, "a nail") *phalanges* have proximal extremities like those of the second row, with the addition of a palmar depression for the long flexor tendons. The shaft tapers to the flattened, expanded, horseshoe-shaped distal extremity, of which the smooth dorsal surface supports the nail, and the rough palmar surface the pulp of the finger.

Taken together, the phalanges of the middle finger are the longest, and next those of the ring, index, little finger, and thumb, in the order named.

THE BONES OF THE LOWER LIMB.

The bony pelvis includes, besides the sacrum and coccyx, already described, the two hip-bones or the *pelvic girdle*. The skeleton of the lower limb comprises, besides the hip-bones, the femur in the thigh, the tibia and fibula in the leg, and the tarsal, metatarsal, and phalangeal bones in the foot. A large sesamoid bone, the patella, is found at the knee.

THE HIP-BONE.

The *hip-bone*, or *os innominatum* ("unnamed bone") (Figs. 166, 167), is irregular in form and shaped somewhat like the blade of a screw-propeller. It is narrowed in the middle, where the *acetabulum*, or socket for the femur, is seen externally, and expanded above and below. The large upper portion forms the *false pelvis* ("basin"), a part of the abdominal wall; the lower portion, perforated by the large *thyroid* ("shield-like") or *obturator* ("stopper") *foramen*, forms the lateral and front parts of the *true pelvis*, curving inward to meet its fellow. The hip-bone transmits the weight of the body to the femur. The three parts, *ilium*, *ischium*, and *os pubis*, separate in early life, ankylosed in the adult at the acetabulum, where they meet, are conveniently recognized as distinct in the description of the bone. In following the description hold the back of the cotyloid notch downward, in the natural position of the bone.

The Ilium.

The *ilium* ("twisted") is the large, upper expanded portion, whose lower limit forms the upper two-fifths of the acetabulum, and whose upper border, the *crest*, presents three lips for attachment of the flat muscles of the abdomen. The crest is sinuous, *f*-shaped, irregularly thickened, and subcutaneous.

To the outer lip are attached the tensor vaginæ femoris in front, the obliquus externus in the ventral half, the latissimus in the dorsal half, and the gluteal portion of the fascia lata in the entire length; to the middle ridge, the obliquus internus in the ventral two-thirds; to the inner lip, the transversalis in the ventral three-fourths, the quadratus lumborum and erector spinæ behind, and the iliac fascia in the entire length.

The crest ends in front in the prominent *anterior superior spine*, to which the inguinal (Poupart's) ligament, the tensor vaginæ femoris, and the sartorius are attached. The latter extends on to the notch below, which transmits the external cutaneous nerve, and separates the superior from the *anterior inferior spine*. From the latter, situated above the acetabulum, the straight tendon of the rectus femoris and the ilio-tibial band take origin. Below this spine and between it and the ilio-

pectineal eminence, where the ilium and os pubis meet, is seen the *inferior iliac notch*. This is situated in front of, and above, the acetabulum, and is traversed by the ilio-psoas muscle.

The crest ends behind in the *posterior superior spine*, affording ligamentous attachment, separated by a slight notch from the *posterior inferior spine*, at the

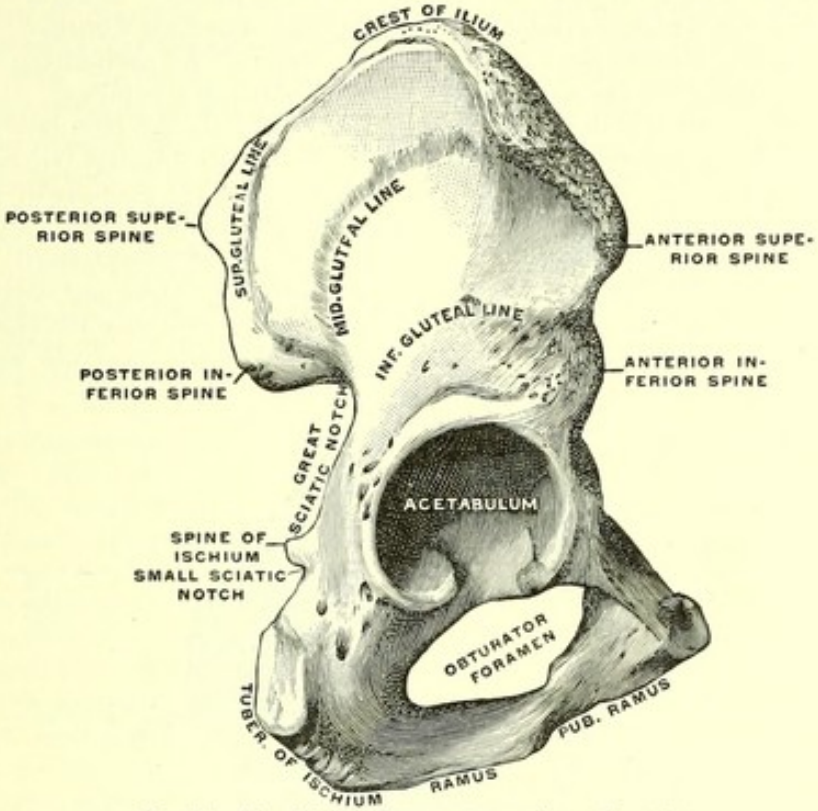

FIG. 166.—The right hip-bone, outer surface. (Testut.)

lowest and hindermost point of the auricular articular surface. Below the spines is the *great sacro-sciatic* ("sacro-ischiatic") *notch*, bounded above by the ilium, below and in front by the dorsal border of the ischium.

The *external surface*, or *dorsum*, flat or convex in front and behind, concave in the middle, is marked by the superior, middle, and inferior gluteal lines, which form the lower limit of the origin of the glutei maximus, medius, and minimus respectively. The *superior gluteal line* begins at the crest about 2 inches in front of its dorsal end, and curves downward to the hind part of the great sciatic notch. To the lower part of the space behind it the pyriformis is often attached. The *middle gluteal line* curves backward and downward from the crest, 1 inch behind its anterior end, to the upper border of the great sciatic notch. The *inferior gluteal line* passes backward from just above the anterior inferior spine to the front of the great sciatic notch. Between the inferior gluteal line and the margin of the acetabulum, and a little behind the anterior inferior spine, is a rough surface for the reflected tendon of the rectus femoris.

On the *internal surface* of the ilium is seen in front a smooth, concave, triangular area, the *iliac fossa*, giving origin to the iliacus muscle, and behind a smaller, uneven surface. The latter is divided into an inferior *auricular* (ear-shaped) cartilage-covered surface for articulation with the sacrum, and a superior rough surface for the attachment of the posterior sacro-iliac ligaments below and the erector spinæ above. The iliac fossa is limited below by the *ilio-pectineal* ("ilio-pubal") *line*, which forms the brim of the true pelvis, and extends between the auricular surface and the spine of the os pubis. Below the auricular surface and the dorsal end of the ilio-pectineal line is a small, smooth area of the ilium, which forms a small part of the wall of the true pelvis.

The Ischium.

The *ischium* ("hip"), situated dorso-inferiorly, forms superiorly the dorsal and lower two-fifths of the acetabulum and nearly all of its non-articular base; and below it terminates in the *tuberosity*. This is the thickest part of the bone, upon which the body rests in sitting, and from which the *ramus* ("branch") ascends to join that of the os pubis to assist in bounding the obturator foramen. The triangular upper part, or *body*, presents externally, between the acetabular rim and the tuberosity, a groove for the upper border of the obturator externus. Internally it and the tuberosity form a flattened surface, which bounds the true pelvis laterally, and from which the obturator internus arises. Its dorso-internal border completes the great sacro-sciatic notch, which is limited below by the prominent *spine* of the ischium. To the spine the small sciatic ligament is attached behind, the coccygeus and levator ani internally, and the gemellus superior dorso-externally, where the spine is crossed by the internal pudic vessels and nerve. The cartilage-clad small sciatic notch, over which the obturator internus glides, separates the spine from the tuberosity below. The *tuberosity* presents behind a rough quadrate surface, from

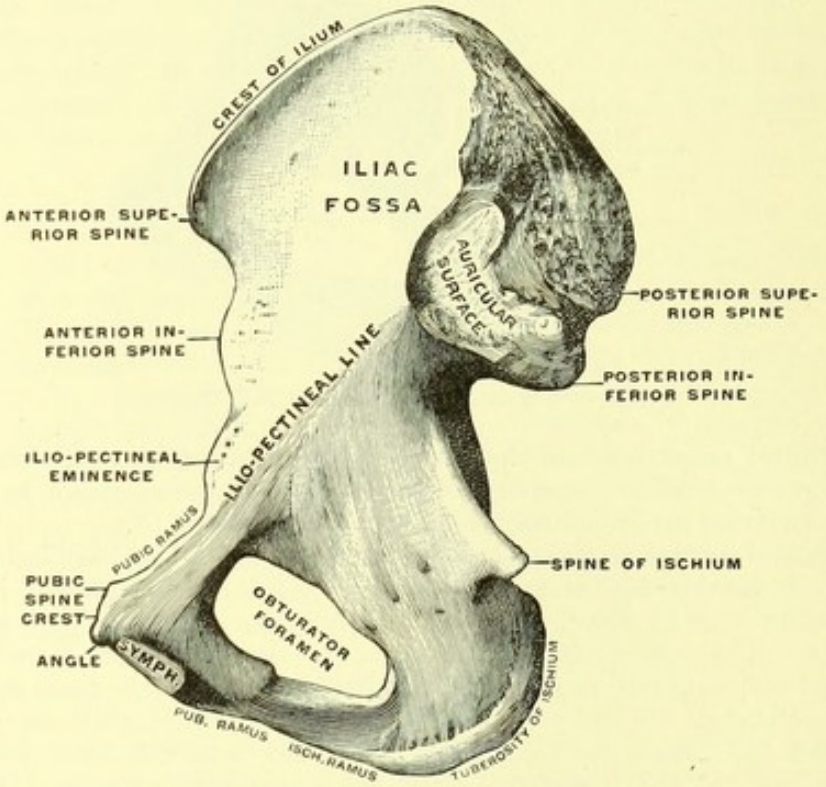

FIG. 167.—The right hip-bone, inner surface. (Testut.)

the upper and outer portion of which the semi-membranosus arises, and from the lower and inner part the semi-tendinosus and biceps. This area is separated by a transverse ridge from a pyriform, rough surface in front of it, which is continuous with the lower border of the ramus and attaches the adductor magnus. The sharp inner lip of the tuberosity attaches the falciform prolongation of the great sacro-sciatic ligament, and from the outer lip the quadratus femoris arises. The *ramus*, flattened like the descending ramus of the os pubis, with which it is continuous, presents a thin upper margin bounding the obturator foramen, and a thicker, everted, lower margin for ligamentous and muscular attachment. From its outer surface the obturator externus and adductor magnus arise, and from its inner surface arise the obturator internus, crus penis, erector penis, and, dorsally, the transversus perinei.

The Os Pubis.

The *ossa pubis* ("bones of the pubic") form the front wall of the pelvis. Each consists of a flat, quadrate body, situated internally and joined with the ilium and ischium, respectively, by two rami, the horizontal and descending. The *ventral surface of the body and of the descending ramus*, continuous with it, is rough for the origin of muscles. The corresponding dorsal or *pelvic surface* is smooth. From the ventral surface arise the obturator externus, the gracilis, and the three adductors; from the dorsal surface, the obturator internus, levator ani, compressor urethræ, erector penis, and the crus penis. The *inner border of the combined pubic and ischiatic rami* of the two sides, forming the pubic arch, is rough and more or less everted, especially in the female. The *outer border of the body and descending ramus* is narrow, and bounds the obturator foramen. The *inner border of the pubic body* presents an elongated, oval surface which is joined by cartilage to the opposite bone, forming the *symphysis pubis*. The broad, rough *upper border* or *pubic crest* stretches from the upper end of the symphysis, *the angle*, outward to the prominent *spine of the os pubis*. To the crest are attached the rectus abdominis and pyramidalis and the conjoined tendon; to the spine, the inguinal (Poupart's) ligament. The *horizontal ramus* extends from the body to the ilium at the ilio-pectineal eminence, and expands at its outer end to form the ventral fifth of the acetabulum. More or less triangular on section, its *upper border* is the pubic portion of the *ilio-pectineal line*, to which Gimbernat's ligament and a part of the conjoined tendon are attached internally. The triangular surface in front of this line gives origin to the pectineus, and is bounded below by the prominent *obturator crest*, which extends from the pubic spine to the cotyloid notch. The under surface bounds the obturator foramen superiorly, and presents externally the deep oblique *obturator groove* for the obturator vessels and nerve.

The *acetabulum* ("small cup"), or *cotyloid cavity*, is a nearly hemispherical cavity which looks outward, downward, and forward. It consists of a horseshoe-shaped marginal articular portion, which lodges the femoral head, and a central and inferior depressed, non-articular portion, which lodges a mass of fat. The upper part of the margin is the stoutest and most prominent; the lower part is deficient close to the obturator foramen, forming the *cotyloid notch*, which is bridged across by the transverse ligament, forming the *cotyloid foramen* for the passage of a nerve and vessels into the joint and to the head of the femur. To the margin of the articular portion the cotyloid ligament is attached, deepening the cavity so as to be more than a hemisphere, and outside of this the capsular ligament arises.

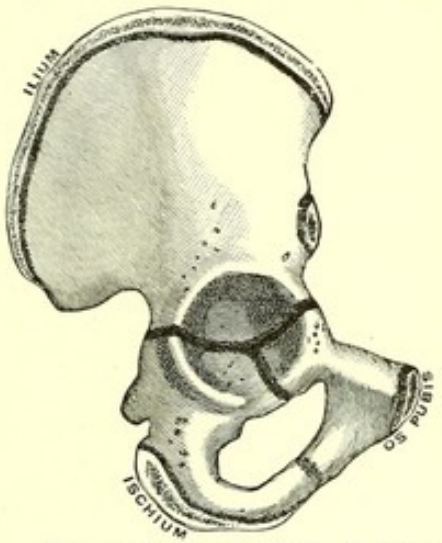

FIG. 168.—Development of the hip-bone, showing the union of the three portions in the acetabulum. (Testut.)

The *obturator* or *thyroid foramen*, below and internal to the acetabulum, is formed by and situated between the ischium and os pubis. It is closed by the fibrous obturator membrane, which is attached to its margins except near the groove for the obturator vessels and nerve, in its upper margin. In the female it is broad and triangular, in the male oval and elongated downward and backward.

The iliac crest, pubic spine, tuberosity of the ischium, and combined rami of the os pubis and ischium (bounding the perineum) can be felt subcutaneously. The anterior superior iliac spine and the pubic spine are of great importance as landmarks. The hip-bone is much thickened along the lines of greatest pressure —*i. e.*, between the auricular surface and the upper part of the acetabulum and tuberosity of the ischium. There is a thick ridge running from the acetabulum to the crest, but the centres of the iliac fossa and of the acetabulum are both thin.

Ossification (Fig. 168) takes place in cartilage from a centre for each of the three parts, ilium, ischium, and os pubis. A secondary centre appears later in the Y-shaped cartilage, where they meet in the acetabulum. This fuses with and joins together the three parts from the sixteenth to the twentieth year. Secondary nuclei appear for the iliac crest, the anterior inferior spine, the ischial tuberosity, and the pubic crest from the fifteenth year on, and unite with the main bone about the twentieth year.

THE PELVIS.

The pelvis (Figs. 169, 170), whose constituent parts, the two hip-bones, connected behind by the sacrum and coccyx, have already been described, is divided into two parts by a plane passing through the sacral promontory behind, the iliopectineal lines laterally, and the pubic crests in front. The part above this plane, composed of the ilia, belongs to the abdominal cavity, but is called the *false pelvis*. The limiting line is called the *brim*, and the included heart-shaped space the *inlet* of the lower part, or *true pelvis*. The *outlet*, or lower circum-

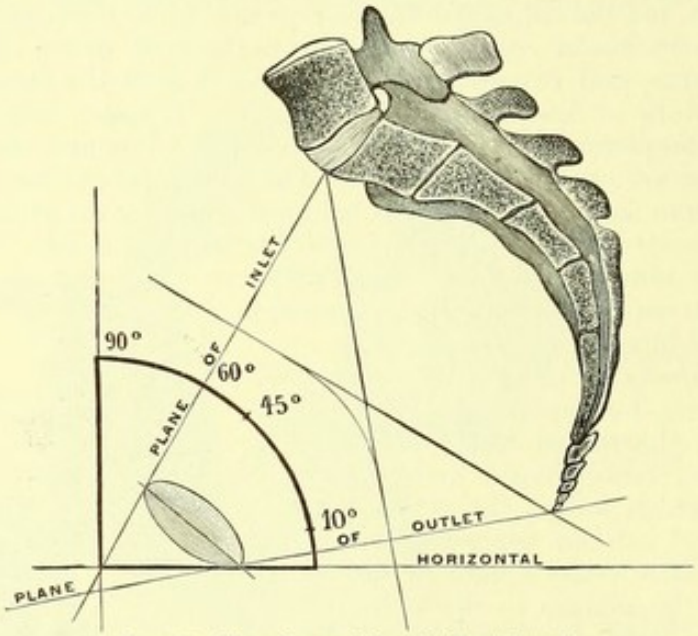

Fig. 169.—The planes of the pelvis. (Testut.)

ference of the pelvic cavity, presents three prominences—the ischial tuberosities laterally and the coccyx behind—separated by three notches, the pubic arch in front and the two sciatic notches behind. The *pubic arch* is the angular space in front beneath the symphysis and bounded by the combined rami of the ischia and ossa pubis. The sciatic notches are bridged across and converted into foramina by the sacro-sciatic ligaments, which bound the outlet of the pelvis as well as the perineum dorso-laterally.

The *cavity* of the pelvis is shallow (1½–2 inches) in front, where it is bounded by the os pubis, and deepest (5–5½ inches) behind, where the curved sacrum and coccyx form its bony wall. The ischia form the lateral walls. The *axis* of the pelvis, or the line drawn through the centres of the planes of the inlet, cavity, and outlet of the pelvis, is curved with its concavity forward.

The *position of the pelvis* in the erect attitude of the body is so tilted or inclined that the plane of the inlet forms an angle of 50° to 60° with the horizon, so that a line drawn at right angles to the centre of the plane of the inlet, if prolonged upward, would about meet the umbilicus. Furthermore, the base of the sacrum is raised about 3½ inches above the upper margin of the symphysis pubis, and the tip of the coccyx is ½–1 inch above the lower end of the symphysis. The plane of the outlet is more nearly horizontal, forming an

angle of about 15° with the horizon. This tilting of the pelvis brings the sacrum more or less on top, where, however, it does not form the keystone of the arch, for its widest aspect looks downward into the pelvis; and the bone is held in place mainly by the strong posterior sacro-iliac ligaments, and only slightly by the projection of the lower and ventral margins of the ilio-auricular surfaces. The weight of the body is transmitted from the sacro-iliac joint in an arch along the massive ilio-pectineal line to the acetabulum in the standing position, and to the ischial tuberosities in the sitting posture. The horizontal rami of the ossa pubis

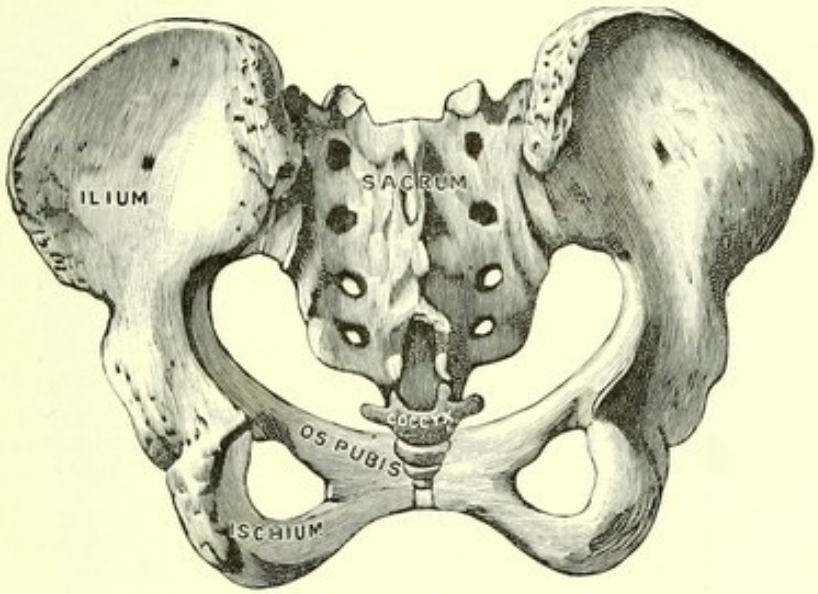

FIG. 170.—The female pelvis, rear view. (Testut.)

form the counter-arches or ties to the former arch, the combined ischial and pubic rami to the latter arch. The pressure along the arches and counter-arches when the bones are softened by rickets or osteomalacia causes various deformities of the pelvis.

Sex differences relate to both size and form. In the female the bones are lighter and smoother. The cavity is broader, more capacious, and less deep. The symphysis is not so deep, the pubic arch wider, the ischial tuberosities more expanded, and the sacrum flatter and broader. The sacral promontory is less projecting, giving the pelvic inlet a more oval shape. The thyroid foramina are more triangular. The differences of sex are noticeable in early life; but in general all pelves are more or less of the male type until about puberty, when the female characteristics become marked.

The following table represents the average measurements of the pelvis in inches:

Diameters.	Male.			Female.		
	Brim.	Cavity.	Outlet.	Brim.	Cavity.	Outlet.
Greatest transverse	5	4⅜	3½	5⅛	5	4⅜
Conjugate or ventro-dorsal	4	4¼	3¼	4½	5	4½
Oblique (from the sacro-iliac joint to the ilio-pectineal eminence)	4¾	4½	4	5	5¼	4½

THE FEMUR.

The *femur* (Figs. 171, 172), the largest and longest bone in the body, is inclined inward and slightly backward, so as to approach its fellow inferiorly. It extends between and articulates with the hip-bone above and the tibia below.

The *upper extremity* includes the head, the neck, and the two trochanters,

which attach the rotator muscles. The *neck* extends inward, upward, and slightly forward from the shaft to the head. It is compressed from before backward, but vertically expanded, especially where it joins the shaft. Its length is greater behind and below, and it is concave behind. Its axis forms an angle of 125° with that of the shaft. At birth this angle averages 160°. During growth, owing to the weight of the body, it decreases to from 140° to 110°; but after growth is completed it remains fixed. It is less in females and short subjects.

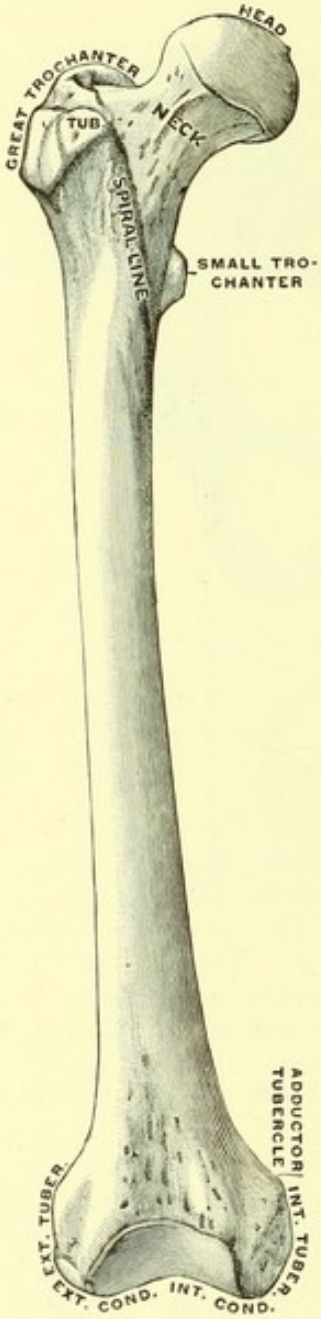

FIG. 171.—The right femur, front view. (Testut.)

FIG. 172.—The right femur, rear view. (Testut.)

The *head* is received into the acetabulum of the hip-bone. It forms more than half a sphere, and is covered with cartilage, except at a small pit behind and below the centre, to the upper half of which the ligamentum teres is attached. At the junction of the neck and shaft the two trochanters project. The *great trochanter* is a stout, quadrilateral plate, continuous with the outer surface of the shaft, which reaches nearly to the highest level of the neck. On its outer surface the gluteus medius is attached to an oblique line extending downward and forward

from its dorso-superior angle. The lower limit of this surface and the upper extent of the vastus externus are marked by a horizontal line, which, in front of the trochanter, ascends to an eminence, the *tubercle*, at the junction of the trochanter with the neck. Internal to the trochanter and between it and the neck is the deep *digital* or *trochanteric fossa*, which receives the tendon of the obturator externus. Above and in front of this fossa the obturator internus and the gemelli are attached. Behind the latter the pyriformis is attached to the narrow free *upper border*. The gluteus minimus is inserted upon the *anterior border*, while the thick, rounded *posterior border* is continuous with the *posterior intertrochanteric line*, which runs downward and inward to the small trochanter and limits the neck behind. The *small trochanter*, receiving the insertion of the ilio-psoas, projects as a pyramidal eminence from the dorso-internal aspect, where the lower end of the neck joins the shaft. The *anterior intertrochanteric line* limits the neck in front, and attaches the thickened front part of the capsular ligament. It is the upper part of the *spiral line*, which runs from the tubercle of the femur downward and inward to the linea aspera, passing a little in front of the small trochanter.

The *shaft*, arched convexly forward, is nearly cylindrical, except for a flattening in front and a prominent buttress-ridge, the linea aspera (" rough line ") behind ; so that three rather indistinct surfaces, a ventral and two lateral, may be distinguished, which are covered by the three vasti muscles. The shaft expands as it approaches the lower extremity. The *linea aspera* presents in the central third two lips and a rough, narrow interval often called the middle lip. In the upper third the external lip extends up to the great trochanter as the prominent *gluteal ridge* for the gluteus maximus. The internal lip is continuous with the spiral line, while a third line, giving insertion to the pectineus, ascends to the small trochanter from the intermediate space. Inferiorly the two lips diverge, and extend to the condyles as the *external* and *internal condylar ridges*, enclosing a flat triangular area, the floor of the upper part of the popliteal space. The inner ridge is interrupted by the crossing of the femoral vessels in the upper part, and ends below in the sharp *adductor tubercle*, to which the lowest fibres of the adductor magnus are attached. The *canal of the nutrient artery* is directed upward in the linea aspera a little above its centre. The following muscles, besides those already mentioned, are attached to the linea aspera and its prolongations : To the inner lip is attached the vastus internus, and to its lower two-thirds the adductor longus ; to the outer lip the vastus externus ; and to its lower two-thirds and the external condylar ridge the short head of the biceps. The adductor magnus is inserted below into the inner condylar ridge and the adductor tubercle, above, just internal to the gluteal ridge, as far as the quadratus femoris, and in the middle third to the intermediate space. The adductor brevis is attached to the upper third of the intermediate space below and external to the pectineus. A faint line, the *linea quadrati*, for insertion of the quadratus femoris, is sometimes visible, and passes upward from the outer side of the small trochanter to the middle of the posterior intertrochanteric line, where the *tubercle of the quadratus* is sometimes seen. Part of the iliacus is attached to an area below the small trochanter, internal to the pectineus.

The *lower extremity* presents *two condyles*, external and internal, most prominent behind, where they are separated by the deep *intercondylar notch*, while in front they are united by the *trochlear* (articular) *surface* for the patella. The part of the trochlea external to its vertical groove is the larger, and is very prominent along its outer edge, serving to resist the tendency to outward dislocation of the patella. Continuous with the trochlea are the cartilage-clad lower and dorsal surfaces of the condyles, which, though of different curvatures in different parts, articulate with the tibia. The external condyle is the broader, the internal the narrower and the more prominent laterally and behind, while in front it bends outward to the patellar surface. In the natural or oblique position of the bone the lower surfaces of the two condyles are in the same plane ; but if held verti-

cally the inner is the lower. On the lateral surface of each condyle the corresponding lateral ligament of the knee-joint is attached to a rough *tuberosity*. Below the outer tuberosity the popliteus arises from a depression, from which a groove passing backward and upward is occupied by the tendon of the muscle in flexion of the knee. To the mesial surfaces bounding the intercondylar notch the crucial ligaments are attached, the anterior to the external condyle behind, the posterior to the internal condyle in front. Immediately above and behind condyles the two heads of the gastrocnemius muscle arise, and above its outer head is the origin of the plantaris.

The great trochanter, the two condyles, and, during flexion, the trochlear surface for the patella, are the only subcutaneous parts of the bone. The great trochanter is an important landmark.

The femur averages 18 inches in length in the European male, and 17 inches in the female. It is inclined inward at an angle of about 9° with the sagittal plane in the male, and at a greater angle in the female. The femur presents an angle of torsion between the upper and lower extremities, but in the opposite direction to that of the humerus, and ranging between 5° and 20°. The lamellæ of the cancellous tissue at the upper extremity are arranged in arches, which cross one another and strengthen the neck of the bone, through which the weight of the body is transmitted from the head to the shaft. A nearly vertical plane of compact bone (*calcar femorale*, " femoral spur ") projects into the interior, toward the great trochanter, from a little in front of the small trochanter, and strengthens the concave side of the neck. It is liable to absorption in old age. The depression for the ligamentum teres is wanting in a small proportion of cases, and in a still smaller number is replaced by a tubercle. The gluteal ridge is sometimes so prominent as to be called the *third trochanter*.

Ossification occurs in the shaft from one centre, which appears very early. The lower epiphysis appears as a single centre. One after another centre appears for the head, great and small trochanters. These join the shaft as follows : small trochanter, seventeenth year ; great trochanter, eighteenth year ; head, nineteenth year ; condyles, twentieth to twenty-first year. The neck is an outgrowth from the shaft. The line of fusion of the condylar epiphysis with the shaft is below the adductor tubercle and the origins of the gastrocnemius muscle.

THE PATELLA.

The *patella* (" little dish "), or *knee-pan* (Figs. 173, 174), is a flattened, triangular sesamoid bone in the quadriceps extensor tendon at the front of the knee-joint.

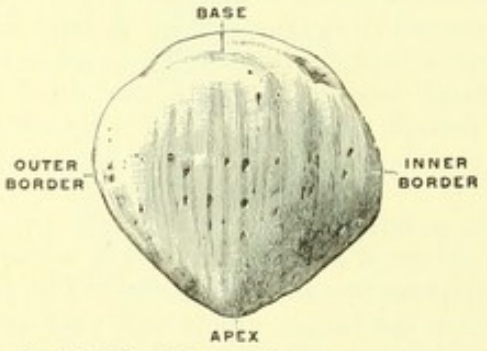

FIG. 173.—The right patella, ventral surface. (Testut.)

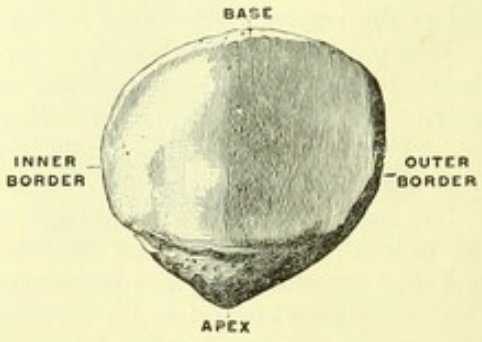

FIG. 174.—The right patella, dorsal surface. (Testut.)

Its slightly convex *ventral surface* is longitudinally striated for the fibrous expansion of the tendon. Its *dorsal surface* is mostly cartilage-clad to articulate with the trochlear surface of the femur, and is divided by a vertical ridge into a larger outer, concave portion and a smaller inner, convex one, to articulate with the

outer and inner sides respectively of the trochlear surface. The *upper border*, or *base*, is bevelled in front, and attaches the tendons of the muscles composing the quadriceps extensor. The *apex*, directed downward, and the border on either side of it attach the ligamentum patellæ, while the rough area of the dorsal surface above the apex is in relation to a mass of fat. In front of the patella is a bursa separating it from the skin. The entire articular surface is not in contact with the femur at any time, but one part after another as the knee is moved.

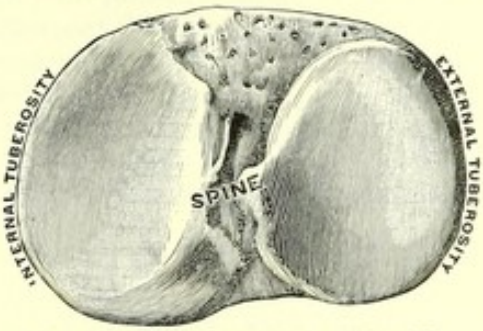

FIG. 175.—The upper surface of the right tibia. (Testut.)

The patella is liable to transverse fracture from muscular action, and, as its blood-supply comes largely from above, care should be taken in dealing with the upper fragment not to strangulate it.

THE TIBIA.

The *tibia* ("shin") (Figs. 175–177) is the inner, larger, and more forward of the bones of the leg, and conveys the weight of the body from the femur to the astragalus.

The *upper extremity*, or *head*, is thick and inclined slightly backward. It is expanded on each side into a massive *tuberosity*, whose upper aspect presents a slightly concave articular surface, which receives the condyles of the femur. Of these *articular surfaces*, the inner is longer from before backward and more concave; the outer is smaller, flatter, and more circular. Both are flattened peripherally, where the semilunar fibrocartilages rest upon them and deepen the socket for the femoral condyles. Projecting upward, between these surfaces, is the *spine* of the tibia, which is laterally bifid. To rough depressions between the articular surfaces are attached in front of the spine the anterior crucial ligament, with the forward extremities of the semilunar cartilages, and behind the spine the posterior crucial ligament with the hind extremities of the semilunar cartilages. The depression behind the spine is continued backward into a notch, the *popliteal notch*, which separates the tuberosities posteriorly. In front the tuberosities are continuous, and form on the anterior surface of the head a triangle whose apex points downward and ends at the *tubercle*, the lower end of which attaches the ligamentum patellæ, its upper smooth part being separated from the ligament by a bursa. Upon it the body rests in

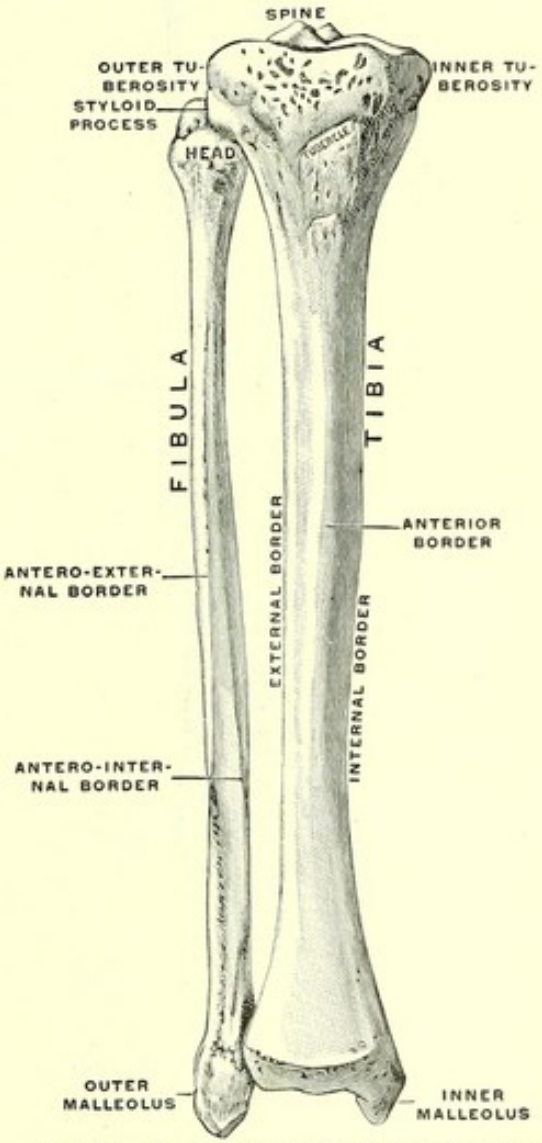

FIG. 176.—The right tibia and fibula in their normal relations, front view. (Modified from Testut.)

kneeling. At the outer angle of this triangular surface is a prominence to which the ilio-tibial band of the fascia lata is attached. The larger, internal tuberosity is marked behind by a horizontal groove for the insertion of the semi-membranosus tendon, and the external tuberosity presents postero-externally a rounded *articular facet* for the head of the fibula.

The three-sided *shaft* of the tibia is very thick above and tapers toward the lower end, where it again expands slightly. The *internal surface* is convex and subcutaneous, except at the upper end, where, internal to the tubercle, the sartorius, gracilis, and semi-tendinosus tendons are attached. The *external surface* is concave in its upper two-thirds, where it gives origin to the tibialis anterior, convex below, where it looks more forward and is covered by the extensor tendons. On the *posterior surface* the popliteus is inserted on a triangular area at the upper end, limited below by the *oblique line*, which passes from the fibular facet downward and inward to the internal border, and attaches the soleus muscle. Below the oblique line this surface is divided by a longitudinal ridge into an inner portion giving origin to the flexor longus digitorum, and an outer for the tibialis posterior. At the upper part of this surface and below the oblique line is found the large *foramen for the nutrient artery*, directed downward. The *anterior border*, or *shin*, commencing above, just below the tubercle, is subcutaneous, sinuous, and sharp in its upper two-thirds, rounded in its lower third, where it passes to the front of the internal malleolus. The *external* or *interosseus border* attaches the interosseous membrane and bifurcates near the lower end, thus enclosing a triangular area for the inferior interosseous ligament. The *internal border* extends from the back of the internal tuberosity above to the back of the internal malleolus below. The internal lateral ligament is attached to its upper 3 inches, the soleus muscle to its middle third.

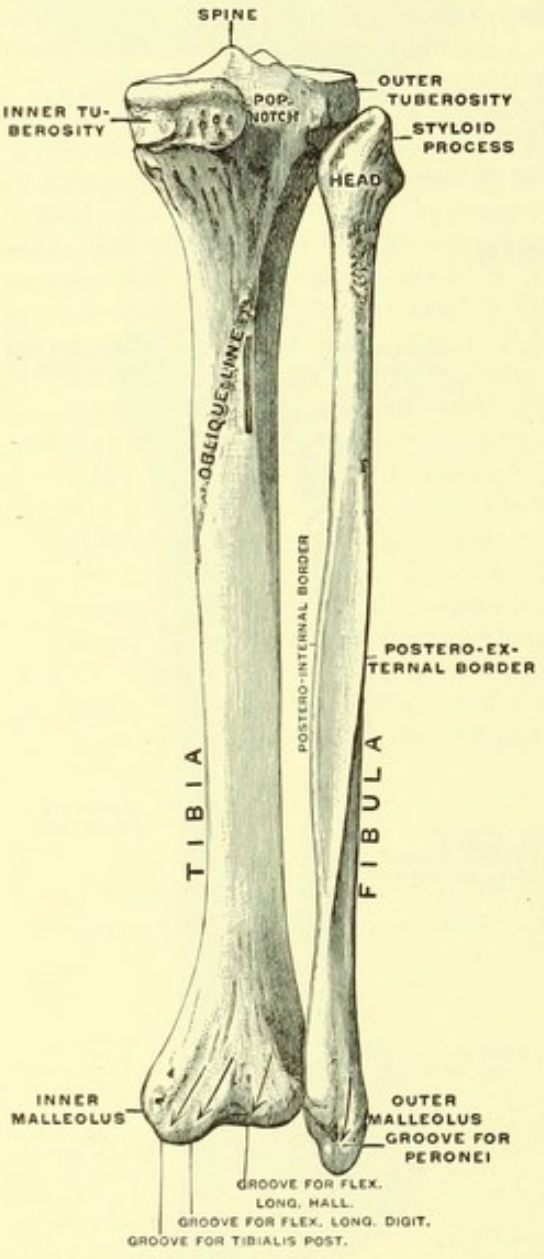

FIG. 177.—The right tibia and fibula in their normal relations, rear view. (Testut.)

The *lower extremity* is somewhat quadrilateral, and is expanded transversely. It is prolonged downward, internally, as a flattish, subcutaneous process, the *internal malleolus*, from the tip and margins of which the internal lateral ligament of the ankle arises. The fore part of its external surface is articular, for the inner lateral facet of the astragalus, and is continuous with the inferior quadrilateral articular surface of the extremity, which articulates with the upper surface of the astragalus. This inferior facet is concave from before backward, and is narrower, and descends lower behind than in front. Behind the malleolus is a groove for the tibialis posterior and the flexor longus digitorum, while farther externally the flexor longus pollicis slightly

grooves the posterior border. The external surface of the lower extremity of the bone, except for a narrow articular border below, is rough for ligaments which attach it to the fibula.

The tibia is twisted, so that when the axis of the upper end is transverse that of the lower end is inclined from without inward and forward at an angle averaging 5°–20°, but sometimes varying between 0° and 48°.

Ossification.—Each epiphysis ossifies from a single centre. That in the upper end includes the tubercle and appears first. The lower end unites with the shaft at the eighteenth or nineteenth year, the upper end in the twenty-first or twenty-second year.

THE FIBULA.

The *fibula* ("clasp" or "brace") (Figs. 176, 177) is the slender outer bone of the leg. It reaches lower than, but not as high as, the tibia. Its upper end is behind the plane of the lower end, and its shaft is slightly curved and very variable in its contour. (The Greek name of this bone is *perone*, the adjective from which ("peroneal") is synonymous with "fibular.")

The *upper extremity* or *head* is irregularly expanded, and presents above and internally a small obliquely placed articular facet, looking upward, inward, and forward, articulating with the facet on the outer tuberosity of the tibia. Behind and slightly external to the facet rises a conical eminence, the *styloid process*, to which the short external lateral ligament of the knee is attached, while to a slight depression in front of and external to it are attached the external lateral ligament and the tendon of the biceps.

The *lower extremity* is a thick pyramidal process which forms the *external malleolus* ("little hammer"). The latter is lower, more posterior, and more prominent than the internal malleolus. Its *inner surface* presents in front a triangular facet for articulation with the outer facet on the astragalus, above which is a rough triangular surface for the inferior interosseous ligament. Behind the facet is a rough depression for the attachment and reception of the hind fasciculus of the external lateral ligament of the ankle. The *posterior surface* is grooved for the peronei longus and brevis. The *external surface* is subcutaneous and continuous with a subcutaneous triangular surface tapering upward for two or three inches upon the shaft.

The *shaft* has four variable surfaces, each giving origin to a muscle or a group of muscles which produce a particular motion of the foot. The four borders limiting these surfaces attach fibrous septa separating the muscles or muscle-groups. The lower fourth of the shaft is twisted outward. The well-marked *antero-external border* begins in front of the head, and bifurcates in the lower

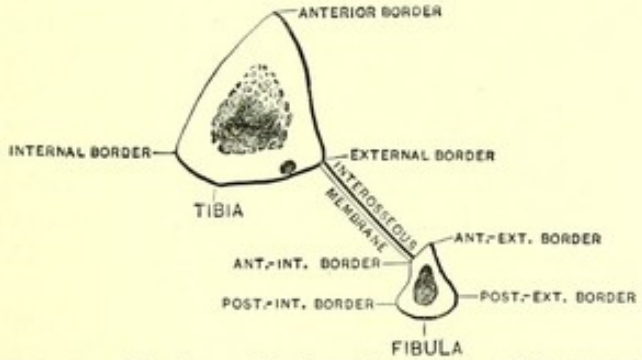

FIG. 178.—Horizontal section of the bones of the leg at the junction of the upper and middle thirds, showing their borders and surfaces and the relations of the interosseous membrane. (Testut.)

fourth to include the triangular subcutaneous surface above mentioned. To it is attached the anterior tibial fascia which separates the peronei longus and brevis, which pronate the foot and occupy the *external* or *pronator surface*, from the extensores longus digitorum and proprius hallucis and the peroneus tertius, which

arise from the narrow *anterior* or *flexor surface*, and flex the ankle on continuing their primary action. The *external surface* turns dorsally in the lower fourth to become continuous with the posterior surface of the malleolus. The *antero-internal* or *interosseous border* (Fig. 178) is close to the antero-external border above but diverges from it below, where, an inch or more above the malleolus, it ends at the apex of a rough triangular area which attaches the inferior interosseous ligament. This border attaches the interosseous membrane which separates the muscles arising from the anterior surface from the tibialis posterior, which supinates the ankle and arises from the fusiform *internal* or *supinator surface*. The latter surface occupies the upper two-thirds only of the shaft. It is separated from the posterior surface by the *postero-internal border*, which joins the interosseous border in the lower third, and attaches a fibrous septum separating the muscles which arise from the surfaces on either side. The *posterior* or *extensor surface*, becoming more internal below, attaches the soleus above and the flexor longus hallucis below. The latter muscles are separated from the peronei by a septum attached to the prominent *postero-external border*, which passes from the styloid process to the back of the malleolus. The *nutrient foramen*, directed downward, is seen in the middle third of the posterior surface.

The head, the outer surface of the malleolus, and the triangular area above it are subcutaneous; otherwise the shaft is covered by muscles. Fracture occurs very commonly an inch or two above the malleolus.

Ossification.—The lower epiphysis, although it ossifies first, joins the shaft about the twentieth or twenty-first year, while the upper or more vestigial epiphysis remains separate until the twenty-second to the twenty-fourth year.

THE BONES OF THE FOOT.

The skeleton of the foot is composed of three groups of bones—those of the *tarsus* ("the flat of the foot"), *metatarsus* ("beyond the tarsus"), and *digits*. The bones of the foot, although resembling those of the hand, are modified in the direction of greater firmness, and are in a position of permanent pronation and dorsal flexion.

THE TARSAL BONES.

The *tarsus* contains seven bones—the astragalus, calcaneum, cuboid, navicular, and the three cuneiform bones.

The Astragalus.

The *astragalus* ("a die"), or *talus* (Figs. 179, 181, 183, 184), occupies the upper part of the arch of the foot, where it articulates with the tibia above and internally, and with the fibula externally. It receives the weight of the body from the tibia, and transmits it by articulation to the calcaneum below and the navicular in front. Its long axis is directed forward and inward to the convex anterior extremity, or *head*, which is joined by a slightly constricted *neck* to the main part, or *body*, behind. The *upper surface* is occupied by the trochlear articular surface for the tibia. This is convex from before backward, and slightly concave transversely. It is broader in front than behind, and continuous with the lateral facets for the malleoli. The facet on the *outer surface*, for the external malleolus, is triangular and vertically concave; that on the *inner surface*, for the internal malleolus, is smaller, narrow, and pyriform; and to the rough surface below is attached the deep portion of the deltoid ligament. The *under surface* presents a deep groove for the interosseous ligament, which passes from within obliquely

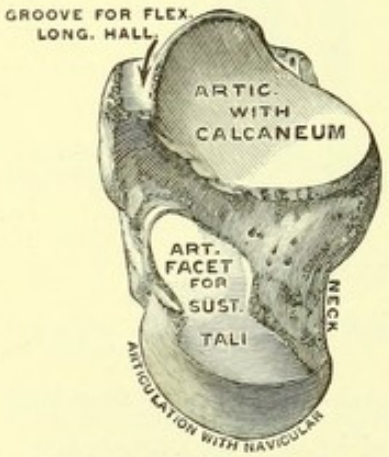

FIG. 179.—Right astragalus, under surface. (Testut.)

outward and forward to the neck, and separates the two facets which articulate with the calcaneum. The posterior facet is concave from behind forward; the anterior is convex and rests upon the facet on the sustentaculum tali of the os calcis. The anterior facet is continuous in front with the oval facet on the head, for the navicular, though there intervenes between them internally a small facet which rests upon the inferior calcaneo-scaphoid ligament. The *posterior surface* is a mere narrow border, grooved internally for the flexor longus hallucis. The *tubercle* bounding this groove externally attaches the posterior band of the external lateral ligament of the ankle, and sometimes is found as a separate bone, the *os trigonum* ("triangular bone").

The Calcaneum.

The *calcaneum* ("heel") or *os calcis* (Figs. 180–183), the largest bone of the foot, projects backward and downward to form the heel, which acts as a fulcrum for the calf-muscles, and transmits most of the weight of the body to the ground. Its long axis is directed forward and a little outward from its enlarged posterior extremity.

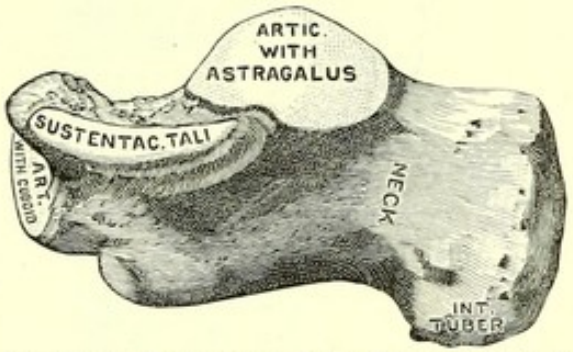

FIG. 180.—Right calcaneum, internal surface. (Testut.)

The *upper surface* presents in its fore part two facets for articulation with the astragalus. The larger, hinder, and external facet is convex from before backward; the forward one is long, concave, often subdivided, and is located on the upper surface of the *sustentaculum tali* ("support of the astragalus"), a flat, shelf-like process projecting inward on a level with the upper surface. Between these two facets is a groove for the interosseous ligament, passing obliquely forward and outward to a rough surface where the extensor brevis digitorum arises. The *under surface* is narrow, rough, and transversely convex. It ends behind in two tubercles, which attach plantar muscles and the plantar fascia. The inner tubercle is the larger, the outer the more prominent. In front of these the long plantar ligament is attached while the short plantar ligament is attached to the anterior tubercle at the fore end of this surface and to the shallow groove in front of it. The *inner surface* presents a concavity between the inner tubercle behind and the sustentaculum tali in front. The under surface of the latter presents a groove continuous with that at the back of the astragalus for the flexor longus hallucis. The *outer surface*, rough, flat, and subcutaneous, presents at its fore part two slight grooves, the upper for the peroneus brevis, the lower for the peroneus longus, separated by a ridge or tubercle, the *peroneal spine*. The *posterior surface* is smooth above, and separated by a bursa from the tendo-calcaneus (Achillis), which is attached below. On the *anterior surface* is a saddle-shaped articular facet for the cuboid.

The calcaneum and astragalus are both very vascular. The veins of the former emerge mostly on the inner side, where they are less exposed to pressure.

The Cuboid.

The *cuboid* ("cube-like") (Figs. 181–183) lies on the outer side of the foot, between the calcaneum behind and the fourth and fifth metatarsals in front. Although cuboidal, the four surfaces adjoining the external converge to it, giving the bone a pyramidal shape. *Posteriorly*, it articulates with the calcaneum by a saddle-shaped facet prolonged backward at the lower and internal angle, beneath the calcaneum. *Anteriorly*, a smaller facet is divided into an outer triangular and an inner quadrilateral portion for the fifth and fourth

metatarsal bones respectively. The *upper surface*, directed somewhat outward, is flat and non-articular. The *lower surface* presents a prominent ridge or *tuberosity*, directed obliquely inward and forward, in front of which is a deep groove for the peroneus longus. To the ridge and the triangular surface behind it are attached the plantar ligaments. On the narrow *external surface* or border the outer end of the ridge is usually facetted for the bend in the peroneus longus tendon. The *internal surface* presents near its middle and upper part a facet for the external cuneiform, and oftentimes behind this a second facet for the navicular, while the rest of the surface is rough for interosseous ligaments.

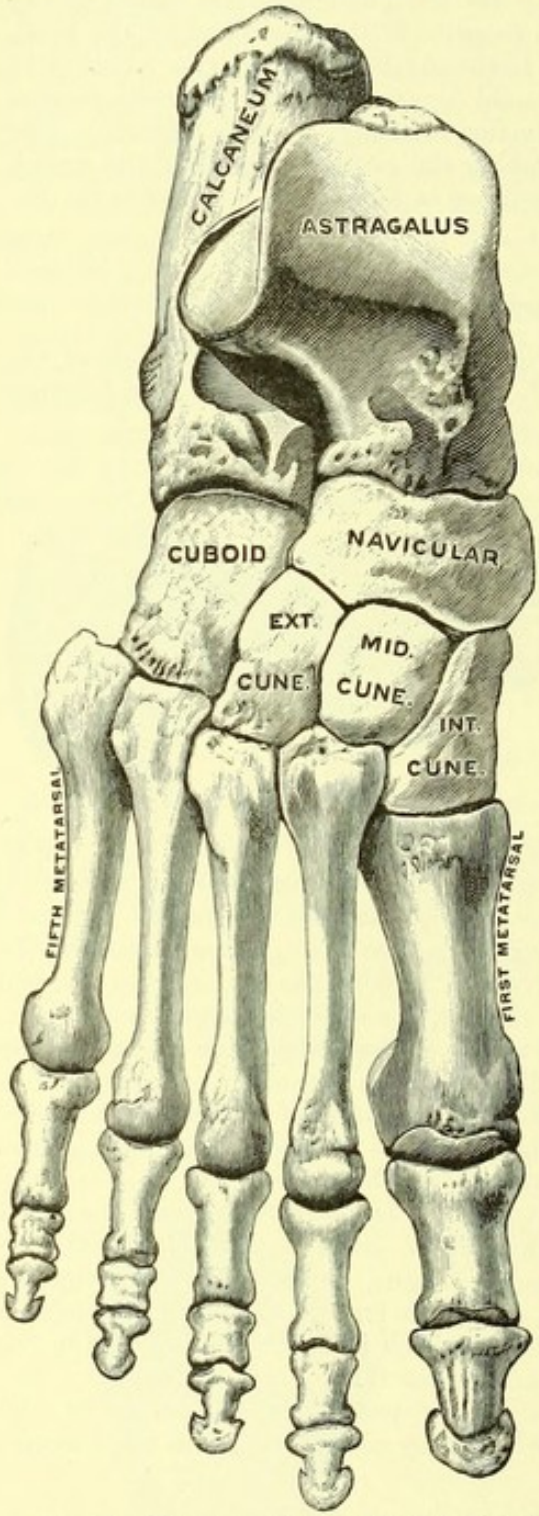

FIG. 181.—The bones of the right foot, viewed from above. (Testut.)

The Navicular.

The *navicular* ("boat-shaped") or *scaphoid bone* (Figs. 181–184), situated on the inner side of the foot between the astragalus and the cuneiform bones, is compressed from before backward. Proximally its concavity articulates with the head of the astragalus. Its convex *distal surface* is subdivided into three triangular facets for the cuneiform bones. *Above* it is rough and convex, *below* more narrow and uneven, *externally* rough for ligaments, with an inconstant facet for the cuboid. *Internally* it is prolonged downward and inward into the prominent *navicular tuberosity*, which attaches part of the tibialis posterior, and, being subcutaneous, is an important landmark in finding the medio-tarsal (Chopart's) joint.

The Cuneiform.

The *three cuneiform bones*, named respectively from their position from within outward, *internal*, *middle*, and *external*, are wedge-shaped, and lie between the navicular and the three inner metatarsal bones. Their proximal surfaces, articulating with the navicular, are concave and in the same transverse line; their distal surfaces, articulating with the three inner metatarsals, are convex or flat, and the middle cuneiform being the shortest, a deep recess is formed, into which the base of the second matatarsal is received.

The Internal Cuneiform.

The *internal cuneiform* (Figs. 181, 182, 184), the largest of the three, has the base of the wedge directed downward on the inner border of the foot. The distal,

kidney-shaped facet for the base of the first metatarsal is much larger than the proximal pyriform facet for the navicular. On the internal surface is an oblique shallow groove for the tibialis anterior tendon, leading to an oval facet antero-inferiorly where the tendon is in part attached. On the rough, concave external surface there is an L-shaped facet along the upper and hind borders, which articulates with the middle cuneiform, except in front, where a distinct facet is marked off for the inner side of the base of the second metatarsal bone.

The Middle Cuneiform.

The *middle cuneiform* (Figs. 181–183), the smallest of the three, has its base directed upward. The facets in front and behind are wedge-shaped, that in front for the second metatarsal being slightly smaller. On the inner surface is an L-shaped facet along its upper and hind borders corresponding with that on the internal cuneiform. On the outer surface a facet along its hind border articulates with the external cuneiform.

The External Cuneiform.

The *external cuneiform* (Figs. 181–183) also has its base directed upward. Continuous with the triangular facet for the base of the third metatarsal, at the fore part of each lateral surface, are small facets, internally for the second metatarsal and externally for the fourth metatarsal. The internal surface has in addition a facet along its hind border for the middle cuneiform, and the external surface has a larger facet behind and above for the cuboid.

The Metatarsal Bones.

The five *metatarsal bones* (Figs. 181–184) are numbered from within outward. They closely resemble the metacarpal bones in having irregular cuboidal bases, articulating with the same number of bones as do the metacarpal; in having tapering triangular shafts, slightly concave from end to end on the plantar aspect; and in having laterally compressed heads with articular facets extending onto the plantar surfaces, where they are grooved for the flexor tendons, and with lateral tubercles and depressions for the lateral ligaments. The line of their bases slopes from within outward and backward, and is interrupted by the mortising of the second between the internal and external cuneiform bones.

The *first metatarsal*, the stoutest and shortest, has on its *base* a large, slightly concave, kidney-shaped facet for the internal cuneiform, and an inconstant facet externally for the second metatarsal. The lower part of the base projects downward and slightly outward as the *tuberosity*, which attaches part of the peroneus longus externally and of the tibialis anterior internally. On the plantar surface of the large *head* are two deep grooves for the sesamoid bones.

The *second metatarsal* is the longest; the others diminish in length to the fifth. Its base articulates in the mortise with the three cuneiform bones, and externally by two facets with the third metatarsal, and occasionally internally with the first metatarsal.

The *base* of the *third metatarsal* articulates proximally with the external cuneiform, internally by two facets with the second metatarsal, and externally by a single facet with the fourth metatarsal.

The *base* of the *fourth metatarsal* articulates proximally with the cuboid, internally with the third metatarsal by a single facet, and usually with the external cuneiform. Externally there is a single facet for the fifth metatarsal, bordered by a deep groove for ligaments.

The *base* of the *fifth metatarsal* articulates proximally with the cuboid, internally with the fourth metatarsal. On its outer aspect it projects as a large rough *tuberosity* upon which the tendon of the peroneus brevis is inserted. Being subcutaneous, it is an important landmark on the outer border of the foot.

THE PHALANGES.

The *phalanges* (Figs. 181–184) resemble so closely those of the fingers that only the differences need be noticed. Those of the great toe are larger than those of the thumb, while those of the other toes are much smaller than those of the

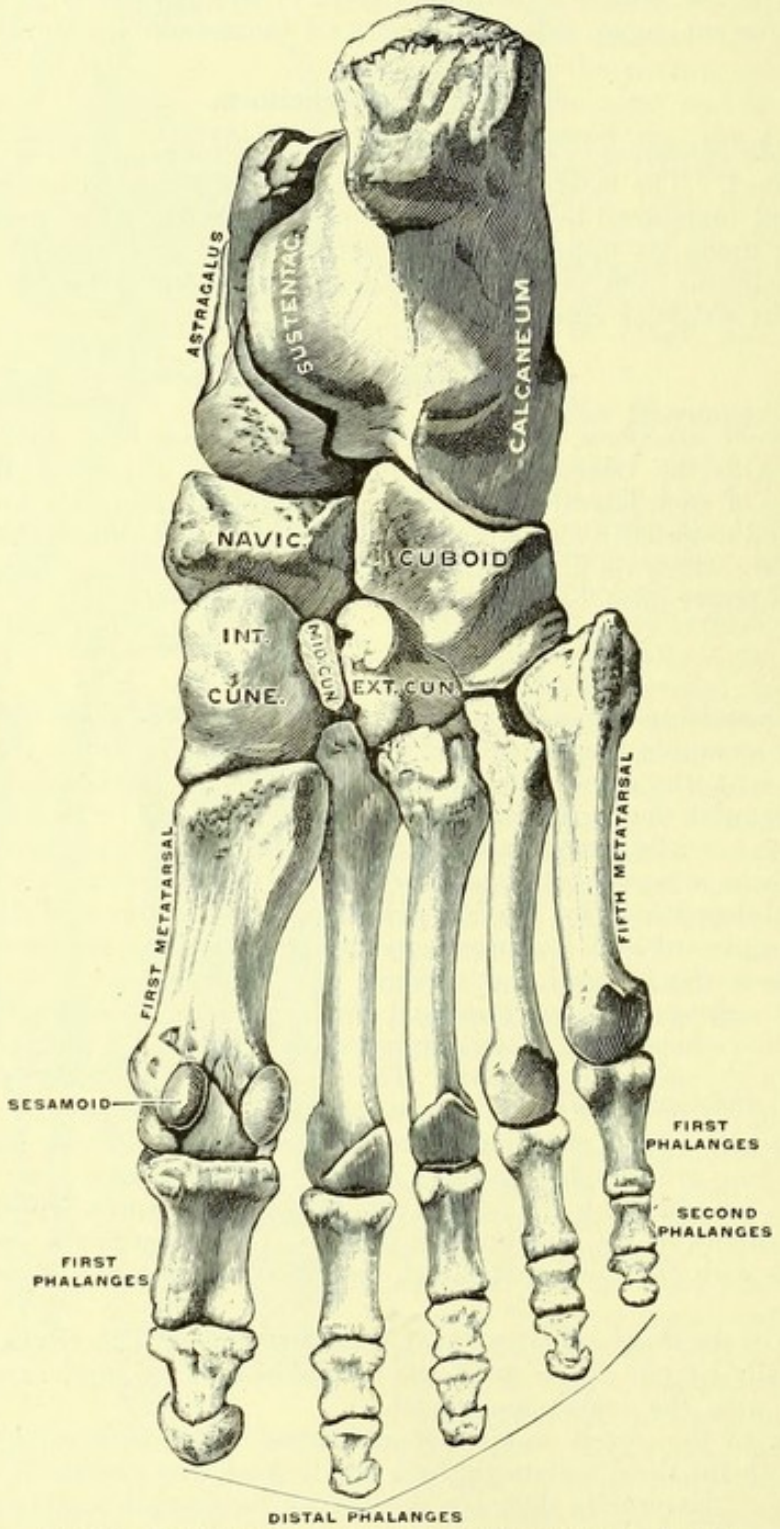

FIG. 182.—The bones of the right foot, viewed from below. (Testut.)

corresponding fingers. The shafts of the phalanges of the *first row*, in the four smaller toes, are narrowed in the middle, being compressed laterally. In the same toes the phalanges of the *second row* are very short and stunted, especially

those of the fourth and fifth toes, which are not infrequently ankylosed with the terminal phalanges.

The two *sesamoid bones* in the tendon of the flexor brevis hallucis glide in the two grooves on the plantar aspect of the head of the first metatarsal bone. Sesamoid bones occasionally occur elsewhere in the foot.

Ossification.—The metatarsal and phalangeal bones ossify exactly like the corresponding bones in the hand.

THE FOOT AS A WHOLE (Figs. 181–184).

The foot is narrowest at the heel and widens to the heads of the metatarsal bones. The bones of the foot form a *longitudinal arch* with a single pier, the calcaneum, behind, while the forward pier is formed by the heads of the metatarsal bones. It may be divided longitudinally into two parts in front, with a common support behind. The inner division consists of the hind two-thirds of

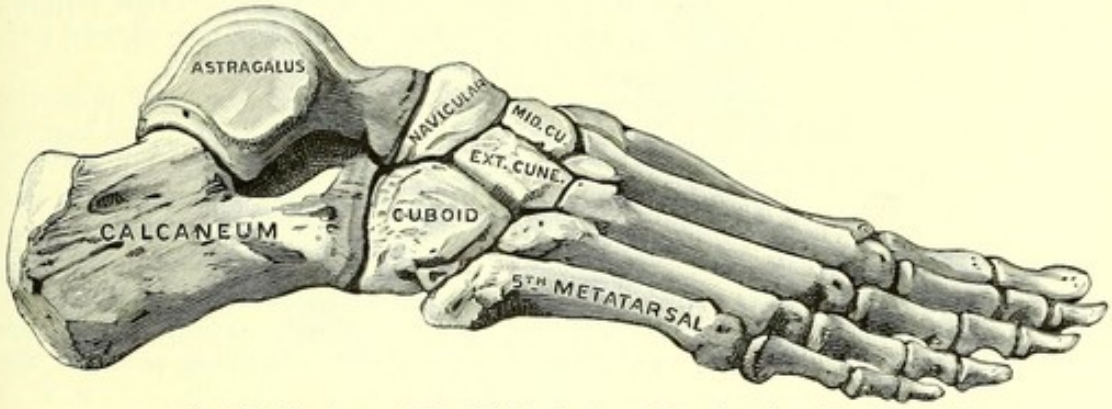

FIG. 183.—The bones of the right foot, viewed from the outer side. (Testut.)

the calcaneum, the astragalus, navicular, cuneiforms, and the three inner metatarsals. It bears the greater part of the weight, and is the most raised from the ground. The outer division is formed by the calcaneum, bearing the cuboid and the two outer metatarsals, and acts mainly as a buttress to the inner arch. The longitudinal arch is supported largely by the plantar ligaments, while a *transverse arch*, having its two internal piers at the internal cuneiform and the first metatarsal, and its external piers at the cuboid and the fifth metatarsal, is formed by the wedge-shape of the cuneiform bones and of the bases of the metatarsals.

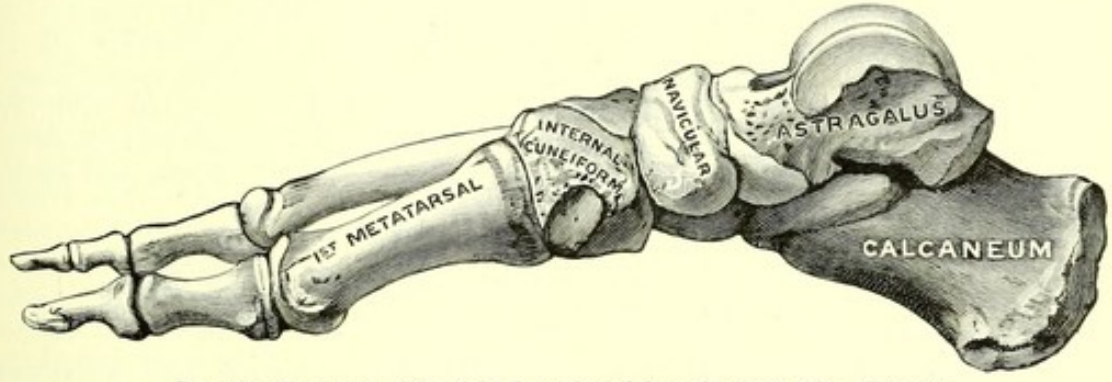

FIG. 184.—The bones of the right foot, viewed from the inner side. (Testut.)

The longitudinal arch is weakest between the astragalus and navicular, where it is liable to yield, giving rise to flat-foot. In this condition it is well seen that the arch is not quite straight from the heel to the toes, but is slightly convex internally and concave on the outer border. The astragalus inclining inward

and the calcaneum outward in front, the upper and outer border of the former is found over the middle of the latter, making the internal malleolus appear more prominent. In infancy the head of the astragalus is inclined inward more than in the adult, so that the foot is then naturally inverted.

The tuberosity of the navicular on the inner border of the foot and that of the base of the fifth metatarsal on the outer border, both readily felt through the soft parts, are the best guides to the medio-tarsal and tarso-metatarsal joints. The tuberosity of the fifth metatarsal is a finger's breadth in front of the medio-tarsal, and directly in front of the tarso-metatarsal joint; that of the navicular is two fingers' breadth behind the tarso-metatarsal and directly in front of the medio-tarsal joint.

Homologies of the Bones of the Two Extremities.

The following conclusions are generally admitted: The thoracic and pelvic limbs are constructed on the same type in their attaching girdles and their several segments. In the pelvic and shoulder girdles the ilium corresponds to the scapula, the ischium to the coracoid process, and the os pubis to the precoracoid, and perhaps to the clavicle.

At an early stage of embryonic life the limbs are folded ventrally upon the body, and present pre- and post-axial borders and dorsal or extensor and ventral or flexor surfaces. Later, the upper limb rotates outward 45°, and the lower limb rotates inward 90°. This brings the flexor surface in the upper limb forward and inward, and in the lower limb backward. The small trochanter and internal condyle of the femur, the tibia, and the great toe in the lower limb are pre-axial, and correspond respectively to the great tuberosity and outer condyle of the humerus, the radius, and the thumb in the upper limb, etc. The patella in the lower limb and the olecranon in the upper have no corresponding parts in the other limb.

The adult human skeleton is adapted in every part to maintain with ease the erect attitude by being nearly balanced around the line of the centre of gravity in the standing posture, and in this respect it differs from that of other mammals. Stability and strength are provided in the lower limbs, mobility and lightness in the upper.

THE SKULL.

The bones of the head, composing the skull, contain and protect the brain and sense-organs, as well as the commencement of the alimentary and respiratory tracts. With the exception of the lower jaw, the bones are immovably joined together by sutures, forming a bilaterally symmetrical, spheroidal figure, somewhat compressed laterally. It is supported upon the vertebral column, with the upper segment of which it articulates. For description, the twenty-two bones of the skull are divided into two sets. The *cranium*, or brain-case, is the part above and behind, and comprises eight bones—viz.:

Basilar bones, { Occipital. Sphenoid. Two temporals. Ethmoid. } Roof bones, { Two parietals. Frontal. }

The *face* is the lower and fore part, composed of six pairs and two single bones, or fourteen in all—viz.: in pairs, the maxillæ, palate, inferior turbinate, nasal, lachrymal, and malar; single bones, the vomer and mandible. The hyoid bone may also be classed here, as appendicular to the bones of the head. The base of the skull is preformed in cartilage, the roof and sides in membrane.

THE BONES OF THE CRANIUM.

THE OCCIPITAL BONE.

This lozenge-shaped bone (Figs. 185 and 186) forms the back and a part of the base of the skull. Its long diameter is directed from behind downward and forward. It consists of four parts, which meet around the *foramen magnum*. These parts are distinct at birth, and are represented by separate bones in lower vertebrates. Of these parts, the broad, flat, curved portion behind the foramen magnum, called the *squamo-occipital*, consists of two parts. The upper triangular segment lying above the highest curved line represents the *interparietal bone* of lower vertebrates, and is sometimes separate in man. The two *exoccipitals* or *condylar portions* lie one on either side of the foramen magnum, and include the

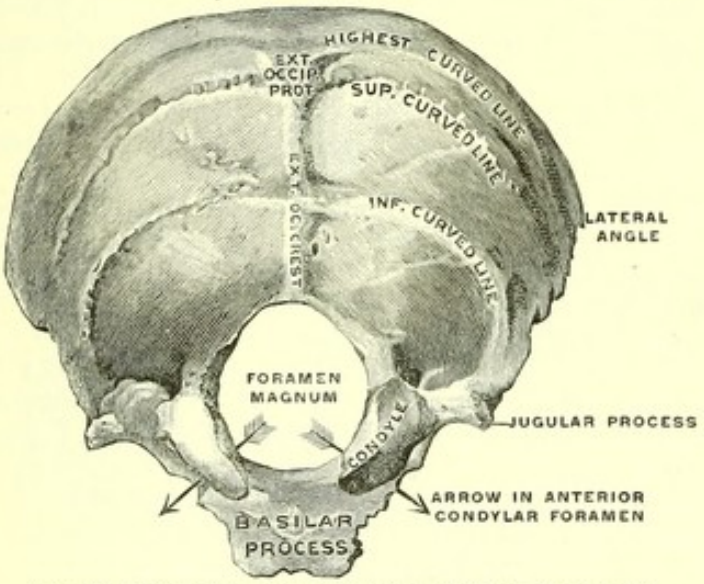

FIG. 185.—The occipital bone, viewed from below. (Spalteholz.)

condyles and jugular processes. They join the squamo-occipital behind and the *basi-occipital* or *basilar process* in front. The latter extends forward from the foramen to the sphenoid line. The entire bone is flattened and much curved, and presents a concave cerebral surface and a convex external surface.

The **external surface** is convex, and looks downward and backward behind, downward and forward in front. It presents behind, about the centre of the squamous portion, a well-marked prominence, the *external occipital protuberance*—an important landmark to be felt through the scalp. From this a median ridge, the *external occipital crest*, leads to the back of the foramen magnum. The protuberance and crest give attachment to the ligamentum nuchæ. A transverse ridge extends laterally on each side from the external occipital protuberance called the *superior curved line* (or middle nuchal line). It arches outward toward the lateral angle, and attaches the trapezius internally, and parts of the occipitalis, sterno-cleido-mastoid, and splenius capitis externally. Above this line is sometimes to be seen a fainter ridge, the *highest curved line* (linea suprema or superior nuchal line). This is more curved, most marked mesially, and extends laterally toward the lateral angle, enclosing with the superior curved line a smooth, dense, semilunar area. It is often absent, but when present attaches the epicranial aponeurosis and a few fibres of the occipitalis. The surface above this line is evenly convex. The rough surface between the superior curved line and the foramen magnum is divided into two rough areas on each side by the *inferior curved* (or nuchal) *line*, which curves outward and then downward from near the middle of the crest to the jugular process. The space above the inferior line receives the complexus mesially. The lower space is occupied by the recti capitis

posteriores major and minor and the obliquus superior. On the *external* or under *surface of the condylar portions* we see the *condyles*, which lie at the sides of the anterior half of the foramen magnum. Through them the head rests upon and articulates with the atlas. Their smooth, elliptical, convex surfaces, cartilage-clad in the recent state, converge in front and look downward and outward. On the median side of each is a rough impression or *tubercle* for the lateral odontoid or check-ligaments. Behind each condyle is a depression, the *posterior condylar fossa*, which receives the hind edge of the articular facet of the atlas in extension of the head. At the bottom of the depression is sometimes seen the external opening of the *posterior condylar foramen*, for the passage of a vein from the lateral sinus. It is frequently absent on one or both sides. The base of the condyle is traversed by the *anterior condylar foramen*, which passes outward and forward from the cranium above the foramen magnum, and transmits the hypoglossal nerve. External to each condyle the *jugular* (from *jugulum*, "throat") *process* presents an inferior rough surface, which lies above the transverse process of the atlas, and gives insertion to the rectus capitis lateralis. The *inferior surface of the basilar portion* is inclined forward, is narrower in front than behind, and is transversely convex. It presents a small median *pharyngeal tubercle*, attaching a process from the fibrous aponeurosis of the pharynx. On either side of this it is rough for the recti capitis anteriores, major and minor. A part of this surface can be palpated, though not easily, through the mouth.

On the **internal** or **cerebral surface** the *squamous* ("scaly") *portion* presents a concave surface divided by a transverse and a longitudinal ridge into four fossæ, the two superior for the occipital cerebral lobes and the two inferior for the cerebellar hemispheres. The intersection of these ridges is marked by the *internal occipital protuberance*. The longitudinal ridge above the protuberance extends to the superior angle, and is grooved for the superior longitudinal sinus, the edges of which attach the falx cerebri. The transverse ridges extend to the lateral angles, are similarly grooved for the lateral sinuses, and to the edges of the groove is attached the tentorium cerebelli. The groove for the longitudinal sinus passes to one side, usually the right, of the internal occipital protuberance, where the groove is deeper and lodges the *torcular Herophili* ("wine-press of Herophilus"). The sharp vertical ridge below the protuberance, called the *internal occipital crest*, attaches the falx cerebelli. It passes to the foramen magnum and spreads out into its margin. On the upper surface of the *jugular process* is seen a deep groove leading to a notch, the *jugular notch*, on the anterior border of the jugular process. This notch is joined by a notch on the petrous portion of the temporal bone, and thus forms the *jugular foramen* (foramen lacerum posterius). The groove lodges part of the sigmoid or terminal portion of the lateral sinus. Separating this groove from the foramen magnum is the *jugular eminence*, with the intracranial opening of the anterior condylar foramen internally, and that of the posterior condylar foramen externally (on the side of the groove). The upper surface of the *basilar process* presents a central groove, the *basilar groove*, slanting upward and forward for the medulla. On either margin of this surface is half of the groove for the inferior petrosal sinus.

Angles.—The *superior angle*, as well as the two lateral, belong to the squamous portion. It fits into the angle formed by the meeting of the posterior superior angles of the parietal bones, and corresponds to the posterior fontanelle in the fœtus. The *lateral angles* at the outer ends of the superior curved lines occupy the angles between the parietal bone and the mastoid portion of the temporal on either side. The *anterior* or *inferior angle* is represented by the oblong, anterior surface of the basilar portion, united to the body of the sphenoid by cartilage until the age of twenty years, afterward by bone.

Borders.—The *two superior borders* extend between the superior and lateral angles, and are convex and deeply serrated. They articulate with the posterior borders of the parietals, and form the *lambdoid* ("lambda-like") or *parieto-occipital suture*. The *two inferior borders* extend between the lateral and antero-

inferior angles, and are uneven and less deeply serrated. Between the lateral angles and the jugular processes they articulate with the mastoid portions of the temporals in the *occipito-mastoid suture*. The small rough extremity of each jugular process articulates with the jugular facet of the petrous portion of the temporal bone by synchondrosis until about the twenty-fifth year, when the union becomes osseous. In front of the jugular process is the smooth jugular notch (see above). Between this notch and the antero-inferior angle the borders are rough for articulation with the petrous portion of the temporal bone. A somewhat octagonal form is not infrequently presented by this bone, due to the projection of the jugular processes and the middle of the superior borders.

The *foramen magnum* is oval in shape, with the long axis directed from before backward. It is encroached upon laterally in its fore part by the condyles, and transmits the upper end of the spinal cord with its membranes and accompanying structures. From the condyles, thick ridges of bone, which strengthen the skull and transmit its weight to the condyles, pass in four directions—viz., for-

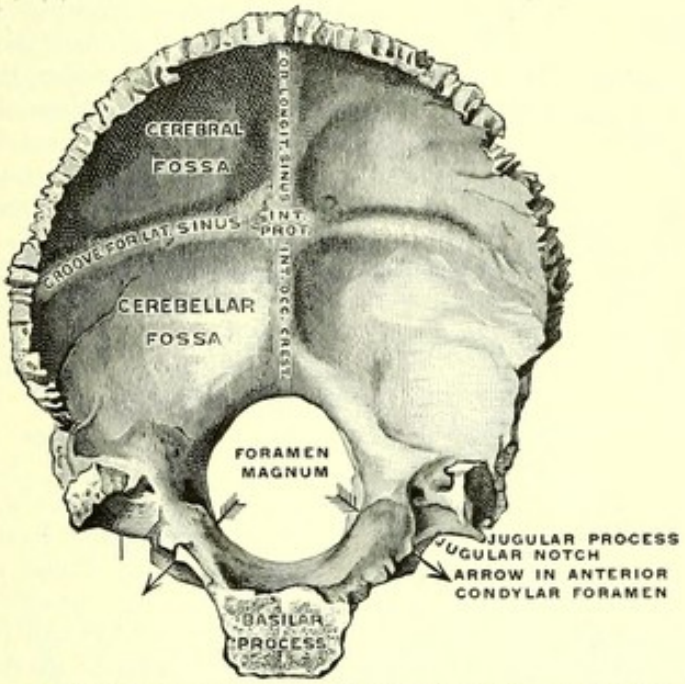

FIG. 186.—The occipital bone, viewed from above. (Spalteholz.)

ward into the basilar process, laterally into the jugular processes, backward around the foramen, and thence upward as the occipital crest, etc.

Development.—The basilar and condylar portions ossify each from a single centre. The squamous portion has four centres in two laterally disposed pairs—a pair above in the interparietal portion, and a pair below in the supraoccipital portion. These two pairs usually unite, but may remain separate through life, forming an interparietal bone, as in lower vertebrates; or, more commonly, two lateral fissures remain, a condition usually found at birth. The condylar portions join the squamous in lines extending outward from the posterior margin of the foramen magnum, and they join the basilar portion in lines passing through the anterior extremities of the condyles. The centres for the interparietal portion are deposited in membranes, those for the rest of the bone in cartilage.

Varieties.—There is sometimes seen a groove for the occipital sinus along the internal occipital crest. The jugular notch is often found partly subdivided by a small *intrajugular process*, and it is frequently separated from the groove for the sinus by a thin transverse ridge. A projection sometimes found beneath the jugular process, the *paramastoid process* of many mammals, may rarely be so long as to meet the transverse process of the atlas. Frequently the anterior con-

dylar foramen is subdivided by a thin bony spicule. Rarely the basilar process at the margin of the foramen articulates with the odontoid process. A median membranous space from the foramen magnum backward to the middle of the supraoccipital is of interest, because in rare cases, when not ossified, it may allow hernia of the brain and its membranes.

Articulations.—By sutures the occipital bone is connected with the two parietals, the two temporals, and the sphenoid, and by the condyles it articulates with the atlas.

THE PARIETAL BONE.

The *parietal* ("wall") *bones* (Figs. 187, 188) are two symmetrical, quadrilateral plates which form a large part of the vault and sides of the skull, and are interposed between the frontal and the occipital bones.

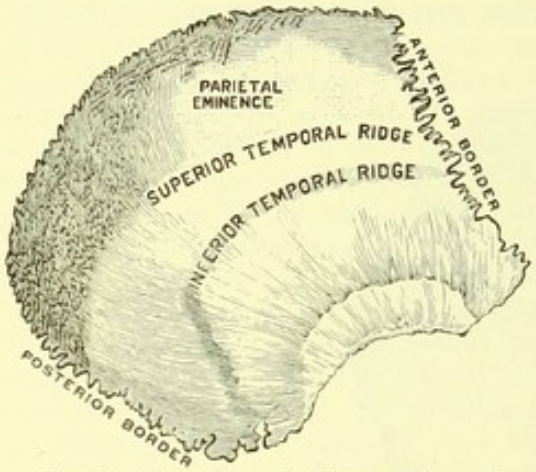

FIG. 187.—The right parietal bone, outer surface. (Henle.)

The **external surface** is convex, the convexity being greatest near the centre, at the *parietal eminence*, most marked in young bones. Arching across the bone just below this are the *superior* and *inferior temporal ridges*, the bone between which is smoother than elsewhere. The *lower ridge*, better marked and more constant, limits the temporal fossa and the attachment of the temporal muscle. The *upper ridge*, when present, gives attachment to the temporal fascia. The surface above it is covered by fascia and the scalp. Not far from the hind end of the upper border is the small *parietal foramen* when present.

The **internal surface** is concave, and marked by shallow depressions and ridges for the cerebral convolutions, and by narrow grooves for branches of the middle meningeal artery, which run upward and backward from below. The largest of these runs from the projecting *anterior inferior angle*, often as a canal, for a short distance, and is useful in determining the side to which the bone belongs. Along the superior border is a half-groove, completed by the one on the opposite bone, and lodging the superior longitudinal sinus. Near this groove, in bones of adults, and especially of the aged, small irregular depressions for the Pacchionian bodies are seen. A small part of the groove for the lateral sinus often crosses the inner aspect of the posterior inferior angle.

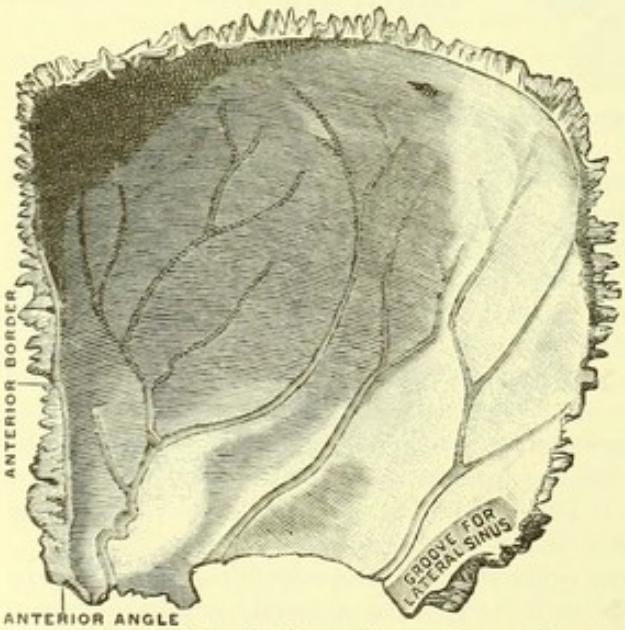

FIG. 188.—The right parietal bone, inner surface. (Testut.)

Borders.—The *superior*, *anterior*, and *posterior borders* are deeply serrated, and the latter two, and to a less extent the first, are alternately bevelled at the expense of the outer and inner surfaces, thus alternately overlapping and being overlapped by the adjacent bones. The bone is thus so strongly wedged in as to

prevent dislocation and to strengthen the cranial vault. The superior border forms with that of the opposite bone the *sagittal* ("arrow-like") *suture*. The anterior borders of the pair articulate with the frontal bone in the *fronto-parietal* or *coronal* ("crown") *suture*, and meet one another at nearly a right angle in European skulls, while the posterior borders, which form the *lambdoid suture* by articulation with the occipital, meet at an obtuse angle. The *inferior border* has three divisions. Behind, it is serrated for a short distance to articulate with the mastoid portion of the temporal bone in the *parieto-mastoid suture*. In front of this the border is thin, concave, and externally bevelled and fluted, where it is overlapped by the squamous portion of the temporal in the *squamous suture*. The great wing of the sphenoid overlaps the front inch or so, forming the *spheno-parietal suture*.

Angles.—Of the superior angles the anterior is at the *bregma* ("sinciput"), the posterior at the *lambda* (Greek letter *Λ*). The projecting anterior inferior angle is at the *pterion* ("wing"), and is sometimes excluded from articulation with the sphenoid by the contact of the squamosal and frontal.

Ossification occurs in membrane from a single centre and commences at the site of the parietal eminence.

Varieties.—Rarely a horizontal suture divides the bone into two parts. A large opening is very rarely seen at the site of the parietal foramen.

THE FRONTAL BONE.

The *frontal* ("forehead") *bone* (Figs. 189–191) forms the skeleton of the forehead, and receives the frontal lobes of the brain in the concavity between the

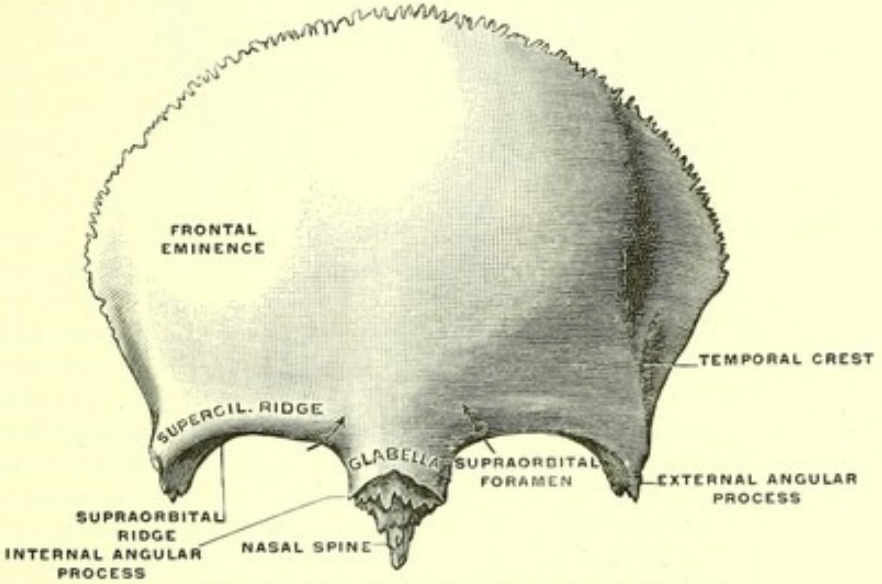

FIG. 189.—The frontal bone, seen from in front. (Testut.)

main or *vertical portion*, which arches upward and backward from the orbital margin, and the two thin horizontal or *orbital plates*, which extend backward from the same point, separated by a median gap, the *ethmoidal notch*.

The **anterior** or **external surface** is convex, and most strongly so at the *frontal eminences*, a little below the centre of each lateral half. Below and separated from these by shallow grooves are the arched *superciliary* ("above the lashes") *ridges*, converging in the median line to the *nasal eminence*, below which is the smooth *glabella* ("little smooth place"). Traces of the *metopic* ("frontal") *suture*, which originally separated the two halves of the frontal, usually persist in the glabella. Behind the superciliary ridges lie the *frontal sinuses*, which cause the prominence of the ridges in the male. The arched *supraorbital* ("above the orbit") *ridges*, more sharply marked externally, limit this surface below and form the anterior

margin of the orbital roofs. At about the junction of their inner and middle thirds is the *supraorbital notch*, sometimes a foramen, for the supraorbital nerve and artery. The supraorbital arch ends in two downward projections, the *external* and *internal angular processes*, of which the external is a strongly projecting landmark, which articulates with the malar bone, while the internal is slightly marked and articulates with the lachrymal bone. From the external angular process the *temporal crest* arches upward and backward, continuous with the ridges on the parietal bone. It separates the frontal part from the temporal area, below and behind it, which forms part of the temporal fossa and attaches the temporal muscle.

The **inferior surface** consists of the orbital surfaces of the triangular *orbital plates*, which form the greater part of the roof of the orbits. Their inner margins are parallel; the outer pass backward and inward. Close behind the outer part

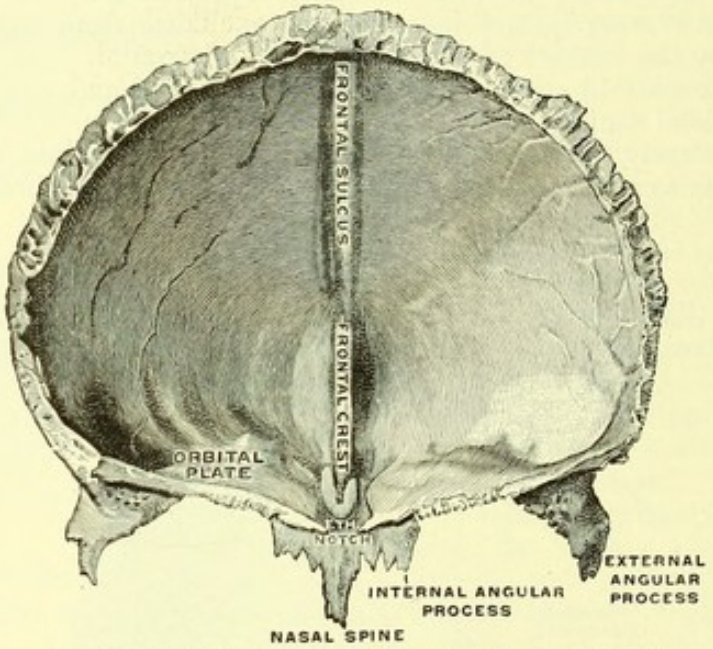

FIG. 190.—The frontal bone, seen from behind. (Spalteholz.)

of the supraorbital ridge this surface presents the *lachrymal fossa* lodging the lachrymal gland; and behind the inner end of the ridge there is a depression, the *trochlear fossa* (more rarely a tubercle), for the pulley of the superior oblique muscle of the orbit. Between and in front of the internal angular processes is the *nasal notch*. This is bounded above by a semilunar, serrated surface, which articulates with the upper ends of the nasal bones mesially and the nasal processes of the superior maxillæ laterally. It is bounded behind by a rough, nearly vertical surface, the *nasal process* (Henle), which projects behind, supports and articulates with the upper ends of the nasal and maxillary bones, which form the bridge of the nose. From the centre of this surface the *nasal spine* projects downward and forward as a sharp process, which forms a part of the septum of the nose, between the crests of the nasal bones and the vertical plate of the ethmoid. The spine commences behind the nasal process as a median ridge, on either side of which is a narrow groove forming a small part of the roof of the nasal fossæ. Between the back of these grooves and the internal angular process notice the openings of the two *frontal sinuses*, which are placed between the outer and inner tables of the bone. The sinuses lie behind the superciliary ridges, extend a variable distance over the orbits, and are separated by a thin vertical partition, usually displaced to the left. Behind these openings, and between the ethmoidal notch and the inner margins of the orbital surfaces, are a series of depressions forming the roofs of cells, and two transverse grooves. These are completed by articulation with the lateral masses of the ethmoid to form respectively the

ethmoidal cells and the *anterior* and *posterior ethmoidal canals.* The anterior canals transmit the nasal nerve and anterior ethmoidal vessels; the posterior canal, the posterior ethmoidal vessels.

The cerebral surface forms a deep concavity, encroached upon but slightly by the convexity of the upper surfaces of the orbital plates, which form the greater part of the floor of the anterior cranial fossa. The orbital plates and the adjoining bone present marked depressions and ridges for the frontal convolutions.

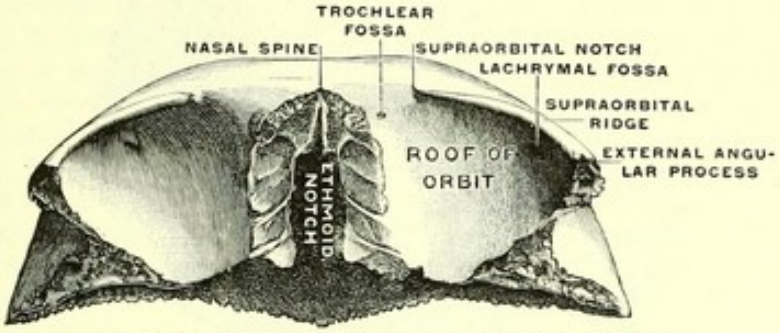

FIG. 191.—The frontal bone, seen from below. (Testut.)

Elsewhere the bone is smoother, except for a median furrow, the *frontal sulcus.* This starts from the upper border, with pits for Pacchionian bodies on both sides, and narrows down below to the thin prominent *frontal crest.* The superior longitudinal sinus is lodged in the sulcus, and the falx cerebri is attached to the crest and the ridges of the sulcus. The termination of the crest, by articulation with the crista galli of the ethmoid, completes the *foramen cæcum* ("blind hole"). When not closed below, this foramen transmits a small vein from the nose.

Borders and Articulations.—The *posterior border* articulates with the parietal bone in the *coronal suture,* nearly as far outward as a rough triangular surface. This triangular surface articulates with the great wing of the sphenoid, forming the posterior half of the outer margin of the orbital plate. It is continuous behind with the thin posterior margin of the orbital plate, which articulates with the small wing of the sphenoid. The malar bone articulates with the fore part of the outer margin of the orbital plate. The parallel inner borders of the orbital surface articulate with the os planum of the ethmoid behind and the lachrymal in front. The margins of the ethmoidal notch articulate with the cribriform plate of the ethmoid laterally, and the crista galli in front. (The articulations of the nasal notch and spine have been described above.)

Ossification proceeds from two centres in the membrane at the site of the frontal eminences. At birth there are two separate lateral halves, soon united by the median *frontal* or *metopic suture,* which is usually obliterated by ossification, except for a trace at the glabella, but sometimes persists throughout life. The frontal sinuses appear about the seventh year as forward growths from the anterior ethmoidal cells, and increase up to old age. They may invade the roof of the orbit quite extensively.

THE TEMPORAL BONE.

The *temporal* ("temple") *bone* (Figs. 192–195) forms part of the side and base of the skull, contains the organ of hearing, and articulates with the lower jaw. Although it is usually described in three parts—viz. squamous, mastoid, and petrous—the three parts separable at birth are the squamous, petro-mastoid, and tympanic.

The Squamous Portion.—This is a thin plate, extending upward and forward at right angles to the petrous, and forms part of the side-wall of the middle fossa of the skull. The *outer surface,* but slightly convex, is smooth, except for a vertical groove above the external auditory meatus for the middle temporal artery.

It forms part of the temporal fossa, and is delimited from the mastoid surface behind by the curved *supramastoid crest*. This crest is continued forward, just above the external auditory meatus, to the *zygoma* ("yoke"), a process of bone which projects, shelf-like, from the lower part of this surface outward, and then, twisted on itself, continues forward. In its forward projection the smooth inner

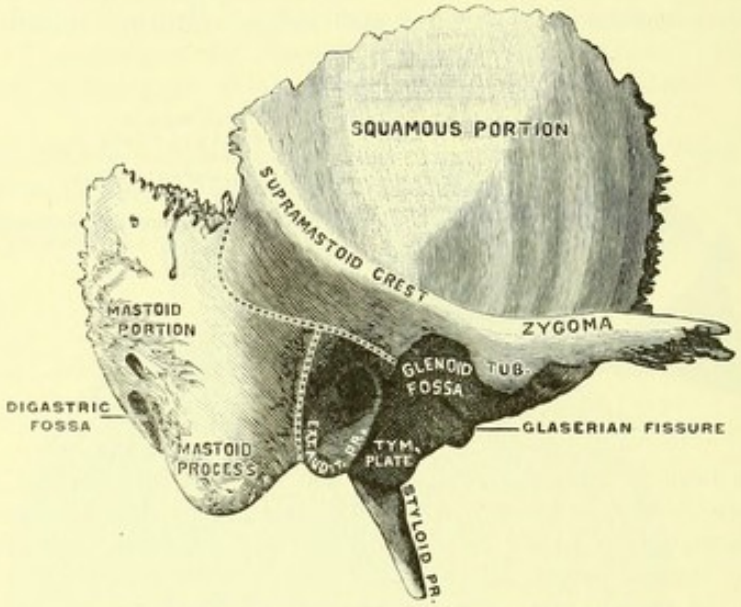

FIG. 192.—The right temporal bone, outer surface. (Testut.)

surface and lower border give origin to the masseter, the sharp upper border attaches the temporal fascia, and the serrated and bevelled anterior extremity articulates with the malar. Two ridges, or *roots*, extend from its base, the posterior backward and the anterior inward, enclosing between them a transversely oval, smooth depression, the *glenoid fossa*, divided into two parts by the nearly

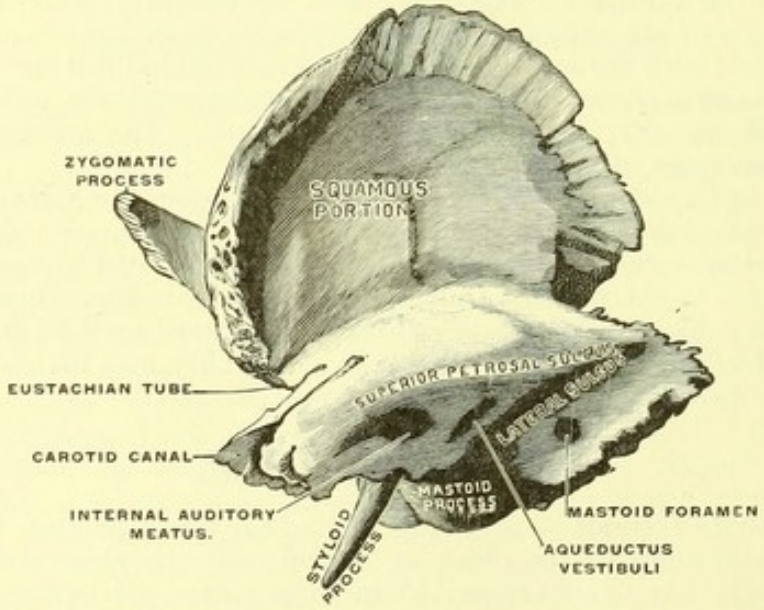

FIG. 193.—The right temporal bone, viewed from the mesial plane. (Testut.)

transverse *fissure of Glaser*. For articulation with the lower jaw the front half of the fossa is coated with cartilage, together with the convex nearly transverse ridge, the *eminentia articularis*, which limits it in front and forms the anterior root of the *zygoma*. At the outer end of the latter root is a tubercle (preglenoid)

for attachment of the external lateral ligament of the lower jaw. The posterior root divides into two branches, of which the upper is the supramastoid crest, and the lower descends in front of the external auditory meatus to the tympanic bone at the Glaserian fissure as the *postglenoid process*, very prominent in young bones. In front of the articular eminence is a small, smooth triangular surface belonging to the zygomatic fossa, and separated from the temporal surface by a slight ridge. The external pterygoid muscle glides over it.

The *internal surface* is marked by impressions for the cerebral convolutions and by grooves for the middle meningeal arteries. Where it joins the petrous portion there is seen in young, and often in old, bones the remains of the *petro-squamous suture* passing from the angle between these two portions in front to the *parietal notch* between the squamous and mastoid portions behind. The *arched border* between these two angles or notches describes about two-thirds of a circle, and is thin, bevelled, and fluted on its inner surface above, overlapping the parietal, and in front is serrated and bevelled on its inner surface above and on its outer surface below, articulating with the great wing of the sphenoid.

The Petro-mastoid Portion.—This segment of the temporal is an irregular, four-sided pyramid of very dense bone, whose rough truncated apex is directed forward and inward to the foramen lacerum medium, and whose base, directed outward and backward, is formed by the less dense mastoid portion. It is usually described as three-sided, the fourth or outer surface being mostly covered by the tympanic bone.

The **mastoid portion** of the petrosal presents a triangular rough *external surface*, prolonged downward and forward into the nipple-shaped *mastoid process*, which affords attachment to the sterno-mastoid, splenius capitis, trachelo-mastoid, and occipitalis. Internal to the mastoid process is the deep *digastric groove* for the digastric muscle, internal to which is the shallow groove for the occipital artery. Its *internal* or *cerebral surface* forms a small part of the posterior cranial fossa, and is separated from the petrosal pyramid by the deep groove for the sigmoid portion of the lateral sinus. The *mastoid foramen*, transmitting a vein, opens internally on or near the rear wall of this groove, and externally near the posterior border of the mastoid portion. The *upper border* of this portion articulates with the parietal, the *posterior border* with the occipital. The suture-line between the squamous and mastoid portions lies a little below the supramastoid crest, and runs from the parietal notch to the middle of the external meatus. The mastoid process about puberty enlarges and becomes filled with a number of air-cells (*mastoid cells*), connected with a larger cavity, the *mastoid antrum* ("cave"), which is present and comparatively large at birth, and communicates with the upper part of the middle ear or tympanum. The antrum is bounded externally by that part of the squamous portion below the supramastoid crest, which is exceedingly thin in children, while superiorly the back of the roof of the tympanum (*tegmen tympani*, "cover of the drum") separates it from the middle cranial fossa.

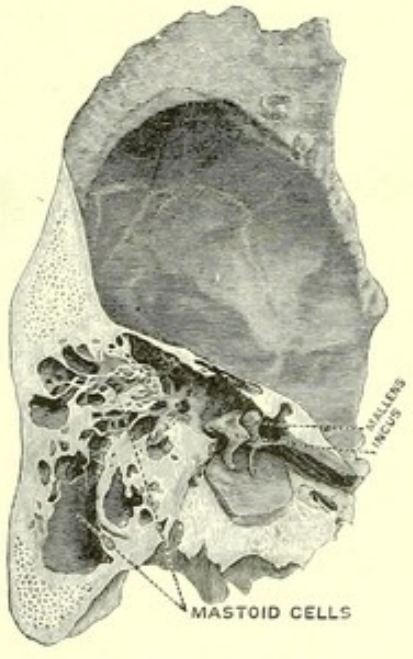

FIG. 194.—Section through the mastoid cells, showing their communication with the middle ear. (W. W. Keen.)

The Petrous Portion.—Of the two intracranial surfaces of this portion, the *posterior surface* looks backward, inward, and slightly upward into the posterior fossa of the base of the skull. From near its centre the *internal auditory meatus*, which transmits the facial and auditory nerves, passes outward for about two-fifths of an inch to a plate of bone, the *lamina cribrosa* ("sieve-like layer").

This is so called from the number of larger and smaller apertures for the subdivisions of the eighth or auditory nerve on either side of a transverse *falciform* ("sickle-shaped") *crest*, above which, in front, is the internal orifice of the *aqueduct of Fallopius* for the seventh or facial nerve. The aqueduct of Fallopius passes outward to the *genu*, where it bends backward to pass along above and internal to the tympanum, behind which it bends sharply downward to the *stylomastoid foramen*. Behind the meatus is the small, slit-like opening of the *aqueductus vestibuli* ("water-pipe of the vestibule"), occupied in the adult by vessels and a process of dura, and above and in front of the latter is a small opening, the remains of the *floccular fossa*, very large in young bones.

The *anterior surface* looks forward, outward, and upward into the middle cranial fossa. A depression is seen near the apex for the Gasserian ganglion, external and inferior to which is the end of the bony carotid canal. Behind this are two small grooves leading backward and outward to foramina—the larger and internal to the *hiatus* ("gaping") *Fallopii*, which leads to the geniculate ganglion in the aqueduct of Fallopius, and transmits the great superficial petrosal nerve, while the smaller and external is for the small petrosal nerve. Behind these, and between the petro-squamous suture externally and an eminence formed by the superior semicircular canal internally, the bone is thin and forms the roof of the tympanum.

The *inferior* or *basilar surface* presents posteriorly, between the mastoid and styloid processes, the *stylo-mastoid foramen*, the exit of the facial nerve from the aqueduct of Fallopius. The *styloid process* itself projects downward and forward, for possibly 2 inches, from its base, which is imbedded between the vaginal process of the tympanic and the petrosal bone. It attaches two ligaments and three

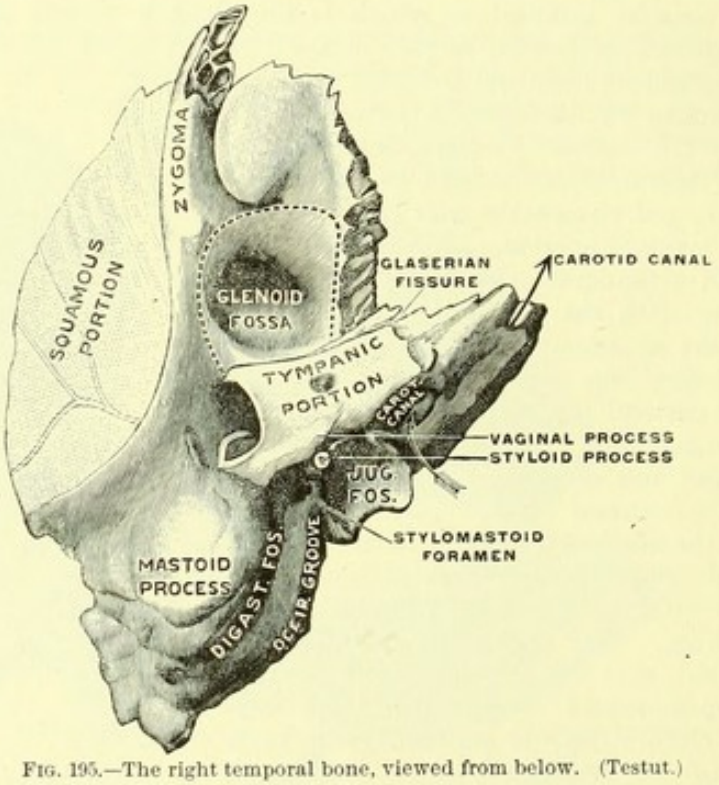

FIG. 195.—The right temporal bone, viewed from below. (Testut.)

muscles. Internal to this foramen and process is the small quadrilateral *jugular facet*, with which the jugular process of the occipital unites by cartilage until ossification at the twentieth year. In front of and internal to this facet is the smooth, deep *jugular fossa*, which with the jugular notch of the occipital completes the jugular foramen. In front of the fossa is the *carotid foramen*, the lower end of the *carotid canal*, for the internal carotid artery, which ascends vertically,

and then passes horizontally forward and inward to the outer side of the apex of the bone at the *foramen lacerum medium* ("middle torn hole"). Internal to the carotid foramen and reaching to the apex is a quadrilateral surface for the origin of the tensor tympani and levator palati muscles. *Small Foramina on this Surface.*—1. Between the jugular fossa and the carotid foramen is the *tympanic canaliculus* for Jacobson's nerve (the tympanic branch of the glosso-pharyngeal). 2. In the jugular fossa is the foramen for the auricular branch of the vagus nerve. 3. Small tympanic branches of the carotid plexus pierce the walls of the carotid canal. 4. The aqueduct of the cochlea begins in a triangular depression of the posterior inferior margin, just below the internal meatus.

The narrow *external* or *tympanic surface* looks slightly forward, and is hidden by the tympanic plate, except for a variable extent of the outer wall of the carotid canal in front. On removal of the tympanic bone this surface is seen to form the *inner wall of the tympanum* ("drum"). In the angle between it and the tympanic roof is seen the projection of the *Fallopian canal*, which bends downward in the angle between the inner and posterior tympanic surfaces, and lodges the facial nerve. Below this is the *fenestra ovalis* ("oval window"), opening into the vestibule and situated above the *promontory*, which is grooved for the tympanic plexus of nerves. Below and behind the promontory is the *fenestra rotunda* ("round window"), opening into the cochlea. The surface narrows in front to the bony canals for the tensor tympani muscle above and the Eustachian tube below, which are completed externally by the tympanic plate. The two canals are separated by the delicate *processus cochleariformis* ("conchshell-shape"), which projects outward and upward.

The *superior border*, grooved for the superior petrosal sinus, attaches the tentorium cerebelli, a process of which bridges over a notch (*trigeminal notch*) near the apex of the bone for the passage of the trigeminal or fifth nerve. A spicule of bone near the front end of this border is often continued by a fibrous band, rarely by bone (*petro-sphenoidal ligament* or process), to the side of the dorsum sellæ of the sphenoid, completing a foramen for the sixth nerve and the inferior petrosal sinus. The *posterior inferior border* completes the groove for the inferior petrosal sinus by its articulation with the occipital bone internal to the jugular foramen. The *anterior superior* and *anterior inferior borders* are shortened by articulation with the squamosal and tympanic bones respectively. The angle between the squamous and petrous portions receives the spine of the sphenoid and presents the front orifice of the bony *Eustachian canal*, to which the cartilaginous part is attached.

The Tympanic Bone.—In the adult this part of the temporal forms the *tympanic plate*. This constitutes the hind, non-articular portion of the glenoid fossa, which lodges part of the parotid gland, and is separated from the squamous portion in front by the Glaserian fissure. Inferiorly it forms the sharp, projecting *vaginal* ("sheath-like") *process;* superiorly it coalesces with the squamous portion, and forms the front, lower, and part of the rear walls of the bony external auditory meatus. The latter projects outward in the curved, rough, free margin of the *external auditory process*, which attaches the cartilage of the ear. Internally it fuses with the petrosal, and forms the outer wall of the tympanum. Behind it joins the mastoid portion in the *auricular fissure*.

The bony *external auditory meatus* is elliptical, slightly constricted in the middle, and directed inward and a little forward to the tympanum. Its internal orifice is smooth and grooved for the tympanic membrane; the external orifice is bounded by the external auditory process except above, where the posterior root of the zygoma bounds it. Externally the Glaserian fissure is closed; internally it is double, and is occupied by a descending process of the tegmen tympani of the petrous portion, which separates the tympanic and squamosal bones, and forms most of the outer wall of the Eustachian and tensor tympani canals. Between this process and the tympanic plate the fissure transmits to the tympanum the tympanic branch of the internal maxillary artery, and lodges the slender process

of the malleus. More internally it presents the *canal of Huguier*, by which the chorda tympani nerve issues.

Articulations.—The temporal bone articulates above with the parietal, in front with the sphenoid and malar, below with the mandible, behind and internally with the occipital.

Ossification.—The squamosal and tympanic bones ossify in membrane, each from a single centre; the petrous portion and styloid process in cartilage, the former from four centres, the latter from two. The fœtal tympanic bone forms an incomplete ring, which encloses the tympanic membrane. It is open above with its free ends united to the squamosal. Two tubercles growing from the front and back of this ring meet in the floor of the meatus, enclosing a foramen, which is gradually (though not always) closed, and thus the tympanic plate is formed. At birth the mastoid process, articular eminence, and tympanic ring are flat, the glenoid fossa is shallow, and the hiatus Fallopii opens at the genu of the canal.

THE SPHENOID BONE.

The *sphenoid* or *wedge-bone* (Figs. 196–198) forms a part of all three fossæ of the base of the skull and of the orbits and nasal fossæ. It is very irregular

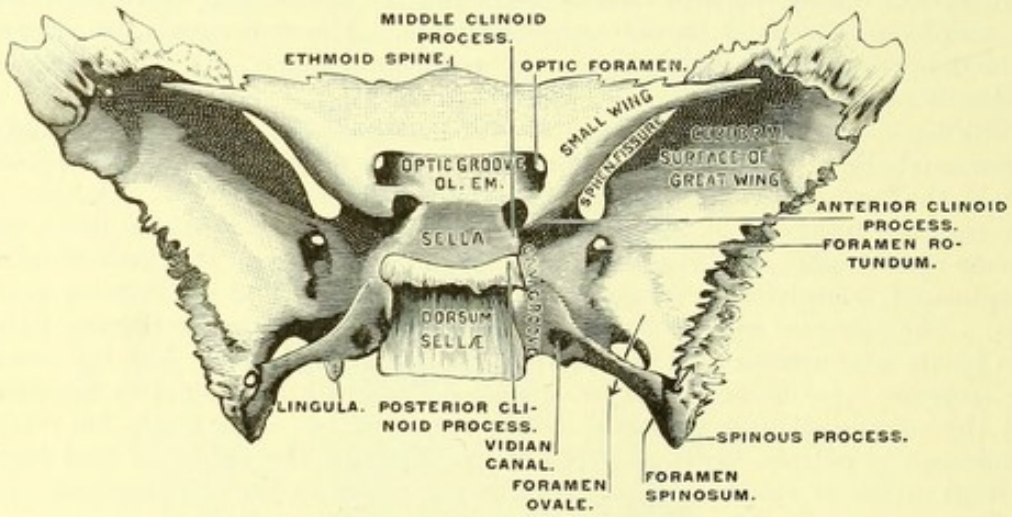

FIG. 196.—The sphenoid bone, viewed from above. (Testut.)

in shape, and consists of a body, two pairs of wings, and a pair of pterygoid processes.

Body.—The central cuboidal part or *body* presents a *superior surface*, which in its hind part, in the posterior cranial fossa, continues the basilar groove of the occipital and slants upward and forward to a quadrilateral projecting plate, the *dorsum sellæ* ("back of the saddle"). The upper angles of the latter project outward as the *posterior clinoid* ("bed-like") *processes*, attaching the tentorium cerebelli. It overhangs a deep depression, the *pituitary fossa* or *sella turcica* ("Turkish saddle"), which lodges the pituitary body and forms the isthmus or narrow median portion of the middle cranial fossa. This depression is bounded in front by a transverse elevation, the *olivary eminence*, behind which on each side projects a small tubercle, the *middle clinoid process*. In front of the eminence the slight *optic groove* supports the optic commissure, and leads laterally to the *optic foramina*. The surface in front of this is on a slightly higher level, and forms part of the floor of the anterior cranial fossa. It ends in front in a projection, the *ethmoidal spine*, for articulation with the cribriform plate of the ethmoid, and laterally it is continuous with the superior surfaces of the small wings. Each lateral margin of this surface is bevelled by the winding *cavernous groove*, which lodges the internal carotid artery in its forward passage and the cavernous sinus. The hind end

of this groove is bounded on either side by a bony projection, internally by the *petrosal process*, which springs from the side of the base of the dorsum sellæ and fits against the apex of the petrous portion of the temporal bone, and externally by the *lingula* ("little tongue"), a thin lamella projecting backward between the body and the great wing. The *posterior surface* is united to the basilar process of the occipital by cartilage in early life, and by bony union in the adult. On

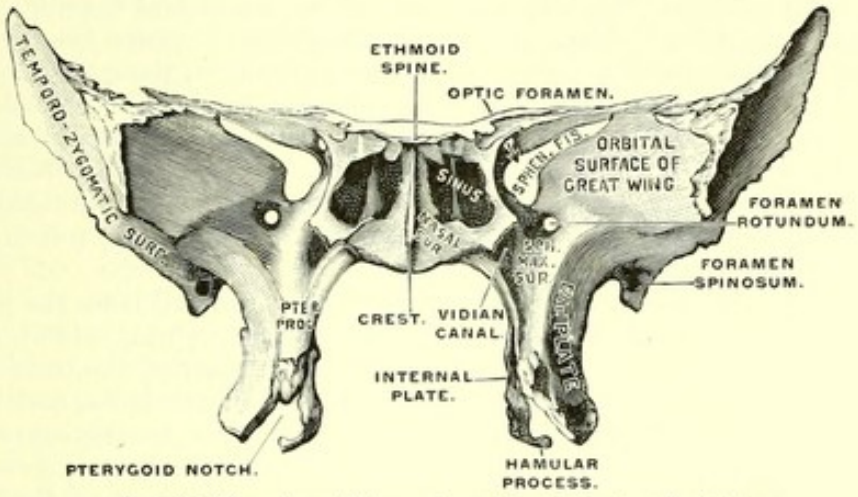

FIG. 197.—The sphenoid bone, viewed from in front. (Testut.)

the *anterior surface* the vertical *sphenoidal crest* projects in the middle line, below the ethmoidal spine, and articulates with the vertical plate of the ethmoid. On either side, superiorly, are the rounded orifices of the *two sphenoidal sinuses*, which occupy much of the body of the bone. They are unequally divided by a vertical lamina, the sphenoidal septum, continued back from the crest. These openings and the surfaces beneath them are on the roof of the nasal fossæ, and the rough surfaces on either side articulate with the lateral masses of the ethmoid above and with the orbital processes of the palate bones below. Much of this surface on either side, between the articular areas and the crest and below the orifices, is formed by the *sphenoidal turbinate* ("top-shaped") *bones*. These are triangular

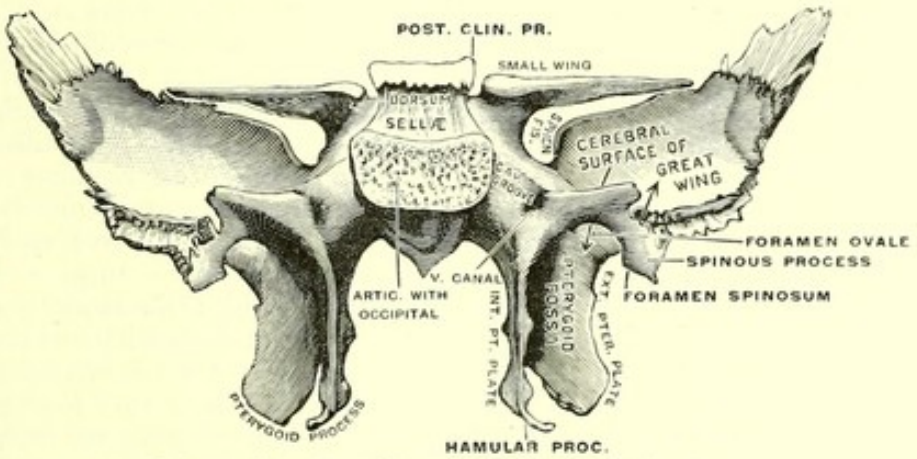

FIG. 198.—The sphenoid bone, viewed from behind. (Testut.)

or conical in shape, with the apex directed downward and backward. They are formed separately, often come away with the ethmoid or palate bones in disarticulating, and sometimes appear in the orbit. The *inferior surface* presents in front a median ridge, the *rostrum* ("beak"), continuous with the crest and received between the alæ and the vomer. The surface on either side forms part of the roof of the pharynx, and is partly covered by the vaginal processes of the inter-

nal pterygoid plate. Each *lateral surface* attaches the two wings, and between the latter forms the inner boundary of the sphenoidal fissure and the back of the inner orbital wall.

The **small** or **orbital wings** are thin, triangular, horizontal plates, extending outward from the fore part of the lateral surfaces on a level with the corresponding part of the superior surface. Their smooth *superior surfaces* form the hind part of the floor of the anterior cranial fossa; the *inferior surfaces* form the back of the roof of the orbits and the upper margin of the sphenoidal fissures. The serrated *anterior border* articulates with the orbital plate of the frontal bone, by which it and the pointed *outer extremity* are separated from the great wing, external to the sphenoidal fissure. The free *posterior border* is received into the Sylvian fissure of the brain. It is the boundary between the anterior and middle cranial fossæ, and ends postero-internally in a knob, the *anterior clinoid process*, which attaches the tentorium cerebelli. The *base* of the wing is divided into two roots by the outward and forward passage of the *optic foramen*, which transmits the optic nerve and the ophthalmic artery.

The **great** or **temporal wings** project outward and upward from the lower part of the sides of the body, and present three surfaces—cerebral, orbital, and temporo-zygomatic. The concave *cerebral surface* forms part of the middle cranial fossa, and presents at the fore part of its junction with the body, and below the sphenoidal fissure the forward-directed *foramen rotundum* for the superior maxillary nerve. Behind and a little external to this is the large *foramen ovale*, directed downward, for the inferior maxillary nerve. This part of the bone projects horizontally backward into the sharp *alar* ("wing-like") *spine* of the sphenoid, which occupies the angle between the squamous and petrous portions of the temporal bone. From its under surface the sharp *spinous process* projects downward, attaching the spheno-mandibulary ligament. The small *foramen spinosum* perforates the spine and transmits the middle meningeal artery, grooves for which cross this surface. The *external* or *temporo-zygomatic* surface forms part of the temporal fossa above and of the zygomatic fossa below the transverse *pterygoid* ("wing-like") *ridge* which crosses it. The *zygomatic surface* looks downward, is continuous with the outer surface of the external pterygoid plate, and presents the lower orifices of the foramina ovale and spinosum. The *anterior* or *orbital surface* looks forward and inward. Its upper quadrilateral part forms the greater part of the outer wall of the orbit, which is separated by a ridge, forming the outer lip of the *spheno-maxillary fissure*, from a small area below, which looks into the spheno-maxillary fossa and presents the anterior orifice of the foramen rotundum. The *posterior border* in its inner third bounds the foramen lacerum medium in front, and presents the posterior opening of the *Vidian canal*. This canal tunnels the base of the internal pterygoid plate sagittally and transmits the Vidian nerve and artery. In its outer two-thirds this border articulates with the petrosal, completing inferiorly a groove for the cartilage of the Eustachian tube. The *external border* is bevelled internally below and externally above, and articulates with the squamosal. The *superior border* overlaps the anterior inferior angle of the parietal bone. Internal to and in front of this articulation is a rough triangular surface which articulates with a similar rough triangular surface on the frontal, and is formed between the upper margins of the three surfaces. The cranial and orbital surfaces converge and meet in a sharp free border which bounds the *sphenoidal fissure* inferiorly. The *anterior margin* or *malar crest* separates the orbital and temporal surfaces, and articulates with the malar bone and sometimes with the superior maxilla at its lower angle. The obliquely elongated *sphenoidal fissure* between the body and the two wings is closed externally by the frontal bone, and transmits to the orbit the third, fourth, sixth, and ophthalmic divisions of the fifth nerves, and the ophthalmic vein.

The **two pterygoid processes** consist each of two plates, joined in front, but diverging behind, which project downward and slightly forward from the lower aspect of the base of the great wing.

The *external pterygoid plate*, broad and thin, lies in a plane directed backward. The *internal surface* affords origin to the internal pterygoid muscle, the *external surface* to the external pterygoid muscle. This plate forms the inner boundary of the zygomatic fossa, and the outer boundary of the *pterygoid fossa*, which lies between and behind the two plates. The *internal pterygoid plate*, longer and narrower than the external, forms the outer boundary of the posterior naris, where it is partly covered by the sphenoidal process of the palate-bone. From the upper end of the internal surface on each side a thin plate, the *vaginal process*, projects inward to articulate with the ala of the vomer, and in front with the sphenoidal process of the palate, the latter converting a groove beneath the base of the vaginal process into the *pterygo-palatine canal*. Posteriorly at the base of the internal plate is the small *pterygoid tubercle*, between which and the lingula is the Vidian canal, and below which is the shallow *scaphoid fossa*, in which the tensor palati muscle arises. The *posterior border* is prolonged below into the slender, *hamular* ("hook-like") *process*, grooved externally above for the passage of the tendon of the tensor palati muscle. It is often to be felt behind and within the last upper molar tooth. In front the two plates are joined above, and form a smooth triangular surface, which makes the back wall of the spheno-maxillary fossa, and presents superiorly the anterior orifice of the Vidian canal. Below, the two plates are separated in front by the *pterygoid notch*, which is occupied by the pyramidal process of the palate-bone. The cartilage of the Eustachian tube is attached and supported along the hind, inner, and upper part of the internal plate.

Articulations.—The sphenoid articulates with all the other bones of the cranium, which it binds firmly together, and with five of the facial bones—viz., two malar, two palate, and the vomer, and sometimes one or both superior maxillæ.

Varieties.—The ligaments normally connecting the clinoid processes may become ossified. The *foramen of Vesalius*, for an emissary vein, is sometimes present internal to the foramen ovale.

Ossification occurs in cartilage from twelve centres in two divisions, a pre- and a post-sphenoid, which join at the olivary eminence, and are distinct in many animals. The sphenoidal sinuses begin to hollow out the body in the sixth year, before which they are confined to the sphenoidal turbinate bones, which develop separately in cartilage.

THE ETHMOID BONE.

The *ethmoid* or *sieve-bone* (Figs. 199–201) is roughly cuboidal, and projects downward from the ethmoidal notch of the frontal bone between the orbits to form part of the orbits, nasal fossæ, and base of the cranium. It is very light, being largely composed of cavities bounded by thin walls. It consists of a vertical and a horizontal plate, and of two lateral masses, the last suspended from the margins of the horizontal plate.

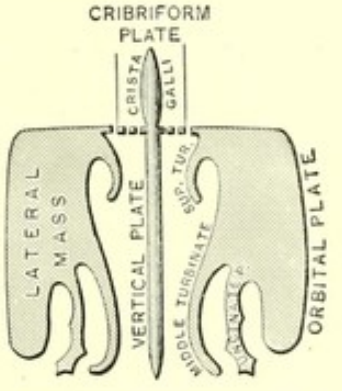

FIG. 199.—Diagram of the ethmoid bone in transverse, vertical section. (Testut.)

The *vertical plate* forms the upper third of the median (though often deflected) septum of the nose, and is grooved for the olfactory nerves. It projects into the cranial cavity above the horizontal plate as the median triangular *crista galli* ("crest of the cock"). This is most prominent in front, and along its thin posterior border it attaches the falx cerebri. In front it divides into two lateral alæ, which articulate with the frontal, and usually complete the foramen cæcum. The vertical plate articulates in front with the nasal spine of the frontal and the crest of the nasal bones, below and in front with the triangular septal cartilage, below and behind with the vomer, and behind with the crest of the sphenoid.

The *horizontal* or *cribriform plate* is so named from a number of perforations arranged in three rows, of which those in the inner and outer rows are the larger and transmit the olfactory nerves to the inner and outer walls of the nasal fossæ. This plate forms the depressed *olfactory groove* of the anterior cranial fossa, which lodges the olfactory bulbs on either side of the crista galli. On each side of the fore part of the latter is a longitudinal slit for the nasal branch of the fifth nerve.

The *lateral masses* or *labyrinths* contain a number of irregular, thin-walled *ethmoidal cells* between their two lateral walls. The thin, smooth, oblong *outer wall* forms most of the inner wall of the orbit, and is called the *os planum* ("smooth bone") or *orbital plate*. The borders of this plate and of the lateral mass articulate in front with the lachrymal, below with the superior maxilla and palate-bones, behind with the sphenoid and sphenoidal turbinate bones, and above with the orbital plate of the frontal. The latter articulation completes the two horizontal, transverse grooves in each bone into the *anterior* and *posterior ethmoidal canals*. These articulations (together with that of the nasal process of the maxilla with the fore part of the lateral mass internally) close the exposed half-cells of the ethmoid. The *ethmoidal cells* are lined by a continuation of the nasal

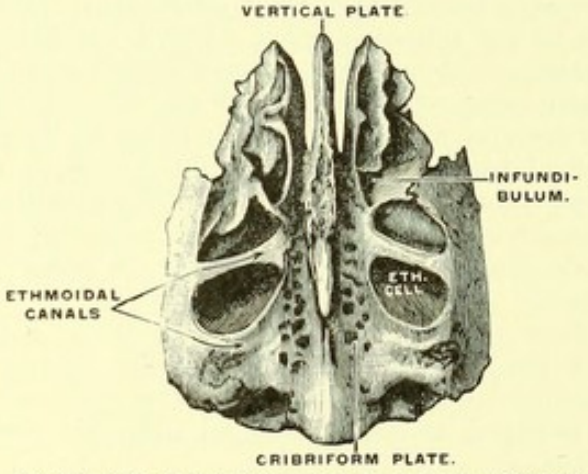

FIG. 200.—The ethmoid bone, seen from above. (Testut.)

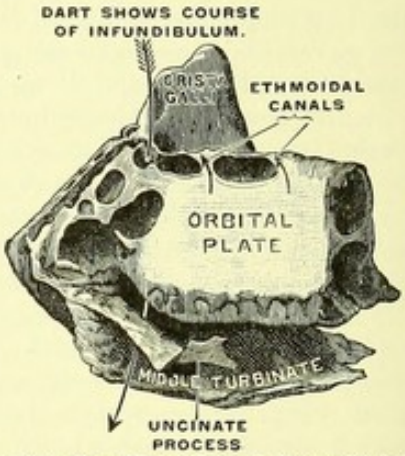

FIG. 201.—The ethmoid bone, its left side. (Testut.)

mucous membrane, and are divided by a transverse septum into an anterior and a posterior set. The anterior set opens into a sinuous canal, the *infundibulum*, which leads from the frontal sinuses to the middle meatus of the nose; the posterior cells open into the superior meatus. The cells are sometimes divided into posterior, middle, and anterior sets, the two latter opening together. The *inner wall* forms the upper part of the outer wall of the nasal fossa, and is grooved for olfactory nerves and blood-vessels. It consists of the *superior* and *middle turbinate bones*, which have attached upper borders, but are free and somewhat rolled outward inferiorly. They are continuous in front, but separated in the posterior half by a channel, the *superior meatus* of the nose, directed forward from the posterior border. The middle turbinate extends the length of the bone, and overhangs and bounds superiorly the *middle meatus* of the nose. From beneath the fore part of the os planum a long, thin lamina of bone, the *uncinate* ("hook-like") *process* projects backward and downward in the outer wall of the middle meatus, where it articulates with the ethmoidal process of the inferior turbinate bone, and helps to close the inner wall of the antrum of the maxilla.

Articulation occurs with thirteen bones—viz., the frontal and sphenoid of the cranium, and the vomer, two nasal, two lachrymal, two maxillæ, two palate, and two inferior turbinate bones of the face.

Ossification proceeds in cartilage from three centres—one in the perpendicular plate and one in each lateral mass. True bony ethmoidal cells do not appear until the third year.

THE BONES OF THE FACE.

THE MAXILLA, OR SUPERIOR MAXILLARY BONE.

The *maxilla* or *upper jaw-bone* (Figs. 202–204) forms the largest part of the facial skeleton, including part of the floor and outer wall of the nasal fossa, the roof of the mouth, and the floor of the orbits, and in it are lodged the upper teeth. It comprises a central hollow body and four processes. Its shape is characteristic of man and of his food and the mode of employing it. Surgically, it is important from its many diseases.

The Body.—The *facial surface* looks forward and outward, and presents a prominent ridge, due to the fang of the canine tooth, which separates two shallow depressions, the *incisive fossa* in front and the *canine fossa* behind. Above the

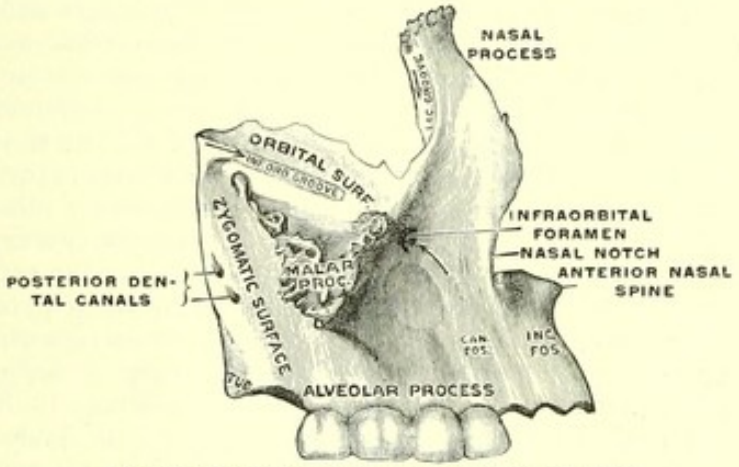

FIG. 202.—The right maxilla, outer surface. (Testut.)

latter and just below the orbital margin is the *infraorbital foramen*, where the infraorbital nerve and artery emerge. The inner margin presents the deep *nasal notch*, attaching the soft parts of the nose. The lower edge of the notch is prolonged forward internally into the *anterior nasal spine*. The convex *posterior* or

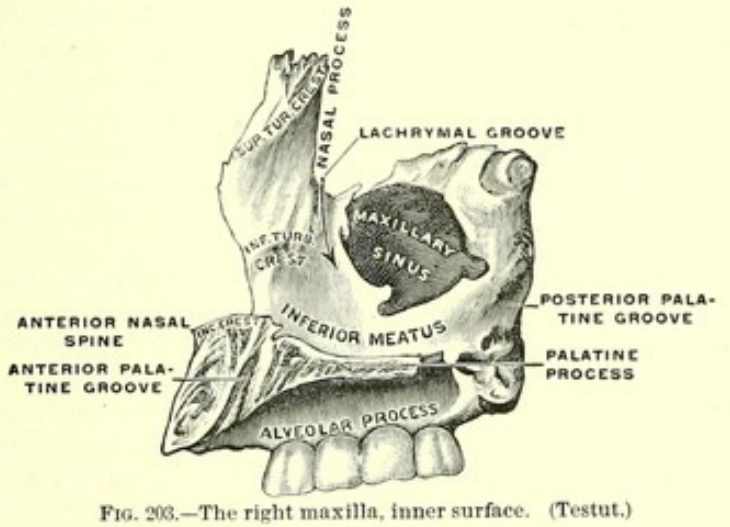

FIG. 203.—The right maxilla, inner surface. (Testut.)

zygomatic surface is separated from the facial surface by a ridge ascending from the socket of the first molar tooth to the malar process. This surface forms the anterior boundary of the zygomatic fossa, and above and internally it bounds the spheno-maxillary fossa in front. Near its centre are the apertures of the two or more *posterior dental canals* for nerves and vessels of that name. The prominent

posterior inferior angle is the *tuberosity*, which attaches a few fibres of the internal pterygoid, and articulates along its rough internal border with the tuberosity of the palate-bone. The *nasal* or *internal surface* forms the outer wall of the nasal fossa in the lower and middle meatuses, and presents in front a ridge, the *inferior turbinate crest*, which articulates with the inferior turbinate bone. Above and behind the surface is deficient, presenting the large irregular *opening into the antrum*. Above this opening there are one or two half cells, which complete as many ethmoidal cells. Behind it the surface is rough for articulation with the vertical plate of the palate-bone, except for a smooth groove directed downward and forward from the posterior border, which is completed by the palate-bone into the *posterior palatine canal*. The *posterior border* is separated from the pterygoid process of the sphenoid by the tuberosity of the palate-bone. Behind the nasal process and between it and this surface notice the *lachrymal groove*, which descends with a backward and a slight outward inclination. This is completed into a canal for the nasal duct by the lachrymal and inferior turbinate bones, and opens below into the inferior meatus. The smooth, triangular *orbital* or *upper surface* forms the floor of the orbit and the inner part of its lower margin. Internally it articulates from before backward with the lachrymal, ethmoid, and palate bones. At the anterior end of this border is the outer part of the upper orifice of the lachrymal groove. The free, smooth, *postero-external margin* bounds the spheno-maxillary fissure in front and internally, and presents about its middle the commencement of the *infraorbital groove*, which passes forward in the orbital surface to the canal and foramen of the same name. From the canal the *middle* and *anterior dental canals*, for nerves and vessels of the same name, run downward in the facial portion of the bone. The *antero-external margin* of this surface bounds the rough upper surface of the thick triangular *malar process*, which articulates with the malar bone. This process is continuous in front with the facial surface and behind with the zygomatic surface of the body.

The *nasal process* is a triangular plate of bone which projects upward and slightly inward. It presents *externally* a smooth surface continuous with the facial surface of the body. The *internal surface* is crossed by the *superior turbinate crest*, which articulates with the middle turbinate bone. Above the crest it articulates with the ethmoid (closing its foremost cells), and below it this surface forms part of the outer nasal wall in the middle meatus. The serrated *summit* articulates with the frontal, the *anterior border* with the nasal, and the *posterior border* is marked by the lachrymal groove, which lodges the lachrymal sac. The sharp internal border of this groove articulates with the lachrymal bone, while the smooth external border forms the inner margin of the orbit, the point of whose junction with the lower margin is marked by the *lachrymal tubercle*. The *alveolar process* is the thick, arched lower border of the bone, which contains the *alveoli* ("little hollows") or tooth-sockets, corresponding in shape and number to the roots of the eight teeth which occupy them. The *palate process*, projecting horizontally inward from the junction of the body and the alveolar process, articulates with its fellow of the opposite side to form the forward three-fourths of the hard palate, the upper surface of which belongs to the floor of the nose, the lower to the roof of the mouth. The upper transversely concave surface is smooth, while the lower vaulted surface is rough and marked at its lateral margin with a groove for the vessels and nerves passing forward from the posterior palatine canal. The *posterior border* articulates with the horizontal plate of the palate-bone, which completes the hard palate, while the *median border* joins with its fellow to form, superiorly, the vertical grooved *nasal crest*, which receives the vomer. In front of the vomer this crest, suddenly becoming much higher, is called the *incisor crest*, which supports the septal cartilage of the nose, and ends in front in the nasal spine. On each side of this crest, where it joins the upper surface, is seen the *incisor* or *Stenson's foramen*, for the terminal branches of the posterior palatine arteries. These two foramina converge downward and forward, and open on the roof of the mouth into a single canal, the *anterior palatine fossa*, common

to them and the two *foramina of Scarpa*, which are placed in front of and behind the former in the median suture, and transmit the naso-palatine nerves. In young bones the *premaxillary suture* extends from this fossa on each side to, but not through, the outer alveolar border, internal to the canine socket. The part in front of this suture represents the *premaxillary bone* of the lower animals, and includes the incisor teeth. It is separately formed, and sometimes remains separate on one or both sides in cases of cleft-palate.

The *antrum of Highmore*, or *maxillary sinus*, is a pyramidal air-chamber occupying the body of the bone. Its thin walls correspond to the surfaces of the body. The apex corresponds to the malar process, and the base to the nasal surface, the large opening in which is partly closed by the palate-bone behind, the inferior turbinate bone inferiorly, and the uncinate process of the ethmoid and the lachrymal above and in front. It is made still smaller by the mucous membrane, and opens into the middle meatus of the nose by one or sometimes two apertures. Along the lower angle the roots of the first two molars often project into the cavity. The antrum may sometimes be partly, rarely completely, subdivided.

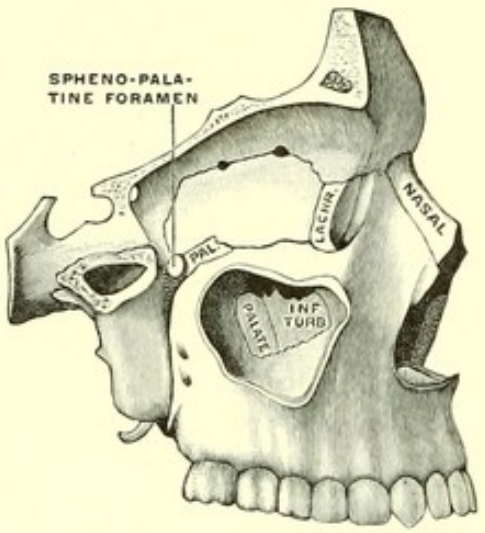

FIG. 204.—The maxillary sinus and the inner wall of the orbit. The apex of the sinus and the outer wall of the orbit have been removed. (Testut.)

Articulations.—The maxilla articulates with its fellow and with the nasal, frontal, lachrymal, ethmoid, palate, vomer, inferior turbinate, and malar bones, and sometimes with the sphenoid.

Ossification occurs early in membrane from four centres, and some of the lines between the parts are often to be seen in the young adult bone, especially in the floor of the orbit. The antrum appears in fœtal life.

THE PALATE-BONE.

The *palate-bone* (Figs. 205, 206) is L-shaped, and is wedged in between the maxilla and the pterygoid process of the sphenoid, forming the back part of the hard palate, of the lateral wall of the nose, and of the floor of the orbit. It has a horizontal and a vertical plate, united at a right angle. The tuberosity projects backward and outward from the rear of this angle, and the vertical plate is surmounted by two processes, the orbital and sphenoidal.

The **horizontal plate** completes the hard palate, and presents a smooth, concave *upper surface* and a rough *lower surface*. The latter presents behind a transverse ridge which attaches the aponeurosis of the soft palate, connected with the tensor palati muscle. The *anterior border* articulates with the palate process of the maxilla; the *internal border* articulates with its fellow, forming the continuation of the nasal crest which supports the vomer, and ends at the posterior border in the *posterior nasal spine*. The free and sharp *posterior border* bounds the posterior nares inferiorly, and attaches the soft palate.

The **vertical plate** is thin and presents a rough *outer surface*, which, applied against the maxilla, completes the groove near its hind border into the *posterior palatine canal*. Behind the groove is a smooth surface superiorly, forming part of the inner wall of the *spheno-maxillary fossa*, below which the surface is rough for articulation with the pterygoid process and the maxilla successively. In front this surface overlaps the opening of the antrum by a thin projection, the *maxillary process*. The *inner* or *nasal surface* presents the hind part of the inferior and middle meatuses of the nose, each limited above by a *transverse ridge* or crest,

articulating with the inferior and middle turbinate bones respectively. Above the upper ridge the two processes ascend, separated by the deep *spheno-palatine notch*, which is converted into a foramen of the same name by articulation with the sphenoid bone. This foramen connects the spheno-maxillary and nasal fossæ,

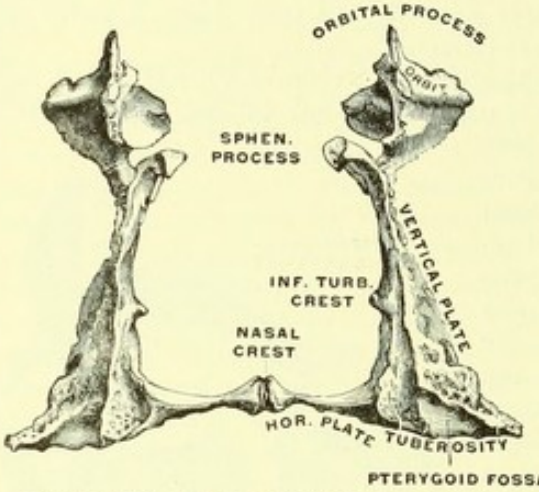

FIG. 205.—The two palate-bones in their natural position, dorsal view. (Testut.)

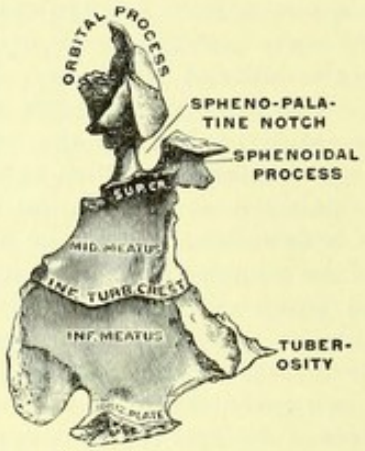

FIG. 206.—The right palate-bone, inner surface. (Testut.)

and transmits the spheno-palatine artery and nerve. At the lower end of each process internally is a grooved surface entering into the superior meatus.

The five-sided *orbital process* surmounts the anterior border of the vertical plate, and articulates with the maxilla in front, the sphenoid behind, and the ethmoid internally. The ethmoidal cells or the sphenoidal sinus may extend into its hollow body. Of the two free surfaces the superior forms the rear angle of the orbital floor, and the external looks into the spheno-maxillary fossa, while the border between them bounds the spheno-maxillary fissure internally at its hind end. The *sphenoidal process* curves upward and inward, and articulates externally and superiorly with the base of the internal pterygoid plate and of the sphenoidal body, completing with the former the pterygo-palatine canal. At its lower part, in front, a small surface looks outward into the spheno-maxillary fossa. The inner surface looks into the nasal fossa, and above, where it touches the ala of the vomer, forms a part of its roof. The *tuberosity* or *pyramidal process* is wedged in between the tuberosity of the maxilla and the pterygoid process. It presents externally a small free surface in the zygomatic fossa. Posteriorly it fills the pterygoid notch, and completes the pterygoid fossa by a smooth triangular surface lying between two rough grooves, which articulate with the anterior borders of the two pterygoid plates. Inferiorly, near its junction with the horizontal plate, with which it is continuous, are seen the lower orifices of the accessory, posterior, and external palatine canals.

Articulation.—The palate articulates with its fellow, the vomer, maxilla, inferior turbinate, sphenoid, and ethmoid.

Ossification proceeds from a single centre in the membrane of the nasal capsule.

THE VOMER.

The *vomer* ("ploughshare") (Fig. 207) is a thin, irregular quadrilateral plate forming the lower and back part of the nasal septum. It is usually deviated from the vertical plane, most often to the left. Each *lateral surface* is covered with muco-periosteum, and presents a faint groove running downward and forward to conduct the naso-palatine nerve to Scarpa's canal. The thick *superior border* splits into two *alæ* ("wings"), which embrace the rostrum of the sphenoid, while their margins meet the vaginal processes of the sphenoid and the sphenoidal

processes of the palate-bones. The oblique *anterior border* joins the vertical plate of the ethmoid above, and below it is grooved for the septal cartilage. The *inferior border* is received into the groove of the nasal crest of the maxillæ and palate-

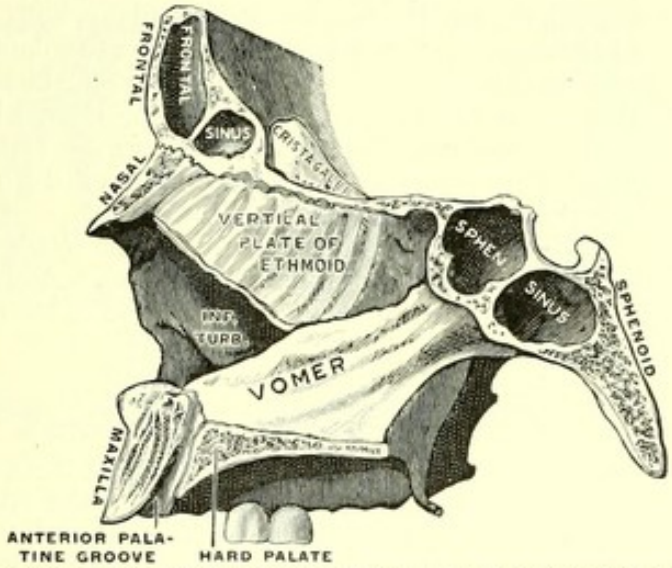

FIG. 207.—Sagittal section of face, a little to the left of the middle line, showing the vomer and its relations. (Testut.)

bones. The truncated *anterior angle* fits in behind the incisor crest of the maxillæ. The thin, free *posterior border* separates the two posterior nares.

Ossification proceeds from a single centre in membrane, and forms two lamellæ, which cause the absorption of the intervening cartilage.

THE INFERIOR TURBINATE BONE.

Each *inferior turbinate bone* (Figs. 208, 223) is a scroll-like lamella which separates the middle from the inferior meatus of the nasal fossa, and is attached above to the outer wall of the nose, but is free below. Its convex *inner surface*, marked by pits and longitudinal grooves for vessels, ends below in the convex, thickened *free border*, which is rolled upon itself. The attached *upper margin* articulates in front with the inferior turbinate crest of the maxilla, behind which it rises abruptly into the *lachrymal process*, which articulates with the lachrymal bone and helps to close the lachrymal canal. Behind this is the *maxillary process*, bent downward and closing the lower part of the opening of the antrum. Above and behind the latter process the *ethmoidal process* rises to join the uncinate process of the ethmoid. The posterior part of this margin is attached to the inferior turbinate crest of the palate-bone. The posterior *angle* is sharp, the anterior more blunt. The *outer surface* is concave and grooved.

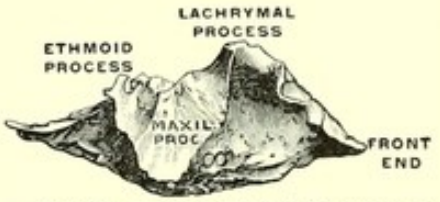

FIG. 208.—Right inferior turbinate bone, external surface. (Testut.)

Ossification.—This bone ossifies from a single centre in cartilage, and may be regarded as a detached portion of the ethmoid.

THE NASAL BONE.

The two oblong *nasal bones* (Fig. 209) form the bridge of the nose. The *facial surface* of each is vertically concave above and convex below, and transversely convex. The *posterior* or *nasal surface*, transversely concave, is rough

above, where it rests upon the nasal process of the frontal. Below it forms part of the roof of the nose, and presents a longitudinal groove for the nasal nerve. This groove ends in a small notch near the inner end of the thin *lower border*, which attaches the lateral nasal cartilage. The short, thick *upper border* articulates with the nasal notch of the frontal. The long *outer border* articulates with the nasal process of the maxilla. The *inner border*, thicker above, meets that of its fellow, with which it is prolonged backward into a median crest, which from above downward rests upon the nasal spine of the frontal, the vertical plate of the ethmoid, and the septal cartilage of the nose.

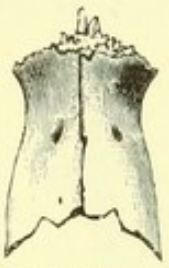

FIG. 209. — Nasal bones, viewed from before. (Testut.)

Ossification proceeds from a single centre in membrane overlying cartilage, which is absorbed. At birth the bone is relatively broad. The shape of the nose depends largely upon that of these bones.

THE LACHRYMAL BONE.

The *lachrymal bone* (*os unguis*), "nail-bone" (Figs. 210, 211), is a thin quadrilateral scale of bone forming the front of the inner wall of the orbit. Its *external* or *orbital surface* presents a larger, flat hind or *orbital part*, and a smaller grooved fore part, forming the *lachrymal sulcus* or *groove* for the lachrymal sac. These portions are separated by a sharp vertical ridge, the *lachrymal crest*, which is prolonged forward at its lower end into the *hamulus*, which often articulates with the lachrymal tubercle of the maxilla, and bounds the orifice of the lachrymal canal externally.

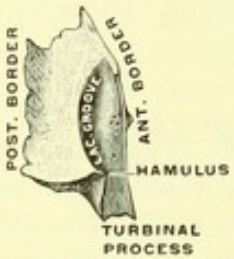

FIG. 210.—Right lachrymal bone, outer surface. (Testut.)

FIG. 211.—Right lachrymal bone, inner surface. (Testut.)

The *internal surface* closes some of the front ethmoidal cells above, and below looks into the middle meatus of the nose. The anterior border articulates with the nasal process of the maxilla, the superior with the internal angular process of the frontal, and the posterior with the orbital plate of the ethmoid. The inferior border behind the crest joins the orbital plate of the maxilla, and in front it is prolonged downward as the *descending* or *turbinal process*, which joins the lachrymal process of the inferior turbinate bone to complete the lachrymal canal.

The lachrymal *ossifies* from a single centre in membrane, and is a diminishing element.

THE MALAR BONE.

The quadrangular *malar bone* (Figs. 212, 213) forms the prominence of the cheek and helps to separate the orbit from the temporal fossa. The *outer surface* is convex, and presents near its centre the orifice of the malar canal. The concave *inner surface* looks into the temporal fossa above, the zygomatic fossa below, and articulates in front by a rough triangular surface with the malar process of the maxilla. The four angles are directed vertically and horizontally. The prominent, serrated *upper angle* or *frontal process* articulates with the external angular process of the frontal, and the *posterior angle* or *zygomatic process* is bevelled above, and articulates with the end of the zygoma. The sinuous *temporal border* between these two angles is continuous with the upper edge of the zygoma below and the tem-

poral ridge above, and attaches the temporal fascia. The *posterior inferior* or *masseteric border* completes the lower edge of the zygomatic arch and attaches some fibres of the masseter. The *antero-inferior* or *maxillary border*, the inferior angle,

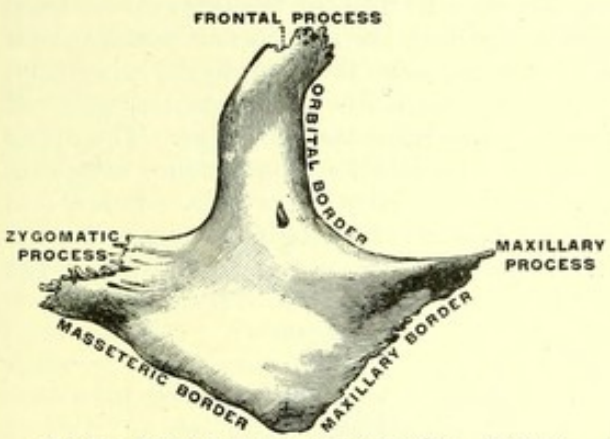

FIG. 212.—Right malar bone, outer surface. (Testut.)

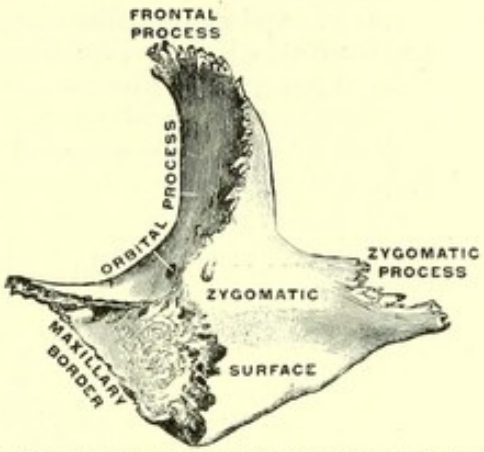

FIG. 213.—Right malar bone, inner surface. (Testut.)

and the anterior angle or *maxillary process* articulate with the maxilla. The *antero-superior* or *orbital border* is curved to form the outer margin and the outer half of the lower margin of the orbit. From this border the curved, triangular *orbital process* projects backward and inward, and forms the anterior boundary of the temporal fossa and the fore part of the outer wall and floor of the orbit. It articulates above with the frontal, and behind with the great wing of the sphenoid and the orbital plate of the maxilla. Between the articulations with the latter two bones there is usually a free margin bounding the spheno-maxillary fissure in front. The *temporal* and *malar canals*, for the temporo-malar branches of the fifth nerve, are seen on the orbital surface.

Ossification proceeds in membrane from two or sometimes three centres, and the adult bone is occasionally divided by a horizontal suture into two unequal parts.

THE MANDIBLE, OR INFERIOR MAXILLARY BONE.

The *lower jaw-bone* (Figs. 214, 215) is a large, strong, horseshoe-shaped bone, forming the lower third of the facial skeleton, and articulating by means of a pair of condyles with the glenoid fossæ of the temporal bones. It consists of a nearly horizontal body in front and two posterior vertical portions or rami.

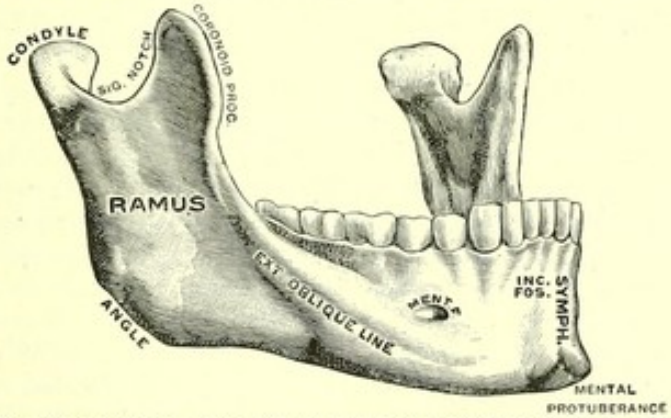

FIG. 214.—The mandible, viewed from the right and a little in front. (Testut.)

The **body** consists of two symmetrical, lateral halves, whose *symphysis* ("together-growth") or union in the middle line is marked on the *external surface* by a faint vertical ridge which expands below into the triangular *mental protuberance* or chin. The centre of the base of the protuberance may be

slightly depressed, and from its prominent lateral angles, or *mental* ("chin") *tubercles*, the rather faint *external oblique line* extends backward and upward to become continuous with the anterior border of the coronoid process. Below the incisor teeth on each side is the *incisor fossa*. Midway between the upper and lower borders and in line with the second bicuspid tooth, or the interval between the two bicuspids, is the *mental foramen*, transmitting the mental nerve and vessels from the dental canal. The *internal surface* presents at the symphysis, superiorly, a linear groove, ending below in a small foramen, below which are two pairs of *genial* ("chin") *tubercles*, sometimes fused into a single median ridge. The upper pair attaches the genio-hyoglossi muscles, and a small median ridge, attaching the genio-hyoid muscles, usually takes the place of the lower pair. Below and on each side of this, and close to the lower border, is a rough depression for the anterior belly of the digastric muscle. Beginning above the latter and at the

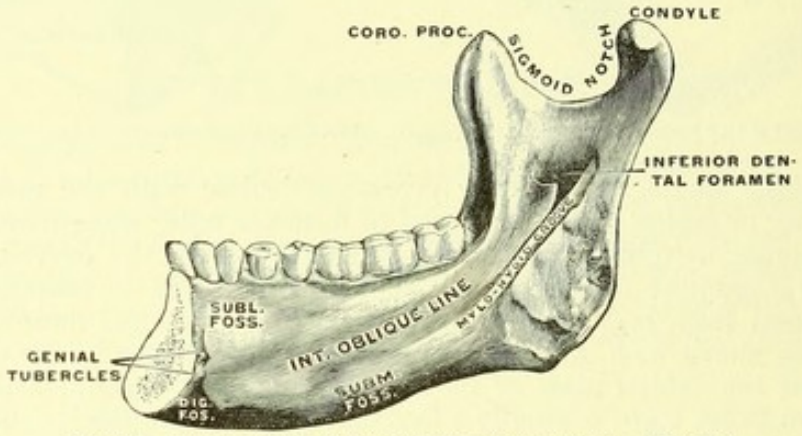

FIG. 215.—The right half of the mandible, inner surface. (Testut.)

side of the lower genial tubercle on each half of the bone, the *internal oblique line* or *mylo-hyoid ridge* passes backward and upward to the ramus. This attaches the mylo-hyoid muscle, and, at the posterior end, the superior constrictor muscle and the pterygo-maxillary ligament. Above the line, on each side of the symphysis, is the shallow *sublingual fossa* for the sublingual gland; and below it, at the side, is the *submaxillary fossa* for the submaxillary gland. The *superior* or *alveolar border* on each side presents the sockets for the roots of eight teeth, and externally attaches the buccinator as far forward as the first molar. The *inferior border*, thick, smooth, and rounded, projects beyond the upper, and is grooved for the facial artery near its junction with the ramus.

The **ramus** is quadrilateral and thinner than the body. The masseter muscle is inserted on its *external surface*. On the *internal surface*, about its middle, is the *inferior dental foramen*, leading to the *inferior dental canal* for the inferior dental vessels and nerves. This canal is nearer the inner surface behind and the outer in front where it connects with the mental foramen. It communicates by a series of fine channels with the bottom of each tooth-socket. The front and inner edge of the foramen is sharp and prominent, forming the *lingula*, which attaches the spheno-mandibular or long internal lateral ligament of the jaw. Behind the lingula and below the foramen the *mylo-hyoid groove* (sometimes a canal at first) starts in its downward and forward course beneath the mylo-hyoid ridge, and lodges the mylo-hyoid nerve and vessels. Between this groove and the angle the internal pterygoid muscle is inserted on a rough triangular space. The lower border, continuous with that of the body, meets the posterior border at the *angle* of the jaw. This is usually slightly everted, and attaches behind the stylo-mandibular fold of fascia. The sharp, concave upper border, known as the *sigmoid notch*, separates the two processes, and is crossed by the masseteric nerve and artery. The hind process, or *condyle*, surmounts the posterior border on a constricted portion, or *neck*, in front of which, internally,

is a depression for the insertion of the external pterygoid muscle. The condyle is convex and transversely elongated on an axis which, prolonged, would meet that of its fellow near the front of the foramen magnum. Its prominent outer end, beyond the articular surface, forms a *tubercle*, to which the external lateral ligament is attached. The thin *coronoid process* tapers upward and outward from the anterior border, and to its tip, borders, and internal surface the temporal muscle is attached. The inner surface presents a ridge, continuous below with the internal oblique line and the inner alveolar edge. Between this ridge and the anterior border is a groove for the insertion of the temporal muscle above, and, for a short distance, for the buccinator below.

The *changes according to age* (Figs. 216, 217) are so ordered that the upper and lower gums, or teeth, as the case may be, meet in biting. Thus, at birth the angle is about 175°, the body is shallow and consists mostly of alveolar process, and the mental foramen is near the lower border. At about four years of age, after the first dentition, the angle is reduced to 140°, as the body plus the teeth is much deeper. In adult life the depth of the body has

FIG. 216.—The mandible in infancy. (Testut.)

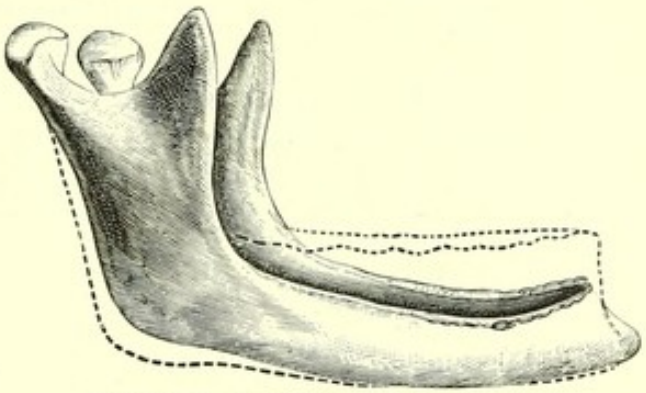

FIG. 217.—The mandible in old age. (Testut.)

so increased below, in the basal part, that the foramen is midway between the borders, and the angle is 120° to 110°, or even less. In old age the alveoli are absorbed, the foramen is near the upper border, the body is basilar, and the angle is increased to 140° or so, thus allowing the gums to meet. This throws the chin forward, and the pressure of the tightened lips presses back the upper border of the bone in front.

Ossification proceeds at a very early period from four to six centres on each side. The part from the symphysis to the mental foramen is ossified in the anterior end of Meckel's cartilage, the condyle and angle from separate centres in cartilage, and the rest in membrane. At birth the two halves are united by fibrous tissue.

THE HYOID BONE.

The *hyoid* ("like Greek letter upsilon") or *lingual bone* (Fig. 218) is a small U-shaped bone which may be felt at the base of the tongue, between the chin and the thyroid cartilage. It has a body and two pairs of cornua.

The oblong *body* has a smooth, concave *posterior surface*, looking backward and downward toward the epiglottis. Its convex *anterior surface*, looking upward and forward, is divided by a transverse and sometimes a median vertical ridge into depressions for muscular attachment. The *superior border* attaches the thyro-hyoid membrane.

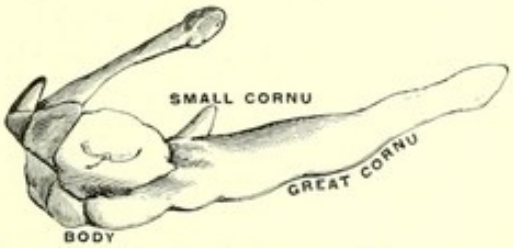

FIG. 218.—The hyoid bone. (F. H. G.)

The *great cornua* taper backward and upward from the sides of the body, ending in rounded tubercles to which the thyro-hyoid ligaments are attached. The cornua are flattened above and afford

attachment to muscles. The *small cornua* are small conical pieces of bone, often partly, and sometimes wholly, cartilaginous, which project upward and backward from the junction of the great cornua and the body. Their extremities attach the stylo-hyoid ligaments, which suspend the hyoid from the styloid processes of the temporal bones.

Ossification occurs in the cartilage of the second visceral arch, continuous with the styloid process. There is a centre for each cornu, and for each half of the body. The synchondrosis of the great cornu usually ossifies after middle life. The synovial articulation of the small cornu seldom ankyloses.

THE SKULL AS A WHOLE.

The Sutures.

The *sutures* are the closely-fitted articulations of the uneven edges of the bones of the skull, in which the bones are separated only by a fibrous *suture membrane*, continuous with the periosteum and dura, except in the two synchondroses of the jugular and basilar portions of the occipital bone, at the base of the skull, where cartilage intervenes until it is ossified in adult life. The sutures allow the rapid growth of the skull in early life, diminish shocks, and, by being alternately bevelled on each side, bind the bones so firmly together that dislocation is next to impossible. Many of them are often, but not always, obliterated by ossification in adult life. The time when this commences is very variable, but it usually begins where they last came together—*i. e.*, near the posterior, anterior, or antero-lateral fontanelles.

Though the sutures are best named from the bones which form them, those around the parietal bones have received special names from their shape, direction, etc., as the *sagittal* (interparietal), the *coronal* (fronto-parietal), the *lambdoidal* (occipito-parietal), and the *squamous* (squamo-parietal).

The **fontanelles** ("little springs") are unossified, membranous spaces which exist before, at, and for a time after birth at the angles of the parietal bone. Their existence and position are due to the fact that, while the bones are quadrilateral, ossification proceeds radially or circularly, so that the angles are the last to ossify. The larger, diamond-shaped *anterior fontanelle* is an important landmark at parturition. It serves for a safety-valve for the rapidly varying intracranial pressure of early infancy, and closes during the second year. The *anterior* and *posterior lateral fontanelles* are closed in fœtal life. The *posterior fontanelle* is often filled up before birth, but the bones are then movable upon each other, and the triangle of their converging margins may be felt as a landmark during parturition. Wormian bones often assist in the closure of the lateral and posterior fontanelles.

Wormian bones are small, irregular ossicles from supernumerary ossific centres which are found in varying numbers in the sutures, especially in those about the parietal bones, and chiefly near the fontanelles. They are most numerous and largest in the lambdoid suture, but must be distinguished from the interparietal portion of the occipital bone when it exists as a separate bone. A small ossicle, the *epipteric* ("upon the wing") *bone*, is found in most skulls in each anterior lateral fontanelle up to the fifteenth year, after which it usually joins the great wing of the sphenoid.

The Exterior of the Skull.

The skull is bilaterally symmetrical. The **superior region** includes the smooth convex surface. It is covered by the occipito-frontalis muscle and aponeurosis and the scalp, which extends from the supraorbital margins in front to the superior curved lines of the occipital bone behind and between the superior temporal lines laterally. The skull, viewed from above, is broader behind than in front, and is oval

in outline, with slight projections at the frontal and parietal eminences and at the occipital protuberance. At the meeting of the sagittal and coronal sutures is the *bregma*, at the site of the anterior fontanelle; and the *lambda* is where the sagittal and lambdoid sutures meet, at the site of the posterior fontanelle. The occipital protuberance is known as the *inion* ("occiput"). Except in very broad skulls the zygomatic arches are visible from above.

The **lateral or temporal region** (Figs. 219, 220) presents the *temporal fossa*, formed by the temporal, parietal, sphenoid, frontal, and malar bones, and occu-

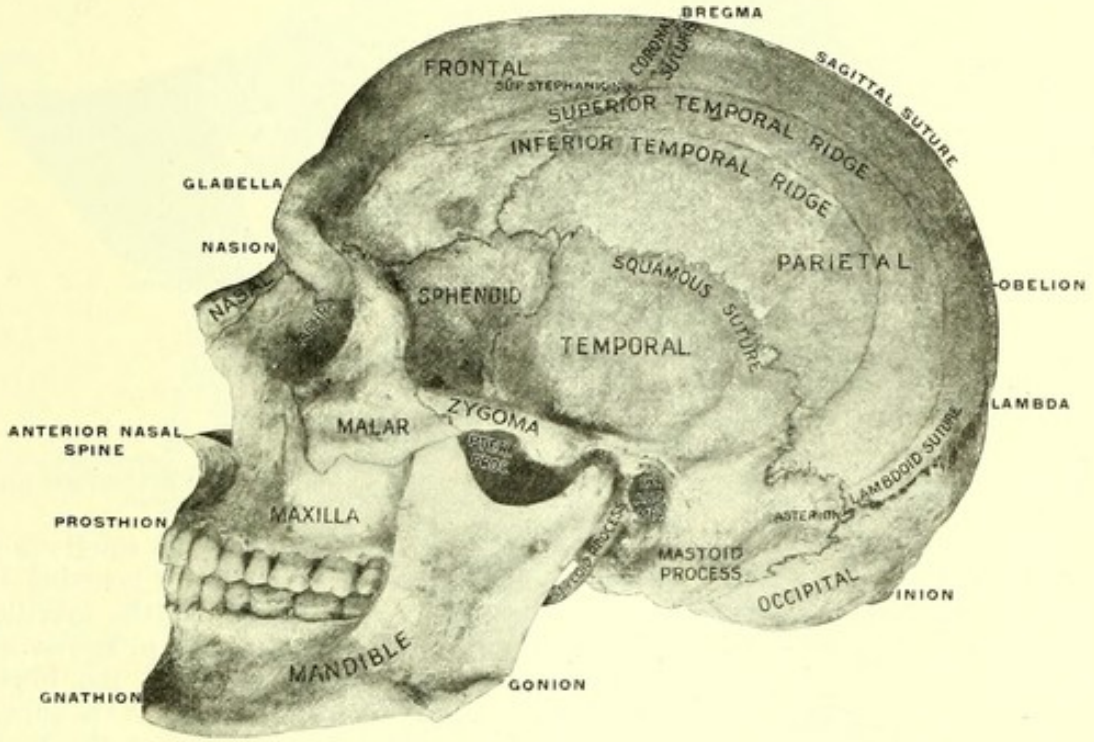

FIG. 219.—Skull, viewed from the left side, showing the principal craniometric points.

pied by the temporal muscle. It is limited below by the zygomatic arch externally and the pterygoid ridge of the sphenoid internally. Above it is bounded by the *temporal ridge*, which, starting at the external angular process of the frontal bone, arches upward and backward, and then downward. Near the coronal suture it usually divides into a *superior* and an *inferior ridge*. The latter limits the origin of the temporal muscle, and is continuous behind with the supramastoid crest and the posterior root of the zygoma. The former, less constant and not as marked, attaches the temporal fascia and arches down to the mastoid process near the *asterion* ("starry") at the site of the posterior lateral fontanelle. The *pterion* ("wing"), at the site of the anterior lateral fontanelle, is where the parietal, frontal, sphenoid, and temporal bones come together. The temporal fossa communicates with the zygomatic fossa through the opening bounded externally by the zygomatic arch.

The *zygomatic fossa* is bounded in front by the zygomatic surface of the maxilla, internally by the external pterygoid plate, externally by the zygomatic arch and ramus of the jaw, and superiorly by a small triangular surface on the squamosal and by the great wing of the sphenoid internal to the pterygoid ridge. Posteriorly it is limited by a line drawn from the sphenoidal spine to the zygomatic tubercle. It is occupied by the pterygoid and temporal muscles and the coronoid process of the lower jaw. Internally, between its anterior and internal boundaries, is the vertical *pterygo-maxillary fissure*, between the maxilla and the anterior border of the external pterygoid plate. This connects the zygomatic with the *spheno-maxillary fossa*. Above and at right angles to the pterygo-maxillary

fissure is the *spheno-maxillary fissure*, which connects the upper part of the zygomatic and of the spheno-maxillary fossæ with the orbit. This fissure lies nearly horizontally between the free margins of the orbital surfaces of the maxilla and the palate-bone internally and the sphenoid externally. In front it is usually

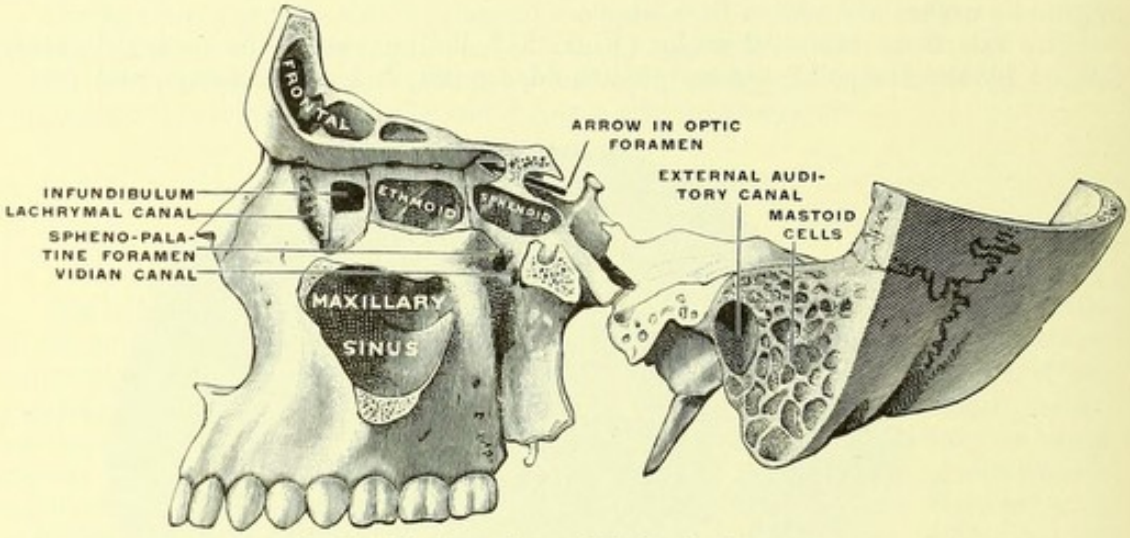

FIG. 220.—The bony sinuses of the head. (Testut.)

limited by the malar bone, though the maxilla and sphenoid may articulate and exclude it.

The *spheno-maxillary fossa*, shaped like an inverted pyramid, is a small space between the maxilla and the root of the pterygoid process. It is bounded in front by the upper and inner part of the zygomatic surface of the maxilla, internally by the vertical plate and the orbital and sphenoidal processes of the palate-bone, behind by the roots of the pterygoid process and the lower part of the anterior surface of the great wing of the sphenoid. The apex leads into the posterior palatine canal, the base into the back of the orbit through the hind part of the spheno-maxillary fissure. Internally the spheno-palatine foramen connects it with the nasal fossa, and behind are seen the foramen rotundum, Vidian canal, and pterygo-palatine canal (in the order named, from above and without, downward and inward.) The fossa contains Meckel's ganglion, with its roots and branches, and the terminal branches of the internal maxillary artery enclosed in a mass of fat.

The lateral region presents postero-inferiorly the external auditory meatus, nearly in the same vertical transverse plane with the bregma, and behind this the mastoid process, with the variable mastoid foramen behind and above it.

The **base of the skull externally** (Fig. 221) from the incisor teeth to the external occipital protuberance is very irregular, and may be studied in three divisions.

The *anterior* or *palate division* includes the *hard palate*, formed by the palate processes of the maxillæ and the palate-bones, and bounded laterally and in front by the *alveolar arch*. Medially in front notice the *anterior palatine fossa*, into which four foramina open, and from which, in young skulls, the suture separating the premaxillary bone runs to the outer side of each lateral incisor tooth. At the posterior angles are the lower openings of the *posterior palatine canals*, from each of which a groove runs forward in the angle between the palate and the alveolar arch for the anterior palatine nerve and the posterior palatine vessels. The *hamular processes* are seen at the postero-lateral limits of the hard palate, behind and internal to the last molar teeth. Between these and the posterior palatine canal are the openings of the accessory and external palatine canals.

The *middle* or *suberanial division* extends back to a line joining the tips of the mastoid processes. It slopes upward and forward from behind, and is at a higher level than the anterior division. Between these two divisions are the following

vertically-placed structures: Mesially are the *posterior nares*, separated by the vomer, and bounded below by the horizontal plates of the palate-bones, laterally by the internal pterygoid plates, and above by the body of the sphenoid and the

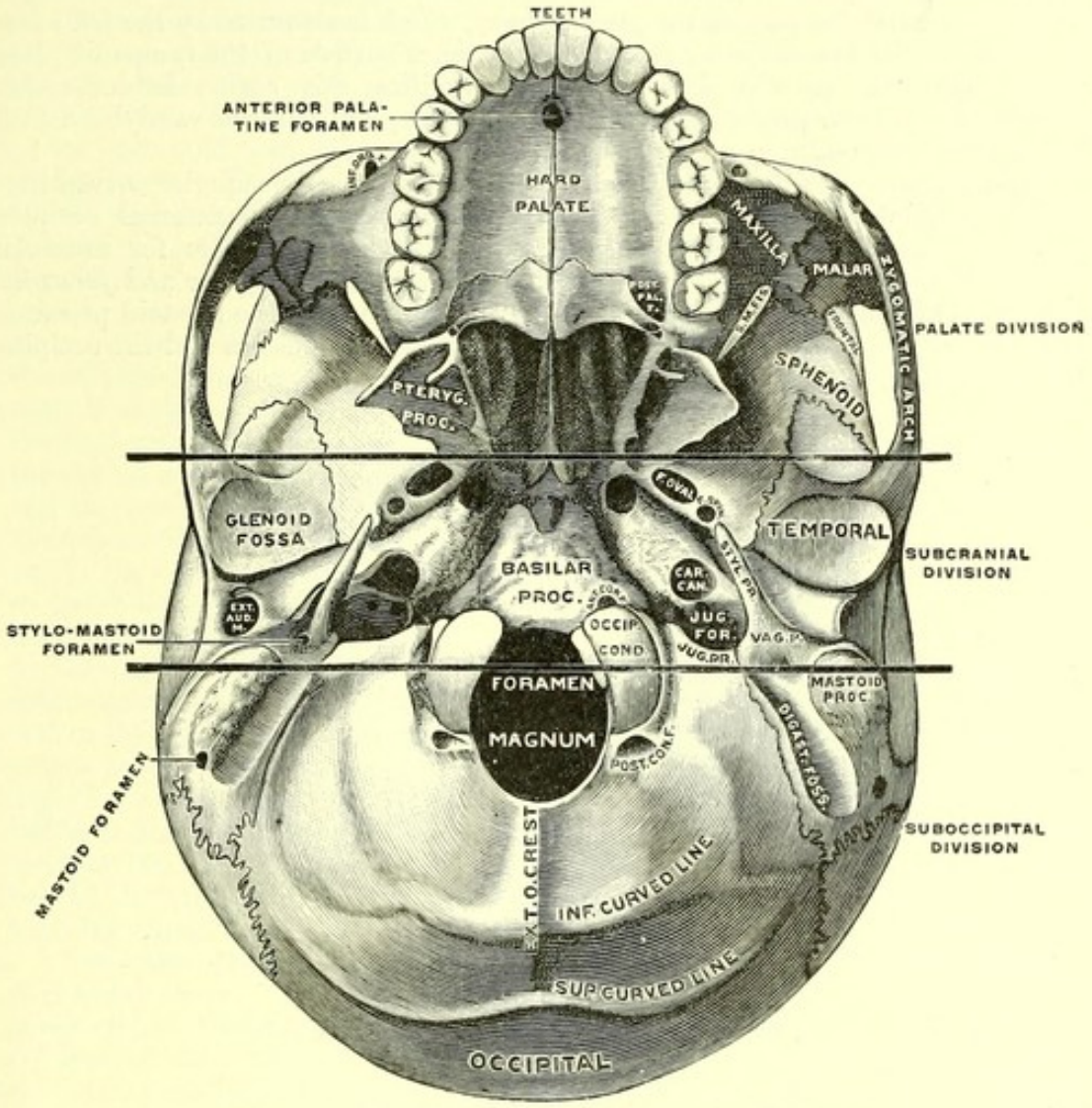

FIG. 221.—Base of the skull, viewed from below. (Testut.)

alæ of the vomer. On each side is seen the *pterygoid fossa*, completed by the tuberosity of the palate-bone below, and lodging the internal pterygoid and tensor palati muscles. The latter muscle arises from the *scaphoid fossa*, a subdivision at the upper part of the pterygoid fossa. External to the pterygoid fossa is the *zygomatic fossa*, whose roof forms part of the base of the skull.

The basilar process of the occipital bone and a small part of the body of the sphenoid occupy the *median portion* of the middle division, while *laterally* are the petrosals and a small portion of the great wings of the sphenoid, of the squamosals, and of the occipital bone. In the median line we notice the *pharyngeal tubercle* and the front margin of the *foramen magnum*, termed the *basion*. Laterally, in a nearly sagittal line, we notice from before backward the *foramen ovale*, the *foramen spinosum*, the opening of the bony and the groove for the cartilaginous *Eustachian canal*, the entrance of the *carotid canal*, and the *jugular fossa* and *foramen*. Internal to the latter is the *anterior condylar foramen*, and externally the *stylo-mastoid foramen*. Between the extremities of the petrous portion of the temporal bone and of the basilar process of the occipital and the sphenoid we notice the *foramen lacerum medium*, filled by fibro-cartilage in

the recent state. In an oblique line from the mastoid process to the external pterygoid plate we find projecting the *styloid process*, the *vaginal process* of the tympanic bone, and the *spine of the sphenoid*, the latter at the inner end of the Glaserian fissure. On this surface is seen laterally the *eminentia articularis* in front of the articular part of the *glenoid fossa*, which is separated by the *Glaserian fissure* from the non-articular portion on the outer surface of the tympanic plate, which lodges the parotid gland. The line limiting this region behind passes through the jugular processes of the occipital bone, and cuts the condyles a little behind their centre.

The *posterior* or *suboccipital division* extends back to the superior curved lines of the occipital bone, divided into two lateral halves by the external occipital crest. It includes, mainly, rough lines and intervening spaces for muscular attachment. Behind the condyles are the *posterior condylar fossæ* and *foramina* when the latter are present. Internal to and slightly behind the mastoid processes are the digastric and occipital grooves, for the digastric muscles and the occipital arteries respectively.

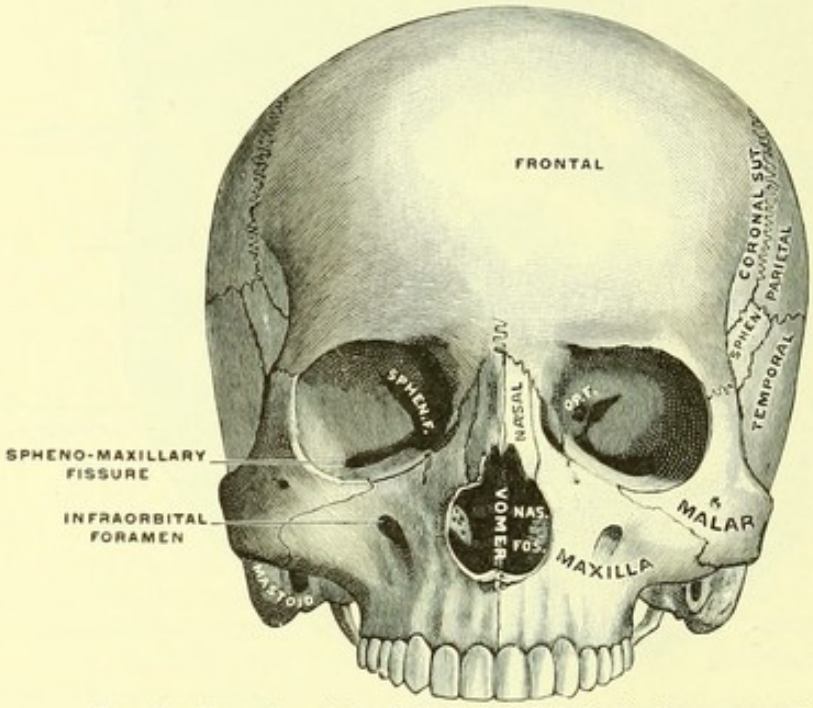

FIG. 222.—Front view of the skull, the mandible having been removed. (Testut.)

The **anterior or facial region** (Fig. 222) presents the *nasion*, in the centre of the naso-frontal suture, below the glabella. Below the nasion is the prominent *bridge of the nose*, formed by the nasal bones and the nasal processes of the maxillæ. Below this is the *anterior nasal aperture*, which is shaped like an inverted heart and is often unsymmetrical. Its thin margins attach the nasal cartilages, and its lower border projects forward as the *anterior nasal spine*. In the recent state it is bisected by the septal cartilages. Below this, on either side, are the incisor fossæ. On either side of the bridge of the nose are the *orbits*, below which are the *canine fossæ*, and external to the latter the prominences of the cheeks, formed by the malar bones. The *teeth* are a prominent feature of this region, and below them the body of the lower jaw completes the anterior surface. The three large *foramina*, *supraorbital*, *infraorbital*, and *mental*, each for a branch of one of the three divisions of the fifth nerve, lie in a nearly vertical line drawn through the second lower bicuspid tooth or the interval between the two lower bicuspids. The small malar canal is situated more laterally on the malar bone.

The **orbits** are two irregularly quadrilateral, pyramidal fossæ which lodge the eyeballs and their muscles, nerves, and vessels. The *base* of each, directed for-

ward and slightly outward, is formed by the *orbital margin*, which is quadrilateral in shape with rounded angles. It is bounded above by the frontal, with the supraorbital notch or foramen at the junction of its inner and middle thirds; internally by the nasal process of the maxilla; below by the infraorbital margins of the maxilla and malar, and externally by the malar bone. The concave *roof* of each orbit is formed by the orbital plate of the frontal and the small wing of the sphenoid. The *outer walls* of the orbits diverge so as to be almost at right angles with each other, and are formed by the orbital surfaces of the great wings of the sphenoid and the malar bones, the latter containing the temporal and malar canals. The *floor*, sloping from within downward and outward, is formed by the maxilla, with the orbital process of the palate-bone behind and a small part of the malar bone in front. The *inner walls* of the two cavities are nearly parallel, and are so continuous with the floors as to give a triangular shape to the orbit in some specimens, which is especially marked at birth. Each is formed, from before backward, by the nasal process of the maxilla, the lachrymal bone, the os planum of the ethmoid, and the body of the sphenoid. The *apex* of the orbit is at the inner extremity of the sphenoidal fissure, whose outer end separates the back part of the roof and outer wall. The *optic foramen* lies at the back of the orbital roof, above and internal to the apex. In the angle between the roof and the inner wall lie the anterior and posterior ethmoidal foramina in the ethmoidal section of the *transverse suture*. The latter extends horizontally from one to the opposite external angular process of the frontal bone, along the margins of the orbital plates of the frontal and the nasal notch between. In the angle between the roof and the outer wall, in front, is the *fossa for the lachrymal gland*. In the angle between the outer wall and the floor in its posterior two-thirds is the *spheno-maxillary fissure*, communicating behind with the spheno-maxillary fossa, and in front with the zygomatic fossa. From its inner border the *infraorbital groove* passes forward in the floor of the orbit to the *infraorbital canal*. In the angle between the floor and the inner wall, and just behind the orbital margin, the *lachrymal groove* passes down into the *lachrymal canal*. A depression, sometimes a tubercle, for the pulley of the superior oblique muscle is seen a little behind the supero-internal angle of the orbital margin. The orbits communicate with the cranial cavity and the nasal, spheno-maxillary, and zygomatic fossæ.

The **nasal fossæ** (Fig. 223) are two irregular, oblong cavities of a truncated pyramidal shape. They are narrow transversely, especially above, but have a considerable diameter vertically and from before backward. They extend from the base of the skull to the upper surface of the hard palate, and open in front by the anterior nasal aperture, and behind into the pharynx by the posterior nares. They are situated one on each side of a median, vertical *septum nasi* or *internal wall*, formed by the vertical plate of the ethmoid, the vomer, the rostrum of the sphenoid, the nasal spine of the frontal, and the crests of the nasal, maxillary, and palate bones. The angular interval between the vomer and the ethmoid plate in front is filled by the septal cartilage, which with the bony septum is usually deflected to one side, most commonly to the left. The narrow *roof* of each fossa has a middle *horizontal part* formed by the cribriform plate of the ethmoid, with its many small apertures leading from the anterior cranial fossa, and an anterior and a posterior part sloping downward. The anterior slope is formed by the nasal bones and the nasal spine of the frontal. The posterior slope is formed by the body of the sphenoid, the sphenoidal turbinate bones, the alæ of the vomer, and the sphenoidal processes of the palate-bones, and it contains the openings of the sphenoidal sinuses. The *floor* of each fossa, wider than the roof, is smooth and concave transversely, with a slight backward slope. It is formed by the palate processes of the maxilla and palate-bone, and presents in front, close to the septum, the *incisor foramen* (or *canal*), leading to the oral cavity. The extensive *outer wall*, sloped downward and outward, is formed by the nasal, maxillary, lachrymal, ethmoid, inferior turbinate, and palate bones, and the inner surface of the internal pterygoid plate. It presents three horizontal recesses or *meatuses*,

overhung by three *turbinate plates*, of which the upper two belong to the ethmoid, and the lower is the inferior turbinate bone.

The *superior meatus*, between the superior and inferior turbinate plates of the ethmoid, is very short, being limited to the posterior half of the fossa. It opens behind only, and into it open the posterior ethmoidal cells and the spheno-palatine

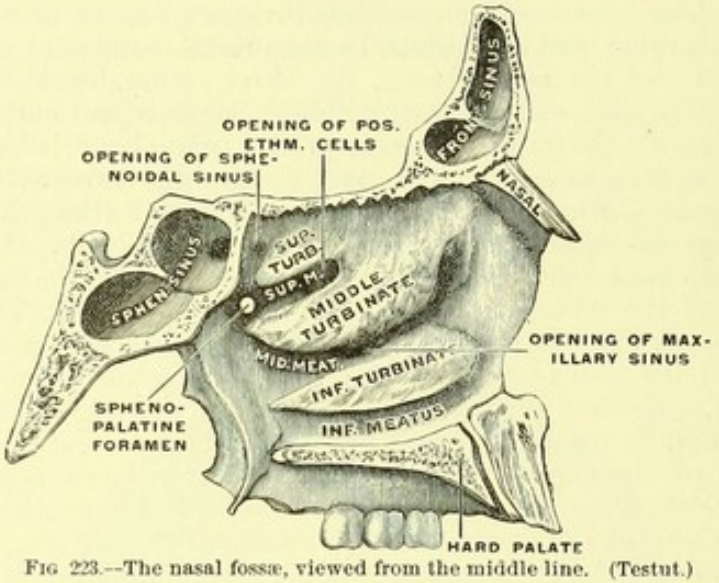

FIG 223.—The nasal fossæ, viewed from the middle line. (Testut.)

foramen, which connects it with the spheno-maxillary fossa. The *middle meatus*, between the inferior turbinate plate of the ethmoid and the inferior turbinate bone, is longer than the former. It opens both in front and behind, and into it open the maxillary sinus or antrum, and, by means of the infundibulum, the frontal sinus and the anterior ethmoidal cells. The *inferior meatus*, the longest and widest, also opens both in front and behind, and lies between the inferior turbinate bone and the floor of the nasal fossa. The nasal duct opens into it superiorly in front and connects it with the orbit. The nasal fossæ thus communicate by narrow passages with all the neighboring fossæ and air-sinuses. The latter are hollow spaces within the maxilla, sphenoid, ethmoid, and frontal, already described in connection with those bones. With the exception of the antrum, which exists during fœtal life, they originate during childhood, and all increase in size rapidly at puberty, and more slowly throughout adult life.

The Interior of the Cranium.

In a skull bisected horizontally or vertically notice the great proportionate size of the brain-cavity and the thickness and composition of its *walls* (Fig. 224). The latter consist of *an outer* and *an inner table* of compact bone and the intervening cancellous *diploë* ("fold"). The *inner table*, called the *vitreous table* from its hardness and brittleness, has a smooth, shining surface, marked with impressions for the convolutions of the brain and with grooves for blood-vessels. The skull-cap or *calvaria* averages one-fifth of an inch in thickness, but along certain ridges, and especially at the base, the thickness is much greater. Thinner areas exist in the cribriform plate of the ethmoid and the orbital plates of the frontal bone, where there is no diploë, and also in the lower occipital fossæ, the squamous portions and glenoid fossæ of the temporal bones.

The **calvaria** or **skull-cap** consists of a vaulted dome, formed by the frontal and parietal bones and the interparietal portion of the occipital bone. Its inner surface presents in the median line the *groove* for the *superior longitudinal sinus*, ending in front in the *frontal crest*, and behind at the *internal occipital protuberance*. On either side of the groove are varying numbers of *depressions for Pac-*

chionian bodies. This surface is marked by shallow cerebral impressions and grooves for meningeal vessels. The *parietal foramen*, for an emissary vein, is found, when present, at the side of the longitudinal sulcus near the postero-superior angle of the parietal bone.

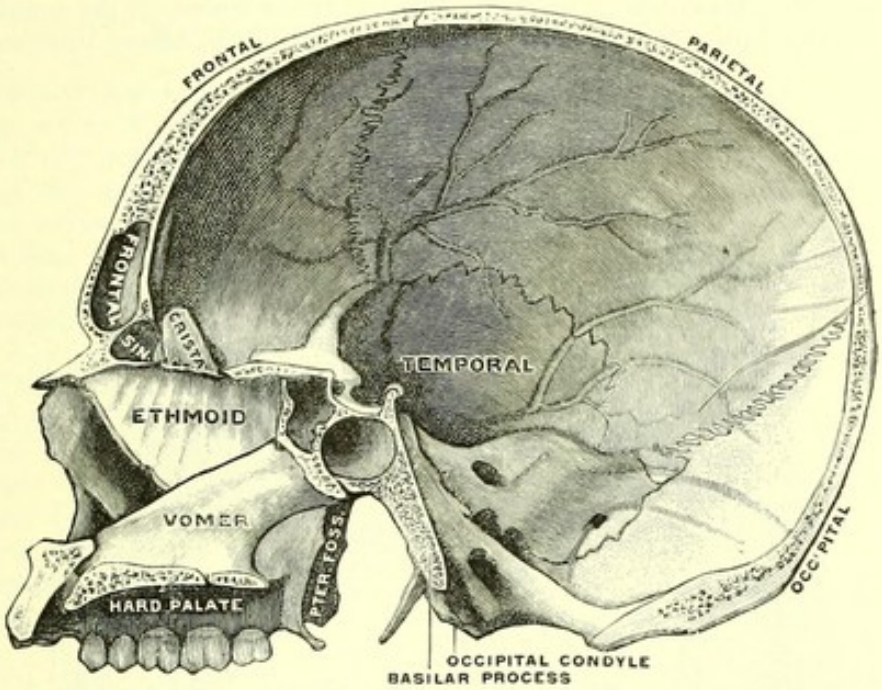

FIG. 224.—Sagittal section of skull, a little to the left of the middle line, the inner surface of the right half. (Testut.)

The **base or floor of the cranial cavity** (Fig. 225) presents three irregular fossæ, termed anterior, middle, and posterior.

The *anterior fossa*, on a higher level than the rest of the cranial floor, supports the frontal lobes of the cerebrum, and is formed by the orbital plates of the frontal bone, the cribriform plate of the ethmoid, and the small wings and part of the body of the sphenoid. Over the orbits it is convex, but mesially it is depressed into the olfactory grooves for the olfactory bulbs on either side of the crista galli. In front of the crista is the foramen cæcum. The floor of the olfactory grooves presents the numerous apertures of the cribriform plate for the olfactory nerves, mesially the slit-like foramen through which the nasal nerve passes into the nose, and laterally the internal openings of the anterior and posterior ethmoidal canals.

The *middle fossa*, on a lower level than the anterior, presents a central isthmus and two lateral depressed parts. The small median part, formed by the sella turcica and the olivary eminence, is limited behind by the dorsum sellæ, and in front by the anterior margin of the optic groove. It lodges the pituitary body and the optic commissure, and presents laterally the grooves for the carotid arteries from the foramina lacera media forward to the optic foramina. The lateral part on each side, limited behind by the superior border of the petrous portion of the temporal bone and in front by the free margin of the small wing of the sphenoid, is formed by the great wing of the sphenoid, the squamous portion, and the anterior surface of the petrous portion of the temporal. It lodges the temporal lobe of the cerebrum, and presents the following foramina from before backward: the *sphenoidal fissure* leading into the orbit; the *foramen rotundum*, leading into the spheno-maxillary fossa; the *foramen ovale* and the *foramen spinosum*, leading into the zygomatic fossa; the *foramen lacerum medium*, through which the carotid artery and plexus enter the cranial cavity; and the *hiatus Fallopii*. Grooves for the middle meningeal artery pass from the foramen spinosum outward, upward,

and backward on the great wing of the sphenoid, the squamous portion of the temporal, and the parietal bone.

The *posterior fossa*, the deepest and largest, lodges the cerebellum, medulla oblongata, and pons, and is formed by the occipital bone, the petrous and mastoid portions of the temporal, the postero-inferior angle of the parietal, and the body of the sphenoid. Its anterior limits are the posterior limits of the middle fossa, and its posterior limits the grooves for the lateral sinuses, whose limiting ridges

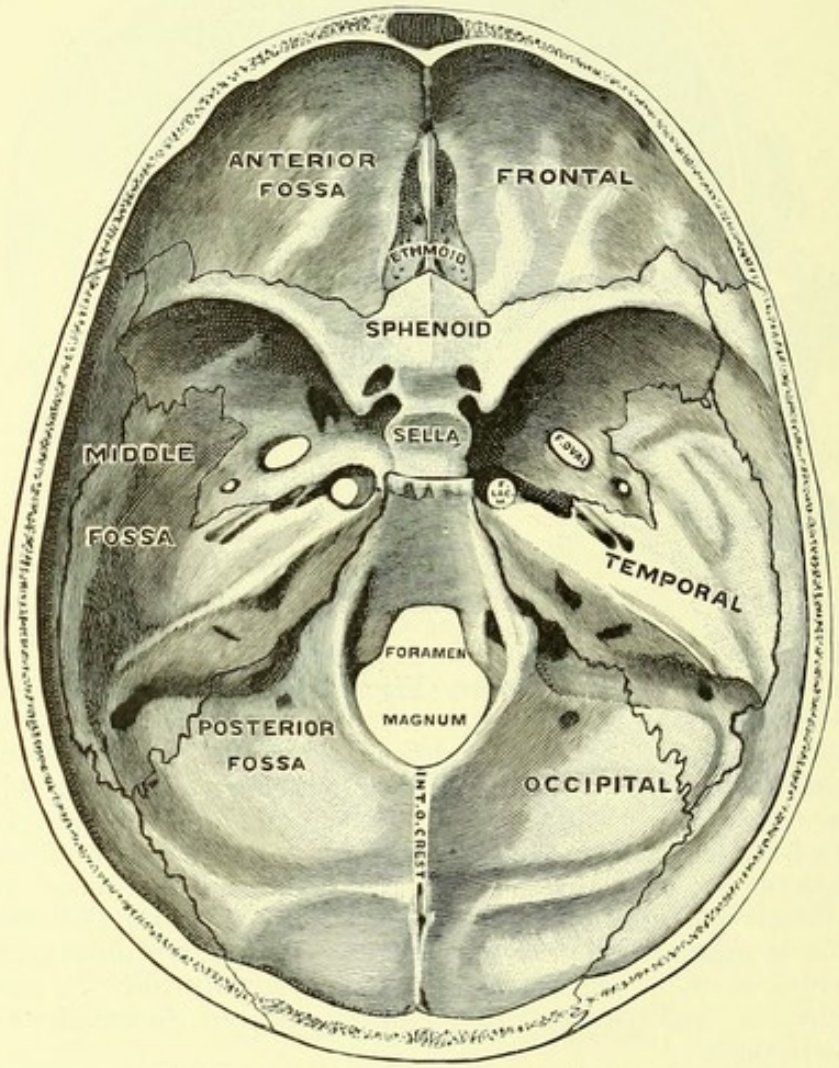

FIG. 225.—Base of the cranium, inner surface. (Testut.)

attach the tentorium cerebelli. The *foramen magnum* occupies the centre, and external to it from within outward are seen the *anterior condylar foramen*, the *jugular foramen*, and the *internal auditory meatus*. Behind the jugular foramen is the opening of the *posterior condylar foramen* when present, and more externally, in the sigmoid sulcus, is the more constant *mastoid foramen*. The grooves for the lateral sinuses pass outward from the internal occipital protuberance, usually cross the posterior inferior angle of the parietal bone, and thence bend sinuously down and in on the mastoid portion of the temporal bone, and onto the occipital bone, where they curve forward and end at the posterior division of the jugular foramina. The grooves for the inferior petrosal sinuses lie along the suture between the petrous portion of the temporal bone and the occipital, and end in the anterior division of the jugular foramina. The *jugular foramen* (foramen lacerum posterius) is usually unsymmetrical and of a somewhat pyriform shape. It is often divided into three compartments by two more or less marked con-

strictions. Through the largest and most posterior of these the lateral sinus passes into the internal jugular vein, and a small meningeal branch of the ascending pharyngeal artery ascends; the middle compartment transmits the glossopharyngeal, vagus, and spinal accessory nerves, and the anterior (sometimes completely separated) transmits the inferior petrosal sinus.

General Morphology of the Skull.

The cranial nerves pass through the skull in foramina occupying sutures or indicating points of union of two or more ossific centres. The foramen rotundum is the only exception to this rule in the skull, and this is probably a separated segment of the sphenoidal fissure. The division into primary foramina, or those where the nerves pass through the dura (or original brain-case), and secondary foramina, which are bony tunnels or canals not found in simpler skulls, though interesting, is not of sufficient importance for further description here. The remarkable constancy of the relation of the nerve foramina to the osseous elements has, with other facts, led to the conception of the vertebrate theory of the skull, which supposes that the skull is made up of a series of altered vertebræ, the neural arches of which have become greatly expanded to enclose the brain. Among the facts leading to this theory is the *apparent construction of the skull* in *three parts:* 1, the *central* or *basilar*, prolonging forward the vertebral axis around and beyond the end of the notochord in the *cranio-facial axis*[1]; 2, the *superior arches*, three[2] in number, enclosing the brain; 3, an equal number of *inferior arches*[3] surrounding the visceral cavity, as represented by the nose, mouth, and pharynx. But, although from analogy we may imagine that the primitive human skull was segmented like the vertebral axis, there is no evidence of this, and for a number of other reasons the division of the head into vertebral segments is untrustworthy and fanciful.

In the *development of the skull* three stages may be recognized: 1, the *membranous stage*, in which the brain is enclosed in a membrane representing the dura of the adult; 2, the *chondral stage*, in which the base and lower parts of the sides of the brain-case become cartilaginous, leaving the sides and roof membranous; 3, the *osseous stage*, in which both cartilage and membrane become ossified from a large number of ossific centres, which first appear in the membrane. Along the sides and in front sense-capsules become invaginated, and indent the skull-wall in the ears, eyes, and nose. Some of the bones of the skull are developed wholly, others partly, in the basal cartilage and its forward prolongation, the cartilaginous nasal capsule, or in the cartilaginous visceral arches; while some are developed wholly, others partly, in the membrane of the cranial vault, in that around the nasal capsule (forming the greater part of the upper face), and in that connected with the visceral arches.

The *human skull*, as compared with the skulls of lower vertebrates, is characterized by—1, its enormous brain-space and the corresponding expansion of the bones of the cranial vault; 2, the proportionally smaller development of the face, and especially of the jaws (bringing the face under the front of the cranium); 3, its being balanced and supported on the vertebral column (adapting it to the erect position) by a sudden bend in the vertebro-cranial axis, and a great posterior development of the cranium, bringing the occipito-vertebral articulation at the centre of gravity of the skull; 4, the downward opening of the nostrils and the diminished size of the nasal fossæ, bringing the orbits nearer together, so as

[1] This is drawn from the basion to the anterior extremity of the sphenoid, and thence to the end of the anterior nasal spine (subnasal point), forming an angle, the *cranio-facial angle*.

[2] These consist of—1, the squamosal part of the occipital bone; 2, the great wings of the sphenoid, the squamosals of the temporal bones, and the parietals; 3, the small wings of the sphenoid and the frontal bone.

[3] These include in the first arch the pterygoids, the palate, and the maxillary bones; in the second, the mandible, the spheno-mandibular ligament, and the malleus of the ear; in the third, the styloid process, the hyoid bone, and the stylo-hyoid ligaments, plus the incus, and perhaps part of the malleus of the ear.

to be nearly parallel internally and to look forward. The bones of the human skull are more completely consolidated, so that the total number is less than in the lower vertebrates. Thus the pre- and post-sphenoids, the interparietals, the squamosals, the styloids, the pterygoids, and the premaxillæ are often separate bones, and the frontal bone and mandible are frequently divided into two halves in vertebrate skulls.

The Various Forms of the Skull.

The *skull at birth* is characterized by the small size of the face and the very large size of the cranium, the smallness of the base, the prominence of the parietal and frontal eminences, the absence of the mastoid processes, the diploë, the suture serrations, the impressions, grooves, and ridges, and by the existence of the fontanelles. The temporal squama and the great wings of the sphenoid do not extend far upward, and the glenoid fossæ are quite flat and small.

Variations with Age.—The skull grows very rapidly during the first seven years. *During the first dentition* the fontanelles close, the face enlarges, the jaws lengthen, and the zygoma projects. *By the seventh year* some parts, such as the circumference of the foramen magnum, the petrous portion of the temporal bones, the body of the sphenoid, and the cribiform plate, have attained their definitive size, while other parts are quite immature. *Near the approach of puberty* a second period of active growth begins, and results in the elongation of the face, due to the increased height of the nasal fossæ, the expansion of the air-sinuses, the enlarged teeth of the second dentition, and the augmented height of the alveolar arches of the jaws. Ossification becomes completed, and the adult shape and size are attained. The capacity increases but little after thirteen years of age. *In later years* the muscular crests develop, the frontal region elongates, and the air-passages and cells expand, the latter process continuing in old age. *In old age* the skull undergoes atrophy, becoming thinner, lighter, and, often a little smaller by absorption on the outer surface. The air-cells expand as the capacity diminishes, and the face becomes smaller by absorption of the alveolar processes and the loss of the teeth, causing the upper jaw to retreat and the lower to project at the chin.

Sexual Variations.—The *male skull* is larger, heavier, and of greater capacity (11 : 10), especially in the frontal and occipital regions, than the female, and the ridges, occipital protuberance, mastoid processes, zygomatic arches, and frontal sinuses are more developed. The *female skull* preserves a look of immaturity in the smaller proportion of the face, the narrower and less prominent jaws, the prominence of the parietal eminences, and the smoothness of the surface.

Race differences, except among three or more large general classes, are often so slight, taking averages, as to require accurate and uniform cranial measurement or craniometry for their determination. Of the measurements the most important are the following, with the data of the average European skulls for each : (1) The *capacity*, 1450 c.c., affording a convenient indication of the development of the brain. (2) The *circumference*, 52 cm., taken in a plane passing behind through the *occipital point* (or the point of the occipital bone in the median plane farthest removed from the glabella), and in front through the *ophryon* (or the middle of the line drawn across the narrowest part of the forehead). (3) The *length*, 17 cm., from the ophryon to the occipital point. This is above the frontal sinus, and gives the length of the brain-case only, while the *maximum length* is between the glabella and the occipital point. (4) The *maximum breadth* is the greatest breadth between the parietals ; the breadth at the level of the zygomata is 12.5 cm. (5) The *height* from the basion to the bregma is nearly the same as the breadth. The *cranio-facial angle* is about 96°. For the ready comparison of race-measurements the breadth and height are reduced to indexes by comparison with the length as follows : $\frac{100 \times \text{breadth or height}}{\text{length}}$.

Furthermore, the shape of the transverse arch of the cranium, the fusion or complexity of the sutures, the degree of projection of the jaws (indicating an approach to, or a removal from, the animal type), the relation between the height and the width of the anterior nasal aperture (or nasal index), and of the base of the orbits (or orbital index), are subject to variation among different races. The *facial angle* (of Cloquet), which helps to determine the relative development of the face and the frontal part of the cranium, is that formed by two lines meeting in the median line at the alveolar border of the maxilla, and drawn, one from the most prominent median frontal point and the other from the middle of the external auditory meatus. Several other measurements for more accurate determination of the form of the cranium are in use, for which Broca's or other works on craniology should be consulted.

The *situation and direction of the foramen magnum* differ greatly in man and the lower animals, and to some extent among the different races of man. In quadrupeds it is placed dorsally and looks backward, in man at or near the centre of the base, and looks downward and slightly forward in the European, downward and slightly backward in the negro; while in the anthropoid apes it is intermediate in position and direction as compared with that in man and the quadrupeds.

The most frequent *irregularity of form* is want of symmetry, which is usually present to a slight degree. Asymmetry usually depends upon premature synostosis or closure of one or more sutures, preventing growth in a direction at right angles to the line of that suture, and tending to increase the growth in other directions. Artificial pressure applied in early life may also cause irregularity of form, as seen in the case of the Flat-headed Indians.

THE ARTICULATIONS.

By GEORGE WOOLSEY.

THE *articulations*, or *joints*, are the connections existing between contiguous parts of the recent human skeleton. Softer substances intervene between the ends of the bones, and a fibrous capsule, with or without accessory ligaments, binds them together.

The articular surfaces, or ends of the bones, which are expanded in the case of long bones, are coated by a layer of connective tissue, or hyaline, or white fibro-cartilage. When hyaline cartilage is present as *articular cartilage*, its free surfaces are very smooth, and thus minimize friction, and it serves to diminish jars by its elasticity. It is thickest where the pressure is the greatest. The white fibro-cartilage occurs as *connecting fibro-cartilage* in the discs between the vertebræ and in the symphysis pubis; as *interarticular fibro-cartilage* in the plates in the temporo-mandibular and sterno-clavicular joints, and in the menisci in the knee-joint; and as *marginal fibro-cartilage* in the shoulder and hip-joints, where it deepens the sockets. The interarticular fibro-cartilages partly or completely divide the joint into two halves; they adjust dissimilar bony surfaces, increase the motion and security, and act as buffers to break shocks. Connective tissue exists between contiguous bones of the skull as *suture membrane*.

The *ligaments*, which are the principal objects of study in this section, are strong, inextensible, but pliant bands of white fibrous tissue, continuous with the periosteum of the bones they unite. They occur in the shape of a more or less perfect *capsule*, usually reinforced where there is the most strain by external accessory bands or ligaments derived from intermuscular septa, modified tendons, or regressed muscles.

In joints moving on many axes the entire capsule and surrounding muscles are nearly uniformly strong; in those moving on one axis the lateral parts of the capsule are strengthened and designated as lateral ligaments. In some cases ligaments are formed of yellow elastic tissue, as the ligamenta subflava, where the parts united are not in contact.

The deep surface of the capsule is lined by the *synovial membrane*, which extends to, but not over, the articular cartilage. In the shape of folds or fringes it frequently projects into the joint-cavity, especially near the margin of the cartilage, where, often padded with fat, it fills up the interstices between the bones. This part of the membrane is highly vascular and liable to become villous and pedunculated, in which case it may cause pain by being pinched between the joint-surfaces. It secretes a thick, glairy fluid called *synovia*, which lubricates the joint. The synovial cavity sometimes communicates with bursæ and vaginal synovial membranes in the neighborhood of a joint.

Embryologically, a joint is formed from the tissue between the adjacent parts of the skeleton. This embryonic tissue may become the fibrous tissue of the suture membrane where the bones are developed in membrane, as in most of the bones of the skull; or it may become the thicker fibro-cartilage of the intervertebral discs, symphysis pubis, etc., where the bones are developed in cartilage. A partial synovial membrane may occur in this intervening cartilage. In more movable joints the synovial sac is more extensive, and the fibro-cartilage is inter-

articular, separating two synovial sacs, as in the sterno-clavicular joint, etc. These plates of fibro-cartilage may be perforated, or form merely a meniscus, attached to the inner surface of the capsule, as in the knee, or they may be wanting altogether, as in most of the more movable joints.

In accordance with these various differences, articulations are more or less movable. The classification of joints now employed is largely physiological, depending upon the degree and kind of motion, as follows:

Kinds of Joints.

A. **Synarthrosis** is the primary form of articulation, and includes those *immovable joints* (1) in which the contact of the adjacent surfaces is prevented only by a thin layer of fibrous tissue, continuous with the periosteum, as in many of the bones of the head; and (2) those where bone and cartilage are directly united, as in the case of the first rib and sternum, etc. Nearly all of this class are liable to bony union at different periods in advanced life, and in early life permit interstitial growth. In the skull these articulations are called *sutures*, of which we distinguish three varieties.

True sutures include *serrated and dentated sutures*, where the margins are interlocked, as in the sagittal and lambdoid sutures, respectively.

False sutures include *harmonic sutures*, where there is simple apposition, as between the two halves of the palate, and *squamous sutures*, where bevelled edges overlap one another, as in the squamo-parietal suture.

Grooved suture, or *schindylesis*, is where an edge of one bone fits into a groove in another, as in the case of the rostrum of the sphenoid and the vomer.

Synchondrosis is generally a temporary form of joint, where the thin layer of cartilage between the bones usually ossifies before adult life, as in the union between the epiphysis and shaft of long bones, and between the sphenoid and occipital bones.

B. **Amphiarthrosis** applies to joints which permit of slight movement, and include *symphysis*, where the opposed surfaces are united by a disc or plate of white fibro-cartilage, as between the bodies of the vertebræ or the pubic bones; and *syndesmosis*, where an interosseous ligament unites the surfaces, as in the lower tibio-fibular articulation.

C. **Diarthrosis** applies to the more perfect and movable joints containing synovial cavities. Except for the smooth cartilage-clad ends of the bones, these are lined by synovial membrane, secreting synovia, which serves for the lubrication of the joint. The bones are bound together by fibrous ligaments, forming more or less perfect capsules, which, tightened in some positions of the bones, relaxed in others, are often chiefly controllers of movement, while the surrounding muscles, aided by atmospheric pressure, hold the bones together. The following varieties are distinguished:

Arthrodia, or *gliding joints*, admit of but a limited amount of gliding motion, in one or more directions, between two nearly flat articular surfaces, as in the carpus and tarsus, and between the articular processes of the vertebræ.

Ginglymus, or *hinge-joints*, allow only movements of flexion and extension on one axis, between the cylindrical or trochlear convex and concave surfaces, as in the elbow and ankle.

Condyloid joints present spheroidal articular surfaces, which allow abduction, adduction, and circumduction, besides flexion and extension, as in the metacarpo- and metatarso-phalangeal articulations.

Saddle joints allow the same motions as condyloid. The surfaces are reciprocally saddle-shaped; hence they are sometimes called joints by *reciprocal reception*. The carpo-metacarpal joint of the thumb is an example.

Ball-and-socket joints (*enarthrosis*) permit movement in every direction between the spherical head and socket, as in the shoulder and hip. They are the most movable of joints.

Trochoides, diarthrosis rotatoria, lateral ginglymus, or *pivot joint* is a joint between a pivot and a ring, as in the radio-ulnar and atlanto-axial articulations, which allows only of rotation.

Kinds of Movement.

The various kinds of movement depend on the shape of the articulating surfaces, and are limited by the connecting ligaments and to a less extent by the surrounding soft parts. The different kinds of movement are often combined and merged into one another in one joint.

Rotation is the movement of a bone about some longitudinal axis, often its own axis, without much change of position.

Angular movement increases or decreases the angle between two bones. When this movement takes place around a transverse axis, it is called *flexion* and *extension*, according as the angle is increased or diminished. When it takes place toward or from the median plane of the body, the middle finger of the hand, or the second toe of the foot, it is called *adduction* and *abduction* respectively.

Circumduction is a combination of the four angular movements, so that the moving bone describes a cone-like figure, with the apex at the joint, the base at its distal end.

Gliding is the simplest form of movement, and consists of a simple sliding or displacement without marked angular or rotatory motion. It is common to all diarthrodial joints, and is the only movement between the plane surfaces of arthrodial joints.

Morphologically, many ligaments are formed by the metamorphosis or regression of muscles, due to loss of function, or by the migration of muscles, or by the degeneration of osseous and cartilaginous tissue. This is shown by a comparative study of vertebrate ligaments, muscles, and bones; and atavistic examples are occasionally met with in the human subject.

The ligaments are never strained by muscles tending to pull the bones apart, for, on the contrary, the action of the muscles braces the bones firmly together. Many long muscles passing over two or more joints co-ordinate their movements, and so economize power. Some long muscles act as elastic ligaments, often diffusing the movement produced by the short muscles over more than one joint. Two or more joints are sometimes combined, and thus acquire strength, security, and a variety of motions, as in the wrist and ankle.

THE ARTICULATIONS OF THE TRUNK AND HEAD.

1. The Articulations of the Vertebral Column.

There are two sets of articulations between the movable vertebræ—those between the bodies and those between the articular processes. These parts are connected together by ligaments; but *intermediate ligaments*, not connecting parts in contact, help to limit the movements of the spine and to complete the spinal canal.

The **articulations between the bodies of the vertebræ** (Figs. 226, 230) are *amphiarthrodial*. The following ligaments bind them together:

The *intervertebral discs* are tough, elastic, but compressible plates, which are placed between and firmly unite the vertebral bodies from the axis to the coccyx; but in the sacrum and coccyx they are ossified on the surface or throughout. They are firmly attached to the opposed surfaces of the bodies, these surfaces being covered by a thin layer of cartilage, except near their margins. Their shape and size are the same as those of the surfaces of the bodies they connect. They are thinnest between the second and third cervical (the weakest spot in the cervical column), and thickest and largest in the lumbar region. In the cervical and lumbar regions they are thicker in front than behind, and thus cause the

convexity forward in the former, and increase that in the latter, region. Those in the thoracic region are thicker behind, if anywhere, and so increase its curve. They form in the aggregate one-quarter of the length of the movable part of the vertebral column, which assumes a single curve, concave in front, the *curve of old age*, if the discs are removed or dried up. In structure the discs are made up of two parts. The *external* or *laminar portion* forms more than half the

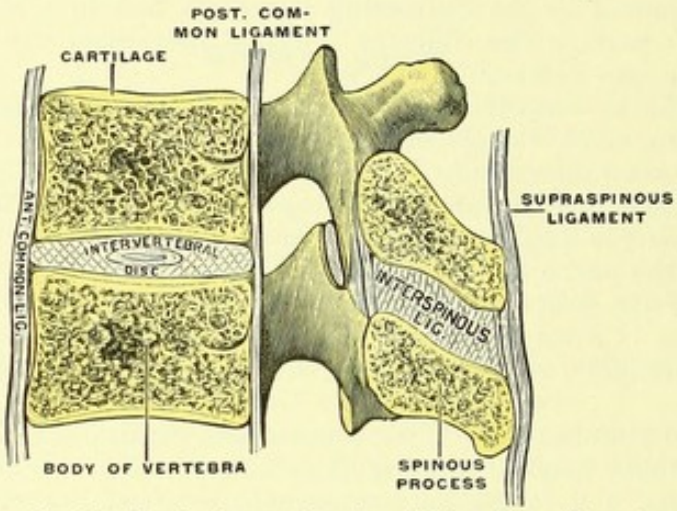

FIG. 226.—Two lumbar vertebræ in sagittal section. (Testut.)

mass, and consists of concentric layers of fibrous tissue with more and more cartilage-cells toward the centre. The fibres pass obliquely between the vertebræ and in the reversed direction in adjoining layers. Some layers are found only in front, making this part of the disc thicker, so that the *central* or *pulpy portion* is situated a little behind the centre. The latter is a yellowish elastic, ball-like mass, composed of a fine fibrous matrix, imbedded in which is a net-work of angular, branching cells, more numerous toward the centre. It is a remnant of the notochord. On section of the disc through the pulpy portion the latter bulges out above the rest, showing that it is compressed by the laminar portion, so that it forms, as it were, a ball or pivot upon which the vertebral bodies move. A synovial cavity is described by Luschka in each central pulpy portion. The intervertebral discs are surrounded on all sides by a sheath of fibrous ligaments, incomplete laterally where the thin and more or less scattered fibres reach from one bone to the next, and are sometimes called the *lateral* or *short vertebral ligaments.* The *anterior common ligament* is the strong band on the front of the bodies of the vertebræ. It extends from the under surface of the occipital bone, in the median line in front of the foramen magnum, to the front of the sacrum, reappearing below as the *anterior sacro-coccygeal ligament.* Above it is narrow and cord-like, and forms the thickened central portion of the *anterior occipito-atlantal* and of the *anterior atlanto-axial ligaments.* Below this it becomes broader as it descends. Of its fibres, which are dense, well-marked, and longitudinal, the superficial pass over several, the deep only between adjacent vertebræ. The fibres are attached to the intervertebral discs and to the edges of the vertebral bodies, and bridge over the median depressions of their ventral surface, thus rendering this surface more even. It limits extension.

The *posterior common ligament* extends along the dorsal surface of the bodies of the vertebræ within the spinal canal from the basilar groove of the occipital bone to the coccyx. Its upper end, often bilaminar, forms the *posterior occipito-axial ligament* between the axis and occipital bone. It is broad and even in the neck, extending completely across the vertebral bodies, narrower and dentated below. The broad dentations are at its attachment to the discs and margins of the vertebræ, and between them are the narrowed portions, separated from the backs of the bodies by venous plexuses. The superficial fibres extend over several

vertebræ, the deep over one or two. Its smooth, shining, dorsal surface is separated from the dura by loose connective tissue except at the foramen magnum. It limits flexion.

The **joints between the articular processes** are arthrodial or gliding joints. They are provided with synovial cavities, enclosed by capsular ligaments, which are loosest in the neck, strongest and tighter in the lumbar region, and tightest in the thoracic region. In the neck the inner part of the capsule is formed by the elastic tissue of the ligamenta subflava, which form more and more of the capsule in the thoracic and lumbar regions.

Intermediate Ligaments Uniting the Neural Arches.—The *ligamenta subflava*, composed of yellow fibrous tissue, connect the laminæ of adjacent vertebræ from the axis to the sacrum. In the upper two spaces they are continued, with less, or no, elastic tissue, under special names. Superiorly they are attached to the ventral surface of the laminæ, above their lower borders, and inferiorly to the upper borders and the adjacent parts of the dorsal surfaces. They become thicker and stronger below, and are best seen from in front. Laterally they are continuous with, and form part of, the capsular ligaments, reaching as far as the intervertebral foramina; mesially the lateral halves unite beneath the roots of the spines, from which point the *interspinous ligaments* extend back as membranous bands between the adjacent borders of the spines. These are best marked in the lumbar region, where the fibres extend from the root of one spine to the tip of the next above. In the cervical region they are replaced by the interspinales muscles. They extend dorsally to the *supraspinous ligaments*, which form a continuous cord along the tips of the spines from the spine of the seventh cervical vertebra to the coccyx, covering the lower end of the sacral canal. They consist of longitudinal fibres, of which the deep fibres connect the tips of adjacent spines, and the superficial pass over several. Above it is continued to the external occipital protuberance as the *ligamentum nuchæ* (Fig. 227), from which a thin median septum passes forward to be attached to the occipital crest and the cervical spines. In the lower animals the nape ligament is strong and elastic, and supports the head; in man it is of mixed white and yellow fibrous tissue in structure, and forms a median intermuscular septum of no great importance.

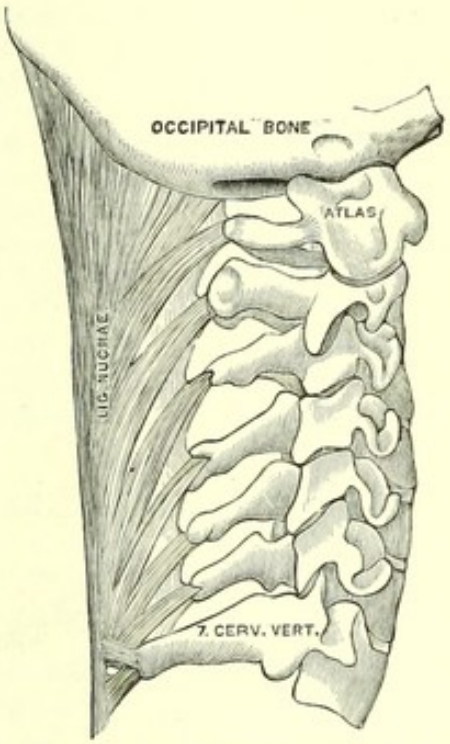

FIG. 227.—The ligamentum nuchæ, seen from the right side. (Henle.)

The *intertransverse ligaments* are unimportant and indistinct bands between the transverse processes. They are rounded and small in the thoracic region; they correspond to the ventral part of the superior costo-transverse ligaments in the lumbar region, and are wanting or replaced by the intertransversales muscles in the cervical region.

Movements.—The spinal column must combine strength with mobility, for, as the axis of the skeleton, it has to bear great weight and resist shocks. For this reason, and to avoid injury to the contained spinal cord, it is necessary that the movement between any two vertebræ should be slight, while that of the column, as a whole, is very considerable. *Motion* occurs *in all directions* around the pulpy portion of the discs as a centre, and is limited in part by the ligaments, in part by the articular processes, which thus steady the column. Motion is most free where the bodies are smallest or the intervertebral discs thickest. The former

condition is found in the cervical, the latter in the lumbar region, and these are the two most movable parts. The direction of motion in any region is regulated by the shape of the articular processes.

In the neck all movements are permitted by the obliquity of the articular processes. *Extension* is more free than elsewhere, and *flexion* is free, but less than in the lumbar region. *Lateral flexion* is more extensive than in any other region, but it is a combination with *rotation*, neither motion occurring freely by itself, except in the lower cervical region, where rotation is free. But little motion is allowed between the axis and the third cervical vertebra, owing to the thinness of the disc and the overlapping of the axis in front.

In the thoracic region extension is checked by the overlapping of the laminæ and spines, as well as by the shape of the articular processes. The latter also prevent *flexion*. As the articular processes lie in the arc of a circle of which the centre is in front between the bodies, *rotation* is permitted and is most free in the upper part. *Lateral flexion*, otherwise possible, is prevented by the ribs.

In the lumbar region, owing to the thickness of the discs (especially between the lower three vertebræ), *flexion* is very free, *extension* moderately so. The centre of the circle in which the articular processes lie is situated behind; but, owing to the fact that these processes do not fit closely together, a slight amount of *rotation* and some *lateral flexion* are permitted, the lateral motion being also limited by the great transverse diameter of the bodies.

Motion is therefore most free in regions whose curve is convex forward, whose spinal canal and the contained spinal cord are largest, and where there are no bony cavities containing viscera. The ligamenta subflava complete the spinal canal, prevent the capsular ligaments from being nipped between the articular surfaces during motion, and restore these surfaces to their normal position after movement. They have but little, if any, effect in limiting flexion or restoring the column to the erect position after flexion.

2. The Articulations and Ligaments Between the Atlas, Axis, and Occipital Bone.

The essential difference between these and the intervertebral articulations in general lies in the absence or modification of the intervertebral discs. The specialization of motion between these three bones results in some differences in the ligaments, though most of them are the continuation of the series found below.

A. **The Articulations between the Axis and the Atlas** (Figs. 228, 229).—There are here two sets of *synovial joints* or articulations:

1. The joints between the superior articular processes of the axis and the lateral masses of the atlas are *arthrodial*. Each is surrounded by a *capsular ligament*, strengthened at the inner and dorsal aspect by an *accessory ligament*, which passes from the back of the body of the axis upward and outward, along the outer edge of the occipito-axial ligament, to the lateral mass of the atlas behind the transverse ligament.

2. The articulations of the odontoid process in the ring between the ventral arch of the atlas in front and the transverse ligament behind are of the *trochoides* class. There are two *synovial sacs*—one in front, between the odontoid process and the atlas; the other and more extensive one behind, between the odontoid process and the transverse ligament. These two sacs are separated by transverse fibres, which pass from the sides of the odontoid process to the atlas, in front of the tubercles for the transverse ligament. The *transverse ligament* is a thick, dense, and very strong band, which passes across the ring of the atlas between the tubercles on the inner side of its lateral masses. It is arched slightly backward, flattened from before backward, and cartilage-clad in front as it passes behind the narrowed and faceted neck of the odontoid, which it holds in place, and by doing this preserves our lives. From and across the centre of its dorsal

aspect thin bundles of fibres pass upward and downward to the cranial aspect of the anterior border of the foramen magnum and to the dorsum of the body of the axis respectively. These with the transverse portion form a cross, hence the name *crucial ligament*, sometimes applied to the group. Two other ligaments unite the axis and atlas. The *anterior atlanto-axial ligament* is a thin membrane between the ventral arch of the atlas and the front of the body of the axis, rep-

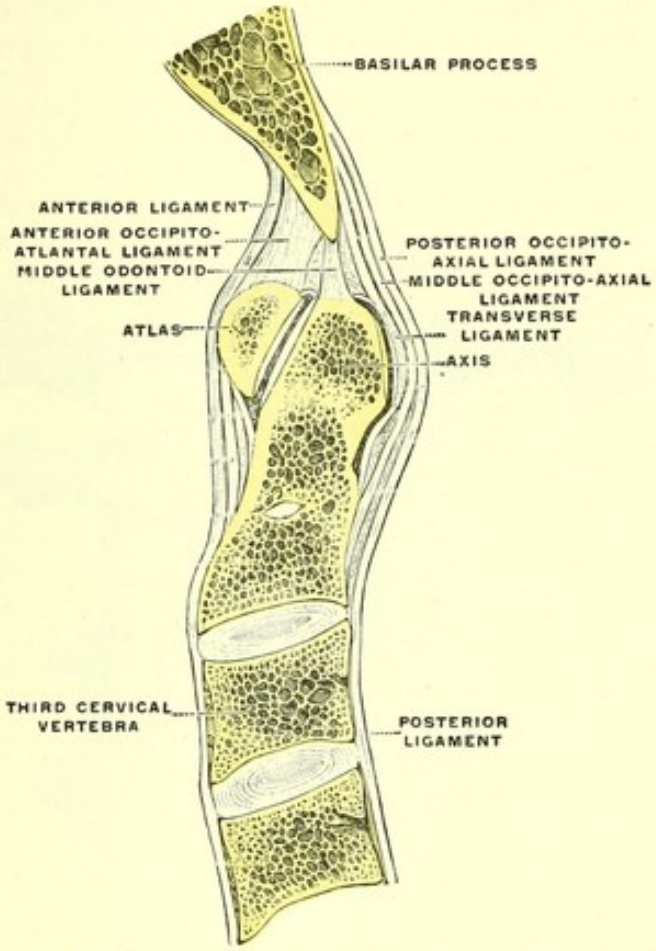

FIG. 228.—Sagittal section of the joints between the occipital bone and the atlas and axis. (Testut.)

resenting the anterior common ligament, whose direct upward continuation is seen as a median cord-like thickening of the ligament attached to the ventral tubercle of the atlas. The *posterior atlanto-axial ligament* represents the ligamenta subflava, but has little elastic tissue. It loosely connects the dorsal arch of the atlas and the laminæ of the axis, and is perforated on each side by the second cervical nerves.

B. **Ligaments between the Axis and the Occipital Bone** (Figs. 228, 229).—The *occipito-axial* or *occipito-cervical ligament* is the upper end of the posterior common ligament extending from the third and second cervical vertebræ to the basilar groove of the occipital bone. Some of its fibres pass over the axis without attachment, giving rise to two layers, of which the hind one may be designated the *posterior*, and the forward one the *middle*, *occipito-axial ligament*. The *lateral odontoid*, *alar*, or *check ligaments* are two strong fibrous cords, which extend from the sides of the summit of the odontoid process transversely outward to the rough impression on the inner side of each occipital condyle. They lie at a little higher level than the transverse ligament. Each is made tense by turning the head to the opposite side. The *middle odontoid* or *suspensory ligament* (anterior occipito-axial ligament) is a slender, median, fibrous band connecting the apex of the odontoid and the fore part of the margin of the foramen magnum. It is relaxed by flexion, tightened by extension.

The suspensory ligament is derived from the sheath of the notochord, between the first vertebral centrum and the basi-occipital, and is homologous with an intervertebral disc. The transverse and cheek ligaments are each derived from the *conjugal ligaments* (ligamentum conjugale costarum). These, in the embryo, connect the heads of each pair of ribs or costal processes around the back of the intervertebral discs, and persist as the interarticular ligaments of the heads of the ribs.

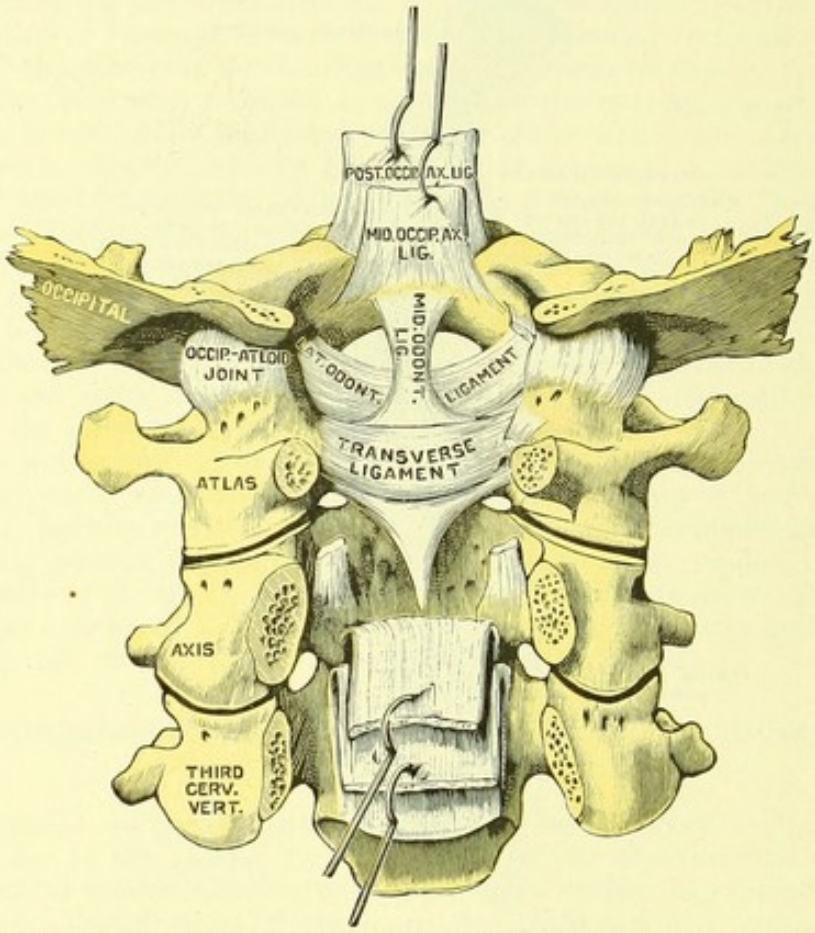

FIG. 229.—Articulations of the occipital bone with the upper cervical vertebræ. The arches have been removed, and the spinal canal is thus exposed. (Testut.)

Movements.—In the atlanto-axial articulation rotation of the head together with the atlas takes place around the odontoid process as a pivot for about 30° to either side in a nearly horizontal plane. It is limited by the check and atlanto-axoidean ligaments. As both facets in each lateral atlanto-axoidean articulation are convex, with the convexities in contact when the head looks forward, rotation causes the convexities of the atlantal facets to descend from those of the axis. This decreases the space and relaxes the ligaments between the bones, thus allowing further rotation, with security in all positions. Slight flexion and extension and some lateral flexion are also allowed between the atlas and the axis.

C. **The Articulations of the Atlas with the Occipital Bone.**—This consists of a symmetrical pair of condylar joints between the occipital condyles and the upper facets of the lateral masses of the atlas. Each joint is provided with a rather lax *capsular ligament*. In front and behind these the ventral and dorsal arches of the atlas are connected with the margins of the foramen magnum by the *anterior* and *posterior occipito-atlantal ligaments* respectively. The *anterior occipito-atlantal ligament* is thin and membranous, strengthened in front in the median line by a round *accessory ligament*, which is the upper end of the anterior common ligament. The *posterior occipito-atlantal ligament* represents the ligamentum subflavum, but is without elastic fibres, and is also thin and membranous.

This ligament does not limit motion between the bones. The dura is adherent to its ventral surface, and the dorsal surface lies in the floor of the suboccipital triangle. A band of fibres at the lateral margins of the ligament arches over the back of the vertebral groove on each side to the superior articular process, completing a foramen for the vertebral artery and the suboccipital nerve. The *lateral occipito-atlantal ligaments* are strong fibrous bands between the transverse processes of the atlas and the jugular processes of the occipital on each side, which strengthen the capsular ligaments externally, and lie behind the rectus capitis lateralis muscles.

Movements of *flexion* and *extension* are freely allowed. Extension is checked by the anterior occipito-atlantal, flexion by the occipito-axial and hind part of the capsular ligaments. Some *lateral gliding* is also allowed, by which the outer edge of the condyle on the one side is depressed, and on the other is elevated in relation to its socket. Or the movement may be *obliquely lateral*, one condyle advancing slightly at the same time that it is depressed toward the median line, while the opposite condyle takes the reverse position. This is the position of greatest stability, and is assumed in the most easy and natural attitudes. *Lateral movements* are restrained by the check ligaments and the lateral parts of the capsules. No true *rotation* is allowed.

The symmetrical and bilateral arrangement of these joints, combined with the median odontoid pivot, provides the strength and security which are necessary to life, and which are greater than are obtained in a ball-and-socket joint, with equal freedom of motion. A passageway for the cord is also provided, subject to less motion than in case the joint were of the ball-and-socket variety.

The ligaments passing over and between the odontoid process and the occiput by being lax in the erect position allow of flexion, which tightens them. The head balances upon the fore part of the condyles when the orbits look a little upward. By this arrangement, characteristic of the human figure, the head is held erect without undue muscular effort or a strong ligamentum nuchæ. If the muscles relax, the head will nod either forward or backward according as the centre of gravity is in front or behind the balance line.

3. **The Articulations of the Thorax.** (Figs. 230, 231.)

A. The **Costo-vertebral Articulations**, or those between the ribs and the vertebræ, are subdivided into *costo-central* and *costo-transverse articulations*.

(*a*) In the *costo-central articulation* the head of the rib is united to the body of a single vertebra in the case of the first, tenth, eleventh, and twelfth ribs, elsewhere to the bodies of two vertebræ and the intervening intervertebral disc. When the rib-head articulates with a single vertebra, there is a single *synovial sac*, otherwise two separate sacs, surrounded by a *capsular ligament*, which is composed of short fibres and is reinforced in front by the *anterior costo-central* or *stellate ligament*. This consists of pearly-white fibres, radiating from the front of the head of the rib upward to the body of the vertebra above, forward to the intervertebral disc, and downward to the body of its proper vertebra. In the case of the first, tenth, eleventh, and twelfth ribs the stellate arrangement of fibres is not quite as distinct. The *interarticular ligament* is a thin, transverse band of short, strong fibres between the intervertebral discs and the ridge separating the two facets on the head of the rib, excepting the first, tenth, eleventh, and twefth, where it is wanting. It separates the two synovial sacs, and is loose enough to allow of moderate rotation.

(*b*) The *costo-transverse articulation* is between the tubercle of each rib of the upper ten pairs and the front of the tip of the transverse process of the vertebra bearing the same number as the rib. Each joint has a thin, loose *capsular ligament*, enclosing a *synovial sac*, and strengthened on three sides by the costo-transverse ligaments. The *middle costo-transverse* or *interosseous ligament* consists of short horizontal fibres between the back of the neck of the rib and the front

of the corresponding transverse process, and extending from the capsule of the costo-central to that of the costo-transverse articulation. It is best seen in a transverse section, and is rudimentary in the case of the eleventh and twelfth ribs. The *posterior costo-transverse ligament* is a short strong band extending from the outer end of the transverse process outward and upward to the rough non-articular part of the tubercle of the corresponding rib. It is wanting to the eleventh and twelfth ribs. The *superior costo-transverse ligament* consists of a broad, flat, fibrous band between the upper border of the neck of each rib below the first, and the lower border of the transverse process next above it. Two layers are often distinguishable—the ventral, passing upward and outward, the dorsal and more scattered fibres passing upward and inward. Externally this ligament is continuous with the fascia lining the external intercostals; internally it is free and thickened; in front it is in relation with the intercostal vessels and nerves.

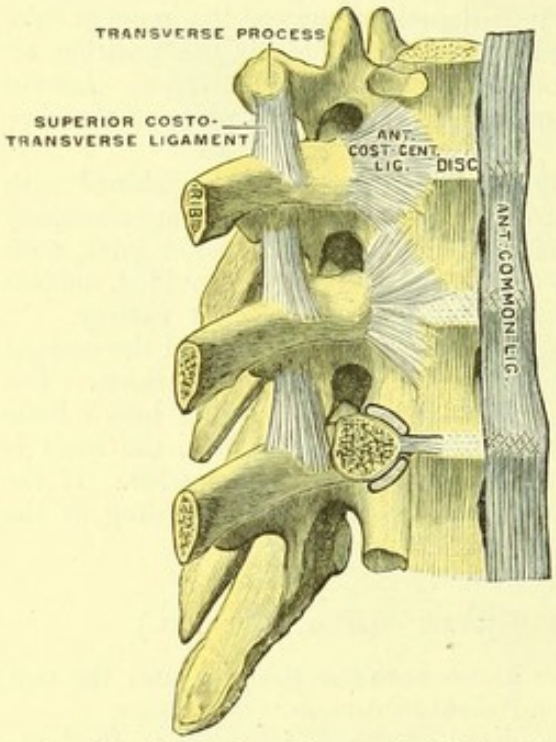

Fig. 230.—Articulation of the vertebral bodies with each other, and of the ribs with the spine. (Testut.)

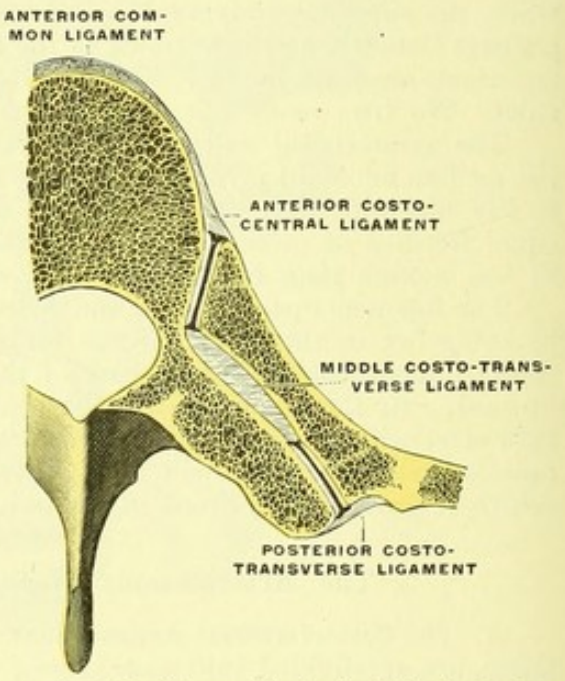

Fig. 231.—Costo-vertebral articulations in horizontal section: upper surface of lower segment, right side. (Testut.)

B. The **Costo-chondral Synarthroses.**—The costal cartilages are joined to the cup-shaped ends of the ribs by the continuity of the investing perichondrium and periosteum.

C. The **Chondro-sternal Articulations** are between the fossæ on the lateral borders of the sternum and the inner ends of the cartilages of the upper seven (the sternal) ribs. The *first rib* is joined by *synarthrosis* to the sternum. The others have *synovial joints*, generally single, but in the case of the second rib usually double on one or both sides. When the synovial sac is double, an *interarticular ligament* connects the ridge on the facet of the cartilage with the fibro-cartilage between the manubrium and body of the sternum. A similar ligament sometimes exists in the other joints. The synovial sac is frequently obliterated in the joints of the sixth and seventh cartilages. The chondro-sternal joints are surrounded by short *capsular ligaments*, most developed in front, above, and below, where they are called, respectively, *anterior*, *superior*, and *inferior chondro-sternal ligaments*. In the *anterior ligament* the fibres radiate from the front of the inner end of the cartilage to the front of the sternum, where they decussate with the opposite ligament and adjoin those above and below. The so-called *posterior chondro-sternal ligament* is little more than the continuity of periosteum and perichondrium

with a few accessory capsular fibres. The *chondro-xiphoid ligament* is a flat band connecting the front of the xiphoid cartilage with that of the seventh, and often of the sixth, costal cartilage.

D. The **Interchondral Articulations** are arthrodial joints between the cartilages from the sixth to the ninth (inclusive), situated a little in front of their upward bend, where blunt processes on the lower edges come in contact with the upper margins of the cartilages below. They have a complete *capsule* enclosing a *synovial sac*, and reinforced by oblique fibres from the anterior intercostal fascia.

E. **Sternal Articulations.**—The union of the manubrium and body of the sternum forms a symphysis in which the connecting fibro-cartilage may contain a partial synovial cavity with a layer of cartilage above and below. The fibres of the radiating chondro-sternal ligaments and the periosteum, reinforced by longitudinal fibres in front and behind, but especially behind, strengthen the union of these two parts. The xiphoid cartilage is similarly united synarthrodially to the lower end of the body of the sternum, at a level somewhat behind that of the ventral surface of the sternum. The chondro-xiphoid ligament is an accessory ligament of this joint. The connecting cartilage may ossify in old age.

Movements of the Ribs and of the Thorax as a Whole (Fig. 232).—In inspiration the thorax is enlarged in its three diameters, transverse, antero-posterior, and vertical. The increase in the vertical diameter is caused partly by the elevation of the upper ribs, and the resulting widening of the intercostal spaces, but is mainly due to the action of the diaphragm. The increase in the other two directions is due to the movements of the ribs, which are greatest where the ribs are longest, most oblique, and most curved at their angles (*i. e.*, at the sixth, seventh, and eighth ribs opposite the bulkiest part of the lungs), and least in the short flat first and second ribs.

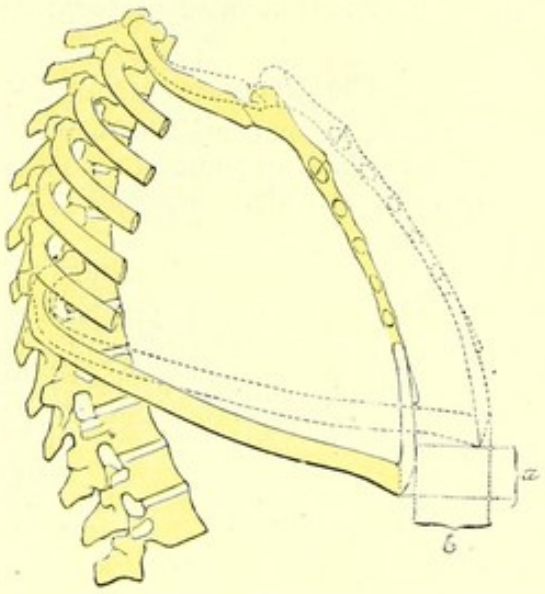

FIG. 232.—Diagram of the displacement of the ribs and sternum in inspiration: *a* indicates the degree of upward movement; *b*, that of forward movement. (Testut.)

As the ribs articulate with the vertebræ by two series of closely approximated joints, the axis of *rotation*, which is the chief movement here, must pass through both joints—*i. e.*, obliquely outward, backward, and somewhat downward. When the *upward rotation of inspiration* occurs, the ventral ends of the ribs, which are inclined obliquely downward, are elevated. By thus decreasing the obliquity of the ribs the front wall of the thorax is carried upward and forward, and its cavity is enlarged sagittally. The ventral ends of the ribs cannot be elevated without straightening out the angles with the costal cartilage, which throws this end of the ribs outward, increasing the transverse diameter in front. The return of the costal cartilages to the natural angle after inspiration is a principal factor in the resiliency of the thorax, to which quiet expiration is due. As the *axis of rotation* is *oblique*, upward rotation also elevates the lateral part of the ribs and everts their lower borders, thus increasing the transverse diameter behind. In the first ribs the axis is more nearly transverse; hence their motion is mostly a slight elevation and depression of their fore parts. But as the obliquity of the axis increases from above downward, the outward movement becomes more extensive in the lower ribs. Owing to the plane and sloping articular surfaces on the transverse processes of the vertebræ, from the seventh to the tenth only, there is, besides rotation, a slight backward and upward motion in inspiration and

the opposite in expiration, which is still more marked in the eleventh and twelfth ribs, where there are no costo-transverse articulations. In the upper six ribs, where the facets on the transverse processes are situated lower and are more concave as we ascend, there is rotation only. In the case of the eleventh and twelfth ribs there is little elevation, and the twelfth rib may even be drawn downward in inspiration by the quadratus lumborum. The widening of the lower part of the thorax in inspiration increases the power of the diaphragm and counteracts the compression of the abdominal viscera. The costo-vertebral articulations with their ceaseless movement are remarkable for their freedom from disease.

At the chondro-sternal articulations, except the first, there is a slight hinge-motion on two axes, sagittal and obliquely vertical. Owing to these two movements the sternum is carried neither so far forward nor upward as the anterior ends of the ribs and cartilages. Otherwise its motion would be detrimental to the heart, etc. behind. In the interchondral joints only a limited gliding is allowed, and the sternal articulations merely increase the elasticity and strength of the sternum.

The hinge-motion, often wrongly ascribed to the ribs at the costo-central joints, can only occur with a sliding motion at the costo-transverse articulation. Although this may occur in the lower ribs, it cannot in the upper, owing to the rounded concavities in the transverse processes. Slight rotation on a single axis, as above indicated, accounts for all the motions ascribed to the ribs.

4. **The Temporo-mandibular Articulation** (Figs. 233-235).

This articulation consists of a pair of symmetrically placed *ginglymo-arthrodial* joints. Their dissimilar articular surfaces, the ventral halves of the glenoid fossæ, and the articular eminences of the squamous portions of the temporal bones

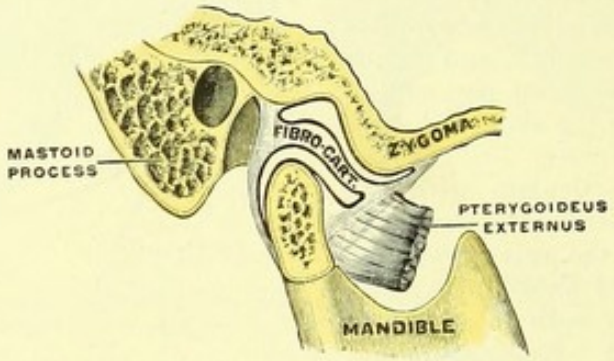

FIG. 233.—Temporo-mandibular articulation in sagittal section. (Testut.)

above and the condyles of the mandible below, are adjusted together by the interposed interarticular cartilages. It is best seen when the jaw is divided in front of the ramus, and the latter is freed of its attachments.

The bones are united by a thin loose *capsular ligament* attached outside of the articular surfaces on the two bones. The *external lateral ligament* consists of those accessory fibres, strengthening the capsule, which pass from the lower border and tubercle of the zygoma downward and backward to the outer side and back of the neck of the condyle. This ligament on one side serves as the internal ligament of the opposite side. The inner part of the capsule, sometimes called the short internal lateral ligament, does not deserve the name.

The *interarticular cartilage* is a thin, oval plate of fibro-cartilage, concavo-convex from before backward on its upper aspect to fit the temporal surface, and concave below to receive the condyle of the lower jaw. It is thickest behind, and thinnest at the centre, where it is sometimes perforated. By the close attachment of its circumference to the capsule the joint is divided into *two synovial cavities*, of which the upper is the larger and looser, and the lower extends lower

down behind than in front. The two sacs communicate when the cartilage is perforated. Some fibres of the external pterygoid muscle are inserted into the cartilage in front.

The *accessory ligaments* are—(1) the *spheno-mandibular* or *long internal lateral ligament*, a thin band some little distance from the joint, extending from the

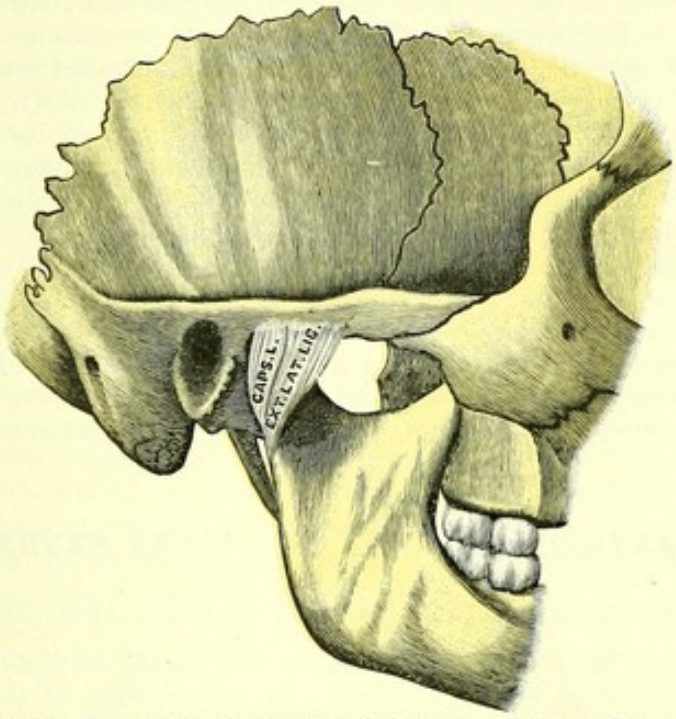

FIG. 234.—Temporo-mandibular articulation, external view. (Testut.)

spine of the sphenoid downward and a little forward to the lingula of the mandible. Separating it from the joint and the ramus are the external pterygoid muscle, the internal maxillary vessels, the inferior dental nerve and vessels, the auriculo-temporal nerve, and the middle meningeal artery. It represents the fibrous remains of a part of Meckel's cartilage. (2) The *stylo-mandibular ligament* is a specialized band of the deep cervical fascia extending from near the tip of the styloid process to the angle and the hind border of the ramus of the jaw, between the masseter and internal pterygoid muscles. It separates the submaxillary from the parotid gland.

The *movements* in this joint are—(1) the *hinge-motions* of *elevation* and *depression*, and (2) the *gliding motions* of *protrusion* and *retraction*, both (*a*) simple and (*b*) oblique or grinding. The movements in the two synovial compartments are of different kinds. In the upper there is a protrusion and a retraction, or a forward and backward gliding, of the cartilage together with the condyle on the temporal bone, due to the closer connection of the cartilage with the condyle than with the temporal bone, and to the insertion of the external pterygoid or protrusor muscle into both cartilage and condyle. In the lower part there is a hinge-motion, on a transverse axis, between the condyle and the cartilage.

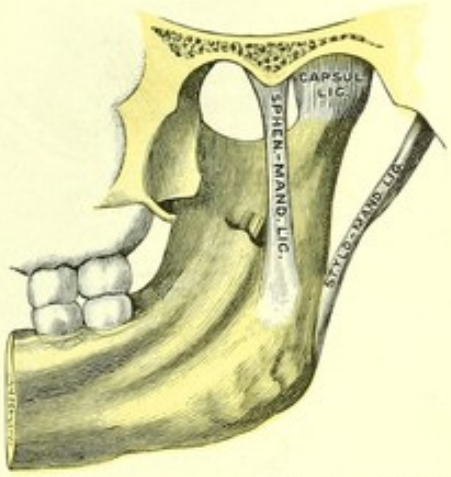

FIG. 235.—Temporo-mandibular articulation, mesial view. (Testut.)

In opening the mouth the (1) hinge and (2*a*) simple gliding motions are combined. When the mouth is opened but slightly (as in talking) there is simply a

hinge-motion in the lower compartment. When, however, the mouth is opened more and more widely, besides an increased hinge-motion, the cartilage and condyle glide forward onto the articular eminence. The condyle does not normally reach the summit of the eminence, but when, as in a convulsive yawn, it glides over the summit, it slips into the zygomatic fossa, and there is a dislocation with rupture of the back of the capsule. As the cartilage and condyle glide forward the external lateral ligament remains always tense on account (1) of the downward movement onto the eminence, and (2) of the increased hinge-motion which the ligament allows when its obliquity is straightened by the forward movement of the condyle. The point of least motion, or the axis of motion, in the combined movement is approximately at the inferior dental foramen, and thus stretching of the nerve is avoided. The combination of hinge and gliding motion gives a tearing as well as a cutting action to the incisors.

(2*a*) There may be a *simple protrusion and retraction* of the lower jaw by a gliding motion in the upper compartment. A slight lowering of the rami occurs as the cartilages and condyles pass downward and forward onto the eminences. (2*b*) An *obliquely horizontal* or *rotary grinding* motion is caused by the alternate gliding forward and inward on one side, and backward and inward on the other.

The *nerves* supplying the joint are branches of the masseteric and auriculotemporal.

THE ARTICULATIONS OF THE UPPER EXTREMITY.

1. The Sterno-clavicular Articulation. (Fig. 236.)

The arthrodial joint between the inner end of the clavicle and the superior angle of the manubrium sterni, together with the cartilage of the first rib, is the only point of attachment of the skeleton of the shoulder-girdle and upper limb to that of the trunk. The dissimilar articular surfaces are harmonized by the intervening *fibro-cartilage*, and are connected together by a fairly tight *capsular ligament*, whose fibres pass obliquely upward and outward from the circumference of the sternal to that of the clavicular facet. This capsule is strongest behind and in front, where it is called respectively the *posterior* and *anterior sterno-clavicular ligaments*. Above it is supplemented and strengthened by the dense *inter-*

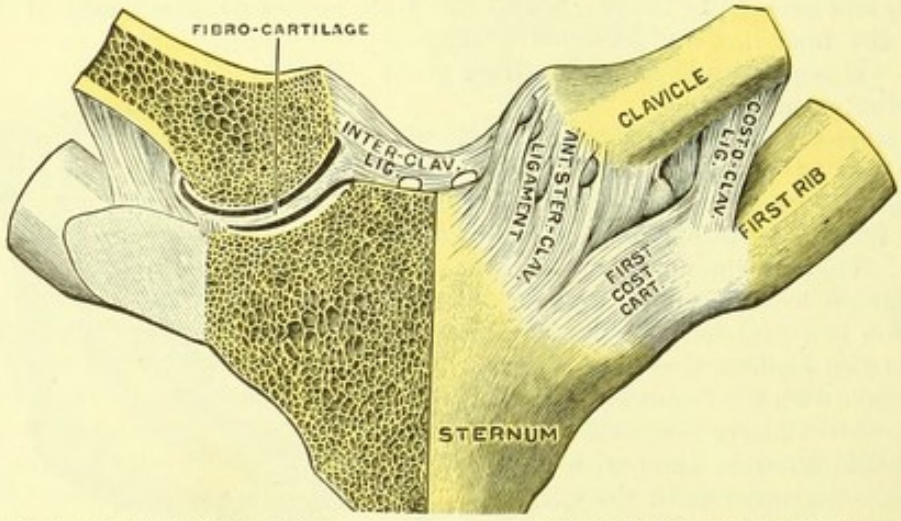

FIG. 236.—Sterno-costo-clavicular articulation, front view. The right half is seen in coronal section. (Testut.)

clavicular ligament which passes between the upper and back parts of the sternal ends of the two clavicles and their capsular ligaments, and dips down in the middle to be attached to the hind border of the interclavicular notch of the sternum. Below, where the capsule is thinnest, is the strong, dense, accessory band,

the *costo-clavicular* or *rhomboid ligament*. This is directed obliquely upward, outward, and backward from the front and upper aspect of the first costal cartilage to the rhomboid impression on the under surface of the inner end of the clavicle.

The *interarticular fibro-cartilage* is a flattened disc of about the same shape and size as the inner articular surface of the clavicle. It is thinnest at the centre and below, thickest above. It is attached above to the upper and dorsal border of the articular surface of the clavicle and below to the inner end of the cartilage of the first rib. By the attachment of its circumference to the inner surface of the capsule the joint is divided into two *synovial cavities*, of which the outer is the looser, and is continued a short distance beneath the clavicle on the first costal cartilage. The two occasionally communicate through a perforation in the centre of the fibro-cartilage.

The fibro-cartilages and interclavicular ligament together represent the episternal bone of lizards.

Movements.—The clavicle carrying the scapula, to which the coraco-clavicular ligaments closely bind it, may move on its inner end as a centre in an upward and downward direction on a sagittal axis; in a forward and backward direction on a vertical axis; or, by a combination of these, a circumductory motion may be obtained, in which the clavicle describes a cone of which the base is at its outer end. A slight rotation of the clavicle on its long axis is also permitted by which its ventral surface is turned upward as the arm is raised, and *vice versâ*.

The fibro-cartilage serves as an elastic buffer to break shocks and resist pressure from the shoulder, as well as to connect the bones and prevent inward displacement. The interclavicular and rhomboid ligaments are safeguards against upward displacement of the inner end of the clavicle in depression and elevation of the arm, and the rhomboid ligament also resists backward displacement. When one clavicle is much depressed the interclavicular ligament draws the other one up—a fact to be remembered in fracture of the bone. In forced depression of the clavicle it presses on the first rib, which acts as a fulcrum, so that the inner end is raised and its ligaments are put on the stretch.

2. The Scapulo-clavicular Articulation.

The **acromio-clavicular joint** is an arthrodial articulation between the bevelled outer end of the clavicle and the inner margin of the acromion process, in which the bones are held together by a somewhat lax capsule, which allows some play between the surfaces. The capsule, whose fibres pass from the acromion inward and backward, is especially strong above, forming the *superior acromio-clavicular ligament*, and is here also strengthened by the fascia of the trapezius and deltoid. The inferior part, *inferior ligament*, is weak, as is also the posterior. The *synovial cavity* is sometimes partially, rarely completely, divided into two by a small wedge-shaped *interarticular fibro-cartilage*, attached by its base to the superior ligament, and usually occupying the upper part of the joint only.

The **coraco-clavicular ligament**, which binds the clavicle to the coracoid process of the scapula, is the strongest connection between the clavicle and scapula, and consists of two parts: (1) The *conoid ligament*, the dorsal and internal fasciculus, is a strong triangular band attached by its apex to the inner and hind part of the root of the coracoid process, from which its fibres spread upward, backward, and outward to and about the conoid tubercle of the clavicle. (2) The *trapezoid ligament* is the flat, quadrilateral, outer and fore part, whose fibres slope upward, backward, and outward from the upper surface of the dorsal half of the coracoid process to the trapezoid ridge on the under surface of the clavicle. A small bursa often exists between these two ligaments.

Movements in the acromio-clavicular joint may take place on a *vertical axis* by which the glenoid cavity is turned farther backward or forward, thus enabling it

to keep its relative position in forward or backward movement, respectively, of the shoulder-girdle. Or movement may take place on a *horizontal axis*, by which the glenoid cavity is turned farther upward or downward, as when the arm is raised or lowered. This motion, combined with elevation and depression of the clavicle, is spoken of as *rotation of the scapula* on a dorso-ventral axis passing through its centre or its upper angle. The movements at the acromio-clavicular joint, modifying the relation of the scapula to the clavicle, rarely take place by themselves, but only in connection with the movements of the sterno-clavicular joint. In the combined movements of the clavicle and scapula the movements of the scapula are restricted by the shape of the chest-wall on which it lies, so that its principal movements are upward and forward, and downward and backward. In the above movements the vertebral border and the lower angle of the scapula are generally kept in contact with the thorax by the muscles attached—a condition allowed only by the acromio-clavicular joint. The conoid ligament suspends the scapula from the clavicle; the trapezoid is tightened when the shoulder is pressed inward.

The **Ligaments of the Scapula** (Fig. 237).—The *coraco-acromial ligament* is a flat, triangular band attached by its broad base to the outer border of the coracoid process and by its blunt apex to the tip of the acromion. Binding together the acromion and coracoid processes, it forms an arch over the shoulder-joint which holds off the deltoid, and supports and protects the joint. Its ventral and dorsal margins are thick aad strong, leaving a thin membranous part between, with often a gap near the coracoid process. The deltoid covers its upper surface, which also looks a little forward; its lower surface is separated by a bursa from the capsule of the shoulder-joint. From its outer edge, which projects over the centre of the head of the humerus, a thin, tough fascia is continued under the deltoid and over the subacromial bursa and the shoulder-joint. The *transverse, coraco-scapular* or *suprascapular ligament*, continuing the upper border of the scapula, bridges across the suprascapular notch, converting it into a foramen, through which the suprascapular nerve passes, while the corresponding artery commonly passes above it. It is thin and flat, and is sometimes replaced by bone. The *spino-glenoid ligament* comprises a few lax fibres which, by passing between the outer border of the spine and the margin of the glenoid cavity, bridge over the suprascapular vessels and nerves in passing between the supra- and infraspinous fossæ.

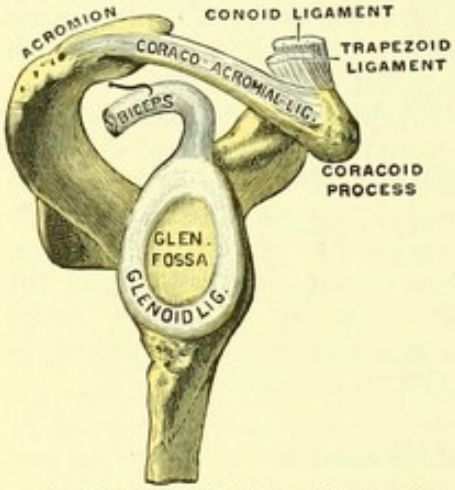

Fig. 237.—Glenoid fossa of right side. (Testut.)

3. The Shoulder-joint. (Figs. 238–240.)

This ball-and-socket joint, between the large humeral head and the smaller, shallow glenoid cavity of the scapula, is one of the most perfect and most movable of joints. The surrounding muscles give strength and security to the joint, and, together with atmospheric pressure, hold the bones in position much more than do the ligaments. The glenoid fossa is deepened by the *glenoid ligament*, triangular on section with the base attached around the margin of the fossa. It is composed of fibro-cartilage with scattered cartilage-cells. To its upper end is attached the long tendon of the biceps, which, dividing, is continued into both sides. Outside of this ligament the *capsular ligament* is attached to the scapula around the glenoid margin, sometimes reaching as far as half an inch from it in front. From this attachment it passes to the anatomical neck of the humerus. At the lower and inner part of the latter it is attached some distance from the

articular surface, and in front, between the tuberosities, it covers over and is attached to the transverse ligament, thus giving passage to the long tendon of the biceps. The capsule is composed of longitudinal fibres, with some oblique and circular fibres interwoven, and is strongest on its superior aspect. It is so lax

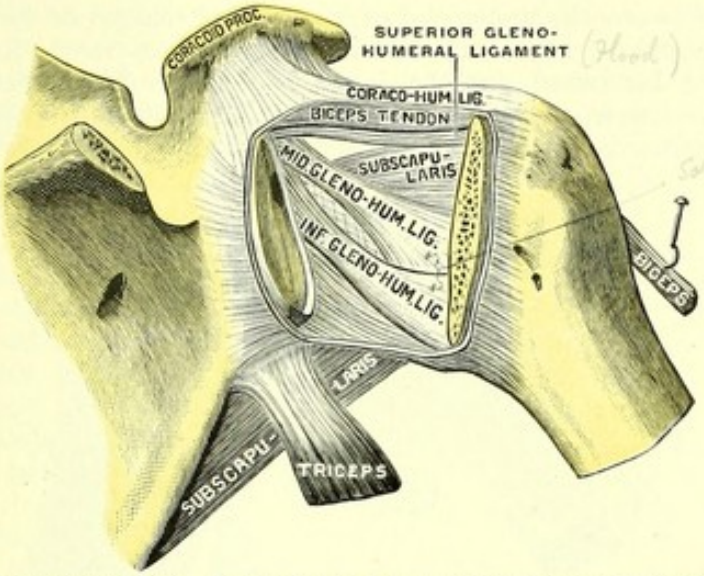

FIG. 238.—Shoulder-joint, rear view. The hind part of the capsular ligament and most of the head of the humerus have been removed. (Testut.)

that alone it does not keep the bones in contact. Above and behind the tendons of the supraspinatus, infraspinatus, and teres minor, in front that of the subscapularis and below the long head of the triceps are intimately connected with and strengthen the capsule. Between the subscapularis and triceps tendons is an

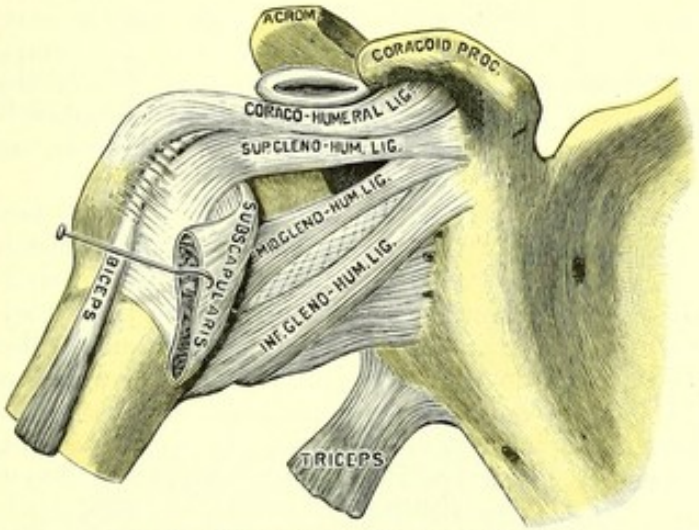

FIG. 239.—Shoulder-joint, front view. (Testut.)

unprotected and weak part of the capsule, usually torn by the passage of the head in dislocations, to which the shoulder is very liable, owing in part to the looseness of its capsule. Besides the overlying tendons the capsule has two sets of accessory folds.

(1) The *coraco-humeral ligament* extends as a strong, broad band from the outer border and root of the coracoid process, beneath the coraco-acromial ligament, obliquely over the joint to the anatomical neck of the humerus above the great tuberosity, being intimately connected with the capsule. Seen from in front, it appears as a fan-shaped process lying over and above the capsule, with which it

appears continuous as viewed from behind. This ligament represents a detached part of the pectoralis minor tendon. (2) The *gleno-humeral bands*, three in number, extend between the ventral margin of the glenoid fossa and the neck of the humerus. They are seen projecting on the interior of the inner and fore part of the capsule when the joint is opened from behind. The *superior gleno-humeral band* extends between the upper end of the ventral margin of the glenoid cavity and the upper end of the small tuberosity of the humerus, forming a slight groove, directed backward, for the inner edge of the biceps tendon. It may occasionally be quite free from the capsule, and it lies above the opening by which the bursa beneath the scubscapularis tendon communicates with the synovial

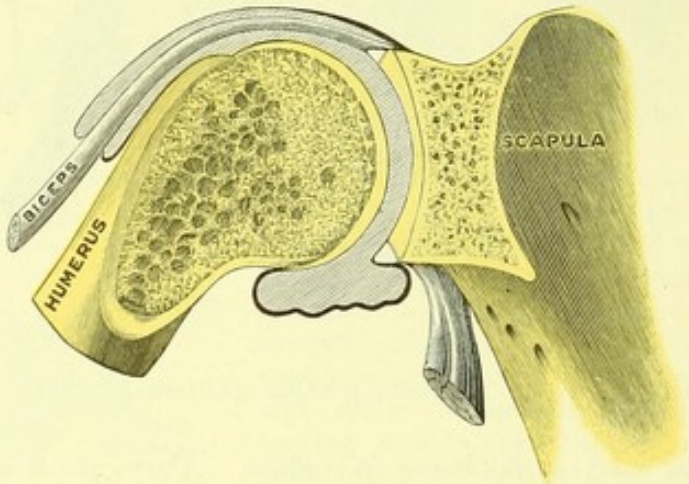

FIG. 240.—Shoulder-joint in coronal section, front view. The synovial sac is distended. (Testut.)

cavity of the joint. The *middle gleno-humeral band* lies below this opening, along the lower border of the subscapularis, arises from the glenoid margin with the superior band, and is attached to the inner side of the small tuberosity of the humerus. The *inferior gleno-humeral band* is the strongest, and passes between the middle part of the ventral border of the glenoid rim and the lower part of the neck of the humerus. The superior gleno-humeral band represents the divorced tendon of the subclavius muscle as seen in birds, and corresponds to the ligamentum teres in the hip.

The *transverse ligament*, by its fibres passing transversely between the tuberosities, forms a canal of that part of the bicipital groove which belongs to the epiphysis. The capsular ligament is attached to it superficially.

The *synovial membrane* lines both free surfaces of the glenoid ligament, and is thence reflected over the inner surface of the capsule to the humeral neck, where in front it passes down the bicipital canal for a distance, and there is reflected onto the biceps tendon, which it sheathes, as it passes through the joint, as far its attachment to the glenoid ligament. Between the superior and middle gleno-humeral bands there is usually an opening where the synovial membrane is continuous with that lining the bursa beneath the subscapularis tendon. It occasionally communicates with a bursa beneath the infraspinatus muscle.

The articular cartilage is thicker near the centre of the head on the humerus and at the margins of the glenoid fossa, thus deepening it.

Nerves from the suprascapular, circumflex, and subscapular supply the joint.

Movements.—Flexion and extension, abduction and adduction, circumduction and rotation are allowed to a degree determined by the extent of the humeral articular surface, the length of the capsule, and the resistance of the overlying parts. Flexion and extension, or the movements forward and slightly inward, and backward and slightly outward, take place on an axis corresponding to that of the head and neck of the humerus, which is nearly perpendicular to the centre of the glenoid cavity. Flexion is much more free than extension, and between

the extremes of both there is about 90° of motion. In abduction and adduction the arm moves away from or toward the body, respectively, on a horizontal axis at right angles with that last named, and parallel to the surface of the glenoid fossa. Rotation occurs in an outward (or backward) and in an inward (or forward) direction on an axis drawn from the centre of the head to the inner condyle of the humerus, and over a range of between 90° and 100°. In extreme abduction (*i. e.*, to about 90°) or extension the great tuberosity strikes against the coraco-acromial ligament and the acromion process, and further motion is thus limited. In extreme abduction the lower part of the capsule is tense. In outward rotation the coraco-humeral ligament is made tense, and in both inward and outward rotation the upper part of the capsule is tightened by twisting. Otherwise, the muscles rather than the ligaments restrain the movements. The great freedom of motion at the shoulder, by which the arm can be raised so as to be nearly vertical, is in part due to the movement of the scapula, which always accompanies movements at the shoulder-joint. Both abduction and flexion over 90° are due to rotation of the scapula, by which the glenoid cavity is turned outward and upward, or forward and upward. In dislocation the coraco-humeral ligament is thought to be important in determining the position of the dislocated limb and the manipulation for its reduction.

The *subacromial bursa* lies between the joint-capsule, with its attached tendons, and the arch formed by the coracoid and acromion processes and the coraco-acromial ligament, and it also extends beneath the deltoid muscle. It facilitates the movements of the upper end of the humerus. The coraco-acromial arch forms a sort of secondary socket, against which the head and tuberosities of the humerus are pressed when the weight of the body is supported by the arms.

The *biceps* tendon acts as a ligament of the joint, preventing the humerus from being pulled up forcibly against the acromion, and keeping the head in the glenoid socket, especially when the arm is away from the side of the body and is pulled down by the pectoralis major and latissimus dorsi muscles.

4. **The Elbow-joint** (Figs. 241–243).

This is a true hinge-joint between the trochlear surface of the humerus and the great sigmoid cavity of the ulna. It is broadened, and thereby secured against

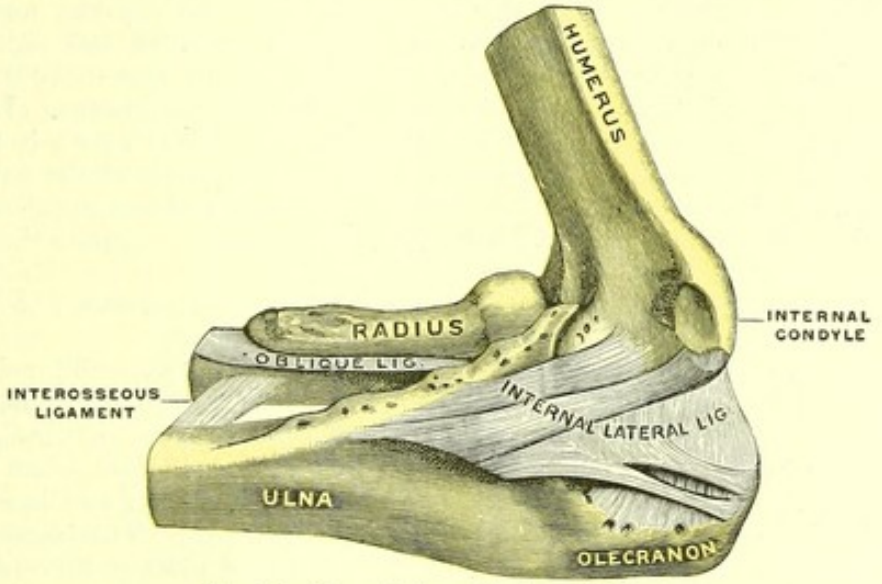

FIG. 241.—Elbow-joint, mesial view. (Poirier.)

lateral motion or displacement, by the articulation of the upper end of the radius with the capitellum of the humerus. To the shape of the bones is due the strength and security of the joint. Beneath the surrounding muscles and ten-

dons, which further strengthen the joint, lies the fibrous *capsule*, reinforced internally and externally, and therefore described in four parts.

The triangular *internal lateral ligament* is attached by its apex to the lower aspect of the internal condyle, and by its base to the inner margin of the coronoid and olecranon processes. It is divided into two smaller triangles, ventral and dorsal, by an intermediate thinner part attached to the meeting-point of these two processes. This ligament is the strongest part of the capsule.

The *external lateral ligament*, shorter and narrower than the internal, radiates from its upper attachment on the lower part of the external condyle to the outer side of the orbicular ligament. A few fibres reach the neck of the radius.

The *anterior ligament* is the thin, fore part of the capsule between the lateral ligaments. Superiorly it is attached above the coronoid and radial depressions, and includes them within the joint; inferiorly it is attached, just beyond the articular margin, to the front of the coronoid process and to the orbicular ligament, some fibres passing to the neck of the radius. It is reinforced by the adhesion of some of the fibres of the brachialis, which draws it up in flexion and prevents it from being nipped between the bony margins.

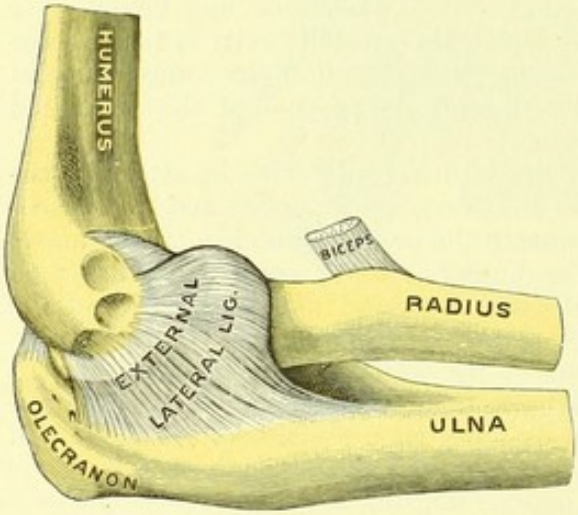

FIG. 242.—Elbow-joint, outer side. (Testut.)

The *posterior ligament* is thin and weak, like the anterior. By its attachment above and at the sides of the olecranon fossa it includes the latter within the joint. Its upper fibres pass transversely across the fossa. Inferiorly it is attached to the olecranon process, near the upper and outer margins of the great sigmoid cavity, to the orbicular ligament, and to the ulna behind the small sigmoid cavity. It is strengthened by the adhesion of the triceps, which draws it up during extension.

The *synovial membrane* lines the inner surface of the capsule, and thence passes onto the humerus, where it lines the olecranon, coronoid, and radial fossæ, and extends to the articular cartilage. Projecting into the above fossæ are masses of fat placed between the capsule and the synovial membrane. Inferiorly the membrane extends into the superior radio-ulnar joint, where it lines the orbicular ligament, thence passing onto and around the neck of the radius, and so up to its articular cartilage. A fold of synovial membrane, projecting into the joint from in front opposite the outer lip of the trochlea, suggests the division of the joint into two parts.

The *nerve-supply* is mainly from the musculo-cutaneous, with a few filaments from the musculo-spiral, median, and ulna.

Movements are confined to flexion and extension on an axis obliquely placed at an angle of about 84° with the shaft of the humerus, so that in extension the forearm is inclined outward and in flexion inward. Flexion occurs through 140°, and is limited by the contact of the soft parts; extension is limited, when the ulna and humerus are nearly in line, by the tension of the soft parts and ligaments in front, and of the ventral portions of the lateral ligaments. The olecranon and coronoid processes do not arrest normal but only forced motion, by contact with the bottoms of their respective fossæ. The head of the radius moves on the capitellum, and is in most complete contact with it in semiflexion, in which position it rotates best on the humerus in pronation and supination. Except possibly to a very limited extent, owing to the slight incongruence of the surfaces, lateral motion is prevented by the lateral ligaments and the shape of the bones.

When the elbow is extended the tip of the olecranon lies on or just below a line connecting the two condyles: when flexed to a right angle it lies a little more than one inch below, and midway between these two points.

5. Radio-ulnar Articulations and Ligaments.

Two joints and an intermediate fibrous union connect the ulna and radius firmly together.

(A) The **Superior Radio-ulnar Articulation.**—The rim of the head of the radius is held in contact with the small sigmoid cavity of the ulna by the strong encircling *orbicular ligament*. This forms four-fifths of a circle and is attached to the ventral and dorsal lips of the small sigmoid cavity, which completes the ring. It forms part of the capsule of the elbow-joint, and inserted into it are the external and parts of the ventral and dorsal portions of this capsule. Its lower border tightly girdles the neck of the radius. From this border membranous fibres pass to the neck of the radius loosely enough to allow of rotation of the radius on its long axis. It is lined by *synovial membrane* continuous with that of the elbow-joint.

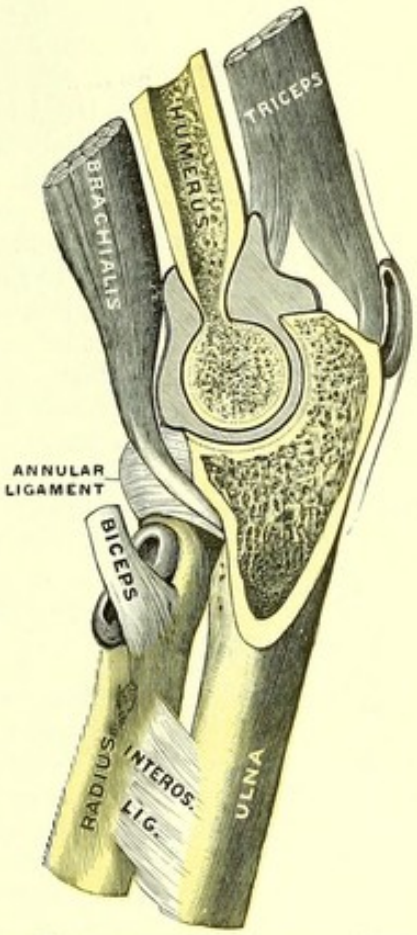

FIG. 243.—Elbow-joint in sagittal section, showing the articular synovial sac and the bursæ of the olecranon and the biceps. (Testut.)

(B) The **middle radio-ulnar union** is accomplished by two ligaments. (1) The *oblique ligament* is a flattened band, which passes obliquely downward and outward from the lower and outer part of the tuberosity of the ulna, at the base of the coronoid process, to the radius, directly below and behind the bicipital tuberosity. Below this ligament is a space through which the posterior interosseous vessels pass, and which is bounded below by the strong (2) *interosseous membrane*. The fibres of the latter pass mostly obliquely downward and inward from the interosseous border of the radius, commencing about one inch below the tuberosity, to the whole length of the interosseous border of the ulna. A few fibres on its dorsal surface are parallel with the oblique ligament, decussating with the other fibres. The interosseous space is widest in the middle third, and is wider in supination than in pronation.

(C) The **inferior radio-ulnar articulation**, between the sigmoid cavity of the radius and the lower end of the ulna, is separated from the wrist-joint by the *triangular fibro-cartilage*. This thick plate is the most important structure in this joint, not only as the strongest bond of union between the two bones, but also in limiting their movements. It is attached by its base to the margin of the radius, which separates the sigmoid cavity from the carpal facet, and by its apex to the fossa at the base of the styloid process of the ulna externally. This ligament separates the lower end of the ulna, which rests on its upper smooth, concave surface, from the cuneiform bone of the carpus. Some scattered fibres from the two ends of the sigmoid cavity of the radius pass to the ventral and dorsal surfaces of the lower end of the ulna above its articular surface. They are called *anterior* and *posterior radio-ulnar ligaments*, and are connected with the borders of the fibro-cartilage inferiorly, and with the interosseous membrane superiorly, thus completing the *capsule*. Lining the capsule is the *synovial membrane*, which

is remarkably loose. Besides extending upward between the radius and ulna, it lines the upper surface of the fibro-cartilage beneath the latter.

The *nerve-supply* comes from the anterior and posterior interosseous nerves.

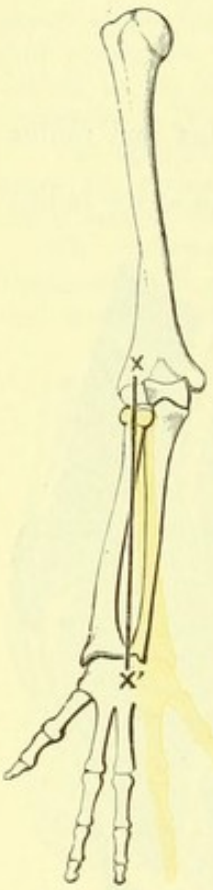

Fig. 244.—Mechanism of pronation and supination. (Testut.)

Movements.—The upper end of the radius rotates on a longitudinal axis passing through its head and neck, while the lower end rotates around the head of the ulna, having the attachment of the apex of the fibro-cartilage as its centre (Fig. 244). The entire bone thus describes rather less than 180° of a cone, with its apex above and its base below, its axis extending from the centre of the radial head to the outer side of the styloid process of the ulna. In these movements the radius carries the hand. The forearm is said to be supinated when its two bones lie nearly parallel and the dorsum of the hand looks backward, and pronated when the radius lies obliquely across the ulna, and the palm of the hand looks backward.

The power of supination is much greater than that of pronation. In the above movements the ulna is thought by many to undergo slight circumduction. This implies a little lateral movement at the elbow, which, if it occurs at all, must be very trifling and due to a slight incongruence of the surfaces. Supination and pronation with a straight arm are apparently much increased by the rotation of the humerus at the shoulder. The interosseous membrane, from the direction of its fibres, transmits the weight of the body from the ulna to the radius or the shock of a fall on the hands from the radius to the ulna.

6. The Wrist-joint or Radio-carpal Articulation (Figs. 245, 246).

The lower end of the radius and of the triangular fibro-cartilage presents a surface slightly concave transversely, as well as from before backward, which receives the correspondingly convex upper articular surfaces of the scaphoid, semilunar, and cuneiform bones. The latter surfaces are prolonged farther upon the dorsal than upon the palmar aspect. The ulna is excluded from the joint by the triangular cartilage; and the pisiform bone of the first row does not enter into the articulation. The joint is condyloid in action.

The rather loose *capsule* is described as four ligaments, which are, however, continuous. The *internal lateral ligament* is attached above as a rounded cord to the styloid process of the ulna, and spreads out below onto the cuneiform and pisiform bones. The *external lateral ligament* radiates from the summit of the radial styloid process onto the outer, back, and front surfaces of the scaphoid, some fibres being continued to the trapezium and os magnum. It is in relation with the radial artery and the extensor tendons of the thumb. The *anterior ligament* is broad, strong, and membranous. Its fibres pass for the most part obliquely from the anterior border of the lower end of the radius downward and inward to the palmar aspect of the scaphoid, semilunar, and cuneiform bones, especially the latter. Some fibres pass over to the os magnum. Another group of fibres passes more vertically from the ulnar styloid process to the semilunar and cuneiform bones. The *posterior ligament*, thinner and less strong than the anterior, is strengthened by the extensor tendons in relation with it. Its fibres also pass for the most part obliquely downward and inward from the dorsal border of the lower end of the radius to the first row of carpal bones, especially to the cuneiform bone.

The *synovial membrane* lines the capsule between the articular surfaces.

7. The Carpal Articulations.

The bones of each of the two rows of the carpus, exclusive of the pisiform, are connected together by *dorsal*, *palmar*, and *interosseous ligaments*, passing nearly transversely between adjacent bones. The palmar are stronger than the dorsal ligaments.

The **joint between the pisiform and cuneiform bones** is arthrodial, and has a thin,

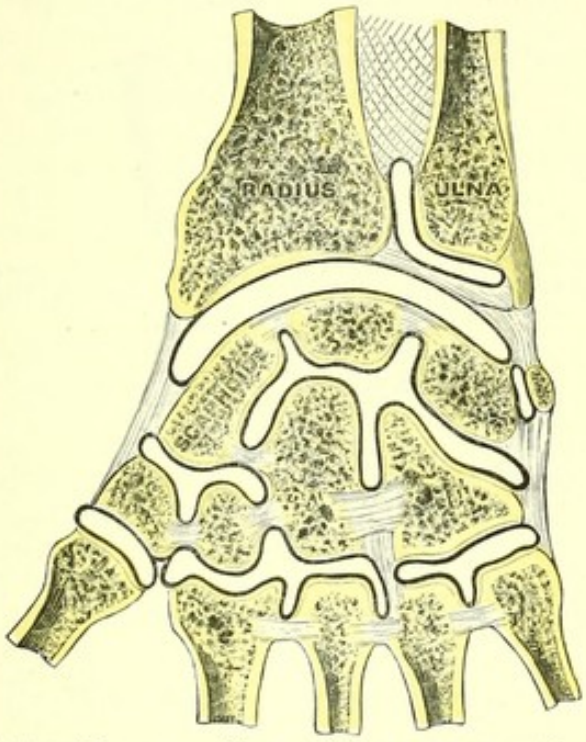

FIG. 245.—The articulations of the carpus. The synovial sacs are represented as distended. (Testut.)

loose *capsule* lined by *synovial membrane* and strengthened by a fibrous band passing to the hook of the unciform, by another passing to the base of the fifth metacarpal, and by the insertion of the tendon of the flexor carpi ulnaris from above.

The Medio-carpal or Transverse Carpal Articulation.—This joint is between the lower aspect of the first carpal row, which is concave except for the convex outer part of the scaphoid, and the upper surface of the second carpal row, concavo-convex from without inward. It is united by *dorsal* and *palmar*, *internal* and *external lateral ligaments*. The *lateral ligaments*, prolonged from the lateral ligaments of the wrist-joint, connect the lateral surfaces of the outer and inner bones of the two rows. The *dorsal ligaments* extend obliquely between the dorsal surfaces of the bones of the two rows. The stronger *palmar ligaments* are composed of fibres which for the most part radiate from the os magnum to the bones of the upper row.

The *synovial membrane* is extensive. From the medio-carpal joint it sends two processes upward between the three bones of the upper row (exclusive of the pisiform); and between the four bones of the lower row it sends three processes downward, which are continued into the four inner carpo-metacarpal and the three intermetacarpal articulations. It is nearly always separated from that of the wrist by the interosseous ligaments between the bones of the upper row, which make their convex upper surfaces uniformly even.

The *nerve-supply* of the radio-carpal and carpal joints is from the ulna and median in front and the posterior interosseous behind.

8. The Carpo-metacarpal and Intermetacarpal Articulations.

The proximal ends of the inner four metacarpal bones are united to the inner three bones of the lower row of the carpus by dorsal and palmar ligaments. Of the *dorsal ligaments* the second and third metacarpals receive two or three each, the fourth two, and the fifth one. The latter is continuous internally with the palmar ligament, forming a partial capsule between the unciform and the fifth metacarpal, open externally. The *palmar ligaments* are weaker and less defined;

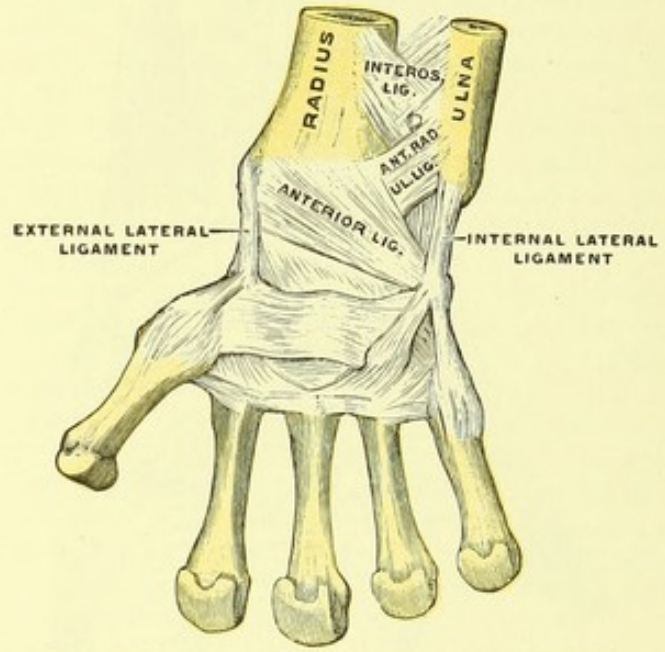

FIG. 246.—Ligaments of the carpus, front view. (Testut.)

the third metacarpal receives three, the others one each. An *interosseous ligament* also connects the contiguous lower angles of the os magnum and the unciform with the adjacent surfaces of the third and fourth metacarpals, occasionally shutting off the synovial sac between the inner two metacarpals and the unciform from the common synovial sac, which is continuous with that of the carpal joints. A strong band from the trapezium to the outer aspect of the base of the second metacarpal helps to close the radial side of the joint of the latter.

The bases of the inner four metacarpal bones are bound together by transverse, *palmar*, *dorsal* and *interosseous ligaments*. Their distal ends are united by transverse fibres passing between the margins of the palmar or glenoid ligaments of the metacarpo-phalangeal joints, and forming the *transverse metacarpal ligament*, which limits the separation of the metacarpal bones. The first metacarpal bone is free from the others at both ends. In the *carpo-metacarpal joint of the thumb* there is a thick, loose *capsule*, strongest dorsally and externally, which connects the margins of the articular surfaces of the trapezium and the first metacarpal. It is lined by a separate *synovial membrane*.

Movements of a similar nature occur in the *radio-carpal* and *medio-carpal joints*. These movements are *flexion* and *extension*, *abduction* and *adduction*, and *circumduction*. Extension is more free than flexion in the radio-carpal joint, owing to the greater extent of the carpal articular surfaces dorsally than ventrally; but flexion is more free than extension at the medio-carpal and carpo-metacarpal joints, and it is the more free of the two motions in the wrist as a whole. Abduction and adduction, on an antero-posterior axis, occur principally at the radio-carpal joint. Adduction is much the more free, for the ulna does not extend as low as the radius, and does not help the external lateral ligament to check adduction as the radius does the internal lateral ligament to check abduction. The lack of rotation in the wrist is compensated for by the pronation and supination of the fore-

arm, in which the hand rotates with the radius. In the medio-carpal joint, besides very free flexion, moderately free extension, and slight lateral motion, there is very limited rotation of the head of the os magnum and the unciform in the socket formed by the upper row, while the trapezium and trapezoid glide back and forth on the scaphoid. In the central carpo-metacarpal joints flexion and extension are slight. The fifth metacarpal is capable of more flexion than are the second, third, and fourth, and this flexion is directed outward as well as forward, producing opposition, or narrowing and hollowing of the hand, as in the closed fist. The movements of the first metacarpal are regulated principally by the saddle-shape of the surfaces, and consist of flexion and extension, abduction and adduction, and circumduction. Flexion is most free, and occurs obliquely forward and inward, thus allowing the opposing of the thumb to any of the fingers. Abduction is also very free, adduction less so. Movements between bones of the same row in the carpus are limited to slight gliding, which gives elasticity to the carpus, breaks jars and shocks, and thus strengthens the wrist.

9. Metacarpo-phalangeal and Interphalangeal Articulations.

The cup-shaped bases of the proximal phalanges receive the rounded heads of the metacarpal bones to form a condyloid joint whose *capsule* is very weak behind, where the joint is covered by the expansion of the extensor tendons, but is reinforced laterally in front. The strong *lateral ligaments* are attached to the lateral tubercles and the depressions in front of them on the heads of the metacarpal bones, and pass downward and forward to the lateral margins of the bases of the phalanges and to the palmar or glenoid ligaments. The *anterior*, *palmar*, or *glenoid ligament* is a thick fibro-cartilaginous plate, attached closely to the phalanx, loosely to the metacarpal. It is continuous laterally with the lateral ligaments and the transverse metacarpal ligament. Its palmar surface is slightly grooved for the flexor tendons, the sheaths of which are attached to its margins. Its dorsal surface helps to support the head of the metacarpal bone. In the thumb (and occasionally elsewhere) the fibro-cartilage ossifies into two sesamoid bones, receiving the insertion of the short muscles and forming a groove for the long flexor muscle.

The *interphalangeal articulations* are in every way similar, except for slight differences in the shape of the articular surfaces, which influence the action. A *synovial membrane* lines the inner surface of the connecting ligaments of each joint.

Movements.—In the metacarpo-phalangeal joint of the thumb motion is limited to flexion and extension, owing to the width of the surfaces. In the four other fingers abduction and adduction, in relation to the middle finger as the axis, are also quite free in the extended position. Flexion is the freest movement, owing to the greater extent of the articular facet in front and to the forward obliquity of the lateral ligaments. Flexion to a right angle and extension to a little beyond a straight line are permitted. Although abduction and adduction may occur separately, flexion and adduction and extension and abduction are associated together. The movements in the interphalangeal joints are limited to flexion and extension. Flexion is the more free for the same reason as above given, and in the proximal joint it exceeds a right angle; in the distal joint it may be rather less. The greater freedom of the thumb is due to the motion in the carpo-metacarpal rather than in the lower joints.

THE ARTICULATIONS OF THE PELVIS (Figs. 247, 248).

The Articulations of the Pelvis with the Last Lumbar Vertebra.

The fifth lumbar is united to the first sacral vertebra by such joints and ligaments as are found between the vertebræ above, with the addition of two special accessory ligaments on each side, as follows: The *lumbo-sacral ligament* is

a strong, triangular band, with its apex above and internally, where it is attached to the lower and front part of the transverse process of the last lumbar vertebra, from which it radiates downward and outward to the lateral surface of the base of the sacrum, blending with the anterior sacro-iliac ligament. The *ilio-lumbar ligament* also is a strong triangular band, which passes from the apex of the transverse process of the fifth lumbar vertebra outward and somewhat backward, expanding to its attachment along the dorsal two inches of the inner lip of the iliac crest. It represents the thickened lower edge of the ventral layer of the lumbar fascia covering the quadratus lumborum, and gives origin to that muscle. It also helps to complete the dorsal boundary of the false pelvis.

The Sacro-coccygeal and Intercoccygeal Articulations.

The sacrum is united to the coccyx by an oval *intervertebral disc*, by an *anterior* and a stronger *posterior sacro-coccygeal ligament*, the continuations of the anterior and posterior common ligaments of the vertebræ; and by *lateral ligaments* passing between the cornua of the two bones, and between the transverse processes of the first coccygeal vertebra and the lateral angles of the sacrum. The ligaments connecting the cornua of the two bones are sometimes called *inter-articular*, as the cornua represent articular processes; but the ligament is probably the continuation of the supraspinous ligament, which roofs over the lower end of the spinal canal.

The several pieces of the coccyx are held together by the continuation of the anterior and posterior ligaments described above. Small discs of fibro-cartilage also connect them as long as they remain separate bones.

The Sacro-iliac Joint.

This is a synchondrosis in which the cartilage-clad auricular surfaces of the sacrum and ilium are bound together by a thin stratum of softer fibro-cartilage, which may contain a synovial-like cavity. In some cases also interosseous fibrous tissue partly binds the surfaces together, especially near the dorsal superior border, behind and above which the short transverse fibres of the deep part of the posterior sacro-iliac ligament sometimes receive the name of *interosseous ligament*.

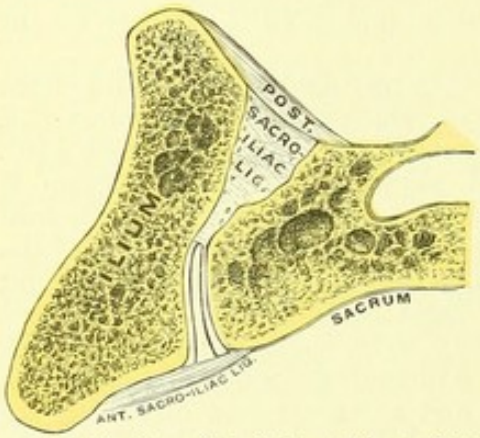

FIG. 247.—Sacro-iliac joint, cut in a plane parallel to that of the superior strait through the second sacral vertebra. (Testut.)

The *anterior sacro-iliac ligament* consists of a thin layer of fibres covering the front or pelvic surface of the joint, between the pelvic brim and the great sacro-sciatic notch. The *posterior sacro-iliac ligament* is very strong. The deeper bundles of fibres pass inward and slightly downward from the rough area above and behind the auricular surface of the ilium to the back of the lateral mass of the sacrum. A more dorsal or superficial band, sometimes called the *long* or *oblique sacro-iliac ligament*, passes from the back of the posterior superior iliac spine downward and slightly inward to the back of the third sacral vertebra. The cartilage connecting the auricular surfaces of this joint tears away, as one mass, from one or the other surface when the bones are forcibly separated. The sacro-sciatic ligaments also help to support this joint.

The *great* or *posterior sacro-sciatic ligament* is thin and flat at its attached ends, narrower and thicker in the centre, which thus divides it into two triangles, of which the broader is attached to the posterior inferior iliac spine and the sides of the sacrum and coccyx, and the narrower to the inner margin of the ischial

tuberosity, sending its *falciform process* along the inner margin of the ischial ramus. The free, sharp edge of the falciform process is continuous with the posterior border of the ligament and with the obturator fascia. Some fibres pass over the tuberosity into the tendon of the biceps, of which this ligament represents the proximal continuation. The direction of this ligament is from above downward, outward, and slightly forward. It assists in bounding the pelvic outlet and the perineum laterally, and between it and the hip-bone is a large space subdivided by the *small* or *anterior sacro-sciatic ligament* into the *great sacro-sciatic foramen*

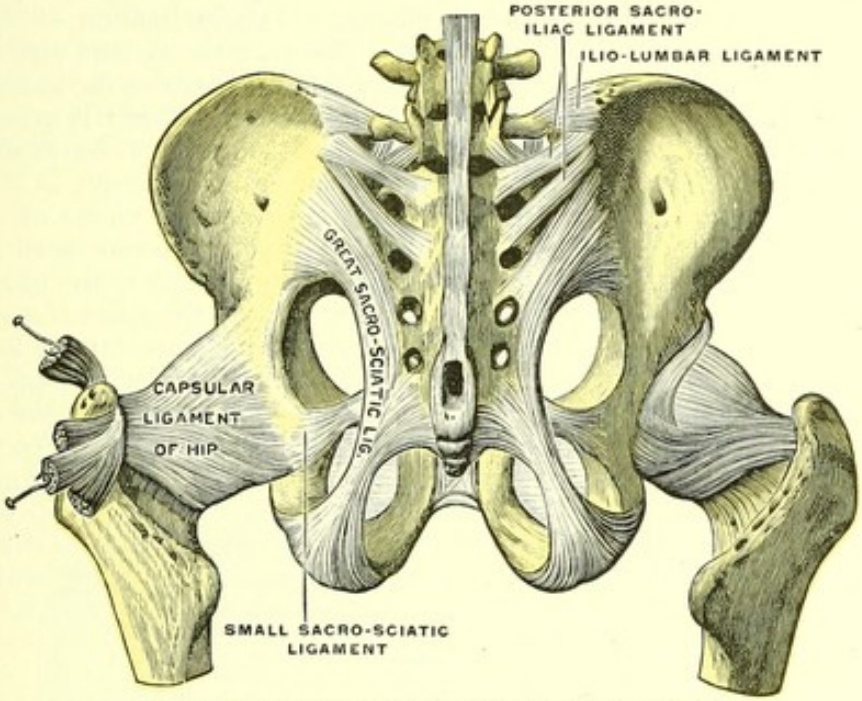

FIG. 248.—Articulations of the pelvis, rear view. (Testut.)

above and the *small sacro-sciatic foramen* below. This ligament lies in front of the preceding, and is triangular in form, its wide base attached to the side of the sacrum and coccyx, its apex to the ischial spine. Its deep surface is closely connected with the coccygeus muscle, of which it represents the thickened sheath. Through the great sacro-sciatic foramen pass the pyriformis muscle, and above the muscle the gluteal vessels and superior gluteal nerve, below the muscle the sciatic and internal pudic vessels and nerves, the inferior gluteal nerve, and the nerves to the obturator internus and quadratus femoris muscles. The small sacro-sciatic foramen is the smaller space below the small sciatic ligament. It is bounded behind by the great sacro-sciatic ligament and in front by the smooth cartilage-clad surface between the ischial spine and tuberosity, over which passes the obturator internus muscle. The internal pudic vessels and nerve and the nerve to the obturator internus pass in through this foramen.

The Symphysis Pubis.

The opposed median surfaces of the pubic bones are each covered with a thin layer of hyaline cartilage, united into a single *interpubic disc* by an interposed layer of fibro-cartilage. The latter is broader in front and below, and bulges especially behind. It is attached to the surrounding ligaments on all sides, and often contains a cleft. This cleft or cavity is usually nearer the upper and back part, does not reach the surface, is not lined by synovial membrane, and is larger in the female, though not greatly affected by pregnancy. A fibrous *capsule* surrounds the joint, which is further strengthened by tendinous attachments. The *superior* and *posterior ligaments* are but slightly marked transverse fibres strength-

ening the periosteum. The *anterior ligament* is stronger, and consists of deep transverse fibres and superficial oblique, decussating fibres connected with the tendons of the muscles arising from the body of the os pubis. The *inferior* or *subpubic ligament* is a thick triangular mass of transverse and curved fibres, rounding off the subpubic angle of the pubic rami, which forms the ventral angle of the pelvic outlet.

Movements, Mechanism, etc.—Owing to the thickness of the disc between the fifth lumbar vertebra and the sacrum, movements are more free here than between any two lumbar vertebræ, and especially flexion and extension, which occur in sitting or in rising from the sitting posture. The inclination of the pelvis depends partly upon the sacro-vertebral angle between the sacrum and the spine, but also, and in great part, on the obliquity of the hip-bones to the sacrum at the sacro-iliac joint. At the sacro-iliac joint there is no movement: it merely serves to break shocks. In the erect position the base of the sacral wedge is directed so largely forward, and the ventral or broader surface of the sacrum is directed so largely downward, that the sacrum is not held in place by virtue of its wedge shape, but is suspended from the ilia by the very strong posterior sacro-iliac ligaments in such a way that the greater the pressure the tighter is the union. The tendency to rotation of the sacrum, due to the weight of the spine transmitted to its forward projecting base, is resisted above by the ilio-lumbar and below by the sacro-sciatic ligaments (the former directed backward, the latter forward from the sacrum). At the pubic symphysis there is only a slight yielding of the cartilage, which may occur at childbirth, when the cartilage is softer and more vascular; but the decussating tendinous fibres of the abdominal muscles, which cross it in front, would tend to brace the bones more tightly together by their contraction during labor. The sacro-coccygeal joint allows of flexion and extension. In defecation and parturition the coccyx is pushed backward. This joint may be ankylosed in adult life, but less often in females than in males, and its mobility seems to increase during pregnancy.

THE ARTICULATIONS OF THE LOWER LIMB.

1. The Hip-joint (Figs. 249–251).

In this typical ball-and-socket joint the round head of the femur is received into the acetabulum of the hip-bone. The cartilage-clad surface of the acetabulum is horseshoe-shaped, broader above and behind, and deficient below at the cotyloid notch and in the depression at the bottom of the acetabulum, which is occupied by a mass of fat covered by synovial membrane—the so-called *synovial* (Haversian) *gland*. The articular cartilage of the head of the femur is thicker above, where it bears the weight of the body, and is only wanting a little behind and below the centre at the depression for the ligamentum teres. The acetabular rim is completed below by the transverse and decussating fibres of the *transverse ligament*, which bridges over the cotyloid notch, and converts it into a foramen through which articular vessels pass. This ligament blends with and helps to support the *cotyloid ligament*, a thick fibro-cartilage, triangular on section, firmly attached by a broad base to the rim of the acetabulum, which it deepens to more than a hemisphere. Its concave inner surface and thin free margin tightly embrace the head of the femur a little beyond its greatest circumference and, aided by atmospheric pressure, hold it in place when its ligaments are divided. Its fibres pass obliquely from without inward, and its outer convex surface is in contact with the capsular ligament. It is covered on both sides by synovial membrane.

The *capsular ligament* is one of the strongest in the body. Surrounding the joint, it is attached to the pelvis at or near the rim of the acetabulum, outside of the cotyloid ligament, and to the transverse ligament. On the femur it is attached in front to the anterior intertrochanteric line, from the tubercle above to

the level of the lower part of the small trochanter below; behind and below, to the neck, one-half to two-thirds of an inch internal to the posterior intertrochanteric line; and above, at the base of the great trochanter, internal to the digital fossa. The innermost capsular fibres are reflected upon the neck of the femur toward the articular margin, blending with the periosteum and forming three flat bands or *retinacula*, one behind and one at either end of the anterior intertrochanteric line. The capsule is somewhat loose, and its fibres run longitudinally with some circular fibres interwoven. The circular fibres are found most abundantly behind and below, where they form a band arching around the neck of the femur. The longitudinal fibres are much thickened in parts by *accessory bands*, inseparable from the capsule, which greatly strengthen the joint. Many of these bands are derived from the fascial sheaths of the surrounding muscles, which are—in front, the ilio-psoas, partly separated from the capsule by a bursa; internally, the pectineus; below and behind, the obturator externus; behind, the

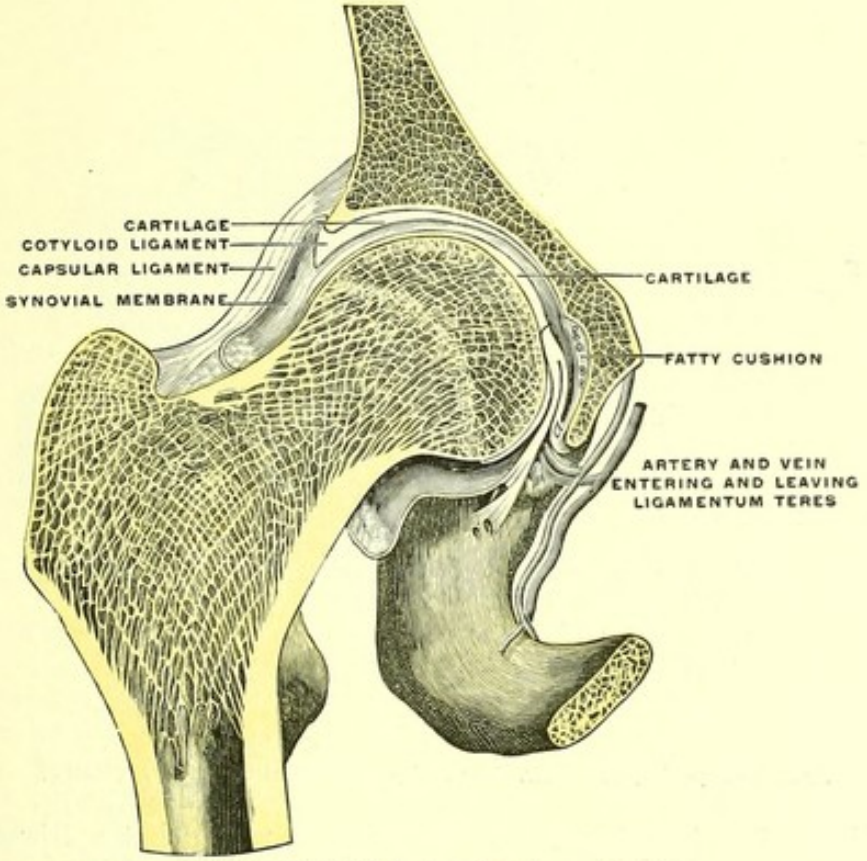

FIG. 249.—Hip-joint in coronal section. (Testut.)

obturator internus with the two gemelli and the pyriformis; above or externally, the rectus femoris and the gluteus minimus. The obturator internus acts like a powerful strap at the back of the joint.

Of the three principal accessory bands, the *ilio-femoral band* is the strongest and most important. Superiorly attached to the ilium, below and behind the anterior inferior spine, it spreads out triangularly to the anterior intertrochanteric line of the femur. Its inner and outer borders form two very strong bands, between which the capsule is thinner, so as sometimes to suggest the name of the inverted Y-ligament given it by Bigelow. This ligament is rarely torn, and forms the fulcrum for the manipulation in reducing dislocations of the thigh. The outer or upper part of this band, passing to the upper end of the anterior border of the great trochanter, is sometimes described as the *ilio-trochanteric ligament*.

The *pubo-femoral band* is the weakest, and passes from between the pectineal eminence and the cotyloid notch to the neck of the femur, above and behind the

inner band of the ilio-femoral ligament. It is derived from the fascia between the pectineus and the obturator externus. The capsule is thinnest between this and the ilio-femoral band, where it is perforated by an opening between the synovial cavity and the bursa beneath the psoas. The *ischio-femoral band* consists of strong fibres from the ischium just below the acetabulum, which curve upward and outward to the base of the great trochanter internal to the digital fossa. In flexion of the thigh they pass almost straight to their femoral attachment. The capsule is weak dorsally below this band, where it usually tears in dislocation. Between this and the ilio-femoral band superiorly the capsule is strong, and is further strengthened by bands from the gluteus minimus and from the reflected tendon of the rectus. From the latter the *tendino-trochanteric band* passes to the upper end of the vastus externus muscle.

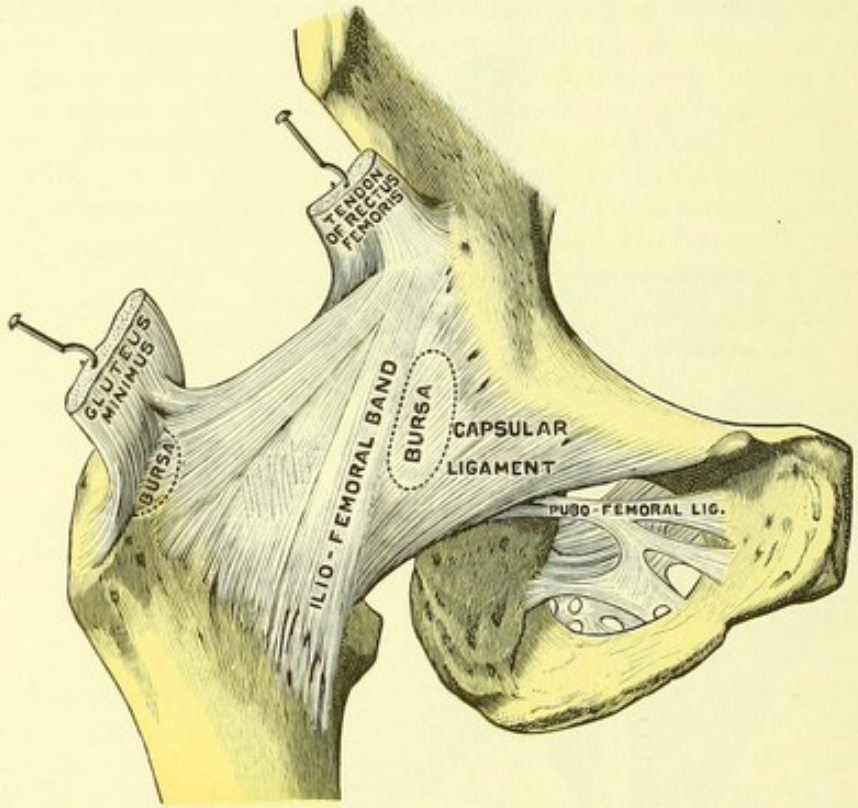

FIG. 250.—Hip-joint, front view. The cavity is distended artificially. (Testut.)

The *ligamentum teres* (round ligament) is not round, but a triangular, flat interarticular band attached by its apex to the upper half of the depression on the head of the femur, and by its base to the transverse ligament and the margins of the cotyloid notch, the ischial portion being the stronger. It is surrounded by synovial membrane, and represents a migrated portion of the pectineus muscle. It conveys a small branch of the obturator artery to the head of the femur. It is torn in dislocation of the femur.

The *synovial membrane* lines the inner surface of the capsule, from which it is reflected onto the neck of the femur as far as the articular margin, and onto the two free surfaces of the cotyloid ligament, thence being continued to the pad of fat at the bottom of the acetabulum, and as a tubular covering of the ligamentum teres.

Nerves.—The obturator, accessory obturator, anterior crural, and great sciatic, or the sacral plexus, supply the joint.

Movements.—All the movements of a ball-and-socket joint are permitted. The obliquity of the neck of the femur allows flexion and extension to take place by a rotation of the head without its cartilage-clad surface leaving the

socket, thus securing strength for these, the most important movements. Extension is limited by the strong ilio-femoral band, which helps to maintain the erect position without muscular exertion by preventing over-extension in standing, in which position the centre of gravity descends behind the centre of the joint. Flexion takes place through about 140°, until checked by the contact of the thigh and abdomen if the knee is flexed; otherwise, it is checked at about 90° by

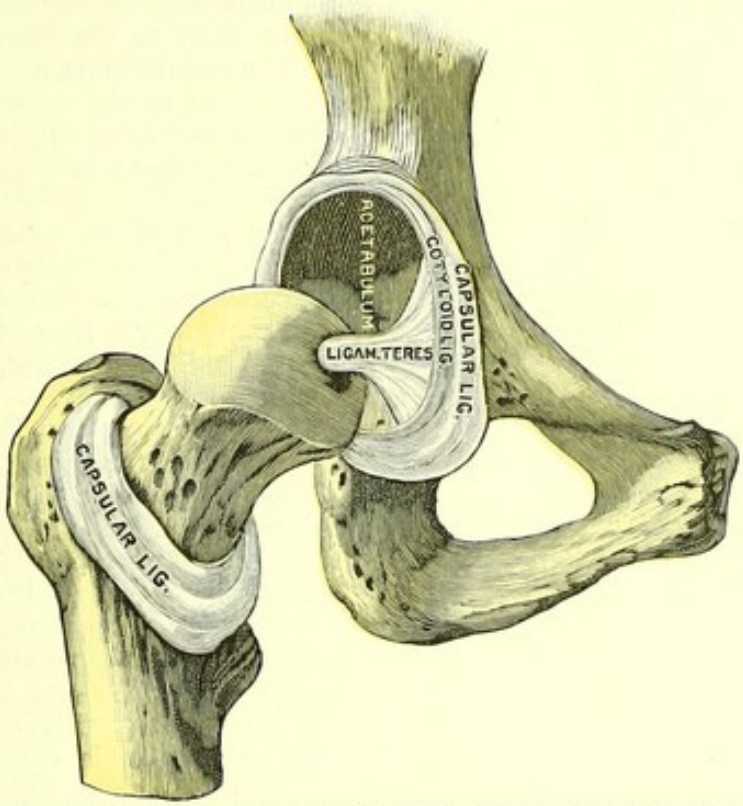

FIG. 251.—**Hip-joint, front view.** The capsular ligament has been largely removed. (Testut.)

the hamstring muscles. In all the other movements the articular portion of the head projects beyond the cotyloid rim on the side opposite to that toward which the movement takes place. Abduction is limited by the pubo-femoral band, adduction by the outer part of the ilio-femoral band and the upper part of the capsule. Rotation takes place on a vertical axis passing from the head above to the lower extremity of the femur below. (This axis is not coincident with that of the shaft.) Inward rotation is limited by the ischio-femoral band, outward rotation by the ilio-femoral band (its inner part during extension, its outer during flexion). The ligamentum teres is put on the stretch in flexion with abduction or outward rotation, or both, but it is too weak to be of use in resisting these movements or in strengthening the joint.

2. **The Knee-joint** (Figs. 252–255).

This, the largest joint in the body, is a modified hinge-joint, whose bony articular surfaces (the condyles and trochlear surface of the femur, the tuberosities of the tibia and the patella) are not adapted to one another except by means of soft parts and the interposed fibro-cartilages. The knee is very superficial, and is strong only by reason of the number and strength of the ligaments and surrounding tendons and muscles, which, as well as the width of the bony surfaces, resist dislocation in spite of the leverage of the longest two bones in the body. It represents two morphologically distinct joints, the patello-femoral and the tibio-femoral, the latter also composed of two laterally placed joints, the median division between which is represented by the crucial and mucous ligaments. The synovial

membrane of these joints has blended into one. The *fibrous capsule* of the knee is strengthened in places by strong bands derived from the surrounding tendons, closely adherent to its outer surface, and known as the *external* (superficial) *set of ligaments*.

1. The *internal lateral ligament* is a long, flat, strong band which extends from the internal tuberosity of the femur (close to the adductor magnus tendon, of which it was originally a continuation) to the inner surface and border of the tibia, descending below the level of the tubercle. Blended above and internally with the fibro-cartilage and capsule, it is separated from the latter below, and bridges over part of the semimembranosus tendon and the inferior internal articular vessels. Superficially, it is separated by a bursa from the tendons of the sartorius, gracilis, and semitendinosus.

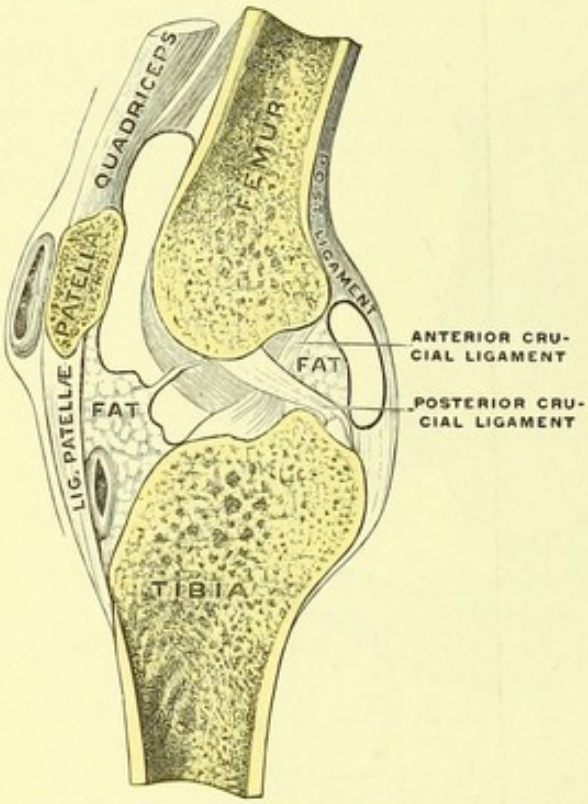

FIG. 252.—Knee-joint in sagittal section. (Testut.)

2. The *external lateral ligament* extends downward and slightly backward as a rounded cord from the external tuberosity of the femur to the middle of the outer surface of the head of the fibula. It crosses superficially over the popliteus tendon and the external inferior articular vessels, and is separated by a bursa from the biceps tendon, which splits to embrace it. It is continuous below with the origin of the peroneus longus, of which it represents the detached femoral origin. A little behind this ligament is the broader but less constant and defined *short* or *posterior external lateral ligament*, which extends from the external condyle of the femur, in connection with the external gastrocnemius tendon, to the styloid process of the fibula. It blends with, and is really a portion of, the posterior ligament. Both internal and external lateral ligaments are situated behind the centre of the joint.

3. The *posterior ligament* proper is a strong flat band which ascends obliquely upward and outward as an expansion from the semimembranosus tendon, from the back of the inner tuberosity of the tibia, to the external condyle of the femur, joining the outer head of the gastrocnemius. The rest of the so-called posterior ligament underlies this oblique portion, and is a part of the capsule which occupies the interval between the lateral ligaments behind. It is a broad membrane composed of nearly vertical bundles of fibres, which pass from the upper margins of the intercondylar notch and of the articular surfaces of the femur to the dorsal margin of the head of the tibia.

4. The *ligamentum patellæ* is the strong, flat infrapatellar tendon of the quadriceps extensor, extending from the apex and lower border of the patella to the lower part of the tubercle of the tibia (where it descends lower on the outer side). A *synovial bursa* separates the ligament from the upper part of the tubercle, above which a mass of fat separates it from the synovial membrane.

5. The *capsular ligament* is seen only in the intervals between the above ligaments. Behind it is thickened to form most of the posterior ligament, in front it is wanting beneath the patella and its tendons, between which and the lateral ligaments it is strengthened by the fascia lata and the lateral fibrous expansions of the quadriceps extensor tendon. These expansions, passing down from the vasti

muscles, are attached to the sides of the patella[1] and the ligamentum patellæ, and to the tibia along the oblique lines extending from the tubercle to the inner and outer tuberosities. They reach as far as the lateral ligaments. Externally, the ilio-tibial band of the fascia lata, attached to the external one of the above oblique lines, adds largely to the strength of the capsule. The capsule is therefore made up of two or three layers, and between the deeper layer, or the capsular mem-

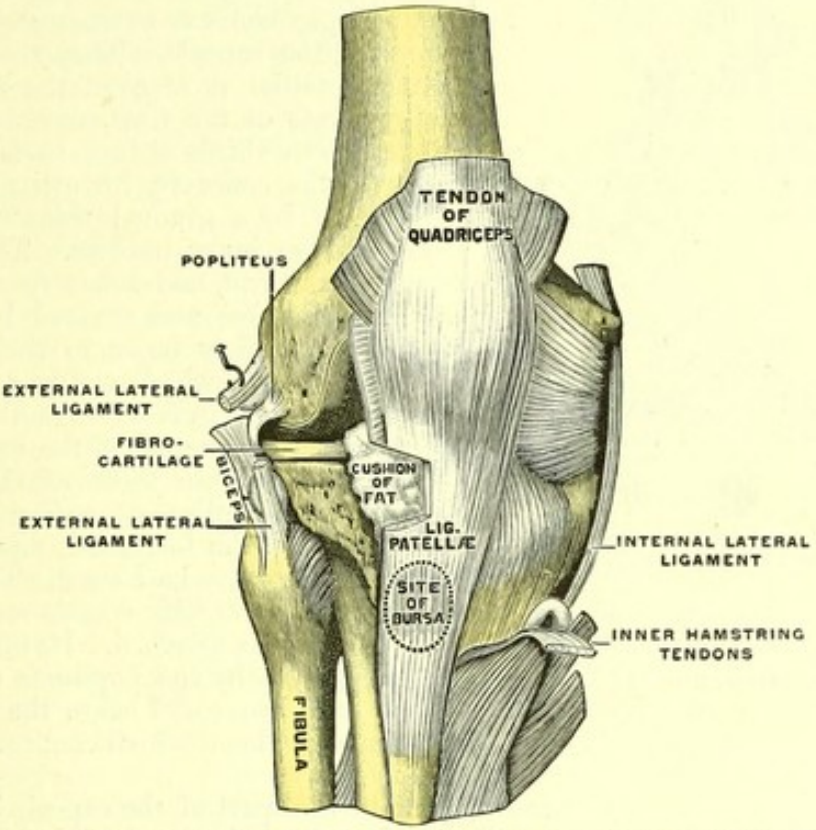

FIG. 253.—Knee-joint, front view. Part of the ligaments have been removed on the right side. (Testut.)

brane proper, and the outer layers there often exists a thin layer of fatty tissue. The capsular membrane is attached to the femur and tibia not far from their articular margins, and is adherent to the semilunar cartilages.

Of the so-called *internal* (deep) *set of ligaments*, most may be well seen by dividing the quadriceps tendon above the patella, continuing the section laterally and downward to the lower ends of both lateral ligaments, and turning down the flap thus made.

6. *Synovial Ligaments.*—From the synovial membrane lining the pad of fat behind the ligamentum patellæ two thin lateral folds of membrane extend upward, one on each side of the patella, known as the *alar ligaments*. From the middle of the surface of the pad a flattish fold, the *ligamentum mucosum*, extends backward and upward to the front of the intercondylar notch. It represents the remains of the synovial partition between the two halves of the tibio-femoral joint and between the patello-femoral and tibio-femoral joints.

On dividing the ligamentum mucosum we see

7. The *anterior crucial ligament*, which extends upward, backward, and outward from its lower attachment to the inner half of the depression in front of the spine of the tibia, and between the fore ends of the semilunar cartilages, to the hind part of the inner surface of the outer condyle of the femur.

8. The *posterior crucial ligament* is stronger, shorter, and more vertical than the anterior. From behind the tibial spine, from the popliteal notch, and receiving fibres from the posterior cornu of the external semilunar cartilage, its

[1] Forming what has been called the *lateral patellar ligaments.*

fibres ascend slightly forward and inward to the front of the outer side of the internal condyle of the femur. Behind and below it is adherent to the posterior ligament. It crosses the anterior crucial ligament on its inner side, and is blended with it below, but separated from it above by a V-shaped space. The synovial membrane is prolonged over them both.

The *external* and *internal semilunar fibro-cartilages* are two crescentic plates, of a dense, compact structure, attached by their thick, convex, outer margins to the inside of the capsule. They rest upon the circumferential portions of the upper articular facets of the tibia, covering a little less than two-thirds of these surfaces. They increase the concavity for articulation with the femur by a gradual thinning to their concave, free inner borders. Their upper, concave, femoral, and lower flattened tibial surfaces are free and covered by synovial membrane. They taper to their attached ends or *cornua*, which are purely fibrous, and are fastened in front of and behind the tibial spine, the cornua of the external cartilage being within those of the internal. The external semilunar cartilage is therefore more circular, the internal is more oval and longer from before backward. The external is also more movable, from the close approximation of its cornua and from the greater laxity of the part of the capsule to which it is attached. Its outer margin is grooved behind, and separated from the capsule by the popliteus tendon, the bursa surrounding which connects with the joint above and below the cartilage.

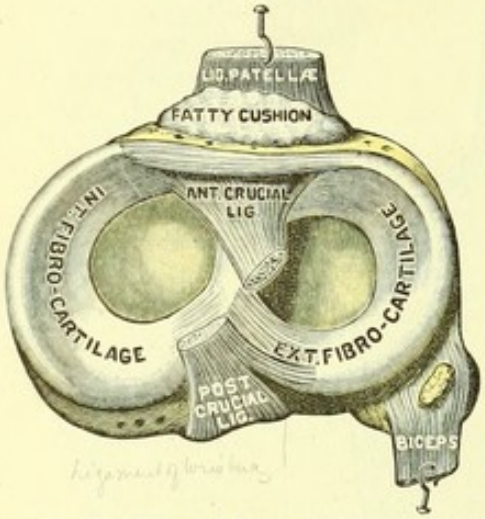

FIG. 254.—The semilunar cartilages of the right knee-joint. (Testut.)

The *transverse ligament* is a variable transverse band which connects the outer borders of the two semilunar cartilages in front.

Coronary ligament is a name applied to that part of the capsule between its attachment to the semilunar cartilages above and the head of the tibia below, which holds the cartilages in apposition with the tibia.

The *synovial membrane*, the largest in the body, lines the capsule of the joint. Above the patella, in front of the femur and beneath the extensor tendon, it forms a large pouch, communicating in most cases with a *bursa* above it, which lies between the extensor tendon and the front surface of the femur, above the attachment of the capsular membrane. Traced downward, it is found to line the capsule until it meets the semilunar cartilages, where it is reflected onto their upper surfaces, around their free margins, onto their lower surfaces, and so back to the portion of the capsule called the coronary ligament, which it lines down to its tibial attachment. From the capsule behind and the semilunar cartilages below this membrane is reflected onto the crucial ligaments, which it invests, except behind and below, and thus shuts them out of the synovial cavity. It also forms the alar and mucous ligaments. *Synovial bursæ* beneath and between the gastrocnemius and semimembranosus internally, and beneath the popliteus tendon externally, may connect with the synovial cavity.

The *nerve-supply* comes from the internal and external popliteal, the anterior crural, and the obturator nerves.

Movements.—The principal movements are those of flexion and extension, which result from a combination of gliding and hinge rotation, not on a fixed axis, but on one which shifts with the points of contact from behind forward in extension, and *vice versâ* in flexion. The points of contact of the articular surfaces are constantly changing from the flattish lower surface of the femoral condyles in extension to their more sharply curved hind surfaces in flexion, and from the fore part of the tibial surfaces in extension to their hind part in flexion. The looseness

of attachment of the semilunar cartilages allows them to adapt themselves to the differently curved surfaces of the femur.

As the knee is moved from the flexed to the extended position the crucial ligaments become tense, and keep pulling back the articular surface of the tibia, so that the points of contact of both tibia and femur are shifted forward. This relaxes the ligaments and allows the motion to continue. The anterior crucial ligament also resists the tendency of the extensor muscle to displace the tibia forward in extension. In flexion the crucial ligaments cause a shifting of the points of contact in the opposite direction, and the posterior crucial ligament prevents the tibia from being pulled backward by the flexor muscles.

FIG. 255.—Knee-joint, outer side. The synovial sacs are artificially distended. (After Poirier.)

At the end of extension there is a slight outward rotation of the tibia and foot on a vertical axis, and at the commencement of flexion a similar rotation in the opposite direction. This is due in part to the greater length of the inner condyle, onto the outwardly directed fore part of whose articular surface the inner facet of the tibia glides forward in outward rotation at the end of extension, and backward in inward rotation at the beginning of flexion. Extension is checked by the lateral and posterior ligaments and the anterior crucial ligament. Flexion is checked by contact of the soft parts at about 135°. In extreme flexion the ligamentum patellæ, the fore part of the capsule, and the posterior crucial ligaments are tightened. The relaxation of the ligaments in the partly flexed position allows an inward and outward rotation, on a vertical axis, in which the semilunar cartilages slide back and forth on the tibia. This rotation is impossible in the extended position owing to the tension of the ligaments. Rotation inward is checked by the anterior crucial ligament, rotation outward by the lateral ligaments. The erect position, in which the line of gravity descends in front of the knee, is maintained, in great measure, without muscular effort by the resistance offered to over-extension by most of the ligaments.

The movements between the patella and the femur are a combination of sliding and coaptation. In moving from the extended to the flexed position the lower, middle, and upper parts of the patellar facets are successively in contact with the upper, middle, and lower parts of the trochlear surface of the femur. In extreme flexion a narrow vertical surface on the inner side of the patellar facet is in contact with the fore part of the outer border of the inner condyle of the femur, the patella being turned more outward by the external condyle, against which its upper and outer part rests.

3. The Tibio-fibular Union.

The tibia and fibula are united at their upper and lower ends by joints, and between them by an interosseous membrane.

A. **The Superior Tibio-fibular Articulation.**—In this joint the oval, flattened, oblique articular surface on the head of the fibula is connected with that on the external tuberosity of the tibia by a *capsular ligament*, strengthened in front and behind by fibres which pass downward and outward from the tibia to the fibula—

the *anterior* and *posterior superior tibio-fibular ligaments*. The capsule is not infrequently imperfect above and behind, where the synovial cavity of this joint may communicate with that of the knee through the medium of the bursa beneath the popliteus tendon.

B. The **Interosseous Membrane** extends between the outer border of the tibia and the interosseous border of the fibula as a firm aponeurotic membrane, whose fibres descend for the most part from the tibia to the fibula, with a few in the opposite direction. It is separated from the superior tibio-fibular joint by an oval opening through which the anterior tibial vessels pass, and below it is continuous with the inferior interosseous ligament, being perforated by the anterior peroneal vessels. It serves mainly for muscular attachment.

C. **The Inferior Tibio-fibular Articulation** (Fig. 256).—The rough triangular surfaces on both bones, formed by the bifurcation of their interosseous borders, are firmly united by the short, strong, obliquely transverse fibres of the *inferior interosseous ligament*, to within one-fourth an inch of the facets for the astragalus, where two narrow articular facets, continuous with those for the astragalus, are in contact. The union is strengthened in front and behind by the *anterior* and *posterior inferior tibio-fibular ligaments*, flat bands which extend across the joint from the lower end of the tibia obliquely outward and downward to the lower end of the fibula.

The *transverse ligament* is a thick, strong band, below the posterior ligament, which extends from the posterior border of the lower articular surface

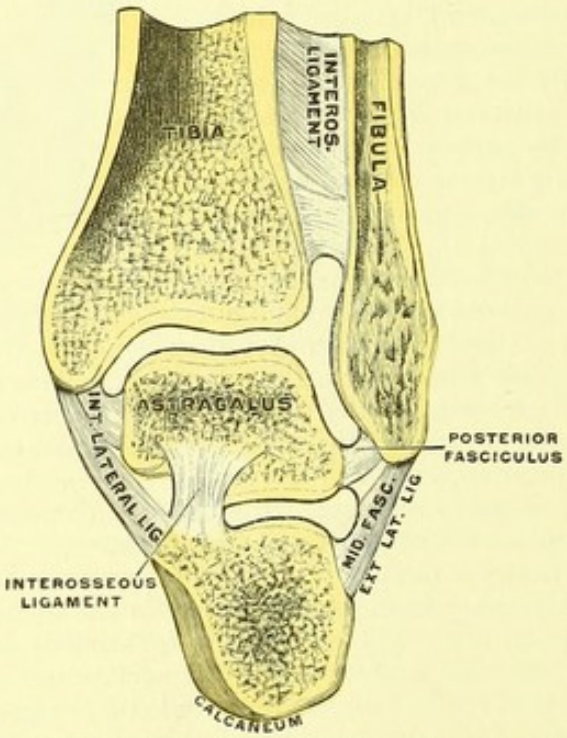

FIG. 256.—Tibio-tarsal and calcaneo-astragaloid articulations, in coronal section. The synovial sacs are distended. (Testut.)

of the tibia outward, downward, and a little forward to the inner surface of the external malleolus, in and above the fossa. The *synovial membrane*, continuous with that of the ankle, extends up between the bones as far as the inferior interosseous ligament.

The *movements* in these joints consist in a slight yielding or vertical sliding, which is allowed by the obliquity of the ligaments. The upward sliding of the fibula is accompanied by a slight widening of the tibio-fibular mortice, which occurs in flexion of the ankle. The inferior interosseous ligament is put to a great strain in the injuries producing "Pott's fracture."

4. **The Ankle-joint** (Figs. 256, 257).

The ankle is a hinge-joint, in which the articular surfaces of the lower end and internal malleolus of the tibia and of the external malleolus of the fibula form a mortice, into which the upper and lateral facets of the astragalus fit as a tenon. The transverse ligament helps to complete the tibio-fibular socket behind. The *capsule*, strengthened and protected by the strong tendons passing over it, is divided, for description, into the following ligaments:

The *internal lateral* or *deltoid ligament* is a strong, flat, triangular band which radiates from the lower and ventral borders of the internal malleolus downward and backward to the rough inner surface of the astragalus, downward to the sustentaculum tali of the os calcis, and downward and forward to the navicular and the margin of the inferior calcaneo-scaphoid ligament. A so-called *deep portion* descends from the notch on the lower border of the malleolus to the depression on the inner surface of the astragalus.

The *external lateral ligament* presents three separate diverging bands: 1. The

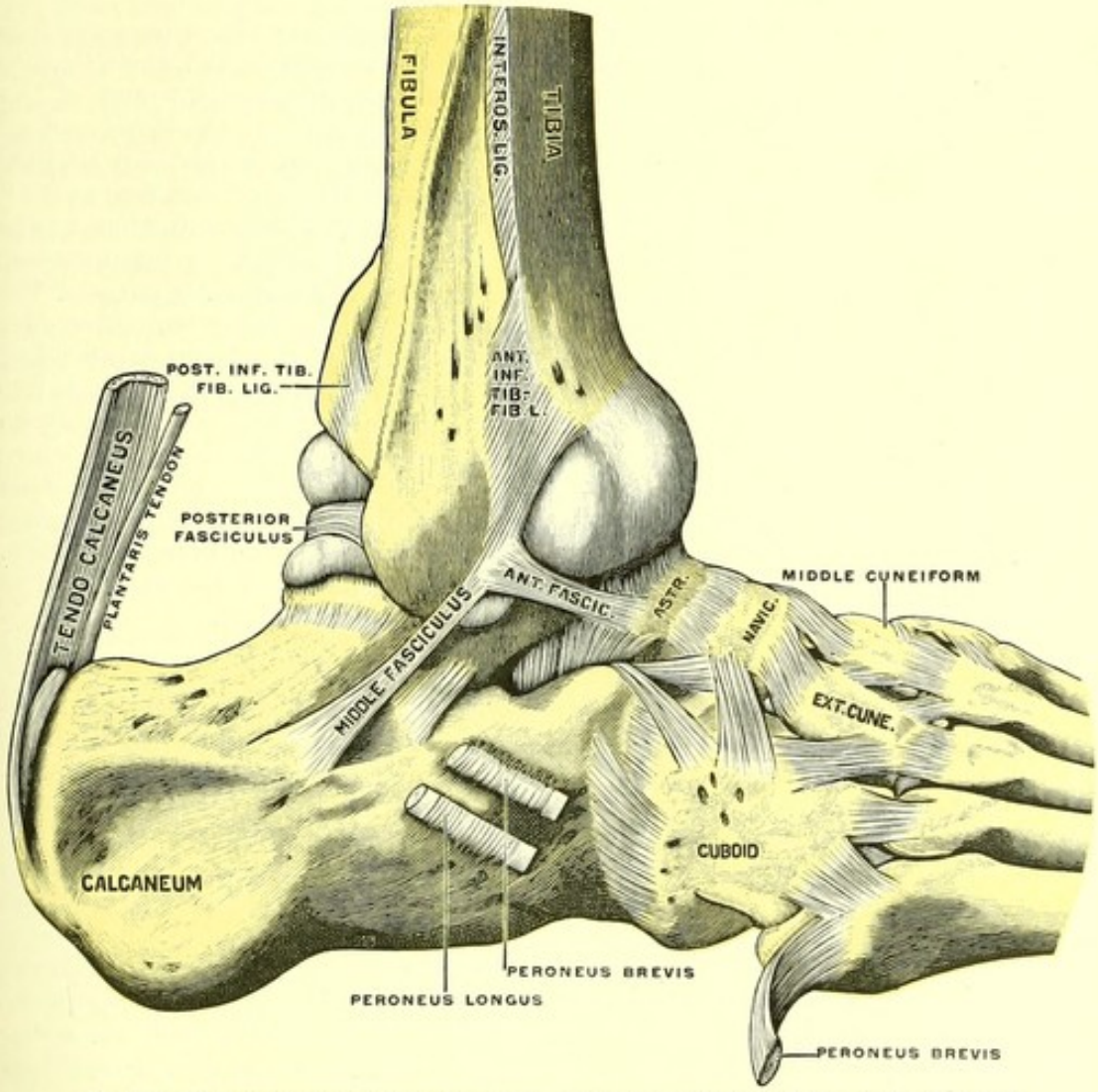

FIG. 257.—Tibio-tarsal articulation, outer side. The cavity is artificially distended. (Testut.)

anterior fasciculus, short and ribbon-like, passes from the ventral border of the external malleolus obliquely forward and upward to the astragalus, in front of its external lateral facet. 2. The *middle fasciculus*, strong and round, descends slightly backward from the tip and the fore part of the outer surface of the external malleolus to the middle of the outer surface of the os calcis. 3. The *posterior fasci-*

culus is the strongest, and passes from the hind border and the fossa on the inner side of the external malleolus almost horizontally inward to the outer surface of the astragalus, behind the facet, and to its external tubercle.

The *anterior ligament* is a thin, loose membrane between the lateral ligaments in front. It is attached above to the ventral margin of the lower end of the tibia, above a slight transverse groove, and below to the rough upper aspect of the head of the astragalus. A mass of fat beneath it rests in the groove of the neck of the astragalus.

The *posterior ligament* is very thin and weak, and consists of scattered oblique fibres between the dorsal margins of the articular surfaces of the tibia and the astragalus. The flexor longus hallucis tendon serves largely as a posterior ligament.

The *synovial membrane* is very loose on the anterior and posterior ligaments, forming folds between the tibia and the astragalus. It forms a short *cul-de-sac* between the tibia and fibula, in addition to lining the ligaments of the ankle.

Nerves.—Branches from the anterior and posterior tibial and the internal saphenous supply the joint.

The *movements* of the ankle are flexion and extension through a range of less than 90°. Flexion or dorsal flexion, in which the dorsum of the foot and toes approaches the leg, is limited by the posterior ligament, the posterior parts of the lateral ligaments, and by the contact of the ventral margin of the lower end of the tibia with the neck of the astragalus. In extreme flexion the fibula is slightly raised and spread somewhat from the tibia, accommodating the wide fore part of the upper articular surface of the astragalus. Extension or plantar flexion, where the toes are brought nearly into line with the leg, is limited by bony contact behind and by the tension of the anterior ligament and the anterior parts of the lateral ligaments. Extreme extension is accompanied by some adduction and slight supination of the foot, which probably occurs in the tarsal joints; for, although in this position the narrow dorsal part of the astragalus facet is less tightly held in the wide fore part of the tibio-fibular mortice, yet probably no lateral motion normally occurs except from external force. In the erect posture the line of gravity falls a little in front of the axis of the ankle, which is directed from within outward and backward. This obliquity of the axis helps to secure stability in the erect attitude, which is otherwise dependent on muscular action. The lateral ligaments are often partly ruptured in sprains of the ankle and in "Pott's fracture."

5. **The Tarsal Joints** (Figs. 256–259).

The articulations of the astragalus consist of (1) a *posterior* and *external astragalo-calcaneal joint*, and (2) an *anterior* and *internal calcaneo-astragalo-scaphoid joint*, the fore part of which, or the astragalo-scaphoid portion, is partly supported and encapsulated by the two calcaneo-scaphoid ligaments uniting the os calcis and scaphoid bone.

(1) In the *posterior astragalo-calcaneal joint* the dorsal pair of facets between these two bones are held together by a *capsule*, split up into several distinct slips as follows: An *internal astragalo-calcaneal band* passes from the internal tubercle of the astragalus, on the inner side of the groove for the flexor longus hallucis tendon downward and forward to the back of the sustentaculum tali. The *posterior astragalo-calcaneal ligament*, attached above to the external tubercle of the astragalus, spreads out onto the adjacent upper and inner surfaces of the os calcis. An *external ligament* connects the two bones beneath and in front of the middle slip of the external lateral ligament of the ankle, with which its fibres are parallel. The *interosseous ligament* is a strong band of fibres passing vertically between the grooves of the astragalus and os calcis, which together form the *sinus pedis*. It separates the two articulations between the astragalus and the os calcis, and consists of imperfectly separate layers, one of which serves as the anterior ligament of the posterior joint, and the other as the posterior ligament

of the anterior joint. Furthermore, those parts of the lateral ligaments of the ankle which reach the os calcis help to unite it with the astragalus.

(2) The *calcaneo-astragalo-scaphoid joint* is between the anterior facet on the upper surface of the os calcis and the facets on the lower surface of the head and neck of the astragalus, and between the head of the astragalus and the navicular. The bones are held together by the following ligaments, in addition to the interosseous ligament, which limits the joint postero-externally.

Calcaneo-scaphoid Ligaments.—The *inferior* or *internal ligament* is broad, thick, and partly fibro-cartilaginous. It firmly unites the front and inner edges of the sustentaculum tali with the inferior surface of the navicular and its inner surface behind the tubercle. Its upper surface is smooth and articular, and completes the socket for the head of the astragalus below and internally. The upper part of its under surface presents a smooth facet for the tendon of the tibialis posterior, which aids in supporting the head of the astragalus. It is blended internally with the internal lateral ligament of the ankle, and externally and below with the *external* or *superior calcaneo-scaphoid ligament*. The strong fibres of the latter ligament pass obliquely forward and inward from the fore part of the upper surface of the os calcis, external to its front upper facet, to the outer surface of the scaphoid. It limits both the anterior astragalo-calcaneal and the astragalo-scaphoid joints externally. The capsule is completed superiorly by the *astragalo-scaphoid ligament*, a broad, thin, membranous band, which converges from the upper surface of the head of the astragalus to the upper surface of the navicular.

The *synovial membrane* of the posterior astragalo-calcaneal and that of the calcaneo-astragalo-navicular joints are distinct, and separated from one another by the interosseous ligament.

The **calcaneo-cuboid articulation**, between the contiguous facets of the os calcis and the cuboid, forms, with that between the astragalus and scaphoid, the *medio-tarsal*, *transverse tarsal*, or *Chopart's joint*. The surfaces are held together by the following ligaments: The *inferior calcaneo-cuboid ligaments* consist of two por-

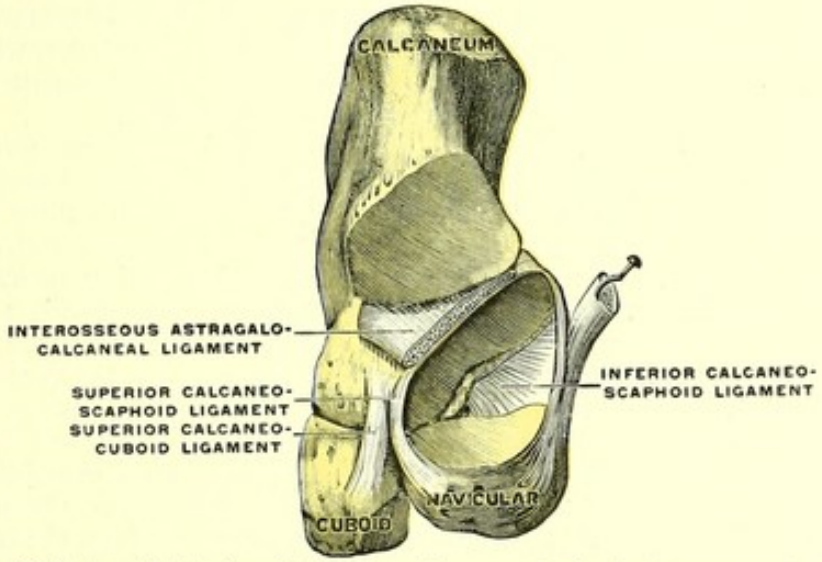

FIG. 258.—Medio-tarsal joint, viewed from above, the astragalus having been removed. (Testut.)

tions, known as *plantar ligaments*. The superficial part, or *long plantar ligament*, arises from the under surface of the os calcis between the tubercles, and extends forward to the oblique ridge on the under surface of the cuboid. From this ridge some fibres continue forward, bridging over and converting into a canal the groove for the peroneus longus tendon, and are attached to the bases of the outer four metatarsal bones. The deep portion, or *short plantar ligament*, attached to the under surface of the os calcis, to and in front of the anterior tubercle, extends forward and inward to the depression on the under surface of the cuboid behind the

oblique ridge. The *superior calcaneo-cuboid ligament* connects the adjacent parts of the upper surfaces of the two bones, blending externally with the outer part of the short plantar ligament, and internally with the *internal* or *interosseous calcaneo-cuboid ligament*. This strong band connects the inner surfaces of the two bones near their articular margins, lying deeply in the hollow between the os calcis and astragalus, where it is closely connected with the external calcaneo-scaphoid ligament.

The *synovial membrane* is separate from that of the other tarsal joints.

Movements.—The movements of the fore part of the foot on the hind part take place at the medio-tarsal joint. The movements at the calcaneo-astragaloid joints are inversion and eversion (turning of the sole inward and outward respectively), and adduction and abduction (the movement of the front of the foot to and from the median line respectively). Both of these forms of movement occur also in the medio-tarsal joint, and besides them there is here quite free flexion and extension around an oblique axis, extending from within outward and somewhat backward and downward. Flexion is simultaneous with extension at the ankle, and extension, which is more limited, is simultaneous with flexion at the ankle. Thus, the variety and range of motion of the foot are increased beyond the limited flexion and extension allowed in the ankle. The astragalo-scaphoid joint is of the ball-and-socket variety, but, owing to the connection of the scaphoid and cuboid bones, its motions are so restricted by the concavo-convex calcaneo-cuboid joint that adduction and inversion are combined with flexion and abduction, and eversion with extension, the latter being limited by the plantar ligaments. The calcaneo-scaphoid ligaments also limit motion here. At the medio-tarsal and astragalo-calcaneal joints increase of the arch, combined with adduction and inversion, or decrease of the arch with abduction and eversion, may occur, leading respectively to club- or flat-foot, when for any reason these positions are exaggerated and permanent.

In the Cubo-scaphoid joint the cuboid and navicular are united by—(1) a *dorsal ligament*, passing obliquely forward and outward from the scaphoid to the cuboid; (2) a *plantar ligament*, similarly disposed on the plantar surface; and (3) a strong *interosseous ligament*, connecting their contiguous surfaces, which, when they touch, present small articular facets, whose connecting ligaments are lined by an extension of the scapho-cuneiform *synovial membrane*.

The Scapho-cuneiform Articulation.—The navicular is united in one continuous joint to the three cuneiform bones in front of it by (1) strong *dorsal ligaments* from the upper surface of the scaphoid to that of each of the three cuneiform bones; and (2) by *plantar ligaments* similarly disposed beneath and continuous with the fibres of the tibialis posterior tendon, which, by passing outward as well as forward, strengthens the transverse arch of the foot. The dorsal and plantar ligaments are continuous on the inner aspect of the internal cuneiform bone.

The Cubo-cuneiform Articulation.—Transverse fibres unite the dorsal, plantar, and contiguous surfaces of the cuboid and external cuneiform bones, forming the *dorsal*, *plantar* and *interosseous ligaments*.

Intercuneiform Articulations.—The three cuneiform bones are similarly connected by transverse *dorsal* and strong *interosseous ligaments*. On the plantar surface there is a strong band passing outward and forward from the inner to the middle cuneiform bone, but the *tibialis posterior tendon* serves for the plantar ligaments.

Synovial Membrane.—A single synovial cavity is common to the scapho-cuneiform and the intercuneiform joints, and usually to the cubo-cuneiform joint, though the latter may have a separate synovial cavity. The synovial cavity between the cuneiform bones usually extends between the internal and middle cuneiform, to become continuous with that of the tarso-metatarsal joints between the middle and external cuneiforms behind and the second and third metatarsals in front.

The *movements* in the above arthrodial joints, between the tarsal bones in

front of the medio-tarsal joint, are limited to a slight gliding, due to the weight of the body rather than to muscular action, whereby the transverse arch of the foot is either flattened or deepened, thus increasing the elasticity and pliancy of the tarsus.

6. Tarso-metatarsal and Intermetatarsal Articulations.

The front surfaces of the three cuneiform bones and of the cuboid articulate with the proximal facets of the five metatarsals along a line (Hey's line) made irregular by the forward projection of the internal and external cuneiform bones. The first, second, and third metatarsals articulate with the internal middle and external cuneiform bones respectively, the fourth and fifth with the cuboid. The second metatarsal is wedged in between the internal and external cuneiforms, and the fourth usually articulates with the external cuneiform laterally. The surfaces are held together by dorsal, plantar, and interosseous ligaments. The *dorsal ligaments* are flat, thin bands which pass forward from the tarsal to the metatarsal bones. The first metatarsal bone receives one from the internal cuneiform; the

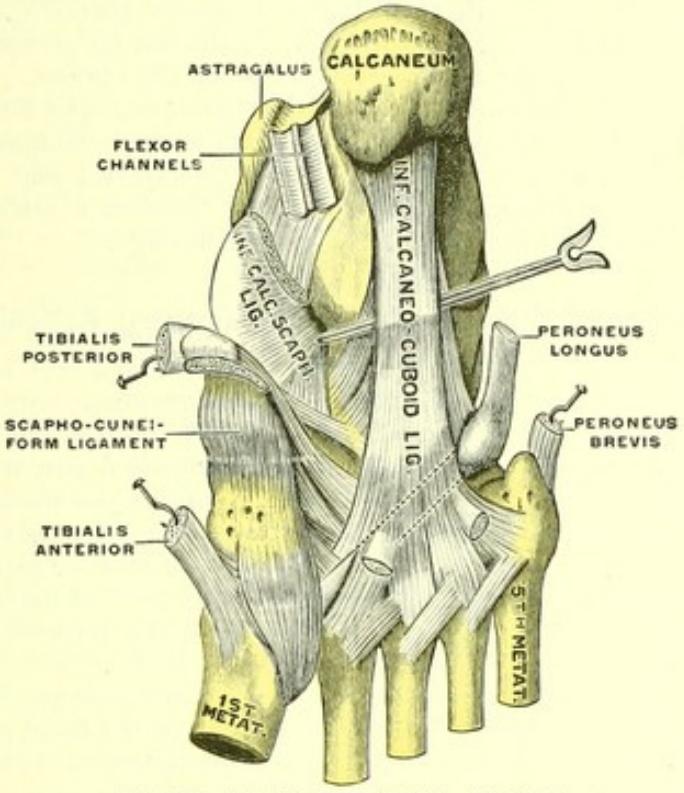

FIG. 259.—The plantar ligaments. (Testut.)

second, one from each cuneiform; the third, one from the external cuneiform; the fourth, one from the external cuneiform and one from the cuboid; the fifth, one from the cuboid. The *plantar ligaments* are more irregular, and are strengthened by the expansions of the tibialis posterior and peroneus longus tendons and the long plantar ligament. A strong plantar band connects the internal cuneiform with the first metatarsal, and another with the second and third metatarsal bones. Other slender plantar bands connect the metatarsal with their corresponding tarsal bones.

The *interosseous ligaments*, three in number, divide the synovial cavities of the tarso-metatarsal and intermetatarsal joints into three distinct parts, and offer resistance to disarticulation at this joint: (1) A strong interosseous ligament passes from the outer surface of the internal cuneiform to the contiguous non-articular portion of the inner surface of the second metatarsal, and shuts off the synovial cavity of the first tarso-metatarsal joint from that of the second and

third, which also extends between the bases of the second and third and between the third and fourth metatarsal bones, and is continuous with that of the naviculo-cuneiform joints, etc. (2) Another interosseous ligament separates the last-described synovial cavity from that between the fourth and fifth metatarsals and between them and the cuboid, by passing from the antero-external edge of the external cuneiform to the inner surface of the fourth and the opposed non-articular surfaces of the third and fourth metatarsal bones. (3) A slender interosseous ligament often passes from the inner and front edge of the external cuneiform to the outer side of the second metatarsal bone.

Intermetatarsal Articulations.—*Proximal.*—The four outer bones articulate with one another laterally, and are firmly bound together by short transverse *dorsal*, *plantar*, and *interosseous ligaments*. The *interosseous ligaments* connect the rough parts of the lateral surfaces in front of the articular facets, and are very strong. The *dorsal ligament* between the internal cuneiform and the second metatarsal takes the place of one between the first and second metatarsal bones, between which there is often a bursa with a facet on the first metatarsal only. *Distal.*—The digital extremities are loosely connected on their plantar aspect by four transverse bands blending with the plantar sesamoid plates. These form the *transverse metatarsal ligament*, which differs from the similar structure in the hand in having a band between the first and second metatarsal bones.

Movements.—In the tarso-metatarsal joints there are slight flexion and extension, combined in the first, fourth, and fifth joints with ab- and adduction, which are most free in the fifth joint. In the tarso-metatarsal and intermetatarsal joints there are also gliding movements, whereby the arch is altered and the foot adapted to the ground and made more elastic and flexible.

7. Metatarso-phalangeal and Interphalangeal Articulations.

The rounded heads of the metatarsal bones and the concave bases of the first phalanges form articulations similar to the corresponding joints of the hand. They are connected by *lateral ligaments* and a thick fibrous *plantar sesamoid plate*, ossified laterally in the great toe-joint into two *sesamoid bones*, which attach the flexor brevis tendons and bound a groove for the long flexor tendon.

The **phalanges** articulate with one another in the same manner as in the hand, and with the same ligaments (*i. e.*, lateral and an inferior or glenoid ligament), except that the second and third phalanges are often ossified together in the foot. The dorsal ligaments of the above joints are principally formed by the extensor tendons. Each joint has a separate synovial membrane.

The *movements* also are similar to those in the hand, except that at the metatarso-phalangeal joints extension is more free than in the hand; lateral motions (adduction and abduction) are less free, and take place to and from the second toe as a centre; and the movements of the great toe are much more limited than those of the thumb.

Mechanism.—In walking the heel is the first part of the foot to touch the ground, and the weight of the body is transmitted to it through the posterior calcaneo-astragaloid joint, the foot being slightly adducted. As the other foot swings forward the outer border of the supporting foot is raised from the ground and the weight is transmitted to the inner toes; the foot becomes abducted, and leaves the ground by means of flexion of the great toe. In standing, the longitudinal arch is supported and the weight of the body borne by the plantar and calcaneo-navicular ligaments. The oblique direction of the expansion of the tibialis posterior and peroneus longus tendons, forward and outward and forward and inward respectively, help to support the longitudinal as well as the transverse arch of the foot. The latter is also supported by the transverse plantar and interosseous ligaments. The heads of the metatarsal bones, on which, and not on the toes, the foot rests in front, are somewhat spread out by the weight of the body, when the foot is raised on the toes.

THE MUSCLES.

By F. H. GERRISH.

A **muscle** is an organ whose essential part is a mass of striated muscular tissue, prolonged at its opposite ends or margins by cords, bands, or sheets of white fibrous tissue, which are fastened to other structures, usually bones. The muscular tissue is contractile, and is the active portion of the organ; the fibrous is strong and flexible, but is only passive. The contractile portion is called the *muscle proper*, the *belly*, or the *body of the muscle*; the fibrous extensions are called *tendons* (sinews), and sometimes, when greatly expanded, *aponeuroses*. The muscle proper may be compared to an engine, in which force is generated; its tendons to the ropes by which the power is applied to distant objects.

The relation of the tendons to the body of the muscle varies greatly in different muscles, both as regards their proportion and their arrangement. The belly may have tendinous structure only at its extremities, or one or both of the tendons may start far back upon the surface of the contractile mass, or a tendon may be in large part concealed in the midst of the muscular tissue. Several plates of tendon may be thus embedded, all connected with the terminal cord. When the tendons are found only at the ends of a muscle, the fibres of the two kinds of tissue are substantially in the same axis; but, when one of the other arrangements obtains, the muscular fibres are placed at an angle to the tendinous, as the barbs of a feather are related to the quill.

In a few muscles there is a *third tendon* midway of its contractile mass, which is thus divided into two, becoming *double-bellied*—in technical phrase, *digastric* or *biventral*. One or more narrow, fibrous interruptions, partial or complete, may occur in some long muscles, constituting *tendinous inscriptions*.

Bones in Tendons.—Small osseous masses, called *sesamoid* ("like sesame") *bones*, are sometimes developed in tendons at points where they play over joints and are exposed to great pressure. Some of these are constant, as the patella, which is a sesamoid bone in the great muscle which straightens the leg on the thigh.

Synovial Sheaths of Tendons.—Synovial membrane of the vaginal form is developed around many tendons which run in canals, as in the case of various digital muscles. *Bursal synovial membranes* are found at very many spots where tendons press upon one another or upon other organs, especially where they pass over prominences of bone. An *articular synovial membrane* may be prolonged beyond its joint, and furnish a lubricating sheath to the tendon of a neighboring muscle.

Attachments of Tendons.—A tendon may be long or short; it may resemble a cord, a ribbon, or a sheet. In the last case it is commonly called an aponeurosis—an undesirable, because etymologically misleading, name, but now firmly fixed by eminent sanction. Tendons are usually fastened to bones and cartilages, but may be attached to ligaments, skin, and other soft parts. The fibrous tissue of the tendon intermingles, and becomes continuous, with the periosteum of the bone, the perichondrium of the cartilage, or the deep layer of the skin, thus blending with a structure which is histologically identical with itself. When one con-

siders the intimacy of relation between periosteum and bone, he is not surprised at the infrequency of the separation of a tendon from its osseous attachment.

Proportionate Increase of Tendons with Age.—The tendinous portion of a muscle increases with years, and on this account the muscles of an adult are stiffer than those of a child, and the range of joint-movement is diminished. A child's extended lower limb may be kept at a right angle with his trunk for a long time without causing him any discomfort; but the same procedure cannot be practised upon an adult without producing great suffering and perhaps injury. The difference is due to the normal muscular extensibility in the infant on the one hand, and the equally normal tendinous inextensibility in the adult on the other.

Origin and Insertion of Muscles.—A muscle is attached to two objects, and by its contraction lessens the distance between them. The part which is fastened to the more fixed of these objects is called the *origin*, the other the *insertion*. The origin is generally, especially in the limbs, proximal, the insertion distal. But the terms are entirely physiological and largely conventional, for in case of many muscles there is room for difference of opinion as to which portion is the more entitled to be called origin—the action being as frequently from one end as from the other.

Fasciæ.—The muscles in a region are maintained in close relations with each other by strong sheets of white fibrous tissue, which are wrapped firmly around them and often send shelves between them. These fibrous expansions are called *fasciæ* ("bandages"), and also *aponeuroses of investment*. They will be described in detail after the muscles have been considered. It will suffice here to remark that it is common for muscles to have extensive attachments, either of origin or insertion, to the fasciæ which enwrap them.

Ligamentous Action of Muscles.—The muscles perform a valuable service in keeping the cartilaginous surfaces of the movable joints in contact. The ligaments proper are in many cases utterly inadequate for this work, as witness the joint between the shoulder and arm: remove the muscles and the humerus drops away from the glenoid fossa. But the muscles, which normally are never fully relaxed, keep up a tireless pressure, and, excepting violent accidents, never allow a separation to occur. This unvarying normal tension of muscular tissue is an obstacle to the reduction of fractures and dislocations; for as soon as a bone is thrown out of its position, or a breach in the continuity of its substance occurs, the neighboring muscles, in demonstration of their being constantly somewhat tense, pull the luxated bone still further out of place, or cause the fragments to overlap each other. The muscular force is often so great as to require much strength, or anæsthesia, or both, to overcome it.

The Mechanics of Muscular Attachments.—The points of attachment of most muscles are such as to place these organs at a great mechanical disadvantage. This is very evident in a large part of the muscles of the limbs. Take, for example, a muscle which bends the forearm upon the arm. It is attached to the lower half of the front of the humerus, crosses the elbow-joint, and just below this is attached to the ulna (Fig. 260). The loss of power involved here is illustrated in a homely way by comparing the effort required to close a door by pulling it toward one, when it is grasped at a point near the hinges, with that which suffices when it is seized near its free edge, where the knob is usually placed. Manifestly the latter method is vastly easier. If the same plan were adopted in the flexion of the forearm, the muscle would be attached high on the humerus and low on the ulna (Fig. 261). But, although this would be advantageous as regards the expenditure of force, it would be strikingly otherwise in directions of quite as much importance. In the first place, the contraction of muscular tissue shortens it to one-half its length and no more, on which account the forearm could be bent upon the arm only to B, instead of to a much higher point, C, which is normally reached. In the second place, there would be a loss of rapidity

of movement of the lower end of the limb about proportionate to the gain of power; for the nearer to the hinge the force is applied, the more rapid will be the movement of the long arm of the lever. Then, the occupation by the muscle of each successive portion of the great triangular space included by it and the two bones when in flexion would be an intolerable interference with the usefulness of the limb, practically reducing the carrying power of the front of the forearm to

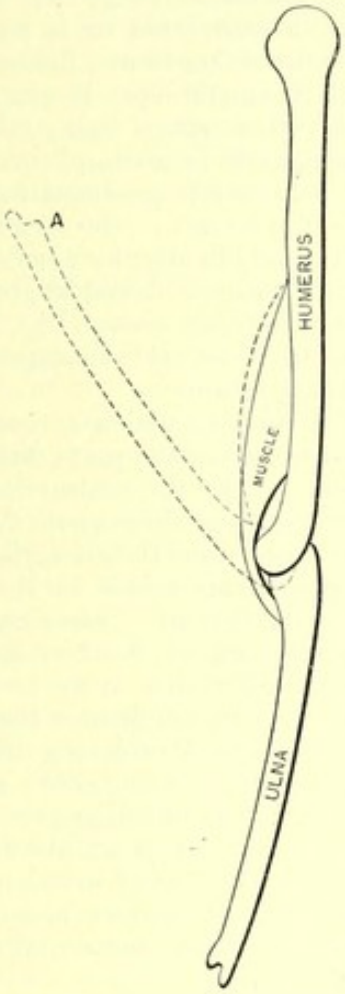

FIG. 260.—Diagram showing the mechanical disadvantage of the points of attachment of many muscles. (F. H. G.)

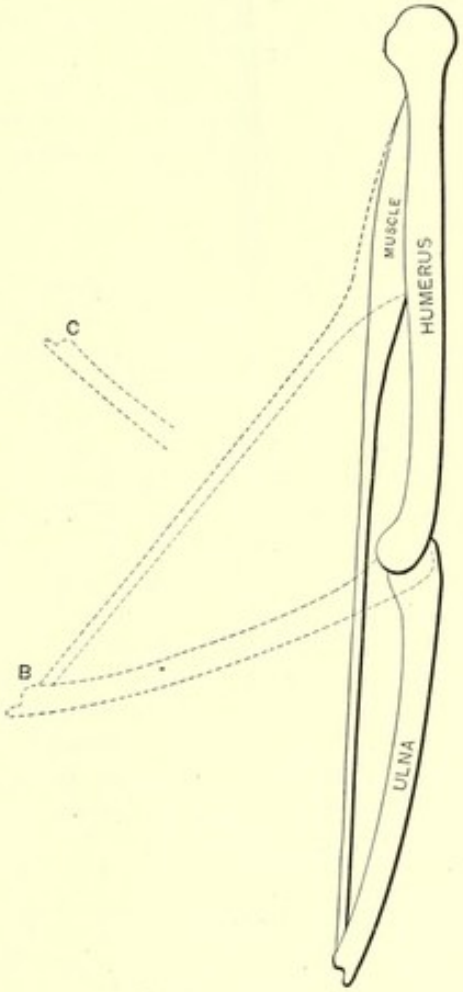

FIG. 261.—Diagram showing the effect of attaching a limb-muscle at points of the greatest mechanical advantage. (F. H. G.)

nothing. There would also be a loss of a great deal of the important ligamentous work of the muscles by their removal from close contact with the joints during their most pronounced activity. Thus it will be seen that the condition which exists, while extremely costly in the matter of muscular expenditure, is attended with advantages which are more than compensatory.

Change in Direction of Muscular Force.—Tendons are often made to pass around prominences and through loops, the force originating in the muscle, thus experiencing a change of direction, as in the case of a rope which runs from an engine through a pulley to an object which is to be hoisted. The contractile force of such a muscle is applied in line with the portion of its tendon lying between the last angle which it makes and the point of its attachment to the object to be moved. On account of the lubrication of the tendon by synovia, which is always present in such cases, no appreciable loss of power is experienced by the change of direction.

Primary, Secondary, Direct, and Reversed Actions.—A muscle which crosses

only one joint has but two possibilities of action: one, which may be called its *direct action*, is from a fixed origin to a movable insertion; the other, its *reversed action*, is from a fixed insertion to a movable origin. But many muscles cross two or more joints, and by so much is the number of their movements augmented. For instance, the superficial flexor of the fingers primarily and directly flexes the second phalanges upon the first phalanges (Fig. 262, A); but, when this movement is completed or is prevented, continuance of the contraction causes flexion of the first phalanges upon the metacarpal bones, and this may be called the *direct secondary action* (Fig. 262 B). When this movement is accomplished or arrested, still further contraction produces flexion of the whole hand upon the forearm—the *direct tertiary action* (Fig. 262, C); and, finally, by persistence in the performance, the forearm is flexed slightly upon the arm—the *direct quaternary action* (Fig. 262, D). The reversed actions in these various stages are too obvious to require description.

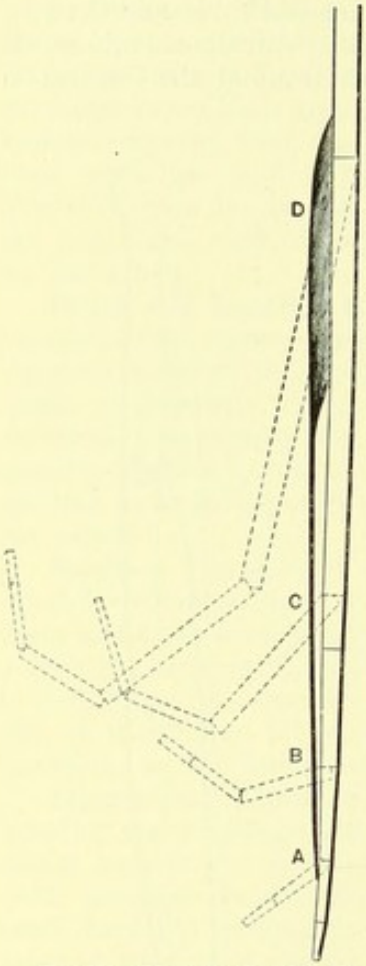

FIG. 262.—Diagram showing the primary, secondary, tertiary, etc. actions of a muscle. (F. H. G.)

The segment of a limb on which a muscle acts carries with it, of course, all of the parts distal to it; and the movement effected by the contraction of the muscles is more manifest upon those parts than upon the segment bearing them, since they describe larger arcs. This is particularly noticeable in the pronation and supination of the radius. The change in the relation of the lateral parts of the forearm is far less apparent than the alteration in the attitude of the hand, which passively accompanies the radius.

The Blending of Muscles.—Muscles are often associated in groups so intimately that, either at origin or insertion, there is an actual blending of substance. Myologists have not agreed upon an absolute rule for the settlement of the question of division or unification in these cases, some describing as two or three distinct muscles what others regard as a compound one. There is much in this connection which is conventional and arbitrary, and, consequently, perplexing.

The Muscles in Pairs.—Almost all of the skeletal muscles are arranged in pairs, and thus a description of one on either side will answer for its mate on the opposite side. A few are single and located about the median line, and in these there is generally a bilateral symmetry.

The Size of Muscles varies from a fraction of an inch to many inches. In form they are extremely diverse, and only in a small proportion is their resemblance to familiar objects sufficiently striking to justify the application of names intended to be descriptive of their shape.

The Nomenclature of Muscles.

Latinity of Names.—The muscles are almost always called by their Latin names. A few have become Anglicized, commonly by the omission of the termination (as *deltoid* instead of *deltoideus*); but the attempts which have been made to displace the Latin appellations by substituting English translations of them have always failed. The student, however, should learn the exact meaning of every name, as this knowledge cannot fail to be of great assistance to him. For example, almost one-half of the names of the muscles moving the several

segments of the upper limb, are descriptive of the action of these muscles, and nearly two-thirds of these convey some additional information—of form, situation, or size. The majority of the names of the other half of this group indicate position, and the residue call attention to some characteristic of shape or resemblance. From this it will be seen that the names are not arbitrary, but are designed to be descriptive, and, consequently, are helpful in the first learning and in the permanent retention of the facts.

The Latin word *musculus* ("muscle") is always implied in the name of a muscle, and the part which is expressed is either an adjective or a noun in apposition, with or without limiting words.

Reasons for the Names of Muscles.—Muscles are named from various considerations, and occasionally more than one of these is appealed to in the selection of a name. It is noticeable that the names of individuals are not used in the nomenclature of muscles, as they are in almost every other branch of anatomy.

The following are the principal derivations of the names of muscles: 1, *action* or supposed action, as levator scapulæ, "the lifter of the shoulder-blade," supinator, "the muscle producing supination"—turning the part onto its back; 2, *form*, as gracilis, "the slender muscle," serratus, "the saw-toothed muscle;" 3, the *form of two muscles* symmetrically located on opposite sides of the body, as trapezius, "the table-like muscle," though each trapezius is not trapezoid but triangular; 4, *resemblance to a natural object*, as lumbricalis, "the earthworm muscle," soleus, "the sole-fish muscle;" 5, *situation*, as frontalis, "the forehead muscle," subclavius, "the muscle under the collar-bone;" 6, *attachments*, as coracobrachialis, "the muscle connecting the coracoid process and the arm," brachioradialis, "the muscle connecting the arm and the radius;" 7, *size*, either absolute, as vastus, "the great muscle," or comparative, as latissimus, "the broadest muscle;" 8, *division*, as quadriceps, "the four-headed muscle," multifidus, "the muscle of many clefts;" 9, *paired condition*, as gemellus, "the twin muscle;" 10, *supposed singleness*, as azygos uvulæ, "the uvula muscle not yoked to a mate;" 11, *involvement of structure*, as complexus, "the complicated muscle;" 12, *direction of fibres*, as rectus, "the straight muscle," transversalis, "the transverse muscle;" 13, *relative proportion of contractile and non-contractile tissues*, as semimembranosus, "the half-membrane muscle," semitendinosus, "the half-tendon muscle;" 14, existence of a *tendon midway between two contractile portions*, as digastric and biventer, "the muscles with two bellies;" 15, *occupation* in which the muscle is thought to be useful, as sartorius, "the tailor's muscle," buccinator, "the trumpeter's muscle;" 16, *expression produced*, as risorius, "the laughing muscle;" 17, *the subordinate character of the work done*, as accessorius, "the assistant muscle."

Names of Movements Produced.—Most of the movements of the parts upon which muscles act have received specific names, some of which are applied also to the attitudes resulting from these movements. When one part is bent upon another, the movement is called *flexion* ("a bending"); when the part is straightened out, the action is *extension* ("a stretching"); and thus flexion and extension are antagonistic actions and attitudes. The moving of a part further away from the middle line (the median plane of the whole body being meant, unless otherwise specified) is *abduction* ("a drawing from"); the opposite movement, by which the part is restored to its former position, is *adduction* ("a drawing to"). The slight difference between these antipodal words should be noted—the one begins with *ab*, the Latin for "from," the other with *ad*, the Latin for "to." When a part is made to revolve upon its long axis, the movement is *rotation*, ("a revolving"); and when its lower extremity is caused to describe a circle, and the part itself thus traverses the periphery of a cone, the action is *circumduction* ("a drawing around"). The movement which turns a part onto its face is *pronation* ("a bending forward"), and the reverse is *supination* ("lying on the back").

The Order of Study.—The muscles will be considered in the following order:

The muscles of THE UPPER LIMB.
The muscles of THE LOWER LIMB.
The muscles of THE TRUNK.
(*a*) those of *the back*, including the dorsum of the neck.
(*b*) those of *the abdomen*.
(*c*) those of *the thorax*.
The muscles of THE NECK, at the front and sides.
The muscles of THE HEAD.

The muscles of the *tongue*, *pharynx*, and *soft palate* will be presented in connection with the organs of digestion; those of the *larynx* with the respiratory system; those of the *eye* and *ear* with special sense organs; and those of the *perineum* with the genitals.

Illustrative Pictures are provided so liberally in this chapter, and show certain details so clearly, that it is practicable to omit from the verbal descriptions many things which are usually given in them, and this, too, not only without diminution of clearness, but often with distinct advantage in this regard, since facts can usually be more quickly apprehended and more firmly held when presented by pictorial means, than when introduced into the mind through the medium of words. Thus, the form of a muscle, the most important relations of its contractile and tendinous portions, and its principal relations to neighboring muscles are generally shown so plainly in the drawings of dissections, that their description can safely and profitably be omitted from the text.

The Outline Drawings *of individual muscles show in each instance the location and proportionate size of the areas of osseous origin and insertion, and also the margins of the entire muscle from the selected point of view, thus suggesting its action. In cases where a surface of attachment or a part of the outline is not visible from the chosen point, the concealed portion is drawn in dots or broken line, and is represented as if the intervening skeletal structure were transparent.*

Minuteness of verbal description of muscular attachments, while morphologically interesting, is of little or no practical value to the physician and surgeon, and, consequently, is not attempted. The essential facts are presented in the text, and in most cases are abundantly illustrated in the outline drawings.

Connection with Neighboring Soft Parts.—The attachments to superjacent fasciæ, intermuscular septa, and other soft parts will often be omitted from the text for the sake of brevity, especially when these are of insignificant extent, or have already been mentioned in connection with the group of muscles concerned. It may usually be assumed that a muscle has some attachment to the fibrous structures—investing sheets, partitions between it and its immediate neighbors, ligaments, etc.—with which it is in close contact.

The Action assigned to a muscle is that effected by its contraction from a fixed origin to a movable insertion—the direct primary action—unless otherwise specified. The direct secondary and all reversed actions can be worked out correctly and easily by one who has learned the direct primary action and the anatomical reasons for it.

Classification of the Limb Muscles.—The classification of the muscles of the limbs which is here given is physiological, being based upon their primary and most characteristic action. Although this grouping is very different from that which is generally followed, it is believed to be more useful as an aid in learning the facts of greatest importance in myology, and in applying the knowledge thus gained in medical and surgical practice. Of course, it is not claimed that this classification is perfect—none which rests upon a physiological basis can be; but long employment of it has demonstrated its utility in attracting and holding the interest of the student, and this mainly because there is kept constantly in view the application of the facts which he is learning. After the muscles of a limb have been described, their classification on a regional basis will be presented.

THE MUSCLES OF THE UPPER LIMB.

Movements of the Upper Limb.

Each of the four primary segments of the upper limb is capable of a wide range of action.

Movements of the Shoulder.—In the chapter on the joints the scapula is shown to be somewhat movable upon the clavicle; but, in studying the principal action of the muscles, the movements of the claviculo-acromial joint may be ignored without serious departure from the fact, and the skeleton of the shoulder may be regarded as practically a single bone. This framework is pivoted upon the trunk at the sterno-clavicular articulation, and is proximally attached at other points by muscles only. The movements of the shoulder, therefore, centre on the upper end of the sternum, and are made upward, downward, forward, and backward, the terms used to designate them—elevation, depression, etc.—requiring no explanation.

Movements of the Arm.—The arm, being united to the shoulder by means of a ball-and-socket joint, can be moved in every direction which is consistent with the integrity of the articular structures and with the retention of the humeral head in the glenoid fossa. Its movement forward is *flexion*, backward is *extension*, outward is *abduction*, inward is *adduction*. When it is rolled on its own axis so that its front turns toward the trunk, the movement is *inward rotation*; when it revolves so as to turn its front away from the trunk, the action is *external rotation*. Its *circumduction* is *inward* when the front semicircle described by the lower end of the arm is made from the outside toward the mid-line, and the opposite movement is *outward circumduction*.

Movements of the Forearm.—The elbow-joint proper is a hinge, allowing motion between the forearm and arm only forward, which is *flexion*, and backward, which is *extension*. Between the two forearm bones, however, are movements which consist in the overlapping of the ulna by the radius, *pronation*, and the opposite action by which the parts are restored to their anatomical attitude, *supination*.

Movements of the Hand.—The articulation between the forearm and carpus permits motion of the hand forward, which is *flexion*, backward which is *extension*, sidewise toward the mid-line, *adduction*, and from this line, *abduction*. *Circumduction*, which is accomplished by a combination of these movements, is inward or outward, according to the rule given above. In these various movements of the whole hand some motion takes place in the joints between the carpal bones; but these are so slight as to be practically inappreciable, and require no further mention.

Movements of the Metacarpal Bones.—The *second*, *third*, and *fourth metacarpal bones* are so firmly joined to the carpus that but little motion is possible, even when their respective digits are most forcibly acted upon. The *fifth metacarpal bone* has an appreciable forward movement, which is *flexion*, a backward, which is *extension*, and slight lateral motions, *abduction* and *adduction*. The *first metacarpal* is so articulated at the wrist that its range is very great, and this freedom of action is more than a compensation for the deficiency of a phalanx in its digit.

Movements of the Common Digits.—Forward movement of the *fingers* and of each of their phalanges is *flexion*, and backward movement is *extension*. The lateral movements of the fingers are called *abduction* and *adduction*; but the median line of the body is not here taken as the plane from and to which the action is reckoned, a line drawn through the middle of the middle finger when it is in repose being substituted. There is practically no lateral motion at the interphalangeal joints.

Movements of the Thumb.—It is to be particularly noticed that the first metacarpal is so placed that the thumb is in advance of the plane of the other digits and its palmar aspect is about at a right angle with theirs. Consequently, a bending at the joints of the thumb toward its palmar aspect, which is *flexion*, as in the case of the other digits, causes it to cross the palm of the hand toward the hypothenar eminence. The restoring movement is *extension*. *Abduction* of

the thumb is in the direction of flexion of the fingers, and its *adduction* is in the direction of their extension. Its circumduction requires no especial description.

It will be observed that, from the shoulder-joint down, the *forward movements are flexions*, and the *backward movements are extensions*—the thumb offering the only exceptions. In the lower limb this rule does not apply.

Classification of the Muscles of the Upper Limb on the Basis of their Principal Action.

Moving the Shoulder.

Upward and backward.	*Downward and forward.*
Trapezius.	Serratus magnus.
Levator scapulæ.	Pectoralis minor.
Rhomboideus minor.	Subclavius.
Rhomboideus major.	

Moving the Arm.

Abductors.	*Adductors.*
	Pectoralis major. } *also flexors.*
Deltoideus.	Coraco-brachialis. }
Supraspinatus.	Latissimus. } *also extensors.*
	Teres major. }

Outward Rotators.	*Inward Rotator.*
Infraspinatus.	Subscapularis.
Teres minor.	

Moving the Whole Forearm.

Flexors.	*Extensors.*
Biceps flexor cubiti.	Triceps extensor cubiti.
Brachialis.	Anconeus.
Brachio-radialis.	

Moving the Outer Part of the Forearm.

Pronators.	*Supinator.*
Pronator teres.	Supinator.
Pronator quadratus.	

Moving the Whole Hand.

Flexors.	*Extensors.*
Flexor carpi radialis.	Extensor carpi radialis longus.
[Flexor] palmaris longus.	Extensor carpi radialis brevis.
Flexor carpi ulnaris.	Extensor carpi ulnaris.

Moving the Fingers and the Fifth Metacarpal Bone.

Flexors.	*Extensors.*
Flexor sublimis digitorum.	Extensor communis digitorum.
Flexor profundus digitorum.	Extensor minimi digiti.
*Flexor ossis metacarpi minimi digiti.	Extensor indicis.
*Flexor brevis minimi digiti.	
*Lumbricales.	

Abductors.	*Adductors.*
*Interossei dorsales.	*Interossei palmares.
*Abductor minimi digiti.	

Moving the Thumb and its Metacarpal Bone.

Flexors.	*Extensors.*
*Flexor ossis metacarpi pollicis.	Extensor ossis metacarpi pollicis.
*Flexor brevis pollicis.	Extensor brevis pollicis.
Flexor longus pollicis.	Extensor longus pollicis.

Abductor.	*Adductor.*
*Abductor pollicis.	*Adductor pollicis.

* Situated entirely in the hand.

MUSCLES MOVING THE SHOULDER.

Upward and backward.	*Downward and forward.*
Trapezius.	Serratus magnus.
Levator scapulæ.	Pectoralis minor.
Rhomboideus minor.	Subclavius.
Rhomboideus major.	

All of these muscles arise from the trunk, excepting one, which has its origin in the neck. All are inserted into the skeleton of the shoulder.

Trapezius (Figs. 263, 264).—So called from the resemblance which it with its mate bears to a four-sided table (Greek *trapeza*, "a table"). *Synonym*, cucullaris,

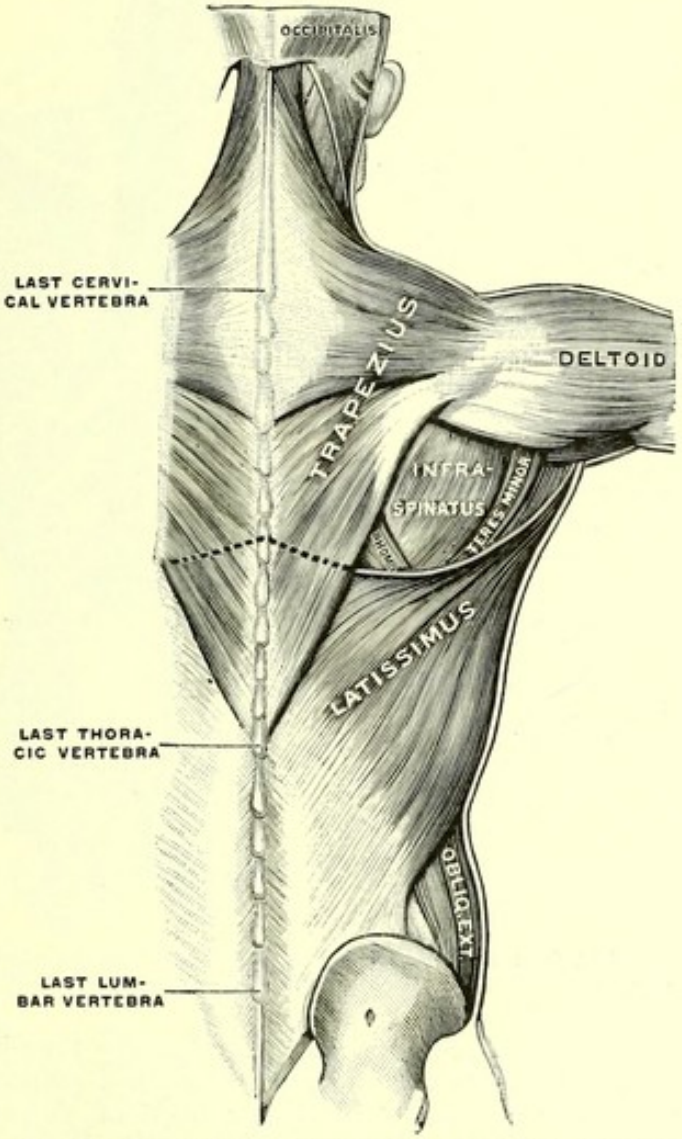

FIG. 263.—Muscles in the superficial layer of the back. (Testut.)

from the likeness of the pair to a monk's hood (Latin *cucullus*). *Situation*, superficial, on the dorsal aspect from the occiput to the base of the thorax, and lat-

erally to the peak of the shoulder; also, at the side of the neck, and the top and front of the shoulder. *Origin*, the inner third of the superior curved line and the protuberance of the occipital bone, the ligamentum nuchæ, the spines of the last cervical and all of the thoracic vertebræ, and their supraspinous ligament. *Direction* of fibres, convergent: the upper, down-, out-, and forward; the middle, outward; the lower, up- and outward. *Insertion*, the outer third of the hind border of the clavicle, the inner border of the acromion, the upper border of the scapular spine, the tubercle near its inner end. *Action*: the upper

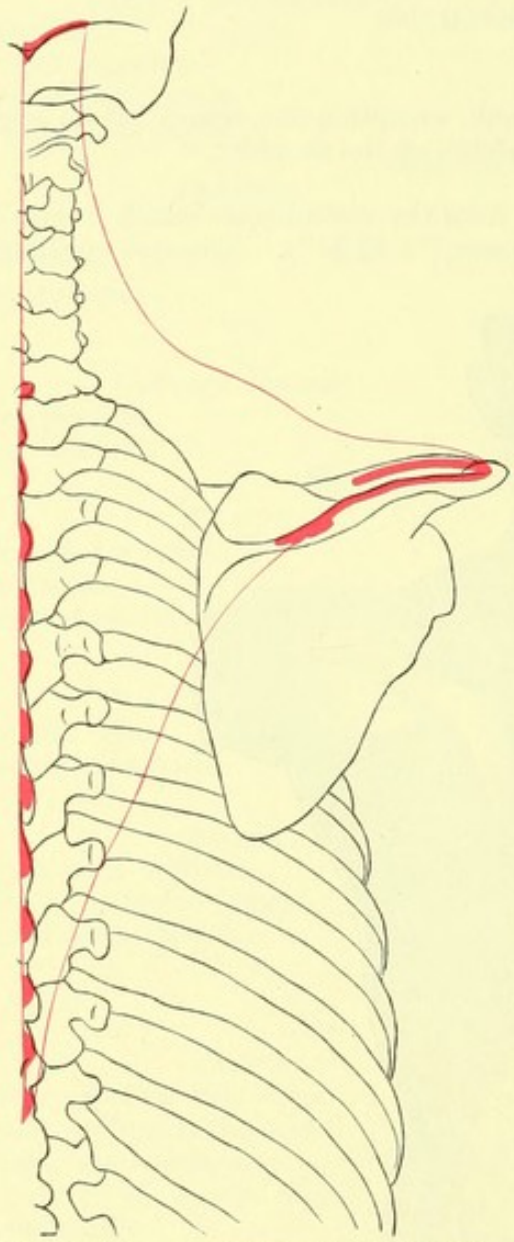

Fig. 264.—Trapezius of right side: outline and attachment-areas. (F. H. G.)

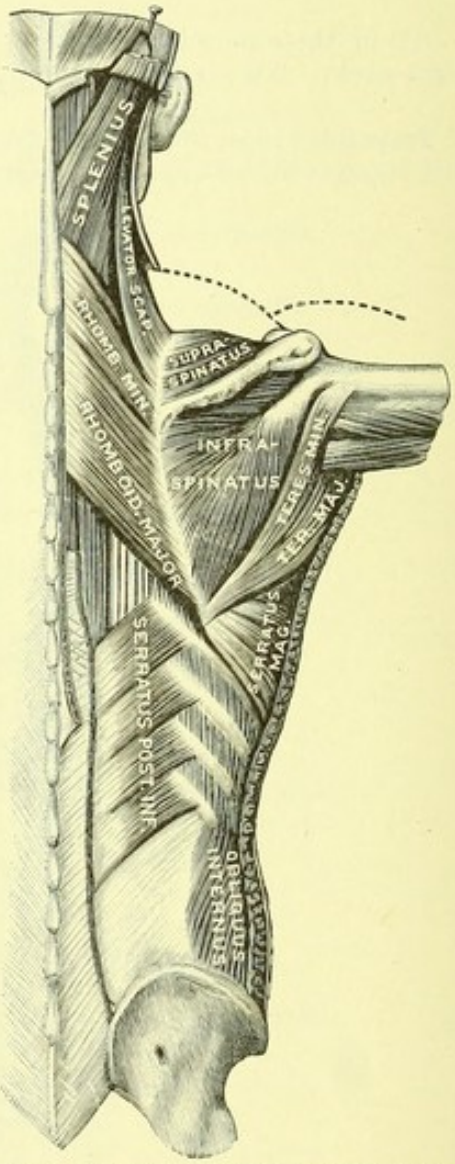

Fig. 265.—Muscles in the second layer of the back and on the dorsum of the shoulder. (Testut.)

part raises the shoulder, the middle draws the shoulder toward the spine, the lower pulls the scapula down- and inward, and tilts the acromion upward. All together lift the shoulder and rotate the lower angle of the scapula outward. *Nerves*, the spinal accessory, and the third and fourth cervical.

Levator Scapulæ (Figs. 265, 266).—"The lifter of the scapula." *Synonym*, levator anguli scapulæ, "the lifter of the angle of the scapula." *Situation*, on the side of the neck from the vertebræ to the upper scapular angle. *Origin*, the hind

tubercles of the transverse processes of the upper four or five cervical vertebræ. *Direction*, down-, out-, and backward. *Insertion*, the vertebral border of the scapula from the upper angle to the root of the spine. *Action*: it lifts the upper angle of the scapula and depresses the tip of the shoulder. *Nerves*, the third, fourth, and fifth cervical.

Rhomboideus Minor (Figs. 265, 267).—"The smaller rhomb-shaped muscle." *Situation*, in the back, between the spinal column and the scapula. *Origin*, the

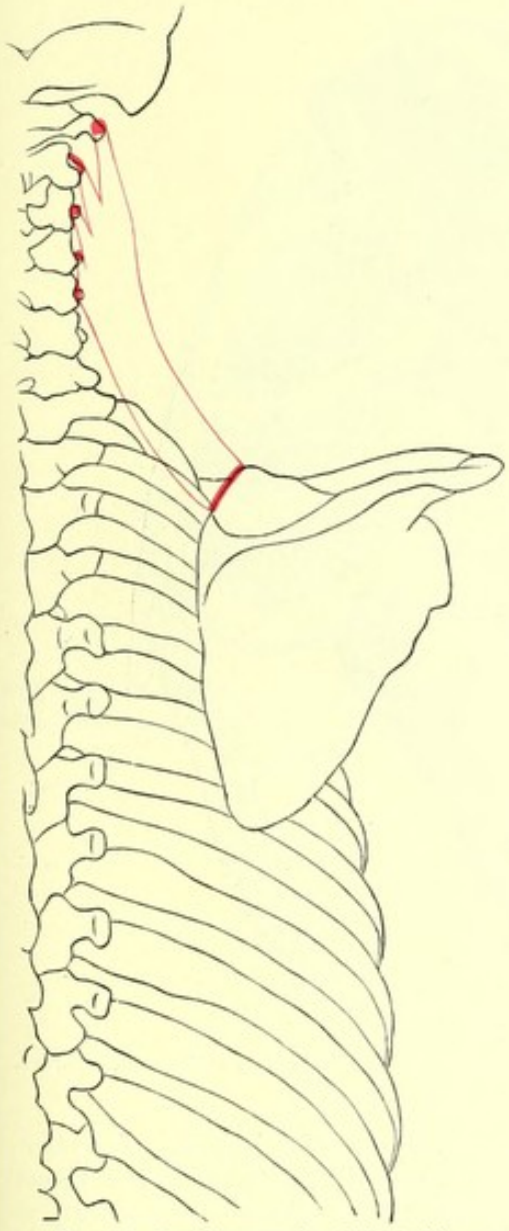

FIG. 266.—Levator scapulæ of right side, rear view: outline and attachment-areas. (F. H. G.)

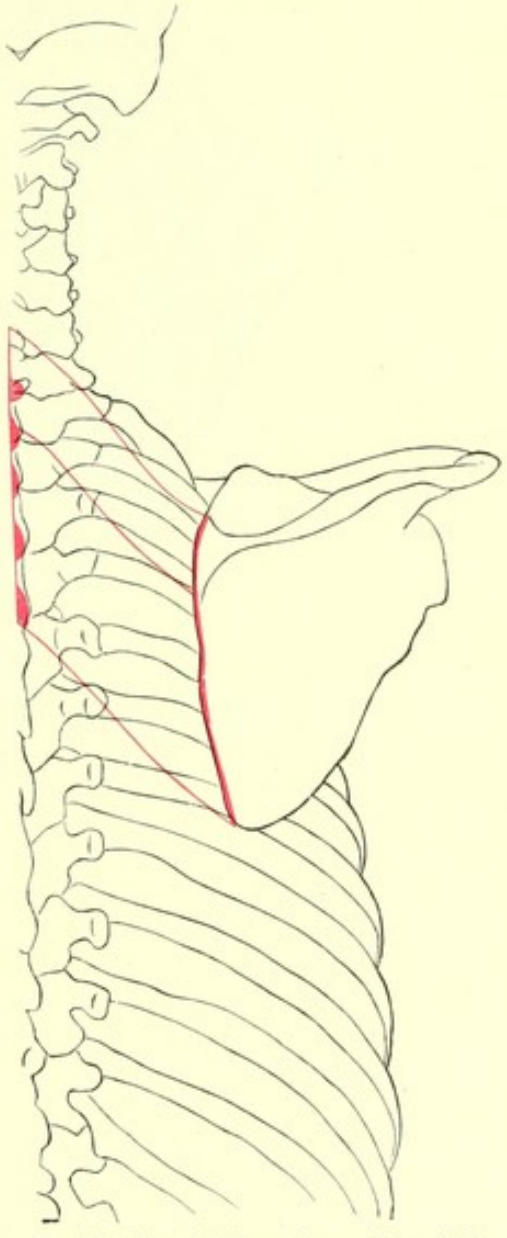

FIG. 267.—Rhomboideus minor and rhomboideus major of right side: outline and attachment-areas. (F. H. G.)

lower part of the nape ligament, the spines of the seventh cervical and first thoracic vertebræ. *Direction*, down- and outward. *Insertion*, the vertebral border of the scapula at the root of its spine. *Action*: it draws the scapula up- and inward, and depresses the tip of the shoulder by rotating the scapula. *Nerve*, the fifth cervical. This muscle is often united with the following:

Rhomboideus Major (Figs. 265, 267).—"The larger rhomb-shaped muscle." *Situation*, in the back, between the spinal column and the scapula. *Origin*, the spinous processes of the upper four or five thoracic vertebræ and the corresponding supraspinous ligament. *Direction*, down- and outward. *Insertion*, the ver-

tebral border of the scapula, between the root of the spine and the lower angle. *Action*: it draws the scapula up- and inward. *Nerve*, the fifth cervical.

Serratus Magnus (Fig. 268).—"The great saw-toothed muscle." *Synonym*, serratus anterior. *Situation*, on the upper two-thirds of the side of the chest. *Origin*, by digitations from the outer surface of the upper eight or nine ribs,

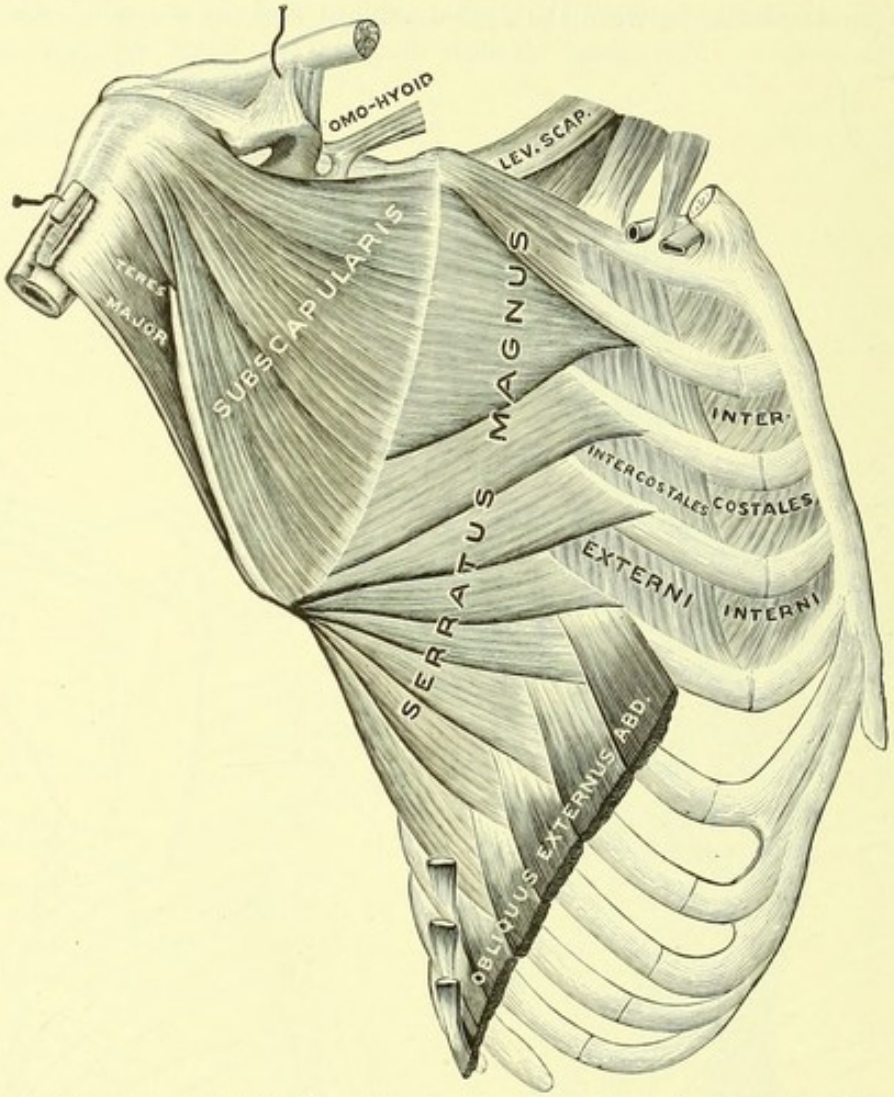

FIG. 268.—Serratus magnus of right side. The scapula has been turned backward and drawn outward. (Modified from Testut.)

several inches from their front ends. *Direction*, up- and backward. *Insertion*, the front of the vertebral border of the scapula, and the surfaces at the upper and lower angles. The first digitation, which comes from the second, as well as from the first rib, runs to the surface at the upper angle; the second and third digitations connect the corresponding ribs with the vertebral border from near the upper to near the lower angle; the rest of the slips converge to the surface at the lower angle. *Action*: it draws the shoulder forward, as in pushing; the lower segment rotates the apex of the scapula upward. *Nerve*, the posterior thoracic. The lower five points of origin interlock with similar slips of the obliquus externus abdominis.

Pectoralis Minor (Fig. 269, 270).—"The smaller breast-muscle." *Situation*, in the front of the chest. *Origin*, the outer surfaces of the third, fourth, and fifth ribs, near their cartilages. *Direction*, up- and outward. *Insertion*, the coracoid process of the scapula. *Action*: it draws the shoulder down- and forward. *Nerve*, the internal anterior thoracic.

Subclavius (Fig. 269).—"The under-the-clavicle muscle." *Situation*, indi-

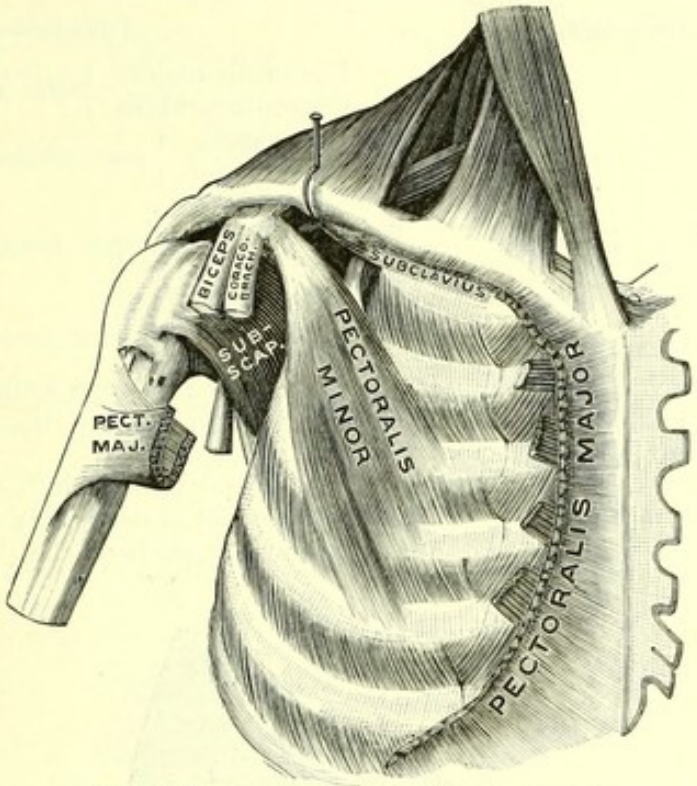

FIG. 269.—Pectoralis minor of right side. (Testut.)

cated by its name. *Origin*, the first rib and its cartilage, at their junction. *Direction*, out- and upward. *Insertion*, the groove in the under surface of the clavicle.

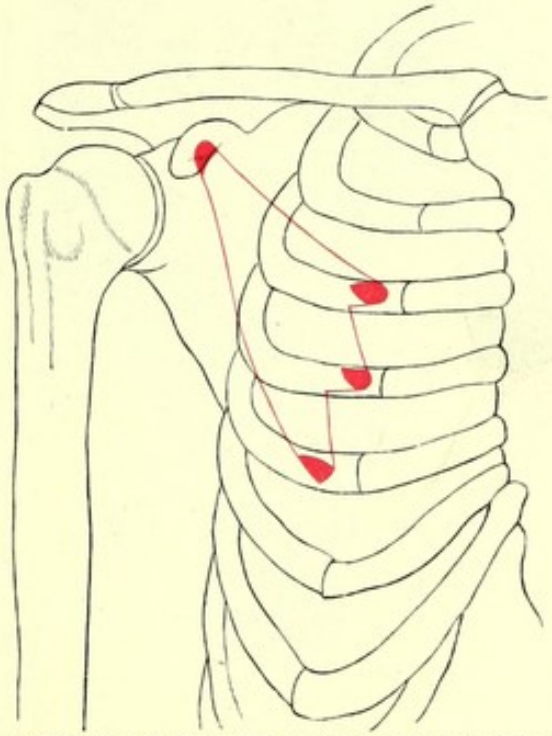

FIG. 270.—Pectoralis minor of right side: outline and attachment-areas. (F. H. G.)

Action: it draws the shoulder down- and forward. *Nerve*, from the fifth and sixth cervical.

MUSCLES MOVING THE ARM.

Abductors.	*Adductors.*
Deltoideus.	Pectoralis major. } *also flexors.*
Supraspinatus.	Coraco-brachialis. }
	Latissimus. } *also extensors.*
	Teres major. }

Outward Rotators.	*Inward Rotator.*
Infraspinatus.	Subscapularis.
Teres minor.	

The largest two of these muscles arise mostly from the trunk, and in some part from the shoulder; but the majority arise wholly from the shoulder. All of them are inserted into the humerus in its upper half.

Deltoideus (Figs. 271, 272, 289).—"The delta-like muscle"—"delta" being the name of a Greek letter of triangular shape. It is commonly Anglicized into "deltoid." *Situation*, between the most prominent parts of the shoulder and the

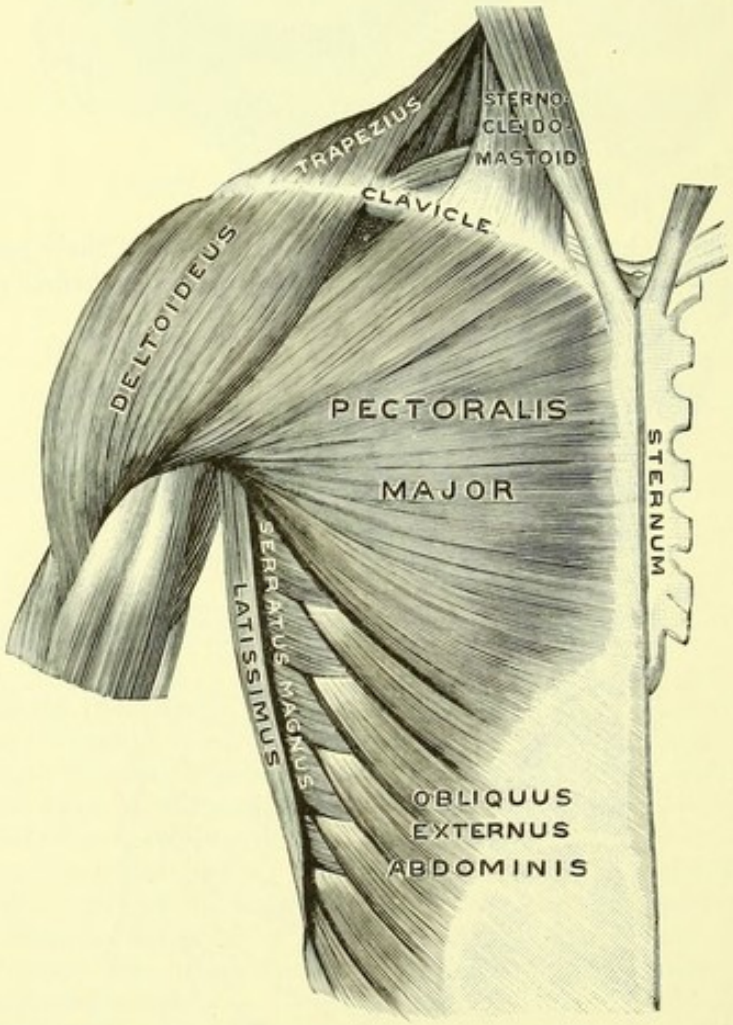

FIG. 271.—Front of chest and shoulder of right side, superficial muscles. (Testut.)

middle of the outside of the arm. *Origin*, the front of the outer third of the clavicle, the outer border of the acromion, and the lower border of the spine of

the scapula—corresponding closely with the insertion of the trapezius. *Direction*, from the clavicle and the scapular spine down- and outward, from the acromion

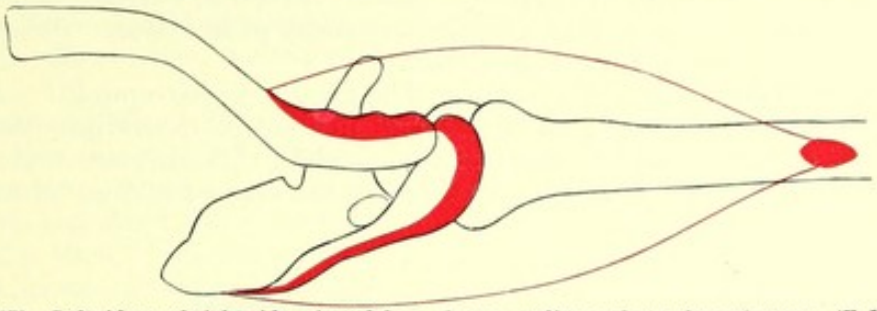

FIG. 272.—Deltoideus of right side, viewed from above: outline and attachment-areas. (F. H. G.)

downward—all parts converging. *Insertion*, the deltoid eminence (or impression) of the humerus. *Action*: it abducts the arm, lifting it to the horizontal. The

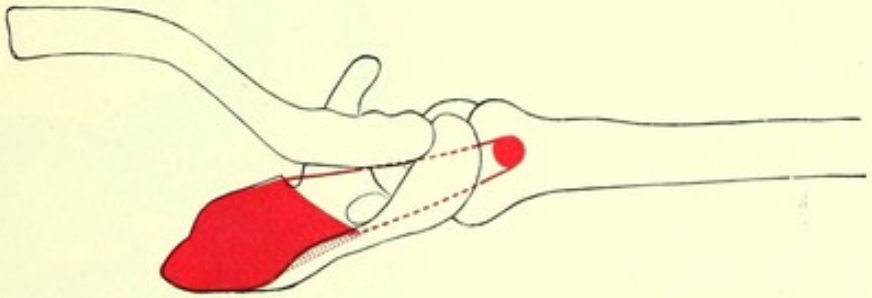

FIG. 273.—Supaspinatus of right side, viewed from above: outline and attachment-areas. (F. H. G.)

clavicular portion acting alone draws the arm forward; that from the scapular spine by itself carries the arm backward. The arm, being raised as far as the

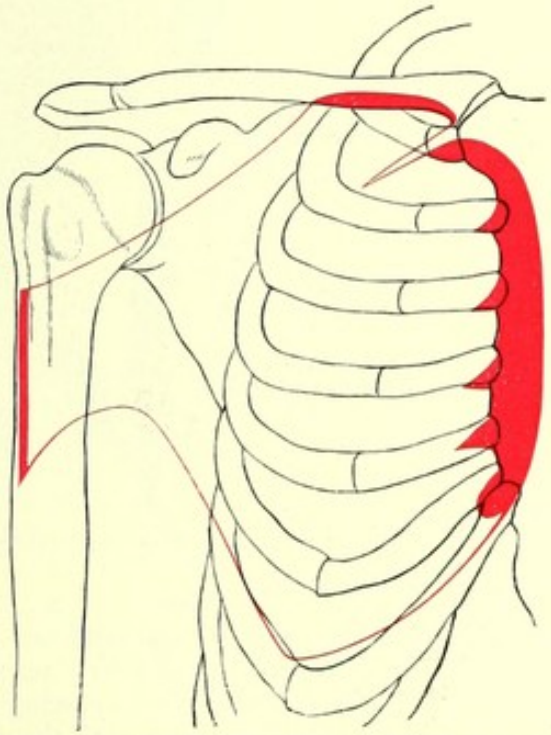

FIG. 274.—Pectoralis major of right side: outline and attachment-areas. (F. H. G.)

deltoid can affect it, is elevated to the perpendicular by the trapezius, the two muscles being almost continuous in structure—practically one muscle with an osseous inscription. *Nerve*, the circumflex.

Supraspinatus (Figs. 273, 278).—"The muscle above the spine" of the scapula. *Situation*, in the supraspinous fossa and above the head of the humerus. *Origin*, inner two-thirds of supraspinous fossa. *Direction*, outward beneath acromion. *Insertion*, uppermost facet of great tuberosity of humerus. *Action*, abduction of the arm. *Nerve*, the suprascapular.

Pectoralis Major (Figs. 271, 274).—"The greater breast-muscle." *Situation*, in the upper, anterior part of the chest, and in front of the axilla. *Origin*, the sternal half of the anterior surface of the clavicle, the anterior surface of the sternum (except the appendix), the cartilages of the upper six ribs. *Direction*: of

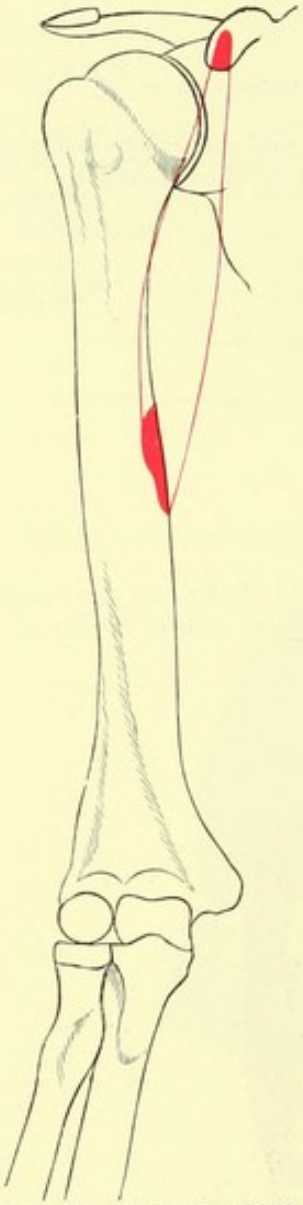

FIG. 275. — Coraco-brachialis of right side: outline and attachment-areas. (F. H. G.)

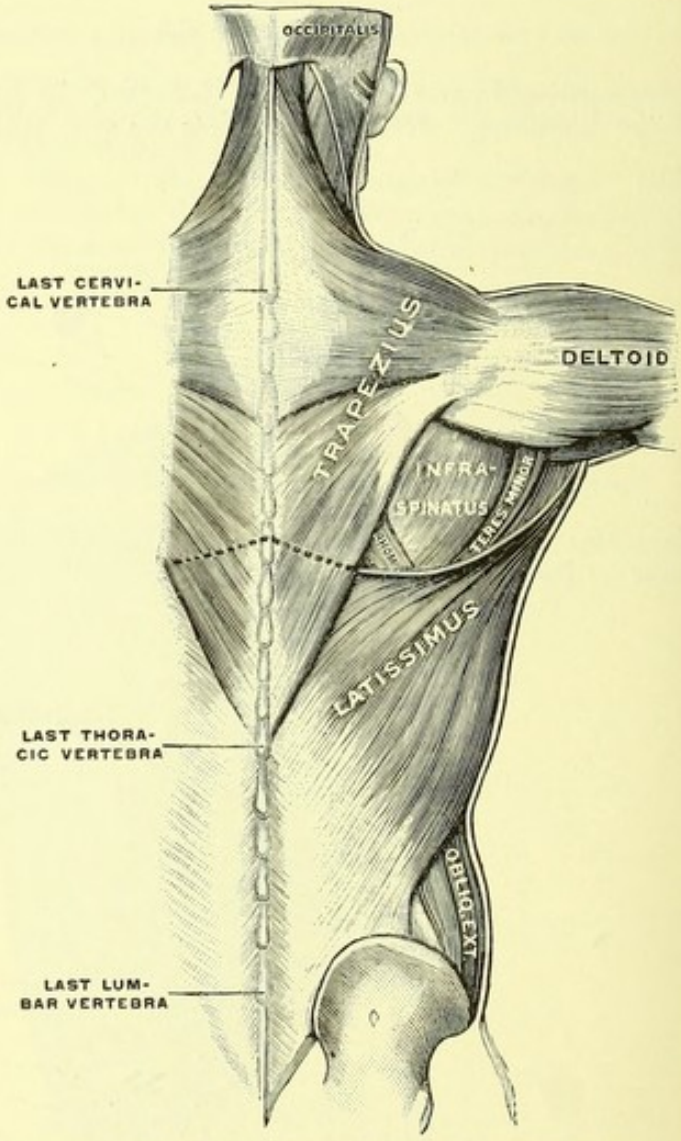

FIG. 276.—Muscles in the superficial layer of the back. (Testut.)

the clavicular portion (which is separate at its origin) down- and outward; of the central, outward; of the lower, out- and upward—all parts converging to one broad tendon, which twists on itself, the lower fibres passing behind and becoming uppermost. *Insertion*, the external bicipital ridge of the humerus. *Action*: it draws the arm inward and forward, and rotates it inward. *Nerves*, the internal and external anterior thoracic.

Coraco-brachialis (Figs. 275, 283, 285).—"The coracoid (process)- arm muscle"—the name being derived from the parts connected. *Situation*, in the inner

side of the upper half of the arm. *Origin*, the coracoid process of the scapula. *Direction*, downward and slightly outward. *Insertion*, the inner border of the humerus at the middle of the shaft. *Action*, adduction and flexion of the arm. *Nerve*, the musculocutaneous.

Latissimus (Figs. 276, 277).—"The broadest muscle"—from the Latin *latus*, "broad." *Synonym*, latissimus dorsi, "the broadest of the back." *Situation*, in the back, from the lower half of the spine to the upper part of the arm. *Origin*, the spines of six or seven lower thoracic vertebræ, and, through the lumbar fascia, the spines of the lumbar and sacral, and the back of the outer lip of the iliac crest, the last three or four ribs, and often the lower angle of the scapula. *Direction*, upward, outward, and forward, converging to the insertion, the tendon twisting from above downward and backward, so that its front is continuous with the back of the muscle. *Insertion*, the floor of the bicipital groove. *Action*, adduction, extension, and rotation inward. *Nerve*, the long subscapular. The costal points of origin interlock with those of the obliquus externus abdominis.

Teres Major (Figs. 278, 279).—"The greater round muscle." *Situation*, between scapula and upper end of arm, in hind wall of armpit. *Origin*, the oval surface on the back of the scapula at its lowerangle. *Direction*, up-, out-, and forward. *Insertion*, the inner bicipital ridge. *Action*, adduction, extension, and inward rotation of arm. *Nerve*, the lower subscapular.

Infraspinatus (Figs. 278, 280).—"The muscle below the spine" of the scapula. *Situation*, in the infraspinous fossa and behind the head of the humerus. *Origin*, the inner two-thirds of the infraspinous fossa. *Direction*, outward. *Insertion*, the middle facet of the great tuberosity of the humerus. *Action*, external rotation of the arm. *Nerve*, the suprascapular.

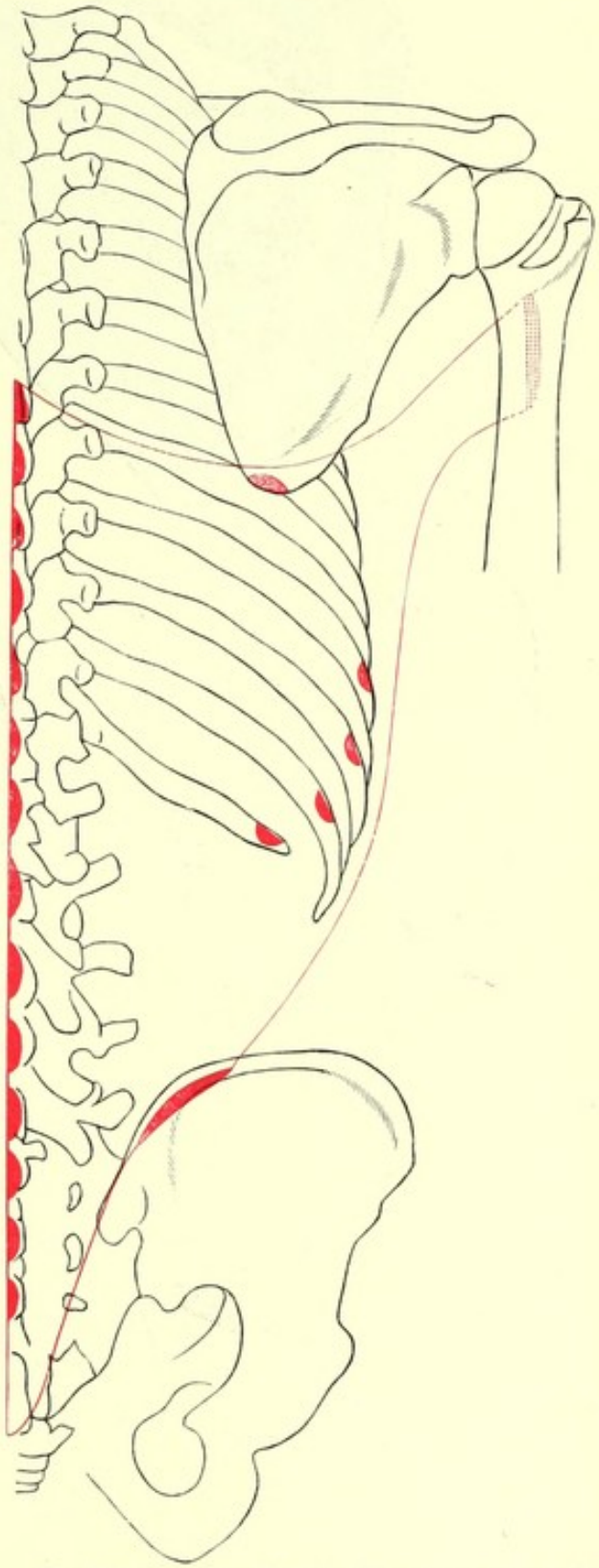

FIG. 277.—Latissimus of right side: outline and attachment-areas. (F. H. G.)

Teres Minor (Figs. 278–281).—"The smaller round muscle." *Situation*, between the scapula and the upper end of the arm, in the hind wall of the arm-

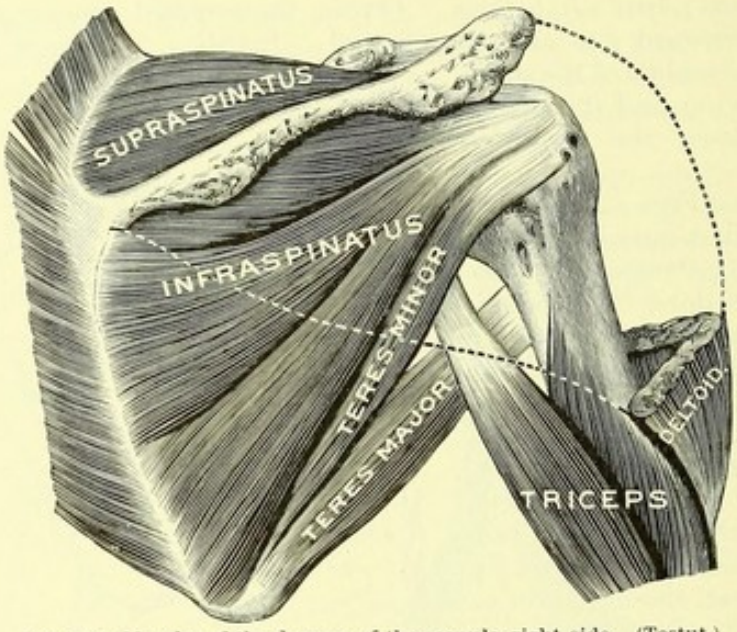

FIG. 278.—Muscles of the dorsum of the scapula, right side. (Testut.)

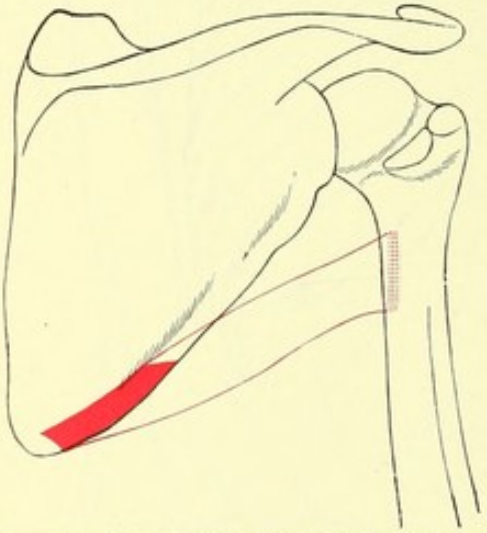

FIG. 279.—Teres major of right side: outline and attachment-areas. (F. H. G.)

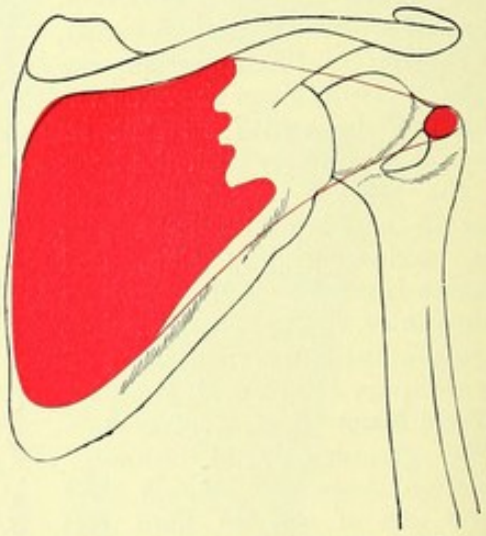

FIG. 280.—Infraspinatus of right side: outline and attachment-areas. (F. H. G.)

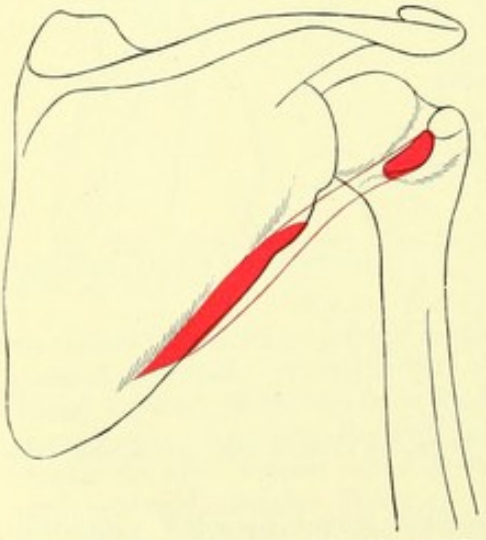

FIG. 281.—Teres minor of right side: outline and attachment-areas. (F. H. G.)

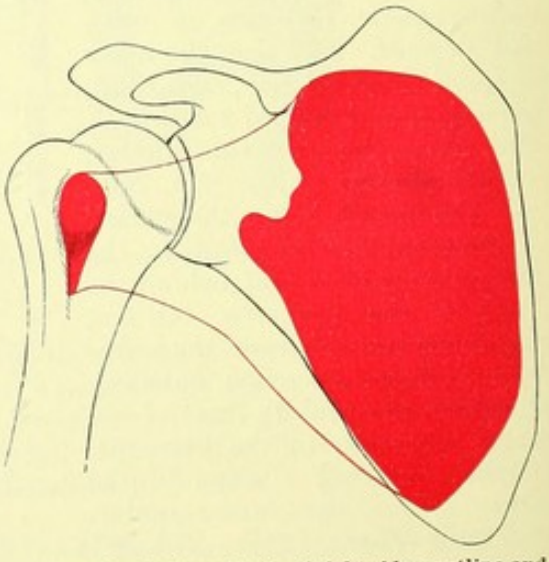

FIG. 282.—Subscapularis of right side: outline and attachment-areas. (F. H. G.)

pit. *Origin*, the dorsum of the scapula, along its axillary border. *Direction*, upward and outward. *Insertion*, the lowest facet on the great tuberosity of the humerus. *Action*, external rotation of the humerus. *Nerve*, the circumflex.

Subscapularis (Figs. 282, 283).—"The muscle under the scapula"—though it is beneath the bone only when the body is prone. *Situation*, in front of the scapula and the head of the humerus. *Origin*, the greater part of the venter of the scapula. *Direction*, outward and forward. *Insertion*, the small tuberosity of the humerus. *Action*, inward rotation of the humerus. *Nerves*, the upper and lower subscapular.

MUSCLES MOVING THE WHOLE FOREARM.

Flexors.	*Extensors.*
Biceps flexor cubiti.	Triceps extensor cubiti.
Brachialis.	Anconeus.
Brachio-radialis.	

One of these muscles arises from the scapula, one from the scapula and humerus, and three from the humerus alone. All are inserted into the skeleton of the forearm.

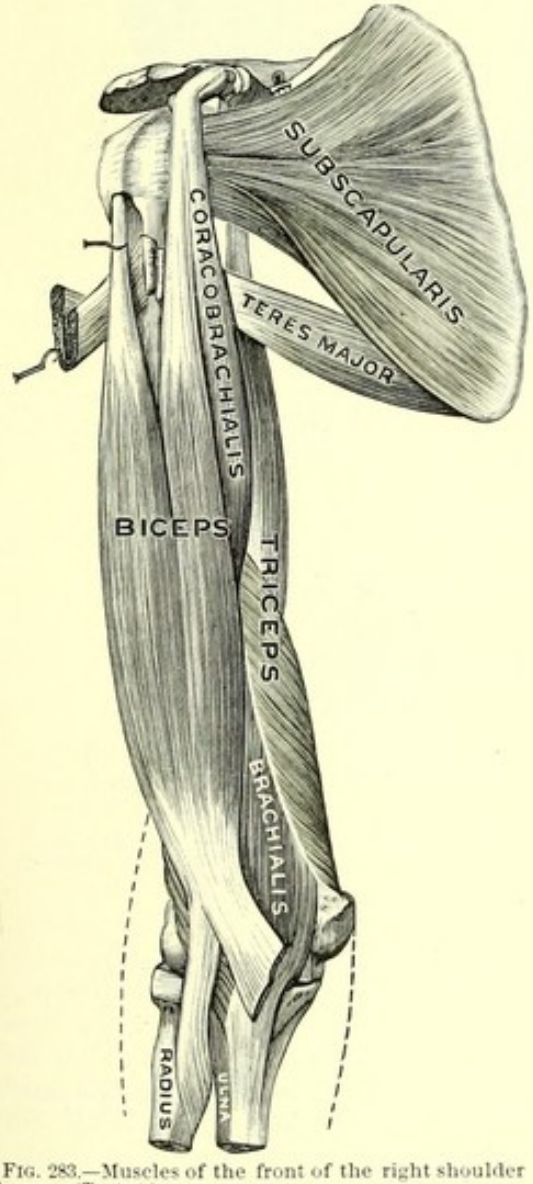

FIG. 283.—Muscles of the front of the right shoulder and arm. (Testut.)

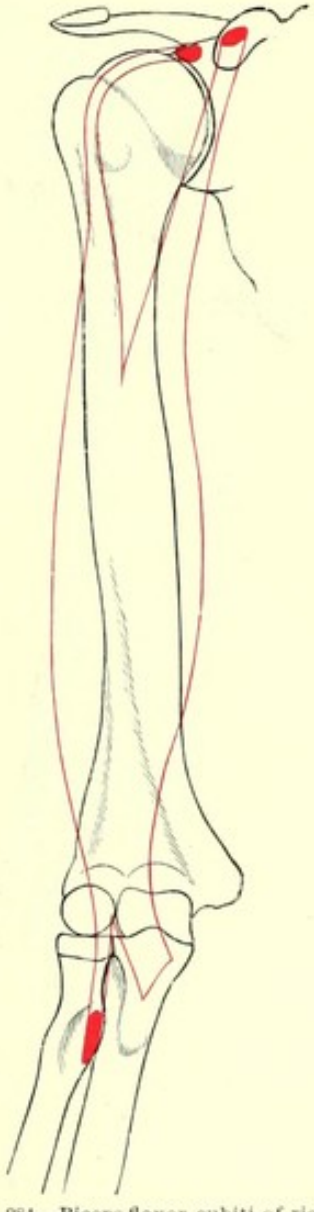

FIG. 284.—Biceps flexor cubiti of right side: outline and attachment-areas. (F. H. G.)

Biceps Flexor Cubiti (Figs. 283, 284).—"The two-headed flexor of the fore-

arm." *Situation*, in the front of the arm. *Origin*, the scapula—the long head: the upper border of the glenoid fossa; the short head: the coracoid process. *Direction*, the long head: over the caput humeri, through the shoulder-joint, in the bicipital groove, and down to the forearm; the short head unites with the long about one-fourth way down the arm. *Insertion*, the main tendon to the hind part of the radial tuberosity; a secondary tendon (called also the semilunar or bicipital fascia) passes obliquely inward, and ends in the deep fascia of the forearm over the pronator teres. *Action*, flexion of forearm. If the hand is pronated, the biceps supinates it. The second tendon of insertion tightens the forearm fascia. *Nerve*, the musculo-cutaneous. The synovial membrane of the shoulder-joint is prolonged downward, and invests the tendon of the long head.

Brachialis (Figs. 285, 286).—"The muscle of the arm." *Synonyms*, brachialis anterior, brachialis anticus, "the front muscle of the arm." *Situation*, in the

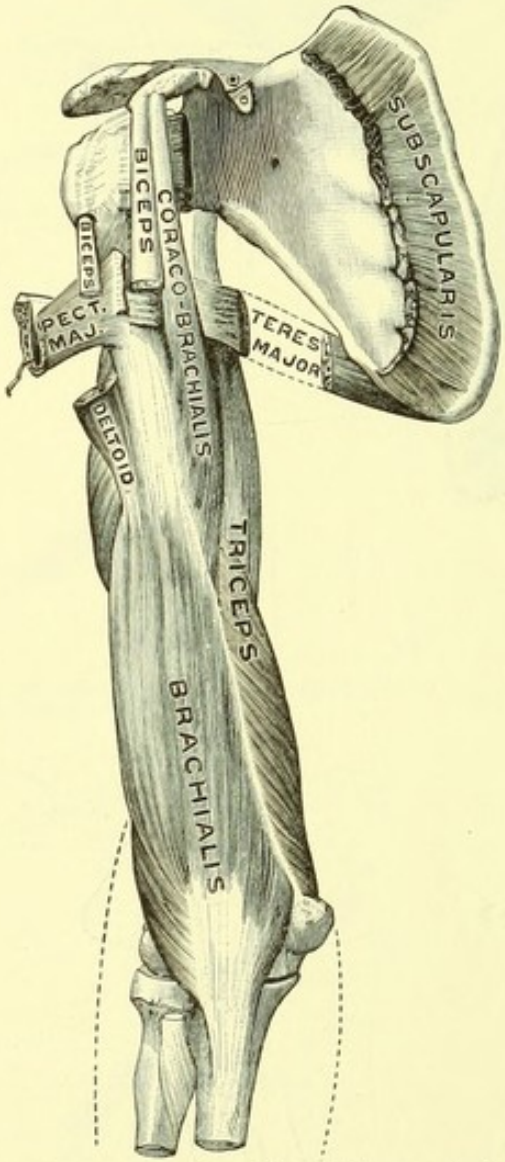

FIG. 285.—Muscles of the right arm, front view, the biceps having been removed. (Testut.)

FIG. 286.—Brachialis of right side: outline and attachment-areas. (F. H. G.)

front of the arm. *Origin*, the lower half of the front of the humerus. *Direction*, downward to the forearm. *Insertion*, the inner part of the coronoid proc-

ess of the ulna. *Action*, flexion of the forearm. *Nerves*, the musculo-cutaneous and (slightly) the musculo-spiral.

Brachio-radialis (Figs. 287, 288, 303).—"The arm-radius muscle," from its attachments. *Synonym*, supinator longus, "the long supinator." *Situation*, the outer and front part of the lower fourth of the arm and of the whole forearm.

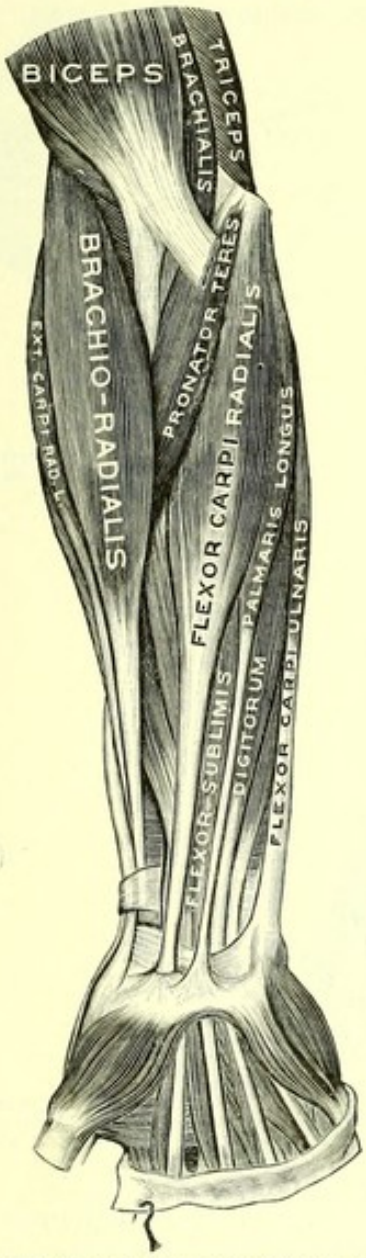

FIG. 287.—Superficial muscles of front of right forearm. (Testut.)

FIG. 288.—Brachio-radialis of right side, outside view: outline and attachment-areas. (F. H. G.)

Origin, the upper two-thirds of the external condylar ridge of the humerus. *Direction*, downward. *Insertion*, the base of the styloid process of the radius. *Action*, mostly flexion of the forearm; but, when the hand is prone, this muscle is capable of nearly half-supinating it; after strong supination, the muscle will partially effect pronation. *Nerve*, the musculo-spiral.

Triceps Extensor Cubiti (Figs. 289–291).—"The three-headed extensor of the forearm." *Situation*, in the back of the arm. *Origin*, the long (middle) head: below the glenoid fossa of the scapula on the neck and upper part of the axillary border; the external head: the hind surface of the humerus above the musculo-spiral groove; the internal (deep) head: the hind surface of the humerus below

the musculo-spiral groove. *Direction*, downward, all the heads uniting in a common tendon. *Insertion*, the tuberosity of the olecranon process of the ulna. *Action*, extension of forearm. *Nerve*, the musculo-spiral.

Anconeus (Figs. 289, 292, 310).—"The elbow muscle." *Situation*, at the back and outer side of the elbow-joint, mostly in the forearm. *Origin*, the hind

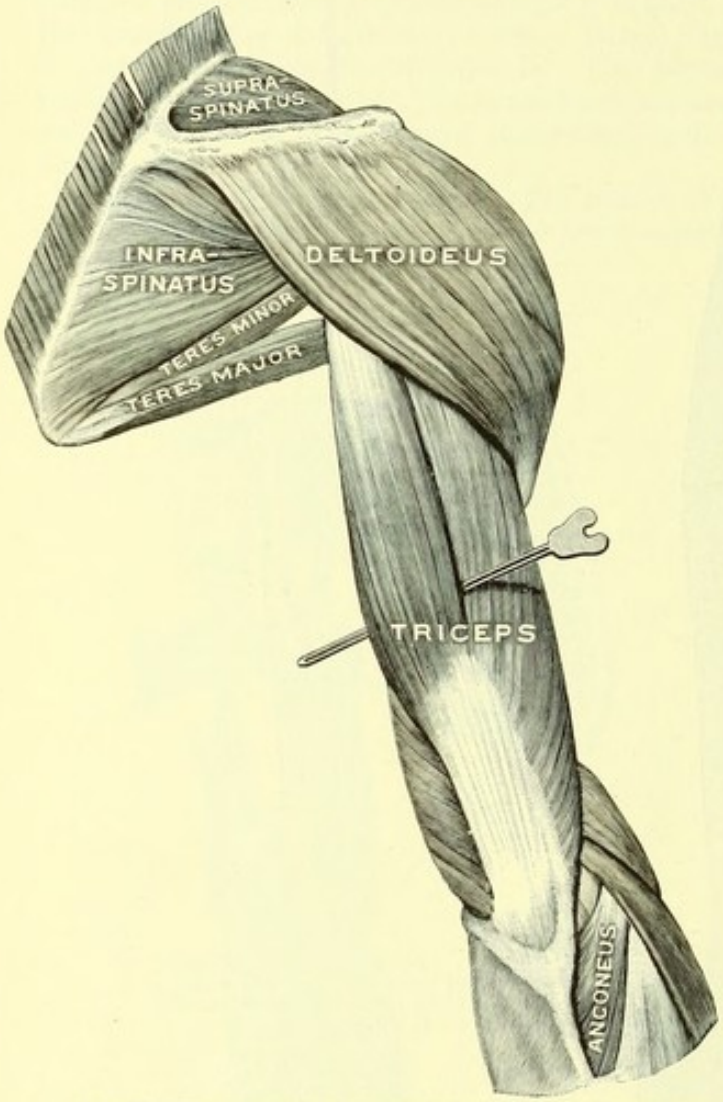

Fig. 289.—Muscles on the dorsum of the right shoulder and arm. (Testut.)

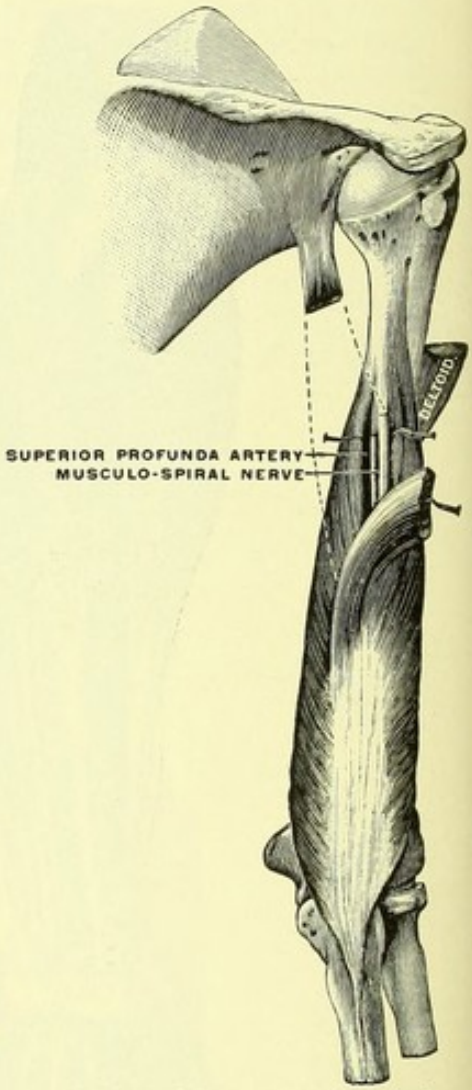

Fig. 290.—Triceps extensor cubiti of right side: part of the scapular head has been removed and shows in outline. (Testut.)

part of the external condyle of the humerus. *Direction*, obliquely downward. *Insertion*, the outer side of the olecranon process, and the upper fourth of the back of the shaft of the ulna. *Action*, extension of forearm. *Nerve*, the musculo-spiral. The anconeus is a continuation of the triceps, and is sometimes described as the fourth head of the latter, thus converting it into a quadriceps, or four-headed muscle.

MUSCLES MOVING THE OUTER PART OF THE FOREARM.

Pronators.	*Supinator.*
Pronator teres.	Supinator.
Pronator quadratus.	

Of the pronators one arises from the humerus and ulna, the other from the ulna only. The supinator arises from the humerus and ulna. All are inserted

into the radius, which alone of the forearm bones is moved in pronation and supination.

Pronator Teres (Figs. 287, 293).—"The round pronator." *Situation*, in the front of the forearm. *Origin*, the superficial head: the inner condyle of the humerus and a small part of the ridge above it; the deep-head: the inner border of the coronoid process of the ulna. *Direction*, out- and downward. *Insertion*, the middle of the outer surface of the radius. *Action*, pronation

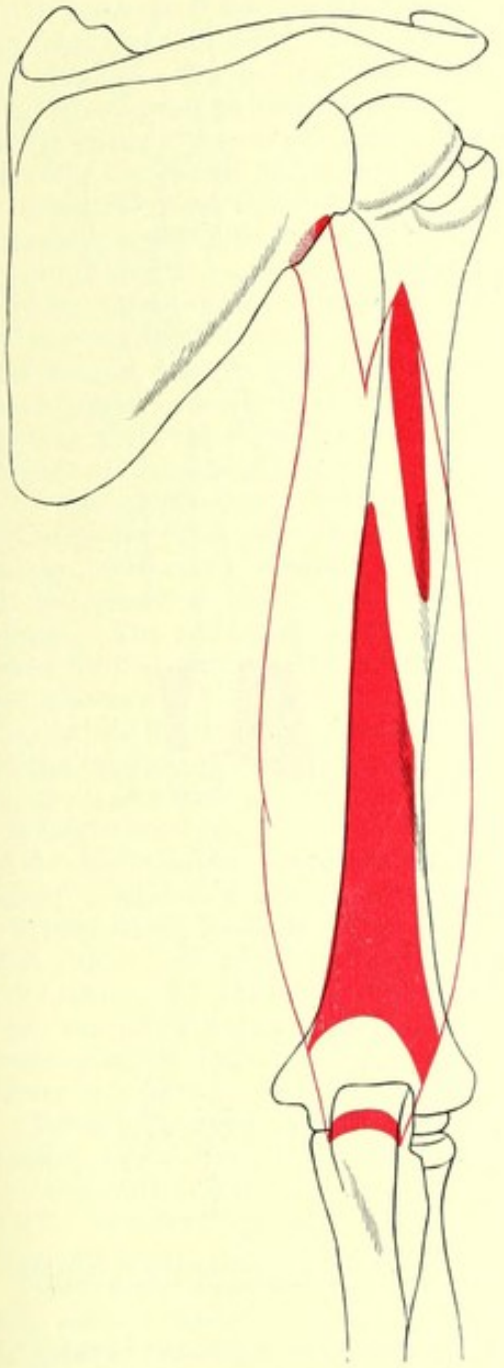

FIG. 291.—Triceps extensor cubiti of right side: outline and attachment-areas. (F. H. G.)

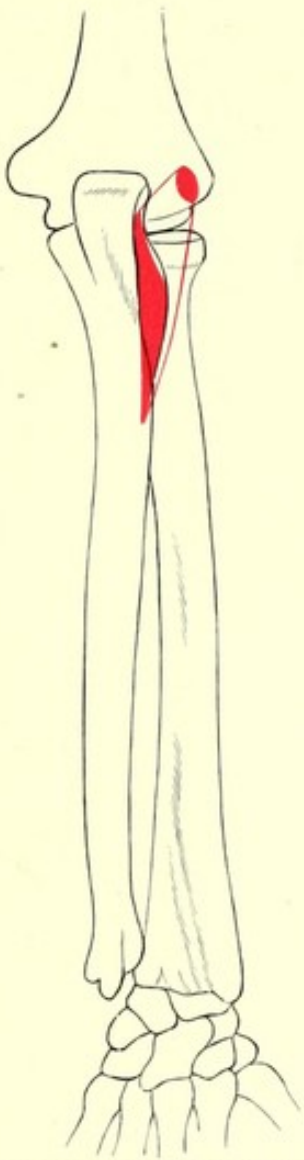

FIG. 292.—Anconeus of right side: outline and attachment-areas. (F. H. G.)

of the hand by moving the radius to which the hand is articulated; also slight flexion of the forearm. *Nerve*, the median.

Pronator Quadratus (Figs. 294, 318).—"The square pronator." *Situation*, in the lower quarter of the front of the forearm, close to the bones. *Origin*, the

inner part of the lower fourth of the front surface of the shaft of the ulna. *Direction*, outward. *Insertion*, the lower fourth of the front of the radius. *Action*, pronation of radius, and, consequently, of the hand. *Nerve*, anterior interosseous branch of the median.

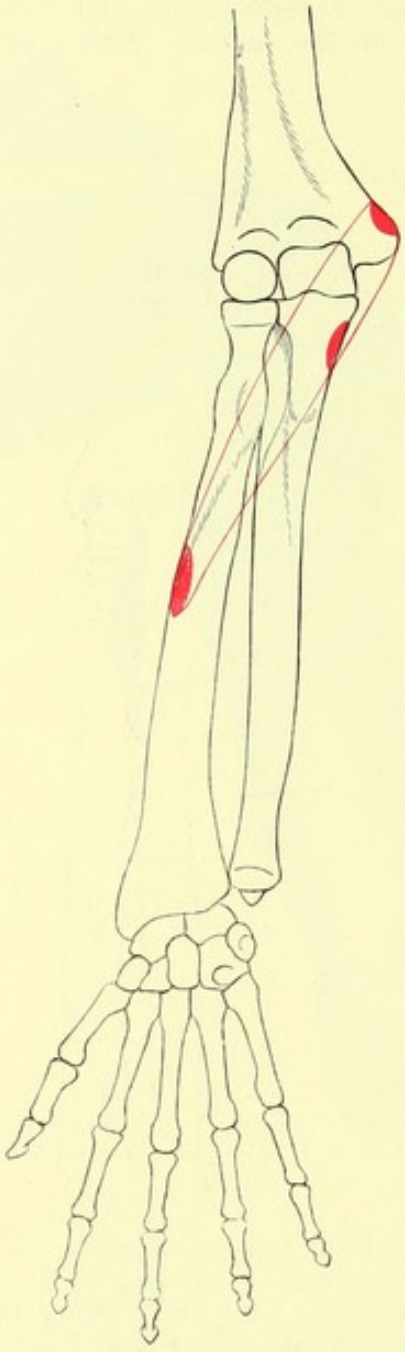

FIG. 293.—Pronator teres, right side: outline and attachment-areas. (F. H. G.)

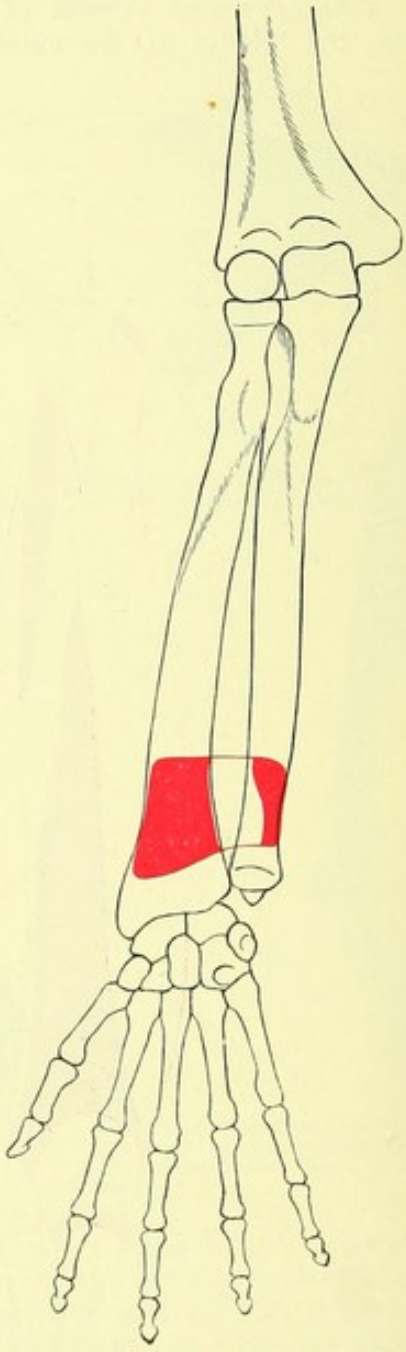

FIG. 294.—Pronator quadratus of right side: outline and attachment-areas. (F. H. G.)

Supinator (Fig. 295).—"The supinator." *Synonym*, supinator brevis, "the short supinator." *Situation*, deeply in the upper third of the outer part of the forearm. *Origin*, the external condyle of the humerus, the external lateral and orbicular ligaments, the triangular area below the small sigmoid cavity. *Direction*, out- and downward, wrapping the upper part of the radius in a sling. *Insertion*, the back of the neck, and the hind and outer surfaces of the shaft of the radius above the oblique line. *Action*, supination. *Nerve*, the posterior interosseous division of the musculo-spiral.

MUSCLES MOVING THE WHOLE HAND.

Flexors.	*Extensors.*
Flexor carpi radialis.	Extensor carpi radialis longus.
[Flexor] palmaris longus.	Extensor carpi radialis brevis.
Flexor carpi ulnaris.	Extensor carpi ulnaris.

All arise from the humerus, and the flexor and extensor on the ulnar side come from the ulna also. The palmaris longus is inserted into the palmar fascia. All which have "carpi" in their names are inserted into *meta*carpal bones, and only one of them into any part of the carpus also. Their action, however, is correctly indicated by their names, the wrist, carrying the rest of the hand, being alternately flexed and extended. The second, third, and fourth metacarpal bones have practically no motion on the carpus, and the first and fifth are moved by special muscles. The palmaris longus, though primarily a tensor of the palmar fascia, secondarily is a flexor of the hand —just as the tensor vaginæ femoris is first a tightener of the fascia lata, and then an abductor of the thigh—and, therefore, a bracketed word implying this, and aiding the grouping by making a uniformity of name which corresponds with the practical identity of action, has been prefixed. The adduction of the hand is accomplished by the simultaneous action of the flexor carpi ulnaris and the extensor carpi ulnaris ; its abduction by the simultaneous action of the flexor carpi radialis and the extensor carpi radialis longus. Observe that the external part of the lower end of the humerus gives origin to the extensors, the internal to the flexors. At their origin from the internal condyle and its neighborhood the flexors of the hand are so blended with the pronator teres and the flexor sublimis digitorum as to constitute one mass. On and about the external condyle is a similar association of extensors and supinator.

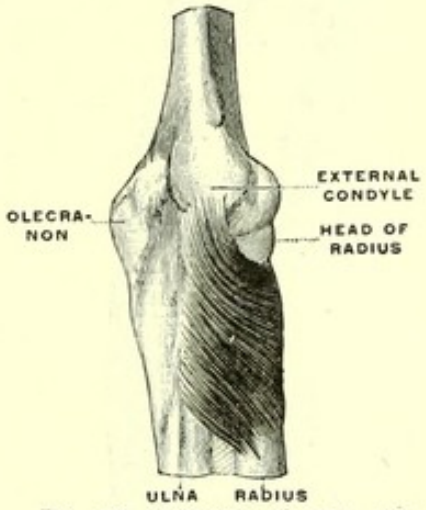

FIG. 295.—Supinator of right side. (Testut.)

Flexor Carpi Radialis (Figs. 296, 297).—"The flexor of the wrist on the radial side." *Situation*, in the front of the forearm. *Origin*, the inner condyle of the humerus. *Direction*, downward and a little outward. *Insertion*, the base of the second metacarpal bone on its palmar aspect. *Action*, flexion and slight pronation of the hand. In conjunction with the extensor carpi radialis longus it abducts the hand. *Nerve*, the median.

[Flexor] Palmaris Longus (Fig. 296).—"The long palmar [flexor] muscle." *Situation*, in the front of the forearm. *Origin*, the inner condyle of the humerus. *Direction*, downward and slightly outward. *Insertion*, the palmar fascia and anterior annular ligament. *Action* : it tightens the fascia of the palm, and then flexes the hand. *Nerve*, the median.

Flexor Carpi Ulnaris (Figs. 296, 298, 310).—"The flexor of the wrist on the ulnar side." *Situation*, in the front and inner border of the forearm. *Origin*, one head : the inner condyle of the humerus ; the other head : the inner side of the olecranon and the upper two-thirds of the hind border of the ulna. *Direction*, downward. *Insertion*, the pisiform, unciform, and fifth metacarpal bones. *Action*, flexion of the hand. In conjunction with the extensor carpi ulnaris it adducts the hand. *Nerve*, the ulnar.

Extensor Carpi Radialis Longus (Figs. 299, 300).—"The long extensor of the wrist on the radial side." *Situation*, in the outer border of the forearm. *Origin*, the lower third of the external condylar ridge of the humerus. *Direc-*

tion, downward and a little backward. *Insertion*, the base of the second metacarpal, behind and on the radial side. *Action*, extension of the hand. In conjunction with the flexor carpi radialis it abducts the hand. *Nerve*, the musculo-spiral.

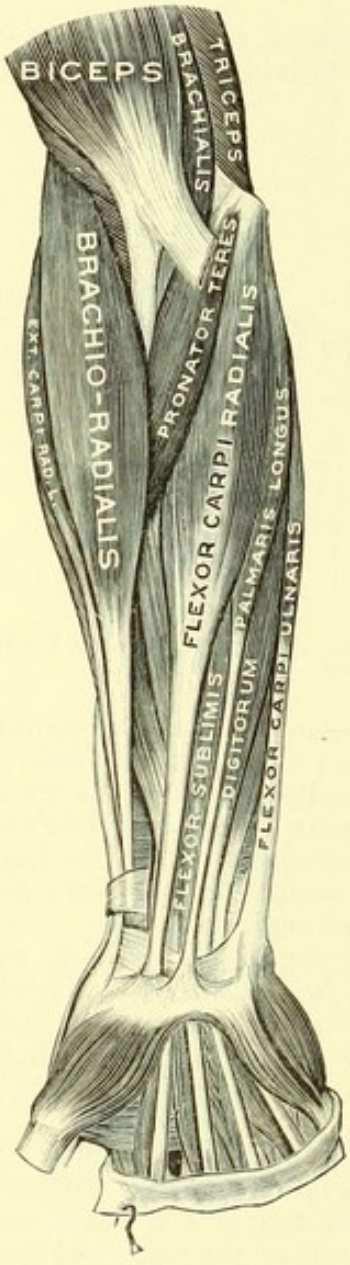

FIG. 296.—Superficial muscles of front of right forearm. (Testut.)

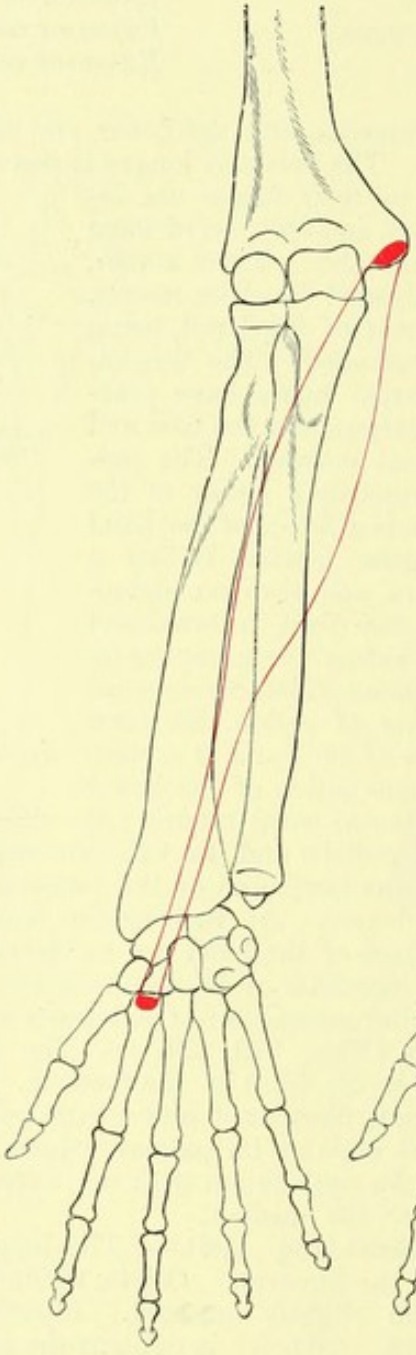

FIG. 297.—Flexor carpi radialis of right side: outline and attachment-areas. (F. H. G.)

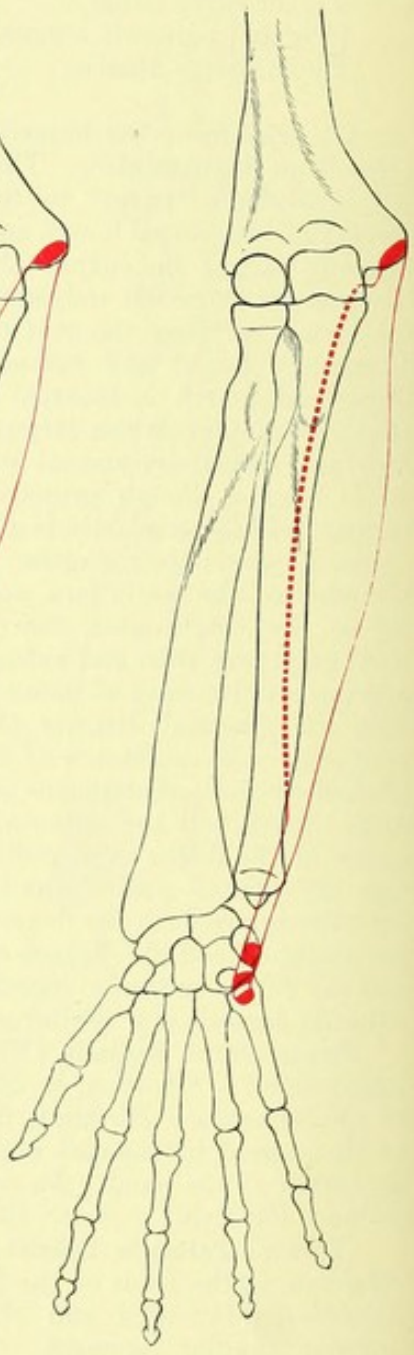

FIG. 298.—Flexor carpi ulnaris of right side: outline and attachment-areas. (F. H. G.)

Extensor Carpi Radialis Brevis (Figs. 299–301).—"The short extensor of the wrist on the radial side." *Situation*, the outer border of the forearm. *Origin*, the outer condyle of the humerus. *Direction*, downward and a little backward. *Insertion*, the base of the third metacarpal bone, behind and on the radial side. *Action*, extension of the hand. *Nerve*, the posterior interosseus branch of the musculo-spiral.

Extensor Carpi Ulnaris (Figs. 302, 310).—"The extensor of the wrist on the ulnar side." *Situation*, the back of the forearm on the ulnar side. *Origin*, the

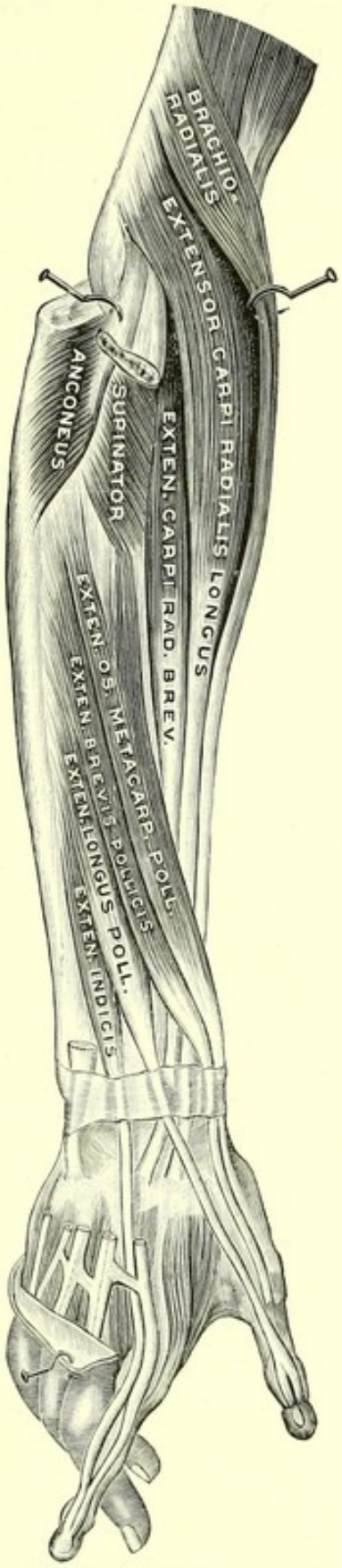

FIG. 320.—Muscles in radial region of right forearm, and deep muscles in its dorsum. (Testut.)

external condyle of the humerus and the middle third of the posterior border of the ulna. *Direction*, downward and inward. *Insertion*, the base of the fifth

FIG. 300.—Extensor carpi radialis longus of right side: outline and attachment-areas. (F. H. G.)

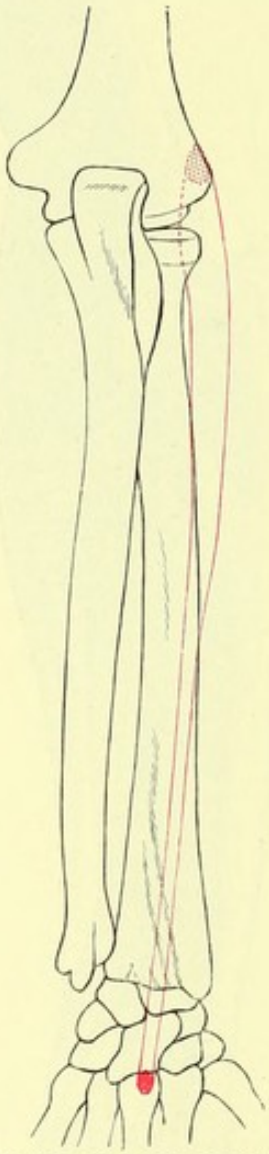

FIG. 301.—Extensor carpi radialis brevis of right side: outline and attachment-areas. (F. H. G.)

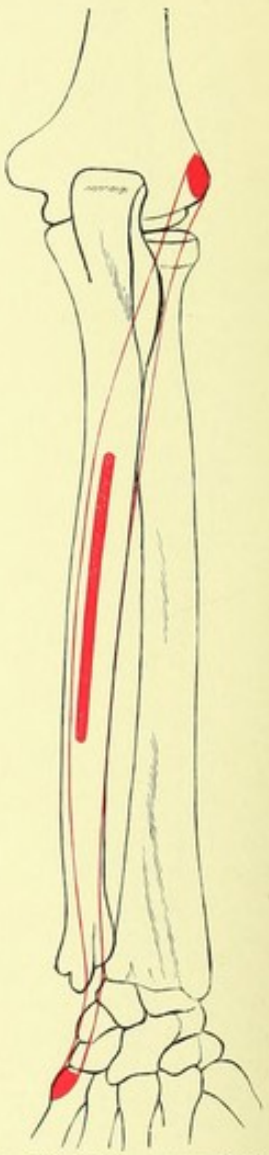

FIG. 302.—Extensor carpi ulnaris of right side: outline and attachment-areas. (F. H. G.)

metacarpal bone on its dorsal aspect and ulnar border. *Action*, extension of the hand. In conjunction with the flexor carpi ulnaris it adducts the hand. *Nerve*, the posterior interosseous branch of the musculo-spiral.

MUSCLES MOVING THE FINGERS and the Fifth Metacarpal Bone.

(Those which are situated entirely in the hand are indicated by a star.)

Flexors.	*Extensors.*
Flexor sublimis digitorum.	Extensor communis digitorum.
Flexor profundus digitorum.	Extensor minimi digiti.
*Flexor ossis metacarpi minimi digiti.	Extensor indicis.
*Flexor brevis minimi digiti.	
*Lumbricales.	

Abductors.	*Adductors.*
*Interossei dorsales.	*Interossei palmares.
*Abductor minimi digiti.	

Of the five of these muscles located mainly in the forearm two arise from the humerus, one from the humerus, radius, and ulna, and two from the ulna only. Every one in the group is inserted into one or more of the fingers, excepting the flexor of the fifth metacarpal bone, which is admitted to this company of finger flexors on account of the similarity of its action.

Flexor Sublimis Digitorum (Figs. 303–305).—"The superficial flexor of the digits"—meaning the four fingers as distinguished from the thumb. *Synonym*, flexor perforatus, "the perforated flexor"

FIG. 303.—Flexor sublimis digitorum of right side. (Testut.)

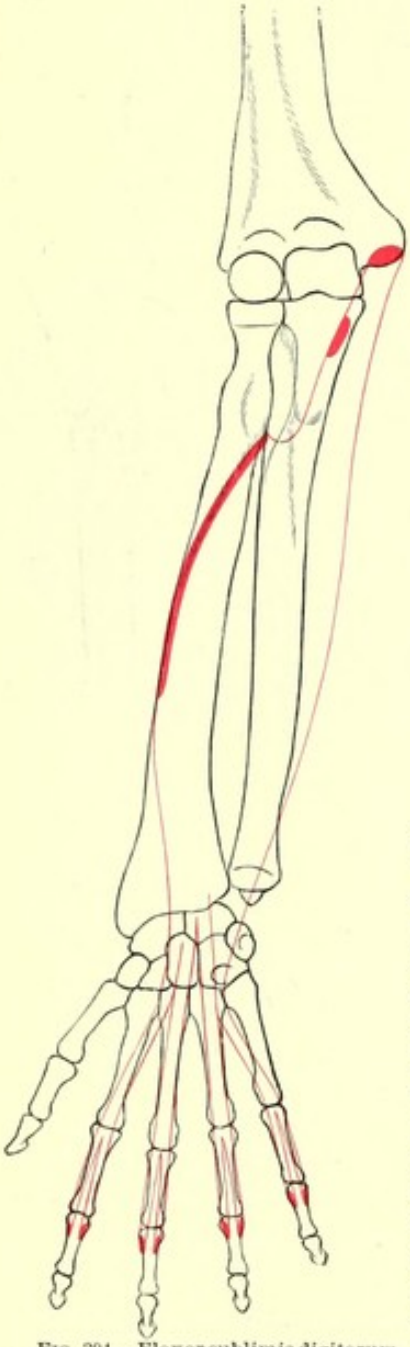

FIG. 304.—Flexor sublimis digitorum of right side: outline and attachment-areas. (F. H. G.)

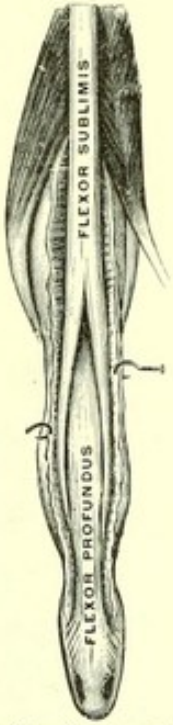

FIG. 305.—Tendon of flexor sublimis perforated by tendon of flexor profundus. (Testut.)

—from the openings through which the tendons of the deep flexor pass. *Situation*, in the front of the forearm and hand, deeper than the flexors of the whole hand, but superficial to the other flexors. *Origin*, first head: the inner condyle of the humerus; second head: the inner border of the coronoid process of the ulna; third head: the oblique line and part of the anterior border of the radius. *Direction*, downward to all of the digits but the thumbs. *Insertion*, by four tendons, each to the sides of a second phalanx. As the tendons pass through the annular ligament, those for the middle and ring-fingers are side by side in front, the others behind them. Each tendon

is accompanied by a tendon of the flexor profundus, and permits the passage of the latter through a split which occurs opposite the first phalanx. The separated halves become united behind the tendon of the deep flexor, opposite the base of the second phalanx, but almost immediately separate again, and are inserted into the sides of the second phalanx. The tendons are bound down to the phalanges by a ligamentous sheath. *Action*, primary, flexion of the second phalanges; secondary, flexion of first phalanges. *Nerve*, the median.

Flexor Profundus Digitorum (Figs. 306–308).—"The deep flexor of the digits"—meaning the fingers as distinguished from the thumb. *Synonym*, flexor perforans, "the perforating flexor"—from the fact that its four tendons perforate the corresponding tendons of the flexor sublimis. *Situation*, deeply in the front of the forearm and hand. *Origin*, three-fourths of the inner and anterior surfaces of the ulna, the adjacent half of the interosseous membrane, and the common tendon of it and the flexor and extensor carpi ulnaris on the hind border of the ulna. *Direction*, downward. *Insertion*, each of the four tendons into the front of the base of a last phalanx. Each tendon perforates a tendon of the superficial flexor opposite the first phalanx; each is bound to the first and second phalanges by ligaments which form a sheath common to this and the sublimis tendon. *Action*, flexion of third phalanges primarily, and, after this, flexion of the second, and, slightly, of the first. *Nerves*, the ulnar and the anterior interosseous branch of the median.

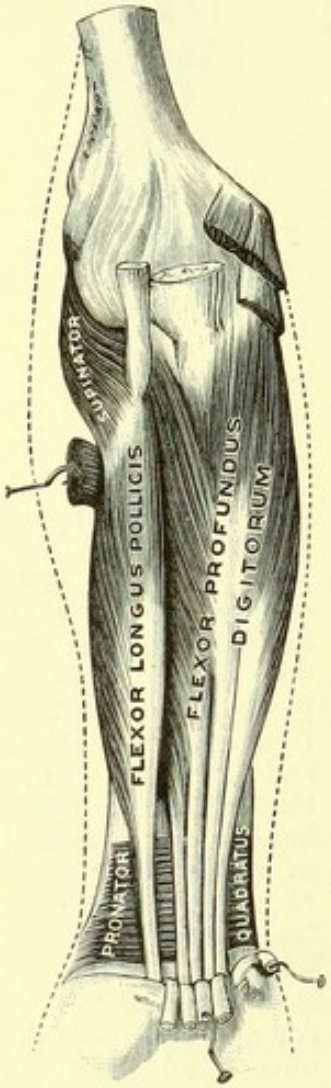

Fig. 306.—Muscles in the right forearm, the deepest layer. (Testut.)

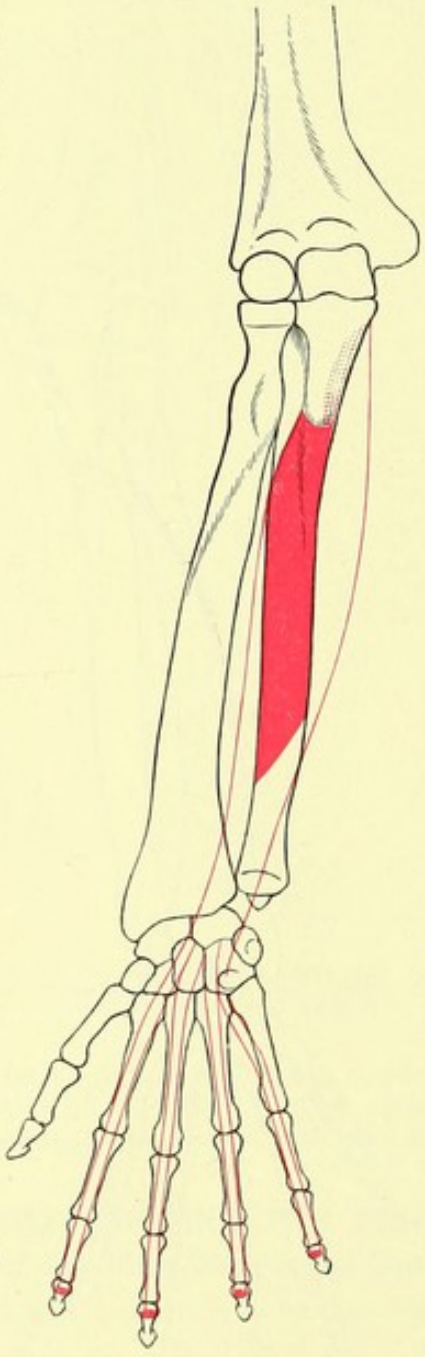

Fig. 307.—Flexor profundus digitorum of right side: outline and attachment-areas. (F. H. G.)

Fig. 308.—Tendon of flexor profundus perforating tendon of flexor sublimis. (Testut.)

Flexor Ossis Metacarpi Minimi Digiti (Fig. 309).—"The flexor of the metacarpal bone of the least digit"—*i. e.*, of the little finger. *Synonyms*, opponens minimi digiti, and opponens digiti quinti, "the opposing muscle of the least (or fifth) digit," so called from its drawing the hypothenar eminence toward the thenar, thus narrowing and deepening the palm. *Situation*, deep in the hypo-

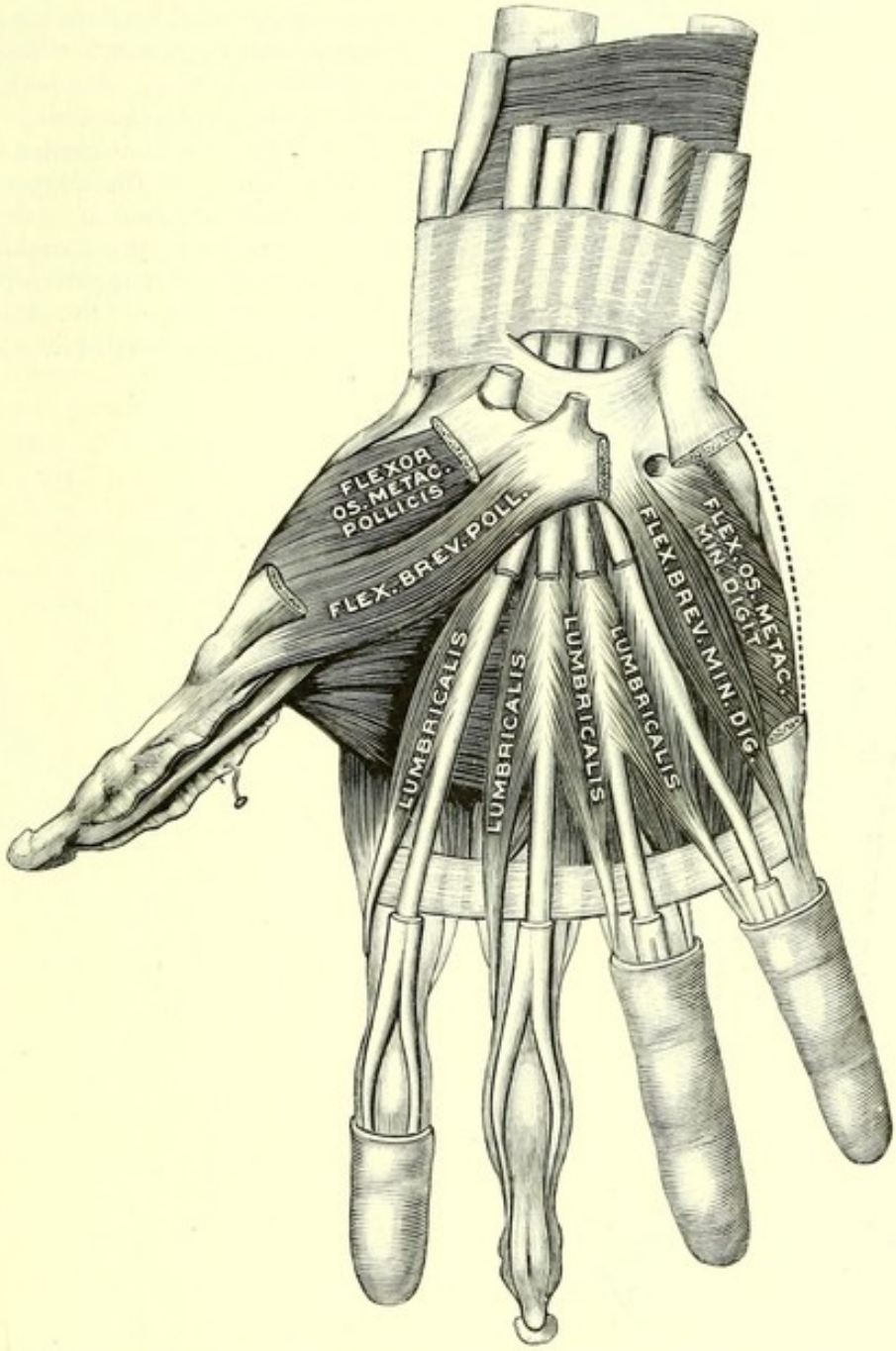

FIG. 309.—Muscles of the right palm. The abductors of the thumb and little finger have been removed. (Testut.)

thenar eminence. *Origin*, the unciform process and the annular ligament. *Direction*, downward and toward ulnar margin of the hand. *Insertion*, the whole of the ulnar side of the fifth metacarpal. *Action*, flexion of the fifth metacarpal and slight adduction toward the mid-line of the hand. *Nerve*, the deep branch of the ulnar.

Flexor Brevis Minimi Digiti (Fig. 309).—"The short flexor of the least digit"—*i. e.*, of the little finger. *Synonym*, flexor digiti quinti brevis, "the short flexor

of the fifth digit." *Situation*, subcutaneously in the centre of the hypothenar eminence. *Origin*, the unciform process and the annular ligament. *Direction*, downward and inward. *Insertion*, the base of the first phalanx of the little finger on the ulnar border. *Action*, flexion of the first phalanx of the little finger. *Nerve*, the deep branch of the ulnar.

Lumbricales (Fig. 309).—"The earth-worm muscles," from fancied resemblance to angle-worms (*lumbrici*). *Number*, four. Each is a lumbricalis. *Situation*, in the palm on the plane of the flexor profundus digitorum. *Origin* of the first and second: the palmar aspect and radial border of the corresponding deep flexor tendon; of the third and fourth: the two tendons between which

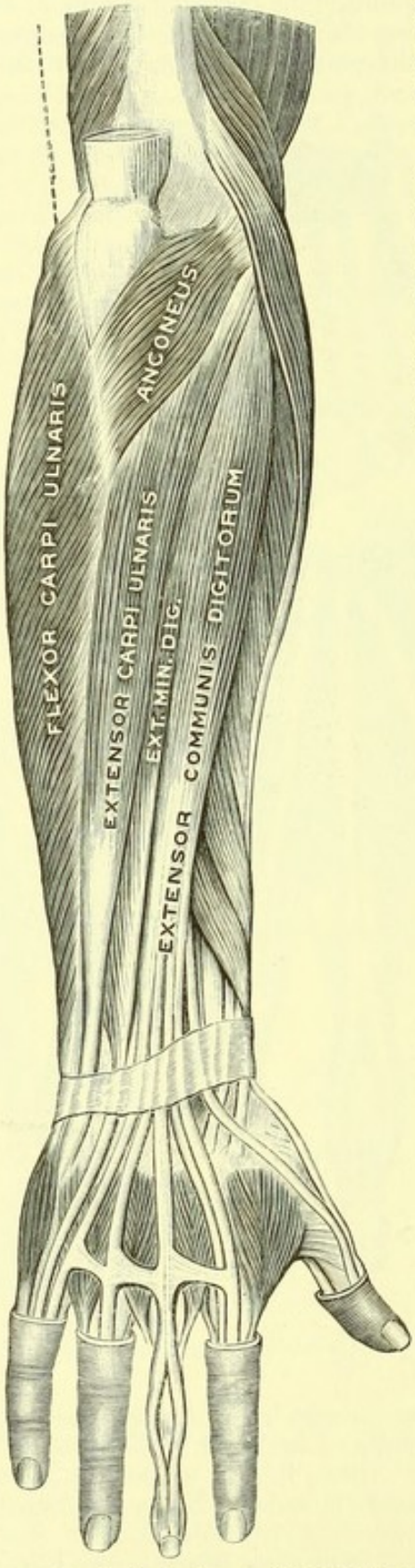

FIG. 310.—Muscles in the dorsum of the right forearm and hand. (Testut.)

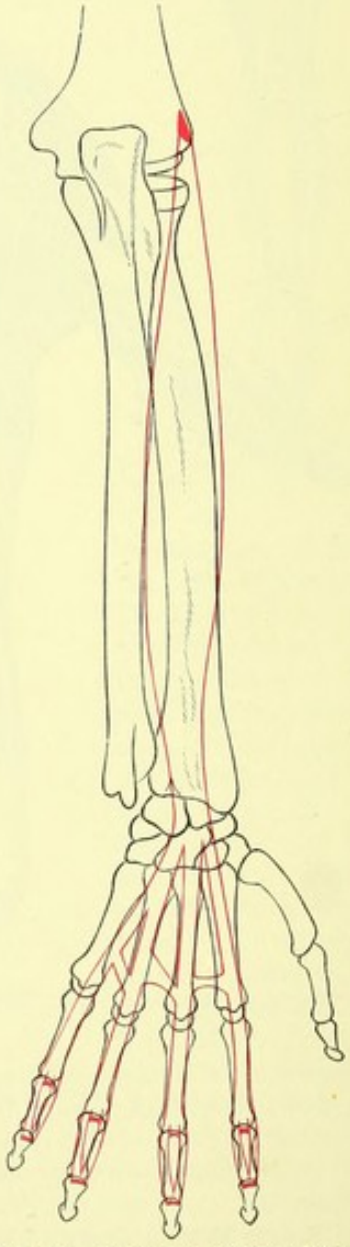

FIG. 311.—Extensor communis digitorum of right side: outline and attachment-areas. (F. H. G.)

each respectively lies. *Direction*, downward and then backward, on the radial side of the digits. *Insertion*, each to extensor communis tendon of corresponding finger on the radial side of the first phalanx. *Action*, flexion of the first phalanges, and extension of the second and third phalanges. The first and second slightly abduct the index and middle fingers from the middle line of the hand, the third and fourth slightly adduct the ring and little fingers to that line. *Nerves*, the median for the outer two, the ulnar for the inner two.

Extensor Communis Digitorum (Figs. 310–312).—"The common extensor of the digits"—*i. e.*, of the fingers, as distinguished from the thumb. *Situation*, superficially on the back of the forearm and hand. *Origin*, the outer condyle of the humerus. *Direction*, downward. *Insertion*: each of the four tendons finally divides into three slips opposite the first phalanx, and the middle one is attached to the back of the base of the second phalanx; the others, after uniting, are attached to the back of the base of the third phalanx. The first tendon receives the insertion of the extensor indicis at the base of the finger; the fourth tendon unites with

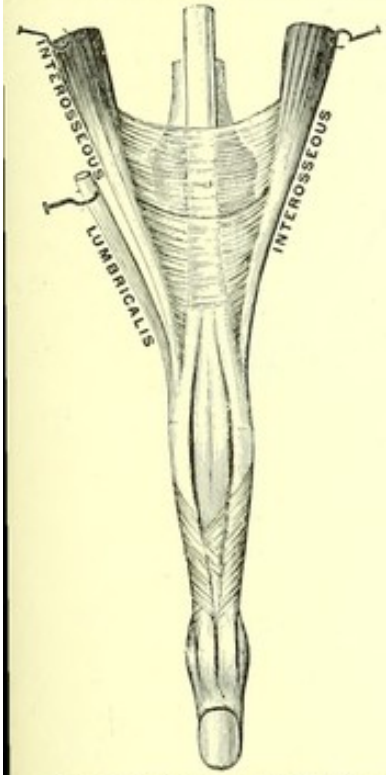

FIG. 312.—Relations of the interosseous and lumbrical muscles to the extensor tendons. (Testut.)

FIG. 313.—Extensor minimi digiti of right side: outline and attachment-areas. (Testut.)

FIG. 314.—Extensor indicis of right side: outline and attachment-areas. (F. H. G.)

that of the extensor minimi digiti at a similar point. The fourth divides: one part unites with the tendon of the medius, the other with that of the extensor minimi digiti. A strong band connects the tendons of the ring and middle fingers. *Action*, extension of the fingers. The oblique branches at the sides of the third tendon greatly limit the extension of the ring finger, when its immediate neighbors are

flexed, and this fact explains the difficulty experienced by pianists in lifting the annularis separately from the keys. *Nerve*, the posterior interosseous branch of the musculo-spiral.

Extensor Minimi Digiti (Figs. 310–313).—"The extensor of the smallest digit"—*i. e.*, of the little finger. *Synonym*, extensor digiti quinti proprius, "the proper extensor of the fifth digit"—"proper" to distinguish it from the part of the extensor communis which acts upon this finger. *Situation*, in the back of the forearm and hand. *Origin*, the external condyle of the humerus. *Insertion*: its tendon, which is commonly split, blends with the fourth tendon of the extensor communis above the metacarpo-phalangeal joint, and the resulting tendon goes to the second and third phalanges of the little finger (see extensor communis digitorum). *Action*, extension of the second and third phalanges of the little finger. *Nerve*, posterior interosseous branch of the musculo-spiral.

Extensor Indicis (Figs. 299, 314).—"The extensor of the index finger." *Synonyms*, extensor indicis proprius, "the proper extensor of the index finger"—"proper" to distinguish it from the part of the extensor communis which acts upon this digit; the indicator muscle. *Situation*, the back of the lower part of the forearm and hand. *Origin*, the back of the ulna below the extensor longus pollicis, and a little of the interosseous membrane. *Direction*, downward and outward. *Insertion*, the first tendon of the extensor communis digitorum, near the metacarpo-phalangeal joint (see extensor communis digitorum). *Action*, extension and slight adduction of the index. *Nerve*, the posterior interosseous branch of the musculo-spiral.

Interossei Dorsales (Fig. 315).—"The muscles between the bones on the back"

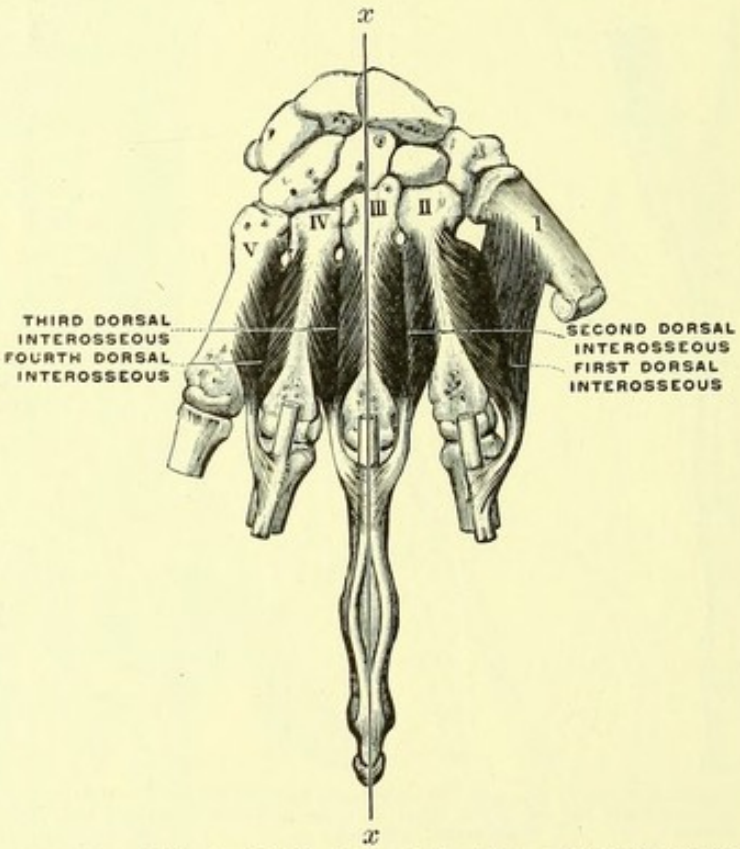

FIG. 315.—Interossei dorsales of right hand. The line *x x* is that from which abduction is made. (Testut.)

of the hand. *Number*, four. The first and largest is called *abductor indicis*, "the abductor of the index finger." The abductor minimi digiti belongs functionally in this group; but it is not interosseous. *Situation*, one in each metacarpal interspace near the dorsal aspect. *Origin*, each from the two bones

between which it lies. *Direction*, downward. *Insertion*, each into the base of a first phalanx, and also into the extensor tendon of the same finger, the first on the radial side of the index, the second on the radial side of the medius, the third on the ulnar side of the medius, the fourth on the ulnar side of the annularis. *Action*: each abducts from a line coinciding with the long axis of the middle finger. This digit, having two interossei inserted into it, is abducted toward the radial side by one, and toward the ulnar side by the other; thus, each in turn becomes an adductor, for the finger being abducted by one is then restored to the mid-line (*i. e.*, adducted) by the other. They also flex the first phalanges and extend the second and third. *Nerve*, the deep branch of the ulnar.

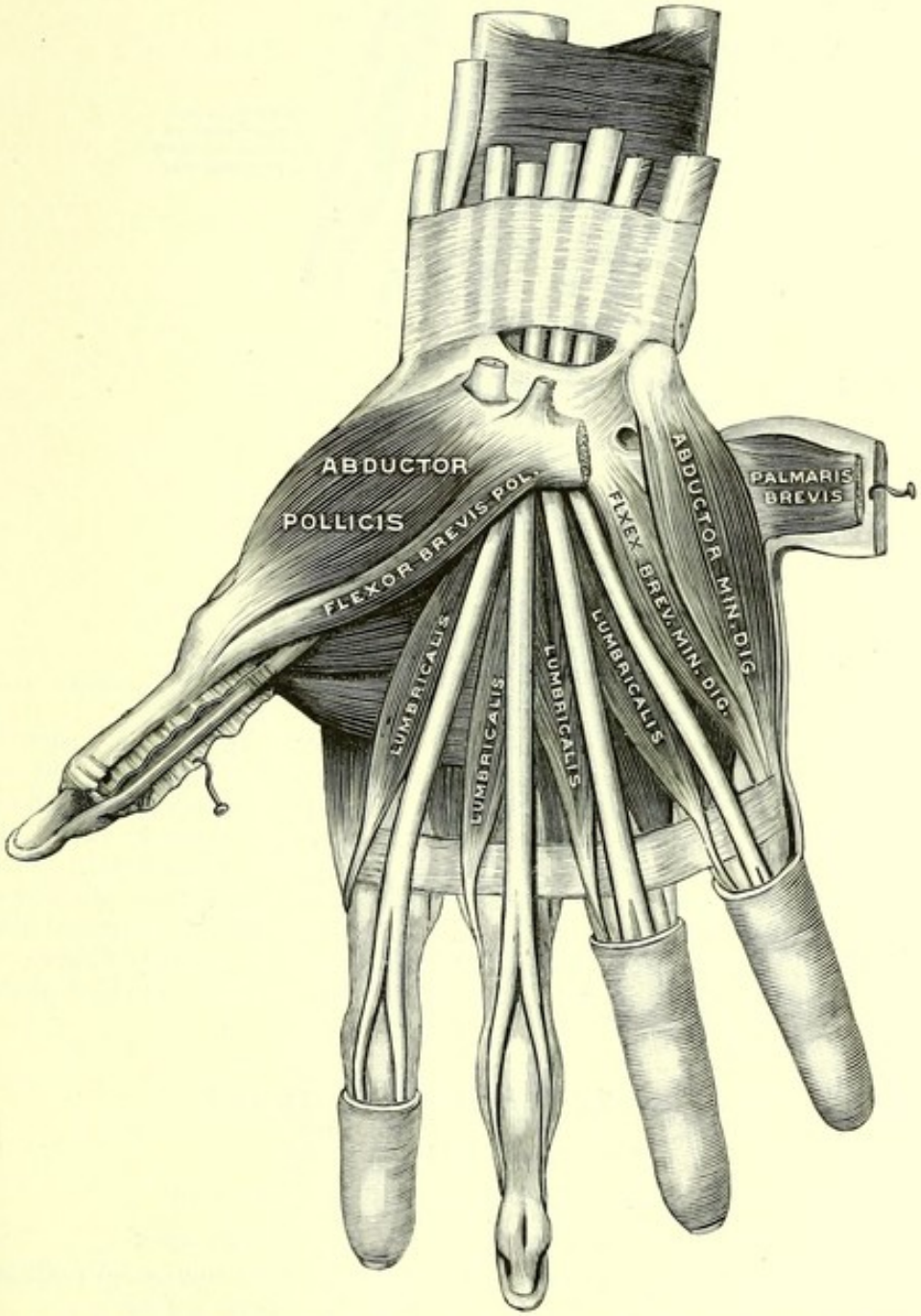

FIG. 316.—Muscles of the right palm. The palmaris brevis is reflected to the ulnar side. (Testut.)

Abductor Minimi Digiti (Fig. 316).—"The abductor of the least digit"—*i. e.*, of the little finger. *Synonym*, abductor digiti quinti, "the abductor of the fifth

digit." *Situation*, the ulnar border of the hand. *Origin*, the pisiform. *Direction*, downward. *Insertion*, the ulnar border of the base of the first phalanx of the little finger and the tendon of the extensor minimi digiti. *Action*, abduction of little finger. *Nerve*, the ulnar. Its function puts it in the group with the interossei dorsales, as it draws its digit from the mid-line of the hand.

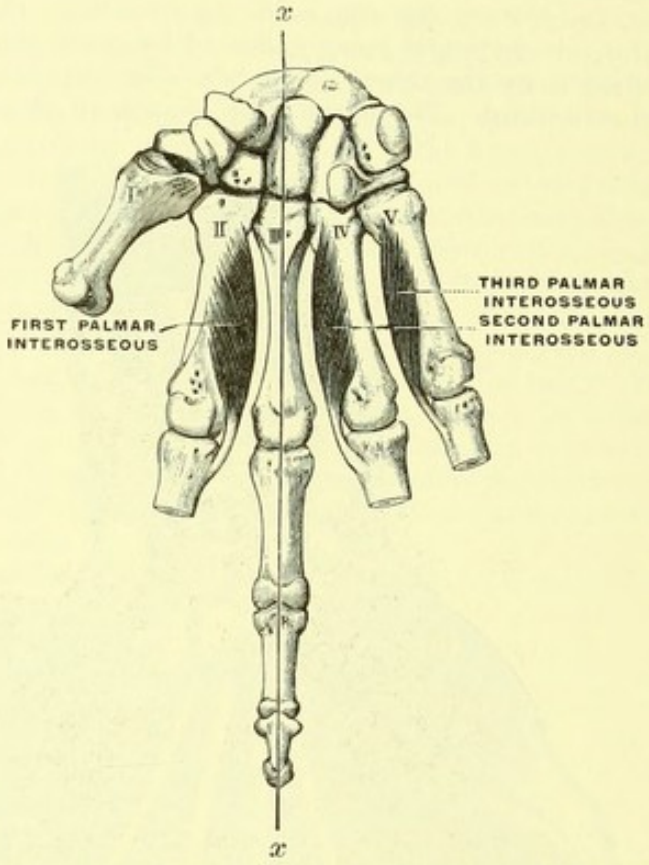

FIG. 317.—Interossei palmares of right hand. The line *x x* is that to which adduction is made. (Testut.)

Interossei Palmares (Fig. 317).—"The muscles between the bones in the palm." *Synonym*, interossei volares. *Number*, three. *Situation*, in the second, third, and fourth metacarpal interspaces, near the palmar surfaces of the bones. *Origin*, the first: ulnar side of second metacarpal; the second: radial side of fourth metacarpal; the third: the radial side of the fifth metacarpal. *Direction*, downward. *Insertion*, each into the side of the base of the first phalanx of the digit from whose metacarpal bone it arises, and also into the corresponding extensor tendon. *Action*, each adducts its digit toward the middle finger; also, it flexes the first phalanx of its digit, and extends the second and third phalanges. *Nerve*, the deep branch of the ulnar.

MUSCLES MOVING THE THUMB

and its Metacarpal Bone.

(Those entirely in the hand are indicated with a star.)

Flexors.	*Extensors.*
*Flexor ossis metacarpi pollicis.	Extensor ossis metacarpi pollicis.
*Flexor brevis pollicis.	Extensor brevis pollicis.
Flexor longus pollicis.	Extensor longus pollicis.
Abductor.	*Adductor.*
*Abductor pollicis.	*Adductor pollicis.

The movements of the first metacarpal bone are so closely associated with those of the phalanges which it carries, that it is profitable to consider its special muscles in the group with those of the thumb. The longer name of the metacarpal flexor is preferred as indicating its action as well as "opponens pollicis," and at the same time expressing much more clearly the antagonism between it and the metacarpal extensor.

Flexor Ossis Metacarpi Pollicis (Figs. 318, 309).—"The flexor of the metacarpal bone of the thumb." *Synonym*, opponens pollicis, "the opponent muscle of the thumb"—referring to its action in opposing the thenar eminence to the hypothenar, so that the palmar hollow is deepened and narrowed, and a body

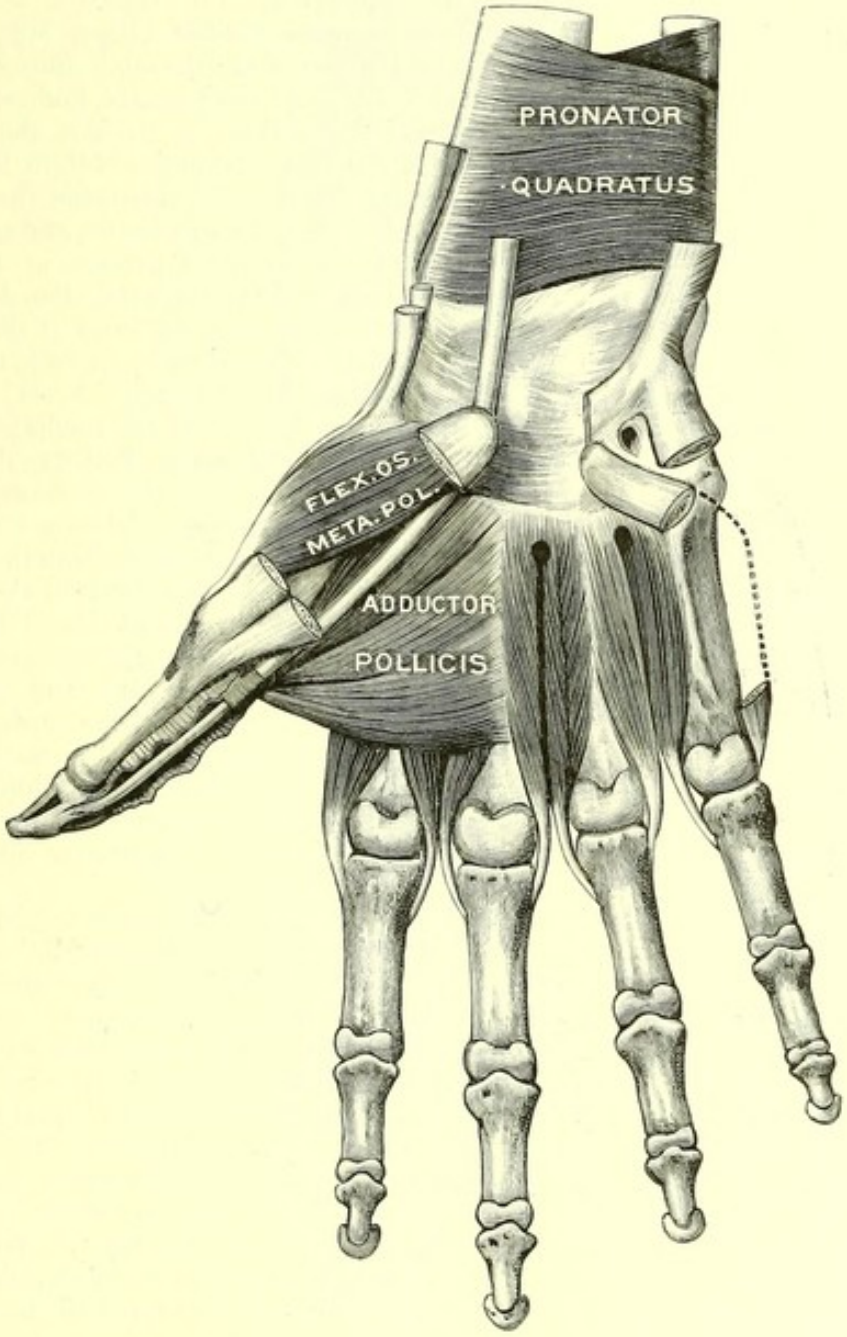

FIG. 318.—Adductor pollicis, flexor ossis metacarpi pollicis, and pronator quadratus. (Testut.)

between these muscular mounds can be grasped by them. *Situation*, deep in the thenar eminence. *Origin*, the palmar aspect of the trapezium and annular liga-

ment. *Direction*, downward and outward. *Insertion*, the whole shaft of the metacarpal bone of the thumb on its radial side and anterior aspect. *Action*, flexion and inward rotation of the first metacarpal bone. *Nerve*, the median.

Flexor Brevis Pollicis (Fig. 309).—"The short flexor of the thumb." *Situation*, deep in thenar eminence. *Origin*, outer (superficial) head : the trapezium and the outer two-thirds of the annular ligament ; inner (deep) head : the proximal part of the first metacarpal on the ulnar side. *Direction*, downward and outward. *Insertion*, outer head : the outer side of the base of the first phalanx of the thumb ; inner head : the inner side of the same. In each tendon of insertion is a sesamoid bone. *Action*, flexion of the first phalanx of the thumb. *Nerves*, outer head : the median ; inner head : the ulnar.

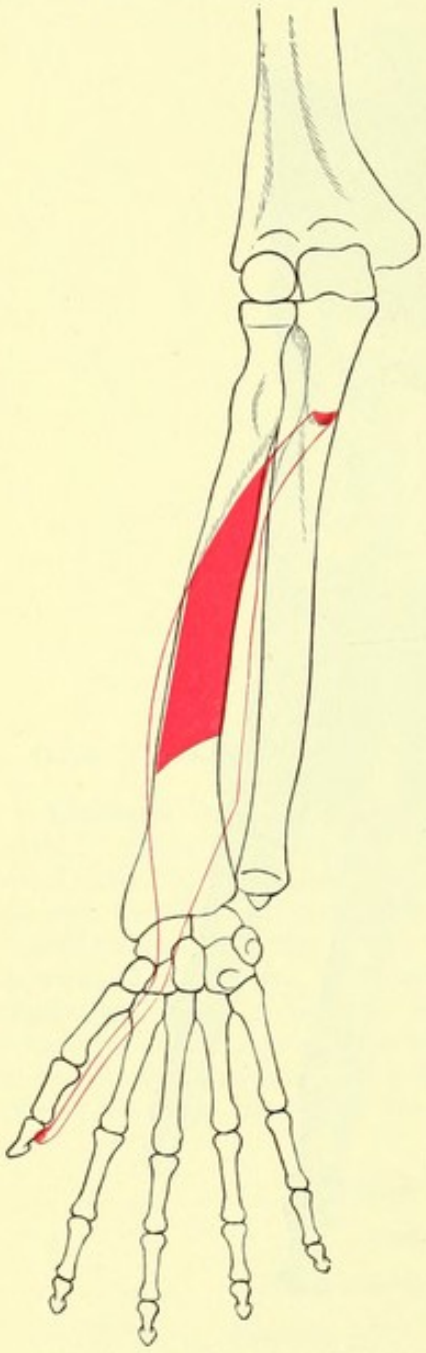

Fig. 319—Flexor longus pollicis of right side: outline and attachment-areas. (F. H. G.)

Flexor Longus Pollicis (Figs. 306, 319).—"The long flexor of the thumb." *Situation*, deep in the front part of the forearm, and on the palmar aspect of the thumb. *Origin*, the anterior surface of the radius from the oblique line to the upper line of the pronator quadratus, the adjacent part of the interosseous membrane, and sometimes the base of the coronoid process of the ulna. *Direction*, downward to the wrist, then downward and outward. *Insertion*, the front of the base of the last phalanx of the thumb. *Action*, flexion of the last phalanx of the thumb. *Nerve*, the anterior interosseous branch of the median.

Extensor Ossis Metacarpi Pollicis (Figs. 320, 321).—"The extensor of the metacarpal bone of the thumb." *Synonym*, abductor longus pollicis, "the long abductor of the thumb." *Situation*, deep in the lower two-thirds of the back of the forearm and in the radial side of the wrist. *Origin*, small areas below attachments of supinator on both radius and ulna, and the interosseous membrane between these surfaces. *Direction*, downward and outward. *Insertion*, the base of the metacarpal bone of the thumb. *Action*, extension and abduction of the metacarpal bone of the thumb. *Nerve*, posterior interosseous branch of the musculo-spiral.

Extensor Brevis Pollicis (Figs. 320, 322).—"The short extensor of the thumb." *Synonym*, extensor primi internodii pollicis, "the extensor of the first phalanx of the thumb." *Situation*, deep in the lower half of the back of the forearm on the outer side, and in the metacarpus. *Origin*, a small area of the radius, just below the extensor ossis metacarpi pollicis, and the adjacent portion of the interosseous membrane. *Direction*, downward and outward. *Insertion*, the back of the base of the first phalanx of the thumb. *Action*, extension of the thumb. *Nerve*, the posterior interosseous branch of the musculo-spiral.

Extensor Longus Pollicis (Figs. 320, 323).—"The long extensor of the thumb." *Synonym*, extensor secundi internodii pollicis, "the extensor of the second phalanx of the thumb." *Situation*, deep in the lower half of the back of forearm and in the thumb. *Origin*, the middle third of

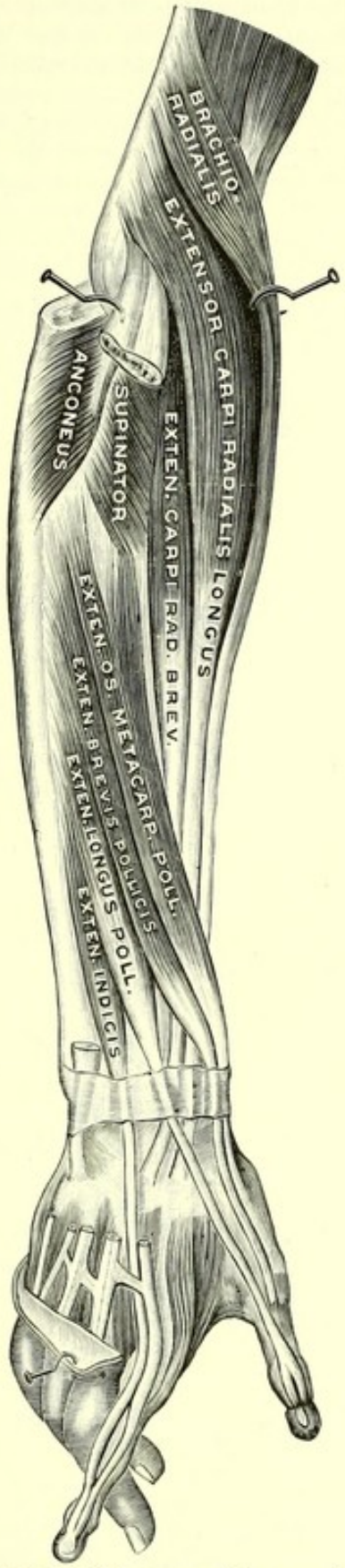

FIG. 320.—Muscles in radial region of right forearm, and deep muscles in its dorsum. (Testut.)

the hind surface of the ulna, below the extensor ossis metacarpi pollicis, and the neighboring part of the interosseous membrane. *Direction*, downward and outward. *Insertion*, the back of the base of the last phalanx of the thumb. *Action*, extension of the last phalanx of the thumb. *Nerve*, the posterior interosseous branch of the musculo-spiral.

Abductor Pollicis (Fig. 316).—"The abductor of the thumb." *Synonym*, abductor pollicis brevis, "the short abductor of the thumb." *Situation*, superficial, on radial side of metacarpal bone of the thumb. *Origin*, the front of the annular ligament, and, to a slight extent, the trapezium and scaphoid. *Direction*, downward and outward. *Insertion*, the base of the first phalanx of the thumb on the outer side. *Action*, abduction of thumb. *Nerve*, the median.

FIG. 321.—Extensor ossis metacarpi pollicis of right side: outline and attachment-areas. (F. H. G.)

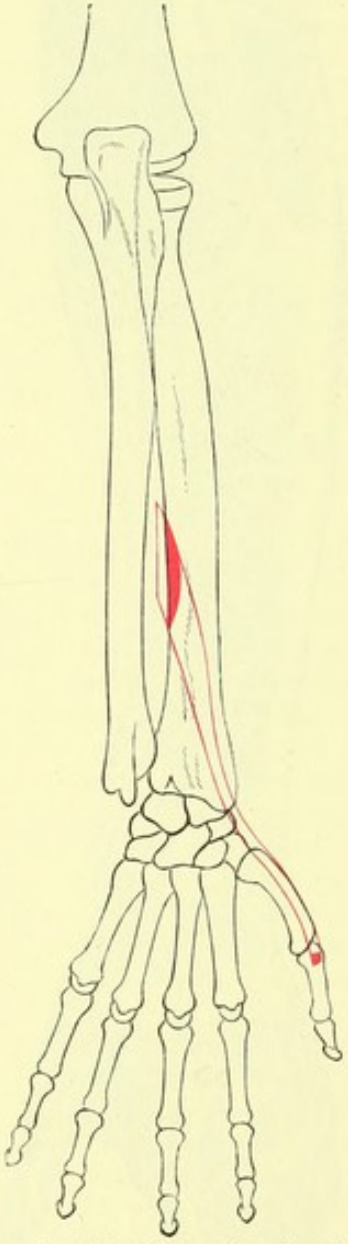

FIG. 322.—Extensor brevis pollicis of right side: outline and attachment-areas. (F. H. G.)

FIG. 323.—Extensor longus pollicis of right side: outline and attachment-areas. (F. H. G.)

Adductor Pollicis (Fig. 318).—"The adductor of the thumb." *Situation*, deep in the outer half the palm. *Origin*, one head: the os magnum, the bases of the second and third metacarpals, and the annular ligament; the other head: the lower two-thirds of the third metacarpal. *Direction*, the upper part: downward and outward; the lower part: outward. *Insertion*, the inner side of the base of

the first phalanx of the thumb. *Action*, adduction and flexion of thumb. *Nerve*, the ulnar.—The upper portion of this muscle is often described as *adductor obliquus pollicis*, and the lower as *adductor transversus pollicis*.

The interossei, the abductor and adductor pollicis, and the abductor minimi digiti may well be considered together as constituting a distinct physiological group, the members of which are concerned either in abduction or adduction, or both (Fig. 324). Each of the five digits has attached to the base of its first

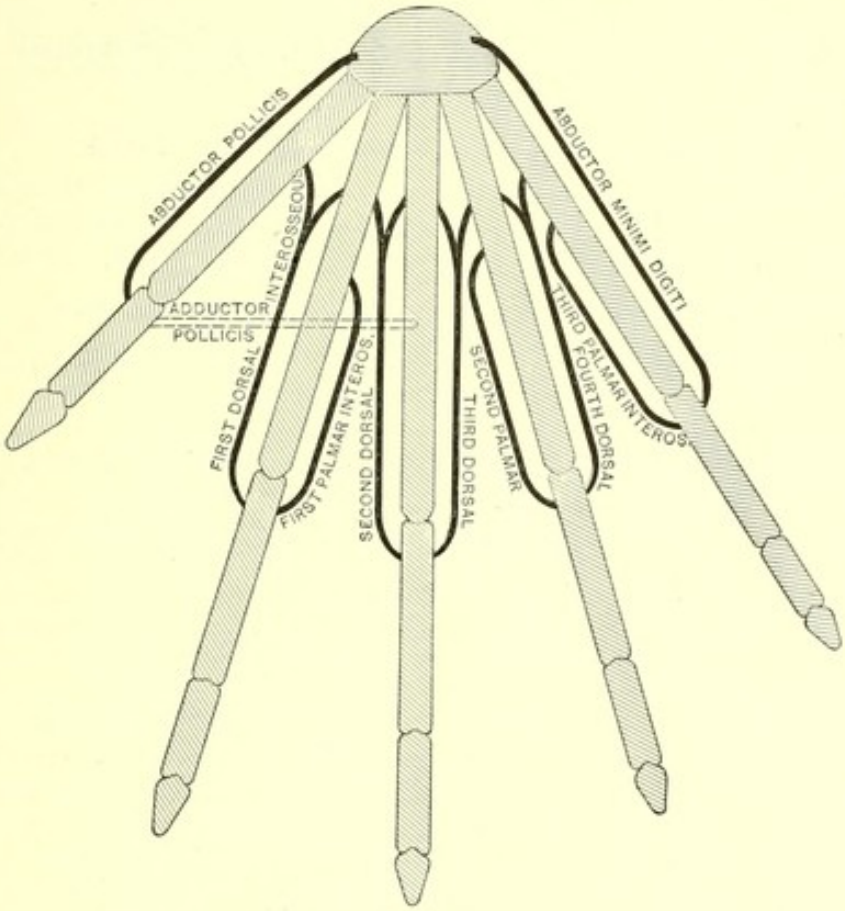

FIG. 324.—Diagram showing the arrangement of the adductors and abductors of the digits of the hand. (F. H. G.)

phalanx two of these ten muscles, one upon the radial, the other upon the ulnar side. The thumb has the *abductor* and *adductor pollicis*; the forefinger has the *first dorsal interosseous* (abductor indicis) and the *first palmar interosseous* (the adductor of the index); the ring finger has the *second palmar interosseous* (the adductor of the annularis) and the *fourth dorsal interosseous* (the abductor of the annularis); the little finger has the *third palmar interosseous* (the adductor of the least digit) and the *abductor minimi digiti*. The lateral opponent muscles of the middle finger are the *second* and *third dorsal interosseous*—the one drawing the digit from the middle line toward the radial side, the other drawing it from the middle line toward the ulnar side—that is, both are abductors. But, the finger being displaced laterally by one of these muscles, is restored to the middle line by the action of the other; and thus it is seen that the second and third dorsal interosseous are, on occasion, adductors as well as abductors.

One other muscle must be described, although it is so diminutive and nearly powerless that it does not deserve a place in any of the specified groups.

Palmaris Brevis (Fig. 316.)—"The short palmar muscle." *Situation*, subcutaneous at the proximal part of the palm. *Origin*, the inner border of the palmar fascia and the middle

of the annular ligament. *Direction*, inward. *Insertion*, the skin at the inner border of the palm. *Action*, wrinkling the skin of the hypothenar eminence and slightly deepening the hollow of the palm. *Nerve*, the ulnar.

Although the classification of the muscles of the upper limb which has been given is regarded as the most helpful to the learner and to the practitioner, it is desirable that they should be studied from other points of view also; and, therefore, a regional classification is herewith presented, based upon the situation of the main portion of each of these structures.

MUSCLES WHICH MOVE THE UPPER LIMB, GROUPED ACCORDING TO THEIR LOCATION.

In the Superficial Layer of the Back of the Trunk.

Trapezius. Latissimus.

In the Second Layer of the Back of the Trunk.

Levator scapulæ. Rhomboideus minor.
Rhomboideus major.

On the Front of the Chest.

Pectoralis major. Pectoralis minor.
Subclavius.

On the Side of the Chest.

Serratus magnus.

In the Back Part of the Shoulder.

Supraspinatus. Infraspinatus.
Teres major. Teres minor.
Subscapularis.

In the Outer Part of the Shoulder.

Deltoideus.

In the Inner Side of the Arm.

Coraco-brachialis.

In the Front Part of the Arm.

Biceps flexor cubiti. Brachialis.

In the Back Part of the Arm.

Triceps extensor cubiti.

In the Front Part of the Forearm.

Pronator teres. Flexor carpi ulnaris.
Flexor carpi radialis. Flexor sublimis digitorum.
[Flexor] palmaris longus. Flexor profundus digitorum.
Pronator quadratus.

In the Outer Part of the Forearm.

Brachio-radialis. Extensor carpi radialis longus.
Extensor carpi radialis brevis.

In the Back Part of the Forearm.

Anconeus.
Extensor communis digitorum.
Extensor minimi digiti.
Extensor carpi ulnaris.
Extensor ossis metacarpi pollicis.
Extensor brevis pollicis.
Extensor longus pollicis.
Extensor indicis.
Supinator.

In the Thenar Eminence.

Abductor pollicis.
Flexor ossis metacarpi pollicis.
Flexor brevis pollicis.
Adductor pollicis.

In the Hypothenar Eminence.

Abductor minimi digiti.
Flexor ossis metacarpi minimi digiti.
Flexor brevis minimi digiti.
Palmaris brevis.

In the Palm of the Hand between the Eminences.

Lumbricales.
Interossei palmares.
Interossei dorsales.

The student is advised to make other classifications of the muscles moving the limbs, in order to obtain as complete a practical knowledge of them as possible. For example, let him group the muscles *according to the parts which they connect*, under some such headings as the following:

Connecting the head, neck, and (or) trunk with the shoulder.
Connecting the trunk with the arm.
Connecting the shoulder with the arm.
Connecting the shoulder with the forearm.
Connecting the arm with the forearm.
Connecting the bones of the forearm.
Connecting the arm with the hand.
Connecting the forearm with the hand.
Connecting the parts of the hand with each other.

Again, let him enumerate the muscles which would be *cut by plane sections made transversely through the limb* at different levels, as, for example, at the middle of the arm, in the lower third of the arm, in the upper quarter of the forearm, and so on. The more ways he adopts for considering the subject, the more exact, permanent, and usable will be his knowledge.

THE MUSCLES OF THE LOWER LIMB.

In making a physiological classification of the muscles of the lower limb, we notice at the outset that there is a great difference between the mobility of the first segment of the upper limb and that of its homologue in the lower: the shoulder is freely movable, the hip is almost immovably fixed. There is no group of muscles devoted to moving the pelvic girdle at all comparable with those concerned in the movements of the shoulder. The great muscles of the abdominal wall lift the front of the pelvis; but this is accompanied to no appreciable extent by movement of the hip-bones at their articulations with the sacrum, but by the curving of the vertebral column. The very inconstant psoas parvus is sometimes asserted to flex the pelvis; but this may well be questioned,

and the muscle, which is frequently absent, probably has no effect except in tightening the iliac fascia. No group of muscles, therefore, will be presented as acting upon the hip.

Movements of the Thigh.—The ball-and-socket joint at the hip permits movement of the thigh in every direction. That forward is called *flexion*, backward is *extension*, outward is *abduction*, inward is *adduction*. *Rotation* and *circumduction* are like the same movements in the upper extremity.

Movements of the Leg.—At the knee the joint is a hinge, and the movements of the leg are forward, which is *extension*, and backward, which is *flexion*. Between the two long bones of the leg there is no movement comparable with the pronation and supination of the radius.

Movements of the Foot.—At the ankle is another hinge with movement of the foot forward (upward), which is *flexion*, and backward (downward), which is *extension*. The lateral movements of the foot are chiefly at the astragalo-calcanean and the medio-tarsal articulations.

Movements of the Digits.—The metatarso-phalangeal and interphalangeal articulations are almost identical with their homologues in the hand, the main difference being that the first metatarsal is like all of its fellows in its practical immobility, and thus the hallux has nothing like the capacity of the pollex—there is no power of grasping in the sole as there is in the palm. Motion of the toes forward (upward) is *extension*, in the opposite direction is *flexion*. Thus, we see that the series of forward movements presents alternately flexion and extension—of the thigh flexion, of the leg extension, of the foot flexion, of the toes extension; and the backward movements are alternately, beginning with the thigh, extension and flexion. In the upper extremity the forward movements, it will be remembered, are all flexion. The movements of the toes sidewise are *abduction* and *adduction* with reference to a line running through the normal long axis of the second digit of the foot, and not the third, as it is in the hand.

Classification of the Muscles of the Lower Limb on the Basis of their Principal Action.

Moving the Thigh.

Flexors.	*Extensor.*
Psoas magnus. Iliacus.	Gluteus maximus.
Abductors.	*Adductors.*
Tensor vaginæ femoris. Gluteus medius. Gluteus minimus.	Adductor magnus. Adductor longus. Adductor brevis. Adductor gracilis. Pectineus.
Internal Rotators.	*External Rotators.*
(The same as the abductors.)	Obturator externus. Quadratus femoris. Pyriformis. Gemellus superior. Obturator internus. Gemellus inferior.

Moving the Leg.

Flexors.	*Extensor.*
Sartorius.	Quadriceps extensor cruris, comprising :
Biceps flexor cruris.	Rectus femoris.
Semitendinosus.	Vastus externus.
Semimembranosus.	Vastus internus.
Popliteus.	Vastus intermedius.

Moving the Foot.

Flexors.	*Extensors.*
Tibialis anterior.	Tibialis posterior.
	Gastrocnemius.
	Soleus.
	Plantaris.
	Peroneus longus.
Peroneus tertius.	Peroneus brevis.

Moving the Digits of the Foot.

(Those situated entirely in the foot are indicated by a star.)

Flexors.	*Extensors.*
Flexor longus hallucis.	Extensor proprius hallucis.
*Flexor brevis hallucis.	
Flexor longus digitorum.	Extensor longus digitorum.
*Flexor accessorius.	
*Flexor brevis digitorum.	*Extensor brevis digitorum.
*Flexor brevis minimi digiti.	
*Lumbricales.	

Abductors.	*Adductors.*
*Abductor hallucis.	*Adductor obliquus hallucis.
*Abductor minimi digiti.	*Adductor transversus hallucis.
*Interossei dorsales.	*Interossei plantares.

MUSCLES MOVING THE THIGH.

Flexors.	*Extensor.*
Psoas magnus.	Gluteus maximus.
Iliacus.	

Abductors and Internal Rotators.	*Adductors.*
Tensor vaginæ femoris.	Adductor magnus.
Gluteus medius.	Adductor longus.
Gluteus minimus.	Adductor brevis.
	Adductor gracilis.
	Pectineus.

External Rotators.

Obturator externus.	Gemellus superior.
Quadratus femoris.	Obturator internus.
Pyriformis.	Gemellus inferior.

The *flexors of the thigh* arise partly from the lumbar vertebræ, partly from the inner surface of the false pelvis, and are inserted upon the small trochanter.

The *great extensor* arises from the back part of the hip-bone, sacrum, and coccyx, and is inserted into the small trochanter and the fascia lata.

The *abductors*, which are also *internal rotators*, arise from the outer aspect of the hip-bone, and are inserted into the great trochanter and the neighboring fascia lata.

The *adductors* arise from the hip-bone near the middle line of the body, and four of the five pass outward and downward with varying degrees of obliquity to their insertion into the back part of the shaft of the femur, the fifth one going below the knee-joint to the upper part of the tibial shaft. They are to a considerable extent external rotators.

The *external rotators* arise partly from the inside and partly from the outside of the bony pelvis, and are all inserted about the upper end of the femur.

Psoas Magnus (Figs. 325, 326).—"The great loin muscle." *Synonym*, psoas major. *Situation*, in the hind wall of the abdomen and upper part of the thigh. *Origin*, the front of the transverse processes and side of bodies of lumbar vertebræ

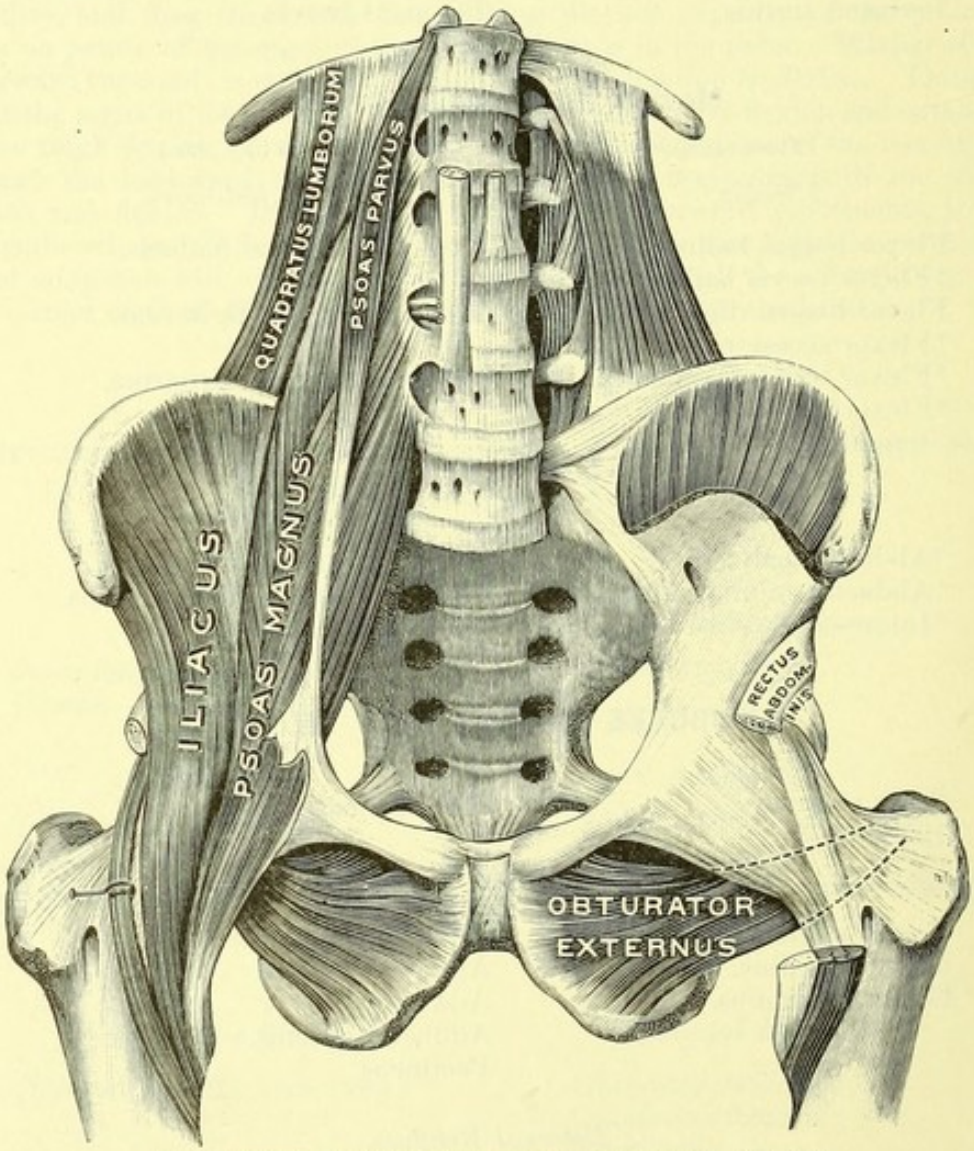

FIG. 325.—Psoas, iliacus, and obturator externus muscles. (Testut.)

and side of body of the last thoracic, with included intervertebral cartilages. *Direction*, down- and forward, and finally down- and backward. *Insertion*, the

small trochanter of the femur. *Action*, flexion of the thigh. *Nerves*, the second and third lumbar.

Iliacus (Figs. 325, 327).—"The iliac muscle." *Synonym*, iliacus internus, "the internal iliac muscle." *Situation*, in iliac fossa and upper part of thigh. *Origin*, the upper two-thirds of the iliac fossa and the ala of the sacrum. *Direction*, down- and inward. *Insertion*, the tendon of the psoas magnus, the front of the small trochanter and the small surface below it. *Action*, flexion of the thigh. *Nerve*, the anterior crural.

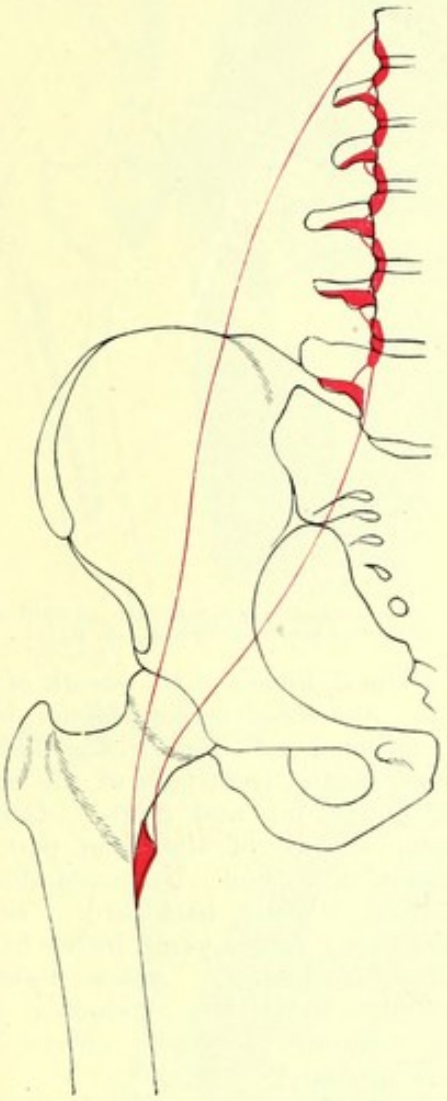

FIG. 326.—Psoas magnus of right side: outline and attachment-areas. (F. H. G.)

FIG. 327.—Iliacus of right side: outline and attachment-areas. (F. H. G.)

The two preceding muscles—psoas and iliacus—are sometimes treated as one muscle, called *ilio-psoas*.

Gluteus Maximus (Figs. 328, 329).—"The largest muscle of the buttock." *Situation*, subcutaneous in the back of the hip and upper part of the thigh. *Origin*, the hind fourth of the iliac crest, the outer surface of the ilium between the crest and the superior gluteal line, the hind surface of the lower two segments of the sacrum and upper three of the coccyx, the great sacro-sciatic ligament, and the aponeurosis of the erector spinæ. *Direction*, down- and outward. *Insertion*, the lower half to the gluteal ridge of the femur, the upper to the fascia lata. *Action*, extension and external rotation of the thigh. *Nerve*, the inferior gluteal.

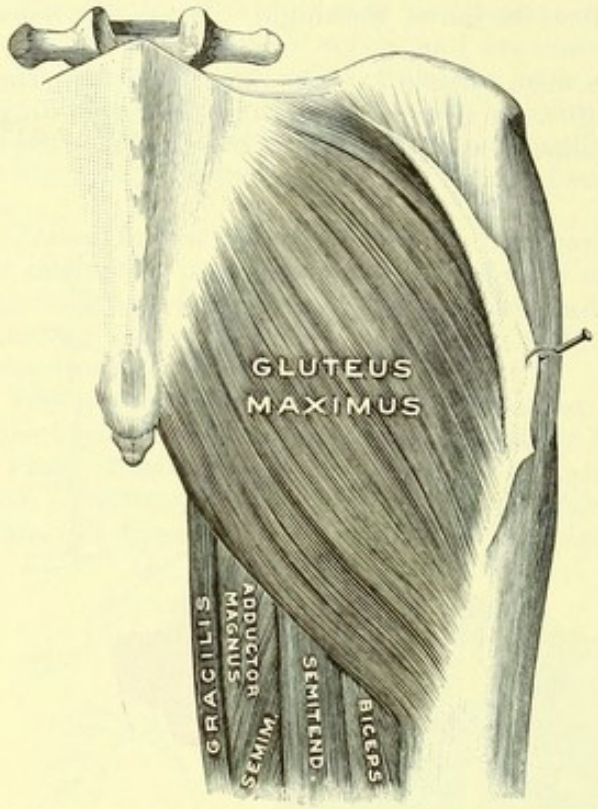

FIG. 328.—Gluteus maximus of right side. (Testut.)

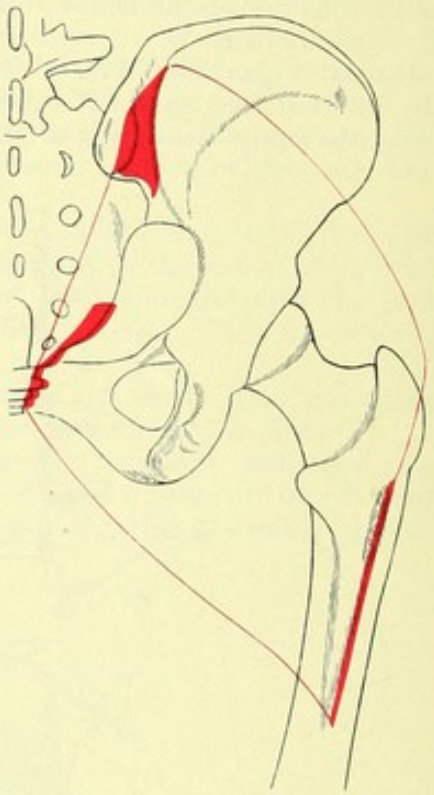

FIG. 329.—Gluteus maximus of right side: outline and attachment-areas. (F. H. G.)

Tensor Vaginæ Femoris (Figs. 330, 348).—"The tightener of the sheath of the thigh." *Synonym*, tensor fasciæ latæ, "the tightener of the broad fascia." *Situation*, in the front part of the outer aspect of the hip and thigh. *Origin*, the outer surface of the front part of the crest of the ilium. *Direction*, downward and slightly backward. *Insertion*, the fascia lata several inches below the great trochanter. *Action*, tightening of the fascia lata, abduction and inward rotation of thigh. *Nerve*, the superior gluteal.

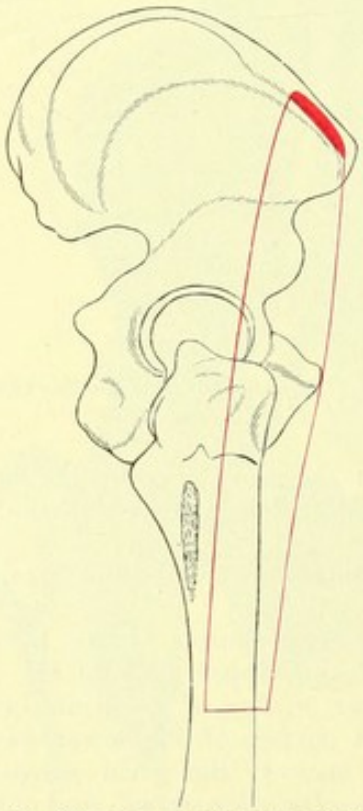

FIG. 330.—Tensor vaginæ femoris of right side: outline and attachment-areas. (F. H. G.)

Gluteus Medius (Figs. 331, 332).—"The middle buttock-muscle." *Situation*, in the outer part of the hip from the iliac crest to the trochanter major. *Origin*, the external surface of the ilium between the crest and the superior and middle gluteal lines. *Direction*, downward. *Insertion*, the outer surface of the trochanter major. *Action*, abduction of the thigh, and, when the thigh is flexed, inward rotation. *Nerve*, the superior gluteal.

Gluteus Minimus (Figs. 333, 334).—"The smallest buttock-muscle." *Situation*, in the outer part of the hip, from the front part of the crest to the great trochanter. *Origin*, the external surface of the ilium, between the middle and

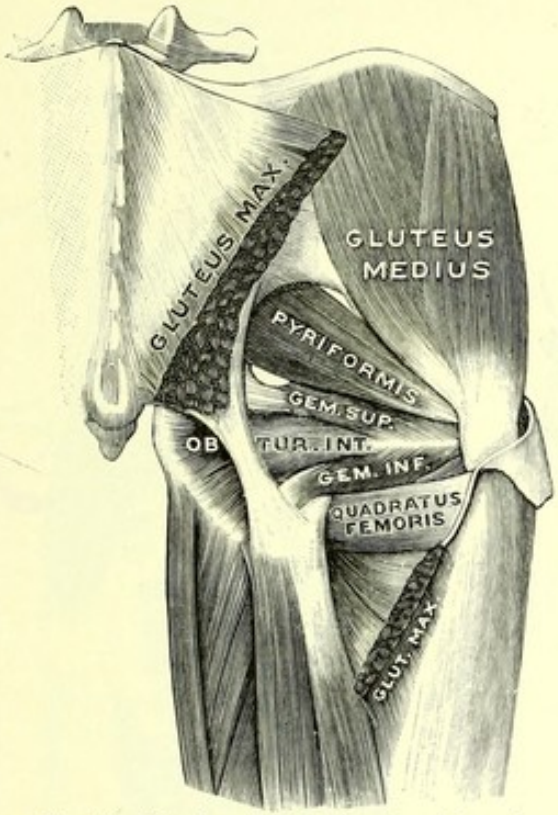

FIG. 331.—Muscles of right hip, viewed from behind, the gluteus maximus having been cut away. (Testut.)

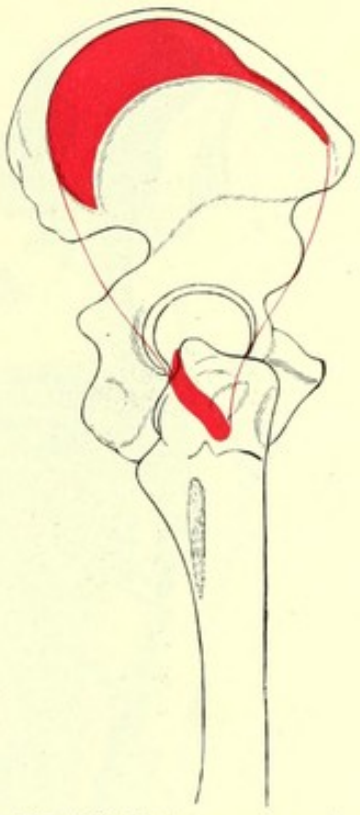

FIG. 332.—Gluteus medius of right side: outline and attachment-areas. (F. H. G.)

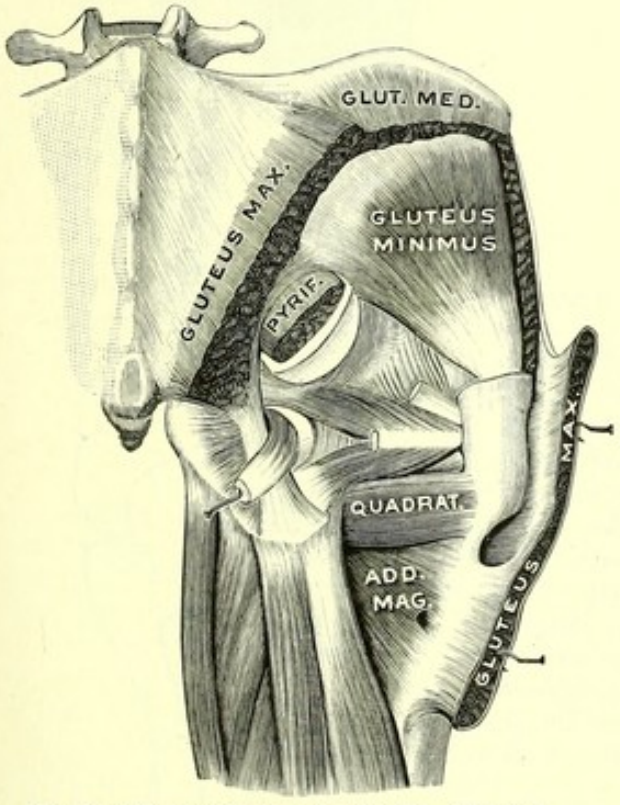

FIG. 333.—Gluteus minimus of right side. (Testut.)

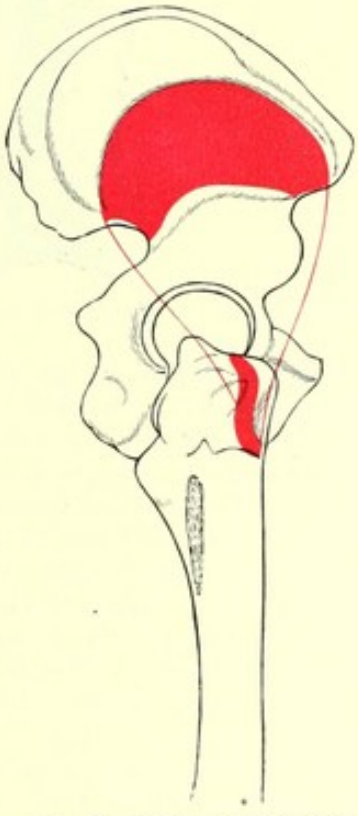

FIG. 334.—Gluteus minimus of right side: outline and attachment-areas. (F. H. G.)

inferior gluteal lines. *Direction*, down- and outward. *Insertion*, the front of the great trochanter. *Action*, abduction of the thigh, when it is extended; inward rotation, when it is flexed. *Nerve*, the superior gluteal.

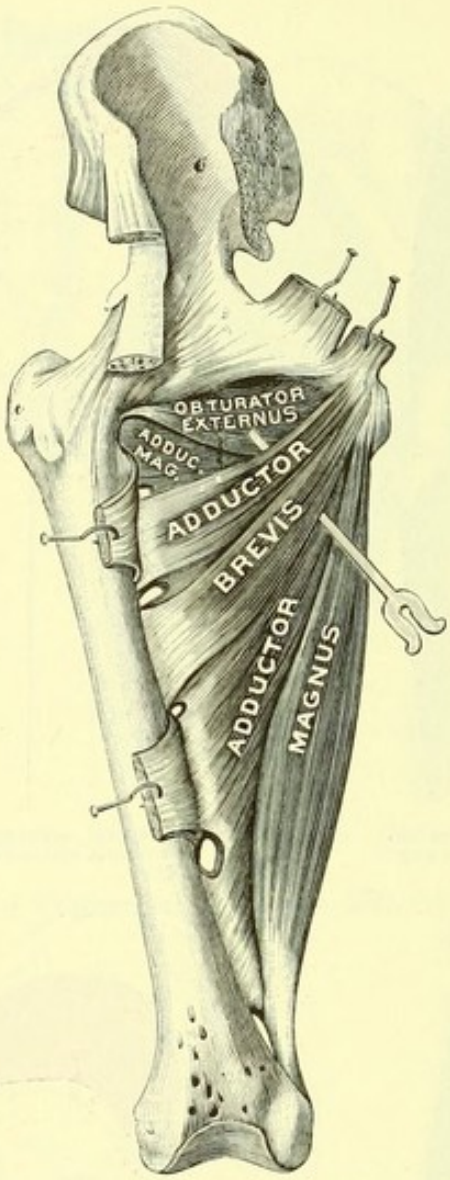

FIG. 335.—Adductores magnus and brevis of right side. (Testut.)

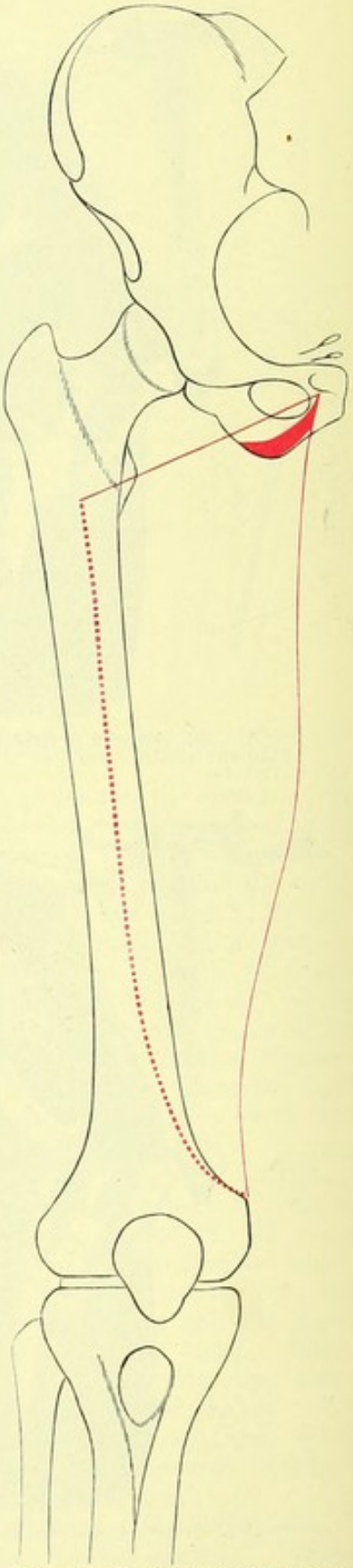

FIG. 336.—Adductor magnus of right side; outline and attachment-areas. (F. H. G.)

Adductor Magnus (Figs. 335, 336, 353).—"The great adductor." *Situation*, in the inner side of the thigh. *Origin*, the ramus of the os pubis, the ramus and tuberosity of the ischium. *Direction*, from the ischial tuberosity downward; from the pubic body outward, from the intermediate parts obliquely downward and outward. *Insertion*, the gluteal ridge, the inner lip of the linea aspera, the internal supracondylar ridge and the adductor tubercle. The femoral attachment is broken by several arches. *Action*, adduction and external rotation of thigh. The part from the ischial tuberosity is extensor. *Nerves*, the obturator and the great sciatic.

Adductor Longus (Figs. 337, 338).—"The long adductor." *Situation*, in the inner side of the thigh. *Origin*, the body of the os pubis near the angle. *Direction*, down-, out-, and backward. *Insertion*, the inner lip of the linea aspera about the middle third

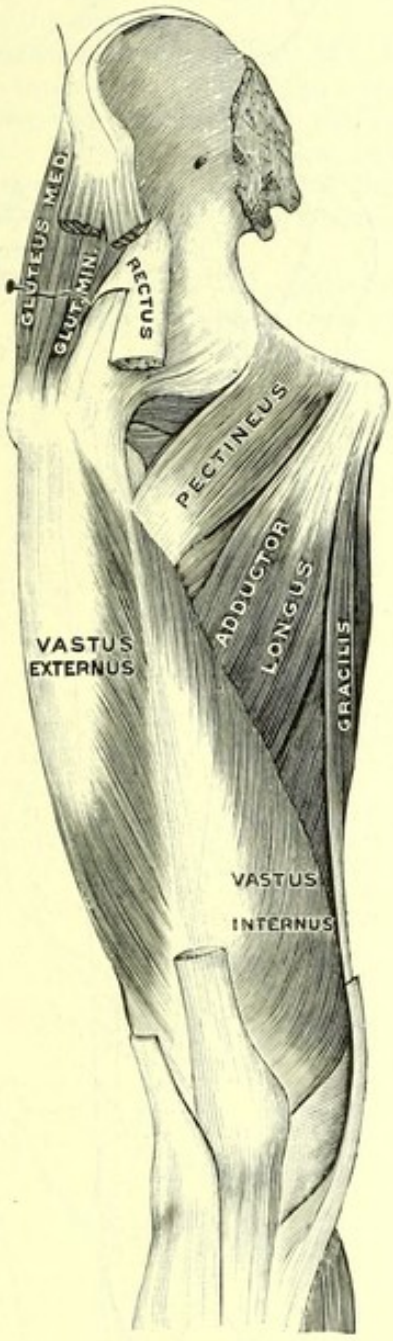

FIG. 337.—Muscles in the right thigh, viewed from in front, after removal of the rectus and sartorius. (Testut.)

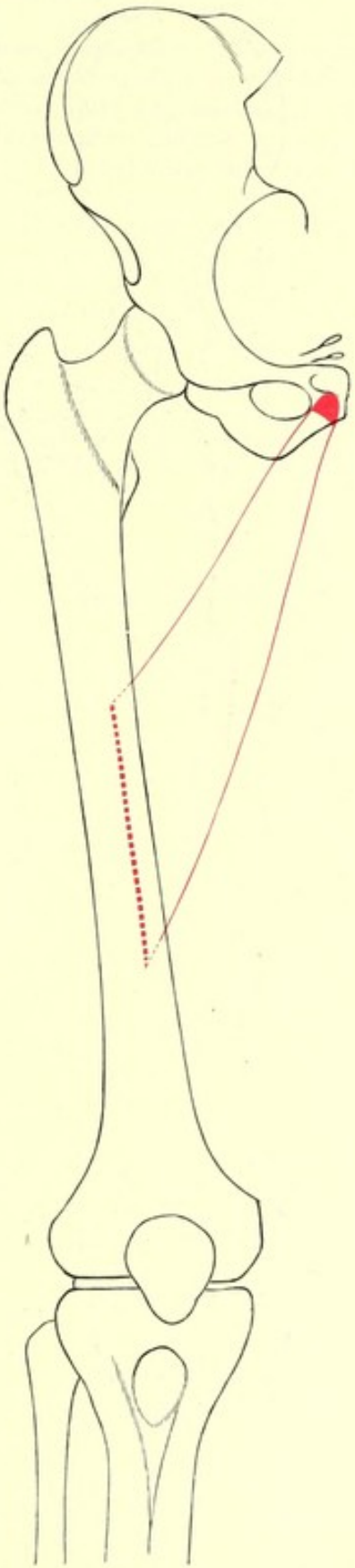

FIG. 338.—Adductor longus of right side: outline and attachment-areas. (F. H. G.)

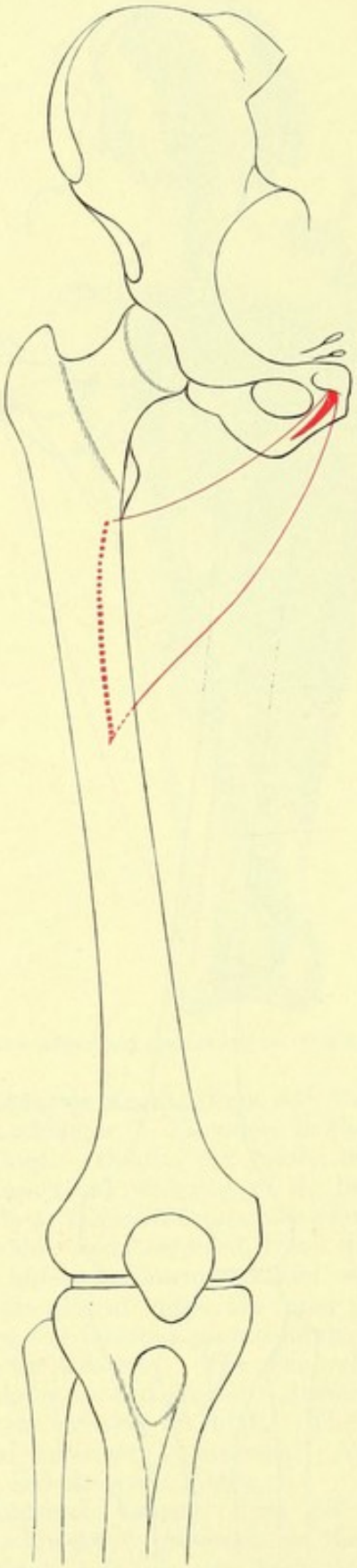

FIG. 339.—Adductor brevis of right side: outline and attachment-areas. (F. H. G.)

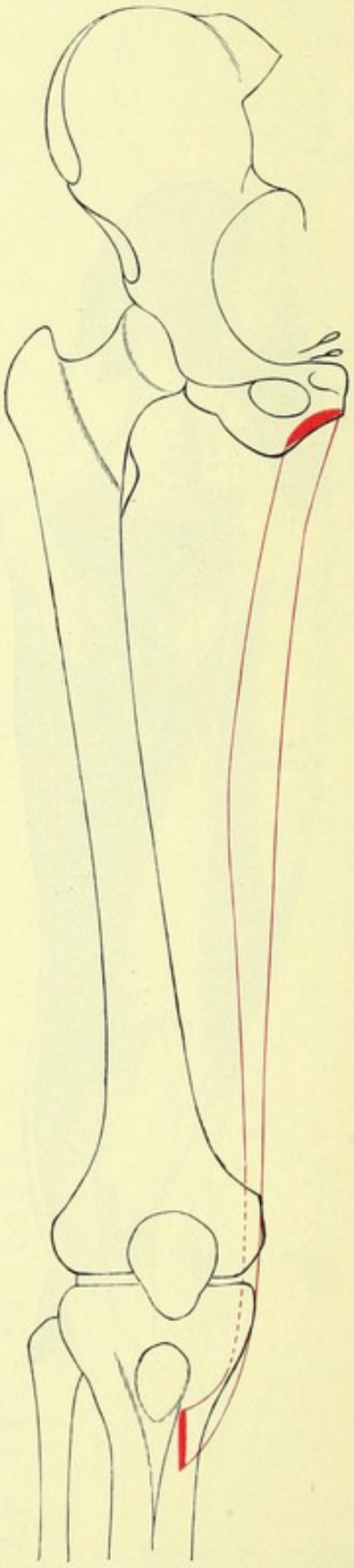

FIG. 340.—Adductor gracilis of right side: outline and attachment-areas. (F. H. G.)

of the thigh. *Action*, adduction, flexion, and external rotation of thigh. *Nerve*, the obturator.

Adductor Brevis (Figs. 335, 339).—"The short adductor." *Situation*, in the inner and upper part of the thigh. *Origin*, the outer surface of the body and descending ramus of the os pubis. *Direction*, down-, out-, and backward. *Insertion*, the line from the small trochanter to the linea aspera and the upper part of the linea aspera. *Action*, adduction, flexion, and external rotation of the thigh. *Nerve*, the obturator.

Adductor Gracilis (Figs. 337, 340, 352).—"The slender adductor." *Situation*, in the inner side of the thigh near the surface. *Origin*, the inner margin of the os pubis, the lower half of the symphysis, and the whole length of the inferior ramus. *Direction*, downward, behind the inner condyle of the femur, and, below the knee, forward. *Insertion*, the upper part of the inner surface of the tibia. *Action*, adduction of thigh; also, flexion and inward rotation of leg. *Nerve*, the obturator.

Pectineus (Figs. 337, 341).—"The pubic muscle." *Situation*, between the pubic bone and the upper, back part of the thigh. *Origin*, the ilio-pectineal line

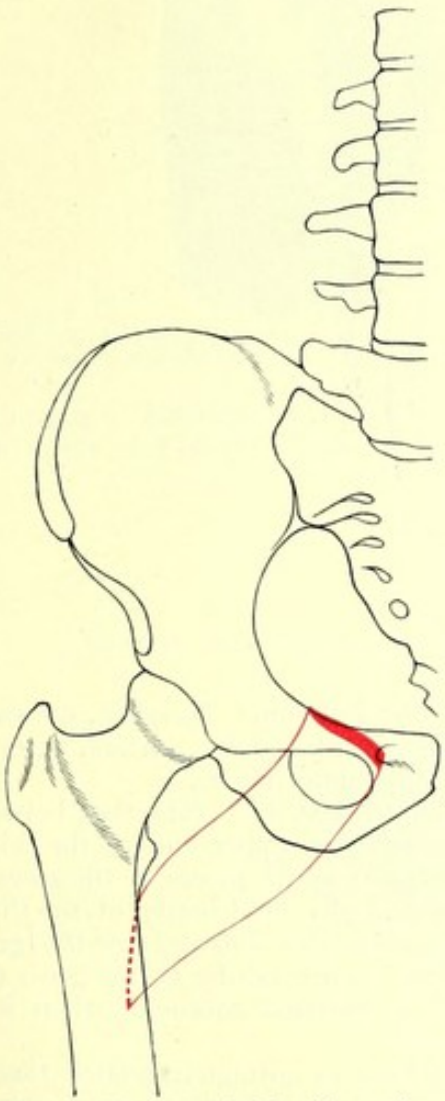

FIG. 341.—Pectineus of right side: outline and attachment-areas. (F. H. G.)

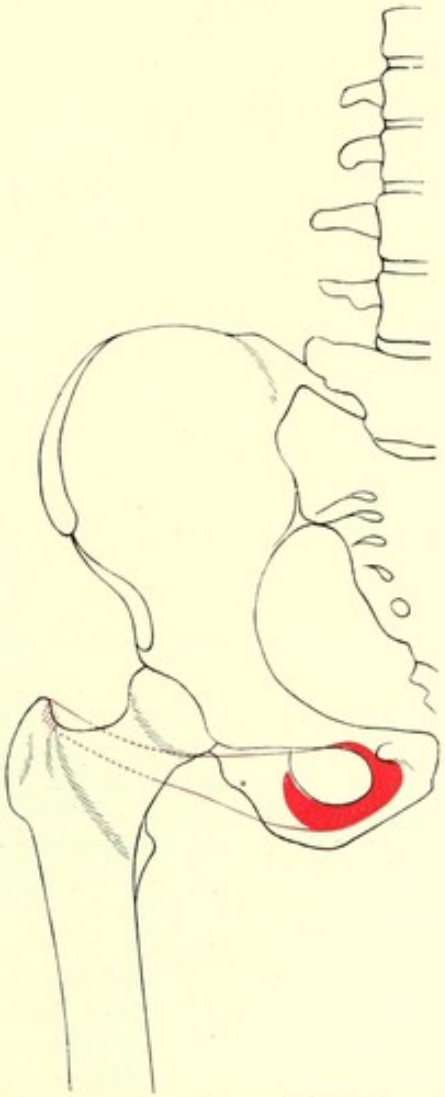

FIG. 342.—Obturator externus of right side: outline and attachment-areas. (F. H. G.)

and the surface in front of it. *Direction*, down-, out-, and backward. *Insertion*, the rough line from the small trochanter to the linea aspera. *Action*, adduction,

flexion, and outward rotation of thigh. *Nerves*, the anterior crural and the obturator.

Obturator Externus (Figs. 335, 342).—"The outer obturator muscle," so called from its origin. *Situation*, between the obturator region on the outer surface of the pelvis and the digital fossa of the femur, behind and beneath the hip-joint. *Origin*, the inner half of the outer surface of the obturator membrane, the adjoining surfaces of the pubic body, and the pubic and ischial rami. *Direction*, outward, then backward and upward, close to the under and hind surfaces of the cervix femoris. *Insertion*, the bottom of the digital fossa. *Action*, outward rotation, adduction, and flexion of thigh. *Nerve*, the obturator.

Quadratus Femoris (Figs. 331, 333, 343).—"The square muscle of the thigh." *Situation*, between the tuber ischii and the upper part of the shaft of the femur.

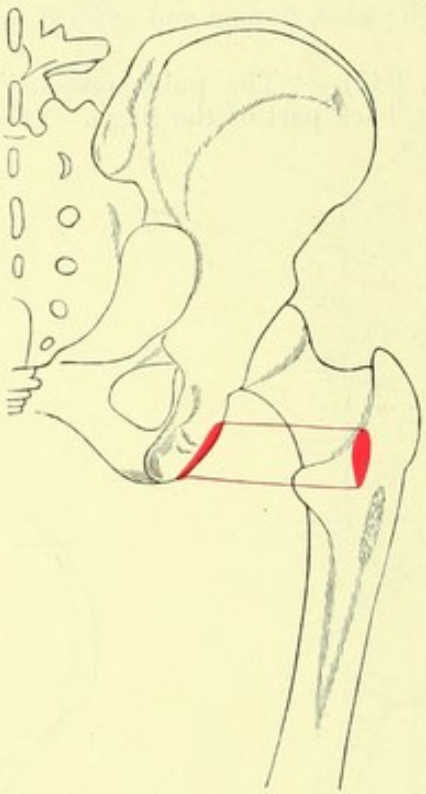

Fig. 343.—Quadratus femoris of right side: outline and attachment-areas. (F. H. G.)

Origin, the outer border of the tuberosity of the ischium. *Direction*, outward. *Insertion*, the quadrate tubercle and the surface just below it. *Action*, external rotation and adduction of thigh. *Nerve*, from the sacral plexus.

Pyriformis (Figs. 344, 345).—"The pear-shaped muscle." *Situation*, between the front of the hind wall of the true pelvis and the upper end of the thigh. *Origin*, the ventral surface of the second, third, and fourth pieces of the sacrum, between and outside of the anterior foramina and the hind border of the ilium below the inferior spine. *Direction*, nearly horizontally outward by the great sacro-sciatic foramen. *Insertion*, the front of the upper border of the great trochanter. *Action*, when the femur is extended, external rotation; when it is flexed, abduction. *Nerve*, from the sacral plexus.

The obturator internus and the two gemelli are so intimately related that it would be rational to consider them as a single muscle; but, as they are always treated as separate organs, the conventional rule is here observed.

Gemellus Superior (Fig. 344).—"The upper little twin muscle." *Situation*, above the tendon of the obturator internus. *Origin*, the spine of the ischium. *Direction*, outward. *Insertion*, the front of the inner surface of the great tro-

chanter. *Action*, assistant to the obturator internus. *Nerve*, from the sacral plexus.

Obturator Internus (Fig. 346).—"The internal obturator muscle," referring to

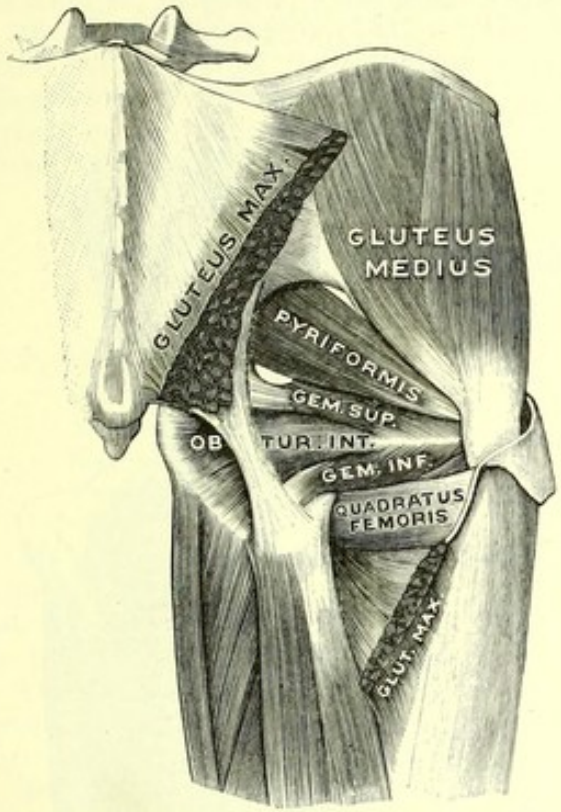

FIG. 344.—Muscles of right hip viewed from behind, the gluteus maximus having been cut away. (Testut.)

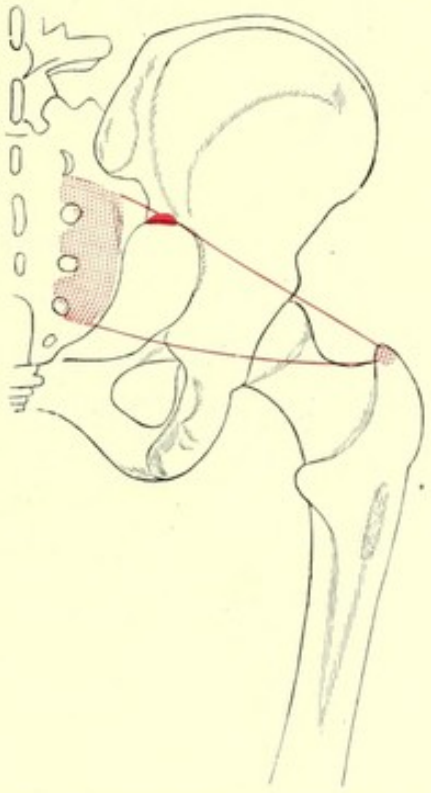

FIG. 345.—Pyriformis of right side: outline and attachment-areas. (F. H. G.)

its origin. *Situation*, largely within the pelvis on its lateral wall, and partly in the upper end of the thigh. *Origin*, the inner surface of the obturator mem-

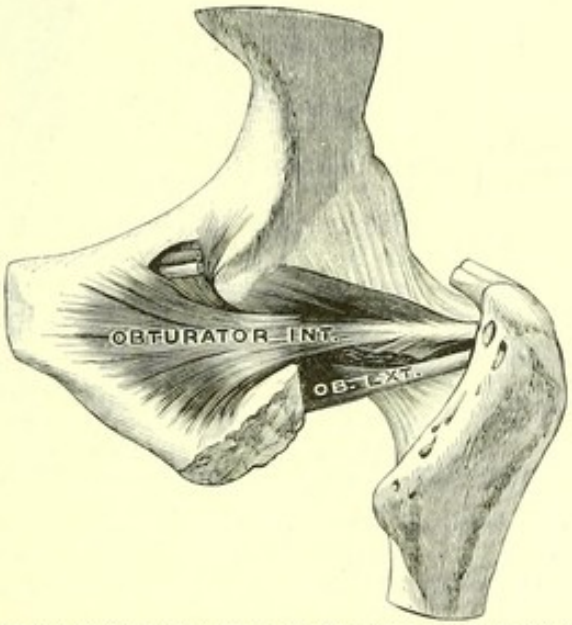

FIG. 346.—Obturator internus of right side. The gemellus superior is shown, but the inferior is mostly removed. (Testut.)

brane, except a little of its lower part; a large area between the obturator foramen, ilio-pectineal line, and the great sacro-sciatic foramen; the front and lower

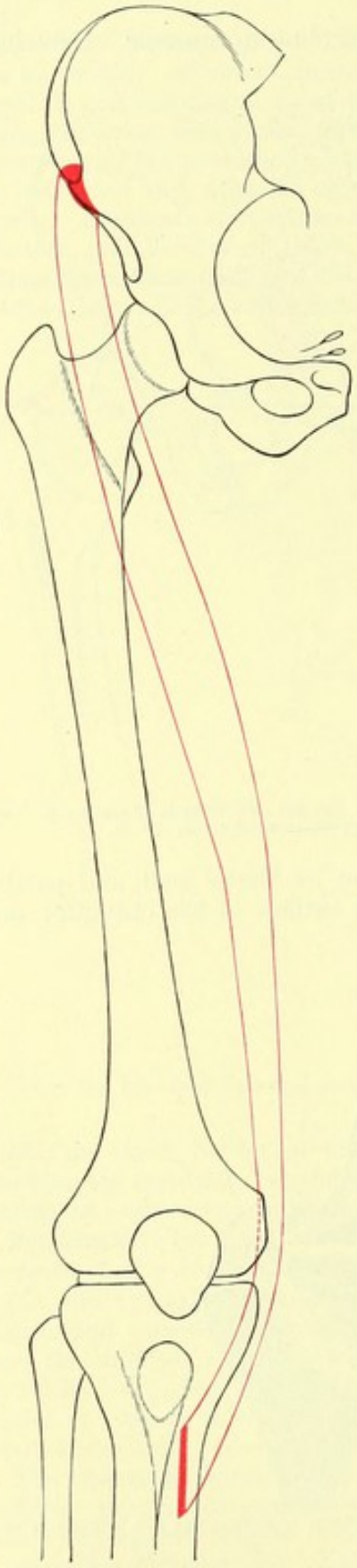

FIG. 347.—Sartorius of right side: outline and attachment-areas. (F. H. G.)

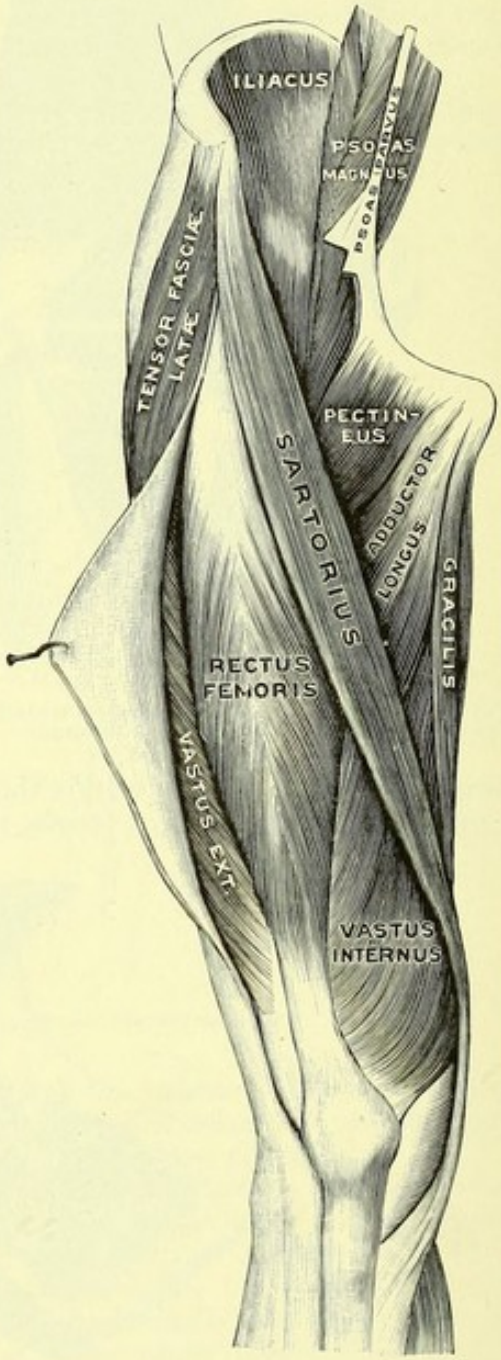

FIG. 348.—Superficial muscles in front part of the right thigh. (Testut.)

margins of the latter foramen. *Direction*, backward to the small sacro-sciatic foramen, around the ischium, and thence outward. *Insertion*, the front part of the inner surface of the great trochanter. *Action*, in extension of the thigh, external rotation; in flexion of the thigh, abduction.

Gemellus Inferior (Fig. 344).—"The lower little twin muscle." *Situation*, below the tendon of the obturator internus. *Origin*, the upper part of the tuberosity of the ischium. *Direction*, outward. *Insertion*, the front of the inner surface of the great trochanter. *Action*, assistant to the obturator internus. *Nerve*, from the sacral plexus.

MUSCLES MOVING THE LEG.

Flexors.	*Extensor.*
Sartorius.	Quadriceps extensor cruris, comprising:
Biceps flexor cruris.	Rectus femoris.
Semitendinosus.	Vastus externus.
Semimembranosus.	Vastus internus.
Popliteus.	Vastus intermedius.

Of the five flexors three arise from the pelvis alone, one from the pelvis and femur, and one from the femur alone. Thus, four of them cross both the hip- and the knee-joints, and become extensors of the thigh, whenever flexion of the leg is prevented or fully accomplished.

One head of the multiple extensor arises from the pelvis, the others from the femur. The part which crosses the hip-joint as well as the knee-joint acts as a flexor of the thigh, when extension is completed or the knee is fixed.

Sartorius (Figs. 347, 348, 352).—"The tailor's muscle," so called from its action, which assists in producing the cross-legged position assumed by tailors in sitting on the bench. *Situation*, in the front and inner side of the thigh, between the ilium and tibia. *Origin*, the anterior superior iliac spine and part of the notch below. *Direction*, downward and inward across the front of the thigh, then behind the inner condyle of the femur, and finally forward. *Insertion*, the inner surface of the tibia, near the tubercle. *Action*, flexion of the leg and thigh, and synchronous abduction of the thigh; then outward rotation. *Nerve*, the anterior crural.

Biceps Flexor Cruris (Figs. 349, 350, 352).—"The two-headed flexor of the leg." *Situation*, in the back of the thigh, between the ischium and fibula. *Origin*, the long head: the inner impression on the ischial tuberosity, in common with the semitendinosus; the short head: the outer lip of the linea aspera and the upper two-thirds of the outer supracondylar ridge. *Direction*, downward and a little outward. *Insertion*, the head of the fibula and (slightly) the outer tuberosity of the tibia. Its tendon forms the outer hamstring. *Action*, flexion of the leg, and then external rotation; also, from its pelvic origin, extension of the thigh. *Nerve* of the long head, the internal popliteal; of the short head, the external popliteal.

Semitendinosus (Figs. 349, 351, 352).—"The half-tendon muscle." *Situation*, in the back of the thigh toward the inner side, between the ischium and tibia. *Origin*, the inner impression of the ischial tuberosity, in common with the biceps. *Direction*, downward and a little inward. *Insertion*, the upper part of the inner surface of the tibia. *Action*, flexion of the leg, and then inward rotation; also, from its pelvic origin, extension of the thigh. *Nerve*, the internal popliteal.

Semimembranosus (Figs. 353, 354, 349).—"The half-membrane muscle," so called from the peculiar disposition of its tendons. *Situation*, in the hind and inner part of the thigh, from the ischium to the tibia. *Origin*, the upper and outer facet of the ischial tuberosity. *Direction*, downward and a little inward.

Insertion, mainly the groove on the back of the inner tuberosity of the tibia; also, a reflection upward and outward to the posterior ligament of the knee, and one downward and outward to the fascia covering the popliteus. *Action*, flexion of leg, and then inward rotation; also, extension of thigh. *Nerve*, the internal popliteal. The tendons of this muscle, the semitendinosus, and the gracilis from the inner hamstring.

Popliteus (Figs. 353, 355).—"The ham muscle." *Situation*, behind the knee-joint and in the upper part of the leg. *Origin*, the outer side of the external condyle of the femur, within the capsule of the joint. *Direction*, down- and inward. *Insertion*, the triangular surface above the oblique line of the

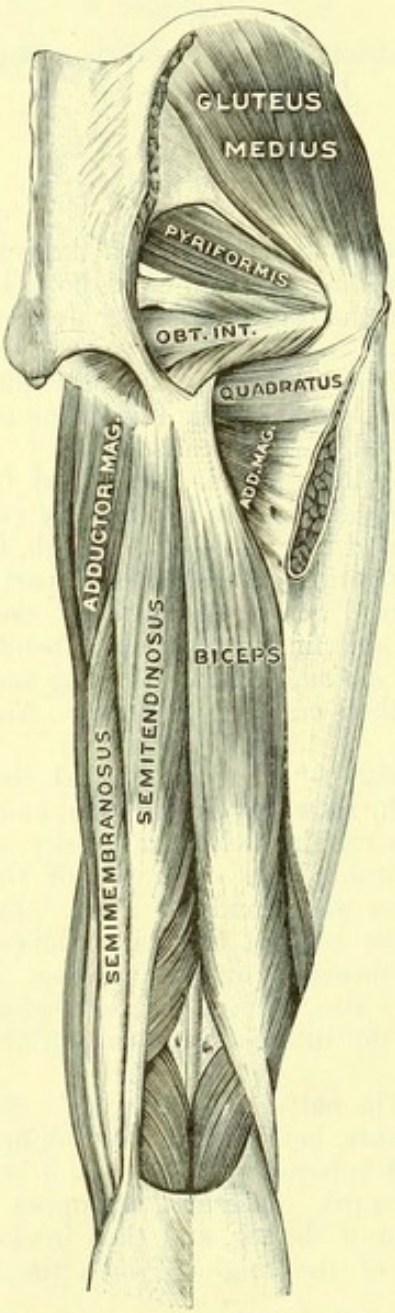

FIG. 349.—Muscles in the dorsum of the right thigh. (Testut.)

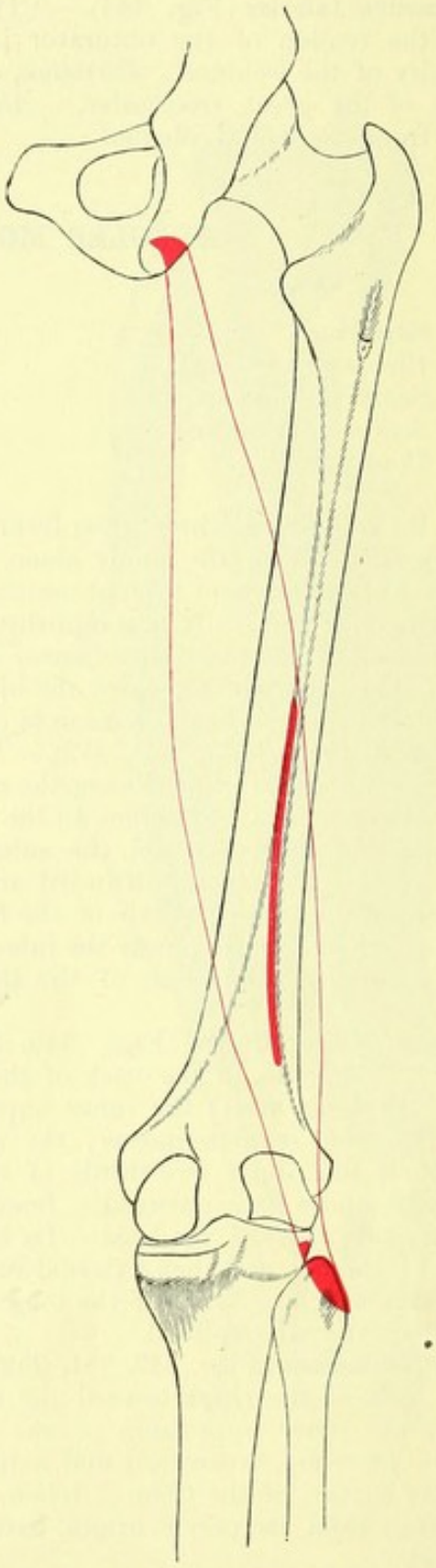

FIG. 350.—Biceps flexor cruris of right side: outline and attachment-areas. (F. H. G.)

tibia. *Action*, flexion and inward rotation of the leg. *Nerve*, the internal popliteal.

Quadriceps Extensor Cruris.—"The four-headed extensor of the leg." *Synonym*, quadriceps extensor femoris, "the four-headed extensor of the thigh"—a misleading name considered from the physiological point of view, because this muscle does not extend the thigh.

General Description.—Three of the four heads arise from the femur, one from the ilium. Each segment is described as a separate muscle, but all unite in a common tendon of insertion, which is attached to the tubercle of the tibia. The lowest part of this tendon is usually called the *ligamentum patellæ*; but, philosophically considered, it is tendon rather than ligament, and the patella is only a sesamoid bone developed in it, exactly as such osseous formations appear in the short flexor tendons of the great toe. The iliac part of the quadriceps is distinct from the rest nearly to the patella; but the others are more or less blended, and enclose the shaft

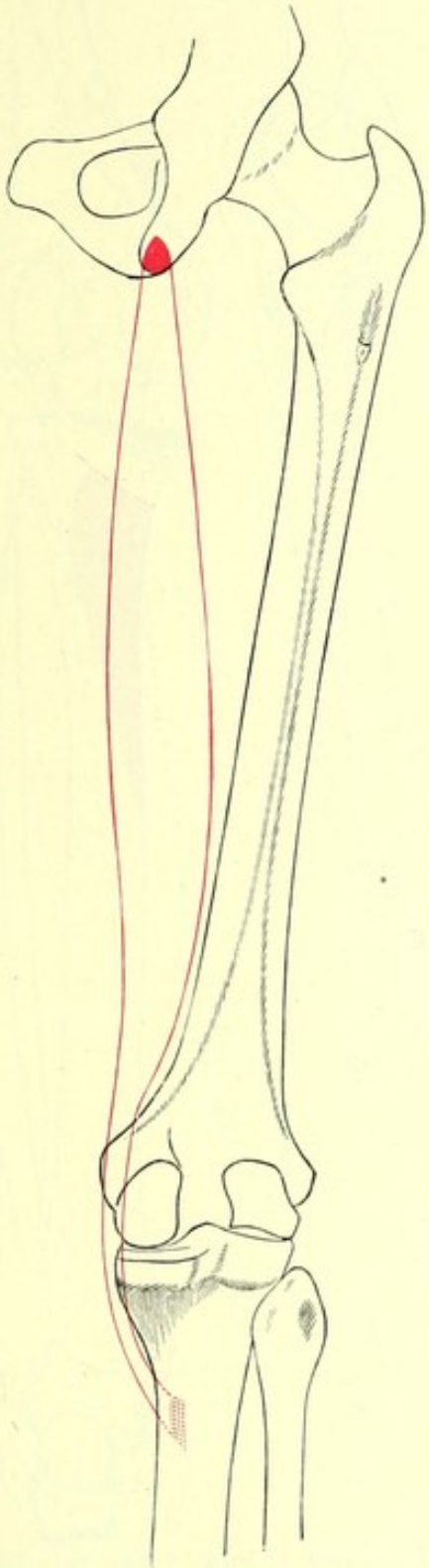

FIG. 351.—Semitendinosus of right side: outline and attachment-areas. (F. H. G.)

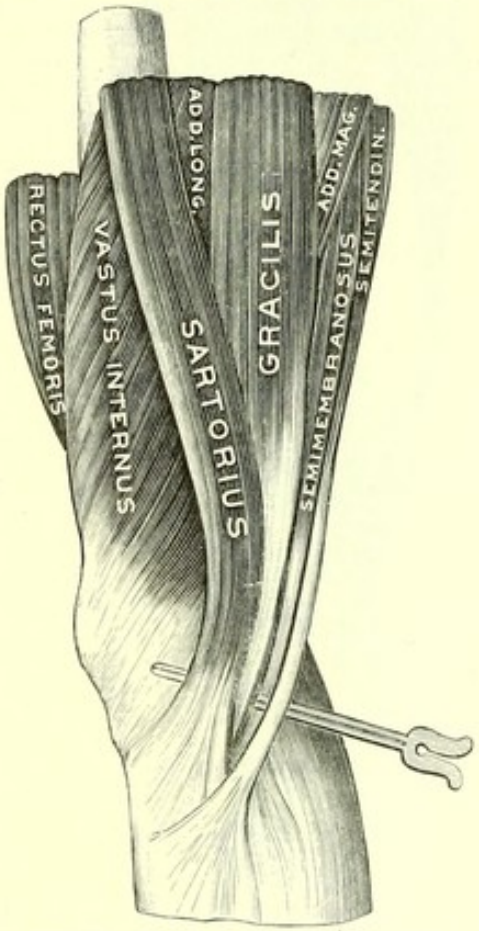

FIG. 352.—The inner hamstring muscles at their insertion. (Testut.)

of the femur to such an extent as to leave hardly anything of it uncovered excepting the linea aspera. The four component parts are the rectus femoris,

vastus externus, vastus internus, and vastus intermedius, and they will be described separately.

Rectus Femoris (Figs. 348, 356).—"The straight muscle of the thigh." *Situation*, subcutaneous, in the front of the thigh. *Origin*, one head: the anterior inferior iliac spine; the other head: the surface just above the acetabulum. *Direction*, downward and slightly inward. *Insertion*, the upper border of the patella. *Action*, extension of the leg; also, from its iliac origin, slight flexion of the thigh. *Nerve*, the anterior crural.

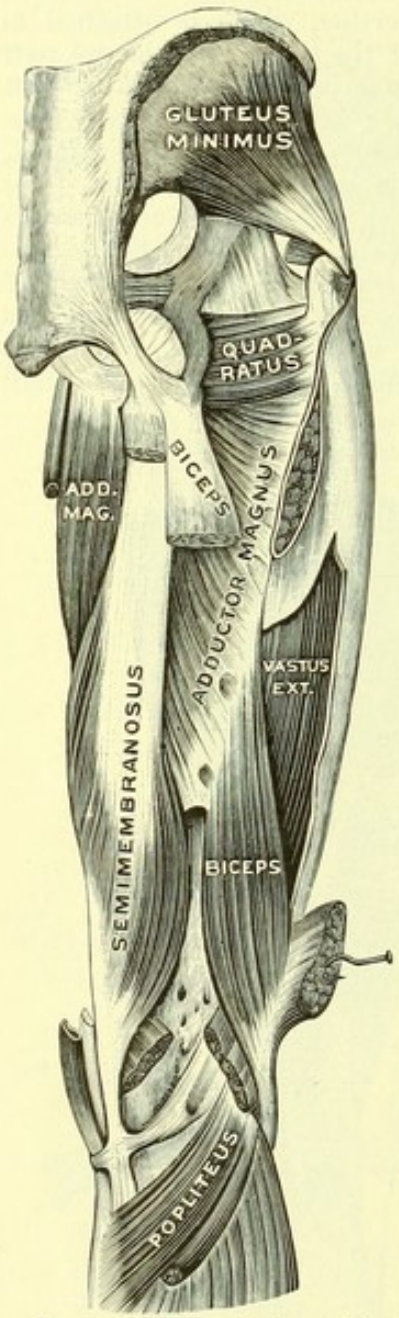

FIG. 353.—Muscles in deep portion of dorsum of right thigh, the semitendinosus and most of the biceps having been removed. (Testut.)

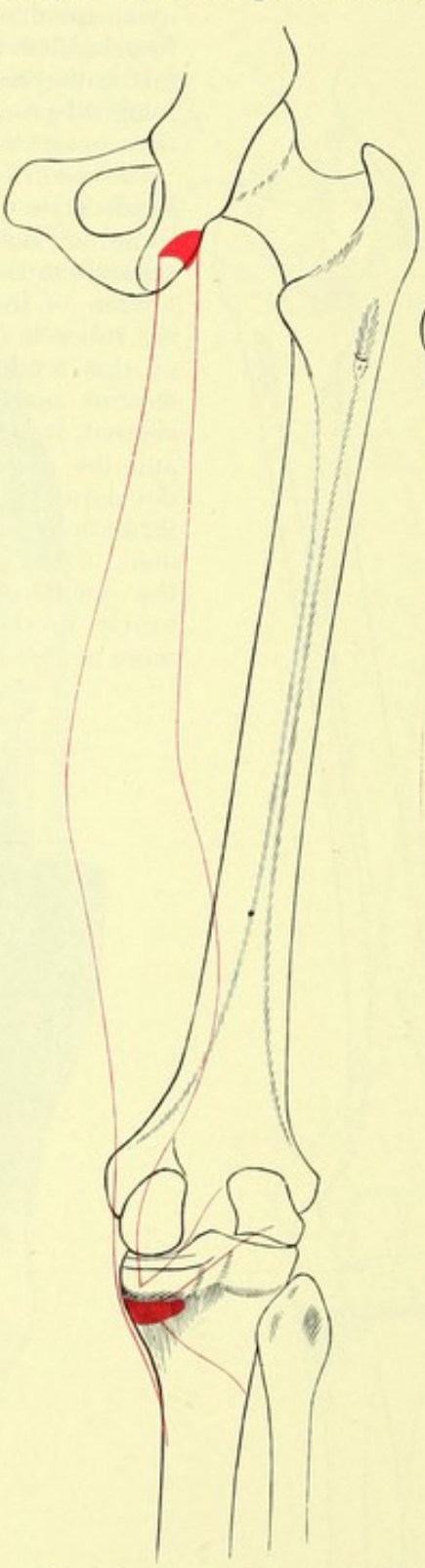

FIG. 354.—Semimembranosus of right side: outline and attachment-areas. (F. H. G.)



FIG. 355.—Popliteus of right side: outline and attachment-areas. (F. H. G.)

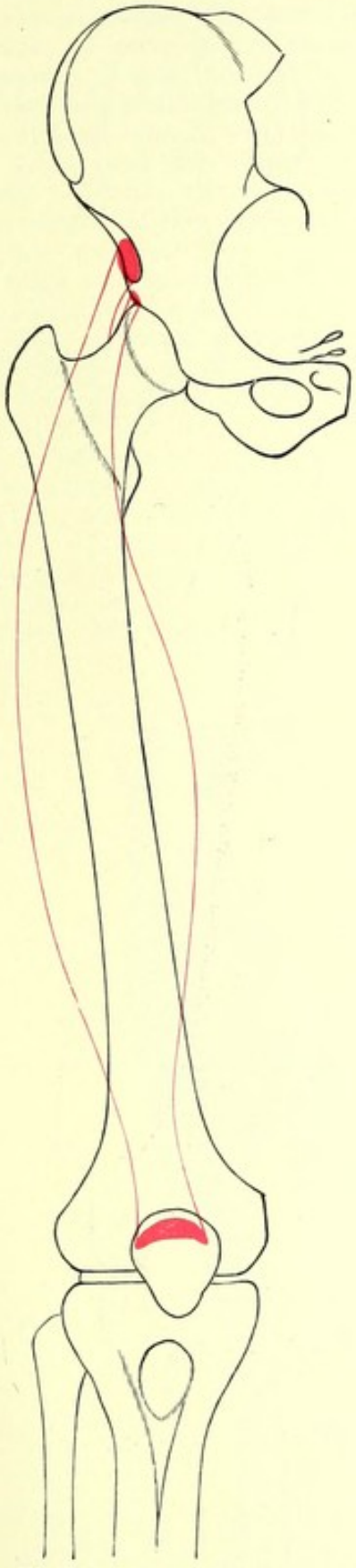

FIG. 356.—Rectus femoris of right side: outline and attachment-areas. (F. H. G.)

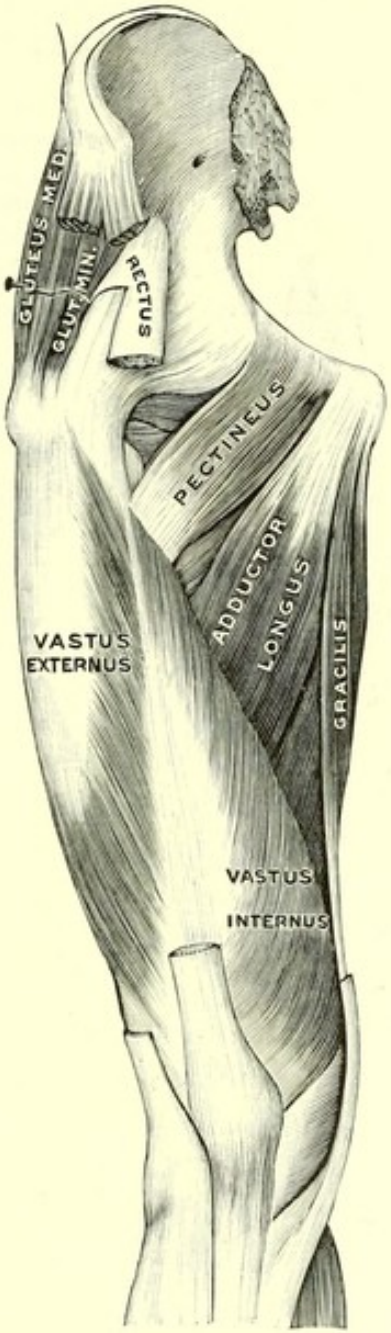

FIG. 357.—Muscles in the right thigh, viewed from in front, after removal of the rectus and sartorius. (Testut.)

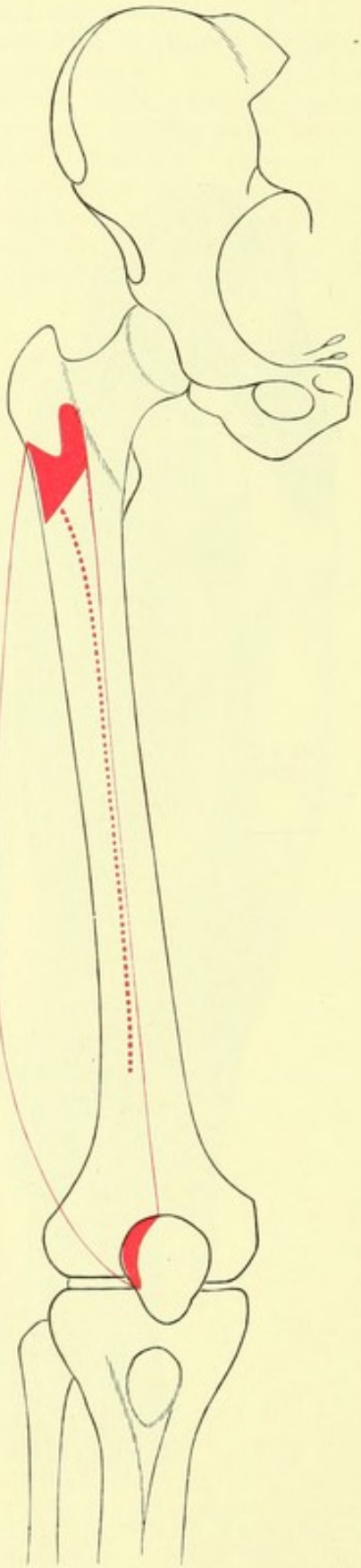

FIG. 358.—Vastus externus of right side: outline and attachment-areas. (F. H. G.)

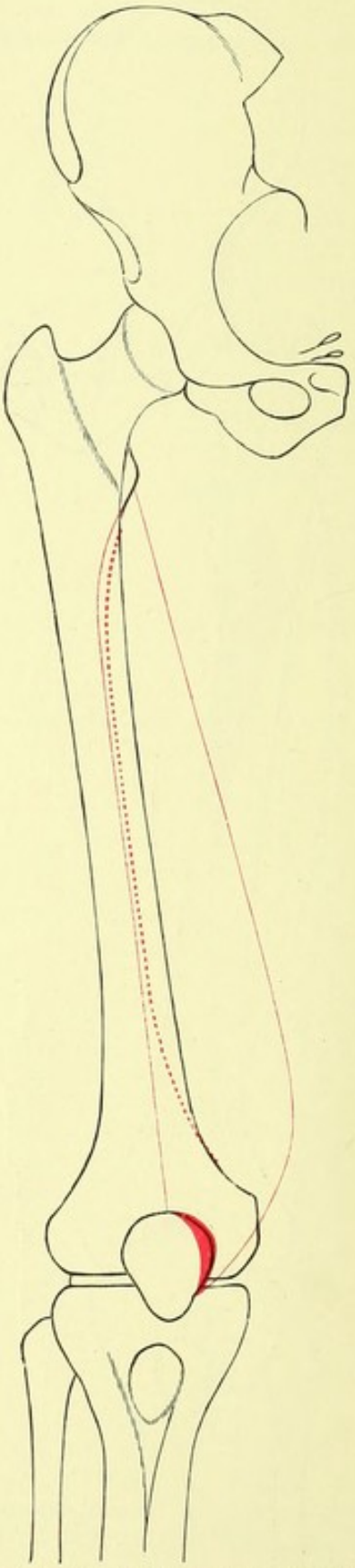

FIG. 359.—Vastus internus of right side: outline and attachment-areas. (F. H. G.)

Vastus Externus (Figs. 357, 358, 348).—"The outer immense muscle." *Synonym*, vastus lateralis, "the lateral immense muscle." *Situation*, the outer part of the thigh, mostly subcutaneous. *Origin*, the anterior intertrochanteric line, the base of the great trochanter, the gluteal ridge, and the outer lip of the linea aspera. *Direction*, down- and forward, then downward and inward. *Insertion*, the upper and outer borders of the patella. *Action*, extension of the leg. *Nerve*, the anterior crural.

Vastus Internus (Figs. 357, 359, 348).—"The internal immense muscle." *Synonym*, vastus medialis, "the immense muscle toward the median line." *Situation*, in the inner part of the thigh, mostly subcutaneous. *Origin*, the spiral line of the femur, the inner lip of the linea aspera, and the internal supracondylar ridge; also, the tendons of the adductor longus and adductor magnus. *Direction*, down- and forward, then down- and outward. *Insertion*, the inner and upper borders of the patella. *Action*, extension of the leg. *Nerve*, the anterior crural.

Vastus Intermedius (Figs. 360, 361).—"The

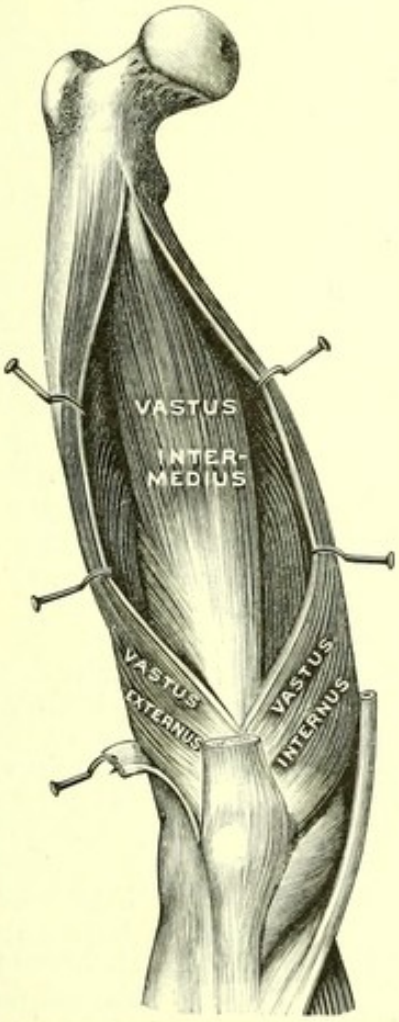

FIG. 360.—Vastus intermedius of right side. (Testut.)

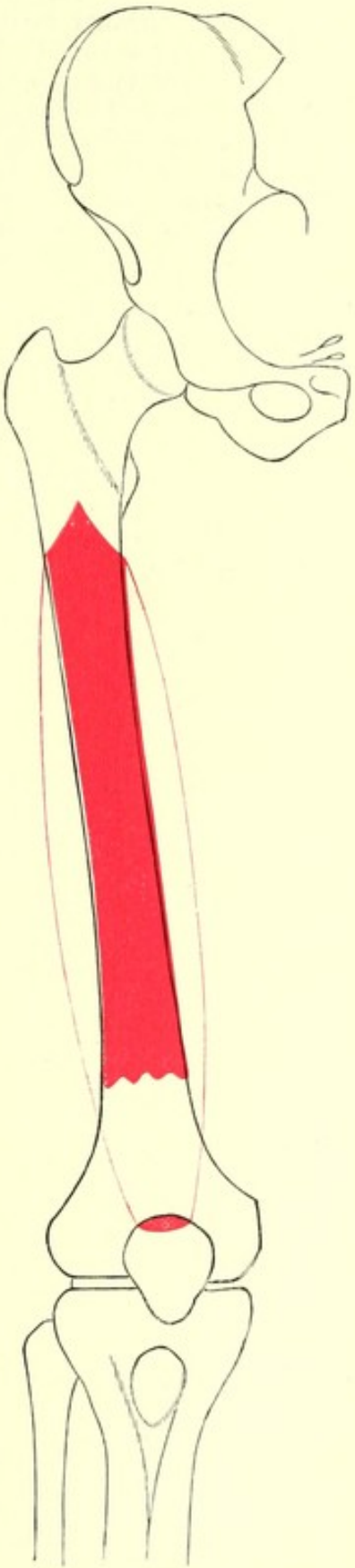

FIG. 361.—Vastus intermedius of right side: outline and attachment-areas. (F. H. G.)

intermediate immense muscle." *Synonym*, crureus, "the leg muscle"—the common name, but very faulty, because it implies location in the leg, whereas this is a muscle altogether in the thigh. *Situation*, close to the shaft of the femur. *Origin*, the upper two-thirds of the anterior surface of the femur, the outer surface in front of and below the origin of the vastus externus, and the lower half of the external intermuscular septum. *Direction*, mainly downward. *Insertion*, the upper border of the patella. *Action*, extension of the leg. *Nerve*, the anterior crural. A narrow interval, extending downward from near the small trochanter, separates the vastus intermedius from the internus. Close to the bone the intermedius and externus are blended, but are distinct from each other elsewhere.

Slightly distal to the lowest part of the origin of the vastus intermedius a few small fasciculi arise from the ventral surface of the femur and pass downward to the proximal part of the synovial membrane of the knee-joint. They are usually spoken of as the subcrureus, but would better be called *musculus articularis genu*, "the knee-joint muscle."

MUSCLES MOVING THE WHOLE FOOT.

Flexors.		*Extensors.*
Tibialis anterior.	(On the inner side.)	Tibialis posterior.
	(Central group.)	Gastrocnemius. Soleus. Plantaris.
Peroneus tertius.	(On the outer side.)	Peroneus longus. Peroneus brevis.

All of these muscles find insertion in the foot, and all arise entirely in the leg, excepting one, which has its origin upon the thigh, and, since it crosses both knee- and ankle-joints, is a flexor of the leg, when the foot is fixed or fully extended.

The extensors are more numerous and powerful than the flexors, the group which occupies the central position in the leg acting upon the foot purely as extensors. The inner and outer muscles respectively turn the foot inward and outward in addition to their work of flexion and extension.

Tibialis Anterior (Figs. 362, 363).—"The anterior tibial muscle." *Synonym* and commoner name, tibialis anticus. *Situation*, in the front part of the leg and inner side of the foot. *Origin*, the external tuberosity and upper two-thirds of the outer surface of the tibia, and the front of the corresponding and adjacent portion of the interosseous membrane. *Direction*, downward and inward. *Insertion*, the inner surface of the internal cuneiform and the hind end of the first metatarsal. *Action*, flexion of foot and elevation of its inner border; also adduction of front of foot. *Nerve*, the anterior tibial.

Peroneus Tertius (Figs. 362, 364).—"The third fibular muscle." *Situation*, in the front of the leg and dorsum of the foot. *Origin*, the lower fourth of the anterior surface of the fibula, and the corresponding and adjacent portion of the interosseous membrane. *Direction*, downward, then forward and outward. *Insertion*, the upper surface of the base of the fifth metatarsal. *Action*, flexion of the foot, elevation of its outer border, and abduction of its front end. It is inseparable at its origin from the extensor longus digitorum.

Tibialis Posterior (Figs. 365, 366, 374, 378).—"The hind tibial muscle." *Synonym* and commoner name, tibialis posticus. *Situation*, deep in the back part of the leg and inner part of the foot. *Origin*, the hind surface of the interosseous membrane, the upper half of the contiguous portion of the tibia, and the inner surface of fibula. *Direction*, downward and inward to the back of the inner malleolus, then forward. *Insertion*, the tuberosity of the navicular, with offshoots to

the three cuneiform, the cuboid, the bases of the second, third, and fourth metatarsal, and the sustentaculum tali. *Action*, extension of the foot, elevation of its inner border, and adduction of its front end. *Nerve*, the posterior tibial.

Gastrocnemius (Figs. 367, 368, 371).—"The belly-of-the-leg (or calf) muscle." *Situation*, superficial in the back of the leg. *Origin*, the outer head: the outer side of the external condyle of the femur, and the surface just above; the inner head: the upper part of the inner condyle, and the lower end of the ridge above. *Direction*, downward. *Insertion*, the hind part of the tuberosity of the calcaneum, in common with the

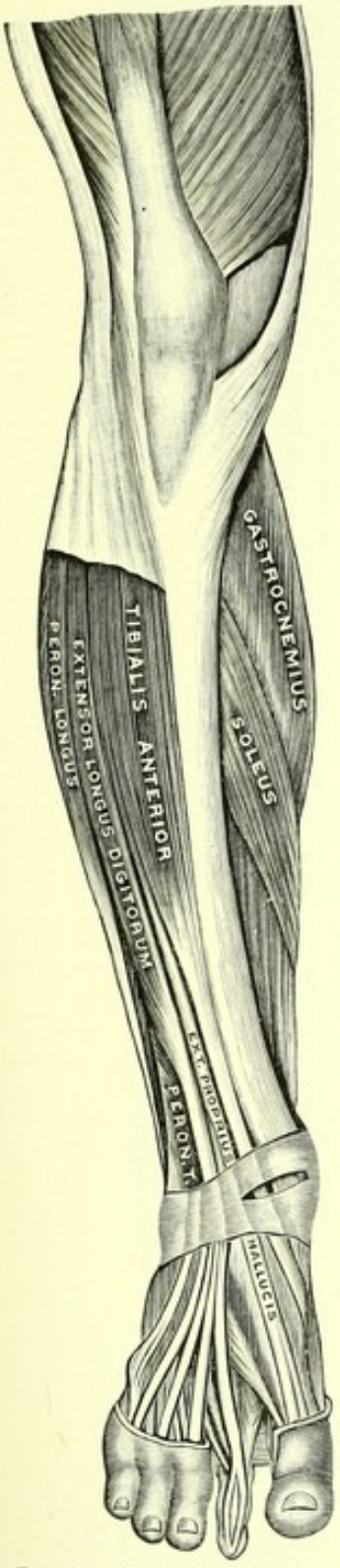

FIG. 362.—Muscles in the right leg, viewed from in front. (Testut.)

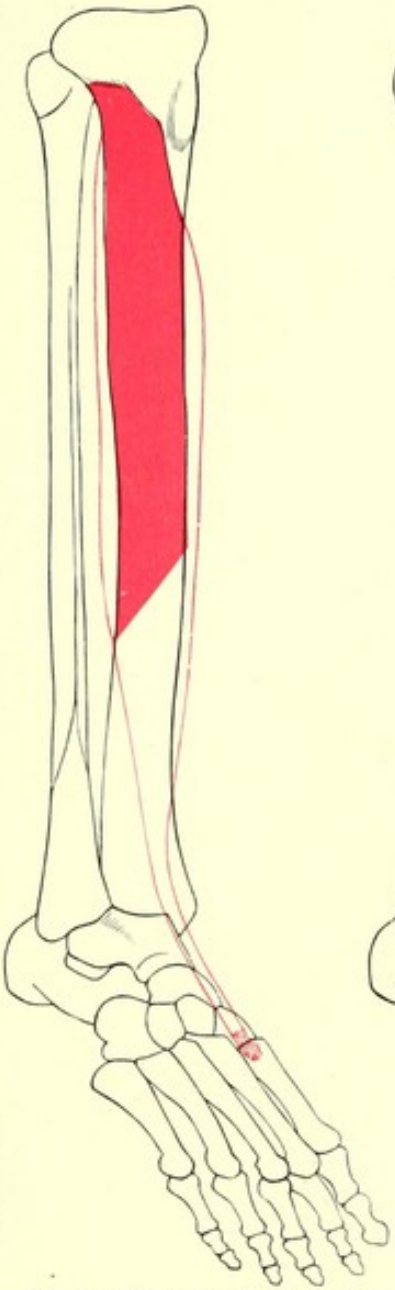

FIG. 363.—Tibialis anterior of right side: outline and attachment-areas. (F. H. G.)

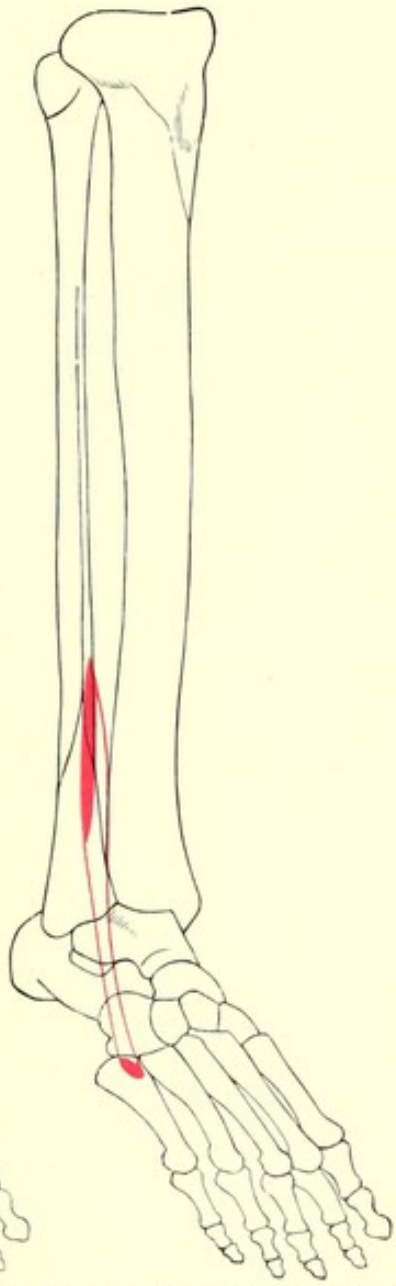

FIG. 364.—Peroneus tertius of right side: outline and attachment-areas. (F. H. G.)

soleus. *Action*, extension of the foot; also, when the ankle-joint is fixed, flexion of the leg. *Nerve*, the internal popliteal.

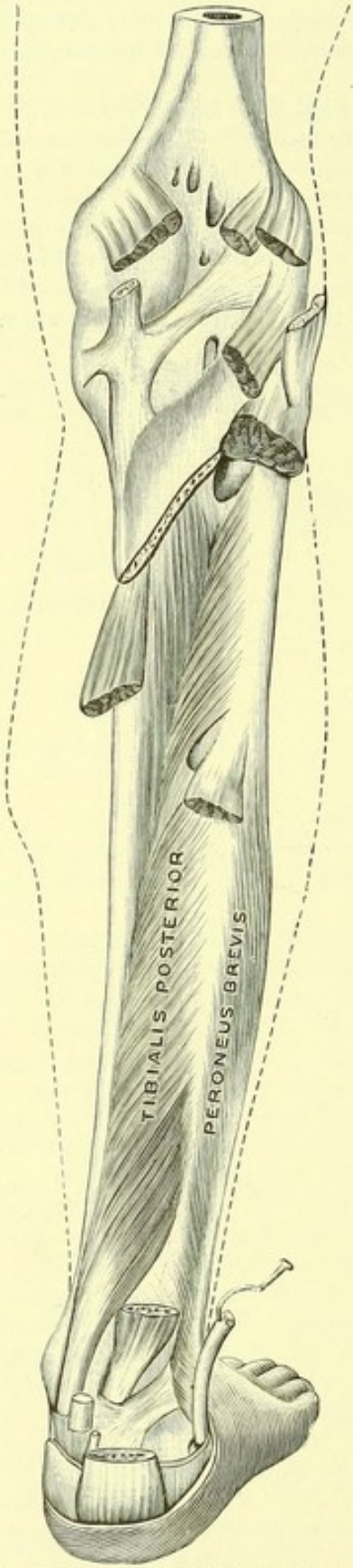

FIG. 365.—Tibialis posterior of right side. (Testut.)

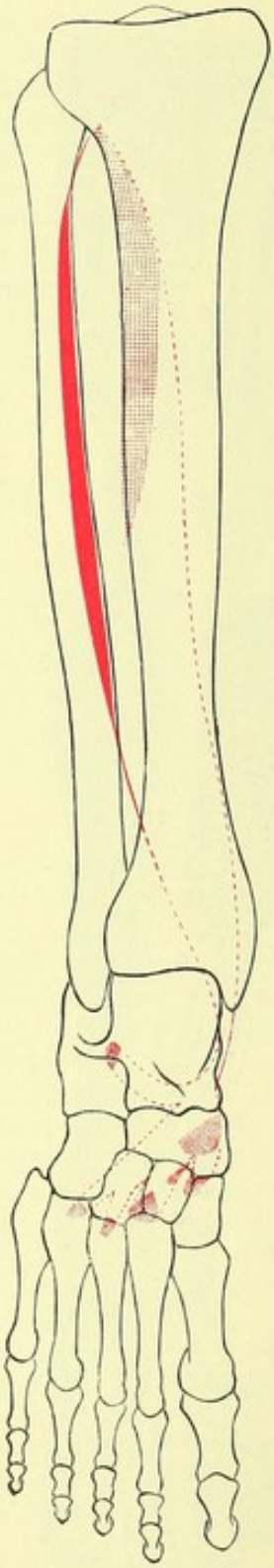

FIG. 366.—Tibialis posterior of right side: outline and attachment-areas. The most of the muscle is represented as if seen through the bones. (F. H. G.)

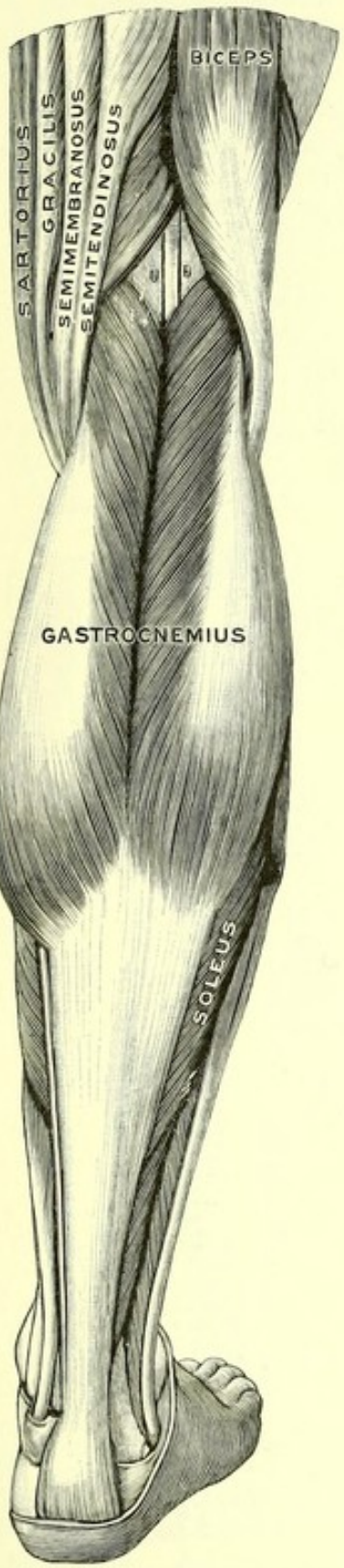

FIG. 367.—Gastrocnemius of right side. (Testut.)

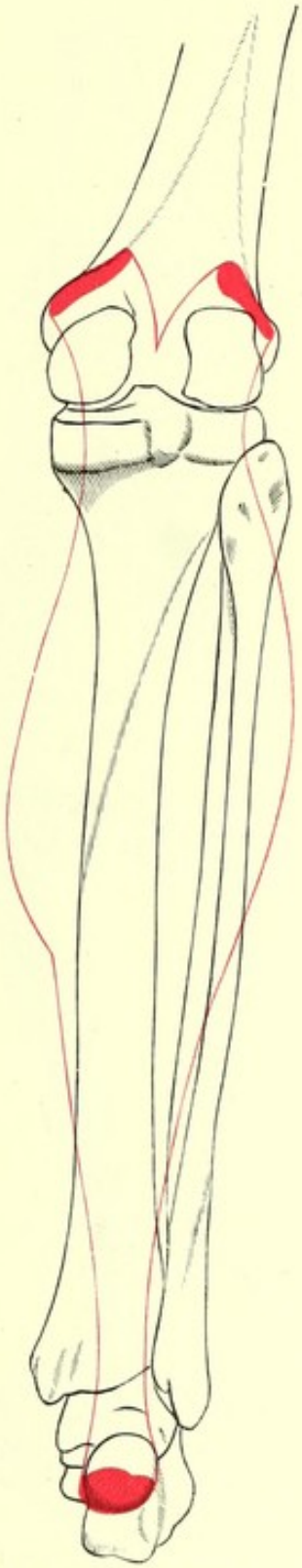

FIG. 368.—Gastrocnemius of right side: outline and attachment-areas. (F. H. G.)

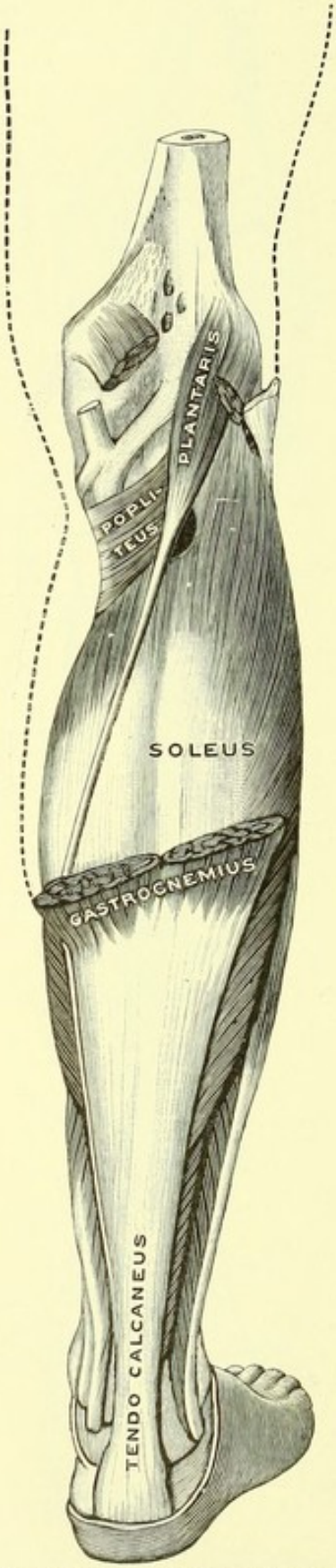

FIG. 369.—Soleus and plantaris of right side. (Testut.)

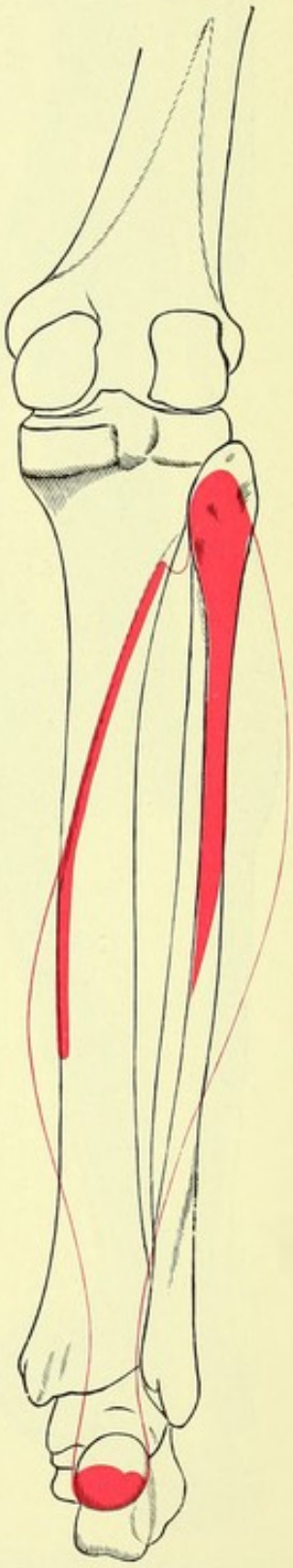

FIG. 370.—Soleus of right side: outline and attachment-areas. (F. H. G.)

Soleus (Figs. 369–371).—"The sole-fish muscle," so called from its shape. *Synonym*, gastrocnemius internus," the internal belly-of-the-leg muscle." *Situation*, in the back part of the leg, in front of the gastrocnemius. *Origin*, the head

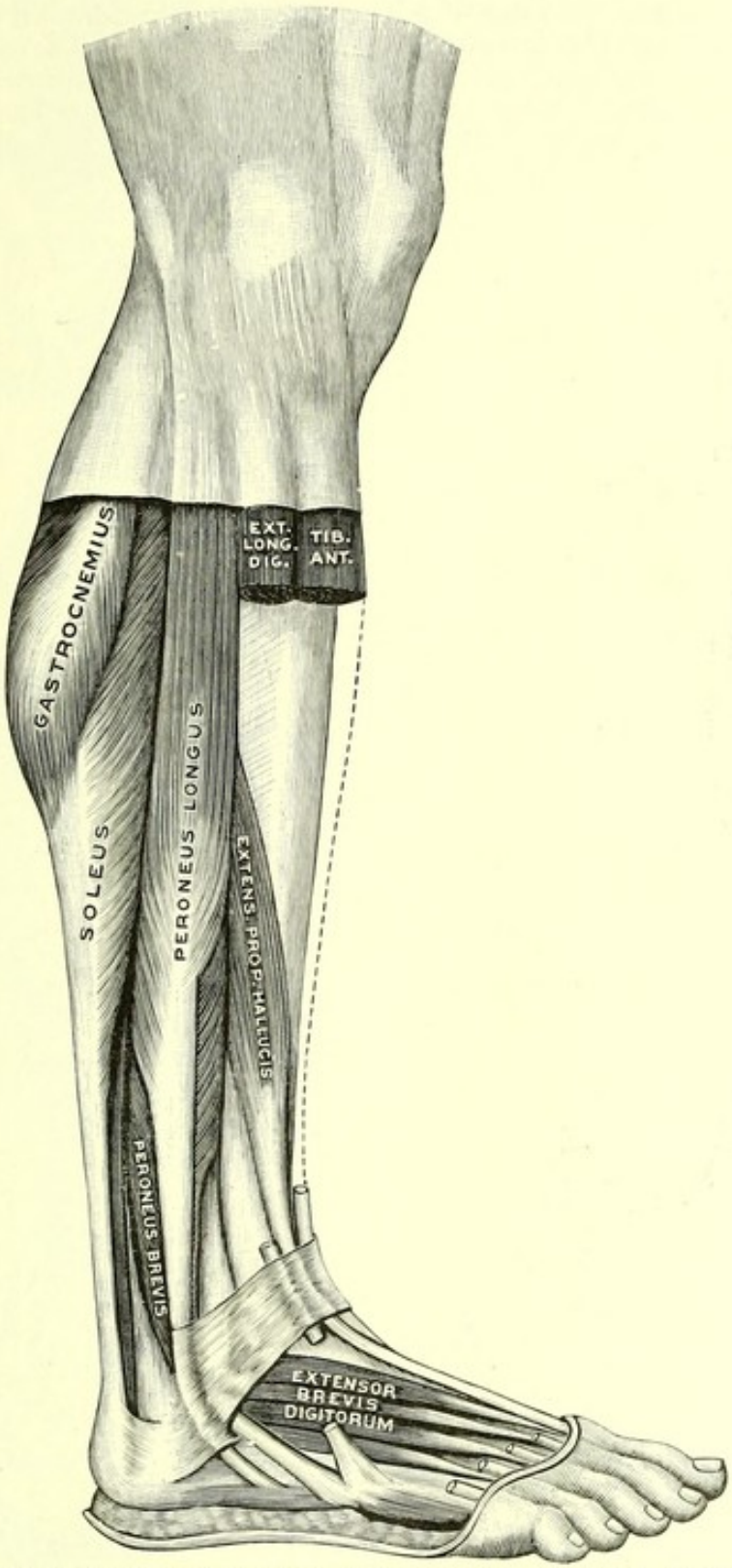

FIG. 371.—Muscles in the outer side of right leg and dorsum of foot. (Testut.)

and upper third of the hind surface of the fibula, and the oblique line and internal border of the tibia to the middle of its shaft. *Direction*, downward and a

little backward. *Insertion*, the hind part of the tuberosity of the calcaneum, in common with the gastrocnemius. *Action*, extension of the foot. *Nerves*, the internal popliteal and posterior tibial.

The gastrocnemius and soleus are sometimes and not fancifully considered as a single muscle under the name of *triceps suræ*, "the three-headed muscle of the calf"—the former furnishing two heads, and the latter, one. The common tendon is called *tendo calcaneus*, "the heel tendon," and also more commonly, *tendo Achillis*, "the tendon of Achilles," in allusion to the legendary hero, whose only vulnerable part was his heel. This tendon is the largest in the body, is about six

FIG. 372.—Peroneus longus of right side: outline and attachment-areas. (F. H. G.)

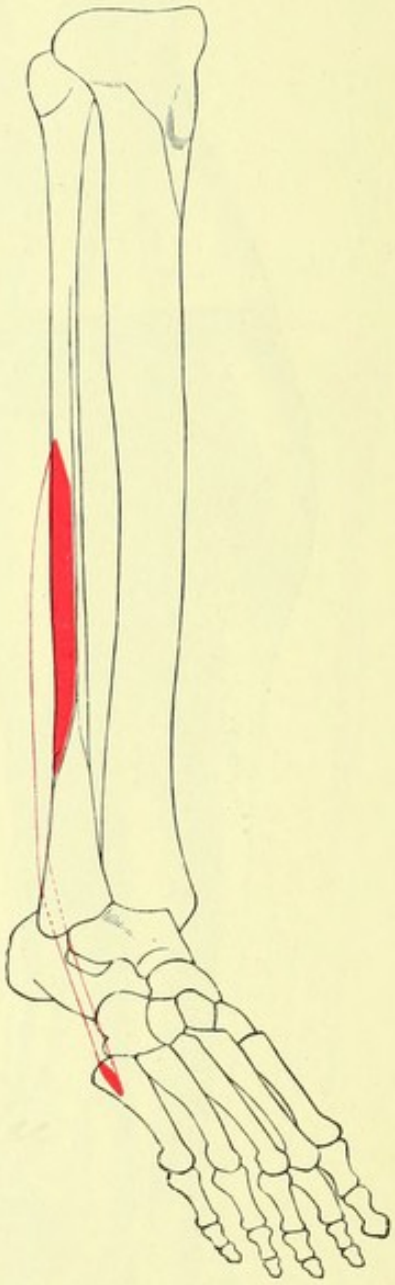

FIG. 373.—Peroneus brevis of right side: outline and attachment-areas. (F. H. G.)

inches long, narrowest at the level of the ankle-joint, and receives muscular fibres almost to its insertion.

Plantaris (Fig. 369).—"The sole-of-the-foot muscle," referring to its occasional insertion into the plantar fascia. *Situation*, in the back of the leg between the gastrocnemius and soleus. *Origin*, the ridge above the external condyle of the

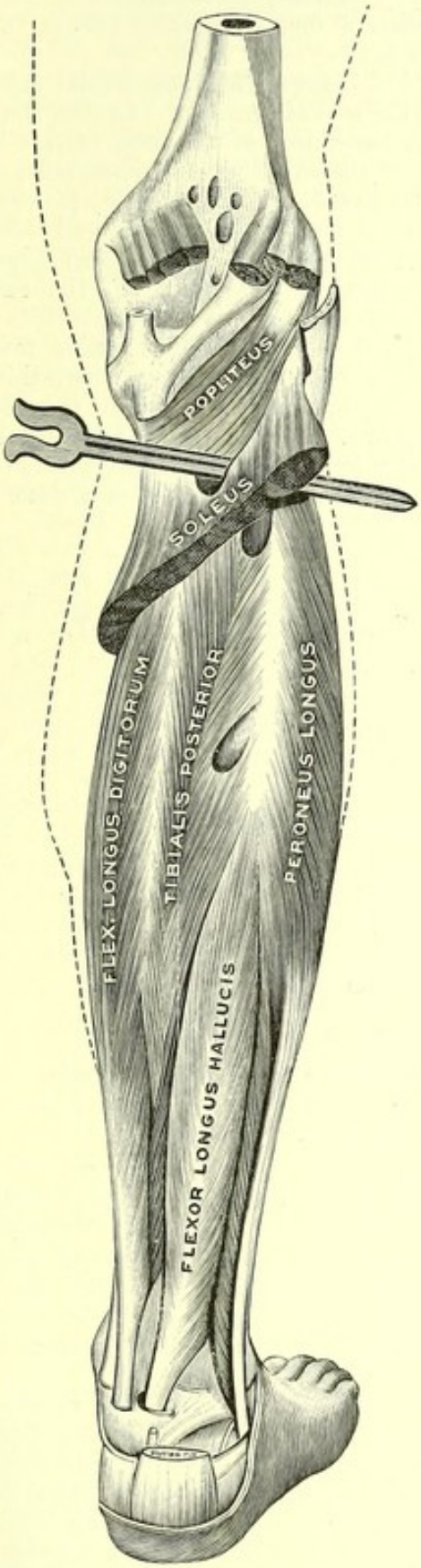

FIG. 374.—Muscles in the deep layer of the dorsum of the right leg. (Testut.)

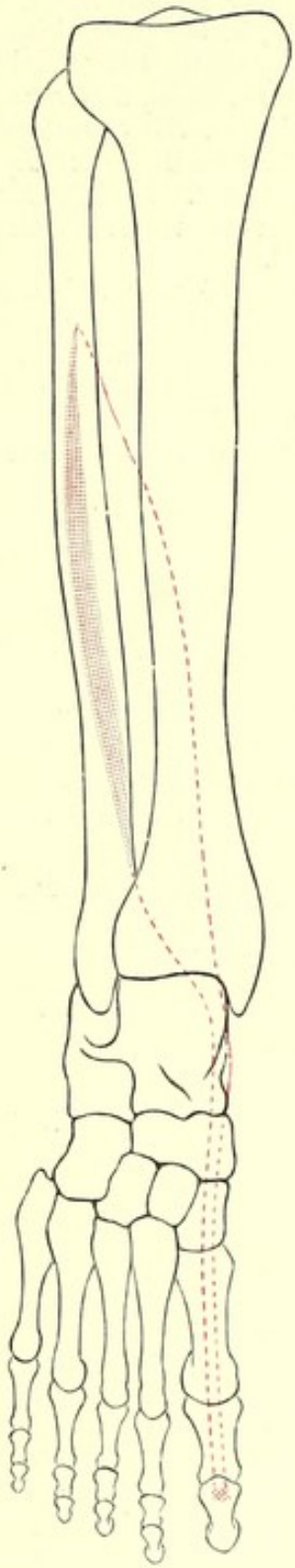

FIG. 375.—Flexor longus hallucis of right side: outline and attachment areas. The muscle is represented as seen from the front through the bones. (F. H. G.)

femur. *Direction*, downward and inward. *Insertion*, the calcaneum at the inner side of the tendo Achillis. *Action*, extension of foot and flexion of leg. *Nerve*, the internal popliteal.

Peroneus Longus (Figs. 371, 372, 374, 378).—"The long fibular muscle." *Situation*, in the outer side of the leg and the sole of the foot. *Origin*, the outer tuberosity of the tibia, the head and upper two-thirds of the outer surface of the fibula. *Direction*, downward to the back of the outer malleolus, forward on the outer side of the calcaneum, through the groove of the cuboid, inward and forward across the sole. *Insertion*, the base of the first metatarsal and the internal cuneiform. *Action*, extension of the foot, elevation of its outer edge, and abduction of its front end. *Nerve*, the musculo-cutaneous of the external popliteal.

Peroneus Brevis (Figs. 371, 373, 365, 378).—"The short fibular muscle." *Situation*, in the outer side of the leg and foot. *Origin*, the lower two-thirds of the outer surface of the fibula. *Direction*, downward to behind the external malleolus, then forward and a little downward. *Insertion*, the outer side of the tuberosity of the fifth metatarsal. *Action*, extension of the foot, elevation of its outer edge, and abduction of its front end. *Nerve*, the musculo-cutaneous of the external popliteal.

MUSCLES MOVING THE DIGITS OF THE FOOT.

(Those situated entirely in the foot are indicated by a star.)

Flexors.	*Extensors.*
Flexor longus hallucis.	Extensor proprius hallucis.
*Flexor brevis hallucis.	
Flexor longus digitorum.	Extensor longus digitorum.
*Flexor accessorius.	
*Flexor brevis digitorum.	*Extensor brevis digitorum.
*Flexor brevis minimi digiti.	
*Lumbricales.	

Abductors.	*Adductors.*
*Abductor hallucis.	*Adductor obliquus hallucis.
	*Adductor transversus hallucis.
*Abductor minimi digiti.	
*Interossei dorsales.	*Interossei plantares.

In studying the muscles moving the digits of the foot it is unnecessary to place in a group by themselves those which act upon the great toe, as was done in the case of those of the thumb, for the reason that the first metatarsal bone is as fixed as its four fellows, and does not permit the degree and kind of movement which are so marked a feature of digital action in the hand.

All but four of the twenty-four members of this group are situated entirely in the foot.

Flexor Longus Hallucis (Figs. 374, 375, 378).—"The long flexor of the great toe." *Synonym*, flexor longus pollicis pedis, "the long flexor of the thumb of the foot." *Situation*, deep in the back of the leg on the outer side and in the sole. *Origin*, the lower two-thirds of the hind surface of the fibula, and a little of the interosseous membrane below. *Direction*, downward and inward, behind the inner malleolus, beneath the sustentaculum tali, then forward and inward in the sole. *Insertion*, the under surface of the base of the last phalanx of the first digit. *Action*, flexion of the last phalanx of the great toe. *Nerve*, the posterior tibial.

Flexor Brevis Hallucis (Figs. 376, 379).—"The short flexor of the great toe." *Synonym*, flexor brevis pollicis pedis, "the short flexor of the thumb of the foot." *Situation*, in the third layer of the muscles of the sole on the inner side.[1] *Origin*, the inner border and under surface of the cuboid, and the cuneiform tendon of the tibialis posterior. *Direction*, forward and inward. *Insertion*, one (the inner) tendon: the inner side of the base of the first phalanx of the great toe on the plantar aspect, fused with the abductor; the other tendon: the outer side of the same bone, symmetrical with the inner tendon, and conjoined with the adductor. *Action*, flexion of the whole of the great toe. *Nerve*, the internal plantar.

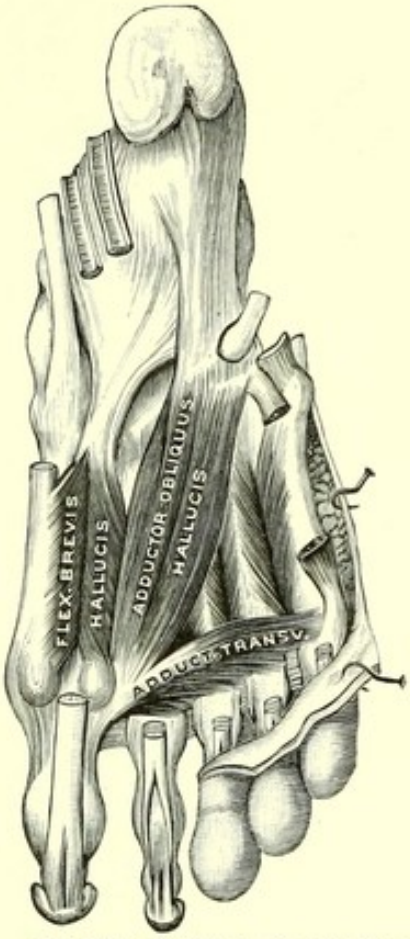

FIG. 376.—Muscles in the third layer of the right sole. (Testut.)

Flexor Longus Digitorum (Figs. 374, 377, 378).—"The long flexor of the digits" of the foot, meaning the four small toes. *Synonym*, flexor perforans digitorum pedis, "the perforating flexor of the digits of the foot," referring to the passage of its tendons of insertion through the corresponding tendons of the flexor brevis digitorum. *Situation*, deep in the back of the leg on the inner side, and in the sole. *Origin*, the middle two-fourths of the inner part of the hind surface of the tibia. *Direction*, downward behind the inner malleolus, then forward and outward into the sole. *Insertion*, by four tendons, each into the base of a third phalanx on the plantar surface. The undivided tendon is superficial to that of the flexor longus hallucis. Each digital tendon perforates the corresponding tendon of the flexor brevis, just as the flexor profundus perforates the flexor sublimis in the hand. *Action*, flexion of the last phalanges of the four small toes. *Nerve*, the posterior tibial.

Flexor Accessorius (Fig. 379).—"The adjunct flexor," this being assistant to the flexor longus digitorum. *Synonyms*, flexor accessorius digitorum pedis, and quadratus plantæ, "the square muscle of the sole." *Situation*, in the hind part of the second muscular layer of the sole. *Origin*, the calcaneum—one head being attached to the inner surface, the other to the outer surface in front of the external tubercle. *Direction*, forward. *Insertion*, the outer (hind) border and upper surface of the flexor longus digitorum. *Action*, flexion of the four small toes. It also brings the line of action of the flexor longus digitorum into the long axis of the foot. *Nerve*, the external plantar.

Flexor Brevis Digitorum (Fig. 380).—"The short flexor of the digits," meaning the four small toes. *Synonym*, flexor perforatus digitorum pedis, "the perforated flexor of the digits of the foot." *Situation*, in the first muscular layer or the sole, midway between its sides. *Origin*, the front of the inner tubercle of the calcaneum. *Direction*, forward. *Insertion*, by four tendons into the sides of the second phalanges of the four small toes on their plantar aspect. Each tendon is perforated opposite the first phalanx by the corresponding tendon of the long flexor. *Action*, flexion of the second phalanges of the four small toes. *Nerve*, the internal plantar.

Flexor Brevis Minimi Digiti Pedis (Fig. 379).—"The short flexor of the least

[1] The layers of plantar muscles are numbered from the surface of the sole upward, as they occur in dissection.

digit of the foot"—*i. e.*, of the little toe. *Synonym*, flexor digiti quinti brevis, "the short flexor of the fifth digit." *Situation*, in the third muscular layer of the sole on its outer border. *Origin*, the under surface of the base of the fifth metatarsal. *Direction*, forward. *Insertion*, the outer side of the base of the first phalanx of the fifth toe on its plantar aspect. *Action*, flexion of the fifth toe. *Nerve*, the external plantar.

Lumbricales (Fig. 379).—"The earth-worm muscles," from their fancied resemblance to common angle-worms (*lumbrici*). Each is a lumbricalis. *Number*, four. *Situation*, in the fore part of the second muscular layer of the sole. *Origin*, from the digital tendons of the flexor longus digitorum. *Direction*, forward to the inner side of the four small toes. *Insertion*, the extensor tendon on the dorsum of the first phalanx. *Action*, first, flexion of the first phalanges; second, extension of second and third phalanges. *Nerves*, for the inner two, the internal plantar; for the others, the external plantar.

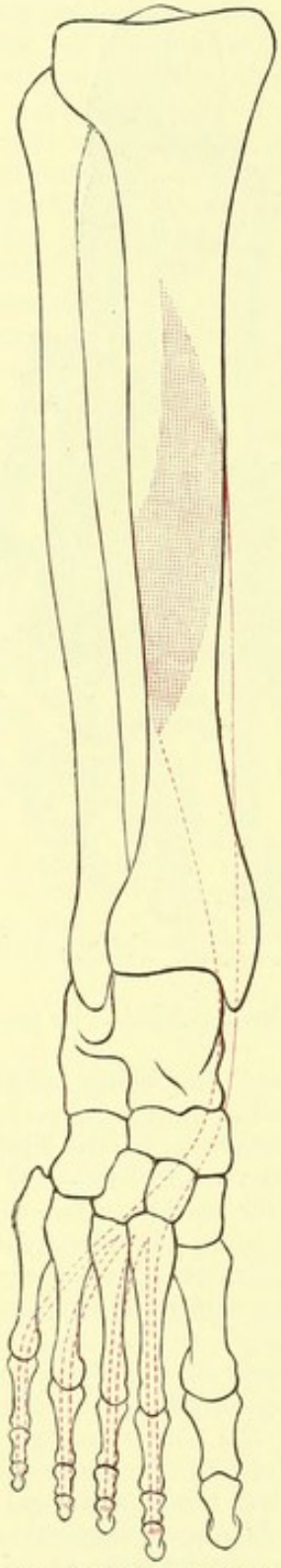

Fig. 377.—Flexor longus digitorum of right side: outline and attachment-areas. The muscle is represented as seen from in front through the bones. (F. H. G.)

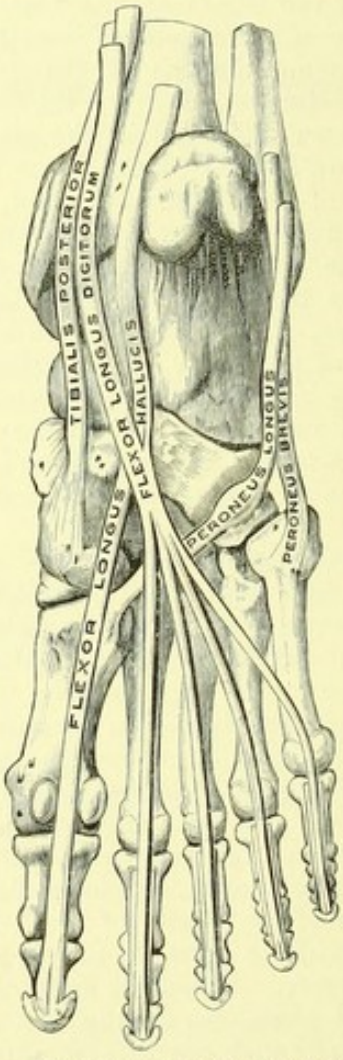

Fig. 378.—Tendons in the right sole. (Testut.)

Extensor Proprius Hallucis (Figs. 381, 382, 362).—"The proper extensor of the great toe." *Synonyms*, extensor longus hallucis, extensor proprius pollicis, extensor longus pollicis pedis. "Proprius" is preferable to "longus" in naming this muscle, because extension of the great toe is partly effected through the inner tendon of the extensor brevis digitorum, a muscle not special (proprius) to

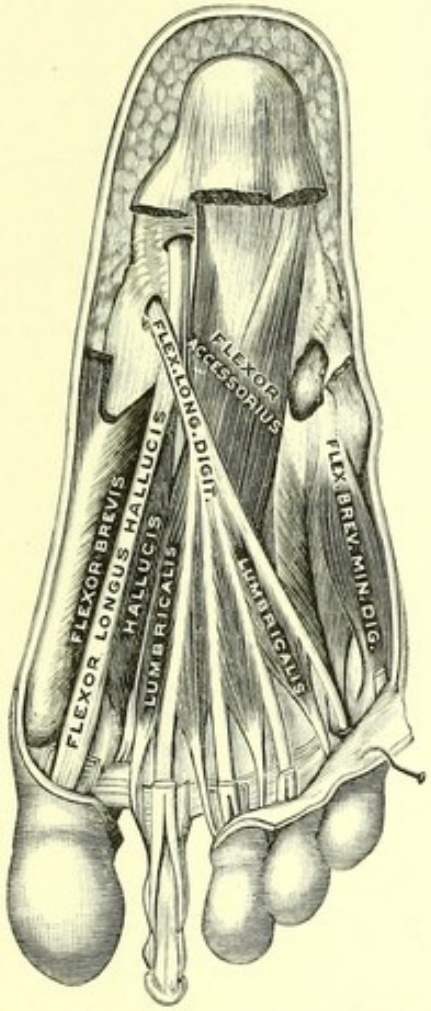

FIG. 379.—Flexor accessorius and lumbricales of right foot. (Testut.)

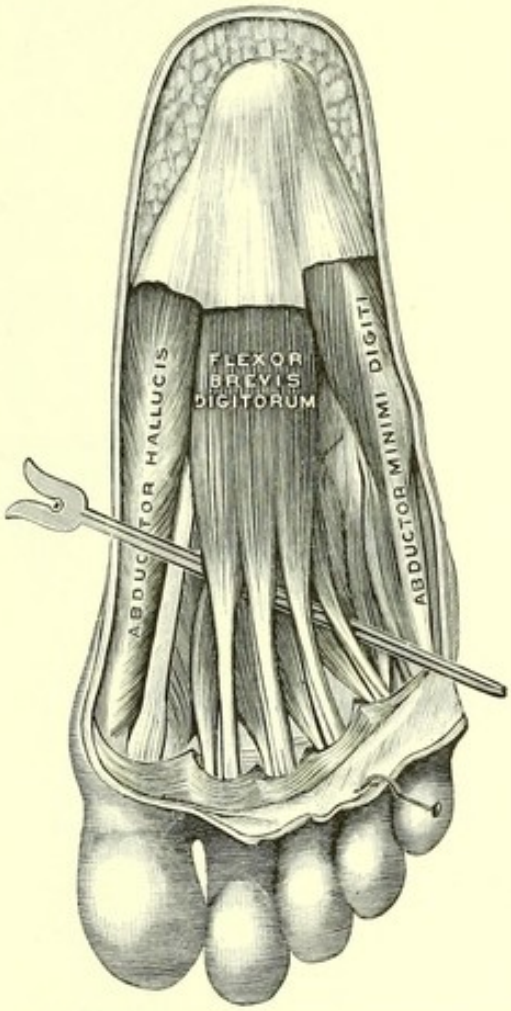

FIG. 380.—Muscles of the superficial layer of the right foot. (Testut.)

this digit, but also concerned in extending three other toes. *Situation*, in the front of the leg and dorsum of the foot. *Origin*, the middle two-fourths of the anterior surface of the fibula and adjacent part of the interosseous membrane. *Direction*, downward, through the annular ligament, then forward, inward, and a little downward. *Insertion*, the dorsum of the base of the last phalanx of the hallux. *Action*, extension of great toe. *Nerve*, the anterior tibial.

Extensor Longus Digitorum (Figs. 362, 383).—"The long extensor of the digits," meaning the four small toes. *Situation*, in the front of the leg and dorsum of the foot. *Origin*, the external tuberosity of the tibia, the head and two-thirds of the anterior surface of the fibula, and a little of the upper part of the interosseous membrane. *Direction*, downward through the annular ligament, then forward and a little downward. *Insertion*, by a tendon for each of the small toes. Each tendon divides into three parts, of which the middle is attached at the base of the second phalanx on its dorsal aspect, the lateral parts uniting and finding attachment at the base of the last phalanx. *Action*, extension of the four small toes. *Nerve*, the anterior tibial.

Extensor Brevis Digitorum (Figs. 384, 381).—"The short extensor of the

digits" of the foot. *Situation*, in the dorsum of the foot. *Origin*, the front of the upper and outer surface of the calcaneum. *Direction*, forward, and a little inward and downward. *Insertion*, by four tendons: the first at the base of the

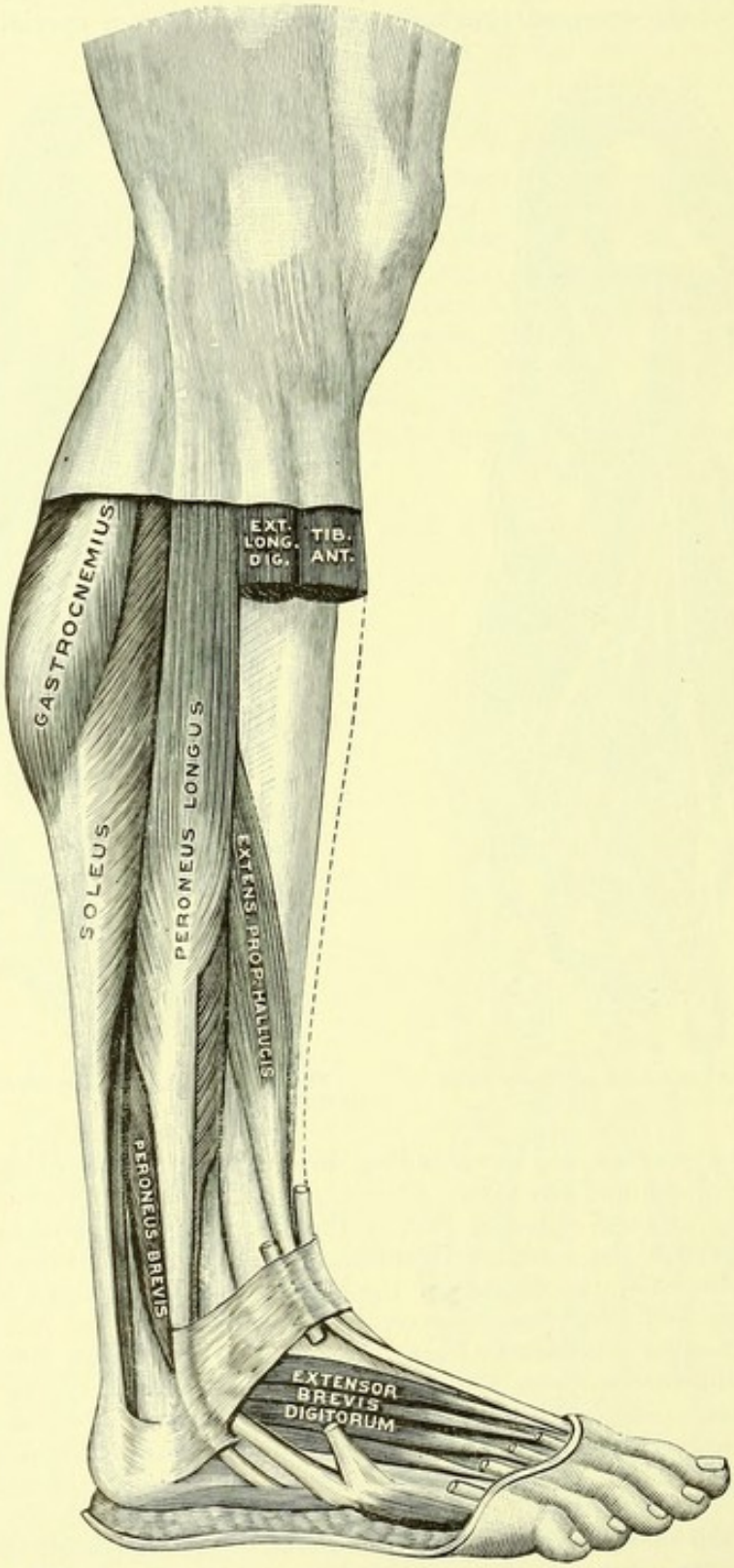

FIG. 381.—Muscles in the outer side of right leg and dorsum of foot. (Testut.)

first phalanx of the great toe on its dorsal aspect; the others on the outer borders of the long extensor tendons of the second, third, and fourth toes respectively.

Action, of first tendon : extension of first phalanx of the great toe, and slight adduction ; of the others : assistance to the long extensor. *Nerve*, the anterior tibial.

It should be observed that this muscle does not act upon just the same digits as does the long extensor. The extensor brevis is inserted into the great toe, but not into the little ; the extensor longus into the little toe, but not into the great.

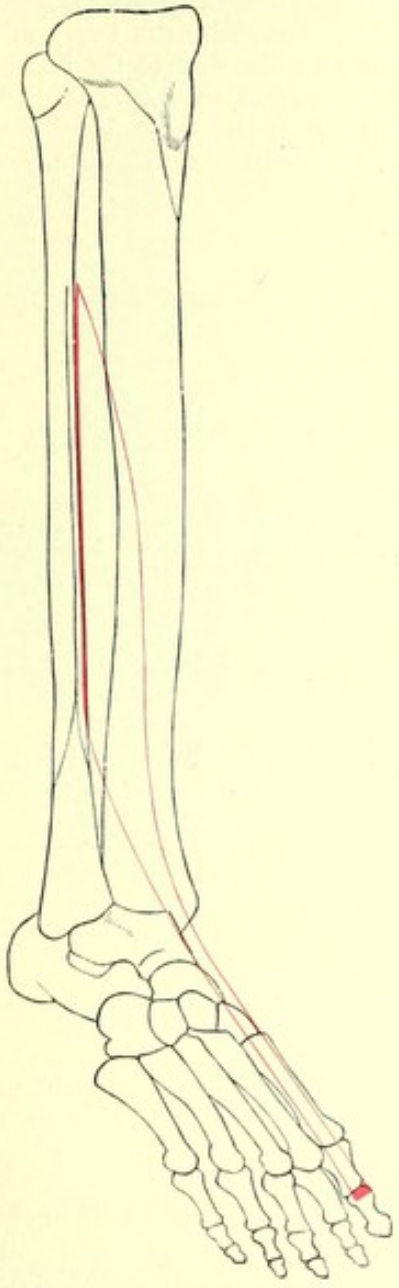

FIG. 382.—Extensor proprius hallucis of right side: outline and attachment-areas. (F. H. G.)

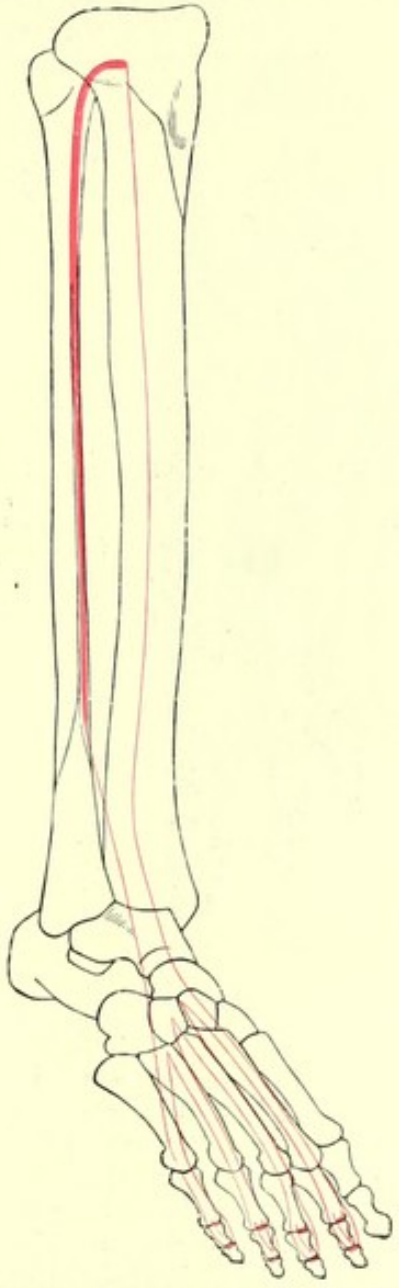

FIG. 383.—Extensor longus digitorum of right side: outline and attachment-areas. (F. H. G.)

Abductor Hallucis (Figs. 380, 381).—"The abductor of the great toe." *Synonym*, abductor pollicis pedis, "the abductor of the thumb of the foot." *Situation*, in the first muscular layer of the sole on the inner side. *Origin*, the inner tubercle of the calcaneum. *Direction*, forward and a little inward. *Insertion*, the inner side of the base of the first phalanx of the great toe, conjoined with the inner head of the flexor brevis hallucis. *Action*, abduction and flexion of the great toe. *Nerve*, the internal plantar.

Abductor Minimi Digiti Pedis (Figs. 380, 384).—"The abductor of the smallest digit of the foot." *Synonym*, abductor digiti quinti, "the abductor of the fifth digit." *Situation*, in the first muscular layer of the sole on the outer side.

Origin, both tubercles of the calcaneum. *Direction*, forward and a little outward. *Insertion*, the outer side of the base of the first phalanx of the little toe. *Action*, abduction of the fifth digit. *Nerve*, the external plantar.

Interossei Dorsales Pedis (Fig. 385).—"The dorsal interosseous muscles of the foot." *Number*, four. *Situation*, one in each of the four spaces between the metatarsal bones. *Origin*, each from the adjacent sides of two metatarsal bones. *Direction*, forward. *Insertion*, the bases of the first phalanges, as follows: the first to the inner side of the second toe, the second to the outer side of the second toe, the third to the outer side of the third toe, the fourth to the outer side of the fourth toe;

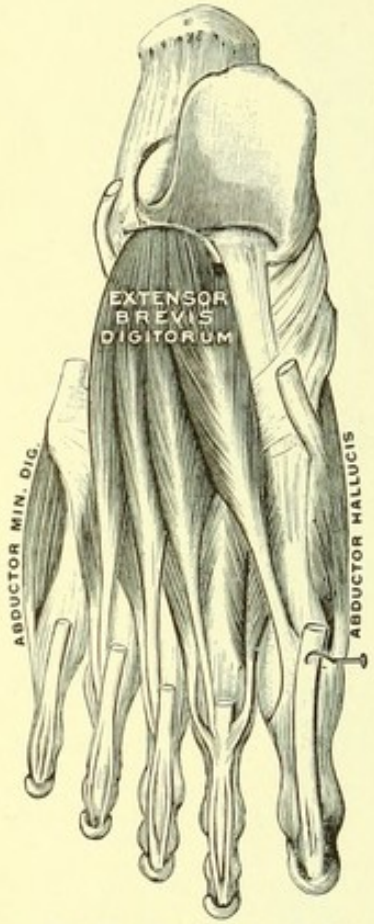

FIG. 384.—Extensor brevis digitorum of right foot. (Testut.)

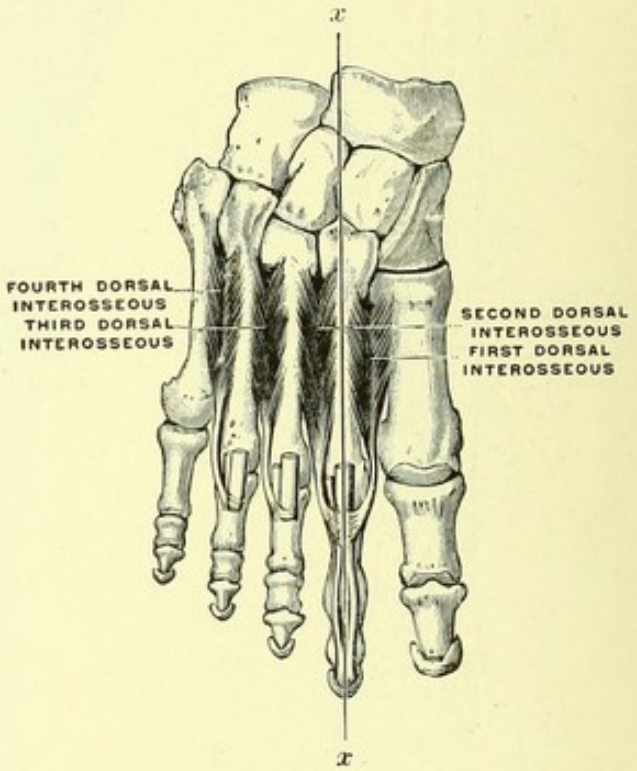

FIG. 385.—Interossei dorsales of right foot. The line *xx* is that from which abduction is made. (Testut.)

also, each to the extensor tendon of the corresponding toe. *Action*: each abducts from a line drawn through the long axis of the second toe. Those acting on the second toe are alternately abductors and adductors: when one of them has abducted the toe, the other restores it to its attitude of rest by adduction. The dorsal interossei also flex the first phalanges, and afterward extend the second and third. *Nerve*, the external plantar.

Adductor Obliquus Hallucis (Fig. 386).—"The oblique adductor of the great toe." *Synonym*, adductor pollicis pedis, "the adductor of the thumb of the foot." *Situation*, in the fore and middle part of the third muscular layer of the sole. *Origin*, the proximal ends of the second, third, and fourth metatarsals. *Direction*, forward and inward. *Insertion*, the outer side of the base of the first phalanx of the great toe, in common with the adductor transversus and the outer head of the flexor brevis hallucis. *Action*, adduction and flexion of the great toe. *Nerve*, the external plantar.

Adductor Transversus Hallucis (Fig. 386).—"The transverse adductor of the great toe." *Synonym*, transversus pedis, "the transverse muscle of the foot." *Situation*, in the third muscular layer of the sole, across the distal end of the metatarsus. *Origin*, the lower metatarso-phalangeal ligaments of the outer three toes and the transverse metatarsal ligament. *Direction*, transversely inward.

Insertion, the base of the first phalanx of the great toe, conjointly with the adductor obliquus and the outer head of the flexor brevis. *Action*, adduction of great toe. *Nerve*, the external plantar.

Interossei Plantares (Fig. 387).—"The plantar interosseous muscles." *Number*, three. *Situation*, the second, third, and fourth spaces between the metatarsal bones, on the plantar aspect. *Origin*, the inner and under surfaces of metatarsal bones, as follows: the first on the third bone, the second on the fourth, the third on the fifth. *Direction*, forward. *Insertion*, each on the inner side of the base of the first phalanx of the corresponding toe and

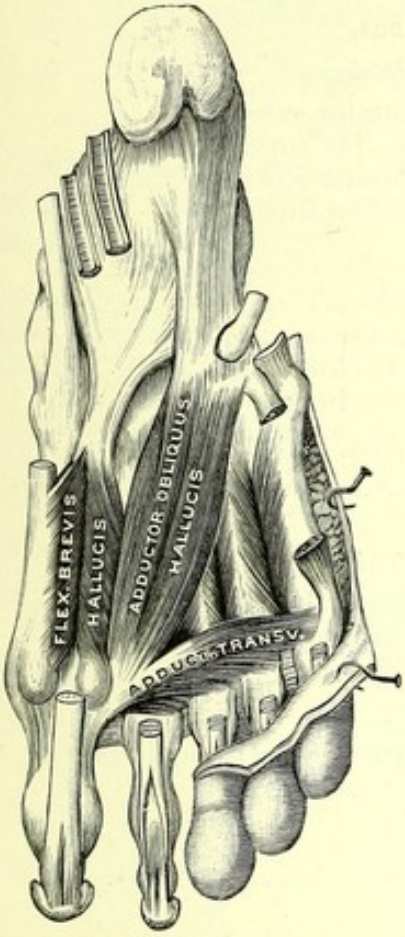

FIG. 386.—Muscles in the third layer of the right sole. (Testut.)

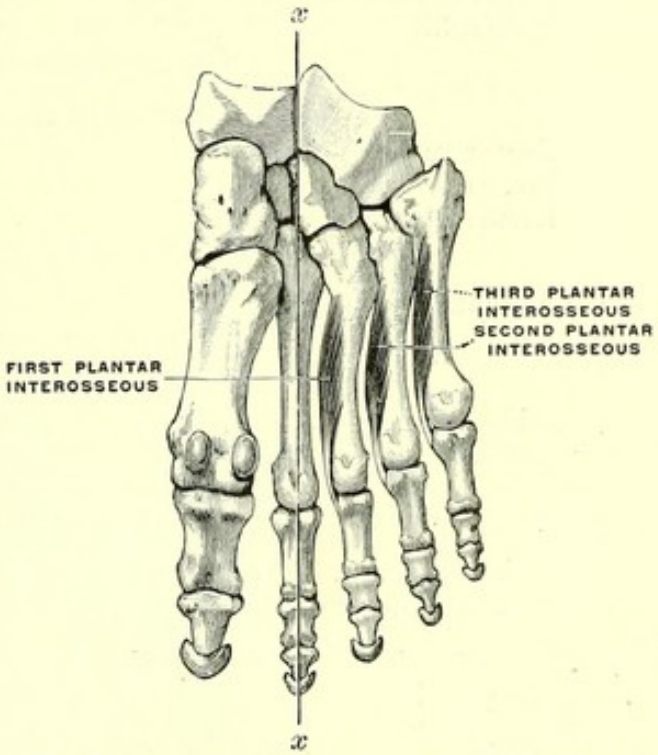

FIG. 387.—Interossei plantares of right foot. The line *xx* is that to which adduction is made. (Testut.)

its extensor tendon. *Action*, adduction toward the second toe; also, flexion of the first phalanges, and afterward extension of the second and third phalanges. *Nerve*, the external plantar.

The interosseous muscles, the abductor and the two adductors of the hallux, and the abductor minimi digiti are physiologically upon the same plane, forming a group whose members produce the lateral movements of the toes. The great toe has one muscle (abductor hallucis) inserted on the inner side of the base of the first phalanx, and two adductors on the opposite side of the same bone; each of the other toes has two muscles similarly attached. They are arranged as follows, the inner muscle in each case being named first: the second toe has the first dorsal interosseous and the second dorsal interosseous; the third toe has the first plantar interosseous and the third dorsal; the fourth toe has the second plantar interosseous and the fourth dorsal; the fifth toe has the third plantar interosseous and the abductor minimi digiti. The interossei inserted upon the second toe are alternately abductors and adductors; the other dorsal interossei are always abductors, and all of the plantar interossei are adductors, the middle line of the second toe when at rest being the line from and to which movements are reckoned. Compare the arrangement with that of the homologous parts in the upper limb.

Psoas Parvus (Fig. 325).—"The little loin-muscle" is small, flat, inconstant, of irregular origin, situated in front of the psoas magnus. Most frequently it arises from the bodies of

the lowest thoracic and the highest lumbar vertebræ and the disc between them. Its body is short, and its long tendon, blended with the iliac fascia, is inserted into the ilio-pectineal eminence. It is a tensor of the iliac fascia.

Muscles which Move the Lower Limb, Grouped According to Their Location.

In the Pelvis and Upper Part of the Thigh.

Psoas magnus. — Iliacus.

In the Region of the Buttock.

Gluteus maximus.
Gluteus medius.
Gluteus minimus.
Pyriformis.
Obturator externus.
Gemellus superior.
Obturator internus.
Gemellus inferior.
Quadratus femoris.

In the Front of the Thigh.

Tensor vaginæ femoris.
Sartorius.
Rectus femoris.
Vastus externus.
Vastus internus.
Vastus intermedius.

In the Back of the Thigh.

Semimembranosus. — Semitendinosus.
Biceps flexor cruris.

In the Mesial Part of the Thigh.

Adductor magnus.
Adductor longus.
Adductor brevis.
Adductor gracilis.
Pectineus.

In the Front of the Leg.

Tibialis anterior.
Extensor longus digitorum.
Extensor proprius hallucis.
Peroneus tertius.

In the Outer Part of the Leg.

Peroneus longus. — Peroneus brevis.

In the Back of the Leg.

Gastrocnemius.
Soleus.
Plantaris.
} *Superficial group.*

Popliteus.
Flexor longus hallucis.
Flexor longus digitorum.
Tibialis posterior.
} *Deep group.*

In the Dorsum of the Foot.

Extensor brevis digitorum.

In the Sole of the Foot.

Abductor hallucis.
Flexor brevis digitorum.
Abductor minimi digiti.
} *First (superficial) layer.*

Flexor accessorius.
Lumbricales.
} *Second layer.*

Flexor brevis hallucis.
Adductor obliquus hallucis.
Adductor transversus hallucis.
Flexor brevis minimi digiti.
} *Third layer.*

Interossei plantares.
Interossei dorsales pedis.
} *Fourth layer.*

THE MUSCLES OF THE TRUNK.

These will be considered in three groups, as follows :

A. The muscles of the *back*, including those in the dorsum of the neck.
B. The muscles of the *abdomen*.
C. The muscles of the *thorax*.

THE MUSCLES OF THE BACK,
including the Dorsum of the Neck:

The muscles situated in the back of the trunk and neck are arranged in a number of groups, which are usually described as layers, although the lamination of those most deeply located is not distinct.

The first, or *superficial layer*, comprising the trapezius and latissimus, and the *second layer*, made up of the levator scapulæ and the two rhomboidei, have already been described in connection with the muscles of the upper limb, as they functionally belong in that class.

Muscles in the Third Layer of the Back.

Serratus posterior superior.
Serratus posterior inferior.
Splenius capitis.
Splenius cervicis.

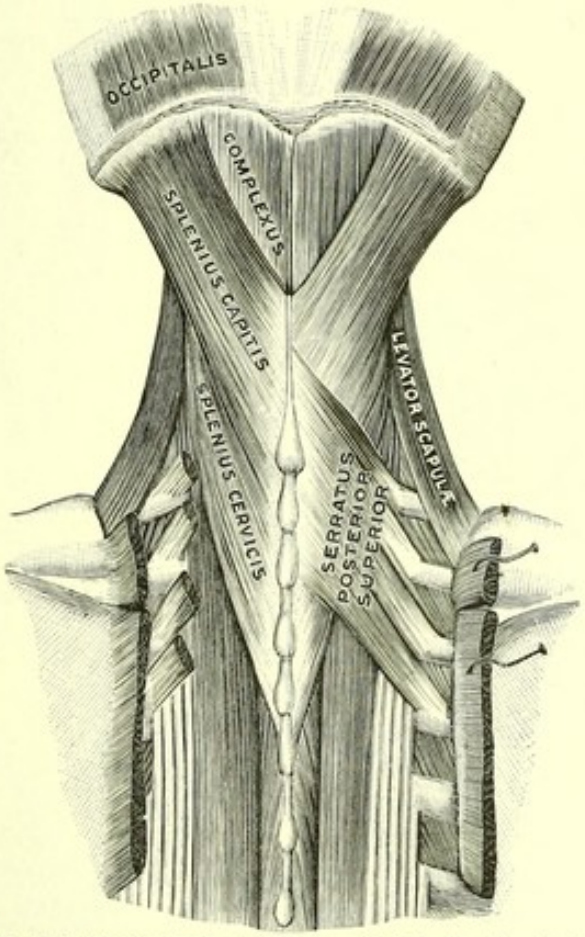

FIG. 388.—Muscles in the third layer of the back. (Testut.)

Serratus Posterior Superior (Fig. 388).—"The upper, hind, saw-toothed muscle." *Synonym*, serratus posticus superior. *Situation*, at the base of the neck and upper part of the thorax, nearly covered by the levator scapulæ and rhomboidei. *Ori-*

gin, the lower part of the nape ligament, and the spines of the last cervical and two or three upper thoracic vertebræ. *Direction*, down- and outward. *Insertion*, the second, third, fourth, and fifth ribs beyond their angles. *Action*, elevation of the ribs of its insertion. *Nerves*, the second and third intercostals.

Serratus Posterior Inferior (Fig. 389).—"The lower, hind, saw-toothed muscle." *Synonym*, serratus posticus inferior. *Situation*, the upper loin and lower thoracic regions. *Origin*, the spines of the lower two thoracic and upper two or three lumbar vertebræ. *Direction*, outward and upward. *Insertion*, the lower borders of the lower four or five ribs, beyond the line of the costal angles. *Action*: it draws the lower ribs backward and downward. *Nerves*, the intercostal.

Splenius Capitis (Fig. 388).—"The strap-shaped muscle of the head." *Situation*, in the back of the neck, in front of the trapezius.

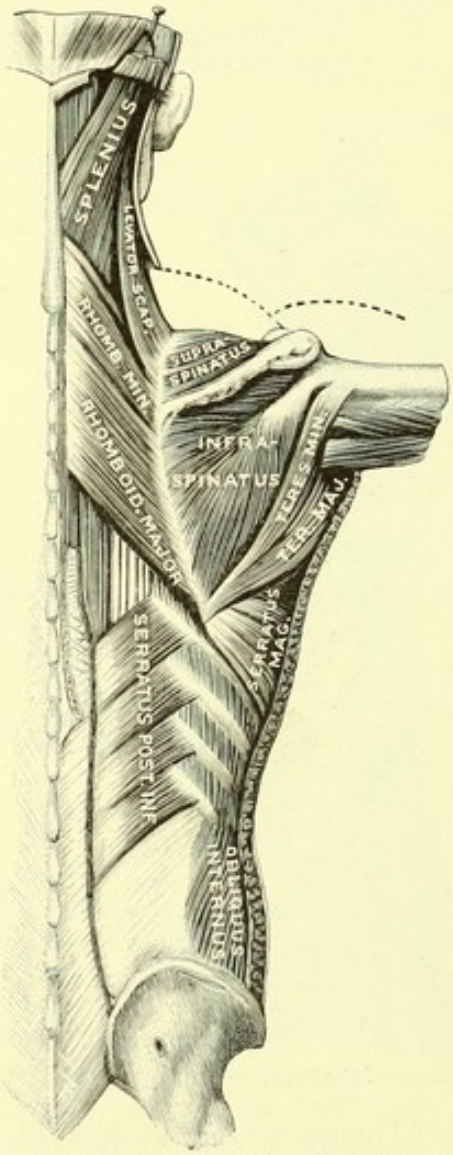

FIG. 389.—Muscles in the second layer of the back and on the dorsum of the shoulder. (Testut.)

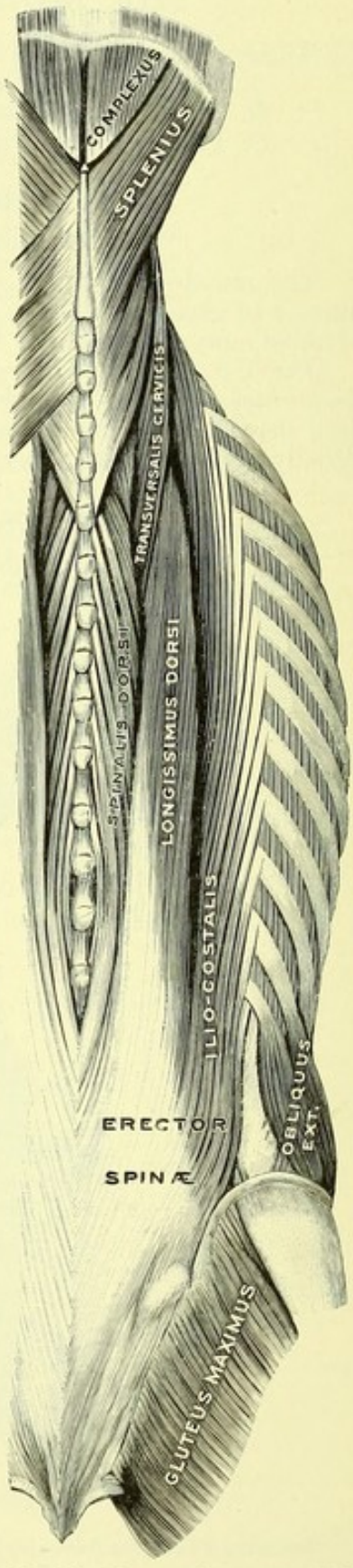

FIG. 390.—Erector spinæ, superficial view. (Testut.)

Origin, the lower two-thirds of the nape ligament, and the spines of the seventh cervical and first and second thoracic vertebræ. *Direction*, upward and outward. *Insertion*, the mastoid process of the temporal, and the superior curved line of the occipital. *Action*, extension of head, and its rotation to the side on which the muscle lies. *Nerve*, the posterior primary branches of the middle cervical.

Splenius Cervicis (Fig. 388).—"The strap-shaped muscle of the neck." *Synonym*, splenius colli. *Situation*, in the back of the neck, in front of the trapezius. *Origin*, the spines of the third, fourth, and fifth thoracic vertebræ. *Direction*, upward, outward, and forward. *Insertion*, the hind tubercles of the transverse processes of the upper two, three, or four cervical vertebræ. *Action*, extension of the neck, and its rotation to the side on which the muscle lies. *Nerves*, the posterior branches of the lower cervical.

Muscles in the Fourth Layer of the Back.

The *fourth layer* is formed by the erector spinæ (the erector of the spine—that is, the muscle which extends it). It constitutes the greater part of the long, rounded mass, which runs parallel to the series of vertebral spinous processes, and projects so far backward that, when a view is taken of the entire back, the bones seem to be sunk in a valley between two mounds, instead of protruding conspicuously, as in the skeleton.

The **Erector Spinæ** (Fig. 390) is a compound muscle, beginning below in a single mass, but soon dividing into three portions, which pass upward and end at different heights, that nearest the middle line going no further than the upper part of the thorax, the outermost passing well into the neck, and the middle reaching to the base of the skull. The second and third of these do not proceed to their respective destinations uninterruptedly, but by a series of steps, each making three. The arrangement suggests the simile of scaling a cliff: as the muscle climbs up the back, it does not relinquish one foothold until it has established a new one—it takes a fresh grip before it lets go the old; and, as a result, there is not merely continuity of structure, but overlapping, one segment beginning back (sometimes far back) of the ending of the segment below it. The various portions are described as separate muscles. The name erector spinæ properly includes them all; but it is often used in a restricted sense to designate the undivided mass from which these prolongations arise.

Scheme of the Erector Spinæ.

Erector spinæ
- *Outer division*:
  - Ilio-costalis.
    - Accessorius ad ilio-costalem.
    - Cervicalis ascendens.
- *Middle division*:
  - Longissimus dorsi.
    - Transversalis cervicis.
    - Trachelo-mastoideus.
- *Inner division*:
  - Spinalis dorsi.

The **Erector Spinæ** arises from the lowest two or three thoracic and all of the lumbar and sacral spines, the transverse processes of several lower thoracic vertebræ, the lower and back part of the sacrum, and the hind fifth of the iliac crest. From this beginning come the three divisions—the outer, the middle, and the inner.

The **outer division** starts off just below the last rib as the *ilio-costalis* (Fig. 390), so called from its connecting the ilium with certain ribs. It is also known

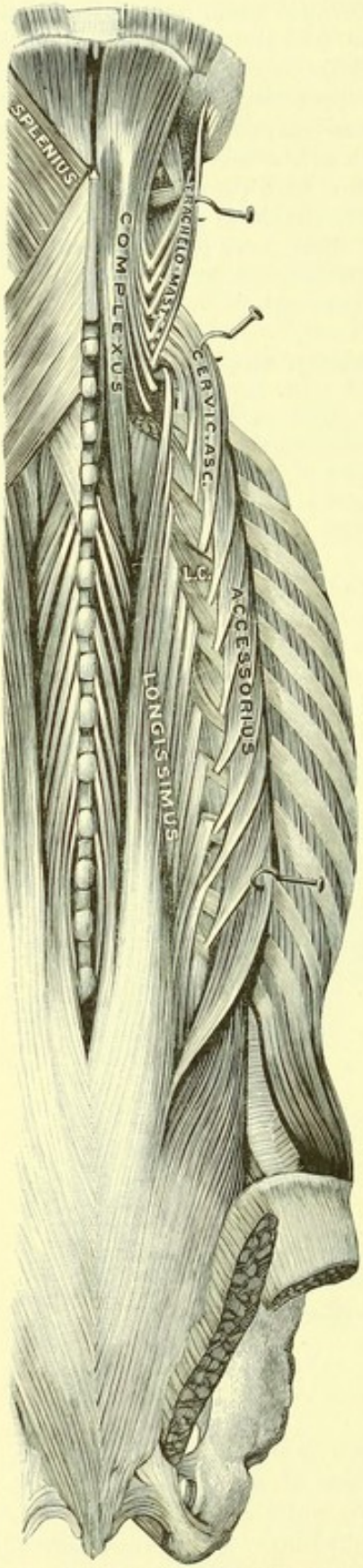

FIG. 391.—Erector spinæ. The outer series is pulled outward. (Testut.)

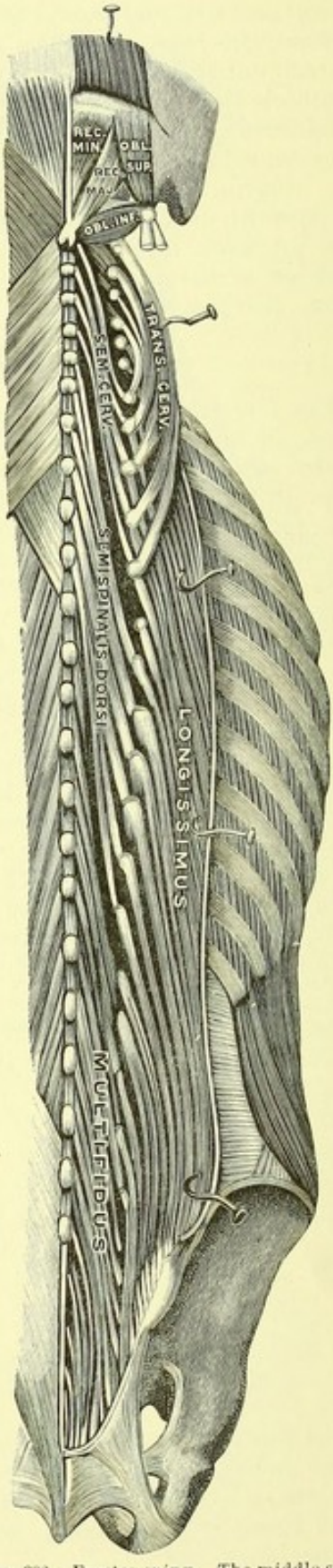

FIG. 392.—Erector spinæ. The middle series is pulled outward. (Testut.)

as the sacro-lumbalis, as it begins in the sacral region and runs to the lumbar. It is inserted into the lower six or seven ribs at their angles, or in the line of the costal angles. From the same ribs, a trifle toward the middle line from these points of insertion, springs the *accessorius ad ilio-costalem* (Fig. 391), "the adjunct to the ilio-costalis," which passes up and is inserted into the upper six ribs (at the angles of those below the first, and on that one near the tubercle), and the transverse process of the vertebra prominens. On the four or five ribs above those from which the accessorius arises, a little mesially from its line of costal insertion, are the points of origin of the *cervicalis ascendens* (Fig. 391), "the ascending neck muscle," which thus sustains a relation to the accessorius like that of the latter to the ilio-costalis. It is inserted into the transverse processes of the fourth, fifth, and sixth cervical vertebræ. These three muscles—the ilio-costalis, accessorius, and cervicalis ascendens—are in appearance and in effect practically one.

The **middle** and largest **division** of the erector spinæ begins as the *longissimus dorsi* (Figs. 390–392), "the longest muscle of the back." It is inserted into the transverse processes of all the thoracic and the accessory processes of the lumbar vertebræ, and into most of the ribs between the tubercles and angles. Its upward prolongation is called *transversalis cervicis* (Figs. 390, 392), a name which refers to the attachments of the muscle to transverse processes. It arises from the transverse processes of from four to six upper thoracic vertebræ, internally to the insertions of the longissimus, and is inserted into the transverse processes of cervical vertebræ from the second to the sixth. The last segment of this division is the *trachelo-mastoideus* (Figs. 391, 393), "the neck-mastoid muscle," so called from its situation and insertion. It arises from the transverse processes of from four to six upper thoracic vertebræ with the transversalis cervicis, and also from the articular processes of the lower three or four cervical ; and it is inserted into the mastoid process of the temporal.

The **third** and smallest **division** is nearest the median line, and is given off from the main mass of the erector above the middle of the thorax. It is called the *spinalis dorsi* (Fig. 390), "the spinal muscle of the back," with reference to its bony attachments. It is a continuation of that portion of the common mass which arises from the lumbar and thoracic spines, and is inserted into the spines of a variable number of vertebræ in the upper thoracic region.

The effect of this arrangement is such that the erection of the vertebral column is accomplished, not as it would be by a muscle which had no attachments between the sacrum and cranium, but by a continuous succession of contractions from one small division of the column to another only a short distance away. Thus, a variety of actions is effected, and strength and steadiness of movement insured.

The nervous supply of the entire series comes through the dorsal primary branches of the spinal nerves.

Muscles in the Fifth Group of the Back.

The *fifth series* of muscles lies in front of the erector spinæ. They are all characterized by the direction of their fibres, which is from below upward and inward. Nearly all of the points of origin are on transverse processes of vertebræ, and most of the insertions are on spinous processes, the fibres passing from a transverse process to the spinous process of the fourth, fifth, or sixth vertebra above. They are the following :

Complexus.
Semispinalis cervicis.
Semispinalis dorsi.
Multifidus.
Rotatores.

Complexus (Figs. 393, 391), "the intricate muscle," sometimes is called *semispinalis capitis*, but without good reason ; for the term "semispinalis" in connection with other muscles is used to signify that one attachment is upon spinous processes of vertebræ. It arises from the transverse processes of the upper six

or seven thoracic vertebræ and the last cervical, and from the articular processes of cervical vertebræ from the third to the sixth. It is inserted into the occipital bone, on the mesial part of the surface between the curved lines. The portion nearest the middle line is somewhat detached, and has a tendinous inscription about half way of its length, on account of which it is often reckoned as a separate muscle, the *biventer cervicis*. It extends the head, drawing it to one side. Its nerve-supply is from several upper cervical nerves.

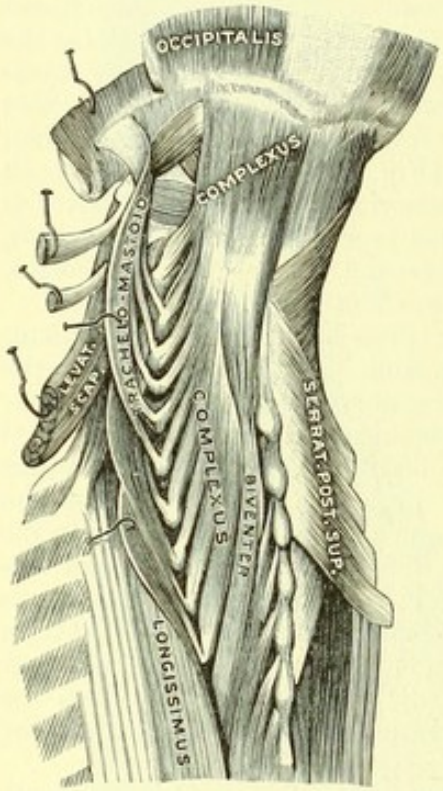

FIG. 393.—Trachelo-mastoid and complexus. (Testut.)

Semispinalis cervicis (Fig. 392), the name meaning "the muscle of the neck, one extremity of which is attached to spinous processes," arises from the transverse processes of the upper five or six thoracic vertebræ, and is inserted into the spinous processes of cervical from the second to the fifth. It extends the neck, and rotates it to the opposite side. Its nerves are branches from the lower cervical and upper thoracic.

Semispinalis dorsi (Fig. 392), "the muscle of the back, one end of which is attached to spinous processes," arises from the transverse processes of thoracic vertebræ from the sixth to the tenth, and is inserted into the spinous processes of the last two cervical and of the upper four, five, or six thoracic vertebræ. Its principal action is extension of the lower cervical and upper thoracic regions. It is supplied by thoracic spinal nerves.

Multifidus (Fig. 392), "the many-cleft muscle," occupies the greater part of the gutter beside the vertebral spines from the sacrum to the axis. Its fibres pass from some part (usually a process) of one vertebra to the spinous processes of several vertebræ above it, generally the second, third, and fourth. It arises from the groove on the back of the sacrum, the mammillary processes in the lumbar region, the transverse in the thoracic region, and the articular of the lower four cervical vertebræ, and is inserted into all the spinous processes of the true vertebræ. It extends, bends sidewise, and rotates to the opposite side the spinal column. The posterior branches of the spinal nerves supply it.

Rotatores, rotators of the spine, lie covered in by the multifidus, and are by some regarded as part of it. They are constant only in the thoracic region, are eleven in number, and each passes between the transverse process of one vertebra and the lamina of the next above. They produce rotation of the spine to the opposite side, and also bend it backward and sidewise. Their nerves are the thoracic.

In the cervical and lumbar regions are found a series of small muscles, called *interspinales*, which pass from one spinous process to the next above; and another series, the *intertransversales* (*intertransversarii*), which connect one transverse process with the next above. The former assists in extension of the spine, the latter in its lateral flexion.

Suboccipital Muscles.

Rectus capitis posterior major.	Obliquus capitis inferior.
Rectus capitis posterior minor.	Obliquus capitis superior.

Rectus Capitis Posterior Major (Fig. 392).—The name means literally "the greater straight hind muscle of the head." It arises from the spine of the axis,

passes upward and outward, and is inserted into the outer part of the inferior curved line of the occipital, and the surface in front of it. It extends the head, and rotates it to the same side. The suboccipital nerve supplies it and all the others of this group.

Rectus Capitis Posterior Minor (Fig. 392), "the smaller straight hind muscle of the head," arises on the tubercle of the posterior arch of the atlas, runs upward and outward, and is inserted into the inner part of the inferior curved line of the occipital and the area in front of it. It extends the head.

Obliquus Capitis Inferior (Fig. 392), "the lower oblique muscle of the head," arises from the spine of the axis, goes upward and outward, and is inserted into the transverse process of the atlas. Its principal action is to rotate the atlas to the same side.

Obliquus Capitis Superior (Fig. 392), "the upper oblique muscle of the head," arises from the transverse process of the atlas, passes upward, backward, and inward, and is inserted into the surface behind the inferior curved line of the occipital. It extends the head.

THE MUSCLES OF THE ABDOMEN.

Rectus abdominis.	Obliquus internus abdominis.
Pyramidalis.	Transversalis.
Obliquus externus abdominis.	Quadratus lumborum.

Of these muscles the rectus and pyramidalis are in front, the quadratus is behind, and the contractile portion of the obliquus externus, obliquus internus, and transversalis are at the side, their fibrous part extending forward and inward to the median line of the belly.

Rectus Abdominis (Fig. 394).—"The straight muscle of the abdomen." *Situation*, in the front wall of the belly. *Origin*, the pubic crest and symphysis, the tendon from the latter point coming from the opposite side and crossing its fellow. *Direction*, upward, curving with convexity forward, corresponding with the contour of the belly. *Insertion*, the fifth, sixth, and seventh costal cartilages. Several tendinous intersections (*inscriptiones tendineæ*), usually not occupying the whole thickness of the muscle, cross it, generally one at the level of the ensiform appendix, one at that of the navel, one between these, and often one below. The sheath of the muscle is formed by the tendons of the lateral muscles. (See below.) *Action*, depression of the thorax, and compression of the abdominal viscera. *Nerves*, the lower intercostal and the ilio-hypogastric.

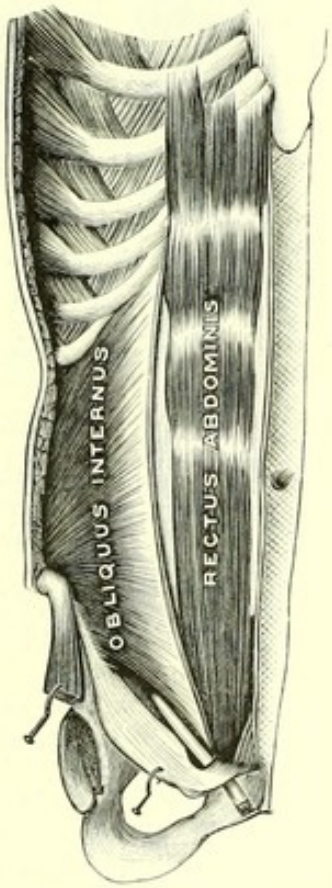

FIG. 394.—Rectus abdominis and obliquus internus of right side. (Testut.)

The three lateral muscles constitute three nearly co-extensive layers, and their broad tendons of insertion (called "aponeuroses"), separate at first, become blended along a slightly curved, nearly vertical line (called *linea semilunaris*, "the half-moon line") just at the outer edge of the rectus. This combined tendon then splits vertically into laminæ of equal thickness, which separate and embrace the rectus, one going in front, the other behind, and finally meet again at the median line, where they fuse with each other and with the corresponding structures of the opposite side, making a strong, perpendicular, fibrous band called *linea alba*, "the white line," which runs from ensiform appendix above to symphysis pubis below. The

inclusion of the rectus by these tendons obtains, however, only in the upper three-fourths of its extent: the tendons all pass in front of the muscle in the lower quarter, leaving the corresponding hind surface free.

Pyramidalis (Fig. 394).—"The pyramidal muscle." It arises from the front of the os pubis, runs up in the sheath of the rectus a short distance, and is inserted in the linea alba. It is very inconstant in presence, size, and shape. It is adjunct to the rectus.

Obliquus Externus Abdominis (Fig. 395).—"The external oblique muscle of the abdomen." *Situation*, superficial, in the side and front walls of the belly. *Origin*, the outer surface of the lower eight ribs. *Direction*, downward in the hind part; downward, forward, and inward elsewhere. *Insertion*, the front half of the outer lip of the iliac crest, the pubic spine and crest, the ilio-pectineal line, and the linea alba. The points of origin make a saw-toothed line, the upper digitations interlocking with similar points of the serratus magnus, the lower with those of the latissimus. The tendon of insertion is a broad sheet, which passes to the mid-line, and there fuses with its fellow opposite and with the tendons of the external oblique and transversalis. The part of the tendon extending from the anterior superior iliac spine to the pubic spine is thicker than the rest, and its edge is curled backward, forming a narrow shelf. This thick part is the *inguinal ligament*, commonly called Poupart's ligament. From its pubic end extends backward to the neighboring extremity of the ilio-pectineal line a flat, triangular process, having a free, concave outer border, and known as Gimbernat's ligament, or the *lacunar ligament*. Just above the pubic body the tendon presents an opening, the *external abdominal ring* (Fig. 396), which results from a separation of the fibres. The aperture slopes upward and outward, and would be triangular were it not for certain fibres, which cross all but the lowest and widest inch of it, and are called intercolumnar, because they are between the pillars, as the inner (upper) and outer (lower) edges of the tendon, which margin the sides of the hole, are called. The inner pillar runs to the symphysis, the outer to the spine of the pubic bone. Thus, the ring is bounded below by the pubic crest, above by the inner pillar, outside by the intercolumnar fibres, and elsewhere by the outer pillar. The ring is occupied by the spermatic cord in the male, by the round ligament of the womb in the female. *Action*, compression of abdominal viscera, rotation of the pelvis to the same side, flexion of pelvis on chest. *Nerves*, the lower intercostal, ilio-inguinal, and ilio-hypogastric.

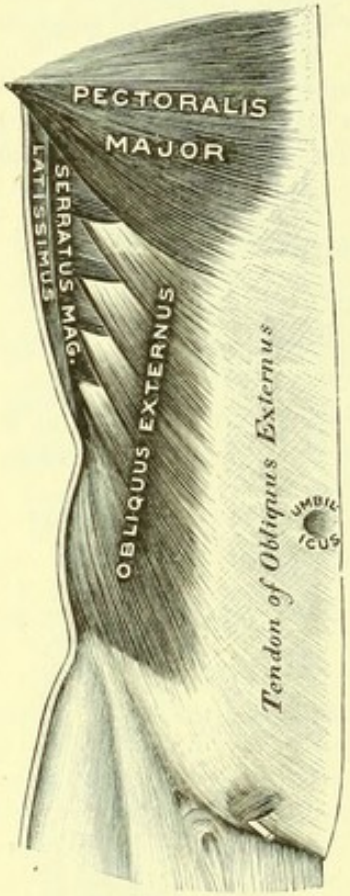

FIG. 395.—Obliquus externus abdominis of right side. (Testut.)

Obliquus Internus Abdominis (Fig. 394).—"The internal oblique muscle of the abdomen." *Situation*, in the side and front of the belly-wall, next deeper than the external oblique. *Origin*, the outer half of the inguinal ligament, two-thirds of the middle lip of the iliac crest, and, slightly, the lumbar fascia. *Direction*, in general, forward, inward and upward; also, directly upward behind, and downward in front. *Insertion*, the lower borders of the costal cartilages from the twelfth to the seventh, the ensiform appendix, the linea alba, the front of the os pubis, and the ilio-pectineal line. The portion inserted into the pubic bone and ilio-pectineal line enters into the formation of the *conjoined tendon* of the internal oblique and transversalis. The lower portions of the internal oblique give off a series of muscular slips, which are arranged in loops in front of and embracing

the spermatic cord. They constitute the *cremaster muscle* ("the supporting muscle"), and the fascia in the spaces between them is the *cremasteric fascia*. The

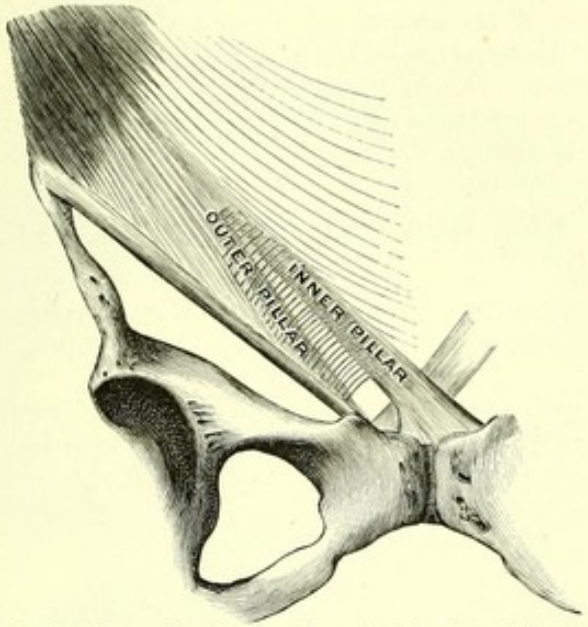

FIG. 396.—External abdominal ring of right side. (Testut.)

cremaster lifts the testicle. *Action*, the internal oblique compresses the abdominal viscera, depresses the ribs, flexes the chest upon the pelvis, and rotates it to the side on which the muscle acts. *Nerves*, the ilio-hypogastric, ilio-inguinal, and lower intercostals.

Transversalis Abdominis (Fig. 397).—"The transverse muscle of the abdomen." *Synonym*, transversus abdominis. *Situation*, deep in the side and front walls of the belly. *Origin*, the inner surfaces of the lower six costal cartilages, the transverse processes of the lumbar vertebræ, the anterior two-thirds of the inner lip of the iliac crest, and the outer third of the inguinal ligament. *Direction*, forward and inward, and in lowest part downward. *Insertion*, the linea alba and (by the conjoined tendon of this muscle and the internal oblique) the front of the os pubis and the neighboring part of the ilio-pectineal line. The transversalis at its upper origin interdigitates with the diaphragm. Between its costal and iliac regions its origin is tendinous, and lies between the erector spinæ and quadratus lumborum. This tendon is otherwise known as the middle layer of the lumbar fascia, and extends from the last rib to the ilio-lumbar ligament. *Action*, compression of the abdominal viscera. *Nerves*, the lower intercostal, ilio-hypogastric, and ilio-inguinal. The muscular fibres at the upper third of the transversalis extend toward the middle line so far as to lie behind the rectus.

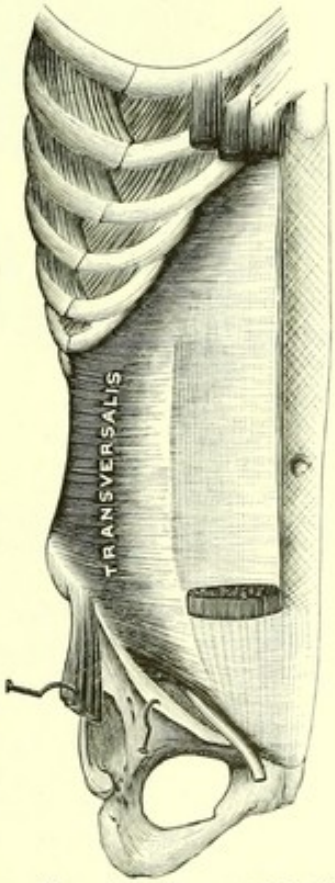

FIG. 397.—Transversalis abdominis of right side. (Testut.)

It is well to note that the three muscles in the side of the abdomen are attached to ribs or costal cartilages above and to iliac crest below, respectively, as follows: the outer muscle to the outer surface and outer lip, the inner muscle to the inner surface and inner lip, the middle muscle to the middle surface (the border) and the middle lip. The obliquity

of the fibres of these muscles to each other contributes greatly to the strength of the abdominal wall, and is a safeguard against hernia.

Quadratus Lumborum (Fig. 325).—"The square muscle of the loins." *Situation*, in the hind wall of the abdomen. *Origin*, the back part of the inner lip of the iliac crest, the ilio-lumbar ligament, and the transverse processes of several lower lumbar vertebræ. *Direction*, upward. *Insertion*, the last rib and the transverse processes of several upper lumbar vertebræ. *Action*, depression of last rib, and lateral flexion of spine. *Nerves*, the last thoracic and the upper lumbar.

THE MUSCLES OF THE THORAX.

Diaphragma.	Levatores costarum.
Intercostales externi.	Triangularis sterni.
Intercostales interni.	Subcostales.

Diaphragma (Figs. 398, 399).—"The diaphragm," meaning etymologically "a partition." *Synonym*, the midriff. The diaphragm is the septum between

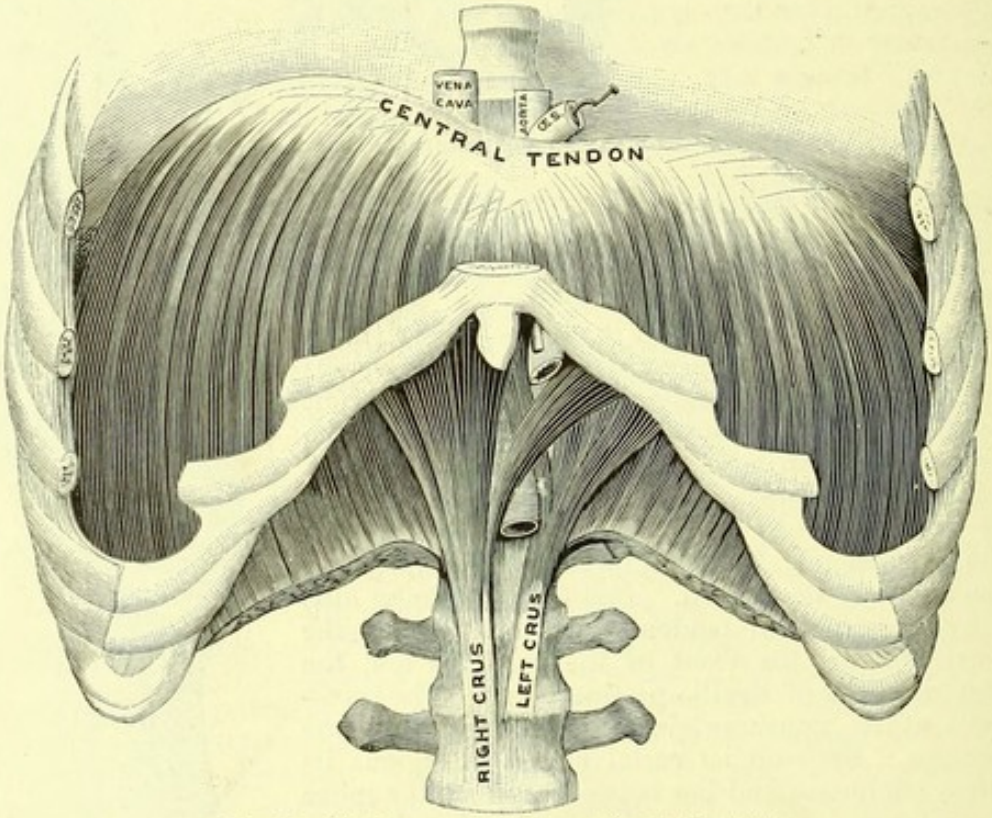

FIG. 398.—Diaphragm, viewed from in front. (Testut.)

the two great cavities of the trunk, forming the convex floor of the thorax and the vaulted roof of the abdomen. Its tendon is centrally located, and is, consequently, its highest part; and to this the muscular portion, which is peripheral, rises from its extensive origin at the lower boundaries of the thoracic framework—the sternum, some costal cartilages, several vertebræ, and certain fibrous bands between these vertebræ and the last rib.

From the front of the bodies of the upper two lumbar vertebræ (on the right side one or two more) and the related cartilages rise two processes, called *crura*, which unite and arch over the aorta just below the last thoracic vertebra, the mesial fibres crossing to the opposite side. From the body of the first lumbar vertebra springs a fibrous band, which arches over to the tip of the transverse process, and from this point to the last rib a second band is stretched. The first

is called *ligamentum arcuatum internum* ("the inner arched ligament"), and the other, *ligamentum arcuatum externum* ("the outer arched ligament"). Both give origin to muscular fasciculi. The largest part of the diaphragm arises from the

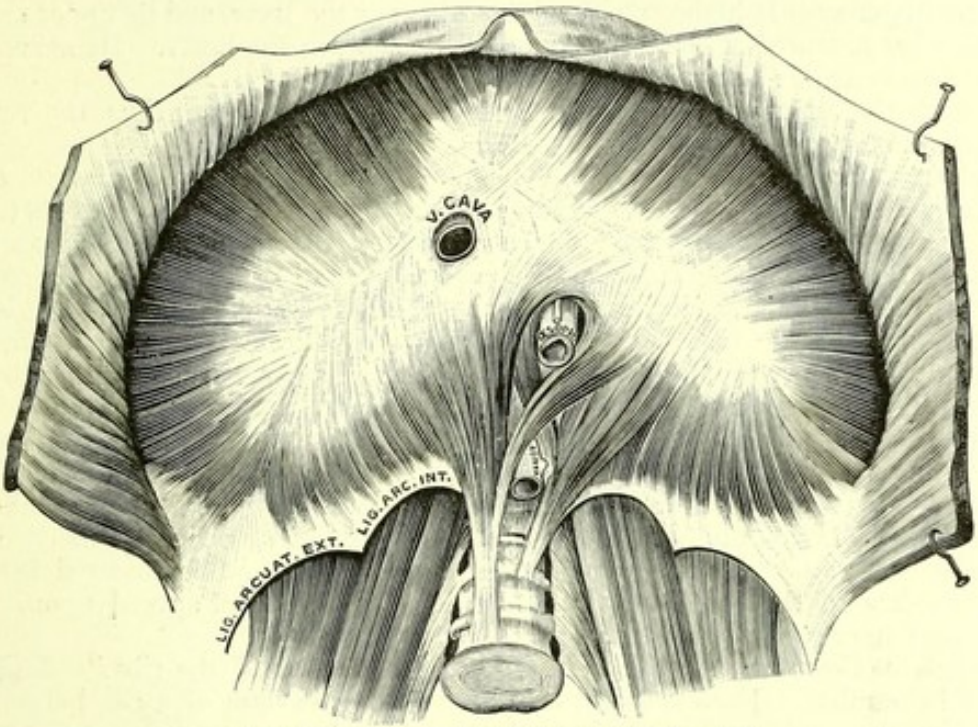

FIG. 399.—Diaphragm, viewed from below. (Testut.)

inner surface of the last six costal cartilages, interdigitating with the transversalis abdominis. Finally, the ensiform cartilage gives attachment to a small

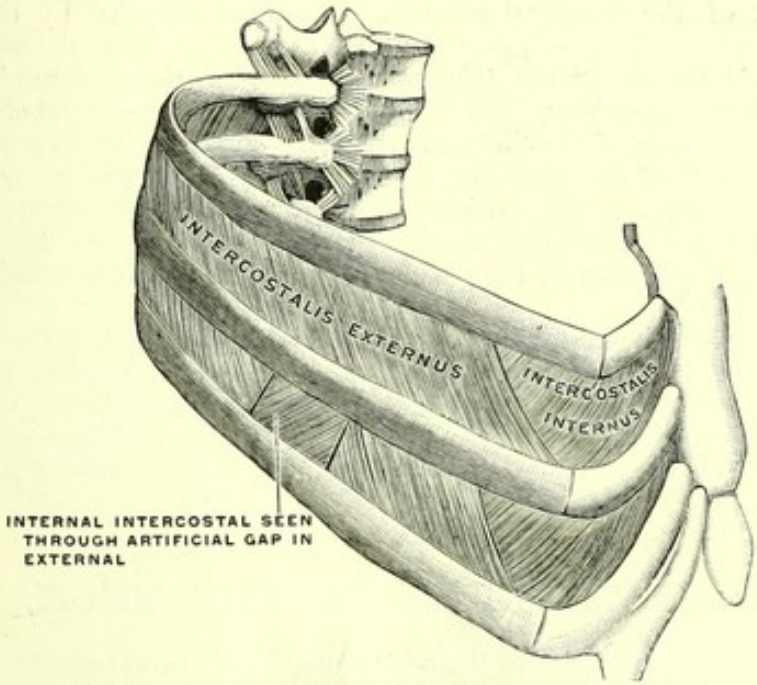

FIG. 400.—Intercostal muscles in right wall of thorax. (Testut.)

band. The central tendon looks something like a trefoil, is very large, and to it the muscular bundles converge from the entire margin of the muscle.

The aortic opening, already described, gives passage to the aorta, thoracic duct,

and large azygos vein. In front of this and higher up is an opening which transmits the œsophagus and pneumogastric nerves. Still higher and to the right is a third large aperture, devoted to the vena cava. Besides these great perforations are a number of small holes, which transmit nerves and vessels.

The diaphragm is higher on the right side over the liver, and its upper surface is somewhat indented at the front central part, beneath the heart. Its nerve-supply is mainly from the phrenics.

When the diaphragm contracts, its arch is flattened, and thus the vertical capacity of the chest is increased.

Intercostales Externi (Fig. 400).—"The external between-the-ribs muscles," the muscles in the outer layer between the ribs. Their number corresponds to that of the intercostal spaces. They generally extend from the tuberosities of the ribs to the junction of the cartilages; the remainder of each space is occupied by a fibrous membrane. A similar membrane lines the muscles from the angles of the ribs backward. Each muscle arises from the lower border of a rib, runs downward and forward, and is inserted into the upper border of the rib next below. Their action lifts the ribs. Their nerves are the intercostal.

Intercostales Interni (Fig. 400).—"The internal between-the-ribs muscles." Their number is that of the intercostal spaces. They occupy these spaces from the sternum to the angles of the ribs, and beyond these points fibrous membranes fill the spaces. Each muscle arises on the inner surface of a rib and its cartilage, just above its lower border, runs down- and backward, and is inserted into the inner surface of the rib just beneath. Their action is not agreed upon. The intercostal nerves supply them.

Levatores Costarum (Fig. 391, L. C.).—"The lifters of the ribs." They are twelve in number. Each is inserted into the outer surface of a rib, between its tuberosity and angle, and arises from the tip of the transverse process of the vertebra immediately above. A few of those which are lowest in the series have each an insertion also into a rib beyond that proper to itself. The name of these muscles indicates their supposed action—elevation of the ribs; but it is probable that, instead of this, they contribute to the extension and lateral flexion of the thoracic part of the vertebral column. They are supplied by the intercostal nerves.

Triangularis Sterni.—"The triangular muscle of the sternum." *Synonym*, transversus thoracis anterior, "the front transverse muscle of the chest." *Situation*, on the inner side of the thoracic cage in front. *Origin*, the ensiform appendix, the lower part of the gladiolus, and the cartilages of the lower two or three true ribs. *Direction*, partly horizontal, partly oblique, partly nearly vertical. *Insertion*, the outer extremities of the costal cartilages from the second to the sixth. *Action*, depression of the ribs, to whose cartilages it is attached. *Nerves*, the intercostal.

Subcostales.—"The under-the-ribs muscles." *Synonym*, infracostales, "the beneath-the-ribs muscles." These are small, inconstant muscles, found usually near the angles of the ribs, on the inner surface of these bones, and extending over two intercostal spaces. Their direction is down- and backward, and their nerves, the intercostal. Their action, which must be very insignificant, is not yet determined.

THE MUSCLES OF THE NECK.

A number of the muscles in the neck have already been considered in connection with those of the back, the continuity of tissue or the close functional relation between the former and the latter making this arrangement most convenient in all cases, and inevitable in others.

There remain for study those muscles which are located in the ventral and lateral portions of the neck.

MUSCLES OF THE FRONT AND SIDE OF THE NECK.

Superficial.

Platysma.
Sterno-cleido-mastoideus.

Infrahyoid.

Sterno-hyoideus.
Omo-hyoideus.
Sterno-thyroideus.
Thyro-hyoideus.

Suprahyoid.

Digastricus.
Stylo-hyoideus.
Mylo-hyoideus.
Genio-hyoideus.

Deep Lateral.

Scalenus anterior.
Scalenus medius.
Scalenus posterior.
Rectus capitis lateralis.

Prevertebral.

Rectus capitis anterior major.
Rectus capitis anterior minor.
Longus colli.

Platysma (Fig. 401).—"The broad sheet muscle." *Synonym*, platysma myoides, "the muscle-like sheet." *Situation*, in the front and side of the neck, and the lower part of the side of the face. *Origin*, the skin and areolar tissue covering the upper part of the pectoralis major, deltoideus, and trapezius, and, sometimes, the scapula and clavicle. *Direction*, upward and inward. *Insertion*, the outer surface of the mandible as far back as the masseter, and the muscular structures about the angle of the mouth and lower lip. Some fibres cross to the opposite side. *Action*: it draws the angle of the mouth and the lower lip downand outward, and contracts the skin of the neck. *Nerve*, the facial.

Sterno-cleido-mastoideus (Fig. 402).—"The sternum-clavicle-mastoid-process muscle." *Synonym*, sterno-mastoideus. *Situation*, in the side of the neck. *Origin*, the front of the manubrium and inner third of the clavicle. *Direction*, upward and backward. *Insertion*, the mastoid process of the temporal, and the outer half of the superior curved line of the occipital. An interval exists between the sternal and clavicular origins. The muscle divides the lateral area of the neck into two triangles. *Action*: it draws the head toward the shoulder, and rotates the face toward the opposite side. When the two muscles act, the head is extended.

Sterno-hyoideus (Fig. 403).—"The sternum-hyoid-bone muscle." *Situation*, in the front of the neck. *Origin*, the back of the manubrium, and inner end of the clavicle. *Direction*, upward. *Insertion*, the body of the hyoid. *Action*, depression of the hyoid. *Nerve*, the hypoglossal.

Omo-hyoideus (Figs. 402, 403).—"The shoulder-hyoid-bone muscle." *Situation*, the upper part of the shoulder and the front of the neck. *Origin*, the scapula, near the suprascapular notch. *Direction*, forward and inward to behind the sterno-cleido-mastoid, and then upward and a little inward. *Insertion*, the body of the hyoid. This is a slender, double-bellied muscle. The middle tendon is held down by a loop of deep fascia, which is attached below to the sternum and cartilage of the first rib. *Action*, depression of the hyoid. *Nerve*, the hypoglossal.

Sterno-thyroideus (Fig. 403).—"The sternum-thyroid-cartilage muscle." *Situation*, the front of the neck, behind the sterno-hyoid. *Origin*, the back of the manubrium, and cartilage of the first rib. *Direction*, upward. *Insertion*, the oblique line on the ala of the thyroid cartilage. *Action*, depression of thyroid cartilage. *Nerve*, the hypoglossal.

Thyro-hyoideus (Fig. 403).—"The thyroid-cartilage-hyoid-bone muscle." *Situation*, in the front of the neck. *Origin*, the oblique line on the ala of the thyroid cartilage. *Direction*, upward. *Insertion*, the body and great cornu of the hyoid. *Action*, depression of the hyoid; by reversed action, elevation of the thyroid cartilage. *Nerve*, the hypoglossal.

Digastricus (Figs. 402, 403).—"The two-bellied muscle." *Situation*, the uppermost part of the side of the neck. *Origin*, the digastric fossa of the temporal. *Direction*, forward, inward, and downward, then forward, downward, and slightly inward. *Insertion*, the mandible, at its lower border near the symphysis. The tendon between the bellies is held down to the hyoid bone by a fibrous loop and the stylo-hyoid muscle, and the change in direction is effected at this point.

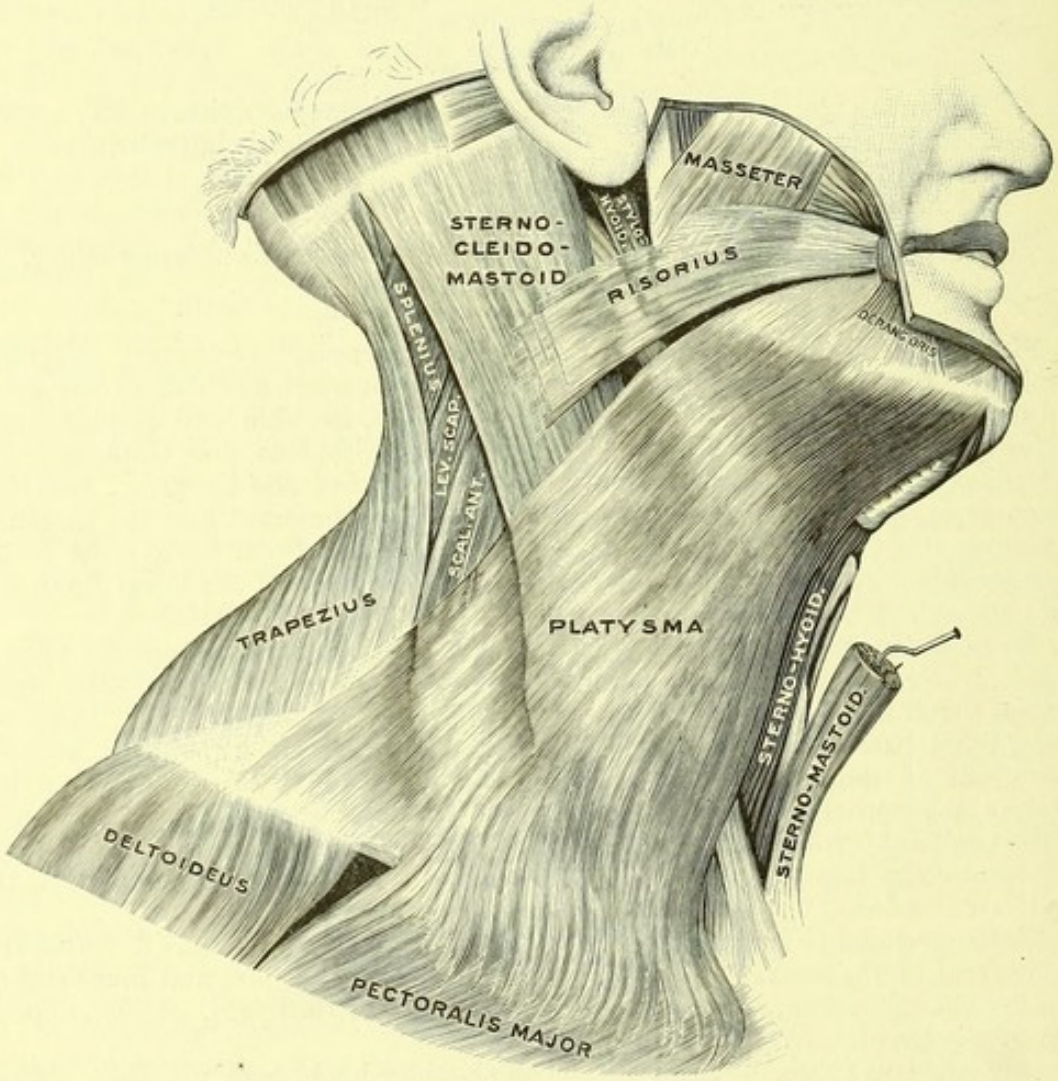

FIG. 401.—Superficial muscles of side of neck. (Testut.)

Action, elevation of the hyoid, if the mandible is fixed; depression of the mandible, if the hyoid is fixed. *Nerves*, the facial for the hind belly, the inferior maxillary division of the trifacial for the front belly.

Stylo-hyoideus (Fig. 402).—"The styloid-process-hyoid-bone muscle." *Situation*, in the uppermost part of the side of the neck, along the upper border of the hind belly of the digastricus. *Origin*, the root of the styloid process of the temporal. *Direction*, down- and forward. *Insertion*, the hyoid. Near its insertion it is perforated by the digastricus. *Action*: it lifts the hyoid, and pulls it backward and sidewise. *Nerve*, the facial.

Mylo-hyoideus (Fig. 402).—"The molar-teeth-hyoid-bone muscle," so-called

from its attachments near the molars of the lower jaw and to the hyoid bone. *Situation*, in the floor of the mouth. *Origin*, the mylo-hyoid ridge of the mandible. *Direction*, down-, back-, and inward. *Insertion*, behind to the hyoid, in the middle line to its fellow opposite. *Action*: it lifts and advances the hyoid and the floor of the mouth. *Nerve*, the inferior maxillary division of the trifacial.

Genio-hyoideus (Fig. 403).—"The chin-hyoid-bone muscle." *Situation*, in the floor of the mouth, above the mylo-hyoideus. *Origin*, the lower genial tubercle.

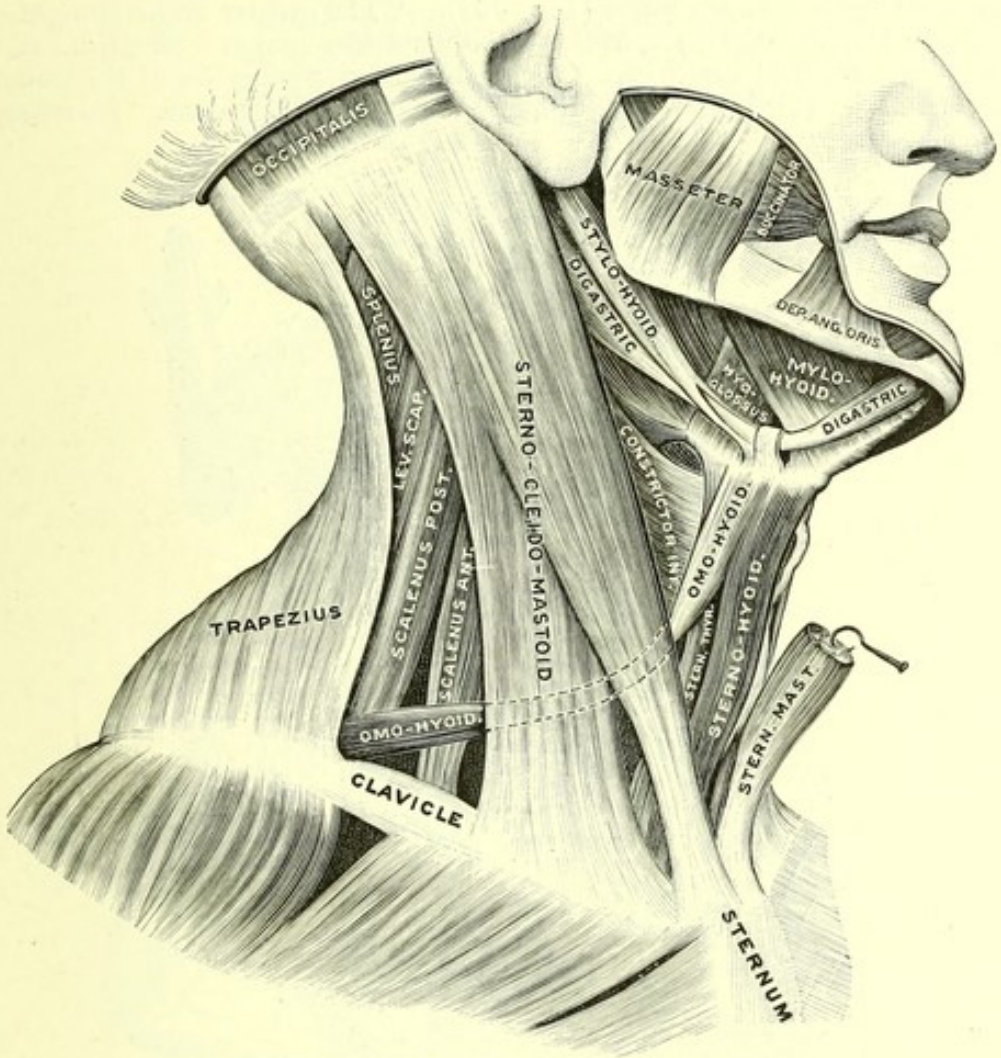

FIG. 402.—Muscles in front and side of neck. (Testut.)

Direction, backward and a little downward. *Insertion*, the body of the hyoid. *Action*: it lifts and advances the hyoid. *Nerve*, the hypoglossal.

Scalenus Anterior (Fig. 404).—"The front scalene muscle"—*i. e.*, triangular with unequal sides. *Situation*, deep in the side of the neck. *Origin*, the anterior tubercles of the transverse processes of the third, fourth, fifth, and sixth cervical vertebræ. *Direction*, down-, out-, and forward. *Insertion*, the tubercle on the upper surface of the first rib. *Action*, elevation of the first rib. *Nerves*, the neighboring cervical.

Scalenus Medius (Fig. 404).—"The middle scalene muscle." *Situation*, deep in the side of the neck. *Origin*, the posterior tubercles of the transverse processes of all of the cervical vertebræ. *Direction*, down-, out-, and forward. *Insertion*, the upper surface of the first rib. *Action*, elevation of the first rib. *Nerves*, the neighboring cervical.

Scalenus Posterior (Fig. 404).—"The hind scalene muscle." *Situation*, deep in the side of the neck. *Origin*, the posterior tubercles of the transverse processes of the lower two or three cervical vertebræ. *Direction*, down-, out-, and forward. *Insertion*, the outer surface of the second rib. *Action*, elevation of the second rib. *Nerves*, the neighboring cervical.

Rectus Capitis Lateralis (Fig. 404).—"The side straight muscle of the head." *Situation*, the side of the highest part of the neck. *Origin*, the transverse process of the atlas. *Direction*, upward. *Insertion*, the jugular process of the occipital. *Action*, tilting the head sidewise. *Nerve*, the first cervical.

Rectus Capitis Anterior Major (Fig. 404).—"The greater front straight muscle of the head." *Synonym*, rectus capitis anticus major. *Situation*, in front of the upper cervical vertebræ. *Origin*, the anterior tubercles of the transverse processes of the third, fourth, fifth, and sixth cervical vertebræ. *Direction*, up-

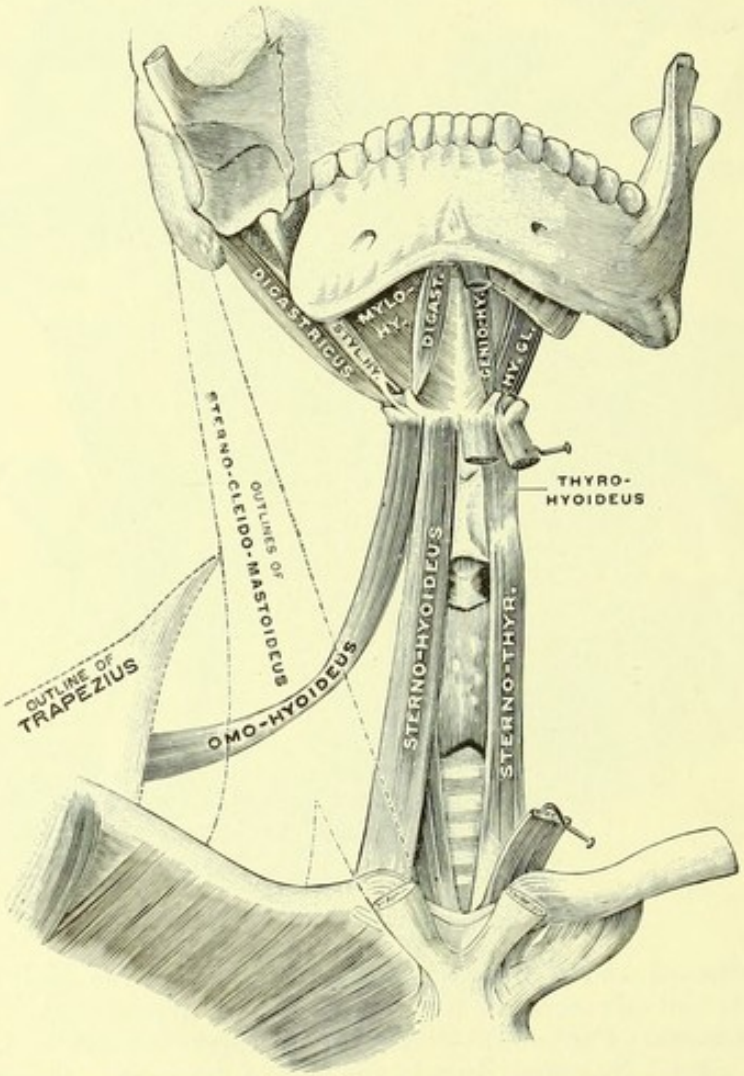

FIG. 403.—Infrahyoid and suprahyoid groups of muscles. (Testut.)

and inward. *Insertion*, the basilar process of the occipital. *Action*, flexion of the head on the spine. *Nerves*, the neighboring cervical.

Rectus Capitis Anterior Minor (Fig. 404).—"The smaller front straight muscle of the head." *Synonym*, rectus capitis anticus minor. *Situation*, between the atlas and occipital bone in front. *Origin*, the front of the transverse process of the atlas. *Direction*, up- and inward. *Insertion*, the basilar process of the occipital. *Action*, flexion of the head. *Nerve*, the first cervical.

Longus Colli (Fig. 404).—"The long muscle of the neck." *Situation*, in front of the cervical and upper thoracic vertebræ. *Division*, into three parts: the vertical or middle, the lower oblique, and the upper oblique. The *vertical part* arises from the bodies of the last two cervical and two or three thoracic vertebræ, and the transverse processes of the last three or four cervical, and is inserted into the bodies of the second, third, and fourth cervical. The *lower oblique part* arises from the bodies of the upper two or three thoracic vertebræ, and is inserted

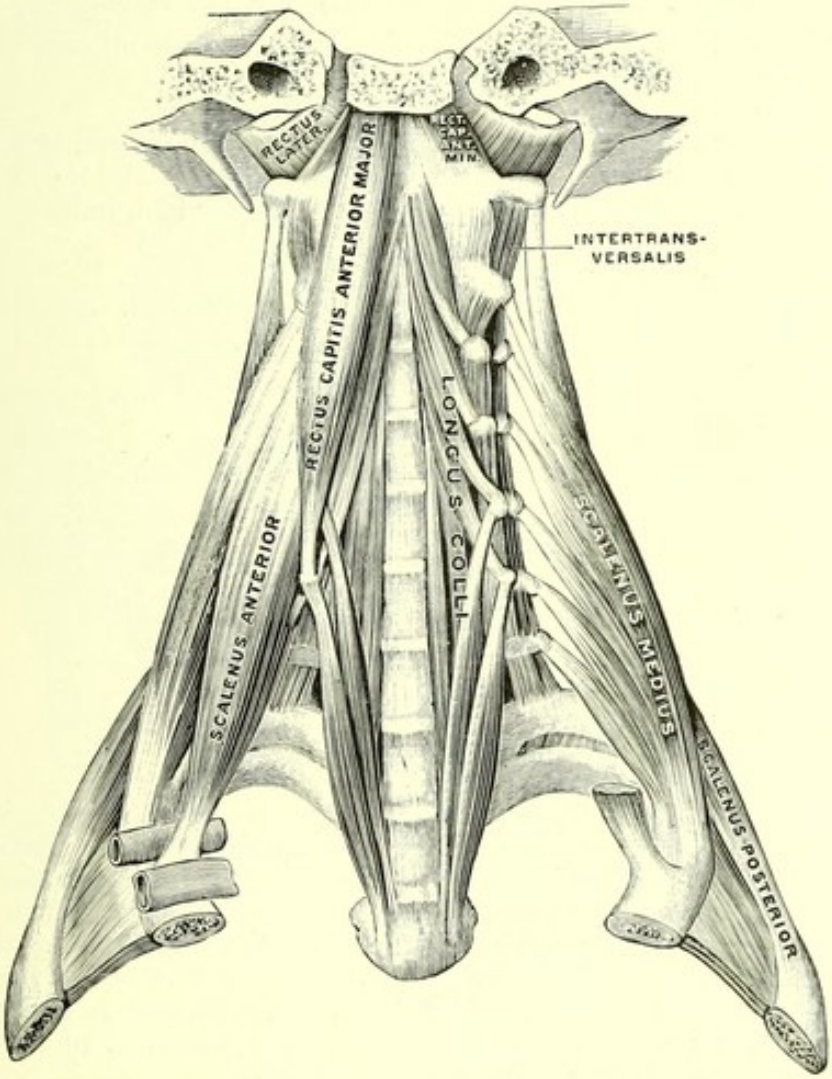

FIG. 404.—Deep lateral and prevertebral muscles of the neck. (Testut.)

into the anterior tubercles of the transverse processes of the fifth and sixth cervical. The *upper oblique part* arises from the anterior tubercles of the transverse processes of the third, fourth, and fifth cervical vertebræ, and is inserted into the anterior tubercle of the atlas. *Action*, mostly, flexion of the neck; also, rotation. *Nerves*, the neighboring cervical.

THE MUSCLES OF THE HEAD.

In the head are many muscles which are most conveniently treated of in connection with certain special organs, as the tongue, palate, pharynx, eye, and ear. In this place, therefore, there will be considered only the superficial muscles.

SUPERFICIAL MUSCLES OF THE HEAD.

Muscles of Mastication.

Masseter.
Temporalis.
Pterygoideus internus.
Pterygoideus externus.

Muscles of Expression.

1. *Muscles Affecting the Orifice of the Mouth.*

Orbicularis oris.
Levator labii superioris alæque nasi.
Levator labii superioris proprius.
Zygomaticus minor.
Zygomaticus major.
Levator anguli oris.
Risorius.
Buccinator.
Depressor anguli oris.
Depressor labii inferioris.
Levator labii inferioris.

2. *Muscles of the Nose.*

Pyramidalis nasi.
Compressor naris.
Levator labii superioris alæque nasi.
Depressor alæ nasi.

3. *Muscles of the Lids.*

Orbicularis palpebrarum.
Tensor tarsi.
Levator palpebræ.

4. *Muscles of the Forehead.*

Corrugator supercilii.
Frontalis.

5. *Muscle of the Occiput.*

Occipitalis.

The Muscles of Mastication.

Masseter (Figs. 407, 402).—"The chewing-muscle." *Situation*, in the back part of the side of the face. It consists of two portions, the superficial and the deep, which blend at their insertion. The *superficial portion* arises from the lower margin of the anterior two-thirds of the zygoma, passes down- and backward, and is inserted on the outside of the lower half of the ramus of the mandible. The *deep portion* arises from the entire inner surface and the hind third of the lower border of the zygoma, passes downward, and is inserted into the upper half of the ramus of the mandible. *Action*, elevation of the lower jaw. *Nerve*, the inferior maxillary division of the trifacial.

Temporalis (Fig. 405).—"The temple muscle." *Situation*, in the temporal fossa. *Origin*, the entire temporal fossa, except the anterior wall. *Direction*, downward. *Insertion*, the coronoid process of the mandible. *Action*, elevation of the lower jaw, and, when this has been drawn forward, its retraction. *Nerve*, the inferior maxillary division of the trifacial.

Pterygoideus Internus (Fig. 406).—"The internal pterygoid muscle," so-called from its position and origin. *Synonym*, the internal masseter. *Situation*, the inner side of the ramus of the mandible. *Origin*, the inner surface of the external pterygoid plate of the sphenoid, and the tuberosities of the palate and superior maxillary bones. *Direction*, down-, back-, and outward. *Insertion*, the inner side of the ramus of the mandible, between the angle and the dental foramen. *Action*, elevation of the lower jaw. When the jaw is closed, the muscle draws it forward. *Nerve*, the inferior maxillary division of the trifacial.

Pterygoideus Externus (Fig. 406).—"The external pterygoid muscle," named from its position and origin. *Situation*, in the zygomatic fossa. *Origin*, by two

heads : the upper head, the zygomatic surface of the great wing of the sphenoid ; the lower head, the outer surface of the external pterygoid plate. *Direction*, out- and backward. *Insertion*, the neck of the mandible, and the interarticular fibro-

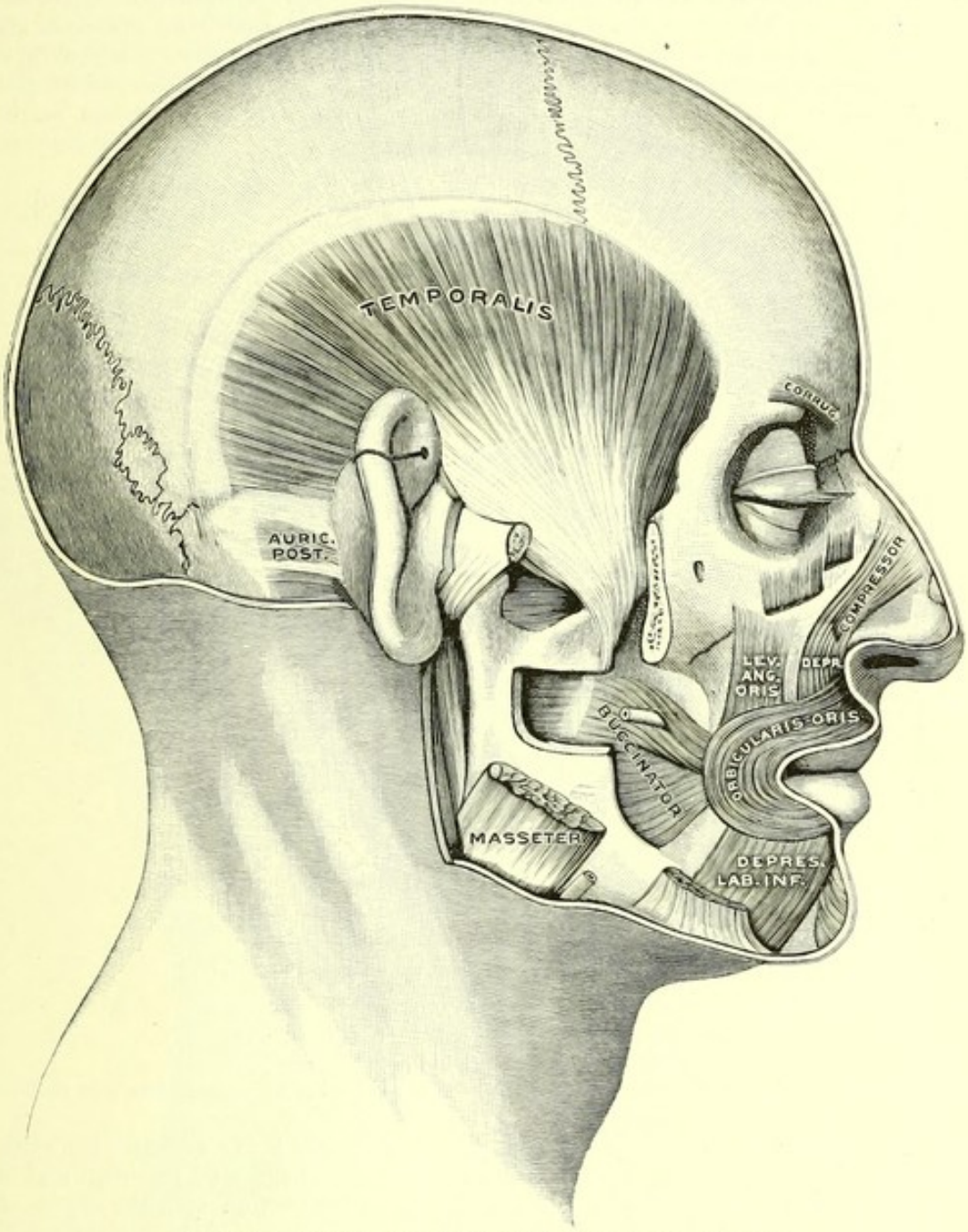

FIG. 405.—Temporal and deep muscles about the mouth. (Testut.)

cartilage of the temporo-mandibular joint. *Action* : it draws the condyle of the mandible and the interarticular cartilage forward and inward. *Nerve*, the inferior division of the trifacial.

The Muscles of Expression.

The muscles of expression are sometimes called "the mind muscles," from the indications which they may afford of the mental state of the individual. The majority of them are small, often poorly defined, and so blended with each other and the skin that their dissection is frequently difficult and unsatisfactory. They

are all supplied by the facial nerve. It is helpful to group them according to their situation into those related to the orifice of the mouth, those of the nose, those of the eyelids, those of the forehead, and that of the occiput. Besides these are others, which, in a secondary though important way, contribute to expression. The muscles which move the eyes are very effective in betraying emotion, and the muscular tongue, usually concealed in the oral cavity, may, either with or without partial protrusion from its retreat, be made to convey as distinct an idea as can be given by articulate speech. Even the muscles of the pinna might, without unwarrantable stretch of terms, be included in this group, since they are

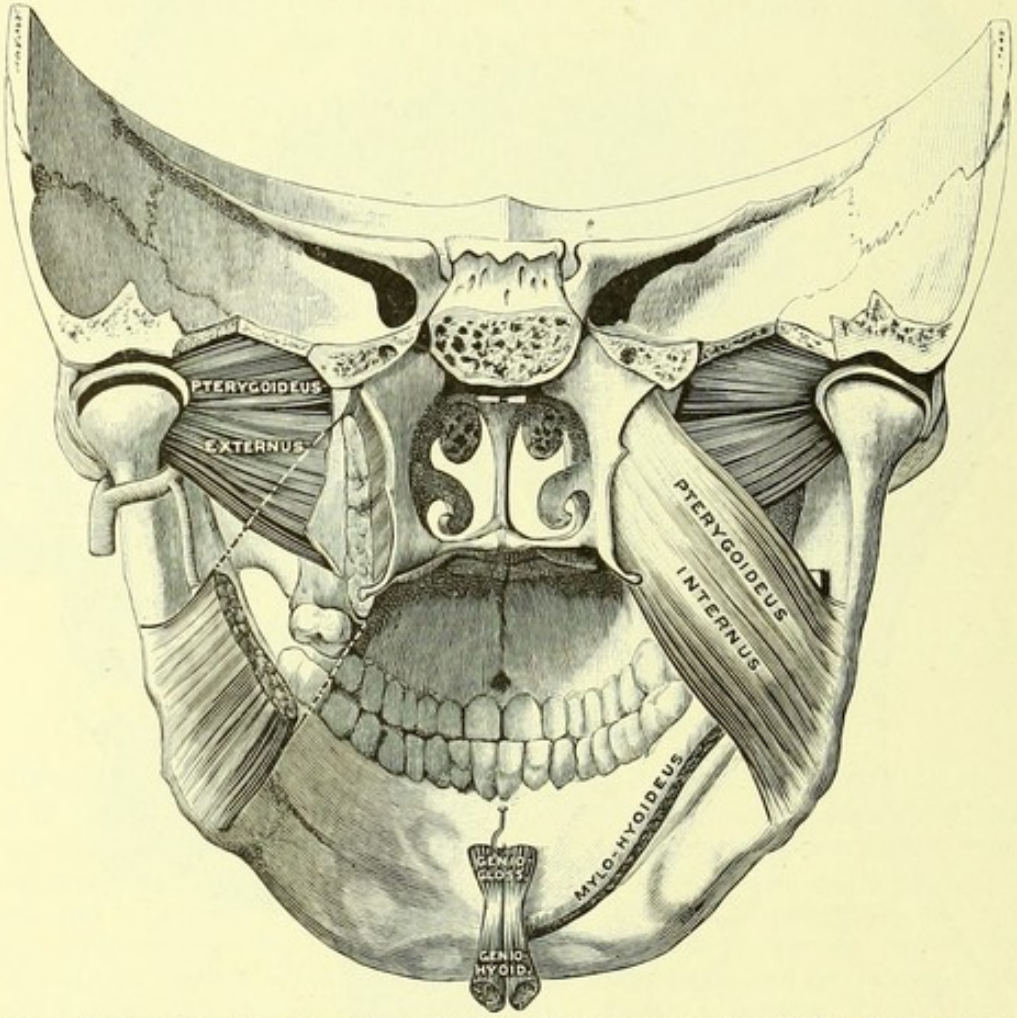

FIG. 406.—Pterygoid muscles, viewed from behind, the back portion of the skull having been removed. (Testut.)

the rudimentary homologues of organs, which, in many lower animals, are strikingly useful in expressing various feelings. But the muscles of the orbit and of the external ear are treated more appropriately in connection with the organs of the special senses; and those of the tongue are best presented, in company with the palatal and pharyngeal, as parts of the alimentary system, just as the laryngeal are discussed most conveniently with the respiratory system, and the perineal with the generative system.

MUSCLES AFFECTING THE ORIFICE OF THE MOUTH.

Orbicularis oris.
Levator labii superioris alæque nasi.
Levator labii superioris proprius.
Zygomaticus minor.
Zygomaticus major.
Levator anguli oris.
Risorius.
Buccinator.
Depressor anguli oris.
Depressor labii inferioris.
Levator labii inferioris.

Orbicularis Oris (Fig. 407).—"The orbicular muscle of the mouth"—that is, encircling the oral orifice. Surrounding the opening of the mouth, and extending from the nose above to the chin below, is an elliptical muscle, which forms a great part of the bulk of the lips, and constitutes a sphincter to the aperture. It does not, however, consist of concentric bundles of fibres, but is made up very largely of prolongations from various muscles of the face, which converge to its margin. It is attached above to the partition between the nostrils and to the incisor fossæ

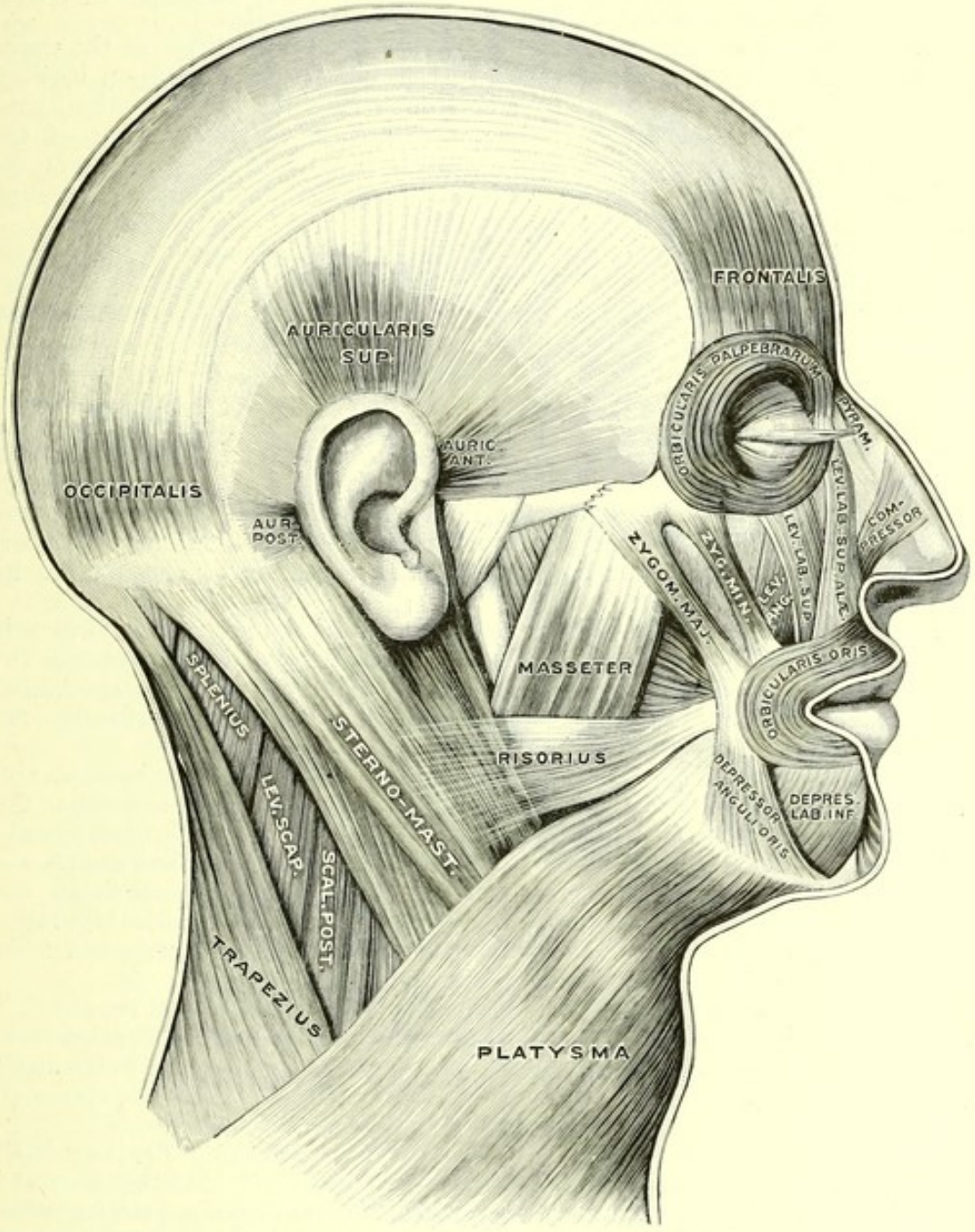

FIG. 407.—Superficial muscles of head and neck. (Testut.)

of the upper jaw-bones, and below to the incisor fossæ of the mandible. It is covered in front by skin, behind and on its free border by mucous membrane. The action of this muscle is to close the lips and press them against the teeth. It antagonizes all of the remaining members of this group, except the levator labii inferioris.

The nine following muscles arise from structures, principally osseous, in the face, converge to the margin of the orbicularis, and are either inserted into it or the skin covering it. Six are close to the surface, and three are more deeply situated. All of them by their action oppose that of the orbicularis, and in various directions enlarge the opening of the mouth.

Levator labii superioris alæque nasi (Fig. 407), "the lifter of the upper lip and of the wing of the nose," arises from the nasal process of the superior maxillary bone, passes downward and outward, and is inserted partly into the wing of the nose, partly into the orbicularis. Its name describes its action.

Levator labii superioris proprius (Fig. 407), "the proper lifter of the upper lip," the last word of the name being used to emphasize the distinction between this and the preceding muscle, which does other than the special work of this. It arises just above the infra-orbital foramen and the neighboring part of the malar bone, runs downward and inward, and is inserted into the margin of the orbicularis and the skin of the lip. It raises the part of the lip near the median line.

Zygomaticus minor (Fig. 407), "the smaller zygomatic muscle." The name implies attachment to the zygoma, but was unwisely given on account of its nearness to a muscle which somewhat merits the title zygomatic. It arises from the front and lower part of the malar bone, and is inserted into the orbicularis and the skin, just outside of the levator labii superioris proprius. It raises and draws outward the upper lip.

Zygomaticus major (Fig. 407), "the larger zygomatic muscle," arises from the malar near its zygomatic suture, passes downward and inward, and is inserted into the skin at the angle of the mouth. It draws the angle upward and outward.

Levator anguli oris (Fig. 405), "the lifter of the angle of the mouth," arises below the infra-orbital foramen, passes downward, and is inserted into the orbicularis and the skin near the corner of the mouth. Its name implies its action.

Risorius (Figs. 401, 407).—The name means "the laughing muscle," but it is not descriptive. The muscle extends from the fascia over the masseter to the skin and orbicularis at the angle of the mouth. It is regarded as a specialized part of the platysma. It draws the mouth outward horizontally, widening the cleft.

Buccinator (Fig. 405), "the trumpeter's muscle," arises from the back part of the outer surface of the alveolar processes of both jaw-bones, and from the pterygo-maxillary ligament. Its different parts converge to the angle of the mouth, and there blend with the orbicularis. It pulls the angle outward, and compresses the contents of the vestibule of the mouth. If the cheek bulges with air, the buccinator presses it out, measurably regulating its expulsion, as in blowing a horn (hence the name); and it keeps the mass of food during mastication from escaping outward from the grasp of the molar teeth.

Depressor Anguli Oris (Fig. 407).—"The depressor of the angle of the mouth." *Synonym*, triangularis menti, "the triangular muscle of the chin." It arises from the external oblique line of the mandible, passes upward, converging to the angle of the mouth, where it blends with the orbicularis. It pulls down the corner of the mouth.

Depressor Labii Inferioris (Figs. 405, 407).—"The depressor of the lower lip." *Synonym*, quadratus menti, "the square muscle of the chin." It arises from the mandible, from near the symphysis to beyond the mental foramen, passes upward and inward, and merges with the orbicularis. It draws the lower lip downward and slightly outward.

Levator Labii Inferioris.—"The lifter of the lower lip." *Synonym*, levator menti, "the lifter of the chin." It arises from the incisor fossa of the mandible, passes downward, and is inserted into the skin of the chin. It differs from the other muscles which act upon the oral aperture in not participating in the structure of the lips or cheeks, and in not antagonizing the orbicularis; but, while its

force is primarily directed to the chin, which it elevates, its practical effect is to lift the lower lip, which is carried upward by the movement of the chin, and made to protrude. Thus, it assists the lower half of the orbicularis, helping to close the opening and hold it tightly.

In the play of the features which the muscles about the mouth produce they almost always act in pairs, and one pair rarely acts alone. This is illustrated in the display of the opposite emotions of mirth and grief. In the former the lifters of the angles and the zygomatics draw the corners upward and outward, the risorii widen the aperture still more, and the lifters of the upper lip pull it upward. In the latter the depressors of the angles drag downward the corners of the mouth, the risorii widen the slit, and the lifters of the upper lip draw it upward. In both of these cases it will be observed that the transverse crevice of the mouth is widened, the upper lips are elevated, uncovering the front upper teeth, and the angles of the mouth are drawn outward. By this last procedure the cheeks are pulled upward, and a bulging forward of the structures under the orbits and a partial closure of the lower lids are thus produced. The main difference, then, between the facial manifestation of joy and that of sorrow consists in the up-and-down movements of the angles of the mouth. The risorius does not deserve the name of the laughing muscle as well as does the zygomaticus major.

Muscles of the Nose.

Pyramidalis nasi.
Compressor naris.
Levator labii superioris alæque nasi.
Depressor alæ nasi.

Pyramidalis nasi (Fig. 407), "the pyramidal muscle of the nose," arises at the lower border of the nasal bone, passes upward, is inserted into the skin between the brows, and by its action draws this skin downward, producing a horizontal wrinkle. The fibres often seem to be continuous with the median portion of the frontalis.

Compressor Naris (Figs. 405, 407).—"The compressor of the nostril." *Synonyms*, compressor narium, "the compressor of the nostrils;" compressor nasi, "the compressor of the nose." It arises from the nasal bone and adjacent cartilage near the mid-line, passes downward and backward, and is inserted partly into the superior maxillary near the nasal opening, and partly into the levator labii superioris alæque nasi. It pulls inward the muscle to which it is attached, thus wrinkling the nose vertically; and it slightly compresses the nose.

Levator labii superioris alæque nasi has been described on page 346.

Depressor alæ nasi (Fig. 405), "the depressor of the wing of the nose," arises from the incisor fossa of the superior maxillary bone, passes upward and outward, and is inserted into the cartilage of the wing of the nose and into the septum. It draws the wing of the nose downward and inward.

Besides these muscles there are sometimes found two minute and indistinct bundles, which descend to the margin of the ala from the cartilages just above, and have been dignified by names which are descriptive of the slight action of these structures. They are *levator proprius alæ nasi anterior*, "the front proper lifter of the wing of the nose," otherwise called *dilatator naris anterior*, "the front widener of the nostril;" and *levator proprius alæ nasi posterior*, "the hind proper lifter of the wing of the nose," sometimes known as *dilatator naris posterior*, "the hind widener of the nostril." Finally, running from the cartilage of the wing to the skin at the tip of the nose is the inconstant and insignificant *compressor narium minor*, "the smaller compressor of the nostrils."

Muscles of the Forehead.

Corrugator supercilii.
Frontalis.

Corrugator supercilii, "the wrinkler of the brow," arises from the superciliary

ridge, passes outward and upward, and is inserted into the skin above the middle of the upper margin of the orbit. It draws the skin toward the middle line, causing vertical wrinkles in the central lower part of the forehead.

From the brows to the superior curved lines of the occipital bone the vault of the skull is covered by a musculo-membranous structure, which is by some anatomists regarded as a digastric muscle, the *occipito-frontalis*; but the contractile portions will here be described as separate organs, one as a muscle of the forehead, the other as a muscle of the occiput; and the intervening membrane as the epicranial aponeurosis. It will be well to consider the last before the others.

The *epicranial aponeurosis* is a wide, firm, fibrous sheet, running antero-posteriorly over the summit of the cranium, attached before to the frontalis muscle, behind to the occipitalis and the occipital protuberance. It is thickest near the middle, and very thin at the sides. It is closely adherent to the skin which covers it, but only loosely to the pericranium over which it lies.

Frontalis (Fig. 407), "the forehead muscle," arises from the anterior end of the epicranial aponeurosis, passes downward, and is inserted into the skin and muscles from the root of the nose to the outer end of the eyebrow. It elevates the brows, causing transverse wrinkling of the forehead.

Muscle of the Occiput.

Occipitalis (Fig. 407), "the occipital muscle," is situated at the back of the head. It arises from the outer two-thirds of the superior curved line of the occipital bone and the mastoid portion of the temporal, passes upward, and is inserted into the epicranial aponeurosis. It acts in direct line with the frontalis, and emphasizes its action—that is, the transverse wrinkles of the forehead caused by the frontalis are made more conspicuous when the occipitalis acts at the same time. Alternate contraction of these two muscles in some persons produces a fore-and-aft movement of the scalp. The occipitalis is a weak muscle, but what force it has is exerted in the direction of expression.

THE FASCIÆ.

By F. H. GERRISH.

THE word *fascia*, meaning literally a "band" or "bandage," is applied to fibrous, membranous expansions of greater or less density, which are wrapped around various organs, most conspicuously muscles, and serve to keep them in definite and intimate relation with one another. The term is also used to designate certain strong, fibrous sheets which are stretched between bony parts.

Fasciæ are conventionally divided into two groups or varieties—the superficial and the deep. These terms, however, convey very little useful information about the organs to which they are applied. Some members of each group are structurally indistinguishable from typical specimens of the other. The ground of distinction upon which the names are based is their situation; but one variety will frequently be found to shade off by almost imperceptible gradations into the other, even on the same plane. In their typical forms, however, the superficial fascia is a loose, extensible structure; the deep fascia is firm, strong, and inextensible.

THE SUPERFICIAL FASCIA.

Immediately beneath the skin in almost every part of the body is a continuous layer of areolar tissue, which is called the *superficial fascia*. In most cases it differs in no essential respect from the areolar tissue in other localities: it contains fat-cells, it furnishes a suitable medium for the lodgement of vessels and nerves on their way to and from various organs, and it both connects and separates structures between which it is interposed—always the skin on one surface, and usually the deep fascia on the other. It varies greatly in thickness, in some places being extremely thin and delicate, and in others very thick and large-meshed, the belly and buttock furnishing striking illustrations of the latter condition. Though it usually permits free movement of the skin on the subjacent parts, there are notable exceptions to the rule, as in the palm and sole, where it contains strong bands which lash down the skin tightly, and almost deprive it of mobility.

The superficial fascia is in some parts peculiarly modified: in the scrotum it contains no fat-cells, has mingled with its fibrous tissues a quantity of unstriped muscle, and is known as the *dartos*; in certain places it becomes condensed into a fibrous film, as in the *cribriform fascia*, which is stretched across the saphenous opening. Sometimes it is directly continuous with the other (deep) fascia, the latter thinning out and gradually losing itself in the areolar tissue. Occasionally the superficial adheres to the deep along a line of considerable length, as on the thigh near the inguinal ligament, and thus a subcutaneous accumulation of fluid is steered off in a special direction, as would not be the case but for this peculiarity. Two distinct layers are found in certain situations, as on the front of the abdomen, and they may differ considerably in structure, the more superficial generally containing more fat-cells, the deeper being more condensed. The veins which

course through this tissue are in some situations large and conspicuous, as on the dorsum of the hand and foot. Other organs are located in it, of which the most notable is the mammary gland.

The occasions for calling this structure other than subcutaneous areolar tissue are very infrequent; and, as the name "fascia," unless limited by an adjective, is usually employed in surgical parlance to designate the deep fascia, it will be thus used in the remainder of this chapter, unless specific exception is made.

THE DEEP FASCIÆ.

The typical deep fasciæ are close sheets of fibrous tissue, in which the white variety exists in an almost unadulterated form. On account of this histological composition these fasciæ are pearly white, flexible, strong, and inelastic. Their structure and physical qualities immediately bring to mind the characteristics of ligaments and tendons, which have identical structure; and the suggestion is especially apt for the reason that some fasciæ are really interosseous ligaments, and a number are properly to be regarded as tendons. Moreover, the employment of the word "fascia" is ofttimes arbitrary, as, for example, in the case of the transversalis abdominis muscle, whose tendon of origin is almost always described as a layer of the lumbar fascia, and whose tendon of insertion is conventionally dubbed an aponeurosis, although in both situations the tendons are sheet-like expansions, which serve for the ensheathing of muscles.

In this connection it is interesting and useful for the student to observe anew the continuity of the fibrous membranes—ligaments, tendons, and fasciæ blending with periosteum, tendons and fasciæ serving as ligaments, tendons losing themselves in fasciæ, tendons of some muscles acting as fasciæ for other muscles, and so on.

THE FASCIÆ OF THE HEAD.

A structure which may fairly be included in this group is the *epicranial aponeurosis*, which has already been described in connection with the muscles of the region (page 348).

The Temporal Fascia.

The *temporal fascia* has its superior attachment on the upper temporal ridge, its inferior on both borders of the zygoma, splitting into two layers just before reaching this arch. It encloses the temporal muscle, and is partially covered by the epicranial aponeurosis, the orbicularis palpebrarum, attrahens aurem, and attolens aurem.

The Masseteric Fascia.

The *masseteric fascia* is directly continuous with the cervical fascia. It covers the masseter muscle, and ends above at the lower border of the zygoma. In front it is in part attached to the coronoid process and in part blends with the buccinator fascia. Traced backward it is found to cover the parotid gland, and this portion is often called the *parotid fascia*. From the hind part of the last named a fibrous band is given off, connecting the angle of the lower jaw-bone with the styloid process of the temporal, the *stylo-mandibular ligament*. (See outer cervical fascia.)

The Buccinator Fascia.

The *buccinator fascia* covers the buccinator muscle. Above and below it is attached to the alveolar processes of the jaw-bones, behind is continuous with the masseteric fascia, and in front gradually thins out into areolar tissue.

THE CERVICAL FASCIA.

The deep fascia of the neck is conveniently divided for description into three portions : the outer or superficial, the middle, and the inner or deep, all of which, however, are continuous (Fig. 408).

The Outer Cervical Fascia.

The *outer portion* forms a firm investment for the organs of the neck, its shape being suggestive of a hollow cylinder. Its upper limit extends from the

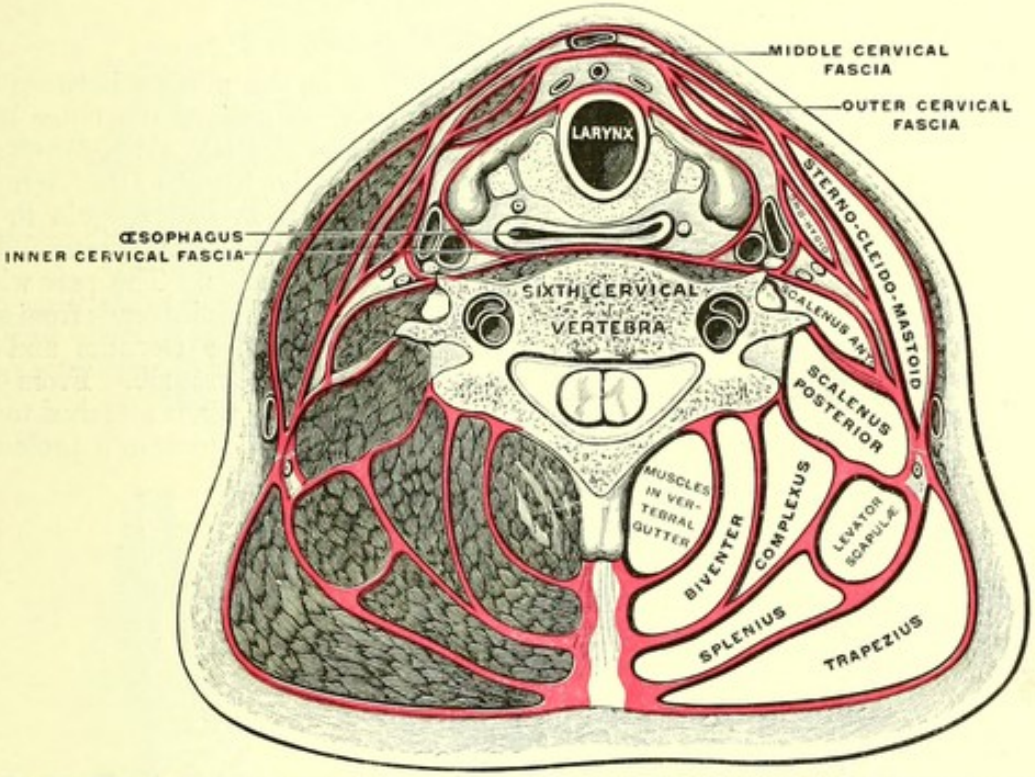

FIG. 408.—The cervical fascia, as seen in a horizontal section of the neck at the level of the sixth cervical vertebra. (Testut.)

external occipital protuberance to the lower part of the symphysis of the mandible, attaching itself to the series of skeletal prominences most nearly coinciding with a line drawn around the head and intersecting these points. Below it is fastened to the sternum, clavicle, acromion, and scapular spine, beyond the last named losing itself in the fascia of the back. Thus it includes, especially in its lower parts, somewhat more than the strict anatomical neck. It is attached behind to the ligamentum nuchæ, and in front it is continuous across the middle line. In its course around the side of the neck it splits twice, first embracing the trapezius, and then the sterno-mastoid, forming strong sheaths for these muscles. Traced from below upward in the region in front of the sterno-mastoid, it is found to be attached to the hyoid, from which it runs to its upper limit on the lower border of the mandible (Fig. 409). From the hyoid insertion it sends to the internal oblique line of the mandible a lamella, which lines the

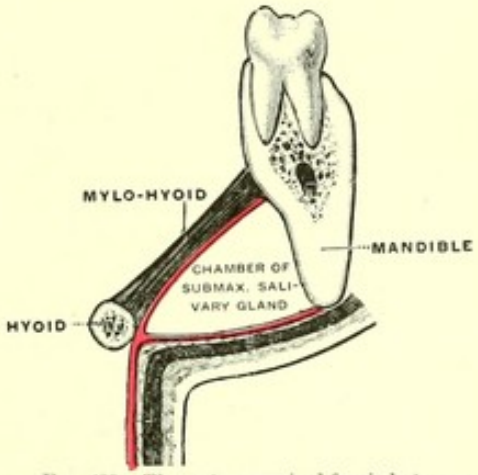

FIG. 409.—The outer cervical fascia between the hyoid and mandible. (Testut.)

under surface of the mylo-hyoid muscle. Thus it may be said that the fascia splits at the hyoid, and encloses between its two lamellæ a space, which is triangular in vertical section, and forms a chamber occupied by the submaxillary salivary gland. Below and in the middle line in front the fascia separates into two layers, one going to the anterior, the other to the posterior border of the top of the manubrium (Fig. 410). From the front of the portion of the fascia which forms a sheath for the sterno-mastoid, and where it is continuous with the masseteric fascia, a prolongation is given off forward and inward, is attached to the angle of the lower jaw, passes behind the parotid gland, and ends by insertion into the styloid process of the temporal, forming thus the *stylo-mandibular ligament.*

The Middle Cervical Fascia.

The *middle portion* of the cervical fascia—that is, the portion between the superficial and deep layers—lies close behind the front part of the outer layer (Figs. 410, 411), arching between the omo-hyoids of the two sides, forming a sheath for each of them, and extends vertically from the hyoid to the sternum, and laterally from one scapula to the other, its side borders corresponding with the omo-hyoids. The part which ensheathes these muscles sends from each a band down to the sternum and the cartilage of the first rib. From the point where the fascia is attached to the middle line of the sternum a prolonga-

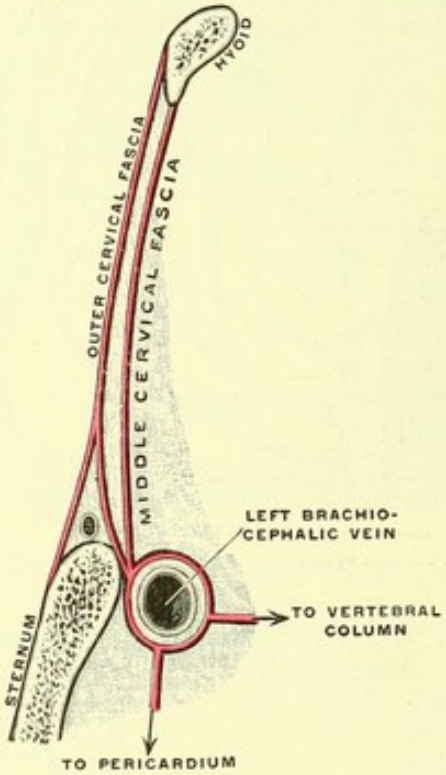

Fig. 410.—The cervical fascia between the hyoid and sternum. (Testut.)

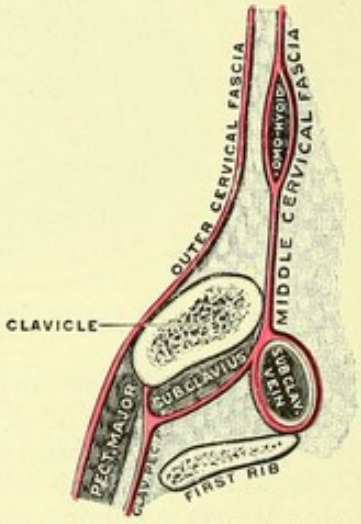

Fig. 411.—The cervical fascia in the clavicular region. (Testut.)

tion of it encircles the left brachio-cephalic vein (Fig. 410), and then passes down into the thorax and blends with the pericardium. On each side it is fastened to the clavicle, gives off expansions which encase the subclavian vein, and then are attached to the first rib and become continuous with the neighboring fasciæ (Fig. 411). A continuation of the middle layer enters into the formation of the sheath of the axillary vessels and nerves. Prolongations also are sent inward and furnish the neck muscles with sheaths; for the most part, however, these processes have not the firmness of the main layer, but are areolar in character.

The Inner Cervical Fascia.

The *inner* or *deep layer* of the cervical fascia, known also as the *prevertebral*, is continuous with the middle portion at the sheaths of the carotid arteries and internal jugular veins. It is attached above to the basilar process of the occipital bone, at the sides to the transverse processes of the cervical vertebræ, and below

gradually thins out and merges into the areolar tissue of the posterior mediastinum. In front of it are the pharynx and œsophagus, behind it the prevertebral muscles.

Peculiar interest attaches to these different portions of the cervical fascia on account of their influence upon the direction which accumulations of fluid will take when occurring in this region (Fig. 412). Fluid in front of the outer layer

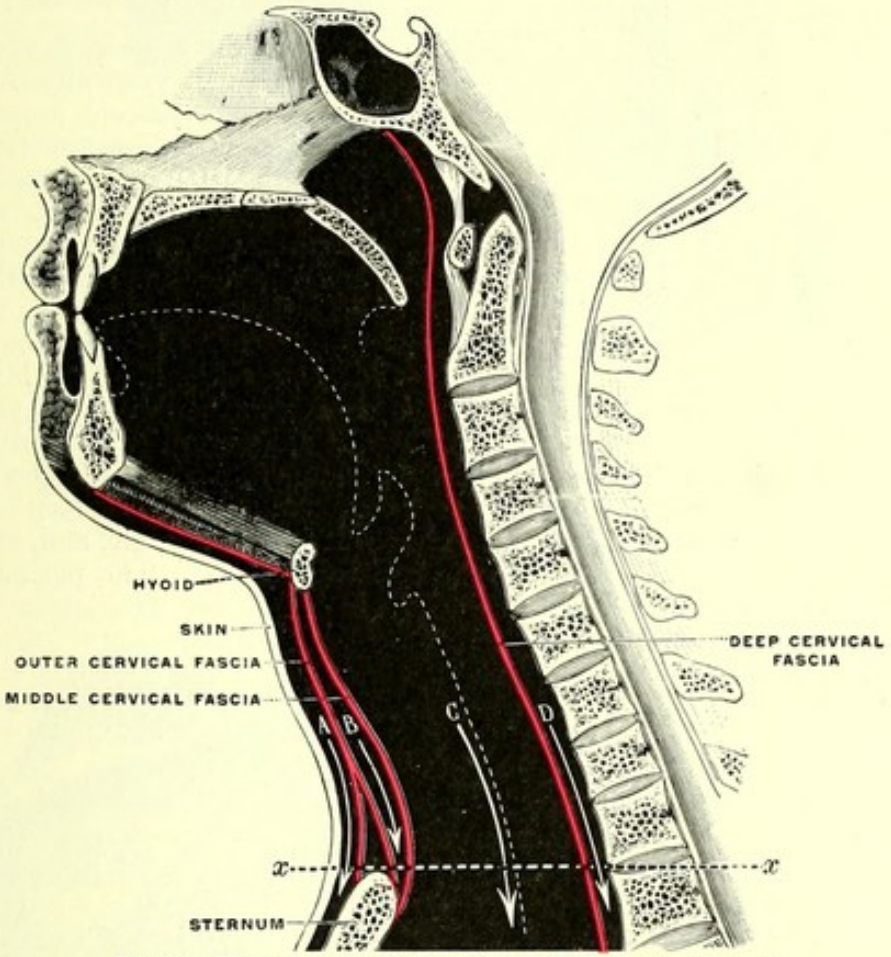

FIG. 412.—The cervical fascia as seen in sagittal section. (Testut.)

is confined to the subcutaneous region; between the outer and middle layers is kept from descending by the sternum; between the middle and inner or prevertebral is guided into the pharynx and œsophagus, or possibly into the larynx; and behind the last layer may be steered into the mediastinum.

THORACIC FASCIA.

This name, though often limited to the fascia of the pectoralis major, is much more fittingly applied to the entire series of fasciæ of the antero-lateral region of the chest, and is here employed in this sense.

The Pectoral Fascia.

The *pectoral fascia* (Fig. 413), thin and weak, covers the pectoralis major, and its attachments coincide with the margins of origin of this muscle. It turns around the lower border of the muscle and spreads upward over the hind surface. At the line where it makes the bend it is continuous with the true *axillary fascia*, a thick, strong membrane, which crosses the base of the armpit, describing an arch in its course, unites with the fascia which encases the latissimus, and through

this last becomes attached to the spines of the thoracic vertebræ. At its outer side the axillary fascia merges with the sheath of the vessels and is continuous with the fascia of the arm; it is also connected with the fascia of the shoulder.

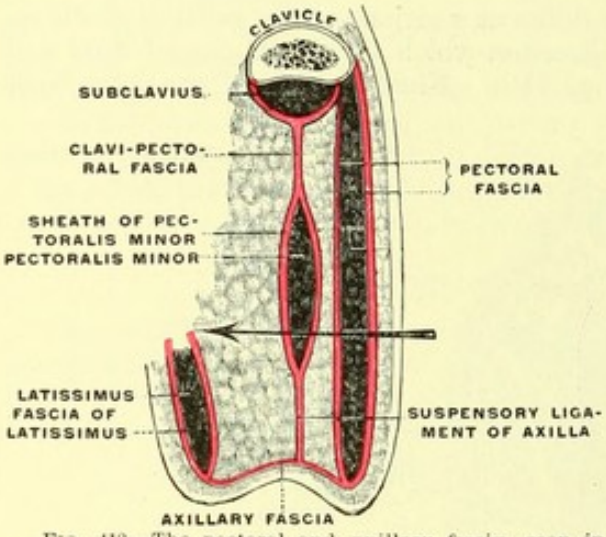

FIG. 413.—The pectoral and axillary fasciæ, seen in sagittal section. (Testut.)

The Clavi-coraco-axillary Fascia.

This is a quadrilateral sheet which runs vertically from the clavicle and coracoid process above to the fascia of the armpit below, and lies just behind the pectoralis major (Fig. 414). It has a double attachment to the clavicle, one layer being in front, the other behind, and between them is lodged the subclavius, to which they furnish a strong sheath. The hind layer is continuous with the sheath of the axillary vessels, which extends downward from the cervical fascia. In the middle of its course the clavi-coraco-axillary fascia splits and closely embraces the pectoralis minor between its layers. From the lower (outer) border of this muscle it is again single, and, extending outward, unites with the sheath of the coraco-brachialis. The portion of the fascia above the pectoralis minor, being fastened internally to the first rib, is named the *costo-coracoid membrane* and *clavi-pectoral fascia*. The uppermost part of it is the strongest, and is called the *costo-coracoid ligament*. The portion of the fascia between the pectoralis minor and the coraco-brachialis is triangular, its apex being at the coracoid process, its base at the lowest part of the axilla. It serves to preserve the hollow of the armpit, and has, consequently, been named the *suspensory ligament of the axilla*.

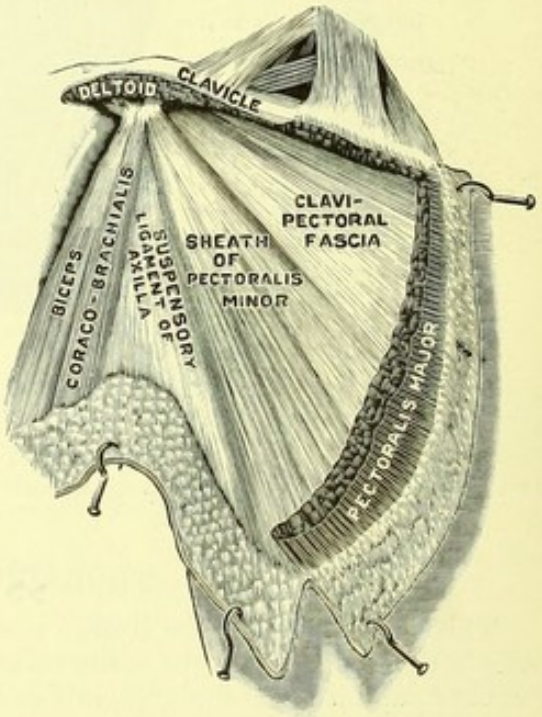

FIG. 414.—The clavi-coraco-axillary fascia of right side, front view. (Testut.)

The Intercostal Fasciæ.

The external intercostal muscles are covered on their outer surfaces and the internal intercostal on their inner surfaces by the fibrous membranes, which are called respectively the *external* and *internal intercostal fasciæ*. They are most pronounced in the portions of the spaces between the ribs which are not occupied by both varieties of these muscles. A thinner fascia separates the muscles of each space.

THE FASCIÆ OF THE SHOULDER.

In the region of the shoulder are the subscapular, supraspinous, infraspinous, and deltoid fasciæ (Fig. 415).

The Subscapular Fascia.

The *subscapular fascia* is attached to the margins of the fossa of the same

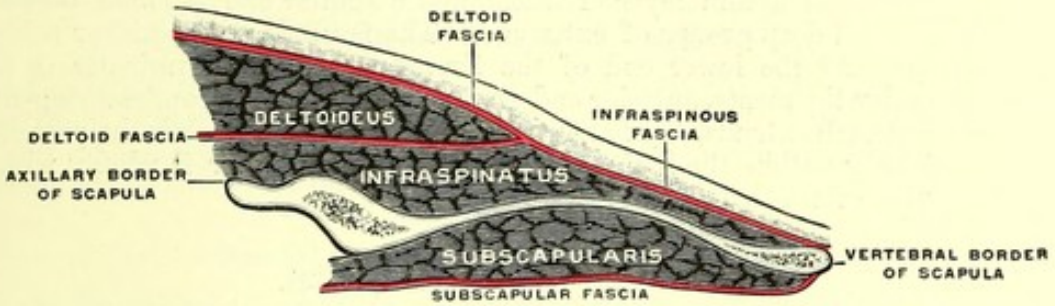

FIG. 415.—The fasciæ of the shoulder, seen in horizontal section. (Testut.)

name, and forms a covering for the subscapularis muscle.

The Supraspinous Fascia.

The *supraspinous fascia*, dense and strong, is attached to the borders of the fossa above the spine of the scapula, thus completing the osseo-fibrous chamber, which is filled by the supraspinatus muscle.

The Infraspinous Fascia.

The *infraspinous fascia* is like the last named in structure and similar in arrangement, being attached at the edges of the lower fossa on the dorsum of the scapula, thus forming with the bone a cavity, which is completely occupied by the infraspinatus. Where this muscle is overlapped by the hind border of the deltoid the fascia splits, one layer passing upon the latter muscle and forming part of the deltoid fascia, the other going in front of the deltoid and ending by fusion with the fibrous structure of the shoulder-joint.

The Deltoid Fascia.

The *deltoid fascia* covers in the deltoid muscle. It is continuous behind with the infraspinous fascia, in front with the pectoral. It is fastened above to the bones from which the muscle takes origin, and is continuous below with the fascia of the arm.

THE FASCIA OF THE ARM.

The *brachial fascia* is continuous above with the pectoral and axillary fasciæ, as well as with that of the shoulder, and below with that of the forearm. It is attached to the condyles of the humerus and the olecranon process. It not only enwraps the muscles of the brachial region, but from its inner surface sends septa between them. The greater part of these partitions are merely areolar, but two are strong and rigid, and need especial mention. One of them is attached to the outer border of the bicipital groove, the outer condylar ridge, and the intervening portion of the shaft; the other is similarly situated on the inner side—thus being formed the *external* and *internal intermuscular septa*, which divide the muscles into an anterior and a posterior set.

THE FASCIA OF THE FOREARM.

The *forearm fascia* is a direct continuation of the brachial fascia above, and ends below in the fascia of the hand. It has attachments to the olecranon and the posterior border of the ulna. From its inner surface many septa are given

off and extend between the muscles. For the most part these are areolar; but near the elbow, where groups of muscles arise from the condyles, the fibrous partitions are well marked. Between the first and second layers of the flexor muscles is stretched a thin layer of fascia, and a similar one is found between the superficial and deep groups of extensors. The fascia is much thicker behind than in front. At the lower end of the forearm the fascia terminates in the so-called annular ligaments, anterior and posterior. The name implies a ring-like structure; but each extends only half-way round the limb, and, while the posterior is almost entirely within the limits of the forearm, the anterior is wholly within the boundaries of the hand.

The Posterior Annular Ligament.

The *posterior annular ligament* (Fig. 417) is chiefly composed of transverse bundles of fibres constituting a broad and strong band, which has bony attachments on the inner side to the styloid process of the ulna, the cuneiform and the pisiform, on the outer side to the lower end of the external border of the radius, and between these extremities to the vertical ridges on the back of the radius. In this way are formed six osseo-fibrous passages, lined with synovial membrane, and occupied by the tendons of the extensor muscles of the forearm which are inserted in the hand.

THE FASCIÆ OF THE HAND.

In the hand are the anterior annular ligament, the palmar fascia, the interosseous fasciæ, the superficial transverse ligament, the dorsal fascia, and the sheaths of the tendons of the digital muscles.

The Anterior Annular Ligament.

The *anterior annular ligament* runs transversely across the front of the carpus from the scaphoid and trapezium on the outer side to the pisiform and unciform on the inner, thus converting the groove of the carpus into a tubular passage, through which run the flexors of the digits. It is continuous above with the forearm fascia, and below with the palmar fascia.

The Palmar Fascia.

The *palmar fascia* is divided into three parts, a middle and two lateral. Of these the middle is the most important, and often no other part is intended when the term "palmar fascia" is employed.

The *middle palmar fascia* is thick and strong, and seems to be in great part an expansion of the palmaris longus, though there appears to be no lack of the fascia in cases where the muscle is absent. Other portions originate from the anterior annular ligament. The fascia spreads out in fan-shape as it descends, is firmly adherent to the skin, and is inserted into the bases of the four fingers by a division for each. From these divisions slips are sent to the skin, the anterior metacarpo-phalangeal ligament, the sides of the neighboring metacarpal bones, and the digital sheaths, which will presently be described. From the lateral borders of the fascia a partition passes backward to the interosseous fascia, and in this way is formed a canal in which are lodged the tendons which traverse the palm.

The *lateral portions of the palmar fascia* are thin, cover the thenar and hypothenar groups of muscles, and, extending around the borders of the hand, become continuous with the dorsal fascia.

The *anterior interosseous fascia* is a thin layer which lies in front of the interosseous muscles, and is attached to the anterior ridges of the metacarpal bones.

In the interdigital commissures is a thin band, which extends from the index to the little finger, and forms the basis of the webs. It is called the *superficial transverse ligament*.

The Dorsal Fascia of the Hand.

This is a thin layer, continuous on each side with the lateral parts of the palmar fascia, above with the fascia of the forearm, and below with the sheaths of the extensor tendons. Between the metacarpal bones are stretched delicate fasciæ, which cover the dorsal interosseous muscles.

Fascial Sheaths of Tendons in the Hand.

On the palmar aspect of the digits each flexor tendon runs in a tubular canal, made by the concaved phalangeal surfaces and strong fibrous bands, which arch over these from the lateral margins of the bones. The bands are called *vaginal ligaments*, because they help to form the sheath (*vagina*) of the tendon. They are very dense opposite the shaft of the phalanx, much thinner opposite the joints. Each of the canals is provided with a vaginal synovial membrane (Fig. 416). Those of the index, middle, and ring fingers are independent, cylindrical sheaths, covering the length of two phalanges; that of the thumb, also, is separate, and extends from about two inches above the radiocarpal joints to the interphalangeal articulation; and that of the little finger, starting a trifle higher in the forearm, reaches to the distal end of the second phalanx, and includes also the flexor tendons of the other fingers as far as half-way down the palm.

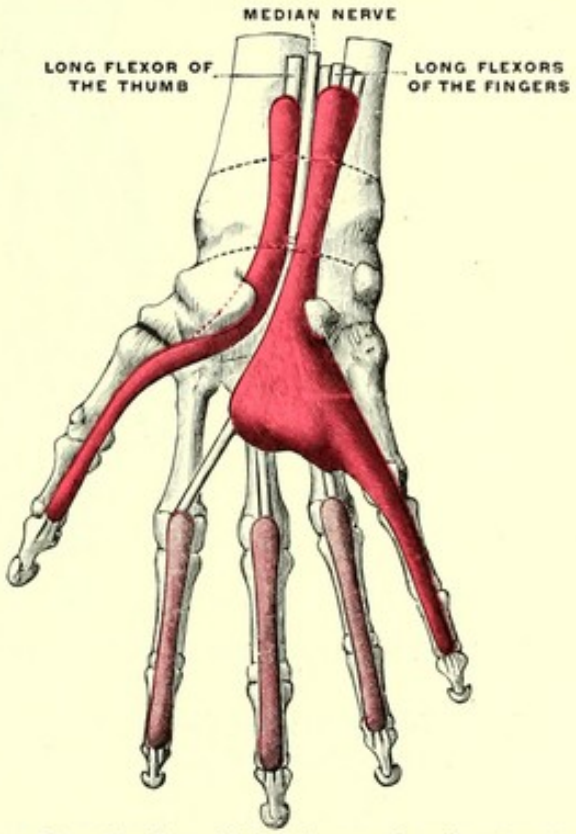

Fig. 416.—Synovial membranes of tendons in the palm, artificially distended. (Testut.)

On the dorsal aspect of the hand a different arrangement obtains (Fig. 417). The tendons of the digital extensors spread out upon the back of the first and second phalanges and blend at the sides with the lateral ligaments of the joints from the metacarpo-phalangeal down, themselves acting as posterior ligaments. As has already been said, the posterior annular ligament forms with the hind surface of the adjacent bones of the forearm a series of tubular canals, through which extensor tendons pass. These channels are provided with vaginal synovial membranes, which extend above and below the limits of the ligament. They contain tendons as follows: the first—that on the radial border—the extensor ossis metacarpi pollicis and the extensor brevis pollicis; the second, the extensores carpi radiales longus and brevis; the third, the extensor longus pollicis; the fourth, the extensor communis digitorum and the extensor indicis; the fifth, the extensor minimi digiti; and the sixth—that on the ulnar border—the extensor carpi ulnaris.

THE FASCIÆ OF THE BACK.

The Vertebral Fascia.

The *vertebral fascia* is an extension downward of the back part of the outer layer of the cervical fascia. It stretches from the spinous processes of the thoracic vertebræ to the angles of the ribs, covering in the deep vertical muscles of the

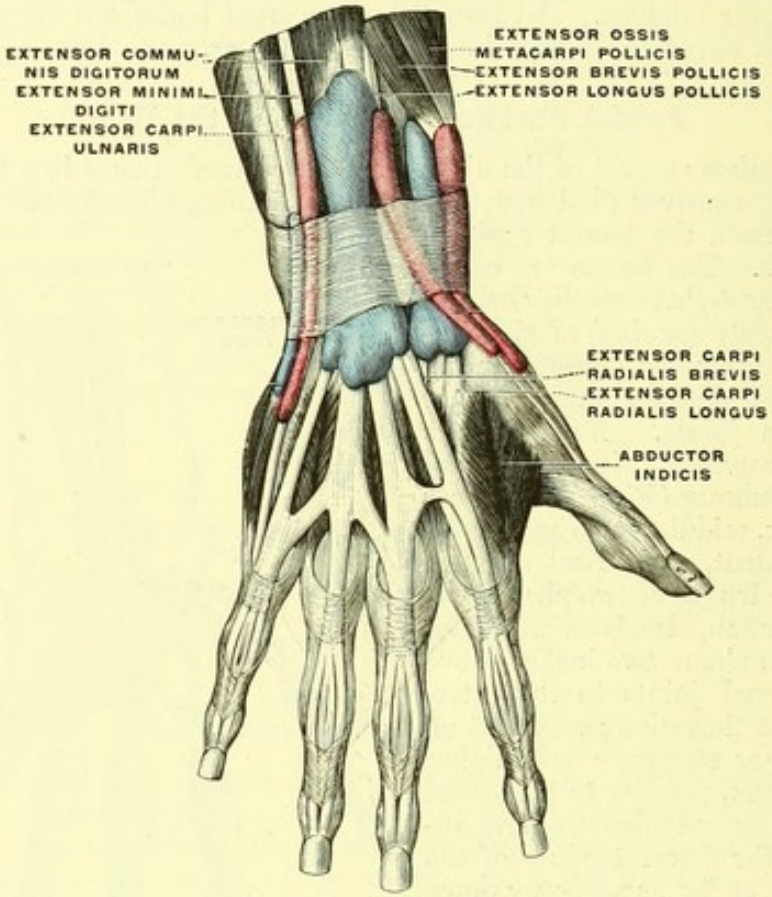

FIG. 417.—Synovial membranes of tendons in the dorsum of the forearm and hand, artificially distended. (Testut.)

back, passing in front of the serratus posterior superior, and becoming continuous below with the lumbar fascia.

The Lumbar Fascia.

The *lumbar fascia* (Fig. 418) is, in reality, rather a combination of tendons than a true fascia of investment, although it serves also in the latter capacity. The latissimus, serratus posterior inferior, obliquus internus abdominis, and transversalis abdominis all participate in its formation. Regarded as a fascia, it springs from the vertebral column in three layers, the outer or posterior, the middle, and the inner or anterior. The *outer layer* begins at the tips of the spinous processes of the lumbar and sacral vertebræ, forming a direct downward continuation of the vertebral fascia. It is attached above to the last rib, and below to the hind third of the outer lip of the iliac crest and the ilio-lumbar ligament. The *middle layer* starts from the free ends of the transverse processes of the lumbar vertebræ; and the *inner layer* arises from the front of the bases of the same processes. The outer and middle unite at the outer edge of the erector spinæ, which occupies the space between them; and this double layer is joined by the inner a little farther away from the middle line, the enclosure thus bounded being filled by the quadratus lumborum. The fascia resulting from the combination of the three layers gives

origin to the transversalis abdominis; the obliquus internus abdominis is inserted into a secondary lamella, which splits off from the outer layer; and the latissimus and serratus posterior inferior arise from still another lamina, which separates from the main fascia nearer the median line.

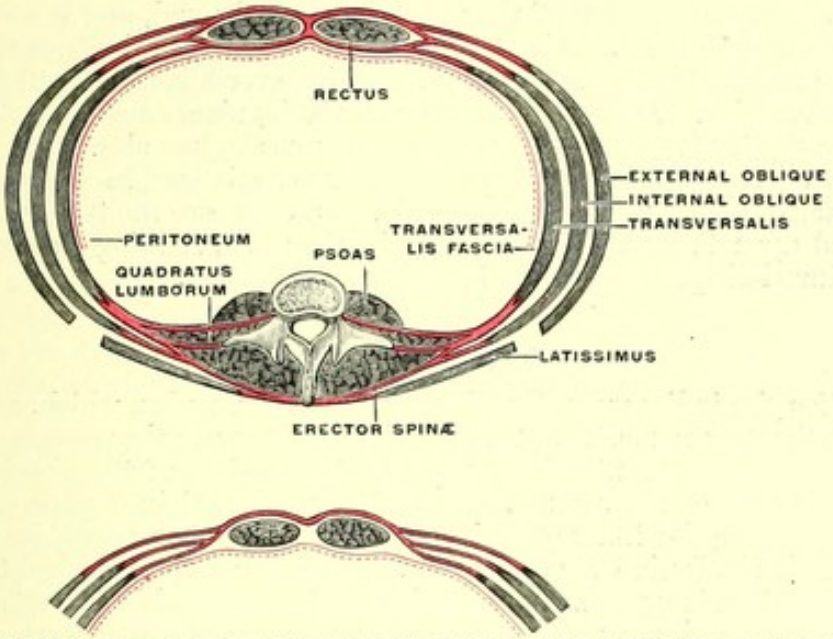

FIG. 418.—Semidiagrammatic horizontal section of trunk to show the lumbar fascia and the tendons of the lateral abdominal muscles. The upper figure shows the complete sheathing of the rectus in its superior portions; the lower shows the arrangement in its inferior fourth. (Testut.)

The front portions of the abdominal wall are largely made up of the tendons of insertion of the external oblique, internal oblique, and transversalis muscles, and these tendons are fasciæ in the same sense that the different tendons are, which constitute the lumbar fascia; but they are rarely mentioned other than as aponeuroses of insertion—a term which implies their tendinous character.

THE FASCIÆ OF THE ABDOMINAL CAVITY.

The abdominal cavity is everywhere lined with a serous membrane, the peritoneum. Between this, which furnishes the free surface of the cavity, and the muscular portion of the abdominal walls is interposed a delicate membrane, which, in the greater part of the abdomen proper, is known as the *transversalis fascia*, on account of its intimate connection with the great muscle against whose inner surface it lies, and, in the back part of the abdomen proper and in the pelvis, is called the *iliac fascia*, because the iliacus is one of the great muscles with which it is in close relation, the other being the psoas. Each of these fasciæ is somewhat prolonged beyond the abdominal cavity, as will presently be detailed.

The Transversalis Fascia.

The *transversalis fascia* is thickest at the groin, gradually becomes thinner as it is traced upward, and is nothing but areolar tissue where it lines the under side of the diaphragm. It is attached to the inner border of the iliac crest, the outer half of Poupart's ligament, the spine of the pubic bone, and the ilio-pectineal line. Beneath Poupart's ligament, a little to the inner side of its middle, the great vessels of the thigh, the femoral artery and vein, are found, the vein nearer the median line of the body. In front of these vessels this fascia is prolonged, forming the anterior part of their common sheath (the *femoral* or *crural sheath*), the posterior part being contributed by the iliac fascia. As the transversalis fascia escapes from the abdomen at this point, it is strengthened by a band, which

curves over the vessels, and is called the *deep crural arch*. The inner portion of this arch is the part of the fascia which is attached to the os pubis and ilio-pectineal line. Between the femoral vein and Gimbernat's ligament is a little gap, the *femoral ring*, through which hernia is most liable to occur in females, this being the weakest spot in the inguinal region of the members of this sex. It is the abdominal opening of the femoral or crural canal, and is occupied by a lymph-node and some fat. About half-an-inch above the middle of the inguinal (Poupart's) ligament is an oval opening in the transversalis fascia, called the *internal abdominal ring*. It is the beginning of the inguinal canal, the other end of which is in the tendon of the external oblique muscle, just above the crest of the pubic bone. Through this canal passes the spermatic cord in the male and the round ligament of the uterus in the female. In each case the transversalis fascia is extended upon the structure contained in the canal, forming a covering which from its funnel-shape is called the *infundibuliform fascia*.

The Iliac Fascia.

The *iliac fascia* lies upon the iliacus and psoas muscles, which, as has been said, are intimately connected. The portion which covers the psoas is attached to the vertebral column coextensively with the front origin of the muscle, and also to the upper part of the sacrum. From this mesial origin it runs outward, its upper part joining the inner (anterior) layer of the lumbar fascia, its lower part blending with the fascia over the iliacus. Its upper end is attached to the ligamentum arcuatum internum. The portion of the fascia which invests the iliacus stretches from the inner margin of the iliac crest to the iliac part of the ilio-pectineal line, and is also attached to the outer half of the inguinal (Poupart's) ligament. It accompanies the united muscles out of the pelvis into the thigh, and, running behind the femoral artery and vein, furnishes the posterior part of the sheath of these vessels, the front part of which is derived from the transversalis fascia. It finally becomes continuous with the pubic portion of the fascia of the thigh, at the line of fusion of the two a partition being given off between the psoas and pectineus to the ilio-pectineal eminence and the capsular ligament of the hip.

THE PELVIC FASCIA.

In direct downward continuation of the transversalis and iliac fasciæ, which belong to the abdomen proper, is the *pelvic fascia*, which, as the name implies, lines that portion of the belly-cavity which is known as the true pelvis.

Besides the osseous and ligamentous structures presenting surfaces in the pelvic cavity, there are the internal obturator muscles at the sides, the pyriformis muscles behind, and the levatores ani and coccygei below. The levators arise along a line from the body of the pubic bone to the ischial spine, pass downward toward the median line, and there blend, thus forming the greatest part of the sagging floor of the pelvic cavity. This floor is perforated by the rectum, and in the female by the vagina also, and it separates the pelvic cavity from the subjacent perineal or ischio-rectal space. All of these parietal structures are lined by the pelvic fascia, which also gives support to the viscera.

Two principal portions of the pelvic fascia are recognized—the obturator fascia and the recto-vesical fascia.

The Obturator Fascia.

The *obturator fascia*, so named from its lying upon the surface of the obturator internus muscle, is attached to the bone around the margin of the muscle, being continuous with the obturator membrane beneath the obturator vessels, and, extending back to the front of the sacrum, covers the pyriformis and the sacral nerves, in this region being much attenuated. This hind portion is sometimes

called the *pyriformis fascia*. As the obturator internus leaves the pelvis it takes with it a reflection of its fascia, which thus becomes continuous with the fascia which invests the muscles in the hip and thigh.

The Recto-vesical Fascia.

Along the curved line which marks the upper border of the origin of the levator ani (*i. e.*, from the symphysis pubis to the ischial spine) the fascia is somewhat thickened, and is called the *white line* (arcus tendineus, linea albuginea). From this line the *recto-vesical fascia* arises, and extends toward the median line in close contact with the upper surface of the levator ani. When it reaches the bladder, it splits into two layers, one of which spreads upward and disappears in the wall of this viscus, and the other passes downward upon the prostate gland, and thus forms its sheath. The portion around the prostate is continuous with the upper layer of the triangular ligament, which will presently be described.

When the recto-vesical fascia reaches the rectum, its fibres intermingle with those of this intestine. In the female the fascia forms a partial covering to the vagina.

Certain portions of the recto-vesical fascia are described as the *true ligaments of the bladder*; but the lateral and the posterior are generally so indistinct as to be demonstrable with difficulty, if at all, and only the anterior are constantly worthy of mention.

A little to each side of the median line a fold of the fascia runs forward from the bladder, and attaches itself to the body of the pubic bone. This fold encloses a small bundle of muscular tissue, which is called, from the parts which it connects, the *vesico-pubic muscle*. Thus are formed the *anterior ligaments of the bladder*. Between these two ridges is a median depression, in which the fascia is thin.

THE FASCIÆ OF THE PERINEUM.

The *deep fascia of the perineum* forms a triangle with its apex forward. It extends nearly horizontally sidewise between the lateral walls of the pelvis, and ventro-dorsally from the pubic symphysis to the central point of the perineum, which is about an inch in front of the anus. At the base of the triangle the fascia is single, but immediately splits into two layers, the superficial and the deep, between which are situated the constrictor muscle of the urethra, Cowper's (sub-urethral) glands, vessels and nerves, as well as a part of the urethra. From this last fact and its shape the fascia is most commonly known as the *triangular ligament of the urethra*.

The *superficial* (inferior) *layer* stretches between the ischio-pubic rami, strengthened near the front by a fibrous band, called the *transverse ligament of the pelvis*.

The *deep* (superior) *layer* is fastened laterally to the obturator fascia, just above the latter's attachment to the pubic and ischial rami.

In the female the vagina perforates this fascia.

The *superficial fascia* requires more attention in the perineum than in most other localities. Its *deep layer* is rather firm and close, and is attached at the sides to the entire lower border of the ischio-pubic rami and the ischial tuberosities. Its hind margin is united to that of the triangular ligament, between which structure and it are the transversus perinei muscles. Between this deep layer and the skin is the *superficial layer*, loose and areolar, its spaces occupied with fat-cells.

The name *ischio-rectal fossa* is applied to the considerable space on each side between the sagging floor of the pelvis and the osseo-muscular pelvic wall. These fossæ are commonly filled with adipose tissue, which is continuous with that subjacent to the skin of the buttocks.

THE FASCIÆ OF THE HIP AND THIGH.

These structures are not separated by a clearly defined boundary, and will be considered as one, which, on account of its great extent, is commonly called *fascia lata* ("the broad band"). It is cylindrical in shape, and extends from the highest margin of the hip to the lowest limit of the thigh. At its upper end it is attached along an irregular line, which lies successively upon the coccyx, sacrum, iliac crest, the inguinal (Poupart's) ligament, the body and descending ramus of the os pubis, ascending ramus and tuberosity of the ischium, and the great sacro-sciatic ligament, thus completing the circuit. It also has an attachment to the ilio-pectineal line, which will be mentioned again presently. It is continuous below with the fascia of the leg, is attached by its deep surface to the bony prominences around the knee, and contributes to the formation of the capsular ligament of this joint. In most parts it is a single layer, but, in the region of the gluteus maximus, it has two lamellæ, which ensheathe the muscle, and a similar arrangement obtains in the case of the tensor vaginæ femoris, otherwise called the tensor fasciæ latæ. The portion of the fascia on the outer aspect of the thigh is the strongest, and is called the *ilio-tibial band*, from its attachments at the iliac crest and the outer tuberosity of the tibia. The fascia sends inward to the femur two *intermuscular septa*, which partition the thigh into an anterior compartment and a posterior, the former containing the quadriceps and sartorius, the latter the other muscles. These septa, external and internal, have their osseous attachments respectively upon the outer and inner lips of the linea aspera and their upward and downward prolongations. Other and less important septa also occur. Just below the median end of the inguinal (Poupart's) ligament is an oval hole, measuring about an inch in its long (vertical) diameter, and called the *saphenous opening*, from its transmission of the long saphenous vein. The part of the fascia at the outer side of this aperture is the *iliac portion*; the part at the inner side is the *pubic portion*. The saphenous opening may be regarded as a notch in the upper border of the fascia, the angles of the notch overlapping each other without contact, so that the opening has not a continuous margin. The part of the margin which comes in front is continuous with the inner end of the inguinal (Poupart's) ligament; that which goes to the rear curves backward, and is attached to the ilio-pectineal line. The upper, outer, and under portions of the rim taken together are sickle-shaped, and bear the name of *falciform process*. It is attached to the front of the sheath of the femoral vessels. Behind the plane of the saphenous opening are the upper parts of the femoral vessels, enclosed in a funnel-shaped sheath, which lies close to the artery, but is separated from the vein by an interval. This space constitutes a passage, the *femoral* or *crural canal* (Fig. 419), whose upper or abdominal end has already been described as the femoral or crural ring. It is through this canal that a femoral hernia descends. The saphenous opening is closed in by a thin layer of areolar tissue (superficial fascia), which, from its being perforated by many vessels, suggests a sieve, and hence is called the *cribriform fascia*.

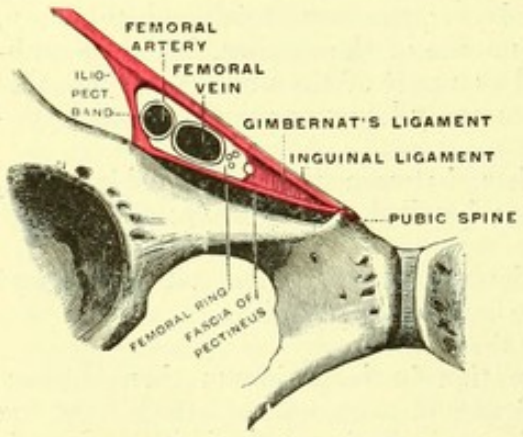

FIG. 419.—The femoral canal. (Testut.)

THE FASCIÆ OF THE LEG.

The principal fascia of the leg is directly continuous with that of the thigh above and that of the foot below. It is not, however, a complete enclosure for

the leg, being deficient at the places where the bony framework is subcutaneous. For example, at the inner surface of the tibia the fascia merges with the periosteum at the borders of this area; and it is disposed in like manner at the heads of the tibia and fibula, and at the malleoli. It sends *intermuscular partitions* inward at several points, the most perfect of them being two on the outer side of the leg, which have bony attachments along the neighboring borders of the fibula, and separate the peronei longus and brevis from the front and back groups of muscles respectively. Between the muscles which are inserted into the calcaneum and the other posterior muscles is stretched the *deep transverse fascia*, attached to the tibia and fibula, and binding down the muscles in front of it.

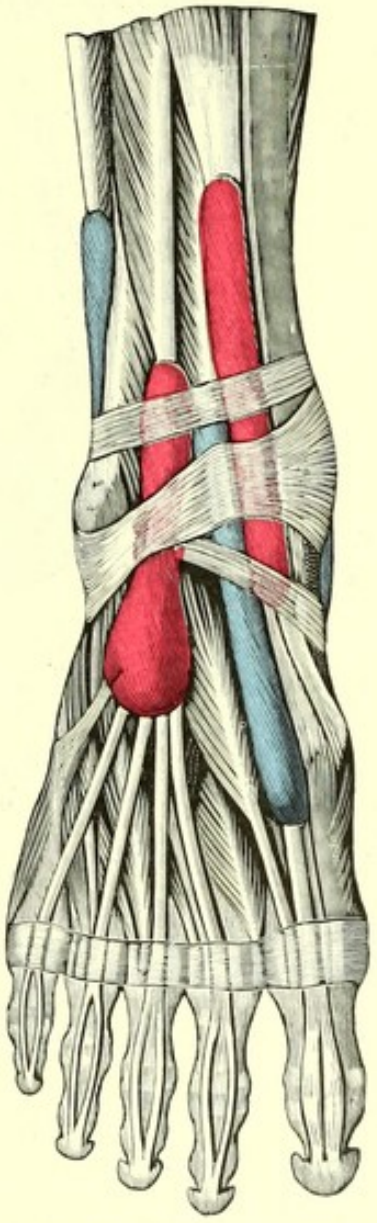

FIG. 420.—The anterior annular ligament of the ankle and the synovial membranes of the tendons beneath it artificially distended. (Testut.)

In the region of the ankle the fascia is strengthened and to some extent prolonged into the foot by a series of transverse bands, which nearly encircles the limb, each of its primary divisions being called an annular ligament. They are three in number—anterior, internal, and external. The *anterior annular ligament* (Fig. 420) consists of two parts, an upper and a lower. The *upper band* runs across the front of the leg between the anterior borders of the tibia and fibula, just above the malleoli, keeping the vertical tendons in place. The *lower band* begins on the outer side of the calcaneum, and splits into two layers at the outer border of the peroneus tertius, one going in front and the other behind; at the inner border of the extensor longus digitorum the layers unite, thus forming a channel through which these two muscles pass. The band then divides into two branches—a superior, which goes upward to the front of the inner malleolus, and is there attached; and a lower, which crosses to its insertion on the scaphoid and internal cuneiform bones and in the plantar fascia. These bands confine the tendons of the tibialis anterior and extensor proprius hallucis closely to the subjacent structures. Each of the last-named has a synovial sheath, but the extensor longus digitorum and peroneus tertius have one in common. The *internal annular ligament* (Fig. 421) is stretched between the internal malleolus and the postero-inferior part of the inner surface of the os calcis. From its deep surface processes are given off to the neighboring ridges of bone, thus forming compartments through which pass the tendons of muscles from the back of the leg to the sole of the foot, as follows: next behind the malleolus the tibialis posterior, then the flexor longus digitorum, and, finally, after an interval in which lie the vessels and nerves, the flexor longus hallucis. Each of the tendons has its separate synovial membrane. The *external annular ligament* (Fig. 422) runs from the tip of the external malleolus to the outer side of the calcaneum, binding down the peroneus longus and peroneus brevis, which are enclosed together in a single synovial membrane.

THE FASCIÆ OF THE FOOT.

The homology of the fasciæ of the foot and hand is so marked that it is unnecessary to dwell minutely upon the former, the latter having been already described. That in the sole is called the *plantar fascia*, and is divided into three parts. The central portion starts from the inner tuberosity of the calcaneum, runs forward below the flexor brevis digitorum, and terminates in front in a process for each toe and in slips for the skin. At the sides it is continuous with

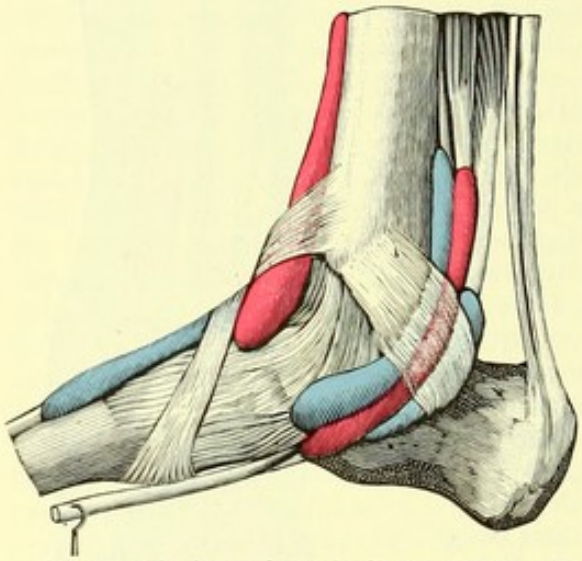

FIG. 421.—The internal annular ligament of the ankle and the artificially distended synovial membranes of the tendons which it confines. (Testut.)

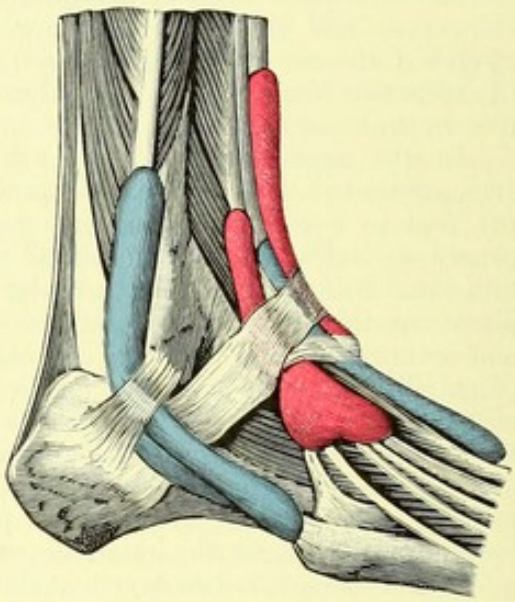

FIG. 422.—The external annular ligament of the ankle and the artificially distended synovial membrane of the tendons which it confines. (Testut.)

the lateral portions, which extend around the margins of the foot. Where the central portion joins each lateral a process passes upward, and thus are formed partitions between corresponding groups of muscles. The external lateral portion is attached behind to the calcaneum, the internal to the internal annular ligament. The interosseous fasciæ, the dorsal fascia, and the superficial transverse ligament of the toes, all are similar to their homologues in the upper limb, but the last named connects five digits, instead of only four. The tendons of the toes are kept in place by fibrous bands, and are provided with synovial membranes, as are the corresponding organs in the hand.

THE BLOOD-VASCULAR SYSTEM.

THE *blood* is the vehicle by which nourishing materials are carried to the tissues, and many effete substances conveyed away from them. It is contained in a continuous series of chambers and tubes, which constitute the blood-vascular system. The chambers are the compartments of the heart, and the tubes are the arteries, the capillaries, and the veins—including under the last term not only the veins proper, but also certain channels which are called venous sinuses. The *arteries* are the vessels which carry blood *from the heart* to the tissues; the *capillaries* are those through whose delicate walls the interchange of nutrient and waste matters takes place *in the midst of the tissues*; and the *veins* are the vessels which convey the blood from the tissues *to the heart*. The whole blood-vascular system is closed in the normal condition, and no blood escapes from it, with two exceptions, which are as follows: in the female, during the child-bearing portion of her life, there is a periodical discharge of blood through ruptured vessels; and in the spleen of all persons the blood leaves the minute vessels, and flows through wall-less tubes in the parenchyma of the organ.

In the entire blood-vascular system *one structural feature is constant*—the serous membrane which lines it. Muscular and fibrous coats in most parts are found surrounding the serous, but they are not, like it, invariable. The importance of this smoothest of all membranes as a lining for the heart and vessels is appreciated, when we consider that any roughness of a surface over which blood flows causes clotting of the fluid, and this results in the plugging of vessels, and the consequent starvation of the parts which they should supply with blood.

THE HEART.

By F. H. GERRISH.

THE *heart* (Latin *cor*, or *cardia*) is the central organ of the vascular system. It is the force-pump which propels the blood through the vessels. In some animals it has but one cavity, in others it has two, in still others three. In man there are really two hearts, each having two chambers. The two hearts in the adult may be compared to a block of two houses, which are independent of each other except for the fact that the partition wall between them is common to both. During intrauterine life there is a door of communication between the upper chamber of one and the corresponding cavity of the other; but this is closed at birth, and thenceforward the blood cannot get from one side to the other without leaving the heart and going by a roundabout path.

These two hearts are called, on the basis of their independence, the *right heart* and the *left heart* respectively; on the ground of their union, they are named the right side of the heart and the left side of the heart respectively. Both sets of designations are misleading as regards the relative situation of the two organs (or sides of the same organ), for they are not placed right and left, but one—the right—is in front of the other. One chamber of each is called *auricle*, because of the resemblance of an appendage of it to an animal's external ear; the other

chamber is named *ventricle*, from its bulging like a prominent abdomen. The auricles are spoken of as if they were entirely on a higher level than the ventricles, whereas they are nearly on the same plane.

Each auricle receives blood from veins, and delivers it to the corresponding ventricle, which then discharges it through an artery.

The Circulation of the Blood.

The course of the blood is as follows: (Fig. 423) Beginning in the auricle of the right side, the blood, which has just come from the tissues of the entire body, passes through the large aperture by which the auricle communicates with its ventricle, and which is called the right auriculo-ventricular opening; from the right ventricle it is driven through the pulmonary artery to the lungs, through the walls of whose capillaries it loses certain impurities and gains oxygen from the air, thus being changed from venous blood to arterial; from the lungs it flows through the pulmonary veins to the left auricle, thence through the left auriculo-ventricular opening to the left ventricle, whence it is forced into the aorta, the great trunk of the general arterial system, and by this and its branches it is distributed throughout the body. From the twigs of the arterial system the blood is poured into the capillaries, and here parts with nourishing materials, synchronously receiving a load of effete substances, in this way being altered from arterial to venous. From the capillaries it courses into the veins, which conduct it to the right auricle, the place from which the reckoning began. This description of the track of the blood confirms the statement previously made that the communication between the right and left sides of the heart is not direct, through the partition wall, but is entirely indirect—it being necessary for the blood to go out of the heart and through the capillaries of some organ in order to get from either side to the other.

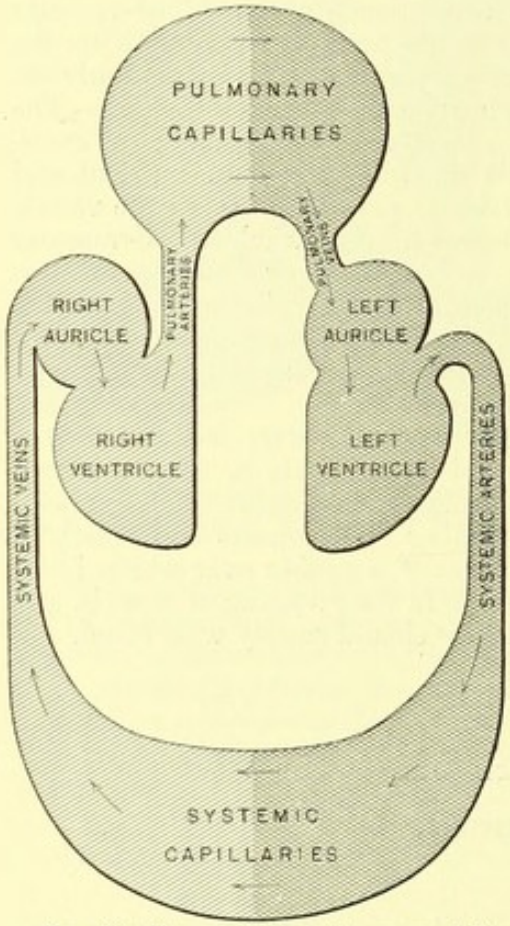

FIG. 423.—Diagram to show the course of the blood in passing from a given point through the two sets of capillaries to the starting point. (F. H. G.)

The journey of the blood from the right heart to the left through the capillaries of the lungs is the less or *pulmonary circulation*; and the passage of the blood from the left heart to the right through the capillaries of the organs of the body is the great or *systemic circulation*. It is to be noted that, in going through the lung-capillaries, the blood is changed from venous to arterial; and that, in its course through the capillaries of the general system, the reverse occurs—it is altered from arterial to venous. The kind of blood contained in a vessel does not, however, make the latter either vein or artery, as the pulmonary artery bears foul or venous blood, and the pulmonary veins are full of purified or arterial blood. *Arteries* carry blood, red or blue, *from the heart*; *veins* carry blood, blue or red, *to the heart*.

The Tissues of the Heart.—The lining of the heart, like that of all other parts of the vascular system, is serous membrane, and is called *endocardium* ("within the heart"). The outer covering, too, is serous, and is called *pericardium*

("around the heart"). It will be described in detail on a subsequent page. Between the endocardium and the pericardium is a middle coat, which is muscular and fibrous, and, on account of the enormous preponderance of the contractile tissue, is named *myocardium* ("muscle of the heart"). The muscular tissue is of the cardiac variety. The arrangement of the bundles of fibres is extremely intricate, and not yet fully understood in all of its details.

The Thickness of the Cardiac Walls.—The muscular walls of the right auricle are thin and so flabby that they fall together when the cavity is empty; they have to drive the blood but a short distance—only into the ventricle—and through a very large opening. The right ventricle has thick, firm walls, so powerful that by them the blood is sent through the pulmonary artery and its branches, into and through the numberless capillaries of the lungs, through the pulmonary veins, and into the left heart. The left auricle has walls but little thicker than those of the right, yet quite equal to the trifling labor placed upon them—that of forcing the blood through the large auriculo-ventricular orifice into the left ventricle. The left ventricle by its contraction must drive the blood through the vessels of the systemic circulation; and, as these are much more numerous than those of the pulmonary set, and present, on account of their situation, far greater frictional resistance to the passage of the blood in proportion to their number, there is necessity for vastly greater power in the ventricular walls, which, in fact, are three times as thick as those of the right ventricle (Fig. 424). The bulging of the interventricular septum into the right ventricle is due to this greater thickness of the parietes of the left; indeed, this whole partition has the appearance of being formed by the latter.

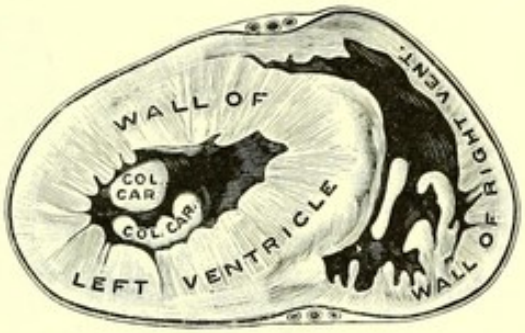

FIG. 424.—Cross-section through both ventricles, showing the shape of their cavities and the relative thickness of their walls. (Testut.)

The auriculo-ventricular openings and those of the pulmonary artery and the aorta are guarded by valves, which do not interfere with the passage of the blood in the course already described, but do serve to prevent a return of blood to a cavity from which it has been discharged.

The heart is situated in the lower and front part of the chest, extending much farther to the left side than to the right. It lies obliquely, the auricles being at the right of and a little higher than the ventricles.

The Right Auricle (Fig. 425), when viewed from the inside, presents a main chamber, the *atrium* ("hall"), and a little ante-chamber, the cavity of the appendix, the latter being at the front and upper part of the auricle. A number of openings are seen. At the back the two *venæ cavæ* enter, the superior above, the inferior below. The floor of the atrium is largely formed by a trap-door, the tricuspid valve, which closes the oval *auriculo-ventricular opening*. Several *cardiac veins* of considerable size, returning blood from the substance of the heart itself, open directly into the cavity. The largest of these is called the *coronary sinus*, and enters between the inferior vena cava and the auriculo-ventricular orifice, its orifice being protected by a serous fold, the valve of Thebesius. There are also some very small veins, *venæ minimæ cordis* ("the least veins of the heart"), whose apertures, together with others of similar appearance, which are said to be blind depressions, have been named *foramina Thebesii* ("holes of Thebesius"). On the hind wall, which is the partition between the two auricles, is a shallow depression, the *fossa ovalis* ("oval pit"), bordered, except below, by a ridge, the *annulus ovalis* ("oval ring"). The fossa marks the site of a hole (*foramen ovale*), which exists in the *septum auricularum* ("partition of the auricles") in intrauterine life, and at birth becomes permanently closed by a flap of membrane. Various projections from the surface are observed, some

being muscular, others merely folds of endocardium. A network of muscular ridges covers the wall of the appendix, and on the right wall of the atrium is a series of vertical bands of nearly equal size, not inaptly named *musculi pectinati* ("comb-like muscles"). Connecting the margin of the inferior vena cava and the anterior edge of the annulus ovalis is a membranous fold, the *Eustachian valve*, which is prominent in proportion to the youth of the individual. In the fœtus it serves to guide the blood from the inferior vena cava through the foramen ovale of the septum into the left auricle. Between the openings of the venæ cavæ is an indistinct projection, the tubercle of Lower.

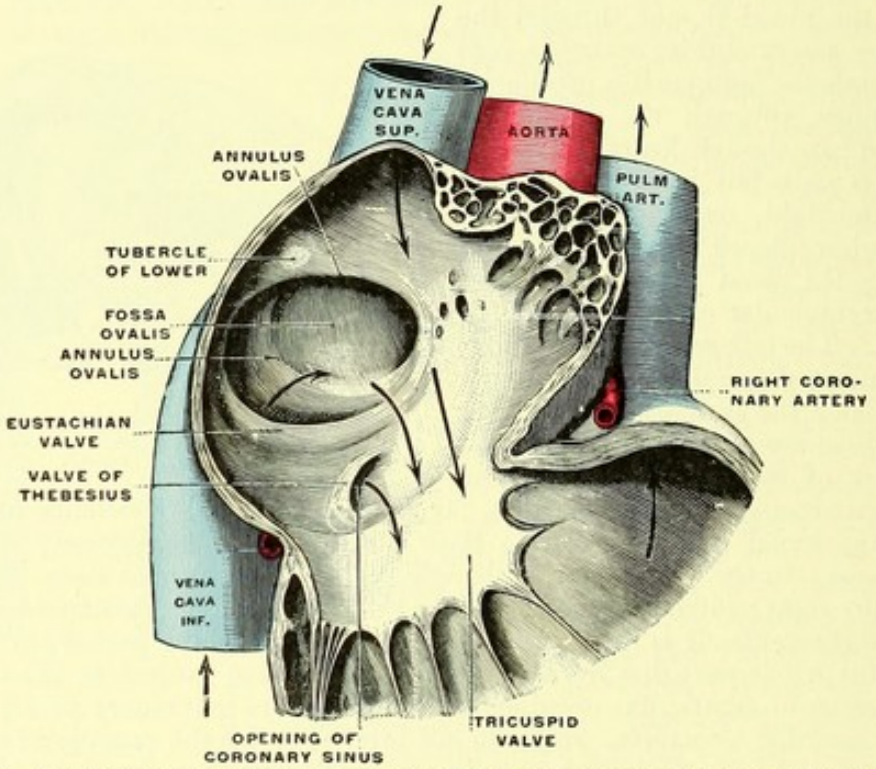

FIG. 425.—Right auricle and part of right ventricle, the front wall having been removed. (Testut.)

The Right Ventricle has an irregular cavity, concave in front and convex behind, where the *septum ventriculorum* ("partition of the ventricles") bulges into it. There are two large openings—the *auriculo-ventricular orifice*, and that of the *pulmonary artery*, the latter being at the apex of the *infundibulum*, a somewhat funnel-shaped portion of the chamber toward the left side. The auriculo-ventricular opening is closed by the *tricuspid valve*, so called from its three conspicuous segments. These are of unequal size and irregular shape, having ragged and frayed free edges, and between their attached borders frequently small secondary segments. One flap is at the left, one at the right, and one behind. They are composed of white fibrous tissue, and their attached borders are united to a fibrous ring, which encircles the orifice. At the junction of the pulmonary artery with the heart is the *pulmonary valve*, made up of three fibrous festoons of semilunar shape (Fig. 429). The free edge of each is marked at its middle by a nodule, the *corpus Arantii* ("body of Arantius"). The attached margin is strengthened by a ring of fibrous tissue. Behind each flap is an enlargement of the arterial bore, making a little recess, the *sinus of Valsalva*. Many large muscular prominences, *columnæ carneæ* ("fleshy columns"), are observed everywhere, except in the infundibulum (Fig. 426). Of these there are three kinds: those that are sculptured in high relief from the wall—attached at both ends and all of one side; those that are fastened at both ends and nowhere else; and those that have only one extremity secured to the wall. The last are known as *papillary muscles*, because they stand out like nipples, and they are arranged in two princi-

pal sets, anterior and posterior. From their summits project delicate tendons, *chordæ tendineæ*, which are inserted into the free edges and under sides of the flaps of the tricuspid valve. Running across the chamber obliquely is usually a prominent muscular beam, the *moderator band*.

Action.—When the muscular wall of the ventricle contracts, the cavity is practically obliterated, and its contents are discharged. As soon as contraction begins, the tricuspid valve is closed, and, were it not for the special restraining apparatus, its flaps would be swept into the auricle, and the greater part of the blood in the ventricle would go with them. But the papillary muscles come into action simultaneously with all other parts of the wall, and pull the valve downward exactly to the extent that the blood tends to push it upward beyond the plane at which the free margins of its segments come in close contact. Thus regurgitation is prevented, and the blood is forced through the only other avenue of escape, the pulmonary artery. The contraction of the ventricle ceasing, the distended artery has a tendency to return some of its contents to the ventricle; but, as soon as the column of fluid starts backward, the semilunar festoons, which have been flattened by the outrush of blood from the heart, are closed with a snap, the accumulation in the sinuses behind them giving the first impulse, and the pressure of the fluid in the artery completing the act. In this way not a drop is allowed to regurgitate. The columnæ carneæ of the second and third varieties are useful in regulating contraction and evenly distributing pressure, the moderator band being of especial service in preventing too great distention and in causing approximation of the opposite walls.

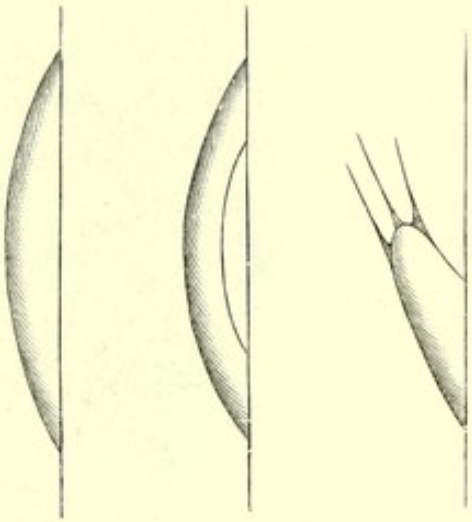

FIG. 426.—The three varieties of columnæ carneæ. (F. H. G.)

The Left Auricle presents fewer irregularities of internal surface than does the right (Fig. 427). The *musculi pectinati* are less numerous and less pronounced. Toward the rear on each side are the orifices of two *pulmonary veins*. The position of the fœtal foramen ovale is indicated by a slight indentation on the septal wall. The *auriculo-ventricular opening* is much like that in the right heart, but a little smaller. It is guarded by the bicuspid valve.

The Left Ventricle has a capacity equal to that of the right, but its cavity has a different shape, being ovoidal. In general features it strongly resembles the other ventricle. The three varieties of *columnæ carneæ* are present; but, while these muscular bundles are more numerous, they are of less size. The *papillary muscles* are disposed in two series. A band, similar to the moderator of the right ventricle, but much smaller, crosses the chamber. At the uppermost part of the septum the wall is fibrous and very thin, constituting a weak area, sometimes called the undefended space. The auriculo-ventricular orifice and that of the aorta are very close together, the former being toward the rear, the latter near the front. The *auriculo-ventricular valve* is called *bicuspid*, on account of its having two chief segments, and *mitral*, because these flaps, when open, are somewhat suggestive of a bishop's mitre (Fig. 428). One segment lies close to the hind wall, the other and larger is between the two orifices. Frequently small secondary segments are found between the two great flaps. The valve is connected with papillary muscles by *chordæ tendineæ*, and in general features of structure is like the tricuspid, already described. The valve at the base of the aorta (Fig. 429) is a repetition of that of the pulmonary artery, except that in almost every respect its characteristics are more pronounced. The semilunar segments are situated

respectively in front, at the left behind, and at the right behind. From the sinus of the first of these is given off the *right* (anterior) *coronary artery*, and from that of the second the *left* (posterior) *coronary artery* springs. These vessels are

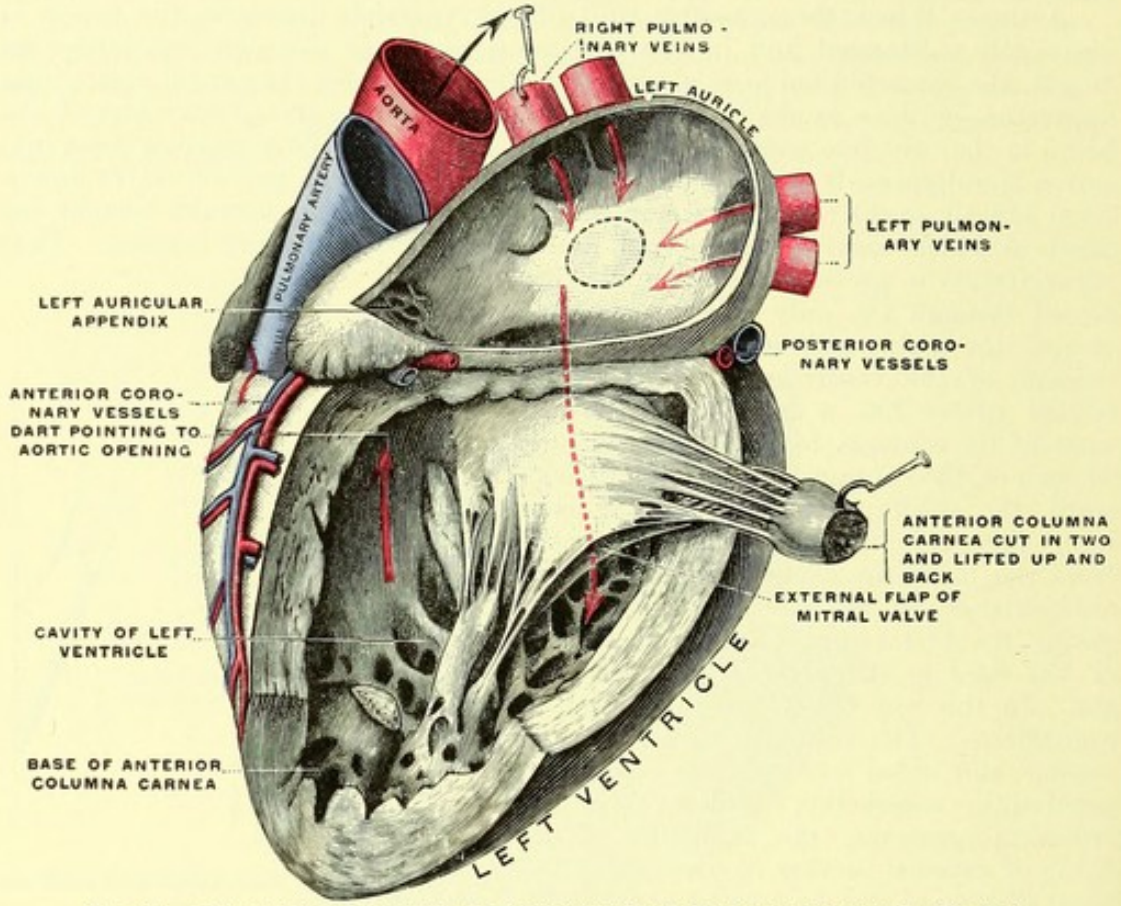

FIG. 427.—Left auricle and ventricle, the hind wall of each having been removed. (Testut.)

called coronary because they encircle the heart like the band of a crown. They are the first branches of the aorta, and feed the heart. Between the auriculo-

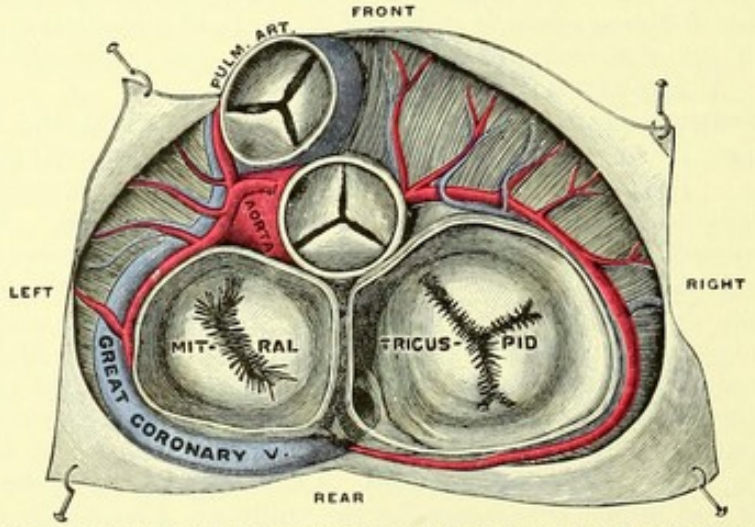

FIG. 428.—Valves of the heart and great arteries, viewed from above, the auricles having been removed. (Testut.)

ventricular and aortic orifices is a mass of mingled white fibrous tissue and white fibro-cartilage, from which are given off fibrous prolongations forming rings around the openings, and so stiffening their margins that stretching is prevented.

The *bulk* of the heart has been said to be approximately that of the fist of its owner; but to this rough-and-ready rule there are so many exceptions as to render it of little value. During life the diameters of the heart are constantly changing, and measurements made after death may be misleading. It increases in weight and volume with rather unsteady progression to the end of life. Its average *weight* in the male is about eleven ounces; in the female it is somewhat less. Its *blood-vessels* are the coronary arteries and veins. It has numerous lymphatics. The *nerve-supply* is derived from the pneumogastric and from fibres of the cervical and thoracic ganglia of the sympathetic.

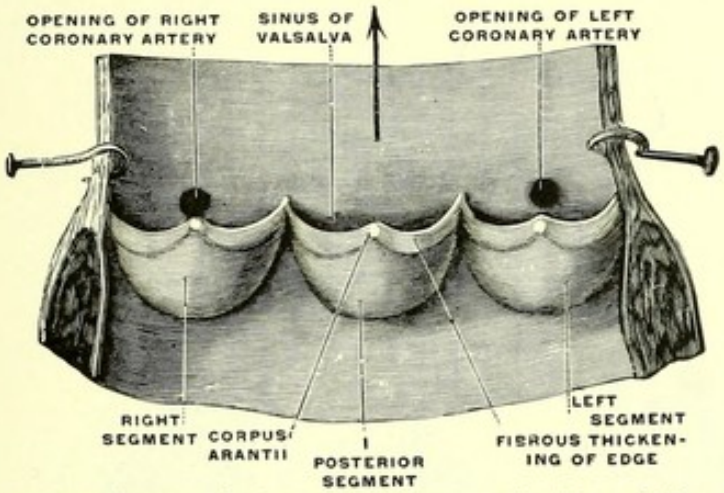

FIG. 429.—Aortic valves. The artery has been cut open between the right and left segments, and spread out. (Testut.)

The External Configuration of the Heart.

The Grooves of the Heart.—The surface of the heart is marked by a series of grooves, which indicate the superficial limits of the various cavities.

Between the auricles and ventricles is the *auriculo-ventricular groove*, which is incomplete in front, where the anterior surface of the pulmonary artery is continuous with that of the right ventricle. This vessel occupies the broad ventral depression between the auricles—the *anterior interauricular groove*. The *posterior interauricular groove* lies between the right pulmonary veins and the portion of the right auricle which connects the superior and inferior venæ cavæ.

Between the ventricles are the interventricular grooves, which are continuous at the right of the apex of the heart. The *anterior interventricular groove* begins between the pulmonary artery and the left auricular appendix, and runs downward upon the ventral surface of the heart. The *posterior interventricular groove* starts at the left of the inferior vena cava, almost in continuation of the posterior interauricular groove, and courses forward upon the inferior surface of the organ.

The Surfaces of the Heart.—When the heart has been hardened while maintaining its natural relations with contiguous organs, it presents six surfaces, separated from one another by borders, which are defined with varying degrees of distinctness.

The Ventral Surface (Fig. 430) is slightly convex, irregularly quadrilateral, and looks forward and a little upward. It presents the front of the right ventricle, a part of the right auricle, of both appendixes, and of the left ventricle. The right (anterior) coronary artery is seen in the right auriculo-ventricular groove, giving off branches, of which the principal are the preventricular above, and the right (anterior) marginal below, the latter running to the left near the lower border. The anterior interventricular groove lodges a branch of the left (posterior) coronary artery and the great coronary vein. The ventral surface is bounded by the ill-defined *right border*, which falls upon the convex surface of

the right auricle; below by the *antero-inferior border*, which separates it from the inferior surface, and is so sharp that it is called *margo acutus*; on the left by the *left border*, on the marked convexity of the left ventricle; and above by the line of junction of the pulmonary artery with the heart, and by the upper margin of the appendixes.

The Dorsal Surface (Fig. 431) is irregularly convex, looks backward, and presents the greater part of the left auricle. Above are the horizontally directed primary divisions of the pulmonary artery, the right and left pulmonary arteries; at the right the posterior interauricular groove; below, the auriculo-ventricular

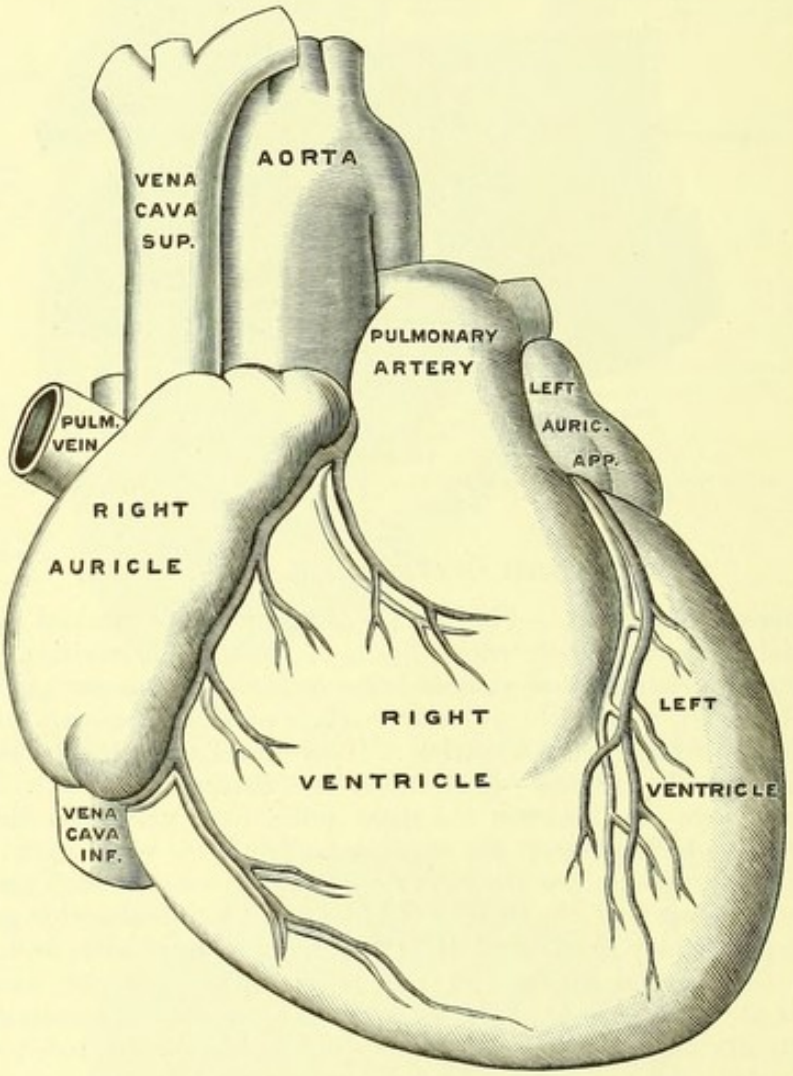

FIG. 430.—Front view of the heart. The auriculo-ventricular and anterior interventricular grooves and the vessels in them are not labelled, but cannot be mistaken. (From the His cast. F. H. G.)

groove; at the left a line leading downward from the left pulmonary veins, commonly marked by the oblique vein (of Marshall), which ends below in the coronary sinus.

The Right Surface is convex, quadrilateral, and exhibits nearly all of the right auricle which is not included in the ventral surface. At the postero-inferior angle the vena cava inferior enters, and the vena cava superior is seen above. Behind is the posterior interauricular groove; below, the auriculo-ventricular groove; and in front is the right border, already mentioned.

The Left Surface is unevenly convex and somewhat triangular. It presents above and behind a part of the left auricle, and in front of this a portion of its appendix; below, the left ventricle, tapering to the apex, and showing in the

midst of this space the marginal branch of the left coronary artery and the left marginal vein; and, between the auricle and ventricle, the great coronary vein.

The Inferior Surface is nearly flat, and looks downward and backward, conforming to the sloping upper surface of the anterior portion of the diaphragm. Here are seen parts of both ventricles, separated by the posterior interventricular groove, which lodges the interventricular branch of the right coronary artery and the middle cardiac vein; and at the back and right a small part of the right auricle and the aperture of entrance of the vena cava inferior.

The Upper Surface is small and irregular, and is occupied by the great vessels which form the bulk of the stem of the heart—the pulmonary artery, the aorta, and the vena cava superior.

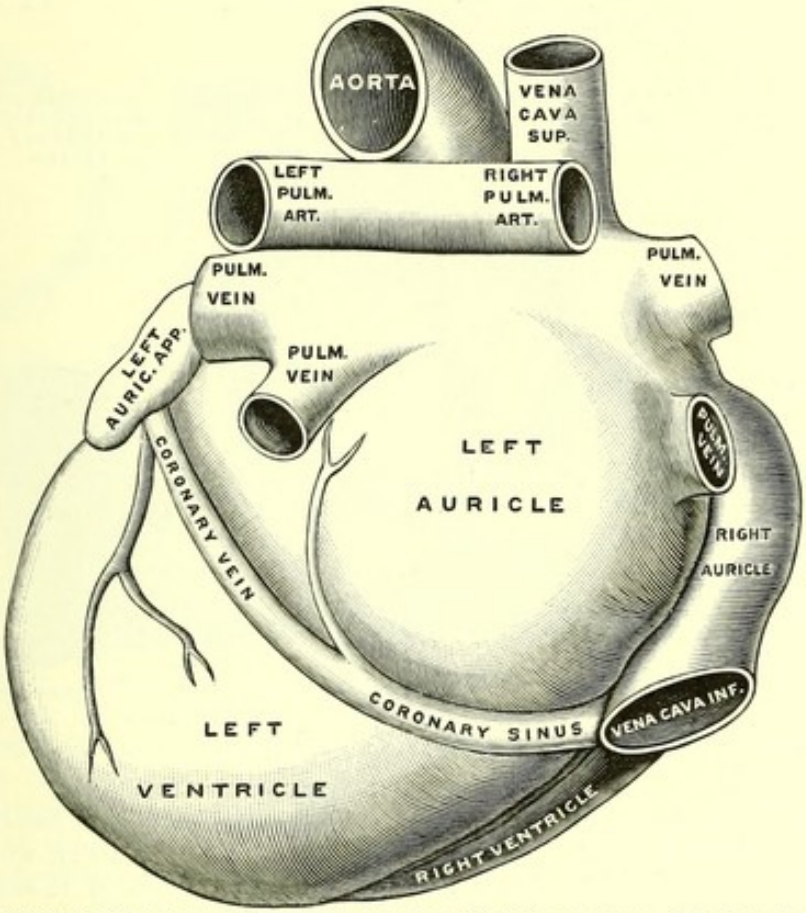

FIG. 431.—Rear view of the heart, showing the dorsal and inferior surfaces. The latter is represented as convex, but should be nearly flat. (Modified from the His cast. F. H. G.)

The ventral, inferior, and left surfaces converge at the left anterior portion of the heart to a blunted point, called *the apex*. This is constituted entirely by the left ventricle, owing to the fact that the wall of this chamber is very much thicker than that of the right ventricle. The apex lies behind the space between the fifth and sixth costal cartilages, about three and a half inches from the middle line.

THE PERICARDIUM.

The *pericardium* ("around the heart") is the sac in which the heart is contained (Fig. 432). It consists of two parts: (1) an external, fibrous portion, and (2) an internal, serous portion.

The *fibrous bag*, composed mostly of white fibrous tissue, somewhat loosely encloses the heart, and is attached to various structures in the immediate neighborhood. Inferiorly it is firmly adherent to the diaphragm, with whose central

tendon its fibres are intermingled. It extends upward onto the great vessels for two inches or more, blending with their sheaths; and in this region it is also continuous with a downward prolongation of the cervical fascia. In front it is connected with the breast-bone by two fibrous bands, the *superior* and *inferior sterno-pericardial ligaments*; and the parietal pleuræ are adherent to its lateral surfaces.

The *serous membrane* furnishes a lining to the fibrous bag, and is thence reflected onto the contained organs, giving them a closely attached covering. The lining of the fibrous pouch is the parietal portion of the serous membrane, and

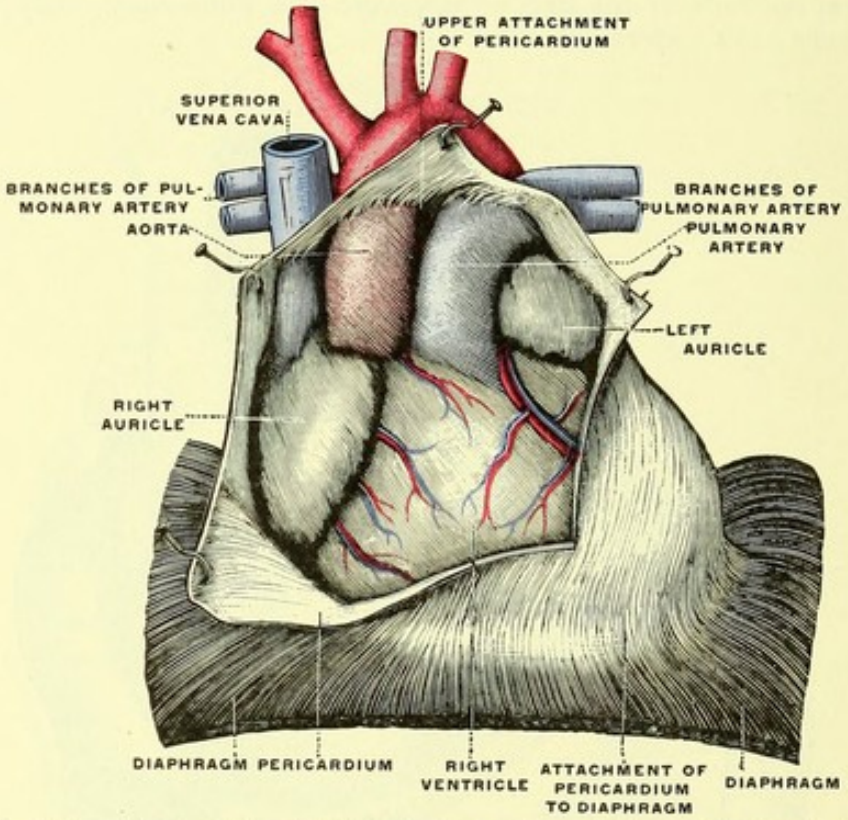

FIG. 432.—The heart *in situ*. The pericardium has been cut open in front, and reflected. (Testut.)

the clothing of the heart and vessels is the visceral portion, the latter sometimes being called the *epicardium* ("upon the heart"). Thus, the heart, which changes its position seventy times a minute all through life, is enabled to move with the least possible friction.

The pericardium does not completely encase all of the vessels attached to the heart. The aorta and pulmonary artery are enclosed in one sheath, the others are only partially covered. Many pouches of pericardium are found between the vessels at the lines of reflection of the membrane.

The *arteries* which supply the pericardium are the internal mammary, phrenic, pericardiac, œsophageal, and bronchial. Its *nerve-supply* comes from the pneumogastric, phrenic, and sympathetic.

THE PHYSIOLOGICAL ANATOMY OF THE BLOOD-VESSELS.

Before one studies the systematic anatomy of the blood-vessels, it is important that he should know their physiological anatomy. The few succeeding pages, therefore, will be devoted to a presentation of the principal features of the structure of the different kinds of vessels, with especial reference to the relations between their histological composition and their functions.

The Arteries.

The arteries (*arteriæ*) are the tubes by which blood is carried away from the heart. The name etymologically conveys the idea that these vessels are air-bearers, the ancients regarding them as performing the function of distributing air to the tissues, because they contain no blood or other liquid after death. But although this belief was long ago exploded, the name is not altogether inappropriate, and may be considered a prophetic blunder; for physiology demonstrates that the blood in the arteries is laden with oxygen, which is the essential nourishing ingredient in the air, and the most important element in the income of the body.

The Coats of Arteries.—An artery has three coats—an inner, a middle, and an outer. The points of especial practical value about these tunics are as follows: the *inner coat* (tunica intima) is serous, like the lining of every other portion of the vascular system; the *outer coat* (tunica adventitia) is composed of white fibrous tissue, with its bundles arranged longitudinally; and between these two is the *middle coat* (tunica media), made up of plain muscular and yellow fibrous tissues (Fig. 433).

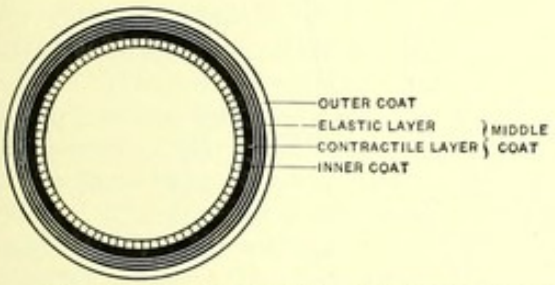

FIG. 433.—Diagram of a cross-section of an artery, showing the composition of its tunics. (F. H. G.)

While this statement of the structure of the arteries embraces the essential features of their physiological anatomy, a somewhat detailed description will not be out of place. The inner coat has three layers: an epithelial, consisting of flat, polygonal cells; a subepithelial, of white fibrous tissue, with sometimes yellow fibrous; and an elastic, of yellow fibrous tissue, closely reticulated. The middle coat is composed of plain muscular fibres, arranged crosswise in layers (Fig. 434), between which there is more or less yellow fibrous tissue. The outer coat, mostly of white fibrous, contains yellow fibres. Thus it appears that each tunic has some elastic tissue, the bulk of which, however, is an ingredient of the middle one.

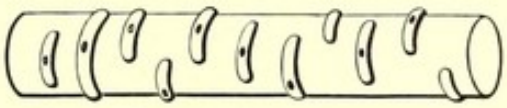

FIG. 434.—Diagram of the arrangement of muscle-cells in an arteriole. (F. H. G.)

The Functions of the Arterial Coats.—The inner tunic by its smoothness reduces the friction of the blood-current to its lowest terms; the outer by its strength and toughness is protective; the middle by virtue of its elasticity enables the vessel to return passively to its average diameter after it has been distended, and on account of its contractility serves actively to reduce the bore of the tube to less than its average. The larger the artery the greater is the relative amount of yellow fibrous tissue; and the smaller the artery the greater the relative amount of muscular tissue. The relativity of the quantity of these ingredients should be carefully noted; for, while the comparative contribution of muscle to a minute artery is great, its absolute amount is very small. From these facts it may be inferred that the large arteries are very elastic and but slightly contractile; the small are highly contractile, and only feebly elastic; and those of medium size possess both of these attributes to a considerable extent, the one or the other predominating according to the degree of nearness to the distal or the proximal limits of the arterial system.

Vessels and Nerves of Arteries.—Outside of the artery is an enclosing *sheath* of areolar tissue, in which are situated the nerves and blood-vessels of the artery itself. These are called respectively *nervi arteriarum* and *vasa arteriarum*; but, as the veins are similarly provided, generic, instead of the above specific, names are more frequently used—*nervi vasorum* and *vasa vasorum*, respectively "the nerves of the vessels" and "the vessels of the vessels." In surgical operations

it is important to avoid unnecessary separation of the sheath from the artery, because the destruction of the feeding vessels of the latter deprives the part of its nourishment, and results in its death. The vasa vasorum are either branches of the artery which they supply, being given off a little distance above their areas of distribution, or else they are contributed by a neighboring artery.

The Branching of Arteries.—The arterial system is aptly compared to a tree, from whose trunk many large branches spring, each of these giving origin to smaller branches, and so on until the most diminutive twigs are reached. Various methods of branching are observed in arteries (Fig. 435). Often an artery

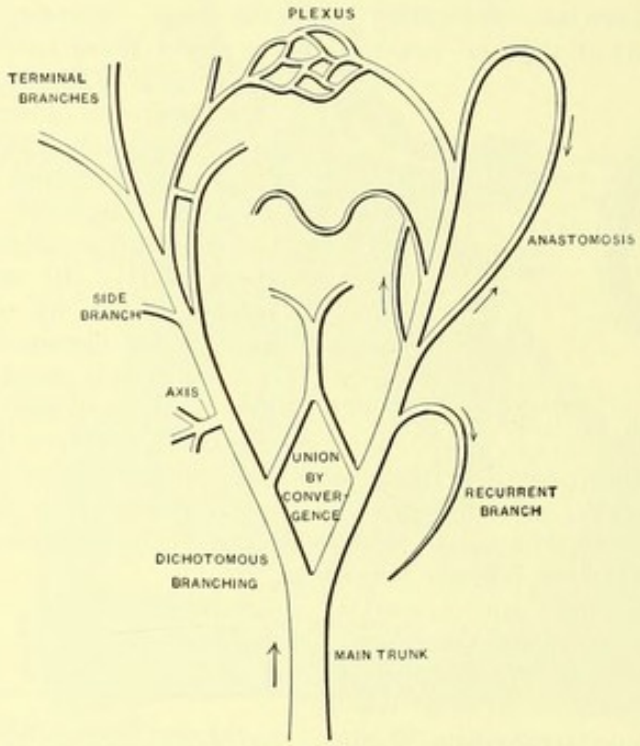

FIG. 435.—Diagram showing the branchings, anastomoses, and confluence of arteries. (F. H. G.)

divides into two terminal branches of nearly equal size, this method being called dichotomous, because the end of the vessel is split in two. Rarely an artery terminates in three approximately equal branches that diverge from the parent stem, which hence is called an *axis*. Most branches spring from the sides of an artery, and are, consequently, said to be given off in its course. These lateral branches usually form acute angles with their trunk, but sometimes right angles, and occasionally obtuse.

The *sectional area of an artery* is always less beyond the point at which a branch springs from it; but the combined sectional area of the immediate branches of an artery is always greater than that of the trunk from which they originate. Consequently, the capacity of the arterial system at any given distance from the heart exceeds that at any plane proximal to this, and thus there is vastly more blood in the smallest arteries (arterioles) than in the aorta and pulmonary artery, which receive the fluid directly from the heart.

Arteries generally pursue a course which is substantially straight or describes a generous curve; but some are serpentine, presenting a tortuous appearance, and this condition obtains in localities where the parts are liable to great changes of form, in some of which the vessel, if straight during quiescence, would be subjected to destructive stretching.

The *course of the blood* in the arteries is, as a rule, from centre to periphery; but exceptions occur, as in the case of the so-called recurrent arteries, which run backward, carrying the blood toward the heart. These vessels are frequent about

movable joints, and insure a plentiful supply of blood, when extreme flexion interferes with the direct and usual provision.

When the distal end of one artery is united to the end of another, so that the blood can flow in either direction, the arrangement constitutes an *anastomosis*, because the tubes are "mouth to mouth," and is also called an *inosculation*, which means "a kissing by mouths." Frequently a number of arteries form many and free inosculations within a limited area, thus making a network or *plexus*. Two arteries of equal size may unite, not by anastomosis, but to form a trunk, just as two venous radicles combine to constitute a larger vein. The vertebrals thus constitute the basilar artery.

The Capillaries.

At the periphery of the arterial system the vessels are microscopic, and consist of hardly more than the epithelium of the intima and a few scattered muscle-cells. When this imperfect contractile covering disappears, the vessel ceases to be an artery and becomes a capillary. The name *capillary* means hair-like; but these vessels are much finer than hairs, some of them having so narrow a lumen that a colored corpuscle of the blood cannot pass through it without being squeezed out of its normal shape. The length of a capillary is only a minute fraction of an inch. The wall of the tube is epithelial (Fig. 436), and is so thin that the materials of the blood pass through it into the spaces around the tissues, and the waste substances of the tissues traverse it in the opposite direction, and enter the blood. The capillaries are arranged in networks. The fineness of the vessels and the size and shape of the areas between them vary greatly. Thus, in the muscles the capillaries run between the fibres, and for the most part have a direction parallel with the fibres, the longitudinal being connected by obliquely crossing vessels, and enclosing long, narrow spaces, bounded by nearly straight lines; but in the air-vesicles of the lungs the capillaries are tortuous, very large, irregular, and so closely placed that the distance between them in some places is less than their own diameter. Some capillary vessels come from veins instead of arteries. For example, the interlobular branches of the portal vein give off the capillary plexus within the lobule, and from this the blood is collected by the intralobular vein.

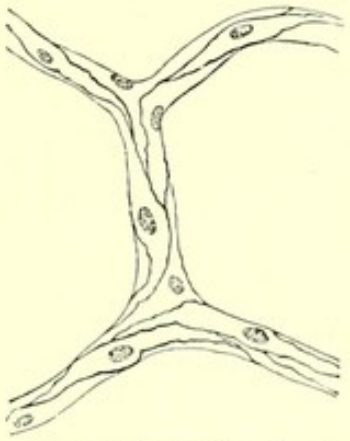

FIG. 436.—Capillaries, showing the shape and arrangement of the cells which make their wall. (Carpenter.)

The Veins.

The *veins* are vessels which conduct the blood from the periphery toward the centre of the vascular system. They begin where the capillaries end. As the loss of the last semblance of a middle coat changes an arteriole into a capillary, so the addition of a tunic, however scanty, to a capillary converts it into a *venule* ("little vein"). The venous system is comparable to the portion of a tree which is in the ground. It begins in rootlets at the distal end of the capillaries (Fig. 437). These minute veins are properly called *radicles*, and the same term is used to designate veins of any size, which by their confluence form a larger vessel. They are often called branches instead of radicles; but the term "branches" should be restricted to vessels resulting from division rather than from union. The desirability of the distinction is perceived in cases where a vein divides into two or more veins. The last are clearly branches of a parent stem, but, at the same time, are radicles of one or more veins nearer the heart.

The veins are more numerous than the arteries, and the capacity of the venous system is considerably greater than that of the arterial.

The veins have a structure, which in the main, is like that of the arteries ; but there are such variations of detail that, in some respects, the two sets of vessels behave very differently. The *inner coat* is essentially like the arterial intima, with the addition of numerous transverse folds, which, strengthened by plates of white fibrous tissue, form *valves* (Fig. 438). The *middle tunic* is thinner than that of the arteries of comparable size, contains less muscle, more white fibrous, and only a little yellow fibrous tissue. The *external coat* is very like that of the arteries. This combination results in vessels which are very strong, capable of sustaining more strain than arteries without giving way, but so flabby that they collapse when emptied of blood ; whereas arteries, stiffened as they are with elastic and a large amount of muscular tissue, stand open in similar circumstances.

FIG. 437.—Diagram, showing the formation of large veins by convergence of small, and the branching of veins. (F. H. G.)

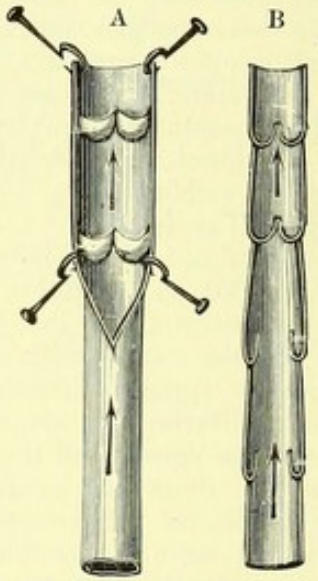

FIG. 438.—Valves of veins. A shows a vein cut open between the segments of two valves. B shows appearance of valves closed and open. (Testut.)

The *valves* are not found in all veins. They generally have two flaps each, which are directed toward the heart, when open. At the base of each valve the vein bulges, forming a *sinus*, into which the blood enters as soon as any obstruction to its flow occurs, and causes instant closure of the valve.

A few *exceptions* are found to the rule that capillaries intervene between arterioles and venules. In the interior of erectile organs small arteries may open directly into venous cavities ; and in the spleen the arteries discharge into the interstices of the organ.

THE ARTERIES.

By A. D. BEVAN.

THE arteries are the vessels which carry the blood from the right and left ventricles of the heart to all parts of the body. There are two sets of arteries, the *pulmonary* ("lung"), and the *systemic*. Each system begins as a single tube, continues as a single tube for a short distance, and then divides into branches. Each system resembles a tree with its trunk and branches. In studying each system the student should regard it as a whole, remembering that many of the divisions made are artificial, and that the whole system forms one continuous series of tubes. In the study of the arteries the student should follow some systematic plan, which will so fix in his memory a picture of the origin, and course, and relations of the arteries to surrounding structures, that this knowledge can be of service to him in his practical work. The pulmonary system is simple and easily mastered; the systemic requires much study. In studying the systemic system the student should make a syllabus of the entire system; then, beginning with the aorta, he should study each anatomical division separately, and should learn of each vessel the following facts: Its origin, course, termination, relations, branches, distribution, anastomoses, variations, and surgical anatomy. In studying the vessels the drawing of longitudinal sketches and of sketches of transverse sections of the limbs and trunk at different levels, showing the position of the vessels and the relation of the vessels to surrounding structures, will be found to be of great value. The vessels are best studied in the dissecting-room, but another valuable method of studying them is upon a living model. The external landmarks which guide the operator in the finding of, or in the avoiding of, a vessel in an operation are best fixed in the mind by the study of the living model. We shall follow therefore in this description of the systemic arteries the course outlined:

I. A syllabus of the entire system.

II. A detailed description of each vessel, giving its origin, course, termination, branches, distribution, relations, anastomoses, variations, and surgical anatomy.

We shall combine the study of the longitudinal course of the arteries with that of the vessels in transverse section, and shall study also the surgical anatomy involved in the ligation of the arteries. Before taking up the study of the systemic arteries, let us dispose of the pulmonary system, which can be briefly done.

THE PULMONARY ARTERIAL SYSTEM.

The **Pulmonary Artery** (Fig. 439) carries the venous blood from the right ventricle to the lungs. Its *origin* is from the right ventricle; its *course* is upward, backward, and to the left for the distance of two inches, the vessel being contained in the pericardial cavity. Its *termination* is at a point beneath the transverse portion of the aorta opposite the fifth dorsal vertebra. Here it *divides into* the right and left pulmonary. Its *relations* are as follows:

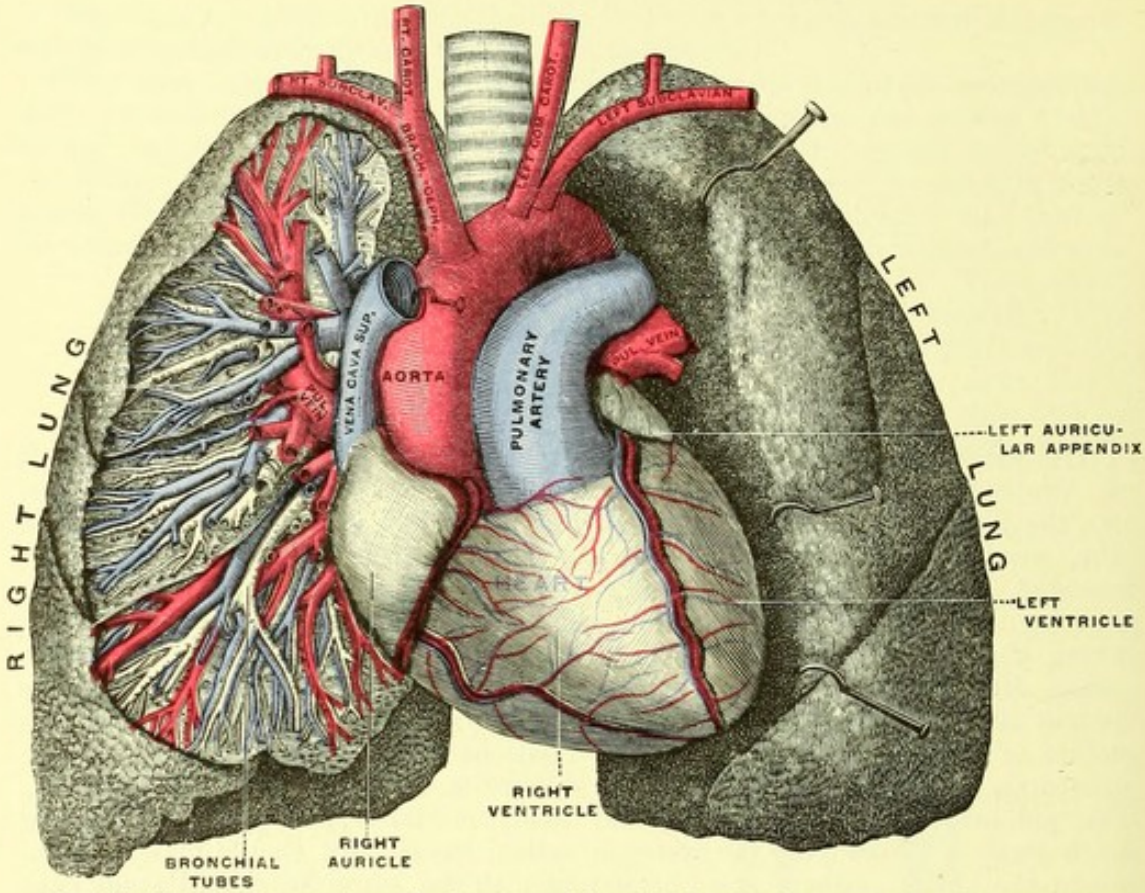

FIG. 439.—The pulmonary artery. The front part of the right lung has been removed, and the pulmonary vessels and the bronchial tubes are thus exposed. (Testut.)

In front.

Sternum and pericardium.

To the right.		*To the left.*
Ascending aorta.		Pericardium.
Right auricle.	**Pulmonary**	Left pleura.
Right coronary artery.	**Artery.**	Left auricle.
		Left coronary artery.

Behind.

Arch of aorta and left auricle.

Its branches are the right and left pulmonary. The *right pulmonary artery* passes beneath the aortic arch to the right lung, breaks up into three sets of branches supplying the upper, the middle, and the inferior lobes.

The *left pulmonary artery* passes in front of the descending aorta to the left lung, and breaks up into two sets of branches supplying the upper and lower lobes.

It is to be remembered that the pulmonary arteries carry venous blood to the lobules of the lungs, in which it experiences the changes produced by the function of respiration, the structure of the lungs being supplied with arterial blood by the bronchial arteries, branches of the descending aorta. The branches of the pulmonary arteries do not anastomose with each other : they are terminal arteries.

Passing from the pulmonary artery to the arch of the aorta is a fibrous cord, the remains of the *ductus arteriosus*, a vessel, which in the fœtal circulation carries the blood sent through the pulmonary artery into the aorta. After birth this soon disappears ; but, as an abnormality, it may persist.

A SYLLABUS OF THE SYSTEMIC ARTERIAL SYSTEM.

The systemic arterial system begins as the *aorta* from the left ventricle at a point behind the left half of the sternum on a level with the lower border of the third costal cartilage. From this point it passes upward, forward, and to the right, to a point on a level with the upper border of the second costal cartilage. It then curves backward and to the left, to the lower border of the fourth thoracic vertebra; and then passes downward on the bodies of the thoracic vertebræ, being placed in a position to the left of the median line at first, but gradually approaching the median line as it passes downward. The vessel then passes through the aortic opening in the diaphragm, passes downward on the bodies of the upper four lumbar vertebræ, and on the body of the fourth lumbar vertebra divides into the two common iliac arteries. The aorta is divided into three portions, an *arch* extending from its origin to the lower body of the fifth thoracic vertebra, the *thoracic aorta* from the lower border of the fifth thoracic to the aortic opening in the diaphragm, and the *abdominal aorta* from the aortic opening in the diaphragm to the body of the fourth lumbar, its point of division into the common iliacs. Immediately above the aortic valves the arch gives off two vessels, the right and left *coronary arteries*, which supply the heart. The transverse portion of the arch, as a rule, gives off three vessels, the *brachio-cephalic* (innominate), the *left common carotid*, and the *left subclavian*. The brachio-cephalic ("arm-head") is a short vessel, an inch and a half in length, extending from the transverse portion of the arch to the right sterno-clavicular articulation, where it divides into the *right common carotid* and *right subclavian*. Thus the right subclavian and right carotid differ in their origin and length from the left subclavian and left carotid. The common carotid on both sides terminates at the superior border of the thyroid cartilage, by dividing into the *internal* and *external carotids*, and, as a rule, the common carotids have no other branches. The external carotid terminates a little below the condyle of the jaw by dividing into the *temporal* and *internal maxillary*. The external gives off in addition to its two terminal branches mentioned, the *superior thyroid*, the *lingual*, the *facial*, the *occipital*, the *posterior auricular*, and the *ascending pharyngeal*. Speaking broadly, it supplies the structures of the neck and the face (with the exception of the contents of the orbit and the integument of the forehead), the scalp, and the greater portion of the dura mater. These branches of the external carotid again subdivide into branches which will be studied in detail later. The internal carotid which begins at the superior border of the thyroid cartilage passes up to and through the carotid canal in the petrous portion of the temporal bone, enters the cranial cavity, and breaks up into branches which supply the greater part of the brain and contents of the orbit; the vertebral, a branch of the subclavian, as we shall find, assists the carotid in supplying the brain.

The subclavian artery begins on the right side from the brachio-cephalic, on the left from the arch of the aorta, and passes outward to the lower border of the first rib, where the vessel changes its name and becomes the axillary. The subclavian is divided into three portions according to its relation to the scalenus anterior. It gives off as branches the *thyroid axis*, the *vertebral*, the *internal mammary*, and the *superior intercostal*. The *axillary* begins at the lower border of the first rib and extends to the lower border of the axillary space, where the vessel changes its name and becomes the brachial. The axillary is divided into three parts according to its relation to the pectoralis minor muscle, which is in front of it. The axillary gives off the *superior thoracic*, the *acromio-thoracic*, the *long thoracic*, the *alar thoracic*, the *subscapular*, the *anterior* and *posterior circumflex*.

The *brachial* extends from the lower border of the axillary space to a point a half inch below the elbow, where it divides into the *radial* and *ulnar*. It gives off in its course the *superior profunda*, *muscular*, *nutrient*, *inferior profunda*, and

anastomotica magna. The radial extends from the point of bifurcation of the brachial to the palm of the hand, where it forms the *deep palmar arch*, anastomosing with the deep branch from the ulnar. It gives off in the forearm the *radial recurrent*, the *muscular*, the *anterior carpal*, and the *superficialis volæ*; in the wrist, the *posterior carpal*, the *metacarpal*, the *dorsalis indicis*, and *dorsalis pollicis*; in the hand, the *princeps pollicis*, the *radialis indicis*, the *perforating*, and *interosseous*. The ulnar begins a half inch below the elbow, and like the radial extends into the hand, terminating in the *superficial palmar arch*, anastomosing with the superficialis volæ. In the forearm it gives off the *anterior ulnar recurrent*, the *posterior ulnar recurrent*, the *interosseous*, which divides into an anterior and posterior branch, and *muscular*. In the wrist it gives off *anterior* and *posterior carpal branches*, and in the hand the *deep communicating* branch and the *digital*.

Returning to the aorta, we find that the *thoracic portion*, which begins at the lower border of the fifth thoracic vertebra and terminates at the aortic opening in the diaphragm, gives off branches as follows: *pericardial*, *bronchial*, *œsophageal*, *posterior mediastinal*, and *intercostal*—these branches supplying the walls and contents of the thorax, with the exception of the heart-substance, which is supplied by the coronary arteries.

The abdominal aorta begins at its opening in the diaphragm, and terminates on the body of the fourth lumbar vertebra by dividing into the *common iliacs*. It gives off as branches the *phrenic*, the *cœliac axis*, the *superior mesenteric*, the *renal*, the *suprarenal*, the *spermatic*, the *inferior mesenteric*, the *lumbar*, and the *sacral* arteries. These vessels as a group supply the walls of the abdominal cavity and the viscera contained within that cavity. The common iliac begins on the body of the fourth lumbar vertebra and extends to the intervertebral substance between the last lumbar vertebra and the sacrum. Here it divides into the *internal* and *external iliac* arteries. The common iliac gives off no branches of importance in its course.

The *internal iliac* extends from the intervertebral substance between the last lumbar vertebra and sacrum to the upper margin of the great sacro-sciatic notch, where it divides into an *anterior* and *posterior trunk*, the anterior giving off as branches the *superior vesical*, the *middle vesical*, the *inferior vesical*, the *middle hemorrhoidal*, the *obturator*, the *internal pudic*, and the *sciatic*; also, the *uterine* and *vaginal* in the female. The posterior trunk gives off the *ilio-lumbar*, the *lateral sacral*, and the *gluteal*. As a group, the branches of the internal iliacs supply the walls and viscera of the pelvis. In addition to this, the gluteal, sciatic, and obturator supply the buttock and back part and internal surface of the thigh, and the internal pudic supplies the perineum and external organs of generation. The external iliac extends from the termination of the common iliac to the inguinal (Poupart's) ligament. Here it changes its name and becomes the *femoral*. In its course it gives off two vessels, the *deep epigastric* and *circumflex iliac*.

The *femoral* begins at the inguinal (Poupart's) ligament and extends to the femoral opening in the adductor magnus muscle. Here it passes into the popliteal space and becomes the *popliteal*. In its course it gives off as branches the *superficial epigastric*, the *superficial external pudic*, the *superficial circumflex iliac*, the *deep external pudic*, the *profunda*, the *muscular*, and the *anastomotica magna*. The profunda, which is a large trunk, gives off as branches the *external circumflex*, the *internal circumflex*, and the three *perforating* arteries. The femoral with its branches supplies the thigh. The popliteal extends from the opening in the adductor magnus muscle to the lower border of the popliteus muscle, and here divides into the *anterior* and *posterior tibial* arteries. In its course it gives off *muscular* branches, *superior* and *inferior cutaneous*, *superior external articular*, *superior internal articular*, *azygos articular*, *inferior external articular* and *inferior internal articular* arteries, which as a group supply the tissues in the popliteal space and the knee-joint.

The *anterior tibial* begins at the lower border of the popliteus muscle, per-

forates the interosseous membrane, and passes to the anterior surface of the leg, and thence down to the bend of the ankle, where it changes its name to *dorsalis pedis*. In its course in the leg it gives off as branches the *recurrent tibial*, *muscular*, *internal malleolar*, and *external malleolar* arteries. The dorsalis pedis extends from the bend of the ankle to the back part of the first interosseous space, where it divides into the *dorsalis hallucis* and *communicating*. It gives off as branches the *tarsal*, the *metatarsal*, and the *interosseous*, which supply the dorsum of the foot and toes, and the *communicating*, which anastomoses with the external plantar, thus completing the plantar arch.

The *posterior tibial* passes down the back of the leg to the concavity between the heel and inner ankle, where it divides into the *internal* and *external plantar* arteries. In its course it gives off as branches the *peroneal*, *anterior peroneal*, *muscular*, *nutrient*, *communicating*, and *internal calcanean arteries*, which as a group supply the back of the leg and heel. The internal plantar begins at the point of division of the posterior tibial, and runs forward along the inner side of the great toe, which it supplies. The external plantar passes forward in the sole of the foot, and forms by anastomosing with the communicating branch of the dorsalis pedis, the *plantar arch*, which gives off *posterior perforating*, *digital*, and *anterior perforating* branches, and supplies the sole of the foot and the toes.

The student is strongly advised to draw a rough longitudinal sketch of the entire arterial system following the syllabus given above. This sketch should show the origin, course, termination, and branches of each vessel; as later the vessels are studied in detail, sketches of special portions of the arterial system, as the circle of Willis, the vessels in the triangles of the neck, the axillary space, Scarpa's triangle, the popliteal space, etc., should be made; also sketches of cross-sections of the trunk, neck, and upper and lower extremities at different levels, showing the position of the vessels, and their relation to surrounding structure. Such a method will materially aid the student in the study of the arteries in the dissecting-room and on the living model.

THE AORTA.

The aorta is the main trunk of the systemic system. It begins at the left ventricle and terminates on the body of the fourth lumbar vertebra by dividing into the common iliacs. It is divided anatomically into three portions, the arch, the thoracic aorta, and the abdominal aorta. The *arch of the aorta* extends from the left ventricle to the lower border of the body of the fifth thoracic vertebra; the *thoracic aorta* from this point to the aortic opening in the diaphragm; the *abdominal aorta* from the aortic opening in the diaphragm to the termination of the vessel on the body of the fourth lumbar vertebra. The aorta is divided by some anatomists into an ascending aorta, an arch, and a descending aorta, the ascending aorta corresponding to the ascending portion of the arch in the description which will be followed here, the arch corresponding to the transverse portion of the arch, and the descending aorta beginning at the lower border of the fourth dorsal vertebra, and, therefore, including the descending portion of the arch of the division here adopted.

THE ARCH OF THE AORTA.

The arch (Fig. 440) is divided into three portions: an ascending, a transverse, and a descending portion.

The Ascending Portion of the Arch.—*Origin*: the left ventricle opposite the lower border of the third costal cartilage and behind the sternum. *Course*, upward and to the right to the upper border of second costal cartilage. *Termination*: here the ascending portion bends backward and to the left, and becomes the transverse portion of the arch.

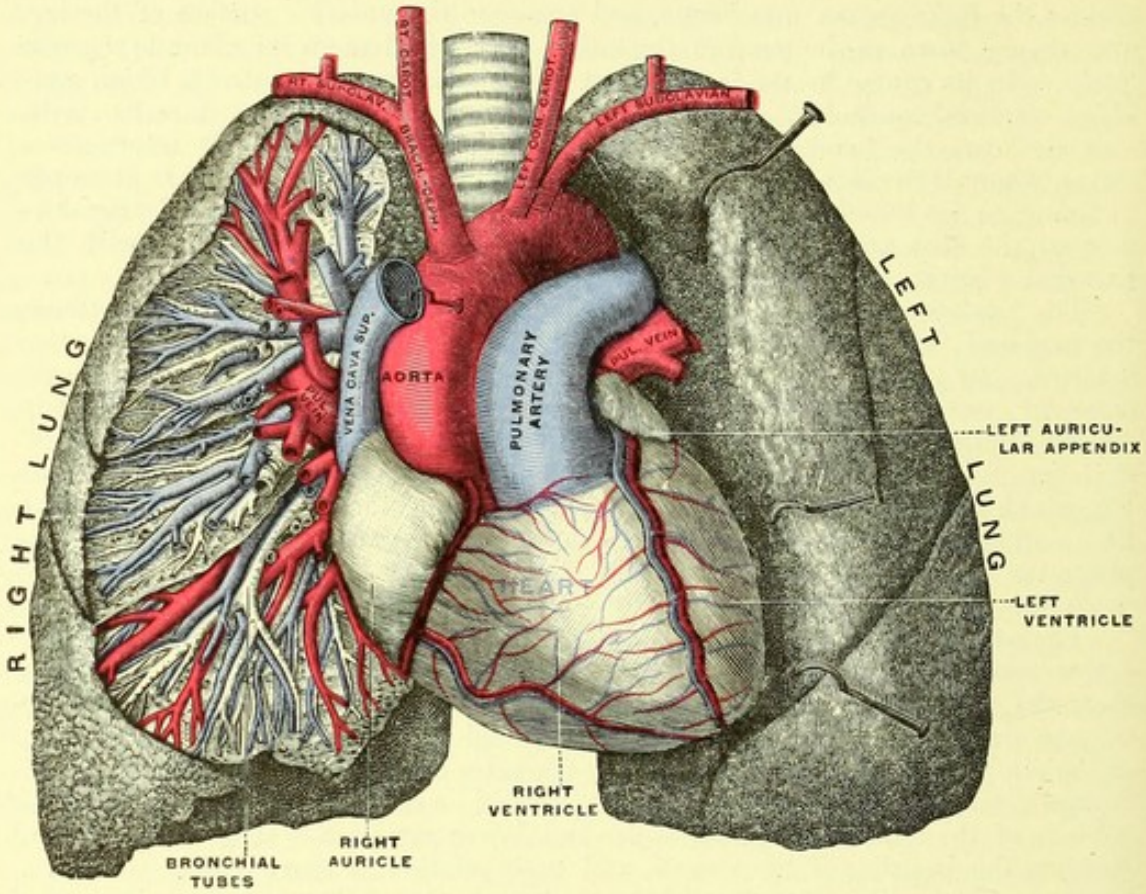

FIG. 440.—Arch of the aorta and its branches. (Testut.)

RELATIONS.

In front.

Pulmonary artery.
Appendix of right auricle.
Pericardium and sternum.

At the right.

Superior cava and right auricle.

Ascending portion of arch.

At the left.

Pulmonary artery.

Behind.

Root of right lung.

The Transverse Portion of the Arch.—*Origin*, on a level with the upper border of second costal cartilage, at which point the aortic arch turns backward and to the left. *Termination*, at the lower border of the fourth thoracic vertebra.

RELATIONS.

Above.

Left brachio-cephalic vein.
Brachio-cephalic artery.
Left carotid.
Left subclavian.

In front.

Left lung and pleura.
Left pneumogastric nerve.
Left phrenic nerve.

Transverse portion of arch.

Behind.

Trachea.
Œsophagus.
Thoracic duct.
Left recurrent laryngeal nerve.

Below.

Bifurcation of pulmonary artery.
Left recurrent laryngeal nerve.
Root of left lung.

The Descending Portion of the Arch.—This is that portion of the aorta in front of the body of the fifth dorsal vertebra and the intervertebral disc above it.

RELATIONS.

In front.

Pleura.
Root of left lung.

Right side.		*Left side.*
Œsophagus. Thoracic duct.	**Descending portion of arch.**	Pleura.

Behind.

Body of fifth dorsal vertebra.

The branches of the arch are the right and left coronary arteries, which arise from just above the anterior and left flaps of the aortic valve; the brachio-cephalic, the left common carotid, and the left subclavian from the transverse portion of the arch.

Varieties.—The position of the vessel varies. It may reach as high as the top of the sternum, or its summit may be as low as the fifth dorsal vertebra; the failure of normal development of the aortic arches of the fœtus may result in the persistence of the ductus arteriosus; there may be persistence of a septum within the vessel, dividing it into two tubes; the presence of a right instead of a left aortic arch, this last being sometimes accompanied with a transposition of the viscera; the presence of a double aortic arch, one on the left, the other on the right, these passing backward, embracing the œsophagus, and uniting to form a single thoracic aorta. The number of branches given off from the transverse portion of the arch varies from one to six; a single trunk may be given off which then divides into the great vessels of the neck and upper extremities. There may be two branches, a right and left brachio-cephalic, or two branches, a right subdividing into the right subclavian, right common carotid, and left common carotid, the other branch being the left subclavian. Four vessels may be given off—right subclavian, right carotid, left carotid, and left subclavian; or four vessels may exist in which the usual brachio-cephalic, the left carotid, and left subclavian are present, but in which the left vertebral arises as a separate trunk from the arch. Five vessels may exist in a case like the above in which the brachio-cephalic is absent, and where we find a right subclavian, right common carotid, left common carotid, left vertebral, and left subclavian arising as separate branches of the arch. Cases of six branches are the same as the above, except that the right vertebral is added as a separate trunk. The surgical anatomy is of special interest in the study of aneurism, which occurs more frequently in the aorta than in any other artery.

The relations of the arch of the aorta to surrounding structures should be studied with reference to the effects of the pressure produced by aneurism upon them, and the resulting symptoms. Aneurism of the ascending portion of the arch may by pressure produce absorption of the costal cartilages, sternum, and ribs, and present itself as a pulsating tumor to the right of the sternum, eventually rupturing and producing death. Aneurism of the transverse portion may produce pressure on the œsophagus, producing difficult deglutition, and simulating stricture of the œsophagus. Such an aneurism may also produce pressure on the trachea and bronchi, the thoracic duct, and the great veins within the

thorax, and interfere with the normal function of these structures. An interesting symptom is hoarseness and loss of voice, due to pressure on the recurrent laryngeal nerve.

Branches of the Ascending Portion of the Arch.—The *coronary arteries* are two in number. The *right coronary* arises from the aorta above the right (anterior) flap of the aortic valve; it winds to the right in the groove between the right auricle and ventricle, until it reaches the septum between the right and left ventricles posteriorly. Here it divides into two branches, one continuing in the groove between the left auricle and ventricle; the other passing downward in the groove between the ventricles to the apex of the heart.

The *left coronary* arises from above the left segment of the aortic valve, passes forward and to the left behind the pulmonary artery, and divides opposite the septum between the right and left ventricles anteriorly into two branches, one descending in the groove between the ventricles to the apex of the heart, the other running to the left and backward in the groove between the left auricle and the left ventricle. The coronary arteries supply the heart-muscle, and send small branches to the contiguous portions of the aorta and pulmonary artery.

The Branches of the Transverse Portion of the Arch.—These are the brachio-cephalic, the left common carotid, and the left subclavian.

THE BRACHIO-CEPHALIC ARTERY.

The *brachio-cephalic* (innominate) artery is a short trunk of about an inch and a half in length, and is the first branch of the transverse portion of the arch. *Origin*, from the transverse portion of the arch opposite the upper border of the second costal cartilage. *Course*, upward and to the right. *Termination*, at the sterno-clavicular articulation by dividing into the right common carotid and right subclavian.

Relations.

In front.

Sternum.
Sterno-hyoid and sterno-thyroid muscles.
Left innominate and left inferior thyroid veins.

Right side.		*Left side.*
Right brachio-cephalic vein. Right pneumogastric nerve. Pleura.	**Brachio-cephalic artery.**	Left carotid. Left inferior thyroid vein. Trachea.

Behind.

Trachea.

Variations.—The brachio-cephalic may be absent, the right common carotid and subclavian springing directly from the aorta. It may be longer or shorter than usual—less than an inch, or more than two inches in length.

Surgical Anatomy (Fig. 442).—The brachio-cephalic may be the site of aneurism, and from its deep position produce pressure-symptoms resembling aneurism of the arch of the aorta—*i. e.*, pressure on the trachea, recurrent laryngeal, œsophagus, roots of the lungs, and the great vessels. The brachio-cephalic has been ligated for aneurism of the carotid and subclavian, but the results have not been encouraging; and although the operation is not a standard surgical procedure and one rarely performed, the description of the dissection necessary to expose the vessel for ligation will be of value in fixing in the student's mind the relation of surrounding structures, and will therefore be given here. The subject is placed on the table with a block beneath the shoulder, so that the head and neck fall backward, and an assistant draws the right upper extremity downward so as to

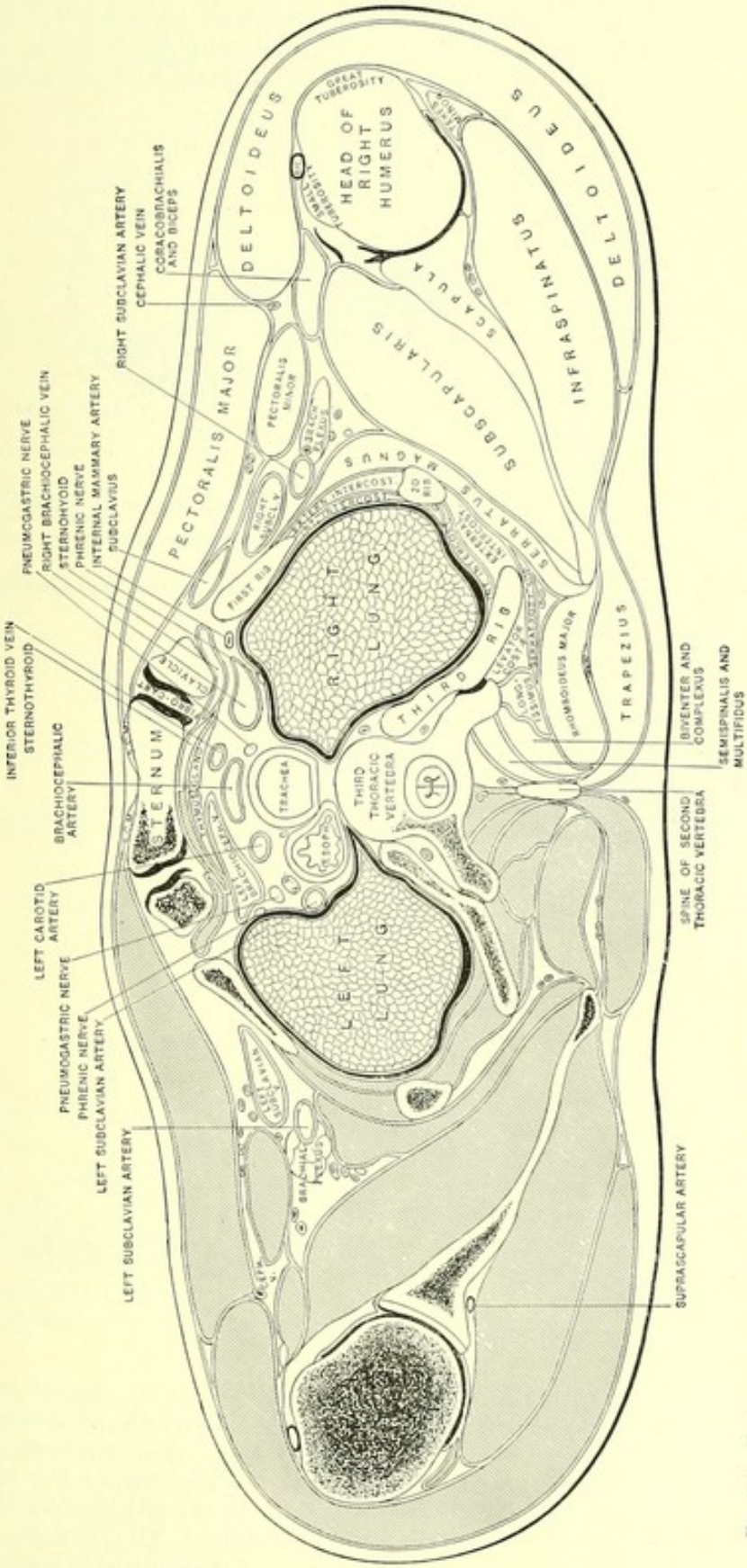

FIG. 441.—Horizontal section through the body of the third thoracic vertebra. The upper surface of the lower segment is shown. On the left side the muscles are shaded; on the right side are their labels. (After Braune.)

draw the clavicle downward, and expose as much of the vessel as possible. An incision four inches in length is made on the inner border of the sterno-cleido-mastoid, extending to the sterno-clavicular articulation. A second incision of the same length is made over the clavicle parallel with it, meeting the first incision. These incisions divide the skin, superficial fascia, and platysma myoid

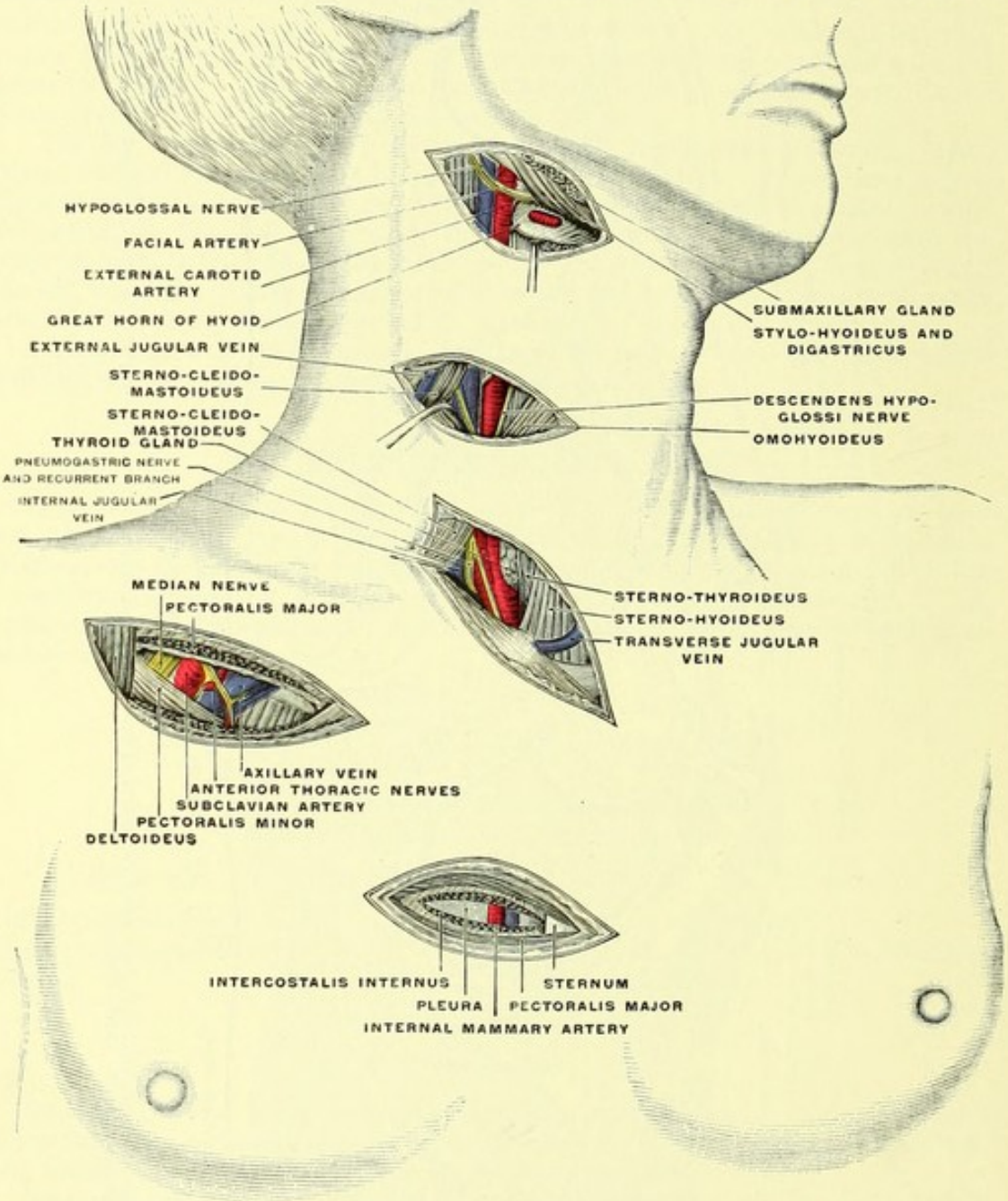

FIG. 442.—Surgical relations of the lingual, external carotid, common carotid, brachio-cephalic, subclavian, and internal mammary arteries. (Kocher.)

muscle, and expose to view the sterno-cleido-mastoid. This should be divided completely across at a point one and a half inches above the sternum, and the lower part turned downward and held out of the way. The sterno-thyroid and sterno-hyoid muscles come now into view, and are divided in the same way. This usually exposes the inferior thyroid veins, which are either carefully pushed out of the way, or are ligated at two points, and divided. The common carotid is now exposed, and followed downward until the brachio-cephalic is reached. The left brachio-cephalic vein crosses the artery in the lower half of its course, the

right brachio-cephalic vein and the pneumogastric nerve are to the right of the vessel, and the pleura and trachea are behind. In passing an aneurism-needle it is best passed from the right to the left behind the vessel, care being taken to avoid injury to the pneumogastric nerve, the brachio-cephalic veins, and the pleura.

Branches.—In addition to the terminal branches, the right common carotid and right subclavian, the brachio-cephalic occasionally gives off a branch, the *thyroidea ima*, which passes upward on the surface of the trachea to the isthmus of the thyroid gland, and the occasional presence of this branch should be remembered in the operations of removal of the thyroid gland, and in low tracheotomy.

The *common carotid arteries* (Fig. 443) differ upon the two sides. The right takes its origin from the brachio-cephalic, the left from the arch of the aorta; the left is, therefore, the longer of the two. In the neck the common carotids are so nearly alike that one description will answer for both. It will be necessary, however, to describe that portion of the left carotid which extends from the arch to the sterno-clavicular articulation.

The Left Carotid Artery in the Thorax.

This portion resembles somewhat the brachio-cephalic artery in length and in its relation to surrounding structure.

RELATIONS.

In front.

Sternum.
Sterno-hyoid and sterno-thyroid.
Left brachio-cephalic vein.

Right side.		*Left side.*
	Left carotid in thorax.	Left pneumogastric nerve.
Brachio-cephalic artery.		Left subclavian.
		Artery.

Behind.

Trachea.
Œsophagus.
Thoracic duct.

THE COMMON CAROTIDS IN THE NECK.

Origin, opposite the sterno-clavicular articulation from the brachio-cephalic on the right side, and from the thoracic portion of the common carotid on the left. *Course*, upward and outward in a line drawn between the sterno-clavicular articulation and a point midway between the angle of the jaw and the mastoid process. The vessel is covered by the sterno-cleido-mastoid muscle, the inner border of which is a good guide to its course. *Termination*: at the level of the upper border of the thyroid cartilage, the common carotid divides into the internal and external carotids.

RELATIONS.

In front.

Integument and superficial fascia.
Platysma and deep cervical fascia.
Sterno-mastoid muscle.
Sterno-hyoid, sterno-thyroid, omo-hyoid muscles.
Descendens noni nerve.
Sterno-mastoid artery.
Superior and middle thyroid veins.
Anterior jugular vein.

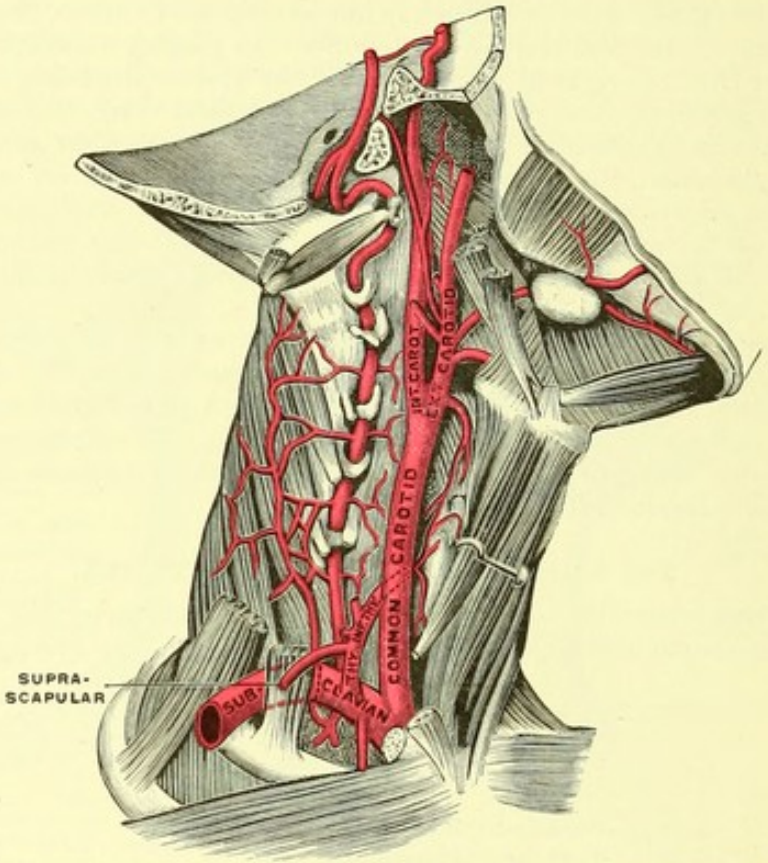

FIG. 443.—Right subclavian and carotid arteries. The vertebral artery is seen threading the costo-transverse processes of the vertebræ. (Testut.)

External.

Pneumogastric nerve.
Internal jugular vein.

Common carotid in neck.

Internal.

Trachea.
Thyroid gland.
Recurrent laryngeal nerve.
Inferior thyroid artery.
Larynx and pharynx.

Behind.

Longus colli.
Rectus capitis anterior major.
Sympathetic nerve.
Recurrent laryngeal nerve.
Inferior thyroid artery.

Variations.—The right common carotid sometimes springs directly from the arch of the aorta; sometimes the left common carotid springs from a left brachio-cephalic artery; the common carotid is sometimes absent, the internal and external carotids springing directly from the arch of the aorta or from a brachio-cephalic artery. In some cases it divides above or below the usual point, low down in the neck or as high as or higher than the hyoid bone.

Surgical Anatomy (Fig. 442).—The common carotid can be ligated in any part of its course; the best point to select is about the level of the cricoid cartilage and above the omo-hyoid muscle, because here the vessel is more accessible than in the lower part of its course. To expose the vessel in the upper part of its course an incision three inches in length is made along the inner border of the sterno-cleido-mastoid muscle, the centre of the incision being opposite the cricoid cartilage. The incision divides the skin, superficial fascia, platysma myoid, and the anterior layer of the deep fascia; the sterno-cleido-mastoid muscle is drawn to the outer side. The sterno-mastoid artery is usually divided, but this is of no

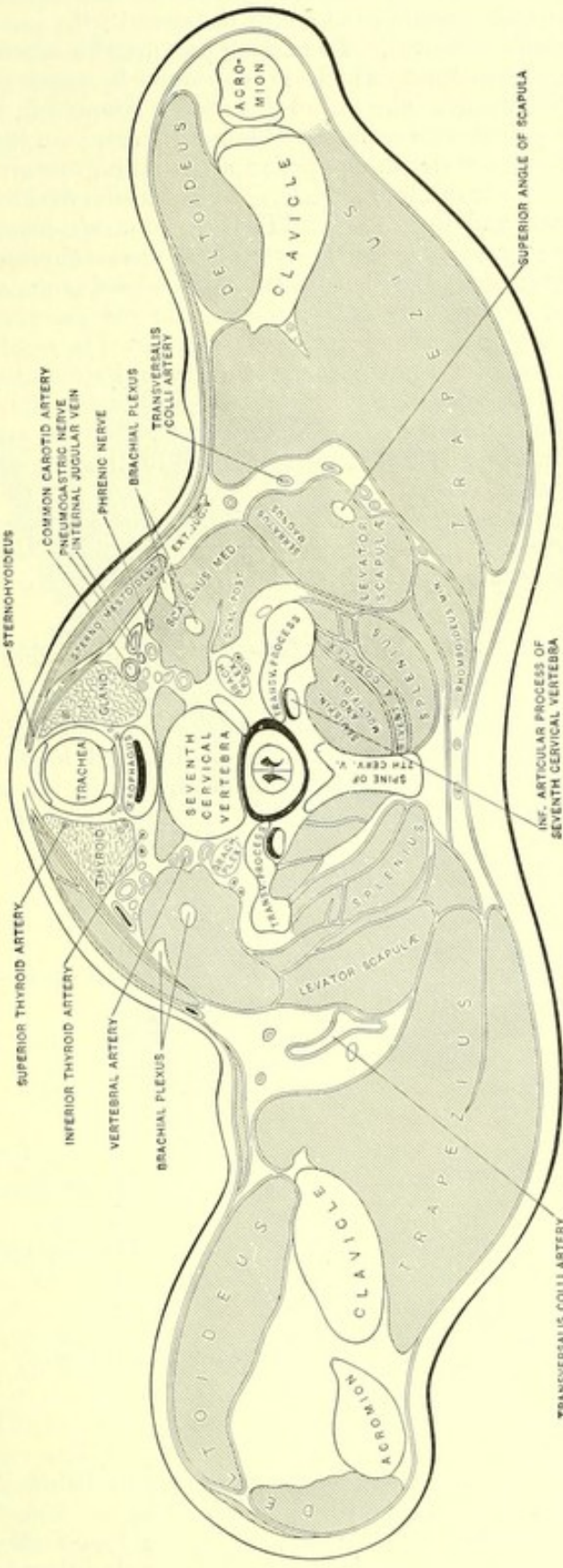

FIG. 444.—Horizontal section through the body of the seventh cervical vertebra. The upper surface of the lower segment is shown. The lack of bilateral symmetry is largely due to the difference in the level of the shoulders—a not unusual condition. (After Braune.)

importance; the sheath is exposed and opened, care being taken not to injure the descendens hypoglossi, which is usually in front of the sheath. The internal jugular vein is external, sometimes overlaps the vessel; the pneumogastric nerve is external and behind the vessel. In passing an aneurism-needle care should be taken to avoid these structures, which is best done by passing the needle from without behind and inward. The vessel lies deeply situated in the lower part of its course, and the operation to expose it is more difficult; an incision four inches in length is made from the sterno-clavicular articulation upward along the inner border of the sterno-cleido-mastoid muscle. This incision divides the skin, superficial fascia, platysma, and deep fascia. The sterno-cleido-mastoid is turned to the outer side; this exposes the sterno-hyoid and sterno-thyroid muscles; these are drawn to the inner side, and the sheath of the vessel is exposed. The internal jugular overlaps and is external to the vessel; the pneumogastric nerve is external and behind. These structures are to be avoided in passing the aneurism-needle. After ligation of a common carotid, collateral circulation is soon established through the free anastomoses which exist between the branches of the internal and external carotids of the opposite side, and the anastomoses which exist between the branches of the external carotid of the side operated upon and the branches of the subclavian.

Branches.—The common carotid, as a rule, does not give off any branches in its course; in rare cases it gives off a superior or an inferior thyroid or the vertebral artery. The terminal branches are the internal carotid and the external carotid.

The External Carotid Artery (Figs. 443, 445).

Origin: the external carotid begins as one of the terminal branches of the common carotid opposite the superior border of the thyroid cartilage. *Course*: it passes upward and outward to a point between the condyle of the jaw and the external auditory meatus. *Termination*: it terminates in the substance of the parotid gland by dividing into the temporal and the internal maxillary arteries.

Relations.

In front.

Integument, superficial fascia, platysma and deep fascia.
Hypoglossal nerve.
Lingual and facial veins.
Digastric and stylo-hyoid muscles.
Parotid gland.
Facial nerve.

Internally.

External carotid artery.

Hyoid bone.
Pharynx.
Inferior laryngeal nerve.

Behind.

Superior laryngeal nerve.
Stylo-glossus and stylo-pharyngeus muscles.
Glosso-pharyngeal nerve.
Parotid gland.

Variations.—The external carotid may arise above or below its usual point—*i. e.*, opposite the superior border of the thyroid cartilage. Sometimes the artery arises as a branch from the aortic arch. Cases are found where the external carotid is altogether absent, the common carotid not dividing into the internal and external carotids, but supplying from a common trunk the branches usually

supplied by these vessels. Variations in the branches of the external carotid are very often met with, and will be described in connection with each branch respectively.

Surgical Anatomy (Figs. 442–446).—To ligate the external carotid in the lower half of its course, an incision should be made three inches in length, beginning an inch below the superior border of the thyroid cartilage, and extending upward along the inner border of the sterno-cleido-mastoid muscle. This incision should divide the skin, superficial fascia, platysma myoid muscle, and deep fascia; the sterno-cleido-mastoid is drawn to the outer side, and the vessel exposed. The vessel is very superficially situated, and the operation is not difficult. To expose the vessel in the upper half of its course, an incision should be made about three inches in length along the inner border of the sterno-cleido-

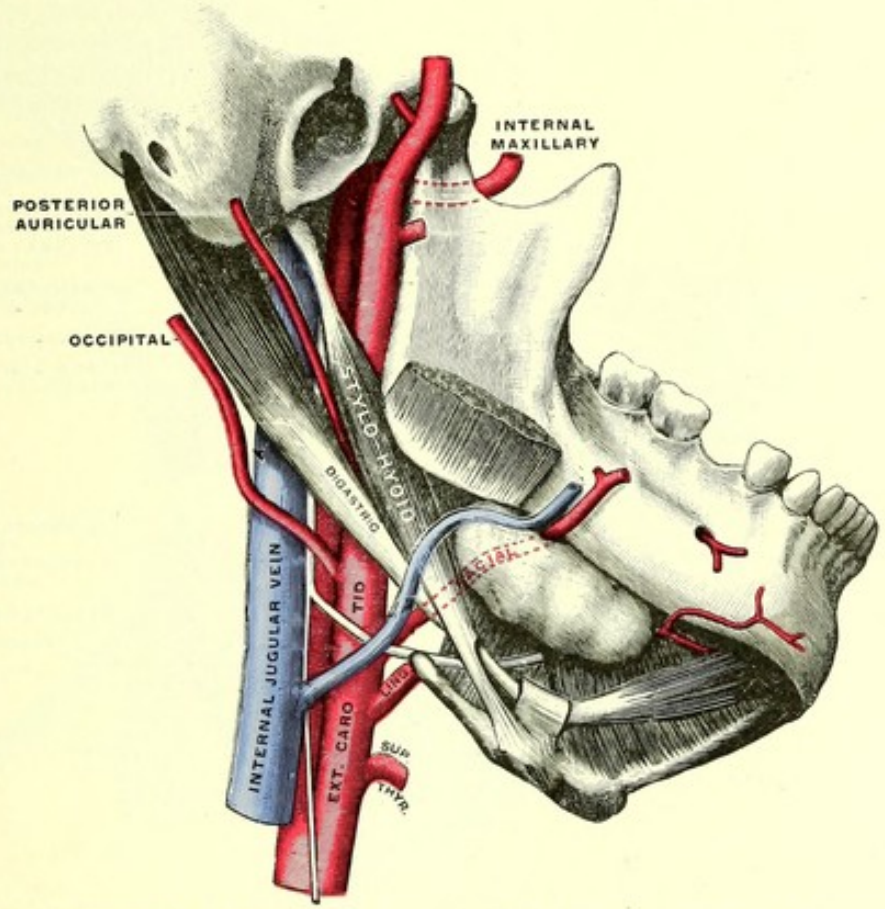

FIG. 445.—The external and internal carotid arteries. The hypoglossal nerve, the digastric and stylo-hyoid muscles, and the internal jugular vein are to be noted. (Testut.)

mastoid, beginning opposite the hyoid bone and extending upward. This incision should divide the skin and superficial fascia, platysma myoid muscle, and the deep fascia. The posterior belly of the digastric muscle and the stylo-hyoid muscles are found crossing the artery, and above these is seen the lower border of the parotid gland. The digastric and stylo-hyoid muscles are drawn downward, and the border of the gland upward, and the vessel is then exposed to view.

Branches.—The external carotid, in addition to its two terminal branches, the internal maxillary and temporal, gives off three anterior branches, the superior thyroid, the lingual, and facial; two posterior branches, the occipital and post-auricular; and one internal branch, the ascending pharyngeal. Although the external carotid in the majority of dissections gives off the branches as described, variations are very common.

Superior Thyroid (Fig. 443).—*Origin*: from the anterior surface of the exter-

nal carotid below the hyoid bone. *Course and termination* : it runs at first upward and inward, and then curves downward and inward beneath the omo-hyoid, sterno-hyoid, and sterno-thyroid muscles to the upper portion of the lateral lobe of the thyroid gland, to which it is distributed.

Relations.—The superior thyroid at its origin is superficially situated and covered by the skin, superficial fascia, platysma, and deep fascia ; before it reaches

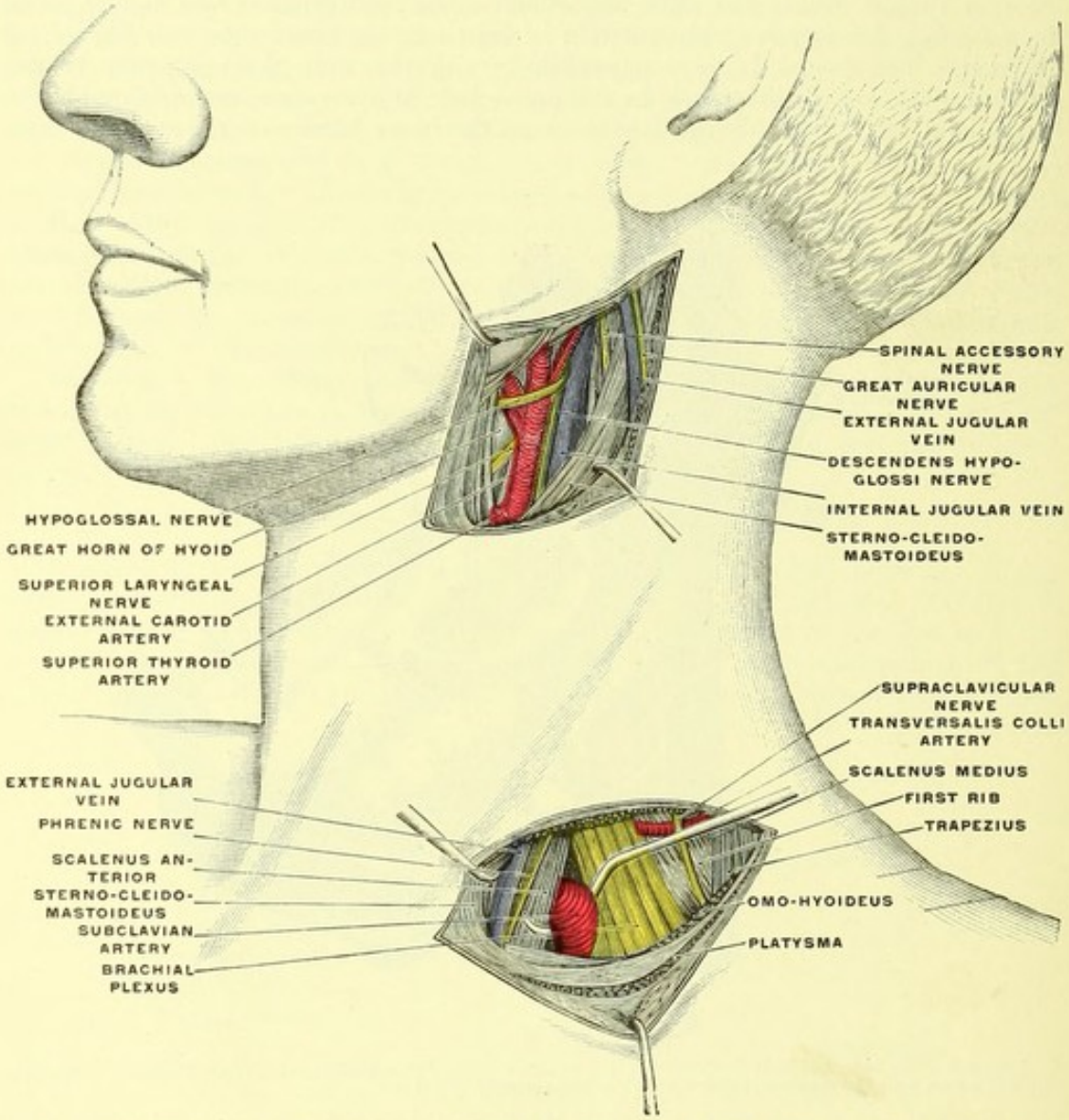

FIG. 446.—Surgical relations of the external carotid, lingual, facial, occipital, subclavian, and transversalis colli arteries. (Kocher.)

the thyroid gland it becomes more deeply situated by passing beneath the omo-hyoid, sterno-hyoid, and sterno-thyroid ~~vessels~~ muscles.

Varieties.—The superior thyroid is sometimes given off as a branch of the common carotid, and sometimes is a branch of a trunk from the external carotid, common to it and the lingual or facial.

Surgical Anatomy.—The superior thyroid can be ligated close to its origin from the external carotid through the same incision described in ligating the external carotid in the lower part of its course. This operation is sometimes done to limit the blood-supply of an enlarged thyroid gland, or in cases of exophthalmic goitre. The artery is ligated in the operation of extirpation of the thyroid.

Branches.—The superior thyroid gives off branches *to the muscles* with which it is in contact, and its terminal branches *to the thyroid gland*; and in its course gives off usually four branches, the hyoid, the sterno-mastoid, the superior laryngeal, and the crico-thyroid. The *hyoid* runs along the lower border of the hyoid bone. The *sterno-mastoid* runs outward and downward to the sterno-mastoid muscle, which it supplies. This vessel is often divided in the many operations on the side of the neck in which the incision is along the inner border of the sterno-mastoid, as in removing tubercular glands of the neck, in the operation for ligating the common carotid, etc. The *superior laryngeal* accompanies the superior laryngeal nerve in its distribution to the interior of the larynx, passing with the nerve through the thyro-hyoid membrane, and supplying the mucous membrane and muscles of the larynx. The *crico-thyroid* artery runs inward on the surface of the crico-thyroid membrane.

The Lingual Artery (Fig. 447).—*Origin* : from the external carotid above the superior thyroid and a little below the hyoid bone. *Course and termination* : the lingual runs along the upper border of the great cornu of the hyoid, then leaves the bone, and passes to the base of the tongue, and runs along the under surface of the tongue, terminating as the ranine artery.

Relations.—The artery is at first superficial, then passes beneath the digastric muscle and hyoglossus muscles, and has in front of it the hypoglossal nerve;

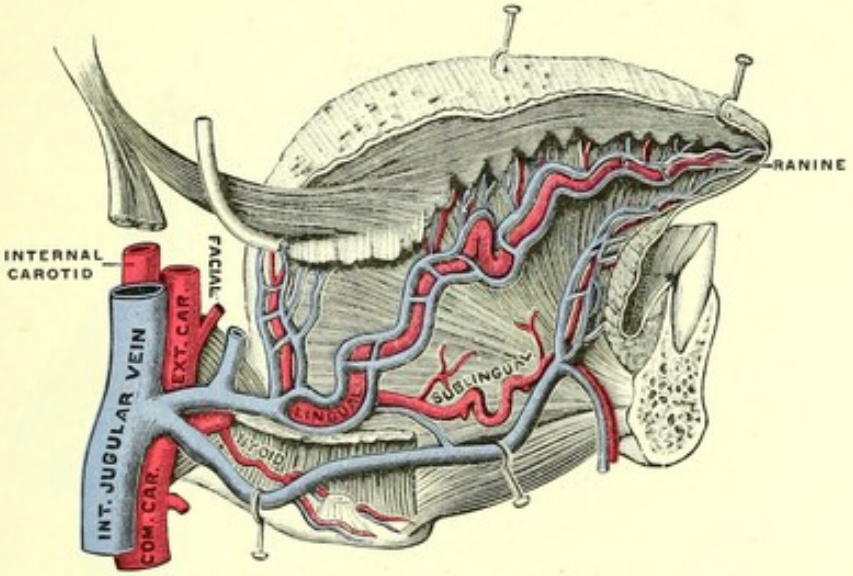

FIG. 447.—Arteries and veins of the tongue, viewed from the right side. (Testut.)

later it is situated in the root of the tongue between the hyoglossus and genio-hyoglossus muscles; it then as the ranine becomes again superficial, being covered only by the mucous membrane of the inferior surface of the tongue.

Varieties.—The lingual artery is sometimes a branch from a trunk of the external carotid common to it and the facial, or to it and the superior thyroid, or the three vessels may arise from a common trunk.

Surgical Anatomy (Figs. 442, 446).—The lingual artery is often injured in cases of cut throat. It may require ligation also as a preliminary step in removal of the tongue for carcinoma. The vessel can be ligated at its point of origin from the external carotid by the incision described to expose that vessel in the lower part of its course, or it can be ligated where the vessel runs parallel with and just above the hyoid bone and covered by the hyoglossus muscle. In order to expose the vessel in this position, a curved incision should be made, beginning a little below the body of the jaw and an inch from the median line, the convexity of the incision downward, reaching the level of the hyoid bone, and the incision terminating below the angle of the jaw. The skin, superficial fascia, platysma,

and deep fascia are divided, and the submaxillary gland is exposed and drawn upward. Beneath the submaxillary gland the digastric tendon is exposed, running upward in each direction to its anterior and posterior belly respectively. Above this tendon is seen the hypoglossal nerve; between the nerve and tendon the hyoglossus muscle is exposed. The fibres of this muscle are separated, and, running parallel with the nerve but beneath it, the lingual artery comes into view. The ranine artery may be ligated by dividing the mucous membrane of the lower surface of the tongue parallel with and external to the raphe.

Branches of the lingual are the hyoid, dorsal lingual, sublingual, and ranine.

The *hyoid* runs along the upper border of the hyoid bone. The *dorsal lingual* runs upward to the mucous membrane of the dorsum of the tongue, which it supplies. The *sublingual* supplies the sublingual gland. The *ranine* gives off branches to the muscles of the tongue, and runs in a tortuous course to its tip, being in the last part of its course superficial, covered only by the mucous membrane.

The Facial Artery (Fig. 448).—*Origin*: from the anterior surface of the external carotid above the hyoid bone. *Course and termination*: the vessel passes upward and forward to the inferior border of the lower jaw. In its course it is

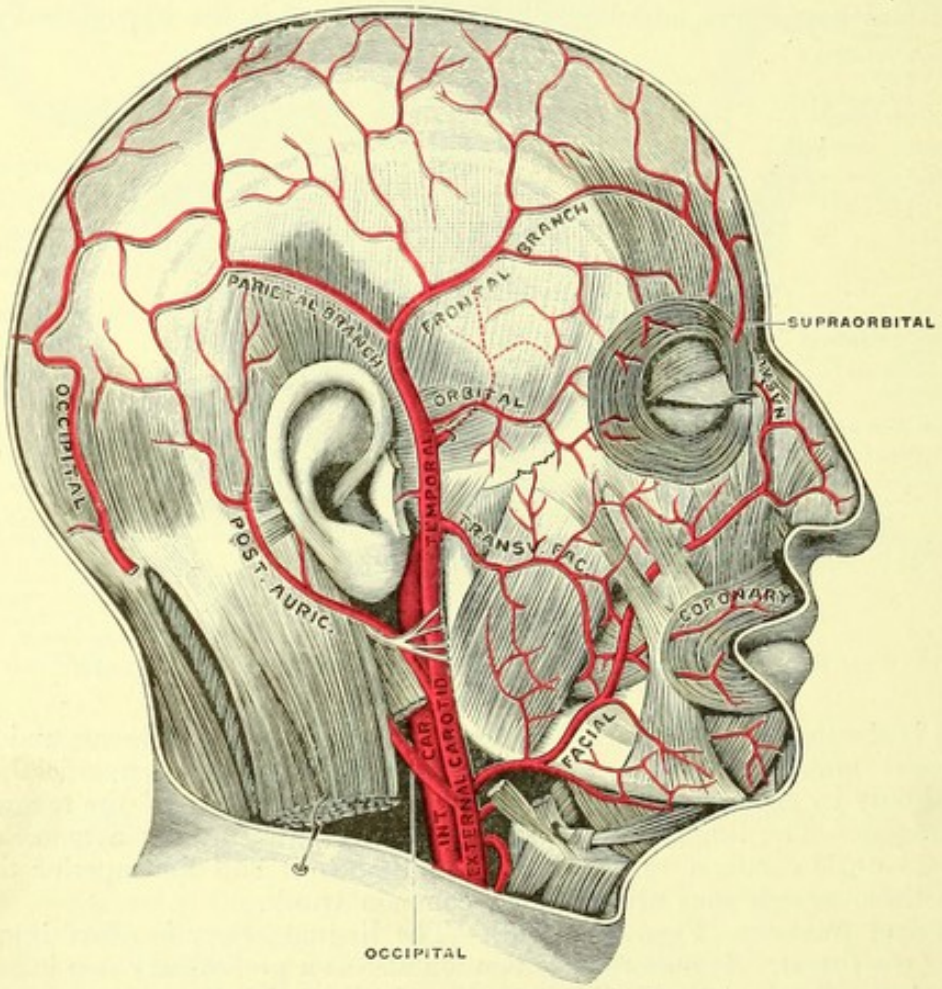

FIG. 448.—Superficial arteries of the head. (Testut.)

covered by the submaxillary gland and partly surrounded by the gland, so that the vessel occupies a groove on its deep surface. The vessel winds over the body of the lower jaw in front of the masseter muscle, marking the bone in this position by a shallow groove. It then passes upward and forward on the face to the side of the nose, and from the side of the nose upward to the angle of the eye, where it terminates as the angular artery.

Relations.—At its point of origin the vessel is superficial, being covered by the skin, superficial fascia, platysma, and deep fascia; it then passes beneath the stylo-hyoid and digastric muscles and the submaxillary gland, and is deeply situated. At the border of the jaw the vessel again becomes superficial, and its pulsations can be readily felt in front of the masseter. In the face it passes through the muscle-fibres of the facial muscles.

Variations.—The variation most commonly met with is the occurrence of a trunk from the external carotid, common to the facial and lingual arteries.

Surgical Anatomy (Fig. 446).—The facial can be ligated at its origin from the external carotid, or at its point of crossing the lower jaw. In operations for the removal of the submaxillary gland the fact should be remembered that the artery occupies a groove on its internal or deep surface, and is in a position to be injured. The course of the branches of the facial should be studied in the many operations on the face.

Branches.—The branches of the facial are divided into two sets, a *cervical set* and a *facial set.*

In the cervical region the facial gives off the ascending palatine artery, the tonsillar, the glandular, the submental, and muscular. The *ascending palatine* passes to the outer side of the pharynx, which it supplies; it also sends a branch to the soft palate, and anastomoses with the descending palatine artery, a branch of the internal maxillary. The *tonsillar* is a branch to the tonsil and tongue. The *glandular* are branches given off to the submaxillary gland. The *submental* is a large branch which runs along the lower border of the jaw to the chin; here the vessel gives off terminal branches, which wind over the jaw, and supply the tissues of the lower lip. *Muscular* branches are given off to the muscles with which the vessel is in contact. The *facial branches* are the inferior labial, the coronary, the lateral nasal, the angular, and muscular. The *inferior labial* runs parallel with the body of the jaw forward to the chin; it supplies the tissues of the chin and lower lip. The *coronary* arteries are given off at the angle of the mouth, and run, one in the tissues of the lower lip, the other in the tissues of the upper lip, in close contact with the mucous membrane. The *lateral nasal* supplies the ala of the nose. The *angular* is the terminal branch of the facial. It ascends to the inner angle of the eye, and supplies the structures in this position, anastomosing with the infra-orbital, and with the nasal branch of the ophthalmic artery.

The Occipital Artery (Fig. 448).—*Origin*: the occipital artery arises from the external and posterior surface of the external carotid, opposite to the facial, at a point a little above the level of the hyoid bone. *Course and termination*: it winds upward and backward to the mastoid portion of the temporal bone, occupying a groove on its inferior surface. The vessel is here covered by the digastric and stylo-hyoid muscles, and crosses the internal carotid, internal jugular vein, and the pneumogastric nerve; it then continues upward and backward beneath the muscles attached to the superior curved line of the occipital bone and the space between this and the inferior curved line, becomes superficial by piercing the trapezius or the fascia between the occipital attachments of the trapezius and sterno-cleido-mastoid, and then runs forward in the scalp tissue to the vertex of the skull, anastomosing with the branches of the temporal and posterior auricular.

Varieties.—The occipital is in rare cases a branch of the internal carotid; sometimes it is given off from the inferior thyroid.

Surgical Anatomy (Fig. 446).—The vessel is deeply situated and seldom wounded; it may become necessary to ligate it for cirsoid aneurism. It can be ligated at its point of origin from the external carotid, or in the scalp tissue just above the superior curved line of the occipital bone.

Branches.—The muscular, sterno-mastoid, auricular, meningeal, and arteria princeps cervicis. *Muscular* branches are given off to the muscles with which it is in contact; one large muscular branch, the *sterno-mastoid*, is given off to the sterno-cleido-mastoid, and is distributed to the muscle with the spinal accessory nerve. The *auricular* branch supplies the posterior portion of the external

ear. The *meningeal* branch becomes one of the posterior meningeal arteries, and enters the skull through the jugular foramen. The *arteria princeps cervicis* passes downward, and, deeply situated, divides into two sets of branches, one anastomosing with the deep cervical branch of the superior intercostal artery, the other with the superficial cervical branch of the transversalis colli.

The Posterior Auricular Artery.—*Origin*: from the external carotid, its posterior surface above the origin of the occipital. *Course and termination*: it passes upward and backward beneath the parotid gland to the scalp tissue behind the ear and in front of the mastoid process, where it divides into two branches: the *mastoid*, supplying the scalp tissue over the mastoid process, and anastomosing with the occipital; and an *auricular* supplying the back of the ear, and anastomosing with branches of the temporal.

Variations.—The posterior auricular artery is sometimes a branch of the occipital. On the other hand, it is sometimes a vessel much larger than the occipital, being distributed to the region usually supplied by the occipital and temporal arteries.

Surgical Anatomy.—The position of the posterior auricular should be remembered in the frequent operations on the mastoid; it is, however, a small vessel and usually easily dealt with surgically.

Branches.—In addition to the two terminal branches, the auricular and mastoid already sufficiently described, the artery gives off a *stylo-mastoid* branch, which enters the stylo-mastoid foramen, and supplies branches to the mastoid cells, tympanum, and internal ear.

The Ascending Pharyngeal Artery.—*Origin*: from the internal and posterior surface of the external carotid, within half an inch of its origin from the common carotid. *Course and termination*: it runs upward on the side of the pharynx and, covered by the internal carotid artery, to the base of the skull.

Variations.—The ascending pharyngeal is sometimes a branch of the internal carotid or common carotid.

Surgical Anatomy.—In part of its course the artery is situated between the tonsil and the internal carotid, and might be injured in operations about the tonsil.

Branches.—The branches of the ascending pharyngeal are the prevertebral, the pharyngeal, and the meningeal. The *prevertebral* branches supply the anterior recti and the longus colli muscles, and the nerves and lymphatic nodes of this region. The *pharyngeal* branches supply the pharynx, tonsil, and soft palate. The *meningeal* are several small vessels entering the skull through the jugular foramen, the anterior condylar foramen, and the foramen lacerum medium.

The Temporal Artery.—*Origin*: it is one of the terminal branches of the external carotid, and begins at a point a little below the condyle of the jaw. *Course and termination*: it passes upward through the substance of the parotid gland external to the zygoma, to a point from an inch and a half to two inches above the zygoma, and here divides into the anterior and posterior temporal arteries.

Variations.—The temporal artery is not frequently subject to variations from the usual type. It may be very small, and its place be taken by a large posterior auricular. The transverse facial may be of large size and take the place of a small facial artery.

Surgical Anatomy.—From its superficial position the temporal and its terminal branches are often injured in scalp wounds; ligation of the main trunk may be required for cirsoid aneurism. The operation can be done by an incision two inches in length, a finger's breadth in front of the ear, the centre of the incision being an inch above the zygoma. The artery here is accompanied by the auriculo-temporal nerve, which should be avoided.

Branches.—The branches of the temporal are its terminal branches, the anterior temporal and the posterior temporal, and the transverse facial, middle temporal, and anterior auricular. The *transverse facial* (Fig. 448) is given off close to the point of origin of the temporal, passes transversely forward across the face

beneath the zygoma, on the surface of the masseter, and anastomoses with branches of the facial. The *middle temporal* branch perforates the temporal fascia, and supplies the temporal muscle, anastomosing with the deep temporal branches of the internal maxillary. The *anterior auricular* branch is distributed to the anterior surface of the external ear. The *anterior temporal* winds forward and upward over the frontal bone, and supplies the scalp structures. In this position the artery is very superficially situated; its pulsations can be readily felt, and often seen. The position of the artery is such that, in giving an anæsthetic the anæsthetizer can from this vessel feel the condition of the pulse. The anterior temporal is the artery usually selected to perform the operation of arteriotomy. The *posterior temporal* passes backward and upward superficially in the scalp to the vertex of the skull, supplying the scalp over the sides of the vertex, and anastomosing with the occipital, the posterior auricular, and the vessel of the opposite side.

The Internal Maxillary Artery (Figs. 449, 450) is one of the terminal divisions of the external carotid. *Origin*: from the external carotid a little below the condyle of the jaw. *Course and termination*: the artery is at first in the substance of the parotid gland, whence it passes inward and forward to the spheno-maxil-

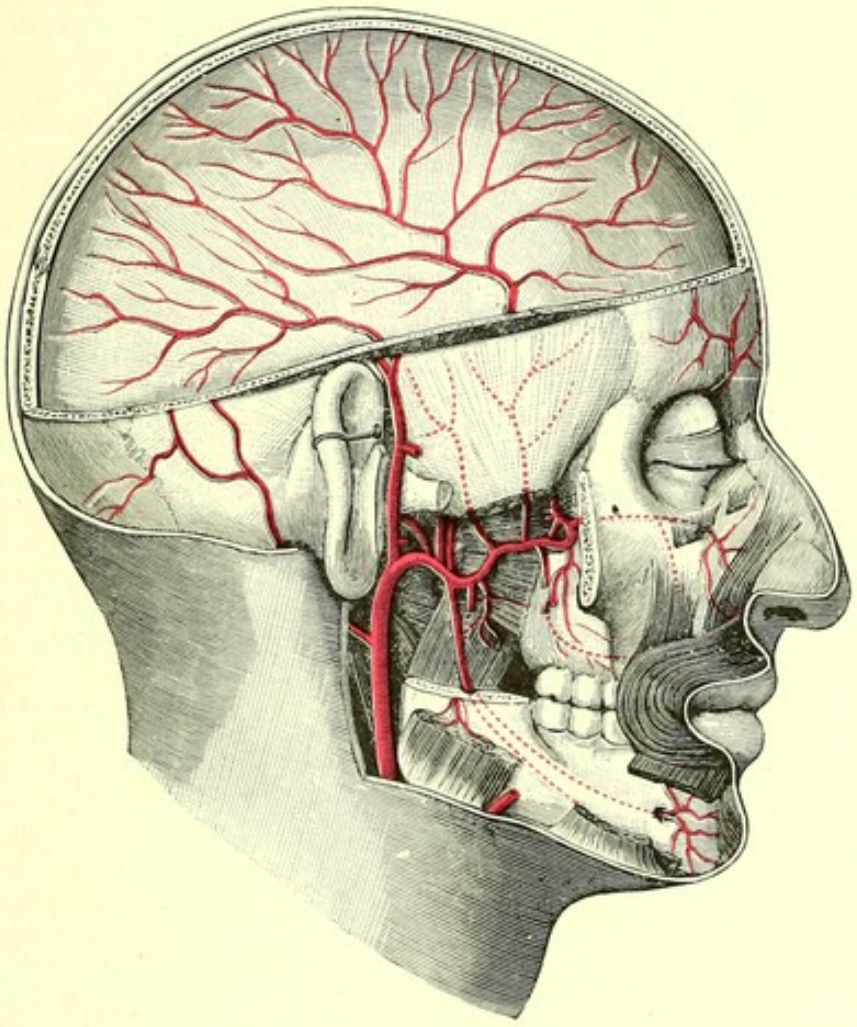

FIG. 449.—Internal maxillary artery. (Testut.)

lary fossa. It is divided into three portions, a maxillary, a pterygoid, and a spheno-maxillary. The *maxillary portion* lies below the inferior border of the external pterygoid muscle; the *pterygoid portion* lies on the anterior surface of the pterygoid muscle; the *spheno-maxillary portion* rests on the superior maxillary bone, and in the spheno-maxillary fossa.

Variations.—The internal maxillary in rare cases is given off as a branch from the facial; the number of branches varies considerably, because very often two or more arise by a common trunk from the artery.

Surgical Anatomy.—The main trunk of the vessel is deeply situated, but may be injured in penetrating wounds of the face. Ligation of the vessel would be difficult, and that of the external carotid would be preferable. Two of the branches of the internal maxillary are of special surgical interest, the middle meningeal artery and the infraorbital artery. The middle meningeal is often injured in cases of fracture of the skull; the artery is situated between the bone and dura, and pressure-symptoms from rupture of this vessel are often characteristic, coming on slowly after an injury. The vessel can be exposed by making an

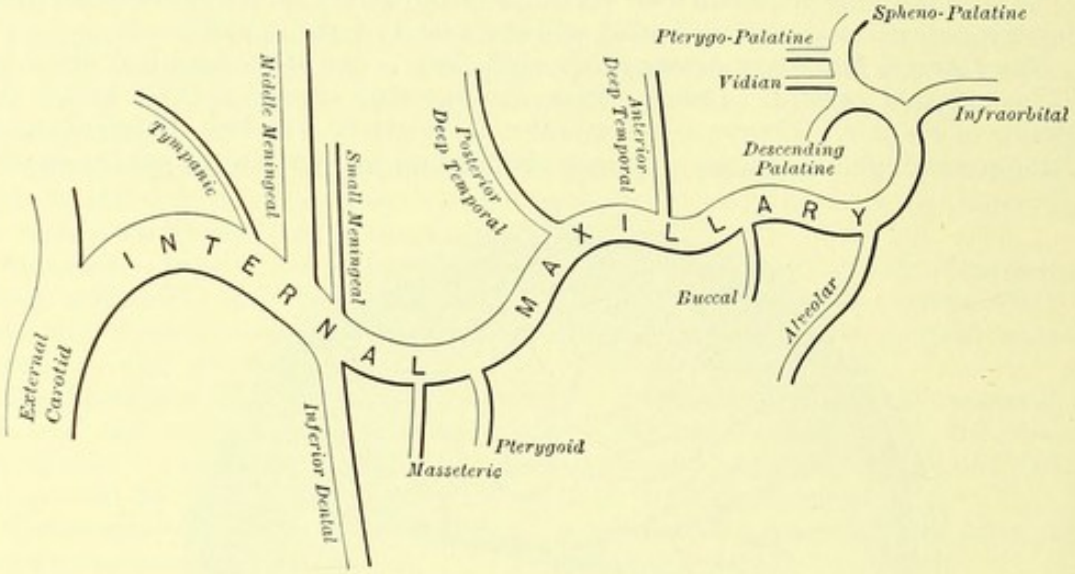

FIG. 450.—Diagram of the internal maxillary artery and its branches.

opening in the skull, the centre of which should be a point an inch and a half behind the external angular process of the frontal bone. In the Hartley operation for removal of the Gasserian ganglion the position of this vessel should be carefully studied. The infraorbital artery is sometimes injured in removing the second division of the fifth pair of nerves back as far as Meckel's ganglion; the blood in such a case might pass into the antrum of Highmore and from this into the nasal cavities. Such hemorrhage could be controlled by plugging the anterior and posterior nares.

Branches.—From the first or *maxillary portion* of the vessel are given off the tympanic, the middle meningeal, the small meningeal, and the inferior dental arteries. The *tympanic* passes through the Glaserian fissure to the tympanum, which it aids in supplying; it gives off branches also to the membrana tympani. The *middle meningeal* enters the skull through the foramen spinosum, occupies a groove in the bone of the middle fossa at the base of the skull, winds upward and outward, and divides into an anterior and posterior branch. These branches groove the inner surface of the bone, running between the bone and the dura, and furnish the principal arterial supply of the latter. The *small meningeal* artery passes through the foramen ovale into the cranial cavity, and supplies the Gasserian ganglion and contiguous dura. The *inferior dental* is a large branch which passes downward to the inferior dental foramen, which it enters with the inferior dental nerve, running forward in the inferior dental canal to supply the inferior maxilla and teeth. Before entering the inferior dental foramen the artery gives off the mylohyoid branch, which is distributed to the mylohyoid muscle, and occupies the mylohyoid groove on the internal surface of the mandible. The artery gives off branches to each tooth, and opposite the mental foramen a mental branch, which passes forward to supply the structures of the chin.

The branches of the *pterygoid portion* of the internal maxillary artery supply the muscles of mastication. They are the *temporal*, the *masseteric*, the *pterygoid*, and the *buccal*, and carry blood to the temporal, the masseter, the internal and external pterygoids, and the buccinator.

The branches from the third or *spheno-maxillary portion* are the alveolar, the infraorbital, the descending palatine, the Vidian, the pterygo-palatine, and the spheno-palatine. The *alveolar* supplies the posterior portion of the alveolar process of the upper jaw, and also the molar and bicuspid teeth. The *infraorbital* passes with the infraorbital nerve along the infraorbital groove and canal, makes its appearance on the face at the infraorbital foramen, and supplies here the soft tissues over the superior maxillary bone, anastomosing with branches from the facial. In the orbit the artery gives off muscular branches, which supply the inferior oblique and inferior rectus muscles, and in the canal branches to the canine and incisor teeth. The *descending palatine* passes with the descending branches of Meckel's ganglion down the posterior palatine canal to the mouth cavity, then runs in a groove on the under surface of the hard palate forward to the anterior palatine canal, where it anastomoses with the anterior palatine artery, and supplies the gums and mucous membrane of the hard palate. The *Vidian* passes backward through the Vidian canal to be distributed to the pharynx and Eustachian tube. The *pterygo-palatine* passes backward through the pterygo-palatine canal, and is also distributed to the upper part of the pharynx. The *spheno-palatine* passes through the spheno-palatine foramen into the nasal cavity. It divides into two branches, the naso-palatine, which runs in a groove of the vomer downward and forward to the anterior palatine foramen, where it anastomoses with the descending palatine artery; and an external branch, which supplies the mucous membrane of the outer wall of the nasal cavity.

The Internal Carotid Artery (Fig. 443).

Origin: from the common carotid opposite the superior border of the thyroid cartilage. *Course and termination*: the vessel runs upward in front of the transverse processes of the upper three or four cervical vertebræ to the carotid canal in the petrous portion of the temporal bones, runs through the canal to its internal opening, and enters the cranial cavity, and then enters the cavernous sinus, occupying a position between the fibrous covering of the sinus and its lining membrane. It leaves the sinus at the internal surface of the anterior clinoid process, and passes to the fissure of Sylvius, where it breaks up into its terminal branches. The artery is distributed mainly to the brain and eye. The vessel is divided into four portions, a cervical, a petrous, a cavernous, and a cerebral, which should be studied in detail.

The cervical portion is that extending from its origin to the lower opening of the carotid canal.

RELATIONS.

In front.

Skin, superficial fascia.
Platysma and deep fascia.
Sterno-mastoid, stylo-glossus, and stylo-pharyngeus muscles.
External carotid and occipital arteries.
Hypoglossal nerve and glossopharyngeal nerve.
Parotid gland.

Externally.		*Internally.*
Internal jugular vein.		Pharynx.
Pneumogastric nerve.	**Internal carotid in the neck.**	Inferior laryngeal nerve.
		Ascending pharyngeal artery.
		Tonsil.

Variations.—The internal carotid sometimes arises directly from the arch of the aorta. It is sometimes absent. It sometimes gives off branches in the neck, which are usually the occipital or ascending pharyngeal.

Surgical Anatomy.—The vessel can be exposed for ligation by an incision along the internal border of the sterno-mastoid. The skin and superficial fascia should be divided, then the platysma and deep fascia; the sterno-mastoid should be drawn to the outer side, and the external carotid to the inner side; care should be taken in passing the needle to avoid the pneumogastric nerve and the internal jugular vein, which accompany the artery.

Branches.—As a rule, the internal carotid gives off no branches of importance in the neck. (See Variations.)

The petrous portion of the vessel is that part contained in the carotid canal. Here the artery makes two sharp turns, which are supposed to diminish the arterial pressure. From this portion of the artery a small branch is given off to the tympanum.

The cavernous portion is that part of the vessel which is in the cavernous sinus. Here the vessel gives off the following branches: the arteriæ receptaculi, the anterior meningeal, and the ophthalmic. The *arteriæ receptaculi* are small vessels which supply the pituitary body and the Gasserian ganglion. The *anterior meningeal* artery is distributed to the dura of the anterior fossa at the base of the skull.

The Ophthalmic Artery (Fig. 451) passes with the optic nerve through the optic foramen into the orbit. It passes first forward and outward, then crosses the optic nerve and passes forward and inward, runs along the inner wall of the orbit, beneath the inner portion of the orbital margin, leaves the orbit, and terminates by dividing into the frontal and nasal arteries. In its course the ophthalmic artery gives off branches to the walls and contents of the orbit. These branches are the central artery of the retina, the ciliary arteries, the lachrymal, the muscular, the supraorbital, the ethmoidal, the palpebral, and the terminal branches, the nasal and frontal arteries. The *central artery of the retina* is given off from the ophthalmic near the optic foramen. It accompanies the optic nerve, and is distributed to the retina. The vessel can be well seen in ophthalmoscopic examinations of the retina. The *ciliary* arteries are divided into three sets—the long, short, and anterior ciliary arteries. The *short ciliary* arteries are eight or ten in number, which pierce the sclerotic coat near the optic nerve, and run forward to supply the choroid. The *long ciliary* arteries, two in number, one on each side, pierce the sclera some distance from the optic nerve, and run forward to supply the ciliary body and iris. The *anterior ciliary* arteries are branches of the muscular branches of the ophthalmic. They pierce the sclera near the cornea and supply the ciliary body and the iris. The anterior and long ciliary arteries form an anastomosis around the outer margin of the iris, and also around the free margin of the iris. The *lachrymal* artery arises from the ophthalmic external to the optic nerve, passes forward and outward to the lachrymal gland, which it supplies, and, leaving the gland, sends small branches to the eyelids, known as external palpebral branches. *Muscular* branches are given off from various portions of the ophthalmic in its course to supply the muscles of the globe. The *supraorbital* artery is a vessel of some size, which runs along the roof of the orbit to the supraorbital notch. Leaving the orbit at this point, it courses upward in the muscles and integument of the forehead. The *ethmoidal* arteries, two in number, are given off from the ophthalmic opposite the anterior and posterior ethmoidal foramina. Entering the cranial cavity through these foramina they give off *anterior meningeal* vessels, supplying the dura in the anterior fossa at the base of the skull. The *anterior ethmoidal* is the larger, and, after giving off a meningeal branch, leaves the cranial cavity with the nasal nerve, passes through an opening in the cribriform plate to the nasal cavity, runs along the inner surface of the nasal bone, and supplies the tip of the nose. The *palpebral* arteries, two in number, the superior and inferior, supply the upper and lower lids. The *nasal*

artery leaves the orbit above the inner canthus, and supplies the bridge of the nose, anastomosing with the angular branch of the facial. The *frontal* leaves the orbit at the upper and inner angle, winds up over the forehead near the median line, supplying the soft tissues in this position.

Variations.—The ophthalmic is sometimes situated beneath the optic nerve, and on the inner side of the orbit throughout its entire course. The ophthalmic is sometimes a branch of the middle meningeal, or sometimes gives origin to the middle meningeal. Variations in the number and position of the branches as described frequently occur.

Surgical Anatomy.—In enucleation of the eye the larger branches of the ophthalmic are, as a rule, not divided, and the resulting hemorrhage is slight and readily controlled.

Aneurism of the ophthalmic occurs, producing exophthalmos and inter-

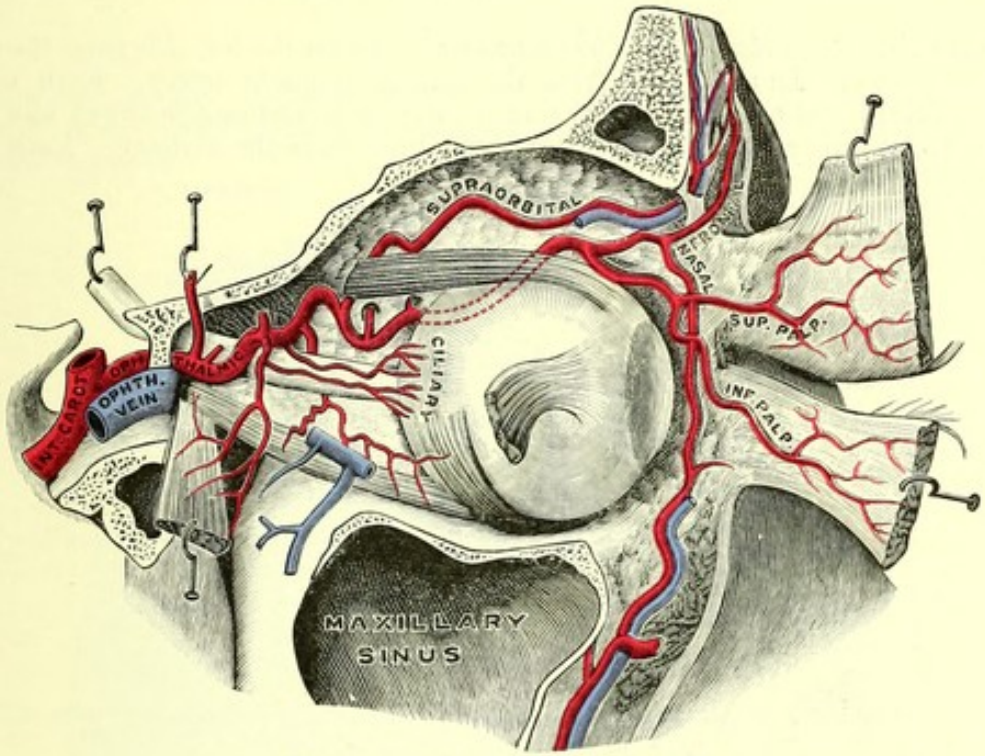

FIG. 451.—Arteries of the orbit. (Testut.)

ference with the function of the eye. To control such a condition ligation of the common carotid or internal carotid might be necessary.

The cerebral portion of the internal carotid has for its branches the posterior communicating, the anterior choroid, the anterior cerebral, and the middle cerebral arteries. The *posterior communicating* passes backward to join the posterior cerebral artery, a branch from the basilar, and forms the lateral portion of the circle of Willis. The *anterior choroid* passes outward and backward to reach the descending horn of the lateral ventricle, where it supplies the choroid plexus. The *anterior cerebral* runs forward and inward to reach the great longitudinal fissure between the hemispheres. In this fissure the artery lies close to its opposite mate, and connecting them is a short trunk, the *anterior communicating*. The vessel winds over the anterior extremity of the corpus callosum to reach its superior surface. It gives off branches to the anterior perforated space, to the under surface of the frontal lobe, and the mesial surface of the hemisphere, and anastomoses with the posterior cerebral artery. The *middle cerebral* artery passes forward and outward to the fissure of Sylvius, and then runs along the fissure of Sylvius to the insula and the external surface of the hemisphere. In its course it gives branches, which enter the anterior perforated space, and supply the

ganglia and other structures in the floor of the lateral ventricle. One of these vessels is of special interest, the *lenticulo-striate* artery, called also Charcot's artery of cerebral hemorrhage, because it is a very common site of arterial rupture in cases of apoplexy. This vessel is situated between the external capsule and the corpus striatum. The cortical brain substance of the motor area is also supplied by the middle meningeal (Sylvian) artery, and here arterial lesions are common and often produce localizing symptoms. After discussing the vertebral artery, which with the internal carotid supplies the encephalon, the arterial supply of the brain will be given more in detail.

ARTERIES OF THE UPPER EXTREMITIES.

THE SUBCLAVIAN ARTERY.

The *subclavian artery* (Fig. 452) takes its origin on the left side from the arch of the aorta, on the right side from the brachio-cephalic artery. Each vessel passes upward and outward into the neck, and then arches downward and outward to terminate at the lower border of the first rib in the axillary. Each ves-

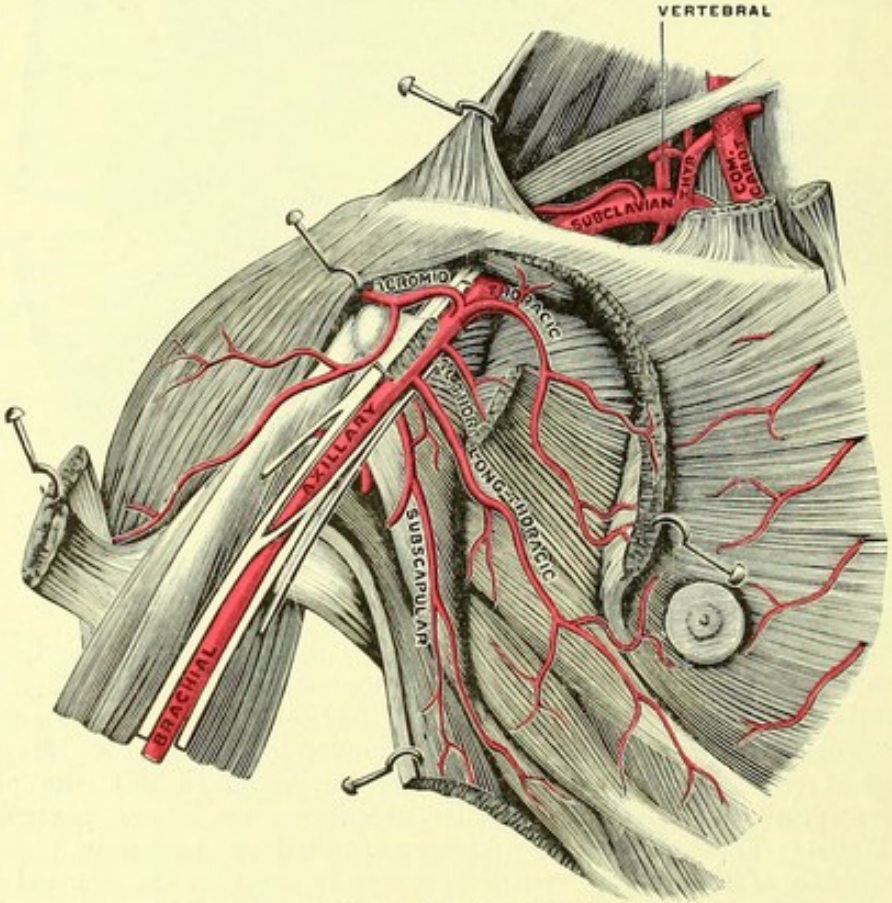

FIG. 452.—Subclavian and axillary arteries. (Testut.)

sel is divided into three portions, according to its situation with reference to the scalenus anterior muscle. The first portions of the subclavian arteries differ, and must be described separately. A single description will answer for the second and third portions of both arteries.

The first portion of the left subclavian arises from the arch of the aorta, and extends to the inner border of the scalenus anterior muscle. The vessel is deeply situated and in the lower part of its course somewhat resembles the brachio-cephalic artery.

RELATIONS.

In front.

Pleura and lung.
Pneumogastric and phrenic nerves.
Left carotid artery.
Left internal jugular and brachio-cephalic veins.
Sterno-hyoid, sterno-thyroid, and sterno-mastoid muscles.

Inner side.		*Outer side.*
Trachea. Œsophagus. Thoracic duct.	**First portion of left subclavian.**	Pleura.

Behind.

Œsophagus.
Thoracic duct.

The first portion of the right subclavian takes its origin from the brachio-cephalic artery, and extends upward and outward to the inner border of the scalenus anterior.

RELATIONS.

In front.

Skin, superficial fascia.
Platysma, deep fascia.
Sterno-mastoid, sterno-hyoid, sterno-thyroid muscles.
Internal jugular vein.
Pneumogastric and phrenic nerves.

Beneath.

Pleura.	**First portion of right subclavian.**

Behind.

Recurrent laryngeal nerve.

The second portion of the subclavian is behind the scalenus anterior muscle.

RELATIONS.

In front.

Skin, superficial fascia.
Platysma, deep fascia.
Sterno-mastoid and scalenus anterior muscles.
Phrenic nerve.
Subclavian vein.

Above.		*Below.*
Brachial plexus.	**Second portion of subclavian artery.**	Pleura.

Behind.

Scalenus medius muscle.
Pleura.

The third portion of the subclavian extends from the outer border of the scalenus anterior to the lower border of the first rib.

RELATIONS.

In front.

Skin, superficial fascia.
Platysma, deep fascia.
Suprascapular artery.
External jugular vein.
Clavicle.

Above.		*Below.*
Brachial plexus. Omo-hyoid muscle.	**Third portion of subclavian.**	First rib.

Behind.

Scalenus medius.

Variations.—The subclavian is sometimes on both sides a direct trunk from the aortic arch, or on both sides a branch from a right and left brachio-cephalic artery. The vessel is usually at its high point in the neck a half inch above the clavicle, but sometimes it rises considerably higher; sometimes it is beneath the clavicle entirely. The branches of the subclavian often present variations which are of importance and which will be discussed in studying the individual branches.

Surgical Anatomy (Figs. 442, 446).—The surgical anatomy of the first and second portions of the subclavian is not of great importance, because, owing to the great depth of the vessel and its relations to important structures, it is seldom interfered with surgically. The vessel, however, can be and has been ligated in the first two portions of its course. The surgical anatomy of the third portion is of great importance, and should be carefully studied. The blood supply of the upper extremity can be controlled by compressing the subclavian digitally against the upper surface of the first rib. This method is now, however, seldom employed. Ligation of the third portion of the subclavian may be required for injuries of the arteries of the upper extremity below this point, or for aneurism. It is also a preliminary step in the amputation of the entire upper extremity. The operation is made in the following way: An incision four inches in length is made over the clavicle beginning a little external to the sterno-clavicular articulation. This incision divides the skin, superficial fascia, platysma, and deep fascia. In making this superficial incision the external jugular is exposed, and may be drawn to the inner side or divided between two ligatures. The subclavian triangle is now outlined, bounded below by the clavicle, above by the posterior belly of the omo-hyoid, and internally by the sterno-cleido-mastoid. The suprascapular artery crosses this triangle above and parallel with the clavicle. Carefully dividing the areolar tissue at the floor of this triangle, a second triangle is exposed; this second triangle is bounded above by the brachial plexus, below by the first rib, and internally by the scalenus anterior muscle. The third portion of the subclavian artery is in this small triangle. In ligating the vessel care should be taken to avoid the subclavian vein, which is below, the brachial plexus, which is above, and the phrenic nerve, which lies on the anterior surface of the scalenus anterior. Collateral circulation is usually readily established between the branches of the first portion of the subclavian, and the branches from the axillary, external carotid, intercostals, and deep epigastric.

Branches.—The branches of the subclavian are, as a rule, four in number, and given off from the first portion of the vessel, although sometimes the superior intercostal is given off from the second portion, and the posterior scapula is often a branch from the third portion. They are the vertebral, the internal mammary, the thyroid axis, and the superior intercostal.

The **Vertebral** (Fig. 443) is given off from the posterior surface of the sub-

clavian; it passes upward to reach the vertebral opening in the costo-transverse process of the sixth cervical vertebra, and continues upward through the vertebral foramina of the cervical vertebræ above; reaching the atlas it winds over the upper surface of the posterior arch in a groove or foramen behind the superior articular process, and passes into the cranial cavity through the foramen magnum; the two vertebral arteries within the skull unite to form the *basilar*, which then breaks up into branches, which assist the internal carotid in supplying the encephalon. *Variations.*—The vertebral is sometimes a branch of the aortic arch; sometimes a branch of the common carotid. Although as a rule it enters the vertebral foramen of the sixth cervical, it in some cases enters none below that of the fifth, or even the third.

Surgical Anatomy (Fig. 453).—The ligation of the vertebral is a deep operation, but can be readily done if the anatomical position of the vessel and the landmarks leading to it are understood. An incision is made along the inner border of the sterno-mastoid, beginning just above the sterno-clavicular articulation and extending upward for four or five inches. The skin, superficial fascia, platysma and deep fascia are divided; the carotid is drawn to the outer side, the

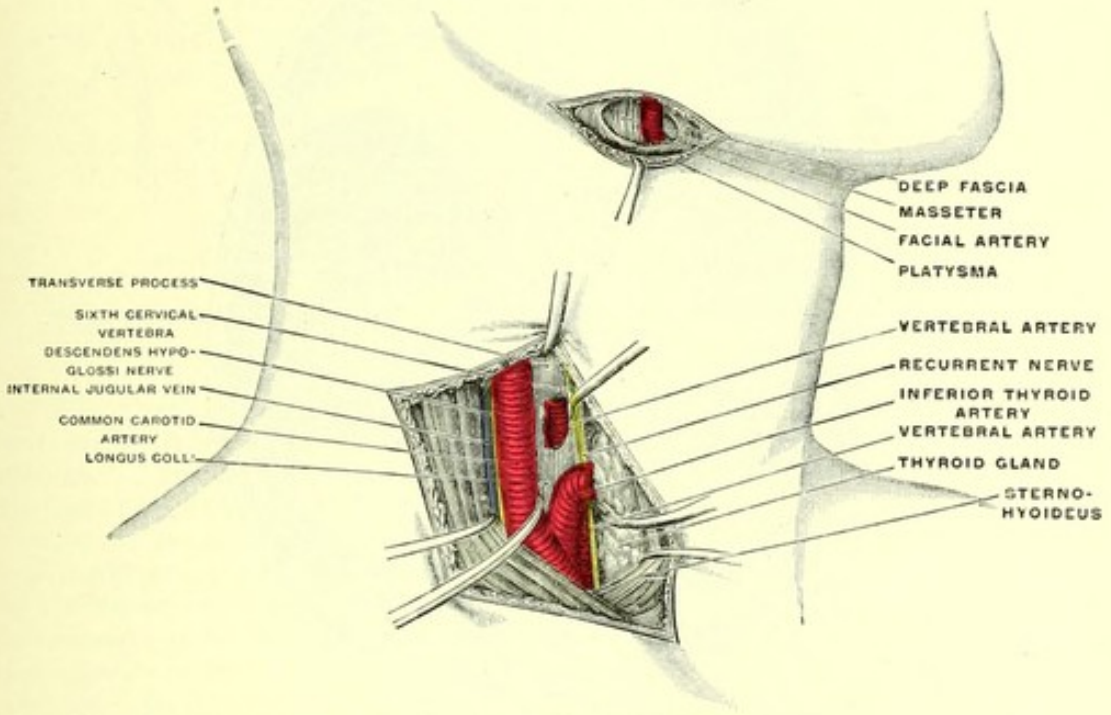

FIG. 453.—Surgical relations of the facial, vertebral, and inferior thyroid arteries. (Kocher.)

transverse process of the sixth cervical is sought, and below this point and between the scalenus anterior and the longus colli muscles the vertebral artery is found. The vessel may be approached by an incision of sufficient length made along the outer border of the sterno-cleido-mastoid, instead of along its inner border. In this case the muscle and deep vessels are drawn to the inner side.

Branches.—The branches of the vertebral are divided into two sets; those in the neck, and those in the cranium. The branches in the neck are the lateral spinal and the muscular. The *spinal* branches enter the spinal canal through the intervertebral foramina, and supply the membranes of the cord and the vertebræ. *Muscular* branches are distributed to the deep muscles of the neck. The branches in the cranium are the posterior meningeal, the posterior inferior cerebellar, and the spinal. The *posterior meningeal* branches are small vessels supplying the dura of the posterior fossa. The spinal arteries are divided into two sets, the anterior and posterior spinal. The anterior spinal branch unites with its fellow of the opposite side and forms the single *anterior spinal* artery. The *posterior*

spinal descends along the cord in front of the posterior roots of the spinal nerves, and communicates with the lateral spinal. The *posterior inferior cerebellar* artery supplies the posterior and inferior surfaces of the cerebellum, and gives off small branches to the medulla and the choroid plexus of the fourth ventricle.

The **Basilar Artery** (Figs. 454, 455) is formed by the union of the vertebral arteries; it runs forward and upward in the groove on the under surface of the pons, and divides into the posterior cerebral arteries. In its course it gives off as branches the transverse, the anterior inferior cerebellar and superior cerebellar arteries. The *transverse* arteries supply the pons, and one branch enters the internal auditory meatus with the facial and auditory nerve. The *anterior inferior cerebellar* arteries supply the anterior portion of the inferior surface of the cerebellum. The *superior cerebellar* arteries wind backward and upward to the upper surface of the cerebellum, which they supply.

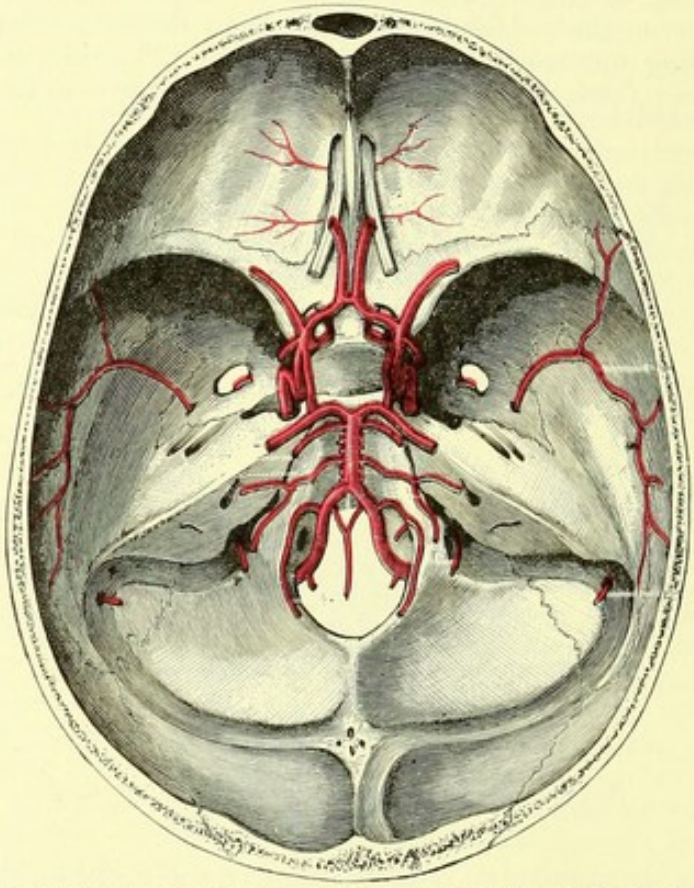

FIG. 454.—Arteries at the base of the brain, seen in their relations to the skull. (Testut.)

The terminal branches of the basilar, the *posterior cerebral* arteries, are vessels of large size, which anastomose with the posterior communicating to complete the circle of Willis behind. They pass to the under surface of the occipital lobe, which they supply; giving off also a choroid branch.

With this knowledge of the distribution of the internal carotid and vertebral arteries, we can study the free anastomosis of the arteries at the base of the brain, known as the circle of Willis.

The **Circle of Willis** is formed in front by the anterior cerebral arteries and the anterior communicating which unites them; behind by the division of the basilar into the posterior cerebral; and laterally by the internal carotid and posterior communicating. From the cerebral arteries close to, within an inch of, the circle of Willis deep ganglionic branches are given off which penetrate the brain substance, and are distributed to the great ganglia at the base of the brain and the contiguous brain structures. Beyond this the vessels supply the cortical portions

of the encephalon. A point of practical importance in this connection is the fact that the arteries which supply the brain are terminal arteries, and that there is no anastomosis between the vessels supplying the ganglia and central structures of the brain and the vessels supplying the cortex. As a result, whenever an injury or lesion to an artery of the brain occurs, the portion of the brain tissue supplied by the vessel beyond the point of the lesion has its arterial supply permanently cut off, and necrosis and softening follow.

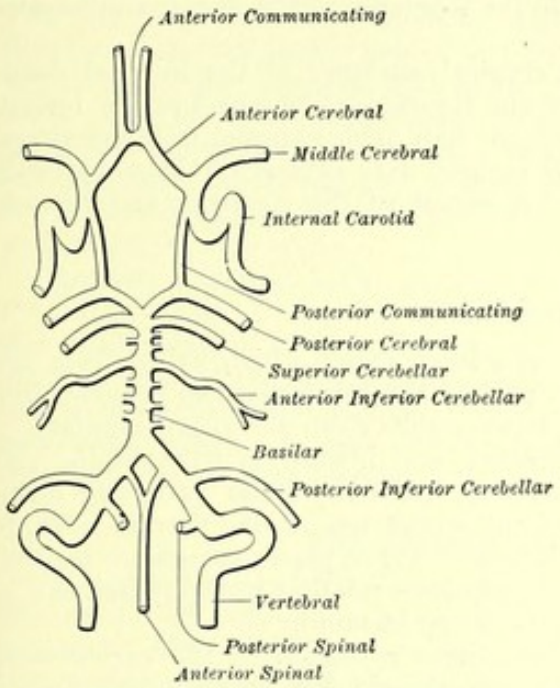

FIG. 455.—Key to Fig. 454.

The Internal Mammary Artery (Fig. 456).

This vessel is given off from the anterior surface of the first portion of the subclavian. It passes downward to the inner surface of the cartilage of the first rib, runs downward between the costal cartilages and the pleura, about half an inch external to the border of the sternum, to the sixth intercostal space, and there divides into the superior epigastric and musculo-phrenic arteries. In its course it gives off the superior phrenic, the mediastinal, the anterior intercostal, and the anterior perforating. The *superior phrenic* accompanies the phrenic nerve in its distribution. The *mediastinal* branches are distributed to the structures of the anterior mediastinum. The *anterior intercostals* are given off at each of the upper five or six intercostal spaces and supply the anterior portion of those spaces, anastomosing with the aortic intercostal arteries. The *perforating* branches pierce the intercostal muscle in each space, and pass forward and outward to supply the pectoral muscle, the mammary gland, and the integument over the pectoral region. The terminal branches are the musculo-phrenic and superior epigastric. The *musculo-phrenic* winds outward and downward along the inner

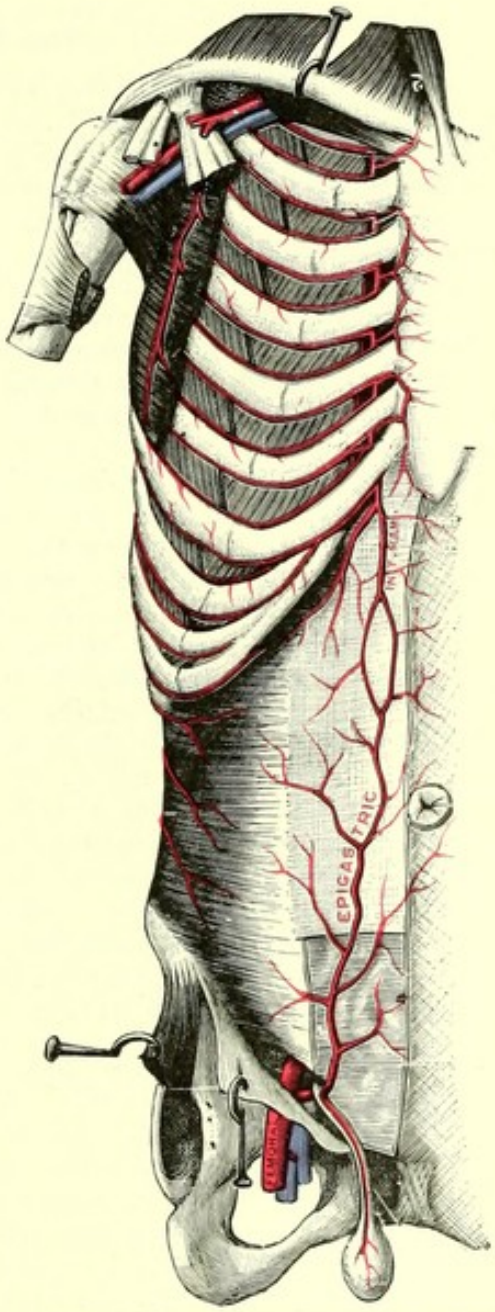

FIG. 456.—Internal mammary and deep epigastric arteries. (Testut.)

surface of the costal arch, and opposite each one of the lower intercostal spaces. It gives off an intercostal branch, and sends also a number of muscular branches to the diaphragm. The *superior epigastric*, the other terminal branch, descends into the abdominal wall, at first occupying a position between the rectus muscle and its posterior sheath, then passing into the substance of the rectus, and anastomoses with the deep epigastric artery.

Surgical Anatomy (Fig. 442).—The surgical anatomy of the internal mammary includes the discussion of aneurism and injuries. The vessel can be ligated in any of the six upper intercostal spaces one-half inch external to the sternum. The best plan of operation is a transverse incision over a costal cartilage, exposure of the cartilage for an inch, removal of a section of the cartilage, and ligation of the vessel beneath.

The Thyroid Axis.

The *thyroid axis* (Fig. 443, THY.) is a large trunk which arises from the anterior and superior surface of the first part of the subclavian, and divides into three branches, the inferior thyroid, the transversalis colli, and suprascapular.

The **Inferior Thyroid Artery** passes upward and inward in front of the vertebral and behind the common carotid artery, internal jugular vein, and pneumogastric nerve to the inferior portion of the lateral lobe of the thyroid body, to which it is distributed. The recurrent laryngeal nerve passes sometimes in front and sometimes behind the artery; it is in intimate relation to the vessel, and in ligating the artery this relationship must be borne in mind.

Varieties.—The inferior thyroid is sometimes a branch of the vertebral or the common carotid, or instead of arising from the thyroid axis may be a branch from the subclavian.

Surgical Anatomy (Fig. 453).—The inferior thyroid is sometimes ligated in lesions of the thyroid gland for the purpose of diminishing the blood supply. It must be ligated during the operation of extirpation of a thyroid lobe. Ligation of the inferior thyroid can be made by exposing the vessel by an incision along the inner border of the sterno-mastoid, beginning at the sterno-clavicular articulation and passing upward for four inches. After dividing the superficial structures the carotid artery is drawn outward and the vessel is found external to the trachea; the recurrent laryngeal nerve is in close contact with the vessel, and in the groove between the œsophagus and trachea, usually in front of the vessel, and must be carefully avoided.

Branches of the inferior thyroid are the muscular, ascending cervical, inferior laryngeal, tracheal and œsophageal. *Muscular* branches are given off to the muscles with which it is in contact. The *ascending cervical* branch passes upward and outward over the scalenus anterior muscle, and anastomoses with branches from the occipital and ascending pharyngeal. The *inferior laryngeal* accompanies the recurrent laryngeal nerve in its distribution to the larynx. The *tracheal* branches are distributed to the trachea, and the *œsophageal* to the œsophagus.

The **Suprascapular Artery** passes outward and backward to the upper border of the scapula. The vessel at first runs almost parallel with the clavicle. Reaching the upper border of the scapula, it winds into the supraspinous fossa, supplying the supraspinatus muscle, then passes into the infraspinous fossa supplying the infraspinatus muscle; its branches anastomose with branches from the posterior scapular and the dorsal scapular arteries.

Varieties.—This vessel is sometimes a separate branch from the subclavian, sometimes a branch from the axillary.

Surgical Anatomy.—The vessel can be ligated by the same incision already described for the ligation of the third portion of the subclavian.

Branches, in addition to the terminal branches already given, are, *muscular* to contiguous muscles, *suprasternal* to the integument over the sterno-clavicular

articulation, *nutrient* to the clavicle, *supra-acromial* to the tissues over the acromion, and *subscapular* to the subscapularis muscle.

The **Transversalis Colli Artery** passes outward and backward in front of the scaleni muscles and the brachial plexus to the trapezius muscle; here it divides into two branches, the superficial cervical and the posterior scapular. The *superficial cervical* passes behind the trapezius muscle upward, and supplies the trapezius, levator scapulæ, and splenius. The *posterior scapular* passes downward along the vertebral border of scapula to its inferior angle. In its course it is covered by the rhomboid muscles, and anastomoses with the scapular arteries—suprascapular, dorsal scapular, and subscapular.

Varieties.—The posterior scapular is very often a separate branch of the third portion of the subclavian.

Surgical Anatomy.—The presence of the posterior scapular as a branch from the third portion of the subclavian is to be borne in mind in ligating that vessel; and in amputation of the entire upper extremity, the operator should know that, after ligation of the subclavian, all bleeding of consequence is controlled, except that from the posterior scapular, when it is a branch from the third portion of the subclavian, which may give rise to considerable hemorrhage, when the scapula is removed, and requires ligation.

The Superior Intercostal Artery.

This vessel arises from the posterior surface of the subclavian, either from its first or second portion. The artery passes backward and is divided into two branches. One, the *deep cervical*, passes upward, deeply situated behind the transverse processes, and anastomoses with the princeps cervicis branch of the occipital. The other branch passes downward in front of the neck of the first rib to the first intercostal space, which it supplies, and gives off also a branch to the second intercostal space.

Variations.—The superior intercostal is sometimes a branch of the thyroid axis. The deep cervical is sometimes a branch from the subclavian, sometimes from the posterior scapular.

THE TRIANGLES OF THE NECK.

The quadrilateral surface of the neck, which is bounded below by the clavicle, above by the inferior border of the lower jaw and a line drawn from the angle of the jaw to the mastoid process, behind by the anterior border of the trapezius muscle, and in front by the median line of the neck, is divided by the sterno-cleido-mastoid muscle into two triangles, called the *anterior* and *posterior triangles* of the neck. These two triangles are subdivided, the posterior into two, the *occipital*, and the *subclavian*, by the posterior belly of the omo-hyoid; the anterior into three by the anterior belly of the omo-hyoid, and the two bellies of the digastric. These are called the *inferior carotid*, the *superior carotid*, and the *submaxillary* triangles. These triangles are important anatomical regions and must be carefully studied. The student is advised to draw a sketch of these triangles, and, at this stage of his study, to add the arteries which are found in them; later, as the subjects of the veins, lymphatics, and nerves have been mastered, these structures should be added to the sketch, and the topographical anatomy completed.

The *occipital triangle* has but one vessel of large size, the transversalis colli. The *subclavian triangle* contains the subclavian and the origin of its branches. The *inferior carotid triangle* contains the common carotid, the inferior thyroid, and the vertebral. The *superior carotid triangle* contains the common carotid, the internal and external carotids, and the first portions of all the branches of the external carotid, except the terminal branches, the temporal and internal maxillary, and usually the posterior auricular. The *submaxillary triangle* contains the upper portion of the external carotid with its branches—the temporal, internal

maxillary, and posterior auricular—the internal carotid deeply situated, and the facial and lingual.

THE AXILLARY ARTERY (Fig. 457).

The *axillary artery* begins where the subclavian ends, at the lower border of the first rib, passes downward and outward through the axillary space to its lower margin—*i. e.*, the outer edge of the latissimus, and there terminates by becoming the brachial. The artery is crossed by the pectoralis minor muscle, which divides it into three portions. The first portion is between the lower border of the first rib and the inner margin of the pectoralis minor; the second portion is behind the pectoralis minor; and the third portion is between the outer border of the pectoralis minor and the lower border of the axillary space. The relations of these three portions differ, and it is well to study them separately.

Relations of the First Portion of the Axillary Artery.

In front.

Skin, superficial and deep fasciæ.
Pectoralis major.
Costo-coracoid membrane.

Outer side.		*Inner side.*
Brachial plexus of nerves.	**First portion of axillary artery.**	Axillary vein.

Behind.

First intercostal space.
Serratus magnus muscle.

Relations of the Second Portion of the Axillary Artery.

In front.

Skin, superficial and deep fasciæ.
Pectoralis major.
Pectoralis minor.

Outer side.		*Inner side.*
Outer cord of brachial plexus.	**Second portion of axillary artery.**	Axillary vein. Inner cord of brachial plexus.

Behind.

Subscapularis muscle.
Posterior cord of brachial plexus.

Relations of the Third Portion of the Axillary Artery.

In front.

Skin, superficial and deep fasciæ.
Pectoralis major.
Inner head of median nerve.

Outer side.		*Inner side.*
Coraco-brachialis muscle. Median and musculo-cutaneous nerves.	**Third portion of axillary artery.**	Ulnar nerve. Internal cutaneous nerve. Axillary vein.

Behind.

Subscapularis muscle.
Latissimus and teres major muscles.
Musculo-spiral and circumflex nerves.

Variations.—The axillary sometimes gives off one of the arteries of the forearm. This is usually the radial, but is sometimes the ulnar, and sometimes the interosseous. Very often the usual number of branches from the axillary is diminished by the origin of two or more from a common trunk. The third portion of the axillary is sometimes crossed by a muscular slip extending from the pectoralis major to the latissimus dorsi.

Surgical Anatomy (Fig. 458).—The artery may be ligated in any portion of its course. The vessel is easily found and ligated in the third portion, and may be exposed and ligated by a deep dissection in the first portion. The second portion is so covered by the pectoralis minor that a division of this muscle would be necessary to expose the artery; and, therefore, this portion would not be selected

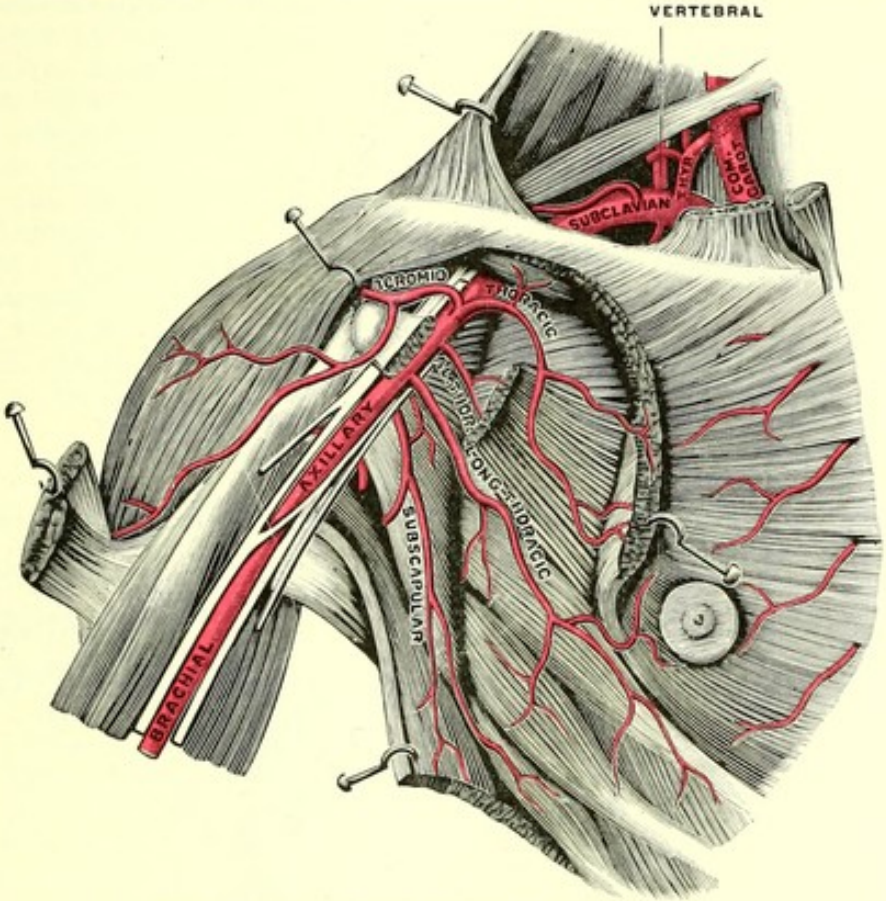

FIG. 457.—Axillary and subclavian arteries. (Testut.)

for ligation. Ligation of the first portion of the axillary can be done in the following way: An incision four inches in length is made below the middle of the clavicle and parallel with the clavicular fibres of the pectoralis major muscle. This incision should divide the skin, superficial and deep fasciæ, and expose the pectoralis major muscle. The muscle-fibres should not be cut across, but separated by blunt dissection, held apart by retractors, and the pectoralis minor muscle sought for and exposed. Between the clavicle and the inner border of the pectoralis minor stretches a strong fibrous layer, the costo-coracoid membrane, which being divided, the axillary artery will be exposed, with the axillary vein situated internally and beneath, and the brachial plexus above and externally. These structures are to be avoided in applying a ligature. The ligation of the third portion of the artery requires but a superficial dissection. If the axillary space is divided from before backward into thirds, the vessel will be found at the junction of the anterior with the middle third. An incision two and a half inches long is made at this point, and parallel to the course of the vessel. The skin and superficial and deep fasciæ being cut through, the vessel will be exposed,

with the axillary vein internally and beneath, and the ulnar nerve to the inner side. The median nerve is externally and above, its inner head crossing in front of the artery. These structures are to be avoided in passing the aneurism-needle.

The **Branches** of the axillary artery are usually seven in number, two, the

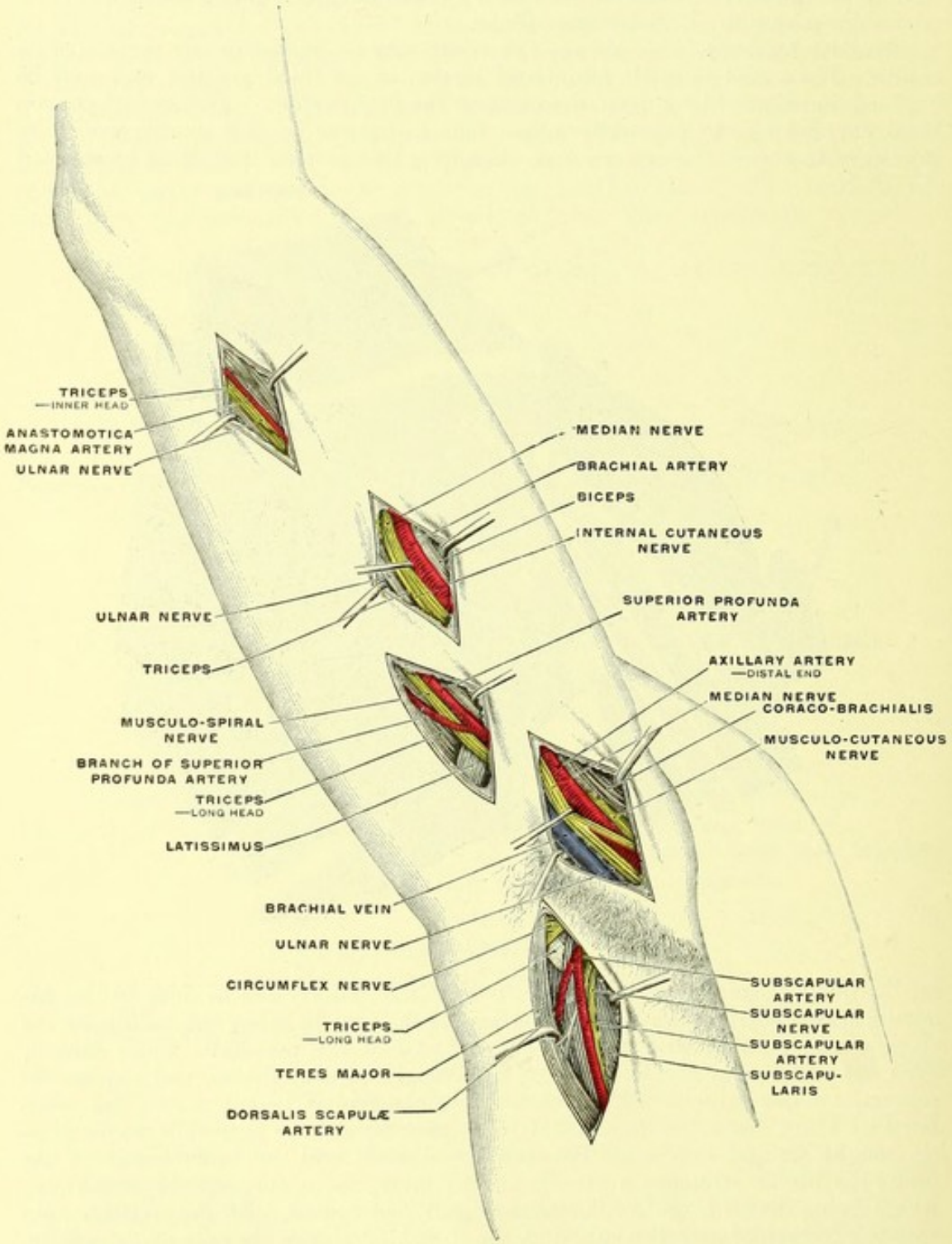

FIG. 458.—Surgical relations of the axillary, subscapular, brachial, superior profunda, and anastomotica magna arteries. The right arm is represented as raised almost to the perpendicular. (Kocher.)

superior thoracic and acromio-thoracic, from the first portion; two, the long thoracic and alar thoracic from the second; and three, the subscapular and the anterior and posterior circumflex, from the third portion. The *superior thoracic* arises from the first portion of the axillary, and passes downward and forward to

supply the pectoralis major and minor muscles. The *acromio-thoracic* artery arises from the first portion of the axillary; it breaks up into three sets of branches: one passes outward to the acromion, the second passes down the arm with the cephalic vein, and the third supplies the pectoral and the serratus magnus muscles. The *long thoracic* artery arises from the second portion of the axillary, passes downward along the outer border of the pectoralis minor, and sends branches to the serratus magnus, the pectorales major and minor, and the mammary gland. The *alar thoracic*, arising from the second portion, consists either of a single branch or a number of small branches, distributed to the lymphatic glands, the fat and the areolar tissue of the axilla. The *subscapular* artery is a large branch which arises from the third portion of the axillary. It passes downward on the subscapularis muscle, and, at about the centre of the axillary border of the scapula, it gives off a large branch, the *dorsalis scapulæ* artery, which winds into the infraspinatus muscle, and anastomoses with the suprascapular and posterior scapular arteries. The rest of the artery passes downward on the chest wall, and is distributed to the muscles in this region—the subscapularis, the serratus magnus, the latissimus, and the teres major. The *posterior circumflex* is larger than the anterior. It arises from the third portion of the axillary, and winds backward between the teres muscles, and between the humerus and long head of the triceps. It accompanies the circumflex nerve, and supplies the deltoid and other structures about the shoulder-joint. The *anterior circumflex* arises from the third portion of the axillary artery. It passes forward in front of the humerus, is covered by the coraco-brachialis and the tendon of the biceps, sends branches to the shoulder-joint, and anastomoses with the posterior circumflex artery.

THE AXILLARY SPACE.

At this stage the student is advised to draw the axillary space, its boundaries, and the arteries contained in it. Later, as the subjects of the veins, lymphatics, and nerves are mastered, these should be added to the sketch.

The **Axillary Space** is one of much practical importance, for it is often invaded by the surgeon in operative work, such as clearing the axilla in connection with the removal of carcinoma of the mammary gland. This operation practically amounts to a dissecting of the axilla and demands a thorough knowledge of the anatomy of the part.

The axilla or arm-pit is the wedge-shaped space between the inner surface of the arm and the side of the chest. It presents for examination as boundaries anterior, posterior, internal, and external walls, a base and an apex. The *anterior wall* is formed by the pectoral muscles; the *posterior wall* by the latissimus, the teres major, and the subscapularis muscles; the *inner wall* by the upper four ribs and intercostal spaces, covered by the serratus magnus muscle; and the *outer wall* by the humerus, covered by the coraco-brachialis muscle and the biceps tendons. The *apex* corresponds to the small area above the first rib from which the brachial plexus, and the axillary artery and vein emerge. The *base* is formed by the integument and fascia which stretch across the arm-pit from the pectoralis major to the latissimus dorsi. The arterial contents are the axillary artery and its branches. In addition the space contains the accompanying veins, the brachial plexus of nerves, the axillary lymphatic nodes and vessels, and considerable fat and areolar tissue. The position of these structures in the space and their relations to each other should be carefully studied.

THE BRACHIAL ARTERY (Fig. 459).

The *brachial artery*, the continuation of the axillary, begins at the outer border of the axillary space. It passes down the inner aspect of the arm, covered by the deep fascia, and lying on the inner border of the coraco-brachialis and biceps muscles; it terminates in the forearm about half an inch below the bend of the elbow

by dividing into the ulnar and radial. The artery is usually accompanied by venæ comites.

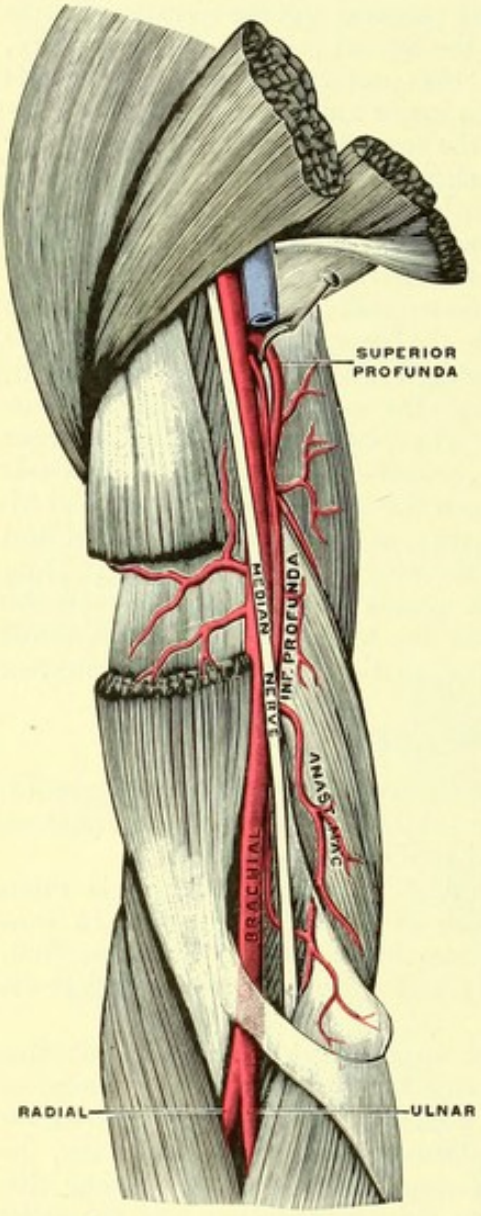

FIG. 459.—Brachial artery. (Testut.)

RELATIONS OF THE BRACHIAL.

In front.

Skin, superficial fascia.
Deep fascia.
Median nerve.
Basilic vein.

Outer side.		*Inner side.*
Coraco-brachialis and biceps muscles.	**Brachial artery.**	Ulnar and internal cutaneous nerves.

Behind.

Musculo-spiral nerve.
Superior profunda artery.
Triceps and brachialis muscles.

Variations.—High division of the brachial is frequently seen, and has been noted at all parts of its course. The vessel given off high up is usually the radial, sometimes the ulnar, rarely the interosseous.

Surgical Anatomy (Fig. 458).—The brachial artery may be exposed for ligation in any part of its course. The vessel is superficially situated and readily exposed, the landmarks being the inner border of the coraco-brachialis muscle in the upper part of the arm, and the inner border of the biceps in the middle and lower portions of its course. An incision is made two inches in length parallel with the inner border of those muscles, the skin, superficial fascia and deep fascia are divided, and the artery is exposed. In the superficial fascia the basilic vein often lies in the course of the artery; the median nerve is usually superficial, external above and internal below; the ulnar nerve is internal, and the vessel is accompanied by venæ comites.

The **Branches** of the brachial are the superior profunda, muscular, nutrient, inferior profunda, and anastomotica magna. The *superior profunda* accompanies the musculo-spiral nerve in the musculo-spiral groove between the internal and external heads of the triceps. Above the elbow it winds to the anterior surface of the forearm, and anastomoses with the recurrent branches of the arteries of the forearm. *Muscular* branches are given off to the muscles of the arm. The *nutrient* branch is given off to the humerus, entering the nutrient foramen in the shaft of the bone. The *inferior profunda* artery accompanies the ulnar nerve to the posterior surface of the elbow, and anastomoses with the recurrent branches of the arteries of the forearm. The *anastomotica magna* arises from the brachial two inches above the elbow, winds backward to the posterior surface of the internal condyle, and anastomoses with the recurrent branches of the arteries of the forearm.

The Ulnar Artery (Figs. 462-465.)

The ulnar artery arises as one of the terminal branches of the brachial half an inch below the bend of the elbow, and passes inward and downward along the anterior and inner portion of the forearm, between the two layers of muscles on

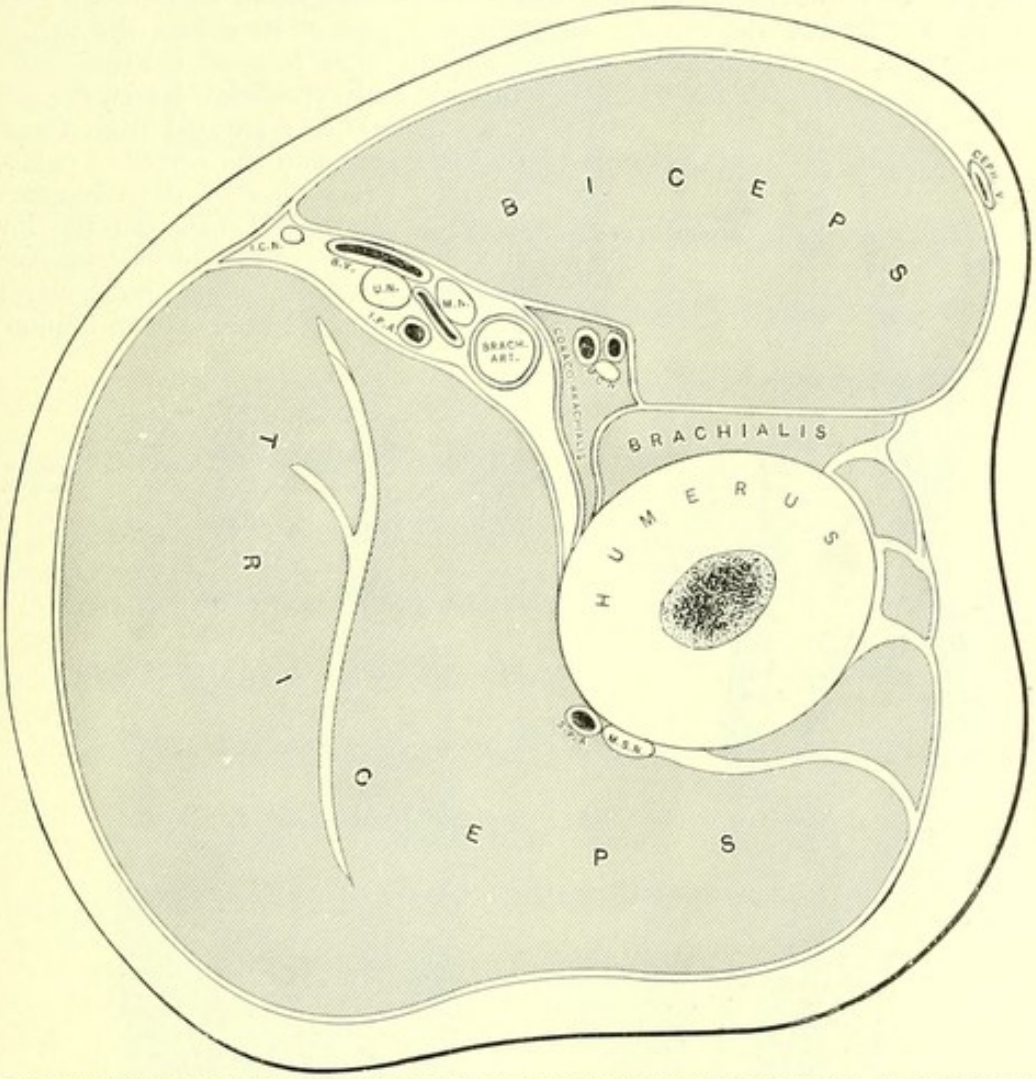

FIG. 460.—Horizontal section at middle of right arm—upper surface of lower segment. B. V., basilic vein; CEPH. V., cephalic vein; I. C. N., internal cutaneous nerve; I. P. A., inferior profunda artery; M. C. N., musculo-cutaneous nerve; M. N., median nerve; M. S. N., musculo-spiral nerve; S. P. A., superior profunda artery; U. N., ulnar nerve. (After Braune.)

its anterior surface. It becomes superficial in the lower part of the forearm, and occupies a position between the tendons of the flexor carpi ulnaris and flexor sublimis. Reaching the wrist it passes over the anterior annular ligament into the palm of the hand, and forms the superficial palmar arch.

RELATIONS OF THE ULNAR ARTERY.

In front.

Skin, superficial and deep fasciæ.
Superficial layer of anterior muscles of forearm.

Internally.		*Externally.*
Flexor carpi ulnaris. Ulnar nerve.	**Ulnar artery.**	Flexor sublimis digitorum.

Behind.

Brachialis.
Flexor profundus digitorum.

Variations.—The ulnar often arises from the brachial in the arm, and sometimes even from the axillary. The vessel is occasionally superficially situated, being in front of the superficial flexor muscles instead of covered by them.

Surgical Anatomy (Fig. 463).—The ulnar artery can be exposed for ligation in any part of its course, the muscle and tendon of the flexor carpi ulnaris being the guide for finding the vessel. In the upper part of its course the artery is covered by the superficial flexor muscles, and, in order to reach it after dividing the skin and superficial fascia, the flexor carpi ulnaris is separated from the rest of the group, and the artery is exposed, with its venæ comites, the ulnar nerve being to the outer side. In the lower half of its course the artery is superficial, and can be exposed by an incision made along the outer border of the tendon of the flexor carpi ulnaris, which should divide the skin, superficial fascia, and deep fascia. The artery is here accompanied by the ulnar nerve which is internal and also by venæ comites.

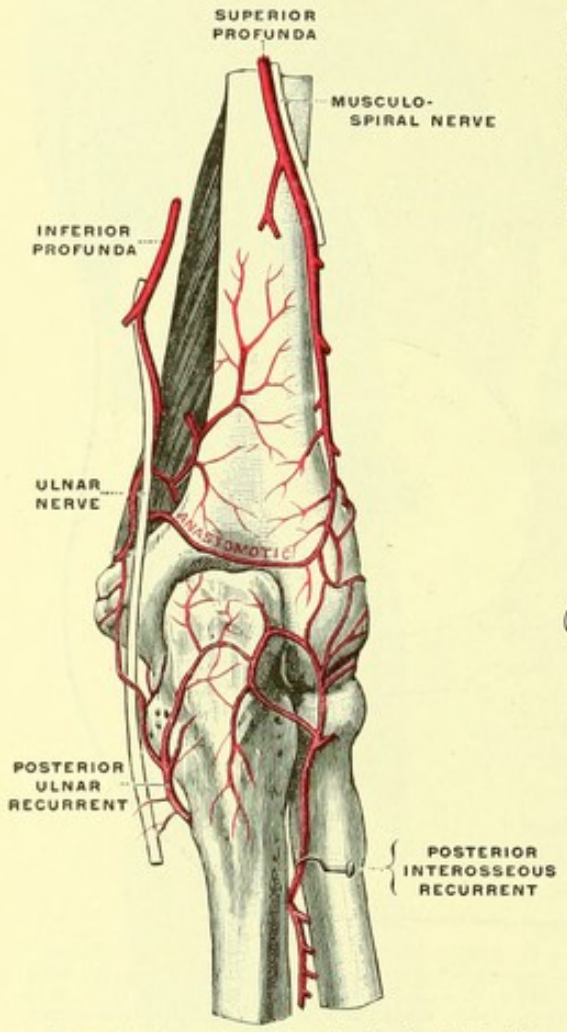

FIG. 461.—Anastomoses at the back of the elbow. (Testut.)

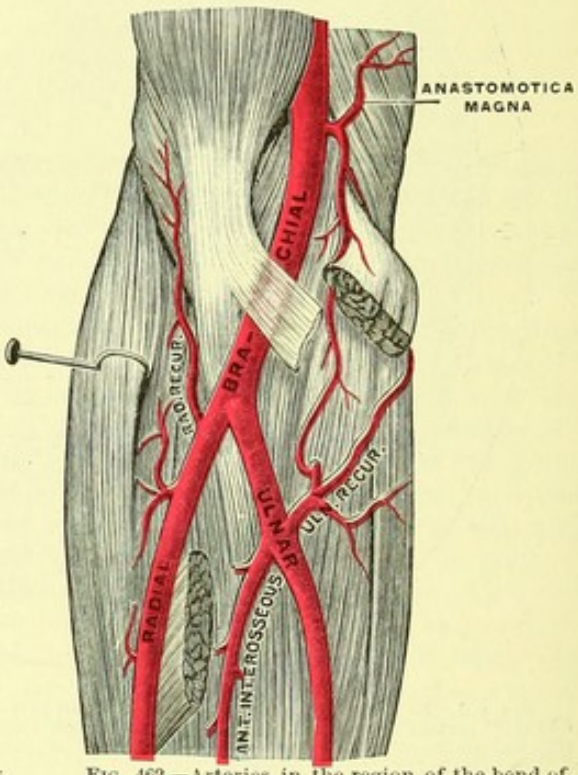

FIG. 462.—Arteries in the region of the bend of the elbow. (Testut.)

The **Branches** of the ulnar are divided into three groups, those in the forearm, those in the wrist, and those in the hand.

In the **forearm** the branches are the recurrent arteries, anterior and posterior, the interosseous, and the muscular. The *recurrent* branches wind upward and inward, the anterior in front and the posterior behind the inner condyle, to anastomose with the inferior profunda and anastomotica magna branches of the brachial. The *interosseous* is a short trunk which divides into two branches. The *anterior interosseous* passes downward on the anterior surface of the interosseous membrane to the carpus, and supplies the deep layer of muscles. The *posterior interosseous* arises above the upper margin of the interosseous membrane, to the posterior surface of which it runs; here it gives off an ascending, or recurrent, branch, which passes up to the posterior surface of the internal condyle to

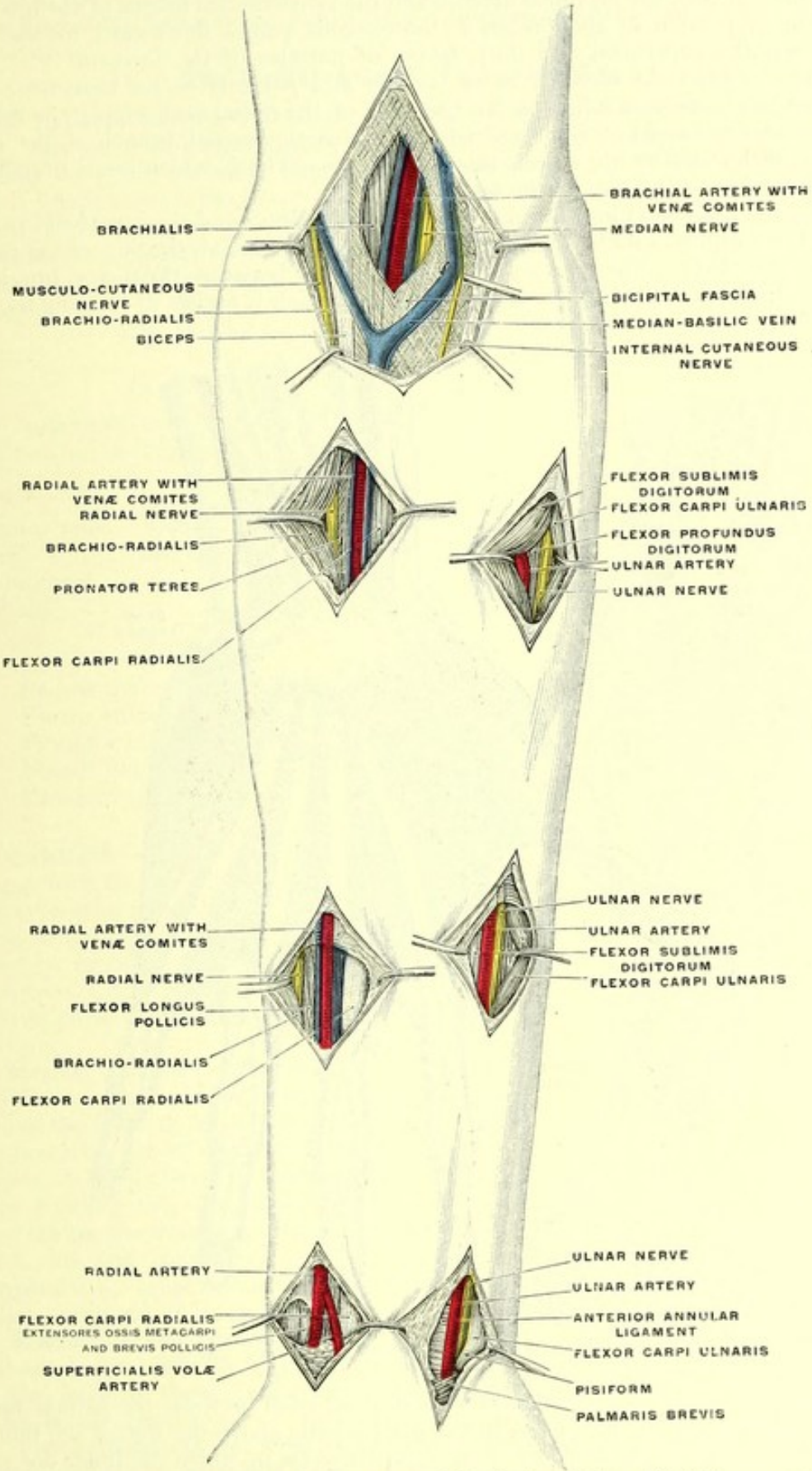

FIG. 463.—Surgical relations of the radial and ulnar arteries. (Kocher.)

anastomose with the profunda arteries and the anastomotica magna of the brachial; the main portion of the posterior interosseous passes downward to the wrist between the superficial and deep layers of muscles of the forearm.

In the **wrist** the ulnar gives off *anterior* and *posterior carpal* branches; these branches anastomose with similar branches of the radial and supply the carpus; the posterior carpal of the ulnar with the posterior carpal branch of the radial form on the back of the carpus the *posterior carpal arch*, which sends branches to the interosseous spaces and the fingers.

In the **hand** the ulnar divides into the deep palmar and the superficial palmar, which latter forms with the superficialis volæ of the radial, the superficial palmar arch (Fig. 464). The *deep palmar* branch passes between the flexor brevis and the abductor minimi digiti to reach the radial, which it assists in forming the deep

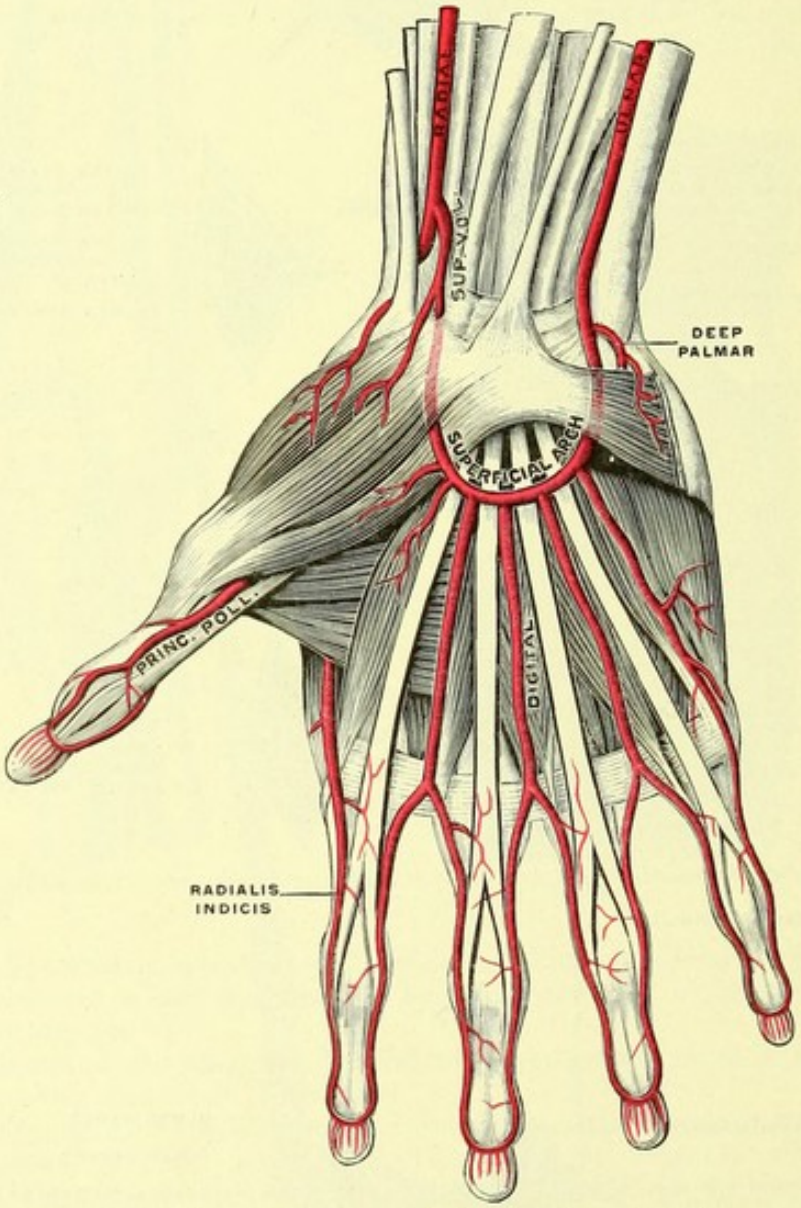

FIG. 464.—Superficial palmar arch and its branches. (Testut.)

palmar arch. The *superficial palmar arch* is situated between the palmar fascia and the flexor tendons at a point in the hand a little above the web of the thumb. The branches of the arch are the *four digital arteries*, of which the inner one supplies the inner side of the little finger, the second the contiguous sides of the little and ring fingers, the third the contiguous sides of the ring and middle fingers, and

the fourth the contiguous sides of the middle and index fingers; opposite the web of the fingers the arteries are joined by the interosseous branches from the deep palmar arch.

The Radial Artery (Figs. 462, 465).

The radial artery arises from the brachial a half inch below the bend of the elbow. It passes downward along the radial side of the forearm, internal to the muscular belly and tendon of the brachio-radialis muscle; a little above the wrist-joint it winds around the lower end of the radius to the posterior surface of the carpus; then passes into the hand at the base of the first interosseous space, and forms the deep palmar arch by anastomosing with the communicating or deep palmar branch of the ulnar.

Relations of the Radial in the Forearm.

In front.

Skin, superficial and deep fasciæ, belly of brachio-radialis.

Internally.		*Externally.*
Pronator radii teres.	**Radial artery.**	Brachio-radialis.
Flexor carpi radialis.		Radial nerve.

Behind.

Radius covered by supinator.
Flexor sublimis digitorum.
Pronator teres.
Flexor longus pollicis.
Pronator quadratus.

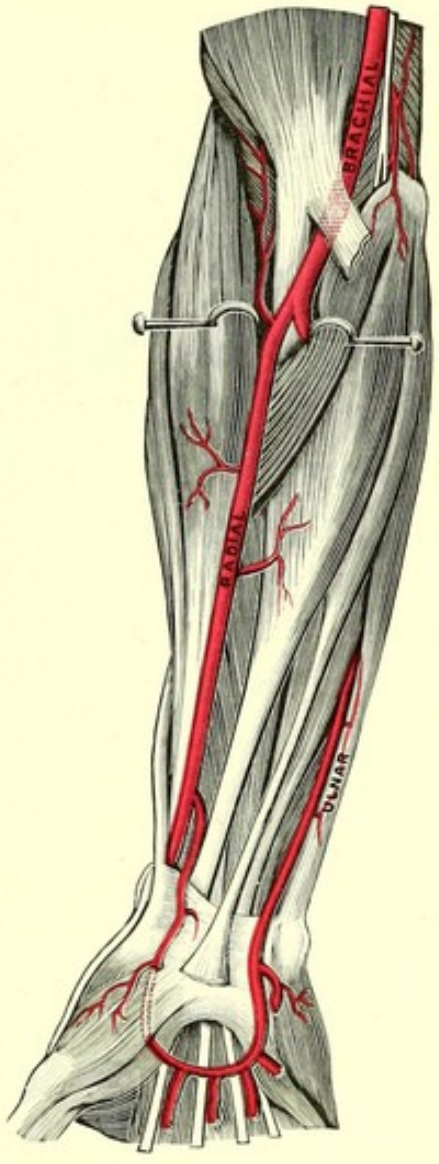

Fig. 465.—Arteries of the forearm—front view. (Testut.)

Variations.—The radial frequently springs from the brachial in the arm, and may even arise from the axillary. Sometimes it is very small, its place being taken by branches from the ulnar and interosseous, and in this case it may be that no pulse can be found in the usual position.

Surgical Anatomy (Fig. 463).—The radial can be exposed for ligation in any part of the forearm by an incision along the inner border of the brachio-radialis muscle, its belly above, its tendon below; after dividing the skin, superficial and deep fasciæ, the muscle is drawn to the outer side and the artery exposed, accompanied by venæ comites and by the radial nerve, which is external.

Branches.—The branches of the radial are divided into three groups: those in the forearm, those in the wrist, and those in the hand.

The branches *in the forearm* are radial recurrent, muscular, anterior radial carpal, and the superficialis volæ. The *radial recurrent* passes upward between the brachialis and the brachio-radialis to the anterior aspect of the external con-

dyle, where it anastomoses with the superior profunda of the brachial. *Muscular* branches are given off from the radial to the muscles of the forearm with which it is in contact. The *anterior carpal* branch of the radial supplies the anterior surface of the carpus, anastomosing with the anterior ulnar carpal artery. The *superficialis volæ* arises from the artery above the wrist, passes through the muscles of the thenar eminence, and anastomoses with the superficial palmar arch.

The branches *in the wrist* are the posterior carpal, the first dorsal interosseous, the dorsal artery of the thumb, and the dorsal artery of the index finger. The *posterior carpal* (Fig. 467) supplies the posterior surface of the carpus, anastomosing with the posterior carpal branch of the ulnar. The first dorsal interosseous artery supplies the interosseous space between the index and middle fingers. The *dorsal artery of the thumb* (dorsalis pollicis) runs over the dorsal

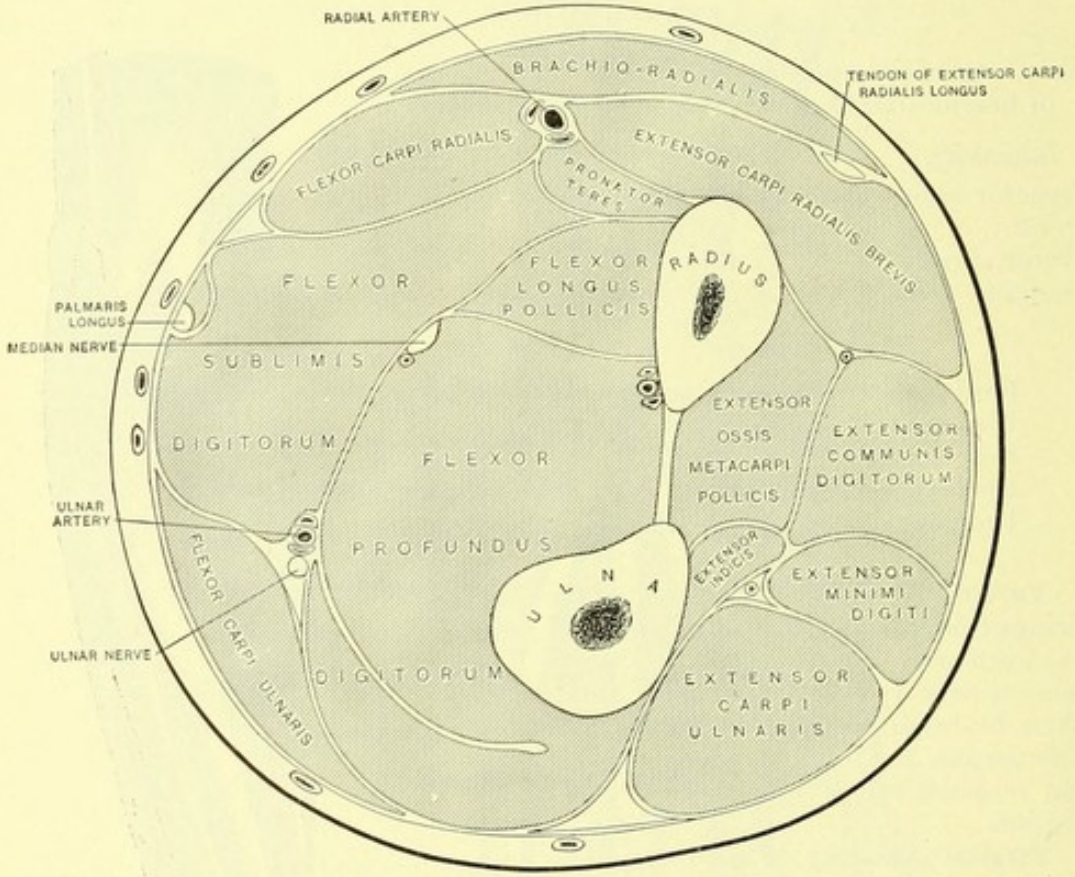

FIG. 466.—Horizontal section at middle of right forearm—upper surface of lower segment. (After Braune.)

aspect of the thumb, dividing into two branches, which supply both sides of the dorsum of the thumb. The *dorsal artery of the index finger* (dorsalis indicis) supplies the outer side of the dorsal surface of the index finger.

In the hand the radial gives off the following branches—the main artery of the thumb (princeps pollicis), the radial artery of the index finger, the perforating, the interosseous, and the recurrent. The *princeps pollicis* passes downward in front of the metacarpal bone of the thumb to its head, where it divides into two branches, which supply the inner and outer surfaces of the thumb. The *radialis indicis* passes along the radial side of the metacarpal bone of the index finger, and supplies the radial side of this digit to its tip. The *deep palmar arch* (Fig. 468) is situated on the bases of the metacarpal bones, with the flexor tendons in front; it is completed by the anastomosing of the radial with the deep communicating branch of the ulnar. The deep arch is about half an inch nearer the wrist than the superficial. From the arch are given off the *interosseous* arteries, three in

number, which run downward in the inner three interosseous spaces to join the digital arteries of the superficial arch above the webs of the fingers. The deep arch gives off also a *recurrent* branch to the wrist, and *perforating* branches,

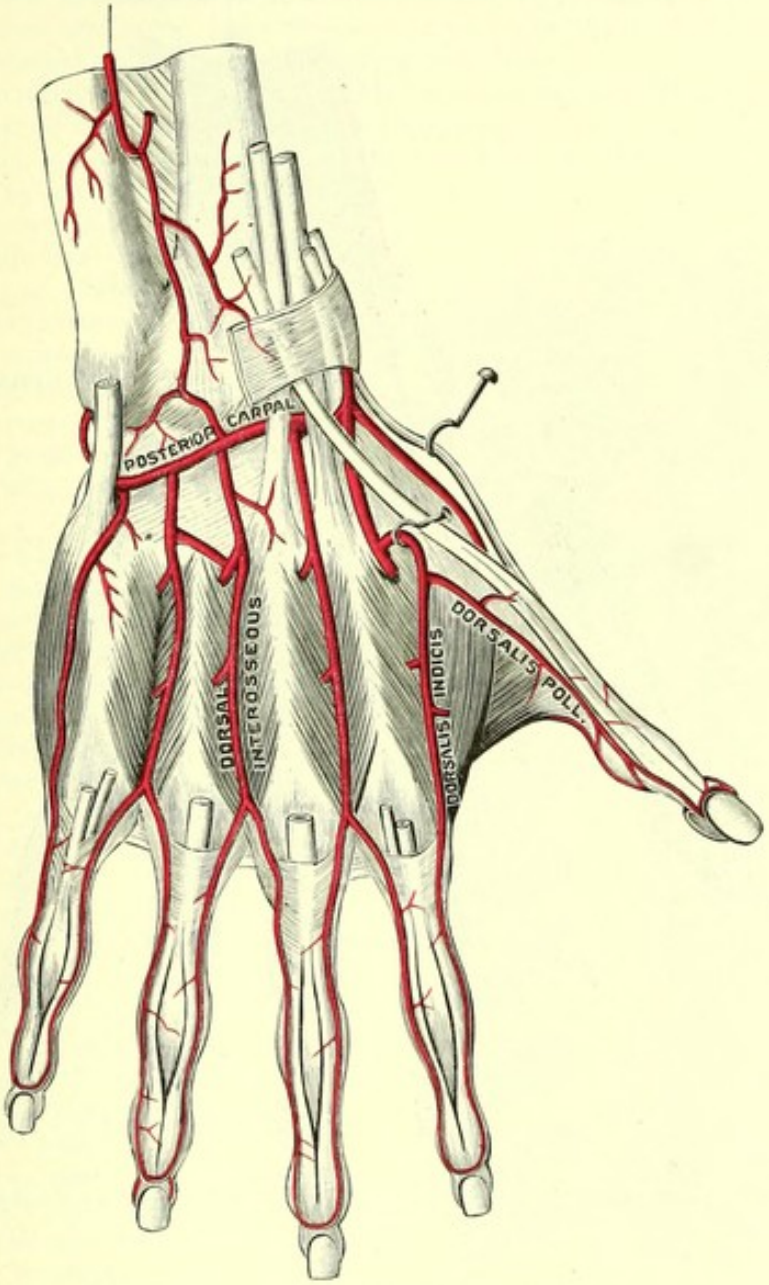

FIG. 467.—Arteries of the dorsum of the hand. (Testut.)

which pierce the bases of the three inner interosseous spaces, and anastomose with the dorsal interosseous arteries.

THE DESCENDING AORTA.

The *descending aorta* begins at the lower border of the fifth thoracic vertebra, passes downward in the thoracic and abdominal cavities in front of the spinal column to the fourth lumbar vertebra, where it divides into the common iliac arteries. It is divided into two portions, the thoracic in the chest-cavity, and the abdominal in the belly-cavity.

The **thoracic aorta** (Fig. 469) extends from the lower border of the fifth dorsal

vertebra to the aortic opening in the diaphragm. The vessel is at first a little to the left of the median line, but gradually approaches the median line at its termination. It is in the posterior mediastinal space.

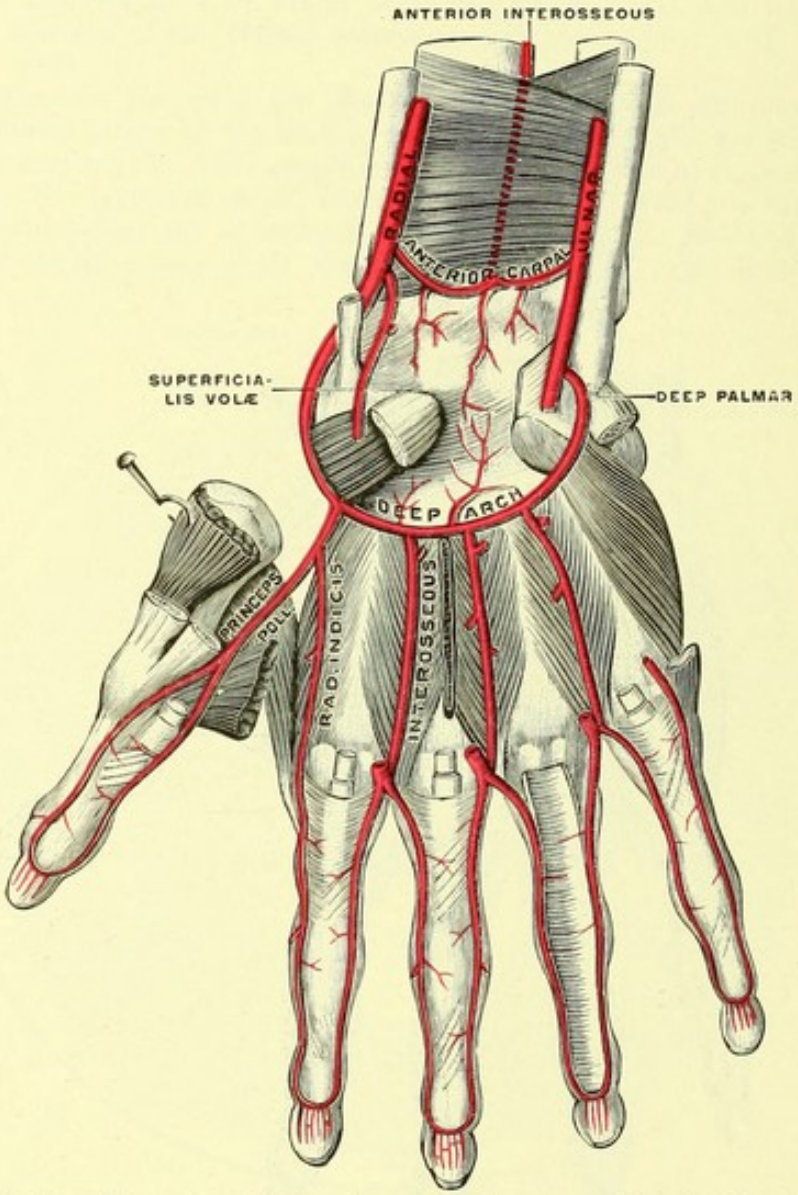

FIG. 468.—The deep palmar arch and its branches. The first metacarpal bone has been disarticulated to show the course of the radial around the wrist. (Testut.)

RELATIONS OF THE THORACIC AORTA.

In front.

Root of the left lung.
Œsophagus.
Pericardium.

Right side.		*Left side.*
Œsophagus above.	**Thoracic aorta.**	Pleura and lung.
Thoracic duct.		Œsophagus below.

Behind.

Thoracic vertebræ.

Variations.—Variations are often found in the number of intercostal arteries given off from the aorta; frequently the arteries of two or more intercostal spaces are given off by a common trunk. A few cases are reported of obliteration of the aorta below the ductus arteriosus. These cases are consistent with life, a collateral circulation existing between the intercostals and branches given off from the great arteries springing from the arch above the point of obliteration, and between the internal mammary and the deep epigastric.

Surgical Anatomy.—The relations of the thoracic aorta should be studied with special reference to the pressure symptoms occurring in aneurism. The aneurism may by pressure produce absorption of the bodies of the thoracic vertebræ, may produce pain by pressure on the spinal nerves and the sympathetic nerves, may produce difficult deglutition by pressure on the œsophagus. The œsophagus is at first at the right of the vessel, then crosses in front of the vessel to occupy a position to the left below. By pressure on the thoracic duct, root of the left lung, the heart, and the great vessels, an aneurism may interfere with the function of these structures.

FIG. 469.—Thoracic aorta. (Testut.)

Branches.—The branches of the thoracic aorta are the pericardial, bronchial, œsophageal, posterior mediastinal, and intercostal arteries.

The *pericardial* are vessels of small size which supply the pericardium. The *bronchial* arteries supply the lung structure with arterial blood. There are usually one or two vessels for each side, as a rule one for the right and two for the left. In addition to supplying the lungs the bronchial arteries send branches to the bronchial lymphatic nodes, the pericardium, and the œsophagus. The *œsophageal* arteries are small vessels, from three to five in number, given off from the course of the thoracic aorta, and supplying the œsophagus. The *posterior mediastinal* are small vessels of little moment, which pass backward to the thoracic vertebræ, and supply the lymphatic nodes in the posterior mediastinum, and also the posterior portion of the diaphragm. The *intercostal* arteries arise from the posterior and lateral surfaces of the thoracic aorta and run outward to the intercostal spaces; they vary from nine to eleven in number. The upper two intercostal spaces are supplied, as already described, by the superior intercostal branch of the subclavian. Often, however, an aortic intercostal is sent to the second intercostal space. These vessels run in, or just below, the well-marked intercostal grooves on the inner surfaces and lower borders of the ribs; and running forward in the intercostal spaces to the anterior chest wall, they anastomose with the intercostal branches from the internal mammary and musculo-phrenic. In their course the intercostals give off posterior branches which pass backward through the intercostal space to reach the deep muscles of the back, which they supply. *Spinal* branches to the cord and its membranes and to the vertebral column are derived from these. The *collateral*

intercostal branch runs from the main artery at a point opposite the angle of the rib to the upper border of the rib below and runs forward in the intercostal space; this branch is much smaller than the intercostal itself. In their course the intercostal arteries and their branches send vessels to the thoracic walls, the parietal layer of the pleura, and the muscles covering the thorax; several branches of good size are sent to the mammary gland, usually from the third and fourth intercostal arteries.

The Abdominal Aorta (Fig. 470).

The abdominal aorta begins at the aortic opening in the diaphragm, extends downward retroperitoneally on the bodies of the lumbar vertebræ, either in the median line or a little to the left of it, and terminates on the body of the fourth

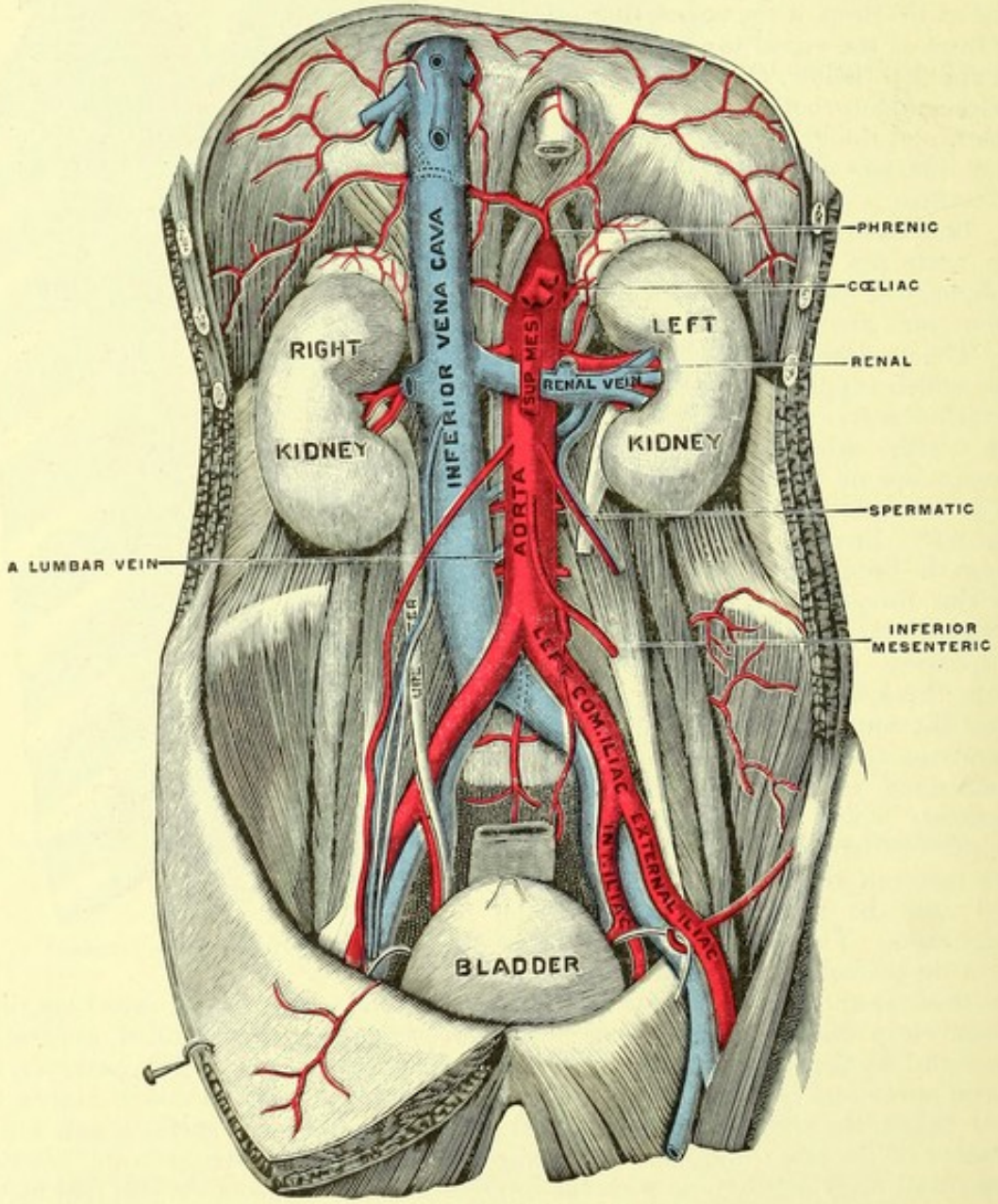

FIG. 470.—Abdominal aorta. (Testut.)

lumbar by dividing into the two common iliac arteries. This point is on a line drawn through the highest level of the iliac crests.

RELATIONS OF THE ABDOMINAL AORTA.

In front.

Peritoneum.
Stomach.
Pancreas.
Duodenum.
Splenic vein.
Left renal vein.
Intestines.
Solar plexus.

Right side.

Inferior vena cava.
Thoracic duct.
Right crus of diaphragm.
Right semilunar ganglion.

Abdominal aorta.

Left side.

Left crus of diaphragm.
Left semilunar ganglion.
Tail of pancreas.

Behind.

Vertebral column.
Receptaculum chyli.
Thoracic duct.

Variations.—These are commonly variations in length; the vessel has been found to divide on the third lumbar or on the fifth lumbar, above or below the usual point.

Surgical Anatomy.—Aneurism of the abdominal aorta is frequently met with; the relations of the aorta to surrounding structures should be carefully studied in order to interpret the pressure symptoms which may arise. By pressure on the lumbar vertebræ atrophy and absorption of the bodies may result. Pressure on the spinal nerves and the sympathetic system produces pain and interference with the function of the structures and organs supplied by these nerves. The normal abdominal aorta in thin subjects is very readily outlined, and its pulsations distinctly felt, and with the pressure of a stethoscope a murmur can be often produced and heard, which must not be mistaken for aneurism. Ligation of the abdominal aorta has been performed, but always with fatal result. Successful cases of treating aneurism, by mechanical pressure and by operative interference in which silver wire was introduced into the sac, are recorded.

Branches.—The branches of the abdominal aorta can well be divided into two groups—a visceral group to the viscera of the abdominal and in part to the pelvic cavities, and a parietal group to the walls of the abdominal cavity. The *visceral group* consists of the cœliac axis, the superior mesenteric, the inferior mesenteric, the suprarenal, the renal, and the spermatic. The *parietal group* consists of the phrenic, the lumbar, and the sacra media.

The **Cœliac Axis** is given off from the abdominal aorta just below the aortic opening in the diaphragm; it is a large short trunk, about a half inch in length, and divides into the gastric, the hepatic, and the splenic arteries.

The **gastric artery** (Fig. 471) runs from the cœliac axis upward and to the left to the œsophageal orifice of the stomach; thence it passes from left to right along the small curvature of the stomach to the pyloric opening. In the first part of its course it gives off branches to the œsophagus. The vessel is the smallest branch of the cœliac axis.

The **hepatic artery** passes transversely to the right to the right free edge of the small omentum; thence it passes upward in front of the foramen of Winslow to the transverse fissure of the liver, and divides into two branches to supply the right and left lobes of the liver.

Variations.—The hepatic artery is sometimes a separate trunk from the aorta; sometimes an accessory hepatic artery is given off from the gastric, usually supplying the left lobe of the liver.

Surgical Anatomy.—The position of the hepatic artery and its relation to the common bile-duct and the portal vein must be carefully studied in operations on the common duct. These structures all lie in the free edge of the small omentum, which bounds the foramen of Winslow in front. The common duct is in front, the hepatic artery is to the left, and the portal vein is behind.

Branches.—The branches of the hepatic are the pyloric, the gastro-duodenalis, and the cystic arteries. The *pyloric* branch passes to the pyloric end of the stomach, anastomosing with the pyloric branches from the gastric artery. The *gastro-duodenalis* is a short, large vessel which passes downward and to the right

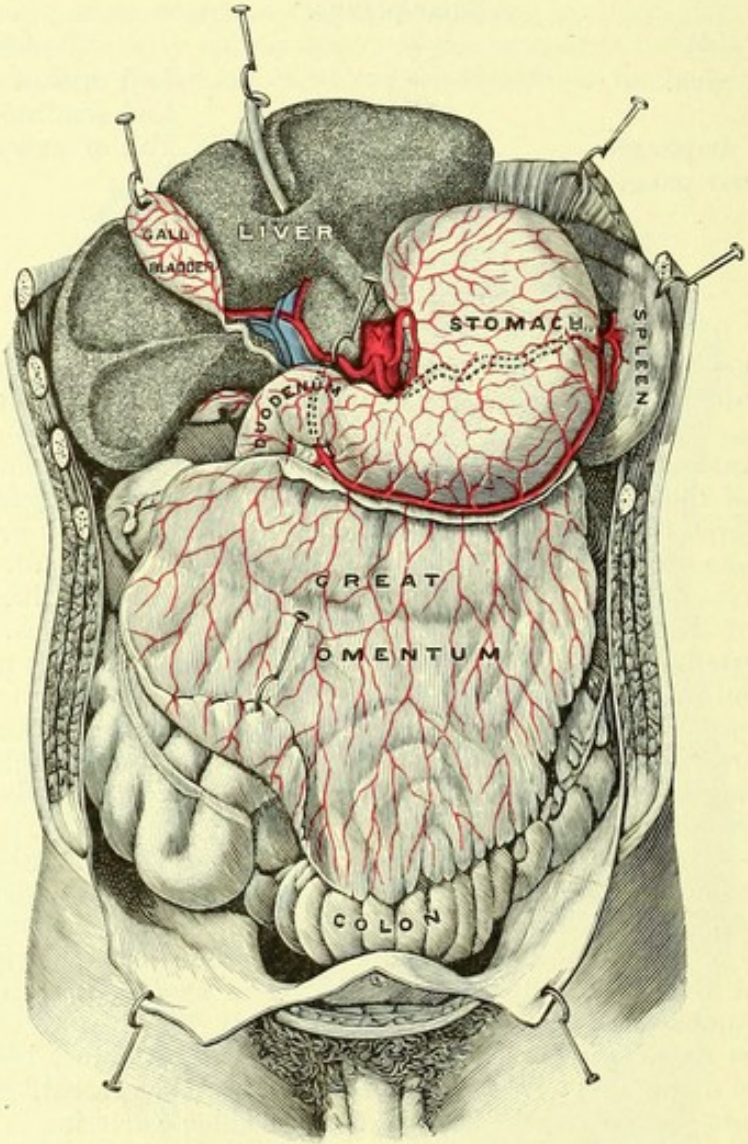

FIG. 471.—Arteries of the stomach, liver, and great omentum. (Testut.)

between the head of the pancreas and the duodenum, and divides into the gastro-epiploica dextra and the superior pancreatico-duodenalis. The *gastro-epiploica dextra*, a vessel of large size, winds from right to left along the great curvature of the stomach between the folds of the great omentum, supplies the stomach and anastomoses with the gastro-epiploica sinistra of the splenic. The *superior pancreatico-duodenalis*, a small vessel, winds downward between the head of the pancreas and the duodenum, supplying these structures and anastomosing with the pancreatico-duodenalis inferior of the superior mesenteric. The *cystic* artery or arteries are usually branches of the right hepatic; they supply the gall-bladder.

The **Splenic Artery** is the largest branch of the cœliac axis; it runs from right

to left along the upper surface of the pancreas to the spleen, where it breaks up into a number of branches which enter the hilum and supply that organ.

Variations.—The splenic sometimes gives off a hepatic branch to the left lobe of the liver, and, rarely, branches to the intestines.

Surgical Anatomy.—The position of the splenic artery should be carefully studied with reference to the operation of removal of the spleen. The fact that the artery does not enter the spleen as a single trunk, but as several branches, and often that these vessels enter the spleen at wide distances from each other, should be carefully noted.

Branches of the splenic artery are the pancreatic, the short gastric, and the gastro-epiploica sinistra. The *pancreatic* are numerous branches supplying the pancreas; one large trunk accompanies the main duct of the pancreas from left to right, and is called the pancreatica magna. The *short gastric*, half a dozen vessels of small size, supply the left extremity of the stomach. The *gastro-epiploica sinistra* winds along the great curvature of the stomach, and anastomoses with the gastro-epiploica dextra.

The Superior Mesenteric (Fig. 472).—The *superior mesenteric* arises from the

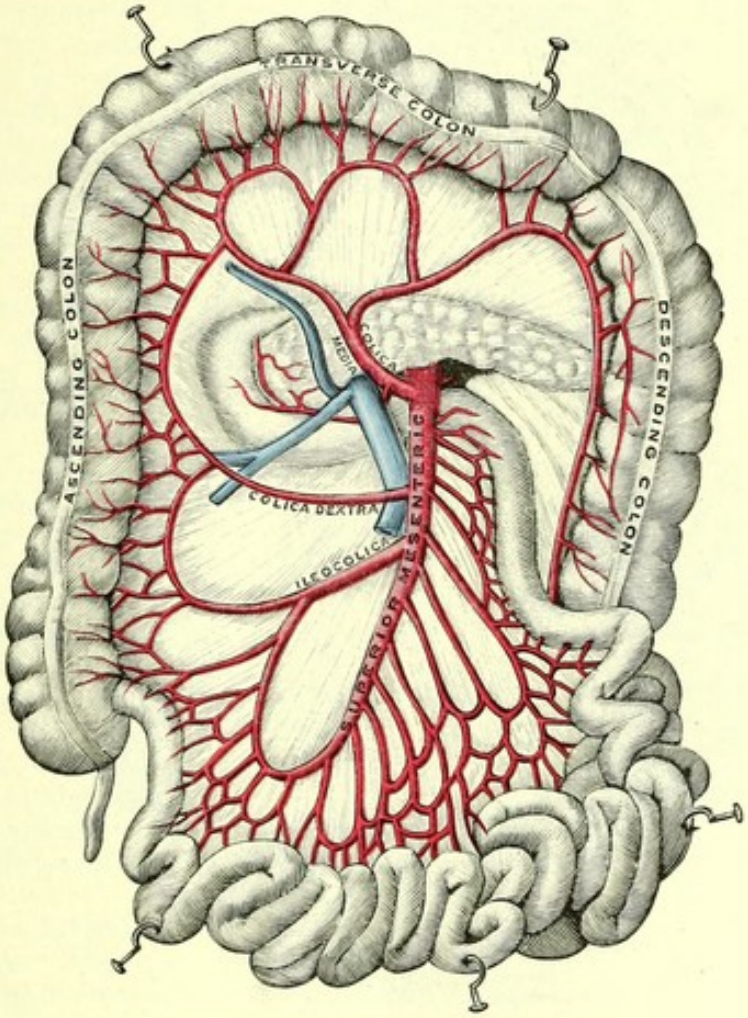

FIG. 472.—Superior mesenteric artery. (Testut.)

anterior surface of the abdominal aorta below the cœliac axis and behind the pancreas. It passes downward between the folds of the mesentery, and breaks up into branches which supply the small intestines, the cæcum, and the ascending and transverse colon.

Variations.—The superior mesenteric sometimes gives off a hepatic branch, and sometimes supplies the descending colon.

Surgical Anatomy.—The position of the mesenteric branches in the mesentery should be carefully noted in operations for the removal of sections of the intestines. Although the branches anastomose freely in the mesentery, when they reach the intestine and are distributed to it, they wind between its walls at right angles to its long axis, and do not anastomose freely with each other; and, as a result of this fact, a separation of the mesentery for any considerable extent from the intestine cuts off the blood supply of the gut, and gangrene results.

The **Branches** of the superior mesenteric are the inferior pancreatico-duodenalis, the intestinal and the colic arteries. The *inferior pancreatico-duodenalis* runs between the head of the pancreas and the duodenum, supplying those structures, and anastomosing with the pancreatico-duodenalis superior. The *intestinal* branches supply all of the small intestines except the duodenum. The *colic* branches are divided into the ileo-colic, the colica dextra or right colic, and the colica media or middle colic. The *ileo-colic* supplies the cæcum, the ileum adjoining it, and the appendix. The *right colic* supplies the ascending colon; the *middle colic*, the transverse colon, and anastomoses with the left colic.

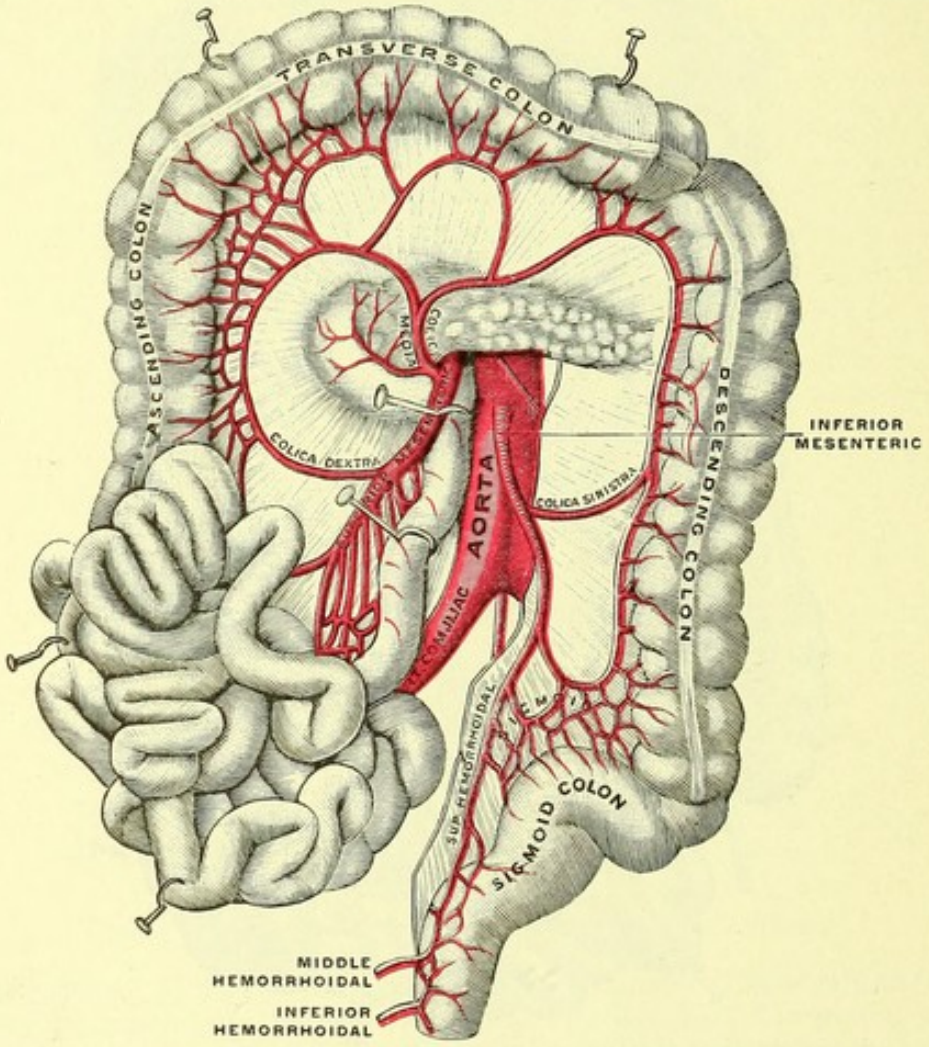

FIG. 473.—Inferior mesenteric artery. (Testut.)

The Inferior Mesenteric (Fig. 473).—The inferior mesenteric arises about an inch and a half above the termination of the aorta. It passes between the layers of the meso-colon and supplies the left portion of the transverse colon, the descending colon, and the sigmoid colon.

Variations.—The inferior mesenteric is occasionally absent, its place being supplied by branches from the superior mesenteric.

Surgical Anatomy.—The distribution and position of the superior hemorrhoidal branch and the blood supply of the rectum should be carefully studied in operations for removal of the rectum.

Branches of the inferior mesenteric are the left colic or colica sinistra, the sigmoid, and the superior hemorrhoidal. The *left colic* supplies the descending colon, and anastomoses with the middle colic of the superior mesenteric and with the sigmoid branch. The *sigmoid* supplies the sigmoid colon, and anastomoses with the left colon and the superior hemorrhoidal. The *superior hemorrhoidal* is a vessel of some size which passes down between the folds of the meso-rectum to the rectum; it then divides into two vessels which run on either side of the bowel for some distance, finally perforate the muscular coat, and divide into branches which run down the bowel beneath the mucous membrane to its lower end, and anastomose with the middle and inferior hemorrhoidal.

The Suprarenal Artery.—The *suprarenal* are vessels of small size, which arise from the lateral surfaces of the aorta opposite to the origin of the superior mesenteric, and pass transversely outward to the suprarenal bodies, which they supply.

The Renal Artery.—The *renal arteries* are vessels of very large size, which arise from the lateral surface of the aorta about half an inch below the origin of the superior mesenteric. They pass transversely outward to the hilum of the kidneys, where they rapidly break up into branches supplying this organ. In their course they are in contact with the renal vein in front and the ureter behind.

Variations.—Frequently an additional renal artery exists, and there may be several renal arteries.

Surgical Anatomy.—The position of the renal artery should be carefully studied in the operations on the kidney. In extirpation of the kidney it should be remembered that more than one renal artery occurs in about one out of five cases.

The Spermatic Artery.—The *spermatic artery* arises from the anterior surface of the aorta below the renal artery; it passes downward behind the peritoneum and in front of the psoas magnus muscle; it crosses the ureter, enters the internal abdominal ring and forms one of the structures of the cord; it is distributed to the testicle.

Variations.—The spermatic is sometimes a branch of the renal, sometimes two spermatic arteries occur on each side, sometimes both spermatics arise from a common trunk.

Surgical Anatomy.—In operations on or about the cord, as in castration, the position of the artery should be carefully noted.

The Ovarian Artery of the female corresponds to the spermatic of the male. It takes the same course behind the peritoneum, but as it reaches the broad ligament it passes between its folds to the ovary, and sends a branch of some size to the uterus.

Variations.—The same variations are noted in the ovarian as those described as occurring in the spermatic.

Surgical Anatomy.—The position and relations of the ovarian artery should be carefully studied with reference to the many operations in which the broad ligament is involved.

The Phrenic Arteries arise from the aorta above the cœliac axis, sometimes as a single trunk. They pass upward to the diaphragm, which they supply, and they anastomose with the musculo-phrenic and superior phrenic branches of the internal mammary.

Variations.—The origin of the phrenic arteries varies greatly: they may arise as a single trunk or as separate vessels from the aorta, or from the cœliac axis.

The Lumbar Arteries correspond to the intercostals. They are four or five in number on each side, and arise from the postero-lateral surface of the aorta. Passing outward behind the psoas magnus muscle, between the transverse processes of the lumbar vertebræ, each divides into a dorsal and an abdominal branch. The dorsal branch passes backward, supplies the deep muscles of the back, and

gives off a spinal branch, which furnishes branches to the spinal cord and membranes and to the lumbar vertebræ. The abdominal branch passes either in front of or behind the quadratus lumborum muscle to the muscles of the abdominal walls, winds forward, and anastomoses with the intercostal arteries and branches from the external iliac, which supply the walls of the abdomen.

Variations of the lumbar arteries are not common. Two or more of the arteries are at times found to arise by a common trunk.

Surgical Anatomy.—In the operations to expose the kidney by lumbar incision, the position of the lumbar arteries should be remembered.

The Sacra Media (middle sacral) artery arises from the lower end of the abdominal aorta, passes down the middle line of the last lumbar vertebra and sacrum, and to the tip of the coccyx, where it terminates in the structure known as Luschka's gland. It anastomoses freely in front of the sacrum with the lateral sacral arteries, and gives some branches to the rectum.

Variations.—The middle sacral is sometimes a branch from a lumbar artery, sometimes from the common iliac.

Surgical Anatomy.—In the operation known as Kraske's operation, where the lower portion of the sacrum is removed, this artery is to be regarded.

THE COMMON ILIAC ARTERIES (Figs. 470, 474).

The common iliac arteries take their origin from the aorta where it bifurcates opposite the fourth lumbar vertebra. They pass downward and outward behind

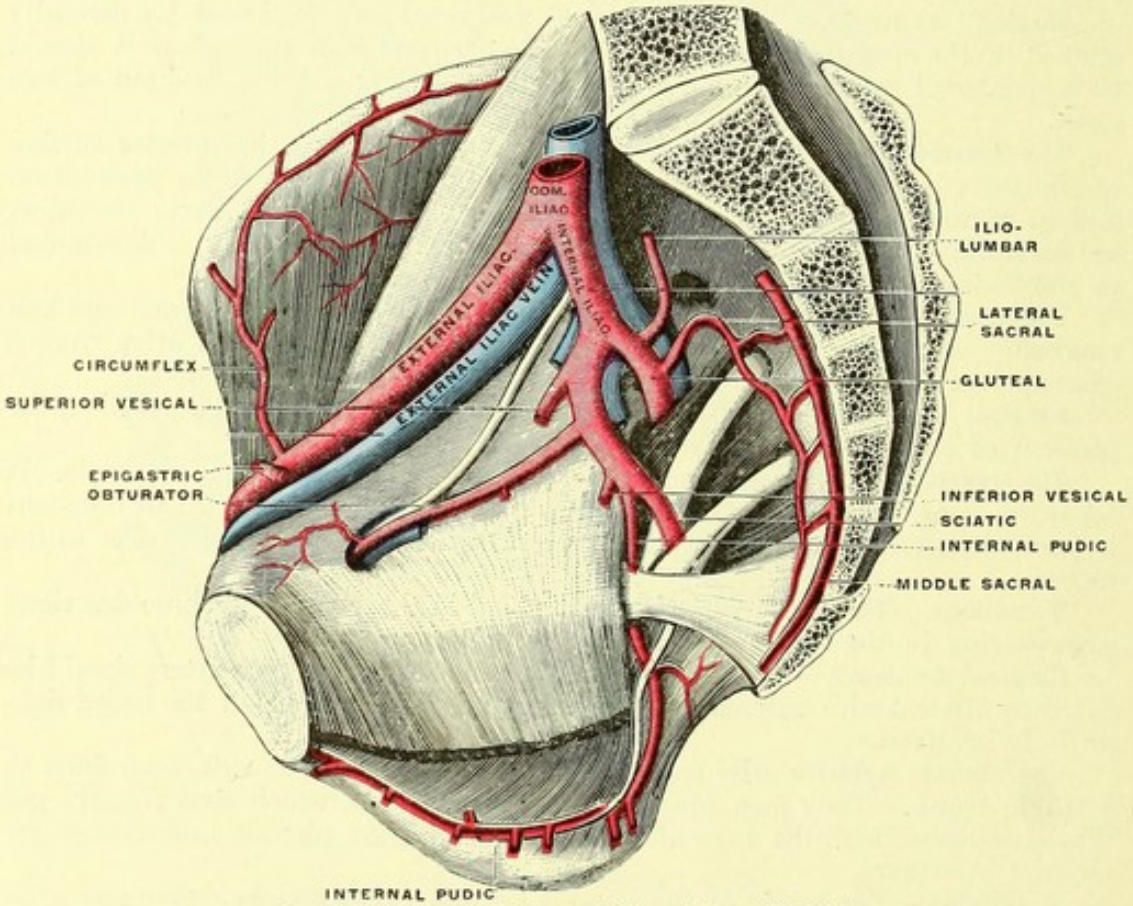

FIG. 474.—External and internal iliac arteries. (Testut.)

the peritoneum to the articulation between the last lumbar vertebra and the sacrum, and divide into the external and internal iliac arteries.

The **Relations** of the common iliac arteries differ on the two sides, owing to the fact that the common iliac veins both pass to the ascending vena cava, which is to the right of the aorta.

Relations of the Right Common Iliac.

In front.

Peritoneum.
Small intestines.
Ureter.

Inner side.		*Outer side.*
Right iliac vein. Left iliac vein.	**Right common iliac artery.**	Psoas magnus muscle. Ascending vena cava. Right iliac vein.

Behind.

Lower two lumbar vertebræ.
Both common iliac veins.

Relations of the Left Common Iliac.

In front.

Peritoneum.
Small intestines.
Ureter.
Superior hemorrhoidal artery.

Inner side.		*Outer side.*
Left common iliac vein.	**Left common iliac artery.**	Psoas magnus muscle.

Behind.

Lower two lumbar vertebræ.
Left common iliac vein.

Variations.—The length of the common iliac varies with the point of bifurcation of the abdominal aorta. When the abdominal aorta bifurcates high up, as it does sometimes, on the third lumbar vertebra, the common iliacs are long. When the bifurcation is opposite the fifth lumbar we find very short common iliacs. In rare cases the common iliac is absent, the external and internal iliacs springing directly from the aorta. The common iliac sometimes gives off the middle sacral or a lateral sacral branch.

Surgical Anatomy.—The common iliac has been successfully tied for aneurism below this point. The majority of the operations have been extraperitoneal. The easiest and best method, however, is the transperitoneal. An incision is made in the median line below the umbilicus, with the patient in the Trendelenburg position; the intestines are held up out of the way, the posterior parietal peritoneum is divided over the artery, and the vessel isolated and ligated. Great care must be taken to avoid injury to the iliac veins, which, as has been seen, differ in their relations to the vessel on the two sides; and the ureter, which, as a rule, crosses the lower portion of the vessel, must also be recognized and avoided.

Branches.—As a rule there are no branches given off in the course of the vessel. (See Variations.)

The Internal Iliac Artery (Fig. 474).

The *internal iliac artery* takes its origin at the point of bifurcation of the common iliac opposite the articulation between the last lumbar vertebra and the sacrum, and runs downward to the upper border of the great sacro-sciatic notch, where it bifurcates into an anterior and posterior trunk.

RELATIONS OF THE INTERNAL ILIAC ARTERY.

In front.

Peritoneum.
Ureter.

Outer side.		*Inner side.*
Psoas magnus muscle.	**Internal iliac artery.**	Internal iliac vein.

Behind.

Internal and external iliac veins.
Lumbo-sacral nerve.
Sacrum.

Variations.—The principal variations found relate to its length, which varies from one to three inches. Sometimes the branches are given off from the vessel without a previous division into an anterior and a posterior trunk.

Surgical Anatomy.—Ligation of the internal iliac is sometimes required. The ligation can be made extraperitoneally, but is best made by the same transperitoneal incision described for ligation of the common iliac.

Branches of the internal iliac artery. From the anterior trunk are given off the vesical arteries, the middle hemorrhoidal, the uterine and vaginal in the female, the obturator, internal pudic and sciatic arteries. From the posterior trunk are given off the ileo-lumbar, lateral sacral, and gluteal.

The **Vesical Arteries** are three in number, the superior, middle, and inferior vesical, which supply the bladder, prostate, and seminal vesicles. From the superior vesical a fibrous cord passes upward to the umbilicus. This is the remains of the umbilical artery, which becomes obliterated after birth.

The **Middle Hemorrhoidal Artery** supplies the middle portion of the rectum, anastomosing with the superior hemorrhoidal, a branch from the inferior mesenteric, and with the inferior hemorrhoidal, a branch from the internal pudic.

The **Uterine Arteries** are vessels of good size which run to the neck of the uterus, ascend along its lateral wall in the folds of the broad ligament to the fundus, and anastomose with the ovarian and vaginal arteries.

The **Vaginal Arteries** are, as a rule, two or three branches which supply the vaginal walls.

Surgical Anatomy.—The position of the uterine artery and its relations to the uterus and the broad ligament should be carefully studied in connection with the many operations performed on the uterus and its appendages.

The **Obturator Artery** runs downward and forward to the upper part of the obturator foramen. Here it passes out of the pelvis through an opening in the upper part of the obturator fascia, to be distributed to the upper and inner aspect of the thigh.

From the portion of the artery within the pelvis several small branches are given off, an *iliac* branch to the iliac fossa, a *vesical* branch to the bladder, and a *pudic* branch, which winds upward along the inner margin of the femoral ring. In the thigh the obturator divides into an internal and an external set of branches. The *internal* passes downward on the inner surface of the thigh to be distributed to the adductor muscles. The *external* winds outward behind the femur to be distributed to the external rotators of the thigh.

Variations.—The variations of the obturator are frequent, and should be carefully noted in connection with the study of femoral hernia. In almost one-third of dissections the vessel, instead of arising from the internal iliac, is a branch from the deep epigastric. In some cases it is given off from the external iliac.

Surgical Anatomy.—When the obturator is given off from the deep epigastric, it winds downward to reach the obturator foramen. In the majority of cases it is

in close contact with the iliac vein, and, therefore, would be external to a femoral hernia. In a small proportion of cases it winds along the inner border of the femoral ring and would be internal to a femoral hernia. In operations for the relief of strangulated femoral hernia this possibility must be borne in mind.

The **Internal Pudic Artery** (Figs. 474–476) is one of the terminal branches into which the anterior trunk of the internal iliac divides, the other being the sciatic. The internal pudic supplies the perineum and the external genitals. It is larger in the male than in the female. The internal pudic leaves the pelvis

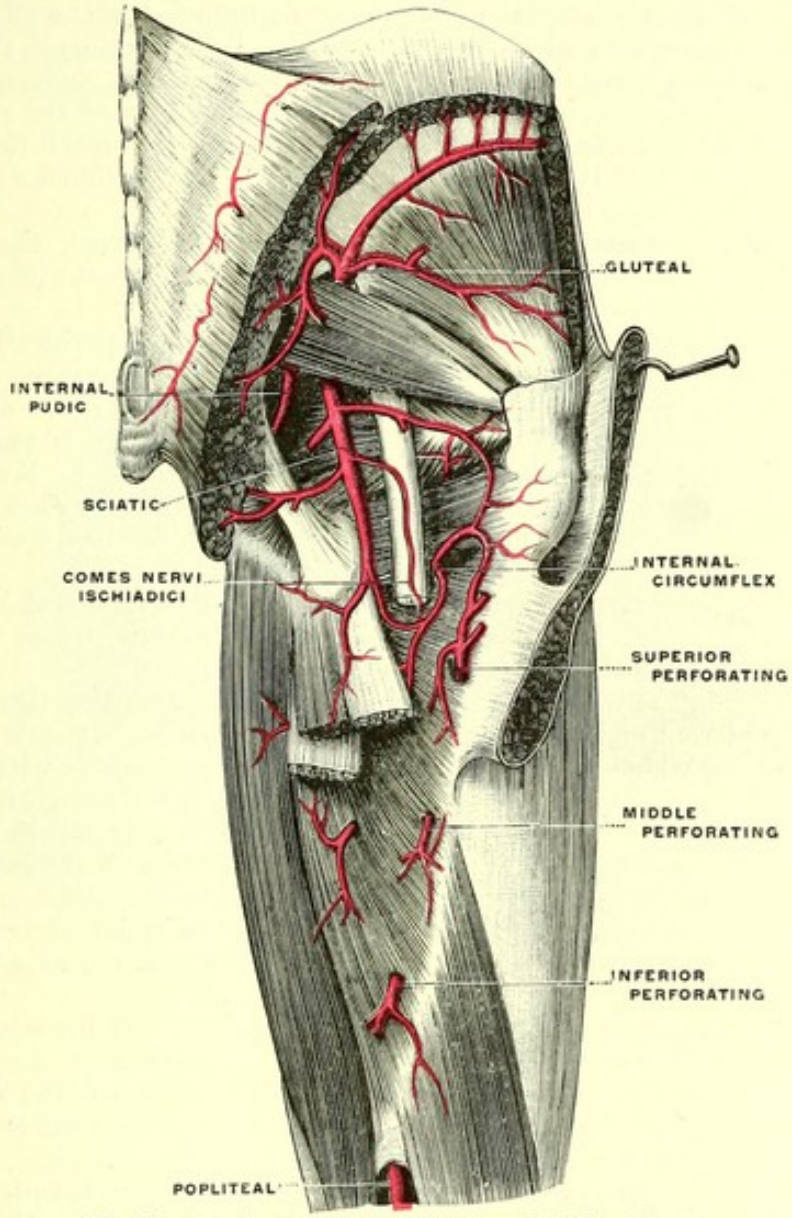

FIG. 475.—Arteries of the back of the hip and thigh. (Testut.)

through the great sacro-sciatic foramen below the pyriformis muscle, winds over the spine of the ischium, enters the pelvis again through the small sacro-sciatic foramen, runs in a groove along the ascending ramus of the ischium, enters the perineum, and breaks up into branches, which supply the perineum and the external genital organs.

Variations.—The most frequent variation is the occurrence of an accessory pudic branch, which runs to the anterior angle of the outlet of the pelvis below the symphysis pubis, perforates the triangular ligament, and supplies branches to the external genitals.

Surgical Anatomy.—The position of the pudic artery and its branches must be carefully studied with reference to the many operations performed on the perineum and on the external genitals. In the old lateral operation for stone the artery, or one of its large branches, may be wounded, and give rise to serious hemorrhage. In external urethrotomy and in median lithotomy the roof of the membranous urethra should be avoided, as immediately above it lies the large artery of the bulb, a branch of the internal pudic. The artery can be ligated at two points of its course; the first where it crosses the outer surface of the spine of the ischium, and second along the ascending ramus of the os pubis.

The **Branches** of the internal pudic are small branches given off within the pelvis to the muscles with which it is in contact. In the perineum the branches are the inferior hemorrhoidal, superficial perineal, transverse perineal, artery of the bulb, artery of the corpus cavernosum, and dorsal artery of the penis.

The **inferior hemorrhoidal** crosses the ischio-rectal fossa to reach the lower end of the bowel, to which it is distributed, as well as to the contiguous integument. It anastomoses with the other hemorrhoidal arteries.

The **superficial perineal** winds upward and inward beneath the superficial perineal fascia, and supplies the superficial muscles and integument of the perineum proper.

The **transverse perineal** (often a branch of the superficial perineal) runs along the transversus perinei to the median line to the bulb of the urethra.

The **artery of the bulb** is a vessel of good size which is given off from the internal pudic between the layers of the triangular ligament. It passes upward and inward to the bulb, which it supplies. This vessel and its branches often give rise to troublesome or even serious hemorrhage in the operation of external urethrotomy or median lithotomy, in which the bulb is divided; or the artery may be wounded in operations for lateral lithotomy.

The **artery of the corpus cavernosum** runs upward and inward between the layers of the triangular ligament to the corpus cavernosum, which it supplies, breaking up into the cavernous spaces of that structure.

The **dorsal artery of the penis** passes upward to the suspensory ligament of the penis, which it pierces, and runs along the fibrous sheath of the upper surface of the penis to the glans, which it supplies. This vessel communicates with the artery of the corpus cavernosum. In amputations of the penis these vessels must be ligated. The arteries of the corpus cavernosum are best controlled by sewing up the strong fibrous sheath of each corpus. The distribution of the internal pudic in the female is practically the same as in the male, but the vessel is smaller. The artery of the bulb supplies the bulbus vestibuli, and the terminal branches send an artery to the corpus cavernosum of the clitoris and a dorsal artery to the clitoris.

The **Sciatic Artery** (Fig. 475) is one of the two terminal branches from the anterior trunk of the internal iliac. It leaves the pelvis through the great sacro-sciatic foramen below the pyriformis muscle, and passes down the back of the thigh in close company with the sciatic nerves to supply the buttock and upper portion of the posterior aspect of the thigh.

Variations.—The sciatic sometimes arises by a common trunk with the gluteal. Rarely the sciatic is a vessel of great size, and is the main source of blood for the lower extremity, practically taking the place of the femoral.

Surgical Anatomy.—The sciatic may be ligated as it leaves the pelvis. An incision should be made in a line drawn from the posterior superior spine of the ilium to the tuberosity of the ischium, the fibres of the gluteus maximus separated, the pyriformis muscle exposed, and beneath its lower border the sciatic artery is found. The same incision exposes the internal pudic, as it winds over the surface of the spine of the ischium.

Branches.—Within the pelvis the artery gives off small branches to the muscles with which it is in contact. After leaving the pelvis it gives off coccygeal, inferior gluteal, muscular and articular branches, and a branch which accompanies

the sciatic nerve. The *coccygeal* branches supply the tissues about the coccyx. The *gluteal* branches supply the lower portion of the gluteus maximus muscle. The *comes nervi ischiadici* supplies the great sciatic nerve, running for some distance along its sheath. The *muscular* branches are distributed to the external rotator muscles of the thigh. The *articular* branches are distributed to the hip-joint.

The *branches from the posterior trunk* of the internal iliac are the gluteal, ilio-lumbar, and lateral sacral.

The **Gluteal Artery** (Fig. 475) is a vessel of large size which leaves the pelvis through the great sacro-sciatic foramen above the pyriformis muscle. It then divides into a superficial and deep branch. The superficial runs into the gluteus maximus muscle, and is distributed to its substance. The deep branch runs

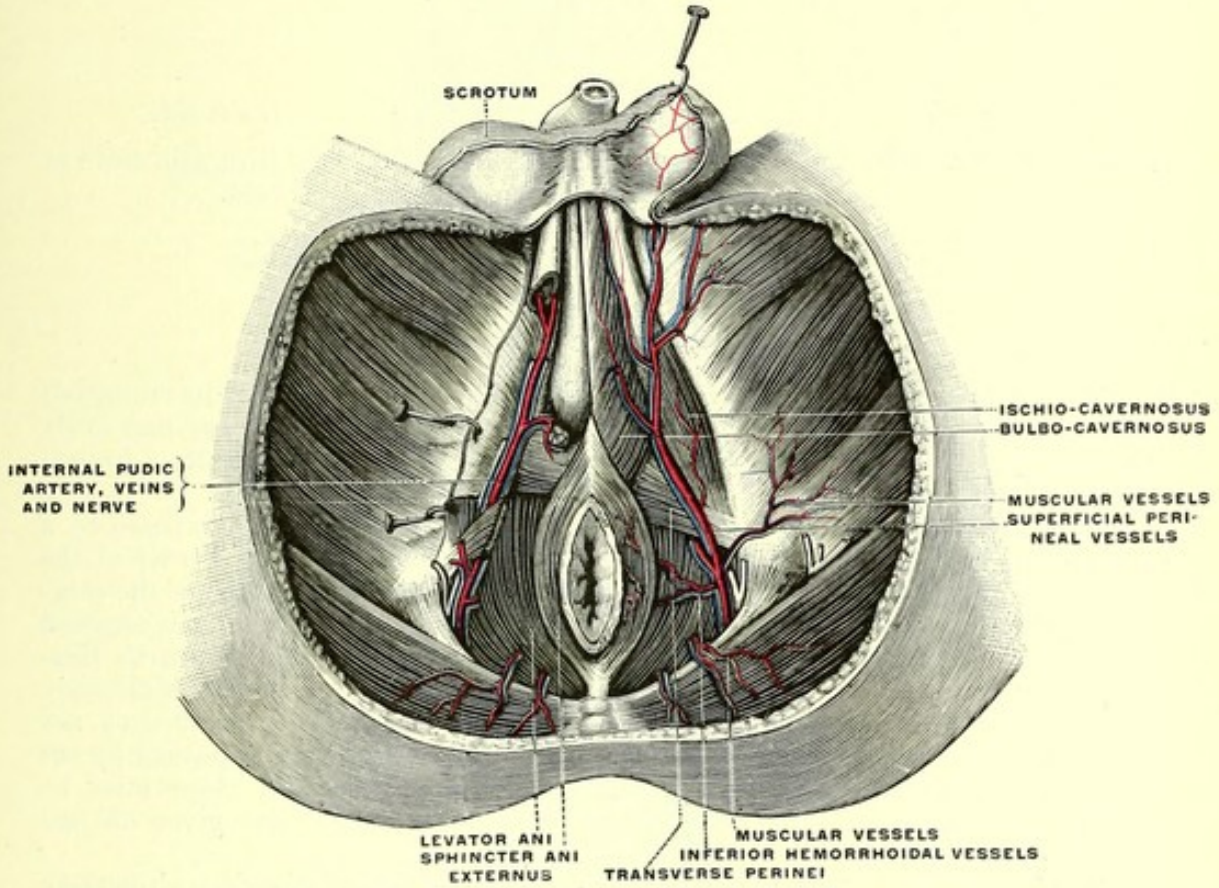

FIG. 476.—Arteries of the perineum. (Testut.)

between the gluteus medius and gluteus minimus, and breaks up into two sets of vessels, a superior and inferior, which supply these muscles. *Variations* of the gluteal are rare. The gluteal may arise by a common trunk with the sciatic, or may be absent, and its place be taken by a large branch from the femoral.

Surgical Anatomy.—The gluteal may be ligated by making an incision on a line drawn from the posterior superior spine of the ilium to the great trochanter. The fibres of the gluteus maximus are separated, and the upper border of the pyriformis muscle is exposed. At about the junction of the upper and middle thirds of the surface-line the artery is found.

The **Ilio-Lumbar Artery** passes outward behind the iliac vessels and psoas magnus muscle. Behind the muscle it divides into two sets of branches; the lumbar which are distributed to the psoas magnus and the quadratus lumborum muscles, and an iliac set, which are distributed to the iliacus muscle.

The **Lateral Sacral Arteries** are two in number, sometimes arising from a common trunk. They pass to the anterior surface of the sacrum, where they are dis-

tributed to the pyriformis and coccygeus muscles, and to the sacral nerves. Branches are sent into the anterior sacral foramina, where they supply the contents of the sacral canal and the bone.

The External Iliac Artery (Figs. 470, 474).

The *external iliac artery* arises from the division of the common iliac opposite the articulation between the last lumbar vertebra and the sacrum, passes downward and outward behind the peritoneum and along the inner border of the psoas magnus muscle to the inguinal (Poupart's) ligament, where it becomes the femoral.

Relations of the External Iliac Artery.

In front.

Peritoneum.
Intestines.

Outer side.		*Inner side.*
Psoas magnus muscle.	**External iliac artery.**	External iliac vein and vas deferens.

Behind.

External iliac vein.
Psoas magnus muscle.

Variations.—The external iliac is sometimes of small size; its resulting femoral is small, and the lower extremity usually then receives a large part of its blood supply from a large sciatic artery. The obturator is occasionally a branch of the external iliac.

Surgical Anatomy.—The first portion of the external iliac is best exposed by a transperitoneal incision either in the mid-line or along the outer border of the rectus, with the patient in Trendelenburg's position, as in the ligation of the common or internal iliac arteries. The lower portion of the external iliac is exposed best by an extraperineal operation. An incision is made above Poupart's ligament, the layers of the abdominal muscles are separated, as in the McBurney and McArthur incision for appendicitis; the peritoneum is exposed, but not divided. With the fingers the peritoneum in front of the artery is pushed up out of the way, and the vessel exposed with its accompanying vein. Care must be taken not to injure the two large branches of the external iliac given off just above the inguinal (Poupart's) ligament.

Branches of the external iliac are the deep epigastric and the deep circumflex iliac arteries.

The **Deep Epigastric** (Fig. 456) arises from the external iliac just above the inguinal ligament. It passes inward and a little downward at first, then upward and inward between the transversalis fascia and the peritoneum to the posterior surface of the rectus muscle, continues upward, breaking into branches in the substance of the rectus, and anastomoses with the superior epigastric branch of the internal mammary.

Variations.—The deep epigastric may take origin higher up from the external iliac, from any part of its course. As already noted the deep epigastric very often gives off the obturator artery.

Surgical Anatomy.—The deep epigastric artery has an important relation to inguinal hernia. The vessel in the first part of its course is situated between the two rings and will therefore be internal to an oblique hernia, and external to a direct hernia. Its position should be carefully noted in operations for hernia.

The **Branches** of the deep epigastric are the cremasteric, pubic, and muscular branches. The *cremasteric* artery supplies the coverings of the spermatic cord.

The *pubic* winds around the inner margin of the femoral ring, and anastomoses with a similar branch from the obturator. *Muscular* branches are distributed to the muscles of the abdominal wall.

The **Deep Circumflex Iliac Artery** arises from the outer surface of the external iliac just above Poupart's ligament. It runs upward and outward, covered by the transversalis fascia, to the anterior superior spine of the ilium. It then runs along the crest of the ilium to about its centre, pierces the abdominal muscles, and breaks up into branches supplying them.

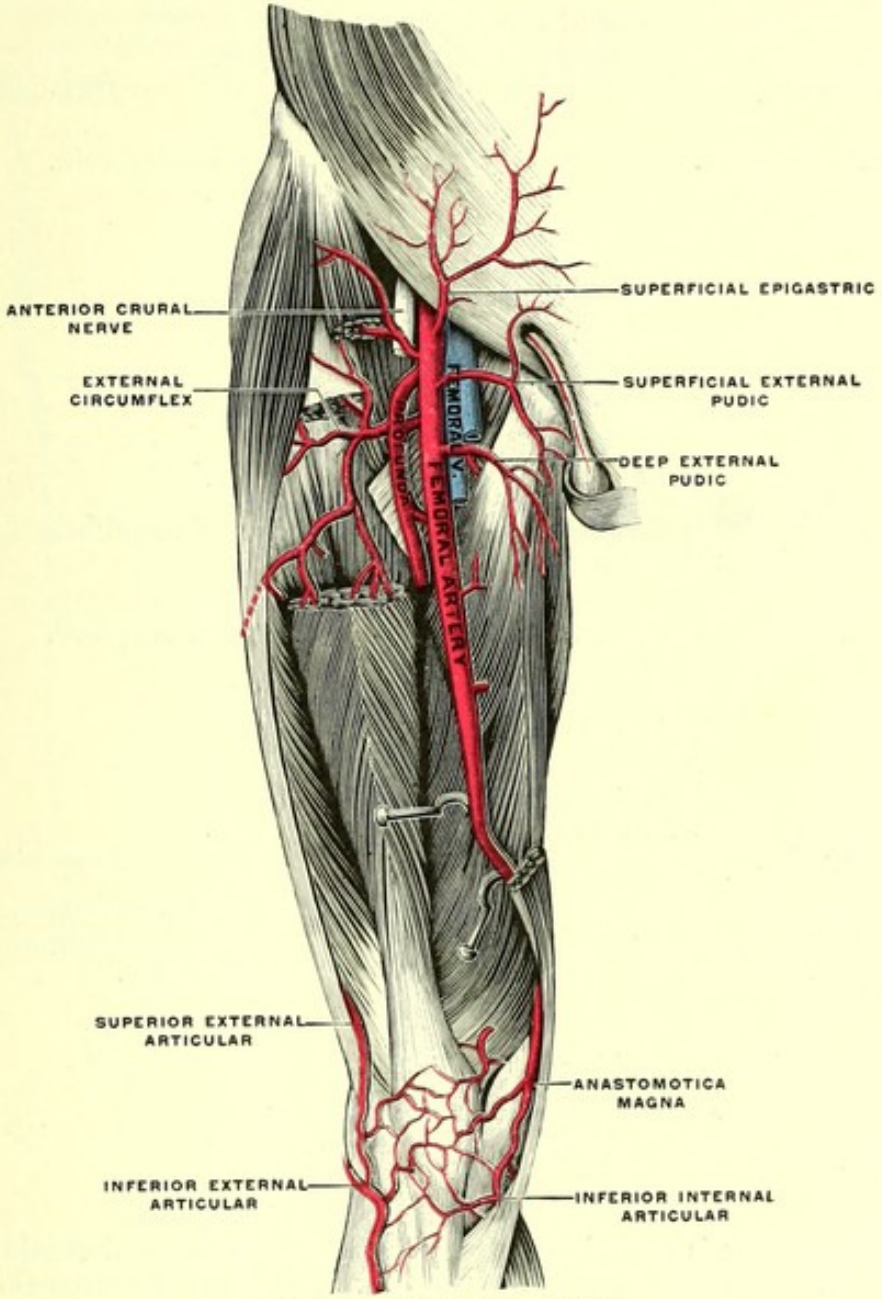

FIG. 477.—Femoral artery. (Testut.)

The Femoral Artery (Fig. 477).

The femoral artery is the continuation of the external iliac opposite the inguinal ligament, about midway between the superior anterior spine and the symphysis pubis. It passes down the anterior and inner side of the thigh and terminates at the opening in the adductor magnus muscle by becoming the popliteal. In about the upper half of its course it lies in a surgical region called

Scarpa's triangle; in the lower half in an aponeurotic and muscular passage, called Hunter's canal. The vessel divides or rather gives off a large branch, the deep femoral (profunda), about two inches below the inguinal ligament. The portion of the vessel above this branch is called the common femoral, and its continuation is called the superficial femoral.

RELATIONS OF THE COMMON FEMORAL ARTERY.

In front.

Skin and superficial fascia.
Iliac portion of fascia lata.

Outer side.		*Inner side.*
Anterior crural nerve.	**Common femoral artery.**	Femoral vein.

Behind.

Pubic portion of fascia lata.
Psoas magnus muscle.
Pectineus muscle.
Capsular ligament of hip.

The Superficial Femoral Artery.

This vessel extends from the point at which the deep femoral branch is given off to the opening in the adductor magnus muscle.

RELATIONS OF THE SUPERFICIAL FEMORAL ARTERY.

In front.

Skin and superficial fascia.
Fascia lata.
Sartorius muscle.
Fibrous covering of Hunter's canal.

Outer side.		*Inner side.*
Long saphenous nerve. Vastus internus muscle. Femoral vein.	**Superficial femoral artery.**	Adductor longus. Adductor magnus. Sartorius.

Behind.

Femoral vein.
Profunda vessels.
Pectineus muscle.
Adductor longus muscle.
Adductor magnus muscle.

Scarpa's Triangle is a surgical region of much importance, and should be carefully studied. The student is advised to draw a sketch of the triangle and its contents. It is *bounded* above by the inguinal (Poupart's) ligament, externally by the sartorius muscle, internally by the adductor longus muscle. The *floor* of this space is formed by the adductor longus, adductor brevis, pectineus, psoas magnus, and iliacus muscles. The *contents* are the femoral vessels and their branches, and the anterior crural nerve. The space contains also the superficial lymphatic nodes which receive the lymph from the lower extremity.

Hunter's Canal is a three-sided, fibro-muscular canal, occupied by the femoral vessels and the internal saphenous nerve. A strong fibrous layer, extending

in front of the vessels, and between the vastus internus on the outer side and adductor magnus and longus on the inner, forms its anterior boundary, and the muscles named make its other sides. Superficial to the canal is the sartorius muscle.

Variations.—The femoral may be very small, and terminate in the upper part of the thigh; and the lower limb in such cases receives its blood supply in large part from a very large sciatic artery. The femoral has been seen to divide into two vessels and then unite to form a single popliteal. Variations in branches are frequently noted. The circumflex arteries, one or both, are sometimes derived from the common femoral instead of from the profunda. The profunda is sometimes given off from the inner side of the vessel instead of the outer side.

Surgical Anatomy (Fig. 478).—The femoral artery is, of course, ligated in

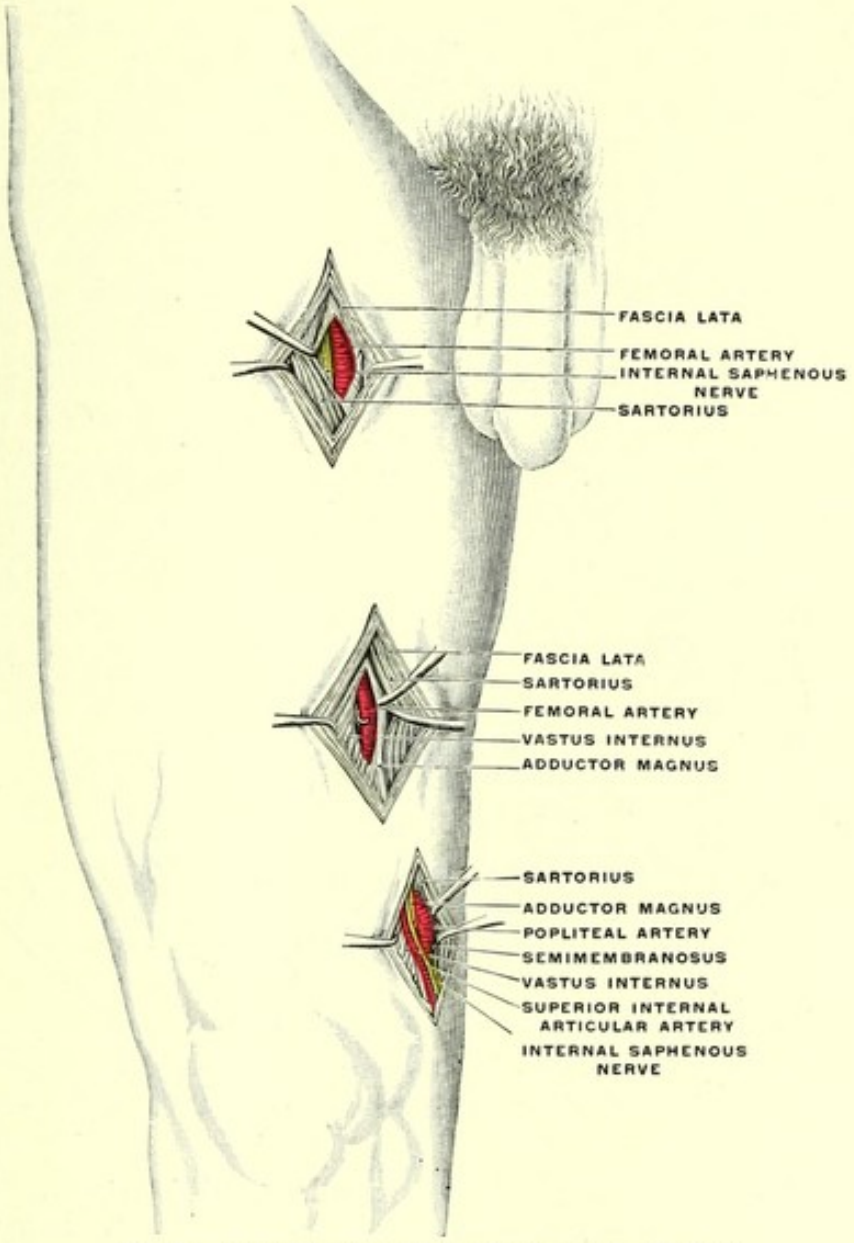

FIG. 478.—Surgical relations of the femoral artery. (Kocher.)

amputations of the upper two-thirds of the thigh, and the exact position of this vessel and its branches should be studied in cross-sections of the thigh. The student is advised to make sketches of such transverse sections at various levels, and learn in this way the relations of the structures as they present themselves in

circular amputations of the thigh. The femoral can be ligated at any part of its course. To ligate the common femoral make an incision in a line which bisects Scarpa's triangle, passing from the middle of the base to the apex. Beginning at the inguinal (Poupart's) ligament and passing downward three inches, divide skin, superficial and deep fascia. The common femoral will be exposed, with the vein situated internally and in close contact, and with the anterior crural nerve externally, and separated from it by a distance of a half inch.

The femoral can be ligated at the apex of Scarpa's triangle by an incision along the inner border of the sartorius muscle in this position. The muscle

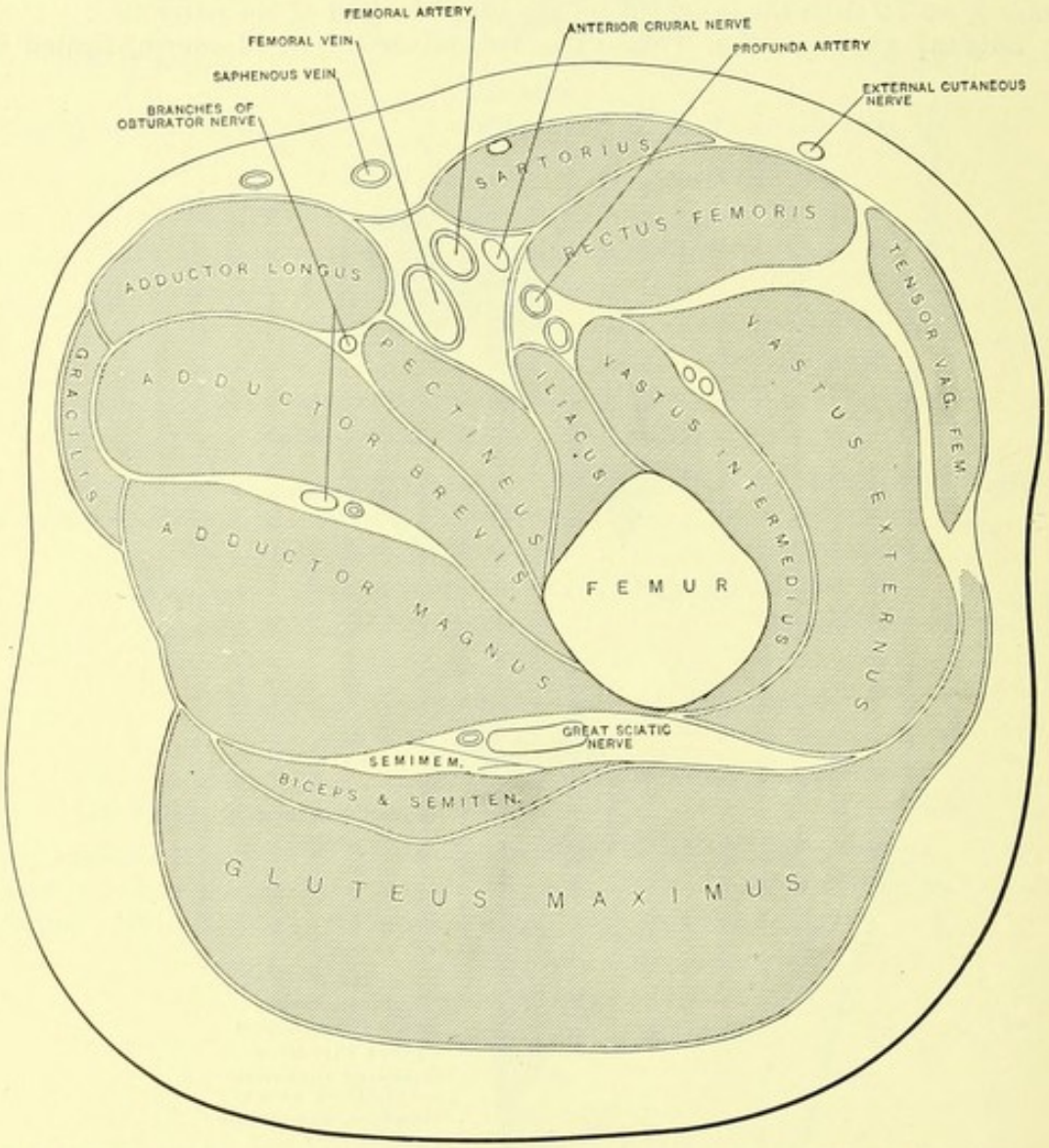

FIG. 479.—Horizontal section of the right thigh near the perineum—upper surface of the lower segment. (After Braune.)

is drawn outward, the deep fascia divided, and the vessel is exposed. The vein is here posterior to the artery, and the internal saphenous nerve is to the outer side.

The femoral can be ligated in Hunter's canal by an incision along the outer border of the sartorius in this position; the sartorius is drawn inward, the fibrous covering of the canal divided, and the artery exposed, with the vein behind or external, and the internal saphenous nerve superficial and external.

The **Branches** of the femoral are the superficial epigastric, superficial external

pudic, superficial circumflex iliac, deep external pudic, profunda (deep femoral), muscular, and anastomotica magna arteries.

The **Superficial Circumflex Iliac** is given off from the femoral just below the inguinal (Poupart's) ligament. It is a vessel of small size. It runs upward and outward in the superficial fascia to the anterior superior spine of the ilium.

The **Superficial Epigastric** is given off immediately below the inguinal (Poupart's) ligament, and winds up over this structure to the lymphatic nodes and superficial structures in the inguinal region.

The **Superficial External Pudic** is given off a little lower than the preceding, passes upward and inward, crosses the spermatic cord close to the inguinal canal, and supplies the integument in the hypogastric region and that of the external genitals. This artery is almost always divided in operations for hernia and for varicocele.

The **Deep External Pudic** runs inward for some distance beneath the fascia lata to reach the perineum and external genitals, to which it is supplied.

The **Profunda** (Fig. 477) or deep femoral, a branch of large size, is given off usually from the outer side of the femoral, two inches below the inguinal (Poupart's) ligament. It passes downward, at first external to the femoral vessels, then behind them to the posterior surface of the adductor longus muscle, and terminates by perforating the adductor magnus muscle to reach the posterior surface of the thigh.

The *branches* of the profunda are the external circumflex, the internal circumflex, and the perforating arteries.

The *external circumflex* is given off from the outer surface of the first portion of the profunda. It passes outward beneath the rectus femoris muscle to the outer aspect of the thigh, and divides into three branches, ascending, transverse, and descending. The ascending passes up to the buttock, and anastomoses with the gluteal arteries; the transverse winds around the thigh, supplying the vastus externus, and vastus intermedius; the descending passes downward on the outer aspect of the thigh, as far as the knee. The *internal circumflex* (Fig. 475) is given off from the inner aspect of the profunda near its origin. It winds backward between the psoas and pectineus muscles to the lesser trochanter of the femur, near which it divides into two sets of branches, the ascending and transverse. The ascending follows the obturator externus to its insertion in the great trochanter. The transverse winds backward around the femur just below the great trochanter. The internal circumflex gives off also an articular branch to the hip-joint. The *perforating arteries*, three or four in number, are given off from the course of the profunda artery behind the adductor magnus; they perforate the adductor magnus, reach the posterior surface of the thigh, wind around the femur in close contact with the bone, supply the hamstring muscles, and terminate in the vastus externus and vastus intermedius muscles. The *nutrient artery* of the femur is derived from the third perforating artery. Muscular branches are given off from the femoral in its entire course to the contiguous muscles.

The **Anastomotica Magna** is given off from the femoral just before its termination. The artery passes downward, and divides into two branches: a superficial branch, which accompanies the internal saphenous nerve and vein, supplying the integument, and a deep branch, which passes down between the vastus internus and the adductor magnus to terminate in the popliteal space. Both branches anastomose with the articular branches of the popliteal artery.

The **Popliteal Artery** (Fig. 480) is a continuation of the femoral. It begins at the opening in the adductor magnus muscle through which the femoral passes, extends downward through the centre of the popliteal space, resting on the femur, posterior ligament of the knee-joint and the popliteus muscle, to the lower border of the latter, where it divides into its two terminal branches, the anterior and posterior tibial.

Relations of the Popliteal Artery.

In front.

Femur.
Posterior ligament of knee.
Popliteus muscle.

Inner side.		*Outer side.*
Inner hamstring muscles. Inner head of gastrocnemius.	**Popliteal artery.**	Biceps. Outer head of gastrocnemius.

Behind.

Skin, superficial and deep fasciæ.
External saphenous vein.
Internal popliteal nerve.
Popliteal vein. It is partially covered, behind by the muscles forming the boundaries of the space.

The **Popliteal Space** is the diamond-shaped area at the back of the knee-joint. The student is advised to make a sketch of this space, its boundaries, and contents. The popliteal space is bounded above by the inner hamstring inter-

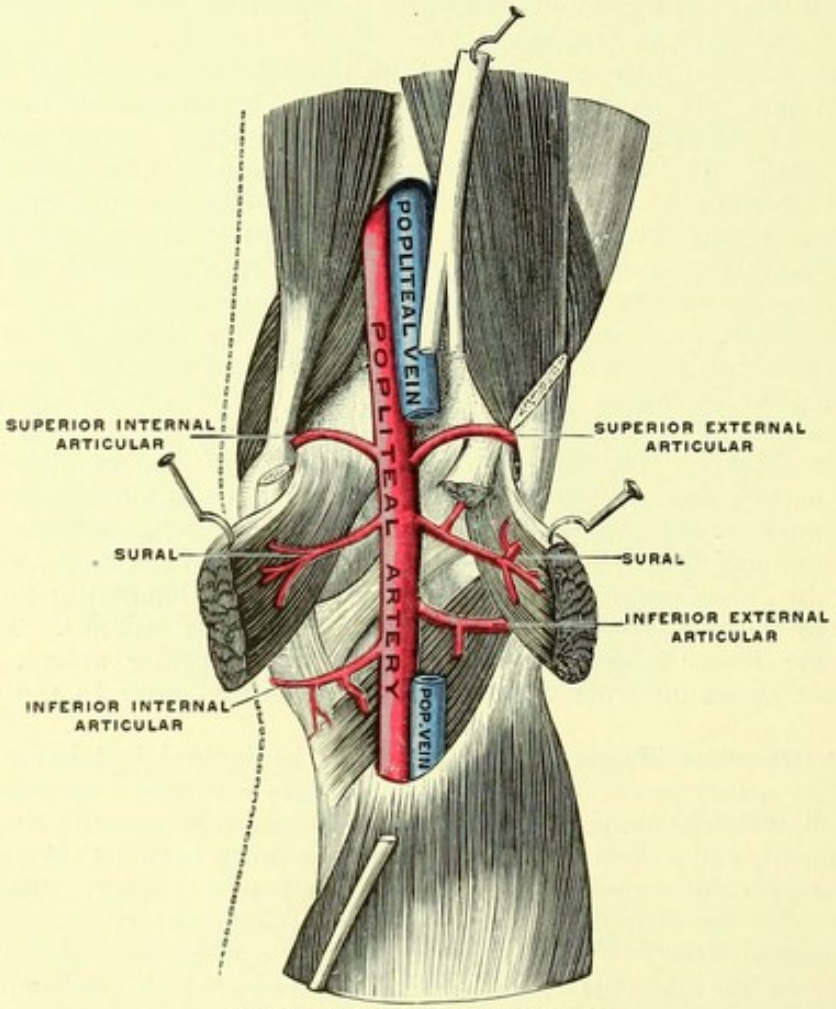

Fig. 480.—Popliteal artery. (Testut.)

nally, and by the outer hamstring externally. It is bounded below by the inner and outer heads of the gastrocnemius muscle. The floor of the space is formed above by the posterior surface of the femur, in the centre by the posterior liga-

ment of the knee-joint and below by the popliteus muscles. The space contains the popliteal artery in close contact with its floor, the popliteal vein superficial to the artery and the internal popliteal nerve superficial to the vein, these structures being almost in the mid-line of the space. The external popliteal nerve runs along the outer and upper border of the space, in close contact with the biceps. The space contains much fat and areolar tissue, and a few lymphatic nodes.

Variations.—The popliteal sometimes divides into three branches, the anterior tibial, the posterior tibial, and the peroneal; at times into the anterior tibial and peroneal, the peroneal supplying the place of the posterior tibial. Sometimes a high division of the popliteal occurs opposite the knee-joint.

Surgical Anatomy (Fig. 481).—The popliteal is sometimes injured in fracture

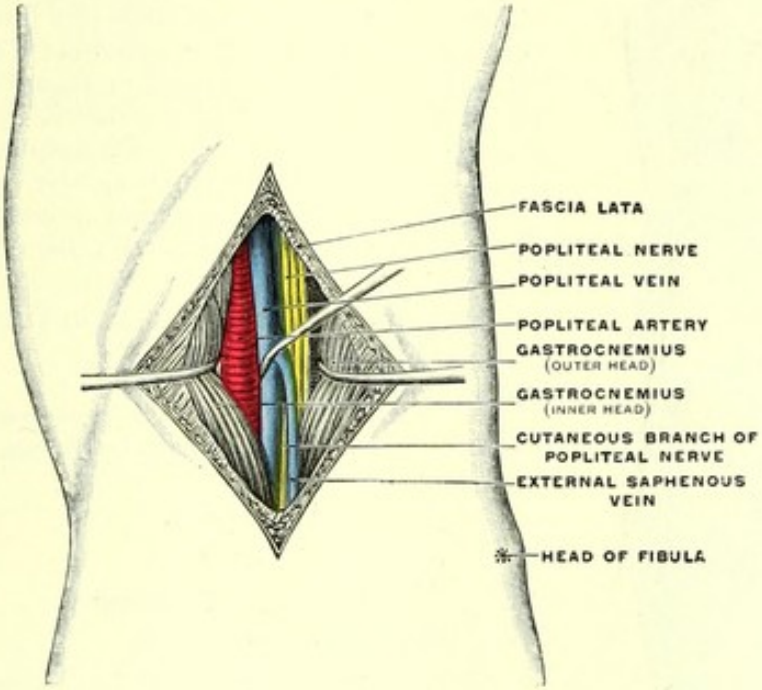

FIG. 481.—Surgical relations of the popliteal artery. (Kocher.)

of the lower end of the femur. When the lower end of the femur is divided in operations to correct the deformity of knock-knee, the artery must be carefully avoided. The popliteal artery, next to the aorta, is the most common site of aneurism. This condition is relieved usually by pressure, or the ligation of the femoral, although at times the aneurismal sac is dissected out, and the artery ligated above and below the lesion. The popliteal can be exposed and ligated at any part of its course. The artery is more superficial in the upper and lower portions of the popliteal space than in the middle portion. In exposing the vessel in any part of its course the fact that the internal popliteal nerve and the popliteal vein are superficial to the artery must be borne in mind, and these structures avoided.

The **Branches** of the popliteal artery are the muscular, the cutaneous, the articular, and the anterior and posterior tibial. The *muscular* are distributed to the muscles forming the boundaries of the popliteal space, a superior set to the hamstring muscles, and an inferior set to the gastrocnemius, plantaris, soleus, and popliteus. The *cutaneous* branches supply the integument over the calf of the leg. The *articular* branches are five in number: the superior internal, the superior external, the azygos, the inferior internal, and the inferior external articular arteries. The *superior* and *inferior articular* arteries wind around the knee-joint, and form an anastomosis with each other around the patella. These vessels anastomose with the recurrent branches from the arteries of the leg, with the anastomotica magna of the femoral, and with the perforating

of the profunda. The *azygos articular* penetrates the posterior ligament of the knee-joint, and supplies the intra-articular ligaments and synovial membrane.

The Posterior Tibial Artery (Fig. 482).

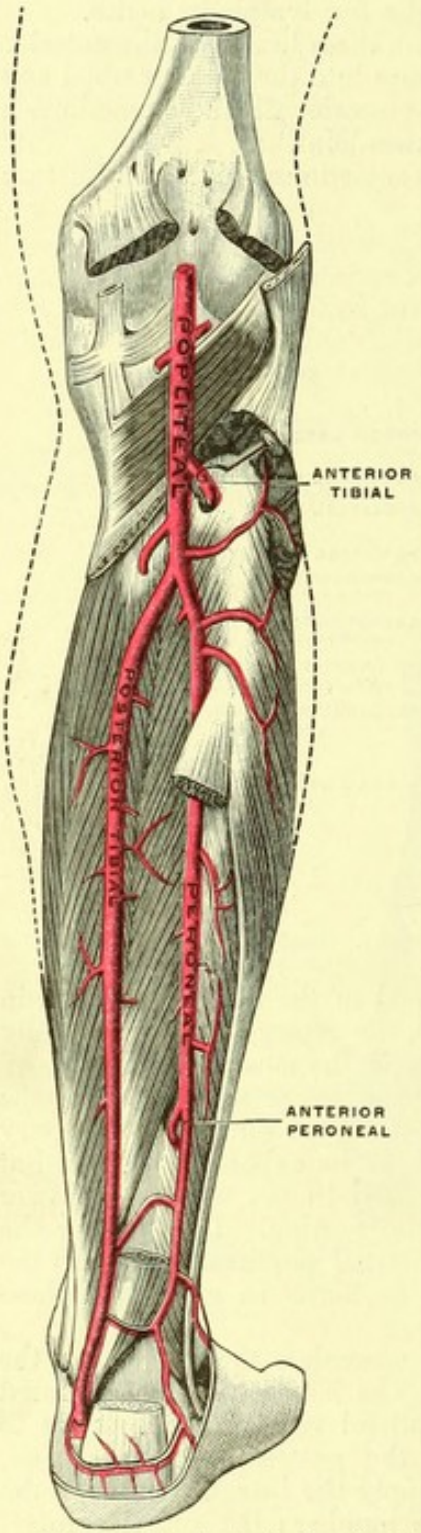

FIG. 482.—Arteries in the dorsal part of the leg. (Testut.)

The posterior tibial artery is the larger of the two terminal branches of the popliteal, and appears as though it were the continuation of the latter. It passes down the leg on the tibial side between the deep and superficial layers of muscles on the back of the leg, covered also by the deep transverse fascia of the leg, until it reaches the inner ankle, where it divides into the internal and external plantar arteries. The important points to be remembered in regard to the course of the posterior tibial are that it is on the tibial side of the leg, between the deep and superficial layers of muscles, covered also by the deep transverse fascia of the leg, and accompanied by the posterior tibial nerve and venæ comites.

Relations of the Posterior Tibial Artery.

In front.

Tibialis posterior muscle.
Flexor longus digitorum.
Tibia.
Ankle-joint.

Inner side.		*Outer side.*
Vena comes.	**Posterior tibial artery.**	Vena comes.

Behind.

Skin, superficial and deep fasciæ.
Gastrocnemius.
Soleus.
Deep transverse fascia.
Posterior tibial nerve.

Variations.—The posterior tibial may be small, its place being taken by a large peroneal artery. The vessel may arise from a high division of the popliteal.

Surgical Anatomy (Fig. 483).—In amputations of the leg the posterior tibial is found between the superficial and deep muscles on the tibial side. Ligations of the posterior tibial may be required for injury or aneurism. The vessel may be ligated at any part of its course. In the middle of the leg the artery can be exposed by an incision a finger's breadth behind and parallel with the inner border of the tibia. The skin, superficial and deep fasciæ are divided, the tibial origin of the soleus is exposed and divided, and the deep transverse fascia, which now comes into view, is also divided. The vessel is found accompanied by the posterior tibial nerve and the

venæ comites. In the lower part of its course, opposite the inner ankle, the vessel occupies a position midway between the internal malleolus and the os calcis. It can be exposed by a curved incision dividing the skin, superficial and deep fasciæ, and the internal annular ligament. The position of the vessel at the inner ankle should be noted in making tenotomies of the tibialis posterior tendon.

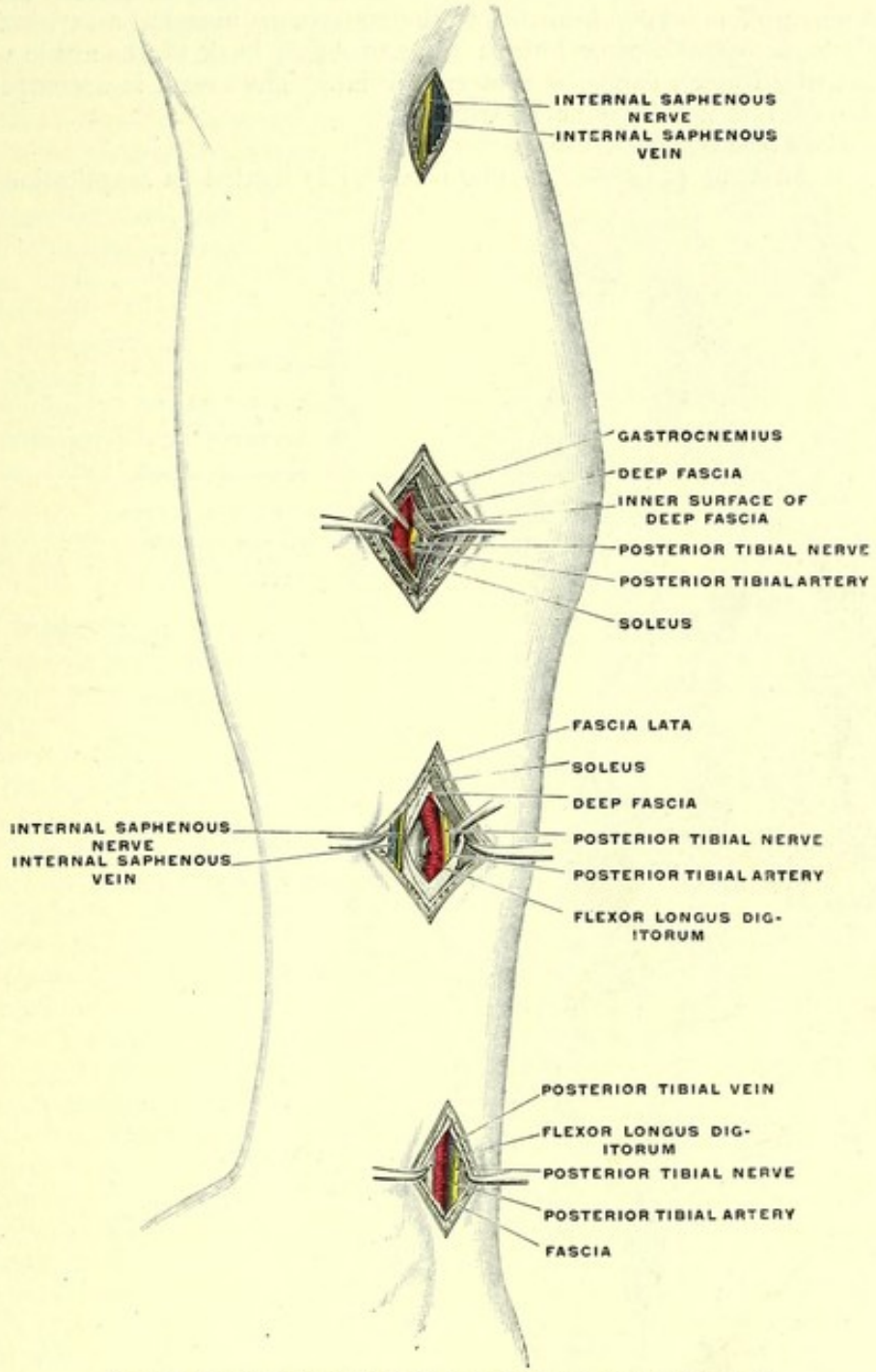

FIG. 483.—Surgical relations of the posterior tibial artery. (Kocher.)

The **Branches** of the posterior tibial are the muscular, peroneal, nutrient, communicating, internal calcanean, and its terminal branches, the internal and external plantar.

The *muscular* are distributed to the deep layer of muscles on the back of the leg.

The **Peroneal** (Fig. 482) is a large artery, which is given off an inch or more

below the origin of the posterior tibial. It passes down the fibular side of the leg close to the fibula, either lying on or contained in the fibres of the flexor longus hallucis muscle. At the lower border of the interosseous membrane it gives off an anterior peroneal branch, which runs forward to the anterior and outer surfaces of the ankle. The rest of the vessel is continued downward, to the posterior surface of the outer ankle and the os calcis. In its course the peroneal gives off *muscular* branches to the contiguous muscles, a *nutrient* branch to the fibula, a *communicating* branch to anastomose back of the ankle with the communicating branch from the posterior tibial. The vessel is accompanied by venæ comites, but not by a nerve-trunk.

Variations (see posterior tibial artery).

Surgical Anatomy (Fig. 484).—The peroneal is ligated in amputations of the

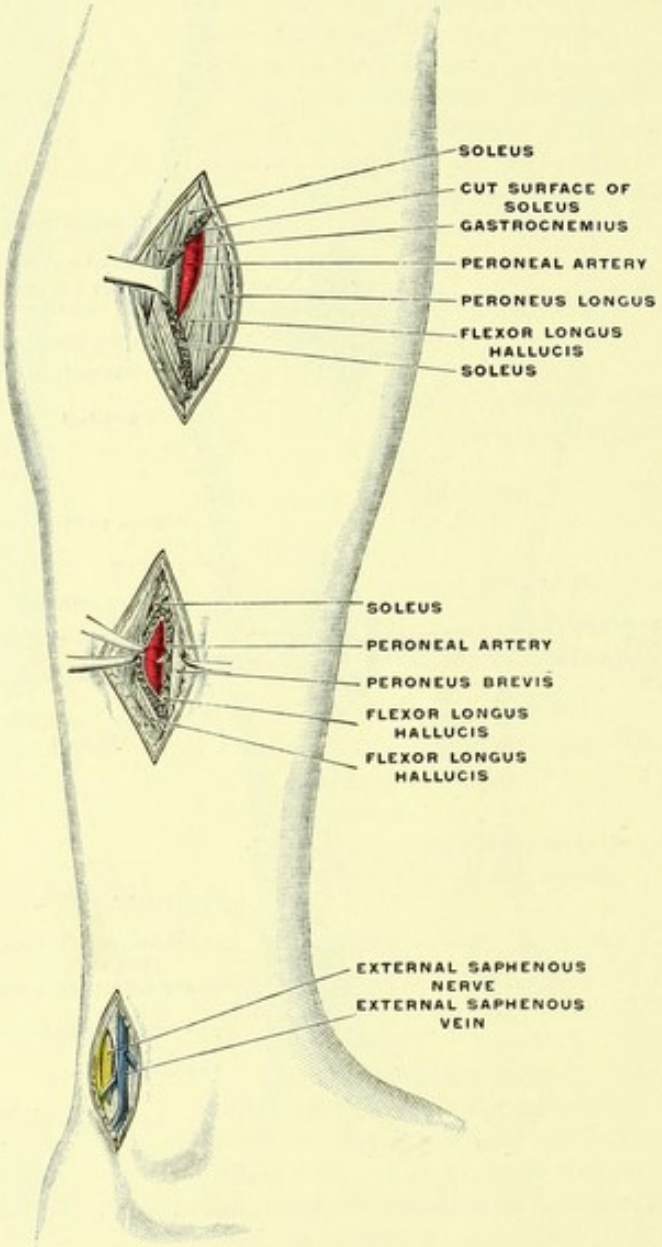

FIG. 484.—Surgical relations of the peroneal artery. (Kocher.)

leg. The position of the vessel on the fibular side of the leg between the deep and superficial muscles, or in the substance of the flexor longus hallucis, should be noted. The peroneal artery can be ligated in the middle portion of its course through an incision a finger's breadth behind and parallel to the fibula. The

skin, superficial and deep fasciæ are divided, and the fibular origin of the soleus then comes into view. This is divided, and the deep transverse fascia is exposed; this is also divided, and the artery is found accompanied by venæ comites, either lying on or in the muscular substance of the flexor longus hallucis.

The **nutrient artery** from the posterior tibial is a vessel of large size, which enters the nutrient foramen in the tibia on its posterior surface. The *communicating* branch passes from the posterior tibial outward just above the ankle-joint to anastomose with a similar branch from the peroneal.

The **Internal Calcanean Arteries** are given off from the posterior tibial just above the ankle; they supply the tissues of the heel. The position of these vessels is of importance in amputations, such as Syme's and Pirogoff's. Care should be taken not to injure these vessels in making the heel flap, because, if they are injured, sloughing is apt to result.

The *terminal branches* of the posterior tibial are the internal and external plantar.

The **Internal Plantar** (Fig. 485) arises from the posterior tibial at the inner ankle, passes forward along the inner side of the foot, and terminates at the inner side of the great toe. It supplies the inner side of foot and great toe.

The **External Plantar** is a vessel of large size; it passes outward and forward to the base of the metatarsal bone of the little toe, being covered by the plantar fascia. It then winds inward and forward on bases of the metatarsal bones to the interosseous space between the great and second toes, and here anastomoses with the deep, communicating branch from the dorsalis pedis, thus completing the *plantar arch*.

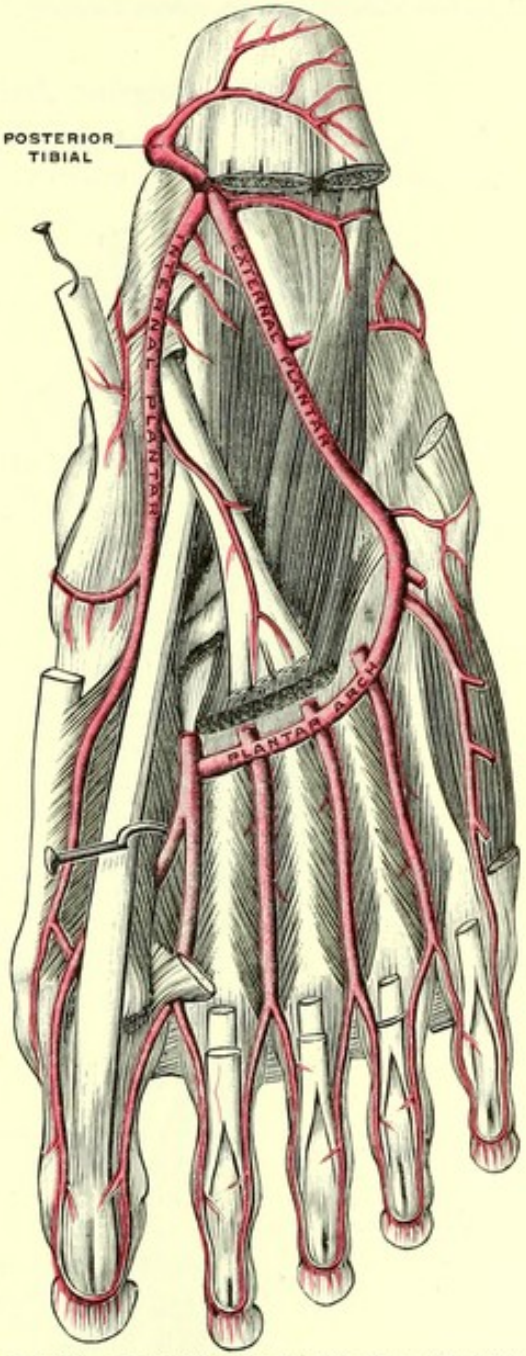

FIG. 485.—Arteries in the sole of the foot. (Testut.)

Variations.—The plantar arteries vary somewhat in size. In some cases the internal plantar is larger than usual, and supplies two or more toes, the external plantar being correspondingly smaller.

Penetrating wounds of the plantar arch may give rise to severe hemorrhage. This, however, can usually be controlled by pressure, or by a free dissection, the bleeding points being found and ligated.

The **Branches of the External Plantar** are small muscular, cutaneous, and articular branches to the contiguous muscles, integument, and joints, and the posterior perforating and digital branches. The *posterior perforating* are small trunks which perforate the second, third, and fourth interosseous spaces to communicate with the dorsal interosseous arteries. The *digital* arteries are four in number, and supply the outer side of the little toe and the contiguous sides of

the second and third, the third and fourth, the fourth and fifth. The contiguous sides of the great toe and second toe will be found, in the description of the dorsalis pedis, to be supplied by its deep plantar branch. Opposite the web of the toes each digital branch gives off a perforating artery, which anastomoses with the dorsal interosseous arteries.

The Anterior Tibial Artery (Fig. 486).

The *anterior tibial artery* begins at the bifurcation of the popliteal, at the lower border of the popliteus muscle. It passes between the heads of origin of the tibialis posterior muscle, above the upper border of the interosseous membrane, to the anterior surface of the leg, runs downward on the anterior surface of the interosseous membrane, accompanied by the anterior tibial nerve and venæ comites, and in a position external to the tibialis anterior muscle, to the bend of the ankle. Here the vessel becomes the dorsalis pedis.

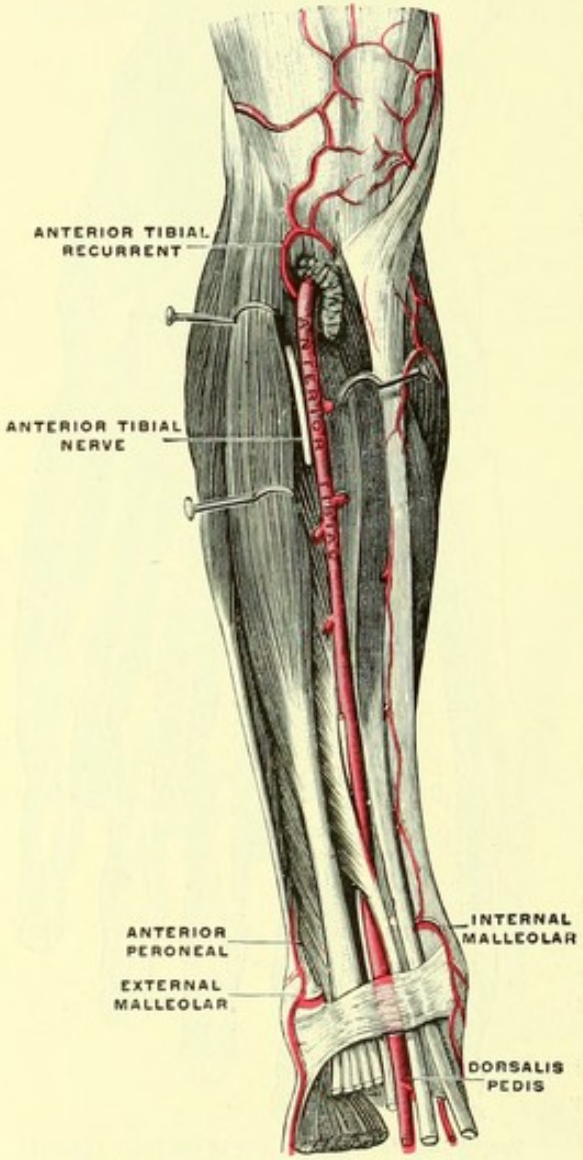

Fig. 486.—Anterior tibial artery. (Testut.)

Relations of the Anterior Tibial Artery.

In front.

Skin, superficial and deep fasciæ.
Tibialis anterior muscle.
Tendon of the extensor proprius pollicis.

Inner side.		*Outer side.*
Tibialis anterior.	**Anterior tibial artery.**	Anterior tibial nerve. Extensor longus digitorum. Extensor proprius hallucis.

Behind.

Interosseous membrane.
Tibia.

Variations.—The anterior tibial may be very small, or absent, its place being taken by branches from the posterior tibial or peroneal. It has been seen to accompany the musculo-cutaneous nerve, winding around the fibula to reach the front of the leg.

Surgical Anatomy (Fig. 487).—In amputations of the leg the anterior tibial is ligated. It should be noted that it lies in front of the interosseous membrane, and external to the tibialis anterior, and that it is accompanied by venæ comites and the anterior tibial nerve. The anterior tibial can be ligated at any part of its course through an incision along the line of the outer border of the tibialis anterior muscle. This incision should divide the skin, superficial and deep fasciæ. The outer border of the tibialis anterior is found ; this muscle is then separated from the two other muscles on the front of the leg : the extensor longus digitorum and

the extensor proprius hallucis. The artery will be found on the interosseous membrane, accompanied by venæ comites, and with the anterior tibial nerve to the outer side.

Now that the student has reviewed the arteries of the leg, it is advised that sketches be made of transverse sections at several levels showing the position of the vessels and their relation to other structures.

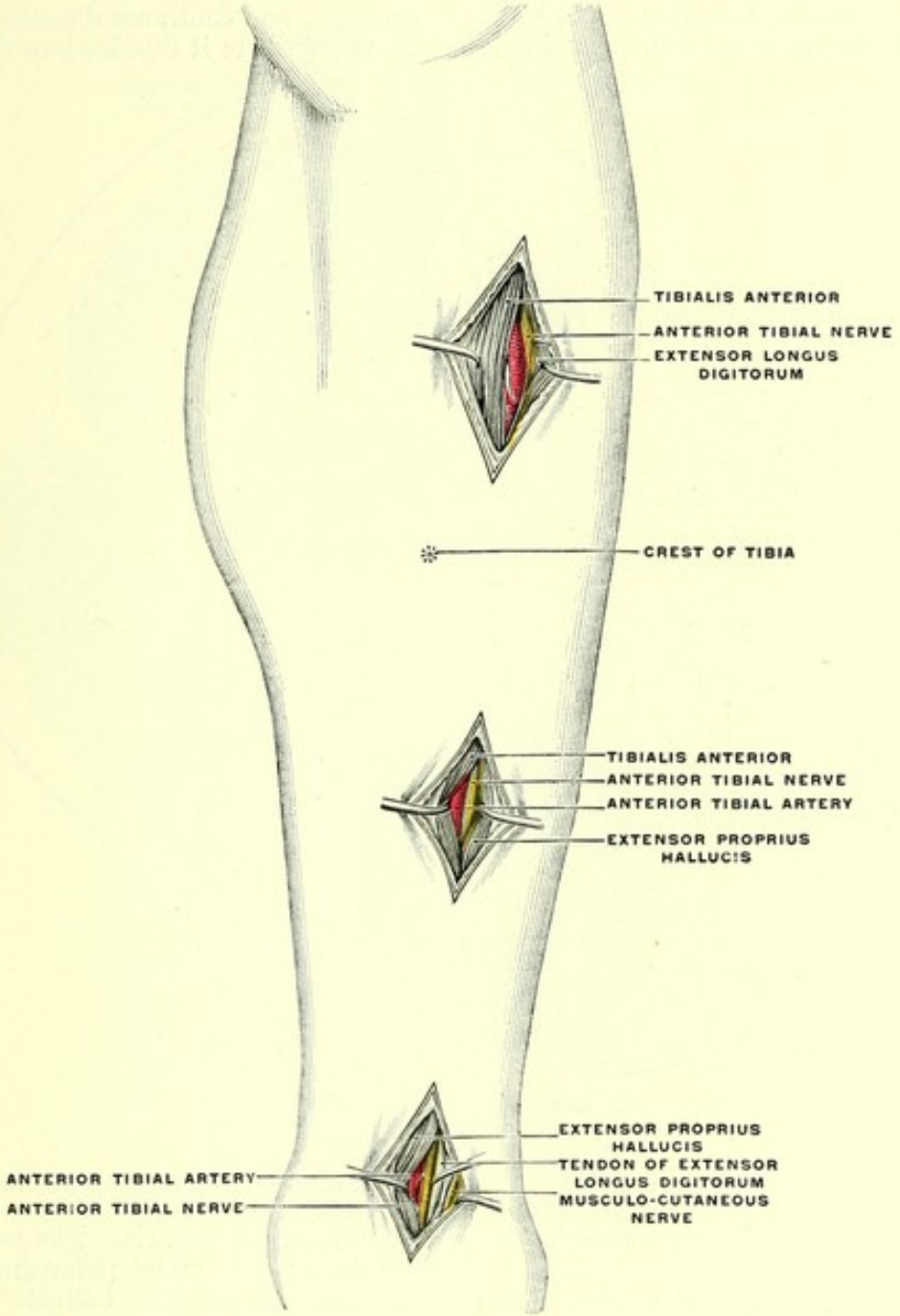

FIG. 487.—Surgical relations of the anterior tibial artery of the right leg. (Kocher.)

Branches of the anterior tibial are the anterior tibial recurrent, the posterior tibial recurrent, muscular, and the internal and external malleolar arteries. The *posterior tibial recurrent* is given off from the vessel before it gains the anterior aspect of the leg. It passes upward to the popliteal space, and anastomoses with the inferior articular branches of the popliteal. The *anterior tibial recurrent* is given off from the vessel immediately after it appears on the anterior surface of

the leg. It winds upward in the substance of the tibialis anterior to the patella, and anastomoses with the arteries forming the patellar anastomosis. *Muscular* branches are given off to the muscles on the anterior surface of the leg. The *malleolar* arteries are small branches given off from the lower portion of the anterior tibial. The external malleolar supplies the tissues over the outer ankle, the internal malleolar those over the inner ankle.

The Dorsalis Pedis (Fig. 489).—The dorsalis pedis is the continuation of the anterior tibial. It begins at the bend of the ankle, and continues downward and forward to the base of the first interosseous space, where it divides into the dor-

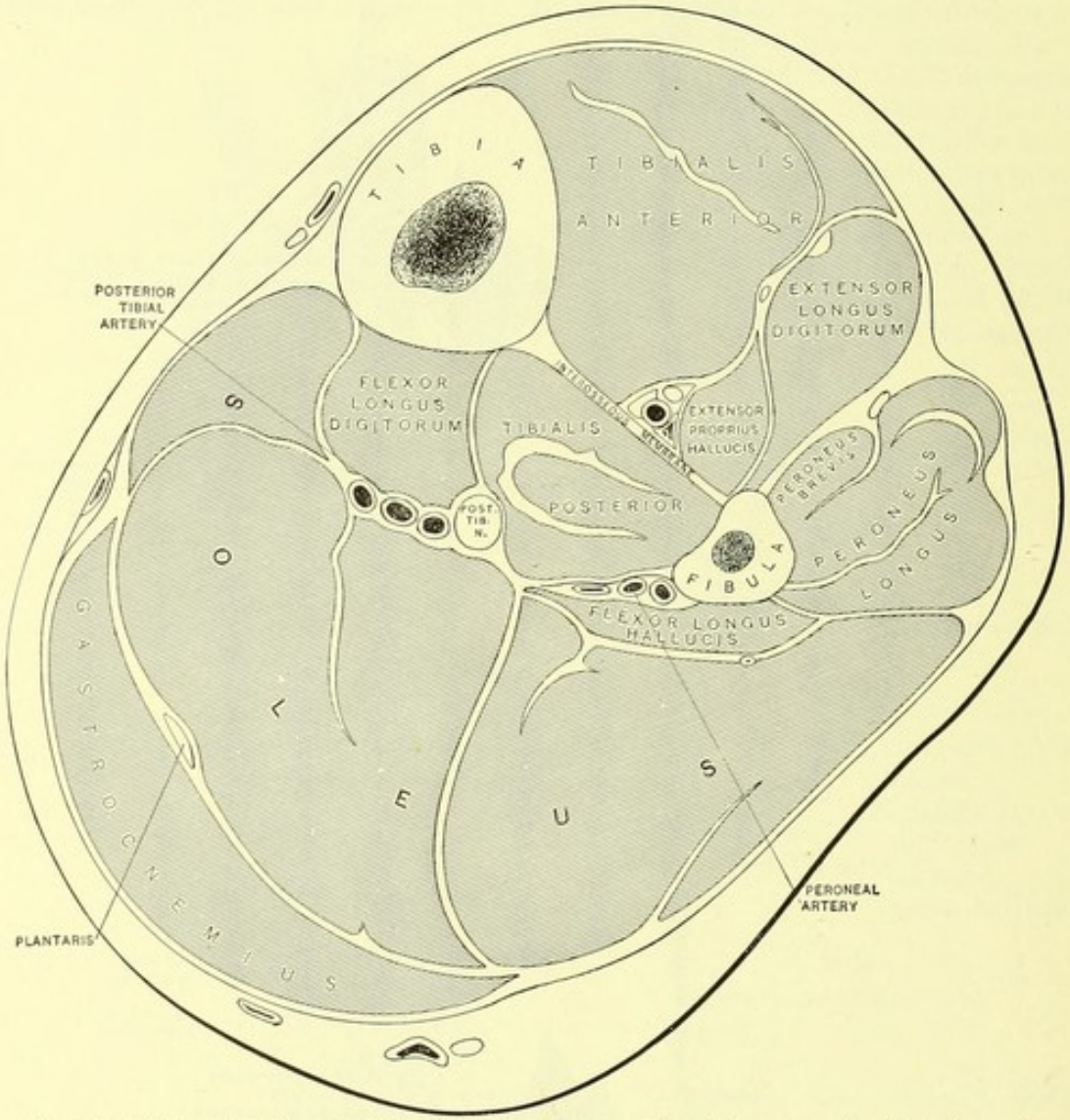

FIG. 488.—Horizontal section at middle of right leg—upper surface of lower segment. (After Braune.)

salis hallucis and the communicating or plantar digital branch. The vessel is superficial in position; it is accompanied by the anterior tibial nerve and venæ comites; it is external to the tendon of the extensor proprius hallucis.

Variations.—The dorsalis pedis varies in size greatly; when large, it assists materially the plantar arteries in supplying the sole of the foot; when small, the plantar arteries may furnish a large part of the supply for the dorsum.

Surgical Anatomy.—The dorsalis pedis can be exposed by an incision along the outer side of the tendon of the extensor proprius hallucis. It is accompanied by the anterior tibial nerve and by venæ comites.

The **Branches** of the dorsalis pedis are the tarsal, metatarsal, dorsalis hallucis, and communicating or plantar digital. The *tarsal* artery winds outward over the

dorsal surface of the tarsal bones, supplying them and contiguous structures. The *metatarsal* winds outward over the bases of the metatarsal bones, forming an arch from which three interosseous branches are given off, which run forward in the three interosseous spaces to the webs of the toes, where they anastomose with the digital branches of the plantar arch. At the origin of these interosseous branches, perforating branches from the plantar arch communicate with each vessel. The *dorsalis hallucis* runs forward in the first interosseous space to the web

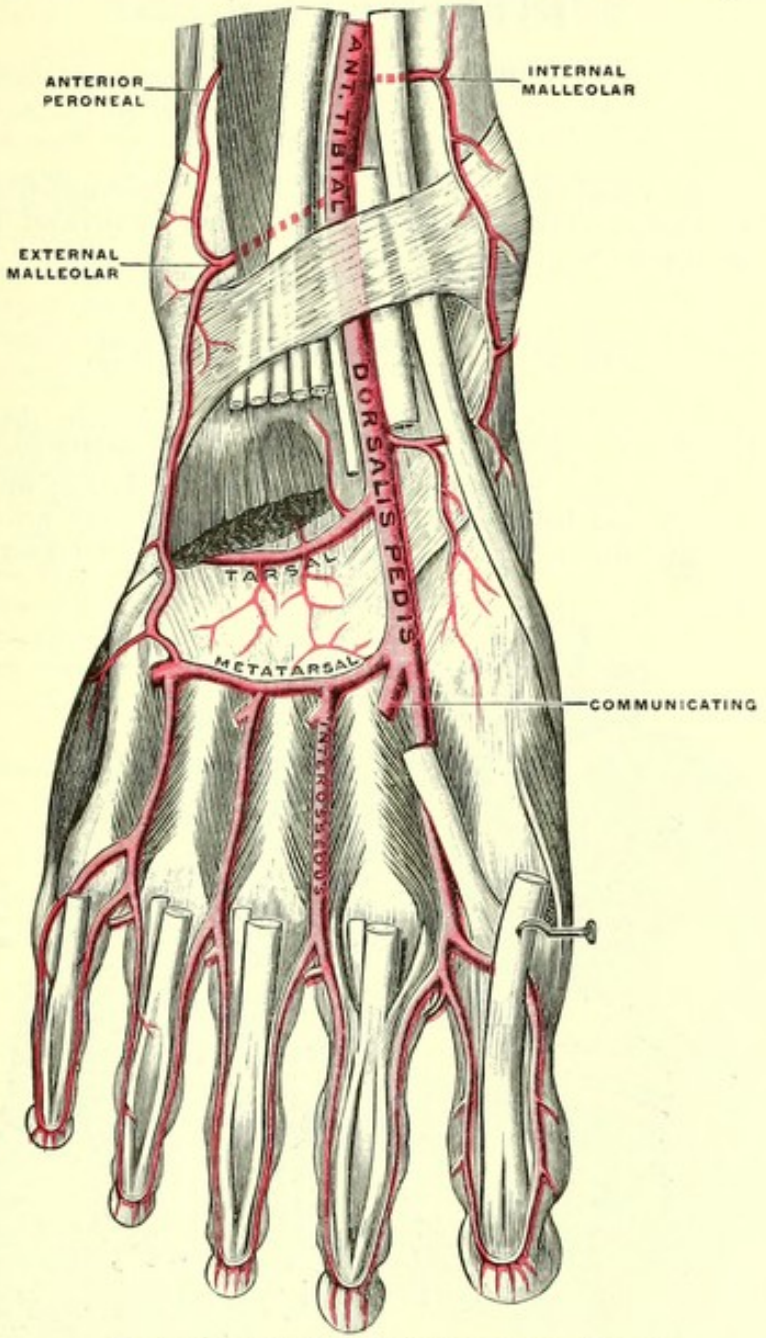

FIG. 489.—Arteries of the dorsum of the foot. (Testut.)

of the toes; here it divides into two branches, supplying the contiguous sides of the great and second toe. The *communicating* or plantar digital branch perforates the first interosseous space to reach the plantar surface of the foot. Here it anastomoses with the external plantar, and completes the plantar arch. It then continues forward in the plantar surface of the first interosseous space to the web of the toes. Here it divides into two branches which supply the contiguous surfaces of the great and second toes.

THE VEINS.

By G. WOOLSEY.

THE *veins* are the vessels through which the blood is returned from the capillaries to the heart. Like the arteries, they may be divided into the *pulmonary* and the *systemic*.

THE PULMONARY VEINS.

These consist of two large, short trunks on either side, in the root of the corresponding lung (Fig. 490). They extend nearly horizontally inward and forward from the hilum of the lung to the upper part of the back of the left auricle. They lie in front of and below the corresponding pulmonary arteries, and on piercing the pericardium they are invested on their ventral aspect only by the

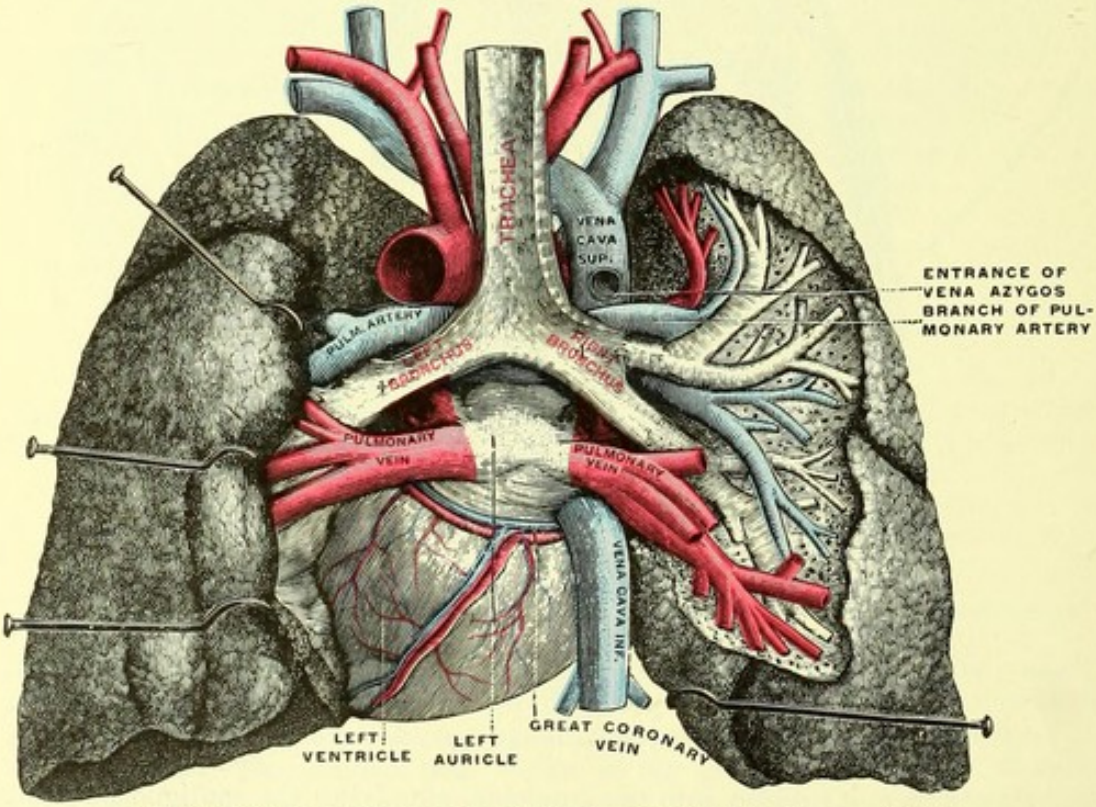

FIG. 490.—Pulmonary veins, seen in a dorsal view of the heart and lungs. (Testut.)

serous layer of that membrane. The two *right pulmonary veins* pass behind the superior vena cava, the ascending portion of the aorta, and the right auricle. The two *left pulmonary veins* pass in front of the descending portion of the aorta. They convey arterial blood, and have no valves.

The pulmonary veins are but little larger than the arteries they accompany. The right superior pulmonary vein commonly receives the vein from the middle lobe of the right lung, but sometimes the latter continues to the auricle separately as a third vein. The two pulmonary veins, on a side, more often on the left, sometimes unite, and terminate in a single trunk.

THE SYSTEMIC VEINS.

These convey the blood from the capillary plexuses of the rest of the body to the right auricle of the heart, which most of the veins of the heart enter by the coronary sinus, and the veins of the remainder of the body by the superior and inferior venæ cavæ. They differ from the arteries in their larger capacity, their greater number, their thinner walls, their larger and frequent anastomoses, and the occasional presence of more or less perfect valves, which prevent backward circulation. The veins from the stomach, intestines, spleen, and pancreas differ from the others in that, after joining to form a single trunk, the portal vein, the latter breaks up in the substance of the liver into a capillary network, from which the blood is collected by the hepatic veins, and emptied into the inferior vena cava.

The veins may be divided into *two sets*, the superficial and the deep, between which are frequent communications. The *superficial* or *subcutaneous veins* lie between the layers of the superficial fascia, and do not usually accompany an artery. The *deep veins* usually accompany the arteries, sometimes as a single trunk, as with the larger arteries (axillary, femoral, etc.), sometimes as a frequently anastomosing pair, the *venæ comites*, one on either side of the smaller arteries (radial, tibial, etc.).

The *venous sinuses* of the cranium differ from the veins in distribution and in structure, being formed by a separation of the two layers of the dura, and lined by epithelium.

In the following pages a detailed description is necessary only for those veins which do not accompany an artery. The systemic veins are naturally divided into three groups, according as they empty into the heart through the superior or the inferior vena cava, or the coronary sinus.

THE VEINS OF THE HEART.

The *cardiac* or *coronary veins* (Fig. 491), which return the blood from the substance of the heart, accompany the arteries, but have not an exactly similar course, as the arteries start in front, while the veins empty into the coronary sinus behind.

The **Coronary Sinus** is situated in the dorsal part of the groove between the left auricle and ventricle. About an inch in length, it is covered by the muscular fibres of the auricles, and its termination in the right auricle, between the opening of the inferior vena cava and the auriculo-ventricular aperture, is guarded by the coronary or Thebesian valve. Where the cardiac veins (excepting the oblique vein) join the coronary sinus they are guarded by valves, which are wanting in the rest of their course.

The **oblique vein** of Marshall, which runs over the back part of the left auricle in the vestigial fold of the pericardium, enters the left extremity of the sinus without a valve. The oblique vein with the coronary sinus represents the left superior vena cava, or the left duct of Cuvier and part of the sinus venosus of the fœtus. This vein is often represented in great part by a fibrous cord.

The **Great Cardiac Vein** (anterior coronary vein) ascends from near the apex of the heart in the ventral interventricular groove to the auriculo-ventricular groove, in which it turns to the left and passes backward to terminate in the left end of the coronary sinus, which appears as the dilated continuation of this vein.

It accompanies first the anterior and then the posterior branch of the left coronary artery, and receives branches from either side of its course, one of which, ascending along the left margin of the heart (*left marginal vein*) is of some size.

The **Middle Cardiac Vein** (*posterior interventricular vein*) ascends from the apex of the heart in the dorsal interventricular groove to empty into the right extrem-

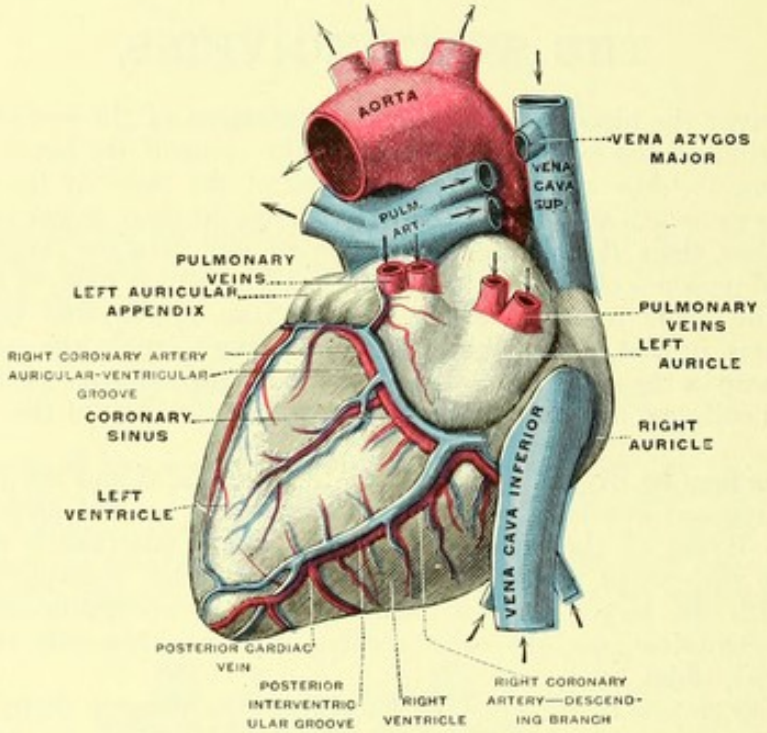

FIG. 491.—Cardiac veins, dorsal view. (Testut.)

ity of the great coronary sinus. It receives branches from the dorsal surface of both ventricles.

The **Posterior Cardiac Veins** are three or four small vessels, which ascend on the dorsal surface of the left ventricle to open along the lower border of the coronary sinus.

The **Right or Small Coronary Vein** passes along the right auriculo-ventricular groove to convey the blood from the hinder parts of the right auricle and ventricle into the right end of the coronary sinus.

The following small vessels empty directly into the heart without the intervention of the coronary sinus. The **Anterior Cardiac Veins** are two or three small vessels, which collect the blood from the ventral surface of the right ventricle, and ascend to enter the lower part of the right auricle. One larger than the others (*right marginal vein* or *vein of Galen*) runs along near the antero-inferior border of the heart. The **smallest cardiac veins** (*venæ cordis minimæ, Venæ Thebesii*) are numerous small veins within the substance of the heart, which open into some of the small foramina Thebesii in the right auricle. Similar veins are said to open into the other heart-cavities.

THE SUPERIOR VENA CAVA AND ITS TRIBUTARIES (Figs. 491, 493).

The *superior* (*descending*) *vena cava* is formed by the confluence of the right and left brachio-cephalic (innominate) veins behind the lower part of the junction of the first right costal cartilage with the sternum. From this point it passes nearly vertically downward, with a slight convexity to the right, for about three inches, to empty into the right auricle on a level with the third costal cartilage. Its lower inch and a half are contained within the pericardium, the serous layer of which invests it except along its hind border. It receives the blood returned

from the head, neck, upper extremities and thoracic walls. It contains no valves. *Relations.*—On its *right side* are the right lung and pleura, with the phrenic nerve between. On its *left side* lies the brachio-cephalic artery above, and the ascending portion of the aortic arch below. *In front* it is overlapped by the right pleura and lung. The root of the right lung lies *behind* it.

Its *lateral tributaries* are the great azygos vein, which enters it just before it penetrates the pericardium, and small veins from the pericardium and mediastinum.

The Brachio-cephalic Veins.

The *brachio-cephalic* or *innominate veins* return the blood from the head, neck, upper extremities, and a part of the thoracic walls. They are formed by the union of the subclavian and internal jugular veins, behind the sternal end of each clavicle, and unite below, opposite the lower border of the first right costal cartilage, at its junction with the sternum, to form the superior vena cava. At the angle of junction of the subclavian and jugular veins there open into the venous circulation the thoracic duct on the left side and the right lymphatic duct on the right side. There are no valves in the brachio-cephalic veins.

The **Right Brachio-cephalic Vein**, only about an inch in length, descends nearly vertically on the outer side of, and superficial to, the brachio-cephalic and the commencement of the subclavian arteries. The right lung and pleura lie on its right side and in front, with the phrenic nerve between.

The **Left Brachio-cephalic Vein**, two and a half to three inches long, passes from left to right with a slight downward inclination to join the right vein. In front of it lies the upper part of the manubrium sterni, with the lower ends of the sternal muscles, below it the arch of the aorta, and behind it the three branches of the arch, and the left phrenic and pneumogastric nerves.

Lateral Tributaries.—Each brachio-cephalic vein receives the vertebral, inferior thyroid, and internal mammary veins of its own side, and, in addition, the left vein receives the left superior intercostal vein, and small thymic, mediastinal, and pericardial branches.

Variations in the Superior Vena Cava and Brachio-cephalic Veins.—These are mostly due to a persistence of the left duct of Cuvier of the fœtus, which may form a left superior vena cava. This descends from the commencement of the left brachio-cephalic vein, in front of the aortic arch and the root of the left lung, to the heart, where it is continued in the usual position of the coronary sinus to open into the right auricle. The usual left brachio-cephalic vein may persist as a small communicating branch between the right and left superior venæ cavæ, or it may be altogether wanting. In a few cases besides those of transposition of the viscera the superior vena cava is found on the left side, the right brachio-cephalic vein taking a transverse course similar to that usually taken by the left.

Veins of the Head and Neck.

I. Veins of the Surface of the Head and Face (Fig. 492).

A. ANTERIOR REGION.

The *superficial veins* of the face and the fore part of the head and the deep veins of the face unite to form two trunks, the facial and the temporo-maxillary veins, while the occipital and posterior auricular veins collect the blood from the hind part of the scalp. Valves are generally absent in the veins of the head and neck, except at the lower end of the internal and external jugular veins.

The **Facial Vein** (*anterior facial*) collects the blood from the fore part of the face and scalp. It commences at the side of the nose, on a line with the lower margin of the orbit, as the direct continuation of the angular vein. It is less

tortuous than the facial artery, behind which it passes downward and outward to and around the lower border of the jaw, in front of the masseter muscle. Below the lower border of the jaw it inclines backward beneath the platysma muscle, to empty into the internal jugular vein near the level of the hyoid bone. Below the digastric muscle it is joined by the anterior division of the temporo-maxillary vein, and the trunk thus formed is called the *common facial vein*. A communi-

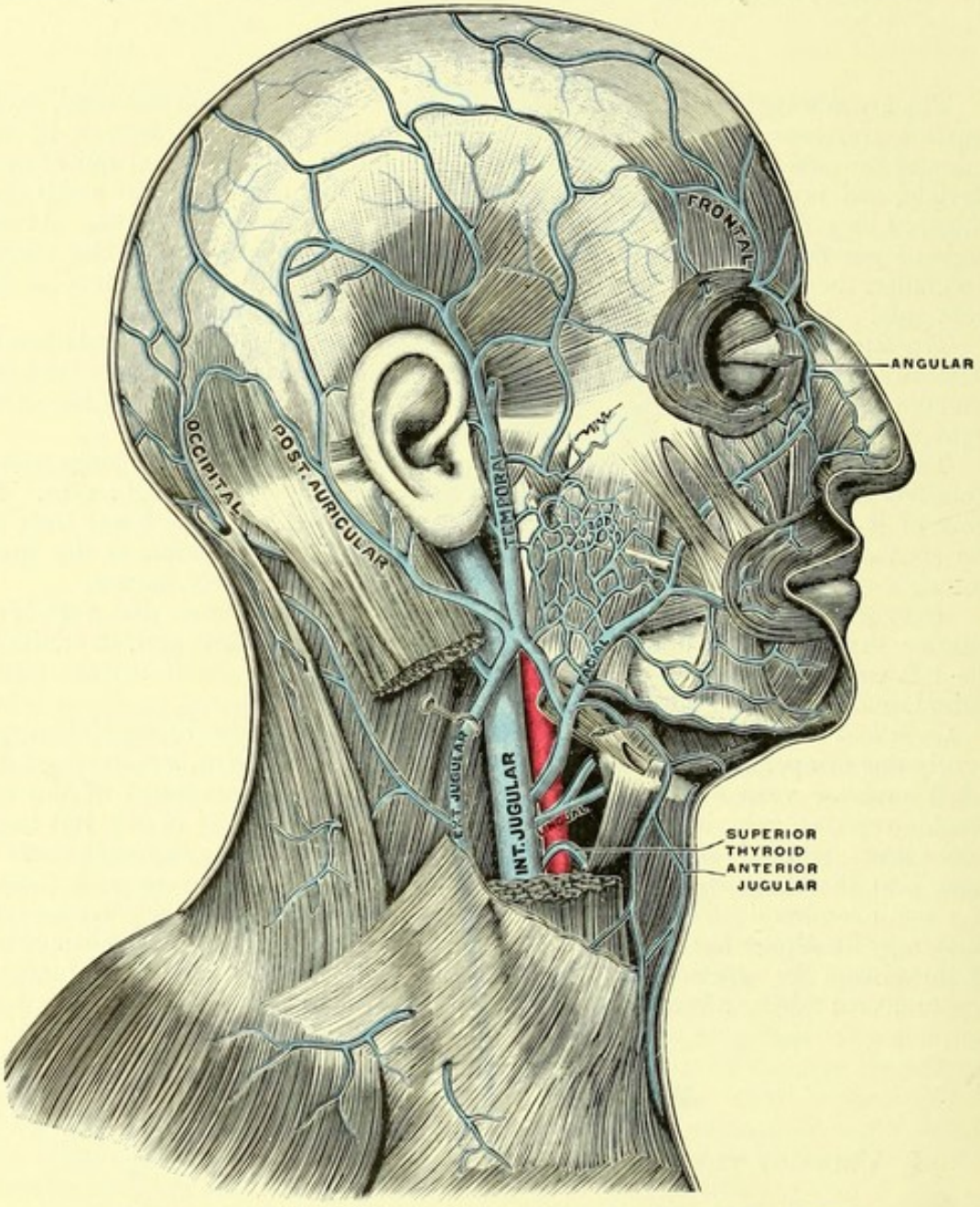

FIG. 492.—Superficial veins of the cranium and face, right lateral view. (Testut.)

cating branch passes downward along the ventral margin of the sterno-mastoid muscle to join the anterior jugular vein.

The **Angular Vein**, on each side, lies along the side of the root of the nose from a point a little below the level of the eyebrow, where it is formed by the junction of the frontal and supra-orbital veins, to the lower margin of the orbit, where it becomes the *facial vein*. It appears as the continuation of the frontal vein, lies internal to the lachrymal sac, receives branches from the nose and upper eyelid, and communicates with the superior ophthalmic vein.

The **Transverse Nasal Vein** arches across the bridge of the nose, and unites the two angular veins, or the lower ends of the frontal veins.

The **Frontal Vein** is formed by branches from the forehead and the forepart of the scalp, which communicate with the anterior division of the temporal vein. These tributaries pass downward and inward to form a trunk which, connected with its fellow by cross-branches, descends nearly vertically on the side of the median line to a point a little below the inner end of the eyebrow, where it is joined by the supra-orbital vein and becomes the angular vein. The right and left frontal veins sometimes unite into a single median trunk, which bifurcates at the root of the nose into the two angular veins.

The **Supra-orbital Vein** is a smaller vessel which collects the blood from the lower and lateral part of the forehead, upper eyelids, etc., and passes obliquely downward and inward to join with the frontal vein in forming the angular. It communicates laterally with the temporal, and dorsally with the ophthalmic vein and the frontal vein of the diploë.

The *facial vein* receives *lateral tributaries*, corresponding to the branches of the artery (*i. e.*, inferior palatine, submaxillary, submental, inferior labial, inferior and superior coronary, and lateral nasal) and in addition the following:

The **inferior palpebral veins**, two or three in number, descend from the lower eyelid, where a communication with the infra-orbital vein is established.

The **anterior internal maxillary vein** or *deep facial vein* passes downward and forward from the pterygoid plexus. It crosses the zygomatic surface of the maxilla, and opens into the facial vein beneath the zygomaticus major muscle.

Small **buccal, masseteric,** and **parotid veins** are received from the buccinator and masseter muscles and the glandula socia parotidis, respectively.

Sometimes the lingual vein joins the facial. (See lingual vein.)

The free communications between the facial vein and its tributaries and the ophthalmic vein, none of which contain valves, account for the danger of septic thrombi extending backward through the ophthalmic vein to the cranial sinuses in case of carbuncle or anthrax of the face.

B. LATERAL REGION.

The **Temporo-maxillary Vein** (*posterior facial*) is formed by the union of the temporal and maxillary veins in the substance of the parotid gland behind the neck of the mandible. It descends in the substance of the parotid gland superficial to the external carotid artery to about the angle of the jaw, where it divides into two parts. The *anterior division* passes downward and forward to join the facial vein, forming the common facial vein, while the *posterior division* is joined by the posterior auricular vein to form the external jugular vein.

The posterior auricular vein may join the temporo-maxillary vein before bifurcation of the latter, in which case the anterior division is properly a branch of the external jugular vein.

The **Superficial Temporal Vein** collects the blood from the parietal region of the scalp, where communicating branches connect it with the supra-orbital and frontal veins in front, the veins of the opposite side above, and the posterior auricular and occipital veins behind. Its branches unite into two trunks which, corresponding to the divisions of the artery, converge and unite in front of the ear into a single trunk.

The **Middle Temporal Vein** receives the blood from the temporal muscle, and is joined by the orbital branch, which, corresponding to the artery of the same name, communicates with the ophthalmic vein. Piercing the fascia near the zygoma it joins the superficial temporal to form the *common temporal vein*. The *middle temporal vein* communicates with the pterygoid plexus through the deep temporal veins, a branch of that plexus corresponding to the arteries of the same name.

The **Common Temporal Vein** crosses the base of the zygoma just in front of the ear, and thence descends in the parotid gland external to the temporal artery. It

joins the internal maxillary vein opposite the neck of the jaw to form the temporo-maxillary vein.

The temporal vein also receives *anterior auricular veins* from the external ear, *transverse facial veins* from the masseter muscle, *parotid veins* from the gland, and branches from the plexus around the temporo-maxillary articulation, which receives a branch from the tympanum, through the fissure of Glaser.

The **Internal Maxillary Vein** is a short vessel, which passes backward from the pterygoid plexus, accompanying the corresponding artery as a single or a double trunk to join with the common temporal vein in forming the temporo-maxillary vein.

The **Pterygoid Plexus** surrounds the pterygoid muscles and corresponds to the second and third portions of the internal maxillary artery, by the companion veins of whose branches it is made up. It communicates in front with the facial vein, through the deep facial vein, above with the inferior ophthalmic vein and the cavernous sinus, and behind with the plexus from which the middle temporal vein arises.

The **Posterior Auricular Vein** descends from a plexus on the lateral aspect of the scalp, which communicates with the temporal and occipital veins and with the vein of the opposite side. It is large in comparison with its companion artery, which it leaves below the ear, and inclines forward toward the angle of the jaw to join the posterior division of the temporo-maxillary vein, and form the external jugular vein.

C. POSTERIOR REGION.

The **Occipital Veins** collect the blood from the hind part of the venous plexus of the scalp, and descend, as one or two trunks, with the occipital artery deeply into the neck, where they are continuous with the *deep cervical vein*. An emissary vein, passing through the mastoid foramen, connects the lateral sinus with this vein, or, in some cases, with the posterior auricular vein.

2. Veins of the Neck (Fig. 493).

The **External Jugular Vein**, formed by the union of the posterior auricular vein and the posterior division of the temporo-maxillary vein, descends nearly vertically from its commencement near the angle of the jaw to terminate opposite the middle of the clavicle in the subclavian vein. It lies beneath the platysma, and crossing the sterno-mastoid muscle obliquely it follows the hind border of the latter in its lower half. Near the clavicle it pierces and is closely connected with the deep cervical fascia, which holds it open. It has a pair of imperfect valves at its entrance into the subclavian vein, and another an inch or two above the clavicle, and the part between them is called the *sinus*, being often dilated. Its *lateral tributaries* are the following:

The **posterior external jugular vein.** This descends behind the sterno-mastoid muscle, from the skin and superficial muscles of the upper and back part of the neck and the lower occipital region, to open below the middle of the external jugular vein. It may communicate with the occipital vein.

The **transverse cervical and suprascapular veins** accompany their corresponding arteries, and open into the external jugular vein a little above its termination. They sometimes present a plexiform arrangement in the subclavian triangle. These veins have valves near their termination and may sometimes open into the subclavian vein.

The **anterior jugular vein** takes origin below the chin from small branches which communicate with the lower radicles of the facial vein. It descends at a variable distance from the median line to near the inner end of the clavicle, where it perforates the deep fascia and turns outward beneath the sterno-mastoid muscle to open into the lower end of the external jugular vein, or sometimes into

the subclavian vein. It receives a branch from the facial vein which descends along the ventral border of the sterno-mastoid muscle. A transverse branch connects the lower ends of the veins of the two sides, and others may exist higher up.

Its position behind the origin of the sterno-mastoid should be remembered in tenotomy of that muscle. It varies in size inversely with that of the external jugular vein.

The **Internal Jugular Vein** receives the blood from the cranial cavity. It begins at the enlarged *sinus* or bulb of the sigmoid sinus, which is lodged in the large dorsal compartment of the jugular foramen. After a nearly straight

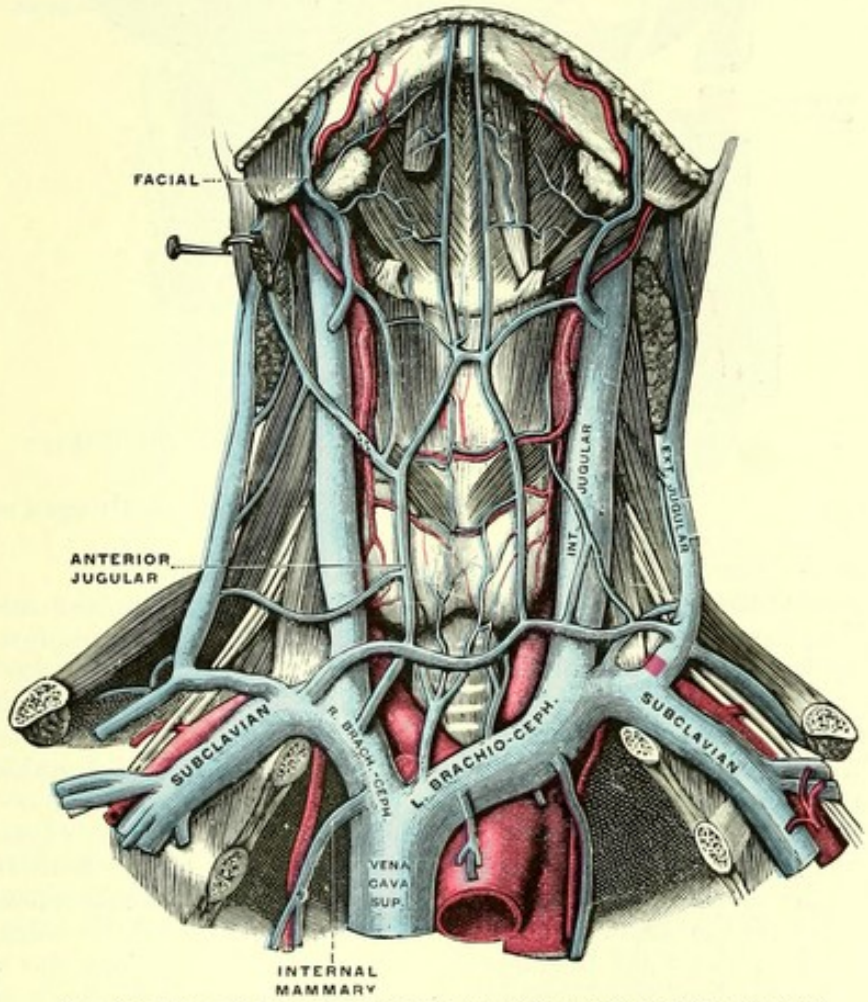

FIG. 493.—Veins of the neck and upper part of thorax, front view. (Testut.)

course it ends behind the sternal end of the clavicle, where it joins the subclavian vein to form the innominate vein. At the base of the skull it is behind and then becomes external to the internal carotid artery. Lower down it lies external to and in the same sheath with the common carotid artery, overlapping it below, especially on the left side. A pair of imperfect valves is found about an inch above its termination. It has the following *lateral tributaries.*

The **inferior petrosal sinus** opens into the bulb or into the commencement of the internal jugular vein.

The **pharyngeal plexus**, on the outer surface of the pharynx, receives the blood from the neighboring parts, and opens into the jugular vein directly or through the common facial vein. It communicates above with the pterygoid plexus and receives branches from the soft palate and Eustachian tube.

The **lingual vein** (Fig. 494). Two small venæ comites usually accompany the lingual artery, but most of the blood is returned from the tongue by the *ranine*

vein, which starts near the tip of the tongue, and passes backward beneath the mucous membrane of its under surface. As it continues backward it is separated from the lingual artery by the hyoglossus muscle, on the outer surface of which it lies below the hypoglossal nerve. It is joined by the lingual venæ comites and by branches corresponding to the branches of the artery, and empties into the

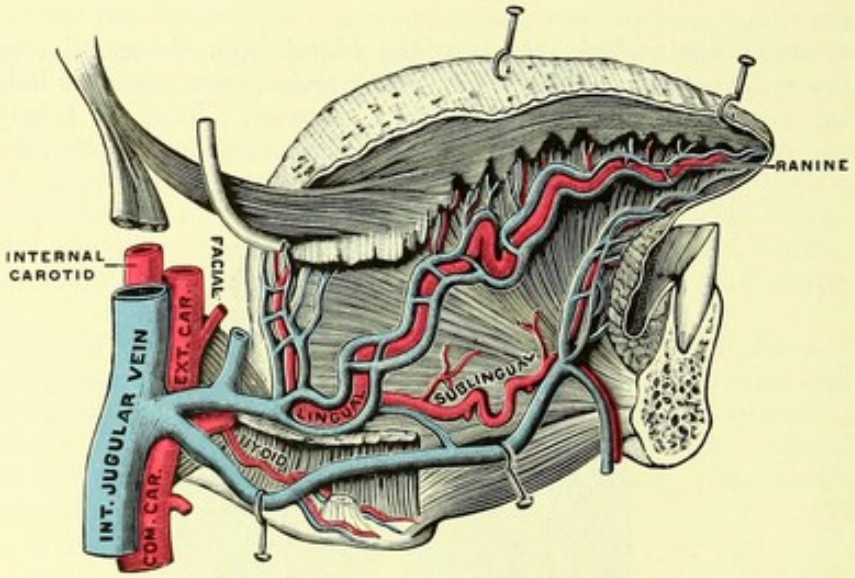

FIG. 494.—Arteries and veins of the tongue, viewed from the right side. (Testut.)

internal jugular or the facial vein. Its tributaries not infrequently open separately into the internal jugular or into the facial vein.

The **common facial vein** has been described above.

The **superior thyroid vein** corresponds to the artery of the same name, and, after crossing the upper end of the common carotid artery, it empties into the internal jugular or the common facial vein. The three thyroid veins on each side communicate freely with each other and with those of the opposite side.

The **middle thyroid vein** emerges from the lower part of the lateral lobe of the thyroid body, and, after crossing the common carotid artery, empties into the internal jugular vein, a little below the level of the cricoid cartilage.

The **Inferior Thyroid Veins** descend from the lower part of the thyroid body, one on either side of the trachea. Frequent anastomoses form a kind of plexus, from which the left vein descends to empty into the left brachio-cephalic vein, the right vein into the angle of union of the two brachio-cephalic veins, or into the lower end of the right brachio-cephalic vein, or it may join the left vein. They lie under cover of the sterno-hyoid muscles, and receive inferior laryngeal, tracheal, and œsophageal veins. They are guarded by valves at their termination. They may seriously embarrass the surgeon in performing low tracheotomy.

The **Vertebral Vein** corresponds to the cervical portion only of the vertebral artery. Commencing in the suboccipital triangle in a plexus of small veins, it accompanies the vertebral artery in a plexiform manner through the foramina of the transverse processes of the upper six cervical vertebræ. Thence as a single vessel it descends across the subclavian artery to open into the upper end of the brachio-cephalic vein, dorsally.

Tributaries.—At its upper end it communicates with the occipital, deep cervical, and intraspinal veins. It receives branches from the dorsal spinal veins of the neck, the lateral spinal veins, and the plexus on the ventral surface of the bodies of the cervical vertebræ. Near its lower end it is joined by the deep cervical and anterior vertebral veins, and usually by the first intercostal vein, which accompanies the superior intercostal artery.

The **anterior vertebral vein** descends from in front of the cervical vertebræ,

accompanying the ascending cervical artery, and receiving branches from the neighboring muscles.

The **deep cervical vein** (*posterior vertebral*) descends at the back of the neck, in company with the deep cervical artery, from the suboccipital plexus, through which it receives the occipital vein. Below the transverse process of the seventh cervical vertebra it turns forward to empty into the lower end of the vertebral vein.

The Veins of the Diploë (Fig. 495).

These are contained in a plexus of bony channels in the cancellous tissue of the bones of the roof and sides of the skull. They are arranged in four groups,

Fig. 495.—Veins of the diploë. The outer table of cranial bones is removed. (Testut.)

whose trunks descend to communicate with the meningeal veins, the sinuses of the dura and the veins of the scalp. They are named from their position.

The **frontal veins** of the diploë open into the supra-orbital vein at the bottom of the supra-orbital notch or foramen.

The **anterior temporal veins** open into the deep temporal veins through an opening in the great wing of the sphenoid.

The **posterior temporal veins** join the lateral sinus through the mastoid foramen or an opening at the dorso-inferior angle of the parietal bone.

The **occipital veins** open into the occipital vein externally, or into the lateral sinus internally.

In fœtal life the veins of each bone are distinct, but they anastomose freely after the bones come together.

The Venous Sinuses of the Cranium (Figs. 496, 497).

These are venous channels situated between the two layers of the dura, and lined by a continuation of the lining membrane of the veins. They collect the blood from the brain, orbit, and eyeball, and some of that from the meninges and diploë, and empty into the internal jugular vein. They communicate with the superficial veins by means of the *emissary veins*, passing through certain foramina in the cranium. They may be divided into two groups, the one situated above and behind, the other at the base of the skull; the former including the superior and inferior longitudinal, the straight, the lateral, and the occipital sinuses, while the latter embraces the cavernous, the circular, the basilar, and the inferior and superior petrosal sinuses.

The **Superior Longitudinal Sinus** extends in the median line along the attached

margin of the falx cerebri, increasing constantly in size, from the foramen cæcum in front to the internal occipital protuberance behind, where, turning sharply to one side, usually the right, it is continuous with the lateral sinus. Its triangular lumen is crossed by a number of fibrous bands (the cords of Willis), and projecting into it at intervals are the Pacchionian bodies. It receives the superior cerebral veins, which enter it mostly from behind forward (*i. e.*, against the blood-stream). It often communicates through the parietal foramen with the temporal veins of the scalp, and regularly in early life through the foramen cæcum with the veins of the nose. On approaching the internal occipital protuberance it inclines slightly to the side to which it bends, and presents a dilatation, the *torcular Herophili* ("the wine-press of Herophilus"), which is lodged in a depression on the side of the internal occipital protuberance. The torcular usually receives the occipital sinus, and gives a cross-branch to the straight sinus, where the latter bends into the opposite lateral sinus.

The **Inferior Longitudinal Sinus** is a small vessel of cylindrical form, which occupies the hind half or more of the lower border of the falx cerebri. It receives some branches from the falx and the median surface of the brain, and terminates in the straight sinus.

The **Straight Sinus**, triangular on section, extends downward and backward along the line of junction of the falx cerebri and the tentorium cerebelli, to the internal occipital protuberance, where it bends sharply to the side, usually to the

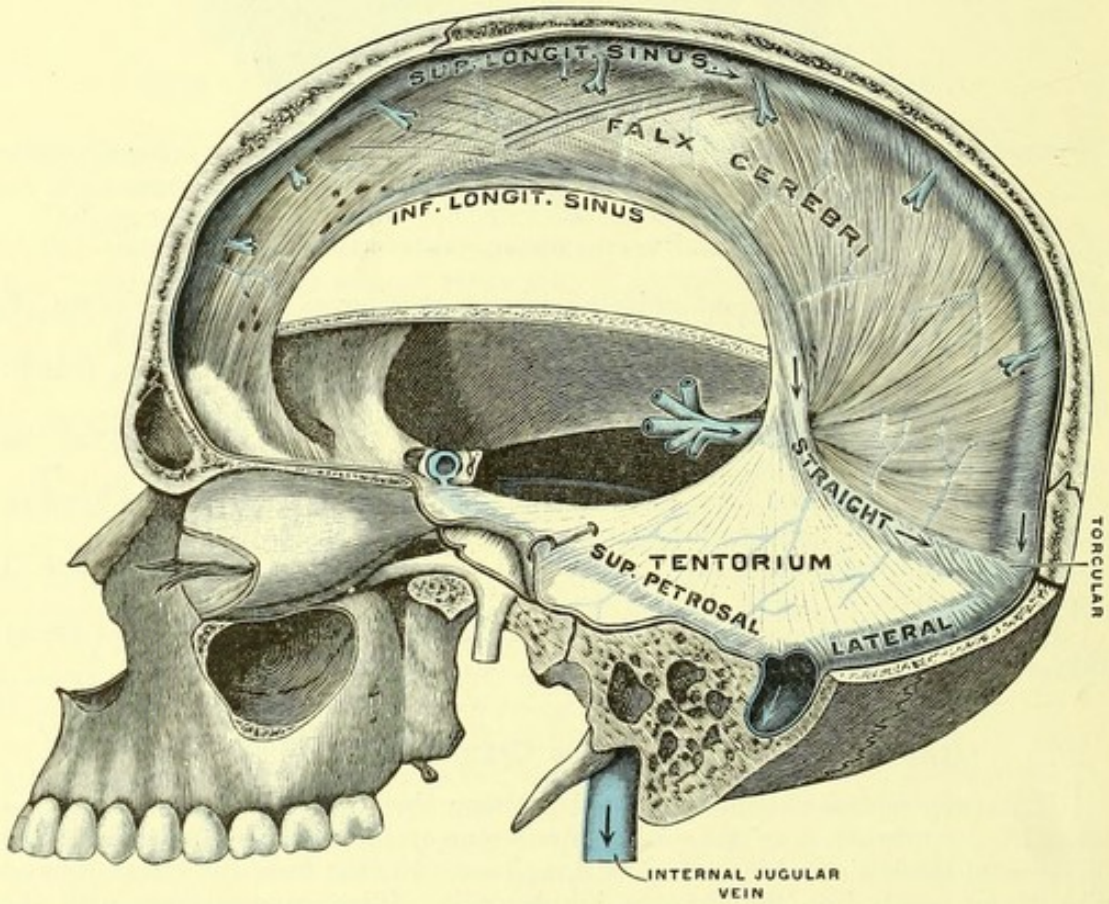

FIG. 496.—Sinuses of the dura, left lateral view. (Testut.)

left, and is continued into the lateral sinus, being connected by a cross-branch with the torcular. It is formed in front, at the margin of the tentorium, by the union of the inferior longitudinal sinus with the great vein of Galen from the interior of the brain.

The **Lateral Sinuses** commence at the internal occipital protuberance, and end at the jugular foramina in the bulbs or sinuses which are continuous with the internal

jugular veins. Each sinus passes at first nearly horizontally outward, with a slight convexity upward, in the groove on the occipital bone and the dorso-inferior angle of the parietal bone, along the attachment of the tentorium cerebelli. Thence it curves downward and inward in the groove on the inner surface of the mastoid, leaving the tentorium after receiving the superior petrosal sinus (and, when present, the petro-squamous sinus). Finally it curves forward onto the jugular process of the occipital bone to the jugular foramen. That part of the sinus on the mastoid bone and the jugular process of the occipital is called the *sigmoid sinus*, from its S-shaped course. This part is semicylindrical in shape, communicates with the occipital sinus through the marginal sinus, and with the occipital and vertebral veins through the mastoid and posterior condylar foramina. The lateral sinus receives veins from the temporal lobe of the brain, from the upper and lower surfaces of the cerebellum, and from the medulla, pons, and diploë. The right lateral sinus is considerably larger than the left, except in cases where the superior longitudinal sinus is continued into the left sinus.

The *position* of the lateral sinus may be represented on the exterior of the skull by a line curved slightly upward from the external occipital protuberance to

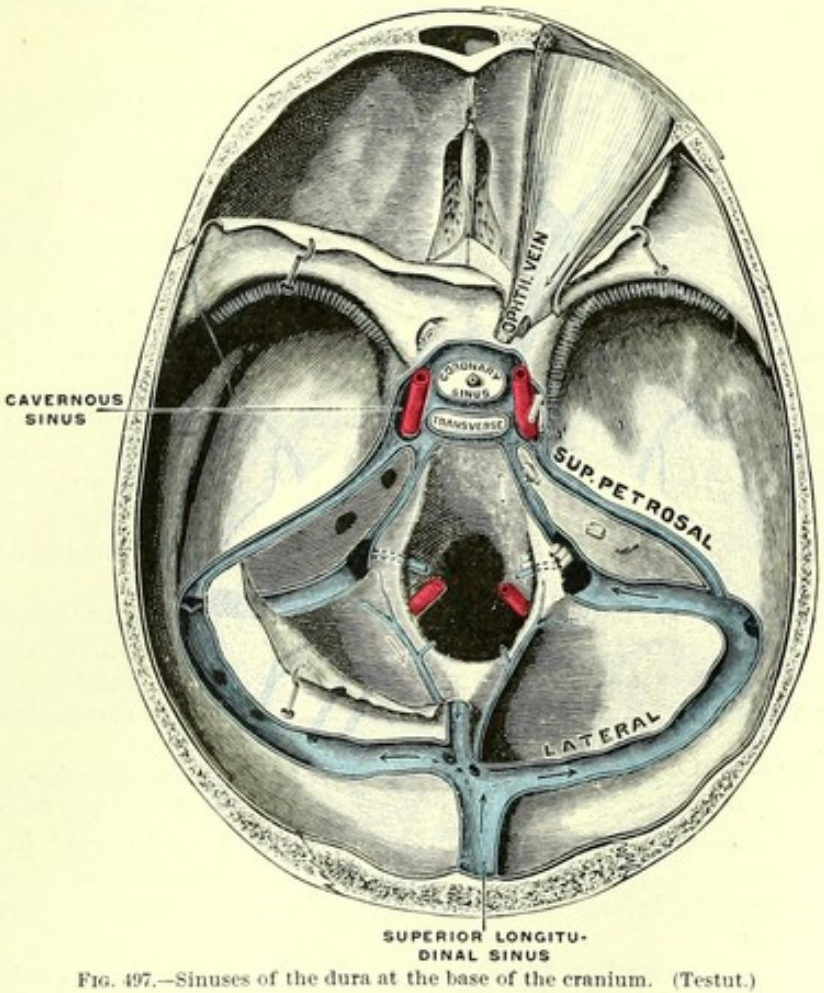

FIG. 497.—Sinuses of the dura at the base of the cranium. (Testut.)

the base of the mastoid process, and thence its sigmoid portion bends downward and inward toward the tip of the process, making a forward bend or knee which extends to within half an inch or less of the upper part of the bony external auditory meatus.

The **Occipital Sinus** ascends mesially, along the line of attachment of the falx cerebelli to the occipital bone, from the foramen magnum in front to the torcular behind. Its tributaries pass around one or both sides of the foramen magnum, as marginal sinuses, one or both of which communicate with the lower end of the

lateral sinuses. It communicates with the posterior spinal veins, and receives inferior cerebellar veins.

The **Cavernous Sinuses** (Fig. 498) lie between the layers of the dura, one on each side of the body of the sphenoid bone. They extend from the sphenoidal fissure in front, where they receive and are practically continuous with the ophthalmic veins, to the apex of the petrous bone behind, where they end in the petrosal sinuses. The two are connected across the middle line in front, behind, and often below the pituitary body, by vessels which are called *anterior*, *posterior*, and *inferior intercavernous sinuses*, and which together form the *circular* or *coronary sinus*. Each cavernous sinus is bridged across by fibrous bands, so that its cavity resembles cavernous tissue, from which it derives its name. In the outer wall are the third, fourth, and ophthalmic divisions of the fifth nerve, which lie in the order named from above downward and from within outward. The internal carotid artery and the sixth nerve also pass along in the sinus separated from its lumen

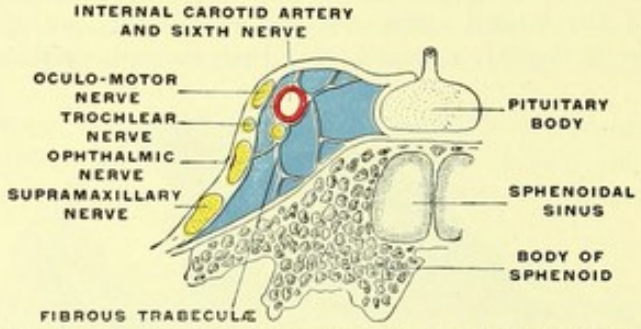

FIG. 498.—Cavernous sinus, as shown by transverse section through the middle of the sella turcica. (W. Keiller.)

by its endothelial lining only. This sinus receives some inferior cerebral veins, and communicates with the pterygoid plexus through the ophthalmic vein, and through a slender vein passing through the foramen of Vesalius and another through the foramen ovale. It also communicates with the pharyngeal plexus and the internal jugular vein, by branches passing through the foramen lacerum medium and the carotid foramen respectively. This sinus also receives in front the small *spheno-parietal sinus*, which, communicating with the middle meningeal veins, near the apex of the small wing of the sphenoid, runs inward on the under surface of this bony process.

The **Superior Petrosal Sinus** extends backward as a narrow channel in the attached margin of the tentorium cerebelli, along the groove in the upper border of the petrous bone, from the cavernous sinus in front to the lateral sinus behind. It receives veins from the temporal lobe of the brain, the cerebellum, and the tympanum.

The **Inferior Petrosal Sinus**, larger but shorter than the superior, runs backward and downward in a groove along the petro-occipital suture, from the hind end of the cavernous sinus in front to the upper end of the internal jugular vein, which it reaches after passing through the forward compartment of the jugular foramen. It receives inferior cerebellar veins, and veins from the medulla, pons, and internal ear.

The **Transverse** or **Basilar Sinus** (*basilar plexus*). Connecting the two inferior petrosal sinuses across the median line is a plexus of veins, lying in the dura on the basilar process of the occipital bone. It communicates below with the anterior spinal veins.

The **petro-squamous sinus** is sometimes found in the adult in a groove along the petro-squamous suture, opening behind into the lateral sinus, where the latter bends downward onto the mastoid bone. It represents the remains of an early fœtal condition, in which the lateral sinuses are continued forward in this course to open into the primitive (afterwards the external) jugular vein, before the development of the internal jugular vein.

The Ophthalmic Veins.

Commencing near the inner canthus of the eyelid, where it communicates freely with the angular, frontal, and supra-orbital veins, the principal or *Superior Ophthalmic Vein* extends backward and inward to the inner end of the sphenoidal fissure, through which it passes to end in the fore part of the cavernous sinus. In the orbit it crosses above the optic nerve, a little in front of the artery, and receives branches similar to those of the artery.

The Inferior Ophthalmic Vein.—Formed by the union of some inferior muscular branches with the lower posterior ciliary branches, this smaller ophthalmic vein runs backward in the floor of the orbit, beneath the optic nerve. It terminates by joining the superior ophthalmic vein to form the short *common ophthalmic trunk*, or by opening separately into the cavernous sinus. A branch, and occasionally the entire vein, descends through the spheno-maxillary fissure to join the pterygoid plexus.

As the ophthalmic veins have no valves, the blood, under certain conditions, may flow from behind forward into the angular vein or its branches, and thus obviate pressure in the veins of the retina, when the cavernous sinus is obstructed.

The Emissary Veins.

These pass through foramina in the skull to connect the cranial sinuses with the surface veins of the scalp. The blood-current may be in one or the other direction under varying conditions of intracranial pressure. They may serve as the channels along which infection is carried from the surface to the interior of the cranium. The following communications occur through emissary veins. (*A*) The *longitudinal sinus* communicates with the temporal veins through one or both parietal foramina when present, and, in the child, with the veins of the nose through the foramen cæcum. (*B*) The *lateral sinus* is connected with the occipital (or posterior auricular) vein through the mastoid foramen (the largest and most constant emissary), and sometimes with the vertebral vein through the posterior condylar foramen. (*C*) The *cavernous sinus* communicates with the pterygoid plexus through the foramen of Vesalius and the foramen ovale, as well as through the inferior ophthalmic vein; with the pharyngeal plexus through the foramen lacerum medium; and with the internal jugular vein by the carotid plexus through the carotid canal. (*D*) The *occipital sinus* communicates with the vertebral and extraspinal veins through the anterior condylar foramen. (*E*) A small vein occasionally passes to the *torcular* through a foramen in the occipital bone, near the external occipital protuberance.

The Veins of the Brain.

These open into the cranial sinuses and have several peculiarities.

The Veins of the Cerebrum.

These have very thin walls from the absence of muscular tissue, and contain no valves. They are more numerous than the arteries, and, for the most part, do not accompany them. Those veins opening into the superior longitudinal sinus enter it against its current, after ascending with the arteries, instead of descending with the ascending arteries.

The cerebral veins may be divided, like the arteries, into a *superficial set* on the surface, which anastomose freely together, and a *deep set*, which emerge from the ventricles by the transverse fissure.

The **Superficial Veins** run in the fissures, and occasionally across the gyri, and are subdivided into superior and inferior groups.

The **Superior Cerebral Veins**, eight to twelve in number on each side, pass inward and slightly forward from the upper surface of the cerebrum. After

joining others from the mesial surface, they open into the longitudinal sinus, running for some distance in its walls.

The **inferior cerebral veins** collect the blood from the outer and under surfaces of the cerebrum, and open into the cavernous, superior petrosal, or lateral sinuses, according to their position. The *Middle Cerebral Vein* is one of large size, which overlies the fissure of Sylvius, receiving branches from adjoining lobes, and ends in the cavernous sinus. The *Great Anastomotic Vein* of Trolard, by anastomosing on the parietal lobe with a branch of the middle cerebral vein and with one of the superior veins, establishes a communication between the cavernous and the superior longitudinal sinuses. Similarly the *Posterior Anastomotic Vein* of Lubbe connects the cavernous and lateral sinuses, by anastomosing with the middle cerebral vein on the temporal lobe.

The **Deep Cerebral Veins** join to form two trunks, the *Veins of Galen*, which, beginning near the foramen of Monro by the union of the choroid vein and the vein of the corpus striatum on each side, pass back, parallel with and near each other, between the layers of the velum interpositum. Beneath the splenium of the corpus callosum they pass out of the brain at the great transverse fissure, after joining to form a single trunk (vena magna Galeni), which ascends to enter the straight sinus.

The choroid vein runs forward and upward along the outer border of the choroid plexus (the blood of which it returns) to its fore part where, near the foramen of Monro, it joins the vein of the corpus striatum. The latter runs forward in the groove between the corpus striatum and the optic thalamus, receiving branches from them and the neighboring parts. It joins the choroid vein as above described.

Each vein of Galen, just before it joins its fellow, receives the basilar vein of each side which, formed by the union of the anterior cerebral vein, the deep Sylvian vein, and the inferior striate vein, passes backward and around the crus cerebri to its termination. The *anterior cerebral vein* runs from the genu of the corpus callosum, the *deep Sylvian veins* from the insula and adjacent parts (communicating with the middle cerebral vein), and the *inferior striate vein* descends through the anterior perforated space from the corpus striatum.

The Veins of the Cerebellum.

These are divided into two sets, superior and inferior, according to their position. Of the *superior cerebellar veins* some run inward and upward to the straight sinus and the great vein of Galen, others run outward to the superior petrosal and lateral sinuses. The *inferior cerebellar veins* are larger than the superior, and some of them together with the veins of the oblongata and pons, run outward and forward to the inferior petrosal and lateral sinuses, while others pass backward to the occipital sinus.

THE VEINS OF THE UPPER EXTREMITY.

Two sets of veins are distinguished in the extremities, *superficial* and *deep*, the latter of which accompany the arteries, while the superficial set are larger, return more of the blood, and lie between the layers of the superficial fascia. The two sets communicate at frequent intervals. Valves are numerous in both sets, but more so in the deep veins, and are regularly found where a branch joins a trunk, or the deep veins join the superficial.

The Superficial Veins of the Upper Extremity (Figs. 499, 500).

These commence in two plexuses, viz., a large *plexus on the dorsum of the hand*, which receives the digital veins from the fingers, and is sometimes subdivided into two parts, a radial and an ulnar; and a smaller *plexus on the front*

of the wrist, which receives a few branches from the palm and the thumb. The superficial veins of the forearm communicate freely with one another.

The **Radial Vein**, commencing in the radial side of the dorsal plexus runs up the radial side of the forearm to a little above the bend of the elbow, where, on the outer side of the biceps-tendon, it joins the median cephalic vein to form the cephalic vein. On the hand it communicates with the deep veins of the palmar arch, and along its course it receives many superficial tributaries.

The **Posterior Ulnar Vein** begins in the ulnar side of the dorsal plexus, and, after communicating with the deep palmar veins, it extends upward along the dorsal aspect of the ulnar side of the forearm. Near the bend of the elbow it usually receives the anterior ulnar vein, and, just below the internal condyle of the humerus, the resulting *common ulnar vein* turns forward to join the median basilic to form the basilic vein.

The **Anterior Ulnar Vein** is smaller than the foregoing, which it joins near the bend of the elbow, except rarely when it enters the median basilic vein separately. It ascends from the wrist along the ulnar side of the front of the forearm.

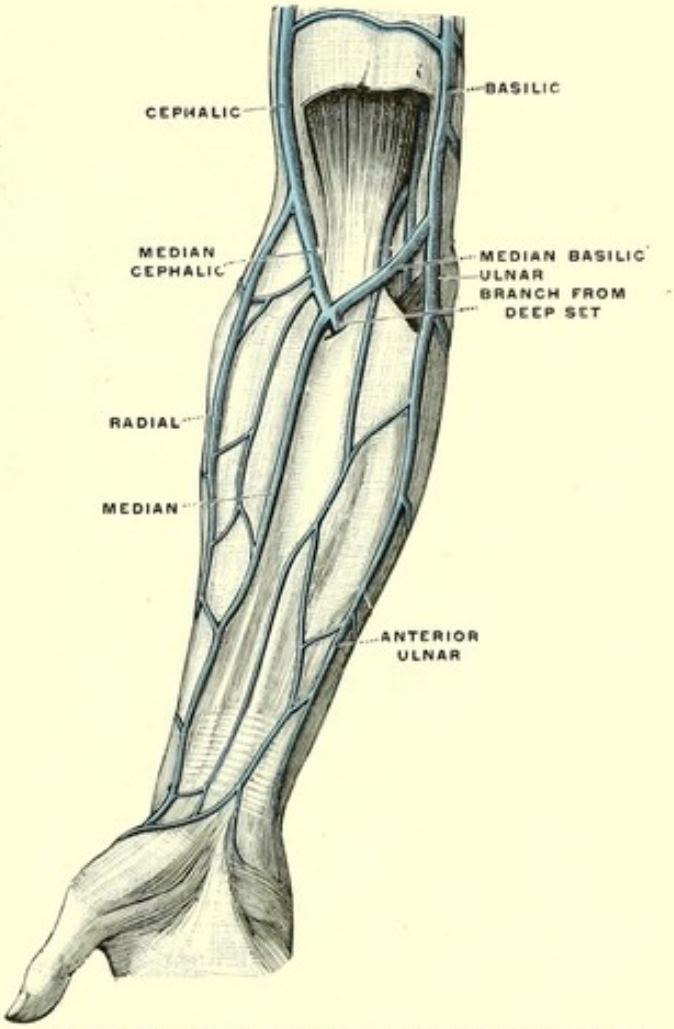

FIG. 499.—Superficial veins of front of forearm and lower part of arm. (Testut.)

The **Median Vein** ascends along the front of the forearm from the plexus on the front of the wrist to the bend of the elbow, where, after receiving the *deep median vein* from the deep set of veins, it immediately bifurcates into the median basilic and the median cephalic veins.

The **Median Basilic Vein**, the larger of the two divisions, is directed upward and inward to the groove internal to the biceps, where it forms the basilic vein by joining the common ulnar trunk or one of the ulnar veins. It crosses the brachial artery, from which it is separated by the fascial tendon of insertion of the biceps; hence in venesection, in which this vein was the one commonly chosen, on account of its size, constancy, and accessibility, the artery was sometimes punctured, leading to arterio-venous aneurism, etc. Branches of the internal cutaneous nerve cross in front of and behind it.

The **Median Cephalic Vein** runs upward and outward in the groove between the biceps and brachio-radialis muscles to form the cephalic vein, by uniting with the radial vein just above the bend of the elbow. The musculo-cutaneous nerve passes beneath it.

The **Basilic Vein** ascends in the groove, on the inner side of the biceps, a little internal to the course of the brachial artery. Perforating the deep fascia below the middle of the arm, it ends by joining the inner vena comes of the brachial artery to form the axillary vein.

The **Cephalic Vein**, the smaller of the veins of the arm, ascends in the groove external to the biceps and then in the interval between the deltoid and pectoralis major muscles to a little below the clavicle, where it perforates the costo-coracoid

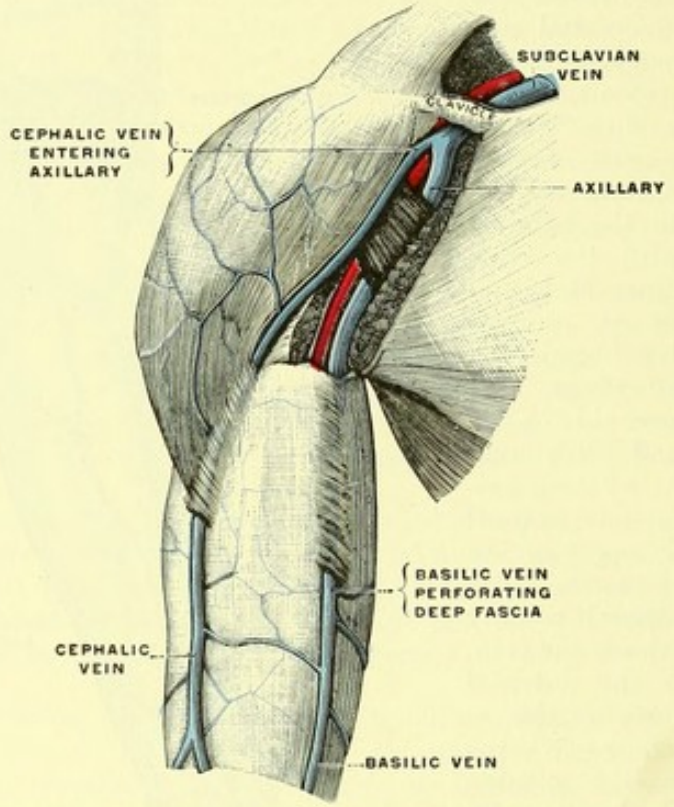

FIG. 500.—Superficial veins of front of arm and shoulder. (Testut.)

membrane, and ends in the axillary vein, after crossing the first portion of the axillary artery. Sometimes a branch, and rarely the entire vein, crosses over the clavicle to end in the external jugular vein.

The Deep Veins of the Upper Extremity.

The arteries below the axillary are accompanied by two *venæ comites* ("companion veins") with frequent cross-branches. They communicate with the superficial veins, especially in the hand and at the elbow. Near the lower border of the teres major or the subscapularis muscle, the inner brachial vena comes joins the basilic vein to form the single *Axillary Vein*. This accompanies and has the same relations as the axillary artery, lying to its inner side, and ends at the outer border of the first rib in the subclavian vein. It collects all the blood of the upper extremity, receiving the cephalic vein and the radicles which correspond to the branches of the axillary artery.

The **Subclavian Vein** continues the axillary vein from the outer border of the first rib to the sterno-clavicular articulation, where it ends in the brachio-cephalic vein. It lies in front of and at a somewhat lower level than the subclavian artery, from which it is separated by the scalenus anterior muscle and the phrenic nerve. It lies in the groove on the first rib in front of that of the artery. Close to the outer border of the sterno-mastoid muscle the external jugular vein empties into it, and just external to this point the vein is provided with a pair of valves.

The Veins of the Thoracic Wall.

The **Internal Mammary Veins** accompany each internal mammary artery and its branches in anastomosing pairs, which unite into a single trunk a short distance below their termination in the lower part of the brachio-cephalic vein.

The Superior Intercostal Veins.—The veins from the two to four intercostal spaces below the first join together to form a short trunk, which on the *right side* descends to empty into the upper part of the great azygos vein, and on the *left side* ascends across the arch of the aorta to empty into the left brachio-cephalic vein. The left superior intercostal vein communicates inferiorly with the left upper azygos vein, and sometimes receives the left bronchial vein. It is often connected with the oblique vein of Marshall by a fibrous cord, traceable through the vestigial fold of the pericardium and representing the left duct of Cuvier. The veins of the upper intercostal space, or sometimes the upper two intercostal spaces, ascend to join the vertebral or brachio-cephalic vein of the corresponding side.

The Azygos Veins (Fig. 501).

The **Azygos Veins**, developed from the primitive cardinal veins, form an anastomosis between the inferior and superior venæ cavæ, which is of importance in obstruction of the inferior vena cava. They receive the venous blood of most of the dorsal and lateral thoracic walls. The azygos veins are three in number, and lie on the sides of the front of the vertebral bodies.

The **Right or Great Azygos Vein** (*vena azygos major*) commences in the abdomen as an upward continuation of the ascending lumbar vein, which communicates with the common iliac vein, and is often connected with the inferior vena cava and the renal vein. It ascends through the aortic opening of the diaphragm on the right of the aorta and the thoracic duct, in which position it continues upward in the posterior mediastinum in front of the right intercostal arteries, grooving the dorsal border of the right pleura. Opposite the lower end of the fourth thoracic vertebra it bends forward over the root of the right lung, to empty into the superior vena cava at a point just above where the latter pierces the pericardium.

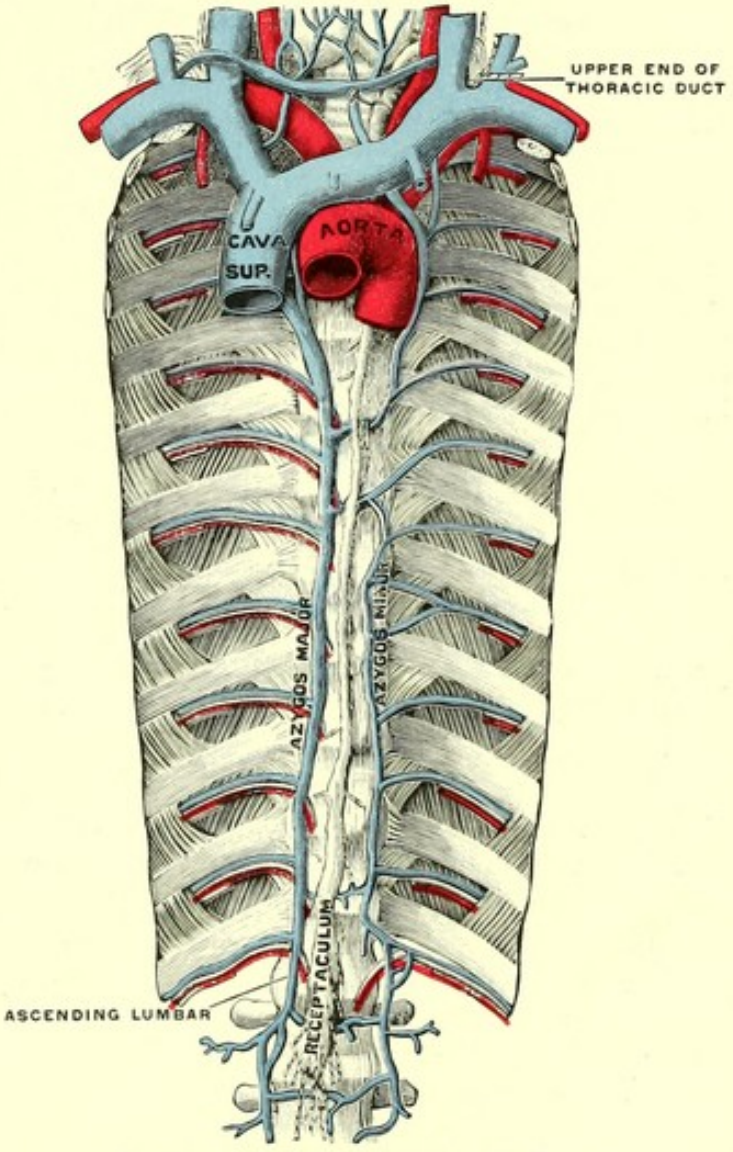

FIG. 501.—Azygos and intercostal veins. (Testut.)

Tributaries.—It recieves (1) the right subcostal vein; (2) the seven or eight lower right intercostal veins; (3) the right superior intercostal vein; (4) the right bronchial veins; (5, 6) the left lower and the left upper azygos veins, and some small (7) œsophageal; (8) pericardial; and (9) mediastinal veins.

The **Left Lower** or **Small Azygos Vein** (*vena hemiazygos, vena azygos minor*) commences in the abdomen on the left side, in a manner similar to the great azygos on the right side, the branch from the renal vein being more constant, and sometimes the principal source. It ascends through the left crus of the diaphragm, and in the posterior mediastinum it lies in front of the left intercostal arteries as far as the eighth thoracic vertebra, where it crosses beneath the thoracic aorta and thoracic duct to join the great azygos vein.

Tributaries.—It receives (1) the left subcostal vein below the diaphragm; and above it (2) the lower four left intercostal veins; (3) the left upper azygos (sometimes); and some small (4) œsophageal; and (5) mediastinal veins.

The **Left Upper Azygos Vein** (*vena hemiazygos accessoria*) varies in size with that of the left superior intercostal and the left lower azygos veins, between which it is placed, receiving two or three intercostal veins. It connects above with the superior intercostal vein, and opens below into the left lower azygos vein, or, crossing the sixth or seventh thoracic vertebra, ends in the great azygos vein. It often receives the left bronchial vein. It is quite variable and often absent, when its radicles, the fifth, sixth, and seventh intercostal veins, open directly into the great azygos vein.

The **Intercostal Veins** accompany the arteries as a single trunk, lying above them. They receive large dorsal branches from the muscles of the back, the dorsal spinal plexus, and the spinal canal. They are eleven in number, one for each intercostal space, the lowest thoracic vein being called the *subcostal vein*, from its position. They terminate variously in different subjects and on the two sides. (See azygos, superior intercostal, and vertebral veins.)

The **Bronchial Veins** accompany the bronchial arteries, only part of whose blood they return, that distributed to the smaller bronchi entering the pulmonary veins. They pass out at the back of the root of the lung, and enter the upper end of the vena azygos major on the right side, and the left upper azygos or the left superior intercostal vein on the left side.

Veins of the Spine (Figs. 502, 503).

These form complicated plexuses, situated without and within the spinal canal and on the spinal cord, which communicate with one another and with the veins of the neck and trunk. They contain no valves and may be described in groups as follows:

I. **Extra-spinal Veins.**—The *Dorsal Spinal Veins* form a plexus over the laminæ and adjacent processes of the vertebræ, where they receive tributaries from the skin and muscles of the back, the larger of which run forward along the interspinous ligaments. They communicate with the posterior longitudinal spinal veins by branches perforating the ligamenta subflava, and open laterally into the vertebral or the dorsal branches of the intercostal and lumbar veins, according to the region, by branches passing forward between the transverse processes.

II. The **Veins of the Vertebral Bodies** (*venæ basis vertebrarum*) occupy horizontal bony channels in the vertebral bodies and communicate with the veins in front of and at the sides of them. They open behind, through the large single or double foramen on the dorsal surface of the bodies of the vertebræ, into the transverse connecting branches of the anterior longitudinal spinal veins.

III. **Intra-spinal Veins.**—(A) The *Meningo-rachidian Veins* are those within the spinal canal between the dura and the walls of the canal.

The *Anterior Longitudinal Spinal Veins*, large and plexiform, extend the entire length of the spinal canal behind the bodies of the vertebræ, one on either side of the posterior common ligament. Opposite the bodies of the vertebræ they are dilated and communicate with each other by transverse trunks, placed between the posterior common ligament and the body of each vertebra, which receive the veins of the vertebral bodies. Opposite the intervertebral discs they

are constricted, and send lateral branches through the intervertebral foramina to join the vertebral, intercostal, lumbar, or sacral veins according to the region. They communicate with the basilar plexus above, and with the posterior spinal veins throughout the spinal canal. Together with the posterior spinal veins and the marginal part of the occipital sinus they form a venous ring around the foramen magnum.

The *Posterior Longitudinal Spinal Veins*, smaller than the foregoing, are situated one on each side at the back of the spinal canal, and extend throughout

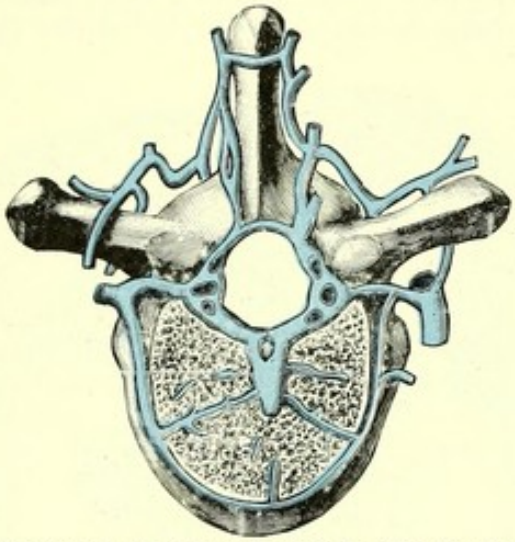

FIG. 502.—Veins of the spine, seen in a transverse horizontal section of a thoracic vertebra. (Testut.)

its entire length. They communicate with one another, by frequent transverse branches in front of the vertebral arches, with the dorsal spinal veins through the ligamenta subflava, with the anterior spinal veins by lateral branches, and above with the occipital sinus. Lateral branches also pass out through the intervertebral foramina to join those from the anterior spinal veins.

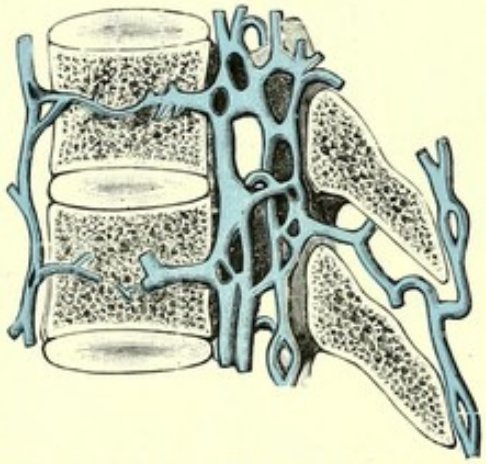

FIG. 503.—Veins of the spine, seen in a sagittal section of two thoracic vertebræ. (Testut.)

(B) The *Veins of the Spinal Cord*, of small size, run tortuously in the pia of the cord, and are disposed in longitudinal trunks over the median fissures and laterally, with plexiform communications between. Branches accompany the nerve-roots to the intervertebral foramina, where they join the lateral branches from the veins of the spinal canal. Above they join the veins of the pons and cerebellum.

The principal blood-current through the veins of the spine is probably in a horizontal direction in the venous rings, formed by the communications between

the anterior and posterior veins, which send lateral branches through the intervertebral foramina.

THE INFERIOR VENA CAVA AND ITS TRIBUTARIES.

The Veins of the Abdomen (Fig. 504).

The **Inferior** or **Ascending Vena Cava** returns to the heart the blood from the lower extremities, the pelvis, and the abdomen, except that returned by the azygos and superior epigastric veins. It is a large vessel, which is formed by the union of the two common iliac veins in front of the right upper segment of

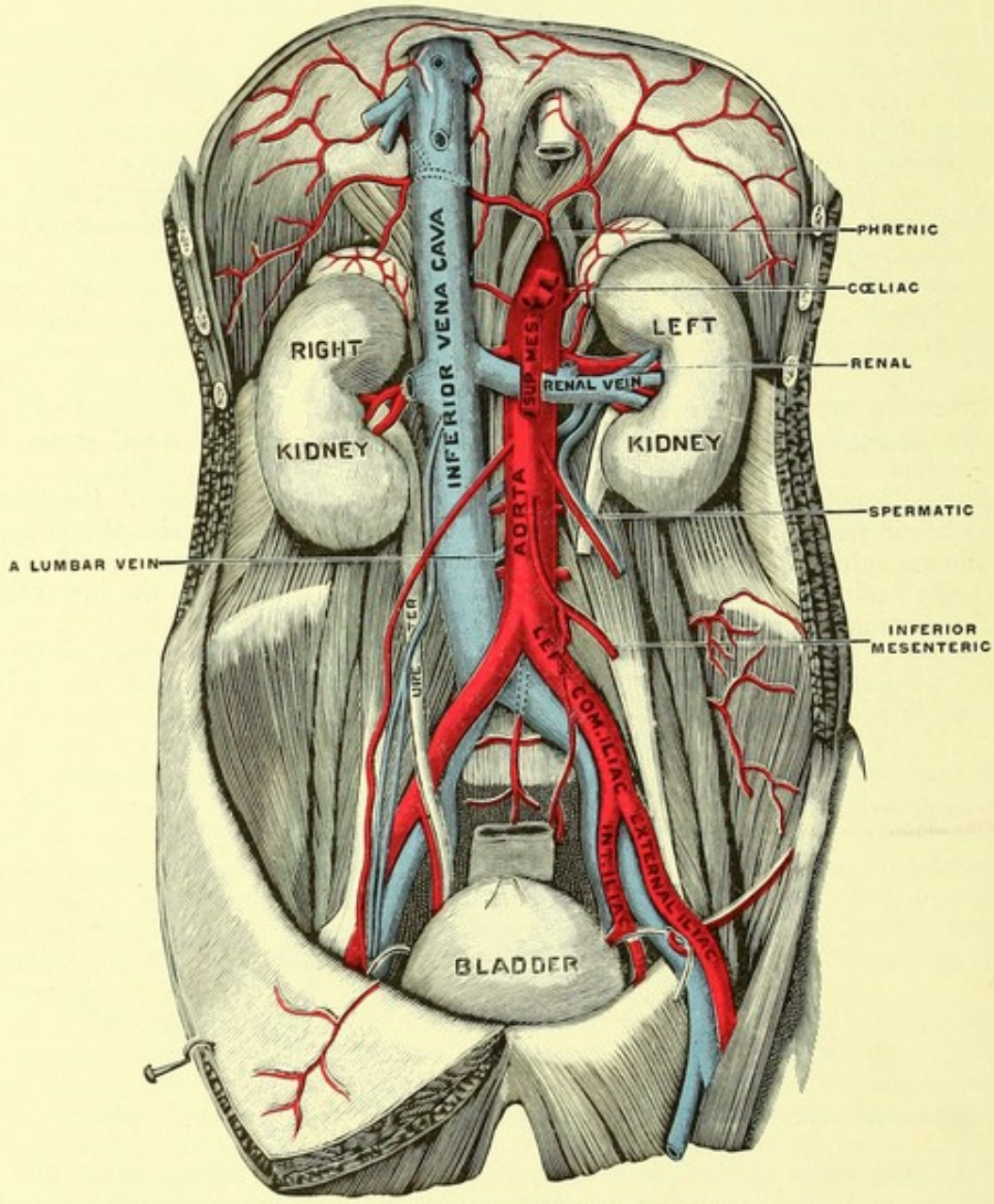

Fig. 504.—Inferior vena cava and its tributaries.

the fifth lumbar vertebra. Thence it runs upward to the right of the aorta, from which it is separated above by the right crus of the diaphragm and the lobus Spigelii of the liver as it inclines forward and lies in the groove or canal on the dorsal surface of the liver. On passing through the caval opening in the central tendon of the diaphragm, to the margins of which it is attached, it immediately

enters the pericardium, through which it passes for about half an inch, only partly invested by its serous layer, to open into the lower and back part of the right auricle, opposite the upper border of the ninth thoracic vertebra. In the abdomen the liver, pancreas, duodenum, mesentery, portal vein, and right spermatic (or ovarian) artery, lie in front of it; the vertebræ, right renal and lumbar arteries, and the right crus of the diaphragm, behind it.

Tributaries.—The *hepatic veins* converge from the substance of the liver to the groove or canal occupied by the inferior vena cava, into which they empty in two or three trunks. The veins from the right and left lobes open so obliquely that the semilunar folds, presented at the lower border of their orifices, take the place of valves, which are otherwise wanting. These veins are of large size, and return the blood of the hepatic artery and the portal vein.

The *phrenic* (or *inferior phrenic*) *veins* accompany the phrenic arteries. The right one opens directly into the vena cava just below the diaphragm, on the right side, while the left often joins the left suprarenal, or sometimes the left renal vein.

The *suprarenal veins.*—One vein on each side returns all the blood supplied by the three suprarenal arteries. The right vein terminates in the vena cava, the left in the left renal or phrenic vein.

The *renal veins* are large, short trunks, which run in front of the corresponding arteries from the hilum of the kidney to the vena cava, into which they empty nearly at right angles, the left a little above the right. The left renal vein is larger than the right, has to cross the aorta, which it does just below the origin of the superior mesenteric artery, after receiving the spermatic (or ovarian) vein, often the suprarenal vein, and sometimes the phrenic vein of the same side. Rudimentary valves are found, especially on the left side. The shortness of the right renal vein should be remembered when dealing with the pedicle in nephrectomy.

The *spermatic veins* (Fig. 505) return the blood from the testicle and epididymis, from which they emerge dorsally, and, ascending to and through the inguinal canal, form a thick plexus (*pampiniform* ("tendril-shaped") *plexus*) in front of the vas deferens and the spermatic artery. On entering the abdomen through the internal abdominal ring the plexus merges into two or three veins, which accompany the spermatic artery beneath the peritoneum, on the psoas muscle and across the ureter. In their course they join to form a single trunk, which opens into the vena cava on the right side, and on the left side into the renal vein, which it meets at a right angle. Imperfect valves are found in the pampiniform plexuses, but the valve described at the termination of the vein may be absent in the vein of the left side, which moreover is usually slightly longer than the right vein and passes beneath the sigmoid colon, where it may be subjected to pressure.

The above differences combined are held to account for the greater frequency of varicocele on the left side. A few small veins ascend from the testicle behind the spermatic artery and the vas deferens and join the epigastric veins above. They are commonly not ligated in the operation for varicocele.

The *ovarian veins* are analogous to the spermatic veins and terminate in the same manner. The *ovarian* or *pampiniform plexus*, in which they begin, lies near the ovary between the layers of the broad ligament, and communicates freely with the uterine plexus, as well as with the *ovarian bulb*, a plexus of fine veins at the hilum of the ovary. They follow the course of the ovarian arteries.

The *lumbar veins*, usually four in number on each side, accompany the lumbar arteries. They are formed by the union of ventral branches from the abdominal walls, where they communicate with the epigastric and internal mammary veins, and dorsal branches, which receive tributaries from the muscles of the back and the veins of the spine. The lumbar veins pass forward upon the bodies of the vertebræ beneath the psoas muscle, and on the left side beneath the aorta, to empty into the back of the vena cava. In front of the transverse processes and

behind the psoas muscle the lumbar veins of each side are connected by continuous vertical branches, called the *ascending lumbar vein*, which communicates below with the ilio-lumbar, common iliac, and lateral sacral veins, and is usually continued above as the azygos vein of the corresponding side.

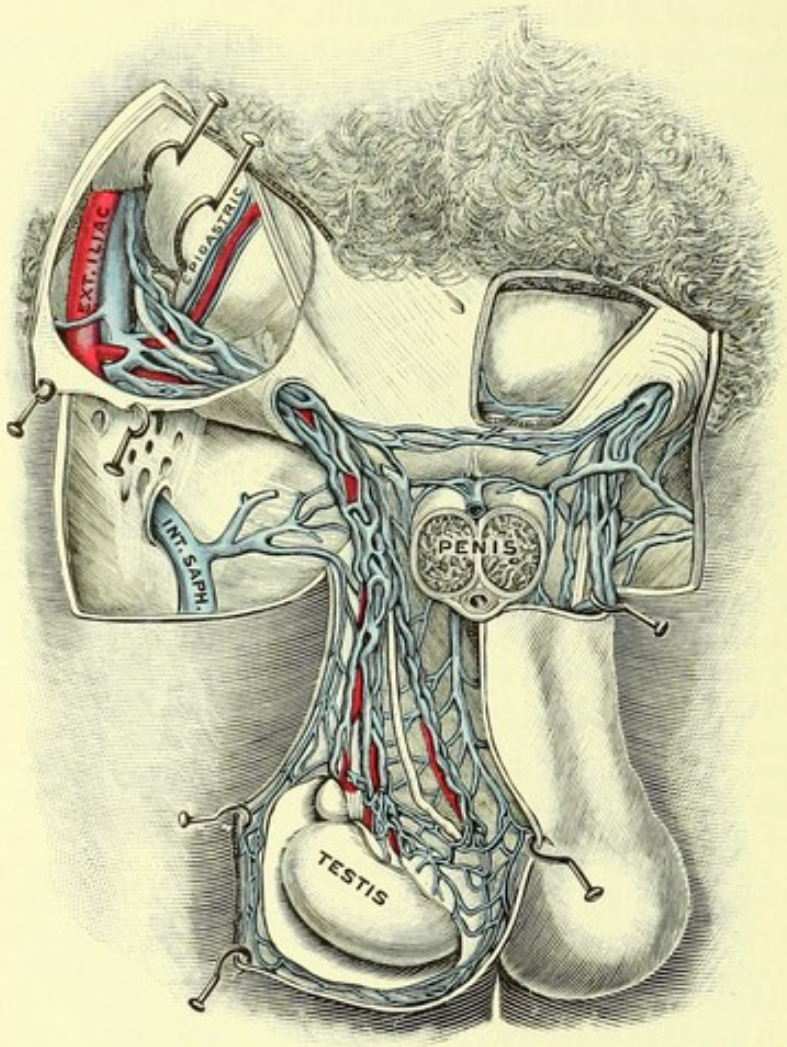

FIG. 505.—Spermatic veins. (Testut.)

The Common Iliac Veins.

The *Common Iliac Veins*, formed opposite the sacro-iliac articulations by the confluence of the internal and the external iliac veins, converge as they ascend, and unite opposite the right upper segment of the fifth lumbar vertebra to form the inferior vena cava. The *right vein*, shorter and more vertical than the left, lies behind and internal to its artery below, but above crosses obliquely behind it to its outer or right side, where it is joined by the *left vein*. The latter lies internal to the left common iliac artery and then crosses behind the upper end of the right artery to join the right vein. They contain no valves, except an occasional one in the left vein.

Tributaries.—The *ilio-lumbar veins* follow the ilio-lumbar arteries, and enter the common or internal iliac veins. They resemble the lumbar veins in their course, formation, and connections. The *middle sacral veins*, one on each side of the artery of the same name, ascend on the front of the sacrum to open into the left common iliac vein, after uniting into a single trunk. Occasionally this trunk enters the angle of junction of the two common iliac veins. These veins anastomose with the lateral sacral and the hemorrhoidal veins.

The External Iliac Vein (Fig. 506).

This is the continuation of the femoral vein, and extends from the level of the inguinal (Poupart's) ligament to the sacro-iliac articulation, where it joins the internal iliac vein. While it is internal to the artery on both sides below, on the

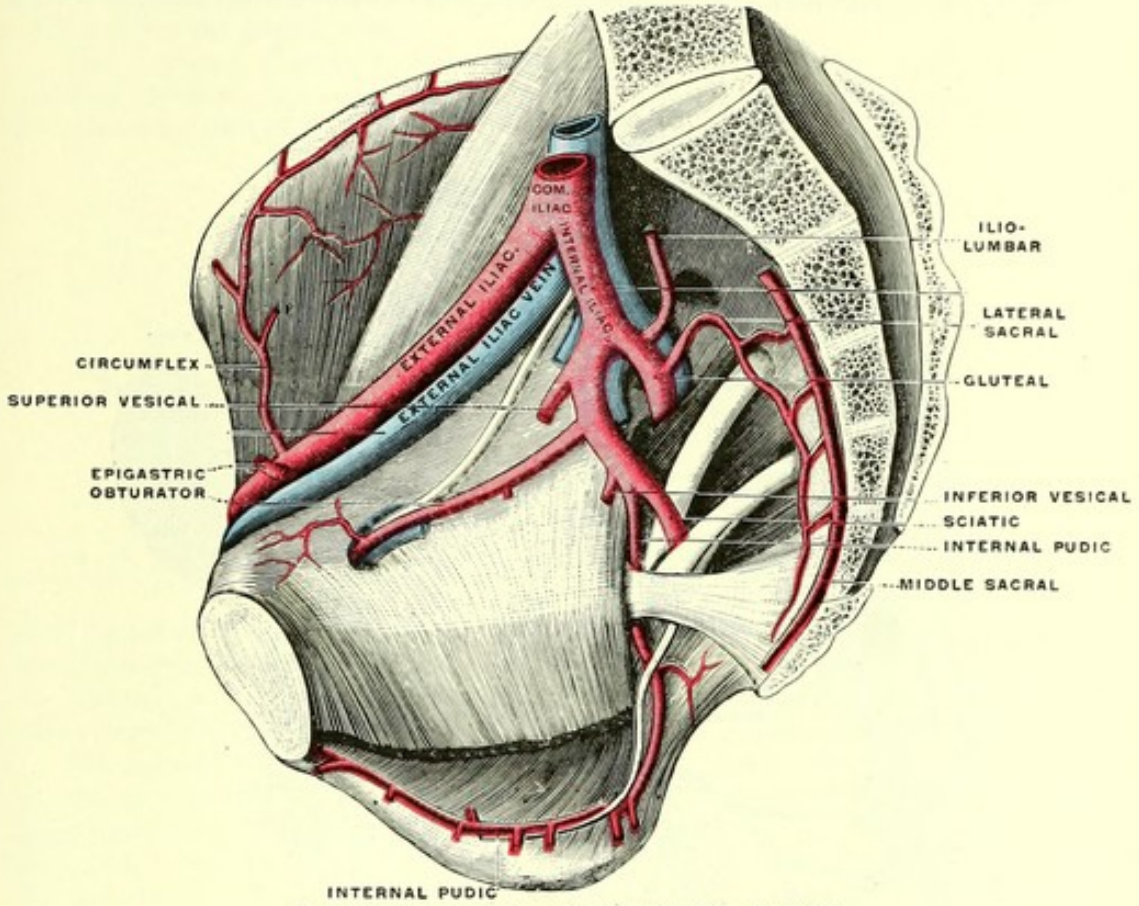

FIG. 506.—External iliac vein of right side. (Testut.)

right side above it inclines behind it. It contains one or two valves, and just above the inguinal ligament it receives the deep epigastric and the deep circumflex iliac veins, which accompany the corresponding arteries. A pubic vein, corresponding to the pubic branch of the obturator artery, ascends from the obturator vein to join the external iliac vein, and sometimes forms the main outlet of the obturator vein.

The Portal System of Veins (Fig. 507).

These are distinguished from other veins by beginning and ending in capillaries. The portal vein collects the blood from the chylopoiëtic viscera (the stomach, intestines, and pancreas), as well as from the spleen and the gall-bladder, and conveys it to the liver, to the capillaries of which it is distributed to be collected, together with the blood from the hepatic artery, by the hepatic veins, and so carried to the vena cava. The veins of this system have no valves.

The **Portal Vein** (*vena porta*) (Fig. 508) is formed by the union of the splenic and the superior mesenteric veins, behind the upper end of the head of the pancreas, in front of the vena cava, and opposite the right side of the body of the first lumbar vertebra. From this point it runs upward and somewhat to the right for about three inches, to near the right end of the transverse fissure of the liver. Here it is somewhat enlarged (*sinus of the portal vein*), and divides into right and left branches, which enter their respective lobes and divide into

branches, in company with the hepatic artery and the hepatic duct. In its upward course it passes behind the first part of the duodenum, and then between the two layers of the right border of the small omentum, where it lies behind and between the hepatic artery on the left, and the common bile-duct on the right, and in front of the foramen of Winslow. These three structures, with the accompanying nerves and lymphatics, are enclosed by a connective-tissue sheath

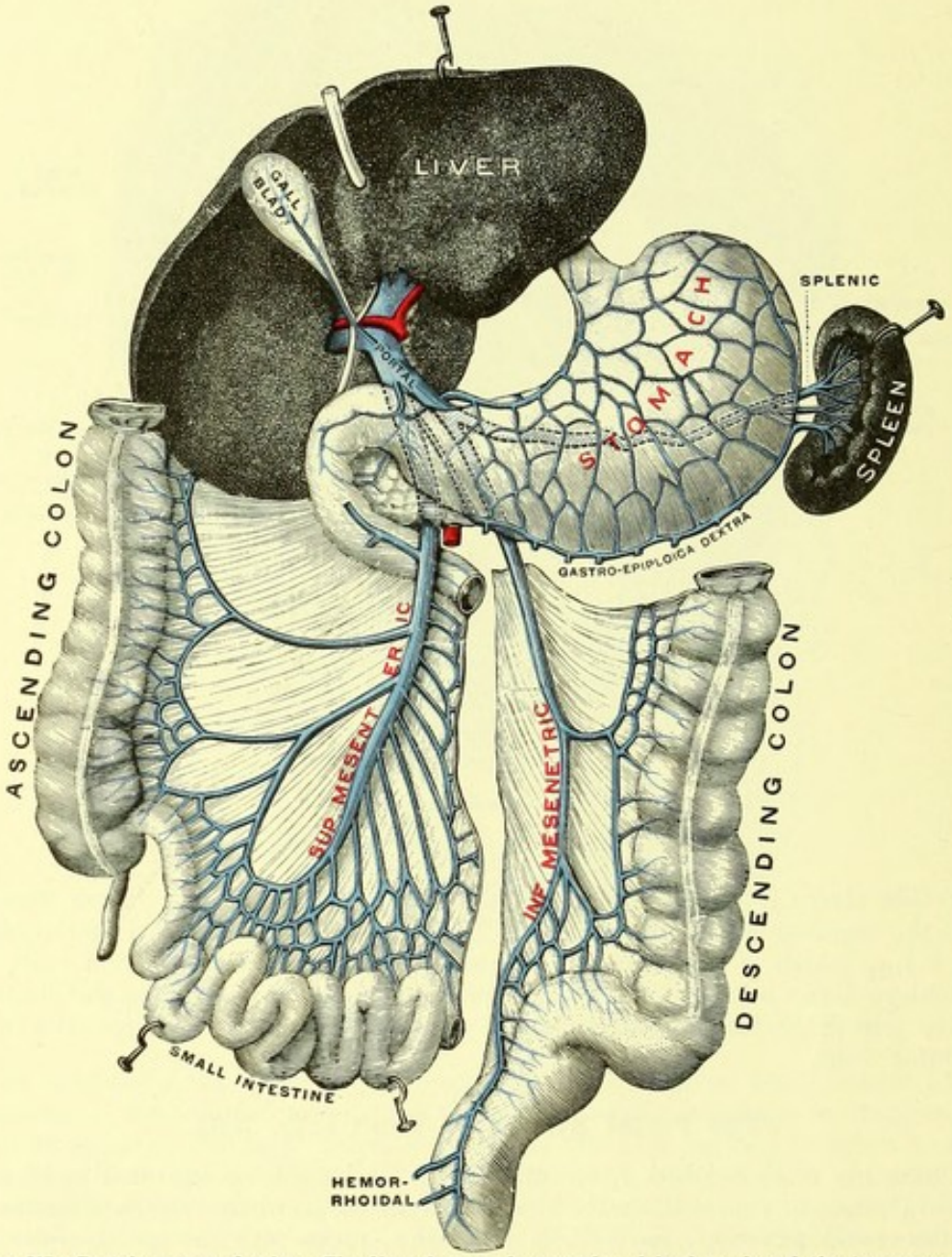

FIG. 507.—Portal system of veins. The liver is turned upward and backward, and the transverse colon and most of the small intestines are removed. (Testut.)

called the capsule of Glisson. The *left branch* is longer and smaller than the right, and where it crosses the umbilical fissure it is joined in front by the round ligament, the remains of the fœtal umbilical vein, and behind by another fibrous cord, the remains of the ductus venosus.

Tributaries.—Besides the superior mesenteric and the splenic veins, which by their union form the portal vein, the latter receives the pyloric and coronary veins from the stomach, and sometimes the cystic vein, which usually runs into the right branch.

The *Superior Mesenteric Vein* accompanies the corresponding artery, lying to the right and in front of it, and returns the blood from the parts supplied by it (the small intestine, cæcum, ascending and transverse colon) by branches corresponding to those of the artery. It passes upward between the layers of the mesentery, and then in front of the third part of the duodenum and behind the pancreas, where, after receiving the right gastro-epiploïc vein, it joins the splenic vein to form the portal vein.

The *Inferior Mesenteric Vein* returns the blood from the rest of the large intestine (rectum, sigmoid flexure, and descending colon). Commencing in the hemorrhoidal plexus of the lower end of the rectum, where it freely anastomoses

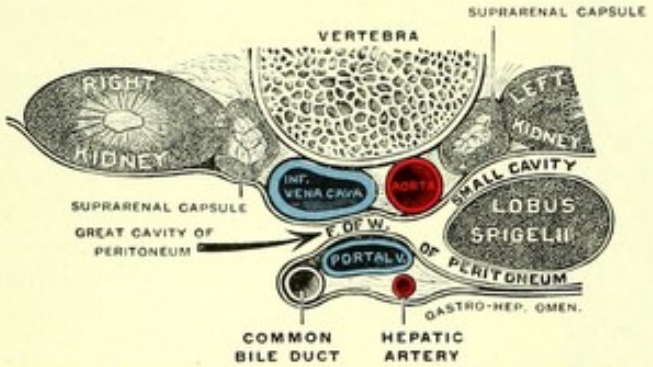

FIG. 508.—Transverse horizontal section through the foramen of Winslow, showing the relations of the portal vein. (Testut.)

with branches of the internal iliac vein, it passes up and out of the pelvis to the left of the inferior mesenteric artery. Above the origin of the latter it ascends, behind the peritoneum on the left side of the aorta, to the deep surface of the pancreas, where, inclining to the right, it joins the splenic vein near its termination.

The *Splenic Vein* is a vessel of large size, which passes from left to right below its companion artery, behind the pancreas. It commences by the union of several large branches from the hilum of the spleen, and ends, after crossing in front of the aorta, by joining the superior mesenteric vein, nearly at a right angle, to form the portal vein. It receives branches corresponding to those of the artery, and, in addition, the inferior mesenteric vein.

The *Pyloric Vein* is a small vessel which runs along the small curvature of the stomach from left to right in company with the (superior) pyloric artery. It opens into the lower part of the vena portæ.

The *Coronary* or *Gastric Vein* is a larger vessel, which accompanies the artery of the same name along the small curvature of the stomach from right to left. Near the cardiac orifice of the stomach it receives œsophageal branches and turns to the right across the spine, to end in the portal vein a little above the foregoing.

The Veins of the Pelvis.

The **Internal Iliac Veins** are short trunks without valves, which lie behind and to the inner side of the internal iliac arteries. They extend from the upper part of the great sacro-sciatic foramina to the sacro-iliac articulations, where they join the external iliac to form the common iliac veins. Each is formed by the union of veins corresponding to the branches of the internal iliac artery, excepting the ilio-lumbar vein, which opens into the common iliac vein, and the fœtal umbilical veins, which connect with the left branch of the portal vein.

The *Tributaries* correspond to the branches of the artery, except that the pudic vein does not begin in the dorsal vein of the penis, but in the veins of the corpus cavernosum.

The visceral veins are characterized by their large size, the number of their valves, and their frequent anastomoses, by which several connected plexuses are formed—*i. e., prostatic, vesical, vaginal, uterine,* and *hemorrhoidal.*

The *Lateral Sacral Veins.*—These parietal tributaries also form a plexus, the *sacral plexus*, over the front of the sacrum, by anastomoses with one another and with the middle sacral veins. This plexus communicates with the veins of the spine through the anterior sacral foramina.

The *Dorsal Vein of the Penis* (Fig. 509), beginning in a plexiform circle of veins around the corona glandis, passes backward in the median dorsal groove of the penis, between the two dorsal arteries. At the root of the penis it continues backward through the suspensory ligament, and then through the triangular ligament, whereupon it divides into two lateral branches, which enter the prostatic plexus. It receives branches from the substance and surface of the penis. In front of the triangular ligament it communicates with the internal pudic veins. The dorsal vein may commence as two lateral branches in front, which unite at a variable distance from the root of the penis.

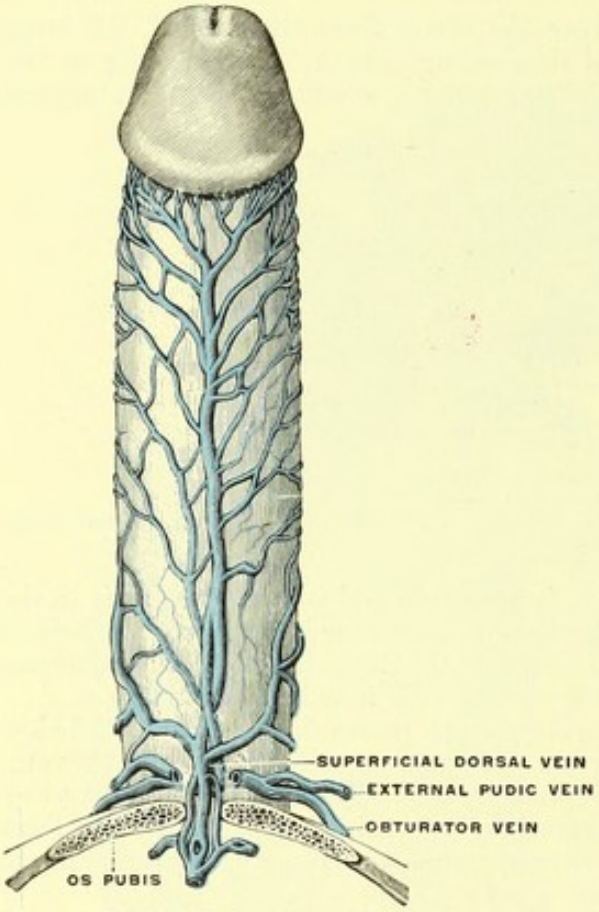

FIG. 509.—Veins of the penis. (Testut.)

The *Gluteal*, *Sciatic*, *Obturator*, and *Internal Pudic Veins*, save for the exception above noted in the case of the internal pudic vein, correspond with the arteries and arterial branches which they accompany.

The *Prostatic Plexus* surrounds the prostate, especially at its base, sides, and in front, and lies beneath the sheath derived from the recto-vesical fascia. Besides the veins of the prostate it receives the dorsal vein of the penis in front, and communicates with the vesical and hemorrhoidal plexuses. It is frequently much enlarged and varicose in old men, and often contains phleboliths or vein stones.

The *Vesical Plexus* surrounds the bladder beneath its peritoneal coat. It is particularly developed at the base and neck of the organ, where it communicates with the hemorrhoidal plexus, and with the prostatic plexus in the male, the vaginal plexus in the female. The prostatic and vesical plexuses open into the internal iliac veins by vessels passing from their lateral aspect. An abundant plexus of veins is often met with on the anterior surface of the bladder on opening that organ by the suprapubic incision.

The *Vaginal Plexus* surrounds the lower part of the vagina, and communicates with the vesical and hemorrhoidal plexuses and with the veins of the uterus.

The *Uterine Plexus* empties in part through the ovarian veins, and in part through the veins which accompany the uterine arteries. It is much enlarged during pregnancy.

The *Hemorrhoidal Plexus* lies beneath the mucous membrane of the lower part of the rectum. It communicates with the plexuses in front of it, and empties through the superior, middle and inferior hemorrhoidal veins, which accompany the arteries of the same name.

As the superior hemorrhoidal vein is a tributary of the portal system through the inferior mesenteric vein, and the other hemorrhoidal veins enter the internal iliac vein, a free anastomosis is thus established between the two

through this plexus. The veins of this plexus have no valves; hence the frequency of hemorrhoids from obstruction of the portal circulation in the liver.

VEINS OF THE LOWER EXTREMITY.

These, like the veins of the upper extremity, are divided into two sets, superficial and deep.

Superficial Veins of the Lower Extremity (Figs. 510–512).

These consist of two main trunks, internal and external, which commence in an arched plexus over the instep and on the dorsum of the foot, called the *dorsal plexus.*

The **Dorsal Plexus** receives the *dorsal digital veins* and branches from the small but numerous plexiform veins of the sole, which pass up behind the clefts of the toes and around the outer and inner borders of the foot. The veins are provided with numerous valves.

The **Internal** or **Long Saphenous Vein** commences at the inner part of the dorsal plexus, where it receives a vein of large size from the inner side of the great toe, and ends in the femoral vein an inch and a half below the inguinal ligament, after perforating the fascia lata of the saphenous opening. In its course it ascends in front of the internal malleolus, along the inner side of the leg, with the internal saphenous nerve, then behind the internal condyle of the femur, and finally upward and somewhat outward on the inner and forepart of the thigh. It is joined by various superficial tributaries along its course, by communicating branches from the deep veins of the sole, leg, and thigh, and, just below its termination, by the *superficial circumflex iliac*, *superficial epigastric*, and *external pudic veins*, which accompany the arteries of the same name, and also in many cases by a large anterior branch, which ascends over the front of the thigh. This vein contains from seven to twenty valves, more numerous in the thigh than in the leg.

The **External** or **Short Saphenous Vein**, commencing at the outer part of the dorsal plexus, ascends behind the external malleolus and then on the outer and back part of the leg, with the external saphenous nerve, to the lower part of the popliteal space, where it perforates the deep fascia, and ends in the popliteal vein.

Along its course it is joined by superficial branches from the foot, the heel, and the back of the leg, and communicates with the deep veins at the ankle and in the leg. Near its termination a communicating branch usually runs upward and forward to the internal saphenous vein, and sometimes forms the main outlet of the external saphenous vein. This vein contains from nine to fourteen valves.

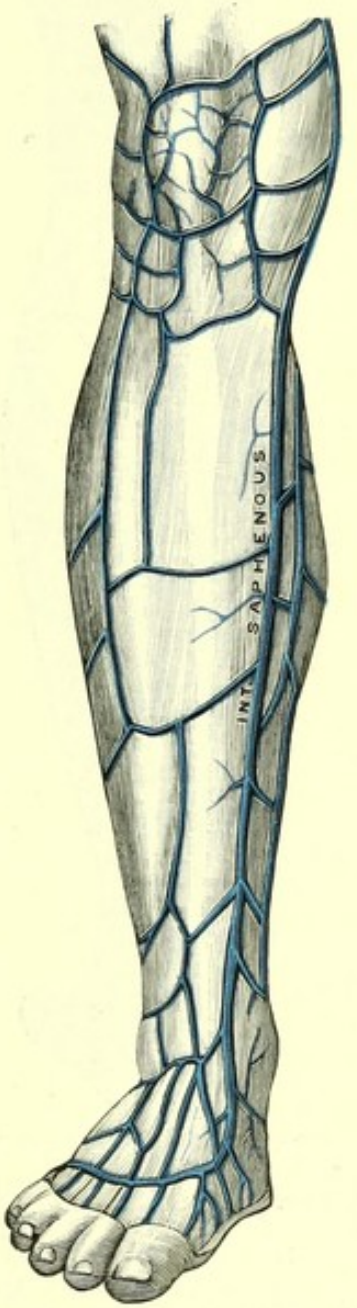

FIG. 510.—Superficial veins of the front of the leg and foot. (Testut.)

Deep Veins of the Lower Extremity.

Below the knee the deep veins accompany the respective arteries in pairs, as venæ comites.

The single **Popliteal Vein** is formed by the junction of the venæ comites of the anterior and posterior tibial arteries, near the lower border of the popliteus

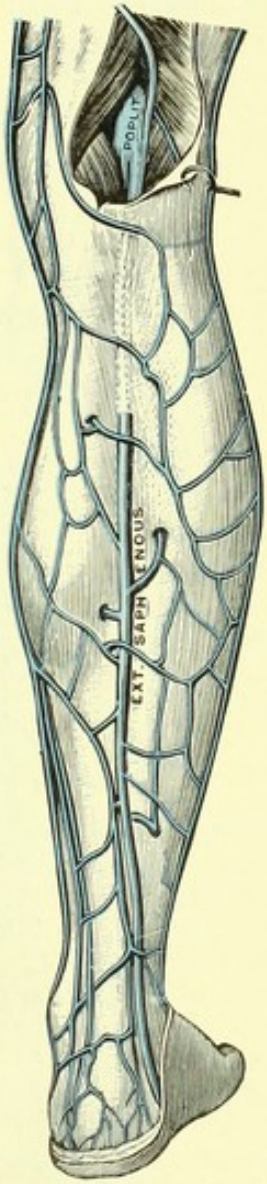

FIG. 511.—Superficial veins of the dorsum of the leg. (Testut.)

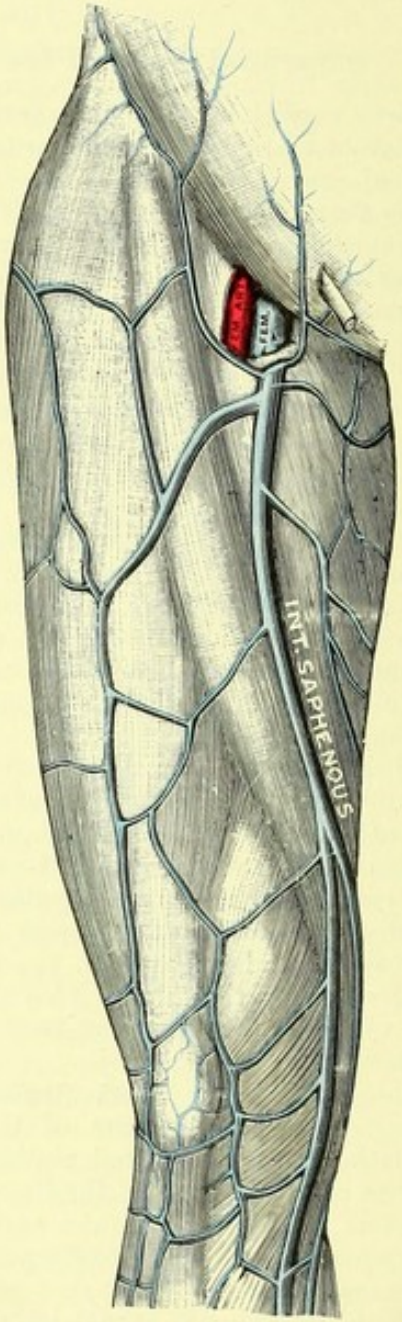

FIG. 512.—Superficial veins of the front of the right thigh. (Testut.)

muscle. This vein lies superficial to its artery throughout, internal to it below, and external to it above, after crossing it obliquely. It receives radicles corresponding to the branches of the artery, and in addition the external saphenous vein. Two or three valves are usually present. After passing with its artery through the opening in the adductor magnus, it is continued as the *Femoral Vein* up to the level of the inguinal ligament. Below, in Hunter's canal, the femoral vein lies behind and somewhat to the outer side of its artery, but, as it ascends, it

crosses obliquely behind the artery, so as to be internal to it in the upper part of Scarpa's triangle. It is joined by tributaries corresponding to the branches of the artery, including the *Deep Femoral Vein* (which ascends in front of its artery), and also, near its upper end, by the internal saphenous vein. It contains three or four valves, one of which is just above the opening of the profunda vein, and another just below the inguinal ligament. At its upper end it is separated internally from the crural canal by a thin septum of fascia, passing between the front and rear walls of the femoral sheath.

THE LYMPHATIC SYSTEM.

By F. H. GERRISH.

THE lymphatic system begins in the microscopic crevices between the cells and fibres of almost all tissues. These diminutive spaces are called "juice channels" or "juice canals," because they are the receptacles of the fluids which exude from the adjacent blood-vessels and tissues. They communicate very freely among themselves, and also with the beginnings of the capillary tubes, which are the radicles of the lymph-vessels, and into the latter they discharge their contents.

THE LYMPH-VESSELS.

The plan upon which the lymphatics are constructed is almost identical with that of the venous system. The small vessels unite and form larger, these in turn act as the radicles of others of still greater size, and after this manner the

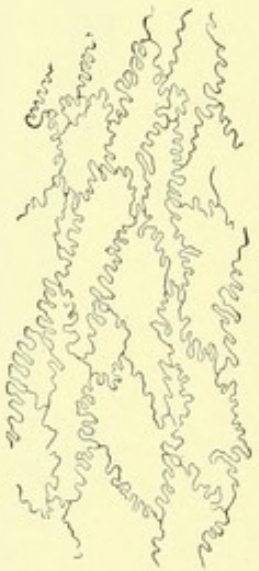

FIG. 513.—Epithelium lining lymph-vessel. (Testut.)

FIG. 514.—Lymph-vessel laid open lengthwise, showing arrangement of valves.

process continues until the largest tubes are reached. There is constant increase in size and diminution in number from the periphery to the centre of the system. But the lymphatics are much smaller than the corresponding veins. Upon the surface of the body frequent plexuses of minute vessels are found, which present an intricate and very delicate reticular appearance.

All lymph-vessels contain lymph, and those of the small intestine at certain

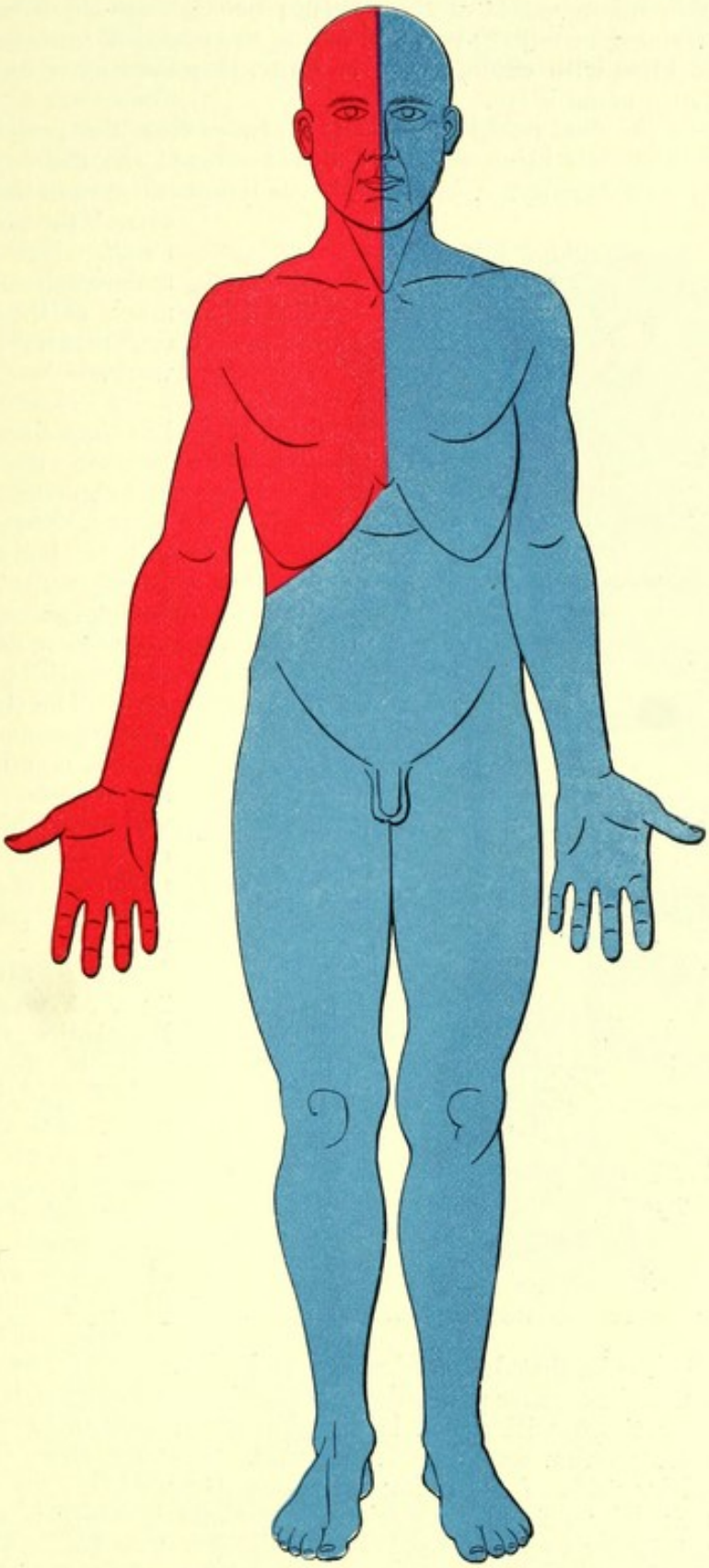

FIG. 515.—The regions whose lymph flows into the right lymphatic duct are suggested by the red area; those which are tributary to the thoracic duct by the blue. (F. H. G.)

times carry chyle also (see page 57). The chyle-bearing lymphatics do not differ structurally from other vessels of the system; but they are often called *lacteals* (literally "pertaining to milk") because, during the period of intestinal digestion, when they are filled with chyle, which is white, they look as if distended with milk, whose Latin name is *lac*.

The course of the fluid in the lymphatics is always from the periphery toward the centre, the materials being sucked up, as it were, in the distal parts of the body, and carried proximally. Consequently the lymphatic system is often spoken of as "the absorbent system." But this is an undesirable name, inasmuch as the veins, also, do considerable absorption work.

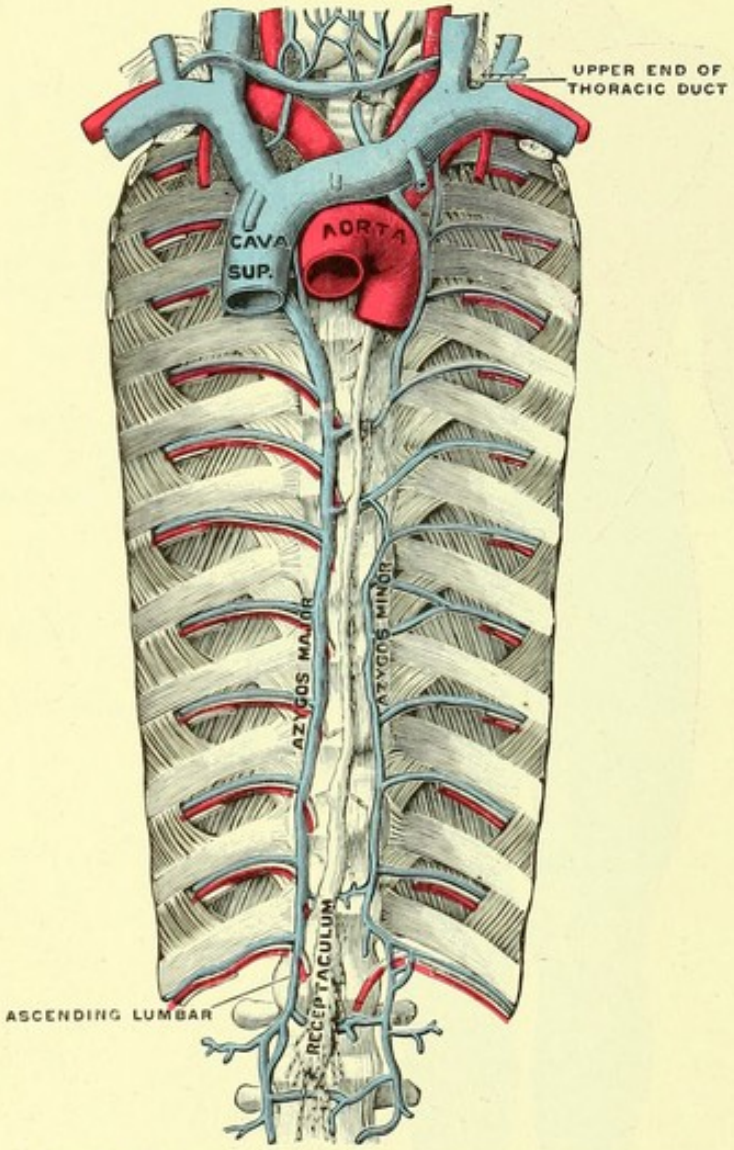

FIG. 516.—The thoracic duct and right lymphatic duct. (Testut.)

A close relationship has long been recognized between the lymphatics and the true serous membranes. These closed sacs are to be regarded as prodigiously expanded lymph-spaces, and are sometimes and appropriately called *lymph-chambers*. The true stomata of these serous membranes are the mouths of lymphatic vessels. The recognition of this continuity of lymphatic and serous surfaces is of great physiologic and pathologic importance.

The Structure of Lymph-vessels.—The lymphatics resemble the veins in their structure, as well as in their arrangement. The smallest have but a single coat, composed of epithelial cells with notched edges, which fit accurately with those of the adjacent cells (Fig. 513). The larger vessels have three tunics: an inner one of epithelium (like that described above) and a little yellow fibrous tissue; a middle, made up of muscular and yellow fibrous tissues; and an outer, consisting of white fibrous tissue, with which is mixed a small amount of yellow. All of the coats are so thin as to be transparent. At very short intervals are valves, formed by folds of the lining membrane (Fig. 514). The position of a valve is marked by a circular constriction, proximal to which is a pronounced bulge; and in this way a peculiar beaded or moniliform ("necklace-like") appearance is produced. The valves prevent backward flow of the lymph.

The lymphatics are divided into two sets, the superficial and the deep, according to their situation. *The superficial lymph-vessels* course in the subcutaneous areolar tissue. In the limbs they are more abundant upon the inner and flexor

aspects than upon the outer and extensor. They are especially numerous at the junction of the skin with mucous membrane. *The deep lymph-vessels* accompany the blood-vessels. There is free communication between the vessels of the same set; but there is no connection between the superficial and deep, except as they empty into the same nodes.

Ultimately the lymphatics end in veins; and thus the lymphatic system is seen to be an adjunct to the blood-vascular system. The lymph mingles with the venous blood, and the leucocytes, which were lymph-corpuscles a moment ago, are colorless blood-corpuscles now.

There are two points at which the lymph is poured into the blood, one on each side, where the internal jugular and subclavian veins unite to form the brachio-cephalic (Fig. 516). On the right side the vessel, called the *right lymphatic duct*, is an inch or less in length, and receives the lymph from the right side of the head, neck, and chest, the right lung, the right heart, the right upper limb, and the upper surface of the liver. A double valve guards its proximal opening. On the left side the vessel, called the *left lymphatic duct*, or, more commonly, the *thoracic duct*, is a large trunk, which has its tributaries in all portions of the body not just enumerated. The parts drained by each are suggested with practical accuracy by a glance at Fig. 515. The thoracic duct begins in a pear-shaped dilatation, called the *receptaculum chyli*, situated in front of the second lumbar vertebra. It runs upward at the right of the aorta to the level of the fourth thoracic vertebra, where it passes behind that great vessel and the left subclavian artery, and then arches outward and downward to its termination. It is as large as a goose-quill, and from fifteen to eighteen inches long. It has numerous valves, a double one standing at its junction with the venous system.

LYMPH-NODES

AND OTHER LYMPHADENOID STRUCTURES.

Besides the lymph-vessels, which have just been described, the lymphatic system comprises a large amount of a compound tissue, known as *lymphadenoid tissue*. The framework of this material is adenoid reticular tissue (see page 50), and in its meshes are irregular masses of leucocytes. This lymphadenoid tissue exists in several forms, which differ from each other mainly in the degree of their compactness, some being firm, well-defined, and encapsuled, others extremely diffuse, and still others presenting various stages intermediate to these.

Sometimes, as in the mucous membrane of the intestines, the peculiar material is infiltrated, has no clearly defined boundaries, and hence is called *diffuse lymph-adenoid tissue*. It is a mere network of adenoid reticular tissue enclosing colorless corpuscles. A step beyond this condition occur small masses in the submucous or subserous membrane, distinctly defined, and encircled by a series of lymph-vessels. A typical example of this class is seen in the so-called *solitary glands* of the intestine. When a number of such bodies are grouped into a coherent mass, the resulting structure is known as an *agminated gland*. Somewhat more distinct aggregations of lymphadenoid tissue, encased in a well-marked capsule, are frequently found located in small depressions in mucous membrane, illustrations of which are seen in the tongue, the tonsils, and the pharynx.

The most sharply defined collections of lymphadenoid tissue are the *lymph-nodes*—commonly, but less appropriately, called lymphatic glands. They are not, as are the varieties mentioned above, connected directly with a mucous surface; they always are furnished with a distinct capsule, which maintains their characteristic form; and they always occur in the course of lymph-vessels.

LYMPH-NODES.

A lymph-node (Fig. 517) is a small, roundish or ovoid body, situated in the course of a lymph-vessel. Upon its proximal aspect is usually a little depression

or notch, called the *hilum*, at which its arteries enter, and its veins and efferent vessels emerge. The capsule of the node is mainly composed of white fibrous tissue, but has a slight admixture of smooth muscular tissue. From its inner surface *trabeculæ* ("little beams") project toward the centre of the node, these being broad and shelf-like at the periphery, which is called the *cortex* ("bark"), but narrow and like slender rafters in the central portion, the *medulla* ("pith"). In no part are the spaces which these enclose completely circumscribed, and thus, as in areolar tissue, there is free intercommunication between them. The irregular spaces are occupied by a rather solid mass of *pulp*, which, however, does not quite fill them, as it never touches the capsule and trabeculæ, but leaves a narrow interval between itself and them. This open interval, which appears in a section of the node like a channel, is the *lymph sinus*, and is crossed by a network of delicate adenoid reticular tissue, which is continuous on the one hand with the trabeculæ or capsule, and on the other with a still finer plexus of the same character, which pervades the pulp and forms the framework upon which the essential constituents of the pulp are supported.

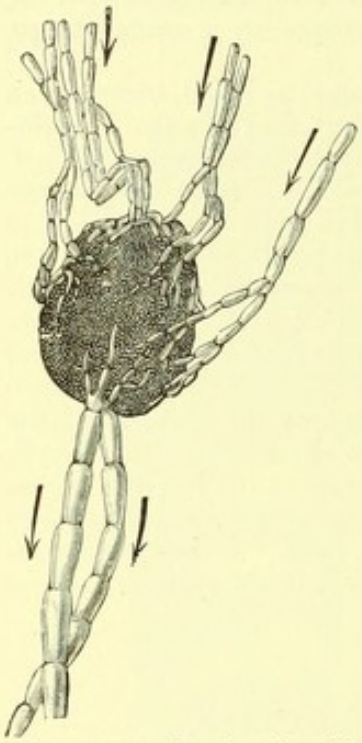

FIG. 517.—A lymph-node with its afferent and efferent vessels. (Testut.)

The *pulp* or proper substance of the node is a mass of leucocytes, held together by the fine reticulum just mentioned. The cells at the periphery of the collection are in a condition of multiplication by karyokinesis, and it is believed that the newly formed cells are continually liberated into the lymph sinus. The lymphadenoid tissue is well supplied with blood-vessels.

The *lymph sinus* is a complicated series of freely communicating passages into which a number of lymph-vessels pour their contents, and from which a smaller number of lymph-vessels receive lymph. The inner coat of the entering (*afferent*) and emerging (*efferent*) vessels is continuous with the epithelial lining of the lymph sinus and the epithelial covering of the trabeculæ which traverse it. Thus there is no breach in the continuity of the surface over which the lymph flows, whether it is in the vessels or in the channels of the nodes.

The nodes, with the exception of the superficial inguinal, are situated beneath the deep fascia, though not always under its immediate covering. All told there may be nearly 700 nodes, of which the greatest part are in the chest- and belly-cavities. The face and neck have a considerable number, the limbs a few, and the brain-case none. In size they vary from that of a large bean to such diminutiveness that they escape gross observation, unless they have become enlarged by disease. In the groin they can easily be felt, but not in the axilla. Those of very small size are called *nodules*.

As age creeps on, the lymphatic tissues undergo senile atrophy. The thymus gland, whose nature is essentially lymphatic, diminishes and generally entirely disappears before adult life. The ordinary lymph-nodes gradually shrink in old age, though they do not altogether vanish, and all of the other lymphatic structures pursue a similar degenerative course.

The effect of lymphadenoid tissue upon the lymph which passes through it is very marked. For example, the lymph which enters a node has fewer corpuscles and less albuminoid material than that which flows out of it. We thus see that the influence of the node is toward the enrichment of the lymph. Extraneous matters absorbed by the lymph-vessels from the juice-channels are caught in the reticular tissue, which crosses the sinus, and are detained temporarily or even permanently. When these particles are bacteria they are liable to set up patho-

logic processes. The nodes act as sieves, which prevent to a considerable extent the infection of parts proximal to themselves.

The great majority of the nodes are arranged in colonies, a few stand singly by themselves. Each node or group of nodes receives lymph from fairly well-defined areas and parts. But at the periphery of these areas or parts abundant inosculation with vessels of contiguous regions occurs, and along the boundary lines the lymph may flow into one or the other, or even into both sets of vessels. A single organ may be supplied with lymph-vessels which are tributary to two or even more groups of nodes, as, for example, the uterus, the mamma, the penis, the pericardium.

It is of great importance that the sources of supply of lymph for each colony of nodes should be well understood, on account of their frequent infection by the absorption of disease materials. When a single node or colony is invaded by pathologic germs, attention is immediately directed to the region in which must be sought the lesion by which toxic material has been introduced. Consequently, it is evident that the most useful, because the most practical, method of studying the lymphatic system is to ascertain what groups of nodes there are, and what vessels are tributary to each of them. The accompanying diagrams have been devised with the idea of supplementing the verbal descriptions by graphic representations, and of enabling one to see at a glance what region or regions to examine for lesions when any particular colony of nodes is diseased. As has been already remarked, the frequent anastomoses of vessels at the boundaries of contiguous regions should be borne in mind; and additionally it must be remembered that the nodes of each group communicate freely with each other, and that every cluster of nodes is more or less intimately connected with its neighbors.

The nodes will now be studied systematically according to the regions in which they are situated, and will be taken up in the following order: nodes of the head and neck; nodes of the upper limb; nodes of the lower limb; nodes of the thorax; nodes of the abdomen.

In every surgical operation involving the cutting of soft parts, lymphatic vessels are necessarily severed; but, unless the thoracic duct or the right lymphatic duct is wounded (and these accidents are very rare) the results are trivial. The lymph-vessels generally are so small and so delicate that it is impossible to see them in ordinary, normal conditions, and, consequently, it is impracticable to avoid them. Therefore, it seems undesirable to burden the following descriptions with the exact course pursued by the majority of the small lymphatics. The situation of the several colonies of nodes will be described, the areas and organs which drain into each enumerated, and the destination of its efferents mentioned; and these are the essential practical points of the subject.

THE NODES OF THE HEAD AND NECK

and their Tributary Vessels.

The nodes of the head and neck (Figs. 518, 519) are so intimately associated that it is most convenient to consider them together.

The Deep Cervical Nodes.—The most numerous series is the *deep cervical chain*, which lies along the course of the internal jugular vein. Into this group, either directly or indirectly, is poured the lymph from the entire head and neck. It is divided into two sets—the upper deep cervical and the lower deep cervical—the first extending from the base of the skull to the level of the upper border of the thyroid cartilage, the second reaching from that line to the clavicle. The *upper deep cervical nodes* receive immediately the efferents of the parotid, the internal maxillary, the submaxillary, the suprahyoid, and the lingual nodes, and the vessels from the deep muscles of the head and neck, the tonsil, the thyroid body, the lower part of the pharynx, and the upper portion of the larynx. The *lower deep cervical nodes* take the lymph from the upper deep cervical and the superficial cervical, the lower part of the larynx and thyroid, the upper parts of the

trachea and œsophagus, and the inferior portions of the neck. The efferents of the deep cervical nodes connect with the superior mediastinal and axillary nodes.

The Superficial Cervical Nodes.—The superficial cervical nodes follow the line of the external jugular vein, occupying the posterior triangle of the neck. Their afferents come from the suboccipital, mastoid, and submaxillary nodes, the integument of the neck and that of the external ear. Their efferents run to the lower deep cervical.

The **Suboccipital Nodes** lie just below the superior curved line of the occipital bone, taking lymph from the back part of the scalp, and passing it along to the mastoid and superficial cervical nodes.

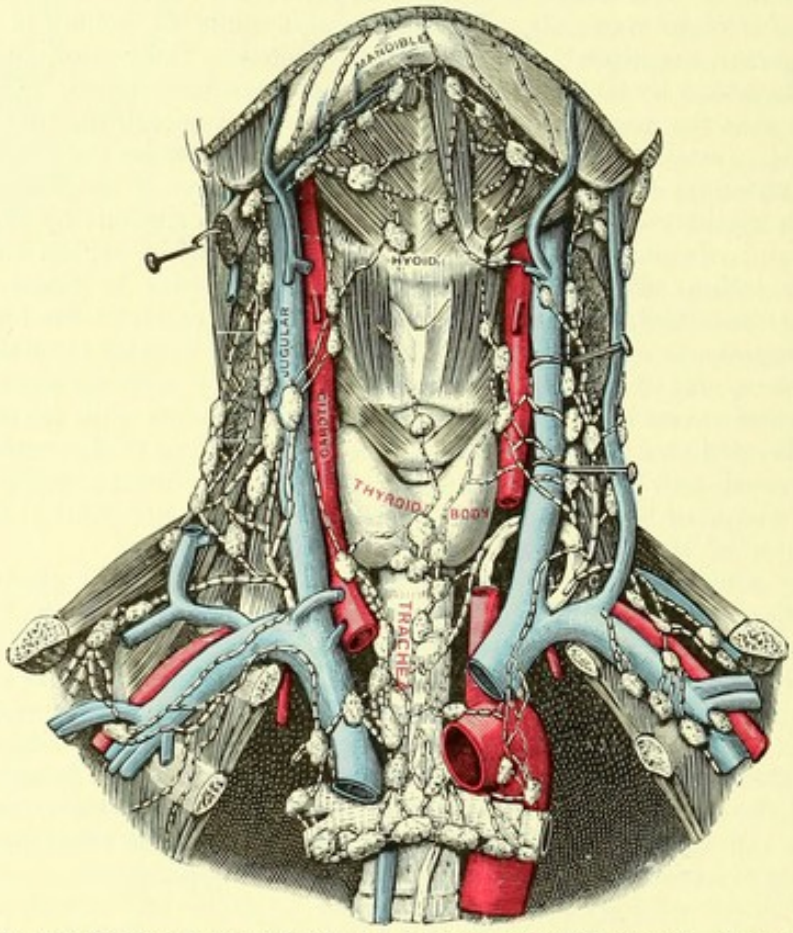

FIG. 518.—The lymph-nodes of the neck and upper part of the thorax. (Testut.)

The **Mastoid Nodes** are located behind the ear, drain the scalp in that region, and receive efferents from the suboccipital nodes. Their lymph goes to the superficial cervical.

The **Submaxillary Nodes** form a chain below and about parallel with the under margin of the mandible. They gather the lymph from the submaxillary and sublingual salivary glands, the lips, the front part of the tongue, the floor of the mouth, the nose, the frontal region, and the nasal half of both eyelids. The *buccal nodes*, which are situated upon the outer surface of the buccinator muscle, interrupt the flow in some of the vessels that bring lymph from the fore part of the face. The efferents of the submaxillary nodes empty into the upper deep cervical and the superficial cervical.

The **Suprahyoid Nodes**, which lie between the anterior bellies of the digastric muscles, are sometimes counted as belonging to the submaxillary group. They collect lymph from the middle of the lower lip and from the chin, and pour it into the upper deep cervical.

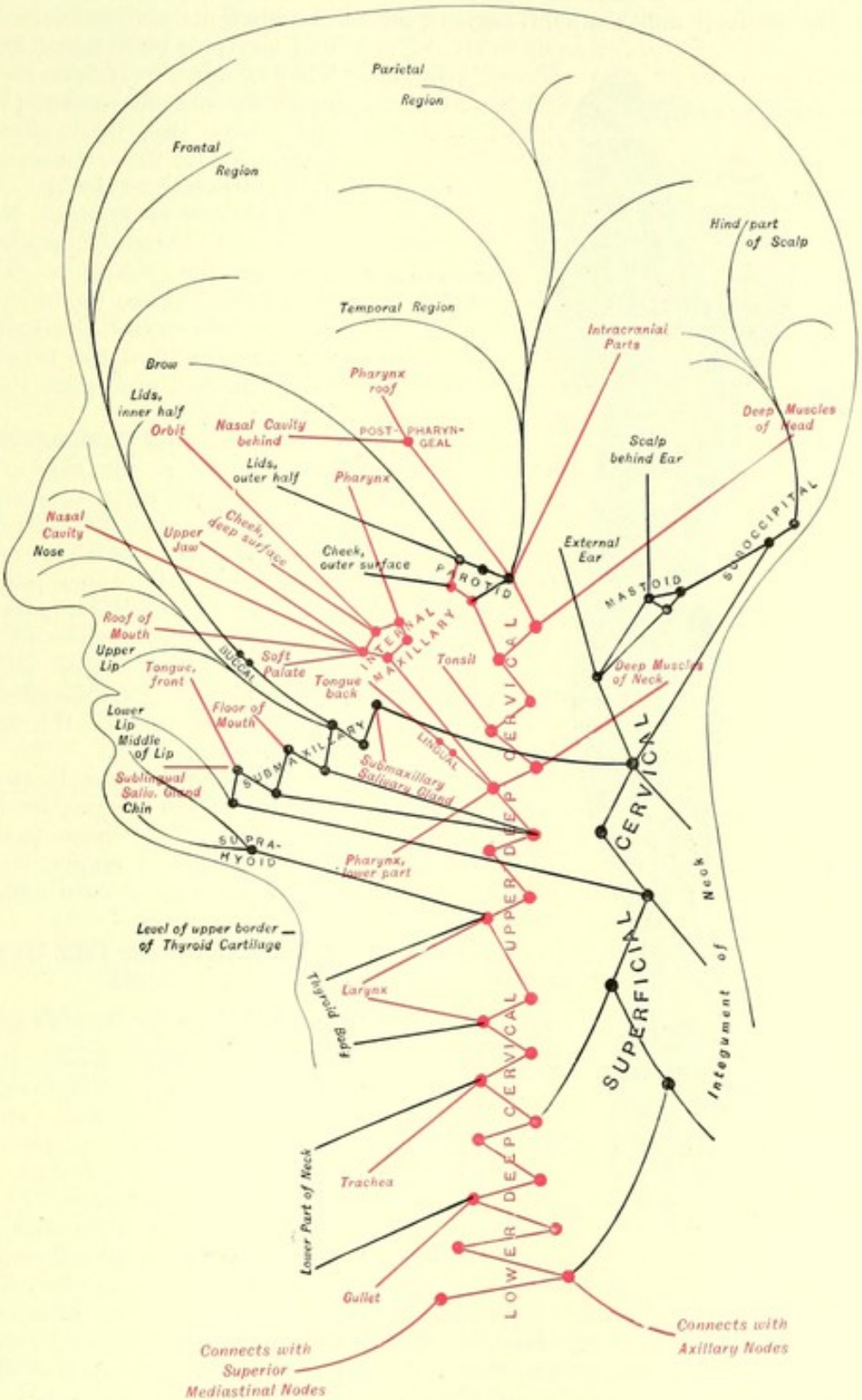

FIG. 519.—Diagram of the nodes and vessels of the head and neck, showing the regions which are drained into each group of nodes. Deep structures in red, superficial in black. (F. H. G.)

The **Parotid Nodes** are situated in the region of the ear, some being *superficial* to the great salivary gland, and others being *deep* in its substance. They derive their lymph from the outer surface of the cheek, the outer half of the lids, the brow, the parietal and temporal regions, all of the parts within the brain-case, and the post-pharyngeal nodes. They send the lymph to the upper deep cervical nodes. (Walsham says that their efferents terminate in the submaxillary and superficial cervical.)

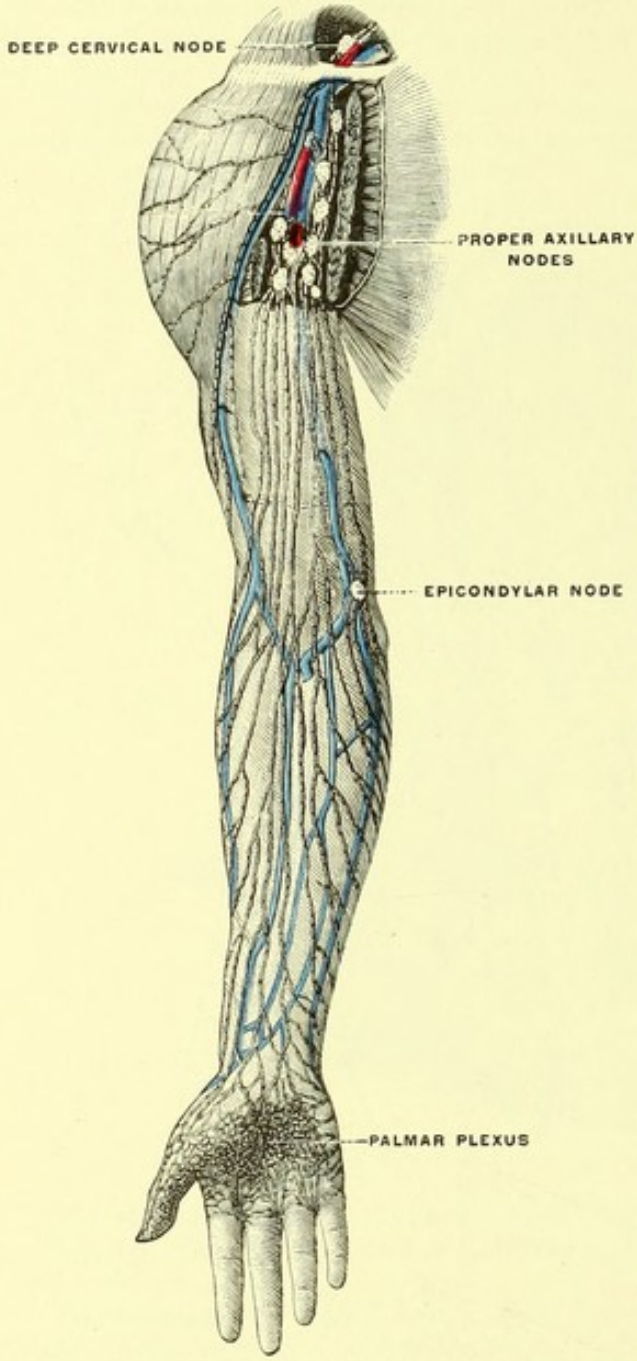

FIG. 520.—The nodes and vessels of the upper limb. (Testut.)

The **Post-pharyngeal Nodes** are placed behind the uppermost part of the pharynx. Their lymph comes from the hind part of the nasal cavity, the roof of the pharynx, and the prevertebral muscles, and goes to the parotid nodes.

The **Internal Maxillary Nodes** are situated at the side of the anterior part of the pharynx. Its afferents bring lymph from the orbit, the greater part of the nasal cavity, the upper jaw, the roof of the mouth, the soft palate, the deep surface of the cheek, and the largest portion of the pharynx ; and its efferents carry the lymph to the upper deep cervical.

The **Lingual Nodes,** located on the side of the tongue, get their lymph from the back part of that organ, and empty it into the upper deep cervical nodes.

THE NODES OF THE UPPER LIMB

and their Tributary Vessels.

The **Axillary Nodes** (Figs. 520, 521) comprise four tolerably distinct groups : the axillary proper, arranged around the great vessels of the armpit ; the pectoral, in the course of the long thoracic artery ; the subscapular, along the subscapular artery ; and the subclavian, on the costo-coracoid membrane, between the deltoid and greater pectoral muscles. There exists a free communication not only between the nodes of each set, but between the different groups ; so that infection of any one may extend to all of the others. The efferents of all of these groups discharge into the thoracic duct or the right lymphatic duct.

The *proper axillary nodes* collect the lymph from the epicondylar node, the entire arm, except the surface of the outer side, and all of the forearm and hand, except a portion of the surface which drains into the epicondylar node.

The *pectoral nodes* drain the greater part of the mammary gland, the integuments of the side and front of the chest, and those of the abdomen above the level of the navel.

The *subscapular nodes* receive lymph from the superficies of the back of the neck, the shoulder, and most of the trunk above the crest of the ilium.

The *subclavian nodes* derive their lymph from the skin of the deltoid region and the outer aspect of the arm. They connect with the deep cervical.

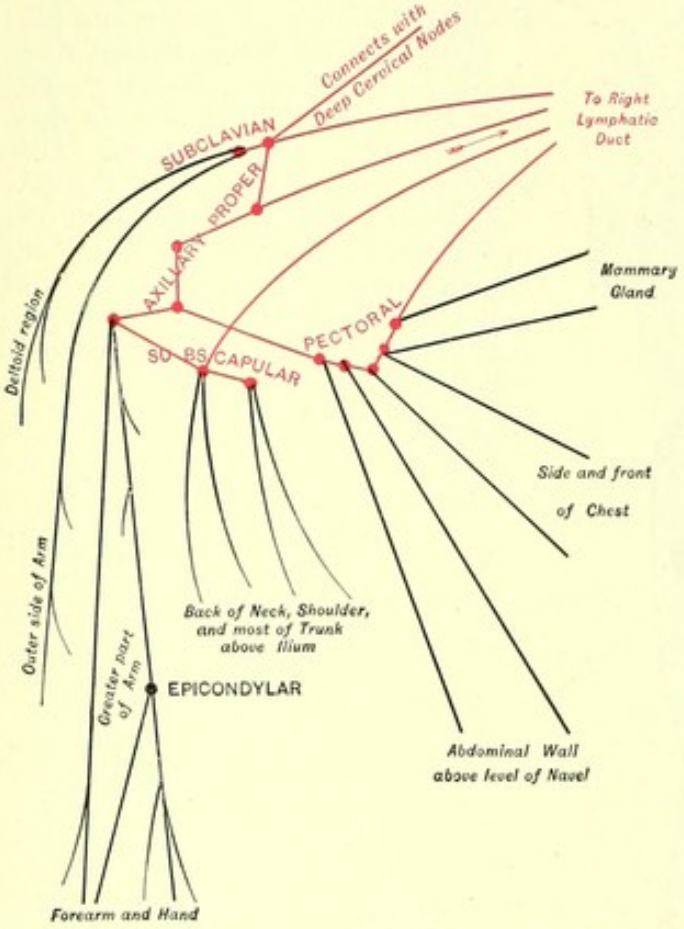

FIG. 521.—Diagram of the nodes of the right upper limb and their superficial tributaries, showing the areas drained by each group. Deep structures in red, superficial in black. (F. H. G.)

The **Epicondylar Node**, situated above the internal condyle of the humerus, gets its lymph from the inner portion of the surface of the hand and forearm, and its efferents carry it to the proper axillary nodes.

THE NODES OF THE LOWER LIMB

and their Tributary Vessels.

The nodes of the lower limb (Figs. 522, 523) are the superficial and deep inguinal, the popliteal, and the gluteal.

The **Superficial Inguinal Nodes** are arranged in two series—a superior or oblique, and an inferior or vertical.

The *superior set* is situated close to the inguinal ligament, and is subdivided into three groups—the external, the middle, and the internal—each comprising about three nodes. Their lymph comes from the integuments of the buttock and the skin around the anus, the lower and outer part of the back above the buttock, the belly below the level of the navel, and the penis (Fig. 524); also from the distal portion of the urethra in both sexes, and from the vulva and the lower third of the vagina in the female. The scrotum and the superficial portion

of the perineum frequently drain into this set; and occasionally vessels from the uterus end in it.

The *inferior set* is situated at the saphenous opening. It takes the lymph from the superficial parts of the thigh, and of the entire leg and foot, except their outer side; also from the scrotum and the integuments of the perineum, and sometimes the penis, vulva, urethra, and lower part of the vagina.

The superficial inguinal nodes discharge partly into the deep inguinal and partly into the external iliac.

The **Popliteal Nodes**, located deeply in the ham-space, get their lymph from the surface of the outer side of the leg and foot, and the deep structures of the same segments of the limb. Their efferents join the deep lymphatic vessels of the leg.

The **Deep Inguinal Nodes** are grouped around the upper end of the femoral artery and vein. Their afferent vessels come from the superficial inguinal nodes and from the deep structures of the greater part of the limb; and their efferents run to the external iliac nodes.

FIG. 522.—The nodes and vessels of the lower limb. (Testut.)

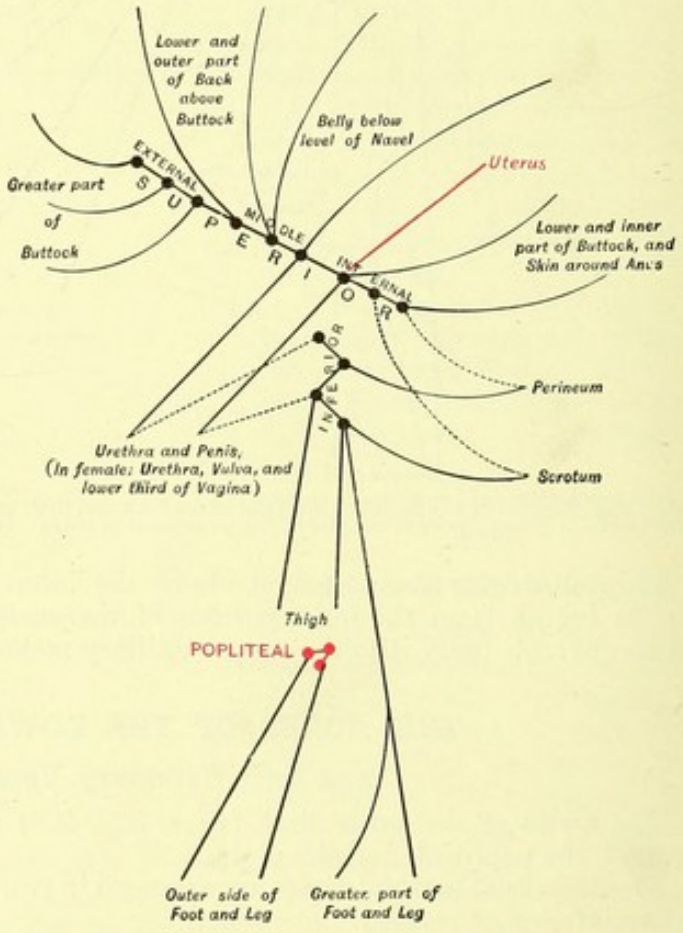

FIG. 523.—Diagram of the superficial inguinal and the popliteal nodes of the right side and their superficial tributaries, showing areas drained by each subgroup. Deep structures in red, superficial in black. Frequent variations in dotted lines. (F. H. G.)

The **Gluteal Nodes**, lying near the pyriformis muscle, derive their lymph from the deep parts of the buttocks, and transmit it to the internal iliac nodes.

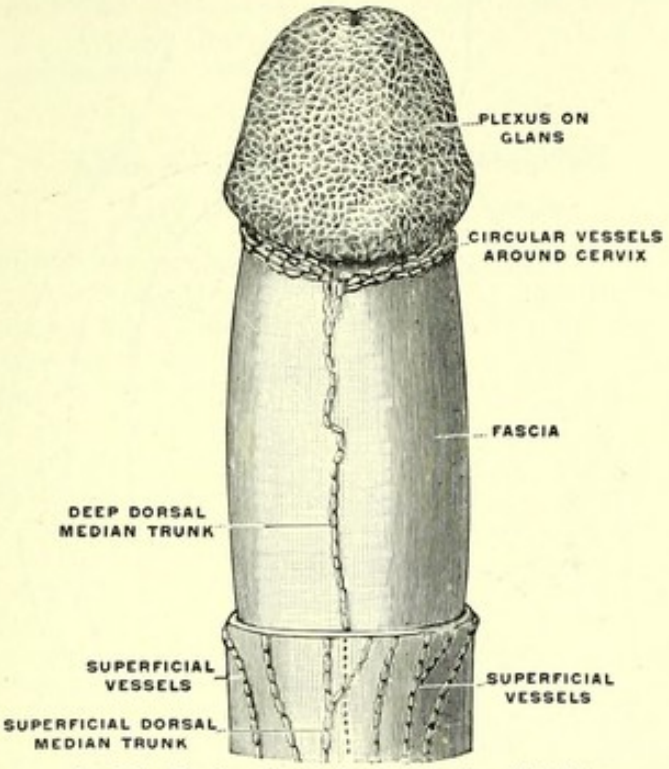

FIG. 524.—The lymph-vessels of the penis. (Testut.)

THE NODES OF THE THORAX

and their Tributary Vessels.

The nodes of the thoracic cavity (Fig. 525) are all deep, and derive their lymph from deep structures; that is, not at all from integumentary organs. They are disposed in the following groups: the sternal, the intercostal, the anterior mediastinal, the posterior mediastinal, the superior mediastinal, the bronchial, and the vena-caval. They discharge into the thoracic and right lymphatic ducts.

The **Sternal Nodes** lie in the spaces between the costal cartilages close to the borders of the breast-bone. Lymph flows to them from the deep portions of the mammary glands, from the anterior and lateral walls of the chest, from the upper part of the front and sides of the abdominal walls, from the diaphragm, and from the anterior mediastinal nodes.

The **Intercostal Nodes** are lodged in the hindmost part of the intercostal spaces. They drain the thoracic part of the spinal canal, the costal pleuræ, and the posterior and lateral portions of the chest-walls.

The **Anterior Mediastinal Nodes** are situated in front of the heart. Their lymph comes from the pericardium, the diaphragm, the liver, and the sternal nodes, and goes partly directly to the great terminal vessels of the system, and partly to superior mediastinal and sternal nodes.

The **Posterior Mediastinal Nodes**, located around the aorta, have afferents from the heart, the pericardium, the lower part of the œsophagus, and the diaphragm, and communicate freely with the bronchial nodes.

The **Superior Mediastinal Nodes** lie in front of the arch of the aorta. Their tributaries come from the thymus gland, the heart, the pericardium, the anterior mediastinal and the bronchial nodes. There is a direct connection between this group and the deep cervical nodes.

The **Bronchial Nodes** (Fig. 518), gathered at the roots of the lungs, take lymph from the lungs, the pulmonary pleuræ, the lower part of the trachea, the bronchi, the bronchioles, and the pericardium, and communicate with the superior and the posterior mediastinal nodes.

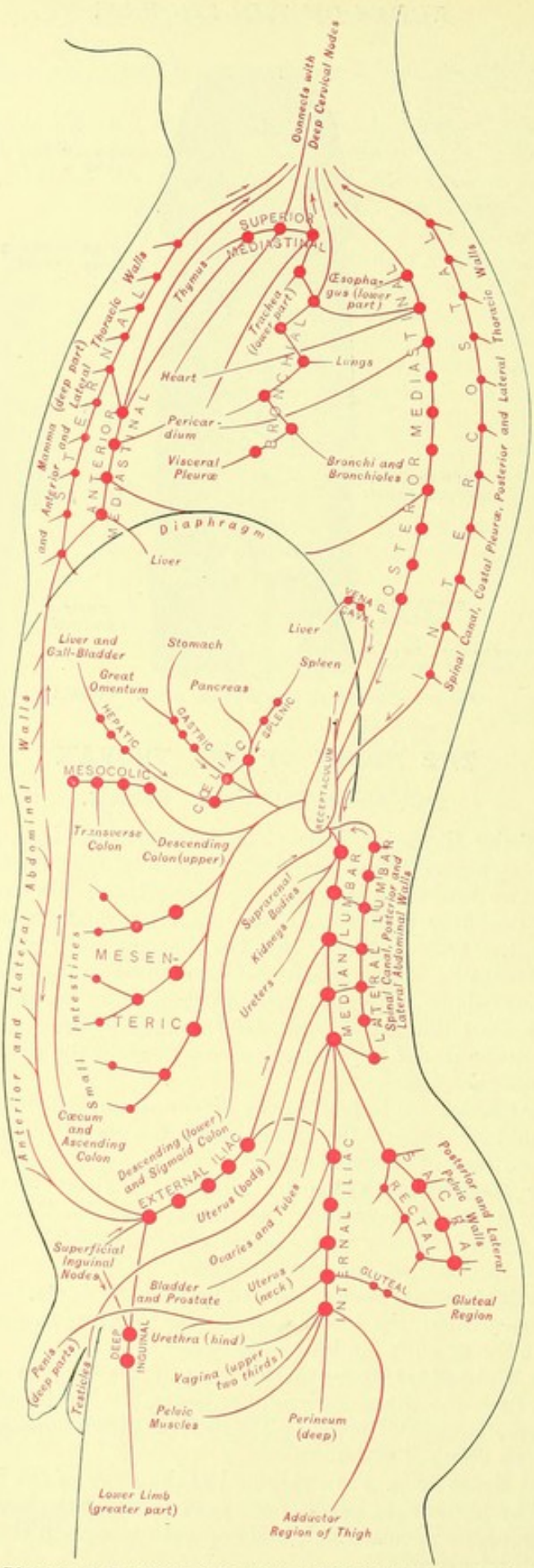

FIG. 525.—Diagram of the nodes of the trunk and their tributary vessels. (F. H. G.)

The **Vena-caval Nodes**, few and small, are placed close to the upper end of the inferior vena cava. Vessels from the upper and hind part of the liver perforate the diaphragm, and discharge into them.

THE NODES OF THE ABDOMEN
and their Tributary Vessels.

Like the thoracic, the abdominal nodes (Fig. 525) are all deep, and, with a single exception, their immediate source of lymph is other than superficial. They are arranged in the following groups: the mesenteric, the mesocolic, the cœliac, the hepatic, the gastric, the splenic, the median lumbar, the lateral lumbar, the external iliac, the internal iliac, the sacral, and the rectal.

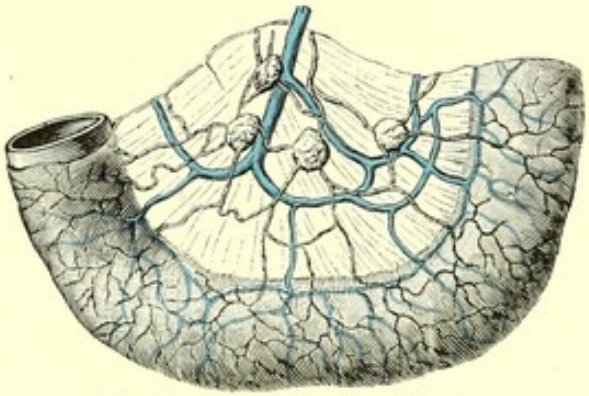

FIG. 526.—Mesenteric nodes. (Testut.)

The **Mesenteric Nodes** (Fig. 526), lodged between the layers of the mesentery, take the lymph from the small intestines through the lacteal vessels. They discharge by a large trunk into the receptaculum chyli.

The **Cœliac Nodes**, grouped in the region of the cœliac axis, receive lymph from the liver and the gall-bladder, the stomach, the pancreas, the spleen, and the great omentum, and empty it into the efferent trunk of the mesenteric. In the course of the vessels which carry lymph from the liver, stomach, and spleen to this group are small nodes, called respectively hepatic nodes, gastric nodes, and splenic nodes.

The **Mesocolic Nodes** lie between the layers of the mesocolon. Their afferents come from the cæcum, the ascending and transverse colon, and the upper portion of the descending colon; and their efferents run to the mesenteric efferent trunk.

The **Median Lumbar Nodes** are situated close to the abdominal aorta. Their supply of lymph comes from the body of the uterus, the ovaries and the Fallopian tubes, the testicles, the kidneys, the ureters, the diaphragm, the suprarenal bodies, the external iliac, internal iliac, sacral and lateral lumbar nodes; and the trunk by which they discharge into the receptaculum is joined by the efferents of the lower part of the descending and the whole of the sigmoid colon.

The **Lateral Lumbar Nodes** lie in the spaces between the transverse processes of the lumbar vertebræ. Their afferents come from the lower part of the spinal canal, and the dorsal and lateral portions of the abdominal walls; and their efferents run to the median lumbar nodes and the receptaculum.

The **External Iliac Nodes**, situated along the line of the external iliac vessels, take lymph from the ventral and lateral parts of the walls of the abdomen, and from the superficial and deep inguinal nodes. They have a communication with the internal iliac nodes, and discharge into the median lumbar.

The **Internal Iliac Nodes**, lying around the internal iliac vessels, have tributaries from the deep parts of the penis, the proximal portion of the urethra, the bladder, the prostate, the neck of the uterus, the upper two-thirds of the vagina, the deep layers of the perineum, the pelvic muscles, the adductor region of the thigh, and the gluteal nodes. They send their lymph to the median lumbar nodes, and have connection with the external iliac.

The **Sacral Nodes**, situated in the curve of the sacrum, have afferents from the dorsal and lateral pelvic parietes and from the *rectal nodes*, which take their lymph from the rectum.

THE CEREBRO-SPINAL AXIS.

By F. H. GERRISH.

THE great nervous mass which occupies the main cavity of the cranium is known as the *encephalon* ("in the head") or *brain*; and the prolongation of this, which is lodged in the canal made by the vertebræ and the cartilaginous plates between them, is called the *myelon* ("marrow") or *spinal cord*. Radiating from these structures are many cords, called nerves; and this fact suggested the name *axis* for these combined central organs, the distinguishing adjective *cerebro-spinal*, which is usually associated with the noun, deriving its first part from "cerebrum," which is the most conspicuous portion of the encephalon, and its last part from the column of bones in which the myelon is located (Fig. 527).

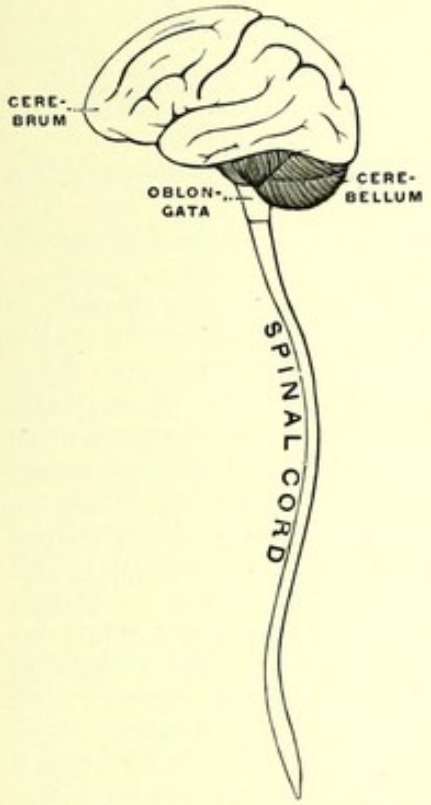

FIG. 527.—Semidiagrammatic view of the cerebro-spinal axis, left side. (Testut.)

FIG. 528.—Diagram of the conversion of the dorsal groove into a canal.

The cerebro-spinal axis is first observed in the embryo as a longitudinal groove on its dorsal aspect. Its edges grow up at the sides, curve toward the midline, meet there, and fuse together (Fig. 528). The result is that the gutter is changed into a tube. One end of the tube enlarges into a sac, and this develops into the encephalon (Fig. 529). The remainder of the tube becomes the spinal cord. The cavity of the encephalon is always continuous with that of the spinal cord.



FIG. 529.—Diagram of first stage of axial cavity.

Great changes take place in both parts, especially in the encephalon; but throughout these modifications, certain things are almost invariable. In nearly all of the amazing complications of encephalic growth, three things remain as in the simplest form of encephalon in the embryo: (1) a cavity-wall of nervous tissue; (2) a

lining of epithelium; and (3) a membranous covering, which is essentially a network of blood-vessels (Fig. 530).

(1) The nervous substance is gray, or white, or both of these. In different parts this nervous wall receives distinguishing names—gyrus, lamina, nucleus, commissure, etc.

(2) The lining is serous in character, and secretes a watery fluid, which moderately fills the entire cavity. The membrane is called *ependyma*, or merely

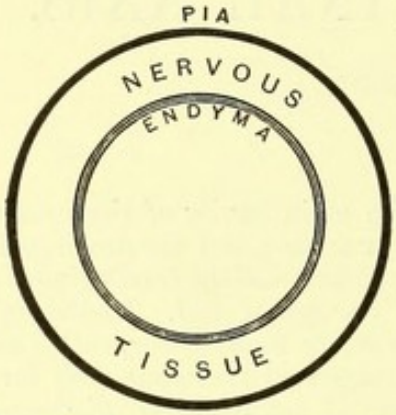

FIG. 530.—Diagram of transverse section of typical wall of cavity of cerebro-spinal axis.



FIG. 531.—Diagram of transverse section of axis, where a portion of the nervous wall has disappeared, allowing pia and endyma to come together.

endyma ("garment"). The fluid is called *cerebro-spinal fluid*, or *cephalo-rachidian fluid*.

(3) The covering sends nutrient vessels into the substance of the wall, and is called the *pia*, or *pia mater* ("the tender mother").

The solid wall may grow to a thickness of several inches, it may dwindle to the thinness of paper, or it may even disappear altogether (Fig. 531); but endyma and pia are persistent. The endyma is a perfect shut sac, save for a diminutive aperture at a single point, by which a communication is established with another serous cavity lying outside of the axis. Real comprehension of the subject cannot be acquired without appreciation of these primary conditions, here repeated: that *the encephalon is a hollow organ, filled with fluid*; that *it has everywhere a serous lining*; that *it has a vascular plexus for its outer investment*; and that *it has nearly everywhere between its lining and its covering a solid wall of nervous tissue*, which varies immensely in thickness in different parts.

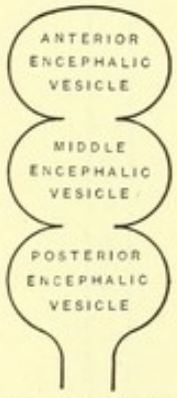

FIG. 532.—Diagram of the three secondary vesicles of the brain.



FIG. 533.—Diagram of the five ultimate vesicles of the brain.

The encephalon, at first a single vesicle, soon becomes elongated, and then constricted circularly and deeply at two equidistant points. In this way three secondary vesicles are formed (Fig. 532). They do not, however, long remain in this condition; for, while the middle one continues single, the front one and the rear one are soon constricted transversely and divided, each forming two. Thus, there is a series of five vesicles of sub-

stantially equal size, whose cavities communicate through central apertures (Fig. 533). These five vesicles are the primary forms of the five grand divisions of the adult encephalon, and are named in order, from before backward, *prosencephalon*, *diencephalon*, *mesencephalon*, *epencephalon*, and *metencephalon*. The first and second show a tendency in the developed state to revert to their original condition of unity, and the same is true of the fourth and fifth ; but the third remains single and distinct from its earliest appearance to its most complete development.

Vernacular names also are given them—forebrain, betweenbrain, midbrain, hindbrain, afterbrain—but only the first of them is so clearly descriptive as to convey infallibly the idea intended, and it would be better to discard them for the technical appellations, which, while etymologically not greatly superior, are widely used by the scientific with definite meanings, and are understood by all anatomists.

When these vesicles are first observed, they are, as has been said, about equal in size and very similar in form ; but the likeness which they bear to each other does not long continue : they grow at very different rates of speed, and, when fully developed, are so dissimilar in appearance that it is difficult to understand that they could have been of almost identical shape and bulk at any former period. Some parts, which are brought into close contact with others, seem to blend ; while others, in nearly similar conditions, undergo shrinkage, and finally disappear.

THE CAVITY OF THE CEREBRO-SPINAL AXIS.

Let us first consider the *cavity* of the cerebro-spinal axis, ignoring for the while the enclosing walls ; and, when we have gained a comprehension of this, we can proceed more understandingly to the study of the surrounding solid material.

Suppose the cavities of the five encephalic vesicles to be of equal size, and that of the spinal cord to be a cylindrical continuation from the fifth or hindmost vesicle. We have then, to start with, a series of chambers, each communicating freely with the one next behind it. This continuity of the cavities is always maintained, even though the original chambers undergo alterations of form so prodigious that only a very slight resemblance to the primitive shape remains.

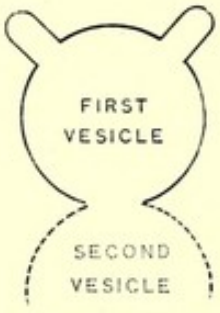

FIG. 534.—Diagram of the formation of the portæ.

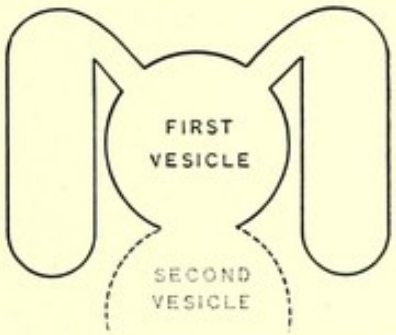

FIG. 535.—Diagram of the formation of the bodies of the lateral ventricles.

For the sake of simplification we will first examine the subject diagrammatically, taking the vesicles one by one in regular order ; and, in considering each, we will ignore as far as possible the changes which in nature take place in its immediate neighbors synchronously with those in itself.

To begin with we have the *first vesicle*, the most anterior—the prosencephalon—which ultimately becomes the cerebral hemispheres. From the upper and front part of its globular cavity on each side a little sprout is put forth (Fig. 534). The distal end of this protrusion enlarges, and becomes of much greater size than the parent cavity (Fig. 535). Then each of the new appendages sends out a prolongation forward, a second backward, and a third which curls sidewise and downward. These, from their shape, are called *horns* or *cornua* (Fig. 536). In this process of enlargement the original vesicle is so far outgrown by its offshoots that it is in great danger of being lost sight of. The chief cavity on each side is called a *ventricle*, and, from its being at the side, *lateral*. Of the *lateral*

ventricle the main part is known as the *body*, and the prolongations from it are named respectively *anterior horn*, *middle* or *descending horn*, and *posterior horn*. The original sprout now serves for a passage of communication between the primary vesicle and the ventricle, and is known commonly as the *foramen of Monro*; but it is better designated as *porta* ("the doorway"). The original cavity of the vesicle, now subordinate in extent to the large chambers to which it has given rise, is called *aula* ("the hall"). Thus we have from the cavity of the first vesicle the following parts: the aula in the centre, and on each side a porta, and a lateral ventricle with its three horns (Figs. 536, 537). Notice that the aula is distinctly below the plane of the body of the ventricle, and that the middle horn descends to a level much below that of the aula.

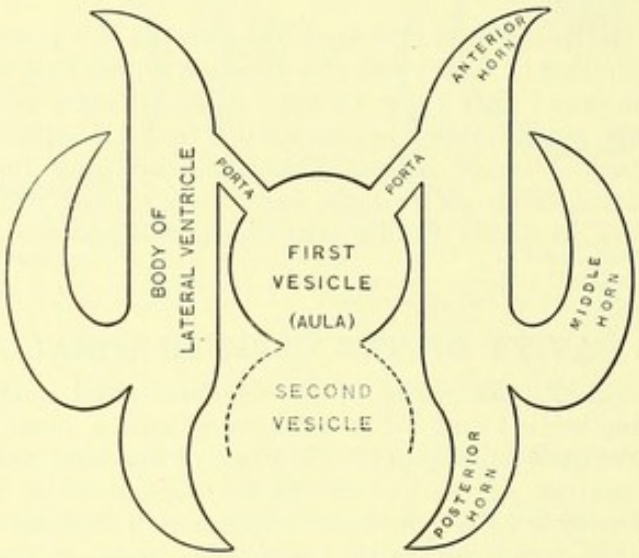

FIG. 536.—Diagram of the full development of the lateral ventricles and their cornua—view from above.

Passing to the cavity of the *second encephalic vesicle*—the diencephalon—we find that it considerably outgrows the aula, which is just in front of it. Its enlargement is very slight sidewise and is almost entirely up-and-down and backward, as if the vesicle had been squeezed between two vertical planes at the sides (Figs. 538, 539). The result of this development is to make the second vesicle a long, deep, narrow chink in the middle line—a fore-and-aft median crevice, with the aula in front and the third vesicle behind. The original constriction between this cavity and that of the first vesicle becomes practically

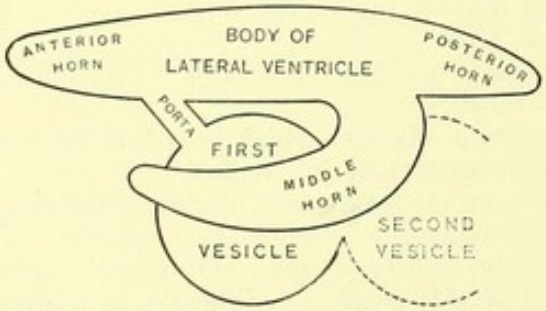

FIG. 537.—Same as Fig. 536—view from the left side.

obliterated, and, consequently, the cavities of the aula and the second vesicle merge into one, the greater portion of which is contributed by the second vesicle, that furnished by the first vesicle being located at the upper and fore part. This composite cavity, made of the whole of the second and a part of the first vesicle,

is usually called the *third ventricle*, the first and second ventricles being the lateral, which are never designated in a numerical way, but always as right lateral ventricle and left lateral ventricle. It will now be seen that the third ventricle communicates with each lateral ventricle by a separate porta.

Next we study the cavity of the *third encephalic vesicle*—the mesencephalon. This assumes a shape as if it were stretched between its neighbor in front and the one behind: it is drawn out into a small tube, and thus constitutes a long and narrow channel from the vesicle before to that behind (Fig. 540). It is named the *aqueduct* (*aqueductus Sylvii*—from Sylvius, a celebrated anatomist), and also by another name, which will be better understood a little later.

The cavity of the *fourth encephalic vesicle*—the epencephalon—instead of retaining its globular shape, is flattened from above downward, as if it had been compressed between plane surfaces applied obliquely to its dorsal and ventral aspects;

FIG. 538.—Diagram of changes in second vesicle—view from above.

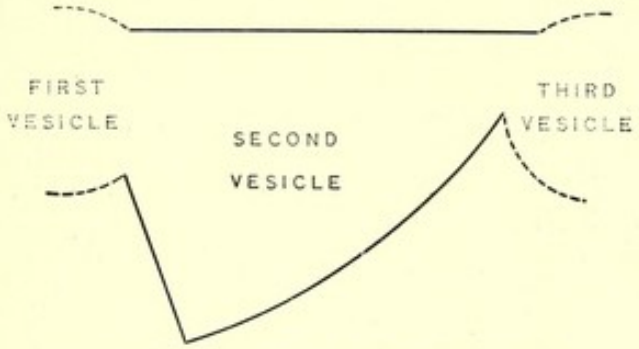

FIG. 539.—Same as Fig. 538—view from left side.



FIG. 540.—Diagram of changes in third vesicle.

and it is widened out behind, assuming a triangular form, the apex being forward (Figs. 541, 542). A little of the constriction between it and the fifth vesicle is still observable, even in the developed condition.

The cavity of the *fifth encephalic vesicle*—the metencephalon—undergoes changes in its fore part almost identical with those experienced by that of the fourth; but the triangle which it forms has its base forward, applied to the base of the triangle of the fourth vesicle, and its apex backward, and the obliquity of the surfaces is opposite to that of those of the fourth (Figs. 543, 544). Thus, the two vesicles form a single shallow cavity

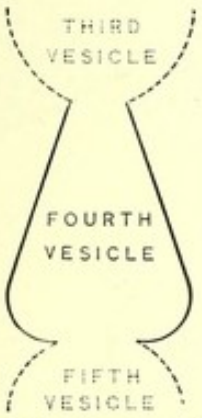

FIG. 541.—Diagram of changes in fourth vesicle—view from above.

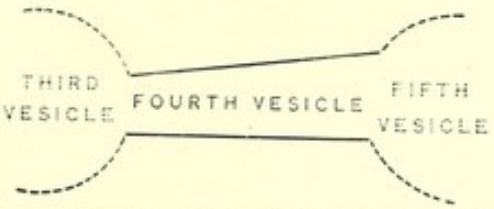

FIG. 542.—Diagram of changes in fourth vesicle—view from left side.

of rhomboidal form, when viewed from above. The hind part of this fifth vesicle is drawn out into a tube, and is continuous with the cavity of the myelon. The combined cavities of the fourth and fifth vesicles form what is commonly known as the *fourth ventricle*. We note that this fourth ventricle is connected with the third ventricle by the aqueduct, the other name of which, promised

above, can now be appreciated. It is *iter a tertio ad quartum ventriculum* ("the passage from the third to the fourth ventricle"), a name with the merit of descriptiveness, but with the fault of tiresome length.

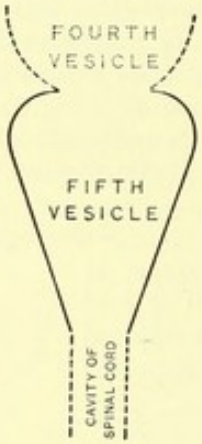

FIG. 543.—Diagram of changes in fifth vesicle—view from above.

The *cavity of the myelon* or spinal cord retains its original, cylindrical shape, and is called the *central canal of the spinal cord*. It is continuous at its cephalic end with the fourth ventricle.

The preceding diagrams have been drawn as if all of the vesicles were upon the same plane, for the sake of simplicity; but, during their synchronous development, a marked

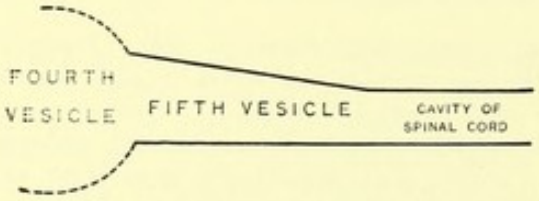

FIG. 544.—Diagram of changes in fifth vesicle—view from left side.

curve with a ventral concavity takes place at about the junction of the third ventricle and the aqueduct, and thus the long axis of the spinal cord is brought nearly to a right angle with the plane of the lateral ventricles.

The description of the encephalic vesicles here given is not designed for a portrayal of the process which is discovered by embryological research, but is intended merely to present in a diagrammatic manner the main features of the results which are reached by the developmental process.

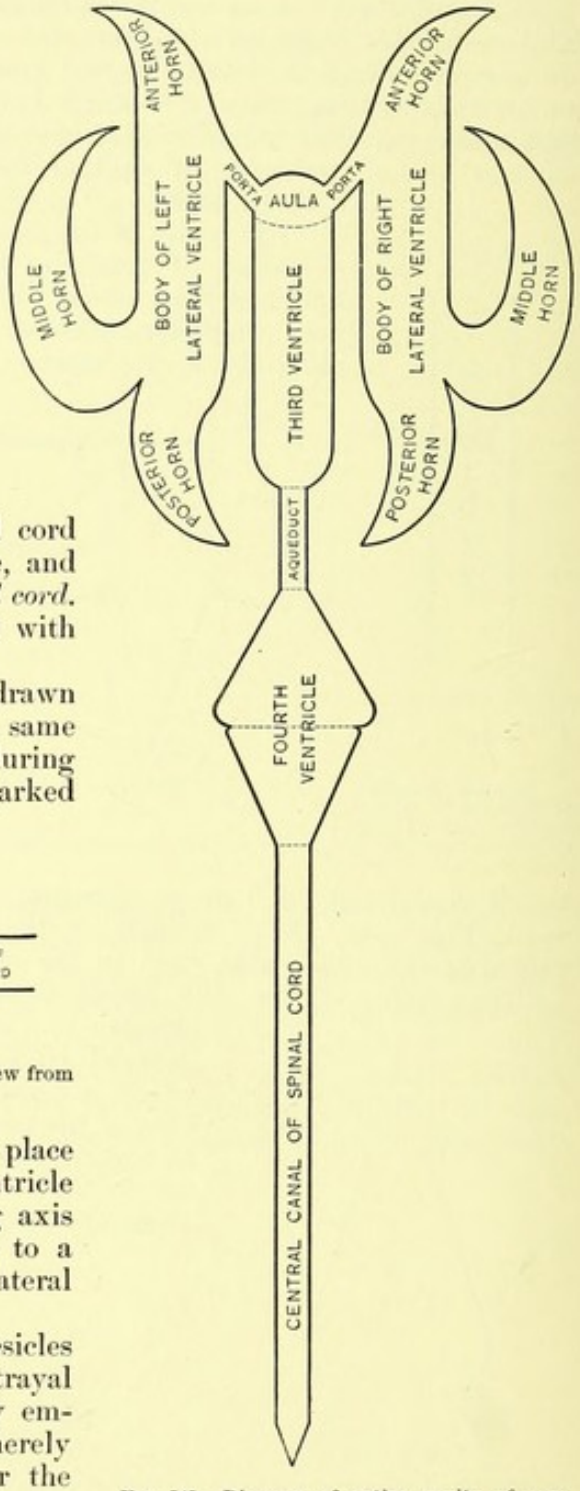

FIG. 545.—Diagram of entire cavity of cerebro-spinal axis—view from above.

The shape and relative size of these different cavities, when fully formed, can be seen in Fig. 546, which represents a cast, made by filling them with a liquid material, which solidified on standing. The surrounding solid tissue being removed, we obtain a perfect cast of the *general ventricular cavity*, as the combined chambers and tubes of the encephalon are called.

The general ventricular cavity is moderately filled with a serous fluid, the cerebro-spinal, which mingles with the fluid occupying the serous space outside of the encephalic mass through a small hole, the *foramen of Magendie* (metapore), in the roof of the fourth ventricle.

To illustrate the complexity and also the continuity of this cavity of the encephalon, imagine the shortest course which a small, aquatic insect must pursue in going from the apex of the middle horn of the lateral ventricle to the canal of the spinal cord, without leaving the cavity. First it would swim outward, and then successively backward, upward, inward, and forward, following the peculiar curves of the middle horn, before it could reach the body, the main hall, of the lateral ventricle. It would then pass forward and upward, for the floor of the ventricle slopes down from its front end. At the median side of the fore part of the ventricle, just at the beginning of the anterior horn, the little creature would work its way through the porta, a brief passage-way, which would let the traveller down into the third ventricle. Coursing backward through this deep crevice to its hind end, a narrow channel, the aqueduct, would be entered and traversed in a direction backward and downward. Emerging from this contracted passage, it would find itself in the shallow fourth ventricle, the long axis of which is somewhat backward, but more downward. Going from one end of this chamber to the other, it would arrive finally in the central canal of the spinal cord.

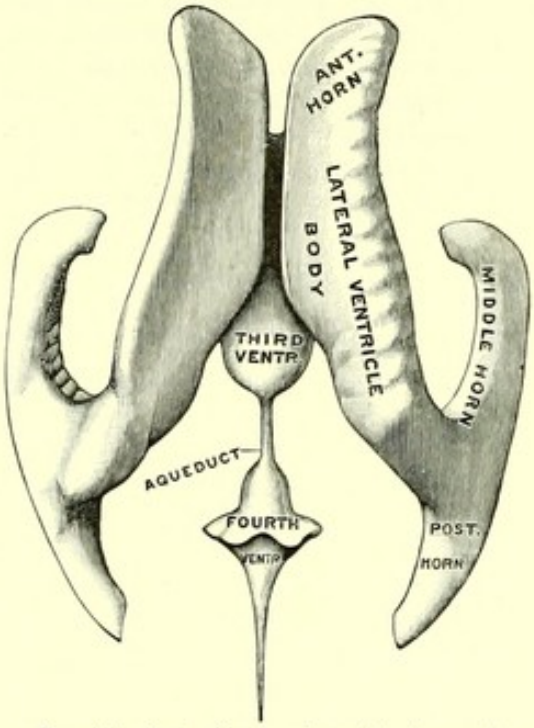

FIG. 546.—Cast of general ventricular cavity—view from above. (Testut.)

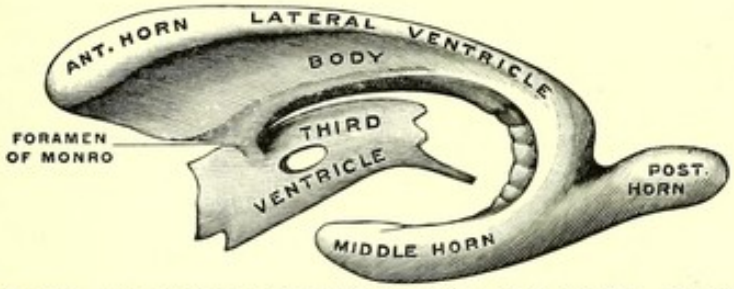

FIG. 547.—Cast of left lateral and third ventricles, from left side. (Testut.)

THE WALLS OF THE CEREBRO-SPINAL AXIS.

Having now obtained an adequate idea of the cavity of the cerebro-spinal axis we proceed to study the *walls* which enclose this space. As has been said, they are composed of nervous tissue, which is lined with endyma and clothed with pia. The mass thus constituted may be conveniently considered in sections. Thus, we will take successively the walls of the lateral ventricles, of the third ventricle, of the aqueduct, of the fourth ventricle, and of the central canal of the spinal cord (Fig. 548). The several sections of the encephalon in their developed condition are commonly known by names other than those given to the primary vesicles, with a single exception. The walls of each lateral ventricle constitute a

cerebral hemisphere, the two hemispheres making the *cerebrum*; the region of the third ventricle is known as the *thalamencephalon*, on account of its walls consisting to a very large extent of two great bodies called thalami; the aqueduct is enclosed in a nervous mass, which is often known by its original name, mesencephalon, sometimes as the *isthmus*, from its forming a connecting bond between the parts before and those behind it, and, perhaps most frequently, as the *crura cerebri* ("the legs of the cerebrum"), from the stalk-like appearance of its ventral portion; and the fourth ventricle is surrounded by nervous masses so differentiated from each other that they are not designated by a single collective term, but are referred to as separate organs. Of these the principal are the *cerebellum* ("the little cerebrum" or "little brain"), the *pons* ("the bridge" or "the bridge of Varolius"), and the *medulla oblongata* ("the oblong marrow"), also called by either of its names singly—preferably by the latter, as this gives no suggestion of the medulla spinalis ("the spinal marrow"), a name formerly much used instead of *spinal cord*, which is the final segment of the cerebro-spinal axis, and surrounds the central canal of the spinal cord.

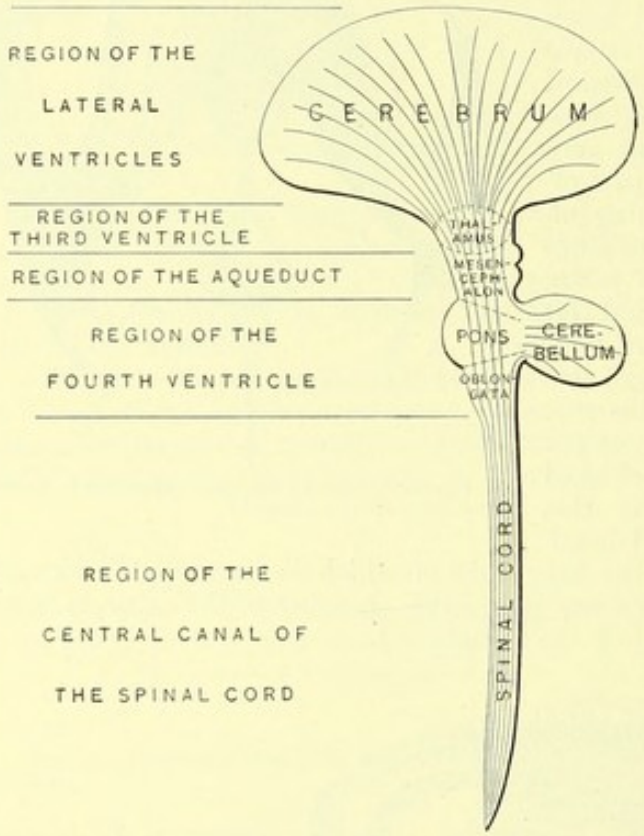

FIG. 548.—Diagram to show the relations of the cavity to the principal divisions of the axis.

The relative proportion and disposition of the gray and white nervous matter are very different in the various parts. For example, in the cord the gray occupies a central position, while in the cerebrum the greater part of this kind of material is at the surface. In the encephalon we find also many collections of gray nervous tissue, which seem to casual observation isolated, and independent of the gray at the surface and of the rather regular, continuous, and orderly arranged gray substance of the cord. The white nervous tissue is somewhat more easily understood, as we can trace a continuity in its mass for very considerable distances, indeed, practically from one extremity of the axis to the other. Beginning our inspection in the cord, we follow the fibres successively into and through the regions of the fourth ventricle, of the aqueduct, of the third ventricle, and last into the region of the lateral ventricles, where we find them ending in the gray matter of the very surface of the cerebrum.

A Diagrammatic Description of the Brain.

The relations of the primary segments of the encephalon in their fully developed state are so complex that a diagrammatic presentation of the subject is a helpful introduction to its fuller study.

The First Vesicle.—As would be expected from the great size and wide expansion of its cavity, the first vesicle attains a volume far in excess of that reached by any other; indeed, so large does it become that its bulk surpasses that of all the others together, and it overlaps them to such an extent as to conceal them com-

pletely in the view from above. Imagine it growing as the cavity has been represented to spread out—its central part (the aula) increasing little, the lateral portions much—and suppose that in the median line the wall is relatively very thin, and almost everywhere else very thick. The result is that there is an immense mass on each side, the two separated by a deep fore-and-aft cleft, and held together by bands near the bottom of this dividing fissure. As in all other parts of the encephalon, there is substantially a bilateral symmetry in these structures; that is, the portion on one side is a reversed repetition of that on the opposite side. Seen from above each suggests by its form a half-globe; and, although the resemblance is not observed from other points of view, the name *hemispheres* is given to these cerebral masses. If the encephalon is cut in two exactly in the middle line, and an inspection is made of the left surface of the right half, we have such a view of the first and second vesicles as is shown in Fig. 549, only that the diagram, instead of displaying them in contact, as they lie in nature, represents the upper of the two segments as if nearly separated from the lower by a tilting up of its hind end and a corresponding depressing of its front, the pivotal point being the region of the porta (foramen of Monro), represented by a circle at the left of the label "thalamus" and a little above it. The red line indicates pia. Between the porta and the label is the aula (the median portion of the first vesicle), from the front and upper part of which the porta opens into the lateral ventricle. The aula and all above and in front of it is cerebrum, the development of the first vesicle. Observe that the pia is applied to the hemisphere and is reflected from it to the thalamus, which constitutes the main portion of the wall of the second vesicle. The part marked *callosum* is the cut surface of the great bond of union between the hemispheres. This body reaches far into the substance of the hemisphere, and forms the roof of the lateral ventricle. In the picture all above, before, and behind the callosum is free surface of the hemisphere, not cut by the median incision. A little below the callosum is an arched structure, labelled *fornix*, cut through by the incision. Between callosum above and fornix below is stretched a thin plate, the *septum lucidum*. Going down to the region of the second encephalic vesicle, we find that its cavity has been completely exposed by the median cut, and its lateral wall, marked *thalamus*, displays a free surface; but when we look for the cavity of the first vesicle, we find only the aula and the porta; that is to say, the front and upper part of the third ventricle, and the hole of communication between the third ventricle and the lateral ventricle, the last named chamber being shut from our sight by the septum lucidum. To get a view of the lateral ventricle our best plan is to slice off the mass of the hemisphere which lies over the callosum, and then to cut through the latter near the median line, removing as much of the structure as is necessary to expose the cavity beneath it. We shall then observe what is shown in Fig. 550. The right lateral ventricle has been unroofed by this removal and its floor is laid bare. This has a very uneven surface from the irregularity of the contour of the structures which form it. The intrusions of substance are due in one place to the thickening of the wall of the cavity, and in another to the infolding of the wall where it is rather thin. At the front part is an illustration of the former, the *caudate nucleus* bulging into the chamber in a region where there is a bulky

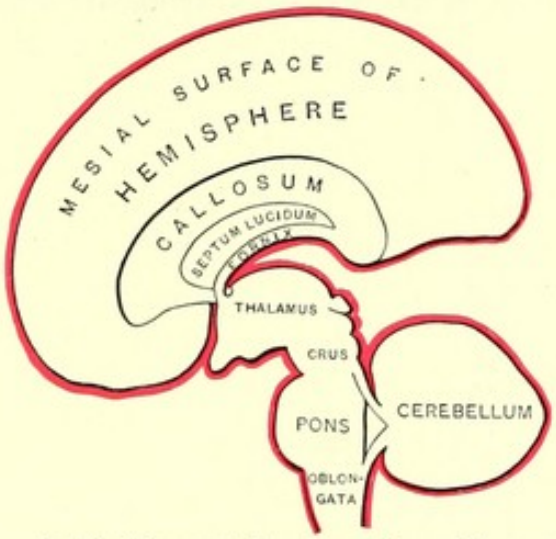

FIG. 549.—Diagram to show the relations of the parts developed from the first vesicle to the parts developed from the second vesicle. The hemisphere is tilted forward. (F. H. G.)

wall; and at the back part is an example of the latter kind, the *calcar* being a rounded ridge, which marks the location of a deep impression on the sloping area of the under surface of the hemisphere.

In the floor of the ventricle are seen, in regular order from front to back, the gray *caudate nucleus*, around the fore part of which bends the shallow anterior cornu, while the mesial border of the mass is marked by a white ribbon-like band, the *tænia semicircularis*; next and parallel to the last, a long, purplish body, the *choroid plexus*, composed of clumps of blood-vessels; then a white structure, the *fornix*, whose outer margin is named *fimbria*; and, finally, the *calcar*, which forms the floor and mesial side of the posterior cornu. At the hind end of the fornix begins the middle cornu, which extends far down and forward, below the level of the parts seen by the removal of the callosum. Into it are prolonged

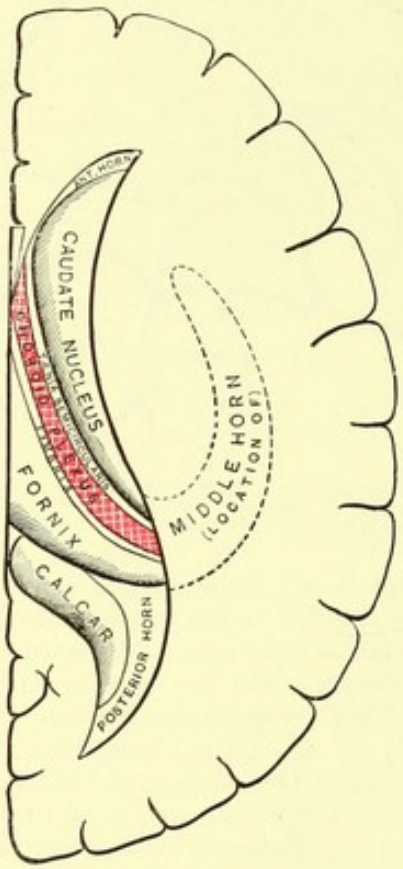

FIG. 550.—Sketch of the right lateral ventricle from above, its roof having been cut away. (F. H. G.)

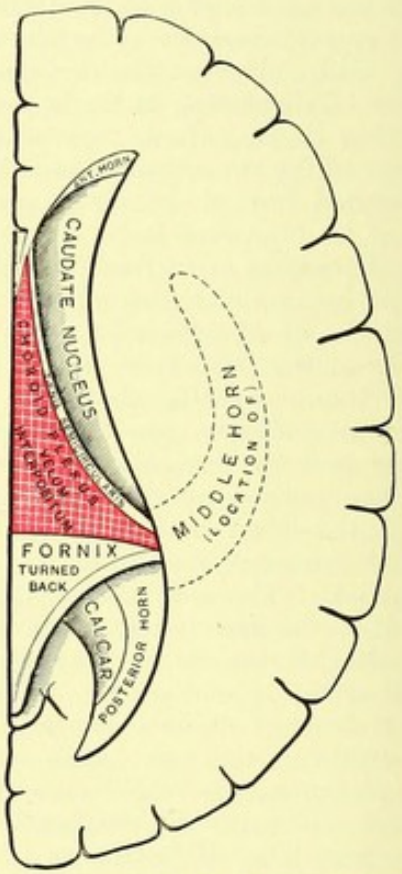

FIG. 551.—Same as Fig. 550, except that the fornix has been folded back, exposing the velum interpositum. (F. H. G.)

the caudate nucleus with its tænia, the choroid plexus, and the fornix with its fimbria. In Fig. 549 the fornix is shown as the undermost of the nervous structures concerned in forming the lateral ventricle in the median region, and its outer surface (which is underneath), like all external surfaces of the encephalon, is covered with pia, the vascular membrane. If we cut away the fornix (as seen in Fig. 550), peeling it off carefully from the pia beneath it, we shall expose the attached surface of this membrane, and find that the object, which we have called choroid plexus, is the fringed and crumpled edge of this part of the pia, which has intruded itself into the lateral ventricle between the free border of the fornix and the free border of the caudate nucleus—that is, between the corpus fimbriatum and the tænia semicircularis (Fig. 551). This intrusion is made possible by the disappearance of the nervous tissue along this line, and thus the pia covering the part and the endyma lining its cavity are brought into contact. The choroid plexus, like all the other parts of the wall of the ventricle, has its investment of endyma.

The Second Vesicle.—The walls of the second encephalic vesicle, enclosing the most of the third ventricle, are strikingly unequal in their development. At the sides they become very thick, forming the masses called the thalami; in front and below the walls are very thin; and at the top the nervous tissue disappears entirely, leaving the serous lining in contact with the vascular covering—the endyma and the pia thus constituting the roof of the cavity.

In Fig. 549 the cerebral hemisphere is pictured as hinged at the region of the porta and canted forward, in order that it may be more easily regarded independently of the second encephalic segment. Now, let us replace the hemisphere in the position which it normally occupies, namely, resting upon the second segment, the thalamencephalon (Fig. 552). The pia underlying the fornix and the pia overlying the thalamus are thus brought together, and in this way a double layer of vascular membrane is made to intervene between the bottom of the first encephalic segment and the top of the second. These layers fuse together and constitute the *velum interpositum* ("the interposed veil").

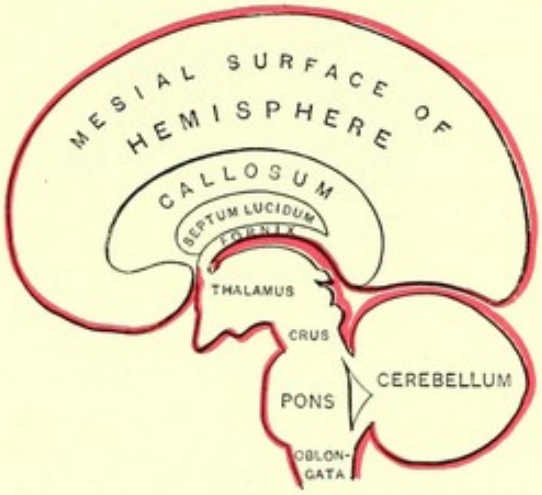

FIG. 552.—Diagram like Fig. 549, except that the hemispheres have been put back in their normal position. (F. H. G.)

The first two encephalic segments have more in common than their connection in the region of the porta and the blending of the layers of pia which come between them. There is a continuation into the hemisphere of great columns of nerve-tissue from the thalamencephalon, which receives them from the parts behind and below itself; and these will be described later.

The Third Vesicle.—Passing from the thalamencephalon we come to the mesencephalon, the region of the third encephalic vesicle, which contains the aqueduct. Here the walls are everywhere thickened, and, when viewed on their ventral aspect, look like two strong pillars, the *crura cerebri*; but their dorsal aspect presents four knobs, called *corpora quadrigemina* ("the four-twin bodies").

The Fourth Vesicle.—The ventral wall of the fourth encephalic vesicle is thick, constituting the *pons*; the side walls, the *pedunculi*, are rather thin; and the true dorsal wall, the *valvula*, is very thin. But a large, solid mass, the *cerebellum*, overhangs the rest of the segment, and to casual inspection conveys the idea of an enormous thickening of the dorsal wall.

The Fifth Vesicle.—The fifth encephalic vesicle, the *oblongata*, is the part least altered from the form of the spinal cord, with which it is continuous. It looks as if it were split in the middle behind, and its upper part widely spread open. Stretching across the cavity from one of these spread edges to the other is a layer of endyma, covered by a thin layer of pia, without the intervention of any nerve-tissue, constituting the roof of this segment.

The preceding diagrammatic presentation of the salient points in the structure of the encephalon will serve as a framework on which to build up more detailed information on the subject.

THE CEREBRUM.

The Surface of the Cerebrum.

The surface of each hemisphere of the cerebrum is composed of a layer of gray nervous tissue of variable thickness in different parts. The convex, external surface, the flat mesial surface, the irregular under surface—all present an outer stratum of cellular nerve-material, called the *cortical layer*, because it is a

covering, like the bark (*cortex*) of a tree. In the young fœtus this cortex is smooth and uncreased (Fig. 553); but, as months go by, it becomes wrinkled, narrow depressions occurring all over it, and getting deeper and more numerous with its development (Fig. 554). These creases are infoldings of the cortex; and, consequently, the more numerous and the deeper they are the greater is the amount of the peripheral gray substance. They are called *fissures*, or *sulci*. To the uncritical eye they seem to be nearly or quite without system in their arrangement, and they give the cerebrum an appearance not inaptly compared to that of the mass of small intestines, which is seen when the abdomen is laid open and the omentum is lifted off. This coiled look has given the parts between the fissures the name of convolutions, or, better, *gyri* (Anglicized into "gyres"). Though at first glance apparently disposed without order, the fissures and

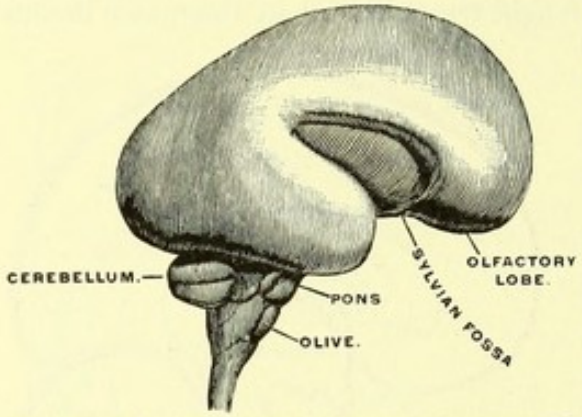

FIG. 553.—Brain of six-months' human embryo, natural size. (Kölliker.)

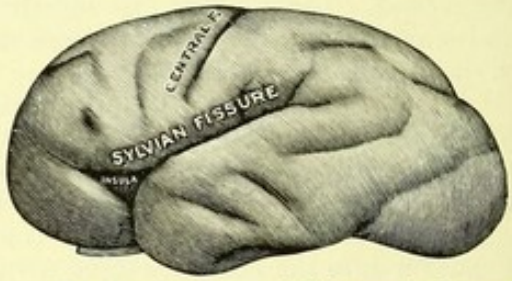

FIG. 554.—Cerebrum of eight-months' human embryo, left side. The insula is nearly covered in. (Testut.)

gyri have been discovered to be for the most part so constant and regular that they have received names intended to be descriptive of their location or shape. They are similar on the two sides, but not identical, and are subject to considerable variations in different individuals. But before giving further consideration to the gyri and the fissures separating them, it is important to notice a few clefts which make larger divisions.

The Longitudinal Fissure.—The two hemispheres are separated by the great *longitudinal fissure*. This goes through from top to bottom of the cerebrum in front and behind; but for the middle two-fourths or more of its antero-posterior length it is stopped when half-way down by the chief of the bands or commissures which connect the hemispheres, namely, the callosum (corpus callosum). All of the other fissures are found alike in each hemisphere, except the transverse, which is half in one hemisphere and half in the other.

The Sylvian Fissure.—Inspecting the hemisphere from the side or from below, the most pronounced peculiarity of its form is seen to be due to the presence of a cleft, which starts near the centre of the base (at the anterior perforated space), and, going upward and backward, cuts so deeply as to mark off very conspicuously a large mass from the middle portion of the hemisphere at its lowest part. This fissure is the *Sylvian* (*fissura Sylviana*) (Figs. 554, 555, 559). The greatest part of the undivided fissure is plainly seen only on the base of the hemisphere, but its divisions are visible only from the side. A little of the fissure proper shows laterally, but it divides immediately into *anterior* and *posterior limbs*, the former subdividing into two short *branches*, *ascending* and *horizontal*. The posterior limb courses backward and a little upward, ending with a decidedly upward inclination at about two-thirds of the distance from the front to the back of the hemisphere, and half-way between summit and base.

The Central Fissure.—In the middle region of the lateral surface above the Sylvian fissure is the *central fissure* (Rolandic) (Fig. 555), extending in an undulating course from the longitudinal fissure forward and downward almost (or quite) to the Sylvian. It begins behind the half-way point between front and

back, and ends anteriorly to this plane, thus obliquely dividing the surface into approximately equal parts.

The Parieto-occipital Fissure.—Far back on the upper margin of the hemisphere, as it slopes toward the base, is seen a notch, which marks the beginning of a fissure of the mesial surface, the *parieto-occipital fissure*, which will be described later.

The Lobes on the External Surface (Fig. 555).—In these three fissures we have the basis for a division of the lateral surface into lobes; and, although the division is rather artificial, and "lobe" is not an ideal name for the segments, it is necessary to have some means of designating the various parts, and this plan is convenient. The lobes visible on this convex surface are the frontal, the parietal, the occipital, and the temporal; but, though bearing the names of certain cranial bones, the limits of the lobes do not coincide with those of the osseous structures nearest which each respectively lies and from which it gets its name. If a line is drawn from the parieto-occipital fissure downward and forward to a point on the lower border beneath the rear end of the Sylvian fissure, usually marked by a notch, the pre-occipital, and another line in prolongation of the nearly horizontal part of the Sylvian fissure is made to touch the first one a little above its middle, the delimitation of the lobes is effected. Behind the parieto-

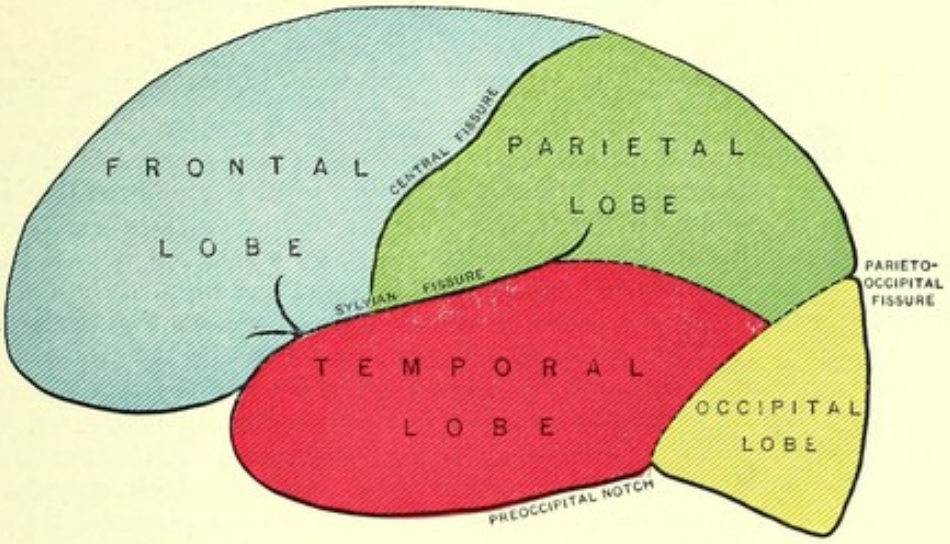

FIG. 555.—The lobes of the convex surface of the hemisphere, left side.

occipital line is the *occipital lobe*; in front of this and beneath the Sylvian fissure and its extension is the *temporal lobe* (temporo-sphenoidal); in front of the central fissure is the *frontal lobe*; and the residue, the area bounded in front by the central fissure, below by the Sylvian, behind by the parieto-occipital and its imaginary prolongation, and above by the longitudinal fissure, is the *parietal lobe*.

The Insula.—If the lower and front part of the parietal lobe and the lower and back part of the frontal lobe are lifted away from the Sylvian fissure, and the adjacent part of the temporal lobe is pressed down, there is brought into view a fifth lobe, which, from its situation, is called the *central lobe*, but is more commonly known as the *insula* ("the island") or the island of Reil (Fig. 556). Until fœtal life is half completed this lobe is distinctly superficial; but then its immediate neighbors increase so rapidly in size as to outstrip the insula in the race of growth—the parietal folds down, the frontal bulges back, the temporal crowds up from below—and among them it gets completely covered in; and in this process the Sylvian fissure is formed, the portion between the frontal and temporal lobes being the main fissure, that between parietal and temporal being the posterior limb, and that within the frontal the anterior limb. Morphologically the insula is the oldest lobe, and it stands, as will soon be shown, in

closer relation than any other to the great ganglia at the base of the hemisphere. The insula is sometimes called *gyri operti* ("the covered gyres"); and the parts of the frontal and parietal lobes which overlap the insula are known as the *operculum* ("the cover").

The Lobes of the Mesial and Tentorial Surfaces.—The *mesial surface* of the hemisphere cannot be seen plainly without dividing the encephalon in the middle line, and removing the hemispheres from each other; and the surface which con-

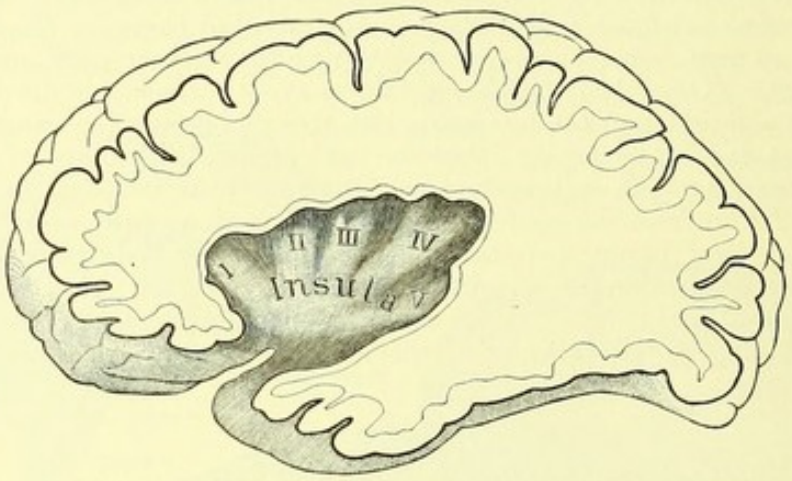

FIG. 556.—The left insula, the overlapping parts of the hemisphere having been removed. The numerals specify the gyri. (Dalton).

tinues the mesial downward (called the *tentorial surface*, on account of its resting in part upon the tentorium) is brought into view from the middle line by the removal of the crus and all below it. This dissection exposes a number of objects huddled together in the centre of the field, of which the largest, highest, and most conspicuous is the callosum, already mentioned as the great bond of union between the hemispheres. This displays a broad, cut surface, which forms a flattened arch from the front to the back of this mid region, and under the arch are gathered many structures, which, being internal, will be passed by until the study of the periphery is completed. When we look directly upon the flat, mesial surface of the hemisphere, the tentorial surface, into which the mesial runs at its lower border, slopes away from us to the lower margin of the convex, external surface, as is shown by Fig. 557. Thus, when viewed from the median line the tentorial surface is a good deal foreshortened.

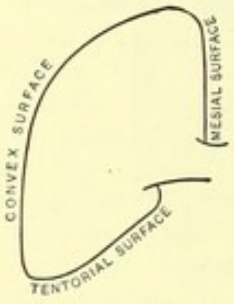

FIG. 557.—Outline of coronal section of hemisphere, showing slope of tentorial surface.

On the mesial surface (Fig. 558) are parts of two fissures already mentioned as appearing on the convex surface: the *central*, the upper end of which notches the sharp border more than half-way back; and the *parieto-occipital*, which, from its small beginning on the convexity of the hemisphere, is continued over the border, and then downward and forward, joining the calcarine at an acute angle. The *calcarine fissure* (from calcar, "a spur") runs from near the rather pointed hind end of the hemisphere upward and forward, and just beyond its middle, at the point where it receives the parieto-occipital, bends downward, and terminates beneath the rear end of the callosum. Encircling the callosum is a fissure, called the *callosal*. Beginning below the front end of the callosum is a fissure, which runs in a curve nearly concentric with that of the callosal and also with that of the margin of the hemisphere, until a point above the hind end of the callosum is reached, at which the fissure turns, and runs upward and backward to the upper border. Its situation gives it the name *calloso-marginal fissure*. Coursing in the general direction of the body of this fissure, between it and the parieto-

occipital, is frequently an irregular, somewhat broken fissure, the *precuneal* or subparietal; and running nearly horizontally in the midst of the sloping tentorial

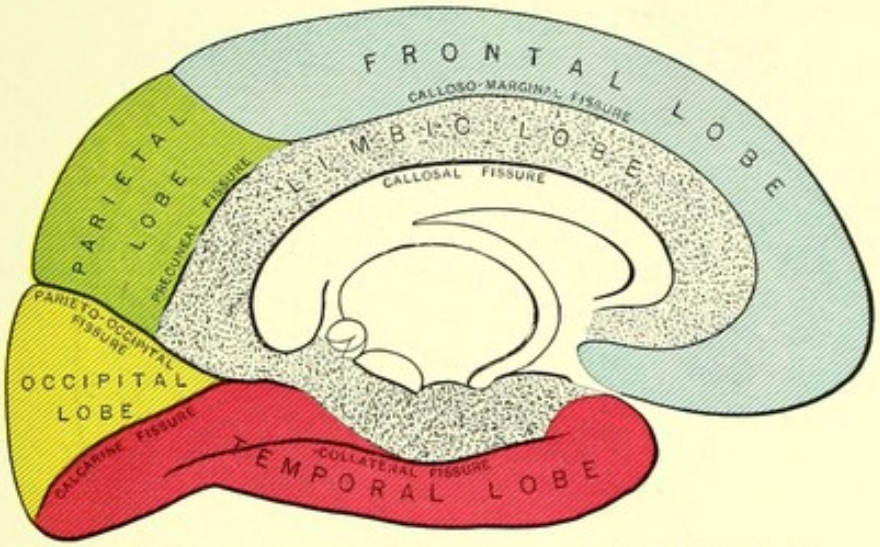

FIG. 558.—The lobes of the mesial and tentorial surfaces of the left hemisphere.

surface is the *collateral fissure*. The area between the calloso-marginal fissure and the upper edge of the hemisphere belongs to the frontal lobe; that bounded by the upturned end of the calloso-marginal fissure, the free border, the parieto-occipital, and the precuneal fissures is a part of the parietal; that between the parieto-occipital and the calcarine fissures is a portion of the occipital; and all below the level of the anterior limb of the calcarine is often assigned to the temporal. But the part of the temporal mass which is anterior to the tip of the calcarine fissure and above the collateral fissure is better associated with the area which is bounded peripherally by the calloso-marginal, precuneal, and calcarine fissures, to which (with several other structures, which need not be mentioned at present) are given the names of *limbic lobe* and *falciform lobe*, the former from its forming a border for the callosum, the latter because the sweep of its curve is suggestive of a sickle.

If we look at the hemisphere from below, we see parts of the temporal, limbic, frontal, and occipital lobes (Fig. 559).

We have now before us the primary superficial divisions of the hemisphere, namely, the insula, the frontal lobe, the parietal lobe, the occipital lobe, the temporal lobe, and the limbic lobe, and are prepared to consider the subdivisions of each of them. These secondary parts are *gyri*, and are separated from each other by fissures.

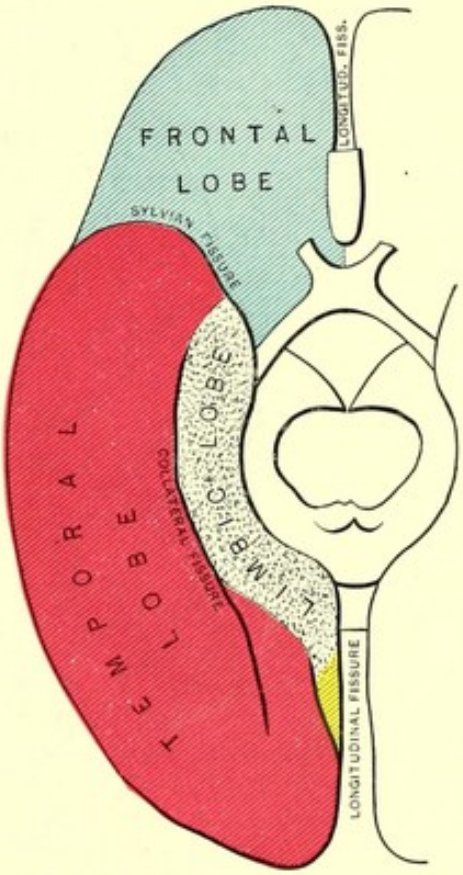

FIG. 559.—The lobes of the left hemisphere, seen from below.

Gyri of the Insula.—The *insula* or central lobe has five gyri, which radiate from the narrow lower part, like the folds of a fan from its handle (Fig. 556). They are separated from each other by simple fissures,

and the lobe is margined at the sides and top by the *circular fissure* (fissura limitans insulæ).

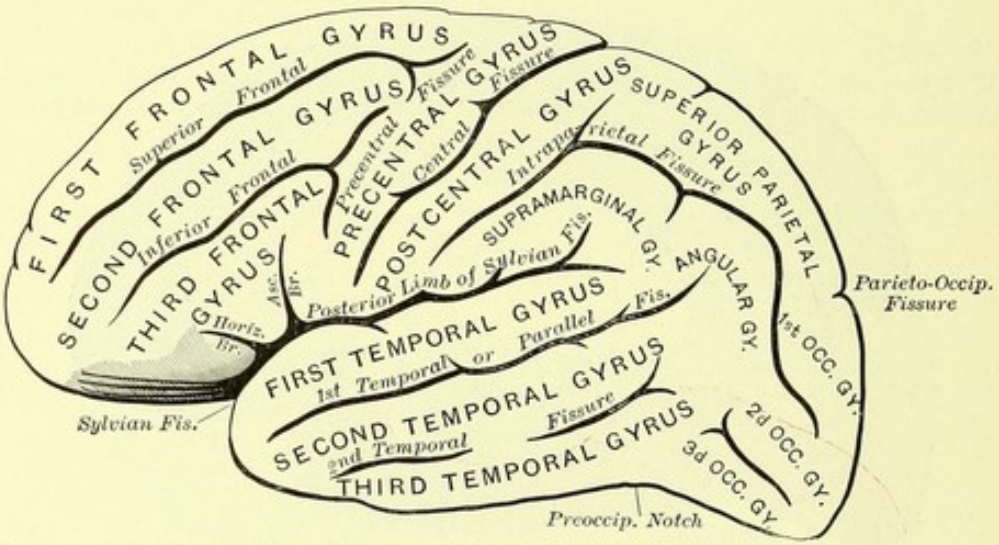

FIG. 560.—The gyri and fissures of the external lobes of the left hemisphere.

Frontal Gyri (Figs. 560–563).—On the convex surface of the frontal lobe are three *fissures*, two of which, the *superior* and *inferior frontal*, have a general fore-

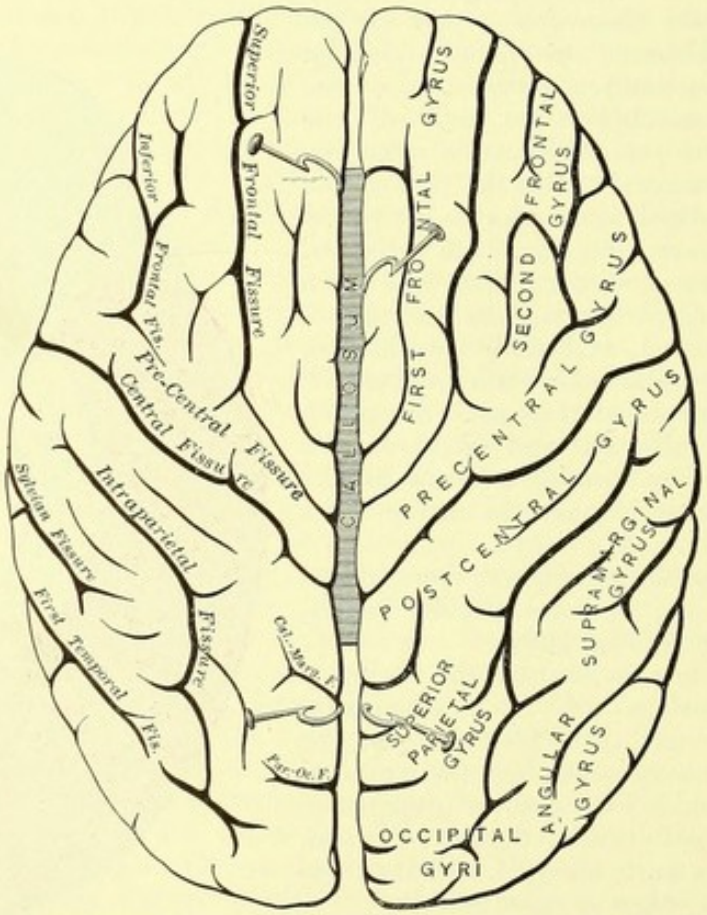

FIG. 561.—The hemispheres viewed from above. The fissures are labelled on the left side, the gyri on the right.

and-aft direction, and the third, the *precentral* (commonly broken), is substantially parallel with the central fissure. By these fissures the lobe is divided into four

gyri: the *first* (superior) *frontal*, between the longitudinal fissure and the superior frontal; the *second* (middle) *frontal*, between the superior and inferior frontal fissures; the *third* (inferior) *frontal*, beneath the inferior frontal fissure, capping the anterior limb of the Sylvian fissure; and the *precentral* (anterior central, ascending frontal) between the precentral and central fissures.

On the under surface the frontal lobe has two principal fissures. The first runs parallel with the great longitudinal and close to it, and is called the *olfactory fissure* from its giving lodgement to the olfactory nerve and its bulb. The other, the *supra-orbital fissure*, is very irregular, generally starting near the Sylvian fissure, coursing forward and then outward, and sending offshoots in various directions. The narrow gyrus between the longitudinal and the olfactory fissures is a continuation of the *first frontal gyrus* of the convex surface, the gyrus between

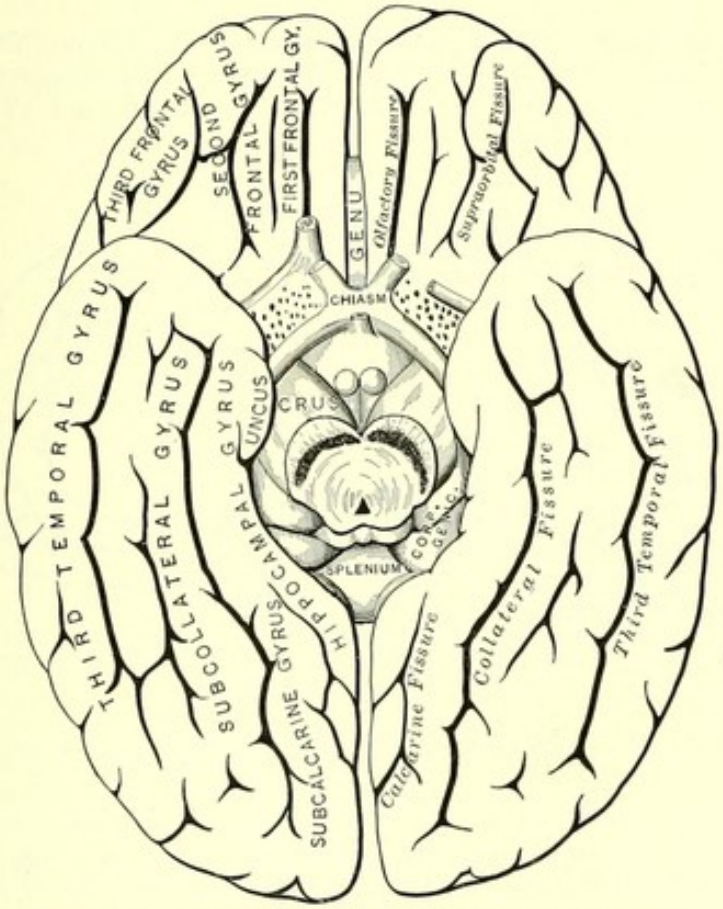

FIG. 562.—The hemispheres viewed from below. The gyri of the right hemisphere are labelled, the fissures of the left.

this and the supra-orbital fissure is continuous with the *second frontal* of the convexity, and the residue of the surface is continuous with the *third frontal*.

On the mesial surface the gyrus which begins under the front end of the callosum, and is bounded at first above, then behind, and then below by the calloso-marginal fissure, is continuous with the first frontal over the edge of the great longitudinal fissure. It is called the *marginal gyrus* from its situation. It really overlaps by a little the parietal region of the convex surface, and the central fissure appears as a notch in its hindmost part. A vertical fissure marks off a squarish area in this region, called the *paracentral gyrus*, because it is continuous with the gyri before and behind the central fissure of the convexity.

Parietal Gyri (Figs. 560–563).—The parietal lobe does not appear on the under surface. On the outer surface is the *intraparietal fissure*, which starts near the Sylvian, passes up a short distance, and then swings back and runs almost

parallel with the longitudinal. As has already been seen, the upturned end of the Sylvian fissure is within the parietal lobe. The *gyri* are the *post-central* (posterior central, ascending parietal) just behind the central fissure; the *superior parietal*, above the intraparietal fissure; the *supra-marginal*, above the hind part of the Sylvian fissure and arching over its end; and the *angular*, which occupies the remainder of the area, and is at the lower, rear corner of the lobe.

Continuous with the lateral surface over the edge of the longitudinal fissure is the mesial surface of the parietal lobe; but it has less width than the external surface, inasmuch as the calloso-marginal fissure does not end coincidently with the central, but a little to its rear, and the difference makes an addition to the frontal lobe by subtraction from the expected domain of the parietal. The mesial parietal gyri make a four-sided area, called the *precuneus*, from its relation to the wedge-shaped occipital gyrus adjoining, and "quadrate lobule" from its squarish shape.

Occipital Gyri (Figs. 560–563).—The convex area of the occipital lobe is conventionally divided into *three gyri* by two fissures; but these are very inconstant and irregular, and the typical arrangement is apparently not yet discovered—

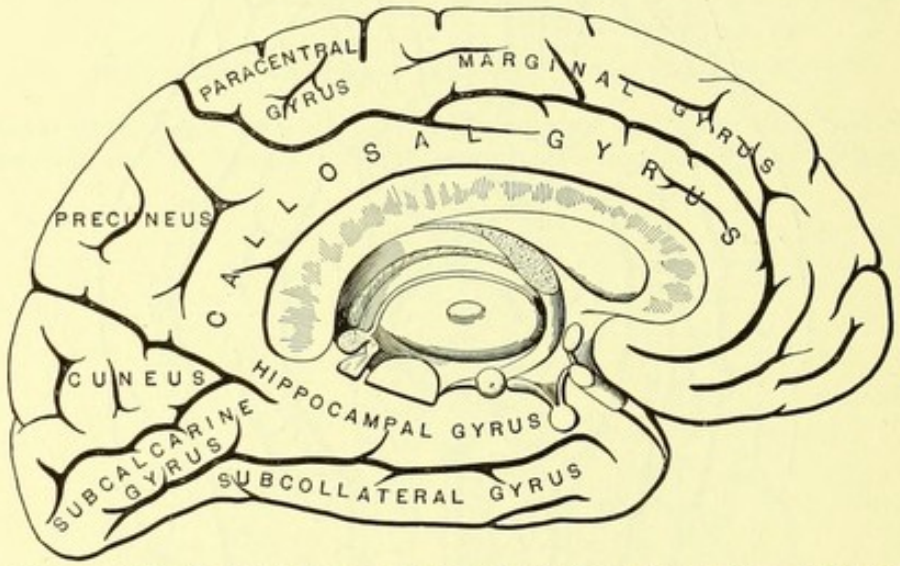

FIG. 563.—The mesial and tentorial surfaces of the left hemisphere, showing the gyri. The fissures have been named in Fig. 558.

certainly it is not agreed upon by the anatomists of the largest observation. The triangular form of the mesial occipital surface has led to its being named *cuneus* ("wedge"). It is continuous with the convex surface over the edge of the longitudinal fissure.

Temporal Gyri (Figs. 560, 562, 563).—The temporal (temporo-sphenoidal) lobe is marked by three fissures, which have a general fore-and-aft direction, two of them appearing on the lateral surface, and being called respectively the first or superior temporal or *parallel fissure* (the latter name from its relation to the posterior limb of the Sylvian fissure) and the *second* or inferior *temporal* fissure. The *third temporal fissure* is largely on the line between the lateral and under surfaces. The front half of the collateral fissure separates the temporal from the limbic lobe, and its rear half lies in the hind part of the temporal. The temporal *gyri* are the *first* (superior), the *second* (middle), and the *third* (inferior) on the outer surface, and, on the base or tentorial surface, the *subcollateral*, which is beneath the collateral fissure, and the *subcalcarine*, which lies between the calcarine fissure and the rear of the collateral.

Limbic Gyri (Figs. 562, 563).—The limbic lobe consists primarily of the *callosal gyrus*, which arches over the callosum, and the continuation of this which courses forward on top of the temporal lobe, and is known as the *hippocampal*, or

uncinate, *gyrus*. The first name of the latter gyrus comes from its relation to a structure which is seen in the middle horn of the lateral ventricle; the second refers to its hook-like distal end. But, in addition, there are included in this lobe other parts, dissimilar in appearance and errant from the structural character, which we associate with the idea of a lobe of the brain. They are the lateral half of the septum lucidum, the dentate gyrus, the fornix, the striæ longitudinales of the callosum, and the peduncles of the callosum, and have been grouped with the great gyri just named on grounds of morphology and embryology, rather than from considerations based upon adult structure.

In the limbic lobe are the *callosal fissure*, previously described, and the *hippocampal fissure*, which marks the upper boundary of the hippocampal gyrus,

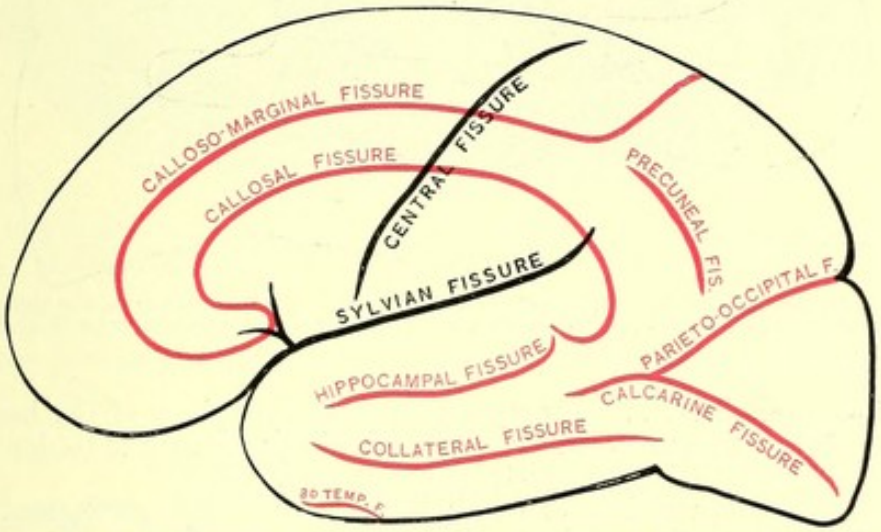

FIG. 564.—Diagram to show position which fissures of mesial and tentorial surfaces would occupy if projected in a horizontal plane sidewise to the outer surface. (F. H. G.)

extending from the back of the splenium of the callosum into the embrace of the hook of the gyrus. Seemingly lodged in the hippocampal fissure is a long slender roll of gray substance, notched upon its exposed surface, and called the *dentate gyrus* (fascia dentata). It begins behind the splenium, receiving here the striæ longitudinales of the callosum, runs to the end of the hippocampal fissure, and terminates by bending up over the uncus. Above it lies the fimbria, and between the two is a shallow cleft, called the *fimbrio-dentate fissure*.

Relation of the Principal Lobes to the Parts of the Lateral Ventricle.

The cavity of the *frontal* lobe is the anterior horn; that of the *parietal* lobe is the body; that of the *occipital* lobe is the posterior horn; and that of the *temporal* lobe is the middle horn (Fig. 565).

Situation of the Lobes in the Cranium.

The frontal rests upon the orbital plates of the frontal bone; the temporal occupies the middle fossa of the base of the skull; the occipital is supported upon the tentorium, being thus separated from the cerebellum, which fills the posterior fossa; and the parietal is held up by the subjacent cerebral structures, and is covered by the sides and vertex of the skull.

The Callosum.

Almost every part of the cortex of one hemisphere is connected with the corresponding part of the other hemisphere by nerve-fibres. In and near the median

line of the cerebrum all of these fibres are compressed vertically and, to a less degree, antero-posteriorly into a solid mass. Consequently the fibres seem to radiate from each side of this condensed body—going out, up, down, forward,

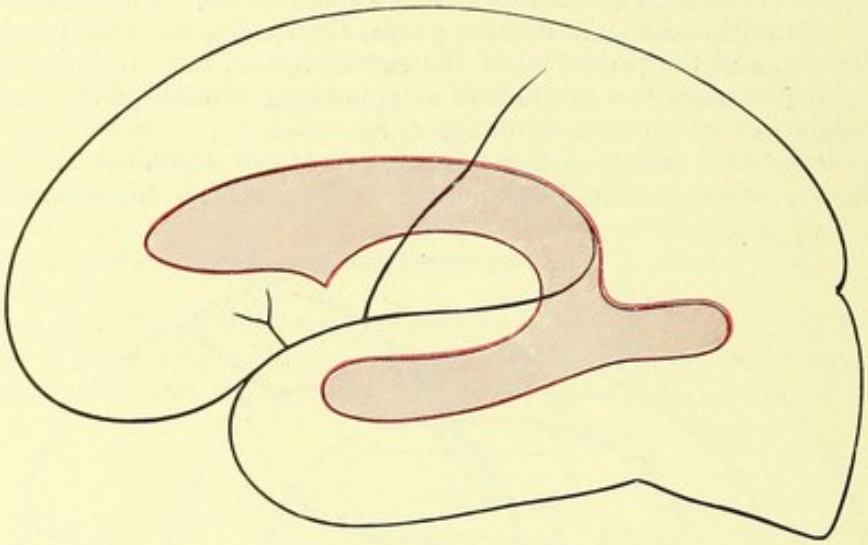

FIG. 565.—Diagram to show planes of lateral ventricle projected upon the outer surface of the hemisphere, as if the ventricle were filled with opaque pigment, and were seen through transparent wall of hemisphere. (F. H. G.)

backward—to terminate in the gray matter at the periphery of the hemisphere (Figs. 566, 567). The mass (with a slight addition, presently to be described) is the *corpus callosum* ("the hard body"), called, also, merely *callosum*. The middle of it can be seen by drawing the upper portions of the hemispheres apart, so as to widen the great longitudinal fissure, and looking directly downward into this enlarged cleft

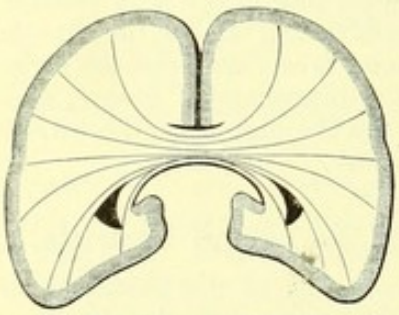

FIG. 566.—Diagram of coronal section of cerebrum to show course of fibres of callosum. (Testut.)

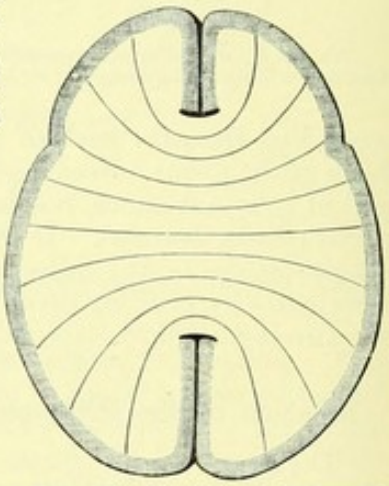

FIG. 567.—Diagram of horizontal section of cerebrum to show course of fibres of callosum. (Testut.)

(Fig. 561). It presents a free surface on top, in front, and behind; but its shape and size are not appreciated until sections of the cerebrum are made in various directions. A vertical median division of the cerebrum shows a cut surface of the callosum, which reveals its form and extent from before backward (Fig. 568). It is seen to be a long, thick, irregularly flattened arch. Its front end is curled back underneath, and is called the *genu* ("knee"). This thins out rapidly to an edge, the *rostrum* ("beak"), which is connected with the front part of the wall of the third ventricle by a delicate plate, the *basal white commissure*, or copula. The hind end, also, is rounded, its lower part being folded sharply forward, and is named the *splenium* ("bandage"). The portion between the genu and splenium is the *body*. If the cerebral tissues which overlie the callosum at the sides are cut away, it is found to be depressed along the middle line, and to

rise at the sides into the substance of the cerebrum (Fig. 569). The part of the

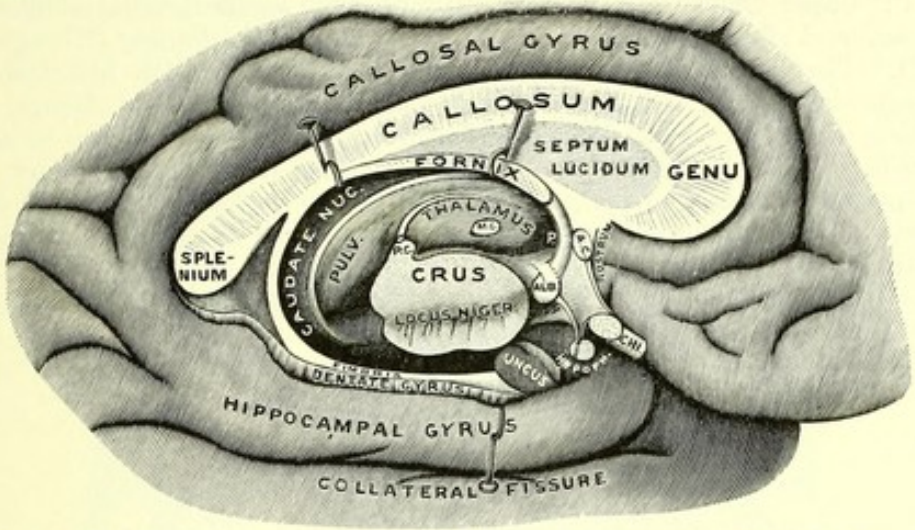

FIG. 568.—Parts of mesial and tentorial surfaces of left hemisphere, showing callosum in sagittal section with many of its relations. A.C., anterior commissure; ALB., corpus albicans; CHI., chiasma; HYPOPH., hypophysis; P., porta. (Modified from Testut.)

callosum which curves forward on each side from the genu into the frontal lobe is called the *forceps anterior* or *minor*; and that which projects backward in a

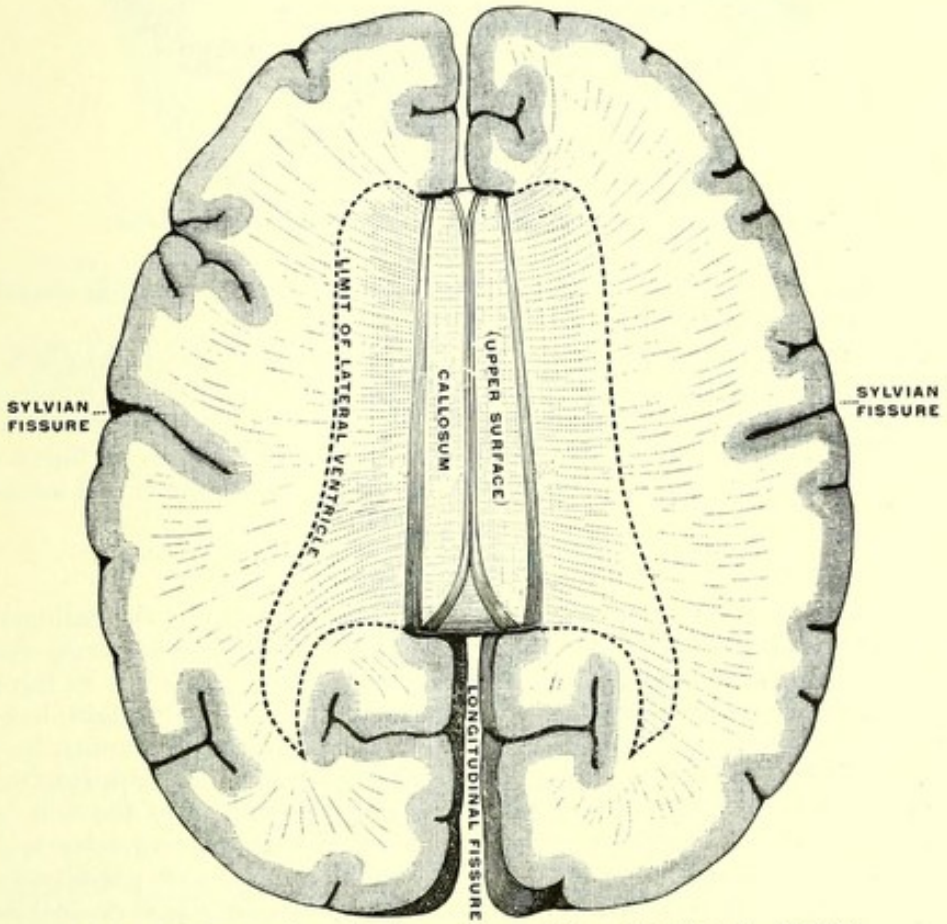

FIG. 569.—Upper surface of callosum, the overlying parts cut away. (Testut.)

corresponding manner from each side of the splenium into the occipital lobe is known as the *forceps posterior* or *major*. Between the two forceps of each side

is a plate, which extends laterally into the temporal lobe, and is named the *tapetum* ("mat").

On the upper free surface of the callosum some small bundles of fibres run lengthwise, and from this fact are called *striæ longitudinales* ("longitudinal stripes"). They are in two sets on each side: a median, which lies close to the central depression; and a lateral, which is lodged in the callosal fissure, and is named *tenia tecta* ("the concealed band"), from its being covered up by the callosal gyrus. These bundles diverge in front along the inner boundary of the anterior perforated spaces, constituting the *peduncles of the callosum*, and are lost in the beginning of the Sylvian fissures. Behind they are traced into the back part of the hippocampal gyri.

The fore-and-aft median *measurement* of the callosum is about five inches; its depth behind is nearly an inch, in front a little less.

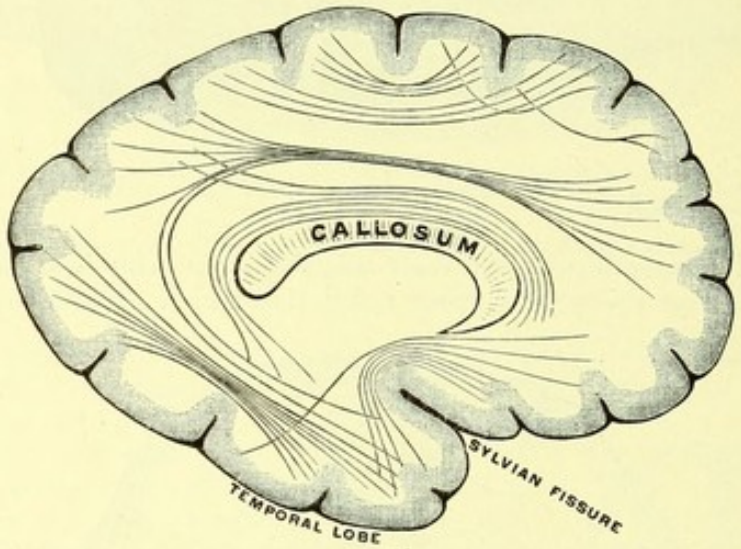

FIG. 570.—Diagram showing association-fibres of the hemisphere. (Testut.)

The callosum forms the roof of the lateral ventricles, the tapetum covering in the posterior and middle horns.

As the fibres of the callosum radiate to the cortex of the hemisphere, they interlace with those of the great columns ascending from the lower levels of the encephalon, and the two sets together constitute the chief bulk of the white substance of the cerebrum. But there are also unnumbered bundles of fibres which connect near or remote gyri, as shown in Fig. 570. They are called *association fibres*.

The Fornix (Figs. 571, 568, 572).

In the median section of the encephalon there is seen below the callosum and attached to the back part of its lower surface a white body, which curves forward and downward, then downward, and then downward and backward to the under surface of the brain, where it seems to double upon itself in a tight loop, and then to course upward, backward, and a little outward to the thalamus, in which it is lost. This is a part of the *fornix* ("arch"), the remainder requiring another dissection for its exhibition. The callosum and all the structures above it having been removed, we can look down upon the floor of the lateral ventricles, and thus obtain a view of the upper surface of the fornix. It is now perceived to be bilaterally symmetrical. A little of the anterior, descending part is seen in this view, and just behind this the two halves are joined together for a short distance. Traced backward, however, the bands diverge, swing off to the sides, and disappear at the upper ends of the middle horns of the ventricles. Cutting away the roof of these cornua, we find the bands following the curve of these cavities, and

partly spreading out over the hippocampus, partly continued on the inner wall of the horn. Between those parts of the diverging bands which lie in the bodies of the ventricles is stretched a thin layer of fibres. The part of the fornix which

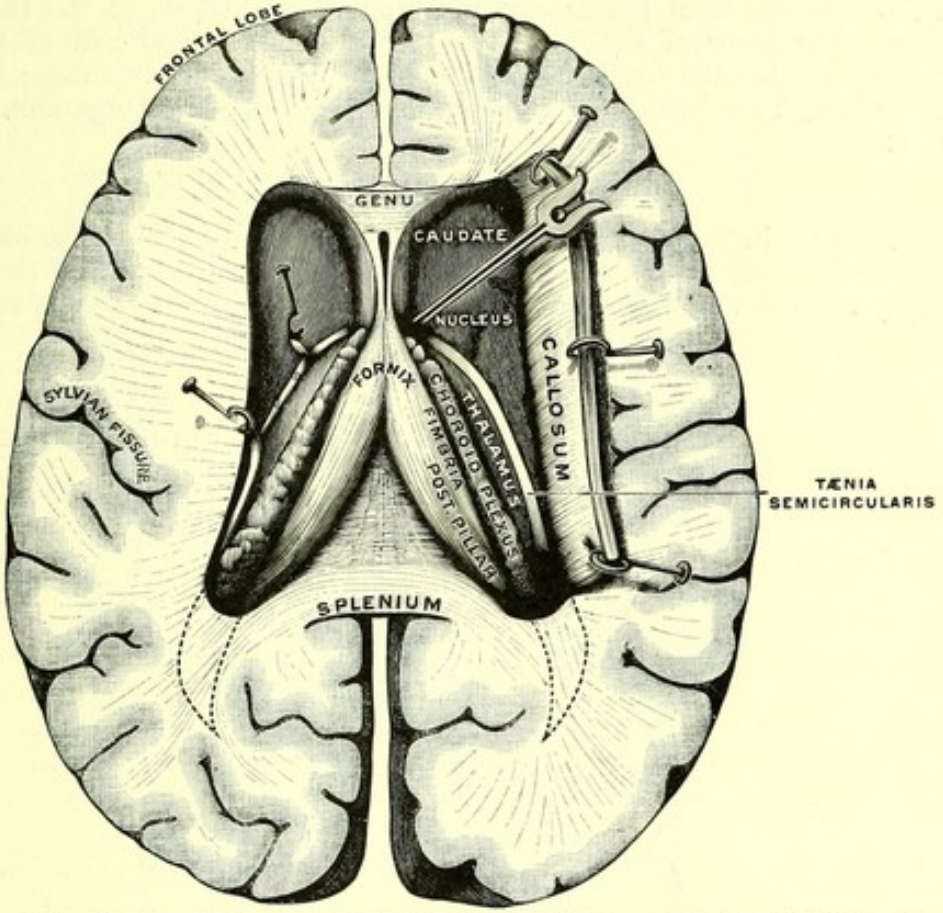

FIG. 571.—Floor of the lateral ventricles. On the left side the vein of the corpus striatum is lifted up. The director is in the right porta. Dotted outlines indicate the position of the posterior cornua. (Testut.)

results from the direct union of the two lateral bundles is its *body*; the portion in front of the body is the *anterior pillars*; the diverging bands behind the body are the *posterior pillars*; the little triangular sheet connecting the posterior pillars is

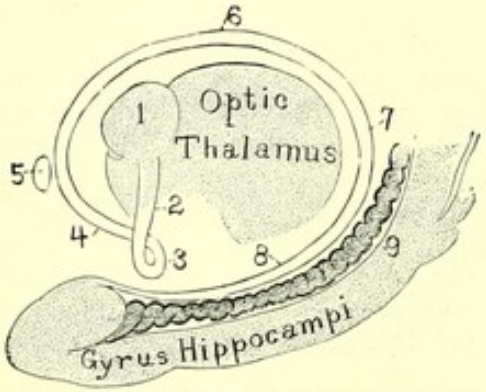

FIG. 572.—Diagram of thalamus, fornix, and hippocampal gyrus of right side, seen from middle line. *1*, anterior tubercle of thalamus; *2*, bundle of Vicq d'Azyr; *3*, corpus albicans; *4*, anterior pillar of fornix; *5*, anterior commissure; *6*, body of fornix; *7*, posterior pillar of fornix; *8*, fimbria; *9*, dentate gyrus. (Dalton.)

the *lyra*; the outer free edge of the body and posterior pillar is the *fimbria*, or corpus fimbriatum ("fringed body"); the little knobs produced by the abrupt reversal of direction of the anterior pillars at the base of the brain are the *cor-*

pora albicantia ("whitish bodies"), otherwise called corpora mammillaria ("teat-like bodies"). The upward-passing cord from the corpus albicans of each side to the corresponding thalamus is known as the *bundle of Vicq-d'Azyr*.

Thus it appears that the fornix is a fore-and-aft commissure, pursuing a circuitous course from the base of the brain in the region of the thalami to the descending horns of the lateral ventricles. Each lateral half of the fornix is principally devoted to the association of the parts on its own side; but each also has, through the lyra, a connection with the corresponding organs on the opposite side.

The Anterior Commissure (Fig. 573).

Directly in front of the anterior pillars of the fornix a rope-like bundle of nerve-fibres runs across from the front part of one temporal lobe to the corresponding part upon the opposite side. It describes in its course a large curve with its

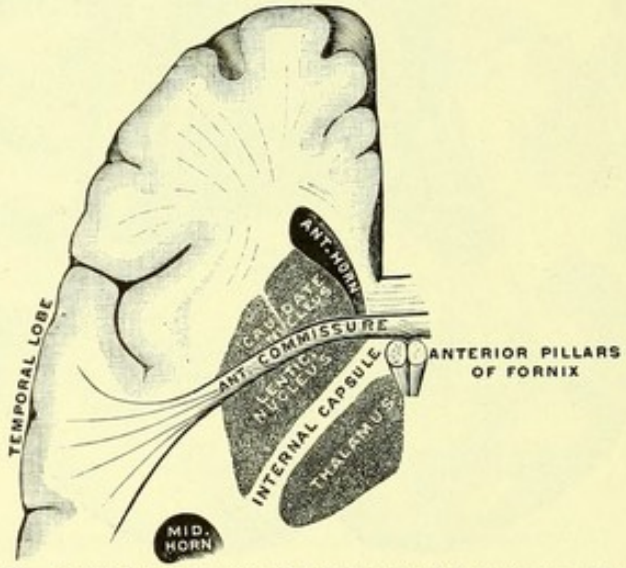

FIG. 573.—Anterior commissure, left half, viewed from above. (Testut.)

convexity forward and a little upward. It passes through the lenticular nuclei, and finally spreads out in the temporal lobes. This is the anterior commissure.

The Septum Lucidum.

Occupying the space between the under surface of the callosum and the upper surface of the fornix is a structure, called the *septum lucidum* ("the clear partition") (Fig. 568). It forms the dividing wall between the lateral ventricles. It consists of two layers of nervous tissue, enclosing a small, perfectly closed cavity, a mere crevice, which has no communication with any of the chambers of the encephalon. This hollow space is formed by a process of vacuolation, which means substantially that the middle part of the single thick plate, of which the septum originally consisted, was withdrawn by gradual absorption, leaving in its stead a chink, which is the *cavity of the septum lucidum* (Fig. 577). This space is occupied by a little serous fluid. The wall next to the cavity is gray, but is white on the outside—that is, next to the lateral ventricle.

The Ganglia of the Hemisphere.

Embedded in the substance of the hemisphere are several masses of gray matter, which seem upon casual inspection to be detached collections, quite independent of the cortex. On careful examination, however, they are found to be continuous with the superficial gray substance, and even with each other. They are

the caudate nucleus, lenticular nucleus, claustrum, and amygdaloid nucleus, or amygdala (Fig. 574).

The caudate nucleus and the lenticular nucleus have commonly been described

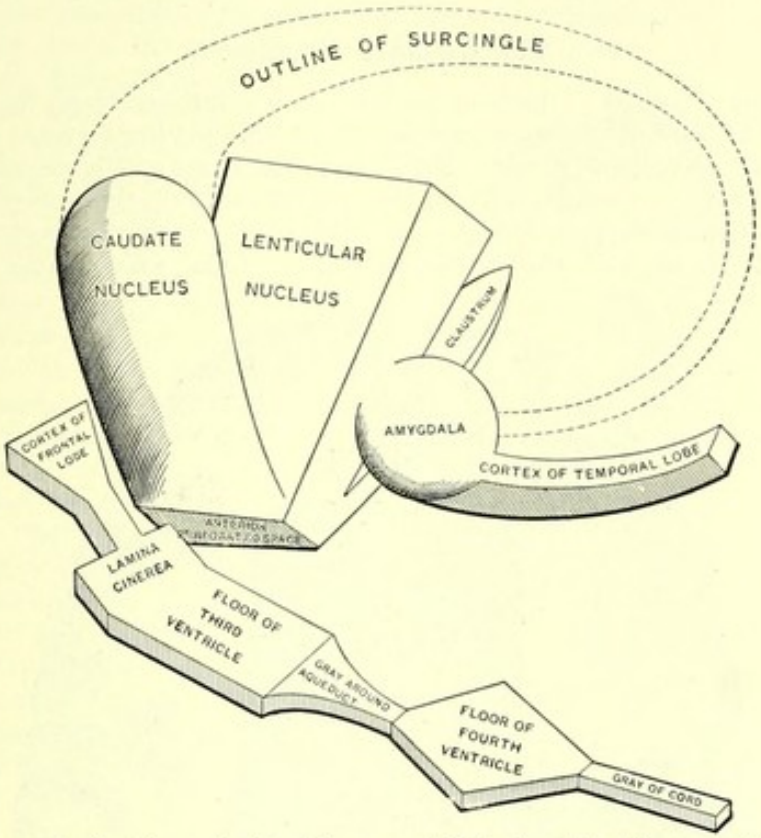

FIG. 574.—Diagram to show the continuity of the gray of the basal ganglia of the cerebral hemispheres, the cortex, and the lower segments of the cerebro-spinal axis. (F. H. G.)

as parts of a single body, called *corpus striatum* ("striped body"), on account of the peculiar, striped appearance of the surfaces resulting from its section; but description is facilitated by treating them as independent structures. The *caudate*

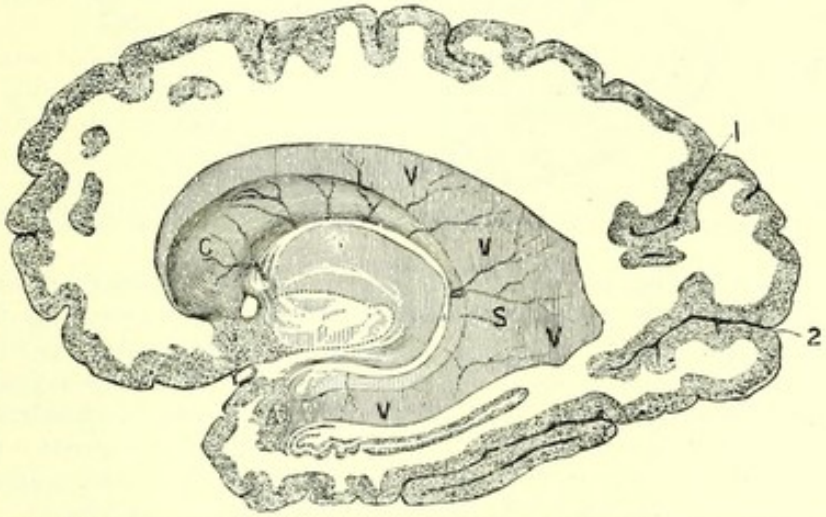

FIG. 575.—Right lateral ventricle opened from its mesial side. *A*, amygdala. *C*, caudate nucleus. *S*, surcingle. *V*, cavity of ventricle. 1, parieto-occipital fissure. 2, calcarine fissure. (Dalton.)

nucleus presents a free surface in the floor of the lateral ventricle, and hence is sometimes spoken of as the intraventricular portion of the corpus striatum; the *lenticular nucleus* does not appear at all in the ventricle, and, consequently, is

occasionally referred to as the extraventricular portion of the corpus striatum. The *claustrum* is a plate of gray substance, embedded between the lenticular nucleus and the insula. The *amygdaloid nucleus* is a collection of gray matter near the apex of the temporal lobe.

The Caudate Nucleus.

The caudate ("tailed") nucleus protrudes into the cavity of the lateral ventricle at the fore part of the floor, the anterior horn curving forward and outward around its most prominent portion (Fig. 576). The front end is rounded, and faces upward, forward, and inward. From this large beginning the nucleus diminishes in size as it is traced backward, and hence the most conspicuous part of it is pear-shaped. But the stem of the pear—the tail or cauda, which gives its name to

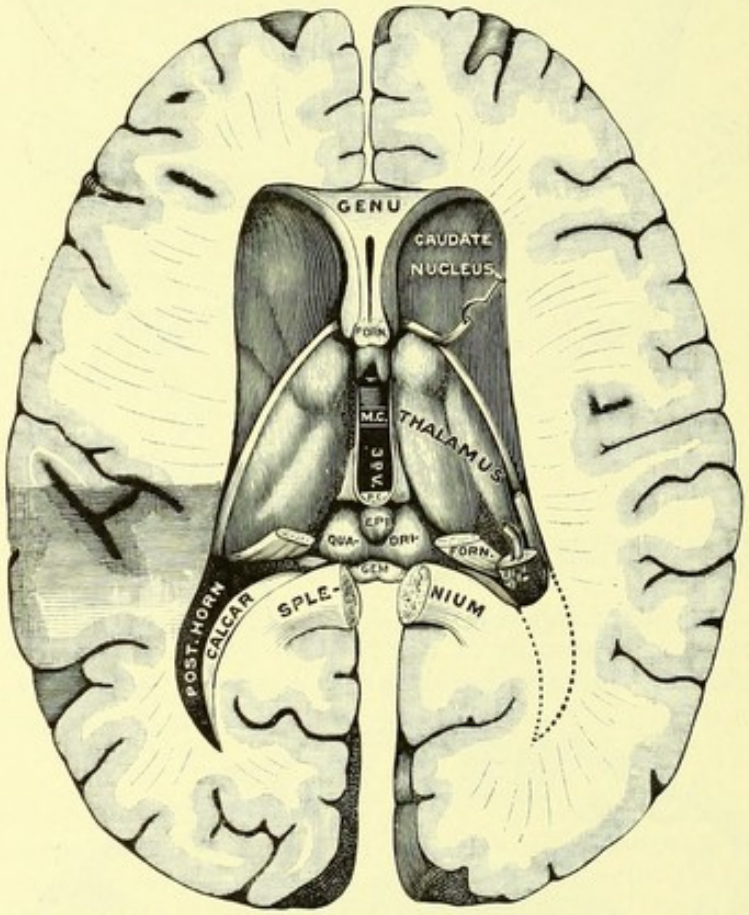

FIG. 576.—Lateral and third ventricles from above. The fornix and velum interpositum have been removed. EPI., epiphysis. M. C., middle commissure. P. C., posterior commissure. (Testut.)

the nucleus—stretches backward and outward as a slender prolongation through the body of the ventricle to the rear end, and thence in a sweeping curve into the middle horn and even to its extremity, clinging to the roof of the cornu (Fig. 575). It thus describes almost a circle, the tip of it reaching a point nearly underneath the blunt beginning. As it embraces in its loop a considerable mass of brain-tissue, it has been named the *surcingle*. It is not of regular outline, but is alternately and unevenly constricted and enlarged (Fig. 578). The caudate nucleus ends in the amygdala at the front end of the temporal lobe.

Along the inner border of the caudate nucleus is a band of fibres, which may fairly be regarded as its proper edge. It is called the *tænia semicircularis* ("the half-circle ribbon") (Figs. 576, 550). It accompanies the tail of the nucleus in the roof of the middle horn even to the amygdala. In the body of the ventricle it is covered by the vein of the corpus striatum.

The Lenticular Nucleus.

In order to obtain an adequate view of the lenticular ("lens-like") nucleus, it is necessary to make horizontal and vertical sections through that part of the substance of the hemisphere in which it is located. By such means we learn that this gray mass lies at the outer side of the caudate nucleus, but is for the most part separated from it by a thick plate of white nervous tissue, the *internal capsule*. Its shape is that of an irregular, three-sided pyramid (Figs. 577, 578). It is divided into three unequal portions by two layers of white matter, the *internal* and *external medullary laminæ*. The outer portion is the largest, is of a deep, red hue, is streaked at its inner part with nearly horizontal, white lines, and is called the *putamen* ("husk"). The other portions are yellowish-gray, and together constitute the *globus pallidus* ("the pale sphere").

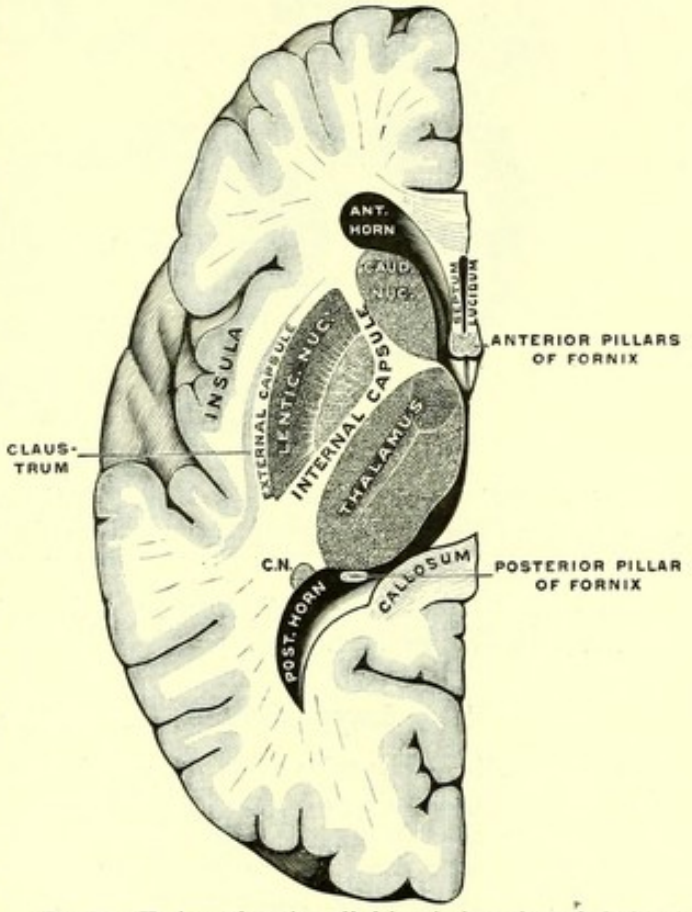

FIG. 577.—Horizontal section of left hemisphere through the basal ganglia, viewed from above. C. N., caudate nucleus. (Testut.)

The lenticular nucleus is not entirely embedded in the brain substance: a portion of it is at the surface of the base of the cerebrum, at the outer side of the chiasma and behind the roots of the olfactory lobe, in the *anterior perforated space*. The internal capsule does not wholly separate the lenticular and caudate nuclei, the two masses being united below and in front of it, and being further connected by thin cords of gray matter, which cross the capsule. The claustrum is fused with the lenticular nucleus at the anterior perforated space; the amygdala is united with its hind and lower part; and through the amygdala the nucleus is continuous with the cortex of the hemisphere. From these facts concerning the association of the gray masses of the hemisphere, we see that there is good reason for regarding them as thickenings of the peripheral gray substance.

The **Anterior Perforated Space** is situated at the base of the brain at the point from which the Sylvian fissure starts. The optic tract lies obliquely behind it, mesially it is continuous with the lamina cinerea, in front is the orbital surface of the frontal lobe. It is marked by numerous holes, through which pass blood-vessels to the lenticular nucleus. Fig. 562 shows it on each side of the chiasm.

The Claustrum (Fig. 577).

Just outside of the lenticular nucleus is a thick stratum of white tissue, called the external capsule, which will be described later. Between this external capsule and the white substance which furnishes the backing of the gray of the insula is a thin lamina of gray tissue, called the *claustrum* ("barrier"). Its surfaces are directed respectively toward the insula and the lenticular nucleus. In

horizontal or vertical section its outline is undulating. The adherent tissues being dissected away, it is seen to be of triangular shape, with its apex above; and its base, which is its thickest part, is found to reach to the surface of the brain at the anterior perforated space, where it is united to the lenticular nucleus.

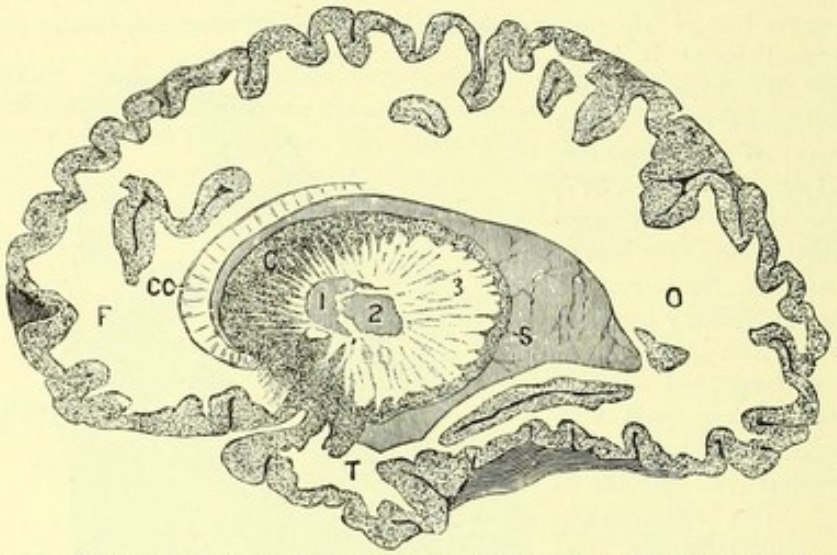

FIG. 578.—Longitudinal section through the entire right caudate nucleus, viewed from mid line. The plane of the section is not perpendicular, but has followed the surcingle outward. C, caudate nucleus. CC, front part of callosum. F, frontal lobe. O, occipital lobe. T, temporal lobe. S, surcingle. 1, 2, inner and middle zones of lenticular nucleus. 3, internal capsule. Observe the continuity of the gray substance. (Dalton.)

The *olfactory lobes*, the *optic tracts*, and the *chiasma* will be considered in connection with the cranial nerves.

The Amygdaloid Nucleus (Figs. 581, 586, 575).

This ganglion, otherwise called *amygdala*, is a mass at the tip of the temporal lobe, due to a thickening of the cortex of this region. It is of sufficient size to cause a protrusion into the roof of the middle horn of the lateral ventricle, at whose distal end it receives the extremity of the surcingle. It is continuous in front and above with the lenticular nucleus.

The Velum Interpositum.

Although it is a part of the parietes of the third ventricle, the *velum interpositum* ("interposed veil") requires description here because its fringed edges, the *choroid plexuses*, appear in the floor of the lateral ventricles, and cannot be understood except in connection with the velum. It will be recalled (Figs. 549, 552) that the pia of the under side of the developing first brain-vesicle is brought by the backward and downward growth of that segment directly in contact with the pia of the upper surface of the second brain-vesicle. The combination of the two layers of pia constitutes the velum interpositum—the veil placed between the prosencephalon and the thalamencephalon. It lies just beneath the part of the fornix which appears in the bodies of the lateral ventricles, and just above the cavity of the third ventricle, resting at the sides upon the upper surfaces of the thalami. In the floor of each lateral ventricle, between the fimbria, which makes the edge of the fornix, and the tænia semicircularis, which margins the caudate nucleus, is a narrow strip of the parietes of the first encephalic vesicle in which there is an entire absence of nervous tissue, and, consequently, the wall of the vesicle in this area consists merely of endyma and pia. The fimbria and tænia are prolonged from the body of the lateral ventricle into its middle horn; and the wall between them here is like that between them in the body of the ventricle—merely pia and endyma in close contact, the nervous tissue which once existed in this narrow area having

disappeared. The highly vascular pia, wherever it covers nervous tissue, sends branches of its vessels into the surface layers of this tissue; but along this line, which extends from the porta (foramen of Monro) to the tip of the middle horn, the pia lies against no such resistant material, being applied closely to the delicate endyma. Its branches, becoming dilated and prolonged, push the filmy serous membrane inward, so that an irregular, clumpy mass of vessels, covered everywhere with endyma, encroaches upon the space originally devoted to the ventricular cavity. This vascular structure is called the *choroid plexus* ("leather-like network") (Fig. 571). It is convenient to speak of the "intrusion" of the choroid plexus into the ventricular cavity; but as the cavity is limited by the endyma, and no breach is made in this membrane, the expression is not strictly correct, the fact being that the wall of the cavity is bent inward, and the contained space is by so much diminished. All of the choroid plexuses are explained in the same way. It is to be noted that, while the choroid plexus of the body of the lateral ventricle is derived from the velum, the choroid plexus of the posterior horn is derived from the pia which clothes the limbic lobe.



FIG. 579.—Diagram of transverse section of axis where a portion of the nervous wall has disappeared, allowing pia and endyma to come together.

The diagram (Fig. 580) will aid one in understanding this. In it the velum is shown as a triangle marked with transverse red lines; the choroid plexuses are in solid red; the tæniæ semicirculares are in blue; and the outline of the fornix and fimbriæ is indicated by broken lines. We are looking down upon these objects. On the right of the diagram the tænia and fimbria, with the intervening choroid plexus, are represented as straightened out, as if the temporal lobe and



FIG. 580.—Diagram to show relations of tænia, fimbria, and choroid plexus in body of lateral ventricle and in middle horn. On the right side the parts are straightened out, on the left they are curved in their natural shape. (F. H. G.)

the adjacent part of the limbic lobe had been stretched backward. On the left the parts are shown with the curve naturally described by the middle horn. In making the curve the parallelism between the two nervous bands is substantially

maintained, but the tænia gets above the fimbria. The middle horn is much nearer to the mesial than to the outer surface of the temporal lobe, so near, in fact, that the fimbria is covered with pia. In the region of the velum the choroid plexus is formed by the pia which makes the velum; beyond the hind edge of the velum the plexus is made from the pia immediately on the surface of the brain.

The crevice through which the invagination of the pia is effected is called the *transverse fissure*, or the *choroid fissure*; and it extends from the porta (foramen of Monro) nearly to the distal end of the middle horn on each side.

In **the posterior horn** of the lateral ventricle (Fig. 581) the inner wall, which slopes outward toward the floor, presents a prominent protrusion, caused by the pushing in of the entire wall of the cavity at this point in correspondence with the depression upon the tentorial surface of the hemisphere, which we know as

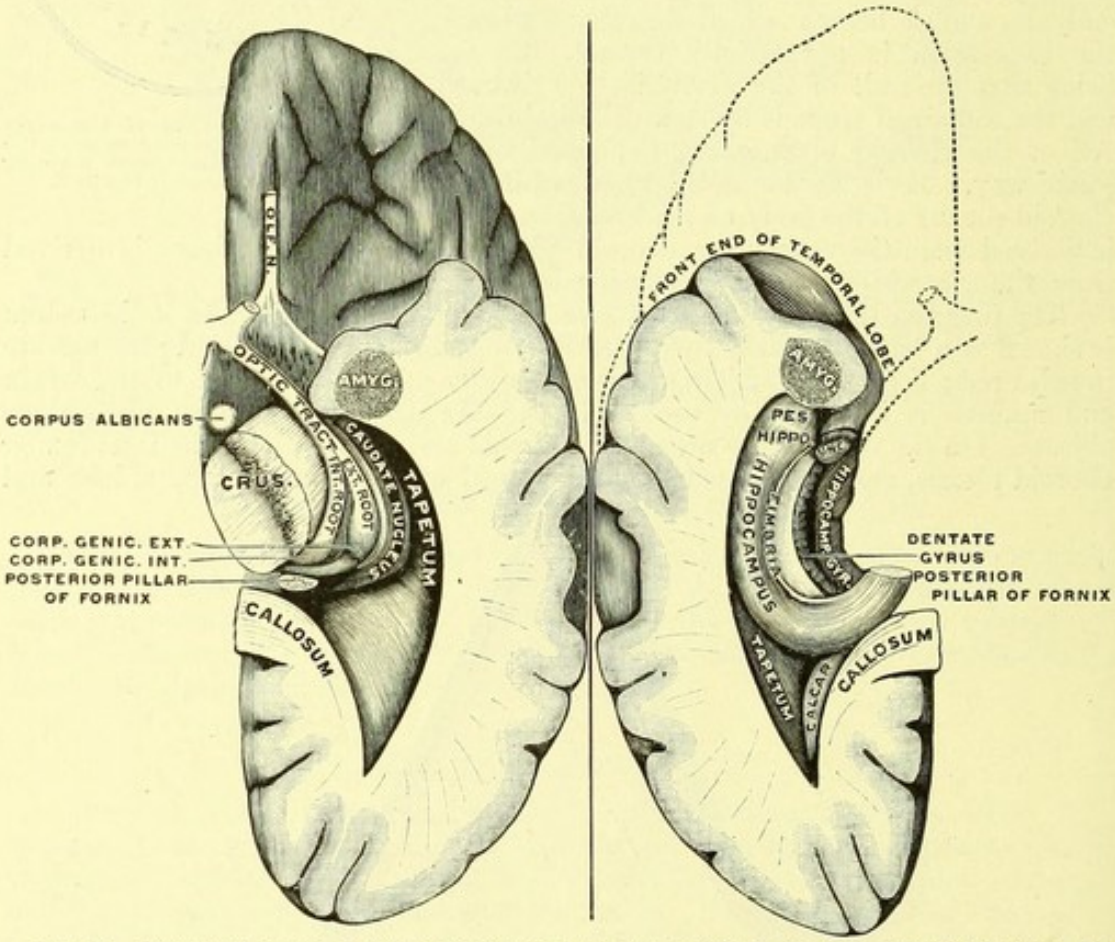

FIG. 581.—Horizontal section of left hemisphere, opening the middle horn of the lateral ventricle. The upper segment, containing the roof of the horn, has been turned off to the left. (Testut.)

the calcarine fissure. The elevation is well called the *calcar* ("spur"), although a less suggestive and helpful name, hippocampus minor ("the smaller sea-horse") is more commonly used. Just above the calcar is another prominence, the *bulb*, produced by the posterior forceps of the callosum. The roof of this cornu, as stated previously, is furnished by the tapetum of the callosum. Finally, the floor is triangular, has a convex surface, owing to the intrusion of the wall caused by the formation of the collateral fissure, and is called the *eminentia collateralis*. The posterior horn gets its peculiar curve from the intrusion of the parieto-occipital fissure on the mesial surface of the hemisphere (Fig. 558).

In **the middle horn** of the lateral ventricle the parietes are the *internal* (mesial) *wall*, the *floor*, and the *roof* (Figs. 575, 578, 581, 582). The inner wall swells outward, so that it is seen in large part in a view from above; the floor is rounded

up in the middle like a turnpiked road ; and the roof, which presents the broadest surface of this prismatic cavity, is slightly arched. The bulging of the mesial wall corresponds to the depression in the cortex, which is named hippocampal fissure, and itself is called the *hippocampus* ("sea-horse")—sometimes *major* ("the greater") being added. This peculiar elevation widens as it extends toward the apex of the horn, and terminates in a blunt indented end, called the *pes hippocampi* ("the foot of the hippocampus") from its resemblance to the paw

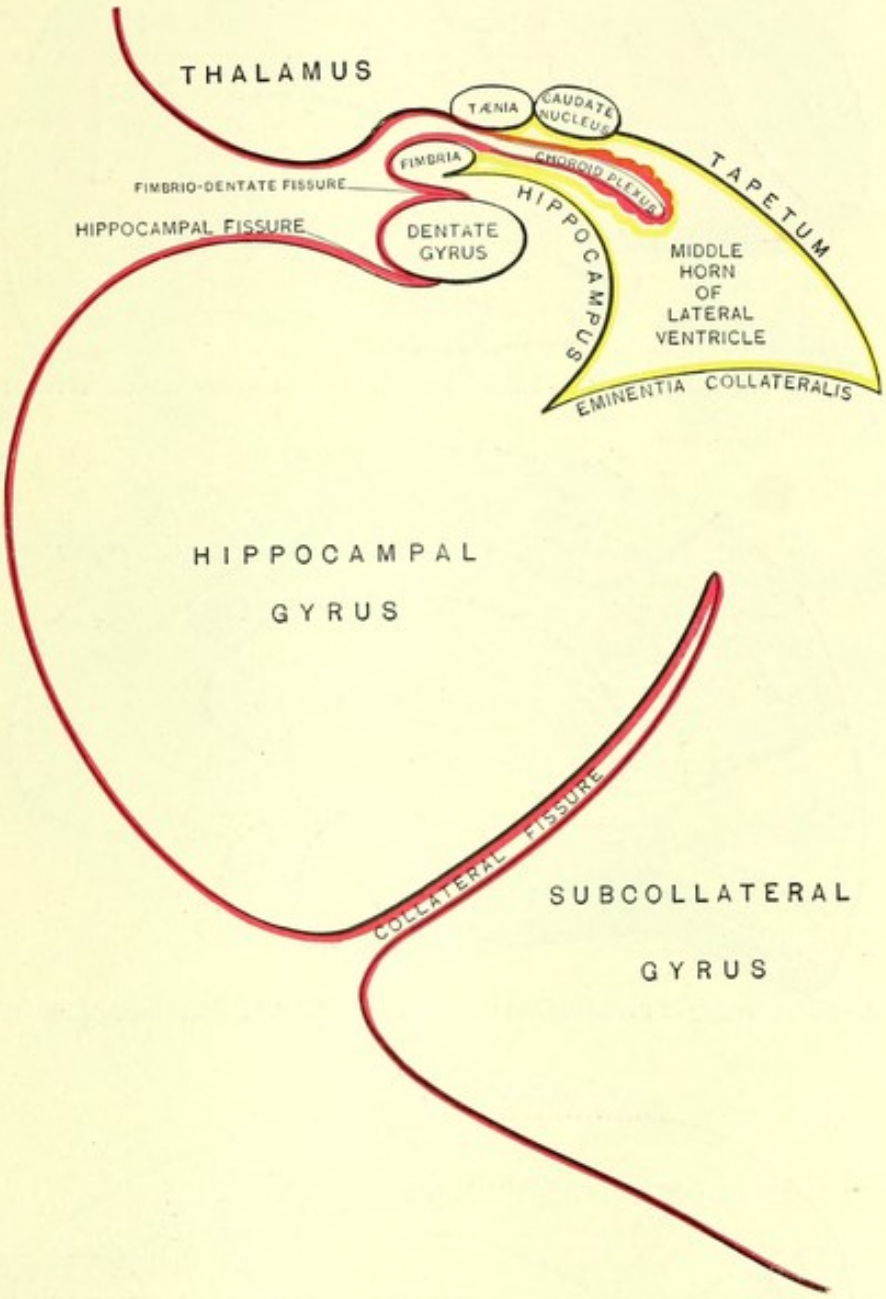

FIG. 582.—Semidiagrammatic coronal section through the middle horn of the right lateral ventricle. We look upon the hind surface of the front segment, and forward into the cavity. (F. H. G.)

of some animal. The convexity of the floor results from the bending inward of this part of the parietes of the cavity caused by the collateral fissure, anterior to the part which causes the prominence in the floor of the posterior horn. Attached to the roof, which is made by the tapetum, are the *tail of the caudate nucleus* and the *tænia semicircularis*, side by side, as they were in the body of the ventricle from which they are traced, and ending in front in the *amygdala*. Along the top

of the hippocampus courses the *fimbria*, continued from the posterior pillar of the fornix, of which organ it has become the sole representative. Between the

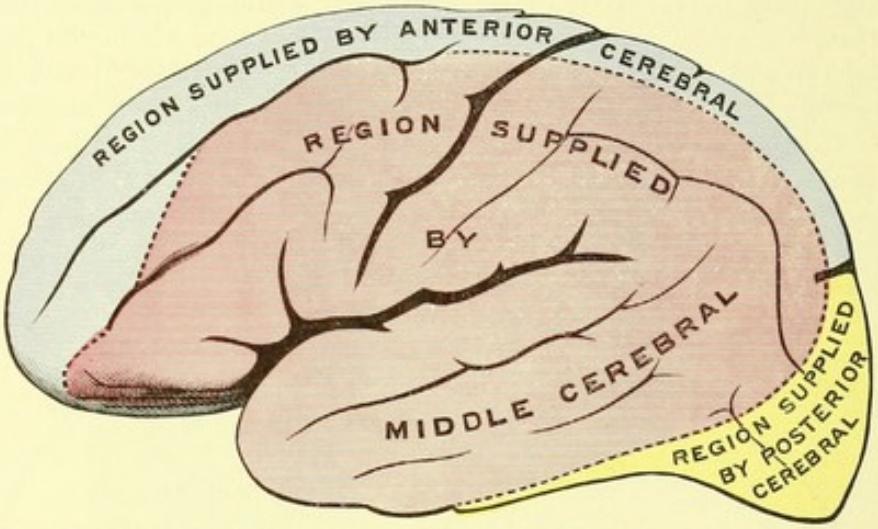

FIG. 583.—Arterial supply of the lateral surface of the cerebral hemisphere. (Testut.)

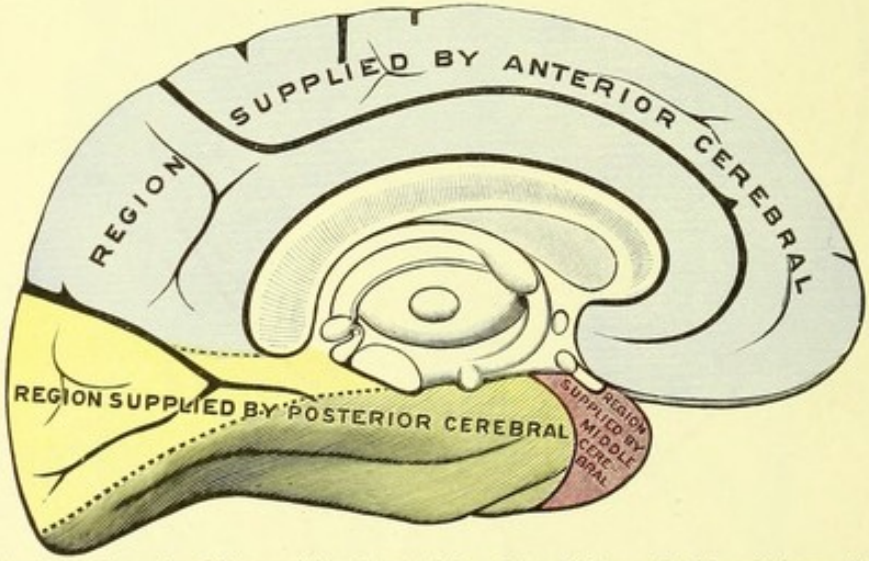

FIG. 584.—Arterial supply of the mesial and tentorial surfaces of the cerebral hemisphere. (Testut.)

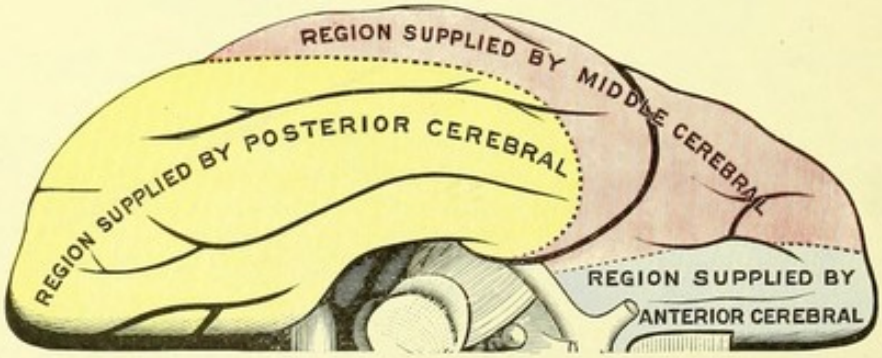

FIG. 585.—Arterial supply of the base of the cerebral hemisphere. (Testut.)

fimbria and the tænia the *choroid plexus* juts into the horn, dangling, as it were, from the junction of the mesial wall and the roof.

Arteries of the Hemisphere.—The cerebral hemispheres are supplied with

blood by the anterior, middle, and posterior cerebral arteries, which have been described in a previous chapter. It is only necessary here to refer to that account for details of course and distribution, and to call attention to Figs. 583–585, which show most impressively the regions to which each of these vessels furnishes nourishment.

THE REGION OF THE THIRD VENTRICLE—THE THALAMENCEPHALON.

The third ventricle comprises the parts developed from the second encephalic vesicle and, in addition, the aula of the first vesicle—the latter constituting the front and upper portion, as has been related in the early part of this chapter.

The *third ventricle* (Figs. 586–588) is a narrow, deep, median crevice, on a plane distinctly below that of the body of the lateral ventricle. It opens at its

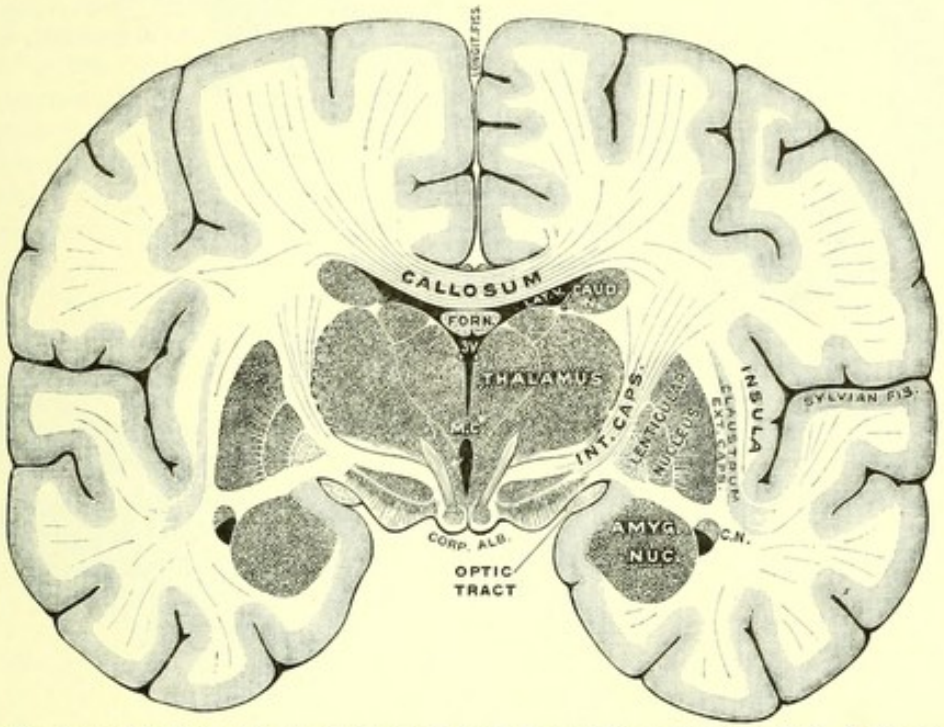

FIG. 586.—Coronal section of the hemispheres through the middle commissure, M. C. C. N., caudate nucleus in the roof of the middle horn of the right lateral ventricle. (Testut.)

upper, outer and front angles into the portæ (foramina of Monro), by which communication is established with the lateral ventricles; and high up on its hind wall it is continuous with the aqueduct. Its lateral boundaries are made by the thalami; its roof is furnished by the median part of the velum interpositum; it is bounded in front by the anterior pillars of the fornix and the lamina cinerea; behind are the epiphysis (pineal gland), the posterior commissure, and the aperture of the aqueduct; its floor, reckoning from behind forward, is made by the tegmenta of the crura cerebri, the posterior perforated space, the corpora albicantia, and the tuber cinereum with the infundibulum and hypophysis (pituitary body); crossing it from side to side is the middle commissure; and hanging down into it from the roof are the choroid plexuses of the third ventricle.

As the thalamencephalon is intimately connected with the mesencephalon, it is necessary to present a brief description of the latter at this stage of our study.

The mesencephalon is the *isthmus* between the higher and lower parts of the brain. It is perforated from end to end by the *aqueduct*. In front of this passage are the *crura cerebri* ("legs of the cerebrum"), two great columns which are diverging, upward continuations of the white substance from the pons and cerebellum. The ventral part of each crus is called *crusta*, the dorsal part *tegmentum*. Behind the aqueduct the material is arranged in four distinct knobs, the *corpora quadrigemina*.

The Thalami (Figs. 587, 588).

The thalami, often called *thalami optici* ("optic couches"), are large masses of gray substance of irregular shape, presenting mesial, upper, and back surfaces,

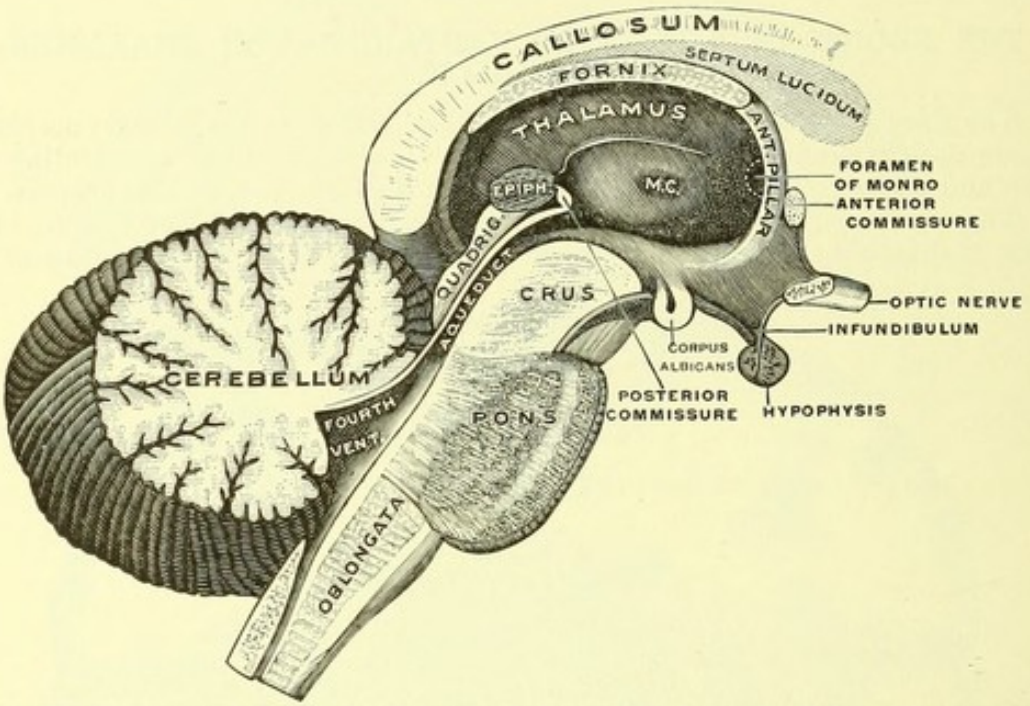

FIG. 587.—Median section through the third and fourth ventricles. Left half. M. C., middle commissure. (Testut.)

which are free, and under and outer surfaces, which are attached, being blended with contiguous parts of the brain. The free surfaces are covered with a thin layer of white nervous tissue. The *mesial surface* of each is flattened, and forms

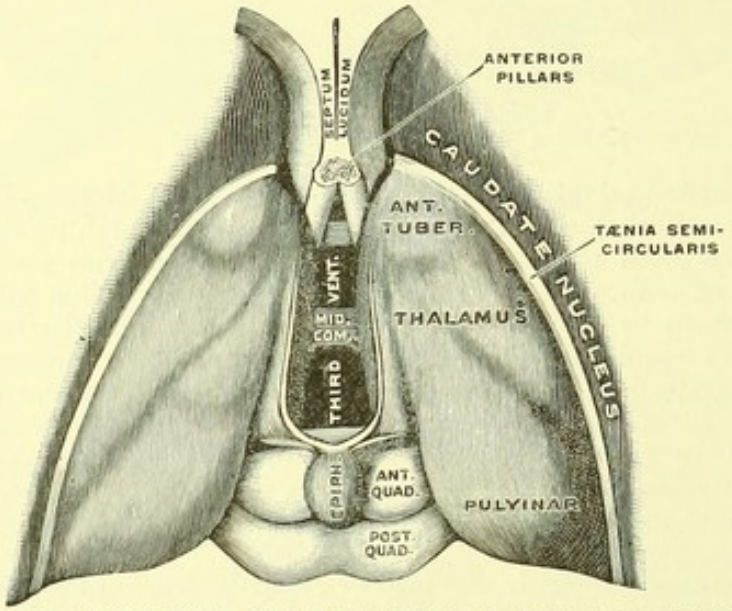

FIG. 588.—Third ventricle from above. The upper surface of the thalami, the epiphysis, and the corpora quadrigemina are seen. (Testut.)

a side wall of the third ventricle from floor to roof. The boundary between the mesial and upper surfaces is marked by a white band, the stalk of the epiphysis, extending from the anterior pillar of the fornix in front to the epiphysis behind.

Along the mesial surface from the porta to the aqueduct is a groove, the *sulcus of Monro* (usually but faintly marked), indicating the line of junction of the dorsal and ventral zones, into which morphologists divide the encephalon.

The *upper surface* is divided into a postero-internal portion and an antero-external portion by an oblique groove. Upon the former of these areas lies the velum interpositum, whose free edge, the choroid plexus of the lateral ventricle, rests upon the latter area. A portion of this surface beyond the plexus is often, perhaps usually, seen in the floor of the lateral ventricle, separated from the caudate nucleus by the tænia semicircularis. In the diagrams (Figs. 549 and 552), which represented the first and second vesicles developing separately, the thalamus manifestly could have no place in the lateral ventricle; and it is held by Wilder that it is always absolutely excluded from this cavity. At the extreme front of this surface is a rounded end, the *anterior tubercle*. Behind at the inner side of the thalamus is another tubercle, the *pulvinar* ("couch"), which extends downward, and occupies the posterior surface. At the lower and outer portion of the posterior surface are the two *corpora geniculata* ("the bended-knee bodies"), internal and external (Fig. 597), connected behind with the corpora quadrigemina by the *posterior* and *anterior brachia*, and in front continued into the optic tract.

The *outer surface* and anterior end are closely related to the internal capsule, into which they send many fibres.

The *under surface* rests upon a forward extension of the tegmentum.

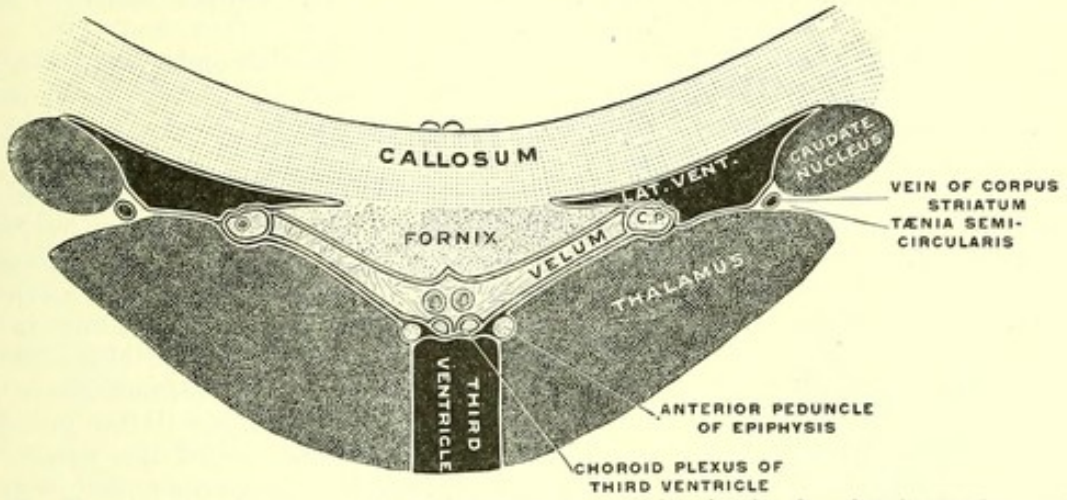

FIG. 589.—Coronal section through the lateral and third ventricles, showing the velum interpositum pushing the choroid plexuses (C. P.) into the lateral ventricles above the thalami. (Semidiagrammatic.) (Testut.)

The great bulk of the thalamus is gray substance, which is divided into *outer* and *inner nuclei* by a thin, curved, white layer. The two thalami are connected by a gray band, the *middle* (soft) *commissure*, which crosses the third ventricle nearly at its centre. They are also united by the floor of the ventricle.

The *roof* of the third ventricle is formed by the *velum interpositum* (Fig. 589), which has already been described. The endyma lining the ventricular cavity is reflected from the thalami onto the under surface of the velum along the lines marked by the peduncles of the epiphysis (pineal body). From the under surface of the velum hang the choroid plexuses of the third ventricle, covered, of course, by the endyma.

Authors differ widely concerning the extent of the floor of the third ventricle. Some include every part of the walls excepting the sides and roof, thus making the floor embrace all of the parts on or near the middle line below the plane of the stalks of the epiphysis (pineal peduncles), which indicate the uppermost lateral boundaries. Others apply the name "floor" only to the structures extending from the location of the optic chiasma back to the opening of the aqueduct, considering all from the chiasma to the junction of the pineal peduncle with the fornix as

anterior wall. The latter method is pursued here, although one sees specimens which justify the subdivision of this floor-space so that a posterior wall of considerable extent may be described.

From the aperture of the aqueduct the *floor of the third ventricle* slopes quite sharply downward and forward, and is made by (1) the tegmenta of the mesencephalon, (2) the posterior perforated space, (3) the corpora albicantia, and (4) the tuber cinereum, whose central part is the infundibulum, to which the hypophysis is attached.

The tegmenta abut abruptly upon the ventricular cavity. The surface which they present is slightly convex, and is covered with a continuation of the gray matter which surrounds the aqueduct. This sheet of gray is extended forward beyond the limits of the tegmenta, and forms the greatest part of the floor. Furthermore, it rises for a little distance upon the mesial surface of the thalami, and thus covers the lower part of the anterior pillars of the fornix, where they lie against these bodies. The part of the floor in front of the tegmenta presents a free under surface, which is visible on the base of the brain. This area is rhombic, and margined in its rear portion by the diverging crura cerebri, in its front by the converging optic tracts. The surface area included by these structures is called the *interpeduncular space*, from its being, in part, between the cerebral crura or peduncles. It is composed almost wholly of gray substance, and is a bond of union between the two thalami. In its hind portion is the *posterior perforated space*; in its fore part is the *tuber cinereum* ("ashen knob"). Between these two the *corpora albicantia* ("whitish bodies") are inserted.

The **Posterior Perforated Space**, so called from its situation and appearance, is a forward continuation of the gray matter in the wall of the aqueduct, and stretches laterally between the diverging crura. Its numerous apertures give passage to small vessels.

The **Tuber Cinereum** is continuous behind with the posterior perforated space, and in front with the lamina cinerea, which forms a part of the anterior wall of the third ventricle. The central part of the tuber cinereum is prolonged downward in the shape of a cone, the *infundibulum*, whose funnel-like cavity is a part of the third ventricle (Fig. 590). To the apex of the infundibulum is attached the *hypophysis* ("the growth underneath") also called the *pituitary gland*, from the erroneous notion, formerly entertained, that it secreted the mucus (pituita), which is discharged from the nose. This body is lodged in the sella Turcica of the sphenoid bone, in which it is firmly held by the dura, the fibrous membrane lining the brain-case. The hypophysis is composed of two parts, essentially different in origin and histological character. The posterior portion is the smaller, and is a process from the ventricular wall, at first being hollow and communicating with the ventricle, but ultimately losing its cavity, and consisting of nervous matter intermingled with much fibrous tissue. The anterior portion is much the larger, and partly embraces the posterior. It is derived from the primitive oral cavity, and its structure bears a resemblance to that of the thyroid body. The hypophysis has been found greatly enlarged in many cases of giantism, and hence has been supposed to sustain a relation to the stature of the individual.

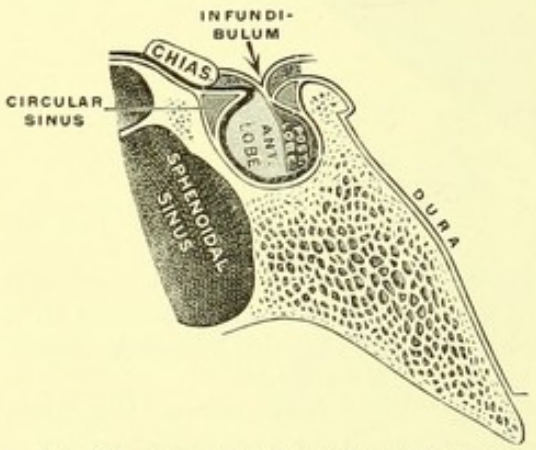

FIG. 590.—Sagittal section through the hypophysis, mesial surface of right segment. (Testut.)

The **Corpora Albicantia** (Figs. 572, 586, 587), situated about midway of the floor of the third ventricle, are parts of the anterior pillars of the fornix. The

pillars are traced down from their beginning in the lateral ventricles, form a part of the front wall of the third ventricle, curve backward in their descent, and perforate the floor of the third ventricle near its centre, thus interrupting what, without them, would be the complete continuity of the expanse of gray matter in this region. Each pillar then turns abruptly on itself, forming the bunch which is named corpus albicans, and extends upward and outward to the thalamus of its own side, in the substance of which it disappears. In composition these bodies are white nervous tissue enclosing gray. They are connected with the crura cerebri by white fibres embedded in the gray material of the floor. The cord which extends from the corpus albicans to the thalamus, and which is called the *bundle of Vicq d'Azyr*, though seemingly a prolongation of the fornix, is now thought to have no histological continuity with it.

The *anterior wall* of the third ventricle consists in its lower part of the *lamina cinerea*, otherwise called *lamina terminalis*. The first of these names implies that it is composed of gray matter, and the second that it is the uttermost boundary of the third ventricle. It is continuous below with the tuber cinereum, which it joins behind the *chiasma*, or optic commissure, and it blends at its sides with the anterior perforated spaces. Together with the tuber cinereum and posterior perforated space it makes up the *basal gray commissure*. Its upper border is connected in the middle with the rostrum of the callosum by the basal white commissure, and laterally is continuous with the gray substance of the gyri of the under surface of the frontal lobes. It passes in front of the anterior commissure, which consequently lies between it and the anterior pillars of the fornix.

The upper part of the anterior wall is supplied by the *anterior pillars of the fornix*. The lower portion of each pillar is close to the thalamus of the same side, and is covered, as is the neighboring surface of the thalamus, by a thin layer of gray matter, which is a lateral extension of the basal gray commissure.

On each side between the anterior pillar of the fornix and the thalamus is the *porta* (foramen of Monro), an opening with a well-defined, oval margin. This is the developed condition of the lumen of the little sprout, which budded from the upper, front part of the wall of the first encephalic vesicle, and expanded at its distal end into the body of the lateral ventricle. It connects the third ventricle with the lateral. There is no passage directly from one lateral ventricle to the other, because the third ventricle intervenes between the two portæ. It is, however, interesting to observe that the most nearly direct course between the cavities of the lateral ventricles is across the fore and upper part of the third ventricle—the portion which is developed from the aula, the first encephalic vesicle, from which the lateral ventricles themselves are derived. Each porta permits the passage of a prolongation of the choroid plexus of its lateral ventricle.

The remaining portion of the wall of the third ventricle is found in the small space between the long stalk of the epiphysis (pineal peduncle) and the opening of the aqueduct. It may be called the *rear wall*. The upper lip of the aperture of the aqueduct is formed by the anterior border of the quadrigeminal mass, at this point thickened and folded back, thus making a ridge, which stretches from side to side, and constitutes the *posterior commissure*. The fibres of this body apparently connect the thalami, and probably also extend into the white substance of the hemispheres.

Above the posterior commissure is the *epiphysis* ("the growth upon"), otherwise called *conarium* and *pineal gland*, these last names being given on account of the fancied resemblance of the body to a pine cone. Epiphysis is the best of the names, because this object is an upgrowth from the second encephalic vesicle. At first it is hollow; but it soon loses its connection with the ventricular cavity, and becomes filled with epithelial cells and particles of earthy material, called *brain-sand*. The ancients had a grotesque theory that the epiphysis is the favorite and peculiar abiding place of the human soul. Modern morphologists have shown it to be the homologue of the third eye which some reptiles possess. It projects outside of the ventricle, and rests upon the two upper quadrigemina. It has

a *double stalk* on each side. One of these is very short, and is connected with the posterior commissure; the other, already described, extends from the epiphysis to the anterior pillar of the fornix, and indicates the upper, lateral boundary of the third ventricle.

The walls of the third ventricle are so intimately blended at various points with those of the lateral ventricles that it is impracticable to determine the exact line of union; but a portion of it doubtless lies in the internal capsule.

There is *an unbroken continuity of gray matter* from the lamina cinerea at the front of the third ventricle to the gray surrounding the central canal of the spinal cord. The lamina cinerea is connected in front not only with the callosum, but also with the gyri of the frontal lobe, and at its sides it joins the anterior per-

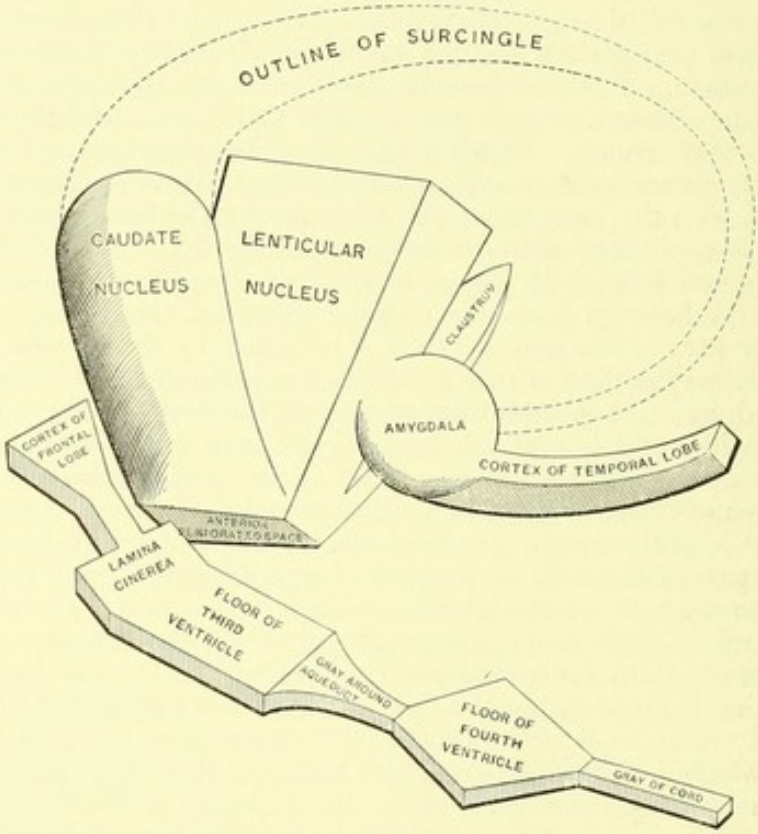

FIG. 591.—Diagram to show the continuity of the gray of the basal ganglia of the cerebral hemispheres, the cortex, and the lower segments of the cerebro-spinal axis. (F. H. G.)

forated space, which is the surface area of the lenticular and caudate nuclei and the claustrum; and these are connected with the gyri of the temporal lobe through the amygdala, which is fused with the lenticular nucleus. Keeping these facts in mind, it is easy to understand that the great ganglia are only local thickenings of the gray matter surrounding the cavity of the cerebro-spinal axis, which in the adult displays in the spinal cord the least change from the original condition.

The Subthalamic Region.—The mass upon which the thalamus rests is made up mostly of a forward continuation of the tegmentum of the mesencephalon. Three layers are distinguished: the *stratum dorsale*, which is superior; the *zona incerta* ("the uncertain zone"), a reticulated, fibrous collection, the origin of which is doubtful and its boundaries obscure; and the *corpus subthalamicum* ("body under the thalamus"), derived from the locus niger, which lies between the tegmentum and crusta of the mesencephalon. Dorsal and mesial to the corpus subthalamicum is an extension of the red nucleus of the tegmentum. The subthalamic region thins out as it extends forward and outward, and finally becomes continuous with the anterior perforated space.

The Internal Capsule.

A horizontal section through the lenticular nucleus at any but its lowest levels displays this great ganglion surrounded by a thick layer of white substance. The portion of this enclosing material on the mesial side is the *internal capsule*, and that between the nucleus and the claustrum is the *external capsule*.

The internal capsule (Figs. 577, 586, 578, 592), as seen in horizontal section, following the mesial surfaces of the lenticular nucleus, forms a bend with its convexity toward the middle line. The part at the angle is the *genu*; that in front of it is the *anterior segment*; and that behind is the *posterior segment*. The anterior segment separates the lenticular nucleus from the caudate; the posterior divides it from the thalamus; and the genu comes up to the tænia semicircularis, pushing in between the caudate nucleus and the thalamus.

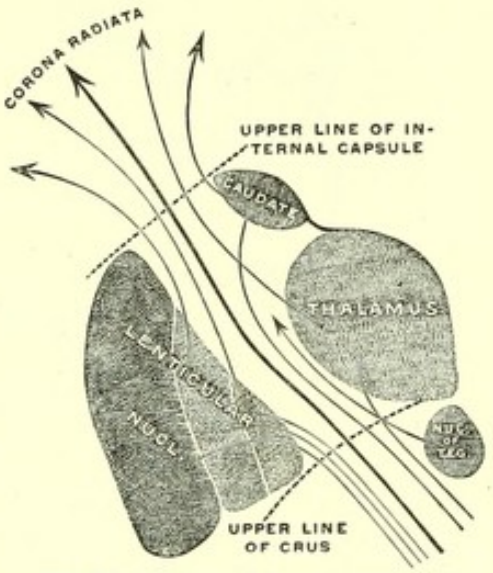

FIG. 592.—Diagram of the composition of the internal capsule. (Testut.)

The internal capsule is largely composed of fibres which run between the cortex of the hemisphere above and the crura cerebri below. But it has ingredients which connect these parts only indirectly. Some fibres enter it from the end, which do not leave it, but plunge into the surrounding ganglia—the thalamus, the caudate and lenticular nuclei. Others enter at its sides from the same gray masses, and emerge from the end. Certain fibres come to it from the subthalamic region, and still others from the hemisphere of the opposite side through the callosum. The general drift of its direction, however, is between the lowest and the highest centres of the cerebro-spinal axis—from below upward and outward. Tracing the fibres upward we find that, immediately on emerging from the capsule, they spread out in every direction toward the cortex, constituting the *corona radiata* ("the radiant crown").

The anterior segment is chiefly composed of fibres coursing longitudinally between the thalamus and the cortex of the frontal lobe. The hind portion of the posterior segment is a continuation of the lemniscus, and the remaining portions are connected with the region of the cortex about the central (Rolandic) fissure.

At various places, particularly in its anterior part, the internal capsule is streaked with cords of gray, which cross it between the caudate and lenticular nuclei.

The **External Capsule** (Fig. 577), which is situated between the lenticular nucleus and the claustrum, is united to the internal capsule below and behind. It is composed of fibres contributed partly by the anterior commissure, and partly by the subthalamic region.

Diagrammatic Description of the Lowest Parts of the Brain.—Before entering upon the detailed study of the remaining structures of the brain, which are related to one another in a very intimate and complex manner, it is well to consider them in a schematic way, by which the principal features of their gross anatomy shall be presented clearly and form the groundwork for the more minute consideration of the subject (Fig. 593). This, in part, has been done on a previous page, but may profitably be reviewed at this stage.

The cerebral hemispheres and the parts in the region of the third ventricle, already described, are developed from the first and second encephalic vesicles. From the third vesicle is developed the mesencephalon, from the fourth the pons and cerebellum, and from the fifth the oblongata.

The *mesencephalon* is often called the isthmus of the brain, because it is the narrow neck by which the great cerebral mass above is connected with the structures below. Its ventral part is shaped like two pillars converging to the pons, and is called the crura cerebri ; its dorsal protrudes in four tubercles, the corpora quadrigemina. Its cavity is the aqueduct.

The *cerebellum* is a large, solid body, the second of the brain-masses in size, and constitutes the dorsal portion of the wall of the fourth ventricle. It is connected above by the superior cerebellar peduncles with the quadrigemina ; in front by the middle cerebellar peduncles with the pons ; and below by the inferior cerebellar peduncles with the oblongata.

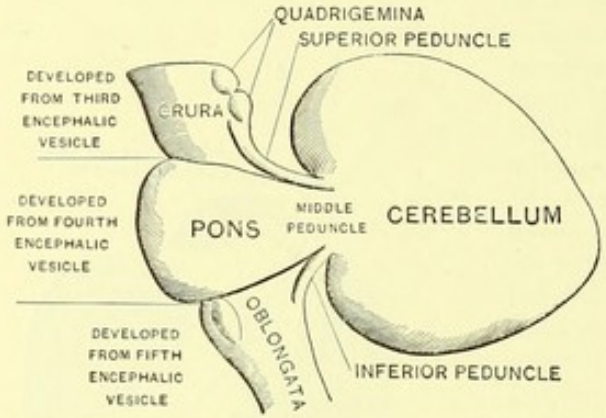

FIG. 593.—Diagram of the parts of the encephalon below the thalami, left side.

The *pons* is situated between the isthmus above and the oblongata below, and forms the ventral part of the wall of the fourth ventricle. It bulges in front and laterally, and runs back on each side into the middle cerebellar peduncle. Between the dorsal surface of the pons and the ventral surface of the cerebellum is the upper half of the fourth ventricle.

Below the pons is the *oblongata*, developed from the fifth vesicle. It is shaped like an irregular, inverted, truncated cone. Below it is continuous with the spinal cord. The upper part of its cavity is the lower part of the fourth ventricle proper, and the rest of it is tubular and directly continuous with the central canal of the spinal cord.

The columns of fibrous nervous tissue are chiefly continued upward from the spinal cord through the oblongata, the pons, and the isthmus, to the higher levels of the brain ; but some of them switch off dorsally to the cerebellum, thus constituting the inferior peduncle of that body. The gray nervous tissue, also, is continued upward from the cord, and a portion of it is thus connected with the highest collections of gray matter in the cerebrum ; but in the oblongata considerable masses are detached by the intrusion and crossing from one side to the other of large bundles of white nervous tissue, and at various points are found new collections of nerve-cells, which are not the representatives of any nuclei at lower levels.

THE MESENCEPHALON:

The Region of the Aqueduct.

Next below the thalamencephalon comes the mesencephalon, otherwise known as the *mid-brain*, from its situation, and as the *isthmus cerebri*, because it is the constricted bond of union between the parts which result from the development of the first and second encephalic vesicles and those which come from the fourth and fifth. Its direction is from before backward and a little downward. Viewed from below it displays a ventral surface, which is marked by two short, thick, white columns, converging toward the pons, like the limbs of the letter V, and called the *crura cerebri* ("legs of the brain"), and also the *cerebral peduncles* ("little feet") (Fig. 596). Between the crura is a triangular area, already described as the hind part of the interpeduncular space (see page 534).

The dorsal surface is not visible until certain overlying structures have been removed. It then presents to view four prominent knobs, the *corpora quadrigemina* ("four-twin bodies"), and the upper portion of the superior cerebellar peduncles (Fig. 597). The quadrigemina are arranged in pairs, an upper (anterior) pair,

sometimes called the *nates*, and a lower (posterior), known also as the *testes*. A median groove separates the right tubercles from the left, and ends above at the posterior commissure; and the superior are divided from the inferior by a transverse gutter. At the outer sides the quadrigemina run upward and forward into the brachia (Fig. 597).

A cross-section of the isthmus (Figs. 594, 595) shows that each lateral half is divided into two unequal parts by a band of nerve-cells, so deeply pigmented as to have received the name of *locus niger* ("the black place"). Ventrally to this is the column of white nervous tissue which forms a side boundary to the interpeduncular space, and is called the *crusta* ("crust"). Dorsally is a mass of mingled white and gray, the *tegmentum* ("covering"). At each border the locus niger comes to the surface at a groove, that which is mesial being the place of emergence of the third cranial nerve, and the other, called the *lateral groove*, runs from the internal geniculate body to a point between the superior and middle peduncles of the cerebellum. The crusta is largely composed of flat bundles of white tissue which present their edges at the free surface. The part of the crusta close to the locus niger is the *stratum intermedium*. The tegmentum extends from

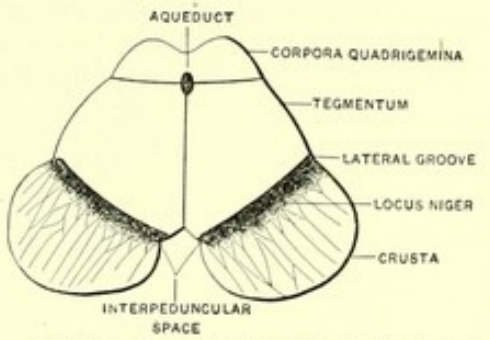

FIG. 594.—Transverse section of the mesencephalon. (Testut.)

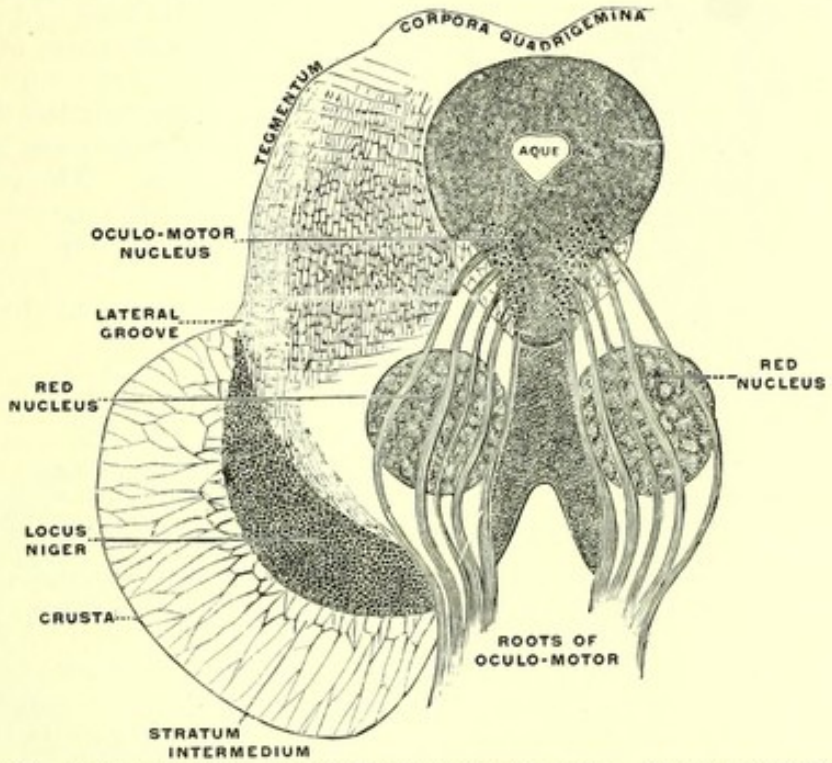

FIG. 595.—Transverse section through the anterior quadrigemina. (Testut, after Stilling.)

the locus niger up to the level of the aqueduct, and above this plane is the *lamina quadrigemina*, upon which the corpora quadrigemina rest. The *aqueduct* is a small canal and is surrounded by a considerable thickness of gray, in which are embedded clusters of nerve-cells, which are connected with the roots of the third, fourth, and fifth cranial nerves. In the fore part of the tegmentum is a globular collection of cells, the *red nucleus*, through which pass the roots of the oculo-motor (third) nerve. On the surface of the tegmentum above the lateral groove appears the external portion of the *lemniscus*. The anterior extremity of the

tegmentum is convex, and slopes downward and forward, forming a part of the floor of the third ventricle. Upon this surface is extended the forward continuation of the gray of the aqueduct. The locus niger can be traced backward to the upper margin of the pons, and forward to the corpora albicantia. The white around the red nucleus is an extension of the greater part of the superior cerebellar peduncle of the opposite side—decussation taking place across the middle line in the *raphe*. As a whole the white of the crura is a continuation of bundles from the internal capsule and subthalamic region.

THE EPENCEPHALON.

This segment of the brain comprises the parts developed from the fourth encephalic vesicle, namely, the pons and the cerebellum.

The Pons.

The pons, otherwise called *pons Varolii* ("bridge of Varolius") and *tuber annulare* ("annular protuberance"), consists largely of white nervous tissue, the greater part of which is divided into two groups of bundles, according to the direction in which they run (Figs. 587, 596). One set courses nearly vertically from the mesencephalon to the oblongata, occupying the central portion of the pons; the other, mainly superficial to this, is disposed horizontally, and is seen at the front and sides, projecting beyond the surface plane of the crura and the oblongata. The horizontal part gives the name to the whole, because it suggests the arch of a bridge connecting the lateral halves of the cerebellum. The ventral portion of the arch has the greatest vertical diameter, and the sides taper as they go dorsally, being smallest where they enter the cerebellum, constituting the middle peduncles of this organ.

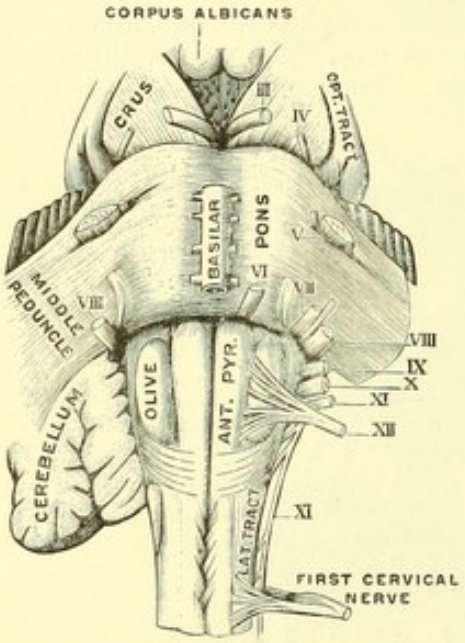

FIG. 596.—Ventral view of mesencephalon, pons, and oblongata. (Testut.)

By removing the cerebellum, a view is obtained of the dorsal aspect of the pons (Fig. 597). On each side is seen a superior peduncle of the cerebellum, running downward and outward from the quadrigemina. Between these two diverging masses is stretched a flat, triangular plate, consisting of two layers of nervous tissue, the ventral being white, the dorsal gray. This structure is variously called the *valvula*, the valve of Vieussens, and the anterior medullary velum. It forms the upper part of the dorsal wall or roof of the fourth ventricle. Cutting away the valvula, we look into the fourth ventricle, and see the upper portion of its ventral wall or floor, overlapped at its sides by the mesial borders of the superior cerebellar peduncles. In the entire middle line of this triangular area is a groove, close to which and to the oblongata is a rounded projection, the *eminentia teres* ("the round eminence"). Beside this is a shallow depression, the *fovea superior* ("the upper little pit"), and above the latter a deeply pigmented area, the *locus ceruleus* ("the blue place").

A cross-section of the upper portion of the pons shows that the bulk of its ventral and larger part is composed of transverse bundles, with which are intermingled those which run longitudinally. The dorsal and smaller portion has a reticular formation in the centre, behind which is a thin layer of gray tissue, and in front of it a part of the fillet or lemniscus—a structure which will

be described later, when all the segments of the encephalon in which it is found have been considered.

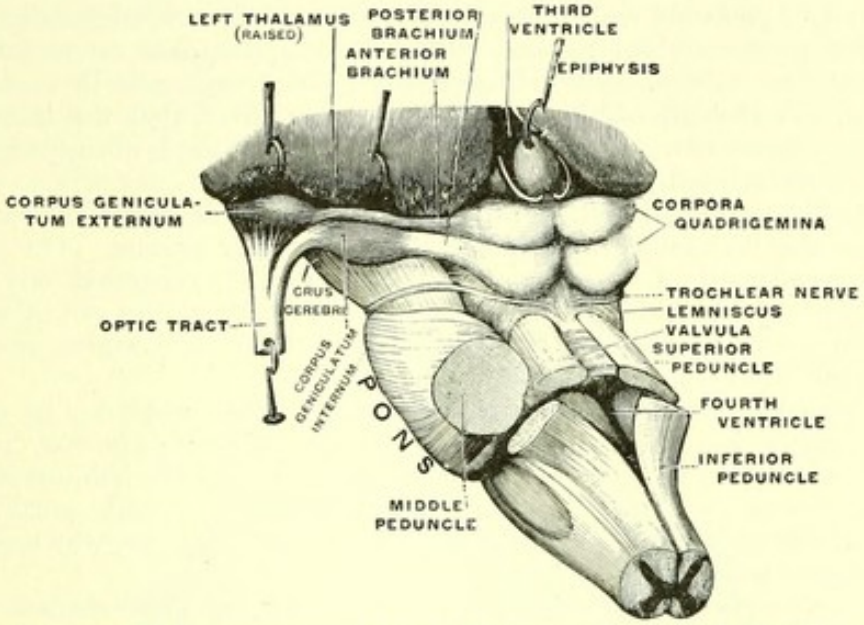

FIG. 597.—Dorsal view of the mesencephalon, pons, and oblongata. The thalami and epiphysis are drawn upward, the optic tract downward. (Testut.)

The Cerebellum.

The cerebellum is the great, solid, nervous mass lying dorsal to, and on the same plane with, the pons, with which it is developed from the fourth encephalic vesicle (Fig. 598). It is situated in the posterior fossa of the cranium, and is

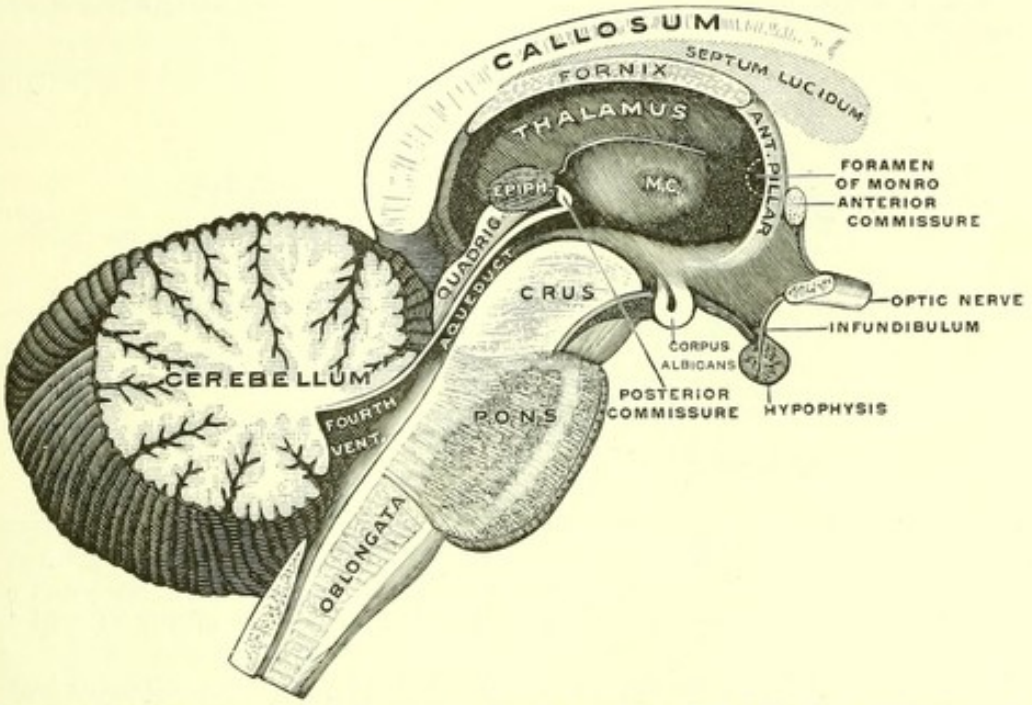

FIG. 598.—Median section through the third and fourth ventricles. Left half. M. C., middle commissure. (Testut.)

shielded from the pressure of the overlying cerebral hemispheres by a strong, tightly stretched prolongation of dura, called the tentorium. It has no cavity

proper to itself, but it participates in the formation of the roof of the fourth ventricle. Its main portion consists of three parts, a median and two lateral, all continuous and of substantially the same structure.

The lateral parts are called *hemispheres*—a piece of nomenclature imitative of that of the great cerebral masses, rather than appropriate on account of its inherent descriptiveness. These bodies attain a size so greatly in excess of that reached by the median portion, which is between them, that the latter is comparatively insignificant, and its obscuration by them on the lower aspect is almost complete in the normal position of the parts.

The median portion is called the *vermis* ("worm") or vermiform process, on account of the undulatory appearance of its irregular surface. On the upper aspect of the cerebellum the vermis and hemispheres are separated only by slight grooves; but on the under surface the vermis is sunk almost out of sight in a deep dorso-ventral depression, the *vallecula* ("little vale"), which ends behind in a deep notch, in front in a shallow one.

The cerebellum is connected with other parts of the encephalon by six bands, three on each side. To the oblongata run the *inferior peduncles*, previously described as the restes. To the quadrigeminal bodies of the isthmus stretch the *superior peduncles*, which have been seen to bound the pontile portion of the fourth ventricle laterally. To the pons go the *middle peduncles*, which spread out into its ventral protuberance.

The upper surface of the cerebellum is nearly flat, the lower surface decidedly convex. Both surfaces are marked with *fissures* which run in a generally transverse direction, and are so close together as to divide the cerebellar substance into layers or leaves, whence it is said to be laminated or foliated. These *folia* are very different in gross appearance from the gyri of the cerebrum, presenting a sharp border instead of a rounded surface; but they are homologous with these gyri in that they have a basis of white substance and upon this a covering (*cortex*) of gray. The clearest conception of the depth and arrangement of the folia is obtained by making sections, especially in a vertical direction, through the cerebellum at different planes (Fig. 599). It is then seen that the white substance

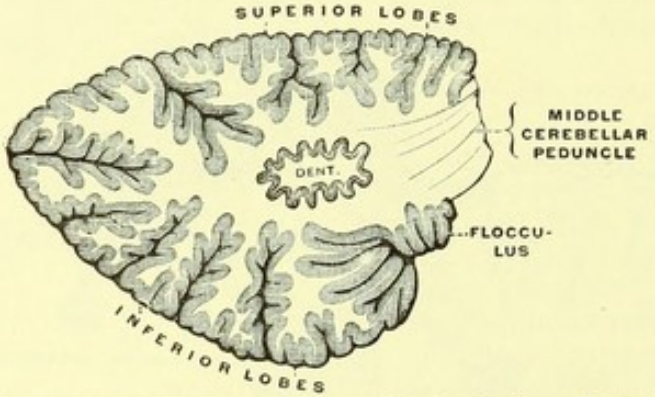

FIG. 599.—Sagittal section of left cerebellar hemisphere. (Testut.)

forms a large core or trunk, the *trapezium*, from which a number of primary branches are given off. Each of these in its turn divides, and, as the ultimate rami, as well as the original, are clothed in gray, an appearance is presented suggestive of a cedar tree, whence the name *arbor vitæ* ("tree of life"), which is given to it.

The upper and lower surfaces are separated by a rather prominent border, partly upon and partly near which runs the longest and deepest of the fissures, the *great horizontal* or *longitudinal fissure*.

The **upper surface** is marked in the middle line by the *superior vermis*, whose central and most pronounced prominence is the *monticulus* ("little mountain"). On each side of the vermis is a shallow groove, beyond which is a hemisphere.

The deep fissures divide the entire upper portion of the cerebellum into segments, which are seen most favorably in sagittal sections. For each segment of the vermis there is a corresponding and connected part of each hemisphere. These do not appear plainly in the picture (Fig. 600), but will be understood by reference to the schematic arrangement, in which the segments are named in order from before backward, with the fissures which separate them. The segments of the vermis are the *lingula* ("little tongue"), the *central lobe*, the *culmen* ("summit"), the *clivus* ("slope"), and the *cacumen* ("top"); and the parts of the hemisphere respectively corresponding are the *frenulum* ("little bridle"), the *ala* ("wing"), the anterior or *ventral crescentic lobe*, the posterior or *dorsal crescentic lobe*, and

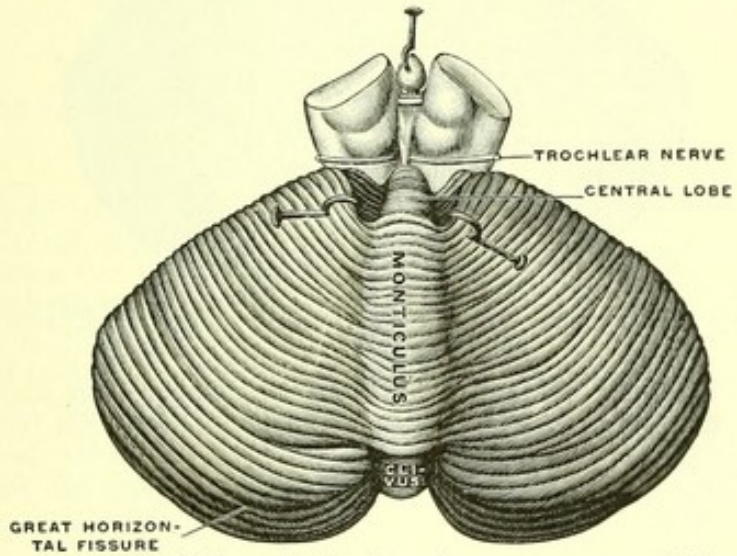

FIG. 600.—Upper surface of cerebellum. The lingula and cacumen are concealed by overhanging parts. Compare with scheme of this surface. (Testut.)

the *dorso-superior lobe*. The fissures are named with reference to their situation in front of or behind the central lobe and the clivus—*precentral fissure*, *postcentral fissure*, *preclival fissure*, and *postclival fissure*.

UPPER SURFACE OF CEREBELLUM.

VERMIS.		HEMISPHERE.
LINGULA.		FRENULUM.
	PRECENTRAL FISSURE.	
CENTRAL LOBE.		ALA.
	POSTCENTRAL FISSURE.	
CULMEN.		VENTRAL CRESCENTIC LOBE.
	PRECLIVAL FISSURE.	
CLIVUS.		DORSAL CRESCENTIC LOBE.
	POSTCLIVAL FISSURE.	
CACUMEN.		DORSO-SUPERIOR LOBE.

The **under surface** presents in the mid-line the *inferior vermis*, separated superficially from the hemispheres by lateral grooves. Here, as on the upper aspect of the cerebellum, the deep fissures cut so far into the substance as to mark off segments; but the portions of the hemispheres are less easily seen to be related to correspondent parts of the vermis than in the former case. The fissures are not as regularly disposed, and the whole arrangement is complicated. Close examination, however, reveals a more systematic relation than casual inspection promises, and this is shown diagrammatically in the schematic table, which would

best be studied in connection with the picture (Fig. 601). From before backward are seen in the vermis the *nodule*, the *uvula*, the *pyramid*, and the *dorsal tuber* (tuber posticum); and in the hemisphere the *flocculus* ("little tuft of wool"), the *amygdala* ("almond"), the biventral or *digastric lobe*, the *slender lobe*, and the *dorso-inferior lobe*. The uvula and amygdalæ are so named on account of their

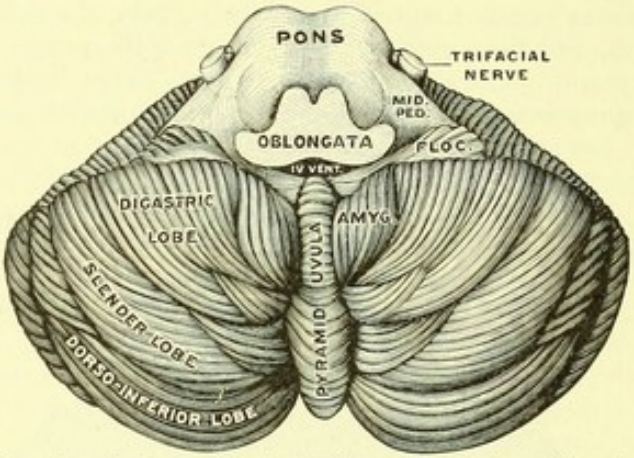

FIG. 601.—Under surface of cerebellum. The hemispheres are pulled apart to give a view of the inferior vermis. The nodule does not appear; the tuber is not labelled. Compare with scheme of this surface. (Testut.)

resemblance to the parts of the same name in the pharynx, as seen through the open mouth. The fissures are named from their position with reference to the nodule, the pyramid, and the slender lobe—the *postnodular fissure*, the *prepyramidal fissure*, the *postpyramidal fissure*, and the *postgracile fissure*.

UNDER SURFACE OF CEREBELLUM.

VERMIS.	HEMISPHERE.
NODULE.	FLOCCULUS.
POSTNODULAR FISSURE.	
UVULA.	AMYGDALA.
PREPYRAMIDAL FISSURE.	
PYRAMID.	DIGASTRIC LOBE.
POSTPYRAMIDAL FISSURE.	
DORSAL TUBER.	SLENDER LOBE.
	POSTGRACILE FISSURE.
	DORSO-INFERIOR LOBE.

Embedded in each hemisphere is a nucleus, called the *corpus dentatum* ("toothed body") from its jagged outline (Fig. 602). Its centre is white, and on the mesial side near the front the gray wall is deficient. Near this are three other masses of gray of small size—the *nucleus emboliformis* ("pluglike"), the *nucleus globosus* ("spherical"), and the *nucleus fastigii* ("of the summit").

The general method of arrangement of the fibres traced into the cerebellum from its peduncles is shown in Fig. 603.

The *superior peduncle* is mainly made up of fibres from the corpus dentatum and the cerebellar cortex. The *middle peduncle* is composed of fibres from cells in the cortex. They run to cells on both sides of the pons, and do not, as gross appearances suggest, go around from one side of the cerebellum to the other. The *inferior peduncle* receives fibres from cells of the cerebellar cortex and the oblongata, from the direct cerebellar tract of the spinal cord, and from the nuclei gracilis and cuneatus.

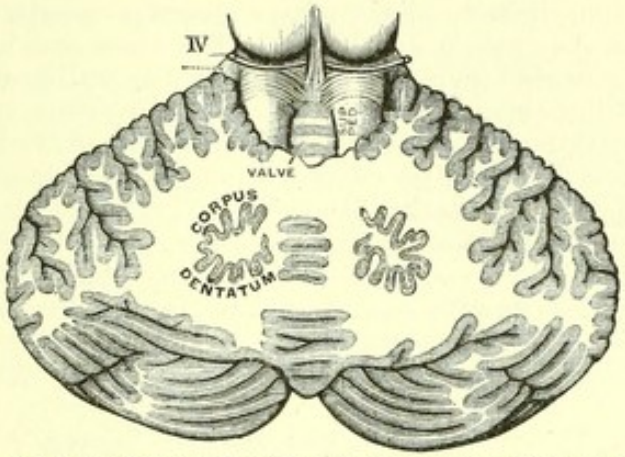

FIG. 602.—Cerebellum in nearly horizontal section—the upper surface of the lower section. (Testut.)

THE OBLONGATA.

The *oblongata*, also called *medulla oblongata* ("the oblong marrow"), and the *spinal bulb*, extends from the lower margin of the pons to a plane passing transversely just below the decussation of the pyramids, at which level the spinal cord begins. It is shaped somewhat like an inverted truncated cone, flattened ventro-dorsally. It lies upon the basilar process of the occipital bone, the inclination of which indicates the attitude of the oblongata.

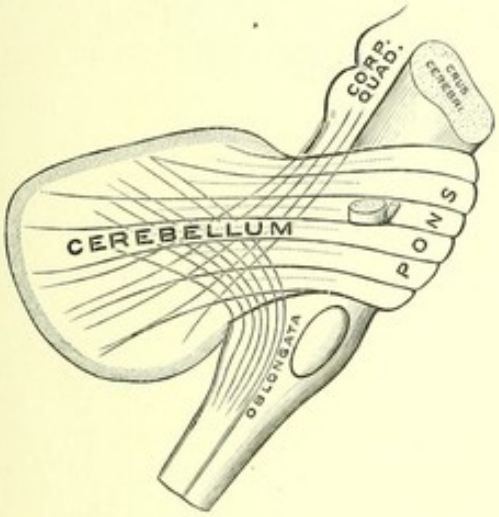

FIG. 603.—Semidiagram of the three cerebellar peduncles. (Testut.)

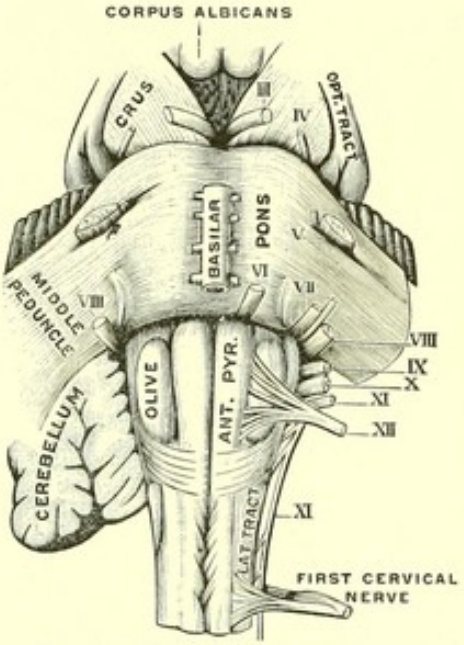

FIG. 604.—The pons and oblongata, ventral view. (Testut.)

On the *ventral surface* is a longitudinal cleft, the *ventro-median fissure*, which begins above in a little pit, the *foramen cæcum* ("blind hole"), and is interrupted below by a criss-cross of nerve-bundles. On each side of the ventro-median fissure is a white body, gradually dwindling from above downward, and seeming to be directly continuous with the ventral column of the cord. These are the *ventral pyramids*, and the interlocking of the bundles at their lower part across the ventro-median fissure (constituting the above-mentioned criss-cross) is called the *decussation of the pyramids*. At the outer side of each pyramid is a cleft, the *ventro-lateral fissure*, which is in line with the series of origins of the ventral roots of the spinal nerves.

On each side the oblongata presents a vertical mass, the *lateral column*, or *lateral tract*, which is apparently continuous below with the lateral column of the cord, and above is encroached upon at the front part by a large ovoid mass,

the *olive* (olivary body, inferior olive), whose presence crowds the column backward, and compresses it into a small band. The olive and lateral column are separated from the ventral pyramid by the ventro-lateral fissure, and from the dorsal structure of the oblongata by the *dorso-lateral fissure*, in which is seen a series of root-bundles, ranged in line with the dorsal roots of the spinal nerves.

The *dorsal surface* (Fig. 605) of the oblongata is wide above and narrow below, and may well be described as consisting of upper and lower halves. The upper half presents at each side a column of white nervous material, the *restis*, or *restiform* ("rope-like") *body*—another name for the inferior cerebellar peduncle—which is prolonged downward into the fasciculus cuneatus, the last being continuous with the dorso-lateral column (tract of Burdach) of the cord. The two restes are widely separated above, but converge toward the middle line below. On

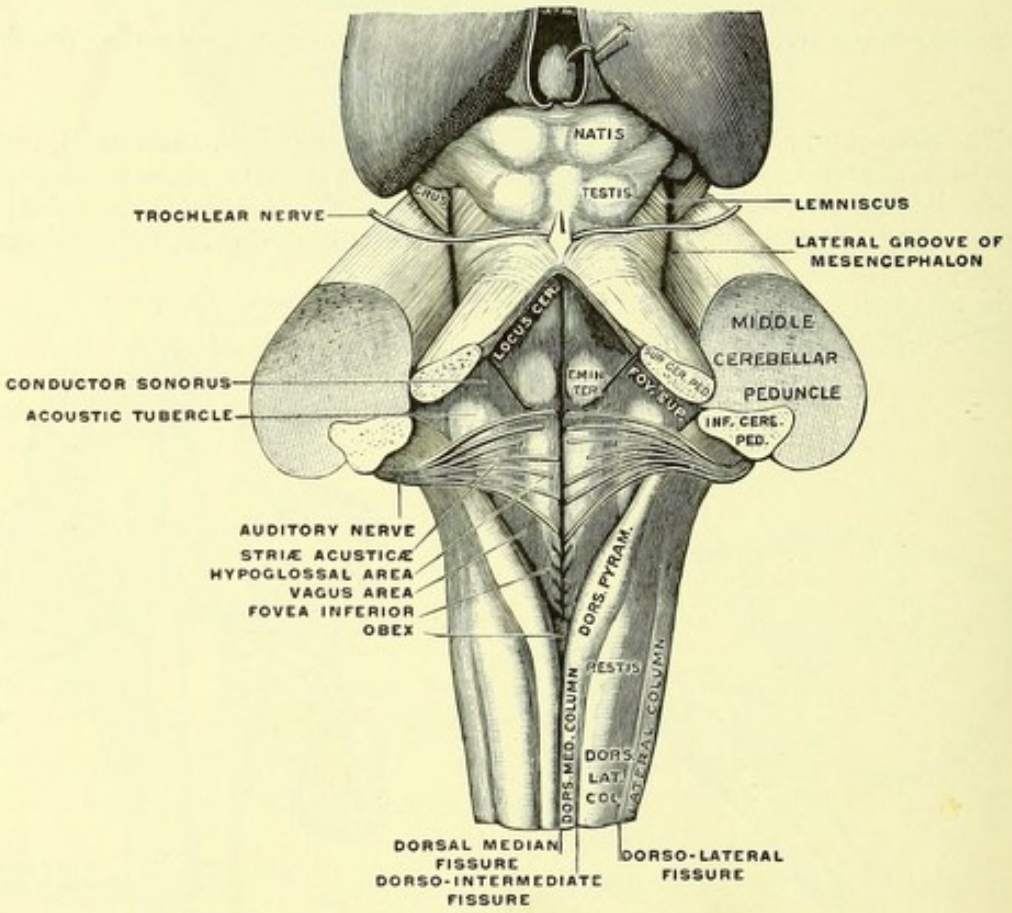

FIG. 605.—Fourth ventricle laid open by removal of its roof. (Testut.)

the mesial side of the restis is a band, which from a thin beginning, thickens as it passes downward, and becomes continuous with the fasciculus gracilis, which is prolonged into the dorso-mesial column of the cord (tract of Goll), separated from its fellow of the opposite side by the dorso-median fissure. It is called the *dorsal pyramid* (posterior pyramid).

The restis and dorsal pyramid of each side together form a prominent ridge, and the two ridges by their convergence enclose a triangular space. Stretched across this space is a membrane, consisting of a ventral layer of endyma and a dorsal layer of pia. This is one of the places where the nervous tissue of the encephalic wall has completely disappeared, and has left its serous lining and vascular covering, which have come together, and formed a membrane, here called the *posterior medullary velum*, or *metatela*. From its ventral surface depend small clumps of blood-vessels, covered, of course, by endyma, and named the *choroid plexuses of the fourth ventricle*. Below its middle is a perforation—the

foramen of Magendie, or *metapore*, through which the cerebro-spinal fluid mingles with the fluid in the serous cavity which surrounds the axis. In connection with the membrane should be mentioned the *obex*, a small layer of gray substance, which is stretched across the very apex of the triangle; and the *ligula*, a small irregular lamina of white nervous tissue, which projects slightly over the membrane from each lateral border. Both of these structures are rudimentary.

If the membrane is removed, the cavity of the fourth ventricle is exposed, and we see the part of its floor which is directly continuous with the portion provided by the pons. The space presents a triangle, whose base is applied to that of the pons. The apex of the triangle has been likened to the nib of a pen, and, consequently, is referred to as the *calamus scriptorius* ("the writing pen"). The median cleft of the pons is continued down through the oblongata, and on each side of it are arranged from within outward three somewhat triangular areas—the internal white, the middle gray, and the external white—the first and third standing in relief. Running from the mid-line outward is a variable number of nervous threads, *striæ acusticæ* ("auditory stripes"), which turn around the restes, and end in the auditory nerve.

The *lower half* of the dorsal part of the oblongata is marked by the dorso-median fissure and on each side by the dorso-lateral fissure, and between them is the *dorsal column*, which is unequally divided by the dorso-intermediate fissure into a smaller, mesial column, the *fasciculus gracilis* ("slender bundle"), which is continued downward into the dorso-mesial column of the spinal cord (the tract of Goll), and a larger column, the *fasciculus cuneatus* ("wedge-shaped bundle"), which is prolonged downward into the dorso-lateral column of the cord (the tract of Burdach). At about the junction of the lower part of the oblongata with its upper, expanded portion the fasciculi gracilis and cuneatus contain each a mass of gray, which is known as its nucleus. Thus we have the *nucleus gracilis* and the *nucleus cuneatus*. The cavity of this part of the oblongata is tubular, like that of the cord into which it runs.

Internal Structure of the Oblongata.

Transverse sections of the oblongata at different levels show marked variations in the disposition of its constituent elements. It is manifest that the outline of these sections will be strikingly different, for, as we know, the uppermost portion is spread out laterally, while the lowest is bunched together into a compact cylinder. The change in the arrangement of the included parts follows this general trend, and is shown particularly well in the case of the gray masses—these being small and dispersed in the higher levels, and being gradually gathered together as they are traced downward, until they are united into a single, coherent mass of definite form.

A horizontal section *at the middle of the olives* shows the cavity of the fourth ventricle at the extreme dorsal limit (Fig. 606). The dorsal boundary is broad and nearly flat, the ventral is narrow and broken in the middle by the ventro-median fissure, and each lateral undulates between these two, the whole periphery being described in generous curves. A *median raphe* is made by a criss-cross of white fibres, and on each side of it the surface is divided into three unequal territories by the fibres of the tenth and twelfth cranial nerves. The *tenth* (pneumogastric) *nerve* marks off a dorso-lateral portion, the *twelfth* (hypoglossal) a ventro-mesial area, and the large space enclosed between these two has its superficial margin at the side. In the ventro-mesial area is the *pyramid*, and just dorsal to it is the *fillet*—which will be described as a whole later. The *arciform nuclei* are partly wrapped around the pyramids. In the lateral area appears the *nucleus of the olive*, here looking like a broad, crinkled band of gray and nearly surrounding a space of white. The toothed appearance of this capsule has led to its being called the *dentate nucleus*. Two *accessory olivary nuclei* are observed, one showing as a short, broad line, near the opening of the main nucleus, the other on the

mesial side of the hypoglossal nerve and parallel to it. Following the hypoglossal dorsally we find it terminating in a nucleus in the floor of the fourth ventricle; and its accessory nucleus near the olive is connected with its main nucleus by a band. Partly merged with this accessory nucleus is the *nucleus ambiguus*, which is the motor centre of certain mixed nerves, and a band parallel to that joining the two hypoglossal nuclei connects the ambiguus with a mass of gray in the floor of the ventricle—the *sensory nucleus* of the same mixed nerves. Fol-

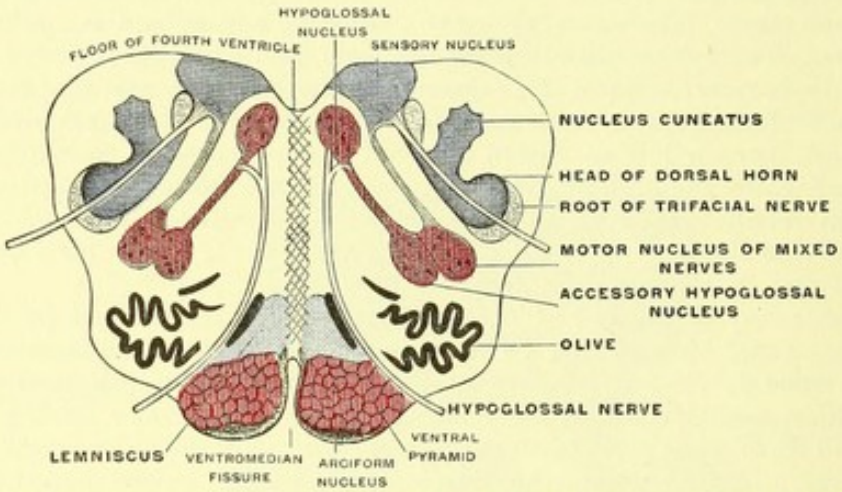

FIG. 606.—Transverse section of the oblongata at the middle of the olives. (Testut, after Duval.)

lowing the line of the pneumogastric nerve, we see that it courses through a mass of gray tissue, a sprout from which is the *cuneate nucleus*, and its rounded end the *head of the dorsal horn*—a name which will be appreciated a little later, when the various nuclei are brought together. Capping the head of the dorsal horn is a bunch of fibres, constituting a *root of the fifth nerve*—the trifacial; and between the sensory and cuneate nuclei is a bundle known as the *solitary fasciculus*.

A parallel section *through the lower end of the olives* shows a different arrangement (Fig. 607). The general outline approaches the circular, the tenth nerve is

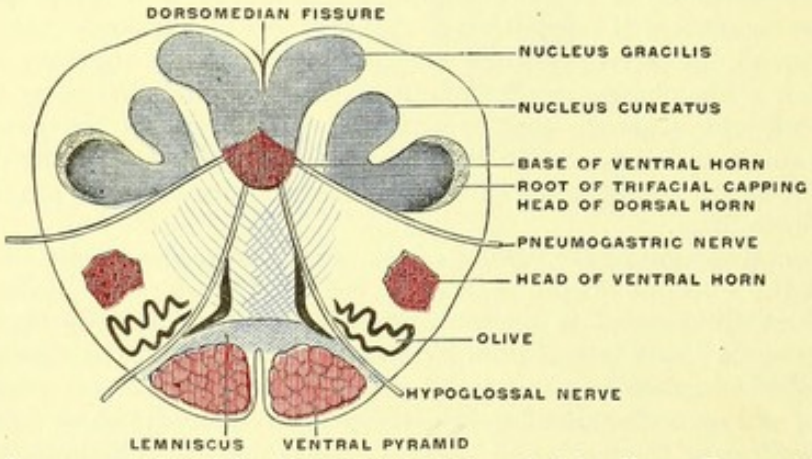

FIG. 607.—Transverse section of the oblongata at the lower end of the olives. (Testut, after Duval.)

near the transverse axis, and the nuclei dorsal to it are larger and nearer to each other. The pyramid is smaller; the fillet has spread out, and its lateral edge is almost at the surface; the corrugated nucleus of the olive is shrunken, its mesial accessory nucleus is larger, its other accessory has disappeared; in the lateral area appears the *head of the ventral horn*, the base of the same occupying a median position at the focal point of the tenth and twelfth nerves; just dorsal to the base of the ventral horn is that of the dorsal horn, from which curves dorsally the *nucleus gracilis* (Goll), separated but a little from its lateral companion, the

nucleus cuneatus (Burdach); and connected with the last is the head of the dorsal horn, related, as in the first section, to a root of the trifacial nerve.

A *lower section* exhibits further changes (Fig. 608). The pyramid and fillet are smaller; the head and base of the ventral horn are nearer; the tenth nerve has vanished; all of the remaining gray masses are drawing together; the sides

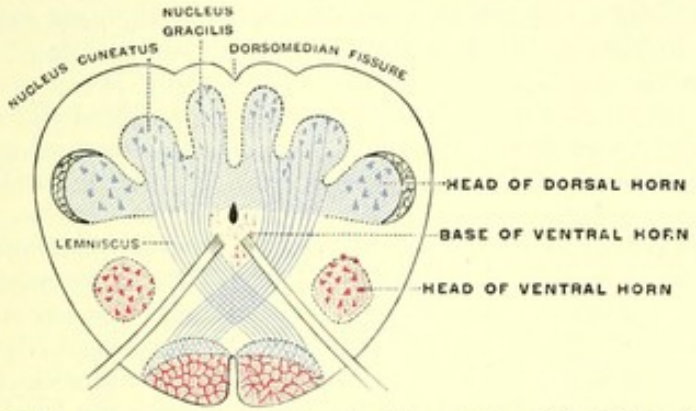

FIG. 608.—Transverse section of oblongata at the crossing of the fillets. (Testut.)

of the oblongata have grown up around the middle line, and have shut in deeply the ventricle, which in this lowest part is tubular; and from the nuclei gracilis and cuneatus *thick bundles of fibres course ventrally*, decussate in the middle line, and end in the fillet of the opposite side.

Through *the middle of the decussation of the pyramids* the section has a practically circular outline (Fig. 609). The pyramid is smaller than before, and from it runs dorsally a bundle of fibres, which crosses its fellow of the opposite side in the middle line. The fillet is no longer seen; the base and head of the ventral horn are closer, being now separated only by the decussating bundles of the pyramid; the base of the dorsal horn is nearer the centre of the section, its head is smaller; the nucleus cuneatus is lost, and the nucleus gracilis stretches out as a long process from the base of the dorsal horn. The ventral and dorsal median fissures are shallow, and from the latter a neurogliar septum stretches to the central gray mass. Nerve-roots are given off from the heads of both horns.

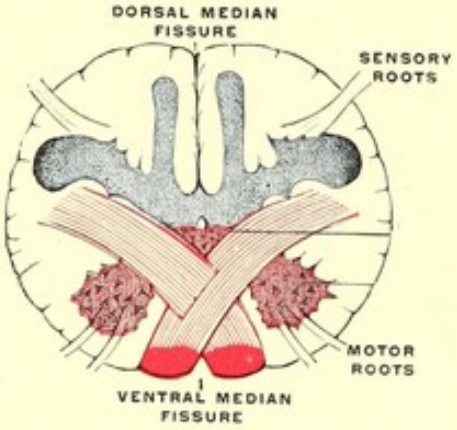

FIG. 609.—Transverse section of oblongata at the decussation of the pyramids. (Testut, after Duval.)

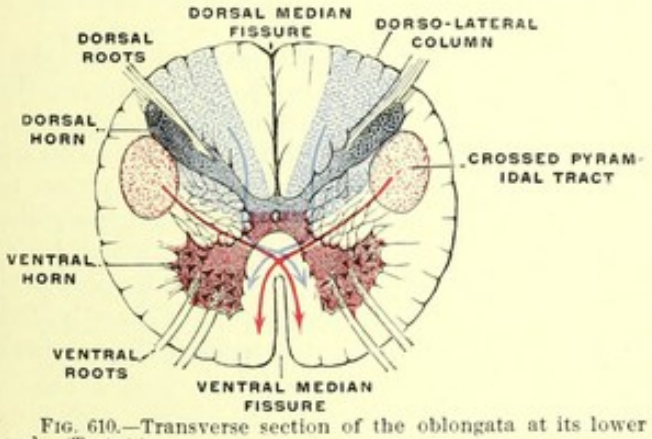

FIG. 610.—Transverse section of the oblongata at its lower end. (Testut.)

Finally, a section *at the line between oblongata and cord* (Fig. 610) shows that the nucleus gracilis has been left above, and that the other gray masses are completely united, and are arranged in a form suggestive of the letter X, the canal being in the centre of the crossing arms. The dorsal limbs of the X are the dorsal horns, the ventral limbs the ventral horns, the base of each horn being the part near the centre, the head being the free extremity. In each lateral half, between the dorsal horn and the

side, is an oval area, which indicates the destination of the part of the ventral pyramid which has crossed the middle line in the process of decussation.

This series of sections clearly reveals the fact that, progressively from above downward, there is a diminution in the amount of gray material, and a drawing together of its scattered masses.

Proceeding in the other direction—*from below upward*—we see that there is an addition of nuclei, a breaking up and dispersion of the gray mass of the lowest level, and that this scattering is caused by the oblique crossing from one side to the other of motor and sensory bundles. Examining the series of sections in reversed order, it is found that, at the first step, the heads of the ventral columns are amputated by the great bundles of fibres from the decussating pyramids, and the dorsal horns have had added to them the nuclei graciles. Next, the nuclei cuneati appear, and large fasciculi from them and the nuclei graciles sweep forward and inward, cross their opposite fellows at the middle line, and turn up at the back of the pyramids, forming the fillets. This performance results in the decapitation of the dorsal horns, just as the pyramidal bundles cut off the heads of the ventral horns. The succeeding step marks more emphatically the separation of the various heads from their respective bases, and introduces the olive. At last, the lateral spreading of the dorsal portion throws the hind parts outward, brings the cavity and the bases of the horns to the rear, while the nuclei graciles disappear. What has before been called the base of the ventral horn now assumes the *rôle* of the hypoglossal nucleus, and the head of this horn has become the accessory hypoglossal nucleus and the nucleus ambiguus.

At several points in the description of the lower segments of the brain, it has been necessary to refer to the lemniscus or fillet, but a complete account of its course could not be appreciated until the structures of which it formed a part were measurably understood. Now, however, it may be considered with profit.

The Lemniscus.

The lemniscus ("the fillet") (Figs. 605–607) is a band, extending from the middle horizontal plane of the oblongata to the level of the quadrigemina. Its principal portion originates in the nuclei gracilis and cuneatus, which are situated in the dorsal part of the oblongata, and are the terminal stations of the funiculi gracilis and cuneatus, which are the upward prolongations of the dorsal tracts of the cord. It begins by running nearly horizontally forward and inward across the middle line of the oblongata, decussating with its opposite fellow above the plane of the pyramidal decussation, and reaching the dorsal surface of the pyramid. At this point it bends upward, and courses along close to the pyramid, being joined in this region by the fibres of the ascending lateral tract (Gowers) of the cord, which has come up through the lateral tract of the oblongata and its lateral nucleus (Rolando). Thus it is seen that the lemniscus embraces all of the sensory fibres which have come from the cord.

Passing into the pons, the lemniscus occupies the ventral stratum of the dorsal part, enters the mesencephalon, where a portion appears on the surface of the tegmentum, and almost all of it courses dorso-ventrally through this segment of the brain to the subthalamic region. There its fibres divide into two sets, one of which runs through the dorsal limb of the internal capsule, and thence passes to the cortex of the central area; while the second set, of greater size, enters the thalamus, and ends there in arborizations around the cells—from which last, however, other fibres run to the gyri around the central fissure, like the first group. The essential difference between the two sets is that one goes directly, the other through a thalamic interruption, to the sensori-motor area of the cerebral cortex.

The Fourth Ventricle.

We have now studied separately the various structures enclosing the part of the encephalic cavity which is known as the fourth ventricle, and it will be well

to consider them in their natural connections as the continuous walls of this chamber.

The upper, wide-spread portion of the fourth ventricle (that part which is usually thought of when the ventricle is named) is nearly rhomboidal or lozenge-shaped. It presents a ventral part, called the *floor*; a dorsal part, the *roof*; an upper or anterior angle, a lower or posterior, and two lateral *angles*. The upper or anterior *sides* are formed by the superior cerebellar peduncles, the lower or posterior sides by the inferior cerebellar peduncles, all of which overlap the floor a little.

The Floor (Fig. 605).—The upper portion of the floor is furnished by the pons, the lower by the oblongata. In its whole extent the floor is cleft longitudinally by a median fissure, and a description of one half answers perfectly for the other.

In the Pontile Portion.—Sloping down from the upper angle, parallel with and close to the superior peduncle is a strip of bluish hue, the *locus ceruleus*. In

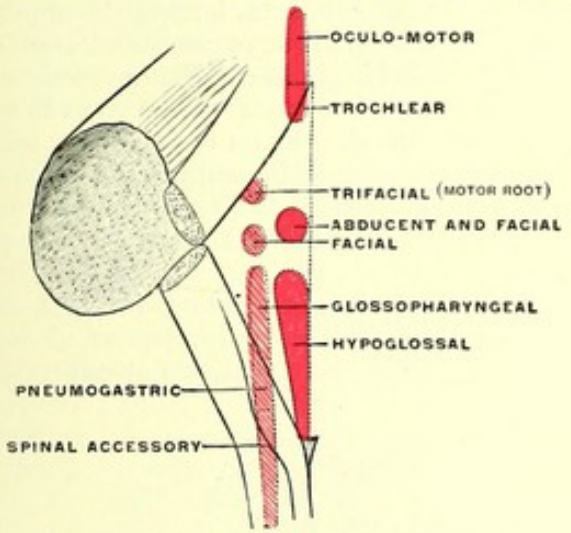

FIG. 611.—Diagram of the motor nuclei in and near the floor of the fourth ventricle. (Testut.)

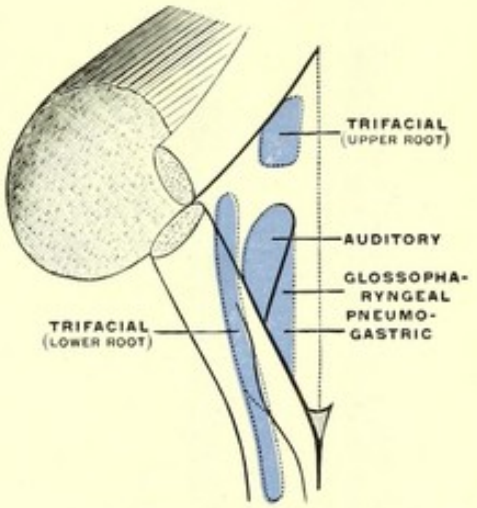

FIG. 612.—Diagram of the sensory nuclei in the floor of the fourth ventricle. (Testut.)

line with this and below it at the lateral angle is a shallow depression, the *fovea superior*. Between the fovea and the middle line is a white tubercle, the *eminentia teres*.

In the Oblongatal Portion.—Below the eminentia teres and, like it, close to the median cleft, is another and larger white projection, forming a triangular ridge which extends nearly to the lower angle. It is the *hypoglossal area*. At the outer side of the last is the pneumogastric or *vagus area*, a gray, somewhat triangular space, the lowest part of which is slightly depressed, and is called the *fovea inferior*. Between the vagus area and the lateral angle is a white elevation, the *auditory area*, whose upper part is called the *acoustic tubercle*. Large white threads, the *striæ acusticæ*, pass outward from the mid-line, and are gathered into a bundle beneath the projecting restis, forming a root of the auditory nerve. At the lower angle is the *obex*.

The Roof (Fig. 598).—The roof is formed above by the *valvula*, which stretches between the superior peduncles; below by the *metatela*, which spans the space between the inferior peduncles. The lower edge of the valvula is continued downward and backward into a thin white layer, derived from the centre of the cerebellar vermis; and the upper border of the metatela is continuous with the pia and endyma, respectively covering and lining a similar layer which runs downward and backward from the white of the vermis. Thus, the roof is farthest from the floor, and forms a *tent*, at the point where these cerebellar laminæ separate—the one to go up (forward) to the valvula, the other to go down (backward) to end by a free edge of nervous tissue, from which the roof is con-

tinued by a membrane of vascular and serous tissues. In the centre of this membrane is an aperture, the *metapore*, or foramen of Magendie.

It is interesting and very important to observe (Figs. 611, 612) how large a part of the cranial nerves have their deep (real) origin in and close to the floor of the fourth ventricle.

The *average weight* of the normal adult encephalon is in the region of 49 ounces for the male, and about five ounces less for the female.

THE SPINAL CORD.

The *spinal cord* (Fig. 613) is the terminal portion of the cerebro-spinal axis, and is a direct continuation of the oblongata, having its upper limit at the lowest level of the pyramidal decussation. It is contained in the canal of the vertebral column. Like all other parts of the axis, it is bilaterally symmetrical. From it are given off almost all of the nerves which supply the voluntary muscles of the parts below the head, and to it go the sensory nerves of the corresponding regions.

Its *shape* approaches the cylindrical. It is slightly flattened ventro-dorsally, tapers at its caudal end, and presents a fusiform swelling in

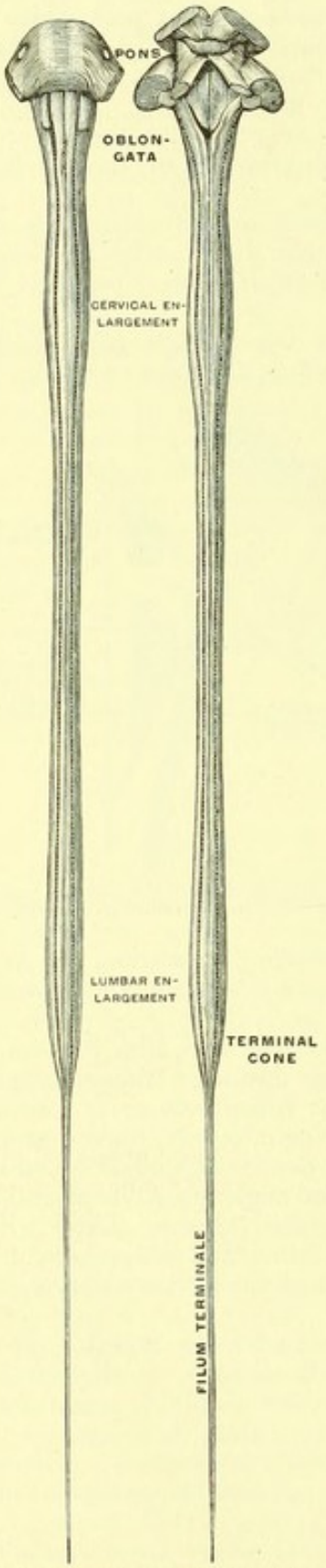

FIG. 613.—Spinal cord, oblongata, and pons. Left-hand figure is ventral view, right-hand is dorsal. (Testut.)

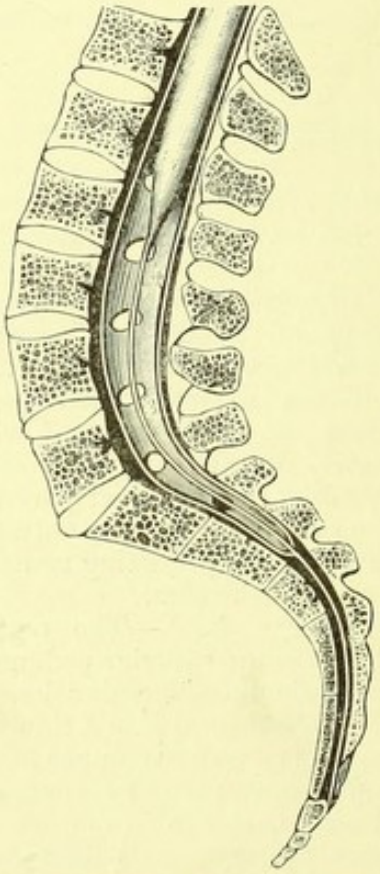

FIG. 614.—Sagittal section of the spinal canal, showing the lower end of the cord and the filum terminale. The dura is seen extending to the third sacral vertebra. (Testut.)

the cervical region, and another in the thoracico-lumbar region. The *cervical enlargement* extends from the third cervical vertebra to the second thoracic, and corresponds to the origin of the nerves of the upper limbs. The *lumbar enlargement*, which marks the origin of the nerves of the lower limbs, begins at the ninth thoracic vertebra, attains its greatest size at the twelfth, and thence rapidly dwindles in a *terminal cone*, from the apex of which extends a delicate prolongation, the *filum terminale* ("the end thread"), whose upper part presents the essential histologic elements of the cord (Fig. 614). It is customary, however, to regard the tip of the cone as the distal end of the spinal cord, as the filum is plainly only a rudimentary structure.

The cord presents two curves, which correspond to those of the parts of the column which it occupies: a *cervical curve*, with its convexity forward, and a *thoracic curve*, with its concavity forward. The cord proper extends from the plane of the occipito-atloid joint to that of the body of the second lumbar vertebra, and the filum continues from this point to the base of the coccyx. The *length* of the cord proper is about eighteen inches, its *transverse diameter* one half-inch or less, and its *weight* nearly an ounce.

Fissures and Columns.—External inspection of the cord shows upon its surface a number of creases, running from end to end. In the middle line in front is a deep cleft—the *ventro-median fissure*; in the middle line behind a shallow one—the *dorso-median fissure*; at each side of the latter, nearly a quarter of the way around to the front is a shallow *dorso-lateral fissure*; and between the dorso-lateral and the dorso-median, and much nearer the latter, is the *dorso-intermediate fissure*. The dorso-lateral fissures are occupied by the *dorsal roots* of the spinal nerves. The *ventral roots* of the spinal nerves come off on each side from a vertical strip of the surface which is about as far from the ventro-median fissure as the dorsal roots are from the dorso-median fissure. Thus, each lateral half of the cord is divided into three parts: one between the ventro-median fissure and the ventral roots—the *ventral* (anterior) *column*; a second between the ventral roots and the dorsal roots—the *lateral column*; and a third between the dorsal roots (or dorso-lateral fissure) and the dorso-median fissure—the *dorsal* (posterior) *column*, which is subdivided by the dorso-intermediate fissure into the *dorso-lateral column*, and the *dorso-mesial column*. All of these structures are composed of white nervous tissue.

The Gray Matter of the Cord (Fig. 615).—A transverse section of the cord shows a mass of gray nervous tissue, enclosed by the white. The gray of each side is somewhat crescentic in form, or the whole mass may perhaps be more aptly likened to two commas, one of which is reversed, the two placed back to back, and their convexities connected by a narrow band. The head of each comma is ventral, its tail dorsal. The two portions of each are called horns or *cornua*.[1] The *ventral horn* points forward and outward, but does not come nearly to the margin. The free end of it is the head, the attached part is the base. From the head project numerous spine-like processes; from the concave side of the base juts out a triangular mass—the *lateral horn*, which is most pronounced in the upper thoracic region. The *dorsal horn* is directed backward and outward, and quite or nearly reaches the periphery of the cord at the dorso-lateral fissure. It is divided into three parts: the base, which is continuous with that of the ventral horn; the head, which ends behind in a point, called the apex; and the neck, which connects the base and head. Near the hind part of the head is a crescentic portion, the *substantia gelatinosa* ("gelatinous substance"). From the concavity of the comma, at the base of the dorsal horn, projects a network of gray tissue, enclosing in its meshes little masses of white. This is the *processus reticularis*

[1] The term horn or cornu employed generally to designate a portion of the gray matter of the cord is strictly adapted only for use in the description of transverse sections; for it is manifest that the gray of the cord, equally with the white, is arranged in columnar masses. But, as practically we do not see the gray except in cross-sections, the word horn or cornu is sufficiently accurate and not misleading.

("reticular process"), or *reticula*, and it is most marked in the upper cervical region. The base of the dorsal horn bulges toward the middle line of the cord, forming the *column of Clarke*, a structure found in the thoracic region and a little above and below it. The band connecting the two commas is the *gray commissure*, and it contains the *central canal of the spinal cord*, a minute channel, continuous with the fourth ventricle of the brain, from which it extends to the middle of the filum terminale. It is not patent in every part of its course.

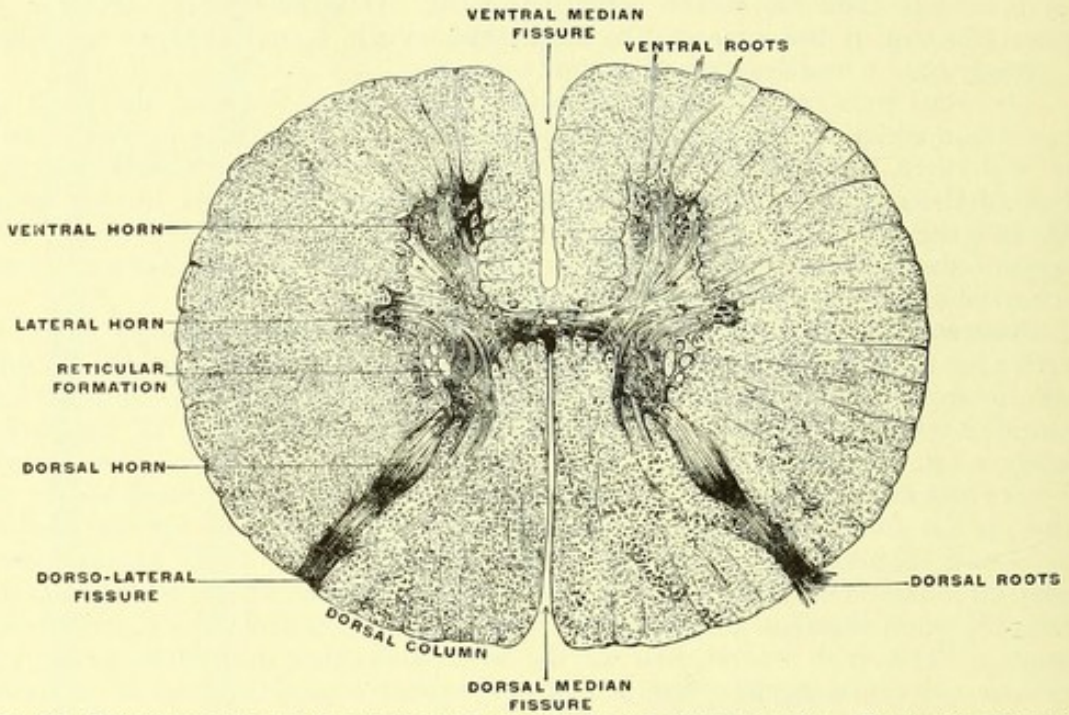

FIG. 615.—Transverse section of the spinal cord at the middle of the thoracic region. (Testut, after Pierret.)

The various fissures which have been mentioned are all seen to have little depth, excepting the ventro-median, which cuts far into the substance of the cord, and reaches almost to the gray commissure. Between the dorso-median fissure and the gray commissure is a septum of neuroglia, which separates the two dorsal columns from each other. The ventral and lateral columns are continuous around the head of the ventral horn, and, on this account, it is not uncommon to speak of them as a single structure—the *ventro-lateral column*. The two ventral columns are connected in their deepest parts by the *white commissure*, which is in contact with the gray commissure. These facts are shown diagrammatically in the left half of Fig. 616.

A knowledge of the obvious features which have been mentioned, while necessary for purposes of description, affords little practical help in the study of the physiology of the cord; and, consequently, it is essential to know the delimitations of the paths by which motor impulses and sensory impressions are conducted to and fro in this organ of intermediation between the highest centres of the cerebrum and the most distant areas of the periphery. To a large extent these paths have been ascertained, and will now be indicated. It will be seen that there is little in the gross appearance of the cord to give information as to the boundaries of these cables of telegraphic communication. The right half of the diagram (Fig. 616) will aid in the understanding of the few succeeding paragraphs.

The Conduction Paths of the Cord.—In the ventral column a narrow triangular area is marked off next to the ventro-median fissure. This is the *direct pyramidal tract*—"pyramidal," because it is a downward extension of a part of the pyramid of the oblongata; "direct," because this path is on the same side of the middle line in encephalon and in cord. It gradually diminishes in size from above downward, and disappears at the level of the root of the last lumbar nerve.

At the back part of the lateral column, close to the dorsal horn, is an oval area, the *crossed pyramidal tract*—"pyramidal," for the reason just given; "crossed," on account of the decussation which occurs in the oblongata. It dwindles as it descends, and ceases at the third or fourth sacral nerve-root.

Between the outer side of the crossed pyramidal tract and the surface of the lateral column is the dorsal part of a long, narrow area, the *direct cerebellar tract*, so called because its fibres course upward through the oblongata as straight as possible to the cerebellum. It appears at the level of the eighth or ninth thoracic nerve-root, and progressively increases, as it ascends.

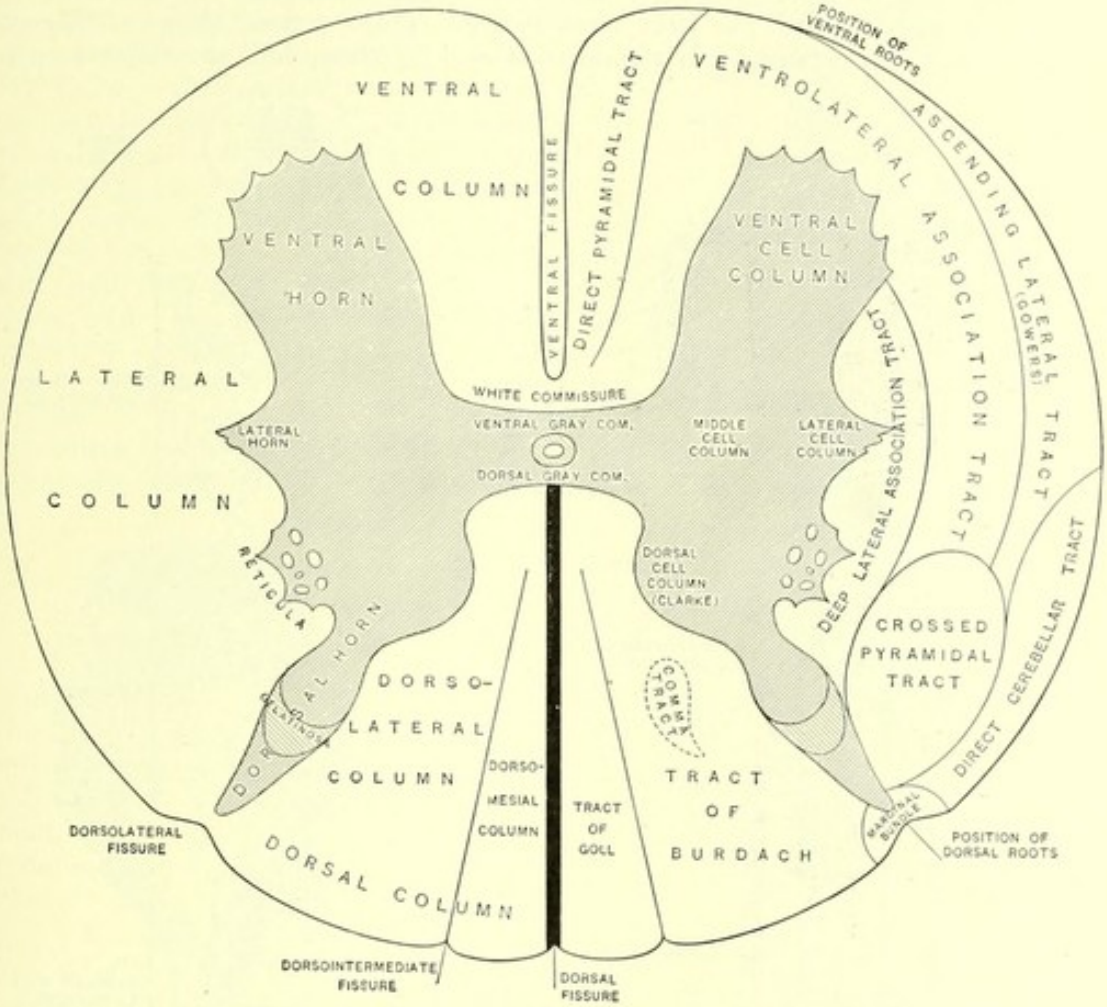

FIG. 616.—Diagrammatic ideal transverse section of the spinal cord. On the left side are shown the gross divisions; on the right side, the conduction paths. (F. H. G.)

Anterior to this is a somewhat triangular area, which extends to, perhaps beyond, the place of exit of the ventral roots, the *ascending lateral tract*, or the Gowers tract—named "ascending," from the direction in which it carries impressions; "lateral," from its position. It occupies the whole length of the cord, and increases in size from below upward.

Lodged in the curve of the gray comma, and penetrated by the interlocking strands of the reticula, where the latter exists, is the *deep lateral association tract* (otherwise known as the mixed lateral). The first and second words in this title are self-explanatory; the third is chosen because it is descriptive of the function of the fibres composing this tract. These fibres originate in cells of the gray substance of the cord, run a short course, then turn into the gray, and end in arborizations around its cells. Thus, they act as longitudinal commissures, associating each part of the cord with parts a short distance above and below.

The remaining areas in the ventral and lateral columns are perfectly con-

tinuous around the head of the ventral horn, except for the interruption occasioned by the passage of the ventral roots from the surface to the ventral horn. They are often called the fundamental tracts, or ground tracts of their respective columns; but a simpler and more instructive name is the *ventro-lateral association tract*—an appellation which indicates at once the location and the service of the structure, whose function is to connect parts of the cord situated at different levels. The association tracts are found in the whole length of the cord, and are subject to but slight variations of size.

In the dorsal column are two tracts, separated from each other by a line running from the dorso-intermediate fissure to a point near the junction of the neurogliar septum and the gray commissure. These tracts, then, correspond exactly to the dorso-mesial and the dorso-lateral columns, and are called respec-

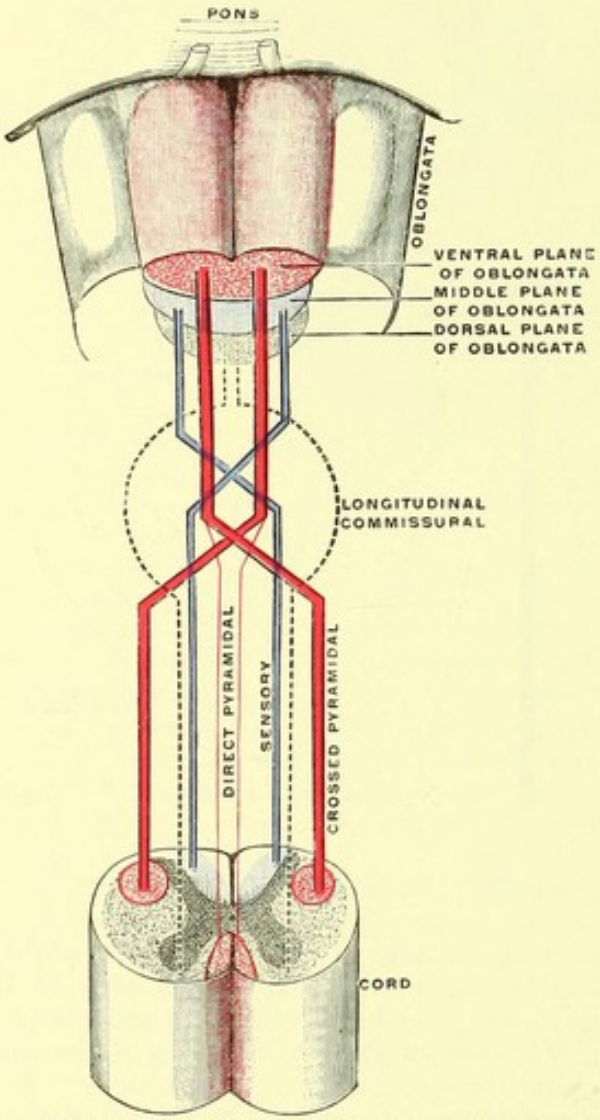

FIG. 617.—Diagram to show the crossing of the pyramids (red) and of the lemniscus (blue). (Testut.)

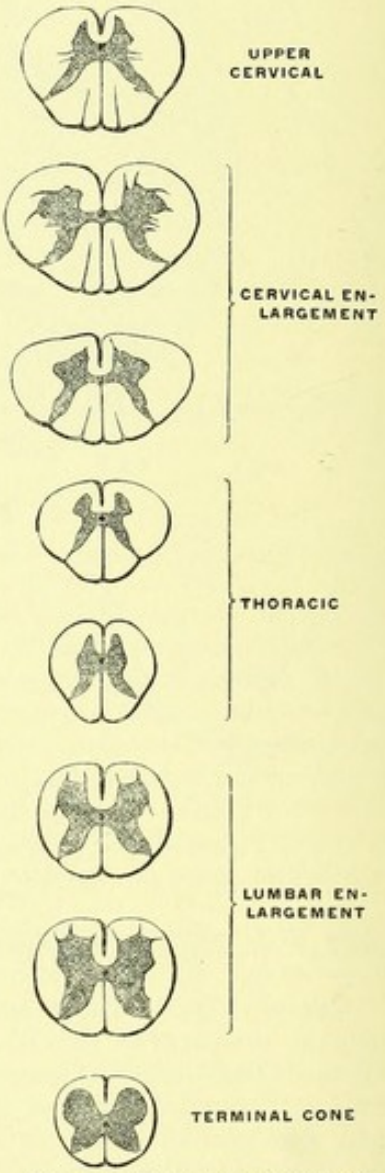

FIG. 618.—Transverse sections of the spinal cord at different levels. (Testut, after Erb.)

tively the *tract* (or column) *of Goll*, and the *tract* (or column) *of Burdach*. The Goll tract increases in size as it ascends; the Burdach tract varies but little from its average at different levels.

Finally, at the dorso-lateral fissure is a small irregular area, the *marginal bundle*, called also by the names of the men who simultaneously described it, the *Spitzka–Lissauer tract*.

From what has been said it must be evident that the size and shape of the cord, and the absolute and relative amounts of white and gray matter vary greatly in different parts. This is shown pictorially in Fig. 618.

The Spinal Nerve-roots (Fig. 619).—The roots of the nerves which arise from the spinal cord are in two sets, dorsal and ventral. The *dorsal* leave the cord in a continuous series at the dorso-lateral fissure, the *ventral* along a narrow vertical strip of the surface nearest to the head of the ventral horn. At fairly regular intervals the roots in each series are bunched together, and then the fagot of the dorsal set is united to that of the ventral, the result being a single bundle, which is a *spinal nerve*. In this nerve the fibres from the two roots are intimately mingled, and thus the spinal nerves are *mixed nerves*. On the dorsal bundle of each nerve is a *ganglion*, situated at the distal part of the root and outside of the sheath of dura. The upper roots are short and horizontal, and those below these are progressively longer and more nearly perpendicular. The lowest come off from the tapering cone at the end of the cord proper, are very long and perpendicular in direction. From its resemblance to a horse's tail the collection of these roots is called the *cauda equina* (Fig. 620).

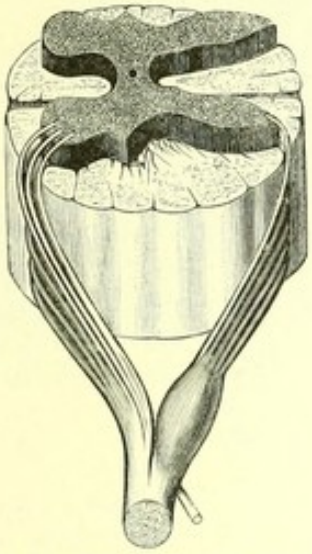

Fig. 619.—Formation of a spinal nerve. (Testut.)

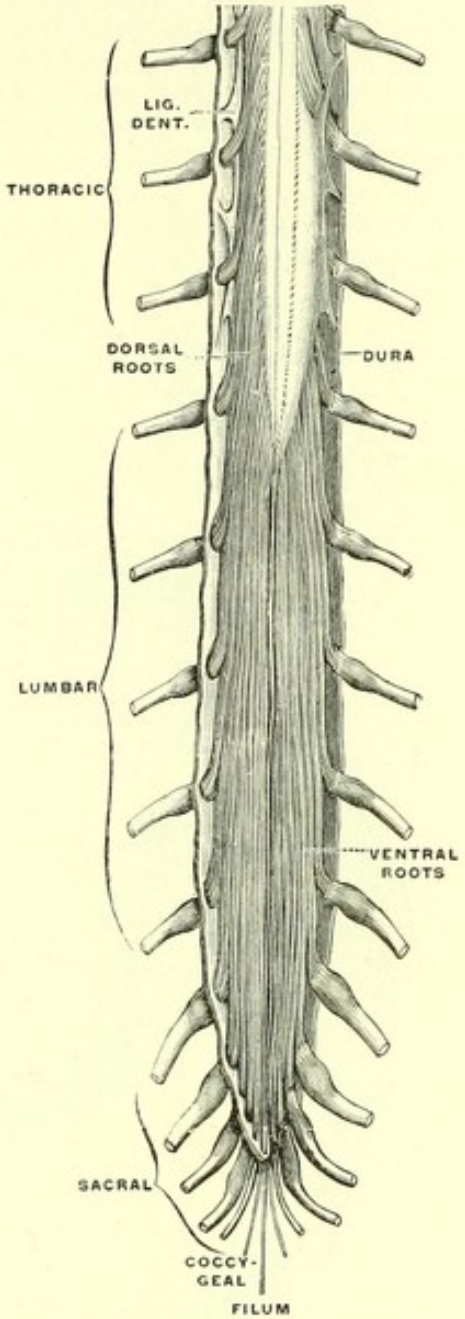

Fig. 620.—Lower end of the spinal cord and the cauda equina, dorsal aspect. The dorsal roots of the right side have been removed. (Testut.)

THE MEMBRANES
of the Cerebro-spinal Axis.

The brain and spinal cord are enveloped in three membranes (*meninges*), of which the innermost is called the *pia*, the middle one the *arachnoid*, and the outermost the *dura*. Each of these is a covering for every part of the axis; but they have such variations of structure and arrangement in different parts as to make it best to consider separately the membranes of the brain and those of the spinal cord.

The Membranes of the Brain.

The **Dura**, formerly called *dura mater* ("severe mother"), is a strong, thick membrane, composed of white fibrous tissue with a small admixture of yellow fibres, and lodging a great number of blood-vessels. It is arranged in two layers, which are closely united in most parts, the outer one being decidedly the more vascular. Externally the dura is firmly adherent to the inner surface of the bones which form the brain-case, and is for them the internal periosteum, known as *endocranium* ("within the cranium"). When the dura is peeled off from the bones its outer surface is seen to be flocculent, owing to the vessels which pass from it into the bone being pulled partly out of the channels in which they were lodged, and torn off, and to the similar treatment of certain small, fibrous processes of the membrane. The endocranium is continuous with the pericranium at the margin of the various holes which perforate the skull. The dura extends outward through the basal foramina, and becomes continuous with the areolar sheath of the nerves which pass through them.

Several broad prolongations of the dura extend from the periphery toward the centre of the cavity of the brain-case. In their formation the inner layer of

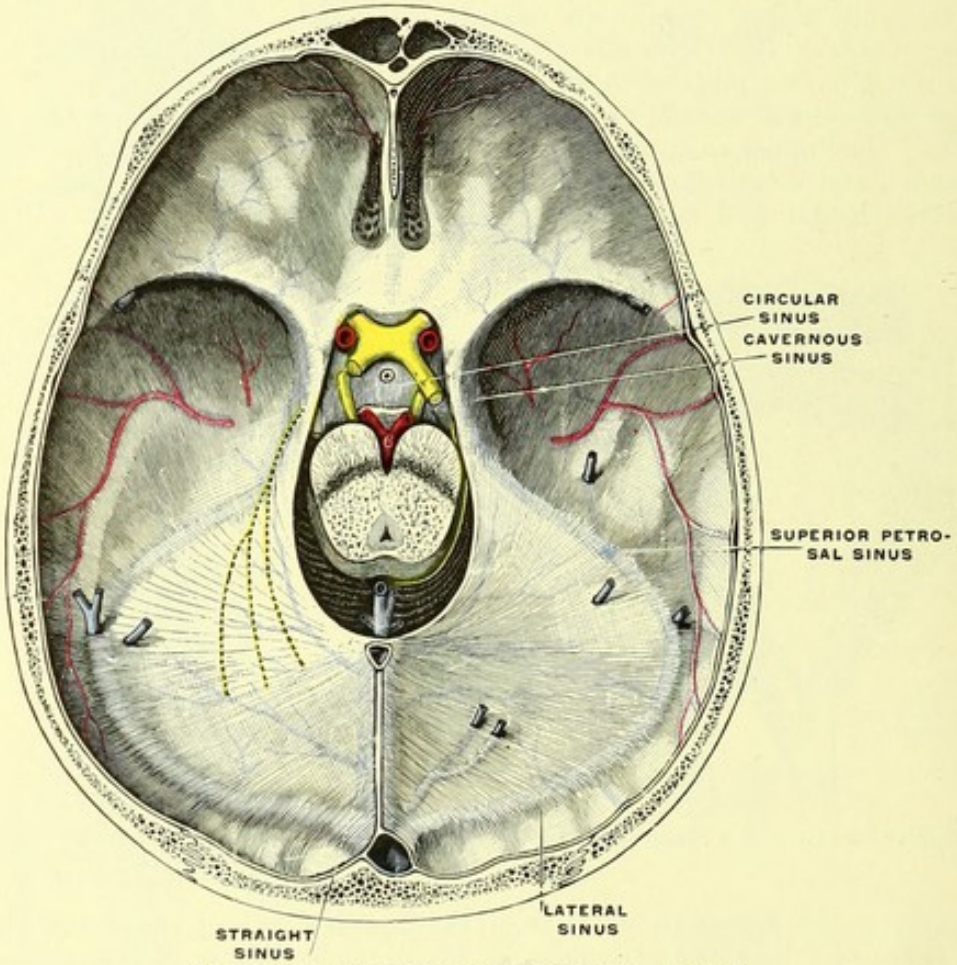

FIG. 621.—The tentorium, viewed from above. (Testut.)

the dura separates from the outer along a definite line and projects centrally. Presently it comes in contact with a corresponding and opposite plate, which has been formed in the same manner, and the two blend, and, thus united, stretch toward the centre as a strong, partial partition. At the attached border of these shelf-like structures is left a prismoid space, whose base is bounded by the outer layer of the dura, and its sides by the prolongations from the inner layer. These spaces are lined by an extension from the tunica intima of the veins, and thus constitute the venous sinuses, already described.

The principal processes of the dura are the tentorium, the falx cerebri, and the falx cerebelli.

The **tentorium** ("tent") springs from the borders of the superior petrosal and the horizontal part of the lateral sinuses. From this origin it rises toward the centre, and terminates in a free border, which extends forward and is attached on each side to the anterior and posterior clinoid processes. There is thus left a large opening, in which is situated the mesencephalon. The tentorium is spread between the cerebellum and the occipital portion of the cerebrum, protecting the former from the superincumbent pressure of the latter.

The **falx cerebri** ("sickle of the brain") is so called from its shape. It is attached anteriorly to the crista galli, posteriorly to the median part of the upper

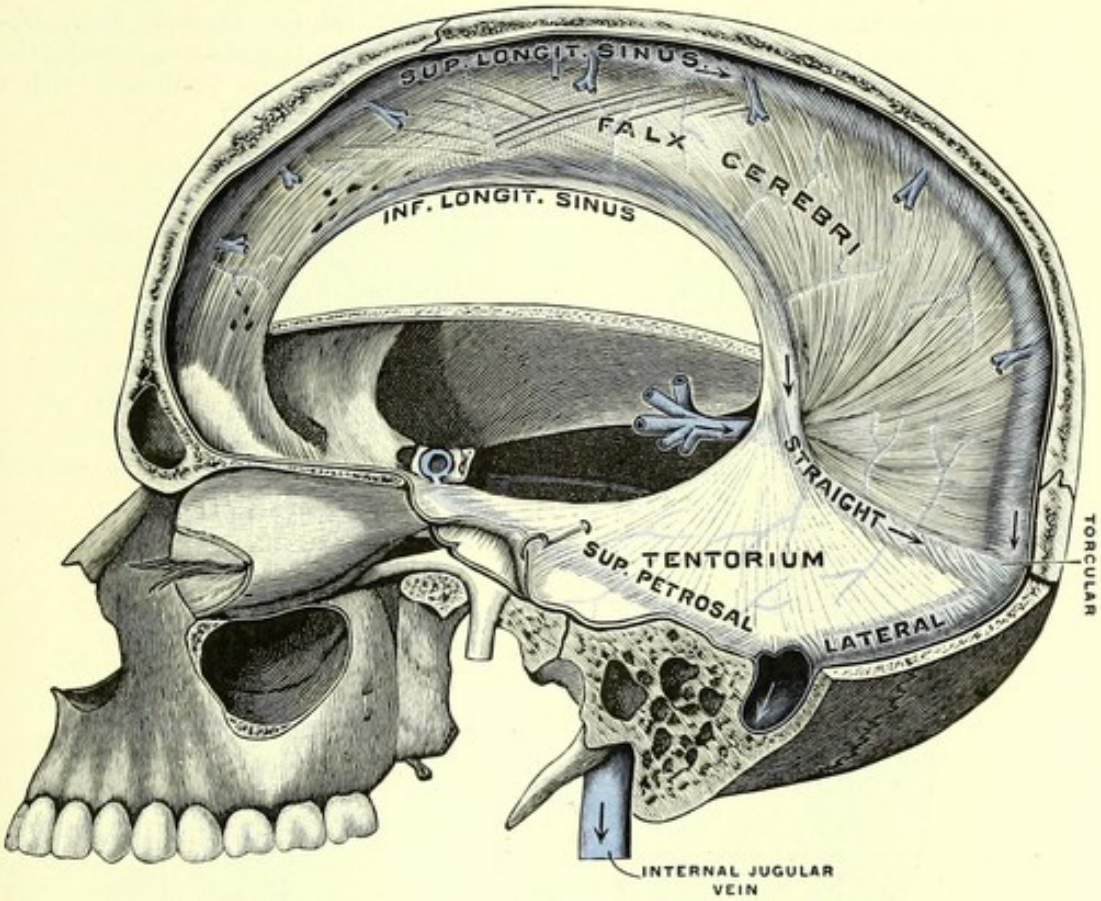

FIG. 622.—Falx cerebri and tentorium, left lateral view. (Testut.)

surface of the tentorium, and for the rest of its extent to the ridges bounding the great longitudinal sinus. It dips into the great fissure between the hemispheres, deeply behind, and progressively less so as it is traced to the front. It thus forms a tightly stretched, median septum, which prevents the pressure of one hemisphere upon the other in the lateral movements of the head, just as the fore-and-aft partition in a vessel keeps the cargo from shifting from side to side in the lurchings of the craft at sea. The falx cerebri encloses the superior longitudinal sinus peripherally, the straight sinus in its tentorial attachment, and the inferior longitudinal sinus in its free border.

The **falx cerebelli** is a small median septum between the cerebellar hemispheres behind. It is broadest above, where it is attached to the under surface of the tentorium, and tapers rapidly as it descends. It encloses the occipital sinus in its posterior border.

Under the names of *diaphragm of the sella* and *tentorium of the hypophysis* a small double fold of the dura extends inward from all sides over the sella turcica, covering the hypophysis, and leaving a little aperture for the apex of the

infundibulum. The presence of this fold accounts for the fact that the hypophysis is usually torn away when the brain is removed.

The arteries of the dura are branches of the occipital, vertebral, ascending pharyngeal, internal maxillary, internal carotid, and ophthalmic.

The **Pia**, formerly called *pia mater* ("affectionate mother"), consists of blood-vessels arranged in the form of a membrane, and supported by areolar tissue. It is the nourishing tunic of the brain, and lies close to its surface everywhere, dipping down to the bottom of every fissure, and sending the branches of its arteries into the nervous substance. It is prolonged onto the roots of the nerves, and becomes continuous with their connective-tissue sheath. The velum interpositum and choroid plexuses, already described, are pial structures.

The **Arachnoid** ("like a spider's web") is a thin, delicate membrane, situated between the pia and the dura, much nearer the latter, and, for the most part, substantially parallel with it. It does not follow the pia into the fissures, except the great longitudinal. The external surface of the arachnoid is furnished with a

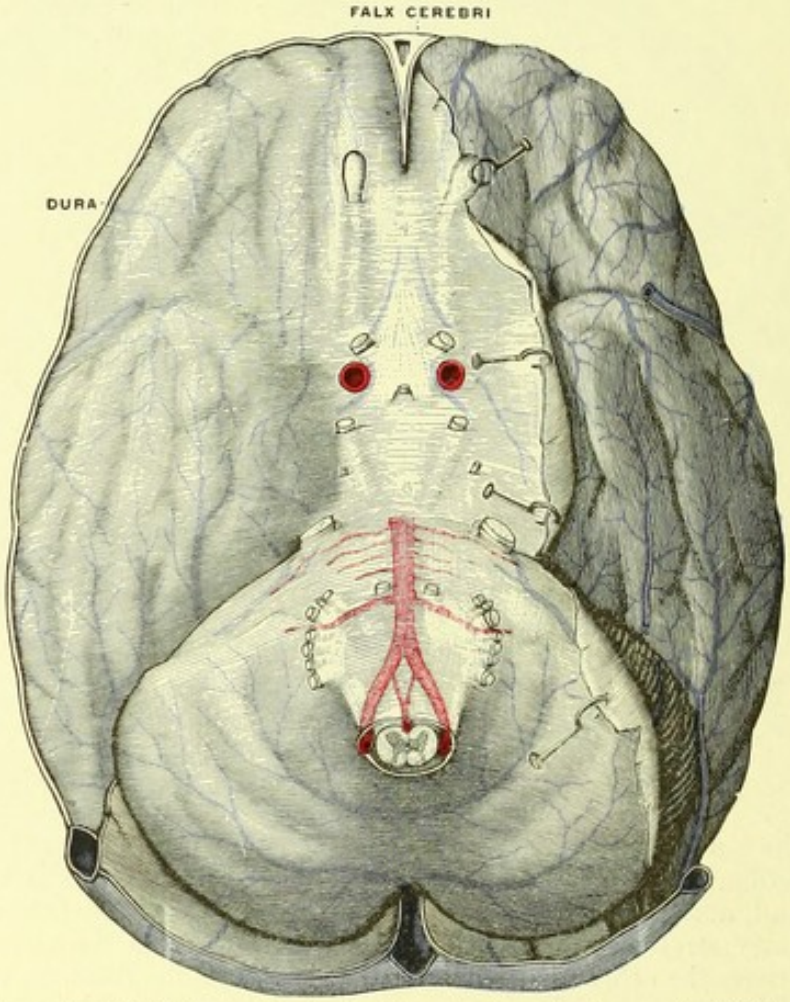

FIG. 623.—The arachnoid at the base of the brain. The membrane has been peeled off from the left hemisphere. (Testut.)

single layer of flattened epithelial cells, which is continuous with the lamina of similar cells on the inner surface of the dura. Between them is a little serous fluid. Thus we have the elements of a serous membrane, and it is proper to consider the arachnoid such. The interval between the dura and the arachnoid is the *subdural space* or *arachnoid cavity*. It is crossed obliquely by little fibrous bundles, which connect the two membranes. The cavity is normally merely virtual, its opposite sides being in contact; but it may become actual in disease. The under surface of the arachnoid is connected with the outer surface of the

pia by numberless trabeculæ of fibrous tissue, which form a delicate network. In some situations these are very abundant, in others much less so; but everywhere they are covered with flattened epithelial cells. The interval between the arachnoid and the pia is the *subarachnoid space*. It is essentially lymphatic in character, and contains cerebro-spinal fluid. At certain places the subarachnoid space is quite deep, and the trabeculæ are comparatively few. Such enlargements are known as *cisternæ arachnoidales* ("arachnoid reservoirs"). The metapore (foramen of Magendie) in the roof of the fourth ventricle permits a communication between the ventricular cavity and the subarachnoid space. At irregular intervals, principally near the longitudinal sinus, the arachnoid buds out into tufts, which press upon the structures peripheral to themselves, and even produce marked pits in the inner table of the bones. These bodies are called *glandulæ Pacchionii* ("little glands of Pacchioni"). Sometimes they contain minute, hard particles, called *brain-sand*.

The Membranes of the Spinal Cord.

In considering the meninges which enclose the cord it will be sufficient to indicate the characteristics in which they are unlike the corresponding structures in the head.

The Dura.—The feature in which the dura of the cord differs most strikingly from that of the brain is in its not being the internal periosteum of the bones of the cavity in which it is contained. Each of the segments of the vertebral column has its own periosteum. The dura is reflected from the brain-case at the margin of the foramen magnum, and below this hangs as a long tube (*theca*, "case") between the periphery of the spinal canal and the surface of the spinal cord, having attachments to the upper three cervical vertebræ and low down to the posterior common ligament. Between the dura and the vertebræ is the *epidural* ("upon the dura") *space* occupied by areolar tissue, in whose meshes are many fat-cells and a plexus of spinal veins. The outer, as well as the inner surface, is furnished with a single layer of epithelial cells.

The **Pia** is more fibrous and less vascular than that of the encephalon. From each side extends a long ribbon of connective tissue, the outer edge of which is marked by long, shallow notches

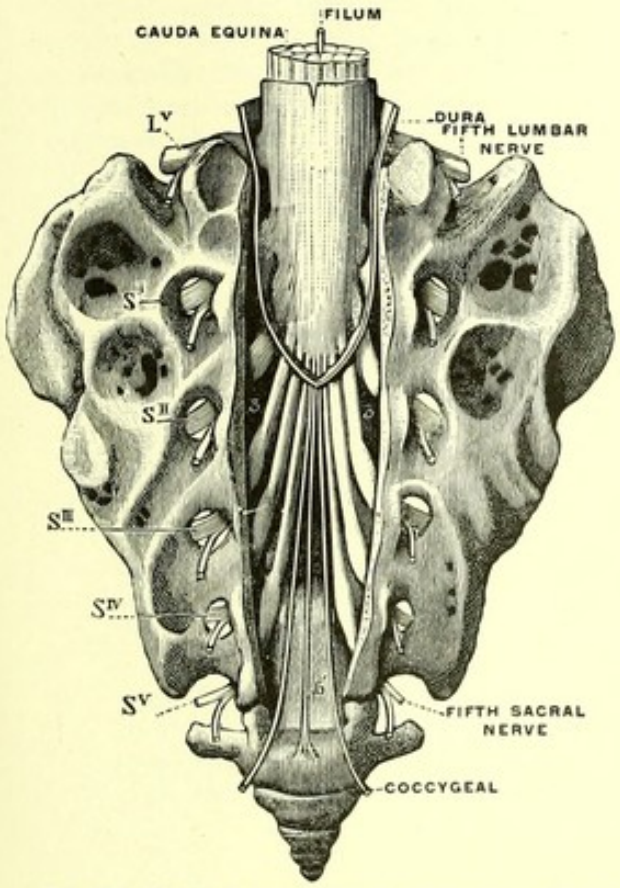

FIG. 624.—Pouch at lower end of spinal dura, and the sacral nerves. (Testut.)

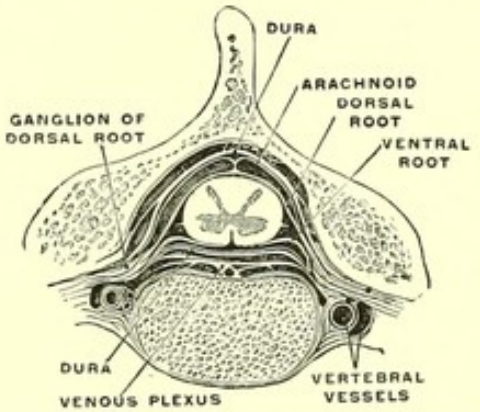

FIG. 625.—Horizontal section of vertebral column, showing spinal cord and its membranes. (Gegenbaur.)

and intervening sharp projections. From the appearance thus produced this structure has been called the *ligamentum denticulatum* ("toothed ligament"). The projections are attached to the dura between the places where the spinal nerves perforate that membrane.

The **Arachnoid** lies near the dura and far from the cord, and, consequently, the subdural space is small and the subarachnoid is large. The latter space has few trabeculæ as compared with that of the brain; but a dorsal median partition, the *septum posterius*, passes from the arachnoid to the pia, giving passage to vessels. The space is crossed also by the ligamenta denticulata.

THE NERVES.

By W. KEILLER.

IN this chapter will be described, first, the nerves which connect the brain and spinal cord with the skin, muscles, and viscera, and the nuclei in which these nerves take origin; and, second, the sympathetic system. The mode in which the nerves end in skin, muscles, and other organs is dealt with in the chapter on histology, or in the sections of the work describing the organs themselves.

THE CEREBRO-SPINAL NERVES.

The *cerebro-spinal nerves* are those which spring directly from the brain or spinal cord. Those which pass to their destination through foramina in the base of the skull are called *cranial nerves*. The rest are called *spinal nerves*, as they spring from the sides of the spinal cord and emerge through the intervertebral foramina, excepting the last spinal or coccygeal nerve, which passes through the lower extremity of the neural canal. The first spinal nerve, however, is somewhat exceptional, arising from the oblongata, and emerging from the neural canal between the occipital bone and the atlas. All these nerves are paired and symmetrically distributed, the apparent asymmetry of the vagus being due to developmental changes. As the nerves leave the brain or cord and pierce the membranes, they receive investments from the pia, arachnoid, and dura, which blend with the epi- and perineurium; but fluid, injected forcibly into the subarachnoid or subdural space, will find its way readily along the nerves for some distance. In the case of the optic nerve each sheath remains distinct as far as the eyeball.

Typical Constitution of a Cerebro-spinal Nerve.—All spinal nerves and most cranial nerves are mixed; that is, are both motor and sensory in function, the function of each fibre depending on its mode of origin and termination; and, since cranial nerves, though sometimes obscurely, follow the same plan of formation as spinal nerves, we shall take the latter as the type for study.

The diagrammatic representation of a spinal nerve in Fig. 626 shows that it arises by two roots from the spinal cord. The dorsal root is sensory, has a ganglion on it, and springs by one compact bundle from the dorsal horn of gray matter and dorso-lateral aspect of the cord. The ventral root is motor, has no ganglion, and springs by several bundles from the ventral horn of gray matter and the ventral aspect of the cord. The points by which these several bundles leave the cord form collectively the *superficial origin* of the nerve. Each fibre of the motor root is the axis-cylinder process of one of the nerve-cells of the ventral horn of gray matter, the finer branching processes of this cell connecting it with higher centres. While the nerve-cell lives, the fibre lives; when the cell dies the fibre dies. These cells of the ventral horn form collectively the *deep* or *nuclear origin* of the motor root, which their axis-cylinder processes unite to form.

The *ganglion* on the dorsal root contains the cells whose axis-cylinder processes form the sensory segment of the nerve. Though separated from the spinal

cord in the adult, it is an outgrowth from it in the embryo. The cells of this ganglion are bipolar, sending one process centrifugally into the nerve-trunk, and the other centripetally into the spinal cord. The latter bifurcates, one branch

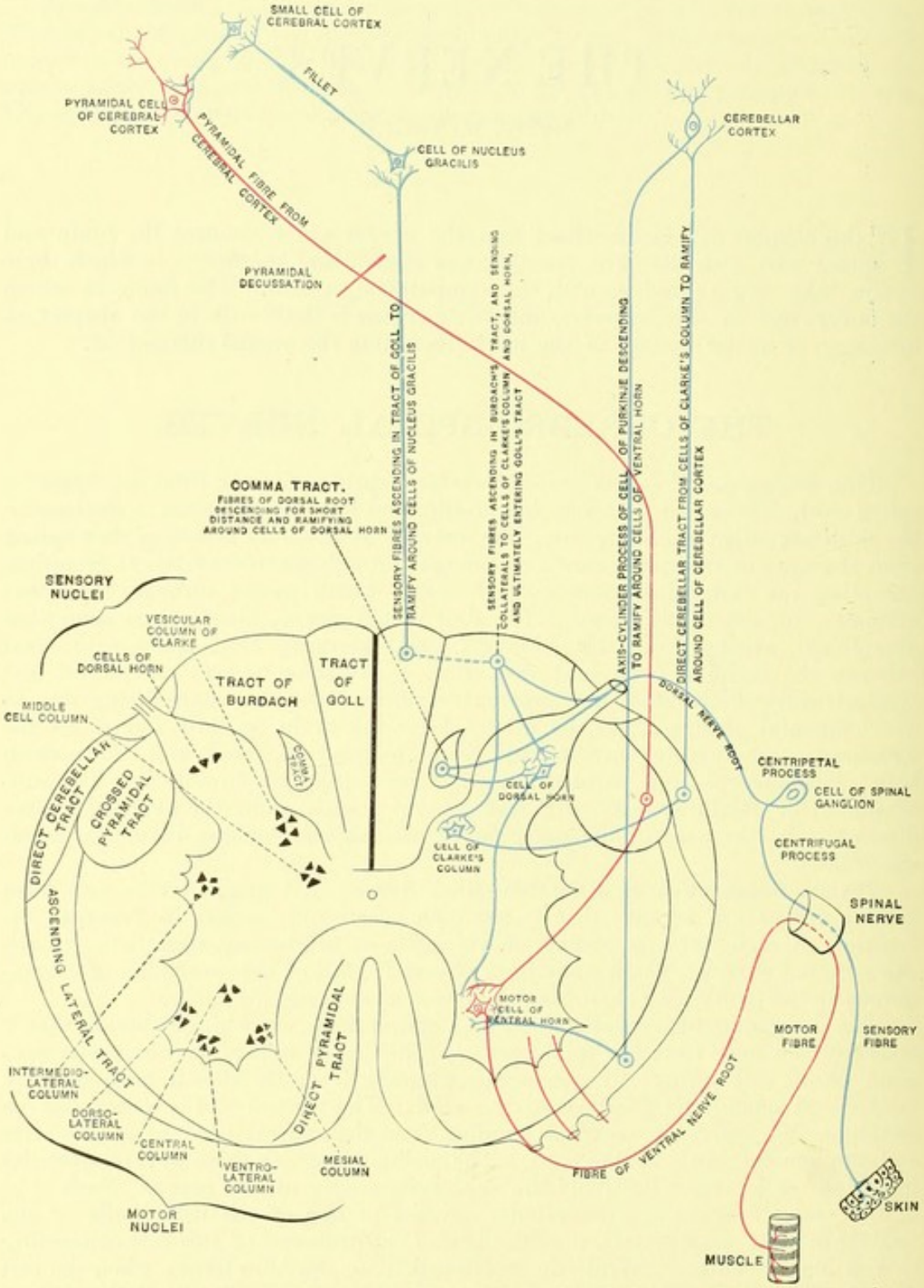

FIG. 626.—Diagram to explain the formation and connections of a spinal nerve. Motor tracts are red, sensory blue. A circle with a central dot indicates where the nerve takes a vertical direction. The presence of descending fibres in the lateral tract is to be noted. (W. Keiller.)

descending in the cord to enter into relationship with the cells of the dorsal horn of gray matter, and the other ascending to form branching processes round the

cells of Clarke's column, and of the nucleus gracilis and nucleus cuneatus in the oblongata, and others which need not be mentioned.

Thus a dorsal nerve-root is related to two groups of cells, viz., those of its ganglion and a number of widely scattered cells of the gray matter of the spinal cord and oblongata. The ganglion is homologous with the Gasserian ganglion on the fifth cranial nerve, the jugular ganglion on the ninth, the ganglia of the tenth, and the nerve-cells of the olfactory bulb, retina, and spiral ganglion of the cochlea; and the cells of the dorsal horn of gray matter, with which the sensory fibres are related, collectively represent what are described as the *sensory nuclei* of the cranial nerves.

The mixed cranial nerves, such as the fifth, ninth, and tenth, follow this type very closely; the third, fourth, sixth, seventh, eleventh, and twelfth are purely motor nerves, and correspond developmentally with the motor root of a spinal nerve; while the first, second, and eighth are purely sensory, and are constituted like the sensory root of a spinal nerve.

THE CRANIAL NERVES.

The *classification of the cranial nerves* into twelve pairs is based upon their mode of distribution. It was proposed by Sœmmering, and is now generally adopted, in preference to the older classification of Willis into nine pairs, which had reference to their mode of piercing the dura. The following table gives at a glance the numerical and the ordinary name of each nerve, and a summary of its function and area of distribution.

Table of the Cranial Nerves.

Classification of Sœmmering.	Other Names.	Distribution.	Function.
First.	Olfactory.	Upper third of nasal cavity.	SPECIAL SENSE (Smell).
Second.	Optic.	Retina.	SPECIAL SENSE (Sight).
Third.	Oculomotor.	Muscles of eyeball (except external rectus and superior oblique).	MOTOR.
Fourth.	Trochlear.	Superior oblique of eyeball.	MOTOR.
Fifth.	Trifacial.	*Sensory part* to face, fore part of scalp, external ear, eye, teeth, gums, cheek, fore part of tongue. *Motor part* to muscles of mastication.	*ORDINARY SENSE.* MOTOR.
Sixth.	Abducent.	External rectus of eyeball.	MOTOR.
Seventh.	Facial.	Superficial muscles of face, frontalis, platysma, stylohyoid, and posterior belly of digastric.	MOTOR.
Eighth.	Auditory.	Membranous labyrinth of ear.	SPECIAL SENSE (Hearing and Equilibrium).
Ninth.	Glossopharyngeal.	Pharynx and hind part of tongue, some motor fibres.	SPECIAL SENSE (Taste). *ORDINARY SENSE.* MOTOR.
Tenth.	Pneumogastric, or vagus.	*Sensory* to external ear. *Motor* and *sensory* to pharynx, larynx, trachea, lungs, œsophagus, stomach, heart. Some fibres to liver.	*ORDINARY SENSE.* MOTOR.
Eleventh.	Spinal accessory.	Motor to trapezius and sternomastoid muscles. The rest is accessory to the pneumogastric.	MOTOR. *ORDINARY SENSE.*
Twelfth.	Hypoglossal.	Muscles of the tongue.	MOTOR.

Superficial Origins (Fig. 627).—The cranial nerves spring from the under surface of the brain in the order of their names. Thus, the first appears in front of the anterior perforated spot; the second springs from the chiasma, the optic tracts being superficially traceable to the corpora quadrigemina; the third nerve arises from the inner side of the crus cerebri close to the pons; the fourth winds round

the outer side of the pons, and can be traced dorsally to the valvula, whence it emerges. The fifth arises by two bundles from the side of the pons, the smaller motor root being in front of and ventral to the larger sensory root. The sixth springs from the groove between the pons and anterior pyramid, the seventh and eighth from the same groove but more laterally. A small bundle between the seventh and eighth, called the pars intermedia, furnishes an additional root to the seventh. The ninth, tenth, and eleventh arise as a series of small bundles from the side of the oblongata in a vertical line, dividing the restiform body from the olive and lateral column of the cord. The spinal portion of the spinal accessory emerges by numerous bundles from the side of the cord in a direct line with the rest of this group, extending as far down as the fifth, sixth, or even seventh cervical nerve. The twelfth nerve springs by ten or twelve small bundles from the groove between the olivary body and anterior pyramid, and thus lies ventral to the pre-

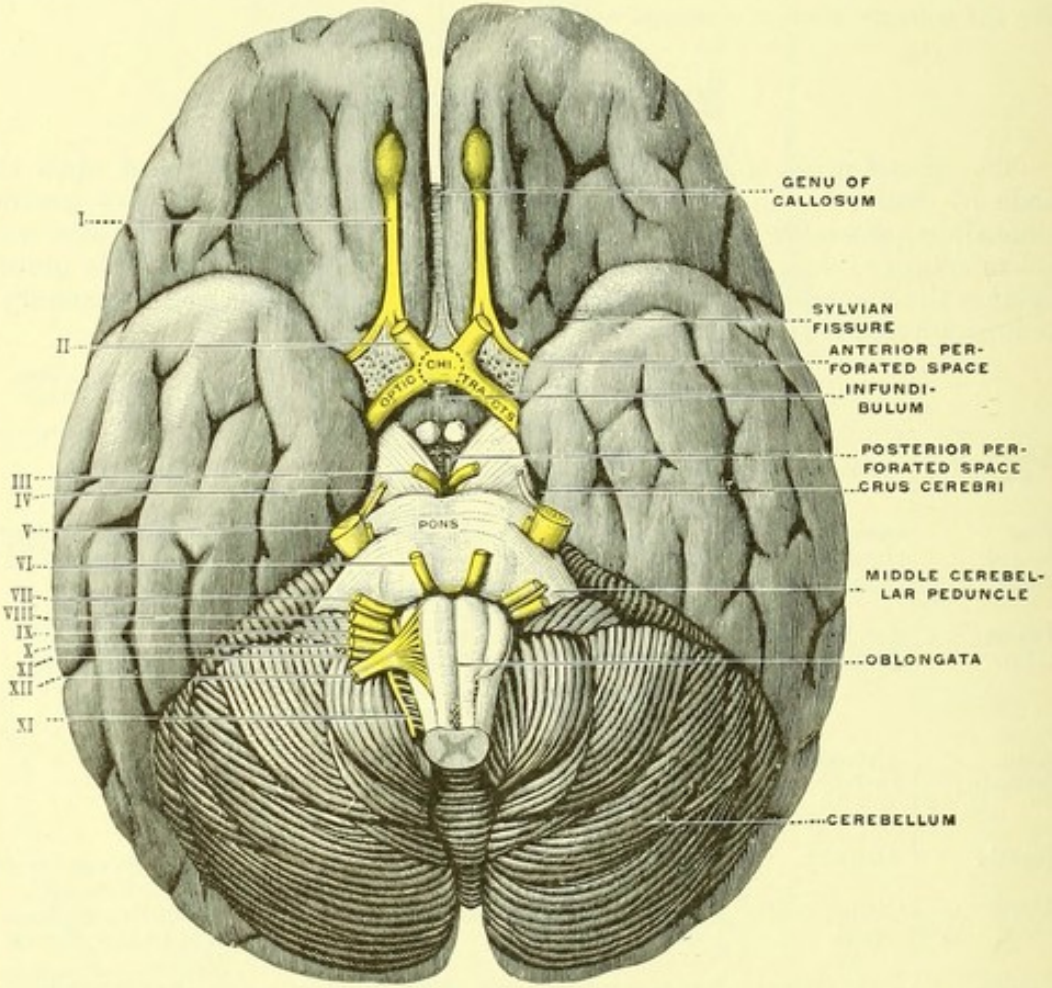

FIG. 627.—Under surface of the brain, showing the superficial origins of the cranial nerves. The Roman numerals indicate the nerves. (Testut.)

ceding series, and nearer the pons than the last of them. It lies in series with the anterior roots of the first spinal nerves.

Deep or Nuclear Origins of the Cranial Nerves.—Like the spinal nerves the cranial nerve-roots can be traced till they come into close relationship with certain groups of cells, which, for anatomical and physiological reasons, we regard as their deep origins. It is impossible for the student to study this subject till he has thoroughly mastered the anatomy of the brain and especially of the oblongata and pons; but, when he has learned the gross anatomy of the central nervous system, he will find much living interest in what is now known of this obscure but vitally important section.

Deep Origin of the First or Olfactory Nerve.—When we speak of the first or olfactory ("smelling") nerve, we usually mean the olfactory tract with its three roots and terminal bulb, and regard the twenty or more filaments, which spring from the bulb, as branches of the nerve. Embryology teaches us, however, that the tract is really a hollow outgrowth of the lateral ventricle, that the cells in the inferior segment of the bulb are homologous with the nucleus of a sensory nerve, and that the filaments which pierce the cribriform plate collectively represent the sensory nerve itself.

The **olfactory tract** is a flattened band which lies in the olfactory fissure on the orbital surface of the frontal lobe. On its under surface it is flat and lies on the olfactory groove of the sphenoid; superiorly it presents a ridge which fits into the olfactory fissure. Posteriorly it springs from the cerebral cortex in front of the anterior perforated space by three roots; anteriorly it ends in the olfactory bulb. Microscopically the tract presents on transverse section, (*a*) a thin, gray cortex, continuous with the cortex cerebri; (*b*) an inner layer of medullated nerve-fibres, thick inferiorly and thinning off above; and (*c*) some central gray substance consisting of neuroglia and fibrous tissue—the remains of the ependyma of the embryonic ventricular cavity, which in adult man is obliterated.

The **internal** or **mesial root** is a band of medullated nerve-fibres, running into the great longitudinal fissure, where it is lost in the anterior end of the callosal gyrus.

The **external** or **lateral root**, larger than the internal, is a white band which crosses backward and outward over the anterior perforated space toward the extremity of the temporal lobe, where it ends in the hippocampal gyrus and perhaps the amygdala.

The **middle** or **gray root** is best called the trigonum olfactorium, being only a slight elevation in the angle between the two roots just mentioned, and containing no non-medullated band of fibres which could properly be called a gray root.

The **olfactory bulb** is oval in shape, about two-fifths of an inch long and a third as broad. Its upper surface presents a ridge continuous with the ridge of the olfactory tract, and like it received into the olfactory fissure of the frontal lobe. Its under surface is slightly convex, and lies on the cribriform plate of the ethmoid, and from it spring the twenty or more filaments which collectively form the olfactory nerve. The dorsal portion of the bulb consists of medullated nerve-fibres; its ventral segment contains the nerve-cells, whose axis-cylinder processes form the medullated nerves of the tract, and whose branching processes come into close relationship in the olfactory glomeruli with the branching ends of the olfactory filaments. These cells, therefore, form the nucleus of the olfactory nerve.

It will be convenient here to complete the description of the olfactory nerve.

The Olfactory Nerve (Figs. 628, 629).

This nerve is represented by the twenty or more fine bundles of non-medullated fibres, which spring from the under surface of the olfactory bulb. They pierce the foramina in the cribriform plate of the ethmoid bone, each receiving an investment of dura. Those piercing the inner line of foramina supply the upper third of the nasal septum (Fig. 628); the outer group supplies the lateral wall of the nose as low as the lower border of the superior turbinated bone (Fig. 629). The fibres communicate freely, forming a fine network. They commence as axis-cylinder processes of the olfactory cells of the Schneiderian membrane, and terminate by minutely branching processes in the glomeruli of the olfactory bulb.

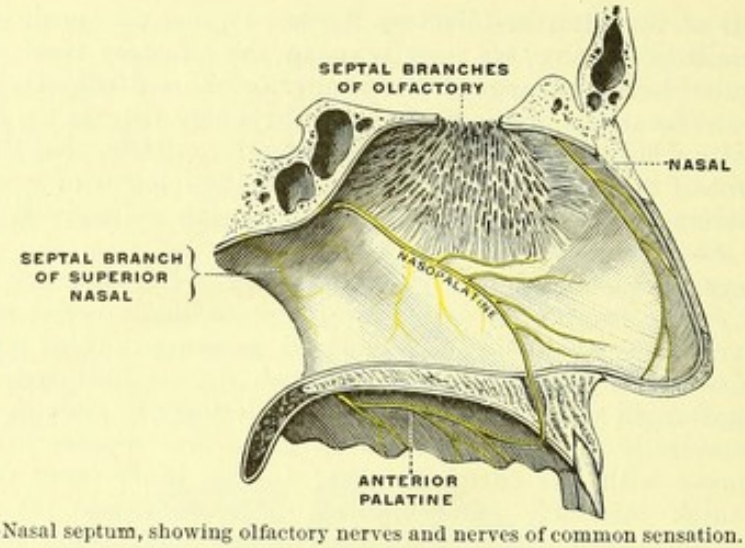

FIG. 628.—Nasal septum, showing olfactory nerves and nerves of common sensation. (Testut.)

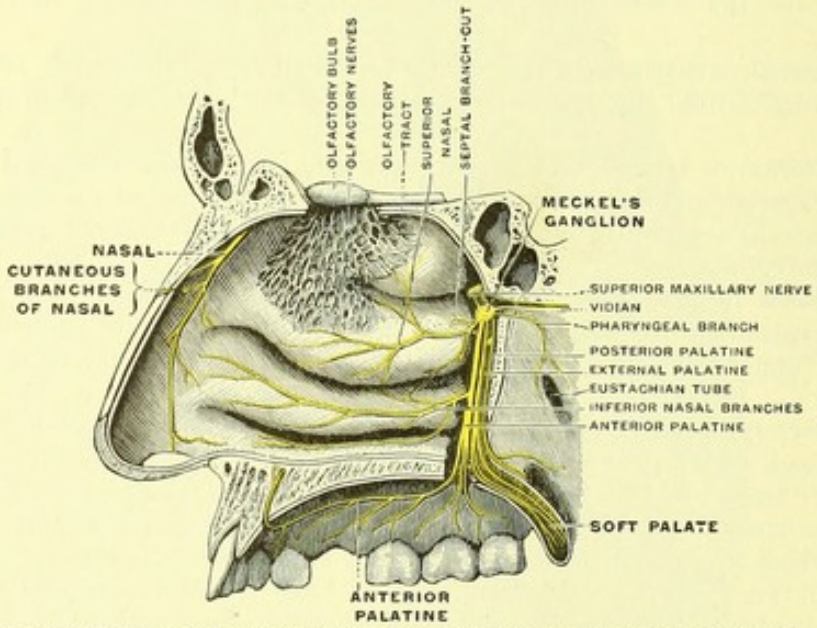

FIG. 629.—Outer wall of nose, showing olfactory nerves and nerves of common sensation. (Testut.)

The Second or Optic Nerve.

Traced backward from the eyeball the *optic* ("seeing") *nerves* (Fig. 630) are seen to meet on the under surface of the brain in the *optic commissure* or *chiasma*, where they partially decussate, and whence two flattened bands, the *optic tracts*, pass backward round the crura cerebri to the thalami and quadrigeminal bodies.

The **optic tract** (Fig. 630) arises by two roots from the pulvinar of the optic thalamus, the corpora geniculata, and the superior quadrigeminal body. Thence it bends round the upper end of the crus cerebri to which it is attached as a flattened, white band, and becoming more rounded, passes between the anterior perforated space and the interpeduncular space to end in the chiasma.

The **optic commissure** or **chiasma** ("like X") is oblong, the longest diameter being transverse. It rests on a groove above the olivary eminence of the sphenoid and has the internal carotid artery on either side of it. From its extremities in front spring the optic nerves.

The **optic nerve** enters the orbit by the optic foramen, accompanied by the ophthalmic artery, which lies below and external to it. In the orbit it runs forward, outward, and a little downward to the back of the eyeball,

which it pierces one-eighth inch to the inner side of the optic axis. Its fibres then radiate in all directions over the anterior surface of the retina. As the nerve enters the orbit it receives an investment from the dura, which sends a layer also to blend with the periosteum. The pial, arachnoid, and dural sheaths remain distinct as far as the sclerotic, with which they blend, and well-marked subdural and subarachnoid spaces can be demonstrated. In the orbit the nerve is closely surrounded posteriorly by the recti muscles; but farther forward is separated from them by fatty tissue. The ciliary vessels and nerves surround it, especially above and below, the ophthalmic artery and nasal nerve cross over it

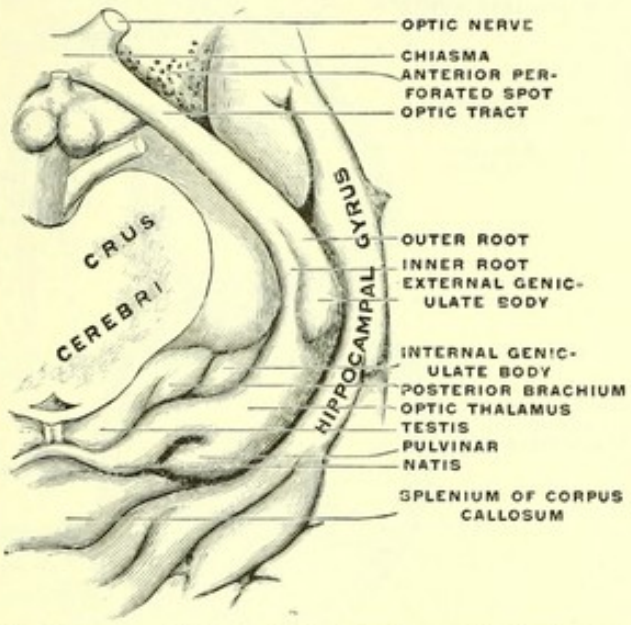

FIG. 630.—Origin and relations of optic tract. Part of the base of the brain: temporal gyri drawn aside, pia removed. (W. Keiller.)

from without inward, and the ciliary ganglion lies on its outer surface. It is pierced by the arteria centralis retinæ and its vein.

In *the chiasma* (Fig. 631) a partial decussation takes place. The outer fibres do not decussate, but connect the outer half of the retina with the geniculate and quadrigeminal bodies of the same side; the inner fibres decussate completely, connecting the inner half of the retina with these nuclei on the opposite side. Thus, the right optic tract conveys fibres from the right halves of both retinæ to the right side of the brain, and the left behaves similarly. The lateral portions of the chiasma consist of uncrossed fibres, the central portion contains intercrossed fibres from the nasal (inner) sides of both retinæ. Besides these the posterior part of the chiasma is occupied by a band of fibres which, after partial interruption in the cells of the internal geniculate bodies, unite the inferior corpora quadrigemina with each other. This is called Gudden's commissure, and appears to have nothing to do with sight.

The fibres of the optic nerve commence as axis-cylinder processes of the large ganglionic cells of the retina, and end in branching processes round the cells of the external geniculate body, superior quadrigeminal body, and optic thalamus, which cells, therefore, form the nucleus of the optic nerve; thence fibres pass by the optic radiation to the cuneus in the occipital lobe of the cerebrum. Imperfectly traced connections exist between the visual centres and the nuclei of the third, fourth, and sixth nerves.

General View of the Nuclei of the Third to the Twelfth Cranial Nerves (Figs. 632, 633).—The nuclei of the third to the twelfth cranial nerves inclusive lie in the central gray matter of the brain from the level of the posterior commissure to that of the decussation of the pyramids, the nucleus of the spinal accessory,

and the ascending vago-glossopharyngeal and fifth roots extending still lower down. In Fig. 632 the motor nuclei are represented (in red), in Fig. 633 the

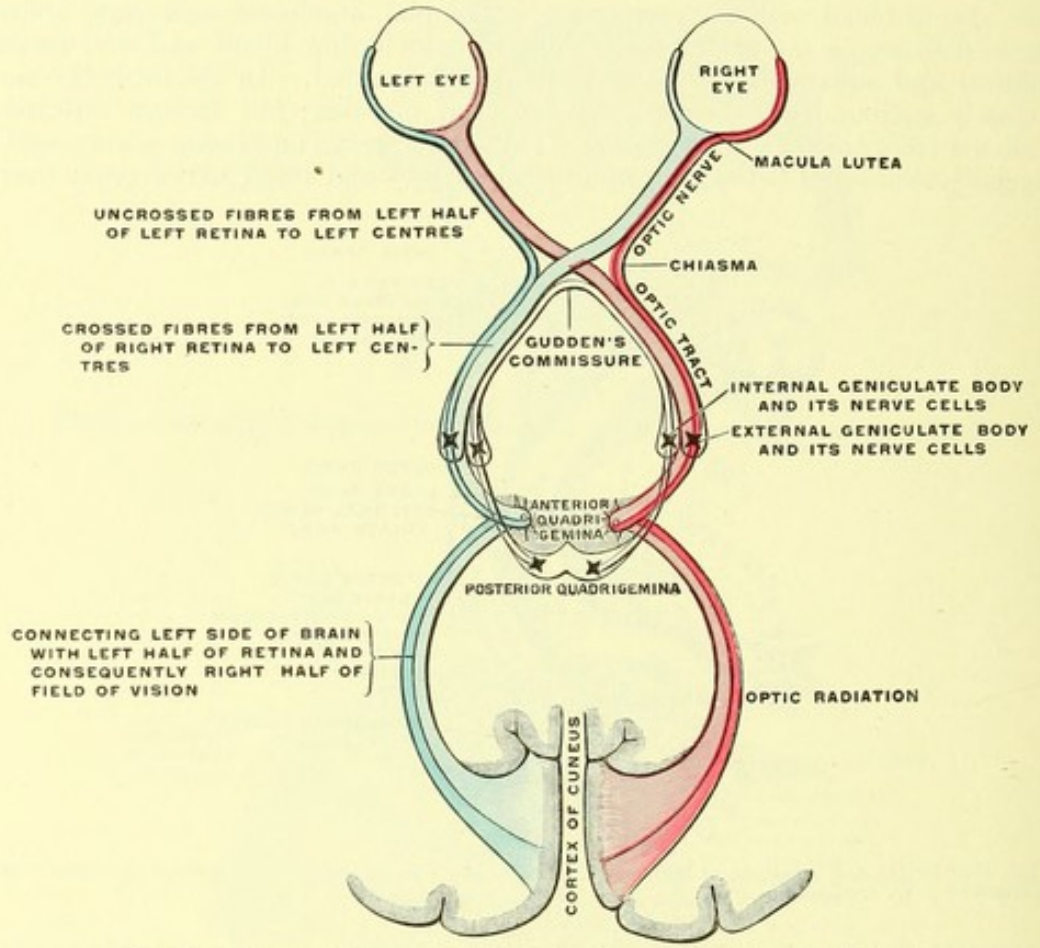

FIG. 631.—Diagram of the course of the optic fibres. (W. Keiller, after Testut.)

sensory nuclei (in blue). The *motor nuclei* are arranged in two interrupted columns, the third, fourth, sixth, and twelfth motor nuclei forming one column close to the middle line, and very near the floor of the aqueduct, fourth ventricle or central canal; while the motor nuclei of the fifth, seventh, ninth, tenth, and eleventh form another column, more deeply and more laterally situated than the first and deviating somewhat toward the side above, where the ventricle is widest. The fifth nerve has a well-marked ascending root, which is probably motor, as well as a crossed motor root. The spinal portion of the spinal accessory arises from the cells of the ventral horn of gray matter as low as the sixth or seventh cervical nerve.

Coming now to the *sensory nuclei*, each sensory nerve has an ascending root. Thus the fifth, eighth, ninth, tenth, and accessory portion of the eleventh have each an ascending root which appears to bring it into relation with the nucleus of the funiculus cuneatus and gelatinous substance of Rolando (compare the connection of the sensory roots of the spinal nerves with the same nuclei). Each nerve has in addition a special sensory nucleus—the eighth nucleus is divisible into three groups—near the level of its point of exit and dorso-lateral to the motor nuclei.

In *longitudinal extent* the nucleus of the third nerve occupies the floor of the aqueduct from the posterior commissure to the groove between the superior and inferior quadrigeminal bodies, the nucleus of the fourth lies ventrally to the testis, the fifth nucleus nearly corresponds to the lateral recess, the sixth lies under the eminentia teres, the eighth nuclei are on a level with the striæ acusticæ, and the

seventh on the same level, but more mesial. Lastly the ninth, tenth, and eleventh form two columns (sensory and motor), and the twelfth a third column, which extend almost the whole length of the oblongata.

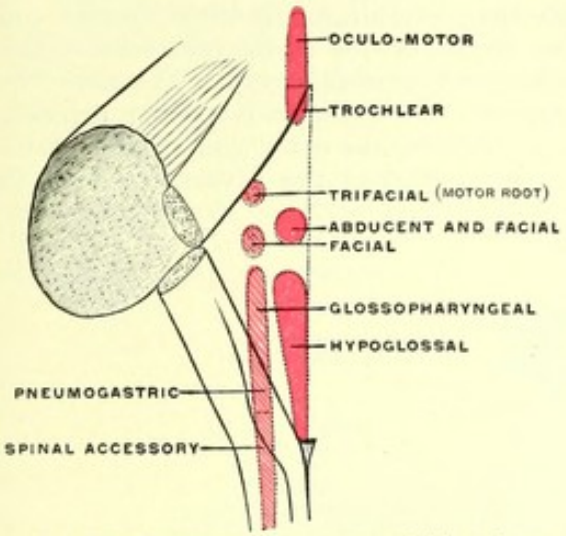

FIG. 632.—Diagram of the motor nuclei in and near the floor of the fourth ventricle. (Testut.)

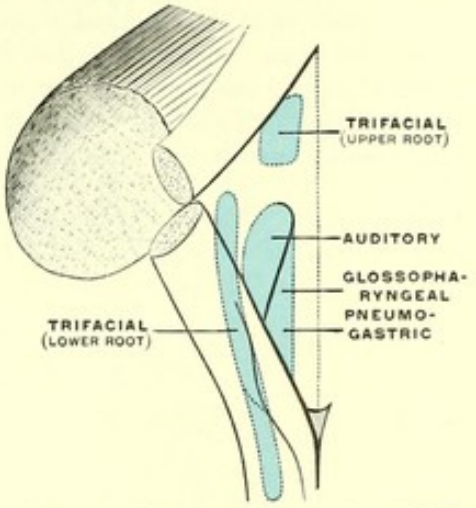

FIG. 633.—Diagram of the sensory nuclei in the floor of the fourth ventricle. (Testut.)

CONNECTIONS OF THE NUCLEI OF THE CRANIAL NERVES WITH THE CORTEX CEREBRI.

The cortical connections of the olfactory and optic nerves have already been described. The motor tract for the other cranial nerves seems to run from the motor area of the cerebral cortex, down through the genu of the internal capsule, pyramidal segment (middle third of the crusta) of the crus cerebri, and pyramidal tract of the pons and medulla to nearly opposite their respective nuclei. It then crosses through the raphe and passes the formatio reticularis to the motor nuclei of the opposite side. Round the cells of the motor nuclei the pyramidal fibres end, and from these cells fresh fibres pass by the motor nerve-roots to the periphery. The cortical centre for the facial occupies the lower ends of the precentral and postcentral gyri; the hypoglossal centre is in the lower end of the precentral and posterior end of the inferior frontal gyri.

The sensory tract is less known but, on leaving the sensory nuclei, it appears to cross to the opposite fillet, and thus pass to the superior quadrigeminal body and subthalamic region or thalamus, some part of it going through the posterior third of the hind limb of the internal capsule to the cortex cerebri behind the motor area.

The *course of the nerve-roots* from their nuclei to superficial origins is as follows: The roots of the third, fifth, sixth, eighth, twelfth, and the sensory roots of the ninth, tenth, and eleventh, run in nearly straight lines ventro-laterally from nucleus to point of superficial emergence. The fourth is altogether exceptional (see special description). The motor roots of the seventh, ninth, tenth, and eleventh run at first dorso-mesially toward the floor of the ventricle and then bend outward, and lastly ventrally to join the sensory roots, the seventh running upward for some distance before it turns outward.

We now pass to a *particular description of the cranial nerves from the third to the twelfth*, inclusive of both. The first and second nerves have already been fully considered.

The Third or Oculo-motor Nerve.

The nucleus of the third nerve (Fig. 635), the oculo-motor ("eye-mover"), consists of several distinct groups of cells, lying on the floor of the aqueduct,

close to the middle line, and nearly corresponding in position to the superior quadrigeminal body. It is just dorsal to the posterior longitudinal fasciculus, which appears to connect it with the nuclei of the seventh and eighth, and with the sixth nucleus of the opposite side. From its nucleus the nerve issues in many small bundles, running ventrally through the posterior longitudinal bundle and red nucleus to the oculo-motor groove, on the inner side of the crus cerebri just above the pons. The nuclei of both sides communicate freely. The nerve so formed passes between the posterior cerebral and superior cerebellar arteries, forward and a little outward, piercing the dura on the outer side of the posterior clinoid process, and so entering the outer wall of the cavernous sinus, in

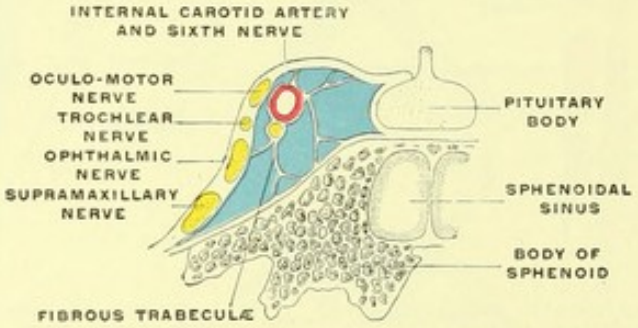

FIG. 634.—Cavernous sinus, as shown by transverse section through the middle of the sella turcica. (W. Keiller.)

which it is embedded (Fig. 634). Between layers of the dura it enters the sphenoidal fissure, having divided into a superior and inferior division. Thus it enters the orbit, passing between the two heads of the external rectus, the two divisions being separated by the nasal nerve.

The **superior division** is directed inward and forward over the optic nerve, and

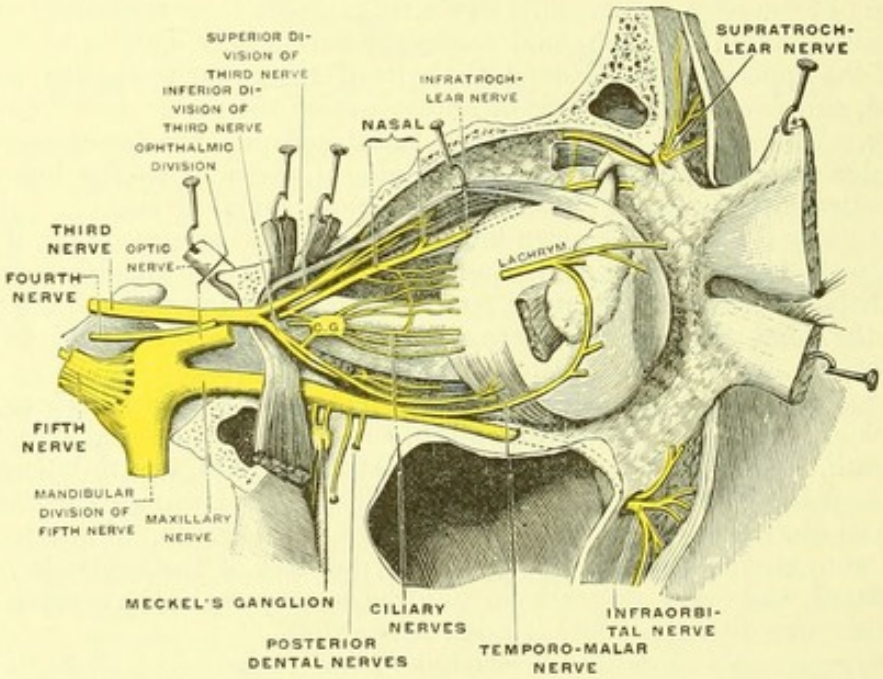

FIG. 635.—Oculo-motor nerve and ciliary ganglion (C. G.). (Testut.)

pierces the rectus superior to terminate in the levator palpebræ superioris, supplying these two muscles.

The **inferior division** splits into three branches. Of these, one supplies the internal rectus, another the inferior rectus, and the third, larger than either of the

others, passes between the inferior and external recti to enter the posterior border of the inferior oblique. This branch gives a short, thick offset to the ciliary ganglion, thus furnishing its motor root, and also contributes some twigs to the inferior rectus.

The third nerve supplies all the orbital muscles, except the superior oblique (supplied by the fourth nerve) and external rectus (sixth nerve). It also, through the ciliary ganglion, supplies the ciliary muscle and sphincter iridis. It is further to be noted that the nucleus of this nerve, through communication with the roots of the facial, supplies the orbicularis palpebrarum, occipito-frontalis, and corrugator supercilii; and that the fibres of the third nerve to the internal rectus are derived from the sixth nucleus of the opposite side. It may be well to note here that all the orbital muscles are supplied by their nerves on their surfaces next the eyeball, except the inferior oblique which is pierced by its nerve on its

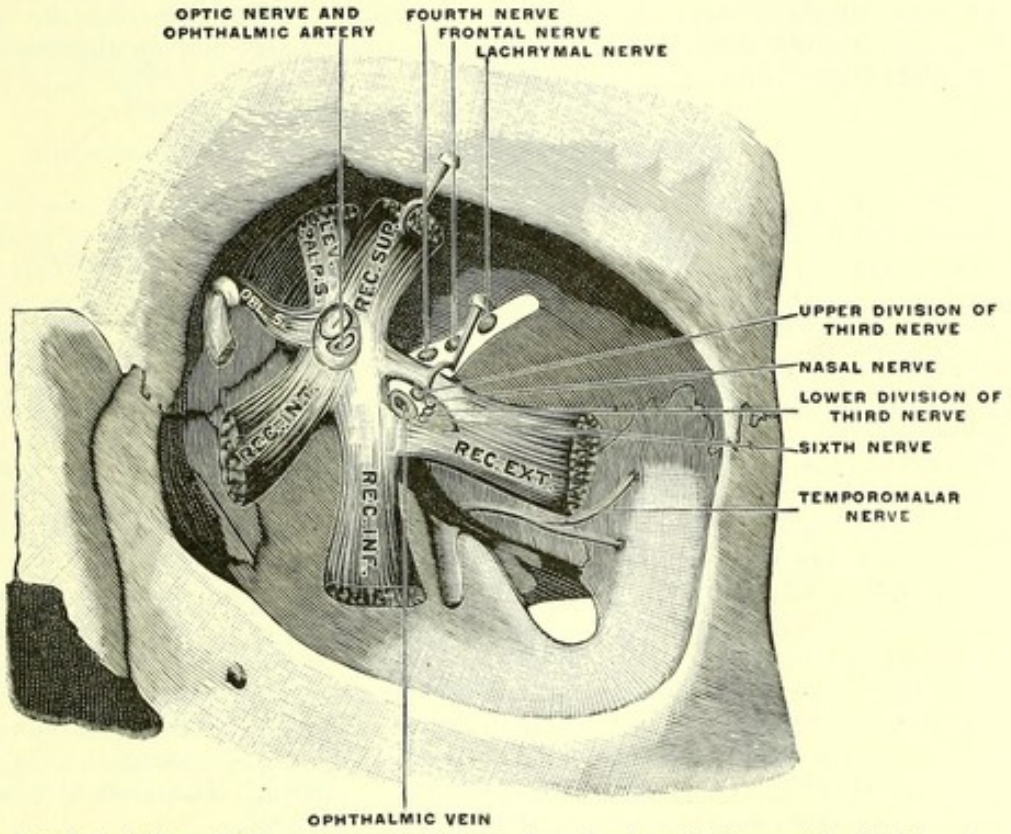

FIG. 636.—Back of the orbit, showing passage of nerves through sphenoidal fissure. (Modified from Testut.)

posterior border, and the superior oblique which is supplied by the fourth nerve on its orbital surface.

Observe here, also, the *relations of the orbital nerves in the cavernous sinus and sphenoidal fissure* (Fig. 636).

The third and fourth nerves and ophthalmic division of the fifth lie embedded in the outer wall of the *cavernous sinus*, while the sixth nerve and internal carotid artery pass through the sinus, the nerve lying beneath the artery, and both being separated from the blood of the sinus by an endothelial lining supported by delicate fibrous tissue.

In the *sphenoidal fissure* the fourth, frontal, and lachrymal nerves are arranged along its upper boundary in the order mentioned from within outward; the superior and inferior divisions of the oculo-motor, the nasal, and sixth nerves pass between the two heads of the external rectus, the nasal lying between the first two and the sixth most inferiorly. The ophthalmic vein leaves the orbit through this fissure internally to the sixth nerve.

The Fourth or Trochlear Nerve.

The fourth nerve (called *trochlear* because its tendon runs through a pulley) arises in a short column of cells almost continuous with the third nucleus, and commensurate with the inferior quadrigeminal body. Thence the root runs dorso-laterally, and after descending for a short distance crosses inward in the valvula, where it decussates with its fellow, and emerges as a slender round bundle immediately behind the testis on the opposite side from its nucleus. The decussation of this nerve is altogether a peculiar feature.

It now passes outward across the superior peduncle of the cerebellum, and forward round the outer side of the crus cerebri to pierce the dura under cover of the free margin of the tentorium, external to the posterior clinoid process and third nerve. It is embedded in the outer wall of the cavernous sinus between the oculo-motor and ophthalmic nerves, afterward crossing the oculo-motor to lie in the inner angle of the sphenoidal fissure through which it reaches the orbit. Here it runs inward above the levator palpebræ superioris and is distributed to the obliquus superior on its upper (orbital) surface.

The Fifth or Trifacial Nerve.

The fifth nerve is called *trifacial* because it has *three* grand divisions, which are distributed to the *face*; and sometimes it is called *trigeminal* ("three double" or "three twins"), referring to the arrangement of the divisions on the two sides of the head. It is mixed in function, closely resembling a spinal nerve in that the motor and sensory roots arise separately from the encephalon, the sensory root possessing a ganglion similar in constitution and development to that of a posterior spinal nerve-root, while the motor root joins the nerve on the distal side of the ganglion.

The *motor root* arises from a group of cells lying deeply in the floor of the fourth ventricle at a point corresponding to the lateral recess. It is joined by the *descending root* which appears to arise from cells in the aqueduct and by a *crossed motor root* of doubtful connections.

Most of the fibres of the sensory portion are traceable into the so-called *ascending root* which appears as a crescentic band of fibres outside the gelatinous substance of Rolando. The fibres appear to arise as axis-cylinder processes of the cells of the Gasserian ganglion and to terminate as minutely branching processes round the cells of the gelatinous substance and funiculi gracilis and cuneatus (compare sensory spinal nerve-root). Many sensory fibres end in the *superior sensory nucleus*, which lies just outside the motor nucleus. The crossed sensory and cerebellar roots are imperfectly understood.

Thus, then, two roots can be seen coursing through the pons from whose ventral surface they emerge near its anterior border. The larger, sensory root (portio major) being ventro-lateral to the smaller, motor root (portio minor).

The larger root runs forward beneath the tentorium, where, just under the fourth nerve and near the apex of the petrous portion of the temporal bone, it enters a recess between the two layers of the dura (Meckel's space). Here the larger root spreads out, forming a plexiform network, and enters the Gasserian ganglion.

The smaller root, from being dorsal to the portio major at its origin, winds spirally round the latter, gaining its inner and then its ventral (under) surface, and crosses beneath the Gasserian ganglion to join the third division only, which emerges from that structure.

The Gasserian or Semilunar Ganglion.—This body lies on a special depression on the anterior surface of the petrous bone; it is crescent-shaped, the convexity being directed forward. Its surfaces are adherent to the dura, flattened, and much striated; and it is rich in ganglionic cells. It is joined by filaments from the carotid plexus of the sympathetic, and sends recurrent fibres to the dura.

From its convex border the sensory portion of the trifacial emerges in three trunks, the ophthalmic, superior maxillary, and inferior maxillary or mandibular, and the third of these alone is joined by the motor root after its emergence.

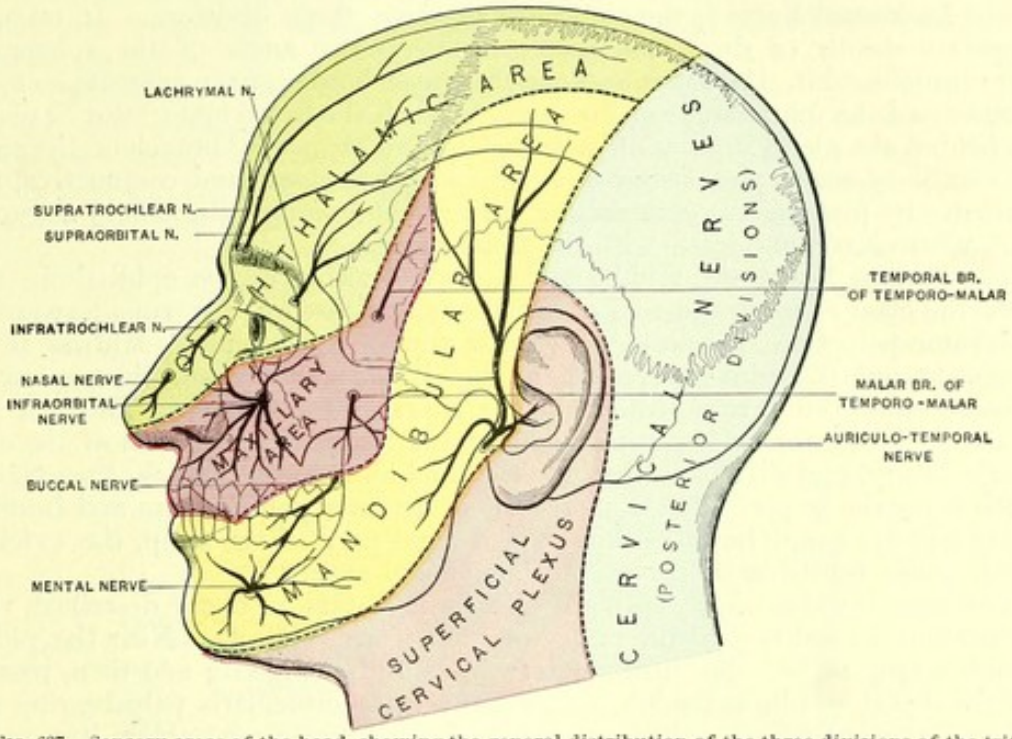

FIG. 637.—Sensory areas of the head, showing the general distribution of the three divisions of the trifacial nerve. (Modified from Testut.)

A general idea of the cutaneous distribution of these nerves will be got from a glance at Fig. 637.

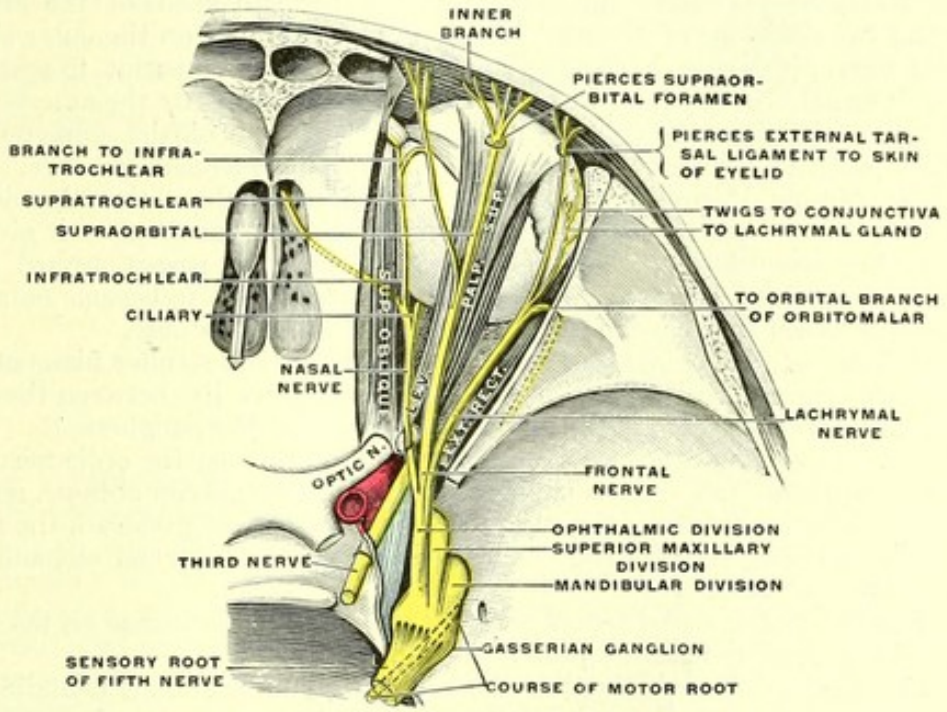

FIG. 638.—Ophthalmic division of the trifacial nerve. (Testut.)

First or Ophthalmic Division of the Fifth Nerve (Fig. 638).—The first or ophthalmic ("eye") division of the fifth nerve is a flattened trunk, one inch long,

which runs forward and upward in the outer wall of the cavernous sinus under the fourth nerve. Between layers of dura it reaches the sphenoidal fissure, which it passes through in three divisions, the lachrymal, frontal, and nasal. It gives offsets to the third, fourth, and sixth nerves, as these enter the orbit.

The **Lachrymal Nerve** is the outermost of these three divisions. It occupies a separate sheath of dura, and passes by the outer angle of the sphenoidal fissure into the orbit. Here it runs along the upper border of the external rectus to the outer and the upper angle of the cavity to reach the lachrymal (" tear ") gland. Just behind the gland it gives off a *branch to join the orbital* branch of the superior maxillary nerve, and *branches to the lachrymal gland* and conjunctiva, and terminates by piercing the external tarsal ligament to supply the *skin of the upper eyelid*, where it communicates with the facial nerve.

The **Frontal Nerve**, the middle and largest division of the ophthalmic, also enters the orbit close to the roof of the sphenoidal fissure. It runs forward on the levator palpebræ superioris, between it and the periosteum. Midway in its passage through the orbit it gives off the *supratrochlear nerve*, and then, assuming the name *supraorbital*, runs straight to the supraorbital foramen. Through this foramen it leaves the orbit accompanied by the supraorbital branch of the ophthalmic artery, and divides into an internal and an external branch, the external branch being the larger. These pierce the orbicularis palpebrarum and frontalis very obliquely, supplying the skin of the front part of the scalp, the external branch being traceable as far as the lambdoidal suture.

The *supratrochlear nerve*, springing from the frontal, as above described, runs forward and inward toward the pulley of the superior oblique. Near the pulley it sends a twig to join the infratrochlear branch of the nasal; and then, passing over the superior oblique tendon, it lies between the orbicularis palpebrarum and the bone, as it passes over the inner angle of the orbital arch. Here it supplies twigs to the eyelid and conjunctiva, and then pierces the frontalis to reach the skin of the forehead over the glabella. It is accompanied by the frontal artery. These, like all other sensory branches of the fifth nerve, communicate with the facial.

The **Nasal Nerve** enters the orbit between the two heads of the external rectus and two divisions of the oculo-motor nerve. At first on the outer side of the optic nerve, it crosses it obliquely beneath the rectus superior to reach the anterior internal orbital canal, through which, accompanied by the anterior ethmoidal vessels, it enters the cranium. In the orbit it gives off the sensory root to the ciliary ganglion, two long ciliary nerves, and the infratrochlear nerve.

In the cranium it runs forward on the cribriform plate of the ethmoid and passes to the nasal fossa through the nasal slit. In the roof of the nose it gives off an internal or septal branch, and an external branch, and passes onward as the anterior or superficial branch in a groove on the nasal bone to become cutaneous by passing between that bone and the lateral cartilage of the nose.

Branches.—(*a*) The *branch to the ciliary ganglion* is a slender filament, one-quarter inch long, which is given off when the nasal nerve lies between the heads of the external rectus. It furnishes the sensory root of the ganglion.

(*b*) One or two *long ciliary nerves* pierce the sclerotic near the optic nerve.

(*c*) The *infratrochlear nerve* runs forward beneath the superior oblique, receives a communicating branch from the supratrochlear, and, passing beneath the pulley to the inner canthus, supplies the conjunctiva, caruncle, lachrymal sac, and skin of the eyelids and nose.

(*d*) The *internal* or *septal branch* supplies the mucous membrane on the upper and anterior part of the nasal septum.

(*e*) The *external branch* supplies the outer wall of the nose, including the anterior ends of the middle and inferior turbinated bones.

(*f*) The *anterior* or *superficial branch* pierces the compressor naris and is distributed to the skin of the lower part of the nose.

Sporadic Ganglia connected with the Fifth Nerve.—There are four small gan-

glia connected with the fifth nerve—the ophthalmic, sphenopalatine, otic, and submaxillary. Each of these has three roots, derived from motor, sensory, and sympathetic nerves respectively, and a varying number of branches of distribution. Their cells are multipolar, thus resembling the cells of sympathetic ganglia, and differing from those of the ganglia of the posterior spinal nerve-roots and Gasserian ganglion.

The Ophthalmic, Ciliary, or Lenticular Ganglion (Fig. 635).—The ciliary ganglion is a small reddish body about the size of a large pin-head (one-twelfth of an inch in long diameter), compressed laterally, and quadrilateral in shape, presenting four angles. It lies at the back of the orbit, between the external rectus and the optic nerve, and is often in contact with the ophthalmic artery.

Its long (sensory) root is derived from the nasal nerve, entering its supero-posterior angle. Often incorporated with this or entering the ganglion by its side is the sympathetic root, derived from the cavernous plexus; and its motor root is a short, comparatively thick offset from the branch of the third nerve to the inferior oblique, which enters the postero-inferior angle of the ganglion.

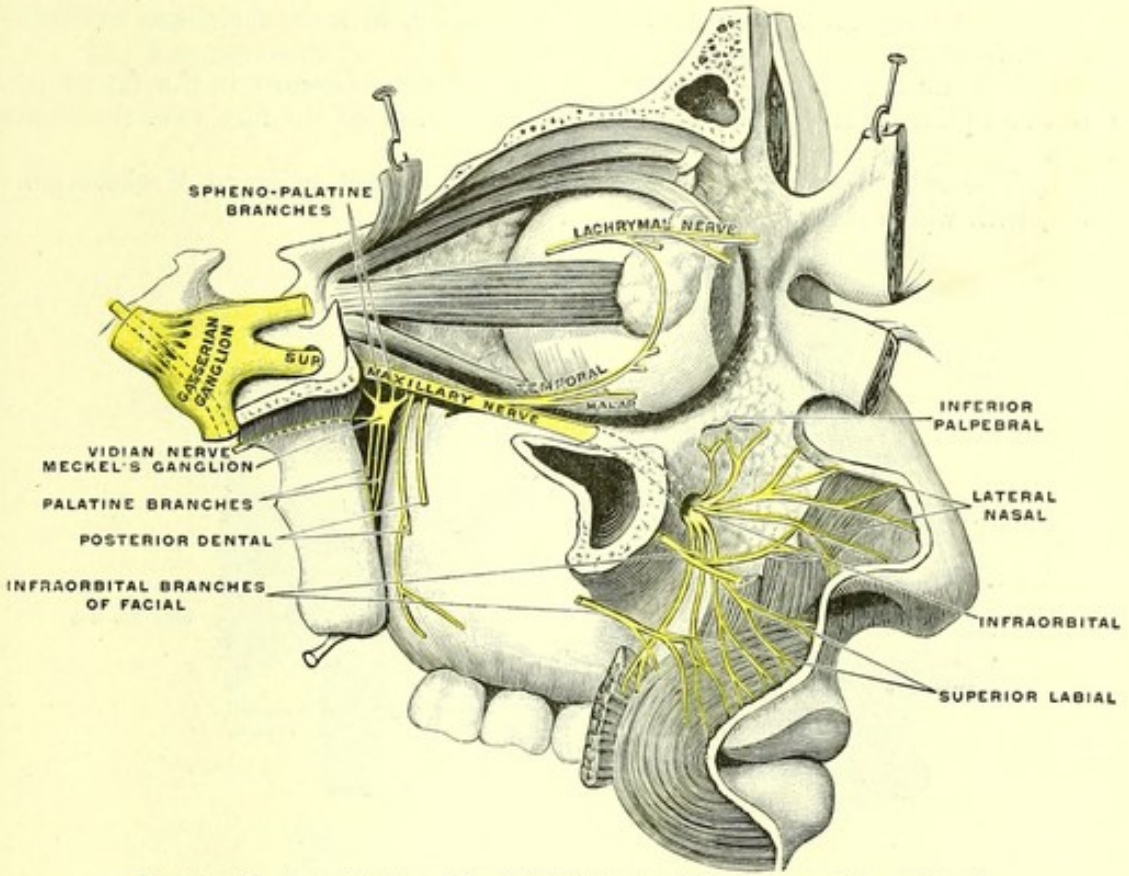

FIG. 639.—Maxillary division of the trifacial nerve and Meckel's ganglion. (Testut.)

From the anterior angles of the ganglion spring its branches of distribution called the *short ciliary nerves*. There are at first six to eight of them, arranged in two groups, superior and inferior, the inferior group being joined by the long ciliary nerves from the nasal. They pass along the upper and lower surfaces of the optic nerve, subdividing until about twelve to eighteen fine filaments reach the sclerotic, and pierce it in a circle round the optic nerve. They supply nerves of ordinary sensation and trophic nerves to the eyeball (derived from the nasal), motor nerves to the ciliary muscle and sphincter iridis (derived from the oculo-motor), and sympathetic nerves to the dilatator fibres of the iris.

The Second or Maxillary Division of the Fifth Nerve (Fig. 639).—The *maxillary (superior maxillary) nerve* is intermediate in size and position between the two other divisions of the fifth nerve, and like the first is purely sensory. After a

very short intracranial course it passes through the foramen rotundum, crosses the sphenomaxillary fossa, and enters the orbit through the sphenomaxillary fissure to occupy the infraorbital groove in its floor. It is here joined by the infraorbital branch of the internal maxillary artery, and together they enter the infraorbital canal to reach the face beneath the orbit, where the nerve divides into its terminal branches.

Branches.—(*a*) **Recurrent branch.** Within the cranium it gives a *recurrent* branch to the dura and middle meningeal artery.

(*b*) The **orbital branch** (*temporo-malar nerve*) is given off in the sphenomaxillary fossa. It enters the orbit through the sphenomaxillary fissure, and divides into two branches, *temporal* and *malar*.

The *temporal branch* runs upward along the outer wall of the orbit, gives a communicating filament to the lachrymal nerve, and passing obliquely through the periosteum enters the sphenomalar canal. It thus passes to the temporal fossa, where, running upward between the temporal muscle and the bone, it pierces the deep and superficial layers of the temporal fascia very obliquely, and emerges subcutaneously one inch above the zygoma, where its twigs perforate the orbicularis palpebrarum to the skin, communicating with the facial and auriculo-temporal nerves.

The *malar branch* (*ramus subcutaneus malæ*) runs forward in the fat of the orbit, and pierces through the malar canal to the skin of the face over the malar bone.

(*c*) The **sphenopalatine branches** are two short, stout twigs to Meckel's ganglion, with which they will be described.

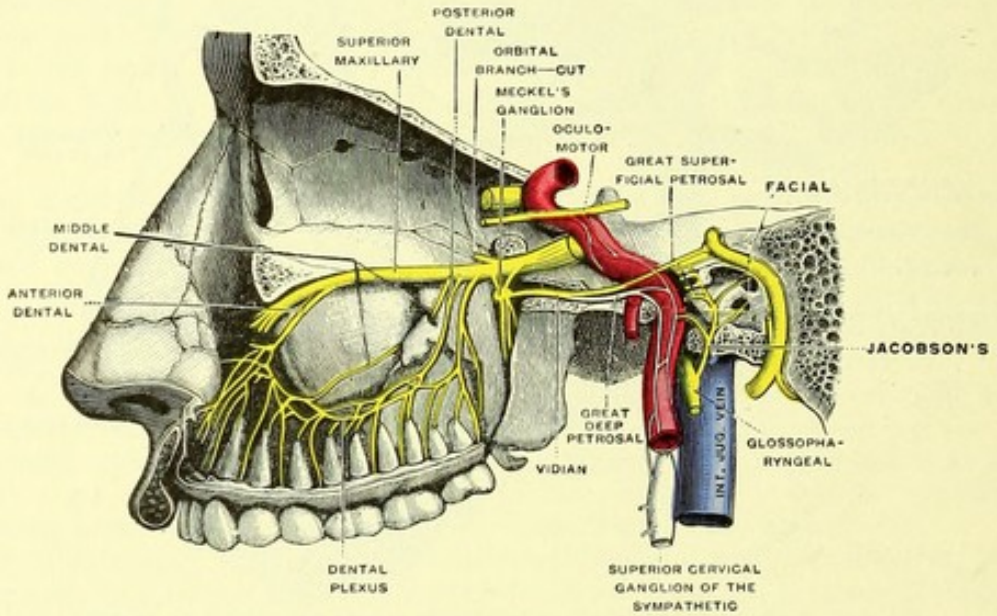

Fig. 640.—Dental branches of superior maxillary nerve and sphenopalatine ganglion. (Testut.)

(*d*) The **posterior superior dental nerves** (Fig. 640), the last branches given off in the sphenomaxillary fossa, are usually two in number, or may arise together. Running downward on the back of the superior maxilla, in the grooves which lead to the posterior dental canals, they give fibres to the gums and buccal mucous membrane (nervuli gingivales) and then enter these canals to supply the molar teeth and antrum.

(*e*) The **middle superior dental nerve** is given off in the hind part of the infra-orbital canal. It descends in a minute canal or groove in the outer wall of the antrum to supply the bicuspid teeth.

(*f*) The **anterior superior dental nerve** commences in the fore part of the infra-orbital canal. It also descends in the wall of the antrum, dividing into two

branches : a *nasal branch* which supplies the mucous membrane of the anterior part of the inferior meatus and floor of the nasal fossa ; and a *dental branch* to the incisor and canine teeth.

These three dental nerves form loops (the superior dental plexus) in the minute canals provided for them in the maxilla, and from the loops filaments pass to the foramina at the tips of the fangs, and supply the dental pulp.

(*g*) **Infraorbital Nerve.**—From the time the maxillary nerve enters the infraorbital canal it is called the *infraorbital nerve*, and under that name it emerges on the face, where it lies deeply under cover of the levator labii superioris proprius. Here it divides into seven or more branches. Two of these, called *inferior palpebral*, turn upward to the skin and conjunctiva of the lower eyelids ; two or three pass inward between the fibres of the levator labii superioris alæque nasi to the side of the nose (*lateral nasal*) ; and three or four *superior labial* branches run downward, piercing the fibres of the elevators of the upper lip and angle of the mouth to the skin of the lips and cheek, and sending large twigs to the mucous membrane.

These infraorbital nerves communicating with the facial form the infraorbital plexus.

The Sphenopalatine or Meckel's Ganglion (Figs. 640, 641).—The *sphenopalatine*, or *Meckel's ganglion*, is a small, reddish, triangular body, one-fifth of an inch in its long diameter, and flattened at the sides. It is situated in the upper part of the sphenomaxillary fossa, just under the superior maxillary nerve, where it is embedded in fat and surrounded by the terminal branches of the internal maxillary artery. Only its posterior segment contains nerve-cells.

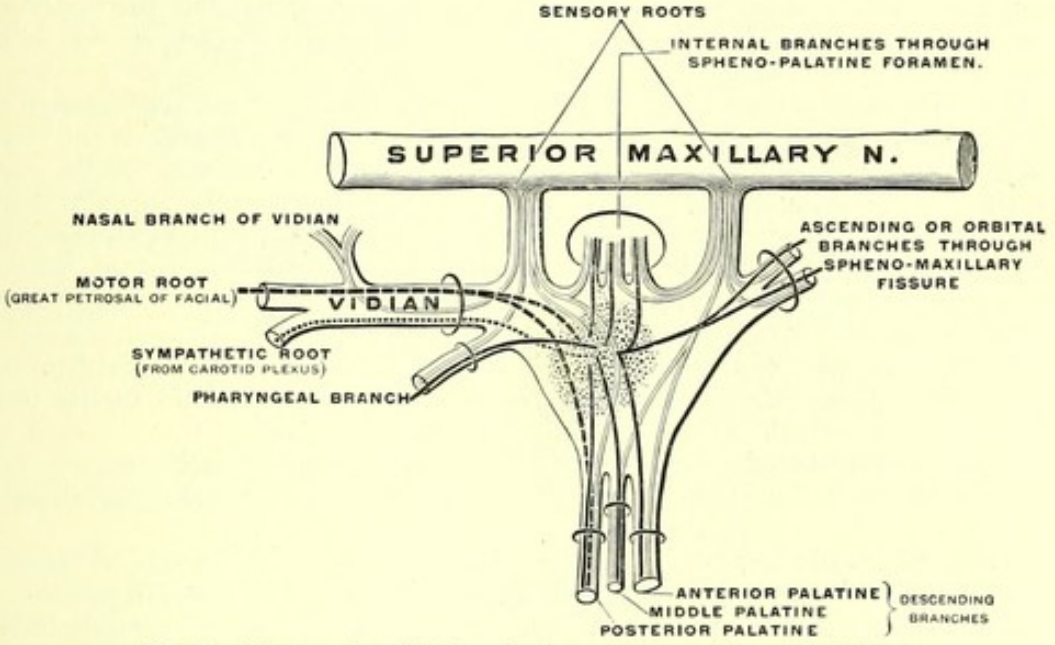

FIG. 641.—Diagram of constitution of sphenopalatine ganglion. (W. Keiller.)

Its *sensory root* is represented by two short, stout nerves, which attach its two superior angles to the superior maxillary nerve, forming its *sphenopalatine branches*. The greater part of these roots passes on without interruption in ganglion-cells into the palatine, nasal, and pharyngeal branches of the ganglion.

Its *motor and sympathetic roots* are contained in the *Vidian nerve*.

The **Vidian Nerve** is a compound nerve, formed by the junction of the *great superficial* and *great deep petrosal* nerves. Tracing the *Vidian nerve* backward to its sources, it leaves the postero-superior angle of the ganglion, passes through the Vidian canal (accompanied by the artery of the same name) in which it gives off small twigs to the back of the nose and pharynx, and divides into two branches.

Of these the *great superficial petrosal nerve* enters the cranium through the cartilage which closes the foramen lacerum medium by the outer side of the internal carotid artery, and, passing backward and outward in a groove on the petrous bone under the Gasserian ganglion, enters the hiatus Fallopii to join the geniculate ganglion of the facial nerve. It receives a twig from the tympanic branch of the glossopharyngeal. The *great deep petrosal nerve*, which joins this to form the Vidian nerve just outside the Vidian canal, can be traced to the plexus of the sympathetic on the internal carotid artery. Some works describe this as the carotid branch of the Vidian, and give the name of great deep petrosal to the twig from the glossopharyngeal which joins the great superficial petrosal. The *branches of distribution of Meckel's ganglion* are grouped as ascending, internal, descending, and posterior.

(*a*) **Ascending Branches.**—These are the *orbital branches*, two or three exceedingly minute twigs which pass through the sphenomaxillary fissure to the periosteum of the orbit, and the mucous membrane of the posterior ethmoidal and sphenoidal sinuses.

(*b*) **Internal branches** are partly derived from the ganglion ; but are largely traceable over its inner surface into the sensory roots. They are *superior nasal* and *nasopalatine*.

The *superior nasal nerves* are several small twigs which enter the nose through the sphenopalatine foramen, to supply the mucous membrane over the upper and back part of the superior and middle turbinated bones and septum, as well as the posterior ethmoidal cells.

The *nasopalatine nerve* (Fig. 628) passes to the nasal septum, also through the sphenopalatine foramen. It runs downward and forward in a groove on the vomer between the periosteum and mucous membrane, contributing some small septal branches and communicating with the nasal branch of the anterior superior dental nerve. The two nasopalatine nerves, one on each side of the nasal septum, thus reach the median segments of the anterior palatine canal (foramina of Scarpa), through which they pass to the roof of the mouth, the left nerve occupying the anterior foramen.

In the lower part of the anterior palatine canal they unite in a plexiform network, and are then distributed to the mucous membrane behind the incisor teeth, communicating with the anterior palatine nerve.

(*c*) **Descending Branches** (Fig. 629).—These are the three palatine nerves, anterior or great, posterior or small, and external. They are frequently given off as one trunk.

The *great* or *anterior palatine nerve*, springing from the lower angle of Meckel's ganglion, descends in the posterior palatine canal, and runs forward, in grooves, on the hard palate, supplying the gums and roof of the mouth, and communicating with the nasopalatine nerve. It contributes *inferior nasal branches* to the back part of the inferior turbinated bone and middle and inferior meatus.

The *small* or *posterior palatine nerve* descends in one of the accessory palatine canals to the tonsil, uvula, and soft palate, and through it motor fibres possibly pass from the facial nerve to the levator palati and azygos uvulæ, though the pars accessoria ad vagum is now regarded as supplying these muscles.

The *external palatine nerve* occupies another accessory palatine canal, in which it descends to the soft palate and tonsil. It is occasionally absent.

(*d*) **Posterior Branches.**—The twigs supplied by the Vidian in the Vidian canal to the upper part of the nose are derived from the sphenopalatine roots of the ganglion, and only accompany the Vidian nerve.

The *pharyngeal branch* springs from the ganglion beside the Vidian, with which it may be incorporated. It runs backward in the pterygopalatine canal with the vessel of that name to the posterior nares and nasopharynx, Eustachian tube, and sphenoidal sinuses.

The Third, Inferior Maxillary, or Mandibular Division of the Fifth Nerve (Fig. 642).—The *mandibular division of the fifth nerve* is larger than either of the

others, and is formed by the third segment of the sensory root with the entire motor root, the two leaving the cranium through the foramen ovale, and uniting almost immediately afterward to form a single mixed nerve-trunk. About one-fourth of an inch below the base of the skull this short trunk divides under cover of the external pterygoid muscle into a smaller or anterior, and a larger or posterior, division.

Before it divides, the trunk gives off a recurrent nerve, and the nerve to the internal pterygoid.

The **recurrent branch** enters the cranium through the foramen spinosum, and sends a twig to the lining membrane of the mastoid cells, and another to the substance of the petrous bone.

The *nerve to the internal pterygoid* passes under the posterior border of that muscle supplying it on its deep surface. Near the origin of the nerve and lying on it is the otic ganglion, to which it contributes its sensory root.

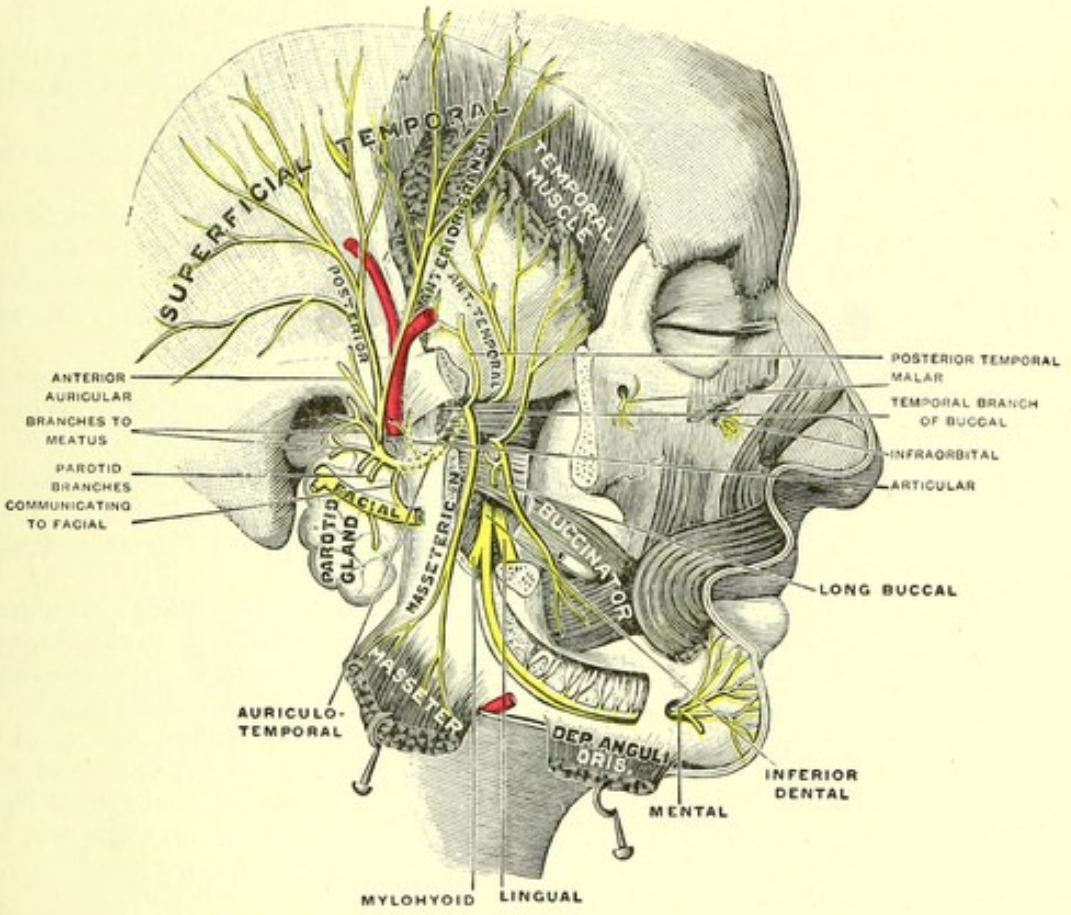

FIG. 642.—Mandibular division of the trifacial nerve. (Testut.)

The **smaller** or **anterior division** of the mandibular trunk is mainly motor in function. Its branches are as follow :

(*a*) The *deep temporal nerves, anterior* and *posterior*. Of these the posterior frequently springs from one common trunk with the masseteric nerve. They run upward over the upper border of the external pterygoid muscle and between the temporal muscle and the bone, supplying the latter muscle on its deep surface.

(*b*) The *masseteric nerve*, frequently starting in common with the posterior deep temporal nerve, passes over the upper border of the external pterygoid, and through the sigmoid notch of the mandible behind the insertion of the temporal muscle, accompanied by the masseteric vessels. It enters the deep surface of the masseter muscle. It supplies a filament to the temporomaxillary articulation.

(*c*) The *external pterygoid nerve* is given off from the *long buccal* nerve, which also contributes some fibres to the temporal muscle.

(*d*) The *long buccal nerve*, with the exception of those branches just mentioned, is purely sensory. It passes between the two heads of the external pterygoid muscle, and runs downward and forward under cover of the temporal muscle and anterior border of the masseter to the buccinator. Between the masseter and buccinator it divides into branches to the skin and mucous membrane of the cheek, the latter piercing the fibres of the buccinator. It communicates with the facial, forming a plexus around the facial vein called the buccal plexus.

The **larger** or **posterior division** is almost entirely derived from the sensory root, the only motor fibres it contains passing along the inferior dental nerve to form its mylohyoid branch. Its branches are as follow :

(*a*) The *auriculotemporal nerve* arises by two roots which usually enclose the middle meningeal artery. It passes backward and outward close under the temporomaxillary articulation, then upward between it and the external auditory meatus, under cover of the upper part of the parotid gland. Emerging from under the gland it crosses the root of the zygoma with the superficial temporal artery slightly behind which it lies, and divides into superficial temporal branches to the skin of the temple.

In this course it gives off (1) *articular twigs*, one or two fine filaments to the temporomaxillary articulation.

(2) *Communicating branches*, consisting of one or two stout branches to the facial nerve ; and slender filaments to the otic ganglion, which latter are important because they conduct secretory fibres from the glossopharyngeal nerve to the parotid gland, by way of the lesser petrosal nerve, otic ganglion, and parotid branches of the auriculotemporal.

(3) Two nerves *to the meatus* pass between the bony and cartilaginous part of the external auditory meatus, and supply the skin of the meatus, contributing a twig to the tympanic membrane.

(4) Several *parotid branches* pass from the nerve itself, or its communicating branches to the facial nerve, into the gland substance.

(5) Two *anterior auricular branches* supply the skin over the tragus and upper part of the pinna.

(6) The *superficial temporal nerve* is the termination of the auriculotemporal. The posterior division breaks up into branches which cross the posterior branch of the temporal artery, the anterior division communicates with the temporal branches of the facial nerve. They supply the skin of the temporal region.

(*b*) The *Inferior Dental Nerve* (Fig. 643) is the largest branch of the mandibular division of the fifth nerve. It emerges from under the lower border of the external pterygoid muscle, and running downward upon the internal lateral ligament of the lower jaw, with the inferior dental artery behind and the lingual nerve in front of it, it enters the inferior dental canal. Before entering the canal it gives off the mylohyoid nerve.

In the inferior dental canal it runs forward toward the symphysis menti, supplying *branches to the teeth and gums*, and opposite the mental foramen it divides into a mental and an incisive branch. The *incisive branch* runs forward in the continuation of the dental canal to supply the canine and incisor teeth and corresponding part of the gums ; while the *mental branch* appears on the face by issuing through the mental foramen with a companion artery, and, under cover of the depressor anguli oris, divides into a descending branch to the integument of the chin, and two ascending branches to the skin and mucous membrane of the lower lip. It communicates with the supramandibular division of the facial nerve.

The *mylohyoid branch* of the inferior dental nerve is rather to be regarded as coming straight from the motor root and only accompanying the inferior dental in its sheath as far as the inferior dental canal. It occupies the mylohyoid groove with an artery of the same name, and runs in the recess under the mylohyoid

muscle and between it and the mandible, supplying that muscle and the anterior belly of the digastric.

(*c*) The *Lingual* (wrongly called the gustatory) *Nerve* (Figs. 643, 644) lies at first under cover of the external pterygoid muscle, in front of and a little deeper than the inferior dental nerve, to which it is connected by a short branch. Here, also, it is joined at an acute angle by the chorda tympani nerve from the facial. It runs downward and forward on the internal pterygoid muscle and mandibular attachment of the superior constrictor of the pharynx, and reaches the inner side of the lower jaw, close under the last molar tooth, where it lies immediately under the mucous membrane, and may be readily reached by the surgeon, or injured in careless dentistry. It then lies between the hyoglossus and mylohyoid muscles above the deep portion of the submaxillary gland, and crosses Wharton's duct obliquely as it bends upward toward the tip of the tongue.

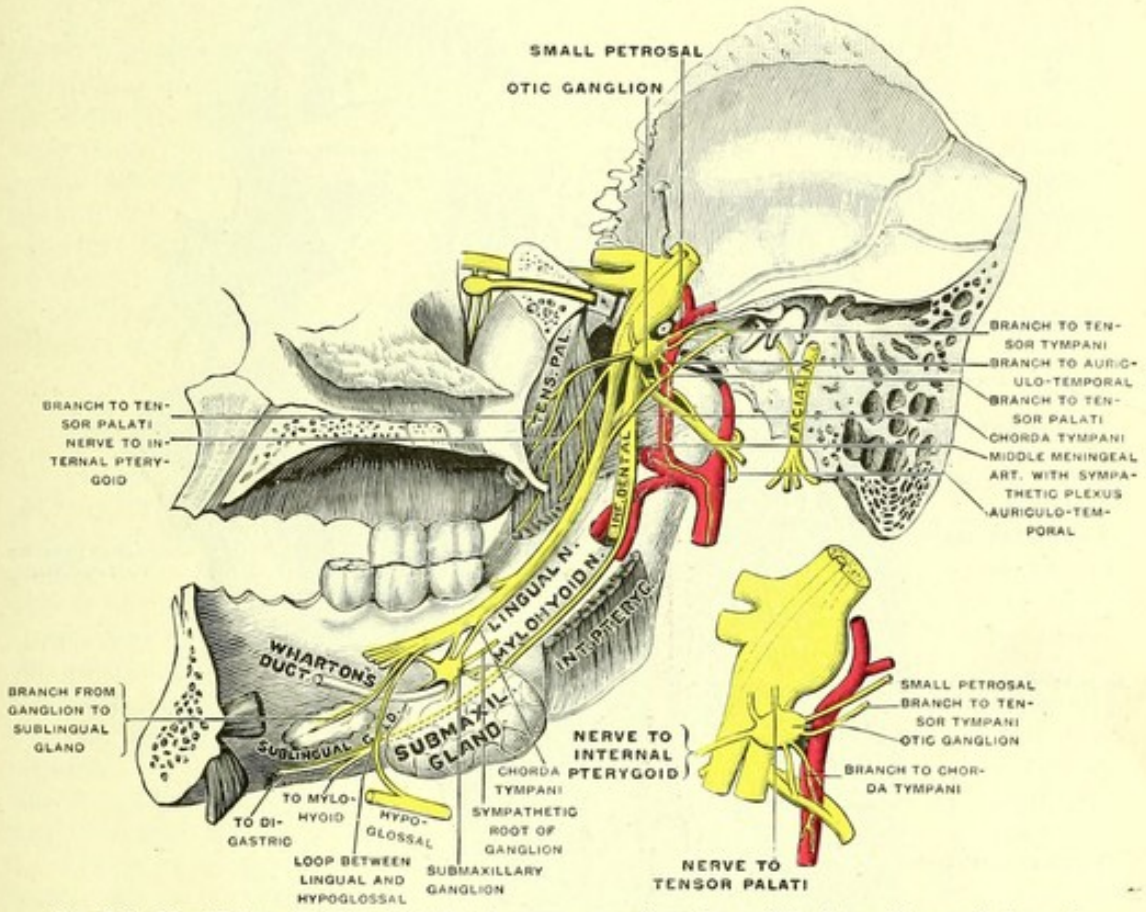

FIG. 643.—Mandibular division of trifacial nerve, seen from the middle line. The small figure is an enlarged view of the otic ganglion. (Testut.)

Its *communicating branches* are those above mentioned—namely, to the inferior dental, and by the chorda tympani to the facial nerve, in addition to which there are the motor and sensory roots to the submaxillary ganglion, and one or two filaments which, under the mylohyoid muscle, join it with the hypoglossal nerve.

It distributes twigs to the mucous membrane of the floor of the mouth between the tongue and the gums, a branch to the sublingual gland (from the chorda tympani nerve), and ends by breaking up into fibres for the anterior two-thirds of the tongue, supplying chiefly the fungiform and filiform papillæ.

The Submandibular (Submaxillary) Ganglion (Fig. 643).—In a small triangular space under cover of the mylohyoid muscle, having the lingual nerve above, Wharton's duct below, and the submaxillary gland behind, lies a reddish body about the size of a pin-head, the *submandibular (submaxillary) ganglion*. *Its roots* are represented by one branch (or several) running downward and forward to it from the

lingual, conveying to it chorda-tympani and trifacial fibres (motor and sensory), and filaments which join it from the sympathetic plexus round the facial artery. It *distributes* branches to the submaxillary gland and Wharton's duct, and a branch to the sublingual gland, which reaches the gland by joining the lingual, assuming the appearance of another root.

The Otic Ganglion (Fig. 643).—The *otic* ("ear") *ganglion* is a small reddish gray, oval body, compressed from side to side, and about one-sixth of an inch in its long diameter. It is closely attached to or may surround the nerve to the internal pterygoid muscle, lying on the inner side of the mandibular trunk

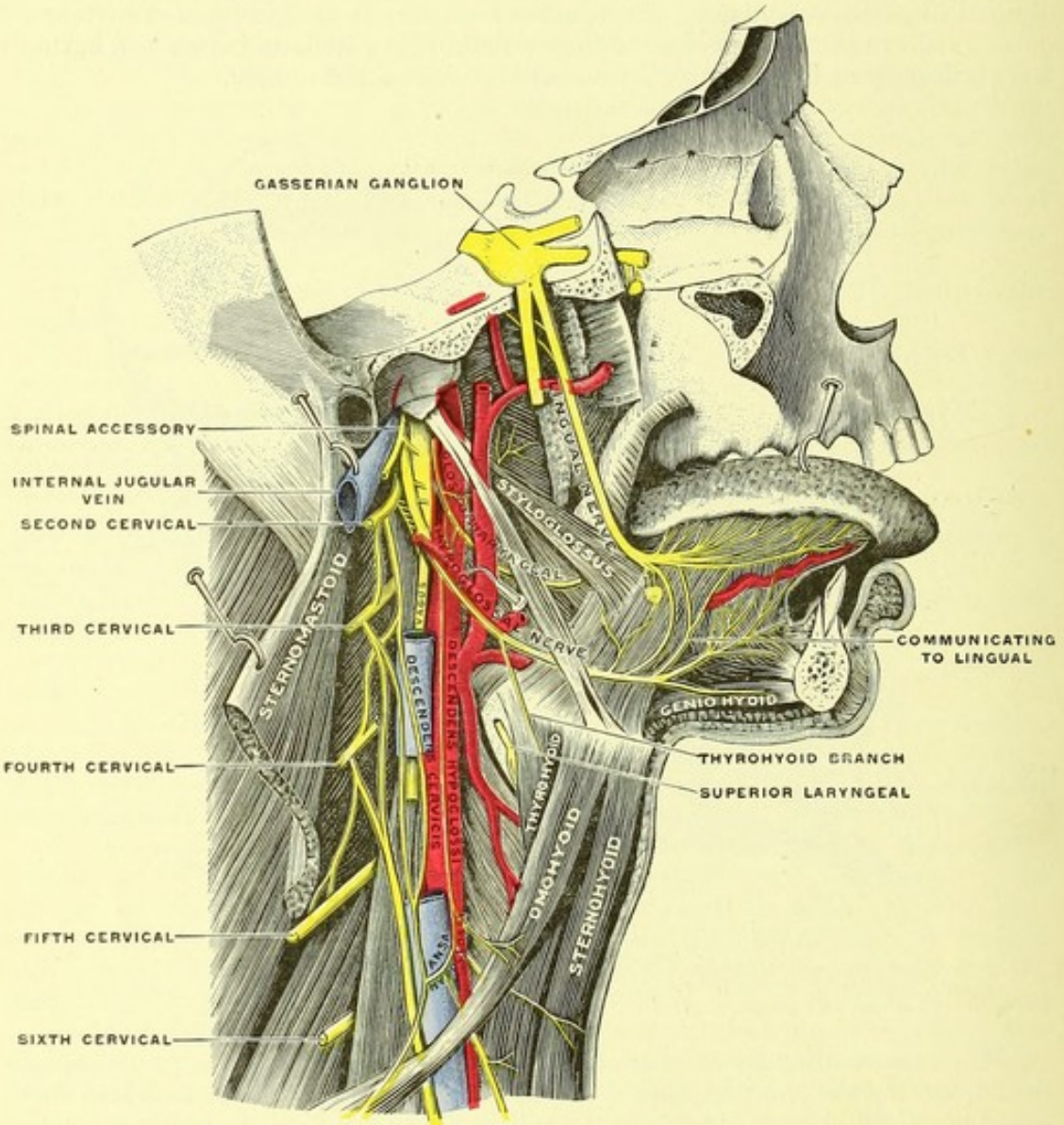

FIG. 644.—Nerves of the tongue. (Testut.)

close to the foramen ovale. Behind it is the middle meningeal artery, and on its inner side are the Eustachian tube and tensor palati muscle.

Its *motor* and *sensory* roots reach it through the nerve to the internal pterygoid muscle; but it is also connected with the facial and glossopharyngeal nerve through the small superficial petrosal nerve. From the plexus round the middle meningeal artery it receives its *sympathetic* root.

It *distributes* branches to join the auriculotemporal, by which route the parotid gland is supplied from the glossopharyngeal nerve; also muscular twigs to the tensor palati and tensor tympani, and a communicating filament to the chorda

tympani nerve. Of the muscular fibres most may be traced to the trunk of the mandibular division of the fifth nerve, without interruption in the ganglion-cells.

The Sixth or Abducent Nerve.

The sixth nerve (Fig. 636) is purely motor, supplying the external rectus muscle of the eyeball. Its nucleus consists of a compact group of cells in the floor of the fourth ventricle, which forms the prominence known as the eminentia teres. It is in series with the third, fourth, and twelfth nuclei, and is surrounded by the seventh or facial roots, but has no connection with them. Its most important connection is with the opposite oculomotor root by fibres which cross over and ascend in the posterior longitudinal bundle; and thus the nucleus of the sixth nerve supplies the external rectus of its own side directly, and the internal rectus of the opposite side indirectly, through the opposite third nerve.

The nerve roots run ventrolaterally through the pons to emerge as a flattened band from the groove between the oblongata and pons, just external to the anterior pyramid. This soon becomes rounded and pierces the dura at the side of the dorsum sellæ, behind and internal to the fifth nerve. It passes through the cavernous sinus, lying under the carotid artery, and gains the orbit through the sphenoidal fissure, where it lies between the two heads of the external rectus, beneath the inferior division of the third nerve, and above the ophthalmic vein. It then runs forward on the inner surface of the external rectus muscle, which it supplies. In the cavernous sinus the sixth nerve receives filaments from the carotid plexus of the sympathetic and, as it enters the orbit, it communicates with the ophthalmic division of the fifth.

The Seventh or Facial Nerve.

The seventh nerve (Fig. 645), excepting what will be described as the pars intermedia, is purely motor to the face muscles. Its nucleus lies deeply embedded in the pons on a level with the striæ acusticæ. It is in line with the motor nuclei of the fifth and ninth. The root of this nerve pursues a very circuitous course through the pons, running first dorsally, then upward, next laterally above, and finally ventrally on the outside of the sixth nucleus. It emerges from the groove between the pons and oblongata, external to the olivary body and in the same transverse plane as the eighth nerve. Between its superficial origin and that of the eighth nerve, springs a small bundle called by Wrisberg the *pars intermedia*. The seventh, eighth, and pars intermedia run together outward into the internal auditory meatus, the seventh nerve lying in a groove on the upper and fore part of the auditory nerve, the pars intermedia being between them.

The *pars intermedia*, in spite of some apparent connections with the eighth nerve, has no real continuity with it. It arises from the upper part of the glossopharyngeal nucleus, joins the facial nerve immediately after the latter enters the aqueductus Fallopii, and is probably the main constituent of the chorda tympani nerve.

At the bottom of the internal auditory meatus the facial nerve enters the aqueductus Fallopii. In this canal it runs first outward between the cochlea and vestibule till it abuts on the inner wall of the tympanum; backward in the substance of the inner tympanic wall, above the fenestra ovalis, being here separated from the tympanum by a thin lamina of bone and the lining membrane of the middle ear; and lastly it turns somewhat acutely downward behind the pyramid and posterior tympanic wall to appear at the base of the skull through the stylomastoid foramen.

At the point where it bends sharply backward the bend is capped by a somewhat conical swelling called the *geniculate ganglion*.

On issuing from the petrous bone the facial nerve runs downward and forward through the substance of the parotid gland, superficial to the external

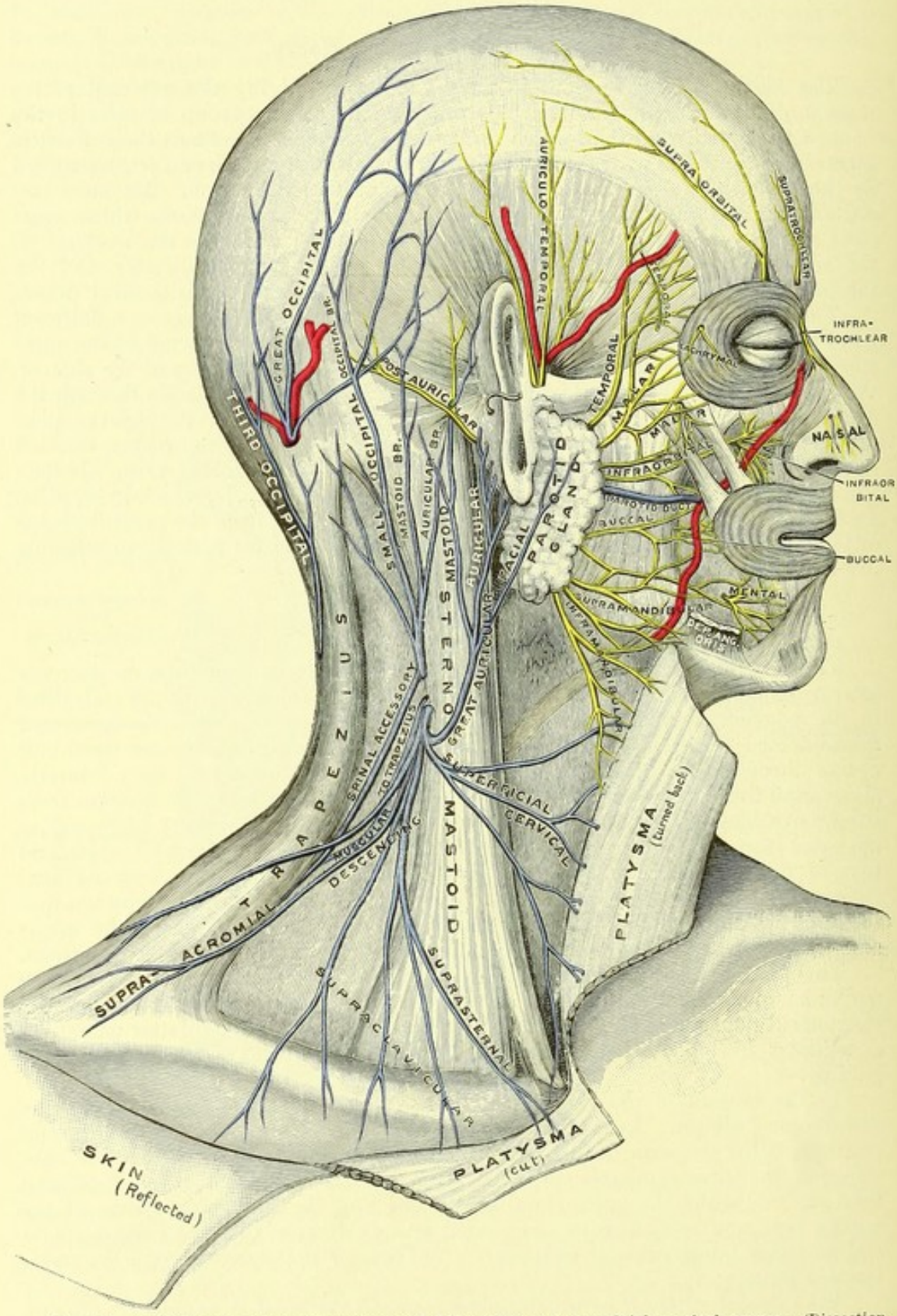

FIG. 645.—Facial nerve, cutaneous branches of fifth nerve, and superficial cervical nerves. (Dissection and drawing by W. Keiller.)

carotid artery, and behind the ramus of the lower jaw divides into a superior or *temporofacial* and an inferior or *cervicofacial division*, which break up into the numerous branches distributed to the face and submandibular region.

The *branches* of the facial nerve may be divided into three groups: (*A*) those given off in its course through the petrous bone, (*B*) those arising from the trunk at the base of the skull, and (*C*) those springing from its two great terminal divisions.

(*A*) Branches of the Facial Nerve in its Course through the Petrous Bone.—(*a*) Filaments connect the geniculate ganglion with the vestibular division of the auditory.

(*b*) The **great superficial petrosal nerve** is the largest of the three branches given off from the geniculate ganglion. It has been described with Meckel's ganglion, of which it forms the motor root.

(*c*) The **small superficial petrosal nerve** is also given off from the geniculate ganglion. It traverses a canal just external to the hiatus Fallopii, where it is joined by a branch from the tympanic plexus of the glossopharyngeal. It goes to the otic ganglion, leaving the cranium in the interval between the great wing of the sphenoid and petrous bone, or through a small canal beside the foramen ovale.

(*d*) The **external superficial petrosal nerve**, the last of the three branches from the geniculate ganglion, traverses a small canal in the petrous bone, and passes to the sympathetic plexus on the middle meningeal artery. It is not constant.

(*e*) A **branch to the stapedius** muscle is given off from the facial nerve as it descends behind the pyramid.

(*f*) The **chorda tympani nerve**, given off from the facial at the lower end of the aqueductus Fallopii and containing nearly the whole pars intermedia, enters the back part of the tympanum, crosses that cavity on the inner side of the handle of the malleus under a covering of the lining membrane, and gains the base of the cranium by a canal at the inner side of the Glaserian fissure. It runs downward and forward under cover of the external pterygoid muscle, and joins the lingual nerve, after receiving twigs from the otic ganglion. It is conducted by the lingual nerve to the submaxillary ganglion, and to the anterior two-thirds of the tongue, forming the path for the sense of taste between that section of the organ and the glossopharyngeal nucleus.

(*g*) Just before leaving the aqueductus Fallopii the facial nerve gives a twig to the auricular branch of the pneumogastric, as it courses through the temporal bone.

(*B*) Branches given off between the Base of the Skull and its Final Division.—(*a*) The **posterior auricular nerve** commences just after the facial nerve has appeared at the base of the skull. It passes backward in the deep recess between the mastoid process and the external ear, communicating with the auricular branch of the pneumogastric, and sends a *vertical branch* upward to the retrahens aurem, attollens aurem, and small muscles on the cranial surface of the auricle, and a *horizontal branch* backward over the temporal bone to the occipitalis.

It communicates with the great auricular and small occipital nerves.

(*b*) Just below the preceding nerve arises the *nerve to the posterior belly of the digastric*. One of its branches frequently joins the glossopharyngeal nerve.

(*c*) The *nerve to the stylohyoid muscle* may be given off along with the last in one common trunk or separately at the same level.

(*d*) A **lingual branch** is described. It passes on the outer side of the stylopharyngeus muscle to the side of the pharynx, where it is joined by twigs from the glossopharyngeal. It then passes between the palatoglossus and the tonsil, and at the base of the tongue divides into filaments to the mucous membrane and palatoglossus and styloglossus muscles.

(*C*) The two great Terminal Divisions of the facial are distributed in a manner which may be summarized as follows:

Running forward in the substance of the parotid gland, in which they cross superficially to the external carotid artery and temporo-maxillary vein, the *temporofacial* division after receiving a stout branch from the auriculo-temporal nerve, subdivides into *temporal*, *malar*, and *infraorbital* branches, and the *cervicofacial division* into *buccal*, *supramandibular*, and *inframaxillary* branches; the parotid duct separating the infraorbital from the buccal nerve. Leaving out the inframandibular nerve, these branches spread all over the face, each occupying mainly the region which its name indicates. They form, by interlacing with each other and with the various cutaneous branches of the fifth nerve, an intricate network called the *pes anserinus* ("goose's foot"), and supply all the face-muscles, including the buccinator, the frontalis, and the anterior muscles of the auricle.

The **inframandibular branch** emerges from the parotid gland behind the angle of the lower jaw, runs downward and forward under the platysma over the inframandibular and adjacent region of the neck, communicating freely with the great auricular and superficial cervical nerves, and supplying the platysma on its under surface.

It should further be said that the zygomatic muscles and levator labii superioris lie superficial to the infraorbital branch, and the risorius, depressor anguli oris, and depressor labii inferioris cross the supramandibular branch; but with these exceptions the branches of the facial nerve are superficial.

Branches from the Temporofacial Division.—The **temporal branch** of the temporofacial division of the facial nerve passes upward through the parotid gland, over the zygoma, and divides into branches, which supply the orbicularis palpebrarum, frontalis, corrugator supercilii, attrahens and attollens aurem, and small muscles of the front of the pinna. Its branches form numerous communications with each other, with the malar branch, and with the auriculotemporal, temporal, lachrymal, and supraorbital branches of the fifth nerve.

Note.—The branches to the frontalis and orbicularis palpebrarum are derived from the nucleus of the third nerve.

The **malar branch** runs forward over the malar bone, and is distributed mainly to the orbicularis palpebrarum. It sends filaments to both eyelids and communicates freely with the temporal and infraorbital branches of the facial, and the supraorbital, lachrymal, malar, and infraorbital branches of the fifth nerve.

The **infraorbital branch** emerges from the anterior border of the parotid gland just above the parotid duct, and divides into branches which radiate to the region of the face between the orbit and the mouth. They pass under the zygomatic muscles and the levator labii superioris, under the latter muscle forming with the infraorbital branch of the fifth nerve the *infraorbital plexus*. It communicates also with the neighboring facial branches (malar and buccal) and with the buccal, malar, nasal, and infratrochlear branches of the fifth; and supplies the zygomatic muscles, levator anguli oris, levator labii superioris, levator labii superioris alæque nasi, pyramidalis nasi, compressor nasi, and depressor alæ nasi; also the buccinator and orbicularis oris.

Branches from the Cervicofacial Division.—The *cervicofacial division* runs downward and forward in the parotid gland crossing the external carotid artery. In the substance of the gland it receives fibres from the great auricular nerve. It divides into the following three branches:

The **buccal branch** emerges from the parotid gland under the parotid duct, crosses the masseter muscle, and breaks up into twigs to the buccinator and orbicularis oris. It communicates with neighboring branches of the facial and with the long buccal nerve.

The **supramandibular branch** crosses the masseter muscle and facial vessels on the body of the mandible, and under the risorius and depressors of the lower lip passes toward the chin. It supplies the risorius, depressor anguli oris, depressor labii inferioris, and levator menti, and communicates with the buccal and inframandibular branch of the facial and with the mental branch of the inferior dental nerve.

The **inframandibular branch** has already been sufficiently described.

(*Note.*—The fact that the frontalis, orbicularis palpebrarum, and corrugator supercilii, escape in cortical facial paralysis, furnishes clinical evidence of a connection between the facial nerve and the oculo-motor nucleus, which probably takes place through the posterior longitudinal bundle. The association of the movements of the lips and tongue, and the involvement of the orbicularis oris in bulbar paralysis suggest that this muscle is supplied from the hypoglossal (twelfth) nucleus. This is probably effected by a communication from the nucleus of the twelfth to the facial nerve through the posterior longitudinal fasciculus.)

The Eighth or Auditory Nerve.

Nucleus of the Eighth or Auditory Nerve (Fig. 646).—The auditory nerve springs from the lower border of the pons, just external to the facial, by two bundles. The more lateral or posterior of these is mainly distributed to the

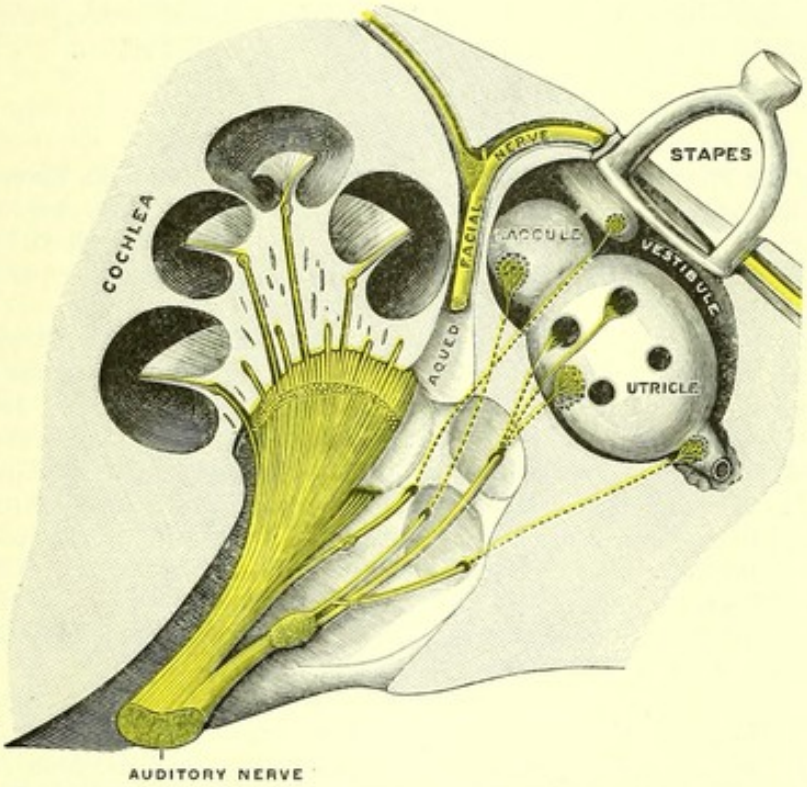

FIG. 646.—Distribution of the auditory nerve. (Semidiagrammatic.) (Testut.)

cochlea, and is regarded as the true nerve of hearing; the mesial or anterior bundle supplies the semicircular canals (except the posterior) and its function is to convey the sense of equilibrium. As these roots plunge into the pons, they separate so as to pass one on each side of the restiform body.

The *lateral* or *cochlear root* is divisible into several parts. The outer fibres pass dorsally along the outer side of the restiform body, and enclose a large number of cells, similar to those of a spinal ganglion, which form the *ganglion of the cochlear root*. Thence fibres pass dorsally to end in the dorsal nucleus and striæ medullares. The more mesial fibres of the cochlear root come into relation with a triangular group of cells, which lies ventral to the restiform body and forms the *accessory* or *ventral auditory nucleus*. Other fibres pass by the trapezium to the superior olive of the same and opposite sides. It is also connected with the flocculus. The *mesial* or *vestibular root* passes to the inner side of the restiform body, between it and the ascending root of the fifth nerve. When it reaches the dorsomesial side of the restiform body, most of its fibres bend caudally, and run

along the inner side of the restiform body and cuneate nucleus forming the *ascending root*. The fibres of this ascending root probably end in arborizations round the cells of the cuneate nucleus. The rest of the fibres of the vestibular root pass dorsally to end in the *internal auditory* or *dorsal nucleus*, which is a large group of cells corresponding in position to the tuberculum acusticum, and lying close to the floor of the ventricle dorsomesially to the restiform body. This nerve is homologous with the dorsal root of a spinal nerve, and the ganglion radicis cochlearis, spiral ganglion of the cochlea, and vestibular ganglion together represent an intervertebral ganglion. On emerging from the pons the two roots unite to form one trunk, again dividing at the bottom of the internal auditory meatus. The trunk runs upward, outward, and forward round the middle cerebellar peduncle to the internal auditory meatus, where it becomes concave on its upper surface and lodges the facial nerve, pars intermedia, and internal auditory artery in the groove so formed. It is united to these structures by loose connective tissue, which contains no nerve-fibres. At the bottom of this canal it divides into an upper, *vestibular division* to the utricle and ampullæ of the superior and external semicircular canals, and a lower, *cochlear division* to the saccule, ampulla of the posterior semicircular canal, and cochlea.

Ninth, Tenth, and Eleventh Nerves.

Nuclei of the Ninth, Tenth, and Vagus-accessory Portion of the Eleventh Nerves.—The various origins, motor and sensory, of these three nerves being all continuous columns or series of cells and fibres, they are best described together, the distinction between the nerves being a matter of higher or lower point of origin and ultimate distribution.

The *sensory nucleus* is an elongated column of cells mainly corresponding in position to the inferior fovea and trigonum vagi (or ala cinerea) in the floor of the fourth ventricle. It extends the whole length of the oblongata. In the lower part it lies dorsally to the twelfth nucleus, and dorso-laterally to the central canal; but as the central canal opens out into the fourth ventricle, it is shifted so as to lie laterally to the nucleus of the twelfth nerve, and close to the floor of the ventricle. From it bundles of fibres pass ventro-laterally to emerge from the side of the oblongata, between the olivary and restiform bodies, or further down between the last named structure and the lateral column. The upper bundles form the sensory fibres of the glossopharyngeal nerve, the lower are grouped into the pneumogastric and pars accessoria ad vagum.

The *ascending vago-glossopharyngeal* root (funiculus solitarius, fasciculus rotundus) is a well-marked rounded bundle of fibres, which ascends on the outer side of the sensory nucleus from the funiculus gracilis and gelatinous substance of Rolando. Its main connections seem to be with the funiculi graciles of both sides and with the opposite fillet. It contributes fibres to the pneumogastric, but mainly emerges as the upper bundle of the glossopharyngeal nerve.

The *motor nucleus* (nucleus ambiguus) is a column of large multipolar cells, undoubtedly representing part of the ventral horn of the spinal cord. It lies deeply in the formatio reticularis of the oblongata in line with the nucleus of the facial nerve. From it the motor roots of the three nerves under consideration pass in bundles, first dorsally toward the floor of the ventricle, and then outward and ventrally in line with the sensory bundles.

Connection of the Vagus-accessory with the Twelfth Nucleus.—The involvement of the palate and vocal cords in bulbar paralysis appears to indicate that the motor fibres to these structures, which reach them through the vagus-accessory, are derived from the nucleus of the twelfth nerve.

Nucleus of the Spinal Portion of the Eleventh Nerve.—The spinal portion of the spinal accessory is a purely motor nerve. It arises from a distinct column of cells in the ventral horn of the cervical spinal cord. From this bundles of nerve-fibres pass upward for a little way, then dorso-laterally through the gray

matter, to emerge from it at the junction of the two horns; thence outward through the crossed pyramidal tract and direct cerebellar tract to their superficial origin, between the ligamentum denticulatum and dorsal nerve roots. It extends as low as the sixth or seventh cervical nerve.

The Ninth or Glossopharyngeal Nerve.

The *glossopharyngeal* ("tongue-pharynx") *nerve* (Fig. 647) is formed by the union of the upper five or six bundles of nerve-fibres, which arise from the side of the oblongata between the olivary and restiform bodies.

It passes outward in front of the flocculus to the jugular foramen, by the middle compartment of which it leaves the cranium antero-internally to the vagus and spinal accessory, and in a special sheath of dura. In this foramen it lies in a groove or canal on the posterior border of the petrous bone, and here it possesses two successive gangliform enlargements, the jugular ganglion and petrous ganglion, respectively. It then passes for a short distance downward between the internal carotid artery and internal jugular vein, lying at first close to the vagus. It soon winds forward, under the styloid process and its muscles and superficial to the internal carotid artery, till, reaching the lower border of the stylopharyngeus muscle, it runs forward on it to the back of the tongue, where, under cover of the hyoglossus, it breaks up into its terminal branches.

The *jugular ganglion* is situated at the upper margin of the jugular foramen. It is very small, not constant, only involves the posterior fibres of the nerve, and gives off no branches. It is regarded as a displaced portion of the lower ganglion, and together they are taken to represent the ganglion on the sensory root of a spinal nerve.

The **petrous ganglion** lies in a groove on the petrous bone at the lower margin of the jugular foramen. It is not more than one-fourth of an inch long, and involves the whole nerve. It gives off the tympanic nerve, and twigs which communicate with the pneumogastric and sympathetic.

Branches.—(*a*) **Meningeal branches** are distributed to the pia and arachnoid membranes within the cranium.

(*b*) The **tympanic branch** (*nerve of Jacobson*) is a minute but important nerve, which is given off from the petrous ganglion. It enters the tympanum through a small foramen situated on the ridge between the carotid canal and jugular fossa, and on the promontory divides into several branches, which form the *tympanic plexus*. Of these the principal branch pierces the roof of the tympanum *to join the small petrosal nerve*, of which it probably forms the main constituent. By this means glossopharyngeal fibres pass to the otic ganglion and so to the parotid gland. Another filament joins the great superficial petrosal nerve; and a twig called the *small deep petrosal nerve* joins the carotid plexus of the sympathetic. In addition to these, filaments are distributed to the lining membrane of the *mastoid cells*, the *fenestra ovalis*, *fenestra rotunda*, and *Eustachian tube*.

(*c*) Three **communicating branches** arise from the petrous ganglion, namely, filaments to the upper cervical ganglion of the sympathetic, the auricular branch of the vagus, and to the root-ganglion of that nerve. Immediately below the petrous ganglion a twig is given off to the lingual branch of the facial nerve.

(*d*) A **muscular branch** is supplied to the stylopharyngeus, which also sends filaments to the mucous membrane of the pharynx.

(*e*) **Pharyngeal branches**, two or three in number, spring from the nerve just below the petrous ganglion. The main branch passes downward over the internal carotid artery, and joins the pharyngeal branch of the vagus to form the pharyngeal plexus with the assistance of branches from the superior cervical ganglion of the sympathetic.

(*f*) The **tonsillar branches** are two or three nerves which ascend under the hyoglossus to form a plexus on the tonsil called the *circulus tonsillaris*, from which twigs proceed to the soft palate and isthmus faucium.

(*g*) The **lingual branches** supply the posterior third of the dorsum of the tongue, and the side of the tongue over its posterior half, where they join the lingual nerve. The circumvallate papillæ receive the most minute nerve-supply.

The posterior branches also supply the anterior surface of the epiglottis.

Testut describes, in addition to the above, *carotid branches* to join the carotid plexus and *muscular twigs* to the digastric, stylohyoid, and styloglossus muscles.

The Tenth, Pneumogastric, or Vagus Nerve.

The tenth or pneumogastric ("lung-stomach") nerve (Fig. 647) is formed by the junction of from ten to fifteen filaments, which arise from the oblongata in front of the restiform body and lateral tract, in series with and just below the roots of the glossopharyngeal nerve.

They form together a flattened band which passes outward and a little forward beneath the flocculus to reach the jugular foramen, through which it leaves the cranium between the inferior petrosal and lateral sinuses, in the same sheath of dura as the spinal accessory, and external to and a little behind the glossopharyngeal nerve. In the jugular foramen its *root-ganglion* is found, and half an inch below this is a second ganglion called the *ganglion of the trunk*. This last is formed as the nerve runs downward from the base of the skull between the internal jugular vein and the internal carotid artery. In this situation, that is, immediately below the cranial base, the hypoglossal nerve winds spirally round the vagus, lying first internally, then passing behind and round across its outer side. They are united to each other by fibrous tissue and some nerve-fibres which pass between the trunk ganglion and the hypoglossal nerve. Here also the superior cervical ganglion of the sympathetic and spinal accessory lie behind the vagus, and the glossopharyngeal nerve in front of it. The pneumogastric now passes downward, behind and between the internal carotid artery and internal jugular vein, and lower down maintains the same relation to that vein and the common carotid artery, being enclosed within the same fibrous sheath as these vessels.

From the level of the clavicle downward the courses of the two nerves differ considerably, the differences, however, being readily explained by the mode of development of the great vessels, stomach, etc.

The **Right Pneumogastric Nerve** enters the thorax by passing in front of the first portion of the subclavian artery, and between it and the right brachiocephalic vein. Bending backward to the side of the trachea, it gains the posterior surface of the root of the right lung, on which it breaks up into a coarse meshwork which forms, with fibres from the sympathetic, the *posterior pulmonary plexus*. From this plexus two distinct cords represent the continuation of the vagus to the right side of the œsophagus.

Around this tube a new plexus is formed, called the *œsophageal plexus*, in which a free interchange of fibres occurs between the nerves of both sides.

Again converging to form a single trunk the right vagus passes to the back of the œsophagus at its lower extremity, and, entering the abdomen through the œsophageal opening in the diaphragm behind that tube, spreads out on the posterior surface of the stomach.

The **Left Pneumogastric Nerve** enters the thorax between the left common carotid and left subclavian arteries, and behind the left brachiocephalic vein, and then passing a little backward crosses the root of the subclavian artery and the left side of the aortic arch under cover of the pleura. Reaching the back of the root of the left lung, it behaves on the left side as its fellow does on the right side; but its terminal trunk lies in front of the œsophagus, and its final branches supply the front of the stomach.

The *ganglion of the root* is formed within the jugular foramen and is about one-sixth of an inch long. It has branches by which it communicates with the petrous ganglion of the glossopharyngeal, the spinal accessory nerve, the superior

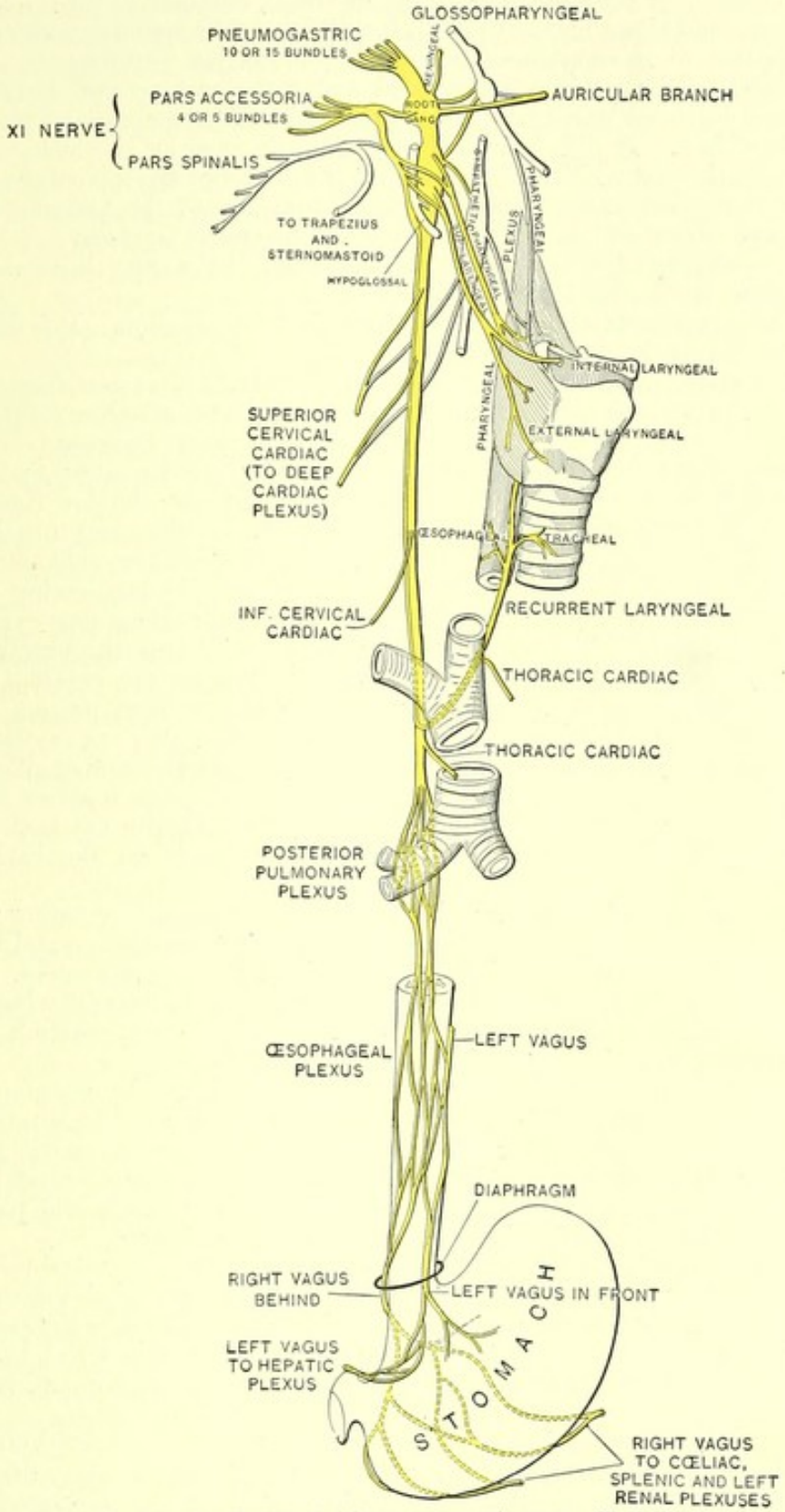

FIG. 647.—Distribution of right pneumogastric nerve. (W. Keiller.)

cervical ganglion of the sympathetic, and two branches of distribution, namely, a recurrent filament to the dura and Arnold's nerve.

The *ganglion of the trunk* is fusiform in shape, one-half to three-quarters of an inch long, and about one-sixth of an inch thick. The spinal accessory nerve is closely applied to it, communicates with it by branches entering its substance, and contributes fibres to the pharyngeal and superior laryngeal nerves, which course over its outer surface. The hypoglossal nerve winds round it and communicates with it. It also communicates with the superior cervical ganglion of the sympathetic, and with the loop between the first and second cervical nerves; and the pharyngeal and superior laryngeal branches of the pneumogastric are derived partly from this ganglion, partly from the spinal accessory.

Branches.—(*a*) The **communicating branches** have just been sufficiently noticed with the two ganglia.

(*b*) The **recurrent branch** is given off from the root-ganglion. It is distributed to the dura round the jugular foramen.

(*c*) The **auricular branch**, or *nerve of Arnold* (Fig. 648), arises from the root-ganglion. After receiving a filament from the petrous ganglion of the glossopharyngeal, it passes backward on the outer surface of the jugular sinus, and enters a small canal in the jugular fossa of the petrous bone. In this canal it arches backward close to the inner side of the aqueductus Fallopii, communicating with the facial nerve, and curving downward, issues from the temporal bone through the auricular fissure, between the external auditory meatus and the mastoid process. It now divides into two parts, one of which joins the posterior auricular branch of the facial nerve, while the other supplies the lower and back part of the external auditory canal and the skin on the back of the pinna.

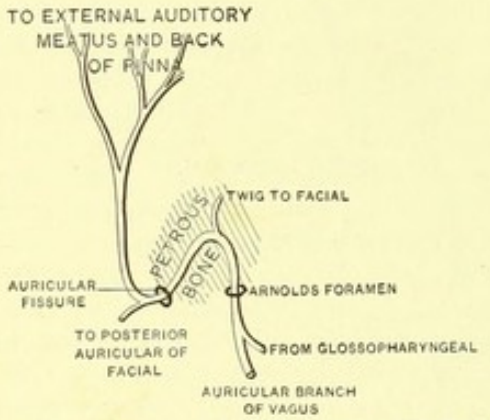

Fig. 648.—Plan of Arnold's nerve. (W. Keiller.)

(*d*) The **pharyngeal branch** may be single, or represented by two or three, of which one is usually large. It comes off from the trunk-ganglion, and is largely formed of fibres derived from the pars accessoria of the eleventh nerve. Running downward and forward superficial to the internal carotid artery, it winds inward behind the external carotid artery to the back of the pharynx, where it joins the pharyngeal plexus.

(*e*) The **superior laryngeal nerve**, springing also from the ganglion of the trunk, is, like the last, derived largely from accessory fibres. It is much larger than the pharyngeal branch, and passes downward and forward on the deep surface of the internal and external carotid arteries. After receiving communicating branches from the superior cervical ganglion of the sympathetic and pharyngeal plexus, it divides into the internal and external laryngeal nerves.

The *internal laryngeal branch* perforates the thyrohyoid membrane under cover of the thyrohyoid muscle, accompanied by the laryngeal branch of the superior thyroid artery. It breaks up into diverging branches which supply the mucous membrane on both surfaces of the epiglottis, the interior of the larynx, and the back of the cricoid cartilage, the descending branch forming a loop behind the ala of the thyroid cartilage with the recurrent laryngeal nerve.

The *external laryngeal branch* runs downward under the sternothyroid muscle to end mainly in the cricothyroid muscle, supplying on the way branches to the inferior constrictor of the pharynx, pharyngeal plexus, laryngeal mucous membrane, and a twig which joins one of the cardiac branches of the sympathetic.

(*f*) The **inferior or recurrent laryngeal nerve** differs somewhat in its course on the two sides of the body (Fig. 649).

On the *right side* it arises at the root of the neck, in front of the subclavian artery, winds beneath, and then upward and inward behind that vessel, and behind the common carotid and inferior thyroid arteries, to the recess between the œsophagus and trachea. At the lower border of the cricoid cartilage it enters the pharynx by passing beneath the inferior constrictor.

Under cover of the ala of the thyroid cartilage it divides into branches to all the intrinsic laryngeal muscles except the crico-thyroid, and to the mucous membrane of the larynx below the rima glottidis, joining the internal laryngeal nerve.

In its course upward it gives off thoracic cardiac branches, twigs to the inferior cervical ganglion of the sympathetic, œsophageal and tracheal branches, and muscular twigs to the inferior constrictor of the pharynx.

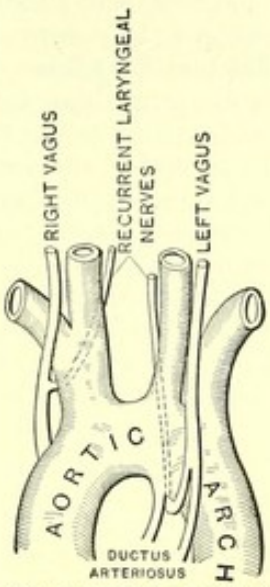

FIG. 649.—Relations of pneumogastric and recurrent laryngeal nerves to the great vessels. (W. Keiller.)

The *left recurrent laryngeal nerve* springs from the vagus as it crosses the arch of the aorta, winds round the concavity of the arch just behind the ductus arteriosus, and runs upward behind the origin of the left common carotid artery to reach the œsophagus. The rest of its course is similar to that of the right nerve.

(*g*) **Cervical cardiac and thoracic cardiac branches** are given off by each pneumogastric nerve. There are usually two superior cervical cardiac branches, one inferior cervical cardiac, and two or more thoracic cardiac branches—the latter arising from the trunk and recurrent nerve on the right side, from the recurrent nerve only on the left side. These for the most part join cardiac branches of the sympathetic, and all, with one exception, go to the deep cardiac plexus, the left inferior cervical cardiac nerve being the only one which goes directly to the superficial cardiac plexus.

The *superior cervical cardiac nerves* join the corresponding branches of the sympathetic beneath the carotid sheath.

The *left inferior cervical cardiac nerve* descends on the left of the horizontal portion of the aortic arch, having the left phrenic nerve in front of it and the superior cervical cardiac branch of the sympathetic behind it. It joins the superficial cardiac plexus.

The *right inferior cervical cardiac nerve* runs downward on the side of the brachiocephalic artery and trachea to the deep cardiac plexus.

The *right thoracic cardiac nerves*, two or three in number, arise from the vagus trunk and from the recurrent laryngeal nerve. They run inward to the bifurcation of the trachea, where the deep cardiac plexus is formed. *On the left side* the thoracic cardiac branches spring from the recurrent laryngeal nerve only.

(*h*) The **pulmonary branches** form two plexuses, one in front of and one behind the root of the lung.

The *anterior pulmonary plexus* is small, consisting of a few filaments which spring from the vagus above the root of the lung, and form a meshwork in front of the bronchus, uniting with sympathetic fibres from the pulmonary artery.

The *posterior pulmonary plexus* is large and important, involving the whole trunk of the nerve. Behind the root of the lung the vagus spreads out into an intricate network and is supplemented by fibres from the second, third, and fourth thoracic ganglia of the sympathetic; from these plexuses branches accompany the bronchi in all their ramifications. A free interchange of fibres takes place between the plexuses of the two sides.

(*i*) **Œsophageal Branches.**—Above the pulmonary plexus many small twigs are distributed to the œsophagus both from the trunk of the vagus and from its recurrent laryngeal branch. Below that point the right and left vagi unite in forming a long-meshed plexus round the tube, from which its muscular and mucous coats get their nerve supply.

(*j*) **Abdominal Branches.**—The *left vagus* distributes fibres all over the front of the stomach, large branches accompanying the coronary artery on its small curvature, and so joining the hepatic plexus of the sympathetic. The *right vagus* supplies the posterior surface of the stomach, sending branches to the cœliac, splenic, and left renal plexuses of the sympathetic.

The Pharyngeal Plexus.—Two or three twigs from the superior cervical ganglion of the sympathetic, the pharyngeal branches of the glossopharyngeal and vagus, and branches from the external and recurrent laryngeal nerves, unite in forming a plexus on the surface of the constrictors of the pharynx, from which the pharyngeal muscles and mucous membrane are supplied, as well as the levator palati and azygos uvulæ. The motor nerves are derived from the pars accessoria.

The Eleventh or Spinal Accessory Nerve.

The *eleventh nerve* (Fig. 647) consists of two parts, an *accessory portion to the pneumogastric* (pars accessoria ad vagum) and a *spinal portion* (pars spinalis).

The **Accessory Portion** is formed by some four or five fasciculi, which spring from the medulla in series with the pneumogastric roots. They unite to form a trunk which, with the spinal portion, to which it is united by some fibres or with which it may be entirely joined for a short distance, leaves the cranium in the same sheath of dura with the pneumogastric. In the jugular foramen it sends fibres to the root-ganglion of the vagus, and then partly joins the trunk-ganglion of that nerve; but many of its fibres are continued over the surface of the trunk-ganglion into the pharyngeal and superior laryngeal nerves, and down the vagus trunk itself into the recurrent laryngeal nerve. It will be seen that most of the motor fibres of the pneumogastric are derived from its accessory portion.

The **Spinal Portion** of the spinal accessory arises by a long series of roots from the lateral column of the spinal cord extending as low as the sixth or seventh cervical nerve-roots. They issue from the lateral column between the attachment of the ligamentum denticulatum and the posterior nerve-roots, approaching closer to the latter as they ascend. They join to form an ascending trunk, which enters the cranium, and unites wholly or partly with the accessory portion; but, beneath the jugular foramen, leaves the pars accessoria and bends acutely backward, usually superficially to the internal jugular vein, to enter the deep surface of the sternomastoid muscle, which it supplies, and where it communicates with a branch from the second cervical nerve. Emerging from the posterior border of the sternomastoid, it crosses the posterior triangle of the neck obliquely to end under the trapezius, a short distance above the clavicle. On the deep surface of the trapezius it is joined by fibres from the third and fourth cervical nerves, thus forming the subtrapezial plexus, from which that muscle is supplied.

The Twelfth or Hypoglossal Nerve (Fig. 644).

The twelfth or hypoglossal ("under the tongue") nerve is exclusively motor in function, and its nucleus lies in series with those of the third, fourth, and sixth nerves. Its upper part lies close to the floor of the fourth ventricle near the median sulcus in the elevation known as the trigonum hypoglossi; lower down it lies ventro-lateral to the central canal. It extends the whole length of the oblongata, and its cells are large and multipolar like those of the anterior horn. The fibres spring in two vertical series of small bundles from the ventral aspect

of the nucleus, and running ventrally and a little outward through the inferior olive (with which, however, they have no connection) emerge in a linear series of from ten to twelve fasciculi along the groove between the olive and anterior pyramid.

Connections of the Hypoglossal.—Its main connections are as follow: 1. Commissural fibres join the nuclei of the two sides; 2. Motor fibres pass from the nucleus of the hypoglossal by the posterior longitudinal bundle to join the pars accessoria ad vagum and the genu of the facial nerve of the same side; 3. Fibres pass to the opposite posterior longitudinal bundle.

The roots of the twelfth nerve pass outward above the vertebral artery, and opposite the anterior condylar foramen pierce the dura through two distinct foramina in two bundles. In its passage through this foramen the two bundles unite to form one trunk, which at first lies very deeply on the inner side of the internal carotid artery and pneumogastric nerve. It descends in a spiral manner round the trunk-ganglion of the latter nerve, and between the internal jugular vein and internal carotid artery, being closely united to the ganglion by fibrous tissue, and receiving some communicating branches from it. It now appears at the lower border of the digastric muscle, and curves forward under the occipital artery (by the sternomastoid branch of which vessel it is kept in place) and across the external carotid artery. It reaches the upper border of the great cornu of the hyoid bone, where it lies on the middle constrictor of the pharynx and above the lingual artery. Passing under cover of the posterior belly of the digastric and the stylohyoid muscles, it lies on the hyoglossus muscle just above the central tendon of the digastric. Here it is accompanied by the lingual vein, and is separated from the lingual artery by the hyoglossus. Passing beneath the mylohyoid, it curves upward on the genioglossus, communicating in a loop with the lingual nerve and terminating beneath the tip of the tongue.

The branches of this nerve are divisible into two sets, namely, true hypoglossal branches which are distributed exclusively to the extrinsic and intrinsic muscles of the tongue, and branches which are really derived from the cervical plexus, and are only adherent to the hypoglossal nerve for some part of their course.

True Hypoglossal Branches.—(*a*) *Communicating branches* unite the hypoglossal nerve with the trunk-ganglion of the vagus and superior cervical ganglion of the sympathetic, and in a manner to be explained later, with the loop between the first and second cervical nerves. At the tip of the tongue it communicates with the lingual nerve, and a small twig, called the *lingual branch of the vagus*, joins it from the pharyngeal plexus.

(*b*) The *meningeal branch* is given off in the anterior condylar foramen, and enters the cranium to supply the dura round the foramen magnum and diploë of the occipital bone.

(*c*) *Muscular branches* are distributed beneath the mylohyoid to the hyoglossus, styloglossus, and genioglossus, and also to the intrinsic muscles of the tongue.

Branches of the Cervical Plexus Adherent to or Associated with the Hypoglossal Nerve (Fig. 656).—A considerable branch from the loop between the first and second cervical nerves joins the hypoglossal just beneath the base of the cranium. It is incorporated with the hypoglossal nerve till it winds round the occipital artery, where part of the cervical branch leaves the hypoglossal under the name of the *descendens hypoglossi*. A smaller branch is given off lower down to supply the thyrohyoid muscle, and the remainder of this cervical nerve accompanies the hypoglossal under the mylohyoid to supply the geniohyoid muscle.

The *descendens hypoglossi* springs from the trunk of the twelfth nerve where it crosses the occipital artery, and passes downward and a little forward on the sheath of the great vessels and beneath the sternomastoid for a variable distance, but usually to nearly on a level with the cricoid cartilage. Here it forms a loop with the *ramus cervicalis descendens* (communicans hypoglossi), which is formed by the union of two branches from the second and third cervical nerves respectively.

This loop is called the *ansa hypoglossi*. From the descendens hypoglossi a twig is given to the anterior belly of the omohyoid. From the loop, branches are given to the sternohyoid, sternothyroid, and posterior belly of the omohyoid, the last twig passing backward through the loop of deep cervical fascia, which binds down the central tendon of its muscle. The nerves to the sternohyoid and sternothyroid enter the posterior borders of these muscles low down, and may extend into the thorax and communicate with the phrenic nerve.

THE SPINAL NERVES.

In introducing the subject of the cranial nerves we entered pretty fully into the mode of formation of a spinal nerve, taking it as the type on which the

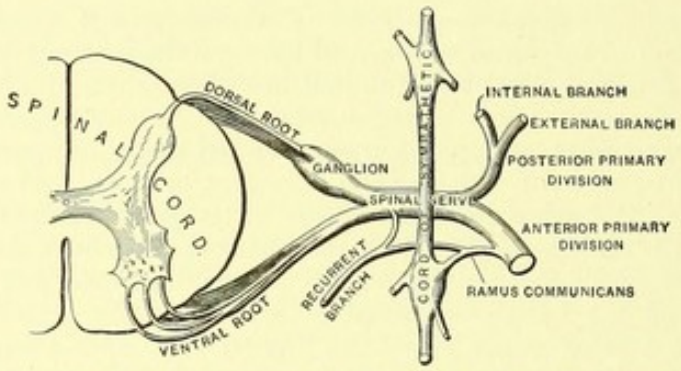

FIG. 650.—Plan of the constitution of a spinal nerve. (W. Keiller.)

cranial nerves, also, are more or less closely planned. We refer the student again to page 563, and here supplement what is there said by additional matter necessary to the present subject.

Fig. 650 illustrates the mode of origin and constitution of a spinal nerve. It is seen to spring from the spinal cord by two roots, ventral and dorsal.

The *ventral root* is *motor* in function, and springs from the ventro-lateral aspect of the cord by from four to six bundles. They unite to form two strands, which enter a sheath of dura, in which they are at first separated from the dorsal root by a fibrous septum. Within the sheath and as they traverse the intervertebral foramen, the ventral root unites with the dorsal to form a spinal nerve.

The *dorsal roots*, usually larger than the ventral, are *sensory* in function, and spring from the dorso-lateral aspect of the cord by from six to eight fasciculi, which with their fellows are arranged in a single linear series all down the cord. They unite to form two bundles and within the dural sheath enter a ganglion, from which they emerge as one bundle, and immediately join the ventral root to form a spinal nerve.

A *spinal ganglion* is an ovoid body, bifid at its proximal extremity where the

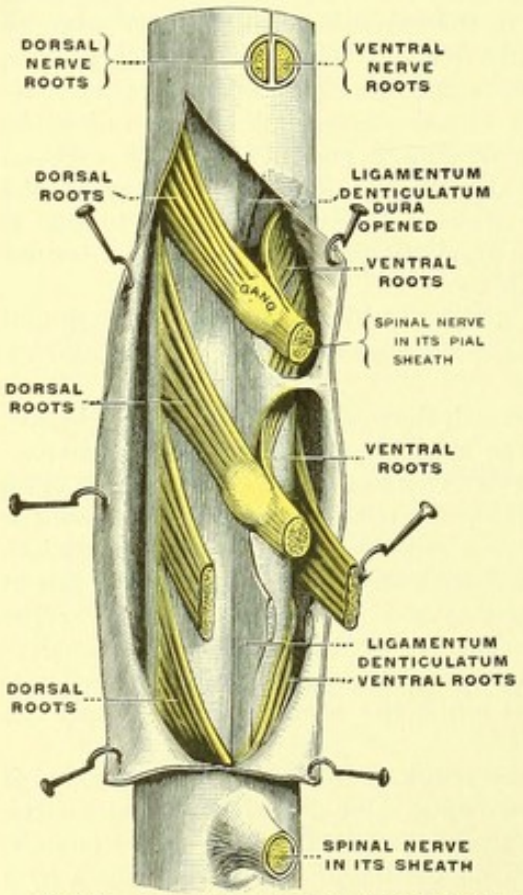

FIG. 651.—A portion of the spinal cord, showing its right lateral surface. The dura is opened and arranged to show the nerve-roots. (Testut.)

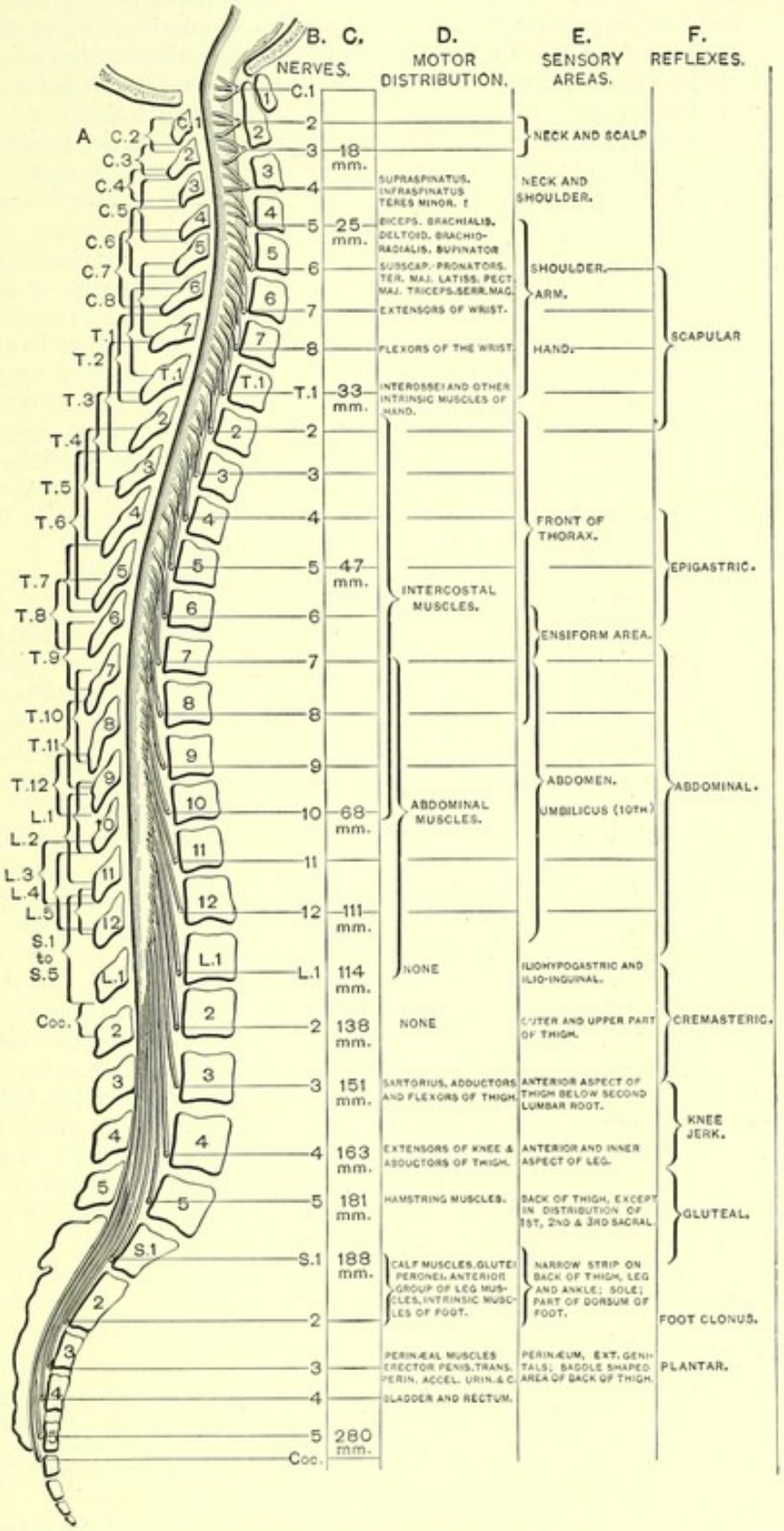

FIG. 652.—Topography and distribution of the spinal nerve-roots.

two bundles of dorsal nerve-roots enter it. It consists of bipolar nerve cells, one pole or process of each cell forming the peripheral portion of a sensory nerve fibril, the other pole or process forming its central continuation. With the exceptions to be mentioned, they are placed in the intervertebral foramina immediately beyond the point where the roots enter the dural sheath provided for them by the theca vertebralis.

The ganglia of the first and second cervical nerves lie on the laminæ of the atlas and axis respectively; those of the sacral and coccygeal nerves are found within the spinal canal, at a variable distance from their points of emergence from it.

The *course of the nerve-roots* within the spinal canal varies considerably at different levels, the growth of the spinal cord not being equal to that of the vertebral column; for, while the cord occupies the whole length of the canal in the fœtus, it only reaches as low as the body of the first lumbar vertebra in the adult. Thus the first spinal nerve ascends slightly to reach the space between the atlas and occipital bone, through which it leaves the spinal canal; the second and third are nearly horizontal; the fourth runs obliquely downward and outward and the obliquity of the others within the vertebral canal steadily increases from here downward till the nerve-roots of the lumbar and sacral nerves run vertically downward for an increasing distance, thus forming the cauda equina. This will be easily appreciated by a glance at Figures 652 and 653.

Topographical Anatomy of the Cord and Spinal Nerve-roots (Fig. 652).—It is important for surgical purposes to determine the relationship between the bony landmarks furnished by the spines of the vertebræ, and the superficial origins of the spinal nerves. The main surgical data are graphically described in Fig. 652. The brackets in column A show the extreme limits between which in different subjects examined by Reid each group of nerve-roots was found to arise. B shows each nerve cut off at the level of its intervertebral foramen, thus affording a ready estimate of the obliquity of its course in the neural canal; C gives the vertical distance in millimeters which in Testut's case of a subject of eighteen years of age separated the superficial origin of each of the nerves marked from its intervertebral foramen; and the other columns will be readily intelligible to the senior student. It is be noted that the distribution marked in D, E, and F is only broadly true and does not pretend to anatomical minuteness; but it is for that reason all the more valuable for clinical purposes.

Nomenclature (Fig. 653).—There are thirty-one pairs of the spinal nerves, namely, eight cervical, twelve thoracic, five lumbar, five sacral, and one coccygeal. It will be noted that these numbers correspond with the number of vertebræ in each region except the cervical nerves, which are one in excess. The first cervical nerve leaves the vertebral canal above the dorsal arch of the atlas, between it and the occipital bone; the eighth passes through the intervertebral foramen between the seventh cervical and first thoracic vertebræ. Thus the first seven cervical nerves are named from the vertebræ below them; the eighth cervical has no corresponding vertebra, and the thoracic, lumbar, and other nerves are named from the vertebræ above them.

Mode of Distribution.—A spinal nerve, formed as above by the union of a motor and a sensory root, is a short trunk, which, immediately after its exit from the intervertebral foramen, gives off a small recurrent branch, and then divides into a ventral and a dorsal primary division (Fig. 650).

The *dorsal primary divisions*, except those of the first and second cervical nerves, are smaller than the ventral. They pass backward and divide into two branches, external and internal. They supply the skin of the back of the head, neck, trunk, and gluteal region, and the muscles which act directly upon the spinal column.

The *ventral primary divisions*, with the two exceptions above mentioned, are larger than the posterior. Each ventral division is joined by one or two *branches from the neighboring sympathetic ganglion* by which it receives non-medullated

fibres for distribution to the vessels which it innervates, and contributes medullated fibres to the sympathetic trunk. The ventral primary divisions of the thoracic nerves (except the first) form intercostal nerves, and are distributed each to its own area, but in all the other regions intricate plexuses are formed by neighboring nerves before their branches of distribution are given off.

The *recurrent branch* is a small twig given off from the nerve immediately after it leaves the intervertebral foramen. It receives a communication from the sympathetic and re-enters the spinal canal to supply the meninges and blood-vessels.

Dorsal Primary Divisions of the Spinal Nerves.—*General Statement.*—The dorsal primary divisions of the spinal nerves (Fig. 654) are destined for the supply of the skin of the back of the scalp, trunk, and gluteal region, and the muscles of the posterior spinal group, except those connected with the upper limb, the serrati posteriores, and the levatores costarum. With the few exceptions mentioned below, each nerve passes backward between the transverse processes of the adjacent vertebræ and spinal muscles, dividing into an internal and an external branch. From the sixth thoracic nerve upward the internal branches are larger and are mainly cutaneous, the external branches are smaller and purely muscular; below that point the arrangement is reversed, the external branches being the larger, and mainly distributed to the skin, the internal branches small and chiefly distributed to the erector spinæ and deeper spinal muscles.

Exceptions to this general type are as follow:

The dorsal primary division of the first cervical (suboccipital) nerve does not divide, is usually purely muscular, and requires special description.

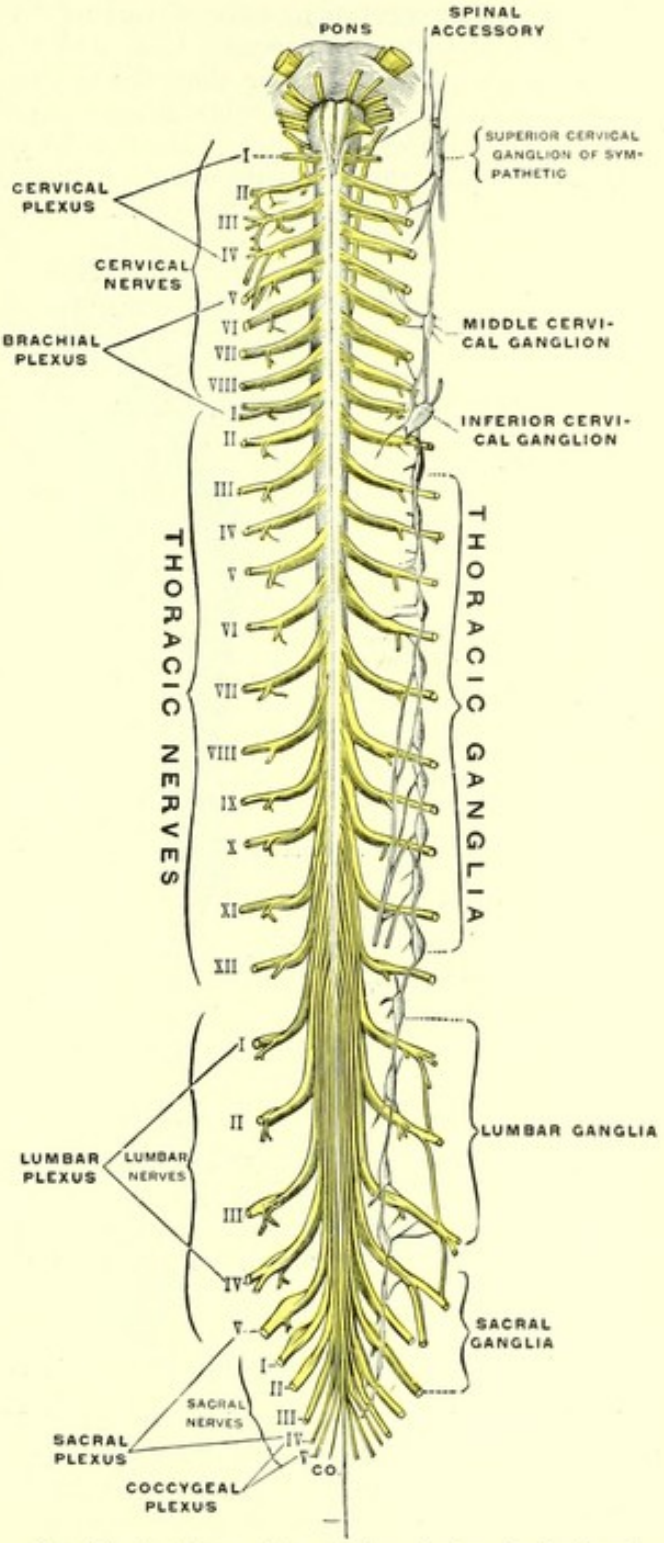

FIG. 653.—Anterior surface of the spinal cord, showing the spinal nerves and their connections with the sympathetic trunk on one side. (Testut.)

The dorsal divisions of the fourth and fifth sacral nerves and the coccygeal nerve do not divide, but form loops with each other, and are purely cutaneous.

The dorsal divisions of the sixth, seventh, and eighth cervical nerves divide like the others into internal and external branches; but both these branches are distributed to muscles only.

The Dorsal Primary Division of the First Cervical or Suboccipital Nerve (Fig. 655).—The first cervical or suboccipital nerve leaves the cranio-vertebral canal by passing between the occipital bone and the dorsal arch of the atlas. The dorsal division, slightly larger than the ventral, passes backward under the vertebral artery, and enters the suboccipital triangle. This space is bounded by the rectus capitis posterior major internally, the obliquus inferior infero-externally, and the obliquus superior supero-externally. Here the nerve divides into the

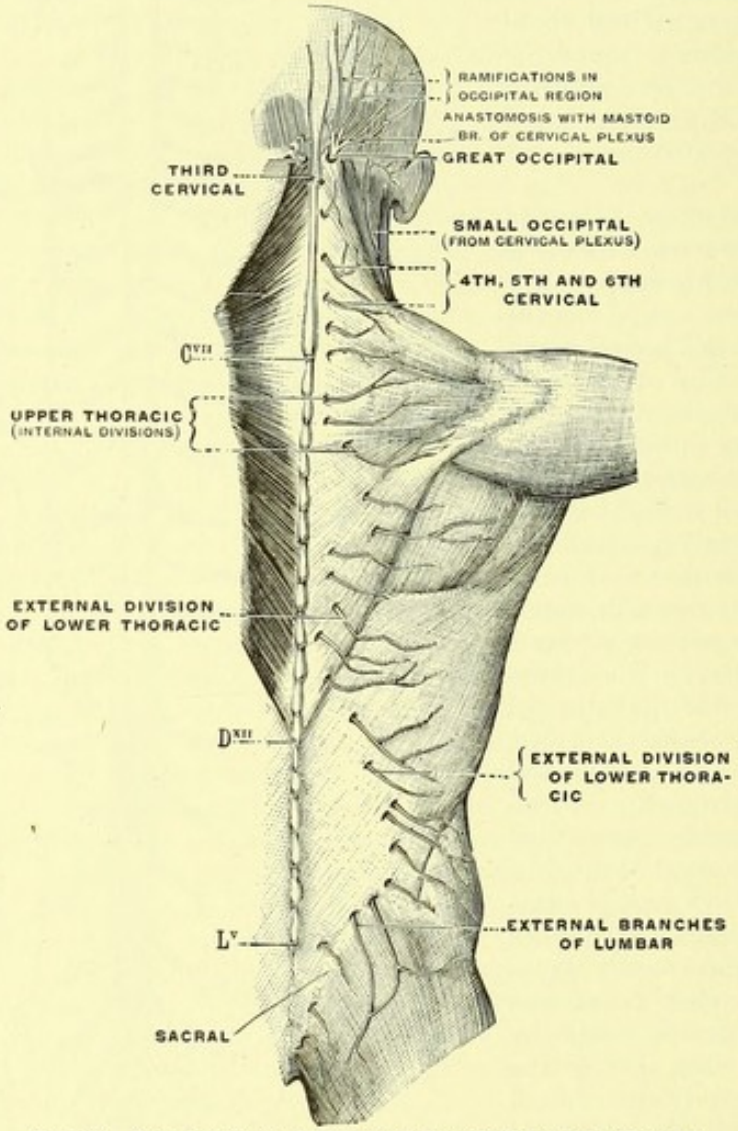

FIG. 654.—Dorsal primary divisions of the spinal nerves. (Testut.)

following four branches: (*a*) a branch to the obliquus inferior which furnishes an anastomotic filament to the great occipital nerve; (*b*) a branch running upward to the recti capitis posteriores major and minor; (*c*) a third branch enters the obliquus superior; (*d*) and a fourth branch supplies the complexus on its deep surface.

The Great Occipital Nerve (Figs. 654, 655).—The dorsal primary division of the *second cervical nerve* is three or four times as large as the ventral division. Its *external branch* is small and is distributed to the inferior oblique, complexus, and trachelomastoid; but the *internal branch* is large, and from its size and distribution is called the *Great Occipital Nerve.* After communicating with the first and

third cervical nerves, and thus forming what has been called the dorsal cervical plexus, it winds upward over the obliquus inferior, supplies a twig to the complexus, and then pierces it and the trapezius to become cutaneous beneath the superior curved line of the occipital bone, about one inch from the middle line. Accompanied by branches of the occipital artery, it supplies the skin over the upper

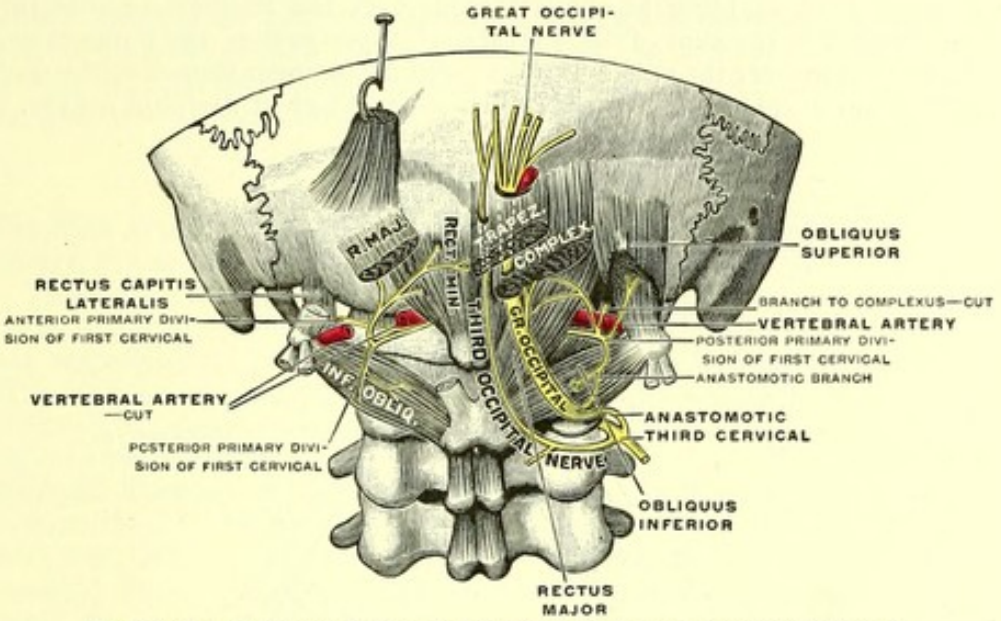

FIG. 655.—Dorsal primary divisions of the upper three cervical nerves. (Testut.)

part of the occipital bone and posterior parietal region, interlacing with the small occipital externally, and with the cutaneous branch of the third cervical nerve (third occipital nerve) internally.

The Third Occipital Nerve.—The internal branch of the dorsal division of the third cervical nerve is directed upward beneath the complexus to reach the skin of the occiput internally to the great occipital, with which it communicates. Its distribution has led to its being called the *third occipital nerve.*

The Anterior Primary Divisions.

CERVICAL NERVES.

The *upper four cervical nerves* unite to form the *Cervical Plexus*, and supply the skin and muscles of the neck. The lower four unite with the first thoracic nerve to form the brachial plexus by which the upper limb is supplied.

THE CERVICAL PLEXUS (Fig. 656).

The first cervical nerve (ventral division), after leaving the vertebral canal in the groove on the dorsal arch of the atlas, winds round to the front on the inner side of the vertebral artery and bends downward over the transverse process to join the second nerve. The ventral division of the second nerve leaves the vertebral canal behind the articular process of the axis; those of the rest of the cervical nerves pass outward in the intervertebral foramina, behind the vertebral artery and between the rectus capitis anterior major and the scalenus medius.

On the surface of the levator scapulæ and scalenus medius, and under cover of the sternomastoid these four nerves form three loops; and from these loops, or from the nerves themselves, spring the branches of the plexus. These are divisible into a superficial cutaneous set, and a deep series, including muscular and communicating nerves.

Superficial Branches (Fig. 645).—These are ascending, transverse, and descending.

ASCENDING BRANCHES.

1. The **Small Occipital Nerve** is derived from the second cervical nerve. It passes backward under the sternomastoid muscle to its dorsal border, then upward along that border, dividing at about the level of the mastoid process into an *auricular branch* to the skin of the dorsal and upper part of the pinna, a *mastoid branch* to the skin over the mastoid region, and an *occipital branch* to the occipital area. It communicates with the great auricular and great occipital nerves.

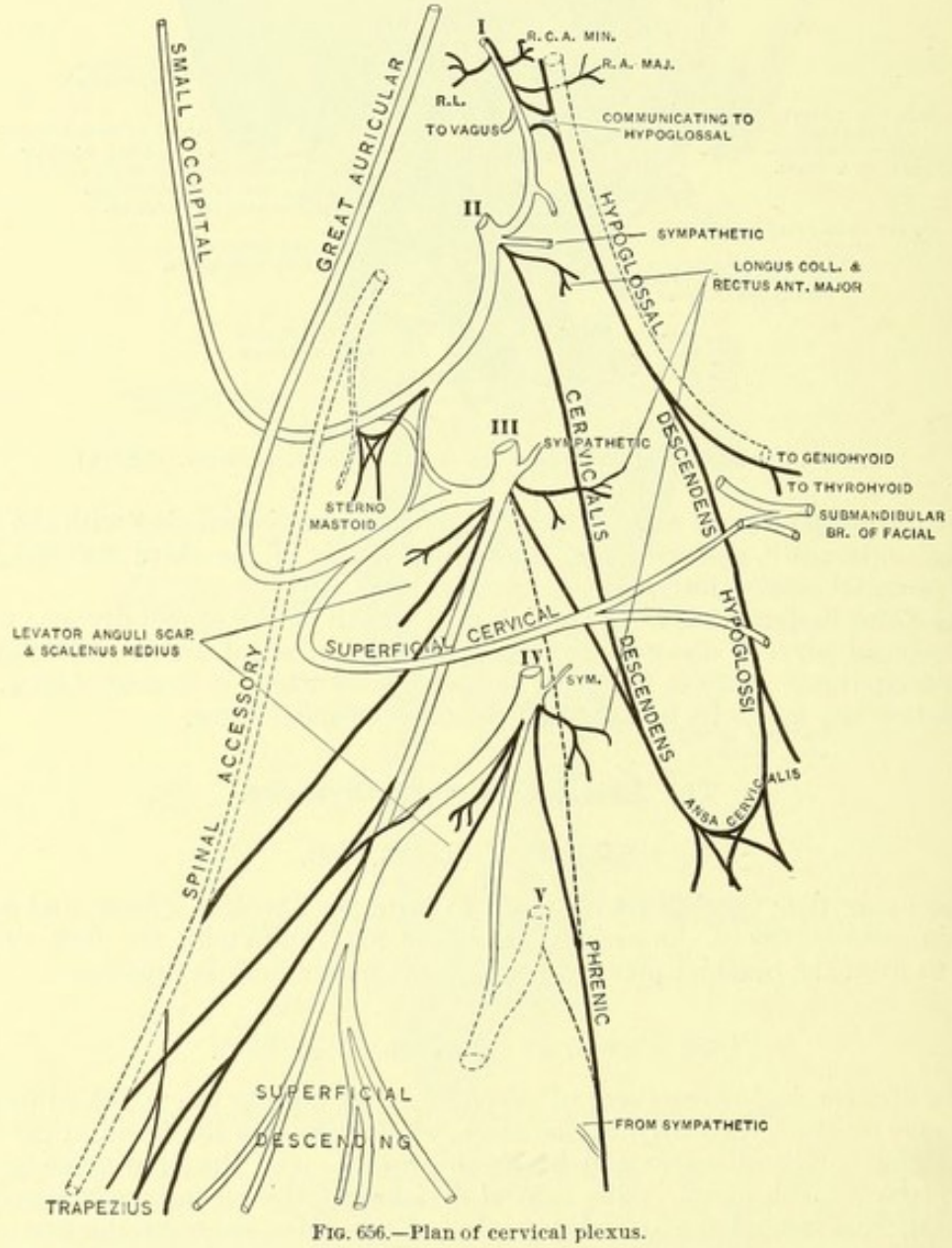

Fig. 656.—Plan of cervical plexus.

2. The **Great Auricular Nerve** springs by two roots from the second and third cervical nerves. Reaching the dorsal border of the sternomastoid, it crosses it diagonally in running upward to the back of the auricle. It supplies a small *mastoid branch* to join the mastoid branches of the small occipital nerve, numerous large *auricular branches* to the back of the pinna in its lower two thirds, one or two of these piercing the cartilage to the front of the lobule and helix; and a

small *facial branch* to the skin of the parotid, masseteric, and buccal regions. These branches join the facial nerve.

TRANSVERSE BRANCH.

The **Superficial Cervical Nerve,** rising with the last from the second and third cervical nerves, curves round the dorsal border of the sternomastoid muscle about its middle and spreads out into branches, which ramify between the platysma and deep fascia over the carotid triangle. Its ascending branch forms one or more loops with the inframandibular branch of the facial nerve. It supplies the skin of the front of the neck from chin to sternum.

DESCENDING BRANCHES.

Branches from the third and fourth nerves form a large trunk, which pierces the deep fascia at the dorsal border of the sternomastoid and just below its middle. This soon divides into three or four branches, which descend between the platysma and deep fascia to the skin of the *sternal*, *clavicular*, and *acromial regions* respectively, and are named according to that distribution.

Muscular branches to the trapezius are usually associated with this trunk.

DEEP BRANCHES.—The deep branches may be conveniently divided into muscular and communicating.

Muscular Branches are distributed to the rectus capitis lateralis and recti anteriores from the loop between the first and second nerves. A branch to the sternomastoid from the second nerve enters the under surface of that muscle near the mastoid process, and there communicates with the spinal accessory nerve.

From the second and third nerves two branches join to form the *ramus cervicalis descendens*, already described with the hypoglossal nerve. It supplies the depressors of the hyoid bone. From these nerves also twigs pass to the longus colli. The levator scapulæ receives two or three branches from the third and fourth nerves, and the *scalenus medius* receives branches from the same trunks. Branches to the trapezius are derived from the descending cutaneous trunk (third and fourth nerves), and these unite under the trapezius with the termination of the spinal accessory nerve, thus forming the *subtrapezial plexus.*

The **phrenic nerve** is the most important branch of the cervical plexus. Its most constant root is from the fourth nerve, but it may have other roots from the third or fifth, or both. Where the root from the fourth nerve is absent, it usually receives a twig from the nerve to the subclavius. In addition to these, it receives a communication from the cervical sympathetic. It takes a very constant and definite course downward and forward over the scalenus anterior, and beneath the omohyoid muscle and transversalis colli and suprascapular arteries, and, on the left side, the thoracic duct. Passing behind the subclavian vein it enters the thorax, the internal mammary artery crossing behind it to reach the sternum. On the *right side* it now descends on the outer side of the right brachio-cephalic vein, superior cava, and pericardium in front of the root of the lung and between these structures and the pleura, to the diaphragm, which it pierces and supplies on its abdominal surface. On the left side it crosses the second part of the arch of the aorta and descends on the pericardium in front of the root of the lung to the diaphragm, being covered, of course, by pleura.

Branches.—Twigs are supplied to the pleura and pericardium, and on the right side it communicates with the diaphragmatic plexus of the sympathetic, forming a small ganglion.

Communicating Branches of the Cervical Plexus.—From the loop between the first and second nerves branches pass to the vagus and hypoglossal, the branch to the hypoglossal being destined for hyoid muscles. The muscular branches from the second to the sternomastoid and from the third and fourth to the trapezius communicate with the spinal accessory; and each nerve is connected with the superior cervical ganglion of the sympathetic.

The Brachial Plexus (Fig. 657).

The anterior primary divisions of the fifth, sixth, seventh, and eighth cervical nerves join with the first thoracic nerve to form the brachial plexus. Communications are also received from the fourth cervical and second thoracic nerves. The cervical nerves emerge from the grooves on the transverse process of the

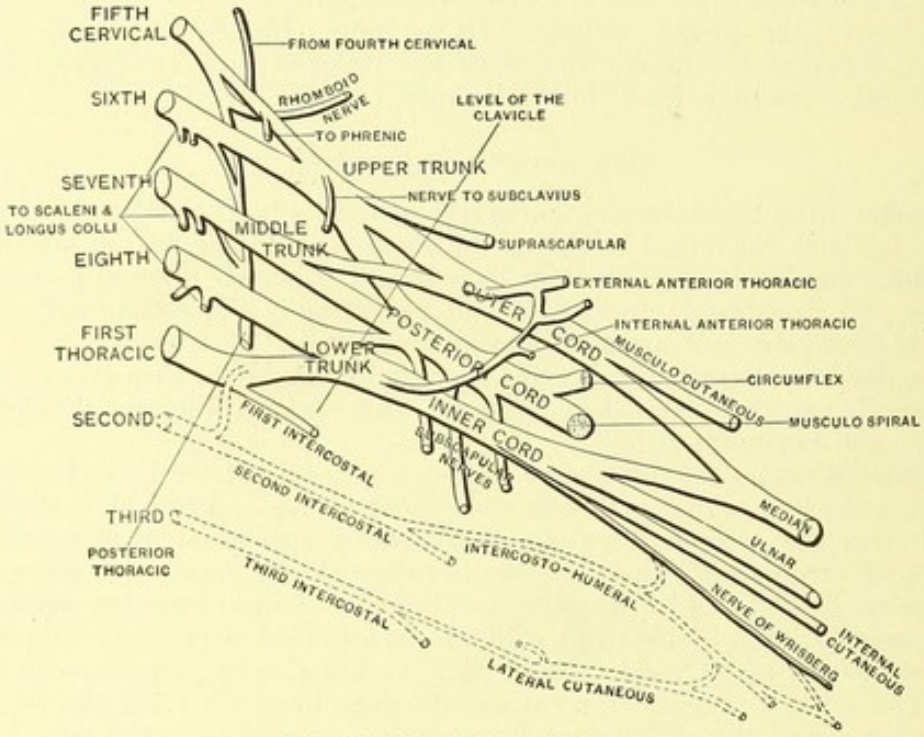

Fig. 657.—Plan of brachial plexus.

vertebræ, between the scalenus medius and anterior, and run downward in front of the former muscle. The first thoracic nerve emerges from between the first and second thoracic vertebræ, gives off a small branch to the first intercostal space, and ascends over the first rib to join the eighth cervical nerve. On the surface of the scalenus medius three primary trunks are formed, the fifth and sixth nerves uniting to form the *upper trunk*, the seventh alone forming the *middle trunk*, and the eighth cervical and first thoracic nerves forming the *lower trunk*. These run together downward and outward in the subclavian triangle above the subclavian artery. In this situation each trunk splits into an *anterior* and *posterior division*. The anterior divisions of the two upper trunks unite to form the *outer cord*; the *inner cord* is the continued anterior division of the lower trunk; and the three posterior divisions together form the *posterior cord*. These three cords lie to the outer side of the first part of the axillary artery, distribute themselves round its second part in such positions as their names designate, and at the level of the third part of the vessel each cord has divided into separate nerves, which bear to the artery the same relations as the cords from which they spring.

This is the usual arrangement, but there are numerous variations.

The branches of the brachial plexus are classified into *supraclavicular* and *infraclavicular*.

Branches Given off Above the Clavicle.

1. The **nerve to the rhomboids** (5. c.) is a long slender branch which springs from the fifth cervical nerve, close to the intervertebral foramen and in common with the first root of the posterior thoracic nerve. It enters the substance of the

scalenus medius and emerges from its external border. Passing beneath the levator scapulæ, it supplies some twigs to that muscle, and reaches the deep surface of the rhomboids, where it is joined by the posterior scapular artery. It ends in the rhomboid muscles.

2. The **nerve to the subclavius** (5. c.) springs from the upper trunk. As a long slender filament it descends in front of the plexus and subclavian artery to supply the muscle from which it is named. It frequently contributes a filament to the phrenic nerve.

3. The **suprascapular nerve** (5. c.) (Fig. 658), also derived from the upper trunk, runs downward, outward, and backward over the scalenus medius and under the trapezius and omohyoid. It passes through the suprascapular notch, beneath the transverse ligament, and, after supplying a twig to the shoulder-joint,

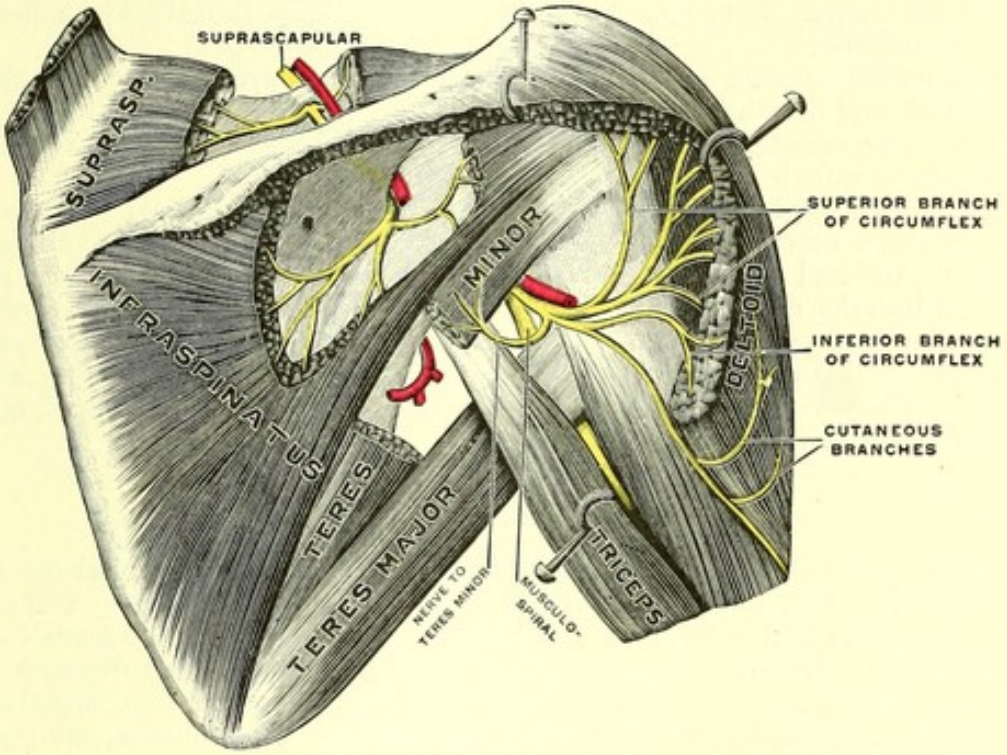

FIG. 658.—Suprascapular and circumflex nerves of right side, seen from behind. (Testut.)

divides into branches to the supraspinatus and infraspinatus, the former turning outward into its muscle, and the latter passing round the great scapular notch, and terminating in the infraspinatus.

4. The **posterior thoracic nerve** (5. 6. 7 ? c.) (*external respiratory nerve* of Bell) is formed by the union of three roots, from the fifth, sixth, and seventh nerves respectively. The first two roots pierce the scalenus medius and supply twigs to the upper digitations of the serratus magnus. They are afterward joined by the seventh root, which passes in front of the scalenus medius. The nerve descends behind the brachial plexus and the first portion of the axillary artery, and runs along the chest wall on the serratus magnus, rather behind the lateral prominence of the ribs, sending a twig to each digitation of that muscle.

5. The **scaleni** and **longus colli** are supplied by twigs from the lower three cervical nerves.

Branches Given off below the Clavicle.

Of these the *external* and *internal anterior thoracic* and three *subscapular* nerves are distributed to parts about the axilla; the rest supply the arm and forearm.

1. The **External Anterior Thoracic Nerve** (6. 7. c.) springs from the outer cord, pierces the costo-coracoid membrane above the pectoralis minor, and supplies the pectoralis major.

2. The **Internal Anterior Thoracic Nerve** (8. c., 1. th.) is derived from the inner cord. It passes forward between the axillary artery and vein, and enters the deep surface of the pectoralis minor. After supplying this muscle, it pierces it to reach the pectoralis major, in which it ends. Thus the pectoralis major is supplied by two nerves.

These two nerves are usually united by a loop which crosses in front of the axillary artery.

3. The **Subscapular Nerves** supply the muscles which form the posterior axillary wall, and are all branches of the posterior cord.

The *upper subscapular* (5. 6. c.), sometimes represented by two branches, lies high in the axilla. It is very short and plunges at once into the upper part of the subscapularis.

The **middle** or **long subscapular nerve** (7. c.) accompanies the subscapular artery and supplies the latissimus.

The **lower subscapular nerve** (5. 6. c.) sends twigs to the lower part of the subscapularis muscle and ends in the teres major.

Terminal or Long Branches.—The *outer cord* divides into the musculo-cutaneous and outer head of the median; the *inner cord* into the small internal cutaneous, internal cutaneous, ulnar and inner head of the median, and the *posterior cord* into the circumflex and musculo-spiral. These branches are arranged around the third part of the axillary artery in the same manner as their parent cords, except that the small internal cutaneous nerve is separated from the artery by the axillary vein, and the internal cutaneous nerve and inner head of the median lie in front of the vessel.

4. The Musculo-cutaneous Nerve.

The musculo-cutaneous nerve (5. 6. c.) (Figs. 659, 666, 667), arising from the outer cord of the plexus, lies first on the outer side of the axillary and afterward of the brachial artery. It sends some fibres to the coraco-brachialis, and its main trunk perforates that muscle in a downward and outward direction near the lower border of the axilla. Passing obliquely across the arm between the biceps and brachialis anterior it gives branches to both these muscles, and reaches the surface at the outer border of the biceps a little above the bend of the elbow. Here it perforates the deep fascia, and divides into an *anterior* and a *posterior division*, which supply the skin on the anterior and posterior aspects of the radial side of the forearm. Of these the anterior division is large, and reaches as far down as the thenar eminence; the posterior division is shorter and only reaches as low as the wrist. Both divisions communicate with the radial nerve. At the bend of the elbow the nerve is crossed by the median cephalic vein.

5. The Median Nerve.

The median nerve (6. 7. 8. c., 1. th.) (Figs. 659, 660, 661, 663, 666, 667) arises by two heads, one from the inner and one from the outer cord. The inner head crosses in front of the third part of the axillary artery to join the outer head, and the resulting nerve runs down the arm on the outer side of the axillary and brachial arteries, and slightly under cover of the biceps. Near the middle of the humerus it crosses in front of the brachial artery to reach its inner side, which it keeps till the vessel bifurcates. It then passes between the two heads of the pronator teres, crossing the ulnar artery but separated from the vessel by the ulnar head of the muscle, and courses down the middle of the forearm on the flexor profundus digitorum under the flexor sublimis. At the wrist it is found beneath the deep fascia between the flexor sublimis and flexor carpi radialis and

just to the outer side or under cover of the palmaris longus. It now passes beneath the anterior annular ligament, where it is invested by the synovial membrane, and whence it emerges as a flattened band and divides into inner and outer terminal divisions.

BRANCHES.—The median nerve gives no branches to the upper arm, but supplies the *elbow-joint*, all the anterior group of forearm muscles, except the

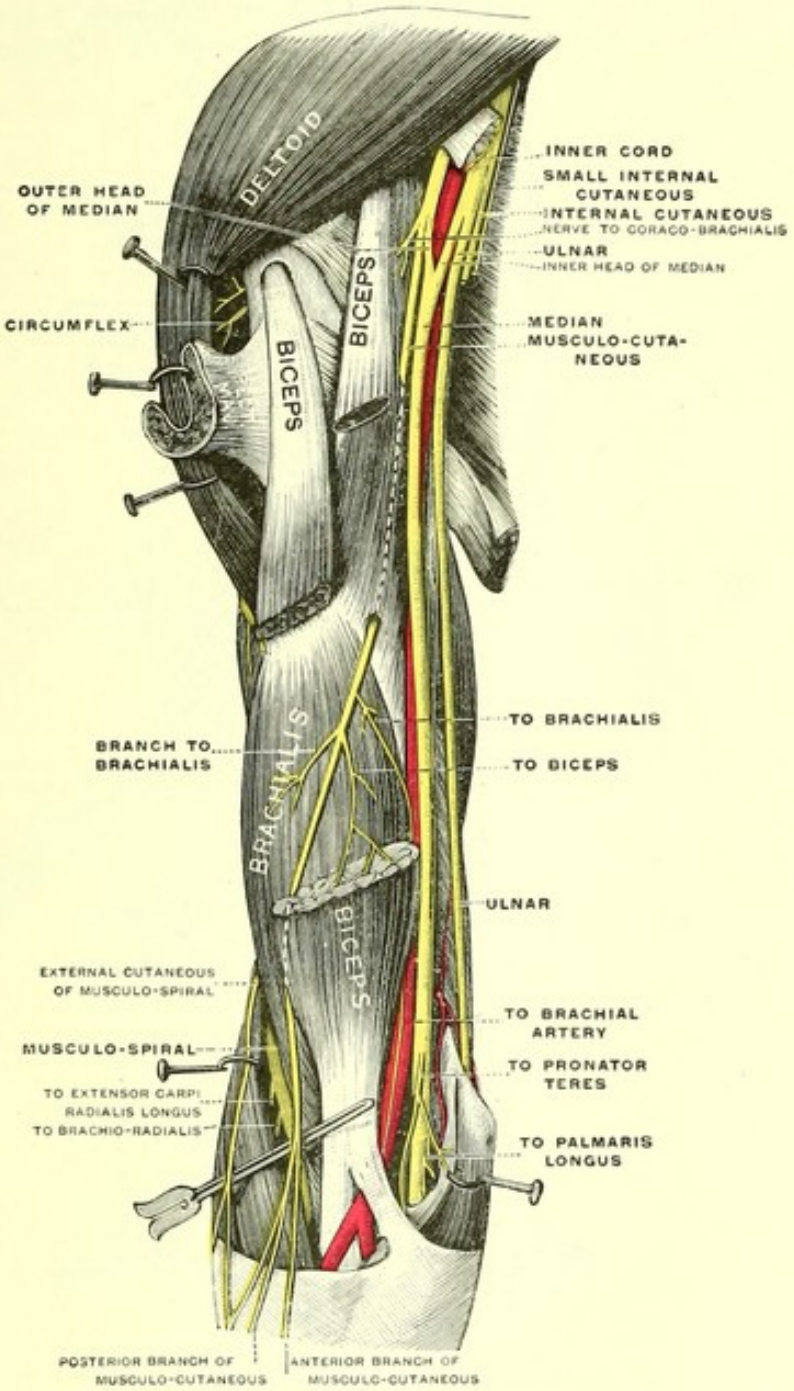

FIG. 659.—Deep nerves of the front of the right arm. (Testut.)

flexor carpi ulnaris and half of the flexor profundus, and the short muscles of the thumb that are on the radial side of the flexor longus pollicis. Its cutaneous branches supply the hollow of the palm, the thumb, index, middle and half of the ring fingers on their palmar aspect and nail-beds, and the two outer lumbrical muscles.

Muscular Branches.—The branch to the pronator teres (6. c.) is given off just above the bend of the elbow, those for the palmaris longus (7. 8. c., 1. th.), flexor carpi radialis (6. c.), and flexor sublimis digitorum (7. 8. c., 1. th.) a little lower down.

The **anterior interosseous nerve** (7. 8. c., 1. th.) (Figs. 660, 663) is the muscular

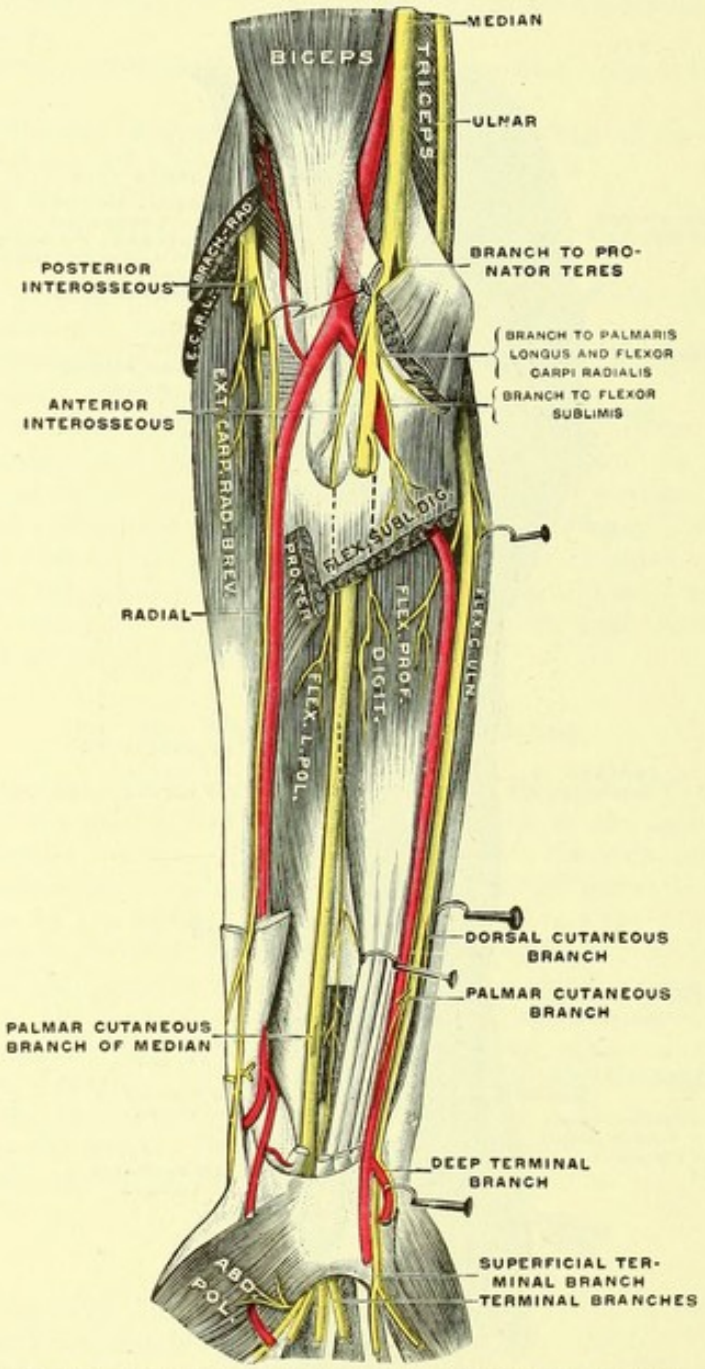

FIG. 660.—Deep nerves of the front of the right forearm. (Testut.)

branch of the median to the deep muscles of the forearm. Commencing opposite the bicipital tuberosity of the radius, it accompanies the anterior interosseous artery and lies on the interosseous membrane between the flexor profundus digitorum and flexor longus pollicis. It supplies branches to both these muscles, that to the flexor profundus communicating with the corresponding branch of the ulnar nerve. The nerve accompanies the artery under the pronator quadratus; but, instead of following the vessel through the interosseous mem-

brane to the back, terminates by supplying the pronator quadratus and wrist joint.

The muscular branch to the abductor pollicis, flexor ossis metacarpi pollicis, and outer head of the flexor brevis pollicis is a short, stout twig derived from the external terminal division.

The **Cutaneous Branches** of the median are the palmar cutaneous and two terminal divisions.

The **palmar cutaneous branch** is a small twig given off above the anterior annular ligament. It crosses in front of that ligament and supplies the palm and

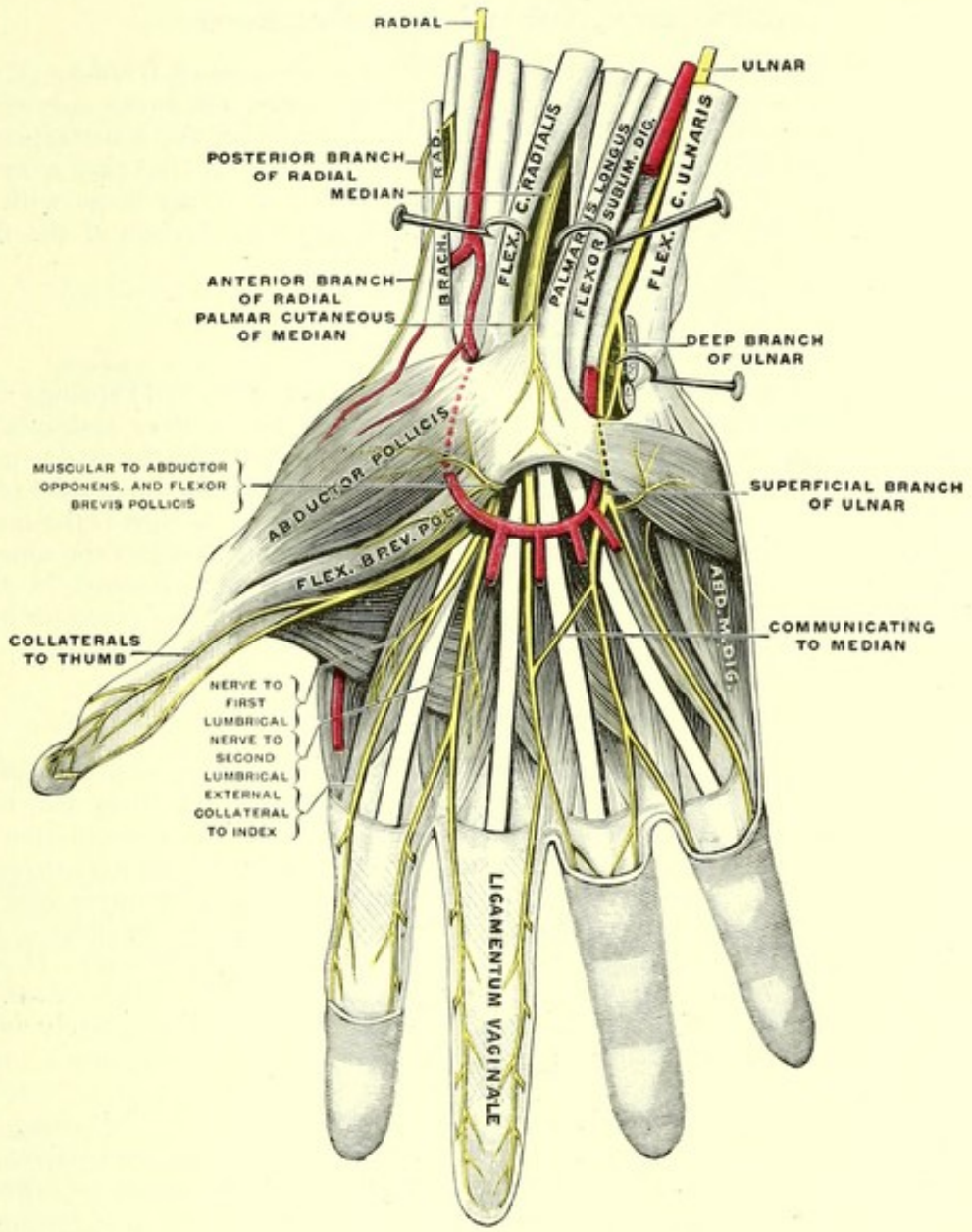

FIG. 661.—Superficial palmar nerves. (Testut)

inner side of the thenar eminence, communicating with the musculo-cutaneous nerve.

The **external terminal division** divides into an outer branch which crosses the flexor longus pollicis to the outer side of the thumb, and an inner branch which sends collaterals to the inner side of the thumb and outer side of the index finger and intervening skin.

The **internal terminal division** splits into two branches which proceed to the next two finger clefts, passing under the superficial palmar arch, but superficial to the tendons. At the level of the metacarpo-phalangeal joints they appear between the divisions of the palmar fascia and split into collaterals to the contiguous sides of the index and middle, and middle and ring fingers respectively. Each of these nerves supplies the palmar surface of the finger to which it belongs and gives a dorsal twig to the nail matrix. Twigs from the digital branches supply the two outer lumbrical muscles, and the innermost digital branch communicates with the ulnar nerve.

6. The Small Internal Cutaneous Nerve.

The small internal cutaneous nerve (Figs. 659, 666), or *nerve of Wrisberg* (1. th.), arises from the inner cord of the plexus, and descends on the inner side of the axillary vein, and then under the fascia, which it pierces on the inner aspect of the arm about the middle. It bends backward and supplies the skin over the olecranon and lower third of the arm. In the axilla it forms loops with the intercostohumeral, and sometimes also the lateral cutaneous branch of the third intercostal nerve.

7. The Internal Cutaneous Nerve.

The internal cutaneous nerve (8 c., 1. th.) (Figs. 659, 666, 667) springs from the inner cord below the last. It descends in front of the axillary and brachial arteries, pierces the deep fascia with the basilic vein about two-thirds down the arm, and divides into an anterior and posterior branch. About the middle of the arm it gives a twig to the skin over the biceps. The *anterior branch* is the larger. It passes in front of or behind the median basilic vein, and supplies the anterior ulnar area of skin as low as the wrist. The *posterior branch* descends in front of the internal condyle, and winds sharply backward to supply the posterior ulnar region.

8. The Ulnar Nerve.

The ulnar nerve (8. c., 1. th.) (Figs. 659–667), which is the largest branch of the inner cord, descends between the axillary artery and vein, and along the inner side of the brachial artery in the upper third of the arm. It then pierces the internal intermuscular septum with the inferior profunda artery, and descends beneath the deep fascia to the interval between the internal condyle and the olecranon process, where it passes between the two heads of the flexor carpi ulnaris to run between that muscle and the flexor profundus digitorum. It joins the ulnar artery and lies on the inner side of that vessel in the lower two-thirds of the forearm, crossing the anterior annular ligament with it immediately external to the pisiform bone. In the palm it divides, like the artery, into a superficial and a deep division.

Branches.—As of the median nerve the first branches of the ulnar are *articular filaments* to the elbow joint, which are given off as it passes between the heads of the flexor carpi ulnaris. In the forearm it supplies *muscular branches* (8. c., 1. th.) to the *flexor carpi ulnaris* and inner half of the *flexor profundus digitorum*.

The **palmar cutaneous branch** is given off near the middle of the forearm. It descends in front of the ulnar artery, supplies twigs to that vessel, and terminates in the skin of the palm.

The **dorsal branch** (8. c.) arises about two inches above the wrist joint, passes backward beneath the flexor carpi ulnaris, and is distributed to the skin on the dorsum of the hand, little finger, and inner side of the ring finger, communicating with the radial.

The **superficial terminal branch** of *the ulnar nerve* (1. th., or 8. c. 1. th.) behaves similarly to the median nerve, with which it communicates; but it supplies no muscles. It is distributed to the little and inner side of the ring finger.

The **deep branch** (8. c.) accompanies the deep branch of the ulnar artery

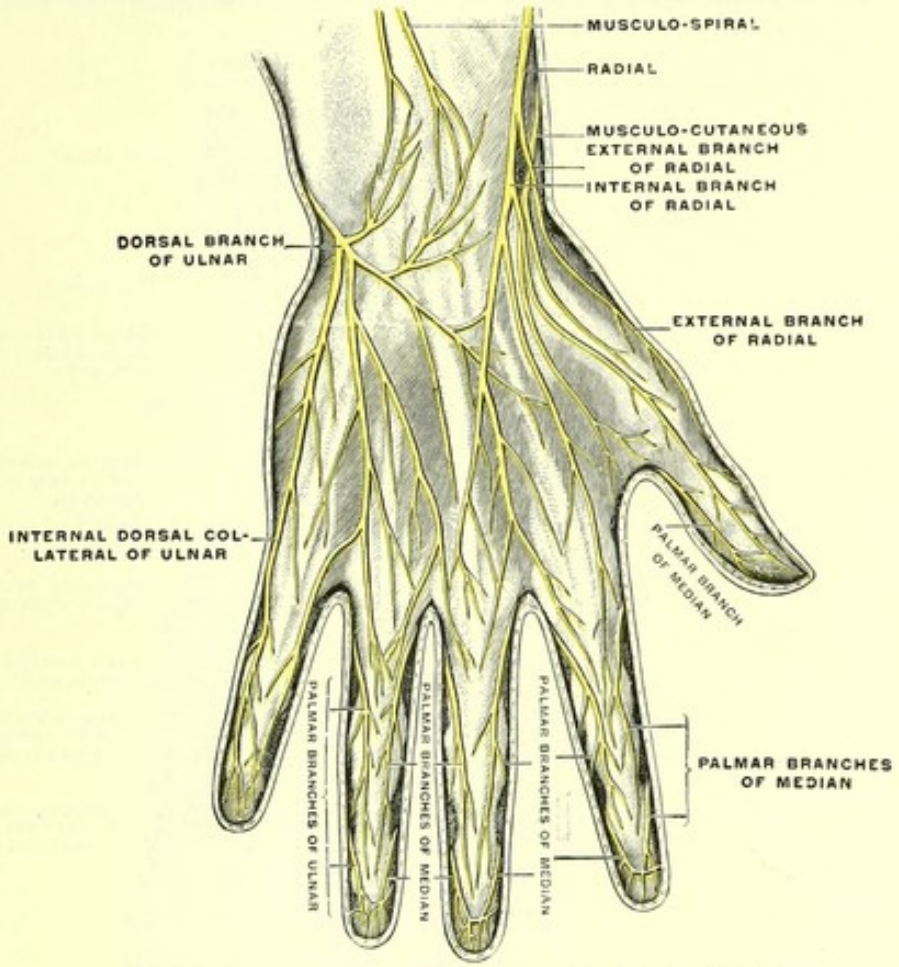

FIG. 662.—Cutaneous nerves of the dorsum of the hand. (Testut.)

between the abductor and flexor brevis minimi digiti. It supplies all the short muscles of the little finger, all the interossei, the inner two lumbricals, and those thumb muscles, which are on the inner side of the flexor longus pollicis.

9. The Circumflex Nerve.

The circumflex nerve (5. 6. c.) (Figs. 658, 664, 666, 667) is one of the terminal divisions of the posterior cord. It turns round the lower border of the subscapularis, and accompanies the posterior circumflex artery to the back of the shoulder, through the quadrilateral space, bounded by the subscapularis, teres major, triceps, and the surgical neck of the humerus. It gives an *articular* twig to the shoulder-joint, and divides into an anterior and a posterior branch.

The **anterior branch** winds round the humerus with the posterior circumflex artery, and sends many branches into the anterior part of the deltoid, some of which reach the skin.

The **posterior branch** sends a nerve to the teres minor, which has an ovoid, gangliform swelling on it, and supplies the posterior part of the deltoid muscle and skin over the lower deltoid region.

10. The Musculo-spiral Nerve.

The musculo-spiral nerve (6. 7. 8. c.) (Figs. 664, 659, 662, 666, 667) is the terminal and largest branch of the posterior cord. Placed at first behind the third part of the axillary artery and upper part of the brachial, it soon leaves the latter vessel, and, accompanied by the superior profunda artery, pierces the internal

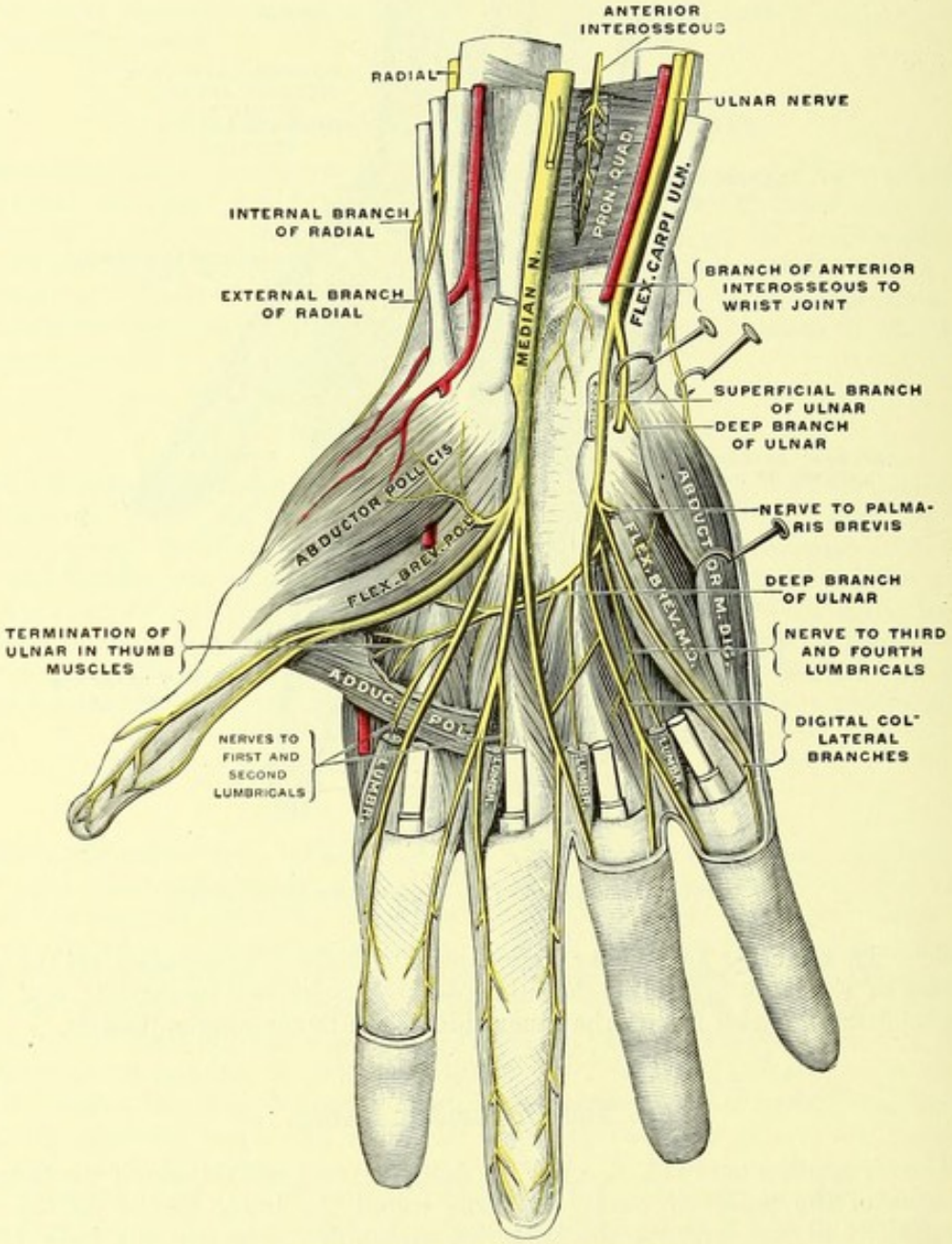

FIG. 663.—Deep palmar nerves. (Testut.)

intermuscular septum, winds obliquely round the humerus in the spiral groove between the triceps and the bone, and reaching the external intermuscular septum, pierces it to gain the interval between the brachialis anterior and brachio-radialis, where it divides into the radial and posterior interosseous nerves.

Before its final division it gives off an internal and an external cutaneous, and muscular branches to the triceps, anconeus, brachialis anterior (6. c.), brachio-radialis (6. c.), and extensor carpi radialis longus (6. 7. c.). Of the muscular branches those to the last three muscles are given off between the brachio-radialis and brachialis

anterior, branches to the inner and outer heads of the triceps and anconeus arise while the nerve is in the spiral groove, and important branches are contributed to the middle and inner heads of the triceps, while the parent nerve lies behind the brachial artery. One of these last, called by Krause the *ulnar collateral*, accompanies the ulnar nerve for some distance.

The **internal cutaneous branch** (8. c.) arises within the axilla, and supplies a

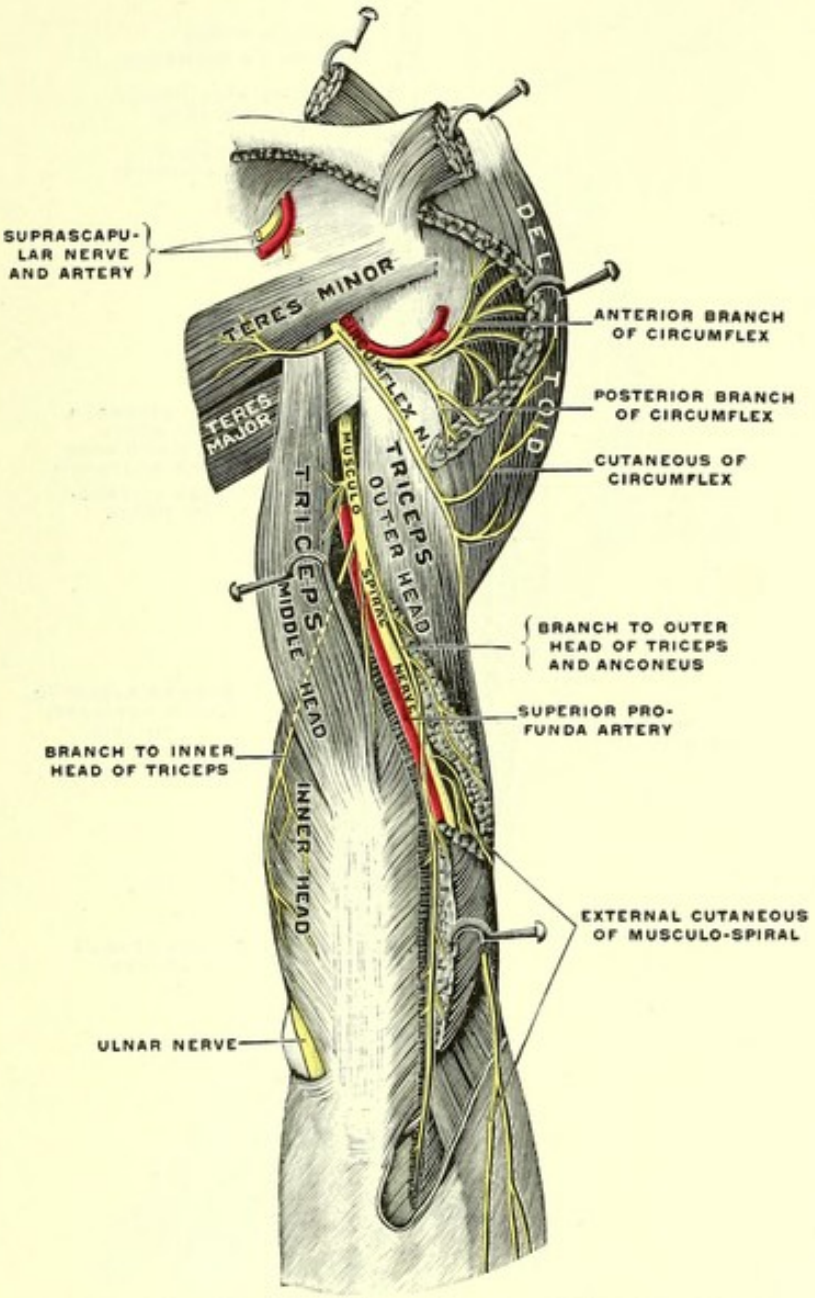

FIG. 664.—Musculo-spiral and circumflex nerves of right side. (Testut.)

strip of skin down the inner side of the arm, between the intercosto-humeral and circumflex areas.

The **external cutaneous branches** are two in number, the *upper* (6. c.) being the smaller. It pierces the deep fascia in the line of the intermuscular septum, and supplies the skin over the lower and outer part of the biceps. The *lower branch* (6. 7. 8. c.), becoming superficial a little below the last, descends behind the external condyle, and supplies the skin of the posterior radial region from elbow to wrist.

The **posterior interosseous nerve** (6. 7. c.) (Fig. 665), which is the *terminal muscular branch* of the musculo-spiral, is destined for the posterior group of forearm muscles. It descends between the brachialis anterior and extensor carpi radialis longus, where it gives branches to the extensor carpi radialis brevis and supinator (6. 7. c.), and then enters the substance of the latter muscle, in which it winds round the radius to gain the interval between the superficial and deep

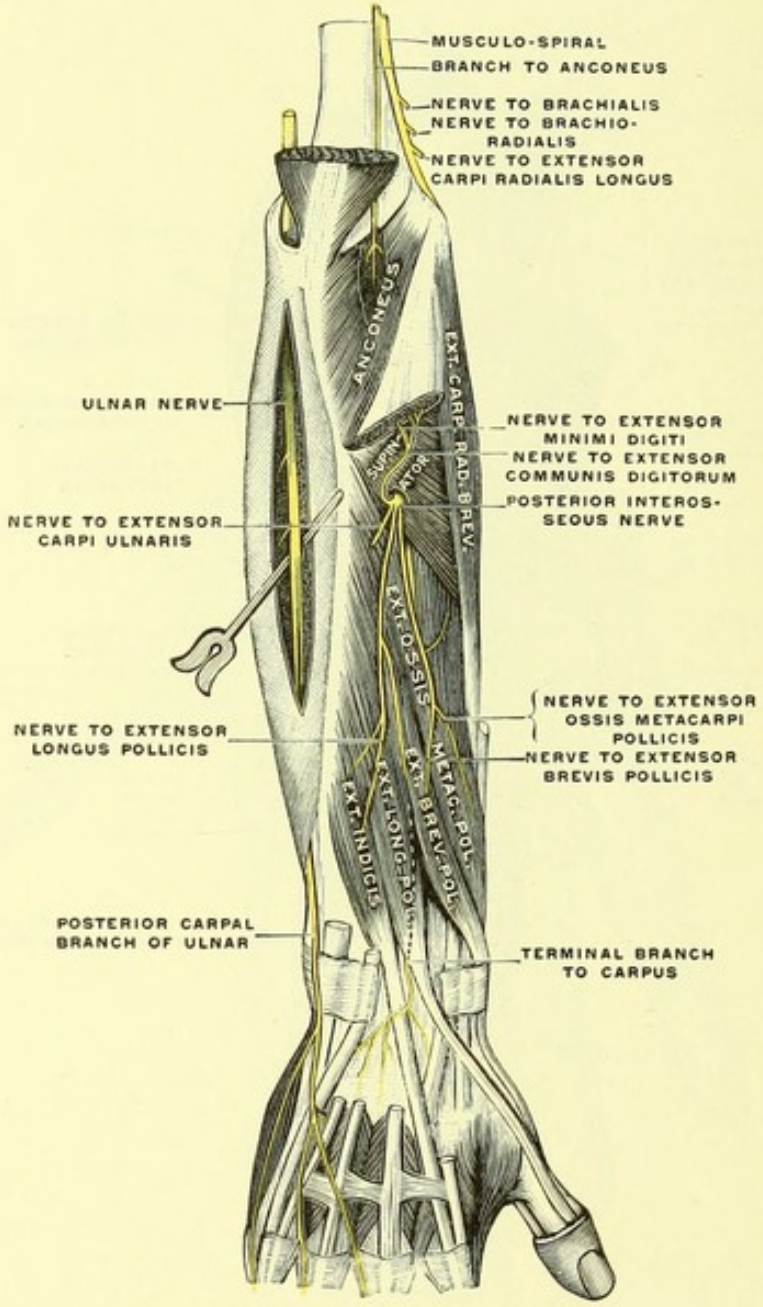

FIG. 665.—Posterior interosseous nerve. (Testut.)

muscles on the back of the forearm. Here it distributes twigs to all the surrounding extensors (7. c.) and passes to the interosseous membrane in the lower third of the forearm, where it joins the anterior interosseous artery. It descends beneath the posterior annular ligament under the extensor communis, and expands into a gangliform enlargement, from which branches are supplied *to the carpal joints.*

The **radial nerve** (6. c.) (Figs. 660, 661, 662, 666, 667) is the other terminal division of the musculo-spiral, and is *purely cutaneous* in its distribution. It

descends beneath the brachio-radialis, and joins the radial artery, on whose outer side it runs in the middle third of the forearm. It then turns sharply backward beneath the brachio-radialis tendon. Piercing the deep fascia two inches above the styloid process of the radius, it sends a twig to the outer side of the thumb

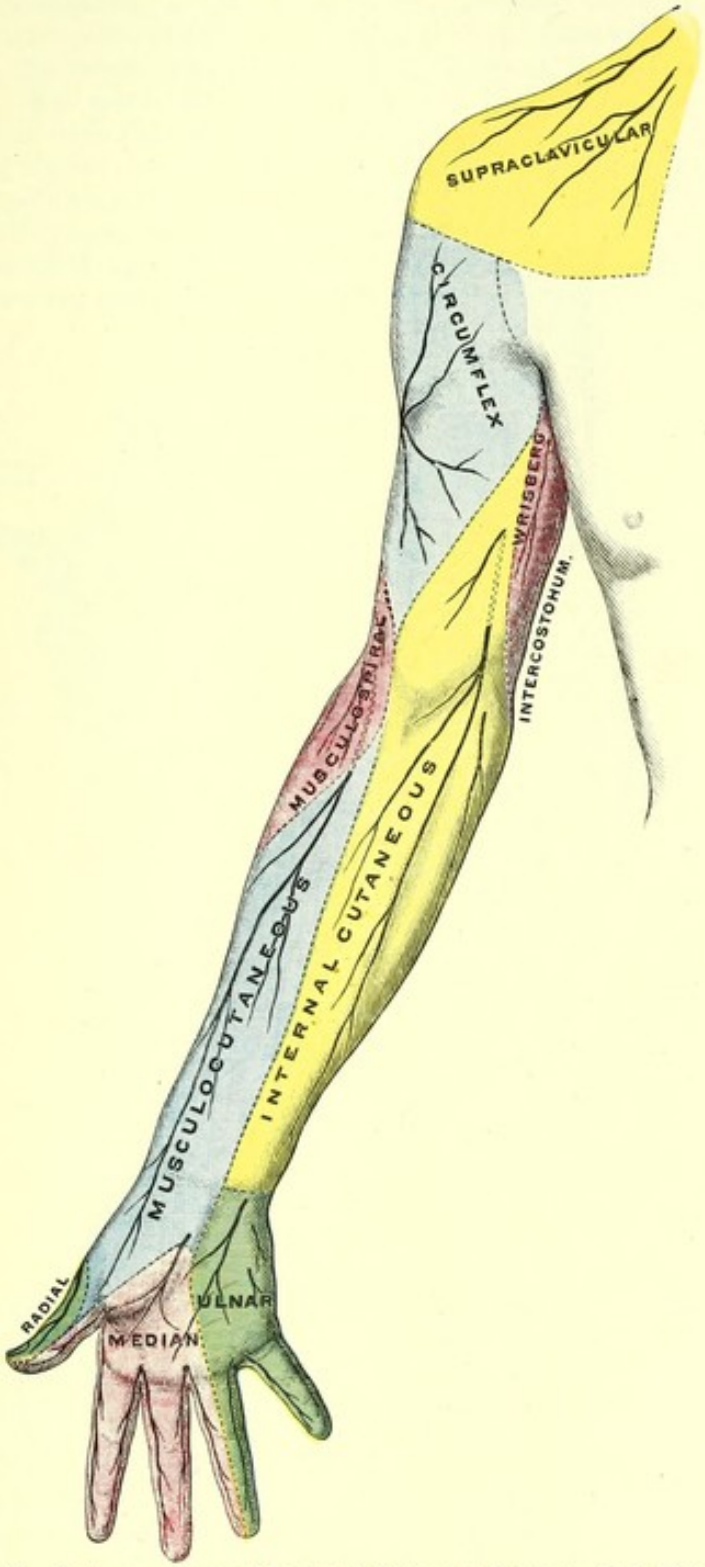

FIG. 666.—Cutaneous nerves of the upper limb, ventral aspect. (W. Keiller.)

and divides into four branches, which spread fan-like over the back of the hand and fingers supplying the outer three and a half fingers up to, but not including, the terminal phalanges. It is here joined by the ulnar nerve.

Observe that the nail matrices and surrounding skin are supplied by the palmar nerves, that the little finger and inner side of the ring finger are supplied on both aspects by the ulnar nerve, and that the rest of the fingers are supplied by the median on the palmar, and by the radial on the dorsal surface.

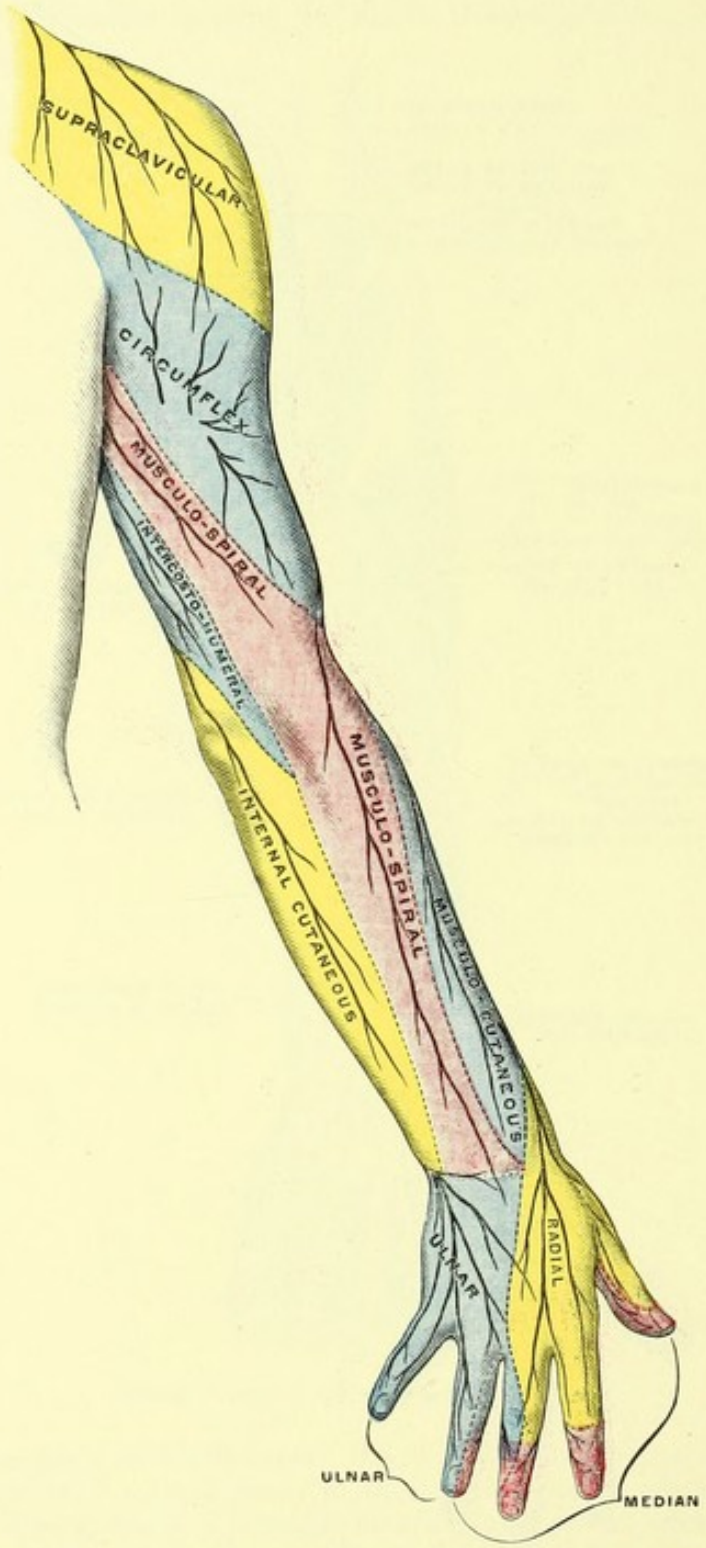

FIG. 667.—Cutaneous nerves of the upper limb, dorsal aspect. (W. Keiller.)

On the dorsum of the hand the radial and ulnar nerves overlap considerably.

For a general view of the cutaneous nerve-supply of the arm compare Figures 666 and 667.

THE THORACIC NERVES.

The thoracic nerves differ from all the other spinal nerves in that they enter into the formation of no plexus; but each is distributed to a transverse segment of the trunk, corresponding to the vertebræ from between which it emerges.

The *first thoracic nerve* sends a small branch to the interval between the first and second ribs, the main trunk, ascending in front of the first rib to join the brachial plexus. Its intercostal branch behaves like the others about to be described, but with rare exceptions has no lateral cutaneous branch.

The upper six thoracic nerves run round the chest wall in the spaces between the vertebro-sternal ribs; the remaining six pursue a transverse course through the abdominal wall where the ribs are deficient in front.

A **typical intercostal nerve** (Fig. 668), after receiving two *rami communicantes* from the corresponding ganglion of the sympathetic, passes outward between the

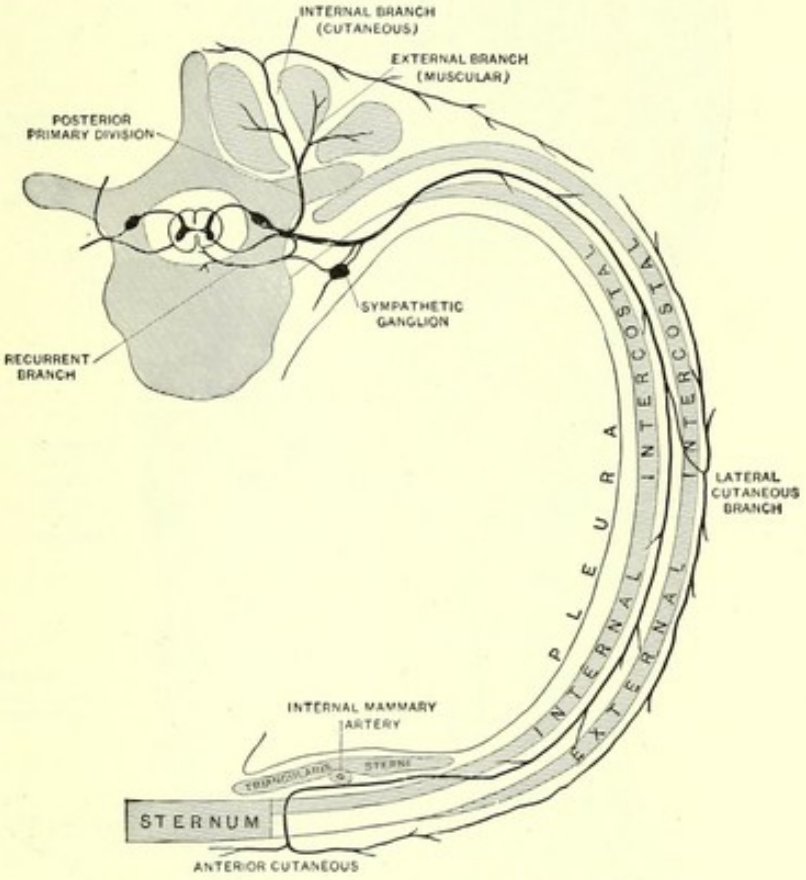

FIG. 668.—Plan of a typical intercostal nerve. (W. Keiller.)

posterior intercostal aponeurosis and the pleura, beneath the intercostal artery. It enters the interval between the internal and external intercostal muscles, and runs in it till the external intercostal muscle becomes deficient in front. It then dips under the internal intercostal muscle, and, between it and the internal mammary artery and triangularis sterni, reaches the side of the sternum, where it pierces the chest wall to become cutaneous.

The *lower intercostals*, from the seventh to the eleventh inclusive, enter the interval between the transversalis and internal oblique muscles, where the ribs are deficient in front. They run forward in the abdominal wall, enter the sheath of the rectus abdominis, and pierce that muscle near the middle line to supply the skin.

Lateral Cutaneous Branches (Figs. 669, 670).—The first intercostal nerve has no lateral cutaneous branch.

The *lateral cutaneous branch of the second intercostal nerve* is called the *intercosto-humeral*. It crosses the floor of the axilla just under the deep fascia, joins the nerve of Wrisberg, and supplies a strip of skin on the inner and posterior aspect of the arm.

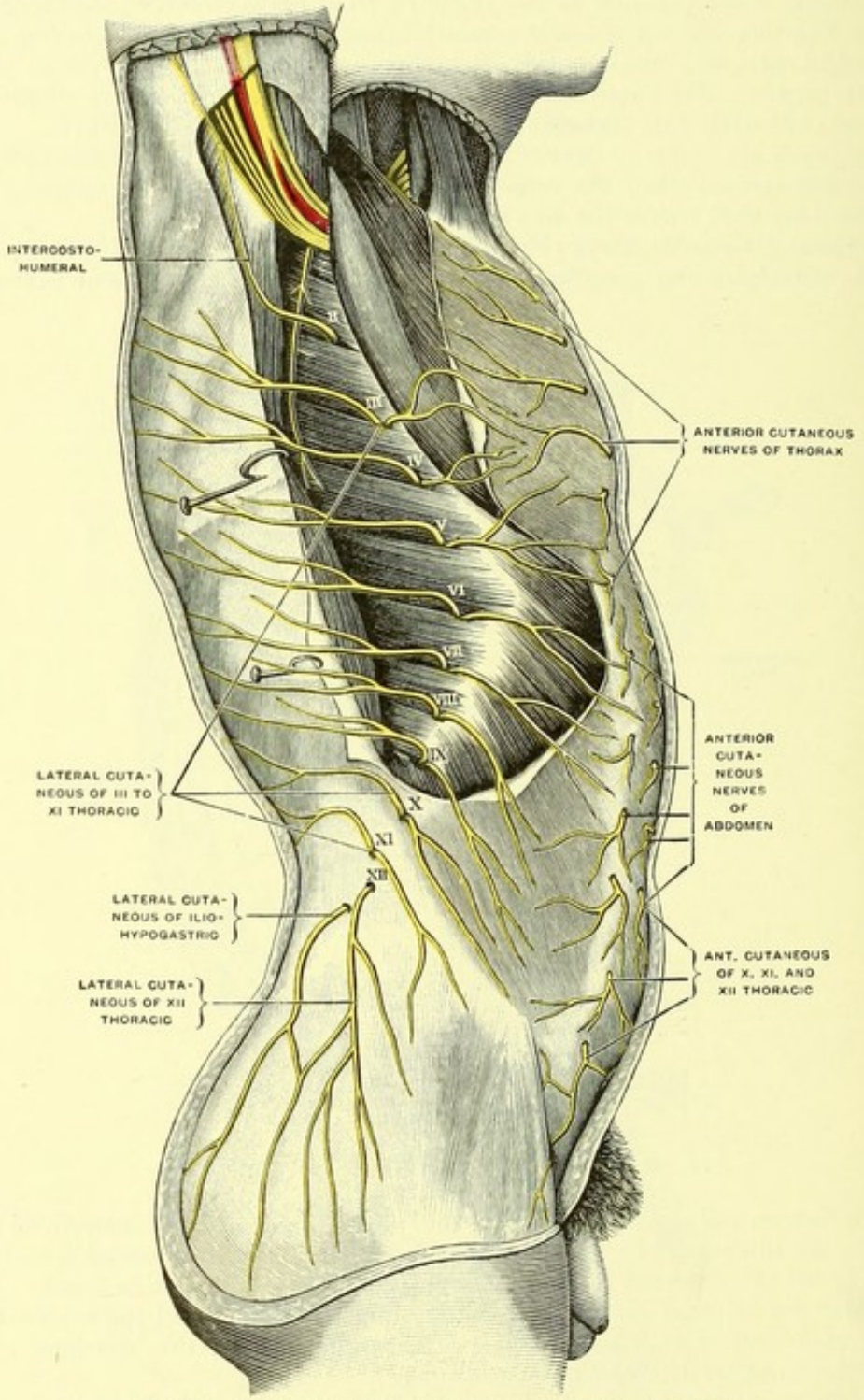

FIG. 669.—Cutaneous distribution of thoracic nerves. (Testut.)

The *lateral cutaneous branch of the third intercostal nerve* has a small anterior branch which passes forward over the pectoralis major, and a large posterior branch, which, after communicating with the intercosto-humeral nerve, is distributed to the skin of the axilla and dorsum of the scapula, a small branch reaching the arm.

The *lateral cutaneous branches* of the rest of the intercostal nerves (except the twelfth) pierce the superficial thoracic or abdominal muscles, in a vertical line a little behind the pectoral border of the axilla. Each divides into an *anterior* and a *posterior branch* for the supply of the skin over an intercostal space or corresponding area. The lateral cutaneous branches of the abdominal intercostals supply the external oblique muscle.

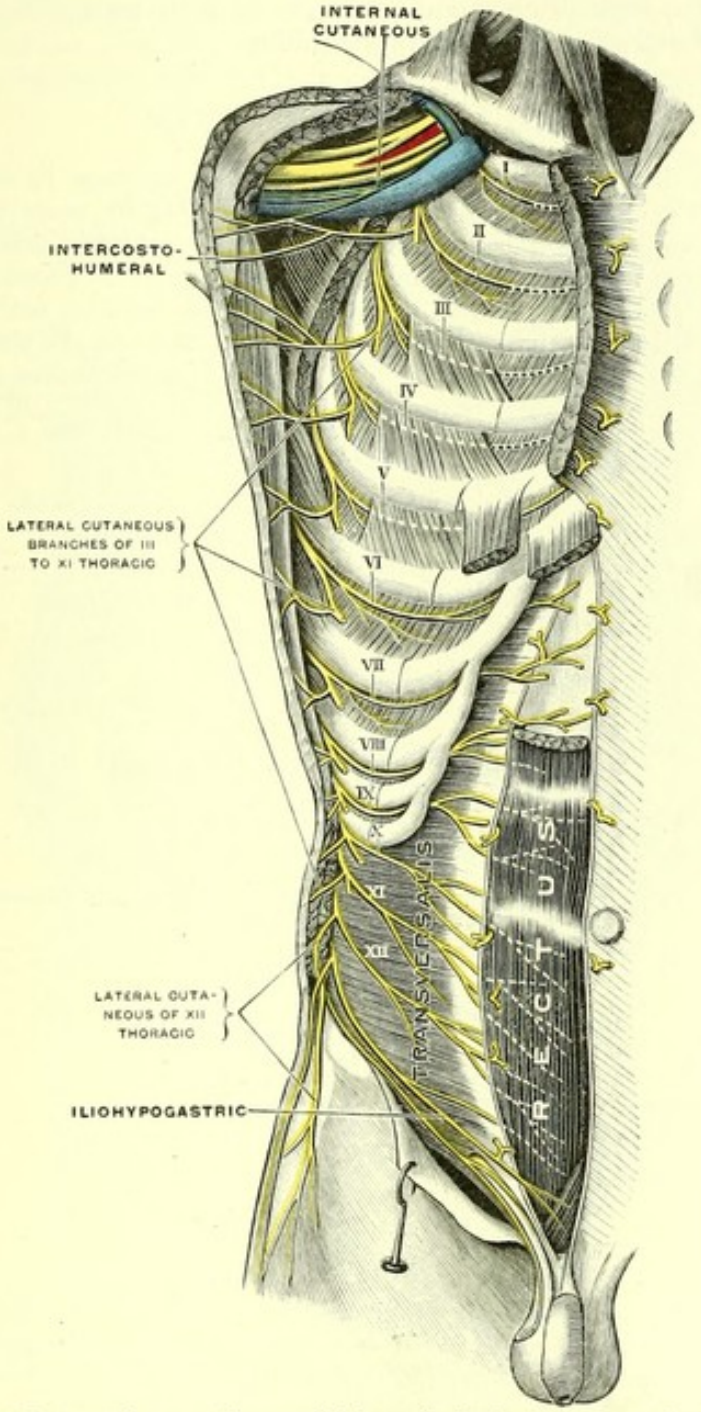

FIG. 670.—Intercostal nerves, the superficial muscles having been removed. (Testut.)

The *anterior cutaneous nerves of the thorax and abdomen* are the terminations of the intercostals. They reach the surface close to the middle line and turn outward. Those of the abdomen are small and pierce the sheath of the rectus rather irregularly. The tenth thoracic nerve supplies the skin about the umbilicus.

The **twelfth thoracic nerve** after communicating with the sympathetic and

sending a branch to join the first lumbar nerve, passes outward beneath the external arcuate ligament of the diaphragm and enters the abdomen. It runs along the lower border of the last rib, and enters the space between the transversalis and internal oblique, and is afterward arranged as one of the lower intercostals. Its lateral cutaneous branch remains undivided and is distributed to the gluteal region a little behind the anterior superior iliac spine.

The **muscles supplied by the intercostal nerves** are the levatores costarum, serrati posteriores, intercostals, triangularis sterni, transversalis abdominis, external and internal oblique, rectus, and pyramidalis.

THE LUMBAR NERVES.

The anterior divisions of the five lumbar nerves increase in size from above downward. They communicate with the sympathetic by rami communicantes which reach them by running along the sides of the lumbar arteries under the fibrous arches from which the psoas muscle takes origin. Of these five nerves the upper three, with a communication from the twelfth thoracic and a considerable part of the fourth lumbar nerve, from the *lumbar plexus*, and the rest of the fourth lumbar nerve, with the whole of the fifth, join the sacral nerves in forming the sacral plexus.

The Lumbar Plexus (Fig. 671).

This plexus is found embedded in the substance of the psoas muscle, which must be removed piece by piece for its proper demonstration.

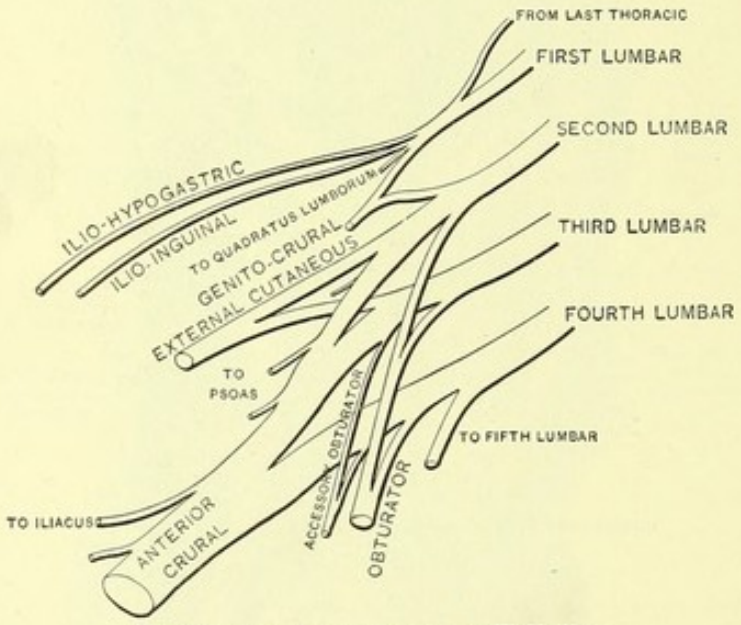

FIG. 671.—Plan of lumbar plexus. (W. Keiller.)

A glance at the diagram will show its general constitution. From the *first lumbar* nerve spring the *iliohypogastric* and *ilioïnguinal* nerves, from the *first* and *second* the *genitocrural*, from the *second* and *third* comes the *external cutaneous*, while large sections of the *second*, *third*, and *fourth* nerves form the *anterior crural*, and smaller more anterior sections of the same trunks unite to form the *obturator nerve*. The *accessory obturator* is a small, inconstant branch derived from the *third* and *fourth* nerves, and branches supply the *psoas* and *quadratus lumborum* from nearly all the nerves in a somewhat irregular manner.

Regarding their relations to the psoas muscle, the iliohypogastric, ilioïnguinal, external cutaneous, and anterior crural nerves emerge from its outer border, the last nerve running down its outer side to pass under the inguinal (Poupart's)

ligament; the genitocrural nerve pierces the anterior surface of the muscle and descends to the pelvis in its sheath; and the obturator and accessory obturator nerves and the lumbar contribution to the sacral plexus cross the pelvic brim along its inner side.

1. The Iliohypogastric Nerve.

The *iliohypogastric nerve* (Figs. 672, 678) rises in common with the *ilioïnguinal* from the first lumbar, and occasionally blends with it to form one nerve. Emerging from the outer border of the psoas it crosses the quadratus in the subperitoneal areolar tissue, and enters the space between the transversalis and inter-

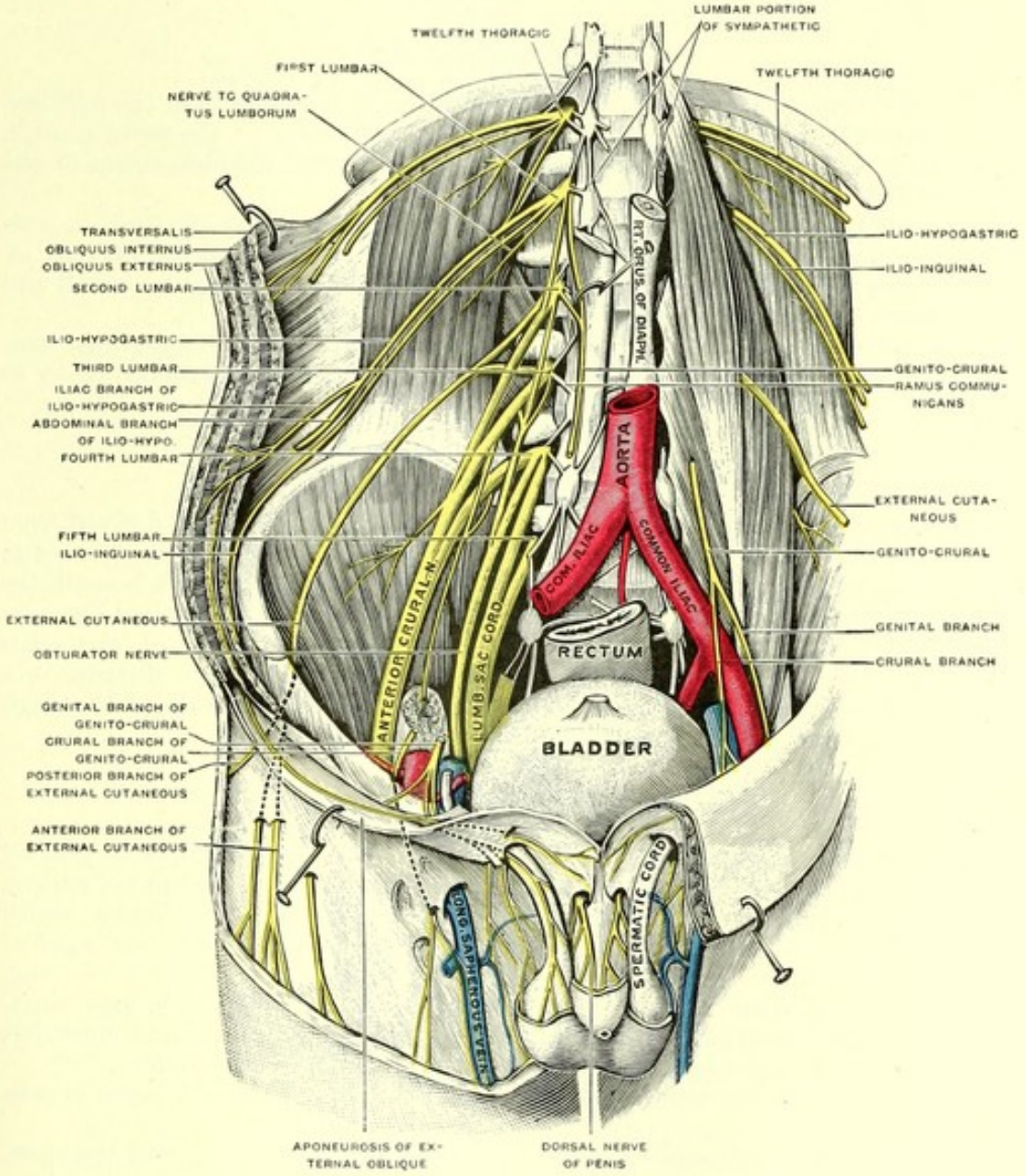

FIG. 672.—Deep and superficial dissection of the lumbar plexus. (Testut.)

nal oblique. It runs parallel with the iliac crest and, about two and a half inches behind the anterior superior iliac spine, gives off its *iliac branch*. Continuing onward the nerve pierces the internal oblique near the iliac spine, and becomes cutaneous about an inch above the external abdominal ring.

Its **iliac branch** pierces the abdominal muscles and, like the corresponding

branch of the last thoracic nerve, crosses the iliac crest to the gluteal region, supplying the skin between the crest and the great trochanter.

2. The Ilioïnguinal Nerve.

The *ilioïnguinal nerve* (Figs. 672, 673, 685, 686) arises in common with the last and accompanies it as far as the iliac spine but a little lower, uniting with it in a plexiform manner. It gains the inguinal canal and appears at the external abdominal ring in front of the spermatic cord, dividing into branches to the inner side of the thigh, and the scrotum or labium majus according to sex. These two nerves supply twigs to the muscles of the abdominal wall.

3. The Genitocrural Nerve.

The *genitocrural nerve* (Figs. 672, 673, 677, 685, 686) arises from the first and second lumbar nerves. It appears on the anterior surface of the psoas muscle, on which it descends, dividing into two branches near the commencement of the external iliac artery or anywhere above this point.

The **internal** or **genital branch** joins the external iliac artery, to which it contributes a twig, and then enters the inguinal canal. It is found on the back of the cord and is distributed to the *cremaster* muscle. In the female it is small and accompanies the round ligament.

The **external** or **crural branch** accompanies the psoas under the inguinal ligament and pierces the deep fascia just outside of the common femoral artery to supply the skin in front of the thigh.

4. The External Cutaneous Nerve.

The *external cutaneous nerve* (Figs. 672, 673, 675, 678, 685, 686), derived from the second and third lumbar nerves, pierces the outer border of the psoas and descends across the iliacus and under the fascia iliaca to the notch beneath the anterior superior iliac spine. Here it enters the thigh under the inguinal ligament and divides into a small *posterior branch* to the skin in front of the great trochanter, and a large *anterior branch* which descends for some distance in a sheath of fascia lata, and is distributed to the skin on the outer side of the thigh as low as the knee, where it joins the plexus patellæ.

5. The Anterior Crural Nerve.

The *anterior crural nerve* (Figs. 672, 673, 675) is the largest trunk formed by the lumbar plexus. It springs from the second, third, and fourth lumbar nerves, the roots uniting in the substance of the psoas muscle to form one trunk, which descends along its outer side to accompany the muscle under the inguinal ligament to the thigh. In the thigh the nerve is separated from the common femoral artery by about half an inch, and divides immediately into a large number of branches which may conveniently be classified as cutaneous and muscular, some of the latter furnishing articular twigs to the hip and knee-joints.

(*a*) The *nerves to the iliacus* are given off in the abdomen as the nerve crosses the muscle.

(*b*) The *nerve to the pectineus* arises immediately below the inguinal ligament, and crosses outward to its muscle behind the common femoral vessels.

(*c*) The *nerves to the rectus and vastus externus* run downward and outward beneath the former muscle, that *to the vastus internus* runs parallel with the long saphenous nerve as far as Hunter's canal. Of these the nerve to the rectus sends a twig to the hip-joint and each of the others sends articular branches to the knee.

(*d*) The **middle cutaneous nerve** (Figs. 673, 674, 675, 685, 686) consists of two strong branches, one of which pierces and supplies the sartorius. They

perforate the deep fascia half way down the thigh, and supply the skin in front as far down as the knee-joint, joining the plexus patellæ.

(*e*) The **internal cutaneous nerve** (Figs. 675, 685, 686, 688, 690) crosses obliquely over the superficial femoral artery in Scarpa's triangle, and divides into an *anterior* and a *posterior branch*, which follow the anterior and posterior borders of the sartorius respectively. They pierce the fascia lata in the lower third of the thigh and supply the skin on its inner aspect as low as the knee. The anterior branch joins the plexus patellæ, and the posterior branch the subsartorial plexus.

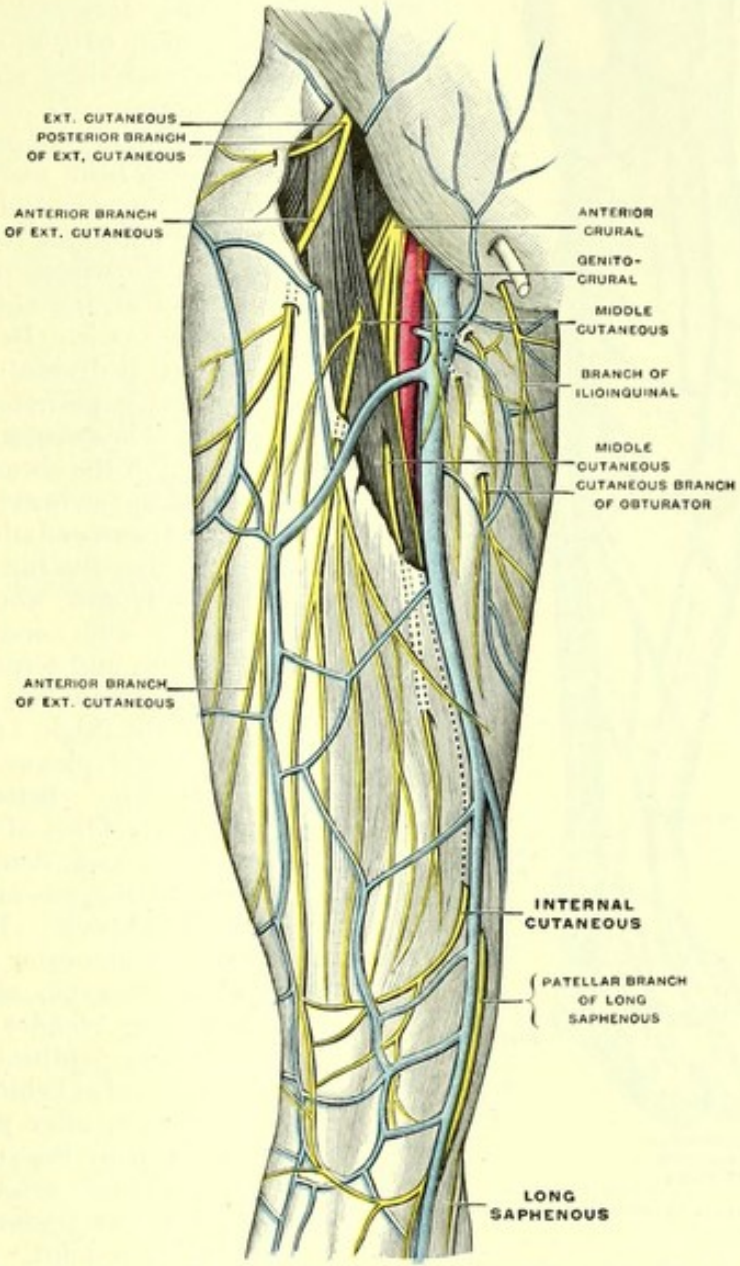

FIG. 673.—Superficial nerves of the anterior surface of the thigh. (Testut.)

(*f*) The **internal or long saphenous nerve** (Figs. 674, 675, 680, 683, 684, 685, 686, 688, 690) accompanies the nerve to the vastus internus to the apex of Scarpa's triangle. Here it enters Hunter's canal, in which it descends in front of the femoral artery. At the lower end of the canal it seeks the surface, by passing with the superficial branch of the anastomotica magna artery between the sartorius and gracilis, and piercing the deep fascia just below the knee. It then joins the long saphenous vein, distributes branches to the skin all down the

inner side of the leg, and, descending in front of the internal malleolus, ends on the inner side of the ball of the great toe.

Its **patellar branch** is given off as it leaves Hunter's canal. It perforates the sartorius and supplies the skin on the inner side of the knee-joint, joining the plexus patellæ.

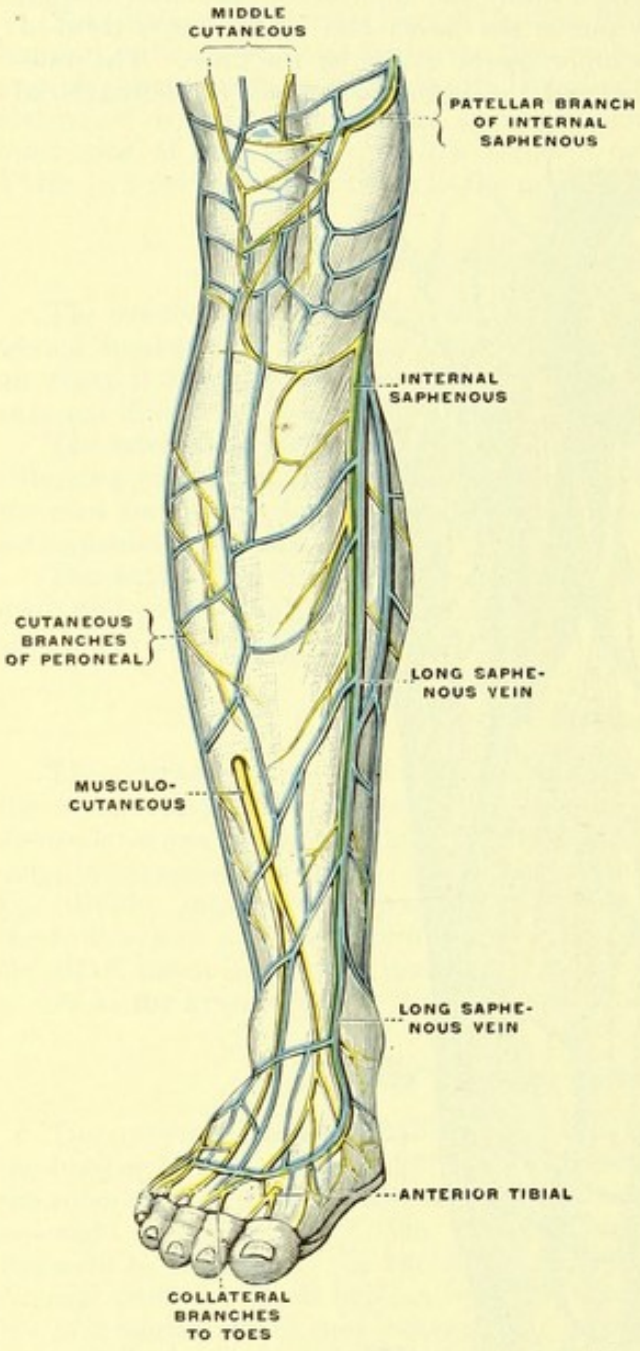

FIG. 674.—Superficial nerves of the front of the leg. (Testut.)

6. The Obturator Nerve.

The *obturator nerve* (Figs. 672, 673, 675, 677) arises from the second, third, and fourth lumbar nerves. It descends on the inner side of the psoas muscle to the pelvic brim, and then between the peritoneum and pelvic fascia to the obturator foramen, which it pierces where the membrane is deficient, the obturator artery lying below it. In the obturator foramen it divides into an anterior and a posterior branch.

(*a*) The **anterior branch** passes in front of the obturator externus and adductor brevis, and behind the pectineus and adductor longus. It supplies the hip-joint, the adductor longus and brevis, the gracilis, and occasionally the pectineus, and terminates by becoming cutaneous to the inner side of the thigh, and joining the subsartorial plexus.

(*b*) The **posterior branch** pierces the fibres of the obturator externus, and descends on the adductor magnus and behind the adductor brevis. It supplies the hip-joint, obturator externus, and adductor magnus, and terminates in a long slender fibre, which enters the popliteal space on the inner side of or behind the femoral artery, and, after giving a twig to accompany the superior internal articular artery, ends by piercing the posterior ligament of the knee-joint.

7. The Accessory Obturator Nerve.

The *accessory obturator nerve* is a small inconstant branch, derived from the obturator or from the same lumbar nerves. It crosses the ascending ramus of the os pubis under the pectineus, and supplies that muscle and the hip-joint, forming a loop with the anterior branch of the obturator.

The Plexus Patellæ.—The external, middle, and internal cutaneous nerves and

patellar branch of the long saphenous interlace with each other as they supply the skin round the patella.

The **subsartorial plexus** is formed under the sartorius, in the lower third of the thigh by interlacing branches of the internal cutaneous, obturator, and long saphenous nerves.

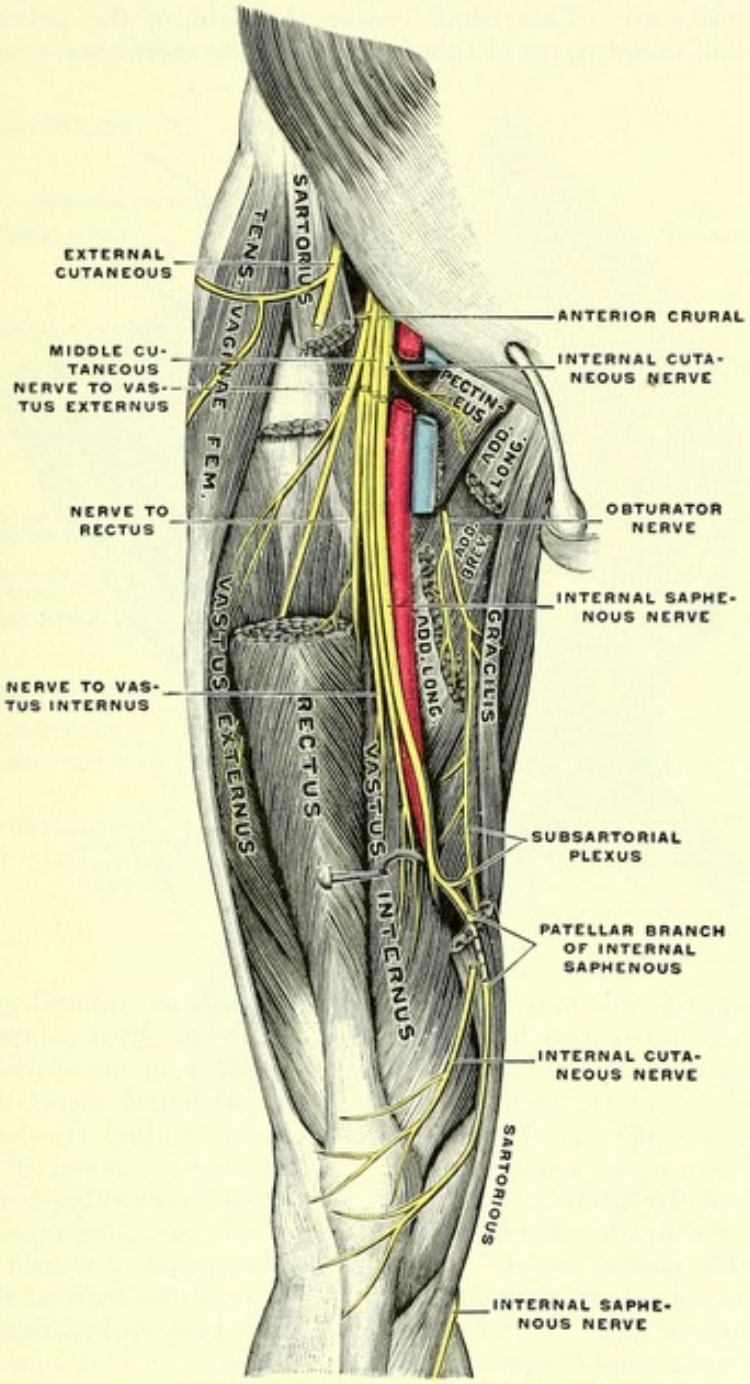

FIG. 675.—Deep nerves of the front of the thigh. (Testut.)

THE SACRAL AND COCCYGEAL NERVES.

The anterior divisions of the upper four sacral nerves enter the pelvic cavity through the anterior sacral foramina, the fifth sacral nerve passes forward between the sacrum and cornu of the coccyx, and the coccygeal nerve leaves the spinal canal through its terminal opening. The upper three sacral nerves join with part of the fourth and the whole of the fifth lumbar nerves, and part of the fourth

sacral nerve to form the sacral plexus; the rest of the fourth sacral and remaining nerves form the coccygeal plexus.

The Sacral Plexus (Fig. 676).

A variable portion of the fourth lumbar nerve joins the fifth lumbar to form the lumbo-sacral cord. This trunk crosses the brim of the pelvis, pierces the pelvic fascia, and under cover of this fascia joins the sacral nerves on the ventral

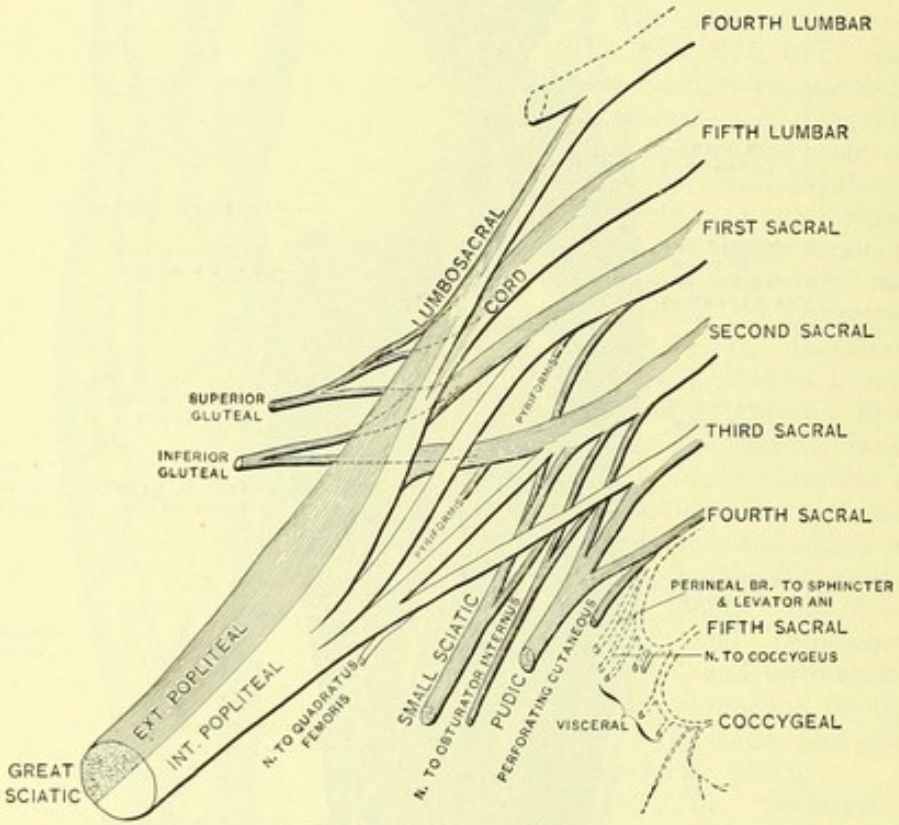

Fig. 676.—Plan of sacral plexus.

surface of the pyriformis muscle. With the first and second and greater part of the third sacral nerves the lumbo-sacral cord forms a great compound nervous trunk called the great sciatic nerve. A small band from the second sacral unites with the remainder of the third sacral and with the fourth sacral nerves to form the internal pudic nerve. Thus the two main or terminal trunks are formed; but, in addition to these, numerous collateral branches are given off: the superior gluteal, the inferior gluteal, the small sciatic, the perforating cutaneous, and nerves to the pyriformis, obturator internus, gemelli and quadratus femoris. The branches of this plexus are divisible into a dorsal and a ventral set. In the diagram the dorsal set are shaded. They spring from the back of the plexus and supply the extensor aspect of the limb; the ventral set spring from the anterior surface of the plexus and supply the flexor muscles.

COLLATERAL BRANCHES.

The twigs *to the pyriformis* are derived from the first and second sacral nerves.

The nerve *to the quadratus femoris* lies on the ventral surface of the plexus, its fibres springing from the lumbo-sacral cord and first sacral nerve. On the hip it is seen descending under the obturator internus and gemelli to reach the ventral surface of the quadratus, distributing on its way branches to the inferior gemellus and hip-joint.

The nerve *to the obturator internus*, from the fifth lumbar and upper two sacral nerves, appears on the hip beneath the pyriformis, crosses the spine of the ischium outside the internal pudic vessels, and passes through the small sacrosciatic foramen to the obturator internus, supplying the superior gemellus as it passes.

The **superior gluteal nerve** (Figs. 677, 679), springing from the back of the lumbo-sacral cord and first sacral nerve, leaves the pelvis through the great sacro-

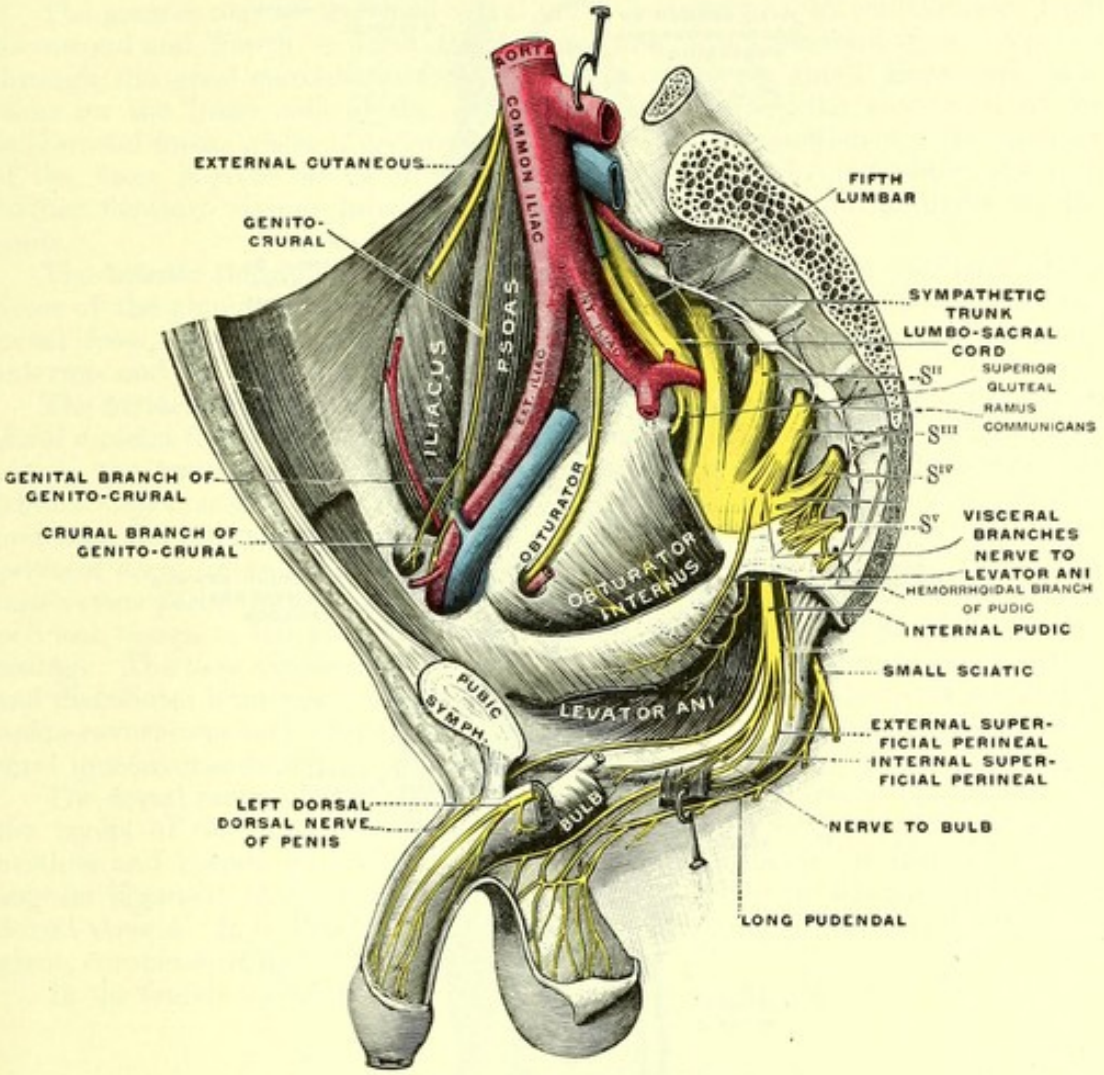

Fig. 677.—Sacral plexus of the right side. (Testut.)

sciatic foramen with the gluteal vessels, and under the gluteus medius divides into a small superior branch to that muscle, and a larger inferior branch, which accompanies the inferior branch of the gluteal artery and is distributed to the gluteus medius and minimus, and tensor vaginæ femoris.

The **inferior gluteal nerve** (Fig. 679) arises from the lumbo-sacral cord and first and second sacral nerves, and is frequently closely associated with the small sciatic nerve. It emerges from the great sacrosciatic foramen beneath the pyriformis, and enters the deep surface of the gluteus maximus, which it supplies.

The **small sciatic nerve** (ischiatic nerve) (Figs. 677, 678, 679, 687, 688) is a purely cutaneous nerve, supplying the skin of the buttock, perineum, and back of the thigh and popliteal region. It springs from the back of the upper three sacral nerves, and appears on the buttock beneath the pyriformis, and on the surface of the great sciatic nerve. At the lower border of the gluteus maximus it lies under the deep fascia on the middle line of the back of the thigh. Distributing cutaneous filaments as it descends, its terminal fibres pierce the deep fascia

at the bend of the knee, and end in the skin of the calf, joining the external saphenous nerve. Its *cutaneous branches to the gluteal region* are two or three in number, and bend upward over the lower border of that muscle to the skin of the lower and outer part of the buttock.

Its *inferior pudendal branch* turns inward beneath the tuber ischii and pierces

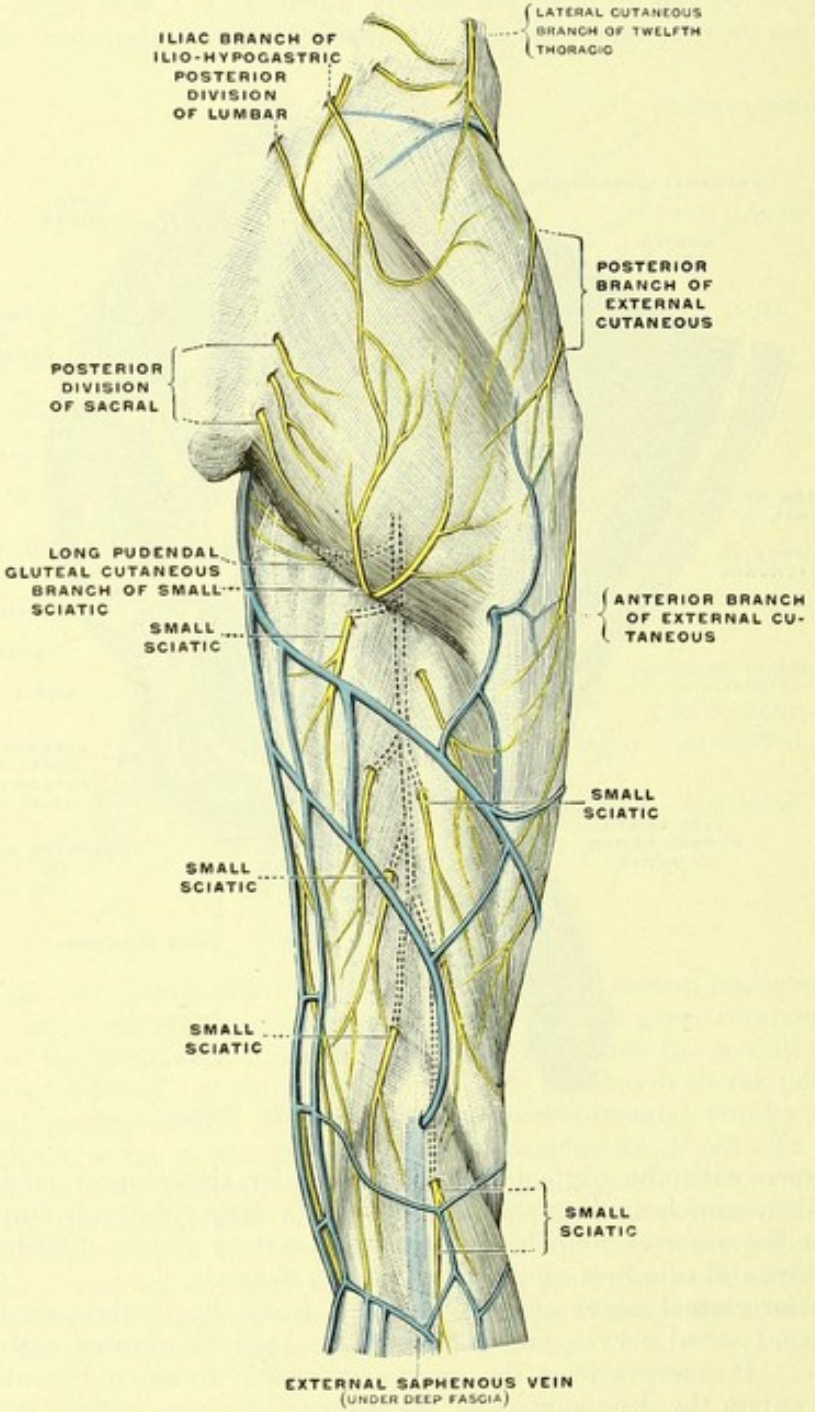

FIG. 678.—Superficial nerves of buttock and back of thigh. (Testut.)

the fascia lata on the inner side of the thigh about one inch in front of the tuberosity. It supplies the skin in this region, and passes forward and inward to the scrotum or labium majus, joining the external superficial perineal branch of the internal pudic nerve.

The **perforating cutaneous nerve** is a small twig from the second and third

sacral nerves, which pierces the great sacrosciatic ligament to reach the skin over the lower and inner part of the gluteus maximus.

TERMINAL BRANCHES.

The Pudic Nerve (Figs. 677, 679).

The greater part of the third sacral nerve is augmented by contributions from the second and fourth to form the pudic trunk, which emerges from the pelvis through the great sacrosciatic foramen, hooks round the small sacrosciatic ligament on the inner side of the pudic vessels, and enters the outer wall of the ischiorectal fossa, where it accompanies the vessels just mentioned. At the back of the fossa it gives off its inferior hemorrhoidal branch, and about one inch farther forward divides into the perineal nerve and the dorsal nerve of the penis.

The **Inferior Hemorrhoidal Nerve** pierces the obturator fascia well back under cover of the gluteus maximus, and crosses inward through the fat of the ischiorectal fossa, distributing its branches in fan-like manner to the sphincter ani externus and the skin round the anus.

The **perineal nerve** consists of a superficial and a deep division. The *superficial division* forms two nerves. The *posterior* or *external superficial perineal nerve* crosses the transverse perinei superficially, and runs forward in the scrotum or labium majus outside the superficial perineal vessels. It interlaces with the long pudendal and internal superficial perineal nerve. The *anterior* or *internal superficial perineal nerve* enters the ischiorectal fossa in front of the preceding, pierces the transversus perinei muscle, and passes forward on the inner side of the superficial perineal vessels to the scrotum or labium majus, interlacing with the nerve preceding. The *deep division* crosses inward parallel with the transversus perinei, and distributes branches to the external sphincter, levator ani, transversus perinei, ischio-cavernosus, and bulbo-cavernosus, and to the corpus spongiosum and urethral mucous membrane.

The **dorsal nerve of the penis** passes with the internal pudic vessels between the layers of the triangular ligament. Here it sends twigs to the constrictor urethræ and corpus cavernosum, and then pierces the inferior layer of the triangular ligament, appearing on the dorsum of the penis on the outer side of the dorsal vessels. It is distributed to the skin covering the corpus cavernosum and glans, communicating with sympathetic fibres.

In the female a similar but much smaller nerve is distributed to the clitoris.

The Great Sciatic Nerve.

The great sciatic nerve (Figs. 679, 681) is a compound trunk consisting of two great divisions—the peroneal (external popliteal) and the popliteal (internal popliteal). With the latter are associated the nerves which supply the hamstrings and adductor magnus. These are usually united to form one great trunk, which divides into popliteal and peroneal a little below the middle of the thigh; but they may be actually separate, or easily separated by dissection, as far as their constituent elements in the sacral plexus. Thus analyzed, the popliteal segment is seen to consist of ventral portions of the lumbosacral cord and upper three sacral nerves, and the peroneal nerve is traceable to the dorsal surface of the lumbosacral cord and upper two sacral nerves.

The great sciatic nerve appears on the buttock at the lower border of the pyriformis, crosses the gemelli, obturator internus, and quadratus femoris under cover of the gluteus maximus. At the lower border of the last muscle it is found midway between the tuber ischii and the great trochanter in an angle formed by the gluteus maximus and biceps. It now descends on the adductor

magnus, and is crossed obliquely by the long head of the biceps, dividing at a variable distance down the thigh into the (internal) popliteal and peroneal nerves.

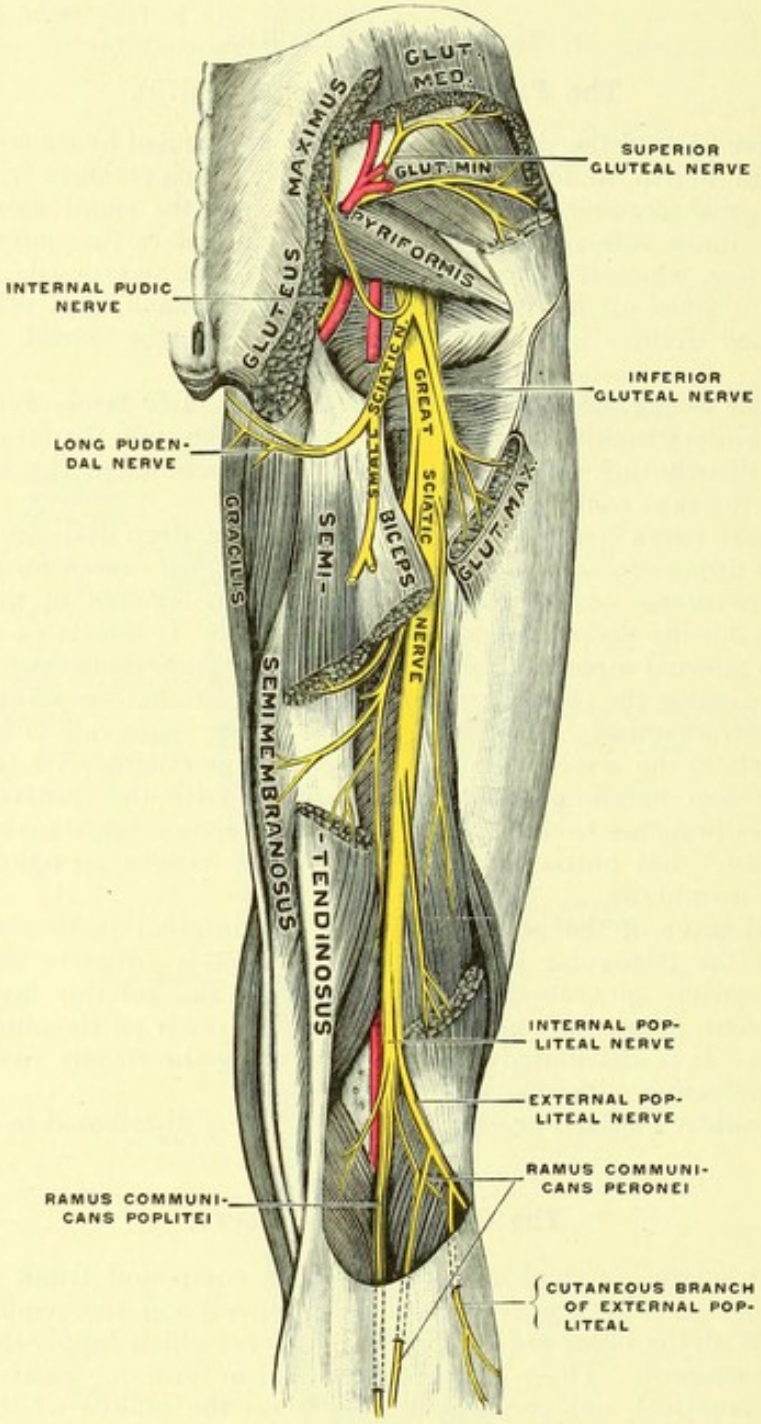

FIG. 679.—Deep nerves of buttock and back of thigh. (Testut.)

It gives off four branches, viz., one to the semitendinosus, one to the semimembranosus and adductor magnus, and one to each head of the biceps.

The Internal Popliteal Nerve (Figs. 679, 680, 681).

The internal popliteal (nervus tibialis) descends vertically down the middle of the popliteal space, till, reaching the lower border of the popliteus muscle, it is named the *posterior tibial nerve*. At first some distance on the outer side of

the popliteal vessels, where these vessels reach the middle line, it is closely adherent to the posterior surface of the vein, tending toward the inner side below.

BRANCHES.—The **articular branches**, usually three in number, accompany the superior and inferior internal articular, and azygos articular arteries to the knee-joint. The upper is frequently absent.

The **muscular branches** are distributed to the gastrocnemius (1. 2. s.), plantaris (4. 5. l, 1. s.), soleus (5. l, 1. 2. s.), and popliteus (4. 5. l, 1. s.). Of these the nerve to the popliteus is given off under the gastrocnemius and descends on the outer side of the popliteal vessels to reach the lower border of its muscle. It winds beneath it and supplies the muscle on its anterior surface, giving also a branch to the tibia accompanying its medullary artery, one to the interosseous membrane and inferior tibiofibular joint, and another to the superior tibiofibular articulation.

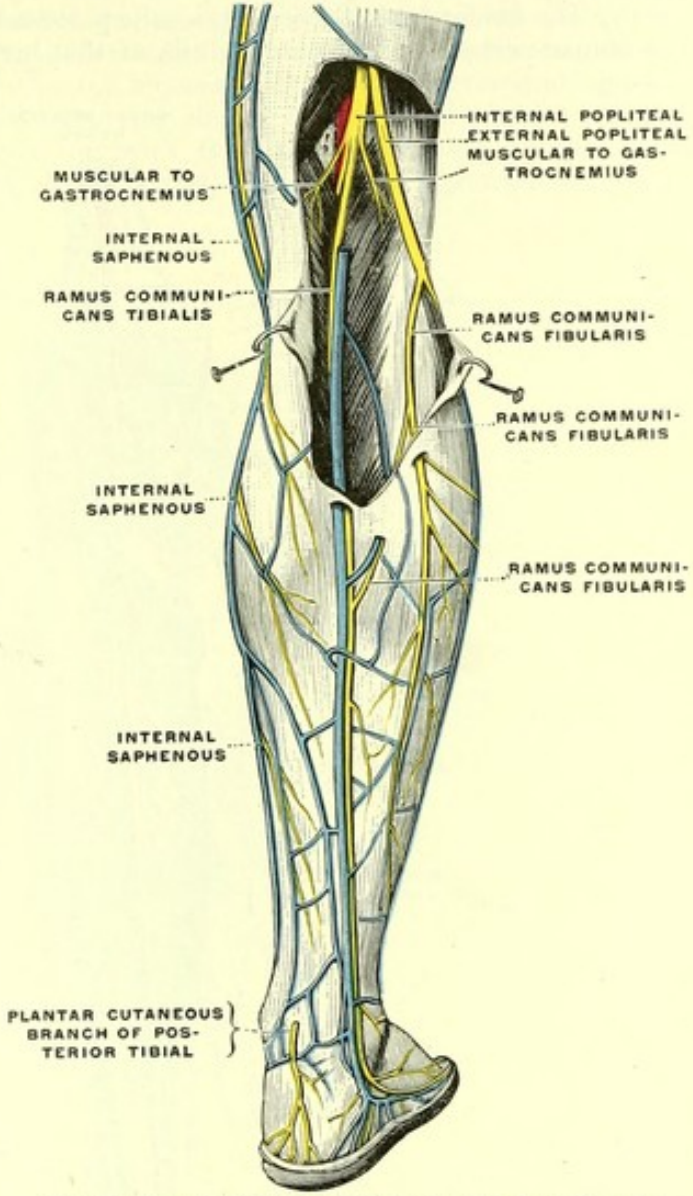

FIG. 680.—Superficial nerves of the back of the leg. (Testut.)

The **cutaneous branch** (ramus communicans tibialis vel poplitei) descends along the middle of the leg in the groove between the heads of the gastrocnemius, and pierces the deep fascia about half way down, to be joined by a similar branch from the peroneal nerve (ramus communicans peronei). Together they form the short or external saphenous nerve, which now accompanies the short saphenous vein beneath the external malleolus to the outer side of the foot, where it supplies the outer side of the foot and little toe, communicating with the musculocutaneous. It distributes branches to the skin on the back of the leg, external calcanean branches to the outer side of the heel, and articular branches to the ankle and astragalo-calcanean joints.

Posterior Tibial Nerve (Fig. 681).

At the lower border of the popliteus muscle the popliteal nerve is called the posterior tibial. It passes down the middle of the leg on the deep muscles, and beneath the deep transverse sheet of fascia. The posterior tibial artery is at first on the outer side of the nerve, but, after giving off the peroneal artery, it crosses abruptly a little inward beneath the nerve, and then descends on its inner side.

Between the internal malleolus and the inner tuberosity of the os calcis the posterior tibial divides into the internal and external plantar nerves.

Branches.—(*a*) **Muscular branches** (5. l., 1. 2. s.) supply the tibialis posterior, flexor longus digitorum, and flexor longus hallucis; besides which there is a supplementary branch to the soleus.

(*b*) The **fibular branch** accompanies the peroneal artery, supplying these vessels, the fibular periosteum and the medulla of that bone.

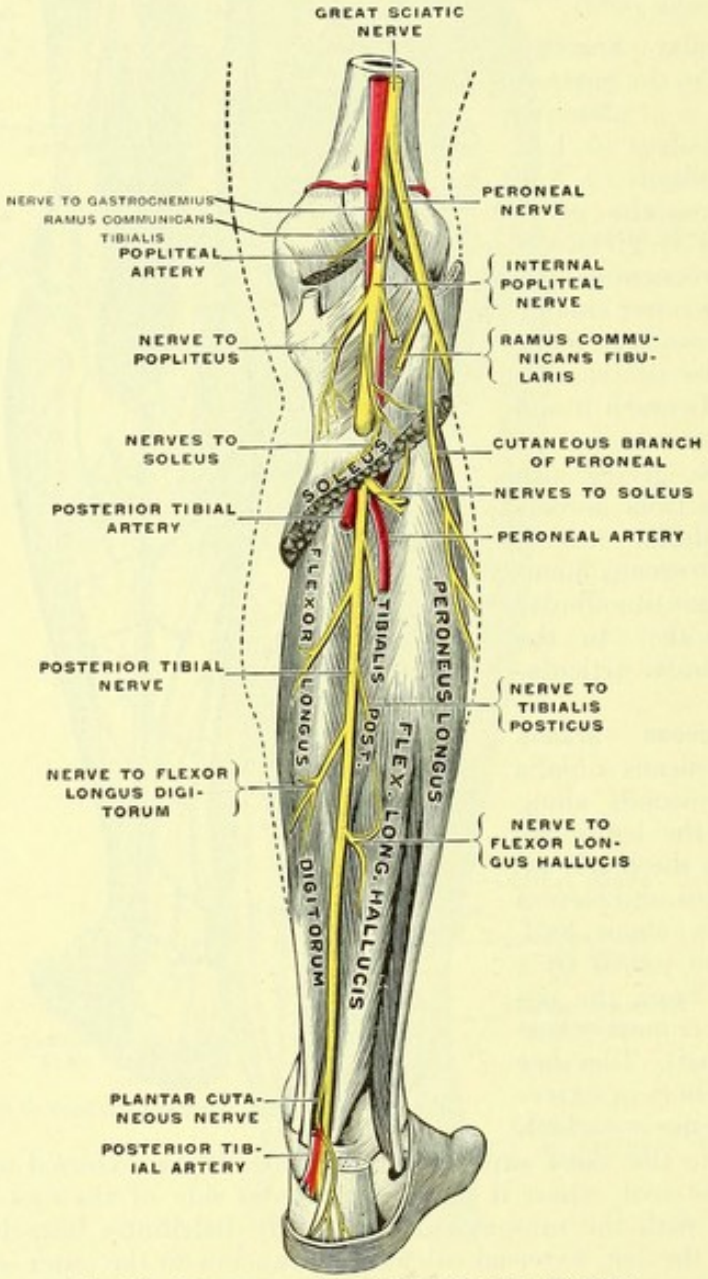

Fig. 681.—Deep nerves of the back of the leg. (Testut.)

(*c*) The **calcaneo-plantar** nerve (1. 2. s.), arising from the posterior tibial in the lower fourth of the leg, becomes cutaneous by piercing the internal annular ligament. It then divides into *internal calcaneal* branches to the skin of the heel, and *plantar cutaneous* branches to the inner side of the sole.

(*d*) **Articular filaments** supply the ankle-joint.

The **Internal Plantar Nerve** (Figs. 682, 684, 686, 689, 690) (4. 5. l., 1. s.) is slightly the larger of the two terminal divisions of the posterior tibial. It distributes cutaneous nerves to the inner three and a half toes, and supplies the

abductor hallucis, flexor brevis digitorum, flexor brevis hallucis, and inner lumbrical muscle. It passes forward under the origin of the abductor hallucis, then in the groove between that muscle and the flexor brevis digitorum, accompanying the internal plantar artery. Under cover of the plantar fascia it divides into *four digital nerves*. Of these the innermost passes undivided to the inner side of the great toe, giving a branch on its way to the flexor brevis hallucis, the remaining three nerves, emerging between the processes of plantar fascia, divide each into two collateral branches for the adjacent sides of the corresponding toes, the digital nerve to the first cleft supplying the inner lumbrical muscle, and the most external branch communicating with the external plantar nerve. The *muscular branches* to the abductor hallucis and flexor brevis digitorum are given

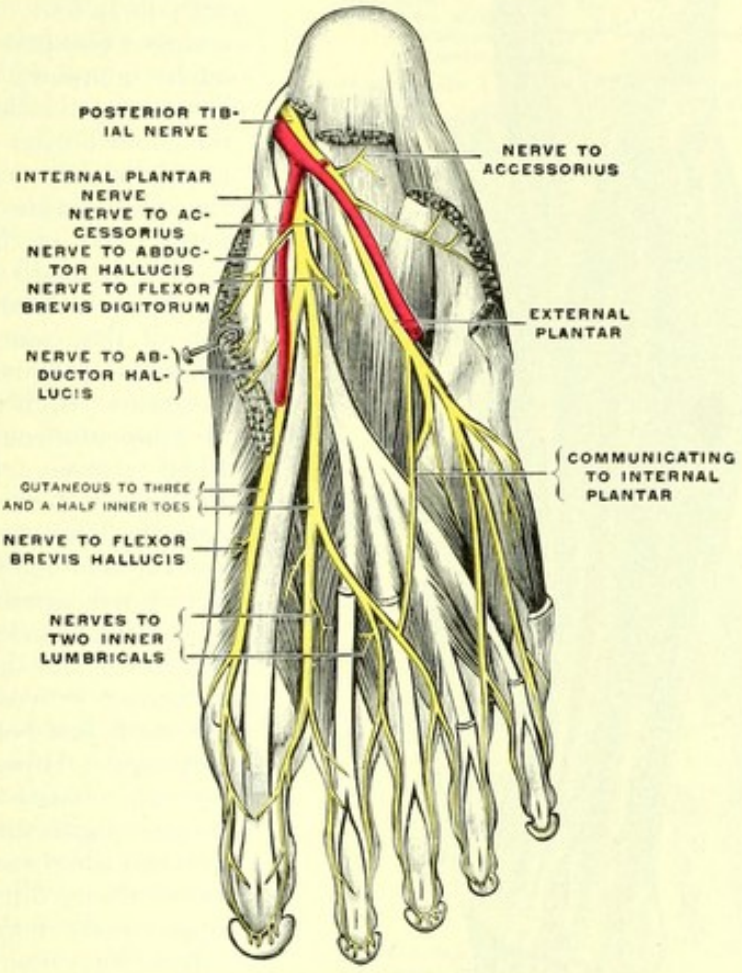

FIG. 682.—Plantar nerves. (Testut.)

off near the commencement of the nerve, *articular* fibres supply some of the joints of the foot, and *plantar cutaneous* twigs are distributed to the sole. As in the case of the corresponding nerve of the hand, the plantar digital nerves supply the skin on the dorsum of the ungual phalanx and the bed of the nail.

The **External Plantar Nerve** (Figs. 682, 684, 689, 690) accompanies the external plantar artery between the flexor brevis digitorum and flexor accessorius, till, gaining the hollow between the former muscle and the abductor minimi digiti, it divides into a superficial and a deep branch. Before dividing, it gives branches to the flexor accessorius and abductor minimi digiti.

The *superficial terminal* branch sends one digital branch to the outer side of the little toe, and a second, which, passing beneath the plantar fascia to the cleft between the fourth and fifth toes, divides into collateral branches to their adjacent surfaces, first communicating with the internal plantar nerve. The outer digital

branch supplies a twig to the flexor brevis minimi digiti, and occasionally supplies the interosseous muscles of the fourth space.

The *deep branch* of the external plantar nerve continues to accompany the external plantar artery beneath the long flexor tendons. It supplies branches to all the interosseous muscles (except occasionally those of the fourth space), the outer three lumbricals, and the adductor obliquus and adductor transversus hallucis; as well as articular filaments to the tarso-metatarsal and metatarso-phalangeal joints.

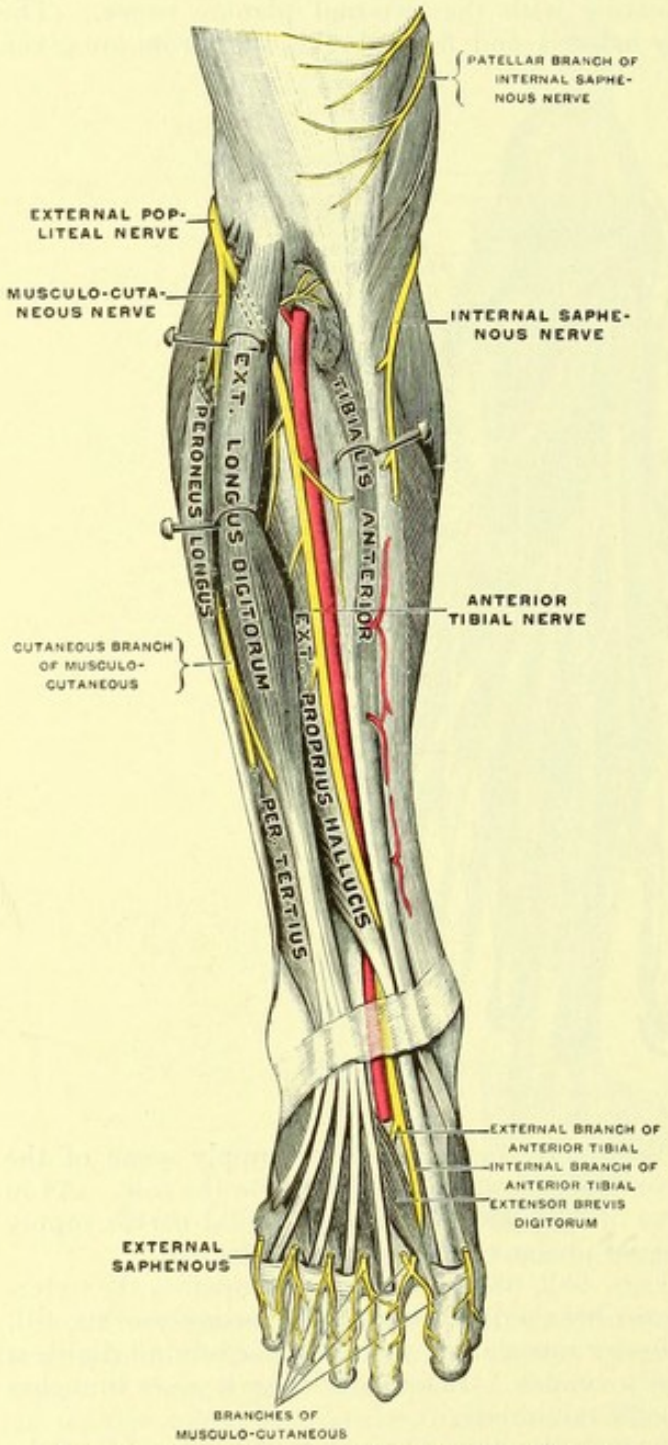

FIG. 683.—Deep nerves of the front of the leg. (Testut.)

External Popliteal or Peroneal Nerve (4. 5. l; 1. 2. s.).

This nerve (Figs. 674, 679, 680, 681, 683, 686, 688) descends obliquely along the outer boundary of the popliteal space following closely the inner border of the biceps muscle and its tendon as far as the fibula, thus crossing the outer head of the gastrocnemius. Beneath the head of the fibula it winds round the outer side of that bone, piercing the peroneus longus, and in its substance dividing into the musculocutaneous and anterior tibial nerves. Shortly after its formation it gives off, frequently by one common trunk, two *external articular branches*, which accompany the superior and inferior external articular arteries to the knee-joint. A *recurrent articular branch* is given off just before the nerve bifurcates. It passes under the peroneus longus and extensor longus digitorum to join the anterior tibial recurrent artery. Many of its fibres end in the upper end of the tibialis anterior, but some pass to the superior tibio-fibular joint, the periosteum over the outer tuberosity of the tibia and the knee joint.

Of the two *cutaneous branches* (5. l., 1. 2. s.) the *ramus communicans peronei* or *fibular communicating branch* joins the tibial, communicating below the middle of the leg to form the short saphenous nerve. Sometimes they do not join, and then this nerve usually ends on the heel or outer side of the foot. The *lateral cutaneous branch* of the peroneal nerve supplies the skin along the outer side of the upper two thirds of the leg.

The **Musculocutaneous Nerve** (4. 5. l., 1. s.) (Figs. 674, 683, 684, 685, 686) descends obliquely beneath the peronei muscles, and between them and the extensor longus digitorum, supplies *muscular branches* to the peroneus longus and brevis, and pierces the deep fascia near the middle line of the leg near its lower fourth. It then divides into two branches, internal and external, which descend in the superficial fascia to the dorsum of the foot, supplying filaments to the skin on the front of the leg, as they proceed downward.

The **internal branch** sends a branch to the inner side of the great toe, communicating with the long saphenous nerve, a second branch to join the anterior tibial nerve as it divides into collaterals to the contiguous side of the first and second toes, and a third branch to supply collaterals to the second and third toes.

The **external branch** supplies digital nerves to the contiguous sides of the third and fourth, and fourth and fifth toes, and communicates with the short saphenous nerve.

It will thus be seen that the short saphenous nerve supplies the outer side of the little toe, the anterior tibial supplies the contiguous surfaces of the first and second toes, and the musculocutaneous nerve supplies all the rest of the dorsum of the foot; the long saphenous nerve stopping short at the ball of the great toe.

The **Anterior Tibial Nerve** (4. 5. l., 1. s.) (Figs. 674, 683, 684, 685, 686) descends obliquely through the peroneus longus and extensor longus digitorum to lie on the interosseous membrane and anterior tibial artery. It reaches the side of that vessel about the junction of the upper and second fourths, descends a short distance on its outer side, and then in front of it, to be again placed on the outer side (occasionally inner side) of the vessel beneath the anterior annular ligament. Here it divides into an internal and an external branch.

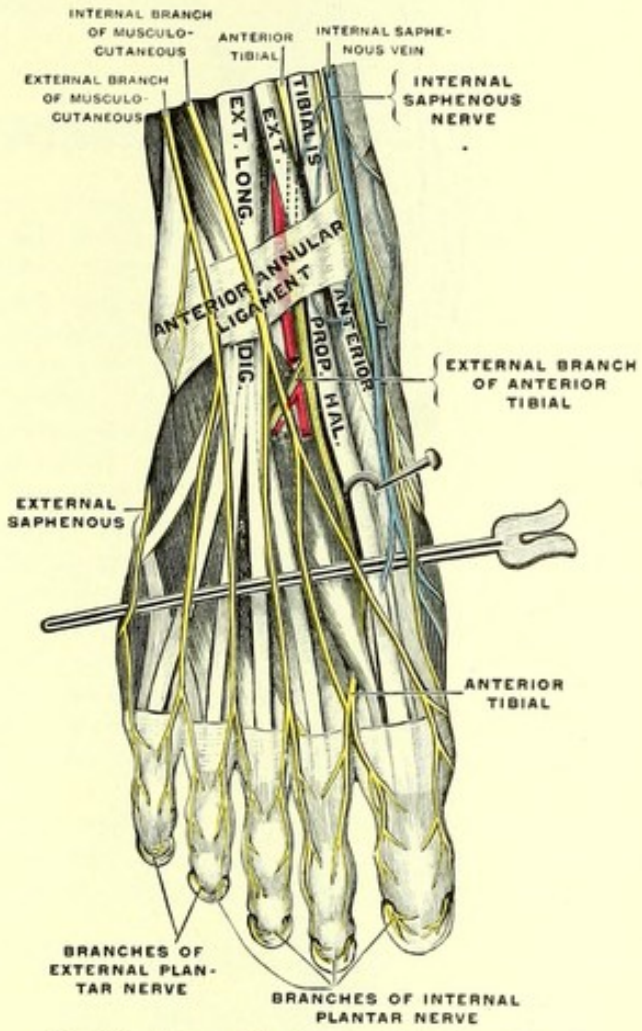

FIG. 684.—Nerves of the dorsum of the foot. (Testut.)

BRANCHES.—(*a*) *Muscular branches* supply the tibialis anterior, extensor longus digitorum, extensor proprius hallucis, and peroneus tertius.

(*b*) An *articular filament* supplies the ankle-joint.

(*c*) The **external branch** crosses outward under the extensor brevis digitorum, becomes enlarged like the posterior interosseous in the hand, and breaks up into branches, which supply the extensor brevis digitorum and the tarsal joints.

(*d*) The **internal branch** appears to be the direct continuation of the nerve, as it accompanies the dorsalis pedis artery, lying usually on its outer, sometimes on its inner side. Opposite the tarso-metatarsal joint it communicates with the musculo-cutaneous, and divides into branches to the outer side of the great, and inner side of the second, toe.

Fourth and Fifth Sacral and the Coccygeal Nerves.

The Fourth Sacral Nerve.—As already described, a small portion of the fourth sacral nerve ascends to join the sacral plexus. The remainder divides into visceral and muscular branches and a communicating filament to the fifth sacral.

The *visceral branches* descend on the pelvic surface of the coccygeus and levator

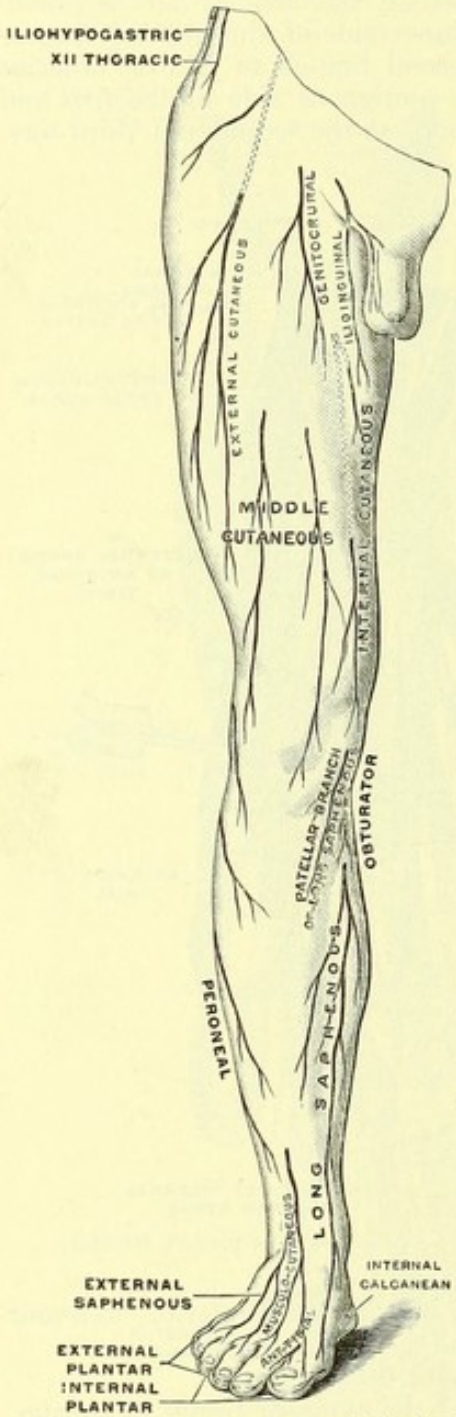

FIG. 685.—Cutaneous nerves of the front of the lower limb. (W. Keiller.)

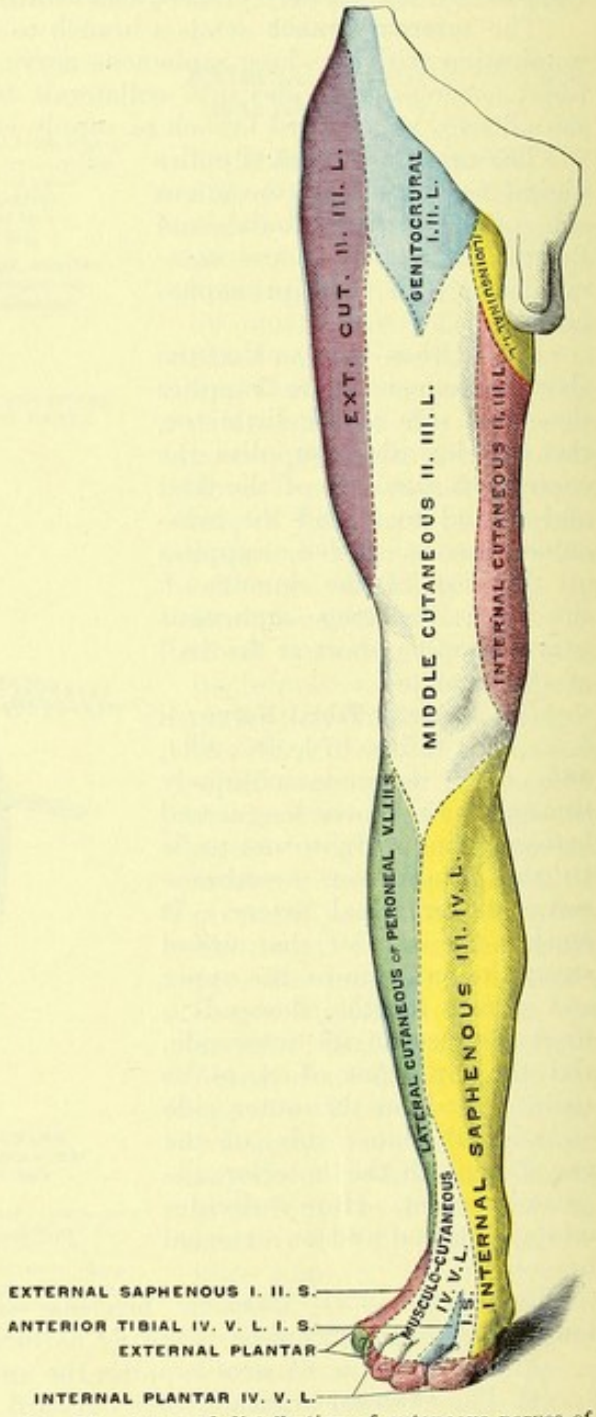

FIG. 686.—Areas of distribution of cutaneous nerves of the front of the lower limb. (W. Keiller, after Testut.)

ani to the bladder, rectum, and, in the female, the uterus and vagina. They communicate freely with the pelvic sympathetic and visceral branches of the third sacral nerve.

The *muscular branches* supply the levator ani and coccygeus on their pelvic surface, and a twig to the external sphincter (perineal branch) pierces the coccy-

geus or passes between it and the levator ani to the postero-internal angle of the ischio-rectal fossa, thus reaching its muscle and supplying it and the skin around the anus.

The **Fifth Sacral Nerve,** emerging from the spinal canal between the sacrum and cornu of the coccyx, enters the pelvis, and on the pelvic surface of the coccygeus muscles gives an *ascending filament* to join the fourth sacral, a *descending filament* to unite with the coccygeal nerve. It then descends on the coccygeus toward the tip of the coccyx, supplies twigs to the coccygeus muscle, and finally pierces that muscle to end in the skin over the coccyx.

The **Coccygeal Nerve** is an exceedingly small filament, which emerges from the lower end of the spinal canal, and pierces the sacrosciatic ligaments and coccygeus muscle to join the fifth sacral nerve.

The connection between the fourth and fifth sacral and coccygeal nerves is called the *coccygeal plexus.*

THE SYMPATHETIC NERVES.

The sympathetic system consists of two chains of ganglia, lying one on each side of the spinal column, which are developed as outgrowths from the spinal cord, and remain permanently connected with the spinal nerves. Its function is to innervate the viscera, glands, heart and blood-vessels, and the unstriped muscles of the body generally. This system presides in fact over the vital or vegetative, as contrasted with the voluntary or exclusively animal functions of the body, remaining, however, under control of the central nervous system.

If we take the arrangement in the thorax as typical, the ganglia should correspond in number with the spinal nerves; but in the neck there are only three ganglia, several being fused into one, and in the abdomen also the number is short; so that, while there are 31 spinal nerves on each side, there are only 20 to 23 ganglia. *Each ganglion* is reddish-gray in color, somewhat fusiform in shape and softish in consistence, but enclosed in a strong fibrous sheath. It is connected with that above and below it by *an ascending* and *a descending trunk*, and with at least one spinal nerve by one or two *rami communicantes*. Each ganglion distributes *rami efferentes*, which either directly or through the intervention of a secondary plexus supply blood-vessels or viscera, the efferent branches to the limbs and body-wall, however, joining the spinal nerves by the gray rami communicantes, and thus reaching their destination.

The gangliated cords are connected superiorly with the upper cranial nerves by branches which enter the cranium with the internal carotid artery, and inferiorly they converge over the front of the sacrum to meet in a single ganglion in front of the coccyx.

In addition to these two chains the following also belong to the sympathetic system:

1. **Sporadic ganglia**, namely the ciliary, Meckel's, otic, and submandibular, connected with cranial nerves and described with them.

2. The great **prevertebral plexuses**, consisting of aggregations of nerves and ganglia, which are connected with the gangliated cords and cerebro-spinal nerves on both sides of the body, and meet in front of the vertebral axis. These are, the *cardiac plexus*, lying above the heart and supplying it; the *solar plexus*, situated in the abdomen behind the stomach, and supplying most of the abdominal viscera and their vessels; and the *hypogastric plexus*, which is placed between the two common iliac arteries, and supplies the pelvic viscera.

3. **Secondary Plexuses.**—Many of the viscera possess minute secondary gangliated plexuses of their own, the ganglia being often microscopic in size; *e. g.*, the heart, suprarenal bodies, uterus, and intestines.

The ganglia of the sympathetic cords (vertebral ganglia) (Fig. 691) consist of nerve-cells, and medullated and non-medullated nerve-fibres. The medullated

nerve-fibres are derived probably wholly from the motor roots of spinal or cranial nerves, and form the white rami communicantes. They terminate in arborizations round the cells of the vertebral ganglia, or pass through these without interruption to enter into relationship with the cells of the prevertebral plexuses.

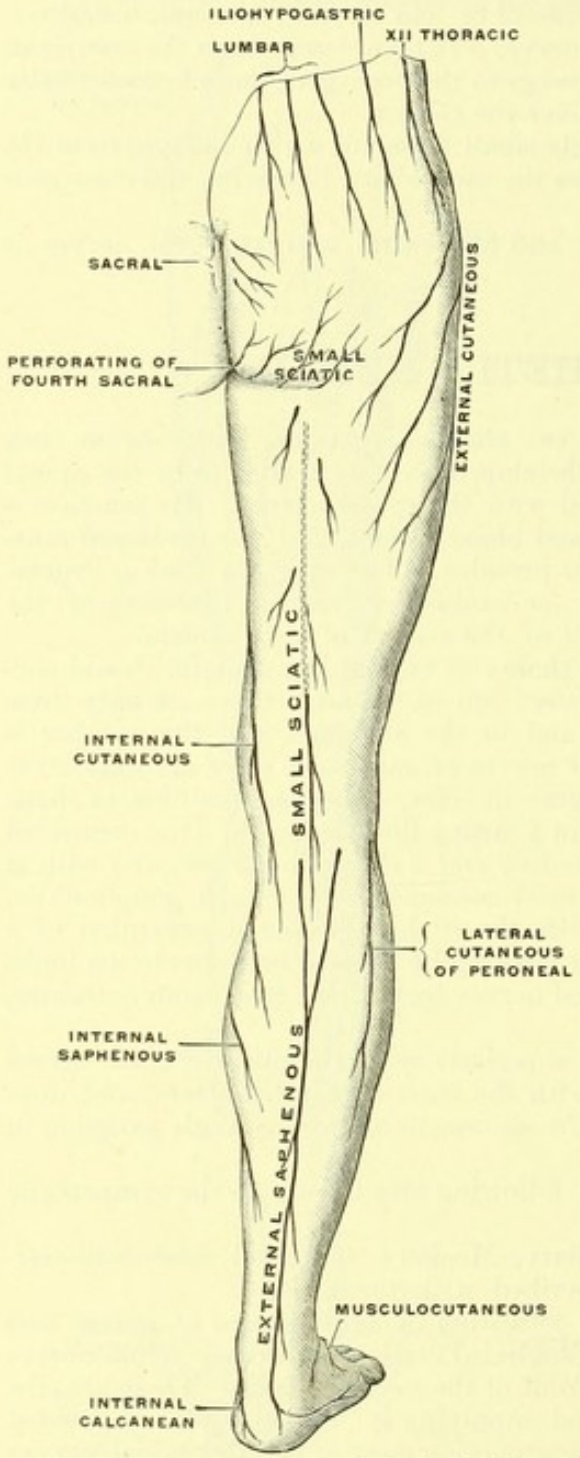

Fig. 687.—Cutaneous nerves of the back of the lower limb. (W. Keiller.)

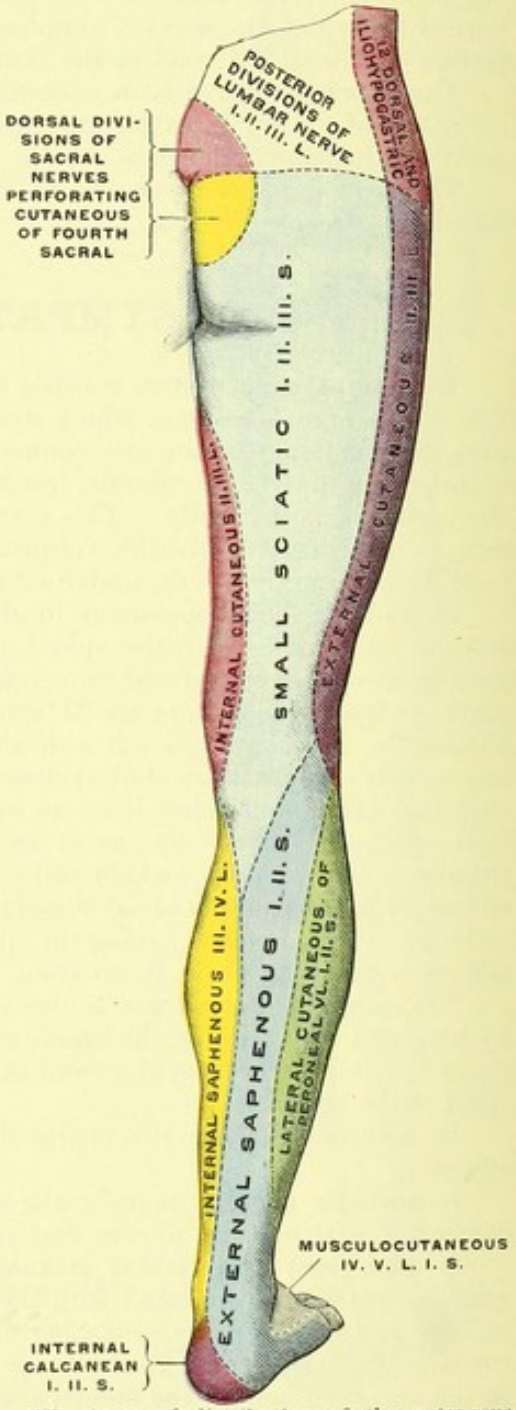

Fig. 688.—Areas of distribution of the cutaneous nerves of the back of the lower limb. (Testut.)

Medullated nerves (forming white rami communicantes) are not furnished to the sympathetic cords by all the cerebro-spinal nerves. In man white rami communicantes are derived from the thoracic and the first (and perhaps the second) lumbar nerves; while the short root of the ciliary ganglion from the third nerve, the visceral branches of the facial, glossopharyngeal, vagus, and spinal accessory, and

the visceral branches of the second, third, and fourth sacral nerves may be classed in the same category, though most of these join the subsidiary plexuses and not the gangliated cords.

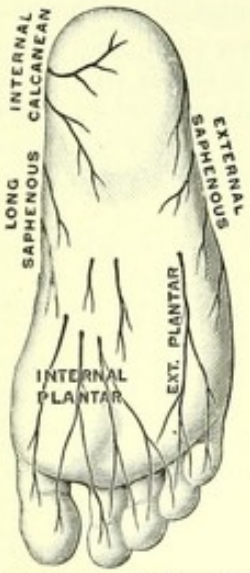

FIG. 689.—Cutaneous nerves of the sole. (W. Keiller.)

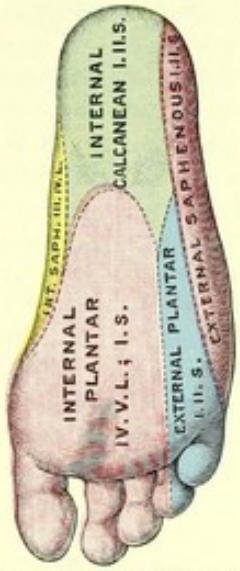

FIG. 690.—Areas of distribution of the cutaneous nerves of the sole. (W. Keiller.)

The *non-medullated nerves* commence as axis-cylinder processes of the ganglion cells. Some are distributed in gray rami communicantes to spinal nerves, and in them reach the vessels, fasciæ, bones, etc., for which they are destined;

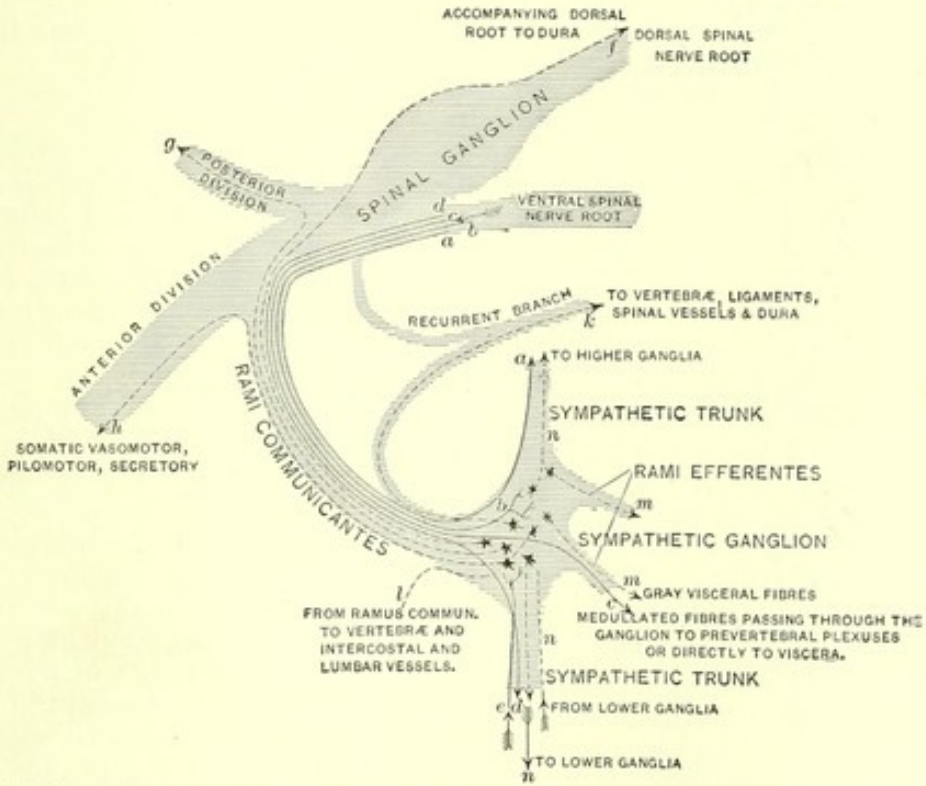

FIG. 691.—Plan of a vertebral ganglion of the sympathetic cord and its connections. Medullated fibres represented by continuous lines, non-medullated fibres by interrupted lines. For references to letters see text. (W. Keiller.)

some join neighboring ganglia, and others pass in rami efferentes directly to viscera and vessels or to the prevertebral plexuses.

These connections will be better understood by examining the plan drawn out in Fig. 691. There *a* represents a medullated nerve-fibre from a ventral nerve-root, passing by a white ramus communicans through the ganglion directly connected with that spinal nerve to a ganglion higher up, where it will form an arborization round a nerve-cell, like *e*; *b*, a medullated nerve-fibre forming an arborization round a cell of the ganglion of its own segment; *c*, a fibre passing through the ganglion without interruption and leaving it by one of its efferent branches to a prevertebral plexus or directly to some viscus; *d*, a fibre passing through the ganglion to some lower ganglion, there to end round some nerve-cell, or pass out through an efferent ramus; *e*, a medullated nerve from a lower ganglion, behaving as *a*.

The dotted lines are non-medullated nerves. The fibre, *f*, arises as the axis-cylinder process of a ganglion cell, and passes by a gray ramus communicans along the sheath of the posterior nerve-root to the spinal meninges; *g* passes by the posterior division to supply sympathetic fibres to its area of distribution; *h* enters the anterior division and is similarly distributed; *k* joins the spinal recurrent branch to supply the interior of the vertebral canal, and *l* passes for a little way along the gray ramus communicans, but leaves it to be distributed to the sides of the vertebræ and intercostal or lumbar vessels. Gray fibres to the prevertebral plexuses, vessels, or viscera, are represented by *m*, *m*; and *n*, *n* are non-medullated fibres joining neighboring ganglia. In addition to these, sensory fibres from the ganglia of the posterior spinal nerve-roots pass through the sympathetic ganglia to viscera without interruption.

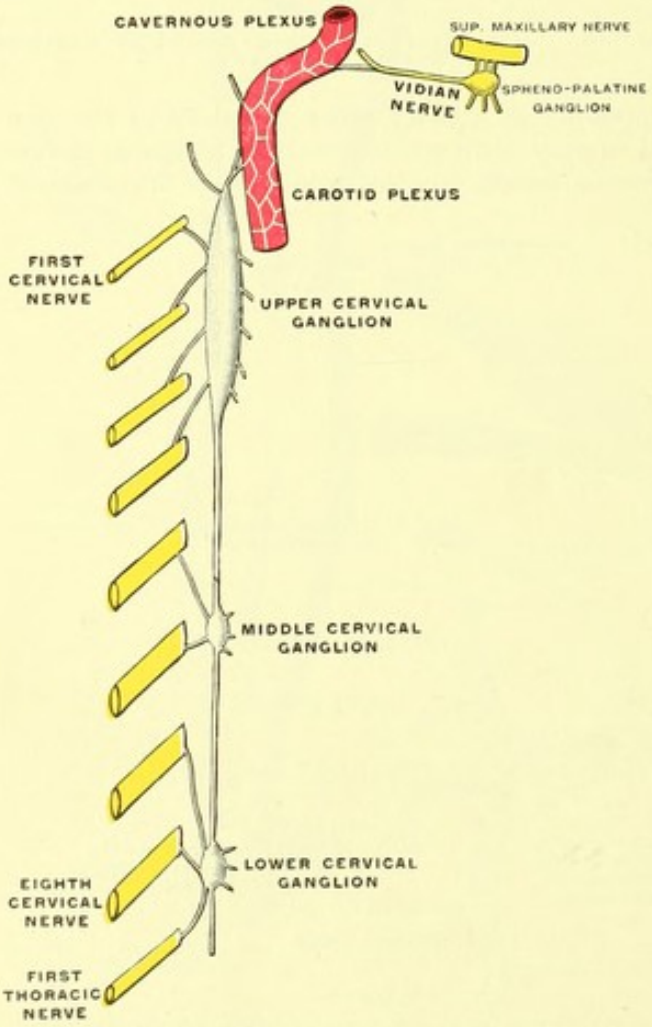

Fig. 692.—Diagram of the cervical sympathetic. (Testut.)

The Sympathetic in the Neck.

In the neck there are only three ganglia (Fig. 692). The upper one, however, is an inch or more in length, and is frequently constricted at intervals. It is connected with the four upper cervical nerves and appears to consist of four ganglia fused together.

The second ganglion is small, but is connected with two nerves; and the third ganglion, intermediate in size, is connected with the lower two cervical nerves. These ganglia and their intervening cord lie in front of the transverse processes of the cervical vertebræ, being separated from them by the rectus capitis anterior major above and longus colli below with the prevertebral fascia. The common and internal carotid arteries and the carotid sheath lie in front of them, and the vagus nerve lies to the outer side.

The Superior Cervical Ganglion.—This ganglion is fusiform in shape, reddish-

gray in color, an inch to an inch and a half long, and is placed in front of the transverse processes of the second and third cervical vertebræ, and rectus capitis anterior major. In front of it is the internal carotid artery, and to its outer side the vagus nerve.

Connections.—Its *ascending branch* enters the cranium; its lower end is connected to the second ganglion. Gray *rami communicantes* pass from it to the four upper cervical nerves, while its medullated connections with the spinal cord take a circuitous course, being derived from the upper dorsal nerves, and ascending to join it through the sympathetic trunk.

Besides connections with cranial nerves, through its ascending branch (about to be described), it is joined by filaments to the lower ganglion of the vagus and the hypoglossal nerve; and a small *jugular branch* ascends to the jugular foramen, and there divides into two, one branch going to the root ganglion of the pneumogastric, and the other to the petrosal ganglion of the glossopharyngeal.

It distributes pharyngeal branches to the pharyngeal plexus, filaments to the upper cervical vertebræ and their ligaments, and branches to blood-vessels; and from it also springs the upper cardiac nerve.

The Ascending Branch.—The *ascending* or *carotid branch* runs upward on the inner side of the carotid artery to the carotid canal where it divides into an inner and an outer division. Each division gives off some special branches, and then they both ascend on the termination of the carotid artery, supply that vessel, and terminate in plexuses on the ophthalmic and anterior and middle cerebral arteries.

The *outer division*, as it ascends on the outer side of the carotid trunk, receives one or two *carotico-tympanic* filaments from the tympanic branch of the glossopharyngeal, and then forms the *carotid plexus* on the carotid artery, as it lies in the carotid canal. This plexus gives a *twig to the sixth nerve* as the latter crosses the carotid artery, some filaments to the *Gasserian ganglion*, the *large deep petrosal nerve* to the Vidian, and the *small deep petrosal nerve* to the tympanic plexus.

The *inner division* ascends on the inner side of the carotid artery, and forms a plexus on that vessel as it lies in the wall of the cavernous sinus, which is hence called the *cavernous plexus*. From this plexus filaments are given to the *third nerve* near its bifurcation, and to the *fourth nerve* as it runs in the outer wall of the cavernous sinus. The *sympathetic root of the ciliary ganglion* and filaments to the *pituitary body* are also derived from this plexus.

The *pharyngeal branches* of the sympathetic arise from the fore part of the ganglion. They descend on the side of the pharynx and unite with the pharyngeal branches of the pneumogastric and glossopharyngeal to form the *pharyngeal plexus*.

The *superior cardiac branch* of the sympathetic springs by two or more branches from the ganglion and sometimes from the sympathetic trunk below it. It descends behind the carotid sheath on the longus colli muscle and prevertebral fascia, crosses over or beneath the inferior thyroid artery, and beneath the recurrent laryngeal nerve. As they enter the thorax the two nerves differ in their courses. The *right nerve* runs in front of or behind the subclavian artery and along the brachio-cephalic artery to the back of the aortic arch, where it joins the deep cardiac plexus. It is usually joined by the superior cardiac branches of the right vagus.

The *left superior cardiac nerve*, behaving similarly to the right nerve in the neck, enters the chest along the side of the left common carotid artery, and crosses the aortic arch to join the superficial cardiac plexus. Occasionally it passes behind the aortic arch to the deep cardiac plexus.

Besides the branch described to the internal carotid artery, this ganglion supplies filaments, which form a *plexus on the external carotid artery* and its various branches. From the plexus on the facial artery a branch is sent to the *submaxillary ganglion*; and the plexus on the middle meningeal artery supplies the otic ganglion with its sympathetic root, and sends a filament to the geniculate ganglion of the facial nerve.

The Middle Cervical Ganglion.—The middle cervical ganglion is much the smallest of the three. It is sometimes absent and occasionally double. When single it is usually situated where the cord crosses the inferior thyroid artery opposite the sixth or seventh cervical vertebra. It is joined by gray rami communicantes to the fifth and sixth cervical nerves. It gives off *thyroid branches*, which run on the inferior thyroid artery to the thyroid gland, communicating with the recurrent and external laryngeal and the upper cardiac nerves.

The *middle cardiac branch* of the sympathetic, springing from this ganglion on the *right side*, descends in front of or behind the subclavian artery and on the side of the trachea to the deep cardiac plexus, communicating with the upper cardiac nerve and recurrent laryngeal branch of the vagus.

On the *left side* this nerve descends between the left carotid and subclavian arteries to the deep cardiac plexus, uniting on its way with the left inferior cardiac nerve.

The Inferior Cervical Ganglion.—The inferior cervical ganglion is larger than the last, and irregular or semilunar in shape. It lies just over the neck of the first rib and under cover of the vertebral artery. To the middle cervical ganglion it is united by two or more cords, one usually passing behind the vertebral artery, one in front of it, and one forming a loop round the subclavian artery (ansa subclavia Vieussenii). It may blend with the first thoracic ganglion or be united to it by a short intervening cord. Gray *rami communicantes* pass from this ganglion to the seventh and eighth cervical nerves. Its *efferent* branches are the inferior cardiac nerve and offsets to blood-vessels.

The *inferior cardiac nerve*, springing from this ganglion or the first thoracic, on the right side communicates behind the subclavian artery with the middle cardiac and recurrent laryngeal nerves, on the left side usually forms a common trunk with the middle cardiac nerve. Both go to the deep cardiac plexus.

The vascular branches of this ganglion and the first thoracic unite in forming the plexus on the vertebral artery, and ascend on that vessel to the basilar artery and its branches within the cranium.

(*Note.*—The gross anatomy of the cervical sympathetic gives no idea of its true anatomical relations as revealed by physiological experiments and pathological phenomena. The physiological connections as at present understood may be summarized as follows:

1. Pupillo-dilator fibres pass by white rami communicantes from the first, second, and third thoracic nerves, ascend in the sympathetic cord to the superior cervical ganglion to form arborizations round its cells. Thence gray fibres pass to the Gasserian ganglion and reach the eyeball by the ophthalmic division of the fifth and long ciliary nerves.

2. Motor fibres to the involuntary muscles of the orbit and eyelids from the fourth and fifth thoracic nerves follow a similar course.

3. Vasomotor fibres to the head, secretory fibres to the submaxillary gland, and pilomotor fibres to the head and neck are derived from the upper thoracic nerves and reach their areas of distribution after similar interruption in the superior cervical ganglion.

4. The accelerator fibres of the heart are derived from the upper thoracic spinal nerves, and end similarly in the middle and lower cervical ganglia, gray fibres in the cervical cardiac nerves completing the connection.)

The Thoracic Portion of the Gangliated Cord.

In the thorax the sympathetic cord (Fig. 693) presents eleven, seldom twelve, ganglia, the first thoracic ganglion frequently blending with the last cervical. When existing separately the first ganglion lies beneath the head of the first rib; the rest, with the exception of the twelfth, lie on the heads of the ribs, under cover of the pleura, the intervening cord lying in front of the intercostal vessels. The twelfth thoracic ganglion approaches nearer to the middle line, lying on the

side of the twelfth thoracic vertebra, between it and the diaphragm, and from it the cord descends into the abdomen through the crus of the diaphragm to unite the last thoracic to the first lumbar ganglion.

Rami Communicantes.—Two rami communicantes, sometimes called the *external branches*, unite each ganglion to its corresponding spinal nerve. Of these one is usually white, the other gray.

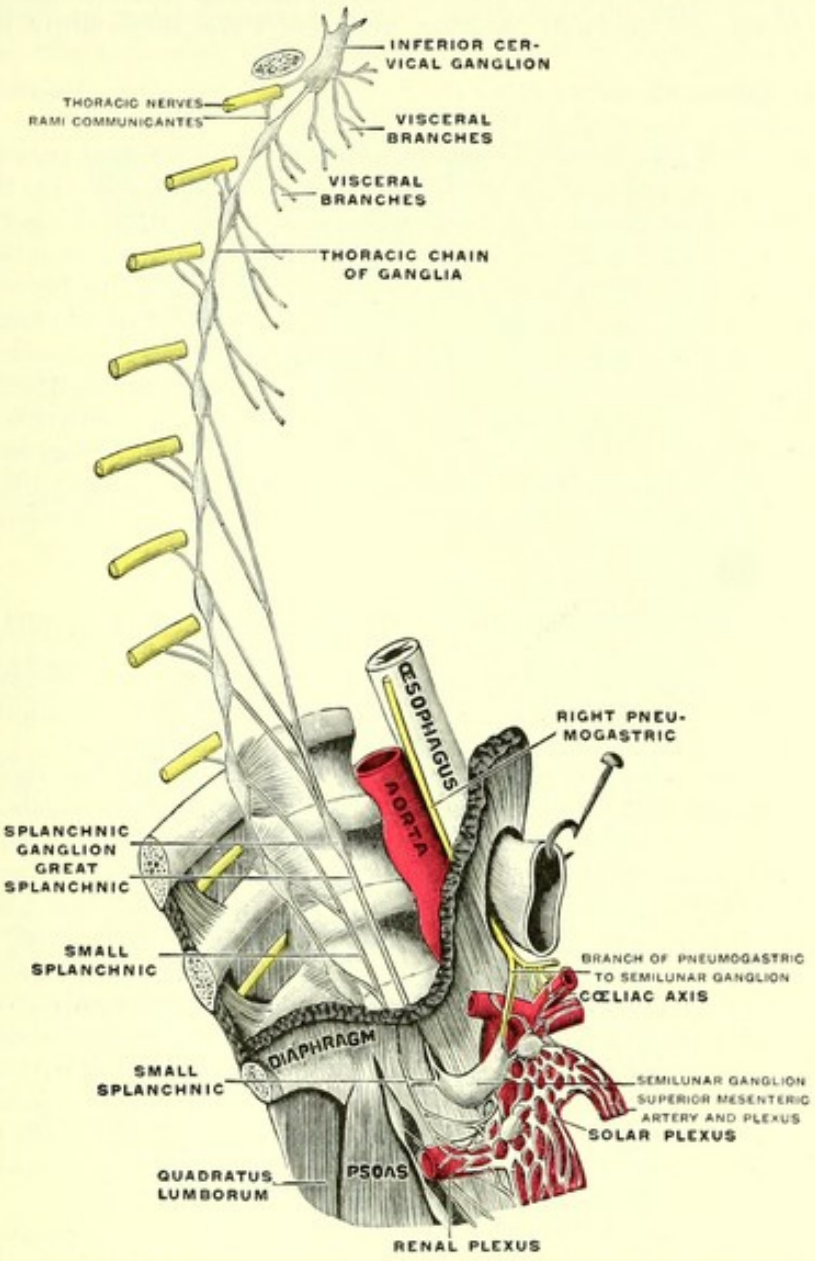

FIG. 693.—Plan of right sympathetic cord and splanchnic nerves. (Testut.)

The *rami efferentes*, called the *internal branches*, are divisible into an upper and a lower series. The *upper series* proceeds from the upper four or five ganglia to the aorta, forming with branches from the splanchnic the thoracic aortic plexus. Other slender filaments supply the vertebræ and ligaments, and the second, third, and fourth ganglia send branches to the posterior pulmonary plexus.

The *lower series* includes the internal branches of the lower six or seven ganglia. They form the great, small, and least splanchnic nerves.

The **great splanchnic (visceral) nerve** is formed by the convergence on the sides of the vertebræ of the internal branches of the fifth or sixth to the ninth or tenth ganglia inclusive. These branches and the resulting trunk distribute fila-

ments to the vertebræ and aorta as they descend, the trunks then piercing the crus of the diaphragm, and entering the upper angle of the semilunar ganglion. It occasionally sends fibres to the suprarenal body and renal plexus. This nerve largely consists of medullated fibres, some of which may be traced in the sympathetic cord till they join the third thoracic nerve.

The **small splanchnic nerve**, rising from the ninth and tenth, or ninth, tenth, and eleventh ganglia, passes beneath the crus or internal arcuate ligament of the diaphragm, to the aortico-renal ganglion, and sometimes sends fibres to the renal plexus.

The **least splanchnic nerve**, from the last thoracic ganglion, descends beneath the internal arcuate ligament to the renal plexus.

(*Note.*—It should be remembered that most of the white rami communicantes, which pass from the spinal cord to the sympathetic trunk, do so by the thoracic nerve; but that they do not by any means all end in thoracic ganglia. For example, the pupillo-motor fibres, vasomotor fibres of the head and neck, secretory fibres of the submaxillary gland and accelerator fibres of the heart leave the spinal cord by upper thoracic nerves and ascend in the sympathetic trunk to form arborizations round the cells of the cervical ganglia.

In the dog and cat the white rami communicantes from the thoracic nerves have been shown to contain, in addition to the above, vaso-constrictor fibres of the pulmonary vessels, and of the vessels of the fore and hind limbs, and secretory fibres to the sweat glands and pilo-motor fibres to the hair of both limbs, as well as viscero-inhibitory fibres to the stomach and intestines, and vasomotor nerves to the abdominal vessels.)

The Lumbar Portion of the Gangliated Cord (Fig. 694).

There are usually four lumbar ganglia, which lie in front of the vertebral bodies on the inner side of the psoas muscles, the left trunk and its ganglia being overlapped by the aorta, and the right by the inferior vena cava.

The ganglia are generally connected somewhat irregularly by white and gray rami communicantes with the lumbar nerves, which reach the ganglia by passing beneath the fibrous arches of the psoas muscle. Efferent branches join the aortic and hypogastric plexuses, and small filaments pass to vertebræ and ligaments.

(*Note.*—The lumbar sympathetic is connected with the lower limb, rectum, penis, bladder, uterus, and vas deferens, while the other abdominal viscera are connected through the solar plexus with the lower six thoracic nerves.)

From these ganglia and the intervening meshwork are given off plexuses, which correspond in name and distribution to the upper branches of the abdominal aorta. Thus the *diaphragmatic* or *phrenic plexuses* spring from the upper part of the semilunar ganglia. They accompany the phrenic arteries, and are joined by the phrenic nerves. A ganglion is formed at their junction on the right side (wanting on the left side) whence branches pass to the vena cava, suprarenal body, and hepatic plexus.

Suprarenal plexuses accompany the arteries of the same name from the phrenic artery, aorta, and renal artery. They are thus derived from the phrenic, solar and renal plexuses. They contain many minute ganglia.

The *renal plexus* springs from the aortico-renal ganglion, and solar and aortic plexuses, and receives the small splanchnic nerve. It accompanies the renal artery to the kidney substance, and gives branches to the suprarenal body, spermatic plexus and ureter, and on the right side the vena cava.

The *spermatic plexus* springs from the renal and aortic plexuses and accompanies the spermatic artery to the testis, receiving an accession from the pelvic sympathetic along the vas deferens.

In the female it is represented by the *ovarian plexus* to the ovary and uterus.

The *cœliac plexus* is large in accordance with the size and extensive distribution of the cœliac axis. It gives off secondary plexuses corresponding in names

and distribution to the branches of that vessel. Of these plexuses the hepatic and coronary are joined by branches of the left pneumogastric, and the splenic plexus is reinforced from the right pneumogastric.

The *superior mesenteric plexus* is derived from the solar plexus, superior mesenteric ganglion, and right pneumogastric. It is distributed to the intestine, at first following the branches of its artery closely; but its finer filaments leave the vessels.

The *aortic plexus* is formed of two cords and an intervening network, which descend on the abdominal aorta beneath the superior mesenteric artery. It is

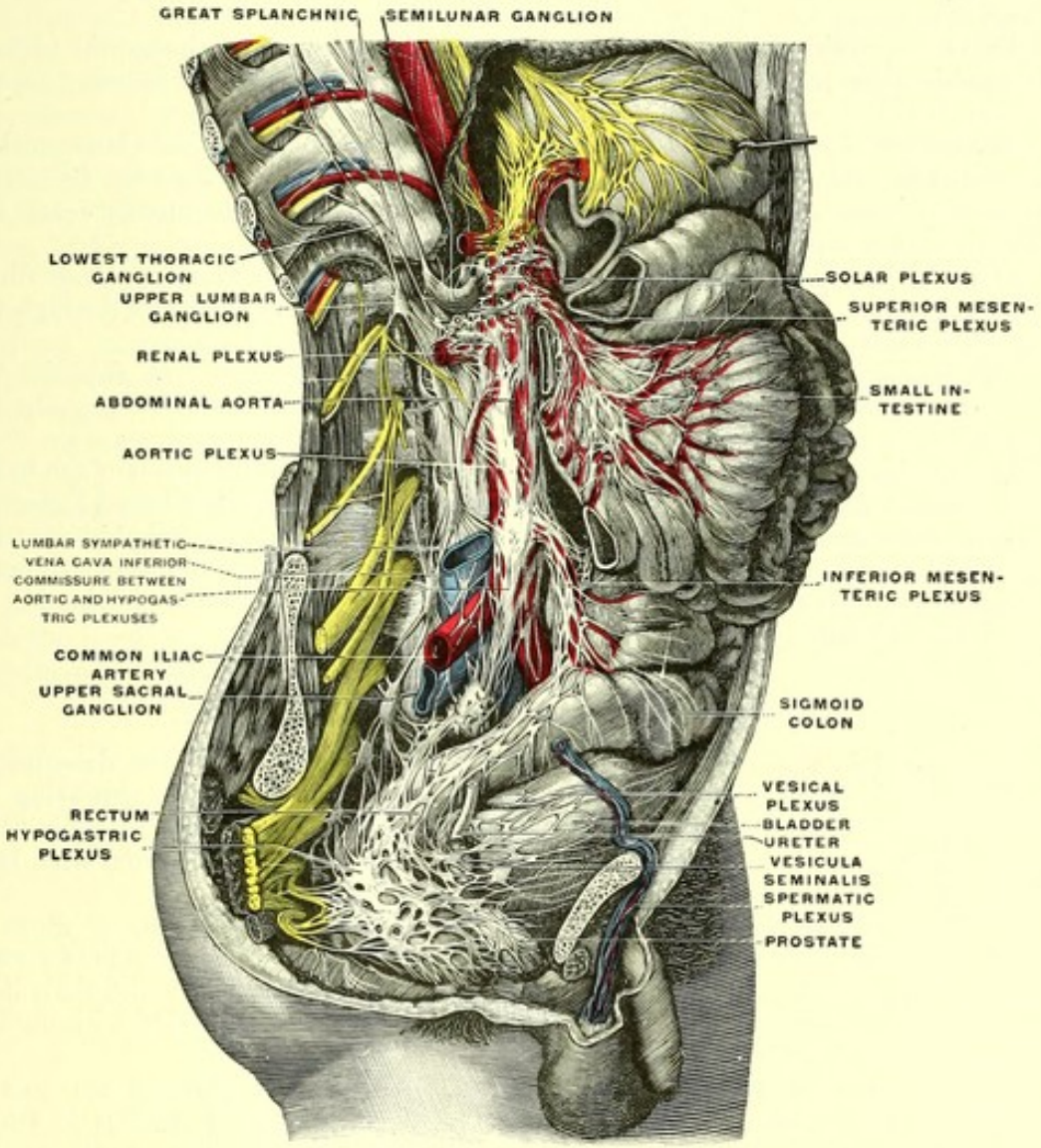

FIG. 694.—Lower half of right sympathetic cord. (Testut, after Hirschfeld.)

joined by branches from the lumbar ganglia, gives off the inferior mesenteric plexus and branches to the spermatic plexus and inferior vena cava, and ends below in the hypogastric plexus.

The *inferior mesenteric plexus* is derived from the aortic. It corresponds in distribution and communications with the artery of the same name.

The Hypogastric Plexus.—Branches from the aortic plexus descend on the aortic bifurcation to the front of the fifth lumbar vertebra, where they are joined by strong fibres from the lower lumbar sympathetic ganglia, which cross over the common iliac arteries. These form together in front of the fifth lumbar vertebra a coarse meshwork invested in dense fibrous tissue, called the hypogastric plexus.

It contains no ganglia. In front of the sacrum it splits into two lateral portions, which join the pelvic plexuses.

The Pelvic Plexus.—Lying on each side of the rectum and bladder in the male, and of the rectum, vagina, and bladder in the female, is a network, rich in ganglia where the fibres interlace, formed by the continuation of the hypogastric plexus, offsets from the upper sacral ganglia, and branches from the second, third, and fourth sacral nerves. This is the *inferior hypogastric* or *pelvic plexus*. From this branches are distributed to the pelvic viscera, which at first follow the branches of the internal iliac artery, their terminal twigs leaving the vessels and entering the substance of the organs. Thus the following secondary plexuses are formed, viz :

The *hemorrhoidal plexus*, derived from the upper part of the pelvic plexus, accompanies the middle hemorrhoidal artery and joins with the plexus on the superior hemorrhoidal vessels in supplying the rectal wall.

The *vesical plexus* is a close network, rich in spinal fibres, which is best marked over the sides and base of the bladder. It gives off plexuses to the vasa deferentia and vesiculæ seminales, of which the former join the spermatic plexuses and the latter receive communications from the prostatic plexus.

The *prostatic plexus*, lying between the prostate and levator ani, sends fibres backward to join the plexuses on the vesiculæ seminales and forward through the triangular ligament to the corpus cavernosum.

The *vaginal plexus* is largely composed of spinal nerves. It supplies the mucous membrane and erectile tissues of the vagina, and sends twigs to the clitoris.

The *uterine plexus* is mainly derived from the pelvic continuation of the hypogastric plexus and third and fourth sacral nerves. It enters the broad ligament, communicates there with the ovarian plexus, and is mainly distributed over the neck and lower part of the body of the uterus. It contains numerous ganglia. The apparent hypertrophy of these nerves in pregnancy is due to thickening of their fibrous sheaths.

The Sacral Portion of the Gangliated Cord.

In the pelvis the sympathetic trunks, much diminished in size, descend on the inner sides of the anterior sacral foramina, a ganglion usually appearing for each of the four upper sacral nerves. In front of the coccyx the two cords unite in one ganglion, called the *ganglion impar*, which is usually connected with both coccygeal nerves.

Short rami communicantes connect each of these ganglia with one or more of the sacral nerves, and rami efferentes join the pelvic plexus, while others form a plexus on the middle sacral artery or pass to the sacrum and coccyx and their ligaments. Through the pelvic plexus the pelvic viscera are supplied with motor, vasomotor, and secretory fibres.

The Prevertebral Plexuses of the Sympathetic.—These plexuses are named respectively the cardiac, solar, hypogastric, and pelvic. Each plexus is single and median, and is composed of nerves derived from both sympathetic trunks, with others derived from the cerebro-spinal nerves. Ganglia are developed in their meshes and from them subsidiary plexuses are formed.

The Cardiac Plexus.—Beneath and behind the aortic arch is a meshwork of nerve-fibres, which for convenience of description is divided into a superficial and a deep portion, though the two form one continuous plexus. The nerves entering into this plexus are the superior and inferior cervical cardiac branches of the vagi, the thoracic cardiac branches of the same nerves, and the superior, middle, and inferior cardiac branches of the sympathetic.

Of these nerves the superior cardiac branch of the left sympathetic trunk, and the lower cervical cardiac branch of the left pneumogastric form, in the concavity of the aortic arch, the *superficial cardiac plexus*. In its meshes is a small ganglion,

the *ganglion of Wrisberg*. It sends branches to the right coronary plexus and left anterior pulmonary plexus, the latter accompanying the left branch of the pulmonary artery.

All the other cardiac nerves above mentioned join in forming the *deep cardiac plexus* which lies in the bifurcation of the trachea behind the aortic arch. From it branches are distributed to both auricles, both coronary plexuses, and both pulmonary plexuses.

Of the *coronary plexuses* the right is the smaller. It is derived from both cardiac plexuses, its branches surrounding the root of the aorta. It descends on the right coronary artery, sending filaments to ramify between the pericardium and muscular wall of the heart, the ultimate fibres entering the muscle substance.

The left coronary plexus is derived from the deep cardiac plexus. It passes between the pulmonary artery and left auricular appendix, and accompanies the left coronary artery.

The Solar or Epigastric Plexus.—Lying in front of the crura of the diaphragm and at the sides of the aorta, just after that vessel appears in the abdomen, are two large ganglionic masses united to each other by a coarse network of nerve fibres, which surrounds the origins of the cœliac axis and superior mesenteric arteries. This is the *solar* or *epigastric plexus*. It lies behind the stomach, above the pancreas, and between the suprarenal bodies.

Each ganglionic mass presents one large irregular body at its upper part, called the *semilunar ganglion*, which receives the great splanchnic nerve at its upper angle.

Continuous with the semilunar ganglion, but marked off from it by a constriction, is a smaller body, the *aortico-renal ganglion*, which receives the small splanchnic, and gives off the greater part of the renal plexus ; while a still smaller body, lying to the right of the superior mesenteric artery, forms the *superior mesenteric ganglion*.

Through this plexus the abdominal viscera above the pelvis are connected with the lower six thoracic ganglia and thoracic spinal nerves, and it is significant that these last supply the abdominal wall.

THE ORGANS OF THE SPECIAL SENSES.

THE five senses of touch, taste, smell, hearing, and sight have as their special organs the skin, the tongue, the nose, the ear, and the eye respectively. Of the five the commonest, the least specialized sense is that of touch, and its organ is of the greatest extent and the smallest differentiation. The other senses display progressively increasing delicacy in the order as named above: touch is excited only by the impact of some body; taste requires the contact of the solution of a sapid substance; smell is produced by the impression of volatilized materials; hearing results from the agitation of the endolymph (a fluid contained in the ear), whose wavelets beat upon the auditory surface; and sight is called into being only by the undulations of the ether which is believed to pervade all space. The organs of the senses above the tactile are either localized, inward extensions of the integument or inversions of it, which have become completely isolated. In every case there is a modification of the epithelium of the area concerned, amounting to a specialization. These epithelial cells have already been mentioned, as forming the variety called *neuro-epithelium* for the reason that they are so peculiarly related to specialized portions of the nervous system. From all of these facts it will be seen that tactile sensibility is the humble progenitor of every other sense, and that, unlikely as it seems to one who does not consider everything which is involved, sight is but touch glorified.

THE SKIN.

By W. KEILLER.

AS one of the main functions of the skin is *the sense of touch*, it may be conveniently described among the sensory organs; though, in addition to serving this function, it is protective, and excretory, and an important regulator of the body temperature.

It consists (Fig. 695) of a deep layer, called the *true skin* or *corium*, which contains nerve endings, vessels, sweat glands, hairs, and sebaceous glands, embedded in a fibrous matrix; and a superficial, epithelial layer, the *epidermis or cuticle*, which covers and protects the whole, and furnishes the epithelial elements of the glands and hairs just mentioned.

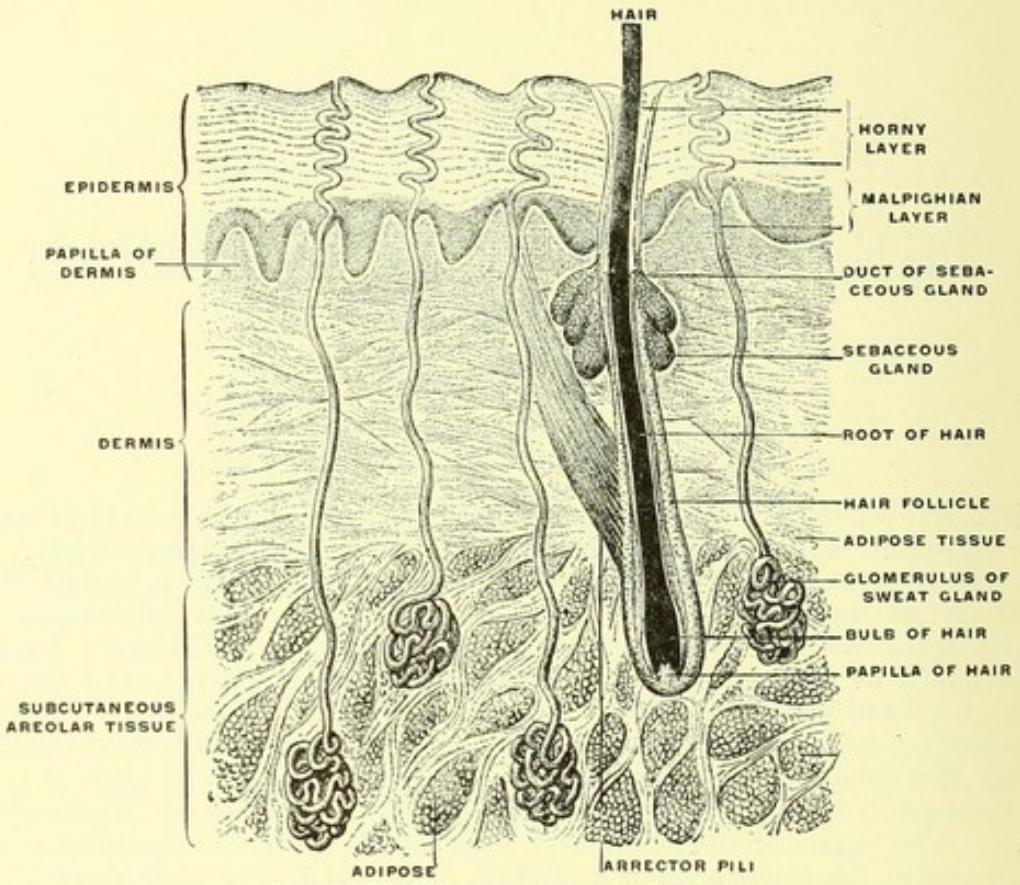

FIG. 695.—Vertical section of the skin. (Testut.)

Examined on the surface the skin varies much in texture, being rough and thick on the palms of the hands and soles of the feet, even of the newborn child; of medium thickness on the scalp and dorsal surface of the trunk, and thinnest on the ventral surface of the trunk and inner surfaces of the limbs. It is marked throughout by furrows which differ in character. Over most of the body the furrows are like those on the back of the hand, shallow and intersecting each other so as to enclose angular areas, the hairs usually springing from intersecting points. On the palm and sole the furrows run in parallel lines, forming definite patterns (Fig. 696), which, while they correspond in the main, are peculiar to each individual, and never change throughout life in spite of the passage of the soft palm of babyhood into the horny hand of age and toil. Hence the value of the hand impression in wax as a means of identification. These ridges and grooves are formed in the true skin on which the cuticle is accurately moulded. Deep and long grooves subtend the joints. The true skin blends with the loose subcutaneous tissue, and by its agency is made freely movable on the deep fascia. On the palms, soles, scalp, and pinna, however, the skin is closely bound to the deeper aponeurotic structures. The hairs and nails are modified epidermis, the sweat and sebaceous glands epithelial invaginations.

FIG. 696.—Arrangement of the papillary folds on the palmar surface of the distal segment of the thumb. (Testut.)

The **Epidermis** (cuticle, scarfskin) is formed of stratified epithelium in many layers. It varies from $\frac{1}{240}$ to $\frac{1}{24}$ of an inch in thickness, being thickest on the palms and soles. It is roughly divisible into two strata, the *Malpighian layer*

(which includes the four deep layers to be described) and a superficial, *horny layer*. Next to the true skin is a single layer of *columnar cells*, the parent cells of the rest; then come *polyhedral cells* to a considerable depth, each communicating with its neighbors by strands of protoplasm, giving them a prickly appearance (hence the term "prickle cells"). This stratum is covered by two thin strata, which exhibit changes antecedent to their assuming the characters of the horny layer, namely the *stratum granulosum* and the *stratum lucidum*. Their peculiar appearance is due to a progressive accumulation in droplets of a substance called eleidin. Superimposed on these is the horny layer (*stratum corneum*), the cells of which become gradually more flattened toward the surface, lose their nuclei, and have their substance converted into keratin. During life the superficial cells of this layer are being constantly shed and renewed from those beneath. The pigment in the skin of the negro, as well as that of the nipple and elsewhere in white races, is found in the deepest cells of the Malpighian layer.

The **True Skin** (*cutis vera*, *derma*, *corium*) consists of a fibrous matrix with vessels, lymphatics, and nerves embedded therein. It blends gradually with the superficial fascia, in which, with the exception of that on the penis, scrotum, labia minora, and eyelids, clusters of fat cells are accumulated. This loose areolar subcutaneous layer enables the skin to move freely on the deep fascia. The true skin is formed of interlacing bundles of white fibrous tissue with numerous elastic fibres and connective-tissue corpuscles. In connection with the hairs, and in the cutis vera of the scrotum, penis, perineum, areola of the nipple, and the nipple itself, smooth muscular fibres are found in fasciculi. The free surface of the corium is raised to form the ridges already described as seen on the surface of the skin, and on their summits simple and compound *papillæ* are developed, which are received into pits on the deep surface of the cuticle (Fig. 697). These papillæ are most numerous where sensation is most acute, as on the

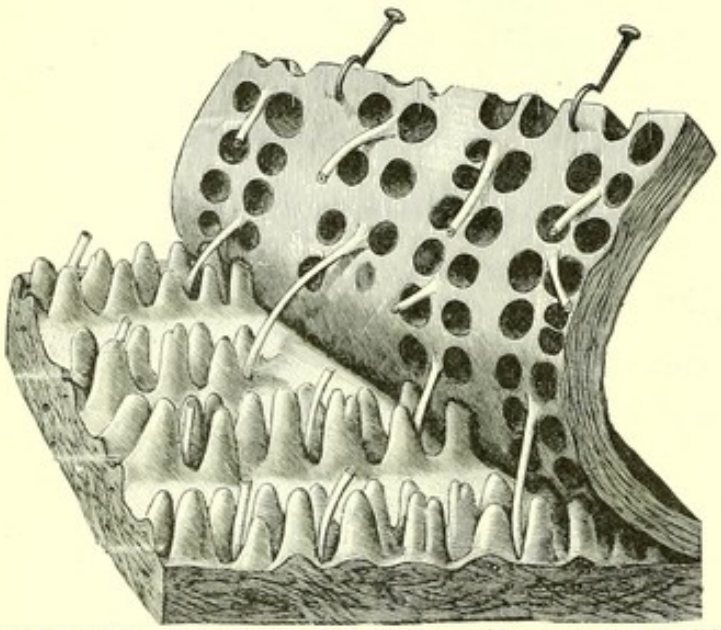

FIG. 697.—Papillæ of the skin. The epidermis has been loosened by maceration and lifted off, and its under surface shows the pits into which the papillæ fitted. Sweat-glands are stretched or broken across. (Testut.)

pulp of the fingers. On the palm, sole, and nipple they are numerous and measure from $\frac{1}{200}$ to $\frac{1}{100}$ inch in height. They are few and small on the face, and in some parts are altogether absent. Some of these papillæ have vascular loops prolonged into them, some have touch-corpuscles (Fig. 698).

The *bloodvessels* of the skin are found in the cutis vera only. They form a capillary network from which branches pass to the hairs, glands, and fat, and capillary loops project into the papillæ. The *lymphatics* form a deep and super-

ficial network accompanying the vessels. As in other tissues they originate in the intercellular spaces.

The **cutaneous nerves** form a subepithelial plexus, from which twigs are given

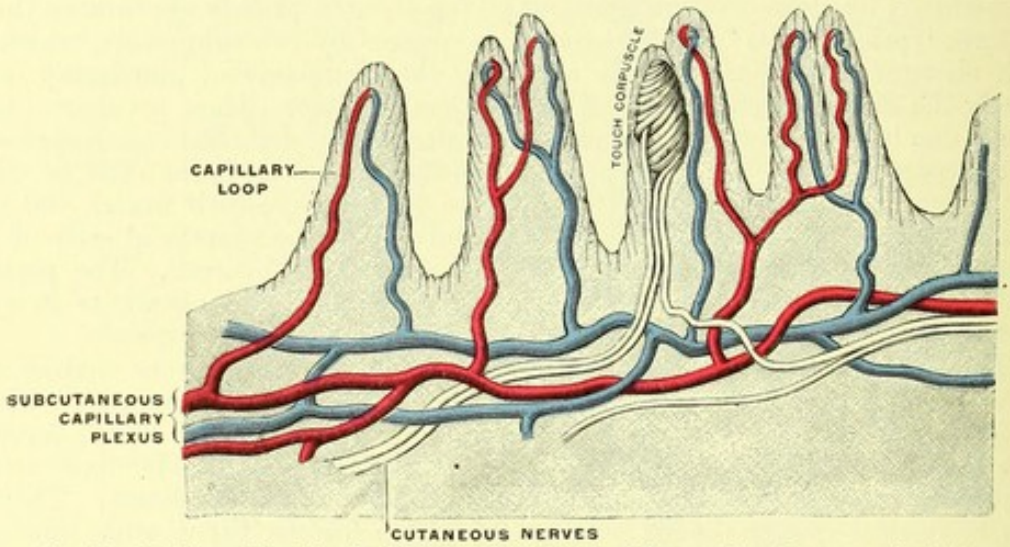

FIG. 698.—Papillæ of the skin, showing the arrangement of the vessels and nerves. (Testut.)

off to end in special terminal bodies of varied character, or, again, each fibre may divide and redivide dichotomously, soon losing its medullary sheath, the axis cylinder ultimately breaking up into its constituent fibres, which end in minute

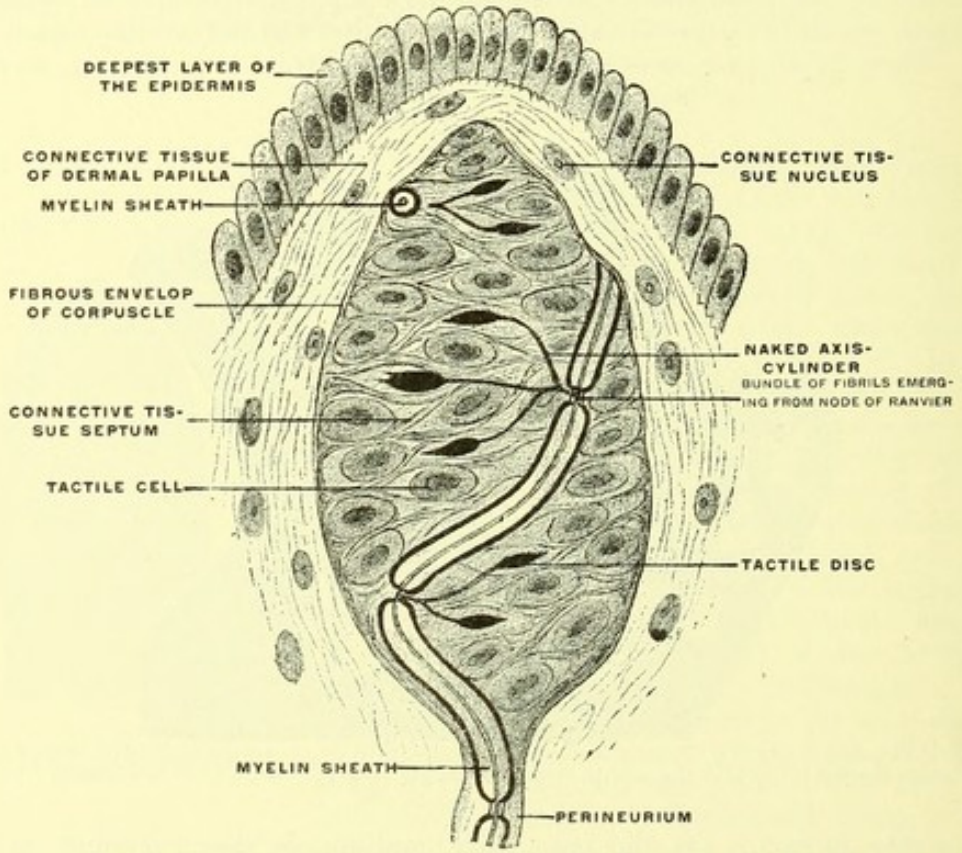

FIG. 699.—Touch-corpuscle in vertical section. Semidiagrammatic. (Testut.)

knob-like processes among the cells of the Malpighian layer. The forms of end organs are very numerous, but we will describe only those known as touch-corpuscles, end bulbs, and Pacinian bodies.

Touch-corpuscles (Fig. 699) are found in the dermal papillæ of the palm and sole, nipple, conjunctiva, lips, and tip of the tongue. They are ovoid bodies with

a fibrous capsule sending septa into the interior. One or more medullated fibres either at once enter the corpuscle, or first wind round it several times. On entering, the nerve loses its medullary sheath, and its axis cylinder breaks up into fibrils, which ramify minutely through the corpuscle, oval swellings forming on the branches.

End bulbs of spheroidal form are found in the papillæ of the skin of the lips, of the glans penis and glans clitoridis, in the conjunctiva, in the mucous membrane of the cheeks, soft palate, tongue, epiglottis, and rectum. Similar organs are found in the sheaths of nerve trunks. These bodies consist of a connective-tissue capsule containing nucleated cells, among which the axis cylinder of the nerve terminates.

Pacinian Corpuscles (Fig. 700) are small, seed-like bodies, $\frac{1}{15}$ to $\frac{1}{10}$ of an inch long, and $\frac{1}{26}$ to $\frac{1}{20}$ of an inch thick, found in clusters on the digital nerves of the hand and foot, and in many other situations. A Pacinian corpuscle is lamellated like an onion, having in some cases 40 to 60 coats, the inner laminæ thinner and more closely packed than the outer. The lamellæ are fibrous in character,

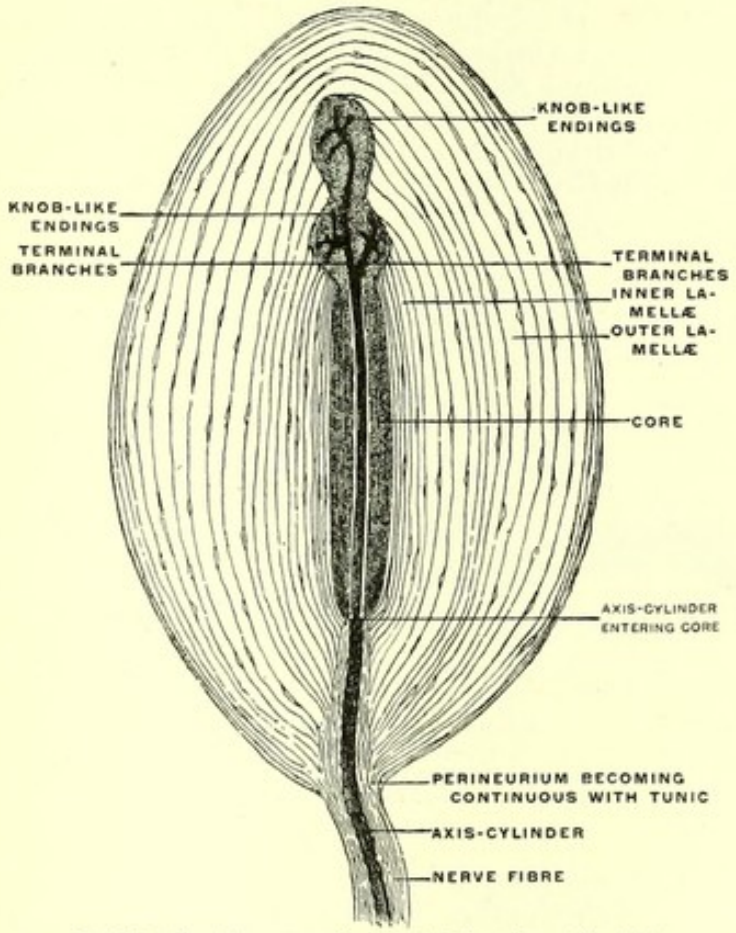

FIG. 700.—Pacinian corpuscle in vertical section. (Testut.)

continuous with the layers of the perineurium, and have lymph-spaces between them. In the centre of the body is an elongated, homogeneous core, into which the nerve penetrates. It courses along the middle of the core till it approaches the opposite end of the corpuscle, and then divides into processes, which end in bulbous extremities. Each corpuscle is supplied with a small capillary vessel, and has a distinct fibrous capsule.

NAILS AND HAIRS.

The nails and hairs are formed of modified epithelium on a special dermal substratum.

Nails.

Each nail (Figs. 701–703) consists of a *body*, which is translucent, showing readily the red glow of the underlying capillary vessels, except at its proximal extremity, where it is more opaque over a crescentic area called the *lunula*. The opacity and consequent whitish color is due to the greater thickness of the Malpighian layer in this situation. The *free edge* of the nail overhangs the tip of the digit; its *root* is embedded proximally in a deep groove in the skin, from which an epidermal *mantle* projects over the lunula. Its lateral *borders* are sunk in furrows, which have an overhanging *nail-wall* of upfolded skin. From free edge to lunula the nail is closely adherent to an epidermal *nail-bed*, but from the lunula to the proximal margin of the root this bed is called the *matrix*, because it is here only that the growth of nail takes place. The *nail-substance* consists of flattened, closely-packed cells, which, on addition of an alkali, swell up and are seen to retain their nuclei; hence they represent a condensed stratum lucidum. The nail-bed is essentially the Malpighian layer, its cells being more heaped up over the matrix, as already stated. The dermal constituent of the matrix is exceedingly vascular, and studded with large vascular papillæ, while the derma under the nail-bed is raised into parallel longitudinal ridges.

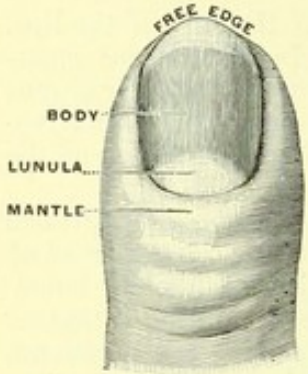

FIG. 701. — Thumb-nail. (Testut.)

Hairs (Figs. 704, 705).

With a few exceptional areas the whole skin is studded with hairs, varying in texture from the fine down (*lanugo*), scarcely projecting beyond the hair

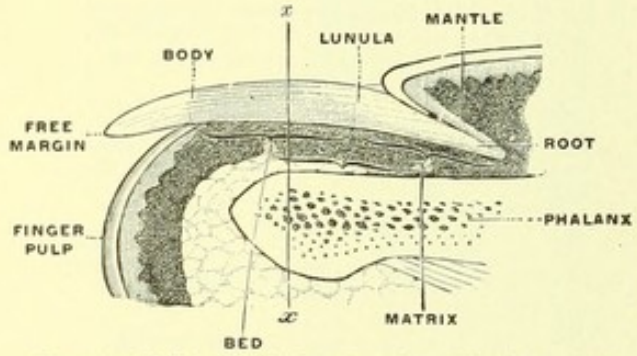

FIG. 702.—Nail in longitudinal section. The line *xx* indicates the plane of the section shown in the following figure. (Testut.)

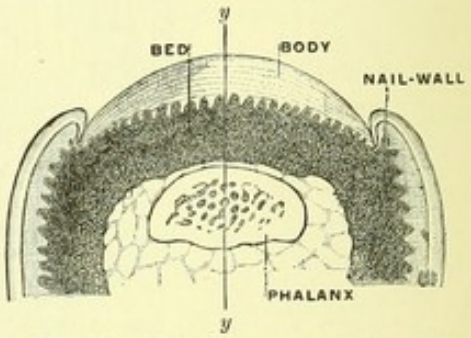

FIG. 703.—Nail in transverse section. The line *yy* indicates the plane of the section shown in the preceding figure. (Testut.)

follicles, found on the eyelids and inner surface of the labia majora, to the long hairs of the scalp, and short, crisp, thick hairs of the beard and pubes. The skin of the palms and soles, the dorsal surfaces of the third phalanges of the fingers and toes, the inner surface of the prepuce in the male, the labia minora in the female, the glans penis and glans clitoridis are devoid of hairs. In straight-haired races the hairs are thick, coarse, and cylindrical, in crisp-haired races thin and flattened, being oval on section. Dark hairs are coarser than those of lighter color.

The portion of a hair projecting beyond the surface is its *shaft* or *stem*, that embedded in the skin is its *root*. The root ends in a *bulbous enlargement*, which is implanted on a dermal *papilla*. It is contained in an invaginated tube of skin, called a *follicle*, which furnishes it with an outer *dermic* and an inner *epidermic coat*.

A hair has on its surface a single layer of thin, imbricated, scale-like cells,

their free margins pointing outward. These form the hair *cuticle*. Next comes the *cortical substance*, some hairs having in addition a medulla or pith. The cortical substance consists of closely set elongated cells, which still retain a trace of a nucleus. The cells and intercellular spaces contain pigment, varying in amount with the color of the hair. Between the cells are air-spaces, the air being most abundant in white hair. In the thick, short hairs of the pubes, the hair of the beard, and in white hair in the scalp there is a central *pith*. It is composed of irregular, polyhedral cells, containing many air-spaces. The pith does not extend to the point of the hair, is not present in children under five years of age, and is not found in the colored hairs of the scalp, or in fine hairs.

Toward the bulb the cells which form the hair become polyhedral, and resemble the cells of the Malpighian layer. The bulb expands to enclose a vascular papilla of cutis vera.

The **hair follicle** (Fig. 705) has dermic and epidermic constituents. The dermic coat consists of three layers. The outer layer is formed of longitudinally

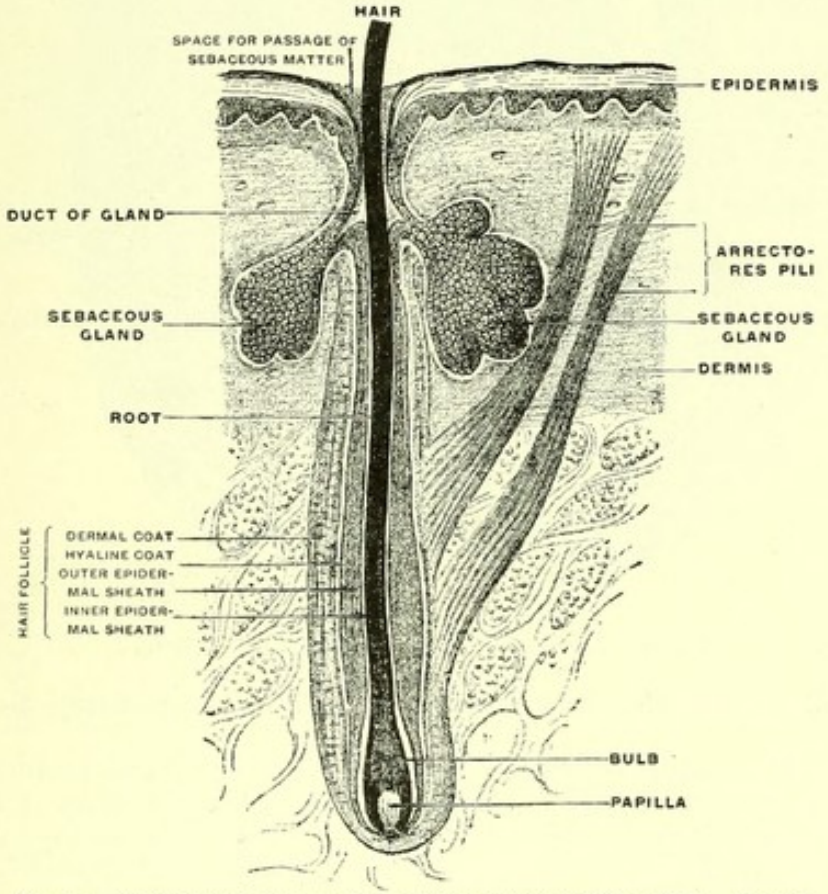

FIG. 704.—Vertical section of the skin, showing a hair and its follicle. (Testut.)

arranged white fibres with connective-tissue corpuscles, and numerous vessels and nerves. It is continuous with the reticular layer of the corium. Within this is a layer of circular fibres, which appears to represent the papillary layer of the corium, and within these is a structureless lamina (the hyaline layer), representing the basement membrane of fœtal skin. These two inner layers extend out from the bottom of the follicle to the openings of the sebaceous glands. The *epidermic coat* is divisible into two parts, the *outer root-sheath*, which is simply the Malpighian stratum of the epidermis, and the *inner root-sheath*, which may be taken as representing the stratum lucidum, and presents three characteristic layers. On the outside, and next to the outer root-sheath is *Henle's layer*, a single layer of non-nucleated, flattened cells; then comes *Huxley's layer*, consisting of polyhedral cells, two or three deep; and lastly the *cuticle of the root-sheath*, a

single layer of flattened cells, imbricated on each other, so as to fit into the depression on the hair cuticle, their free edge thus being directed downward. All the layers of the root-sheath blend at the bottom of the follicle, and become continuous with the cells of the hair bulb. The inner root-sheath ceases where the sebaceous gland enters the hair follicle. Lastly the stratum corneum dips a little way into the mouth of the follicle.

The **hair-papilla** is a fungiform process, consisting of connective tissue with

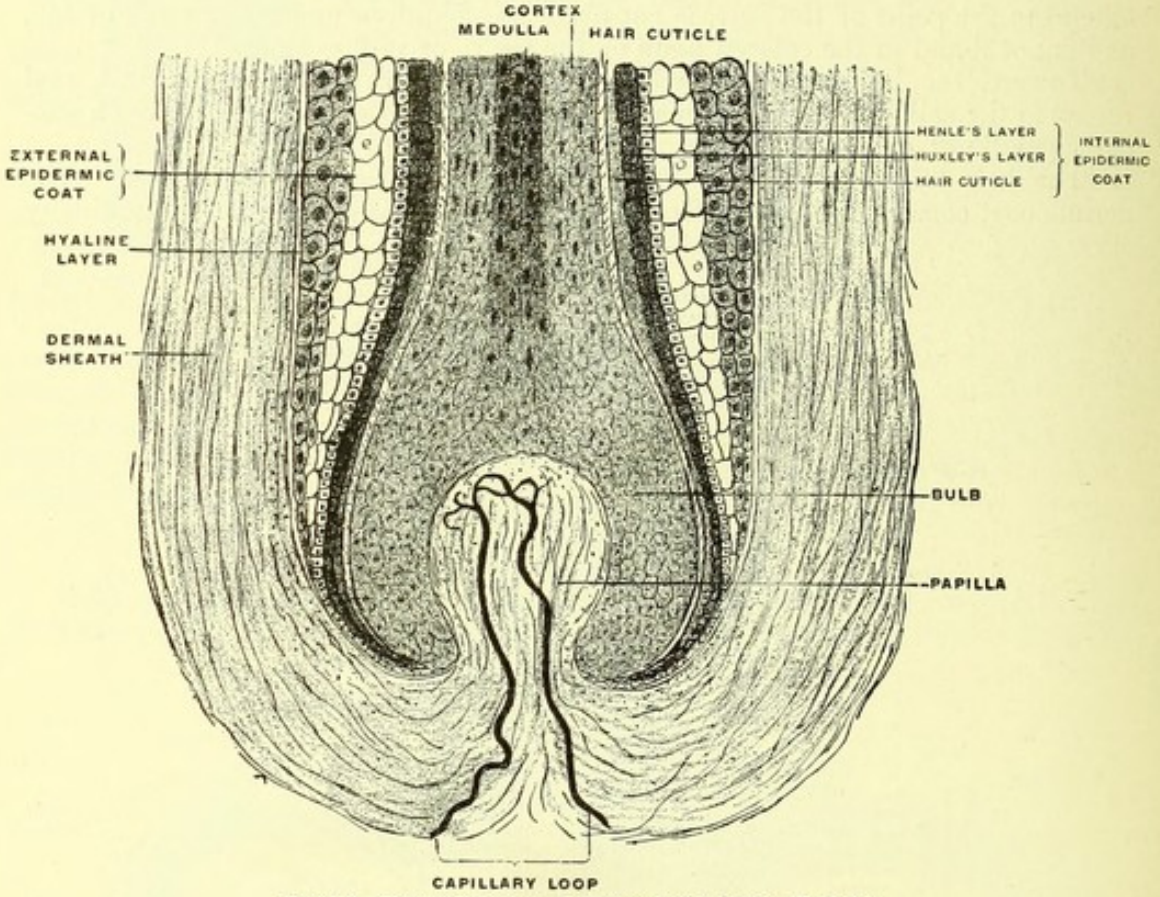

FIG. 705.—Vertical section of the root of a hair. (Testut.)

pigment cells and blood-vessels, which projects into a cup-shaped cavity in the bulb.

Muscles of the Hairs.—Slender bundles of unstriped muscle, the *arrectores pilorum* ("erectors of the hairs"), arise from the superficial layers of the corium and run obliquely inward to be attached to the fibrous coat of the hair follicles on the side toward which the hairs lie. They cause the hairs to stand erect.

Nerves are supplied to the fibrous coat and outer root-sheath, and perhaps to the papilla. They form a delicate plexus round the root-sheath.

The Sebaceous Glands (Fig. 704).

The sebaceous ("fat") glands usually open into the hair follicles, and are found wherever hairs are. But in addition they occur on the labia minora, prepuce, glans penis and glans clitoridis, the red edge of the lips, and, in a modified form, as Meibomian glands, in the eyelids. They are small on the head, large on the nose and most of the face, mons Veneris, labia majora, and scrotum. They are seldom simple, usually compound, saccular glands with short ducts, and lie between the hairs and their arrector muscles, so that the action of the arrectors will expel their fatty secretion. The number of acini in a single gland varies from four or five to twenty.

The Sweat-Glands (Fig. 695).

Except in the depths of the external auditory meatus and on the tympanic membrane, sweat-glands are found over the whole integument. They are most numerous on the palms of the hands and soles of the feet, 2800 to the square inch; on the back of the neck and trunk there are only 400 to 600 in the same area. They vary much in size, being largest in the axilla and groin. Krause estimates their total number as about two millions.

A *sweat-gland* is an invaginated, epithelial tube, which sinks through the corium into the subcutaneous fatty tissue, and there coils up into a ball. Thus it is a simple tubular gland, the coiled-up extremity being the secreting portion, the straight tube its excretory duct. In the epidermis the *duct* is a simple channel with no definite walls, and where the horny layer is thick it twists in cork-screw fashion. As it passes through the corium, the duct derives from it a richly vascular fibrous coat, within which is a basement membrane. The duct, much smaller than the coiled, secreting portion of the tube, is lined by small polyhedral cells, two deep, whose free surface is condensed into an appearance suggesting a delicate cuticle. In the *secreting segment* a layer of smooth muscular fibres, longitudinally arranged, is placed next the basement membrane, and on this a single layer of columnar cells with nuclei near their attached extremities. The ceruminous glands of the ear and the glands of Moll in the eyelid are modified sweat-glands. The sweat-glands in the axilla and round the anus and, of course, the ceruminous glands have an oily secretion; the rest secrete a colorless, slightly turbid, aqueous fluid, the perspiration.

THE TONGUE.

By F. H. GERRISH.

THE tongue has various functions. It is necessary for articulate speech, performs valuable service in the processes of mastication and deglutition, possesses tactile sensibility to a high degree, and is the principal organ of taste. It is only in its sensory relations that it will be considered in this place. Its other features will be described in connection with the other parts of the mouth and pharynx.

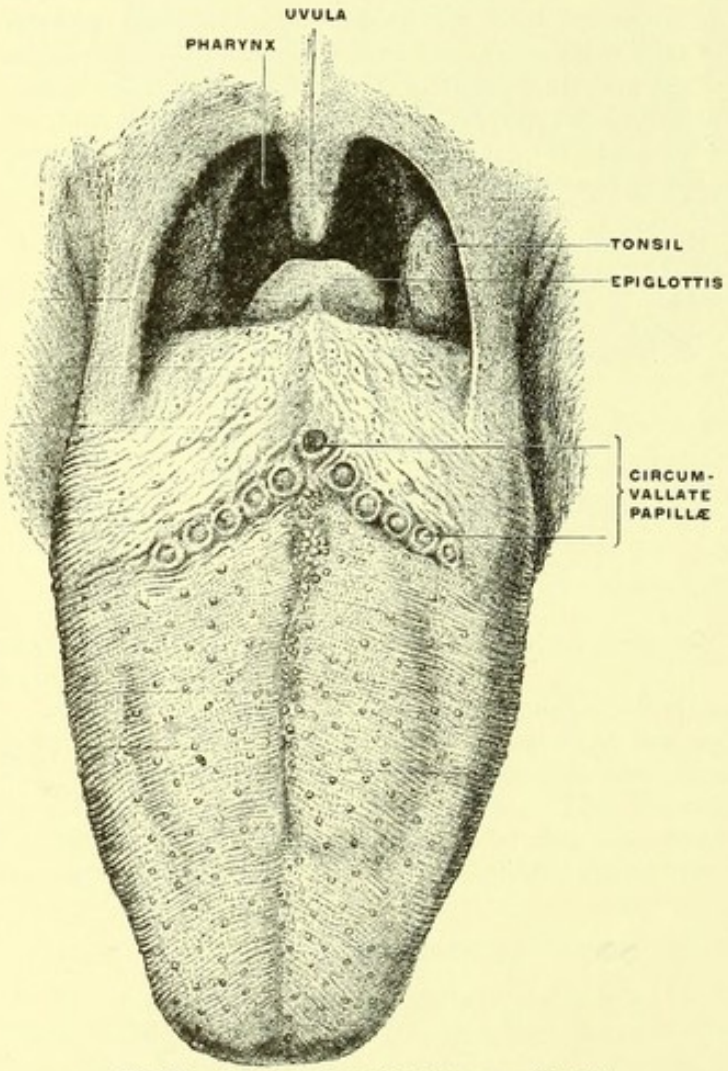

FIG. 706.—Dorsal surface of the tongue. (Testut.)

The *mucosa of the dorsum* (Fig. 706) is the only part of the tongue having gustatory capacity. The anterior two-thirds of this surface presents in the mouth, the posterior third in the pharynx, the boundary between the two being marked by a line of large projections, the *circumvallate papillæ*, arranged like an inverted V, with widely spread branches.

The *oral part* of the dorsum is besprinkled with smaller processes, the *fungiform papillæ*, and elsewhere this surface is completely covered with closely set ranks of a third variety, the *filiform papillæ* marshalled for the most part, especially behind, in lines nearly parallel on each side with the circumvallate.

The *pharyngeal part* of the dorsum is occupied by mucous glands, and small lymphoid masses, structurally similar to the tonsils, and arranged in lines parallel with the circumvallate papillæ.

The **Circumvallate** ("walled-around") **Papillæ** (Fig. 707) vary in number from seven to twelve. The base of each is broad, its summit wider still. Its core is a prolongation of the corium of the mucous membrane, and many *secondary*

papillæ project from its top. A thick, stratified epithelium, similar to that of the skin, covers the papilla completely, the superficial layers giving no evidence of the existence of papillæ beneath. Around the main papilla at a little distance is a circular rampart, whose top is as high as that of the papilla, and its structure identical with that of the latter. Occupying the entire thickness of the epithelium of the lateral surface of the papilla is a multitude of flask-shaped bodies, called *taste-buds* (Fig. 708). They are composed of two kinds of epithelial cells, gustatory and sustentacular, packed together closely.

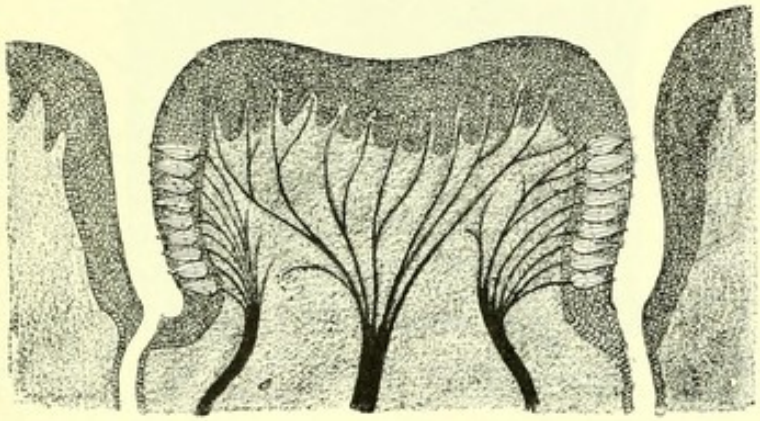

FIG. 707.—Circumvallate papilla in vertical section, showing arrangement of the taste-buds and nerves. (Testut.)

A *gustatory cell* is slender, except at its centre, which is bulged in every direction by a large nucleus. Its proximal end is often branched, and extends to the corium; its distal extremity is surmounted by a stiff cilium, which reaches almost to the surface. The *sustentacular cells* are fusiform, and are mostly situated in the peripheral parts of the taste-bud, though some of them are mingled with the gustatory. They furnish mechanical support to the other cells, and form a firm casing to the bud. The stratified, flattened epithelium, which clothes the papilla, presents a perforation, called a *gustatory pore*, at the spot where the distal extremity of the taste-bud approaches the surface, and thus the hairs of the gustatory cells can be affected by the direct contact of sapid solutions.

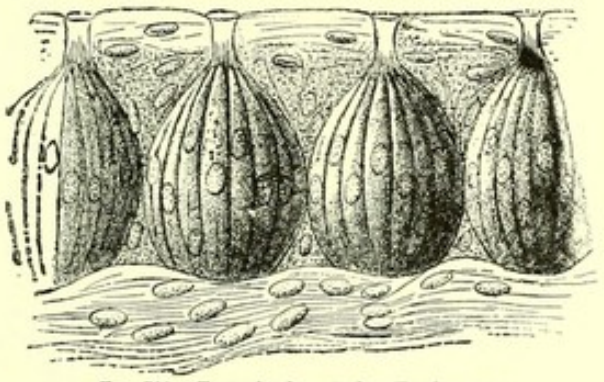

FIG. 708.—Taste-buds. (After Engleman.)

Taste-buds are found, also, in the wall surrounding the papilla, presenting their open ends toward the intervening ditch, as do those of the papilla itself.

The **Fungiform** ("mushroom-shaped") **Papillæ** (Fig. 709) are pediculated knobs, upon the rounded upper surface of which are many *secondary papillæ*. In the fungiform are found many taste-buds.

The **Filiform** ("thread-shaped") **Papillæ** (Fig. 709) are small, somewhat cylindrical, and bear *secondary papillæ*, upon which the epithelium is particularly dense, and drawn out into long, tapering threads.

To all of the varieties of papillæ *nerves* are supplied, entering through their bases, and sending filaments between the epithelial cells, but not establishing absolute continuity with them. The glossopharyngeal furnishes the hind third of the mucosa of the dorsum of the tongue, the lingual the remainder.

Taste-buds are scattered over the dorsal surface independently of papillæ, and are especially numerous in the posterior part.

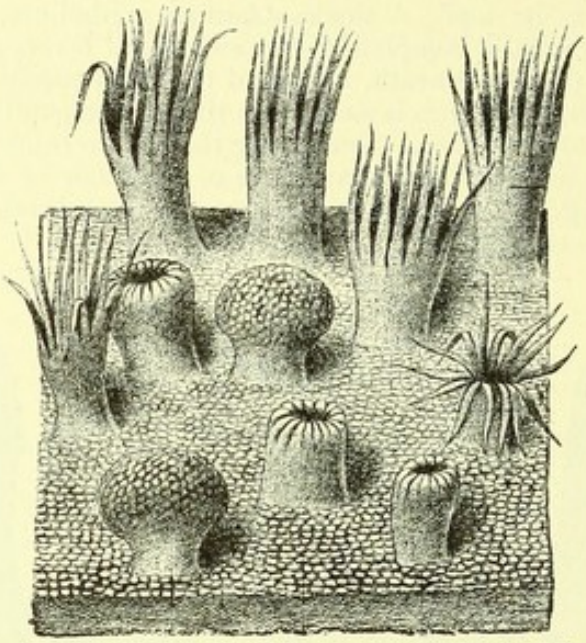

FIG. 709.—Semidiagrammatic view of a portion of the mucous membrane of the tongue. Two fungiform papillæ are shown. On some of the filiform papillæ the epithelial prolongations stand erect, in one they are spread out, and in three they are folded in. (Testut.)

Other Organs of Taste.

Although the tongue is the principal organ of the sense of taste, it has not a monopoly of this peculiar endowment. Taste-buds are found in the mucosa of the back part of the hard palate, on the anterior surface of the soft palate, and to some extent in other parts of the pharynx.

THE NOSE.

By W. KEILLER.

THE *nose* is the organ of *the sense of smell*. It forms on the face a prominence partly bony, partly cartilaginous. Its *root* springs from the *naso-frontal groove*, except in the Grecian type, where the dorsum of the nose is in a straight line with the forehead. The mesial ridge is called the *dorsum*, of which the upper bony segment forms the *bridge*. It ends below in the *tip*, which is continuous with the horizontal free edge of the septum, called the *columna nasi*. The sides of the nose form an angle with the face, which increases as it descends (the *naso-facial angle*). The rounded, lateral boundary of the nostril is called the *ala*.

The **Nasal Cavity** consists of two *fossæ*, separated from each other by a mesial *septum*. They open anteriorly by the two *nostrils* or *anterior nares*, and posteriorly by the *posterior nares* or *choanæ* ("funnels") into the upper part of the pharynx. The anterior nares are guarded by hairs, *vibrissæ*, which spring from their inner surface. Each expands into a smooth-walled, front chamber called the *vestibule*, the rest of the nasal cavity being divisible into three channels called *meatuses*. The width of the nostrils bears in different races a very varying relation to its length measured vertically.

The *skin* of the nose is fine and movable over the bony part, thick, adherent, and closely studded with large sebaceous glands over the tip and alæ. Its *vessels*

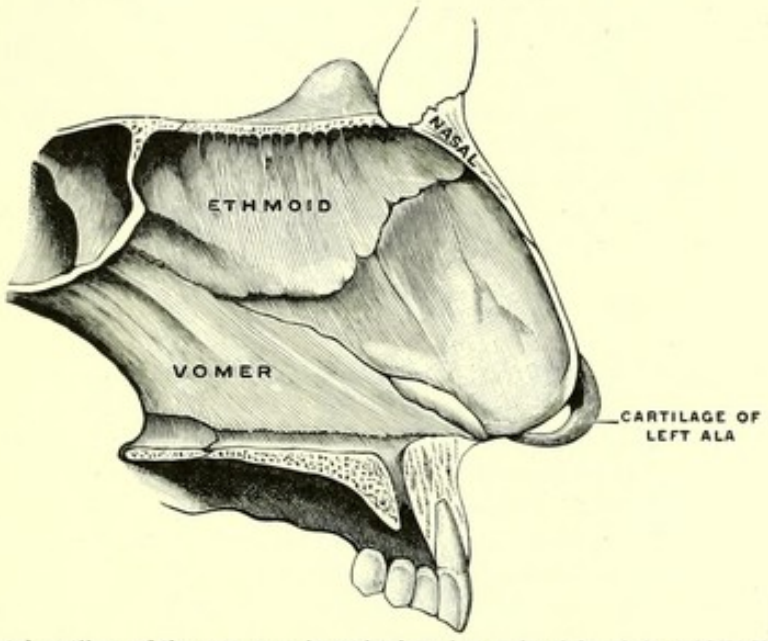

Fig. 710.—Septal cartilage of the nose, seen in sagittal section at the right of the middle line. (Testut.)

are derived from the ophthalmic and facial, and, being terminal, readily indicate the state of circulation. The lymphatics drain into the submaxillary nodes. The *sensory nerves* are derived from the infratrochlear, nasal, and infraorbital branches of the fifth; the *motor nerves* from the seventh. The *muscles* have been described among the muscles of the face.

The Nasal Cartilages.

At least two-thirds of the facial portion of the nose, and one-third of its septum have a framework of cartilage. Beginning with the *cartilage of the septum* (Fig. 710), the mesial plate is quadrilateral in form, completing the nasal septum. It articulates above with the nasal bones, behind with the vertical plate of the ethmoid, postero-inferiorly with the vomer, and nasal spine of the maxillæ, and antero-inferiorly with the septal portion of both lower lateral cartilages. In the fœtus, and occasionally in the adult, it sends a long limb or *processus posterior* into the ethmo-vomerine suture. The *upper lateral cartilages* (Fig. 711) are two lateral wings of the septal cartilage, which bend over to form part of the sides of the nose. They are triangular in shape, continuous with the septal cartilage in the middle line above, but separated from it below by a fissure, and articulate posteriorly with the free margins of the nasal bone and nasal processes of the maxillæ, small islets of cartilage sometimes intervening (cartilagines epactiles). Inferiorly they articulate with the lower lateral cartilages. Each *lower lateral cartilage* consists of two plates joined at an acute angle along the dorsum of the nose. The mesial plate is placed in apposition with its fellow to form the antero-inferior angle of the septum and part of the columna, a deep groove separating them in the middle line in front, while above they articulate with the cartilage of the septum. The lateral plate forms the lower part of the side of the nose, articulating above with the upper lateral cartilage, and posteriorly with the superior maxilla, two or three separate cartilages (*minor* or *quadrate cartilages*) being placed in the fibrous tissue which joins them. The lateral cartilages keep the anterior nares expanded. The ala contains no cartilage, but consists of skin and fibrous tissue only. Tough fibrous tissue fills in the interstices of this framework, and is continuous with periosteum and perichondrium. Two small strips of cartilage, not always separate from the septal cartilage, are interposed between the latter and the vomer. They enclose the organ of Jacobson, and are relatively large in the fœtus and in animals in whom the organ of Jacobson is well developed.

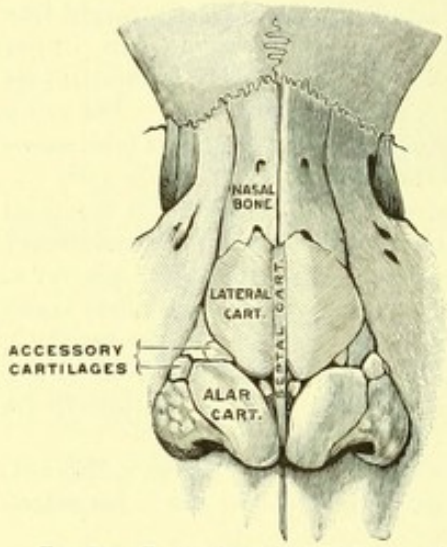

FIG. 711.—Front view of the skeleton of the nose. The upper lateral cartilage is labelled "lateral cart.," the lower, "alar cart." (Testut.)

THE NASAL FOSSÆ.

The *nasal fossæ* (Figs. 712, 713) have a very different appearance as seen with their mucous covering from that of their bony framework as described in the section on osteology. This difference is mainly due to the thickness of the mucous membrane, the complete closure of nervous or vascular foramina, and the narrowing of those openings which conduct to the air sinuses.

The upper part of each fossa, which corresponds in extent to the superior turbinate, is narrowed above at the roof, expanded below. It is the only part of the fossa which possesses the olfactory function. Below this the walls are nearly parallel. The anterior part of the fossa is unbroken by irregularities, and forms an expanded *vestibule*, into which the anterior aperture or nostril leads. Behind this each fossa has three awning-like processes projecting from its outer wall, formed by the turbinate bones, which, when covered with mucous membrane, nearly meet the septum. Thus three passages are formed. The *inferior meatus* is horizontal, lies along the floor half covered by the inferior turbinate, and extends from the vestibule to the pharynx. The *middle meatus* is overhung by

the middle turbinate, and is shorter and more oblique than the inferior; and the *superior meatus*, beneath the superior turbinate, is very short and oblique, and

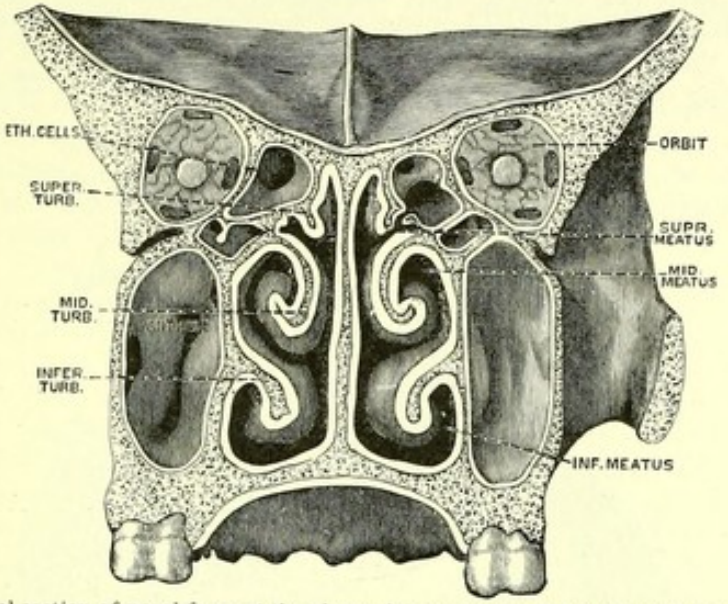

FIG. 712.—Coronal section of nasal fossæ at the plane of the second molar tooth, seen from behind. (Hirschfeld.)

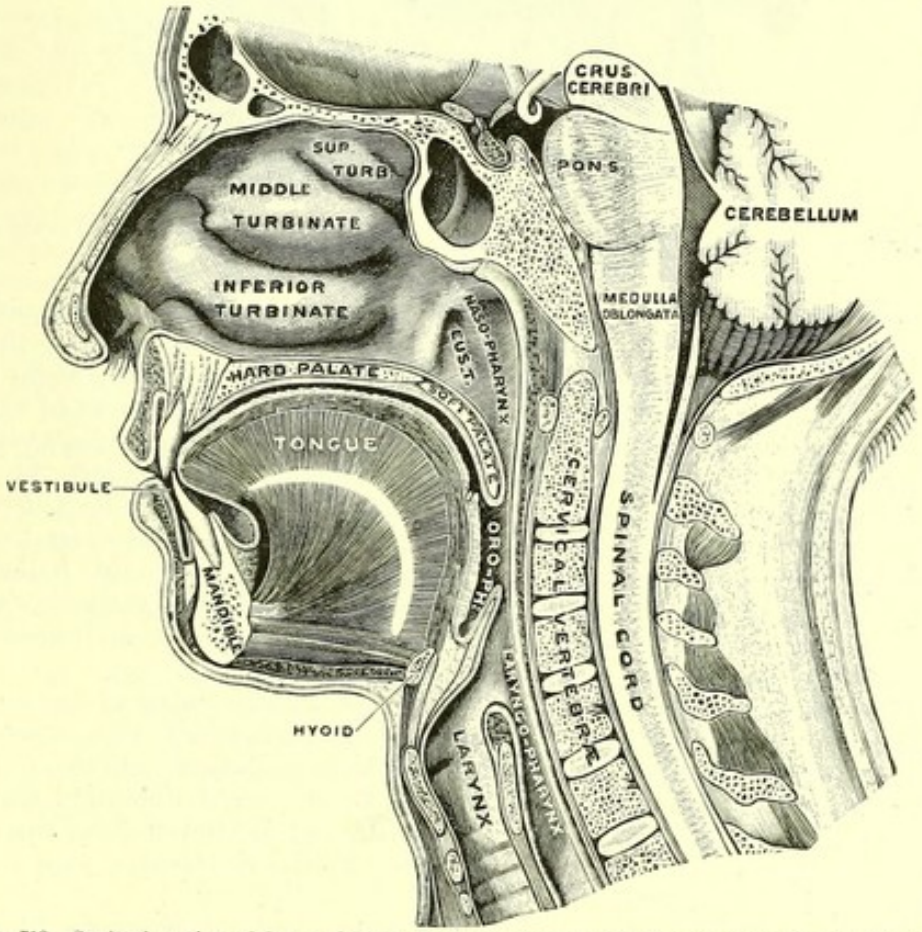

FIG. 713.—Sagittal section of face and neck, showing external wall of right nasal fossa. (Testut.)

confined to the supero-posterior angle of the fossa. Above the superior turbinate and between it and the sphenoid is an angular recess called the *spheno-ethmoidal recess*.

Cavities Opening Into the Nasal Fossæ (Fig. 714).

Various passages open into the nasal fossæ. Under cover of the anterior end of the inferior turbinate is the inferior opening of the *nasal duct*. It is guarded by a single or sometimes double fold of mucous membrane. In the floor of the nose, at the site of the nasopalatine canal, is a funnel-shaped tube of mucous membrane of varying depth called *Stenson's canal*. It is the relic of the communi-

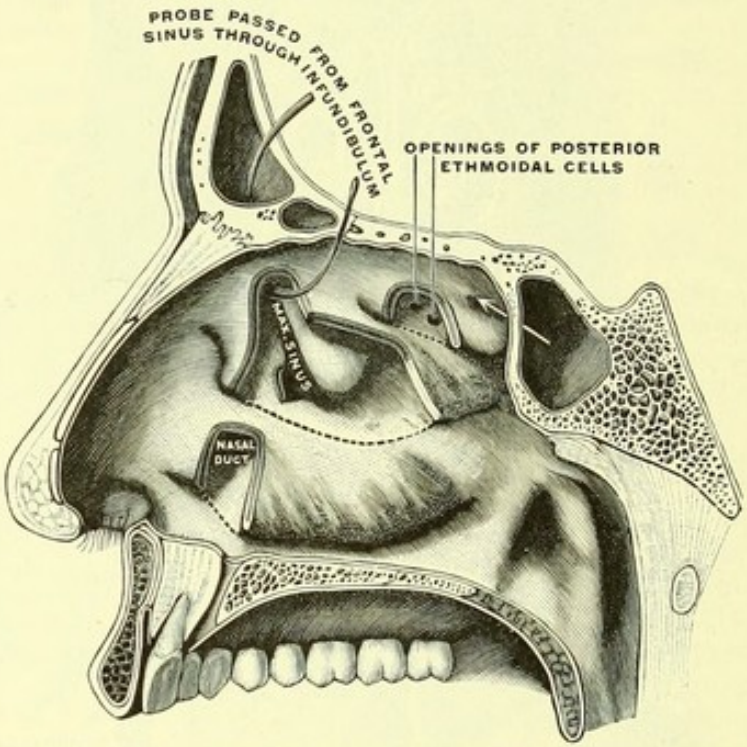

FIG. 714.—External wall of right nasal fossa, parts of the turbinates having been cut away to show the orifices of the sinuses which open into the meatuses. (Testut.)

cation between the nasal and buccal cavities, found in the early fœtus and permanent in some animals. Just above this there is sometimes seen on the nasal septum a depression leading into a minute canal, which runs backward for a short distance. This is the rudimentary *organ of Jacobson*. Under cover of the anterior extremity of the middle turbinate is a deep depression ; the *hiatus semilunaris* ("half-moon gap") which leads up to the *infundibulum* and thus into the *frontal sinuses*. In the bottom of the hiatus semilunaris is the *opening of the anterior ethmoidal cells*, the *maxillary antrum* communicating with the nose by the same aperture, or by a separate opening a little farther back. Above this is the orifice of the *middle ethmoidal cells*. Into the superior meatus the *posterior ethmoidal cells* open by one or two apertures, and the *sphenoidal antrum* communicates with the *spheno-ethmoidal recess*.

The **Pituitary Membrane** (*Schneiderian*) is the mucous lining of the nose. It is inseparably united with the periosteum and perichondrium over which it lies. In the nostril it is continuous with the skin. It is prolonged into the maxillary, frontal, ethmoidal, and sphenoidal sinuses. By the nasal duct and lachrymal canaliculi it is continuous with the conjunctiva, and behind it joins the mucous membrane of the pharynx, and communicates by the Eustachian tube with the middle ear and mastoid cells.

The *thickness and vascularity* of the membrane and the character of its epithelium vary in different situations. It is thickest and most vascular over the turbinates and septum, not so thick on the floor of the nose, and thin and pale in the sinuses. The character of the epithelium and the distribution of the nerves divide the nose into an upper, olfactory part, comprising the upper turbinate and

a corresponding area of the septum, and a lower, respiratory part, from the level of the lower border of the upper turbinate downward. The vestibule is lined with a continuation of the external skin, which presents a stratified, squamous epithelium, with hairs, sebaceous glands, and sweat-glands. The rest of the respiratory area of the nose is covered with stratified, ciliated, columnar epithelium, with goblet cells, on a delicate basement membrane. The *tunica propria* of the mucosa is composed of white fibrous tissue, rich in leucocytes, and traversed by a wide venous plexus, so that it resembles cavernous tissue. Compound, racemose glands open freely on the surface, and between them is much lymphoid tissue, sometimes accumulated into nodules, and some plain muscular fibres. The various air-cavities (ethmoidal, frontal, etc.) are very sparingly supplied with glands, and in them the tunica propria is very thin.

The mucosa of the olfactory area is yellowish brown in color. Its epithelium presents two kinds of cells, namely sustentacular and olfactory. The *sustentacular cells* are columnar in form, possess no cilia, have their nuclei oval and arranged in a single row near their embedded extremities, and end in branching processes, which fill the spaces between the expanded, nucleated portions of the olfactory cells. The *olfactory cells* are thickly set between those just described. Each cell has an expanded portion in the middle enclosing a round nucleus, and from this two processes project. A thicker rod-like process extends forward toward the surface between the sustentacular cells, ending in the frog in a tuft of fine hairs, and described by some observers as possessing in man exceedingly short hair-like processes. From the proximal end of the nucleated expansion a fine varicose filament courses through the tunica propria, and is continuous with a nerve-fibril, which joins the plexus formed by the olfactory nerve, and thus ends in arborizations in the glomeruli of the olfactory bulb. The nuclei of the olfactory cells are situated at various depths, so that the zone of spherical nuclei is of considerable thickness. Beneath these and lying directly on a thin basement membrane some observers describe a layer of small polygonal cells. The submucous tissue is rich in veins, which here also give the mucous membrane almost a cavernous character; and many tubular glands, either simple or only slightly branched, called the glands of Bowman, are embedded in the submucous tissue.

Nerves.—The olfactory region is supplied by the olfactory nerve and by branches of the fifth; the respiratory area by branches of the fifth only. The fifth nerve forms fine terminal ramifications among the epithelial cells. For the further description of these nerves see the section on the peripheral nerves.

The *organ of Jacobson* is an accessory olfactory organ, well developed in the rabbit, guinea-pig, and some other mammals, but rudimentary in man. It lies, as already described, embedded in the cartilage of Jacobson on each side of the septal cartilage near the floor. In man sustentacular cells only are found, but no true olfactory cells.

Vessels.—Branches of the internal maxillary, ophthalmic, and facial arteries supply the mucous membrane. The veins form so marked a plexus in the deeper parts of the mucosa as to cause it to resemble cavernous tissue. This is most pronounced over the lower turbinate, lower and hind part of the middle, and hind end of the upper turbinate, and the lower and hind part of the septum, and over the nasal duct. The lymphatics are very numerous. They join the lymph-spaces round the olfactory nerve, and thus communicate with the subdural and subarachnoid spaces.

THE EAR.

By F. H. GERRISH.

THE ear is the organ of the sense of hearing. In the animal in which it occurs in its simplest form it is merely a sac, lined with a sensitive membrane and filled with fluid. Agitation of the medium in which the animal lives causes waves in the fluid of the sac, their striking upon the sensitive membrane produces a thrill in the nerve, and this, being transmitted to the nerve-centre, is there interpreted as sound.

Next higher in the scale is an ear, which, in addition to the elements above named, has minute stony bodies in its cavity. The effect of these particles is to heighten the impression which the waves of fluid bearing them produce upon the sensitive nerve.

The human ear is an extremely complicated organ, but the essential part of it is constructed on precisely the plan of this primitive ear. The organ consists of three portions, named respectively the *internal ear*, the *middle ear*, and the *external ear*. Of these only the first, the internal ear, is of indispensable importance; the others are merely accessory to it.

THE INTERNAL EAR OR LABYRINTH.

The essential part of the internal ear is a *sac, lined with a sensitive membrane, and filled with a fluid, in which are hard particles.* The sac is so very intricate that it is called the *labyrinth*, and, to distinguish it from the bony cavity in which it is lodged, the adjective *membranous* is applied to it. The membranous labyrinth is situated in the petrous portion of the temporal bone. It does not completely fill the excavation which it occupies, but between it and the surrounding bony wall there is a space, which is filled with a fluid, called *perilymph* ("the water around").

The Membranous Labyrinth (Figs. 715, 717).

General Description.—The membranous labyrinth is a closed bag of fantastic shape, consisting of several segments, which have received distinguishing names. At the middle of the series are two sacs, of which the larger and posterior is called the *utricle*, and the smaller and anterior, the *saccule*. From the utricle extend three long loops, the *semicircular canals*; from the saccule one long, coiled process, the *canal of the cochlea*; and from each of the sacs a minute tube, which unites with its fellow, and thus completes the continuity of the labyrinthine cavity. The fluid which fills this unbroken series of chambers and tubes is called *endolymph* ("the water within").

The membranous labyrinth is lined throughout with epithelium, which is simple and flattened, except over the areas where the branches of the auditory nerve are distributed, and in these places it is especially modified.

The Utricle.—The utricle is a sac of irregular shape. Upon that part of its inner surface to which a branch of the nerve of hearing is distributed is an area, called the *macula acustica* ("auditory spot"), in which the wall is thickened, and the epithelium peculiarly modified, being changed from flattened into *neuro-epithelium*. Some of the cells become conoidal and have upon their free ends each a strong, stiff hair; and others, longer than these and resting upon the basement

membrane, act as mechanical supports for the hair-cells. Among the cells are twined many ultimate filaments of the auditory nerve. On the free surface of the macula is a plate of gelatinous material containing a vast number of crystals of carbonate of lime, called *otoliths* ("ear-stones"). These, being driven by the waves of endolymph forcibly against the projecting hairlets, produce a much more profound impression than would the waves, if their impact was not thus accentuated.

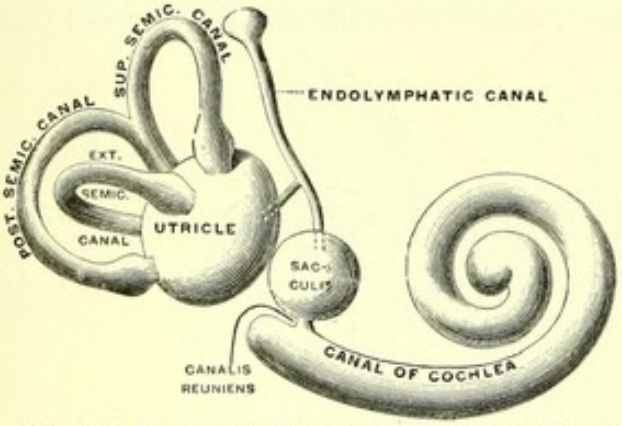

FIG. 715.—Membranous labyrinth of the right ear, viewed from the outer side. (Testut.)

The Semicircular Canals.—From the utricle the three semicircular canals are given off. They are named from their position the *superior*, the *posterior*, and the *external*. The superior and posterior extend upward and backward, but the planes of their curves are nearly at right angles to one another; the external passes horizontally outward. Each of these canals is dilated at one end into an *ampulla* ("a wine-jug"). At the other end the superior and posterior unite before reaching the utricle, and enter it by a common opening. Thus, there are but five apertures in the utricle for the three semicircular canals. In each ampulla is a marked ridge, the *septum transversum*, due to a thickening of the wall, and this is surmounted by the *crista acustica* ("auditory crest"), made up of peculiar neuro-epithelial cells (Fig. 716). From the top of the uppermost of each of these cells projects a very long, rigid, hairlike process, the series of them spreading out widely like an opened fan, and reaching half-way or more to the opposite side of the ampulla. Below these *hair-cells* are *sustentacular cells*, which support them on every side; and between the cells of both kinds are filaments of the auditory nerve, which, though in contact with the cells, have no continuity of tissue with them.

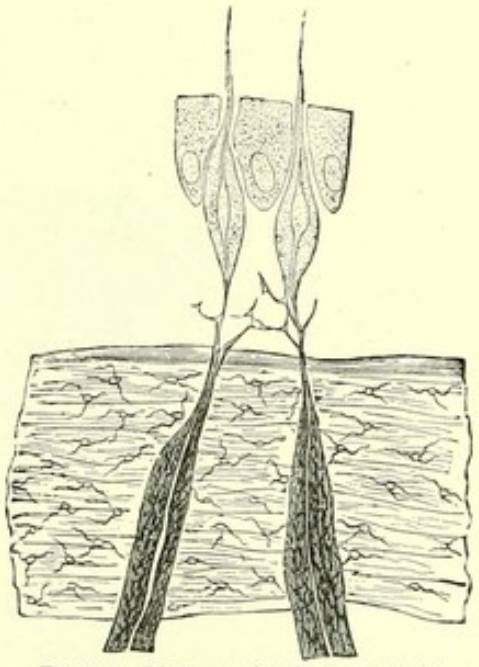

FIG. 716.—Diagram of auditory epithelium, and the mode of termination of the nerves of the ampullæ. (M. Schultze.)

The Saccule.—The saccule is much smaller than the utricle, and is situated farther forward and a little lower, but very close to it. It has a *macula acustica*, which is so like that of the utricle that it needs no separate description.

A minute tube, the *canalis utriculo-sacculuris*, is prolonged from the utricle, and a mate to it is given off from the saccule. The two unite and form the *ductus endolymphaticus*, a long tube, which ends in a bulbous expansion, the *saccus endolymphaticus*. Thus, though the utricle and saccule do not communicate directly, their cavities are connected by means of these ducts. From the saccule another tube gives a communication with the canal of the cochlea.

The Canal of the Cochlea[1] (Fig. 718).—The canal of the cochlea (also called

[1] In describing the cochlea, it is a matter of convenience to ignore its actual attitude, and to speak as if its summit were upward, its base downward; and this plan, which is conventional, will be followed here.

ductus cochlearis, and *scala media*, "the middle staircase") is a tube which, if straightened, would measure nearly one inch and a half in length. It communicates with the saccule through a short, narrow tube, the *canalis reuniens* ("the

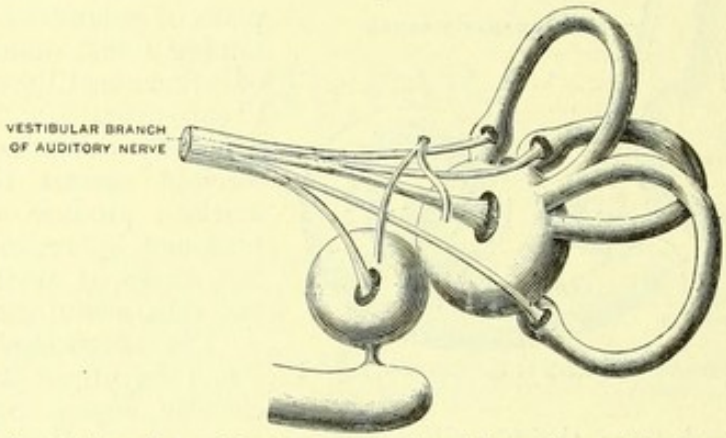

FIG. 717.—Saccule, utricle, and semicircular canals, viewed from the mesial side, showing points of entrance of the auditory nerve. (Testut.)

reuniting canal"). In shape it is prismoid, blunt at each end, tapering from its beginning to its apex, and coiled into a spiral. Of its three sides the upper is flat, and is made by the thin *membrane of Reissner*. Its outer wall is somewhat

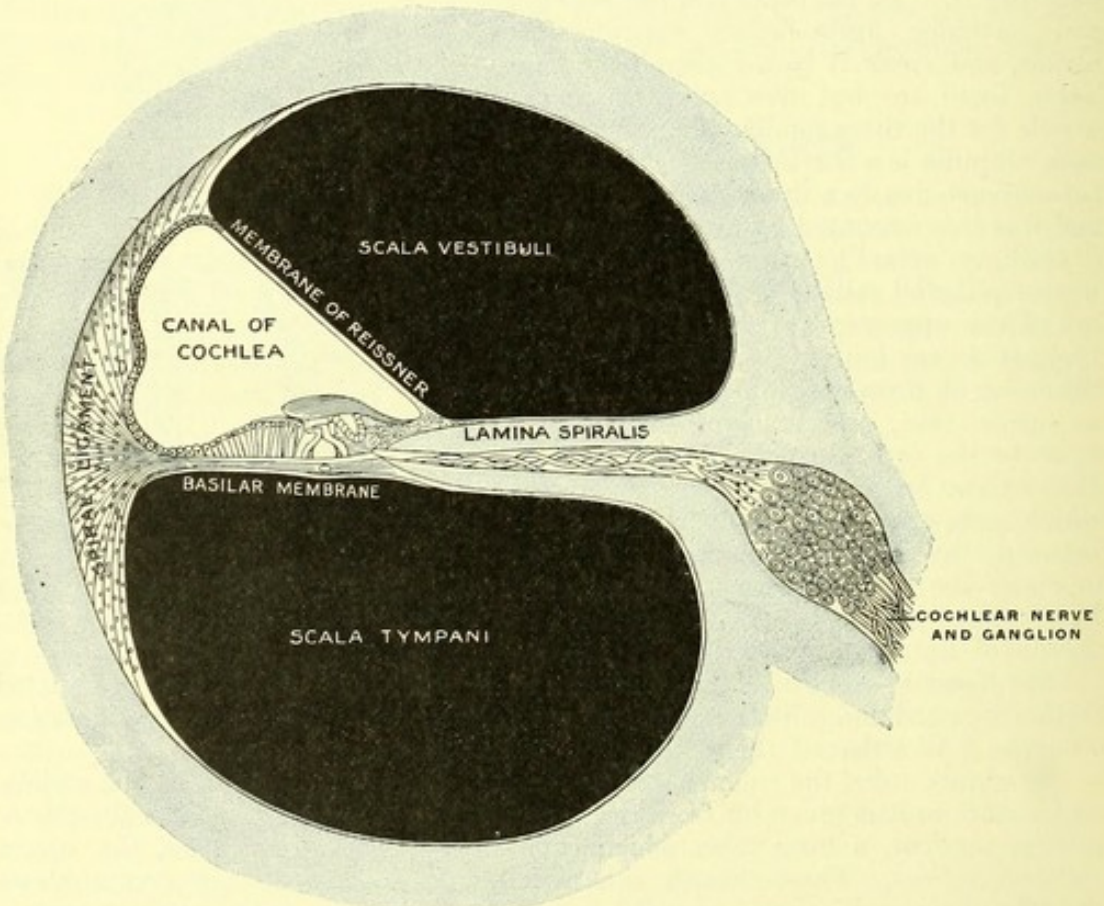

FIG. 718.—Cochlea in transverse section. Observe especially the canal of the cochlea, which is a part of the membranous labyrinth. (Testut.)

curved, with its concavity inward. The lower side is flat, and is composed mostly of a strong, fibrous sheet, called the *basilar membrane*, between which and the membrane of Reissner the angle is acute. Upon the basilar membrane are

located the structures which give the canal of the cochlea its peculiar interest. In the main these are especially modified epithelial cells, to which the principal part of the nerve of hearing is distributed. The greater portion of these cells

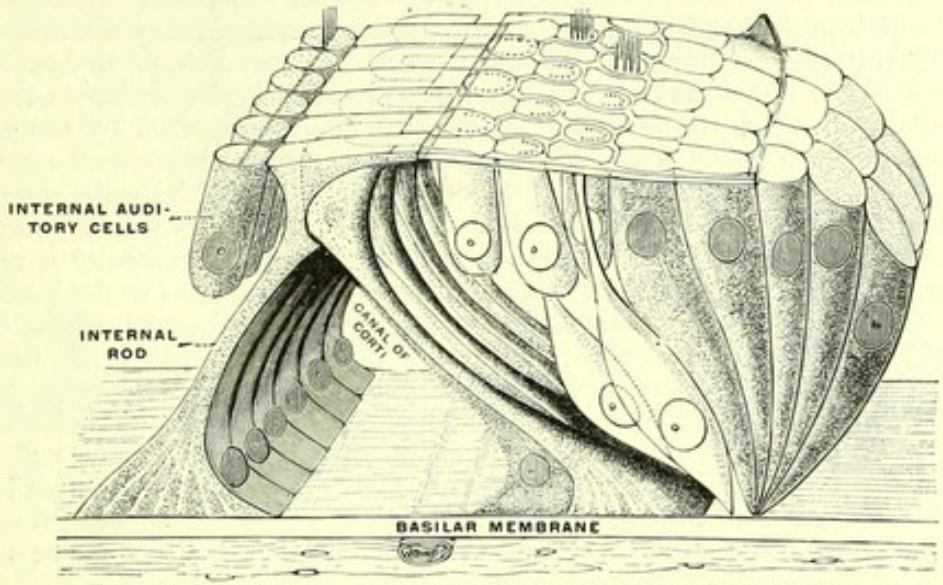

FIG. 719.—Organ of Corti. Diagrammatic view of a small portion. (Testut.)

constitute the *organ of Corti* (Fig. 719), and the parts of this around which the other elements are grouped are the *rods of Corti*. They are called *inner rods* and *outer rods*, according as they are nearer to or farther from the acute angle of the

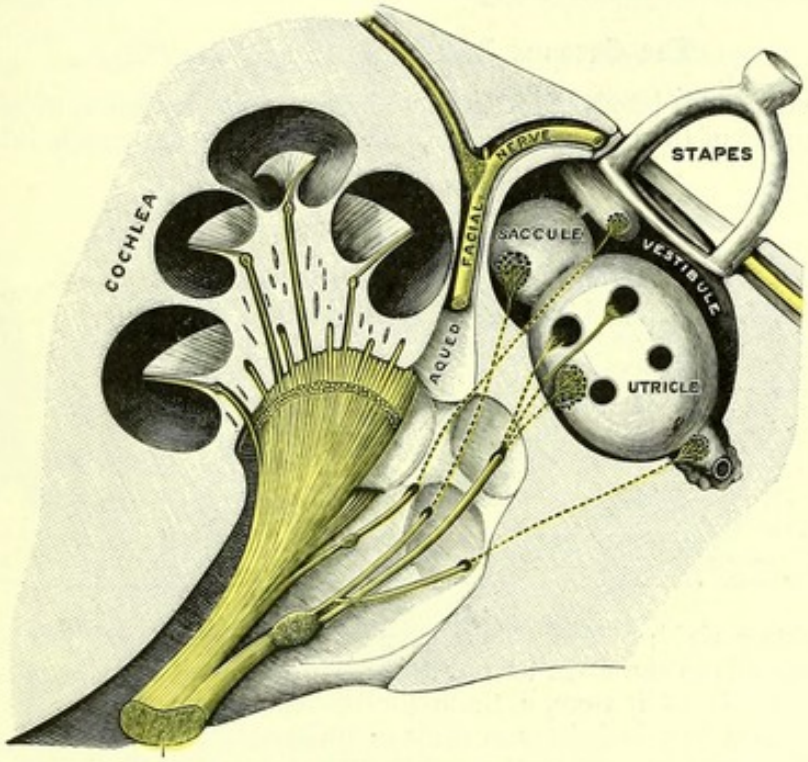

FIG. 720.—Distribution of the auditory nerve. Semidiagrammatic. (Testut.)

tube. The bases of these cells are broad, and securely fastened to the basilar membrane; their shafts are slender, and their upper ends enlarged, that of the inner suggesting the proximal extremity of the ulna, that of the outer looking considerably like the head of a swan. The rods of each set constitute a continuous row from end to end of the canal. The two sets incline toward each other

and meet above, a tunnel thus being formed, to which the name, *canal of Corti*, is given. Certain cells, called *basilar*, are attached to the bases of the rods on the side which presents toward the cavity, and seem to serve as buttresses to them. At the inner side of the inner rods is a row of short cells, from the upper end of which project stiff cilia, and from these circumstances they are called *inner hair-cells* (internal auditory cells), beneath which are roundish, protoplasmic cells. On the farther side of the outer rods are several rows of cells similar to the inner hair-cells, and called the *outer hair-cells*, these being supported by the *cells of Deiters*, which are fusiform and send long processes upward between the hair-cells to the surface. Still farther toward the outer side are conoidal cells, the *cells of Claudius*, each row of which is of less height than that toward its inner side, until the level of the undifferentiated cells lining the cavity generally is reached. Similar, but less numerous, cells of Claudius are arranged next to the inner hair-cells. Over the outer hair-cells and some adjacent rows is spread a membranous network, the *reticular lamina*, through which the hairs protrude. At the inner side of the internal cells of Claudius is a groove, the *sulcus spiralis*, running parallel with the organ of Corti. From a line near the acute angle of the cochlear canal starts a fold, at first thin, but soon enlarging into a thick pad, which stretches out over, and rests upon, the rods and hair-cells. It is called the *tectorial* ("covering") *membrane*. Likeness has been suggested between this membrane and the gelatinous pads, loaded with otoliths, which cover the maculæ acusticæ of the utricle and the saccule.

Branches of the auditory nerve (Fig. 720) enter among the structures which compose the organ of Corti, some being distributed to the inner hair-cells, while others end between the inner rods, and others still cross the canal of Corti and go to the outer hair-cells. Endolymph occupies the canal of the cochlea and also the canal of Corti and all of the spaces between the cells of the organ of Corti.

The Osseous Labyrinth (Figs. 721, 722).

The membranous labyrinth is situated in the petrous portion of the temporal bone. The part of the osseous tissue which immediately surrounds it is extremely

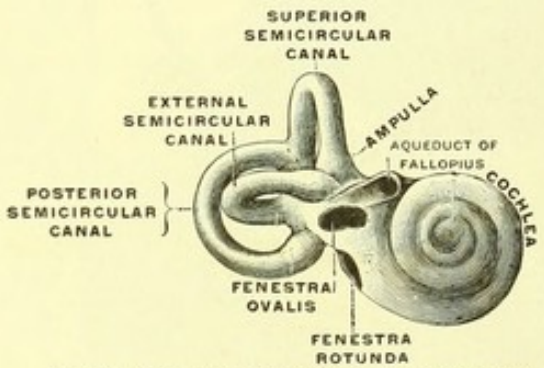

FIG. 721.—Osseous labyrinth, isolated and viewed from the outer side. (Testut.)

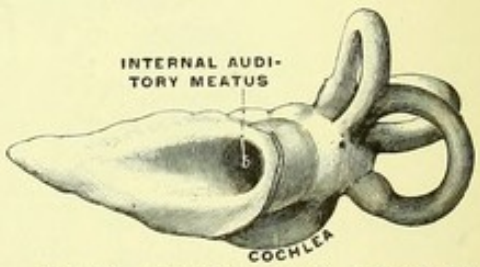

FIG. 722.—Osseous labyrinth, isolated and viewed from the mesial side. (Testut.)

dense, forming a rigid, protective shell for it. This is the *osseous labyrinth*. Its shape corresponds in the main to that of the complicated membranous labyrinth. But, although it is, as it were, a tunic for the latter, the fit is a very loose one. The membranous labyrinth in most parts occupies not more than a third, in places only a fifth, of the diameter of the cavity of the osseous labyrinth. The membranous, however, does not lie free in the cavity of the osseous, but at every part of its course is fastened to its containing case, usually as much as a quarter of its circumference being thus attached. Where the nerve-bundles enter the membranous labyrinth, it is always closely applied to the osseous. The osseous labyrinth is *lined with periosteum*, and where the membranous comes in contact with it, bands of fibrous tissue are added, and serve to confine it in place.

Fibrous trabeculæ cross from the membranous labyrinth to the opposite side of the osseous in various parts, and assist in the fixation. The *free surface of the periosteum* is covered with delicate, flattened cells, developed from fibrous-tissue corpuscles.

The Vestibule.—The central portion of the osseous labyrinth is a chamber of sufficient size to give lodgment to the utricle and saccule. It is called the *vestibule*. On its outer side is an opening, the *fenestra ovalis* ("oval window"), which looks into the middle ear; but it is always closed in the recent condition. A depression at the front part of the mesial wall, called the *fovea hemispherica*, lodges the saccule; and another hollow, the *fovea hemielliptica*, behind and above

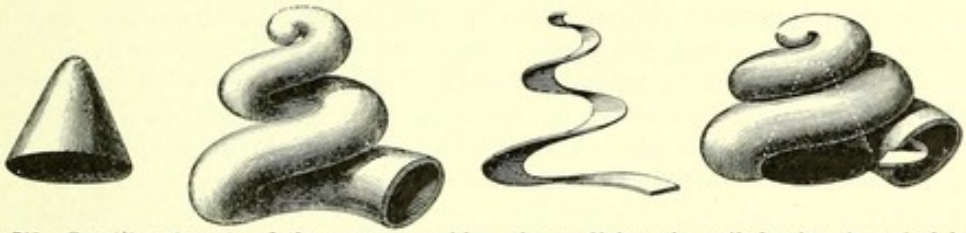

FIG. 723.—Constituent parts of the osseous cochlea—the modiolus, the coiled tube, the spiral lamina—isolated in the first three pictures, and combined in the fourth. Diagrammatic. (Testut.)

the last, holds the upper part of the utricle. Between the two is a ridge, the *crista vestibuli*, which divides below, and encloses a little pit in which lies the lower extremity of the canal of the cochlea. Close to this is the opening of the *aqueductus vestibuli*, holding the ductus endolymphaticus. Behind are the five apertures of the three *semicircular canals*. The canals bear a close resemblance in shape and direction to those of the membranous labyrinth which they enclose. The *scala vestibuli* of the cochlea begins at a large opening in the front and lower part of the vestibule.

The Bony Cochlea (Figs. 723, 724).—In front of the vestibule the osseous labyrinth presents the *cochlea*, which looks very like a coiled shell, as its name

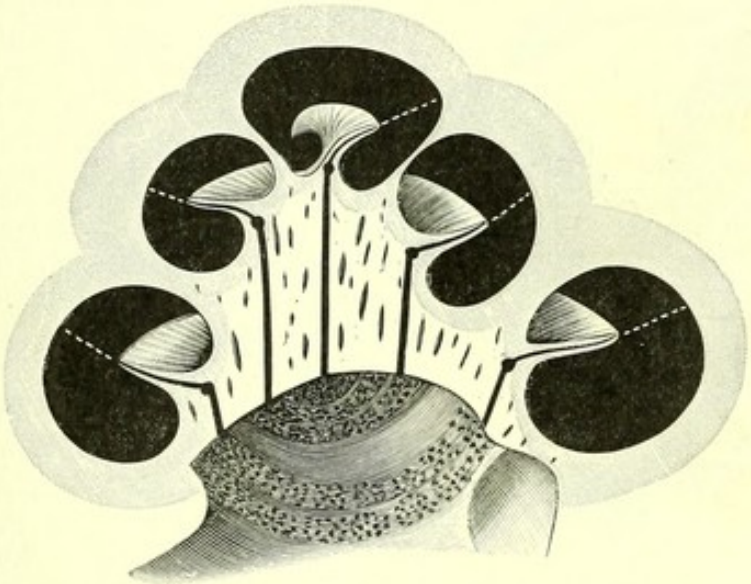

FIG. 724.—Osseous cochlea in vertical section. The broken, white lines indicate the position of the basilar membrane of the canal of the cochlea. Semidiagrammatic. (Testut.)

implies. Its base faces inward, forward, and upward, its apex in the opposite direction. It is in reality, as in appearance, a tube, gradually diminishing in size from base to apex, and twined nearly three times around a central, conical core, the *modiolus*. From the side of the tube nearer the modiolus a thin shelf of bone, the *lamina spiralis*, projects about half way across its lumen.

Like other portions of the osseous labyrinth the cochlea is lined with *periosteum*. Upon the upper surface of the bony, spiral lamina, however, the periosteum is greatly modified, being much thickened, and ending above the free border of the lamina in a deeply grooved edge, the *sulcus spiralis*, already mentioned. This pad of modified periosteum is the *limbus* ("border"). Along the free edge of the spiral lamina the basilar membrane of the canal of the cochlea is attached, and stretches straight across to the opposite wall, where the periosteum is very thick and projects to meet it, constituting the *spiral ligament*. The membrane of Reissner is attached to the upper surface of the limbus. Thus it is seen that the lamina spiralis and the canal of the cochlea together divide the lumen of the bony cochlea into two unequal parts—one, the smaller, above, called the *scala vestibuli*, because it opens into the vestibule; and the other, and larger one, below, called the *scala tympani*, because its lower end presents at the *fenestra rotunda* ("round window"), where it would be in continuity with the tympanum (the drum of the ear), were it not for the complete closure of this window. It is now clear why the canal of the cochlea, which is between the scalæ vestibuli and tympani, is sometimes called the *scala media*.

The scalæ vestibuli and tympani have communication only by a small opening, the *helicotrema* ("hole of the coil") at the highest point, the *cupola*, of the cochlea.

From the scala tympani near its large end a little canal, the *aqueductus cochleæ*, gives passage to a little vein into the inferior petrosal sinus near the jugular fossa.

The Auditory Nerve.—The base of the modiolus presents toward the internal auditory meatus, from which it receives a large part of the auditory nerve. The fibres of the nerve run in the modiolus to the attached edge of the spiral lamina, and then through this to its free edge, whence they are distributed to the organ of Corti, as previously detailed. The fibres destined for the lower turn of the spiral are at the outside of the bundle, those for the apex in the centre. Within the lamina the nerves pass through a mass of cells, constituting the *spiral ganglion*.

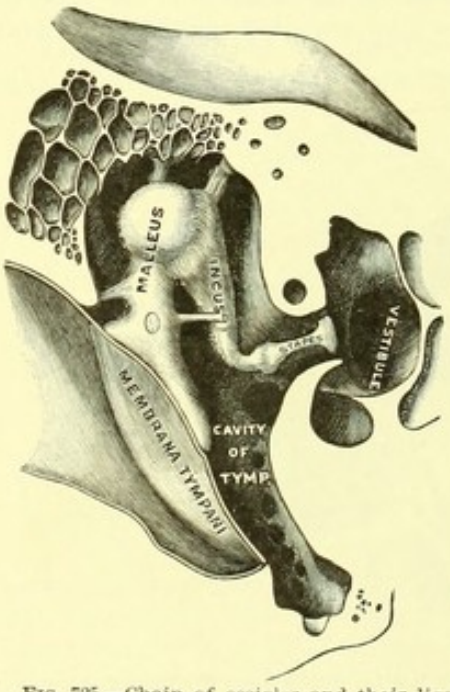

FIG. 725.—Chain of ossicles and their ligaments, seen from the front in a vertical, transverse section of the tympanum. (Testut.)

As has been already stated, the space between the membranous labyrinth and the osseous labyrinth is filled with perilymph. This space communicates through the sheath of the auditory nerve with the subdural and subarachnoid spaces, whose fluid is lymphatic in character, like that of all serous membranes. Communication has also been shown to exist between the cavity of the membranous labyrinth and the subdural space by means of the saccus endolymphaticus.

THE MIDDLE EAR OR TYMPANUM.

The middle ear (Figs. 725, 726) is situated at the outer side of the inner ear or labyrinth, and between the latter and the external ear. It is known as the *tympanum* or *drum of the ear*, and various features of its structure justify the name. Like the labyrinth the tympanum is located in the petrous portion of the temporal bone. It is a fore-and-aft cleft, deep, long, and narrow. Its roof is formed by a rather thin plate of bone, which separates its cavity from that of the cranium. Its external and internal walls present the greatest expanses of surface, and converge to its floor, which has hardly any width. The tympanum is lined

throughout with mucous membrane, which covers every object contained in the cavity.

The **outer wall** is composed almost entirely of a broad, fibrous sheet, the *membrana tympani* ("membrane of the drum"), and the rim of bone to which it is attached. The membrana tympani has as its basis a firm layer of white fibrous tissue. On its inner side is a lining of mucosa, and on its outer a coat of skin. The membrane is moderately tight everywhere except at the very top, where there is a small area, which is comparatively flaccid. The membrane is not flat, but its centre presents a prominence upon the mesial side. It slopes markedly from above downward and inward.

The **inner wall** of the tympanum has a very uneven surface. The most marked prominence is the *tuber cochleæ*, produced by the protrusion of the first turn of the cochlea. Below this is a round hole, the *fenestra rotunda*, closed by a fibrous membrane, but for which communication would be established between the tympanum and the scala tympani. The membrane is called the *secondary membrane of the tympanum*—the second head to the drum. At a little higher level than the tuber is the *fenestra ovalis*, also stopped with a fibrous membrane, to which is attached an ossicle, presently to be described. Above this oval window is a ridge, which shows the situation of the aqueduct of Fallopius, in which is the facial nerve.

At the rear and upper part the tympanum communicates through a large hole with a series of irregular and connected cavities in the mastoid portion of the temporal bone, the most considerable and the nearest of these being the *mastoid*

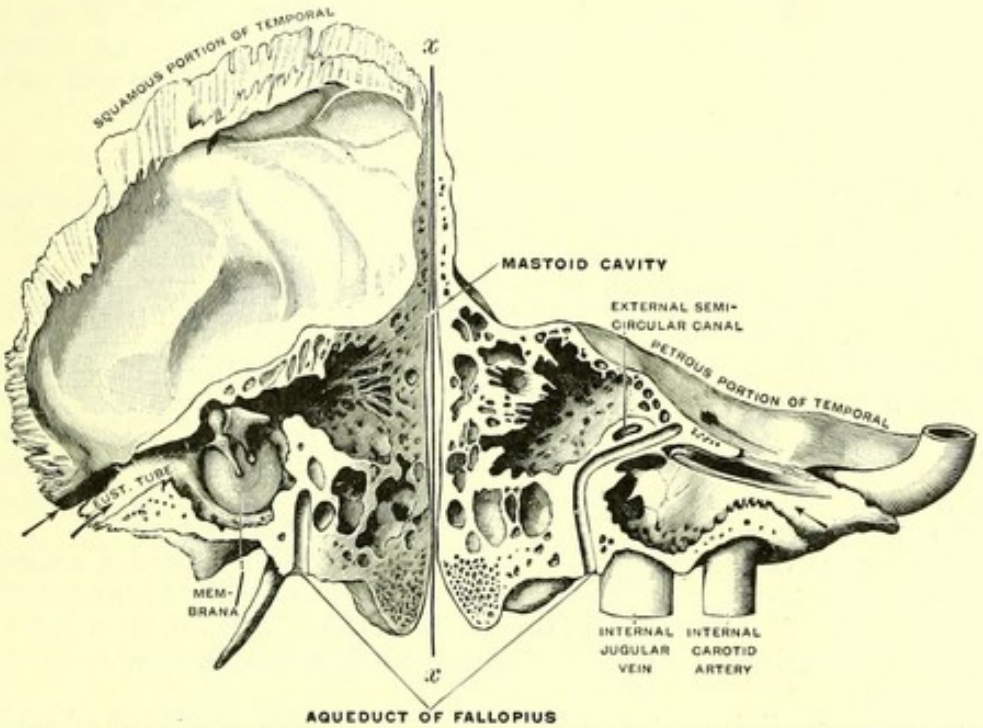

FIG. 726.—Coronal section of the right temporal bone, passing through the Eustachian tube and the middle of the tympanum. Both surfaces of the section are shown, the parts being hinged on the line *zz*. (Testut.)

antrum, the others being the *mastoid cells*. These cavities are all lined with mucous membrane, continued into them from the tympanum. Lower down on the hind surface is a prominence of bone, called from its shape the *pyramid*, from the apex of which projects the tendon of the stapedius muscle.

In front and below, the tympanum slopes into a long channel, the *Eustachian tube*, the distal end of which opens into the pharynx. Through this tube air is admitted to and expelled from the middle ear, and thus atmospheric pressure on the inner and outer sides of the membrana tympani is equalized. The tube does

the service to the tympanum that is rendered by the hole in the side of the kind of drum which is accounted a musical instrument.

The **Eustachian tube** (*tuba auditiva*) (Fig. 727) is about an inch and a half long. It extends downward, forward, and inward, and its lower end presents a

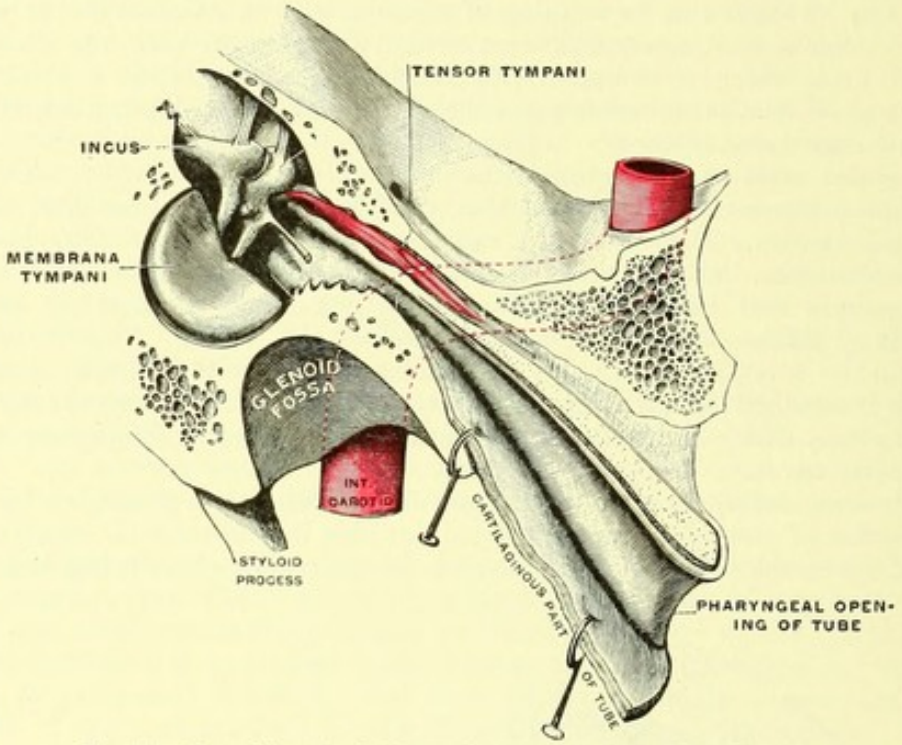

FIG. 727.—Eustachian tube, laid open by a cut in its long axis. (Testut.)

projecting margin on the lateral wall of the pharynx, close by the inferior meatus of the nose. Its upper part is bony, its lower is cartilaginous. It is lined with mucous membrane.

Above and parallel with the Eustachian tube is a *bony canal*, lodging the tensor tympani muscle, whose tendon projects into the tympanic cavity.

The Ossicles (Fig. 725).—Extending across the tympanum from side to side is a chain of three little bones, the *ossicula auditus* ("ossicles of hearing"). From without inward they are the malleus, the incus, and the stapes. The malleus is attached to the membrana tympani, the stapes to the membrane of the fenestra ovalis, and the incus is between and connects the others, with each of which it has a movable articulation.

The **malleus** ("hammer") has a roundish *head*, which is upward, a constricted *neck*, and a long tapering *handle* (*manubrium*), which extends downward and a little backward. A *long process* runs downward and forward from below the neck to the Glaserian fissure; and a *short process* passes outward to the membrana tympani.

The **incus** ("anvil") presents a *body*, upon the anterior surface of which is an articular area by which it is jointed to the malleus; a *short process*, which runs to the posterior wall near the opening of the mastoid antrum; and a conical, *long process*, which extends at first downward and at last mesially, ending in a knob, the *orbicular process*, which articulates with the stapes.

The **stapes** ("stirrup") bears a remarkable resemblance to the object from which it is named. Its *base*, the foot-piece, is broad and very nearly fills the fenestra ovalis, to whose membrane it is attached. The side-pieces, *crura*, converge to the *neck*, beyond which is the *head*, cupped on its outer surface, and articulating with the orbicular process of the incus.

Besides the attachment of the malleus to the membrana tympani and that of

the stapes to the membrane of the fenestra ovalis, *ligaments* running to different parts of the bony walls serve to hold the ossicles in place.

Muscles of the Tympanum.—Two muscles are connected with the series of ossicles, the tensor tympani and the stapedius.

The **tensor tympani** ("tightener of the drum") (Fig. 727) is principally situated in the canal above the Eustachian tube. Its tendon bends outward on escaping from the canal, and is inserted into the handle of the malleus near the neck. Contraction of the muscle pulls the membrane of the drum inward, and thus tightens it.

The **stapedius** arises in the cavity of the pyramid, from the apex of which its tendon passes forward into the tympanic cavity, and is inserted into the neck of the stapes. This muscle rocks the base of the stapes in the fenestra ovalis, and thus causes pressure upon the perilymph of the labyrinth.

The **mucous membrane** of the tympanum projects from the roof into the cavity in several folds, which are very variable in number, form, and size. The epithelium of the mucosa is partly columnar and ciliated, and for the rest flattened and not ciliated.

Just below the pyramid the *chorda tympani* nerve enters the middle ear, and runs forward across the handle of the malleus to its aperture of exit near the Glaserian fissure. Like the other intratympanic structures it is invested with mucosa.

THE EXTERNAL EAR.

The external ear comprises (1) the external auditory meatus, the tube leading from the outer wall of the tympanum to the surface of the head, and (2) the auricle or pinna, the flaring body, which projects from the side of the head.

The **External Auditory Meatus** (Fig. 728) is about an inch long. It is of

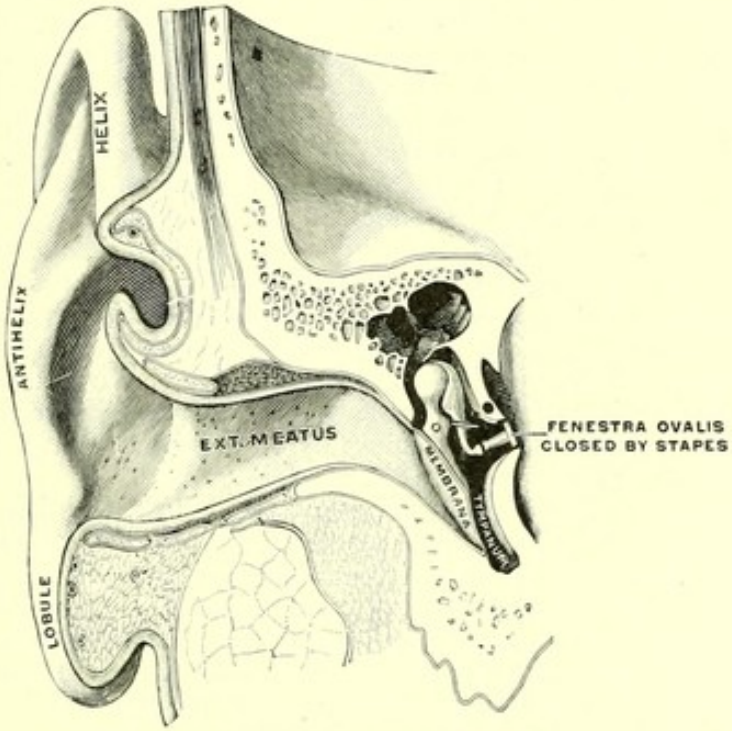

FIG. 728.—Vertical section through the external auditory meatus and tympanum, passing in front of the fenestra ovalis. (Testut.)

greatest diameter near its outer end, and of least near its middle part. Its direction varies in different portions. As it is traced inward, it goes at first forward and upward, then backward, and finally forward and downward; but its dominant trend is inward and forward. The tube rises toward the middle of its course,

and beyond this it descends. Its floor is longer than its roof on account of the obliquity of the position of the membrana tympani.

The mesial portion has a basis of *bone*, its peripheral, one of *yellow fibro-cartilage*, pieced out with fibrous tissue. The flexibility of the latter portion renders it practicable to make the meatus nearly straight by pulling the pinna (with which it is continuous) upward and backward.

The meatus is lined throughout with *skin*. In the cartilaginous part and the adjacent portion of the osseous there is a great number of glands, which structurally are identical with ordinary sweat-glands, only larger; but, instead of secreting perspiration, they form *cerumen*, commonly called "ear-wax"—a substance thought to be offensive to insects, and, consequently, a defence against their intrusion. The glands are called *ceruminous*. Near the outer end of the tube are many short *hairs* and *sebaceous glands*. The skin which clothes the membrana tympani is very delicate, and is free from hairs and glands.

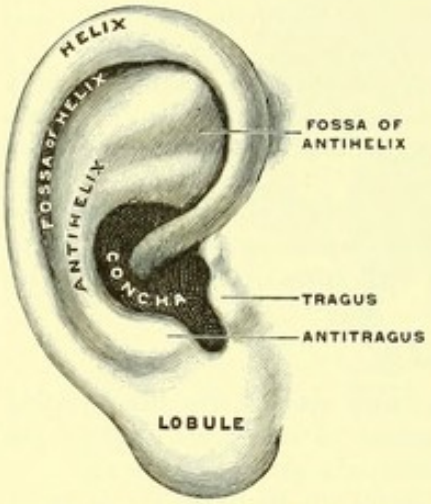

FIG. 729.—Right pinna. (Testut.)

The **Pinna** (Fig. 729) is of irregularly oval shape, and is an abrupt expansion of the meatus. Its central portion is shell-like in form, and hence is called the *concha*. Beginning near the middle of the concha is a ridge, which runs forward and upward to the front margin of the pinna, whence it continues around nearly to its lowest part, forming a prominent rim, called the *helix* ("coil"). The rim of the concha itself begins at its front and lower part in a prominent tubercle, the *antitragus* ("opposite the tragus"), and runs backward, then upward, and lastly forward, dividing at the junction of its hind and upper parts into two branches, which enclose a triangular hollow. This margin of the concha is the *antihelix* ("opposite the helix"), and the area embraced by its division is the *fossa of the antihelix*. Between the antihelix and the helix is the *fossa of the helix*, overlapped by the incurved lip of the helix. In front, between the origins of the helix and antihelix, is a backward projecting plate, which covers the orifice of the meatus at a little distance, and is called the *tragus*. The lowest portion of the pinna is a flat, soft, pendulous body, the *lobule*.

All portions of the pinna, except the lobule, are composed almost entirely of *yellow fibro-cartilage*, which is continuous with that in the peripheral part of the meatus, and clothed with *skin*. Except upon the convexity of the helix, the skin is very thin and closely adherent to the cartilage. The lobule has no cartilage, and is merely a bag of skin, containing areolar and adipose tissues.

The pinna is attached to the cranium by *ligaments* which run forward to the root of the zygoma and backward to the mastoid process.

The *shape of the pinna* is practically the same all through life, changing less than that of any other feature; and, as no two ears are exactly alike, the recognition of this maintenance of the characteristic peculiarities of each individual ear has established what is probably the surest method of physical identification.

Muscles.—Half a dozen muscles, called *intrinsic*, connect different parts of the pinna with one another. But, as they are all rudimentary in man, are, indeed, often impossible of demonstration, and never of any practical importance, they will receive no further attention.

There are three *extrinsic muscles* (Fig. 407) which require mention, though almost always imperfectly developed and incapable of action. Occasionally, however, there is an individual, who possesses in a measure the ancestral capacity of moving his ears voluntarily.

The **attollens aurem** ("lifting the ear") or *auricularis superior*, the largest of the trio, arises from the lower border of the epicranial fascia, narrows as it

descends, and is inserted into the mesial surface of the helix and the prominence, which is collocated with the fossa of the antihelix.

The **attrahens aurem** ("drawing the ear toward," *i. e.*, forward) or *auricularis anterior*, the smallest of the group, arises from the epicranial fascia below the front part of the preceding muscle, passes backward, and is inserted into the fore part of the helix.

The **retrahens aurem** ("drawing back the ear") or *auricularis posterior*, arises from the mastoid process of the temporal bone, passes forward, and is inserted into the back of the concha.

The *arteries* of the pinna are the posterior auricular and the superficial temporal. The *nerves* are the great auricular, posterior auricular of the facial, the auriculo-temporal of the fifth, and the small occipital.

THE EYE.

By W. KEILLER.

THE *eyeball*, which is the essential *organ of the sense of sight*, is a somewhat spherical body, occupying the cavity of the orbit, where it lies embedded in a mass of fat and loose connective tissue. From the posterior two-thirds of the surface of the eye this bed is walled off by a membrane known as the *capsule of Tenon* (Fig. 730) between which and the globe of the eye there is a lymph-space

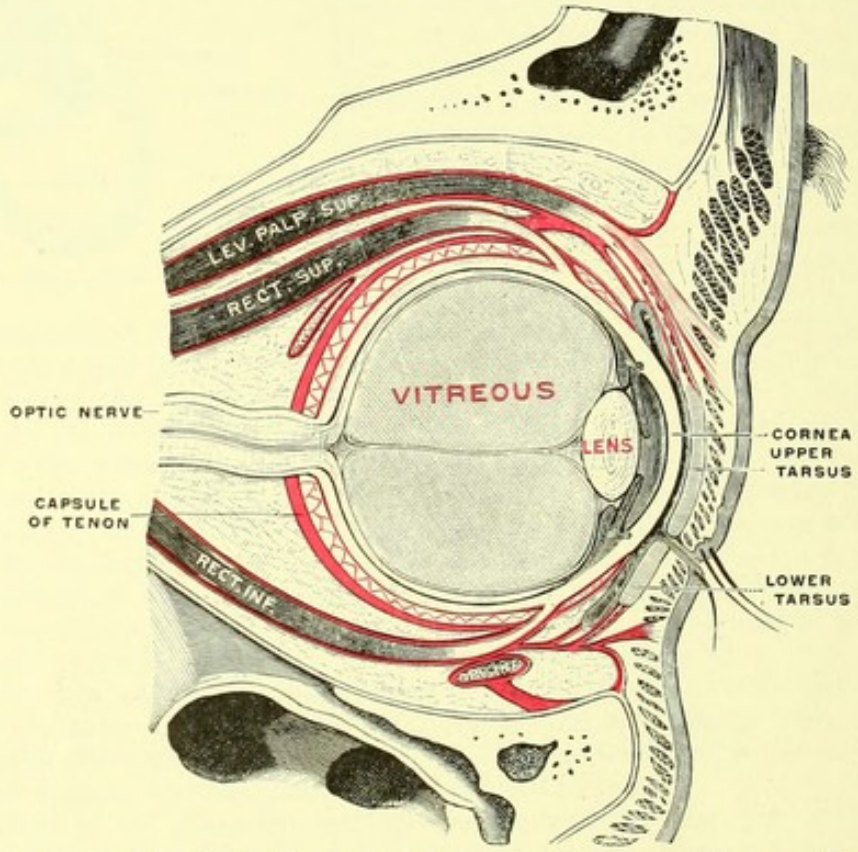

FIG. 730.—The right eye in sagittal section, showing the capsule of Tenon. Semidiagrammatic. (Testut.)

occupied by very loose areolar tissue, the whole forming a pliable socket, within which the eye rotates with the utmost freedom. The anterior third is covered by the *conjunctiva*, a mucous membrane reflected onto the globe from the deep aspect of both eyelids. The surface of the globe is pierced by numerous vessels and nerves, and gives attachment at certain points to the muscles, by which the movements of the eyeball are accomplished.

A lateral view of the eye on the living subject reveals the fact that its surface is not all uniformly curved. In such a view the anterior, clear portion, known as the *cornea*, will be seen to bulge out appreciably beyond the normal curve of the posterior, white, or *sclerotic* portion. It thus appears that the eye-

ball is not strictly a sphere, but is composed of segments of two unequal spheres, an anterior, smaller segment (of a smaller sphere), forming about one-sixth of the whole, superposed upon a posterior, larger segment (of a larger sphere), forming the remaining five-sixths.

For descriptive purposes certain points and lines in relation to the eyeball must be defined. The *anterior pole* is the centre of the front surface of the cornea; the *posterior pole* is the centre of the back surface of the sclerotic; a straight line joining these poles is the *sagittal axis*. The *equator* of the eyeball is a line around its surface equally distant at all points from the two poles; its plane divides the globe into *anterior* and *posterior hemispheres*. The inner side of the eye is appropriately termed the *nasal side*; the outer, the *temporal*.

To prevent misconception, it is necessary to say here that, even if its segmented formation be disregarded, the eyeball is still not a perfect sphere. The transverse diameter (about one inch) is the greatest, the antero-posterior slightly less, and the vertical the least. It may be added that, in an antero-posterior, vertical section of the eyeball, passing through the sagittal axis, the inner or nasal division will be slightly smaller than the outer or temporal.

Anatomically considered, the eye may be regarded as a hollow sphere (Fig. 731), whose wall is composed of three tunics and whose cavity is filled by three refracting media. The three tunics are (1) an outer, *fibrous tunic*, consisting of

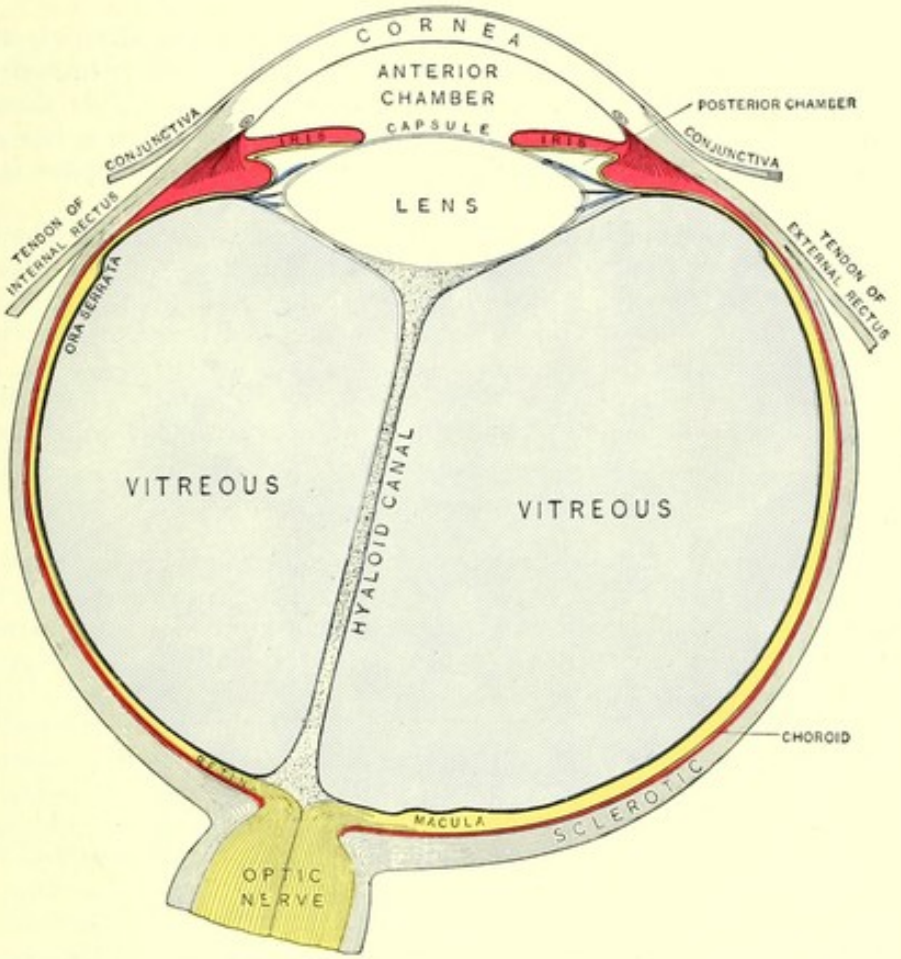

FIG. 731.—The right eye in horizontal section, showing the upper surface of the lower segment. Diagrammatic. (Testut.)

sclerotic and cornea; (2) a middle, *vascular tunic*, comprising choroid, ciliary zone, and iris; (3) an inner, *nervous tunic*, the retina. The three refracting media are the *aqueous humor* in front, the *vitreous humor* behind, and the *lens* between the two others. Each of these will be considered in turn.

THE EXTERNAL OR FIBROUS TUNIC.

The two parts of the outer, fibrous tunic, though continuous in structure, differ much in appearance, the cornea in front being perfectly clear and transparent, and the sclerotic behind, white and opaque. Both are dense and firm, and serve to preserve the form of the eyeball. At their junction all around is a wide, shallow depression, the *scleral sulcus*.

The Sclerotic.

The posterior surface of the sclerotic is pierced by the optic nerve, an eighth of an inch internal to the posterior pole. Here the dural sheath of the nerve blends with the sclerotic, and the nerve fibres, in many small bundles, enter through distinct minute pores. The part of the sclerotic thus perforated is called the *lamina cribrosa* ("sieve-like layer"). Around the optic nerve-entrance, and more or less adjacent to it, the sclerotic is pierced by the ciliary nerves, and the long and short posterior ciliary arteries; while, farther toward the equator, four or five apertures transmit the large veins called from their mode of formation the *venæ vorticosæ* (Fig. 732). A little way ($\frac{1}{12}$ inch) behind the corneo-scleral junction the sclerotic is pierced by the anterior ciliary arteries. Somewhat anterior to the equator it gives attachment to the four recti muscles, the two obliqui being attached behind.

On the deep surface of the sclerotic, between it and the choroid, there is a layer of loose, pigmented connective tissue, the *lamina fusca* ("brown layer"), which imparts to its inner surface a dingy, brownish hue. This tissue really occupies a lymph-space between the two tunics. Thus the sclerotic has a lymph-space on each side of it, and the surface that looks toward each space is covered by epithelium.

The sclerotic consists of bundles of connective tissue, containing elastic fibres, and having connective-tissue corpuscles lodged in cell spaces. The tissue is disposed in laminæ, in some of which the fibers run longitudinally and in others transversely. The laminæ are not separable owing to a frequent interchange of fibres.

The scant blood-supply of the sclerotic is derived from the short ciliary and the anterior ciliary arteries, and its more scant nerve-supply, from the ciliary nerves.

The Cornea.

The cornea, devoid of blood-vessels and perfectly transparent, is the window which admits light to the interior of the eye. It is set in the sclerotic in much the same way as a watchglass is set in its frame. Here the resemblance ends, however, for the sclerotic and cornea are perfectly continuous. Viewed from behind, the cornea is perfectly circular, but a front view shows its transverse slightly greater than its vertical measurement. This is due to the sclerotic's overlapping it more above and below than laterally. The cornea is always more curved than the sclerotic, but its curvature varies in different individuals and at different periods of life, being greatest in youth and diminished in old age. Its outer surface is covered by conjunctival epithelium of the stratified flattened variety, several cells deep. Its posterior surface is lined by a firm, elastic, homogeneous membrane, the *membrane of Descemet*, structurally distinct from its own proper substance. Shreds of this membrane stripped off of the cornea tend to curl up with the attached surface inward. Around the margin of the cornea the membrane of Descemet becomes fibrillar, and breaks up into bundles, some of which attach themselves to the sclerotic and choroid, while others bridge over the irido-corneal angle, and attach themselves to the front of the iris. These latter constitute the *ligamentum pectinatum iridis* ("the combed ligament of the iris") or pillars of the iris. The sponge-like formation, produced around its border

by the breaking up of the membrane of Descemet, contains a number of minute spaces, *the spaces of Fontana*, which communicate with the aqueous chamber on the one hand, and, on the other, with a minute venous sinus contained in a canal in the sclerotic, which encircles the margin of the cornea. This is the *canal of Schlemm*.

The *substantia propria* of the cornea is composed of many superposed layers of connective tissue, the fibres of contiguous layers having different directions, and all being inseparably held together, as in the sclerotic, by many interchanges of fibres. Between the layers, and even between the bundles and fibrils of which they are composed, there is an interstitial cement substance, in which are found lymph-spaces, occupied, but not filled, by the corneal corpuscles, and all directly or indirectly communicating so as to provide for a very complete lymph-vascular circulation.

Unlike the sclerotic, the cornea is richly supplied with nerves, which are derived from the ciliary. They first form a plexus around its margin; then, losing their medullary sheath, they form another plexus in the laminated structure; from this branches proceed to form a third plexus on the corneal surface beneath the conjunctival epithelium; finally, fibrils pass in among the epithelial cells, and reach their terminal distribution almost at the free surface of the conjunctiva.

THE MIDDLE OR VASCULAR TUNIC.

In the vascular tunic, or *uveal tract*, of the eye (Fig. 732) three parts may be distinguished: the *choroid* behind, the *iris* in front, and the *ciliary zone*, or *body*,

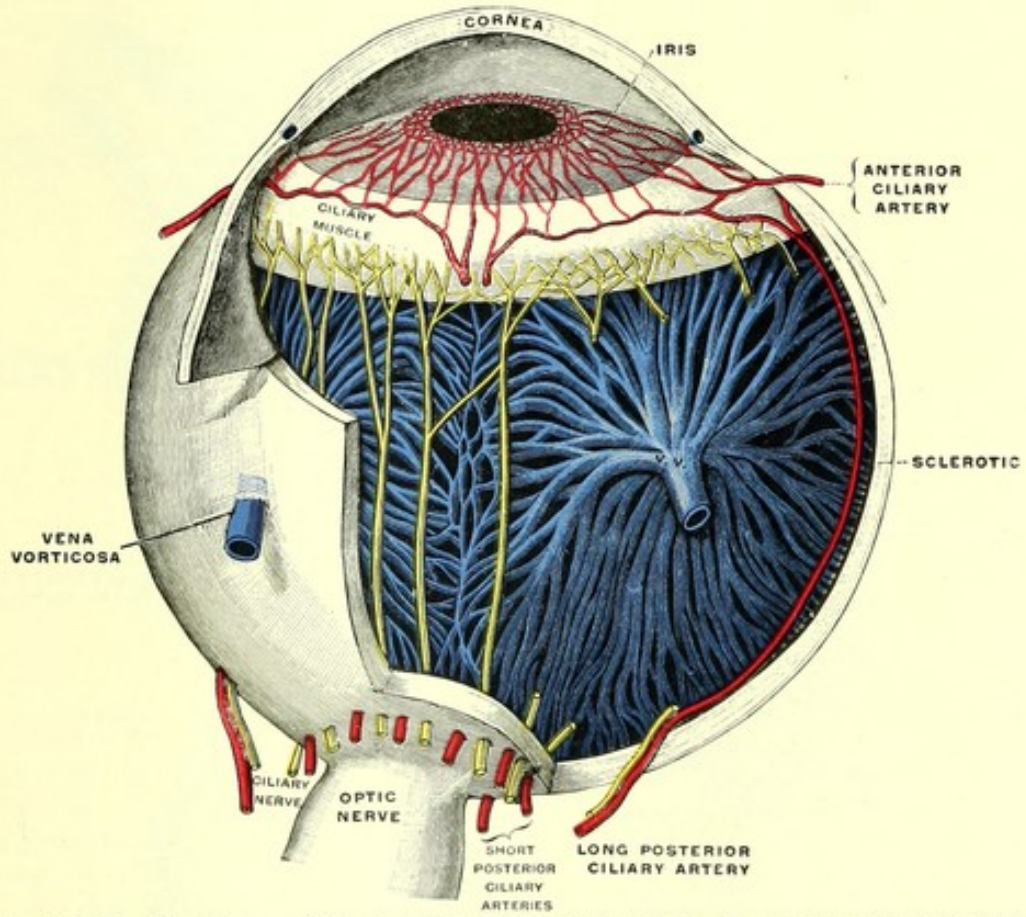

FIG. 732.—Vessels and nerves of the choroid and iris, seen from above. The sclerotic and cornea have been largely removed. (Testut.)

between. The choroid and ciliary zone are applied to the inner surface of the sclerotic; but, except at the optic nerve entrance and the attachment of the ciliary

muscle to the sclerotic, the adhesion between them is very loose, a lymph-space, as already stated, being left between them. The iris, attached only at its circumference, hangs vertically in the aqueous humor about $\frac{1}{10}$ inch behind the cornea, its pupillary margin resting lightly against the lens. The choroid is pierced behind by the optic nerve. On its outer surface the ciliary nerves, about fifteen in number, and the two long posterior ciliary arteries, after piercing the sclerotic, run forward to the iris.

The Choroid.

The choroid is a dark brown structure, whose stroma consists of blood-vessels, held together by delicate connective tissue, containing pigmented cells. The stroma is limited on both surfaces by non-vascular membranes, the pigmented *membrana suprachoroidea* on the outside, and the unpigmented *vitreous lamina* on the inside. The vessels of the stroma exhibit two well-marked layers, a superficial venous layer formed of the vasa vorticosa, and a deep, closely-packed, capillary layer, the *chorio-capillaris*. Between these layers the short ciliary arteries run forward, giving off as they go the vessels of the chorio-capillaris and terminating in those of the ciliary processes.

The Ciliary Zone.

The *ciliary zone* or *ciliary body* differs from the choroid, not so much in the composition of its vascular stroma, as in the fact that it contains a deposit of muscle-tissue, the *ciliary muscle* (Fig. 733), and presents on its deep surface a

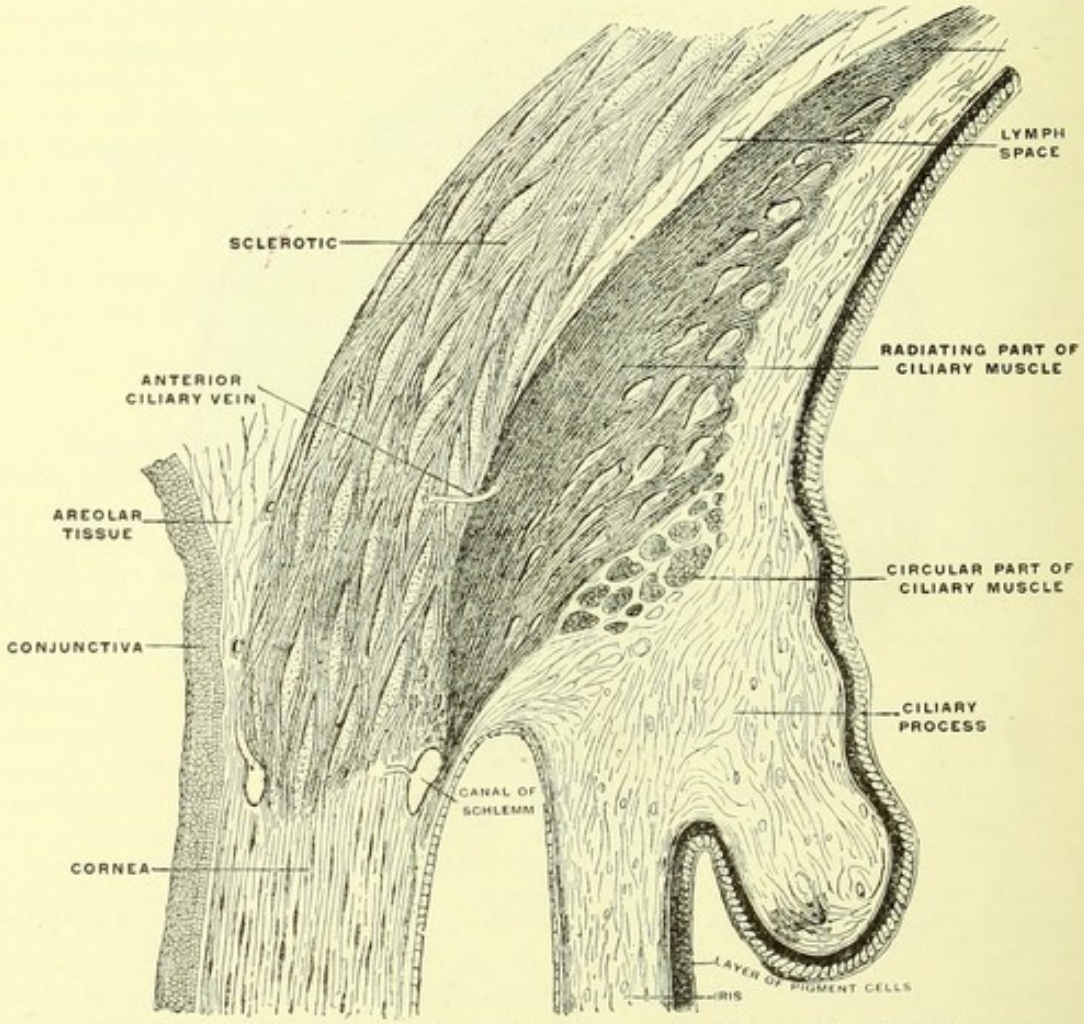

FIG. 733.—Meridian section of the eye in the region of the ciliary muscle. (Testut.)

series of radial thickenings or ridges, the *ciliary processes* (Fig. 735), about seventy in number, which, rising gradually from the anterior limit of the choroid, reach their greatest elevation a little behind the corneo-scleral junction, where they terminate abruptly in a series of prominences, the *corona ciliaris*. Superficial to these lies the ciliary muscle, containing both radiating and circular fibres. The former arise from the deep surface of the sclerotic near the cornea, where they are attached to the bundles of the membrane of Descemet already referred to. Extending backward they are inserted into the outer surface of the ciliary body and choroid. The circular fibres are placed on the deep surface of the radiating portion, and form a muscular ring around the circumference of the iris. When the ciliary muscle contracts, it draws forward the choroid and ciliary body, thus relaxing the suspensory ligament, which allows the lens to become more convex for near accommodation.

The Iris (Figs. 734, 735).

The iris is the colored membrane, which hangs like a screen in the aqueous chamber behind the cornea. In its centre is the aperture called the *pupil*, which, through the contractile power of the iris, varies in size and is thus adapted to regulate the amount of light admitted to the retina. At its circumference the iris is continuous with the ciliary body, and, through the ligamentum pectinatum iridis, with the cornea also. Faint, wavy lines on its anterior surface, converging

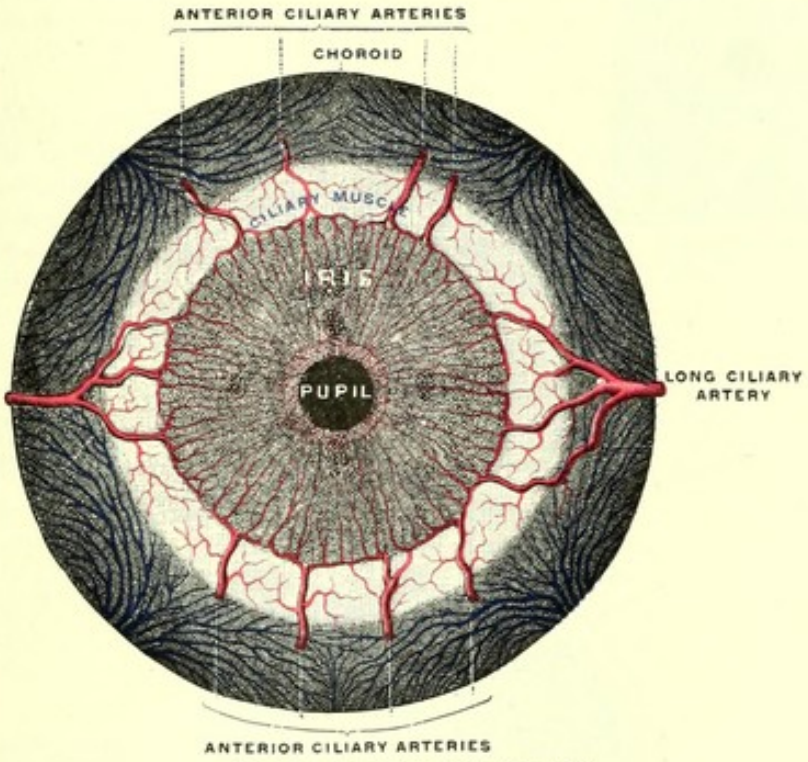

FIG. 734.—Iris, front view. (Testut.)

toward the pupil, mark the situation of subjacent blood-vessels. Its posterior surface is covered by a layer of dark pigmented epithelium, which belongs morphologically to the retina. Its stroma is formed of delicate connective tissue, containing a variable number of pigmented cells, and carrying numerous vessels and nerves. The color of the iris depends partly on the pigment cells of the stroma, and partly on the retinal layer behind. When the pigment is abundant in the stromal cells, it controls the color,—some shade of gray, brown, or black; but when it is scanty or absent, that of the retinal cells behind showing through the stroma imparts to the iris one of the various shades of blue.

Near the pupillary border of the iris there lies embedded in the stroma a circular band of smooth muscle-fibres, the *sphincter iridis*, whose action contracts the pupil. On the deep surface of the sphincter is a membrane formed of straight fibres, stretching from the circumference of the iris to the sphincter. Whether these are muscle-fibres or merely elastic is still unsettled, but the view prevails that they cause dilatation of the pupil.

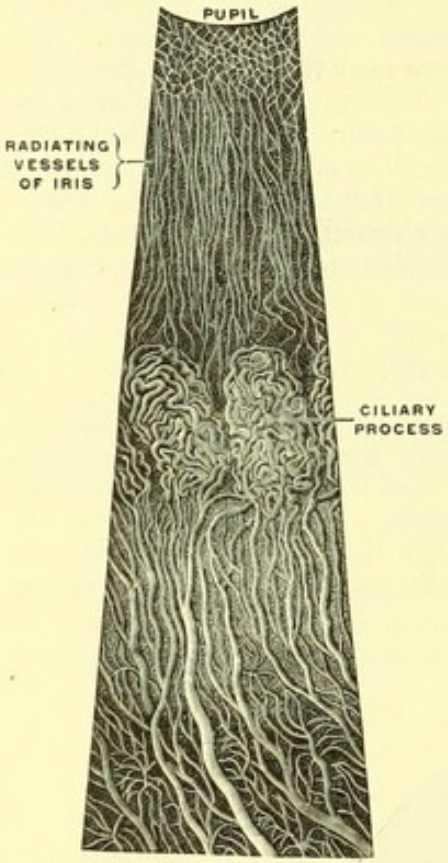

FIG. 735.—Segment of the iris, ciliary body, and choroid, view from the internal surface. (Testut.)

Vessels and Nerves of the Iris.—The two *long ciliary arteries* run forward along the outer and inner aspects of the globe, between the sclerotic and choroid, to the attached border of the iris. Here each divides into a superior and an inferior branch, which, by anastomosing with one another and with the *anterior ciliary arteries* (from the muscular branches of the ophthalmic), form a vascular ring in this situation, the *circulus major iridis*. From this branches are given off, which converge toward the pupil, where, by dividing and anastomosing, they form the *circulus minor iridis*. The arrangement of the veins corresponds to that of the arteries. They communicate with the sinus in the canal of Schlemm.

The *ciliary nerves*, after furnishing a gangliated plexus to the vessels of the choroid, enter the ciliary muscle, where they form another plexus. From this latter filaments pass into the iris, where they follow the course of the blood-vessels, finally ending in the sphincter iridis.

THE INNER OR NERVOUS TUNIC.

The **Retina** (Fig. 736) constitutes the innermost coat of the ocular wall. It is everywhere in close contact with the uveal tunic. Developmentally it is laid

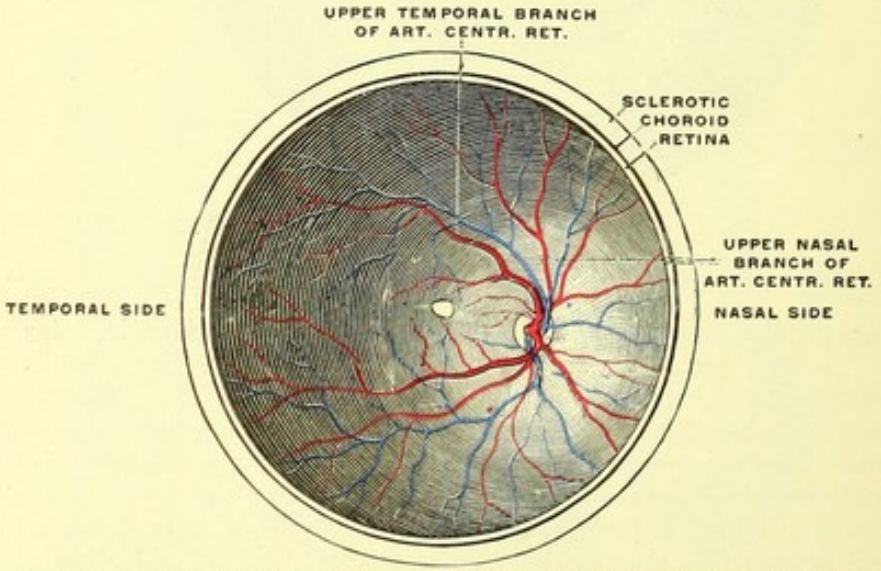

FIG. 736.—Retina of the right eye, front view. The macula lutea is seen in the middle, and the porus opticus at the right of it. (Testut.)

down in two strata, an outer pigmented stratum, which lines the inner surface of the middle coat, and an inner stratum, which differs in different parts.

Beneath the choroid is the *retina proper*, the part directly engaged in vision. It reaches from the optic entrance to the outer or posterior limit of the ciliary zone, where it terminates in an indented border, the *ora serrata*. Beyond this the inner stratum exists as a single layer of unpigmented, columnar epithelium, with no admixture of nerve-fibres, and is called the *pars ciliaris retinæ*. It reaches to and over the tips of the ciliary processes, whence it is continued as a pigmented layer, *pars iridica retinæ*, to the pupillary border of the iris. Here it doubles outward upon itself and becomes continuous with the outer pigmentary stratum. Thus there is on the hind surface of the iris a double layer of pigmented epithelium, belonging developmentally to the retina.

The inner surface of the retina proper rests upon the vitreous body. In its centre, and hence in the axis of the eyeball, is the *macula lutea* or *yellow spot*, the point of acutest vision. The *fovea centralis* is the name given to a dimple or depression in the middle of the macula lutea. About $\frac{1}{8}$ inch to the nasal side of the yellow spot is the pale disc of the *porus opticus* ("optic passage"). Here the optic nerve appears through the retina, and spreads out to form its innermost layer. From the centre of the porus opticus the *arteria centralis retinæ* emerges, dividing into an upper and a lower branch. These again divide and subdivide dichotomously giving offsets to the retina till they reach the ora serrata. Their ramifications anastomose neither with one another nor with any other vessels. The corresponding veins converge toward the porus opticus, where they enter the optic nerve in two divisions, which soon unite. Retinal vessels are absent near the macula lutea.

All these objects, but not the retina itself, are visible in an ophthalmoscopic view of the fundus of the eye. The veins appear darker and larger than the arteries. The general, red reflex which pervades the interior comes from the vessels of the chorio-capillaris.

The retina is a very complex membrane, consisting of several layers of nerve-cells, and specialized nerve-epithelium, all held together by sustentacular fibres (of Müller), which pass vertically through the layers from the inner almost to the outer surface.

The limits of this book preclude a detailed account of the structure of this interesting organ, but some idea of its complexity may be gathered from Fig. 737. What is definitely known and what may usefully be introduced here are embraced in the following statements:

1. The layer of rods and cones and the overlying pigmented cells are the only parts molecularly affected by light.

2. Except between the nerve-fibres of the innermost layer and the nerve-cells of the adjacent layer, there is no direct anatomical continuity between the elements of the different strata. An *apparent* exception occurs in the case of the outer nuclear layer; but it is only apparent, for here the granules are not separate elements, but swellings on the axis-cylinder processes of the rods and cones.

3. The retina with the optic nerve may practically be regarded as a nerve chain of three links establishing connection between the rods and cones (the special sensory cells of the retina) and the brain cells, from which the fibres of the optic nerve come off. These links are—

(1) The rods and cones with their axis-cylinders (including the outer granules).

(2) The bipolar cells of the inner nuclear layer with their axis-cylinders.

(3) The ganglionic nerve-cells and the optic nerve-fibres which, as before intimated, are in direct anatomical continuity.

4. The two molecular layers mark the situations at which connections are made between these nerve links. Thus, in the outer molecular layer the axis-cylinders of the rods and cones connect by arborization and interlacement with

processes from the cells of the inner nuclear layer. In the inner molecular layer the processes from the opposite ends of the same cells connect similarly with those from the ganglionic cells. These being in direct continuity with the fibres of the optic nerve, are thus connected with cells of the visual centres in the brain.

5. The internal and external limiting membranes mark the inner and outer limits of the sustentacular fibres. They are not separate or independent structures, and the external, at least, is more imaginary than real as a membrane. The internal membrane is formed by contact of the expanded bases of the fibres of Müller.

6. All the layers become extremely thin over the fovea centralis, both the

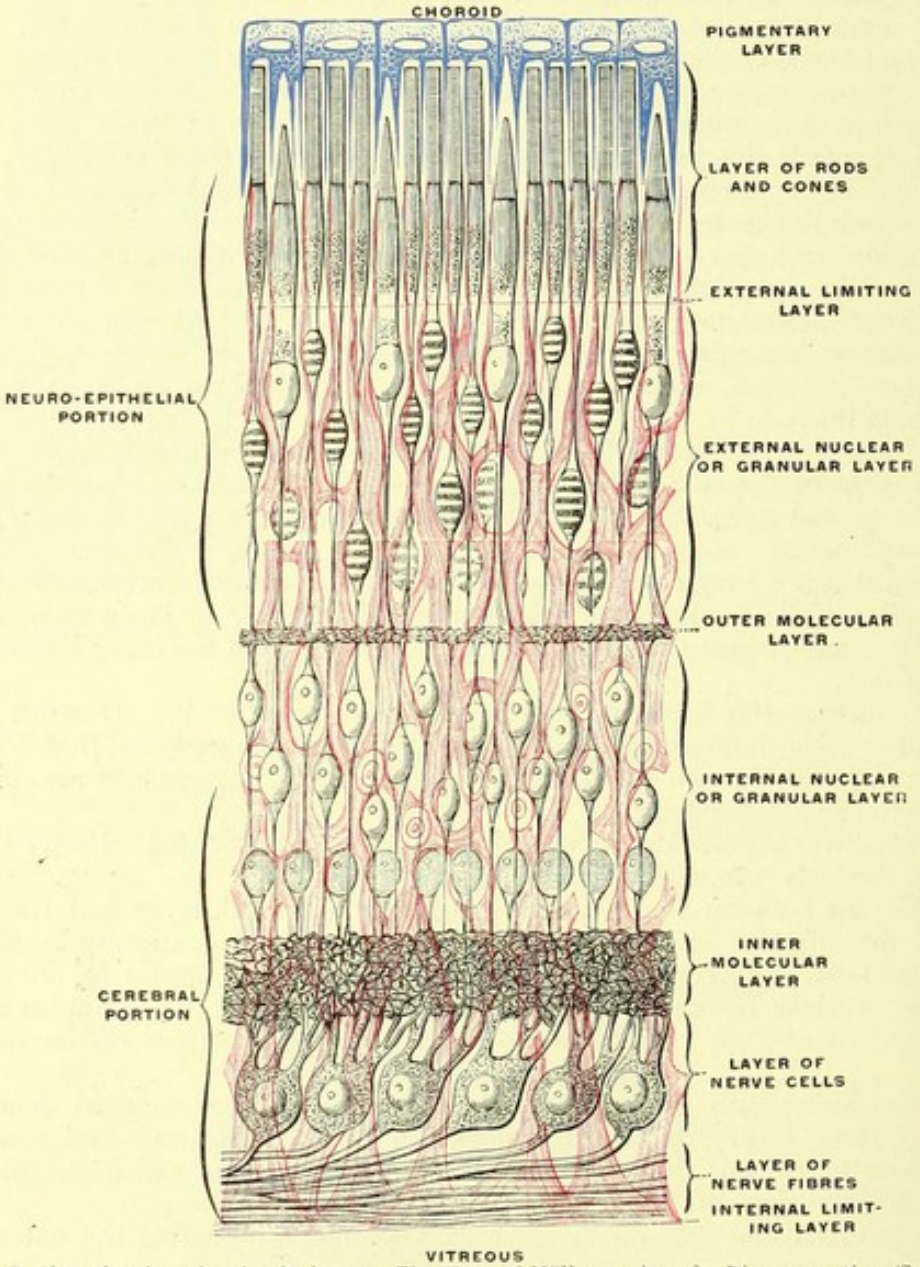

FIG. 737.—Section of retina, showing its layers. The fibres of Müller are in red. Diagrammatic. (Schultze.)

layer of nerve-fibres on the inside and the rods on the outside being completely wanting. Around the border of the fovea they rapidly thicken, however, and over the rest of the macula lutea are thicker than anywhere else in the retina. At the ora serrata all the layers disappear abruptly, and only the layer of columnar epithelium before referred to takes their place in the pars ciliaris retinæ.

THE MEDIA.

As already stated, the vitreous body, the lens, and the aqueous humor completely fill the cavity of the eyeball. The aqueous is perfectly fluid, the vitreous semi-fluid, and the lens solid. All are transparent and colorless.

THE VITREOUS.

The vitreous ("glassy"), also called "vitreous humor" and "vitreous body" (Fig. 731), fills the posterior four-fifths of the globe. It is enclosed in a thin, *hyaloid membrane*, which has some attachment to the retina at the porus opticus, and furnishes a suspensory ligament to the lens. Elsewhere it is perfectly separable from its surroundings. Through the centre of the vitreous body a canal, lined by a tube of the hyaloid membrane, runs from the porus opticus to the back of the lens, where it ends blindly. It marks the course of a vessel, which, in the fœtus, passed from the central artery of the retina to the capsule of the lens. It is known as the *canal of Stilling*. Beyond the ora serrata the surface of the vitreous body is grooved by the ciliary processes, while, anteriorly, it presents a deep concavity, the *fossa patellaris*, for the posterior convexity of the lens.

Subjacent to the ciliary zone the hyaloid becomes thick and fibrous, and adheres closely to the pars ciliaris retinæ. Here it splits, giving off from its under surface the true hyaloid, which is continued over the fossa patellaris, while the outer fibrous portion, the *zonula of Zinn*, stretches inward and forward as a distinct membrane to gain attachment to the capsule of the lens a little in front of its equator. Some scattered bundles from the zonula are attached at the equator and some on the posterior surface also. The free portion of the zonula between the ciliary processes and the lens-capsule constitutes the *suspensory ligament* of the lens. A space around the circumference of the lens, bounded by the suspensory ligament in front and by the vitreous (covered by hyaloid) behind, is the *canal of Petit*. It is filled with fluid, which may reach it from the aqueous chamber through extremely fine clefts, which have been demonstrated in the suspensory ligament.

THE LENS.

The *lens* (Fig. 731) is a biconvex body occupying the fossa patellaris in front of the vitreous. Its anterior surface looks toward the aqueous chamber, and is in light contact with the pupillary margin of the iris. The circumference or equator all round looks toward the ciliary processes. In this position the lens is safely anchored by the suspensory ligament already described.

The posterior surface is considerably more curved than the anterior, and the curvature of each varies with the period of life. In the fœtus, the lens is almost spherical; in the adult, of medium convexity; and in the aged, considerably flattened. Besides this the curvature is constantly changing for near or distant accommodation.

The lens is inclosed in a structureless, elastic, non-vascular *capsule*, which is much thicker in front than behind. When ruptured or cut through, this membrane shows a tendency to curl outward away from the lens. The lenticular substance immediately beneath the capsule is soft and gelatinous, but deeper it becomes hard and firm. The central hard core is sometimes called the *nucleus* of the lens, while the outer soft part is known as the *cortex*.

THE AQUEOUS.

The *aqueous humor* is a watery fluid, occupying the space which is bounded by the cornea in front and by the lens, suspensory ligament and ciliary body behind. This space is known as the *aqueous chamber* (Fig. 731). The iris partially divides

it into an anterior and a posterior chamber, which, however, are continuous through the pupil. The aqueous humor is thought to be secreted in the posterior chamber, whence it finds its way through the pupil into the anterior chamber. From this it is drained away through the spaces of Fontana into the canal of Schlemm.

Although the vitreous, the aqueous, and the lens are commonly spoken of as the "refracting media" of the eye, it should be understood that of the three the lens alone has any considerable effect in changing the direction of the rays of light, which enter the eye, and furthermore, that the cornea, often referred to as if it had an indifferent influence in this regard, is really very powerfully refractive.

THE MUSCLES OF THE EYEBALL.

There are seven muscles (Fig. 738) in the cavity of the orbit, but only six are attached to the eyeball. These are arranged in three opposing pairs, viz., the *superior* and *inferior recti*, the *internal* and *external recti*, and the *superior* and *inferior obliqui*. All except the inferior oblique arise from the immediate vicinity of the optic foramen, either from the bone-surface or from an aponeurotic ring, the *ligament of Zinn*, which is attached around the upper, inner, and lower edges of the foramen, and bridges over the sphenoidal fissure. The external rectus is attached to this latter part, as well as to the bones on each side of the fissure. Hence the

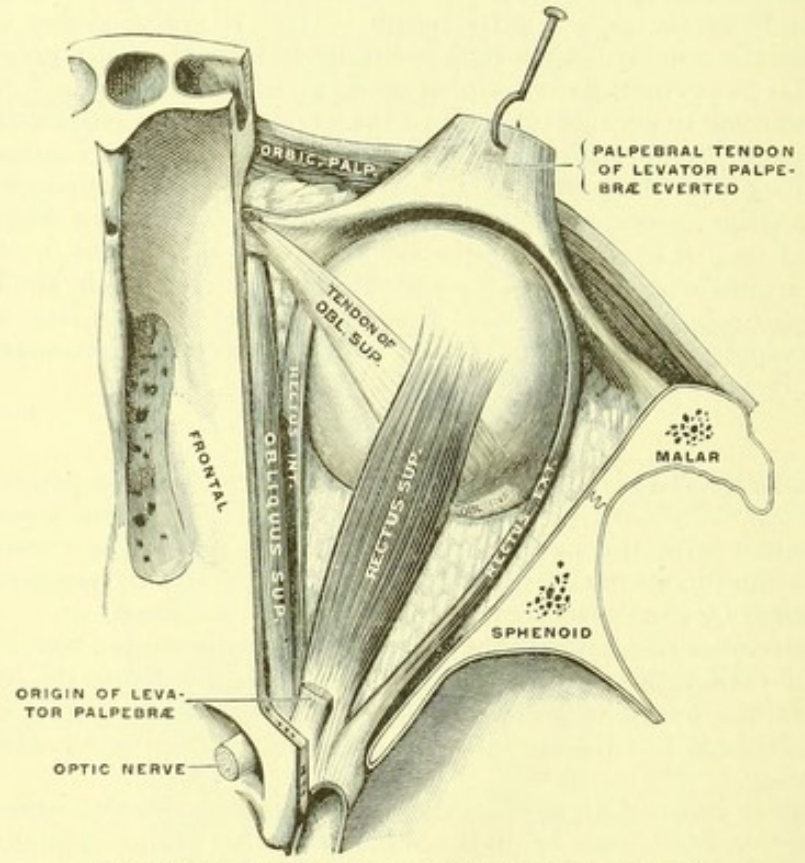

FIG. 738—Muscles of right eye, viewed from above. (Testut.)

two heads, from which it is said to arise, are really continuous. The superior rectus has some attachment to bone above the foramen and to the sheath of the optic nerve, as well as to the aponeurotic ring referred to. The superior oblique arises wholly from bone beyond the ring and above the inner edge of the foramen.

Diverging as they come forward, the *four recti* go straight to their insertions into the sclerotic in front of the equator, and on the aspects of the eyeball corresponding to their names. The *superior oblique* courses upward, inward, and forward to the supero-internal angle of the orbit, where it passes through a fibro-

cartilaginous loop or pulley, attached to the orbital surface of the internal angular process of the frontal bone. It then bends back at an acute angle, and passes downward, backward, and outward beneath the superior rectus to its insertion in the sclerotic behind the equator, between the superior and external recti.

The *inferior oblique* arises from the orbital plate of the superior maxilla just outside the lower end of the lachrymal groove, whence it passes backward and outward beneath the inferior rectus (*i. e.*, between it and the orbital floor); then, turning slightly upward, it reaches its insertion into the sclerotic between the optic entrance and the attachment of the external rectus.

Action.—These muscles rotate the eye in different directions, but without changing its position in the orbit. Omitting refinements for the present, it may be stated that the superior and inferior recti rotate the eyeball on a transverse axis, thus raising and depressing the cornea; the internal and external recti rotate it on a vertical axis, thus turning the cornea inward and outward, *i. e.*, adducting and abducting it; and the superior and inferior obliques rotate it on a sagittal axis, thus turning the cornea round like a wheel on its axis.

Besides its main action, the superior rectus adducts and slightly rotates the cornea inward, and to correct this tendency is the special function of the inferior oblique. Again, the inferior rectus in addition to its main action, tends to adduct the cornea and rotate it outward; but the superior oblique opposes both these tendencies. What has been described as their main actions are the sole actions of the two lateral recti.

The *levator palpebræ superioris* ("lifter of the upper lid") may appropriately be described in this connection. It arises from the small wing of the sphenoid above the origin of the superior rectus, and passing forward close to the roof of the orbit, is inserted by a broad aponeurosis into the tarsus of the upper lid. It also sends a more superficial fibrous expansion forward among the fasciculi of the orbicularis palpebrarum, and this gains an attachment to the skin of the eyelid. Its action is to elevate the lid.

Nerve-supply.—The superior oblique is supplied by the fourth cranial nerve, the external rectus by the sixth, and all the rest by the third in two divisions. The superior division is given to the levator palpebræ and superior rectus; the inferior to the inferior and internal recti and the inferior oblique.

THE SUPERFICIAL APPENDAGES OF THE EYE.

Under this head come the eyelids, conjunctiva, and lachrymal apparatus.

The Eyelids.

The *eyelids* (*palpebræ*) are two loose, tegumentary folds, which when brought together, cover the front of the eyeball. The upper is larger and more movable than the lower, and takes by far the greater part in opening and closing the eye. About half an inch above its free margin a transverse wrinkle, the *superior palpebral fold*, divides it into an upper or *orbital portion* and a lower or *palpebral portion*. Over the former part the skin is extremely loose, and lends itself readily to subcutaneous hemorrhage and conditions of œdema. Over the lower part it is closely adherent to the subjacent tissue. There is an *inferior palpebral fold* in the skin of the lower lid, but it is not as well marked, unless the eye is widely open. The space between the free margins of the lids, the *palpebral aperture*, varies a good deal in different individuals, and even in the same individual according as the pupil is directed upward, downward, or straight forward. In the first position the space is greatest, in the second, least. The angles formed by the lids at their inner and outer ends are called the *canthi*, of which the outer is sharp, the inner rounded. The free margins of the lids are flat, and present an anterior rounded angle and a sharp posterior one in contact with the eyeball. Along the anterior angle project two or three rows of short, strong

hairs, the *cilia* or *eyelashes*, which curve away from the palpebral aperture. Behind these and nearer to the posterior angle are the openings of the ducts of the *Meibomian glands*, twenty or thirty in number and more numerous in the

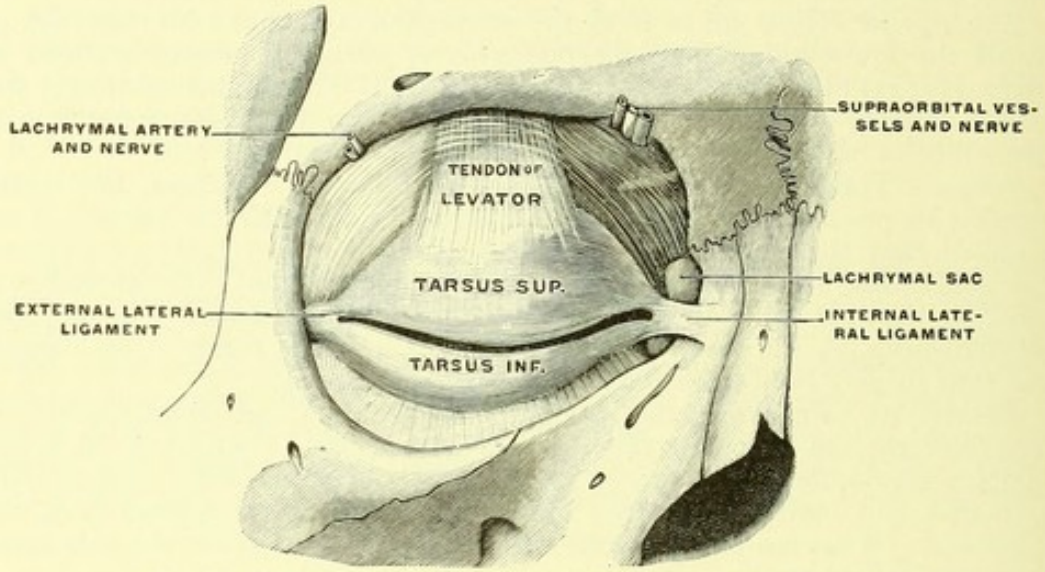

FIG. 739.—The tarsi and their ligaments—right eye, front view. (Testut.)

upper lid than in the lower. There are also modified sweat and sebaceous glands in this situation.

For the first fifth inch out from the inner canthus the divergence of the lids is very gradual and then suddenly becomes more marked. Along this part the lids have no cilia and are not in contact with the eyeball. Nestling in between them in this situation, and resting against the globe of the eye, is a little fleshy protuberance, the *caruncula lachrymalis* ("the little fleshy body pertaining to tears"), which has all the characteristics of true skin, although quite isolated from the adjacent integument. The depression here between the lids, from the bottom of which the caruncle protrudes, is known as the *lacus lachrymalis* ("lake of tears").

Just at the points where the divergence of the lids becomes suddenly more pronounced a small prominence may be noticed on the margin of each lid. This is the *papilla lachrymalis*, and on its summit is the minute opening, *punctum lachrymale* of the *lachrymal canal*, leading into the *lachrymal sac*. The lower punctum is slightly farther out than the upper. The puncta are applied to the surface of the globe and are not seen unless the lids are slightly everted.

Structure of the Eyelids (Fig. 740).—On their superficial aspect the eyelids have a covering of *skin*, very thin and delicate, and containing fine hairs, sebaceous follicles, and sweat glands. On their posterior surface they are covered by a *mucous membrane*, called the *conjunctiva*, which, at a certain distance back from the free margin, is reflected onto the eyeball. Between these two coverings various other structures enter into the formation of the lid. Immediately beneath the skin is a layer of loose, fatless, *areolar tissue*, which provides for the laxity of the integument. Embedded in this tissue is the *orbicularis palpebrarum muscle*, the sphincter of the palpebral aperture, serving by its contraction to approximate the lids, and thus close the eye. Deeper than this is the *tarsus* (often, though improperly, called "tarsal cartilage") (Fig. 739), a thin plate of dense, fibrous tissue devoid of cartilage cells, which strengthens the margin of the lid, and stretches from the inner to the outer orbital wall. The upper tarsus is much stronger and thicker than the lower, and about twice as wide. Each tarsus is thickest at its free border and widest in the middle. They thin off toward the attached edges above and below, and taper toward the ends. Their attachments to the inner and outer orbital margins are known as the *inner*

and *outer palpebral ligaments*. The former, which is much the stronger and more marked, is often called the *tendo oculi*. It is attached to the nasal process of the superior maxilla in front of the lachrymal groove, and to the ridge on the lachrymal bone. Between these points it arches round the front and outer walls of the lachrymal sac. Where the two tarsi blend into this ligament it gives origin to the palpebral portion of the orbicularis muscle, and when this muscle contracts, closing the lids, it produces an enlargement of the cavity of the lachrymal sac thus causing it to suck in the tears from the lacus lachrymalis. To the upper edge

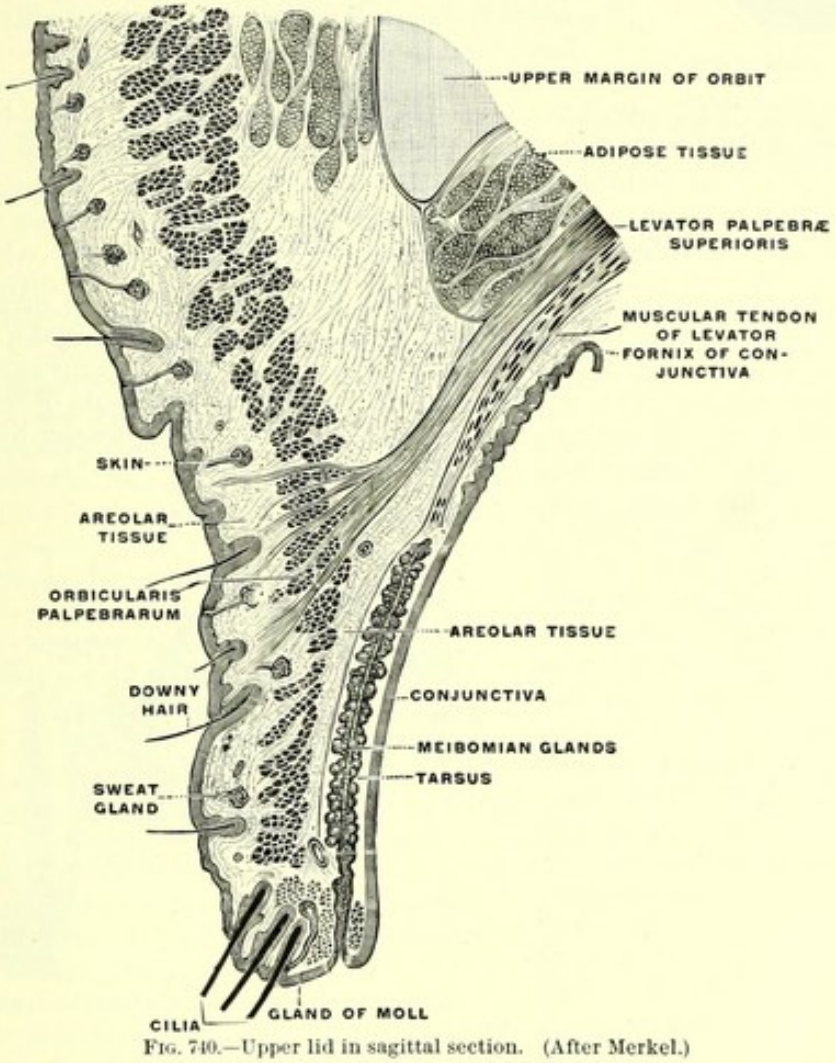

FIG. 740.—Upper lid in sagittal section. (After Merkel.)

of the superior tarsus is attached the wide tendon of the levator palpebræ, and to the lower edge of the inferior tarsus a fibrous expansion from the sheath of the inferior rectus. Embedded in the deep surface of each tarsus are the Meibomian glands, longer and more numerous in the upper lid than in the lower. On everting the eyelid they may be noticed as faint pearly lines running beneath the conjunctiva toward the free margin of the lid. They are a variety of sebaceous glands and their secretion prevents any adhesion between the lids, and keeps the tears from flowing over onto the face until considerably heaped up in the palpebral aperture.

The Conjunctiva (Fig. 741).

The *conjunctiva* is a mucous membrane, which, as before stated, lines the inner surface of the eyelids (*palpebral conjunctiva*) and is reflected from them onto the surface of the eyeball (*ocular conjunctiva*). The fold of reflection is the con-

junctival *fornix*. It is deeper in the upper than in the lower lid. To that part of the lid to which the skin is closely adherent on the outside the conjunctiva is equally adherent on the inside. Over the rest of the lid, and over the eyeball as far as the cornea it is comparatively loose. On the cornea it adheres firmly. The palpebral conjunctiva is thick, vascular, and highly sensitive. On the sclerotic the ocular conjunctiva becomes thin and transparent, and in the healthy condition is only slightly vascular. On the cornea it becomes reduced to a layer of stratified, flattened epithelium, several cells deep.

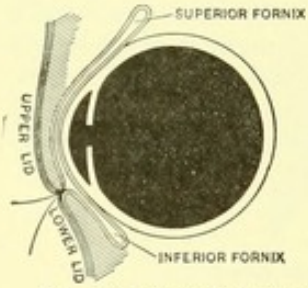

FIG. 741.—Sagittal section of eye, showing superior and inferior fornices of the conjunctiva. (Testut.)

Just outside the caruncula lachrymalis there is a semilunar fold of conjunctiva stretching between the lids with its concavity toward the cornea. This is the *plica semilunaris*, the rudimentary homologue of the membrana nictitans, or third eyelid, in birds.

The Lachrymal Gland (Fig. 742).

This organ is situated in the upper, outer, and anterior part of the orbital cavity, occupying a fossa in the orbital plate of the frontal bone at the inner side of the external angular process. It rests upon the upper and outer aspect of the eyeball (separated from it by conjunctiva) between the attachments of the superior and external recti. It consists of two portions, partially separated by a fibrous septum, an upper, larger part lying against the orbital roof, and a smaller, lower part, which reaches forward almost to the margin of the orbit, and outward as far as the external canthus. The ducts of the gland, seven or eight in number, open in a row on the upper and outer part of the palpebral conjunctiva near the fornix. The progressive closure from without inward of of the lids in winking disperses the lachrymal secretion over the whole surface of the eye, and tends to collect it in the lacus lachrymalis. Here it is sucked into the lachrymal canals through the puncta, which are applied closely to the surface of the eye, and is conveyed by them to the lachrymal sac, into which they open separately, or by a common tube. From this it is conveyed downward through the nasal duct into the inferior meatus of the nose, where it helps to moisten the inspired air.

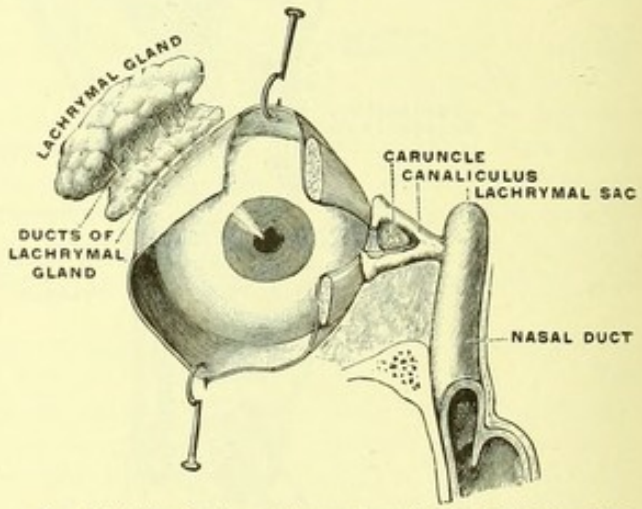

FIG. 742.—The lachrymal apparatus of the right eye. (Testut.)

The *lachrymal canals* are first vertical in direction in both lids, then horizontal and convergent inward—points to be remembered in attempts to pass a probe or bristle. The *lachrymal sac* is the upper enlarged end of the nasal duct. Its upper extremity is blind, and reaches higher than the openings of the canals. It is lodged in the groove formed by the lachrymal bone and superior maxilla, and is continuous below with the *nasal duct*. Both form a tube of mucous membrane, which is continuous with that of the nose below and with the conjunctiva above. The bony canal in which this tube lies is lined throughout by periosteum, between which and the mucous membrane there is a layer of loose, connective tissue. This is particularly abundant around the lachrymal sac, thus allowing considerable distension of that organ.

THE ORGANS OF DIGESTION.

By F. H. GERRISH.

IN the lowest forms of animal life there is no differentiation of organs, each part of the body being equally capable of performing every kind of work within the sphere of the creature's possibilities. The little animal called *amœba* furnishes a good illustration of this fact. The whole creature may be regarded as a minute mass of living protoplasm. A particle of nutritious material coming in contact with the sensitive surface of an amœba is seized by little protrusions which are thrust out around it, and is presently enclosed completely by the prolongations. In the containing cavity thus formed the particle is held until the animal has absorbed all of the food which it can get from this source. Then the little projections which have enwrapped the nutrient material are withdrawn, the cavity which they formed is thus obliterated, and the residue of the bit of pabulum is released. Soon, it may be, the very portion of the amœba, which was just now a recess, becomes a protrusion, fastens to some fixed object, and by its contractile power pulls the bulk of the animal up to the point of attachment, itself becoming effaced in the process. Thus, it will be seen that a single portion of the creature's body can serve as an organ of sensation, an organ of prehension, an organ of absorption, and an organ of locomotion: feeling, grasping, abstracting, moving from place to place are all in turn shown to be capabilities of one small part, which in no way differs from every other part. Each of these organs was merely temporary: the impact-perceiving surface was transformed into seizing hands; these presently became a stomach; this soon turned into a leg; and the leg disappeared by flattening itself out into a sensitive surface, capable of appreciating the touch of a particle brought in contact with it.

Differentiation of Organs.—In animals a little higher in the scale of being a depression is seen at some point of the surface, forming a permanent recess, into which minute bits of pabulum are received and deprived of their nourishing material, after which process the unserviceable remnants are expelled by the door which gave them admission (Fig. 743). A step farther up we find the receptacle deeper, more capacious, and capable of effecting such changes in the food introduced into it as will make a larger proportion available for absorption into the system. In the next grade beyond this, the cavity becomes so long as nearly to reach the surface opposite to that at which its opening is located. One slight additional extension in the direction of previous growth results in perforation of the tissues intervening between the cavity and the surface; and, thus, the deep depression is converted into a tube, reaching from one end of the animal to the other, and permitting the expulsion of the unused portion of the food by an opening other than that by which it was introduced.

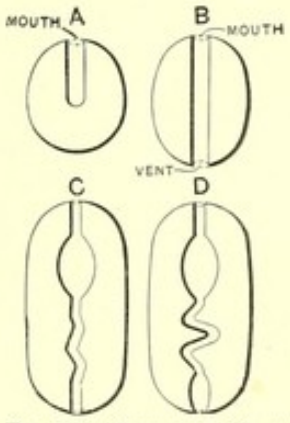

FIG. 743.—Diagram to illustrate the gradual development of the alimentary tube. (Testut.)

This tube, short and simple, is the type upon which is constructed every alimentary canal, however complicated. *Elaboration* of this structure is accom-

plished in several directions: (1) *by enlargement longitudinally*, so that the length of the canal becomes in some animals many times greater than that of a straight line between its two extremities, thus furnishing an immensely more extensive surface, without corresponding increase in the size of the individual; (2) *by dilatation at various places*, and by the formation of transverse folds projecting into the bore, by which is gained not only augmentation of area, but also, what is of great advantage, temporary detention of the contents so that they may be modified in ways which would be impossible during their rapid passage; (3) *by the addition of certain structures* and materials to the walls of the tube, which thus can effect the comminution of introduced material, furnish solvent fluids of different kinds, and influence the acceleration or retardation of the current of the matters contained in the canal; (4) *by the development of accessory organs*, which, though originating as mere buds from the sides of the tube, grow and develop until they attain considerable —perhaps immense—size, and supply secretions of essential importance; and (5) *by the formation of a reservoir*, in which waste matters can be stored until it is convenient to void them.

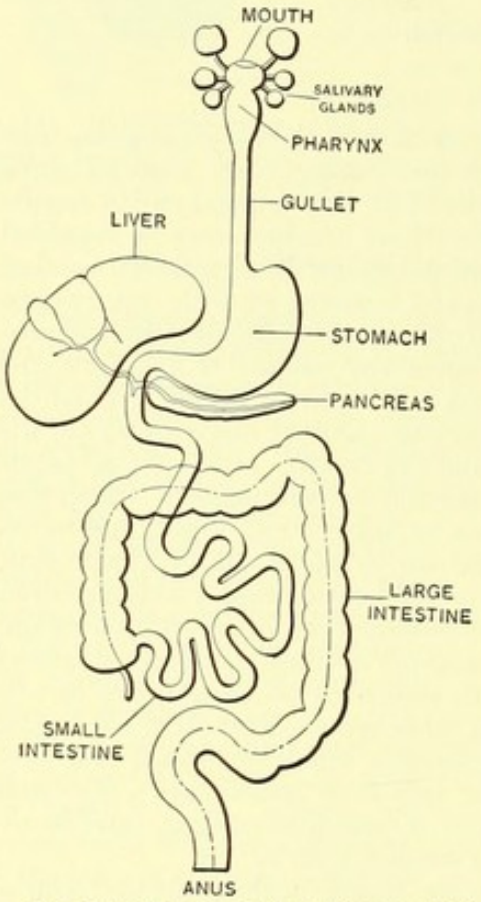

FIG. 744.—Diagram of the alimentary tube and its appendages. (Testut.)

The Human Alimentary System (Fig. 744).—These features are all illustrated in the human alimentary system. *The tube measures* thirty feet from the aperture of introduction, the mouth, to the opening of expulsion, the vent or anus; but the distance between these points in a direct line is not more than the same number of inches. Connected with the initial segment of the canal is *an apparatus, which minces and crushes* hard masses of aliment, thus prodigiously increasing the surface of the matters to be acted upon by the solvent fluids, and, consequently, expediting the liquefactive process. *The lining membrane* of the entire tube is of the mucous variety; but it does much more, in the greater part of its course, than furnish a protective smear, for it is so modified by the formation in its very substance of a numberless *multitude of peculiar glands*, that it affords various juices, by whose agency important changes in the preparation of food for absorption are brought about. From one end of the canal to the other its walls contain *muscle*, which by its contraction carries the contents onward with sufficient speed. A short distance from its beginning the tube expands into a *large cavity*, the stomach, which delays the swallowed food, as a pond in the course of a river causes a diminution in the rapidity of the current. Throughout the most of the remainder of the canal we find *little shelves*, extending into the lumen from the sides, and causing at once increase of surface and retardation of the stream. There are also *glands* —the salivary, the pancreas, the liver—which, although entirely outside of the limits of the alimentary tube in their developed condition, originate from it, discharge their peculiar products into it, and are thus accessory in their action to the glands which make a part of the walls of the canal itself. Finally, the last great segment is so constructed that it acts as a *receptacle* in which unappropriated parts of the food and certain effete substances from the system can be retained until the arrival of suitable times for their evacuation.

Segments of the Alimentary Tube.—The alimentary canal is naturally divided into a number of segments, which occur in the following order, beginning at the upper end: mouth, pharynx, gullet, stomach, small intestine, large intestine, anal canal. It is usual to reckon the anal canal as a part of the large intestine; but, later in this chapter, it will be seen that there is good reason for giving it a place as a separate segment, since it should be regarded as a tubular passage rather than as a mere opening.

Tunics of the Alimentary Canal.—Every portion of the inner surface of the canal is covered by *mucous membrane*, with the exception presented by the crowns of the teeth. Even this, to the philosophical anatomist, does not seem an exception; for he recalls the fact that the teeth, though so dense and white as to afford a very striking contrast to the soft and reddish membrane from which they project, are epithelial in their mode of development, and that the glistening, dry enamel, which encrusts their crowns, is strictly and wholly epithelium, originally like that which surmounts the dull and moist mucosa. Outside of this inner, mucous tunic is one of *areolar tissue*, almost everywhere very distinct, but, in a few places of no great extent, very condensed. Still another coat is found external to the areolar, the *muscular*, usually arranged in two layers, an internal, whose fibres are circular in direction, and an external, in which they run longitudinally. Finally, in that portion of the canal, which lies below the diaphragm, there is almost everywhere a fourth tunic, composed of *serous membrane*.

The Service of each Tunic.—Calling to mind the character and functions of these various membranes and tissues, as described in the chapter on histology, we shall quickly obtain a general idea of the physiological capabilities of the tube whose wall they compose.

Mucous membrane is a soft, moist structure, secreting a glairy fluid, which serves to smear the surface, and thus at once prevents its becoming dry, and protects from the injury which the contact of foreign substances might otherwise occasion. In the larger part of the alimentary canal the membrane contains great numbers of small, tubular glands, which, instead of secreting mucus alone, as is the case with the corresponding structures in the respiratory tubes, the urinary bladder, and other organs, manufacture different fluids, possessed of such qualities that they can effect important changes in food which is taken, and put it in condition to undergo absorption into the blood and incorporation into the tissues of the body. Mucosa is not an elastic structure: it will bear very little stretching without harm. But we find that, where it lines hollow organs, which are liable to become distended, it is, at almost every part of the surface, so loose in the collapsed condition of the viscus that it is deeply wrinkled, and lies in well-marked folds. When the cavity is filled, these loose ridges are smoothed out and disappear, and the mucosa is evenly spread, but not rendered tense; and, thus, it suffers no harm.

This passive movement of the membrane would not be practicable except for the *areolar coat*, which connects it with the muscular. Areolar tissue is strong, flexible, elastic, and full of spaces in the meshes of its network. It, therefore, holds the mucosa firmly but gently in place at all times, regulating its wrinkling so that its folds are evenly distributed, and permitting its extension without displacement from its proper relation to the muscular coat.

The areolar coat affords an easy and safe bed for the vessels and nerves, whose twigs, and rootlets, and filaments form networks throughout the two tunics, between which this coat is situated.

The **muscular coat** is that by which active movements of the tube are produced. Its tissue is nearly all of the involuntary variety. Its movements are mostly of a vermicular kind, and serve to carry the contents of the canal from the upper to the lower end.

The **serous membrane** clothes the tube in its abdominal portion—that in which there is the largest variation in the size of the organs, the greatest necessity for activity of movement, and the most frequent liability to pressure from without.

But all of these things—distension, contraction, peristalsis, compression—can take place without making trouble, for the organs have so slippery an outer surface that they glide freely on one another during the less movements, and slide elusively out of the way of extraneous force.

Gas in the Alimentary Tube.—The tube in the larger part of its course generally contains more or less gas, which, by keeping the opposite walls somewhat separated from each other, prevents the injury which would probably come from the prolonged rubbing together of these soft and delicate surfaces. In some regions, however, as in the gullet, the opposite surfaces of the membrane are in contact nearly all of the time; but in these cases the structure is very different from that in the stomach and intestines, especially as regards the epithelium, which, instead of being tender and in a single lamina, as in the latter organs, is hard and stratified, and capable of withstanding the influence of incessant pressure and friction.

THE MOUTH.

The mouth (*os*) (Fig. 745) is the organ in which are accomplished wholly or in part the functions of prehension, mastication, insalivation, gustatory sensation, and articulation.

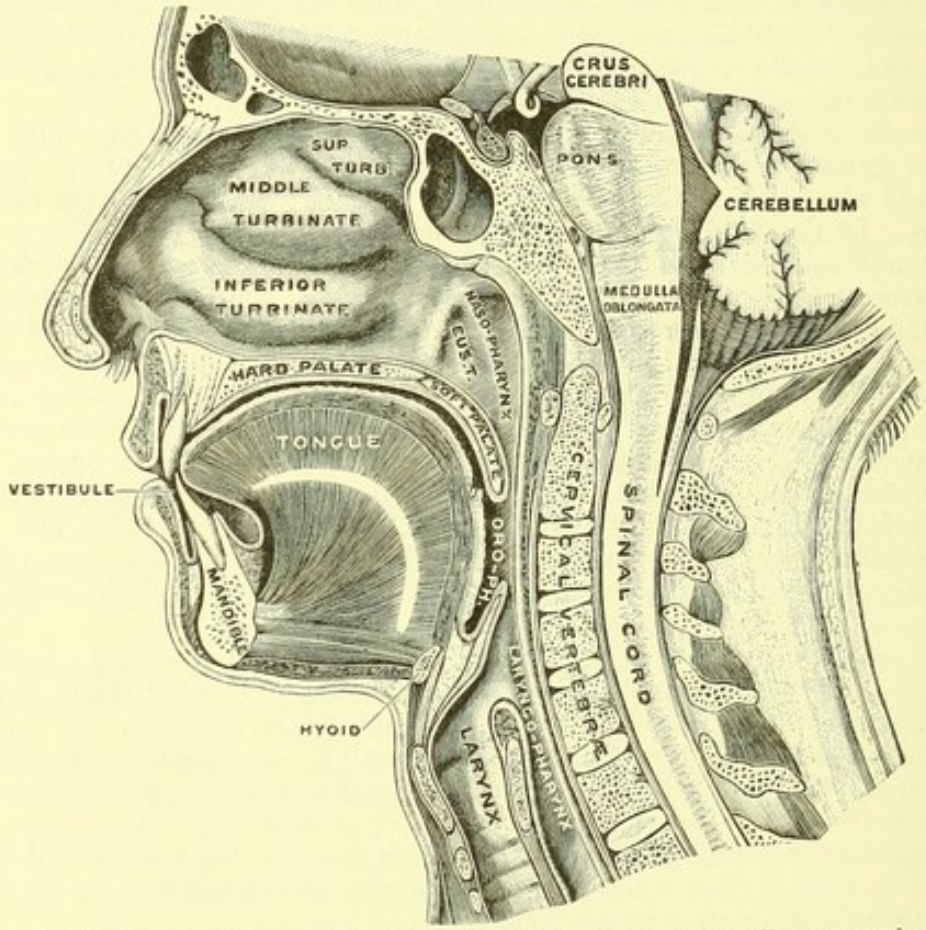

FIG. 745.—Sagittal section of the face and neck, showing the first portions of the alimentary and respiratory tracts. (Testut.)

Its name is applied popularly not only to the cavity in the face, which constitutes the initial segment of the alimentary canal, but also to the aperture of entrance and to the lips; but anatomists use it only in the first sense. It is not always an actual cavity—a fact demonstrated in sagittal frozen sections, in which

commonly its floor and roof are in contact, and its side walls hug the dental arches. Between this merely potential cavity and that of wide expansion is a great distance, within which are countless variations in shape; but the mouth may conventionally be regarded as a rather oval, horizontal slit, presenting marked irregularities of size and form. Its virtual cavity is made real by separation of the lips or cheeks from the teeth, by the flattening of the tongue, or by the depression of the lower jaw. The oral space is divided by the apposed dental arches into the vestibule and the mouth proper. The former, *vestibulum oris*, has in front the lips, at the sides the cheeks, and its opposite boundaries are made by the outer surface of the gums and teeth; the latter, *cavum oris*, is bounded above by the hard palate, below by the tongue and the sublingual space, in front and at the sides by the inner surface of the gums and teeth, and behind by the soft palate and the aperture beneath it by which the mouth opens into the pharynx. The two portions communicate with one another by the gaps between the teeth and by the considerable space behind the last molar teeth.

The Lips.

The lips (*labia*), upper and lower, are musculo-membranous folds, enclosing the transverse slit which is the front aperture of the mouth. Each is attached to a jaw-bone just beyond the base of the alveolar process. The external limits have been given on page 23. From before backward they are composed of skin, muscle, areolar tissue containing glands, and mucous membrane, the last forming the free border as well as the lining. The skin, adherent to the muscle, presents no especial peculiarities, except the growth of strong hairs in the adult male. The muscular layer is mostly formed by the orbicularis oris, into which other muscles from various regions of the face are inserted. The areolar lamina is occupied by an almost continuous layer of racemose *glands*, called *labial*, which are practically identical in structure with the salivary glands. The mucous membrane is smooth and moist, and is reflected from the lips to the gums. A fold of it in the middle line at the junction with the gums forms a bridle, *frænum labii*, for each lip. On its free border the lip is abundantly supplied with papillæ. Everywhere its epithelium is flattened and stratified.

The Cheeks.

The surface-limits of the cheek have been detailed on page 23. A considerable part of its surface is attached to the bones of the face; only the central portion is free, and clothed with mucous membrane, this being continuous with that of the lips, and, like it reflected to the gums. Five layers go to compose the cheek: skin, areolar tissue, deep fascia, muscle, and mucosa. The skin is continuous with that of the lips, and in the adult male is, to a large extent, covered with strong hairs. The areolar tissue is usually laden with fat-cells, these being most numerous in children and young women, and least abundant in the aged. The next layer is formed by the fasciæ of the masseter and buccinator, which muscles constitute a large part of the fourth lamina. The mucous membrane, continued from that of the lips, is similar to it, but there is no glandular layer connected with it, as in the labial region. There are, however, a number of *mucous glands*, called *buccal* and *molar*, on the outer surface of the buccinator, each of which sends its excretory duct through the mucous membrane, and pours its fluid into the mouth. Here, too, the mucosa is perforated by the duct from the parotid gland.

The Hard Palate.

The hard palate (*palatum durum*) forms the roof of the mouth. Its basis is made by the palate processes of the upper jaw-bones and the horizontal plates of

the palate bones, which, immovably united and bordered in front and laterally by the drooping alveolar process, make a flattened vault of horse-shoe shape. Mucous membrane, smooth, tough, and continuous with that of the gums, lines the roof, being closely adherent to the periosteum at the alveolar margin and mid line; but, where such attachment does not exist, there is a compact layer of racemose glands, called *palatine glands*, resembling the salivary, and embedded in areolar tissue, which hugs the periosteum. Each of these glands sends its duct through the mucosa, so that the latter is plentifully dotted with their minute openings. The surface is roughened, especially in front, with low, obliquely transverse ridges, has numerous small papillæ, and displays a median raphé, at whose anterior end is a tubercle, which marks the inferior orifice of the anterior palatine canal.

The Soft Palate (Fig. 746).

Attached to the hind end of the hard palate, and drooping obliquely backward from it with perfect continuity of surface, is the soft palate (*palatum molle*), also called the *velum pendulum palati* ("pendulous veil of the palate"), which extends from side to side, and terminates below in an arched border, from the centre of which dangles a teat-like process, the *uvula* ("little grape"). From the base of the uvula on each side the lower edge of the velum is, as it were, split, one part going outward, downward, and forward to the side of the tongue, the other outward, downward and backward to the side of the pharynx, leaving between them on the side wall of the region a triangular recess with its base toward the tongue. The former ridge is the *anterior pillar of the palate*, the latter the *posterior pillar*. The irregular opening bounded by the anterior pillars and the dorsum of the tongue is the *isthmus of the fauces*, the aperture by which the mouth communicates with the pharynx. The front (antero-inferior) surface, therefore, of the velum marks the posterior limit of the mouth, and all of the cavity behind this plane belongs to the pharynx. The free edges of the posterior pillars are nearer together than are those of the anterior pair, and hence both sets are seen distinctly, if the mouth is widely opened, and the tongue depressed.

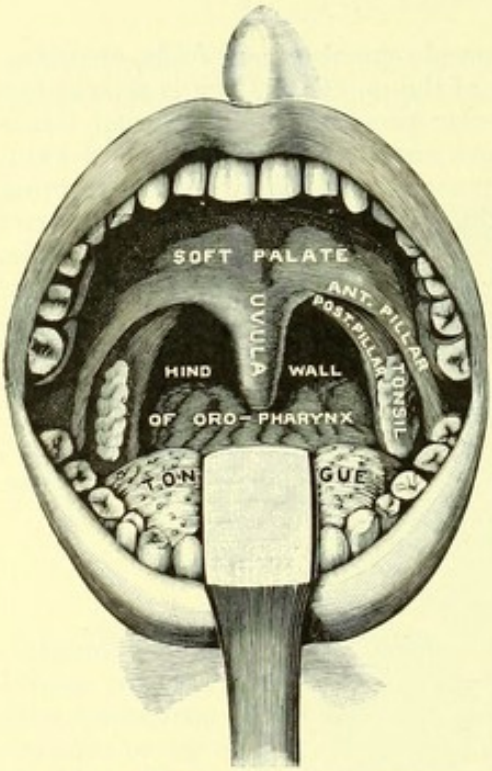

FIG. 746.—The soft palate and tonsillar regions. (Testut.)

Structure of the Soft Palate.—The soft palate is built upon a fibrous framework, which hangs down from the hind border of the hard palate. Into this are inserted various muscles, which constitute the bulk of the organ. Mucous membrane covers every part of it, that visible from in front being like the buccal, smooth, rosy, covered with stratified, flattened epithelium, while that on the opposite surface resembles the nasal mucous membrane, being uneven, red, and clothed with ciliated, cylindrical epithelium, except at its lowest part, where the cells are like those in front. Beneath the mucosa are many glands, the majority being on the oral side, and continuous with those of the hard palate.

During swallowing the veil is lifted backward to the hind wall of the pharynx; but in suction it is drawn down to the tongue. In articulation it is made to assume every attitude between these extremes.

Muscles of the Soft Palate.

The muscles of the soft palate are the palatopharyngeus, palatoglossus, levator palati, tensor palati, and azygos uvulæ.

Palatopharyngeus (Fig. 747) ("the palate-pharynx muscle").—*Situation*, at the side and back of the soft palate. *Origin*, in the velum, embracing the levator palati and azygos uvulæ. *Direction*, downward, outward, and backward. *Insertion*, the upper and hind borders of the thyroid cartilage (mingling with the stylopharyngeus), and the lower part of the pharynx, extending to the middle line. *Action*: it lifts the larynx and the tongue, pulls down the velum, and approximates the posterior pillars, shutting off the oropharynx from the naso-pharynx. *Nerves*, probably from the pharyngeal plexus through the eleventh cranial. Covered by mucous membrane, it forms the posterior pillar of the soft palate. This is joined by a fasciculus arising from the cartilage of the Eustachian tube, which has been described as a separate muscle, under the name of the *salpingo-pharyngeus*—the first part of the title referring to the trumpet-shape of the end of the tube.

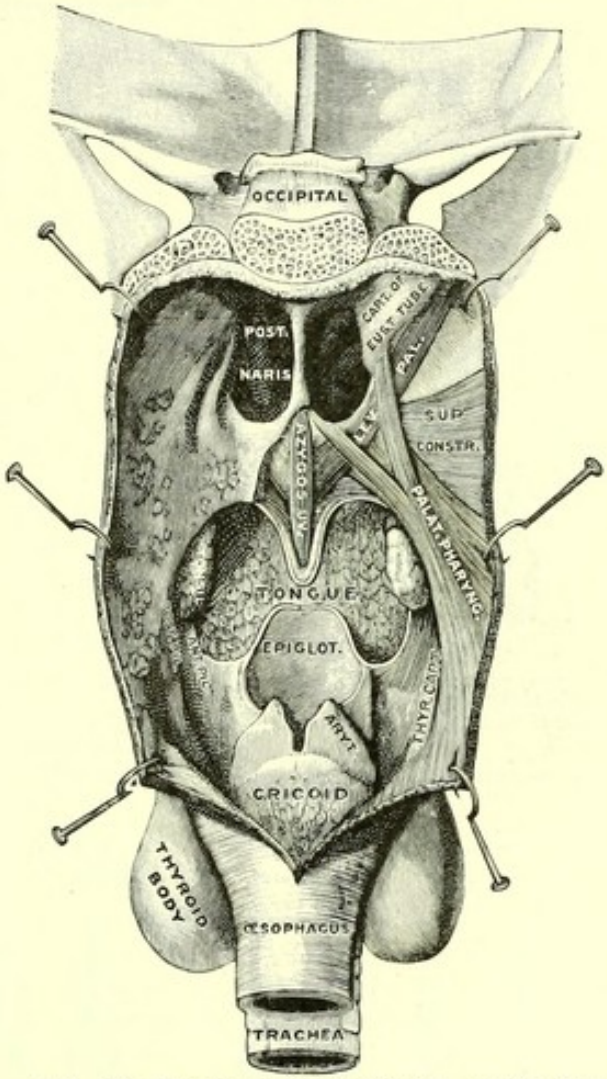

Fig. 747.—Muscles of the soft palate, viewed from behind. The dorsal wall of the pharynx has been laid open. (Testut.)

Palatoglossus (Fig. 759) ("the palate-tongue muscle").—*Synonym*, constrictor isthmi faucium, "the constrictor of the isthmus of the fauces." *Situation*, at the side and front of the soft palate. *Origin*, in the velum, being continuous with its opposite fellow. *Direction*, downward, outward, and forward. *Insertion*, at the side of the tongue. *Action*: it lifts the tongue, pulls down the velum, and approximates the anterior pillars, closing the pharynx from the mouth. *Nerves*, probably from the pharyngeal plexus through the eleventh cranial. Covered by mucous membrane, it forms the anterior pillar of the soft palate.

Levator Palati (Fig. 747) ("the lifter of the palate").—*Situation*, in the upper part of the velum. *Origin*, the under surface of the petrous portion of the temporal bone, in front of the carotid canal. *Direction*, downward, inward, and forward. *Insertion*: it blends with its opposite fellow. *Action*, lifting the velum. *Nerve*, probably the spinal accessory, through the pharyngeal plexus.

Tensor Palati ("the tightener of the palate").—*Synonym*, circumflexus, "the muscle which bends around." *Situation*, in the velum. *Origin*, the root of the internal pterygoid plate, the spine of the sphenoid, the Eustachian tube. *Direction*, downward to the hamular process, then inward. *Insertion*, the middle of the soft palate, and the under surface of the palate bone. *Action*, tightening the velum. *Nerve*, the third division of the fifth.

Azygos Uvulæ (Fig. 747) ("the unyoked (not-paired) muscle of the uvula," —a misnomer, as there are two muscles).—*Situation*, in the soft palate, close to the mid line. *Origin*, posterior nasal spine. *Direction*, downward. The muscles of the two sides unite below, and terminate in a free, dangling end, making the bulk of the uvula. *Action*, shortening the uvula. *Nerve*, probably the spinal accessory, through the pharyngeal plexus.

THE TEETH.

The teeth are dense, white structures, firmly implanted in sockets in the alveolar processes of the jaw-bones. They are essential parts of the chewing-apparatus, and are concerned in articulation. Each consists of three portions—a root or fang, a neck, and a crown. The surface toward the tongue is called "inner," and the opposite one is called "outer."

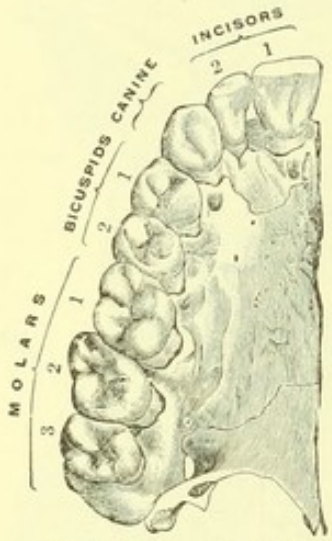

FIG. 748.—The teeth of the right half of the upper jaw in their sockets, viewed from below.

The *root* is embedded in the bone, has a tapering shape, and fits accurately in its socket—an arrangement which ensures a distribution of pressure over the surface, and the removal of pressure from the tip of the fang, where the vessels and nerves pass to and from the tooth-cavity. The *crown* is the portion which projects beyond the gum. The *neck* is a narrow strip between the fang and crown, is slightly, if at all, constricted, and is embraced by the border of the gum.

In each jaw are sixteen teeth, arranged with bilateral symmetry, and all set obliquely, except the two nearest the middle line in the mandible. Classifying them according to their shape, and reckoning from the median line, we find in each lateral half of each jaw two incisors, one canine, two bicuspids, and three molars (Fig. 748).

The **Incisors** (Fig. 749) ("cutters") are the teeth by which portions of food are bitten off. The root of an incisor is a long cone;

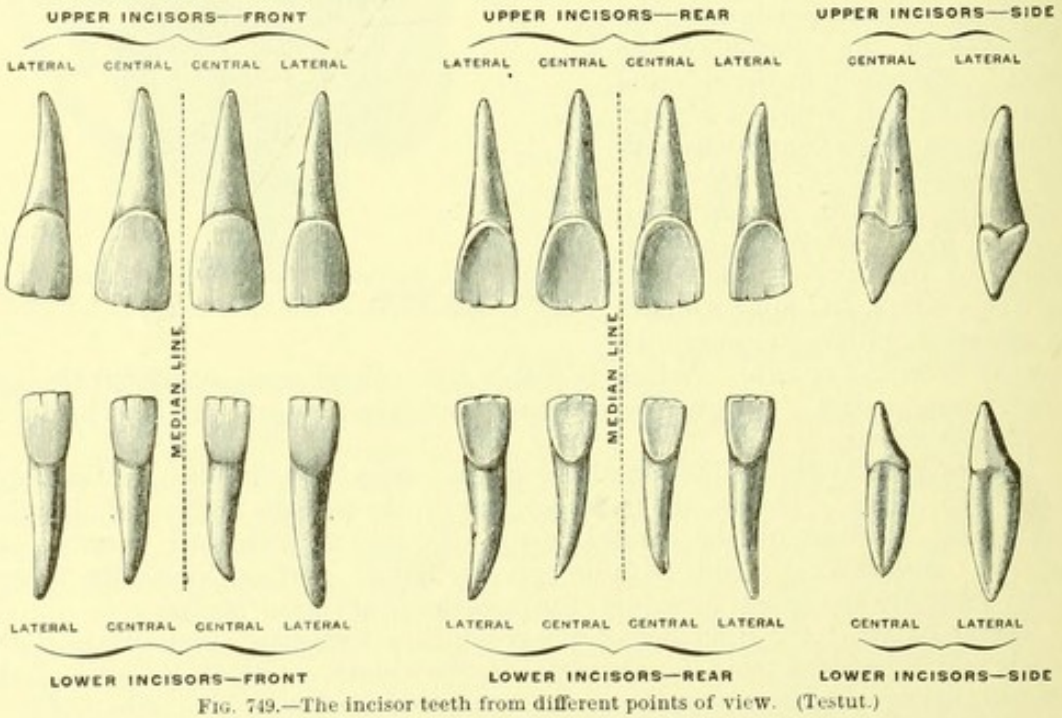

FIG. 749.—The incisor teeth from different points of view. (Testut.)

its crown presents an anterior, slightly convex surface, and a posterior, slightly concave surface, the two meeting in a sharp free edge. The central incisors (those

nearest the mid-line) of the upper set are larger than the lateral; but the central incisors of the lower jaw are smaller than their laterals.

The **Canine** (Fig. 750), so-called from its prominence in animals of the dog-tribe, has a longer fang than an incisor. Its crown terminates in a sharp point, technically a *cusp*, from which comes the name, "cuspidate," occasionally employed. An upper canine is vulgarly called an *eye-tooth*, and a lower a *stomach-tooth*, each from the direction of its fang.

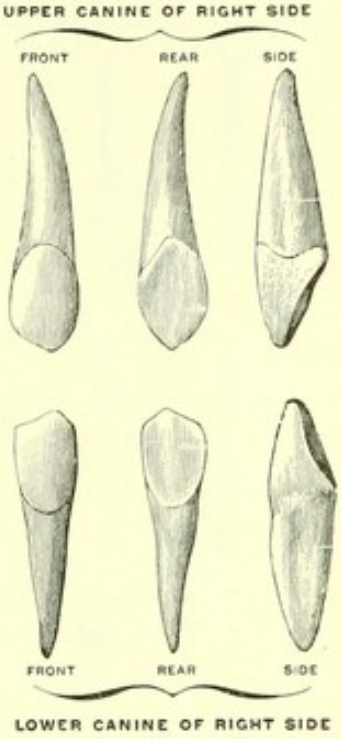

FIG. 750.—The canine teeth from different points of view. (Testut.)

A **Bicuspid** (Fig. 751), as its name implies, has two prominences or cusps on its crown. From its situation in front of the next group it is also called *premolar*. Its root shows an attempt at division.

Molars ("millstones") (Figs. 752, 753) are thus named from their being concerned in grinding the food, and are also called *multicuspids* from their having three or more cusps on their summits, *double teeth* from their size, and *jaw-teeth* from the room which they occupy. In the upper set the molars have three fangs each; their mates in the lower have but two each. The third molar is, with fine irony, called the *wisdom-tooth*, because it does not appear until the late teens. The absence of this tooth about once in eight times, and its crowded condition in many cases, when present, point to the gradual lessening of the size of the jaws in proportion to the diminution of the work required of them in civilized life.

Excepting the last upper molar, *each tooth touches two in the opposite set*, when the jaws are closed (Fig. 754). The upper dental arch is a little larger than its fellow, and overlaps it in front, so that the cutting edge of the superior incisors glides downward on the anterior surface of the lower, as one blade of a pair of scissors acts upon the other.

Sets of Teeth.

The teeth grow in two series, the one in infancy, the other in childhood and youth. The former are displaced by the latter, and, therefore, are named *temporary*, or *first teeth*. They are also called *deciduous*, because they are shed, and *milk-teeth* on account of their development during the period of lactation. Those of the later set are called *permanent*, or *second* teeth, and it is they which have just been described (Fig. 755).

The **Temporary Teeth** are twenty in number, there being five in each lateral half of each jaw, namely two incisors, one canine, and two molars. It will be observed that there are no bicuspids, and no third molar. The bicuspids of the permanent set take the place of the temporary molars, and the jaw grows sufficiently to give room for the permanent molars, which are the successors of no other teeth.

Eruption of the Teeth.—The temporary teeth usually begin to appear when the baby is about seven months old, and he has his full score by the time that he is two years of age. Before any of the milk-teeth are shed, the first grinders of the second set are fully developed. They are called the *six-year molars* in celebration of the time of their advent. The others of the series consume a dozen years in their "cutting," as their protrusion through the gum is commonly called.

There are so many exceptions to any rule, which states the precise date of appearance of the teeth, that it is well nigh useless to present such a formula. But it is desirable to know the order in which they may be expected, and this is

presented in Fig. 755. The diagram also gives the position in the dental arch of the teeth of each set and shows what kind of permanent tooth succeeds each

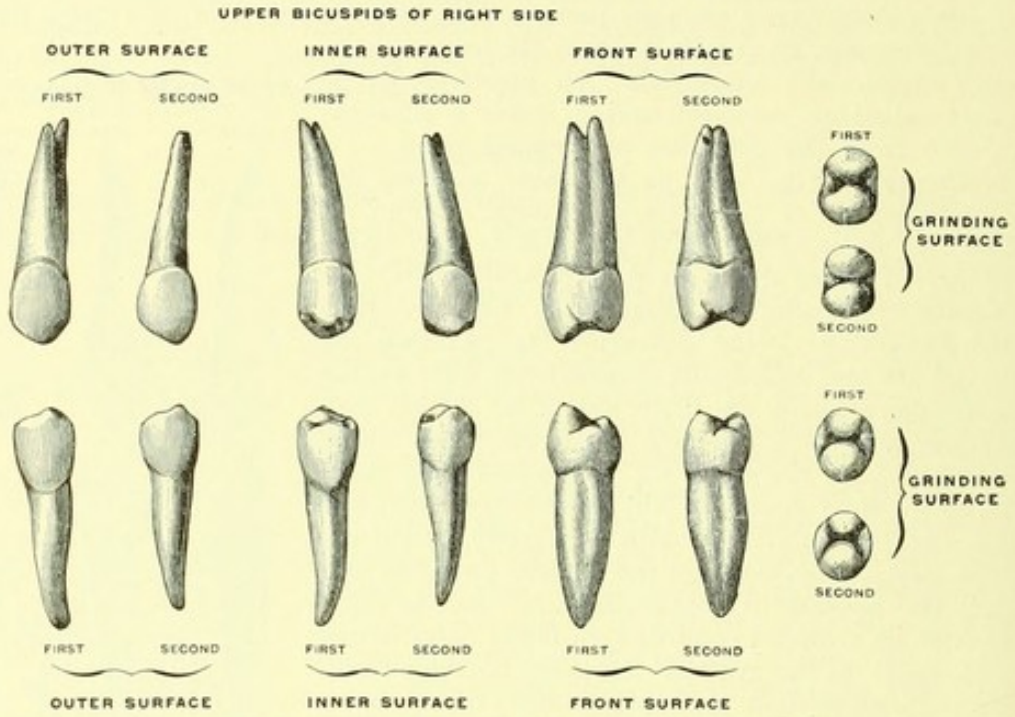

FIG. 751.—The bicuspid teeth from different points of view. (Testut.)

temporary tooth. It is to be noted, however, that the permanent teeth appear in the jaw on the lingual side of the temporary, and not, as might be inferred from

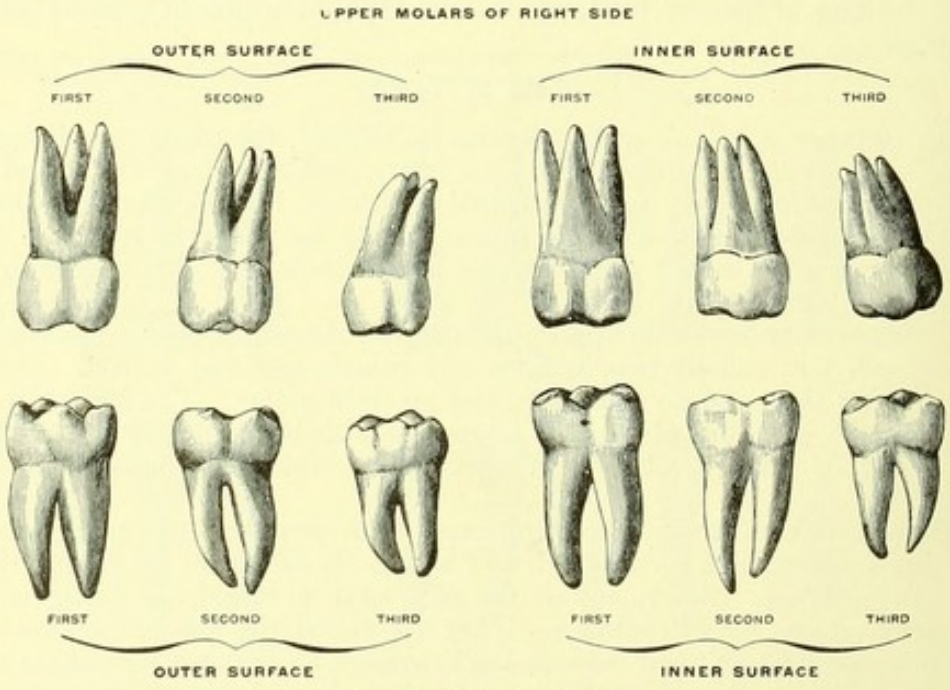

FIG. 752.—The molar teeth viewed from the outer and inner sides. (Testut.)

this diagram, on the labio-buccal side. The lower tooth of a given kind usually is cut just before its mate above appears.

Method of Displacement of Temporary Teeth.—The temporary teeth are replaced by the permanent in the following manner: the tooth which is to succeed the deciduous tooth is pushed upward by the continual growth of the dentine of its fang. Its enamel is crowded against the root of the milk-tooth, cuts off its nutrition, and, by the incessant pressure of its dense substance upon the less hard materials composing the root of the tooth above, causes the latter to dwindle away, particle by particle, the molecules disappearing by absorption, until all of

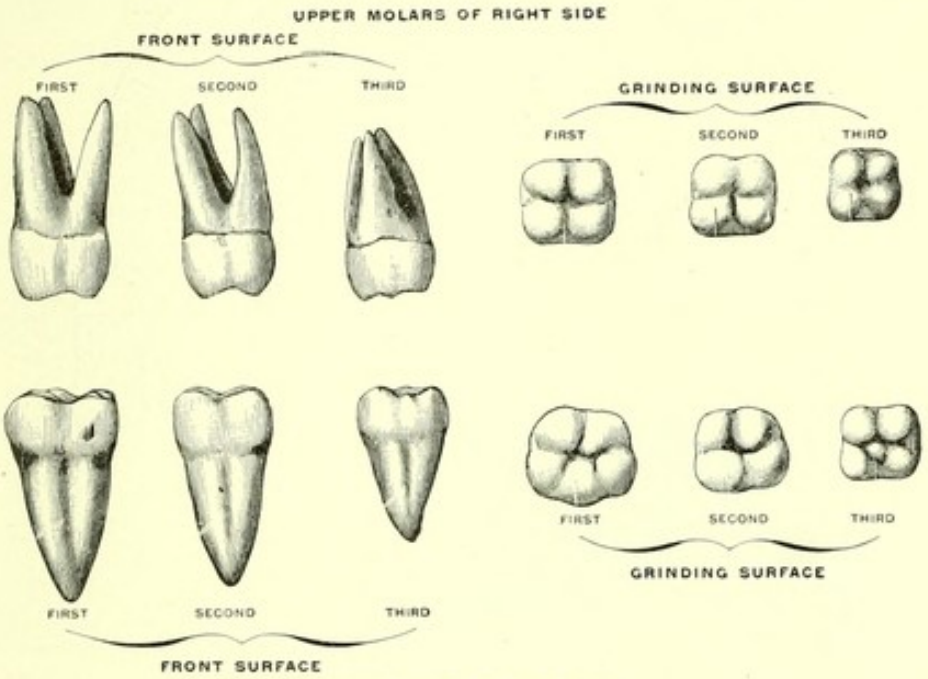

FIG. 753.—The molar teeth—their front and grinding surfaces. (Testut.)

the root has vanished, and the only support of the crown is that afforded by the adhesion of the gum to the neck. Then the crown is knocked off by some slight force, and in its place appears that of its permanent successor. When the permanent tooth is not aimed accurately at the root of the temporary, but shoots by it, the latter remains undisturbed.

Morphological Character of a Tooth.—A tooth, though intimately connected

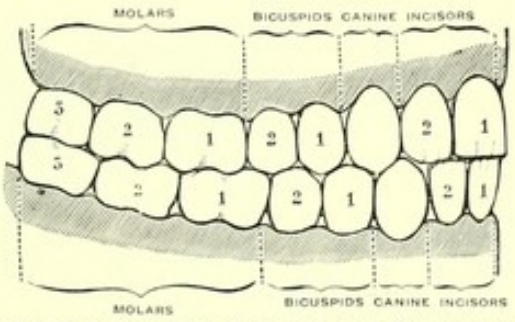

FIG. 754.—Diagram of the dental arches, seen from the right side, showing their reciprocal relations. (Testut.)

with the bony skeleton, is really a calcified papilla of the mucous membrane. A portion of the alveolar process grows around its base, and furnishes a snug socket for it; but, in spite of its density and the solidity of its implantation, it is comparable with other papillæ, such as that of a hair-follicle. The changes in the epithelium of the hair-papilla are unlike those which take place in that of the tooth-papilla, and, consequently, the result is very different, although in both cases the modification is in the direction of hardening; but, philosophically con-

sidered, the hair and the teeth are closely related, as will be seen, if one studies the development of the two.

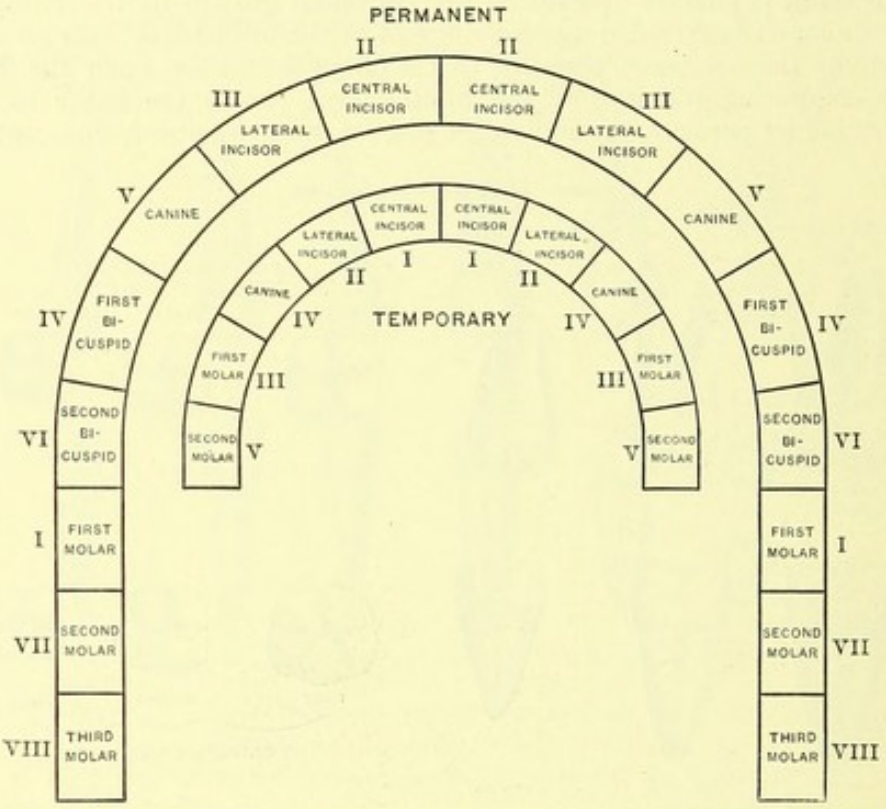

FIG. 755.—Diagram showing what permanent tooth replaces each temporary tooth, and also the order of succession of the teeth of each set. (F. H. G.)

Just before the six-year molars are erupted from the gum, forty-eight teeth in various stages of formation and retrogression can be recognized in the two jaws

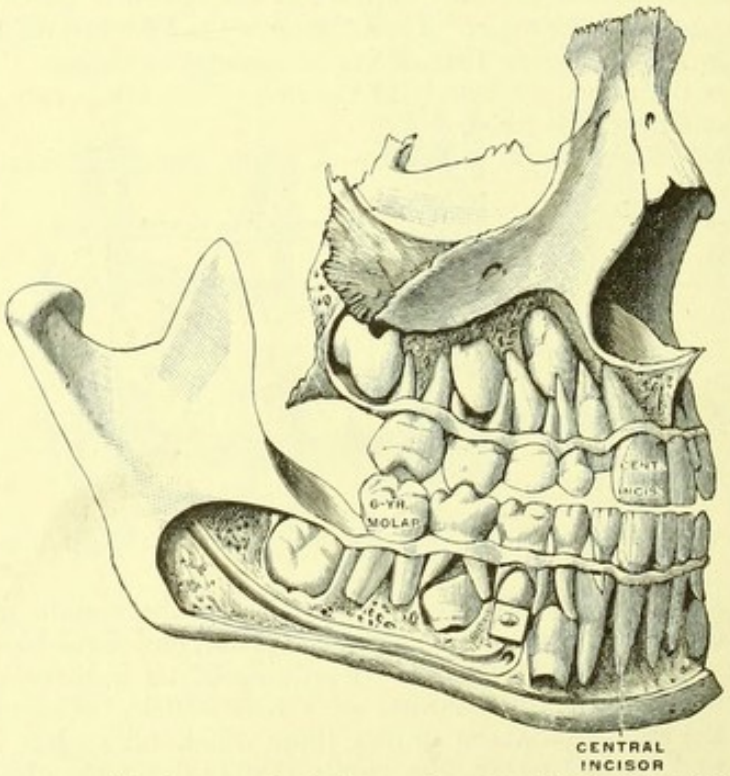

FIG. 756.—The jaws of a child of seven and a half years, the external table of bone having been cut away to show the stage of second dentition. (Testut.)

—twenty of the temporary set, and twenty-eight of the permanent. The four wisdom-teeth at this time are only embryonic buds (Fig. 756).

The Gums.

The gums (*gingivæ*) are dense, smooth mucous membrane, fused upon the periosteum of the alveolar processes. They are very resistant to pressure, and have comparatively slight sensitiveness.

The floor of the mouth is formed mainly by the tongue, in small part by the sublingual structures.

THE TONGUE.

The tongue (*lingua*) (Fig. 757) is composed mostly of voluntary muscles, which give it protean power of changing its shape. Its upper surface can be convexed or concaved; its point can be thrust forward beyond the lips, drawn backward nearly or quite to the junction of the hard and soft palates, swept over the entire surface of the vestibule above and below; in short, the free portion of this organ can be made to assume such a multitude of forms as to defy description. This capacity accounts for its varied usefulness in the processes of prehension, chewing, swallowing, speech, touch, taste, and expression.

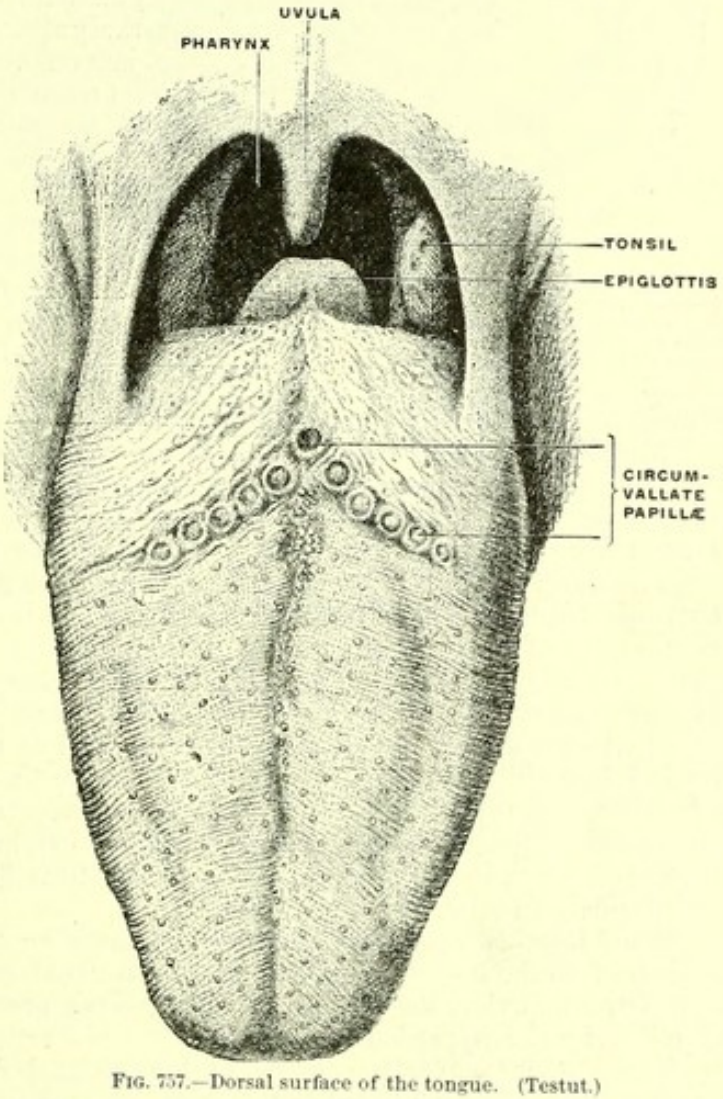

FIG. 757.—Dorsal surface of the tongue. (Testut.)

The part of the tongue which presents a free surface upward and backward is called the *dorsum*. The anterior two-thirds of this is in the floor of the mouth, the posterior third in the front wall of the pharynx. The pharyngeal part of the dorsum forms the very sloping floor of the space marked off on each side by the two pillars of the soft palate. It has a mammillated appearance, caused by the presence of numerous racemose glands and lymphoid masses. Just behind the apex of the series of circumvallate papillæ (described on a previous page) is a little aperture, the *foramen cæcum* ("blind hole"), the remnant of a fœtal canal. At the lowest part of the pharyngeal surface the mucosa is raised into three sagittal folds connecting the tongue with the larynx, the central one being the largest, and inserted into the upper surface of the epiglottis. The oral portion of the dorsum, when entirely at rest, is convex in every

direction. It ends anteriorly in a somewhat pointed *tip*. Its mucosa is specialized, and has already been described in the chapter on the organs of the special senses.

The Sublingual Space (Fig. 758).—Lifting up the tip of the tongue we obtain a view of the sublingual space. We see that the mucous membrane of the under side of the tongue is smooth, and not furnished with such specialized papillæ as mark the upper surface. A fore-and-aft fold, the *frænum linguæ* ("bridle of the tongue"), in the mid line, connecting the tongue with the jaw, limits the backward movements of the apex. On each side of this bridle opens a duct from the *submaxillary salivary gland*. The sublingual salivary gland forms an elongated elevation in the gutter between the tongue and the jaw on each side, and the openings of its many ducts are found in the region of the frænum. Beneath the rest of the mucous membrane in this space are various lingual muscles.

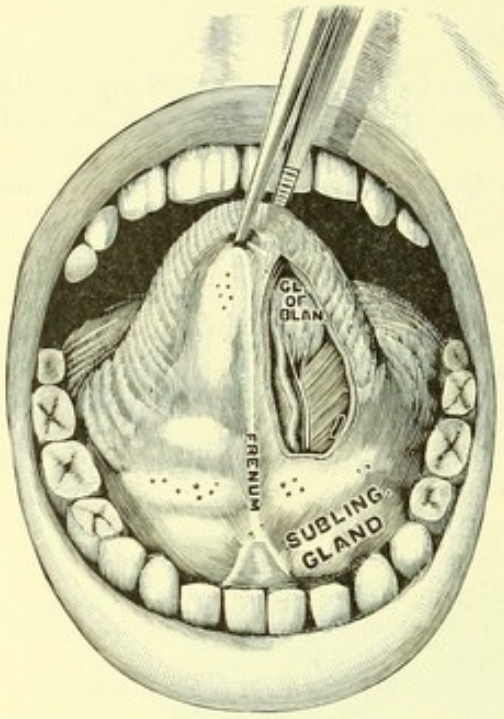

FIG. 758.—Under surface of tongue and the sublingual space, showing openings of salivary ducts. The mucosa of the left side is partly removed, and shows the ranine artery, the lingual nerve, and the gland of Blandin. (Testut.)

Structure of the Tongue.—As previously stated the tongue is made up largely of muscles. These are arranged in pairs with bilateral symmetry, and when we speak of the action of a given muscle, we shall imply the simultaneous contraction of its fellow of the opposite side.

Mingled with the muscles of the tongue are fibrous, and adipose tissues, and many vessels and nerves. Its framework consists of a vertical, median, fibrous plate, extending from the hyoid bone to the tip of the tongue, and a fibrous lamina near the surface of the dorsum and edges in each lateral half.

The muscular part of the tongue comprises two groups—the intrinsic and the extrinsic muscles. The distinction between them is somewhat arbitrary. If the connections of the tongue with the hyoid bone, the styloid process of the temporal, the mandible, the velum palati, and the pharynx be severed (the muscles in each case being traced to their attachments) and the organ be then removed, we shall see that there is a firm central portion of definite shape, tapering from behind forward, and that from this body project a number of muscular bands of various forms and sizes. The intrinsic muscles are found only in the central mass; the projecting bands are parts of the extrinsic muscles, the other parts being embedded in the central mass, in which their fibres decussate with those of the intrinsic muscles.

The Lingualis Muscle.—The intrinsic mass or tongue proper is sometimes spoken of as the *lingualis muscle*; but it is convenient to divide it into four portions—the superior, the inferior, the transverse, and the vertical. They are all supplied by the hypoglossal nerve.

The **superior lingualis** consists of longitudinal fasciculi, which lie near the upper surface from the hyoid to the apex, attachments being made all along with the submucous tissues. Its action produces shortening of the tongue, and longitudinal grooving of its dorsum.

The **inferior lingualis** is a large bundle, which runs under the edge of the tongue in its whole length. It shortens the tongue and rounds up its dorsum.

The **transverse lingualis** is made up of fibres which arise in the median septum

and run to the dorsum and margin, where they are inserted into the fibrous lamina. It diminishes the width and increases the length of the organ.

The **vertical lingualis** is composed of small fasciculi, which course from the

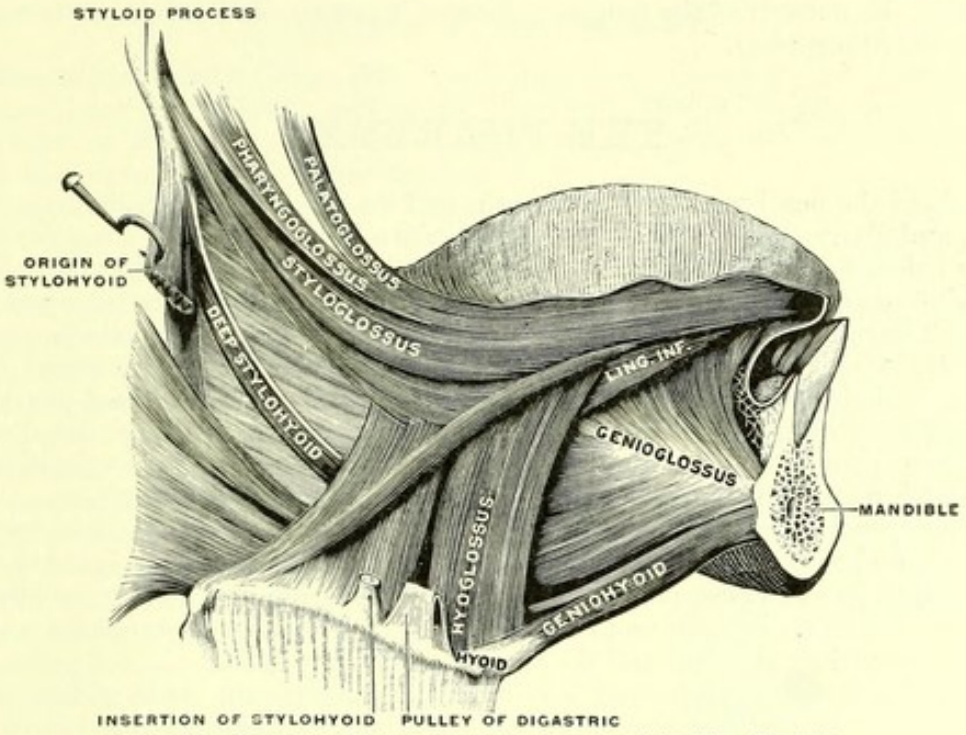

FIG. 759.—Muscles of the tongue, viewed from the right side. (Testut.)

dorsum to the under surface, curving with their concavity outward. Its fibres are interlaced with those of the transverse lingualis. It broadens and flattens the tongue.

The Extrinsic Muscles of the Tongue.

The extrinsic muscles of the tongue are the genioglossus, the hyoglossus, the styloglossus, and the chondroglossus. To this list is sometimes added the palatoglossus; but it seems better to include this with the muscles of the soft palate, already described.

Genioglossus (Fig. 759) ("the chin-tongue muscle").—*Synonym*, geniohyoglossus, "the chin-hyoid-tongue muscle." *Situation*, in the middle line of the tongue. *Origin*, the upper genial tubercle. *Direction*, divergent—backward, upward, and to all points between. *Insertion*, the hyoid bone and the whole length of the tongue in and at the sides of the mid line. *Action*: the back part thrusts the tongue forward; the front part retracts the tip of the tongue; the part between the apex and the base depresses the mid line, thus forming a gutter. *Nerve*, the hypoglossal.

Hyoglossus (Figs. 759, 760) ("the hyoid-tongue muscle").—*Situation*, between the hyoid and the side of the tongue. *Origin*, the great cornu and the body of the hyoid. *Direction*, upward and forward. *Insertion*, the side and dorsum of the tongue, blending with the styloglossus. *Action*, retraction and depression of the tongue. *Nerve*, the hypoglossal.

Styloglossus (Figs. 759, 760) ("the styloid-process-tongue muscle").—*Situation*, between the side of the base of the skull and the side of the tongue, outside of the pharynx. *Origin*, the front of the styloid process of the temporal bone, and the stylomandibular ligament. *Direction*, forward, downward, and a little inward. *Insertion*, the whole length of the side and under part of the tongue. Its fibres blend with those of the hyoglossus and palatoglossus. *Action*: it draws the tongue backward, and lifts its base. *Nerve*, the hypoglossal.

Chondroglossus.—"The cartilage-tongue muscle," so called from its attachments to the small cornu (which is usually cartilaginous) of the hyoid and to the tongue. *Situation*, at the side of the tongue below, under cover of the hyoglossus. *Origin*, the small cornu and body of the hyoid. *Direction*, upward and forward. *Insertion*, the dorsum of the tongue. *Action*: it retracts and depresses the tongue. *Nerve*, the hypoglossal.

THE PHARYNX.

Behind the nasal passages, the mouth, and the larynx, beneath the base of the skull, and above the upper end of the gullet, is a hollow organ of irregular shape, which belongs not only to the alimentary tube, but to the respiratory system, also. It has no name in our vernacular, but is known technically as the *pharynx* (Fig. 745). The upper part, behind the nose, is the *naso-pharynx*; the middle portion, back of the mouth, is the *oro-pharynx*; and the lowest segment, dorsal to the larynx, is the *laryngo-pharynx*. The anterior lower limit of the naso-pharynx is at the border of the hard palate; of the oro-pharynx at the upper level of the hyoid bone; and of the laryngo-pharynx at the lower level of the cricoid cartilage, which nearly coincides with that of the fifth cervical vertebra.

Food passes from the mouth into the oro-pharynx, through the laryngo-pharynx, and into the gullet; and inspired air goes from the nose into the naso-pharynx, through the oro-pharynx, and enters the larynx. Thus the middle segment of this organ is common to the alimentary and respiratory systems, and the tracks followed by the food and the air cross obliquely in it.

Like the mouth the pharynx is bilaterally symmetrical. It is widest (nearly one inch and a half) in the upper laryngeal portion, and narrows above and below, having its least diameter (half an inch) at its junction with the gullet. Ventro-dorsally its measurement is everywhere small, only opposite the mouth being more than four-fifths of an inch. It is about five inches long. In short, the cavity of the pharynx may fairly be regarded as a wide side-to-side chink, in front of the upper five cervical vertebræ.

Openings of the Pharynx.—In the naso-pharynx are four openings—one at each side for the Eustachian tube, leading to the middle ear, and one forward for each of the lateral halves of the nose,—the posterior nares. In the oro-pharynx is the opening from the mouth, the isthmus of the fauces, between the anterior pillars of the palate. The laryngo-pharynx opens at its lower end into the gullet, and at its upper, anterior part into the larynx.

The pharynx is firmly fastened to the neighboring parts at its summit, and in the front part of its nasal and oral portions; but its attachments elsewhere are areolar and loose, so that its lower third can be elevated, and its rear wall advanced, as in swallowing.

Tunics of the Pharynx.—Here, as elsewhere in the alimentary tube, the wall is composed of three coats; but the middle one is so much condensed that its areolæ are largely obliterated, and the tunic is more like a fascial layer.

The **mucous membrane**, continuous with that of the nose, middle ears, mouth, larynx, and gullet, is covered with ciliated cells as far down as the level of the hard palate, but below this is flattened and non-ciliated. On the back (dorso-superior surface) of the soft palate the cells are ciliated, except at the free edge. In and beneath the mucosa are many racemose, mucous glands. The corium is particularly rich in lymphoid tissue, and at the pharyngeal vault and across the posterior part of the oro-pharynx are accumulations of lymphoid material, which, on account of similarity of structure, have been named the *pharyngeal tonsil*. High up in the middle line, and running upward and backward to the base of the skull is a blind depression, called the *pharyngeal bursa*.

The **muscular tunic** is composed of five pairs of muscles, of which three are constrictors—upper, middle, and lower—having for their function the diminution

of the calibre of the pharynx, and the others—the stylopharyngeus and palato-pharyngeus—are elevators, which lift up the pharynx and larynx. The last of these has already been described in connection with the soft palate.

Muscles of the Pharynx.

Constrictor Inferior (Figs. 760, 761) ("the lower constrictor").—*Situation*, the side and back of the lower part of the pharynx. *Origin*, the cricoid and thyroid cartilages of the larynx. *Direction*, backward, inward, and upward, diverging from its origin. *Insertion*, the median tendon, common to it and its fellow opposite, extending nearly to the basilar process of the occipital bone. It overlaps the middle constrictor. *Action*: it compresses the pharynx, mainly ventro-dorsally; it also moves the larynx upward and backward. *Nerves*, from the pharyngeal plexus, and the external and inferior laryngeal.

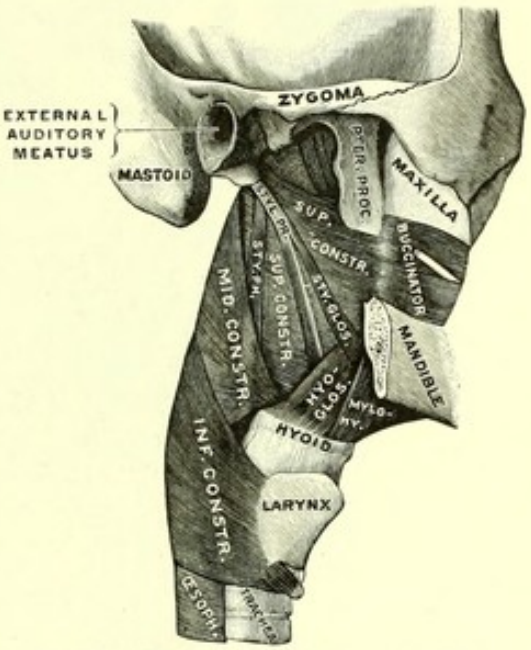

Fig. 760.—Muscles of the pharynx, viewed from the right side. (Testut.)

Constrictor Medius (Figs. 760, 761) ("the middle constrictor").—*Situation*, at the side and back of the middle part of the pharynx. *Origin*, the cornu of the hyoid, and stylohyoid ligament. *Direction*, divergent—all portions backward and inward, the inferior downward, and the superior upward. *Insertion*, the common tendon in the middle line in almost the entire length of the pharynx. *Action*: it compresses the pharynx, chiefly ventro-dorsally; and it draws the hyoid backward and upward. *Nerves*, from the pharyngeal plexus.

Constrictor Superior (Figs. 760, 761) ("the upper constrictor").—*Situation*, at the side and back of the upper part of the pharynx. *Origin*, the side of the tongue, the mucosa of the mouth, the mylohyoid ridge, the pterygomaxillary ligament, and the lower fourth of the hind border of the internal pterygoid plate. *Direction*, divergent—all parts backward and inward, the superior upward, and the inferior downward. *Insertion*, the common tendon in the middle line from the basilar process half way, or more, to the gullet. *Action*, approximation of the lateral walls of the upper part of the pharynx. *Nerves*, from the pharyngeal plexus.

The name *pharyngoglossus* (glossopharyngeus) is applied to certain fasciculi which extend from the superior constrictor to the tongue—the upper losing itself in the palatoglossus and styloglossus, the lower merging into the hyoglossus, genioglossus, and lingualis.

Stylopharyngeus (Figs. 760, 761) ("the styloid-process-pharynx muscle").—*Situation*, at the side of the pharynx, and mesial to the middle and lower constrictors. *Origin*, the styloid process of the temporal bone. *Direction*, downward and inward. *Insertion*, the upper and hind borders of the thyroid cartilage, mingling with the palato-pharyngeus. *Action*, lifting the pharynx and larynx. *Nerve*, the glosso-pharyngeal.

The Tonsils (Fig. 746).

In the recess formed by the divergence of the pillars of the palate on each side is a flattened, ovoid body, the tonsil (*tonsilla*) or almond (*amygdala*), whose

mesial face can easily be seen, when the mouth is widely opened and the tongue depressed. Its position is internal to that of the angle of the jaw. Its external surface is attached to the upper constrictor by areolar tissue.

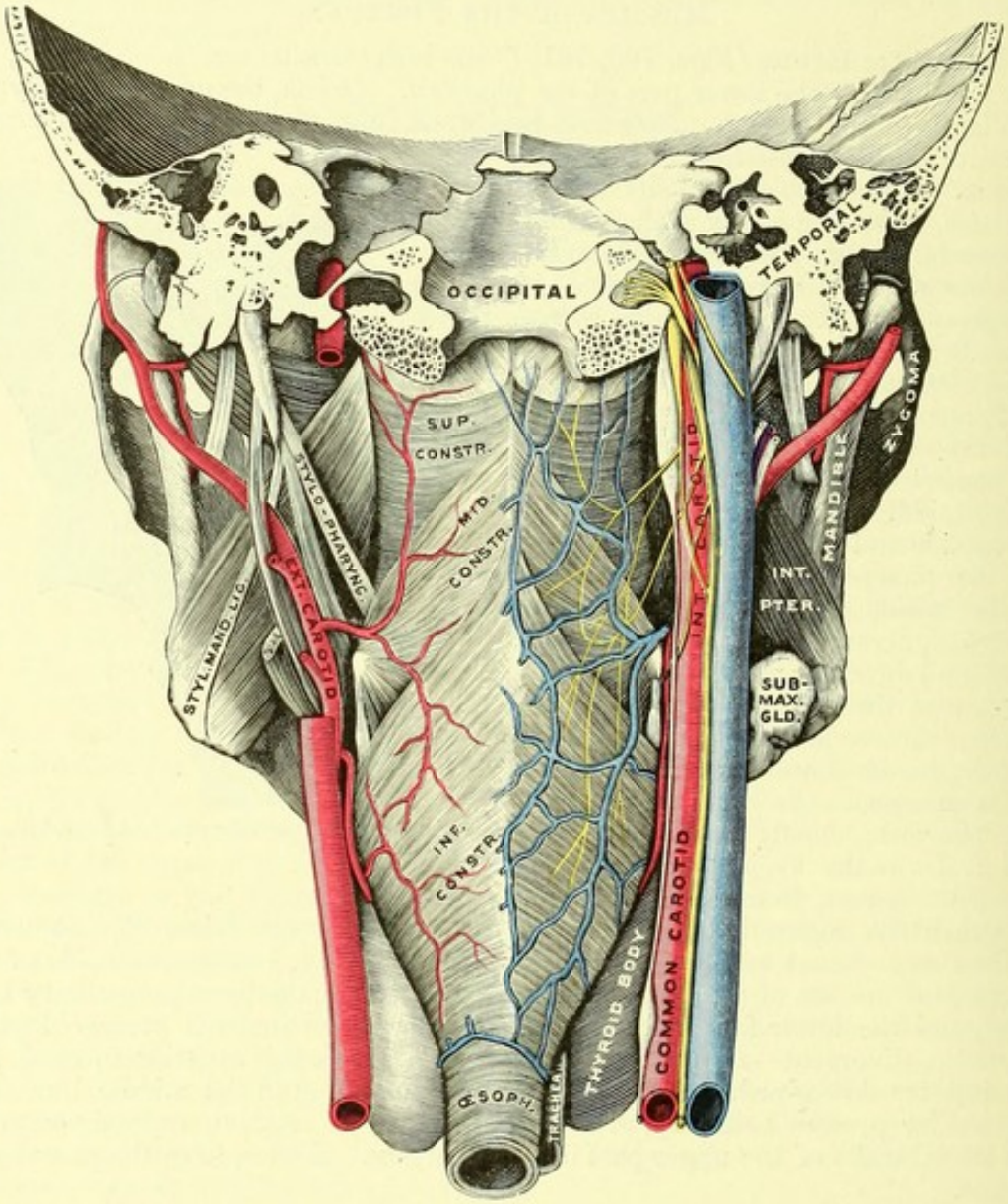

FIG. 761.—Muscles of the pharynx, viewed from behind, together with the associated vessels and nerves. (Modified from Testut.)

The tonsil is substantially a collection of lymph-nodules, with a distinct capsule on its attached surface, and a continuation of the mucosa of the pharynx on its exposed surface, which is irregularly pitted with blind holes of varying size. Mucous glands open into these pits, and with their secretion are mingled great numbers of lymph-cells, many of which appear in the spittle as salivary corpuscles.

THE GULLET.

Between the levels of the upper border of the sixth cervical vertebra and that of the eleventh thoracic—a distance of about ten inches—extends the *gullet* or *œsophagus* ("carrying eatables"), the tube connecting the pharynx and the

stomach (Fig. 762). Its direction is nearly that of the part of the spinal column near which it runs—slightly curved with its concavity forward. It presents slight lateral bends of no practical importance. It gradually expands at its lower part, and then is a little constricted at its passage through the diaphragm. Excepting during the passage through it of distending substances, its condition is one of collapse, its dorsal and ventral walls being in contact, its mucosa folded into longitudinal rugæ, and the bore of the tube obliterated.

The *mucosa*, like that in the succeeding portions of the alimentary canal, is limited in its depths by a muscularis mucosæ. Its free surface has a stratified, flattened epithelium. The *areolar coat* is thick, and contains many mucous glands, which open into the lumen. The *muscular tunic* displays a peculiar transition from the striated variety, which alone is seen in the pharynx, to the smooth, which is the only kind occurring in the stomach. For a short distance from the beginning we find only striped muscle; then for a little way a mixture of the two varieties; and, finally, in the lower half, nothing but the muscular tissue of organic life. The inner layer is circular, the outer longitudinal. The gullet is connected with the structures in the midst of which it lies by a sheath of areolar tissue.

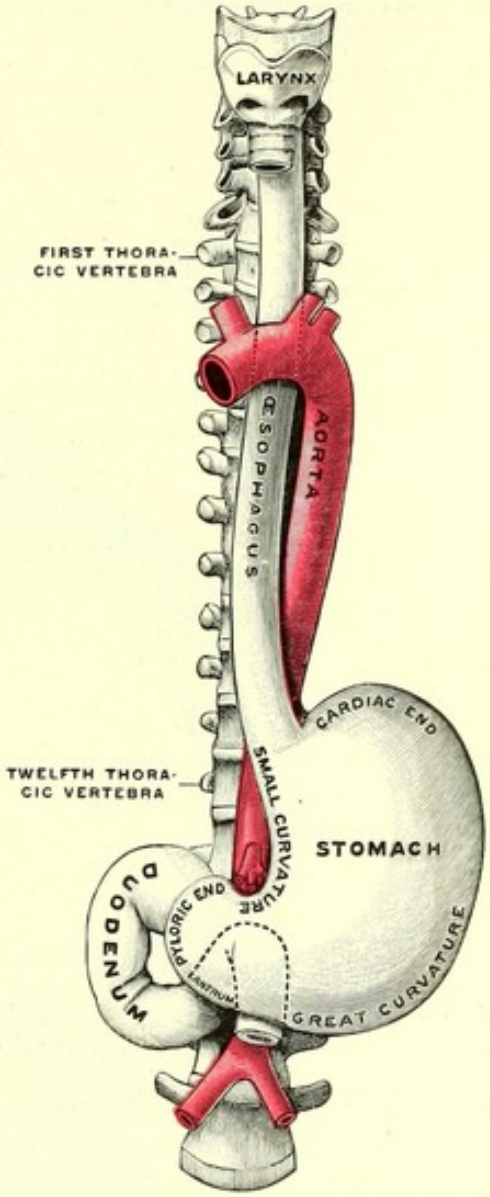

FIG. 762.—Œsophagus and stomach in their natural relations to the vertebral column and the aorta. (Testut.)

THE ABDOMINAL CAVITY.

The portion of the alimentary canal which is below the diaphragm is contained in the abdomen, and it is desirable to study this cavity before proceeding to the consideration of the viscera which it holds.

The boundary between the thorax and abdomen is made by the diaphragm. This muscle forms a dome over the belly-cavity, its highest part rising to the level of the junction of the fourth costal cartilage with the sternum, and, consequently, the abdomen greatly encroaches upon the space, which a superficial inspection of the thoracic cage would lead one to assign to the chest. The cubic capacity of the thorax is very small compared with that of the abdomen, largely owing to this invasion of its (expected) territory.

The lower end of the abdomen is limited by the structures which clothe the inner surface of the bony pelvis. Muscles form the bulk of the front and lateral walls, and a good part of the dorsal, the last being completed by a portion of the vertebral column.

It has a serous lining, outside of which is a fibrous or areolar tunic, which is variously named in different parts. (See Fasciæ, pages 359–361.) Apertures in its walls give passage to numerous organs: the aorta, inferior vena cava, œsophagus, and various nerves, above; the rectum, urethra, spermatic cords or round ligaments of the uterus, the vessels and nerves of the lower limbs, and, in the

female, the vagina, below; besides which should be mentioned the openings of the oviducts (Fallopian tubes) of the female.

Regions of the Abdomen (Fig. 763).

For generations it has been customary to divide the abdomen into nine regions for convenience of description: one near the centre, called *umbilical*, with a *lumbar* on each side; above the umbilical, the *epigastric* ("upon the stomach"), with a *hypochondriac* ("under the cartilage") on each side; and below the umbilical, the *hypogastric* ("under the stomach"), with an *iliac* on each side. The delimitation of these regions is not uniformly made by authors. The writer called attention to this fact and to the need of agreement among anatomists some years ago, and embodied his suggestions in a paper read to the Association of American Anatomists in 1892. Having seen no proposition which appears more reasonable and useful in the premises, he presents his plan here.

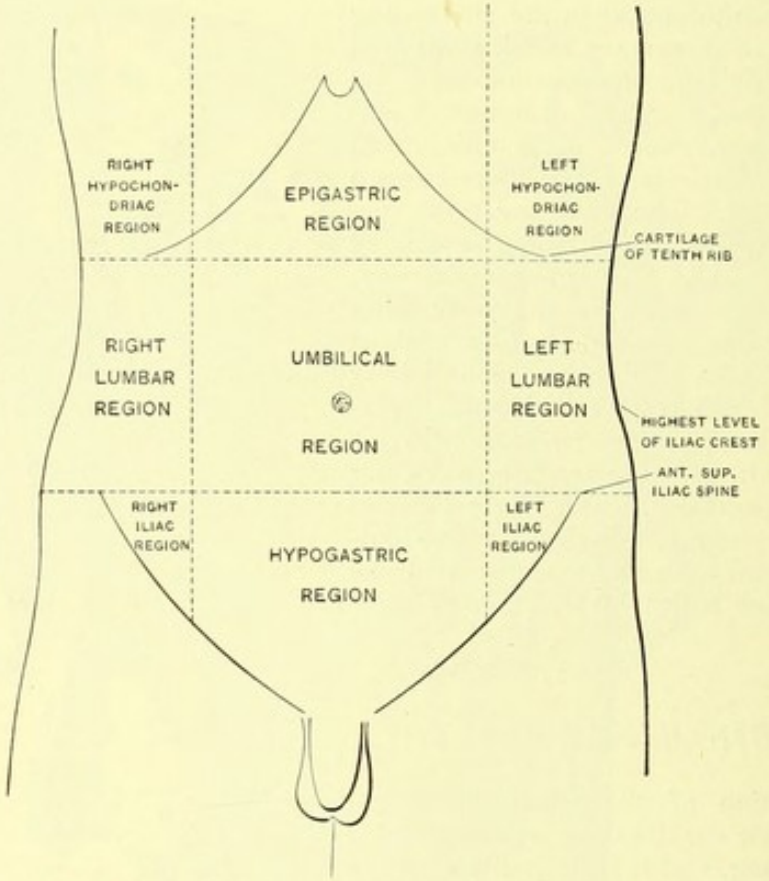

FIG. 763.—Regions of the abdomen, delimited by the author's method. (F. H. G.)

A line is drawn around the body at the level of the *anterior superior spinous processes* of the ilium, and another at the *lowest point of the tenth costal cartilages.* These lines stand for the peripheries of horizontal planes, which completely divide the abdomen into three sections. Each section is cut into three by a vertical plane running ventro-dorsally through *the middle of each inguinal* (Poupart's) *ligament.*

These are superficially indicated on the front of the abdomen in Fig. 763.

The advantages of this method are that it brings the umbilicus wholly into the umbilical region, which is rather rarely the case, when the lower horizontal is drawn at the level of the iliac crests; that the guide to the upper horizontal is a prominence easily found through the integuments, and that this plane divides the part of the abdomen above the lower horizontal more equally than does that

usually given; and, finally, that the perpendicular plane on each side starts from a prominent landmark, and fairly apportions each of the three zones.

The abdominal cavity is lined with the largest of the serous membranes, the *peritoneum*. At various places this membrane is reflected from the wall onto the contained viscera, to some of which it furnishes a slight, to others a considerable, and to others still a practically complete outer tunic, thus justifying its name, which means literally something "stretched around." Until the anatomy of the abdominal viscera is learned, a description of the peritoneum cannot be appreciated; and, therefore, further consideration of the subject will be deferred until the discussion of the digestive organs has been completed.

THE STOMACH.

The gullet perforates the diaphragm, and almost immediately ends in the stomach (*stomachus, gaster*), the tube expanding into a great bag (Fig. 764). The

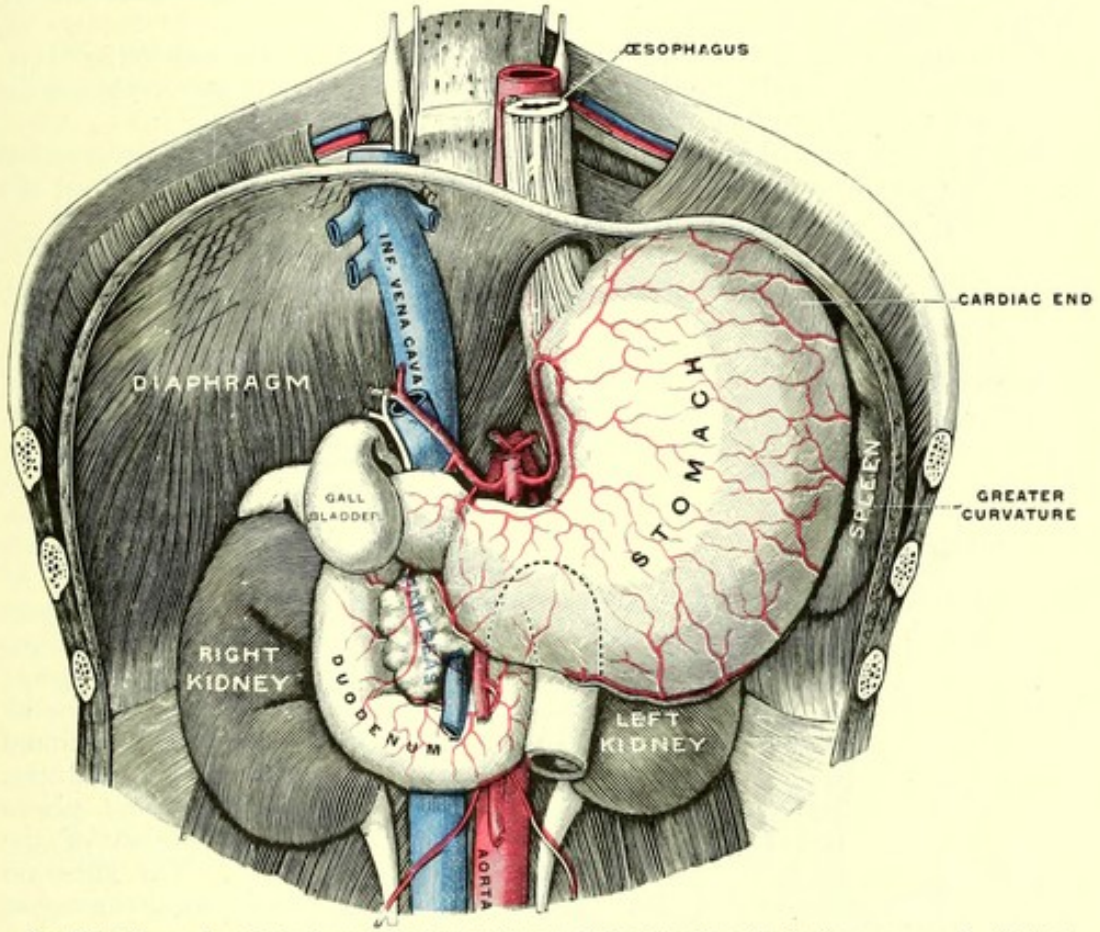

FIG. 764.—Stomach and duodenum, the liver and most of the intestines having been removed. (Testut.)

stomach is just beneath the diaphragm and behind the anterior abdominal wall, in the epigastric and left hypochondriac regions. Its *shape* and *attitude* are worthy of especial attention. It looks somewhat like a pear with the large end up, and the small end bent sidewise to the right. Its front and rear surfaces are moderately convex. Looking at it from before, it is seen that a continuation of the right margin of the œsophagus downward coincides with the upper two-thirds of the right border of the stomach, the remaining third of this border bending sharply to the right and backward, thus completing what is known as the small curvature. The great curvature begins at the end of the gullet on the opposite side, making a somewhat acute angle with the left border of this tube. It then

passes upward and to the left to the diaphragm, is in contact with the under surface of the latter for some distance, sweeps downward in a generous curve with its convexity to the left, continues in a somewhat flattened line to the right, is here a little indented, and finally turns abruptly up and back, terminating at the outlet-end, close to the small curvature.

Particular attention is called to the following facts: the general direction of the long axis of the stomach is vertical; the small curvature faces mostly to the right; the great curvature is directed mainly to the left; the aperture of entrance (œsophageal opening) is but slightly to the left of the middle line of the body, and looks downward; the hole of exit (intestinal opening) is on a lower plane, close to the mid line, and looks directly backward—a point not well shown in Fig. 764. The curvatures or borders are the lines of reflection of the peritoneum.

The preceding statements apply to the organ when it is not distended; but, *when it is distended*, some differences are observed. Then the great curvature is tilted toward the front, the small end is moved two inches or more toward the right, and the pressure on the diaphragm may be such as to interfere seriously with the freedom of action of the heart, which is situated in part immediately over the stomach on the upper surface of the diaphragm.

The large end of the stomach is called, on account of its nearness to the heart, the *cardiac end*, or simply the cardia; the small is named the *pyloric end*, from the pylorus, presently to be described.

The before-mentioned indentation of the great curvature near the lower end is a part of a slight constriction, and the portion of the cavity between it and the intestinal opening is called the *antrum pylori cum* ("pyloric cave").

The Tunics of the Stomach.

The tunics of the stomach conform to the rule previously stated.

The Serosa.—Passing from the transverse fissure of the liver are two layers of serous membrane, which constitute the *gastro-hepatic* ("stomach-liver") *omentum*. After continuing downward for about two inches, they reach the small curvature of the stomach, where they divide, clothe respectively the front and back surfaces of this viscus, meet along the great curvature, unite again, and continue downward to help form the great omentum. A very narrow strip of uncovered surface may be found along each of the two curvatures, indicating respectively the places of separation and reunion of the peritoneal lamellæ. The adhesion of the serosa is closest at the centre of the front and back surfaces, but gradually becomes looser toward the borders.

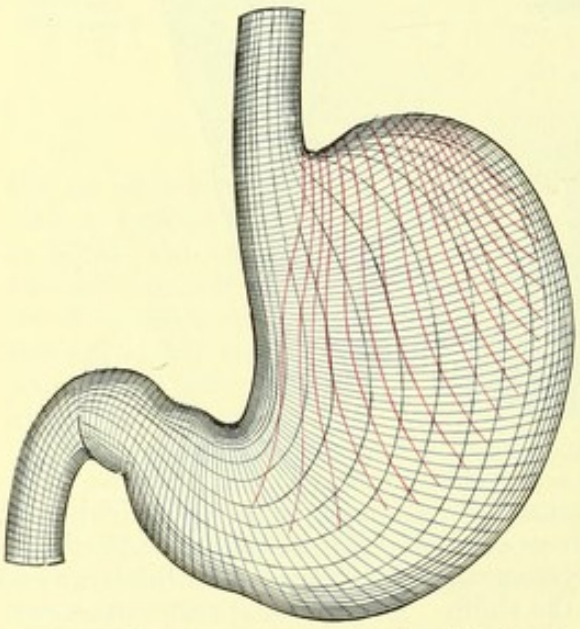

FIG. 765.—Diagram to show the direction of the fibres in the three muscular layers. (Testut.)

The **Muscular Coat** has two complete layers—an outer, longitudinal, and an inner, circular (Fig. 765). Besides these two distinct layers some oblique fasciculi are found, internal to the circular. This criss-cross arrangement of the layers contributes greatly to the strength of the stomach-walls. The circular layer increases in thickness toward the small end, and there is such an augmentation of its fibres around the intestinal opening as to con-

stitute a thick, circular sphincter, called the *pylorus* ("gate-keeper"), the side toward the stomach sloping, and that toward the bowel being abrupt. The aperture is the *pyloric orifice* (Fig. 766).

The **Areolar Coat**, called also submucous and vascular, is loose, and its meshes are largely occupied with the vessels and nerves going to and from the coats between which it lies.

The **Mucous Membrane** is thrown into irregular, longitudinal folds (*rugæ*) when the organ is flaccid, but becomes smooth during distension. Its corium is mostly occupied by tubular glands, between which is fibrous tissue, containing capillaries and nerves; and beneath these structures is a muscularis mucosæ, which sends some of its fibres up between these follicles. The surface epithelium consists of a single layer of columnar cells, many of which are goblet. The glands are all tubular depressions of the surface, and their length is but a trifle less than the thickness of the membrane. They are of two varieties, one, the *cardiac glands* or proper gastric glands, being found in the large end and middle third of the stomach; and the other, the *pyloric glands*, in the region of the small end. They are arranged in little groups, which are bounded by minute elevations of the surface.

The **cardiac glands** (Fig. 767) are simple tubular depressions, consisting of a *duct*, *neck*, and *fundus* or body. The duct is short, has a wide mouth, and is lined with columnar epithelium, a continuation of that upon the general, free surface. Its cells overlap one another a little. In the neck the cells become short and broad. The fundus is wavy or spiral, and is furnished with two kinds of *cells*: the *central*, rather conoidal, and more numerous; the *parietal*, larger, usually not reaching the bore of the tube, but communicating with it through minute cracks between the overlying central cells.

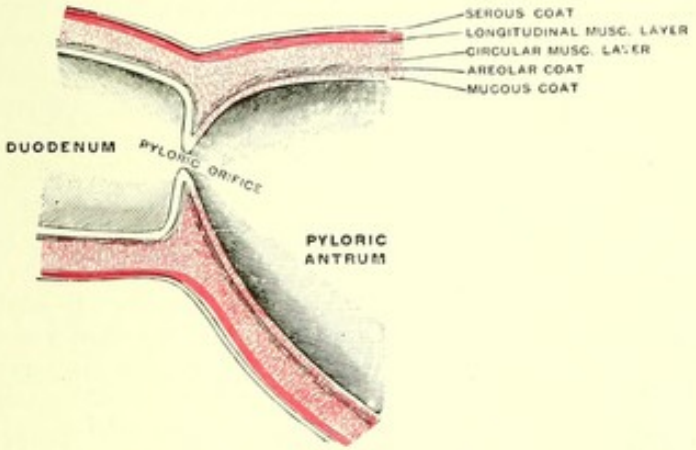

Fig. 766.—Vertical section at the junction of the stomach and duodenum, showing the disposition of the coats. Semidiagrammatic. (Testut.)

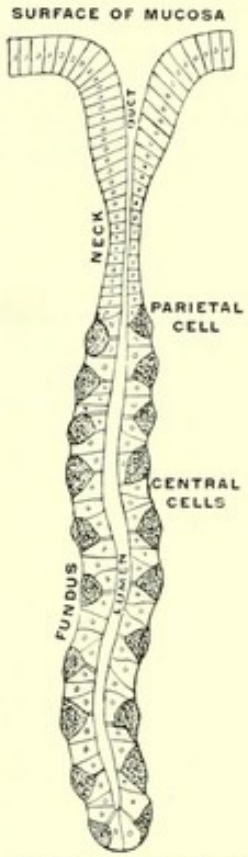

Fig. 767.—Cardiac gland in longitudinal section. (F. H. G.)

The **pyloric glands** have a very wide and deep duct, into the bottom of which open several divisions (funduses), which are wavy or even tortuous. The epithelium is in all parts very similar to that on the surface of the mucosa. Between the divisions is the true corium material, and at frequent intervals are irregular masses of lymph-adenoid material.

THE SMALL INTESTINE.

The small intestine (*intestinum tenue*) (Fig. 779) is that portion of the alimentary canal which begins on the distal side of the pyloric valve, and ends on the proximal side of the ileo-cæcal. In other words it extends between stomach

above and large intestine below. Its average length is twenty feet or more; and, as it is all contained in the abdominal cavity, which also lodges many other organs, it is necessarily subjected to numerous bendings, and consequently, when the anterior wall of the belly is laid open, presents the appearance of inextricably tangled convolutions.

From above downward it gradually diminishes in size, thickness of wall, and complexity of structure. Its diameter near its beginning is nearly two inches, but becomes steadily less, and is hardly an inch at its lower end. Its loss in structural elaborateness will be described in detail later on.

It occupies the umbilical and hypogastric regions and the adjacent portions of the lumbar, being to a large extent within the area bounded by the colon.

Parts of the Small Intestine.—It is usually described as consisting of three parts—the duodenum, jejunum, and ileum. The first of these is limited by distinct natural boundaries, and is strikingly different from the rest in other respects. The second and third are not thus differentiated, and there is no manifest advantage in continuing the attempt to distinguish them from one another. But as the names are fastened in our nomenclature, they will be used to designate respectively the uppermost and lowermost portions of the small intestine distal to the duodenum, without the suggestion of a definite line or even region of demarcation between them; and the name *jejuno-ileum* will be employed to indicate the continuous, undivided whole which the two constitute.

Tunics of the Small Intestine.

The small intestine has four tunics, which correspond in general character and arrangement with those of the stomach.

The **Serous Coat** (Fig. 768) furnishes a practically complete covering for the whole tube, excepting the duodenum, which is but scantily clad with it. This membrane is reflected from the dorsal wall of the abdomen, runs forward for a distance, which varies in different parts, reaches the intestine, which it closely enwraps, and, returning almost to its line of first contact, turns toward its parietal origin, keeping in practical apposition with its outgoing layer, until it arrives at its starting-point, where it is reflected toward the opposite side of the body. Thus is formed not only a snug investiture for the gut, but also a double-layered mooring, fastened at one end to the hind wall of the abdomen, at the other to the intestine, and permitting large freedom of movement. This structure is the *mesentery* ("in the midst of the intestines"), and between its two layers are the arteries, veins, lymphatic vessels, and nerves required by the bowel, a great number of lymph-nodes, and usually a quantity of adipose (Fig. 769). The proximal (attached, parietal, dorsal) border of the mesentery extends from the left side of the second lumbar vertebra to the right mesocolon, its direction being from above downward and to the right, and its measurement eight or ten inches. The distal (free, intestinal, ventral) border is vastly longer, being frilled out to the length of the jejuno-ileum, and thus suggestive of a widely opened fan. Its sides are right or superior, and left or inferior. Its length is from the attached to the free border, and varies from one inch to ten inches.

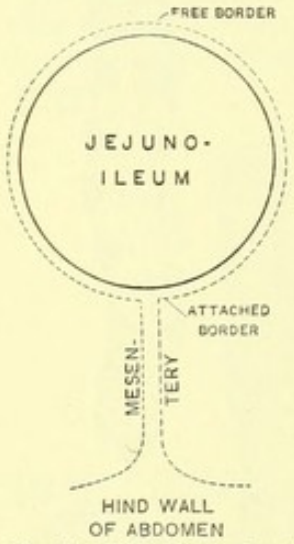

FIG. 768.—Diagram to show the relation of the peritoneum (broken line) to the greater part of the small intestine.

The **Muscular Coat** lies just within the serous, which covers it perfectly, except for a very narrow strip between the lines of attachment of the mesenteric layers. This bare area marks what is called the *attached border* of the intestine,

and the exactly opposite portion of the gut is known as the *free border*. The *outer layer* of the muscular tunic is complete, thin, composed of bundles arranged lengthwise, and thickest in the region of the free border. The *inner layer*, also, is complete, but is thicker, and its fasciculi are transverse, forming a circular layer. This coat thins out gradually as the intestine approaches its lower end.

The Areolar Coat.—Inside of the muscular is the areolar (submucous, vascular) coat, in whose meshes are networks of blood-vessels, lymphatics and nerves.

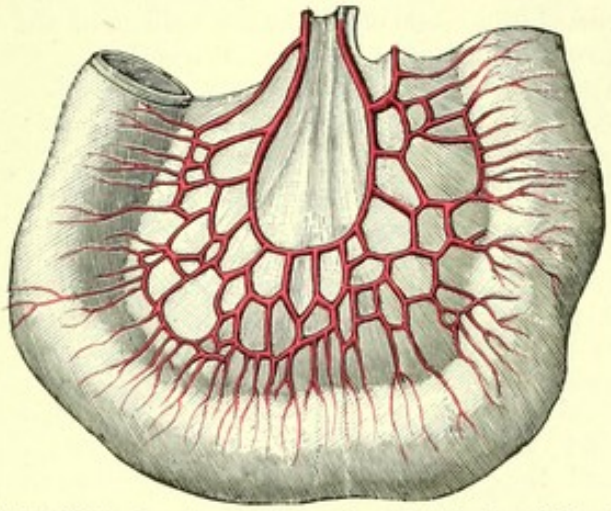

FIG. 769.—A loop of small intestine, showing the mode of distribution of the arteries. (Testut.)

The Mucous Coat.—Finally, we reach the mucous membrane, which is attached by its outer aspect to the areolar tunic, and presents a free surface to the bore of the tube. Its corium contains lymphoid tissue, with many leucocytes, and a rich supply of vessels and nerves. Outside of this is a distinct muscularis mucosæ, with an inner plate of circular, and an outer plate of longitudinal fibres. Inside

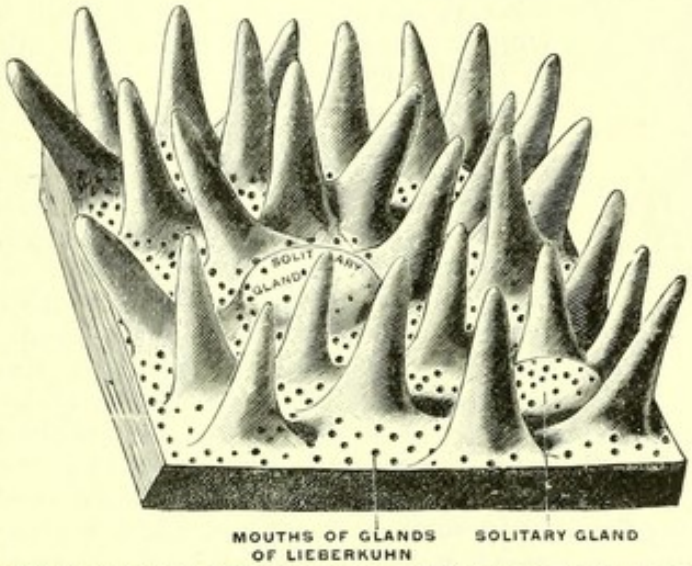

FIG. 770.—Free surface of the mucous membrane of the small intestine, showing villi, solitary glands, and openings of the intestinal glands. Semidiagrammatic. (Testut.)

of the corium is a basement membrane, surmounted by a single layer of prismatic, columnar, epithelial cells, which are characterized by the presence of a delicate plate on the free end of each, marked with vertical lines. Among these epithelial cells are many of the goblet variety.

The Villi (Fig. 770).—A peculiarity, which distinguishes the mucous membrane of the small intestine is the presence everywhere of minute projections,

called *villi,* which are so abundant as to give a velvety appearance to the surface. They are organs of absorption. Their number has been variously estimated at from four to ten millions. In the upper part of the intestine they are so closely set as to seem to leave no space between. The tallest are scarcely one twenty-fifth of an inch in height. In shape they are commonly cylindrical; but conical, filiform, mammillary, and lamellar varieties are observed. A lymph-vessel (lacteal) occupies the centre of the villus, a plexus of capillary blood-vessels surrounds this, a few threads of smooth muscle run up from the depths of the membrane, all these are embedded in a mass of nucleated cells, and the whole villus is covered by the columnar epithelium already mentioned.

The Valvulæ Conniventes.—Another feature which characterizes this tunic and is observed from an inch or two below the pylorus to within a foot or more of the end of the gut, is the presence of transverse folds of mucous membrane, each strengthened internally by a projection from the areolar coat. They are called *valvulæ conniventes* ("winking-valves"). Unlike the rugæ of the stomach, which are effaced when that organ is filled, they are not obliterated by the distension of the intestine. This permanency is due to several causes. First, these projections are not produced by a wrinkling of the membrane during relaxation, as are the ridges of the stomach, but are actual outgrowths of the mucosa, giving it an immense increase of surface, even during distension. Second, the valves do not extend completely around the circumference, but only a quarter, half, or (rarely) three-quarters way round, one considerably overlapping the lines of its next neighbors, and thus guarding against the effacement which might occur during extreme stretching, if each of them described a complete circle. In other words, an internal pressure, which might be able to unfold a perfect ring, is thwarted by a device which distributes that force to several separate segments and to a considerable extent of surface. And, third, the transverse arrangement of the valves is more favorable to their continuance than the longitudinal would be, as the stretching of the tube from within takes place almost altogether laterally and but slightly lengthwise, and, consequently, these folds are subjected to hardly any strain in these circumstances.

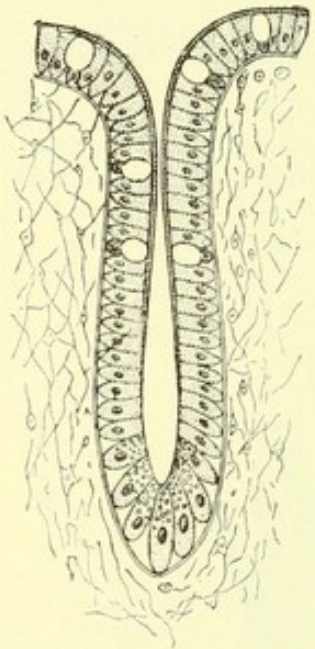

FIG. 771.—Intestinal gland in longitudinal section. (Testut.)

The valvulæ conniventes are somewhat crescentic in shape, may be as much as a fourth or third of an inch deep in the middle, and diminish in depth toward the ends, which often bifurcate, and finally shade off into the surrounding surface. There are usually eight or nine hundred of them.

Glands in the Mucosa.—Almost the entire substance of the corium is occupied by tubular depressions, which are lined with epithelium, very similar to that on the exposed surface, being columnar with frequent interruptions by goblet cells. These are the *intestinal glands,* more frequently called the follicles or *crypts of Lieberkühn* (Fig. 771). Their secretion is chiefly intestinal juice, though they furnish also some of the mucus, which is always present.

Lymph-structures in the Mucosa.—Embedded in the mucous coat and often encroaching upon the areolar are little globular or ovoid bodies, one-twelfth inch or less in diameter, which are structurally closely related to the lymph-nodes, being composed of a multitude of leucocytes, held together by an adenoid reticular framework, and drained by lymphatic vessels. They are sprinkled rather uniformly throughout the length of the viscus, though in some spots they are scarce, in others very numerous. They are the *solitary lymph-nodules,* but they are most frequently called *solitary glands* (Fig. 772), though no more entitled to the name than are the nodes, which occur in the course of lymphatic vessels,

having no secreting apparatus. We may fairly regard them as the picket-line of the great army of nodes, which occupy the mesentery.

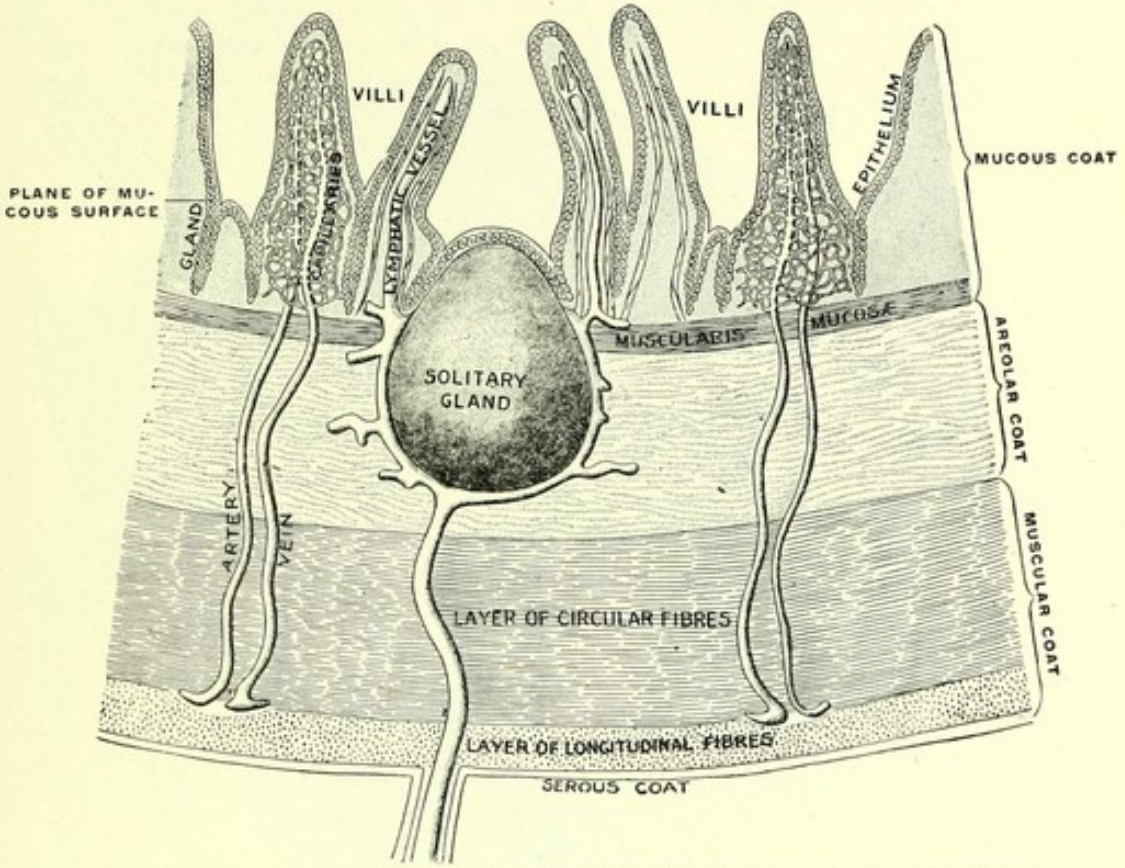

FIG. 772.—Mucosa of small intestine in ideal vertical cross-section. (Testut, after Heitzmann.)

Having now considered the features common to the whole of the small intestine, we will study each portion of it in detail.

THE DUODENUM.

The duodenum (Fig. 773) differs from the jejuno-ileum in many respects. It is much wider, thicker in wall, more deeply situated, more complex in structure, contains certain glands peculiar to it, and is the part into which the ducts from the liver and pancreas discharge; but it is much shorter, far less mobile, has only a scanty serous covering, and has none of the aggregated lymph-nodules. Its length is ten inches or less, its width two inches or less. It extends in a tortuous course from the pyloric opening to the point where the mesentery first embraces the gut, that is, at the left side of the second lumbar vertebra. It is conveniently divided into four portions, of which the first, about two inches long, runs back, up, and to the right under the quadrate lobe of the liver to the neck of the gall-bladder; the second descends for about three inches along the right edge of the head of the pancreas, to the level of the lower border of the third lumbar vertebra; the third passes to the left horizontally two inches and a half, which brings it to the middle of the vertebral column, where it is crossed by the superior mesenteric vessels; and the fourth ascends on the left of the column and ends in the jejuno-ileum, which descends from the line of junction very abruptly. Thus, the duodenum, after describing an irregular curve, suggestive of an imperfect circle, almost returns to its starting-point.

Its *serous coat* is incomplete and irregularly applied. The first part is covered like the stomach; the second is clothed in front; the third above, below,

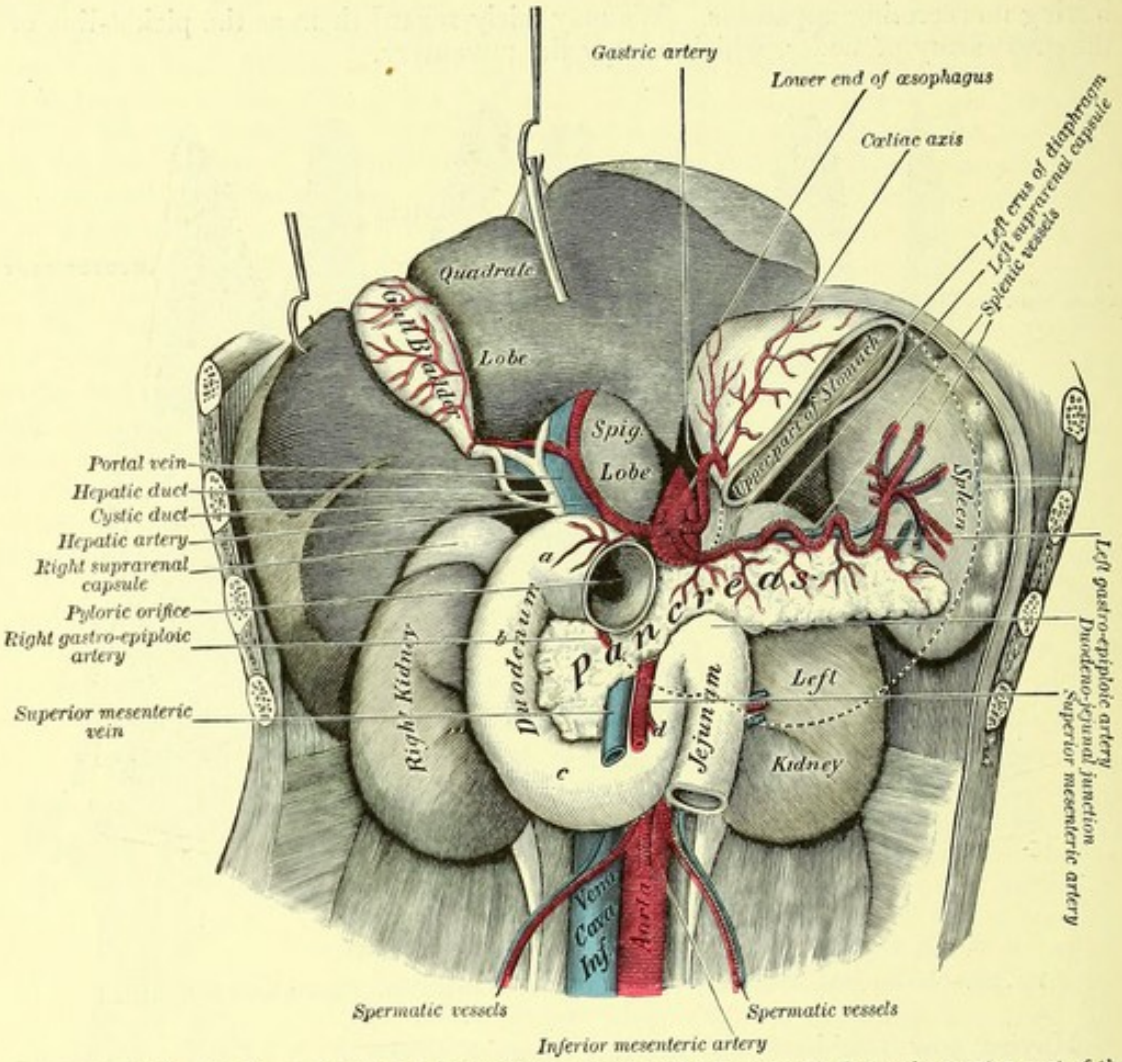

FIG. 773.—The duodenum, its four parts marked *a*, *b*, *c*, *d*. The liver is lifted up; the greater part of the stomach is removed, broken lines indicating its former position. (Testut.)

and in front; the fourth in front and partly at the sides. The second part is closely adherent to the front of the right kidney and the head of the pancreas,

FIG. 774.—Diagram of cross-section of the first part of the duodenum, to show its peritoneal relations.

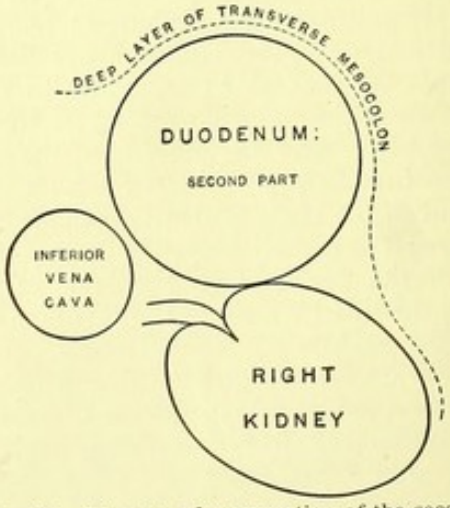

FIG. 775.—Diagram of cross-section of the second part of the duodenum, to show its peritoneal relations.

and includes in its wall the terminal portions of the common bile-duct and the pancreatic duct; the third part is attached to the vena cava inferior, the aorta, and the right crus of the diaphragm; and the fourth is fastened to the left side of the vertebral column, the left kidney and its vessels. The relations of the peritoneum to each of the parts of the duodenum will be seen easily by consulting the diagrams, Figs. 774–777. The first part is somewhat movable, but the others are so bound down by the peritoneum and their close connections with other structures as to be practically fixed in their places. Still another agency contributes to this immobility—the *suspensory muscle*, a delicate, flat, fibro-

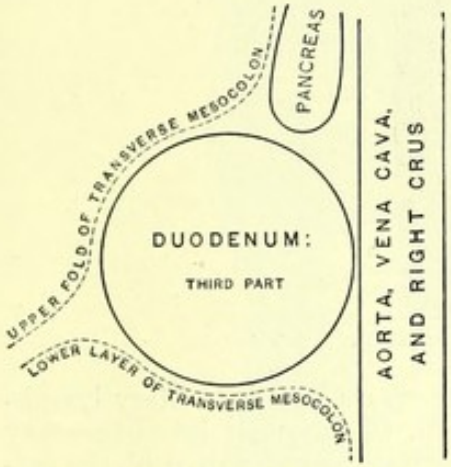

FIG. 776.—Diagram of the third part of the duodenum, to show its peritoneal relations.

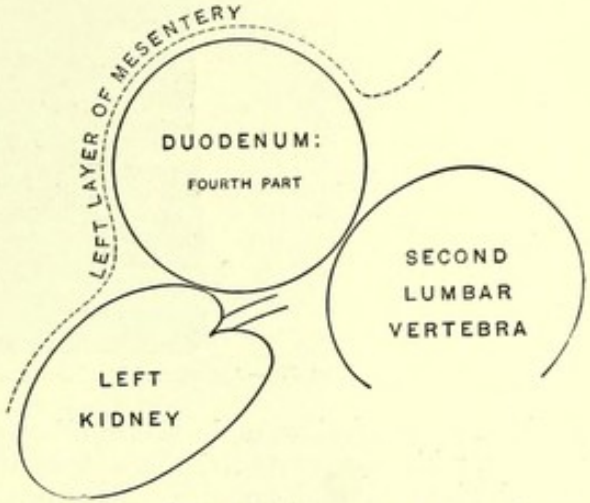

FIG. 777.—Diagram of the fourth part of the duodenum, to show its peritoneal relations.

muscular band, which starts from the left crus of the diaphragm, and runs downward to its insertion on the duodeno-jejunal angle and the dorso-mesial aspect of the fourth part of the duodenum.

The *valvulæ conniventes* are particularly well developed in this bowel. In the areolar coat are situated many spheroidal, compound, racemose glands, which open upon the free surface. They form an almost complete layer under the true mucosa at the upper part of the duodenum. They are peculiar to this portion of the small intestine, and hence are called *duodenal glands*, although they are often known as the *glands of Brunner*.

About the middle of the concave side of the descending (second) part is the common *opening of the pancreatic and bile ducts*.

THE JEJUNO-ILEUM.

The principal features of the small intestine having been presented, the jejuno-ileum, which is the main part of it, requires but little special attention.

Beginning at the termination of the duodenum, it is thrown into convolutions so numerous and so irregular in their disposition that it is impossible to lay down a rule by which sight alone can distinguish a proximal from a distal portion. However, in general there is some probability that its proximal half is located above and at the left, its distal below and at the right.

To determine whether a knuckle of intestine is proximal or distal to another, one is assisted by digital examination of the part of the mesentery belonging to each. The convolution whose mesentery is the higher is nearer the stomach. This method not only is more expeditious, but it prevents the injury which the bowels may suffer from prolonged manipulation.

The last portion of the jejuno-ileum reaches the large intestine from the left and below.

The jejuno-ileum begins with a diameter of nearly an inch and a half, with closely set villi, long, deep, and numerous valvulæ conniventes, and a fairly thick muscular coat; it ends with a cross-measurement of hardly an inch, with scanty villosities, no connivent valves, and a thinner musculature. In a single direction only has it made a gain—the addition of the *aggregated lymph-nodules*, otherwise called the agminated glands and the *patches of Peyer* (Fig. 778). These

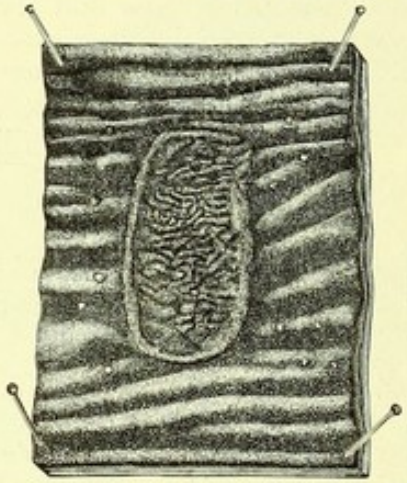

FIG. 778.—Aggregated lymph-nodule (Peyer's patch). (Testut.)

are local accumulations of bodies in all essential respects like the solitary lymph-nodules, which are scattered throughout the length of the small intestine—they are colonies of lymph-nodules. They produce scarcely any elevation of the surface, but are not crossed by connivent valves; they are always situated at the free border of the tube, with their greater diameter lengthwise of it; are rarely found in the upper half, and become larger and more numerous as the large intestine is approached; vary in size from a half inch in both directions to a width of about an inch and a length of ten inches, or possibly more; are thirty or more in number on the average; and tend to disappear gradually after middle life, so that in old people they may be recognizable only as areas of discoloration. They are the seat of the lesion in enteric (typhoid) fever.

The **blood-supply** of the jejuno-ileum is derived from the superior mesenteric artery, whose branches course between the two layers of the mesentery, are distributed beneath the serous coat, anastomose on the free border, and perforate the muscular layers, forming a rich plexus in the areolar tunic, from which the mucous and muscular are furnished with their supply of arterioles and capillaries. The *veins* correspond. Ordinary *lymphatics*, originating in the other parts, are joined by those from the villi (lacteals), and leave by way of the mesentery to empty into the receptaculum.

The **nerves** come from the superior mesenteric plexus, accompany the vessels, and form one network between the layers of the muscular tunic, another in the areolar. Their exact terminations are not understood. The duodenum gets a part of its arterial blood from the superior mesenteric, and the rest through branches of the hepatic.

THE LARGE INTESTINE.

The largeness which gives a name to the next grand division of the alimentary canal is in its transverse, not in its longitudinal, diameter; for it is hardly more than a quarter as long as the small intestine, but is much wider, being two and a half inches across in its broadest part.

The large intestine (*intestinum crassum*) (Fig. 779) is divided for description into three parts—cæcum, colon, and rectum—and has so little mobility that the

location and relations of each of these segments are fairly constant—a respect in which it materially differs from the small intestine.

It begins in the right and lower portion of the abdomen, passes upward and backward to the under surface of the liver, thence across the belly to the spleen,

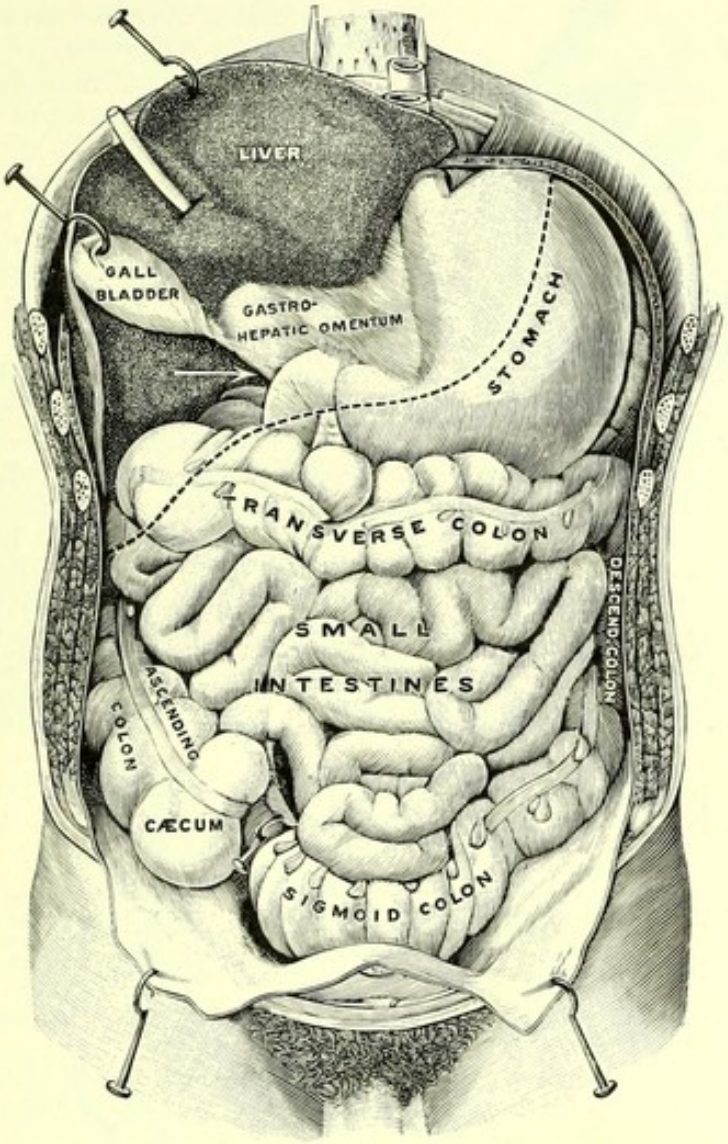

FIG. 779.—The stomach and intestines, front view, the great omentum having been removed, and the liver turned up and to the right. The dotted line shows the normal position of the anterior border of the liver. The dart points to the foramen of Winslow. (Testut.)

from this point downward and forward to the left and lower part of the abdomen, here makes a number of curves, and finally plunges into the pelvis at its back part, and ends close to the perineum, near the inner opening of the anal canal.

Tunics of the Large Intestine.

Its wall is thicker than that of the small intestine. Its tunics are four in number, and have the same names and the same order of arrangement as do those of the stomach and small intestine. The serous coat of each portion will be described in connection with it; the areolar presents no peculiarities requiring especial mention.

The **Muscular Coat** (Fig. 780) of all but the last few inches of the length is remarkable in that its *outer, longitudinal layer*, instead of being disposed in an

unbroken sheet, as is that of the small intestine, is almost wholly gathered into three equal, ribbon-like bands (*tænia coli*), one-third of an inch, or a little more, in width, which are placed lengthwise at equidistant intervals, the small remaining portion being spread in a delicate lamina over the residue of the tube. The *inner, circular layer*, like the subjacent areolar and mucous tunics, forms an even tube from end to end; but these outer strips of muscle are much shorter than this musculo-areolo-mucous tube, and, as their extremities are attached to its corresponding extremities, there necessarily ensues a great puckering included in their grasp. Between the bands are deep, transverse creases, each bounded by prominent bulges; and an inspection of the bore of the tube shows a sharp ridge (*plica sigmoidea*), corresponding to each depression of the outer surface, and a large recess (*haustrum*), collocated with each external protrusion. This sacculation and the cause of it are characteristic. Whenever one is in doubt as to whether a given knuckle belongs to large or small intestine, the presence or absence of the longitudinal ribbons will settle the question at once.

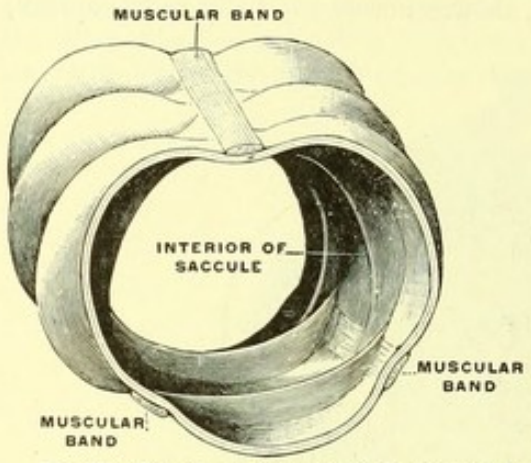

FIG. 780.—Segment of large intestine, showing the characteristic features of its structure. (Testut.)

Although the ridges, which encroach upon the lumen of this gut, look like overgrown valvulæ conniventes, their structural character is radically different. A connivent valve (Fig. 781) is merely a fold of mucous membrane, strengthened by a thin plate of areolar tissue; but a plica sigmoidea (Fig. 782) is the result of an infolding of everything inside of the muscular ribbons. Remove these bands from the bowel, and straighten it, and the plicæ will disappear, leaving an even, uninterrupted bore; but no such result will ensue, if you dissect off the longitudinal lamina of muscle from the small intestine: the little valves will remain exactly as before.

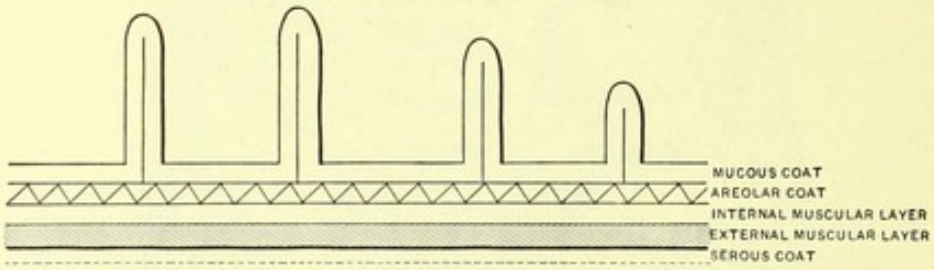

FIG. 781.—Diagram to show the structure of the valvulæ conniventes. Compare with next cut. (F. H. G.)

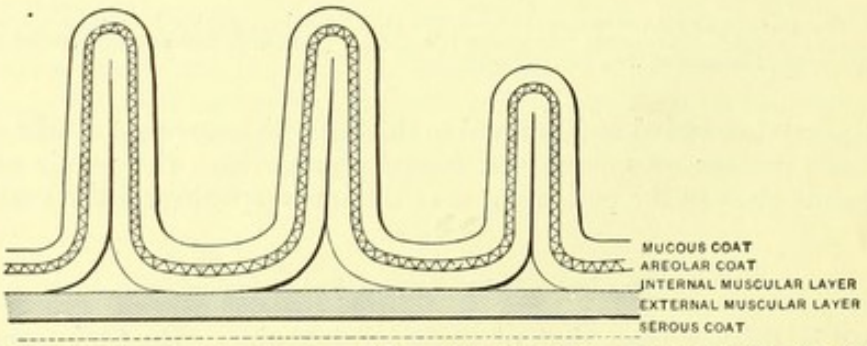

FIG. 782.—Diagram to show the structure of the plicæ sigmoideæ. Compare with the preceding cut. (F. H. G.)

The **mucous membrane** is paler, somewhat firmer, and much simpler than that of the small intestine: there are no connivent valves, no villi, no glands of Brunner, no patches of Peyer. But there are many so-called solitary glands, though they are less numerous than in the upper bowel; and the thickness of the mucosa is occupied by simple, tubular glands, larger than those met with previously, and containing a much greater proportion of goblet cells. Indeed, in not infrequent cases, it is found that the majority of the epithelial cells are of this variety.

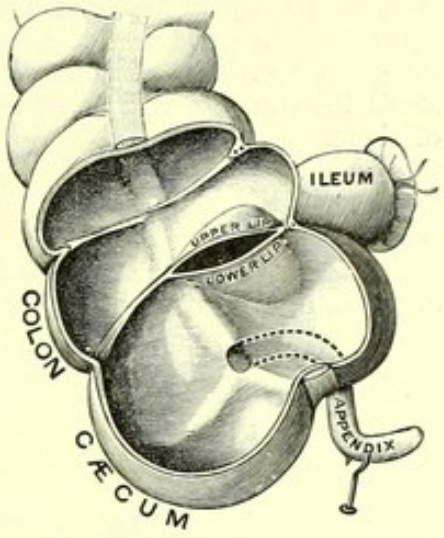

FIG. 783.—Cavity of the cæcum, its front wall having been cut away. The ileo-cæcal valve and the opening of the appendix are shown. (Testut.)

THE CÆCUM.

The cæcum (*cæcus*, "blind") (Figs. 783, 785) is thus named because it is a pouch, a no-thoroughfare. Its blind end points downward, its open end upward, passing directly into the colon, of which this gut seems to be the beginning, justifying its old name, *caput coli*, "the head of the colon." The line of separation between them is at the level of the opening from the small intestine, on the left side and behind, about two and a half inches from the lower end. Here is the *ileo-cæcal* or *ileo-colic valve*, which protects the ileum against the backward flow of fæces from the large intestine. If the extremity of the ileum was simply attached to the margin of a circular hole of its own diameter in the side of the large intestine, there would be a frequent reflux from the latter, and the

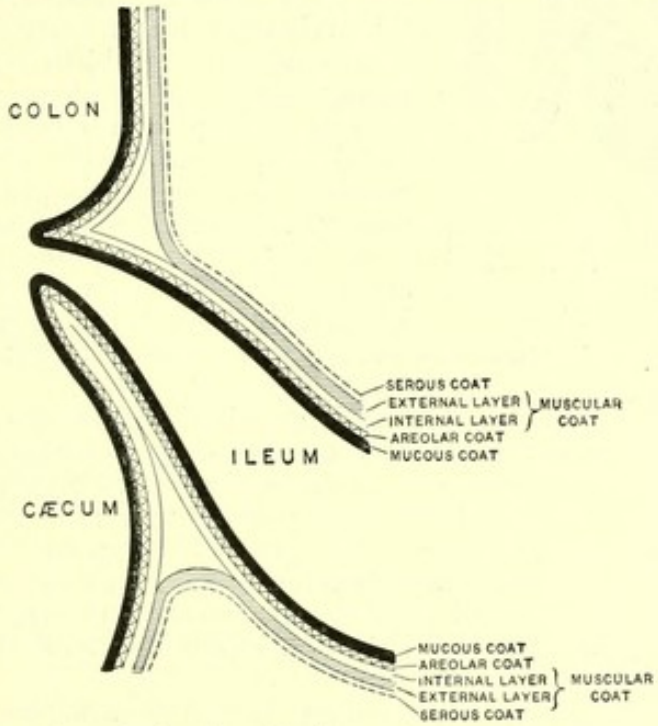

FIG. 784.—Diagram of a vertical section of the ileo-cæcal valve, showing its structure. (F. H. G.)

lower ileum would be only a receptacle for excrement. But, at the junction of the two guts, the ileum is flattened from above downward, and the serous coat and the outer layer of the muscular coat are so shortened that the other tunics are thrust into the cavity of the large intestine, forming two lips, an upper and a lower, with

a horizontal cleft, like a button-hole, between them (Fig. 784). The permanency of the lips is maintained by the shortness of the outer muscular layer. The ileum enters the large intestine obliquely from below ; and thus, when there is an accumulation of fæces in the cæcum, the two lips will be pressed together, and regurgitation prevented ; but there is nothing in the conformation of the valve to interfere with the passage of material in the other direction. From each commissure of the lips extends a ridge, which, after going part way round the bowel, shades off into the general surface. Upon that aspect of these lips which is contributed by the small intestine are villi ; that which is furnished by the large intestine is devoid of them.

The Appendix.

Springing from the rear of the cæcum toward its inner aspect is a blind tube, about as thick as an ordinary lead-pencil, and varying from three to six (or even more) inches in length, called the *appendix vermiformis cæci* (" the worm-like appendage of the blind gut ") (Fig. 785). It has a mesentery for about half its length ; its serous, muscular, and areolar coats are similar to those of the small intestine ; its mucous coat has intestinal glands, and so many so-called solitary glands as to constitute a nearly complete layer in and just beneath the mucosa. Its attitude varies enormously : it may stand up behind the colon, hang down behind the cæcum, lie forward toward the surface of the belly, curve to the outside, or twine around the ileum. Its development is peculiar. The cæcum is relatively much longer in the fœtal than in the adult condition. At birth it is a long cone, hardly suggesting the shape which it finally assumes. The portion nearest the colon grows and develops equally with the latter ; but the remainder ceases to develop, and, being vastly outgrown and overshadowed by the upper portion, becomes an appendage to what was originally the smaller part of the blind gut. We see, therefore, that this worm-like organ has reached its present condition as the result of arrested development, and not of degeneration.

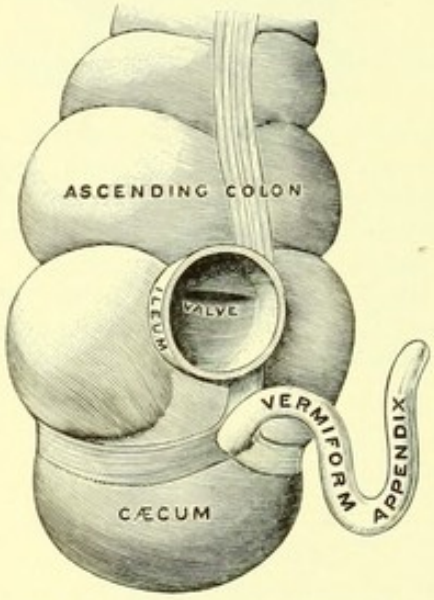

FIG. 785.—The cæcum, dorso-mesial view, showing the ileum-side of the ileo-cæcal valve, and the beginning of the three muscular ribbons. (Testut.)

The three *ribbons of muscle* previously described begin at the attached end of the appendix. One runs up close behind the ileo-cæcal junction ; another curves downward, inward, and then upward on the front ; and the third turns downward, outward, and then upward. From their position they are called respectively postero-internal, anterior, and postero-external. The appendix would be at the lowest extremity of the cæcum, in the adult as it is in the fœtal condition, but for the bulging of the front part of the latter downward, and especially outward, a change which brings the opening of the appendix behind and toward the middle line of the body.

The cæcum has a complete investment of serous membrane, but it has no mesentery.

THE COLON.

The colon comprises all but a mere span of the large intestine. It diminishes in size gradually from its beginning to its end. It presents four well-marked

segments: the ascending colon, the transverse colon, the descending colon, and the sigmoid colon. Its serous membrane is marked at irregular intervals along the line of one of the muscular bands by little tassel-like protrusions, the *appendices epiploïcæ* ("omental appendages"), containing adipose tissue. They do not appear until after childhood, and are pronounced in proportion to the fatness of the individual.

The Ascending Colon.

The ascending colon (Fig. 786) begins at the level of the ileo-cæcal valve, passes upward and backward, and ends at the under surface of the right lobe of the liver, where it is received in the colic impression. It has no inherent peculiarities to distinguish it from other segments except in its serous tunic. The disposition of this coat determines the mobility or fixity of the part. Generally only the front and sides are clad in peritoneum, which is reflected laterally to the abdominal wall; but not very infrequently a distinct mesentery, here called *ascending mesocolon*, is found. In the former case this part is immovable; in the latter its mobility is regulated by the length of its mesentery.

The Transverse Colon.

The transverse colon (Fig. 786) begins at the *hepatic flexure*, which is the angle made between it and the preceding portion, and passes almost horizontally to a nearly corresponding point on the left side, where it terminates in a bend, the *splenic flexure*, between it and the descending colon. In crossing the trunk, however, it does not go in a straight line, but, keeping close to the anterior wall, describes a curve with its concavity backward, and displays thrice the length that it would, if it ran directly from side to side. It often sags a little in the middle. This part of the colon is provided with a mesentery, the *transverse mesocolon*, which varies greatly in length in different subjects. Its proximal border is fastened to the hind wall of the abdomen, its distal is attached to the gut along the line of the postero-inferior muscular band. The antero-inferior band is decorated with appendices epiploïcæ, and the superior is the base from which depend the hind layers of the great omentum.

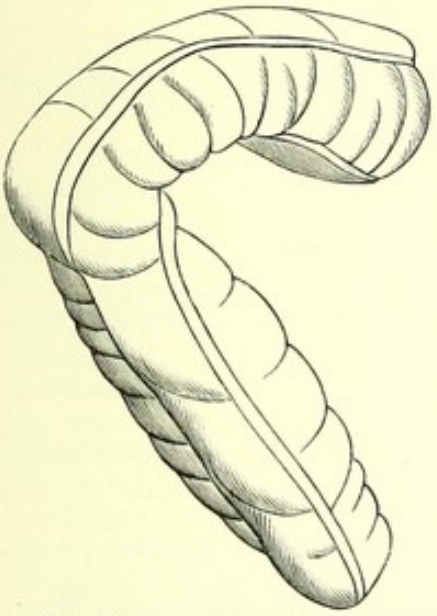

FIG. 786.—Ascending and transverse colons, viewed from the right side. (Drawn from the His cast. F. H. G.)

The Descending Colon.

The descending colon is almost the exact counterpart of the ascending; but it is a little smaller in bore, a trifle longer—the great thickness of the liver preventing the ascending colon from reaching quite as high a plane as that from which the descending starts—and somewhat farther back in its upper portion. It ends at the level of the crest of the ilium—an arbitrary and conventional limit, there being no inherent, natural mark of separation between it and the next division. Finally, it is hardly ever furnished with a mesentery, and its hind surface is generally bare of serous membrane.

The Sigmoid Colon.

The sigmoid colon (Figs. 787–789) is often called the sigmoid flexure; but as the term "flexure" is used to designate the bends between the horizontal and the two vertical portions—mere angles in, and not parts of, the tube—it is confusing to have the same name applied to a portion of the bowel, which, while the seat of complicated flexions, includes a considerable length of the intestine. "Sigmoid colon" signifies a part of this intestine, whose form is so tortuous as to suggest the Greek letter sigma, and seems, on the whole, to be the best of its numerous titles.

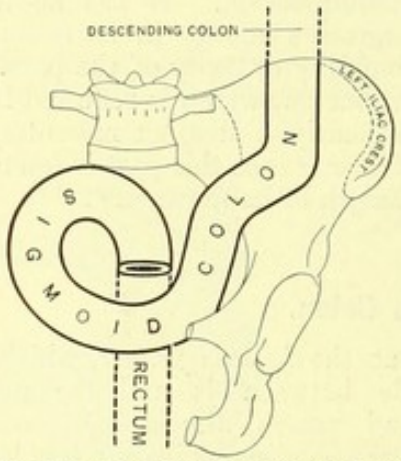

Fig. 787.—Sigmoid colon, front view. Semidiagrammatic. (Testut.)

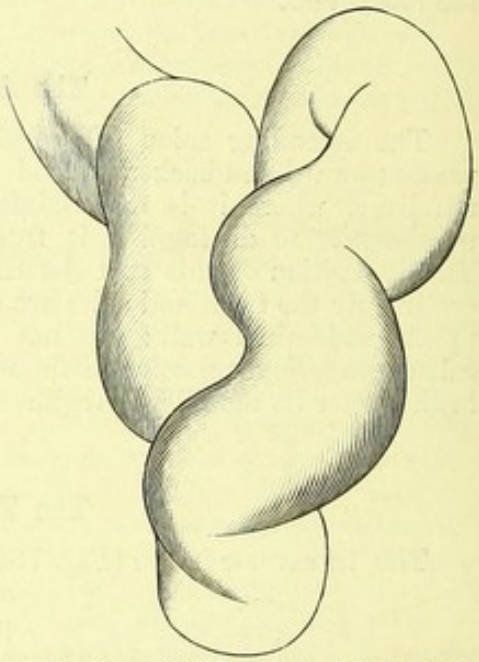

Fig. 788.—Sigmoid colon, dorsal view. (Drawn from the His cast. F. H. G.)

The Limits of the Sigmoid Colon.—The sigmoid colon is the most movable and the most variable of the divisions of the large intestine. It is continuous below with the rectum, and most authors fix the dividing line between the two opposite the joint of the left hip-bone with the sacrum. But the result of many careful observations shows that, while the large intestine crosses this articulation in some cases, in the majority this condition does not obtain. Even if the classical description were in accordance with the fact, there would seem to be little wisdom in separating these two territories of intestinal surface by this extraneous and purely arbitrary boundary, thus depriving the sigmoid colon of a portion of intestine exactly like its major part in structure, and bestowing it upon the rectum, from which it materially differs. A few recent writers, recognizing the expediency of adopting the intrinsic dividing line, which nature has established, have discarded the extrinsic and artificial boundary, and confine the application of the name "rectum" to that portion of the bowel below the brim of the true pelvis which has no mesentery. This method is here adopted.

The sigmoid colon (Fig. 787) begins on the plane of the crest of the left ilium, and thence usually passes down to within an inch and a half of the inguinal (Poupart's) ligament, bends sharply toward the middle line, crosses the psoas magnus muscle, dips into the cavity of the true pelvis, rises to the brim on the right side, and thence curves backward, downward and inward to about the third sacral vertebra at the median line, where it becomes continuous with the rectum. It is 14 or more inches long. For its uppermost three inches it has a serous covering on its front and sides only; but below this it has a mesocolon in its entire length. The *sigmoid mesocolon* is much longer in the middle portions than toward the ends. The diameter of this part of the intestine is less than that of the preceding, and constantly, though gradually, diminishes toward its lower end. The three longitudinal bands are continued on the sigmoid colon for most of its course; but, as the end is approached, those which are behind spread out and

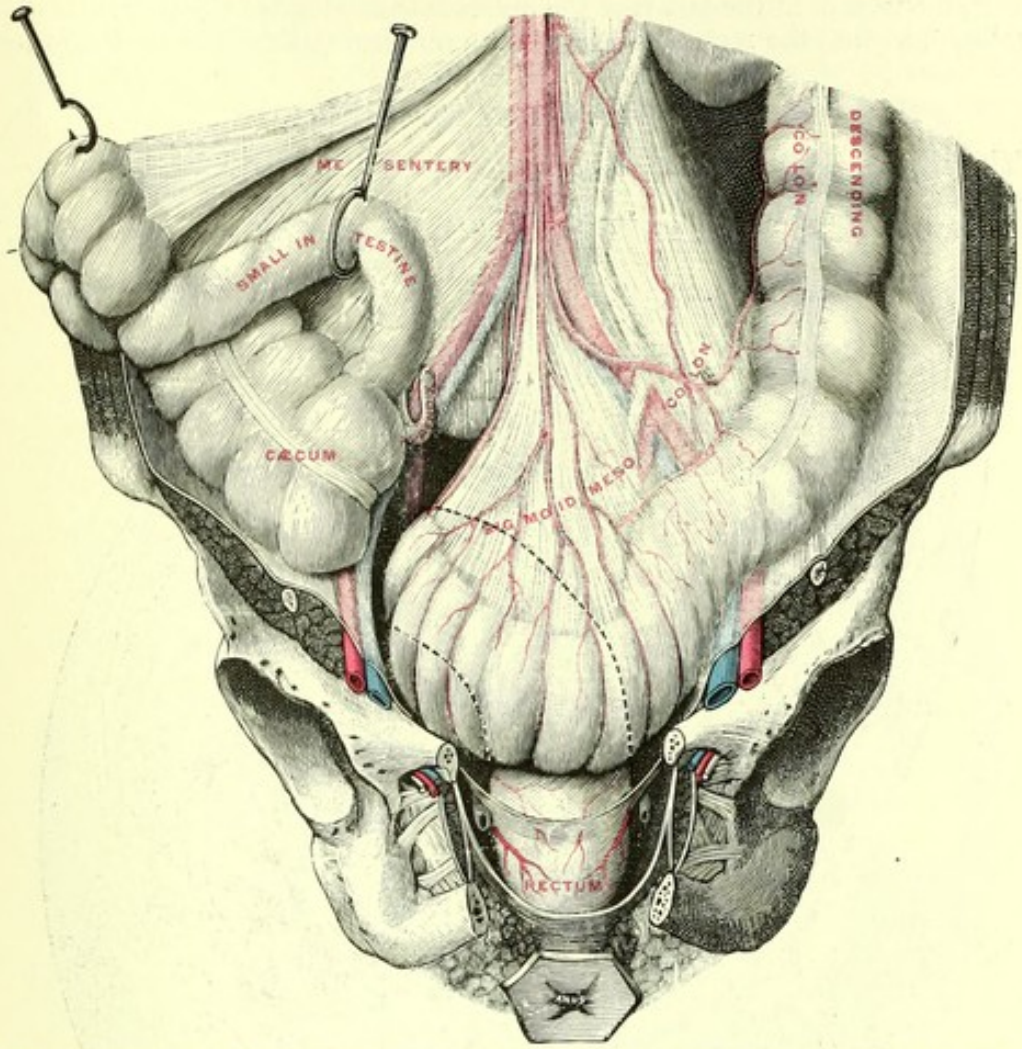

FIG. 789.—Sigmoid colon and rectum, front view. The broken lines indicate the situation of the concealed part of the sigmoid colon. The small intestine is drawn away, and the anus is turned forward. (Testut.)

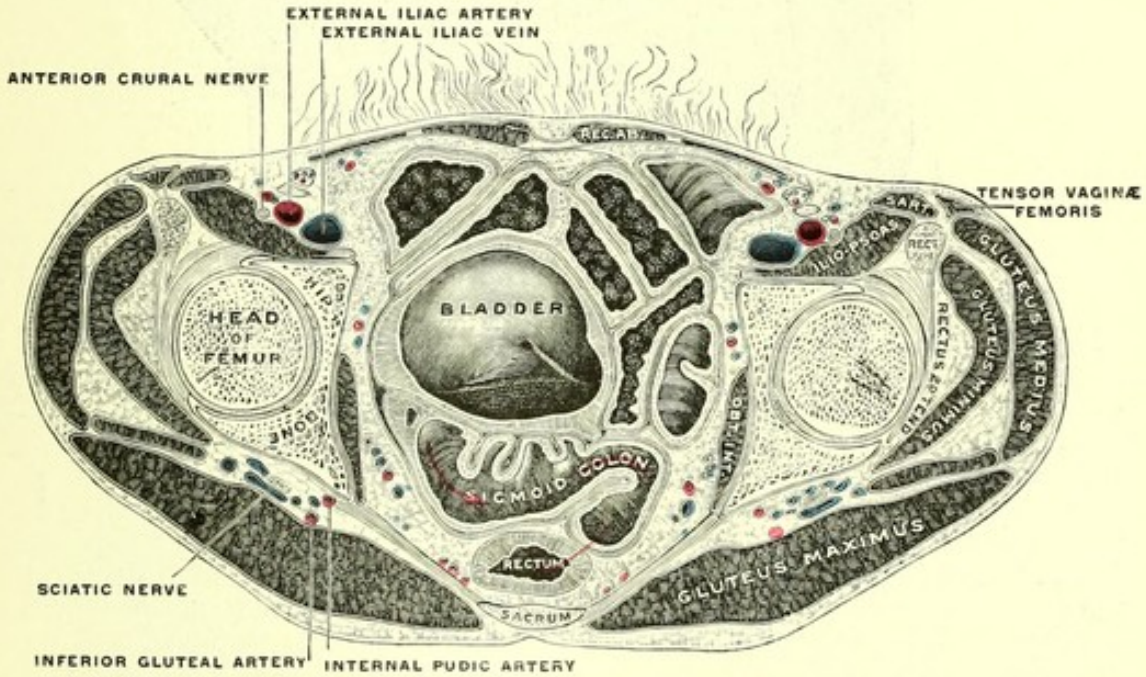

FIG. 790.—Horizontal section three inches below the sacral promontory. The upper surface of the lower segment. (Testut.)

unite into one, and at the last part the anterior has extended sidewise, and joined its fellows, so that the rectum begins with a uniform outer layer of its muscular tunic.

THE RECTUM.

The rectum (Figs. 791, 792) begins at the point where the large intestine ceases to be provided with a mesentery, that is, in general, at the front of the third sacral vertebra in the middle line. Its name, which means "straight," is

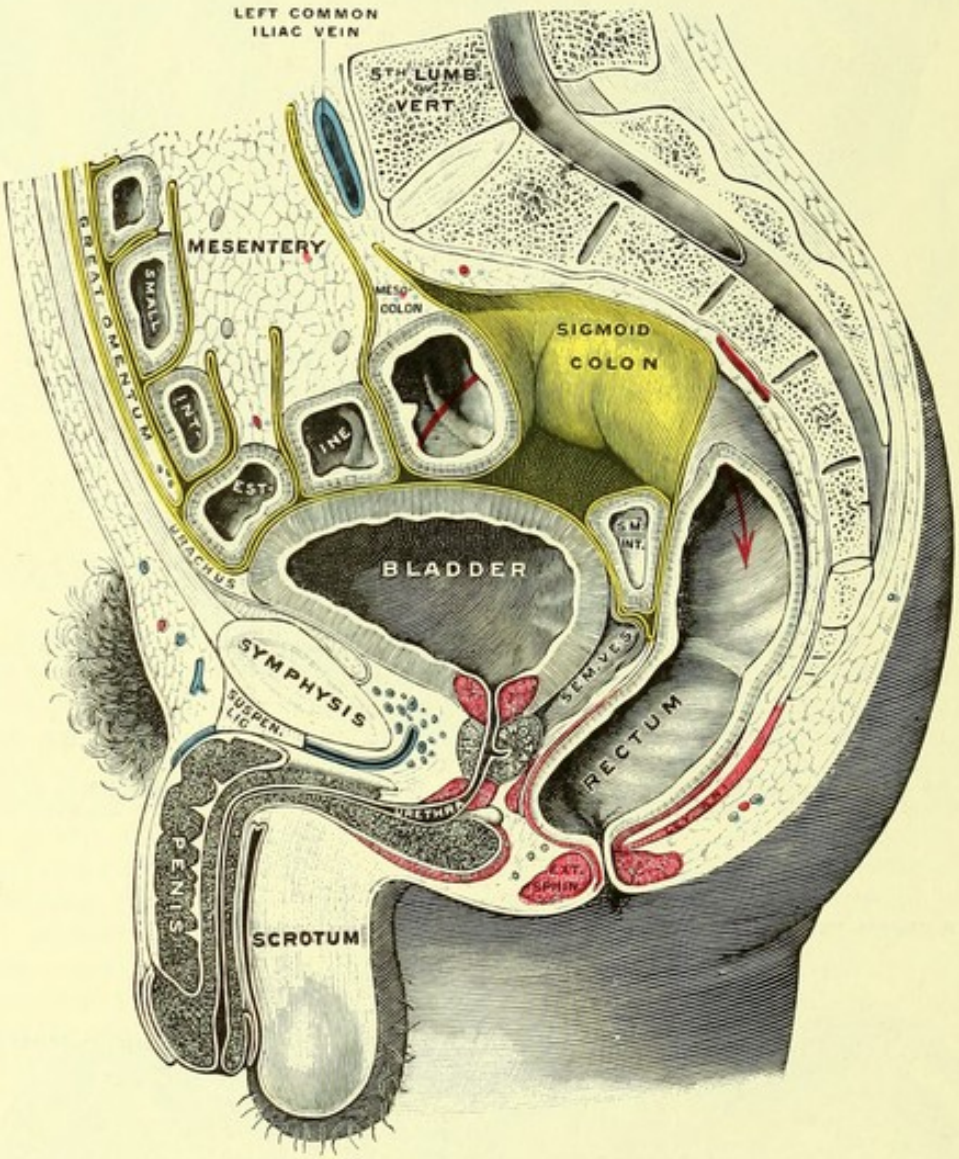

FIG. 791.—Sagittal section of the lower part of a male trunk, the right segment. (Testut.)

made less absurd by the adoption of our present plan of delimitation of the intestines in this region, than it was when this segment was made to start at the sacro-iliac joint; for then it was crooked from every point of view, while now, when looked at from in front, it comes near deserving its title.

It occupies the middle line, and is divided into an upper part, which is furnished with a covering of peritoneum, and a lower, which is not. The *upper part*, about three inches long, extends from the third sacral vertebra to the tip of the coccyx, and its shape conforms to the curve of these bones, to which it is attached behind. The *lower part*, shorter than the upper, is continued with the same dorsoventral curve, and terminates in a forward pouch, which is close to the prostate gland in the male and to the lower part of the vagina in the female.

If the lower opening of the alimentary canal were made at the end of this pouch, and in the line of its curve, the anus would be situated in the male just back of the attachment of the scrotum and in the female near the vaginal entrance. The curve of the rectum, thus extended, would present an even sweep from its

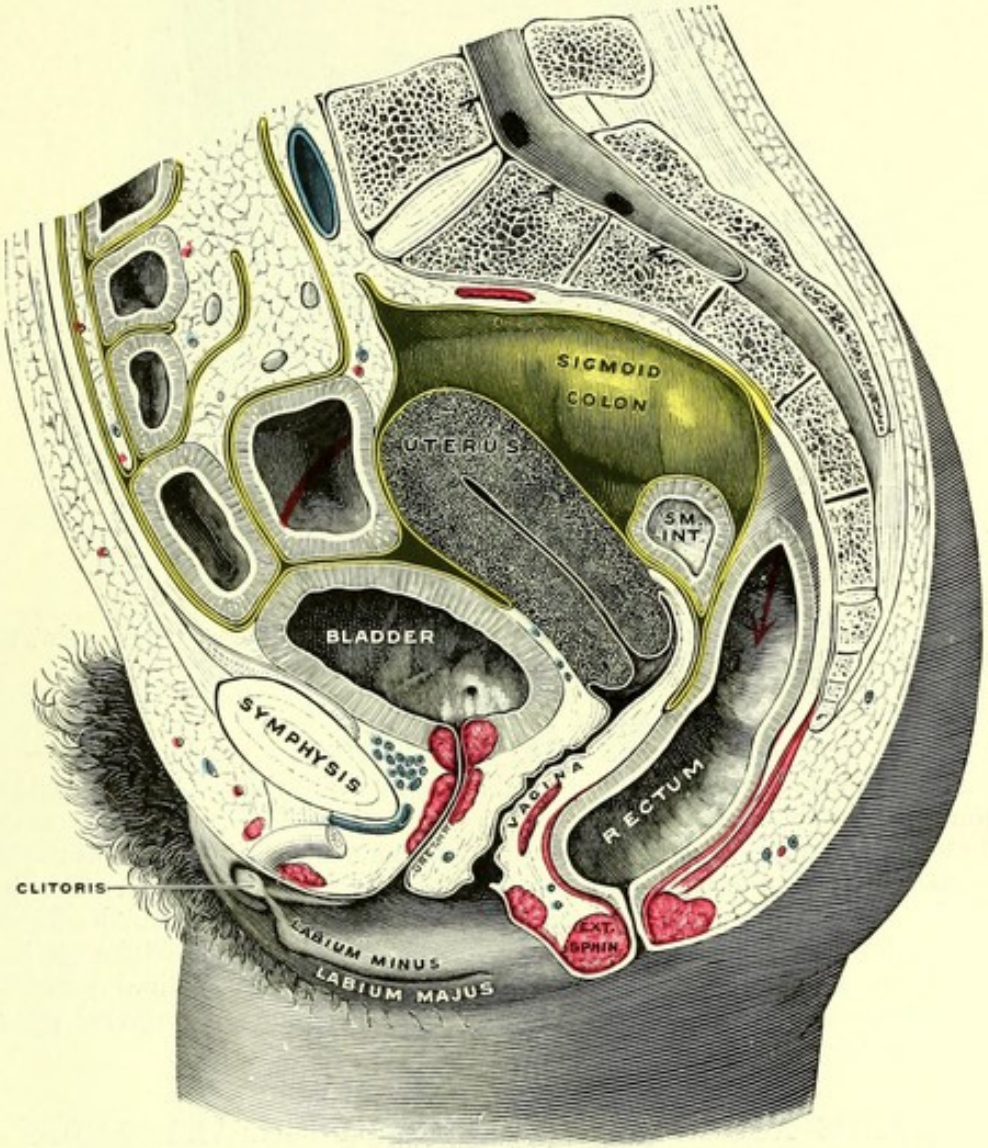

FIG. 792.—Sagittal section of the lower part of a female trunk, right segment. (Testut.)

upper to its lower end. The opening, however, is not thus placed, but is located in the under side of the rectum, considerably to the rear of its blunt end. The part of the intestine in front of this opening is called the *rectal ampulla*.

The **muscular coat** is thick and strong at all points, and consists of two layers, the external being the longitudinal, the internal the circular, and both evenly spread.

The **serous tunic** covers only a portion of the first part, and none of the second. This coat is most extensive in front, and is absent behind; and the line at which it leaves the gut slopes from above downward and forward very rapidly. It is reflected onto the bladder in the male, and the vault of the vagina and the uterus in the female. Where there is no serous coat the rectum is covered with strong areolar tissue.

The **mucous membrane** is thicker and denser than that of the colon, and its hue deepens to a decided red in the lower part. It usually presents from one to three transverse folds, *plicæ recti*, which may go a third of the way around the lumen,

and are thought to be permanent. At the margin of the opening from the rectum to the anal canal are five or six small crescentic loops, *semilunar valves* (Fig. 793),

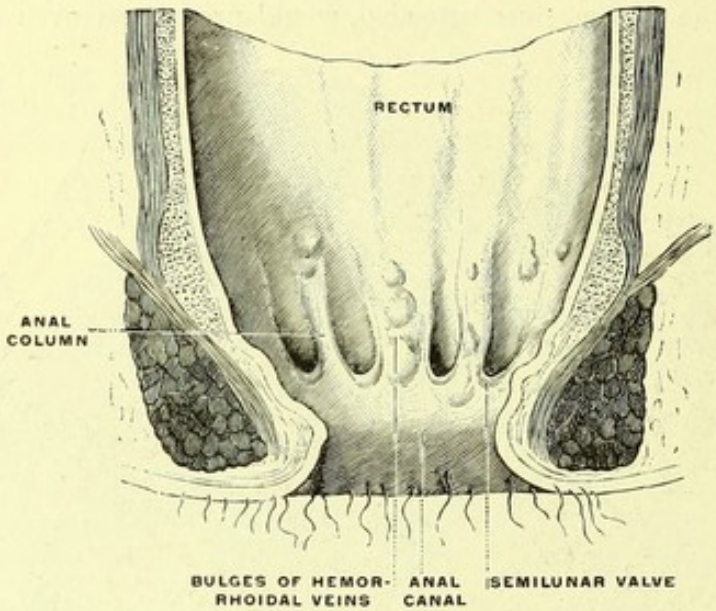

FIG. 793.—The anal canal and lower part of the rectum, laid open. (Testut.)

separated by vertical ridges, the *anal columns*, upon which are little protrusions due to hemorrhoidal veins.

THE ANAL CANAL.

The anal canal (Figs. 791–793) is the channel by which the rectum is placed in connection with the external surface of the body. It is an inch long, and runs downward and backward. It is lined with a membrane, which is mucous at the upper end, cutaneous at the lower, and a cross between the two elsewhere. Outside of this lining is an embracing muscle, the *internal sphincter*, composed of bundles of smooth fibres, arranged circularly. The lateral walls of the tube are in contact, and the lining membrane is disposed in small, longitudinal folds. The distal aperture is the *anus*, and around it the skin is dark brown, and puckered in radiating lines.

GLANDS ACCESSORY TO THE ALIMENTARY TUBE.

In the development of the digestive canal bud-like processes grow out from it at several points, and ultimately become glands, furnishing abundant secretions, which are discharged into the tube through ducts. These glands are the salivary, the pancreas, and the liver, and they will now be considered in the order given.

THE SALIVARY GLANDS.

The *saliva* is a compound fluid, resulting from the mixture of the secretions of a number of glands, which discharge their products into the mouth. There are many *mucous glands*, two collections of which on each side require mention. One is at the hind part of the oral portion of the tongue, at the side and below, and is called the *gland of Weber* (Fig. 794, GL. W.). The other is beneath the lateral border of the tongue near the tip, and is known as the *gland of Blandin* (Fig. 794, GL. B. and Fig. 758). The so-called salivary corpuscles are derived from the *tonsils*. But the great volume of the saliva is furnished by three pairs of glands—the parotid, the submaxillary, and the sublingual. Of these the first

produces a watery (serous) secretion, the third a glairy (mucous) one, and the second a fluid which is between the two in consistency.

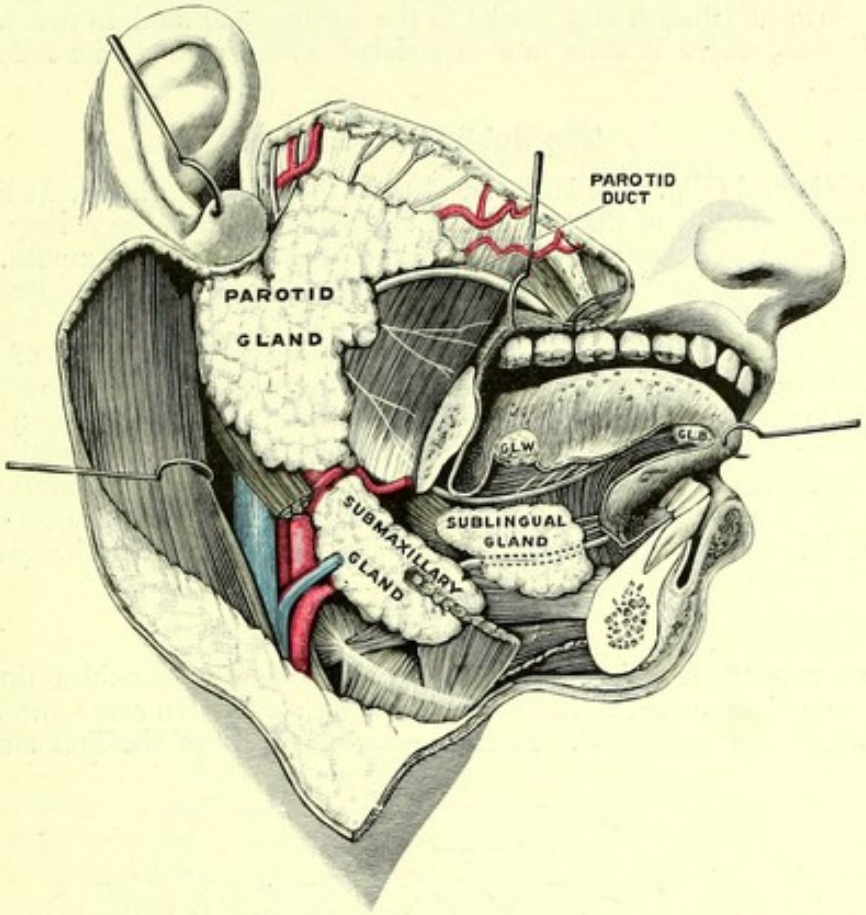

FIG. 794.—The salivary glands. The right half of the body of the mandible has been removed. GL. W., gland of Weber. GL. B., gland of Blandin. (Testut.)

The Parotid Gland.

The parotid ("near the ear") gland (Fig. 794) is the largest salivary gland, and is situated in the side of the face, extending from the zygoma to the angle of the mandible, and from the external auditory meatus forward upon the masseter, dipping deeply between the ramus and the mastoid, and pushing in between the pterygoid muscles. It is bound down by the masseteric fascia. The *parotid* (Stenson's) *duct*, by which the saliva is discharged, leaves the gland at its front border, and passes forward horizontally about three-quarters of an inch below the zygoma for two and a half inches. On reaching the anterior margin of the masseter, it turns mesially, and perforates all of the buccal layers, except the mucosa, on the outer surface of which it then courses forward until it reaches a point opposite the second upper molar tooth, where it pierces the membrane, and ends in a contracted orifice. Usually an appendage, the *glandula socia parotidis*, lies above the first part of the duct, and pours its secretion into it.

In the substance of the parotid gland the external carotid artery makes its terminal division, the facial nerve radiates into its branches, and the temporomaxillary vein, some lymph-nodes, and branches of the great auricular nerve are situated.

The Submaxillary Gland.

The submaxillary gland (Fig. 794) is about a third as large as the parotid. It is lodged in a chamber of the deep cervical fascia, mostly below the body of

the mandible, and upon the mesial side of its angle. The stylomandibular ligament runs between it and the parotid. The facial artery grooves its back and upper border. The *submaxillary duct* (Wharton's) is two inches long, runs forward and inward beneath and mesial to the sublingual gland to the side of the frænum linguæ, where it ends in a constricted orifice, close to its fellow of the opposite side.

The Sublingual Gland.

The sublingual (Fig. 794) is the smallest of the salivary glands. It lies in the gutter between the side of the tongue and the mandible, forming a long elevation beneath the mucous membrane of this part of the floor of the mouth. It has twenty or less ducts, which open for the most part directly above the gland, a few perhaps into the duct of the submaxillary.

Structure of the Salivary Glands.—All of the salivary glands are of the compound racemose variety. They consist of lobules, which are held together by a variable amount of areolar tissue. Each lobule is an aggregation of acini ("grapes") or alveoli, which are the globular or tubular sacs, constituting the active part of the organ. These sacs are so nearly filled with secreting epithelial cells that the central channel is extremely small. The ducts nearest the acini are the radicles of the great stem which finally emerges from the gland.

THE PANCREAS.

The pancreas ("all flesh") (Figs. 795, 796) so closely resembles the parotid that it is sometimes called the *abdominal salivary gland*. In some lower animals it is known as the *sweetbread*. It lies across the front of the first and second

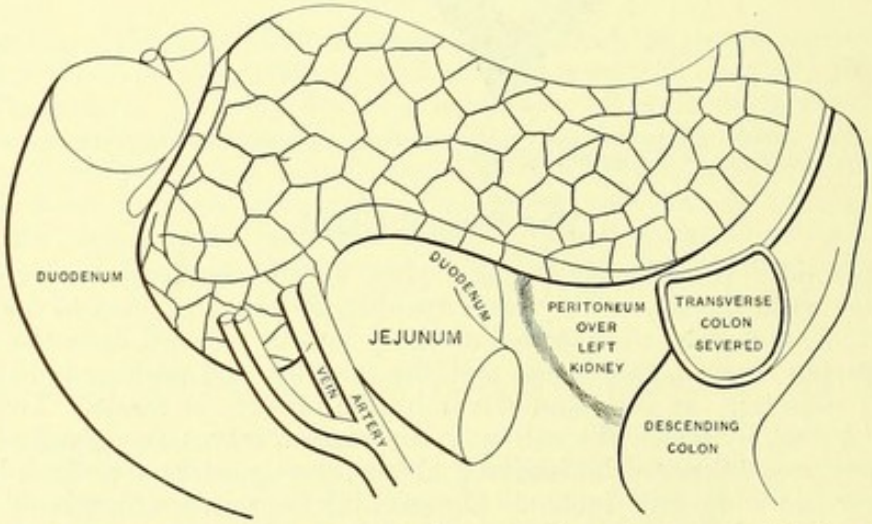

FIG. 795.—The pancreas, ventral view. The superior mesenteric vessels are seen at the lower part of the head. (Drawn from the His cast. F. H. G.)

lumbar vertebræ, and behind the stomach. It is covered anteriorly by the upper of the two layers, which go to form the transverse mesocolon. Its numerous lobes are held together so loosely that the whole mass is flabby, and can easily be moulded into shapes which are only remotely suggestive of the normal, which was not known until revealed by modern methods. It is a body of irregular form, flattened from before backward, and curved from right to left over the vertebral column. We recognize anterior and posterior surfaces of considerable extent, a very narrow upper surface, a lower border, and right and left extremities. Its right end spreads out into a *head*, which fills the curve of the duodenum, to which it is firmly attached. Its left extremity is the *tail*, and reaches into the left hypochondriac region, even to the spleen. The intervening portion is the

body, and on its hind surface is marked off from the head by a vertical depression, sometimes called the *neck*, in which are lodged the portal vein and the superior mesenteric vessels. All of the pancreas except the head is quite movable.

The *color* of the gland is pinkish, its *weight* between two and three ounces, its

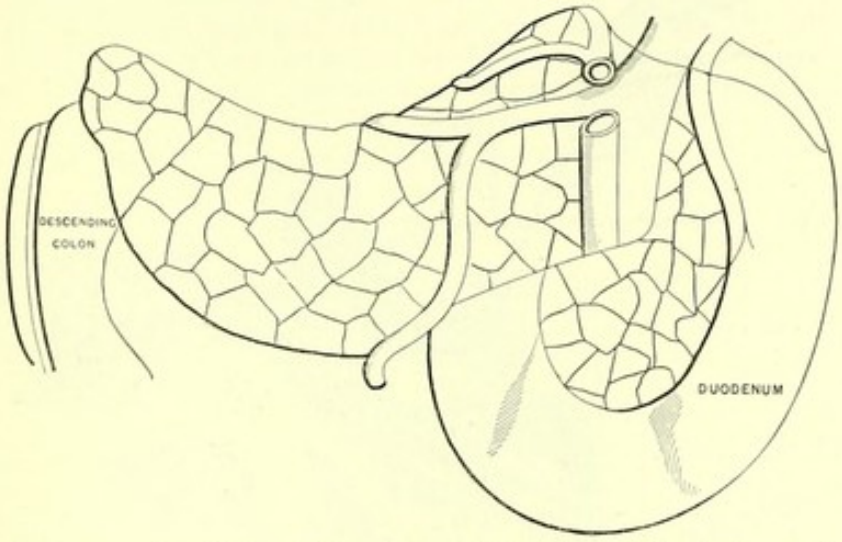

FIG. 796.—The pancreas, dorsal view. The head is seen in the embrace of the duodenum. The portal vein and superior mesenteric artery lie behind the neck. (Drawn from the His cast. F. H. G.)

length about six inches, its *breadth* two inches, and its *thickness* about half an inch. In infancy and early youth it grows rapidly, and in old age it undergoes atrophy.

The Structure of the Pancreas (Fig. 797).—Structurally it is a compound acinous gland, consisting of minute tubes, coiled up in little masses, called lobules. These are bunched together into lobes, and all the parts are held in more or less close relation to one another by areolar tissue, which spreads out over the surfaces everywhere, and is also continuous with that of the immediate neighborhood.

The *secretory cells* are commonly short cones, whose apices point toward the lumen of the tube. Besides these are certain cells of spindle-shape, lying against the free ends of the first mentioned, and protruding into the bore —called the centro-acinous cells.

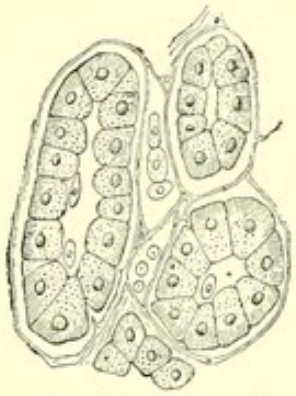

FIG. 797.—Cross section of pancreatic acini. (Testut.)

The **excretory ducts** at their beginning are fine tubes, consisting of a single layer of flattened epithelium, and lying in the delicate connective tissue. The union of these forms larger ducts, and these in turn join to make those of greater size, until a single great channel, the *pancreatic duct*, results. As the tubes increase in size, a fibrous coat is added outside of the epithelial, and this is thickest in the largest ducts.

The **pancreatic duct** (Fig. 798) runs from the tail to the head, in the very centre of the gland, and then bends downward, leaves the pancreas, enters the wall of the duodenum in the concavity of its second portion, unites with the common bile-duct, and the compound duct perforates the mucous membrane. An *accessory duct* is usually found, springing from the main duct at about the neck of the gland, and emptying into the duodenum an inch above the other.

Development.—The pancreas begins in the embryo as a sprout from the intestine, and this initial tube and its branches become the ducts of the mature organ, the true gland tissue budding from these little stalks as leaves form upon a twig.

The vessels follow the interlobular connective tissue, and, as in all glands, are supplied as capillaries to the secreting organism.

The *arteries* of the pancreas are branches of the splenic and hepatic, and the inferior pancreatico-duodenalis from the superior mesenteric. Its *nerves* come from the solar plexus.

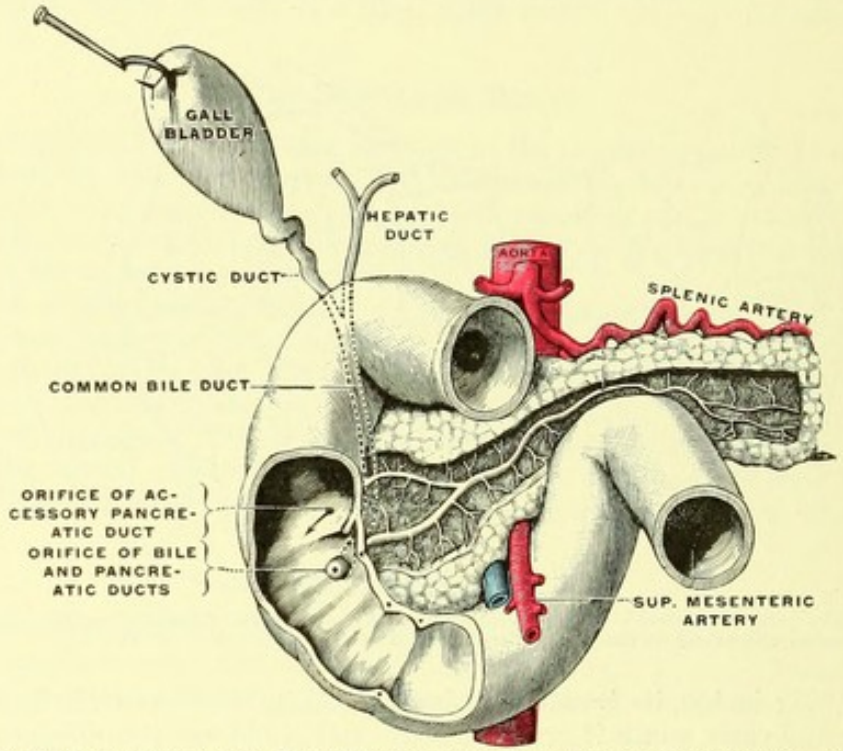

FIG. 798.—Ducts of the pancreas. Part of the front wall of the duodenum is cut away. (Testut.)

THE LIVER.

The largest and most complex of the appendages of the alimentary tube is the liver (*hepar*). Starting as a bud from the duodenum in the second week of embryonic life, it grows with such rapidity that by the second month its weight is one-third of that of the entire body. Though not retaining this relative magnitude, it remains as the greatest gland of the body, and the most intricate.

PHYSIOLOGICAL ANATOMY OF THE LIVER.

Physiologically considered it is a community of minute livers, all substantially alike; and thus a comprehension of one of them is sufficient to put us in possession of the anatomical facts requisite for understanding the functions of the entire system.

We are assisted in our study of the liver by comparing it to a great manufacturing town, made up of a vast number of establishments, each of which is identical with every other in its organization, size, facilities for work, and the quality and quantity of its products. Formerly it was supposed that the only service of the liver was the formation of bile; and although it is now known that the secretion of this fluid is only one of several offices performed by this organ, it is convenient for our present purpose to take bile-making as the type and representative of the entire group of functions.

A Typical Lobule.

We will begin by studying a single factory, that is, a separate *lobule of the liver*. It is an irregular, polyhedral body, a twelfth of an inch or less in diameter. As in every other true gland, the secreting cells are the essential part of the

lobule, and of these there is a multitude, packed together so closely that only enough room is left between them to permit the passage of the minute vessels and nerves. The *hepatic cells* are the workmen of the factory. To them the materials out of which they are to make bile are brought in the blood of the *portal vein*. Unlike veins generally, the portal divides into a vast number of branches, and a network of these encloses the lobule. From these embracing vessels, which are very minute, capillaries are sent inward between the cells of the lobule in such abundance that each cell is surrounded by them, and is thus plentifully supplied with blood containing the raw materials which the cell is capable of working over into a new product, the bile. The cells having abstracted the stuff which they require in their manufacturing processes, the blood passes on, and, at the centre of the lobule, to which point all of the capillaries converge, it enters a vein which runs perpendicularly to the course of the peripheral vessels, and carries the blood away from the lobule.

Beginnings of the Bile-ducts.—The surfaces of the cells are grooved in such a manner that the gutters on the adjacent surfaces of two cells fit together and make a cylindrical channel; and into this passage-way, which may be regarded as a drain-pipe, the bile is poured as soon as it is formed by the cell. These channels form a network among the cells throughout the lobule, as intricate as the plexus of blood-vessels; and from this network the bile is discharged into ducts, which ramify abundantly upon the surface of the lobule.

The Supply of Nutrient Blood.—When we remember that the blood furnished to the lobule by the portal vein is venous, we perceive that, however rich it may be in the materials necessary for the making of bile, it is not adapted to the nourishing of the lobule; it does not contain the substances needed for the repair of the factory or the feeding of the operatives. These nutritious and restorative matters are furnished by a separate vessel, the *hepatic artery*, which sends to each lobule branches which course over its surface and give off capillaries inward between the cells; and thus another plexus is formed in the lobule. There is not, however, a separate vein devoted to the task of removing from the lobule the blood introduced by the branches of the hepatic artery: its capillaries enter the plexus of portal-vein capillaries near the centre of the lobule, and the hepatic-artery blood mingles with the venous, flowing out with it through the central, perpendicular vein.

Lymphatics.—Besides the materials of various kinds which are carried away from the bile-factory by the channels already mentioned, there are certain unconsumed nutritious substances and certain waste products, which are removed by lymphatic vessels. These originate in irregular spaces in the lobule, form a network around it, and their current is in the direction of the stream of outflowing bile, that is, toward the portal at which the blood is introduced into the liver. Finally, there are *nerves* by which a regulation of the different processes is effected and harmony maintained among them.

Arrangement of the Vessels.

As previously remarked, the lobule is physiologically a minute liver—it is the hepatic unit; and the liver itself is merely an enormous aggregation of countless lobules, packed together as solidly as is consistent with the presence of the numerous tubes required for its nutrition and the performance of its work. But this intimate association of a multitude of lobules necessitates some modification of the description which has been given of a single one. The branches of the portal vein and of the hepatic artery, and the radicles of the bile-ducts and lymphatics, all of which have been described as ramifying upon the outside of the lobule, are seen, when the lobules are packed together, to be between the lobules; for the close approximation of a number of lobules brings the networks of vessels on the surface of each in contact with the similar plexuses on the surfaces of all of its immediate neighbors. Thus, one set of vessels can be made to

supply the lobules on both sides of it, as easily as upon one side, and this is exactly what obtains. As the vessels are between lobules, they receive the name implying this, *interlobular*; the capillary networks inside of the lobule are called *intralobular* ("within the lobule"), and the same name is applied to the central vein which carries away from the lobule the blood which is brought to it both by the portal vein and by the hepatic artery (Fig. 799.) The *intralobular veins* in a given region discharge into a very much larger vein, upon whose outer surface rest a vast number of lobules; and, therefore, the name *sublobular* ("under the lobule") is given to this kind of veins. These last empty into still larger veins, the *hepatic*, the greater part of them converging to a few large trunks, which terminate in the *inferior vena cava*, where it lies embedded in the posterior surface of the gland, and the remainder of them reaching the same destination directly.

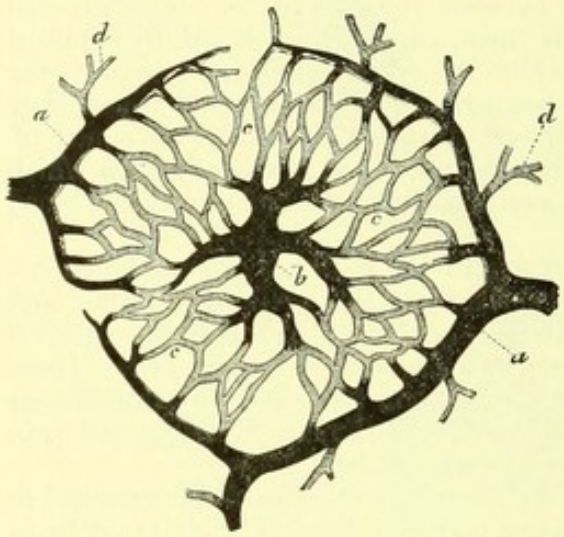

FIG. 799.—Hepatic lobule in transverse section, showing the distribution of its blood-vessels. *a*, *a*, interlobular veins; *b*, intralobular vein; *c*, *c*, *c*, plexus of capillary blood-vessels within the lobule; *d*, *d*, twigs of interlobular vein, passing to the adjacent lobules. (Dalton.)

Thus it is seen that the blood which enters the portal vein and passes through the liver, by way of any lobule, must traverse the following vessels in succession: portal vein, interlobular vein, intralobular capillary plexus, intralobular vein, sublobular vein, hepatic vein, inferior vena cava. The nourishing blood passes by way of the following vessels: hepatic artery, interlobular artery, its own intralobular capillaries, portal intralobular capillary plexus, intralobular vein, sublobular vein, hepatic vein, inferior vena cava,—its course beyond its own plexus being identical with that pursued by the portal blood.

The **Hepatic Cells**, which are the essential elements in the lobule,—the active workers in the bile-factory—are irregular bodies, with flattened sides, and each measures about one thousandth of an inch in diameter. They are composed of granular protoplasm, have no cell-wall, but each has a single, clear, central nucleus.

The Form of the Liver.

Although the liver is a solid organ, its consistency is not sufficient to prevent its changing its shape materially when it is removed from the body. If placed upon a board, its weight so causes it to sprawl in different directions as to produce an exaggerated idea of its lateral and antero-posterior dimensions, and an inadequate conception of its greatest thickness. When it is made to rest upon its upper surface, its mass sags to such an extent that the proper distinction between its inferior and posterior surfaces is obliterated, and the two seem to be one. To obtain a correct view of the liver, it should be hardened by some process while in its natural relations with contiguous organs. The pictures of its surfaces here given have been drawn from a cast of a liver frozen *in situ*. If the student will but remember that the vena cava inferior, which is for some inches actually embedded in the liver, always pursues a substantially perpendicular course, he will have no difficulty in seeing that the part of the viscus containing this great vessel must be behind and not beneath. Vesalius, the father of modern anatomy, described and figured the posterior surface in his great folio of 1555; but the correct view was lost sight of, and the grossly perverse presentation has been allowed to pass muster without question until very recent years, and even now the hind surface is not universally recognized.

The liver is located in the uppermost part of the abdomen, immediately beneath the diaphragm, and more on the right than on the left.

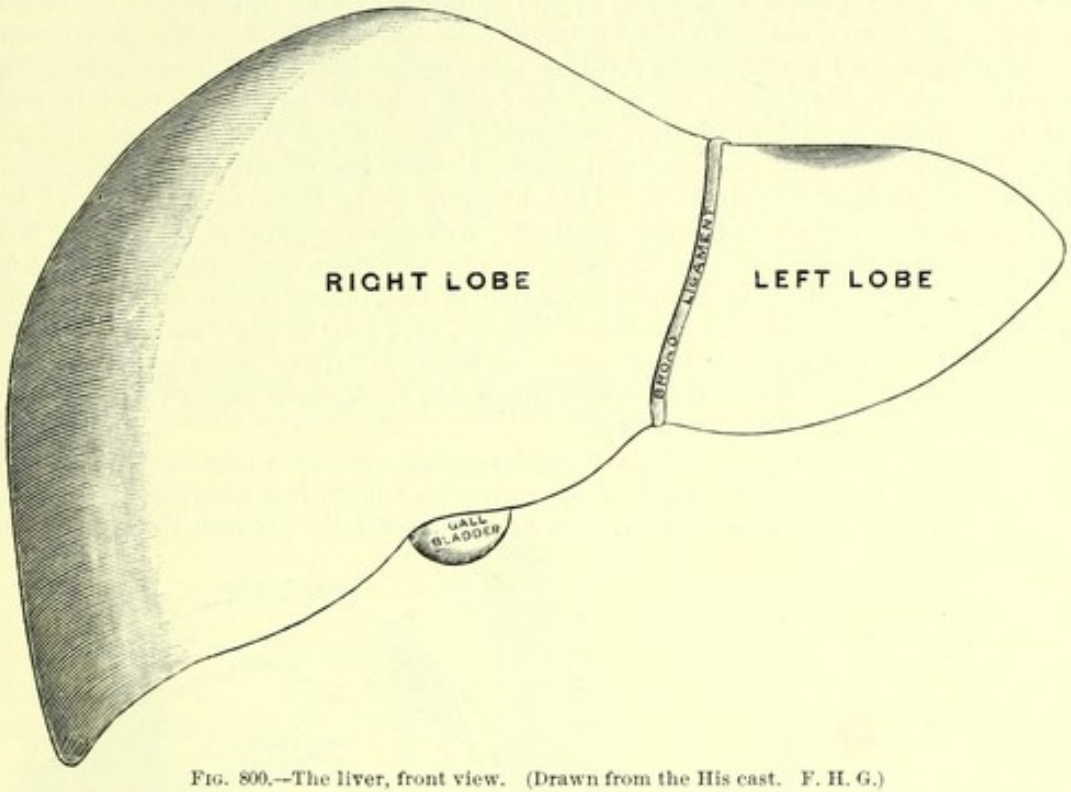

FIG. 800.—The liver, front view. (Drawn from the His cast. F. H. G.)

The liver has *three surfaces*: an upper, or superior, an under, or inferior, and a hind, or posterior; *three borders*, an anterior, a postero-superior, and a postero-inferior; and *two extremities*, a right, and a left.

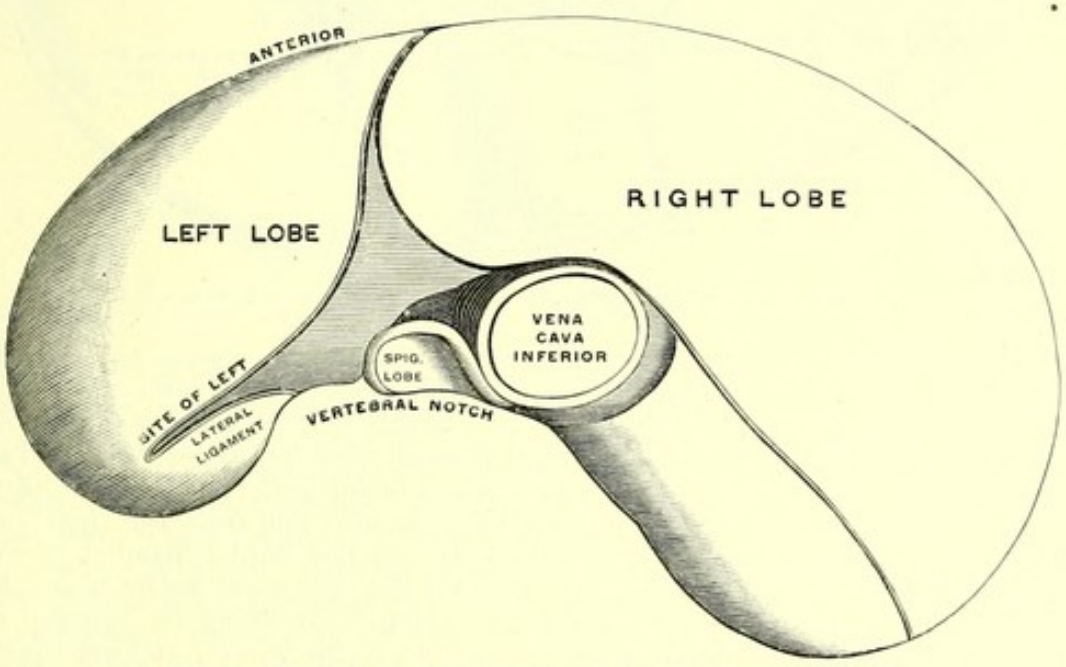

FIG. 801.—The liver, upper surface. (Drawn from the His cast. F. H. G.)

The Surfaces of the Liver.

The **Upper Surface** (Fig. 801) is smooth, and is applied evenly to the under surface of the diaphragm from the extreme right side to about half way between

the middle line and the left abdominal wall. This surface, consequently, is markedly convex on the right, slightly concave near the middle of the body, where the heart causes a sagging of the diaphragm, and moderately convex at the left. It is covered with serous membrane—a reflection of the peritoneum—excepting a very narrow strip running from before backward, and marking the line along which the membrane from the right side and that from the left meet and turn upward, and form the suspensory ligament, which thus divides the upper surface into two very unequal parts, a *right lobe* of extensive area, and a *left lobe*, which is much smaller. This division of the liver into right and left portions is observed on the hind and under surfaces also, and is made by a continuation upon them of the line marked out by the suspensory ligament. Thus, if a cord is carried directly around the organ in this plane, it will nearly coincide on the under surface with the umbilical fissure, and on the hind surface with the ductus-venosus fissure. On these surfaces, however, all of the right portion is not called right lobe, for certain subdivisions are recognized, upon each of which distinctive titles have been bestowed.

The **Under Surface** (Fig. 802) is very irregular and unevenly concave. It is divided into right and left portions by a groove, which, beginning at a notch in the anterior border, runs backward on a line substantially beneath the attachment

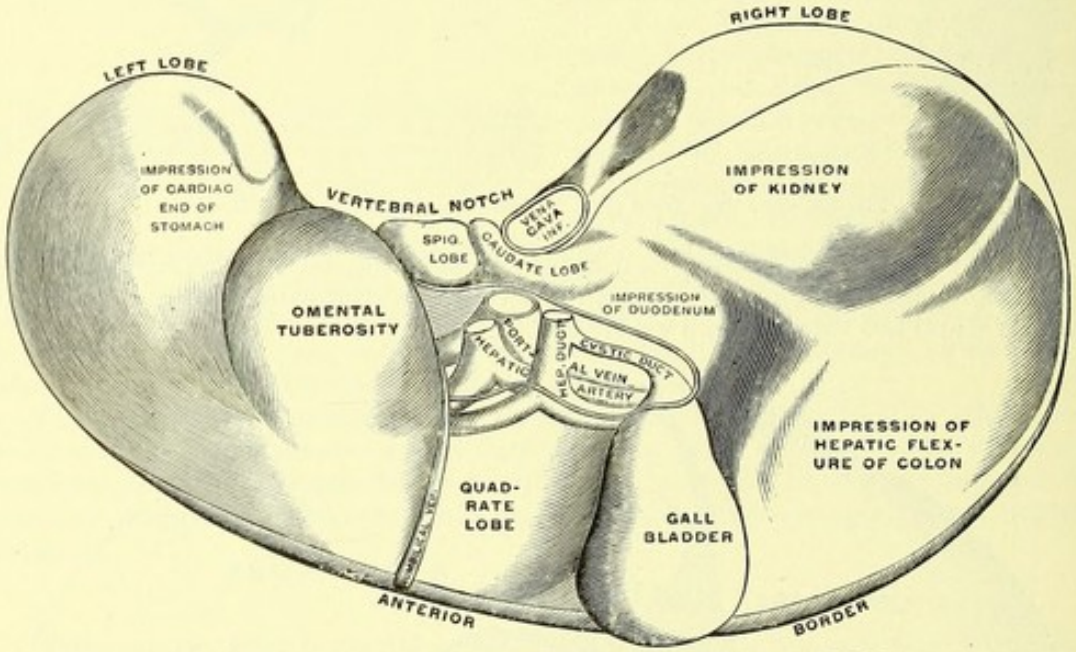

FIG. 802.—The liver, lower surface. (Drawn from the His cast. F. H. G.)

of the suspensory ligament on the upper surface. This groove gives lodgment to the shriveled remains of the umbilical vein—an important fœtal structure—from which fact it is named the *umbilical fissure*. The part of the surface at the left of this crease is the *left lobe*; that at the right is subdivided into three lobes, by two grooves. Near the hind edge of this surface is a broad gutter, which runs laterally from and at a right angle to the umbilical fissure; and from the right end of this a wide, shallow depression runs to the anterior border, parallel to the umbilical fissure. The first of these is called the *transverse fissure*, from its lateral direction; the *portal fissure*, from its being the opening or doorway at which vessels, ducts, and nerves pass into and out of the viscus; and sometimes the *hilum*, a name often given to similar inlets in other glands. The second groove is named the *gall-bladder fissure*, from the reservoir of the bile, which occupies it. Between the umbilical fissure at the left, the portal fissure behind, the gall-bladder fissure at the right, and the anterior border in front, is a squarish area, which is called the *quadrate lobe*, from its shape. At the right of

the gall-bladder fissure is a large, uneven area, the *right lobe*. Behind the left portion of the portal fissure appears the lower edge of the *Spigelian lobe*, the main portion of which is visible only from behind. Finally, a narrow ridge behind the portal fissure connects this inferior border of the Spigelian lobe with the right lobe, and is dubbed the *caudate lobe*, from its fancied resemblance to the tail of an animal. About one-half the area of the right lobe at the front and right is notably concave and receives the hepatic flexure of the colon. At the left of this, and obliquely behind the gall-bladder, is a small impression in which a knuckle of the duodenum is located ; and behind both of these areas is a somewhat rhomboidal hollow which is occupied by the upper end of the right kidney. A considerable part of the surface of the left lobe is concave and fits the bulging fundus of the stomach ; but there is a prominent protuberance at the right and behind (the tuber omentale) against which lie the gastro-hepatic omentum, and the smaller curvature of the stomach.

The **Hind Surface** (Fig. 803) presents two parallel, vertical grooves : one, narrow and shoal, connecting the umbilical fissure of the under surface with the

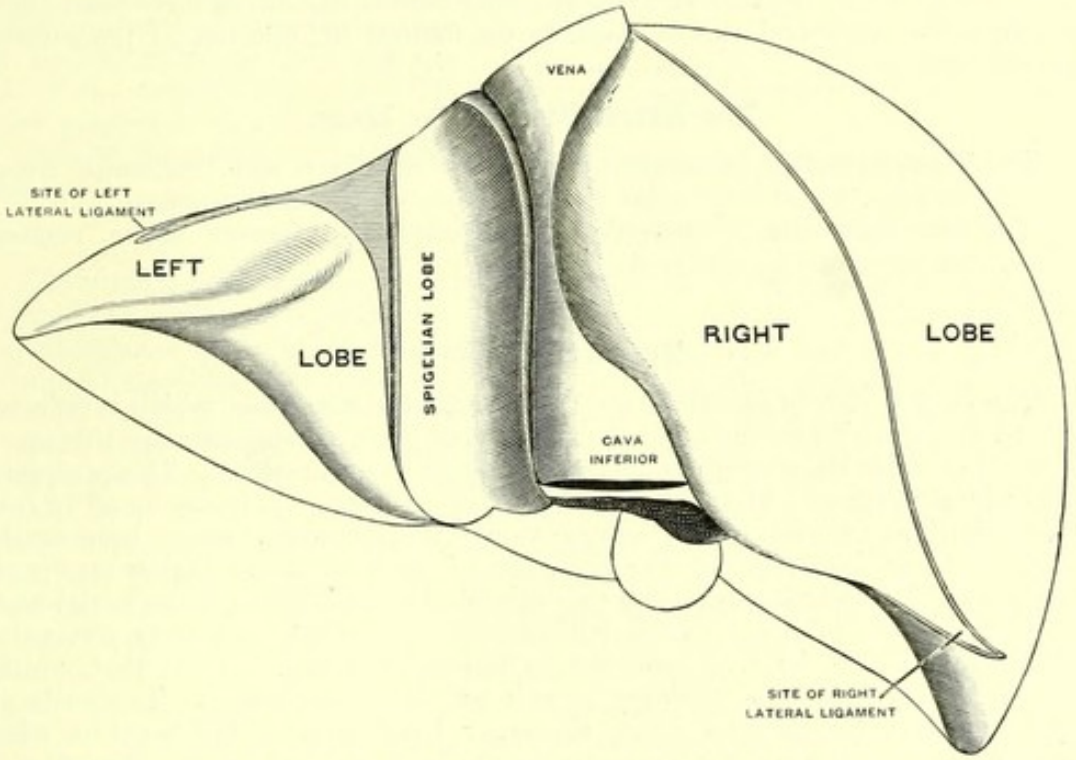

Fig. 803.—The liver, posterior surface. A part of the under surface is seen from the rear view, and this is shown merely in outline. (Drawn from the His cast. F. H. G.)

posterior end of the space between the two layers of the suspensory ligament on the upper side, and containing the shrunken remnant of the *ductus venosus* of fœtal life ; the other, broad and deep, corresponds to the gall-bladder fissure of the under side, at the lower end is separated from it only by the breadth of the caudate lobe, and furnishes a spacious lodging for some inches of the *vena cava inferior*. These fissures are known by the names of the structures which are embedded in them. Between them lies a rectangular space called the *Spigelian lobe*, whose lower margin is seen on the inferior surface, and whose upper edge is visible from above. At the right of the vena-cava fissure is the large, convex *right lobe* ; and at the left of the ductus-venosus fissure is the *left lobe*, small in extent, somewhat triangular in shape at the right, and rapidly tapering at the left and becoming a mere margin, which is directly continuous around the left extremity of the liver with the anterior border.

Borders of the Liver.

The **Anterior Border** separates the upper and under surfaces in front. It is thin, sharp, and bevelled at the expense of the inferior surface. It is continuous around the right and left extremities of the viscus with the postero-inferior border. It is slightly notched at the beginning of the umbilical fissure, and more widely so where the gall-bladder touches it.

The **Postero-inferior Border** separates the hind and under surfaces. It is well defined, except upon the left lobe between the Spigelian lobe and the place where the posterior surface is lost in the margin.

The **Postero-superior Border**, that between the hind and upper surfaces, is marked far less distinctly than the others by any conformation of hepatic substance. At the left of the vena cava the upper end of the Spigelian lobe and a ridge from it to the beginning of the posterior margin indicate sufficiently the line of separation; but on the other side of the vein the dome-like superior surface of the right lobe slopes without break to the back of the organ. There is, however, a line along which the serous covering of the upper surface is reflected to the hind wall of the abdomen—a line seen with equal distinctness from above and from the rear—and this is taken as the natural delimitation of the surfaces in question.

The Extremities of the Liver.

The **Right Extremity** is massive, evenly convex above, and terminated below by a sharp edge, which is bevelled at the expense of the under surface.

The **Left Extremity** is thin, flattened horizontally, convex above, concave below, and margined by a very distinct edge.

Tunics of the Liver.

The liver is closely invested by a delicate *areolar membrane*, which is reflected inward at the portal fissure upon the vessels and ducts passing through this opening, and encloses them even to their interlobular ramifications. This wrapping of the hepatic tubes is known as the *capsule of Glisson*. It is not found in connection with any vessels of the hepatic vein series, because it ceases between the lobules, and at least half of the diameter of each of these bodies intervenes between the interlobular space and the intralobular vein, which is the initial rootlet of the system of hepatic veins. These last vessels are, as it were, channeled in the substance of the liver, and are so intimately adherent to it that, unlike most veins, they show no tendency to collapse, when cut across. The walls of the branches of the portal vein, on the other hand, tend to fall together when severed, the investment of areolar tissue not holding them open. The fibrous coat of the liver is most distinct at the areas over which there is no serous membrane.

Like most other organs in the abdomen the liver has a *serous tunic*, derived from the peritoneum. From the small curvature of the stomach there passes to the portal fissure the double peritoneal layer which is known as the gastro-hepatic omentum, one layer coming from the front, the other from the hind surface of the stomach. The anterior of these spreads out upon the under surface of the liver, turns up over the anterior border and the two extremities, and then covers the upper surface, except small areas at the back edge of the right and left lobes, and except, also, where the membrane which comes from the right end meets that from the left. Here a very narrow strip of surface, widening into a triangular area behind, is left bare; and on each side the membrane is reflected upward to the diaphragm, on reaching which the layers turn to the right and left respectively, and line its under surface. This double membrane is prolonged forward and downward to the anterior abdominal wall as far as the navel, and in the free edge (the hind border) of the part of it below the liver is included the obliterated

umbilical vein. Thus is formed the *suspensory ligament*, a sickle-shaped structure, with the *round ligament* in that part of its cutting edge which projects beyond the anterior border of the liver (Fig. 804).

The posterior layer of the gastro-hepatic omentum spreads out upon the hind surface of the liver, but does not nearly cover it, the back of the right lobe being entirely bare. This layer is reflected onto the rear wall of the abdomen, along an irregular line, extending from just above the lower end of the right lobe behind, along the postero-inferior border to the vena cava, in front of this vessel, up by its left side, and then on the upper surface of the left lobe slightly in front of its posterior margin, thus constituting the lower portion of the *coronary ligament*. The upper portion of this large ligament is made by the corresponding reflection of the serous membrane from the upper surface.

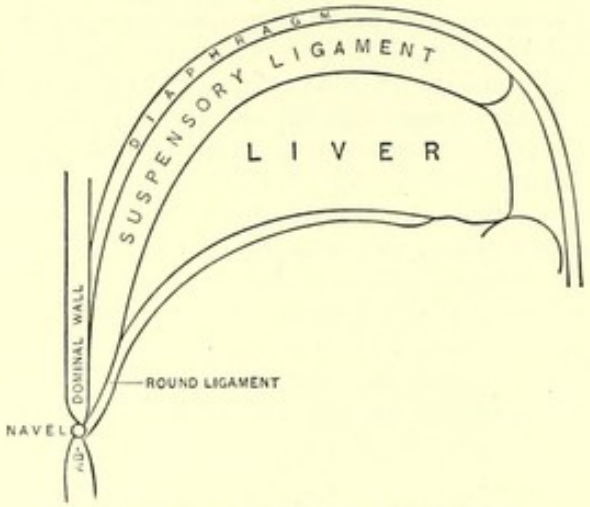

FIG. 804.—Diagram to show the relations of the suspensory and round ligaments to the liver and the abdominal wall. (F. H. G.)

Supports of the Liver.

The liver is held in place by various agencies. Probably the most important of these is its intimate connection with the *vena cava inferior*. This great vessel, passing upward to the heart, is closely adherent to the back wall of the abdomen, is deeply lodged for some inches of its upper portion in the substance of the liver, and receives from this viscus the few great and many small hepatic veins, some of which come to it from a distance of nearly two inches. The support afforded by the *underlying hollow viscera*—the stomach and bowels—is not to be ignored. Usually these are occupied to a considerable extent by gas, and thus act as a sort of air-cushion upon which their bulky associate can repose. The fibrous cord, which results from the atrophy of the umbilical vein of intrauterine life, and is known as the *round ligament* of the liver, does its share in holding up the organ. Its upper part is firmly fastened in the umbilical fissure, from the front end of which it passes down, close to the anterior abdominal wall, enclosed in the free edge of the falciform ligament, and terminates in the navel, with the cicatricial tissue of which its end is fused. Finally, there are four ligaments formed by folds of peritoneum. Of these the superior has already been described in connection with the serous tunic. It is called *suspensory*, because the liver seems to hang from it; *broad*, in comparison with its fellows; and *falciform*, from its resemblance to the blade of a sickle. The *coronary ligament* is so named because it encloses or crowns an area, which results from the backward reflection of the serous covering of the upper and under surfaces to the hind walls of the abdomen. This ligament is short, and its two layers come together at the right and also at the left. Just beyond each of the points of junction of these layers and continuous with them there is a small, triangular, double fold of peritoneum, which lies between the liver and the diaphragm, and can be best seen by drawing the adjacent side of the muscle away from the viscus. These are the *lateral ligaments*, the right and the left.

Vessels of the Liver.

The vessels of the liver are the portal vein, the hepatic artery, the hepatic veins, and the lymphatics. The first two of these pass from between the layers

of the gastro-hepatic omentum into the liver at the transverse fissure, their branches are embraced by the capsule of Glisson, and they are distributed as has been already stated, the one contributing material upon which the hepatic cells are to act, the other furnishing nourishing blood to the various structures of the liver. The hepatic veins receive the blood from the capillaries both of the portal vein and the hepatic artery, and discharge it into the ascending vena cava.

The *lymphatics* of the liver are both deep and superficial. The deep are divided into a set associated with the portal vessels, and a set accompanying the hepatic veins. The former emerge through the portal fissure, and pass through the hepatic nodes on their way to the cœliac ; the latter empty into the vena-caval nodes. The superficial lymph-vessels of the under surface are tributaries of the hepatic nodes, while those from the upper and hind surfaces drain into the anterior mediastinal and vena-caval.

The *nerves of the liver* are derived from the left pneumogastric, and from the solar plexus, the latter being distributed mainly to the hepatic artery, though to some extent to the portal vein.

The Bile-ducts.

The minute, intralobular bile-channels empty into delicate interlobular tubes, lined with very thin cells, which are continuous with the bile-secreting cells. These ducts unite and form larger tubes, lined with columnar epithelium, and constitute an interlobular plexus. Passing toward the portal fissure in the capsule of Glisson, they attain great size, and present a distinct mucous lining and a thick fibrous coat, in which are many circular and longitudinal bundles of smooth muscular tissue, irregularly disposed. One trunk from the left and one from the right unite in the portal fissure and form the *hepatic duct*, which runs two inches downward and to the right, and there joins the *cystic* (gall-bladder) *duct*, thus forming the *common bile duct* (*ductus communis choledochus*), a tube about three inches long, which passes downward and backward to the second part of the duodenum, where it pierces the muscular wall of that bowel, runs in the submucous space for a half-inch or more, and opens in conjunction with the pancreatic duct into the lumen of the duodenum, about four inches below the pylorus.

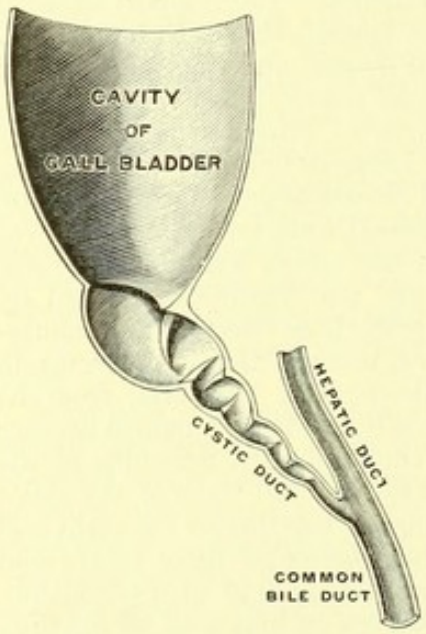

FIG. 805.—The cystic duct in section, with part of the gall-bladder, hepatic and common bile ducts. (Testut.)

The Gall-bladder.

The gall-bladder (*vesica fellea*) (Fig. 805), the reservoir of the bile, is a pear-shaped bag, nearly four inches long, an inch and a half wide, and with a capacity of rather more than an ounce. It lies in the wide fissure to which it gives its name, sometimes projecting a little beyond the front margin of the liver, covered on its blunt (forward) end, its sides, and its under surface by serous membrane, which is stretched across from the right lobe to the quadrate. Its principal coat is composed of condensed areolar tissue, in which are irregularly disposed many bundles of unstriped muscle. The lining of mucous membrane has a honey-comb appearance. The tube of discharge, the *cystic duct*, about an inch long, has a structure like the other bile ducts, but presents the peculiarity of a number of oblique folds of its mucous membrane, which project into the bore and suggest the thread of a screw. All through the large bile ducts and in the gall-bladder there are mucus-secreting glands.

Size and Weight of the Liver.—The adult liver measures 10 or 12 inches from end to end, 6 or 7 inches fore-and-aft, 3 or 4 vertically in the thickest part. Its weight is from three to four pounds. Its weight relatively to that of the entire body varies enormously at different periods, being one-third when the embryo is two months old, and one thirty-sixth or less in middle life. It diminishes in size and weight as old age creeps on. It is brownish-red in color, often presenting a mottled appearance. It is firm to the touch, but rather friable; and, when torn across, the exposed surface is seen to be distinctly granular on account of the presence everywhere of the lobules.

Situation of the Liver (Fig. 806).—The position of the liver in the right hypochondriac, epigastric, and left hypochondriac regions is not entirely unchangeable, but is modified by a number of circumstances, particularly by respiration, the

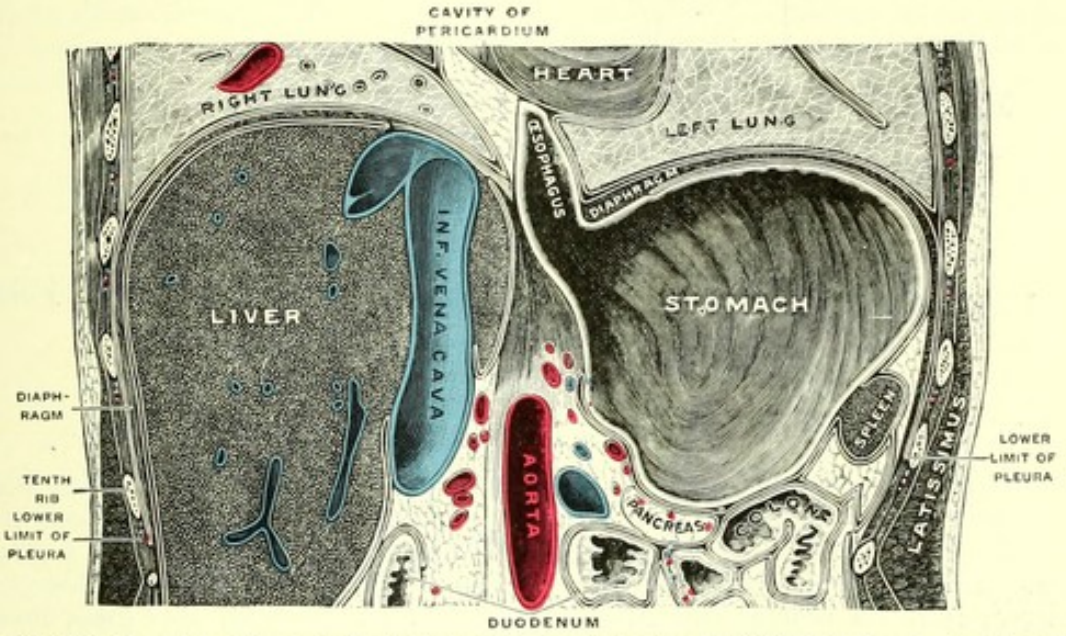

FIG. 806.—Coronal section of trunk, showing relations of thoracic and abdominal viscera. Front surface of rear segment. (Testut.)

attitude of the body, the distension or emptiness of stomach and colon, and the tightness of the clothing of the thorax. To these influences, which are not pathological, may be added various others, which result from disease. In forced inspiration the dome of the right lobe may be driven down to the level of the ninth thoracic vertebra; in forced expiration it may rise as high as the upper border of the eighth thoracic vertebra. If a knife were to be inserted horizontally into the thorax on the plane of the fourth costo-chondro-sternal junction, it would be likely to shave the summit of the hepatic dome. This gives one a good idea of the greatness of the encroachment of the abdomen upon the space which the lower margins of the thoracic cage suggest to the casual observer as belonging to the chest cavity.

Relations of the Liver.—The liver is in relation above with the diaphragm, which separates it from the heart and lungs, the first of these organs making its position apparent by a shallow depression on the top of the left lobe, and the others, more yielding in their nature, indicating their location by the great bulges which they permit the liver to make into their under surfaces. Its upper surface is also in contact with the anterior wall of the abdomen above a line drawn from the eighth costal cartilage on the right to the middle of the seventh on the left; for the upper surface slopes markedly forward and downward, and justifies the name which is sometimes given it—the antero-superior surface. The Spigelian lobe lies against the right crus of the diaphragm, opposite the tenth and eleventh thoracic vertebræ. The relations of the other portions of the liver with contiguous

viscera are so clearly indicated in the pictures that it is unnecessary to recapitulate them.

Partial Summary.—Some of the principal facts of gross, hepatic anatomy may be tabulated for mnemonic purposes as follows:

Five Fissures	Umbilical Fissure	on under surface.
	Gall-bladder Fissure	
	Portal, or Transverse Fissure	
	Ductus-venosus Fissure	on hind surface.
	Vena-cava Fissure	
Five Lobes	Left.	
	Right, subdivided into	
	Quadrate, Caudate	on under surface.
	Spigelian	on hind surface.
Five Sets of Vessels	Branches of Portal Vein.	
	Branches of Hepatic Artery.	
	Radicles of Hepatic Veins.	
	Bile Ducts.	
	Lymphatics.	
Five Ligaments	Suspensory, Broad, or Falciform.	Peritoneal Folds.
	Coronary.	
	Right Lateral, or Right Triangular.	
	Left Lateral, or Left Triangular.	
	Round—obliterated Umbilical Vein.	

THE PERITONEUM.

In the preceding descriptions of the abdominal digestive organs it has been necessary to make frequent reference to their serous coat. In every case this covering is a part of the *peritoneum*; and, although one organ which is completely invested, and several which are only partly clothed by it, are yet to be considered, it seems best at this stage to present an account of this great membrane as a whole.

It may be well for the student to refresh his memory by referring to what is said of serous membranes in general on page 66, and of the development of the intestines on page 88.

The peritoneum is by far the most extensive and most complicated of the serous membranes. Its extreme complexity is due to changes in the position of the viscera in their development, and to obliterations which have taken place on account of the adhesion of certain apposed surfaces. It does not meet all of the requirements of a typical serous membrane, because in females it is not a shut sac, there being a continuity of its surface and that of the mucous membrane lining the oviduct, and, consequently, a communication between its cavity and the surface of the body.

Between it and the parietal structures which it lines is a variable amount of *areolar tissue* called *subperitoneal*, sometimes containing fat-cells. This permits a degree of motion of the peritoneum upon subjacent parts. The connection between the serosa and its viscera is usually much closer.

The viscera are connected to the abdominal parietes and to each other by folds of peritoneum. These have received various names, as mesenteries, omenta, and ligaments.

Mesenteries.

A *mesentery* is a double fold of peritoneum, enclosing the vessels, nerves, etc., devoted to a portion of intestine. Specifically, and always when used alone, the name refers to the mesentery of the small intestine, described on page 718; but the term is often employed in a larger and generic sense to indicate a similarly

constituted structure, attached to any organ. Thus, we may speak of the mesentery of the gall-bladder, seen in cases where this reservoir, instead of being held close to the liver, as is usually the fact, hangs away from it at some little distance, depending from a double, serous fold, which encloses its vessels and nerves.

The mesenteries of portions of the large intestine are called by specific names, as *transverse mesocolon*, *sigmoid mesocolon*; and exceptionally we find an *ascending mesocolon*, or a *descending mesocolon*. The mesentery of the vermiform appendix is called the *mesenteriolum* ("the little mesentery").

The **Mesentery proper** extends from the left side of the second lumbar vertebra obliquely downward to the right iliac fossa. The transverse mesocolon crosses the abdomen horizontally at the level of the third portion of the duodenum. The sigmoid mesocolon begins in the left iliac fossa, passes downward and to the right until it reaches the middle line of the sacrum, in which it then goes downward a short distance. The occasional *ascending mesocolon* lies behind the portion of intestine to which it belongs, and the same is true of the rare *descending mesocolon*.

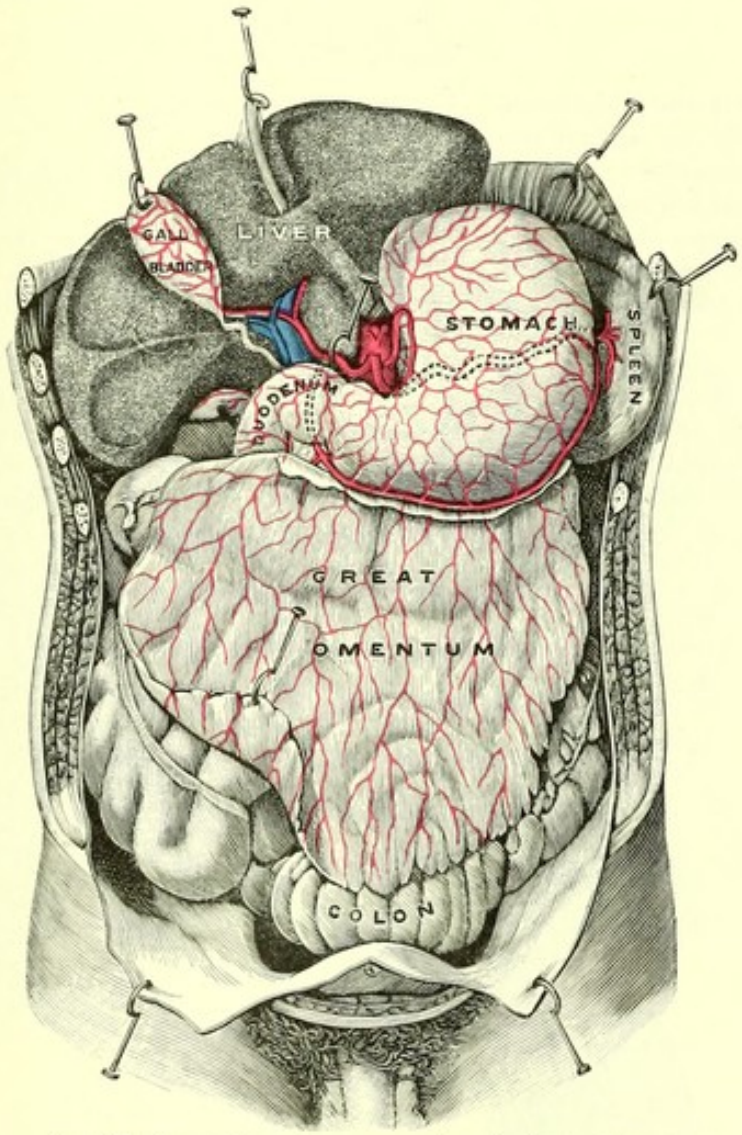

FIG. 807.—The great omentum as seen from the front. (Testut.)

Omenta.

Omentum (epiploön) is a term applied to a fold of peritoneum connecting the stomach with some other viscus.

The **gastro-hepatic** ("stomach-liver") **omentum** or *small omentum* extends from

the small curvature of the stomach and the adjacent first part of the duodenum to the portal fissure of the liver, and encloses the tubes which enter and leave this opening.

The **gastro-colic** ("stomach-colon") **omentum** or *great omentum* (Fig. 807) connects the great curvature of the stomach and the adjoining first part of the duodenum with the transverse colon. This omentum is far more voluminous than is necessary to establish a bond of union between the stomach and colon: it hangs downward in front of the mass of small intestines like an apron, and carries in the interstices of its structure an amount of adipose tissue, which varies according to the fatness of the individual. This protective organ, so serviceable in keeping the bowels warm, justifies the alleged origin of its name, which makes it mean "coverlet."

The **gastro-splenic** ("stomach-spleen") **omentum** is a double fold of peritoneum, passing from the dorsal surface of the stomach, near its left border, backward and inward to the anterior margin of the hilum of the spleen. It runs below into the gastro-colic omentum. It is often called the gastro-splenic ligament.

Ligaments.

Other folds of peritoneum, connecting two viscera, or a viscus with the abdominal wall, are called *ligaments.*

The name *hepato-duodenal ligament* is sometimes applied to the right, free margin of the gastro-hepatic omentum, which connects the liver and duodenum.

The ligaments of the liver, which are formed from peritoneum—suspensory, coronary, lateral—have already been discussed.

The *lieno-renal* ("spleen-kidney") *ligament*, including the *lieno-pancreatic ligament*, which is its ventral layer, will be described in connection with the spleen. The peritoneal ligaments of the bladder and the uterus will be more fittingly treated of in the chapters on the urinary and the reproductive organs.

The *phreno-colic* ("diaphragm-colon") *ligament*, also called *costo-colic*, is a small fold stretching from the diaphragm near the tenth or eleventh rib of the left side to the colon near the spleen, and giving mechanical support to the last-named organ.

General View of the Peritoneum.

The *peritoneum as a whole* is to be regarded as a bag, constricted to a mere passage-way at one point, so that there are formed two cavities, a great one and a small one, communicating through a narrow throat.

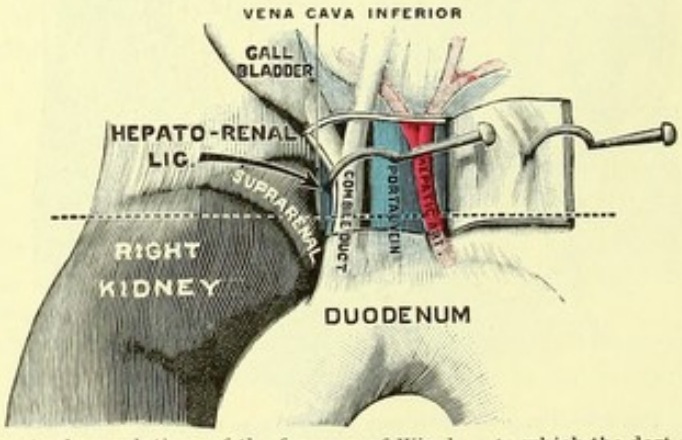

FIG. 808.—Dissection to show relations of the foramen of Winslow, to which the dart points. The front of the right portion of the gastro-hepatic omentum has been cut and turned off to the left, and the liver lifted up and back, displaying the objects in the front wall of the foramen. The horizontal broken line marks the position of the section from which the next picture was made. (Testut.)

The *small sac* of the peritoneum lies behind the large sac, and furnishes the serous surface for the back of the stomach, the Spigelian lobe of the liver, and the

front of the pancreas. The other abdominal viscera have their serosa from the *great sac*.

The narrow strait between the great and small cavities of the peritoneum is called the *foramen of Winslow*, and *foramen epiploïcum* (Figs. 808, 809). It is bounded in front by the vessels entering and leaving the portal fissure of the liver,

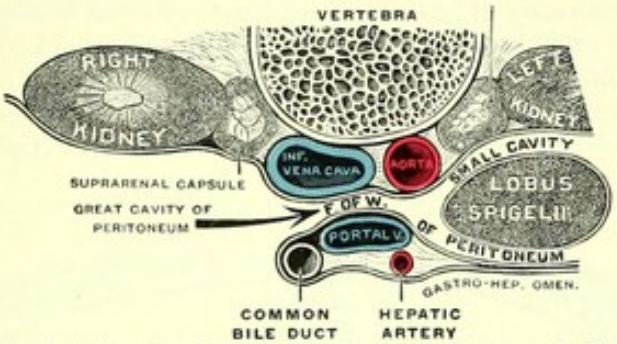

FIG. 809.—Transverse horizontal section through the foramen of Winslow. The lower end of the Spigelian lobe has been shaved off, and the upper surface of the piece is seen. (Testut.)

behind by the vena cava inferior, above by the caudate lobe of the liver, and below by the duodenum. It is large enough to admit two fingers.

The Small Sac of the Peritoneum (Figs. 810, 811).—In the embryo the small sac reaches at first but little lower than the stomach; but afterward it enlarges rapidly by extension downward, and forms a pouch, which hangs from the great curvature of the stomach in front of the intestines, and contracts adhesion to and blends with the front part of the serous coat of the transverse colon, thus estab-

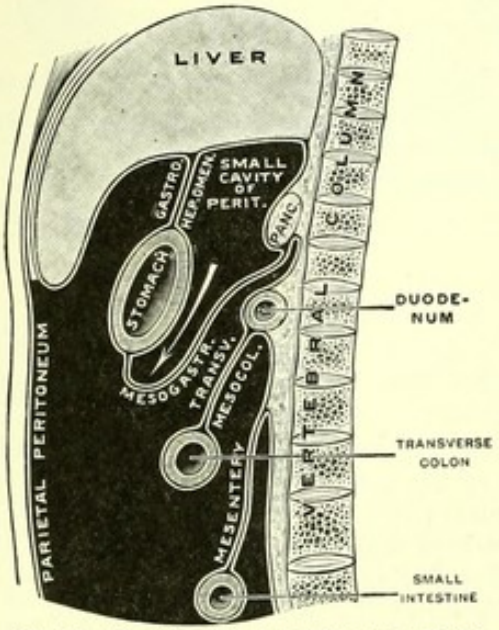

FIG. 810.—Diagram of a sagittal section of the abdomen of an embryo, showing the reflections of the peritoneum in the great cavity and the small cavity. (Testut.)

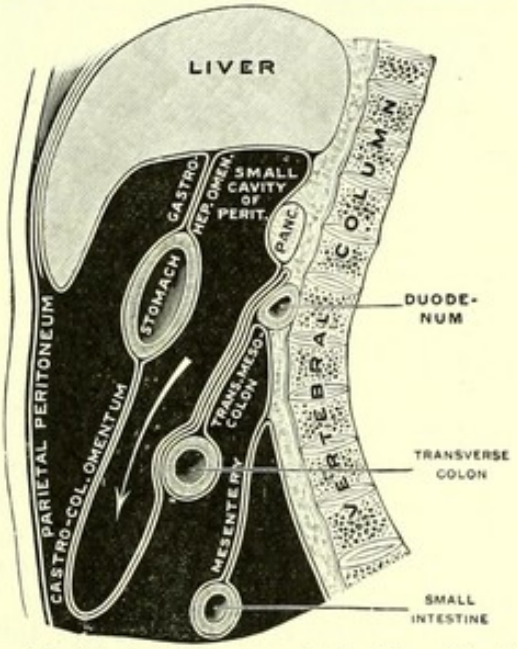

FIG. 811.—Diagram of a sagittal section of the abdomen of an adult, showing the growth of the small cavity, and the application of its rear wall to the transverse colon and mesocolon. Compare with preceding figure. (Testut.)

lishing a connection between the stomach and colon, which is called the *gastro-colic omentum*, on account of the organs which it unites, and *great omentum*, because it is so much larger than the gastro-hepatic. It is thus seen that the name "cavity of the great omentum" is synonymous with "the small cavity of the peritoneum."

Not only does the small sac become adherent to the colon, but its posterior double layer becomes attached to and merged with the anterior (upper) surface of the transverse mesocolon; and so intimate is this connection that this part of the

colon seems to be entirely surrounded by the rear wall of the sac. Furthermore, adhesion takes place between the layers of the pouch which are below the level of the transverse colon, absorption occurs at many points, and the four-layered apron is converted into a coarse lace-work, in whose meshes a considerable deposit of fat appears.

It is useful to trace the course of the peritoneum at different planes in order to obtain a comprehension of its continuity, the relations which it sustains to the abdominal viscera, and the relations which it maintains between them.

If we make a horizontal section of the abdomen a little above the iliac crests, and inspect the upper surface of the lower segment, we shall obtain such a view as is presented in the semidiagram, Fig. 812. Beginning at the descending colon,

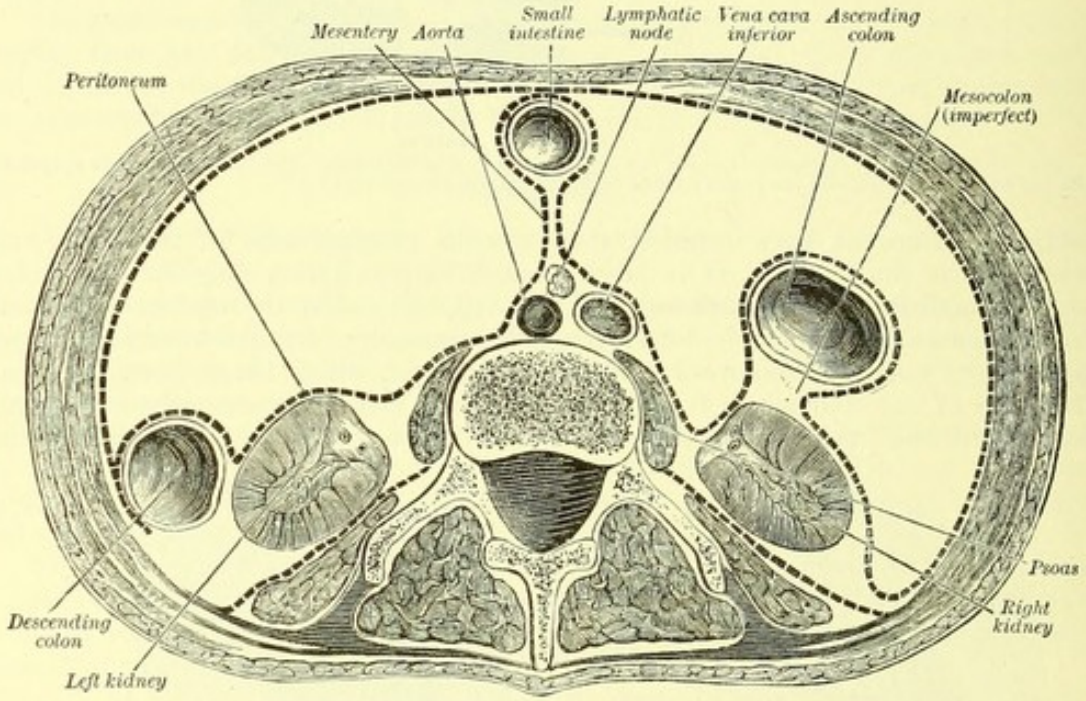

FIG. 812.—Course of the peritoneum, as seen in a horizontal section above the iliac crests. Semidiagrammatic. (Tillaux.)

we trace the peritoneum over its left side, front, and part of its right side, but not upon its back, for it has no mesentery; thence it extends to the face of the left kidney, which, like its mate, lies entirely behind the serosa, in other words is retroperitoneal; from this organ the peritoneum stretches over the psoas magnus and onto the vertebral column and the aorta, which rests on its ventral surface; then it passes forward as the left side of the mesentery, covering the vessels, nerves, nodes, and fat which are the essential parts of that structure, envelops the small intestine, and returns to the vertebral region as the right side of the mesentery; here it partially coats the inferior vena cava, runs onto the right psoas, touches the right kidney, and turns around the ascending colon, giving it a larger covering than it favored the descending colon with, though it leaves its dorsal part nearly or quite bare; thence it again reaches the right kidney, whose anterior aspect it partially clothes, and from this is reflected to the abdominal wall, and sweeps around to the starting point in a great expanse of parietal peritoneum.

If we examine the surface of this anterior wall at a lower level, we shall observe a median ridge from the bladder to the umbilicus, due to the urachus; on each side of this a ridge, sloping down and outward from the navel, these being caused by the obliterated hypogastric arteries; nearly parallel with these and further to the side, are slight elevations, which are produced by the epigastric vessels; and, running down and inward from the iliac spines, the inguinal liga-

ments. In the angle between the epigastric vessels and the inguinal ligament is a slight depression, the *external inguinal fossa*, marking the internal abdominal ring, the beginning of the inguinal canal; in the angle between the hypogastric ridge and the inguinal ligament is the *middle inguinal fossa*; below this, toward the side and beneath the inguinal ligament, is the *femoral fossa*; and between the urachus and the hypogastric artery is the *internal inguinal fossa*.

If we trace the peritoneum vertically, beginning on the superior surface of the liver, we pass down to its anterior border, back and upward on its inferior surface to the portal fissure, where we come in contact with the small omentum, which guides us downward to the front of the stomach, passing over which we reach the anterior surface of the great omentum, and this, being followed over its lower edge and posterior aspect, leads to the transverse colon; thence beneath the transverse mesocolon the course lies upward and backward to the third part of the duodenum, where an abrupt change of direction occurs, and the membrane is traced downward over the mesentery and jejuno-ileum, and back on the other side of the mesentery to the hind wall of the abdomen, which is again left to form the serous part of the sigmoid mesocolon and the outer tunic of the sigmoid colon. After this the course is different in the two sexes. In the male the peritoneum goes from the rectum to the bladder a short distance above the prostate gland, forming the *recto-vesical pouch*, covers the superior surface, and thence extends to the front abdominal wall. In the female it passes from the rectum to the upper extremity of the vagina and the uterus, forming the *recto-vaginal* or *recto-uterine pouch*, called also the *cul-de-sac of Douglas*; then covers the supravaginal part of the uterus, from which it extends to the bladder, and then to the anterior wall of the abdomen. Its course upward requires no especial mention, other than that already given it, until the navel is reached. Above this there runs upward and slightly to the right a ridge which ends above at the anterior border of the liver, and encloses the round ligament of the liver. At the sides of this elevation the peritoneum is traced smoothly over the anterior belly-wall and onto the under surface of the diaphragm, from which it turns to the upper surface of the liver, where the excursion was begun.

Variations from these two simple tracings occur, as the planes of the sections are made in different directions; but these examples give a correct idea of the chief features of the peritoneal complications.

Retroperitoneal Fossæ.

At certain places the peritoneum is marked by the presence of one or more crescentic folds, bordering the openings of distinct pouches or fossæ, which are of practical interest as being the sites of retroperitoneal herniæ. They occur in the regions of the duodenum, the sigmoid colon, and the cæcum.

About the duodenum, three of these pits are recognized. The most common is the *inferior duodenal fossa*, situated in the lower and external portion of the fourth part of this intestine, its mouth directed upward. The *superior duodenal fossa*, also in connection with this part, opens downward, its orifice facing that of the superior fossa. Both of the preceding are frequent. The *duodeno-jejunal fossa* is rare. It begins on the back of the jejunum, and extends upward to the duodeno-jejunal junction.

The *intersigmoid fossa* begins in the left iliac fossa at the proximal part of the sigmoid mesocolon, and runs upward behind the peritoneum of the dorsal abdominal wall.

In the cæcal region a number of fossæ may be found, of which the most important is the *postcæcal fossa*, which extends upward behind cæcum and ascending colon for a variable distance. It may include the proximal part of the appendix vermiformis, and cause annoyance in operations upon this organ.

THE ORGANS OF RESPIRATION.

By F. H. GERRISH.

PHYSIOLOGICAL ANATOMY.

RESPIRATION is a dual function, consisting of the simultaneous expulsion of certain waste matters and appropriation of a nourishing material. The substance which is introduced in this process is gaseous, and the things which are eliminated are either gaseous or vaporized. The double performance is popularly called breathing.

The *apparatus* necessary for respiration consists of a thin, moist membrane, exposed on one side to air, and on the other to a moving stream of blood (Fig. 813). Each of these fluids gains something from, and loses something to, the

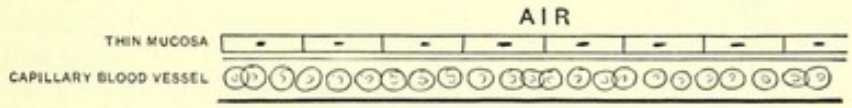

FIG. 813.—Diagram of the essentials of a respiratory apparatus. (F. H. G.)

other: the air parts with oxygen and takes on a load of effete materials; while, at the same time, the blood gives up certain waste products and appropriates the oxygen—the most important item of the body's income—these various substances passing readily through the delicate membrane, which is mucous.

In different classes of animals the necessary structural conditions are afforded in various ways. In some aquatic creatures the respiratory membrane is spread over the surface of a plume-like organ that projects from the body and waves about in the water, which always contains air (Fig. 814). A more common device is that of gills, in which the mucous membrane is disposed in layers, between which the air-laden water is drawn, being taken in at the mouth and ejected at the sides of the head. In the tadpole, which lives entirely in the water, the breathing organs are gills; but the frog, into which the tadpole develops, has a very different apparatus. Gradually the structural peculiarities of the aquatic animal are lost, and those of the amphibian are acquired; and, synchronously with the shrinkage of the fish-like tail, and the growth of the limbs, is observed the development of a new breathing-apparatus, unfit for abstracting oxygen from the air which is contained in water, but capable of taking the gas directly from the ordinary atmosphere. It is a sac, wholly contained in the trunk, and into it, at brief intervals, a quantity of air is drawn, permitted to remain a short time, and then expelled by the channel of entrance. This sac is lined with a delicate

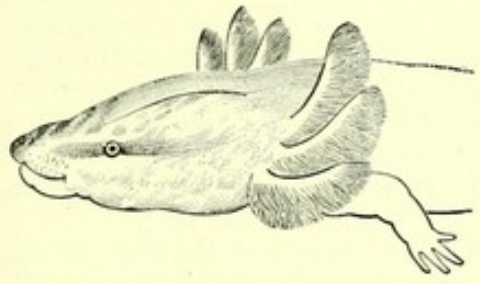

FIG. 814.—Head and gills of Menobranchus. (Dalton.)

mucosa, with the attached surface of which a network of capillaries is in contact. It is a very simple kind of lung, and yet is the type on which the most complex respiratory organ is constructed.

An animal which requires, on account of the rapidity of his tissue-changes, a very large supply of oxygen, would find locomotion impracticable, if his respiratory membrane was at the surface, projecting like a tree, or arranged like gills; but it is manifest that there is not sufficient room in the entire body for a simple sac, whose lining would afford a surface large enough to meet the requirements of the case. The problem presented is that of providing a great extent of surface within a limited cubic space. It is the same question as that which confronts the librarian, whose books are vastly too numerous to be accommodated by the entire available area of the walls of the room. He neither appropriates more apartments, nor builds an addition to the house; but he constructs partial partitions, projecting from the walls toward the centre of the room, making alcoves of the intervening spaces, and thus enormously multiplies the shelving capacity. Nature adopts this plan in the lung, and, by forming alcoves at the periphery of the original sac, augments its available surface without increasing its cubic capacity. The lung of the frog illustrates this fact; a sectional view (Fig. 815) shows that the mucosa is folded into partial partitions, between which are little recesses around the periphery, all opening into a clear, central passage.

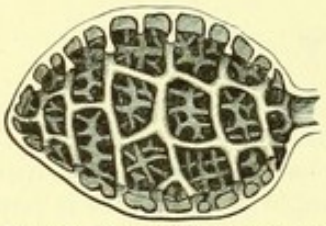

FIG. 815.—Lung of frog, cut open, showing its internal surface. (Dalton.)

The complex lung of man is built upon this type. But the complexity of the human lung arises not largely from elaboration of the plan, but from immense multiplication of the structure. The great size of the human being and his relatively greater activity require not a different kind of lung, but a host of lungs of the same kind. Therefore, the human lung may well be regarded as a vast community of batrachian lungs, with the addition of such accessories as the immensity of the collection makes necessary.

The alcoves—to repeat the library simile—are called *air-vesicles*, *alveoli*, or air-cells—the last name being objectionable on account of the different use of the word "cell" in histology. A collection of alveoli around a central hall constitutes an *infundibulum*, so called from its funnel-shape. A group of closely related infundibula makes a *lobule*. A great community of lobules is a *lobe*. Two or three lobes make a *lung*.

In mode of development and general appearance a lobule bears a striking resemblance to a racemose gland. The stem of a lobule is an air-duct, and from this, within the lobule, branch the more minute tubes, which serve as stems for the infundibula, three of the latter often being connected with one of the former.

The duct of the lobule unites with another of like size, making a larger one; this last joins with its equal, and so on progressively until tubes of considerable size are reached, which either pursue this method, or enter the sides of those which are larger. Finally, for each of the two lungs a single tube results, and the two combining form a great median pipe. Beyond this the air-channels do not have the regularity of shape which has characterized the system up to this point. They are the larynx, the pharynx, and the passages of the nose.

Tracing the air-ducts in reversed order from the surface of the body to the depths of the lung, we have—

1. The nasal passages.
2. The upper and middle portions of the pharynx.
3. The larynx.
4. The trachea (the windpipe).
5. The two bronchi—one bronchus for each lung.
6. The bronchia (bronchial tubes, bronchioles) of all sizes from the largest to the smallest.

The *nasal passages*, as cavities in the skull, are treated of in the chapter on osteology, as olfactory structures, in the chapter on the organs of the special senses. The *pharynx*, being an alimentary as well as a respiratory organ, has already been presented as a part of the digestive tract. The *larynx*, which is the organ of voice, is the highly specialized upward continuation of the trachea, and its description would best be deferred until the simpler structures have been considered.

We now have before us an outline of the physiological anatomy of the breathing apparatus, and are prepared to study the structures in detail. This can most profitably be done by beginning with the windpipe and proceeding in an unbroken course to the air-vesicles.

THE TRACHEA.

The *trachea* (so called from the Greek word for "rough," on account of the marked inequalities felt on its surface), or *windpipe* (Fig. 816), is a straight tube, situated in the middle line of the lower and front part of the neck and the upper part of the thorax, in front of the œsophagus, extending from the lower border of the larynx downward and backward to its division in the bronchi, and from the plane of the sixth cervical to that of the fourth thoracic vertebra. When the face is directed forward, the trachea is a little more than four inches in length; but this measurement may be increased by the forcible extension of the neck and diminished by sharp flexion, the variation between the shortest and longest measurements exceeding one and a half inch. Its average transverse diameter in the cadaver is four-fifths of an inch, the antero-posterior a trifle less; but both are smaller during life on account of the activity of the muscular part of the pipe. It is convex and rigid in front and at the sides, flat and flexible behind.

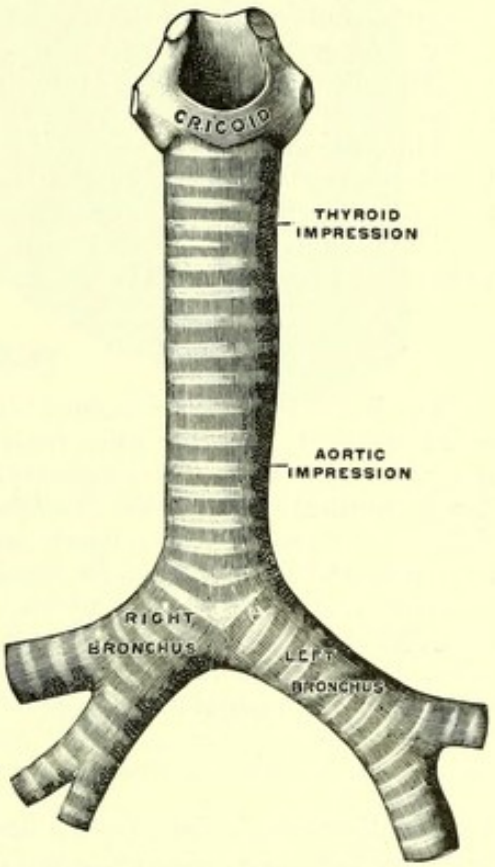

FIG. 816.—Trachea and bronchi, front view. (Testut.)

The *framework* of the trachea consists of mixed white and yellow fibrous tissue, and strips of pure cartilage, the latter being embedded in the front and sides of the tube made by the former. The *pieces of cartilage* are very irregular in shape—some being of nearly uniform width from one end to the other, some bifurcating at one end, some having a branch near the middle; but their general direction is horizontal, and, seen from the front or side, they produce the effect of nearly parallel bands. But they are not rings, though often so called; for they do not encircle the trachea, but always end at the border of its flat, hind surface. They vary in number from fifteen to twenty. The highest one is wide and firmly attached to the lowest cartilage of the larynx; the lowest sends a spur downward and backward from its centre, between the origins of the bronchi. The fibrous mass in which the cartilages are embedded is caused by them to bulge in transverse lines, thus being produced the irregularities which give the trachea its name. Ossification of the cartilages begins at forty or fifty years of age.

The flat, *hind wall*, instead of being stiffened with cartilage, is made contrac-

tile by a continuous sheet of *unstriped muscle* which it encloses. The bundles of muscular fibres run horizontally, and are attached to the ends of the cartilages where these exist, and to the fibrous wall in the interspaces. In front of the muscle are conspicuous longitudinal bundles of yellow fibrous tissue.

The *cartilages* serve the purpose of preventing the collapse of the trachea from external pressure or from sudden internal suction. The necessities of human respiration require permanence of the lumen of the pipe, a condition which would not be satisfied by a less rigid material than cartilage. The elasticity of the *yellow fibrous tissue* permits the considerable elongation which movements of the head demand, and ensures perfect restoration and even some shortening beyond the average length. The *white fibrous tissue* gives strength, flexibility, and toughness. The *muscular tissue* in the flat, hind portion causes approximation of the ends of the cartilages under nervous stimulus, and diminution of the calibre of the tube.

The *lining* of the trachea is smooth *mucous membrane*, the epithelium of which is columnar, stratified, and ciliated. The deepest layer of the corium is composed almost wholly of yellow fibrous tissue. The submucous, *areolar coat*, connecting the mucosa with the fibrous tunic (in which, as has been already said, are the cartilaginous and muscular elements), contains many racemose *mucous glands*, the ducts of which discharge into the tube. The greater part of these glands are in the spaces between the cartilages and in the hind wall.

The principal *arteries* of the trachea are the inferior thyroid, its *lymphatics* are tributaries of the bronchial and deep cervical nodes, and its *nerve-supply* is derived from the pneumogastric and great sympathetic.

The trachea lies in the midst of an abundant mass of areolar tissue, which is so loose as to permit free movement up, down, and horizontally.

THE BRONCHI.

The lower end of the trachea bifurcates laterally into the *bronchi* (Fig. 817), which strangely get their name from the Greek word for "throat." They pass to the right and left lungs respectively. In structure and general form they are exact continuations of the trachea, with convex front and sides, which are stiffened with cartilaginous bands embedded in fibrous tissues, a flat back, which is fibrous and muscular, and a lining of mucous membrane, whose epithelium is cylindrical, ciliated, and in layers. The *right bronchus* is the shorter (a scant inch), wider ($\frac{3}{5}$ inch), and more nearly horizontal; the *left bronchus* is the longer (about two inches), narrower ($\frac{2}{5}$ inch), and more nearly vertical. They are supplied by the bronchial arteries, and by nerves from the pulmonary plexus.

THE BRONCHIA.

The air-ducts, leading from a bronchus into the depths of the lung, are called *bronchia*, *bronchial tubes*, or *bronchioles* (Fig. 817). The right bronchus gives three branches to its lung, the left only two. The tubes divide progressively, (sometimes dichotomously, sometimes otherwise), into smaller tubes down to the infundibula, the ducts of which are about $\frac{1}{125}$ inch in diameter. Although the bronchioles are continuous with the bronchi, as the latter are with the trachea, they have a different shape—the bronchi and windpipe being flat behind, all the other tubes perfectly cylindrical. In other words, the outline of a transverse section of every pipe concealed within the lung is circular, while that of those which are outside of the lung is convex only in front and at the sides.

The bronchioles have three coats—mucous, muscular, and fibrous. The *mucous membrane* is everywhere provided with ciliated epithelium, the lashes of which beat always toward the larger tubes, thus preventing an accumulation of mucus in the air-vesicles. Glands are numerous, except in the very small tubes. The muscle fibres of the *middle coat* are transversely arranged, and are relatively

most conspicuous in the smallest tubes. The *fibrous coat* contains not only white fibrous tissue, but also many yellow fibres. It diminishes in thickness as the tubes become smaller, and is extremely thin within the lobules. In the tubes which have a diameter of $\frac{1}{25}$ inch or more this coat is strengthened by *cartilagin-*

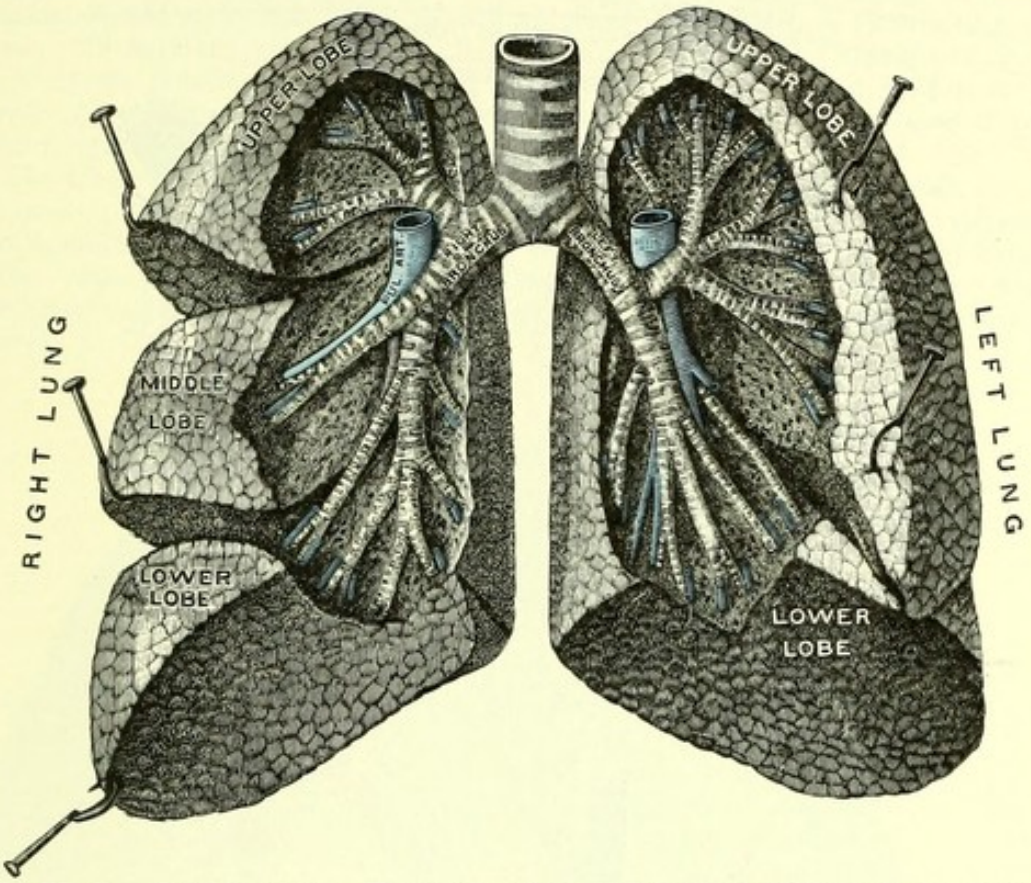

FIG. 817.—Bronchi and bronchioles. The lungs have been widely separated, and tissue cut away to expose the air-tubes. (Testut.)

ous plates, not disposed in an annular way, as in the trachea and bronchi, but irregularly scattered through the tunic.

The tubes which have no cartilages are also deficient in glands; but their lining membrane is kept moist by a smear of mucus furnished by goblet cells. The muscular tunic in these minute tubes, although scanty, is important, as it possesses the power of narrowing their calibre, and thus diminishing the size of the air-current. In asthma the exaggeration of the normal action of this coat is responsible for the difficulty in breathing.

MINUTE ANATOMY OF THE LUNGS.

Upon the walls of the minute bronchioles little bulges appear, at first rarely, but with increasing frequency as the distal end of the tube is approached. Finally the bronchium widens out and terminates in an irregular chamber, the sides and blind end of which are closely set with these little protrusions, and we have the ultimate and essential part of the respiratory apparatus—an *infundibulum*. The minute blebs on the tubes seem to be the result of an effort of nature to form an infundibulum before all of the necessary conditions are favorable. Again and again the attempt is made, always with greater results, and at last the whole remainder of the tube undergoes the transformation. The pouches are the *alveoli* (air-sacs, air-vesicles, air-cells). The infundibula are not always funnel-shaped, as the name implies, but are often very irregular in form.

Structure of an Infundibulum (Fig. 818).—The framework of an infundibulum

is very thin, transparent, and composed of *fibrous tissue*, the yellow variety being conspicuous, and forming a delicate network. A few smooth *muscular fibres* are

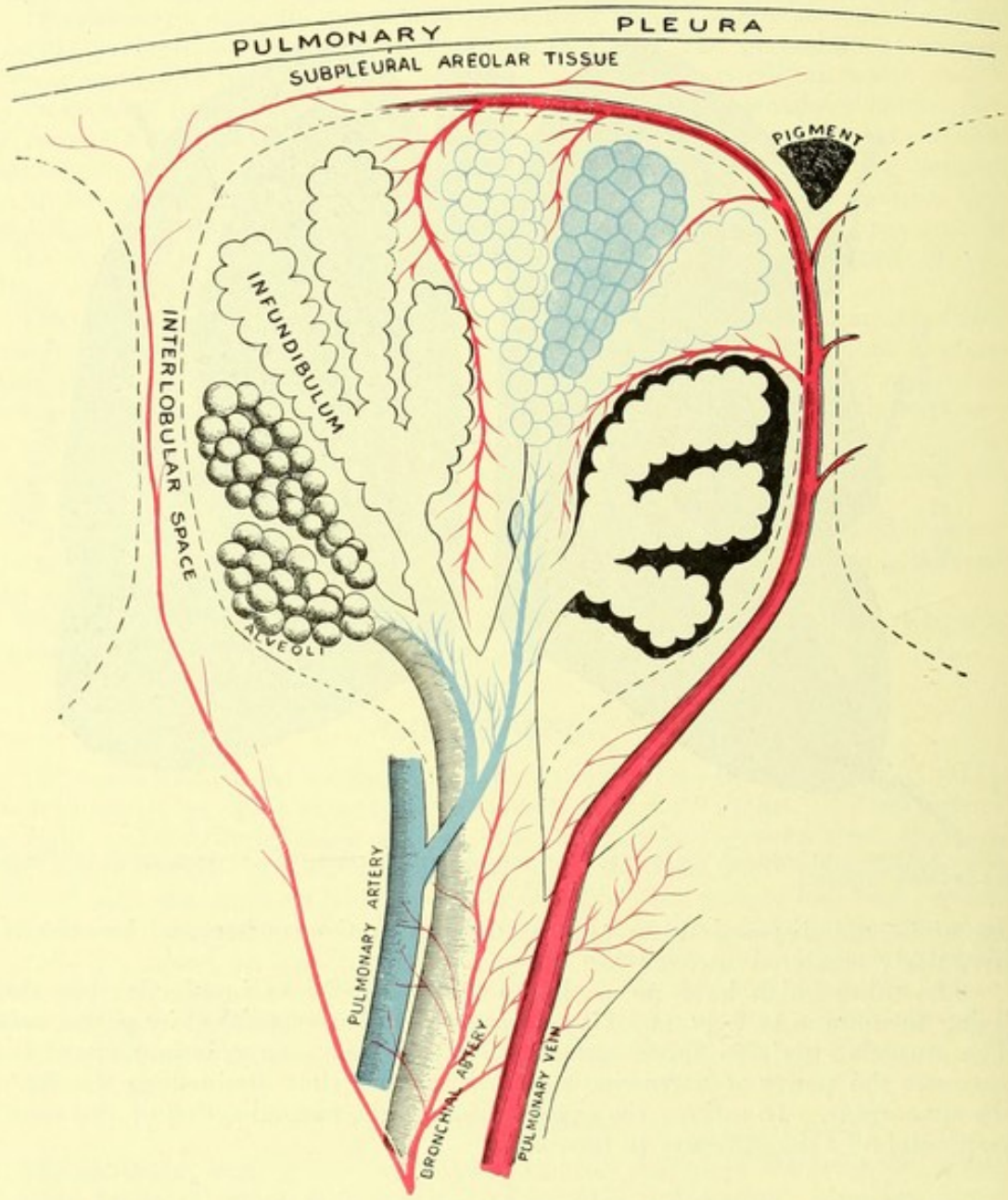

Fig. 818.—Diagram of a lobule of the lung. A bronchiole is seen dividing into two branches, one of which runs upward and ends in the lobule. In the lobule are four groups of infundibula. At the left are two infundibula the alveoli of which present their outer surfaces. Next are three infundibula in vertical section, the alveoli of each opening into the common passageway. Upon the ultimate bronchiole of this group are alveoli. In the next group the first infundibulum shows a pulmonary arteriole surrounding the opening of each alveolus, and the second gives the same with the addition of the close capillary network in the wall of each alveolus. The same arrangement of vessels is seen in the alveolus upon the bronchiole of this group. Around the fourth group is a deep deposit of pigment, such as occurs in old age, and in the lungs of those who inhale coal-dust and the like. On the bronchiole lies a branch of the pulmonary artery (blue), bringing blood to the infundibula for aëration. It also supplies nourishing blood to the tubes and other structures within the lobule. Beginning between the infundibula are the radicles of the pulmonary vein (red), a root of which lies upon the bronchiole. The bronchial artery is shown as a small vessel bringing nutrient blood to the bronchiole (outside of the lobule), the artery and vein, and all of the structures between and around the lobule. No attempt is made to show the sustentacular tissue which occupies the spaces within and around the lobule. (F. H. G.)

found between the air-vesicles. Next to this wall is a dense network of *capillaries*, the spaces between which are not as wide as the vessels themselves.

The lining of an infundibulum and its air-vesicles is a delicate *epithelium*, which is directly continuous with that of the mucosa of the tubes. It is chiefly

composed of broad, flattened, non-ciliated cells of extreme thinness, among which are scattered here and there little clusters of small polygonal cells, like those which in the fœtus form the entire epithelium of this part. The first full expansion of the vesicle by the inrush of air after birth stretches out almost all of the cells, but leaves in their embryonic condition the few which, if enlarged like the majority, would make the lining too voluminous. The cells are so thin that the blood in the capillaries is separated from the air by so small an amount of tissue that the least possible resistance to the passage of gases back and forth is interposed. At points where the edges of several cells converge are often seen minute stomata, opening into lymph-channels of the areolar tissue.

The free edges of the air-vesicles support a fine *arteriole*, which twists in and out, now on this and then on that side of the dividing line between two adjacent alveoli, and from this tortuous encircling vessel the *capillary network* is given off to the neighboring vesicles. Those portions of this plexus which are on walls between alveoli have two surfaces exposed to air, one in one vesicle and one in another.

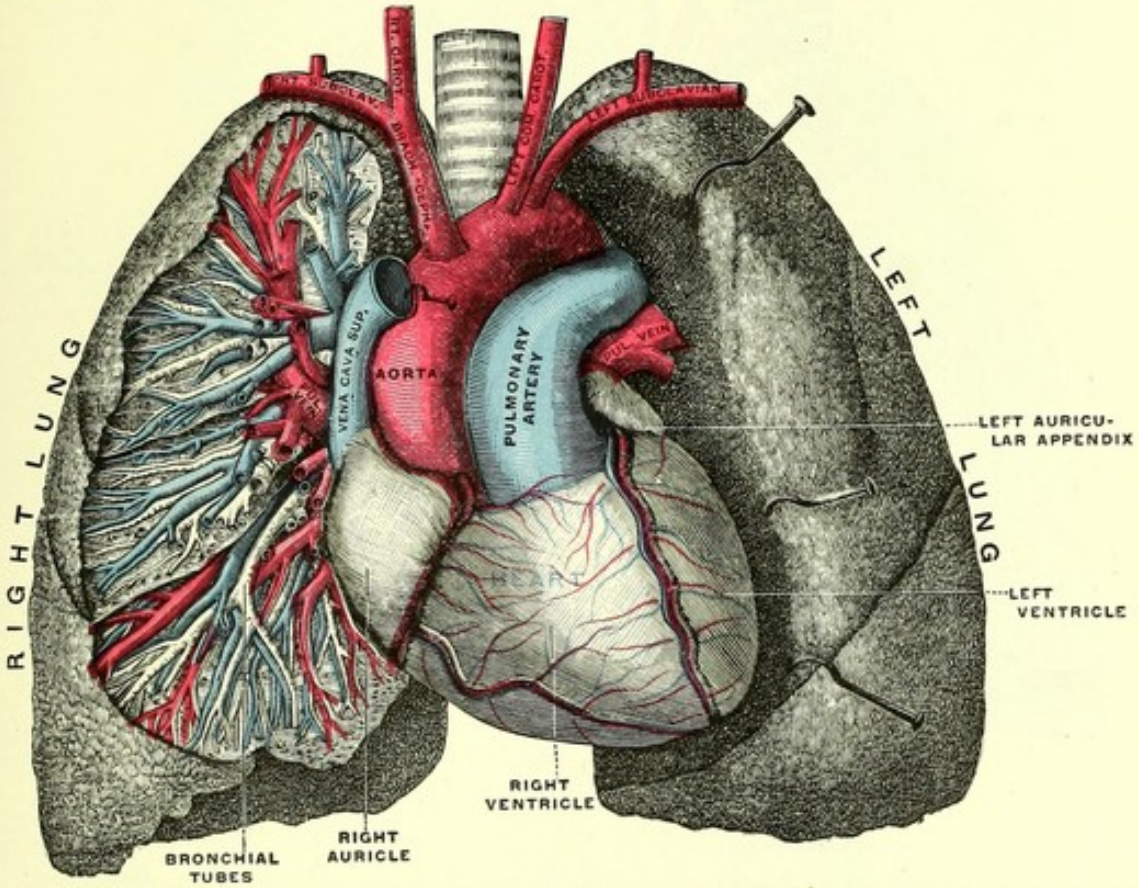

FIG. 819.—The pulmonary artery. The front part of the right lung has been removed, and the pulmonary vessels and the bronchial tubes are thus exposed. (Testut.)

Two or three infundibula may start from the end of one bronchiole. The infundibula are gathered into groups of approximately uniform size, which, with the necessary vessels, nerves, and uniting areolar tissue, constitute *lobules*. The lobules at the periphery of a lung are more or less pyramidal ; but the others are packed together so closely that they have become reciprocally compressed into various and fantastic forms.

Between the lobules is *areolar tissue*, which is abundant in the infant, scanty in the adult ; consequently their isolation is easy in the former, and difficult or even impossible in the latter case. This interlobular areolar tissue and also that between the alveoli after early life is the seat of a deposit of carbonaceous matter, doubtless inhaled, and carried by lymph-channels to this tissue and to lymph-

nodes. This deposition of pigment makes clear the outlines of the lobules and even of the bases of the infundibula.

Blood-vessels of the Lungs.—Two sets of blood-vessels are distributed to the lung and to all of its lobules—the branches of the *pulmonary artery* and those of the *bronchial arteries*. The latter furnish nourishing blood to the organ; the former carry to it venous blood, which is to be aërated, that is to say, to be relieved of certain materials which are the result of tissue-waste, and to be loaded up from the air with oxygen—the most important of the articles of physiological income.

The *pulmonary artery* (Fig. 819), by its branches, accompanies the tubes and carries the greatest part of its blood to the capillary plexus of the alveoli; but some of it is supplied to the mucous membrane of those bronchioles which are near the infundibula—those which have air-vesicles upon them. The *pulmonary veins* (Fig. 820) begin by radicles at the margin of the capillary network of the

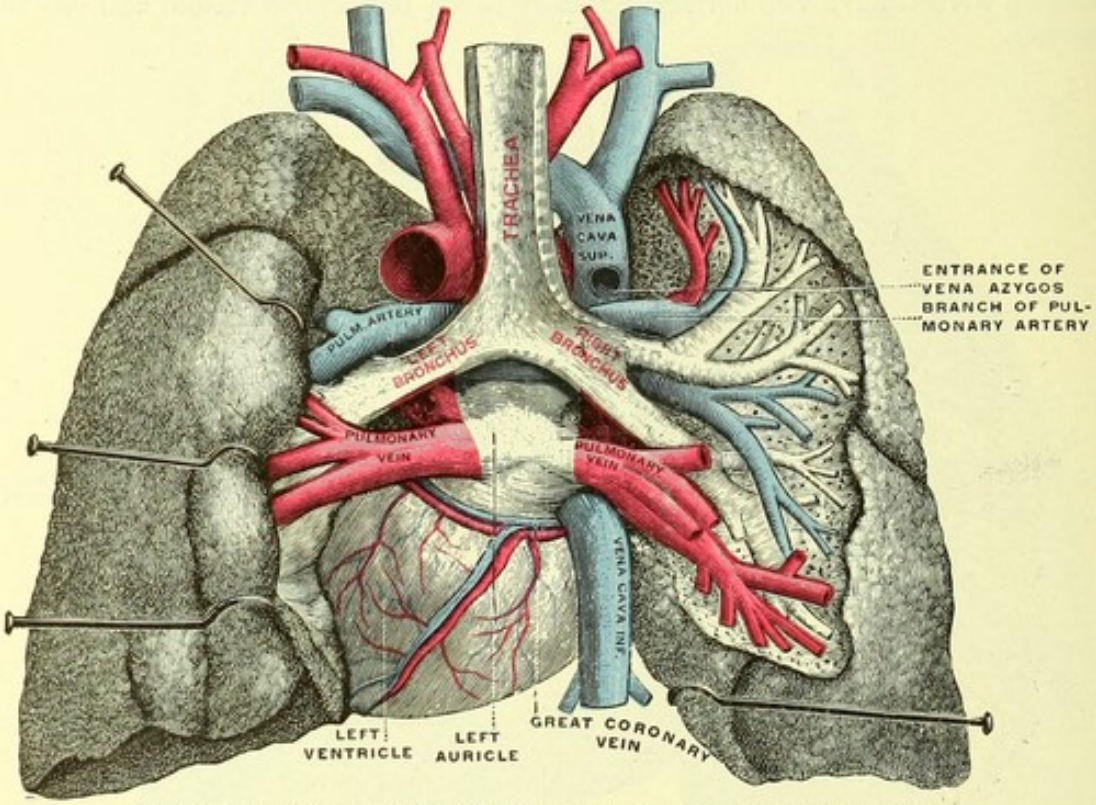

FIG. 820.—Pulmonary veins, seen in a dorsal view of the heart and lungs. (Testut.)

alveoli and the minute tubes—that is, they take blood from the parts to which the pulmonary artery is distributed.

The *bronchial arteries* follow the divisions of the air-tubes, and supply arterial blood to the walls of the tubes (except the smallest), the coats of the large vessels, to which they are *vasa vasorum*, the bronchial lymph-nodes, the pleura, the areolar tissue beneath the pleura, and that between the lobules. The *bronchial veins* gather the blood from all of the parts to which the bronchial artery supplies it, excepting a little, which on account of a communication of the networks on the intralobular tubes and those which form the stems of the lobules, mingles with the blood furnished by the pulmonary artery, and is, consequently, taken up by the radicles of the pulmonary vein.

GROSS ANATOMY OF THE LUNGS.

The *lungs* (Figs. 821–823) (Latin *pulmones*, from which comes "pulmonary") are two large organs, which occupy a great part of the chest cavity, one in each side of it, and separated from each other by the heart, the gullet, the great blood-

vessels, and other structures in the mediastinal space. Each lung presents an *outer surface*, which is convex, and adapted to the inner surface of the chest-wall of one side; an internal or *mesial surface*, which is irregularly concave and occupied by mediastinal organs; an *under surface* or base, very concave and fitting to the upper surface of the diaphragm; a summit or *apex*, which rises an inch above the level of the first rib; a *hind border*, rounded, vertical, and adjusted to the

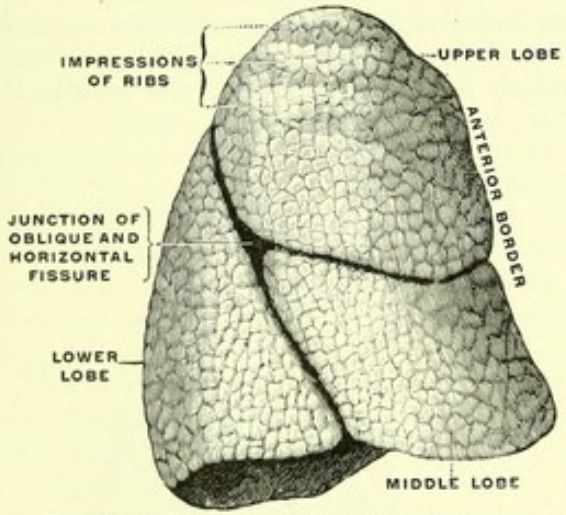

FIG. 821.—Right lung, outer surface. (Testut.)

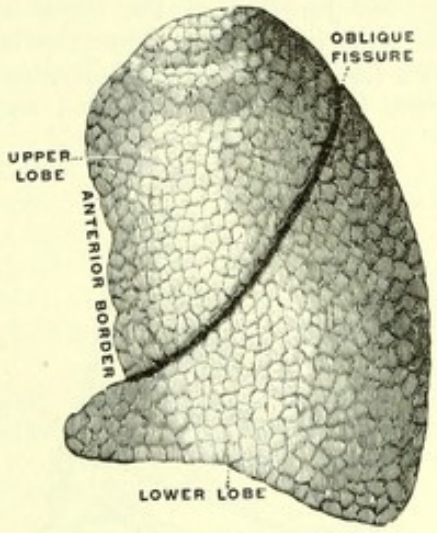

FIG. 822.—Left lung, outer surface. (Testut.)

long hollow made by the bodies of the thoracic vertebræ and the proximal portion of corresponding ribs; a *front border*, thin, irregular, and sloping from above downward and outward to the level of the fifth or sixth rib; and a *lower border*, bevelled sharply at the expense of the lower surface, and marking the under limit of the outer surface.

On the inner surface, three quarters way back from the front line, and about

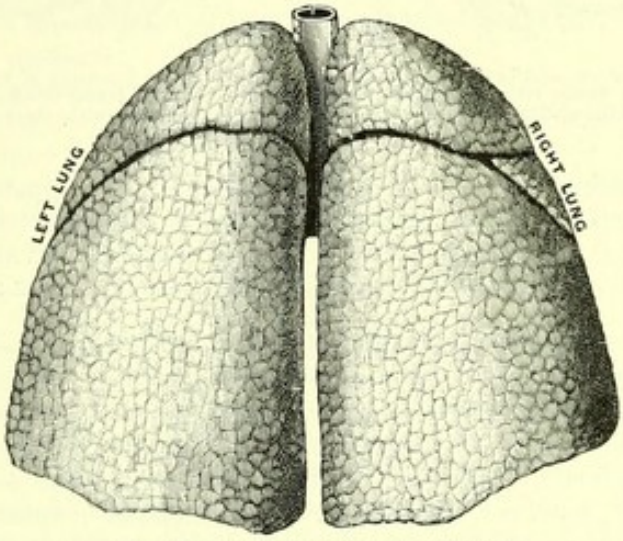

FIG. 823.—Lungs, dorsal view. (Testut.)

equally distant from apex and base, is a vertical notch, the *hilum*, two inches long and an inch or more broad, which gives passage to the air-ducts, pulmonary artery and veins, bronchial artery and veins, lymph-vessels, and nerves, and affords lodgment to a considerable number of lymph-nodes. These different organs in the hilum are united into one large fagot, called the *root of the lung*.

The inner surface of the left lung is much more deeply concaved than that of the right, on account of the greater encroachment of the heart upon the space at

the left of the middle line. The front border, also, for the same reason, is deeply notched.

The right lung is on a somewhat higher plane than the left, on account of the greater elevation of the right half of the diaphragm, upon which muscle the lungs rest.

Each lung is marked by a deep fissure (Fig. 824), which starts on the hind surface about three inches below the apex, and runs spirally around, terminating near the junction of the inner and lower borders. This fissure is very deep, extending inward nearly to the hilum, and dividing the lung into an *upper lobe* and a *lower lobe*. About half way of this oblique fissure on the right lung a second fissure (Fig. 825) begins and runs nearly horizontally toward the middle line,

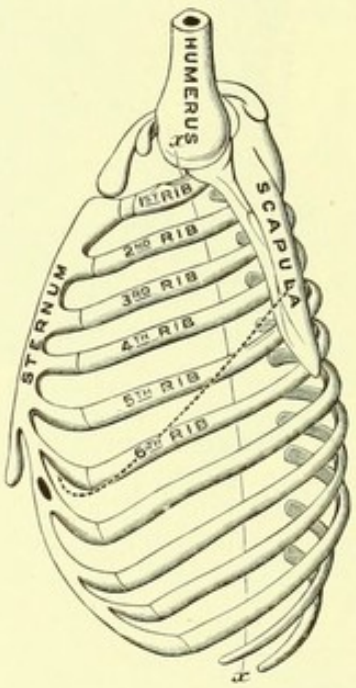

FIG. 824.—Position of the oblique fissure of the left lung with reference to the ribs. The humerus is raised. The line *xx* is the axillary line. (Testut.)

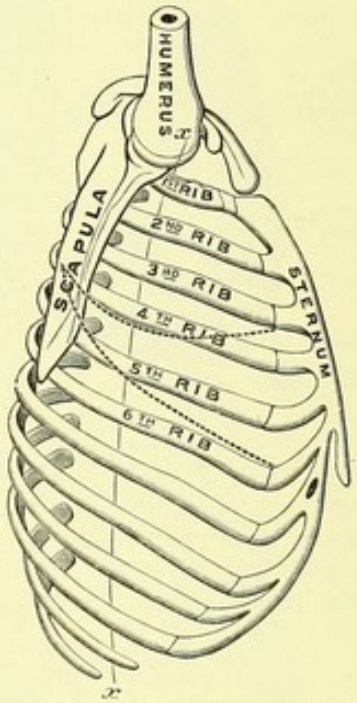

FIG. 825.—Position of the fissures of the right lung with reference to the ribs. The humerus is raised. The line *xx* is the axillary line. (Testut.)

ending at the anterior border. This fissure divides the upper lobe of the right side into two, which are called the *middle lobe* and the *upper lobe*.

The left lung is taller, narrower, and more deeply excavated on its median surface; the right is shorter, wider, less indented, and weighs a fifth more than the left.

The *volume of the lungs* varies with the amount of contained air. In a newborn child, who has not breathed, the lungs occupy but a small part of the chest, seeming to be crowded upward and backward by the diaphragm, which stands at the level of the third rib. But they quickly expand when respiration is established, and thenceforth occupy all of the chest, except the central portion, as before stated. As, however, the capacity of the thorax is constantly fluctuating, owing to the respiratory movements, the lungs, which accompany the chest-walls in all of their advances and retreats, experience coincident and corresponding variations.

The *average capacity of the lungs* is estimated to be nearly seven and a half pints. The entire respiratory surface at a moderate calculation is more than 870 square feet, and some estimates place it very much higher.

On account of the contained air the lungs are very light, and float readily in water. *Fœtal pulmonary tissue*, however, never having contained air, is not very unlike liver in its specific gravity, as well as in its appearance, and sinks in

water; and the presence or absence of the capacity of floating is a ready test of the establishment of breathing, where infanticide is suspected.

The *lung substance* or parenchyma is soft and spongy, and gives a crackling sound and a corresponding tactile sensation, when it is pressed between the finger and thumb, probably due to the crushing of the walls of the air-vesicles. The cohesive power of the lung is great, and it resists a high degree of pressure without rupturing. On account of the great figure played by the elastic tissue in the structure of the pulmonary substance, the lungs return readily to their former size immediately on the removal of the force which has caused their expansion. The yellow fibrous tissue is always on the stretch in the normal condition, but never has an opportunity to assert its full power, even after death, unless the chest-cavity is opened. At a post-mortem examination the removal of the sternum and costal cartilages is instantly followed by the sudden collapse of the lungs, which are reduced to one-third (or less) of their normal bulk, the explanation being simply this: during life the air-pressure on the inside of the lung is sufficient to prevent the full action of the elastic tissue; but, air being let in on the outer surface of the lung, the atmospheric pressure inside exactly balances that outside, and the elasticity of the pulmonary substance, being unresisted, displays its full power.

The *color of the lung* differs widely according to age. Before respiration is established, it is a deep reddish-brown; on inflation it changes to a beautiful rose-pink; in early adult life it is grayish-white; in early middle life it becomes brownish in spots and streaks; and in old age it is often bluish-black. The alteration from the antenatal hue to the postnatal is manifestly due to the distention of the lung with air—the color is diluted by distribution over a multiplied surface; but the other changes are largely caused by the deposition, in the areolar tissue between the infundibula and between the lobules, of carbonaceous particles, which have been taken up by the lymphatics. In the lungs of people who breathe air highly contaminated with such materials the changes occur much earlier in life, and are much more pronounced. This deposit makes a great deal clearer the outlines of the lobules, and upon the free lung-surface their bases may be observed, occupying irregular polygonal areas from one-quarter of an inch and upward in diameter. Within these may be seen the outlines of the air-vesicles, measuring perhaps $\frac{1}{70}$ inch across.

Lymphatics are abundant in the areolar septa and in the bronchial mucous membrane, and are said to have been traced upon the walls of the alveoli. They drain these parts into the nodes in the root of the lung.

The nerve-terminations are not known. The *nerve-supply* is from the pneumogastric and the sympathetic.

THE PLEURÆ.

Each lung is invested with a serous membrane, the *pleura* (from the Greek word for "side") (Fig. 826). It is a perfectly typical shut-sac, one portion of which closely envelops the lung, entering its fissures and clothing their walls to the very bottom, and is called the visceral layer, or the *pulmonary pleura*; and the other portion lines the walls of the great space in which the lung is contained, and is called the parietal layer. Different portions of the parietal layer are distinguished by special names, which indicate their position. That which lines the ribs, costal cartilages, and intermediate muscles is the *costal pleura*; that which is attached to the diaphragm is the *diaphragmatic pleura*; that which is applied to the adjacent structures in the mediastinum is the *mediastinal pleura*; and that rising into the root of the neck and covering the dome of the lung is the *cervical pleura*.

As a general rule the pulmonary or visceral pleura is in contact with some part of the parietal pleura; but in the fissures of the lung two layers of visceral pleura are in contact, and below the sharp, inferior border of the lung the two

layers of the parietal pleura come together; for, although the lung everywhere else fills the space delimited by the pleura, it does not, even in the fullest inspira-

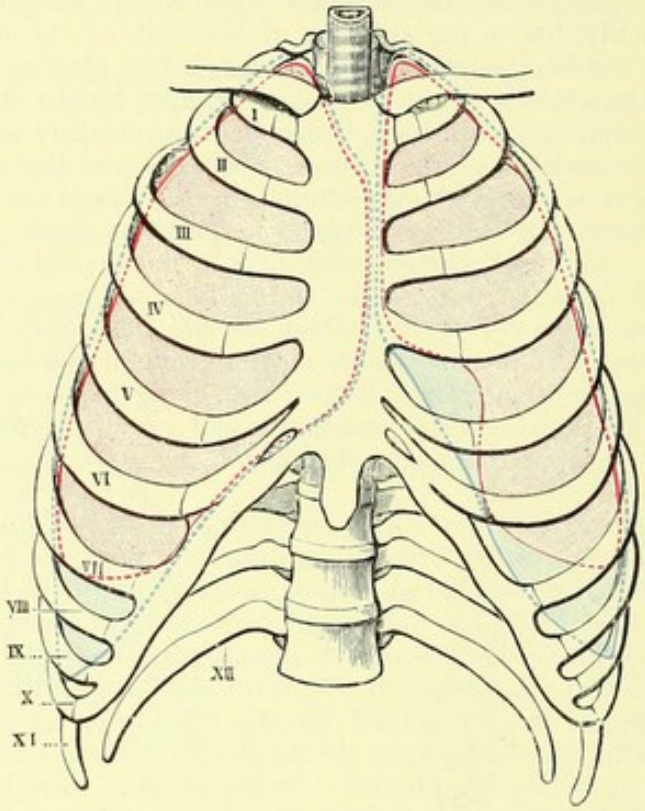

FIG. 826.—Relations of lungs (red) and pleuræ (blue) to the front walls of chest. (Testut.)

tion, reach completely to the depths of this extra space (Fig. 827). We speak of a *pleural cavity*, but this is merely a term of convenience, and is not descriptive

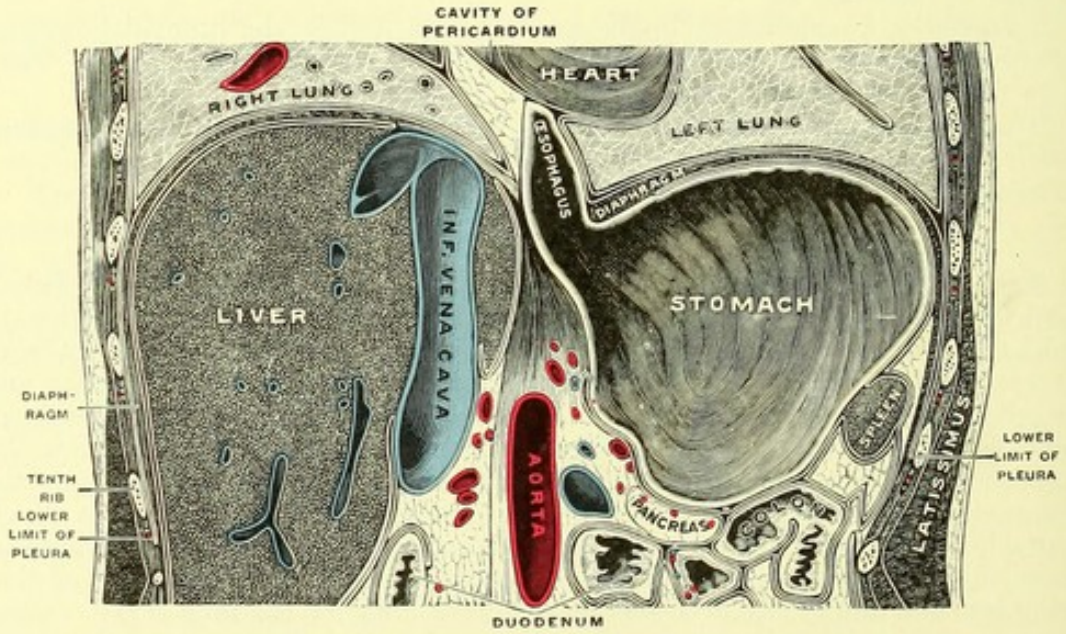

FIG. 827.—Coronal section of trunk, showing relations of thoracic and abdominal viscera.

of anything which normally exists. The pleural cavity is virtual, and becomes actual only when some fluid (air, serum, pus) gets between the layers as a result

of accident or disease. In health only enough serous fluid is found between the layers to lubricate them and allow slipping of one upon the other with the least possible friction.

The right pleura extends downward in the axillary line to the lower border of the ninth rib; the left pleura goes to the border of the tenth rib, the greater thickness of the liver on the right side explaining the difference. The pleural sacs of the two sides nearly meet at the mid-line of the sternum.

At the hilum of the lung the pulmonary pleura from above is reflected to the root, and thence to the mediastinal pleura; the visceral layers in front of and behind the vertical plane of the hilum not only cover the root, but come together directly beneath it, and form a double-layered, triangular sheet, extending vertically from the root of the lung to the diaphragm, and laterally from the lung to the mediastinal pleura. This fold is the *broad ligament of the lung*.

The pleura upon the lung is delicate and so closely attached that it cannot be readily separated. The costal pleura is thick, and easily detached. The cervical pleura is liable to be injured in operations just above the clavicle.

The visceral pleura is supplied by the bronchial arteries; the diaphragmatic and costal by the diaphragmatic and intercostal arteries; and the mediastinal by the posterior mediastinal, bronchial, internal mammary, and superior diaphragmatic. The nerves of the parietal pleura are the intercostal, pneumogastric, phrenic, and sympathetic; of the pulmonary pleura branches from the pulmonary plexus.

THE LARYNX.

The larynx is that portion of the air-passages which is so specially modified that it serves as the principal organ of voice. It connects the upper end of the trachea with the pharynx, and lies in front of the lowest segment of the latter, being itself thinly covered anteriorly by muscles, fasciæ, and skin. It is the occasion of the protrusion (*pomum Adami*) which is plainly to be felt, and in adult males generally to be seen, in the middle of the fore part of the neck. Its framework consists of a series of firm cartilages, held to each other, to the windpipe and to the hyoid bone by ligaments, which permit varying degrees of motion. Mucous membrane, continuous with that of the pharynx above, and the trachea below, lines the larynx, the cavity of which is wide at both ends, but constricted in the middle in such a way that a median, fore-and-aft cleft, the *glottis* (*rima glottidis*, "the cleft of the glottis") is produced. During ordinary, easy breathing, the cleft is wide open, and no noise is made; but, if it is narrowed, voice is caused by the forcible discharge of air from the lungs, and the pitch is determined by the degree of the narrowing, a nearly complete closure resulting in a high tone, and a large separation determining a low one. The sides of the glottis are composed of fibrous bands, which are approximated and separated by the action of the muscles which cause movements of the cartilages. These bands are known as the true vocal cords, and are the most essential portion of the organism of the larynx, the work of other parts being directed to the production of proper attitudes in these cords.

Besides its conspicuous function in the production of voice the larynx performs an important service in preventing the entrance to the air-passages below it of substances in process of being swallowed. This is accomplished mainly by the complete closure of the chink of the glottis. The same act, accomplished when the lungs are full, serves to prevent the expiration of the air, and thus to fix the diaphragm and make possible such compression of certain hollow organs of the abdomen as is necessary for the expulsion of their contents, as in defecation, micturition, vomiting, parturition.

The Cartilages of the Larynx.

The principal cartilages of the larynx are the cricoid, thyroid, arytenoid, and epiglottic.

The **cricoid cartilage** (Fig. 828) is the lowest, and a firm union exists between it and the uppermost cartilage of the trachea. It derives its name from its

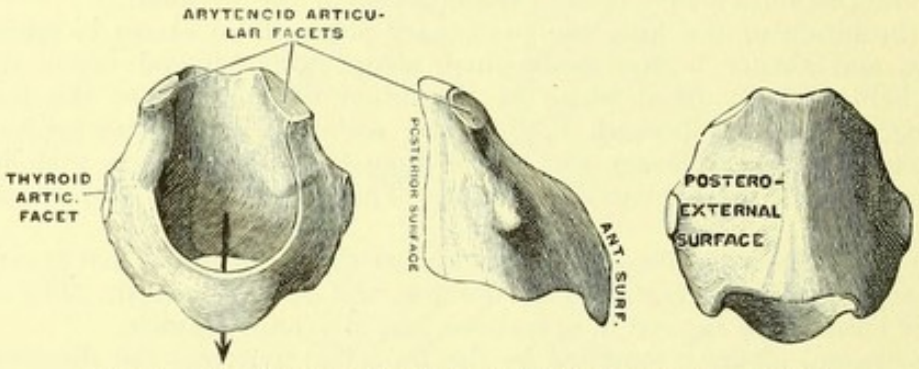

FIG. 828.—Cricoid cartilage, front, right lateral, and rear views. (Testut.)

resemblance to a finger-ring, and it is so placed that the signet of the ring is behind, its hoop in front.

The **thyroid cartilage** (Fig. 829), so named from its resemblance to a shield, is

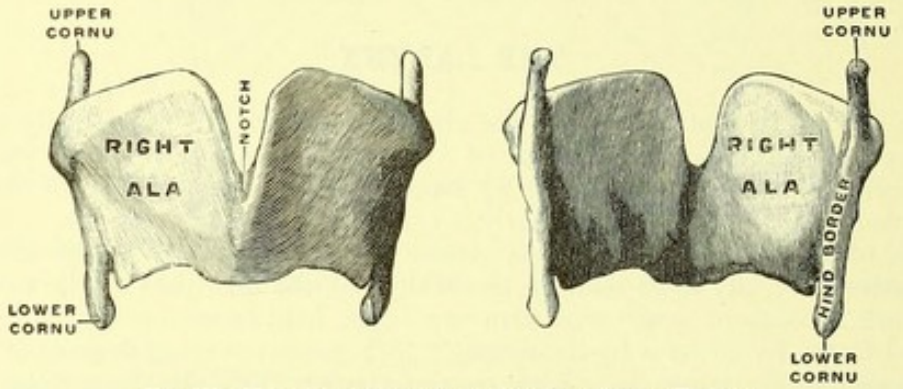

FIG. 829.—Thyroid cartilage, front and rear views. (Testut.)

the largest of the set, and rests upon the cricoid. At each side it presents a squarish plate, and the two unite in a median line at the lower half of their front edges, leaving a deep notch above their line of union. The hind border of each

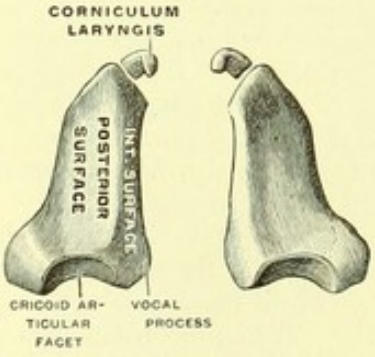

FIG. 830.—Arytenoid cartilages, hind view. (Testut.)

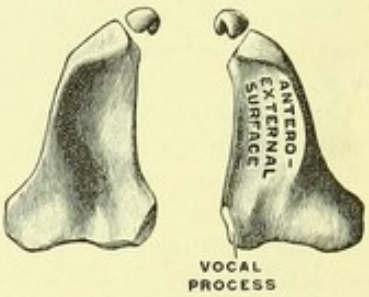

FIG. 831.—Arytenoid cartilages, front view. (Testut.)

plate is projected downward in a process, and upward and backward in another process.

The **arytenoid cartilages** (Figs. 830, 831), fancifully named "pitcher-like," are

two in number, are located upon the upper and back part of the cricoid, and are irregularly pyramidal in shape. Upon the summit of each is a *corniculum laryngis* ("little horn of the larynx"), somewhat cone-shaped, and bent backward and downward. (The cuneiform cartilages will be mentioned later.)

The **epiglottic cartilage** (Fig. 832), situated, as its name implies, upon (or over) the glottis, is shaped like an oval leaf, its stem being received in the notch between the two wings of the thyroid. Its hind surface is concave above, and is convex below this, the prominence in the centre being called the cushion.

The cricoid, the thyroid, and the arytenoids (except the apices of the last) are composed of pure cartilage; the rest of the cartilages are of the yellow variety. The true cartilages are liable to ossify at any time after maturity is attained. At puberty the larynx undergoes great changes of growth, which are especially marked in the male, and are prevented by castration.

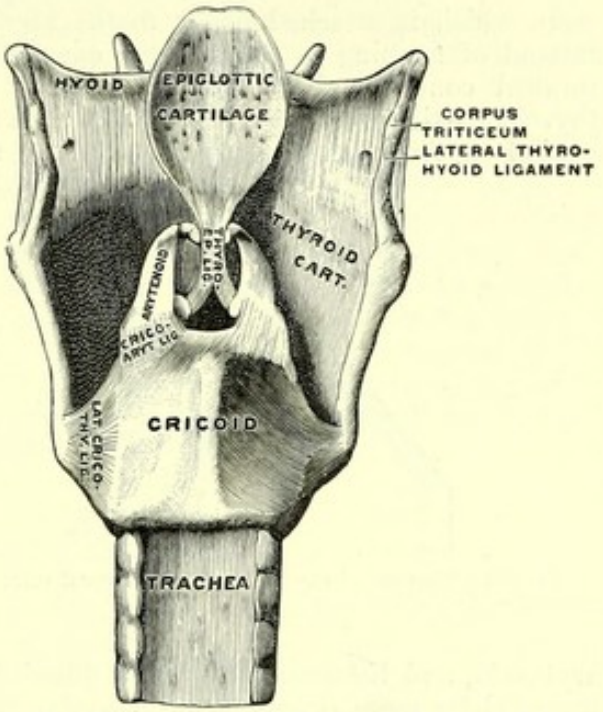

FIG. 832.—Laryngeal cartilages and ligaments from behind. (Testut.)

The position and relations of each of the cartilages are shown in Fig. 832.

The Ligaments of the Larynx.

The cartilages of the larynx are movably articulated with one another at various points. The lower cornua of the thyroid articulate with the raised oval facets on the outer side of the cricoid; the arytenoids are jointed with the surfaces at the upper and outer parts of the signet of the cricoid; and the corniculа are usually attached to the apices of the arytenoid pyramids in such a way that motion is permitted. In all of these cases the movement is gliding, or rotary, or both, the cartilages concerned in a joint are united by a capsular ligament, and the articulation has a true synovial membrane.

In addition to these there are numerous ligamentous bands, the most of them largely composed of yellow fibrous tissue, which serve to close in the gaps between nearly related cartilages, and by their elasticity to restore the connected parts when they have been displaced by the action of muscles. The names which these ligaments bear are suggestive of situation and action, as they are mostly composed of the names of the cartilages which they connect, and usually also contain some indication of their relative position.

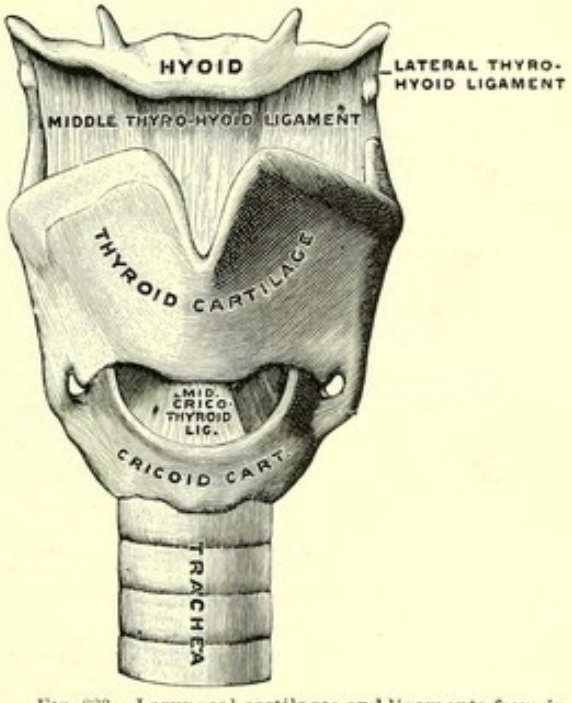

FIG. 833.—Laryngeal cartilages and ligaments from in front. (Testut.)

The *middle crico-thyroid ligament* (Fig. 833) connects in front the upper border of the cricoid with the lower border of the thyroid. On each side this ligament is prolonged backward as the *lateral crico-thyroid ligament* (Figs. 834, 835), which is attached below to the upper margin of the cricoid, but above, instead of running to the opposed edge of the thyroid, it slopes inward in its upward course, and is attached in front to the thyroid cartilage at the angle between the wings, behind to the anterior angle of the base of the

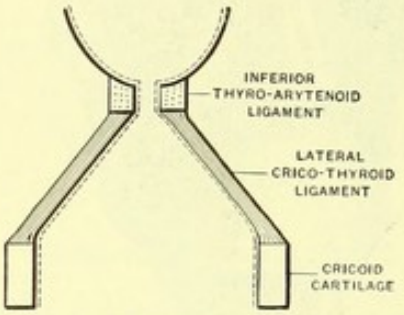

FIG. 834.—Diagram of coronal section of lateral crico-thyroid ligaments. (F. H. G.)

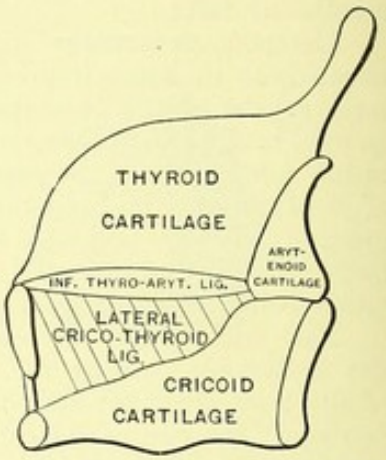

FIG. 835.—Diagram of sagittal section of larynx, showing lateral crico-thyroid ligament of right side. (F. H. G.)

arytenoid, and between these two points it is unattached. From its connections it would be more descriptively named crico-thyro-arytenoid. Its free margin, stretching between the thyroid and the arytenoid, is often called the *inferior thyro-arytenoid ligament*. This last is thick, flattened toward the middle line, and sharp on the upper edge. Covered with mucous membrane it constitutes one of the *true vocal cords* (Fig. 836).

Close to the inferior is the *superior thyro-arytenoid ligament*, arising a little above it on the thyroid, and inserted upon the ridge on the front surface of the arytenoid. It is small, and with its covering of mucous membrane forms the upper or *false vocal cord* (Fig. 836).

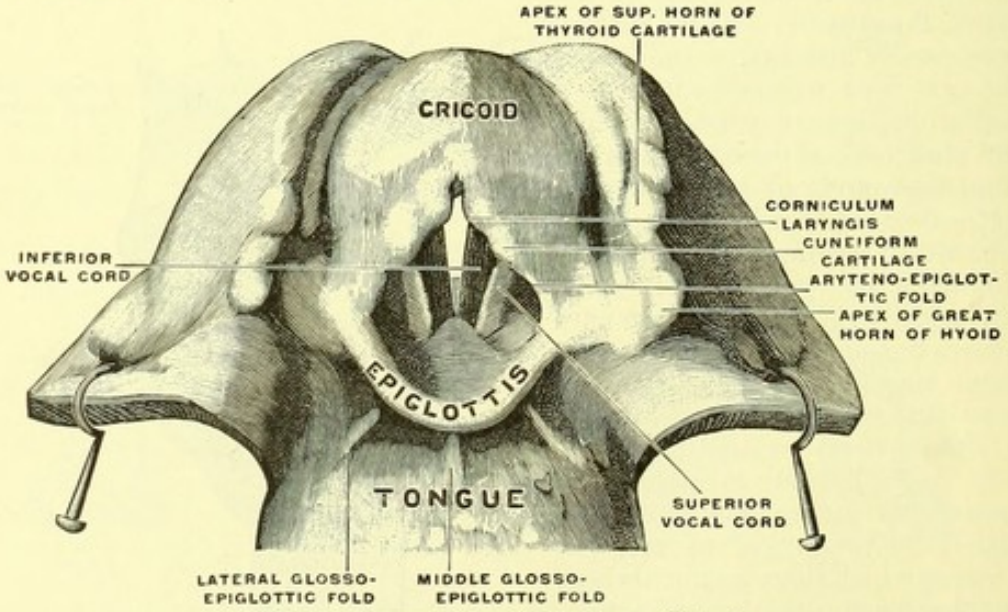

FIG. 836.—Larynx, viewed from above. (Testut.)

From the cricoid to the inner, lower, and back part of the arytenoid is the *crico-arytenoid ligament*. The epiglottic cartilage is attached to the thyroid in the angle between its alæ by the *thyro-epiglottic ligament*. Finally from the antero-

external surface of the arytenoid to the lateral border of the epiglottic cartilage runs the *aryteno-epiglottic ligament*, in which is usually found a small, yellow fibro-cartilage, called the *cuneiform cartilage*.

All of these ligaments are in symmetrical pairs, except the middle crico-thyroid and the thyro-epiglottic, which are single and median, with bilateral symmetry.

Besides these ligaments, which are called "intrinsic" from their forming a part of the larynx, there are others which connect it with the hyoid bone above and the trachea below, and are named "extrinsic" on account of their situation outside of the larynx (Fig. 833). The connection between the larynx and trachea is almost precisely like that between neighboring cartilages of the latter. From the anterior notch of the thyroid to the body of the hyoid extends the somewhat elastic *middle thyro-hyoid ligament*; and from the upper edges of the alæ and front margins of the superior horns of the thyroid to the lower borders of the great cornua of the hyoid stretch the very elastic *lateral thyro-hyoid ligaments*, each perforated by the superior laryngeal vessels, and having in its hind edge a little bit of cartilage, the *corpus triticeum* ("wheat-like body").

The Muscles of the Larynx.

The muscles of the larynx, like its ligaments, are divided into two groups—the extrinsic, which are outside of, but act upon, it; and the intrinsic, which are attached at both ends to parts of the larynx, and move these parts upon each other. The former are the sterno-thyroideus, thyro-hyoideus, stylo-pharyngeus, palato-pharyngeus, and constrictor inferior pharyngis, and are described in other places. The intrinsic are the following: Crico-thyroideus, crico-arytenoideus posterior, crico-arytenoideus lateralis, thyro-arytenoideus, thyro-epiglottideus, aryteno-epiglottideus, arytenoideus.

All of these muscles are in symmetrical pairs, except the last, which is single, but bilaterally symmetrical. Their names are a guide to their situation, and suggestive of their action. They are members of the rather small class of muscles whose names are almost invariably Anglicized among English-speaking people, generally by the elimination of the terminal *eus*, and, in the case of the third, of the last two letters of *lateralis* also. They are so plainly exhibited in the figures that elaborate description is unnecessary. Normally, they always act in pairs, and their action affects two things—the width of the aperture of the glottis, and the tension of the true vocal cords.

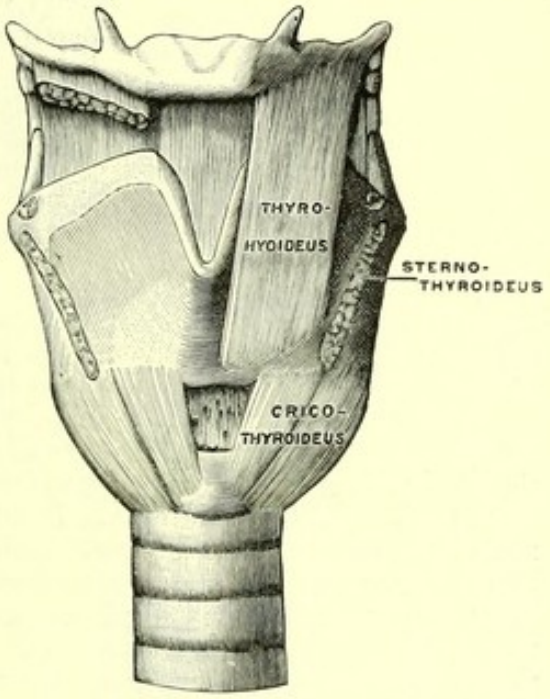

FIG. 837.—Muscles of larynx, front view. The sterno-thyroids and right thyro-hyoid have been removed. (Testut.)

The **crico-thyroid muscle** (Fig. 837) arises from the lower border of the ala of the thyroid and the front edge of its lower horn, converges downward and forward, and is inserted into the front and side of the cricoid. The thyroid being fixed, the anterior part of the pair of muscles lifts the front of the cricoid upward, and the portion of the cricoid behind the crico-thyroid articulation is, consequently, tilted downward, and, as this carries the arytenoids with it, the true vocal cords are tightened. The hind

part of the muscle contributes to this result by drawing the cricoid backward. Nerve, the superior laryngeal.

The **posterior crico-arytenoid muscle** (Figs. 838, 839) arises from nearly a lateral half of the hind surface of the cricoid, and converges to the outer angle of the base of the arytenoid, into which it is inserted. The two muscles draw their points of insertion backward and toward each other, and thus cause a divergence of the anterior processes and the vocal cords which are attached to them. Nerve, the inferior laryngeal.

The **lateral crico-arytenoid muscle** (Fig. 838) arises from the side of the upper border of the cricoid, passes upward and backward, and is inserted into the exter-

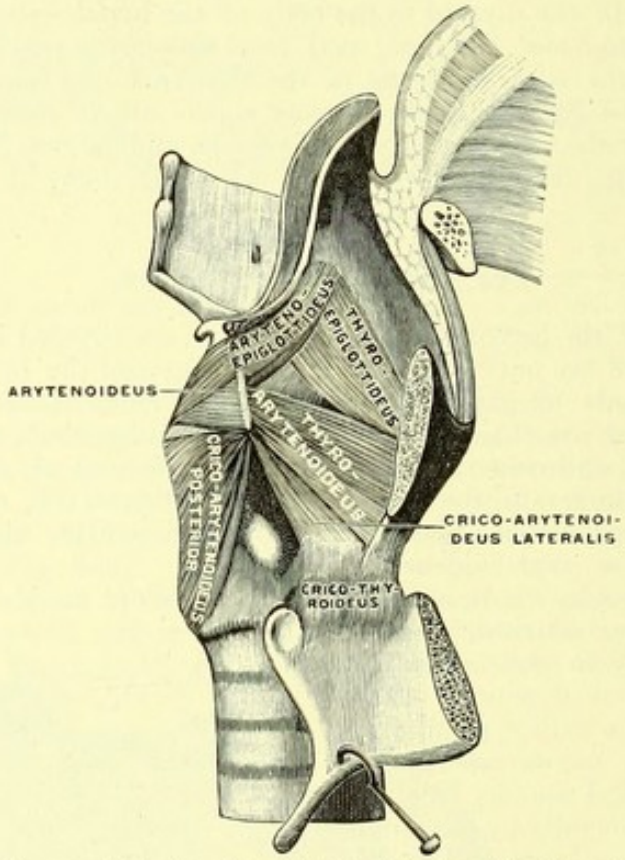

FIG. 838.—Muscles of larynx, right side. The right ala of the thyroid cartilage has been cut through and turned down. (Testut.)

nal angle of the arytenoid. The two cause approximation of the vocal cords by pulling the external arytenoid angles forward and downward, thus turning the anterior angles inward. Nerve, the inferior laryngeal.

The **thyro-arytenoid muscle** (Fig. 838) consists of an internal portion, which occupies the most of the triangular space included in the mucous fold enwrapping the true vocal cord; and a broad, external portion, flattened laterally against the inner surface of the thyroid ala. It arises from the lower half of the hind surface of the thyroid near its angle, and from the adjacent surface of the crico-thyroid ligament. It converges backward, outward, and upward, and is inserted (internal part) into the vocal process and (external part) into the adjacent portion of the outer surface and the outer angle of the arytenoid. The pair draws the arytenoids forward, relaxing the vocal cords. Nerve, the inferior laryngeal.

The **thyro-epiglottic muscle** (Fig. 838) arises from the thyroid, just above the thyro-arytenoid, passes upward and backward, and is inserted into the side of the epiglottic cartilage. It depresses the epiglottis. Nerve, the inferior laryngeal.

The **aryteno-epiglottic muscle** (Fig. 838) arises near the apex of the arytenoid, passes forward and upward, and is inserted into the side of the epiglottic cartilage. With its mate it draws the epiglottis backward and downward. Nerve, the inferior laryngeal.

The **arytenoid muscle** (Fig. 838) (ary-arytenoid) connects the two arytenoid cartilages, being attached to the outer half of the concavity on the back of each. The ventral fibres are transverse, but the dorsal are arranged in two oblique bundles, which cross each other, and are continued into neighboring muscles—the thyro-arytenoid, aryteno-epiglottic, and lateral crico-arytenoid—as well as inserted each into the highest part of the opposite arytenoid cartilage. The muscle draws the arytenoid cartilages together, thus closing the part of the rima glottidis included between them. Nerves, the superior and inferior laryngeal.

It will be observed that the arytenoid muscle has both the superior and inferior laryngeal nerves distributed to it; the crico-thyroid the superior only; and all of the other muscles the inferior only.

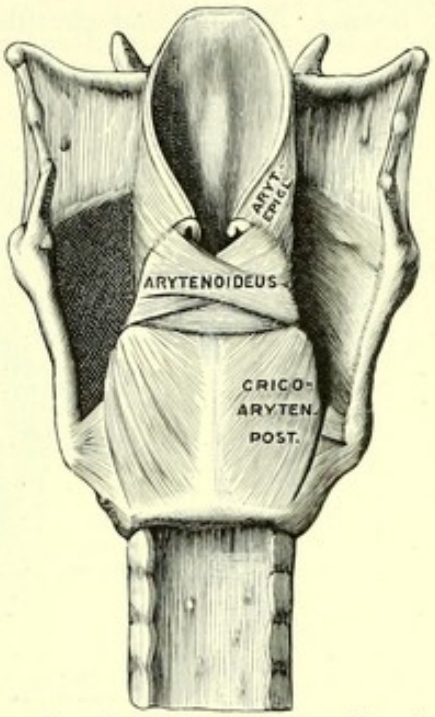

FIG. 839.—Muscles of larynx, from behind. (Testut.)

The Lining of the Larynx (Figs. 840, 841).

Mucous membrane lines the larynx throughout. It is continued from the mucosa of the tongue and pharynx, extends over the epiglottic cartilage and from the aryteno-epiglottic ligaments downward and inward to the superior thyro-arytenoid ligaments, which it covers on their median and under surfaces, constituting with them the superior, or false, vocal cords. The membrane is continuous below with that of the trachea, and lines the inner surface of each of the lateral crico-thyroid ligaments and the inner and upper surfaces of the thyro-arytenoid ligaments, which with it compose the inferior, or true, vocal cords. Between the false and true vocal cords of each side is a narrow horizontal opening of fusiform outline, the aperture of a cavity, called the *ventricle of the larynx*, which extends outward and then bends upward just on the mesial side of the upper part of the thyro-arytenoid muscle, and is lined with mucous membrane prolonged from that of the vocal cords. From the front of the ventricle extends upward a *laryngeal pouch* (*sacculus laryngis*), which is narrow, long, and embedded in fat.

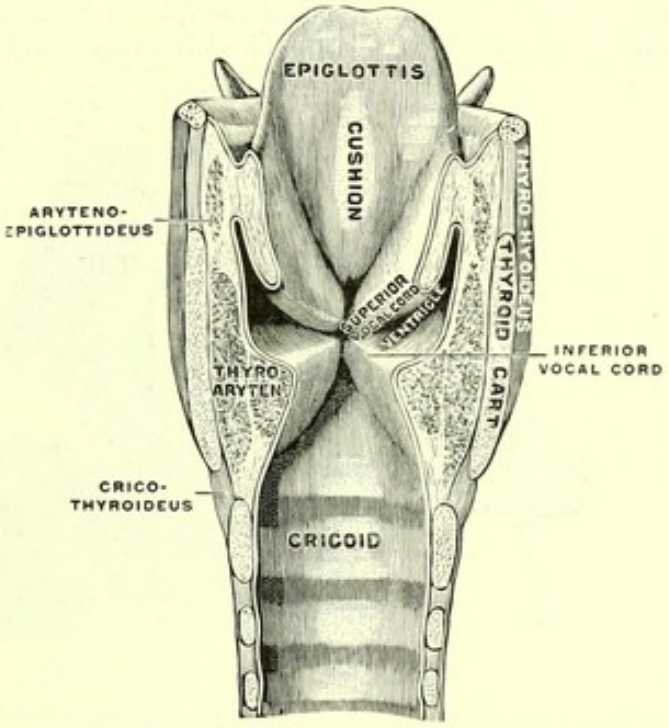

FIG. 840.—Coronal section of larynx, rear view of front half. (Testut.)

The mucosa is pale and thin, especially upon the true vocal cords. In most parts its epithelium is columnar and ciliated, but just above the false vocal cords it becomes flattened and stratified, and it is of this kind also upon the true vocal

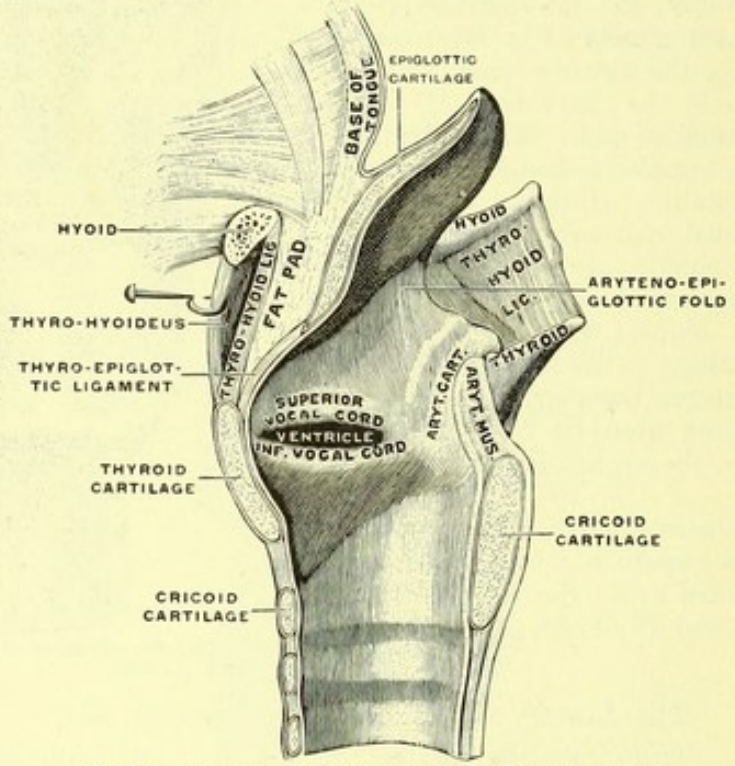

FIG. 841.—Sagittal section of larynx, right half. (Testut.)

cords, and in small areas elsewhere. Beneath the membrane in the aryteno-epiglottic region is a good deal of loose areolar tissue. Mucous glands are numerous and large, excepting on and about the true vocal cords.

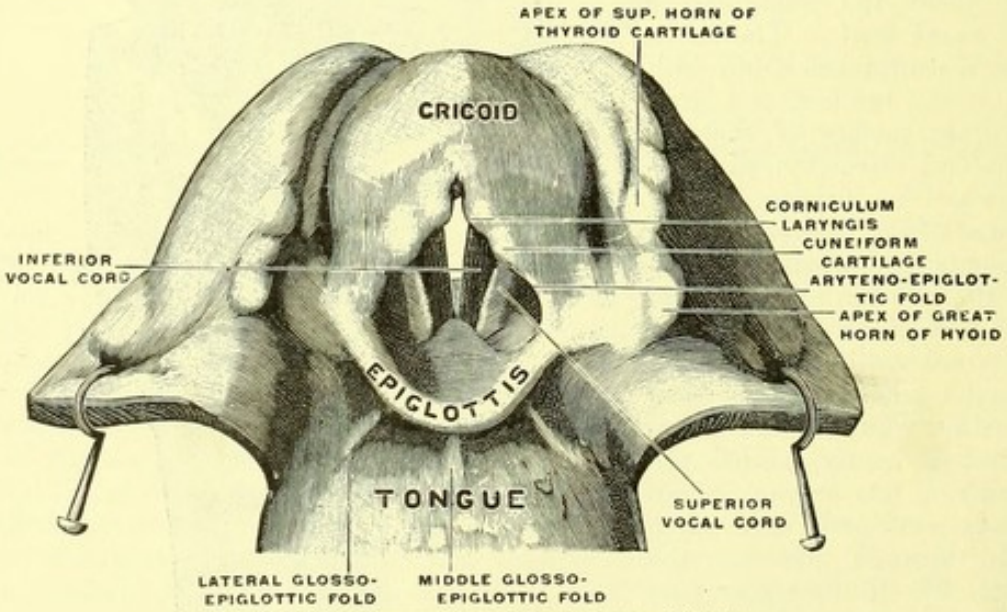

FIG. 842.—Larynx, viewed from above. (Testut.)

Viewing the larynx from above (Fig. 842), an upper opening is seen, its front wide and semicircular, its sides drifting together behind and below in an undulating curve. The anterior boundary of this aperture is made by the epi-

glottis, the downward-sloping sides by the aryteno-epiglottic folds of mucous membrane, which run from the sides of the epiglottis to the tops of the arytenoid cartilages, and are nodulated by the cuneiform and corniculate cartilages. Through this wide aperture are seen in front the backward projection from the surface of the epiglottis called its *cushion*; on the sides, diverging backward and outward, the upper or false vocal cords; farther down in the cavity and nearer the median line the true vocal cords, and, on a level with them, the inner margins of the bases of the arytenoid cartilages; and finally, occupying the middle line and a little space on each side of it, the rima glottidis. This chink of the glottis is about an inch in its fore-and-aft measurement, the front two-thirds of this being bounded laterally by the true vocal cords, the hind third by the arytenoid cartilages. The portion between the vocal cords is called the vocal part, from its function in the production of voice; the portion between the arytenoids is known as the respiratory part, on account of its use in the process of breathing.

THE URINARY SYSTEM.

By F. H. GERRISH.

THE double function of appropriation and elimination belongs both to the alimentary and to the respiratory systems, each being concerned in the supply of new material, and also in the casting off of effete substances. But the urinary system is simply excretory: its only office is relieving the body of certain waste products, which, if allowed to remain in it, would injure the organism, and ultimately destroy life.

The organs of the urinary system are the two *kidneys*, which form the urine from materials furnished by the blood; the *ureters*, ducts which convey the urine away from the kidneys; the *bladder*, a reservoir in which the urine is stored until circumstances are convenient for its discharge; and the *urethra*, a tube through which the urine passes from the bladder, and is finally voided.

THE KIDNEYS.

The essential organs of the urinary system are the kidneys. The materials which they abstract from the blood are in solution in water, and this solution is the *urine*. The formation of this fluid is constant; and, as fast as it is produced, it is conducted to the bladder. In some details of gross anatomy the two kidneys differ slightly, as will be related subsequently; but functionally they are identical, and the physiological anatomy of one is exactly like that of the other.

A kidney is a compound, tubular gland—a vast multitude of microscopic tubes, all lined with epithelial cells, and abundantly supplied with blood-vessels. The study of a single one of these tubes reveals the physiological anatomy of the kidney, and with that it is best to begin.

A *uriniferous tube* starts as a hollow globe (the capsule); then come in regular succession a constricted part (the neck), a tortuous (the proximal convoluted tube), an undulating and twisted (the spiral tube), a long portion bent so abruptly near its middle that the two parts are parallel (the looped tube), a portion with a zigzag contour, full of short lines and marked angles (the irregular tube), a second tortuous part (the distal convoluted tube), a short, arching part (the junctional or arched collecting tube), and, finally, a long portion (the straight collecting tube), the wide, terminal part of which is called the excretory tube.[1]

The various parts of this long tube differ not only in shape and direction but in diameter. All of these features will be seen in the part of Fig. 846, at the extreme left.

Structure of a Uriniferous Tube.—The tube is composed of a basement membrane and a single layer of epithelial cells, which rest upon it and vary in form according to their situation. In most narrow portions of the tube and in the capsule they are flattened; in the neck and collecting tubes they are cuboidal or columnar; and elsewhere they are somewhat cuboidal and granular toward the

[1] The capsule is called also the capsule of Bowman, the looped tube is known as Henle's, the irregular bears the name of Schachowa, and the excretory is known as the duct of Bellini.

bore (this part containing a large nucleus), and toward the membrane they look like a mass of rods and their sides are grooved. Where the tube is not very small, the lumen occupies only about one-third of the entire diameter on account of the relative thickness of the cells.

The tube is enveloped in a network of blood-vessels, from whose contents its cells abstract the ingredients of the urine. The vascular apparatus will be described later on.

Lobes of the Kidney.—It has been estimated that each kidney contains about half a million capsules, and fifteen miles of tubing. The disposition of this vast number of tubes is very intricate, and yet so regular as to produce practically invariable gross appearances in different parts of the compound organ. In some lower animals the kidney, instead of being a single, coherent mass, consists of a number of similar lobes, so slightly united that the appearance of the organ suggests a bunch of grapes. A condition approaching this obtains in the human embryo, though the independence of the lobes is not as marked (Fig. 843). The study of the naked-eye appearances of a separate lobe is necessary to an understanding of the arrangement of the tubes.

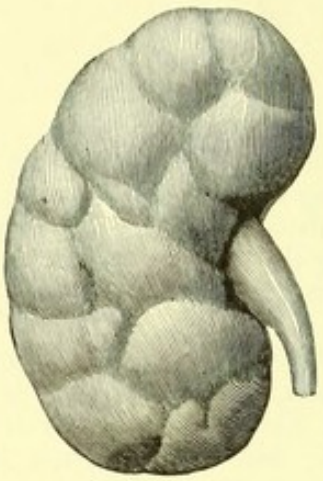

FIG. 843.—Fœtal kidney, showing lobes. (Testut.)

An Ideal Lobe.—Each lobe is like a cone whose apex has been cut off, and its place supplied by the apex of a smaller cone (Fig. 844). A vertical section through the middle of this cone brings to view a cut surface in which are seen two apparently distinct kinds of material (Fig. 845). Within is a triangular portion, red and streaked with alternating dark and light lines from base to apex; and, enclosing this, except at

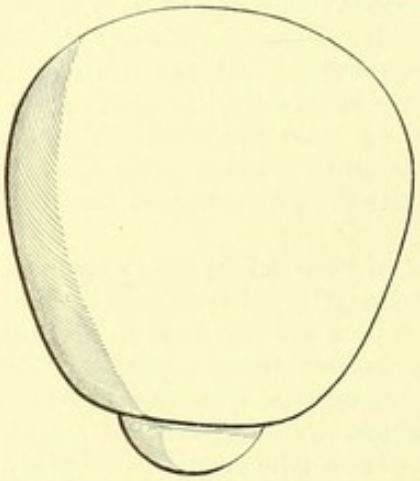

FIG. 844.—Diagram of a lobe of the kidney. (F. H. G.)

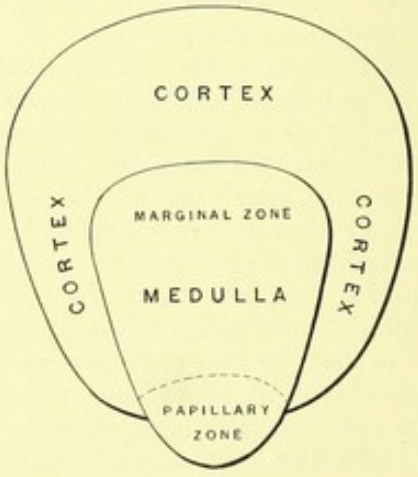

FIG. 845.—Diagram of a vertical section of a lobe of the kidney. (F. H. G.)

the apex, is a thick, lighter colored, granular part. The former is the *medulla* ("the pith"), or *medullary pyramid*; the latter is the *cortex* ("the bark"), or *cortical portion*. Reckoning from the base to the apex of the lobe, the cortex occupies a little more than a third of the distance. A fibrous capsule covers it, and a thin stratum of the cortex just beneath this is called the subcapsular layer. The pyramid is divided into two parts—a smaller called the *papillary zone*, from its including the apex (papilla), and a larger, known as the *marginal, boundary,* or *limiting zone*, this being darker and more distinctly striated. Intruding from

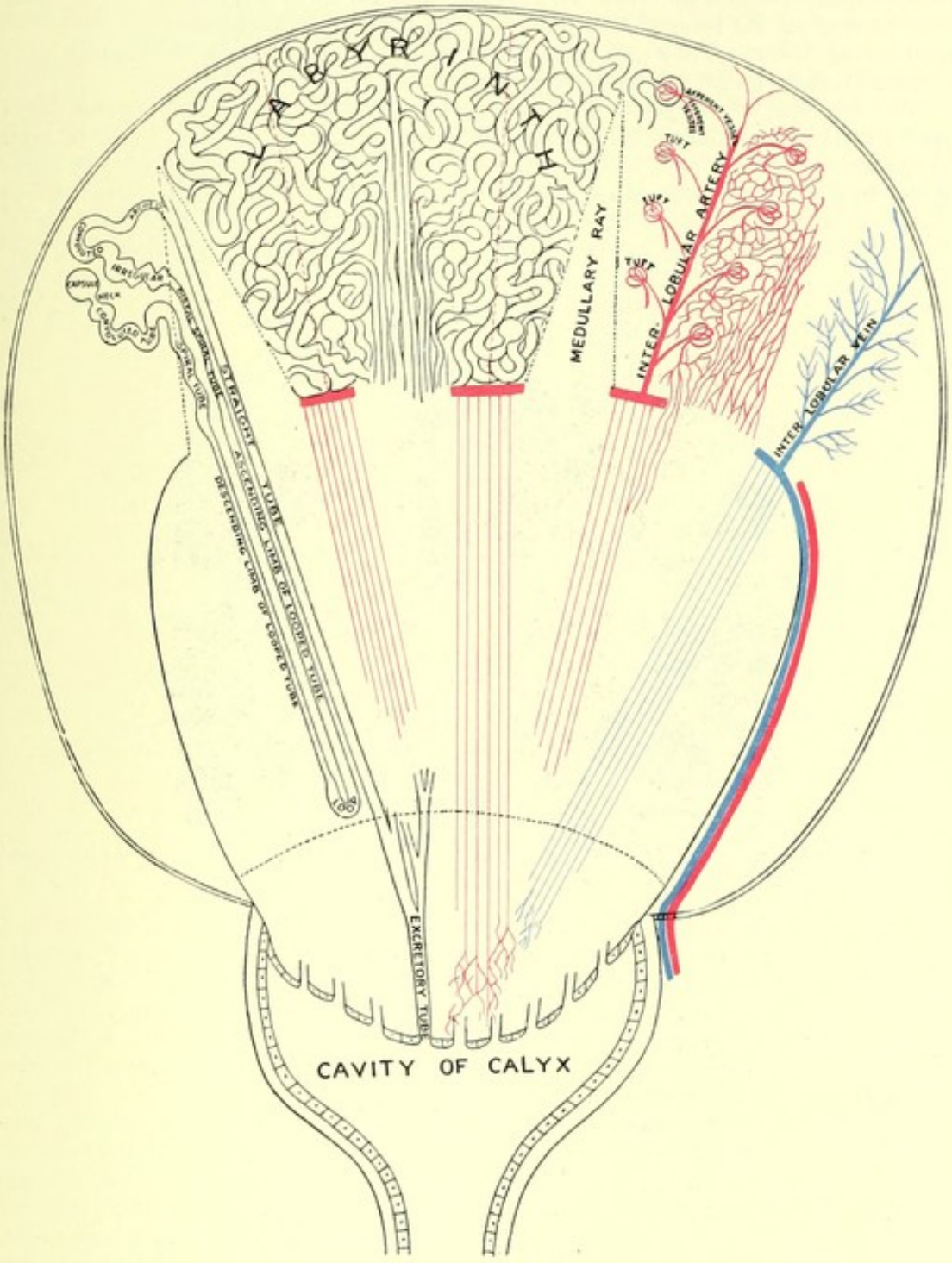

FIG. 846.—Diagram of the structure of a lobe of the kidney. The lobe is seen in vertical section, the cortex being marked off from the medulla. Four medullary rays encroach upon the cortex. At the left is shown the course of a single, continuous series of tubes—the straight and spiral tubes appearing in the medullary ray, the straight, looped, and excretory in the medulla proper, the capsule, neck, convoluted, irregular, and arched in the cortex proper. Next is seen the labyrinth, composed of a mass of tubes in the cortex, with a medullary ray for a centre. Equidistant from the ray on each side is a broken red line, marking the position of an interlobular artery. The parts between these lines constitute a lobule. Farther to the right is an interlobular artery, giving off lateral branches (afferent vessels), each of which ends in a tuft of capillaries, from which the blood is collected by an efferent vessel. The uppermost of the tufts is shown enclosed in a capsule. On the right of the interlobular artery the efferent vessels break up into a capillary network, which surrounds the (unrepresented) tubes in the cortex and ray. The lowest efferent sends vertical vessels also into the medulla. On the right the interlobular vein is seen gathering the blood from all the parts supplied by the interlobular artery. A branch of the renal artery courses upward between cortex and medulla, and forms an arch (here broken) over the base of the medulla. From it the interlobular arteries pass upward into the cortex, and straight branches go downward into the medulla, supplying its structure, and ending at the apex in the capillaries. From the last the radicles of the renal vein arise, and accompany the straight arteries to the base of the medulla, where a venous arch is formed, continuous with which is the vena comes of the entering artery. The calyx embraces the apex of the medullary pyramid. It is lined with epithelium, which continues from it over the apex, the latter being perforated with the many apertures of excretory tubes.

the medullary portion into the cortical are a number of narrow triangles, their bases resting on the base of the pyramid, and their apices reaching nearly to the subcapsular layer. They are called *medullary rays* (pyramids of Ferrein), on account of their radiation from the medulla.

The diagram (Fig. 846) will show that these various appearances are due principally to the arrangement of the different portions of the tubes. It will be seen that in the medullary rays are all of the spiral tubes, and the uppermost parts of the straight collecting tubes and of the ascending limbs of the looped tubes (distal spiral tubes), these being placed side by side in line with the chief axis of the ray, the longest being in the middle. In the remaining and greater part of

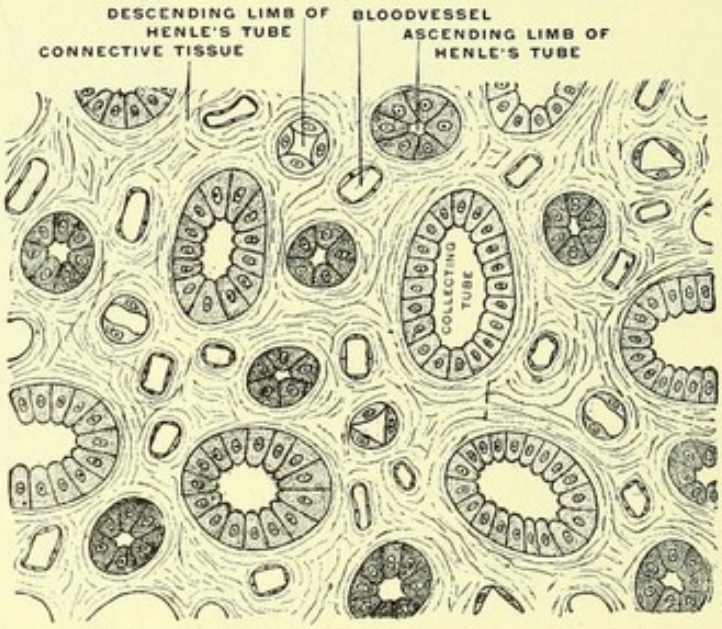

FIG. 847.—Transverse section of kidney, made in the marginal zone—greatly magnified. Observe the amount of the interstitial connective tissue. (Testut.)

the cortex are the capsules and their necks, and the convoluted, irregular, and arched collecting tubes, all so intricately intermingled as to produce the granular look of the part, and to merit the name of *labyrinth*. The medulla contains the greater part of the length of the looped and of the collecting tubes; and, as these are straight and side by side, the delicate striation of the medulla is explained. The broad alternating dark and light streaks in the pyramid are due to a vascular distribution as will presently be seen.

The Vessels of the Kidney.—The *arteries* enter the lobe in the cortical substance at the sides of the pyramid. When they reach the level of the base of the pyramid, they turn inward and run across between the medullary and cortical portions, constituting the *arterial arches*, and giving branches upward into the cortex, and, according to most authorities, branches downward into the medulla. The branches to the cortex, called *interlobular*, enter the cortex half way between the medullary rays, and give off short side-twigs, the *afferent vessels* ("the vessels carrying to"), each of which terminates in a globular bunch of capillaries, the *glomerulus*, or Malpighian tuft. This tuft is commonly described as being inside of the capsule, which is the beginning of a uriniferous tube, and, in one sense, this is correct. But, from the physiological point of view, the tuft is outside of the capsule; for it is related to it only as if it had pushed in and stretched the capsular wall at a point opposite the neck, carrying everything before it until the cavity was nearly obliterated. The cells now lining the capsule are comparable with the parietal layer of a serous membrane, and those covering the glomerulus with its visceral layer. The capsule and tuft together are called the *Malpighian body*. The blood leaves the tuft through a vessel, called *efferent* ("carrying

from"), which emerges beside the afferent. It is probably an artery, although it is often spoken of as a vein. It breaks up into a close capillary plexus, which surrounds the secreting tubes in the cortex. From this network come venous radicles, which empty into minute veins, the *interlobular*, accompanying the interlobular arteries. These veins terminate in *venous arches* between the cortex and medulla, and thence leave the lobe by the track taken by the artery in entering. The lowest efferent vessels give pencils of capillaries to the tubes in the medulla.

The branches from the under side of the arterial arches, always accompanied by corresponding radicles of the venous arches, lie between the tubes of the pyramid in regular parallel groups, producing the darker lines in the alternating series of stripes of the boundary zone. These vessels are named *vasa recta*. On their way to the papilla the arterioles give capillaries to the tubes, and at the papilla these end in venous radicles, which run straight up to the suprapyramidal venous arches.

The *vessels in the cortex*, which run vertically to the vascular arches, mark the limits of the primary lobules of the labyrinth, and hence are called "*interlobular*." A transverse section of the cortex shows the lobulation, each lobule having a circular bundle of tubes, the medullary ray in its centre, and a tangled mass of tubes around it.

At the apex of the papilla the uriniferous tubes end as the *excretory tubes* (ducts of Bellini) in from ten to eighty openings, called *foramina papillaria*, producing the appearance of the nozzle of a watering-pot, through which the urine constantly trickles. As it escapes it is received into the upper end of the excretory duct of the lobe, which is here expanded and resembles a cup, from which it is named the *calyx*. The rim of the calyx is attached around the base of the papilla. The surface of the papilla is covered with mucous membrane, which is continuous with that lining the calyx and the rest of the excretory duct.

Framework of the Kidney.—The *capsule* which covers the lobe is a condensed areolar tissue, which is continuous with that clothing the calyx, and immediately beneath it is a delicate stratum of unstriped muscular tissue. Quite a bundle of this last material surrounds the pyramid just above the attachment of the calyx.

The tubes and vessels are supported by *interstitial connective tissue*, which is small in amount, except around the Malpighian bodies and in the papillary region. It is condensed at the surface, where it is intimately connected with the true capsule.

Coalescence of the Lobes (Fig. 848).—There are from eight to twenty lobes in a kidney, and each of them answers to the foregoing description. Beginning as separate parts, they afterward coalesce at their adjacent surfaces, and the fusion is so perfect that the included portions of the tunic disappear, and the lines of contact cannot be traced. The apices of the lobes converge, and the papillæ project into a central cavity, the *sinus*. A section of the kidney after the union of its lobes shows that the pyramids are separated by masses of cortical substance, the *columns of Bertin*, and that there is more of this between the pyramids than there is elsewhere. The incongruity of calling that part of an organ its bark, which is mostly not on the outside, is not dissipated until one learns that the name "cortex" is applied primarily to the outer layer of renal substance in the individual lobes—a use of the term eminently descriptive in the circumstances—and it is not abandoned when the lobes are fused. The part of the cortex, whose title to the name in the compound kidney no one would think of disputing, presents in vertical section the appearance of curving across the base of each pyramid from one column to another, whence the name *cortical arches*.

The coalescence of the lobes often goes so far that the apices of two pyramids become fused into one, their bases continuing separate; so that in a kidney with fourteen pyramids there may be only ten papillæ.

Gross Features of the Kidney (Figs. 849, 850).—The kidney (in Latin *ren*, from which comes the adjective "renal"), made up of lobes as just described, is somewhat bean-shaped, presenting a convex front surface, and a flattened back

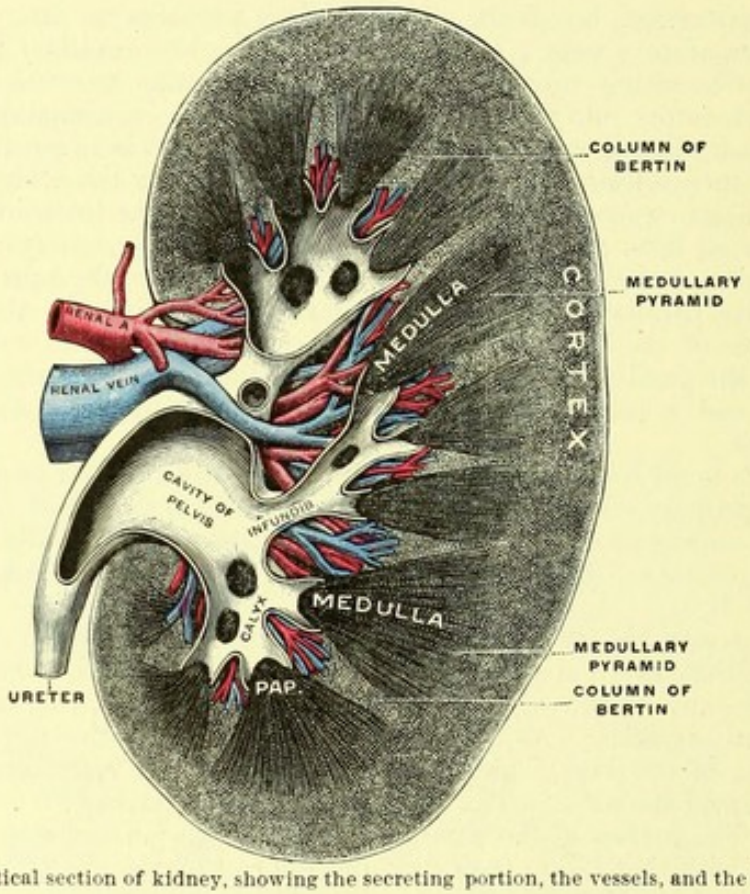

FIG. 848.—Vertical section of kidney, showing the secreting portion, the vessels, and the beginnings of the ureter. (Testut.)

surface; rounded upper and lower ends, the former being a little the larger; a convex outer border, and an inner border, which has a notch, called the *hilum*.

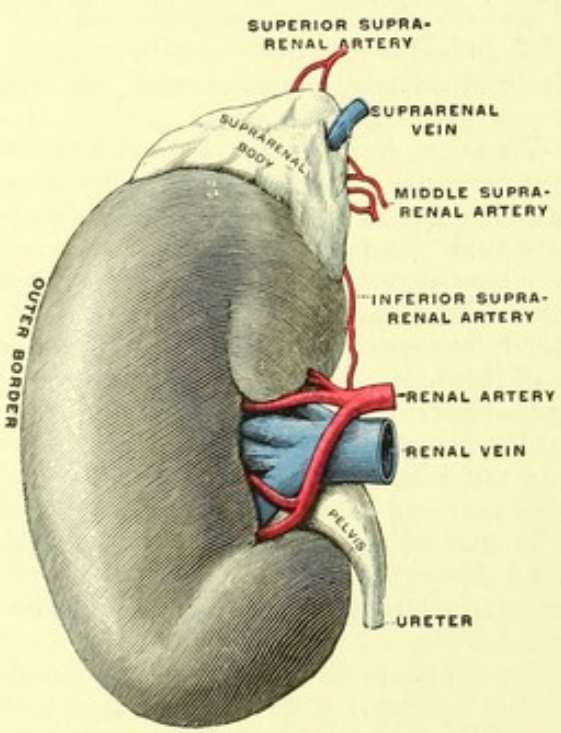

FIG. 849.—Right kidney, ventral aspect. (Testut.)

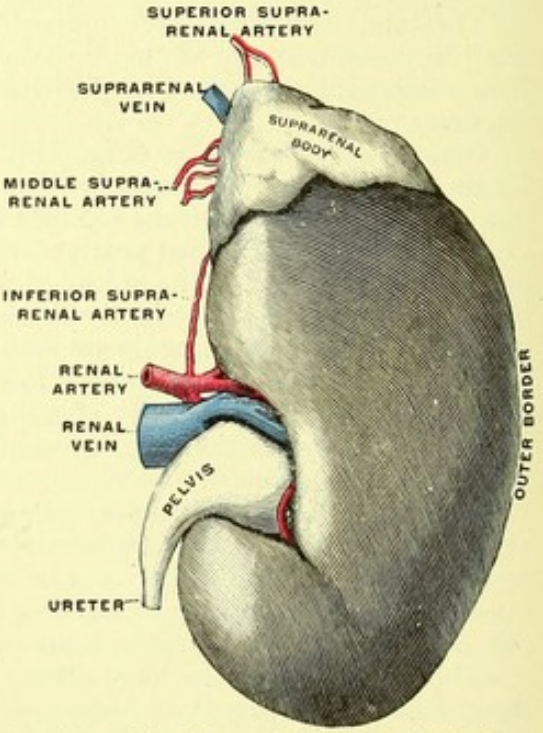

FIG. 850.—Right kidney, dorsal aspect. (Testut.)

The hilum presents a vertical cleft, with rounded front and back lips, and this is the narrowed entrance to the cavity (sinus) of the kidney. The *sinus* is a deep

excavation, flattened from before backward, and reaching half way from border to border. The papillæ project into it, and it encloses the divisions of the renal vessels, the beginnings of the excretory apparatus, lymphatic vessels and nodes, nerves, and a quantity of adipose tissue, which fills the spaces left unoccupied by these structures, and affords an elastic bed upon which they rest. The outer tunic extends into the sinus through the hilum, becomes continuous with the sheaths of the vessels, and is reflected onto the calices.

The kidney is about $4\frac{3}{4}$ inches *long*, $2\frac{3}{4}$ inches *wide*, and $1\frac{1}{4}$ inch *thick*. It *weighs* from 4 to $4\frac{1}{2}$ ounces. Its *surface* is smooth, no traces of the fœtal separation of the lobes remaining. It is of a reddish-brown *color*. It has a firmer *consistence* than either liver or spleen, but is lacerated by moderate force.

The *artery of the kidney* is the renal, and is large relatively to the size of the organ it supplies (Fig. 851). It divides into four branches, which pass into the sinus, and then break up into vessels, which enter the columns of Bertin, and pursue a course, which has already been described. The surface of the kidney receives small branches from the suprarenal, spermatic, and lumbar arteries. The *veins* course side by side with the arteries. The *lymphatic vessels* are numer-

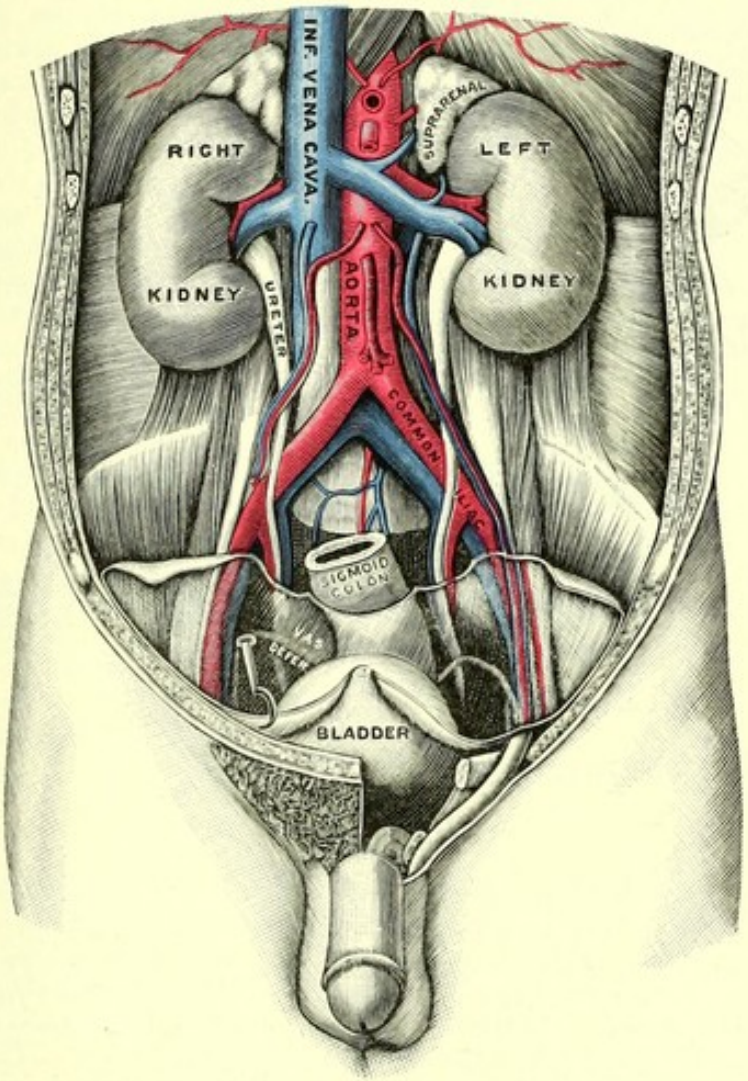

FIG. 851.—The kidneys, the ureters, and the bladder, in their normal position. (Testut.)

ous, especially in the labyrinth, and there are several nodes in the sinus. Both the superficial and deep lymphatics are tributary to the lumbar nodes. The *renal nerves* come from the renal plexus and small splanchnic. They accompany the arteries, but have not been traced beyond the interlobular. Some fibres from the

pneumogastric, also, have been observed. About two-thirds of the anterior surface is invested with *peritoneum*.

Situation of the Kidneys.—The kidneys are situated at the back of the abdomen, one on each side of the spinal column, behind the peritoneal cavity, on a level with the bodies of the twelfth thoracic and upper two or three lumbar vertebræ, the right being about one-half inch lower than the left. The long axis of each is directed from above downward and a little outward, so that the upper ends are nearer the middle line than are the lower. Their hind surfaces look backward and inward. Their lower ends are two inches or less above the iliac crests.

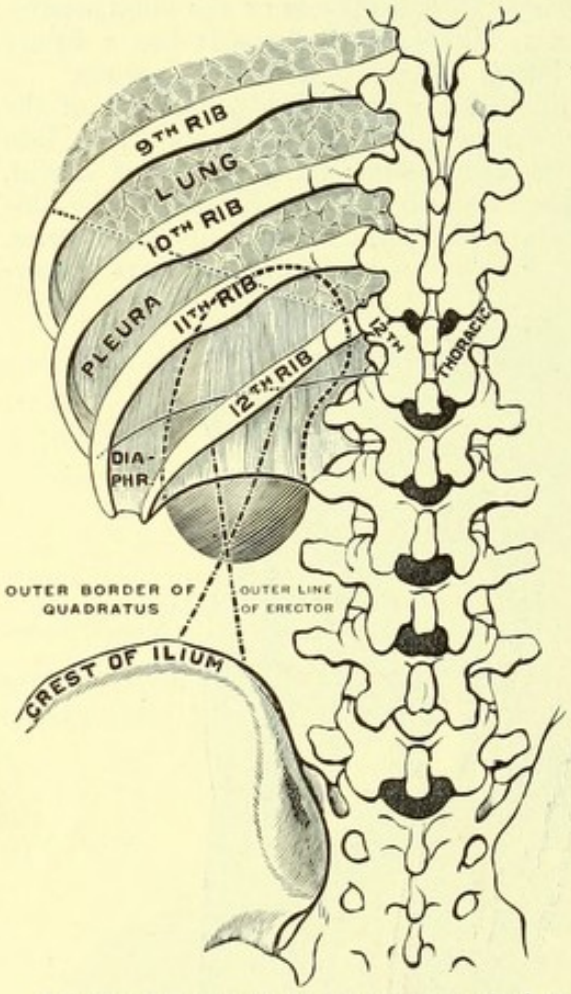

FIG. 852.—Relations of the left kidney to the lung, pleura, ribs, spine, muscles, and hip-bone. (Testut.)

Supports of the Kidneys.—The kidneys are kept in place by their vessels, the peritoneum, and the abundant fatty tissue in which they are embedded, and which constitutes the "*adipose capsule*" of some authors.

Relations of the Kidneys (Fig. 852).—The upper end of each kidney is capped by a suprarenal body, which laps over upon the front surface and inner border. The hind surface of each is in relation to the last rib, the diaphragm, and the quadratus lumborum and psoas magnus muscles. The anterior surface of the right kidney is related from above downward to the suprarenal body, liver, duodenum, ascending colon, and jejuno-ileum; the anterior surface of the left kidney to the suprarenal body, spleen, stomach, pancreas, splenic flexure, descending colon, and jejuno-ileum.

THE EXCRETORY APPARATUS OF THE KIDNEYS.

The urine is conducted from the kidneys by the ureters, by them poured into the bladder, and finally discharged from this reservoir through the urethra.

The Ureters.

The ureter for each kidney begins with the *calices* which enclose the papillæ. They are somewhat fewer than the papillæ, because one calyx may embrace two or even three of them. By the convergence and union of the calices in the upper, middle, and lower regions of the sinus respectively three funnel-shaped tubes, the *infundibula*, are formed; and these focus upon and empty into a large dilatation, the *pelvis* ("basin"), which terminates in the *ureter proper*. The pelvis lies partly within and partly outside of the sinus. When seen from front or back its form is suggestive of the bowl of a tobacco-pipe, the tubular ureter standing for the stem; but it is much compressed antero-posteriorly, having to emerge from the sinus through the hilum, which, although but a narrow slit, gives passage also to the renal vessels, the latter lying in front of the pelvis. The ureter proper is as large as a small goose-quill, about 14 inches long, and passes downward and

inward to the upper level of the sacrum, and thence forward and inward to the base of the bladder, whose outer coat it perforates, and running obliquely between this and the inner tunic for three-quarters of an inch, opens into the cavity of the bladder by a narrow slit, which is one and a half inch or less from its opposite fellow and from the beginning of the urethra (Fig. 853). The practical effect of this arrangement is to prevent the reflux of urine from the bladder; for, although the admission of the fluid is not interfered with, distension of the bladder so presses together the sides of the channel that not a drop can return to the ureter.

FIG. 853.—Diagram showing method of entrance of the ureter into the bladder. (F. H. G.)

Structure of the Ureter.—The ureter has three coats: an inner or mucous, a middle or muscular, and an outer or fibrous. The *mucous coat* is continuous with that of the bladder below and with that covering the renal papillæ above. Its epithelium is stratified, the upper layer consisting of cuboidal cells, with concavities on their attached surfaces, into which fit the blunt ends of the pyriform cells next below, the taper ends of the latter fitting in between the processes of fusiform cells underlying them, and last of all a stratum of irregular cells. There is no well-defined submucous coat. The membrane displays longitudinal folds. The *muscular tunic* has two layers, an outer longitudinal and an inner circular. The *fibrous coat* is a mixture of the white and yellow varieties; it is continuous with the renal capsule, which, entering at the hilum, is reflected upon the calices. The ureter is surrounded by areolar tissue.

Branches from the renal, spermatic, internal iliac, and inferior vesical arteries supply the ureter, its veins correspond to these, its lymphatics run to the pelvic and lumbar nodes and to the receptaculum chyli, and its innervation comes through the inferior mesenteric, spermatic, and hypogastric plexuses.

In its descent the ureter is behind the peritoneum all of the way.

The pelvis is opposite the spine of the first lumbar vertebra. Behind the ureter are the psoas muscle, the sacro-iliac synchondrosis, and the common or external iliac vessels. It is covered in front by the spermatic vessels, and the vas deferens runs between it and the bladder. The right ureter has the vena cava inferior at its inner side. In the female the ureter courses beside the cervix uteri, but at the distance of nearly or quite half an inch, and then it obliquely crosses the upper third of the vagina.

The Bladder.

The bladder (*vesica urinaria*, "the urinary bladder," always being meant when the noun is not qualified) is the reservoir in which the urine is collected from the ureters, and contained until a convenient time for evacuation. It has four tunics: the mucous, which is that nearest the cavity, and then in order the areolar, the muscular, and the serous. The *mucosa* has a stratified epithelium, similar to that of the ureter, is loosely attached to the muscular coat by the areolar, is deficient in well-defined glands and in muscularis mucosæ, is smooth when spread out by accumulation of urine, but, during the empty condition is thrown into irregular rugæ, excepting in a small, triangular space (*trigonum*) between the openings of the ureters and the urethra. This little area is never wrinkled, but is marked in the median line by a slight ridge, the *uvula vesicæ*. The *muscular tunic* has an outer, longitudinal layer, which runs sagittally; inside of this a stratum in which the fibres are intricately and irregularly criss-crossed, but have a general transverse (circular) direction, and internal to this an imperfect, thin, longitudinal layer. The *serous coat* is a reflection of the peritoneum, and is only a partial tunic, covering the superior surface, and the upper and hind part

of the lateral surfaces, and, in the male, the upper part of the posterior surface. The thickness of the combined walls varies much within normal limits, being small in distension, great in collapse, and especially marked if there is good tone to the muscular coat.

Form, Size, and Position of the Bladder.—Without regarding several widely varying, normal circumstances, it is impossible to speak definitely of the form, size, position, and relations of the bladder. One must know the sex and approximately the age of the individual, whether the organ is empty, rather full, or distended, the condition of the muscular coat, and the fact as regards pregnancy. When the bladder is collapsed, its mucous walls fall together in such a way that a sagittal section shows the line between them in the shape of a V with unequal and widely-spread arms, the point of the V indicating the opening of the urethra (Fig. 854). This view affords a means of designation of the most important *surfaces*. The part included within the arms of the V we call *superior* or intestinal surface; that beneath the long arm the *anterior* or pubic surface; and that under the short arm, the *posterior* or rectal surface. Besides these are right and left *lateral* surfaces, which are narrow when the organ is empty.

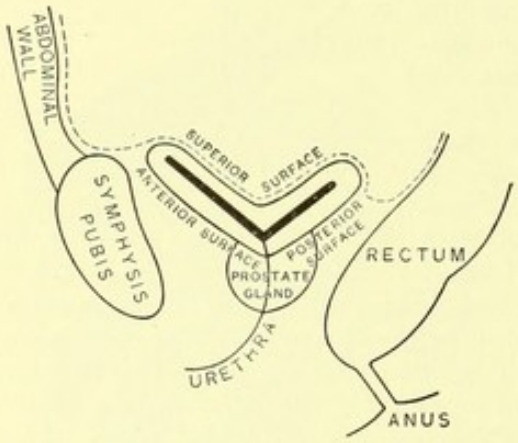

FIG. 854.—Diagram showing the shape, position, and relations of the bladder, when empty. (F. H. G.)

When the bladder is moderately full, its sagittal section is very different (Fig. 855). The upper surface has changed from concavity to convexity, all of the others have become rounded, and the angles between the surfaces have vanished. The bladder in these circumstances holds about eight fluidounces, and has not risen out of the pelvic cavity. But, if this amount of urine is much exceeded, the limit of comfort is passed, and pronounced distention obtains, lifting the organ above the pelvic brim to a height commensurate with the degree of fulness, and bringing it within reach of recognition by abdominal percussion. In the female the bladder is flattened from behind forward, increasing the lateral and diminishing the antero-posterior diameters. In the child the bladder is almost an abdominal organ; but, with increase of years, it sinks to its adult position in the pelvis.

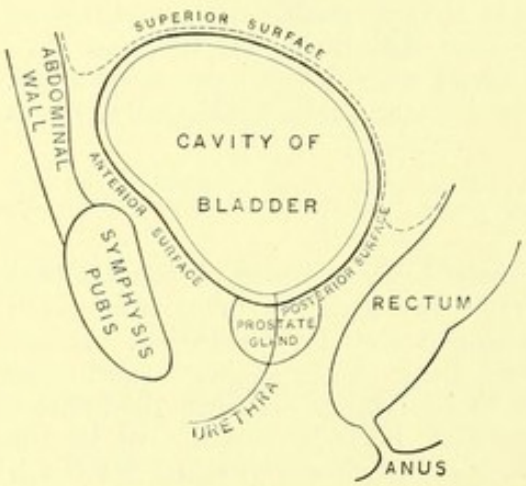

FIG. 855.—Diagram showing the shape, position, and relations of the bladder, when distended. (F. H. G.)

The orifice of the urethra is at the lowest point of the bladder, and is about an inch behind the middle of the pubic symphysis. In old men the posterior wall is liable to sag below this level, and thus permit the retention of a portion of the urine. Enlargement of the prostate gland causes a bulging into the vesical cavity, and raises the opening high above the surrounding walls. There is no constricted part of the bladder which is entitled to be called a neck: the vesical opening of the urethra (*meatus urinarius internus*) is not funnel-shaped, but occurs as an abrupt aperture.

Supports of the Bladder.—The bladder is rather freely movable, but is held within normal limits in various ways. The recto-vesical portion of the pelvic

fascia is an important means of fixation. Around the lower levels of the bladder this fascia is closely united to the muscular tunic, and is sometimes spoken of as a covering of the bladder, thinning out rapidly as it stretches upward. Several parts of this fascia are conventionally described as *true ligaments of the bladder*—two anterior, two lateral, two posterior—but they are usually indistinct, and it is not important to mention more than the two anterior or pubo-prostatic, which connect the lower part of the pubic body with the front of the prostate gland and the adjacent portion of the bladder. Just beneath each of these is a prolongation of the front and lower part of the longitudinal muscular layer, called the *vesico-pubic muscle*, connecting bladder and pubis. The urachus and the obliterated hypogastric arteries extend from the junction of the upper and anterior surfaces to the umbilicus. Folds of peritoneum aid in mooring the bladder, two posterior being reflected to it from the sides of the rectum, the hollow between them being called the *recto-vesical pouch*; two lateral from the iliac fossæ; and one superior, folded over the urachus. These serous reduplications are called *false ligaments*. The continuity of the vesical, prostatic, and ureteral mucous membranes, the strong areolar and adipose connections of the bladder with all of the immediately neighboring organs, and the blood-vessels—all these are factors in the fixation of the bladder.

Relations of the Bladder.—The previous description has involved incidentally so much mention of the relations of the bladder that but little more need be said of them. Its posterior surface, which is the widest, rests in the male upon the rectum (Fig. 856). The serous covering of the superior surface extends for a variable distance upon the posterior, and thence is reflected to the rectum. The line of its lowest attachment to the bladder forms the base of a triangle, whose sides are made by the vasa deferentia. The area thus bounded is accessible to surgical operation through the rectum; but it is unsafe to count upon more than an inch of non-serous surface in the median line between the hind limit of the prostate gland and the fold of peritoneum, though there may be double this amount. In the female the bladder has behind it the vagina and uterus.

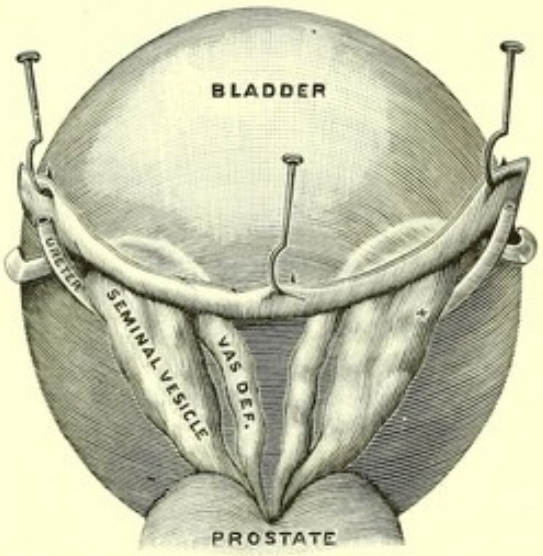

FIG. 856.—Base of the bladder, showing the vasa deferentia and seminal vesicles. The peritoneum is raised by hooks. (Testut.)

When the bladder is distended, the anterior (pubic) surface is so enlarged that it partly rises out of the pelvis, and at the same time the peritoneum is lifted away from the lower part of the abdominal wall, and stretched over the extended area of the superior surface. This leaves a space of two inches or more just above the pubic crest in which an incision can be made without injuring the peritoneum.

The *arteries* of the bladder are the superior and inferior vesical, and, in the female, the uterine also; its *veins* are radicles of the internal iliac; its *lymphatics* are tributary to the internal iliac nodes; and its *nerve-supply* is from the third and fourth sacral, and the hypogastric plexus of the sympathetic.

The Urethra.

The urethra is the tube by which the urine is conducted from the bladder. Its name, like "ureter," is derived from the Greek word which means "to urinate." The male and female urethræ differ so materially that a separate description of each is necessary.

The Female Urethra.

This tube (Fig. 857) begins at the meatus urinarius internus in the bladder, and ends at the meatus urinarius externus in the vulva. It runs downward and

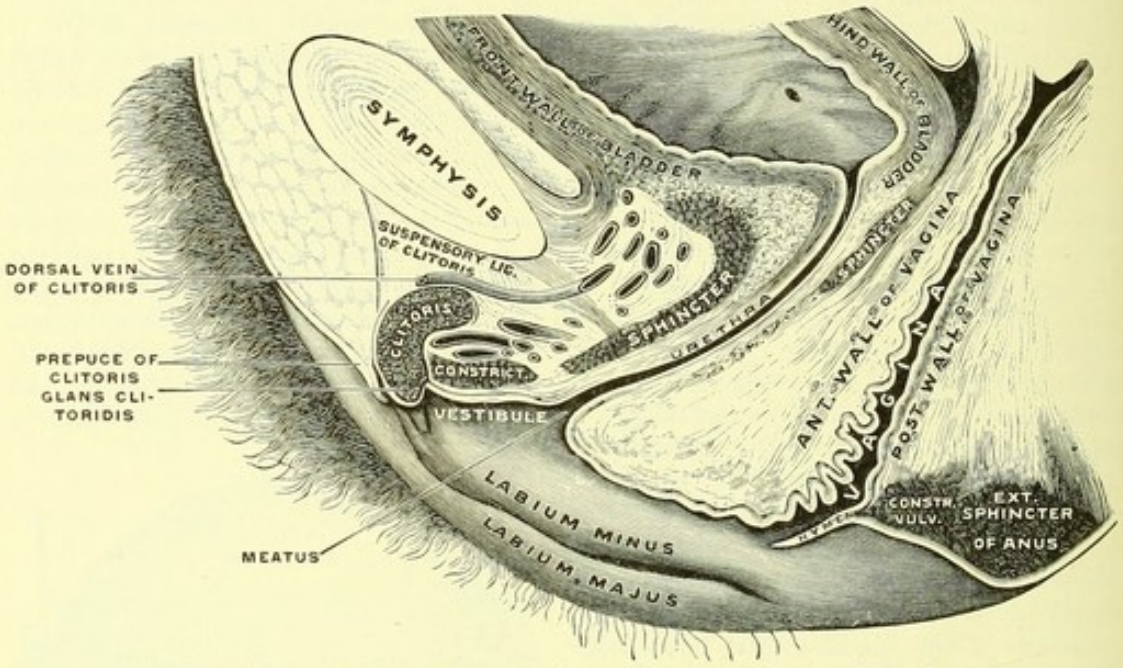

FIG. 857.—The female urethra and surrounding parts seen in sagittal section. (Testut.)

a little forward, curving with the concavity in front. It is about one inch and a half long, and its lumen is about a quarter inch across. It is situated directly in front of, and is closely associated with, the lower part of the anterior wall of the vagina, through which it can be easily felt. Its external orifice is the narrowest part, and is located between the clitoris and the opening of the vagina. The front and rear surfaces of the tube are in contact.

The lining is a pale mucous membrane, and it is gathered into small, longitudinal folds (Fig. 858). Its epithelium is flattened and stratified, except at the uppermost part, where it is transitional; its corium is beset with small papillæ, which are most numerous near the lower end. Mucous glands are abundant. The submucous coat is areolar, and contains an unusual proportion of yellow fibrous tissue. Outside of this is the muscular tunic in two layers, an internal longitudinal, and an external circular. At the vesical end of the tube the circular fasciculi are particularly numerous, and form a ring, which is erroneously called the sphincter of the bladder, but is properly named the *internal sphincter of the urethra*. Between the muscular layers are scattered many elastic fibres. In both layers, and especially in the longitudinal, is a great quantity of blood-vessels, the veins being far more conspicuous by their number and size, and in their arrangement highly suggestive of erectile tissue,

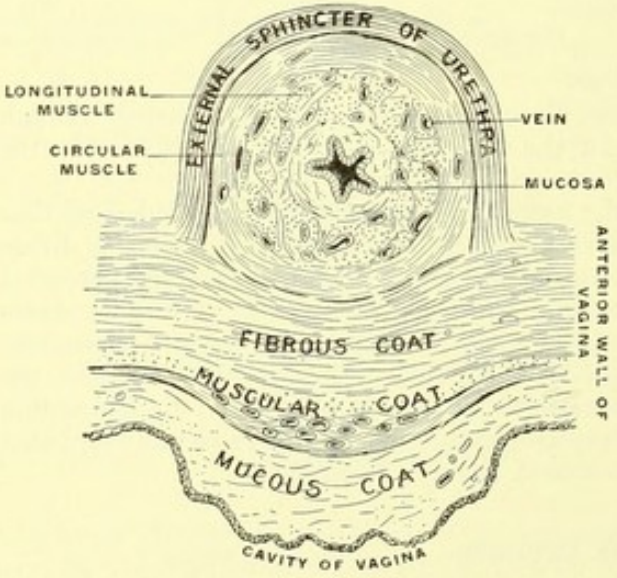

FIG. 858.—The female urethra, seen in coronal section. (Testut.)

though unlike this in being disseminated throughout the muscular coat, instead of constituting a discrete layer.

The female urethra is very distensible, and may be dilated far beyond its usual calibre without loss of its tone.

The Male Urethra.

The male urethra (Fig. 859) is a tube which carries not only urine, but also semen, and only a small portion nearest the bladder is devoted exclusively to the former use. It extends from the meatus urinarius internus in the bladder to the

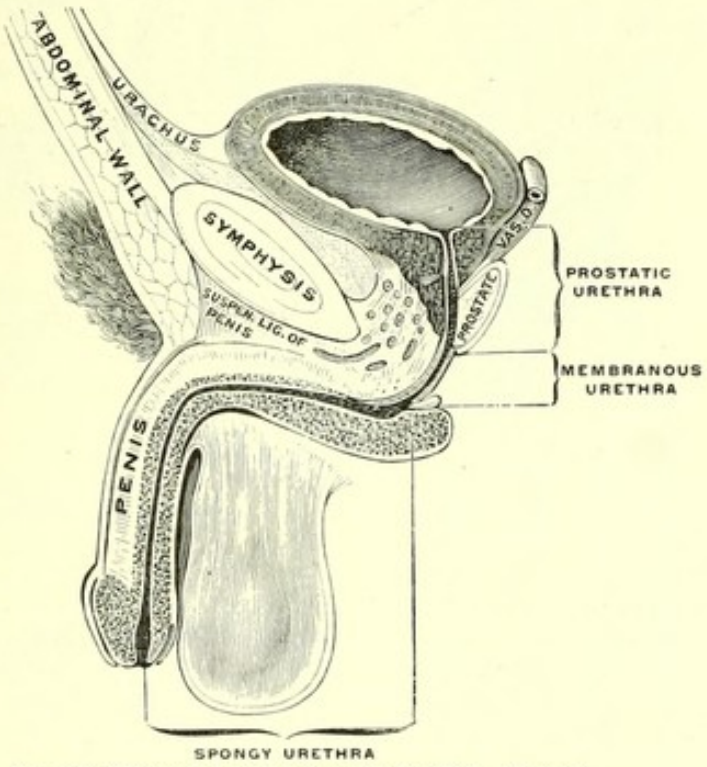

FIG. 859.—The male urethra, in sagittal section. (Testut.)

meatus urinarius externus at the distal end of the penis. It is divided into three portions: first, the *prostatic* (called also the *prostatic urethra*), named from its being contained in the prostate gland; second, the *membranous* (called also the *membranous urethra*), reaching from the distal end of the prostate to the proximal end of the spongy body, and passing through the triangular ligament of the perineum, named because, instead of being embedded in the substance of some organ, as are the other portions, it is a free tube in the greater part of its extent; and third, the *spongy portion* or the *spongy urethra*, which occupies the corpus spongiosum of the penis.

The *length of the urethra* varies at different times in the same individual, owing mainly to physiological changes in the condition of the erectile penis, in which the largest part of the urethra is contained. In the flaccid state it measures $6\frac{1}{2}$ inches; but this length is vastly increased by the erection of the penis. In the common operation of catheterization the urethra is stretched two inches or more. Its length is divided among its three portions as follows: prostatic $1\frac{1}{4}$ inch, membranous $\frac{3}{4}$ inch, spongy $4\frac{1}{2}$ inches. The first and second parts are not subject to great physiological changes such as characterize the third.

The urethra has two pronounced *curves*. In the prostatic portion its course is nearly perpendicularly downward; in the membranous it runs downward with a forward sweep; in the spongy it passes forward almost horizontally for two inches, and then bends sharply downward. Thus, the first and second portions describe

a gentle curve which is concave forward, and the third portion has a curve (so sharp as to be almost an angle) about midway of its length (Fig. 860). This second curve is obliterated when the body of the penis is raised, as in the introduction of an instrument to the bladder through the urethra, and also during erection. The part of the urethra between this curve and the bladder is called

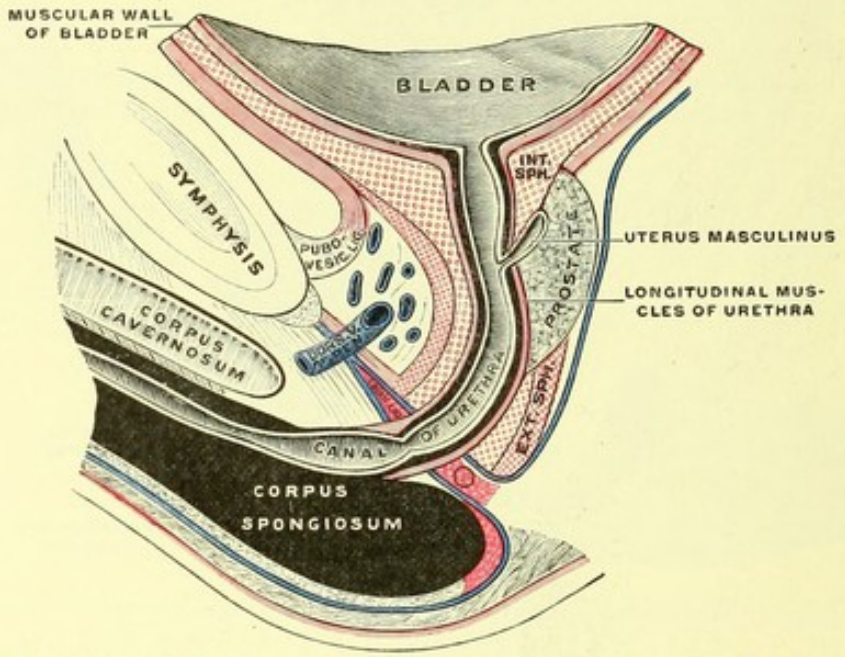

FIG. 860.—Proximal portions of urethra with surrounding parts. (After Testut.)

the fixed portion ; but it is practicable for a skilled hand to pass a straight instrument into the bladder without injuring the tube or its surroundings.

The *bore of the urethra* varies in size and shape in different parts (Fig. 861). The prostatic portion has the largest calibre, measuring one-third of an inch half way of its course, and a little less at its extremities. It is also the most distensible segment. In its hind surface (the floor) is an elevation which rises gradually from behind and then descends more abruptly (Fig. 862). This is called by various names—*verumontanum*, "a mountain spit," *caput gallinaginis*, "the cock's head," *colliculus seminalis*, "the little seminal hill." From the summit of this ridge a little tubular cavity runs upward and backward for about half an inch, called *uterus masculinus*, "the male womb," because it is the homologue of the uterus of the female. It is also called *sinus pocularis*, "the cuplike hollow," and *vesicula prostatica*, "the prostatic vesicle." Upon its lateral lips open the two ejaculatory ducts, through which the semen is squirted into the urethra. On each side of this mound is a groove, the prostatic sinus, into which open the most and the largest of the ducts from the glandular masses of the prostate, the smaller ducts opening in the sides and roof (front surface) of the tube. The presence of the crest causes a transverse section of the urethra to look like an inverted U. The membranous portion has a diameter of one-fifth inch or less, which is also that of the meatus externus. The latter is the least dilatable part, and, consequently, an instrument which will pass the meatus will go through every other portion of the canal. Where the membranous urethra perforates the rigid triangular ligament it is not as readily dilated as elsewhere. The spongy urethra has a calibre between the other portions in size, and uniform except at its extremities. In front for about half an inch it is dilated and thus forms the *fossa navicularis*, "the boat-shaped pit," and behind for nearly an inch it widens in every direction, making the *pars bulbosa*, "the bulbous part."

The lowest point of the membranous urethra is about one inch beneath the pubic arch. The upper part of this portion is in close relation to the rectum.

Structure of the Urethra.—The *inner coat* of the urethra is mucous membrane, continuous above with that of the bladder, below with the skin. It is unusually rich in elastic fibres. It has, most markedly in the spongy portion, fine longitudinal folds, which are effaced during urination. The tube does not stand open, like the trachea or a severed artery, but opposite surfaces (generally the front and rear) of mucosa are in contact. The epithelium of the prostatic portion is similar to the vesical; in most other parts it is a simple columnar, but for a

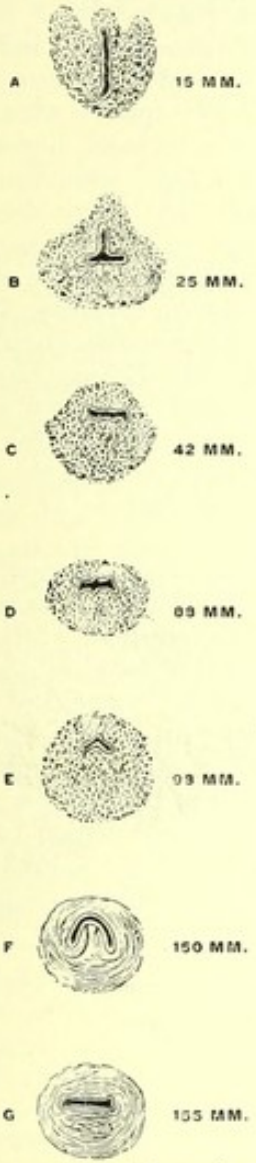

FIG. 861.—Cross sections of the male urethra at various distances from its free end, showing marked alterations of form. (Testut.)

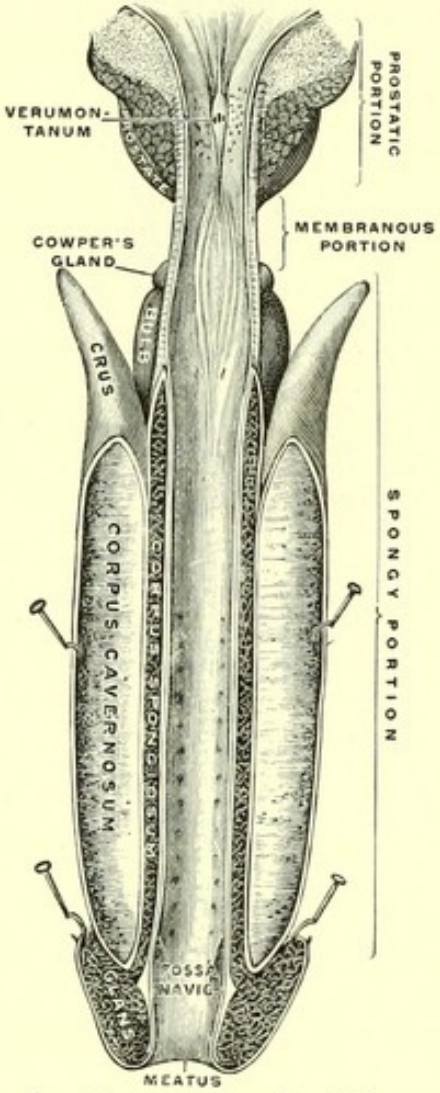

FIG. 862.—The male urethra, laid open on its anterior (upper) surface. (Testut.)

quarter inch back from the meatus it is of the flattened variety and stratified. The corium is plentifully studded with small papillæ. Mucous follicles and racemose glands are practically everywhere proximal to the navicular fossa. There are also many openings which were formerly thought to belong to glandular structures, but have been ascertained to be blind depressions obliquely set in the mucosa, their mouths always directed toward the external meatus (Fig. 863). They are *lacunæ*, "little lakes," and are found in the free spongy portion, proximal to the fossa navicularis, in two sets, large and small. The large are one-third inch deep and occur in a single, median row in the anterior (upper) wall; the small are located principally in the anterior surface and at the sides in

longitudinal rows. Half an inch or more from the meatus externus in the anterior surface is a very large depression, nearly covered by a valve-like fold and, called *lacuna magna*, "the great lacuna." In any of the larger pits the point of a fine instrument may catch, with results diagnostically misleading and therapeutically injurious. Doubtless, also, the obstinacy of gonorrhœal inflammation is often due to the concealment of the specific virus in some of these recesses, beyond the reach of topical remedies. It will be seen that there are many openings upon the surface of the membrane—those of mucous follicles, racemose glands, prostatic glands, ejaculatory ducts, the uterus masculinus, and the lacunæ; to which array must be added the mouths of the ducts of Cowper's glands, in the proximal part of the spongy urethra, the glands themselves being situated one on each side between the two layers of the triangular ligament, close to the membranous portion of the tube.

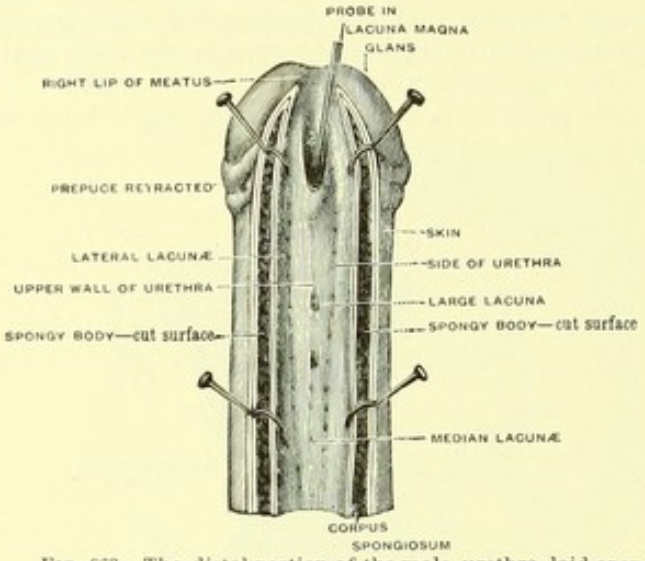

FIG. 863.—The distal portion of the male urethra, laid open on its posterior (under) surface, showing the lacunæ. (Testut.)

The mucous membrane is surrounded by an *areolar coat* of great elasticity, in the meshes of which are large numbers of convoluted vessels, mostly venous, a tissue similar to the true erectile tissues being thus constituted. Outside of this is a *coat of unstriped muscle* in two layers, the inner being longitudinal in the disposition of its fasciculi, the outer circular. The whole is enclosed in a fibrous tunic of variable thickness. In the upper part of the prostatic portion the circular muscular layer is thick, and is sometimes spoken of as the sphincter of the bladder; but it should be called the *internal sphincter of the urethra*. This should not be confounded with the structure of striped muscle which surrounds the membranous portion above the triangular ligament, and is the *external sphincter of the urethra*. The compressor urethræ embraces the membranous portion in the space between the two layers of this ligament.

THE DUCTLESS GLANDS.

By F. H. GERRISH.

THERE are several organs whose general, gross appearance is very similar to that of secreting glands, but which are conspicuously unlike the latter in the respect that they do not possess any duct by which their secretion is discharged. From this fact they have long been called *ductless glands*. This name involves a seeming paradox, for the word "gland" implies the capacity to form a product known as a secretion, and not only had nobody seen a secretion from one of these organs, but the absence of a channel of exit strengthened the idea that there was no such material to be discharged. With this view of the case authors endeavored to devise a name for this class of bodies, which should be more in accordance with the supposed facts. No such name, however, obtained general adoption, and the old title continued to be commonly employed, though with a mental protest by those who disliked inaccurate nomenclature.

In recent years investigations along physiological and pathological lines have shown that some of these organs have a profound influence upon nutritive changes in the body, and have established the fact of "internal secretion." In other words some of these bodies have been found to form substances out of materials brought to them in the circulation, and to discharge these products of their activity into the blood; and it is rendered highly probable that the others of the group have a similar office. Since the fact of internal secretion is so well established, it is unnecessary longer to seek for another name for this class of organs, which, though ductless, are really glands.

These glands are the spleen, the thyroid body, the thymus, the suprarenal capsules, the hypophysis, the parathyroids, and the carotid and coccygeal glands. Some writers include the tonsils and the epiphysis in the enumeration; but the former are more properly counted among the lymphatic structures, and the latter probably has no appreciable use, being an aborted attempt at the formation of a third eye.

It is not inappropriate to remark in this connection that the possession of a secretion and an excretory duct for it does not necessarily prevent an organ's having an additional function of like nature with that of the ductless glands. For example, the liver has other duties besides that of secreting the bile; and the testicles, while forming the essential elements of the semen, exert a profound impression upon the physical and mental attributes of the individual, as best shown in the arrest of development in various directions in those persons who have been castrated before reaching the age of puberty.

THE SPLEEN.

The spleen (*lien*) (Fig. 864) is the largest of the ductless glands. It is situated in the dorsal part of the epigastric and left hypochondriac regions, behind

the stomach, covering the distance from the eighth to the eleventh ribs, and lying with its long axis in line with that of the tenth rib. Its *measurements* are usually not less than five inches for length, three for breadth, and one inch for thickness, and they may be considerably more than the above without departure from the normal, so great are the variations of its size within physiologic limits. Its *weight* also differs, conformably with its size, but will generally be five ounces or more. It is purple in *color*, of a soft *consistency*, rather friable, and sags out of shape by its own weight.

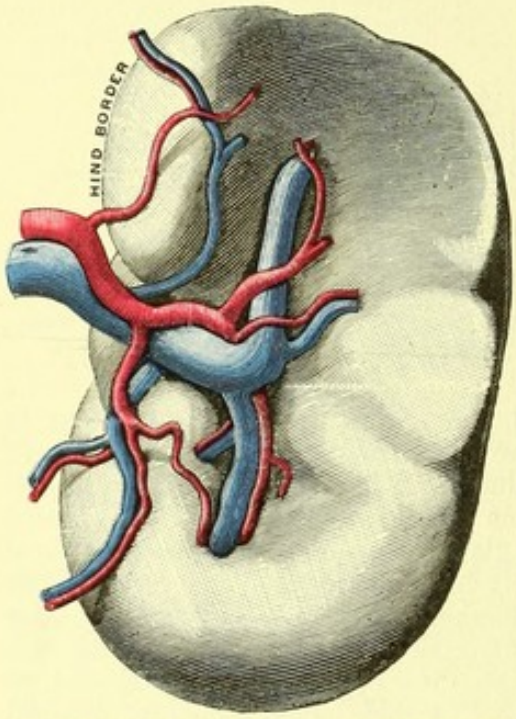

FIG. 864.—The spleen, showing the gastric and renal surfaces and the blood-vessels. (Testut.)

Surfaces and Borders.—It presents three distinct surfaces, separated by three borders. The *phrenic surface*, so called from its relation to the diaphragm, is convex, is as large as both of the others, and faces backward and to the left. The opposite (mesial) area is divided by a lengthwise ridge into a larger, anterior, concave *gastric surface*, in contact with the stomach, and a smaller, posterior, concave *renal surface*, which receives the left kidney. The lower end is blunt, and is sometimes designated as the basal surface. The *anterior border* is between the phrenic and gastric surfaces, is sharp and notched; the *posterior border* separates the phrenic and renal surfaces, and is rounded; the *internal border* is the ridge between the gastric and renal surfaces. Upon the gastric surface, close to the internal border is a notch, the *hilum*, marking the passage of the splenic vessels and nerves.

Structure of the Spleen.

The spleen has a complete serous coat (Fig. 865), which is reflected from it at the hilum, a layer passing to the stomach, as the front lamina of the *gastro-splenic omentum*, the hind lamina being contributed by the small sac of the peritoneum, and another layer passing to the kidney, as the hind lamina of the *lieno-renal ligament*, whose front lamina is furnished by the small sac of the peritoneum. From the upper end of the spleen a serous fold, the *phreno-splenic ligament*, connects it with the diaphragm.

Beneath the serous coat is the *tunica propria*, composed of mingled white and yellow fibrous tissues, the latter material being very abundant, and giving the organ great elasticity. Many cords and bands (*trabeculæ*) project into the organ from the inner surface of this tunic, and some plain muscle-cells are mixed with the fibrous elements. At the hilum the tunica propria is reflected inward upon the vessels, and forms sheaths around them. At some distance from the surface, the arteries having become smaller by branching, the character of the sheath is changed from fibrous material to lymphoid, and at frequent intervals it is thickened so as to present globular or ovoid masses, the *Malpighian corpuscles*, sometimes $\frac{1}{25}$ inch in diameter.

By the entrance of the trabeculæ in one direction and the ensheathed vessels in another, the contained room of the spleen is divided into numberless, minute, irregular, intercommunicating spaces; and these last are subdivided by delicate fibrous strands, connecting trabeculæ and vessel-sheaths, the surfaces of these little cords being covered by branched fibrous-tissue cells. The resulting areolæ

are occupied by the *spleen-pulp*, which is substantially blood, thickened by the addition of great numbers of leucocytes, among which are certain large corpuscles, called *splenic cells*.

The arrangement of the blood-vessels is extraordinary, and altogether peculiar to this organ. The *splenic artery*, which, judged by the standard of the arteries of other organs, is relatively very large, runs in the lieno-renal ligament, and divides into five or six branches before entering the organ. Rapidly breaking

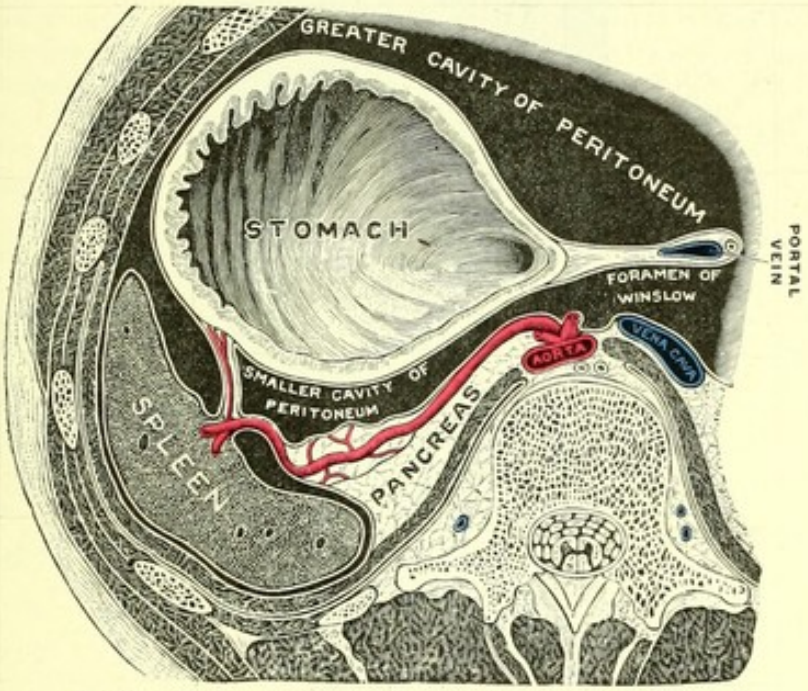

FIG. 865.—Horizontal section in the region of the spleen. (Testut.)

up into smaller vessels, when the minute arteriole stage is reached, which is generally succeeded by the stage of capillaries, the vessels abruptly terminate, and the blood is poured into the wall-less spaces of the spleen-pulp, from which it is collected by venules. The Malpighian corpuscles are factories for leucocytes, and the arterial blood courses among the latter, its flow being impeded by their great number and by the filamentous framework of the pulp-spaces. The blood in the splenic vein is remarkably rich in leucocytes. It is thought that one function of the spleen is the disintegration of worn-out colored corpuscles of the blood, as the pulp contains many fragments of these cells.

The *lymphatics* run in the tunica propria, the trabeculæ, and the walls and sheaths of the vessels. They discharge into the splenic nodes, from which the lymph passes to the cœliac nodes. The *nerves* are derived from the solar plexus.

The structure of the spleen is in some respects very similar to that of the lymph-nodes. The adenoid reticular tissue, the accumulations of lymph-cells, the great relative size in children, the atrophy which occurs in old age—all suggest an immense community of lymph-nodes, especially modified by a peculiar blood-supply.

Not very infrequently *accessory spleens* (*lienculi*) are found. They are globular and small, but otherwise look like the principal spleen, near which they are situated.

THE THYROID BODY.

The thyroid body (*glandula thyroidea*) (Fig. 866) has, independently of its function of internal secretion, a claim to the name of gland, because it began its

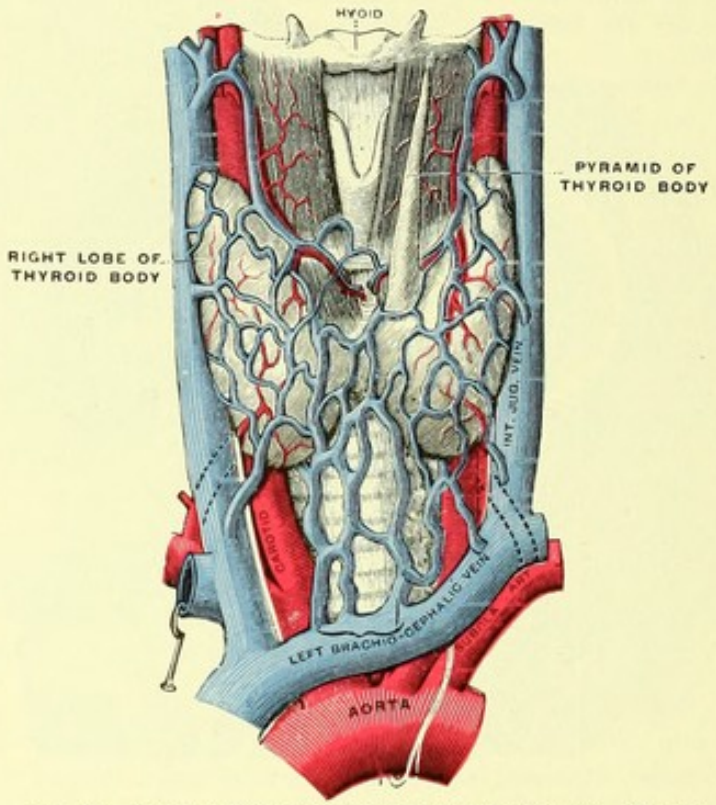

FIG. 866.—The thyroid body and the related blood-vessels. (Testut.)

career as a secreting organ with a duct. In the description of the tongue mention was made of the foramen cæcum, just at the rear of the hindmost circumvallate papilla. This blind hole is a remnant of the *thyro-glossal duct*, the channel through which the thyroid (in the early fœtal condition a compound tubular gland) communicated with the pharynx. In the process of development the duct became shrunken, and finally was nearly obliterated. The acini of the gland, having thenceforth no excretory duct, become dilated with their secretion, which is introduced into the system doubtless through the lymphatics, perhaps also by the veins.

The thyroid gland is commonly described in connection with the organs of respiration; but this association is not justified by likeness of structure or similarity of function, and rests merely upon the circumstance of contiguity.

The thyroid consists of two *lateral lobes*, usually connected at their lower parts by an *isthmus*. The gland extends vertically from the fifth or sixth tracheal ring to the side of the thyroid cartilage, and backward to the side of the pharynx and gullet. When present, the isthmus generally lies across the second, third, and fourth rings. The lobes are broadest below and taper to a point above. They are superficially convex, and adapted to the form of the structures against which they lie. Each is about two inches long, one and a fourth inch wide at its broadest part, and three-fourths of an inch thick; but these figures are subject to great variations in different cases. During menstruation the thyroid of the female is somewhat increased in size. In infancy it is relatively larger than in the adult. The lobes are attached by fibrous tissue to the larynx and trachea, wherever in contact with these organs; and distinct *lateral ligaments* bind them to the cricoid and uppermost part of the windpipe.

Frequently a slender, tapering process, called the *pyramid* (pyramidal process, middle lobe), runs upward to the hyoid between the lateral lobes, from one of which (usually the left) or from the isthmus it arises. This is a part of the remains of the thyro-glossal duct, mentioned above. The gland is commonly of a dark red *color*, and its *weight* is an ounce or more.

The thyroid body has a strong *tunic* of fibrous tissue, from the inner surface of which *trabeculæ* are given off, incompletely dividing the parenchyma into irregular *lobules*. These lobules are composed of closed *vesicles*, which are the original, tubular acini of the gland, matured and altered by reason of the closure of their excretory ducts. The vesicles are of many shapes and various sizes, the largest not exceeding one twenty-fifth inch in diameter. They are lined with a single layer of short, columnar epithelial cells, and filled with a colloid fluid. They are held together by areolar tissue, in which course the vessels and nerves.

The *arteries* of the gland are the superior thyroids, inferior thyroids, and occasionally the thyroidea ima. These vessels are of large size relatively to the volume of the gland, and make abundant anastomoses. The *capillaries* form a close plexus around the vesicles, and even penetrate between their epithelial cells. The *veins* are arranged in an intricate network on the surface of the gland, from which the blood is collected by the superior, middle, and inferior thyroid veins. The *lymphatics* begin in spaces about the vesicles, form a plexus in the capsule of the gland, and empty into the deep cervical nodes. Colloid matter, like that in the cavity of the vesicles, is found in the lymphatics. The *nerve-supply* is rather scanty, and is derived from the middle and inferior cervical ganglia of the sympathetic.

Accessory thyroid glands of small size are occasionally found in this region.

THE THYMUS.

The thymus (Fig. 867) is a temporary organ, growing somewhat rapidly until it attains a considerable size, and then gradually dwindling until it is merely vestigial.

It is *situated* in the anterior mediastinum and lower part of the neck, between

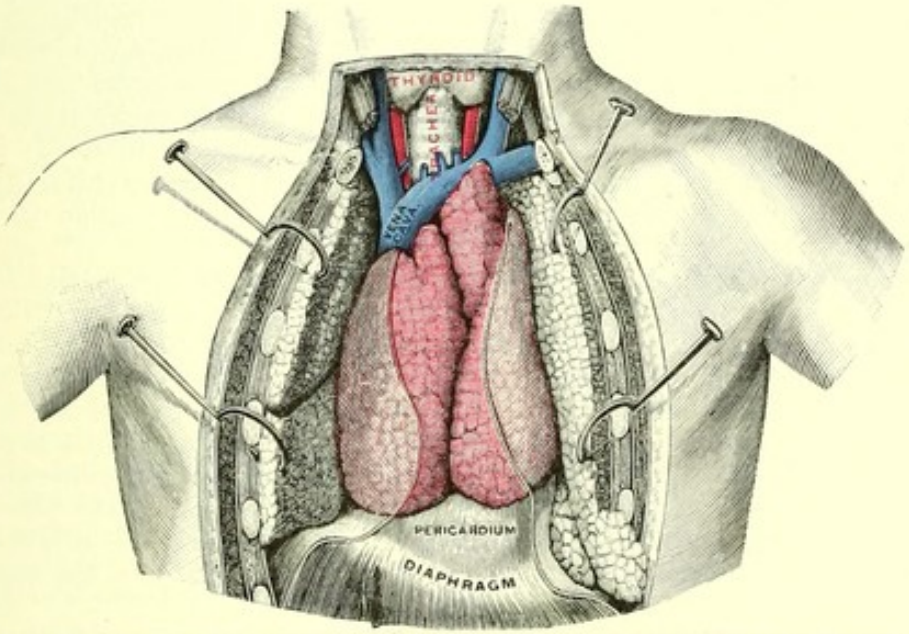

FIG. 867.—The thymus, the sternum and costal cartilages having been removed. (Testut.)

the lungs, in front of the heart, the great vessels, and trachea, and reaching upward nearly to the thyroid. It *appears* at the end of the second month of

intrauterine life. At birth it measures two inches vertically, and half an inch ventro-dorsally and laterally; and it weighs a drachm and a quarter. It is largest when the child is two or three years old, and its *weight* at that time is six drachms. Thereafter it slowly and steadily *atrophies*, and has nearly disappeared by the fifteenth year, although traces of it may be discovered in old age.

It has a rosy hue in the fœtus, is grayish-pink in the infant, and later becomes yellowish. It is soft and compressible, and sags out of shape by its own weight. It is vertically elongated, and is largest below.

It has *two lobes*, approximately symmetrical—the *right lateral* and the *left lateral*—perfectly independent of one another. Each lobe has a delicate fibrous *envelop*, from whose visceral surface *partitions* extend inward, dividing the lobe into a large number of irregular, polyhedral *lobules*. If the envelop is cut between the lobules, the whole lobe can be unfolded, and the lobules are then found to be arranged around a *central cord*, close to which they are continuous with each other, but at the periphery of the lobe are free.

A lobule consists of clusters of little *nodules*, which are essentially lymphatic in character. Each nodule has a *cortical* and a *medullary* portion, the lymph-cells being more numerous in the former, and the latter containing peculiar cells (of Hassall) in nests, the large containing smaller. These medullary corpuscles are the representatives of the epithelium of which the thymus originally was largely composed, before the invasion of lymphatic tissue. A capillary network surrounds the nodule.

As the gland shrinks away the interstitial, connective tissue increases, and multitudes of fat-cells are formed, the last fact accounting for the yellow tinge of the organ during this stage.

The *arteries* of the thymus are derived from the internal mammary, the thyroids, the subclavian, and the carotid. The *veins* run to the left brachio-cephalic. The *lymphatics* empty into the superior mediastinal nodes. The *nerves* come from the pneumogastric and the sympathetic.

THE SUPRARENAL CAPSULES.

Suprarenal bodies, adrenals, *glandulæ suprarenales*—these are the most common of the names given to the two organs, each of which surmounts a kidney, presenting an appearance suggestive of a liberty-cap, rakishly worn (Fig. 868). They are usually classed among the ductless glands, as is done here; but by some they are grouped with the organs of the central nervous system, on account of the prominence of their nerve-tissue, both fibrous and cellular. It is fairly well determined that they are essential to life, inasmuch as their complete removal is speedily followed by death, as also is their entire degeneration in disease. Their precise function is still unknown.

The suprarenal capsules are *situated* in the epigastric region, resting upon the top, and the inner and front surfaces of the kidneys, to which organs they are attached by areolar tissue. They are separated by the vertebral column, the distance between them being about two and a half inches. Their *size* is variable; but the length rarely exceeds two inches, the width one inch and a fourth, and the thickness one-fourth inch. Each weighs about a drachm. The left is a little larger than the right. At birth they have nearly attained their adult size. On the anterior surface is a groove, running nearly crosswise, called the *hilum*.

The **right suprarenal body** is pyramidal. Its anterior surface is nearly covered by peritoneum. It is adherent to the liver in an impression on the under surface of that gland, at the right of the vena cava.

The **left suprarenal body** is not as tall as the right, but extends farther downward on the vertebral border of the kidney. It is in contact with the spleen, stomach, and pancreas. The upper part of its anterior surface is clothed with peritoneum of the small sac.

Structure.—Section of a suprarenal body (Fig. 869) shows it to be composed of a peripheral portion, the *cortex*, and a central portion, the *medulla*—the two being separated by loose, areolar tissue, and the whole mass enclosed in a thin, *fibrous capsule*, which sends inward numerous vertical *trabeculæ*, between which are many connecting bands. Mingled with the fibrous tissue is smooth muscular tissue. Thus are formed spaces in which are lodged the active cells of the organ.

In the *cortex*, which is of a deep yellow color, the *cells*, granular, nucleated, polyhedral, are for the most part arranged in columns, perpendicular to the surface.

The *medulla* is pulpy and dark brown, its color being principally caused by the great abundance of the blood-vessels of the part. The vessels are veins, arranged in a plexus in the fibro-muscular framework, and closely related to groups of large, irregular cells.

The *arteries*, derived from the renal, and the phrenic, as well as directly from the aorta, enter at various points of the surface, and run inward in the trabeculæ,

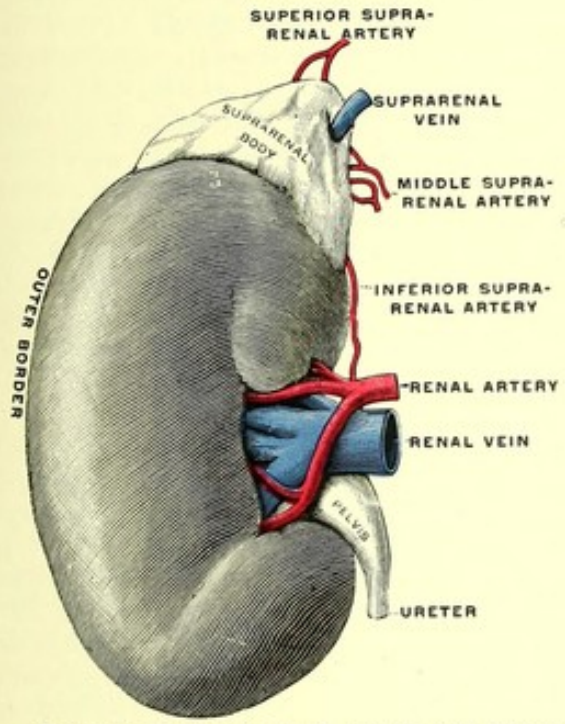

FIG. 868.—Right suprarenal capsule and kidney, viewed from in front. (Testut.)

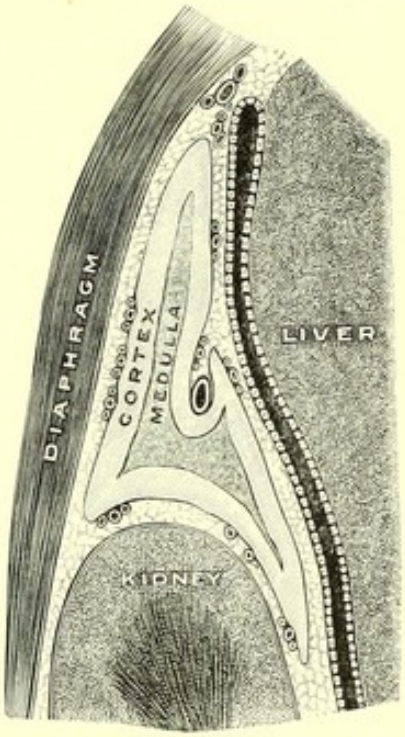

FIG. 869.—Sagittal section of the right suprarenal capsule. (Testut.)

giving off capillaries to the columns and other clusters of cells. The *veins* are nearly all gathered into the medulla, and their efferents are the radicles of a single vessel, which emerges at the hilum, and passes on the right side to the adjacent vena cava, on the left to the corresponding renal. The *lymphatics* begin in lymph-paths between the groups of cells and the framework, and run to the median lumbar nodes.

The *nerves* are derived from the solar and renal plexuses. They are very numerous, and present many ganglia before entering the organ, and ganglion-cells in the medulla.

The suprarenal capsules, like the kidneys upon which they rest, are surrounded by a quantity of adipose tissue. Quite often small accessory bodies of identical structure are found in the immediate neighborhood.

The Parathyroids.

Embedded in the surface of each lateral lobe of the thyroid body are two little masses, each about one-quarter of an inch in diameter, one on the inner and

one on the outer aspect. They are called the parathyroids (*glandulæ parathyroideæ*). They are not like the thyroid in structure, being solid accumulations of epithelioid cells, among which run many blood-vessels. Various theories concerning their function have been advanced, but we are still ignorant of their service.

The Carotid Glands.

The two *glandulæ caroticæ* are thus named because each is situated in the bifurcation of a common carotid artery. They are composed of nodules, each of which is a mass of epithelioid cells, among which are large capillaries. A fibrous capsule covers the gland and sends trabeculæ between the nodules.

The Coccygeal Gland.

The *glandula coccygea* is situated in front of the tip of the coccyx. It is about one-tenth of an inch in diameter, and is very similar in structure to the carotid glands.

The **hypophysis** has already been described.

THE ORGANS OF GENERATION.

By G. D. STEWART.

THE MALE ORGANS OF GENERATION.

THE reproductive organs of the male may be divided into essential and accessory. The former are the *testicles*, two glandular organs, which produce the spermatozoa. The accessory organs are (1) a long canal from each testicle, by means of which the spermatozoa are conveyed into the vagina of the female. This canal is divided into the *vas deferens*, the *ejaculatory duct*, and the *urethra*—the last being single and also belonging to the urinary system. (2) The *seminal vesicles*, reservoirs of the semen; (3) the *prostate gland*, which adds an element to the semen as it passes outward; (4) the *bulbo-urethral glands* (Cowper's), which also contribute to the volume of the semen; (5) the *scrotum*, a pouch, consisting of a series of concentric layers, which envelop the testicles; and (6) the *penis*, the organ of copulation, which encloses the extrapelvic portion of the urethra, and which, when erect, effects the discharge of the semen into the vagina.

THE TESTICLES.

The testicles ("little witnesses" to masculinity), or *testes* (Figs. 870, 871), are two glandular organs which produce the spermatozoa, the principal element of the seminal fluid. They are suspended from the inguinal region by the spermatic cords, and are surrounded and further supported by the scrotum. The left, as a rule, is a little lower than the right, and its spermatic cord is thus a little the longer. Each gland is from one and a half to two inches in length, one and one-quarter inch in width from before backward, a little less than an inch in thickness (measured transversely), and weighs from five to eight drachms. The consistence of the testicle is peculiar, varying somewhat according to the condition of its seminiferous canals. When the latter are engorged it is firm; when they are empty, it is soft.

Each gland is divided into two parts—the testicle proper and the epididymis. The latter must be regarded as the first segment of a canal through which the spermatozoa, after leaving the testicle, must pass to reach the urethra; but it is so intimately connected with the testicle that it may be described with that structure.

The **testicle proper** is ovoid, flattened transversely, and presents two surfaces, two borders, and two extremities. The external surface is convex and turned outward and a little backward; the internal, almost flat, looks in the opposite direction. The anterior border is convex and turned slightly downward; the posterior, almost straight, is directed upward and backward and has attached along its whole length the epididymis. The superior extremity is rounded, and occupies a plane a little external and anterior to the more pointed inferior extremity. The latter gives origin to a fibro-muscular band, the *scrotal ligament*, which is attached by its distal end to the bottom of the scrotum, thus fixing the testicle to its envelops.

The **Epididymis** ("upon the testicle") is a long narrow body, which lies along the posterior border of the testicle, encroaching somewhat on its outer surface. It is composed chiefly of the convolutions of a long canal (to be described later), and is divided into an upper extremity or head, a lower extremity or tail, and an intervening portion called the body. The *head* or *globus major* ("greater globe"), the largest part of the epididymis, is round and smooth. It reposes like a hood on the upper extremity of the testicle, to which it is united by the tunica vaginalis, by an intervening layer of connective tissue, and by the vasa efferentia, which, on emerging from the testicle, immediately enter the globus major and make up the greater part of its bulk. The *body* in horizontal section resembles a comma, and presents in consequence two surfaces and two borders. The anterior surface is concave, the posterior convex. Between the former and the testicle there is a short *cul-de-sac*, the *digital fossa*, which opens outward, and is lined by the tunica vaginalis. The internal border, corresponding to the tail of the comma, is thin, and floats in the cavity of the tunica vaginalis; the external is thick, and lies immediately to the outer side of the vessels and nerves, as they enter the testicle. The tail or *globus minor* ("smaller globe"), intermediate in size between the body and head, is connected to the lower extremity of the testicle by a reflexion of the tunica vaginalis and by loose connective tissue.

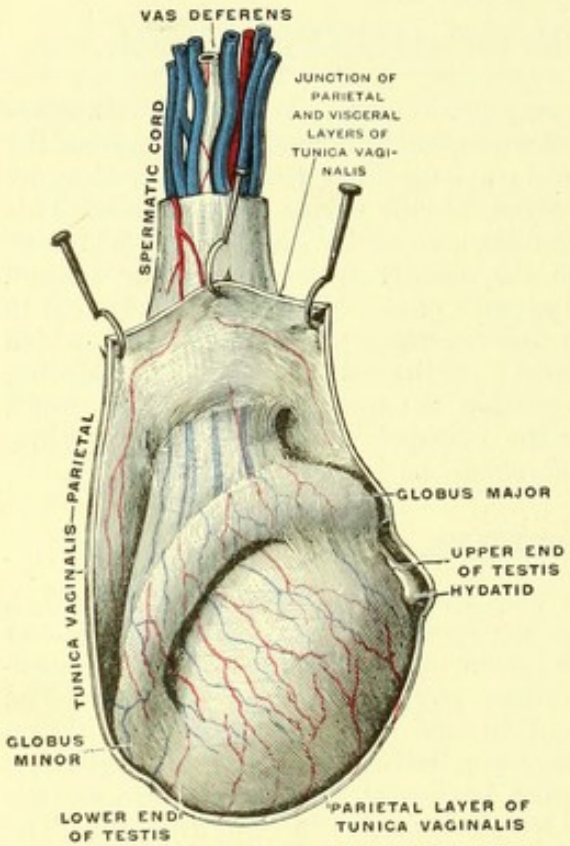

FIG. 870.—Right testicle, its external surface. (Testut.)

Migration of the Testicle.—In early fœtal life the testicle is an abdominal organ lying below the kidney and behind the peritoneum. To its lower extremity there is attached a muscular band, called the *gubernaculum testis* ("rudder of the testis"), consisting of a central bundle of unstriped muscular fibers, which passes through the inguinal canal and is attached to the dartos at the bottom of the scrotum, and of lateral bundles of voluntary muscular tissue, which are derived from the oblique muscles of the abdomen and are, therefore, attached below to the internal ring and the sides of the inguinal canal. Later the peritoneum surrounds the testicle and gubernaculum, forming a mesentery, the testicular portion of which is called the *mesorchium* ("mesentery of the testicle").

Soon there appears on the gubernaculum, at the internal ring, a pouch of peritoneum, the *processus vaginalis* ("sheathlike process"), which elongates gradually and pushes through the inguinal canal into the scrotum, carrying in front of it the subperitoneal tissue, an infundibuliform process of the fascia transversalis, a few fibres of the internal oblique (which form the cremaster muscle), and the intercolumnar fascia. This pouch is then occupied by the testicle, which leaves its abdominal position about the third month of fœtal life, reaches the internal ring about the sixth month, the external by the eighth, and shortly before birth descends into the scrotum.

The cause of this descent is uncertain. That it may be due in small part to the progressive shortening of the gubernaculum is undeniable; that it is in greater measure owing to the fact that the lumbar region grows away from the

testicle, which is fixed by the gubernaculum, is probable. It must be noted too that the peritoneal pouch precedes the testicle, and, since the former is attached to a lower point in the gubernaculum, this fact may be explained in the same way. After descent has been completed, the remains of the central gubernacular

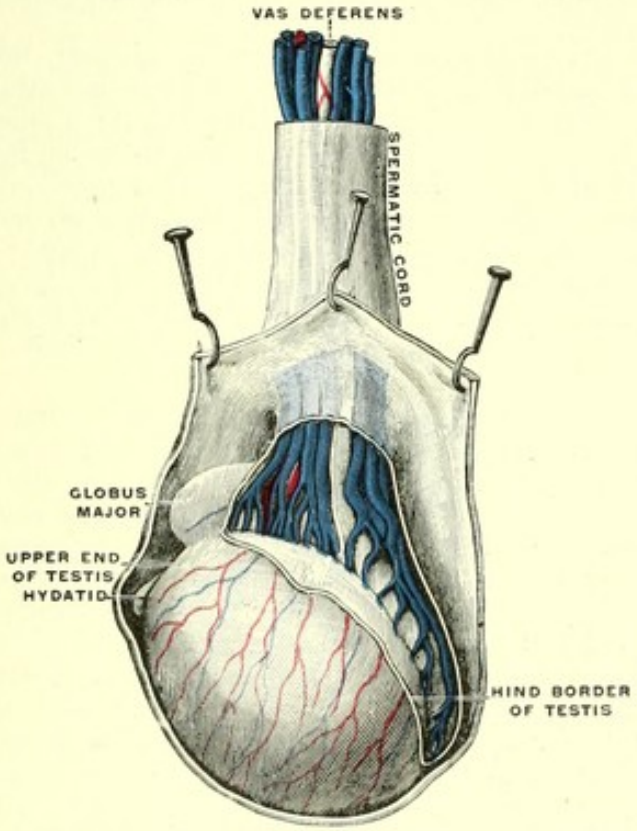

FIG. 871.—Right testicle, its internal surface. (Testut.)

band may be found in the scrotal ligament already described; the lateral bands, having ceased to act after the testicle has reached the external ring, are drawn down, and may be found in the form of scattered bundles (the internal cremaster of Henle), lying amidst the other elements of the spermatic cord.

The peritoneal sac which preceded the testicle is at first continuous with the general peritoneal cavity. Shortly before birth, however, the upper part of the tube of communication becomes closed, and this obliteration extends gradually downward to within a short distance of the testicle. That portion of the sac which surrounds the testicle is thereby completely cut off from the peritoneal cavity, and forms the tunica vaginalis. The obliterated portion of the pouch usually remains as a fibro-cellular thread, lying among the other elements of the cord. Sometimes this may be traced as a distinct band from the peritoneum at the internal ring above to the tunica vaginalis below; sometimes it is lost on the cord.

Occasionally the tube of communication remains open, and then the abdominal viscera may pass into the tunica vaginalis, forming the congenital variety of hernia. In other cases the tube contracts, and forms a very minute canal, which may be traced downward a greater or less distance on the cord. A similar minute tube of peritoneum, observed in connection with the round ligament in the female, is called the *canal of Nuck*.

One or both testicles may fail to reach the scrotum until shortly after birth, or their descent may be delayed until puberty; they may even remain permanently within the abdomen, or be arrested at any part of their course.

The **Tunica Vaginalis** ("sheathlike coat") is a closed serous sac, of peritoneal origin, which invests the testicles and lines the scrotum, and may, therefore, be divided into visceral and parietal portions.

The *visceral layer* is intimately adherent to the tunica albuginea of the testicle proper, except along the posterior border of the gland, where the epididymis is attached, and where the vessels and nerves enter or emerge. It also invests the globus major, lines the digital fossa, and covers the external border and posterior surface of the body of the epididymis, but leaves uncovered almost the whole of the globus minor.

The *parietal layer*, of greater extent than the visceral, lines the infundibuliform fascia, to which it is loosely attached by a prolongation of the subperitoneal tissue. It also covers the spermatic cord for a short distance above the testicle, extending somewhat higher on the inner than on the outer side. At the posterior border of the gland the two layers are, of course, continuous.

The inner surface of the tunica vaginalis is lined by a layer of epithelial cells, and the membrane secretes enough fluid to moisten the apposed surfaces.

Minute Structure of the Testicle.—Structurally the testicle consists of the following parts: (1) a fibrous covering, the tunica albuginea, from which is derived a framework; (2) the tubuli seminiferi; (3) certain excretory canals; (4) interstitial tissue.

The **Tunica Albuginea** ("whitish coat") is a dense, white, fibrous, inelastic capsule, about one-sixteenth of an inch in thickness. Its inner surface reposes on the parenchyma of the testicle; its outer is covered by the visceral layer of the tunica vaginalis. Behind, where the tunica albuginea covers the posterior border of the testicle, it becomes immensely thickened forming a cone-shaped body, the *corpus Highmorianum* or *mediastinum testis* ("standing in the middle of the testis"), which projects forward a varying distance into the mass of the gland. This body approaches a little nearer to the upper than to the lower extremity of the testicle, lies closer to the internal than to the external surface of that organ, and is tunnelled by the larger blood-vessels and a network of ducts, the *rete* ("net") *testis*. By its summit and lateral faces the mediastinum gives origin to a system of thin laminæ and slender trabeculæ, which radiate to become attached to the inner surface of the tunica albuginea, thus dividing the testicle into a varying number (150 to 300) of small pyramidal spaces, called *loculi* ("little places"). In these cavities are lodged the seminiferous canals and the interstitial tissue. The visceral surface of the tunica albuginea and its trabeculæ is covered by a network of minute blood-vessels, connected with the spermatic blood-vessels, and called the *tunica vasculosa*.

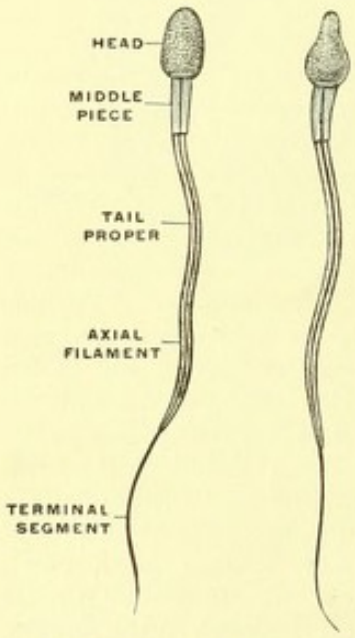

FIG. 872.—Human spermatozoa. The right one is seen in profile. (Testut.)

Histologically the tunica albuginea is composed of bundles of white fibrous tissue, which interlace in every direction, mingled with a small number of fine elastic fibres.

The **Tubuli Seminiferi** ("seed-bearing tubules"), or seminiferous canals, produce the spermatozoa (Fig. 872), and hence form the essential structure of the testicle. They occupy the loculi, and are by the latter divided into a corresponding number (150 to 300) of more or less distinct masses, called *lobules*. These, like their containing loculi, are pyramidal, their bases corresponding to the inner surface of the albuginea, their apices resting on the mediastinum. They each contain two or more seminiferous tubes, making of the latter from five to nine hundred for each testicle.

The tubes vary in diameter from $\frac{1}{100}$ to $\frac{1}{120}$ of an inch, and are so flexuous that, when uncoiled, their length is increased twenty to thirty times (over two feet). They begin near the bases of the lobules by blind extremities. In their course toward the mediastinum they give off two or three cæcal diverticula, and

exhibit frequent anastomoses, particularly near their origin, not only with the tubes of the lobule to which they belong, but with those of adjoining lobules. Near the mediastinum the canals of each lobule unite to form a single straight excretory tube, one of the *tubuli recti*.

The wall of a seminiferous tubule, on cross section, is seen to consist of several concentric layers of epithelial cells. The cells of the innermost layer are united edge to edge to form a basement membrane; the outer layers are incomplete. Within the tubule are several layers of small epithelial nucleated cells, the progenitors of the spermatozoa. (See page 77.)

The **excretory canals** (Fig. 873) of the testicle do not produce spermatozoa, but simply serve to convey the latter from the tubuli seminiferi to the canal of the epididymis. They are the tubuli recti, the rete testis, and the vasa efferentia. The *tubuli recti*, formed in the manner already indicated at the apices of the lobules, are short, straight, and of smaller calibre than the seminiferous canals from which they spring. They penetrate the mediastinum, and in its anterior

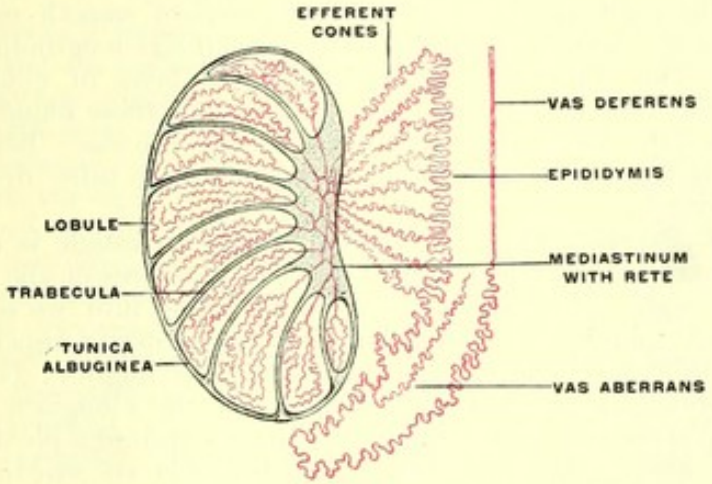

FIG. 873.—Diagram of testicle proper and epididymis. (Testut.)

portion break up into the rete testis. The walls of the straight tubules are made up of the fibrous tissue of the mediastinum, lined by a single layer of prismatic cells. The *rete testis* occupies the whole length of the mediastinum, and is composed of anastomosing vessels of irregular calibre, which vary in diameter, but are always larger than the seminiferous canals or the straight tubules. Like the latter they have no proper wall but are simply channels dug out of the fibrous tissue of the mediastinum, and lined by an epithelium which is here cylindrical, there cubical, or even of the flattened variety. At the upper and back part of the testicle these channels finally unite to form a smaller number of canals, the *vasa efferentia* ("vessels carrying from"). The latter almost immediately escape from the albuginea, and enter the globus major, with which structure they will be described.

The **interstitial tissue** is a very delicate connective tissue, which supports the seminal tubules and the smaller ramifications of the blood-vessels. It is derived from the trabeculæ, and is peculiar in that it contains, besides the ordinary cells of connective tissue, the so-called *interstitial cells*. These are large, rounded or oval corpuscles, some of which exhibit branching processes. Their protoplasm is granular, often filled with fat, and may contain a brown or yellowish pigment. They occupy divers situations, surrounding the smaller vessels and lying between the tubules, and are either a special variety of connective-tissue cells, or are derived from cells of the germinal epithelium, which have not been utilized in forming the tubes. In the spaces of this tissue the lymphatics of the testicles take birth.

Minute Structure of the Epididymis.—The *vasa efferentia*, ten to fifteen in number, carry the spermatozoa from the rete testis to the canal of the epididymis. Emerging from the testicle at its upper and back part, they are at first straight,

but soon become coiled and convoluted, forming a series of cone-shaped masses, the *coni vasculosi*. These cones, their apices turned toward the tunica albuginea, are each about one-third of an inch in length; together they constitute the *globus major*. The tube of which each is composed is about one-thirtieth of an inch in diameter near its origin, about half as large at its termination, and measures when uncoiled from six to eight inches in length. The uppermost vessel merges without line of demarcation into the canal of the epididymis, the remainder open at regular intervals into that canal. The walls of the efferent vessels are made of smooth muscular fibres, circularly arranged, and lined by a ciliated, cylindrical epithelium.

The *canal of the epididymis* takes origin in the globus major in the manner already described. Extending downward, it forms the body and globus minor, and then merges into the vas deferens. It is disposed in numerous coils, held together by areolar tissue. The length of the canal when uncoiled varies from twelve to twenty feet, and its diameter, about one-sixtieth of an inch above, gradually decreases as it approaches the globus minor, to enlarge again beyond that point. The walls are thin, and are composed of smooth muscular tissue, which near the vas may be separated into a superficial longitudinal layer and a circular one. This muscular coat is lined by a layer of ciliated, columnar epithelium. The cilia of the canal are longer than those found in the efferent vessels, but like the latter their motion is toward the vas. Beneath the fixed ends of the columnar cells is found a layer of young cells, destined later to replace the former.

Vessels and Nerves.—The *arterial supply* of the testicle is derived chiefly from the spermatic artery, which joins the other structures of the spermatic cord at the internal ring. Approaching the gland it divides into two sets of branches —testicular and epididymal. The former, at the posterior superior portion of the testicle, subdivides into two sets of branches, as follows: (1) a peripheral group which travels forward in the thickness of the albuginea; (2) a central group, which pierces the mediastinum, and breaks up into a plexus on the walls of the loculi. From this a multitude of fine branches are sent to form plexuses around the walls of the seminiferous canals. The epididymal branches, joining with the terminal twigs of the deferential artery, form a plexus around the canal of the epididymis.

The *veins* pierce the mediastinum, and unite into six or seven trunks, which form a plexus, the *pampiniform* ("tendril-shaped"), surrounding the spermatic artery, and lying in front of the vas. Farther up in the cord the veins become reduced to two or three, and these, following the artery into the abdominal cavity, finally unite to form a single trunk, the *spermatic vein*, which empties on the right into the inferior vena cava, on the left into the corresponding renal vein. The veins from the epididymis form a second group of two or three trunks only, which pass upward in the cord behind the vas, and empty into the deep epigastric veins. The *lymphatics* form a plexus around the seminiferous canals, where they begin as minute spaces lined by epithelial cells. Together with the lymphatics of the epididymis, they accompany the spermatic vessels to end in the lumbar nodes. The *nerves* are derived from the aortic, renal, and hypogastric plexuses of the sympathetic. Branches from these form a secondary plexus around the spermatic artery and the artery of the vas. Their mode of termination is not well understood.

Fœtal Remains.—The *hydatids* ("vesicles") *of Morgagni* are two small bodies —one pediculated, the other sessile—which are found in connection with the globus major and the upper extremity of the testicle. The *pediculated hydatid*, rounded or pyriform in outline, and from one-eighth to one-third of an inch in length, is attached to the head of the epididymis, and covered by the tunica vaginalis. Its cavity, lined by a cylindrical, ciliated epithelium, contains a transparent fluid. This body is not always present, and its morphological significance has not been satisfactorily explained. The *sessile hydatid*, a rounded or flattened

projection of about the same size, is seated either on the front of the globus major, the upper extremity of the testicle, or between the two. It is nearly always present, is sometimes divided into several lobes, and contains in its centre a tubular cavity or canal, which either ends in blind extremities or becomes continuous with a seminiferous canal. Morphologically, this body represents the peritoneal end of the duct of Müller, and is, therefore, homologous with the fimbriated extremity of the Fallopian tube in the female. Sometimes, indeed, it may be found as an empty orifice with fringed borders.

The *organ of Giraldès* or *paradidymis* ("beside the testicle"), a small, irregular, yellowish-white patch, which lies in front of the cord, immediately above the head of the epididymis and beneath the funicular portion of the tunica vaginalis, is made up of several small nodules, each containing a blind convoluted tube, lined with cylindrical, ciliated epithelium. It is a relic of the inferior portion of the Wolffian body.

THE VAS DEFERENS.

The vas deferens ("vessel carrying away") (Figs. 874, 875) is the prolongation of the canal of the epididymis, and extends from the tail of the latter to the base of the prostate gland. It varies in length from sixteen to twenty inches, is cylindrical in outline throughout the greater part of its course, and has an average diameter of about one-tenth of an inch. The vas travels upward in the spermatic cord, and may be divided into four portions as follows: (1) testicular; (2) funicular; (3) inguinal; (4) abdomino-pelvic.

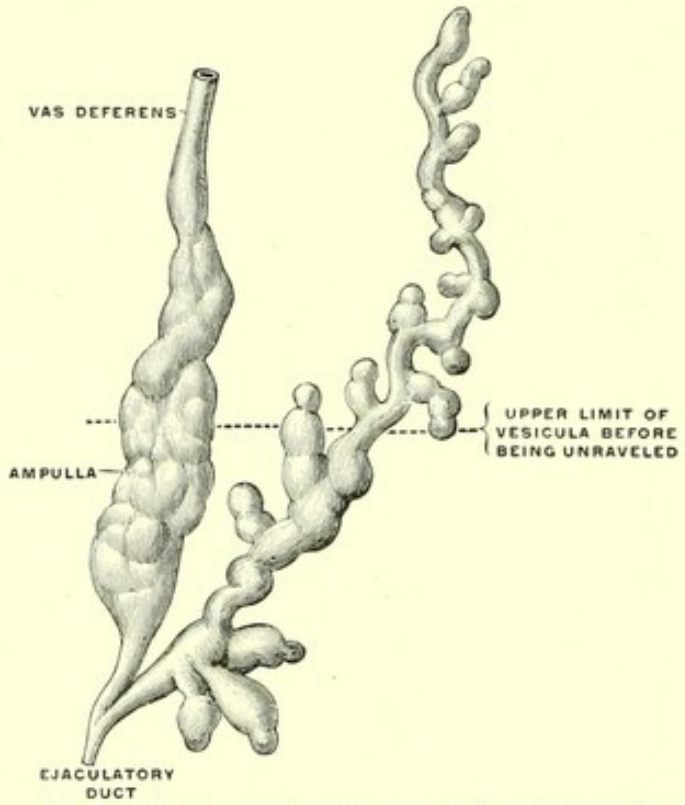

FIG. 874.—Right seminal vesicle, unraveled and viewed from behind. (Testut.)

Direction and Relations.—The *testicular portion*, markedly tortuous, runs from its origin upward and a little forward, to about the middle of the testicle. It lies to the inner side of the epididymis and behind the testicle, and is separated from both by the spermatic vessels and nerves. The *funicular portion* is straight, and is continued vertically upward to the external abdominal ring, lying behind the spermatic artery, nerves, and anterior group of veins, but in front of the posterior veins. The *inguinal portion* occupies the inguinal canal. The *abdomino-pelvic division* is, in the greater part of its course, retro-peritoneal. At the internal abdominal ring it leaves the spermatic vessels and turns inward, curving around the outer side of the deep epigastric artery. Crossing the external iliac vessels on their inner side, it then enters the pelvis close to the ilio-pubic suture, and curves downward and backward on the lateral wall of the bladder, crossing in this part of its course obliquely and to the vesical side of the obliterated hypogastric artery and the ureter. The terminal segment of this division, about two inches in length, runs forward between the bladder and the rectum. It is dilated, flattened from

before backward, sacculated, resembles the seminal vesicle, and is called the *ampulla of Henle*. The anterior surface of the latter is directly applied to the bladder wall; the posterior is separated from the rectum for a short distance above by the recto-vesical pouch of the peritoneum, below this, by the recto-vesical fascia. The external border of the ampulla lies in contact with the inner border of the corresponding seminal vesicle. The ampullæ of opposite sides are separated by a triangular space, the *interdeferential triangle*, the apex of which corresponds to the base of the prostate, and in the opening of which the bladder and rectum are in almost immediate contact, separated only by the recto-vesical fascia. Close to the base of the prostate the ampulla again becomes narrow and straight, and is joined on its outer side by the corresponding seminal vesicle, to form one of the common or ejaculatory ducts.

Minute Anatomy.—The walls of the vas consist of three coats—areolar, muscular, and mucous. The outer or *areolar coat* is composed of fibrous tissue, mixed with blood-vessels, nerves, and smooth muscular fibres, arranged parallel to the long axis of the canal. The *muscular coat* constitutes about four-fifths of the entire thickness of the wall, and gives to the vas a firm, resistant feel, by means of which it may easily be distinguished from the other elements of the cord. It is composed of smooth muscular fibres, arranged in three planes. In the superficial and deep planes the fibres are longitudinal, in the median, which is much the thickest, they are circular. The *mucous coat* is whitish, presents three or four longitudinal folds, which are effaced by distention, and is lined by cylindrical, non-ciliated epithelium. In the ampulla the walls are thinner, and the mucous membrane presents many folds, which, uniting at divers angles, give to this portion an areolar appearance, resembling the seminal vesicles. These areolæ are lined by cubical epithelium.

Vessels and Nerves.—The *artery*, a branch of the superior vesical, joins the vas near its origin, and accompanies it to the testicle, anastomosing in the latter with the spermatic artery. The *veins* empty into the vesico-prostatic plexus and the veins of the cord. The *nerves* come from the inferior hypogastric plexus.

The *vas aberrans* ("vessel wandering from") is a narrow tube which comes from the lower end of the canal of the epididymis, or from the beginning of the vas. Becoming convoluted into an irregular mass, it extends upward between the structures mentioned for an inch or more, and ends in a cæcal extremity. The tube when uncoiled measures from one and a half to fifteen inches in length. It agrees in structure with the vas, and is a relic of the upper part of the Wolffian body.

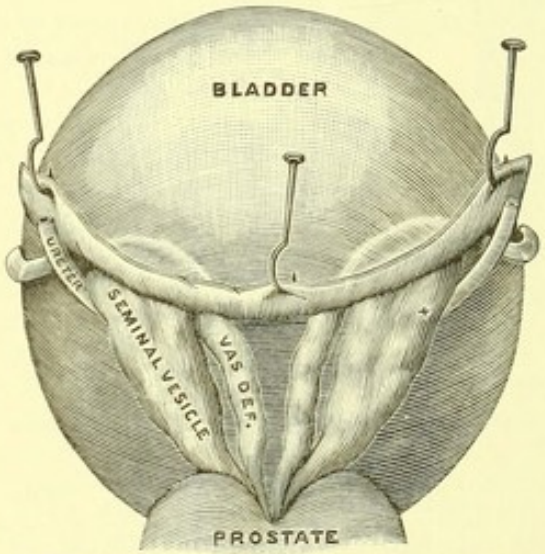

FIG. 875.—Base of the bladder, showing the seminal vesicles and the vasa deferentia. (Testut.)

THE SEMINAL VESICLES.

The seminal vesicles (Figs. 874, 875) are two lobulated pouches, serving as reservoirs for the semen, to which they add a secretion of their own. They are placed one on either side, external to the ampullæ of the vasa deferentia, and between the bladder and the rectum. Each vesicle is pyramidal in form, with the broad end directed backward, measures two inches in length, and about a half inch in breadth at its posterior and widest part, and presents two surfaces, two borders, and two extremities.

The anterior surface is attached to the base of the bladder, overlapping, for a short distance above, the ureter. The posterior surface is convex and covered

above by the recto-vesical pouch of peritoneum, below this, by the recto-vesical fascia, which alone separates it from direct contact with the rectum. The posterior extremities or bases are widely separated; the anterior converge, become narrowed, and near the base of the prostate unite on their inner sides with the corresponding vasa deferentia to form the ejaculatory ducts. Along the inner margin of each vesicle there runs the ampulla of the corresponding vas.

Each vesicle consists of a central tube, four to six inches in length, from which are given off many blind diverticula, the whole being coiled into the form just described, and held thus by dense, fibrous tissue. In minute structure it closely resembles the vas. Like the latter it has an external fibrous coat derived from the recto-vesical fascia, and containing blood-vessels, lymphatics, and nerves. Its middle or muscular coat is thin, but it is arranged in superficial and deep longitudinal layers and a middle plane of circular fibres. The mucous membrane, areolar in structure, like that of the ampulla, is lined with non-ciliated, cylindrical epithelium, beneath which is a deeper layer of polyhedral cells.

Over the posterior surfaces and extending between the two vesicles is found a certain amount of smooth muscular tissue, also some longitudinal fibres, continuous with those of the bladder wall.

THE EJACULATORY DUCTS.

The ejaculatory ducts (Fig. 876), two in number, one right, the other left, are formed close to the base of the prostate by the union, at a very acute angle, of the ampulla of the vas and the corresponding seminal vesicle. They convey the seminal fluid from the vesicles and vasa deferentia into the urethra. From their origins the two ducts run downward and forward, converging as they descend. After a very short course they enter the prostate, and pass forward side by side between its middle and lateral lobes, opening finally into the prostatic urethra by two small elliptical orifices, placed one on either side of the sinus pocularis. Each duct is about three-quarters of an inch in length, and its lumen, diminishing from behind forward, is so small at the urethral end as barely to admit a very fine bristle. The *walls* of this tube are very thin; the outer, areolar coat, found in the vas deferens and vesicula seminalis, has entirely disappeared; and the outer plane of longitudinal muscle-fibres becomes blended with the prostate. The muscular coat proper is therefore reduced to two layers, an outer of circular, an inner of longitudinal fibres. The mucous membrane resembles closely that found in the vas deferens.

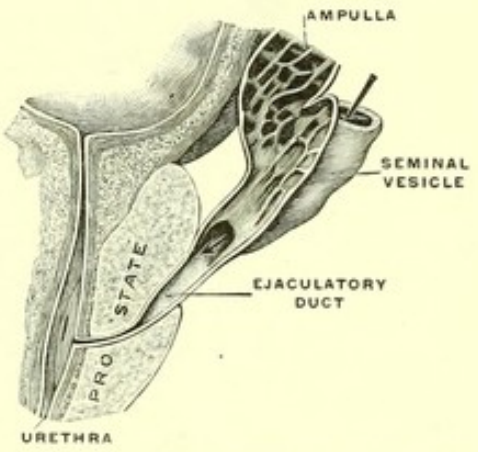

FIG. 876.—Ejaculatory duct in sagittal section. (Testut.)

Arterial branches from the inferior vesical and middle hemorrhoidal supply the seminal vesicles and the extra-prostatic portion of the ejaculatory duct. The *veins* correspond, emptying into the vesico-prostatic plexus; the *nerves* are derived from the hypogastric plexus. The intra-prostatic portion of the ejaculatory duct receives its nutrient and nervous supply from the prostate.

THE SCROTUM.

The scrotum (Fig. 877) is a pouch, which contains the testicles and a part of each spermatic cord. It consists of several layers which are from without inward as follows: (1) the integument; (2) the dartos; (3) the intercolumnar fascia; (4) the cremasteric fascia; (5) the infundibuliform fascia; (6) the sub-

peritoneal tissue; (7) the parietal tunica vaginalis. The integument forms a common covering for both testicles; the remaining layers, meeting in the median line, form the *septum scroti*, which passes inward between the two glands, giving to each a separate compartment.

The **Integument** is thin, very distensible, deeply pigmented, covered with

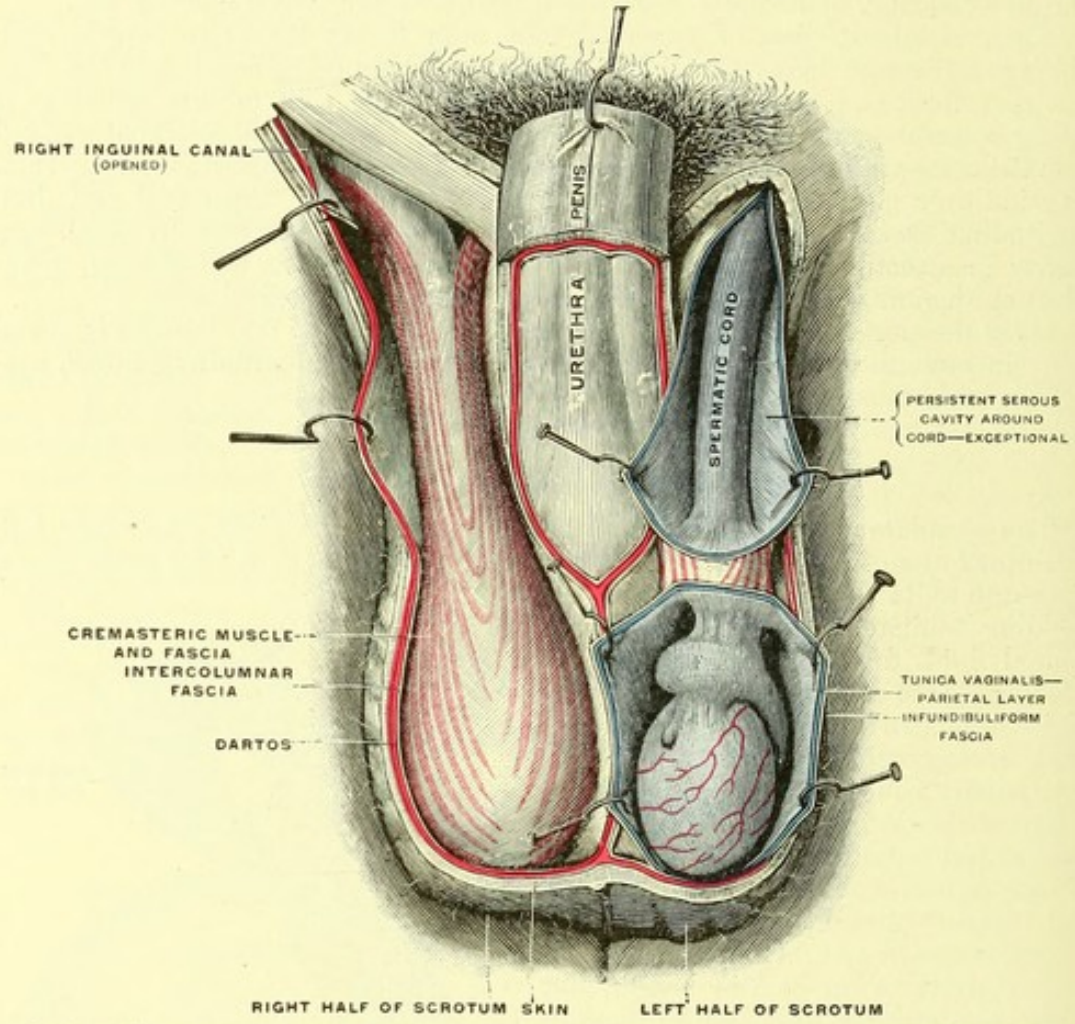

FIG. 877.—The scrotum. On the left side the cavity of the tunica vaginalis has been opened; on the right side only the layers superficial to the cremaster have been removed. (Testut.)

short hairs, and studded with numerous sudoriparous and sebaceous glands. Along its median line there runs a longitudinal ridge or *raphe*, from which numerous folds are directed transversely outward.

The **Dartos** ("flayed") is a thin, reddish, fibrillated layer, which lines and is intimately attached to the deep surface of the integument. It corresponds to the two layers of the superficial fascia, with which it is continuous over the abdomen and groin; but it differs from these in that it consists of elastic tissue, with abundant, smooth, muscular fibres, and contains no fat. The muscular fibres, mostly longitudinal in direction, are attached to the deep surface of the skin. Under the influence of cold, mental emotion, and in the healthy, they are contracted, causing the scrotum thereby to become short and corrugated; in the feeble, and under the influence of warmth, they relax, and the scrotum becomes pendulous, and its ridges almost effaced. The dartos, as such, is continued over the penis and perineum.

The **Intercolumnar Fascia** (*external spermatic*) is a thin, fatless, transparent membrane, which lines the dartos. It is continuous above with the pillars of the external abdominal ring, and with the transverse fibres connecting them.

The **Cremasteric Fascia** (*middle spermatic*) consists of two layers of thin areolar tissue, between which are placed the voluntary muscular bundles—cremaster ("supporting") muscle—derived from the internal oblique. At the bottom of the scrotum this layer blends with the dartos.

The **Infundibuliform Fascia** (*internal spermatic*) is a delicate membrane derived from the fascia transversalis. It lines the cremasteric fascia.

The **Subperitoneal Tissue** does not, properly speaking, form one of the layers of the scrotum. As a loose areolar structure continuous with the subperitoneal tissue of the abdominal wall, it lines the infundibuliform fascia, investing and forming laminæ between the different elements of the spermatic cord. Below, it connects loosely the inner surface of the infundibuliform fascia to the parietal layer of the tunica vaginalis. This with the preceding layer forms the so-called *fascia propria*.

The tunica vaginalis has already been described.

Vessels and Nerves.—The *arterial* supply of the scrotum comes from the superficial and deep external pudic, and from the superficial perineal, a branch of the internal pudic. The cremasteric artery, a branch of the deep

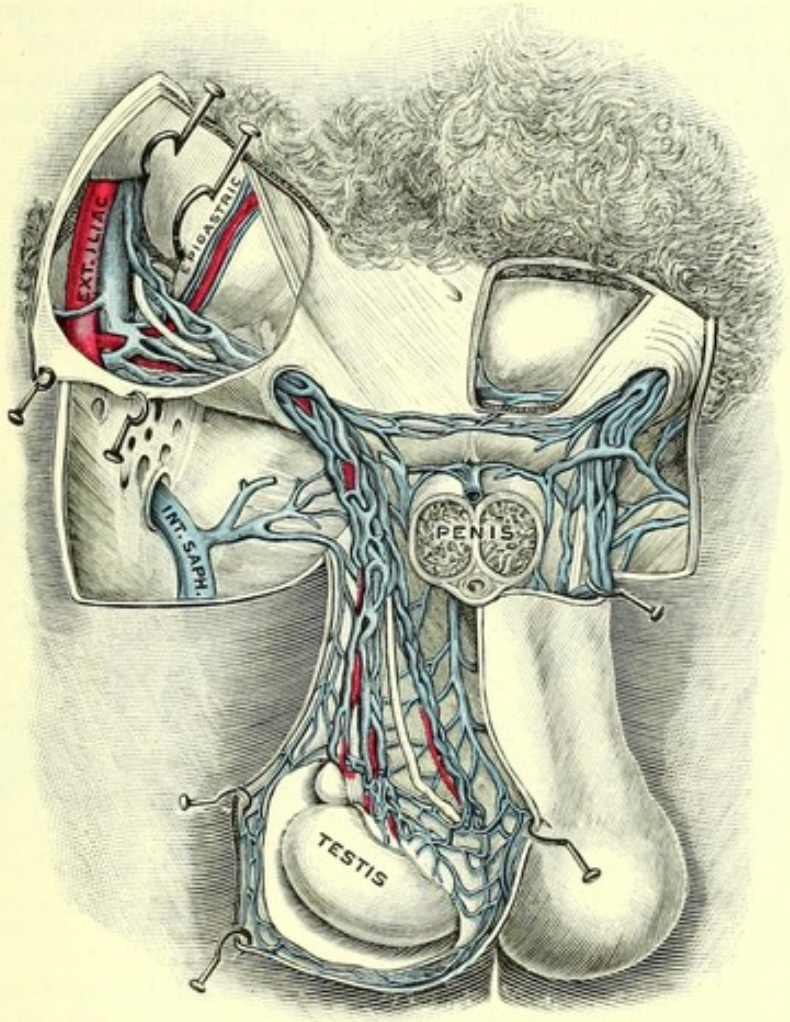

FIG. 878.—Spermatic veins. (Testut.)

epigastric, is distributed chiefly to the cremaster muscle; but it also sends branches to the deeper layers of the scrotum and anastomoses with the arteries of the testicle. The *veins* follow the corresponding arteries, and empty into the external saphenous and internal pudic. The *lymphatics* terminate in the superficial inguinal nodes. The *nerves* are from the ilio-inguinal, the two superficial perineal, the inferior pudendal, and the genital branch of the genito-crural. The latter is distributed chiefly to the cremaster muscle.

THE SPERMATIC CORD.

The spermatic cord forms the pedicle of the testicle, and consists of the following parts: (1) the vas deferens; (2) arteries; (3) veins; (4) lymphatics; (5) nerves; (6) the processus vaginalis; (7) the internal cremaster of Henle. These are cemented together by a loose areolar tissue, continuous with the subperitoneal fascia, and are surrounded by certain layers, continuous with those found in the scrotum.

The *vas deferens* (page 807) forms the nucleus of the cord. The *spermatic artery* lies in front of, the *deferential artery* is placed behind, the vas. The *veins from the testicle*, six or seven in number, form the *pampiniform plexus*, which runs upward in front of and surrounding the spermatic artery. The *veins from the epididymis* form a group of two or three trunks only, which run upward behind the vas. The *lymphatics* accompany the veins. The *nerves* run with the arteries. The *processus vaginalis* may run to the testicle or be lost at any level of the cord. The *internal cremaster of Henle*, in the form of scattered bundles, is supposed to represent the lateral bands of the gubernaculum.

The *coverings* are, from without inward, the skin, dartos or superficial fascia, intercolumnar fascia, cremasteric fascia, and infundibuliform fascia. At the level of the external ring the four outer coverings are lost. From this point the cord traverses the inguinal canal, and at the internal ring its elements diverge, the cord as such ceasing to exist.

THE PENIS.

The penis (Figs. 879–886) is the male organ of copulation. It takes origin in the perineal region between the superficial perineal fascia and the inferior

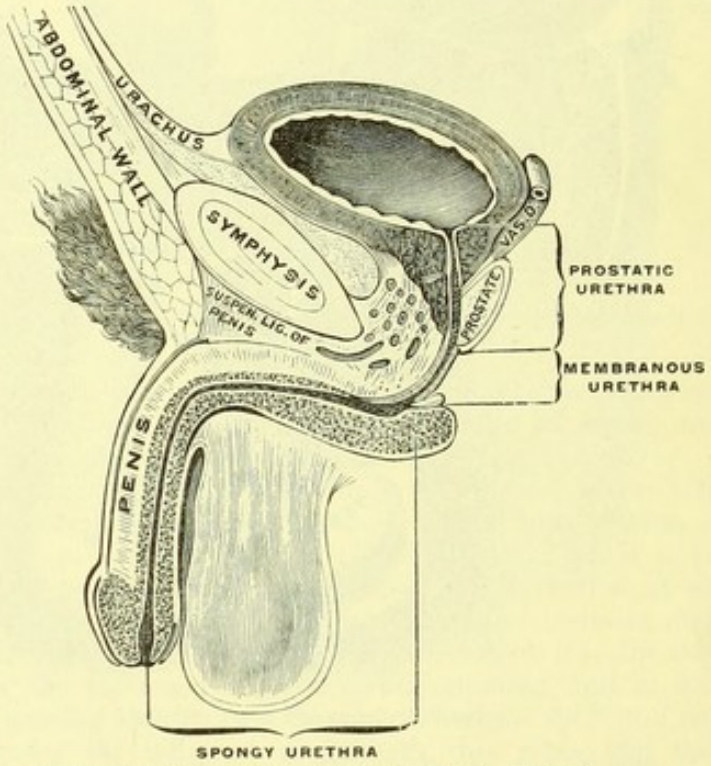

FIG. 879.—The male urethra, in sagittal section. (Testut.)

layer of the triangular ligament. Running upward and forward parallel with the ischio-pubic rami, it reaches a point above the scrotum and in front of the symphysis, where it becomes free and surrounded by a cutaneous covering. It may be divided into an anterior expanded extremity or *glans*, a posterior perineal extremity or *root*, and an intervening portion, called the *body*. The first will be

described with the corpus spongiosum from which it is derived; the other divisions will be taken up separately after the minute anatomy of the organ has been considered.

Structure.—The penis consists of three cylindrical masses of erectile tissue (two corpora cavernosa and a corpus spongiosum), and a system of envelops, which surround and hold these together.

The **Corpora Cavernosa**, each about six inches long and half an inch in diameter, make up the greater part of the body of the penis. They are placed side by side and united along the anterior three-fourths of their extent, their contiguous surfaces being somewhat flattened. Behind they diverge, and, becoming gradually narrower, terminate in pointed extremities, which are inserted, one on either side, into the middle of the ischio-pubic rami. The divergent portions, called the *crura penis* (Fig. 880), are fixed to the descending rami of the pubes by connective tissue, and invested by the ischio-cavernosi (erectores penis) muscles, which surround them more or less completely. In its course each crus presents a slight enlargement called the *bulb*. The distal extremities of the cavernous bodies, conical in outline, are received into corresponding depressions in the base of the glans, where they are firmly secured by fibrous tissue. Two longitudinal grooves, one dorsal, the other ventral, are formed by the union of these

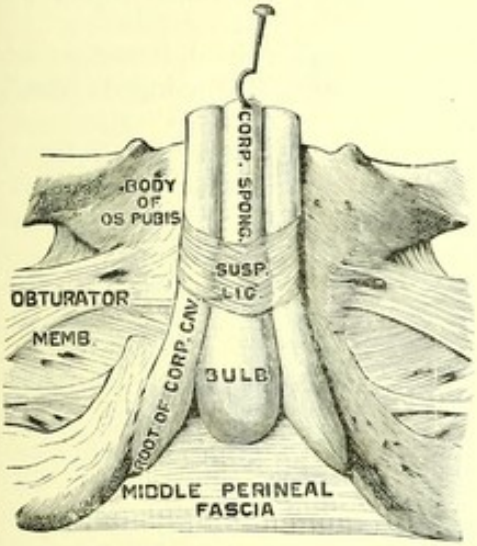

FIG. 880.—The penis, proximal portion, seen from below. (Testut.)

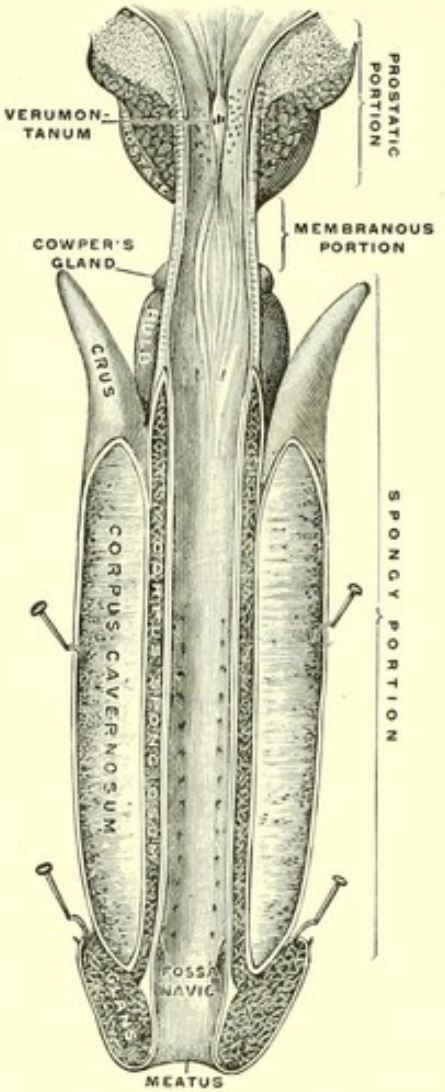

FIG. 881.—The male urethra, laid open on its anterior (upper) surface. (Testut.)

bodies. The former lodges the deep dorsal vein, the latter, much the deeper, is occupied by the corpus spongiosum.

Structurally each corpus cavernosum consists of erectile tissue, invested by a sheath, the *tunica albuginea*. The latter is composed of fibrous and elastic tissue, and is both tough and distensible. It is arranged in two layers, superficial and deep. The former, of longitudinal fibres, is common to both bodies; the latter, of circular fibres, is proper to each. In the median line, where the two bodies touch, these circular fibres blend, making a septum, dense and complete behind, but in its anterior portion interrupted by numerous vertical slits, and hence called the *septum pectiniforme* ("comb-shaped partition"). From the inner surface of

the albuginea, numerous fibro-muscular lamellated or filamentous *trabeculæ* are derived. These become smaller near the central axis of the body, and are stronger behind, in the vicinity of the crura, than in front. Crossing each other in divers directions, the trabeculæ divide the cylindrical cavity of the albuginea into an immense number of spaces, called *areolæ*. The latter communicate freely with each other, and with those of the opposite body through the fissures in the septum. They are lined by epithelial cells, resembling those found in the smallest arterial branches, and, therefore, represent widely dilated capillaries. At several points in their walls these spaces communicate with the arteries; they also give origin to the veins.

The **Corpus Spongiosum** (Fig. 881) is traversed throughout its whole extent by the urethra. Its posterior extremity, somewhat dilated, is called the *bulb*, its anterior extremity, much dilated, makes up the *glans*, while the intervening portion is known as the *body*.

The **bulb** (Fig. 880) is pear-shaped, about one and a half inches in length, and three-quarters of an inch in diameter at its widest part. It is larger than the body, and contains the bulbous portion of the urethra, which is here surrounded by a greater amount of erectile tissue than elsewhere. Its posterior extremity lies about half an inch in front of the anus. Tapering anteriorly, it soon gains the inferior groove, formed by the junction of the corpora cavernosa, and merges into the body. The superior surface of the bulb rests against the inferior layer of the triangular ligament from which it receives an investment; its inferior surface is covered by the bulbo-cavernosi (acceleratores urinæ) muscles. These muscles, two in number, arise from a median raphe on the under surface of the bulb. Diverging they encircle the latter and meet on its dorsal surface. A few of their most anterior fibres are sometimes inserted into the sides of the corpora cavernosa, or into the fascial sheath of the penis, in which case they compress during erection the dorsal vein. The urethra does not occupy the central axis of the bulb, but lies nearer to its superior surface.

The **body** is cylindrical or slightly tapering. It occupies the inferior groove formed by the junction of the cavernous bodies, and is tunnelled along its centre by the urethra.

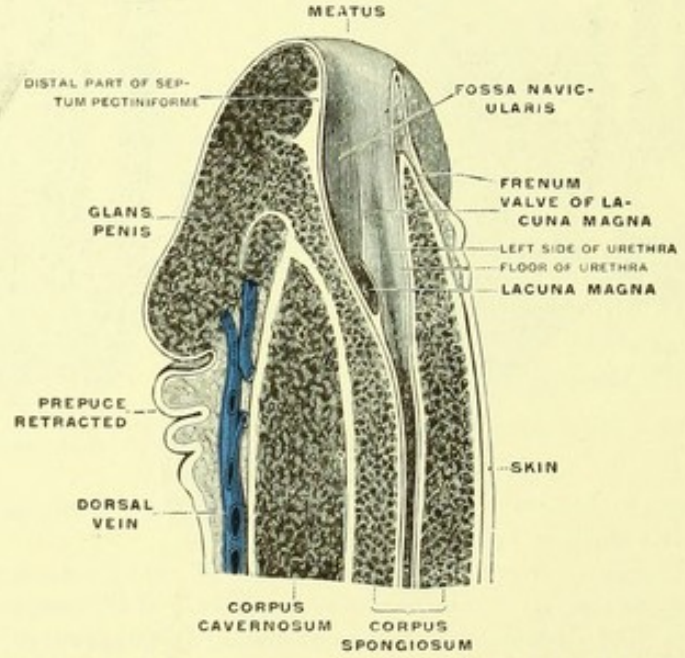

FIG. 882.—The penis, distal end, in sagittal section one-twelfth inch at left of middle line. (Testut.)

The **glans** (Figs. 882–884) forms the anterior extremity of the penis. It is conoidal in outline and presents at its summit a vertical fissure, the *meatus urinarius externus*, the anterior opening of the urethra. Its base, directed backward,

and hollowed to receive the tips of the cavernous bodies, as already mentioned, is not at right angles to the long axis of the penis, but so placed that it extends farther backward on the dorsal than on the ventral aspect of that organ. The prominent border of the base is called the *corona glandis;* the constricted portion of the body behind this, the *cervix*. The external surface of the glans is smooth, and presents below a longitudinal groove, which begins a little behind the meatus, extends backward, and lodges the frenum of the prepuce.

Structure.—The corpus spongiosum is composed of a thin layer of erectile tissue, which surrounds the urethra and is enclosed in a fibrous sheath. It therefore resembles the cavernous bodies; but the sheath is thinner and contains more elastic fibres, and the areolæ are smaller. The erectile layer of the bulb is thickened and prolonged backward, so as to surround the membranous and prostatic portions of the urethra. The erectile structure of the glans is continuous with that of the spongy body, from which, however, it is derived only in small part, the greater portion being developed from the integumental tissues which invest the glans (Retterer). Its trabeculæ are very coarse, its areolæ small. During erection the corpus spongiosum never attains the same degree of rigidity as the cavernous bodies.

The **Envelops of the Penis**, four in number, are concentrically arranged around the erectile cylinders. They are from without inward as follows: (1) the integument; (2) the dartos; (3) an areolar layer; (4) the fascia of the penis.

The **cutaneous envelop** (Figs. 882, 883, 886) is continuous with the integument of the pubic region and scrotum behind, and in front assists in forming the prepuce. It is thin, deeply pigmented, and free from fat; contains abundant elastic tissue; and is remarkable for its distensibility and the laxity of its attachment to the subjacent tissues. It is studded with sebaceous glands, and presents a median raphe on the under (hind) surface of the penis, continuous with that of the scrotum.

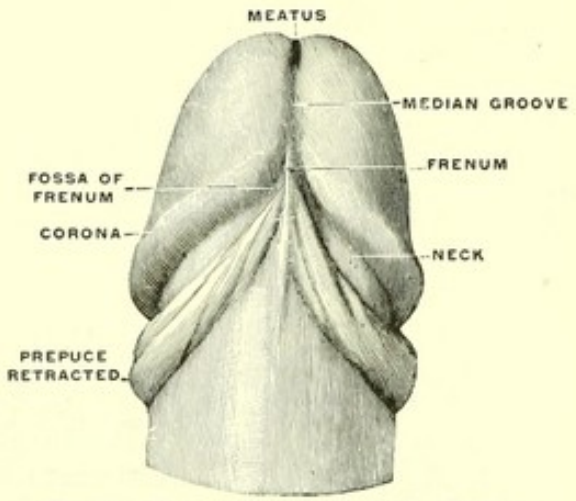

FIG. 883.—Glans penis, under surface. (Testut.)

The **prepuce**, or foreskin, is a tegumentary fold, disposed like a cuff around the glans. It is formed as follows: just behind the cervix the integument leaves the surface of the penis and is continued forward for a varying distance, forming the outer layer of the prepuce; then it turns backward within itself, forming the inner layer, and rejoins the surface at the level of the cervix. From this point the integument is reflected anew over the cervix and glans, to which it is intimately adherent, finally becoming continuous at the meatus with the mucous membrane of the urethra. Thus constituted, the prepuce presents two surfaces, outer and inner, and an anterior opening, the *preputial orifice*. Below, it is drawn forward in a median fold, the *frenum*, which occupies the ventral groove on the glans, and is attached a little behind the urinary meatus. The integument, which forms the inner surface of the prepuce and covers the cervix and glans, is so modified in character as to resemble mucous membrane. Over the cervix and corona it is studded with numerous sebaceous follicles, the *glandulæ odoriferæ*, the secretion of which, added to the desquamated epithelial cells of this vicinity, forms a whitish substance of peculiar odor, the *smegma præputii* ("unguent of the foreskin"). The integument over the glans adheres closely to the erectile tissue beneath, possesses only rudimentary sebaceous follicles, and is beset with large nervous and vascular papillæ.

The **dartos layer** is continuous with a similar structure in the scrotum, and is

formed chiefly of plain muscular fibres, the great majority of which are arranged longitudinally. It extends to the preputial orifice, then like the skin turning backward, it becomes more and more attenuated, and is finally lost on the cervix. When contracted, the dartos compresses the veins, and thus favors engorgement.

The **areolar sheath** lying beneath the dartos, is prolonged forward as far as the preputial orifice. It is loose, rich in elastic fibres, but almost devoid of fat, and contains the superficial vessels and nerves. To this layer the skin owes its mobility.

The **fascia of the penis** reposes on the erectile bodies. Anteriorly it does not enter into the formation of the prepuce, but passes directly to the base of the glans, where it fuses with the integument. Behind, it is continuous with the superficial perineal fascia and the suspensory ligament. Structurally it is composed almost entirely of elastic tissue, and it therefore acts as a compressor of the deep veins.

Conformation and Fixation.—The anterior extremity or glans penis has already been described. The *body*, when flaccid, is soft, cylindrical in outline, and hangs vertically from the front of the symphysis, forming with the root an acute angle, the *angle of the penis;* when erect, it becomes much larger, changes in direction, and is prismatic in outline with rounded borders. The *root* is made up chiefly by the diverging crura. These are held in position by their insertion into the ischio-pubic rami, and by short fibrous bands, which unite them to the pubic arch, the symphysis, and the inferior layer of the triangular ligament. The *suspensory ligament*, a triangular band of elastic tissue, also aids in securing the root. Its apex is attached to the upper part of the symphysis and the neighboring linea alba; its posterior border blends with the front of the symphysis; its anterior border is free. Below, its fibres divide into two groups, median and lateral. The former are inserted into the fascial sheath to the right and left of the dorsal vein, the latter separate to surround the cavernous bodies.

Vessels.—The *arterial supply* (Fig. 884) of the envelops is derived from the external pudic, and from the superficial perineal and dorsal artery of the penis,

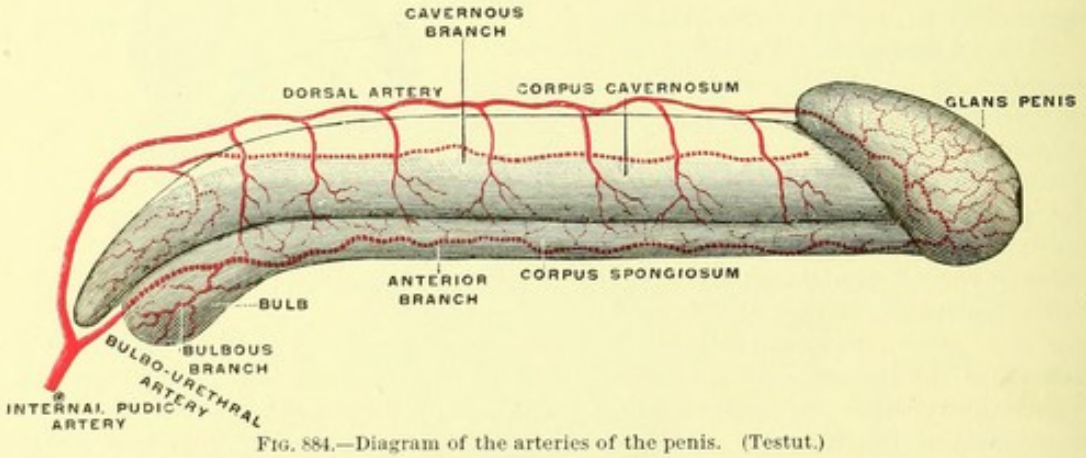

FIG. 884.—Diagram of the arteries of the penis. (Testut.)

branches of the internal pudic. Each cavernous body receives from the corresponding internal pudic a branch, which penetrates the albuginea on its inner side just behind the point where the converging crura meet. This vessel sends a recurrent branch to the crus, and then passes forward in the central axis of the body, anastomosing frequently through the fissures in the septum with its fellow. Small twigs from the dorsal artery of the penis also perforate the albuginea. The bulb and body of the corpus spongiosum are supplied by a branch (artery of the bulb) from each internal pudic. A smaller branch from the same source or from the transverse perineal also enters the dorsal surface of the bulb. The glans is supplied by the dorsal artery of the penis. In the erectile tissue the arteries are supported by the trabeculæ, and are divided into two groups—

nutritive and *functional*. The former supplies the histological elements, breaking up into capillaries, which merge into veins in the ordinary way. The latter, according to Eckhard, forms bouquets of short terminal branches, which open into the areolæ by means of small orifices. These orifices are surrounded by elastic tissue, which keep them closed when the penis is flaccid. Small convoluted twigs, called *helicine arteries*, are sometimes seen projecting into the areolæ.

The *veins* (Fig. 885) from the envelops and the prepuce converge toward the dorsum of the organ, where they form a common canal, the *superficial dorsal vein*, which follows the median line, lying in the areolar layer beneath the dartos, and ends in the external pudic and obturator veins. The veins from the corpus spongiosum emerge along its whole length. Those from the glans pass backward to the excavation at its base, where they form the *deep dorsal vein*, which runs beneath the fascial sheath, in the superior groove formed by the cavernous bodies, and perforates the triangular ligament to end in the prostatic plexus. Those from the body and bulb terminate in the same plexus or in the internal pudic veins. Small venous branches from the cavernous bodies emerge from both the superior and inferior surfaces; the former pass directly into the deep dorsal vein, the latter terminate in the same vessel after first encircling these bodies. The principal efferent trunk, however, comes from the posterior extremity of the cavernous body and perforates the triangular ligament to end in the prostatic plexus or the internal pudic veins.

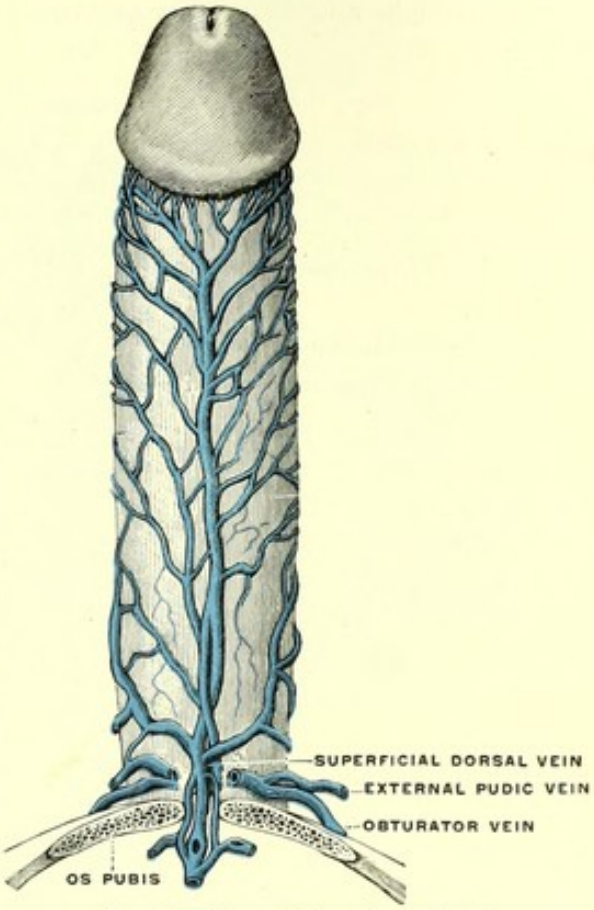

FIG. 885.—Veins of the penis. (Testut.)

The *lymphatics* from the prepuce and envelops form a single superficial dorsal trunk, which accompanies the vein of the same name, and, dividing at the root of the penis into right and left branches, terminates in the superficial inguinal nodes. The deep lymphatics take origin in the erectile structures. In the glans they communicate freely with the lymphatics of the urethra. Behind the glans they form a trunk, which follows the deep dorsal vein, and ends in the internal iliac nodes.

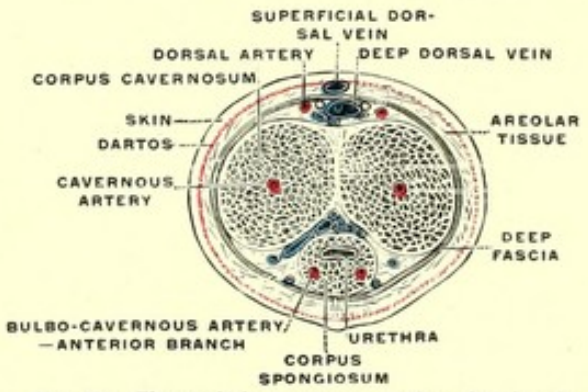

FIG. 886.—The penis in transverse section, showing the blood-vessels. (Testut.)

Nerves.—The coverings of the penis receive their nerve-supply from the genital branch of the genito-crural, and from the inferior perineal branch of the internal pudic. The erectile structures receive sympathetic branches from the hypogastric plexus, and spinal branches from the dorsal nerve of the penis and the superficial perineal.

THE PROSTATE GLAND.

The prostate ("standing in front") (Figs. 887, 888) is a glandular body, situated around the initial portion of the urethra. It develops at puberty, atrophies after castration, and in certain animals increases in size during the breeding season.

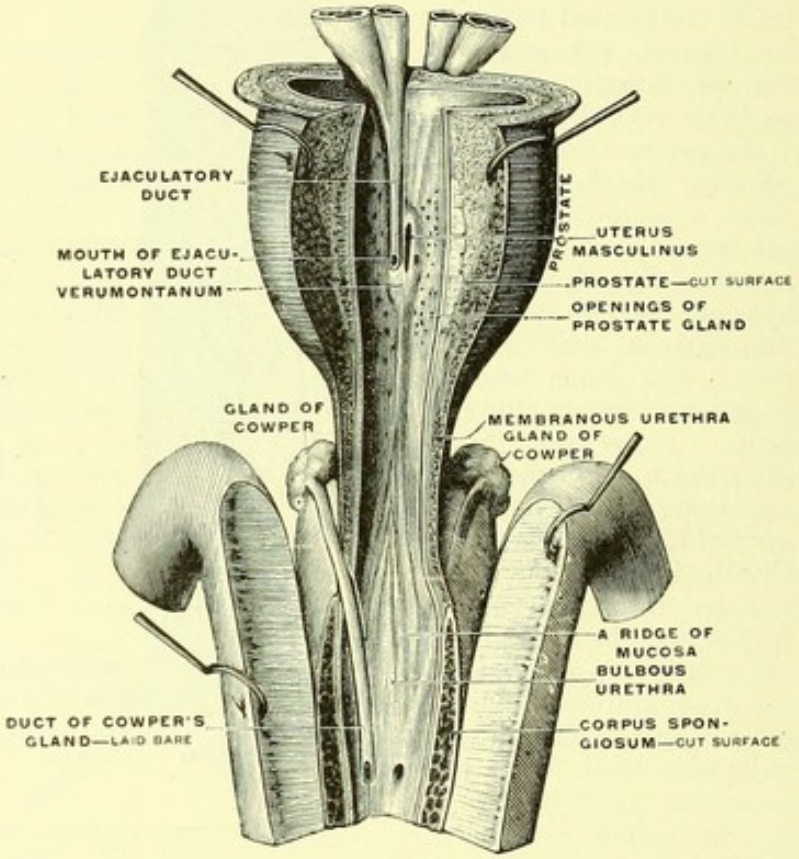

FIG. 887.—Proximal portion of the urethra, laid open by a median, anterior cut. (Testut.)

Form and Location.—It is irregularly cone-shaped, flattened from before backward, and is so directed that its central axis, running downward and forward from base to apex, makes with the vertical an angle of twenty to twenty-five degrees. It occupies the median line, lying below the bladder, above the triangular ligament, behind the symphysis, and in front of the rectal ampulla.

Volume.—In the child the prostate is only rudimentary in size; but at puberty it begins to enlarge, attaining its full development from the twentieth to the twenty-fifth year. Its size, therefore, depends on the age of the subject. In the adult it is about one inch and a quarter in length (from base to apex), one and one-half inch in width at the base, a little over an inch in thickness, and it weighs from four to six drachms. After the sixtieth year of life, often earlier, the prostate frequently becomes enlarged to double or even triple its original size; and this senile hypertrophy, which is probably always pathological, may be confined to the middle lobe, or may affect the entire organ.

Conformation and Relations.—The gland presents for description a base, an apex, an anterior, a posterior, and two lateral surfaces. The *posterior surface*, looking backward and downward, rests on the anterior wall of the rectum, through which it may be felt above the internal sphincter and below and in front of the trigone of the bladder. This surface presents along the median line a shallow groove, which indicates the division of the gland into lobes. The *anterior* or pubic face, convex, shorter, and of less extent than the posterior, is turned toward the symphysis, from which it is separated by the prostatic plexus of

veins, the pubo-prostatic ligaments, and the anterior ligament of the bladder. The *lateral surfaces* are convex, and covered by the anterior margins of the levatores ani muscles, the vesico-prostatic plexus of veins intervening. The *base* is situated immediately below the bladder, with the muscular fibers of which it is directly continuous. The *apex* rests on the upper surface of the superior layer of the triangular ligament, about half an inch behind the symphysis, and a little below the horizontal plane drawn through the highest point of the subpubic arch.

The prostate is traversed from base to apex by the first portion of the urethra, which occupies the median plane, but is nearer to its anterior than to its posterior surface. The direction of the ejaculatory ducts has already been described.

Lobes.—The prostate consists of two lateral lobes, which meet and become continuous both in front of and behind the urethra; and this bilobed condition is indicated by a posterior median groove, the prostatic fissure, which lodges the vasa deferentia and the vesiculæ seminales. On median section, however, the gland is seen to consist of three parts, one in front of and two behind the the urethra. Of the two posterior divisions that above the ejaculatory ducts is called the third or median lobe. It is, of course, continuous at the sides with the lateral lobes. When slightly enlarged the median lobe forms a projection on the middle zone of the base; greater degrees of enlargement cause the posterior wall of the vesico-urethral opening to become convex, thus changing both the length and direction of the urethra, and often interfering with micturition and the passage of sounds.

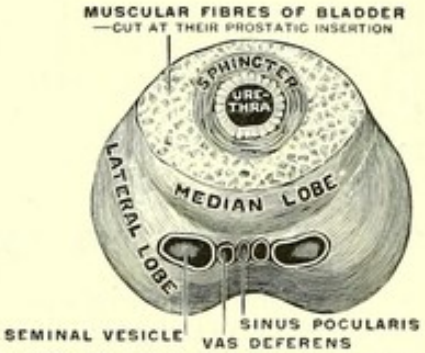

FIG. 888.—Base of the prostate gland. (Testut after Sappey.)

Minute Structure.—Structurally the prostate consists of two principal elements—stroma, and glandular tissue. The *stroma*, made up of connective tissue and smooth muscular fibres, forms for the prostate a sort of external capsule, in the thickness of which are lodged the veins of the prostatic plexus. By its outer surface this capsule is in contact and blended with the recto-vesical fascia and the superior layer of the triangular ligament. The inner surface of the capsule gives birth to a system of *trabeculæ*, which, radiating toward the verumontanum in the floor of the urethra, divide the gland into a number of triangular spaces, in which is lodged the glandular tissue. The *muscular fibres* of the stroma are abundant, constituting about one half of the entire mass of the gland. Above, they are continuous with the muscular fibres of the bladder wall, and form a strong ring surrounding the urethra; below, they are mingled with a small amount of voluntary muscular tissue, derived probably from the transverse perineal muscles.

The *glands* are of the branched or tubular variety, and number 30 or 40. They are disposed in a radiating direction around the urethra. Their ducts communicate with the urethra by minute orifices, opening into the prostatic sinuses on either side of the verumontanum. The glands are lined by a layer of columnar epithelium. They secrete a milky fluid, which at the moment of ejaculation is added to the seminal fluid.

Vessels and Nerves.—The *arterial supply* is derived from the inferior vesical and the middle hemorrhoidal arteries. These furnish branches of small calibre, which ramify in the thickness of the organ, forming capillary plexuses around the walls of the glands. The *veins* empty into the plexus (vesico-prostatic), which surrounds the prostate, terminating finally in the internal iliac vein. The *lymphatics* take origin around the glandular walls, ramify with the venous plexus, and finally end in the internal iliac nodes. The *nerves* are branches of the hypogastric plexus.

THE BULBO-URETHRAL GLANDS.

The bulbo-urethral or *suburethral glands*, more commonly called the glands of Cowper (Fig. 887), are two firm, rounded, somewhat lobulated bodies, about the size of peas. They are situated between the two layers of the triangular ligament, one on either side of the membranous urethra, and immediately above the posterior extremity of the bulb. From the last they are separated by the inferior layer of the triangular ligament, and some fibres of the compressor urethræ muscle.

Each of these bodies represents a compound racemose gland made up of several lobules, held together by fibrous tissue. The ducts of the lobules unite to form a single duct, which escapes from the gland at its anterior and superior aspect. The ducts from both glands pierce the triangular ligament, and converging, run forward beneath the mucous membrane for an inch or more, to open finally by minute orifices into the floor of the bulbous urethra. The acini of the glands are lined with pyramidal epithelium, the ducts by a finely granular epithelium disposed in two layers. The product of these glands is a viscid, transparent, albuminoid fluid, which is mixed with the seminal fluid at the moment of ejaculation.

THE MUSCLES OF THE MALE PERINEUM.

These are divided into two groups, according as they are closely related to the anal canal or to the genito-urinary organs. In the former set are the anal sphinc-

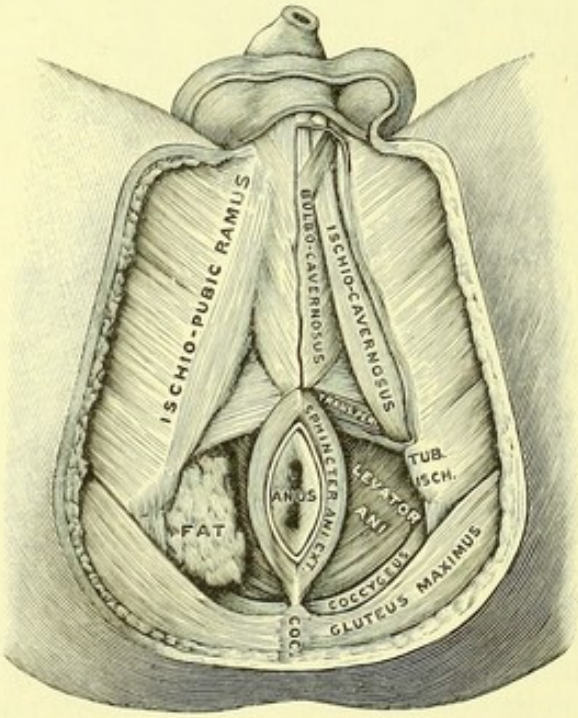

FIG. 889.—Muscles of the male perineum. (Testut.)

ters, the levatores ani, and the coccygei; in the latter are the transversi perinei, the ischio-cavernosi, the bulbo-cavernosi, and the constrictor urethræ. All are in pairs, excepting the sphincters (including the constrictor), which are bilaterally symmetrical.

About an inch in front of the anus four of these muscles—one behind, one in front, and one on each side—unite in a small, tendinous area, called the *central point of the perineum*.

The Anal Group (Fig. 889).

The *internal sphincter* has already been described in connection with the organs of digestion.

Sphincter Ani Externus, "the external sphincter of the anus," surrounds the lower part of the anal canal. It is three or four inches long and two wide. It arises from the tip of the coccyx; its lateral halves run forward, one on each side of the canal, and unite in front of it, where they presently become inserted into the central point of the perineum. It closes the anal canal. Its nerves are the fourth sacral and the inferior hemorrhoidal branch of the pudic.

Levator Ani, "the lifter of the anus," forms the greater part of the floor of the pelvic cavity on each side. It arises partly from bone, but mostly from fascia upon a line which extends from the body of the os pubis to the ischial spine. Its insertions are all at lower levels than any part of its origin, the pelvic floor sagging in the middle. Its front fibres run backward to the central point of the perineum, embracing the prostate; those at the rear pass mesially to the coccyx; and those between the front and rear, constituting the bulk of the muscle, course toward the middle line, and are inserted some into the wall of the anal canal, and some into a median raphe in front of and behind the canal. Its upper surface is covered with the recto-vesical fascia. The two muscles, like all of the perineal muscles, act in concert. Their contraction lifts the pelvic floor and tends to counteract the action of the sphincters, thus aiding in defecation. They also assist in other expulsive movements by compressing the abdomino-pelvic contents. The supplying nerves are the fourth sacral and the perineal branch of the pudic.

Coccygeus, "the coccyx muscle," completes the muscular floor of the pelvis on each side, so largely formed by the levator. It arises from the spine of the ischium, expands into a triangle, and is inserted into the margin of the coccyx and the last segment of the sacrum. It acts with the levator, and pulls the coccyx forward when it has been displaced backward, as in defecation. Its nerve is the fourth sacral.

The Genito-urinary Group (Fig. 889).

Transversus Perinei, "the transverse muscle of the perineum," is sometimes called "superficial" to distinguish it from the "deep transverse,"—a name often given to the constrictor urethræ. It arises from the mesial side of the tuber ischii, passes forward and inward, and is inserted into the central point, fusing with its opposite fellow, the external sphincter, and the bulbo-cavernosus. Its nerve is the perineal branch of the pudic. The transversi serve to fix the central point, and thus aid the action of the other muscles which are attached to it.

Ischio-cavernosus, named from its attachments, is also called *erector penis*. It arises from the mesial surface of the tuberosity and ramus of the ischium at the sides of the crus penis, thus embracing this structure. It is inserted into the external and inferior surfaces of the anterior part of the crus. It is supplied by the perineal branch of the pudic nerve. Its action, by compressing the crus, is to cause and maintain erection.

Bulbo-cavernosus is thus named from its attachments to the bulb of the corpus spongiosum and to the corpus cavernosum. It is also known as the *ejaculator urinæ*, *accelerator urinæ*, and *ejaculator seminis*. From the central point of the perineum a tendinous raphe extends forward in the mid-line upon the bulb. This and the central point give origin on each side to one of these muscles, the fibres passing obliquely forward, embracing the bulb and the part of the corpus spongiosum just in front of it. The greater part are inserted on the dorsum of the spongy body, while the foremost fibres extend around the side of the cavernous body and are inserted on its dorsum in the mid-line. The perineal branch of the pudic nerve supplies it. The two muscles compress the hind part of the spongy urethra and drive its contents forward.

Constrictor Urethræ, also named *compressor urethræ*, is enclosed between the two layers of the triangular ligament, and includes the membranous portion of the urethra, for which it acts as a sphincter. It is sometimes called the *deep transverse muscle*, because it extends across from side to side between the ischio-pubic rami. Part of it goes in front and part behind the urethra. It squeezes the membranous urethra, and thus expels its contents. The dorsal nerve of the penis supplies it.

THE FEMALE ORGANS OF GENERATION.

The female generative organs are divided into an *internal* and an *external group*. The former are contained within the pelvis and comprise the following structures: (1) the *ovaries*, two glandular organs devoted to the production of the ova; (2) the *Fallopian tubes*, canals through which the ova reach the uterine cavity; (3) the *uterus*, a single, median, hollow organ, which receives the fecundated ovum, provides it with nutrition, and expels it at maturity; (4) the *vagina*, a canal by means of which the uterine cavity communicates with the external surface of the body.

The *external organs*, grouped under the common term of *vulva* or *pudendum*, include the vulval canal and certain surrounding and contiguous structures.

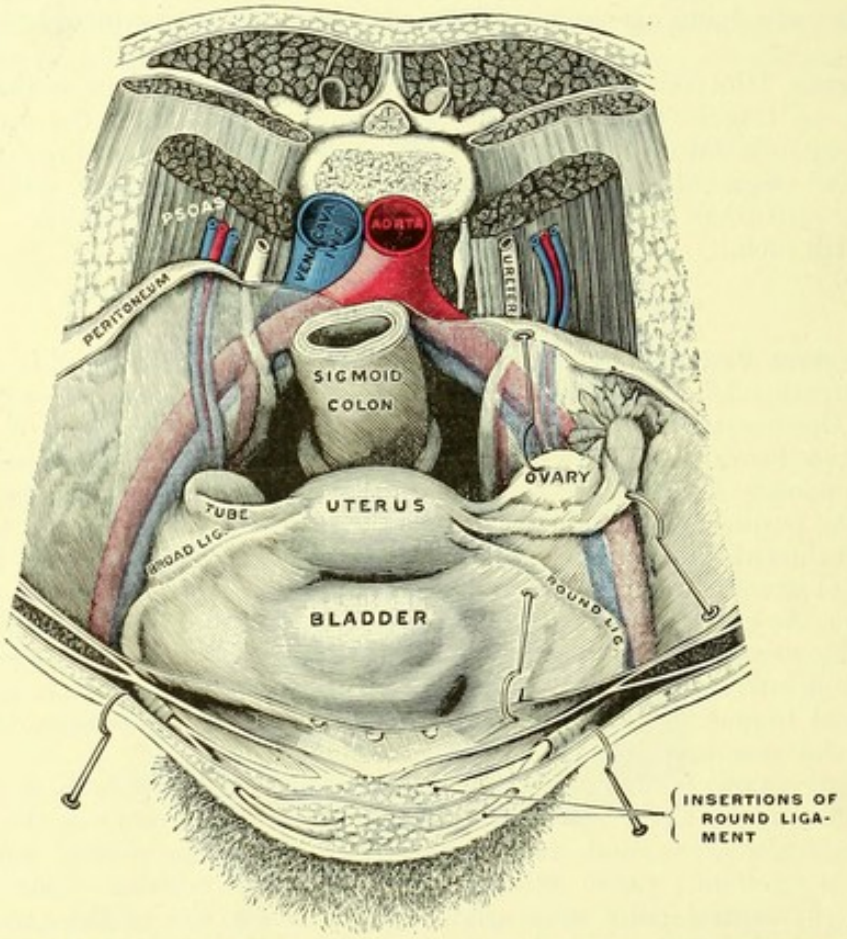

FIG. 890.—Female pelvic viscera, from above. The ovary and tube of the left side have been lifted out of place. (Testut.)

THE OVARIES.

The ovaries (Figs. 890, 891), two in number, are the essential female organs of generation. They are firm, fibrous, ovoid bodies, situated in the retro-uterine

compartment of the pelvis, where they are connected, one on either side of the uterus, with the posterior layer of the broad ligaments. On the surface of the abdominal wall, their position is indicated by the mid-point of a line drawn from the anterior superior spinous process of the ilium to the pubic symphysis.

Dimensions, Color, and Consistence.—Each ovary is about an inch and a half in length, three-quarters of an inch in breadth, from one-third to one-half an inch in thickness, and weighs from one to two drachms. During pregnancy, the gland which contains the corpus luteum is much larger than its fellow. In the child the ovaries are rosy white, in the adult they are reddish; and during menstruation, owing to the vascular engorgement, they assume a deeper tinge. They resemble the testicle in consistence, but are much less dense. In the old, the entire gland atrophies, and becomes hard and fibrous.

Conformation and Relations.—Each ovary presents for examination two surfaces, a superior or mesial, and an inferior or lateral; two borders, an anterior and a posterior; and two extremities, an external or superior, and an internal or inferior. The *superior surface*, convex and free, looks upward, forward, and inward, and is more or less covered by the fimbriæ of the Fallopian tube and the meso-salpinx. The *inferior surface*, turned toward the side wall of the pelvis, often reposes in a shallow depression, the *ovarian fossa*, which is bounded behind and below by the internal iliac vessels and the ureter, above by the external iliac vessels, and in front by the pelvic attachment of the broad ligament. The *anterior border*, almost straight, is attached to the posterior layer of the broad ligament, between the layers of which the vessels and nerves run to enter the ovary at a depression in this border, called the *hilum*. The *posterior border* is free, turned toward the rectum, and covered to a varying extent by the fimbriæ of the Fallopian tube. The *superior extremity* is rounded; the *inferior*, more pointed, does not quite reach to the pelvic floor. (The relation which the ovary bears to the Fallopian tube will be included with a description of the latter structure.)

Fixation.—The ovaries are held in position by their attached anterior borders, and by the utero-ovarian, the tubo-ovarian, and the suspensory ligaments. The

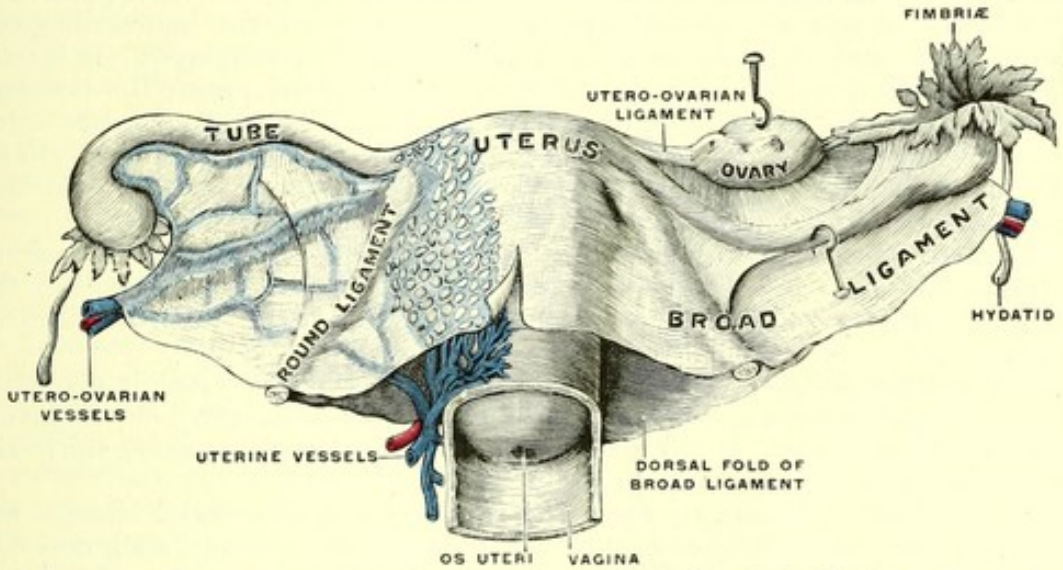

FIG. 891.—The uterus and appendages, front view. On the left side the tube is pulled down, the ovary lifted up. (Testut.)

utero-ovarian ligament is a short rounded cord somewhat over an inch in length, which, running between the folds of the broad ligament, connects the inferior extremity of the ovary with the superior angle of the uterus, where it is attached a little below and behind the origin of the Fallopian tube. It is composed of fibrous tissue and plain muscular fibres, the latter derived from the superficial

muscular layer of the uterus. The *tubo-ovarian ligament*, or *ovarian fimbria*, connects the superior extremity of the ovary with the fimbriated extremity of the Fallopian tube. The *suspensory ligament*, also called the *lumbo-ovarian ligament*, or *ligamentum infundibulo-pelvicum*, is the upper part of the external border of the broad ligament. Running downward from the brim of the pelvis, it is attached to the superior extremity of the ovary and carries between its folds the ovarian vessels and nerves.

Direction.—Usually the ovaries assume a slightly oblique direction, running downward, inward, and a little forward, so that their long axes, if extended below, would meet in front of the uterus. Their direction, however, varies widely within normal limits, and is much influenced by the fact that their ligaments are not only extensible, but two of them, the utero-ovarian and tubo-ovarian, take origin from movable points. Another important factor in determining the direction of the ovary is the condition of the neighboring organs. When the uterus deviates from the median line, the ovary of the side to which the uterus turns is vertical; while that of the opposite side, its lower extremity pulled on by the utero-ovarian ligament, is nearly or quite horizontal. A full bladder or rectum, by changing the position of the uterus, must also modify the direction of the ovary.

Structure.—The ovary consists of a framework of stroma, Graafian follicles, and an epithelial covering continuous with but differing from the peritoneum.

The *stroma* ("bed") is a connective tissue composed of abundant cells, white and yellow fibrous tissue, plain muscular fibres, blood-vessels, and nerves. Many of the cells are spindle-shaped, and are held by some anatomists to be cells of involuntary muscular tissue, while others regard them as connective-tissue cells. From the hilum there projects into the centre of the ovary a core made up wholly of stroma and called the *medullary substance*. It is very vascular and contains no Graafian follicles. From the periphery of this core numerous bands of stroma run toward the surface of the ovary, crossing and intersecting each other in every direction. Arrived at the surface, these bands reunite to form beneath the epithelial covering a thin fibrous layer, the *tunica albuginea ovarii*, which bears, however, but a faint resemblance to the tunica albuginea of the testicle, and cannot be dissected from the subjacent parenchyma. Between the tunica albuginea and the medullary substance is a thin zone called the *cortical layer*. It is only slightly vascular, and contains in various stages of development the Graafian follicles. The *epithelial covering*, composed of a single layer of columnar cells, reposes on the tunica albuginea, and is the remains of the germinal epithelium. The peritoneum, covered by flattened epithelial cells, is totally unlike this structure, which it joins at the level of the attached anterior border.

Graafian Follicles (Fig. 892).—The Graafian follicles contain the ova, and are embedded in the meshes of the ovarian stroma. Their structure depends on the degree of maturity which they have attained, and will therefore be described in several stages.

The *smallest follicles*, varying in size from $\frac{1}{800}$ to $\frac{1}{100}$ of an inch in diameter, consist of a single layer of flattened or spindle-shaped cells, which closely invest a larger cell, the *ovum*. In the young child each ovary contains about thirty-six thousand follicles of this grade.

In a second and *more advanced stage* the following structural changes are noted: (1) The surrounding stroma forms for the follicle a special wall, divisible into two layers—an outer, fibrous layer (*tunica fibrosa*), which encloses the blood-trunks and lymphatic spaces of the follicle; and an inner, vascular layer (*tunica propria*) composed of connective-tissue cells and a capillary plexus. (2) The spindle-shaped cells, which invested the ovum in the earlier stage, now become columnar and proliferate, making two layers, one of which lines the tunica propria, and is called the *membrana granulosa*, while the other invests the ovum and is known as the *discus proligerus*. (3) Between these two layers an albuminous transparent liquid, the *liquor folliculi*, is developed; and it crowds the

ovum to one side of the follicle, usually that nearest to the surface of the ovary, where the cells of the discus proligerus are continuous with those of the membrana granulosa. (4) Between the membrana granulosa and the tunica propria there appears a thin structureless membrane, the *membrana propria*.

The largest follicles are from $\frac{1}{20}$ to $\frac{1}{2}$ an inch or more in diameter. Their increased size is due mainly to an increase of the liquor folliculi. In this stage the membrana granulosa and discus proligerus each consists of several layers of

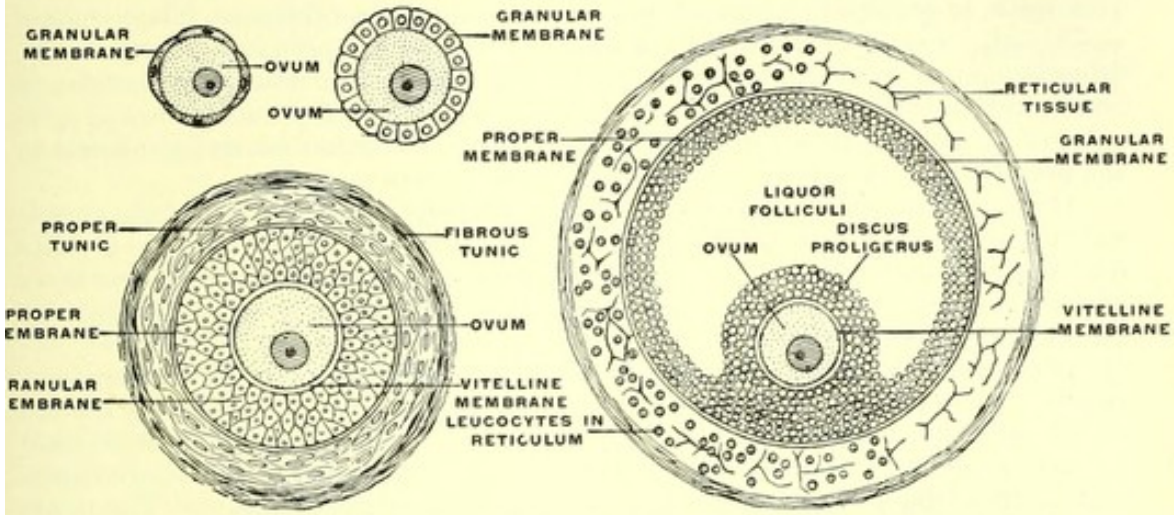

FIG. 892.—Graafian follicles, in different stages of development. Diagrammatic. (Testut.)

cells, derived by proliferation from the pre-existing cells. In the external layer, that is next to the tunica propria and the ovum, the cells retain their columnar outline, but the remaining layers are composed of irregular or rounded cells.

Origin.—In early fœtal life, the ovary is represented by a cellular mass derived from the peritoneal cover of the Wolffian body, and called the *germinal epithelium*. Among the small cells of which it is composed are certain larger, spherical, nucleated cells, the *primordial ova*. Soon, from the fibrous stroma beneath the epithelium, prolongations of connective tissue grow into the mass of cells; and coincidently the cells, themselves becoming involuted at certain points, grow into the stroma. In this way irregular tubes lined with polyhedral or rounded cells are formed. Later, bands of stroma grow across these tubes and divide them into nests of cells. These nests are the future Graafian follicles, and each contains at least one primordial ovum. From the smaller cells are developed the membrana granulosa and discus proligerus. By about the seventh month of intra-uterine life these processes cease, and thereafter the ovary is covered by the single layer of epithelium already described.

Location.—The smallest follicles are found in the outer layer of the cortical zone of the ovary, where they are so numerous as to impart to this region a granular appearance. Many of these never develop. The larger follicles (ten to twenty in each ovary) occupy the deeper layer of the cortical zone. The largest and most mature follicles are in contact with the medullary substance and nourished by its rich vascular supply. Extending entirely across the cortical layer, they project from the surface of the ovary in the form of clear vesicles, $\frac{1}{20}$ to $\frac{1}{6}$ of an inch in diameter.

At puberty a certain number of follicles become enlarged, and from that time until the climacteric new ones are being constantly developed.

Structure of the Ova.—The human ovum in the primordial stage is about $\frac{1}{1000}$ of an inch in diameter, in the mature stage its diameter is increased to $\frac{1}{150}$ of an inch. It is developed from a nucleated cell and presents the following parts: (1) an outer covering representing the cell wall, and called the *zona pellucida* or *vitelline membrane;* (2) within this a mass of protoplasm, the *vitellus* or

yolk; (3) situated excentrically in the vitellus the *germinal vesicle,* which represents the nucleus of the cell; (4) the nucleolus or *germinal spot.*

The *zona pellucida,* a thick strong and transparent membrane, forms the outer covering of the ovum. It is marked by numerous radiating striæ, and for this reason is sometimes called the *zona radiata.* The striæ are supposed to be minute canals, through which nutrition reaches the ovum, while it is still in the Graafian follicle, and through which the spermatozoa may afterward pass in the process of fecundation. The *yolk* or *vitellus* is a soft substance contained within the zona radiata. It consists of granules embedded in a fine reticulum of protoplasm. The *germinal vesicle,* $\frac{1}{1000}$ to $\frac{1}{800}$ of an inch in diameter, lies near the periphery of the ovum. It is composed of a structureless membrane, containing a fine clear matrix, in which are embedded a few granules. The *germinal spot,* or nucleolus, $\frac{1}{3600}$ to $\frac{1}{2500}$ of an inch in diameter, occupies the side of the germinal vesicle nearest to the periphery of the ovum. There may be more than one.

Origin.—The primordial ova are scattered among the other cells of the germinal epithelium, and with them descend into the substance of the ovary, as already described. Some, however, remain behind, and are found among the single layer of columnar cells, which covers the surface of the ovary. These probably undergo no further development.

Discharge.—Rupture of a Graafian follicle, and sometimes more than one, occurs shortly before or during each menstrual period. It takes place at a point in the peripheral pole of the follicle called the *stigma* ("point") or *macula* ("spot") *folliculi.* The wall at this point is scantily supplied with blood-vessels, and, as the follicle nears maturity, it undergoes fatty degeneration. The ovum with the liquor folliculi and cells of the discus proligerus is discharged on the surface of the ovary.

Corpora Lutea.—A corpus luteum ("yellow body") occupies the site of each ruptured Graafian follicle, and is produced by certain changes which take place in the follicular wall. A short time before the follicle is ready to rupture, the cells of the tunica propria begin to proliferate, and the wall of the follicle is thrown into folds, into which project newly formed vascular loops. A blood-clot fills the follicle after rupture, but it is soon absorbed and the folds, growing into the cavity, take its place. In the non-pregnant the whole structure begins to shrink in about two weeks, and in a short time disappears. The corpus luteum of pregnancy differs much from that just described. It is larger and persists for a longer time. As the blood-clot disappears, a peculiar yellowish connective tissue (yellow probably because the cells are loaded with oil-globules) takes its place. After several months the corpus luteum ceases to grow, but it is still present, though much reduced in size, even at the end of pregnancy.

The surface of the ovary is smooth until puberty. After that time it grows more and more uneven, due to the scarring which follows the formation of the corpora lutea.

Vessels and Nerves.—Each ovary is supplied with blood by a branch from the abdominal aorta, the *ovarian artery,* which corresponds to the spermatic in the male. This vessel is carried to the ovary between the layers of the suspensory ligament. It divides into two branches: a tubal, distributed to the Fallopian tube, and an ovarian. The latter runs in a flexuous course along the attached border of the ovary, to which it sends from ten to twelve branches, and ends by anastomosing with the uterine artery near the superior angle of the uterus. The branches to the ovary, also tortuous, end in capillary plexuses in the tunica propria of the Graafian follicles. The *veins* form in the middle of the organ a considerable mass, called the *bulb of the ovary.* Emerging from the hilum, these vessels join with some of the uterine veins to form between the layers of the broad ligament the *pampiniform* ("tendril-form") *plexus.* From this the blood is collected by a single trunk, the *ovarian vein,* which follows the course of the corresponding artery. The right ovarian vein empties into the inferior vena cava, where it is supplied with a valve. The left joins the renal vein at a right angle,

and is without valves. The *lymphatics* begin as minute spaces in the tunica fibrosa of the follicles, around which they form plexuses. At the hilum they are condensed into five or six trunks; and, following the veins, they finally empty into the lumbar nodes. The *nerves* are derived from the ovarian plexus of the sympathetic. An additional supply is probably received from the uterine nerves, branches of the third and fourth sacral.

Migration.—The ovaries are situated primarily in the lumbar region, in front of the psoas, and near the kidney. About the third month of intra-uterine life they begin to descend, and at the ninth month they reach the brim of the pelvis. This descent is chiefly due to the fact that the lumbar region grows away from the ovary. Sometimes, though rarely, the gland may remain in its primitive situation, or it may descend into the inguinal canal, even passing through the external abdominal ring.

THE FALLOPIAN TUBES.

The Fallopian tubes, or *oviducts* ("egg-ducts") (Figs. 890, 891), two in number, are the excretory ducts of the ovaries and serve to convey the ova to the uterine cavity.

Location.—They are situated in the free or upper margin of the broad ligaments, between the ovaries behind and the round ligaments in front. Internally they are continuous with the superior angles of the uterus, externally each tube is attached to the superior or outer extremity of the corresponding ovary. That portion of the broad ligament below each tube, and between it and the ovary, is called the meso-salpinx ("mesentery of the tube"). The oviducts are, therefore, fixed in position by their continuity with the uterus, by their attachments to the ovaries, and by their imprisonment between the two peritoneal laminæ, of which the broad ligaments are composed.

External Conformation.—Each tube is trumpet-shaped, and increases in size from within outward. At the ovarian extremity, it expands to enclose a funnel-shaped space, the *infundibulum* or *pavilion*. It varies in length from four to five inches, and is divided into three parts as follows: (*a*) the inner extremity or interstitial portion; (*b*) the middle portion or body; (*c*) the external or fimbriated extremity. The *interstitial portion* is contained in the thickness of the uterine wall. Its canal, very narrow, is continuous with the uterine cavity through a small opening, the *ostium uterinum* ("door of womb"), which is only large enough to admit a small bristle. The *body* is subdivided into two parts, an inner or isthmus and an outer or ampulla. The *isthmus* is hard, cylindrical, straight, and nearly horizontal. It measures an inch and a half in length, and has a diameter of about one-eighth of an inch. The canal of this division is still very small, though somewhat increased as compared with that of the interstitial portion, with which it is continuous. The *ampulla* ("bottle") or *receptaculum seminis* ("reservoir of seed") extends from the isthmus to the fimbriated extremity. It is distinguished from the former by the fact that it has thinner walls, and is softer, and flattened antero-posteriorly. It is also markedly flexuous, and the diameter is almost twice that of the isthmus. Its canal, increased in size toward the outer extremity, is irregular in calibre, and large enough to admit a uterine sound.

The **fimbriated extremity** (infundibulum) opens downward, backward, and inward. It is the most movable part of the tube, and receives the ova after their discharge from the Graafian follicles. This extremity may be divided for description into an internal and an external surface, a base and a summit. The external surface, continuous with the outer surface of the tube, is smooth and covered by visceral peritoneum. The internal surface is continuous with the corresponding surface of the ampulla, and lined by a prolongation of its mucous membrane. At the summit, the infundibulum communicates with the cavity of the ampulla through a narrow opening, a line to a line and a half in diameter,

called the *ostium abdominale*. The base is festooned by ten to fifteen diverging processes, called *fimbriæ* ("fringes"), which are arranged in two or three concentric circles. The bases of these are attached, their apices are free, and their edges are cut into numerous secondary fringes. The *ovarian fimbria*, longer than its fellows, runs from the lower part of the ampulla, to become attached to the superior extremity of the ovary. On its inner surface a gutter, lined by mucous membrane, extends from the ovary to the ostium abdominale. By its outer surface it is in contact with a band of smooth muscular fibres continued from the muscular tunic of the tube. Sometimes the ovarian fimbria is not quite long enough to reach the ovary; it is then attached through the medium of this muscular band, which also carries the terminal portion of the mucous gutter.

Internal Conformation.—The canal, as already stated, increases in diameter as it passes outward. Its mucous membrane is thrown into folds, making a system of longitudinal plications, which extend throughout the whole length of the canal. In the interstitial portion and isthmus these folds are simple ridges separated by shallow grooves. In the ampulla they increase in number and volume; and the larger, extending clear across the canal, may bear on their sides secondary folds. The outer ends of these plications cross the ostium abdominale and are continued on to the inner surface of the fimbriæ.

Direction.—The Fallopian tubes are freely movable particularly in their outer portion. They are pushed backward by a full bladder, depressed by intestinal folds from above, or pushed forward when the intestines occupy the retro-uterine space. They are affected, too, by any change of position in the uterus. The direction which they pursue is therefore variable. Usually each tube runs from its inner extremity transversely outward to a point opposite the middle of the ovary, a distance of half an inch to one inch. It then runs upward, also a little backward and outward, in front of the attached border of the ovary, near to and parallel with the pelvic wall. Arrived at the superior extremity of the ovary it bends backward, and, after a short course in this direction, terminates by running inward and downward. It thus forms a sort of bay whose concavity, directed downward and inward, embraces the upper end of the ovary, while the fimbriæ lie in contact with the posterior border and mesial surface of the gland.

Structure.—The tube has three tunics—serous, muscular, and mucous. The two laminæ of the broad ligament furnish the *serous covering*, and these, as they approach the tube, diverge, leaving along its lower border a narrow uncovered strip. A layer of loose areolar tissue, continuous with the subperitoneal fascia and rich in elastic fibres and blood-vessels, is found beneath the serous coat. The *muscular tunic* may be divided into two layers, longitudinal and circular. The former is superficial and continuous internally with the uterine muscle; externally it ends at the origin of the pavilion, except for the band, already mentioned, which accompanies the ovarian fimbria. The circular layer, also continuous with the uterine muscle, is thinnest near the fimbriated extremity, and ends at the ostium abdominale. In the vicinity of the uterus some longitudinal fibres are found within the circular. The *mucous coat* is continuous with the mucous lining of the uterus. Having no special submucosa, it is intimately adherent to the muscular layer. It forms the plications already described, and is lined by a single layer of columnar, ciliated epithelium, in which the ciliary motion is toward the uterus. Crossing the ostium abdominale the mucous membrane establishes itself on the inner surface of the fimbriæ. At the borders of the latter, or on their outer surfaces a little beyond the borders, it merges into the peritoneum. It has no glands.

Vessels and Nerves.—*Arteries.*—The external tubular artery is derived from the ovarian, the internal tubular from the uterine. Together these form an arcade, which travels between the layers of the meso-salpinx, and sends branches to the lower borders of the tube. The *veins* form in the meso-salpinx a plexus parallel to the axis of the tube, and finally empty through the pampiniform plexus into the utero-ovarian veins. The *lymphatics*, joining with those of the

ovary and uterus, empty into the lumbar nodes. The *nerves*, derived from a plexus around the uterine and ovarian arteries, are numerous; but their course and mode of termination are not well known.

THE UTERUS.

The uterus or *womb* (Figs. 890, 891, 893), a hollow organ with thick, muscular, contractile walls, is situated in the pelvis between the bladder and the rectum.

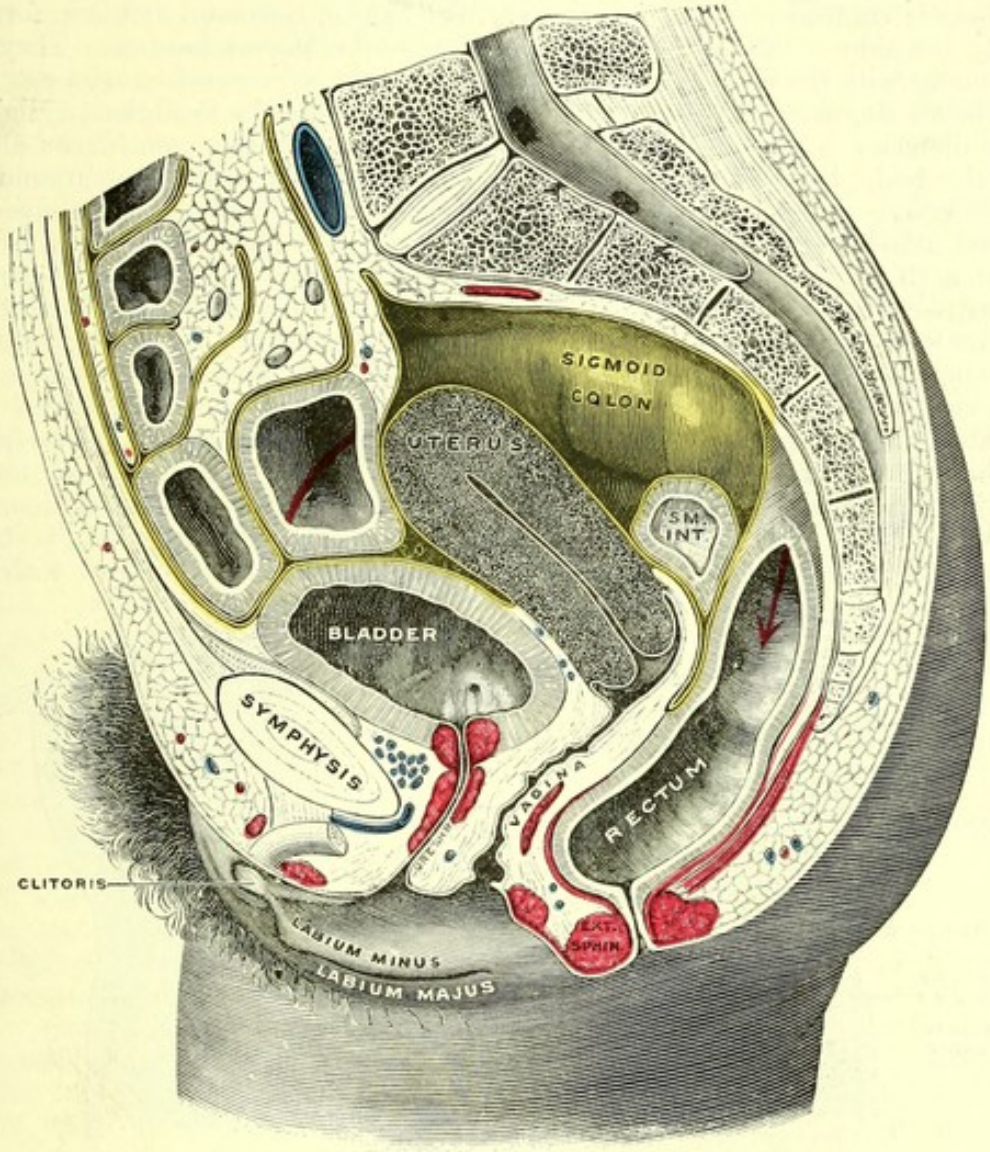

FIG. 893.—Sagittal section of the lower part of a female trunk, right segment. (Testut.)

In its cavity the ovum is received, retained, and developed; and the fœtus, after reaching maturity, is expelled chiefly by the contractions of its muscular fibres.

External Conformation.—The uterus, in form, resembles a truncated cone, whose base, turned upward, reaches to or a little above the level of the pelvic brim; and whose summit, directed downward, projects into the upper extremity of the vagina. It is flattened from before backward, and divided into two parts by a slight circular constriction, called the *isthmus*, which corresponds externally and in front with the point at which the peritoneum is reflected from the uterus to the bladder, while internally it coincides with a narrowing of the uterine canal, known as the *internal os*. In virgins the isthmus is a little below the middle of

the long axis of the uterus; in women who have borne children it is placed at the junction of the middle and lower thirds. It divides the uterus into the body above and the cervix below.

The *body* presents for description two surfaces, two borders, two extremities, and two angles. The anterior surface is slightly, the posterior markedly, convex and both are covered by peritoneum. The lateral borders, also convex, converge a little as they run downward to the isthmus. The superior extremity or *fundus* (sometimes called a border) is broad, convex, and covered by the peritoneum, as it passes from the anterior to the posterior surface. At the inferior extremity the body is continuous with the cervix. The angles, right and left, are formed by the junction of the superior extremity with the lateral borders. They are continuous with the corresponding Fallopian tubes.

The *cervix*, narrower than the body and cylindrical in form, has a slightly wider diameter in the middle than at either extremity. It is continuous above with the body, below it projects into the vagina, which is attached around its circumference somewhat higher behind than in front. That portion above the vaginal attachment (supra-vaginal segment) comprises about two-thirds of the total length of the cervix in front, about one half behind. The middle or vaginal segment—that part to which the vagina is attached—is about one-fifth of an inch in length, and is placed obliquely. The lower or intra-vaginal segment is cone-shaped, covered by mucous membrane like that of the vagina, and presents at its summit a circular or transverse aperture, the *external os*.

Internal Conformation.—The cavity of the uterus is divided into two parts by the internal os. The upper portion belongs to the body, the lower to the cervix. The long axes of these segments may lie in the same straight line, but usually they join to form an angle, opening anteriorly, of 140° to 170° (Testut).

The **cavity of the body** (Figs. 894, 895), triangular in outline and with the

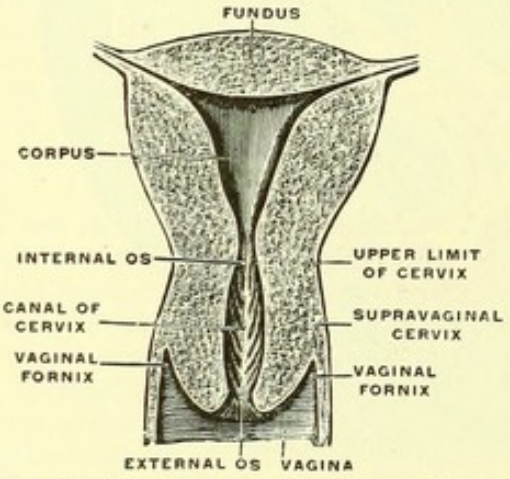

FIG. 894.—The uterus of a virgin, in coronal section.

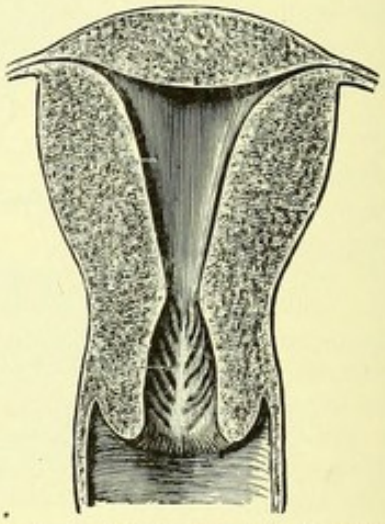

FIG. 895.—The uterus of a woman who has borne a child, in coronal section.

base uppermost, presents two surfaces, three borders, and three open angles. The surfaces, anterior and posterior, are in contact. All the borders, in the virgin, are convex internally; in women who have borne children the two lateral are straight or even concave. At the superior angles the cavity of the body communicates with the oviducts, at the inferior angle, or internal os, it is continuous with the cervical canal.

The **cavity of the cervix**, fusiform in outline, presents two surfaces, two borders, and two openings. The surfaces, distinguished as anterior and posterior, are in contact. On each may be seen a peculiar formation, the *arbor vitæ uterina* ("cedar of the womb"), consisting of a median longitudinal ridge, from which

secondary and parallel ridges pass upward and outward to the lateral borders. In these ridges are smooth muscular fibres derived from the internal muscular layer of the uterine wall. The borders, situated laterally, are concave internally, thus widening the central portion of the cavity. The superior opening (*os uteri internum*) is not a simple opening, but a short canal. The inferior opening (*os uteri externum*) is usually a transverse aperture, about one-twelfth of an inch in length. It is bounded by two lips, an anterior and a posterior. The latter is the longer, due to the higher attachment of the vagina behind, but the former is placed on a lower level and hence appears on palpation to be the longer. Both are normally in contact with the posterior vaginal wall. The outline of the external os is much modified by child-bearing.

Dimensions, Consistence, and Weight.—The uterus is about three inches in length, one and one-half to two inches in breadth at the upper and widest part of the body, and nearly an inch in thickness. In women who have borne children these diameters are all increased. The walls are about three-eighths of an inch in thickness. After death they are dense and resisting, but during life they are soft enough to retain sometimes the imprint of contiguous intestinal folds. The whole organ varies in weight from seven to twelve drachms.

Direction.—The direction of the uterus is variable, and much influenced by the condition of the surrounding organs. Thus, a full bladder will push the uterus toward the sacrum, a full rectum will press it forward. When the bladder and rectum are empty, the fundus looks toward the umbilicus, and the uterus forms with the vagina a right or slightly obtuse angle. As a rule, the organ does not occupy the median line of the body, but is somewhat deflected, usually to the right. There is also present a certain amount of torsion, by means of which the left superior angle is carried a little farther forward than the right.

Peritoneum (Fig. 896).—The peritoneum is reflected from the bladder to the anterior surface of the uterus at a level which usually corresponds to the isthmus, but may be slightly above or below. It then invests in the order named the anterior surface of the body, the fundus, the posterior surface of the body, and the posterior surface of the supra-vaginal segment of the cervix. It is also continued downward over the upper fourth of the posterior vaginal wall, and is then reflected to the front and sides of the rectum. At the lateral borders of the uterus the peritoneum from the anterior surface joins with that from the posterior to make up the broad or lateral ligaments. Certain portions of the cervix have thus no peritoneal covering. They are the intra-vaginal and vaginal segments, and the anterior surface of the supra-vaginal portion. This latter rests against the bladder from which it is separated by areolar tissue, continuous with the subperitoneal fascia. Areolar tissue is also found covering the lower part of the posterior surface of the uterus, and extending outward between the layers of the broad ligaments.

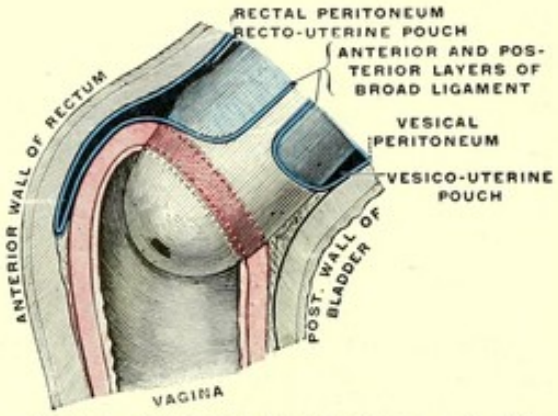

FIG. 896.—The cervix uteri and upper end of the vagina, showing their relations to the peritoneum. Diagrammatic. (Testut.)

Peritoneal Pouches.—The peritoneum, as it dips into the recess between the bladder and the uterus, forms a shallow pouch, the *utero-vesical*, which is occupied, when the bladder is empty, by coils of small intestine. Behind the uterus it forms a second and deeper pouch, the *recto-vesical*, or *cul-de-sac of Douglas*. This is limited in front by the cervix and upper part of the vagina, behind by the rectum, and laterally by two folds of peritoneum, the *folds of Douglas*, which extend from the cervix in front to the sides of the rectum behind. The folds

of Douglas, together with the smooth muscular fibres contained between their layers, constitute the utero-sacral ligaments. Coils of small intestine frequently occupy the upper, but are rarely found in the lower, part of the recto-vaginal pouch.

Ligaments.—The uterus is maintained in position by six important ligaments, arranged in three pairs. They are the broad or lateral, the round, and the utero-sacral.

The **broad or lateral ligaments**, two in number, extend from the lateral borders of the uterus and upper part of the vagina outward to the lateral walls of the pelvis, where they merge into the parietal peritoneum. They are composed of two apposed, serous laminæ, which are continuous with the peritoneum covering the anterior and posterior surfaces of the uterus. Between these laminæ are found the following structures: (*a*) the Fallopian tube; (*b*) the ovary and its ligament; (*c*) the round ligament; (*d*) blood-vessels and lymphatics; (*e*) nerves; (*f*) remains of certain fœtal structures; (*g*) smooth muscular fibres; (*h*) areolar tissue, rich in fat and continuous with the subperitoneal fascia. Each ligament has two surfaces and four borders. At the superior border, which is free, the laminæ are continuous and enfold the Fallopian tube. The inferior border is attached to the floor of the pelvis, areolar tissue intervening between it and the recto-vesical fascia. The ureter crosses obliquely beneath this border. The external border is divided into two portions, upper and lower. The latter is firmly attached to the pelvic fascia, and transmits the uterine artery and the round ligament. The upper and shorter portion is free, and connects the fimbriated extremity of the Fallopian tube with the side of the pelvis. It is called the *ligamentum infundibulo-pelvicum*, and carries between its layers the ovarian vessels. (This is usually described as a part of the superior border.) The internal border is in relation with the side of the uterus and upper part of the vagina, and lying between its laminæ are the utero-vaginal vessels. The anterior lamina, shorter than the posterior, is in relation with the bladder. It is partially raised from the posterior by the round ligament, over which it falls in a more or less definite fold. The posterior lamina, directed toward the rectum, gives off a special extension to enclose the ovary and its ligament. The fold or extension surrounding the Fallopian tube is sometimes called the meso-salpinx; between its layers there are no muscular fibres.

The smooth muscular fibres of the broad ligaments are derived from the superficial muscular layer of the uterus. Passing outward between the laminæ, they become attached to the pelvic fascia and help to sustain the uterus. With the areolar tissue they also form a support for the blood-vessels.

The **round ligaments**, about five inches in length, are also symmetrically arranged, one on either side. Each takes origin from the corresponding superior angle of the uterus in front and a little below the attachment of the Fallopian tube. From this point it runs obliquely forward and outward to gain the internal abdominal ring. Entering this, it traverses the inguinal canal, and, after emerging from the external ring, it finally ends in the tissues of the labia majora and mons Veneris. It is divided into four portions—pelvic, iliac, inguinal, and vulvar. The direction of the pelvic portion is at first a little downward, then upward as it emerges from the pelvis. The iliac portion, lying behind the peritoneum, crosses in front of the external iliac artery and vein. At the internal ring the ligament winds around the outer side of the deep epigastric artery, and the inguinal portion gives off fibres, which are attached to the walls of the canal. The vulvar portion breaks up into numerous divergent, connective-tissue filaments, some of which are attached to the symphysis, while the remainder are lost in the tissues of the mons and labia majora. Structurally the round ligaments are composed of plain and striated muscular fibres, areolar tissue, blood-vessels, and nerves. The plain fibres are derived from the superficial muscular layer of the uterus; the striated, found only in the distal portion of the ligament, are acquired from the internal oblique and transversalis muscles and

represent the cremaster in the male. They help to attach the ligament to the pillars of the external ring and the pubic spine. A tube of peritoneum, representing the processus vaginalis, accompanies the ligament into the inguinal canal. It sometimes remains pervious even in the adult, and is called the *canal of Nuck.*

The **utero-sacral ligaments** are partly serous, partly of smooth muscular fibres. The serous portions are identical with the folds of Douglas already described. They extend between the cervix and sides of the rectum, forming the lateral boundaries of the recto-vaginal pouch. The muscular fibres are continuous with the superficial muscular layer of the uterus and vagina. Running between the layers of the folds of Douglas they serve to connect the cervix and vagina with the sacrum.

The peritoneum at the bottom of the utero-vesical pouch is sometimes referred to as the *anterior ligament of the uterus,* while that which floors the recto-vaginal pouch is called the *recto-vaginal ligament.*

Minute Structure.—The uterus consists of three coats—serous, muscular, and mucous. The serous coat has already been described.

The *muscular coat* makes up the bulk of the uterine walls. It is dense and resisting, cuts with a grating sound, and is grayish on section. It is composed of smooth muscular fibres, intermingled with areolar tissue, vessels, and nerves. The arrangement of these fibres is very complex, but in the gravid uterus they may be divided into three layers, which are, however, not entirely independent.

The *mucous membrane* lining *the body* of the uterus is intimately adherent to the internal muscular layer. It is pale and smooth, and presents the openings of numerous glands. Its external layer, or corium, is composed of embryonic connective tissue in which may be seen numerous round, spindle-shaped, or irregular cells. Lining this is a single, ciliated, columnar epithelium, the ciliary motion being from within outward. The *glands* are of the tubular variety, bounded by a basement membrane, and lined by ciliated, columnar epithelium, continuous with that found on the free surface. They pass obliquely or take a tortuous course through the corium; and their blind extremities, single, bifurcated, or even trifurcated, repose on the internal muscular layer, or penetrate between its fibres. The ciliary motion in the glands is toward the uterine cavity.

The *mucous membrane* of *the cervix* differs from that of the body. It is firmer and thrown into numerous folds, the ridges of the arbor vitæ already described. The corium has fewer cell-elements, but is richer in fibres. The epithelium in the upper part of the cervix is the same as that found in the body; below, at the level of the external os or a little higher, it changes into a laminated epithelium, continuous with that which lines the vagina and covers the external surface of the os. The *glands,* tubular and racemose in type, are numerous and open between the ridges. They are lined in their deeper portions by goblet cells, and produce a thick alkaline mucus. Sometimes by the occlusion of their openings these glands become cystic; they then appear as clear or yellowish vesicles, and are called the *ovula of Naboth.* Vascular papillæ are found in the lower part of the cavity of the cervix, and over the outer surface of its intra-vaginal segment. In the latter situation there are no glands.

Structural Modifications During Menstruation and Pregnancy.—In *menstruation* the more important changes take place in the mucous membrane of the body, which increases in vascularity and becomes thickened. Following this there are disintegration and removal of the superficial part of the membrane, the process beginning at the internal os and extending toward the fundus. Regeneration, brought about by a proliferation of the cells which remain in the deeper portions of the glands, is rapid and complete. In these changes the cervix takes little or no part. In *gestation* the whole organ becomes immensely hypertrophied, increasing in weight from an ounce to a pound and a half or even more. The muscular fibres not only increase in size, but in the early months new ones are added. The mucous membrane is at first the seat of changes similar to those which occur in menstruation, but these proceed further, and later bring about the

formation of the decidua. The membrane, as soon as the ovule has been engrafted upon it, loses its cylindrical epithelium while the cells of the corium increase. The ridges of the arbor vitæ disappear; otherwise there is but little change in the cervix. At parturition the greater part of the mucous membrane is destroyed to be restored in twenty to twenty-five days by the same method as after menstruation.

Following parturition the uterus never attains its former (virgin) size.

Variations Depending on Age.—In the fœtus, the uterus is contained in the abdominal cavity, the cervix is larger than the body, the fundus is undeveloped, and the ridges of the arbor vitæ are distinct. At puberty, the cervix and body are about equal in length, and the fundus has reached the level of the pelvic brim. In the old the entire organ atrophies.

Vessels and Nerves (Fig. 897).—The *arteries* which supply the uterus are arranged in three pairs—the uterine, the funicular, and the ovarian. The *uterine artery* is a branch of the anterior division of the internal iliac. From its origin

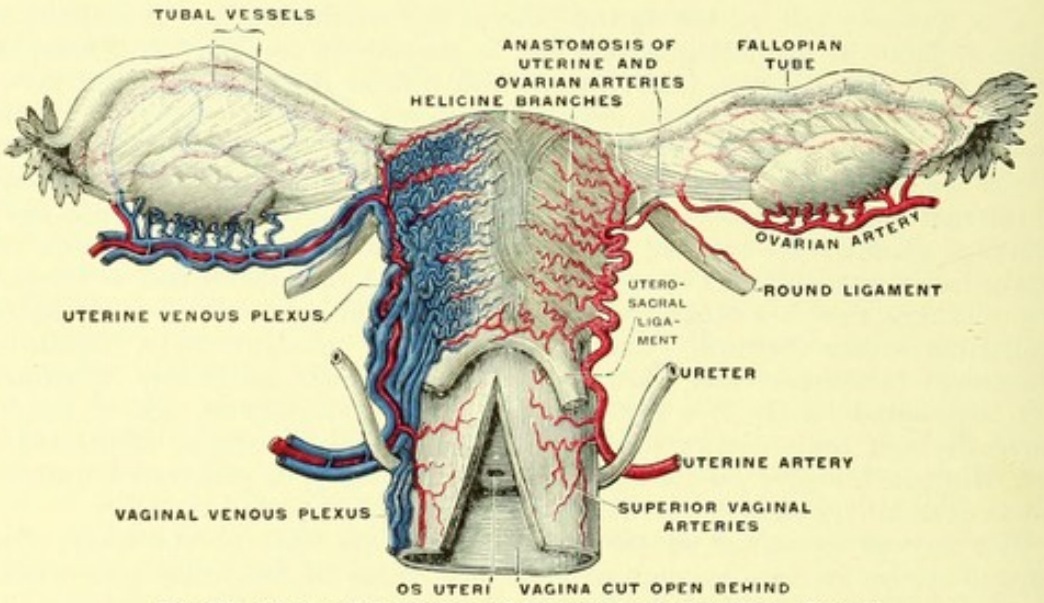

FIG. 897.—Vessels of the uterus and its appendages, rear view. (Testut.)

it descends along the pelvic wall into the base of the broad ligament, then, taking a horizontal course, it crosses in front of the ureter and reaches the side of the cervix at the level of the vaginal insertion or a little below. From this point it is reflected upward, running close beside the lateral border of the uterus until it reaches the superior angle, where it ends by dividing into two branches, one of which anastomoses with the ovarian artery while the other is distributed to the Fallopian tube. From the ascending portion of the vessel numerous transverse tortuous branches are given off to the anterior and posterior surfaces of the uterus. These penetrate the uterine walls, and ramify in the middle muscular layer, where they divide into two sets of branches, superficial and deep. The former return to supply the outer muscular layer and the serous coat, the latter are distributed to the mucous membrane, forming plexuses in its superficial layers and around the glands. At the level of the isthmus the transverse branches are larger than elsewhere, and, with the corresponding divisions of the opposite artery, they form on the outer surface of the uterus the arterial circle of Huguier. Several small branches to the bladder and vagina arise from the uterine artery at or near its point of reflection. The *funicular* ("pertaining to a rope") *artery*, from the superior vesical, joins the round ligament at the internal abdominal ring and divides into two branches, superior and inferior. The former accompanies the ligament to the superior angle of the uterus, where it anastomoses with the uterine and ovarian arteries; the latter follows the ligament to its distal termination,

communicating there with the external pudic. The *ovarian artery*—described with the ovary—aids in supplying the uterus through its communications with the uterine and funicular arteries. The *veins*, which are very large, have no valves. Taking origin in the capillary plexuses, they converge to form a set of special canals, the *uterine sinuses*, which are lodged in the meshes of the middle muscular layer. From this point they are directed to the lateral borders of the uterus, where they form between the layers of the broad ligament the *uterine plexuses*, one on either side. From these the blood is collected by three trunks. One, the uterine vein, accompanying the artery of that name, empties into the internal iliac vein ; a second, by its junction with the veins from the ovary and Fallopian tube, helps to make up the pampiniform plexus ; while a third (unimportant) trunk follows the funicular artery. The *lymphatics* of the mucous membrane begin as minute spaces between the fibres of the corium. Joined by the lymphatics of the muscular coat, they emerge and form beneath the serous covering a rich plexus, from which the lymph is carried by three trunks. The first, collecting chiefly from the body of the uterus, the ovary, and the Fallopian tube, accompanies the ovarian vein and empties into the lumbar nodes ; the second, carrying lymph from the cervix, follows the uterine vein, and ends in the pelvic nodes ; while the third, following the vein of the round ligament, ends in the inguinal nodes. The *nerves*, consisting of both medullated and non-medullated fibres, are derived from the inferior hypogastric and renal plexuses of the sympathetic, and from the third and fourth sacral nerves.

The fœtal remains to be observed in connection with the uterus or its adnexa are the parovarium, the duct of Gärtner, the organ of Giraldès, and the hydatid of Morgagni.

The **parovarium** (epoöphoron, or organ of Rosenmüller) is a vestige of the Wolffian body, and represents the vasa efferentia of the testicle. It consists of twelve to twenty tubules, arranged in the form of a triangle, and contained in the thickness of the broad ligament, between the ovary and the Fallopian tube, where it may be seen by holding the ligament against the light. The apex of the triangle reaches to the attached border of the ovary, the base is turned toward the Fallopian tube. The ovarian ends of the tubules are blind ; their opposite extremities open into a collecting duct which runs parallel with the outer portion of the Fallopian tube, and represents the canal of the epididymis. Both the collecting duct and the tubules are lined with a ciliated, columnar epithelium.

The **canals of Gartner**, always present in certain animals, are the remnants of the lower portions of the Wolffian ducts. The latter, in the male, develop into the tail of the epididymis and the vas deferens ; in the female they usually disappear. When persistent, however, they are found, as minute tubes or fibrous cords, one on either side of the uterus and vagina. Above, these tubes may be continuous with the collecting tubes of the parovarium ; below, they may sometimes be traced to the vicinity of the urinary meatus.

The **organ of Giraldes** in the male, is represented in the female, by a few scattered tubules, remnants also of the Wolffian body, which lie between the layers of the broad ligament, nearer to the uterus than the parovarium.

The **hydatid of Morgagni**, a relic of the Müllerian duct, is usually found in the form of a small pediculated cyst, attached to one of the fimbriæ of the Fallopian tube. It is lined with ciliated, columnar epithelium, and filled with a clear fluid.

THE VAGINA.

The vagina ("sheath") (Fig. 898) is a distensible, musculo-membranous canal, which extends from the uterus to the vulva. It is the organ of copulation in the female, and in addition affords passage to the menstrual flow and the fœtus.

Location, Direction, and Dimensions.—It is situated in the median line of the pelvis, between the bladder and rectum. Running downward and forward, its

lower extremity makes with the horizontal plane an angle of 60° to 70°, opening posteriorly. The axis of the canal is not straight, but presents a posterior concavity, which fits a corresponding convexity of the rectal wall. The anterior vaginal wall measures two to two and a half inches in length; the posterior varies from two and a half to three and a half inches. Continuous above with

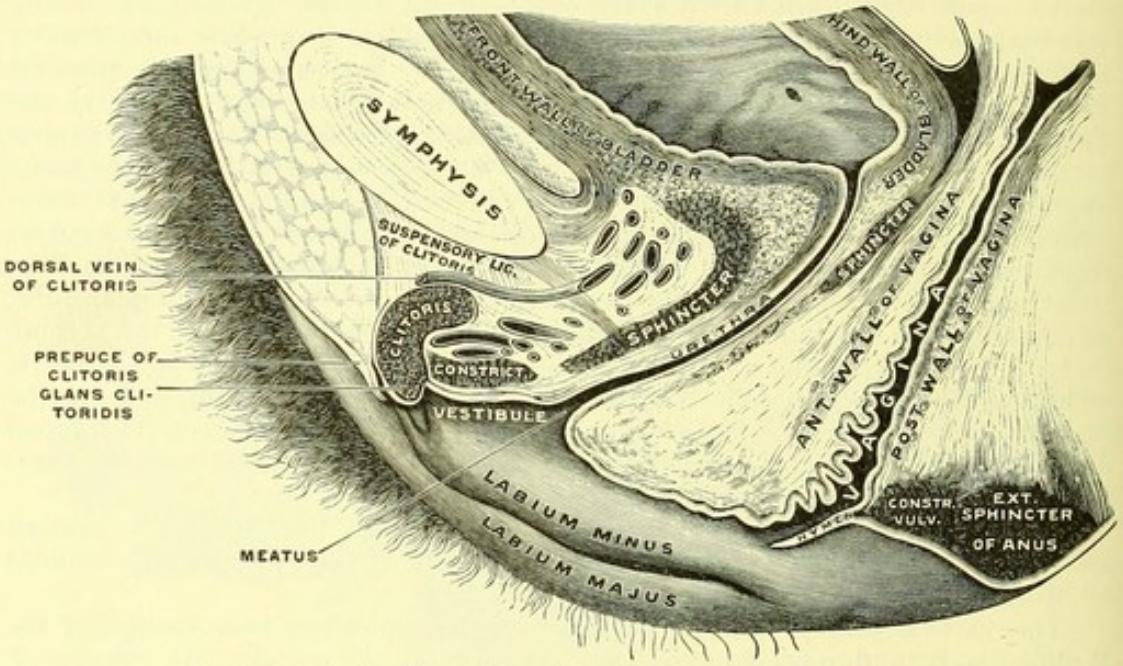

FIG. 898.—Sagittal section of the vagina and neighboring parts. (Testut.)

the cervix, the vagina is further fixed in position by its connections with the bladder, rectum, vulva, and perineum.

Conformation and Relations.—Above, where the vagina embraces the cervix, it is circular; below, at the vulvo-vaginal junction, it is elliptical, with the major axis antero-posterior. Between these points the anterior and posterior walls are in contact, thus reducing the canal to a mere fissure, which on transverse section is H-shaped. The vagina may therefore be divided for further description into two surfaces—the external or attached, and the internal or free; and two extremities—the upper and the lower.

The **external surface** presents two faces, an anterior and a posterior, and two lateral borders. The upper half of the anterior face is in relation with the bladder, the lower half with the urethra. The lower two-thirds of the latter is buried in the anterior vaginal wall, the upper third and the bladder are separated from this face by areolar tissue, continuous with the subperitoneal fascia. In this fascia the terminal segment of the ureter runs obliquely, to open into the bladder wall at a point one and a quarter inches below the level of the external os. (It must not be forgotten that in the female a portion of the base of the bladder rests against the anterior surface of the cervix.) The posterior face is covered above to a varying extent (usually about one inch) by the peritoneum as it dips into the cul-de-sac of Douglas. The middle portion rests against the rectum, from which it is separated by a continuation of subperitoneal fascia. Below, it is widely separated from the termination of the rectum by the triangular perineal body. The lateral borders are in contact above with a small portion of the broad ligaments. In the upper third they are crossed obliquely by the ureters, and below this they are embraced by the anterior margins of the levatores ani muscles and the accompanying recto-vesical fascia. By the side of the upper half of each lateral border may sometimes be found a small tube, the continuation of the duct of Gärtner.

On the **internal** or **mucous surface** are two median longitudinal ridges, the *columns of the vagina*, situated one on the anterior, the other on the posterior wall. The latter is sometimes double. From these, numerous secondary ridges pass transversely outward to the lateral borders. Both the columns and secondary ridges are better marked in the lower portion of the vagina than above. After child-birth they diminish in prominence or entirely disappear.

The *superior extremity* is attached to the circumference of the cervix reaching higher behind than in front. With the outer surface of the intra-vaginal segment of the cervix it makes a circular pericervical trench, the *fornix*, which is deepest behind. The *inferior extremity* pierces the triangular ligament, and is the narrowest and least dilatable portion of the canal.

Structure.—The vaginal wall, about one-sixth of an inch in thickness, consists of three coats—an outer of connective tissue, a middle of muscular tissue, and an inner of mucous membrane. The *connective-tissue coat* is a thin white fibrous structure, derived from the recto-vesical fascia. It contains a few smooth muscular fibres, and carries in its meshes a plexus of veins. The *muscular coat*, of unstriped fibres, may be divided into two layers, superficial and deep. The fibres of the superficial layer, longitudinal in arrangement, are continuous with the superficial muscular layer of the uterus. They are also continuous above with the utero-sacral ligaments, by means of which the vagina is attached to the sacrum. Below, some of the longitudinal fibres are inserted into the ischio-pubic rami, while others are lost on the triangular ligament and recto-vesical fascia. The deep layer is made up of circular fibres, which surround the canal. Near the vulvo-vaginal orifice these fibres are condensed into a ring of some strength, which forms an involuntary sphincter. The striated sphincter of the vagina is derived from the muscles of the perineum. The *mucous coat*, thrown into folds as already described, is covered with stratified epithelium, continuous with that lining the vulva below and covering the cervix above. Its deep layer or corium is closely attached to the muscular tunic, no special submucosa intervening. The lower portion of this coat is studded with numerous conical or filiform papillæ. The upper portion presents a few closed follicles; otherwise the mucous membrane is entirely devoid of glands.

Vessels and Nerves.—The *arteries* are all derived from the internal iliac or its branches. The vaginal artery, corresponding to the inferior vesical in the male, runs along the lateral borders of the vagina, supplying arteries to the anterior and posterior surfaces. A small vaginal branch from the uterine, and anastomosing branches from the remaining vesicals, middle hemorrhoidal, and internal pudic are also supplied. The *veins*, remarkable for their number and volume, direct themselves to the lateral borders, where they form the *vaginal plexuses*, one on either side. These communicate with the veins of the uterus, broad ligaments, bladder, rectum, and bulbs of the vagina, and finally empty through the uterine and vaginal trunks into the internal iliac vein. The *lymphatics* from the lower third of the vagina, joining with those from the vulva, empty into the superficial inguinal nodes; the remainder end in the internal iliac nodes. The *nerves*, derived from the hypogastric plexus, the fourth sacral, and the pudic, are distributed to the mucous and muscular tunics. Their mode of termination is unknown.

THE VULVA.

The vulva or *pudendum* (Fig. 899), ovoid in outline, is bounded in front by the anterior abdominal wall, behind by the perineum, and laterally by the inner surfaces of the thighs. It includes the following parts: (1) the mons Veneris, the labia majora, and the labia minora (all derived from the integument); (2) between the labia a median space called the interlabial or vulval cleft; (3) an erectile apparatus; (4) certain glandular structures.

The Mons Veneris.

The mons Veneris is an elevation situated in front of the upper part of the pubic symphysis. Anteriorly and above, it merges into the integument covering the lower part of the abdomen, posteriorly it is continuous with the labia majora, laterally it is limited by the right and left inguinal folds. In structure the mons consists of modified skin, deeply pigmented, and covered with hair, beneath which is a collection of areolar and adipose tissue, intersected by a series of

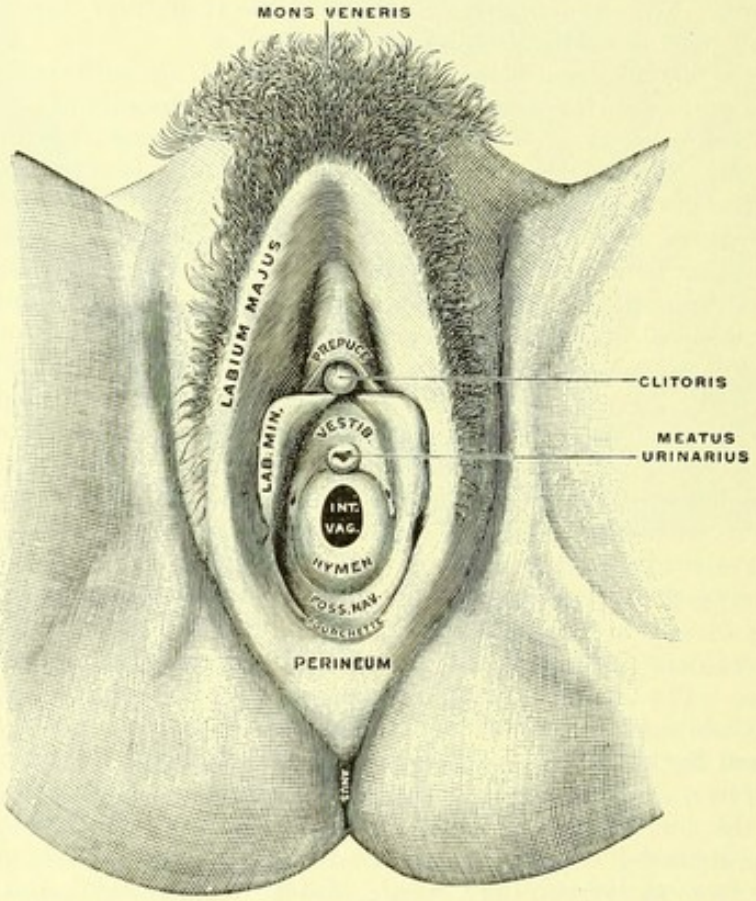

FIG. 899.—Vulva of a virgin. The labia have been widely separated. (Testut.)

elastic laminæ. The latter take origin deeply from the linea alba and abdominal aponeurosis, and end by becoming attached to the deep surface of the skin.

The Labia Majora.

The labia majora ("greater lips"), two longitudinal folds of modified integument, are continuous with the mons Veneris in front, and extend to within an inch of the anus behind. Each fold is about three inches in length, and presents for description two extremities, two surfaces, and two borders. The anterior extremities by their junction with the mons and with each other make up the *anterior commissure;* the posterior, having become very thin, are united by the *posterior commissure* or *fourchette* ("fork"), which constitutes the thin, anterior edge of the perineum. The outer surface, separated from the corresponding thigh by the genito-crural fold, is deeply pigmented, covered with hair, and abundantly supplied with sudoriparous and sebaceous glands; the inner is in contact, when closed, in part with its fellow, in part with the labium minus of the same side. The skin, which lines this surface in the vicinity of the free border, resembles that on the outer surface; more deeply it is rosy, moist, studded with

sebaceous follicles, and presents only rudimentary hairs. The superior or attached borders correspond to the ischio-pubic rami, with which they are connected by numerous fibrous bands. The inferior borders are free, and the fissure between them is called the *rima* ("crack") *pudendi*. In infants, young women, and fleshy subjects the labia majora are firm, and directly applied one to the other; in the old, the thin, and those who have borne many children, they shrivel and gape apart.

Beneath the integument of each labium majus there is found a tissue, resembling the dartos of the scrotum, but much thinner; beneath this a layer of adipose and connective tissue; and still deeper an elastic, pear-shaped sac, called *Broca's pouch*. This contains connective tissue and fat; and its mouth, applied to the external abdominal ring, may sometimes receive the termination of the canal of Nuck. Morphologically the labia majora correspond to the scrotum in the male.

The Labia Minora.

The labia minora ("smaller lips"), or *nymphæ*, are two smaller longitudinal folds, placed within the labia majora, and running from the clitoris downward and backward for about one and one-half inches. They also present two surfaces, two borders and two extremities. The external surfaces are in contact with the labia majora, the internal with each other. The superior borders are attached, the inferior, often crenated, are free. The anterior extremities divide, each into two bands. The superior of these unite above the dorsum of the clitoris to form its prepuce; the inferior, uniting beneath the clitoris to which they are attached, form its frenum. Posteriorly each labium terminates opposite to or a little behind the middle of the rima pudendi. Rarely it is continuous farther backward, and is joined to its fellow by a slender transverse fold, placed on the anterior edge of the posterior commissure. This fold then becomes the fourchette. The nymphæ are composed of modified skin, beneath which is a connective tissue, rich in elastic and smooth muscular fibres, but containing no fat. In the young, where they are protected by the labia majora, they are rosy in color and moist, approaching in character the mucous membranes; when they project beyond the labia majora, however, they become dry and deeply pigmented. Their surfaces are free from hairs and sudoriparous glands, but are abundantly supplied with sebaceous glands, which secrete a thick, white substance, akin to the preputial smegma, and with papillæ, which contain nerves ending in tactile corpuscles.

The Interlabial Space.

The interlabial space or vulval cleft is bounded on either side by the labia majora and minora, in front by the clitoris, and behind by the posterior commissure. It receives the orifice of the vagina and the external opening of the urethra, becoming therefore the common uro-genital opening. Ordinarily, the tissues falling together, the space is obliterated, becoming merely a fissure; but, when the labia are drawn apart, it becomes broad, shallow, and elliptical in outline. Superficially, it is lined with modified skin, deeply with mucous membrane, which merges into that of the vagina and urethra. The line of demarcation between the skin and mucous membrane runs from beneath the prepuce of the clitoris backward along the inner surface and attached border of the labium minus to the outer aspect of the hymen (Hart). In the floor of the interlabial space from before backward may be seen the vestibule, meatus urinarius, orifice of the vagina, hymen, and fossa navicularis.

The **Vestibule** is a shallow triangular space, bounded laterally by the nymphæ, and behind by the orifice of the vagina. Its apex, directed forward, coincides with the clitoris.

The **Meatus Urinarius**, the external opening of the urethra, is situated in the median line, at the back part of the vestibule, about an inch behind the clitoris,

and just in front of the vagina. Directly behind it there is an elevation of mucous membrane, the *vaginal tubercle*, which serves as a guide to the introduction of a catheter.

The **Inferior Orifice of the Vagina** (*introitus vaginæ*), when the hymen has been removed, is elliptical in outline. Its diameters are much greater in women who have borne children than in the nulliparous.

The **Hymen** ("a membrane") (Fig. 900) is placed at the vulvo-vaginal junction, narrowing to a greater or less degree the inferior vaginal orifice. It is composed

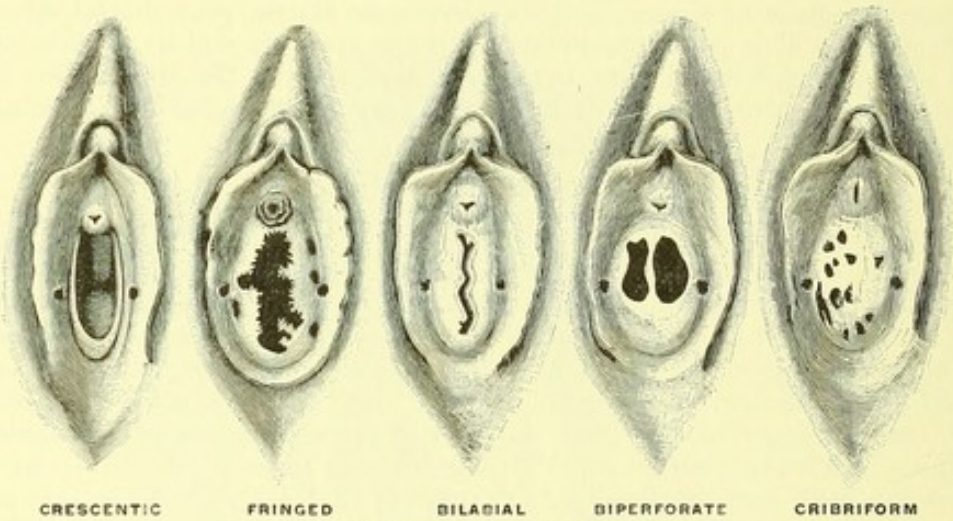

FIG. 900.—Varieties of hymen. (Testut after Roze.)

of a double fold of mucous membrane, between the layers of which is found connective tissue, rich in elastic fibres. In shape it varies widely, the commonest forms being the falciform and the annular. In the former the hymen is semilunar in outline, with the concavity looking forward; in the latter a complete ring, usually widest posteriorly, surrounds the opening. Sometimes it forms a complete septum (imperforate hymen) or has many small openings (cribriform). The hymen is usually torn during the first coition, but may, when very elastic, escape rupture. After parturition there remain of it only some slight rounded elevations, the *carunculæ myrtiformes* ("little masses of flesh like myrtle-berries"), which occupy the site of its attached border.

The **navicular fossa** is that portion of the interlabial space, which lies behind the entrance to the vagina. It is bounded superficially by the fourchette, deeply by the superficial surface of the hymen.

Erectile Organs.

The erectile organs belonging to the vulva are the clitoris and the bulbs of the vagina.

The **Clitoris**, about one inch in length, is situated at the apex of the vestibule, between the anterior extremities of the nymphæ. It is the homologue of the penis, but has no corpus spongiosum, and no urethra. The two corpora cavernosa, of which it is mainly composed, are similar in minute structure to those of the male. Diverging behind, they constitute the crura, which are attached to the ischio-pubic rami superficial to the triangular ligament, and covered by the ischio-cavernosi (erectores clitoridis) muscles. In front the corpora cavernosa unite to form the body of the clitoris, the septum pectiniforme between them being imperfect. Their united distal extremities are surmounted by a glans, composed of very sensitive, spongy, erectile tissue. The clitoris has a prepuce and a frenum, both derived from the nymphæ, and is also provided with a suspensory ligament. It is supplied with helicine arteries and numerous anastomosing veins,

agrees in structure with the erectile tissues described elsewhere, and is capable of erection.

The **Bulbi Vestibuli** (Fig. 901), or bulbs of the vagina, are two pyriform masses of erectile tissue, made up chiefly of a plexus of veins, enclosed in a thin, fibrous tunic. They are about an inch in length, and are placed one on either side of the uro-genital space, a little above the level of the nymphæ. Together they represent the bulb of the corpus spongiosum in the male. They each present two surfaces, two borders, and two extremities. The inner surfaces, covered by mucous membrane, are in close relation with the orifices of the urethra and vagina; the outer are covered by the bulbo-cavernosi muscles (acceleratores urinæ in the male), which here become the constrictors of the vagina. The upper borders are attached to the superficial layer of the triangular ligament, while the lower correspond with the attached borders of the nymphæ. The posterior extremities are rounded, and reach to the navicular fossa. The anterior pointed extremity of each is continued forward by means of a narrower plexus, the *pars intermedia*, which communicates with its fellow beneath the clitoris. The pars intermedia is homologous to that portion of the corpus spongiosum, which lies between the bulb and the glans. It receives veins from the nymphæ, and serves to connect the bulbs with the veins of the glans clitoridis and corpora cavernosa. When engorged the bulbi vestibuli narrow the vaginal orifice.

Glands.

In connection with the vulva are found: (1) the vulvo-vaginal glands; (2) the urethral and peri-urethral glands.

The **Vulvo-vaginal Glands**, or glands of Bartholin (Fig. 901), two in number, are situated one on either side of the vagina posteriorly, between the layers of the triangular ligament. They are round or oval in outline, measuring about half an inch in their longest diameter. Their ducts run forward and inward to open into the vulval canal, one on either side, in the groove between the hymen and labia minora. They are racemose, mucous glands, homologues of the glands of Cowper in the male, and their secretion lubricates the vulval canal.

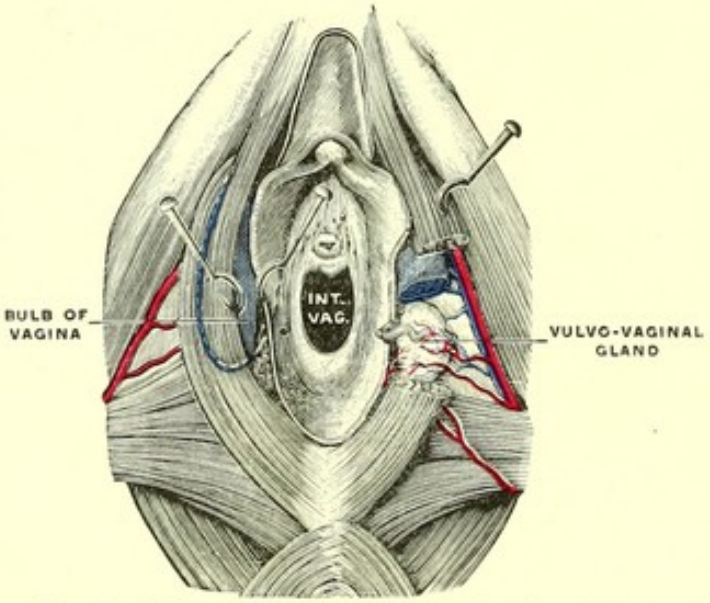

FIG. 901.—Vulvo-vaginal gland. The broken line indicates the limits of the bulb of the vagina. (Testut.)

The **Urethral Glands**, found chiefly beneath the lateral walls and floor of the urethra, vary in structure from simple inversions of the mucous membrane to racemose glands. Their openings are arranged in rows parallel with the long axis of the canal. They secrete mucus, and correspond morphologically with the prostatic glandular structure. Other glands found in the vestibule near to the urethra are designated *peri-urethral* or *glandulæ vestibulares minores*, the latter to distinguish them from the *glandulæ vestibulares majores* or glands of Bartholin.

Vessels and Nerves.—*Arteries.*—The superficial portions of the vulva are supplied by branches of the external and internal pudics; the deeper, by branches of the internal pudics alone. The clitoris and bulbi vestibuli receive branches

from the internal pudics, corresponding in name to similar branches in the male. The *veins* for the most part end in trunks, which accompany the arteries. Those of the labium majus communicate freely with the veins of the round ligament at its distal extremity, while the bulbi vestibuli communicate with the vaginal plexuses, the dorsal vein of the clitoris, the veins of the corpora cavernosa, and the obturator veins. The *lymphatics* accompany the veins and empty into the superficial inguinal nodes.

Nerves.—Sympathetic nerves derived from the pelvic or inferior hypogastric plexus accompany the arteries. In addition spinal branches are supplied by the genito-crural, inferior pudendal, and internal pudic. In the nymphæ and glans clitoridis they end in the tactile corpuscles of Pacini and Meissner, and on the glans alone in the so-called genital corpuscles.

THE MUSCLES OF THE FEMALE PERINEUM.

The muscles of the female perineum (Fig. 902) are the homologues of those in the male.

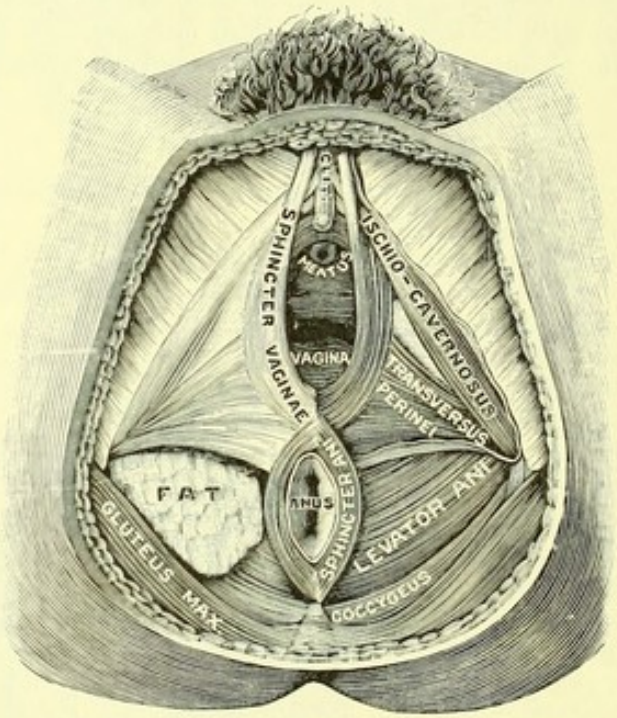

FIG. 902.—Muscles of the female perineum. (Testut.)

The **sphincter ani externus** and **coccygeus** are identical in the two sexes.

The **transversi perinei** and **ischio-cavernosi** differ from their male counterparts only in being smaller. The ischio-cavernosus is more frequently called the *erector clitoridis*, as it sustains the same relations to the clitoris that its enlarged masculine fac-simile does to the penis.

In the **levator ani** the anterior portion courses at the side of the vagina, and the pair of muscles probably produce some constriction of the lumen of the tube.

The **bulbo-cavernosi** are more commonly called the *sphincter vaginæ* or *compressor vaginæ*. They are smaller than in the male, and, instead of being united by a median raphe, are separated, and include in their grasp the opening of the vagina and the bulbs of the vestibule. They are inserted into the cavernous bodies of the clitoris.

The **constrictor urethræ**, or *transversus perinei profundus*, is mainly composed of unstriped muscular tissue. Its origin, as in the male, is from the ischio-pubic rami. The smaller anterior portion stretches across the subpubic arch in front

of the urethra. The larger, posterior portion is lost mesially in the muscular wall of the vagina.

THE MAMMARY GLANDS.

The two mammary glands, *mammæ*, or *breasts*, are accessory organs of generation, their secretion, the *milk*, serving to sustain the infant until it is capable of deriving its nourishment from other sources. Philosophically considered, each mamma is a collection of sebaceous glands, greatly enlarged, and extending far

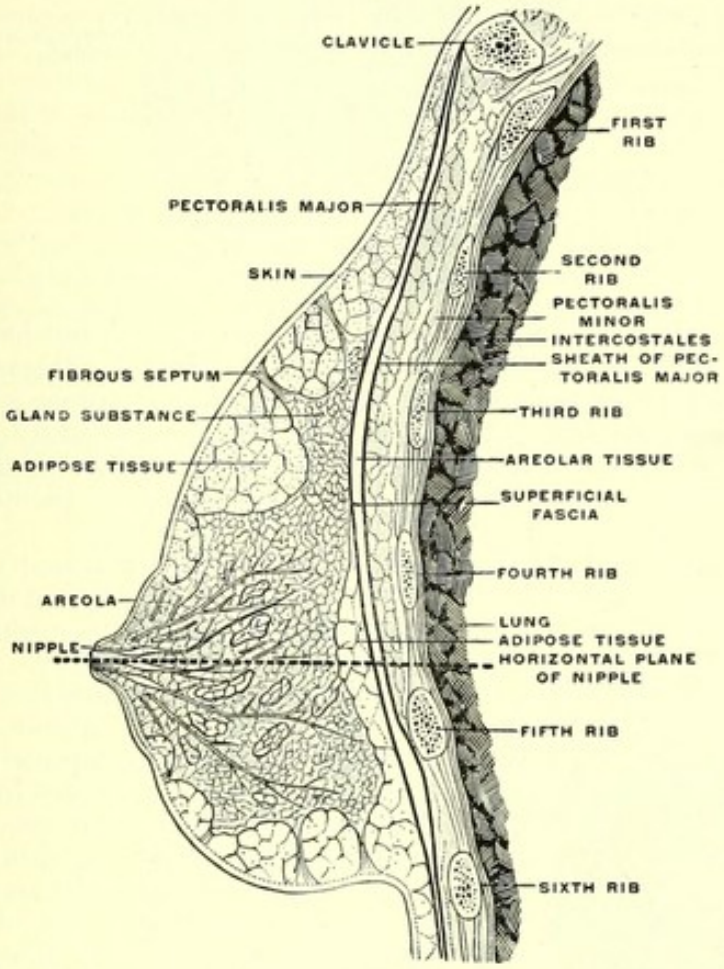

FIG. 903.—Right breast in sagittal section, inner surface of outer segment. (Testut.)

into the subcutaneous region, which here is vastly deeper than elsewhere. The secretion of the sebaceous glands is oily, and that of their prodigious congeners is of the same character, though in the one case the fluid is devoted to purposes of lubrication, in the other to nutritive uses.

Each breast is approximately hemispherical, and a little below the centre of its convexity presents a *mammilla* (nipple, teat, dug), usually shaped like a truncated cone, half an inch long, pointing forward, upward, and outward, and set in the middle of a circular area of darker skin, the *areola*.

The breast covers a nearly circular space, mostly in front of the pectoralis major, extending from the second to the sixth rib, and from the sternum to the border of the armpit. The location of the nipple is usually given as at the level of the fourth rib; but its position is dependent upon various circumstances, such as age, pregnancy, lactation, corpulence, firmness of tissues, race, attitude of body, (not to mention numerous diseases), so that it becomes one of the least trustworthy of landmarks.

The *weight* of the breast is usually above five ounces in the inactive condition.

The secreting structure of the breast consists of from ten to twenty separate lobes, each of which is a compound, racemose, acinous gland. Each of these

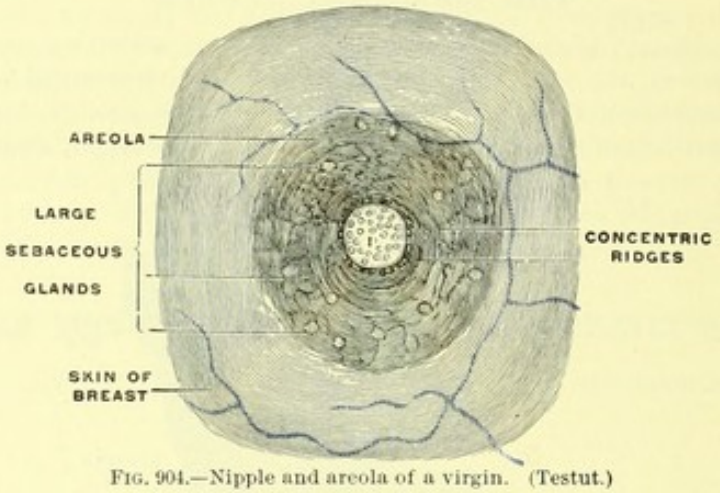

FIG. 904.—Nipple and areola of a virgin. (Testut.)

glands is made up of lobules, which are colonies of alveoli, and has its own ultimate excretory duct, called *galactophorous* or *lactiferous* ("milk-carrying"). The ducts from all parts of the breast converge toward the nipple, and, when they reach the areola, each dilates into a *sinus* or *ampulla*, half an inch long and half as wide, which serves as a little reservoir for the milk. Beyond this the duct is reduced to a small calibre, and terminates at the summit of the nipple in a contracted orifice.

The alveoli and ducts are lined with a simple epithelium, partly flattened and partly cuboidal or cylindrical. The wall of the ducts is composed of mixed white and yellow fibrous tissues, arranged in longitudinal and circular bundles.

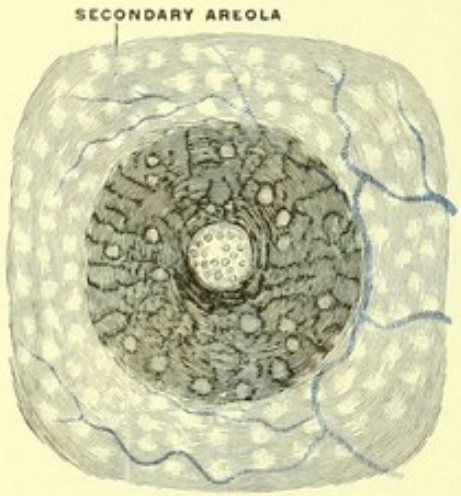

FIG. 905.—Nipple and areolæ of a pregnant woman. (Testut.)

The proper gland-substance is supported on a framework of the fibrous tissues, which also form an enclosing capsule for the organ. This capsule sends processes inward between the lobes and lobules, and processes outward to the deep surface of the skin. Among the masses of glandular material are many nodules of adipose tissue, which are of greatest size near the convex surface, though some considerable collections are found at the flat, hind surface of the gland. No fat, however, appears beneath the nipple and areola.

The *mammilla* is composed of skin, peculiarly modified, and containing the terminal portion of the milk-ducts. It is dark, wrinkled, beset with papillæ, which are extremely sensitive, but has no sweat-glands or hairs. It is very vascular, and among the vessels are many fibres of unstriped muscular tissue—an arrangement which gives it the properties of erectile tissue, so that under the stimulus of contact or even emotion, it may swell and become rigid. Its summit presents the orifices of the many lactiferous ducts.

The *areola* resembles the nipple in color and in structure, being pigmented and somewhat erectile. In addition it is dotted over with little, roundish projections, due to large, sebaceous glands in the skin, in connection with each of which is a delicate, minute hair.

Modifications.—In women who have not become pregnant the glandular tissue

is but slightly developed (even though the breast may be plump and firm), and the nipple and areola are pink. But as early as the second month of pregnancy the color of these parts deepens, and may become dark brown, and the secreting structure begins to develop. A *secondary areola*, much fainter than the primary, may be observed encircling it. The breasts become very large and heavy *during the period of nursing*, but shrink when lactation is completed, and simultaneously the added pigment mostly disappears from the areola and nipple; but the delicate rosy hue of the virgin state is never restored. *After the menopause* the gland shrivels into a thin disc, incapable of function; but this diminution may not be outwardly manifest in the corpulent on account of the great accumulation of fat. *During menstruation* the breasts may swell, owing to sympathetic congestion. In some women the nipple does not project beyond the surface of the breast, and in certain cases it is even retracted, a dimple marking its situation. *In the male* the mammary gland is rudimentary and minute. The nipple is small, and the areola presents a growth of rather strong hairs.

Very rarely women have *supernumerary mammæ*, thus imitating many of the lower animals. One case is recorded in which a woman had eight supplementary breasts, in addition to the usual pair. On the other hand there may be entire *failure of development* beyond the rudimentary condition. Very phenomenally the *male breast* ceases to be a mere rudiment, and becomes capable of furnishing milk.

Vessels and Nerves.—The *arteries* of the mamma are branches of the axillary, internal mammary, and intercostals. The *veins* correspond. The *lymphatics* run to the axillary nodes (primarily to the pectoral group, secondarily to the others) and to the sternal. The *nerves* are chiefly intercostal.

RELATIONAL ANATOMY.

By F. H. GERRISH.

IN the chapters on Systematic Anatomy much has been presented concerning the relations existing between the parts and organs described. It would doubtless be useful to have all of these statements gathered into a single section, but the prescribed limits of this work forbid such a course. The purpose of this chapter is to introduce certain matters which did not conveniently fall into line with any of the topics of Systematic Anatomy, to emphasize some of the most important points which have previously been made, and to show by methods, hitherto little employed, facts of interest and value concerning the structure of the body.

The chapter will be divided into three parts, each of which will be devoted to a different method of studying Relational Anatomy. In the first part will be presented a series of *plane sections* of the trunk and limbs; in the second part, reproductions of *photographs of the surface;* and in the third part, *skiagraphs* of every portion of the body, whose osseous structure can be profitably studied by the aid of the so-called *X*-rays.

However full may be the descriptions in such a chapter, its chief and essential value will always reside in the pictures; and those that are here given are so clear, and tell their own story so distinctly, that only a few words of introduction for each are needed, and the descriptive text can, therefore, be reduced to a minimum.

It is recommended that each of these pictures be studied in connection with everything else in the book which bears upon the subjects involved. For example, in considering the region of the forearm, the systematic anatomy of the bones, muscles, fasciæ, arteries, veins, lymphatics, and nerves of the part should be studied anew; next, the plane section should be examined with care, and the location of every organ fixed in mind; then the various photographs of the surface of the part should receive attention; and, finally, the corresponding skiagraphs should be regarded. By the combination of all these methods the student will be able to obtain all of the anatomical information of the locality that a text-book can afford.

I. PLANE SECTIONS.

In each of these pictures the upper surface of the lower segment resulting from the section is shown—in other words, the upper segment has been removed, and we look down upon the specimen. In the case of the sections of the limbs we may profitably imagine them to be the stumps of amputations of the opposite limbs at the same level—that is, they present such a view as would be given by the cut surface of the proximal part on the other side.

In the representations of sections of the trunk much lack of bilateral symmetry will be found, not only as concerns details, but also in the outlines of the figure. This is due to several causes. Perfect symmetry of contour on the opposite sides is practically unknown; the corresponding parts are rarely exactly

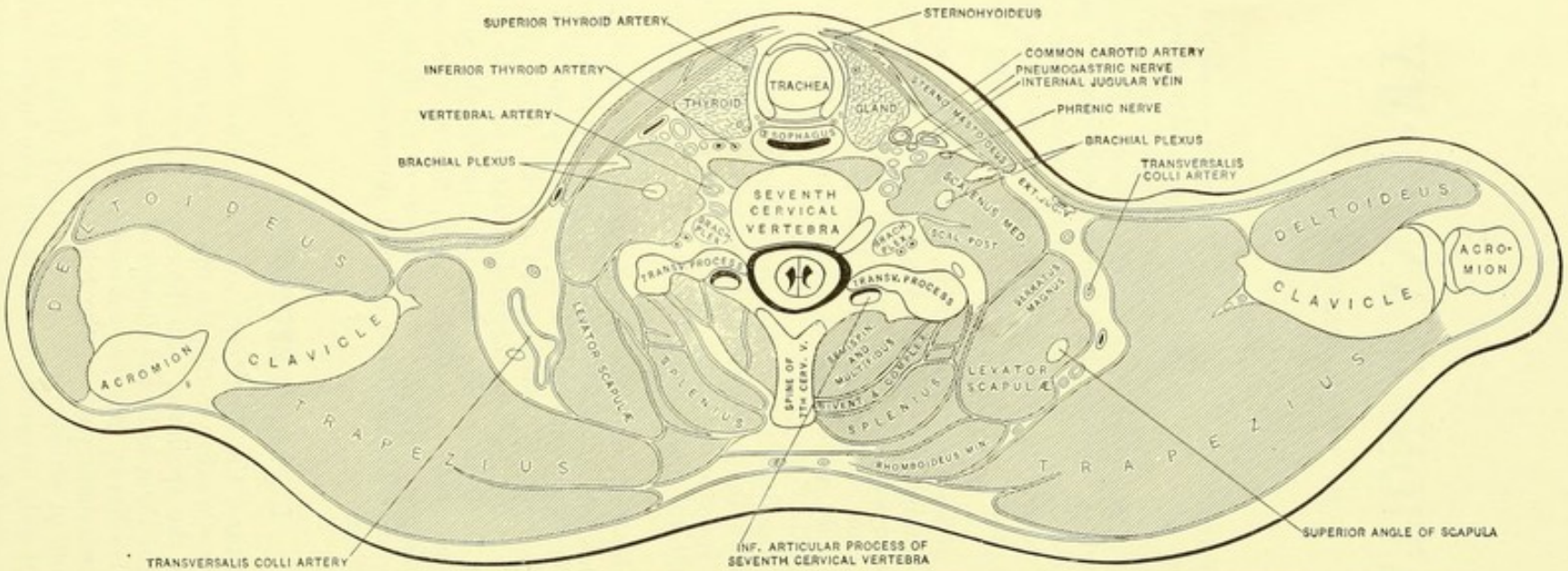

FIG. 906.—Horizontal section through the lowest part of the body of the seventh cervical vertebra, close to junction of neck and trunk. (After Braune.)

The upper cartilage of the trachea is cut, and on the front of it is a small part of the lower portion of the cricoid cartilage. The thyroid vessels are seen in and near the thyroid gland. The head of the first rib appears on the right side of the vertebral body. The transverse processes belong to the first thoracic vertebra. The muscle on the front of the body of the vertebra is the longus colli. The ventral, unlabelled part of the mass of scaleni, is the scalenus anterior. In front of the vertebral artery is the vertebral vein, and in front of the latter, on the right side, is the inferior cervical ganglion of the sympathetic. On each side, between the trachea and œsophagus, is the recurrent laryngeal nerve. The spinal accessory nerve is seen in the right trapezius, close to the clavicle; on the left side it is not drawn. On the right side the section has opened the acromio-clavicular joint; on the left it passes below it. The serratus magnus does not appear on the left. The brachial plexus is seen in three parts, ranged in a ventro-lateral line from the spinal cord.

FIG. 507.—Horizontal section through the body of the third thoracic vertebra. (After Braune.)

S. C. M., sterno-cleido-mastoideus. V. A., vertebral artery. Bic., tendon of long head of biceps. The cut passes through the upper border of the sternum, the spine of the second thoracic vertebra, and the head of each humerus. Between the trachea and œsophagus is the left recurrent laryngeal nerve. Observe that the trachea is much further from the ventral surface than in Fig. 506. The brachio-cephalic artery is median, and obliquely at its left are the left carotid and left subclavian. The brachial plexus is in close relation to the subclavian artery. The apices of the lungs have been cut off.

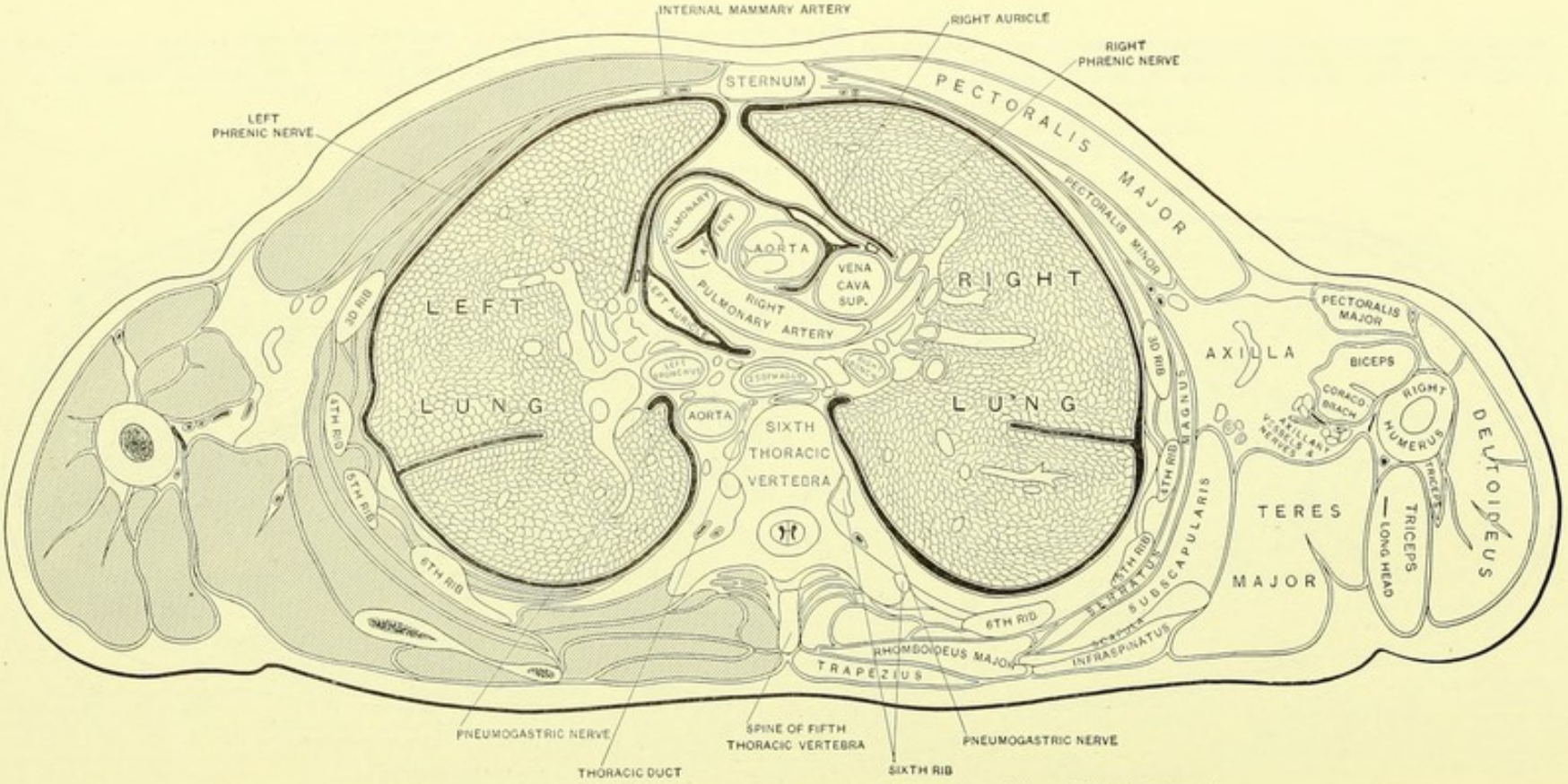

FIG. 908.—Horizontal section through the body of the sixth thoracic vertebra. (After Braune.)

The cut passes through the spine of the fifth thoracic vertebra, the body of the sternum, the humerus just below the tuberosities, and the scapula near the lower angle. The axilla, with its vessels and nerves, is opened. The lungs show their great fissure. The uppermost part of the heart has been removed, and we look down upon the pulmonary and aortic valves. Observe the pericardium and pleurae; the descending aorta at the left of the vertebra; the thoracic duct (here double); and the pneumogastric nerves.

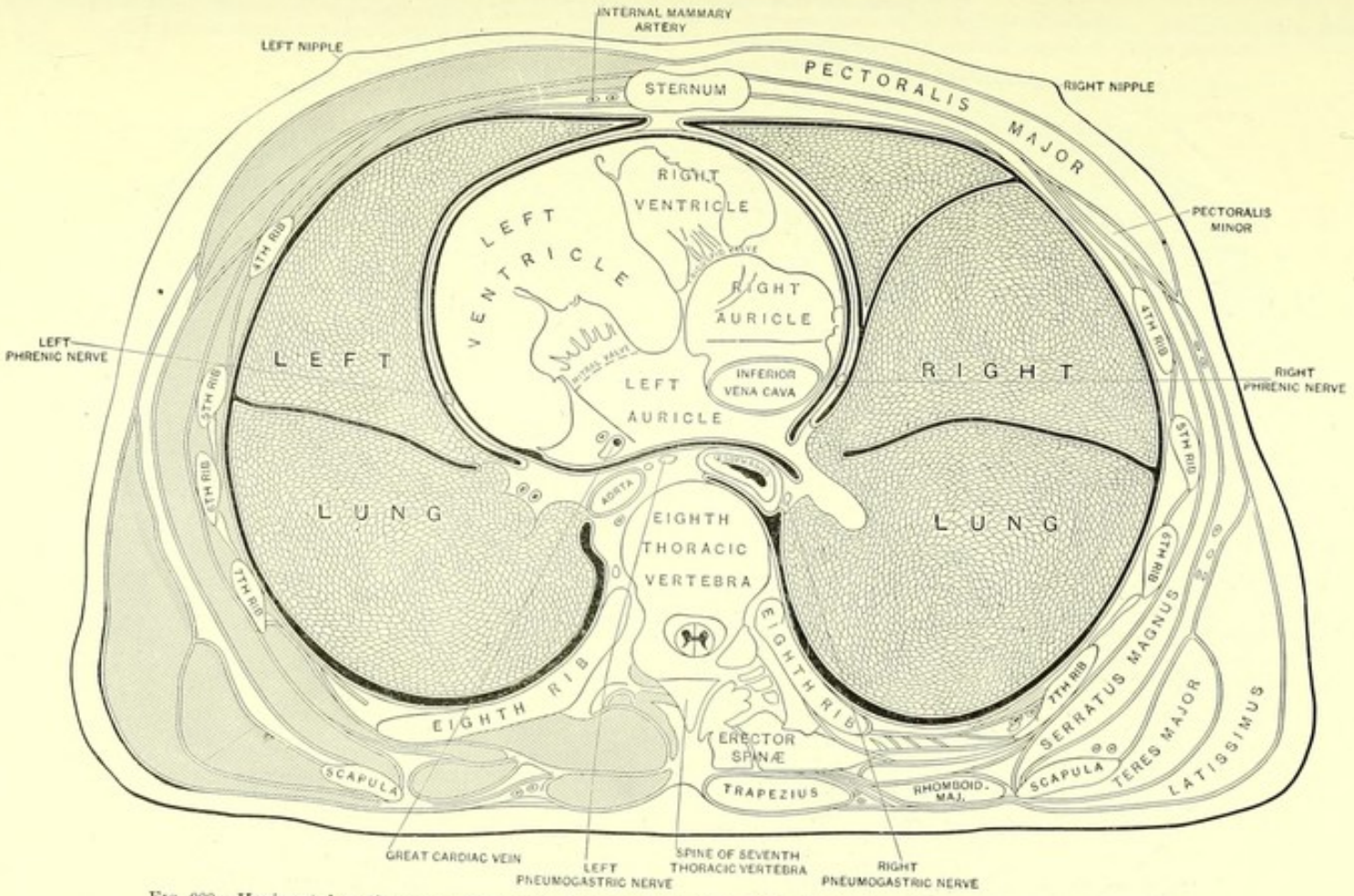

FIG. 909.—Horizontal section through the upper part of the body of the eighth thoracic vertebra. (After Braune.)

The heart has been cut so obliquely that the ventricular walls appear thicker than they are. The lungs present large surfaces, and both fissures appear in the right one. Observe the pericardium, pleuræ, and the position of the aorta and œsophagus. The section being below the axilla, the upper limbs no longer are seen.

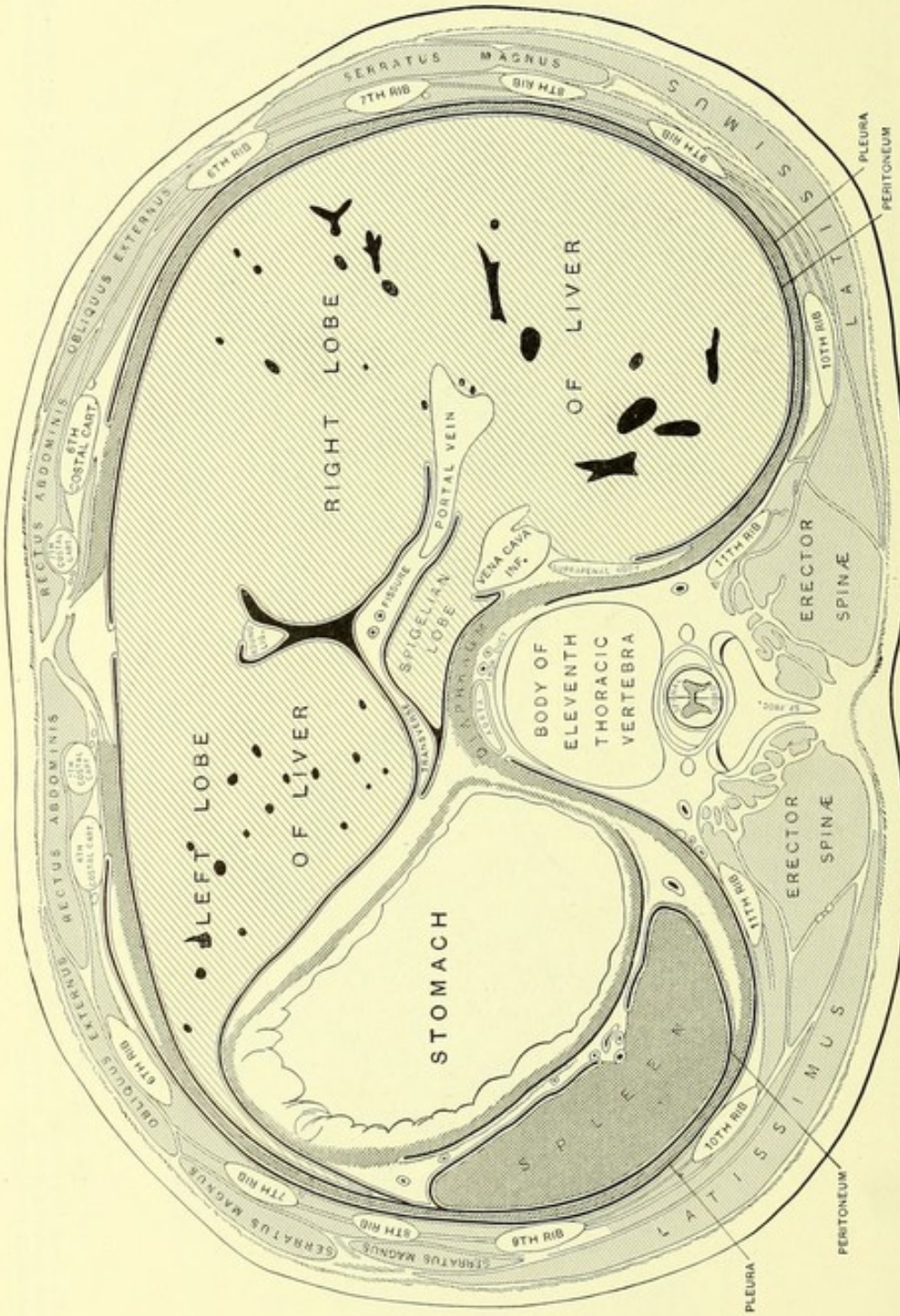

FIG. 910.—Horizontal section through the lower part of the body and arch of the eleventh thoracic vertebra. (After Braune.)

The diaphragm encircles the abdominal cavity, having peritoneum on its inner surface and the pleurae on its outer. Observe the great space occupied by the liver, the relations of the stomach and spleen, the position of the right suprarenal body.

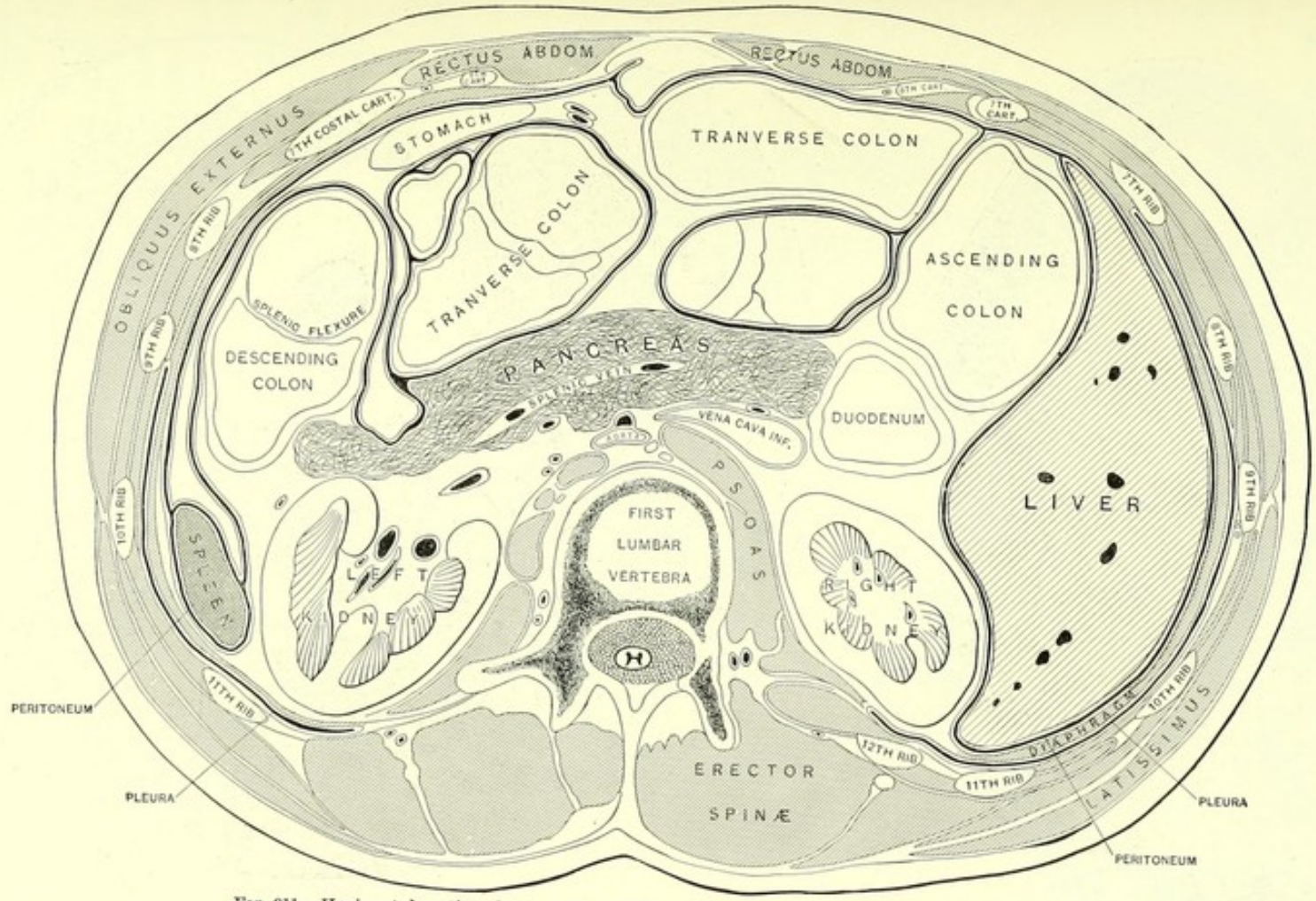

FIG. 911.—Horizontal section through the middle of the first lumbar vertebra. (After Braune.)

The twelfth rib appears on the right, but the section is below it on the left. Between the vena cava and the pancreas is the common bile duct. The lowest parts of pleura, liver, spleen, and stomach are seen. The pancreas is cut in its entire length. The right kidney is cut near its upper end, the left in the middle.

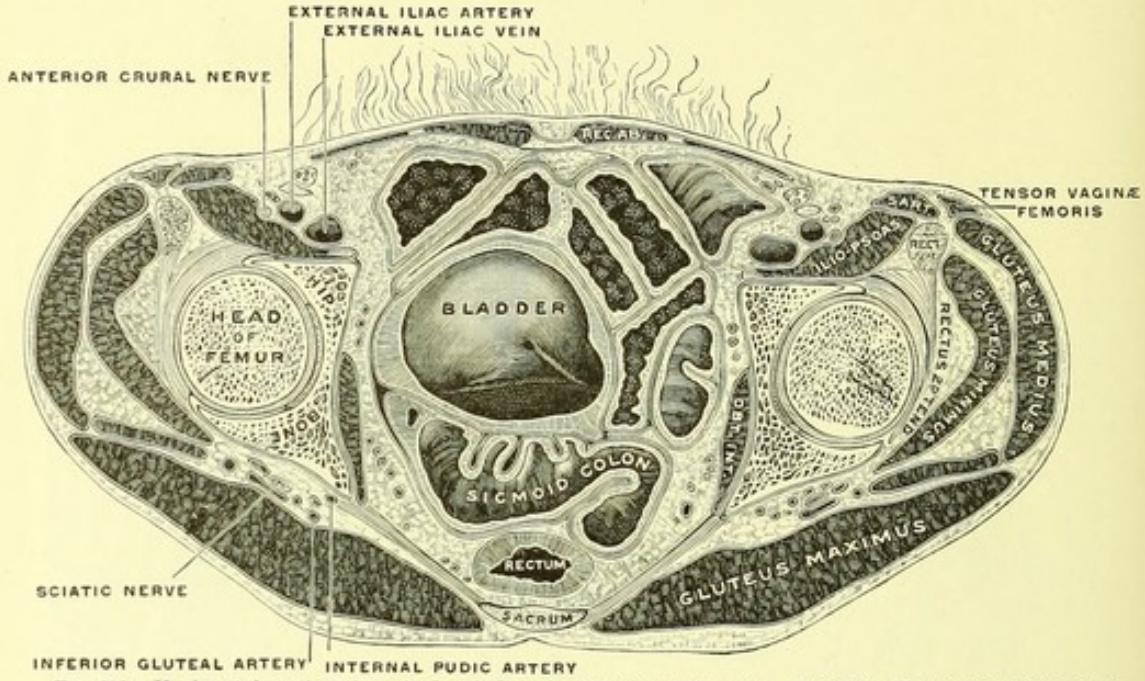

FIG. 912.—Horizontal section three inches below the sacral promontory. (Testut.) The unlabelled parts in front of and at the right of the bladder are coils of small intestine.

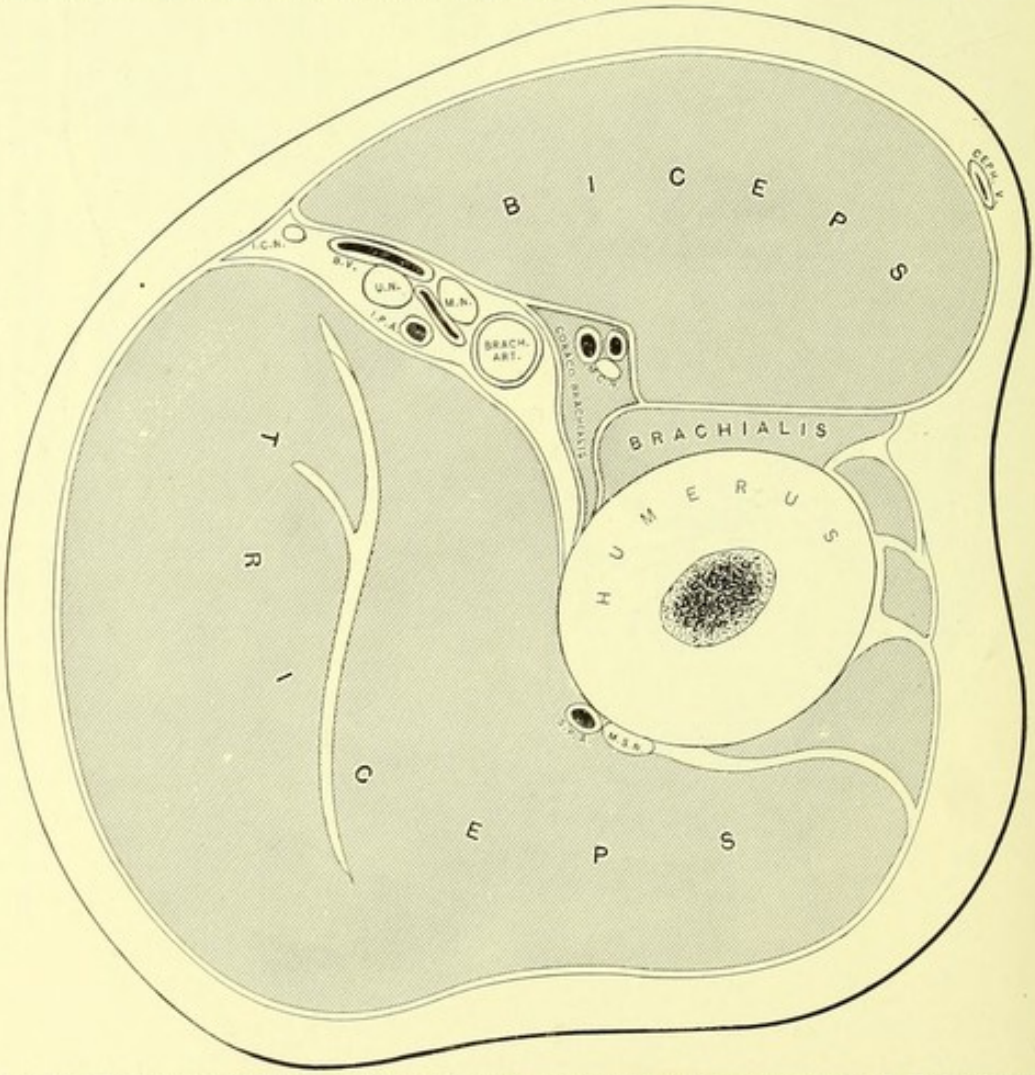

FIG. 913.—Horizontal section at middle of right arm—upper surface of lower segment. B. V., basilic vein; CEPH. V., cephalic vein; I. C. N., internal cutaneous nerve; I. P. A., inferior profunda artery; M. C. N., musculo-cutaneous nerve; M. N., median nerve; M. S. N., musculo-spiral nerve; S. P. A., superior profunda artery; U. N., ulnar nerve. (After Braune.)

mated; and, finally, it is almost impossible to carry the saw with absolute precision through all parts of the plane intended.

The subjects from which these sections were taken were particularly muscular young men, and the appearances differ considerably from those observed in poorly developed or emaciated people. This is very marked in the case of the shoulders, whose high appearance is at least partly due to the very pronounced muscularity.

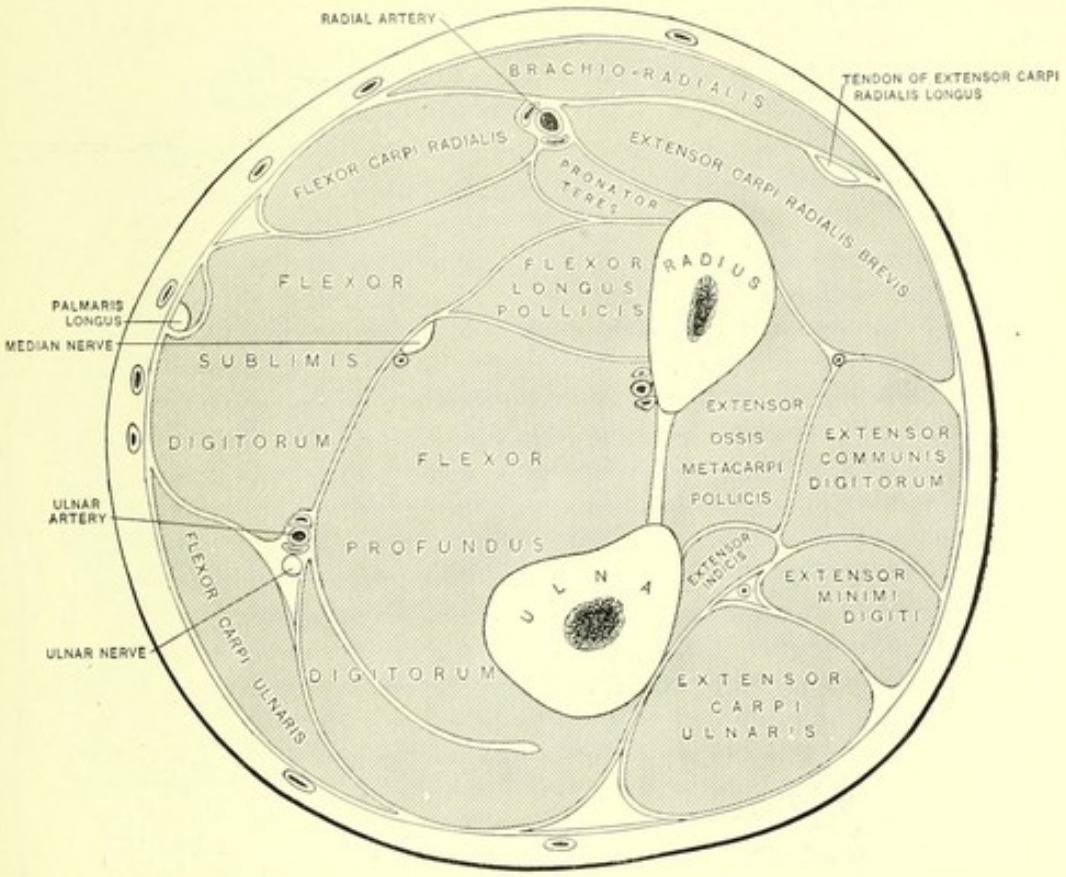

FIG. 914.—Transverse section through the middle of the right forearm, in the position of semipronation. (After Braune.)

In all of these drawings conventionalized shading is employed for the sake of clearness, and thus a somewhat diagrammatic effect is produced. But the purpose is to show relations, and not composition.

The serous and synovial (virtual) cavities are represented by heavy black lines. Only by some such exaggerated method can they be made distinct in plane sections.

Vessels and other tubes, when cut obliquely, present peculiar outlines; and these are more marked the more nearly the section is in line with the long axis of the cylinder.

In the cut surfaces of many muscles will be seen tendons embedded in their substance. This fact is referred to in the general considerations concerning myology, but was purposely omitted from the description of the individual muscles.

In some of the pictures which have substantially bilateral symmetry the parts are labelled on one side only.

The important parts are, as a rule, labelled; but in some cases this method was impracticable, and in these the legend will direct attention to the unlabelled objects.

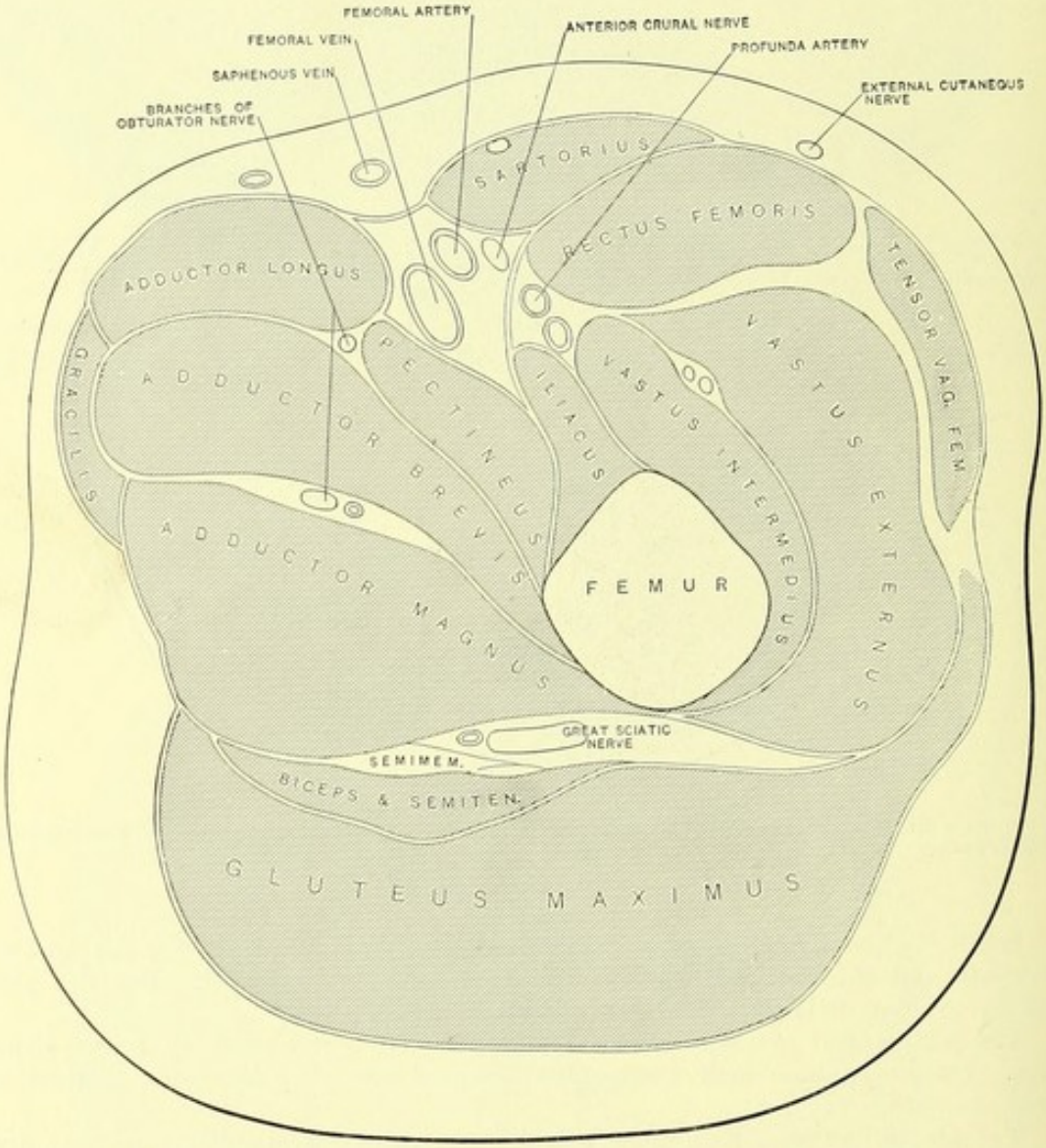

FIG. 915.—Transverse section of the thigh below the trochanter minor. (After Braune.)

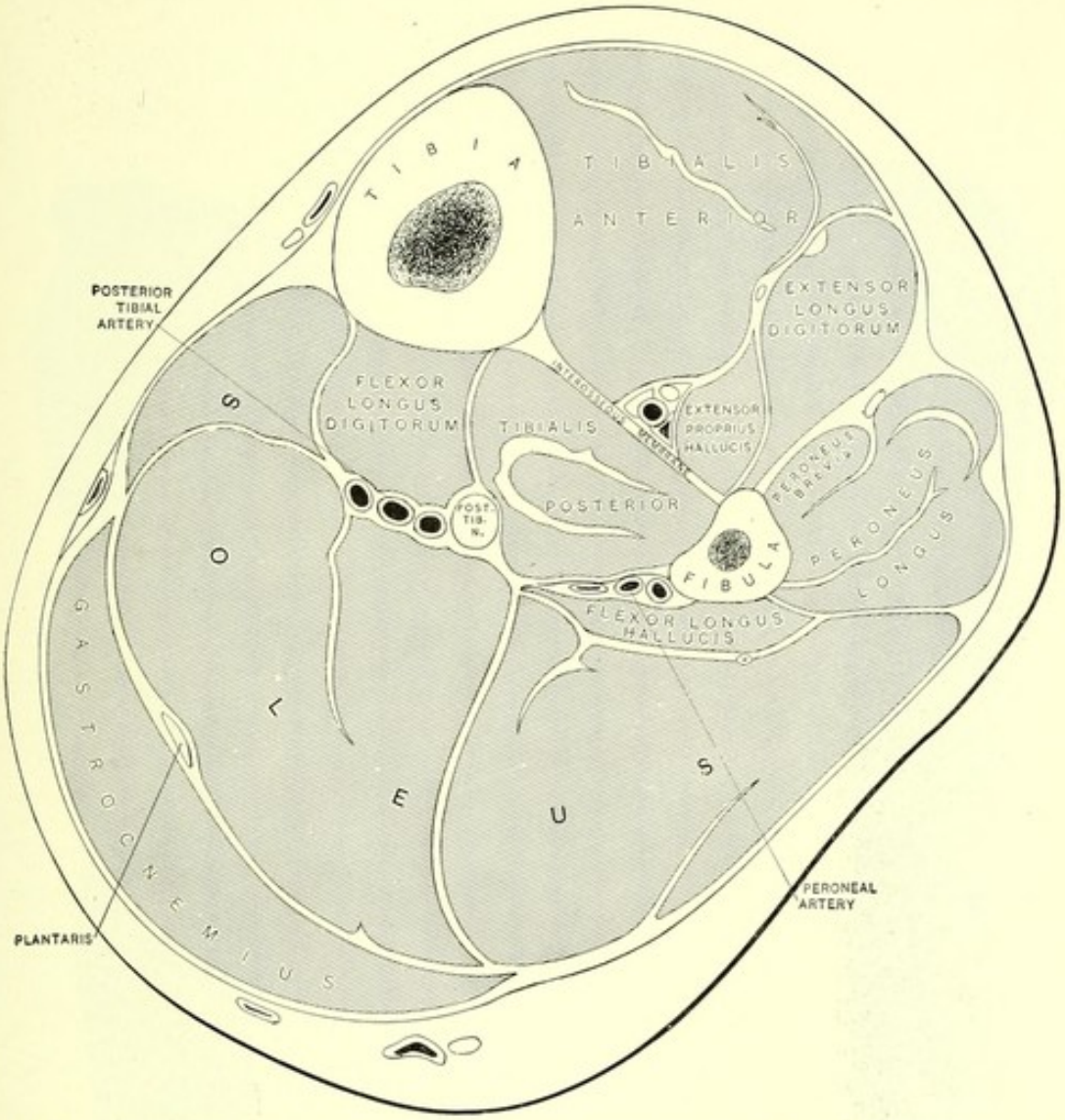

FIG. 916.—Transverse section at the middle of the leg. (After Braune.) In front of the interosseous membrane are the anterior tibial vessels and nerve; in front of the soleus, the posterior tibial vessels and nerve; and close to the fibula, the peroneal vessels.

II. SURFACE ANATOMY.

The subject of the photographs, of which the series of pictures in this section are reproductions, was a young athlete of well-balanced development. It would be easy to procure representations of a man with much larger muscles, but they would be less useful in the illustration of normal anatomy. The main purpose of these engravings is to show the relations of structures, especially muscles, to the surface. The most of them are accompanied by keys, which more than supply the place of verbal description; in the remainder the principal features are sufficiently apparent without explanation other than occurs in the legend.

Every student is earnestly advised to study surface anatomy upon the living model. Each can use his chum for this purpose, if he will reciprocate such favors as he receives; and many things he can learn from his own person, particularly well in front of a large mirror. He should carry his studies in this direction much further than is attempted in this series of pictures, and in this effort he will derive all the help that he needs from the numerous cuts which embellish the pages devoted to descriptive anatomy.

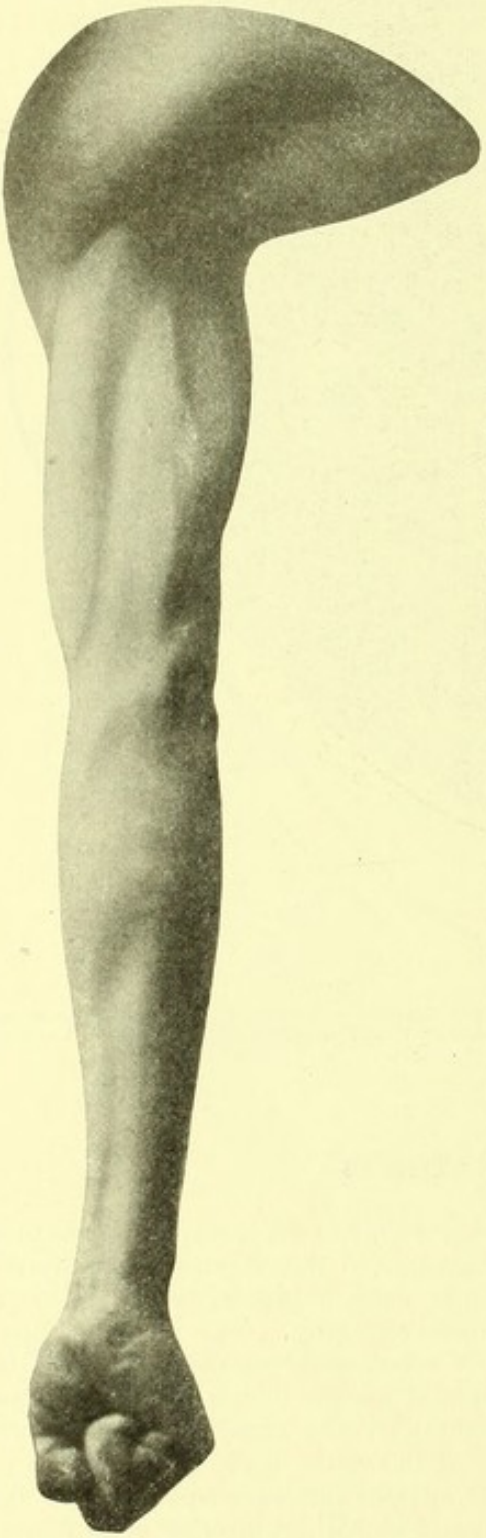

Fig. 917.—The right upper limb abducted and supinated, viewed from in front.

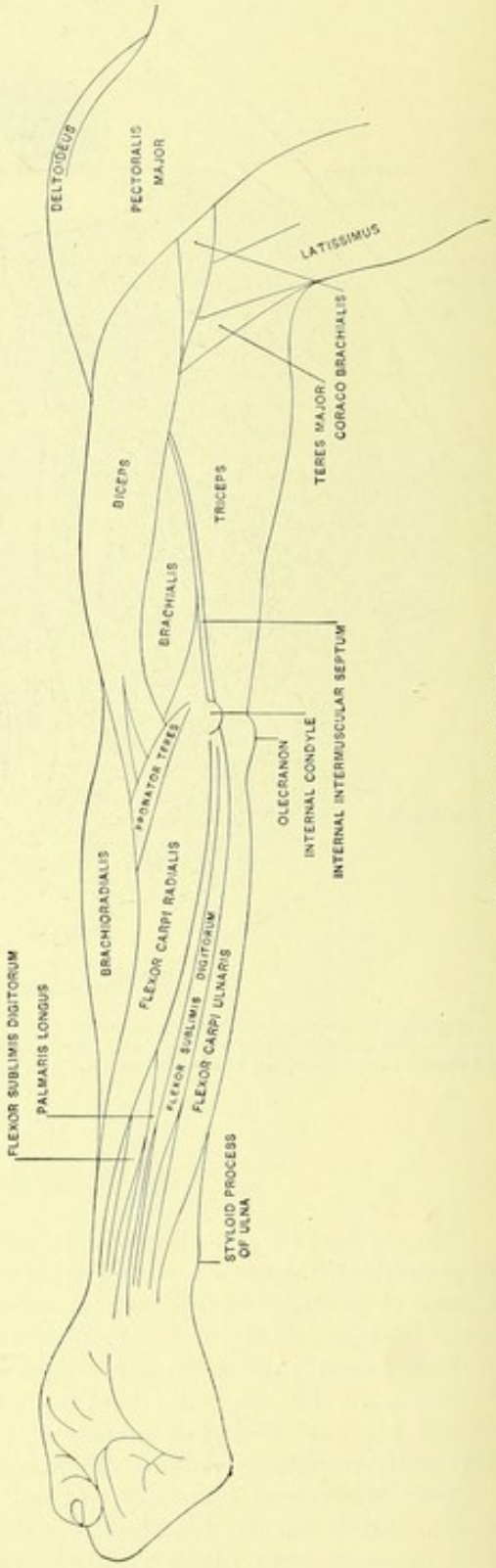

Fig. 918.—Key to Fig. 917.

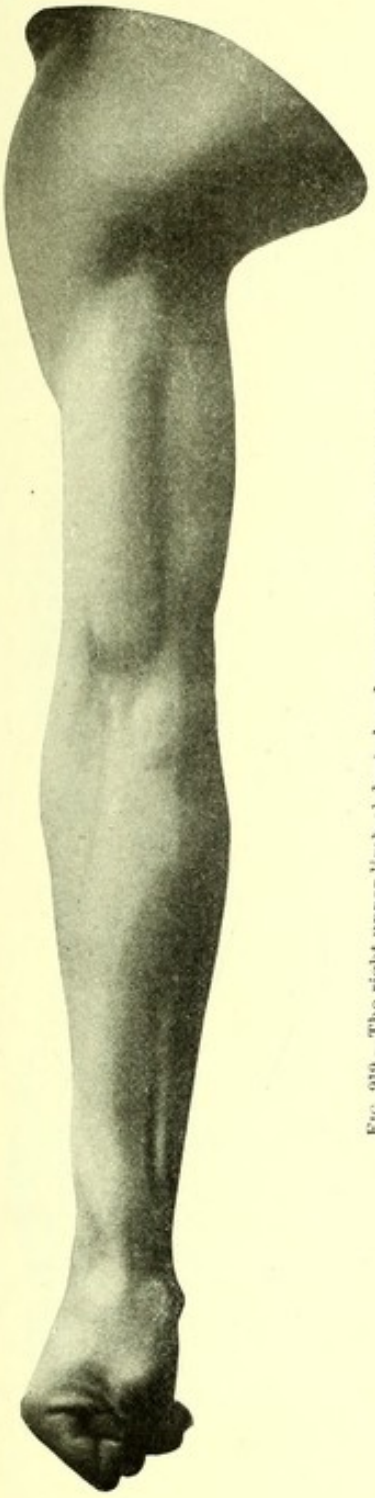

Fig. 919.—The right upper limb abducted and pronated, viewed from in front.

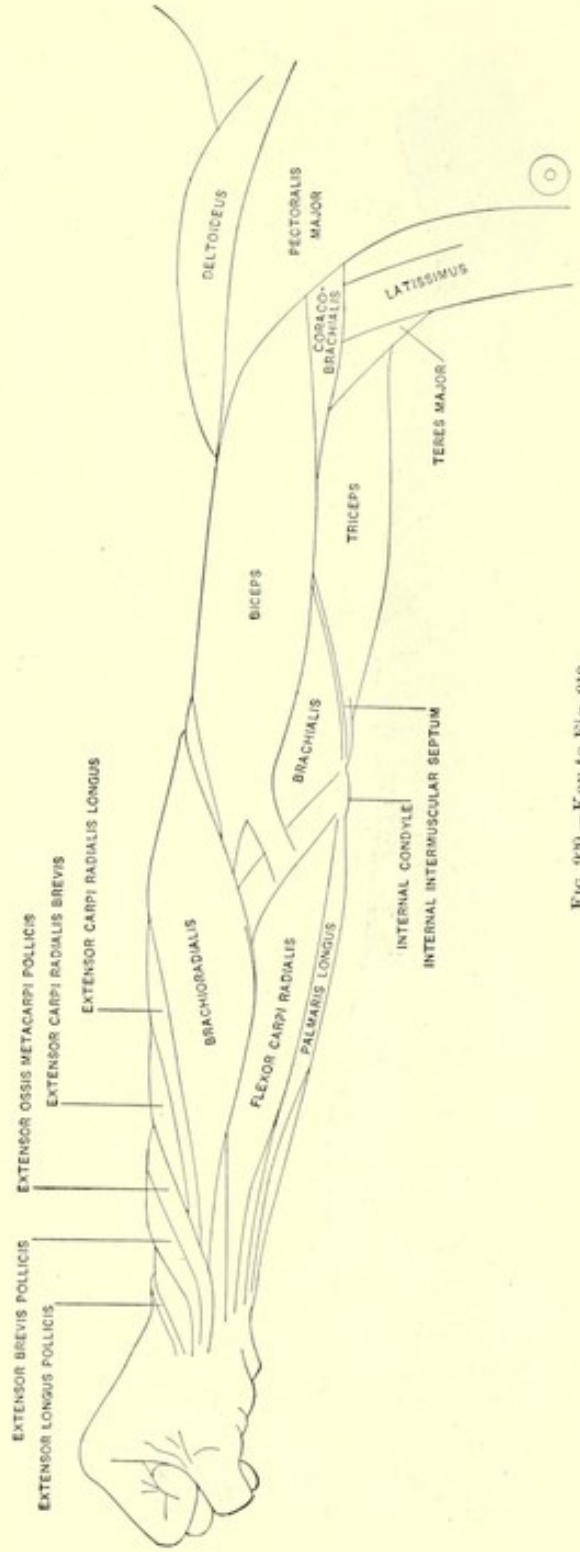

Fig. 920.—Key to Fig. 919.

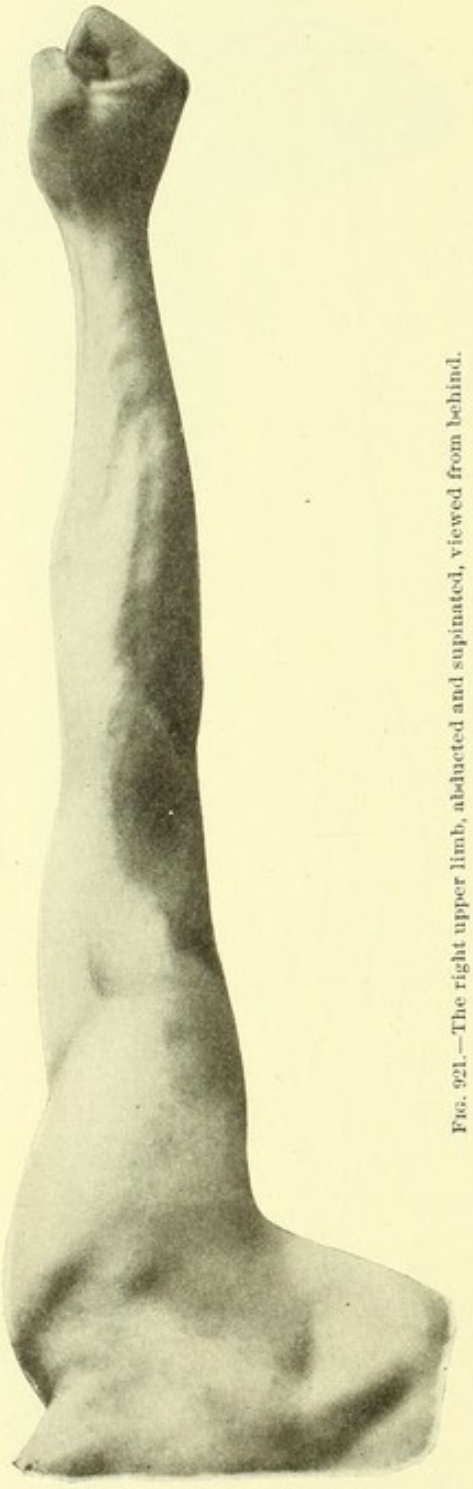

Fig. 921.—The right upper limb, abducted and supinated, viewed from behind.

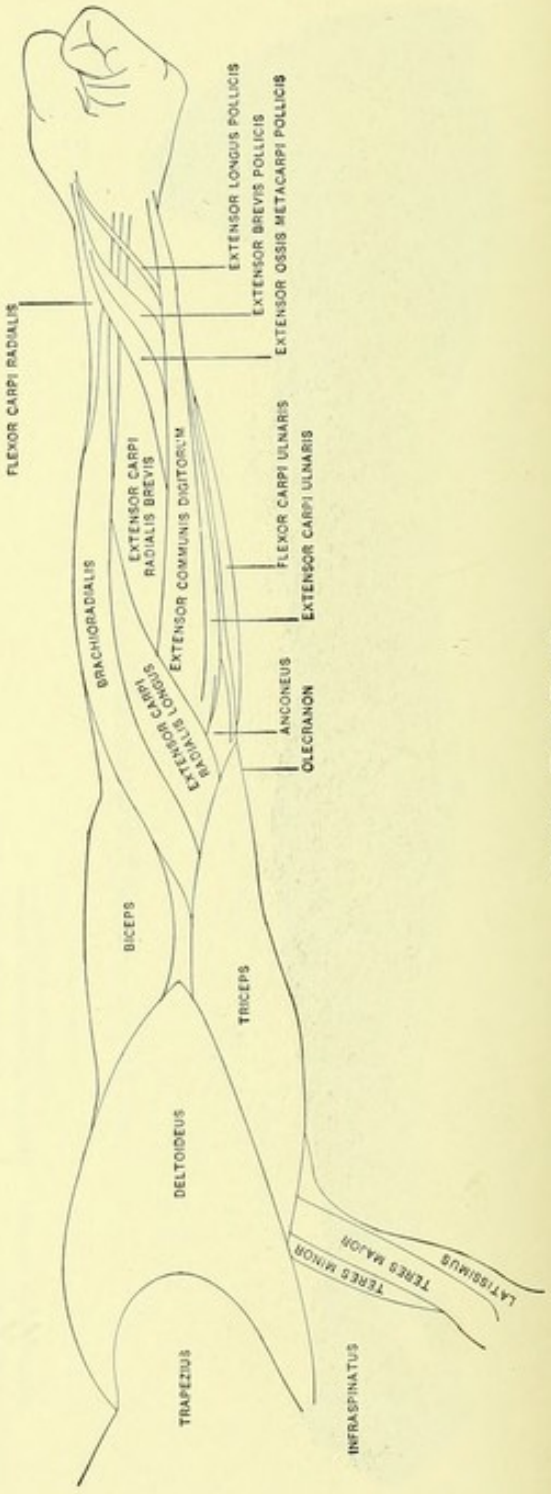

Fig. 922.—Key to Fig. 921.

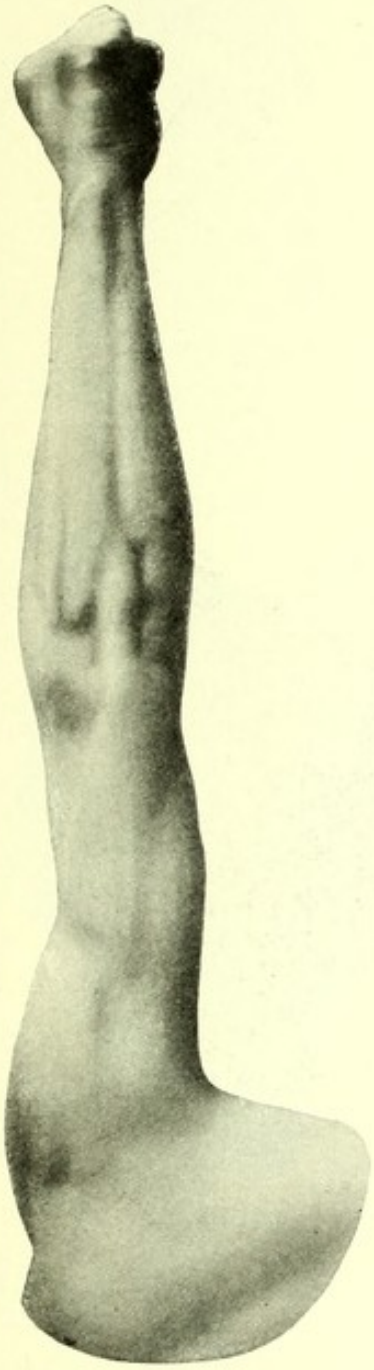

Fig. 923.—The right upper limb, abducted and pronated, viewed from behind.

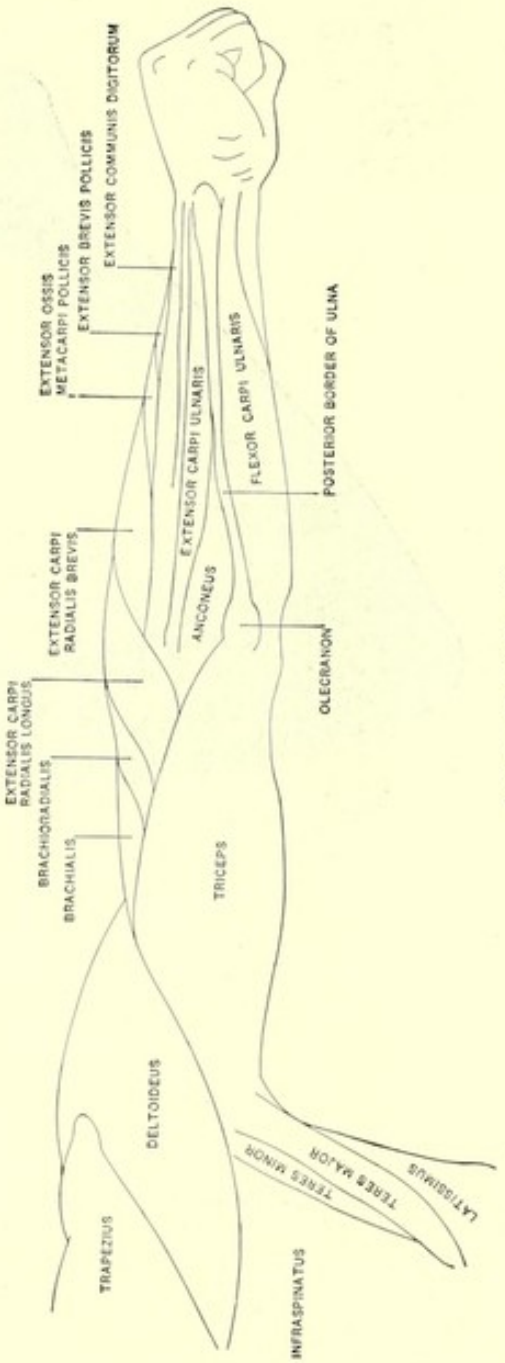

Fig. 924.—Key to Fig. 923.



FIG. 925.—Abduction of the arm with flexion of the forearm and digits.

FIG. 926.—The right lower limb, front view.

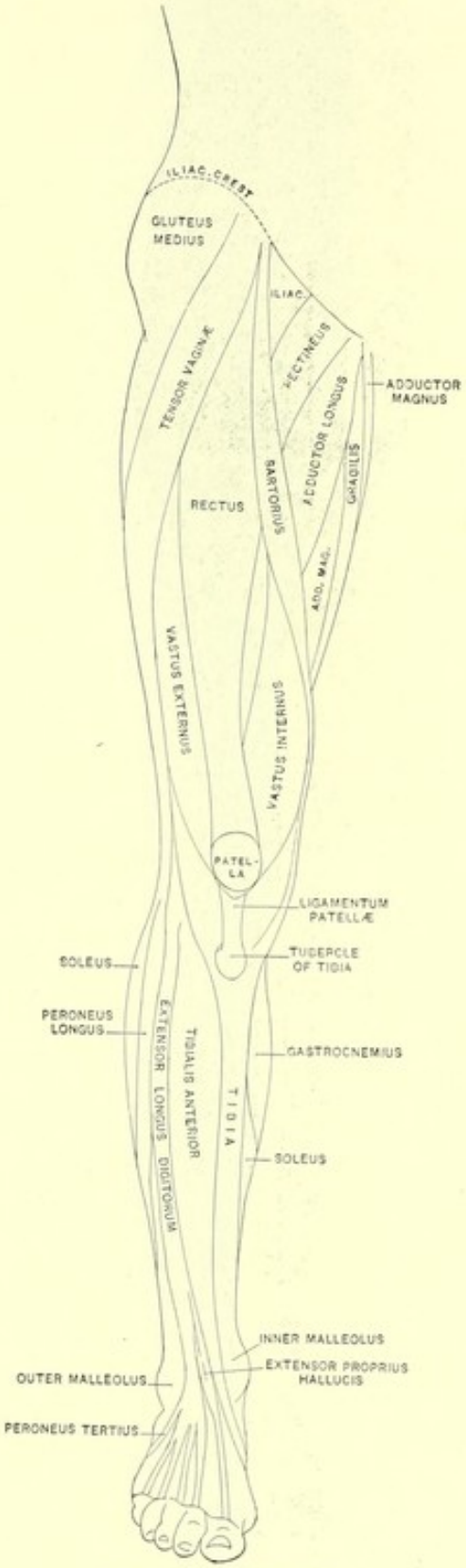

FIG. 927.—Key to Fig. 926.

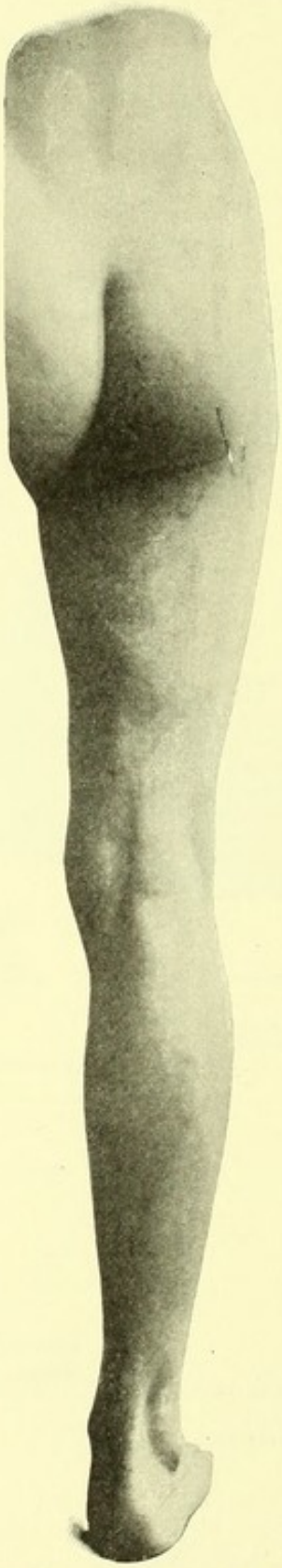

Fig. 928.—The right lower limb, rear view.

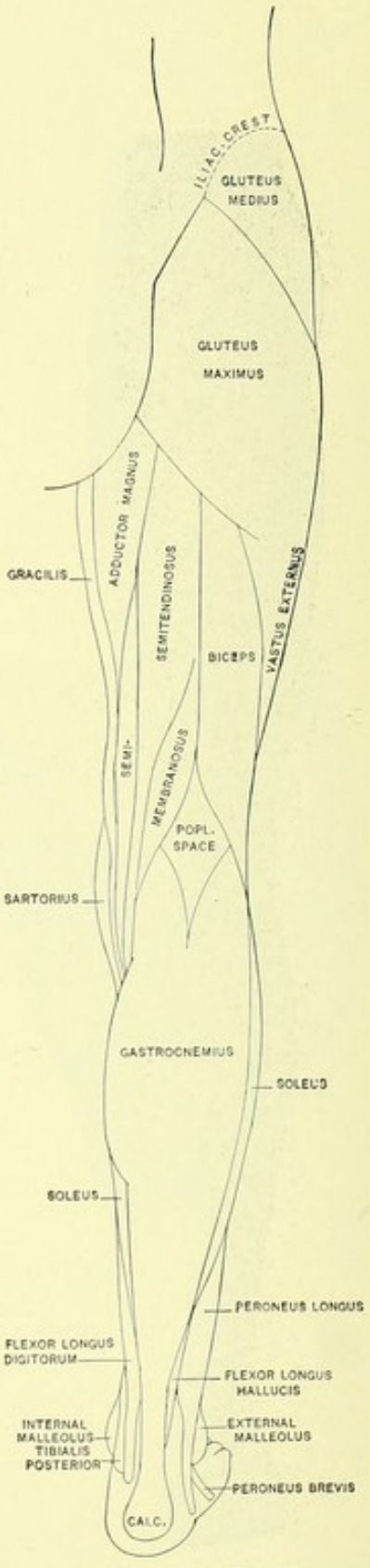

Fig. 929.—Key to Fig. 928.

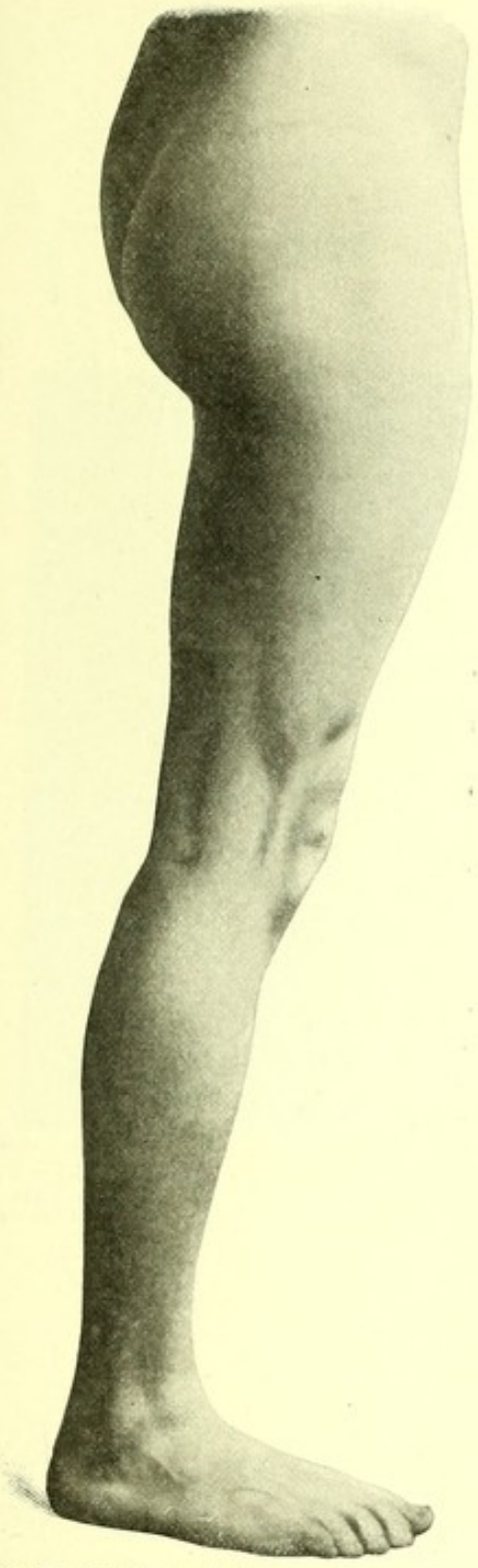

IG. 930.—The right lower limb, external lateral view.

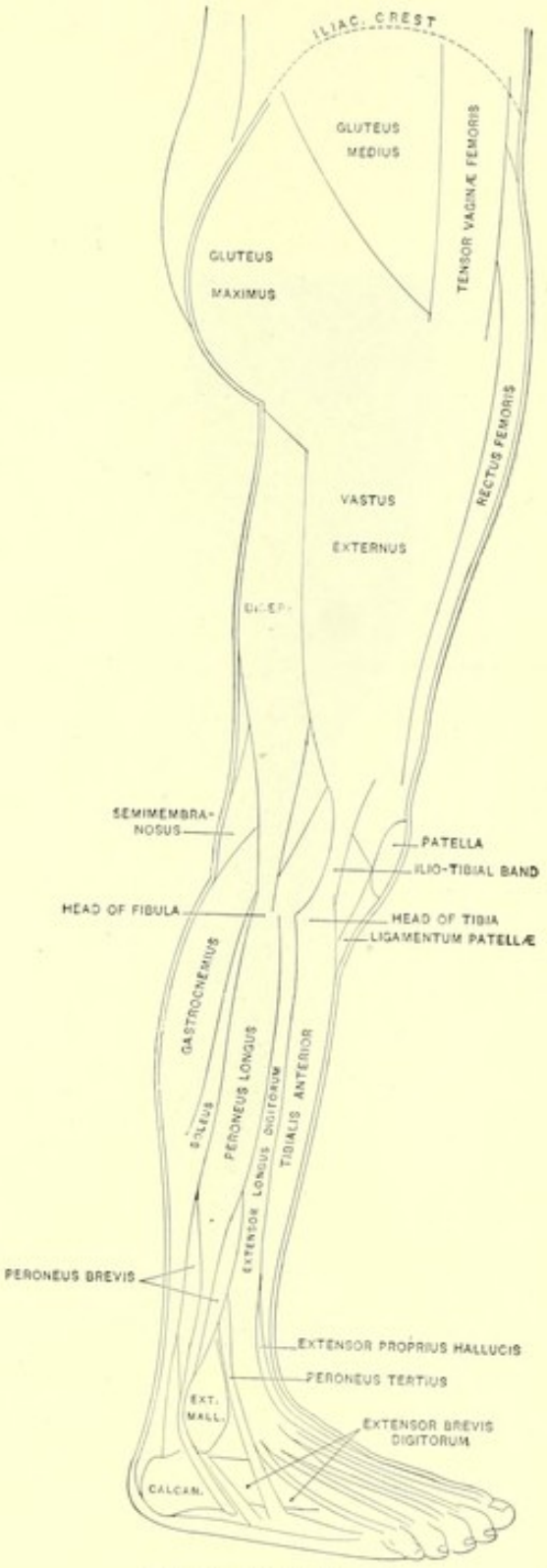

FIG. 931.—Key to Fig. 930.

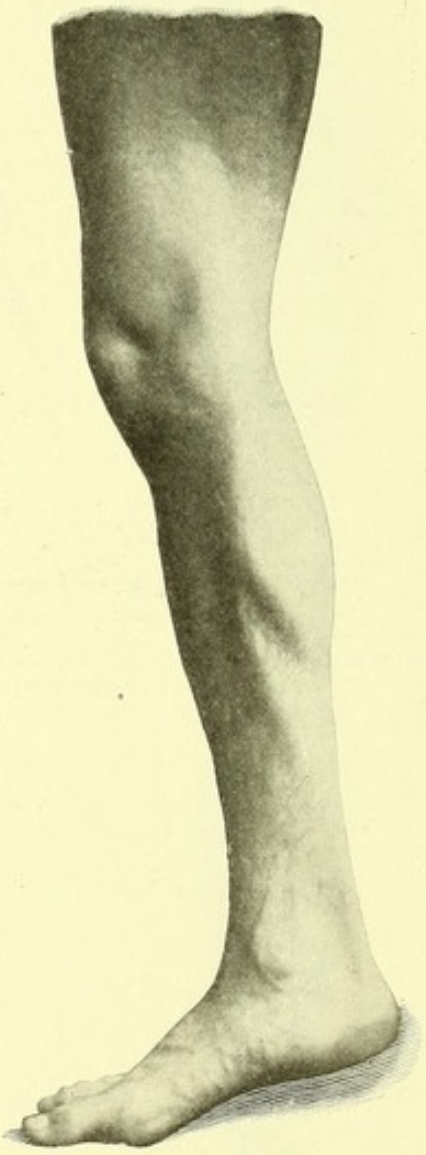

Fig. 932.—The right lower limb, internal lateral view.

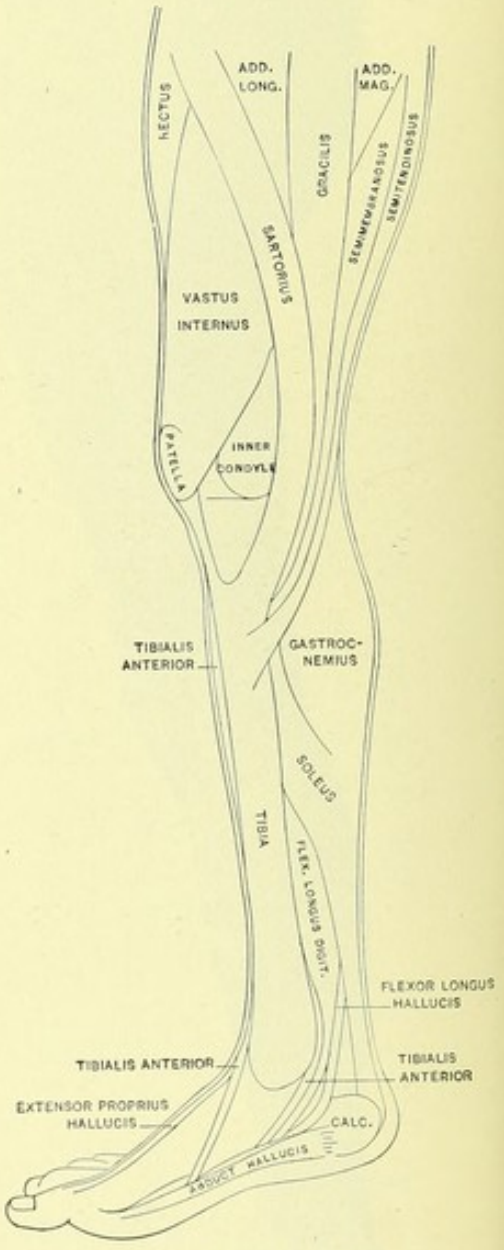

Fig. 933.—Key to Fig. 932.

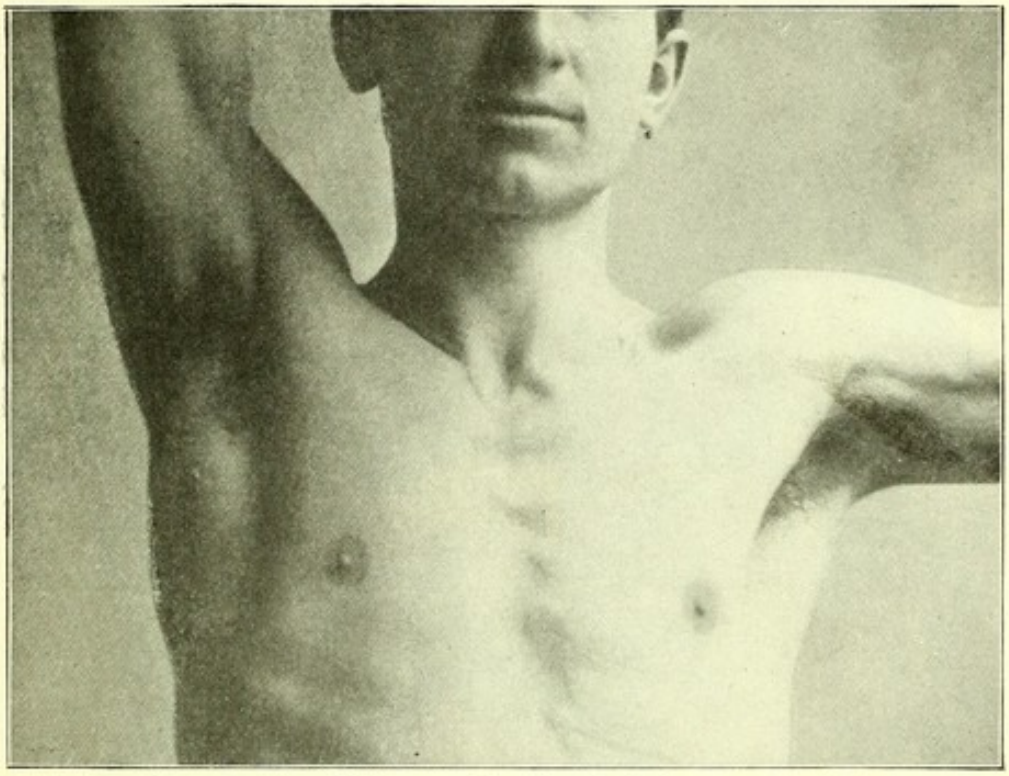

FIG. 934.—Comparison of axillæ with the arm abducted and with the arm vertical. The latter attitude is seen to flatten and nearly obliterate the pit.

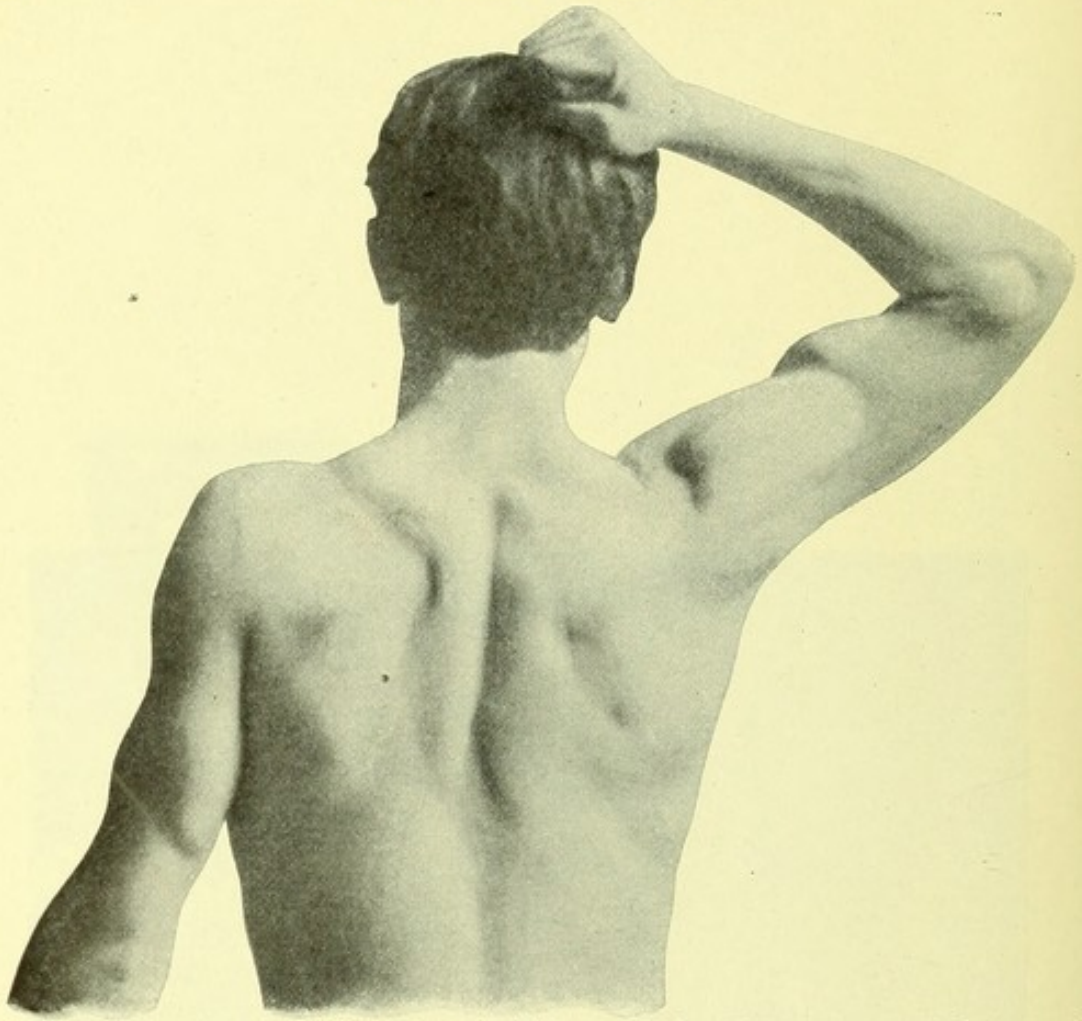

FIG. 935.—Comparison of shoulders and arms in different attitudes. The sliding outward of the scapula when the arm is raised is very marked.

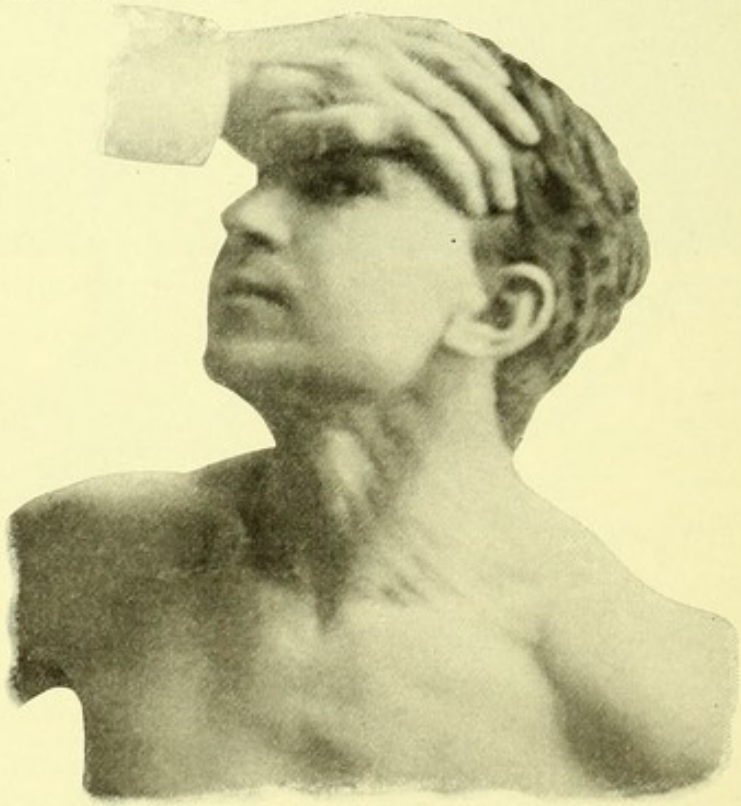

FIG. 936.—The platysma muscle in contraction. The front and rear fasciculi can be brought out more prominently by forcible protrusion of the chin; but strong pressure of the forehead against a resisting object displays the whole muscle more evenly.

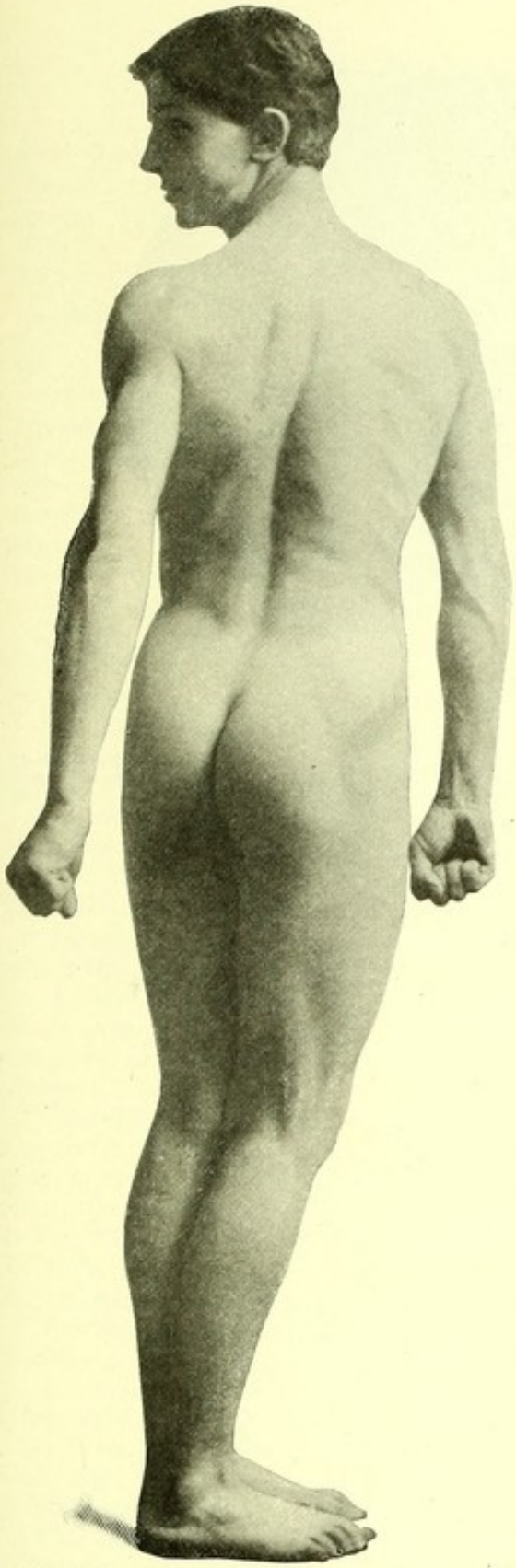

FIG. 937.—This figure and the next one are designed to show the capacity of the body for rotation. The feet point in one direction, the face exactly opposite. This was accomplished without previous practice.

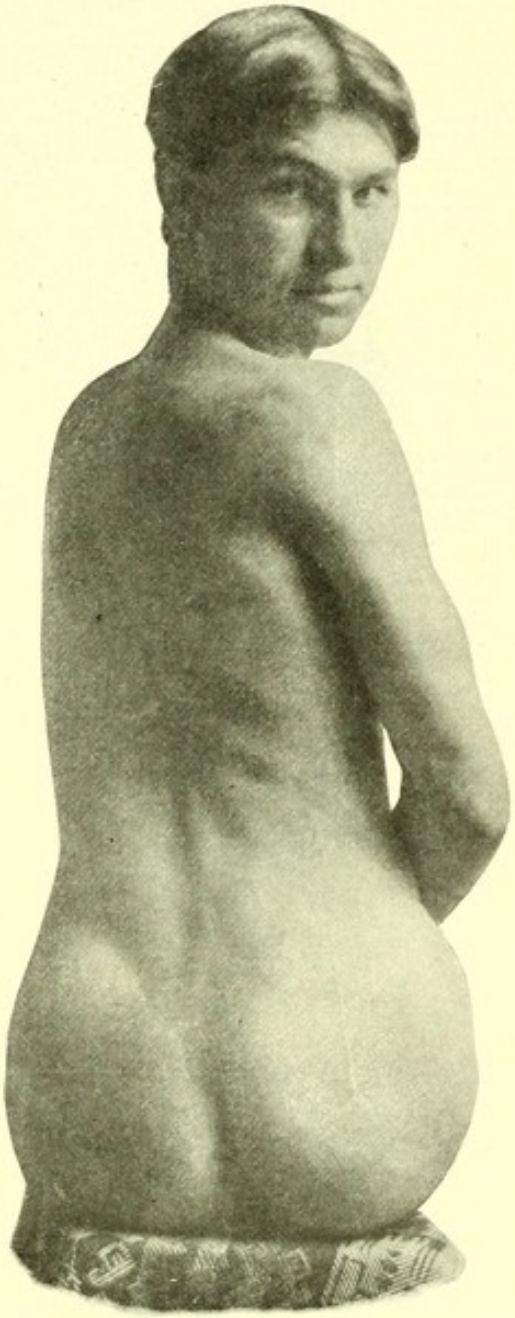

FIG. 938.—To be compared with Fig. 937. The thighs and feet are held pointing away from the spectator, and the sitter has turned to face the camera as squarely as possible. If the effect obtained by this method be subtracted from that in Fig. 937, the amount of rotation below the movable vertebræ will be ascertained.

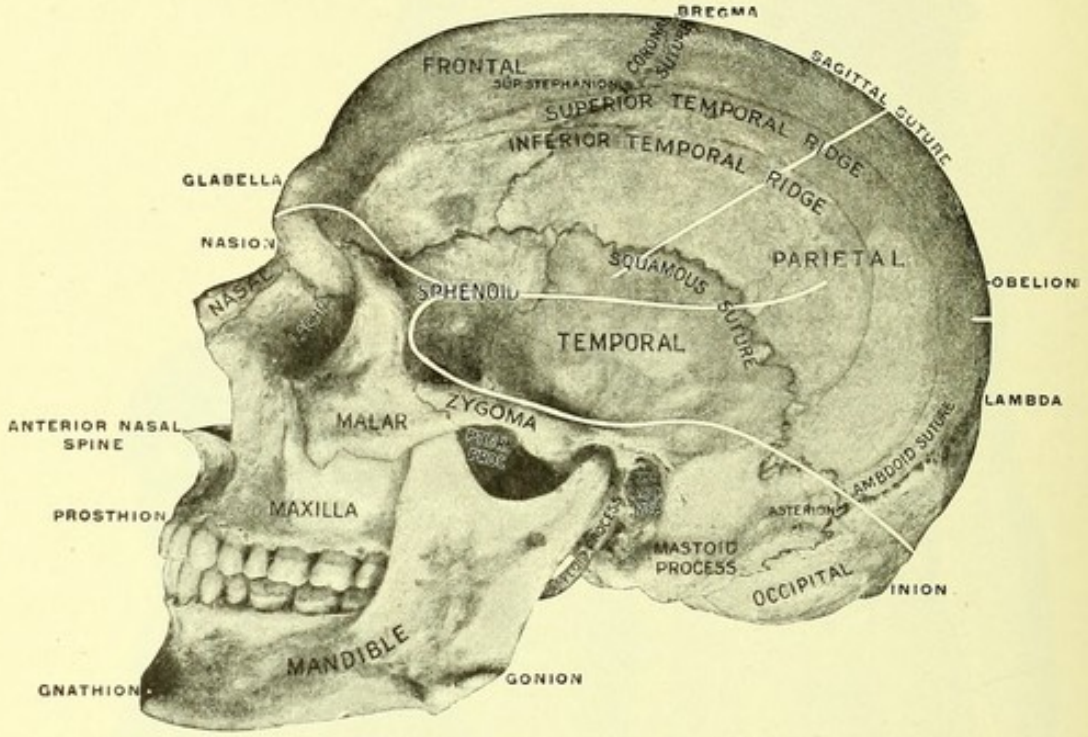

FIG. 939. (Extra-serial.)—The relations of the principal fissures and of the lower borders of the cerebral hemisphere to the surface of the skull. The fissures and borders are not labelled, as the Sylvian, central, and parieto-occipital fissures cannot be mistaken. The inferior line does not show the lowest level reached by the temporal and occipital lobes, but the lowest parts of them that come close to the skull.

III. NORMAL SKIAGRAPHS.

A little more than three years ago it was discovered that certain rays of light have the power of passing through substances which to ordinary rays are impenetrable. On account of their undetermined character they were called originally by the name of the letter which in algebraic formulæ indicates the unknown; and the title *X-rays* is still as well deserved as in the beginning. They are also called, from their discoverer, *Röntgen rays*.

The degrees of perviousness to these rays presented by different substances vary widely. Wood offers but little obstruction to their passage, glass cuts them off. Of the tissues of the body those containing lime salts stop the rays most completely; cartilage permits their passage with great readiness; and the other textures stand at various points between these extremes. The result is, that if a part of the body be suitably placed between an apparatus which generates these rays and a properly sensitized plate, shadows of the intervening structures which interfere with the rays will be cast upon the plate, and fixed there with different degrees of intensity. The plate is a negative from which photographic prints can be made, and these are called *skiagraphs* ("shadow-writings").

That this wonderful discovery could be turned to great advantage in surgery was immediately perceived, and its usefulness in the diagnosis of fractures and dislocations, and in the detection of certain foreign bodies, especially those which are metallic, in the tissues or cavities, has been abundantly demonstrated.

In order, however, to appreciate the existence and degree of the abnormal it is important to become familiar with the normal. Consequently, there are here presented skiagraphs of different portions of the body, pictures from more than one point of view being given wherever it seemed necessary to elucidate relational anatomy by this novel means. No skiagraph of the head is included, as it has not thus far been found practicable to determine anything useful anatomically from those which have been made.

In studying skiagraphs several considerations should be borne in mind, among which the following are prominent:

A more dense portion of a given tissue throws a deeper shadow than a less dense portion of the same. Thus, the expanded extremities of bones, largely composed of cancellated tissue, show lighter than the shafts, where the tissue is compact.

The thickness of the part influences the depth of the shadow. Thus, in a long bone the compact structure of the shaft gives a deeper shade at the sides than in the centre, not because the tissue is denser, but because, from a given point, the rays pass through a greater amount of it. (See the metacarpal bones in Fig. 944.)

An accumulation of tissue of the same or different kinds deepens the shadow. (See the condylar region in Fig. 943.)

The overlapping of one part by another causes a deepening of the shadow. (See the head of the radius and the coronoid process of the ulna in Fig. 943.)

As cartilage gives a ready passage to the rays, the ends of bones in movable joints seem separated by unoccupied spaces, except when a convexity of one bone is received into a concavity of another of sufficient depth to produce apparent continuity of osseous tissue; and epiphyses, not yet united to their diaphyses, are held off from them by obvious gaps.

The outline of a shadow does not necessarily represent the true size or shape of certain parts. For example, the outlines of the skiagraph of the heart, which is in constant active motion, and of the liver, which is in incessant passive motion, include greater areas than do the real shadows at any one moment of time. When such parts can be skiagraphed instantaneously, this objection will be removed.

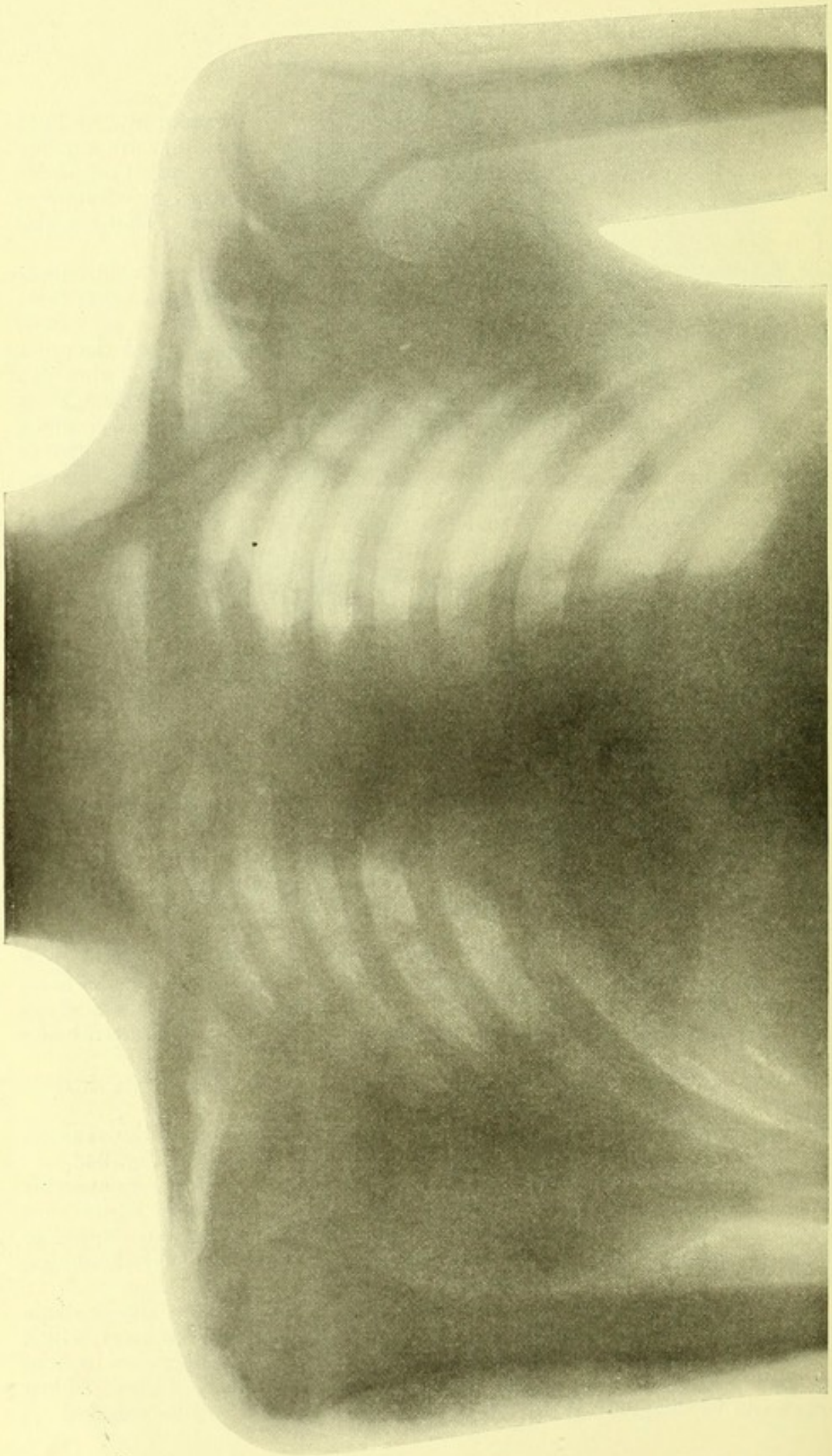

FIG. 940.—The trunk, upper part. From a man of 28 years. The shadow of the heart and great vessels has an obscure outline, owing to their being in incessant motion. The vertebræ do not show plainly; they would be seen much more distinctly in a person in his teens. The lungs interfere very slightly with the passage of the rays.

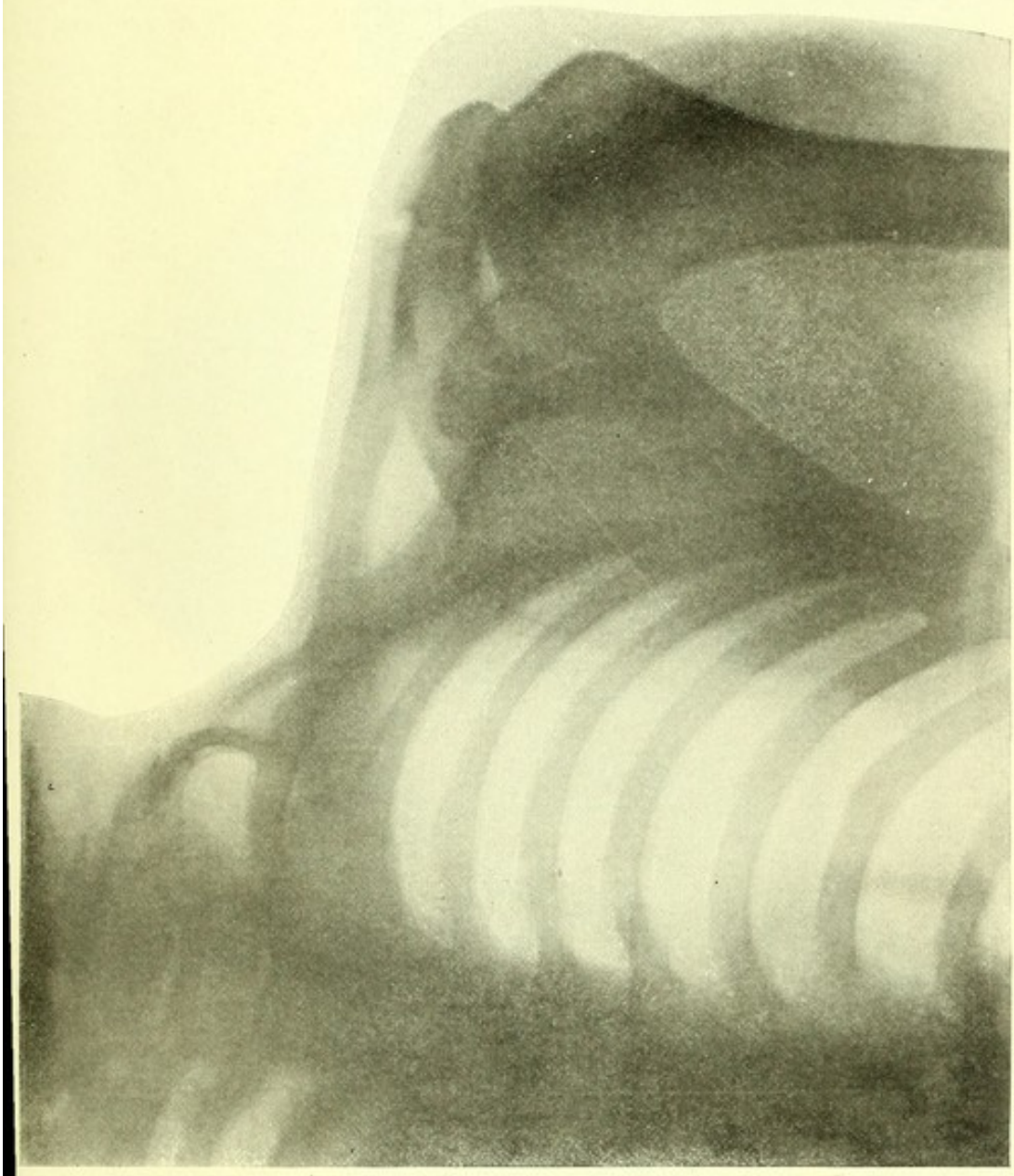

FIG. 941.—The shoulder. From a man of 28 years. Observe the vertebral border of the scapula, faint because thin; its heavy, thick, axillary border; the coracoid process; the spine and acromion; the clavicle; the cartilaginous gap at the acromio-clavicular joint; the upper end of the humerus; the ribs; the vertebral column; and the intervertebral discs in the upper thoracic region.

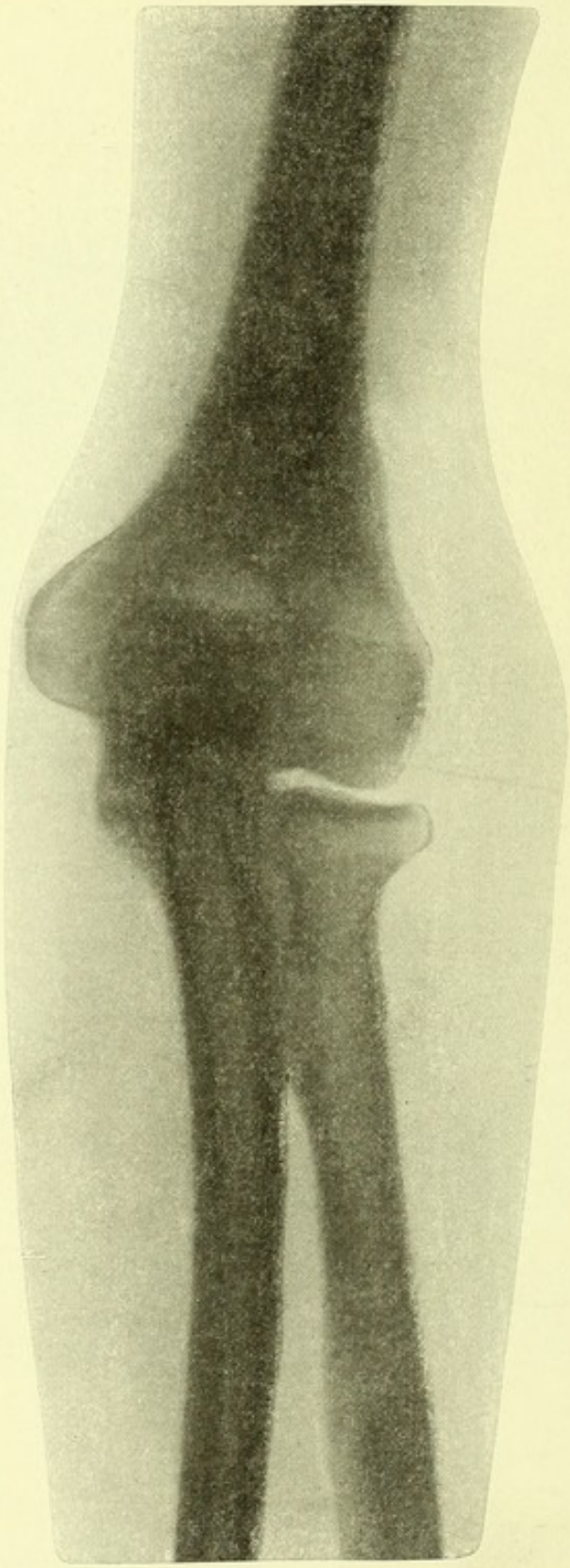

FIG. 942.—The elbow-joint and adjacent parts, ventro-dorsal view. From a man of 28 years.

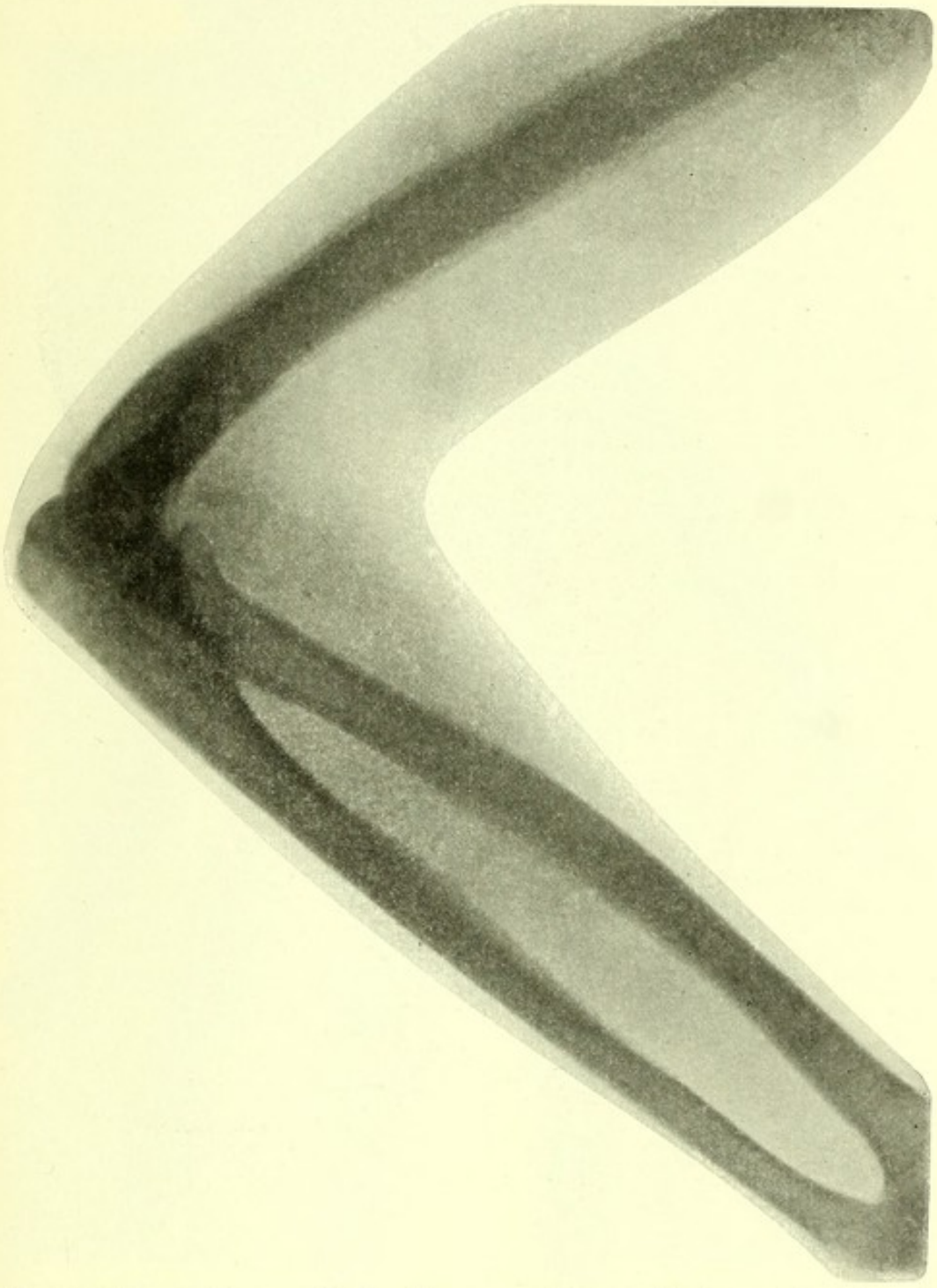

FIG. 943.—The arm and forearm, side view. From a man of 28 years. The forearm is in semipronation. Observe the dense shadows where the head of the radius and coronoid process of the ulna overlap, and where the condyles are most prominent.

FIG. 944.—The hand. From a man of 53 years. Observe the sesamoid bone at the metacarpo-phalangeal joint of the thumb; the different thickness of the folds of skin in the web between the thumb and index-finger; and the faint shadow of the nails, plainest in the ring-finger.

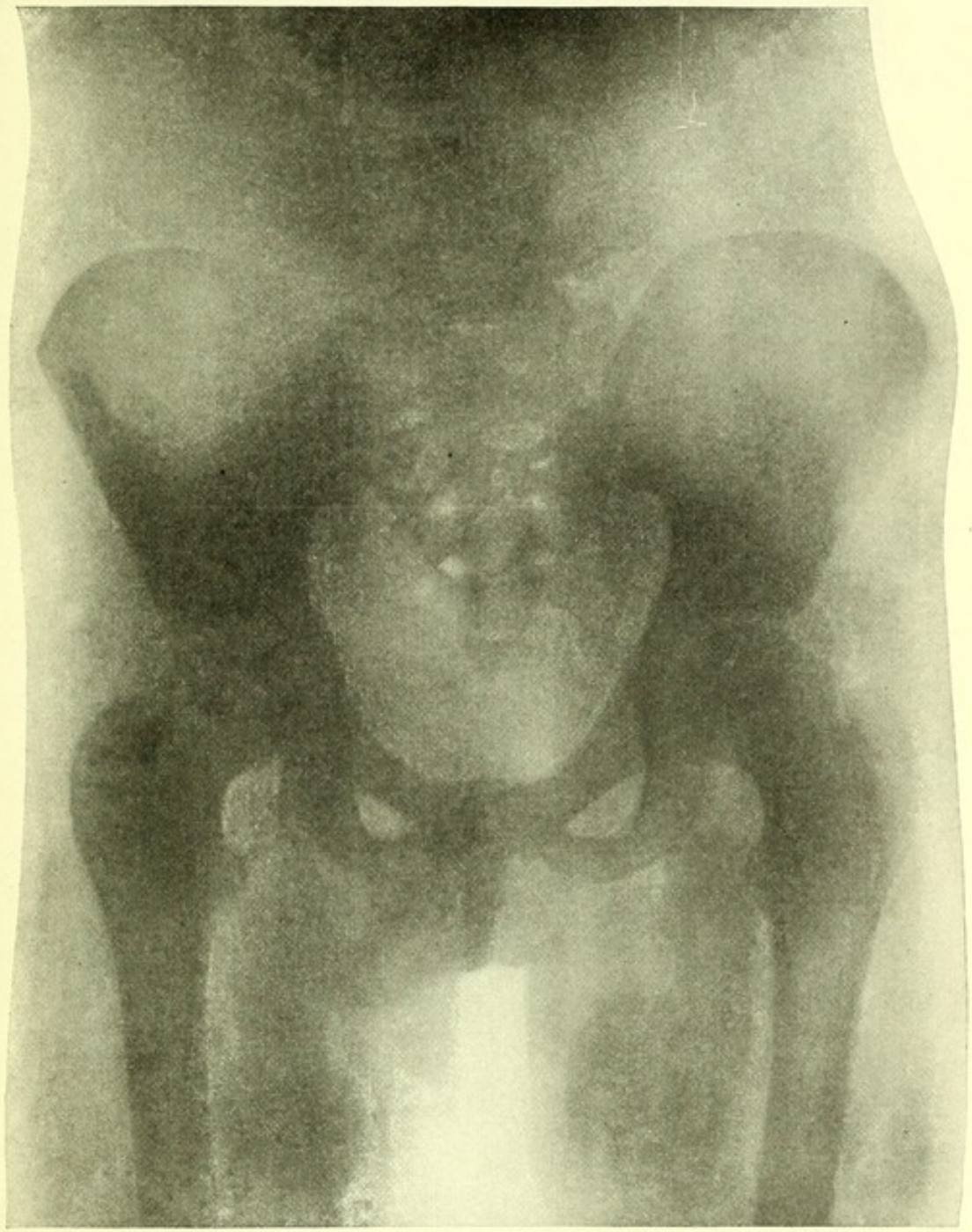

FIG. 945.—The lower part of the trunk and the upper part of the thighs. From a boy of 15 years. Observe the sacral foramina and intervertebral spaces. The hip-bones show with great distinctness. The penis is turned to one side.

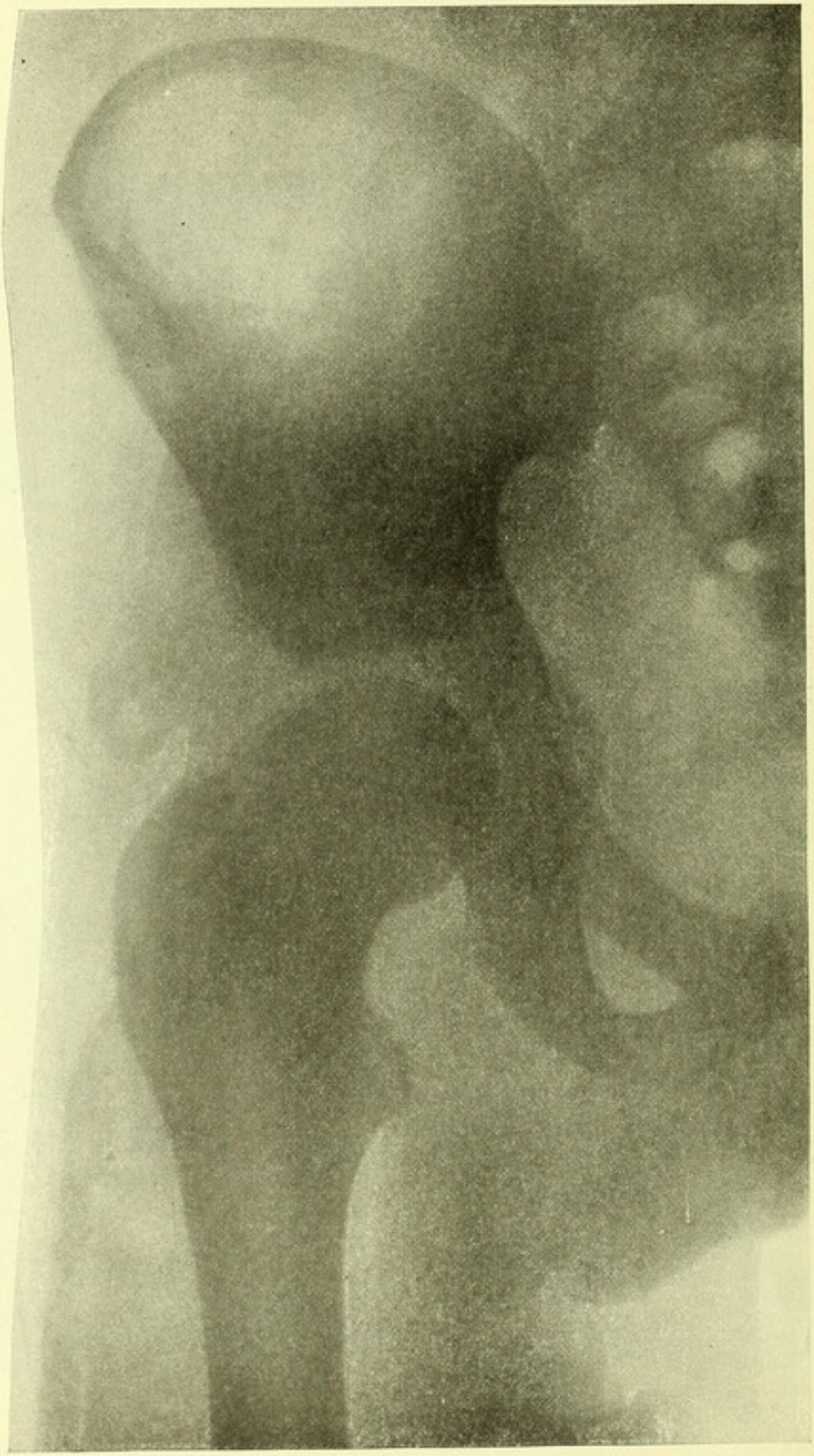

FIG. 946.—The hip-joint and surrounding parts. From the same skiagraph as Fig. 945. The interference of overlapping parts of bone, the thinness of the ilium in the fossa, and the apparent deficiency between the caput femoris and the acetabulum deserve attention.

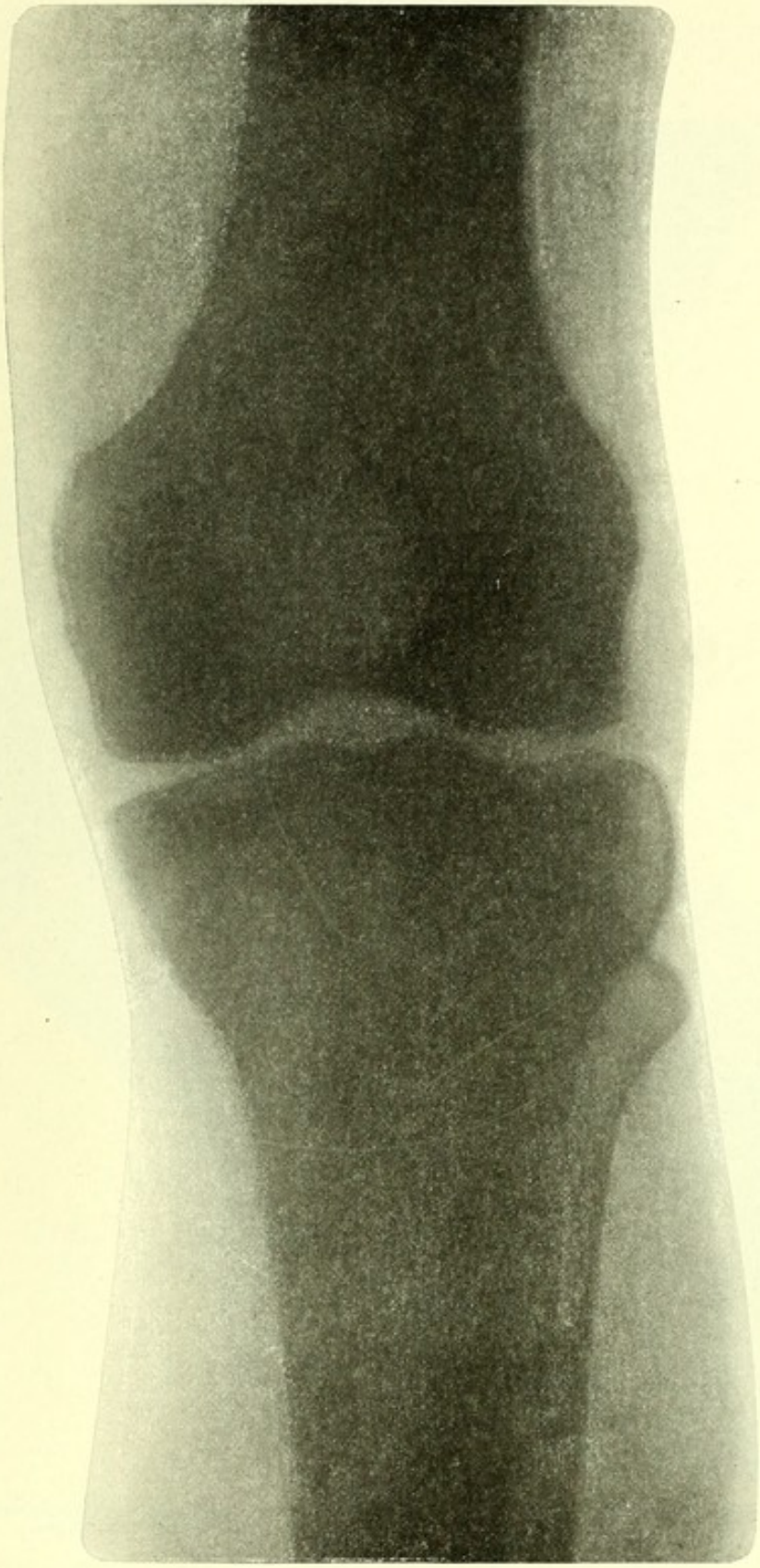

FIG. 947.—The knee, ventro-dorsal view. From a man of 28 years. The tibia and fibula overlap.

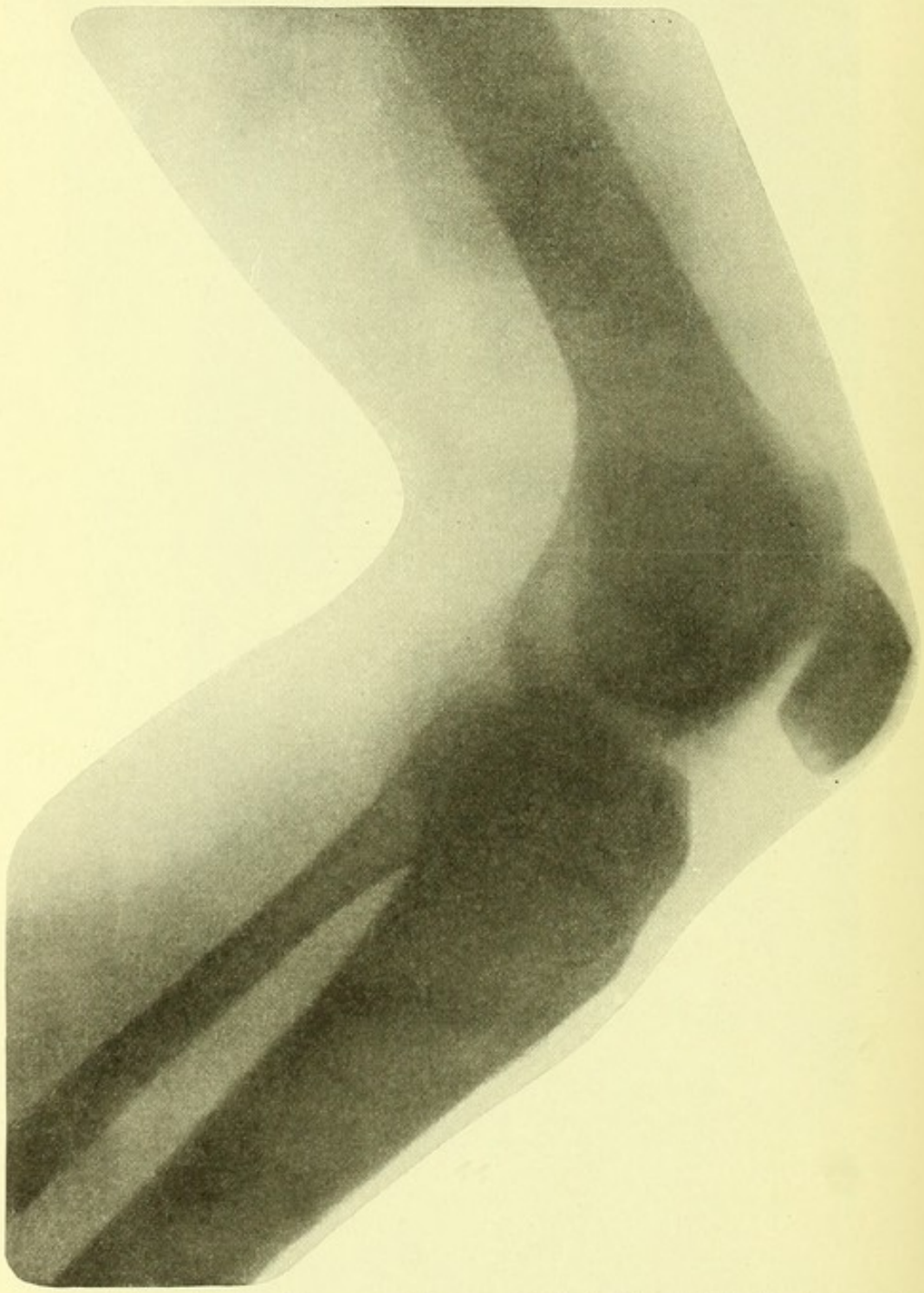

FIG. 948.—The knee, side view. From a man of 28 years. Observe that the patella touches the femur above, but seems to stand away from it below. The ligamentum patellæ makes a slight appearance.

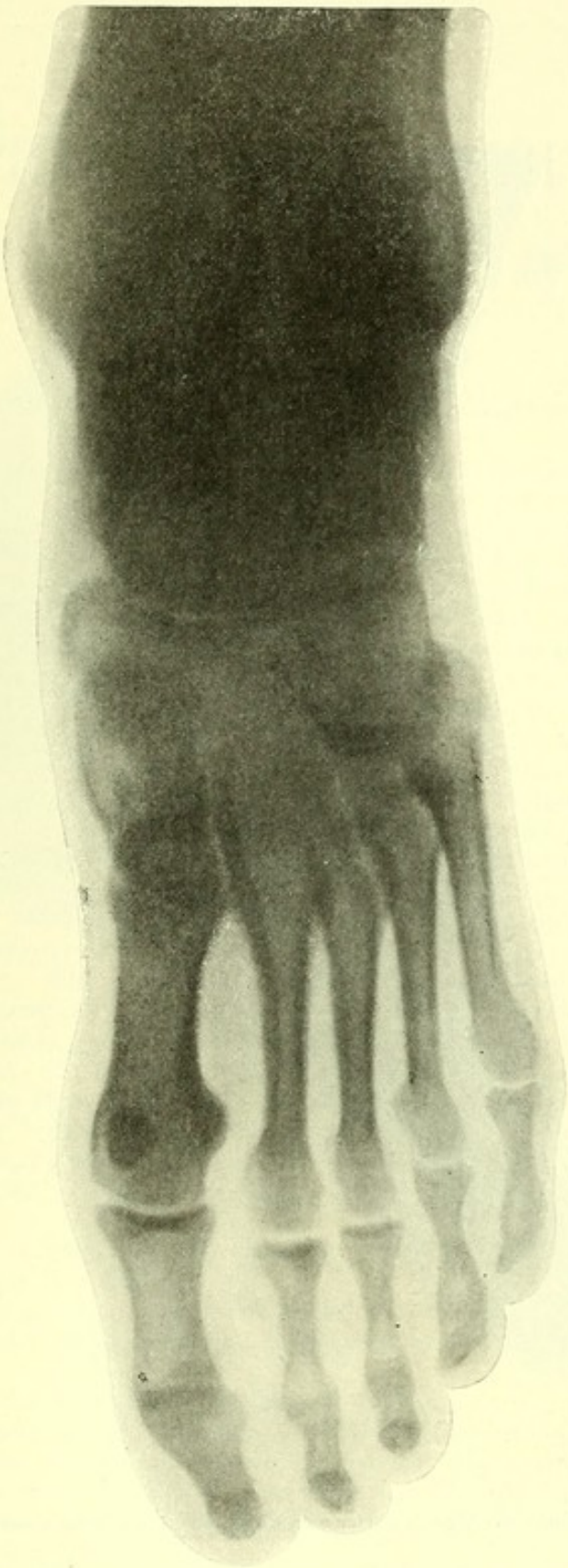

FIG. 949.—The foot in full extension, dorso-plantar view. From a man of 21 years. The first and fifth toes are deformed by the wearing of pointed shoes. The deep shadow about the ankle-joint is due to the great thickness of the bony mass.

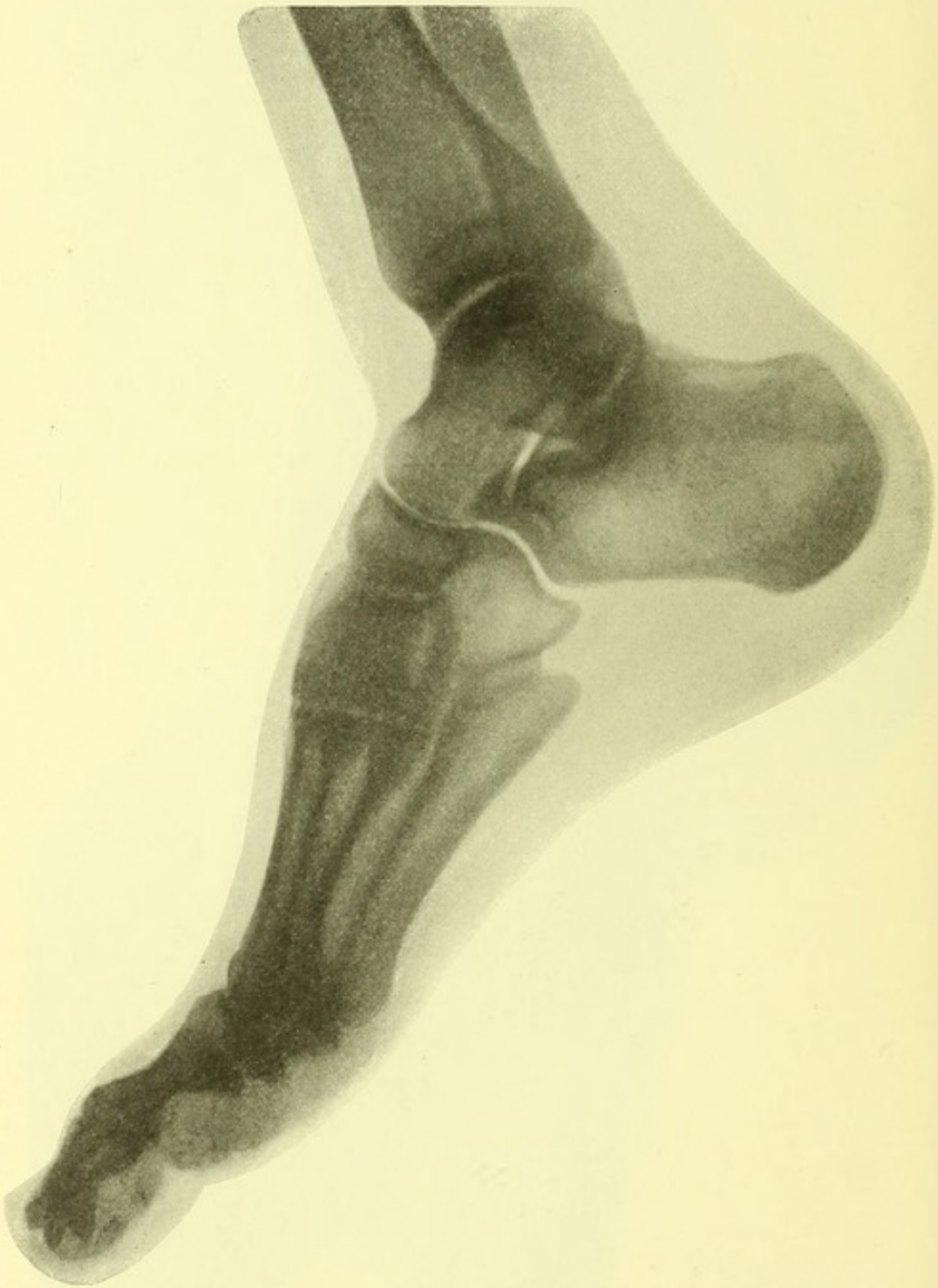

FIG. 950.—The foot, side view. From the same man as Fig. 949. Every bone is more or less overlapped by some other.

PRACTICAL ANATOMY.

By F. H. GERRISH.

IT is the purpose of this final chapter to give directions concerning the conduct of dissections.

Preparatory Study.—There is but little profit in attempting a dissection until one has become familiar with the appearance of the parts involved, and has learned the chief facts concerning their structure. This acquaintance should be gained by careful study of their descriptive anatomy, and by frequent inspection and handling of well-dissected parts, prepared for this very purpose of preliminary drill. Without such equipment it is impossible to follow fully the admirable precept of Oliver Wendell Holmes—"Let the eye go before the hand, and the mind before the eye."

Cooperation in Work.—The men who are dissecting on the same subject should work harmoniously. A spirit of accommodation is essential, for it is necessary that the attitude of a part and even of the whole cadaver should be changed at times, and occasionally this circumstance will oblige a student to alter his order of work temporarily, or even to suspend it altogether for a while. Those whose parts of the subject have a structural continuity or adjacency will sometimes work to best advantage at different hours.

The Taking of Pains.—All work should be done with care and deliberation. Patience and intelligence are essential to good results. Hurry is not only wasteful, but ineffective. The number of days which should be spent upon a stated part is not here prescribed, because competent men work with different degrees of speed. The task is soon enough done, when it is well enough done.

Cleaning Organs.—"The art of dissection consists in the complete removal of this [areolar] tissue from around the other structures, so as to expose the parts enwrapped therein" (Macalister). When the meshes of areolar tissue are occupied by cells of fat, dissection is much more difficult, and the result is less satisfactory. Consequently, when a choice is possible, a subject should be selected which is lean.

Every part as it comes to view should be cleaned thoroughly—that is, freed from enveloping areolar tissue.

In doing this, the cuts of the knife should be parallel with the fibres of the part, if it be muscle, nerve, or fascia; in the direction of its long axis, if it be a vessel.

The vessels and nerves should be cleaned from large trunks to small.

Finish the cleaning of one fasciculus or vessel before attempting another.

In dissecting fine vessels and nerves, the point of the scalpel may be used to advantage; but in the dissection of muscles it is ordinarily advisable to employ the belly of the blade, making long, sweeping cuts. In this way greater smoothness of dissection is obtained.

Whatever the part, it should be made tense before dissection. In the case of muscles the requisite tension may be gained by position; but in the case of a muscle whose fibres run in various directions, it is necessary to place the part in a different attitude for each of them. Blocks of wood, variously adjusted between

the thorax or abdomen and the table, assist greatly in this matter. Nerves may be made taut by the use of the hooks and chains.

Further Directions.—The under surface of a muscle should always be examined carefully to observe the arteries, veins, nerves, and deep attachments.

Every tendon should be followed to its attachment.

In cutting through a muscle in order to remove or reflect it, care must be taken not to injure a subjacent part.

If a muscle is to be reflected, it should, as a rule, be divided in the middle.

When a group of muscles is to be reflected, each should be cut at a different level from the others, as replacement can thus be accomplished more readily and accurately.

Handle parts delicately. Rough manipulation hurts them, especially the bellies of muscles. Forceps tear muscular fibres, and leave a ragged surface; fingers injure them very little, and should always be used, when practicable.

Do not finally remove any part until obliged to do so in order to reach underlying structures. By keeping parts attached a long time, opportunity is afforded for many repeated examinations.

Prevention of Drying.—Every part should be kept a little moist (but not soaked) with some antiseptic liquid. One can learn something, perhaps a good deal, from a decaying organ; nothing from a part which has been allowed to dry.

One of the best preparations for this purpose is composed as follows: Alcohol 30 per cent., glycerine 10, carbolic acid 2, and water 58.

Clearing up after Work.—After the day's dissecting is done, the dissected organs should be slightly moistened with the above fluid, and adjusted as nearly as possible in their natural relations; the edges of the skin should be fastened with a continuous suture; and the whole wrapped in cotton cloth which has been wetted with the same solution. Finally, it is desirable that the entire subject should be covered with a sheet of rubber cloth. If care is taken along these lines, a dissection may be continued a number of weeks without discomfort or offence.

The skin of a part should be saved until the dissection is completed, because it is the best covering. The original incisions should be so made as to leave large flaps of skin, as these are more easily managed.

Disposal of Waste.—As regards the disposal of waste materials: all fluids from the subject should be turned into the waste-pipe connected with the sewer; small fragments should be deposited upon a piece of paper, and the collection from each day's work placed in a box provided for the purpose, which should also receive the large masses, as they are removed; and the box should be buried at the close of the dissecting season, or as soon as it is filled, if that be earlier.

Care of the Hands.—Chaps or abrasions on the hands of the dissector should be protected by small bits of court-plaster, over and around which a coating of flexible collodion is applied. When the hands are to be brought extensively in contact with the viscera, it is well to anoint them with vaseline or some other oil.

Treatment of a Dissection Wound.—If a wound is received from a dissecting instrument or a spicule of bone, it should be encouraged to bleed by holding it in the stream from the hot water faucet, and then sucking it vigorously, so that the poison may be removed before it has a chance to be absorbed. The danger of infection from the dissection material usually provided in our schools is very small, if reasonable precautions are observed.

Cleanliness of Clothing.—In preparation for dissection the student should either clothe himself in an old suit, which thereafter will be used for no other purpose, or else cover his ordinary raiment with a dissecting gown, which reaches nearly to his feet and is gathered in at the wrists. If consideration for his own cleanliness and comfort is not sufficient to suggest some such procedure, a decent regard for the rights of others will forbid his mingling with people of common

sensitiveness with a coat which is in any degree contaminated by contact with dissecting material, however well preserved the latter may be.

Avoidance of Publicity.—The beginner in practical anatomy is usually so impressed with the novelty and interest of his work that he talks about it when among non-medical people, forgetting that to many of them the mention of such topics is offensive. In the interest of his own standing and of the repute of the profession he would far better maintain the strictest reticence in all such matters.

Dissect Often!—Finally, in way of general advice, the student is counselled to lose no opportunity to dissect, bearing in mind that the most accomplished anatomists never consider themselves so perfect in their knowledge that they cannot learn something by another dissection.

Implements Needed.—The following instruments the student should provide himself with: a *large scalpel*, a *small scalpel*, both with the cutting edge markedly convex, a *cartilage knife*, a pair of *scissors*, best curved on the flat, a *dissecting forceps*, a *tenaculum*, a *pair of hooks* connected by a chain, a *grooved director*, a small *blow-pipe*, and a foot of rubber-tubing to fit onto the large end, and a large *straight needle*. The chisel, saw, and hammer, which he will need at times, are a part of the furnishings of the dissecting-room. Additionally he should procure some coarse thread for sewing the skin over the dissection at the close of the day; a pint of the preservative mentioned elsewhere in these directions; a piece of cotton cloth, large enough to enwrap his part of the subject; an ounce of vaseline for his hands; and a good hone and strop for sharpening his knives—the strop never to be employed for other instruments after having been used for dissecting scalpels. He would do well to have his own cake of soap, nail-brush, and towels, for manifest reasons.

The instruments, especially those for cutting, should be of excellent quality. There is no economy in buying inferior tools.

After the day's dissecting is done, every instrument which has been used should be scrupulously cleansed, dried, and made ready for the next session. The hands should be washed with hot water and soap, particular attention being bestowed upon the nails.

DIVISION OF THE CADAVER.

The number of parts into which the body is divided for dissection purposes varies greatly in different schools; but the method of presentation here adopted will readily lend itself to any division which may be preferred.

The organs in a given region are mentioned in the order in which they are encountered in dissecting. The name of each is followed by a numeral which refers to the page of this book upon which it is described, with the exception that a few of the references direct attention to pictures, which are especially serviceable in dissecting, and from which the verbal descriptions can readily be turned to.

Many parts are entered more than once in the enumerations, because they occur in two or more regions.

The small branches of arteries are not generally given, as they will naturally attract attention in connection with the trunks from which they spring. The same omission is commonly made in the case of veins which are companion to arteries of the same name. Reference to a viscus is intended to include its parts, as ducts, vessels, etc.

It is assumed that the dissection is done under the personal supervision of a competent demonstrator, who will prescribe the order in which parts are to be taken, and will give all necessary instructions as to the best method of making primary incisions, reflecting and removing parts, and displaying whatever requires demonstration—points upon which equally competent teachers differ—and, therefore, specific directions on such matters are not here given.

THE THORAX AND UPPER LIMB.

Platysma, 337.
Cutaneous nerves, 605, 619, 621.
Mammary gland, 843.
Cephalic vein, 470.
Acromiothoracic artery, 415.
Deep fascia, 353, 354.
Pectoralis major, 260.
Axillary space, 415.
  Lymph-nodes, 492.
  Axillary vein, 470.
  Axillary artery, 412.
  Brachial plexus, 606.
Pectoralis minor, 256.
Costocoracoid membrane, 354.
Subclavius, 257.
Serratus magnus, 256.
Posterior thoracic nerve, 607.
Intercosto-humeral nerve, 620.
Intercostales externi, 336.
Intercostales interni, 336.
Intercostal nerves, 619.
Intercostal arteries, 425.
Internal mammary artery, 409.
Superior epigastric artery, 410.
Musculophrenic artery, 409.
Sternal lymph-nodes, 495.
Triangularis sterni, 336.

Thoracic Cavity.

Pleuræ, 765.
Anterior mediastinal lymph-nodes, 495.
Lungs, 762.
Roots of lungs, 763.
Phrenic nerve, 605.
Pericardium, 373.
Thymus, 797.
Brachio-cephalic veins, 457.
Superior vena cava, 456.
Inferior vena cava, 474.
Heart, 365.
Coronary arteries, 386.
Cardiac veins, 455.
Cardiac nerves, 595, 643, 644.
Pulmonary artery, 379.
Aorta, 383.
Brachio-cephalic artery, 386.
Left common carotid artery, 389.
Left subclavian artery, 404.
Trachea, 757.
Bronchi, 758.
Pneumogastric nerves, 592.
Recurrent laryngeal nerves, 594.
Gullet, 712.
Branches of descending aorta, 425.
Thoracic duct, 487.
Superior mediastinal lymph-nodes, 495.
Gangliated cord of the sympathetic, 642.
Azygos veins, 471.
Posterior mediastinal lymph-nodes, 495.
Diaphragma, 334.
Costo-vertebral articulations, 211.

Front of the Arm.

Cutaneous nerves, 617.
Superficial veins in arm and at bend of elbow, 468.
Epicondylar lymph-node, 493.
Deep fascia, 355.
External and internal intermuscular septa, 355.
Brachial artery, 415.
Venæ comites of brachial artery, 470.
Internal cutaneous nerves, 612.
Median nerve, 608.
Ulnar nerve, 612.
Musculo-cutaneous nerve, 608.
Biceps, 263.
Coracobrachialis, 260.
Brachialis, 264.

Front of the Forearm.

Superficial veins, 469.
Cutaneous nerves, 617, 618.
Deep fascia, 355.
Intermuscular septa, 356.
Pronator teres, 267.
Flexor carpi radialis, 269.
Palmaris longus, 269.
Flexor carpi ulnaris, 269.
Radial artery, 421.
Flexor sublimis digitorum, 273.
Radial and posterior interosseous nerves, 616.
Ulnar artery, 417.
Interosseous arteries, 418.
Median nerve, 608.
Flexor profundus digitorum, 274.
Flexor longus pollicis, 282.
Pronator quadratus, 267.

The Palm.

Palmaris brevis, 285.
Cutaneous nerves, 617, 618.
Anterior annular ligament, 356.
Palmar fascia, 356.
Synovial sheaths of tendons, 357.
Superficial palmar arch, 420.
Ulnar nerve, 612.

Median nerve, 608.
Abductor pollicis, 284.
Flexor ossis metacarpi pollicis, 281.
Flexor brevis pollicis, 282.
Adductor pollicis, 284.
Abductor minimi digiti, 279.
Flexor brevis minimi digiti, 275.
Flexor ossis metacarpi minimi digiti, 275.
Lumbricales, 276.
Deep palmar arch, 422.
Interossei palmares, 280.

Back of Thorax and Upper Limb.

Deep fascia, 354.
Trapezius, 253.
Latissimus, 261.
Omohyoideus, 337.
Rhomboideus minor, 255.
Rhomboideus major, 255.
Deltoideus, 258.
Circumflex arteries, 415.
Circumflex nerve, 613.
Teres major, 261.
Supraspinatus, 260.
Infraspinatus, 261.
Teres minor, 261.
Subscapularis, 263.
Suprascapular artery, 410.
Suprascapular nerve, 607.
Dorsalis scapulæ artery, 415.

Back of the Arm.

Deep fascia, 355.
Cutaneous nerves, 617, 618.
Triceps, 265.
Musculospiral nerve, 614.
Superior profunda artery, 416.
Ulnar nerve, 612.
Anastomotica magna and anastomoses around elbow, 416.

Back of the Forearm.

Cutaneous nerves, 617, 618.
Deep fascia, 355.
Anconeus, 266.
Brachioradialis, 265.
Extensor carpi radialis longus, 269.
Extensor carpi radialis brevis, 270.
Extensor communis digitorum, 277.
Extensor minimi digiti, 278.
Extensor carpi ulnaris, 270.
Extensor ossis metacarpi pollicis, 282.
Extensor brevis pollicis, 282.
Extensor longus pollicis, 282.
Extensor indicis, 278.
Posterior interosseous artery, 418.
Posterior interosseous nerve, 616.
Supinator, 268.

Back of the Hand.

Radial artery, 422.
Posterior annular ligament, 356.
Digital extensors, tendons, 276.
Posterior interosseous nerve, 616.
Interossei dorsales, 278.
The articulations of the upper limb:
- Sterno-clavicular joint, 216.
- Scapulo-clavicular joint, 217.
- Shoulder joint, 218.
- Elbow joint, 221.
- Wrist joint, 224.
- Joints in the hand, 225–227.

THE ABDOMEN AND LOWER LIMB.

The Abdomen.

Superficial fascia—two layers, 349.
Lymph-nodes in groin, 493.
Cutaneous nerves:
- Anterior cutaneous, 621.
- Lateral cutaneous, 621.
- Ilio-hypogastric, 623.
- Ilio-inguinal, 624.
- Last thoracic, 621.

Superficial pudic arteries, 443.
Superficial epigastric artery, 443.
Superficial circumflex iliac artery, 443.
Obliquus externus, 332.
Linea alba, 331.
External abdominal ring, 332.
Inguinal ligament, 332.
Gimbernat's ligament, 332.
Obliquus internus, 332.
Cremaster, 333.
Nerves in abdominal wall:
- Intercostals—lower six, 619.
- Last thoracic, 621.
- Ilio-hypogastric, 623.
- Ilio-inguinal, 624.

Transversalis, 333.
Rectus abdominis, 331.
Pyramidalis, 332.
Linea alba, 331.
Lumbar fascia, 358.
Transversalis fascia, 359.
Internal abdominal ring, 360.
Objects in anterior abdominal wall below umbilicus, 752.
Deep epigastric artery, 438.

Deep circumflex iliac artery, 439.
Superior epigastric artery, 410.
Musculo-phrenic artery, 409.
Scrotum, 809.
Spermatic cord, 812.
Testicles, 801.
Penis, 812.

Abdominal Cavity.

Abdomen Proper.

Liver, 738.
Spleen, 793.
Stomach, 715.
Gullet, 712.
Jejuno-ileum, 723.
Cæcum, 727.
Colon, 728.
Peritoneum, 748.
Foramen of Winslow, 751.
Mesentery proper, 749.
Lymph-nodes of mesentery, 497.
Superior mesenteric artery, 429.
Inferior mesenteric artery, 430.
Aortic plexus of nerves, 647.
Branches of abdominal aorta, 427.
Portal vein, 477.
Duodenum, 721.
Pancreas, 736.
Pneumogastric nerves, 592.
Solar plexus, 649.
Lumbar lymph-nodes, 497.
Kidney, 777.
Suprarenal capsules, 798.
Ureters, 784.
Diaphragma, 334.
Abdominal aorta, 426.
Receptaculum chyli, 487.
Inferior vena cava, 474.
Ganglia of sympathetic, 646.
Common iliac vessels, 432, 476.
External iliac vessels, 438, 477.
External iliac lymph-nodes, 497.
Iliac fascia, 360.
Psoas magnus, 290.
Iliacus, 291.
Quadratus lumborum, 334.
Psoas parvus, 323.
Lumbar plexus, 622.
Last thoracic nerve, 621.
Ilio-hypogastric nerve, 623.
Ilio-inguinal nerve, 624.
Genito-crural nerve, 624.
External cutaneous nerve, 624.
Anterior crural nerve, 624.

The Pelvic Cavity of the Male.

Hypogastric plexus, 647.
Pelvic fascia, 360.
Bladder, 785.
Ureters, 784.
Prostate, 818.
Rectum, 732.
Seminal vesicles, 808.
Vasa deferentia, 807.
Internal iliac artery, 433.
Obturator artery, 434.
Internal pudic artery, 435.
Sciatic artery, 436.
Ilio-lumbar artery, 437.
Gluteal artery, 437.
Lateral sacral artery, 437.
Internal iliac lymph-nodes, 497.
Superior hemorrhoidal artery, 431.
Middle sacral artery, 432.
Sacral plexus, 628.
Sacral lymph-nodes, 497.
Gangliated cord of sympathetic, 648.
Coccygeal gland, 800.
Obturator internus, 299.
Pyriformis, 298.
Deep inguinal lymph-nodes, 494.
Articulations of pelvis, 227.

The Pelvic Cavity of the Female.

(Organs not in male pelvis.)

Uterus, 829.
Broad ligaments, 832.
Ovaries, 822.
Parovaria, 835.
Fallopian tubes, 827.
Round ligaments, 832.
Urethra, 788.
Uterine artery, 434.
Vaginal artery, 434.
Ovarian artery, 431.

The Male Perineum.

Superficial fascia, 361.
Sphincter ani externus, 821.
Superficial perineal artery, 436.
Transverse perineal artery, 436.
Superficial perineal nerves, 631.
Inferior pudendal nerve, 630.
Ischio-rectal fossa, 361.
Transversus perinei, 821.
Central point of perineum, 820.
Bulbo-cavernosus, 821.
Ischio-cavernosus, 821.
Bulb of corpus spongiosum, 814.
Crura penis, 813.

Internal pudic artery, 435.
Pudic nerve, 631.
Inferior hemorrhoidal artery, 436.
Inferior hemorrhoidal nerve, 631.
Triangular ligament, 361.
Membranous urethra, 789.
Constrictor urethræ, 822.
Bulbo-urethral glands, 820.
Levator ani, 821.
Coccygeus, 821.
Anal canal, 734.
Seminal vesicles, 808.
Prostate gland, 818.

The Female Perineum.

Vulva, 837.
Vagina, 835.
Cervix uteri, 830.
Bulbs of vestibule, 841.
Vulvo-vaginal glands, 841.

Front of the Thigh.

Superficial epigastric artery, 443.
Superficial external pudic artery, 443.
Superficial circumflex iliac artery, 443.
Lymph-nodes, 493.
Internal saphenous vein, 481.
Cutaneous nerves:
  Ilio-inguinal, 624.
  Genito-crural, 624.
  Long saphenous, 625.
  External cutaneous, 624.
  Middle cutaneous, 624.
  Internal cutaneous, 625.
Fascia lata, 362.
  Ilio-tibial band, 362.
  Intermuscular septa, 362.
Saphenous opening, 362.
Inguinal ligament, 332.
Gimbernat's ligament, 332.
Femoral canal, 362.
Femoral sheath, 359.
Scarpa's triangle, 440.
Femoral artery, 439.
Profunda artery, 443.
Deep external pudic artery, 443.
Sartorius, 301.
Adductor (Hunter's) canal, 440.
Anastomotica magna artery, 443.
Femoral vein, 482.
Anterior crural nerve, 624.
External circumflex artery, 443.
Tensor vaginæ femoris, 292.
Rectus femoris, 304.
Vastus externus, 307.
Vastus internus, 307.
Vastus intermedius, 307.
Musculus articularis genu, 308.
Ligamentum patellæ, 303.
Prepatellar bursa, 155.

Inner Side of the Thigh.

Adductor longus, 294.
Profunda femoris artery, 443.
Perforating arteries, 443.
Pectineus, 297.
Internal circumflex artery, 443.
Adductor brevis, 297.
Gracilis, 297.
Adductor magnus, 294.
Obturator externus, 298.
Obturator nerve, 626.
Obturator artery, 434.
Psoas magnus, 290.
Iliacus, 291.

Front of the Leg and Dorsum of the Foot.

Superficial veins, 481.
Cutaneous nerves:
  External popliteal, 636.
  External saphenous, 633.
  Internal saphenous, 625.
  Musculo-cutaneous, 637.
  Anterior tibial, 637.
Deep fascia, 362.
Anterior annular ligament, 363.
Internal annular ligament, 363.
Intermuscular septa, 363.
Tibialis anterior, 308.
Extensor longus digitorum, 319.
Extensor proprius hallucis, 319.
Peroneus tertius, 308.
Anterior tibial artery, 450.
Malleolar arteries, 452.
Dorsalis pedis artery, 452.
Tarsal arteries, 452.
Metatarsal arteries, 453.
Interossei dorsales, 322.
Peroneal artery, 447.
Extensor brevis digitorum, 319.
Anterior tibial nerve, 637.

Outer Side of the Leg.

External annular ligament, 363.
Peroneus longus, 316.
Peroneus brevis, 316.
Peroneal artery, 447.
External popliteal nerve, 636.
Musculo-cutaneous nerve, 637.

Back of the Hip.

Cutaneous nerves:
- Sacral, 628.
- Lumbar, 622.
- Ilio-hypogastric, 623.
- Last thoracic, 621.
- External cutaneous of thigh, 624.
- Small sciatic, 629.

Fascia lata, 362.
Gluteus maximus, 291.
Small sciatic nerve, 629.
Great sciatic nerve, 631.
Internal pudic artery, 435.
Internal pudic nerve, 631.
Pyriformis, 298.
Sciatic artery, 436.
Obturator internus and gemelli, 298–301.
Quadratus femoris, 298.
Obturator externus, 298.
Internal circumflex artery, 443.
Gluteus medius, 292.
Gluteal artery, 437.
Superior gluteal nerve, 629.
Gluteus minimus, 292.

Back of the Thigh.

Cutaneous nerves, 640.
Deep fascia, 362.
Biceps flexor cruris, 301.
Semitendinosus, 301.
Semimembranosus, 301.
Great sciatic nerve, 631.
Perforating arteries, 443.
External saphenous vein, 481.
Small sciatic nerve, 629.
Popliteal space, 444.
Internal popliteal nerve, 632.
External popliteal nerve, 636.
Popliteal artery, 443.
Popliteal vein, 482.
Popliteal lymph-nodes, 494.

Back of the Leg.

Superficial veins, 481.
Cutaneous nerves, 640.
Deep fascia, 363.
Intermuscular septa, 363.
External annular ligament, 363.
Internal annular ligament, 363.
Gastrocnemius, 309.
Plantaris, 314.
Soleus, 313.
Tendo-calcaneus, 314.
Popliteal artery, 443.
Posterior tibial artery, 446.
External popliteal nerve, 636.
Posterior tibial nerve, 633.
Deep transverse fascia, 363.
Popliteus, 302.
Flexor longus hallucis, 316.
Flexor longus digitorum, 317.
Tibialis posterior, 308.
Peroneal artery, 447.

The Sole.

Internal calcaneal nerve, 634.
Plantar fascia, 364.
Abductor hallucis, 321.
Flexor brevis digitorum, 317.
Abductor minimi digiti, 321.
Internal plantar nerve, 634.
Internal plantar artery, 449.
External plantar artery, 449.
External plantar nerve, 635.
Flexor tendons, 318.
Accessorius, 317.
Lumbricales, 318.
Flexor brevis hallucis, 317.
Adductor obliquus hallucis, 322.
Adductor transversus hallucis, 322.
Flexor brevis minimi digiti, 317.
Plantar arch, 449.
Dorsalis pedis, plantar digital branch, 453.
Interossei plantares, 323.
Peroneus longus tendon, 318.
Articulations of lower limb:
- Hip joint, 230.
- Knee joint, 233.
- Ankle joint, 239.
- Tarsal joints, 240.
- Tarso-metatarsal joints, 243.
- Metatarso-phalangeal joints, 244.
- Phalangeal joints, 244.

THE HEAD AND NECK.

Cranial Region.

In the superficial fascia:
- Attollens aurem, 678.
- Attrahens aurem, 679.
- Retrahens aurem, 679.
- Supratrochlear nerve, 576.
- Supraorbital nerve, 576.
- Facial nerve, temporal branches, 588.
- Orbital nerve, 578.
- Auriculo-temporal nerve, 582.
- Posterior auricular nerve, 587.
- Great auricular nerve, mastoid branch, 604.
- Small occipital, 604.

Great occipital nerve, 602.
Epicranial aponeurosis, 348.
Occipitalis, 348.
Frontalis, 348.
Temporal fascia, 350.

Inside of the Cranium.

Encephalon (to be hardened for subsequent study), 509.
Dura, 558.
Venous sinuses of dura, 463.
Cranial nerves at foramina of exit, 565.
Internal carotid artery, 401.
Meningeal arteries, middle and small, 400.
Vertebral arteries, 406.
Hypophysis, 534.

Back of the Neck.

Superficial nerves:
  Great occipital, 602.
  Branches of third, fourth, and fifth cervical, 603–606.
  Small occipital, 604.
  Great auricular, 604.
Trapezius, 253.
Spinal accessory nerve, 596.
Levator scapulæ, 254.
Transversalis colli artery, 411.
Omohyoideus, posterior belly, 337.
Posterior scapular artery, 411.
Suprascapular artery, 410.
Suprascapular nerve, 607.
Vertebral fascia, 358.
Splenius cervicis, 327.
Splenius capitis, 326.
Cervicalis ascendens, 329.
Transversalis cervicis, 329.
Trachelomastoideus, 329.
Occipital artery, 397.
Complexus, 329.
Ligamentum nuchæ, 207.
Arteria princeps cervicis, 398.
Cervical spinal nerves, dorsal primary divisions, 602.
Semispinalis cervicis, 330.
Multifidus, 330.
Rectus capitis posterior major, 330.
Rectus capitis posterior minor, 331.
Obliquus capitis inferior, 331.
Obliquus capitis superior, 331.
Suboccipital nerve, dorsal primary division, 602.
Vertebral artery, 406.

Side of the Neck.

Platysma, 337.
External jugular vein, 460.
Superficial cervical lymph-nodes, 490.
Anterior jugular vein, 460.
Cervical plexus, superficial branches, 604, 605.
Facial nerve, inframandibular branch, 588.
Deep fascia, 351.
Sternocleidomastoideus, 337.
Triangles of the neck, 411.
Subclavian artery, 404.
Suprascapular artery, 410.
Transversalis colli artery, 411.
Brachial plexus, 606.
  Supraclavicular branches:
    to rhomboids, 606.
    to subclavius, 607.
    suprascapular, 607.
    posterior thoracic, 607.
Sternohyoideus, 337.
Omohyoideus, 337.
Sternothyroideus, 337.
Thyrohyoideus, 338.
Stylomandibular ligament, 350, 352.
Digastricus, 338.
Stylohyoideus, 338.
Hypoglossal nerve, 596.
Scalenus anterior, 339.
Scalenus medius, 339.
Scalenus posterior, 340.
Subclavian artery, 404.
Vertebral artery, 406.
Thyroid axis, 410.
Inferior thyroid artery, 410.
Internal mammary artery, 409.
Superior intercostal artery, 411.
Subclavian vein, 470.
Thoracic, or right lymphatic, duct, 487.
Cervical pleura, 765.
Cervical plexus, muscular branches of, 605.
  Ramus cervicalis descendens, 605.
  Phrenic nerve, 605.
  Communicating branches, 605.
Carotid artery (common and internal), 389, 401.
Internal jugular vein, 461.
Pneumogastric nerve, 592.
Deep cervical lymph-nodes, 489.
Carotid gland, 800.
External carotid artery, 392.
  Superior thyroid artery, 393.
  Lingual artery, 395.
  Facial artery, 396.
  Occipital artery, 397.

Posterior auricular artery, 398.
Ascending pharyngeal artery, 398.
Thyroid body, 796.
Trachea, 757.
Gullet, 712.

The Face.

Platysma, 337.
Great auricular nerve, facial branch, 605.
Parotid gland, 735.
(In the parotid: external carotid, temporal, and internal maxillary arteries, temporomaxillary vein, facial, great auricular, and auriculotemporal nerves.)
Temporal artery, 398.
Orbicularis palpebrarum.
Corrugator supercilii, 347.
Eyelids, 691.
Risorius, 346.
Levator labii superioris alæque nasi, 346.
Levator labii superioris proprius, 346.
Zygomaticus minor, 346.
Zygomaticus major, 346.
Levator anguli oris, 346.
Depressor labii inferioris, 346.
Depressor anguli oris, 346.
Buccinator, 346.
Orbicularis oris, 345.
Levator menti, 346.
Nasal muscles, 347.
Facial nerve and branches, 585.
Trifacial nerve and branches, 574.
Facial artery and branches, 396.
Facial vein, 457.
Pinna, 678.
Eyelids, 691.
Levator palpebræ, 691.
Lachrymal gland, 694.
Lachrymal canals, 694.
Nasal duct, 666.
Nasal cartilages, 664.

Temporal and Zygomatic Fossæ.

Temporal fascia, 350.
Masseter, 342.
Temporalis, 342.
Pterygoideus externus, 342.
Pterygoideus internus, 342.
Internal maxillary artery, 399.
Internal maxillary vein, 460.
Trifacial nerve, mandibular division, 580.
Long buccal nerve, 582.
Auriculotemporal nerve, 582.
Inferior dental nerve, 582.
Lingual nerve, 583.
Chorda tympani, 587.
Otic ganglion, 584.

Mandibular Region.

Mylohyoideus, 338.
Hyoglossus, 709.
Styloglossus, 709.
Geniohyoideus, 339.
Submaxillary gland, 735.
Sublingual gland, 736.
Lingual nerve, 583.
Submandibular ganglion, 583.
Hypoglossal nerve, 596.
Genioglossus, 709.
Lingual artery, 395.

Deep Parts of the Neck.

Stylopharyngeus, 711.
Internal carotid artery, 401.
Ascending pharyngeal artery, 398.
Internal jugular vein, 461.
Glossopharyngeal nerve, 591.
Pneumogastric nerve, 592.
Pharyngeal nerve, 594.
Superior laryngeal nerve, 594.
Inferior laryngeal nerve, 594.
Cardiac nerves, 595.
Spinal accessory nerve, 596.
Pharyngeal plexus, 596.
Hypoglossal nerve, 596.
Sympathetic ganglia of neck, 642.
Rectus capitis lateralis, 340.

Prevertebral Region.

Longus colli, 341.
Rectus capitis anterior major, 340.
Rectus capitis anterior minor, 340.
Cervical nerves, 605.
Vertebral artery, 406.

The Orbit.

Eyeball, 381.
Capsule of Tenon, 381.
Frontal nerve, 576.
Supraorbital artery, 402.
Lachrymal nerve, 576.
Nasal nerve, 576.
Lachrymal gland, 694.
Levator palpebræ superioris, 691.
Rectus superior, 690.
Obliquus superior, 690.
Optic nerve, 568.
Ophthalmic ganglion, 577.
Ophthalmic artery, 402.

Rectus externus, 690.
Rectus internus, 690.
Ligament of Zinn, 690.
Oculomotor nerve, 571.
Abducent nerve, 585.
Ciliary nerves, 576, 577.
Obliquus inferior, 691.
Rectus inferior, 690.
Orbital nerve, 578.
The ear, 668.
The mouth, 698.
  Tongue, 707.
The pharynx, 710.
  Soft palate, 700.
  Tonsils, 711.
  Eustachian tube, 676.
The larynx, 767.
The nasal fossæ, 664.

The Back.

Deep fasciæ, 358.
Muscles in third layer, 325.
Muscles in fourth layer, 327.
Muscles in fifth group, 329.
Branches of lower thoracic and upper lumbar nerves, 619.
Intercostal nerves, 619.
  The spinal cord, 552.
  Membranes of cord, 561.

INDEX.

A.

Abdomen, lymph-nodes of, 497
  muscles of, 331
  regions of, 714
Abdominal aorta, 426
  branches of tenth, 596
  cavity, 713
    dissection of, 888
    fascia of, 359
  ring, external, 332
    internal, 360
  walls, dissection of, 887
Abducent nerve, 585
Abductor hallucis, 321
  longus pollicis, 282
  minimi digiti, 279
    pedis, 321
  pollicis muscle, 284
Accessorius ad ilio-costalem, 329
Accessory obturator nerve, 626
  olivary nuclei, 547
  spleens, 795
  thyroid glands, 797
Acetabulum, 149
Acoustic tubercle, 551
Acromio-thoracic artery, 414
Adductor brevis muscle, 297
  gracilis muscle, 297
  longus muscle, 294
  magnus muscle, 294
  obliquus hallucis, 322
  pollicis muscle, 284
  transversus hallucis, 322
Adenoid reticular tissue, 50
Adipose tissue, 49
Adrenals, 798
After-birth, 85
Aggregated lymph-nodules, 724
Agminated glands, 724
Ala, cerebellar, 543
Albicantia, corpora, 522, 534
Alimentary canal, tunics of, 697
Allantois, 83
Alveolar artery, 401
Amniotic cavity, 84
  fold, 83
Amœba, 695
Amœboid movements, 38
Amphiarthrosis, 204
Ampulla of Henle, 808
  rectal, 733
  of semicircular canal, 669
Amygdala, 526, 711
  cerebellar, 544
Amygdaloid nucleus, 526
Anal canal, 734
  columns, 734
Anastomotica magna of brachial, 416
  of femoral, 443
Anatomy, applied, 20
  artistic, 20
Anatomy, clinical, 20
  comparative, 18
  definition of, 17
  descriptive, 18
  general, 19
  gross, 18
  macroscopic, 18
  medical, 18
  microscopic, 18
  minute, 18
  morphological, 20
  normal, 20
  pathological, 20
  philosophic, 20
  physiological, 20
  practical, 20, 883
  regional, 18
  relational, 18, 847
  surface, 857
  surgical, 18
  systematic, 18
  topographical, 18
  transcendental, 20
Anconeus muscle, 266
Angular artery, 397
  gyrus, 516
  veins, 458
Ankle-joint, 239
Annular ligament of ankle, anterior, 363
  external, 363
  internal, 363
  of carpus, anterior, 356
  of forearm, posterior, 356
Annulus ovalis, 367
Ansa hypoglossi, 597
Anterior brachium, 533
  commissure, 522
  crural nerve, 624
  forceps, 519
  interosseus nerve, 610
  ligament of uterus, 832
  nares, 663
  palatine nerve, 580
  perforated space, 525
  superior dental nerves, 578
  tibial nerve, 637
Antihelix, 678
  fossa of, 678
Antitragus, 678
Antrum of Highmore, 183
  mastoid, 675
  maxillary, 666
  pyloricum, 716
  sphenoidal, 666
Anus, 734
Aorta, 383
  abdominal, 426
  arch of, 383
  descending, 423
  thoracic, 423
Aortic plexus, 647
  valve, 369
Aponeurosis, 348
Apophysis, 115
Appendages of the eye, 691
Appendices epiploicæ, 729
Appendix vermiformis, 728
Applied anatomy, 20
Aqueduct of Fallopius, 174
  of mesencephalon, 539
  region of, 538
Aqueductus cochleæ, 674
  vestibuli, 673
Aqueous humor, 689
Arachnoid of brain, 560
  of spinal cord, 562
Arantius, body of, 368
Arbor vitæ, cerebellar, 542
    uterina, 830
Arch, deep crural, 360
    palmar, 422
  neural, 115
  posterior carpal, 420
  superficial palmar, 420
Arciform nuclei, 547
Area, auditory, 551
  embryonic, 82
  hypoglossal, 551
  opaca, 82
  pellucida, 82
  vagus, 551
  vasculosa, 83
Areola of breast, 843, 844
  secondary, 845
Areolar tissue, 47
Arm, back of, dissection of, 887
  fascia of, 355
  front of, dissection of, 886
  muscles moving, 258
Arnold's nerve, 594
Arrectores pilorum, 658
Arteria centralis retinæ, 687
Arterial circle of Huguier, 834
  system, pulmonary, 379
Arteries, helicine, 817
Artery or arteries, 379
  acromio-thoracic, 414
  alar thoracic, 415
  alveolar, 401
  anastomotica magna of brachial, 416
    of femoral, 443
  angular, 397
  anterior auricular, 399
    carpal of radial, 422
      of ulnar, 420
    cerebral, 403
    choroid, 403
    ciliary, 402
    circumflex, 415
    communicating, 403
    ethmoidal, 402
    funicular, 834
    intercostal, 409
    interosseous, 418

Artery or arteries, anterior meningeal, 402
spinal, 407
temporal, 399
tibial, 450
recurrent, 451
articular, of popliteal, 445
of sciatic, 437
azygos, 446
ascending cervical, 410
palatine, 397
pharyngeal, 398
auricular, 397
anterior, 399
posterior, 398
axillary, 412
azygos articular, 446
basilar, 408
brachial, 415
brachio-cephalic, 386
bronchial, 425
buccal, 401
calcanean, internal, 449
carotid, common, in neck, 389
external, 392
internal, 401
left, in thorax, 389
carpal, anterior, of radial, 422
of ulnar, 420
posterior, of radial, 422
of ulnar, 420
recurrent, 423
central of retina, 402
cerebellar, posterior inferior, 408
cerebral, anterior, 403
hemisphere, 530
middle, 403
cervical, ascending, 410
deep, 411
superficial, 411
choroid, anterior, 403
ciliary, 686
anterior, 402
long, 402
short, 402
circumflex, anterior, 415
external, 443
iliac, deep, 439
superficial, 443
internal, 443
posterior, 415
coccygeal, 437
colic, 430
left, 431
middle, 430
right, 430
collateral intercostal, 425
comes nervi ischiadici, 437
common carotid, in the neck, 389
iliac, 432
communicating, anterior, 403
dorsalis pedis, 453
peroneal, 448
posterior, 403
of posterior tibial, 449
coronary, of the face, 397
corpus cavernosum, 436
cremasteric, 438
crico-thyroid, 395
cystic, of hepatic, 428
deep cervical, 411
circumflex iliac, 439
epigastric, 438
Artery or arteries, deep external pudic, 443
palmar, of ulnar, 420
dental, inferior, 400
descending palatine, 401
development of, 95
digital, of external plantar, 449
of ulnar, 420
dorsal interosseous, 422
lingual, 396
of penis, 436
dorsalis hallucis, 453
indicis, 422
pedis, 452
pollicis, 422
scapulæ, 415
epigastric, deep, 438
superior, 410
ethmoidal, 402
anterior, 402
external carotid, 392
circumflex, 443
iliac, 438
obturator, 434
plantar, 449
pudic, deep, 443
superficial, 443
facial, 396
transverse, 398
femoral, 439
frontal, 403
gastric, 427
gastro-duodenalis, 428
-epiploica dextra, 428
sinistra, 429
glandular, 397
gluteal, 437
hemorrhoidal, inferior, 436
middle, 434
superior, 431
hepatic, 427, 739
hyoid, 395, 396
ileo-colic, 430
iliac, common, 432
deep circumflex, 439
external, 438
internal, 433
superficial circumflex, 443
ilio-lumbar, 437
inferior dental, 400
hemorrhoidal, 436
labial, 397
laryngeal, 410
mesenteric, 430
pancreatico-duodenalis, 430
profunda, 416
thyroid, 410
infraorbital, 401
intercostal, 425
anterior, 409
collateral, 425
superior, 411
internal calcanean, 449
carotid, 401
circumflex, 443
iliac, 433
mammary, 409
maxillary, 399
obturator, 434
plantar, 449
pudic, 435
interosseous, anterior, 418
dorsal, 422
posterior, 418
of radial, 422
Artery or arteries, interosseous, of ulnar, 418
intestinal, 430
labial, inferior, 397
lachrymal, 402
laryngeal, inferior, 410
superior, 395
lateral nasal, 397
sacral, 437
spinal, 407
left carotid, in the thorax, 389
colic, 431
lenticulo-striate, 404
lingual, 395
dorsal, 396
long ciliary, 402
thoracic, 415
lumbar, 431
malleolar, 452
mammary, internal, 409
masseteric, 401
maxillary, internal, 399
mediastinal, 409
posterior, 425
meningeal, 398
anterior, 402
middle, 400
posterior, 407
small, 400
mesenteric, inferior, 430
superior, 429
metatarsal, 453
middle cerebral, 403
colic, 430
hemorrhoidal, 434
meningeal, 400
temporal, 399
musculo-phrenic, 409
nasal, 402
lateral, 397
nutrient of brachial, 416
to clavicle, 411
to fibula, 448
to tibia, 449
obturator, 434
external, 434
internal, 434
occipital, 397
œsophageal, 410, 425
of bulb, 436
of upper limb, 404
ophthalmic, 402
ovarian, 431
palatine, ascending, 397
descending, 401
palmar, deep, of ulnar, 420
palpebral, 402
pancreatic, 429
pancreatico-duodenalis, superior, 428
inferior, 430
perforating, 409
of profunda, 443
of radial, 423
posterior, 449
pericardial, 425
perineal, superficial, 436
transverse, 436
peroneal, 447
pharyngeal, 398
ascending, 398
phrenic, 431
superior, 409
plantar, external, 449
internal, 449

Artery or arteries, popliteal, 443
posterior auricular, 398
carpal, of radial, 422
of ulnar, 420
circumflex, 415
communicating, 403
inferior cerebellar, 408
interosseous, 418
mediastinal, 425
meningeal, 407
perforating, 449
scapular, 411
spinal, 407
temporal, 399
tibial, 446
recurrent, 451
prevertebral, 398
princeps cervicis, 398
pollicis, 422
profunda femoris, 443
inferior, 416
superior, 416
pterygoid, 401
pterygo-palatine, 401
pubic, 439
pudic, deep external, 443
internal, 435
superficial external, 443
pulmonary, 379
pyloric, 428
radial, 421
recurrent, 421
radialis indicis, 422
ranine, 396
receptacular, 402
recurrent, anterior tibial, 451
carpal, 423
posterior tibial, 451
radial, 421
ulnar, 418
renal, 431
right colic, 430
sacra media, 432
sacral, lateral, 437
scapular, posterior, 411
sciatic, 436
short ciliary, 402
gastric, 429
sigmoid, 431
small meningeal, 400
spermatic, 431
spinal, 425
anterior, 407
lateral, 407
posterior, 407
splenic, 428
spheno-palatine, 401
sterno-mastoid, 395, 397
stylo-mastoid, 398
subclavian, 404
sublingual, 396
submental, 397
subscapular, 411, 415
superficial cervical, 411
circumflex iliac, 443
epigastric, 443
external pudic, 443
perineal, 436
superficialis volæ, 422
superior epigastric, 410
hemorrhoidal, 431
intercostal, 411
laryngeal, 395
mesenteric, 429
pancreatico-duodenalis, 428
Artery or arteries, superior phrenic, 409
profunda, 416
thoracic, 414
thyroid, 393
supra-acromial, 411
supraorbital, 402
suprarenal, 431
suprascapular, 410
suprasternal, 410
tarsal, 452
temporal, 398, 401
anterior, 399
middle, 399
posterior, 399
thoracic, alar, 415
long, 415
superior, 414
thyroid, inferior, 410
superior, 393
thyroidea ima, 389
tibial, anterior, 450
posterior, 446
recurrent, anterior, 451
posterior, 451
tonsillar, 397
tracheal, 410
transversalis colli, 411
transverse facial, 398
perineal, 436
tympanic, 400
ulnar, 417
recurrent, 418
uterine, 434
vaginal, 434
vertebral, 406
vesical, 434
Vidian, 401
Articular synovial membrane, 70
Articulations, 203
acromio-clavicular, 217
of astragalus, 240
between articular processes of vertebræ, 207
atlas and occipital bone, 210
axis and atlas, 208
and occipital bone, 209
bodies of vertebræ, 205
pisiform and cuneiform, 225
calcaneo-cuboid, 241
carpal, 225
carpo-metacarpal, 226
chondro-sternal, 212
coraco-clavicular, 217
costo-chondral, 212
-vertebral, 211
cubo-cuneiform, 242
-scaphoid, 242
of head, 205
interchondral, 213
intercoccygeal, 228
intercuneiform, 242
intermetacarpal, 226
intermetatarsal, 244
interphalangeal, 227, 244
of lower limb, 230
medio-carpal, 225
metacarpo-phalangeal, 227
metatarso-phalangeal, 244
of pelvis, 227
with last lumbar vertebra, 227
radio-carpal, 224
-ulnar, 223
inferior, 223
Articulations, radio-ulnar, middle, 223
superior, 223
sacro-coccygeal, 228
-iliac, 228
scapho-cuneiform, 242
-clavicular, 217
sternal, 213
sterno-clavicular, 216
tarso-metatarsal, 243
of tarsus, 240
temporo-mandibular, 214
of thorax, 211
tibio-fibular, 237
inferior, 238
superior, 237
transverse, 225
of trunk, 205
of upper extremity, 216
of vertebral column, 205
Articularis genu muscle, 308
Arytenoid cartilages, 768
Aryteno-epiglottideus, 773
Arytenoideus, 773
Ascending colon, 729
vena cava, 474
Association fibres in cerebrum, 520
Astragalus, 158
Atlas, 116
Atrium of right auricle, 367
Attolens aurem, 678
Attrahens aurem, 679
Auditory area, 551
meatus, external, 677
nerve, 589, 674
distribution in labyrinth, 672
organ, development of, 108
Auricle, left, of heart, 369
right, 367
atrium of, 367
Auricular artery, 397
anterior, 399
posterior, 398
nerve, posterior, 587
of tenth, 594
veins, anterior, 460
posterior, 460
Auricularis anterior, 679
posterior, 679
superior, 678
Auriculotemporal nerve, 582
Axilla, 415
suspensory ligament of, 354
Axillary artery, 412
fascia, 353
lymph-nodes, 492
space, 415
veins, 470
Axis, 117
cerebro-spinal, 499
cœliac, 427
thyroid, 410
Azygos uvulæ, 702
veins, great, 471
left lower, 472
lower, left, 472
right, 471
small, 472

B.

Back, dissection of, 893
fascia of, 358
muscles of, 325

Band, ilio-tibial, 362
moderator, 369
Bartholin, glands of, 841
Basal, commissure, gray, 535
white, 518
Basement membrane, 41
Basilar artery, 408
membrane, 670
plexus, 466
sinus, 466
vein, 469
median, 469
Bauchstiel, 83
Bell, nerve of, 607
Bellini, ducts of, 781
Belly-stalk, 83
Bertin, columns of, 781
Biceps flexor cruris, 301
cubiti, 263
Bicuspid teeth, 703
valve, 369
Bile-ducts, 739, 746
Biventer cervicis muscle, 330
Bladder, false ligaments of, 787
gall, 746
ligaments of, 361
trigonum of, 785
urinary, 785
development of, 102
Blandin, gland of, 734
Blastodermic vesicle, 80
Blood, 57
circulation of, 366
islands, 83
-vascular system, 365
-vessels, development of, 93
of lungs, 762
physiological anatomy of, 374
Body-ciliary, 684
Malpighian, of kidney, 780
restiform, 546
thyroid, 796
Wolffian, 99
Bone or bones, 113
astragalus, 158
atlas, 116
axis, 117
calcaneum, 159
carpal, 140
clavicle, 131
coccyx, 122
composition of, 113
cranium, 165
cuboid, 159
cuneiform, of carpus, 141
of tarsus, 160
development of, 113
ethmoid, 179
extremities, development of, 93
of face, 181
femur, 151
fibula, 157
of foot, 158
frontal, 169
functions of, 113
of hand, 140
of hip, 146
humerus, 135
hyoid, 189
ilium, 146
internal arrangement of, 113
ischium, 148
lachrymal, 186
Bone or bones, of lower limb, 146
malar, 186
maxillary, inferior, 187
superior, 181
metacarpal, 144
of metatarsus, 161
nasal, 185
navicular, 160
number of, 113
occipital, 165
os calcis, 159
innominatum, 146
magnum, 143
pubis, 149
outward forms of, 113
palate, 183
parietal, 168
patella, 154
pelvic, 150
phalanges of hand, 144
of foot, 162
pisiform, 143
pyramidal, of carpus, 141
radius, 139
ribs, 127
sacrum, 120
scaphoid, 141
scapula, 133
semilunar, 141
sesamoid, 245
sphenoid, 176
sternum, 126
of tarsus, 158
temporal, 171
tibia, 155
trapezium, 143
trapezoid, 143
turbinate, inferior, 185
tympanic, 175
ulnar, 137
of upper limb, 131
unciform, 143
vertebra prominens, 117
vertebræ, lumbar, 119
peculiar, 118
sacral, 120
thoracic, 117
vomer, 184
Wormian, 190
Bony cochlea, 673
Borders of liver, 744
Bowman, glands of, 667
Brachial artery, 415
fascia, 355
plexus, 606
Brachialis muscle, 264
Brachio-cephalic artery, 386
vein, 457
-radialis muscle, 265
Brachium, anterior, 533
posterior, 533
Brain, 499
arachnoid of, 560
diagrammatic description of, 506
dura of, 558
infundibulum of, 534
membranes of, 558
pia of, 560
-sand, 535, 561
veins of, 467
ventricles of, development of, 103
Branchial cleft, 85
Breast, male, 845
Breasts, 843
Broad ligament of lung, 767
of uterus, 832
Broca, pouch of, 839
Bronchi, 758
Bronchia, 758
Bronchial artery, 425
lymph-nodes, 495
tubes, 758
veins, 472
Bronchioles, 758
Brunner, glands of, 723
Buccal artery, 401
glands, 699
lymph-nodes, 490
nerve, 588
long, 582
veins, 459
Buccinator fascia, 350
muscle, 346
Bulb, arteries of, 436
of corpus spongiosum, 814
of crus penis, 813
end, 655
olfactory, 567
in posterior horn of lateral ventricle, 528
spinal, 545
Bulbi vestibuli, 841
Bulbo-cavernosus muscle, 821, 842
-urethral glands, 820
Bundle of Vicq-d' Azyr, 522
Burdach, tract of, 556
Bursa, pharyngeal, 710
Bursal synovial membrane, 70

C.

Cacumen, 543
Cadaver, division of, 885
Cæcum, 727
Calamus scriptorius, 547
Calcanean artery, internal, 449
Calcaneo-plantar nerve, 634
Calcaneum, 159
Calcar, 528
Calcarine fissure, 512
Callosal fissure, 512
Calloso-marginal fissure, 512
Callosum, 517
peduncles of, 520
Calvaria, 196
Canal or canals, alimentary, tunics of, 697
anal, 734
central, of spinal cord, development of, 103
of cochlea, 669
of Corti, 672
crural, 362
femoral, 362
of Gärtner, 835
development of, 100
Hunter's, 440
lachrymal, 692
of Nuck, 803
of Petit, 689
of Schlemm, 683
semicircular, 669, 673
spinal, 124
Stenson's, 666
of Stilling, 689
Canalis reuniens, 670
utriculo-sacculari, 669

Canine teeth, 703
Canthi, 691
Capsule, external, 537
  of Glisson, 744
  internal, 537
  suprarenal, 798
  of Tenon, 680
Caput coli, 727
  gallinaginis, 790
Cardia of stomach, 716
Cardiac nerves, 643, 644
    cervical, 595
    thoracic, 595
  plexus, 648
  veins, 455
    anterior, 456
    great, 455
    middle, 456
    posterior, 456
    smallest, 456
Carotid artery, external, 392
    internal, 401
  glands, 800
  plexus, 643
Carpal arch, posterior, 420
  artery of radial, anterior, 422
      posterior, 422
    of ulnar, anterior, 420
      posterior, 420
Cartilage, arytenoid, 768
  costal, 129
  cricoid, 768
  cuneiform, 771
  epiglottic, 769
  hyaline, 51
  Meckel's, 92
  nasal, 664
  reticular, 52
  thyroid, 768
  true, 51
  white fibro-, 51
  yellow fibro-, 52
Caruncula lachrymalis, 692
  myrtiformes, 840
Cauda equina, 557
Caudate lobe, 743
  nucleus, 524
Cavernous plexus, 643
  sinus, 466
Cavities opening into nasal fossæ, 666
  in sustentacular tissues, membrane lining, 69
Cavity, abdominal, 713
  amniotic, 84
  of cerebro-spinal axis, 501
      membrane lining, 69
  general ventricular, 504
  nasal, 663
Cavum oris, 699
Cells, 37
  chalice, 44
  of Claudius, 672
  of Deiters, 672
  ethmoidal, 666
  goblet, 44
  hepatic, 740
  mastoid, 675
  prickle, 43
  reproduction, 39
Cement, 87
Central canal of spinal cord, 554
  lobe, 511
  point of perineum, 820
Centrosome, 78
Centrum, 115
Cephalic vein, 470
Cephalo-rachidian fluid, 500
Cerebellar ala, 543
  amygdala, 544
  arbor vitæ, 542
  artery, posterior inferior, 408
  corpus dentatum, 544
  dorsal tuber, 544
  folia, 542
  lingula, 543
  nodule, 544
  peduncles, 542
  pyramid, 544
  trapezium, 542
  uvula, 544
  veins, inferior, 468
    superior, 468
Cerebellum, 541
  development of, 104
  hemispheres of, 542
Cerebral artery, anterior, 403
    middle, 403
  hemisphere, arteries of, 530
  peduncles, 538
  veins, anterior, 468
    deep, 468
    inferior, 468
    middle, 468
    superficial, 467
    superior, 467
Cerebro-spinal axis, 499
    cavity of, 501
    membranes of, 557
    walls of, 505
  fluid, 500
  nerve, typical, 563
Cerebrum, 509
    surface of, 509
Cerumen, 678
Ceruminous glands, 678
Cervical artery, ascending, 410
    deep, 411
    superficial, 411
  cardiac nerves, 595
  curve of spinal cord, 553
  enlargement of spinal cord, 553
  fascia, 351
  ganglion, inferior, 644
    middle, 644
    superior, 642
  lymph-nodes, deep, 489
    superficial, 490
  nerves, 603
    first, 602
    superficial, 605
  plexus, 603
  veins, deep, 463
    transverse, 460
  vertebræ, 116
Cervicalis ascendens, 329
Cervicofacial division of seventh nerve, 588
Cervix of uterus, 830
Chalice cells, 44
Chamber, aqueous, 689
Cheeks, 699
Chiasma, optic, 568
Chink of glottis, 775
Choanæ, 663
Chondroglossus, 710
Chorda tympani, 677
Chordæ tendineæ, 369
Chorio-capillaris, 684
Chorion, 83, 84
Choroid, 684
  anterior, 403
  fissure, 528
  plexuses, 526
    of fourth ventricle, 546
  veins, 468
Chyle, 57
Chyli, receptaculum, 487
Cilia, 692
Ciliary arteries, 686
  artery, anterior, 402
    long, 402
    short, 402
  body, 684
  ganglion, 577
  muscle, 684
  nerves, 686
  processes, 685
  zone, 684
Ciliated epithelium, 43
Cinereum, tuber, 534
Circle of Willis, 408
Circular fissure, 514
  sinus, 466
Circulation of the blood, 366
Circulus major iridis, 686
Circumflex artery, anterior, 415
    external, 443
    internal, 443
    posterior, 415
  nerve, 613
Circumvallate papillæ, 660
Cisternæ arachnoidales, 561
Clarke, column of, 554
Classes of tissues, 41
Claudius, cells of, 672
Claustrum, 525
Clavicle, 131
Clavi-coraco-axillary fascia, 354
Clavi-pectoral fascia, 354
Clefts, branchial, 85, 87
    structures derived from, 87
Clinical anatomy, 20
Clitoris, 840
  development of, 102
Clivus, 543
Cloaca, 102
Coccygeal artery, 437
  gland, 800
  nerves, 627, 639
Coccygeus muscle, 821
Coccyx, 122
Cochlea, bony, 673
  canal of, 669
Cœliac axis, 427
  lymph-nodes, 497
  plexus, 646
Cœlom, 82
Colic artery, 430
    left, 430
    middle, 430
    right, 430
Collar-bone, 131
Collateral fissure, 513
Colliculus seminalis, 790
Colon, 728
  ascending, 729
  descending, 729
  sigmoid, 730
  transverse, 729
Column of Clarke, 554
  lateral, of oblongata, 545
  muscle, 61
  vertebral, 115
Columna nasi, 663

Columnæ carneæ, 368
Columnar epithelium, 42
Columns, anal, 734
of Bertin, 781
of spinal cord, 553
Commissure, anterior, 522
basal gray, 535
white, 518
middle, 533
optic, 568
posterior, 535
of spinal cord, gray, 554
white, 554
of vulva, anterior, 838
posterior, 838
Common bile duct, 746
Communicans hypoglossi nerve, 597
Communicating artery, anterior, 403
posterior, 403
Comparative anatomy, 18
Complexus muscle, 329
Compressor naris muscle, 347
narium minor, 347
urethræ muscle, 822
Conarium, 535
Concha, 678
Conduction paths in spinal cord, 554
Cone, terminal, of spinal cord, 553
Coni vasculosi, 806
Conjunctiva, 693
fornix of, 694
Connective tissue, 46
Constrictor, inferior, 711
medius, 711
superior, 711
Coraco-brachialis muscle, 260
Cord, spermatic, 812
spinal, 499, 552
arachnoid of, 562
central canal of, 554
cervical curve of, 553
enlargement of, 553
conduction paths in, 554
dura of, 561
gray commissure of, 554
length of, 553
lumbar enlargement of, 553
pia of, 561
terminal cone of, 553
thoracic curve of, 553
weight of, 553
white commissure of, 554
umbilical, 83
vocal, false, 770
true, 770
Corium, 653
Cornea, 682
Corniculum laryngis, 769
Corona ciliaris, 685
glandis, 815
radiata, 537
Coronary ligament of liver, 745
plexus, 649
sinus, 455, 466
veins, 455
right, 456
small, 456
Corpora albicantia, 522, 534
cavernosa, 813
geniculata, 533
quadrigemina, 538
Corpora quadrigemina, development of, 105
Corpus Arantii, 368
callosum, 518
genu of, 518
rostrum of, 518
cavernosum, arteries of, 436
dentatum, cerebellar, 544
fimbriatum, 521
Highmorianum, 804
luteum, 826
spongiosum, 814
bulb of, 814
striatum, 523
subthalamicum, 536
triticeum, 771
Corpuscles, Malpighian, 794
muscle, 61
Pacinian, 655
touch, 654
Corrugator supercilii muscle, 347
Corti, canal of, 672
organ of, 671
development of, 109
rods of, 671
Costal cartilages, 129
Costo-colic ligament, 750
-coracoid ligament, 354
membrane, 354
Cowper, glands of, 820
Cranial cavity, floor of, 197
nerves, 565
nuclei of, 569
region, dissection of, 890
Cranium, bones of, 165
cerebral lobes in, 517
inside of, dissection of, 891
interior of, 196
Cremaster of Henle, 812
Cremasteric artery, 438
fascia, 811
Cribriform fascia, 362
Crico-arytenoideus lateralis, 772
posterior, 772
-thyroid artery, 395
-thyroideus, 771
Cricoid cartilage, 768
Crista acustica, 669
vestibuli, 673
Cross-striped muscular tissue, 59
Crura cerebri, 538
penis, 813
Crural arch, deep, 360
canal, 362
nerve, anterior, 624
sheath, 359
Crusta, 539
Crypts of Lieberkühn, 720
Cuboid bone, 159
Cucullaris muscle, 253
Cul-de-sac of Douglas, 831
Culmen, 543
Cuneiform bone of the carpus, 141
external, 161
internal, 160
middle, 161
of tarsus, 160
cartilage, 771
Cuneus, 516
Cupola, 674
Curve, cervical, of spinal cord, 553
thoracic, of spinal cord, 553
Cushion of epiglottis, 775
Cutaneous membrane, 74
nerve of anterior crural, internal, 625
middle, 624
internal, 612
perforating, 630
small internal, 612
of thigh, external, 624
Cuticle, 652
Cutis vera, 653
Cystic duct, 746

D.

Dartos, 810
Decidua reflexa, 84
serotina, 84
vera, 84
Deciduous teeth, 703
Decussation of pyramids, 545
Deep fascia, 350
lymph-vessels, 486
temporal nerve, 581
Deiters, cells of, 672
Delimitations of surface parts, 21
Deltoid fascia, 355
Deltoideus muscle, 258
Dental artery, inferior, 400
nerve, inferior, 582
shelf, 86
Dentate gyrus, 517
nucleus, 547
Denticulate ligament, 562
Dentine, 56
Depressor alæ nasi, 347
anguli oris, 346
labii inferioris, 346
Derma, 653
Descemet, membrane of, 682
Descendens hypoglossi nerve, 597
Descending colon, 729
vena cava, 456
of the abdomen, 474
hepatic, 475
phrenic, 475
renal, 475
suprarenal, 475
Development of arteries, 95
of blood-vessels, 93
of bones, 113
of extremities, 93
of canals of Gärtner, 100
of central canal of spinal cord, 103
of cerebellum, 104
of clitoris, 102
of cloaca, 102
of corpora quadrigemina, 105
of diaphragm, 97
of ear, 108
early stages of, 79
of enamel, 86
of epencephalon, 104
of epididymis, 101
of excretory organs, 98
of eye, 107
of eyelids, 108
of Fallopian tubes, 100
of gubernaculum, 102
of the gustatory organs, 106
of heart, 93
of hydatid of Morgagni, 100
of insula, 106
of intestines, 88

Development of labia majora, 103
minora, 103
of lachrymal duct, 108
glands, 108
of liver, 90
of lungs, 88
of lymphatic vessels, 98
of medulla oblongata, 104
of mesenteries, 88
of metencephalon, 104
of muscular system, 98
of nervous system, 103
of neuroglia, 103
of oblongata, 104
of olfactory organs, 106
of optic thalamus, 105
of organ of Corti, 109
of Giraldes, 101
of ovaries, 99
of pancreas, 91
of paroöphoron, 100
of parovarium, 100
of penis, 102
of perineum, 102
of placenta, 83, 85
of pons, 104
of prosencephalon, 105
of quadrigemina, 105
of reproductive organs, 98
of rhinencephalon, 106
of ribs, 92
of round ligament, 100
of scrotum, 102
of sinus pocularis, 101
of skeleton, 91
of skull, 92
of spleen, 98
of sternum, 127
of stomach, 90
of suprarenal bodies, 98
of the sympathetic system, 106
of the tactile organs, 106
of teeth, 86
of testes, 100
of thalamencephalon, 105
of thymus, 88
of thyroid gland, 88
of tongue, 88
of trachea, 88
of tunica vaginalis, 101
of urachus, 102
of ureters, 99, 102
of urethra, 102
of urinary bladder, 102
of urogenital sinus, 102
of uterus, 100
masculinus, 101
of vagina, 100, 103
of vas deferens, 101
of veins, 96
of ventricles of brain, 103
of vertebræ, 91
Diaphragm, development of, 97
of sella, 559
Diaphragma muscle, 334
Diaphragmatic plexus, 646
Diaphysis, 114
Diarthrosis, 204
Digastric lobe, 544
Digestion, organs of, 695
Digital arteries of ulnar, 420
fossa, 802
nerves of foot, 635
Dilatator naris, anterior, 347
Dilatator naris, posterior, 347
Diploë, veins of, 463
Discus proligerus, 824
Dissection of abdomen and lower limb, 887
of abdominal cavity, 888
walls, 887
of back, 893
of arm, 887
of hand, 887
of hip, 890
of leg, 890
of neck, 891
of thigh, 890
of thorax and upper limb, 887
of cranial region, 890
of deep parts of the neck, 892
of face, 892
of female perineum, 889
of front of arm, 886
of forearm, 886
of leg and dorsum of foot, 889
of thigh, 889
of head and neck, 890
of inner side of thigh, 889
of inside of cranium, 891
of male perineum, 888
of mandibular region, 892
of orbit, 892
of outer side of leg, 889
of palm, 886
of pelvic cavity of female, 888
of male, 888
of prevertebral region, 892
of side of neck, 891
of sole, 890
of temporal and zygomatic fossæ, 892
of thoracic cavity, 886
of thorax and upper limb, 886
Distribution of spinal nerves, mode of, 600
Division of cadaver, 885
Divisions, anterior primary, of spinal nerves, 603
dorsal primary, of first cervical nerve, 602
of spinal nerves, 601
Dorsal artery of penis, 436
nerve of penis, 631
pyramid, 546
tuber, cerebellar, 544
veins of penis, 480
Dorsalis hallucis artery, 453
pedis artery, 452
Dorsum of foot, dissection of, 889
Douglas, cul-de-sac of, 831
folds of, 831
Drum of ear, 674
Ductless glands, 793
Ducts of Bellini, 781
bile, 746
common, 746
cystic, 746
ejaculatory, 809
hepatic, 746
lachrymal, development of, 108
of liver, 739
lymphatic, left, 487
right, 487
Müllerian, 99
nasal, 666, 694
Ducts, pancreatic, 737
of Stenson, 735
thoracic, 487
of Wharton, 736
Wolffian, 98
Ductus arteriosus, 96, 380
cochlearis, 670
communis choledochus, 746
endolymphaticus, 669
venosus fissure, 743
Duodenal glands, 723
Duodenum, 721
Dura mater of brain, 558
of spinal cord, 561

E.

Ear, 668
development of, 108
drum of, 674
external, 677
internal, 668
labyrinth of, 668
middle, 674
Ectoderm, 80
organs derived from, 103
Eighth nerve, 589
Ejaculatory ducts, 809
Elastic tissues, 47
Elbow-joint, 221
Elementary tissues, 37
Eleventh nerve, 596
nuclei of, 590
Embryology, 77
Embryonic area, 82
shield, 80
Eminentia collateralis, 528
teres, 540, 551
Emissary veins, 463
Enamel, development of, 86
organ, 86
second, 87
Encephalic vesicles, 500
Encephalon, 499
weight of, 552
End bulbs, 655
Endocardium, 366
Endoderm, 80
organs derived from, 86
Endomysium, 61
Endoneurium, 64
Endosteum, 53
Endothelium, 41
End-plate, motorial, 65
Endyma, 500
Enlargement, of spinal cord, cervical, 553
lumbar, 553
Ensiform process, 126
Epencephalon, 540
development of, 104
Ependyma, 500
Epicardium, 374
Epicondylar lymph-nodes, 493
Epidermis, 652
Epididymis, 802, 805
canal of, 806
development of, 101
Epidural space, 561
Epigastric artery, deep, 438
superficial, 443
superior, 410
plexus, 649
veins, superficial, 481
Epiglottic cartilage, 769

Epimysium, 61
Epineurium, 64
Epiphyses, 114, 535
Epithelium, 41
ciliated, 43
columnar, 42
flattened, 42
glandular, 44
neuro-, 43
pigmented, 43
prickle cell of, 43
sensory, 43
simple, 44
stratified, 44
transitional, 44
Epoöphoron, 835
Erector penis muscle, 821
spinæ, 327
Eruption of teeth, 703
Ethmoid bone, 179
Ethmoidal artery, 402
anterior, 402
cells, 666
Eustachian tube, 676
valve, 368
Excretory organs, development of, 98
Expression, muscles of, 343
Extensor brevis digitorum, 319
pollicis, 282
carpi radialis brevis, 270
longus, 269
ulnaris, 270
communis digitorum, 277
indicis, 278
longus digitorum, 319
hallucis, 319
pollicis, 282
minimi digiti, 278
ossis metacarpi pollicis, 282
primi internodii pollicis, 282
proprius hallucis, 319
secundi internodii pollicis, 282
External anterior thoracic nerve, 608
auditory meatus, 677
capsule, 537
cutaneous nerve of musculo-spiral, 615
of thigh, 624
ear, 677
laryngeal nerve, 594
medullary lamina, 525
os, 830, 831
palatine nerve, 580
plantar nerve, 635
popliteal nerve, 636
pterygoid nerve, 582
respiratory nerve, 607
spermatic fascia, 810
superficial petrosal nerve, 587
Extraspinal veins, 472
Extremities of liver, 744
Eye, 680
appendages of, 691
development of, 107
Eyeball, muscles of, 690
Eyelashes, 692
Eyelids, 691
development of, 108

F.

Face, bones of, 181
dissection of, 892
Face, coronary artery of, 397
Facial artery, 396
transverse, 398
nerve, 585
region of skull, 194
vein, 457
anterior, 457
common, 458
deep, 459
posterior, 459
transverse, 460
Falciform ligament of liver, 745
lobe, 513
process, 362
Fallopian tubes, 827
development of, 100
fimbriæ of, 828
fimbriated extremity of, 827
Fallopius, aqueduct of, 174
False ligaments of bladder, 787
ribs, 127
vertebræ, 115
vocal cords, 770
Falx cerebelli, 559
cerebri, 559
Fascia or fasciæ, 349
of the abdominal cavity, 359
of the arm, 355
axillary, 353
of the back, 358
brachial, 355
buccinator, 350
cervical, 351
inner, 352
middle, 352
outer, 351
clavi-coraco-axillary, 354
-pectoral, 354
cremasteric, 810
cribriform, 362
deep, 350
transverse, 363
deltoid, 355
dentata, 517
dorsal, of hand, 357
external spermatic, 810
of foot, 364
of forearm, 355
of hand, 356
of head, 350
of hip and thigh, 362
iliac, 360
infraspinous, 355
infundibuliform, 360, 811
intercolumnar, 810
intercostal, 354
external, 354
internal, 354
spermatic, 811
lata, 362
of leg, 362
lumbar, 358
masseteric, 350
middle spermatic, 811
obturator, 360
palmar, 356
parotid, 350
pectoral, 353
pelvic, 360
of perineum, 361
plantar, 364
prevertebral, 352
propria, 811
pyriformis, 361
recto-vesical, 361
Fascia or fasciæ, of shoulder, 354
subscapular, 355
superficial, 349
supraspinous, 355
temporal, 350
thoracic, 353
transversalis, 359
vertebral, 358
Fasciculus cuneatus, 547
gracilis, 547
solitary, 548
Fatty tissues, 49
Fauces, isthmus of, 700
Female perineum, dissection of, 889
Femoral artery, 439
canal, 362
ring, 360
sheath, 359
veins, 482
Femur, 151
Fenestra ovalis, 673, 675
rotunda, 674, 675
Ferrein, pyramids of, 780
Fibres, association, 520
of Sharpey, 54
Fibro-cartilage, white, 51
yellow, 52
Fibrous tissues, white, 46
yellow, 47
tunic of eye, 683
Fibula, 157
Fibular nerve, 634
Fifth nerve, 574
ophthalmic division of, 575
sacral, 639
Filiform papillæ, 661
Fillet, 550
Filum terminale, 553
Fimbria, 521
ovarian, 824, 828
Fimbriæ of Fallopian tube, 828
Fimbriated extremity of Fallopian tube, 827
Fingers, muscles moving, 272
First nerve, 567
cervical, 602
Fissure, calcarine, 512
callosal, 512
calloso-marginal, 512
central, 510, 512
choroid, 528
circular, 514
collateral, 513
ductus venosus, 743
gall-bladder, 742
of Glaser, 172
hippocampal, 517
intraparietal, 515
longitudinal, of cerebrum, 510
olfactory, 515
parallel, 516
parieto-occipital, 511, 512
portal, 742
precentral, 514
precuneal, 513
pterygo-maxillary, 191
Rolandic, 510
spheno-maxillary, 192
of spinal cord, 553
supraorbital, 515
Sylvian, 510
transverse, 528, 742
umbilical, 742
vena caval, 743

Flattened epithelium, 42
Flexor accessorius, 317
  brevis digitorum, 317
    hallucis, 317
    minimi digiti, 275
      pedis, 317
    pollicis, 282
  carpi radialis, 269
    ulnaris, 269
  longus digitorum, 317
    hallucis, 316
    pollicis, 282
  ossis metacarpi minimi digiti, 275
    pollicis, 281
  perforans muscle, 274
  perforatus digitorum pedis, 317
    muscle, 273
  profundus digitorum, 274
  sublimis digitorum, 273
Flexure, hepatic, 729
  splenic, 729
Flocculus, 544
Fluid, cephalo-rachidian, 500
  cerebro-spinal, 500
Fold, amniotic, 83
  of Douglas, 831
Folia, cerebellar, 542
Follicle, Graafian, 824
  hair, 657
Fontana, spaces of, 683
Fontanelles, 190
Foot, bones of, 158
  dorsum of, dissection of, 889
  fasciæ of, 364
  muscle moving the whole, 308
  phalanges of, 162
  as a whole, 163
Foramen cæcum of oblongata, 545
    of tongue, 707
  epiploïcum, 751
  of Magendie, 505, 547
  of Monro, 535
  obturator, 149
  ovale, 367
  of Winslow, 751
Foramina Thebesii, 367
Forceps, anterior, 519
  posterior, 519
Forearm, fascia of, 355
  muscles moving outer part of, 266
    whole, 263
Forehead, muscles of, 347
Foreskin, 815
Form of liver, 740
Fornix, 520
  of conjunctiva, 694
Fossa of antihelix, 678
  digital, 802
  of helix, 678
  ischio-rectal, 361
  nasal, 195, 664
  navicular, 840
  navicularis of urethra, 790
  ovalis, 367
  patellaris, 689
  spheno-maxillary, 191, 192
  temporal, 191
    dissection of, 892
  zygomatic, 191
    dissection of, 892
Fourchette, 838
Fourth nerve, 574
    sacral, 638
  ventricle, 550
Fovea centralis, 687
  hemielliptica, 673
  hemispherica, 673
  inferior, 551
  superior, 540, 551
Frænum labii, 699
  linguæ, 708
  preputii, 815
Framework organs, 32
Frenulum, 543
Frontal artery, 403
  bone, 169
  gyri, 514
  lobe, 511, 513
  nerve, 576
  sinuses, 666
  veins, 459, 463
Frontalis muscle, 348
Fronto-nasal process, 86
Fundus of uterus, 830
Fungiform papillæ, 661
Furrow, spinal, 124

G.

Galactophorous ducts, 844
Galen, veins of, 456, 468
Gall-bladder, 746
  fissure, 742
Ganglia of the hemisphere, 522
  of nerves, 65
  sporadic, of fifth nerve, 576
Gangliated cord, lumbar portion of, 646
    thoracic portion of, 644
Ganglion, aortico-renal, 649
  cervical, inferior, 644
    middle, 644
    superior, 642
  ciliary, 577
  Gasserian, 574
  geniculate, 585
  impar, 648
  jugular, 591
  lenticular, 577
  mesenteric, superior, 649
  ophthalmic, 577
  otic, 584
  petrous, 591
  semilunar, 574
    of sympathetic, 649
  spiral, 674
  submandibular, 583
  submaxillary, 583
Gärtner, canals of, 835
    development of, 100
Gasserian ganglion, 574
Gastric artery, 427
    short, 429
  veins, 479
Gastrocnemius muscle, 309
Gastro-colic omentum, 751
  -duodenalis artery, 428
  -epiploïca dextra artery, 428
    sinistra artery, 429
Gelatinous tissues, 50
Gemellus muscle, inferior, 301
    superior, 298
Generation, organs of, 801
    female, 822
    male, 801
Geniculata, corpora, 533
Geniculate ganglion, 585
Genioglossus, 709
Genio-hyoideus muscle, 339
Genito-crural nerve, 624
Genu of callosum, 518
Germinal epithelium, 825
  spot, 826
  vesicle, 826
Gimbernat's ligament, 332
Gingivæ, 707
Giraldès, organ of, 807, 835
    development of, 101
Gladiolus, 126
Gland or glands, 75
  agminated, 724
  of Bartholin, 841
  of Blandin, 734
  of Bowman, 667
  of Brunner, 723
  buccal, 699
  bulbo-urethral, 820
  carotid, 800
  ceruminous, 678
  coccygeal, 800
  of Cowper, 820
  ductless, 793
  duodenal, 723
  intestinal, 720
  labial, 699
  lachrymal, 694
    development of, 108
  mammary, 843
  Meibomian, 692
  molar, 699
  palatine, 700
  parotid, 735
  periurethral, 841
  pineal, 535
  pituitary, 534
  prostate, 818
  salivary, 734
    development of, 86, 87
  sebaceous, 658
  solitary, 720
  sublingual, 736
  submaxillary, 735
  suburethral, 820
  sweat, 659
  thyroid, 796
  urethral, 841
  vulvo-vaginal, 841
  of Weber, 734
Glandulæ odoriferæ, 815
  Pacchionii, 561
  vestibulares majores, 841
    minores, 841
Glandular artery, 397
  epithelium, 44
Glans penis, 814
Glaser, fissure of, 172
Glisson, capsule of, 744
Globus major, 802
  minor, 802
  pallidus, 525
Glossopharyngeal nerve, 591
Glottis, chink of, 767, 775
Gluteal artery, 437
  lines, 147
  lymph-nodes, 494
  nerve, inferior, 629
    superior, 629
  veins, 480
Gluteus maximus muscle, 291
  medius muscle, 292
  minimus muscle, 292

Goblet cells, 44
Goll, tract of, 556
Gowers, tract of, 555
Graafian follicles, 824
Gracilis muscle, 297
Gray commissure, basal, 535
of spinal cord, 554
matter of spinal cord, 553
Great deep petrosal nerve, 580
occipital nerve, 602
omentum, 751
sciatic nerve, 631
splanchnic nerve, 645
superficial petrosal nerve, 580, 587
Groove, lateral, of mesencephalon, 539
vertebral, 124
Gross anatomy, 18
of lungs, 762
features of kidney, 781
Gubernaculum, 102
testis, 802
Gullet, 712
Gums, 707
Gustatory organs, development of, 106
Gyri, frontal, 514
limbic, 516
occipital, 516
operti, 512
parietal, 515
temporal, 516
Gyrus, angular, 516
dentate, 517
hippocampal, 516
marginal, 515
paracentral, 515
postcentral, 516
precentral, 515
subcalcarine, 516
subcollateral, 516
superior parietal, 516
supramarginal, 516
uncinate, 517

H.

Hair follicle, 657
papilla, 658
Hairs, 656
Hand, back of, dissection of, 887
bones of, 140
fascia of, 356
muscles moving whole, 269
phalanges of, 144
Hard palate, 699
Haustrum, 726
Haversian system, 53
Head, articulations of, 205
fascia of, 350
lymph-nodes of, 489
muscles of, 341
and neck, dissection of, 890
veins of, 457
Heart, 365
apex of, 373
auricle of left, 367
development of, 93
external configuration of, 371
grooves of, 371
infundibulum of, 368
surfaces of, 371
thickness of walls of, 367
tissues of, 366
Heart, veins of, 455
Helicine arteries, 817
Helicotrema, 674
Helix, 678
fossa of, 678
Hemispheres of cerebellum, 542
Hemorrhoidal artery, inferior, 436
middle, 434
superior, 431
nerve, inferior, 631
plexus, 480, 648
Henle, cremaster of, 812
layer of, 657
Hepatic artery, 427, 735
cells, 740
duct, 746
flexure, 729
veins, 740
Hepato-duodenal ligament, 750
Herophilus, torcular of, 166, 464
Hiatus semilunaris, 666
Highmore, antrum of, 183
Hilum of kidney, 782
of liver, 742
of lung, 763
Hip, back of, dissection of, 890
-bone, 146
fascia of, 362
-joint, 230
Hippocampal gyrus, 516
Hippocampus major, 529
minor, 528
Histology, 19
Homologies of bones of the limbs, 164
Horn of lateral ventricle, middle, 528
posterior, 528
Horny layer, 653
Huguier, arterial circle of, 834
Humerus, the, 135
Humor, aqueous, 689
vitreous, 689
Hunter, canal of, 440
Huxley, layer of, 657
Hyaline cartilage, 51
Hyaloid membrane, 689
Hyaloplasm, 38
Hydatid of Morgagni, 806, 835
development of, 100
Hymen, 840
Hyoglossus, 709
Hyoid artery, 395, 396
bone, 189
Hypogastric plexus, 647
Hypoglossal area, 551
nerve, 597
Hypophysis, 534

I.

Ideal lobe of kidney, 778
Ileo-cæcal valve, 727
-colic valve, 727
artery, 430
Iliac artery, common, 432
deep circumflex, 439
external, 438
internal, 433
superficial circumflex, 443
fascia, 360
lymph-nodes, external, 497
internal, 497
Iliac veins, common, left, 476
right, 476
external, 477
internal, 479
superficial circumflex, 481
Iliacus muscle, 291
Ilio-costalis muscle, 327
Iliohypogastric nerve, 623
Ilio-inguinal nerve, 624
-lumbar artery, 437
veins, 476
-psoas muscle, 291
-tibial band, 362
Ilium, 146
Incisor teeth, 702
Incus, 676
Inferior cervical ganglion, 644
dental nerve, 582
fovea, 551
gluteal nerve, 629
hemorrhoidal nerve, 631
laryngeal nerve, 594
maxillary division of fifth nerve, 580
mesenteric plexus, 647
palpebral nerve, 579
petrosal sinus, 461
pudendal nerve, 630
vena cava, 474
vermis, 543
Infracostales muscles, 336
Inframandibular nerve, 588
Infraorbital artery, 401
nerve, 579
of seventh, 588
Infraspinatus muscle, 261
Infraspinous fascia, 355
Infratrochlear nerve, 576
Infundibula of ureter, 784
Infundibuliform fascia, 360, 811
Infundibulum of brain, 534
of heart, 368
of lung, 759
of nose, 666
Inguinal ligament, 332
lymph-nodes, deep, 494
superficial, 493
Innominate veins, 457
Insula, 511, 513
development of, 106
Intercavernous sinus, 466
Interclavicular notch, 127
Intercolumnar fascia, 810
Intercostal artery, 425
anterior, 409
superior, 411
fascia, 354
external, 354
internal, 354
lymph-nodes, 495
nerves, 619
veins, 472
superior, 471
Intercostales externi muscle, 336
interni muscle, 336
Interdeferential triangle, 808
Interlabial space, 839
Interlobular veins, 740
Internal anterior thoracic nerve, 608
capsule, 537
cutaneous nerve, 612
of anterior crural, 625
of musculo-spiral, 615
laryngeal nerve, 594

Internal medullary lamina, 525
os, 829, 831
plantar nerve, 634
popliteal nerve, 632
saphenous nerve, 625
secretion, organs of, 32
spermatic fascia, 811
sphincter, 734
of urethra, 788, 792
structure of oblongata, 547
Interossei dorsales pedis, 322
manus, 278
palmares, 280
plantares, 323
volares muscle, 280
Interosseous artery, anterior, 418
posterior, 418
of radial, 422
of ulnar, 418
membrane, 238
nerve, anterior, 610
posterior, 616
Interpeduncular space, 534
Interspinales muscles, 330
Intertransversales muscles, 330
Interventricular vein, posterior, 456
Intestinal artery, 430
glands, 720
Intestine, large, 724
tunics of, 725
small, 717
tunics of, 718
Intestines, development of, 88
Intestinum tenue, 717
Intralobular veins, 740
Intraparietal fissure, 515
Intraspinal veins, 472
Introitus vaginæ, 840
Iris, 685
Ischio-cavernosus muscle, 821, 842
-rectal fossa, 361
Ischium, 148
Island of Reil, 511
Islands, blood, 83
substance, 83
Isthmus cerebri, 538
of fauces, 700
of thyroid, 796

J.

Jacobson, nerve of, 591
organ of, 666, 667
Jejuno-ileum, 723
Jelly, Whartonian, 83
Joint, elbow-, 221
kinds of, 204
shoulder-, 218
Jugular ganglion, 591
nerve, 643
sinus, 461
veins, anterior, 460
external, 460
posterior, 460
posterior external, 460
internal, 461
Juice canals, 484
channels, 484

K.

Karyokinesis, 39
Kidneys, 777
Kidneys, gross features of, 781
hilum of, 782
labyrinth of, 780
lobes of, 778
sinus of, 781
situation of, 784
vessels of, 780
Knee-joint, 233
Krause, membrane of, 60

L.

Labia majora, 838
development of, 103
minora, 839
development of, 103
Labial artery, inferior, 397
glands, 699
nerve, superior, 579
Labyrinth of ear, 668
of kidney, 780
membranous, 668
Lachrymal artery, 402
bone, 186
canal, 692
duct, development of, 108
gland, 694
development of, 108
nerve, 576
sac, 692
Lactiferous ducts, 844
Lacuna magna, 792
Lacunæ of urethra, 791
Lacunar ligament, 332
Lamina cinerea, 535
cribrosa, 682
external medullary, 525
internal medullary, 525
quadrigemina, 539
reticular, 672
spiralis, 673
terminalis, 535
vitreous, 684
Lanugo, 656
Large intestine, 724
tunics of, 725
Laryngeal artery, inferior, 410
superior, 395
nerve, external, 594
inferior, 594
recurrent, 594
superior, 594
pouch, 773
Laryngo-pharynx, 710
Larynx, 767
cartilages of, 768
ligaments of, 769
lining of, 773
muscles of, 771
ventricle of, 773
Lateral column of oblongata, 545
groove of mesencephalon, 539
ligaments of liver, 745
nasal nerve, 579
sinus, 464
tract of oblongata, 545
ventricle, horn of, middle, 528
posterior, 528
Latissimus muscle, 261
Layer of Henle, 657
horny, 653
of Huxley, 657
Malpighian, 652
Least splanchnic nerve, 646
Left lobe of liver, 742
Leg, back of, dissection of, 890
fascia of, 362
front of, dissection of, 889
muscles moving, 301
outer side of, dissection of, 889
Lemniscus, 539, 550
Lens, 689
suspensory ligament of, 689
Lenticular ganglion, 577
nucleus, 525
Leucocytes, 57
Levator anguli oris, 346
ani muscle, 821, 842
labii inferioris, 346
superioris alæque nasi, 346
proprius, 346
palati, 701
palpebræ superioris, 691
proprius alæ nasi anterior, 347
posterior, 347
scapulæ, 254
Levatores costarum muscle, 336
Lieberkühn, crypts of, 720
Lienculi, 795
Lieno-pancreatic ligament, 750
-renal ligament, 750
Ligament or ligaments, annular, of ankle, anterior, 363
external, 363
internal, 363
of axilla, suspensory, 354
of bladder, false, 787
true, 361
of carpus, anterior, 356
costo-colic, 750
-coracoid, 354
of forearm, posterior, 356
Gimbernat's, 332
hepato-duodenal, 750
inguinal, 332
lacunar, 332
of larynx, 769
of lens, suspensory, 689
lieno-pancreatic, 750
-renal, 750
of liver, coronary, 745
falciform, 745
lateral, 745
round, 745
suspensory, 745
lumbo-ovarian, 824
palpebral, 693
peritoneal, 750
phreno-colic, 750
-splenic, 794
Poupart's, 332
round, development of, 100
of scapula, 218
scrotal, 801
spiral, 674
stylo-mandibular, 350, 352
superficial transverse, 357
suspensory of ovary, 824
of penis, 816
tubo-ovarian, 824
uniting neural arches, 207
of urethra, triangular, 361
utero-ovarian, 823
of uterus, anterior, 832
broad, 832
recto-vaginal, 832
round, 832
utero-sacral, 832

Ligament or ligaments, vaginal, of hand, 357
of Zinn, 690
Ligamentum denticulatum, 562
infundibulo - pelvicum, 824, 832
pectinatum iridis, 682
Ligula, 547
Limb, lower, articulations of, 230
bones of, 146
upper, articulations of, 216
bones of, 131
classification of muscles of, 252
movements of, 251
Limbic gyri, 516
lobe, 513
Limbus, 674
Line, white, 361
Lines, gluteal, 147
Lingua, 707
Lingual artery, 395
dorsal, 396
lymph-nodes, 492
nerve of ninth, 591
of seventh, 587
of vagus, 597
Lingualis, 708
Lingula, cerebellar, 543
Lining of the larynx, 773
Lips, 699
Liquid tissues, 57
Liquor folliculi, 824
Liver, 738
borders of, 744
broad ligament of, 745
development of, 90
extremities, 744
form of, 740
hilum of, 742
lobule of, 738
relations of, 747
situation of, 747
size of, 747
surfaces of, 741
tunics of, 744
vessels of, 739, 745
weight of, 747
Lobe or lobes, central, 511
digastric, 544
on external cerebral surface, 511
falciform, 513
frontal, 511, 513
of kidney, 778
ideal, 778
limbic, 513
of liver, caudate, 743
left, 742
quadrate, 742
right, 742
Spigelian, 743
of mesial and tentorial surfaces, 512
occipital, 511, 513
parietal, 511, 513
slender, 544
temporal, 511, 513
Lobule of ear, 678
of liver, 738
Loculi, 804
Locus ceruleus, 540, 551
lachrymalis, 692
niger, 539
Long buccal nerve, 582
Long saphenous nerve, 625
Longissimus dorsi muscle, 329
Longitudinal fissure of cerebrum, 510
sinus, inferior, 464
superior, 463
Longus colli muscle, 341
Lubbe, veins of, 468
Lumbar artery, 431
enlargement of spinal cord, 553
fascia, 358
lymph-nodes, lateral, 497
median, 497
nerves, 622
plexus, 622
portion of gangliated cord, 646
veins, 475
ascending, 476
Lumbo-ovarian ligament, 824
Lumbricales manus, 276
pedis, 318
Lungs, blood-vessels of, 762
broad ligament of, 767
development of, 88
gross anatomy of, 762
hilum of, 763
infundibulum of, 759
minute anatomy of, 759
Lunula, 656
Lymph, 57
Lymphadenoid structures, 487
tissue, 487
diffuse, 487
Lymphatic duct, left, 487
right, 487
system, 484
vessels, development of, 98
Lymph-chambers, 485
Lymph-node or lymph-nodes, 487
of abdomen, 497
anterior mediastinal, 495
axillary proper, 492
bronchial, 495
buccal, 490
cervical, deep, 489
superficial, 490
cœliac, 497
deep cervical, 489
inguinal, 494
epicondylar, 493
external iliac, 497
gluteal, 494
of head and neck, 489
iliac, external, 497
internal, 497
inguinal, deep, 494
superficial, 493
intercostal, 495
internal iliac, 497
maxillary, 492
lateral lumbar, 497
lingual, 492
of the lower limb, 493
lumbar, lateral, 497
median, 497
mastoid, 490
maxillary, internal, 492
median lumbar, 497
mediastinal, anterior, 495
posterior, 495
superior, 495
mesenteric, 497
mesocolic, 497
Lymph-node or lymph-nodes, parotid, 492
pectoral, 493
popliteal, 494
posterior mediastinal, 495
postpharyngeal, 492
rectal, 497
sacral, 497
sternal, 495
subclavian, 493
submaxillary, 490
suboccipital, 490
subscapular, 493
superficial cervical, 490
inguinal, 493
superior mediastinal, 495
suprahyoid, 490
of thorax, 495
of upper limb, 492
vena-caval, 497
Lymph-nodules, aggregated, 724
solitary, 720
Lymph-vessels, 484
deep, 486
structure of, 485
superficial, 485
Lyra, 521

M.

Macroscopic anatomy, 18
Macula acustica, 668, 669
folliculi, 826
lutea, 687
Magendie, foramen of, 505, 547
Magnum, os, 143
Malar bone, 186
of seventh nerve, 588
Male perineum, dissection of, 888
muscles of, 820
Malleus, 676
Malpighian body of kidney, 780
corpuscles, 794
layer, 653
Mammæ, 843
supernumerary, 845
Mammary artery, internal, 409
glands, 843
veins, internal, 470
Mandible, 187
Mandibular division of fifth nerve, 580
process, 86
region, dissection of, 892
Manubrium, 126
Marginal gyrus, 515
veins, left, 456
right, 456
Marrow, 53, 55
-cavity, 52
Marshall, veins of, 455
Masseter muscle, 342
internal, 342
Masseteric artery, 401
fascia, 350
nerve, 581
veins, 459
Mastication, muscles of, 342
Mastoid antrum, 675
cells, 675
lymph-nodes, 490
Matrix of nail, 656
Maxilla, 181
Maxillary antrum, 666
artery, internal, 399

Maxillary division of fifth nerve, 577
inferior, 580
lymph-nodes, internal, 492
process, 86
veins, anterior internal, 459
internal, 460
Meatus, external auditory, 677
inferior, 664
middle, 664
superior, 665
urinarius externus, 814
female, 839
internus, 786
Meckel, cartilage of, 92
Median nerve, 608
veins, basilic, 469
cephalic, 469
Mediastinal artery, 409
posterior, 425
lymph-nodes, anterior, 495
posterior, 495
superior, 495
Mediastinum testis, 804
Medical anatomy, 18
Medulla oblongata, 545
Medullary lamina, external, 525
internal, 525
velum, posterior, 546
Meibomian glands, 692
Membrana granulosa, 824
suprachoroidea, 684
tympani, 675
Membrane or membranes, 65
basement, 41
basilar, 670
of the brain, 558
of cerebro-spinal axis, 557
costo-coracoid, 354
cutaneous, 74
of Descemet, 682
fibro-serous, 67
hyaloid, 689
interosseous, 238
of Krause, 60
lining cavity of cerebro-spinal axis, 69
cavities in sustentacular tissues, 69
vascular system, 68
mucous, 71
gastro-pulmonary, 71
genito-urinary, 72
pituitary, 666
of Reissner, 670
Schneiderian, 666
serous, 66
proper, 68
of spinal cord, 561
synovial, 69
articular, 70
bursal, 70
vaginal, 70
tectorial, 672
typical, 66
vitelline, 825
Membranous labyrinth, 668
Meningeal artery, 398
anterior, 402
middle, 400
posterior, 407
small, 400
nerve of ninth, 591
of tenth, 597
Meningo-rachidian veins, 472
Mesencephalon, 538
aqueduct of, 539
lateral groove of, 539
nates of, 539
testes of, 539
Mesenchyme, 91
Mesenteric artery, inferior, 430
superior, 429
lymph-nodes, 497
plexus, inferior, 647
superior, 647
veins, inferior, 479
superior, 479
Mesenteries, 748
development of, 88
Mesentery, 718
Mesial surface, 512
Mesocolic lymph-nodes, 497
Mesoderm, 81
organs derived from, 91
Mesodermal somites, 82
Mesonephros, 99
Mesorchium, 802
Mesothelium, 91
Metacarpal bones, 144
Metanephros, 99
Metapore, 547
Metasternum, 126
Metatarsal artery, 453
Metatarsus, bones of, 161
Metatela, 546
Metencephalon, development of, 104
Methods of study, 33
Microscopic anatomy, 18
Mid-brain, 538
Middle cervical ganglion, 644
commissure, 533
cutaneous nerve of anterior crural, 624
ear, 674
horn of lateral ventricle, 528
spermatic fascia, 811
superior dental nerve, 578
Migration of testicle, 802
Milk-teeth, 703
Minute anatomy, 18
of the lungs, 759
Mitral valves, 369
Moderator band, 369
Modiolus, 673
Molar glands, 699
teeth, 703
Monro, foramen of, 531
sulcus of, 533
Mons Veneris, 838
Monticulus, 542
Morgagni, hydatid of, 806, 835
development of, 100
Morphological anatomy, 20
Morphology of skull, 199
of vertebræ, serial, 125
Morula, 79
Motion, organs of, 32
Mouth, 698
Movement, kinds of, in joints, 205
amœboid, 38
Mucus, 73
Mucous membranes, 71
gastro-pulmonary, 71
genito-urinary, 72
Müllerian duct, 99
Multifidus muscle, 330
Muscle or muscles, of the abdomen, 331
Muscle or muscles, abductor hallucis, 321
longus pollicis, 282
minimi digiti, 279
pedis, 321
pollicis, 284
accessorius ad ilio-costalem, 329
accelerator urinæ, 821
adductor brevis, 297
gracilis, 297
longus, 294
magnus, 294
obliquus hallucis, 322
pollicis, 284
transversus hallucis, 322
affecting the orifice of the mouth, 344
anconeus, 266
articularis genu, 308
of back, 325
biceps flexor cruris, 301
cubiti, 263
biventer cervicis, 330
brachialis, 264
brachio-radialis, 265
buccinator, 346
bulbo-cavernosus, 821, 842
cervicalis ascendens, 329
ciliary, 684
classification of, 250
coccygeus, 821
-column, 61
complexus, 329
compressor naris, 347
narium minor, 347
urethræ, 822
vaginæ, 842
constrictor urethræ, 822, 842
coraco-brachialis, 260
-corpuscles, 61
corrugator supercilii, 347
cucullaris, 253
deep transverse, 822
deltoideus, 258
depressor alæ nasi, 347
anguli oris, 346
labii inferioris, 346
diaphragma, 334
digastricus, 338
dilatator naris anterior, 347
posterior, 347
of dorsum of neck, 325
ejaculator seminis, 821
urinæ, 821
erector spinæ, 327
of expression, 343
extensor brevis digitorum, 319
pollicis, 282
carpi radialis brevis, 270
longus, 269
ulnaris, 270
communis digitorum, 277
indicis, 278
longus digitorum, 319
hallucis, 319
pollicis, 282
minimi digiti, 278
ossis metacarpi pollicis, 282
primi internodii pollicis, 282
proprius hallucis, 319
secundi internodii pollicis, 282
penis, 821

Muscle or muscles, of eyeball, 690
of female perineum, 820, 842
in fifth group of back, 329
flexor accessorius, 317
brevis digitorum, 317
hallucis, 317
minimi digiti, 275
pedis, 317
pollicis, 282
carpi radialis, 269
ulnaris, 269
longus digitorum, 317
hallucis, 316
pollicis, 282
ossis metacarpi minimi digiti, 275
pollicis, 281
perforans, 274
perforatus, 273
digitorum pedis, 317
profundus digitorum, 274
sublimis digitorum, 273
of forehead, 347
in fourth layer of back, 327
of front and side of neck, 337
frontalis, 348
gastrocnemius, 309
gemellus inferior, 301
superior, 298
general considerations, 245
genio-hyoideus, 339
gluteus maximus, 291
medius, 292
minimus, 292
gracilis, 297
of head, 341
iliacus, 291
ilio-costalis, 327
ilio-psoas, 291
infracostales, 336
infraspinatus, 261
intercostales externi, 336
interni, 336
interossei dorsales manus, 278
pedis, 322
palmares, 280
plantares, 323
volares, 280
interspinales, 330
intertransversales, 330
ischio-cavernosus, 821, 842
of larynx, 771
latissimus, 261
levator anguli oris, 346
ani, 821, 842
labii alæque nasi, 346
inferioris, 346
superioris proprius, 346
proprius alæ nasi anterior, 347
posterior, 347
scapulæ, 254
levatores costarum, 336
longissimus dorsi, 329
longus colli, 341
of lower limb, 287
classification of, 288
lumbricales manus, 276
pedis, 318
masseter, 342
internal, 342
of mastication, 342
moving arm, 258
digits of foot, 316
fifth metacarpal bone, 272
Muscle or muscles, moving fingers, 272
outer part of forearm, 266
the leg 301
shoulder, 253
thigh, 289
thumb, 280
whole foot, 308
forearm, 263
hand, 269
multifidus, 330
mylo-hyoideus, 338
of neck, 336
nomenclature of, 248
of nose, 347
obliquus capitis inferior, 331
superior, 331
externus abdominis, 332
internus abdominis, 332
obturator externus 298
internus, 299
occipitalis, 348
occipito-frontalis, 348
omo-hyoideus, 337
opponens minimi digiti, 275
pollicis, 281
orbicularis oris, 345
palmaris brevis, 285
longus, 269
papillary, 368
pectineus, 297
pectoralis major, 260
minor, 256
peroneus brevis, 316
longus, 316
tertius, 308
of pharynx, 711
of pinna, 678
plantaris, 314
platysma, 337
popliteus, 302
pronator quadratus, 267
teres, 267
psoas magnus, 290
parvus, 323
pterygoideus externus, 342
internus, 342
pyramidalis, 332
nasi, 347
pyriformis, 298
quadratus femoris, 298
lumborum, 334
plantæ, 317
quadriceps extensor cruris, 303
rectus abdominis, 331
capitis anterior major, 340
minor, 340
lateralis, 340
posterior major, 330
minor, 331
femoris, 304
rhomboideus major, 255
minor, 255
risorius, 346
rotatores, 330
sacro-lumbalis, 329
sartorius, 301
scalenus anterior, 339
medius, 339
posterior, 340
semimembranosus, 301
semispinalis capitis, 329
cervicis, 330
dorsi, 330
semitendinosus, 301
Muscle or muscles, serratus magnus, 256
posterior inferior, 326
superior, 325
of soft palate, 701
soleus, 313
sphincter ani externus, 821
vaginæ, 842
spinalis dorsi, 329
splenius capitis, 326
cervicis, 327
colli, 327
sterno-cleido-mastoideus, 337
-hyoideus, 337
-thyroideus, 337
stylo-hyoideus, 338
subclavius, 257
subcostales, 336
suboccipital, 330
subscapularis, 263
superficial, of head, 342
supinator, 268
supraspinatus, 266
suspensory, 723
temporalis, 342
tensor fasciæ latæ, 292
vaginæ femoris, 292
teres major, 261
minor, 261
in third layer of back, 325
of thorax, 334
thyro-hyoideus, 338
tibialis anterior, 308
posterior, 308
trachelo-mastoideus, 329
transversalis abdominis, 333
cervicis, 329
transversus pedis, 322
perinei, 821, 842
thoracis anterior, 336
trapezius, 253
triangularis sterni, 336
triceps extensor cubiti, 265
suræ, 314
of trunk, 325
of tympanum, 677
of upper limb, 251
vastus externus, 307
intermedius, 307
internus, 307
lateralis, 307
medialis, 307
vesico-pubic, 361, 787
zygomaticus major, 346
minor, 346
Muscular system, development of, 98
tissue, cardiac, 61
cross-striped, 57
plain, 58
Musculi pectinati, 368
Musculo-cutaneous nerve, 608
of leg, 637
-phrenic artery, 409
-spiral nerve, 614
Myelon, 499
Mylo-hyoideus muscle, 308
Myocardium, the, 367

N.

Naboth, ovula of, 833
Nails, 656
matrix of, 656
Nares, anterior, 663
posterior, 663

Nasal artery, 402
lateral, 397
bone, 185
cartilages, 664
cavity, 663
duct, 666, 694
fossæ, 664
cavities opening into, 666
nerve, 576
lateral, 579
superior, 580
veins, transverse, 459
Nasopalatine nerve, 580
Naso-pharynx, 710
Nates of mesencephalon, 539
Navicular bone, 160
fossa, 840
Neck, back of, dissection of, 891
deep dissection of, 892
dorsum of, muscles of, 325
and head, dissection of, 890
lymph-nodes of, 489
muscles of, 336
side of, dissection of, 891
sympathetic nerves in, 642
triangles of, 411
veins of, 457
Nerve or nerves, 563
abdominal, 596
abducent, 585
accessory obturator, 626
afferent, 65
anterior crural, 624
interosseous, 610
palatine, 580
superior dental, 578
tibial, 637
of Arnold, 594
auditory, 589, 674
distribution in labyrinth, 672
auricular, great, 604
posterior, 587
of tenth, 594
auriculo-temporal, 582
of Bell, 607
buccal, 588
long, 582
calcaneo-plantar, 634
cardiac, 643, 644
cervical, 595
thoracic, 595
cerebro-spinal, 563
typical, 563
cervical, 603
cardiac, 595
superficial, 605
chorda tympani, 587
ciliary, 686
short, 577
circumflex, 613
coccygeal, 627, 639
communicans hypoglossi, 597
cranial, 565
deep origins, 566
superficial origins, 565
crural, anterior, 624
cutaneous, external, 624
of musculo-spiral, 615
internal, 612
of anterior crural, 625
of musculo-spiral, 615
middle of anterior crural, 624
perforating, 630
Nerve or nerves, cutaneous, small internal, 612
deep temporal, 581
dental, anterior superior, 578
inferior, 582
middle superior, 578
posterior superior, 578
descendens hypoglossi, 597
digital, of foot, 635
dorsal, of penis, 631
efferent, 65
eighth, 589
eleventh, 596
nuclei of, 590
external anterior thoracic, 608
cutaneous, 624
of musculo-spiral, 615
laryngeal, 594
palatine, 580
plantar, 635
popliteal, 636
pterygoid, 582
respiratory, 607
superficial petrosal, 587
facial, 585
fibular, 634
fifth, 574
mandibular division of, 580
maxillary division of, 577
inferior, 580
sacral, 639
sporadic ganglia of, 576
first, 567
cervical dorsal, primary division of, 602
fourth, 574
sacral, 638
frontal, 576
ganglia of, 65
genito-crural, 624
glosso-pharyngeal, 591
gluteal, inferior, 629
superior, 629
great auricular, 604
deep petrosal, 580
occipital, 602
sciatic, 631
splanchnic, 645
superficial petrosal, 580, 587
hemorrhoidal, inferior, 631
hypoglossal, 596
iliohypogastric, 623
ilioinguinal, 624
inferior dental, 582
gluteal, 629
hemorrhoidal, 631
laryngeal, 594
palpebral, 579
pudendal, 630
inframandibular, 588
infraorbital, 579
of seventh, 588
infratrochlear, 576
intercostal, 619
internal anterior thoracic, 608
cutaneous, 612
of anterior crural, 625
of musculo-spiral, 615
laryngeal, 594
plantar, 634
popliteal, 632
pterygoid process, 581
saphenous, 625
interosseous, anterior, 610
Nerve or nerves, interosseous, posterior, 616
of Jacobson, 591
jugular, 643
labial, superior, 579
lachrymal, 576
laryngeal, internal, 594
superior, 594
lateral nasal, 579
least splanchnic, 646
lingual, 583
of ninth, 591
of seventh, 587
of vagus, 597
long buccal, 582
saphenous, 625
lumbar, 622
malar, of seventh, 588
masseteric, 581
median, 608
external terminal division, 611
internal terminal division, 612
meningeal, of ninth, 591
of tenth, 597
middle cutaneous, of anterior crural, 624
superior dental, 578
musculo-cutaneous, 608
of leg, 637
-spiral, 614
nasal, 576
lateral, 579
superior, 580
nasopalatine, 580
ninth, 591
nuclei of, 590
obturator, 626
accessory, 626
occipital, great, 602
small, 604
third, 603
oculo-motor, 571
œsophageal, 596
olfactory, 567
optic, 568
palatine, anterior, 580
external, 580
posterior, 580
palmar, cutaneous, of median, 611
of ulnar, 612
palpebral, inferior, 579
patellar, 626
perforating cutaneous, 630
perineal, 631
peroneal, 636
petrosal, external superficial, 587
great deep, 580
superficial, 580, 587
small deep, 591
superficial, 587
pharyngeal, of ninth, 591
of sympathetic, 643
of tenth, 594
of Vidian, 580
phrenic, 605
plantar, external, 635
internal, 634
pneumogastric, 592
popliteal, external, 636
internal, 632
posterior auricular, 587

Nerve or nerves, posterior interosseous, 616
palatine, 580
superior dental, 578
thoracic, 607
tibial, 633
pterygoid, external, 582
pudendal, inferior, 630
pudic, 631
pulmonary, 595
radial, 616
recurrent laryngeal, 594
respiratory, external, 607
rhomboid, 606
-roots, spinal, 557
sacral, 627
fifth, 639
fourth, 638
sciatic, great, 631
small, 629
second, 568
seventh, 585
branches of, below base of skull, 587
in petrous bone, 587
cervicofacial division of, 588
pars intermedia of, 585
temporofacial division of, 588
short ciliary, 577
sixth, 585
of skin, 653
small deep petrosal, 591
internal cutaneous, 612
occipital, 604
sciatic, 629
splanchnic, 646
superficial petrosal, 587
spheno-palatine, 578
spinal, 598
accessory, 596
anterior, primary divisions of, 603
dorsal, primary divisions of, 601
mode of distribution of, 600
splanchnic, great, 645
least, 646
small, 646
subclavius, 607
suboccipital, 602
subscapular, 608
superficial cervical, 605
temporal, 582
superior gluteal, 629
labial, 579
laryngeal, 594
nasal, 580
supramandibular, 588
suprascapular, 607
supratrochlear, 576
sympathetic, 639
in the neck, 642
temporal, deep, 581
of seventh, 588
superficial, 582
temporo-malar, 578
tenth, 592
nuclei of, 590
third, 571
occipital, 603
thoracic, 619
cardiac, 595
external anterior, 608
internal anterior, 608
Nerve or nerves, thoracic, posterior, 607
twelfth, 621
tibial, anterior, 637
posterior, 633
tonsillar, of ninth, 591
trifacial, 574
trochlear, 574
twelfth, 596
thoracic, 621
tympanic, 591
ulnar, 612
vagus, 592
Vidian, 579
of Wrisberg, 612
Nervi nervorum, 64
vasorum, 375
Nervous system, development of, 103
tunic of eye, 686
Neural arch, 115
ligaments uniting, 207
Neurilemma, 63
Neuroblasts, 103
Neuro-epithelium, 43
Neuroglia, 50
development of, 103
Neuromeres, 104
Neuron, 62
Neuroplasm, 64
Ninth nerve, 591
nuclei of, 590
Nodes of Ranvier, 63
Nodule, cerebellar, 544
Nomenclature of muscles, 248
Normal anatomy, 20
skiagraphs, 870
Nose, 663
infundibulum of, 666
muscles of, 347
Nostrils, 663
Notch, interclavicular, 127
sacro-sciatic, great, 147
small, 148
Notochord, 81, 91
Nourishment, organs supplying, 31
Nuck, canal of, 803
Nuclei, accessory olivary, 547
arciform, 547
of cranial nerves, 569
Nucleolus, 38
Nucleus, 38
ambiguus, 548
amygdaloid, 526
caudate, 524
cuneatus, 547
dentate, 547
emboliformis, 544
fastigii, 544
globosus, 544
gracilis, 547
lenticular, 525
of olive, 547
red, 539
sensory, of oblongata, 548
Nymphæ, 839

O.

Obex, 547
Obliquus capitis, inferior, 331
superior, 331
externus abdominis, 332
internus abdominis, 332
Oblongata, 545
development of, 104
foramen cæcum of, 545
lateral column of, 545
tract of, 545
olive of, 546
sensory nucleus of, 548
Obturator artery, 434
external, 434
internal, 434
externus muscle, 298
fascia, 360
internus muscle, 299
foramen, 149
nerve, 626
accessory, 626
veins, 480
Occipital artery, 397
bone, 165
gyri, 516
lobe, 511, 513
nerve, great, 602
small, 604
third, 603
sinus, 465
veins, 460, 463
Occipitalis muscle, 348
Occipito-frontalis muscle, 348
Oculo-motor nerve, 571
Odontoblasts, 86
Œsophageal artery, 410, 425
nerves, 596
Œsophagus, 712
Olfactory bulb, 567
fissure, 515
nerve, 567
organs, development of, 106
tract, 567
Olivary nuclei, accessory, 547
Olive of oblongata, 546
Omenta, 749
Omentum, gastro-colic, 751
great, 751
Omo-hyoideus muscle, 337
Oögenesis, 78
Opening, auriculo-ventricular, left, 369
right, 367
saphenous, 362
Operculum, 512
Ophthalmic artery, 402
division of fifth nerve, 575
ganglion, 577
veins, common, 467
inferior, 467
superior, 467
Opponens minimi digiti, 275
pollicis muscle, 281
Optic chiasma, 568
commissure, 568
nerve, 568
tract, 568
Ora serrata, 687
Oral sinus, 86
Orbicularis oris muscle, 345
Orbits, 194
dissection of, 892
Organ or organs, auditory, development of, 108
of Corti, 671
development of, 109
derived from ectoderm, 103
from endoderm, 86
of digestion, 695
enamel, 86

Organ or organs, framework, 32
generative, 801
female, 822
male, 801
of Giraldès, 807, 835
development of, 101
gustatory, development of, 106
of internal secretion, 32
of Jacobson, 666, 667
of motion, 32
olfactory, development of, 106
of relation, 32
removing waste matters, 30
of reproduction, 33
of respiration, 755
physiological anatomy, 755
of Rosenmüller, 835
of special senses, 651
supplying nourishment, 31
systems of, 29
tactile, development of, 106
of taste, 662
Orifice, pyloric, 717
Oro-pharynx, 710
Os calcis, 159
external, 830, 831
internal, 829, 831
innominatum, 146
Magnum, 143
pubis, 149
Osseous labyrinth, 672
tissue, 52
cancellous, 53
spongy, 53
Ossicles of ear, 676
Ossicula auditus, 676
Ossification of sternum, 127
of vertebræ, 124
Ostium abdominale, 828
internum, 827
Otic ganglion, 584
Otoliths, 669
Ovarian artery, 431
fimbria, 824
plexus, 646
veins, 475
Ovaries, 822
development of, 99
Oviducts, 827
Ovula of Naboth, 833

P.

Pacchioni, glandules of, 561
Pacinian corpuscles, 655
Palate bone, 183
hard, 699
pillars of, 700
soft, 700
Palatine artery, ascending, 397
descending, 401
glands, 700
nerve, anterior, 580
external, 580
posterior, 580
Palatoglossus, 701
Palatopharyngeus, 701
Palatum durum, 699
molle, 700
Palm, dissection of, 886
Palmar arch, deep, 422
superficial, 420
artery of ulnar, deep, 420
cutaneous nerve of median, 611
Palmar cutaneous nerve of ulnar, 612
fascia, 356
Palmaris brevis muscle, 285
longus muscle, 269
Palpebræ, 691
Palpebral artery, 402
ligaments, 693
nerve, inferior, 579
veins, inferior, 459
Pampiniform plexus, 475, 806, 812
Pancreas, 736
development of, 91
Pancreatic artery, 429
duct, 737
Pancreatico-duodenalis artery, inferior, 430
superior, 428
Papilla, hair, 658
lachrymalis, 692
Papillæ, circumvallate, 660
filiform, 661
fungiform, 661
Papillary muscles, 368
Paracentral gyrus, 515
Paradidymis, 807
Parathyroids, 799
Parietal bones, 168
gyri, 515
lobe, 511, 513
Parieto-occipital fissure, 511
Paroöphoron, development of, 100
Parotid fascia, 350
gland, 735
lymph-nodes, 492
veins, 459, 460
Parovarium, 835
development of, 100
Pars ciliaris retinæ, 687
intermedia of seventh nerve, 585
iridica retinæ, 687
Patches of Peyer, 724
Patella, 154
Patellar nerve, 626
Pathological anatomy, 20
Paths, conduction, in spinal cord, 554
Pectineus muscle, 297
Pectoral fascia, 353
lymph-nodes, 493
Pectoralis major, 260
minor, 256
Peduncles of callosum, 520
cerebellar, 542, 544
cerebral, 538
Pelvic cavity of female, dissection of, 888
of male, dissection of, 888
fascia, 360
plexus, 648
Pelvis, 150
articulations of, 227
of ureter, 784
veins of, 479
Penis, 812
development of, 102
dorsal artery of, 436
nerve of, 631
veins of, 480
suspensory ligament of, 816
Perforated space, anterior, 525
Perforating artery, 409
Perforating artery, posterior, 449
of radial, 423
cutaneous nerve, 630
Pericardial artery, 425
Pericardium, 366, 373
Perimysium, 61
Perineal artery, superficial, 436
transverse, 436
nerves, 631
Perineum, development of, 102
fascia of, 361
female, dissection of, 889
male, dissection of, 888
Perineurium, 64
central point of, 820
muscles of female, 842
Periosteum, 52
Peritoneal ligaments, 750
Peritoneum, 748
Periurethral glands, 841
Peroneal artery, 447
nerve, 636
Peroneus brevis muscle, 316
longus muscle, 316
tertius muscle, 308
Pes anserinus, 588
hippocampi, 529
Petit, canal of, 689
Petrosal nerve, external superficial, 587
great deep, 580
superficial, 587
small deep, 591
superficial, 580, 587
sinus, inferior, 466
superior, 466
Petro-squamous sinus, 466
Petrous ganglion, 591
Peyer, patches of, 724
Phalanges of foot, 162
of hand, 144
ungual, 146
Pharyngeal artery, 398
ascending, 398
bursa, 710
nerve of ninth, 591
of sympathetic, 644
of tenth, 594
plexus, 461
tonsil, 710
Pharyngoglossus, 711
Pharynx, 710
muscles of, 711
Philosophic anatomy, 20
Phrenic artery, 431
superior, 409
nerve, 605
plexus, 646
Phreno-colic ligament, 750
-splenic ligament, 794
Physiological anatomy, 20
Pia mater, 500
of brain, 560
of spinal cord, 561
Pigmented epithelium, 43
Pillars of palate, 700
Pineal gland, 535
Pinna, 678
muscles of, 678
Pisiform bone, 143
Pituitary gland, 534
membrane, 666
Placenta, development of, 83, 85
Plain muscular tissue, 58
Plantar artery, external, 449

Plantar artery, internal, 449
fascia, 364
nerve, external, 635
Plantaris muscle, 314
Platysma muscle, 337
Pleuræ, 765
Plexus or plexuses, aortic, 647
basilar, 466
brachial, 606
cardiac, 648
carotid, 643
cavernous, 643
cervical, 603
choroid, 526
of fourth ventricle, 546
cœliac, 646
coronary, 649
diaphragmatic, 646
epigastric, 649
hemorrhoidal, 480, 648
hypogastric, 647
inferior mesenteric, 647
lumbar, 622
mesenteric, inferior, 647
superior, 647
ovarian, 480, 646
pampiniform, 475, 806, 812
patellæ, 626
pelvic, 648
pharyngeal, 461
phrenic, 646
prostatic, 480, 648
pterygoid, 460
renal, 646
sacral, 628
solar, 649
spermatic, 646
subsartorial, 627
superior mesenteric, 647
suprarenal, 646
uterine, 480, 648, 835
vaginal, 480, 648
vesical, 480, 648
Plica semilunaris, 694
sigmoidea, 726
recti, 733
Pneumogastric nerve, 592
Pomum Adami, 767
Pons, development of, 104
Varolii, 540
Popliteal artery, 443
lymph-nodes, 494
nerve, external, 636
internal, 632
space, 444
veins, 482
Popliteus muscle, 302
Porta, 535
Portal fissure, 742
system of veins, 477, 739
Porus opticus, 687
Postcentral gyrus, 516
Posterior auricular nerve, 587
brachium, 533
commissure, 535
forceps, 519
horns of lateral ventricle, 528
interosseous nerve, 616
medullary velum, 546
nares, 663
palatine nerve, 580
perforated space, 534
superior dental nerve, 578
thoracic nerve, 607
tibial nerve, 633
Post-pharyngeal lymph-nodes, 492
Pouch of Broca, 839
laryngeal, 773
recto-vesical, 787, 831
utero-vesical, 831
Poupart's ligament, 332
Precentral fissure, 514
gyrus, 515
Precuneal fissure, 513
Precuneus, 516
Prepuce, 815
Prevertebral artery, 398
fascia, 352
Prickle cells, 43
Primitive streak, 81
Primordial ova, 825
Princeps pollicis artery, 422
Process, ensiform, 126
falciform, 362
fronto-nasal, 86
mandibular, 86
maxillary, 86
xiphoid, 126
Processes, ciliary, 685
Processus reticularis, 553
vaginalis, 802, 812
Profunda artery, inferior, 416
superior, 416
Pronator quadratus, 267
teres, 267
Pronephros, 98
Prosencephalon, development of, 105
Prostate gland, 818
Prostatic plexus, 480, 648
Protoplasm, 38
Psoas magnus muscle, 290
parvus muscle, 323
Pterygo-maxillary fissure, 191
-palatine artery, 401
Pterygoid artery, 401
nerve, external, 582
plexus, 460
Pterygoideus externus, 342
internus, 342
Pubic artery, 439
Pudendal nerve, inferior, 630
Pudendum, 837
Pudic artery, deep external, 443
internal, 435
superficial external, 443
nerve, 631
veins, external, 481
internal, 480
Pulmonary arterial system, 379
nerves, 595
valve, 368
veins, 454
Pulvinar, 533
Punctum lachrymale, 692
Pupil, 685
Putamen, 525
Pyloric artery, 428
orifice, 717
veins, 479
Pylorus, 717
Pyramid, cerebellar, 544
decussation of, 545
dorsal, 546
of Ferrein, 780
of tympanum, 675
ventral, 545
Pyramidal bone of carpus, 141
Pyramidalis muscle, 332
nasi muscle, 347
Pyriformis fascia, 361
muscle, 298

Q.

Quadrate lobe of liver, 742
Quadratus femoris muscle, 298
lumborum muscle, 334
plantæ muscle, 317
Quadriceps extensor cruris, 303
Quadrigemina, development of, 105

R.

Radial artery, 421
nerve, 616
recurrent artery, 421
veins, 469
Radialis indicis artery, 422
Radius, 139
Ramus cervicalis descendens, 605
communicans peronei, 636
descendens hypoglossi, 597
Ranine artery, 396
veins, 461
Ranvier, nodes of, 63
Receptaculum chyli, 487
seminis, 827
Recess, spheno-ethmoidal, 665
Rectal ampulla, 733
lymph-nodes, 497
Recto-vaginal ligament, 832
-vesical fascia, 361
pouch, 787, 831
Rectum, 732
semilunar valves of, 734
Rectus abdominis muscle, 331
capitis anterior major, 340
minor, 340
lateralis, 340
posterior major, 330
minor, 331
femoris muscle, 304
Recurrent carpal artery, 423
laryngeal nerve, 594
Red nucleus, 539
Region of aqueduct, 538
subthalamic, 536
of third ventricle, 531
Regional anatomy, 18
Regions of abdomen, 714
Reil, island of, 511
Reissner, membrane of, 670
Relation of lobes to parts of lateral ventricle, 517
organs of, 32
Relational anatomy, 18
Renal artery, 431
plexus, 646
Reproduction, cell, 39
organs of, 33
Reproductive organs, development of, 98
Respiratory nerve, external, 607
Restiform body, 546
Restis, 546
Rete testis, 804
Reticula, 554
Reticular cartilage, 52
lamina, 672
Retina, 686

Retrahens aurem, 679
Rhinencephalon, development of, 106
Rhomboid nerve, 606
Rhomboideus major, 255
minor, 255
Ribs, 127
asternal, 127
development of, 92
false, 127
peculiar, 128
sternal, 127
true, 127
typical, 128
Right lobe of liver, 742
Rima glottidis, 775
pudendi, 839
Ring, external abdominal, 332
femoral, 360
internal abdominal, 360
Risorius muscle, 346
Rods of Corti, 671
Rolandic fissure, 510
Root of lung, 763
Rosenmüller, organ of, 835
Rostrum of callosum, 518
Rotatores muscles, 330
Round ligament, development of, 100
of liver, 745
ligaments of uterus, 832

S.

Sac, lachrymal, 692
Saccule, 669
Sacculus laryngis, 773
Saccus endolymphaticus, 669
Sacral artery, lateral, 437
lymph-nodes, 497
nerves, 627
fifth, 639
fourth, 638
plexus, 628
veins, lateral, 480
middle, 476
Sacro-sciatic notch, great, 147
small, 148
-lumbalis muscle, 329
Sacrum, 120
Salivary glands, 734
Sand, brain, 535
Saphenous opening, 362
veins, external, 481
internal, 481
long, 481
short, 481
Sarcolemma, 61
Sarcoplasm, 60
Sartorius muscle, 301
Scala media, 670
tympani, 674
vestibuli, 674
Scalenus muscle, anterior, 339
medius, 339
posterior, 340
Scaphoid bone of the carpus, 141
of tarsus, 160
Scapula, 133
ligaments of, 218
Scapular artery, posterior, 411
Scarpa, triangle of, 440
Schlemm, canal of, 683
Schneiderian membrane, 666
Sciatic artery, 436
nerve, great, 631
small, 629
Scleral sulcus, 682
Sclerotic, 682
Scrotal ligament, 801
Scrotum, 809
Sebaceous glands, 658
Second nerve, 568
Sella, diaphragm of, 559
Semicircular canals, 669
Semilunar, the, of the carpus, 141
valves of rectum, 734
Semimembranosus muscle, 301
Seminal vesicles, 808
Semispinalis capitis muscle, 329
cervicis muscle, 330
dorsi muscle, 330
Semitendinosus muscle, 301
Sensory epithelium, 43
Septa, intermuscular, of arm, external, 355
internal, 355
of leg, 363
of thigh, 362
Septum auricularum, 367
lucidum, 522
pectiniforme, 813
posterius, 562
transversum, 669
Serratus magnus, 256
posterior, inferior, 326
superior, 325
Sets of teeth, 703
Seventh nerve, 585
Sharpey, fibres of, 54
Sheaths, crural, 359
fascial, of tendons of hand, 357
femoral, 359
Shelf, dental, 86
Shield, embryonic, 80
Shoulder, fascia of, 354
-joint, 218
muscles moving, 253
Sigmoid artery, 431
colon, 730
sinus, 465
Simple epithelium, 44
Sinus or sinuses, basilar, 466
cavernous, 466
circular, 466
coronary, 455, 466
frontal, 666
inferior longitudinal, 464
petrosal, 466
intercavernous, 466
jugular, 461
of kidney, 781, 782
lateral, 464
longitudinal, superior, 463
inferior, 464
occipital, 465
oral, 86
petrosal, inferior, 466
superior, 466
petro-squamous, 466
pocularis, 790
development of, 101
of portal vein, 477
præcervicalis, 87
sigmoid, 465
spheno-parietal, 466
straight, 464
superior longitudinal, 463
Sinus or sinuses, superior petrosal, 466
transverse, 466
urogenital, 102
uterine, 835
of Valsalva, 368
venous, 455
of cranium, 463
Sixth nerve, 585
Skeleton, development of, 91
Skin, 651
nerves of, 654
true, 653
Skull, 164
base of, 197
development of, 92
exterior of, 190
externally, 192
facial region of, 194
morphology of, 199
sutures of, 190
temporal region of, 191
various forms of, 200
as a whole, 190
Slender lobe, 544
Small deep petrosal nerve, 591
internal cutaneous nerve, 612
intestine, 717
tunics of, 718
occipital nerve, 604
sciatic nerve, 629
splanchnic nerve, 646
superficial petrosal nerve, 587
Smegma preputii, 815
Soft palate, 700
muscles of, 701
Solar plexus, 649
Soleus muscle, 313
Solitary fasciculus, 548
glands, 720
lymph-nodules, 720
Somites, mesodermal, 82
Space, axillary, 415
epidural, 561
of Fontana, 683
interlabial, 839
interpeduncular, 534
perforated, anterior, 525
posterior, 534
popliteal, 444
sublingual, 708
Special senses, organs of, 651
Spermatic artery, 431
cord, 812
plexus, 646
veins, 475
Spermatids, 77
Spermatocytes, 77
Spermatogenesis, 77
Spermatogones, 77
Spermatozoa, 77
Sphenoid bone, 176
Sphenoidal antrum, 666
Spheno-ethmoidal recess, 665
-maxillary fissure, 192
fossa, 191, 192
-palatine artery, 401
nerve, 578
-parietal sinus, 466
Sphincter ani externus, 821
internal, 734
of urethra, 788
iridis, 686
vaginæ, 842
Spigelian lobe, 743

Spinal accessory nerve, 596.
artery, 425
anterior, 407
lateral, 407
posterior, 407
bulb, 545
canal, 124
cord, 499, 552
arachnoid of, 561
central canal of, development of, 103
columns of, 553
conduction paths in, 554
dura of, 561
fissures of, 553
gray matter of, 553
membranes of, 561
pia of, 561
topographical anatomy of, 600
tracts of, 554
veins of, 473
furrow, 124
nerve-roots, 557
nerves, 598
veins, dorsal, 472
longitudinal anterior, 472
posterior, 473
Spinalis dorsi muscle, 329
Spine, 115
veins of, 472
as a whole, 123
Spiral ganglion, 674
ligament, 674
Spitzka-Lissauer tract, 556
Splanchnic nerve, great, 645
least, 646
small, 646
Spleen, 793
accessory, 795
development of, 98
pulp, 795
Splenic artery, 428
flexure, 729
veins, 479
Splenium, 518
Splenius capitis muscle, 326
cervicis muscle, 327
colli muscle, 327
Spongioblasts, 103
Spongioplasm, 38
Sporadic ganglia of fifth nerve, 576
Spot, germinal, 826
yellow, 687
Stapedius, 677
Stapes, 676
Stenson, duct of, 735
Stenson's canal, 666
Sternal lymph-nodes, 495
Sterno-cleido-mastoideus muscle, 337
-hyoideus muscle, 337
-mastoid artery, 395, 399
-thyroideus muscle, 337
Sternum, 126
development of, 127
ossification of, 127
Stilling, canal of, 689
Stomach, 715
coronary veins of, 479
development of, 90
tunics of, 716
Stomodæum, 86
Straight sinus, 464
Stratified epithelium, 44
Stratum corneum, 653
dorsale, 536
granulosum, 653
intermedium, 539
lucidum, 653
Streak, primitive, 81
Striæ acusticæ, 547
longitudinales, 520
Striatum, corpus, 523
Structure of tongue, 708
Study, methods of, 33
Styloglossus, 709
Stylo-hyoideus muscle, 338
-mandibular ligament, 300, 352
-mastoid artery, 398
-pharyngeus, 711
Subarachnoid space, 561
Subcalcarine gyrus, 516
Subclavian artery, 404
lymph-nodes, 493
veins, 470
Subclavius muscle, 257
nerve, 607
Subcollateral gyrus, 516
Subcostales muscles, 336
Subdural space, 560
Sublingual artery, 396
gland, 736
space, 708
Sublobular veins, 740
Submandibular ganglion, 583
Submaxillary ganglion, 583
gland, 735
lymph-nodes, 490
Submental artery, 397
Suboccipital lymph-nodes, 490
muscle, 330
nerve, 602
Subsartorial plexus, 627
Subscapular artery, 411, 415
fascia, 355
lymph-nodes, 493
nerves, 608
Subscapularis muscle, 263
Substantia gelatinosa, 553
Subthalamic region, 536
Suburethral glands, 820
Sulcus of Monro, 533
scleral, 682
spiralis, 672
Superficial cervical nerves, 605
fascia, 349
lymph-vessels, 485
temporal nerve, 582
veins, 455
Superior cervical ganglion, 642
fovea, 551
gluteal nerve, 629
labial nerve, 579
laryngeal nerve, 594
mesenteric plexus, 647
nasal nerves, 580
parietal gyrus, 516
vena cava, 456
Supra-acromial artery, 411
Suprahyoid lymph-nodes, 490
Supramandibular nerve, 588
Supramarginal gyrus, 516
Supraorbital artery, 402
fissure, 515
veins, 459
Suprarenal artery, 431
bodies, development of, 98
capsules, 798
Suprarenal plexus, 646
Suprascapular artery, 410
nerve, 607
Supraspinatus muscle, 260
Supraspinous fascia, 355
Suprasternal artery, 410
Supratrochlear nerve, 576
Surcingle, 524
Surface, mesial, of cerebrum, 512
parts, delimitations of, 21
names of, 21
tentorial, of cerebrum, 512
Surfaces of heart, 371
of liver, 742
Surgical anatomy, 18
Suspensory ligament of lens, 689
of liver, 745
of ovary, 824
of penis, 816
muscle, 723
Sustentacular tissues, 45
Sustentaculum tali, 159
Sutures, 204
of skull, 190
Sweat-glands, 659
Sweetbread, 736
Syllabus of the systemic arteries, 381
Sylvian fissure, 510
veins, deep, 468
Sympathetic nerves, 639
system, development of, 106
Symphysis pubis, 149, 229
Synarthrosis, 204
Synovia, 69
Synovial membranes, 69
articular, 70
bursal, 70
vaginal, 70
System, absorbent, 485
blood-vascular, 365
Haversian, 53
lymphatic, 484
urinary, 777
vascular, 30
Systems of organs, 29
functions of, 29
Systematic anatomy, 18
Systemic veins, 455

T.

Tactile organs, development of, 106
Tænia semicircularis, 524
Tarsal artery, 452
Tarsus, 692
bones of, 158
joints of, 240
Taste-buds, 661
organs of, 662
Tectorial membrane, 672
Teeth, 702
bicuspid, 703
canine, 703
deciduous, 703
development of, 86
eruption of, 703
incisor, 702
milk, 703
molar, 703
sets of, 703
temporary, 703
Tegmentum, 539
Temporal artery, 401

Temporal artery, anterior, 399
middle, 399
posterior, 399
bones, 171
fascia, 350
fossa, 191
gyri, 516
lobe, 511, 513
nerve, deep, 581
superficial, 582
region of skull, 191
of seventh nerve, 588
veins, anterior, 463
common, 459
middle, 459
posterior, 463
superficial, 459
Temporalis muscle, 342
Temporary teeth, 703
Temporo-facial division of seventh nerve, 588
-malar nerve, 578
-maxillary veins, 459
Tendons, general considerations, 245
Tendo oculi, 693
Tenia tecta, 520
Tenon, capsule of, 680
Tensor fasciæ latæ, 292
palati, 701
tympani, 677
vaginæ femoris, 292
Tenth nerve, 592
nuclei of, 590
Tentorial surface, 512
Tentorium, 559
of hypophysis, 559
Teres major, 261
minor, 261
Terminal cone of spinal cord, 553
Testes, 801
development of, 100
of mesencephalon, 539
Testicles, 801
migration of, 802
Thalami optici, 532
Thalamencephalon, 531
development of, 105
Thalamus, optic, development of, 105
Thebesius, veins of, 456
Thigh, fascia of, 362
muscles moving, 289
Third nerve, 571
occipital nerve, 603
ventricle, region of, 531
Thoracic aorta, 423
artery, alar, 415
long, 415
superior, 414
cardiac nerves, 595
duct, 487
fascia, 353
portion of gangliated cord, 644
nerve, 619
external anterior, 608
internal anterior, 608
posterior, 607
twelfth, 621
wall, veins of, 470
Thorax, 126
articulations of, 211
lymph-nodes of, 495
muscles of, 334
Thorax as a whole, 130
Thumb, muscles moving, 280
Thymus, 797
development of, 88
Thyro-arytenoideus, 772
-epiglottideus, 772
-glossal duct, 796
-hyoideus muscle, 338
Thyroid artery, inferior, 410
axis, 410
body, 796
cartilage, 768
gland, 796
accessory, 797
development of, 88
isthmus of, 796
veins, inferior, 462
middle, 462
superior, 462
Tibia, 155
Tibial artery, anterior, 450
posterior, 446
recurrent artery, anterior, 451
posterior, 451
nerve, anterior, 637
posterior, 633
Tibialis muscle, anterior, 308
posterior, 308
Tissues, adenoid reticular, 50
adipose, 49
areolar, 47
cardiac muscular, 61
cartilaginous, 51
classes of, 41
connective, 46
dentinal, 56
elastic, 47
elementary, 37
epithelial, 41
fatty, 49
gelatinous, 50
of the heart, 366
liquid, 57
muscular, 58
plain, 58
cross-striped, 59
nervous, 62
osseous, 52
cancellous, 53
spongy, 53
sustentacular, 45
white fibrous, 46
yellow fibrous, 47
Tongue, 660, 707
development of, 88
structure of, 708
Tonsils, 711
pharyngeal, 710
Tonsillar artery, 397
nerve of ninth, 591
Topics, order of, 33
Topographical anatomy, 18
of spinal cord, 600
Torcular Herophili, 166, 464
Touch-corpuscles, 654
Trachea, 757
development of, 88
Tracheal artery, 410
Trachelo-mastoideus muscle, 329
Tract of Burdach, 556
of Goll, 556
of Gowers, 555
lateral, of oblongata, 545
olfactory, 567
optic, 568
Tract of spinal cord, 554
Spitzka-Lissauer, 556
uveal, 683
Tragus, 678
Transcendental anatomy, 20
Transitional epithelium, 44
Transversalis abdominis muscle, 333
cervicis muscle, 329
colli artery, 411
fascia, 359
Transverse colon, 729
fissure, 528, 742
sinus, 466
Transversus thoracis muscle, anterior, 336
pedis muscle, 322
perinei muscle, 821, 842
Trapezium, 143
cerebellar, 542
Trapezius muscle, 253
Trapezoid, 143
Triangle interdeferential, 808
Scarpa's, 440
Triangles of the neck, 411
Triangularis sterni muscle, 336
Triceps extensor cubiti, 265
suræ muscle, 314
Tricuspid valve, 368
Trifacial nerve, 574
Trigonum of bladder, 785
Trochlear nerve, 574
Trolard, veins of, 468
True cartilage, 51
ribs, 127
skin, 653
vertebræ, 115
vocal cords, 770
Trunk, articulations of, 205
muscles of, 325
Tuba auditiva, 676
Tube, Eustachian, 676
Tuber annulare, 540
cinereum, 534
cochleæ, 675
dorsal, cerebellar, 544
Tubercle, acoustic, 551
of Lower, 368
Tubes, bronchial, 758
Fallopian, 827
development of, 100
uriniferous, 777
Tubo-ovarian ligament, 824
Tubuli recti, 805
seminiferi, 804
Tunica albuginea, 804, 813
ovarii, 824
vaginalis, 803
development of, 101
vasculosa, 804
Tunic or tunics, of alimentary canal, 697
of eye, fibrous, 683
vascular, 683
nervous, 686
of liver, 744
of small intestine, 718
of stomach, 716
Turbinate bone, inferior, 185
Twelfth nerve, 597
thoracic nerve, 621
Tympanic artery, 400
bone, 175
nerve, 591
Tympanum, 674

Tympanum, muscles of, 677
Typical cerebro-spinal nerve, 563

U.

Ulna, 137
Ulnar artery, 417
recurrent, 418
nerve, 612
veins, anterior, 469
posterior, 469
Umbilical cord, 83
fissure, 742
vesicle, 83
Unciform, 143
Uncinate gyrus, 517
Ungual phalanges, 146
Urachus, 102
Ureters, 784
development of, 99, 102
infundibula of, 784
pelvis of, 784
Urethra, 787
development of, 102
female, 788
internal sphincter of, 788
male, 789
membranous, 789
prostatic, 789
spongy, 789
triangular ligament of, 361
Urethral glands, 841
Urinary bladder, 785
system, 777
Uriniferous tube, 777
Urogenital sinus, 102
Uterine artery, 434
plexus, 480, 648, 835
sinuses, 835
Utero-ovarian ligaments, 823
-sacral ligaments, 832
-vesical pouch, 831
Uterus, 829
cervix of, 830
development of, 100
fundus of, 830
masculinus, 790
development of, 101
Utricle, 668
Uveal tract, 683
Uvula, 700
cerebellar, 544
vesicæ, 785

V.

Vagina, 835
development of, 103
Vaginal arteries, 434
plexus, 480, 648
synovial membrane, 70
Vagus area, 551
nerve, 592
Vallecula, 542
Valsalva, sinus of, 368
Valve, aortic, 369
bicuspid, 369
Eustachian, 368
ileo-cæcal, 727
-colic, 727
mitral, 369
pulmonary, 368
semilunar, of rectum, 734
tricuspid, 368
of Vieussens, 540 S
Valvula, 540
Valvulæ conniventes, 720
Varolius, bridge of, 540
Vas aberrans, 808
Vascular system, 30
membrane lining, 68
tunic of eye, 683
Vas deferens, 807
development of, 101
Vasa efferentia, 805
vasorum, 375
Vastus externus muscle, 307
intermedius muscle, 307
internus muscle, 307
lateralis muscle, 307
medialis muscle, 307
Vein or veins, anastomotic, great, 468
posterior, 468
angular, 458
anterior auricular, 460
cardiac, 456
facial, 459
internal maxillary, 459
temporal, 463
auricular, anterior, 460
posterior, 460
axillary, 470
azygos, great, 471
left lower, 472
lower, left, 472
right, 471
small, 472
basilic, 469
median, 469
brachio-cephalic, 457
of brain, 467
bronchial, 472
buccal, 459
cardiac, 455
anterior, 456
great, 455
middle, 456
posterior, 456
smallest, 456
cephalic, 470
median, 469
cerebellar, inferior, 468
superior, 468
cerebral, anterior, 468
deep, 468
inferior, 468
middle, 468
superficial, 467
superior, 467
cervical, deep, 463
transverse, 460
choroid, 468
circumflex iliac, superficial, 481
common facial, 459
iliac, 476
temporal, 459
coronary, 455
right, 456
small, 456
of stomach, 479
deep, 455
cervical, 463
facial, 459
Sylvian, 468
development of, 96
digital of foot, dorsal, 481
of diploë, 463
dorsal digital of foot, 481
Vein or veins, dorsal, of penis, 480
spinal, 472
emissary, 463, 467
epigastric, superficial, 481
external iliac, 477
jugular, 460
pudic, 481
saphenous, 481
extraspinal, 472
facial, 457
anterior, 457
common, 458
posterior, 459
transverse, 460
femoral, 482
frontal, 459, 463
of Galen, 456, 468
gastric, 479
gluteal, 480
great anastomotic, 468
cardiac, 455
of head and neck, 457
of heart, 455
hepatic, 740
iliac, common, left, 476
right, 476
external, 477
internal, 479
superficial circumflex, 481
ilio-lumbar, 476
inferior mesenteric, 479
palpebral, 459
striate, 468
thyroid, 462
innominate, 457
intercostal, 472
superior, 471
interlobular, 740
internal jugular, 461
mammary, 470
maxillary, 460
anterior, 459
pudic, 480
saphenous, 481
interventricular, posterior, 456
intralobular, 740
intraspinal, 472
jugular, anterior, 460
external, 460
posterior, 460
internal, 461
posterior external, 460
lateral sacral, 480
left marginal, 456
long saphenous, 481
of lower limb, deep, 482
superficial, 481
of Lubbe, 468
lumbar, 475
ascending, 476
mammary, internal, 470
marginal, left, 456
right, 456
of Marshall, 455
masseteric, 459
maxillary, anterior internal, 459
internal, 460
median, 469
basilic, 469
cephalic, 469
meningo-rachidian, 472
mesenteric, inferior, 479
superior, 479

Vein or veins, middle sacral, 476
temporal, 459
thyroid, 462
nasal transverse, 459
oblique, 455
obturator, 480
occipital, 460, 463
ophthalmic, 467
common, 467
inferior, 467
superior, 467
ovarian, 475
palpebral, inferior, 459
parotid, 459, 460
of pelvis, 479
portal, 477, 739
system of, 477
popliteal, 482
posterior anastomotic, 468
auricular, 460
facial, 459
interventricular, 456
temporal, 463
ulnar, 469
pulmonary, 454
pudic, external, 481
internal, 480
pyloric, 479
radial, 469
ranine, 461
right coronary, 456
marginal, 456
sacral, lateral, 480
middle, 476
saphenous, external, 481
internal, 481
long, 481
short, 481
sciatic, 480
short saphenous, 481
small coronary, 456
spermatic, 475
of spinal cord, 473
of spine, 472
dorsal, 472
anterior longitudinal, 472
longitudinal, anterior, 472
posterior, 473
posterior longitudinal, 473
splenic, 479
striate, inferior, 468
subclavian, 470
subcutaneous, 455
sublobular, 740
superficial, 455
circumflex iliac, 481
epigastric, 481
temporal, 459
superior intercostal, 471
mesenteric, 479
thyroid, 462
supraorbital, 459
suprascapular, 460
of surface of cranium and face, 457
Sylvian, deep, 468
systemic, 455
temporal, anterior, 463
common, 459
middle, 459
posterior, 463
superficial, 459
Vein or veins, temporo-maxillary, 459
of thoracic wall, 470
thyroid, inferior, 462
middle, 462
superior, 462
transverse cervical, 460
facial, 460
nasal, 459
of Trolard, 468
of upper limb, deep, 470
superficial, 468
ulnar, anterior, 469
posterior, 469
vertebral, 462
anterior, 462
bodies, 472
posterior, 463
Velum interpositum, 526
pendulum palati, 700
posterior medullary, 546
Vena azygos major, 471
minor, 472
cava, ascending, 474
descending, 456
inferior, 474
superior, 456
-caval fissure, 743
hemiazygos, 472
accessoria, 472
portæ, 477
Venæ basis vertebrarum, 472
comites, 455
cordis minimæ, 456
Thebesii, 456
vorticosæ, 682
Ventral pyramids, 545
Ventricles of brain, development of, 103
fourth, 550
of larynx, 773
right, 368
Ventricular cavity, general, 504
Vermis, 542
inferior, 543
superior, 542
Vertebra dentata, 117
prominens, 117
typical, 115
Vertebræ, cervical, 116
development of, 91
false, 115
lumbar, 119
ossification of, 124
peculiar, 118
sacral, 120
serial morphology of, 125
thoracic, 117
true, 115
Vertebral artery, 406
bodies, veins of, 472
column, 115
articulations of, 205
fascia, 358
grooves, 124
veins, anterior, 462
posterior, 463
Verumontanum, 790
Vesica fellea, 746
Vesical artery, 434
plexus, 480, 648
Vesicle, blastodermic, 80
Vesicle, encephalic, 500
germinal, 826
seminal, 808
umbilical, 83
Vesico-pubic muscle, 787
Vesicula prostatica, 790
Vessels of liver, 739, 745
Vestibule, 839
of nose, 663
of osseous labyrinth, 673
Vestibulum oris, 699
Vibrissæ, 663
Vicq-d'Azyr, bundle of, 522
Vidian artery, 401
nerve, 579
Vieussens, valve of, 540
Villi, 719
chorionic, 84
Vitelline membrane, 825
veins, 93
Vitellus, 826
Vitreous humor, 689
lamina, 684
Vocal cords, false, 770
true, 770
Vomer, 184
Vulva, 837
Vulvo-vaginal glands, 841

W.

Walls of cerebro-spinal axis, 505
Weber, gland of, 734
Wharton, duct of, 736
White commissure, basal, 518
of spinal cord, 554
fibro-cartilage, 51
fibrous tissues, 46
Willis, circle of, 408
Windpipe, 757
Winslow, foramen of, 751
Wolffian body, 99
duct, 98
Womb, 829
Worm, 542
Wormian bones, 190
Wrisberg, nerve of, 612
Wrist-joint, 224

X.

Xiphoid process, 126

Y.

Yellow fibro-cartilage, 52
fibrous tissues, 47
spot, 687

Z.

Zinn, ligament of, 690
zonula of, 689
Zona incerta, 536
pellucida, 826
Zone, ciliary, 684
Zonula of Zinn, 689
Zygoma, 172
Zygomatic fossa, 191
Zygomaticus muscle, major, 346
minor, 346